



HAL
open science

Les mouvements de membre fantôme : relations entre perceptions motrices et neuro-anatomie fonctionnelle étudiée en IRM fonctionnelle

Estelle Raffin

► **To cite this version:**

Estelle Raffin. Les mouvements de membre fantôme : relations entre perceptions motrices et neuro-anatomie fonctionnelle étudiée en IRM fonctionnelle. Médecine humaine et pathologie. Université Jean Monnet - Saint-Etienne, 2011. Français. NNT : 2011STET007T . tel-00697776

HAL Id: tel-00697776

<https://theses.hal.science/tel-00697776>

Submitted on 16 May 2012

HAL is a multi-disciplinary open access archive for the deposit and dissemination of scientific research documents, whether they are published or not. The documents may come from teaching and research institutions in France or abroad, or from public or private research centers.

L'archive ouverte pluridisciplinaire **HAL**, est destinée au dépôt et à la diffusion de documents scientifiques de niveau recherche, publiés ou non, émanant des établissements d'enseignement et de recherche français ou étrangers, des laboratoires publics ou privés.

THESE

Présentée devant

L'Université Jean Monnet – Saint Etienne

Pour obtenir

LE GRADE DE DOCTEUR

Mention : NEUROSCIENCES

Par

Estelle RAFFIN

**«LES MOUVEMENTS DE MEMBRE FANTOME : RELATIONS ENTRE PERCEPTIONS MOTRICES ET
NEURO-ANATOMIE FONCTIONNELLE ETUDIEE EN IRM FONCTIONNELLE»**

Soutenue publiquement le 29 septembre 2011 devant le jury composé de :

P. GIRAUX (Directeur de thèse)

P. JACKSON (Examineur)

B. LAURENT (Examineur)

J. MATTOUT (Examineur)

J. PAYSANT (Rapporteur)

K. REILLY (Co-directrice de thèse)

C. XERRI (Rapporteur)

Remerciements

Mes premiers remerciements iront bien sûr, à mon directeur de thèse, Pascal Giraux, qui a été un guide précieux pour mes premiers pas dans la recherche. Merci de m'avoir fait confiance. Ces quelques années passées à vos côtés ont été riches d'enseignements et d'échanges... Merci pour l'enthousiasme sans faille et pour la vision d'ensemble sur ces travaux qui m'ont parfois fait défaut. Je tiens également à remercier Karen Reilly, pour avoir co-encadré cette thèse et m'avoir toujours insufflée la rigueur dans mes raisonnements comme dans mes écrits. J'ai pour elle, une grande estime et une profonde admiration, tant sur le plan professionnel que personnel. Je suis très reconnaissante à mes deux directeurs de thèse de m'avoir aidé à mener à bien ce projet.

Je remercie vivement Messieurs Jean Paysant et Christian Xerri, pour avoir accepté d'être rapporteurs de cette thèse, ainsi que Messieurs Phillip Jackson, Bernard Laurent et Jérémie Mattout qui m'ont fait l'honneur d'accepter de faire partie de mon jury.

Je tiens également à adresser un profond remerciement à tous les participants à ces travaux de thèse, patients et volontaires sains. Merci pour votre participation et votre enthousiasme.

Ce travail a été réalisé au sein du service de Médecine Physique et de Réadaptation de l'Hôpital Bellevue à Saint Etienne. J'en profite pour remercier toute l'équipe du MPR, secrétaires, médecins, kinés, ergos... pour votre accueil et votre bonne humeur. Merci à Francis, Lhassan, Xavier, « petit » Pascal... Merci également à l'équipe de Médecine du Sport, Nico, Pierre, Philippe, Elodie, Josy, pour vos coups de main ponctuels et votre soutien.

Je réserve une place toute particulière à ma colloc' de bureau Diana, mon « deuxième modèle ». Elle contribue sans aucun doute à l'atmosphère amicale du MPR et au delà de sa bonne humeur, son expertise dans les rouages de la thèse et sa profonde rigueur scientifique m'ont réellement aidé.

Je suis très reconnaissante à Nathalie Richard, Jérémie Mattout avec qui j'ai eu l'opportunité de collaborer sur ces travaux de thèse et à Isabelle Faillenot et Roland Peyron pour leur aide précieuse et leurs connaissances scientifiques. Merci à l'ensemble de l'équipe INSERM Intégration Centrale de Lyon du Centre de Recherches en Neurosciences de Lyon, dirigée par Monsieur Luis

Garcia-Larrea. Leurs réunions d'équipe resteront pour moi un modèle d'échanges scientifiques, toujours riches d'enseignements. Je profite également de l'occasion pour remercier les membres du CERMEP, Danièle, Jean-Christophe, pour leurs connaissances en l'IRMf, Jamila, pour son aide pour la rédaction du CPP..., Véro, Fabienne et Christine pour leur patience et leur gentillesse.

Je voudrais remercier Florence, qui comme moi, a alterné les cycles d'abattement /enthousiasme au cours ces 4 dernières années... Tu tiens le bon bout, et je suis persuadée que tu seras épatante ! Prochain épisode à Copenhague ?...

Merci à mes ami(e)s de Normandie, Elodie, Vincent, Bérengère, Maryline, Coralie, Cathelyne, Anne-Sophie et Magali, mêmes éloignées, les instants passés ensemble sont toujours des grands moments de joie. Merci aux savoyardes, Mag, Aurélie, Céline, Fanny, Sabrina, les volleyeuses, Véro, Caro, Carotte, Juju... Nadège pour ton petit brin de folie ! Une pensée spéciale aux APA de Grenoble, Julie, Mag, Solène, Renaud, Marion, Blandine, Cécile et Adeline à nos fou-rires et les bons souvenirs d'ascensions hivernales en AX à St Hilaire du Touvet ou aux 7 Laux... A mes binômes de Master, les « Fannies », Krystelle, Julien, Pierre et Marion. Je crois bien que je suis la dernière cette fois...

Enfin, un grand merci à ma famille et belle-famille, à mon frère, ma mère pour son écoute et sa façon de relativiser mes petits tracas... mon père, pour sa disponibilité et ses « dépannages express » via Skype et pour savoir « gérer » mes moments de stress lors de la perte de mes deux derniers ordinateurs...

Merci Julien, d'être là, de me supporter lors de mes coups de blues et de découragements. Tu essaies toujours de me valoriser malgré le syndrome chronique dont je souffre, « d'autodénigrement »...

L'écriture de cette page symbolise la fin de cinq années passées à Saint Etienne et par la même occasion, la fin d'une scolarité relativement longue... qui m'a valu quelques moqueries. L'aboutissement de cette thèse marque également le début d'autre chose, d'autres recherches et d'autres rencontres, qui je l'espère seront fructueuses tant sur le plan scientifique qu'humain.

Résumé

Le membre fantôme correspond à la persistance de perceptions sensibles et motrices attribuées au membre amputé. Des douleurs chroniques parfois invalidantes ainsi que des capacités d'évocation de mouvements dans le membre absent sont fréquemment rapportées. Très peu connue, cette motricité résiduelle est souvent considérée comme de l'imagerie motrice. Le premier objectif de cette thèse est de réinterroger le statut psychologique des mouvements de membre fantôme. Le second objectif est d'étudier le lien entre le contrôle moteur dans le membre fantôme et les réorganisations corticales dans le cortex moteur du sujet amputé. Au moyen de tests comportementaux et d'exams en Imagerie par Résonance Magnétique fonctionnelle (IRMf), ces travaux de thèse ont permis de dissocier expérimentalement une forme de perceptions kinesthésiques associée à de l'imagerie motrice et une autre forme associée à de l'exécution motrice dans le membre fantôme. Cette distinction repose à la fois sur des différences de performances et sur le recrutement de régions cérébrales partiellement distinctes. Au-delà de cette distinction physiologique, les résultats obtenus suggèrent que les mouvements de membre fantôme s'apparentent à une forme d'exécution motrice plutôt qu'à de l'imagerie motrice. A travers le modèle du membre fantôme, ce travail aborde donc la question de la nature des informations menant à la perception d'un mouvement comme étant « exécuté ». Les altérations du fonctionnement cortical mises en évidence chez l'amputé peuvent représenter un modèle d'étude intéressant des différents mécanismes physiopathologiques relevés dans des situations de déficiences liées à une forme de plasticité « maladaptative ». Les observations cliniques et les exams en neuroimagerie menés au cours de cette thèse dressent en effet, un modèle relativement cohérent de l'organisation fonctionnelle du cortex après amputation. En particulier, l'existence d'un lien entre les réorganisations fonctionnelles au sein du cortex moteur et la qualité du contrôle moteur résiduel dans le membre fantôme permet de mieux comprendre les mécanismes sur lesquels reposent certaines thérapies antalgiques, comme les thérapies visuomotrices.

Mots-clés : membre fantôme ; exécution motrice ; imagerie motrice ; réorganisations corticales ; contrôle moteur

Abstract

The phantom limb is a sensory experience that is perceived to originate from the missing part. Amputees report that the phantom limb had certain sensory properties like touch and pain, as well as kinesthetic properties like being able to be moved voluntarily. Phantom limb movements are little-known and generally considered to reflect motor imagery rather than motor execution. The first aim of this thesis is to investigate whether amputees distinguish between executing a movement of the phantom limb and imagining moving the missing limb. The second aim is to examine the link between the quality of the motor control in the phantom limb and cortical reorganizations in the motor cortex of amputees. Behavioral tests and functional Magnetic Resonance Imaging (fMRI) results reveal the ability of amputees to make the distinction between execution and motor imagery in the phantom limb. This distinction is based both on differences in performances associated with the two tasks and the recruitment of partially distinct brain regions. Beyond this physiological distinction, this result suggests that phantom limb movements are similar to executed movements and differ from imagined movements. This raises important questions about the very nature of the processes underlying the awareness of a movement as being executed or imagined. The functional alterations in the motor cortex of amputees are somewhat similar to the pathophysiological mechanisms of maladaptive plasticity. Amputation could be a great model for its study. Indeed, the clinical and neuroimaging examinations conducted during this thesis led to a relatively coherent model of the functional reorganizations in the motor cortex after a limb-amputation and their relationships with behavioral variables. In particular, the relationship between functional reorganizations in the motor cortex and the quality of residual motor control in the phantom limb helps to understand the mechanisms underlying some analgesic therapies, such as the “visuomotor therapy”.

Keywords: phantom limb; motor execution; motor imagery; cortical reorganizations; motor control

SOMMAIRE

RESUME	4
ABSTRACT	5
ETAT DE L'ART	8
1. Le membre fantôme	11
1.1 Identification et terminologie	11
1.2 Analyse phénoménologique	12
1.3 Questions soulevées	17
1.4 Regards contemporains sur le membre fantôme	19
2. Deux perceptions motrices chez l'amputé ?	23
2.1 Dissociation chez le sujet volontaire sain	23
2.2 Dissociation chez le sujet amputé	26
3. Réorganisations corticales et corrélats perceptifs	32
3.1 Composante spatiale des réorganisations corticales	36
3.2 Composante non spatiale des réorganisations corticales	42
3.3 Réflexions et critiques méthodologiques	43
EXPERIMENTATIONS	50
4. Etude 1	51
4.1 Résumé	51
4.2 Article	53
5. Etude 2	84
5.1 Résumé	84
5.2 Article	86
6. Etude 3	115
6.1 Résumé	115
6.2 Article	117

DISCUSSION GENERALE	146
7. Contribution méthodologique : intérêt de l'approche superficielle	147
8. Perceptions motrices dans le membre fantôme	153
9. Un modèle de plasticité « expérience-dépendante »	158
10. Contrôle moteur du membre fantôme et thérapies antalgiques	165
11. Conclusion et perspectives	172
RÉFÉRENCES	173
ANNEXES	207
1 Etude 1	207
2 Matériels et résultats supplémentaires (étude 2)	220

TABLE DES ILLUSTRATIONS

FIGURES

Figure 1 : Formes les plus courantes de postures du membre fantôme (Murray, 2010).

Figure 2 : Carte des sensations référées (Ramachandran and Hirstein, 1998) ; carte *modalotopique* des sensations référées (Borsook et al., 1998)

Figure 3 : Photo de Paul Wittgenstein avec le London Orchestra (Paris, 1933)

Figure 4 : Utilisation de la thérapie miroir (Murray, 2010)

Figure 5 : Enregistrements cinématiques et électromyographiques de mouvements bilatéraux (membre intact et membre fantôme) (Gagné et al., 2009)

Figure 6 : Homoncules sensoriel et moteur (Penfield and Rasmussen, 1950)

Figure 7 : 1ère illustration de la mesure des réorganisations corticales dans S1 (Flor et al., 1995)

Figure 8 : 2ème illustration de la mesure des réorganisations corticales dans S1 (Birbaumer et al., 1997).

Figure 9 : 3ème illustration de la mesure des réorganisations corticales (Lotze et al., 1999).

Figure 10 : Activations sensorimotrices liées à un mouvement du membre fantôme (Flor et al., 2006).

Figure 11 : Utilisation des CoG en IRMf (Giraux et al., 2001)

Figure 12 : Distance euclidienne et distance géodésique dans le cortex moteur primaire

Figures 13-15 : Méthode d'évaluation des réorganisations topologiques sur la surface corticale

Figure 16 : Principe des modèles forward dans le contrôle des mouvements de membre fantôme et réseau cérébral impliqué

Figure 17 : Différentes modalités de pratique associées à la thérapie miroir

LISTE DES ABREVIATIONS

AMS : Aire Motrice Supplémentaire

AVC : Accident Vasculaire Cérébral

BA : Brodmann Area

BPA : Brachial Plexus Avulsion (Avulsion du Plexus Brachial)

CoG : Centre of Gravity (*Centre de Gravité*)

CoM : Centre of Mass (*Centre de Masse*)

DCM : Dynamic Causal Modeling

EEG : ElectroEncéphaloGraphie

EMG : ElectroMyoGraphie

ICMS : IntraCortical MicroStimulation (*Micro Stimulation Intra Corticale*)

IM : Imagerie Motrice

IMK : Imagerie Motrice Kinesthésique

IMV : Imagerie Motrice Visuelle

IRMf : Imagerie par Résonance Magnétique fonctionnelle

M1 : Cortex moteur primaire

MEG : MagnétoEncéphaloGraphie

PEM : Potentiel Evoqué Moteur

PES : Potentiel Evoqué Somesthésique

ROI : Région d'Intérêt

S1 : Cortex somatosensoriel primaire

SDRC : Syndrome Régional Dououreux Chronique

TEP : Tomographie par Emission de Positrons

TMS : Stimulation Magnétique Transcrânienne

GLOSSAIRE

Amputation distale : amputation en dessous du coude

Amputation proximale : amputation au dessus du coude

« En vérité, le chemin importe peu, la volonté d'arriver suffit à tout ».

Albert Camus

Etat de l'art

Le phénomène du membre fantôme se définit comme la persistance de la sensation de présence d'un membre amputé, même si la personne ne le voit plus et le sait absent. Cette perception comprend des douleurs parfois très intenses ainsi que des sensations de natures extéroceptives (tactiles, thermiques) et proprioceptives, dont une capacité à évoquer des mouvements dans le membre absent (Sherman et al., 1984, Jensen et al., 1985). Cette capacité motrice résiduelle est certainement la propriété la moins bien connue de l'ensemble du phénomène de membre fantôme. Il existe très peu de données épidémiologiques sur les mouvements de membre fantôme. Les rares données expérimentales évaluant précisément les capacités de contrôle volontaire du membre fantôme, montrent qu'elles sont très variables selon les patients et selon les moments pour un même patient. Globalement, les capacités motrices semblent être dégradées comparativement au membre intact et cette altération des sensations motrices est d'autant plus marquée que le patient souffre de douleurs du membre fantôme (Gagné et al., 2009).

Bien que peu connue d'un point de vue sémiologique, épidémiologique et physiologique, la motricité fantôme est utilisée dans la pratique médicale. Ainsi chez certains patients amputés, l'entraînement moteur du fantôme (avec ou sans rétrocontrôle visuel) s'accompagne d'un soulagement des douleurs de membre fantôme (par exemple Brodie et al., 2007, Chan et al., 2007, Mercier and Sirigu, 2009). Au-delà du champ de la douleur, l'entraînement moteur du membre fantôme est associé à la réussite de l'appareillage par prothèse myo-électrique (Di Pino et al., 2009). Les patients possédant de bonnes capacités motrices dans le membre fantôme bénéficient de résultats fonctionnels plus rapides et bien souvent meilleurs. L'entraînement moteur du membre fantôme facilite le contrôle des contractions musculaires du moignon commandant les mouvements de la prothèse. La cohabitation entre la présence du membre fantôme et celle de la prothèse est proche de la situation rencontrée lors de greffes de membre. Là encore, la conservation de la fonction motrice du membre amputé et des commandes motrices associées est primordiale pour le réapprentissage des gestes élémentaires (Giroux et al., 2001, Vargas et al., 2009).

Dans ce contexte, il nous apparaît pertinent de réinterroger le statut psychologique de la motricité fantôme. Ce questionnement provient d'un constat clinique réalisé auprès de patients amputés pratiquant des thérapies visuomotrices. La majorité des patients semblent pouvoir éprouver distinctement des sensations kinesthésiques proches de celles d'un vrai mouvement et d'autres se rapprochant davantage de celles perçues lors de mouvements imaginés.

La démonstration expérimentale de la capacité à dissocier l'imagerie motrice de « l'exécution » motrice avec le membre fantôme fera l'objet d'une première expérimentation, et servira de modèle comportemental pour les suivantes. Nous envisagerons ensuite cette problématique sous l'angle neurophysiologique en utilisant l'Imagerie par Résonance Magnétique fonctionnelle (IRMf). Nous examinerons ainsi les substrats neuronaux sous-tendant cette différenciation. Au-delà de la démonstration physiologique d'une double perception motrice chez l'amputé, cette étude permettra de comparer les réseaux cérébraux activés par le membre fantôme et ceux activés par le membre intact. Enfin, dans le but de proposer un modèle global de l'organisation fonctionnelle du cortex moteur après amputation, nous examinerons en IRMf, l'impact des variables comportementales telles que la motricité fantôme et les douleurs sur l'ensemble des perturbations fonctionnelles du cortex moteur.

Dans le contexte médical, les travaux de cette thèse permettront de réinterroger les conditions de pratique des « thérapies-miroir » (ou thérapies visuomotrices) utilisées auprès des patients amputés. Puis l'étude du contrôle moteur du membre fantôme permettra d'explorer plusieurs questions dans le champ du contrôle moteur humain. Tout d'abord, nous verrons en quoi la différenciation entre exécution et imagerie motrice chez l'amputé est un modèle d'étude des prédictions sensorielles dans la perception du mouvement. D'un point de vue neurophysiologique, les résultats obtenus permettront de faire une synthèse des marqueurs neuronaux associés aux difficultés motrices dans le membre fantôme, et d'étudier leurs points communs avec des mécanismes physiopathologiques mis en évidence dans d'autres pathologies. Enfin, l'étude de l'organisation fonctionnelle du cortex chez l'amputé et de ses liens avec la douleur et la motricité permettra de formuler des hypothèses concernant les mécanismes d'action de certaines thérapeutiques antalgiques proposées aux patients amputés.

La première partie de ce document correspond à l'état des connaissances sur le membre fantôme. Il sera question de la prise en compte du phénomène de membre fantôme comme modèle scientifique et de son étude phénoménologique (Chap. 1). Puis en centrant notre problématique sur les perceptions motrices des patients amputés, nous tâcherons à partir des données obtenues chez le sujet volontaire sain, de relever des indices pertinents, permettant de dissocier le mode exécuté du mode imaginé chez l'amputé (Chap. 2). Le chapitre suivant abordera les réorganisations corticales après amputation en accordant une attention particulière aux liens entre les réorganisations et les manifestations perceptives associées à l'amputation (Chap. 3). Les résultats des différentes études réalisées au cours de cette thèse seront exposés (Chap. 4, 5 et 6) pour enfin procéder à une discussion générale de ces travaux, et envisager les perspectives qu'ils offrent (Chap. 7, 8, 9, 10 et 11).

1. Le membre fantôme

Beaucoup de concepts théoriques ont été développés autour du modèle du membre fantôme, dans des contextes psychologiques, philosophiques ou physiologiques. Récemment, le modèle du membre fantôme a connu un regain d'intérêt en neurosciences, parallèlement au développement des techniques d'imagerie cérébrale. Il procure un modèle intéressant permettant d'articuler l'étude des troubles de la perception du corps et l'étude des réorganisations corticales.

1.1 Identification et terminologie

Le membre fantôme n'est décrit dans la littérature médicale qu'à partir du XVI^{ème} siècle par le chirurgien français Ambroise Paré (1510-1590). Le manque de données précoces peut être en partie attribué à la dimension « mystique » que l'on vouait au membre fantôme. Les rares récits médiévaux évoquant le membre fantôme furent retranscrits dans un contexte religieux. Les véritables descriptions scientifiques apparaissent donc à partir de la Renaissance, parallèlement aux progrès des pratiques médicales (Paré, 1551). L'apport des chirurgiens et des philosophes des 18^{ème} et 19^{ème} siècles a ensuite contribué à la prise en compte médicale du membre fantôme. Cependant, la grande majorité des travaux sur le membre fantôme de cette époque sont publiés dans des revues psychiatriques (par exemple James, 1887).

La terminologie définitive du membre fantôme date de 1866, un an après la fin de la Guerre de Sécession aux Etats-Unis. Dans un article anonyme publié dans le magazine populaire « Atlantic Monthly », Silas Weir Mitchell (1829-1914) y donne la première description clinique du membre fantôme ainsi que l'ébauche d'une théorie sur l'origine des douleurs dans le membre absent. « *Le cas de George Dedlow* » retrace la vie d'un assistant-chirurgien de l'armée, Dedlow, qui après une série de graves blessures, se fait amputer de ses quatre membres. Mitchell publia anonymement dans une revue non scientifique, car la communauté scientifique de l'époque était encore très sceptique vis-à-vis du membre fantôme¹. Puis en 1872, Mitchell publie un ouvrage « *Injuries of Nerves and Their consequences* », où un chapitre entier intitulé « Neural Maladies of Stump » traite des différentes perceptions sensorimotrices et des manifestations psychologiques liées au membre

¹ « *The following notes of my own case have been declined on various pretexts by every medical journal to which I had offered them* », *The Case of George Dedlow*, 1866

fantôme (Mitchell, 1872). La prise en compte et la phénoménologie du membre fantôme ont significativement évolué grâce au travail de Mitchell, qui fait encore parti des observations les plus minutieuses et complètes sur le membre fantôme.

1.2 Analyse phénoménologique

Sensations intéroceptives, proprioceptives et extéroceptives

Il existe un sentiment général de présence du membre amputé pour environ 80% des patients amputés (Jensen et al., 1983, Sherman et al., 1984, Kooijman et al., 2000). Cette sensation de présence s'accompagne de capacités de discrimination proprioceptives et extéroceptives (e.g. tactiles, thermiques) (Hunter et al., 2008).

Les sensations proprioceptives de membre fantôme comprennent une perception générale de taille, de forme et de position du membre fantôme (Halligan et al., 1993, Knecht et al., 1995, Aglioti et al., 1997). Concernant la position, le membre fantôme demeure pour la majorité des patients, dans une position de repos. C'est-à-dire pour les amputés du membre supérieur, le coude est partiellement fléchi, avec l'avant bras en position de pronation et les doigts semi-fléchis. Si le membre est perçu dans une position cohérente dans beaucoup de cas (e.g. position assise, jambe fantôme fléchie ou balancement du bras fantôme lors de la marche à pied), sa position peut également se trouver en inadéquation avec le schéma postural. Cette posture inadéquate peut être désagréable et provoquer des douleurs très invalidantes (Lotze and Moseley, 2007).

Seuls 13 à 24% des patients rapportent des sensations extéroceptives (Halligan et al., 1994, Ramachandran and Hirstein, 1998, Fraser et al., 2001). L'incidence de ces sensations est encore plus faible lorsque l'amputation remonte à l'enfance (Jensen et al., 1983, Melzack et al., 1997). Les sensations de membre fantôme sont souvent décrites comme une exagération des sensations non douloureuses ressenties dans une autre partie du corps. Elles se manifestent sous la forme de picotements, de fourmillement ou encore de crampes, mais peuvent couvrir toutes les expériences sensorielles d'un membre intact. Elles s'expriment généralement de façon plus intense dans la main ou les extrémités que dans les parties plus proximales du membre (Ewalt et al., 1947, Henderson and Smyth, 1948, Carlen et al., 1978, Jensen et al., 1985, Sherman, 1989).

Figure 1 : Illustration des postures du membre fantôme les plus courantes (en foncé) pour des amputés du membre supérieur (figures du haut) et du membre inférieur (figures du bas) (d'après C. Murray, 2010).

Altérations des sensations fantômes: atténuation, télescopage et sensations référées

Lorsque l'amputation est d'origine traumatique, le fantôme est présent dès le départ, puis tend progressivement à disparaître de la conscience (Jensen et al., 1983, Hunter et al., 2008). Lorsque le membre fantôme reste intégré dans le schéma corporel du patient, il peut subir des transformations spatiales (Andre et al., 2001). Une impression de raccourcissement (télescopage) est rapportée chez environ 50% des patients, de telle sorte que la main se rattache directement au moignon (Korin et al., 1963, Weiss and Fishman, 1963, Jensen et al., 1983, Hunter et al., 2008). Souvent, seules les parties distales du fantôme restent perceptibles, le reste étant « oublié »². Les raisons de l'atténuation des sensations fantômes et de ce télescopage du membre fantôme ne sont pas complètement élucidées. Il semble néanmoins que le télescopage soit plus fréquent chez les patients souffrant de douleurs de membre fantôme (Flor et al., 2006).

² « *The patients describe themselves as knowing that they have a hand which is connected to the stump, and feel able to move it, but the rest of the limb they are unconscious, and the subjective sensation which are so common are always referred to the hand or foot, and rarely to the continuity of the member ... the lost limb seems to be shortened. This is a sensation which, in many cases is first felt within a week of the amputation, and goes on progressively, the hand, for instance, slowly approaching the stump*» (Mitchell WS, Injuries of nerves and their consequences, 1872).

Les sensations référées sont partagées par environ la moitié des patients (Ramachandran et al., 1992, Elbert et al., 1994, Halligan et al., 1994, Flor et al., 1998, Flor and Birbaumer, 2000, Hunter et al., 2003). Il s'agit de sensations perçues dans le membre fantôme lors d'une stimulation tactile au visage ou au bras. Il existe quelques fois une cartographie très précise des sensations référées sur la partie ipsilatérale du visage ou sur le moignon (figure 2 A). Cette cartographie des sensations référées n'est pas stable dans le temps (Knecht et al., 1998) et peut être modulée à court terme par des mouvements volontaires du fantôme (Ramachandran et al., 2010). La localisation et le type de perception référée varient en fonction de la modalité de la stimulation, y compris lorsque ces stimulations sont appliquées au même endroit (Borsook et al., 1998). On parle de cartographie *modalotopique* des sensations référées (voire Figure 2 B).

Figure 2: Carte des sensations référées organisées topographiquement sur le visage et sur la partie proximale du bras du patient D.S. Les chiffres indiquent les différents doigts (A) (d'après Ramachandran and Hirstein, 1998). Représentation somatotopique des sensations évoquées dans la main fantôme par différents types de stimuli sur le visage d'un patient (légère pression des doigts, brosse, toucher froid et chaud), 24h après l'amputation de son membre supérieur (B) (d'après Borsook et al., 1998)

Douleurs, mouvements fantômes et relations entre ces deux perceptions

Les personnes amputées se plaignent d'une douleur neuropathique aiguë quasi-immédiate et quasi-systématique après l'amputation. Cette douleur est décrite comme une sensation de

brûlure, de crampe ou encore ressenties comme des « coups de poignards » dans le moignon et dans le membre fantôme. L'incidence à court terme de la douleur fantôme est de plus de 72% (Jensen et al., 1983, Ehde et al., 2000). Elle semble plus importante chez les amputés du membre supérieur (85%) par rapport aux amputés du membre inférieur (54%) (Shukla et al., 1982). Ces douleurs fluctuent de l'occasionnel au continu, du paroxystique au plus régulier et de faible à sévère. Les douleurs liées à des rhumatismes ou à de l'arthrose peuvent persister dans le membre absent (par exemple Whyte and Niven, 2001, Giummarra et al., 2011). Ces sensations douloureuses peuvent changer de « modalité » avec le temps (démangeaisons, crampes, picotement, brûlure...) et ont tendance à se confiner aux parties distales du membre fantôme (Hunter et al., 2008). La douleur de membre fantôme peut se chroniciser et se montrer particulièrement résistante aux traitements antalgiques (Sherman et al., 1984, Jensen et al., 1985). Sherman et al. notent que seuls 7% des patients traités par les quelques 60 types de thérapies proposées ressentent un effet bénéfique (Sherman et al., 1989).

S'ajoute à la sensation de présence, une capacité à percevoir des mouvements dans le membre absent³. On distingue une motricité automatique (involontaire) et une motricité volontaire dans le membre fantôme. Parmi les formes de mouvements fantômes involontaires, certains s'apparentent à une sorte de "crampe", qui fige le membre dans une position souvent douloureuse. En parallèle à cette motricité involontaire, il existe une capacité à évoquer des mouvements volontaires avec le membre fantôme. Ces capacités de mouvements sont variables d'un individu à l'autre et évoluent dans le temps pour un même individu⁴. Les parties du fantôme les plus mobiles sont les doigts ou les orteils. Au contraire, les mouvements des poignets sont moins fréquents et les changements de position du coude ou du genou sont très rarement rapportés. Sans avoir été réellement quantifié, il semblerait que le contrôle moteur du membre fantôme tend à diminuer

³ «[The majority of amputees] are able to will a movement, and apparently to themselves execute it more or less effectively.... The certainty with which these patients describe their [phantom motions], and their confidence as to the place assumed by the parts moved, are truly remarkable" (Weir Mitchell, Injuries of Nerves, 1872).

⁴ « Il semblerait que chez les amputés distaux, la mobilisation active soit plus facile mais pour une grande majorité des amputations proximale, le mouvement est toujours diminué par rapport à l'amplitude totale et consiste simplement en des flexions extensions ... la flexion est en générale plus aisée et demeure plus longtemps dans le temps que l'extension des doigts fantômes. Le mouvement du poignet nécessite plus d'efforts, n'est pas toujours possible, est de plus petite amplitude, se limitant à une légère flexion-extension où l'extension cette fois peut se révéler plus facile» Henderson WR, Smyth GE (1948) Phantom limbs. Manchester.

avec le temps (Cronholm, 1951, Ramachandran and Rogers-Ramachandran, 1996). Des études récentes montrent que les mouvements volontaires du membre fantôme recrutent les voies motrices descendantes et peuvent provoquer des contractions musculaires dans le moignon⁵ (Dhillon et al., 2004, Reilly et al., 2006). Ces études viennent confirmer des observations relativement précoces sur l'implication du système moteur dans sa globalité lors de mouvements de membre fantôme⁶.

Ces mouvements provoquent deux types de réactions. Ils peuvent créer une exacerbation des douleurs dans le membre fantôme en particulier dans les zones où les sensations de membre fantôme sont déjà habituellement les plus intenses ou au contraire procurer un effet antalgique, immédiat ou suite à un entraînement moteur du membre fantôme (par exemple Giroux and Sirigu, 2003).

⁵ Le cas du pianiste virtuose autrichien, Paul Wittgenstein illustre cette propriété à travers les écrits d'Erna Otten, élève du pianiste. Blessé au combat pendant la première guerre mondiale, Wittgenstein fût amputé de son bras droit mais continua à jouer du piano. Erna Otten écrit: « *J'ai pu, à nombreuses occasions, voir comment participait son moignon à la recherche de nouveaux doigtés lors d'une nouvelle composition* » « *Il m'a dit plusieurs fois que je devais faire confiance à son choix de doigté, car il ressentait tous les doigts de sa main droite. Régulièrement, je m'asseyais tranquillement et alors qu'il fermait les yeux je regardais son moignon qui s'agitait pendant qu'il s'imaginait jouer. Ceci dura de nombreuses années après la perte de son bras, entre 1933 et 1939* » (Extraits de la correspondance d'Otten Sacks, petit fils d'Erna Otten élève de Wittgenstein, Otten S., *Phantom Limbs*. Volume 39, Number 3, January 30, 1992).

⁶ «... *the effect is apt to excite twitching in the stump.... In some cases the muscles which act on the hand are absent altogether; yet in these cases there is fully as clear and definite a consciousness of the movement of the fingers and of their change of positions as in cases [where the muscles to the hand are partially preserved]*» (Mitchell WS, *Injuries of nerves and their consequences* p.357, 1872)



Figure 3 : **Paul Wittgenstein** avec le *London Orchestra* (Paris, 1933), *Concerto pour la main gauche de Maurice Ravel*

Cette perception de mouvements du membre fantôme est sûrement la propriété la plus surprenante et la moins bien expliquée. Alors qu'il existe une littérature dense sur le phénomène général du membre fantôme, l'intérêt thérapeutique portée à la motricité volontaire du fantôme est très récente. Pourtant il est important d'acquérir des connaissances plus approfondies sur ce phénomène, en particulier pour améliorer la prise en charge des patients amputés à travers l'approche thérapeutique visuomotrice.

1.3 Questions soulevées

Comment comprendre qu'une partie du corps, physiquement absente donne lieu à des perceptions conscientes ? La genèse des perceptions fantômes, l'altération du schéma corporel ou plus récemment les adaptations neurophysiologiques en réponse à la perte d'un membre sont les principales interrogations autour du membre fantôme.

Pour certains auteurs, la cause des sensations fantômes est périphérique. La repousse anarchique des nerfs sectionnés à l'extrémité du moignon (névromes) est à l'origine de messages sensitifs, qui bien qu'inorganisés, se projettent sur le cortex somatosensoriel et entretiennent la perception de la partie de membre amputée ainsi que les douleurs dans le membre absent (Sherman et al., 1989, Devor and Faulkner, 1999). Cette conception périphérique du membre fantôme a trouvé écho dans certaines thérapies analgésiques de massages ou de stimulations électriques du moignon. Des techniques chirurgicales furent également envisagées, comme la

section des nerfs en amont des névromes ou au niveau des racines dorsales de la moelle épinière. Les résultats contrastés de ces techniques réfutent néanmoins cette conception périphérique. En effet, après la résection du névrome, la douleur tend à réapparaître et la sensation de membre fantôme ne disparaît pas. De plus, les sensations fantômes apparaissent généralement dès l'amputation, alors que la constitution du névrome n'est pas immédiate (Wall and Fitzgerald, 1981). Enfin, des sensations fantômes peuvent se développer chez des patients blessés médullaires, alors que le système nerveux périphérique n'est a priori pas endommagé (Hotz-Boendermaker et al., 2008, Curt et al., 2010).

Parallèlement aux théories périphériques, le membre fantôme a longtemps été présenté comme un phénomène aux origines psychiques. Le mauvais ajustement psychologique fut longtemps considéré comme la cause principale d'apparition des sensations fantômes et du maintien des douleurs dans le temps (par exemple Weil, 1991). Cette théorie repose sur le fait que le membre fantôme soit l'objet du désir narcissique à maintenir son intégrité corporelle contre une perte violente d'une partie de soi (Dejours, 2001). L'idée que le membre fantôme reflète le déni de la perte du membre persiste à travers des écrits scientifiques des années 1950 (par exemple Kolb, 1954). Cependant, l'absence de corrélation entre les sensations de membre fantôme et les stratégies d'adaptations ou de *coping*, les scores de dépression ou de détresse émotionnelle contredisent cette théorie (par exemple Fisher and Hanspal, 1998). Même si ces facteurs psychologiques peuvent influencer la manière dont un patient fait face à son amputation et à ses conséquences, le membre fantôme est désormais envisagé comme une entité psychophysiological, où interviennent à la fois des facteurs périphériques, centraux et psychologiques.

Le membre fantôme a également alimenté la réflexion autour du schéma corporel, de l'appropriation et de la conscience du corps. Vers la fin du 19^{ème} siècle, neurologues et psychologues ont conçu une sorte de référentiel auquel l'individu rapporte son expérience psychosomatique. Plusieurs termes existent : cœnesthésie (Reil au début 19^{ème} siècle), schématisie (Bonnier, 1905), somatognosie (Charcot), schéma postural (Head 1911). Paul Schilder propose ensuite une synthèse de ces concepts sous le terme de schéma corporel. Cette notion renvoie à une structure se constituant dans la relation perception / action. En fournissant des réponses motrices, la perception se crée et s'organise en une structure homogène qui permet le sentiment d'unité et

d'individualité du corps. De façon importante dans le cadre de l'amputation, Schilder intègre une dimension psychologique et émotionnelle à la perception / action et propose que le membre fantôme soit la manifestation consciente du fait que le corps imaginé ne s'accorde plus avec le corps «réel» (Schilder, 1968 p.35). Le modèle du membre fantôme et l'étude d'autres situations pathologiques où le schéma corporel est altéré a enrichi les débats sur la perception du corps. Par exemple, le cas de la « femme désincarnée » décrit par Oliver Sacks en 1986, montre comment un défaut de proprioception peut conduire à une perte du sentiment d'appartenance du corps⁷. Ces travaux se confrontent néanmoins aux limites des connaissances contemporaines. Les neurosciences modernes ont apporté par la suite, une série d'arguments qui révèlent en partie le support biologique de ces concepts. En intégrant le phénomène du membre fantôme, elles tentent d'identifier les mécanismes et la nature profonde qu'entretiennent l'esprit et le corps et les mécanismes qui fondent l'unité du corps.

1.4 Regards contemporains sur le membre fantôme

L'intégration du membre fantôme aux théories contemporaines notamment dans le champ de la douleur a participé à une révision des théories périphériques des perceptions sensorielles. Par exemple, pour certains auteurs, le souvenir de la position du membre avant l'amputation, le fait que les fantômes figés soient plus douloureux ou encore l'efficacité des thérapies miroirs (Moseley, 2006, Chan et al., 2007), seraient la preuve de la mise en jeu d'un réseau cérébral responsable de la « mémoire proprioceptive » (Anderson-Barnes et al., 2009). La mise en jeu de structures centrales dans la perception du membre fantôme est d'ailleurs soutenue relativement tôt par des études anatomo-pathologiques. Bornstein (1949) décrit en détails deux patients chez qui les douleurs fantômes disparurent après une lésion du système central indépendante de l'amputation. Appenzeller et Bicknell (1969) exposèrent également le cas de deux patients chez qui, la survenue

⁷ Oliver Sacks consacre également quelques descriptions et théories sur le membre fantôme dans « doigt fantôme, disparition de membres fantômes, fantômes positionnels et fantômes mort ou vif. » Sacks O (1985) *The man who mistook his wife for a hat*.

d'un Accident Vasculaire Cérébral (AVC) causant une lésion du lobe pariétal droit postérieur, élimina les sensations de membres fantômes.

En accord avec ces données anatomo-pathologiques, Ronald Melzack (Melzack, 1990, 1992) a formulé une théorie selon laquelle les sensations fantômes résultent de l'activation d'une neuromatrice cérébrale, formée par un ensemble de neurones distribués dans tout le cerveau. Cette neuromatrice serait responsable de l'expérience unitaire de notre corps et existerait sous la forme de trois réseaux de neurones. Le premier réseau concerne les informations sensorielles du corps y compris ses différentes postures. Il serait formé du thalamus, du cortex somatosensoriel et des régions adjacentes du cortex pariétal. Le deuxième réseau jouerait un rôle critique dans les émotions et des motivations, et siègerait dans le système limbique. Le troisième réseau impliquerait principalement les réseaux corticaux du lobe pariétal associatif en charge des activités cognitives, en particulier du souvenir des expériences passées et de l'interprétation des messages sensoriels concernant le soi. En partie déterminée génétiquement, cette neuromatrice expliquerait la persistance des sensations dans le membre amputé, mais rendait aussi compte des perceptions de membre fantôme lors d'amputation congénitale. Cette théorie présente quelques concepts invérifiables et difficilement compatibles avec la faible incidence des sensations fantômes chez les amputés congénitaux (Melzack et al., 1997, Wilkins et al., 1998).

A l'opposé de cette conception innée des représentations corporelles, une autre voie d'explication plus récente émergea des expérimentations menées sur des modèles d'animaux amputés ou désafférentés (par exemple Kaas et al., 1983, Merzenich et al., 1983a, Pons et al., 1991). Les résultats de ces études montrent des réarrangements de l'architecture et de l'organisation fonctionnelle du cortex somatosensoriel primaire et du cortex moteur primaire. L'hypothèse selon laquelle des réorganisations somatotopiques similaires chez l'homme entretiendraient les sensations référées et les douleurs de membre fantôme a été formulée et testée par la suite (Ramachandran et al., 1992, Flor et al., 1995, Knecht et al., 1996).

Les différentes tentatives de clarification conceptuelle du phénomène du membre fantôme, parallèlement au développement des neurosciences, ont permis d'étudier les processus centraux responsables de la représentation consciente du corps et des sensations nociceptives. L'utilisation de méthodes non invasives comme la stimulation cérébrale et l'imagerie fonctionnelle témoigne de

la pertinence du modèle du membre fantôme dans plusieurs thématiques contemporaines en neurosciences. Le modèle du membre fantôme est donc utilisé dans l'étude de la plasticité cérébrale (Lotze et al., 2001, Maclver et al., 2008) mais aussi pour l'étude des interactions entre modalités sensorielles, en particulier entre la vision et la proprioception (par exemple Ramachandran and Rogers-Ramachandran, 1996, Touzalin-Chretien et al., 2009).

L'utilisation chez l'amputé de techniques utilisant des conflits intersensoriels a montré que même si les sensations de membre fantôme sont majoritairement somesthésiques, elles peuvent être modulées par d'autres modalités sensorielles. La thérapie visuomotrice (ou thérapie miroir) proposée initialement à des fins antalgiques par Ramachandran, repose sur cette propriété (Ramachandran and Rogers-Ramachandran, 1996). Un miroir placé verticalement à l'endroit où est perçu le membre fantôme, permet de restituer un feedback visuel artificiel du membre absent. Le patient fixe son attention sur la projection de sa main intacte en mouvement. La restitution de la congruence visuomotrice entraîne une forme de syncinésie entre le membre fantôme et la main intacte (Figure 4).



Figure 4 : Utilisation de la **thérapie miroir** (D'après C. Murray, 2010)

Les mécanismes neurophysiologiques expliquant les effets antalgiques de cette thérapie ne sont pas clairement définis. Les modalités de pratique sont confuses chez l'amputé, en particulier concernant la tâche que doivent effectuer les patients. Cette tâche motrice est définie de façon variable dans les études : imagerie motrice, tentatives de mouvements ou encore « mouvements virtuels » du membre fantôme (Ramachandran and Rogers-Ramachandran, 1996, Sathian et al., 2000, Giroux and Sirigu, 2003, McCabe et al., 2003, Chan et al., 2007, McCabe et al., 2008, Yavuzer et al., 2008, Cole et al., 2009, Mercier and Sirigu, 2009). Cette confusion provient d'une part de l'absence de contrôle visuel sur la tâche réellement effectuée par les patients, et d'autre part des

études montrant les effets bénéfiques de l'entraînement en imagerie motrice sur les performances réelles de sujets sportifs (Corbin, 1967, Biddle, 1985) ou de patients hémipariés (Jackson et al., 2001, Jackson et al., 2004, Page et al., 2007, Page et al., 2009, Sharma et al., 2009) (voir Dickstein and Deutsch, 2007 pour revue). Cependant les effets antalgiques de l'imagerie motrice semblent plus nuancés (Chan et al., 2007, Gustin et al., 2007, MacIver et al., 2008, Moseley et al., 2008b, Beaumont et al., 2011).

Ces divergences pointent le besoin de mieux comprendre les bases neuropsychologiques et neurophysiologiques des perceptions kinesthésiques rapportées par les amputés.

2. Deux perceptions motrices chez l'amputé ?

L'absence de membre ne rend pas évident la dissociation entre un mouvement imaginé et un mouvement « exécuté » chez l'amputé. Dans ce chapitre, nous rechercherons l'existence d'indices de dissociation entre l'exécution et l'imagination obtenus chez le sujet volontaire sain, extrapolables chez l'amputé.

2.1 Dissociation chez le sujet volontaire sain

L'imagerie motrice consiste à se représenter mentalement une action sans production concomitante de mouvement (Denis 1989). Deux modes d'imagerie existent : un mode d'imagerie motrice visuelle (IMV) dans lequel les sujets doivent « visualiser » l'exécution de l'action, par opposition au mode d'imagerie kinesthésique (IMK), où les sujets doivent « ressentir » les sensations kinesthésiques, proprioceptives ou musculaires éprouvées lors de l'exécution du mouvement. Jeannerod postule qu'une image motrice est une représentation motrice consciente et que par conséquent, ces images motrices sont dotées des mêmes propriétés que les représentations motrices implicites correspondantes (Jeannerod, 1995).

La congruence spatiotemporelle entre les mouvements exécutés et imaginés a été initialement étudiée à travers des tâches de récitation implicite de l'alphabet (Landauer et al., 1962) de tâches de parcours mental (Kosslyn et al., 1978) ou de tâches de rotation mentale (Shepard and Metzler, 1971). La rotation mentale de la main semble être contrainte par les mêmes lois biomécaniques que celles du mouvement physique (Parsons, 1994). Les techniques de chronométrie mentale, qui comparent des durées d'exécution et d'imagination d'une même tâche motrice (Gottsdanker and Shragg, 1985) et évaluent ainsi l'imagerie motrice explicite, montrent qu'il existe une relation de proportionnalité entre les temps d'exécution et d'imagination (Decety et al., 1989). D'autre part, certaines propriétés physiologiques de l'exécution semblent s'appliquer à l'imagerie explicite. La conservation de la loi de Fitts par exemple, signifie que la difficulté de la tâche, influence son exécution et son imagination de façon identique (Decety and Jeannerod, 1995).

Outre ces caractéristiques psychophysiques, la mesure de l'activité du système nerveux autonome, par exemple les réponses électrodermales (e.g. Guillot et al., 2004), thermovasculaires

(e.g. Deschaumes-Molinario et al., 1992) ou cardiorespiratoires (Decety et al., 1991) et la mesure de l'activité neuromusculaire (e.g. Lebon et al., 2008) ont été utilisées pour caractériser les réponses neurophysiologiques de l'imagerie motrice par rapport à celles de l'exécution motrice. Concernant cette dernière mesure, la majorité des études ne montrent pas d'activité EMG pendant l'imagination chez le sujet volontaire sain (par exemple Decety, 1996a, Lotze et al., 1999b, Hanakawa et al., 2003, Mulder et al., 2004, Gentili et al., 2006). Cette absence d'activité EMG pendant l'imagerie motrice est un critère d'évaluation utilisé en particulier dans les études en neuroimagerie, afin de s'assurer que la tâche réalisée est purement cognitive (Lotze et al., 2001, Naito et al., 2002, Hanakawa et al., 2003, Jackson et al., 2003, Hanakawa et al., 2008). Néanmoins, certains auteurs ont enregistré une activité EMG subliminale dans les muscles impliqués dans le mouvement lors de l'imagerie motrice, certes inférieure au seuil de déclenchement d'une contraction phasique (par exemple Gandevia et al., 1997, Dickstein et al., 2005, Guillot et al., 2007, Lebon et al., 2008). Ces résultats contradictoires peuvent s'expliquer par des divergences méthodologiques, comme le type d'électrodes utilisées (Mellah et al., 1990, Jeannerod and Frak, 1999), le type de contractions musculaires impliquées dans le mouvement imaginé (Guillot et al., 2007, Lebon et al., 2008) ou encore par les consignes données aux sujets (imagerie kinesthésique/visuelle ou point de vue interne/externe) (Solodkin et al., 2004, Stinear et al., 2006).

L'approche fondamentale permettant d'élucider les mécanismes cérébraux qui sous-tendent l'exécution d'un mouvement et son imagination, est d'estimer l'activité cérébrale au cours de ces deux tâches et de les comparer. Les études de neuroimagerie fonctionnelle rapportent des activations communes à l'exécution motrice et à l'imagerie motrice, localisées dans les régions prémotrices (dans sa partie ventrale : l'Aire Motrice Supplémentaire (AMS) et dans sa partie dorsale : le Cortex Prémoteur dorsal), dans les lobules pariétaux inférieurs et supérieurs ainsi que dans le cervelet (Decety et al., 1994, Roth et al., 1996, Lotze et al., 1999b, Gerardin et al., 2000, Stippich et al., 2002, Hanakawa et al., 2003, Solodkin et al., 2004, Neuper et al., 2005, Guillot et al., 2008a, b, Hanakawa et al., 2008). Bénéficiant du développement des techniques d'analyses, des dissociations anatomiques au sein de ces régions cérébrales communes ont pu être mises en évidence en fonction de la tâche effectuée par les sujets. L'imagerie motrice recruterait principalement les régions rostrales des aires prémotrices et les régions caudales des lobules pariétaux par opposition à l'exécution qui recruterait davantage les régions caudales du cortex

prémoteur et les régions rostrales des lobules pariétaux (Tyszka et al., 1994, Stephan et al., 1995, Luft et al., 1998, Lotze et al., 1999b, Gerardin et al., 2000, Hanakawa et al., 2003).

L'implication de M1 (ou Cortex Moteur Primaire) pendant l'imagerie motrice est controversée. Certaines études en EEG (Schnitzler et al., 1997), en IRMf (Porro et al., 1996, Roth et al., 1996, Lotze et al., 1999b) ou en TMS (Stimulation Magnétique Transcranienne) (Stinear et al., 2006) montrent un léger recrutement des neurones de M1 pendant l'imagerie motrice, mais l'activité semble transitoire, enregistrée en début de tâche (Dechent et al., 2004), les volumes cérébraux activés sont plus petits et son intensité est plus faible (environ 30% par rapport à l'exécution motrice) (Nair et al., 2003, Solodkin et al., 2004, Lotze and Halsband, 2006, Szameitat et al., 2007). Il est en effet très probable que M1 soit activé pendant l'imagerie motrice, étant donnée que même l'observation d'un mouvement semble activer des régions motrices y compris le cortex moteur primaire, chez le singe (par exemple Dushanova and Donoghue, 2010) ou chez l'homme (par exemple Rizzolatti and Craighero, 2004, Press et al., 2011). Parmi les études en imagerie fonctionnelle, l'implication ou non de M1 pendant l'imagerie motrice peut dépendre du type d'imagerie pratiquée (IMV ou IMK) (Kosslyn, 1999, Solodkin et al., 2004, Guillot et al., 2009), du point de vue dans lequel se place le sujet (interne ou externe) (Ruby and Decety, 2001), de la technique de neuroimagerie utilisée (selon la résolution spatio-temporelle) ainsi que de la méthode d'analyse (en région d'intérêt sur M1 ou en « cerveau-entier »).

Après avoir étudié séparément les réseaux impliqués dans les deux tâches, une façon de les dissocier est d'analyser la dynamique de ces réseaux pendant les deux tâches à l'aide de techniques de connectivité fonctionnelle (Friston et al., 1993, Fair et al., 2007) ou effective (Stephan and Friston, 2010). Une des premières études à s'être intéressée à la comparaison entre l'exécution et l'imagination avec ces techniques d'analyse est celle de Solodkin et al., en IRMf (2004). Les analyses classiques de localisation d'activité montrent deux réseaux partiellement identiques entre l'exécution et l'imagerie kinesthésique. Les résultats de connectivité effective (Structural Equation Modelling) par contre, révèlent des divergences importantes entre les deux réseaux. En particulier, la connexion entre l'AMS et M1 qui est excitatrice pendant l'exécution et inhibitrice pendant l'imagerie kinesthésique. Ce résultat a été confirmé plus tard avec d'autres méthodes de connectivité cérébrale (Kasess et al., 2008, Chen et al., 2009, Gao et al., 2011). Gao et al. (2011) ont montré que l'ensemble des valeurs de connectivité entre les régions cérébrales communes est

globalement plus fort pendant l'exécution, ce qui témoigne d'un échange d'informations plus important. Cette augmentation est d'autant plus forte dans l'hémisphère controlatéral entre S1 et M1, permettant éventuellement un couplage fonctionnel plus efficace entre les deux aires pendant le mouvement exécuté.

Quelques pistes se dessinent permettant de différencier les sensations kinesthésiques chez l'amputé. Tout d'abord des indices neurophysiologiques, comme la mesure de l'activité musculaire ou de l'activité cérébrale pendant l'une et l'autre tâche semblent être intuitivement de bons marqueurs. Des indices comportementaux plus faciles à mettre en œuvre peuvent apporter des informations précieuses concernant l'intégrité des performances associées aux deux tâches. Dans certaines situations pathologiques par exemple, la congruence temporelle entre l'exécution et l'imagination est préservée. Les difficultés à exécuter se répercutent alors sur les capacités à imaginer chez des patients hémiparétiques suites à des lésions pariétales (Sirigu et al., 1996, Johnson, 2000), chez des patients parkinsoniens (Thobois et al., 2000, Helmich et al., 2007), chez des patients présentant un locked-in syndrome (Conson et al., 2008). Au contraire dans d'autres pathologies, les déficiences motrices n'affectent pas les performances en imagerie motrice (par exemple chez les blessés médullaires Alkadhi et al., 2005, Hotz-Boendermaker et al., 2008). Cette dissociation semble indiquer que la représentation du mouvement chez ces patients reste accessible malgré leur déficience motrice. Qu'en est-il de l'exécution et de l'imagerie motrice dans le membre fantôme ?

2.2 Dissociation chez le sujet amputé

La question d'une possible dissociation entre l'exécution et l'imagerie motrice dans le membre fantôme n'est pas abordée dans la littérature, et les propriétés des images motrices chez l'amputé ont été faiblement étudiées. Etant donné que la position de la main affecte les performances aux tâches d'imagerie motrice implicite (e.g. Sekiyama, 1982), Nico et al., ont testé l'effet de l'absence du membre sur les performances de sujets amputés du membre supérieur (Nico et al., 2004). Leurs résultats montrent que les amputés conservent la capacité à juger la latéralité des mains présentées sur des photographies mais les temps de jugement sont plus longs, et ce d'autant plus que le membre amputé est le membre dominant avant l'amputation.

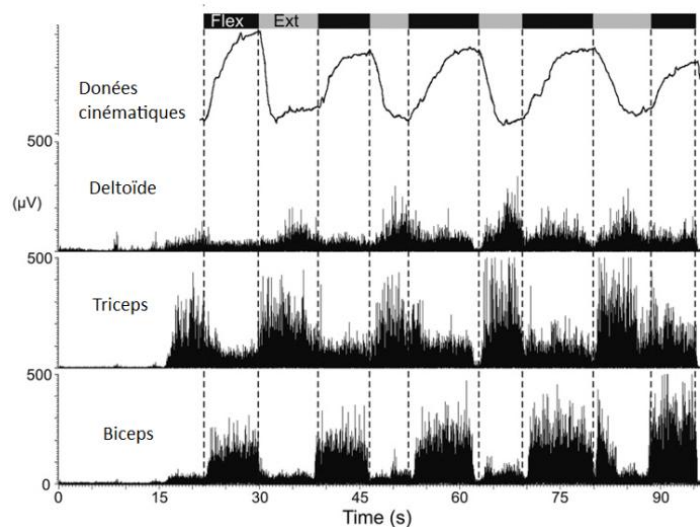
Interroger les performances des patients amputés pendant des tâches d'imagerie motrice explicite est particulièrement intéressant dans le contexte ambigu des situations pathologiques citées précédemment. Il semble que les patients dont la lésion cérébrale touche le cortex moteur⁸, montrent une détérioration identique de leurs performances exécutées et imaginées. Au contraire, les patients présentant une déficience motrice d'origine périphérique (ou ne touchant pas directement les structures motrices centrales) ont des performances normales pendant l'imagerie motrice malgré la difficulté (voire l'impossibilité) à exécuter. Chez des sujets amputés, Lotze et al. (2001) évaluent la capacité à imaginer au moyen d'un questionnaire dans lequel les sujets cotent sur une Echelle Visuelle Analogue (EVA), la qualité des images motrices qu'ils perçoivent lors de différents mouvements de la main fantôme et la main intacte (de 0 [aucune image motrice] à 6 [très bonne image motrice]) (Sheehan, 1967). Ces auteurs notent aucune différence entre le groupe de sujets volontaires sains et le groupe de sujets amputés (avec ou sans douleurs de membre fantôme).

Malouin et al., utilisent trois différentes approches pour mesurer les capacités d'imagerie motrice chez l'amputé du membre inférieur. Tout d'abord, les sujets complètent un questionnaire d'imagerie motrice (KVIQ-20, *Kinesthetic and Visual Imagery Questionnaire*) (Malouin et al., 2007). Ce questionnaire consiste à évaluer la facilité/difficulté à imaginer des mouvements globaux du corps, à partir d'une EVA (de 0 [impossible] à 7 [très facile]). Les résultats globaux ne montrent pas de différence entre le groupe de sujets amputés et le groupe de sujets contrôles. Cependant, les sujets contrôles jugent l'imagerie motrice visuelle plus facile que l'imagerie motrice kinesthésique, alors que les sujets amputés n'ont pas de préférence pour l'une ou l'autre des deux modalités. Les deux autres tests sont des tests de chronométrie mentale. Les résultats des deux tests montrent qu'il n'y a pas de différence entre le côté amputé et le côté intact des sujets amputés mais que les sujets amputés sont globalement un peu plus lents que les sujets contrôles. Le dernier test révèle de façon intéressante que la congruence temporelle entre les mouvements exécutés avec la prothèse et les mouvements imaginés est conservée (Malouin et al., 2009). Il est important de noter que les mouvements exécutés du côté de l'amputation ne concernent pas des mouvements

⁸ On entend par cortex moteur, le cortex moteur primaire, cortex prémoteur, aires pariétales et les noyaux gris centraux

de membre fantôme mais sont réalisés avec une prothèse. De plus l'absence de monitoring EMG ne permet pas d'exclure le fait que les patients aient tenté d'exécuter les mouvements avec leur membre fantôme pendant la tâche d'imagerie motrice.

Très peu d'études se sont d'ailleurs attachées à décrire précisément les mouvements « exécutés » de membre fantôme. Une technique simple, mise au point par Gagné et al., permet de « quantifier » cette motricité. Il s'agit de demander aux sujets amputés de reproduire simultanément les mouvements de leur membre fantôme avec leur membre sain. Il est alors possible d'obtenir des données cinématiques quantifiables des mouvements fantômes à partir d'un gant muni de capteurs accélérométriques et goniométriques équipé sur la main saine. Les données recueillies avec ce type de méthode confirment les difficultés d'exécution décrites par les patients dans le membre fantôme (Reilly et al., 2006, Gagné et al., 2009).



*Figure 5 : Exemple de **données cinématiques** acquises sur la main intacte d'un sujet amputé proximal pendant des mouvements bilatéraux de Flexion-Extension du poignet et **données électromyographiques** dans les muscles du moignon (Deltéroïde, Triceps et Biceps) (d'après Gagné et al., 2009)*

Pendant ces expérimentations, les mêmes auteurs ont enregistré des patterns d'activation EMG et des intensités de contractions musculaires dans les muscles résiduels du moignon, très proches de ceux enregistrés pendant l'exécution d'un mouvement « normal ». Reilly et al. (2006) ont enregistré l'activité EMG des muscles du moignon lors de différents types de mouvements de

membre fantôme et ont montré que chaque type de mouvement était associé à un pattern de contractions musculaires différent. Les amputés seraient capables de moduler les commandes motrices envoyées vers les muscles du moignon, en fonction du mouvement de membre fantôme désiré, générant ainsi des patterns d'activations spécifiques. Par ailleurs, des électrodes implantées dans les motoneurones des nerfs sectionnés du moignon (innervant le territoire de la main amputée), montrent une activité significative lors de mouvements volontaires du membre fantôme (Dhillon et al., 2004, Jia et al., 2007).

Ces résultats suggèrent que la section définitive des nerfs périphériques après une amputation de membre n'élimine pas totalement les connections sensorimotrices avec les structures supérieures. D'autant plus que les études en neuroimagerie (en IRMf, en PET ou en EEG) montrent que les mouvements volontaires de la main fantôme activent des régions du cortex moteur identiques à celles activées lors des mouvements réels de la main intacte (Ersland et al., 1996, Maruno et al., 2000, Willoch et al., 2000, Lotze et al., 2001, Rosen et al., 2001, Roux et al., 2001, Roux et al., 2003, Maclver et al., 2008, Touzalin-Chretien et al., 2009), contrairement aux données acquises auprès de patients amputés congénitaux (Brugger et al., 2000). Ces régions activées sont différentes des régions activées par des mouvements de moignon (Lotze et al., 2001, Roux et al., 2001). De plus, la TMS appliquée sur M1 controlatéral à l'amputation chez des amputés traumatiques induit des sensations de mouvements dans le membre fantôme (Mercier et al., 2006). La même procédure appliquée chez les amputés congénitaux ne provoque pas de sensation de mouvement (Reilly and Sirigu, 2011).

Plusieurs autres résultats défendent la persistance d'une activité corticale motrice résiduelle qui s'apparente davantage au réseau de l'exécution motrice. Les observations récentes en neuroimagerie à la suite d'allogreffe de la main ont montré la résurgence des commandes motrices initiales de la main amputée. De plus, les zones corticales ont conservé leurs propriétés fonctionnelles antérieures à l'amputation (Giroux et al., 2001, Farne et al., 2002). Ainsi, ce territoire semble contenir encore les commandes motrices latentes de la main fantôme puisque très rapidement après la greffe, celles-ci réapparaissent et sont très vite fonctionnelles, de façon parallèle avec la réinstallation progressive de la motricité fine de la main (Vargas et al., 2009). Enfin, les études utilisant le paradigme du miroir chez des sujets amputés (par exemple Giroux and Sirigu, 2003, McCabe et al., 2003, Chan et al., 2007, Mercier and Sirigu, 2009) fournissent aussi des

preuves indirectes concernant le maintien des représentations motrices latentes du membre fantôme dans le cerveau des personnes amputées. L'illusion visuelle créée par la présentation de l'image du membre amputé en mouvement provoque une activation spontanée dans M1 controlatéral à la main amputée (Touzalín-Chretien et al., 2009, Diers et al., 2010) et la pratique répétée d'un entraînement visuomoteur permettrait de réactiver des aires motrices primaires correspondant aux mouvements de la main amputée (Giroux and Sirigu, 2003).

L'ensemble de ces études met en évidence une forme de motricité dans le membre fantôme produisant des réponses neurophysiologiques proches de celles de mouvements exécutés avec un membre intact. Même s'il n'existe pas de comparaison directe chez le sujet amputé, ces réponses neurophysiologiques se distinguent de celles associées à l'imagination motrice chez les sujets volontaires sains. Or, la plupart des études en neuroimagerie chez l'amputé nomment les mouvements fantômes, « mouvements imaginés ». Nous proposons au contraire, que ces mouvements soient apparentés à une forme d'*exécution motrice*. De plus, nous ferons l'hypothèse dans cette thèse, que les patients amputés puissent distinctement évoquer des *images motrices* dans le membre fantôme. Nous chercherons alors à caractériser les performances des sujets amputés lors de l'exécution et de l'imagerie motrice d'un mouvement du membre fantôme.

Certaines données de la littérature évoquées juste avant nous permettent d'ores et déjà de faire quelques prévisions. Les mouvements que nous considérons comme « exécutés » semblent limités en amplitude, demandent beaucoup d'effort et peuvent être associés à des douleurs dans le membre fantôme. Les hypothèses concernant les performances en imagerie motrice chez l'amputé sont plus nuancées. Il se pourrait dans un sens qu'elles soient comme l'exécution, altérées du fait de la présence de douleurs fantômes. En effet, la douleur semble avoir un impact négatif sur les capacités d'imagerie motrice chez des patients présentant un SDRC⁹ (Schwoebel et al., 2001, Moseley, 2004b) ou des douleurs musculo-squelettiques (Coslett et al., 2010a, Coslett et al., 2010b). Au contraire, la préservation des capacités à imaginer chez l'amputé concorde avec les résultats des patients présentant des déficiences motrices d'origine périphérique comme les patients blessés médullaires (par exemple Alkadhi et al., 2005, Hotz-Boendermaker et al., 2008).

⁹ SDRC : Syndrome Dououreux Régional Complexe

Enfin, l'hypothèse d'une dissociation des performances, sous la forme d'une altération de l'exécution mais d'une préservation de l'imagerie motrice dans le membre fantôme repose sur des données d'activations cérébrales. Les données chez le sujet volontaire sain montrent que le cortex sensorimoteur primaire est plus actif pendant l'exécution motrice par rapport à l'imagerie motrice (voire Lotze and Halsband, 2006 pour revue). Or, le cortex sensorimoteur primaire est la seule région à ce jour où des réorganisations corticales ont été démontrées après amputation chez l'homme (par exemple Knecht et al., 1996, Borsook et al., 1998, Roricht et al., 1999, Karl et al., 2001). La contribution différente du cortex sensorimoteur aux deux tâches, pourrait sous-tendre les difficultés d'exécution rapportées par les patients et la possible préservation de l'imagerie motrice dans le membre fantôme.

3. Réorganisations corticales et corrélats perceptifs

Il existe de part et d'autre du gyrus post-central, deux cartes somatotopiques complètes du corps (dénommée homunculus) (Penfield, 1937; Penfield, 1950) (Figure 6). Loin d'être stables, les cartes somatotopiques du cortex somatosensoriel primaire (S1) et du cortex moteur primaire (M1) peuvent être profondément remaniées dans un certain nombre de situations chez l'homme, comme par exemple lors de déafférentations transitoires (Brasil-Neto et al., 1993), de lésions de la moelle épinière (Levy et al., 1990, Topka et al., 1991), de lésions corticales ou encore après une session d'apprentissage moteur (Nudo et al., 1996, Karni et al., 1998, Hayashi et al., 2002) ou de stimulations tactiles répétées (Jenkins et al., 1990, Xerri et al., 1999). Cette organisation résulte donc en partie de l'expérience sensorimotrice individuelle.

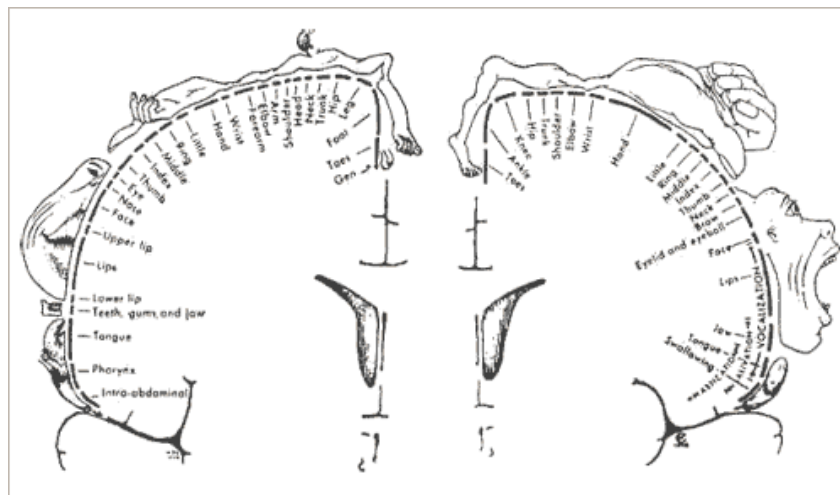


Figure 6 : **Homuncule sensoriel** (hémisphère gauche) et **homuncule moteur** (hémisphère droit) montrant la répartition somatotopique des localisations motrices et sensibles le long de la scissure de Rolando (Penfield and Rasmussen, 1950).

Les techniques d'imagerie in vivo auprès d'animaux déafférentés ou amputés chirurgicalement, ont permis l'élaboration des modèles théoriques de la plasticité corticale chez l'homme. Initialement, la démonstration de la capacité du système nerveux à se réorganiser s'est faite au moyen d'enregistrements multicellulaires dans l'aire 3b. Ces enregistrements électrophysiologiques révèlent qu'après lésions des nerfs périphériques ou amputations de doigts, certaines portions de 3b répondant autrefois à la zone corporelle déafférentée, répondent

désormais à la stimulation des segments adjacents (Kelahan et al., 1981, Kaas et al., 1983, Merzenich et al., 1983a, Merzenich et al., 1983b, Merzenich et al., 1984, Wall et al., 1986, Calford and Tweedale, 1988, Pons et al., 1991, Jain et al., 1998). Les réorganisations du cortex moteur ont été mesurées au moyen de microstimulations intracorticales. Ainsi, des microstimulations appliquées directement dans la région motrice correspondant au membre amputé entraînent des contractions dans les muscles du moignon (Donoghue and Sanes, 1988, Pons et al., 1991, Schieber and Deuel, 1997, Wu and Kaas, 1999, Qi et al., 2000).

La nature invasive des expérimentations animales a l'avantage de procurer des cartographies explicites des réorganisations corticales. L'accès à des mesures relativement fines permet notamment de questionner les limites spatiales de ces déplacements corticaux. Par exemple, la délimitation entre la représentation de la main et celle du visage constitue un critère de jugement fréquemment utilisé chez l'animal dans S1 (Merzenich et al., 1984, Wall et al., 1986, Florence et al., 1994, Garraghty et al., 1994) et M1 (Donoghue and Sanes, 1988, Pons et al., 1991, Schieber and Deuel, 1997, Wu and Kaas, 1999, Qi et al., 2000) et chez l'homme (par exemple Elbert et al., 1994, Yang et al., 1994, Flor et al., 1995, Knecht et al., 1995, Knecht et al., 1996, Elbert et al., 1997, Flor et al., 1998, Montoya et al., 1998). Ce repère spatial, qui permet d'apprécier l'étendue de la plasticité corticale sensorimotrice, ne repose pas sur des bases cytoarchitectoniques mais plutôt sur les limites des différents mécanismes neurophysiologiques impliqués.

Dans une première série d'études chez le singe, la position de cette frontière main/visage dans l'aire 3b reste inchangée malgré la déafférentation complète de la main (Wall et al., 1986, Garraghty and Kaas, 1991, Florence et al., 1994, Garraghty et al., 1994, Jain et al., 1998), ou l'amputation d'un ou plusieurs doigts (Merzenich et al., 1984). La limite supérieure de l'expansion corticale du visage vers la portion de cortex déafférentée est de l'ordre de quelques millimètres (Merzenich et al., 1983b, Manger et al., 1997, Fang et al., 2002), 1 à 2 mm par exemple pour Merzenich et al. (1983). Le substrat neuronal de ce remodelage rapide mais limité spatialement est la présence de connexions intracorticales préexistantes dans S1 (par exemple Jones and Powell, 1969, Burton and Fabri, 1995, Kaas and Florence, 1997, Manger et al., 1997) et M1 (par exemple Donoghue et al., 1990, Huntley and Jones, 1991, Ziemann et al., 1998), qui par un mécanisme de démasquage permet une expansion des cartes corticales. Les connexions horizontales d'un neurone donné dans M1 peuvent s'étendre jusqu'à 1 cm au maximum chez le singe (DeFelipe et al 1986, Huntley & Jones,

1991, Keller, 1993a, Hess & Donoghue, 1994). Ce démasquage est d'autant plus limité dans l'espace car contraint par le faible nombre, voire l'absence de fibres horizontales passant à travers la démarcation main/visage dans S1 comme dans M1. Par exemple, Fang et al. (2002) ont injecté un traceur radioactif, spécifiquement dans la zone corticale de la main et dans celle du visage chez des singes adultes, afin d'évaluer dans quelle mesure, ces deux zones sont interconnectées dans 3b. Leurs résultats montrent que très peu de neurones se projettent à travers la frontière main/visage et les rares inter-connexions existantes restent confinées dans la région frontalière (Fang et al., 2002). De la même façon, il existe une stricte correspondance entre les sites de réorganisations et la distribution spatiale des connexions horizontales au sein de M1 (Huntley, 1997). Du point de vue fonctionnel, ce réseau horizontal possède une activité excitatrice glutamatergique (Keller et al., 1990, Keller, 1993). Cette activité peut être activée par une dépression transitoire du système inhibiteur GABA, comparable à celle obtenue immédiatement après lésions de nerfs périphériques (Jacobs and Donoghue, 1991) ou encore s'opérant après un entraînement moteur ou des stimulations sensibles répétées (Recanzone et al., 1992a, Recanzone et al., 1992b, Xerri et al., 1994, Nudo et al., 1996, Huntley, 1997).

D'autres études rapportent une expansion sensiblement plus importante de la représentation du visage vers la zone corticale présumée « silencieuse » de la main dans 3b. Les déplacements les plus importants rapportés jusqu'ici sont de l'ordre de 10-14 mm mesurés chez des singes macaques déafférentés (Pons et al., 1991), de 5 mm chez des singes hiboux, de plus petite taille (Jain et al., 1997). Dans une étude publiée en 2008, Jain et al. montrent que les champs récepteurs du visage peuvent s'étendre encore au-delà, jusque dans les portions les plus médiales de 3b, à plus de 20 mm de leur position initiale (Jain et al., 2008). De telles expansions, au-delà des limites connues de diffusion des connexions corticocorticales, ne peuvent pas reposer sur un simple démasquage (Nelson and Kaas, 1981, Garraghty et al., 1989, Garraghty and Sur, 1990, Manger et al., 1997, Fang et al., 2002). Ce système horizontal est alors capable d'étendre ses connexions par « sprouting » en cas de modifications durables des afférences sensibles dans S1 (Darian-Smith and Gilbert, 1994, Florence et al., 1998, Jain et al., 2000). Il s'agit d'un mécanisme de modification synaptique à long terme de type LTP/LTD (Long Term Potentiation/ Long Term Depression) (Iriki et al., 1989, Keller et al., 1990). Au niveau du cortex moteur, l'existence d'un mécanisme de potentialisation à long terme des synapses a été également établie (Aroniadou and Keller, 1995, Hess et al., 1996, Hess and Donoghue, 1996a, b). Cependant, l'induction de LTP dans le cortex

moteur mature semble être plus limitée que dans d'autres régions cérébrales ou au cours d'autres périodes développementales. De plus, le déclenchement de modifications de type LTP semble nécessiter un contexte spécifique (Hess and Donoghue, 1996a), notamment à travers une activité extrinsèque répétitive (Hess et al., 1996). Cette activité extrinsèque répétitive peut éventuellement émaner du thalamus (Baranyi and Feher, 1978, Ergenzinger et al., 1998, Jones and Pons, 1998), du tronc cérébral (Florence et al., 2000) (voire Wall et al., 2002 pour revue) ou encore d'autres régions corticales comme le cortex prémoteur, à travers une induction réciproque entre ces régions cérébrales et les cortex sensoriel et moteur primaires. L'expérimentation animale a donc permis de faire la preuve de l'existence de réorganisations également dans le thalamus (Garraghty and Kaas, 1991, Pons et al., 1991), le tronc cérébral (Pons et al., 1991, Florence and Kaas, 1995, Jones and Pons, 1998), et la moelle épinière (Carp and Wolpaw, 1994, Florence and Kaas, 1995).

La démonstration des modifications des cartes corticales chez l'homme est moins évidente. La nature non invasive et donc plus indirecte des expérimentations, nécessite la conception de différents marqueurs pour estimer objectivement l'étendue des réorganisations corticales. L'expérimentation chez l'homme offre néanmoins la possibilité d'étudier les corrélats perceptifs des réorganisations corticales. L'étude des liens entre ces phénomènes perceptifs et les réorganisations corticales, justifie d'autant plus le recours à indicateurs de plasticité de plus en plus fins. Proches des expérimentations chez l'animal, une première catégorie d'études chez l'homme s'est concentrée sur la cartographie des représentations corporelles dans les cortex sensorimoteurs en utilisant divers indices topologiques. La deuxième catégorie d'indicateurs cherche à mettre en avant des perturbations neurophysiologiques du cortex après amputation, comme le degré d'excitabilité corticospinal mesuré en TMS, ou encore le volume cortical activé en IRMf ou en TEP. Nous examinerons parallèlement les bases méthodologiques de ces indicateurs et les résultats obtenus en lien avec des phénomènes perceptifs (douleurs ou sensations référées). Enfin, l'examen des outils méthodologiques de l'évaluation des réorganisations corticales nous mènera à considérer les limites propres à chaque méthode.

3.1 Composante spatiale des réorganisations corticales

Les réorganisations corticales chez l'amputé ont naturellement été traitées du point de vue topologique. Puisque de telles variations topologiques dans l'organisation spatiale des cartes sensorielles et motrices ont été clairement observées chez le singe (Merzenich et al., 1984, Pons et al., 1991, Wu and Kaas, 1999) ou le rat (Kaas et al., 1983, Donoghue and Sanes, 1988, Sanes et al., 1990) les chercheurs ont tenté de répliquer ces résultats chez l'homme avec les techniques de neuroimagerie fonctionnelle.

Les premières études méthodologiquement proches des expérimentations animales se firent néanmoins au moyen de stimulations électriques de la surface corticale lors d'opérations neurochirurgicales chez des patients amputés éveillés (Woolsey et al., 1979, Ojemann and Silbergeld, 1995). Par exemple Ojemann et Silbergeld (1995) observèrent que la stimulation de la zone correspondante à la main amputée dans S1 controlatéral à l'amputation évoquait des sensations dans le membre fantôme. La stimulation de la zone de la main dans M1 controlatéral à l'amputation provoquait des contractions musculaires dans les muscles proximaux et des mouvements de l'épaule par exemple. Ces études de cas (Woolsey et al., 1979, Ojemann and Silbergeld, 1995) suggéraient que les variations spatiales de l'organisation fonctionnelle du cortex somatosensoriel primaire et du cortex moteur primaire observées chez le singe ou le rat après désafférentation sensorielle ou amputation de membre sont également présentes chez l'homme.

Les progrès techniques en neuroimagerie fonctionnelle non invasive ont permis de tester cette hypothèse sur une population plus large de patients et de quantifier ces variations spatiales. La première méthode d'évaluation indirecte des réorganisations corticales fut élaborée en MEG pour le cortex somatosensoriel primaire (Gallen et al., 1993a, Gallen et al., 1993b). Elle consiste à comparer la distance entre la représentation du visage et celle des doigts dans les deux hémisphères. Dans le cas de l'amputation, la position des doigts intacts est projetée dans l'hémisphère controlatéral à l'amputation. Cette projection par rapport à la ligne médiane permet de calculer la distance entre la représentation du visage du côté amputé et la position en miroir des doigts intacts (par exemple Elbert et al., 1994, Knecht et al., 1996). Alors qu'il existe une symétrie de la position du visage chez les sujets sains (Gallen et al., 1993a), les résultats obtenus auprès de sujets amputés montrent que la distance visage/doigts dans l'hémisphère controlatéral à

l'amputation est plus petite d'environ 1 à 4 cm, selon les études, par rapport à l'autre hémisphère, en MEG (Yang et al., 1994, Flor et al., 1995, Knecht et al., 1995, Knecht et al., 1996, Elbert et al., 1997) ou encore en EEG (Elbert et al., 1994, Flor et al., 1998, Montoya et al., 1998). Ce résultat traduit un envahissement de la représentation du visage vers la représentation de la main amputée.

Parallèlement à la quantification du déplacement de la représentation des lèvres, les travaux se sont concentrés sur les éventuels corrélats perceptifs de cet envahissement cortical du visage vers la main. Par exemple, la représentation de la main étant entourée par celle du visage et du membre supérieur, les sensations référées au membre fantôme lors de la stimulation tactile du visage, serait la manifestation du déplacement des lèvres. Elbert et al. (1994) ont utilisé conjointement la MEG et l'EEG chez cinq patients amputés et rapportent ainsi un décalage médial des lèvres dans l'hémisphère controlatéral à l'amputation. Cependant, aucune relation significative ne peut être établie avec l'importance des sensations référées *non douloureuses* dans le membre fantôme. L'absence de relation est également notée dans l'étude de Knecht (1995) en MEG, quelque soit la modalité de stimulation utilisée (cutanée, thermique ou vibratoire) (Knecht et al., 1996). L'absence de corrélation entre les sensations référées non douloureuses et les réorganisations dans S1 pourrait signifier que d'autres aires corticales contribuent à la perception de ces phénomènes fantômes non douloureux comme le gyrus cingulaire postérieur (BA 24), l'aire motrice supplémentaire (AMS) ou le cortex somatosensoriel secondaire (S2) (Kew et al., 1994, Borsook et al., 1998, Flor et al., 2000).

Par contre, Knecht et al., (1996) rapportent une relation de corrélation positive entre l'asymétrie de la position des lèvres dans S1 et le nombre de sites de stimulation provoquant des *douleurs* référées dans le membre fantôme. Il existe d'ailleurs un lien entre les douleurs chroniques et l'asymétrie des lèvres. Flor et al. (1995) montrent que la position de la représentation des lèvres dans les deux hémisphères du groupe d'amputés non douloureux ne diffère que de 0,43 cm en moyenne dans les deux hémisphères (identique aux sujets normaux, voire Gallien et al., 1993), alors que la différence est 5 fois plus importante chez les patients douloureux. Ils notent au sein de leur population de 13 sujets amputés, une relation de corrélation très forte ($r = 0,93$, $p < 0.0001$) entre la l'asymétrie des lèvres et l'intensité des douleurs chroniques.

Figure 7 : Positions des dipôles sur la surface corticale lors de la stimulation du visage et des doigts pour un sujet amputé et position moyenne en miroir des doigts intacts (en rouge) dans l'hémisphère controlatéral à l'amputation. La différence entre la distance doigt/visage dans les deux hémisphères caractérise le degré de réorganisation chez tous les amputés (Flor et al., 1995)

Dans leur étude de 1998, les auteurs ont répliqué ces résultats et ajoutèrent à la comparaison, un groupe d'amputés congénitaux. Les amputés traumatiques sans douleurs et congénitaux affichent un déplacement médial minime des lèvres dans S1, alors qu'il est de 2,22 cm (SD = 0,78) pour le groupe d'amputés traumatiques avec douleurs (Flor et al., 1998). Ce résultat confirme ceux d'autres études portant sur les amputations de la petite enfance ou les agénésies (Montoya et al., 1998, Wilkins et al., 1998, Reilly and Sirigu, 2011). Néanmoins, il est intéressant de noter que concernant l'organisation du cortex moteur, les résultats divergent pour ces patients. Funk et al., (Funk et al., 2008) rapportent une asymétrie de la représentation sensorimotrice des mouvements de lèvres et Kew et al., une activation liée à des mouvements de l'épaule plus diffuse par rapport à des mouvements du côté intact.

L'utilisation d'un nouveau référentiel topologique pour estimer les variations de l'organisation du cortex sensorimoteur, développé par l'équipe d'Herta Flor en Allemagne, a permis de discerner des liens entre les variations spatiales des cartes corticales et certaines données cliniques. Dans cette méthode, le cerveau est assimilé à une sphère pour pouvoir estimer le locus cortical d'un segment corporel à partir de l'angle polaire créé par l'axe vertical passant par le centre du cerveau et le Centre de Gravité (CoG) ou le pic de son activation (Figure 8).

L'utilisation de cet indicateur topologique permet à Birbaumer et al., (1997) d'illustrer la capacité du cortex sensoriel à se remodeler rapidement et de façon réversible. Cette plasticité transitoire a été obtenue lors d'une déafférentation temporaire du moignon par un bloc ischémique du plexus brachial. En stimulant les lèvres bilatéralement les auteurs recueillent les PES (Potentiels Evoqués Somesthésiques) en EEG chez des amputés du membre supérieur, avant, pendant et après l'anesthésie, ainsi que les sensations fantômes. En quelques minutes, le bloc ischémique entraîne un décalage transitoire de la représentation des lèvres dans S1 vers une position plus caudale. Ce décalage transitoire s'accompagne d'une diminution significative des douleurs fantômes. Des observations récentes, liées aux progrès des techniques de greffes ont également démontré la propriété de réversibilité à plus long terme des cartes sensorimotrices dans les mois qui suivent une transplantation des deux mains (Giroux et al., 2001, Farne et al., 2002).

Figure 8 : Coupe coronale à travers le gyrus postcentral (S1) chez un sujet douloureux, montrant le positionnement médial de la représentation des lèvres avant le bloc ischémique dans l'hémisphère controlatéral à l'amputation (à gauche sur la figure), avec un angle polaire entre la verticale et la position des lèvres de 46° pour le côté amputé contre 64° pour le côté intact. Une différence de 18° entre les deux hémisphères représente un déplacement de 36 mm le long de la surface sphérique ajustée au cortex (en rouge) (Birbaumer et al., 1997).

Avec un indicateur topologique identique, Lotze et al., (1999a) ont examiné parallèlement les réorganisations sensorielles et motrices chez 7 amputés du membre supérieur en IRM fonctionnelle. De façon prévisible, les maximums d'activation des lèvres sont décalés vers la main dans le cortex controlatéral à l'amputation d'environ 10,7 ($\pm 7,3$) mm dans S1 mais également dans M1 de 5,8 ($\pm 3,6$) mm, et ce uniquement chez les patients douloureux. Les auteurs rapportent une relation de corrélation entre l'intensité des douleurs de membre fantôme et le déplacement du pic d'activation des lèvres dans S1 ($r = 0.69$, $p < 0.01$) et dans M1 ($r = 0.73$, $p < 0.005$). Cette étude montre

donc une réorganisation parallèle s'opérant dans M1 et S1 (voire également Karl et al., 2001). L'étude de Lotze et al. met également en évidence les effets du port intensif d'une prothèse myoélectrique sur les douleurs de membre fantôme et les réorganisations du cortex sensorimoteur. Les patients porteurs de prothèses myoélectriques de façon intensive n'ont pas de douleur fantôme et présentent des pics d'activation des lèvres symétriques dans S1 et M1, contrairement aux patients ne portant pas de prothèse myoélectrique (douleur moyenne : 2,33/6 ($\pm 1,53$), décalage des lèvres : $10,67 \pm 7,33$ mm dans S1 : $5,84 \pm 3,57$ mm dans M1). Les analyses de corrélation montrent que le port de prothèse est significativement corrélé à la réorganisation dans S1 ($r=-0,55$) et dans M1 ($r=-0,53$) ainsi qu'aux douleurs de membre fantôme ($r=-0,49$) ($p<0.05$). Plus finement, des analyses de corrélations partielles montrent que lorsque la part de variance expliquée par la réorganisation corticale est enlevée, la relation entre les douleurs et le port de prothèse devient non significative ($r=-0.17$). Ce résultat montre que le lien entre la diminution des douleurs et le port de prothèse n'est pas direct mais reposerait sur la normalisation des cartes corticales.

Figure 9 : Méthode d'estimation des réorganisations corticales utilisée par Birbaumer et al., 1997 puis Lotze et al. (1999) et Karlet al. (2001). Elle consiste à ajuster une couronne ellipsoïdale sur la surface corticale. Les angles θ et φ définissent l'emplacement de chaque point sur cette surface. La position du pic ou du CoG est alors définie par les r et φ' (avec $r = \theta$, indiquant la distance entre le CoG ou le pic et le centre de l'ellipsoïde et $\varphi' = \varphi$ désignant l'angle polaire par référence au centre de l'ellipsoïde).

Deux ans plus tard, Lotze et al. publient une autre étude en IRMf portant sur 14 amputés du bras droit (7 avec et 7 sans douleurs de membre fantôme) et 7 sujets contrôles. Comme précédemment, le déplacement médial des lèvres dans le cortex sensorimoteur est présent uniquement chez les patients douloureux (36 mm pour les douloureux contre 8 mm pour les non douloureux). Il s'agit de la première étude ajoutant à l'examen des lèvres, celui de la main fantôme.

Aucune différence spatiale n'est détectée entre la main fantôme et la main intacte, mais une activité plus diffuse est tout de même mesurée pour les amputés douloureux. L'étude conjointe des représentations des lèvres et de la main fantôme montre qu'il existe un recouvrement important dans le cortex sensorimoteur controlatéral à l'amputation chez les patients douloureux : avec d'une part l'expansion de l'activation des lèvres vers celle de la main fantôme et l'activation globalement plus diffuse de la main fantôme. Mais de façon intéressante, seule l'expansion des lèvres vers la main semble être associée à la présence de douleurs fantômes (Lotze et al., 2001, Maclver et al., 2008).

Figure 10 : Activations sensorimotrices liées à un mouvement du membre fantôme (dans l'hémisphère gauche, à gauche de la figure) et activations sensorimotrices associées à un mouvement avec la main intacte (dans l'hémisphère droit, à droite de la figure) (Flor et al., 2006).

Il existe une limite propre aux techniques de neuroimagerie métabolique qui altère la portée des résultats concernant la mesure des réorganisations motrices. Dans les études en IRMf, MEG ou en TEP, les réorganisations motrices sont examinées lors de mouvements volontaires, où il est relativement difficile de dissocier les activations motrices des activations sensorielles (voire Figure 10). Cette co-activation sensorimotrice peut s'expliquer par le fait que le cortex moteur primaire reçoive des réafférences du cortex sensoriel primaire qui modulent son activité. Ainsi, il n'est pas impossible que les résultats concernant le déplacement des activations des lèvres dans M1 soient quelques peu biaisés par la réorganisation corticale plus distinctement mise en évidence dans le cortex sensoriel.

Des explorations complémentaires peuvent donc être menées par l'intermédiaire de techniques non invasives comme la TMS. L'étude des variations topologiques du cortex moteur en TMS chez l'amputé a principalement montré un déplacement latéral des CoG des cartes des

muscles du moignon (e.g. Dettmers et al., 1999, Schwenkreis et al., 2001, Irlbacher et al., 2002). Il existe néanmoins des résultats divergents montrant un déplacement médial des muscles du moignon (Karl et al., 2001), des déplacements mais dans une direction opposée entre les sujets (Gagné et al., 2010) ou encore aucune différence par rapport au côté intact (Roricht et al., 1999). De plus, il existe très peu d'études en TMS ayant recherché des variations spatiales de la représentation des muscles du visage (Pascual-Leone et al., 1996, Karl et al., 2001).

3.2 Composante non spatiale des réorganisations corticales

Certains auteurs ont examiné les perturbations électrophysiologiques du cortex après amputation, à travers des modifications locales du fonctionnement intrinsèque du cortex, selon le niveau d'oxygénation du sang, du métabolisme du glucose cérébral ou encore de l'excitabilité corticospinale. Ces manifestations peuvent refléter une augmentation du nombre de neurones recrutés ou au contraire la mise en place de mécanismes inhibiteurs provenant de l'hémisphère controlatéral ou d'autres régions du cerveau. Les critères utilisés peuvent être le nombre de voxels activés (IRMf ou PET) ou la taille des cartes motrices des muscles stimulés en TMS.

L'utilisation de la TMS permet de préciser les mécanismes neuronaux expliquant les perturbations électrophysiologiques du cortex après amputation. Par exemple, la mesure des seuils moteur est directement le reflet des modifications locales des canaux ioniques voltage-dépendants, tandis que les mesures de l'inhibition intracorticale, avec des paradigmes de double chocs repose sur des mécanismes GABAergiques (par exemple Ziemann et al., 1996, Chen et al., 1998b). De nombreuses études montrent une augmentation de l'excitabilité corticospinale des muscles du moignon, causée notamment par une perturbation des circuits inhibiteurs intra-corticaux: la stimulation des neurones de M1 controlatéral à l'amputation, produit une réponse motrice (Potentiel Evoqué Moteur, PEM) amplifiée pour les muscles du moignon par rapport aux mêmes muscles du côté intact. Irlbacher et al. notent chez 10 amputés distaux un ratio de 2,6 en faveur des PEM obtenues dans les muscles du moignon par rapport aux muscles homologues du côté intact (Irlbacher et al., 2002) (voire également Cohen et al., 1991b, Fuhr et al., 1992, Pascual-Leone et al., 1996, Roricht et al., 1999, Schwenkreis et al., 2000, Cruz et al., 2003). Les seuils moteurs mesurés au repos des muscles du moignon sont inférieurs à ceux du côté intact dans la majorité des études

(Hall et al., 1990, Cohen et al., 1991a, Kew et al., 1994, Ridding and Rothwell, 1995, Pascual-Leone et al., 1996, Chen et al., 1998a, Dettmers et al., 1999, Roricht et al., 1999, Karl et al., 2001, Gagné et al., 2010) (voire également Capaday et al., 2000, Schwenkreis et al., 2001 pour résultats contraires). Contrairement à ces résultats en TMS, il est important de noter que Chen et al. (1998a) rapportent des seuils de stimulation identiques en stimulation électrique (TES) pour évoquer un PEM dans les deux hémisphères de sujets amputés. Ce résultat permet d'exclure la possibilité que la plasticité mesurée en TMS provienne de changements au niveau spinal.

L'examen de ces questions en neuroimagerie métabolique montre une augmentation du volume cérébral activé pour une même tâche du côté amputé. Initialement, la mesure du métabolisme cérébral en TEP a révélé une augmentation atypique du débit sanguin dans la portion déafférentée de M1 lors de mouvements de l'épaule et du visage du côté amputé par rapport aux mêmes mouvements du côté intact (Kew et al., 1994). En IRMf, MacIver et al. (2008) rapportent une activation plus diffuse pendant des mouvements des lèvres dans l'hémisphère controlatéral à l'amputation. Cette augmentation d'activité est corrélée à l'intensité des douleurs de membre fantôme perçues pendant l'examen. L'activité sensorimotrice des mouvements du moignon mesurée en IRMf est également plus diffuse par rapport à l'hémicorps intact (Dettmers et al., 1999). Cette hyperactivité corticale lors de mouvements du moignon ou de l'épaule se retrouve également dans la SMA en particulier pour les sujets douloureux (Dettmers et al., 2001, Roux et al., 2001).

De la même façon, l'étude des mouvements fantômes en IRMf avec ce type d'indicateurs, rend compte d'un fonctionnement cortical perturbé. Le volume cérébral activé par les mouvements de la main fantôme est plus important (Lotze et al., 2001, MacIver et al., 2008). Il est important de noter que cette augmentation d'activité ne provoque pas nécessairement le déplacement des COG et explique pourquoi les études basées sur des indicateurs topologiques ne révèlent pas de différences entre la position des mouvements de main fantôme et des mouvements de la main intacte (Ersland et al., 1996, Roricht and Meyer, 2000, Roux et al., 2001, Roux et al., 2003).

3.3 Réflexions et critiques méthodologiques

L'asymétrie de l'activité corticale du visage (ou des lèvres), et de façon plus limitée des muscles du moignon, a été utilisée pour estimer l'importance des réorganisations spatiales dans S1

et M1. Le déplacement médial des lèvres dans l'hémisphère controlatéral à l'amputation semble être proportionnel aux phénomènes douloureux dans le membre fantôme. Par contre, la plupart des études n'ont pas réussi à démontrer une relation entre le degré de réorganisation et les phénomènes sensorimoteurs non douloureux du membre fantôme ou d'autres facteurs cliniques (âge, ancienneté de l'amputation, télescopage...) (par exemple Elbert et al., 1994, Flor et al., 1995, Grusser et al., 2001). Les perturbations corticales mises en évidence chez l'amputé ne sont pas que spatiales mais concernent également d'autres variables plus globales comme le volume neuronal recruté ou l'intensité à laquelle les neurones peuvent être activés. De cette étude comparative des outils de mesure des réorganisations corticales chez l'amputé, découle quelques réflexions méthodologiques et limitations à prendre en considération. Nous allons dans un premier temps évoquer quelques points méthodologiques critiques, puis nous reviendrons sur les limitations techniques des indicateurs utilisés.

Les critères de comparaison

Les quelques études de somatotopie chez l'amputé testant les mouvements de la main fantôme, utilisent comme critère de comparaison, des mouvements imaginés de la main intacte (Lotze et al., 2001, MacIver et al., 2008). D'un point de vue conceptuel tout d'abord, cela confirme que les mouvements de membre fantôme sont encore largement considérés comme un processus imaginaire. D'un point de vue méthodologique, la comparaison est irrémédiablement faussée. La présence d'une forte activité sensorimotrice primaire et les comptes-rendus des amputés confirment que la tâche « par défaut » effectuée par les patients s'apparent plus à de l'exécution motrice et non à de l'imagerie motrice.

Au delà de la tâche effectuée, le simple fait d'utiliser la main intacte des amputés pour mettre en évidence un phénomène de réorganisation, pose un problème méthodologique. D'un point de vue topologique, Schwenkreis et al. (2003) notent un déplacement du CoG du quadriceps du membre intact chez des amputés du membre inférieur. L'activité du cortex controlatéral au membre intact semble également perturbée avec un volume cortical anormalement élevé (Elbert et al., 1994, Elbert et al., 1997, Lotze et al., 2001, MacIver et al., 2008). Une explication plausible serait l'utilisation accrue du membre intact. Une telle réorganisation de type « usage-dépendante » a été mise en évidence chez le singe (Jenkins et al., 1990, Recanzone et al., 1992a, Recanzone et al., 1992b) et chez l'homme auprès de musiciens (Elbert et al., 1995, Rosenkranz et al., 2008) ou encore

de lecteurs de Braille (Pascual-Leone et al., 1993, Pascual-Leone and Torres, 1993, Sterr et al., 1998). En conclusion, l'utilisation de la main intacte comme référence, a fortiori avec des indicateurs non topologiques, n'est pas pertinente.

Segments corporels étudiés

Le segment corporel choisi pour mettre en évidence une variation topologique semble dépendre de la technique utilisée. Les études en neuroimagerie fonctionnelle sont largement basées sur le déplacement de la représentation des lèvres (Knecht et al., 1996, Elbert et al., 1997, Karl et al., 2001, Lotze et al., 2001, Karl et al., 2004), alors qu'il existe un nombre limité d'études en TMS montrant des changements spatiaux de la représentation des muscles du visage (Pascual-Leone et al., 1996, Karl et al., 2001). Ce parti-pris méthodologique provient du fait qu'il existe une séparation relativement claire entre les aires somatotopiques du visage et de la main (Colebatch et al., 1991, Rao et al., 1995, Sanes et al., 1995, Grafton et al., 1996) contrairement au fort recouvrement spatial des segments corporels adjacents tels que la main, le poignet et l'épaule mis en évidence par l'intermédiaire de micro-stimulation intracrânienne dans le cortex moteur de singes (Donoghue et al., 1992, Schieber and Hibbard, 1993, Schieber, 1999), puis chez l'homme en IRMf (Sanes et al., 1995, Lotze et al., 2000, Meier et al., 2008) ou en TMS (par exemple Devanne et al., 2006, Melgari et al., 2008). De plus, il existe un facteur de confusion assez important lorsque l'on s'intéresse aux mouvements des segments proximaux à l'amputation. Le membre amputé résiduel est très souvent endommagé et très hétérogène d'un sujet à l'autre. Les mouvements du coude ou du moignon sont donc beaucoup moins faciles à standardiser que ceux des lèvres, non lésées par l'amputation. Ceci peut expliquer pourquoi seulement deux études en neuroimagerie fonctionnelle traitent des mouvements de moignon ou du coude (Giroux et al., 2001, Roux et al., 2003) et peut expliquer également les résultats contrastés des études en TMS sur la représentation des muscles du moignon (Pascual-Leone et al., 1996, Dettmers et al., 1999, Roricht et al., 1999, Karl et al., 2001, Schwenkreis et al., 2001, Irlbacher et al., 2002, Gagné et al., 2010).

Limites des indicateurs non spatiaux

Des études méthodologiques ont montré que l'amplitude moyenne d'activation ainsi que les Z scores maximaux ne sont pas très reproductibles en IRMf (Marshall et al., 2004, Bosnell et al., 2008, Suckling et al., 2008, Gountouna et al., 2010). Par ailleurs, comme de nombreuses études

rapportent une activité corticale plus diffuse chez l'amputé, il est également important de connaître des facteurs de confusion de cette mesure. Le volume cérébral recruté pour une même tâche peut être soumis à une certaine variabilité d'un examen à l'autre pour un même sujet (par exemple en IRMf 2000, Marshall et al., 2004, Bosnell et al., 2008) et peut varier simplement parce que l'effort lié à la tâche est plus important pour un patient donné, ou encore refléter un mécanisme d'apprentissage moteur (Walker et al., 2005). De la même façon, la mesure du volume des cartes motrices en TMS n'est pas très reproductible chez l'amputé (Hetu et al., 2011), comme dans la population générale (Uy et al., 2002, Wolf et al., 2004, Livingston and Ingersoll, 2008, Plowman-Prine et al., 2008).

D'autres facteurs confondants, propres à l'étude chez le sujet amputé, peuvent fausser les résultats des examens en TMS. Dans la plupart des études, les mesures électrophysiologiques des muscles du moignon et des muscles du côté intact sont acquises à une intensité absolue de stimulation, *identique* pour les deux hémisphères. Puisque les seuils moteurs des muscles du moignon sont plus bas, il est logique dans ces conditions, de mesurer une augmentation de la surface de représentation des muscles du moignon (Hall et al., 1990, Cohen et al., 1991a, Ridding and Rothwell, 1995, Pascual-Leone et al., 1996, Chen et al., 1998a, Dettmers et al., 1999, Roricht et al., 1999, Karl et al., 2001). Des neurones plus distants par rapport au *hotspot* sur lequel est positionnée la bobine, peuvent être recrutés, car la zone corticale de la main fantôme est stimulée à une intensité relative plus élevée (Ridding and Rothwell, 1995, Siebner and Rothwell, 2003). D'ailleurs, en utilisant le même seuil relatif de stimulation dans les deux hémisphères, Gagné et al. (2010) n'ont pas détecté de différence entre la taille des cartes motrices des muscles du moignon et celles des mêmes muscles du côté sain.

Un autre facteur confondant émerge du résultat initial de Ridding et al. (1995), qui montrait que lorsque les amputés maintiennent une contraction isométrique dans les muscles du moignon, les seuils moteurs des deux côtés sont identiques (voire également Gagné et al., 2010). Or, la plupart des études se fondent sur le seuil moteur de repos (qui est inférieur pour les muscles du moignon) pour caractériser la réorganisation dans le cortex moteur des amputés. Ces résultats montrent que la facilitation corticospinale induite par la contraction musculaire est plus faible dans les muscles du moignon, mais que lors de contractions musculaires dans le moignon, ces

réorganisations disparaissent. Ces résultats soulèvent également la question de la pertinence fonctionnelle de cet indicateur.

Limites des indicateurs spatiaux

Quelque soit la technique d'imagerie utilisée, une variété de repères spatiaux sont utilisés pour refléter les propriétés topologiques des clusters d'activation et estimer par la suite un éventuel déplacement. Les trois principaux repères étant le pic local d'activation du cluster, le Centre de Masse (CoM), correspondant à la moyenne des coordonnées (x, y, z) de tous les points du cluster, et enfin le Centre de Gravité (CoG), qui correspond à la moyenne des coordonnées des voxels activés, pondérée par leur t-scores respectifs. Ces différents repères spatiaux peuvent donner des résultats divergents (Lotze et al., 2000) et tous présentent des limites à considérer. Tout d'abord, la position du pic d'activation ne reflète ni l'étendue d'un cluster d'activation, ni sa « géométrie ». Cette position est en plus biaisée par les différents prétraitements des images fonctionnelle en IRMf et n'est donc pas toujours reproductible (par exemple Andrade et al., 2001, White et al., 2001, Geissler et al., 2005, Jo et al., 2007). Le CoM semble plus reproductible (Waldvogel et al., 1999, Lotze et al., 2000, Loubinoux et al., 2001) et livre une estimation de la somatotopie chez des sujets sains plus claire que les pics d'activation (par exemple Plow et al., 2010). L'utilisation du CoG semble conceptuellement et méthodologiquement plus juste. Par exemple en IRMf, les CoG sont moins sensibles aux fluctuations aléatoires du signal BOLD et aux variations locales du rapport signal/bruit. Par contre, la position des CoG est par nature, sensible au seuil statistique choisi par l'expérimentateur. Dans l'étude comparative de Marshall et al. (2004), la reproductibilité intra-sujet et intra-session de la position des CoG est très bonne (inférieure à 3 mm). De plus, dans l'étude de Lotze et al. (2000), les pics d'activation des doigts et du coude étaient complètement superposés, contrairement aux CoG qui rendaient compte de l'organisation somatotopique des doigts et du coude (voire également Luft et al., 2002).

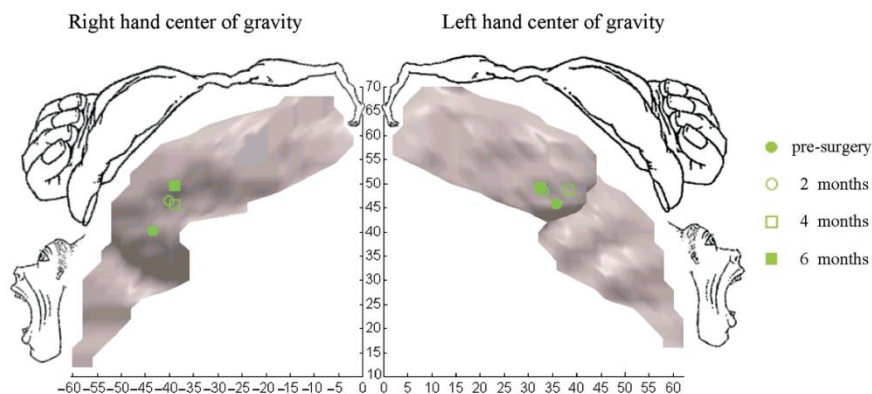


Figure 11 : L'une des premières **utilisations des CoG en IRMf** afin de mettre en évidence le déplacement des représentations de la main chez un patient ayant subi une greffe bilatérale des deux mains (avant l'opération chirurgicale, 2 mois après, 4 mois après et 6 mois après) (Giraux et al., 2001).

Outre la variété des critères d'évaluation, un aspect crucial dans l'estimation des réorganisations topologiques, réside dans la méthode de calcul des distances entre les représentations corporelles dans S1 et M1. Depuis les études initiales chez l'amputé (Yang et al., 1994, Flor et al., 1995, Knecht et al., 1995, Knecht et al., 1996, Elbert et al., 1997), des outils principalement élaborés à partir d'un modèle cérébral volumique (tridimensionnel) sont utilisés. Cette approche volumique correspond au format d'acquisition des données. Par exemple en IRM, les volumes cérébraux sont acquis en coupes et sont traités sous cette forme. Il semble évident cependant que l'analyse volumique, et par conséquent l'utilisation des distances euclidiennes ne convient pas à l'étude de l'activité corticale.

En conclusion, cette lecture critique des résultats et des outils d'évaluation des réorganisations corticales illustre quelques réserves méthodologiques et des imprécisions inhérentes aux techniques de neuroimagerie, en particulier pour caractériser les variations spatiales de l'organisation fonctionnelle de M1 ou S1. Ces constats mettent en évidence la nécessité d'aborder cette problématique avec quelques précautions méthodologiques supplémentaires et éventuellement avec un outil plus précis.

Il apparaît plus intéressant en effet, d'un point de vue anatomique, d'utiliser une approche surfacique pour estimer les réorganisations corticales (voire Figure 12). L'utilisation des distances

euclidiennes entre deux points du cortex, symbolisée par la droite passant par ces deux points est largement rependue dans la littérature mais tend à sous-estimer la distance « réelle » ou géodésique. Contrairement à la mesure euclidienne, la distance géodésique prendra en compte les contraintes topologiques du cortex (Andrade et al., 2001). Cette différence peut revêtir une importance non négligeable dans l'étude de phénomènes très fins touchant des réorganisations corticales chez l'amputé, en particulier dans la région de l'Oméga de la main le long du sillon central, région très sinueuse du cortex (Yousry et al., 1997, Caulo et al., 2007, Shinoura et al., 2009). L'utilisation d'une mesure plus fine en IRM fonctionnelle permettrait d'optimiser les possibilités de l'IRM fonctionnelle dans la localisation des activations et fournir de nouvelles indications sur la signification fonctionnelle des réorganisations corticales, en particulier sur le plan moteur.

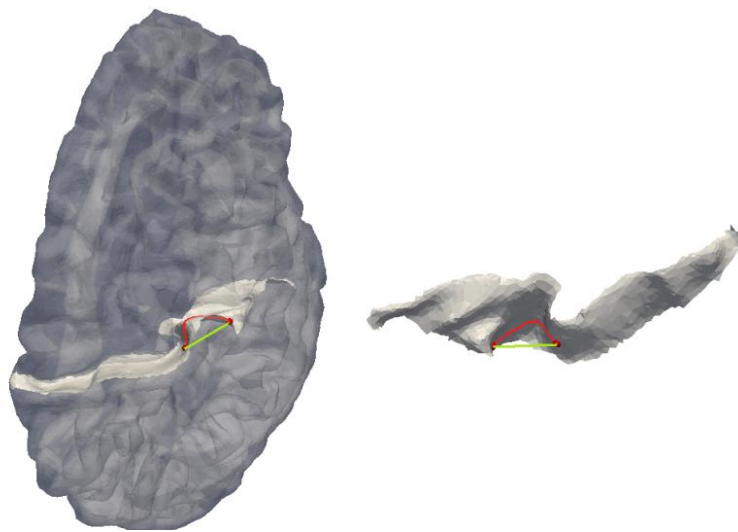


Figure 12 : Exemple d'une distance euclidienne (en vert) et d'une distance géodésique (en rouge) dans le cortex moteur primaire

Expérimentations

Eu regard à l'absence de questionnement dans la littérature sur le véritable statut psychologique des mouvements de membre fantôme, les deux premières études de cette thèse seront menées dans le but de dissocier expérimentalement la double modalité de perceptions motrices éprouvée par les patients amputés. Les données recueillies permettront de comparer les effets de l'absence d'un membre sur les capacités à « exécuter » et à « imaginer » un mouvement de membre fantôme. Elles permettront également de comparer les effets de l'amputation sur l'intégrité des réseaux cérébraux mis en jeu pendant les deux tâches. Enfin la troisième étude aura pour but d'établir un lien entre la motricité résiduelle du membre fantôme et le degré de réorganisation du cortex moteur des amputés.

Toutes les expériences présentées ont fait l'objet d'articles publiés (étude 1), en cours de publication (étude 2 – received revise and resubmit decision from BRAIN) ou en cours de préparation (étude 3). Ils sont incérés au manuscrit dans leur forme originale. Le premier article figure en annexes dans sa forme publiée.

Expérience 1: "The moving phantom: Motor execution or motor imagery?" *Cortex*

Expérience 2: "Disentangling motor execution from motor imagery with the phantom limb", *en révision dans Brain*

Expérience 3: "Primary motor cortex reorganization and activity during phantom hand movements are both related to phantom limb motor control", *en preparation*

4. Etude 1

« Dissociation entre exécution motrice et imagerie motrice dans le membre fantôme »

4.1 Résumé

Problématique

La plupart des personnes amputées ressentent la présence d'un membre fantôme. Une perception de mouvements volontaires dans le membre fantôme peut s'ajouter à ce sentiment de présence. Ces mouvements fantômes sont assez mal connus et restent assimilés à une forme d'imagerie motrice. La possibilité que les personnes amputées puissent distinctement éprouver les sensations kinesthésiques provoquées par des mouvements imaginés et par des mouvements exécutés dans leur membre fantôme reste inexplorée. L'expérience clinique auprès des patients amputés révèle pourtant qu'ils perçoivent clairement deux sensations kinesthésiques différentes dans leur membre fantôme. Le but de cette étude est de mettre en évidence la distinction entre l'exécution motrice de l'imagerie motrice dans le membre fantôme.

Matériels & Méthodes

Dans un premier temps, une évaluation des sensations fantômes incluant un examen des capacités motrices dans le membre fantôme a été pratiquée auprès de dix-neuf sujets amputés du membre supérieur. Dans un second temps, les performances en imagerie motrice des sujets amputés mesurées lors de trois tests d'imagerie motrice ont été comparées aux performances de dix-huit sujets volontaires sains appareillés en âge. Le premier test est un questionnaire évaluant les capacités globales d'imagerie motrice (MIQ-RS) et les deux derniers tests sont des tests de chronométrie mentale. Le dernier test consiste à comparer les temps d'exécution et d'imagerie motrice pour effectuer une séquence d'opposition des doigts. Enfin, l'activité électrique des muscles impliqués dans les mouvements exécutés ou imaginés est mesurée.

Résultats & Discussion

Les différents tests comportementaux utilisés dans cette étude confirment la capacité des sujets amputés à distinguer les mouvements exécutés des mouvements imaginés avec le membre fantôme. Un élément de preuve important de cette dissociation est la présence d'une d'activité EMG significative dans les muscles du moignon uniquement pendant les mouvements exécutés. Par ailleurs, la vitesse des mouvements exécutés est significativement réduite dans le membre fantôme contrairement à l'imagerie motrice. Ce résultat suggère que l'absence d'un membre altère spécifiquement l'exécution de mouvements dans le membre fantôme mais ne perturbe pas les capacités à imaginer. De façon intéressante, ces résultats suggèrent que dans le cas de l'amputation, où les rétrocontrôles sensoriels associés aux mouvements sont faibles et incongruents, la dissociation perceptuelle entre exécution et imagerie motrice ne se ferait pas à partir des rétrocontrôles sensoriels mais en amont, sur la base des prédictions des conséquences sensorielles du mouvement. Ces résultats ont également une implication clinique, en particulier dans le cadre des thérapies antalgiques basées sur la restitution du rétrocontrôle visuel associée à des mouvements du membre fantôme. La possibilité de distinguer l'exécution de l'imagerie motrice dans le membre fantôme devrait être prise en compte lors de ces thérapies. Il est en effet probable que les deux tâches ne mettent pas en jeu les mêmes mécanismes physiologiques.

4.2 Article

The moving phantom: motor execution or motor imagery?

Estelle Raffin (MSc)^{1,2}, Pascal Giraux (MD, PhD)^{1,2}, and Karen T. Reilly (PhD)^{3,4}

¹Department of Physical Medicine and Rehabilitation, Faculty of Medicine of Saint Etienne, University Jean Monnet of Saint Etienne, F-42023 Saint-Etienne, France.

²INSERM U 879, Lyon Neuroscience Research Center, Central Integration of Pain Team, Saint-Etienne and Lyon, France

^{3*} Centre de Neurosciences Cognitives, CNRS UMR 5229, 67 Boulevard Pinel, Bron 69675, France

⁴ University of Lyon 1, Lyon, F-69000, France.

Running title: Phantom movement: imagination or execution?

Corresponding authors:

Karen T. REILLY
*current address
INSERM, U 864 "Espace et Action,"
F-69500 Bron,
FRANCE
karen.reilly@inserm.fr

Pascal GIRAUX
Service de Médecine Physique et de
Réadaptation,
Hôpital Bellevue, CHU de Saint-Etienne,
F-42055 Saint-Etienne cedex 02
FRANCE
pascal.giroux@univ-st-etienne.fr

Summary:

Amputees who have a phantom limb often report the ability to move this phantom voluntarily. In the literature, phantom limb movements are generally considered to reflect motor imagery rather than motor execution. The aim of this study was to investigate whether amputees distinguish between executing a movement of the phantom limb and imagining moving the missing limb. We examined the capacity of 19 upper limb amputees to execute and imagine movements of both their phantom and intact limbs. Their behaviour was compared with that of 18 age-matched normal controls. A global questionnaire-based assessment of imagery ability and timed tests showed that amputees can indeed distinguish between motor execution and motor imagery with the phantom limb, and that the former is associated with activity in stump muscles while the latter is not. Amputation reduced the speed of voluntary movements with the phantom limb but did not change the speed of imagined movements, suggesting that the absence of the limb specifically affects the ability to voluntarily move the phantom but does not change the ability to imagine moving the missing limb. These results suggest that under some conditions, for example amputation, the predicted sensory consequences of a motor command are sufficient to evoke the sensation of voluntary movement. They also suggest that the distinction between imagined and executed movements should be taken into consideration when designing research protocols to investigate the analgesic effects of sensorimotor feedback.

Key words: Phantom limb; motor execution; motor imagery; reorganization

Introduction

In the mid 16th century the French surgeon Ambroise Paré provided the first clinical description of the phenomenon in which amputees continue to perceive the presence of their missing limb. It wasn't until over two centuries later, however, that the first complete clinical description of the phantom limb was published by the American neurologist Silas Weir Mitchell (see Wade, 2009 for a review). Mitchell wrote that after amputation there is often a continued perception of the missing limb and that this phantom limb occupies a distinct body space, and has a particular size, shape, and posture. He also noted that his patients reported that the phantom limb had certain sensory properties like touch and pain, as well as kinaesthetic properties like being able to be moved voluntarily (1872). Despite clearly stating that he was of the opinion that the phantom limb arose from changes in the central and peripheral nervous systems, Mitchell described the phantom as a "sensorial delusion", the result of which was that the majority of physicians considered phantom limbs as a figment of the amputee's imagination, and amputees were therefore referred to mental health practitioners for many years.

Today it is generally accepted that the phantom arises from physiological changes that occur after amputation (Melzack, 1992, Ramachandran and Hirstein, 1998). Despite this, the idea that the phantom is imaginary still lingers. For example, voluntary movements of the missing limb are still described as imaginary movements in the majority of scientific papers (Erslund et al., 1996, Hugdahl et al., 2001, Lotze et al., 2001, Rosen et al., 2001, Roux et al., 2001, Roux et al., 2003, MacIver et al., 2008). The use of this terminology reflects the influence of early psychological theories of the phantom (Wade, 2009), probably persists as a result of the lack of a more descriptive set of terms to describe the phantom, and is reinforced by studies on motor imagery which describe the ability of normal subjects to evoke kinaesthetic sensations without producing any overt movement (e.g. Jeannerod and Decety, 1995). Indeed, since amputees experience kinaesthetic sensations but no movement (because their limb is no longer present) most researchers assume that these sensations fall into the category of motor imagery. This classification implicitly assumes that these sensations arise from the same processes as those involved in motor imagery in normal subjects. One problem with this assumption is that imagined movements in

normal subjects do not, by definition, evoke any visible movement or substantial muscle activity (Gandevia et al., 1997, Hashimoto and Rothwell, 1999, Lotze et al., 1999b, Lacourse et al., 2005) but see (Guillot et al., 2007, Lebon et al., 2008) for a different opinion. Mitchell noted, however, that voluntary movements of the missing limb were sometimes accompanied by stump movements and substantial activity in stump muscles (Mitchell 1872), observations that were recently verified using electromyographic recordings (Reilly et al., 2006). Thus, voluntary movements of the missing limb should not necessarily be classified as imagined movements, but might instead be *real movements without an effector*. Indeed, in a recent review Lotze and Halsband state that “amputees generally perceive movement (sic) of the phantom hand as real movements rather than imaginary movements,...” (2006 p.391). If this is the case then amputees should be able to distinguish between an imagined movement of the missing limb and a voluntarily executed movement of the phantom limb. In both cases there would be no overt movement of the limb (as it is no longer present), but voluntary movements of the phantom would be associated with the sensation that the phantom limb moved whereas imagined movements would not.

Nico and colleagues (2004) examined the ability of upper-limb amputees to judge the laterality of pictures of hands in various orientations and found that amputation did not affect laterality judgements, suggesting that implicit motor imagery processes are preserved after amputation. In a more recent study, Malouin and colleagues (2009) examined the impact of lower limb amputation on explicit motor imagery processes. They found that imagined movements of the amputated limb were less vivid than those of the intact limb, but concluded that explicit motor imagery could still be performed despite the absence of the limb. Our conversations with patients undergoing treatment for phantom limb pain using visuomotor therapy (as described in Giroux and Sirigu, 2003) suggest that explicit motor imagery processes might also be preserved after amputation of the upper-limb; the majority of patients make a clear distinction between executing and imagining a movement with their missing limb and report that the kinaesthetic sensations evoked in both cases are distinctly different. For example, executed movements of the phantom hand are often slower and of smaller amplitude than those of the intact hand (Gagne et al., 2009a), require intense effort, and result in the feeling that the position of the limb has changed in the same way as it would have changed if they had moved their intact limb (Reilly et al., 2006). In contrast, imagined movements require much less effort and the kinaesthetic sensations they evoke are different from those experienced during executed movements. In particular, imagined

movements do not produce the sensation that the limb's position has changed. Furthermore, while amputees have difficulty moving their phantom limb voluntarily, our clinical experience (unpublished observations) suggests that their ability to imagine moving the missing limb is preserved.

There are no reports in the literature directly comparing the ability of amputees to both execute and imagine a movement with their missing limb. The aim of the present study was to investigate whether amputees can indeed distinguish between executing a movement of the phantom limb and imagining moving the missing limb. We hypothesised that amputees would be capable of performing imagery and execution with the phantom limb, with substantial stump muscle activity during execution and none during imagination. We further hypothesised that the absence of the limb would not perturb motor imagery processes but would reduce the speed of motor execution with the phantom.

Materials and methods

Subjects

Nineteen upper-limb amputees were recruited from the outpatient clinic of our institution (4 females and 15 males; mean age 37.2 years, SD 14.1). On average, the accident occurred 9 years and 10 months before testing (range: 5 months–39 years). The Edinburgh Handedness Inventory (EHI) revealed that 18/19 amputees were right hand dominant prior to the amputation. Eighteen age-matched healthy right-handed volunteers (8 females and 10 males; mean age 37.9 years, SD 18.9) were recruited as controls. Neither amputees nor controls had suffered a brain lesion or had a history of neurological or psychiatric illness. The nature of the experimental procedures was explained to all subjects who gave their written informed consent prior to participating in the experiment, which was approved by the Local Ethics Committee of Lyon Sud-Est IV, and conformed to the ethical aspects of the Declaration of Helsinki.

Procedure

All subjects completed a two hour testing session. For amputees the session began with the collection of general clinical data related to the amputation followed by a structured interview to assess phantom sensations and pain (Flor et al., 1995), and an assessment of *phantom* limb motor control. Then, all subjects completed the Movement Imagery Questionnaire - Revised second version (MIQ-RS), which assesses visual and kinaesthetic imagination capacity. This test enabled them to become familiar with the idea of motor imagery and comfortable speaking about imagined movements. Next they performed two mental imagery tests: the 'Visuomotor Incongruency Test' and the 'Finger-to-thumb opposition Task'. When the material was available, surface electromyograms (EMGs) were recorded from stump and intact limb muscles in order to assess whether there was a difference in muscle activity during motor execution and motor imagery (when EMG could not be recorded we palpated the muscles). EMG was recorded during imagery and execution in all control subjects and in 12/19 amputees. At the end of the testing procedure we asked the amputees three open-ended questions about what they felt when executing or imagining phantom limb movements. 1) Were there any differences between executing and imagining a movement with your phantom limb? If so, can you describe them? 2) Were there any differences between moving your intact limb and moving your phantom limb? If so, can you describe them? 3) Were there any differences between imagining moving your intact limb and imagining moving your phantom limb? If so, can you describe them?

Assessment of phantom limb motor control

The sensations of voluntary movement with the phantom were evaluated using a technique similar to that described in Gagne et al. (2009a). Subjects were asked to produce five different cyclic voluntary movements of their phantom and to mimic them simultaneously with their intact limb. These movements were (1) elbow flexion/extension (for above-elbow amputees only); (2) wrist flexion/extension; (3) hand closing/opening; (4) thumb to index opposition; (5) finger abduction/adduction. Subjects were instructed to move their intact limb through the same range and at the same speed as the phantom limb. The amplitude of each of the five movements was expressed

as a fraction of the maximal range of motion of the intact limb on a scale ranging from 0/5 (phantom does not move) to 5/5 (phantom moves through the same range of motion as the intact limb). The difficulty and pain (if any) associated with the execution of each of the five movements were rated on a visual-to-analog scale (VAS) (0 = very easy/no pain, to 10 = impossible/very painful). Because not all movements were possible for all amputees, movement speed was assessed using a single movement, and was quantified as the number of hand opening/closing movement cycles possible during 10 seconds. This movement could be performed by all amputees and when an amputee could perform several movements it was always rated as the easiest.

Assessment of motor imagery

Global motor imagery capacity

We assessed the overall ability of subjects to make imagined movements with the Motor Imagery Questionnaire Revised second version (MIQ-RS) (Gregg et al., 2007). This instrument assesses visual and kinaesthetic movement imagery ability and consists of eight items (four visual and four kinaesthetic) that reflect everyday functional movements. These include one movement involving the lower limb, four movements of the upper-limb performed with one arm, and two movements of the upper-limb performed with both arms. For the upper-limb movements that required only one arm amputees imagined the movements with the intact limb. For those movements that required both arms amputees imagined making the movement with both their intact and amputated arms. When execution was impossible with the amputated limb, they used the unaffected limb only. For each item subjects had to perform the movement, and then imagine the same movement either visually or kinaesthetically. Subjects were instructed to imagine from a first-person perspective. We told them to “see” (for visual) or “feel” (for kinaesthetic) themselves moving their limbs ‘from the inside’. We never instructed them to avoid muscle contractions during motor imagery. After imagining the movement the subject rated the ease (or difficulty) of the imagination task on a 7-point scale from 1 = very hard to see/feel to 7 = very easy to see/feel. This test gave us three subjective measures of the motor imagery capacities of each subject: a measure of the global

capacity to imagine movements (I_G), the capacity to visually imagine (I_V), and the capacity to kinaesthetically imagine (I_K).

Motor imagery capacity with the upper-limb.

Visuomotor Incongruency Test

Adapted from Sirigu and collaborators (Sirigu and Duhamel, 2001), this test consists of two measures of the time taken to imagine a given movement. For the first measure, the actual position of the hand is congruent with the imagined starting position of the hand. That is, subjects are seated with their hand on their thigh and imagine touching their mouth with their hand and then repositioning the hand on the thigh. For the second measure, the actual position of the hand is incongruent with the imagined starting position of the hand. In this condition, subjects are seated with their hand placed behind their back and imagine exactly the same movement as for the first measure. That is, a movement of the hand from the thigh to the mouth and back to the thigh. In each case the experimenter told the subject when to start imagining and the subject verbally indicated when the hand had returned to the thigh. Subjects were told that it was not a test of speed and that they should clearly imagine the task without worrying about the time taken. All subjects (amputees and controls) performed this task with both hands.

To evaluate whether amputees show slower imagination times under conditions of mismatch we calculated the percent change in imagination time when the starting position was incongruent relative to when it was congruent $[(\text{imag. time incongruent} - \text{imag. time congruent}) / \text{imag. time congruent}] \times 100$. For example: if a subject took 3 seconds to imagine in the congruent condition and 4 seconds in the incongruent position the percent change was $(4-3)/3 \times 100\%$ or +33.3%. One-sample Wilcoxon signed rank tests were used to assess whether the percent change in imagination times was significantly different from zero. These tests were performed separately for the intact and phantom limbs of amputees and for the dominant and non-dominant limbs of controls.

Finger-to-thumb opposition task

In this task we compared both the time to imagine making a movement and the time to actually execute the movement, two variables that are highly correlated in normal healthy subjects (Decety et al., 1989). Subjects were required to either execute or imagine opposing each of the four fingertips to their thumb at a self-imposed pace and to repeat this sequence five times. They were instructed to concentrate on the quality of the performance rather than the speed of the movement. For the execution task, the experimenter gave a go signal and recorded the time between this signal and completion of the five movement cycles. For the imagination task, the experimenter gave the go signal to indicate to the subject to start and the subject verbally indicated when they had imagined five movement cycles. All subjects completed the task twice, with the dominant and non-dominant hands for normal subjects, and the intact and phantom hands for amputees.

In order to investigate whether clinical factors associated with the amputation were related to phantom limb imagination or execution times two multiple linear stepwise regressions were performed; one regression for execution times and one for imagination times. The predictors entered into the regressions were: age (years), amputated limb dominant before amputation (yes/no), length of amputated limb (expressed as a % of the length of the intact limb (0-100)), telescoping of the phantom limb (yes/no), pain medication (yes/no), time since amputation (years), average pain rating on VAS during phantom limb movements (0–10), and prosthesis use (yes/no). The ordinal clinical predictors included in the model were normally distributed according to Komolgorov–Simirov tests of normality ($P > 0.05$). The regression analysis was first carried out step by step (forward stepwise regression), resulting in potential significant predictors. The P to enter in the stepwise selection process was set to 0.05, while the P to remove was set to 0.1.

As a result of our relatively small sample sizes and the fact that not all data sets were normally distributed (based on the Kolmogorov-Smirnov test) all statistical analyses (other than the regressions) were performed using non parametric tests. Wilcoxon signed-rank tests were used for one-sample and related sample comparisons and Mann-Whitney tests for independent sample comparisons. All analyses were conducted using STATISTICA 8.0 (StatSoft, Inc. 1984-2007) and medians are reported with the range indicated in brackets, with the exception of the phantom limb motor control data for which means are presented with standard deviations in brackets. Outliers

were excluded if they were more than two standard deviations away from the mean, and the number of subjects included in each statistical analysis is indicated in brackets.

Muscle activation during executed and imagined movements

For twelve amputees, activity was recorded in a separate testing session during a related fMRI study and we recorded activity during execution and imagination of hand opening/closing. Stump muscles were expected to be active during motor execution (Reilly et al., 2006) and inactive during motor imagery (Gandevia et al., 1997, Hashimoto and Rothwell, 1999, Lotze et al., 1999b, Lacourse et al., 2005). For control subjects and below-elbow amputees we monitored the activity of Flexor Digitorum Superficialis (FDS) and Extensor Digitorum Communis (EDC), while for above-elbow amputees we recorded from Triceps Brachii (TB) and Biceps Brachii (BB). The same muscles were recorded from the intact and amputated sides of below-elbow amputees, but for above-elbow amputees the proximal muscles EDC and FDS were recorded from the intact side, as these are the muscles that are primarily active during the hand movements performed in the motor imagery and execution tasks.

For each muscle two silver-chloride surface electrodes of 10-mm diameter were positioned on the muscle with an inter-electrode distance (centre to centre) of 2 cm (with the skin previously shaved and/or cleaned with alcohol). The reference electrode was placed on the lateral epicondyle. EMG signals were amplified, recorded at a frequency of 1000 Hz, band pass filtered (20–400 Hz) and stored for off line analysis using MATLAB[®] software. Separate one way ANOVAs were performed for each muscle on data during rest, imagination, and execution.

Results

The amputees' responses to our questions regarding what they felt when executing or imagining phantom limb movements revealed clear differences between executed and imagined movements. They reported that when they executed a movement the perceived position of the

phantom changed whereas it did not change for imagined movements, and that executed movements required much more effort than imagined movements. A few amputees also reported that executed movements sometimes generated pain, but no one reported that imagined movements generated phantom limb pain. Their responses also revealed that the sensations evoked during imagination were similar for both the phantom and intact hands, but that imagining moving the phantom limb was more difficult. While it has been demonstrated that chronic phantom limb pain affects the speed of executed phantom movements (Gagné et al., 2009), we found that the ability to imagine phantom limb movements was unrelated to chronic pain levels.

Phantom limb motor control characteristics

All nineteen amputees had vivid phantom limb sensations and could perform at least one of the five tested movements, but the majority was unable to perform all five movements. Averaged across the five tested movements, amputees rated that it was relatively difficult to execute movements with the phantom limb (4.7 (2.9) /10 on the VAS), and the average pain rating associated with these movements was 4.5 (3.3) /10 on the VAS. The difficulty and pain ratings for the intact limb were always 0. The amplitude of the possible movements was decreased: on average the phantom moved through only half the range of motion of the intact limb (53% (27%)). Phantom movements were also slower: amputees performed an average of 5.8 (5.3) full hand opening/closing cycles with their phantom during 10 seconds, whereas normal subjects completed more than twice this number of cycles in the same time (and through a greater range of motion). The clinical and phantom limb characteristics of each subject are detailed in Table 1.

Expérimentations : étude 1

Age	Months since amputation	Amputated side/ Dominant side	Proximal or Distal (P/D)/ Stump length (% of residual limb)	Prosthesis use	Number of possible movements (1-5)	Ease of Phantom execution (0 - 10)	Ease of Phantom imagination (0 - 10)	Chronic phantom limb pain intensity (0 - 10)	Phantom pain intensity during movements (0 - 10)
40	102	R/R	P/ 24	myoelectric (permanent)	4	4	5	6	4
55	106	L/R	P/ 15	esthetic (rarely)	2	8	1	6	6
22	38	R/R	P/ 15	no use	2	6	5	4	2
60	120	L/R	P/ 15	no use	2	8	4	8	8
28	204	R/R	D/ 48	no use	3	4	3	2	2
29	281	R/R	D/ 58	esthetic (permanent)	5	2	4	0	2
39	360	L/R	D/ 43	no use	5	0	5	0	0
41	150	R/R	P/ 31	no use	4	6	5	8	10
60	468	L/R	P/ 4	no use	1	10	1	10	10
27	84	L/R	P/ 26	myoelectric (permanent)	3	4	5	2	4
29	44	L/L	P/ 36	no use	3	6	1	7	6
25	48	R/R	D/ 58	esthetic (part-time)	3	0	5	0	0
33	12	L/R	P/ 42	no use	5	4	3	3	6
27	5	R/R	P/ 25	no use	2	6	2	5	6
47	37	L/R	P/ 32	esthetic (permanent)	2	8	3	7	8
18	27	R/R	D/ 69	esthetic	4	2	1	4	2

Expérimentations : étude 1

55	12	R/R	P/ 35	(permanent) mechanic (part-time)	1	8	2	5	6
20	118	R/R	D/ 70	no use	5	2	3	0	0
55	30	R/R	D/ 62	no use	4	2	2	1	2

Table 1. Clinical and phantom limb characteristics of each subject

Motor Imagery Questionnaire Review secondary (MIQ-RS)

This test revealed that the global capacity (I_G) of amputees to imagine movements was similar to that of normal control subjects. The median score for amputees was 66 (46-89) and for normal subjects was 65 (44-72) (Mann-Whitney test on independent samples $U = 144$, $p = 0.412$). Amputees showed no particular preference for either visual (I_V) or kinaesthetic imagery (I_K) (Wilcoxon signed-rank test $Z = 1.21$, $p = 0.222$), but control subjects found visual imagery easier ($Z = 3.31$, $p = 0.0009$).

Visuomotor Incongruency Test

Previous studies of imagined movements in control subjects have shown that when the actual starting position of the limb is incongruent with the limb's imagined starting position the time taken to imagine the movement is longer than when there is a congruence between the actual and imagined starting positions (Parsons, 1994, Sirigu and Duhamel, 2001, Ramsey et al., 2010). We replicated this finding in both the dominant and non-dominant hands of the control subjects and the intact and phantom hands of amputees (see Table 2). It is important to note that it was difficult for some amputees to place their phantom limb behind their back, but that given sufficient time they all managed to put their phantom in the appropriate starting position.

	Controls		Amputees	
	Dominant limb	Non Dominant limb	Phantom limb	Intact limb
Mean % (range)	7.6 (-6.3-21.8)	11.6 (-18.5-27.7)	7.3 (0-30)	14.5 (3.11-40.1)
Z	3.05*	2.39*	3.41*	3.5*

*Table 2. Percent changes in imagination time when the starting position was incongruent relative to when it was congruent for the dominant and non-dominant hands of the controls and for the phantom and intact limbs of the amputees and results on the one-sample Wilcoxon signed rank tests (Z), * Significant values for $P < 0.05$.*

Finger-to-Thumb opposition task

Figure 1A shows the time taken to execute or imagine opposing the thumb to each of the fingers separately for the intact and amputated limbs of amputees. A comparison of the two left-most bars in this figure shows that amputees took nearly one and a half times longer to execute the finger-to-thumb opposition movement with their phantom hand [34.2 (12.2-100)] than with their intact hand [20.6 (8.4-42)], ($Z = 2.01$, $p < 0.05$, Wilcoxon paired tests). For the imagination task, imagination times were similar for the two hands; 33.0 (12.2-81.1) for the amputated hand and 31.9 (13.5-61.1) for the intact hand ($Z = 0.93$, $p = 0.37$). For the intact side, execution was faster than imagination ($Z = 3.82$, $p = 0.0001$), while execution was slightly slower than imagination for the amputated side ($Z = 2.01$, $p = 0.044$).

Figure 1B shows the time taken to execute or imagine opposing the thumb to each of the fingers separately for the dominant and non-dominant hands of control subjects. The average time taken by controls to execute the movement was similar for the dominant [22.4 (15.9-32.1)] and non-dominant hands [19.6 (8.5-31.2)] ($Z = 1.59$, $p = 0.11$). Imagination times were slightly slower for the dominant [28.5(15.3-46.9)] than the non-dominant hand [23.0 (12.3-53.2)] ($Z = 2.15$, $p = 0.03$) – but note that controls always performed the task with their dominant hand first. For both the dominant and non-dominant hands imagination times were always slower than execution times; for the dominant hand: $Z = 3.46$, $p = 0.0005$; for the non dominant hand: $Z = 3.68$, $p = 0.00023$.

We also compared execution and imagination times with the phantom limb with both hands of the controls. This analysis revealed 1) that execution times for the phantom hand were slower than for both the dominant ($U = 297$, $Z = -3.83$, $p < 0.001$) and non-dominant ($U = 308$, $Z = -4.16$, $p < 0.001$) hands of control subjects, and 2) Imagination times for the phantom hand did not differ from imagination times for the dominant hand ($U = 200$, $Z = 0.88$, $p = 0.39$), but were slightly slower than imagination times for the non-dominant hand ($U = 238.5$, $Z = 2.05$, $p = 0.04$).

It is noteworthy that despite their extremely slow performance during movement execution, amputees still showed a positive correlation between the time to execute and the time to imagine with the phantom hand ($r = 0.64$, $P < 0.05$). This was also the case for the intact side ($r = 0.55$, $P < 0.05$) and for both the dominant ($r = 0.74$, $P > 0.05$) and the non dominant hands ($r = 0.54$, $P < 0.05$)

of the control subjects. Furthermore, imagination times with the phantom limb on the thumb-to-finger opposition task were highly correlated with imagination times with the phantom limb on the Visuomotor Incongruity Test ($r = 0.78$, $P < 0.05$).

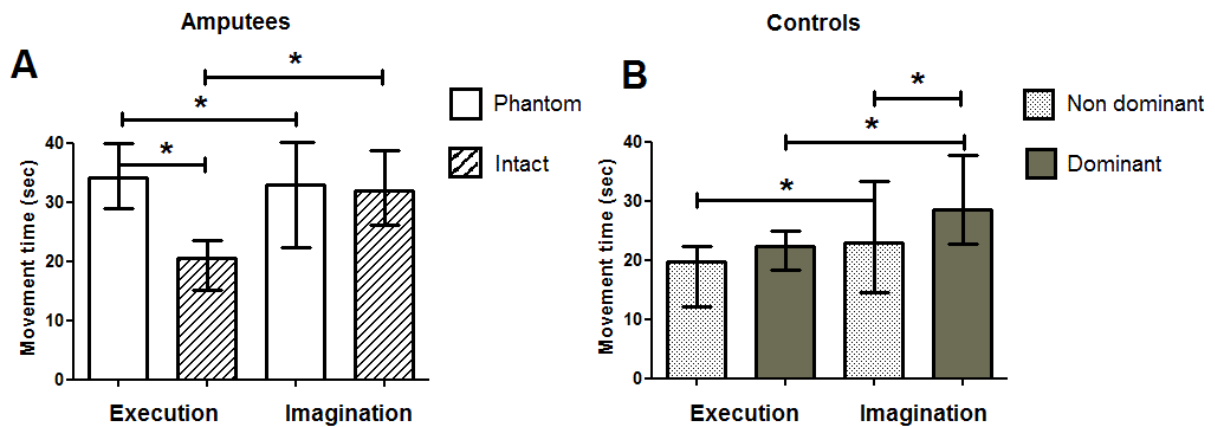


Figure 1: Medians and interquartile ranges of the raw movement times for execution and imagination of five cycles of the thumb-to-finger opposition task. Figure 1A shows the data from the amputated and intact hands of amputees and the data from the non-dominant and dominant hands of control subjects are shown in Figure 1B.

To investigate possible explanatory variables for execution and imagination times we first performed Pearson correlations between phantom execution and imagination times and eight clinical variables; average difficulty during the execution of the five tested phantom movements; chronic phantom pain intensity; average amount of pain experienced during these movements; phantom movement speed; phantom movement amplitude; time since amputation; length of the remaining limb; and amputee's age. Execution but not imagination times were highly correlated with several clinical variables (see Table 3). To further investigate these correlations we conducted several stepwise regressions in which we examined which factors predicted the time to either execute or imagine the finger-to-thumb opposition task. Because chronic and movement-related pain were highly correlated ($r = 0.9$, $P < 0.05$), and because we were interested in motor control of the phantom limb, we chose to perform our regression analyses using only movement-related pain data.

Since the clinical variables pain and length of residual limb were highly correlated with each other ($r = -0.74$, $P < 0.05$), we constructed two separate models for both execution and imagination times; one excluding limb length (Model A) and one excluding pain (Model B). Both Models A and B were significant and explained a large amount of the variance in the execution times. Two factors were retained (Model A; pain and time since amputation; Model B: length of the residual amputated limb and time since amputation). For the imagination time data both Models A and B were significant, but the models explained very little variance. Only one factor was retained (Model A: pain; Model B: length of the residual amputated limb) (see Table 4).

	Clinical variables				Phantom motor control tests			
	% of length of remaining limb	Age	Time since amputation	Chronic phantom pain intensity	Ease of phantom execution	Phantom pain intensity during movements	Phantom movement speed	Phantom movement amplitude
Execution	-0.62*	0.2	0.53	0.58*	0.74*	0.73*	-0.55	-0.2
Imagination	-0.52	0.3	0.3	0.38	0.54	0.55	-0.1	-0.2

Table 3. Summary of correlation analyses for phantom execution and imagination times recorded during the finger to thumb opposition task, * Significant correlations for $P < 0.05$ with Bonferroni corrections for multiple comparisons.

Models				Significant Predictors		
Adjusted R ²	F	df	P	Variable	Beta	P
<i>Model A for phantom motor execution (without limb length)</i>						
0.61	13.3	14	0.000	Pain VAS	0.624	0.001
				Time since amputation	0.390	0.029
<i>Model B for phantom motor execution (without pain)</i>						
0.60	9.67	15	0.007	Limb length	-0.530	0.014
				Time since amputation	0.270	0.050
<i>Model A for phantom motor imagination (without limb length)</i>						
0.25	6.58	15	0.020	Pain VAS	0.552	0.020
<i>Model B for phantom motor imagination (without pain)</i>						
0.22	5.61	15	0.030	Limb length	-0.520	0.030

Table 4: Summary of regression analyses and predictive models: A (without limb length) and B (without pain), for the phantom limb execution and imagination times. The following predictors were entered into the regressions as independent variables using a forward stepwise technique: age (years), amputated limb dominant before amputation (yes/no), length of amputated limb (expressed as a % of the length of the intact limb (0-100)), telescoping of the phantom limb (yes/no), pain medication (yes/no), time since amputation (years), average pain rating on VAS during phantom limb movements (0–10), and prosthesis use (yes/no).

EMG data

For all control subjects and 12 amputees the activity of upper limb muscles was recorded from both limbs. For both controls and amputees the muscle activity during motor execution was significantly greater than during either imagination or rest. A group analysis of the EMG data from the twelve amputees tested in the context of a complementary fMRI study revealed a main effect of task (imagined, executed, rest) for each of the four muscles (phantom flexors: $F = 132.6$, $p < 0.05$; phantom extensors: $F = 43.1$, $p < 0.05$; intact flexors: $F = 85$, $p < 0.05$; intact extensors: $F = 26.4$, $p < 0.05$). Post-hoc t-tests (with Bonferroni corrections) revealed that the activity of the flexors and extensors in both limbs was significantly greater during motor execution than during either motor imagination or rest. Muscle activity during imagination did not differ from that recorded at rest (see Table 5 for statistical data). Figure 2 shows examples of the EMG activity recorded during imagination and execution of hand opening/closing from two different amputees. Both subjects show clear differences between execution and imagination, with no EMG activity during imagination. Interestingly, this pattern is not related to their capacity to execute phantom limb movements, as subject A moved his phantom limb quickly and easily, whereas subject B had a lot of difficulty moving the phantom.

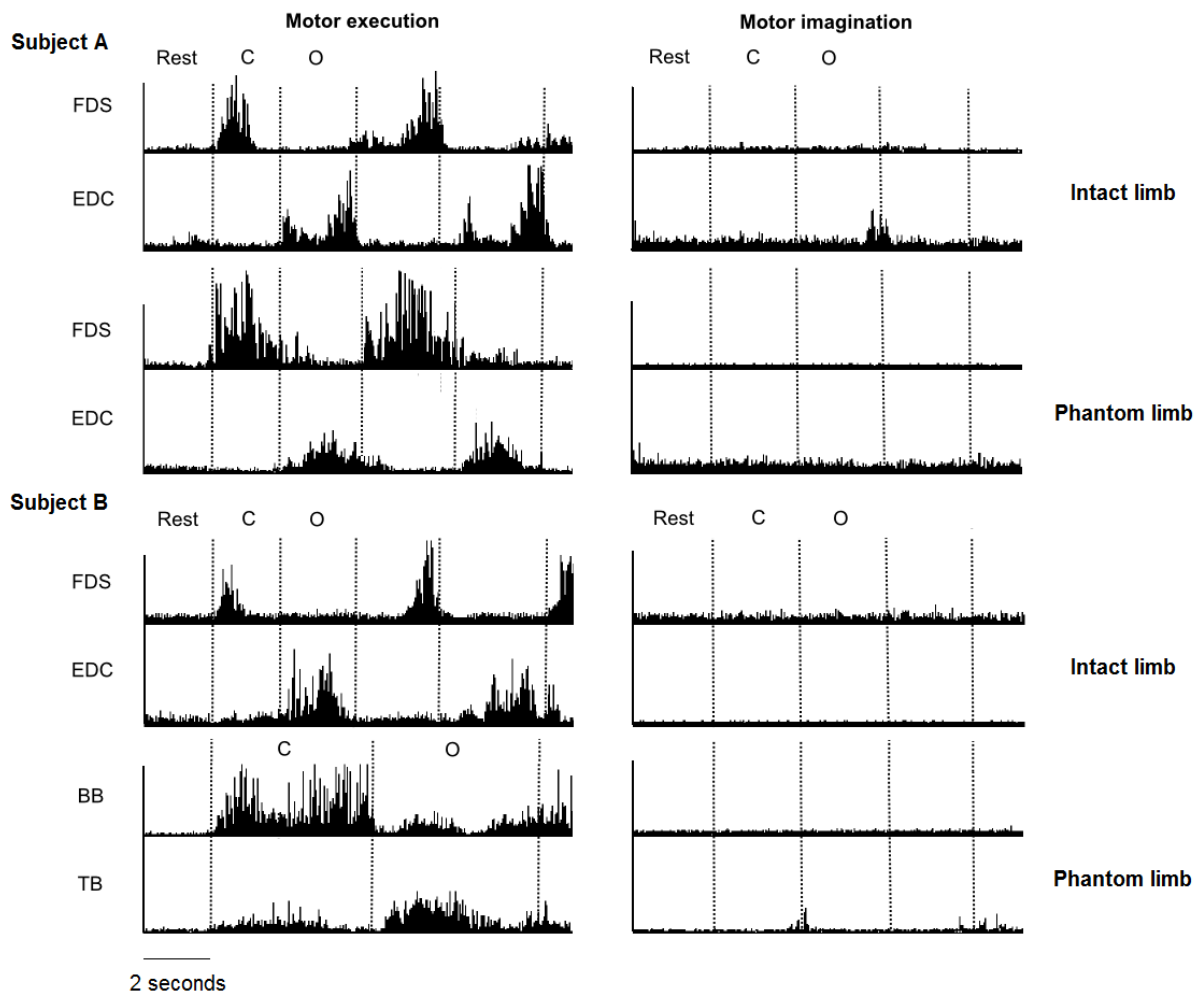


Figure 2: EMG patterns from two representative amputees. A below-elbow amputee (subject A) with a good motor control in his phantom limb and an above-elbow amputee (subject B) with a bad motor control in his phantom limb, during motor execution for the intact limb and the phantom limb (left panel) and motor imagination with the intact limb and the phantom limb (right panel) for an opening (O) / closing (C) hand movement. Recorded muscles for the below-elbow amputee were the Flexor Digitorum Superficialis (FDS) and Extensor Digitorum Communis (EDC) for the intact side and the phantom side. For the above-elbow amputee, recorded muscles were the Biceps Brachii (BB) and the Triceps Brachii (TB) for the amputated side and the FDS and EDC for the intact side. EMG has been scaled to maximize clarity, with EMG from a single muscle on the same scale but different scales for all four muscles.

		Execution		Imagination
		Imagination	Rest	Rest
Phantom limb	Flexors	13.96*	14.24*	0.29
	Extensors	7.94*	8.1*	0.26
Intact limb	Flexors	10.44*	11.82*	1.33
	Extensors	6.21*	6.58*	0.25

Table 5: T values from post tests (with Bonferroni corrections, $P < 0.05$) of the EMG analysis ($n = 12$ amputees) between motor execution, motor imagination, and rest for the flexors and extensors from both the intact and amputated limbs, * Significant values for $P < 0.05$ with Bonferroni corrections for multiple comparisons.

Discussion

In this study we investigated the ability of upper-limb amputees to distinguish between executing a movement of the absent effector (the phantom limb) and imagining moving the missing limb. Our results suggest that amputees are capable of both executing a movement with their phantom limb and imagining moving their missing limb and that execution is affected by the amputation but imagination is not. Specifically, we found that amputation reduced the speed with which amputees made voluntary movements with their phantom limb but did not change the speed of imagined movements of the missing limb, and that imagination times with the phantom limb were similar to those recorded for intact limb imagination. In addition, there was significant EMG activity during movement execution but not during movement imagination.

Moving the phantom limb is not the same as imagining moving the missing limb

Verbal interviews with upper-limb amputees reveal that they feel as though they can both move and imagine moving their phantom limb. Here we investigated the validity of these subjective reports by examining the time taken to either execute or imagine certain tasks with the phantom and intact limbs as well as the amount of EMG activity present during execution and imagination. Previous studies have demonstrated that imagination and execution times are highly correlated and that the time required to imagine a movement from a first person perspective is either equal to or longer than the time required to execute the same movement (Decety et al., 1989, Parsons, 1994, Jeannerod and Decety, 1995, Decety, 1996b, Malouin et al., 2004, Skoura et al., 2008) (see Guillot and Collet, 2005 for a review). For the intact hand of our amputees we replicated these two results; there was a positive correlation between imagination and execution times as well as a slowing of imagination times relative to execution times. This, together with the fact that the intact limb moved during execution (and there was substantial EMG activity in forearm muscles) but did not move during imagination (and there was no EMG activity in forearm muscles) suggests that amputees behave like normal controls with their intact hand and clearly distinguish between execution and imagination.

For the phantom hand we replicated one of the two results found in control subjects; there was a positive correlation between the time to execute and the time to imagine the finger-to-thumb opposition movement. We also found that imagination times for the finger-to-thumb opposition and visuomotor incongruency tasks were highly correlated, suggesting that when amputees make imagined movements with the phantom hand the 'speed of imagination' is determined by similar and stable "laws". Thus, the performance of amputees on imagination tasks was similar for both their intact and phantom hands, and this performance was comparable with that observed in control subjects. It is important to note, however, that the relationship between execution and imagination times for the phantom hand was different from that seen in controls; for the finger-to-thumb opposition task phantom execution times were slightly slower than imagination times, while the reverse was true for the intact hand and both hands of controls. While this reversal means that the relationship between execution and imagination is not identical for the phantom and intact hands, it does not mean that amputees are not able to both execute and imagine movements with their phantom. Indeed, the presence of significant movement-related bursts of EMG activity in stump

muscles during execution and the absence of such activity during imagination suggests that they performed two distinct tasks.

We interpret our results as evidence that amputees moved their phantom limb during our execution condition and imagined moving it during our imagination condition, but several alternative explanations are also possible. First, amputees could have performed exactly the same task during phantom limb execution and imagination, in which case they would have done the same thing regardless of our instructions. While this idea is supported by the observation that phantom execution and imagination times were very similar (although statistically different), it is not supported by the fact that there was no stump muscle activity during imagination but strong movement-related muscle contractions during execution. This, together with the subjective responses to our open-ended questions, argues against the idea that they performed the same task in both conditions.

A second possible interpretation of our results is that instead of performing two distinct tasks for execution and imagination, they did something when asked to execute a movement (as shown by the presence of EMG activity) and nothing when asked to imagine a movement (no EMG activity). Evidence against this idea comes from the absolute time taken to imagine a movement with the phantom limb, which was similar to that recorded from the intact hand and from both hands of control subjects. The correlation between execution and imagination times and between imagination times on different tasks, also argues against this interpretation.

Finally, amputees could have performed two tasks with their phantom limb, but instead of performing execution and imagination, they performed two different types of motor imagery. During our imagination condition they might have performed a type of visual imagery that was relatively effortless and did not produce any muscle contractions. In contrast, during our execution condition, they might have switched to a type of kinaesthetic imagery (or a combination of visual and kinaesthetic) that required more effort and thereby led to the unintentional contraction of stump muscles (Gandevia et al., 1997, Fadiga et al., 1999, Solodkin et al., 2004). In the absence of neuroimaging data it is impossible to completely rule out this possibility but several results suggest that it is unlikely. First, our Motor Imagery Questionnaire revealed that amputees do not find it more difficult to perform kinaesthetic than visual imagery. A similar finding was reported in a study with

lower-limb amputees (Malouin et al., 2009), and it argues against the idea that kinaesthetic imagery is associated with increased effort and therefore significant stump muscle EMG activity. Second, amputees insist upon the fact that the sensations they experience during motor imagery with the phantom hand are similar to those experienced during motor imagery with other body parts, whereas motor execution with the phantom evokes sensations close to those experienced when they actually move a body part. Finally, the argument that our amputees performed a type of kinaesthetic imagery in our execution condition implies that phantom movements belong to the realm of motor imagery and not motor execution, but imaging studies suggest that this is not the case. Imagined movements are rarely associated with a significant level of activity in the primary sensorimotor cortex (Roland et al., 1980, Decety et al., 1994, Stephan et al., 1995, Lotze et al., 1999b, Gerardin et al., 2000, Hanakawa et al., 2003), but a number of studies with amputees report substantial activity within the primary sensorimotor cortex during phantom limb movements (Lotze et al., 2001, Roux et al., 2001, Roux et al., 2003). Thus, amputees are not performing motor imagery when they move their phantom limb.

In conclusion, our results suggest that when asked to execute or imagine a movement with the phantom limb amputees did indeed perform two distinct tasks. While imagined movements of the phantom appear to be similar to imagined movements of intact body parts, the relationship between executed movements of the phantom and intact body parts is more complex. The complete absence of any overt movement in our motor execution condition makes it difficult to assert that phantom movements are real movements in the same way as movements of our intact limbs. We can assert, however, that they are distinct from motor imagery, and there is sufficient evidence to suggest that they are actually a form of “movement without movement”.

Why is motor execution affected after amputation while motor imagery is preserved?

We found that amputees have a preserved ability to imagine moving their missing limb but that their ability to execute movements of the phantom is markedly affected by the limb's absence. This latter observation is consistent with previous studies showing that amputees have a limited number of possible voluntary movements, and that these movements are generally very slow (Reilly et al., 2006, Gagne et al., 2009a). The finding that execution but not imagination is affected after an amputation is also supported by the results of our step-wise regression analyses which showed that

clinical variables related to the amputation itself (time since amputation, length of the remaining amputated limb, pain during movement) were good predictors of the time to execute phantom movements but poor predictors of imagination times. Although there are no studies explicitly examining the relationship between time since amputation and the sensorimotor qualities of the phantom limb, anecdotal reports suggest that phantom limb movements become more difficult over time (e.g. Cronholm, 1951, Ramachandran and Rogers-Ramachandran, 1996). Our sample included a wide range of times since amputation (5 to 468 months), suggesting that the brains of our amputees were at various stages of post-amputation adaptation. Since execution (but not imagination) times increased with increasing time since amputation, we can conclude that post-amputation adaptation processes affect execution but not imagination. This provides yet another argument that phantom execution and imagination are two dissociable tasks.

One explanation for how limb loss could affect execution without affecting imagination might be related to the fact that during movement execution the brain expects to receive sensory feedback whereas during imagination there is no such expectation. Because of the absence of the limb the feedback that the brain receives after movement execution is often weak and/or incongruent with the expected sensory feedback. The incongruence between the expected and actual feedback might explain why amputation affects movement execution but not movement imagination, and is probably an important factor underlying phantom limb pain (Ramachandran and Rogers-Ramachandran, 1996, Harris, 1999, McCabe et al., 2003, McCabe, 2010).

Another possible explanation for the differential effect of limb loss on execution and imagination comes from PET and fMRI imaging studies which show that the primary sensorimotor cortex is more active during motor execution than imagination (see Lotze and Halsband, 2006 for a review). Since the primary sensorimotor cortex is the only location (to date) in which post-amputation reorganisation has been clearly demonstrated in humans (e.g. Flor et al., 1995, Knecht et al., 1996, Borsook et al., 1998, Karl et al., 2001), the differential contribution of this area to motor execution and motor imagery might explain why imagined movements with the missing limb remain unaffected after amputation whereas executed movements of the phantom are significantly slower than movements of the intact limb.

Possible contributions to the debate on movement awareness

Amputees offer the unique case in which neither motor imagery nor motor execution is associated with any overt movement. This raises important questions about the very nature of the processes underlying the awareness of a movement as being executed or imagined. It is likely that after amputation the dissociation between executed and imagined movement does not arise a posteriori on the basis of the presence or absence of sensory feedback. Instead, a large part of the perception of a movement as being executed (versus imagined) arises from the fact that executed movements are associated with expected sensory consequences whereas imagined movements are not. This hypothesis is in accordance with the internal model theory of movement (Wolpert and Ghahramani, 2000): the execution of phantom limb movements involves sending a motor command that then calls up a predictive model of the expected final state of the body which somehow gives rise to the sensation that the limb has moved. This suggests that under some conditions, for example amputation, the predicted sensory consequences of a motor command are sufficient to evoke the sensation of voluntary movement.

Practical implications for patient rehabilitation

Our results show that just because the effector is no longer present we cannot assume that amputees automatically engage in motor imagery when they move the phantom limb. This is particularly important in the context of the growing number of studies investigating the analgesic effects of sensorimotor feedback training in amputees, brachial plexus avulsion patients or stroke patients. These techniques give patients modified visual feedback of their affected limb (using either mirrors or virtual reality systems) and often require patients to perform a motor task with their impaired limb. In most studies patients are explicitly told to execute or to “attempt to execute” voluntary movements (Ramachandran and Rogers-Ramachandran, 1996, Sathian et al., 2000, Giraux and Sirigu, 2003, McCabe et al., 2003, Chan et al., 2007, McCabe et al., 2008, Yavuzer et al., 2008, Cole et al., 2009, Mercier and Sirigu, 2009). In other cases, they are told to imagine moving their affected limb or to simply watch the movements provided by the mirror or virtual reality system (Stevens and Stoykov, 2003, Gaggioli et al., 2004, Murray et al., 2007, MacIver et al., 2008, Michielsen et al., 2010). Differences with respect to the motor task performed by the patient (motor execution, motor imagery, or movement observation), might explain the range of outcomes reported

by these rehabilitation studies. For this reason, it is important to take into account the distinction between imagined and executed movements, to explain this to patients, and to consider it when designing research protocols.

REFERENCES:

- Borsook D, Becerra L, Fishman S, Edwards A, Jennings CL, Stojanovic M, Papinicolas L, Ramachandran VS, Gonzalez RG, Breiter H. Acute plasticity in the human somatosensory cortex following amputation. *Neuroreport*, 9 (6):1013-7, 1998.
- Chan BL, Witt R, Charrow AP, Magee A, Howard R, Pasquina PF, Heilman KM, Tsao JW. Mirror therapy for phantom limb pain. *N Engl J Med*, 357 (21):2206-7, 2007.
- Cole J, Crowle S, Austwick G, Slater DH. Exploratory findings with virtual reality for phantom limb pain; from stump motion to agency and analgesia. *Disabil Rehabil*, 31 (10):846-54, 2009.
- Cronholm B. Phantom limbs in amputees; a study of changes in the integration of centripetal impulses with special reference to referred sensations. *Acta Psychiatr Neurol Scand Suppl*, 72 1-310, 1951.
- Decety J. The neurophysiological basis of motor imagery. *Behav Brain Res*, 77 (1-2):45-52, 1996.
- Decety J, Jeannerod M, Prablanc C. The timing of mentally represented actions. *Behav Brain Res*, 34 (1-2):35-42, 1989.
- Decety J, Perani D, Jeannerod M, Bettinardi V, Tadary B, Woods R, Mazziotta JC, Fazio F. Mapping motor representations with positron emission tomography. *Nature*, 371 (6498):600-2, 1994.
- Ersland L, Rosen G, Lundervold A, Smievoll AI, Tillung T, Sundberg H, Hugdahl K. Phantom limb imaginary fingertapping causes primary motor cortex activation: an fMRI study. *Neuroreport*, 8 (1):207-10, 1996.
- Fadiga L, Buccino G, Craighero L, Fogassi L, Gallese V, Pavesi G. Corticospinal excitability is specifically modulated by motor imagery: a magnetic stimulation study. *Neuropsychologia*, 37 (2):147-58, 1999.
- Flor H, Elbert T, Knecht S, Wienbruch C, Pantev C, Birbaumer N, Larbig W, Taub E. Phantom-limb pain as a perceptual correlate of cortical reorganization following arm amputation. *Nature*, 375 (6531):482-4, 1995.
- Gaggioli A, Morganti F, Walker R, Meneghini A, Alcaniz M, Lozano JA, Montesa J, Gil JA, Riva G. Training with computer-supported motor imagery in post-stroke rehabilitation. *Cyberpsychol Behav*, 7 (3):327-32, 2004.
- Gagne M, Reilly KT, Hetu S, Mercier C. Motor control over the phantom limb in above-elbow amputees and its relationship with phantom limb pain. *Neuroscience*, 2009.
- Gandevia SC, Wilson LR, Inglis JT, Burke D. Mental rehearsal of motor tasks recruits alpha-motoneurons but fails to recruit human fusimotor neurons selectively. *J Physiol*, 505 (Pt 1) 259-66, 1997.

- Gerardin E, Sirigu A, Lehericy S, Poline JB, Gaymard B, Marsault C, Agid Y, Le Bihan D. Partially overlapping neural networks for real and imagined hand movements. *Cereb Cortex*, 10 (11):1093-104, 2000.
- Giraux P, Sirigu A. Illusory movements of the paralyzed limb restore motor cortex activity. *Neuroimage*, 20 Suppl 1 S107-11, 2003.
- Gregg M, Hall C, Butler A. The MIQ-RS: A Suitable Option for Examining Movement Imagery Ability. *Evid Based Complement Alternat Med*, 2007.
- Guillot A, Collet C. Duration of mentally simulated movement: a review. *J Mot Behav*, 37 (1):10-20, 2005.
- Guillot A, Lebon F, Rouffet D, Champely S, Doyon J, Collet C. Muscular responses during motor imagery as a function of muscle contraction types. *Int J Psychophysiol*, 66 (1):18-27, 2007.
- Hanakawa T, Immisch I, Toma K, Dimyan MA, Van Gelderen P, Hallett M. Functional properties of brain areas associated with motor execution and imagery. *J Neurophysiol*, 89 (2):989-1002, 2003.
- Harris AJ. Cortical origin of pathological pain. *Lancet*, 354 (9188):1464-6, 1999.
- Hashimoto R, Rothwell JC. Dynamic changes in corticospinal excitability during motor imagery. *Exp Brain Res*, 125 (1):75-81, 1999.
- Hugdahl K, Rosen G, Erslund L, Lundervold A, Smievoll AI, Barndon R, Thomsen T. Common pathways in mental imagery and pain perception: an fMRI study of a subject with an amputated arm. *Scand J Psychol*, 42 (3):269-75, 2001.
- Jeannerod M, Decety J. Mental motor imagery: a window into the representational stages of action. *Curr Opin Neurobiol*, 5 (6):727-32, 1995.
- Karl A, Birbaumer N, Lutzenberger W, Cohen LG, Flor H. Reorganization of motor and somatosensory cortex in upper extremity amputees with phantom limb pain. *J Neurosci*, 21 (10):3609-18, 2001.
- Knecht S, Henningsen H, Elbert T, Flor H, Hohling C, Pantev C, Taub E. Reorganizational and perceptual changes after amputation. *Brain*, 119 (Pt 4) 1213-9, 1996.
- Lacourse MG, Orr EL, Cramer SC, Cohen MJ. Brain activation during execution and motor imagery of novel and skilled sequential hand movements. *Neuroimage*, 27 (3):505-19, 2005.
- Lebon F, Rouffet D, Collet C, Guillot A. Modulation of EMG power spectrum frequency during motor imagery. *Neurosci Lett*, 435 (3):181-5, 2008.
- Lotze M, Flor H, Grodd W, Larbig W, Birbaumer N. Phantom movements and pain. An fMRI study in upper limb amputees. *Brain*, 124 (Pt 11):2268-77, 2001.
- Lotze M, Halsband U. Motor imagery. *J Physiol Paris*, 99 (4-6):386-95, 2006.
- Lotze M, Montoya P, Erb M, Hulsmann E, Flor H, Klose U, Birbaumer N, Grodd W. Activation of cortical and cerebellar motor areas during executed and imagined hand movements: an fMRI study. *J Cogn Neurosci*, 11 (5):491-501, 1999.
- Maclver K, Lloyd DM, Kelly S, Roberts N, Nurmikko T. Phantom limb pain, cortical reorganization and the therapeutic effect of mental imagery. *Brain*, 131 (Pt 8):2181-91, 2008.
- Malouin F, Richards CL, Desrosiers J, Doyon J. Bilateral slowing of mentally simulated actions after stroke. *Neuroreport*, 15 (8):1349-53, 2004.

- Malouin F, Richards CL, Durand A, Descent M, Poire D, Fremont P, Pelet S, Gresset J, Doyon J. Effects of Practice, Visual Loss, Limb Amputation, and Disuse on Motor Imagery Vividness. *Neurorehabil Neural Repair*, 2009.
- McCabe C. Mirror Visual Feedback Therapy. A Practical Approach. *J Hand Ther*, 2010.
- McCabe CS, Haigh RC, Blake DR. Mirror visual feedback for the treatment of complex regional pain syndrome (type 1). *Curr Pain Headache Rep*, 12 (2):103-7, 2008.
- McCabe CS, Haigh RC, Ring EF, Halligan PW, Wall PD, Blake DR. A controlled pilot study of the utility of mirror visual feedback in the treatment of complex regional pain syndrome (type 1). *Rheumatology (Oxford)*, 42 (1):97-101, 2003.
- Melzack R. Phantom limbs. *Sci Am*, 266 (4):120-6, 1992.
- Mercier C, Sirigu A. Training With Virtual Visual Feedback to Alleviate Phantom Limb Pain. *Neurorehabil Neural Repair*, 2009.
- Michielsen ME, Selles RW, van der Geest JN, Eckhardt M, Yavuzer G, Stam HJ, Smits M, Ribbers GM, Bussmann JB. Motor Recovery and Cortical Reorganization After Mirror Therapy in Chronic Stroke Patients: A Phase II Randomized Controlled Trial. *Neurorehabil Neural Repair*, 2010.
- Mitchell SW (1872) Injuries of nerves and their consequences. Philadelphia: J.B. Lippincott & Co.
- Murray CD, Pettifer S, Howard T, Patchick EL, Caillette F, Kulkarni J, Bamford C. The treatment of phantom limb pain using immersive virtual reality: three case studies. *Disabil Rehabil*, 29 (18):1465-9, 2007.
- Nico D, Daprati E, Rigal F, Parsons L, Sirigu A. Left and right hand recognition in upper limb amputees. *Brain*, 127 (Pt 1):120-32, 2004.
- Parsons LM. Temporal and kinematic properties of motor behavior reflected in mentally simulated action. *J Exp Psychol Hum Percept Perform*, 20 (4):709-30, 1994.
- Ramachandran VS, Hirstein W. The perception of phantom limbs. The D. O. Hebb lecture. *Brain*, 121 (Pt 9) 1603-30, 1998.
- Ramachandran VS, Rogers-Ramachandran D. Synaesthesia in phantom limbs induced with mirrors. *Proc Biol Sci*, 263 (1369):377-86, 1996.
- Ramsey R, Cumming J, Eastough D, Edwards MG. Incongruent imagery interferes with action initiation. *Brain Cogn*, 2010.
- Reilly KT, Mercier C, Schieber MH, Sirigu A. Persistent hand motor commands in the amputees' brain. *Brain*, 129 (Pt 8):2211-23, 2006.
- Roland PE, Larsen B, Lassen NA, Skinhoj E. Supplementary motor area and other cortical areas in organization of voluntary movements in man. *J Neurophysiol*, 43 (1):118-36, 1980.
- Rosen G, Hugdahl K, Erslund L, Lundervold A, Smievoll AI, Barndon R, Sundberg H, Thomsen T, Roscher BE, Tjolsen A, Engelsen B. Different brain areas activated during imagery of painful and non-painful 'finger movements' in a subject with an amputated arm. *Neurocase*, 7 (3):255-60, 2001.
- Roux FE, Ibarrola D, Lazorthes Y, Berry I. Virtual movements activate primary sensorimotor areas in amputees: report of three cases. *Neurosurgery*, 49 (3):736-41; discussion 41-2, 2001.

Roux FE, Lotterie JA, Cassol E, Lazorthes Y, Sol JC, Berry I. Cortical areas involved in virtual movement of phantom limbs: comparison with normal subjects. *Neurosurgery*, 53 (6):1342-52; discussion 52-3, 2003.

Sathian K, Greenspan AI, Wolf SL. Doing it with mirrors: a case study of a novel approach to neurorehabilitation. *Neurorehabil Neural Repair*, 14 (1):73-6, 2000.

Sirigu A, Duhamel JR. Motor and visual imagery as two complementary but neurally dissociable mental processes. *J Cogn Neurosci*, 13 (7):910-9, 2001.

Skoura X, Personnier P, Vinter A, Pozzo T, Papaxanthis C. Decline in motor prediction in elderly subjects: right versus left arm differences in mentally simulated motor actions. *Cortex*, 44 (9):1271-8, 2008.

Solodkin A, Hlustik P, Chen EE, Small SL. Fine modulation in network activation during motor execution and motor imagery. *Cereb Cortex*, 14 (11):1246-55, 2004.

Stephan KM, Fink GR, Passingham RE, Silbersweig D, Ceballos-Baumann AO, Frith CD, Frackowiak RS. Functional anatomy of the mental representation of upper extremity movements in healthy subjects. *J Neurophysiol*, 73 (1):373-86, 1995.

Stevens JA, Stoykov ME. Using motor imagery in the rehabilitation of hemiparesis. *Arch Phys Med Rehabil*, 84 (7):1090-2, 2003.

Wade NJ. Beyond body experiences: phantom limbs, pain and the locus of sensation. *Cortex*, 45 (2):243-55, 2009.

Wolpert DM, Ghahramani Z. Computational principles of movement neuroscience. *Nat Neurosci*, 3 Suppl 1212-7, 2000.

Yavuzer G, Selles R, Sezer N, Sutbeyaz S, Bussmann JB, Koseoglu F, Atay MB, Stam HJ. Mirror therapy improves hand function in subacute stroke: a randomized controlled trial. *Arch Phys Med Rehabil*, 89 (3):393-8, 2008.

Acknowledgment: E Raffin is funded by the French Ministry of Health (PHRC 2007 N°0701040).

Competing interests statement: the authors declare no competing interests.

5. Etude 2

« Réseaux cérébraux associés à l'exécution et l'imagerie motrice dans le membre fantôme »

5.1 Résumé

Problématique

Les amputés peuvent évoquer des mouvements volontaires avec leur membre fantôme. Ces «mouvements sans mouvements» sont le plus souvent considérés comme de l'imagerie motrice plutôt que de l'exécution motrice. Puisque ni l'exécution ni l'imagerie motrice ne produit de mouvement visible, nous faisons l'hypothèse que la différence perceptive entre ces deux tâches motrices repose sur l'activation de réseaux cérébraux distincts.

Matériels & Méthodes

L'activité cérébrale ainsi que les interactions entre deux régions motrices (Dynamic Causal Modeling, DCM) ont été caractérisées en Imagerie par Résonance Magnétique (IRMf) pendant des mouvements imaginés et exécutés des mains intactes et des mains fantômes auprès de 14 amputés du membre supérieur.

Résultats & Discussion

Les résultats de cette étude montrent que deux réseaux distincts, mais partiellement superposables, sont recrutés au cours de l'exécution motrice et de l'imagerie motrice avec le membre fantôme. En particulier, l'analyse en Région d'Intérêt a révélé que l'exécution motrice recrute davantage les aires sensorimotrices primaires et le lobe antérieur du cervelet, tandis que l'imagerie recrute davantage les lobes pariétaux et occipitaux ainsi que le lobe postérieur du cervelet. Dans les régions cérébrales communes, des dissociations anatomiques sont rapportées. Enfin, les résultats de l'analyse en DCM confirment également la dissociation neurophysiologique entre l'imagerie et exécution motrice dans le membre fantôme : les deux tâches motrices ont des effets opposés sur le réseau AMS ↔ M1. Cette étude montre pour la première fois, que le réseau cérébral activé lors des mouvements de membre fantôme est semblable à celui de l'exécution motrice « normale » et diffère du réseau activé par l'imagerie motrice. De plus, nos résultats

montrent que la capacité à bouger le membre fantôme est négativement corrélée à la variabilité de l'activité dans M1 lors de l'exécution de mouvements fantôme, ainsi qu'aux perturbations de la connectivité cérébrale au sein du réseau AMS \leftrightarrow M1. Ces altérations fonctionnelles sont en partie analogues aux mécanismes physiopathologiques mis en évidence dans d'autres altérations motrices. Enfin, l'exécution comme l'imagerie motrice sont de plus en plus utilisées, seules ou avec la restitution du rétrocontrôle visuel pour le traitement des douleurs neuropathiques. Étant donné le rôle clé de M1 dans le traitement des douleurs neuropathiques, et sa forte activité pendant l'exécution, nous suggérons que dans le cadre des thérapies visuomotrices chez l'amputé, l'exécution motrice serait plus efficace que l'imagerie motrice pour soulager les douleurs de membre fantôme.

(le matériel supplémentaire ainsi que les résultats supplémentaires figurent en annexe de ce document)

5.2 Article

Disentangling motor execution from motor imagery with the phantom limb

Running title: Phantom limb motor execution is not motor imagery

Estelle Raffin^{1,2}, Karen T. Reilly^{3,5}, Jérémie Mattout^{4,5} and Pascal Giraux^{1,2}

¹ Department of Physical Medicine and Rehabilitation, Faculty of Medicine, University Jean Monnet of Saint Etienne, F-42023 Saint-Etienne, France.

² INSERM U 879, Lyon Neuroscience Research Center, Central Integration of Pain Team, Saint-Etienne and Lyon, France

³ INSERM U1028, CNRS UMR5292, Lyon Neuroscience Research Center, ImpAct Team, Lyon, France

⁴ INSERM U1028, CNRS UMR5292, Lyon Neuroscience Research Center, Brain Dynamics and Cognition Team, Lyon, France

⁵ University of Lyon 1, Lyon, France

Corresponding authors:

Pascal GIRAUX

Service de Médecine Physique et de
Réadaptation,
Hôpital Bellevue, CHU de Saint-Etienne,
42055 Saint-Etienne
FRANCE
pascal.giroux@univ-st-etienne.fr

Karen T. REILLY

INSERM U1028, CNRS UMR5292
Lyon Neuroscience Research Centre
ImpAct Team
16, avenue Doyen Lépine
69500 Bron
FRANCE
karen.reilly@inserm.fr

Abstract:

Amputees can move their phantom limb at will. These ‘movements without movements’ have generally been considered as motor imagery rather than motor execution, but amputees can in fact perform both executed and imagined movements with their phantom. Since neither execution nor imagination produces any visible movement, we hypothesized that the perceptual difference between these two motor tasks relies on the activation of distinct cerebral networks. Using fMRI and changes in functional connectivity (dynamic causal modeling, DCM) we examined the activity associated with imagined and executed movements of the intact and phantom hands of 14 upper-limb amputees. Distinct but partially overlapping cerebral networks were active during both executed and imagined phantom limb movements. A Region of Interest analysis revealed a “switch” between Execution and Imagination; during Execution there was more activity in the primary sensorimotor cortex and the anterior lobe of the cerebellum, while during Imagination there was more activity in the parietal and occipital lobes, and the posterior lobe of the cerebellum. In overlapping areas, task-related differences were detected in the location of activation peaks. The DCM analysis further confirmed the presence of a clear neurophysiological distinction between Imagination and Execution, as motor imagery and motor execution had opposite effects on the SMA-M1 network. This is the first imaging evidence that the neurophysiological network activated during phantom limb movements is similar to that of executed movements of intact limbs and differs from the phantom limb imagination network. Both Execution and Imagination are increasingly used alone or in combination with visuomotor feedback for the treatment of neuropathic pain. Future studies investigating the efficacy of these techniques should closely monitor the task actually performed by the patients (Execution versus Imagination). Given the key role of M1 in neuropathic pain reduction, we suggest that movement execution and its associated activation of primary motor cortex (M1) might be more efficient for pain relief.

Key words: motor imagery; motor execution; phantom limb; motor control; fMRI

Introduction:

Amputees often continue to feel the presence of their missing limb and report that the phantom limb has certain sensory properties like touch and pain (Mitchell, 1872). The phantom limb may also be endowed with kinaesthetic properties like being able to be moved voluntarily (Jensen et al., 1983). Although scientists and medical doctors agree that the phantom arises from physiological changes that occur after amputation (Melzack, 1992, Ramachandran and Hirstein, 1998), many scientific papers assume that voluntary phantom limb movements are imaginary movements, and do not consider the possibility that they are 'real' movements without movement (e.g. Ersland et al., 1996, Hugdahl et al., 2001, Lotze et al., 2001).

Patients suffering from phantom limb pain are sometimes offered a form of rehabilitation that involves sensorimotor feedback training in which they see modified visual feedback of their missing limb using either mirrors (Ramachandran and Rogers-Ramachandran, 1996, Chan et al., 2007) or pre-recorded and flipped videos of movements of their intact hand (Giroux and Sirigu, 2003, Mercier and Sirigu, 2009). Our conversations with patients undergoing such therapy revealed that some of them spontaneously distinguish between executing and imagining a movement with the absent limb. Since neither execution nor imagination produces any overt movement we administered a series of behavioural tasks to assess the validity of these anecdotal reports and found that the distinct kinaesthetic sensations experienced during phantom limb execution and imagination were paralleled by performance differences (Raffin et al., 2011). Specifically, the time taken to execute a movement with the phantom limb was significantly different from that taken to imagine the same movement. We also found that the time to imagine a movement was similar for both the phantom and intact limbs, whereas motor execution with the phantom was substantially slower than with the intact limb. Together, these results suggest that amputees can perform motor execution and motor imagery with their phantom limb and that limb loss differentially affects these two tasks. Spinal cord injury patients also maintain the ability to perform motor imagery with paralysed body parts while at the same time experiencing modified kinaesthetic sensations during voluntary movements of their phantom limb (Hotz-Boendermaker et al., 2008). In contrast, a number of pathologies affecting either central or peripheral motor pathways lead to altered performance in both motor imagery and execution (Johnson, 2000, Fiorio et al., 2007, Helmich et al., 2007, Conson et al., 2008, Gieteling et al., 2008). In order to understand the differential effect of

amputation on motor imagery and motor execution processes it is essential to examine the neurophysiological networks underlying these two tasks.

A number of studies have examined the cerebral activity associated with phantom limb movements (Erslund et al., 1996, Hugdahl et al., 2001, Lotze et al., 2001, Rosen et al., 2001, Roux et al., 2001, Roux et al., 2003), but in most of these it is unclear whether amputees were asked to execute or imagine, and little (if any) detail is provided concerning the amputees' subjective movement perceptions. All of these studies, however, report activity in motor areas, such as the contralateral primary motor cortex (M1) and the supplementary motor area (SMA), which suggests that the default for amputees might be to make 'real' rather than imagined phantom limb movements. Further evidence that amputees perform motor execution by default comes from an fMRI study by Roux and colleagues who found that executed movements of healthy subjects and 'virtual movements' of amputees activated a similar network, and that this network differed from that activated during imagined movements of healthy subjects (Roux et al., 2003). Taken together, these studies suggest that phantom limb movements are similar to executed movements in healthy subjects and are not a form of motor imagery, but since imagined and executed movements of the phantom limb have never been directly compared using neuroimaging techniques the evidence for this argument remains indirect.

Studies of motor imagery in healthy subjects reveal that motor imagery systematically recruits premotor and parietal areas, as well as the cerebellum (e.g. Roland et al., 1980, Decety et al., 1994, Lotze et al., 1999b, Hanakawa et al., 2003). Some studies also show activity in visual areas, especially if subjects perform visual rather than kinaesthetic motor imagery (Kosslyn, 1999, Solodkin et al., 2004). Activity in M1 is frequently absent during motor imagery of upper limb movement (Decety et al., 1994, Stephan et al., 1995, Gerardin et al., 2000, Romero et al., 2000, Hanakawa et al., 2003, Meister et al., 2004, Hanakawa et al., 2008), and in the few studies that do show M1 activity during imagination there is considerably less activity during imagination than execution (Porro et al., 1996, Roth et al., 1996, Lotze et al., 1999b, Nair et al., 2003, Dechent et al., 2004). Thus, motor execution (without visual feedback) and motor imagery share a partially overlapping network, including parts of the SMA, the lateral premotor cortex, the posterior parietal cortex and the cerebellum. In healthy subjects the two tasks can be dissociated neurophysiologically by 1) the presence or absence of task-specific activity in certain areas; for

example, M1 during execution versus visual areas during imagination (Roland et al., 1980, Decety et al., 1994, Stephan et al., 1995, Gerardin et al., 2000, Hanakawa et al., 2003), and 2) the location of activity within common brain areas; for example, more caudal activations during execution than imagination within the lateral premotor cortex (Decety et al., 1994, Stephan et al., 1995, Grafton et al., 1996, Lotze et al., 1999b, Gerardin et al., 2000). Techniques examining the ‘effective connectivity’ networks underlying motor execution and motor imagery have also shown a neurophysiological dissociation between the two tasks (Solodkin et al., 2004, Chen et al., 2009, Gao et al., 2011). For example, a Dynamical Causal Modeling (DCM) study in normal subjects nicely illustrated that even though SMA is active during both imagination and execution, the functional connectivity between SMA and M1 differs during the two tasks, with a facilitatory effect during execution and an inhibitory effect during imagination (Kasess et al., 2008).

To date there is no data concerning the neurophysiological networks underlying executed (‘real’) and imagined phantom limb movements in amputees. Here, we used functional magnetic resonance imagery (fMRI) and DCM to investigate the cerebral networks recruited during execution and imagination with the phantom limb. We hypothesized that phantom limb execution and imagination would activate two distinct networks and that the functional connectivity between regions common to both networks would differ for the two tasks.

Methods:

Subjects:

14 upper limb amputees (2 females and 12 males), ranging in age from 18 to 68 years (mean age: 36.5, standard deviation (SD): 11.1) participated to the study. Amputation was caused by a traumatic accident 5 months to 30 years before testing (mean: 7.3 years, SD: 8.1). Thirteen were right-handed before the amputation, and there were 9 right amputations and 5 left amputations, 10 above the elbow and 4 below the elbow. All patients had no history of neurological or psychiatric disease; they were paid for their participation and full written consent was obtained from all subjects in accordance with the Declaration of Helsinki. The study was approved by the local ethic committee (A 09-115). Detailed subject characteristics are shown in Table 1.

Table 1: Clinical and phantom limb characteristics of each subject (*VAS: Visual Analogue Scale)

Subjects	Age (years)	Time since amputation (months)	Amputated side/ Dominant side	Amputation level (Proximal/Distal)	Phantom pain intensity (VAS*: 0- 10)	Prosthesis type (% time)	Phantom movement times (seconds)
1	40	102	R/R	P	4	myoelectric (100%)	33.4
2	22	38	R/R	P	6	No	21.4
3	33	204	R/R	D	3	esthetic (100%)	51.7
4	39	360	L/R	D	8	No	44.69
5	41	150	R/R	P	0	No	20.2
6	27	84	L/R	P	9	myoelectric (100%)	55.1
7	29	44	L/L	P	6	No	36.12
8	33	12	L/R	P	5	No	29.27
9	27	5	R/R	P	5	No	39.22
10	47	37	L/R	P	0	esthetic (100%)	13.5
11	55	12	R/R	P	6	mechanic (50%)	41.6
12	20	118	R/R	D	7	No	60.1
13	43	43	R/R	P	4	No	49.6
14	55	30	R/R	D	1	No	42.1

Experimental procedure:

The exam began with the collection of general clinical data related to the amputation and the phantom limb. To ensure that the execution and imagination tasks were correctly understood all subjects were provided with detailed instructions and underwent a short training session before entering the scanner in which the sensations of voluntary movement with the phantom were evaluated: amputees were required to execute with their phantom limb opposing each of the four fingertips to their thumb at a self-imposed pace and to repeat this sequence five times. The experimenter gave the go signal to indicate to the subject to start and the subject verbally indicated when they had imagined five movement cycles.

In addition to assessing the speed at which they could comfortably move the phantom without pain in the scanner, the aim of this training session was also to become familiar with imagined movements in both their intact and phantom limbs. Patients were instructed to feel themselves moving their hands and to use this imagery mode inside the scanner (kinaesthetic imagery).

fMRI task paradigm:

The fMRI experiment was conducted in the context of a conventional block-design in which subjects were required to execute a voluntary movement of the hand (Execution - 15 blocks) or imagine the same movement (Imagination - 15 blocks). Each hand was tested separately. Execution and Imagination blocks lasted 10 seconds and were fully randomized within the run with variable length inter-trial intervals (baselines) of between 5 and 15 seconds. Each block began by presenting a letter on the screen for 1 second to instruct the subject which task to perform in that block ("M" for "Movement" or "I" for "Imagination"). For each amputee, prior to testing we established the pace at which they could open and close their phantom hand without experiencing any pain. Some subjects could make five opening/closing movements within 10 seconds while others could only make two, and within each 10 second block beeps indicated the movement pace (every 2 seconds or every 5 seconds for example). This pace was kept constant for both Execution and Imagination blocks for a given hand and a given subject. Two consecutive 30-blocks runs were

acquired for both the intact and phantom limbs and the order in which the limbs were tested was counterbalanced across subjects. These runs were separated by a few minutes where subjects could relax without moving.

MRI scanning:

Data were obtained on a 1.5T Siemens Sonata MRI system. Functional images were acquired using a gradient echo, echoplanar imaging (EPI) sequence: TR (scan repeat time) = 3030 ms, TE = 60 ms, FOV = 220 mm, flip angle = 90°, matrix size 64 x 64, slice thickness = 6 mm, 28 transversal slices per scan. Because we recorded electromyographic activity from the arm muscles we imposed a gap of 378.75 ms between scans to obtain a brief period during which there was no scan-related artefact within the EMG signal. The imaged volume covered the whole brain. Functional scanning was always preceded by 15.5s of dummy scans to ensure tissue steady-state magnetization. Prior to obtaining the functional measurements, high resolution anatomical T1-weighted images were acquired using a 3D sequence (gradient-echo inversion recovery, repetition time 1600 ms, echo time 5 ms, matrix 256 x 256, field of view 220 x 220 mm²). Each fMRI exam was composed of 4 runs, and each run consisted of 210 scans.

Electromyography recordings:

During the fMRI scanning we monitored the activity of stump muscles on the amputated side (Triceps and Biceps for above-elbow amputees) and Extensor Digitorum Communis (EDC) and Flexor Digitorum Superficialis (FDS) for below-elbow amputees), and EDC and FDS on the intact side. Muscles were expected to be active during motor execution and inactive during motor imagery (Lotze et al., 1999b, Gerardin et al., 2000, Lafleur et al., 2002, Reilly et al., 2006). The absence of activity in these muscles during imagination compared to execution was taken as a sign that the subject had correctly performed the imagination task. For each muscle two silver-silver chloride surface electrodes of 10-mm diameter were positioned on the muscle with an inter-electrode distance (centre to centre) of 2 cm (with the skin previously shaved and/or cleaned with alcohol), and EMG was recorded using fMRI-compatible equipment (Ives et al., 1993, Hanakawa et al., 2003). The reference electrode was placed on the lateral epicondyle. EMG signals were amplified (x2000), recorded at a frequency of 1000 Hz, band pass filtered (20–400 Hz), and stored for off line analysis

using MATLAB® software. For each muscle we computed the mean activation level (root mean square, RMS) in each gap (378.75 ms period in which there was no scan-related artefact) and calculated the average for each condition. Separate one way ANOVAs were performed for each muscle with three conditions (rest, imagination, and execution) and post-hoc tests were conducted using Student's paired t-tests. The results are presented as means and standard deviations. The alpha level was set at $p < 0.05$.

fMRI analysis:

All fMRI analyses were performed in SPM8 (<http://www.fil.ion.ucl.ac.uk/spm/>).

Pre-processing of fMRI data:

The first five volumes of a session and the three last volumes (dummy images) were discarded from further analysis. All functional volumes were spatially realigned. As we had an inhomogeneous sample of patients in terms of side of amputation, data from patients with a right-side amputation were flipped, such that all patients were considered as 'left hand amputated' (same method in MacIver et al., 2008, Diers et al., 2010). To do this, the EPI mean images of each time series were flipped sagittally for the nine patients with a right-side amputation. Before pooling the data, we performed a random effect with a t-test analysis comparing flipped right hand amputees to the left hand amputees (unflipped) to check for the absence of hemisphere specific activation. This analysis revealed no differences between the two groups, which prompted us to proceed with a single group analysis. All EPI images were normalized to fit a symmetric EPI template, consistent with the Montreal Neurological Institute (MNI) reference brain provided by SPM. Finally, the normalized functional images ($2 \times 2 \times 2 \text{ mm}^3$) functional volumes were spatially smoothed by a Gaussian kernel of FWHM 8mm.

Single subject analysis:

We estimated the parameters of a general linear model for each participant to generate voxel-wise statistical parametric maps of brain activation. For each participant we constructed an fMRI design matrix by modelling the following regressors for each session: 'Execution', 'Imagination' (the two regressors being modelled as a 10s duration event at the onset of each trial of the

experimental task). The rest condition was included. The regressors were convolved with a canonical haemodynamic response function and the time series were high-pass filtered with a cut-off at 128 s. For each comparison of interest and for each subject, a contrast of parameter estimates was calculated in a voxel-wise manner to produce a “contrast image”. Contrasts were defined as follows: (i) execution of phantom/intact hand movements versus rest; (ii) imagination of phantom/intact hand movements versus rest, (iii) execution versus imagination of phantom/intact hand movements.

Group analysis:

The parameter estimates from this first-level analysis were then entered into a random (between-subject) effect analysis, and linear contrasts were used to identify responsive regions. Thresholded Z maps were obtained for Execution and Imagination, such that $P < 0.05$ (corrected for multiple comparisons at the cluster level using family-wise error (FWE) correction) and at $P < 0.001$ (uncorrected), respectively. A lower threshold was applied for Imagination to account for the fact that individual subjects used different motor imagery strategies which resulted in more widespread activations than for Execution.

fMRI analysis 1: An *a priori* region of interest analysis was performed. First, we anatomically defined two broad Regions of Interest (ROI) that we expected to distinguish between Execution and Imagination. The first ROI (primary sensory and motor cortices (SM1)) included the contralateral primary sensorimotor cortex (Brodmann Areas (BA) 1, 2, 3, 4). The second ROI (parieto-occipital (PO)) included the bilateral superior and inferior parietal cortex and the primary visual cortex (BA 5, 7, 39, 40 and 17, 18, 19). We chose this very large ROI because we expected that some amputees might encounter difficulties performing Kinaesthetic Imagery (KI) and perform Visual Imagery (VI) instead. Since these two types of motor imagery recruit different brain networks (Solodkin et al., 2004, Guillot et al., 2009), we chose a ROI that included areas specifically activated during visual imagery (primary (BA 17) and associative (BA 18 and 19) visual areas), as well as kinaesthetic imagery (bilateral inferior and superior parietal lobules (BA 5, 7, 39, 40)). All ROI analyses were performed on data normalized according to the number of voxels within each ROI.

For the cerebellum analysis we used pre-existing ROIs: the bilateral anterior lobe (Larsell's lobules I-III) and the bilateral posterior lobe (Larsell's lobules IV-X) of the cerebellum. The ROIs were

defined with WFU PickAtlas Tool Version 2.4 (ANSIR Laboratory, Wake forest University, <http://fmri.wfubmc.edu>). For each subject, the percentage of signal change in the four ROIs was calculated using MarsBar (<http://marsbar.sourceforge.net>) (Brett, 2002). The percentage of activated voxels was computed using a custom-built program implemented in MATLAB®. Wilcoxon tests were conducted using STATISTICA 8.0 (StatSoft, Inc.). Medians are reported with the range indicated in brackets.

fMRI analysis 2: We conducted the same analysis as Gerardin et al. (2000), who compared individual subject activation peaks in the antero-posterior axe during execution and imagination in normal subjects. Y Talairach coordinates for maximal activity in all individual maps associated with motor execution and motor imagery were computed for both limbs in several areas that were activated bilaterally during both tasks. These areas were the lateral premotor cortex (lateral part of BA6), the supplementary motor area (medial part of BA6), the inferior parietal cortex (BA 39 and 40) and the superior parietal cortex (BA 5 and 7). Wilcoxon paired tests ($p < 0.05$) were performed on Y coordinates to find differences between Imagination peak locations and Execution peak locations.

fMRI analysis 3: we used dynamic causal modelling (DCM) (Friston et al., 2003) to assess effective connectivity between the SMA and M1 during motor execution and motor imagination.

Definition of the Dynamic Causal Models:

An additional General Linear Model (GLM) was specially estimated for the DCM analysis in which two regressors were added to Execution and Imagination: PREPA was modelled as the 1-second-long period during which subjects were visually instructed about the task and BEEP corresponding to the auditory pacer for each movement. These two sensory stimulations were considered as the causal inputs to the network, while Execution and Imagination were taken as modulatory (contextual) factors.

Here, we specifically aimed to investigate the influences of Execution and Imagination on the reciprocal connections between SMA (bilateral) and M1 (contralateral) network. BOLD signal time courses were manually extracted from spherical shapes of 5 mm radius for the contralateral Primary Motor Cortex (M1-c) and 6 mm radius for the caudal part of the Supplementary Motor Area (SMA), for each subject (using the “eigenvariate” extraction tool in SPM8). All the subjects demonstrated activation in these regions. Sphere centres were set at the closest maxima within a

distance of 4 mm from the group peaks (individual map threshold, $P < 0.05$) from random effects analysis, and adjusted to the F contrast of each participant (see mean coordinates in supplementary Table 2).

All models included a direct and reciprocal connection between SMA and M1-c. We compared a large number of possible models using Bayesian model comparison and a factorial-like design in model space. The latter was first partitioned into three different families depending on the inputs given to the system (Penny et al., 2010). Family I included input BEEP only, family II included both inputs BEEP and PREPA while family III included PREPA only (see supplementary Figure 1-A). The target regions for each of those inputs family were chosen based on Kassess et al. (2008). In addition, each of the above model families was further partitioned into 7x7 modulatory families. The seven families (A-G) varied as a function of Execution's input locations whereas the seven families (1-7) varied as a function of Imagination's input locations, according to the pattern of models used in Kassess et al. (Kassess et al., 2008). This resulted in 147 different models (see supplementary Figure 1-B), fitted to all the data from $N = 14$ subjects. Each model was estimated separately for each of the two fMRI sessions and for both hemispheres.

Model selection and parameter testing:

As we expected some between-subject variability, we used a 'random effect' (RFX) approach to Bayesian Model Selection in order to compare model families and models within the best family (Stephan et al., 2009). Indeed, the RFX approach accounts for putative differences between subjects in the relative model evidence within each family (Stephan et al., 2009, Kassess et al., 2010, Stephan et al., 2010). Given the factorial nature of our design for model comparison, we could start by comparing the three families of sensory inputs over subjects and for each limb independently. Then, within the best family out of three, we compared families of contextual inputs (Execution or Imagination). Finally, having identified the best subset of models, we compared models within that subset based on their posterior and exceedance probabilities and proceeded with inference on model parameters across models and subjects using Bayesian Model Averaging (BMA). BMA uses the optimal family of models and computes a weighted average of each model parameter, where the weighting is given by the posterior probability for each model. Parameters resulting from the BMA analysis were considered as significant only if their posterior probabilities were significantly different from zero (one sample t-test $p < 0.05$).

Results:

A post-scan debriefing revealed that all amputees were aware of having performed two distinct tasks with both their intact and amputated limbs. This was supported by the EMG data which showed a significant increase in EMG activity in the monitored muscles (relative to baseline) during Execution but not during Imagination (see supplementary Figure 2 and supplementary data for statistical results).

Brain areas recruited during motor execution and motor imagery

The first step in the fMRI analysis was an individual first level analysis. For each subject the statistical maps obtained for the Execution and Imagination tasks corresponded roughly to the cerebral networks generally reported to be active during execution and imagination. Next we performed a random effect group analysis. The left panel of Figure 1 shows that for motor execution of both the intact and phantom limbs there were significant signal changes in the hand area of the contralateral primary motor cortex (M1-c), in the hand area of the contralateral primary somatosensory cortex (S1-c), in the contralateral lateral premotor areas, in the bilateral medial premotor areas, and in the ipsilateral anteromedial part of the cerebellum. The bilateral superior and inferior parietal areas were activated during intact limb execution, whereas only the inferior part of the bilateral parietal area was activated during phantom limb execution. The right panel of Figure 1 shows that for motor imagery of both limbs there were significant activations in the contralateral lateral premotor areas, in the bilateral medial premotor areas, and in the bilateral inferior parietal areas. The group results did not exhibit significant activation in M1-c during motor imagery, but seven subjects showed some activity for the phantom limb and six for the intact limb. Cerebellar activity during Imagination was more posterior and inferior (centred in Larsell's lobule H-VII) than during Execution (centred in Larsell's lobule H-IV).

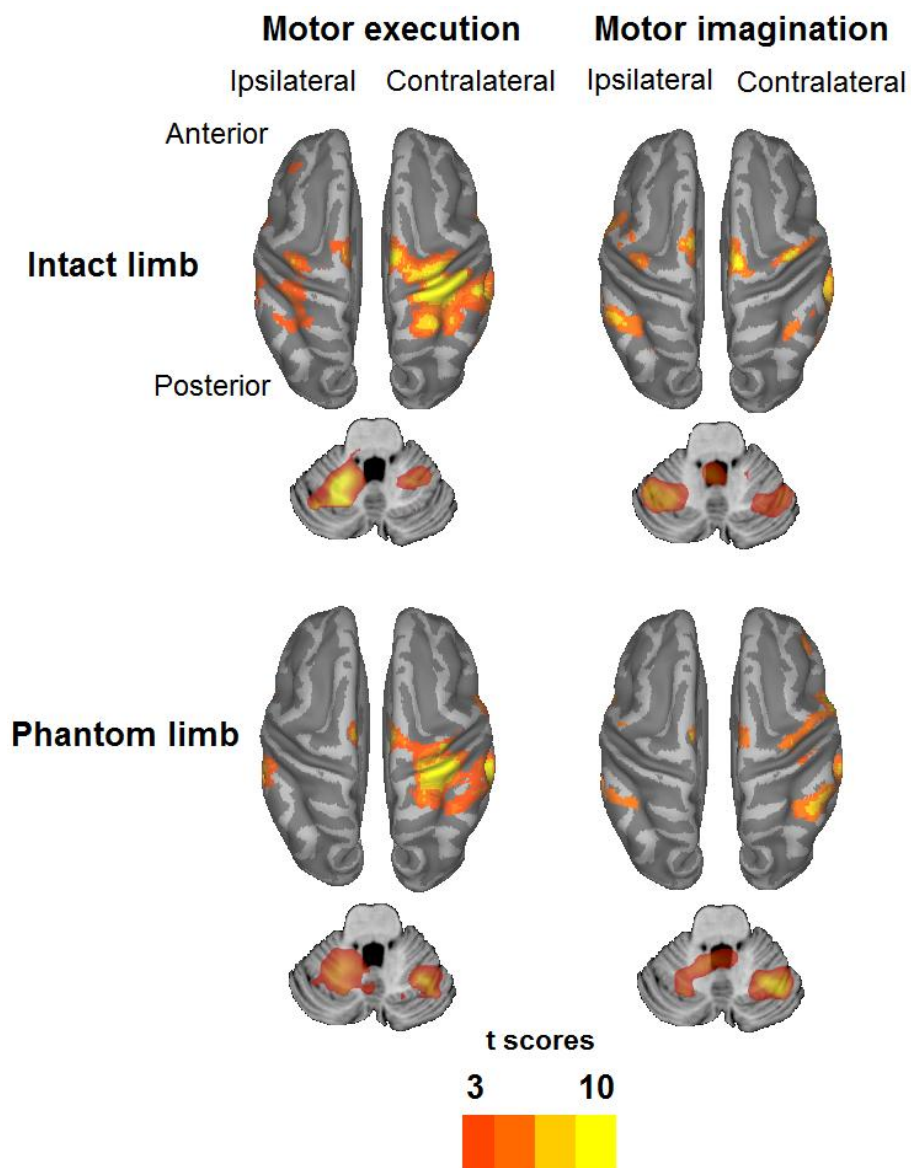


Figure 1: Group results during Execution ($P < 0.05$, FWE) and Imagination ($P < 0.001$, not corrected) for the intact and phantom limbs are overlaid on the PC-CC (PALS Cerebral, Colin Cerebellar) template that has been partially inflated with Caret 5.56 software (<http://brainmap.wustl.edu/caret/>). For both the intact and amputated limbs contralateral primary sensorimotor areas were strongly activated during Execution, whereas the premotor and parieto-occipital areas were predominantly activated during Imagination. In the cerebellum, Imagination activations were located in more posterior–inferior regions (centred in Larsell’s lobule H-VII) than those activated during Execution (centred in Larsell’s lobule H-IV).

While both networks included some common areas each was unique and could be clearly differentiated from the other. Notably, a group comparison between execution and imagination showed that for both limbs, M1-c, S1-c, the contralateral secondary somatosensory cortex (S2-c), and the ipsilateral anterior cerebellum were more active during execution than during imagination (Figure 2).

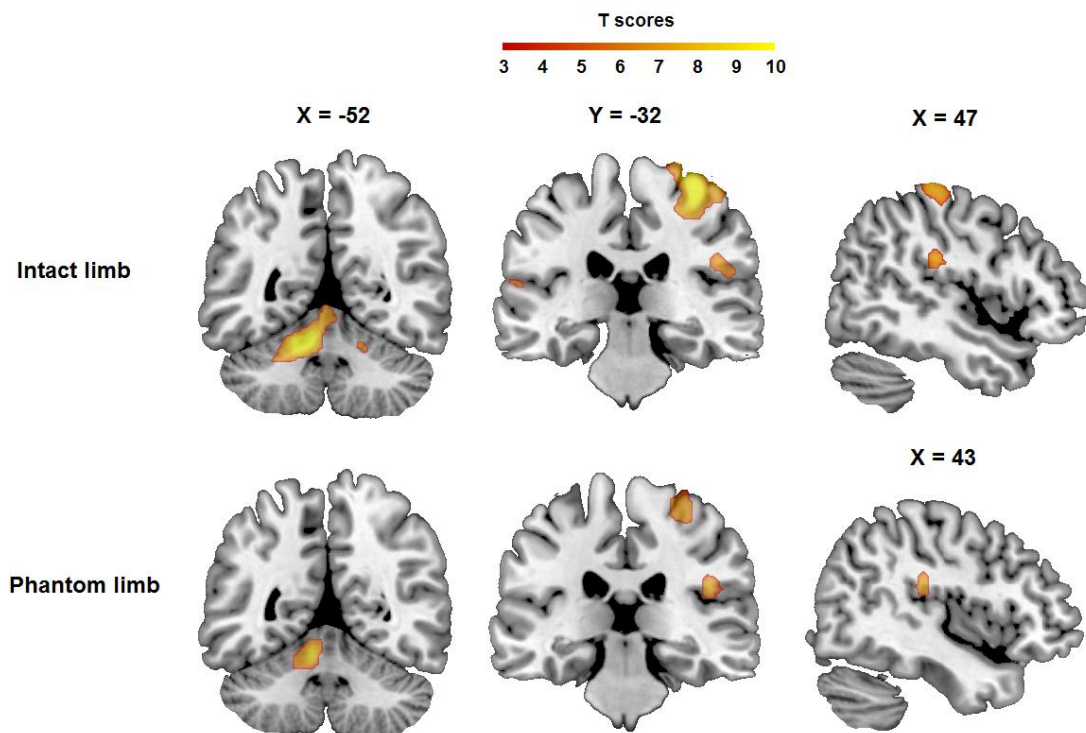


Figure 2: Group comparison between Execution and Imagination for the intact and the phantom limbs (two samples t tests, $p < 0.05$, corrected for multiple comparisons, FWE, with an inclusive mask at $p < 0.05$, uncorrected on the execution contrast). The contralateral primary sensorimotor cortex, the secondary somatosensory cortex (S2-c) and the ipsilateral anterior cerebellum were active during execution but not during imagination S2-c supplementary signal change was located in the parietal operculum (OP 1) based on cortical topography (Eickhoff et al., 2006).

While there were clear differences between Execution and Imagination for both hands, the network activated by each of these tasks did not appear to change according to which hand (phantom or intact) performed the task; a group comparison between phantom and intact limbs

revealed no differences between execution- or imagination- related activations (separate two sample t-tests $p < 0.05$ corrected for multiple comparisons, FWE).

In order to quantify the spatial distribution of activations associated with execution and imagery depicted in Figure 1 we conducted a complementary Region Of Interest (ROI) analysis. Figure 3 (A) shows that for both limbs the percentage of active voxels was significantly greater in the primary sensorimotor cortex (*SM1*) when amputees made an executed movement than when they imagined. In contrast, for the parietal and occipital lobes (*PO*), the imagination percentages were higher than the execution percentages. The same pattern of results was found for signal intensity (Figure 3B). We also examined whether a similar switch occurred in the cerebellum and found that for both limbs the percentage of activated voxels as well as the percentage of signal change were greater in the *anterior lobe* during execution compared with imagination (statistically significant), and in the posterior lobe during imagination compared with execution (non-significant) (Figure 3 C-D, see Supplementary Table 3).

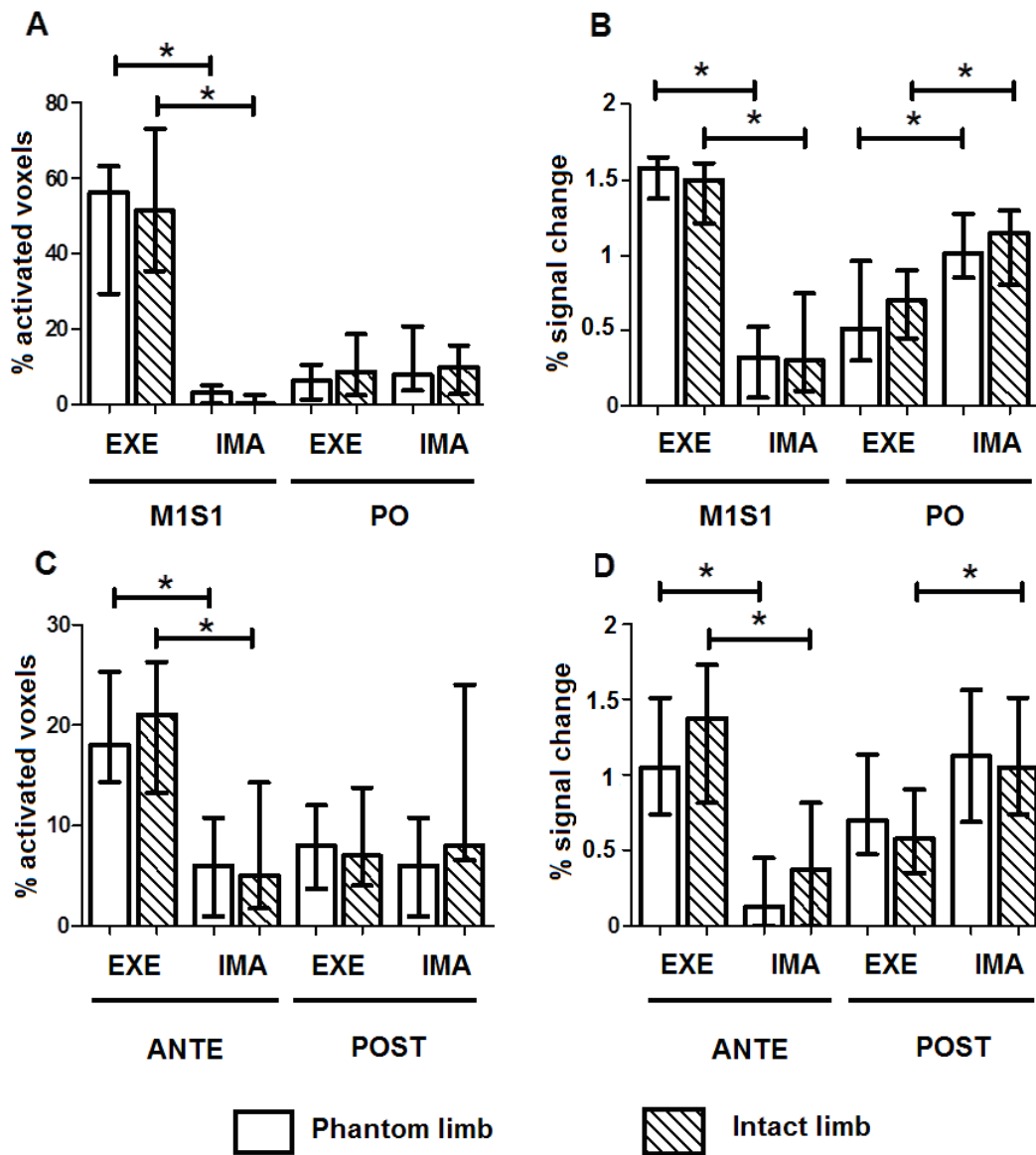


Figure 3 (A): Percentage of activated voxels (B): Percentage of signal change in the contralateral primary sensorimotor cortex (SM1) and in the bilateral parieto-occipital cortex (PO), during Execution and Imagination with the intact and phantom limbs (C): Percentage of activated voxels, (D): Percentage of signal change in the anterior (CB-ANT) and posterior (CB-POST) lobes of the cerebellum during Execution and Imagination with the intact and phantom limbs.

Differences between execution and imagination within common brain areas and changes in the interactions within cortical networks:

For those brain areas that were activated during both motor execution and imagination we calculated the Y coordinates of the maximal activity associated with each task and each limb for all individual maps. In those common brain areas the activation peaks for each task often formed two separate clusters. Compared with execution, activation peaks during imagination were situated in more anterior parts of the SMA and the lateral premotor area (BA6), and in more posterior parts of the parietal areas (BA 5-7, 39-40) (Figure 4 and supplementary table 4).

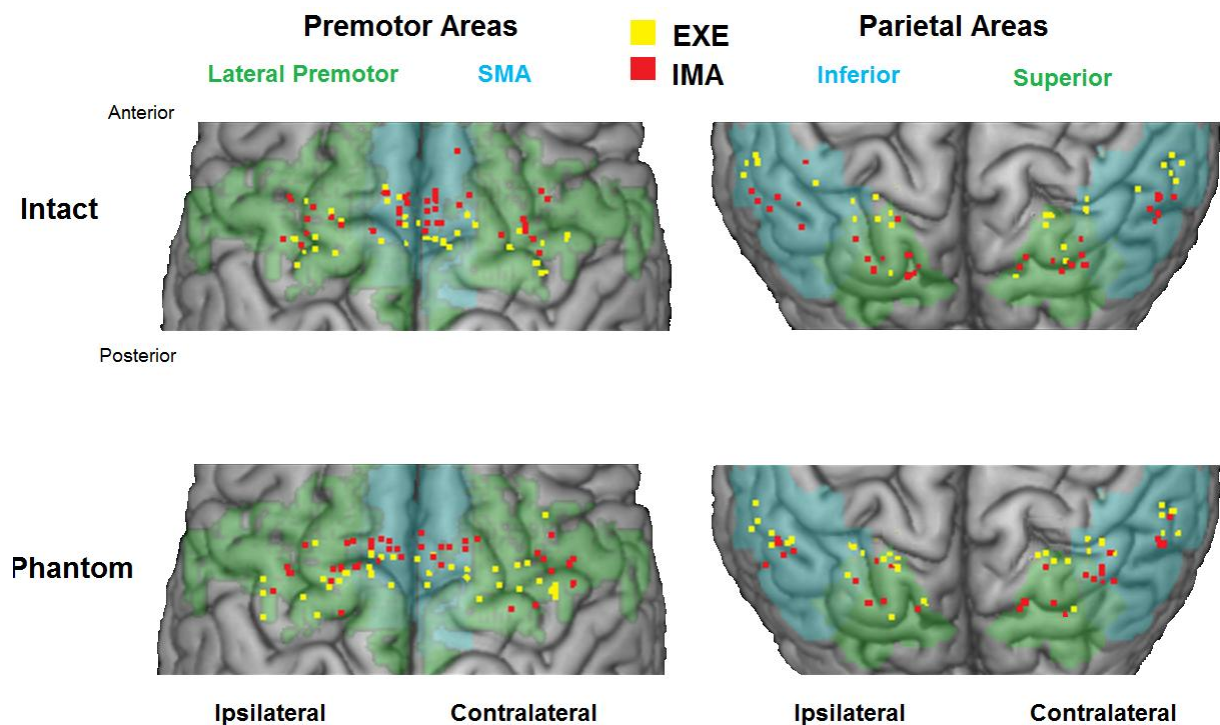


Figure 4: 3D coordinates in Talairach space of the intact limb (upper row) and phantom limb (lower row) activation peaks mapped onto the Ch2better template using MRICron (www.sph.sc.edu/comd/rorden/mricron/) in the supplementary motor area (SMA), the lateral premotor cortex (PM), and the superior and inferior parietal lobes (Sup PAR, Inf PAR). Activations during Imagination were more rostral than during Execution in the SMA and PM cortices (mean Y Talairach coordinates for maximal activity in all subject), but were more posterior in the parietal lobes.

In agreement with the conventional brain activation analyses described above, the results of our DCM analysis also showed a dissociation between Imagination and Execution in the form of a switch in effective connectivity within the network composed of the SMA proper and M1 contralateral to the moving hand. Imagination always exerted a negative (suppressive) influence on the network (mean significant Bayesian model averaging (BMA) parameters for the phantom limb: -0.05 [SD=0.11] and for the intact limb: -0.59 [SD=0.1]). In contrast, execution inputs always showed a positive (enhancing) effect on the system (mean BMA parameters for the phantom limb: 0.05 [SD=0.05] and for the intact limb: 0.89 [SD=0.06]) (one sample t-test, $p < 0.05$) (Figure 5).

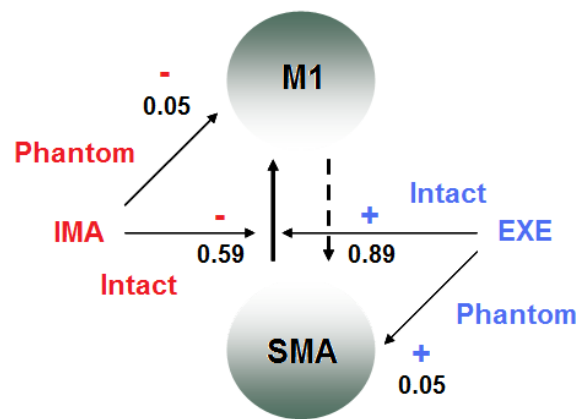


Figure 5: Functional connectivity results. 147 dynamic causal models were defined separately and estimated separately for each hemisphere of the 14 upper-limb amputees using standard procedures in SPM8. All forward and backward connections were specified but only the significant ($P < 0.05$) modulatory effects of motor execution (EXE) in blue and motor imagination (IMA) in red are illustrated. The values on each connection refer to the strengths of modulatory effects expressed by the BMA parameters (in hertz). For the intact limb, Imagination and Execution exert opposite weights on the SMA/M1-c connection. For the phantom hand Imagination and Execution also exert opposite weights, but this time the influence is directly on M1-c and SMA

While the suppressive effect of imagination and enhancing effect of execution was present for both intact and phantom limb movements the DCM analysis revealed several subtle differences between the effective connectivity patterns for phantom and intact limbs. During intact limb

movements (both imagined and executed) the network was modulated at the level of the connection between SMA and M1, whereas during phantom limb movements the modulation directly affected either M1 (imagined) or SMA (executed). Furthermore, the modulation recorded during both phantom limb tasks was weaker than with the intact limb. Additional DCM analyses (not shown in Figure 5) revealed that the reciprocal paths linking the M1-c and SMA regions, (which can be thought of as models of bottom-up (M1-c to SMA) and top-down (SMA to M1-c) control) differed between the intact and phantom limbs. While the bottom-up and top-down modulations were nearly equal for the intact limb (mean BMA parameters for the M1-c to SMA connection: 0.23 [SD=0.09] and for the SMA to M1-c connection: 0.27 [SD=0.04]), this was not the case for the phantom limb in which the top-down connection strength was greater (mean BMA parameters: 0.09 [SD=0.18] and 0.93 [SD=0.59] (see supplementary DCM results, Table 8). To investigate whether the unequal connection strengths between M1-c→SMA and SMA→M1-c for the phantom hand were related to the limited ability of amputees to make voluntarily phantom limb movements we correlated an objective measure of phantom limb motor control (time to execute the finger-to-thumb opposition task) with the difference between the neural coupling rates between SMA→M1-c and M1-c→SMA. There was a significant positive correlation between the difference in coupling rates and phantom limb movement times ($r=0.70$, $p=0.006$); the greater the imbalance the slower the movement time. In a separate analysis we correlated the voxel-wise activation levels for each subject during motor execution with the phantom limb, with the time to execute the finger-to-thumb opposition task. This revealed significant negative correlations between movement time and activity in M1-c: the greater the activity, the faster the movement (M1-c correlation cluster: $k=85$, p (Small Volume Corrected) <0.002 , mean $r = -0.74$); as well as positive correlations between movement time and activity in contralateral SMA: the greater the activity the slower the movement (SMA correlation cluster: $k=59$, p (SVC) <0.003 , mean $r=0.8$).

Discussion:

This study provides the first physiological evidence that amputees perform two distinct tasks when executing and imagining a movement with their phantom limb. We show that Imagination and Execution activate two distinct brain networks that partially overlap, and that these networks are similar to those activated during Imagination and Execution with the intact

limb. We also show that motor execution with both the phantom and intact limbs recruits brain areas typically activated during movement execution in healthy subjects, including the primary sensorimotor cortex, the supplementary motor area, the lateral premotor cortex, and the cerebellum (e.g. Grafton et al., 1996, Gerardin et al., 2000). These findings are consistent with previous amputee studies in which movements of the phantom limb activated a network similar to the one activated by contralateral intact limb movements (Erland et al., 1996, Lotze et al., 2001, Roux et al., 2003), and reinforce the idea that movement execution with the phantom limb is not a form of motor imagery. Further evidence that executed and imagined phantom movements are two distinct tasks comes from our finding that phantom and intact hand Imagination recruited brain areas typically recruited during motor imagery in healthy subjects; the inferior and superior parietal lobules, the supplementary motor area, the lateral premotor cortex, and the cerebellum (e.g. Gerardin et al., 2000, Naito et al., 2002, Nair et al., 2003). Our DCM analysis further supports the idea that there is a clear neurophysiological distinction between Imagination and Execution in amputees, as it shows that each task (regardless of hand) had an opposite effect on the SMA-M1 network. Furthermore, the direction of this effect was identical to that reported by effective connectivity studies in healthy subjects; a suppressive influence of motor imagery and an enhancing influence of motor execution (e.g. Solodkin et al., 2004, Kasess et al., 2008).

While the networks activated by Imagination and Execution were distinct they did share some common brain areas. Interestingly, the location of the activation peaks within these common brain areas depended on the task (Imagination or Execution) but was similar for both hands (phantom or intact). Compared with Execution, activation peaks recorded during Imagination were more rostral in the SMA and the dorsolateral premotor cortex, and more posterior in the inferior and superior parietal lobes. A similar spatial dissociation within these areas has been reported in studies examining imagination and execution in healthy subjects (Stephan et al., 1995, Lotze et al., 1999b, Gerardin et al., 2000, Hanakawa et al., 2003).

There are a number of previous studies showing that phantom and intact limb Execution activate similar networks, but this is the first to show that phantom and intact limb Imagination activate similar brain areas, and that the phantom limb motor imagery network is preserved even in long-term deafferented patients. This is consistent with the finding that Spinal Cord Injury patients have an intact Imagination network (Hotz-Boendermaker et al., 2008), and with our recent behavioural results in amputees showing no performance differences between the intact and

amputated hands on motor imagery tasks (Raffin et al., 2011). While the similarity between the phantom and intact limb Execution networks replicates the results of previous studies, it appears to contradict the results of neuroimaging studies demonstrating asymmetries in movement-related activity in the primary sensorimotor cortices of amputees. Such asymmetries are, however, primarily due to an enlargement and displacement of activations associated with stump and face movements (Lotze et al., 1999a, Karl et al., 2001, Lotze et al., 2001, Karl et al., 2004). Thus, the similarity between our Execution networks for the intact and phantom hands is not inconsistent with the presence of post-amputation reorganisation. Instead, it supports the idea that the hand's representation maintains its original position within M1 despite the reorganisation of other body part representations (Erslund et al., 1996, Roux et al., 2001, Roux et al., 2003, Mercier et al., 2006).

While amputation-related reorganisation does not necessarily lead to the expectation of asymmetries between intact and phantom hand Execution networks, some asymmetries could be expected given the difficulty that amputees experience when trying to move their phantom hand. Despite the fact that the speed and range of motion of phantom hand movements is limited compared with the intact hand (Raffin et al., 2011), our comparison between the amputated and the intact sides did not reveal any statistical difference between the two networks at the level of the group. This was somewhat surprising, as phantom movements are generally considered to be more effortful than intact hand movements (Ramachandran and Rogers-Ramachandran, 1996, Gagne et al., 2009b, Raffin et al., 2011). However, we found no between-side differences in the intensity or area of movement-related activations, particularly in the caudal-SMA and in various parietal areas (Deiber et al., 1991, Grafton et al., 1992, Winstein et al., 1997), suggesting that our subjects exerted similar levels of effort when making intact and phantom hand movements. This might have been due to the fact that phantom and intact hand movements were performed at the same pace, defined as the speed at which opening-closing movements of the phantom hand were comfortable, required little effort, and did not cause any pain.

Although we did detect no between-limb differences during Execution for the group, the between-subject variability in M1 activity levels during phantom hand movements depended upon their ability to move their phantom hand. The correlation analyses revealed a significant negative correlation between the time to perform the finger opposition task and the overall level of activity in M1-c as well as a positive correlation with the SMA-c activity level. If we consider the speed of finger-to-thumb opposition with the phantom as an indirect indicator of the ease/difficulty of

moving the phantom limb, the correlation with M1-c activity level suggests that the easier it is for an amputee to move their phantom the greater the activity level in M1-c. Similarly, the positive correlation with SMA-c suggests that the more difficult it is to move the phantom the greater the activity in SMA-c. This correlation is consistent with reports showing over-activity in premotor areas in a motor deficits associated with movement difficulties (e.g. in stroke patients Chollet et al., 1991, Grefkes et al., 2008). Thus, in patients with motor deficiencies, over-activity in SMA might reflect a compensatory phenomenon in which M1 receives a sustained input from premotor cortex which acts to increase the probability of “triggering” a movement. This hypothesis is supported by our effective connectivity analysis, which demonstrated differences in the connectivity between SMA and M1-c for the phantom limb compared to the intact limb, as well as a significant correlation between reciprocal connection strengths and the ability to voluntarily move the phantom. This parallels the activity and connectivity imbalance between motor areas recently reported in chronic stroke patients with an upper-limb motor deficiency (see for a review Grefkes and Fink, 2011) and in other central neurological motor deficits like Amyotrophic Lateral Sclerosis (Agosta et al., 2011), Parkinson’s disease (Rowe et al., 2010), or multiple sclerosis (Rocca et al., 2007b). The results of these studies contribute to the idea that a major pathophysiological aspect of motor impairment after central lesions arises from pathological interactions among key motor regions. Our findings, in accordance with an earlier report on 2 patients who underwent a unilateral heterotopic hand replantation (Eickhoff et al., 2008), suggest that part of the motor impairments subsequent to peripheral lesions might also result from pathological interactions among key motor regions.

Clinical implications:

Our demonstration that Executed and Imagined phantom limb movements activate two distinct cerebral networks is of particular importance given the increasing interest in treating neuropathic pain using various combinations of visuomotor feedback, voluntary movements, and motor imagery (e.g. Ramachandran and Rogers-Ramachandran, 1996, Moseley, 2006, Chan et al., 2007, Murray et al., 2007, Mercier and Sirigu, 2009, Beaumont et al., 2011). Despite the increasing number of such studies, the evidence is too sparse (and sometimes conflicting) to conclude whether or not these techniques are effective.

It is now clear that M1 plays a key role in reducing neuropathic pain. Evidence for this comes from several sources, including studies using implanted (e.g Saitoh and Yoshimine, 2007) or non invasive stimulation (e.g. O'Connell et al., 2010), and the fact that M1 stimulation can enhance the endogenous opioid system (Maarrawi et al., 2007). The link between M1 and pain also appears to be present in amputees, as those with more phantom limb pain are less able to move their phantom (Gagné et al., 2009, Raffin et al., 2011), and those with poorer phantom motor control have lower M1-c activity levels (present results). This link is further supported by the finding that phantom pain can be reduced and M1 (re)activated after visuomotor training (Giraux and Sirigu, 2003). Together, these results suggest that effective pain relief treatments should probably use behavioural tasks that recruit M1. There is, however, some (weak) evidence that motor imagery alone can effectively treat neuropathic pain (MacIver et al., 2008, Coslett et al., 2010b, McAvinue and Robertson, 2011). Since M1 activation during motor imagery in both amputees and normal subjects is weak and inconsistent (Porro et al., 1996, Roth et al., 1996, Lotze et al., 1999b, Nair et al., 2003, Dechent et al., 2004) the physiological mechanisms underlying pain relief from motor imagery probably involve structures other than M1(e.g. the sensory thalamus, (see for a review Levy et al., 2010)). We suggest that future studies investigating the efficacy of behavioural techniques for pain reduction should closely monitor the motor task actually performed by the patients (Execution versus Imagination) and should include functional imaging in order to clarify the physiological mechanisms underlying their analgesic effects.

REFERENCES

- Agosta F, Valsasina P, Absinta M, Riva N, Sala S, Prella A, Copetti M, Comola M, Comi G, Filippi M. Sensorimotor Functional Connectivity Changes in Amyotrophic Lateral Sclerosis. *Cereb Cortex*, 2011.
- Beaumont G, Mercier C, Michon PE, Malouin F, Jackson PL. Decreasing Phantom Limb Pain Through Observation of Action and Imagery: A Case Series. *Pain Med*, 2011.
- Brett M, Anton J.L., Valabregure R., Poline J.B. (2002) Region of interest analysis using SPM toolbox. In: 8th International Conference on Functional Mapping of the Human Brain Sendai, Japan: NeuroImage.
- Chan BL, Witt R, Charrow AP, Magee A, Howard R, Pasquina PF, Heilman KM, Tsao JW. Mirror therapy for phantom limb pain. *N Engl J Med*, 357 (21):2206-7, 2007.

- Chen H, Yang Q, Liao W, Gong Q, Shen S. Evaluation of the effective connectivity of supplementary motor areas during motor imagery using Granger causality mapping. *Neuroimage*, 47 (4):1844-53, 2009.
- Chollet F, DiPiero V, Wise RJ, Brooks DJ, Dolan RJ, Frackowiak RS. The functional anatomy of motor recovery after stroke in humans: a study with positron emission tomography. *Ann Neurol*, 29 (1):63-71, 1991.
- Conson M, Sacco S, Sara M, Pistoia F, Grossi D, Trojano L. Selective motor imagery defect in patients with locked-in syndrome. *Neuropsychologia*, 46 (11):2622-8, 2008.
- Coslett HB, Medina J, Kliot D, Burkey AR. Mental motor imagery indexes pain: the hand laterality task. *Eur J Pain*, 14 (10):1007-13, 2010.
- Decety J, Perani D, Jeannerod M, Bettinardi V, Tadary B, Woods R, Mazziotta JC, Fazio F. Mapping motor representations with positron emission tomography. *Nature*, 371 (6498):600-2, 1994.
- Dechent P, Merboldt KD, Frahm J. Is the human primary motor cortex involved in motor imagery? *Brain Res Cogn Brain Res*, 19 (2):138-44, 2004.
- Deiber MP, Passingham RE, Colebatch JG, Friston KJ, Nixon PD, Frackowiak RS. Cortical areas and the selection of movement: a study with positron emission tomography. *Exp Brain Res*, 84 (2):393-402, 1991.
- Diers M, Christmann C, Koeppe C, Ruf M, Flor H. Mirrored, imagined and executed movements differentially activate sensorimotor cortex in amputees with and without phantom limb pain. *Pain*, 149 (2):296-304, 2010.
- Eickhoff SB, Amunts K, Mohlberg H, Zilles K. The human parietal operculum. II. Stereotaxic maps and correlation with functional imaging results. *Cereb Cortex*, 16 (2):268-79, 2006.
- Eickhoff SB, Dafotakis M, Grefkes C, Shah NJ, Zilles K, Piza-Katzer H. Central adaptation following heterotopic hand replantation probed by fMRI and effective connectivity analysis. *Exp Neurol*, 212 (1):132-44, 2008.
- Ersland L, Rosen G, Lundervold A, Smievoll AI, Tillung T, Sundberg H, Hugdahl K. Phantom limb imaginary fingertapping causes primary motor cortex activation: an fMRI study. *Neuroreport*, 8 (1):207-10, 1996.
- Fiorio M, Tinazzi M, Ionta S, Fiaschi A, Moretto G, Edwards MJ, Bhatia KP, Aglioti SM. Mental rotation of body parts and non-corporeal objects in patients with idiopathic cervical dystonia. *Neuropsychologia*, 45 (10):2346-54, 2007.
- Friston KJ, Harrison L, Penny W. Dynamic causal modelling. *Neuroimage*, 19 (4):1273-302, 2003.
- Gagne M, Reilly KT, Hetu S, Mercier C. Motor control over the phantom limb in above-elbow amputees and its relationship with phantom limb pain. *Neuroscience*, 162 (1):78-86, 2009.
- Gao Q, Duan X, Chen H. Evaluation of effective connectivity of motor areas during motor imagery and execution using conditional Granger causality. *Neuroimage*, 54 (2):1280-8, 2011.
- Gerardin E, Sirigu A, Lehericy S, Poline JB, Gaymard B, Marsault C, Agid Y, Le Bihan D. Partially overlapping neural networks for real and imagined hand movements. *Cereb Cortex*, 10 (11):1093-104, 2000.

- Gieteling EW, van Rijn MA, de Jong BM, Hoogduin JM, Renken R, van Hilten JJ, Leenders KL. Cerebral activation during motor imagery in complex regional pain syndrome type 1 with dystonia. *Pain*, 134 (3):302-9, 2008.
- Giraux P, Sirigu A. Illusory movements of the paralyzed limb restore motor cortex activity. *Neuroimage*, 20 Suppl 1 S107-11, 2003.
- Grafton ST, Arbib MA, Fadiga L, Rizzolatti G. Localization of grasp representations in humans by positron emission tomography. 2. Observation compared with imagination. *Exp Brain Res*, 112 (1):103-11, 1996.
- Grafton ST, Mazziotta JC, Woods RP, Phelps ME. Human functional anatomy of visually guided finger movements. *Brain*, 115 (Pt 2) 565-87, 1992.
- Grefkes C, Eickhoff SB, Nowak DA, Dafotakis M, Fink GR. Dynamic intra- and interhemispheric interactions during unilateral and bilateral hand movements assessed with fMRI and DCM. *Neuroimage*, 41 (4):1382-94, 2008.
- Grefkes C, Fink GR. Reorganization of cerebral networks after stroke: new insights from neuroimaging with connectivity approaches. *Brain*, 2011.
- Guillot A, Collet C, Nguyen VA, Malouin F, Richards C, Doyon J. Brain activity during visual versus kinesthetic imagery: an fMRI study. *Hum Brain Mapp*, 30 (7):2157-72, 2009.
- Hanakawa T, Dimyan MA, Hallett M. Motor planning, imagery, and execution in the distributed motor network: a time-course study with functional MRI. *Cereb Cortex*, 18 (12):2775-88, 2008.
- Hanakawa T, Immisch I, Toma K, Dimyan MA, Van Gelderen P, Hallett M. Functional properties of brain areas associated with motor execution and imagery. *J Neurophysiol*, 89 (2):989-1002, 2003.
- Helmich RC, de Lange FP, Bloem BR, Toni I. Cerebral compensation during motor imagery in Parkinson's disease. *Neuropsychologia*, 45 (10):2201-15, 2007.
- Hotz-Boendermaker S, Funk M, Summers P, Brugger P, Hepp-Reymond MC, Curt A, Kollias SS. Preservation of motor programs in paraplegics as demonstrated by attempted and imagined foot movements. *Neuroimage*, 39 (1):383-94, 2008.
- Hugdahl K, Rosen G, Erslund L, Lundervold A, Smievoll AI, Barndon R, Thomsen T. Common pathways in mental imagery and pain perception: an fMRI study of a subject with an amputated arm. *Scand J Psychol*, 42 (3):269-75, 2001.
- Ives JR, Warach S, Schmitt F, Edelman RR, Schomer DL. Monitoring the patient's EEG during echo planar MRI. *Electroencephalogr Clin Neurophysiol*, 87 (6):417-20, 1993.
- Jensen TS, Krebs B, Nielsen J, Rasmussen P. Phantom limb, phantom pain and stump pain in amputees during the first 6 months following limb amputation. *Pain*, 17 (3):243-56, 1983.
- Johnson SH. Imagining the impossible: intact motor representations in hemiplegics. *Neuroreport*, 11 (4):729-32, 2000.
- Karl A, Birbaumer N, Lutzenberger W, Cohen LG, Flor H. Reorganization of motor and somatosensory cortex in upper extremity amputees with phantom limb pain. *J Neurosci*, 21 (10):3609-18, 2001.

- Karl A, Muhl nickel W, Kurth R, Flor H. Neuroelectric source imaging of steady-state movement-related cortical potentials in human upper extremity amputees with and without phantom limb pain. *Pain*, 110 (1-2):90-102, 2004.
- Kasess CH, Stephan KE, Weissenbacher A, Pezawas L, Moser E, Windischberger C. Multi-subject analyses with dynamic causal modeling. *Neuroimage*, 49 (4):3065-74, 2010.
- Kasess CH, Windischberger C, Cunnington R, Lanzenberger R, Pezawas L, Moser E. The suppressive influence of SMA on M1 in motor imagery revealed by fMRI and dynamic causal modeling. *Neuroimage*, 40 (2):828-37, 2008.
- Kosslyn SMP-LAFOCSKJTWGG, Sukel K. E. Alpert N. M. The role of area 17 in visual imagery: convergent evidence from PET and rTMS. *Science*, 284 167-70, 1999.
- Lafleur MF, Jackson PL, Malouin F, Richards CL, Evans AC, Doyon J. Motor learning produces parallel dynamic functional changes during the execution and imagination of sequential foot movements. *Neuroimage*, 16 (1):142-57, 2002.
- Levy R, Deer TR, Henderson J. Intracranial neurostimulation for pain control: a review. *Pain Physician*, 13 (2):157-65, 2010.
- Lotze M, Flor H, Grodd W, Larbig W, Birbaumer N. Phantom movements and pain. An fMRI study in upper limb amputees. *Brain*, 124 (Pt 11):2268-77, 2001.
- Lotze M, Grodd W, Birbaumer N, Erb M, Huse E, Flor H. Does use of a myoelectric prosthesis prevent cortical reorganization and phantom limb pain? *Nat Neurosci*, 2 (6):501-2, 1999a.
- Lotze M, Montoya P, Erb M, Hulsmann E, Flor H, Klose U, Birbaumer N, Grodd W. Activation of cortical and cerebellar motor areas during executed and imagined hand movements: an fMRI study. *J Cogn Neurosci*, 11 (5):491-501, 1999b.
- Maarrawi J, Peyron R, Mertens P, Costes N, Magnin M, Sindou M, Laurent B, Garcia-Larrea L. Motor cortex stimulation for pain control induces changes in the endogenous opioid system. *Neurology*, 69 (9):827-34, 2007.
- MacIver K, Lloyd DM, Kelly S, Roberts N, Nurmikko T. Phantom limb pain, cortical reorganization and the therapeutic effect of mental imagery. *Brain*, 131 (Pt 8):2181-91, 2008.
- McAvinue LP, Robertson IH. Individual differences in response to phantom limb movement therapy. *Disabil Rehabil*, 2011.
- Meister IG, Krings T, Foltys H, Boroojerdi B, Muller M, Topper R, Thron A. Playing piano in the mind--an fMRI study on music imagery and performance in pianists. *Brain Res Cogn Brain Res*, 19 (3):219-28, 2004.
- Melzack R. Phantom limbs. *Sci Am*, 266 (4):120-6, 1992.
- Mercier C, Reilly KT, Vargas CD, Aballea A, Sirigu A. Mapping phantom movement representations in the motor cortex of amputees. *Brain*, 129 (Pt 8):2202-10, 2006.
- Mercier C, Sirigu A. Training with virtual visual feedback to alleviate phantom limb pain. *Neurorehabil Neural Repair*, 23 (6):587-94, 2009.
- Mitchell WS (1872) Injuries of nerves and their consequences. Philadelphia: Lippincott.

- Moseley GL. Graded motor imagery for pathologic pain: a randomized controlled trial. *Neurology*, 67 (12):2129-34, 2006.
- Murray CD, Pettifer S, Howard T, Patchick EL, Caillette F, Kulkarni J, Bamford C. The treatment of phantom limb pain using immersive virtual reality: three case studies. *Disabil Rehabil*, 29 (18):1465-9, 2007.
- Nair DG, Purcott KL, Fuchs A, Steinberg F, Kelso JA. Cortical and cerebellar activity of the human brain during imagined and executed unimanual and bimanual action sequences: a functional MRI study. *Brain Res Cogn Brain Res*, 15 (3):250-60, 2003.
- Naito E, Kochiyama T, Kitada R, Nakamura S, Matsumura M, Yonekura Y, Sadato N. Internally simulated movement sensations during motor imagery activate cortical motor areas and the cerebellum. *J Neurosci*, 22 (9):3683-91, 2002.
- O'Connell NE, Wand BM, Marston L, Spencer S, Desouza LH. Non-invasive brain stimulation techniques for chronic pain. *Cochrane Database Syst Rev*, (9):CD008208, 2010.
- Penny WD, Stephan KE, Daunizeau J, Rosa MJ, Friston KJ, Schofield TM, Leff AP. Comparing families of dynamic causal models. *PLoS Comput Biol*, 6 (3):e1000709, 2010.
- Porro CA, Francescato MP, Cettolo V, Diamond ME, Baraldi P, Zuiani C, Bazzocchi M, di Prampero PE. Primary motor and sensory cortex activation during motor performance and motor imagery: a functional magnetic resonance imaging study. *J Neurosci*, 16 (23):7688-98, 1996.
- Raffin E, Giroux P, Reilly KT. The moving phantom: Motor execution or motor imagery? *Cortex*, 2011.
- Ramachandran VS, Hirstein W. The perception of phantom limbs. The D. O. Hebb lecture. *Brain*, 121 (Pt 9) 1603-30, 1998.
- Ramachandran VS, Rogers-Ramachandran D. Synaesthesia in phantom limbs induced with mirrors. *Proc Biol Sci*, 263 (1369):377-86, 1996.
- Reilly KT, Mercier C, Schieber MH, Sirigu A. Persistent hand motor commands in the amputees' brain. *Brain*, 129 (Pt 8):2211-23, 2006.
- Rocca MA, Pagani E, Absinta M, Valsasina P, Falini A, Scotti G, Comi G, Filippi M. Altered functional and structural connectivities in patients with MS: a 3-T study. *Neurology*, 69 (23):2136-45, 2007.
- Roland PE, Larsen B, Lassen NA, Skinhoj E. Supplementary motor area and other cortical areas in organization of voluntary movements in man. *J Neurophysiol*, 43 (1):118-36, 1980.
- Romero DH, Lacourse MG, Lawrence KE, Schandler S, Cohen MJ. Event-related potentials as a function of movement parameter variations during motor imagery and isometric action. *Behav Brain Res*, 117 (1-2):83-96, 2000.
- Rosen G, Hugdahl K, Erslund L, Lundervold A, Smievoll AI, Barndon R, Sundberg H, Thomsen T, Roscher BE, Tjolsen A, Engelsen B. Different brain areas activated during imagery of painful and non-painful 'finger movements' in a subject with an amputated arm. *Neurocase*, 7 (3):255-60, 2001.
- Roth M, Decety J, Raybaudi M, Massarelli R, Delon-Martin C, Segebarth C, Morand S, Gemignani A, Decorps M, Jeannerod M. Possible involvement of primary motor cortex in mentally

- simulated movement: a functional magnetic resonance imaging study. *Neuroreport*, 7 (7):1280-4, 1996.
- Roux FE, Ibarrola D, Lazorthes Y, Berry I. Virtual movements activate primary sensorimotor areas in amputees: report of three cases. *Neurosurgery*, 49 (3):736-41; discussion 41-2, 2001.
- Roux FE, Lotterie JA, Cassol E, Lazorthes Y, Sol JC, Berry I. Cortical areas involved in virtual movement of phantom limbs: comparison with normal subjects. *Neurosurgery*, 53 (6):1342-52; discussion 52-3, 2003.
- Rowe JB, Hughes LE, Barker RA, Owen AM. Dynamic causal modelling of effective connectivity from fMRI: are results reproducible and sensitive to Parkinson's disease and its treatment? *Neuroimage*, 52 (3):1015-26, 2010.
- Saitoh Y, Yoshimine T. Stimulation of primary motor cortex for intractable deafferentation pain. *Acta Neurochir Suppl*, 97 (Pt 2):51-6, 2007.
- Solodkin A, Hlustik P, Chen EE, Small SL. Fine modulation in network activation during motor execution and motor imagery. *Cereb Cortex*, 14 (11):1246-55, 2004.
- Stephan KE, Penny WD, Daunizeau J, Moran RJ, Friston KJ. Bayesian model selection for group studies. *Neuroimage*, 46 (4):1004-17, 2009.
- Stephan KE, Penny WD, Moran RJ, den Ouden HE, Daunizeau J, Friston KJ. Ten simple rules for dynamic causal modeling. *Neuroimage*, 49 (4):3099-109, 2010.
- Stephan KM, Fink GR, Passingham RE, Silbersweig D, Ceballos-Baumann AO, Frith CD, Frackowiak RS. Functional anatomy of the mental representation of upper extremity movements in healthy subjects. *J Neurophysiol*, 73 (1):373-86, 1995.
- Winstein CJ, Grafton ST, Pohl PS. Motor task difficulty and brain activity: investigation of goal-directed reciprocal aiming using positron emission tomography. *J Neurophysiol*, 77 (3):1581-94, 1997.

Supplementary materials: Supplementary materials (concerning the DCM analysis) and Supplementary results are available.

Author Contributions: E.R., K.R., P.G. designed the experiment, E.R. conducted the experiment. E.R, J.M and P.G analyzed the data and E.R., K.R., P.G. and J.M. discussed the results and wrote the paper.

Acknowledgment: E Raffin is funded by the French Ministry of Health (PHRC 2007 N°0701040). We thank D. Ibarrola, J.C. Comte, and D. Sappey-Mariner at the "CERMEP-Imagerie du vivant" research imaging centre of Lyon, France

Competing interests statement: the authors declare no competing interests.

6. Etude 3

6.1 Résumé

Problématique

L'amputation d'un membre induit des réorganisations au sein du cortex moteur primaire controlatéral (M1-c). Dans le cas d'une amputation de la main, les aires corticales du moignon et du visage tendent à se déplacer vers la zone qui auparavant contrôlait les mouvements de la main amputée. Il a été démontré que l'ampleur de cette réorganisation est positivement corrélée avec l'intensité des douleurs de membre fantôme. Nous avons fait l'hypothèse que ces réorganisations pouvaient également être corrélées à la qualité du contrôle moteur dans le membre fantôme. Par ailleurs, malgré ces réorganisations, il y est désormais acquis que le membre fantôme conserve une représentation motrice résiduelle, mais la signification fonctionnelle de cette représentation n'est pas connue. Nous avons donc étudié la relation entre le contrôle moteur dans le membre fantôme, les réorganisations et l'activité résiduelle lors de mouvements du membre fantôme dans M1-c.

Matériels & Méthodes

Nous avons conduit une étude en IRMf auprès de 13 amputés unilatéraux du membre supérieur. Les sujets ont effectué des mouvements de leur main fantôme, de leur coude fantôme (pour les 10/13 amputés au-dessus du coude) et des lèvres. Les activités corticales associées à ces mouvements ont été comparées à celles associées aux mêmes mouvements du côté intact et à celles provoquées par des mouvements des lèvres, des mains et coudes droits et gauches dans une population de 17 volontaires sains. En plus des analyses conventionnelles, les réorganisations motrices ont été évaluées grâce à un outil innovant, basé sur la surface corticale. L'estimation des CoG des activations de chaque mouvement et de leurs positions respectives par rapport au bord médial du cortex moteur procure une mesure précise de l'organisation fonctionnelle de M1-c.

Résultats & Discussion

Nos résultats montrent des réorganisations dans M1-c avec un fort recouvrement spatial des activations motrices de la main et le coude, et de la main et des lèvres dans le cortex moteur primaire controlatéral à l'amputation. La position des CoG des lèvres est significativement plus

médiale et celle des CoG du coude, plus latérale, alors que la position des CoG des mains était symétrique dans les deux hémisphères des sujets amputés. Nous montrons également que ces déplacements du coude et des lèvres dans M1-c ainsi que l'intensité de l'activité corticale motrice pendant des mouvements de la main fantôme sont corrélées à la qualité du contrôle moteur dans le membre fantôme. D'autre part, les volumes d'activations dans M1-c associés aux mouvements de la main intacte sont plus importants que ceux des sujets volontaires sains, ce qui suggère que M1-c correspondant à la main intacte est également réorganisé après amputation. Etant donnée la corrélation négative entre le contrôle moteur et la douleur chronique dans le membre fantôme, ces données suggèrent que les techniques thérapeutiques visant à réduire la douleur du membre fantôme en augmentant le contrôle moteur dans le membre fantôme, induisent une normalisation de l'organisation fonctionnelle du cortex moteur primaire et une «réactivation» de la représentation résiduelle du membre manquant.

6.2 Article

Primary motor cortex reorganisation and activity during phantom hand movements are both related to phantom limb motor control

Running title: M1 reorganisation and phantom motor control

Estelle Raffin^{1,2}, Pascal Giraux^{1,2}, Nathalie Richard^{3,5} and Karen T. Reilly^{4,5}

¹Department of Physical Medicine and Rehabilitation, Faculty of Medicine, University Jean Monnet of Saint Etienne, F-42023 Saint-Etienne, France.

²INSERM U 879, Lyon Neuroscience Research Center, Central Integration of Pain Team, Saint-Etienne and Lyon, France

³Center for Cognitive Neuroscience, UMR 5229, CNRS, Lyon, France

⁴INSERM U1028, CNRS UMR5292, Lyon Neuroscience Research Center, ImpAct Team, Lyon, France

⁵University of Lyon 1, Lyon, France

Corresponding authors:

Karen T. REILLY
INSERM U1028, CNRS UMR5292
Lyon Neuroscience Research Centre
ImpAct Team
16, avenue Doyen Lépine
69500 Bron
FRANCE
karen.reilly@inserm.fr

Pascal GIRAUX
Service de Médecine Physique et de
Réadaptation,
Hôpital Bellevue, CHU de Saint-Etienne,
F-42055 Saint-Etienne
FRANCE
pascal.giroux@univ-st-etienne.fr

Abstract:

Amputation of a limb induces reorganisation within the contralateral primary motor cortex (M1-c). In the case of hand amputation, the stump and the face areas expand toward the area that previously controlled the now-missing hand. It has been shown that the extent of this reorganisation is positively correlated with phantom limb pain severity, and we wondered whether it might also be correlated with other phantom limb phenomena, for example phantom limb motor control. Despite reorganisation in M1-c there is increasing evidence that the missing limb still retains a residual representation, although the functional significance of this residual activity is not known. Here, we investigated the relationship between phantom limb motor control, reorganisation within M1-c, and residual M1-c activity during phantom hand movements. We performed an fMRI study with 13 unilateral upper-limb amputees who made movements of their phantom hand, phantom elbow (for 10/13 who were above-elbow amputees) and lips, and compared the cortical activity during these movements with similar movements executed by the intact upper-limb, and with the right and left hands and lips of a population of 17 healthy subjects. In addition to standard fMRI analyses, M1-c reorganisation was assessed with an original surface-based estimate of the centre of gravity (CoG) of M1-c activations related to each movement: the geodesic distance between the CoG and the medial border of M1-c was used as an estimate of the movement's location within M1-c. Contralateral to the amputation, M1-c was significantly reorganised, both in terms of the location of the lip and elbow COGs, and in terms of the amount of overlap between hand/elbow and hand/lip activations. The lip COG shifted medially and the elbow COG shifted laterally, but the COG for movements of the phantom hand showed no asymmetry when compared with intact hand movements. We show that smaller COG shifts and greater signal change during phantom hand movements are associated with better phantom motor control. Furthermore, movements of the intact hand activated a larger volume of M1 than in control subjects suggesting that the 'intact' hemisphere is also reorganised after amputation. Since phantom motor control and chronic phantom pain are negatively correlated, these data suggest that interventions that aim to reduce phantom limb pain by increasing phantom motor control might achieve their analgesic effect by *re-reorganising* the hemisphere contralateral to the amputation and/or by "reactivating" the residual representation of the missing limb.

Introduction:

The first evidence that the adult brain could undergo large scale reorganisation came from monkey studies examining changes within the sensory cortex after peripheral sensory deafferentation. These groundbreaking studies showed that the cortical region that previously responded to touch on the deafferented body part now responded to touch on body parts with somatotopically adjacent representations (Merzenich et al., 1983a, Merzenich et al., 1983b, Merzenich et al., 1984, Wall et al., 1986, Jain et al., 1998). In the motor cortex it was demonstrated that stimulation of cortical neurons which, before amputation, evoked movements of the hand and forearm evoked movements of the stump and shoulder (Donoghue et Sanes, 1988; Qi, Stepniewska et Kaas, 2000; Schieber, M. H., 1997; Wu et Kaas, 1999). Human studies using non-invasive imagery techniques revealed similar results. For example, transcranial magnetic stimulation (TMS) over the motor cortex of upper-limb amputees produced movements or muscle contractions of parts of the body that are represented in the cortical somatotopic map adjacent to the missing body part (Cohen et al., 1991, Fuhr et al., 1992, Kew et al., 1994, Ridding and Rothwell, 1995, Chen et al., 1998, Roricht et al., 1999, Irlbacher et al., 2002). Studies of the sensory cortex were able to more precisely quantify this reorganisation. Using simultaneous magnetic- and electro- encephalographic recordings in a sample of five upper-limb amputees Elbert and colleagues reported that the source dipole generated by tactile stimulation of the chin ipsilateral to the amputation was shifted medially (towards the hand's representation) when compared with chin stimulation contralateral to the amputation (Elbert et al., 1994). This finding was subsequently replicated (Montoya et al., 1998, Grusser et al., 2001), and expanded by the demonstration of a correlation between the amount of reorganisation (measured by displacement of the lip dipole) and perceptual phenomena related to the phantom limb like the number of sites from which painful stimuli were mislocalised to the phantom (Knecht et al., 1995, Knecht et al., 1996), and most famously, the degree of phantom limb pain (Flor et al., 1995, Flor et al., 1998).

Later studies demonstrated reorganisation within the motor cortex, and as in the sensory cortex, a correlation between the degree to which activations recorded during lip movements had shifted medially and the amount of phantom limb pain (Lotze et al., 1999, Karl et al., 2001, Karl et al., 2004). These findings led to the hypothesis that there might be a functional link between reorganisation and phantom limb pain, and by extension, that protocols that alter sensorimotor

organisation might reduce pain. Birbaumer and colleagues (1997) tested this hypothesis and demonstrated that anesthesia of the amputation stump drastically reduced both phantom pain levels and the distance between the lip representation in the two sensory cortices. Using a different approach, Flor and colleagues (2001, 2002) trained upper-limb amputees to discriminate the frequency and location of tactile stimuli applied to the stump and found that this task improved sensory discrimination, reduced phantom limb pain, and reversed the medial shift in the lip's sensory representation. While these approaches seemed very promising, they have mostly been abandoned for approaches using combinations of visuomotor feedback, voluntary movements, and motor imagery of phantom limb movements (e.g. Moseley, 2006, Chan et al., 2007, Murray et al., 2007, Maclver et al., 2008, Mercier and Sirigu, 2009, Beaumont et al., 2011). One reason for this is that there appears to be a particularly strong (but not yet understood) link between the ability to move the phantom limb and phantom limb pain, and the initial randomised, controlled trials show promising results (Moseley, 2006, Chan et al., 2007).

The link between the ability to move the phantom limb and phantom limb pain was first demonstrated by Ramachandran's startling observation that visual feedback of the missing limb provided by a mirror image of the intact limb can elicit movements in the phantom hand and reduce phantom limb pain (Ramachandran and Rogers-Ramachandran, 1996). The motor training therapies that emerged from this observation are based upon the (implicit) hypothesis that there is a functional link between the ability to move the phantom and phantom limb pain. This is partially supported by the recent finding of a strong correlation between phantom motor control (the ability to move the phantom voluntarily) and phantom limb pain (Gagné et al., 2009, Raffin et al., 2011). But because it was only recently demonstrated that amputees can make both imagined and amputated movements of their missing limb (Raffin et al., 2011) it is unclear whether the patients in the clinical studies imagined moving their limb or actually moved it (Chan et al., 2007, Maclver et al., 2008). Giraux and Sirigu (Giroux and Sirigu, 2003) used a form of visuomotor feedback in which patients actually made voluntary movements with their phantom hand. They found that activity in the hand region of the motor cortex during phantom hand movements increased after training and was associated with significant pain reduction. This suggests not only that there is a link between phantom motor control and phantom limb pain, but that these variables are also related to the "residual" activity in the motor cortex during phantom hand movements.

The idea that there might be some “residual” representation of the missing limb in the sensorimotor cortex is relatively recent. While the shift and/or enlargement of the cortical area devoted to remaining body parts was initially assumed to be synonymous with the disappearance or shrinkage of the representation of the amputated body part (Roricht et al., 1999, Irlbacher et al., 2002), there is now an increasing body of evidence demonstrating that reorganisation does not delete the amputated hand’s representation. For example, sensations in the phantom hand have been evoked after direct stimulation of the sensory cortex in an amputee undergoing surgery for tumour removal (Ojemann and Silbergeld, 1995), and after stimulation of thalamic neurons via microelectrodes (Davis et al., 1998). In the motor cortex, numerous imaging studies have now demonstrated that phantom hand movements activate regions of the motor cortex homologous to those activated during intact hand movements (Lotze et al., 2001, Roux et al., 2001a, Roux et al., 2003), and that stimulation sites which produce phantom hand movements overlap with sites on the opposite hemisphere which evoke contractions in intrinsic hand muscles (Mercier et al., 2006). These data suggest that neuronal activity within the area that was previously devoted to the missing limb continues to be associated with this limb, despite the fact that the limb is no longer present.

To date, no-one has directly investigated the relationship between motor reorganisation, “residual” activity during phantom hand movements, and phantom motor control. In this study we set out to address two main questions. First, are phantom motor control and motor cortex reorganisation related (independently of the relationship between each of these two variables and phantom limb pain)? If the answer to this question is positive it would suggest that the analgesic effect of motor training to improve phantom motor control could be mediated by a reversal of amputation-induced reorganisation. This finding would strengthen the idea that *any* intervention that can act on cortical organisation and potentially reverse amputation-induced reorganisation could be a good candidate for the treatment of phantom limb pain. The second question we were interested in was whether the “residual” activity in the motor cortex during phantom hand movements was related to phantom motor control? If the answer to both this and the first question is positive, it would support the idea that interventions that aim to “reactivate” the phantom limb within the motor cortex could reduce phantom limb pain by improving phantom motor control and subsequently affecting amputation-induced reorganisation.

Materials and Methods

Participants

Thirteen traumatic upper-limb amputees participated in the experiment (mean age 42 years, SD 15.3). On average, the accident occurred 7.5 years [range: 5 months–30 years] before testing. The Edinburgh Handedness Inventory (EHI) revealed that twelve amputees were right hand dominant prior to the amputation, and five of these lost their dominant hand (Table 1). Seventeen healthy volunteers (7 females and 10 males; mean age 32.1 years, SD 10.9, one left-handed person) were recruited from the general population. Neither amputees nor controls had suffered a brain lesion or had a history of neurological or psychiatric illness. The nature of the experimental procedures was explained to all subjects who gave their written informed consent prior to participating in the experiment. This study was approved by the Local Ethics Committee of Lyon Sud-Est IV (A 09-115), and conformed to the ethical aspects of the Declaration of Helsinki.

Table 1: Clinical and phantom limb motor control characteristics of the amputee group (note that the last two amputees did not complete the Finger-to-thumb opposition task).

Age	Months since amputation	Amputated side/ Dominant side	Stump length (% of residual limb)	Prosthetic use	Chronic phantom limb pain intensity (0 – 10)	Time to perform the finger-to-thumb opposition task (sec)
33	84	R/R	80	No use	0	14.7
22	27	L/L	25	No use	4	20.2
39	360	L/R	43	No use	0	20.2
28	204	R/R	48	No use	4	22.5
40	102	R/R	24	Myoelectric (permanent)	6	23.6
29	24	L/R	25	No use	5	36.1
27	12	L/R	42	Mechanic (part-time)	3	41.6
67	37	L/R	32	Esthetic (rarely)	5	42.2
55	106	L/R	15	Esthetic (rarely)	6	46.6
65	5	L/R	24	No use	5	46.6
62	24	L/R	15	Esthetic (permanent)	7	51.7
42	68	R/R	18	Esthetic (rarely)	6	--
37	120	R/R	15	No use	3	--

Assessment of phantom limb pain and phantom motor control

Clinical data related to the amputation were collected with a structured interview evaluating phantom sensations including the rating of their on-going pain intensity on a continuous 10 cm visual-to-analog scale (VAS) (Flor et al., 1995). Amputees were then required to perform a finger

sequence opposition task with their phantom hand by opposing each of the four fingertips to their thumb at a self-imposed pace and to repeat this sequence five times. They were instructed to concentrate on the quality of the performance, i.e. that they should ensure that they clearly 'executed' the movement, and that the quality of the movement prevail over its speed. It is important to note that amputees did not imagine these movements but actually made voluntary executed movements with their phantom hand (see Raffin et al., 2011). The experimenter gave a 'go' signal and recorded the time between this signal and completion of five consecutive finger sequence oppositions (verbally signalled by the amputee). We used the time taken to complete five finger-to-thumb opposition cycles with the phantom hand to measure phantom limb motor control, with faster movements reflecting better phantom motor control.

fMRI paradigm

All subjects (amputees and controls) were scanned using a research-dedicated 1.5T MRI scanner (Siemens Magnetom Sonata, Erlangen, Germany) with an 8 channel head coil. They were scanned with the head immobilized, eyes open, while performing elementary movements with distinct body-parts. For both groups, movements were: 1) opening/closing the fingers and the thumb on the right or phantom hand, 2) opening/closing the left or intact hand, 3) flexion/extension of the right or phantom elbow, 4) flexion/extension the left or intact elbow, 5) lip movements (blowing a kiss). Each movement task was assessed in a separate fMRI run to avoid possible artifacts induced by planning multiple movements. For normal volunteers, the movement rate was fixed at 0.5 Hz for all body parts. For amputees, lip movements and elbow movements (in below-elbow amputees only) were also performed at 0.5 Hz. For the other phantom movements (hand opening/closing in all amputees and elbow flexion/extension in the ten above-elbow amputees), we used a pace at which each amputee experienced no pain and felt comfortable executing movements with the phantom. This pace was established outside the scanner before the start of the experiment, and the same pace was used for both phantom and intact side movements. Movement speeds in the scanner ranged from 5 movements in 10 seconds (0.5 Hz) to one movement in 10 seconds (0.1 Hz). The fMRI block design consisted of 30 movement blocks (block length 10 s) interleaved with rest periods (baselines) of between 5 and 15 seconds. Visual go and stop signals were presented to the subject on a screen at

the end of the MRI tunnel that subjects viewed through a 45° oriented mirror placed above the eyes. Each movement was performed in a separate run and before each runs subjects received verbal instructions about the movement to perform in that run. The order of movements was completely randomised for all subjects.

Thirty-two 5 mm thick axial slices were obtained with a T2* weighted gradient echo, echo planar imaging sequence, using blood oxygen level-dependent contrast (repetition time 3030 ms, echo time 40 ms, flip angle to 90°, matrix 64 x 64, field of view 220 x 220 mm²), and 218 brain volumes were acquired for each of the five runs. The first five and the last three volumes of each run were discarded to reach signal equilibrium. Prior to functional protocol acquisitions, high resolution three-dimensional anatomical images of the whole brain were acquired (gradient-echo inversion recovery, repetition time 1600 ms, echo time 5 ms, matrix 256 x 256, field of view 220 x 220 mm²).

Image processing

Image processing was carried out using Statistical Parametric Mapping (SPM 8, Wellcome Department of Cognitive Neurology, London, UK, www.fil.ion.ucl.ac.uk/spm), implemented in MATLAB 7.6 (Mathworks, Sherborn, MA). Preprocessing included a 3D motion correction and a spatial smoothing with a Gaussian kernel 8x8x8 mm³ full width at half maximum. All data from the five amputees with a right-side amputation were left-right flipped. This meant that all amputees were considered as 'left hand amputated' and 'right hand intact' (This method has been used for example by MacIver et al., 2008, Diers et al., 2010). Functional datasets were then co-registered with the T1-weighted anatomical scan and transformed into standard MNI space. We used a segmentation-based normalization approach (Ashburner and Friston, 2005) which uses an improved registration model and more robust initial affine registration. Preliminary analyses showed that the realignment parameters estimated during spatial preprocessing were sometimes correlated with task design. Therefore we decided to model the realignment parameters in the design matrix as regressors of no interest. The experimental block design was convolved with the canonical hemodynamic response function, and the resulting model was estimated using a highpass filter at 128 seconds to remove low-frequency artifacts.

In the first-level analysis, contrast maps were calculated for the active periods versus rest for each patient and normal volunteer and each session separately. For the second-level analyses, we performed a random effect analysis on the baseline contrasts of task versus rest to show the typical activation patterns related to each body-segment movement with a threshold of $P < 0.05$, corrected for multiple comparisons using Family Wise Error (FWE).

Individual statistical results were mapped onto each subject's 3D mesh of the cortical surface flattened using the multi-fiducial procedure in Caret 5.562 software (Van Essen et al., 2001). Our Region Of Interest (ROI) was manually defined on each subject's flattened anatomic image and included the complete anterior wall of the central sulcus of M1-c which comprises BA 4p and the posterior part of BA 4a (Geyer et al., 1996).

We will use the following notation throughout the text; $M1\text{-c}_{\text{PHANTOM}}$: the hemisphere contralateral to the amputation; $M1\text{-c}_{\text{INTACT}}$: the hemisphere contralateral to the intact limb; $M1\text{-c}_{\text{LEFT}}$: the left hemisphere of controls; $M1\text{-c}_{\text{RIGHT}}$: the right hemisphere of controls.

For each movement, a custom-built program implemented in MATLAB® computed the movement's Centre of Gravity (CoG) on the cortical surface and then the geodesic distance between the CoG and the most medial point of the M1-c ROI (0%). This gave us the exact CoG position relative to the total length of M1-c, on its longitudinal axis.

For each movement we asked whether the CoG positions were asymmetric by comparing the COG positions in each hemisphere (values close to zero represent symmetric locations). We then computed an index of asymmetry for $M1\text{-c}_{\text{PHANTOM}}$ as follows:

$$\left| \text{Elbow CoG}_{(M1\text{-c}_{\text{PHANTOM}})} - \text{Elbow CoG}_{(M1\text{-c}_{\text{INTACT}})} \right| + \left| \text{Lips CoG}_{(M1\text{-c}_{\text{PHANTOM}})} - \text{Lips CoG}_{(M1\text{-c}_{\text{INTACT}})} \right|$$

We also computed the percentage of signal change for each movement (MarsBar) (Brett, 2002). In a final analysis, we calculated the percentage of overlap between the activations associated with any two given movements. This was calculated using a custom-built program implemented in MATLAB®, and the percentage of overlap was computed as follows (similar method used by Plow et al., 2010):

$$\frac{100 \times [\text{No. of Overlapping Voxels}]}{[(\text{Total No. of Voxels Mvt 1} + \text{Total No. of Voxels Mvt 2}) - \text{No. of Overlapping Voxels}]}$$

Statistical analyses

Statistical analyses were performed with non parametric tests: intra-group differences in the position of CoGs and percent of overlapping were assessed with the Wilcoxon rank sum test. Group differences were assessed with the Mann-Whitney U test. Correlation analyses (Spearman's correlation coefficient) with Bonferroni corrections for multiple comparisons were computed. Since some variables were correlated with each other, we also performed Pearson's partial correlations which take into account conditional dependences between variables after ensuring that data were normally distributed (using Kolmogorov-Smirnov tests). Significance was set at 0.05 and all statistical tests were conducted using STATISTICA 8.0 (StatSoft, Inc.). Medians are reported with the range indicated in brackets.

Results

Before the fMRI scan each amputee underwent a detailed interview. This revealed that our sample was heterogeneous in terms of constant pain perceptions: four had a high level of pain (> 6 out of 10 on the VAS), seven had moderate pain, and two had no phantom limb pain at all. The average constant pain intensity for the group was 5/10. All thirteen amputees were able to perform the finger opposition task with their phantom hand and the average time to perform five cycles was 36 seconds [14.7-51.7]. See table 1 for the finger opposition task results and detailed clinical data for each amputee.

A post-scan debriefing revealed that all amputees were able to voluntarily open and close their phantom hand (and flex and extend their phantom elbow for above-elbow amputees) in response to the auditory pacing signal in the scanner, although some of them reported that movement amplitudes were sometimes smaller than for the intact side. The individual first level

analysis showed that the contralateral primary sensorimotor cortex (S1-c and M1-c) was significantly activated in all 13 amputees and in all 17 control subjects for the five different movements). Activity was also present in the ipsilateral M1 and in non-primary sensorimotor areas including the bilateral Supplementary Motor Area (SMA), the bilateral dorsal premotor cortex (dPMC), the cingulate motor area, the bilateral inferior and superior parietal cortices, and the ipsilateral cerebellum. Activation in these areas was less consistent across subjects than S1-c and M1-c activation.

The results of the random effect group analysis are displayed in Figure 1 (control subjects on the left and amputees on the right). For both groups, activity was found in S1-c, M1-c, SMA, and dPMC during all movements. Bilateral inferior and superior parietal cortex activity was present during hand and elbow movements. Although our subsequent analyses focused on activity in M1-c, it is interesting to note that the activity pattern in S1-c was somatotopically ordered, probably because it resulted from movement-related sensory activity. Figure 1 provides an overview of each movement's representation within M1-c (purple zone), and shows that they were roughly positioned in the classical somatotopic order (Penfield, 1937), with the elbow, the hand, and the lips positioned progressively more laterally.

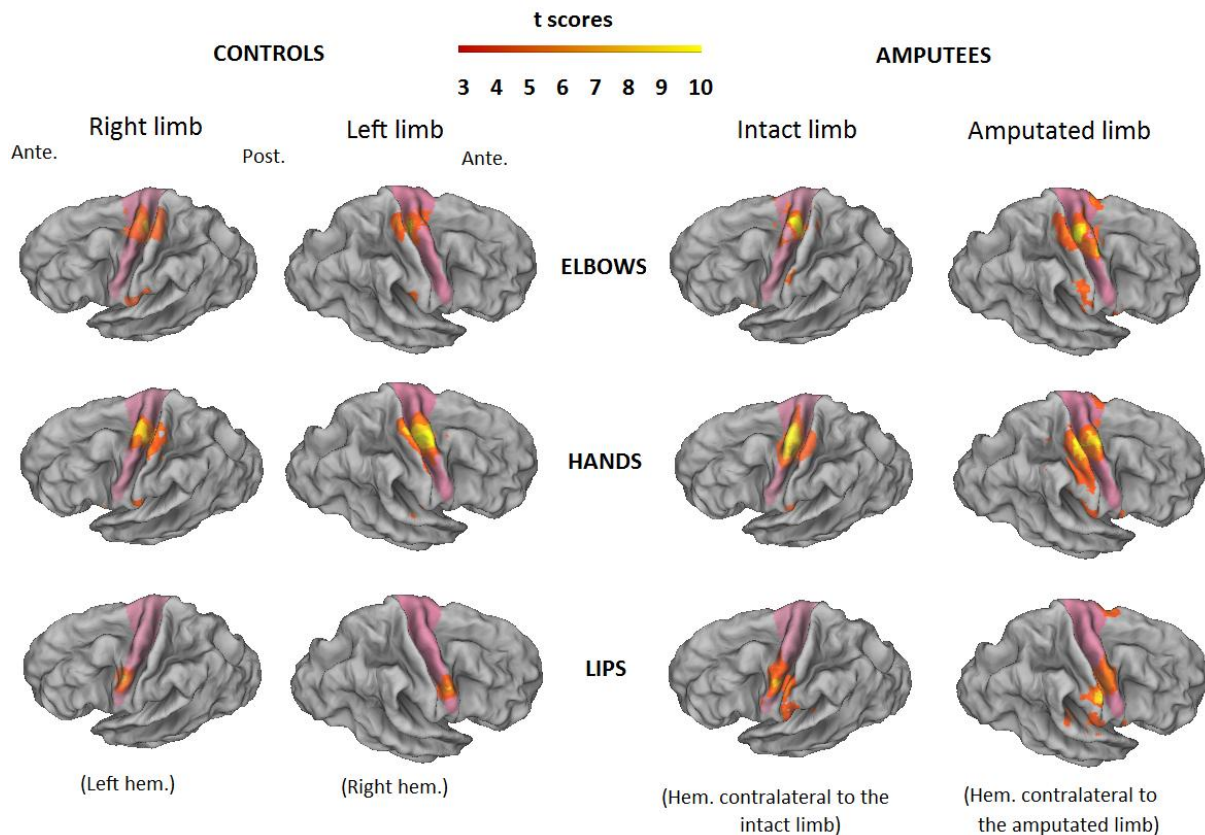


Figure 1: Random effect results in the hemisphere contralateral to the movements (except for lip movements which are bilaterally represented). Elbow, hand and lip activations in M1-c (pink zone) for the right and left limbs of control subjects (left panel) and for the intact and phantom limbs of amputees (right panel) ($p < 0.05$, FWE corrected for multiple comparisons). Note that for amputees, data were flipped so that all images of the right hemisphere correspond to the hemisphere contralateral to the amputated side and all images of the left hemisphere correspond to the hemisphere contralateral to the intact side). Ante.: anterior, Post.: posterior.

The results of the random effect analysis illustrated in Figure 1 show that the general somatotopic organisation of M1- C_{PHANTOM} was maintained, but that the activations overlapped more extensively than in the other hemispheres. Indeed, we found that the overlap Hand/Elbow was greater in the hemisphere contralateral to the amputation (M1- C_{PHANTOM}) compared to the other hemisphere (see Table 2, $Z = 2.27$, $p = 0.02$) and compared with both hemispheres of controls

(M1-c_{PHANTOM} versus M1-c_{LEFT}: $U \approx 0$, $p < 0.0001$; M1-c_{PHANTOM} versus M1-c_{RIGHT}: $U \approx 0$, $p < 0.0001$) (see Table 2)). Interestingly, the number of overlapping voxels was also significantly greater during Hand and Elbow movements in M1-c_{INTACT} than in both hemispheres of controls (M1-c_{INTACT} versus M1-c_{LEFT}: $U = 25$, $p = 0.0004$; M1-c_{INTACT} versus M1-c_{RIGHT}: $U = 25$, $p = 0.0004$). The volume of activation was larger during intact hand movements (2592[SD=666]) than during phantom hand movements (2204[SD=623]) and movements of both hands of controls (Right hand: 2187[SD=528] and Left hand: 1796[SD=764]), but the only significant difference was between the intact hand and the left hand of controls ($U = 37.5$, $p = 0.04$) (Table 3).

Very few voxels overlapped when the Hand and Lip activations were compared (range from 0 to 2.4%) (Table 2). In general, there was more overlap in M1-c_{PHANTOM} and M1-c_{INTACT} than in control subjects. This difference was significant for M1-c_{PHANTOM} which showed more overlap than both hemispheres of controls (M1-c_{LEFT}: $U = 49.5$, $p = 0.006$; M1-c_{RIGHT}: $U = 59.5$, $p = 0.03$), but not for M1-c_{INTACT} (M1-c_{LEFT}: $U = 79$, $p = 0.13$; M1-c_{RIGHT}: $U = 93$, $p = 0.45$). The difference between the two hemispheres in the amputees was not significant ($Z = 1.16$, $p = 0.25$).

Overlapping			
Hand/Elbow		Hand/lips	
CONTROLS			
M1-c_{left}	M1-c_{right}	M1-c_{left}	M1-c_{right}
10.9 % [2.7-26.9]	11.8 % [0-20.8]	0 % [0-4.7]	0 % [0-5]
AMPUTEES			
M1-c_{PHANTOM}	M1-c_{intact}	M1-c_{PHANTOM}	M1-c_{intact}
52.4 % [29.3-80]	32.9 % [6.5-60]	2.4 % [0-5.6]	1.5 % [0-6.1]

Table 2: Medians and ranges overlap (%) (bottom) between Hand/Elbow and Hand/Lips in both hemispheres of controls (M1-c_{RIGHT} / M1-c_{LEFT}) and both hemispheres of amputees (M1-c_{PHANTOM} / M1-c_{INTACT}) ($P < 0.05$, FWE corrected for multiple comparisons).

Volumes of activation					
Elbows		Hands		Lips	
CONTROLS					
M1-c_{left}	M1-c_{right}	M1-c_{left}	M1-c_{right}	M1-c_{left}	M1-c_{right}
1890 [824-3618]	1890 [724-3618]	2187 [783-2700]	1796 [810-3348]	1053 [843-2619]	1296 [912- 2484]
AMPUTEES					
M1-c_{PHANTOM}	M1-c_{intact}	M1-c_{PHANTOM}	M1-c_{intact}	M1-c_{PHANTOM}	M1-c_{intact}
2700 [1485-4860]	1641 [891-3348]	2204 [1378-3726]	2592 [1323-3510]	1567 [1093-1818]	1323 [1023-1974]

Table 3: Medians and ranges of volumes of activation (top) during elbow, hands and lips movements in both hemispheres of controls ($M1-c_{RIGHT}/M1-c_{LEFT}$) and both hemispheres of amputees ($M1-c_{PHANTOM}/M1-c_{INTACT}$) ($P < 0.05$, FWE corrected for multiple comparisons).

The fact that there was significantly more overlap of movement activations in the amputees, particularly in $M1-c_{PHANTOM}$, suggests that the amputation caused some sort of perturbation and/or reorganisation, but because overlap is not a measure that is sensitive to the topography of M1 we performed another analysis to examine whether there had been a shift in the location of movement activations. For each movement, we calculated the Centre of Gravity (CoG) of its activation in M1-c (on the cortical surface - see Material and Methods) and we then measured its position along the longitudinal axis of M1-c (relative to the entire length of M1-c: 0% = CoG positioned in interhemispheric sulcus; 100% = CoG positioned at lateral extremity of M1-c). To assess whether there was an asymmetry in the position of each movement's CoG we then compared the CoG positions within the two hemispheres.

Figure 2 gives an example of the different CoG positions of the elbow, hand, and lip movements in M1-c for one control subject. Figure 3 shows the average data for both groups of subjects. For the controls subjects (Figure 3, left), for all three movements, the average CoG paired-positions were symmetric (elbow: $Z = 0.07$, $p = 0.94$; hand: $Z = 0.4$, $p = 0.69$; lips: $Z = 1.6$, $p = 0.11$).

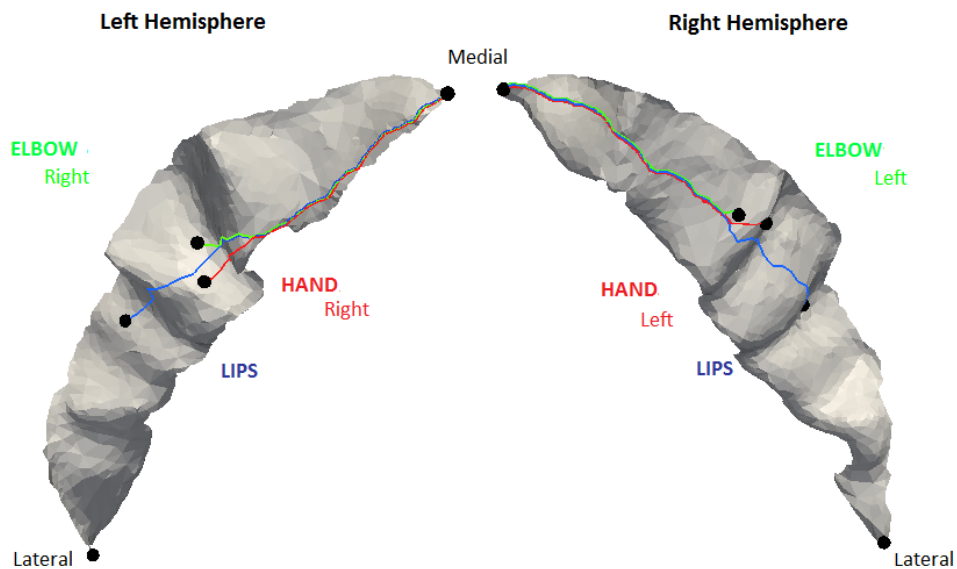


Figure 2: CoG arrangement for one control subject for the elbow, hand and lip movements in the Left and the Right M1-c.

For amputees, while there was no significant difference between the average positions of the hand CoGs ($Z = 0.07$, $p = 0.93$), we found significant differences between the paired-positions of the elbow CoG ($Z = 2.9$, $p = 0.004$) and lip CoGs ($Z = 2.6$, $p = 0.01$) (Figure 3, right). Interestingly, there were also differences between the position of the elbow in M1-c_{PHANTOM} and in M1-c_{LEFT} and M1-c_{RIGHT} (left elbow (almost significant): $U = 63$, $p = 0.07$; right elbow (significant): $U = 57$, $p = 0.04$). The lip CoG in M1-c_{PHANTOM} was also significantly displaced compared with M1-c_{LEFT} ($U = 45$, $p = 0.03$) and M1-c_{RIGHT} ($U = 17$, $p = 0.0003$). In contrast, the position of the elbow CoG in M1-c_{INTACT} was similar to that observed in both hemispheres of controls (M1-c_{INTACT} versus M1-c_{RIGHT}: $U = 99$, $p = 0.84$; M1-c_{INTACT} versus M1-c_{LEFT}: $U = 103$, $p = 0.98$). This was also the case for the position of the hand (hand in M1-c_{INTACT} versus M1-c_{RIGHT}: $U = 61$, $p = 0.11$; M1-c_{INTACT} versus M1-c_{LEFT}: $U = 57$, $p = 0.07$) and lip COGs (lips in M1-c_{INTACT} versus M1-c_{RIGHT}: $U = 68$, $p = 0.2$; lips in M1-c_{INTACT} versus M1-c_{LEFT}: $U = 83$, $p = 0.75$). Overall, our CoG analysis shows that the median position of the elbow activations in M1-c_{PHANTOM} shifted laterally whereas the lip activations in this same hemisphere shifted medially.

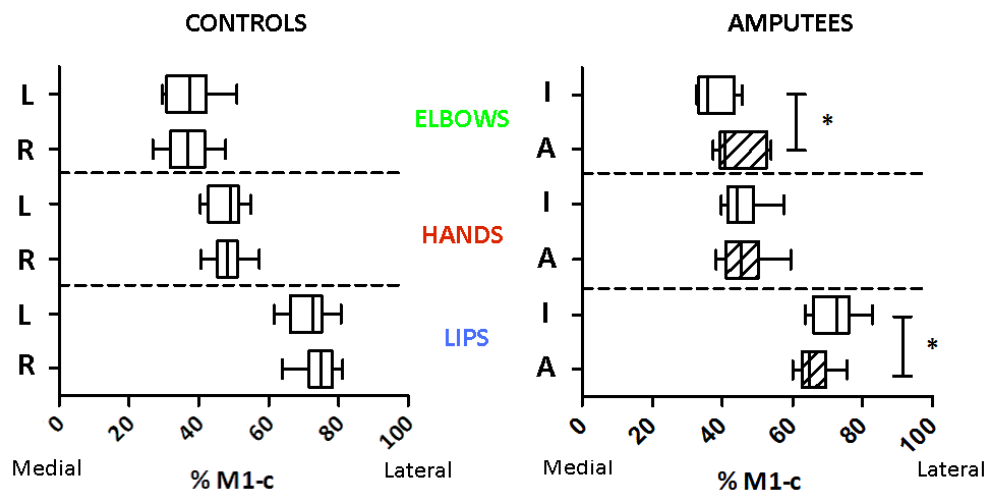


Figure 3: Median (range) CoG positions expressed as a percentage of the length of each individual's M1-c for control (left panel) and amputee subjects (right panel). R: right, L: left, I: intact, A: amputated ($P < 0.05$, FWE corrected for multiple comparisons) (Wilcoxon paired t-tests, $p < 0.05$). Boxes represent the interquartile range.

In order to answer our question of whether the amount of cortical reorganization in $M1-C_{PHANTOM}$ is related to phantom limb motor control we performed a series of correlational analyses. To obtain a measure of reorganisation that took into account the medial shift in the elbow CoG and the lateral shift in the lip CoG we computed an index of asymmetry using the CoG paired-positions for these two movements (we did not include the hand index since the hand was symmetrically represented in both hemispheres). The degree of asymmetry between $M1-C_{PHANTOM}$ and $M1-C_{INTACT}$ was positively correlated with phantom limb control ($r = 0.73$, $p < 0.003$) and with phantom limb pain ($r = 0.89$, $p < 3.5e-5$). When the effect of phantom limb pain was removed by partial correlation, the relationship between phantom limb control and asymmetry between $M1-C_{PHANTOM}$ and $M1-C_{INTACT}$ remained significant ($r = 0.58$, $p = 0.02$). That is, the greater the shift in the elbow and lip representations within $M1-C_{PHANTOM}$, the longer it took to make voluntary movements of the phantom hand.

As overlap is another (non-topographic) measure of reorganisation, we also investigated whether the amount of overlap between the Hand and Elbow activations was associated with the phantom limb motor control or phantom limb pain. We found a positive correlation between the

percent overlap and phantom limb motor control ($r = 0.81$, $p = 0.002$), and a moderate but non-significant correlation with pain ($r = 0.47$, $p = 0.10$). After removing the confounding effects of phantom limb pain, there was still a significant correlation between the amount of overlap and phantom limb motor control ($r = 0.74$, $p = 0.014$).

Although the position of the CoG associated with activity during phantom hand movements was not displaced, we wondered whether other features of the activity in M1-c_{PHANTOM} during phantom hand movements were related to the quality of phantom limb motor control. Since activity in M1-c_{PHANTOM} during phantom hand movements is recorded during a movement of a non-existent articulation we refer to it as “residual” activity. We quantified “residual” activity in M1-c_{PHANTOM} as the volume of activation and the amount of signal change during phantom hand movements. When we correlated these two measures with phantom hand movement times we found no correlation with the area of activation during phantom hand movements ($r = 0.27$, $p = 0.38$) and a negative correlation with % signal change ($r = -0.53$, $p = 0.05$). Amputees who performed the finger to thumb opposition task quickly showed a greater percentage of signal change in M1-c_{PHANTOM} during hand opening/closing. Interestingly, we also found a negative correlation between the index of asymmetry (topological reorganisation within M1-c_{PHANTOM}) and the % signal change in M1-c during phantom hand movements ($r = -0.55$, $p=0.05$), showing that there is also a relationship between “residual” activity during phantom hand movements and the amount of reorganization in M1-c_{PHANTOM}. No such relationship existed for the volume of activation during phantom hand movements ($r = 0.15$, $p>0.61$).

In a final analysis of “residual” activity during phantom hand movements we performed a regression analysis in SPM, which revealed significant activity in M1-c_{PHANTOM} when movement times were entered as a regressor (SVC (42; -15; 63), $k = 6$, $r = 0.83$, $p < 0.05$ FWE corrected at the cluster-level). No relation was found in other cortical regions.

Discussion

Here we examined the physiological changes that occur in the motor cortex contralateral to the amputated (M1-c_{PHANTOM}) and intact (M1-c_{INTACT}) limb following upper-limb amputation. We report two new major findings regarding reorganization within M1-c_{PHANTOM}: 1 - the amount of

reorganization in $M1-C_{\text{PHANTOM}}$ is negatively correlated with phantom motor control; 2 - the location of M1 activity during phantom hand movements is not altered, but its intensity is positively correlated with phantom motor control and negatively correlated with the amount of reorganization in $M1-C_{\text{PHANTOM}}$. We also report changes in $M1-C_{\text{INTACT}}$ following upper-limb amputation, as the area activated during intact hand movements was significantly greater than in control subjects.

The primary motor cortex is organized in a roughly somatotopic manner, with clear representations between major body parts like the head, upper-, and lower-limbs. Despite this, the organization within each body part and the borders between them are less well defined than in the primary somatosensory cortex (Penfield, 1937, Huang et al., 1988, Sato and Tanji, 1989, Donoghue et al., 1992). One consequence of this is that imaging techniques with limited spatial resolution (like fMRI or TMS) frequently reveal overlap in the territories activated by (or projecting to) different body parts (e.g. Devanne et al., 2006, Marconi et al., 2007, Melgari et al., 2008, Plow et al., 2010). It is important to note that by comparing the amount of overlap between territories in the amputated and intact hemispheres of amputees with that observed in control subjects we demonstrate a real physiological correlate of amputation-induced reorganisation, and not the consequence of the inherent overlapping organisation of M1.

Reorganization of $M1-C_{\text{PHANTOM}}$ and $M1-C_{\text{INTACT}}$

Despite amputation of a large part of the upper limb in almost all of our amputees (10/13 were above elbow amputees), the somatotopic organization of $M1-C_{\text{PHANTOM}}$ was preserved, with the lip COG situated most laterally, the elbow most medially, and the hand in between the two. As expected, we observed a certain amount of overlap in the areas activated during elbow and hand movements and lip and hand movements, but this was greater than in $M1-C_{\text{INTACT}}$ or in control subjects (Table 2). This is important, as an “abnormal” amount of overlap between activations associated with two different movements has been associated with motor impairment and sensorimotor reorganization (Yao et al., 2009). Previous studies noted that the overlap in $M1-C_{\text{PHANTOM}}$ appeared to be greater than in $M1-C_{\text{INTACT}}$ or in control subjects, but this increased overlap was never quantified (Giraux et al., 2001, Lotze et al., 2001, Maclver et al., 2008). Our analysis

revealed significant reorganization in M1-C_{PHANTOM} in the form of “abnormal” overlap, as the elbow/hand overlap was significantly greater in M1-C_{PHANTOM} than in either M1-C_{INTACT} or the hemispheres of control subjects, and the hand/lip overlap in M1-C_{PHANTOM} was significantly greater than in either of the hemispheres of control subjects and was greater (but not significantly) than in M1-C_{INTACT}.

An increased overlap between the activity recorded during movements of two body parts could arise from either an increase in the activation areas and/or from a shift in the activated areas. Because we measured both the area activated and the centre of gravity associated with each movement we can say that the increased overlap between movements in M1-C_{PHANTOM} arose from a combination of the two mechanisms; activation areas were significantly larger than in control subjects, and the elbow and lip COGs were shifted significantly. Interestingly, while numerous PET and fMRI studies in amputees have shown a medial shift of the lips (e.g. Grodd et al., 2001, Gitelman et al., 2002, Amunts et al., 2004), the only clear demonstration of a lateral shift of the elbow comes from microstimulation studies in non-human primates (Donoghue et al., 1992, Schieber and Deuel, 1997, Wu and Kaas, 1999, Qi et al., 2000). In humans, TMS mapping data concerning a shift in the motor representation of stump muscles are inconsistent (George et al., 1996, Dettmers et al., 1999, Karl et al., 2001, Roricht et al., 2001, Gothe et al., 2002, Gagné et al., 2010), and fMRI data are limited to a single case report in a bilateral amputee/allograft recipient (Giroux et al., 2001). Here we show that in a population of mainly proximal amputees there is a medial shift in the area activated by lip movements but also that elbow movement activations shift laterally. Thus, we have two separate measures (overlap and COG displacement) that each clearly demonstrate reorganization within M1-C_{PHANTOM}.

The location and the area of M1-C_{PHANTOM} activation during phantom hand movements did not differ from control subjects. Similarly, the intensity of M1-C_{PHANTOM} activation, as assessed by the percent of signal change, was similar to that recorded during intact and control subject hand movements. We did find, however, that within the amputee population, signal intensity was positively correlated with phantom motor control. The level of phantom limb motor control varied within our amputee population, but overall was well preserved (see Table 1). When we correlated phantom limb motor control with percent signal change we found that amputees who moved their

phantom slowly showed less signal change than those who moved their phantom faster and had better phantom limb motor control.

Amputees who have difficulty moving their phantom often exert a lot of effort to move the limb and are frequently exhausted after a visuo-motor feedback training session in which they are required to make repeated phantom limb movements (e.g. Ramachandran and Rogers-Ramachandran, 1996, Moseley, 2006, Chan et al., 2007, Murray et al., 2007, Mercier and Sirigu, 2009, Beaumont et al., 2011). Since amputees with poor motor control showed less signal change during phantom hand movements, the percent signal change does not appear to reflect the effort required to move the phantom. Instead, it might reflect the “ease of access” to motor pathways, with amputees who have greater phantom motor control being better at activating the entire neural circuit associated with phantom hand movements, the result of which is a greater percent signal change in M1.

Our two indicators of cortical reorganization (the displacement of lip and elbow COGs and the abnormal level of hand/elbow and hand/lip overlap) also correlated with the quality of phantom limb motor control. Overall, greater reorganisation within M1-C_{PHANTOM} was associated with worse phantom motor control. Together with the percent signal change data, these results support the idea that good phantom motor control is associated with preserved functional organization of M1-C_{PHANTOM}. This idea is further supported by a separate fMRI study from our group showing greater preservation of the functional connectivity between the SMA and M1 in amputees with good phantom motor control (Raffin et al., submitted).

The level of phantom hand motor control is not the only clinical or behavioral parameter that influenced the functional organization of M1. It is well known that pain is correlated with cortical reorganization within M1 (Knecht et al., 1996, Karl et al., 2001, Lotze et al., 2001, MacIver et al., 2008), and while phantom pain and motor control were highly correlated ($r = 0.68$, $p < 0.05$) we found that both variables were *independently* correlated with reorganisation in M1-C_{PHANTOM}. Thus, our results confirm the finding that reorganisation within M1 is correlated with phantom limb pain, but for the first time demonstrate that it is also correlated with phantom motor control, and that better motor control is associated with less reorganisation in M1-C_{PHANTOM} and more activity during phantom hand movements.

In addition to demonstrating large-scale changes in M1-_{C_{PHANTOM}}, our results also show that the functional organization of M1-_{C_{INTACT}} in upper-limb amputees differs from control subjects. Even though its somatotopic organization, assessed by COG locations, did not differ from that observed in control subjects, the areas activated during hand and elbow movements overlapped significantly more than in control subjects as a result of a significant enlargement of the area activated during intact hand movements. A few previous studies have reported increases in the area activated by intact hand movements (Elbert et al., 1997, Dettmers et al., 2001, Lotze et al., 2001, Maclver et al., 2008), or in their signal intensity (Schwenkreis et al., 2003, Maclver et al., 2008), and there are at least two possible explanations for such changes in the “intact” hemisphere. Numerous animal and human studies have shown that the cortical area associated with an action can increase simply as a result of frequent use or motor learning (e.g. Pascual-Leone and Torres, 1993, Pascual-Leone et al., 1995, Nudo et al., 1996, Classen et al., 1998, Katiuscia et al., 2009, Tyc and Boyadjian, 2011). Thus, the enlarged area activated by intact hand movements might reflect the more frequent and more skilled use of this hand after upper-limb amputation. Alternatively, it might reflect some sort of disinhibition of the ‘intact’ hemisphere arising from a change in inter-hemispheric balance due to the reorganization of M1-_{C_{PHANTOM}}. Indeed, changes in the non-lesioned hemisphere are apparent after stroke as a consequence of alterations in inter-hemispheric inhibitory balance (Liepert et al., 2000, Hamzei et al., 2006).

Two phantom movements, two M1 locations, but one muscle group

Ten of our thirteen amputees did not possess their elbow, so for them the area activated in M1-_{C_{PHANTOM}} during elbow movements was not associated with any physical movement of a body part. The same is true for all of our subjects for hand movements. While there is some confusion about the status of phantom movements (imagined or “real”), there is now sufficient evidence to assert that they are “real” movements that occur in the absence of an effector (Raffin et al., Raffin et al., 2011 submitted). One piece of evidence supporting this assertion is the observation that phantom movements are associated with contractions in stump muscles (Reilly et al., 2006, Gagné et al., 2009). After trans-humeral amputation, the elbow and the muscles controlling the hand are missing, but parts of the muscles that control the elbow remain. Interestingly, in these patients, movements of both the phantom elbow and the phantom hand are associated with contractions in the same group of proximal upper-limb muscles (Reilly et al., 2006, Gagné et al., 2010). In ten of our

thirteen amputees phantom hand and elbow movements were associated with contractions in the same muscles, but while this might partially explain why the cortical activity associated with these two movements overlapped more than in control subjects, it cannot explain why there was a distinct, somatotopically located region of activity associated with each movement.

If the location of motor cortex activity represents which muscles will contract when corticospinal cells in that area depolarize, then it should not be possible to separate fMRI activations associated with phantom elbow and hand movements. The fact that we see distinct and somatotopically ordered activations for these two movements supports the idea that the motor cortex simultaneously represents both muscles and movements (Schieber, 2001). The somatotopic distinction between two movements that are associated with contractions in the same muscle groups might be explained by the fact that a large part of what we observe is activity from higher motor areas related to the incoming motor command, which might maintain its somatotopic relationship with M1 despite the reorganisation of M1 muscle maps. Evidence to support this idea comes from the fact that the location of activity associated with movements of the phantom hand is not affected by the absence of the muscles controlling the hand, but was instead symmetric with the intact hand's location. This finding is in line with previous studies showing that residual motor activity related to the phantom hand maintains its original position within M1-C_{PHANTOM} despite shifts in the location of activity recorded during movements of remaining body parts (Erslund et al., 1996, Roux et al., 2001b, Roux et al., 2003, Mercier et al., 2006).

Therapeutic implications

Despite shifts in the location of activity associated with lip and elbow movements, M1-C_{PHANTOM} was still activated in a somatotopically-appropriate manner during phantom hand movements. This suggests that the reorganization that occurs within M1-C_{PHANTOM} following amputation is not simply the result of a competitive allocation of cortical resources whereby the remaining body parts acquire the deafferented/deafferented territory (Sutton and Reggia, 1994). Indeed, the presence of "residual" phantom-hand-related activity in the reorganised M1-C_{PHANTOM} probably provides the physiological basis for rapid motor improvement following hand allograft

(Giraux et al., 2001). Several studies have demonstrated that reorganisation does not mean deletion of the hand's representation (Ersland et al., 1996, Roux et al., 2001b, Roux et al., 2003, Mercier et al., 2006), but reorganisation and “residual” activity within M1-C_{PHANTOM} have never before been associated with the quality of phantom motor control. Here we show that greater signal change during phantom hand movements and less reorganisation are associated with better phantom motor control. Since phantom motor control and chronic phantom pain are negatively correlated, this suggests that interventions that aim to reverse amputation-induced reorganisation and/or increase the excitability of M1-C_{PHANTOM} should increase phantom motor control and reduce phantom limb pain. Similarly, interventions that aim to increase phantom motor control should reduce phantom pain and *re-reorganise* M1-C_{PHANTOM}. Clinicians have experimented with stimulation of the sensory and/or motor cortex for the treatment of phantom limb pain for many years, but in the few subjects in whom it produces an analgesic effect there is no data concerning the effect on phantom motor control or cortical organisation (Flor et al., 2001, Flor, 2002). Likewise, there are an increasing number of studies examining the analgesic effects of behavioural interventions which aim to reduce phantom pain by increasing phantom motor control, but little physiological data regarding the mechanisms underlying these effects (Ramachandran and Rogers-Ramachandran, 1996, Sathian et al., 2000, Giraux and Sirigu, 2003, McCabe et al., 2003, Chan et al., 2007, McCabe et al., 2008, Yavuzer et al., 2008, Cole et al., 2009, Mercier and Sirigu, 2009). The few studies that examined M1-C_{PHANTOM} activity before and after visuomotor training to improve phantom motor control found that training increased activity levels in M1 during phantom hand movements, improved phantom motor control, and reduced phantom limb pain (Giraux and Sirigu, 2003, Maclver et al., 2008). Future studies need to investigate whether successful interventions also reverse amputation-induced reorganization within M1-C_{PHANTOM}, and whether the initial state of M1-C_{PHANTOM} can explain why certain interventions work for some patients but not others.

REFERENCES:

Ashburner J, Friston KJ. Unified segmentation. *Neuroimage*, 26 (3):839-51, 2005.

Beaumont G, Mercier C, Michon PE, Malouin F, Jackson PL. Decreasing Phantom Limb Pain Through Observation of Action and Imagery: A Case Series. *Pain Med*, 2011.

Birbaumer N, Lutzenberger W, Montoya P, Larbig W, Unertl K, Topfner S, Grodd W, Taub E, Flor H. Effects of regional anesthesia on phantom limb pain are mirrored in changes in cortical reorganization. *J Neurosci*, 17 (14):5503-8, 1997.

- Brett M, Anton J.L., Valabregure R., Poline J.B. (2002) Region of interest analysis using SPM toolbox. In: 8th International Conference on Functional Mapping of the Human Brain Sendai, Japon: NeuroImage.
- Chan BL, Witt R, Charrow AP, Magee A, Howard R, Pasquina PF, Heilman KM, Tsao JW. Mirror therapy for phantom limb pain. *N Engl J Med*, 357 (21):2206-7, 2007.
- Chen R, Corwell B, Yaseen Z, Hallett M, Cohen LG. Mechanisms of cortical reorganization in lower-limb amputees. *J Neurosci*, 18 (9):3443-50, 1998.
- Classen J, Liepert J, Wise SP, Hallett M, Cohen LG. Rapid plasticity of human cortical movement representation induced by practice. *J Neurophysiol*, 79 (2):1117-23, 1998.
- Cohen LG, Bandinelli S, Topka HR, Fuhr P, Roth BJ, Hallett M. Topographic maps of human motor cortex in normal and pathological conditions: mirror movements, amputations and spinal cord injuries. *Electroencephalogr Clin Neurophysiol Suppl*, 43 36-50, 1991.
- Davis KD, Kiss ZH, Luo L, Tasker RR, Lozano AM, Dostrovsky JO. Phantom sensations generated by thalamic microstimulation. *Nature*, 391 (6665):385-7, 1998.
- Dettmers C, Adler T, Rzanny R, van Schayck R, Gaser C, Weiss T, Miltner WH, Bruckner L, Weiller C. Increased excitability in the primary motor cortex and supplementary motor area in patients with phantom limb pain after upper limb amputation. *Neurosci Lett*, 307 (2):109-12, 2001.
- Devanne H, Cassim F, Ethier C, Brizzi L, Thevenon A, Capaday C. The comparable size and overlapping nature of upper limb distal and proximal muscle representations in the human motor cortex. *Eur J Neurosci*, 23 (9):2467-76, 2006.
- Diers M, Christmann C, Koeppel C, Ruf M, Flor H. Mirrored, imagined and executed movements differentially activate sensorimotor cortex in amputees with and without phantom limb pain. *Pain*, 149 (2):296-304, 2010.
- Donoghue JP, Leibovic S, Sanes JN. Organization of the forelimb area in squirrel monkey motor cortex: representation of digit, wrist, and elbow muscles. *Exp Brain Res*, 89 (1):1-19, 1992.
- Elbert T, Flor H, Birbaumer N, Knecht S, Hampson S, Larbig W, Taub E. Extensive reorganization of the somatosensory cortex in adult humans after nervous system injury. *Neuroreport*, 5 (18):2593-7, 1994.
- Elbert T, Sterr A, Flor H, Rockstroh B, Knecht S, Pantev C, Wienbruch C, Taub E. Input-increase and input-decrease types of cortical reorganization after upper extremity amputation in humans. *Exp Brain Res*, 117 (1):161-4, 1997.
- Ersland L, Rosen G, Lundervold A, Smievoll AI, Tillung T, Sundberg H, Hugdahl K. Phantom limb imaginary fingertapping causes primary motor cortex activation: an fMRI study. *Neuroreport*, 8 (1):207-10, 1996.
- Flor H. The modification of cortical reorganization and chronic pain by sensory feedback. *Appl Psychophysiol Biofeedback*, 27 (3):215-27, 2002.
- Flor H, Denke C, Schaefer M, Grusser S. Effect of sensory discrimination training on cortical reorganisation and phantom limb pain. *Lancet*, 357 (9270):1763-4, 2001.

- Flor H, Elbert T, Knecht S, Wienbruch C, Pantev C, Birbaumer N, Larbig W, Taub E. Phantom-limb pain as a perceptual correlate of cortical reorganization following arm amputation. *Nature*, 375 (6531):482-4, 1995.
- Flor H, Elbert T, Muhl nickel W, Pantev C, Wienbruch C, Taub E. Cortical reorganization and phantom phenomena in congenital and traumatic upper-extremity amputees. *Exp Brain Res*, 119 (2):205-12, 1998.
- Fuhr P, Cohen LG, Dang N, Findley TW, Haghghi S, Oro J, Hallett M. Physiological analysis of motor reorganization following lower limb amputation. *Electroencephalogr Clin Neurophysiol*, 85 (1):53-60, 1992.
- Gagné M, Hetu S, Reilly KT, Mercier C. The map is not the territory: Motor system reorganization in upper limb amputees. *Hum Brain Mapp*, 2010.
- Gagné M, Reilly KT, Hetu S, Mercier C. Motor control over the phantom limb in above-elbow amputees and its relationship with phantom limb pain. *Neuroscience*, 162 (1):78-86, 2009.
- Giraux P, Sirigu A. Illusory movements of the paralyzed limb restore motor cortex activity. *Neuroimage*, 20 Suppl 1 S107-11, 2003.
- Giraux P, Sirigu A, Schneider F, Dubernard JM. Cortical reorganization in motor cortex after graft of both hands. *Nat Neurosci*, 4 (7):691-2, 2001.
- Grusser SM, Winter C, Schaefer M, Fritzsche K, Benhidjeb T, Tunn P, Schlag PM, Flor H. Perceptual phenomena after unilateral arm amputation: a pre-post-surgical comparison. *Neurosci Lett*, 302 (1):13-6, 2001.
- Hamzei F, Liepert J, Dettmers C, Weiller C, Rijntjes M. Two different reorganization patterns after rehabilitative therapy: an exploratory study with fMRI and TMS. *Neuroimage*, 31 (2):710-20, 2006.
- Huang CS, Sirisko MA, Hiraba H, Murray GM, Sessle BJ. Organization of the primate face motor cortex as revealed by intracortical microstimulation and electrophysiological identification of afferent inputs and corticobulbar projections. *J Neurophysiol*, 59 (3):796-818, 1988.
- Irlbacher K, Meyer BU, Voss M, Brandt SA, Roricht S. Spatial reorganization of cortical motor output maps of stump muscles in human upper-limb amputees. *Neurosci Lett*, 321 (3):129-32, 2002.
- Jain N, Catania KC, Kaas JH. A histologically visible representation of the fingers and palm in primate area 3b and its immutability following long-term deafferentations. *Cereb Cortex*, 8 (3):227-36, 1998.
- Karl A, Birbaumer N, Lutzenberger W, Cohen LG, Flor H. Reorganization of motor and somatosensory cortex in upper extremity amputees with phantom limb pain. *J Neurosci*, 21 (10):3609-18, 2001.
- Karl A, Muhl nickel W, Kurth R, Flor H. Neuroelectric source imaging of steady-state movement-related cortical potentials in human upper extremity amputees with and without phantom limb pain. *Pain*, 110 (1-2):90-102, 2004.
- Katiuscia S, Franco C, Federico D, Davide M, Sergio D, Giuliano G. Reorganization and enhanced functional connectivity of motor areas in repetitive ankle movements after training in locomotor attention. *Brain Res*, 1297 124-34, 2009.
- Kew JJ, Ridding MC, Rothwell JC, Passingham RE, Leigh PN, Sooriakumaran S, Frackowiak RS, Brooks DJ. Reorganization of cortical blood flow and transcranial magnetic stimulation maps in human subjects after upper limb amputation. *J Neurophysiol*, 72 (5):2517-24, 1994.

- Knecht S, Henningsen H, Elbert T, Flor H, Hohling C, Pantev C, Birbaumer N, Taub E. Cortical reorganization in human amputees and mislocalization of painful stimuli to the phantom limb. *Neurosci Lett*, 201 (3):262-4, 1995.
- Knecht S, Henningsen H, Elbert T, Flor H, Hohling C, Pantev C, Taub E. Reorganizational and perceptual changes after amputation. *Brain*, 119 (Pt 4) 1213-9, 1996.
- Liepert J, Hamzei F, Weiller C. Motor cortex disinhibition of the unaffected hemisphere after acute stroke. *Muscle Nerve*, 23 (11):1761-3, 2000.
- Lotze M, Flor H, Grodd W, Larbig W, Birbaumer N. Phantom movements and pain. An fMRI study in upper limb amputees. *Brain*, 124 (Pt 11):2268-77, 2001.
- Lotze M, Grodd W, Birbaumer N, Erb M, Huse E, Flor H. Does use of a myoelectric prosthesis prevent cortical reorganization and phantom limb pain? *Nat Neurosci*, 2 (6):501-2, 1999.
- MacIver K, Lloyd DM, Kelly S, Roberts N, Nurmikko T. Phantom limb pain, cortical reorganization and the therapeutic effect of mental imagery. *Brain*, 131 (Pt 8):2181-91, 2008.
- Marconi B, Pecchioli C, Koch G, Caltagirone C. Functional overlap between hand and forearm motor cortical representations during motor cognitive tasks. *Clin Neurophysiol*, 118 (8):1767-75, 2007.
- Melgari JM, Pasqualetti P, Pauri F, Rossini PM. Muscles in "concert": study of primary motor cortex upper limb functional topography. *PLoS ONE*, 3 (8):e3069, 2008.
- Mercier C, Reilly KT, Vargas CD, Aballea A, Sirigu A. Mapping phantom movement representations in the motor cortex of amputees. *Brain*, 129 (Pt 8):2202-10, 2006.
- Mercier C, Sirigu A. Training with virtual visual feedback to alleviate phantom limb pain. *Neurorehabil Neural Repair*, 23 (6):587-94, 2009.
- Merzenich MM, Kaas JH, Wall J, Nelson RJ, Sur M, Felleman D. Topographic reorganization of somatosensory cortical areas 3b and 1 in adult monkeys following restricted deafferentation. *Neuroscience*, 8 (1):33-55, 1983a.
- Merzenich MM, Kaas JH, Wall JT, Sur M, Nelson RJ, Felleman DJ. Progression of change following median nerve section in the cortical representation of the hand in areas 3b and 1 in adult owl and squirrel monkeys. *Neuroscience*, 10 (3):639-65, 1983b.
- Merzenich MM, Nelson RJ, Stryker MP, Cynader MS, Schoppmann A, Zook JM. Somatosensory cortical map changes following digit amputation in adult monkeys. *J Comp Neurol*, 224 (4):591-605, 1984.
- Montoya P, Ritter K, Huse E, Larbig W, Braun C, Topfner S, Lutzenberger W, Grodd W, Flor H, Birbaumer N. The cortical somatotopic map and phantom phenomena in subjects with congenital limb atrophy and traumatic amputees with phantom limb pain. *Eur J Neurosci*, 10 (3):1095-102, 1998.
- Moseley GL. Graded motor imagery for pathologic pain: a randomized controlled trial. *Neurology*, 67 (12):2129-34, 2006.
- Murray CD, Pettifer S, Howard T, Patchick EL, Caillette F, Kulkarni J, Bamford C. The treatment of phantom limb pain using immersive virtual reality: three case studies. *Disabil Rehabil*, 29 (18):1465-9, 2007.
- Nudo RJ, Milliken GW, Jenkins WM, Merzenich MM. Use-dependent alterations of movement representations in primary motor cortex of adult squirrel monkeys. *J Neurosci*, 16 (2):785-807, 1996.

- Ojemann JG, Silbergeld DL. Cortical stimulation mapping of phantom limb rolandic cortex. Case report. *J Neurosurg*, 82 (4):641-4, 1995.
- Pascual-Leone A, Nguyet D, Cohen LG, Brasil-Neto JP, Cammarota A, Hallett M. Modulation of muscle responses evoked by transcranial magnetic stimulation during the acquisition of new fine motor skills. *J Neurophysiol*, 74 (3):1037-45, 1995.
- Pascual-Leone A, Torres F. Plasticity of the sensorimotor cortex representation of the reading finger in Braille readers. *Brain*, 116 (Pt 1) 39-52, 1993.
- Penfield WB, E. Somatic motor and sensory representation in the cerebral cortex of man as studied by electrical stimulation. *Brain*, 60 389-443, 1937.
- Plow EB, Arora P, Pline MA, Binstock MT, Carey JR. Within-limb somatotopy in primary motor cortex--revealed using fMRI. *Cortex*, 46 (3):310-21, 2010.
- Qi HX, Stepniewska I, Kaas JH. Reorganization of primary motor cortex in adult macaque monkeys with long-standing amputations. *J Neurophysiol*, 84 (4):2133-47, 2000.
- Raffin E, Giroux P, Reilly KT. The moving phantom: Motor execution or motor imagery? *Cortex*, 2011.
- Raffin E, Reilly K, Giroux P. Disentangling motor execution from motor imagery with the phantom limb.
- Ramachandran VS, Rogers-Ramachandran D. Synaesthesia in phantom limbs induced with mirrors. *Proc Biol Sci*, 263 (1369):377-86, 1996.
- Reilly KT, Mercier C, Schieber MH, Sirigu A. Persistent hand motor commands in the amputees' brain. *Brain*, 129 (Pt 8):2211-23, 2006.
- Ridding MC, Rothwell JC. Reorganisation in human motor cortex. *Can J Physiol Pharmacol*, 73 (2):218-22, 1995.
- Roricht S, Meyer BU, Niehaus L, Brandt SA. Long-term reorganization of motor cortex outputs after arm amputation. *Neurology*, 53 (1):106-11, 1999.
- Roux FE, Ibarrola D, Lazorthes Y, Berry I. Chronic motor cortex stimulation for phantom limb pain: a functional magnetic resonance imaging study: technical case report. *Neurosurgery*, 48 (3):681-7; discussion 7-8, 2001a.
- Roux FE, Ibarrola D, Lazorthes Y, Berry I. Virtual movements activate primary sensorimotor areas in amputees: report of three cases. *Neurosurgery*, 49 (3):736-41; discussion 41-2, 2001b.
- Roux FE, Lotterie JA, Cassol E, Lazorthes Y, Sol JC, Berry I. Cortical areas involved in virtual movement of phantom limbs: comparison with normal subjects. *Neurosurgery*, 53 (6):1342-52; discussion 52-3, 2003.
- Sato KC, Tanji J. Digit-muscle responses evoked from multiple intracortical foci in monkey precentral motor cortex. *J Neurophysiol*, 62 (4):959-70, 1989.
- Schieber MH. Constraints on somatotopic organization in the primary motor cortex. *J Neurophysiol*, 86 (5):2125-43, 2001.
- Schieber MH, Deuel RK. Primary motor cortex reorganization in a long-term monkey amputee. *Somatosens Mot Res*, 14 (3):157-67, 1997.

Schwenkreis P, Pleger B, Cornelius B, Weyen U, Dertwinkel R, Zenz M, Malin JP, Tegenthoff M. Reorganization in the ipsilateral motor cortex of patients with lower limb amputation. *Neurosci Lett*, 349 (3):187-90, 2003.

Sutton GG, Reggia JA. Effects of normalization constraints on competitive learning. *IEEE Trans Neural Netw*, 5 (3):502-4, 1994.

Tyc F, Boyadjian A. Plasticity of motor cortex induced by coordination and training. *Clin Neurophysiol*, 122 (1):153-62, 2011.

Van Essen DC, Drury HA, Dickson J, Harwell J, Hanlon D, Anderson CH. An integrated software suite for surface-based analyses of cerebral cortex. *J Am Med Inform Assoc*, 8 (5):443-59, 2001.

Wall JT, Kaas JH, Sur M, Nelson RJ, Felleman DJ, Merzenich MM. Functional reorganization in somatosensory cortical areas 3b and 1 of adult monkeys after median nerve repair: possible relationships to sensory recovery in humans. *J Neurosci*, 6 (1):218-33, 1986.

Wu CW, Kaas JH. Reorganization in primary motor cortex of primates with long-standing therapeutic amputations. *J Neurosci*, 19 (17):7679-97, 1999.

Yao J, Chen A, Carmona C, Dewald JP. Cortical overlap of joint representations contributes to the loss of independent joint control following stroke. *Neuroimage*, 45 (2):490-9, 2009.

Discussion générale

Nous reviendrons dans un premier temps sur la contribution méthodologique de ce travail. Nous verrons en quoi l'étude du contrôle moteur du membre fantôme s'accorde avec les théories de la perception du mouvement. Puis, nous synthétiserons les différents marqueurs de dysfonctionnement corticaux chez l'amputé et nous ferons un parallèle avec deux autres modèles pathologiques proches du membre fantôme. Enfin, nous replacerons ces résultats dans un contexte médical en discutant de l'intérêt de ces résultats dans la compréhension des mécanismes mis en jeu lors de certaines thérapeutiques antalgiques auprès des personnes amputées, en évoquant quelques pistes de recherche pour le futur.

7. Contribution méthodologique : intérêt de l'approche surfacique

L'approche surfacique des réorganisations corticales après amputation est une méthode innovante développée dans ce travail de thèse.

Rationnel et hypothèses de travail

Cette contribution méthodologique a pour origine la volonté de se rapprocher au mieux de l'architecture et de l'organisation fonctionnelle du cortex. Elle fait suite à d'autres études s'intéressant à la plasticité corticale chez l'amputé. Nous avons détaillé dans le Chapitre 3 de cette thèse les indicateurs topologiques appliqués à l'étude des réorganisations corticales chez l'amputé. Ces indicateurs ont permis notamment de faire apparaître les relations entre les caractéristiques spatiales de l'organisation anatomo-fonctionnelle du cortex sensorimoteur et certaines variables cliniques (Flor et al., 1995, Birbaumer et al., 1997, Lotze et al., 1999a, Giraux et al., 2001). L'approche surfacique que nous proposons permet d'optimiser les possibilités de l'IRM fonctionnelle dans la localisation des activations. Ainsi, le degré de précision atteint avec cette approche surfacique pourrait permettre de décrire des organisations ou réorganisations topologiques indétectables avec les approches volumiques classiques.

Avant de décrire la méthode, nous allons rappeler les fondements théoriques sur lesquels elle repose, et en particulier, les propriétés de l'anatomie microscopique du cortex cérébral. Nous verrons en quoi ces propriétés permettent d'assimiler le cortex, d'un point de vue macroscopique, à une structure à deux dimensions.

Deux notions sont essentielles. D'une part le ruban cortical est organisé en 6 couches horizontales présentes en nombre constant sur toute la surface corticale. Ces couches contiennent des neurones aux propriétés morphologiques et connectiques spécifiques à chacune d'elles, et sont interconnectées verticalement grâce à la présence de colonnes corticales (Toro and Burnod, 2003). L'emplacement des colonnes corticales, leurs caractéristiques et leur organisation définissent localement les caractéristiques cytoarchitectoniques et fonctionnelles du ruban cortical (Mountcastle, 1997). Les relations entre les colonnes sur le ruban cortical définissent différentes sortes de cartes rétinotopiques, tonotopiques ou somatotopiques. Ces caractéristiques microscopiques intrinsèques du ruban cortical forment une structure relativement homogène et

par conséquent, nous permettent d'envisager le cortex comme une surface pour l'analyse de nos données de somatotopie.

En matière de somatotopie précisément, cette approche surfacique permet de résoudre les problèmes géométriques auxquels nous étions confrontés avec des méthodes d'analyse volumique. Par exemple, dans un volume en 3D, deux zones d'activation peuvent être perçues comme très proches, voire superposées alors qu'elles sont en réalité clairement séparées lorsqu'on les représente en 2D sur la surface corticale. L'approche volumique du traitement des données engendre donc des erreurs de localisation ou de mise en correspondance de zones cérébrales, notamment en sous-estimant les distances réelles (Andrade et al., 2001). Ainsi, en plus de procurer une représentation topologiquement et conceptuellement proche de la réalité anatomique du cortex, l'utilisation d'une approche surfacique du cortex permet d'estimer les distances entre les différentes représentations corporelles dans M1 le plus précisément possible en particulier dans les zones très plissées du cortex comme la région de la main du cortex moteur primaire ou « Hand knob » (Rumeau et al., 1994, Yousry et al., 1997, Caulo et al., 2007, Park et al., 2007, Shinoura et al., 2009).

Description de la méthode

Etape 1 : La première étape de traitement consiste à extraire la surface corticale à partir des données d'IRM anatomiques. La reconstruction du cortex est une étape délicate (par exemple Dale et al., 1999). Dans le cadre de l'étude de l'organisation anatomo-fonctionnelle de M1, la topologie, la précision, et la densité du maillage reconstruit, sont les trois principaux critères de qualité. La méthode utilisée est celle implémentée dans le logiciel CARET (Computerized Anatomical Reconstruction and Editing Toolkit), basée sur l'algorithme « SureFit » (Van Essen et al., 2001). En séparant la matière grise de la matière blanche et du liquide céphalorachidien, CARET reforme un maillage triangulaire de la surface médiane du cortex (précisément entre la surface externe de la matière grise et l'interface matière grise/matière blanche). Cette surface médiale permet de concilier une bonne représentation visuelle du cortex et la prise en compte du fond des sillons corticaux qui représente près de 70% de la surface du cortex (Zilles et al., 1988).

Etape 2 : Nous avons ensuite choisi d'introduire une étape intermédiaire de visualisation en deux dimensions grâce à une mise à plat du cortex. En effet, si le cortex peut être considéré comme une surface à deux dimensions, cette surface est fortement convoluée et donc difficile à visualiser. L'algorithme utilisé dans CARET pour aplanir la surface corticale minimise les distorsions métriques en conservant les relations de voisinage (Miller et al., 1993, Christensen et al., 1994). La correspondance anatomique entre la surface aplanie et la surface réelle du cerveau en 3D est préservée. Cette étape permet de définir très précisément sur les maillages individuels de nos sujets, la Région d'Intérêt (ROI) sur laquelle s'effectueront les calculs. Notre ROI comprend la face postérieure du gyrus pré-central de l'Aire de Brodmann (BA) 4, plus précisément, BA 4p et une partie de BA 4a (voire figure 13). D'après les études sur le singe (Strick and Preston, 1982, Kaas and Collins, 2003) et chez l'homme (Geyer et al., 1996), cette région postérieure du cortex moteur présente une activité somatotopique, alors que la partie antéro-médiale de BA 4 ne serait pas mouvement-dépendante mais plutôt impliquée dans les mouvements automatiques (Sharma et al., 2008).

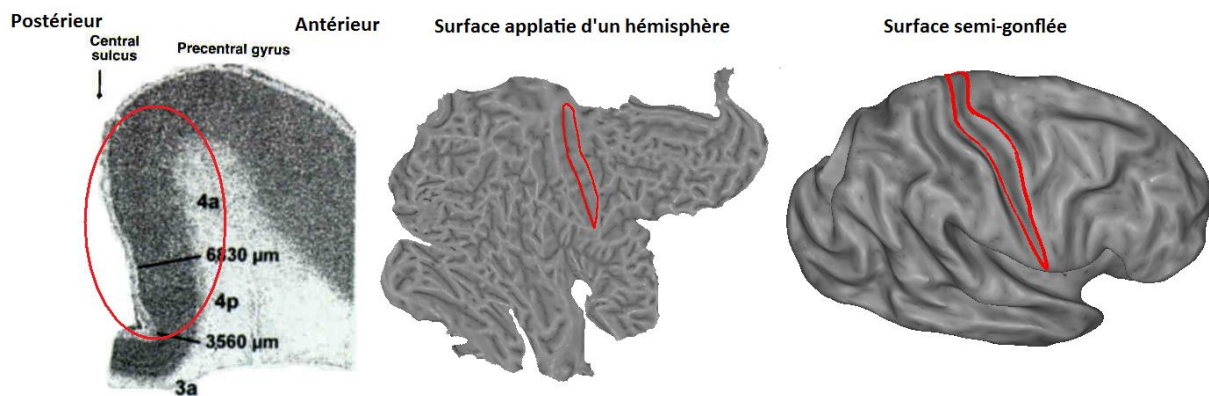


Figure 13 : Coupe transverse du sillon centrale avec la détermination cytoarchitectonique de la séparation entre BA 4a, BA 4p et BA 3a de l'avant vers l'arrière (figure de gauche (d'après Geyer et al., 1996)) ; Région d'Intérêt dessinée sur la flatmap d'un hémisphère d'un sujet (mise à plat de l'IRM anatomique) (figure du milieu) ; Visualisation de la ROI sur une surface partiellement gonflée (inflated) (figure de droite).

Etape 3 : Les cartes statistiques seuillées (SPMt, $p < 0.05$, avec correction pour comparaisons multiples en FWE) correspondant à nos contrastes d'intérêt (chaque mouvement dans notre cas), sont projetées sur le maillage 3D du sujet correspondant. De nombreux travaux ont porté sur les méthodes de projection d'une carte d'activation 3D sur une surface (par exemple Operto et al., 2008). La méthode que nous avons choisi ici fonctionne à partir d'un algorithme de mapping de type « *Interpolated Voxel* » où chaque voxel dans le volume est mis en correspondance avec un nœud du maillage. A ce nœud est attribuée une intensité correspondante à la valeur du voxel central, pondérée par les valeurs des voxels voisins.

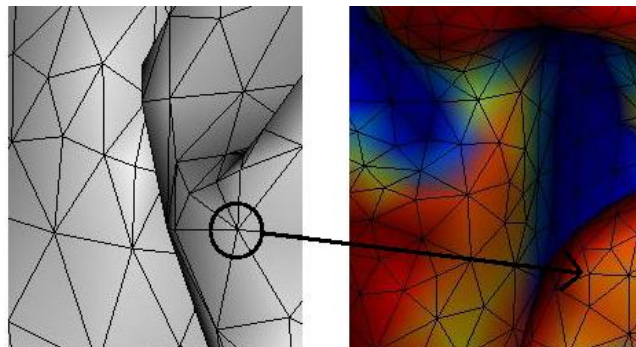


Figure 14 : Une valeur estimée à partir des cartes seuillées (SPMt) est attribuée à chaque nœud du maillage

Etape 4 : Il s'agit d'estimer les Centres de Gravité (CoG) qui serviront de repère pour localiser l'activité somatotopique motrice, à partir des cartes d'activation surfaciques. L'évaluation des distances géodésiques entre les différents CoGs nécessite l'implémentation de l'algorithme de Dijkstra (Dijkstra, 1971 description de l'algorithme p.67 à 73). Cet algorithme permet de résoudre le problème du « plus court chemin » entre deux points, tout en tenant compte des contraintes géométriques du cortex. On obtient alors des mesures de distances basées sur la surface corticale permettant d'estimer des variations très fines dans l'organisation fonctionnelle du cortex.

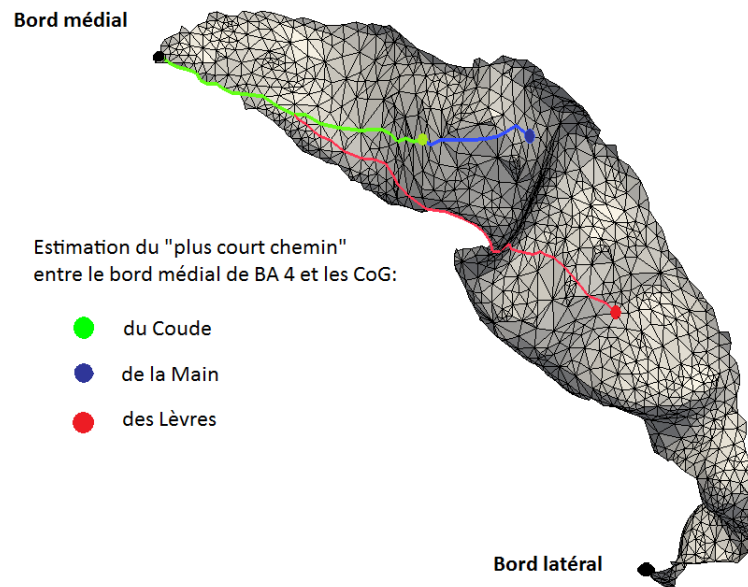


Figure 15 : **Estimation des distances le long de la surface** du mur postérieur de BA 4, entre son bord médial et les CoG des différents mouvements étudiés (main, coude, lèvres).

Perspectives d'évolutions et d'applications de la méthode

Ce travail a nécessité la collaboration de plusieurs chercheurs et l'intégration de différents champs de compétences. A l'heure actuelle, cette méthode est encore fastidieuse. Elle requiert l'utilisation de plusieurs logiciels : SPM pour le calcul des cartes statistiques, CARET pour l'extraction de la surface et des maillages corticaux ainsi que pour la mise à plat du cortex, Matlab pour l'implémentation des calculs et enfin, Paraview pour la comptabilité des formats et la visualisation finale des résultats. Cette méthode d'analyse est un prototype de traitement qui nécessite une intégration. Cette intégration est concevable au sein d'un logiciel de traitement d'imagerie fonctionnelle tel que SPM, sous la forme d'une « toolbox ».

Les intérêts scientifiques d'une telle approche sont multiples, et dépassent notre problématique focalisée sur les réorganisations du cortex moteur. Dans le contexte de l'étude anatomique du cortex, l'approche surfacique permet de quantifier et de comparer la variabilité intra-individuelle ou inter-individuelle particulièrement dans des régions corticales comme la vallée sylvienne (Galaburda et al., 1978), l'aire de Broca (Amunts et al., 1999), ou encore dans le sillon

central (Amunts et al., 1996, Sastre-Janer et al., 1998). La prise en compte de ces variabilités dans les études fonctionnelles peut s'avérer pertinente (Durrleman et al., 2007, Van Essen and Dierker, 2007).

Cette méthode pourrait se généraliser à l'étude de l'organisation topologique d'autres régions corticales. Par exemple, dans l'étude des anomalies de la tonotopie démontrées chez les personnes souffrant d'acouphènes ou de troubles de l'audition (Lutkenhoner and Steinstrater, 1998, Muhlnickel et al., 1998, Thai-Van et al., 2010). Cette méthode peut également s'appliquer à l'étude de l'organisation somatotopique des réponses douloureuses dans le cortex insulaire, cortex qui présente une organisation topologie complexe (Mazzola et al., 2009). Un dernier exemple d'application serait l'étude de la cartographie fonctionnelle des sous-régions pariétales situées au pourtour du sillon intra-pariétal chez l'homme. En effet, cette région a été décrite chez le singe avec une parcellisation en 7 aires distinctes topologiquement organisées (Lewis and Van Essen, 2000), mais chez l'homme cette cartographie fonctionnelle reste à faire.

8. Perceptions motrices dans le membre fantôme

Nous distinguons clairement les sensations kinesthésiques provoquées par l'exécution motrice, de celles provoquées par l'imagerie motrice. Dans les conditions normales, les sensations de mouvements exécutés reposent en grande partie sur des informations sensorielles visuelles, musculaires ou proprioceptives liées au mouvement (par exemple Gandevia and McCloskey, 1976a, Gandevia et al., 2002). Chez l'amputé, la distinction perceptuelle entre mouvement exécuté et imaginé avec le membre fantôme persiste. Mais l'amputation est une situation unique où ni l'exécution, ni l'imagerie motrice ne produisent de mouvement visible.

Un modèle de « mouvements sans mouvement »

Chez l'amputé, les seules informations sensorielles provenant des commandes motrices lors de l'exécution d'un mouvement fantôme sont des contractions musculaires dans le moignon. Ces contractions musculaires sont souvent faibles et incongruentes avec le mouvement désiré ((Reilly et al., 2006). Dans le cas des amputés proximaux (au dessus du coude), ce sont de plus les mêmes muscles du moignon et/ou de l'épaule qui se contractent lors de mouvements fantômes du coude et de la main. Dans ce contexte particulier de réafférences sensorielles faibles et incongruentes, la dissociation entre les mouvements imaginés et les mouvements exécutés est un modèle d'étude du rôle des prédictions sensorielles dans la perception d'un mouvement comme étant exécuté plutôt qu'imaginé.

Nos résultats démontrent l'existence de deux réseaux cérébraux distincts associés à l'exécution et à l'imagerie motrice d'un mouvement de membre fantôme. Les amputés font bien deux tâches différentes dans les deux cas. De manière importante, lorsque les amputés imaginent et exécutent avec leur membre intact, les deux mêmes réseaux sont activés. Par conséquent, il est peu probable que la perception du mouvement « exécuté » chez l'amputé ne repose seulement sur l'interprétation des signaux périphériques liés au mouvement. Si l'on admet qu'un amputé puisse percevoir les sensations d'un véritable mouvement « acté », la mise en jeu d'un réseau cérébral identique dans les deux membres est en faveur d'une origine « endogène » de la perception du mouvement comme étant « exécuté ».

Place de ces résultats dans la théorie des modèles internes

La *théorie des modèles internes* du mouvement (Wolpert et al., 1995) propose que l'exécution d'un mouvement volontaire produise deux sources d'informations: (i) des rétrocontrôles sensoriels des conséquences concrètes du mouvement et (ii) une prédiction de ces rétrocontrôles sensoriels attendus par le mouvement désiré, sous la forme d'une copie d'efférence (von Holst and Mittelstaedt, 1950). Selon ce modèle, ces prédictions sensorielles forment la base de la conscience motrice, alors que les réafférences sensorielles du mouvement produites en cours de mouvement ne sont pas suffisantes ni nécessaires à la perception du mouvement (Blakemore et al., 1998, Wolpert and Ghahramani, 2000, Blakemore, 2003) (Figure 16).

Une extension de cette théorie a été proposée par Grush dans sa *théorie de l'émulation*. Cette théorie permet de comprendre le fonctionnement de l'imagerie motrice dans le cadre des modèles internes (Grush, 2004). Selon Grush, en plus de prédire les conséquences de nos actions, le modèle *forward* permet de générer des images motrices *off line*. Ce type de modèle permet d'éliminer ou d'ajuster le poids des informations sensorielles grâce à un premier comparateur, le filtre de Kalman (Figure 16) (par exemple Gelb, 1974). Le traitement central des retours sensoriels provoqués par le mouvement peut ainsi être atténué voire même annulé. L'anticipation des conséquences de l'action grâce au modèle *forward* permet par exemple de différencier les effets provenant d'un mouvement auto-généré par rapport à une réponse provenant de l'environnement extérieur. Dans le cas de l'imagerie motrice, comme il n'y a pas de prédiction de mouvement par le modèle *forward*, les éventuels signaux périphériques ne sont pas pris en compte. Alors que dans le cas des mouvements exécutés, le filtre de Kalman fait en sorte que les rétrocontrôles du mouvement soient comparés aux prédictions sensorielles du mouvement désiré.

Chez l'amputé, les commandes motrices du membre fantôme sont préservées, ainsi une copie d'efférence « normale » de cet ordre moteur est envoyée aux aires sensorielles. Sur la base de ces copies d'efférence, le modèle *forward* peut estimer la nouvelle position du membre avant même le traitement des informations sensorielles liées au mouvement. Si ces commandes conduisent à la prédiction d'un mouvement, alors un mouvement sera perçu dans le membre fantôme. L'altération des capacités d'exécution motrice dans le membre fantôme pourrait provenir de l'absence de congruence entre les retours sensoriels prédits et réels (voire également

Discussion générale : perceptions motrices dans le membre fantôme

Blakemore et al., 2002). Les mouvements de membre fantôme ne produisent pas les réafférences attendues, créant ainsi une situation d'incongruence lors de la comparaison avec les prédictions du modèle *forward*. La répétition de ces « erreurs » provoquerait un ajustement des modèles internes. Cet ajustement a pour but de réduire l'écart entre les prédictions et les feedbacks réels, engendrant progressivement des difficultés motrices dans le membre fantôme. La préservation des capacités d'imagination, démontrée au cours de cette thèse s'accorde également bien avec cette théorie. En effet, l'imagerie motrice n'étant pas associée à la prédiction d'un mouvement physique, la comparaison entre les retours sensoriels prédits et les retours sensoriels réels (inexistants ou très faibles) ne crée pas de situation d'incongruence. Dans le contexte de ces théories, il n'y a donc pas d'altération des capacités d'imagerie motrice chez l'amputé, mais des capacités d'exécution perturbées.

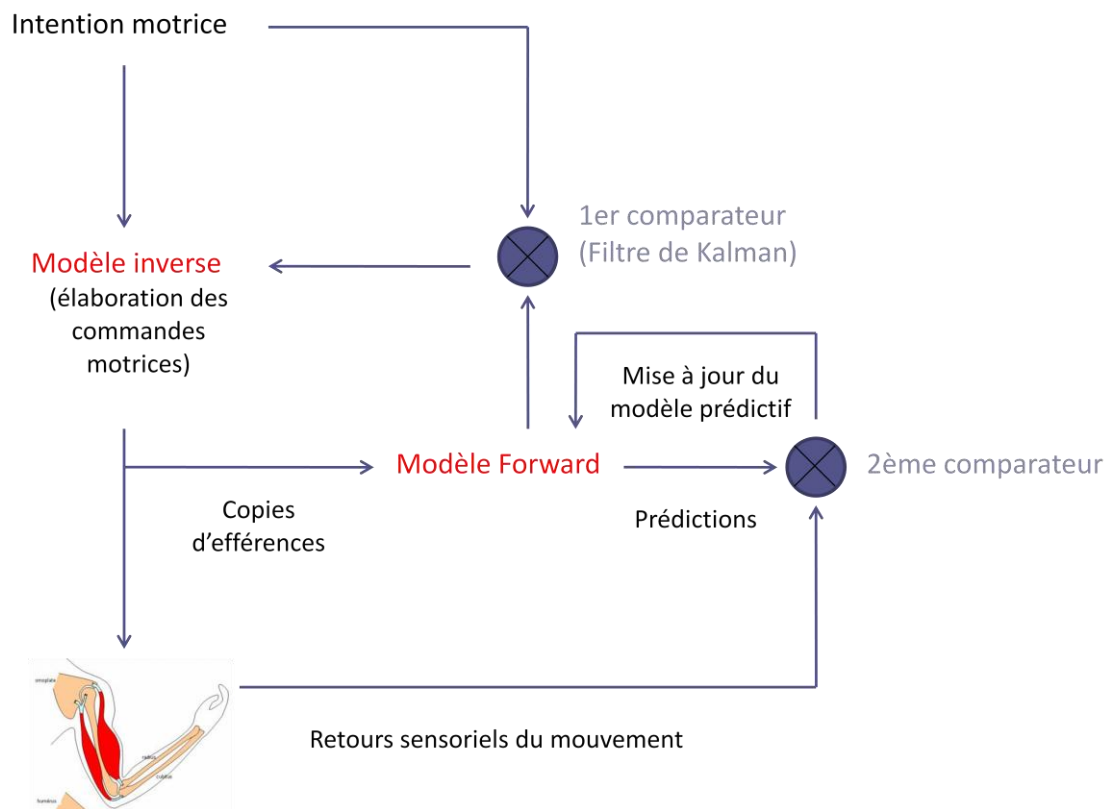


Figure 16 : **Principe des modèles forward** dans le contrôle des mouvements de membre fantôme

L'implémentation cérébrale de la théorie des modèles internes est encore hypothétique et débattue. La perception consciente d'un mouvement reposerait sur un réseau interconnecté qui comprendrait quatre grandes régions: le cortex pariétal postérieur (PPC), l'aire motrice supplémentaire (SMA), le cortex prémoteur (PMC) et le cervelet (Haggard and Whitford, 2004, Gandevia et al., 2006, Desmurget and Sirigu, 2009). De façon intéressante, nos données d'IRM fonctionnelle montrent le recrutement d'aires sensorielles (S1, S2, PPC) et du lobe postérieur du cervelet pendant l'exécution de mouvements de membre fantôme. Ces activations pourraient donc refléter en partie, le traitement des copies d'efférence du mouvement fantôme par les aires sensorielles et ainsi être à la base de la perception du mouvement fantôme comme étant exécuté plutôt qu'imaginé.

Rôle des réafférences ?

Le contrôle des informations proprioceptives pour l'étude de la perception du mouvement implique des techniques complexes d'exclusion fonctionnelle réversible (Gandevia and McCloskey, 1976b, Gandevia et al., 2006), d'exclusion chirurgicale par radicotomie (Taub et al., 1966, Bossom, 1974), ou encore de perturbation sélective par stimulation vibratoire (Goodwin et al., 1972, Romaguere et al., 2003). La pathologie offre également des modèles cliniques de déafférentation dont l'étude est particulièrement intéressante (Rothwell et al., 1982, Jeannerod et al., 1984, Forget and Lamarre, 1987). Les modèles cliniques de déafférentation complète sont très rares (seulement 12 cas recensés dans le monde). Dans ce contexte, l'étude de la motricité fantôme s'avère pertinente. Néanmoins, il est important de reconnaître les limites de ce modèle, le membre fantôme est en fait un « modèle *partiel* » de déafférentation.

Les patients amputés (sans arrachement du plexus brachial) ont des réafférences musculaires provenant du moignon lors de mouvements de membre fantôme. Pour certains auteurs, seule la combinaison des commandes motrices et de des réafférences certes faibles et/ou incongruentes, peut donner des sensations de mouvements dans le membre fantôme. En induisant une ischémie du moignon par brassard pneumatique, Reilly et al. ont provoqué une sensation de paralysie transitoire chez trois amputés distaux testés (Reilly et al., 2006). A l'inverse, une anesthésie locorégionale provoquant une paralysie complète pratiquée chez des sujets volontaires sains, peut induire un « membre fantôme » temporaire, associé à des perceptions de mouvements (Gandevia, 1982, Gandevia et al., 2006, Christensen et al., 2007, Smith et al., 2009). Un autre

modèle pathologique plaide plus radicalement pour une origine «endogène» de la perception du mouvement, il s'agit de l'avulsion du plexus brachial (APB). Ces patients APB peuvent percevoir des sensations de mouvements alors qu'ils n'ont plus du tout de réafférences musculaires ni proprioceptives (Bossom, 1974, Giroux and Sirigu, 2003, Finnerup et al., 2010). Il semblerait donc que dans certains cas pathologiques, les commandes motrices seules suffisent à générer une perception de mouvement.

L'étude des mouvements de membre fantôme ne permet donc pas de conclure définitivement sur l'origine endogène de la perception du mouvement. Nous suggérons néanmoins que les contractions musculaires ne peuvent pas être l'unique explication des différences perceptuelles entre les mouvements exécutés et imaginés chez les amputés. Le recrutement d'aires sensorielles telles que S1 et S2 pendant les mouvements exécutés de membre fantôme ne serait pas complètement induit par les afférences sensitives, mais serait aussi en rapport avec une copie d'efférence. La prédiction des conséquences sensorielles de la commande motrice sous-tendrait la perception du mouvement comme étant exécuté.

La démonstration expérimentale de cette hypothèse nécessiterait dans un premier temps de quantifier précisément l'intensité des rétrocontrôles musculaires dans le moignon pendant les mouvements de membre fantôme et d'observer si cette mesure est corrélée à l'intensité du signal BOLD dans les aires sensorielles. Dans le cas où il n'y aurait pas de corrélation, l'activation des aires sensorielles serait indépendante des afférences sensitives. Une autre perspective d'étude serait de réaliser le même type d'expérience chez des patients BPA. La différenciation entre exécution et imagerie motrice en IRMf chez ces patients BPA qui ont une dé-efférentation complète serait un modèle très intéressant pour rechercher les bases purement cognitives de la perception du mouvement comme étant exécuté.

9. Un modèle de plasticité « expérience-dépendante »

Les perturbations du fonctionnement cortical chez l'amputé sont associées à des difficultés motrices ainsi qu'à des douleurs. L'étude des corrélats neuronaux du contrôle moteur du membre fantôme offre un modèle intéressant de modifications corticales néfastes, identiques à celles générées par des situations extrêmes de sur-utilisation ou de non-usage. Ce modèle permet de synthétiser quelques uns des dysfonctionnements cérébraux communs à d'autres déficiences motrices, au sein d'un cerveau « structurellement *invariant* ».

Réorganisations topologiques du cortex moteur primaire

Les données obtenues au cours de cette thèse confirment les données antérieures montrant l'expansion sélective de l'activation des lèvres vers la zone corticale de la main amputée (Elbert et al., 1994, Knecht et al., 1996, Karl et al., 2001, Lotze et al., 2001, Karl et al., 2004). La comparaison de la position des CoGs des lèvres révèle un déplacement médial d'environ 7% (+/- 9%) dans l'hémisphère controlatéral à l'amputation par rapport à la position des lèvres dans le cortex moteur controlatéral au membre intact. Au-delà de ce résultat attendu, nous avons pu également répliquer les données d'électrophysiologie sur l'animal montrant un déplacement latéral des représentations des muscles proximaux à l'amputation (Donoghue et Sanes, 1988; Qi, Stepniewska et Kaas, 2000; Schieber, M. H., 1997; Wu et Kaas, 1999). La position des CoGs du coude du côté de l'amputation est en moyenne, 4% (+/- 2%) plus latérale. Nous avons montré que ces déplacements topologiques sont corrélés négativement à la qualité du contrôle moteur dans le membre fantôme. En d'autres termes, plus un sujet amputé aura conservé une bonne capacité de mouvement dans son membre fantôme, plus l'organisation somatotopique dans M1 sera préservée.

Recouvrement spatial des activations corticales

La résultante de ces réorganisations topologiques est la présence d'un recouvrement spatial anormal entre les patterns d'activation, en particulier pour le coude et la main fantôme. La signification fonctionnelle de ce recouvrement anormal n'est pas bien connue. Un certain degré de chevauchement entre les représentations des muscles dans M1 garantit son fonctionnement

optimal en permettant une commande motrice intégrée des mouvements complexes (par exemple Devanne et al., 2006, Marconi et al., 2007, Melgari et al., 2008). Néanmoins, une zone corticale spécifique à chaque mouvement serait un pré-requis essentiel pour la production de gestes précis (Meier et al., 2008, Plow et al., 2010). Par exemple, le recouvrement partiel des doigts, du coude et de l'épaule permet le codage des mouvements globaux de préhension, mais la partie corticale spécifique à chaque segment est responsable de la motricité fine. Logiquement, l'exagération du recouvrement cortical mesuré chez l'amputé est corrélée négativement avec la qualité du contrôle moteur dans le membre fantôme. La présence de ce recouvrement cortical anormal pourrait être associée aux difficultés que rapportent les personnes amputées à individualiser les mouvements de membre fantôme et plus globalement à la diminution du répertoire moteur dans le membre fantôme. Ce résultat chez l'amputé est important car corrobore les résultats rapportés chez les patients hémiparétiques présentant des déficits moteurs (Yao et al., 2009). Ce chevauchement important avait précédemment été noté chez l'amputé mais jamais quantifié (Giroux et al., 2001, Lotze et al., 2001, Maclver et al., 2008).

Activité résiduelle du cortex moteur primaire

Les réorganisations topologiques du cortex moteur, qui se manifestent par une expansion des aires corticales adjacentes vers le cortex déafférenté, n'empêchent pas la persistance d'une activité motrice résiduelle liée aux mouvements du membre fantôme. Nous avons confirmé les résultats d'études précédentes montrant que la portion de cortex moteur déafférenté contrôlant autrefois la main amputée continue de contrôler les mouvements de la main fantôme (Lotze et al., 2001, Roux et al., 2001, Roux et al., 2003, Mercier et al., 2006, Maclver et al., 2008, Touzalin-Chretien et al., 2009). Ces résultats suggèrent que plutôt qu'un envahissement drastique des zones corticales adjacentes vers la zone corticale déafférentée, on assisterait à une forme de « cohabitation » au sein du même territoire cortical, entre les représentations des segments adjacents et celle du membre amputé (Reilly and Sirigu, 2008). De manière importante, nous avons montré que l'activité résiduelle du cortex moteur lors des mouvements de membre fantôme présentait un fonctionnement perturbé. Son intensité est dépendante de la qualité du contrôle moteur dans le membre fantôme. Autrement dit, plus un amputé aura conservé de bonnes capacités motrices dans son membre fantôme, plus l'intensité du signal dans le cortex moteur lors des mouvements de la main fantôme sera grande. Il n'y a pas d'étude en neuroimagerie ayant

étudié précisément le lien entre l'activité motrice résiduelle lors de mouvements de membre fantôme et les capacités motrices de ce membre fantôme. Il faut néanmoins noter que les patients recrutés dans nos études présentent une capacité motrice variable, mais globalement bonne comparés à ceux de l'étude de Giroux et al. (2003) qui en conséquence recrutent très peu le cortex moteur primaire lors des mouvements de membre fantôme.

Recrutement d'aires « compensatrices »

En plus de ces trois premiers marqueurs cérébraux reliés à la capacité motrice du membre fantôme, nos données ont montré que les amputés présentant plus de difficultés à exécuter des mouvements avec leur membre fantôme, ont une sur-activation du cortex prémoteur, plus particulièrement de l'Aire Motrice Supplémentaire (AMS). Nous avons interprété cette sur-activité comme un mécanisme de « compensation », tentant de palier à la déficience fonctionnelle de M1 chez ces mêmes sujets.

Connectivité cérébrale altérée

Cette déficience fonctionnelle de M1 s'exprime également à travers les résultats de l'analyse de connectivité cérébrale entre M1 et l'AMS. Alors que dans l'hémisphère correspondant au membre intact, les interactions entre les deux aires corticales sont équilibrées, ce couplage fonctionnel M1 ↔ AMS dans l'hémisphère controlatéral à l'amputation est altéré. Les connections descendantes (de type top-down) entre l'AMS vers M1 sont plus fortes par rapport aux connections ascendantes (de type bottom-up) de M1 vers l'AMS. Ce déséquilibre est d'autant plus marqué chez les patients amputés bougeant très peu leur membre fantôme. Ces résultats ainsi que ceux provenant d'autres pathologies, l'hémiplégie (voire Grefkes and Fink, 2011 pour revue), la maladie d'Alzheimer (par exemple Agosta et al., 2011), la maladie de Parkinson (par exemple Rowe et al., 2010), ou encore la sclérose en plaques (par exemple Rocca et al., 2007a) suggèrent que l'altération des interactions intracorticales entre certaines régions motrices, pourraient être un autre mécanisme physiopathologique de la déficience motrice.

Perturbations de l'excitabilité corticale et altérations morphologiques

Nous n'avons pas utilisé de techniques de TMS permettant d'investiguer les perturbations électrophysiologiques, notamment dans les circuits inhibiteurs intra-corticaux chez nos sujets amputés. Mais les données de la littérature rapportent des signes de perturbation à travers notamment une augmentation de l'excitabilité corticale de l'hémisphère controlatéral à l'amputation (Hall et al., 1990, Cohen et al., 1991a, Kew et al., 1994, Ridding and Rothwell, 1995, Pascual-Leone et al., 1996, Chen et al., 1998a, Dettmers et al., 1999, Roricht et al., 1999, Karl et al., 2001). Il serait alors intéressant d'inclure des mesures en TMS dans les futures études et d'étudier le lien entre ces perturbations et l'excitabilité corticale et d'autres paramètres mesurés en IRM fonctionnelle par exemple.

Par ailleurs, peu d'études ont examiné les altérations structurales du cortex après amputation de membre chez le singe ou chez l'homme (voire Jones, 2000 pour revue). L'analyse morphologique du cortex en VBM (Voxel-based morphometry) (Good et al., 2001) serait intéressante chez l'amputé. Deux études histopathologiques chez le singe après déafférentation suggèrent que le tronc cérébral, les noyaux thalamiques ou le cortex somatosensoriel soient atrophiés (Florence et al., 1998, Jones and Pons, 1998). Une seule étude à notre connaissance a recherché la présence de marqueurs anatomiques de l'amputation chez l'homme. Draganski et al. ont montré en VBM, une diminution de la matière grise dans le thalamus postérolatéral chez les amputés traumatiques par rapport à des sujets volontaires sains. La corrélation positive entre ces variations structurales dans le thalamus et l'ancienneté de l'amputation soutient l'hypothèse que ces altérations se produisent en réponse à l'absence chronique de réafférences provenant du membre absent. De même, l'étude de l'intégrité du faisceau cortico-spinal en DTI (Diffusion Tensor Imaging) (Ciccarelli et al., 2008) serait pertinente chez l'amputé. Les séquences de DTI acquises pendant notre examen de somatotopie (étude 3) pourront procurer des résultats intéressants pour éventuellement rechercher un lien entre les altérations fonctionnelles et/ou anatomiques du cortex, et les altérations du faisceau cortico-spinal.

Comparaison aux autres situations de déficience motrice associées à des perturbations du fonctionnement cortical

Les perturbations du fonctionnement cortical chez l'amputé ne sont pas spécifiques à l'amputation. Un certain nombre de ces phénomènes ont été rapportés dans d'autres situations de déficiences motrices, situations qui de façon importante, ne présentent pas de lésion apparente du névraxe (Tableau 1). Ces altérations, apparentées à des mécanismes de plasticité « expérience-dépendante » sont associées à un déficit moteur et quelques fois au développement d'une douleur neuropathique.

Le modèle le plus simple d'étude de la plasticité « expérience-dépendante » est celui de l'immobilisation de membre. Le mécanisme d'induction, la sous-utilisation prolongée d'un membre, induit des déficits sensorimoteurs (Moisello et al., 2008) ne s'expliquant pas uniquement par des altérations du système musculosquelettique. L'immobilisation entraîne également un certain nombre de changements au sein du système nerveux central comme une diminution de la représentation corticale du membre immobilisé (Liepert et al., 1995), des modifications des propriétés d'excitabilité du cortex moteur (Facchini et al., 2002, Kaneko et al., 2003, Zanette et al., 2004, Roberts et al., 2007) ou encore un recrutement d'aires corticales compensatrices notamment dans le cortex ipsilatéral (Weibull et al., 2011).

Les effets corticaux de l'immobilisation liés à une « déprivation sensori-motrice », se retrouvent chez l'amputé ainsi que dans le Syndrome Dououreux Régional Complexe (SDRC de type I et II). Chez les patients atteints du SDRC, l'organisation somatotopique de M1 et S1 est également perturbée (Juottonen et al., 2002, Maihofner et al., 2003, Pleger et al., 2004, Krause et al., 2006b, a, Pleger et al., 2006, Maihofner et al., 2007), une augmentation de l'excitabilité du cortex moteur controlatéral ((Birklein and Handwerker, 2001) accompagnée d'altérations morphologiques ont été rapporté (Geha et al., 2008). A la différence des patients amputés ou souffrant de SDRC, le système nerveux périphérique est intact dans le cas de l'immobilisation pure.

La dystonie focale est associée à des propriétés corticales en partie communes aux trois autres pathologies. Ce syndrome est développé par des personnes ayant une activité manuelle stéréotypée et intensive, par exemple chez les musiciens ou les écrivains (voire Berardelli et al., 1998 pour revue). Cette situation de sur-utilisation est un modèle fonctionnellement opposé à

celui de l'immobilisation exposé ci-dessus. Ce syndrome se traduit néanmoins par la perte du contrôle moteur d'un ou de plusieurs doigts, associée au niveau des cartes sensorimotrices, à une promiscuité voire à la fusion des représentations somatotopiques des doigts dans M1 et dans S1 (Elbert et al., 1995, Bara-Jimenez et al., 1998, Quartarone et al., 2003). D'autres études en neuroimagerie ont également montré un recrutement plus important du cortex prémoteur (Ceballos-Baumann et al., 1995, Ceballos-Baumann et al., 1997, Playford et al., 1998) ainsi que des anomalies dans la connectivité inter-hémisphérique entre M1 et le cortex pré-moteur (Koch et al., 2008) pendant des mouvements volontaires de la main lésée et des segments de membre intacts. Les patients atteints de dystonie focale de la main présentent également des circuits d'inhibition intra-corticaux altérés (par exemple Rona et al., 1998, Granert et al., 2011). En plus de ces résultats se rapprochant des signes d'altérations corticales rapportés chez l'amputé, les patients atteints de dystonie décrivent fréquemment des sensations de « crampes douloureuses » dans leur main lésée, ce qui est également très proche de ce que rapportent les patients amputés dans le membre fantôme.

Ainsi, des situations extrêmes de sur-utilisation (dystonie focale) ou de non-usage (immobilisation), qui reposent sur des mécanismes fonctionnellement opposés, peuvent partager certains dysfonctionnements corticaux, présents également chez l'amputé. L'exploration comparative des altérations corticales s'appliquant à ces déficiences fonctionnelles, permettrait de mieux caractériser les mécanismes corticaux en partie communs, ou au contraire spécifiques. Il nous semble alors pertinent de chercher à décloisonner la physiopathologie de chacune de ces situations cliniques de dysadaptation. La meilleure connaissance de ces mécanismes permettrait d'envisager des actions préventives et permettrait d'expérimenter de nouvelles pistes thérapeutiques.

	AMPUTATION	DYSTONIE FOCALE	IMMOBILISATION	SDRC I et II
Réorganisation topologique des aires adjacentes	S1 & M1	S1 & M1	S1 & M1	?
Activité résiduelle dans M1 lors de mouvements du membre déficient/absent	↗ ou ≈	↗	↘	↗
Recrutement d'aires "compensatrices"	↗ CPM	↗ CPM	↗ CPM + ↗ Hem ipsilat	↗ S1 et S2
Connectivité cérébrale altérée	AMS ↔ M1	PM, NGC ↔ M1	?	X
Propriétés d'excitabilité de M1-c	↗	↗	↗ (parfois ↘)	↗
Altérations morphologiques Substance grise Substance blanche	↘ Thalamus	↘ M1-c	↘ M1-c	↘ CPFVM, Ins, NGC

Tableau 1 : **Récapitulatif des altérations corticales** rapportés dans l'amputation, la dystonie focale, l'immobilisation de membre et le Syndrome Douleurux Régional Complexe (SDRC) ; M1-c : Cortex Moteur primaire controlatéral; S1-c : cortex somatosensoriel priamire controlatéral; AMS : Aire Motrice Supplémentaire ; CPFVM : cortex pré-frontal ventromédian ; Ins. : Insula ; NGC : Noyaux Gris Centraux ; CPM : Cortex Pré-Moteur.

10. Contrôle moteur du membre fantôme et thérapies antalgiques

Les résultats de cette thèse mettent en évidence les liens entre les dysfonctionnements corticaux chez l'amputé et des variables cliniques modulables de façon comportementale, comme la motricité du membre fantôme. La démonstration de l'existence de ces liens peut apporter des arguments aidant à la compréhension des mécanismes antalgiques de certaines thérapies. Jusqu'alors, seules des preuves indirectes reliaient les réorganisations fonctionnelles du cortex moteur primaire et les capacités motrices du membre fantôme.

Ces preuves indirectes reposent en premier lieu sur les études en neuroimagerie qui établissent une relation de corrélation positive entre l'importance des réorganisations dans le cortex moteur primaire, et l'intensité des douleurs chroniques (par exemple Karl et al., 2001, Lotze et al., 2001). Indirectement, cette première relation est complétée par les résultats des études cliniques interventionnelles qui montrent que l'entraînement moteur du membre fantôme provoque une baisse des douleurs de membre fantôme conjointement à une normalisation du fonctionnement de M1 (Giroux and Sirigu, 2003, Maclver et al., 2008). Puis, la seconde preuve indirecte provient de la démonstration tardive de la relation entre la qualité du contrôle moteur dans le membre fantôme et les douleurs de membre fantôme Gagné et al. (2009). Ces auteurs montrent que les patients les moins rapides pour exécuter un cycle complet de mouvement avec leur membre fantôme, sont les patients les plus douloureux.

En plus d'avoir répliqué ces deux premières relations dans ces travaux de thèse, nos résultats indiquent pour la première fois une relation directe entre la motricité fantôme et les réorganisations fonctionnelles dans M1. Nous montrons qu'un amputé ayant un bon contrôle moteur dans son membre fantôme présente une organisation somatotopique dans M1 préservée, et une activité motrice plus intense lors des mouvements de membre fantôme. Au niveau thérapeutique, ce résultat conforte les résultats cités précédemment suggérant que l'entraînement visuomoteur du membre fantôme permet de « réactiver » le programme moteur correspondant aux mouvements fantômes (Giroux and Sirigu, 2003). Si cette augmentation de l'activité de la main fantôme s'opère, intuitivement, les aires des segments adjacents comme le coude ou les lèvres devraient retrouver progressivement leur locus initial au sein de M1. L'hypothèse d'une *réversibilité* des cartes motrices a été avancée dans certaines études chez l'amputé, par exemple après un

entraînement moteur (Maclver et al., 2008) et également dans S1, après un entraînement tactile (Flor, 2002). Lors d'allogreffe de mains, on observe également une « ré-activation » de la représentation de la main greffée (Giroux et al., 2001) parallèlement à une diminution des aires corticales des segments voisins (Vargas et al., 2009).

Alors que l'entraînement tactile du moignon est moins utilisé cliniquement, la motricité résiduelle du membre fantôme est de plus en plus sollicitée à travers des protocoles d'entraînement moteurs (Sherman et al., 1989, Brodie et al., 2003, Moseley and Brugger, 2009, Ulger et al., 2009), dans le but de freiner voire de renverser les transformations topologiques associées aux douleurs fantômes. Ulger et al. montrent qu'un entraînement moteur du membre fantôme pendant quatre semaines provoque une diminution des douleurs fantômes de façon plus importante qu'un protocole de rééducation classique (Ulger et al., 2009). De même, l'étude de Maclver et al. montre une baisse significative des douleurs après six semaines d'entraînement moteur du fantôme pour neuf patients amputés sur treize. Parallèlement, ces auteurs utilisent l'IRM fonctionnelle chez leurs patients pour mesurer les corrélats neuronaux de cet entraînement moteur. Ils montrent bien que l'envahissement de la représentation des lèvres vers celle de la main amputée, diminue conjointement à la baisse des douleurs dans le membre fantôme après la période d'entraînement moteur (Maclver et al., 2008).

Nos données suggèrent néanmoins, un certain niveau de complexité dans les mécanismes de réversibilité des réorganisations des cartes corticales. Le modèle d'une attribution des ressources corticales de M1, selon un simple processus d'allocation compétitive, permet de comprendre simplement les effets du non-usage du membre, mais n'est pas compatible avec nos résultats. Dans l'étude 3, l'expansion des représentations des segments adjacents vers celle de la main fantôme n'est pas associée à une *diminution en proportion* de l'aire corticale de la main fantôme. Il existe un fort degré de recouvrement spatial entre les activations de la main et du coude du côté de l'amputation, témoignant davantage d'une situation de « désorganisation » que d'une situation de redistribution compétitive des ressources. La réversibilité de cette « désorganisation » ne serait donc pas aussi évidente que dans le cas d'une simple allocation compétitive des ressources.

Cette complexité des mécanismes neuronaux mise en évidence après une amputation est une première explication aux effets contrastés des thérapies proposées aux personnes amputés ciblant la restitution d'une organisation corticale « normale ».

Les études s'intéressant aux effets antalgiques de l'utilisation du rétrocontrôle artificiel du membre absent chez l'amputé reposent majoritairement sur des études de cas ou des études de faibles cohortes, dressant par conséquent, un bilan plutôt optimiste des effets de ces thérapies (Hunter et al., 2003, MacLachlan et al., 2004, Murray et al., 2006, Murray et al., 2007, Schwarzer et al., 2007, Sumitani et al., 2008, Mercier and Sirigu, 2009, Schwarzer et al., 2009, Seidel et al., 2009, Hanling et al., 2010, Sumitani et al., 2010). Il existe seulement quatre études contrôlées et randomisées s'intéressant à l'efficacité des thérapies miroirs chez l'amputé (Brodie et al., 2003, Moseley, 2006, Brodie et al., 2007, Chan et al., 2007). Dans une première étude, Brodie et al. mettent en évidence le rôle facilitateur de la vision sur la motricité fantôme (Brodie et al., 2003) mais dans un second temps, ils montrent une diminution équivalente des douleurs chez 80 patients, qu'ils pratiquent un entraînement moteur du membre fantôme avec ou sans rétrocontrôle visuel (Brodie et al., 2007). Ils concluent donc que la restitution du rétrocontrôle visuel du membre absent a un effet sur les sensations motrices mais n'apporte pas de bénéfice antalgique supplémentaire. Au contraire, Chan et al. (2007) montrent que l'ensemble des 6 patients amputés du membre inférieur ayant pratiqué 4 semaines de 15 minutes de thérapie miroir quotidienne ont une diminution des douleurs fantômes, contrairement aux résultats des deux autres groupes (l'un s'entraînant avec miroir opaque et l'autre pratiquant de l'imagerie motrice seule). Néanmoins, les modalités de pratique dans les trois groupes ne sont pas été décrites en détails (le type de mouvements, le type d'imagerie motrice, le nombre de répétition...).

Certes encourageants, ces résultats sont relativement contrastés en termes d'effets moteurs (jamais quantifiés) et d'intensité/durée de l'effet antalgique. Le faible niveau de détails concernant les modalités de pratique rendent ces études difficilement reproductibles. De plus, la grande majorité des études montrent que seule une partie des patients répond à ce type de thérapie (voire McAvinue and Robertson, 2011 pour revue). Les raisons de cette disparité ne sont pas clairement définies. Giroux et Sirigu proposent que le temps écoulé depuis la déafférentation prédirait négativement l'efficacité de la thérapie miroir (Giroux and Sirigu, 2003). Cette hypothèse demeure cependant très spéculative car des effets antalgiques sont également rapportés par des patients

ayant eu une amputation ou un arrachement du plexus brachial très longtemps auparavant (par exemple Ramachandran and Rogers-Ramachandran, 1996, Murray et al., 2007, Mercier and Sirigu, 2009).

Il se pourrait également que la variabilité inter-patient et inter-étude provienne des consignes données aux patients pendant la thérapie-miroir, qui conduiraient à des modalités de pratiques différentes. Même si selon certains auteurs, le miroir suffit à induire à lui-seul un effet sur la douleur (Garry et al., 2005, Fukumura et al., 2007, Matthys et al., 2009, Michielsen et al., 2011), il est le plus souvent combiné à une tâche motrice. En conséquence, plusieurs modes de pratique naissent des différentes combinaisons possibles entre la restitution du rétrocontrôle visuel du membre absent et la tâche motrice effectuée dans le membre absent/déficient. L'application de la thérapie miroir à d'autres situations pathologiques permet de mieux dissocier les différentes tâches et de mieux comprendre leurs conséquences sur l'entraînement moteur ou les douleurs. Dans le cadre des thérapies miroirs proposées aux patients hémiplésiques ou présentant des douleurs chroniques (par exemple un SDRC), il est possible de distinguer au moins quatre stratégies thérapeutiques pour la main déficiente: l'observation passive (Fukumura et al., 2007, Franceschini et al., 2010) (voire Garrison et al., 2010 pour revue), l'imagerie motrice (Moseley, 2004a, McCabe et al., 2008), la tentative d'exécution motrice (Altschuler et al., 1999, Sathian et al., 2000, Stevens and Stoykov, 2003, Yavuzer et al., 2008), ou encore une mobilisation passive de la main déficiente (par exemple Fukumura et al., 2007) (Figure 17).

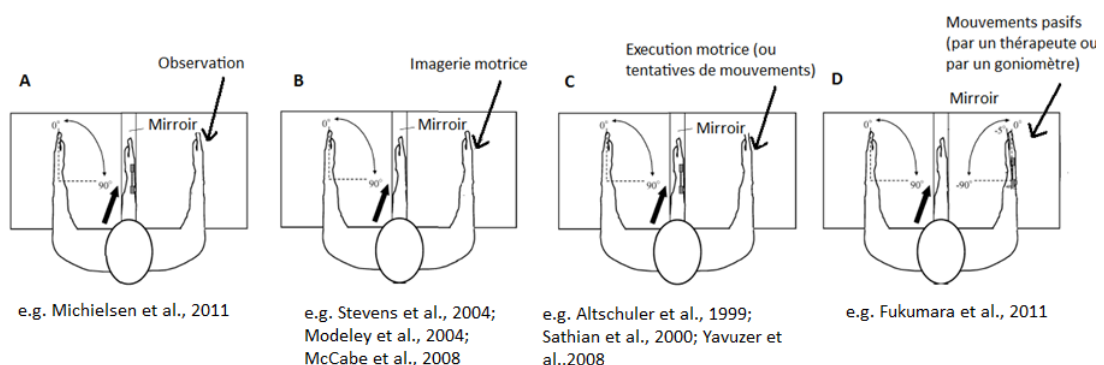


Figure 17 : Différentes modalités de pratique associées à la thérapie miroir (A : Observation, B : Imagerie motrice, C : Exécution motrice ; D : Mouvements passifs)

Altschuler et al. sont les premiers à avoir utilisé la thérapie miroir associée à l'exécution motrice dans le cadre de la récupération motrice du membre supérieur chez le patient hémiplégié. Dans une étude randomisée en cross-over, ils rapportent une augmentation de l'amplitude des mouvements, de la vitesse et de la précision des mouvements du membre supérieur lésé (Altschuler et al., 1999). Quelques études contrôlées et randomisées chez l'hémiplégié (Altschuler et al., 1999, Dohle et al., 2009, Michielsen et al., 2010) ainsi que des séries de cas sans groupe contrôle ont reproduit ces résultats. Cependant la répercussion de ces effets sur le plan fonctionnel reste limitée et ne perdurent pas (Sathian et al., 2000, Yavuzer et al., 2008, Dohle et al., 2009, Michielsen et al., 2010). Il existe également des preuves limitées concernant les effets de la thérapie miroir dans la récupération motrice après fracture (Altschuler and Hu, 2008) ou chirurgie de la main (Rosen and Lundborg, 2005) où les patients exécutent des mouvements de façon symétrique face au miroir (en bougeant le membre lésé du mieux qu'ils peuvent) (voire également Ezendam et al., 2009 pour revue, Rothgangel et al., 2011).

L'imagerie motrice peut être employée en remplacement à l'exécution motrice lorsque celle-ci est impossible ou trop douloureuse. Lorsque l'imagerie motrice est utilisée, couplée à la thérapie miroir, les études de cas chez l'hémiplégié montrent une amélioration de la fonction motrice mesurée par une augmentation du score à l'échelle de Fugl-Meyer (Stevens and Stoykov, 2004). L'utilisation de la thérapie miroir couplée à l'imagerie motrice a également montré des effets antalgiques intéressants auprès de patients atteints de SDRC mais les conditions de pratique restent relativement confuses (McCabe et al., 2003, Karmarkar and Lieberman, 2006, Vladimir Tichelaar et al., 2007, McCabe et al., 2008, Selles et al., 2008, Bultitude and Rafal, 2010, Helekar et al., 2010). Moseley et al. ont obtenu des résultats intéressants avec la thérapie miroir mais lorsque celle-ci est intégrée à un programme rééducatif complet, incluant exercices de rotation mentale et imagerie motrice (Moseley, 2004a, 2005, 2006). La diminution des douleurs chez des patients amputés et des patients souffrant de SDRC est corrélée à l'amélioration des performances en imagerie motrice dans le membre paralysé ou fantôme. Il est cependant impossible de dissocier les effets antalgiques propres à chaque composante de cette thérapie de Moseley (Rotation mentale/Imagerie motrice/Thérapie miroir).

Par ailleurs, l'utilisation de l'imagerie motrice seule (sans rétrocontrôle visuel), dans le cadre de la récupération motrice des sujets hémiplégiés, a montré des résultats controversés avec selon

les études, des effets moteurs significatifs (Dickstein et al., 2004, Dijkerman et al., 2004, Dickstein and Deutsch, 2007), des effets uniquement lorsque l'imagerie motrice est couplée à de la pratique physique (Jackson et al., 2004) ou aucun effet significatif (Ietswaart et al., 2011). Les preuves concernant les effets antalgiques cette fois, de l'imagerie motrice seule, sont également insuffisantes et divergentes (Schwoebel et al., 2001, Moseley, 2004a, Beaumont et al., 2011, Posadzki and Ernst, 2011). Quelques études ont d'ailleurs montré une augmentation des douleurs suite à des programmes d'imagerie motrice chez des patients blessés médullaires ou souffrant de douleurs chroniques (Gustin et al., 2007, Moseley et al., 2008a, Moseley et al., 2008b, Coslett et al., 2010b).

Au niveau physiologique, il est prouvé chez les volontaires sains, que la vision de son propre mouvement à travers un miroir provoque une augmentation de l'excitabilité du cortex moteur (Garry et al., 2005, Funase et al., 2007). Afin de comparer les effets neurophysiologiques de la thérapie miroir associée à différentes modalités de pratique, Fukumura et al. ont examiné les paramètres d'excitabilité de M1, lors de l'observation, de l'imagerie motrice avec ou sans miroir, et enfin de la mobilisation passive face au miroir (Fukumura et al., 2007). Les résultats montrent que les Potentiels Evoqués Moteurs les plus importants, sont produits lors des mouvements passifs. Puis de façon décroissante, viennent l'imagerie motrice avec miroir, l'imagerie motrice sans miroir et enfin l'observation. Même si les auteurs n'ont pas testé l'effet de l'exécution volontaires de mouvements, il est légitime d'attendre un niveau d'excitabilité du cortex moteur primaire encore supérieur par rapport aux quatre dernières situations. Ce résultat supporterait l'hypothèse que les progrès moteurs et les effets antalgiques soient plus importants si le patient privilégie l'exécution motrice. En effet M1 semble tenir un rôle primordial dans le traitement des douleurs neuropathiques, comme le montrent les effets antalgiques de la stimulation invasive (Saitoh and Yoshimine, 2007), comme non invasive (O'Connell et al., 2010) de M1 en agissant directement sur le système opioïde endogène (Maarrawi et al., 2007).

Aux vues des conclusions dégagées des études cités précédemment et de nos résultats montrant que la différenciation entre exécution et imagerie motrice dans le membre fantôme repose principalement sur un recrutement plus important de M1 pendant l'exécution, les conséquences attendues de l'une et l'autre tâche sur les performances motrices et sur les douleurs de membre fantôme ne sont certainement pas du même ordre (voire également Diers et al., 2010). Ce résultat a un impact très important sur la pratique clinique. Il nous paraît donc légitime de

favoriser l'exécution motrice lors des thérapies miroirs chez l'amputé. Pourtant, il est important de nuancer cette conclusion en gardant en mémoire les études rapportant une certaine efficacité des thérapies visuomotrices par imagerie motrice. Cet effet pourrait alors reposer sur la mise en jeu d'autres régions corticales que M1, par exemple le cortex prémoteur.

Dans le but néanmoins de préciser les effets propres à l'imagination et à l'exécution motrice, il conviendrait de mener dans un premier temps des études cliniques en groupe parallèle. La comparaison directe des deux groupes permettra de distinguer l'efficacité relative de chacune de ces deux tâches motrices. Dans un second temps, il serait intéressant de différencier expérimentalement les bases neurophysiologiques de chacune de ces approches motrices en recherchant systématiquement dans les deux populations la présence de marqueurs neurophysiologiques d'une amélioration motrice et d'un soulagement des douleurs fantômes. Toutes ces perspectives futures de recherche devront s'appuyer sur des techniques d'imagerie cérébrale de plus en plus fines pour caractériser le rôle de certaines aires cérébrales qui, comme nous l'avons vu pourraient être des régions clés dans la modulation des douleurs fantômes par le biais de la motricité résiduelle dans le membre fantôme (cortex prémoteur et moteur primaire mais aussi, les ganglions de la base ou le cortex somatosensoriel secondaire). L'hypothèse est que ces marqueurs seraient différents dans les deux cas.

Comme alternative à ces approches comportementales sensorimotrices, une autre piste dans le traitement des douleurs de membre fantôme ou des douleurs du membre résiduel, consiste à injecter de la toxine botulinique dans les muscles du moignon (Jin et al., 2009, Wu et al., 2011). L'injection de toxine botulinique est déjà utilisée chez l'amputé pour diminuer les phénomènes d'hyperhidrose et faciliter le port de la prothèse (Kern et al., 2004, Charrow et al., 2008). De plus, il semblerait que la toxine botulinique de type A ait des propriétés antalgiques, directement liées à son effet myorelaxant dans les muscles du moignon. Cet effet myorelaxant devrait entraîner une paralysie partielle des muscles du moignon et par conséquent une paralysie transitoire du membre fantôme, comme celle rapportée après un protocole d'ischémie du moignon par tourniquet (Reilly et al., 2006). Cet éventuel effet de la toxine botulinique sur la motricité du membre fantôme n'a jamais été quantifié et mériterait une expérimentation approfondie. En effet, il s'agit d'une autre situation d'interaction entre la motricité résiduelle du membre fantôme et les douleurs fantômes.

11. Conclusion et perspectives

L'objectif de cette thèse était de réinterroger le statut psychologique des mouvements de membre fantôme. Les travaux entrepris dans ce but, ont permis de confirmer expérimentalement l'existence de deux perceptions motrices distinctes chez l'amputé. Ces deux perceptions motrices sont associées à des performances différentes et à des réseaux cérébraux partiellement distincts. Les observations cliniques et les recherches expérimentales menées au cours de cette thèse dressent un modèle relativement cohérent de l'organisation fonctionnelle du cortex moteur après amputation en lien avec la variabilité du contrôle moteur chez ces patients.

Les parallèles existant entre les altérations du fonctionnement cortical chez l'amputé et ceux rapportés dans différents modèles cliniques de dysfonctionnements corticaux, permettent d'évoquer quelques pistes de recherche. Le modèle de l'immobilisation des doigts par exemple, peut être employé relativement facilement auprès de volontaires sains, sans provoquer de douleurs ni de lésion cérébrale irréversible. Cette situation de privation sensorimotrice temporaire induit des mécanismes d'adaptation dans le cerveau qui seraient en partie liés au déficit sensorimoteur rapporté à l'arrêt de l'immobilisation. Etant donnés les signes de perturbations corticales discutés dans cette thèse, il serait intéressant de décrire précisément le décours temporel de la mise en place des phénomènes de réorganisation, en relation avec l'altération des performances sensorimotrices. L'exploration des déplacements des représentations motrices des muscles impliqués dans le contrôle moteur des doigts et la dynamique des changements d'excitabilité entre le cortex pré-moteur et le cortex moteur primaire sont des pistes pertinentes de futurs travaux de recherche.

Références

- Aglioti S, Smania N, Atzei A, Berlucchi G. Spatio-temporal properties of the pattern of evoked phantom sensations in a left index amputee patient. *Behav Neurosci*, 111 (5):867-72, 1997.
- Agosta F, Valsasina P, Absinta M, Riva N, Sala S, Prella A, Copetti M, Comola M, Comi G, Filippi M. Sensorimotor Functional Connectivity Changes in Amyotrophic Lateral Sclerosis. *Cereb Cortex*, 2011.
- Alkadhi H, Brugger P, Boendermaker SH, Crelier G, Curt A, Hepp-Reymond MC, Kollias SS. What disconnection tells about motor imagery: evidence from paraplegic patients. *Cereb Cortex*, 15 (2):131-40, 2005.
- Altschuler EL, Hu J. Mirror therapy in a patient with a fractured wrist and no active wrist extension. *Scand J Plast Reconstr Surg Hand Surg*, 42 (2):110-1, 2008.
- Altschuler EL, Wisdom SB, Stone L, Foster C, Galasko D, Llewellyn DM, Ramachandran VS. Rehabilitation of hemiparesis after stroke with a mirror. *Lancet*, 353 (9169):2035-6, 1999.
- Amunts K, Schlaug G, Schleicher A, Steinmetz H, Dabringhaus A, Roland PE, Zilles K. Asymmetry in the human motor cortex and handedness. *Neuroimage*, 4 (3 Pt 1):216-22, 1996.
- Amunts K, Schleicher A, Burgel U, Mohlberg H, Uylings HB, Zilles K. Broca's region revisited: cytoarchitecture and intersubject variability. *J Comp Neurol*, 412 (2):319-41, 1999.
- Amunts K, Weiss PH, Mohlberg H, Pieperhoff P, Eickhoff S, Gurd JM, Marshall JC, Shah NJ, Fink GR, Zilles K. Analysis of neural mechanisms underlying verbal fluency in cytoarchitecturally defined stereotaxic space--the roles of Brodmann areas 44 and 45. *Neuroimage*, 22 (1):42-56, 2004.
- Anderson-Barnes VC, McAuliffe C, Swanberg KM, Tsao JW. Phantom limb pain--a phenomenon of proprioceptive memory? *Med Hypotheses*, 73 (4):555-8, 2009.
- Andrade A, Kherif F, Mangin JF, Worsley KJ, Paradis AL, Simon O, Dehaene S, Le Bihan D, Poline JB. Detection of fMRI activation using cortical surface mapping. *Hum Brain Mapp*, 12 (2):79-93, 2001.
- Andre JM, Paysant J, Martinet N, Beis JM. [Classification and mechanisms of body perceptions in the amputees]. *Ann Readapt Med Phys*, 44 (1):13-8, 2001.
- Appenzeller O, Bicknell JM. Effects of nervous system lesions on phantom experience in amputees. *Neurology*, 19 (2):141-6, 1969.
- Aroniadou VA, Keller A. Mechanisms of LTP induction in rat motor cortex in vitro. *Cereb Cortex*, 5 (4):353-62, 1995.

- Bara-Jimenez W, Catalan MJ, Hallett M, Gerloff C. Abnormal somatosensory homunculus in dystonia of the hand. *Ann Neurol*, 44 (5):828-31, 1998.
- Baranyi A, Feher O. Conditioned changes of synaptic transmission in the motor cortex of the cat. *Exp Brain Res*, 33 (2):283-98, 1978.
- Beaumont G, Mercier C, Michon PE, Malouin F, Jackson PL. Decreasing Phantom Limb Pain Through Observation of Action and Imagery: A Case Series. *Pain Med*, 2011.
- Berardelli A, Rothwell JC, Hallett M, Thompson PD, Manfredi M, Marsden CD. The pathophysiology of primary dystonia. *Brain*, 121 (Pt 7) 1195-212, 1998.
- Biddle SJ. Mental preparation, mental practice and strength tasks: a need for clarification. *J Sports Sci*, 3 (1):67-74, 1985.
- Birbaumer N, Lutzenberger W, Montoya P, Larbig W, Unertl K, Topfner S, Grodd W, Taub E, Flor H. Effects of regional anesthesia on phantom limb pain are mirrored in changes in cortical reorganization. *J Neurosci*, 17 (14):5503-8, 1997.
- Birklein F, Handwerker HO. Complex regional pain syndrome: how to resolve the complexity? *Pain*, 94 (1):1-6, 2001.
- Blakemore SJ. Deluding the motor system. *Conscious Cogn*, 12 (4):647-55, 2003.
- Blakemore SJ, Goodbody SJ, Wolpert DM. Predicting the consequences of our own actions: the role of sensorimotor context estimation. *J Neurosci*, 18 (18):7511-8, 1998.
- Blakemore SJ, Wolpert DM, Frith CD. Abnormalities in the awareness of action. *Trends Cogn Sci*, 6 (6):237-42, 2002.
- Bornstein J (1949) Chirurgie pariétale de la douleur.
- Borsook D, Becerra L, Fishman S, Edwards A, Jennings CL, Stojanovic M, Papinicolas L, Ramachandran VS, Gonzalez RG, Breiter H. Acute plasticity in the human somatosensory cortex following amputation. *Neuroreport*, 9 (6):1013-7, 1998.
- Bosnell R, Wegner C, Kincses ZT, Korteweg T, Agosta F, Ciccarelli O, De Stefano N, Gass A, Hirsch J, Johansen-Berg H, Kappos L, Barkhof F, Mancini L, Manfredonia F, Marino S, Miller DH, Montalban X, Palace J, Rocca M, Enzinger C, Ropele S, Rovira A, Smith S, Thompson A, Thornton J, Yousry T, Whitcher B, Filippi M, Matthews PM. Reproducibility of fMRI in the clinical setting: implications for trial designs. *Neuroimage*, 42 (2):603-10, 2008.
- Bossom J. Movement without proprioception. *Brain Res*, 71 (2-3):285-96, 1974.
- Brasil-Neto JP, Valls-Sole J, Pascual-Leone A, Cammarota A, Amassian VE, Cracco R, Maccabee P, Cracco J, Hallett M, Cohen LG. Rapid modulation of human cortical motor outputs following ischaemic nerve block. *Brain*, 116 (Pt 3) 511-25, 1993.
- Brett M, Anton J.L., Valabregue R., Poline J.B. (2002) Region of interest analysis using SPM toolbox. In: 8th International Conference on Functional Mapping of the Human Brain Sendai, Japan: NeuroImage.

- Brodie EE, Whyte A, Niven CA. Analgesia through the looking-glass? A randomized controlled trial investigating the effect of viewing a 'virtual' limb upon phantom limb pain, sensation and movement. *Eur J Pain*, 11 (4):428-36, 2007.
- Brodie EE, Whyte A, Waller B. Increased motor control of a phantom leg in humans results from the visual feedback of a virtual leg. *Neurosci Lett*, 341 (2):167-9, 2003.
- Brugger P, Kollias SS, Muri RM, Crelier G, Hepp-Reymond MC, Regard M. Beyond remembering: phantom sensations of congenitally absent limbs. *Proc Natl Acad Sci U S A*, 97 (11):6167-72, 2000.
- Bultitude JH, Rafal RD. Derangement of body representation in complex regional pain syndrome: report of a case treated with mirror and prisms. *Exp Brain Res*, 204 (3):409-18, 2010.
- Burton H, Fabri M. Ipsilateral intracortical connections of physiologically defined cutaneous representations in areas 3b and 1 of macaque monkeys: projections in the vicinity of the central sulcus. *J Comp Neurol*, 355 (4):508-38, 1995.
- Calford MB, Tweedale R. Immediate and chronic changes in responses of somatosensory cortex in adult flying-fox after digit amputation. *Nature*, 332 (6163):446-8, 1988.
- Capaday C, Richardson MP, Rothwell JC, Brooks DJ. Long-term changes of GABAergic function in the sensorimotor cortex of amputees. A combined magnetic stimulation and 11C-flumazenil PET study. *Exp Brain Res*, 133 (4):552-6, 2000.
- Carlen PL, Wall PD, Nadvorna H, Steinbach T. Phantom limbs and related phenomena in recent traumatic amputations. *Neurology*, 28 (3):211-7, 1978.
- Carp JS, Wolpaw JR. Motoneuron plasticity underlying operantly conditioned decrease in primate H-reflex. *J Neurophysiol*, 72 (1):431-42, 1994.
- Caulo M, Briganti C, Mattei PA, Perfetti B, Ferretti A, Romani GL, Tartaro A, Colosimo C. New morphologic variants of the hand motor cortex as seen with MR imaging in a large study population. *AJNR Am J Neuroradiol*, 28 (8):1480-5, 2007.
- Ceballos-Baumann AO, Passingham RE, Warner T, Playford ED, Marsden CD, Brooks DJ. Overactive prefrontal and underactive motor cortical areas in idiopathic dystonia. *Ann Neurol*, 37 (3):363-72, 1995.
- Ceballos-Baumann AO, Sheean G, Passingham RE, Marsden CD, Brooks DJ. Botulinum toxin does not reverse the cortical dysfunction associated with writer's cramp. A PET study. *Brain*, 120 (Pt 4) 571-82, 1997.
- Chan BL, Witt R, Charrow AP, Magee A, Howard R, Pasquina PF, Heilman KM, Tsao JW. Mirror therapy for phantom limb pain. *N Engl J Med*, 357 (21):2206-7, 2007.
- Charrow A, DiFazio M, Foster L, Pasquina PF, Tsao JW. Intradermal botulinum toxin type A injection effectively reduces residual limb hyperhidrosis in amputees: a case series. *Arch Phys Med Rehabil*, 89 (7):1407-9, 2008.

- Chen H, Yang Q, Liao W, Gong Q, Shen S. Evaluation of the effective connectivity of supplementary motor areas during motor imagery using Granger causality mapping. *Neuroimage*, 47 (4):1844-53, 2009.
- Chen R, Corwell B, Yaseen Z, Hallett M, Cohen LG. Mechanisms of cortical reorganization in lower-limb amputees. *J Neurosci*, 18 (9):3443-50, 1998a.
- Chen R, Tam A, Butefisch C, Corwell B, Ziemann U, Rothwell JC, Cohen LG. Intracortical inhibition and facilitation in different representations of the human motor cortex. *J Neurophysiol*, 80 (6):2870-81, 1998b.
- Chollet F, DiPiero V, Wise RJ, Brooks DJ, Dolan RJ, Frackowiak RS. The functional anatomy of motor recovery after stroke in humans: a study with positron emission tomography. *Ann Neurol*, 29 (1):63-71, 1991.
- Christensen GE, Rabbitt RD, Miller MI. 3D brain mapping using a deformable neuroanatomy. *Phys Med Biol*, 39 (3):609-18, 1994.
- Christensen MS, Lundbye-Jensen J, Geertsen SS, Petersen TH, Paulson OB, Nielsen JB. Premotor cortex modulates somatosensory cortex during voluntary movements without proprioceptive feedback. *Nat Neurosci*, 10 (4):417-9, 2007.
- Ciccarelli O, Catani M, Johansen-Berg H, Clark C, Thompson A. Diffusion-based tractography in neurological disorders: concepts, applications, and future developments. *Lancet Neurol*, 7 (8):715-27, 2008.
- Cohen LG, Bandinelli S, Findley TW, Hallett M. Motor reorganization after upper limb amputation in man. A study with focal magnetic stimulation. *Brain*, 114 (Pt 1B) 615-27, 1991a.
- Cohen LG, Bandinelli S, Topka HR, Fuhr P, Roth BJ, Hallett M. Topographic maps of human motor cortex in normal and pathological conditions: mirror movements, amputations and spinal cord injuries. *Electroencephalogr Clin Neurophysiol Suppl*, 43 36-50, 1991b.
- Cole J, Crowle S, Austwick G, Slater DH. Exploratory findings with virtual reality for phantom limb pain; from stump motion to agency and analgesia. *Disabil Rehabil*, 31 (10):846-54, 2009.
- Colebatch JG, Deiber MP, Passingham RE, Friston KJ, Frackowiak RS. Regional cerebral blood flow during voluntary arm and hand movements in human subjects. *J Neurophysiol*, 65 (6):1392-401, 1991.
- Conson M, Sacco S, Sara M, Pistoia F, Grossi D, Trojano L. Selective motor imagery defect in patients with locked-in syndrome. *Neuropsychologia*, 46 (11):2622-8, 2008.
- Corbin CB. The effects of covert rehearsal on the development of a complex motor skill. *J Gen Psychol*, 76 (2d Half):143-50, 1967.
- Coslett HB, Medina J, Kliot D, Burkey A. Mental motor imagery and chronic pain: the foot laterality task. *J Int Neuropsychol Soc*, 16 (4):603-12, 2010a.

- Coslett HB, Medina J, Kliot D, Burkey AR. Mental motor imagery indexes pain: the hand laterality task. *Eur J Pain*, 14 (10):1007-13, 2010b.
- Cronholm B. Phantom limbs in amputees; a study of changes in the integration of centripetal impulses with special reference to referred sensations. *Acta Psychiatr Neurol Scand Suppl*, 72 1-310, 1951.
- Cruz VT, Nunes B, Reis AM, Pereira JR. Cortical remapping in amputees and dysmelic patients: a functional MRI study. *NeuroRehabilitation*, 18 (4):299-305, 2003.
- Curt A, Yengue CN, Hilti LM, Brugger P. Supernumerary phantom limbs in spinal cord injury. *Spinal Cord*, 2010.
- Dale AM, Fischl B, Sereno MI. Cortical surface-based analysis. I. Segmentation and surface reconstruction. *Neuroimage*, 9 (2):179-94, 1999.
- Darian-Smith C, Gilbert CD. Axonal sprouting accompanies functional reorganization in adult cat striate cortex. *Nature*, 368 (6473):737-40, 1994.
- Decety J. Do imagined and executed actions share the same neural substrate? *Brain Res Cogn Brain Res*, 3 (2):87-93, 1996a.
- Decety J. The neurophysiological basis of motor imagery. *Behav Brain Res*, 77 (1-2):45-52, 1996b.
- Decety J, Jeannerod M. Mentally simulated movements in virtual reality: does Fitts's law hold in motor imagery? *Behav Brain Res*, 72 (1-2):127-34, 1995.
- Decety J, Jeannerod M, Germain M, Pastene J. Vegetative response during imagined movement is proportional to mental effort. *Behav Brain Res*, 42 (1):1-5, 1991.
- Decety J, Jeannerod M, Prablanc C. The timing of mentally represented actions. *Behav Brain Res*, 34 (1-2):35-42, 1989.
- Decety J, Perani D, Jeannerod M, Bettinardi V, Tadary B, Woods R, Mazziotta JC, Fazio F. Mapping motor representations with positron emission tomography. *Nature*, 371 (6498):600-2, 1994.
- Dechent P, Merboldt KD, Frahm J. Is the human primary motor cortex involved in motor imagery? *Brain Res Cogn Brain Res*, 19 (2):138-44, 2004.
- Deiber MP, Passingham RE, Colebatch JG, Friston KJ, Nixon PD, Frackowiak RS. Cortical areas and the selection of movement: a study with positron emission tomography. *Exp Brain Res*, 84 (2):393-402, 1991.
- Dejours C (2001) *Le corps d'abord: Corps biologique, corps érotique et sens moral*. Paris.
- Deschaumes-Molinario C, Dittmar A, Vernet-Maury E. Autonomic nervous system response patterns correlate with mental imagery. *Physiol Behav*, 51 (5):1021-7, 1992.
- Desmurget M, Sirigu A. A parietal-premotor network for movement intention and motor awareness. *Trends Cogn Sci*, 13 (10):411-9, 2009.

- Dettmers C, Adler T, Rzanny R, van Schayck R, Gaser C, Weiss T, Miltner WH, Bruckner L, Weiller C. Increased excitability in the primary motor cortex and supplementary motor area in patients with phantom limb pain after upper limb amputation. *Neurosci Lett*, 307 (2):109-12, 2001.
- Dettmers C, Liepert J, Adler T, Rzanny R, Rijntjes M, van Schayck R, Kaiser W, Bruckner L, Weiller C. Abnormal motor cortex organization contralateral to early upper limb amputation in humans. *Neurosci Lett*, 263 (1):41-4, 1999.
- Devanne H, Cassim F, Ethier C, Brizzi L, Thevenon A, Capaday C. The comparable size and overlapping nature of upper limb distal and proximal muscle representations in the human motor cortex. *Eur J Neurosci*, 23 (9):2467-76, 2006.
- Devor ST, Faulkner JA. Regeneration of new fibers in muscles of old rats reduces contraction-induced injury. *J Appl Physiol*, 87 (2):750-6, 1999.
- Dhillon GS, Lawrence SM, Hutchinson DT, Horch KW. Residual function in peripheral nerve stumps of amputees: implications for neural control of artificial limbs. *J Hand Surg Am*, 29 (4):605-15; discussion 16-8, 2004.
- Di Pino G, Guglielmelli E, Rossini PM. Neuroplasticity in amputees: main implications on bidirectional interfacing of cybernetic hand prostheses. *Prog Neurobiol*, 88 (2):114-26, 2009.
- Dickstein R, Deutsch JE. Motor imagery in physical therapist practice. *Phys Ther*, 87 (7):942-53, 2007.
- Dickstein R, Dunsky A, Marcovitz E. Motor imagery for gait rehabilitation in post-stroke hemiparesis. *Phys Ther*, 84 (12):1167-77, 2004.
- Dickstein R, Gazit-Grunwald M, Plax M, Dunsky A, Marcovitz E. EMG activity in selected target muscles during imagery rising on tiptoes in healthy adults and poststroke hemiparetic patients. *J Mot Behav*, 37 (6):475-83, 2005.
- Diers M, Christmann C, Koeppe C, Ruf M, Flor H. Mirrored, imagined and executed movements differentially activate sensorimotor cortex in amputees with and without phantom limb pain. *Pain*, 149 (2):296-304, 2010.
- Dijkerman HC, Ietswaart M, Johnston M, MacWalter RS. Does motor imagery training improve hand function in chronic stroke patients? A pilot study. *Clin Rehabil*, 18 (5):538-49, 2004.
- Dijkstra EW (1971) A short introduction to the art of programming.
- Dohle C, Pullen J, Nakaten A, Kust J, Rietz C, Karbe H. Mirror therapy promotes recovery from severe hemiparesis: a randomized controlled trial. *Neurorehabil Neural Repair*, 23 (3):209-17, 2009.
- Donoghue JP, Leibovic S, Sanes JN. Organization of the forelimb area in squirrel monkey motor cortex: representation of digit, wrist, and elbow muscles. *Exp Brain Res*, 89 (1):1-19, 1992.

- Donoghue JP, Sanes JN. Organization of adult motor cortex representation patterns following neonatal forelimb nerve injury in rats. *J Neurosci*, 8 (9):3221-32, 1988.
- Donoghue JP, Suner S, Sanes JN. Dynamic organization of primary motor cortex output to target muscles in adult rats. II. Rapid reorganization following motor nerve lesions. *Exp Brain Res*, 79 (3):492-503, 1990.
- Durrleman S, Pennec X, Trouve A, Ayache N. Measuring brain variability via sulcal lines registration: a diffeomorphic approach. *Med Image Comput Comput Assist Interv*, 10 (Pt 1):675-82, 2007.
- Dushanova J, Donoghue J. Neurons in primary motor cortex engaged during action observation. *Eur J Neurosci*, 31 (2):386-98, 2010.
- Ehde DM, Czerniecki JM, Smith DG, Campbell KM, Edwards WT, Jensen MP, Robinson LR. Chronic phantom sensations, phantom pain, residual limb pain, and other regional pain after lower limb amputation. *Arch Phys Med Rehabil*, 81 (8):1039-44, 2000.
- Eickhoff SB, Amunts K, Mohlberg H, Zilles K. The human parietal operculum. II. Stereotaxic maps and correlation with functional imaging results. *Cereb Cortex*, 16 (2):268-79, 2006.
- Eickhoff SB, Dafotakis M, Grefkes C, Shah NJ, Zilles K, Piza-Katzer H. Central adaptation following heterotopic hand replantation probed by fMRI and effective connectivity analysis. *Exp Neurol*, 212 (1):132-44, 2008.
- Elbert T, Flor H, Birbaumer N, Knecht S, Hampson S, Larbig W, Taub E. Extensive reorganization of the somatosensory cortex in adult humans after nervous system injury. *Neuroreport*, 5 (18):2593-7, 1994.
- Elbert T, Pantev C, Wienbruch C, Rockstroh B, Taub E. Increased cortical representation of the fingers of the left hand in string players. *Science*, 270 (5234):305-7, 1995.
- Elbert T, Sterr A, Flor H, Rockstroh B, Knecht S, Pantev C, Wienbruch C, Taub E. Input-increase and input-decrease types of cortical reorganization after upper extremity amputation in humans. *Exp Brain Res*, 117 (1):161-4, 1997.
- Ergenzinger ER, Glasier MM, Hahn JO, Pons TP. Cortically induced thalamic plasticity in the primate somatosensory system. *Nat Neurosci*, 1 (3):226-9, 1998.
- Ersland L, Rosen G, Lundervold A, Smievoll AI, Tillung T, Sundberg H, Hugdahl K. Phantom limb imaginary fingertapping causes primary motor cortex activation: an fMRI study. *Neuroreport*, 8 (1):207-10, 1996.
- Ewalt JR, Randall GC, Morris H. The phantom limb. *Psychosom Med*, 9 (2):118-23, 1947.
- Ezendam D, Bongers RM, Jannink MJ. Systematic review of the effectiveness of mirror therapy in upper extremity function. *Disabil Rehabil*, 31 (26):2135-49, 2009.

- Facchini S, Romani M, Tinazzi M, Aglioti SM. Time-related changes of excitability of the human motor system contingent upon immobilisation of the ring and little fingers. *Clin Neurophysiol*, 113 (3):367-75, 2002.
- Fadiga L, Buccino G, Craighero L, Fogassi L, Gallese V, Pavesi G. Corticospinal excitability is specifically modulated by motor imagery: a magnetic stimulation study. *Neuropsychologia*, 37 (2):147-58, 1999.
- Fair DA, Schlaggar BL, Cohen AL, Miezin FM, Dosenbach NU, Wenger KK, Fox MD, Snyder AZ, Raichle ME, Petersen SE. A method for using blocked and event-related fMRI data to study "resting state" functional connectivity. *Neuroimage*, 35 (1):396-405, 2007.
- Fang PC, Jain N, Kaas JH. Few intrinsic connections cross the hand-face border of area 3b of New World monkeys. *J Comp Neurol*, 454 (3):310-9, 2002.
- Farne A, Roy AC, Giraux P, Dubernard JM, Sirigu A. Face or hand, not both: perceptual correlates of reafferentation in a former amputee. *Curr Biol*, 12 (15):1342-6, 2002.
- Finnerup NB, Norrbrink C, Fuglsang-Frederiksen A, Terkelsen AJ, Hojlund AP, Jensen TS. Pain, referred sensations, and involuntary muscle movements in brachial plexus injury. *Acta Neurol Scand*, 121 (5):320-7, 2010.
- Fiorio M, Tinazzi M, Ionta S, Fiaschi A, Moretto G, Edwards MJ, Bhatia KP, Aglioti SM. Mental rotation of body parts and non-corporeal objects in patients with idiopathic cervical dystonia. *Neuropsychologia*, 45 (10):2346-54, 2007.
- Fisher K, Hanspal RS. Phantom pain, anxiety, depression, and their relation in consecutive patients with amputated limbs: case reports. *Bmj*, 316 (7135):903-4, 1998.
- Flor H. The modification of cortical reorganization and chronic pain by sensory feedback. *Appl Psychophysiol Biofeedback*, 27 (3):215-27, 2002.
- Flor H, Birbaumer N. Phantom limb pain: cortical plasticity and novel therapeutic approaches. *Curr Opin Anaesthesiol*, 13 (5):561-4, 2000.
- Flor H, Elbert T, Knecht S, Wienbruch C, Pantev C, Birbaumer N, Larbig W, Taub E. Phantom-limb pain as a perceptual correlate of cortical reorganization following arm amputation. *Nature*, 375 (6531):482-4, 1995.
- Flor H, Elbert T, Muhl nickel W, Pantev C, Wienbruch C, Taub E. Cortical reorganization and phantom phenomena in congenital and traumatic upper-extremity amputees. *Exp Brain Res*, 119 (2):205-12, 1998.
- Flor H, Muhl nickel W, Karl A, Denke C, Grusser S, Kurth R, Taub E. A neural substrate for nonpainful phantom limb phenomena. *Neuroreport*, 11 (7):1407-11, 2000.
- Flor H, Nikolajsen L, Staehelin Jensen T. Phantom limb pain: a case of maladaptive CNS plasticity? *Nat Rev Neurosci*, 7 (11):873-81, 2006.

- Florence SL, Garraghty PE, Wall JT, Kaas JH. Sensory afferent projections and area 3b somatotopy following median nerve cut and repair in macaque monkeys. *Cereb Cortex*, 4 (4):391-407, 1994.
- Florence SL, Hackett TA, Strata F. Thalamic and cortical contributions to neural plasticity after limb amputation. *J Neurophysiol*, 83 (5):3154-9, 2000.
- Florence SL, Kaas JH. Large-scale reorganization at multiple levels of the somatosensory pathway follows therapeutic amputation of the hand in monkeys. *J Neurosci*, 15 (12):8083-95, 1995.
- Florence SL, Taub HB, Kaas JH. Large-scale sprouting of cortical connections after peripheral injury in adult macaque monkeys. *Science*, 282 (5391):1117-21, 1998.
- Forget R, Lamarre Y. Rapid elbow flexion in the absence of proprioceptive and cutaneous feedback. *Hum Neurobiol*, 6 (1):27-37, 1987.
- Franceschini M, Agosti M, Cantagallo A, Sale P, Mancuso M, Buccino G. Mirror neurons: action observation treatment as a tool in stroke rehabilitation. *Eur J Phys Rehabil Med*, 46 (4):517-23, 2010.
- Fraser CM, Halligan PW, Robertson IH, Kirker SG. Characterising phantom limb phenomena in upper limb amputees. *Prosthet Orthot Int*, 25 (3):235-42, 2001.
- Friston KJ, Frith CD, Frackowiak RS. Principal component analysis learning algorithms: a neurobiological analysis. *Proc Biol Sci*, 254 (1339):47-54, 1993.
- Friston KJ, Harrison L, Penny W. Dynamic causal modelling. *Neuroimage*, 19 (4):1273-302, 2003.
- Fuhr P, Cohen LG, Dang N, Findley TW, Haghghi S, Oro J, Hallett M. Physiological analysis of motor reorganization following lower limb amputation. *Electroencephalogr Clin Neurophysiol*, 85 (1):53-60, 1992.
- Fukumura K, Sugawara K, Tanabe S, Ushiba J, Tomita Y. Influence of mirror therapy on human motor cortex. *Int J Neurosci*, 117 (7):1039-48, 2007.
- Funase K, Tabira T, Higashi T, Liang N, Kasai T. Increased corticospinal excitability during direct observation of self-movement and indirect observation with a mirror box. *Neurosci Lett*, 419 (2):108-12, 2007.
- Funk M, Lutz K, Hotz-Boendermaker S, Roos M, Summers P, Brugger P, Hepp-Reymond MC, Kollias SS. Sensorimotor tongue representation in individuals with unilateral upper limb amelia. *Neuroimage*, 43 (1):121-7, 2008.
- Gaggioli A, Morganti F, Walker R, Meneghini A, Alcaniz M, Lozano JA, Montesa J, Gil JA, Riva G. Training with computer-supported motor imagery in post-stroke rehabilitation. *Cyberpsychol Behav*, 7 (3):327-32, 2004.
- Gagné M, Hetu S, Reilly KT, Mercier C. The map is not the territory: Motor system reorganization in upper limb amputees. *Hum Brain Mapp*, 2010.

- Gagne M, Reilly KT, Hetu S, Mercier C. Motor control over the phantom limb in above-elbow amputees and its relationship with phantom limb pain. *Neuroscience*, 2009a.
- Gagne M, Reilly KT, Hetu S, Mercier C. Motor control over the phantom limb in above-elbow amputees and its relationship with phantom limb pain. *Neuroscience*, 162 (1):78-86, 2009b.
- Gagné M, Reilly KT, Hetu S, Mercier C. Motor control over the phantom limb in above-elbow amputees and its relationship with phantom limb pain. *Neuroscience*, 162 (1):78-86, 2009.
- Galaburda AM, LeMay M, Kemper TL, Geschwind N. Right-left asymmetries in the brain. *Science*, 199 (4331):852-6, 1978.
- Gallen CC, Sobel DF, Lewine JD, Sanders JA, Hart BL, Davis LE, Orrison WW, Jr. Neuromagnetic mapping of brain function. *Radiology*, 187 (3):863-7, 1993a.
- Gallen CC, Sobel DF, Waltz T, Aung M, Copeland B, Schwartz BJ, Hirschkoff EC, Bloom FE. Noninvasive presurgical neuromagnetic mapping of somatosensory cortex. *Neurosurgery*, 33 (2):260-8; discussion 8, 1993b.
- Gandevia SC. The perception of motor commands or effort during muscular paralysis. *Brain*, 105 (Pt 1):151-9, 1982.
- Gandevia SC, McCloskey DI. Joint sense, muscle sense, and their combination as position sense, measured at the distal interphalangeal joint of the middle finger. *J Physiol*, 260 (2):387-407, 1976a.
- Gandevia SC, McCloskey DI. Perceived heaviness of lifted objects and effects of sensory inputs from related, non-lifting parts. *Brain Res*, 109 (2):399-401, 1976b.
- Gandevia SC, Refshauge KM, Collins DF. Proprioception: peripheral inputs and perceptual interactions. *Adv Exp Med Biol*, 508 61-8, 2002.
- Gandevia SC, Smith JL, Crawford M, Proske U, Taylor JL. Motor commands contribute to human position sense. *J Physiol*, 571 (Pt 3):703-10, 2006.
- Gandevia SC, Wilson LR, Inglis JT, Burke D. Mental rehearsal of motor tasks recruits alpha-motoneurons but fails to recruit human fusimotor neurons selectively. *J Physiol*, 505 (Pt 1) 259-66, 1997.
- Gao Q, Duan X, Chen H. Evaluation of effective connectivity of motor areas during motor imagery and execution using conditional Granger causality. *Neuroimage*, 54 (2):1280-8, 2011.
- Garraghty PE, Hanes DP, Florence SL, Kaas JH. Pattern of peripheral deafferentation predicts reorganizational limits in adult primate somatosensory cortex. *Somatosens Mot Res*, 11 (2):109-17, 1994.
- Garraghty PE, Kaas JH. Functional reorganization in adult monkey thalamus after peripheral nerve injury. *Neuroreport*, 2 (12):747-50, 1991.

- Garraghty PE, Pons TP, Sur M, Kaas JH. The arbors of axons terminating in middle cortical layers of somatosensory area 3b in owl monkeys. *Somatosens Mot Res*, 6 (4):401-11, 1989.
- Garraghty PE, Sur M. Morphology of single intracellularly stained axons terminating in area 3b of macaque monkeys. *J Comp Neurol*, 294 (4):583-93, 1990.
- Garrison KA, Winstein CJ, Aziz-Zadeh L. The mirror neuron system: a neural substrate for methods in stroke rehabilitation. *Neurorehabil Neural Repair*, 24 (5):404-12, 2010.
- Garry MI, Loftus A, Summers JJ. Mirror, mirror on the wall: viewing a mirror reflection of unilateral hand movements facilitates ipsilateral M1 excitability. *Exp Brain Res*, 163 (1):118-22, 2005.
- Geha PY, Baliki MN, Harden RN, Bauer WR, Parrish TB, Apkarian AV. The brain in chronic CRPS pain: abnormal gray-white matter interactions in emotional and autonomic regions. *Neuron*, 60 (4):570-81, 2008.
- Geissler A, Lanzenberger R, Barth M, Tahamtan AR, Milakara D, Gartus A, Beisteiner R. Influence of fMRI smoothing procedures on replicability of fine scale motor localization. *Neuroimage*, 24 (2):323-31, 2005.
- Gelb A (1974) Applied Optimal Estimation. Cambridge,.
- Gentili R, Papaxanthis C, Pozzo T. Improvement and generalization of arm motor performance through motor imagery practice. *Neuroscience*, 137 (3):761-72, 2006.
- George MS, Wassermann EM, Williams WA, Steppel J, Pascual-Leone A, Basser P, Hallett M, Post RM. Changes in mood and hormone levels after rapid-rate transcranial magnetic stimulation (rTMS) of the prefrontal cortex. *J Neuropsychiatry Clin Neurosci*, 8 (2):172-80, 1996.
- Gerardin E, Sirigu A, Lehericy S, Poline JB, Gaymard B, Marsault C, Agid Y, Le Bihan D. Partially overlapping neural networks for real and imagined hand movements. *Cereb Cortex*, 10 (11):1093-104, 2000.
- Geyer S, Ledberg A, Schleicher A, Kinomura S, Schormann T, Burgel U, Klingberg T, Larsson J, Zilles K, Roland PE. Two different areas within the primary motor cortex of man. *Nature*, 382 (6594):805-7, 1996.
- Gieteling EW, van Rijn MA, de Jong BM, Hoogduin JM, Renken R, van Hilten JJ, Leenders KL. Cerebral activation during motor imagery in complex regional pain syndrome type 1 with dystonia. *Pain*, 134 (3):302-9, 2008.
- Giraux P, Sirigu A. Illusory movements of the paralyzed limb restore motor cortex activity. *Neuroimage*, 20 Suppl 1 S107-11, 2003.
- Giraux P, Sirigu A, Schneider F, Dubernard JM. Cortical reorganization in motor cortex after graft of both hands. *Nat Neurosci*, 4 (7):691-2, 2001.

- Gitelman DR, Parrish TB, Friston KJ, Mesulam MM. Functional anatomy of visual search: regional segregations within the frontal eye fields and effective connectivity of the superior colliculus. *Neuroimage*, 15 (4):970-82, 2002.
- Giummarra MJ, Georgiou-Karistianis N, Nicholls ME, Gibson SJ, Chou M, Bradshaw JL. Maladaptive Plasticity: Imprinting of Past Experiences Onto Phantom Limb Schemata. *Clin J Pain*, 2011.
- Good CD, Johnsrude IS, Ashburner J, Henson RN, Friston KJ, Frackowiak RS. A voxel-based morphometric study of ageing in 465 normal adult human brains. *Neuroimage*, 14 (1 Pt 1):21-36, 2001.
- Goodwin GM, McCloskey DI, Matthews PB. The contribution of muscle afferents to kinaesthesia shown by vibration induced illusions of movement and by the effects of paralysing joint afferents. *Brain*, 95 (4):705-48, 1972.
- Gothe J, Brandt SA, Irlbacher K, Roricht S, Sabel BA, Meyer BU. Changes in visual cortex excitability in blind subjects as demonstrated by transcranial magnetic stimulation. *Brain*, 125 (Pt 3):479-90, 2002.
- Gottsdanker R, Shragg GP. Verification of Donders' subtraction method. *J Exp Psychol Hum Percept Perform*, 11 (6):765-76, 1985.
- Gountouna VE, Job DE, McIntosh AM, Moorhead TW, Lymer GK, Whalley HC, Hall J, Waiter GD, Brennan D, McGonigle DJ, Ahearn TS, Cavanagh J, Condon B, Hadley DM, Marshall I, Murray AD, Steele JD, Wardlaw JM, Lawrie SM. Functional Magnetic Resonance Imaging (fMRI) reproducibility and variance components across visits and scanning sites with a finger tapping task. *Neuroimage*, 49 (1):552-60, 2010.
- Grafton ST, Arbib MA, Fadiga L, Rizzolatti G. Localization of grasp representations in humans by positron emission tomography. 2. Observation compared with imagination. *Exp Brain Res*, 112 (1):103-11, 1996.
- Grafton ST, Mazziotta JC, Woods RP, Phelps ME. Human functional anatomy of visually guided finger movements. *Brain*, 115 (Pt 2) 565-87, 1992.
- Granert O, Peller M, Gaser C, Groppa S, Hallett M, Knutzen A, Deuschl G, Zeuner KE, Siebner HR. Manual activity shapes structure and function in contralateral human motor hand area. *Neuroimage*, 54 (1):32-41, 2011.
- Grefkes C, Eickhoff SB, Nowak DA, Dafotakis M, Fink GR. Dynamic intra- and interhemispheric interactions during unilateral and bilateral hand movements assessed with fMRI and DCM. *Neuroimage*, 41 (4):1382-94, 2008.
- Grefkes C, Fink GR. Reorganization of cerebral networks after stroke: new insights from neuroimaging with connectivity approaches. *Brain*, 2011.
- Gregg M, Hall C, Butler A. The MIQ-RS: A Suitable Option for Examining Movement Imagery Ability. *Evid Based Complement Alternat Med*, 2007.

- Grodd W, Hülsmann E, Lotze M, Wildgruber D, Erb M. Sensorimotor mapping of the human cerebellum: fMRI evidence of somatotopic organization. *Hum Brain Mapp*, 13 (2):55-73, 2001.
- Grush R. The emulation theory of representation: motor control, imagery, and perception. *Behav Brain Sci*, 27 (3):377-96; discussion 96-442, 2004.
- Grusser SM, Winter C, Muhlnickel W, Denke C, Karl A, Villringer K, Flor H. The relationship of perceptual phenomena and cortical reorganization in upper extremity amputees. *Neuroscience*, 102 (2):263-72, 2001.
- Guillot A, Collet C. Duration of mentally simulated movement: a review. *J Mot Behav*, 37 (1):10-20, 2005.
- Guillot A, Collet C, Molinaro C, Dittmar A. Expertise and peripheral autonomic activity during the preparation phase in shooting events. *Percept Mot Skills*, 98 (2):371-81, 2004.
- Guillot A, Collet C, Nguyen VA, Malouin F, Richards C, Doyon J. Brain activity during visual versus kinesthetic imagery: An fMRI study. *Hum Brain Mapp*, 2008a.
- Guillot A, Collet C, Nguyen VA, Malouin F, Richards C, Doyon J. Functional neuroanatomical networks associated with expertise in motor imagery. *Neuroimage*, 41 (4):1471-83, 2008b.
- Guillot A, Collet C, Nguyen VA, Malouin F, Richards C, Doyon J. Brain activity during visual versus kinesthetic imagery: an fMRI study. *Hum Brain Mapp*, 30 (7):2157-72, 2009.
- Guillot A, Lebon F, Rouffet D, Champely S, Doyon J, Collet C. Muscular responses during motor imagery as a function of muscle contraction types. *Int J Psychophysiol*, 66 (1):18-27, 2007.
- Gustin SM, Wrigley PJ, Gandevia SC, Middleton JW, Henderson LA, Siddall PJ. Movement imagery increases pain in people with neuropathic pain following complete thoracic spinal cord injury. *Pain*, 2007.
- Haggard P, Whitford B. Supplementary motor area provides an efferent signal for sensory suppression. *Brain Res Cogn Brain Res*, 19 (1):52-8, 2004.
- Hall EJ, Flament D, Fraser C, Lemon RN. Non-invasive brain stimulation reveals reorganized cortical outputs in amputees. *Neurosci Lett*, 116 (3):379-86, 1990.
- Halligan PW, Marshall JC, Wade DT. Sensory disorganization and perceptual plasticity after limb amputation: a follow-up study. *Neuroreport*, 5 (11):1341-5, 1994.
- Halligan PW, Marshall JC, Wade DT, Davey J, Morrison D. Thumb in cheek? Sensory reorganization and perceptual plasticity after limb amputation. *Neuroreport*, 4 (3):233-6, 1993.
- Hanakawa T, Dimyan MA, Hallett M. Motor planning, imagery, and execution in the distributed motor network: a time-course study with functional MRI. *Cereb Cortex*, 18 (12):2775-88, 2008.

- Hanakawa T, Immisch I, Toma K, Dimyan MA, Van Gelderen P, Hallett M. Functional properties of brain areas associated with motor execution and imagery. *J Neurophysiol*, 89 (2):989-1002, 2003.
- Hanling SR, Wallace SC, Hollenbeck KJ, Belnap BD, Tulis MR. Pre-amputation mirror therapy may prevent development of phantom limb pain: a case series. *Anesth Analg*, 110 (2):611-4, 2010.
- Harris AJ. Cortical origin of pathological pain. *Lancet*, 354 (9188):1464-6, 1999.
- Hashimoto R, Rothwell JC. Dynamic changes in corticospinal excitability during motor imagery. *Exp Brain Res*, 125 (1):75-81, 1999.
- Hayashi S, Hasegawa Y, Kasai T. Transcranial magnetic stimulation study of plastic changes of human motor cortex after repetitive simple muscle contractions. *Percept Mot Skills*, 95 (3 Pt 1):699-705, 2002.
- Helekar SA, Shin JC, Mattson BJ, Bartley K, Stosic M, Saldana-King T, Montague PR, Hutton GJ. Functional brain network changes associated with maintenance of cognitive function in multiple sclerosis. *Front Hum Neurosci*, 4 219, 2010.
- Helmich RC, de Lange FP, Bloem BR, Toni I. Cerebral compensation during motor imagery in Parkinson's disease. *Neuropsychologia*, 45 (10):2201-15, 2007.
- Henderson WR, Smyth GE (1948) Phantom limbs. Manchester.
- Hess G, Aizenman CD, Donoghue JP. Conditions for the induction of long-term potentiation in layer II/III horizontal connections of the rat motor cortex. *J Neurophysiol*, 75 (5):1765-78, 1996.
- Hess G, Donoghue JP. Long-term depression of horizontal connections in rat motor cortex. *Eur J Neurosci*, 8 (4):658-65, 1996a.
- Hess G, Donoghue JP. Long-term potentiation and long-term depression of horizontal connections in rat motor cortex. *Acta Neurobiol Exp (Wars)*, 56 (1):397-405, 1996b.
- Hetu S, Gagne M, Reilly KT, Mercier C. Short-term reliability of transcranial magnetic stimulation motor maps in upper limb amputees. *J Clin Neurosci*, 2011.
- Hotz-Boendermaker S, Funk M, Summers P, Brugger P, Hepp-Reymond MC, Curt A, Kollias SS. Preservation of motor programs in paraplegics as demonstrated by attempted and imagined foot movements. *Neuroimage*, 39 (1):383-94, 2008.
- Hugdahl K, Rosen G, Erslund L, Lundervold A, Smievoll AI, Barndon R, Thomsen T. Common pathways in mental imagery and pain perception: an fMRI study of a subject with an amputated arm. *Scand J Psychol*, 42 (3):269-75, 2001.
- Hunter JP, Katz J, Davis KD. The effect of tactile and visual sensory inputs on phantom limb awareness. *Brain*, 126 (Pt 3):579-89, 2003.
- Hunter JP, Katz J, Davis KD. Stability of phantom limb phenomena after upper limb amputation: a longitudinal study. *Neuroscience*, 156 (4):939-49, 2008.

- Huntley GW. Correlation between patterns of horizontal connectivity and the extent of short-term representational plasticity in rat motor cortex. *Cereb Cortex*, 7 (2):143-56, 1997.
- Huntley GW, Jones EG. Relationship of intrinsic connections to forelimb movement representations in monkey motor cortex: a correlative anatomic and physiological study. *J Neurophysiol*, 66 (2):390-413, 1991.
- Ietswaart M, Johnston M, Dijkerman HC, Joice S, Scott CL, Macwalter RS, Hamilton SJ. Mental practice with motor imagery in stroke recovery: randomized controlled trial of efficacy. *Brain*, 134 (Pt 5):1373-86, 2011.
- Iriki A, Pavlides C, Keller A, Asanuma H. Long-term potentiation in the motor cortex. *Science*, 245 (4924):1385-7, 1989.
- Irlbacher K, Meyer BU, Voss M, Brandt SA, Roricht S. Spatial reorganization of cortical motor output maps of stump muscles in human upper-limb amputees. *Neurosci Lett*, 321 (3):129-32, 2002.
- Ives JR, Warach S, Schmitt F, Edelman RR, Schomer DL. Monitoring the patient's EEG during echo planar MRI. *Electroencephalogr Clin Neurophysiol*, 87 (6):417-20, 1993.
- Jackson PL, Doyon J, Richards CL, Malouin F. The efficacy of combined physical and mental practice in the learning of a foot-sequence task after stroke: a case report. *Neurorehabil Neural Repair*, 18 (2):106-11, 2004.
- Jackson PL, Lafleur MF, Malouin F, Richards C, Doyon J. Potential role of mental practice using motor imagery in neurologic rehabilitation. *Arch Phys Med Rehabil*, 82 (8):1133-41, 2001.
- Jackson PL, Lafleur MF, Malouin F, Richards CL, Doyon J. Functional cerebral reorganization following motor sequence learning through mental practice with motor imagery. *Neuroimage*, 20 (2):1171-80, 2003.
- Jacobs KM, Donoghue JP. Reshaping the cortical motor map by unmasking latent intracortical connections. *Science*, 251 (4996):944-7, 1991.
- Jain N, Catania KC, Kaas JH. A histologically visible representation of the fingers and palm in primate area 3b and its immutability following long-term deafferentations. *Cereb Cortex*, 8 (3):227-36, 1998.
- Jain N, Florence SL, Qi HX, Kaas JH. Growth of new brainstem connections in adult monkeys with massive sensory loss. *Proc Natl Acad Sci U S A*, 97 (10):5546-50, 2000.
- Jain N, Qi HX, Collins CE, Kaas JH. Large-scale reorganization in the somatosensory cortex and thalamus after sensory loss in macaque monkeys. *J Neurosci*, 28 (43):11042-60, 2008.
- James W. The consciousness of lost limbs. *Proceedings of the American Society for Psychological Research*, 1 249-58, 1887.

- Jeannerod M. Mental imagery in the motor context. *Neuropsychologia*, 33 (11):1419-32, 1995.
- Jeannerod M, Decety J. Mental motor imagery: a window into the representational stages of action. *Curr Opin Neurobiol*, 5 (6):727-32, 1995.
- Jeannerod M, Frak V. Mental imaging of motor activity in humans. *Curr Opin Neurobiol*, 9 (6):735-9, 1999.
- Jeannerod M, Michel F, Prablanc C. The control of hand movements in a case of hemianaesthesia following a parietal lesion. *Brain*, 107 (Pt 3) 899-920, 1984.
- Jenkins WM, Merzenich MM, Ochs MT, Allard T, Guic-Robles E. Functional reorganization of primary somatosensory cortex in adult owl monkeys after behaviorally controlled tactile stimulation. *J Neurophysiol*, 63 (1):82-104, 1990.
- Jensen TS, Krebs B, Nielsen J, Rasmussen P. Phantom limb, phantom pain and stump pain in amputees during the first 6 months following limb amputation. *Pain*, 17 (3):243-56, 1983.
- Jensen TS, Krebs B, Nielsen J, Rasmussen P. Immediate and long-term phantom limb pain in amputees: incidence, clinical characteristics and relationship to pre-amputation limb pain. *Pain*, 21 (3):267-78, 1985.
- Jia X, Koenig MA, Zhang X, Zhang J, Chen T, Chen Z. Residual motor signal in long-term human severed peripheral nerves and feasibility of neural signal-controlled artificial limb. *J Hand Surg Am*, 32 (5):657-66, 2007.
- Jin L, Kollwee K, Krampfl K, Dengler R, Mohammadi B. Treatment of phantom limb pain with botulinum toxin type A. *Pain Med*, 10 (2):300-3, 2009.
- Jo HJ, Lee JM, Kim JH, Shin YW, Kim IY, Kwon JS, Kim SI. Spatial accuracy of fMRI activation influenced by volume- and surface-based spatial smoothing techniques. *Neuroimage*, 34 (2):550-64, 2007.
- Johnson SH. Imagining the impossible: intact motor representations in hemiplegics. *Neuroreport*, 11 (4):729-32, 2000.
- Jones EG. Cortical and subcortical contributions to activity-dependent plasticity in primate somatosensory cortex. *Annu Rev Neurosci*, 23 1-37, 2000.
- Jones EG, Pons TP. Thalamic and brainstem contributions to large-scale plasticity of primate somatosensory cortex. *Science*, 282 (5391):1121-5, 1998.
- Jones EG, Powell TP. Connexions of the somatic sensory cortex of the rhesus monkey. I. Ipsilateral cortical connexions. *Brain*, 92 (3):477-502, 1969.
- Juottonen K, Gockel M, Silen T, Hurri H, Hari R, Forss N. Altered central sensorimotor processing in patients with complex regional pain syndrome. *Pain*, 98 (3):315-23, 2002.

- Kaas JH, Collins CE. The organization of somatosensory cortex in anthropoid primates. *Adv Neurol*, 93 57-67, 2003.
- Kaas JH, Florence SL. Mechanisms of reorganization in sensory systems of primates after peripheral nerve injury. *Adv Neurol*, 73 147-58, 1997.
- Kaas JH, Merzenich MM, Killackey HP. The reorganization of somatosensory cortex following peripheral nerve damage in adult and developing mammals. *Annu Rev Neurosci*, 6 325-56, 1983.
- Kaneko F, Murakami T, Onari K, Kurumadani H, Kawaguchi K. Decreased cortical excitability during motor imagery after disuse of an upper limb in humans. *Clin Neurophysiol*, 114 (12):2397-403, 2003.
- Karl A, Birbaumer N, Lutzenberger W, Cohen LG, Flor H. Reorganization of motor and somatosensory cortex in upper extremity amputees with phantom limb pain. *J Neurosci*, 21 (10):3609-18, 2001.
- Karl A, Muhl Nickel W, Kurth R, Flor H. Neuroelectric source imaging of steady-state movement-related cortical potentials in human upper extremity amputees with and without phantom limb pain. *Pain*, 110 (1-2):90-102, 2004.
- Karmarkar A, Lieberman I. Mirror box therapy for complex regional pain syndrome. *Anaesthesia*, 61 (4):412-3, 2006.
- Karni A, Meyer G, Rey-Hipolito C, Jezard P, Adams MM, Turner R, Ungerleider LG. The acquisition of skilled motor performance: fast and slow experience-driven changes in primary motor cortex. *Proc Natl Acad Sci U S A*, 95 (3):861-8, 1998.
- Kasess CH, Stephan KE, Weissenbacher A, Pezawas L, Moser E, Windischberger C. Multi-subject analyses with dynamic causal modeling. *Neuroimage*, 49 (4):3065-74, 2010.
- Kasess CH, Windischberger C, Cunnington R, Lanzenberger R, Pezawas L, Moser E. The suppressive influence of SMA on M1 in motor imagery revealed by fMRI and dynamic causal modeling. *Neuroimage*, 40 (2):828-37, 2008.
- Kelahan AM, Ray RH, Carson LV, Massey CE, Doetsch GS. Functional reorganization of adult raccoon somatosensory cerebral cortex following neonatal digit amputation. *Brain Res*, 223 (1):152-9, 1981.
- Keller A. Intrinsic synaptic organization of the motor cortex. *Cereb Cortex*, 3 (5):430-41, 1993.
- Keller A, Pavlides C, Asanuma H. Long-term potentiation in the cat somatosensory cortex. *Neuroreport*, 1 (1):49-52, 1990.
- Kern U, Martin C, Scheicher S, Muller H. Does botulinum toxin A make prosthesis use easier for amputees? *J Rehabil Med*, 36 (5):238-9, 2004.
- Kew JJ, Ridding MC, Rothwell JC, Passingham RE, Leigh PN, Sooriakumaran S, Frackowiak RS, Brooks DJ. Reorganization of cortical blood flow and transcranial magnetic stimulation

- maps in human subjects after upper limb amputation. *J Neurophysiol*, 72 (5):2517-24, 1994.
- Knecht S, Henningsen H, Elbert T, Flor H, Hohling C, Pantev C, Birbaumer N, Taub E. Cortical reorganization in human amputees and mislocalization of painful stimuli to the phantom limb. *Neurosci Lett*, 201 (3):262-4, 1995.
- Knecht S, Henningsen H, Elbert T, Flor H, Hohling C, Pantev C, Taub E. Reorganizational and perceptual changes after amputation. *Brain*, 119 (Pt 4) 1213-9, 1996.
- Knecht S, Henningsen H, Hohling C, Elbert T, Flor H, Pantev C, Taub E. Plasticity of plasticity? Changes in the pattern of perceptual correlates of reorganization after amputation. *Brain*, 121 (Pt 4) 717-24, 1998.
- Koch G, Schneider S, Baumer T, Franca M, Munchau A, Cheeran B, Fernandez del Olmo M, Cordivari C, Rounis E, Caltagirone C, Bhatia K, Rothwell JC. Altered dorsal premotor-motor interhemispheric pathway activity in focal arm dystonia. *Mov Disord*, 23 (5):660-8, 2008.
- Kolb LC (1954) *The Painful Phantom*: Charles C. Thomas.
- Kooijman CM, Dijkstra PU, Geertzen JH, Elzinga A, van der Schans CP. Phantom pain and phantom sensations in upper limb amputees: an epidemiological study. *Pain*, 87 (1):33-41, 2000.
- Korin H, Weiss SA, Fishman S. Pain sensitivity of amputation extremities. *J Psychol*, 55 345-55, 1963.
- Kosslyn SM, Ball TM, Reiser BJ. Visual images preserve metric spatial information: evidence from studies of image scanning. *J Exp Psychol Hum Percept Perform*, 4 (1):47-60, 1978.
- Kosslyn SMP-LAFOCKJTWGG, Sukel K. E. Alpert N. M. The role of area 17 in visual imagery: convergent evidence from PET and rTMS. *Science*, 284 167-70, 1999.
- Krause P, Forderreuther S, Straube A. [Motor cortical representation in patients with complex regional pain syndrome: a TMS study]. *Schmerz*, 20 (3):181-4, 6-8, 2006a.
- Krause P, Forderreuther S, Straube A. TMS motor cortical brain mapping in patients with complex regional pain syndrome type I. *Clin Neurophysiol*, 117 (1):169-76, 2006b.
- Lacourse MG, Orr EL, Cramer SC, Cohen MJ. Brain activation during execution and motor imagery of novel and skilled sequential hand movements. *Neuroimage*, 27 (3):505-19, 2005.
- Lafleur MF, Jackson PL, Malouin F, Richards CL, Evans AC, Doyon J. Motor learning produces parallel dynamic functional changes during the execution and imagination of sequential foot movements. *Neuroimage*, 16 (1):142-57, 2002.
- Lebon F, Rouffet D, Collet C, Guillot A. Modulation of EMG power spectrum frequency during motor imagery. *Neurosci Lett*, 435 (3):181-5, 2008.

- Levy R, Deer TR, Henderson J. Intracranial neurostimulation for pain control: a review. *Pain Physician*, 13 (2):157-65, 2010.
- Levy WJ, Jr., Amassian VE, Traad M, Cadwell J. Focal magnetic coil stimulation reveals motor cortical system reorganized in humans after traumatic quadriplegia. *Brain Res*, 510 (1):130-4, 1990.
- Lewis JW, Van Essen DC. Mapping of architectonic subdivisions in the macaque monkey, with emphasis on parieto-occipital cortex. *J Comp Neurol*, 428 (1):79-111, 2000.
- Liepert J, Tegenthoff M, Malin JP. Changes of cortical motor area size during immobilization. *Electroencephalogr Clin Neurophysiol*, 97 (6):382-6, 1995.
- Livingston SC, Ingersoll CD. Intra-rater reliability of a transcranial magnetic stimulation technique to obtain motor evoked potentials. *Int J Neurosci*, 118 (2):239-56, 2008.
- Lotze M, Flor H, Grodd W, Larbig W, Birbaumer N. Phantom movements and pain. An fMRI study in upper limb amputees. *Brain*, 124 (Pt 11):2268-77, 2001.
- Lotze M, Grodd W, Birbaumer N, Erb M, Huse E, Flor H. Does use of a myoelectric prosthesis prevent cortical reorganization and phantom limb pain? *Nat Neurosci*, 2 (6):501-2, 1999a.
- Lotze M, Halsband U. Motor imagery. *J Physiol Paris*, 99 (4-6):386-95, 2006.
- Lotze M, Montoya P, Erb M, Hülsmann E, Flor H, Klose U, Birbaumer N, Grodd W. Activation of cortical and cerebellar motor areas during executed and imagined hand movements: an fMRI study. *J Cogn Neurosci*, 11 (5):491-501, 1999b.
- Lotze M, Moseley GL. Role of distorted body image in pain. *Curr Rheumatol Rep*, 9 (6):488-96, 2007.
- Lotze M, Seggewies G, Erb M, Grodd W, Birbaumer N. The representation of articulation in the primary sensorimotor cortex. *Neuroreport*, 11 (13):2985-9, 2000.
- Loubinoux I, Carel C, Alary F, Boulanouar K, Viallard G, Manelfe C, Rascol O, Celsis P, Chollet F. Within-session and between-session reproducibility of cerebral sensorimotor activation: a test-retest effect evidenced with functional magnetic resonance imaging. *J Cereb Blood Flow Metab*, 21 (5):592-607, 2001.
- Luft AR, Skalej M, Stefanou A, Klose U, Voigt K. Comparing motion- and imagery-related activation in the human cerebellum: a functional MRI study. *Hum Brain Mapp*, 6 (2):105-13, 1998.
- Luft AR, Smith GV, Forrester L, Whittall J, Macko RF, Hauser TK, Goldberg AP, Hanley DF. Comparing brain activation associated with isolated upper and lower limb movement across corresponding joints. *Hum Brain Mapp*, 17 (2):131-40, 2002.
- Lutkenhoner B, Steinstrater O. High-precision neuromagnetic study of the functional organization of the human auditory cortex. *Audiol Neurootol*, 3 (2-3):191-213, 1998.

- Maarrawi J, Peyron R, Mertens P, Costes N, Magnin M, Sindou M, Laurent B, Garcia-Larrea L. Motor cortex stimulation for pain control induces changes in the endogenous opioid system. *Neurology*, 69 (9):827-34, 2007.
- MacIver K, Lloyd DM, Kelly S, Roberts N, Nurmikko T. Phantom limb pain, cortical reorganization and the therapeutic effect of mental imagery. *Brain*, 131 (Pt 8):2181-91, 2008.
- MacLachlan M, McDonald D, Waloch J. Mirror treatment of lower limb phantom pain: a case study. *Disabil Rehabil*, 26 (14-15):901-4, 2004.
- Maihofner C, Baron R, DeCol R, Binder A, Birklein F, Deuschl G, Handwerker HO, Schattschneider J. The motor system shows adaptive changes in complex regional pain syndrome. *Brain*, 130 (Pt 10):2671-87, 2007.
- Maihofner C, Handwerker HO, Neundorfer B, Birklein F. Patterns of cortical reorganization in complex regional pain syndrome. *Neurology*, 61 (12):1707-15, 2003.
- Malouin F, Richards CL, Desrosiers J, Doyon J. Bilateral slowing of mentally simulated actions after stroke. *Neuroreport*, 15 (8):1349-53, 2004.
- Malouin F, Richards CL, Durand A, Descent M, Poire D, Fremont P, Pelet S, Gresset J, Doyon J. Effects of Practice, Visual Loss, Limb Amputation, and Disuse on Motor Imagery Vividness. *Neurorehabil Neural Repair*, 2009.
- Malouin F, Richards CL, Jackson PL, Lafleur MF, Durand A, Doyon J. The Kinesthetic and Visual Imagery Questionnaire (KVIQ) for assessing motor imagery in persons with physical disabilities: a reliability and construct validity study. *J Neurol Phys Ther*, 31 (1):20-9, 2007.
- Manger PR, Woods TM, Munoz A, Jones EG. Hand/face border as a limiting boundary in the body representation in monkey somatosensory cortex. *J Neurosci*, 17 (16):6338-51, 1997.
- Marconi B, Pecchioli C, Koch G, Caltagirone C. Functional overlap between hand and forearm motor cortical representations during motor cognitive tasks. *Clin Neurophysiol*, 118 (8):1767-75, 2007.
- Marshall I, Simonotto E, Deary IJ, MacLulich A, Ebmeier KP, Rose EJ, Wardlaw JM, Goddard N, Chappell FM. Repeatability of motor and working-memory tasks in healthy older volunteers: assessment at functional MR imaging. *Radiology*, 233 (3):868-77, 2004.
- Maruno N, Kaminaga T, Mikami M, Furui S. Activation of supplementary motor area during imaginary movement of phantom toes. *Neurorehabil Neural Repair*, 14 (4):345-9, 2000.
- Matthys K, Smits M, Van der Geest JN, Van der Lugt A, Seurinck R, Stam HJ, Selles RW. Mirror-induced visual illusion of hand movements: a functional magnetic resonance imaging study. *Arch Phys Med Rehabil*, 90 (4):675-81, 2009.

- Mazzola L, Isnard J, Peyron R, Guenot M, Mauguiere F. Somatotopic organization of pain responses to direct electrical stimulation of the human insular cortex. *Pain*, 146 (1-2):99-104, 2009.
- McAvinue LP, Robertson IH. Individual differences in response to phantom limb movement therapy. *Disabil Rehabil*, 2011.
- McCabe C. Mirror Visual Feedback Therapy. A Practical Approach. *J Hand Ther*, 2010.
- McCabe CS, Haigh RC, Blake DR. Mirror visual feedback for the treatment of complex regional pain syndrome (type 1). *Curr Pain Headache Rep*, 12 (2):103-7, 2008.
- McCabe CS, Haigh RC, Ring EF, Halligan PW, Wall PD, Blake DR. A controlled pilot study of the utility of mirror visual feedback in the treatment of complex regional pain syndrome (type 1). *Rheumatology (Oxford)*, 42 (1):97-101, 2003.
- McGonigle DJ, Howseman AM, Athwal BS, Friston KJ, Frackowiak RS, Holmes AP. Variability in fMRI: an examination of intersession differences. *Neuroimage*, 11 (6 Pt 1):708-34, 2000.
- Meier JD, Aflalo TN, Kastner S, Graziano MS. Complex organization of human primary motor cortex: a high-resolution fMRI study. *J Neurophysiol*, 100 (4):1800-12, 2008.
- Meister IG, Krings T, Foltys H, Boroojerdi B, Muller M, Topper R, Thron A. Playing piano in the mind--an fMRI study on music imagery and performance in pianists. *Brain Res Cogn Brain Res*, 19 (3):219-28, 2004.
- Melgari JM, Pasqualetti P, Pauri F, Rossini PM. Muscles in "concert": study of primary motor cortex upper limb functional topography. *PLoS ONE*, 3 (8):e3069, 2008.
- Mellah S, Rispal-Padel L, Riviere G. Changes in excitability of motor units during preparation for movement. *Exp Brain Res*, 82 (1):178-86, 1990.
- Melzack R. Phantom limbs and the concept of a neuromatrix. *Trends Neurosci*, 13 (3):88-92, 1990.
- Melzack R. Phantom limbs. *Sci Am*, 266 (4):120-6, 1992.
- Melzack R, Israel R, Lacroix R, Schultz G. Phantom limbs in people with congenital limb deficiency or amputation in early childhood. *Brain*, 120 (Pt 9) 1603-20, 1997.
- Mercier C, Reilly KT, Vargas CD, Aballea A, Sirigu A. Mapping phantom movement representations in the motor cortex of amputees. *Brain*, 129 (Pt 8):2202-10, 2006.
- Mercier C, Sirigu A. Training with virtual visual feedback to alleviate phantom limb pain. *Neurorehabil Neural Repair*, 23 (6):587-94, 2009.
- Merzenich MM, Kaas JH, Wall J, Nelson RJ, Sur M, Felleman D. Topographic reorganization of somatosensory cortical areas 3b and 1 in adult monkeys following restricted deafferentation. *Neuroscience*, 8 (1):33-55, 1983a.

- Merzenich MM, Kaas JH, Wall JT, Sur M, Nelson RJ, Felleman DJ. Progression of change following median nerve section in the cortical representation of the hand in areas 3b and 1 in adult owl and squirrel monkeys. *Neuroscience*, 10 (3):639-65, 1983b.
- Merzenich MM, Nelson RJ, Stryker MP, Cynader MS, Schoppmann A, Zook JM. Somatosensory cortical map changes following digit amputation in adult monkeys. *J Comp Neurol*, 224 (4):591-605, 1984.
- Michielsen ME, Selles RW, van der Geest JN, Eckhardt M, Yavuzer G, Stam HJ, Smits M, Ribbers GM, Bussmann JB. Motor Recovery and Cortical Reorganization After Mirror Therapy in Chronic Stroke Patients: A Phase II Randomized Controlled Trial. *Neurorehabil Neural Repair*, 2010.
- Michielsen ME, Selles RW, van der Geest JN, Eckhardt M, Yavuzer G, Stam HJ, Smits M, Ribbers GM, Bussmann JB. Motor recovery and cortical reorganization after mirror therapy in chronic stroke patients: a phase II randomized controlled trial. *Neurorehabil Neural Repair*, 25 (3):223-33, 2011.
- Miller MI, Christensen GE, Amit Y, Grenander U. Mathematical textbook of deformable neuroanatomies. *Proc Natl Acad Sci U S A*, 90 (24):11944-8, 1993.
- Mitchell WS (1872) *Injuries of nerves and their consequences*. Philadelphia: Lippincott.
- Moisello C, Bove M, Huber R, Abbruzzese G, Battaglia F, Tononi G, Ghilardi MF. Short-term limb immobilization affects motor performance. *J Mot Behav*, 40 (2):165-76, 2008.
- Montoya P, Ritter K, Huse E, Larbig W, Braun C, Topfner S, Lutzenberger W, Grodd W, Flor H, Birbaumer N. The cortical somatotopic map and phantom phenomena in subjects with congenital limb atrophy and traumatic amputees with phantom limb pain. *Eur J Neurosci*, 10 (3):1095-102, 1998.
- Moseley GL. Graded motor imagery is effective for long-standing complex regional pain syndrome: a randomised controlled trial. *Pain*, 108 (1-2):192-8, 2004a.
- Moseley GL. Why do people with complex regional pain syndrome take longer to recognize their affected hand? *Neurology*, 62 (12):2182-6, 2004b.
- Moseley GL. Is successful rehabilitation of complex regional pain syndrome due to sustained attention to the affected limb? A randomised clinical trial. *Pain*, 114 (1-2):54-61, 2005.
- Moseley GL. Graded motor imagery for pathologic pain: a randomized controlled trial. *Neurology*, 67 (12):2129-34, 2006.
- Moseley GL, Brugger P. Interdependence of movement and anatomy persists when amputees learn a physiologically impossible movement of their phantom limb. *Proc Natl Acad Sci U S A*, 106 (44):18798-802, 2009.
- Moseley GL, Gallace A, Spence C. Is mirror therapy all it is cracked up to be? Current evidence and future directions. *Pain*, 138 (1):7-10, 2008a.

- Moseley GL, Zalucki N, Birklein F, Marinus J, van Hilten JJ, Luomajoki H. Thinking about movement hurts: the effect of motor imagery on pain and swelling in people with chronic arm pain. *Arthritis Rheum*, 59 (5):623-31, 2008b.
- Mountcastle VB. The columnar organization of the neocortex. *Brain*, 120 (Pt 4) 701-22, 1997.
- Muhn timer W, Elbert T, Taub E, Flor H. Reorganization of auditory cortex in tinnitus. *Proc Natl Acad Sci U S A*, 95 (17):10340-3, 1998.
- Mulder T, Zijlstra S, Zijlstra W, Hochstenbach J. The role of motor imagery in learning a totally novel movement. *Exp Brain Res*, 154 (2):211-7, 2004.
- Murray CD, Patchick EL, Caillette F, Howard T, Pettifer S. Can immersive virtual reality reduce phantom limb pain? *Stud Health Technol Inform*, 119 407-12, 2006.
- Murray CD, Pettifer S, Howard T, Patchick EL, Caillette F, Kulkarni J, Bamford C. The treatment of phantom limb pain using immersive virtual reality: three case studies. *Disabil Rehabil*, 29 (18):1465-9, 2007.
- Nair DG, Purcott KL, Fuchs A, Steinberg F, Kelso JA. Cortical and cerebellar activity of the human brain during imagined and executed unimanual and bimanual action sequences: a functional MRI study. *Brain Res Cogn Brain Res*, 15 (3):250-60, 2003.
- Naito E, Kochiyama T, Kitada R, Nakamura S, Matsumura M, Yonekura Y, Sadato N. Internally simulated movement sensations during motor imagery activate cortical motor areas and the cerebellum. *J Neurosci*, 22 (9):3683-91, 2002.
- Nelson RJ, Kaas JH. Connections of the ventroposterior nucleus of the thalamus with the body surface representations in cortical areas 3b and 1 of the cynomolgus macaque, (*Macaca fascicularis*). *J Comp Neurol*, 199 (1):29-64, 1981.
- Neuper C, Scherer R, Reiner M, Pfurtscheller G. Imagery of motor actions: differential effects of kinesthetic and visual-motor mode of imagery in single-trial EEG. *Brain Res Cogn Brain Res*, 25 (3):668-77, 2005.
- Nico D, Daprati E, Rigal F, Parsons L, Sirigu A. Left and right hand recognition in upper limb amputees. *Brain*, 127 (Pt 1):120-32, 2004.
- Nudo RJ, Milliken GW, Jenkins WM, Merzenich MM. Use-dependent alterations of movement representations in primary motor cortex of adult squirrel monkeys. *J Neurosci*, 16 (2):785-807, 1996.
- O'Connell NE, Wand BM, Marston L, Spencer S, Desouza LH. Non-invasive brain stimulation techniques for chronic pain. *Cochrane Database Syst Rev*, (9):CD008208, 2010.
- Ojemann JG, Silbergeld DL. Cortical stimulation mapping of phantom limb rolandic cortex. Case report. *J Neurosurg*, 82 (4):641-4, 1995.
- Operto G, Bulot R, Anton JL, Coulon O. Projection of fMRI data onto the cortical surface using anatomically-informed convolution kernels. *Neuroimage*, 39 (1):127-35, 2008.

- Page SJ, Levine P, Leonard A. Mental practice in chronic stroke: results of a randomized, placebo-controlled trial. *Stroke*, 38 (4):1293-7, 2007.
- Page SJ, Szaflarski JP, Eliassen JC, Pan H, Cramer SC. Cortical plasticity following motor skill learning during mental practice in stroke. *Neurorehabil Neural Repair*, 23 (4):382-8, 2009.
- Paré A (1551) La Méthode de Traicter les Playes Faictes tant par Hacquebutes que par Fleches. Paris: de Brie.
- Park MC, Goldman MA, Park MJ, Friehs GM. Neuroanatomical localization of the 'precentral knob' with computed tomography imaging. *Stereotact Funct Neurosurg*, 85 (4):158-61, 2007.
- Parsons LM. Temporal and kinematic properties of motor behavior reflected in mentally simulated action. *J Exp Psychol Hum Percept Perform*, 20 (4):709-30, 1994.
- Pascual-Leone A, Cammarota A, Wassermann EM, Brasil-Neto JP, Cohen LG, Hallett M. Modulation of motor cortical outputs to the reading hand of braille readers. *Ann Neurol*, 34 (1):33-7, 1993.
- Pascual-Leone A, Peris M, Tormos JM, Pascual AP, Catala MD. Reorganization of human cortical motor output maps following traumatic forearm amputation. *Neuroreport*, 7 (13):2068-70, 1996.
- Pascual-Leone A, Torres F. Plasticity of the sensorimotor cortex representation of the reading finger in Braille readers. *Brain*, 116 (Pt 1) 39-52, 1993.
- Penfield W, Rasmussen T (1950) The Cerebral Cortex of Man. New York.
- Penny WD, Stephan KE, Daunizeau J, Rosa MJ, Friston KJ, Schofield TM, Leff AP. Comparing families of dynamic causal models. *PLoS Comput Biol*, 6 (3):e1000709, 2010.
- Playford ED, Passingham RE, Marsden CD, Brooks DJ. Increased activation of frontal areas during arm movement in idiopathic torsion dystonia. *Mov Disord*, 13 (2):309-18, 1998.
- Pleger B, Ragert P, Schwenkreis P, Forster AF, Wilimzig C, Dinse H, Nicolas V, Maier C, Tegenthoff M. Patterns of cortical reorganization parallel impaired tactile discrimination and pain intensity in complex regional pain syndrome. *Neuroimage*, 32 (2):503-10, 2006.
- Pleger B, Tegenthoff M, Schwenkreis P, Janssen F, Ragert P, Dinse HR, Volker B, Zenz M, Maier C. Mean sustained pain levels are linked to hemispherical side-to-side differences of primary somatosensory cortex in the complex regional pain syndrome I. *Exp Brain Res*, 155 (1):115-9, 2004.
- Plow EB, Arora P, Pline MA, Binstock MT, Carey JR. Within-limb somatotopy in primary motor cortex--revealed using fMRI. *Cortex*, 46 (3):310-21, 2010.

- Plowman-Prine EK, Triggs WJ, Malcolm MP, Rosenbek JC. Reliability of transcranial magnetic stimulation for mapping swallowing musculature in the human motor cortex. *Clin Neurophysiol*, 119 (10):2298-303, 2008.
- Pons TP, Garraghty PE, Ommaya AK, Kaas JH, Taub E, Mishkin M. Massive cortical reorganization after sensory deafferentation in adult macaques. *Science*, 252 (5014):1857-60, 1991.
- Porro CA, Francescato MP, Cettolo V, Diamond ME, Baraldi P, Zuiani C, Bazzocchi M, di Prampero PE. Primary motor and sensory cortex activation during motor performance and motor imagery: a functional magnetic resonance imaging study. *J Neurosci*, 16 (23):7688-98, 1996.
- Posadzki P, Ernst E. Guided Imagery for Musculoskeletal Pain: A Systematic Review. *Clin J Pain*, 2011.
- Press C, Cook J, Blakemore SJ, Kilner J. Dynamic modulation of human motor activity when observing actions. *J Neurosci*, 31 (8):2792-800, 2011.
- Qi HX, Stepniewska I, Kaas JH. Reorganization of primary motor cortex in adult macaque monkeys with long-standing amputations. *J Neurophysiol*, 84 (4):2133-47, 2000.
- Quartarone A, Bagnato S, Rizzo V, Siebner HR, Dattola V, Scalfari A, Morgante F, Battaglia F, Romano M, Girlanda P. Abnormal associative plasticity of the human motor cortex in writer's cramp. *Brain*, 126 (Pt 12):2586-96, 2003.
- Raffin E, Giraux P, Reilly KT. The moving phantom: Motor execution or motor imagery? *Cortex*, 2011.
- Ramachandran VS, Brang D, McGeoch PD. Dynamic reorganization of referred sensations by movements of phantom limbs. *Neuroreport*, 21 (10):727-30, 2010.
- Ramachandran VS, Hirstein W. The perception of phantom limbs. The D. O. Hebb lecture. *Brain*, 121 (Pt 9) 1603-30, 1998.
- Ramachandran VS, Rogers-Ramachandran D. Synaesthesia in phantom limbs induced with mirrors. *Proc Biol Sci*, 263 (1369):377-86, 1996.
- Ramachandran VS, Rogers-Ramachandran D, Stewart M. Perceptual correlates of massive cortical reorganization. *Science*, 258 (5085):1159-60, 1992.
- Ramsey R, Cumming J, Eastough D, Edwards MG. Incongruent imagery interferes with action initiation. *Brain Cogn*, 2010.
- Rao SM, Binder JR, Hammeke TA, Bandettini PA, Bobholz JA, Frost JA, Myklebust BM, Jacobson RD, Hyde JS. Somatotopic mapping of the human primary motor cortex with functional magnetic resonance imaging. *Neurology*, 45 (5):919-24, 1995.
- Recanzone GH, Merzenich MM, Dinse HR. Expansion of the cortical representation of a specific skin field in primary somatosensory cortex by intracortical microstimulation. *Cereb Cortex*, 2 (3):181-96, 1992a.

- Recanzone GH, Merzenich MM, Jenkins WM, Grajski KA, Dinse HR. Topographic reorganization of the hand representation in cortical area 3b owl monkeys trained in a frequency-discrimination task. *J Neurophysiol*, 67 (5):1031-56, 1992b.
- Reilly KT, Mercier C, Schieber MH, Sirigu A. Persistent hand motor commands in the amputees' brain. *Brain*, 129 (Pt 8):2211-23, 2006.
- Reilly KT, Sirigu A. The motor cortex and its role in phantom limb phenomena. *Neuroscientist*, 14 (2):195-202, 2008.
- Reilly KT, Sirigu A. Motor Cortex Representation of the Upper-Limb in Individuals Born without a Hand. *PLoS ONE*, 6 (4):e18100, 2011.
- Ridding MC, Rothwell JC. Reorganisation in human motor cortex. *Can J Physiol Pharmacol*, 73 (2):218-22, 1995.
- Ridding MC, Taylor JL, Rothwell JC. The effect of voluntary contraction on cortico-cortical inhibition in human motor cortex. *J Physiol*, 487 (Pt 2) 541-8, 1995.
- Rizzolatti G, Craighero L. The mirror-neuron system. *Annu Rev Neurosci*, 27 169-92, 2004.
- Roberts DR, Ricci R, Funke FW, Ramsey P, Kelley W, Carroll JS, Ramsey D, Borckardt JJ, Johnson K, George MS. Lower limb immobilization is associated with increased corticospinal excitability. *Exp Brain Res*, 181 (2):213-20, 2007.
- Rocca MA, Agosta F, Colombo B, Mezzapesa DM, Falini A, Comi G, Filippi M. fMRI changes in relapsing-remitting multiple sclerosis patients complaining of fatigue after IFNbeta-1a injection. *Hum Brain Mapp*, 28 (5):373-82, 2007a.
- Rocca MA, Pagani E, Absinta M, Valsasina P, Falini A, Scotti G, Comi G, Filippi M. Altered functional and structural connectivities in patients with MS: a 3-T study. *Neurology*, 69 (23):2136-45, 2007b.
- Roland PE, Larsen B, Lassen NA, Skinhoj E. Supplementary motor area and other cortical areas in organization of voluntary movements in man. *J Neurophysiol*, 43 (1):118-36, 1980.
- Romaiguere P, Anton JL, Roth M, Casini L, Roll JP. Motor and parietal cortical areas both underlie kinaesthesia. *Brain Res Cogn Brain Res*, 16 (1):74-82, 2003.
- Romero DH, Lacourse MG, Lawrence KE, Schandler S, Cohen MJ. Event-related potentials as a function of movement parameter variations during motor imagery and isometric action. *Behav Brain Res*, 117 (1-2):83-96, 2000.
- Rona S, Berardelli A, Vacca L, Inghilleri M, Manfredi M. Alterations of motor cortical inhibition in patients with dystonia. *Mov Disord*, 13 (1):118-24, 1998.
- Roricht S, Machetanz J, Irlbacher K, Niehaus L, Biemer E, Meyer BU. Reorganization of human motor cortex after hand replantation. *Ann Neurol*, 50 (2):240-9, 2001.
- Roricht S, Meyer BU. Residual function in motor cortex contralateral to amputated hand. *Neurology*, 54 (4):984-7, 2000.

- Roricht S, Meyer BU, Niehaus L, Brandt SA. Long-term reorganization of motor cortex outputs after arm amputation. *Neurology*, 53 (1):106-11, 1999.
- Rosen B, Lundborg G. Training with a mirror in rehabilitation of the hand. *Scand J Plast Reconstr Surg Hand Surg*, 39 (2):104-8, 2005.
- Rosen G, Hugdahl K, Erslund L, Lundervold A, Smievoll AI, Barndon R, Sundberg H, Thomsen T, Roscher BE, Tjolsen A, Engelsen B. Different brain areas activated during imagery of painful and non-painful 'finger movements' in a subject with an amputated arm. *Neurocase*, 7 (3):255-60, 2001.
- Rosenkranz K, Butler K, Williamon A, Cordivari C, Lees AJ, Rothwell JC. Sensorimotor reorganization by proprioceptive training in musician's dystonia and writer's cramp. *Neurology*, 70 (4):304-15, 2008.
- Roth M, Decety J, Raybaudi M, Massarelli R, Delon-Martin C, Segebarth C, Morand S, Gemignani A, Decorps M, Jeannerod M. Possible involvement of primary motor cortex in mentally simulated movement: a functional magnetic resonance imaging study. *Neuroreport*, 7 (7):1280-4, 1996.
- Rothgangel AS, Braun SM, Beurskens AJ, Seitz RJ, Wade DT. The clinical aspects of mirror therapy in rehabilitation: a systematic review of the literature. *Int J Rehabil Res*, 34 (1):1-13, 2011.
- Rothwell JC, Traub MM, Day BL, Obeso JA, Thomas PK, Marsden CD. Manual motor performance in a deafferented man. *Brain*, 105 (Pt 3) 515-42, 1982.
- Roux FE, Ibarrola D, Lazorthes Y, Berry I. Virtual movements activate primary sensorimotor areas in amputees: report of three cases. *Neurosurgery*, 49 (3):736-41; discussion 41-2, 2001.
- Roux FE, Lotterie JA, Cassol E, Lazorthes Y, Sol JC, Berry I. Cortical areas involved in virtual movement of phantom limbs: comparison with normal subjects. *Neurosurgery*, 53 (6):1342-52; discussion 52-3, 2003.
- Rowe JB, Hughes LE, Barker RA, Owen AM. Dynamic causal modelling of effective connectivity from fMRI: are results reproducible and sensitive to Parkinson's disease and its treatment? *Neuroimage*, 52 (3):1015-26, 2010.
- Ruby P, Decety J. Effect of subjective perspective taking during simulation of action: a PET investigation of agency. *Nat Neurosci*, 4 (5):546-50, 2001.
- Rumeau C, Tzourio N, Murayama N, Peretti-Viton P, Levrier O, Joliot M, Mazoyer B, Salamon G. Location of hand function in the sensorimotor cortex: MR and functional correlation. *AJNR Am J Neuroradiol*, 15 (3):567-72, 1994.
- Sacks O (1985) The man who mistook his wife for a hat.
- Saitoh Y, Yoshimine T. Stimulation of primary motor cortex for intractable deafferentation pain. *Acta Neurochir Suppl*, 97 (Pt 2):51-6, 2007.

- Sanes JN, Donoghue JP, Thangaraj V, Edelman RR, Warach S. Shared neural substrates controlling hand movements in human motor cortex. *Science*, 268 (5218):1775-7, 1995.
- Sanes JN, Suner S, Donoghue JP. Dynamic organization of primary motor cortex output to target muscles in adult rats. I. Long-term patterns of reorganization following motor or mixed peripheral nerve lesions. *Exp Brain Res*, 79 (3):479-91, 1990.
- Sastre-Janer FA, Regis J, Belin P, Mangin JF, Dormont D, Masure MC, Remy P, Frouin V, Samson Y. Three-dimensional reconstruction of the human central sulcus reveals a morphological correlate of the hand area. *Cereb Cortex*, 8 (7):641-7, 1998.
- Sathian K, Greenspan AI, Wolf SL. Doing it with mirrors: a case study of a novel approach to neurorehabilitation. *Neurorehabil Neural Repair*, 14 (1):73-6, 2000.
- Schieber MH. Somatotopic gradients in the distributed organization of the human primary motor cortex hand area: evidence from small infarcts. *Exp Brain Res*, 128 (1-2):139-48, 1999.
- Schieber MH, Deuel RK. Primary motor cortex reorganization in a long-term monkey amputee. *Somatosens Mot Res*, 14 (3):157-67, 1997.
- Schieber MH, Hibbard LS. How somatotopic is the motor cortex hand area? *Science*, 261 (5120):489-92, 1993.
- Schilder P (1968) L'image du corps.
- Schnitzler A, Salenius S, Salmelin R, Jousmaki V, Hari R. Involvement of primary motor cortex in motor imagery: a neuromagnetic study. *Neuroimage*, 6 (3):201-8, 1997.
- Schwarzer A, Gludo S, Zenz M, Maier C. [Mirror feed-back - a new method for the treatment of neuropathic pain]. *Dtsch Med Wochenschr*, 132 (41):2159-62, 2007.
- Schwarzer A, Zenz M, Maier C. [Therapy of phantom limb pain]. *Anesthesiol Intensivmed Notfallmed Schmerzther*, 44 (3):174-80, 2009.
- Schwenkreis P, Pleger B, Cornelius B, Weyen U, Dertwinkel R, Zenz M, Malin JP, Tegenthoff M. Reorganization in the ipsilateral motor cortex of patients with lower limb amputation. *Neurosci Lett*, 349 (3):187-90, 2003.
- Schwenkreis P, Witscher K, Janssen F, Dertwinkel R, Zenz M, Malin JP, Tegenthoff M. Changes of cortical excitability in patients with upper limb amputation. *Neurosci Lett*, 293 (2):143-6, 2000.
- Schwenkreis P, Witscher K, Janssen F, Pleger B, Dertwinkel R, Zenz M, Malin JP, Tegenthoff M. Assessment of reorganization in the sensorimotor cortex after upper limb amputation. *Clin Neurophysiol*, 112 (4):627-35, 2001.
- Schwoebel J, Friedman R, Duda N, Coslett HB. Pain and the body schema: evidence for peripheral effects on mental representations of movement. *Brain*, 124 (Pt 10):2098-104, 2001.

- Seidel S, Kasprian G, Sycha T, Auff E.[Mirror therapy for phantom limb pain--a systematic review]. *Wien Klin Wochenschr*, 121 (13-14):440-4, 2009.
- Sekiyama K.Kinesthetic aspects of mental representations in the identification of left and right hands. *Percept Psychophys*, 32 (2):89-95, 1982.
- Selles RW, Schreuders TA, Stam HJ.Mirror therapy in patients with causalgia (complex regional pain syndrome type II) following peripheral nerve injury: two cases. *J Rehabil Med*, 40 (4):312-4, 2008.
- Sharma N, Baron JC, Rowe JB.Motor imagery after stroke: relating outcome to motor network connectivity. *Ann Neurol*, 66 (5):604-16, 2009.
- Sharma N, Jones PS, Carpenter TA, Baron JC.Mapping the involvement of BA 4a and 4p during Motor Imagery. *Neuroimage*, 41 (1):92-9, 2008.
- Sheehan PW.A shortened form of Betts' questionnaire upon mental imagery. *J Clin Psychol*, 23 (3):386-9, 1967.
- Shepard RN, Metzler J.Mental rotation of three-dimensional objects. *Science*, 171 (972):701-3, 1971.
- Sherman RA.Stump and phantom limb pain. *Neurol Clin*, 7 (2):249-64, 1989.
- Sherman RA, Arena JG, Sherman CJ, Ernst JL.The mystery of phantom pain: growing evidence for psychophysiological mechanisms. *Biofeedback Self Regul*, 14 (4):267-80, 1989.
- Sherman RA, Sherman CJ, Parker L.Chronic phantom and stump pain among American veterans: results of a survey. *Pain*, 18 (1):83-95, 1984.
- Shinoura N, Suzuki Y, Yamada R, Tabei Y, Saito K, Yagi K.Precentral knob corresponds to the primary motor and premotor area. *Can J Neurol Sci*, 36 (2):227-33, 2009.
- Shukla GD, Sahu SC, Tripathi RP, Gupta DK.Phantom limb: a phenomenological study. *Br J Psychiatry*, 141 54-8, 1982.
- Siebner HR, Rothwell J.Transcranial magnetic stimulation: new insights into representational cortical plasticity. *Exp Brain Res*, 148 (1):1-16, 2003.
- Sirigu A, Duhamel JR.Motor and visual imagery as two complementary but neurally dissociable mental processes. *J Cogn Neurosci*, 13 (7):910-9, 2001.
- Sirigu A, Duhamel JR, Cohen L, Pillon B, Dubois B, Agid Y.The mental representation of hand movements after parietal cortex damage. *Science*, 273 (5281):1564-8, 1996.
- Skoura X, Personnier P, Vinter A, Pozzo T, Papaxanthis C.Decline in motor prediction in elderly subjects: right versus left arm differences in mentally simulated motor actions. *Cortex*, 44 (9):1271-8, 2008.
- Smith JL, Crawford M, Proske U, Taylor JL, Gandevia SC.Signals of motor command bias joint position sense in the presence of feedback from proprioceptors. *J Appl Physiol*, 106 (3):950-8, 2009.

- Solodkin A, Hlustik P, Chen EE, Small SL. Fine modulation in network activation during motor execution and motor imagery. *Cereb Cortex*, 14 (11):1246-55, 2004.
- Stephan KE, Friston KJ. Analyzing effective connectivity with fMRI. *Wiley Interdiscip Rev Cogn Sci*, 1 (3):446-59, 2010.
- Stephan KE, Penny WD, Daunizeau J, Moran RJ, Friston KJ. Bayesian model selection for group studies. *Neuroimage*, 46 (4):1004-17, 2009.
- Stephan KE, Penny WD, Moran RJ, den Ouden HE, Daunizeau J, Friston KJ. Ten simple rules for dynamic causal modeling. *Neuroimage*, 49 (4):3099-109, 2010.
- Stephan KM, Fink GR, Passingham RE, Silbersweig D, Ceballos-Baumann AO, Frith CD, Frackowiak RS. Functional anatomy of the mental representation of upper extremity movements in healthy subjects. *J Neurophysiol*, 73 (1):373-86, 1995.
- Sterr A, Muller MM, Elbert T, Rockstroh B, Pantev C, Taub E. Perceptual correlates of changes in cortical representation of fingers in blind multifinger Braille readers. *J Neurosci*, 18 (11):4417-23, 1998.
- Stevens JA, Stoykov ME. Using motor imagery in the rehabilitation of hemiparesis. *Arch Phys Med Rehabil*, 84 (7):1090-2, 2003.
- Stevens JA, Stoykov ME. Simulation of bilateral movement training through mirror reflection: a case report demonstrating an occupational therapy technique for hemiparesis. *Top Stroke Rehabil*, 11 (1):59-66, 2004.
- Stinear CM, Byblow WD, Steyvers M, Levin O, Swinnen SP. Kinesthetic, but not visual, motor imagery modulates corticomotor excitability. *Exp Brain Res*, 168 (1-2):157-64, 2006.
- Stippich C, Ochmann H, Sartor K. Somatotopic mapping of the human primary sensorimotor cortex during motor imagery and motor execution by functional magnetic resonance imaging. *Neurosci Lett*, 331 (1):50-4, 2002.
- Strick PL, Preston JB. Two representations of the hand in area 4 of a primate. II. Somatosensory input organization. *J Neurophysiol*, 48 (1):150-9, 1982.
- Suckling J, Ohlssen D, Andrew C, Johnson G, Williams SC, Graves M, Chen CH, Spiegelhalter D, Bullmore E. Components of variance in a multicentre functional MRI study and implications for calculation of statistical power. *Hum Brain Mapp*, 29 (10):1111-22, 2008.
- Sumitani M, Miyauchi S, McCabe CS, Shibata M, Maeda L, Saitoh Y, Tashiro T, Mashimo T. Mirror visual feedback alleviates deafferentation pain, depending on qualitative aspects of the pain: a preliminary report. *Rheumatology (Oxford)*, 47 (7):1038-43, 2008.
- Sumitani M, Miyauchi S, Yozu A, Otake Y, Saitoh Y, Yamada Y. Phantom limb pain in the primary motor cortex: topical review. *J Anesth*, 24 (2):337-41, 2010.

- Szameitat AJ, Shen S, Sterr A. Motor imagery of complex everyday movements. An fMRI study. *Neuroimage*, 34 (2):702-13, 2007.
- Taub E, Ellman SJ, Berman AJ. Deafferentation in monkeys: effect on conditioned grasp response. *Science*, 151 (710):593-4, 1966.
- Thai-Van H, Veuillet E, Norena A, Guiraud J, Collet L. Plasticity of tonotopic maps in humans: influence of hearing loss, hearing aids and cochlear implants. *Acta Otolaryngol*, 130 (3):333-7, 2010.
- Thobois S, Dominey PF, Decety J, Pollak PP, Gregoire MC, Le Bars PD, Broussolle E. Motor imagery in normal subjects and in asymmetrical Parkinson's disease: a PET study. *Neurology*, 55 (7):996-1002, 2000.
- Topka H, Cohen LG, Cole RA, Hallett M. Reorganization of corticospinal pathways following spinal cord injury. *Neurology*, 41 (8):1276-83, 1991.
- Toro R, Burnod Y. Geometric atlas: modeling the cortex as an organized surface. *Neuroimage*, 20 (3):1468-84, 2003.
- Touzalin-Chretien P, Ehrlé S, Dufour A. Behavioral and electrophysiological evidence of motor cortex activation related to an amputated limb: a multisensorial approach. *J Cogn Neurosci*, 21 (11):2207-16, 2009.
- Tyszka JM, Grafton ST, Chew W, Woods RP, Colletti PM. Parceling of mesial frontal motor areas during ideation and movement using functional magnetic resonance imaging at 1.5 tesla. *Ann Neurol*, 35 (6):746-9, 1994.
- Ulger O, Topuz S, Bayramlar K, Sener G, Erbahceci F. Effectiveness of phantom exercises for phantom limb pain: a pilot study. *J Rehabil Med*, 41 (7):582-4, 2009.
- Uy J, Ridding MC, Miles TS. Stability of maps of human motor cortex made with transcranial magnetic stimulation. *Brain Topogr*, 14 (4):293-7, 2002.
- Van Essen DC, Dierker D. On navigating the human cerebral cortex: response to 'in praise of tedious anatomy'. *Neuroimage*, 37 (4):1050-4; discussion 66-8, 2007.
- Van Essen DC, Drury HA, Dickson J, Harwell J, Hanlon D, Anderson CH. An integrated software suite for surface-based analyses of cerebral cortex. *J Am Med Inform Assoc*, 8 (5):443-59, 2001.
- Vargas CD, Aballea A, Rodrigues EC, Reilly KT, Mercier C, Petruzzo P, Dubernard JM, Sirigu A. Re-emergence of hand-muscle representations in human motor cortex after hand allograft. *Proc Natl Acad Sci U S A*, 106 (17):7197-202, 2009.
- Vladimir Tichelaar YI, Geertzen JH, Keizer D, Paul van Wilgen C. Mirror box therapy added to cognitive behavioural therapy in three chronic complex regional pain syndrome type I patients: a pilot study. *Int J Rehabil Res*, 30 (2):181-8, 2007.

- von Holst E, Mittelstaedt H (1950) The reafference principle. Interaction between the central nervous system and the periphery. In: Selected Papers of Erich von Holst: The Behavioural Physiology of Animals and Man (Methuen, ed), pp 39-73 London.
- Wade NJ. Beyond body experiences: phantom limbs, pain and the locus of sensation. *Cortex*, 45 (2):243-55, 2009.
- Waldvogel D, van Gelderen P, Ishii K, Hallett M. The effect of movement amplitude on activation in functional magnetic resonance imaging studies. *J Cereb Blood Flow Metab*, 19 (11):1209-12, 1999.
- Walker MP, Stickgold R, Alsop D, Gaab N, Schlaug G. Sleep-dependent motor memory plasticity in the human brain. *Neuroscience*, 133 (4):911-7, 2005.
- Wall JT, Kaas JH, Sur M, Nelson RJ, Felleman DJ, Merzenich MM. Functional reorganization in somatosensory cortical areas 3b and 1 of adult monkeys after median nerve repair: possible relationships to sensory recovery in humans. *J Neurosci*, 6 (1):218-33, 1986.
- Wall JT, Xu J, Wang X. Human brain plasticity: an emerging view of the multiple substrates and mechanisms that cause cortical changes and related sensory dysfunctions after injuries of sensory inputs from the body. *Brain Res Brain Res Rev*, 39 (2-3):181-215, 2002.
- Wall PD, Fitzgerald M. Effects of capsaicin applied locally to adult peripheral nerve. I. Physiology of peripheral nerve and spinal cord. *Pain*, 11 (3):363-77, 1981.
- Weibull A, Flondell M, Rosen B, Bjorkman A. Cerebral and clinical effects of short-term hand immobilisation. *Eur J Neurosci*, 33 (4):699-704, 2011.
- Weil D (1991) Traitement des états dépressifs succédant aux amputations de membre.
- Weiss SA, Fishman S. Extended and telescoped phantom limbs in unilateral amputees. *J Abnorm Soc Psychol*, 66 489-97, 1963.
- White T, O'Leary D, Magnotta V, Arndt S, Flaum M, Andreasen NC. Anatomic and functional variability: the effects of filter size in group fMRI data analysis. *Neuroimage*, 13 (4):577-88, 2001.
- Whyte AS, Niven CA. Variation in phantom limb pain: results of a diary study. *J Pain Symptom Manage*, 22 (5):947-53, 2001.
- Wilkins KL, McGrath PJ, Finley GA, Katz J. Phantom limb sensations and phantom limb pain in child and adolescent amputees. *Pain*, 78 (1):7-12, 1998.
- Willoch F, Rosen G, Tolle TR, Oye I, Wester HJ, Berner N, Schwaiger M, Bartenstein P. Phantom limb pain in the human brain: unraveling neural circuitries of phantom limb sensations using positron emission tomography. *Ann Neurol*, 48 (6):842-9, 2000.
- Winstein CJ, Grafton ST, Pohl PS. Motor task difficulty and brain activity: investigation of goal-directed reciprocal aiming using positron emission tomography. *J Neurophysiol*, 77 (3):1581-94, 1997.

- Wolf SL, Butler AJ, Campana GI, Parris TA, Struys DM, Weinstein SR, Weiss P. Intra-subject reliability of parameters contributing to maps generated by transcranial magnetic stimulation in able-bodied adults. *Clin Neurophysiol*, 115 (8):1740-7, 2004.
- Wolpert DM, Ghahramani Z. Computational principles of movement neuroscience. *Nat Neurosci*, 3 Suppl 1212-7, 2000.
- Wolpert DM, Ghahramani Z, Jordan MI. An internal model for sensorimotor integration. *Science*, 269 (5232):1880-2, 1995.
- Woolsey CN, Erickson TC, Gilson WE. Localization in somatic sensory and motor areas of human cerebral cortex as determined by direct recording of evoked potentials and electrical stimulation. *J Neurosurg*, 51 (4):476-506, 1979.
- Wu CW, Kaas JH. Reorganization in primary motor cortex of primates with long-standing therapeutic amputations. *J Neurosci*, 19 (17):7679-97, 1999.
- Wu H, Sultana R, Taylor KB, Szabo A. A Prospective Randomized Double-Blinded Pilot Study to Examine the Effect of Botulinum Toxin Type A Injection Versus Lidocaine/Depomedrol Injection on Residual and Phantom Limb Pain: Initial Report. *Clin J Pain*, 2011.
- Xerri C, Merzenich MM, Jenkins W, Santucci S. Representational plasticity in cortical area 3b paralleling tactual-motor skill acquisition in adult monkeys. *Cereb Cortex*, 9 (3):264-76, 1999.
- Xerri C, Stern JM, Merzenich MM. Alterations of the cortical representation of the rat ventrum induced by nursing behavior. *J Neurosci*, 14 (3 Pt 2):1710-21, 1994.
- Yang TT, Gallen CC, Ramachandran VS, Cobb S, Schwartz BJ, Bloom FE. Noninvasive detection of cerebral plasticity in adult human somatosensory cortex. *Neuroreport*, 5 (6):701-4, 1994.
- Yao J, Chen A, Carmona C, Dewald JP. Cortical overlap of joint representations contributes to the loss of independent joint control following stroke. *Neuroimage*, 45 (2):490-9, 2009.
- Yavuzer G, Selles R, Sezer N, Sutbeyaz S, Bussmann JB, Koseoglu F, Atay MB, Stam HJ. Mirror therapy improves hand function in subacute stroke: a randomized controlled trial. *Arch Phys Med Rehabil*, 89 (3):393-8, 2008.
- Yousry TA, Schmid UD, Alkadhi H, Schmidt D, Peraud A, Buettner A, Winkler P. Localization of the motor hand area to a knob on the precentral gyrus. A new landmark. *Brain*, 120 (Pt 1) 141-57, 1997.
- Zanette G, Manganotti P, Fiaschi A, Tamburin S. Modulation of motor cortex excitability after upper limb immobilization. *Clin Neurophysiol*, 115 (6):1264-75, 2004.
- Ziemann U, Hallett M, Cohen LG. Mechanisms of deafferentation-induced plasticity in human motor cortex. *J Neurosci*, 18 (17):7000-7, 1998.

Références

- Ziemann U, Rothwell JC, Ridding MC. Interaction between intracortical inhibition and facilitation in human motor cortex. *J Physiol*, 496 (Pt 3) 873-81, 1996.
- Zilles K, Armstrong E, Schleicher A, Kretschmann HJ. The human pattern of gyrification in the cerebral cortex. *Anat Embryol (Berl)*, 179 (2):173-9, 1988.

Annexes

1 Etude 1

The moving phantom: motor execution or motor imagery?

Estelle Raffin (MSc)^{1,2}, Pascal Giraux (MD, PhD)^{1,2}, and Karen T. Reilly (PhD)^{3,4}

ARTICLE IN PRESS

CORTEX XXX (2011) 1–12

available at www.sciencedirect.comjournal homepage: www.elsevier.com/locate/cortex

Research report

The moving phantom: Motor execution or motor imagery?

Estelle Raffin^{a,b,c}, Pascal Giraux^{a,b,c,**} and Karen T. Reilly^{c,d,*}^aDepartment of Physical Medicine and Rehabilitation, Faculty of Medicine, University Jean Monnet, Saint-Etienne, France^bINSERM, U 879, CNRS, UMR 5292, Lyon Neuroscience Research Center, Central Integration of Pain Team, Lyon, France^cUniversity Lyon 1, Villeurbanne, France^dCognitive Neuroscience Center, CNRS UMR 5229, Bron, France

ARTICLE INFO

Article history:

Received 3 November 2010

Reviewed 10 December 2010

Revised 20 January 2011

Accepted 1 February 2011

Action editor Yves Rossetti

Published online xxx

Keywords:

Phantom limb

Motor execution

Motor imagery

Brain plasticity

ABSTRACT

Amputees who have a phantom limb often report the ability to move this phantom voluntarily. In the literature, phantom limb movements are generally considered to reflect motor imagery rather than motor execution. The aim of this study was to investigate whether amputees distinguish between executing a movement of the phantom limb and imagining moving the missing limb. We examined the capacity of 19 upper-limb amputees to execute and imagine movements of both their phantom and intact limbs. Their behaviour was compared with that of 18 age-matched normal controls. A global questionnaire-based assessment of imagery ability and timed tests showed that amputees can indeed distinguish between motor execution and motor imagery with the phantom limb, and that the former is associated with activity in stump muscles while the latter is not. Amputation reduced the speed of voluntary movements with the phantom limb but did not change the speed of imagined movements, suggesting that the absence of the limb specifically affects the ability to voluntarily move the phantom but does not change the ability to imagine moving the missing limb. These results suggest that under some conditions, for example amputation, the predicted sensory consequences of a motor command are sufficient to evoke the sensation of voluntary movement. They also suggest that the distinction between imagined and executed movements should be taken into consideration when designing research protocols to investigate the analgesic effects of sensorimotor feedback.

© 2011 Elsevier Srl. All rights reserved.

1. Introduction

In the mid 16th century the French surgeon Ambroise Paré provided the first clinical description of the phenomenon in which amputees continue to perceive the presence of their

missing limb. It wasn't until over 2 centuries later, however, that the first complete clinical description of the phantom limb was published by the American neurologist Silas Weir Mitchell (see Wade, 2009 for a review). Mitchell wrote that after amputation there is often a continued perception of the

* Corresponding author. INSERM U1028, CNRS UMR 5292, Centre de Recherche en Neurosciences de Lyon, ImpAct team, bâtiment Inserm, 16 avenue du doyen Lépine, 69676 Bron cedex, France.

** Corresponding author. Service de Médecine Physique et de Réadaptation, Hôpital Bellevue, CHU de Saint-Etienne, F-42055 Saint-Etienne cedex 02, France.

E-mail addresses: pascal.giroux@univ-st-etienne.fr (P. Giraux), karen.reilly@inserm.fr (K.T. Reilly).

0010-9452/\$ – see front matter © 2011 Elsevier Srl. All rights reserved.

doi:10.1016/j.cortex.2011.02.003

Please cite this article in press as: Raffin E, et al., The moving phantom: Motor execution or motor imagery?, Cortex (2011), doi:10.1016/j.cortex.2011.02.003

missing limb and that this phantom limb occupies a distinct body space, and has a particular size, shape, and posture. He also noted that his patients reported that the phantom limb had certain sensory properties like touch and pain, as well as kinaesthetic properties like being able to be moved voluntarily (1882). Despite clearly stating that he was of the opinion that the phantom limb arose from changes in the central and peripheral nervous systems, Mitchell described the phantom as a "sensorial delusion", the result of which was that the majority of physicians considered phantom limbs as a figment of the amputee's imagination, and amputees were therefore referred to mental health practitioners for many years.

Today it is generally accepted that the phantom arises from physiological changes that occur after amputation (Melzack, 1992; Ramachandran and Hirstein, 1998). Despite this, the idea that the phantom is imaginary still lingers. For example, voluntary movements of the missing limb are still described as imaginary movements in the majority of scientific papers (Erslund et al., 1996; Hugdahl et al., 2001; Lotze et al., 2001; Rosen et al., 2001; Roux et al., 2001; Roux et al., 2003; MacIver et al., 2008). The use of this terminology reflects the influence of early psychological theories of the phantom (Wade, 2009), probably persists as a result of the lack of a more descriptive set of terms to describe the phantom, and is reinforced by studies on motor imagery which describe the ability of normal subjects to evoke kinaesthetic sensations without producing any overt movement (e.g., Jeannerod and Decety, 1995). Indeed, since amputees experience kinaesthetic sensations but no movement (because their limb is no longer present) most researchers assume that these sensations fall into the category of motor imagery. This classification implicitly assumes that these sensations arise from the same processes as those involved in motor imagery in normal subjects. One problem with this assumption is that imagined movements in normal subjects do not, by definition, evoke any visible movement or substantial muscle activity (Gandevia et al., 1997; Hashimoto and Rothwell, 1999; Lotze et al., 1999; Lacourse et al., 2005) but see (Guillot et al., 2007; Lebon et al., 2008) for a different opinion. Mitchell noted, however, that voluntary movements of the missing limb were sometimes accompanied by stump movements and substantial activity in stump muscles (Mitchell, 1872), observations that were recently verified using electromyographic recordings (Reilly et al., 2006). Thus, voluntary movements of the missing limb should not necessarily be classified as imagined movements, but might instead be *real movements without an effector*. Indeed, in a recent review Lotze and Halsband state that "amputees generally perceive movement (sic) of the phantom hand as real movements rather than imaginary movements..." (2006 p. 391). If this is the case then amputees should be able to distinguish between an imagined movement of the missing limb and a voluntarily executed movement of the phantom limb. In both cases there would be no overt movement of the limb (as it is no longer present), but voluntary movements of the phantom would be associated with the sensation that the phantom limb moved whereas imagined movements would not.

Nico et al. (2004) examined the ability of upper-limb amputees to judge the laterality of pictures of hands in various orientations and found that amputation did not affect

laterality judgements, suggesting that implicit motor imagery processes are preserved after amputation. In a more recent study, Malouin et al. (2009) examined the impact of lower-limb amputation on explicit motor imagery processes. They found that imagined movements of the amputated limb were less vivid than those of the intact limb, but concluded that explicit motor imagery could still be performed despite the absence of the limb. Our conversations with patients undergoing treatment for phantom limb pain using visuomotor therapy (as described in Giraux and Sirigu, 2003) suggest that explicit motor imagery processes might also be preserved after amputation of the upper-limb; the majority of patients makes a clear distinction between executing and imagining a movement with their missing limb and report that the kinaesthetic sensations evoked in both cases are distinctly different. For example, executed movements of the phantom hand are often slower and of smaller amplitude than those of the intact hand (Gagné et al., 2009), require intense effort, and result in the feeling that the position of the limb has changed in the same way as it would have changed if they had moved their intact limb (Reilly et al., 2006). In contrast, imagined movements require much less effort and the kinaesthetic sensations they evoke are different from those experienced during executed movements. In particular, imagined movements do not produce the sensation that the limb's position has changed. Furthermore, while amputees have difficulty moving their phantom limb voluntarily, our clinical experience (unpublished observations) suggests that their ability to imagine moving the missing limb is preserved.

There are no reports in the literature directly comparing the ability of amputees to both execute and imagine a movement with their missing limb. The aim of the present study was to investigate whether amputees can indeed distinguish between executing a movement of the phantom limb and imagining moving the missing limb. We hypothesised that amputees would be capable of performing imagery and execution with the phantom limb, with substantial stump muscle activity during execution and none during imagination. We further hypothesised that the absence of the limb would not perturb motor imagery processes but would reduce the speed of motor execution with the phantom.

2. Materials and methods

2.1. Subjects

Nineteen upper-limb amputees were recruited from the outpatient clinic of our institution (4 females and 15 males; mean age 37.2 years, SD 14.1). On average, the accident occurred 9 years and 10 months before testing (range: 5 months–39 years). The Edinburgh Handedness Inventory (EHI) revealed that 18/19 amputees were right hand dominant prior to the amputation. Eighteen age-matched healthy right-handed volunteers (8 females and 10 males; mean age 37.9 years, SD 18.9) were recruited as controls. Neither amputees nor controls had suffered a brain lesion or had a history of neurological or psychiatric illness. The nature of the experimental procedures was explained to all subjects who gave their written informed consent prior to participating in the

experiment, which was approved by the Local Ethics Committee of Lyon Sud-Est IV, and conformed to the ethical aspects of the Declaration of Helsinki.

2.2. Procedure

All subjects completed a 2-h testing session. For amputees the session began with the collection of general clinical data related to the amputation followed by a structured interview to assess phantom sensations and pain (Flor et al., 1995), and an assessment of phantom limb motor control. Then, all subjects completed the Movement Imagery Questionnaire – Revised second version (MIQ-RS), which assesses visual and kinaesthetic imagination capacity. This test enabled them to become familiar with the idea of motor imagery and comfortable speaking about imagined movements. Next they performed two mental imagery tests: the 'Visuomotor Incongruency Test' and the 'Finger-to-thumb opposition Task'. When the material was available, surface electromyograms (EMGs) were recorded from stump and intact limb muscles in order to assess whether there was a difference in muscle activity during motor execution and motor imagery (when EMG could not be recorded we palpated the muscles). EMG was recorded during imagery and execution in all control subjects and in 12/19 amputees. At the end of the testing procedure we asked the amputees three open-ended questions about what they felt when executing or imagining phantom limb movements. (1) Were there any differences between executing and imagining a movement with your phantom limb? If so, can you describe them? (2) Were there any differences between moving your intact limb and moving your phantom limb? If so, can you describe them? (3) Were there any differences between imagining moving your intact limb and imagining moving your phantom limb? If so, can you describe them?

As a result of our relatively small sample sizes and the fact that not all data sets were normally distributed (based on the Kolmogorov–Smirnov test) all statistical analyses (other than the regressions) were performed using non-parametric tests. Wilcoxon signed-rank tests were used for one-sample and related sample comparisons and Mann–Whitney tests for independent sample comparisons. All analyses were conducted using STATISTICA 8.0 (StatSoft, Inc. 1984–2007) and medians are reported with the range indicated in brackets, with the exception of the phantom limb motor control data for which means are presented with standard deviations in brackets. Outliers were excluded if they were more than two standard deviations away from the mean, and the number of subjects included in each statistical analysis is indicated in brackets.

2.2.1. Assessment of phantom limb motor control

The sensations of voluntary movement with the phantom were evaluated using a technique similar to that described in Gagné et al. (2009). Subjects were asked to produce five different cyclic voluntary movements of their phantom and to mimic them simultaneously with their intact limb. These movements were (1) elbow flexion/extension (for above-elbow amputees only); (2) wrist flexion/extension; (3) hand closing/opening; (4) thumb to index opposition; (5) finger abduction/adduction. Subjects were instructed to move their intact limb through the same range and at the same speed as the

phantom limb. The amplitude of each of the five movements was expressed as a fraction of the maximal range of motion of the intact limb on a scale ranging from 0/5 (phantom does not move) to 5/5 (phantom moves through the same range of motion as the intact limb). The difficulty and pain (if any) associated with the execution of each of the five movements were rated on a visual-to-analog scale (VAS) (0 = very easy/no pain, to 10 = impossible/very painful). Because not all movements were possible for all amputees, movement speed was assessed using a single movement, and was quantified as the number of hand opening/closing movement cycles possible during 10 sec. This movement could be performed by all amputees and when an amputee could perform several movements it was always rated as the easiest.

2.2.2. Assessment of motor imagery

2.2.2.1. GLOBAL MOTOR IMAGERY CAPACITY.

We assessed the overall ability of subjects to make imagined movements with the MIQ-RS (Gregg et al., 2007). This instrument assesses visual and kinaesthetic movement imagery ability and consists of eight items (four visual and four kinaesthetic) that reflect everyday functional movements. These include one movement involving the lower-limb, four movements of the upper-limb performed with one arm, and two movements of the upper-limb performed with both arms. For the upper-limb movements that required only one arm amputees imagined the movements with the intact limb. For those movements that required both arms amputees imagined making the movement with both their intact and amputated arms. When execution was impossible with the amputated limb, they used the unaffected limb only. For each item subjects had to perform the movement, and then imagine the same movement either visually or kinaesthetically. Subjects were instructed to imagine from a first-person perspective. We told them to "see" (for visual) or "feel" (for kinaesthetic) themselves moving their limbs 'from the inside'. We never instructed them to avoid muscle contractions during motor imagery. After imagining the movement the subject rated the ease (or difficulty) of the imagination task on a seven-point scale from 1 = very hard to see/feel to 7 = very easy to see/feel. This test gave us three subjective measures of the motor imagery capacities of each subject: a measure of the global capacity to imagine movements (I_C), the capacity to visually imagine (I_V), and the capacity to kinaesthetically imagine (I_K).

2.2.2.2. MOTOR IMAGERY CAPACITY WITH THE UPPER-LIMB.

• Visuomotor Incongruency Test

Adapted from Sirigu and collaborators (Sirigu and Duhamel, 2001), this test consists of two measures of the time taken to imagine a given movement. For the first measure, the actual position of the hand is congruent with the imagined starting position of the hand. That is, subjects are seated with their hand on their thigh and imagine touching their mouth with their hand and then repositioning the hand on the thigh. For the second measure, the actual position of the hand is incongruent with the imagined starting position of the hand. In this condition, subjects are seated with their

Please cite this article in press as: Raffin E, et al., The moving phantom: Motor execution or motor imagery?, Cortex (2011), doi:10.1016/j.cortex.2011.02.003

hand placed behind their back and imagine exactly the same movement as for the first measure. That is, a movement of the hand from the thigh to the mouth and back to the thigh. In each case the experimenter told the subject when to start imagining and the subject verbally indicated when the hand had returned to the thigh. Subjects were told that it was not a test of speed and that they should clearly imagine the task without worrying about the time taken. All subjects (amputees and controls) performed this task with both hands.

To evaluate whether amputees show slower imagination times under conditions of *mismatch* we calculated the percent change in imagination time when the starting position was incongruent relative to when it was congruent $\left(\frac{\text{imag. time incongruent} - \text{imag. time congruent}}{\text{imag. time congruent}} \times 100\right)$. For example: if a subject took 3 sec to imagine in the congruent condition and 4 sec in the incongruent position the percent change was $(4-3)/3 \times 100\%$ or +33.3%. One-sample Wilcoxon signed-rank tests were used to assess whether the percent change in imagination times was significantly different from zero. These tests were performed separately for the intact and phantom limbs of amputees and for the dominant and non-dominant limbs of controls.

- Finger-to-thumb opposition task

In this task we compared both the time to imagine making a movement and the time to actually execute the movement, two variables that are highly correlated in normal healthy subjects (Decety et al., 1989). Subjects were required to either execute or imagine opposing each of the four fingertips to their thumb at a self-imposed pace and to repeat this sequence five times. They were instructed to concentrate on the quality of the performance rather than the speed of the movement. For the execution task, the experimenter gave a go signal and recorded the time between this signal and completion of the five movement cycles. For the imagination task, the experimenter gave the go signal to indicate to the subject to start and the subject verbally indicated when they had imagined five movement cycles. All subjects completed the task twice, with the dominant and non-dominant hands for normal subjects, and the intact and phantom hands for amputees.

In order to investigate whether clinical factors associated with the amputation were related to phantom limb imagination or execution times two multiple linear stepwise regressions were performed; one regression for execution times and one for imagination times. The predictors entered into the regressions were: age (years), amputated limb dominant before amputation (yes/no), length of amputated limb [expressed as a % of the length of the intact limb (0–100)], telescoping of the phantom limb (yes/no), pain medication (yes/no), time since amputation (years), average pain rating on VAS during phantom limb movements (0–10), and prosthesis use (yes/no). The ordinal clinical predictors included in the model were normally distributed according to Komolgorov–Smirnov tests of normality ($p > .05$). The regression analysis was first carried out step by step (forward stepwise regression), resulting in potential significant predictors. The p to enter in the stepwise selection process was set to .05, while the p to remove was set to .1.

2.2.3. Muscle activation during executed and imagined movements

For 12 amputees, activity was recorded in a separate testing session during a related functional Magnetic Resonance Imaging (fMRI) study and we recorded activity during execution and imagination of hand opening/closing. Stump muscles were expected to be active during motor execution (Reilly et al., 2006) and inactive during motor imagery (Gandevia et al., 1997; Hashimoto and Rothwell, 1999; Lotze et al., 1999; Lacourse et al., 2005). For control subjects and below-elbow amputees we monitored the activity of Flexor Digitorum Superficialis (FDS) and Extensor Digitorum Communis (EDC), while for above-elbow amputees we recorded from Triceps Brachii (TB) and Biceps Brachii (BB). The same muscles were recorded from the intact and amputated sides of below-elbow amputees, but for above-elbow amputees the more distal muscles EDC and FDS were recorded from the intact side, as these are the muscles that are primarily active during the hand movements performed in the motor imagery and execution tasks.

For each muscle two silver-chloride surface electrodes of 10-mm diameter were positioned on the muscle with an inter-electrode distance (centre to centre) of 2 cm (with the skin previously shaved and/or cleaned with alcohol). The reference electrode was placed on the lateral epicondyle. EMG signals were amplified, recorded at a frequency of 1000 Hz, band pass filtered (20–400 Hz) and stored for off line analysis using MATLAB® software. Separate one-way ANOVAs were performed for each muscle on data during rest, imagination, and execution.

3. Results

The amputees' responses to our questions regarding what they felt when executing or imagining phantom limb movements revealed clear differences between executed and imagined movements. They reported that when they executed a movement the perceived position of the phantom changed whereas it did not change for imagined movements, and that executed movements required much more effort than imagined movements. A few amputees also reported that executed movements sometimes generated pain, but no one reported that imagined movements generated phantom limb pain. Their responses also revealed that the sensations evoked during imagination were similar for both the phantom and intact hands, but that imagining moving the phantom limb was more difficult. While it has been demonstrated that chronic phantom limb pain affects the speed of executed phantom movements (Gagné et al., 2009), we found that the ability to imagine phantom limb movements was unrelated to chronic pain levels.

- Phantom limb motor control characteristics

All 19 amputees had vivid phantom limb sensations and could perform at least one of the five tested movements, but the majority was unable to perform all five movements. Averaged across the five tested movements, amputees rated

that it was relatively difficult to execute movements with the phantom limb [4.7 (2.9)/10 on the VAS], and the average pain rating associated with these movements was 4.5 (3.3)/10 on the VAS. The difficulty and pain ratings for the intact limb were always zero. The amplitude of the possible movements was decreased: on average the phantom moved through only half the range of motion of the intact limb [53% (27%)]. Phantom movements were also slower: amputees performed an average of 5.8 (5.3) full hand opening/closing cycles with their phantom during 10 sec, whereas normal subjects completed more than twice this number of cycles in the same time (and through a greater range of motion). The clinical and phantom limb characteristics of each subject are detailed in Table 1.

- MIQ-RS

This test revealed that the global capacity (I_c) of amputees to imagine movements was similar to that of normal control subjects. The median score for amputees was 66 (46–89) and for normal subjects was 65 (44–72) (Mann–Whitney test on independent samples $U = 144$, $p = .412$). Amputees showed no particular preference for either visual (I_v) or kinaesthetic imagery (I_k) (Wilcoxon signed-rank test $Z = 1.21$, $p = .222$), but control subjects found visual imagery easier ($Z = 3.31$, $p = .0009$).

- Visuomotor Incongruency Test

Previous studies of imagined movements in control subjects have shown that when the actual starting position of the limb is incongruent with the limb's imagined starting position the time taken to imagine the movement is longer than when there is a congruence between the actual and imagined starting positions (Parsons, 1994; Sirigu and Duhamel, 2001; Ramsey et al., 2010). We replicated this finding in both the dominant and non-dominant hands of the control subjects and the intact and phantom hands of amputees (see Table 2). It is important to note that it was difficult for some amputees to place their phantom limb behind their back, but that given sufficient time they all managed to put their phantom in the appropriate starting position.

- Finger-to-thumb opposition task

Fig. 1A shows the time taken to execute or imagine opposing each of the fingers to the thumb separately for the intact and amputated limbs of amputees. A comparison of the two left-most bars in this figure shows that amputees took nearly one and a half times longer to execute the finger-to-thumb opposition movement with their phantom hand [34.2 (12.2–100)] than with their intact hand [20.6 (8.4–42)], ($Z = 2.01$, $p < .05$, Wilcoxon paired tests). For the imagination task, imagination times were similar for the two hands; 33.0 (12.2–81.1) for the amputated hand and 31.9 (13.5–61.1) for the intact hand ($Z = .93$, $p = .37$). For the intact side, execution was faster than imagination ($Z = 3.82$, $p = .0001$), while execution was slightly slower than imagination for the amputated side ($Z = 2.01$, $p = .044$).

Fig. 1B shows the time taken to execute or imagine opposing each of the fingers to the thumb separately for the dominant and non-dominant hands of control subjects. The average time taken by controls to execute the movement was similar for the dominant [22.4 (15.9–32.1)] and non-dominant hands [19.6 (8.5–31.2)] ($Z = 1.59$, $p = .11$). Imagination times were slightly slower for the dominant [28.5 (15.3–46.9)] than the non-dominant hand [23.0 (12.3–53.2)] ($Z = 2.15$, $p = .03$) – but note that controls always performed the task with their dominant hand first. For both the dominant and non-dominant hands imagination times were always slower than execution times; for the dominant hand: $Z = 3.46$, $p = .0005$; for the non-dominant hand: $Z = 3.68$, $p = .00023$.

We also compared execution and imagination times with the phantom limb with both hands of the controls. This analysis revealed (1) that execution times for the phantom hand were slower than for both the dominant ($U = 297$, $Z = -3.83$, $p < .001$) and non-dominant ($U = 308$, $Z = -4.16$, $p < .001$) hands of control subjects, and (2) Imagination times for the phantom hand did not differ from imagination times for the dominant hand ($U = 200$, $Z = .88$, $p = .39$), but were slightly slower than imagination times for the non-dominant hand ($U = 238.5$, $Z = 2.05$, $p = .04$).

It is noteworthy that despite their extremely slow performance during movement execution, amputees still showed a positive correlation between the time to execute and the time to imagine with the phantom hand ($r = .64$, $p < .05$). This was also the case for the intact side ($r = .55$, $p < .05$) and for both the dominant ($r = .74$, $p > .05$) and the non-dominant hands ($r = .54$, $p < .05$) of the control subjects. Furthermore, imagination times with the phantom limb on the finger-thumb opposition task were highly correlated with imagination times with the phantom limb on the Visuomotor Incongruency Test ($r = .78$, $p < .05$).

To investigate possible explanatory variables for execution and imagination times we first performed Pearson correlations between phantom execution and imagination times and eight clinical variables; average difficulty during the execution of the five tested phantom movements; chronic phantom pain intensity; average amount of pain experienced during these movements; phantom movement speed; phantom movement amplitude; time since amputation; length of the remaining limb; and amputee's age. Execution but not imagination times were highly correlated with several clinical variables (see Table 3). To further investigate these correlations we conducted several stepwise regressions in which we examined which factors predicted the time to either execute or imagine the finger-to-thumb opposition task. Because chronic and movement-related pain were highly correlated ($r = .9$, $p < .05$), and because we were interested in motor control of the phantom limb, we chose to perform our regression analyses using only movement-related pain data.

Since the clinical variables pain and length of residual limb were highly correlated with each other ($r = -.74$, $p < .05$), we constructed two separate models for both execution and imagination times; one excluding limb length (Model A) and one excluding pain (Model B). Both Models A and B were significant and explained a large amount of the variance in the execution times. Two factors were retained (Model A; pain and time since amputation; Model B: length of the residual

Table 1 – Clinical and phantom limb characteristics of each subject.

Age	Months since amputation	Amputated side/Dominant side	Proximal or Distal (P/D) /Stump length (% of residual limb)	Prosthesis use	Number of possible movements (1–5)	Ease of phantom execution (0–10)	Ease of phantom imagination (0–10)	Chronic phantom limb pain intensity (0–10)	Phantom pain intensity during movements (0–10)
40	102	R/R	P/24	Myoelectric (permanent)	4	4	5	6	4
55	106	L/R	P/15	Esthetic (rarely)	2	8	1	6	6
22	38	R/R	P/15	No use	2	6	5	4	2
60	120	L/R	P/15	No use	2	8	4	8	8
28	204	R/R	D/48	No use	3	4	3	2	2
29	281	R/R	D/58	Esthetic (permanent)	5	2	4	0	2
39	360	L/R	D/49	No use	5	0	5	0	0
41	150	R/R	P/31	No use	4	6	5	8	10
60	468	L/R	P/4	No use	1	10	1	10	10
27	84	L/R	P/26	Myoelectric (permanent)	3	4	5	2	4
29	44	L/L	P/36	No use	3	6	1	7	6
25	48	R/R	D/58	Esthetic (part-time)	3	0	5	0	0
33	12	L/R	P/42	No use	5	4	3	3	6
27	5	R/R	P/25	No use	2	6	2	5	6
47	37	L/R	P/32	Esthetic (permanent)	2	8	3	7	8
18	27	R/R	D/69	Esthetic (permanent)	4	2	1	4	2
55	12	R/R	P/35	Mechanic (part-time)	1	8	2	5	6
20	118	R/R	D/70	No use	5	2	3	0	0
55	30	R/R	D/62	No use	4	2	2	1	2

Table 2 – Percent changes in imagination time when the starting position was incongruent relative to when it was congruent for the dominant and non-dominant hands of the controls and for the phantom and intact limbs of the amputees and results of the one-sample Wilcoxon signed-rank tests (Z).

	Controls		Amputees	
	Dominant limb	Non-dominant limb	Phantom limb	Intact limb
Mean % (range)	7.6 (–6.3–21.8)	11.6 (–18.5–27.7)	7.3 (0–30)	14.5 (3.11–40.1)
Z	3.05 ^a	2.39 ^a	3.41 ^a	3.5 ^a

^a Significant values for $p < .05$.

amputated limb and time since amputation). For the imagination time data both Models A and B were significant, but the models explained very little variance. Only one factor was retained (Model A: pain; Model B: length of the residual amputated limb) (see Table 4).

- EMG data

For all control subjects and 12 amputees the activity of upper-limb muscles was recorded from both limbs. For both controls and amputees the muscle activity during motor execution was significantly greater than during either imagination or rest. A group analysis of the EMG data from the 12 amputees tested in the context of a complementary fMRI study revealed a main effect of task (imagined, executed, rest) for each of the four muscles (phantom flexors: $F = 132.6$, $p < .05$; phantom extensors: $F = 43.1$, $p < .05$; intact flexors: $F = 85$, $p < .05$; intact extensors: $F = 26.4$, $p < .05$). Post-hoc t -tests (with Bonferroni corrections) revealed that the activity of the flexors and extensors in both limbs was significantly greater during motor execution than during either motor imagination or rest. Muscle activity during imagination did not differ from that recorded at rest (see Table 5 for statistical data). Fig. 2 shows examples of the EMG activity recorded during imagination and execution of hand opening/closing from two different amputees. Both subjects show clear differences between execution and imagination, with no EMG activity during imagination. Interestingly, this pattern is not related to their capacity to execute phantom limb movements, as subject A moved his phantom limb quickly and easily, whereas subject B had a lot of difficulty moving the phantom.

4. Discussion

In this study we investigated the ability of upper-limb amputees to distinguish between executing a movement of the absent effector (the phantom limb) and imagining moving the missing limb. Our results suggest that amputees are capable of both executing a movement with their phantom limb and imagining moving their missing limb and that execution is affected by the amputation but imagination is not. Specifically, we found that amputation reduced the speed with which amputees made voluntary movements with their phantom limb but did not change the speed of imagined movements of the missing limb, and that imagination times with the phantom limb were similar to those recorded for intact limb imagination. In addition, there was significant EMG activity during movement execution but not during movement imagination.

4.1. Moving the phantom limb is not the same as imagining moving the missing limb

Verbal interviews with upper-limb amputees reveal that they feel as though they can both move and imagine moving their phantom limb. Here we investigated the validity of these subjective reports by examining the time taken to either execute or imagine certain tasks with the phantom and intact limbs as well as the amount of EMG activity present during execution and imagination. Previous studies have demonstrated that imagination and execution times are highly correlated and that the time required to imagine a movement from a first-person perspective is either equal to or longer

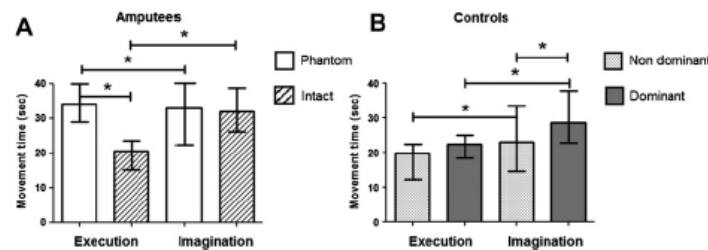


Fig. 1 – Medians and interquartile ranges of the raw movement times for execution and imagination of five cycles of the finger-to-thumb opposition task. Fig. 1A shows the data from the amputated and intact hands of amputees and the data from the non-dominant and dominant hands of control subjects are shown in Fig. 1B.

Please cite this article in press as: Raffin E, et al., The moving phantom: Motor execution or motor imagery?, Cortex (2011), doi:10.1016/j.cortex.2011.02.003

Table 3 – Summary of correlation analyses for phantom execution and imagination times recorded during the finger-to-thumb opposition task.

	Clinical variables				Phantom motor control tests			
	% of length of remaining limb	Age	Time since amputation	Chronic phantom pain intensity	Ease of phantom execution	Phantom pain intensity during movements	Phantom movement speed	Phantom movement amplitude
Execution	-.62*	.2	.53	.58*	.74*	.73*	-.55	-.2
Imagination	-.52	.3	.3	.38	.54	.55	-.1	-.2

a Significant correlations for $p < .05$ with Bonferroni corrections for multiple comparisons.

than the time required to execute the same movement (Decety et al., 1989; Parsons, 1994; Jeannerod and Decety, 1995; Decety, 1996; Malouin et al., 2004; Skoura et al., 2008) (see Guillot and Collet, 2005 for a review). For the intact hand of our amputees we replicated these two results; there was a positive correlation between imagination and execution times as well as a slowing of imagination times relative to execution times. This, together with the fact that the intact limb moved during execution (and there was substantial EMG activity in forearm muscles) but did not move during imagination (and there was no EMG activity in forearm muscles) suggests that amputees behave like normal controls with their intact hand and clearly distinguish between execution and imagination.

For the phantom hand we replicated one of the two results found in control subjects; there was a positive correlation between the time to execute and the time to imagine the finger-to-thumb opposition movement. We also found that imagination times for the finger-to-thumb opposition and Visuomotor Incongruency Tasks were highly correlated, suggesting that when amputees make imagined movements with the phantom hand the 'speed of imagination' is determined by similar and stable "laws". Thus, the performance of amputees on imagination tasks was similar for both their intact and phantom hands, and this performance was comparable with that observed in control subjects. It is important to note,

however, that the relationship between execution and imagination times for the phantom hand was different from that seen in controls; for the finger-to-thumb opposition task phantom execution times were slightly slower than imagination times, while the reverse was true for the intact hand and both hands of controls. While this reversal means that the relationship between execution and imagination is not identical for the phantom and intact hands, it does not mean that amputees are not able to both execute and imagine movements with their phantom. Indeed, the presence of significant movement-related bursts of EMG activity in stump muscles during execution and the absence of such activity during imagination suggests that they performed two distinct tasks.

We interpret our results as evidence that amputees moved their phantom limb during our execution condition and imagined moving it during our imagination condition, but several alternative explanations are also possible. First, amputees could have performed exactly the same task during phantom limb execution and imagination, in which case they would have done the same thing regardless of our instructions. While this idea is supported by the observation that phantom execution and imagination times were very similar (although statistically different), it is not supported by the fact that there was no stump muscle activity during imagination but strong movement-related muscle contractions during

Table 4 – Summary of regression analyses and predictive models: A (without limb length) and B (without pain), for the phantom limb execution and imagination times recorded during the finger-to-thumb opposition task. The following predictors were entered into the regressions as independent variables using a forward stepwise technique: age (years), amputated limb dominant before amputation (yes/no), length of amputated limb (expressed as a % of the length of the intact limb (0–100)), telescoping of the phantom limb (yes/no), pain medication (yes/no), time since amputation (years), average pain rating on VAS during phantom limb movements (0–10), and prosthesis use (yes/no).

Models	Adjusted R ²	F	df	p	Significant Predictors		
					Variable	Beta	p
Model A for phantom motor execution (without limb length)	.61	13.3	14	.000	Pain VAS	.624	.001
					Time since amputation	.390	.029
Model B for phantom motor execution (without pain)	.60	9.67	15	.007	Limb length	-.530	.014
					Time since amputation	.270	.050
Model A for phantom motor imagination (without limb length)	.25	6.58	15	.020	Pain VAS	.552	.020
Model B for phantom motor imagination (without pain)	.22	5.61	15	.030	Limb length	-.520	.030

Please cite this article in press as: Raffin E, et al., The moving phantom: Motor execution or motor imagery?, Cortex (2011), doi:10.1016/j.cortex.2011.02.003

Table 5 – T values from post-hoc t-tests (with Bonferroni corrections, $p < .05$) of the EMG analysis ($n = 12$ amputees) between motor execution, motor imagination, and rest for the flexors and extensors from both the intact and amputated limbs.

		Execution		Imagination
		Imagination	Rest	Rest
Phantom limb	Flexors	13.96 ^a	14.24 ^a	.29
	Extensors	7.94 ^a	8.1 ^a	.26
Intact limb	Flexors	10.44 ^a	11.82 ^a	1.33
	Extensors	6.21 ^a	6.58 ^a	.25

^a Significant values for $p < .05$ with Bonferroni corrections for multiple comparisons.

execution. This, together with the subjective responses to our open-ended questions, argues against the idea that they performed the same task in both conditions.

A second possible interpretation of our results is that instead of performing two distinct tasks for execution and imagination, they did something when asked to execute a movement (as shown by the presence of EMG activity) and nothing when asked to imagine a movement (no EMG activity). Evidence against this idea comes from the absolute time taken to imagine a movement with the phantom limb, which was similar to that recorded from the intact hand and

from both hands of control subjects. The correlation between execution and imagination times and between imagination times on different tasks, also argues against this interpretation.

Finally, amputees could have performed two tasks with their phantom limb, but instead of performing execution and imagination, they performed two different types of motor imagery. During our imagination condition they might have performed a type of visual imagery that was relatively effortless and did not produce any muscle contractions. In contrast, during our execution condition, they might have switched to a type of kinaesthetic imagery (or a combination of visual and kinaesthetic) that required more effort and thereby led to the unintentional contraction of stump muscles (Gandevia et al., 1997; Fadiga et al., 1999; Solodkin et al., 2004). In the absence of neuroimaging data it is impossible to completely rule out this possibility but several results suggest that it is unlikely. First, our MIQ revealed that amputees do not find it more difficult to perform kinaesthetic than visual imagery. A similar finding was reported in a study with lower-limb amputees (Malouin et al., 2009), and it argues against the idea that kinaesthetic imagery is associated with increased effort and therefore significant stump muscle EMG activity. Second, amputees insist upon the fact that the sensations they experience during motor imagery with the phantom hand are similar to those experienced during motor imagery

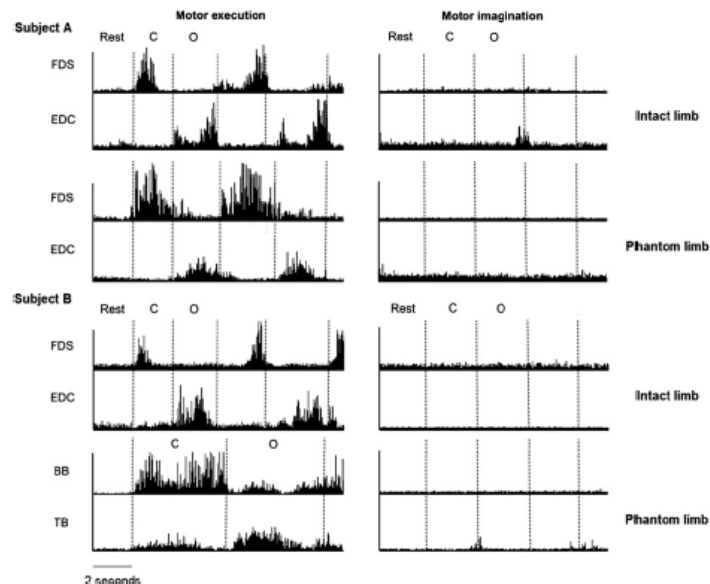


Fig. 2 – EMG patterns from two representative amputees during motor execution (left panel) and motor imagination (right panel) of an opening (O)/closing (C) hand movement. Subject A is a below-elbow amputee with good motor control in his phantom limb and subject B is an above-elbow amputee with bad motor control in his phantom limb. Recorded muscles for Subject A were the FDS and EDC on both the intact and phantom sides. For the Subject B the recorded muscles were the BB and the TB on the amputated side and the FDS and EDC on the intact side. EMG has been scaled to maximize clarity, with EMG from a single muscle on the same scale but different scales for all four muscles.

Please cite this article in press as: Raffin E, et al., The moving phantom: Motor execution or motor imagery?, Cortex (2011), doi:10.1016/j.cortex.2011.02.003

with other body parts, whereas motor execution with the phantom evokes sensations close to those experienced when they actually move a body part. Finally, the argument that our amputees performed a type of kinaesthetic imagery in our execution condition implies that phantom movements belong to the realm of motor imagery and not motor execution, but imaging studies suggest that this is not the case. Imagined movements are rarely associated with a significant level of activity in the primary sensorimotor cortex (Roland et al., 1980; Decety et al., 1994; Stephan et al., 1995; Lotze et al., 1999; Gerardin et al., 2000; Hanakawa et al., 2003), but a number of studies with amputees report substantial activity within the primary sensorimotor cortex during phantom limb movements (Lotze et al., 2001; Roux et al., 2001; Roux et al., 2003). Thus, amputees are not performing motor imagery when they move their phantom limb.

In conclusion, our results suggest that when asked to execute or imagine a movement with the phantom limb amputees did indeed perform two distinct tasks. While imagined movements of the phantom appear to be similar to imagined movements of intact body parts, the relationship between executed movements of the phantom and intact body parts is more complex. The complete absence of any overt movement in our motor execution condition makes it difficult to assert that phantom movements are real movements in the same way as movements of our intact limbs. We can assert, however, that they are distinct from motor imagery, and there is sufficient evidence to suggest that they are actually a form of "movement without movement".

4.2. Why is motor execution affected after amputation while motor imagery is preserved?

We found that amputees have a preserved ability to imagine moving their missing limb but that their ability to execute movements of the phantom is markedly affected by the limb's absence. This latter observation is consistent with previous studies showing that amputees have a limited number of possible voluntary movements, and that these movements are generally very slow (Reilly et al., 2006; Gagné et al., 2009). The finding that execution but not imagination is affected after an amputation is also supported by the results of our stepwise regression analyses which showed that clinical variables related to the amputation itself (time since amputation, length of the remaining amputated limb, pain during movement) were good predictors of the time to execute phantom movements but poor predictors of imagination times. Although there are no studies explicitly examining the relationship between time since amputation and the sensorimotor qualities of the phantom limb, anecdotal reports suggest that phantom limb movements become more difficult over time (e.g., Cronholm, 1951; Ramachandran and Rogers-Ramachandran, 1996). Our sample included a wide range of times since amputation (5–468 months), suggesting that the brains of our amputees were at various stages of post-amputation adaptation. Since execution (but not imagination) times increased with increasing time since amputation, we can conclude that post-amputation adaptation processes affect execution but not imagination. This provides yet another

argument that phantom execution and imagination are two dissociable tasks.

One explanation for how limb loss could affect execution without affecting imagination might be related to the fact that during movement execution the brain expects to receive sensory feedback whereas during imagination there is no such expectation. Because of the absence of the limb the feedback that the brain receives after movement execution is often weak and/or incongruent with the expected sensory feedback. The incongruence between the expected and actual feedback might explain why amputation affects movement execution but not movement imagination, and is probably an important factor underlying phantom limb pain (Ramachandran and Rogers-Ramachandran, 1996; Harris, 1999; McCabe et al., 2003; McCabe, 2010).

Another possible explanation for the differential effect of limb loss on execution and imagination comes from Positron Emission Tomography (PET) and fMRI imaging studies which show that the primary sensorimotor cortex is more active during motor execution than imagination (see Lotze and Halsband, 2006 for a review). Since the primary sensorimotor cortex is the only location (to date) in which post-amputation reorganisation has been clearly demonstrated in humans (e.g., Flor et al., 1995; Knecht et al., 1996; Borsook et al., 1998; Karl et al., 2001), the differential contribution of this area to motor execution and motor imagery might explain why imagined movements with the missing limb remain unaffected after amputation whereas executed movements of the phantom are significantly slower than movements of the intact limb.

4.3. Possible contributions to the debate on movement awareness

Amputees offer the unique case in which neither motor imagery nor motor execution is associated with any overt movement. This raises important questions about the very nature of the processes underlying the awareness of a movement as being executed or imagined. It is likely that after amputation the dissociation between executed and imagined movement does not arise a posteriori on the basis of the presence or absence of sensory feedback. Instead, a large part of the perception of a movement as being executed (vs imagined) arises from the fact that executed movements are associated with expected sensory consequences whereas imagined movements are not. This hypothesis is in accordance with the internal model theory of movement (Wolpert and Ghahramani, 2000): the execution of phantom limb movements involves sending a motor command that then calls up a predictive model of the expected final state of the body which somehow gives rise to the sensation that the limb has moved. This suggests that under some conditions, for example amputation, the predicted sensory consequences of a motor command are sufficient to evoke the sensation of voluntary movement.

4.4. Practical implications for patient rehabilitation

Our results show that just because the effector is no longer present we cannot assume that amputees automatically

Please cite this article in press as: Raffin E, et al., The moving phantom: Motor execution or motor imagery?, Cortex (2011), doi:10.1016/j.cortex.2011.02.003

engage in motor imagery when they move the phantom limb. This is particularly important in the context of the growing number of studies investigating the analgesic effects of sensorimotor feedback training in amputees, brachial plexus avulsion patients or stroke patients. These techniques give patients modified visual feedback of their affected limb (using either mirrors or virtual reality systems) and often require patients to perform a motor task with their impaired limb. In most studies patients are explicitly told to execute or to "attempt to execute" voluntary movements (Ramachandran and Rogers-Ramachandran, 1996; Sathian et al., 2000; Giraux and Sirigu, 2003; McCabe et al., 2003; Chan et al., 2007; McCabe et al., 2008; Yavuzer et al., 2008; Cole et al., 2009; Mercier and Sirigu, 2009). In other cases, they are told to imagine moving their affected limb or to simply watch the movements provided by the mirror or virtual reality system (Stevens and Stoykov, 2003; Gaggioli et al., 2004; Murray et al., 2007; MacIver et al., 2008; Michielsen et al., 2010). Differences with respect to the motor task performed by the patient (motor execution, motor imagery, or movement observation), might explain the range of outcomes reported by these rehabilitation studies. For this reason, it is important to take into account the distinction between imagined and executed movements, to explain this to patients, and to consider it when designing research protocols.

Competing interests

The authors declare no competing interests.

Acknowledgments

E Raffin was funded by the French Ministry of Health (PHRC 2007 N° 0701040).

REFERENCES

- Borsook D, Becerra L, Fishman S, Edwards A, Jennings CL, Stojanovic M, et al. Acute plasticity in the human somatosensory cortex following amputation. *NeuroReport*, 9(6): 1013–1017, 1998.
- Chan BL, Witt R, Charrow AP, Magee A, Howard R, Pasquina FF, et al. Mirror therapy for phantom limb pain. *The New England Journal of Medicine*, 357(21): 2206–2207, 2007.
- Cole J, Crowle S, Austwick G, and Slater DH. Exploratory findings with virtual reality for phantom limb pain; from stump motion to agency and analgesia. *Disability and Rehabilitation*, 31(10): 846–854, 2009.
- Cronholm B. Phantom limbs in amputees; a study of changes in the integration of centripetal impulses with special reference to referred sensations. *Acta Psychiatrica et Neurologica Scandinavica, Supplementum*, 72: 1–310, 1951.
- Decety J. The neurophysiological basis of motor imagery. *Behavioural Brain Research*, 77(1–2): 45–52, 1996.
- Decety J, Jeannerod M, and Prablanc C. The timing of mentally represented actions. *Behavioural Brain Research*, 34(1–2): 35–42, 1989.
- Decety J, Perani D, Jeannerod M, Bettinardi V, Tadary B, Woods R, et al. Mapping motor representations with positron emission tomography. *Nature*, 371(6498): 600–602, 1994.
- Ersland L, Rosen G, Lundervold A, Smievoll AI, Tillung T, Sundberg H, et al. Phantom limb imaginary fingertapping causes primary motor cortex activation: An fMRI study. *NeuroReport*, 8(1): 207–210, 1996.
- Fadiga L, Buccino G, Craighero L, Fogassi L, Gallesse V, and Pavesi G. Corticospinal excitability is specifically modulated by motor imagery: A magnetic stimulation study. *Neuropsychologia*, 37(2): 147–158, 1999.
- Flor H, Elbert T, Knecht S, Wienbruch C, Pantev C, Birbaumer N, et al. Phantom-limb pain as a perceptual correlate of cortical reorganization following arm amputation. *Nature*, 375(6531): 482–484, 1995.
- Gaggioli A, Morganti F, Walker R, Meneghini A, Alcaniz M, Lozano JA, et al. Training with computer-supported motor imagery in post-stroke rehabilitation. *Cyberpsychology & Behavior*, 7(3): 327–332, 2004.
- Gagné M, Reilly KT, Hetu S, and Mercier C. Motor control over the phantom limb in above-elbow amputees and its relationship with phantom limb pain. *Neuroscience*, 162(1): 78–86, 2009.
- Gandevia SC, Wilson LR, Inglis JT, and Burke D. Mental rehearsal of motor tasks recruits alpha-motoneurons but fails to recruit human fusimotor neurons selectively. *The Journal of Physiology*, 505(Pt 1): 259–266, 1997.
- Gerardin E, Sirigu A, Lehericy S, Poline JB, Gaymard B, Marsault C, et al. Partially overlapping neural networks for real and imagined hand movements. *Cerebral Cortex*, 10(11): 1093–1104, 2000.
- Giraux P and Sirigu A. Illusory movements of the paralyzed limb restore motor cortex activity. *NeuroImage*, 20(Suppl. 1): S107–S111, 2003.
- Gregg M, Hall C, and Butler A. The MIQ-RS: A suitable option for examining movement imagery ability. *Evidence-Based Complementary and Alternative Medicine*, 7(2): 249–257, 2007.
- Guillot A and Collet C. Duration of mentally simulated movement: A review. *Journal of Motor Behavior*, 37(1): 10–20, 2005.
- Guillot A, Lebon F, Rouffet D, Champely S, Doyon J, and Collet C. Muscular responses during motor imagery as a function of muscle contraction types. *International Journal of Psychophysiology*, 66(1): 18–27, 2007.
- Hanakawa T, Immisch I, Toma K, Dimyan MA, Van Gelderen P, and Hallett M. Functional properties of brain areas associated with motor execution and imagery. *Journal of Neurophysiology*, 89(2): 989–1002, 2003.
- Harris AJ. Cortical origin of pathological pain. *Lancet*, 354(9188): 1464–1466, 1999.
- Hashimoto R and Rothwell JC. Dynamic changes in corticospinal excitability during motor imagery. *Experimental Brain Research*, 125(1): 75–81, 1999.
- Hugdahl K, Rosen G, Ersland L, Lundervold A, Smievoll AI, Barndon R, et al. Common pathways in mental imagery and pain perception: An fMRI study of a subject with an amputated arm. *Scandinavian Journal of Psychology*, 42(3): 269–275, 2001.
- Jeannerod M and Decety J. Mental motor imagery: A window into the representational stages of action. *Current Opinion in Neurobiology*, 5(6): 727–732, 1995.
- Karl A, Birbaumer N, Lutzenberger W, Cohen LG, and Flor H. Reorganization of motor and somatosensory cortex in upper extremity amputees with phantom limb pain. *The Journal of Neuroscience*, 21(10): 3609–3618, 2001.
- Knecht S, Henningsen H, Elbert T, Flor H, Hohling C, Pantev C, et al. Reorganizational and perceptual changes after amputation. *Brain*, 119(Pt 4): 1213–1219, 1996.
- Lacourse MG, Orr EL, Cramer SC, and Cohen MJ. Brain activation during execution and motor imagery of novel and skilled sequential hand movements. *NeuroImage*, 27(3): 505–519, 2005.

Please cite this article in press as: Raffin E, et al., The moving phantom: Motor execution or motor imagery?, *Cortex* (2011), doi:10.1016/j.cortex.2011.02.003

- Lebon F, Rouffet D, Collet C, and Guillot A. Modulation of EMG power spectrum frequency during motor imagery. *Neuroscience Letters*, 435(3): 181–185, 2008.
- Lotze M, Flor H, Grodd W, Larbig W, and Birbaumer N. Phantom movements and pain. An fMRI study in upper limb amputees. *Brain*, 124(Pt 11): 2268–2277, 2001.
- Lotze M and Halsband U. Motor imagery. *Journal of Physiology – Paris*, 99(4–6): 386–395, 2006.
- Lotze M, Montoya P, Erb M, Hulsmann E, Flor H, Klose U, et al. Activation of cortical and cerebellar motor areas during executed and imagined hand movements: An fMRI study. *Journal of Cognitive Neuroscience*, 11(5): 491–501, 1999.
- MacIver K, Lloyd DM, Kelly S, Roberts N, and Nurmikko T. Phantom limb pain, cortical reorganization and the therapeutic effect of mental imagery. *Brain*, 131(Pt 8): 2181–2191, 2008.
- Malouin F, Richards CL, Desrosiers J, and Doyon J. Bilateral slowing of mentally simulated actions after stroke. *Neuroreport*, 15(8): 1349–1353, 2004.
- Malouin F, Richards CL, Durand A, Descent M, Poire D, Fremont P, et al. Effects of practice, visual loss, limb amputation, and disuse on motor imagery vividness. *Neurorehabilitation and Neural Repair*, 23(5): 449–463, 2009.
- McCabe C. Mirror visual feedback therapy. A practical approach. *Journal of Hand Therapy*, 2010, doi:10.1016/j.jht.2010.08.003.
- McCabe CS, Haigh RC, and Blake DR. Mirror visual feedback for the treatment of complex regional pain syndrome (type 1). *Current Pain and Headache Reports*, 12(2): 103–107, 2008.
- McCabe CS, Haigh RC, Ring EF, Halligan FW, Wall PD, and Blake DR. A controlled pilot study of the utility of mirror visual feedback in the treatment of complex regional pain syndrome (type 1). *Rheumatology (Oxford)*, 42(1): 97–101, 2003.
- Melzack R. Phantom limbs. *Scientific American*, 266(4): 120–126, 1992.
- Mercier C and Sirigu A. Training with virtual visual feedback to alleviate phantom limb pain. *Neurorehabilitation and Neural Repair*, 23(6): 587–594, 2009.
- Michielsen ME, Selles RW, van der Geest JN, Eckhardt M, Yavuzer G, Stam HJ, et al. Motor recovery and cortical reorganization after mirror therapy in chronic stroke patients: A phase II randomized controlled trial. *Neurorehabilitation and Neural Repair*, 25(2): 223–233, 2010.
- Mitchell SW. *Injuries of Nerves and their Consequences*. Philadelphia: Lippincott, 1872.
- Murray CD, Pettifer S, Howard T, Patchick EL, Caillette F, Kulkarni J, et al. The treatment of phantom limb pain using immersive virtual reality: Three case studies. *Disability and Rehabilitation*, 29(18): 1465–1469, 2007.
- Nico D, Daprati E, Rigal F, Parsons L, and Sirigu A. Left and right hand recognition in upper limb amputees. *Brain*, 127(Pt 1): 120–132, 2004.
- Parsons LM. Temporal and kinematic properties of motor behavior reflected in mentally simulated action. *Journal of Experimental Psychology: Human Perception and Performance*, 20(4): 709–730, 1994.
- Ramachandran VS and Hirstein W. The perception of phantom limbs. The D. O. Hebb lecture. *Brain*, 121(Pt 9): 1603–1630, 1998.
- Ramachandran VS and Rogers-Ramachandran D. Synaesthesia in phantom limbs induced with mirrors. *Proceedings of the Royal Society. Biological Sciences*, 263(1369): 377–386, 1996.
- Ramsey R, Cumming J, Eastough D, and Edwards MG. Incongruent imagery interferes with action initiation. *Brain and Cognition*, 74(3): 249–254, 2010.
- Reilly KT, Mercier C, Schieber MH, and Sirigu A. Persistent hand motor commands in the amputees' brain. *Brain*, 129(Pt 8): 2211–2223, 2006.
- Roland PE, Larsen B, Lassen NA, and Skinhoj E. Supplementary motor area and other cortical areas in organization of voluntary movements in man. *Journal of Neurophysiology*, 43(1): 118–136, 1980.
- Rosen G, Hugdahl K, Ersland L, Lundervold A, Smievoll AI, Bamdon R, et al. Different brain areas activated during imagery of painful and non-painful 'finger movements' in a subject with an amputated arm. *Neurocase*, 7(3): 255–260, 2001.
- Roux FE, Ibarrola D, Lazorthes Y, and Berry I. Virtual movements activate primary sensorimotor areas in amputees: Report of three cases. *Neurosurgery*, 49(3): 736–741, 2001.
- Roux FE, Lotterie JA, Cassol E, Lazorthes Y, Sol JC, and Berry I. Cortical areas involved in virtual movement of phantom limbs: Comparison with normal subjects. *Neurosurgery*, 53(6): 1342–1352, 2003.
- Sathian K, Greenspan AI, and Wolf SL. Doing it with mirrors: A case study of a novel approach to neurorehabilitation. *Neurorehabilitation and Neural Repair*, 14(1): 73–76, 2000.
- Sirigu A and Duhamel JR. Motor and visual imagery as two complementary but neurally dissociable mental processes. *Journal of Cognitive Neuroscience*, 13(7): 910–919, 2001.
- Skoura X, Personnier P, Vinter A, Pozzo T, and Papaxanthis C. Decline in motor prediction in elderly subjects: Right versus left arm differences in mentally simulated motor actions. *Cortex*, 44(9): 1271–1278, 2008.
- Solodkin A, Hlustik P, Chen EE, and Small SL. Fine modulation in network activation during motor execution and motor imagery. *Cerebral Cortex*, 14(11): 1246–1255, 2004.
- Stephan KM, Fink GR, Passingham RE, Silbersweig D, Ceballos-Baumann AO, Frith CD, et al. Functional anatomy of the mental representation of upper extremity movements in healthy subjects. *Journal of Neurophysiology*, 73(1): 373–386, 1995.
- Stevens JA and Stoykov ME. Using motor imagery in the rehabilitation of hemiparesis. *Archives of Physical Medicine and Rehabilitation*, 84(7): 1090–1092, 2003.
- Wade NJ. Beyond body experiences: Phantom limbs, pain and the locus of sensation. *Cortex*, 45(2): 243–255, 2009.
- Wolpert DM and Ghahramani Z. Computational principles of movement neuroscience. *Nature Neuroscience*, 3(Suppl): 1212–1217, 2000.
- Yavuzer G, Selles R, Sezer N, Sutbeyaz S, Bussmann JB, Koseoglu F, et al. Mirror therapy improves hand function in subacute stroke: A randomized controlled trial. *Archives of Physical Medicine and Rehabilitation*, 89(3): 393–398, 2008.

2 Matériels et résultats supplémentaires (étude 2)

“Disentangling motor execution from motor imagery with the phantom limb”

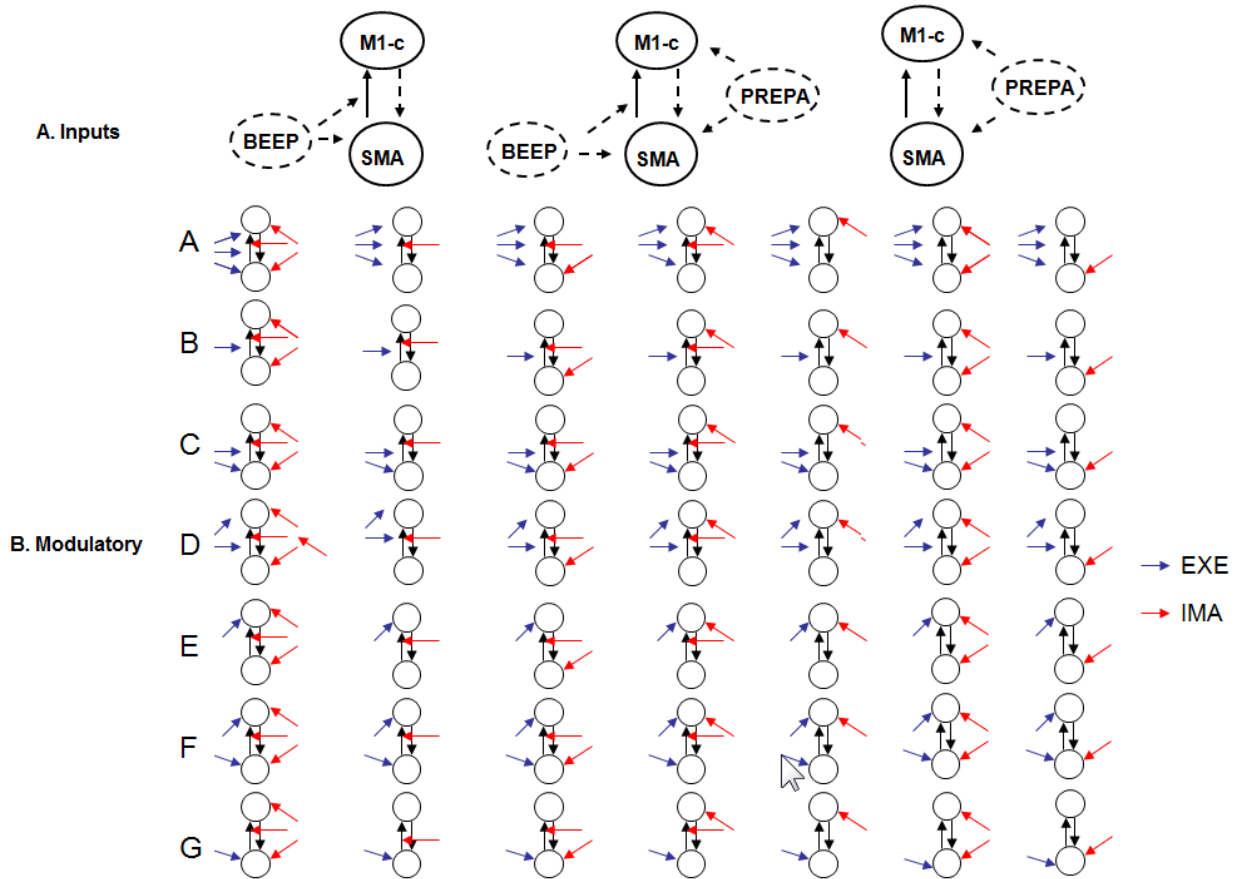
Supplementary materials

DCM analysis:

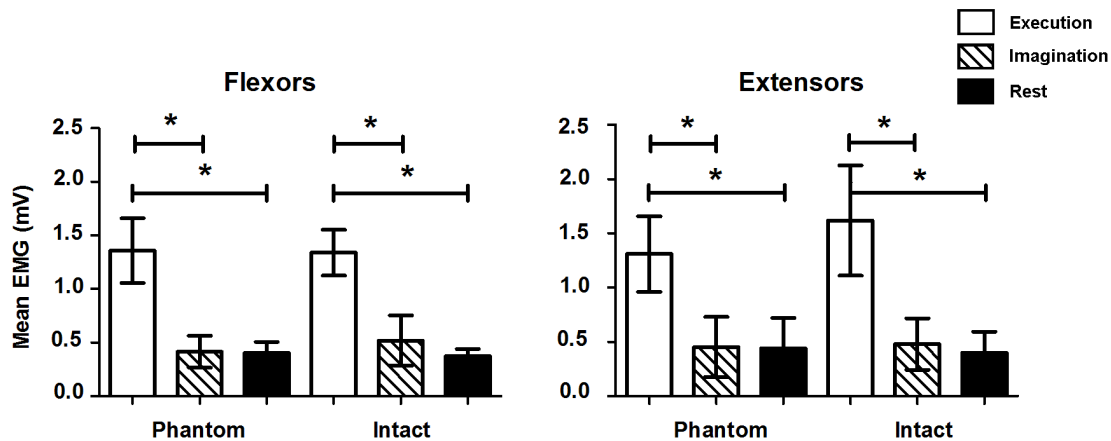
Table 2: Mean (SD) centres of spheres of the volumes of interest for the DCM analysis (x, y, z) and number of voxels (N)

Volumes of interest	MNI coordinates - Mean (SD)			
	x	y	z	N
<i>Intact limb</i>				
Contralateral primary motor area (M1-c)	35 (3)	-26 (6)	70 (5)	78 (5)
Caudal supplementary motor area (SMA)	2 (5)	-10 (5)	70 (7)	97 (38)
<i>Phantom limb</i>				
Contralateral primary motor area (M1-c)	34 (3)	-24 (4)	67 (17)	72 (14)
Caudal supplementary motor area (SMA)	4 (3)	-14 (5)	72 (6)	100 (30)

DCM analysis:



Supplementary Figure 1: Schematic representations of the 3 input families (A) and of the 7x7 modulatory models compared in this study (B). Models are illustrated in sets, grouped by the modulation of EXE inputs (letters A–G) and by the modulation of IMA inputs (columns 1–7).

Supporting results:**EMG data:**

Supplementary Figure 2: Means (and SD) EMG activity of the flexors muscles and the extensors muscles during rest, execution and imagination with the intact limb or the phantom limb (* $P < 0.05$).

One-way ANOVAs revealed a significant effect of condition for each of the four muscles (phantom flexors: $F = 65.6$, $p < 0.05$; phantom extensors: $F = 29.6$, $p < 0.05$; intact flexors: $F = 107.5$, $p < 0.05$; intact extensors: $F = 55.2$, $p < 0.05$). Post-hoc t-tests (with Bonferroni corrections) revealed that flexor activity was significantly greater during motor execution than during both motor imagination and rest for both limbs (phantom limb: execution versus imagination: $t = 9.85$; execution versus rest: $t = 10.00$; intact limb: execution versus imagination: $t = 11.54$; execution versus rest: $t = 13.60$, $p < 0.05$ for all 4 comparisons). Motor imagination did not differ from rest (phantom limb: $t = 0.14$; intact limb: $t = 2.06$, $p > 0.05$ for both comparisons). Extensors showed the same pattern; muscle activity was significantly greater during motor execution than during both motor imagination and rest for both limbs (phantom limb: execution versus imagination: $t = 6.61$; execution versus rest: $t = 6.7$; intact limb: execution versus imagination: $t = 8.76$; execution versus rest: $t = 9.4$, $p < 0.0001$ for all four comparisons). Motor imagination did not differ from rest for either limb (for the phantom limb: $t = 0.26$; for the intact limb: $t = 0.12$, $p > 0.8$ for both comparisons).

	SM1		PO	
	% activated voxels	% signal change	% activated voxels	% signal change
	EXE vs IMA	EXE vs IMA	IMA vs EXE	IMA vs EXE
Intact limb	Z = 3.3; p = 0.0009	Z = 3.3; p = 0.001	Z = 0.41; p = 0.68	Z = 2.3; p = 0.02
Phantom limb	Z = 3.3; p = 0.0009	Z = 3.3; p = 0.001	Z = 1.48; p = 0.14	Z = 2.35; p = 0.02

	CB ANT		CB POST	
	% activated voxels	% signal change	% activated voxels	% signal change
	EXE vs IMA	EXE vs IMA	IMA vs EXE	IMA vs EXE
Intact limb	Z = 3.3; p = 0.05	Z = 2.66, p = 0.0008	Z = 1.32; p = 0.18	Z = 2.79; p = 0.0005
Phantom limb	Z = 3.3; p = 0.0009	Z = 3.3, p = 0.009	Z = 1.8; p = 0.07	Z = 1.32; p = 0.18

Supplementary Table 3 (related to Figure 3 in the main text): Wilcoxon rank test results for the ROI analysis; SM1: primary sensorimotor ROI; PO: parieto-occipital ROI; CB ANT: Anterior lobe of the cerebellum; Posterior lobe of the cerebellum; EXE: motor execution; IMA: motor imagination.

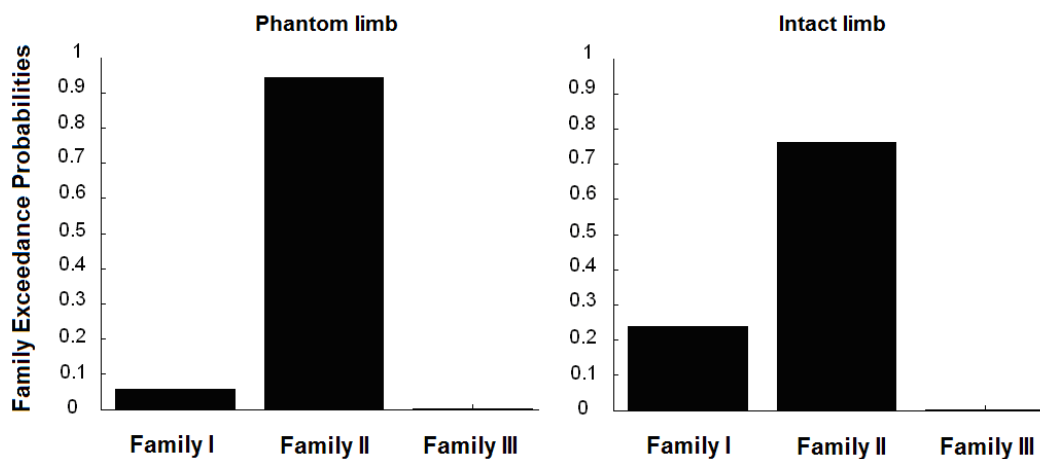
	SMA			Lat Premotor Cortex			Sup Parietal Cortex			Inf Parietal Cortex		
	EXE	IMA	Z (p)	EXE	IMA	Z (p)	EXE	IMA	Z (p)	EXE	IMA	Z (p)
Intact limb	-3 (6)	0 (6)	2.6 (0.008)	-10 (16)	-3 (10)	2.5 (0.01)	-46 (2)	-50 (16)	2 (0.04)	-40 (6)	-46 (8)	1.9 (0.05)
Phantom limb	-1 (2)	2 (7)	2.7 (0.007)	-10 (12)	-2 (6)	2.7 (0.007)	-46 (2)	-48 (10)	2 (0.04)	-40 (0)	-42 (7)	2 (0.05)

Supplementary Table 4 (related to Figure 4 in the main text): Wilcoxon paired test results for the Y coordinates of the peak analysis; Y coordinates (median, quartile range) of the activation peaks during Execution and Imagination within four Regions of Interest, contralateral to the “moving hand” and Wilcoxon paired tests results between Execution and Imagination. Wilcoxon paired tests were not significant for the same analysis within the ipsilateral hemisphere to the “moving hand” ($P < 0.05$); SMA: Supplementary Motor Area; Lat Premotor Cortex: Lateral Premotor Cortex; Sup Parietal Cortex: Superior Parietal Cortex; Inf Parietal Cortex: Inferior Parietal Cortex; EXE: motor execution; IMA: motor imagination.

Supplementary DCM results:**First family-level inference:**

The RFX approach provides 2 values for each family/model: the posterior and the exceedance probabilities. The latter is simply the probability that this family/model is more likely than the others. The posterior and exceedance probabilities sum to 1 over the number of considered families/models.

The inference on model families in the dimension of sensory inputs, whatever the hemisphere, speaks clearly in favour of family II, that is, for models that incorporate both PREPA and BEEP inputs (posterior probability for Family II, $p = 0.94$ for the amputated limb, $p = 0.76$ for the intact limb, Supplementary Figure 3). All the estimated probabilities for each model subset and each hemisphere are summarized in Supplementary Table 5. Importantly, the two separate inferences for each limb yield the same best family of models, which provides a strong argument that both auditory and visual cues were taken into account in motor preparation and planning at the group level.



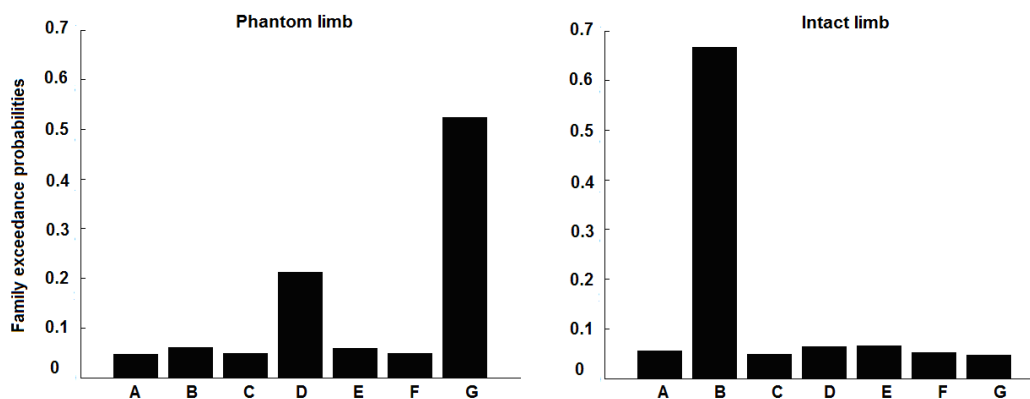
Supplementary Figure 3: Family exceedance probabilities for both amputated and intact sides

SIDE	Family I		Family II		Family III	
	Exp Post	Exc Prob	Exp Post	Exc Prob	Exp Post	Exc Prob
Amputated	0.294	0.056	0.648	0.944	0.059	0.000
Intact	0.387	0.238	0.553	0.762	0.06	0.000

Supplementary Table 5: Estimated family expected posterior (Exp Post) and exceedance probability (Exc Prob) for the 'input family' inference

Second family-level inference (among Family II models)

Proceeding then with the inference on model families of contextual influences, within the optimal family identified above, the optimal subsets differed between the "Amputated" and "Intact" hemispheres (Supplementary Figure 4). On the amputated side, the optimal model was Family G for which EXE affects M1 only (exceedance probability, $p = 0.52$). On the intact side, Family B in which EXE affects the connection SMA to M1-c was significantly more likely ($p = 0.66$).



Supplementary Figure 4: Family exceedance probabilities for both sides

Supplementary Table 6 summarizes the numerical results for the model families of EXE modulations, for both the intact and phantom limbs. Results for the IMA modulations are not presented here since they were very similar to the ones obtained for the EXE modulations.

SIDE	Family A		Family B		Family C		Family D		Family E		Family F		Family G	
	Exp Post	Exc Prob	Exp Post	Exc Prob	Exp Post	Exc Prob	Exp Post	Exc Prob	Exp Post	Exc Prob	Exp Post	Exc Prob	Exp Post	Exc Prob
Amputated	0.049	0.0004	0.062	0.0014	0.049	0.0002	0.215	0.048	0.056	0.0008	0.048	0.0002	0.52	0.949
Intact	0.055	0.000	0.66	0.999	0.049	0.000	0.065	0.000	0.066	0.000	0.05	0.000	0.047	0.000

Supplementary Table 6: Estimated family expected posterior (Exp Post) and Exceedance probabilities (Exc Prob) for the second family-level inference

Model-level inference within the best model family

On the amputated side, there was considerable evidence in favour of model G.5 (posterior probability $p = 0.94$). On the intact side, there was strong evidence in favour of model B.2 ($p = 0.99$). The only difference between model G.5 and model B.2 is how EXE or IMA modulates M1 activity: either directly (G5, phantom limb) or indirectly (B2, intact limb). Interestingly, the architecture of these models (see supplementary Figure 1) is similar to the one previously reported in healthy subjects but with a different paradigm (18). The numerical results for both intact and amputated model selection are summarized in Supplementary Table 7.

SIDE	Model index	Expected posterior	Exceedance probability
------	-------------	--------------------	------------------------

SIDE	Model index	Expected posterior	Exceedance probability
Amputated	G.5	0.941	0.431
Intact	B.2	0.9996	0.626

Supplementary Table 7: Optimal model for the two limbs: model index, expected posterior and exceedance probabilities

Parameter-level inference within the best model family

As B2 and G5 models were not the optimal models for all subjects we provided parameter values from the Bayesian model averaging (BMA) among the optimal family associated with each limb (family G for the phantom limb and family B for the intact limb) (Supplementary Table 8). The intrinsic connections as well as the effect of inputs and experimental conditions on the connections were tested for significance using one-sample t-tests ($p < 0.05$).

Connection names	Phantom limb,	Intact limb,
M1-c to SMA	0.09*	0.23*
SMA to M1-c	0.93*	0.27 *
EXE to SMA	0.05*	--
EXE to M1-c	--	--
IMA to SMA	0.006	--

Connection names	Phantom limb,	Intact limb,
IMA to M1-c	-0.05 *	-0.0001
EXE to SMA/M1	--	0.89*
IMA to SMA/M1-c	-0.04	-0.59*
PREPA to M1-c	0.007	0.009
PREPA to SMA	0.075*	0.13*
BEEP to SMA/M1-c	0.38*	0.07
BEEP to SMA	0.75*	0.2*

*Supplementary Table 8: Parameters values from the Bayesian model averaging within the best model family for the phantom limb and the intact limb. * Values significantly different from zero, ($p < 0.05$), values discussed in the main text are in bold font; non-defined connections are noted with '—'.*