



HAL
open science

**Etude anatomique et fonctionnelle de l'innervation
pelvipérinéale de la femme : cartographie
tridimensionnelle de l'expression de la forme neurale de
l'enzyme de synthèse de l'oxyde nitrique (nNOS)**

David Moszkowicz

► **To cite this version:**

David Moszkowicz. Etude anatomique et fonctionnelle de l'innervation pelvipérinéale de la femme : cartographie tridimensionnelle de l'expression de la forme neurale de l'enzyme de synthèse de l'oxyde nitrique (nNOS). Médecine humaine et pathologie. Université Paris Sud - Paris XI, 2012. Français. NNT : 2012PA114836 . tel-00775860

HAL Id: tel-00775860

<https://theses.hal.science/tel-00775860>

Submitted on 14 Jan 2013

HAL is a multi-disciplinary open access archive for the deposit and dissemination of scientific research documents, whether they are published or not. The documents may come from teaching and research institutions in France or abroad, or from public or private research centers.

L'archive ouverte pluridisciplinaire **HAL**, est destinée au dépôt et à la diffusion de documents scientifiques de niveau recherche, publiés ou non, émanant des établissements d'enseignement et de recherche français ou étrangers, des laboratoires publics ou privés.

UNIVERSITÉ PARIS-SUD 11

ECOLE DOCTORALE

ED 425

« INNOVATION THÉRAPEUTIQUE : DU FONDAMENTAL A L'APPLIQUÉ »

DISCIPLINE : Sciences Chirurgicales

ANNÉE 2012 – 2013

SÉRIE DOCTORAT N° 1189

THÈSE DE DOCTORAT SUR TRAVAUX

Soutenue le 19/10/2012

Par

David MOSZKOWICZ

Etude anatomique et fonctionnelle de l'innervation pelvi-périnéale de la femme : cartographie tridimensionnelle de l'expression de la forme neurale de l'enzyme de synthèse de l'oxyde nitrique.

Directeur de thèse : M. le Pr Gérard BENOIT PU-PH, Université Paris Sud-11, Le Kremlin-Bicêtre

Composition du jury :

<i>Rapporteurs :</i>	M. le Pr Patrick BAQUE	PU-PH, Université de Nice Sophia Antipolis, Nice
	M. le Pr Richard DOUARD	PU-PH, Université Paris Nord-13, Bobigny
<i>Examineurs, co-encadrants :</i>	Me. le Dr Frédérique PESCHAUD	MCU-PH, Université PIFO-UVSQ, Guyancourt
	M. le Dr Thomas BESSEDE	AHU, Université Paris Sud-11, Le Kremlin-Bicêtre
<i>Examineur :</i>	M. le Pr Jean-Marc CHEVALLIER	PU-PH, Université Paris Descartes-5, Paris
<i>Membre invité :</i>	M. le Pr Christophe TRESALLET	PU-PH, Université Paris Curie-6, Paris

UNIVERSITÉ PARIS-SUD 11

ECOLE DOCTORALE

ED 425

« INNOVATION THÉRAPEUTIQUE : DU FONDAMENTAL A L'APPLIQUÉ »

DISCIPLINE : Sciences Chirurgicales

ANNÉE 2012 – 2013

SÉRIE DOCTORAT N° 1189

THÈSE DE DOCTORAT SUR TRAVAUX

Soutenue le 19/10/2012

Par

David MOSZKOWICZ

Etude anatomique et fonctionnelle de l'innervation pelvi-périnéale de la femme : cartographie tridimensionnelle de l'expression de la forme neurale de l'enzyme de synthèse de l'oxyde nitrique (nNOS).

Directeur de thèse : M. le Pr Gérard BENOIT PU-PH, Université Paris Sud-11, Le Kremlin-Bicêtre

Composition du jury :

<i>Rapporteurs :</i>	M. le Pr Patrick BAQUE	PU-PH, Université de Nice Sophia Antipolis, Nice
	M. le Pr Richard DOUARD	PU-PH, Université Paris Nord-13, Bobigny
<i>Examineurs, co-encadrants :</i>	Me. le Dr Frédérique PESCHAUD	MCU-PH, Université PIFO-UVSQ, Guyancourt
	M. le Dr Thomas BESSEDE	AHU, Université Paris Sud-11, Le Kremlin-Bicêtre
<i>Examineur :</i>	M. le Pr Jean-Marc CHEVALLIER	PU-PH, Université Paris Descartes-5, Paris
<i>Membre invité :</i>	M. le Pr Christophe TRESALLET	PU-PH, Université Paris Curie-6, Paris

Résumé

Introduction : Si les connaissances anatomiques supportent l'élaboration des techniques chirurgicales, peu d'informations étaient disponibles sur l'anatomie et la physiologie de l'innervation pelvi-périnéale. La détermination précise de l'origine, du trajet péri-viscéral, des rapports anatomiques avec les organes et les vaisseaux de voisinage et de la terminaison de ces nerfs au niveau d'organes dont ils commandent la fonction était jusqu'alors peu accessible aux techniques anatomiques classiques de dissection macroscopique sur sujet cadavérique. Dans le domaine de la chirurgie pelvienne pour cancer, l'amélioration de la qualité de vie des malades passe par la préservation de ces structures nerveuses, la dimension fonctionnelle étant désormais indissociable des impératifs carcinologiques. En effet, l'intégrité de ces nerfs est indispensable aux fonctions de continence sphinctérienne et de sexualité. Par ailleurs, la majorité des travaux s'intéressant aux séquelles fonctionnelles postopératoires sont réalisés chez l'homme et très peu de travaux concernent exclusivement les femmes dont les troubles sexuels sont plus difficiles à identifier. La réduction de ces troubles fonctionnels postopératoires passe donc par une meilleure compréhension de l'anatomie nerveuse pelvi-périnéale, qui peut être éclaircie par de nouvelles techniques d'étude.

Objectifs : Pour contribuer à améliorer les connaissances anatomiques et physiologiques utiles à l'amélioration des résultats fonctionnels de la chirurgie pelvienne pour cancer chez la femme, les trois objectifs de ce travail étaient : i) d'étudier l'anatomie morphologique et fonctionnelle de l'innervation pelvi-périnéale chez le fœtus féminin en utilisant la technique de Dissection Anatomique Assistée par Ordinateur (DAAO) ; ii) d'établir une cartographie tridimensionnelle des principaux neurotransmetteurs parasymphatiques, sympathiques et sensitifs impliqués dans la physiologie de la fonction sexuelle féminine et de la défécation ; iii) d'établir grâce à cette technique de DAAO un modèle pédagogique tridimensionnel, utile pour l'apprentissage de l'anatomie et de la chirurgie pelvienne.

Matériels et méthodes : Des coupes sériées de 5µm d'épaisseur ont été effectuées tous les 50 à 150 µm sur le bassin de 14 fœtus humains (7 filles, 7 garçons, entre 15 et 31 semaines de gestation) puis étudiées par la technique de Dissection Anatomique Assistée par Ordinateur. Les coupes ont été traitées par l'Hématoxyline-Eosine et le trichrome de Masson puis immunomarquées pour réaliser une dissection immunologique des fibres nerveuses (anticorps anti-protéine S-100), les fibres somatiques (PMP22), les fibres autonomes adrénrgiques (TH) et cholinergiques (VACHT), les fibres sensitives (CGRP) et les fibres pro-érectiles nitrgiques (nNOS) ainsi que l'actine lisse des sphincters. Les lames ont ensuite été numérisées par un scanner de haute résolution optique et les images bidimensionnelles ont été reconstruites manuellement en trois dimensions puis traitées par un logiciel d'animation. Trois sujets féminins adultes ont été étudiés par dissection macroscopique des afférences et efférences du plexus hypogastrique inférieur (PHI).

Résultats : La reconstruction tridimensionnelle des coupes histologiques immuno-marquées a permis d'identifier l'anatomie topographique et fonctionnelle de l'innervation pelvi-périnéale et notamment la distribution de la forme neurale de l'enzyme de synthèse de l'oxyde nitrique impliquée dans la fonction sexuelle et dans la relaxation des sphincters lisses. Les nerfs hypogastriques (NH) étaient en rapport avec le système des fascias pelviens et rejoignaient le plexus hypogastrique inférieur (PHI) homolatéral en regard du bord latéral du cul-de-sac recto-vaginal. Les neurofibres issues de la partie distale du PHI et responsables de l'innervation sphinctérienne et de la fonction sexuelle convergeaient vers le diaphragme urogénital. Elles étaient regroupées et associées au pédicule vasculaire vaginal long pour former

la bandelette neuro-vasculaire (BNV), située à 2 et 10 heures sur la face antérolatérale du rectum, ainsi que le plexus rectal inférieur, en arrière, destiné à la paroi rectale postérolatérale et au sphincter lisse de l'anus. La BNV envoyait des fibres nerveuses à la paroi postérieure du vagin, qui se situaient en avant du septum recto-vaginal. Trois efférences principales étaient issues de cette BNV à hauteur du bas rectum : le plexus urétral, destiné au sphincter urétral, le nerf caverneux, destiné aux corps caverneux du clitoris et le « nerf spongieux », destiné aux bulbes vestibulaires du clitoris. Les voies nerveuses autonomes supra-lévatoriennes et somatiques infra-lévatoriennes communiquaient à trois niveaux : proximal/supra-lévatorien, entre le nerf pudendal et le PHI, intermédiaire/intra-lévatorien et distal infra-lévatorien. Le nerf dorsal du clitoris (NDC) exprimait des neurotransmetteurs sensitifs en distalité et présentait une activité nitrergique segmentaire issue de sa communication avec le nerf caverneux.

Conclusion et perspectives : Notre étude a permis de développer un modèle anatomique et physiologique d'innervation du pelvis et du périnée du fœtus féminin. Nos travaux se poursuivront chez l'animal et le sujet anatomique pour confirmer nos résultats (les données physiologiques seront complétées par une étude moléculaire de la répartition des neurotransmetteurs centraux et périphériques) et chez le malade pour les confronter à la pratique clinique, notamment par un travail prospectif en cancérologie chirurgicale digestive.

Mots clés : anatomie, innervation pelvienne, cancer du rectum, dysfonction sexuelle neurogène de la femme, nerf caverneux, nerf spongieux, nerf dorsal du clitoris, oxyde nitrique synthétase, plexus rectal inférieur, proctectomie.

Morphologic and functional study of female pelvic-perineal innervation

Abstract

Introduction: Anatomical knowledge is required for the development of surgical techniques, but little is known about the anatomy and physiology of innervation in the pelvic/perineal area. The origin, perivisceral trajectory, anatomical relationships to organs and neighbouring vessels and of the endings of these nerves in the organs they control has not, to date, been easy to determine precisely by classical anatomical techniques based on the macroscopic dissection of cadavers. In the domain of pelvic cancer surgery, improvements in the quality of life of patients are dependent on the preservation of these nervous system structures; the maintenance of function cannot be dissociated from oncological imperatives. Indeed, the integrity of these nerves is essential for sphincter continence and sexual functions. Most studies have focused on the functional sequelae of surgery in men. Very few studies have focused exclusively on women, in whom sexual problems are more difficult to identify. The reduction of such postsurgical functional problems thus requires a more complete understanding of the anatomy of the pelvic/perineal nervous system. This may be possible through the use of new investigative techniques.

Objectives: This study aimed to increase our anatomical and physiological knowledge, with a view to improving the functional results of pelvic cancer surgery in women, through three major axes: 1) studies of the morphological and functional innervations of the pelvic/perineal region in female fetuses, based on use of the computer-assisted anatomical dissection (CAAD) approach; 2) three-dimensional mapping of the principal parasympathetic, sympathetic and sensitive neurotransmitters involved in the physiology of female sexual function and defecation; 3) the use of CAAD to establish a three-dimensional pedagogical model to facilitate the learning of pelvic anatomy and surgery.

Materials and methods: Serial sections (5 μm thick) were cut at 50 to 150 μm intervals across the basin of 14 human fetuses (seven fetuses of each sex, between 15 and 31 weeks of gestation) and studied by the CAAD technique. The sections were stained with haematoxylin-eosin and Masson's trichrome and were then immunolabelled for immunological dissection of the nerve fibres (anti-S-100 protein antibody), somatic fibres (PMP22), autonomic adrenergic (TH) and cholinergic (VACHT) fibres, sensitive fibres (CGRP) and nitrenergic proerectile fibres (nNOS) and the smooth actin of the sphincters. The slides were then scanned with a high-resolution optical scanner and three-dimensional images were reconstructed manually from the two-dimensional images obtained and processed with a computer animation program. Three adult female subjects were studied by macroscopic dissection of the afferences and efferences of the inferior hypogastric plexus (IHP).

Results: Three-dimensional reconstruction of the immunolabelled histological sections made it possible to determine the topographic and functional anatomy of pelvic/perineal innervations and, in particular, the distribution of the neural form of the nitric oxide synthase involved in sexual function and in the relaxation of smooth-muscle sphincters. The hypogastric nerves (NH) were connected to the system of pelvic fasciae and connected to the ipsilateral IHP at the lateral edge of the recto-uterine pouch. The nerve fibres from the distal part of the IHP responsible for sphincter innervations and sexual function converged on the urogenital diaphragm. They were clustered together and associated with the long vaginal vascular pedicle to form the neurovascular bundle (NVB) located at positions of 2 o'clock and 10 o'clock on the anterolateral surface of the rectum, and the inferior rectal plexus, at the

back, extending to the posterolateral rectal wall and the smooth-muscle sphincter of the anus. The NVB emits nerve fibres that extend to the posterior wall of the vagina, just before the rectovaginal septum. Three principal efferences were found to emanate from this NVB in the lower rectum: the urethral plexus leading to the urethral sphincter, the cavernous nerves leading to the cavernous body of the clitoris and the “spongious nerve” leading to the vestibular bulbs of the clitoris. The supralelevator autonomic and infralevator somatic nervous system pathways communicate at three levels: the proximal/supralelevator level between the pudendal nerve and the IHP, the intermediate/intralevator level and the distal infralevator level. The clitoris dorsal nerve (CDN) expresses sensitive distal neurotransmitters and presents segmentary nitrenergic activity due to its communication with the cavernous nerve.

Conclusion and perspectives: This study led to the development of an anatomical and physiological model of the innervations of the pelvis and perineum in female foetuses. This work is being pursued in animals and in anatomical subjects, to confirm the results obtained (we will add to the physiological data by carrying out a molecular study of the distribution of central and peripheral neurotransmitters), and in patients, to compare the results obtained with clinical practice, through a prospective digestive cancer surgery study in particular.

Key words: anatomy, pelvic innervation, rectal cancer, female neurogenic sexual dysfunction, cavernous nerve, spongious nerve, dorsal clitoris nerve, nitric oxide synthase, proctectomy.

Au Docteur Marcel Moszkowicz,
Psychiatre-psychanalyste

En préambule à ce mémoire de thèse, je souhaitais adresser mes remerciements les plus sincères aux personnes qui m'ont apporté leur aide et qui ont contribué à l'élaboration de ce travail ainsi qu'à la réussite de ces années universitaires.

Je tiens à remercier tout particulièrement Monsieur le Pr Gérard Benoit, anatomiste et urologue, pour m'avoir accueilli dans son laboratoire et avoir accepté d'encadrer ce travail avec une grande rigueur scientifique et une grande liberté d'esprit.

Je souhaite remercier Monsieur le Pr Patrick Baqué, qui fut à l'origine de ma vocation pour l'anatomie et la chirurgie digestive et m'a fait l'honneur de juger ce travail.

Je souhaite remercier Monsieur le Pr Richard Douard, qui m'a accueilli chaleureusement au sein de l'anatomie Parisienne et m'a fait l'honneur de juger ce travail.

A Monsieur le Pr Jean-Marc Chevallier, qui m'a transmis sa passion pour la chirurgie bariatrique, m'a accordé sa confiance et m'a fait l'honneur d'être présent dans ce jury. Ses enseignements et ses travaux anatomiques sont un modèle.

A Madame le Dr Frédérique Peschaud, anatomiste et chirurgien digestif. Je lui voue une reconnaissance sincère pour sa confiance et son soutien. Elle a donné l'impulsion initiale à mon épanouissement.

A Monsieur le Pr Christophe Trésallet, qui a accepté de participer au comité de mi-parcours. Il est d'une fidélité indéfectible, et m'accompagne depuis le début dans mes parcours de médecine et de sciences.

Aux Drs Thomas Bessède, Bayan Alsaïd et Mazen Zaitouna, compagnons de voyages passionnés.

A mes collègues d'internat et amis, que j'espère avoir convaincu du dynamisme de l'anatomie en 2012 !

A Anne-Sophie, à Simon, à number two pour le soutien et l'inspiration.

Valorisation du travail

1. Publications scientifiques intégrées au mémoire de thèse

1. **Moszkowicz, D.**, Alsaid, B., Bessede, T., Penna, C., Nordlinger, B., Benoit, G., and Peschaud, F. *Where does pelvic nerve injury occur during rectal surgery for cancer?* Colorectal Dis 2011 Dec; 13(12):1326-34. Review.

2. **Moszkowicz D**, Alsaid B, Bessede T, *et al.* *Female pelvic autonomic neuroanatomy based on conventional macroscopic and computer-assisted anatomic dissections.* Surg Radiol Anat 2011 Jul; 33:397-404.

3. **Moszkowicz D**, Alsaid B, Bessede T, *et al.* *Neural supply to the clitoris: immunohistochemical study with three-dimensional reconstruction of cavernous nerve, spongiosus nerve, and dorsal clitoris nerve in human fetus.* J Sex Med 2011 Apr; 8(4): 1112-1122.

4. **Moszkowicz D**, Peschaud F, Bessede T, *et al.* *Internal anal sphincterparasympathetic-nitroergic and sympathetic-adrenergic innervation: a 3D morphologic and functional analysis.* Dis Colon Rectum 2012 Apr; 55(4):473-481.

5. **Moszkowicz D***, Alsaid B*, Peschaud F, *et al.* *Autonomic-somatic communications in the human pelvis: computer-assisted anatomic dissection in male and female fetuses.* J Anat 2011 Nov ; 219(5):565-73.*Contribution équivalente

6. Peschaud F, **Moszkowicz D**, Alsaid B, Bessede T, Penna C, Benoit G. *Preservation of genital innervation in women during total mesorectal excision : which anterior plane ?* World J Surg. 2012 Jan;36(1) :201-7.

7. Publications scientifiques complémentaires, en collaboration avec l'équipe de l'EA 4122

1. Alsaid, B., Bessedé, T., Diallo, D., **Moszkowicz, D.**, Karam, I., Benoit, G., and Droupy, S. (2011). *Division of autonomic nerves within the neurovascular bundles distally into corpora cavernosa and corpus spongiosum components: immunohistochemical confirmation with three-dimensional reconstruction*. Eur Urol 2011 Jun;59(6):902-909.
2. **Moszkowicz D**, Alsaid B, Benoit G, Peschaud F. *Etude anatomique et immunohistochimique de l'innervation pelvipérinéale de la femme avec reconstruction 3D. Peut-on encore diminuer les séquelles sexuelles et urinaires de la dissection rectale pour cancer ?* E-Mem Acad Natl Chir 2011 Jan;10(2):46-51.

8. Communications orales en Français

1. **Moszkowicz D**, Alsaid B, Bessedé T, Karam I, S Droupy S, Penna C, Benoît G et Peschaud F. *Innervation du clitoris : étude immunohistochimique avec reconstruction 3D*. 104^{ème} congrès de l'**Association Française d'Urologie**, novembre 2010, Paris.
2. Bessedé T, Zaitouna M, Alsaid B, **Moszkowicz D**, Benoît G, Droupy S, Peschaud F, Karam I. *Reconstruction tridimensionnelle de l'innervation et cartographie pharmacologique de la jonction urétéro-vésicale*. 104^{ème} congrès de l'**Association Française d'Urologie**, novembre 2010, Paris.
3. **Moszkowicz D**, Alsaid B, Bessedé T, Benoît G et Peschaud F. *Innervation du clitoris : étude immunohistochimique avec dissection anatomique assistée par ordinateur*. **Société anatomique de Paris**, séance du 26/11/2010, Paris.
4. **Moszkowicz D**, ALSAID Bayan, BESSEDE Thomas, ZAITOUNA Mazen, BENOIT Gérard, PESCHAUD Frédérique. *Etude anatomique et immunohistochimique de l'innervation pelvi-périnéale avec reconstruction 3D. Peut-on encore diminuer les séquelles sexuelles lors de la dissection rectale pour cancer ?* 113^{ème} congrès de l'**Association Française de Chirurgie**, octobre 2011, Paris.
5. **Moszkowicz D**, Alsaid B, Benoit G, Peschaud F. *Peut-on encore réduire les séquelles sexuelles de la chirurgie rectale pour cancer*. 3^{ème} congrès de la **Société Française de Chirurgie Oncologique**, 16/09/2011, Nancy. Communication invitée.
6. **Moszkowicz D**, Alsaid B, Benoit G, Peschaud F. *Amélioration de la chirurgie du rectum par l'anatomie 3D*. **Académie nationale de chirurgie**. Séance du 27/04/2011, Paris. Communication invitée.
7. **Moszkowicz D**, ALSAID Bayan, BESSEDE Thomas, ZAITOUNA Mazen, BENOIT Gérard, PESCHAUD Frédérique. *Innervation sympathique-adrénergique et parasymphatique-nitrergique du sphincter anal interne : analyse 3D*. **Société anatomique de Paris**, séance du 27/01/2012, Paris. Diplôme de la meilleure communication orale.

8. **Moszkowicz D**, ALSAID Bayan, BESSEDE Thomas, ZAITOUNA Mazen, BENOIT Gérard, PESCHAUD Frédérique. *La bandelette neurovasculaire urogénitale : étude morphologique et fonctionnelle chez le fœtus humain*. 94^{ème} congrès de l'**Association des Morphologistes**, 17/3/2012, Clermont-Ferrand.
9. BESSEDE Thomas, ZAITOUNA Mazen, ALSAID Bayan, **Moszkowicz D**, BENOIT Gérard. *Reconstruction 3D de l'innervation et cartographie autonome de la jonction urétéro-vésicale*. 94^{ème} congrès de l'**Association des Morphologistes**, 16/3/2012, Clermont-Ferrand.
10. PESCHAUD Frédérique, **Moszkowicz D**, ALSAID Bayan, BESSEDE Thomas, ZAITOUNA Mazen, BENOIT Gérard,. *Etude morphologique et fonctionnelle de l'innervation pelvi-périnéale*. 94^{ème} congrès de l'**Association des Morphologistes**, 16/3/2012, Clermont-Ferrand.

9. Communications orales en Anglais

1. **Moszkowicz D.**, Alsaïd B., Bessedé T., Benoit G., Peschaud F. *Supra and infralevator autonomic-somatic communications: 3D-reconstruction in human fetuses*. **European Association of Clinical Anatomists-British Association of Clinical Anatomists**, 11^{ème} congrès, juillet 2011, Padoue, Italie.
2. **Moszkowicz D.**, Alsaïd B., Peschaud F., Bessedé T., Benoit G. *Computer-assisted anatomic dissection with 3D-reconstruction of male and female urogenital neurovascular bundles*. **European Association of Clinical Anatomists-British Association of Clinical Anatomists**, 11^{ème} congrès, juillet 2011, Padoue, Italie.

10. Communications affichées

1. **Moszkowicz D**, Alsaïd B, Penna C, Benoît G et Peschaud F. *Dissection rectale et troubles sexuels de la femme : zone anatomique à haut risque*. **SFCD-ACHBT**, 6^{ème} congrès, décembre 2010, Paris.
2. Alsaïd B, **Moszkowicz D**, Peschaud F, Bessedé T, Zaitouna M, Karam I, Droupy S, Benoit G. *Supra and infralevator autonomic-somatic communications : Computer-assisted anatomic dissection in male and female fetuses*. **American Association of Anatomists**, avril 2011, Washington DC, USA.
3. **Moszkowicz D**, Alsaïd B, Benoît G, Peschaud F. *Innervation sympathique-adrénergique et parasymphatique-nitrergique du sphincter anal interne : analyse 3D*. 7^{ème} congrès de la **SFCD-ACHBT**, décembre 2011, Paris.
4. **Moszkowicz D**, Alsaïd B, Bessedé T, Peschaud F, Benoît G. *Dissection rectale et troubles sexuels de la femme: focus sur une zone anatomique à haut risque*. **12èmes Journées de l'Ecole Doctorale Innovation Thérapeutique (ADIT 2012)**, 7 et 8 juin 2012, Faculté de pharmacie de Châtenay-Malabry.

11. Relecteur au cours du doctorat, au sujet d'articles portant sur la thématique de recherche

a. Pour la revue *Journal of Sexual Medicine* (Wiley-Blackwell)

1. **JSM-01-2011-54** « Rho kinase-related proteins in human vaginal arteries : an immunohistochemical and functional study” reçu le 06/02/2011.
2. **JSM-08-2011-534** “The G-spot as a distinct anatomic entity: a review” reçu le 23/08/2011.

b. Pour la revue *Techniques in Coloproctology* (Springer)

3. **TCOL-D-12-00115** « Interaction of the pelvic floor muscles : A dynamic magnetic resonance imaging study in normal volunteers” reçu le 16/04/2012

12. Prix et financements obtenus

1. **Prix des Chirurgiens de l'Avenir 2010** (Fondation de l'Avenir, Master 2 sciences chirurgicales, Universités Paris XI et XII): **prix spécial du Jury**, remis le 25/11/2010, 6000 euros.
2. **Bourse de mobilité** accordée par l'ED 425 pour le congrès 2011 de l'association européenne des anatomistes, Padoue, Italie. 350 euros.
3. **Diplôme de la meilleure communication orale** : « *Innervation sympathique-adrénergique et parasymphatique-nitrergique du sphincter anal interne : analyse 3D* ». Société anatomique de Paris, séance du 27/01/2012, Paris ; discerné par le Pr V Delmas.
4. Le 2^{ème} **prix communication orale « Jeunes Morphologistes »**, 94^{ème} congrès de l'Association des Morphologistes, 17/3/2012, Clermont-Ferrand : « *La bandelette neurovasculaire urogénitale : étude morphologique et fonctionnelle chez le fœtus humain* ». 300 euros ; discerné par le Pr JM Rogez.

Liste des abréviations

BNV	bandelette neurovasculaire
BV	bulbes vestibulaires (bulbes du clitoris)
CCC	corps caverneux du clitoris
CGRP	calcitonin gene related peptide
CS	chaîne sympathique para-vertébrale (tronc sympathique)
DAAO	dissection anatomique assistée par ordinateur
ETM	exérèse totale du mésorectum (ou ligament rectal inférieur)
HE	hématoxyline-éosine
NC	nerf caverneux
NDC	nerf dorsal du clitoris
NH	nerf hypogastrique
nNOS	neural Nitric Oxide Synthase
NO	oxyde nitric
NPV	noyau para-ventriculaire de l'hypothalamus
NPY	neuropeptide Y
NS	nerf spongieux
NSP	nerf splanchnique pelvien (<i>nerf érecteur d'Eckart</i>)
NSS	nerf splanchnique sacral
PHI	plexus hypogastrique inférieur (plexus pelvien)
PHS	plexus hypogastrique supérieur
PMI	plexus mésentérique inférieur
PRI	plexus rectal inférieur
PU	plexus urétral
SMA	smooth muscle actin
SP	substance P
SRV	septum recto-vaginal
TH	tyrosine hydroxylase
VACHT	vesicular acetylcholine transporter
VIP	polypeptide vaso-intestinal

Table des matières - Liste des articles

I. Introduction.....	3
I.A. Rappel anatomique.....	3
I.B. Rappel physiologique.....	6
I.B.a Oxyde nitrique (NO) et enzymes de synthèse.....	6
I.B.b Physiologie de la fonction sexuelle de la femme.....	8
I.B.c Physiologie du sphincter lisse de l'an.....	10
I.C. Anatomie nerveuse par dissection immunologique et reconstruction tridimensionnelle...10	
I.D. Applications cliniques.....	11
I.D.a En chirurgie.....	11
I.D.b En pharmacologie.....	12
II. Objectifs.....	14
III. Résultats.....	15
III.A. Article 1 : Quelles sont les zones à risque de blessure nerveuse au cours de l'exérèse rectale pour cancer ?.....	15
III.B. Article 2 : Etude de l'innervation autonome du pelvis de la femme par dissections macroscopique et assistée par ordinateur	25
III.C. Article 3 : Innervation du clitoris : étude immunohistochimique avec reconstruction 3D des nerfs caverneux, spongieux et dorsal du clitoris chez le fœtus humain	35
III.D. Article 4 : Innervation sympathique - adrénérergique et parasymphatique - nitreergique du sphincter anal interne : analyse 3D	49
III.E. Article 5 : Communications intra pelviennes autonomiques -somatiques: dissection anatomique assistée par ordinateur chez le fœtus humain	61
III.F. Article 6 : Préservation de l'innervation à destinée génitale de la femme au cours de l'exérèse totale du mésorectum : quel plan de dissection antérieure ?.....	73
IV. Conclusions et perspectives.....	84
V. Références bibliographiques	87
VI. Annexe	91

I. Introduction

Si les connaissances anatomiques supportent l'élaboration des techniques chirurgicales, peu d'informations étaient disponibles sur l'anatomie et la physiologie de l'innervation pelvi-périnéale. La détermination précise de l'origine, du trajet péri-viscéral, des rapports anatomiques avec les organes et les vaisseaux de voisinage et de la terminaison de ces nerfs au niveau d'organes dont ils commandent la fonction était jusqu'alors peu accessible aux techniques anatomiques classiques de dissection macroscopique sur sujet cadavérique. Dans le domaine de la chirurgie pelvienne pour cancer, l'amélioration de la qualité de vie des malades passe par la préservation de ces structures nerveuses, le résultat fonctionnel étant désormais indissociable des impératifs carcinologiques. En effet, l'intégrité de ces nerfs est indispensable aux fonctions de continence sphinctérienne et de sexualité. Par ailleurs, la majorité des travaux s'intéressant à ces séquelles fonctionnelles sont réalisés chez l'homme [1] et très peu de travaux concernent exclusivement les femmes [2-4] dont les troubles sexuels sont plus difficiles à identifier [5]. La réduction de ces troubles fonctionnels postopératoires passe donc par une meilleure compréhension de l'anatomie nerveuse pelvi-périnéale, qui peut être éclaircie par de nouvelles techniques d'étude.

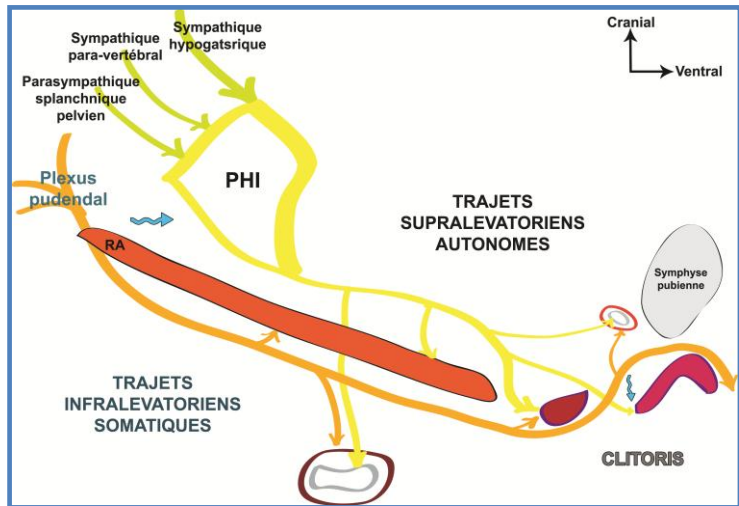
I.A. Rappel anatomique

Le diaphragme pelvien sépare la cavité pelvienne (ou pelvis), située en position supra-lévatorienne (au-dessus du muscle élévateur de l'anus), du périnée situé en position infra-lévatorienne. Dans la région supra-lévatorienne, chemine le système nerveux végétatif ou autonome, représenté majoritairement par le plexus hypogastrique inférieur (PHI), zone de convergence et d'intégration des systèmes sympathique et parasymphatique (figure 1). Dans la région infra-lévatorienne, chemine le système nerveux somatique représenté par le nerf

puddendal et ses branches, dans lequel cheminent également des fibres du système autonome [6, 7].

➤ **Innervation somatique pelvi-périnéale**

L'innervation somatique motrice



pelvi-périnéale dépend essentiellement du plexus nerveux pudendal, issu des rameaux antérieurs des racines nerveuses sacrales S2, S3 et S4. Il présente plusieurs branches collatérales : le nerf du muscle élévateur de l'anus, le nerf du muscle coccygien, le nerf rectal supérieur et le nerf pudendal, nerf mixte sensitivomoteur impliqué dans l'orgasme [8]. Ce nerf pudendal présente 2 branches collatérales : le nerf rectal inférieur et le nerf périnéal [9-11] et se termine par le nerf dorsal du clitoris, branche sensitive assurant l'innervation de la peau du périnée, de ses annexes cutanées et des corps caverneux.

Les neurofibres somatiques sensibles empruntent les mêmes troncs nerveux que les nerfs moteurs.

➤ **Innervation autonome pelvi-périnéale**

Le système nerveux autonome ou végétatif s'organise anatomiquement en centres axiaux, situés dans le système nerveux cérébro-spinal, et en centres extra-axiaux : les chaînes ganglionnaires para-vertébrales et pré-viscérales. Les centres extra-axiaux para-vertébraux sont reliés aux centres pré-viscéraux par les nerfs splanchniques abdominaux et pelviens. L'influx nerveux est conduit par des voies motrices et sensibles bi-neuronales (fibres pré-ganglionnaires myélinisées connectrices cholinergiques et post-ganglionnaires non-myélinisées effectrices), selon deux systèmes sympathique/adrénérique et

parasymphatique/cholinergique, d'actions antagonistes. Les fibres sympathiques et parasymphatiques convergent dans la chaîne pré-viscérale du plexus cœliaque dans l'abdomen et du plexus hypogastrique inférieur (PHI) dans le pelvis. Le système végétatif pelvien assure l'innervation sphinctérienne et génito-sexuelle : le parasymphatique assure la motricité du détrusor et de l'ampoule rectale ainsi que l'érection par vasodilatation des tissus érectiles ; le sympathique contrôle la tonicité cervico-urétrale et anale et, chez l'homme, l'éjaculation par contraction des vésicules séminales et fermeture du col vésical.

- **Branches afférentes au PHI**

Le PHI reçoit des branches nerveuses de cinq sources. Le plexus mésentérique inférieur (PMI) en regard de l'artère mésentérique inférieure, le plexus hypogastrique supérieur (PHS) constitué de fibres provenant de nerfs splanchniques lombaires et du PMI, les nerfs hypogastriques (NH), essentiellement constitués de fibres sympathiques issues du PHS, les nerfs splanchniques pelviens (NSP, *nerfs érecteurs d'Eckhard*) majoritairement parasymphatiques et les nerfs splanchniques sacraux (NSS) issus de la chaîne sympathique latéro-vertébrale (CS) [12].

- **Branches efférentes du PHI**

Les branches efférentes du PHI s'organisent en plexus et sont de trois ordres, vasculaires pour les vaisseaux iliaques internes et leurs branches, péritonéales et viscérales. Ces dernières sont les plus importantes et diffèrent suivant le sexe ; elles sont destinées d'une part aux viscères pelviens digestifs et génito-urinaires et d'autre part aux organes périnéaux érectiles (corps caverneux et spongieux du clitoris) et glandulaires (glandes vestibulaires).

L'anatomie descriptive, topographique et fonctionnelle des structures autonomes neuro-vasculaires n'est pas précisément connue, notamment du fait du manque de modèles expérimentaux adaptés [13, 14].

I.B. Rappel physiologique

I.B.a Oxyde nitrique (NO) et enzymes de synthèse

L'oxyde nitrique (NO) endogène dérive de la L-arginine via une réaction catalysée par une famille de 3 enzymes de synthèse (NOS) : endothéliale, inductible et neurale [15]. Cette dernière, la nNOS, est exprimée principalement par les cellules endothéliales pulmonaires, par certaines glandes endocrines, par les fibres musculaires striées ainsi que par les neurones, les astrocytes et les cellules souches neurales. L'épissage alternatif de son ARNm génère 5 isoformes de nNOS : α , β , μ , γ et 2. Elle est active sous forme dimérique. Son expression est régulée par la cAMP response element-binding protein (CREB). Son activité est régulée par la protéine de choc thermique HSP90/HSP 70, par la protéine inhibitrice de nNOS (PIN), par phosphorylation et déphosphorylation et par la calmoduline (CaM). Elle interagit avec plusieurs protéines dont la protéine post-synaptique de densité 95kD (PSD95) via son domaine N-terminal PDZ, avec la clathrin assembly lymphoid leukemia (CALM) et avec la protéine kinase II alpha dépendante du couple calcium/calmoduline (CAMKIIA) [16, 17] (figure 2).

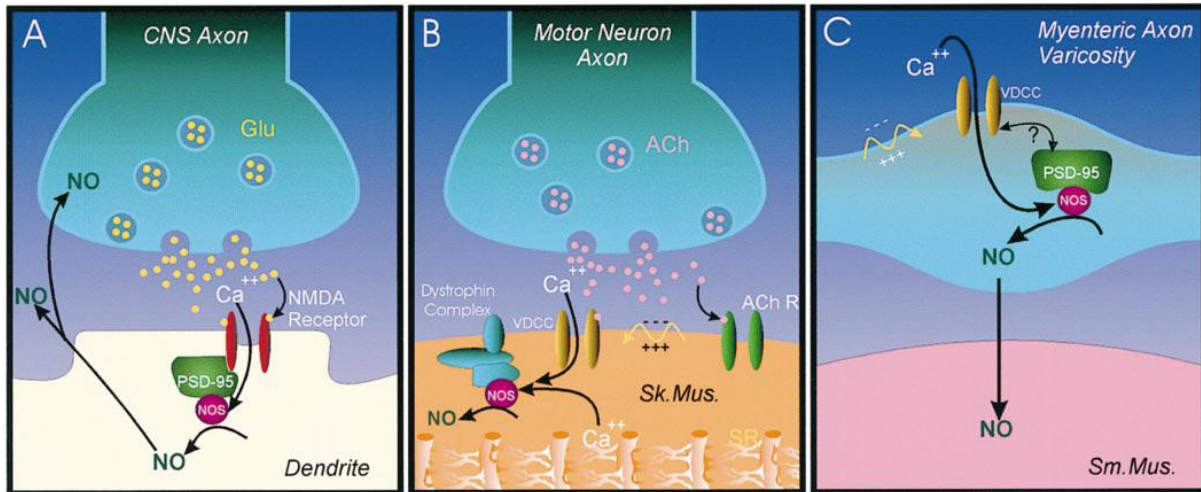


Figure 2: la régulation synaptique de la nNOS au niveau de différents sites (neurones, muscles strié et lisse) implique des interactions protéiques aboutissant à des voies sites-spécifiques de contrôle des flux calciques. (A) Les associations avec PSD-95 médient le couplage de nNOS aux récepteurs NMDA dans le système nerveux central. (B) Dans le muscle squelettique (Sk. Mus.), nNOS interagit avec la dystrophine au sein du sarcolemme. (C) Dans les axones myentériques, où le NO agit comme un neurotransmetteur, l'influx calcique voltage-dépendant déclenche la relaxation musculaire lisse via PSD-95 et la calmoduline. ACh, Acétylcholine; ACh R, acétylcholine récepteur; Glu, glutamate; SR, réticulum sarcoplasmique. Illustration par Naba Bora, Medical College of Georgia; citée dans [18].

Le NO d'origine endothéliale, régule la vasomotricité vaginale en réponse à un stimulus sexuel. Les œstrogènes exercent une régulation post-transcriptionnelle sur la NO synthétase endothéliale par phosphorylation et interaction avec la cavéoline-1 [19].

Le NO d'origine neuronale a plusieurs effets physiologiques. Dans le système nerveux central, il est impliqué dans la neuroplasticité et la genèse de la douleur neurogène [15, 17]. Dans le système nerveux périphérique, il agit comme un neurotransmetteur non-adrénérgique et non-cholinérgique médiant l'action des motoneurones autonomes sur le muscle lisse vasculaire et non-vasculaire, notamment au niveau des corps érectiles et des sphincters lisses [20, 21]. La distribution de ce neurotransmetteur au sein du système nerveux pelvi-périnéal de la femme demeure mal connue.

I.B.b Physiologie de la fonction sexuelle de la femme

L'innervation sexuelle de la femme est complexe et les altérations de la fonction sexuelle sont beaucoup plus difficiles à évaluer que chez l'homme [22]. Les systèmes neurophysiologiques contrôlant les différentes composantes de la réponse sexuelle (désir, excitation et orgasme) ne sont pas totalement élucidés. Cette réponse est régulée par les systèmes nerveux somatique et autonome, périphérique et central, et implique des hormones stéroïdes et peptidiques [23].

➤ *Au niveau périphérique*, la réponse sexuelle dépend de l'activation, par le système autonome, de mécanismes de contrôle des muscles lisses vasculaires impliqués dans l'augmentation du flux sanguin du vagin et des corps érectiles (corps caverneux et bulbes vestibulaires) aboutissant à l'engorgement et à la lubrification de la paroi vaginale, à des modifications de diamètres de la lumière vaginale, ainsi qu'à la tumescence du clitoris. De plus, des arcs réflexes d'afférences génitales passant par les nerfs pudendaux contrôlent la contraction orgasmique des muscles striés ischio-caverneux et bulbo-spongieux [24]. Chez l'homme, l'enzyme de synthèse de l'oxyde nitrique (NO), la NO synthétase (NOS), est exprimée dans les nerfs innervant les corps caverneux et dans les vasa vasorum des artères péniennes [25]. Les différentes isoformes de NOS sont également distribuées dans le tissu caverneux du clitoris et du vagin humains, particulièrement dans les nerfs du système nerveux autonome et les endothéliums vasculaires et sinusoïdaux [26, 27] ainsi que dans le vagin et l'utérus d'animaux [28-30]. La synthèse endothéliale et neuronale de NO, contrôlée par la NO-phosphodiesterase de type 5, permet, par relaxation des muscles lisses et augmentation du flux artériel, l'augmentation de la pression intra-caverneuse et l'engorgement de la paroi antérieure du vagin [31, 32]. Le phénomène de tumescence clitoridienne est aussi probablement commandé par le système nerveux somatique dont certaines fibres nerveuses, probablement d'origine autonome, ont pu être immunomarquées par l'anticorps dirigé contre la forme neurale de la NOS [27]. Par

ailleurs, on a pu mettre en évidence au niveau des parois et des artères vaginales, l'expression de médiateurs non-adrénergiques non-cholinergiques tels que le polypeptide vaso-intestinal (VIP), vasodilatateur artériel, le neuropeptide Y, l'ocytocine et la sérotonine, tous vasoconstricteurs artériels, concentrées au voisinage des fibres musculaires lisses vasculaires et extravasculaires [33-35]. Enfin, la paroi de l'urètre est riche en cellules paracrines mécano-réceptrices contenant de la sérotonine, connue comme potentialisant la sensibilité épicrotisque des terminaisons nerveuses contenues dans la paroi urétrale [36].

- *Au niveau central*, les afférences d'origine génitale activent des voies réflexes spinales modulant la fonction sexuelle. Sont décrits des arcs réflexes caverno-pudendal et bulbo-caverneux impliquées dans la vasodilatation des corps érectiles. Les informations reçues sont transmises à des centres supra-spinaux, notamment l'aire pré-optique médiale et le noyau para-ventriculaire de l'hypothalamus, l'amygdale médiale, la substance réticulée médullaire, l'hippocampe, le thalamus et le cortex cérébral [36]. Les systèmes sérotoninergique et dopaminergique, mais aussi cholinergique, adrénergique, nitrergique et γ -aminobutyrique sont impliqués dans la commande d'origine centrale. Des données récentes ont permis de préciser le rôle des voies nerveuses médullaires descendantes mélanocortinergiques, exprimant le récepteur 4 de la mélanocortine (MC4-R) et contenant de l'ocytocine synthétisée dans l'hypothalamus [37-39]. Des neurones exprimant la NOS ont été mis en évidence dans le NPV [40].

La rupture de l'intégrité des commandes nerveuses périphériques, dont le substratum anatomique demeure mal connu, mais aussi hormonales, musculaires et vasculaires de la réponse sexuelle sont donc susceptibles d'interférer avec la fonction sexuelle et sphinctérienne

[41], bien que des facteurs psychologiques et relationnels puissent jouer des rôles importants [23].

I.B.c Physiologie du sphincter lisse de l'an

Près de 70% du tonus sphinctérien de repos est supporté par le sphincter lisse, participant à la continence anale [11]. Ce sphincter reçoit des neurofibres sympathiques et parasympathiques dont l'origine, la distribution et la fonction restent mal connues. Elles sont impliquées dans la commande du reflexe recto-anal inhibiteur [42]. L'oxyde nitrique est largement distribué au sein du tube digestif et est impliqué dans la relaxation des fibres musculaires lisses intestinales et sphinctériennes [43, 44]. La dénervation du sphincter anal interne (SAI) peut altérer sa fonction après chirurgie du rectum pour cancer mais la distribution des neurotransmetteurs au sein de l'innervation autonome destinée au SAI reste mal connue. L'identification précise de l'origine et de la distribution de l'innervation autonome du SAI pourrait contribuer à une meilleure compréhension de la dysfonction sphinctérienne neurogène postopératoire et à ses traitements.

I.C. Anatomie nerveuse par « dissection immunologique » et reconstruction tridimensionnelle

L'anatomie topographique de l'innervation pelvienne est classiquement étudiée par dissection macroscopique des nerfs sur sujet frais ou formolés. La dissection de l'environnement adipeux et osseux des structures nerveuses présente cependant le risque de détruire les nerfs ou de perturber leur organisation spatiale. L'utilisation combinée du prélèvement macroscopique en bloc des pièces anatomiques et de méthodes immunohistochimiques permet de respecter l'intégrité des nerfs et ainsi d'améliorer la détection des neurotransmetteurs au sein des tissus nerveux (figure 3). Ces travaux permettent d'obtenir des renseignements précis sur le trajet, le type de fibres et leurs rapports anatomiques [45]. De plus à partir de ces coupes histologiques

immunomarquées et des techniques de traitement d'images en 3D par ordinateur, il est possible de reconstruire, de visualiser dans l'espace, et d'animer les structures anatomiques afin de réaliser une *Dissection Anatomique Assistée par Ordinateur (DAAO)* [46]. Cette technique a été développée et améliorée grâce à un travail collaboratif au sein de notre laboratoire, que nous avons initié à l'occasion d'une année de Master 2 [47]. Nous utilisons le logiciel *Winsurf Reconstruction Software (Windows Surfdriver ; The Surfdriver Software Company ; www.akuaware.com; Hawaï, EU)*, sans interface de contournage automatique.

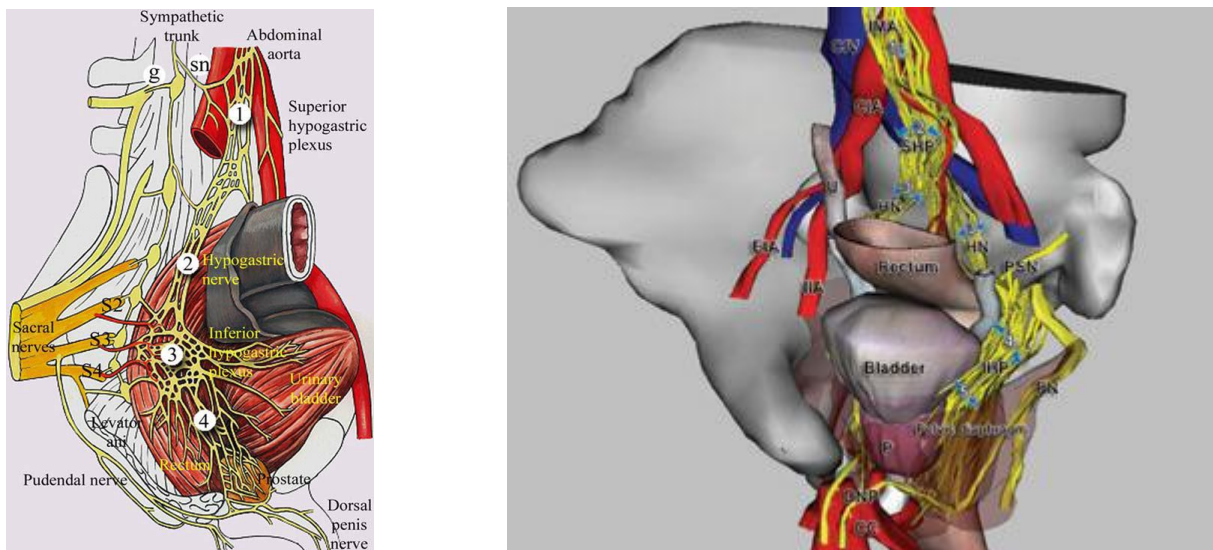


Figure 3: zones à risque de blessure nerveuse au cours de l'exérèse rectale pour cancer ; illustrations par le dessin de données issues de techniques de dissection macroscopique sur sujet anatomique (à gauche) [48] ; reconstruction 3D d'un pelvis de fœtus masculin avec marquage immunohistochimique des nerfs par l'anticorps anti protéine S-100 (à droite, article 1) [49].

I.D. Implications cliniques

I.D.a En chirurgie

La proctectomie avec exérèse totale du mésorectum (ETM, ou ligament rectal inférieur des anatomistes) et préservation nerveuse est la chirurgie de référence du cancer du rectum [50-52]. Cette chirurgie est associée à des séquelles urinaires et sexuelles dans 10 à 70% des cas

[53, 54] liées, notamment, à des lésions iatrogènes des nerfs pelvi-périnéaux [48, 55-59]. Ces nerfs peuvent être lésés en plusieurs endroits (plexus hypogastrique supérieur (PHS), nerfs hypogastriques (NH), plexus hypogastriques inférieurs (PHI) et branches efférentes) [49] (figure 4, *article 1*). Ces lésions peuvent survenir par section directe, écrasement par des écarteurs, thermo-coagulation de voisinage ou étirement par traction manuelle, car leur identification précise peut être difficile en raison de leur taille et de leur proximité avec les organes pelviens [60].

Le syndrome de résection antérieure du rectum observé après proctectomie avec conservation sphinctérienne pourrait être lié en partie à l'interruption de la commande nerveuse du sphincter lisse car ces fibres sont obligatoirement sectionnées lors de l'exérèse du rectum puisqu'elles longent la paroi rectale avant d'atteindre le sphincter. Une meilleure connaissance de la localisation des zones à risque de blessure nerveuse [49] et de la fonction des différentes structures nerveuses permettrait d'adapter les procédures destinées à réduire le risque de troubles fonctionnels post-opératoires : techniques chirurgicales de préservation nerveuse et neurostimulation peropératoire [61, 62].

I.D.b En pharmacologie

L'amélioration de la compréhension de la physiologie sexuelle et sphinctérienne et des facteurs moléculaires impliqués dans sa régulation permettra le développement de nouveaux traitements médicamenteux [63]. Par exemple, l'efficacité des inhibiteurs de phosphodiesterase de type 5 (sildénafil, Viagra[®] par exemple) a été prouvée expérimentalement chez l'animal ovariectomisé, comme ils induisent une augmentation des flux sanguins vaginal et clitoridien et de la lubrification génitale [35]. Ces phénomènes semblent potentialisés en cas de forte imprégnation œstrogénique indiquant que la voie du NO-cGMP est impliquée dans la régulation de la fonction sexuelle [32]. Très peu d'études ont

été réalisées chez le malade après chirurgie pelvienne. Néanmoins, un essai randomisé a évalué l'efficacité du sildénafil versus placebo sur la dysfonction érectile post-opératoire après ETM chez l'homme. Près de 80% (n=11/14) des malades rapportaient une amélioration de la fonction érectile après proctectomie [64]. A notre connaissance, aucune étude n'a été réalisée chez la femme après chirurgie du rectum pour cancer. Néanmoins, si l'effet physiologique de ces molécules est prouvé, leur effet clinique reste discuté chez la femme, notamment du fait de la discordance entre les composantes psychologiques et physiologiques de la réponse sexuelle qui rend difficiles l'évaluation de la fonction sexuelle et l'imputabilité des effets observés après administration de ces molécules [22, 65].

Ainsi, la cartographie 3D des neurotransmetteurs pelvi-périnéaux contribuera à la sélection de molécules pharmacologiques utiles au traitement des troubles primitifs et postopératoires sexuels, de la continence et de l'exonération.

II. Objectifs

Pour contribuer à améliorer les connaissances anatomiques et physiologiques utiles à l'optimisation des résultats fonctionnels de la chirurgie pelvienne pour cancer chez la femme, les trois objectifs de ce travail étaient :

- d'étudier l'anatomie morphologique et fonctionnelle de l'innervation pelvi-périnéale chez le fœtus féminin en utilisant la technique de Dissection Anatomique Assistée par Ordinateur (DAAO)
- d'établir une cartographie tridimensionnelle des principaux neurotransmetteurs parasympathiques et sympathiques (cholinergiques, adrénérgiques et non-cholinergiques/non-adrénérgiques) impliqués dans la physiologie de la fonction sexuelle et sphinctérienne de la femme
- d'établir grâce à cette technique de DAAO un modèle pédagogique tridimensionnel, utile pour l'apprentissage de l'anatomie et de la chirurgie pelvienne

Ces données permettraient le transfert des connaissances anatomiques vers l'application à des techniques chirurgicales visant à préserver les nerfs impliqués dans la continence et la fonction sexuelle au cours de la chirurgie pelvienne et vers le développement de molécules pharmacologiques impliquées dans le traitement des troubles génito-urinaires postopératoires.

Article 1 : Quelles sont les zones à risque de blessure nerveuse au cours de l'exérèse rectale pour cancer ? [49]

Moszkowicz, D. Alsaid, B. Bessedé, T. Penna, C. Nordlinger, B. Benoit, G. Peschaud, F.
Where does pelvic nerve injury occur during rectal surgery for cancer? *Colorectal Dis*
2012;13(12): 1326-1334. Review.
IF 2011: **2,927**

Résumé

Objectifs: le traitement optimal de l'adénocarcinome rectal comprend l'exérèse totale du mésorectum avec préservation nerveuse. Les dysfonctions sexuelles et urinaires sont néanmoins fréquentes dans les suites de cette intervention. Une meilleure connaissance de l'anatomie descriptive des zones à risque de blessure nerveuse au cours de la chirurgie pelvienne permettrait de contribuer à réduire ces séquelles fonctionnelles.

Matériel et méthodes: la base de données MEDLINE a été exploitée pour afin de collecter les articles portant sur l'anatomie des nerfs pelviens et sur les blessures nerveuses occasionnées par l'exérèse rectale, via la recherche des mots clé 'autonomic nerve', 'pelvic nerve', 'colorectal surgery', et 'genitourinary dysfunction'. Toutes les publications en langue Anglaise et Française parue jusque mai 2010 ont été considérées. Les données colligées ont été illustrées par une reconstruction 3D d'un pelvis de fœtus masculin.

Résultats: la ligature de l'artère mésentérique inférieure et la dissection pré-sacrale rétro-rectale peuvent conduire à la blessure des plexus hypogastrique supérieur et mésentérique inférieur et/ou des nerfs hypogastriques. La dissection antérolatérale du rectum dans la zone des ailerons du rectum et la section du fascia de Denonvilliers peuvent conduire à une blessure du plexus hypogastrique inférieur et de ses branches efférentes. La dissection périnéale au cours de l'amputation abdomino-périnéale peut conduire à la blessure indirecte du nerf pudendal et de ses branches.

Conclusions: il est le plus souvent possible de préserver l'innervation pelvienne au cours de la chirurgie du cancer du rectum. Une résection respectant les impératifs carcinologique peut imposer, lorsque la tumeur est antérieure, fixée et que le bassin est étroit, une dissection très à risque pour les structures nerveuses.

➔ Cette revue de littérature est un travail préliminaire. Elle a permis de rappeler les zones clé à risque et de mettre évidence le manque de connaissances acquises, notamment en anatomie topographique (**article 1**) et fonctionnelle (**articles 2-5**). La bandelette neurovasculaire est localisée dans une zone dont la dissection chirurgicale est délicate et qui est peu accessible par l'étude macroscopique de sujets anatomiques. Elle devient donc à haut risque de blessure nerveuse. Elle a fait à ce titre l'objet d'une étude spécifique combinée à celle du septum recto-génital chez le fœtus et l'adulte (**article 6**).

Where does pelvic nerve injury occur during rectal surgery for cancer?

D. Moszkowicz*†, B. Alsaïd*, T. Bessedè*, C. Penna†‡, B. Nordlinger†‡, G. Benoît* and F. Peschaud*†‡

*Laboratory of Experimental Surgery, Faculty of Medicine, University Paris-Sud 11, Le Kremlin-Bicêtre, †Department of Surgery Assistance-Publique-Hôpitaux de Paris, Ambroise Paré Hospital, Boulogne and ‡University PIFO-UVSQ, Guyancourt, France

Received 17 May 2010; accepted 9 June 2010; Accepted Article online 16 August 2010

Abstract

Aim Optimal treatment of rectal adenocarcinoma involves total mesorectal excision with nerve-preserving dissection. Urinary and sexual dysfunction is still frequent following these procedures. Improved knowledge of pelvic nerve anatomy may help reduce this and define the key anatomical zones at risk.

Method The MEDLINE database was searched for available literature on pelvic nerve anatomy and damage after rectal surgery using the key words 'autonomic nerve', 'pelvic nerve', 'colorectal surgery', and 'genitourinary dysfunction'. All relevant French and English publications up to May 2010 were reviewed. Reviewed data were illustrated using 3D reconstruction of the foetal pelvis.

Results The ligation of the inferior mesenteric artery and dissection of the retrorectal space can cause damage

to the superior hypogastric plexus and/or hypogastric nerve. Anterolateral dissection in the 'lateral ligament' area and division of Denonvilliers' fascia can damage the inferior hypogastric plexus and efferent pathways. Perineal dissection can indirectly damage the pudendal nerve.

Conclusions In most cases, the pelvic nerves can be preserved during rectal surgery. Complete oncological resection may require dissection close to the nerves where the tumour is located anterolaterally where it is fixed and when the pelvis is narrow.

Keywords Surgery, rectal cancer, anatomy, pelvic nerve injury, computer-assisted anatomic dissection (CAAD)

Introduction

Optimal treatment of adenocarcinoma of the rectum is based on surgery in which the rectum, with the surrounding mesorectum, is resected as an intact capsule with lymphadenectomy [total mesorectal excision (TME)]. TME is combined with nerve-preserving dissection in an attempt to avoid urinary and sexual dysfunction [1–4]. Lymph nodes at the origin of the inferior mesenteric artery (IMA) [5–7] are also removed [8–10]. Sphincter-saving or abdominoperineal resection (APR) is carried out depending on the level of the tumour [11–15]. With TME and nerve preservation, the rates of genitourinary dysfunction remain around 5–40%

[12,16–18]. These rates may be higher after APR [12,19,20].

Urinary and sexual dysfunction is attributed to somatic and autonomic pelvic nerve damage [21,22]. There are two distinct anatomical compartments in the lower pelvis, above and below the levator ani muscle. Each is innervated by different nerve pathways [23]. The supralelevator pathway is formed by autonomic nerves including the pelvic splanchnic nerves (PSN, parasympathetic); the superior hypogastric plexus (SHP) with hypogastric nerves (HN, sympathetic); and the inferior hypogastric plexus (IHP). The infralevator pathway consists of somatic nerves including the pudendal nerve (PN) and its terminal branches.

Conventional pelvic and perineal dissections are used to study pelvic nerve anatomy, and these are performed through surgical intrapelvic, gluteal and perineal approaches on fresh or frozen cadavers. The standard

Correspondence to: Dr Frédérique Peschaud, Service de Chirurgie Digestive, Hôpital Ambroise Paré, 9 Avenue Charles de Gaulle, 92100 Boulogne, France. E-mail: frederique.peschaud@apr.aphp.fr

means of documenting these dissections is by hand drawings and photography. While dissection of pelvic nerves is technically difficult, the combination of immunostaining and computerized imaging can improve the definition of pelvic organs and clarify their innervation. Three-dimensional (3D) models help to gain a better understanding of complex anatomic structures [24].

In this review of the anatomical and surgical literature, an attempt was made to clarify the anatomy of the pelvic autonomic and somatic nerve pathways with their different sites at risk during surgery for rectal cancer.

Method

Search strategy

Two investigators searched the published literature in the Pubmed database (US National Library of Medicine, Bethesda, Maryland) on pelvic nerve anatomy and nerve damage after rectal cancer surgery up to 2010. The key words used were autonomic nerve, pelvic nerve, colorectal surgery, sexual dysfunction and urinary dysfunction. The 'related articles' algorithm was employed to identify additional articles. Bibliographies of original reports and reviews were scanned for additional references.

Inclusion criteria

All anatomic original articles, reviews and editorial letters that described pelvic and perineal neuroanatomy were included. Descriptions of surgical techniques were included if based on surgical anatomy of the pelvic nerves and nerve preservation techniques. Clinical studies of genitourinary dysfunction following rectal surgery for cancer were also identified.

Exclusion criteria

Only publications in French or English were included. Clinical studies on nonfunctional surgical complications, such as sepsis or adhesive small bowel obstruction, were excluded. Data from patients with recurrence after rectal cancer surgery were also excluded as were anatomical studies and case reports. Data from duplicate studies were analysed without duplication.

Selection of studies

Two of the authors selected studies based on titles or abstracts. Studies that met the inclusion criteria were selected for review. If it was not clear from the abstract whether a study fulfilled the inclusion criteria, the full article was retrieved for further evaluation.

Data extraction and quality assessment of included material

The following data elements were extracted from each anatomic article including publication year, article type, sample size, anatomical subject type, dissection methodology, documentation and illustration modalities and anatomical results including nerve pathways. Additional data were extracted for patients having surgery for rectal cancer from articles on rectal surgery and genitourinary dysfunction, to include planes of rectal dissection, frequency of genitourinary dysfunction and the clinical functional consequences of nerve injury. Data were extracted by two investigators and validated by a third investigator.

Illustrations

The key anatomical zones at risk of pelvic nerve injury during rectal surgery were illustrated by computer-assisted anatomical dissection (CAAD) models. The CAAD reconstruction was obtained from digitized, immunostained histological sections of human male foetuses using Winsurf software [25,26].

Results

Study selection

A total of 189 studies were identified that fell within the scope of this review out of 224 and 41 found on computerized and manual analysis. Of these, 77 were eligible. These consisted of 9 that gave background information and 36 on anatomy. Twenty-one papers gave useful data on rectal surgical anatomy, and 11 studies were included for their clinical analysis of genitourinary complications after rectal surgery (Fig. 1).

Anatomy of the pelvic nerves (Figs. 2 and 3A)

Nerve pathways of the supralelevator compartment

Superior hypogastric plexus (SHP) and hypogastric nerves (HN) The SHP is a network of pre- and postganglionic fibres anterior to the body of L5 arising from T10-L3 and is a continuation of the preaortic sympathetic trunks [27]. It forms the origin of two HN that run over the sacral promontory situated 1 cm on either side of the midline and 2 cm medial to the ureter and iliac artery [28]. They vary in gross anatomy, sometimes consisting of fine filaments that spread out over a width of about 1 cm and

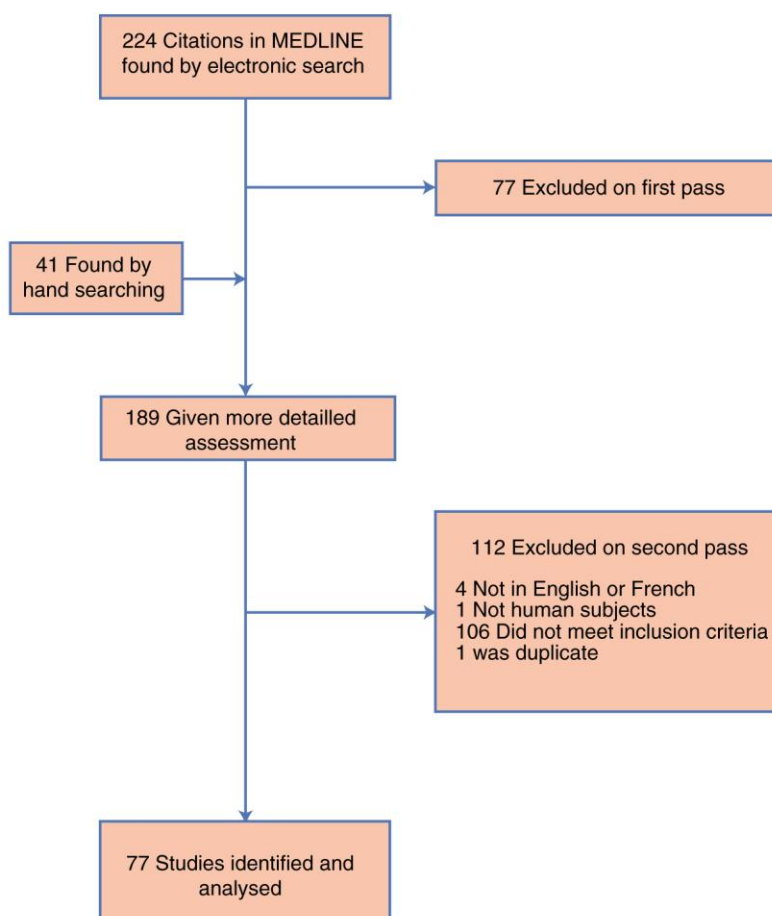


Figure 1 Search strategy and study selection (to May 2010).

sometimes being 5–8 mm wide [29,30]. They join the IHP on each side.

The HN were thought to be sympathetic nerves [31–33]. However, we have recently shown that the pelvic autonomic nervous system is more complex than previously thought, as adrenergic [labelled with anti-tyrosine-hydroxylase (TH) antibody] and cholinergic fibres [labelled with anti-vesicular acetylcholine transporter (VACHT) antibody] were found to coexist within ‘sympathetic’ and ‘parasympathetic’ nerves. In these studies, all fibres within the HN were positive for anti-tyrosine-hydroxylase, and some fibres were positive for anti-VACHT also [25]. SHP and HN damage causes ejaculatory dysfunction (retrograde ejaculation, loss of ejaculation) [34] and urinary urgency and incontinence [16,17,35].

Pelvic splanchnic nerves (PSN) or erectile nerves (Eckard)
The PSNs have been considered to be parasympathetic nerves and generally arise from the ventral roots of S3 to S4 in men [21] and S2 to S4 in women [36]. In some exceptional cases, branches may originate from S5 [37], but never from S1 [38]. These nerves enter the pelvis

through the sacral foramina, posterior to the parietal fascia that covers the piriformis muscle and crosses the retrorectal space, to enter the visceral compartment through the visceral fascia about 4 cm from the midline [28,39].

Small branches of the PSNs that run medially to enter the mesorectum have been identified. These contain the specific parasympathetic fibres of the rectum [40] and make up the medial segment of the IHP. They lie in the lateral ligament that joins the parietal fascia overlying the pelvic sidewall to the fascia propria medially [21]. Sato and Sato [41] showed that the superoanterior part of the ‘lateral ligaments’ contained the middle rectal artery and the inferoposterior part contained the PSNs. However, other authors do not consider the ‘lateral ligaments’ to exist and report that the middle rectal artery is a small, inconstant and frequently unilateral vessel [42].

We have recently demonstrated that the PSNs contain both ‘adrenergic’ and ‘cholinergic’ fibres [25]. These are responsible for detrusor contractility and vaginal lubrication and genital swelling during sexual arousal [43].

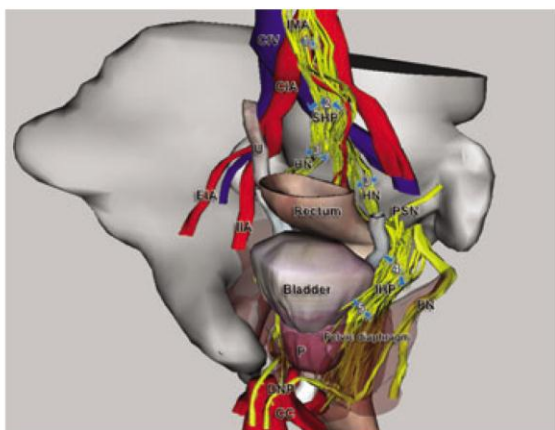


Figure 2 Anterolateral view of foetal pelvic tridimensional reconstruction using computer assisted dissection (CAAD) with immunolabelled pelvic nerves. Blue arrows show key zones at risk during total mesorectal excision (TME): (1) inferior mesenteric artery (IMA) ligation; (2) superior hypogastric plexus (SHP); (3) hypogastric nerves (HN); (4) inferior hypogastric plexus (IHP); and (5) its afferent terminal branches for genito-urinary organs. Other abbreviations: common iliac artery and vein (CIA, CIV), corpus cavernosum (CC), dorsal nerve of the penis (DNP), external and internal iliac arteries (EIA, IIA), pelvic splanchnic nerve (PSN), prostate (P), pudendal nerve (PN) and ureter (U).

Damage to these nerves causes erectile dysfunction and decreased blood flow to the vagina and vulva, which can reduce vaginal lubrication [28].

The inferior hypogastric plexus (IHP) The IHP is a network of sympathetic and parasympathetic fibres arising from HNs and PSNs nerves. It lies outside the fascia propria in the superficial layer of the parietal fascia. The

pararectal fascia and perirectal adipose tissue separate the lateral surfaces of the rectum from the IHP [44]. The IHP is a plaque of nerves measuring 3×4 cm and is located retroperitoneally and laterally on both sides of the rectum close to the prostate and seminal vesicle in men. In females, it radiates from an area anterolateral to the rectum, passes lateral to the cervix and the vaginal fornix and extends to the lateral vaginal wall and base of the bladder. The bulk of the plexus is localized at the level of the vaginal fornix. At this site, fibres and ganglia of the IHP are both sympathetic and parasympathetic. Adrenergic positivity is stronger in the anterior part of the plexus, whereas cholinergic positivity is stronger in its posterior third [25].

The efferent fibres of the IHP innervate the bladder, ureters, seminal vesicles, prostate, membranous urethra, corpora cavernosa, and uterus and vagina. One of these, the cavernous nerve, is mainly responsible for erectile function [23]. In men, this arises from two neurovascular bundles just anterior to the lateral borders of rectoprostatic Denonvilliers' fascia between the rectum and the prostate and seminal vesicles. The nerve penetrates the urogenital diaphragm parallel to the urethra [45]. The female anatomy of the cavernous nerves is poorly understood [46]. The neurovascular bundles are believed to be similar in women. The cavernous nerves originate along the lateral surface of the vagina and travel within the vesicovaginal septum to pass through the urogenital diaphragm [37].

Because the IHP consists of both sympathetic and parasympathetic efferent fibres, any damage to this plexus may cause severe disturbances in urogenital and sexual function including erection and ejaculation. Injury to the cavernous nerve results in erectile dysfunction [47].

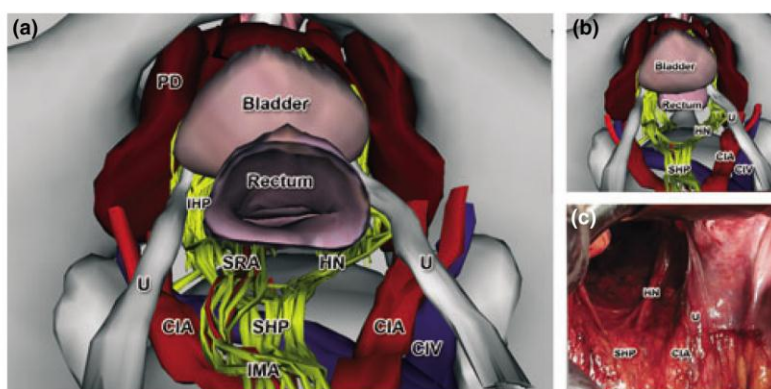


Figure 3 (a) Intra-abdominal view of foetal pelvic tridimensional reconstruction using CAAD with immunolabelled pelvic nerves. Same reconstructed view (b) and intra-operative view (c) after rectal resection during total mesorectal excision (TME). Nerves fibres destined to the rectum and accompanying the inferior mesenteric artery (IMA) and superior rectal artery (SRA) are resected during IMA ligation, but the superior hypogastric plexus (SHP) and hypogastric nerves (HN) must be preserved. Other abbreviations: common iliac artery and vein (CIA, CIV), inferior hypogastric plexus (IHP), pelvic diaphragm (PD) and ureter (U).

Levator ani nerve (LAN) The levator ani nerve, otherwise known as the perineal branch of S4, provides motor innervation to the levator ani muscles (iliococcygeal, pubococcygeal and puborectal), thereby contributing to urinary continence (hammock function) [48]. It originates from S3, S4 and/or S5 and crosses the superior surface of the pelvic floor underneath the lateral parietal fascia, running about 4 cm lateral to the midsagittal plane. At the level of the ischial spine, it runs 3.2 cm medial to the ischial spine according to Barber *et al.* [49]. According to Wallner *et al.* [50], it runs 4 cm lateral to the tip of the coccyx and 9 mm caudal to the ischial spine.

A weaker pelvic floor resulting in the loss of support of the urethra and bladder neck may contribute to the loss of sphincter tone and urinary incontinence [22,49–51].

Nerve pathways of the infralevator compartment

Pudendal nerve The pudendal nerve is a mixed nerve, containing both somatic (sensory and motor) and autonomic sympathetic fibres. It originates from the sacral plexus, frequently from roots S2 to S4 [52–54], sometimes L5 [37] and rarely from S1 to S5 [55]. These come through the anterior sacral foramina and unite to form the nerve trunk. This runs deep in the pudendal canal, deep in the pelvic floor musculature and passes through the ischio-anal fossa where it gives off three terminal branches: (i) the perineal nerve that supplies sensory innervation to the perineal skin and motor innervation to the ischiocavernosus, bulbocavernosus and superficial transverse perineal muscles and to the striated urethral rhabdosphincter; (ii) the inferior rectal nerve that provides motor innervation to the external anal sphincter and sensory innervation to the perianal skin; and (iii) the dorsal penis nerve or clitoris nerve that is also a mixed nerve that supplies the corpus cavernosus [32,47,56].

Damage to the pudendal nerve may cause urinary incontinence and sensory sexual impotence because of its role in orgasm [57]. Faecal incontinence after rectal cancer surgery has been linked to pudendal nerve injury, even when the anal sphincter is not damaged [55,58].

Key zones at risk of pelvic nerve injury during rectal surgery (Fig. 2)

Pelvic nerve damage may occur during ligation of the IMA, at certain points of TME and through the perineal dissection of APR.

Ligation of the inferior mesenteric artery

High ligation of the IMA at its origin from the aorta is intended to achieve complete removal of regional lymph

nodes [59]. There is a general agreement on how damage to the nerves should be avoided during this manoeuvre. The IMA is palpated between two fingers. The nerve plexus is identified as tight cords of nerve fibres that are palpable posterior to the IMA [21]. Division is then performed leaving a short arterial stump (1–2 cm) preserving the pre-aortic connective tissue containing the pre-aortic plexus, SHP and inferior mesenteric plexus [60].

The presacral space at the transition of the mesosigmoid to the mesorectum is then carefully dissected to displace progressively the HN dorsally. Damage to nerves during ligation of the IMA may cause failure of ejaculation [27].

Total mesorectal excision (TME) (Fig. 3)

The main goal of TME is to remove the rectum entirely within the envelope of the fascia propria [2,9,61,62], without breaking into the mesorectum. The cancer and regional lymphovascular drainage are removed in their entirety minimizing the risk of local recurrence [63,64]. In this technique, urogenital dysfunction should be avoided by pelvic autonomic nerve preservation (PANP) [65].

Posterior rectal dissection Sharp dissection is carried out in the avascular plane between the visceral (rectum and mesorectum) and the nervous structures (autonomic nerve plexuses) [65]. There is still some controversy, however, concerning the anatomical basis for this, especially concerning the course of the autonomic nerves. The avascular plane of loose areolar tissue corresponding to the retrorectal space lies between the parietal fascia posteriorly (presacral parietal fascia and prehypogastric nerve fascia) and the fascia propria anteriorly (visceral perirectal fascia), which invests the rectum [66,67]. Dividing the loose connective tissue opens the retrorectal space and allows mobilization of the rectum [21,29].

The correct plane of dissection should expose and preserve the SHP at the level of the sacral promontory. The HNs lie posterior to the peritoneum and directly anterior to the visceral fascia. To spare them, a change in the level of dissection, just medial to the nerve, has to be made from posterior to anterior to the fascia propria. The superior rectal artery lies immediately anterior to the fascia propria at the sacral promontory and can act as a landmark to find the plane [21,29].

The HNs can be damaged if the correct plane is not followed or if direct vision is compromised owing to bleeding [36] (Fig. 3C).

Lateral rectal dissection TME involves dissection of the lateral ligaments that run close the IHP [47,68]. There is

a considerable confusion concerning their nature. Jones *et al.* [42] consider them to be an artefact produced by surgical dissection. For some authors, the lateral ligaments join the parietal fascia to the fascia propria and contain the middle rectal or an accessory middle rectal artery [30,62]. Part of the IHP lies inside the lateral ligament and gives off branches to the rectum on each side about 2 cm below the peritoneal reflection.

Clausen *et al.* [47] consider the lateral ligament to be the only remaining connection between the lateral side of the pelvis and the mesorectum. Injury to the autonomic nerves is most likely when the ligament is dissected too close to the parietal pelvic fascia containing the IHP. Extensive manual traction during the operation may displace the IHP from the lateral pelvic wall rendering it more vulnerable [69]. There is no oncological need to dissect the 'lateral ligament' lateral to its insertion into the parietal pelvic fascia. This is because all lymphatics are located within the mesorectum with the primary regional lymphatic drainage arranged along the branches of the superior rectal artery [41].

During TME, the IHP is rarely seen except in very thin patients and at this level, sharp dissection without the need for clamping or ligation of any important anatomical structure is possible.

Anterior rectal dissection (Fig. 4) Denonvilliers' fascia is very important in rectal dissection. Heald [70] considers that it should be resected in TME surgery because it forms the anterior surface of the mesorectum. However, Lindsey *et al.* [69] suggest that the rectoprostatic fascia should be resected only for specific oncological indications, for example, in the presence of an anterior rectal tumour where the anterior circumferential margin might be threatened. The rectoprostatic fascia is formed during embryonic life by fusion of the two peritoneal leaves of the rectovesical pouch [71]. Richardson [72] identified a dense double layer of elastin posterior to the prostate and seminal vesicles and anterior to the thin anterior mesorectum and the fascia propria [69]. This layer is more closely opposed to the prostate than to the rectum. In women, the posterior layer of the rectovaginal septum is the fascia propria of the rectum, and the anterior layer is the true equivalent of the rectoprostatic fascia in men [73]. The postero-lateral neurovascular bundle [26] is at risk during deep dissection of the anterior extraperitoneal rectum away from the prostate and seminal vesicles.

There is no consensus concerning the anatomical plane of anterior dissection. Lindsey *et al.* [69] described three planes including (i) the close rectal plane that lies immediately on the rectal musculature inside the fascia propria, (ii) the mesorectal plane situated immediately

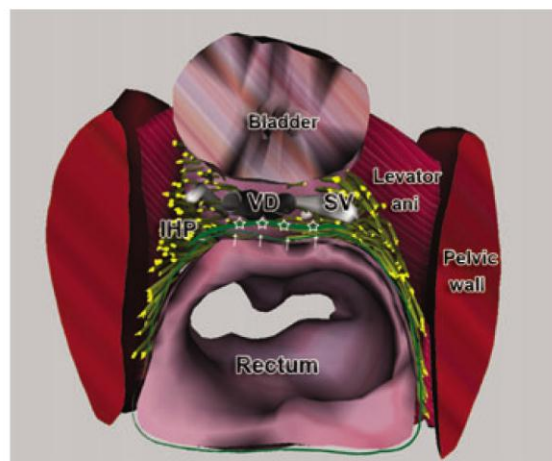


Figure 4 Superior infraperitoneal view of foetal intrapelvic organs using CAAD with immunolabelled pelvic nerves showing position of the inferior hypogastric plexus (IHP) on the lateral aspect of the rectum. Some of the terminal branches of the plexus directed to the seminal vesicles (SV), vas deferens (VD) and prostate are in close relationship with Denonvilliers' fascia. Better pelvic autonomic nerve preservation could be achieved by dissecting between the fascia propria of the rectum (arrows) and Denonvilliers' fascia.

outside the fascia propria; and (iii) the extramesorectal plane that allows resection of the rectoprostatic fascia but involves a high risk of damage to the autonomic nerves at this site.

In practice, therefore, the mesorectal plane within the fascia propria protects the pelvic nerves and is appropriate for posterior or posterolateral rectal tumours. The extramesorectal plane should be used when the anterior circumferential margin is threatened by the tumour. Distinguishing the different planes is not so easy during surgery, however, especially if there is bleeding, a fixed or very low tumour or a narrow pelvis. Care is also needed when performing the dissection with scissors and bipolar coagulation. The use of robot-assisted dissection may improve dissection in this area as it has carried out for radical prostatectomy [69,74].

Abdominoperineal resection (APR) (Fig. 5)

Major complications can occur after APR, which involves resection of the levator ani [75]. The extensiveness of pelvic dissection is directly related to the severity of subsequent bladder and genital dysfunction. These are more frequent and severe for APR than for sphincter-preserving procedures, including intersphincteric resection [19,20]. Enker *et al.* [12] reported preservation of sexual function in 57% of patients undergoing APR and in 85% of patients undergoing sphincter preservation. Permanent impotence has been reported by Santangelo

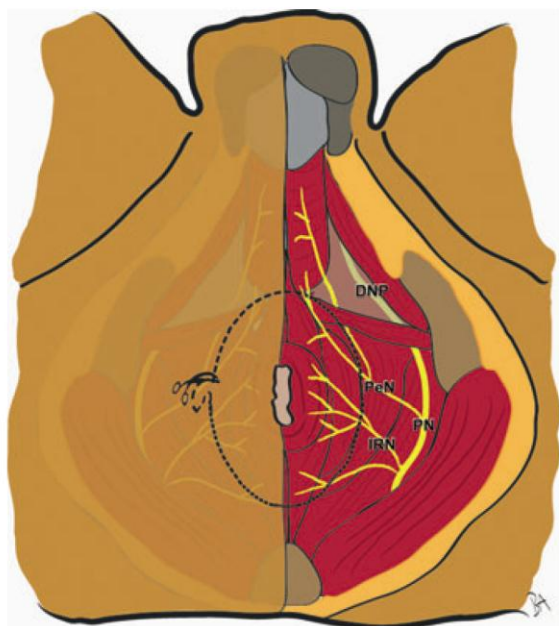


Figure 5 Perineal view of the pelvic diaphragm including its muscles and nerves. Pudendal nerve (PN) branches supplying the anterior perineum [perineal nerve (PeN)] are at risk during abdominoperineal resection (dotted line). Other terminal branches of PN are shown, including the dorsal nerve of the penis (DNP) and inferior rectal nerve (IRN).

et al. [76] in 44% and 25% of patients undergoing APR and low anterior resection.

There are several possible explanations for this difference. Inadvertent damage to the pelvic nerves during the perineal phase of dissection may occur, particularly at the level of the prostate [20]. At about 2 cm above the point where the rectum passes through the levator ani, the fascia propria of the rectum and the parietal pelvic fascia become inseparable and the levator ani nerve is close to the surgical dissection plane [22,50]. The dorsal nerve of the penis/clitoris is the terminal branch of the PN and may play an important role in erection and ejaculation through mediating bulbocavernosus muscle contraction [28,56]. These nerves should not be directly damaged during APR since they are not close to the zone of dissection. However, they may be damaged as a result of excessive traction or prolonged electrocoagulation in the anterolateral plane of dissection.

The primary aim of rectal cancer surgery is survival of the patient and to reduce the risk of local recurrence. The second aim is to maintain function by minimizing injury to the pelvic nerves. In most cases, bladder and sexual dysfunction can be avoided by identifying and preserving the nerves subserving them. Ligation of the IMA and dissection of the retrorectal space are usually uncomplicated manoeuvres and damage to the SHP and the HN

readily can be avoided. However, difficulties can arise during anterior and lateral dissection where the anatomical planes may not be clear. Here, the IHP can be damaged especially its efferent pathways. If the pelvis is narrow or the tumour is anterolateral and fixed, careful dissection using bipolar scissors may be preferable [77]. In the future, robot-assisted dissection might help to reduce the rate of nerve damage.

Acknowledgements

Grant support from the research association: Association Recherche Oncologique Digestive (A.R.O.L.D Boulogne).

References

- MacFarlane JK, Ryall RD, Heald RJ. Mesorectal excision for rectal cancer. *Lancet*, 1993; **341**: 457–60.
- Heald RJ, Ryall RD. Recurrence and survival after total mesorectal excision for rectal cancer. *Lancet*, 1986; **1**: 1479–82.
- Carlsen E, Schlichting E, Guldvog I, Johnson E, Heald RJ. Effect of the introduction of total mesorectal excision for the treatment of rectal cancer. *Br J Surg*, 1998; **85**: 526–9.
- Maeda K, Maruta M, Utsumi T, Hosoda Y, Horibe Y. Does perifascial rectal excision (i.e. TME) when combined with the autonomic nerve-sparing technique interfere with operative radicality? *Colorectal Dis*, 2002; **4**: 233–9.
- Hida J, Yasutomi M, Maruyama T *et al.* High ligation of the inferior mesenteric artery with hypogastric nerve preservation in rectal cancer surgery. *Surg Today*, 1999; **29**: 482–3.
- Pandey D. Survival benefit of high ligation of the inferior mesenteric artery in sigmoid colon or rectal cancer surgery (Br J Surg 2006; 93: 609–615). *Br J Surg*, 2006; **93**: 1023. author reply 1023.
- Kanemitsu Y, Hirai T, Komori K, Kato T. Survival benefit of high ligation of the inferior mesenteric artery in sigmoid colon or rectal cancer surgery. *Br J Surg*, 2006; **93**: 609–15.
- Merchant NB, Guillem JG, Paty PB, Enker WE. T3N0 rectal cancer: results following sharp mesorectal excision and no adjuvant therapy. *J Gastrointest Surg*, 1999; **3**: 642–7.
- Lindmark G, Gerdin B, Pahlman L, Bergström R, Glimelius B. Prognostic predictors in colorectal cancer. *Dis Colon Rectum*, 1994; **37**: 1219–27.
- Law WL, Chu KW. Anterior resection for rectal cancer with mesorectal excision: a prospective evaluation of 622 patients. *Ann Surg*, 2004; **240**: 260–8.
- Tilney HS, Tekkis PP. Extending the horizons of restorative rectal surgery: intersphincteric resection for low rectal cancer. *Colorectal Dis*, 2008; **10**: 3–15. discussion 15–6.
- Enker WE, Havenga K, Polyak T, Thaler H, Cranor M. Abdominoperineal resection via total mesorectal excision and autonomic nerve preservation for low rectal cancer. *World J Surg*, 1997; **21**: 715–20.
- Corman ML. Classic articles in colonic and rectal surgery. A method of performing abdominoperineal excision for carci-

- noma of the rectum and of the terminal portion of the pelvic colon: by W. Ernest Miles, 1869–1947. *Dis Colon Rectum*, 1980; **23**: 202–5.
- 14 Rullier A, Laurent C. Recommendations for clinical practice. Therapeutic choices for rectal cancer. What quality criteria are important for surgical excision of rectal cancer?. *Gastroenterol Clin Biol*, 2007; **31** (Spec No 1): 1S34–51, 1S91–5.
 - 15 Rouanet P. Preoperative treatment impact for ultralow rectal carcinoma sphincter preservation. *Cancer Radiother*, 2006; **10**: 451–5.
 - 16 Maas CP, Moriya Y, Steup WH, Kiebert GM, Kranenbarg WM, van de Velde CJ. Radical and nerve-preserving surgery for rectal cancer in The Netherlands: a prospective study on morbidity and functional outcome. *Br J Surg*, 1998; **85**: 92–7.
 - 17 Kim NK, Aahn TW, Park JK *et al*. Assessment of sexual and voiding function after total mesorectal excision with pelvic autonomic nerve preservation in males with rectal cancer. *Dis Colon Rectum*, 2002; **45**: 1178–85.
 - 18 da Silva GM, Hull T, Roberts PL *et al*. The effect of colorectal surgery in female sexual function, body image, self-esteem and general health: a prospective study. *Ann Surg*, 2008; **248**: 266–72.
 - 19 Hojo K, Vernava AM III, Sugihara K, Katumata K. Preservation of urine voiding and sexual function after rectal cancer surgery. *Dis Colon Rectum*, 1991; **34**: 532–9.
 - 20 Havenga K, Enker WE, McDermott K, Cohen AM, Minsky BD, Guillem J. Male and female sexual and urinary function after total mesorectal excision with autonomic nerve preservation for carcinoma of the rectum. *J Am Coll Surg*, 1996; **182**: 495–502.
 - 21 Bissett IP, Hill GL. Extrafascial excision of the rectum for cancer: a technique for the avoidance of the complications of rectal mobilization. *Semin Surg Oncol*, 2000; **18**: 207–15.
 - 22 Lange MM, Maas CP, Marijnen CA *et al*. Urinary dysfunction after rectal cancer treatment is mainly caused by surgery. *Br J Surg*, 2008; **95**: 1020–8.
 - 23 Walsh PC, Schlegel PN. Radical pelvic surgery with preservation of sexual function. *Ann Surg*, 1988; **208**: 391–400.
 - 24 Marks SC Jr. The role of three-dimensional information in health care and medical education: the implications for anatomy and dissection. *Clin Anat*, 2000; **13**: 448–52.
 - 25 Alsaid B, Bessede T, Karam I *et al*. Coexistence of adrenergic and cholinergic nerves in the inferior hypogastric plexus: anatomical and immunohistochemical study with 3D reconstruction in human male fetus. *J Anat*, 2009; **214**: 645–54.
 - 26 Alsaid B, Karam I, Bessede T *et al*. Tridimensional computer-assisted anatomic dissection of posterolateral prostatic neurovascular bundles. *Eur Urol*, 2010; **58**: 281–287.
 - 27 Lu S, Xu YQ, Chang S, Zhang YZ. Clinical anatomy study of autonomic nerve with respective to the anterior approach lumbar surgery. *Surg Radiol Anat*, 2009; **31**: 425–30.
 - 28 Daniels IR, Woodward S, Taylor FG, Raja A, Toomey P. Female urogenital dysfunction following total mesorectal excision for rectal cancer. *World J Surg Oncol*, 2006; **4**: 6.
 - 29 Bissett IP, Chau KY, Hill GL. Extrafascial excision of the rectum: surgical anatomy of the fascia propria. *Dis Colon Rectum*, 2000; **43**: 903–10.
 - 30 Rutegård J, Sandzén B, Stenling R, Wiig J, Heald RJ. Lateral rectal ligaments contain important nerves. *Br J Surg*, 1997; **84**: 1544–5.
 - 31 Benoit G, Delmas V, Gillot C, Jardin A. The anatomy of erection. *Surg Radiol Anat*, 1987; **9**: 263–72.
 - 32 Benoit G, Droupy S, Quillard J, Paradis V, Giuliano F. Supra and infralevator neurovascular pathways to the penile corpora cavernosa. *J Anat*, 1999; **195**: 605–15.
 - 33 de Groat WC. Anatomy and physiology of the lower urinary tract. *Urol Clin North Am*, 1993; **20**: 383–401.
 - 34 Havenga K, Maas CP, DeRuiter MC, Welvaart K, Trimbos JB. Avoiding long-term disturbance to bladder and sexual function in pelvic surgery, particularly with rectal cancer. *Semin Surg Oncol*, 2000; **18**: 235–43.
 - 35 Akasu T, Sugihara K, Moriya Y. Male urinary and sexual functions after mesorectal excision alone or in combination with extended lateral pelvic lymph node dissection for rectal cancer. *Ann Surg Oncol*, 2009; **16**: 2779–86.
 - 36 Havenga K, DeRuiter MC, Enker WE, Welvaart K. Anatomical basis of autonomic nerve-preserving total mesorectal excision for rectal cancer. *Br J Surg*, 1996; **83**: 384–8.
 - 37 Baader B, Herrmann M. Topography of the pelvic autonomic nervous system and its potential impact on surgical intervention in the pelvis. *Clin Anat*, 2003; **16**: 119–30.
 - 38 Mauroy B, Demondion X, Bizet B, Claret A, Mestdagh P, Hurt C. The female inferior hypogastric (= pelvic) plexus: anatomical and radiological description of the plexus and its afferences – applications to pelvic surgery. *Surg Radiol Anat*, 2007; **29**: 55–66.
 - 39 Mundy AR. An anatomical explanation for bladder dysfunction following rectal and uterine surgery. *Br J Urol*, 1982; **54**: 501–4.
 - 40 Yucel S, Erdogru T, Baykara M. Recent neuroanatomical studies on the neurovascular bundle of the prostate and cavernosal nerves: clinical reflections on radical prostatectomy. *Asian J Androl*, 2005; **7**: 339–49.
 - 41 Sato K, Sato T. The vascular and neuronal composition of the lateral ligament of the rectum and the rectosacral fascia. *Surg Radiol Anat*, 1991; **13**: 17–22.
 - 42 Jones OM, Smeulders N, Wiseman O, Miller R. Lateral ligaments of the rectum: an anatomical study. *Br J Surg*, 1999; **86**: 487–9.
 - 43 Trimbos JB, Maas CP, Deruiter MC, Peters AA, Kenter GG. A nerve-sparing radical hysterectomy: guidelines and feasibility in Western patients. *Int J Gynecol Cancer*, 2001; **11**: 180–6.
 - 44 Spackman R, Wrigley B, Roberts A, Quinn M. The inferior hypogastric plexus: a different view. *J Obstet Gynaecol*, 2007; **27**: 130–3.
 - 45 Lepor H, Gregerman M, Crosby R, Mostofi FK, Walsh PC. Precise localization of the autonomic nerves from the pelvic plexus to the corpora cavernosa: a detailed anatomical study of the adult male pelvis. *J Urol*, 1985; **133**: 207–12.
 - 46 Lindsey I, Mortensen NJ. Iatrogenic impotence and rectal dissection. *Br J Surg*, 2002; **89**: 1493–4.
 - 47 Clausen N, Wolloscheck T, Konerding MA. How to optimize autonomic nerve preservation in total mesorectal

Article 2 : Etude de l'innervation autonome du pelvis de la femme par dissections macroscopique et assistée par ordinateur [66].

Moszkowicz D, Alsaid B, Bessede T, Penna C, Benoit G, Peschaud F. Female pelvicautonomic neuroanatomy based on conventional macroscopic and computer-assisted anatomicdissections. *Surgical and Radiologic Anatomy*. 2011 Jul; 33(5):397-404.

IF 2011 : **1,056**

Résumé

Objectifs : confronter la dissection macroscopique des nerfs, la coloration histochimique, l'immunomarquage nerveux et la dissection anatomique assistée par ordinateur (DAAO) pour identifier l'origine, le trajet, les rapports viscéraux et la terminaison des fibres nerveuses autonomes intra-pelviennes et en élaborer une représentation tridimensionnelle.

Matériel et méthodes: des coupes transverses du pelvis de cinq fœtus humains de sexe féminin (18-31 semaines de gestation), obtenus après autorisation d'autopsie scientifique par l'agence de la Biomédecine et consentement écrit des parents, ont été étudiées par technique histologique (colorations hématoxyline-éosine et trichrome de Masson) et immunohistochimique (anticorps anti-protéine S100), numérisées puis reconstruites manuellement en trois dimensions à l'aide du logiciel Surf driver pour Windows[®] (Winsurf 4.3[®]). Trois sujets féminins adultes ont été étudiés par dissection macroscopique des afférences et des efférences du plexus hypogastrique inférieur (PHI).

Résultats: cette étude multimodale incluant la dissection anatomique assistée par ordinateur (DAAO) a permis d'identifier la localisation et la distribution des nerfs pelviens et leurs rapports avec les viscères. Les nerfs hypogastriques (NH) étaient en rapport avec le système des fascias pelviens et rejoignaient le plexus hypogastrique inférieur (PHI) homolatéral en regard du bord latéral du cul-de-sac recto-vaginal. Le croisement de l'uretère avec la face postérieure de l'artère utérine permettaient de situer la jonction entre NH et PHI. Les branches efférentes antéro-inférieures du PHI se regroupaient en bandelette à la face postéro-latérale du vagin avant d'innover les organes de la continence urinaire et les corps érectiles du périnée.

Conclusions: la DAAO est une technique utile à la recherche et à l'enseignement de l'anatomie. Elle permet, en complément des méthodes de dissection classiques, de fournir les bases anatomiques et physiologiques utiles à la compréhension des dysfonctions sexuelles et urinaires post-opératoires et au développement des techniques chirurgicales de préservation nerveuse.

Female pelvic autonomic neuroanatomy based on conventional macroscopic and computer-assisted anatomic dissections

David Moszkowicz · Bayan Alsaid ·
Thomas Bessede · Christophe Penna ·
G rard Benoit · Fr d rique Peschaud

Received: 14 October 2010 / Accepted: 23 December 2010 / Published online: 12 January 2011
  Springer-Verlag 2011

Abstract

Purpose To confront nerve dissection, tissue staining, nerve immunolabelling and Computer-Assisted Anatomic Dissection (CAAD) in identifying the precise location and origin of intrapelvic autonomic nerve fibers and to provide a three-dimensional (3D) representation of their relationship to other anatomical structures.

Methods Serial transverse sections of the pelvic portion of five human female fetuses (18–31 weeks of gestation) were studied histologically (with hematoxylin/eosin and Masson trichrome) and immunohistochemically (anti-protein S100 antibody) digitized and reconstructed three-dimensionally with Surf driver software for Windows (Winsurf 4.3). Three fresh female adult cadavers were macroscopically dissected to individualize the inferior hypogastric plexus afferences and efferences and their anatomical relationships.

Results This combined investigation including the CAAD technique allowed identifying the precise location and

distribution of the pelvic nerve elements and their relationships to female pelvic organs. Hypogastric nerves (HN) were located in the retrorectal multilaminar structure and joined the homolateral inferior hypogastric plexus (IHP) at the lateral border of the recto-uterine pouch. The intersection of the ureter with the posterior wall of the uterine artery precisely located the junction of HN and IHP. Antero-inferior branches supplying female sexual and continence organs originated from the antero-inferior angle of IHP and were bundled at the posterolateral vaginal wall.

Conclusions CAAD is an encouraging anatomical method for the development of anatomical and surgical research and teaching. Complementary to traditional anatomical studies, it may provide useful anatomical data for the comprehension of postoperative sexual and urinary dysfunction and the development of nerve-sparing surgical techniques.

Keywords Anatomy · Computer-assisted anatomic dissection · Hypogastric nerve · Inferior hypogastric plexus · Nerve-sparing surgery · Three-dimensional reconstruction

D. Moszkowicz · B. Alsaid · T. Bessede · G. Benoit ·
F. Peschaud
Laboratory of Experimental Surgery, EA 4122,
Faculty of Medicine, Bic tre-Paris 11 University,
Le Kremlin-Bic tre, France

D. Moszkowicz · C. Penna · F. Peschaud
Department of Surgery, Assistance-Publique-H pitaux de Paris,
Ambroise Par  Hospital, Boulogne, France

C. Penna · F. Peschaud
University PIFO UVSQ, Guyancourt, France

F. Peschaud ( )
Service de Chirurgie Digestive, H pital Ambroise Par ,
9 Avenue Charles de Gaulle, 92100 Boulogne, France
e-mail: frederique.peschaud@apr.aphp.fr

Introduction

Integrity of the pelvic-perineal innervation is a crucial element to guarantee a normal micturition-continence cycle and a satisfying sexual function. However, this integrity can be disturbed during pelvic surgery, due to the close location of the nervous and visceral structures [8, 22]. For the surgeon, a better understanding of the pelvic-perineal neuroanatomy is essential to develop nerve preservation techniques in order to attain better functional outcomes [13]. Classic anatomical studies based on nerve dissection and documented with photography and hand drawings have

provided details of the pelvic nerve morphology, nature and location [20]. However, dissection of these autonomic nerves is technically complex due to their position, the lamellate arrangement of the inferior hypogastric plexus (IHP) nerve fibers and ganglia, the diversity of its roots and the complex distribution of its terminal projections. The density of the perivisceral connective tissue which needs to be removed during dissection also compromises conservation of the pelvic-perineal architecture. Furthermore, it is thorny to determine the exact relationship between nerves and the pelvic connective tissue. Investigators have favored fetal to adult tissue when studying topographical details of the pelvic nerves due to the nerves bulky nature and the less well-developed pelvic connective and adipose tissue in the fetus [4, 12, 16]. Although meticulous dissection and histological studies provide important knowledge, an investigative approach including immunohistochemically stained serial histological sections and 3-dimensional (3D) imaging may add new information to our understanding of the female pelvic autonomic neuroanatomy [2]. The aim of this study was to provide an immunohistochemistry based 3D-reconstruction of the female pelvic autonomic innervation using the Computer-Assisted Anatomic Dissection (CAAD) technique and to confront obtained data with fresh adult cadaver macroscopic dissection.

Methods

Fetal material

The present work conformed to the provisions of the Declaration of Helsinki in 1995 (as revised in Edinburgh 2000); it included a specific protocol that required examination and approval by the French Biomedicine Agency. The fetal preparations were obtained from miscarriages or legal abortions and were authorized for scientific use by the parents. The fetuses were devoid of maceration or macroscopic abnormalities as could be determined by the pathologists on macroscopic examination. There was no history of prior pathology in the region under examination.

We have studied 5 female fetuses, with a crown-rump length “CRL” (from the highest point of the head to the rump) from 140 to 310 mm and between 18 and 31 weeks of gestation. The gestational age of each fetus was determined from the CRL, the fetal heel-to-toe length, corrected by the first-trimester ultra-sound CRL measurement and confirmed at autopsy by the estimation of organ maturation [14].

Macroscopic dissection

The pelvic organs and surrounding pelvic bones were removed as a single unit and fixed in 10 percent

paraformaldehyde (pH 7.4) for 48 h for further processing. After fixation, stepwise transversal cross-sections were made at 4-mm intervals. Tissue slicing was proceeded on the whole anatomic piece; the slices were placed in baskets, processed and embedded in cardboard moulds filled with paraffin. Series of 5 μm -tick sections were then prepared every 50–200 μm . Alterations in the visceral topographical relationships due to stretching of the thin paraffin sections were prevented by floating the slices in warm before whole-mounting them on Super frost glass slides. Finally, slices were dried at 37°C overnight. In total, 50–150 sections were obtained for each fetus, depending on the age and size of each specimen.

Histological examination

The pelvic autonomic nerves were investigated by conventional histological staining methods (hematoxylin/eosin, Masson trichrome) and immunohistochemical staining of neural structures. All the immunohistochemical detections and colorations were performed manually by the authors.

Stainings and antibody

Hematein-eosin-phloxine and Masson’s trichrome stain

The first transverse section from each level was stained with HE or Masson’s trichrome. Masson’s trichrome stain was intended for the distinguishing of connective tissue, muscles and collagen fibers (collagen fibers are colored in dark blue, cytoplasm in red-pink and nucleuses in black). For HE, we used Harris hematoxylin (réf. HHS32-1L, Sigma-Aldrich, USA) and eosin-phloxin solution (ref. HTT110332-1L, Sigma-Aldrich, USA). For Masson’s trichrome (ref. HT15-1KT, Sigma-Aldrich, USA), we used Weigert hematoxylin (réf. HT1079-1SET, Sigma-Aldrich, USA).

Neuronal immuno-labeling (rabbit anti-cow protein S100, PS100)

PS100 is expressed in neuroectodermal tissues, including Schwann cells of nerves and melanocytes. PS100 is a general immuno-labelling marker for all nerves which specifically identifies the nucleus and cytoplasm of Schwann cells in formalin-fixed paraffin-embedded nerve tissue [1, 15].

Immunohistochemical protocol

Removal of paraffin and rehydration

The slides were placed in a 56°C oven for 15 min, washed twice in xylene for 10 min each, rehydrated in graded

ethanol series (three successive ethanol baths of 100, 90 and 80%, respectively), for 5 min each, rinsed gently in running tap water for 3 min and placed for additional rehydration in phosphate-buffered saline (PBS: 7.65 g NaCl + 0.724 g NaH₂PO₄ + 0.210 g Na₂HPO₄ in 1,000 ml of distilled water) for 30 min at room temperature.

Endogenous peroxidase inactivation

After two successive washes in PBS (5 min each), slides were placed on a flat surface and drops of 3% hydrogen peroxide were added to cover the whole section for 10 min at room temperature. The slides were then rinsed two times for 5 min each in PBS.

Primary antibody incubation

Histological sections were pre-incubated in a blocking solution containing 1% Triton X-100 (4-(1, 1, 3, 3-Tetra-methylbutyl) phenyl-polyethylene glycol, t-Octylphenoxy-polyethoxyethanol, Polyethylene glycol tetra-octylphenyl ether, ref. 9002-93-1, Sigma–Aldrich, USA) and 3% normal goat serum (ref. 16210-004, GeneTex, USA) in PBS for 30 min. The slides were incubated without rinsing in a humidified chamber with 100 µl of the diluted primary antibody anti-protein S100 (ref. Z0311, Dako, DK) at room temperature, during 45 min, at 1/400 dilution.

Secondary antibody incubation

After two successive washes in PBS (5 min each), the slides were incubated with biotinylated goat anti-rabbit secondary antibody (ref. Z0311, DakoCytomation, Denmark), diluted 1/200, for 90 min at room temperature, and then washed two times (5 min each) in PBS. The avidin biotin peroxidase procedure was performed using a Vector ABC Elite kit (antirabbit IgG biotinylated secondary antibodies followed by the avidin–biotin complex, according to the manufacturer's instructions; ref. PK6100, Vector Laboratories, Burlingame, CA, USA), prepared 45 min before use. The slides were incubated for 60 min and then rinsed two times in PBS (5 min each).

Detection

Chromogenic detection was performed with the DAB detection kit. 3, 3'-diaminobenzidine tetrahydrochloride (DAB, ref. SK-4100, Vector Laboratories, Burlingame, California, USA) with 0.0015–0.003% H₂O₂ in 0.01 M PBS was then added to reveal the ABC and the time of the DAB incubation was controlled microscopically (between 3 and 5 min). The reaction product appeared as a dark-brown stain. The slides were rinsed with distilled water,

counterstained in Mayer's hematoxylin solution (ref. MHS32-1L, Sigma–Aldrich, USA) for 2 min, rinsed in running tap water for 5 min, air dried at room temperature and covered using glycerol gelatin aqueous mounting medium (ref. HX755693, Merck, All).

Controls

To confirm the specificity of the reagents, negative control slides were prepared for each subject. The same steps were followed but immunohistochemical analyses were controlled with non immune serum (diluted primary antibody was replaced by diluents). Positive control slides were prepared with male sacral plexus branches.

Three-dimensional reconstruction

Serial 2D sections, stained and immunolabelled for nerve fibers were used to perform 3D reconstructions. Analysis of sections stained with HE or Masson's trichrome under appropriately high magnifications ($\times 4$ to $\times 20$) allowed us to distinguish the various anatomical structures (organs, bones, fascia, nerve and vascular elements). Subsequent section, treated with anti-S100, allowed us to specifically identify pelvic nerves. Sections were almost at the same level; the interval between the sections was negligible (5 µm). The computer system comprised: a personal laptop (Windows 7), Epson perfection V750 digitalization system, SilverFast AI digitalized software, Adobe Photoshop image processing software and Surfdriver software for Windows (WinSurf image reconstruction software, version 4.3). All the sections were digitized with direct scanning at 4,800 dots inch⁻¹ resolution, and then the images were stacked and aligned. Brightness and contrast of histological tissue images were adjusted in Adobe Photoshop 7. The pelvic anatomical structures and the nerve fibers were manually outlined in all histological sections; a 3D analysis of the location, course and distribution of the nerve fibers was performed in the *x*- and *y*-axes as an animated motion picture.

Adult cadaver dissection

We performed dissection of three fresh female adult cadavers, none of which showed any stigmata of subumbilical surgery or undergone any pelvic or abdominal surgery. The subjects had an average age of 85 (77–89). We performed an umbilical-pubic laparotomy with lateral extension. We could then individualize the inferior hypogastric plexus (IHP) afferences and efferences and their relationships to the ureter and uterine artery. We used the cleavage plane between the genital organs and the lateral wall of the pelvis to reach the pelvic floor. It allowed us to

pull forward and downward the genital organs in order to facilitate the dissection of the efferences of the IHP on the lateral surface of the vagina. Dissections were documented with photography.

Results

Afferences of the inferior hypogastric plexus

Nerve fibers of superior hypogastric plexus (SHP), mostly in an inter-iliac position, accompanied the inferior mesenteric and superior rectal arteries between the posterior aspect of the sigmoid and the anterior surface of lowest lumbar vertebra. Sympathetic trunks (ST) were located between iliac vessels and anterior face of lumbar and sacral vertebrae. The majority of SHP fibers divided into two groups of trunks of different size, the left and right hypogastric nerves (HN). HN travelled postero-laterally to the posterior rectal wall behind the ureters and medially to the posterior division branches of internal iliac arteries (Figs. 1, 2). Some fibers split from HN and were destined to postero-lateral rectal wall, bladder wall and ureterovesical junction. Most fibers of HN then accompanied the ureter on its dorsal side. When the ureter was about to

join the wall of the bladder, the HN came to lie at the ventral edge of the lateral rectal wall and this initiated the formation of the IHP. The intersection of the ureter with the posterior wall of the uterine artery precisely located the junction of HN and IHP at its superior angle (Fig. 3). Histological examination with Masson's trichrome demonstrated a fascial retrorectal multilaminar structure (Fig. 2). HNs were bordered anteriorly by a prehypogastric fascia (PHF) between the nerve trunk and the fascia propria of the rectum, and by the parietal presacral fascia posteriorly. Pelvic splanchnic nerves (PSN) identified here originated from the second and third sacral roots and joined IHP at its posterior edge (Fig. 4).

IHP or pelvic plexus

The superior and posterior angle made up the origin of the IHP following on from the homolateral HN. The IHP was a quadrangular shaped plaque of nervous tissue with two aspects (visceral and parietal), four edges (superior 'cranial', anterior 'ventral', posterior 'dorsal' and inferior 'caudal') and four angles (superior, antero-inferior, antero-superior and postero-inferior). IHP dorsal edge was at the point of contact with the sacral roots and receives afferences from it, contained in the uterosacral ligaments. IHP

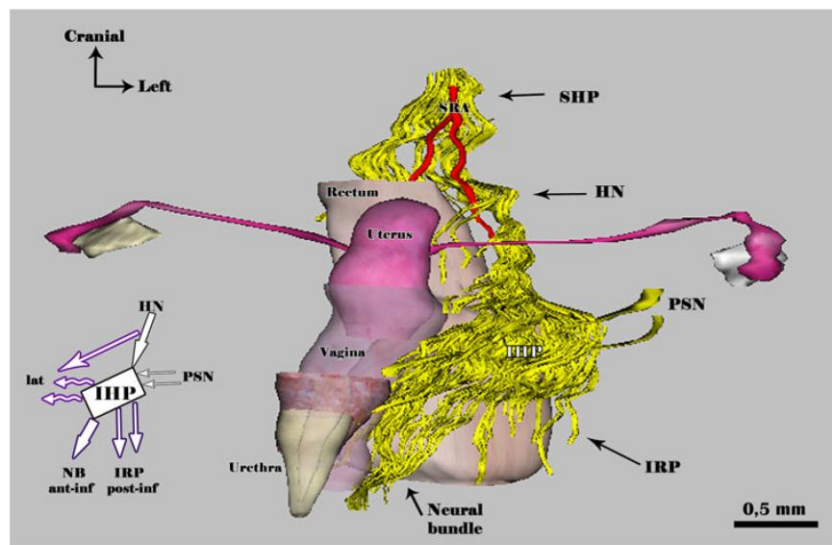


Fig. 1 Computer assisted 3-D reconstruction of a 18-week-old female fetal pelvis, antero-lateral view of the pelvic organs and autonomic nerves with bladder division at the neck level and rectal division at the high rectum level. Nerve fibers are immunolabelled with anti-PS100 antibody (in yellow). Schematic representation of the IHP afferences, efferent projections and relationships is presented on the left side. The hypogastric nerves (HN) originate from the superior hypogastric plexus (SHP) at the posterior rectal wall and join inferior

the hypogastric plexus (IHP) at the lateral rectal wall. Pelvic splanchnic nerves (PSN) join the IHP at its posterior border. Lateral projections coming from the IHP and HN (*lat*) are destined to uterus, vagina, bladder, ureters and rectum anterior wall. Terminal antero-inferior efferences of the IHP join the perineum forming a neural bundle (NB, ant-inf) for the erectile bodies and the urethral sphincter. SRA superior rectal artery, IRP inferior rectal plexus (postero-inferior projection, post-inf)

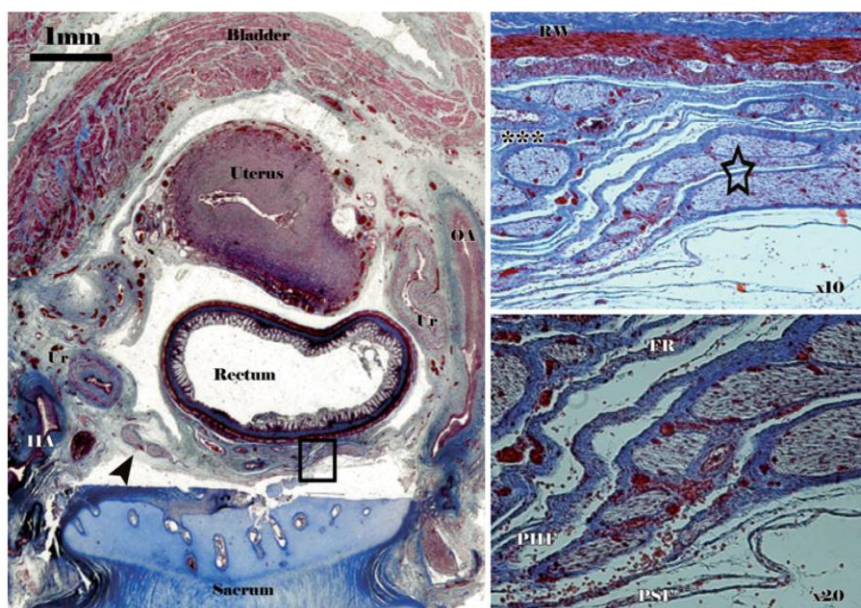


Fig. 2 Transverse section (5 μm thickness) of a 27-week-old female fetus (S2 level) stained with Masson trichrome and scanned at optical resolution of 4,800 dpi. On the left side hand, arrowhead shows left hypogastric nerve (HN) at the posteromedial aspect of the ureter (Ur) and medial side of internal iliac artery (IIA). Black square corresponds to microscopic pictures on the right side hand. HN

(star) is covered with prehypogastric nerve fascia (PHF) and separated from the sacrum anterior aspect by the presacral fascia (PSF). The rectal visceral fascia (FR) surrounds the neural and vascular content of the mesorectum (asterisks). OA ombilical artery, RW rectal wall

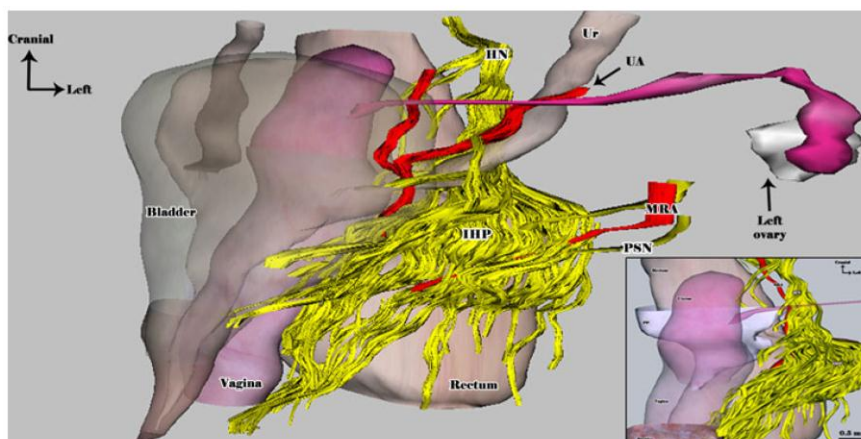


Fig. 3 Computer assisted 3-D reconstruction of a 18-week-old female fetal pelvis, antero-lateral view with bladder transparency and rectal division at the high rectum level. The middle rectal artery (MRA) runs through the IHP before joining the rectal wall. Some fibers leave the hypogastric nerves (HN), pass around the ureter and penetrate the bladder wall at the uterovesical junction. Others join

the posterolateral rectal wall. The intersection of the ureter (Ur) with the posterior wall of the uterine artery (UA) precisely locates the junction of the HN and the IHP. Box shows the HN joining the homolateral IHP at the lateral border of the recto-uterine pouch between the rectum and the vagina

was located on the pelvic side wall, which stretched from the lateral surface of the rectum of the rectum, passed the cervix and the vaginal fornix laterally, and extended to the lateral vaginal wall and the base of the bladder. The bulk of

the IHP was localized at the level of the vaginal fornix. In anteroposterior direction the plexus covered the latero-ventral part of the rectum, the lateral border of the recto-uterine pouch and the lateral edge of the uterus and the

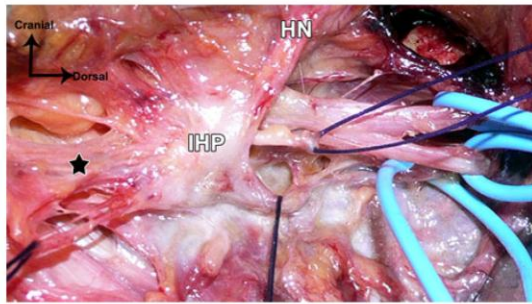


Fig. 4 Pelvic dissection of a 77-year-old female cadaver. The inferior hypogastric plexus (IHP) efferences (*black star*) and afferences are shown. Sacral roots (under *blue loops*) give the pelvic splanchnic nerves (under *black sutures*) which reach the IHP posterior wall. The hypogastric nerve (HN) reaches the IHP superior angle

vagina. It formed a circumferential neural network outside of the visceral walls and lied exactly between the fibrous connective tissue of the rectal adventitia and vaginal serosa medially and pelvic parietal connective tissue laterally (Fig. 5). The cranial portion of the IHP was situated directly beneath the lateral margin of the recto-uterine pouch, where the HN joined the IHP (Figs. 3, 6). The distal IHP efferences accompanied the vagina downwards to the pelvic diaphragm. The middle rectal artery (MRA) was found to run through the IHP before reaching the rectal wall.

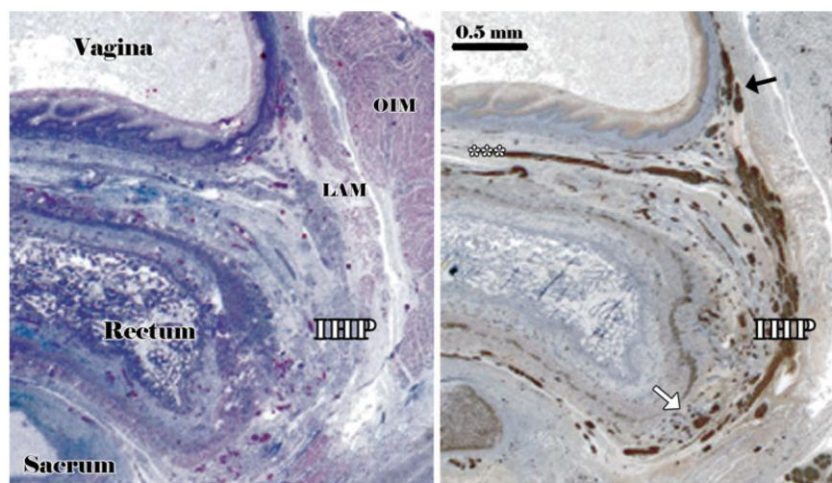


Fig. 5 Serial transverse sections (5 μm thicknesses) of a 20-week-old female fetus (S3 level) scanned at optical resolution of 4800 dpi. The inferior hypogastric plexus (IHP), forming a circumferential network close to the rectal wall, is stained with HE with weak contrast (left figure, **a**) but is well distinguished with anti-PS100 immunolabelling (right figure, **b**). *Asterisks* show the transversal vagino-rectal branches

Efferences from the IHP

The superior part of the rectum received fibers from HN and from the posterior part of IHP. From the anterior part of the IHP, groups of fibers course were responsible for the innervations of the urinary bladder. Branches followed the course of the uterine artery to the cervix. Postero-inferior branches rising from the inferior edge of the IHP form the inferior rectal plexus (IRP) that gave branches to postero-lateral rectal wall and smooth anal sphincter. IHP antero-inferior part converged in a caudal direction and reached down to the pelvic floor. The more the levator ani muscle approached the rectum, the more the distal plexus was pushed into a small triangularly-shaped space bordered by the levator ani muscle laterally, the rectum dorsally and the vagina ventrally. These antero-inferior fibers formed a neural bundle and descended along the vagina at the 4 and 8 o'clock positions (Figs. 1, 6). This bundle then gave two major perineal projections: an anterior projection for the urethral sphincter complex and an inferior projection destined to the perineal erectile bodies.

Discussion

After 8 weeks of gestation (Carnegie stage 23), intrapelvic innervation is mature, stable and comparable with that of the adult. This anatomic layout does not undergo fundamental changes during growth in fetal and post fetal

and *white arrow* shows the postero-inferior projection of the IHP forming the inferior rectal plexus. *Black arrow* shows the antero-inferior projections located at the postero-lateral then lateral vaginal wall and coursing to the perineum. LAM levator ani muscle, OIM obturator intern muscle

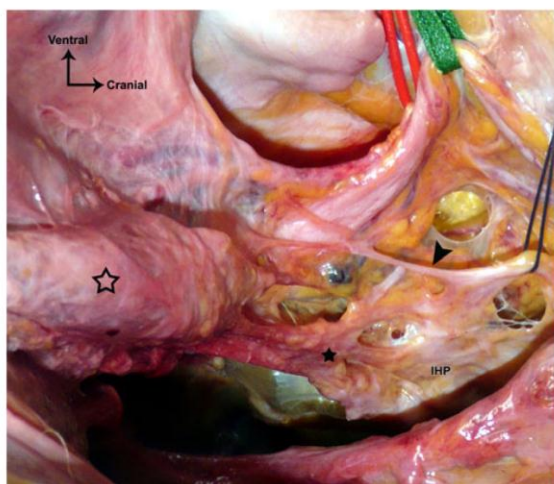


Fig. 6 Pelvic dissection of a 88-year-old female cadaver. The vagina (empty star) and uterus have been pulled downward and forward to visualize the inferior hypogastric plexus (IHP) and its terminal efferences (neural bundle, black star). The hypogastric nerve (HN, blue suture) join the IHP where the uterine artery (red loop) crosses the anterior surface of the ureter (green loop), as it was 3D-reformed in the fetus in Fig. 3. Samely, the HN proximal portion gives branches to the ureter (black arrowhead)

periods [4, 12]. The female fetus is thus a good anatomical and physiological model for studies of pelvic-perineal innervation and results can be extrapolated to adult definitive anatomy. In this study, the HN, specifically identified with anti-PS100 immunolabelling, was constantly a multi-trunked structure with several nerve trunks of variable size coursing at the anterolateral sacral surface. It coursed in a multifascial environment that we could easily recognize with Masson trichrome that permitted a specific blue staining of collagen fibers. In the cadaver study of Paraskevas et al. [23] two distinct HNs at a short distance with each other were found in the majority of subjects. More rarely, they found a wide reticular formation, a band-like nerve trunk consisting of nerve bundles connected with loose connective tissue or, less often, a single thin and rounded nerve. We found here the proximal portion of the uterosacral ligaments (USL) also contained the HN. Authors found, with immunohistochemical studies, that the USL contained the IHP only [9, 24]. As we similarly found with 3D-reconstruction and cadaver macroscopic dissection, the IHP's superior topographic reference is the pelvic ureter at the crossing point of the uterine artery, where HN joins its top angle. To Mauroy et al. [21] the intersection with the uterine artery precisely locates the emergence of the vesical and vaginal efferences and the uterine artery allows them to be individualized, because their division into lateral and medial groups is made directly below the intersection. We found in the fetus, as Baader et al. [5] that

IHP has no obvious layers, without any particular fascial sheet identified with Masson's trichrome. IHP is constantly positioned medial to the blood vessels. Therefore, to reach the pelvic organs, some of the arteries have to penetrate it. It might be the middle rectal artery more commonly, but although the uterine artery, close to where it crosses the ureter, the inferior vesical artery or the superior vesical artery more rarely [5]. We found, as far as our weak number of subjects was concerned, a constant middle rectal artery penetrating the IHP before reaching the lateral rectal wall. We observed that, in fetuses as in adults, the antero-inferior IHP branches which supply the female sexual and continence organs in the perineum are bundled at the posterolateral vaginal wall and anterolateral rectal wall, coursing from the supralelevator compartment to the infralelevator compartment [7]. Others described a "vaginal nervous plexus" originating from the most distal IHP and occupying the 2 and 10 o'clock positions on the anterolateral vagina and travelling at the 5 and 7 o'clock positions along the urethra [26].

3D-reconstruction is a widespread method of medical information diffusion [19]. It might use digital pictures (CT, MRI, PET) [10], serial immunostained animal or human histological sections [6, 17] or anatomical cadavers sections [27]. This is the first 3D reconstruction of female fetal pelvic autonomic anatomy using the computer-assisted anatomic dissection (CAAD) technique based on manual contouring of immunolabelled pelvic nerves with anti-S100 antibody. The method of computerized reconstruction which was used in this study is accurate and can be performed easily by non-professional computer users such as anatomists, morphologists and radiologists [3, 18]. The 3D reconstruction permits to identify the exact organization of the thin nerves elements, their distributions and their relationship to the vascular, visceral, fascial and muscular structures. Thus, the 3D modeling would be a powerful anatomical and surgical educational tool for students and junior surgeons. The interactivity makes it simple, efficient, attractive and easily accessible and diffusible [25]. The 3D obtained structures illustrate the morphology of the studied regions with truthful and straightforward representations, complementary to cadaver dissection and blackboard chalk drawings. It allows the possibility of visualizing one, several or all of the reconstructed structures, with transparency and moving effects, providing a "virtual immunologic dissection". However, our technique steps are totally manual so the technique is much time consuming and require much attentiveness and honesty in the contouring step. More recent work in 3D reconstruction uses 3D imaging in combination with sectioning to ensure that the original 3D shape and geometry is retained and describes systems for undertaking the process of delineation and tracing [11]. These new softwares would be time-

earning and might solve one of the main representation difficulties: “the zigzag” effect due to irregularities of alignment.

Conclusions

The 3D-Computer-assisted anatomic dissection provides a better understanding of the origin, pathways, termination and relationship with the pelvic organs of the nerve elements that play a role in micturition, continence and sexual function. Confirmative studies in wild series of adult cadavers and fetus are required to find inter-individual variations. In association with basic coloration and immunolabelling of tissue sections, and classical anatomical representations by drawing and cadaver dissection, the 3D pictures and corresponding animated sequences might represent precious tools for anatomical and surgical teaching. Furthermore, it would be a powerful method of applying anatomic knowledge to surgical technique to improve nerve preservation and decrease functional complications after pelvic and perineal surgery.

Acknowledgments With many thanks to Dr. Sophie PATRIER (Genetics and medical embryology, Trousseau Hospital, Paris, France) and Dr Jeannine QUILLARD (Pathology, Bicêtre Hospital, Le Kremlin-Bicêtre, France) for scientific collaboration.

Conflict of interest None of the authors has any financial or personal relationship with other people or organizations that might have influenced the present work.

References

- Aigner F, Zbar AP, Ludwikowski B, Kreczy A, Kovacs P, Fritsch H (2004) The rectogenital septum: morphology, function, and clinical relevance. *Dis Colon Rectum* 47:131–140
- Alsaid B, Bessedé T, Karam I et al (2009) Coexistence of adrenergic and cholinergic nerves in the inferior hypogastric plexus: anatomical and immunohistochemical study with 3D reconstruction in human male fetus. *J Anat* 214:645–654
- Alsaid B, Karam I, Bessedé T et al (2010) Tridimensional computer-assisted anatomic dissection of posterolateral prostatic neurovascular bundles. *Eur Urol* 58:281–287
- Arango-Toro O, Domenech-Mateu JM (1993) Development of the pelvic plexus in human embryos and fetuses and its relationship with the pelvic viscera. *Eur J Morphol* 31:193–208
- Baader B, Herrmann M (2003) Topography of the pelvic autonomic nervous system and its potential impact on surgical intervention in the pelvis. *Clin Anat* 16:119–130
- Benoit G, Cailleaux F, Quillard J et al (1991) Computer assisted anatomical reconstruction: a prostate model. *Surg Radiol Anat* 13:45–47
- Benoit G, Droupy S, Quillard J, Paradis V, Giuliano F (1999) Supra and infralevator neurovascular pathways to the penile corpora cavernosa. *J Anat* 195(Pt 4):605–615
- Bisset IP, Chau KY, Hill GL (2000) Extrafascial excision of the rectum: surgical anatomy of the fascia propria. *Dis Colon Rectum* 43:903–910
- Butler-Manuel SA, Buttery LD, A'Hern RP, Polak JM, Barton DP (2000) Pelvic nerve plexus trauma at radical hysterectomy and simple hysterectomy: the nerve content of the uterine supporting ligaments. *Cancer* 89:834–841
- Duan S, He H, Lv S, Chen L (2010) Three-dimensional CT study on the anatomy of vertebral artery at atlantoaxial and intracranial segment. *Surg Radiol Anat* 32:39–44
- Fiala JC (2005) Reconstruct: a free editor for serial section microscopy. *J Microsc* 218:52–61
- Fritsch H (1989) Topography of the pelvic autonomic nerves in human fetuses between 21 and 29 weeks of gestation. *Anat Embryol (Berl)* 180:57–64
- Havenga K, De Ruyter MC, Enker WE, Welvaart K (1996) Anatomical basis of autonomic nerve-preserving total mesorectal excision for rectal cancer. *Br J Surg* 83:384–388
- Hern WM (1984) Correlation of fetal age and measurements between 10 and 26 weeks of gestation. *Obstet Gynecol* 63:26–32
- Hollabaugh RS Jr, Dmochowski RR, Steiner MS (1997) Neuroanatomy of the male rhabdosphincter. *Urology* 49:426–434
- Hounnou GM, Uhl JF, Plaisant O, Delmas V (2003) Morphometry by computerized three-dimensional reconstruction of the hypogastric plexus of a human fetus. *Surg Radiol Anat* 25:21–31
- Kalfa N, Liu B, Cao M, Vilella M, Hsieh M, Baskin LS (2008) 3-dimensional neuroanatomy of the human fetal pelvis: anatomical support for partial urogenital mobilization in the treatment of urogenital sinus. *J Urol* 180:1709–1714 discussion 1714–5
- Karam I, Droupy S, Abd-alsamad I et al (2005) The precise location and nature of the nerves to the male human urethra: histological and immunohistochemical studies with three-dimensional reconstruction. *Eur Urol* 48:858–864
- Marks SC Jr (2000) The role of three-dimensional information in health care and medical education: the implications for anatomy and dissection. *Clin Anat* 13:448–452
- Mauroy B, Bizet B, Bonnal JL, Crombet T, Duburcq T, Hurt C (2007) Systematization of the vesical and uterovaginal efferences of the female inferior hypogastric plexus (pelvic): applications to pelvic surgery on women patients. *Surg Radiol Anat* 29:209–217
- Mauroy B, Demondion X, Bizet B, Claret A, Mestdagh P, Hurt C (2007) The female inferior hypogastric (=pelvic) plexus: anatomical and radiological description of the plexus and its afferences—applications to pelvic surgery. *Surg Radiol Anat* 29:55–66
- Moszkowicz D, Alsaid B, Bessedé T et al. (2010) Where does pelvic nerve injury occur during rectal surgery for cancer? *Colorectal Dis* August [Epub ahead of print]
- Paraskevas G, Tsitsopoulos P, Papaziogias B et al (2008) Variability in superior hypogastric plexus morphology and its clinical applications: a cadaveric study. *Surg Radiol Anat* 30:481–488
- Ramanah R, Parratte B, Arbez-Gindre F, Maillat R, Riethmuller D (2008) The uterosacral complex: ligament or neurovascular pathway? *Anatomical and histological study of fetuses and adults. Int Urogynecol J Pelvic Floor Dysfunct* 19:1565–1570
- Uhl JF, Plaisant O, Ami O, Delmas V (2006) 3D modeling in the field of morphology: methods, interest and results. *Morphologie* 90:5–20
- Yucel S, De Souza A Jr, Baskin LS (2004) Neuroanatomy of the human female lower urogenital tract. *J Urol* 172:191–195
- Zhang SX, Heng PA, Liu ZJ et al (2004) The Chinese Visible Human (CVH) datasets incorporate technical and imaging advances on earlier digital humans. *J Anat* 204:165–173

Article 3 : Innervation du clitoris : étude immunohistochimique avec reconstruction 3D des nerfs caverneux, spongieux et dorsal du clitoris chez le fœtus humain [67].

Moszkowicz D, Alsaid B, Bessedé T, Zaitouna M, Penna C, Benoit G, Peschaud F. Neural supply to the clitoris: immunohistochemical study with three-dimensional reconstruction of cavernous nerve, spongious nerve, and dorsal clitoris nerve in human fetus. *Journal of Sexual Medicine*. 2011 Apr; 8(4):1112-22.

IF 2011 : **3,552**

Résumé

Objectif : Préciser l'anatomie topographique et fonctionnelle de l'innervation du clitoris, son origine, son trajet et sa localisation précise par rapport aux structures pelviennes.

Matériel et méthodes : Des coupes sériées de 5 d'épaisseur ont été effectuées tous les 50 à 150 µm sur le bassin de six fœtus humains de sexe féminin entre 18 et 32 semaines de gestation, obtenus après autorisation d'autopsie scientifique par l'agence de la Biomédecine et consentement écrit des parents. Les coupes ont été traitées par l'Hématoxyline-Eosine et le trichrome de Masson puis immunomarquées pour détecter les fibres nerveuses (anticorps anti-protéine S100), les fibres somatiques (anticorps anti-PMP22), les fibres autonomes adrénergiques (anticorps anti-TH) et cholinergiques (anticorps anti-VACht), les fibres sensibles (anticorps anti-CGRP) et les fibres pro-érectiles (anticorps anti-nNOS) ainsi que l'actine lisse des sphincters (anticorps anti-SMA). Les lames ont ensuite été numérisées par un

scanner de haute résolution optique et les images bidimensionnelles ont été reconstruites manuellement en trois dimensions puis traitées par un logiciel d'animation.

Résultats : La bandelette neurovasculaire (BNV) est la portion terminale du plexus hypogastrique inférieur, riche en fibres pro-érectiles, qui chemine à la face postéro-latérale puis latérale du vagin. Le nerf caverneux est une projection antéro-inférieure de la BNV dont les fibres, organisées en plexus, pénètrent les piliers du clitoris. Il chemine à la face latérale du vagin et de l'urètre. Au sein du nerf caverneux on trouve des fibres adrénérergiques, cholinérergiques et nitrérergiques (parasympathiques pro-érectiles) mais pas sensibles. Le « nerf spongieux » est la branche terminale de la BNV, destinée aux bulbes vestibulaires. Il contient des fibres adrénérergiques, cholinérergiques, nitrérergiques et sensibles. Le nerf dorsal du clitoris, branche sensitivomotrice terminale du nerf pudendal, chemine à la face supérieure des piliers du clitoris et possède une activité pro-érectile (positivité pour l'anticorps anti-nNOS) segmentaire en rapport avec l'existence de branches communicantes avec le nerf caverneux.

Conclusion : Les données apportées par les données immunohistochimiques (bidimensionnelles) et anatomiques (3D) nous ont permis de préciser l'anatomie et la physiologie de l'innervation des corps érectiles de la femme à partir d'un modèle expérimental fœtal. La nNOS est exprimée par les fibres nerveuses autonomes destinées à la fois aux corps caverneux et aux bulbes vestibulaires du clitoris. Ces données permettraient le transfert des connaissances anatomiques vers l'application à des techniques chirurgicales visant à préserver les nerfs impliqués dans la continence et la fonction sexuelle au cours de la chirurgie pelvienne et vers le développement de molécules pharmacologiques impliquées dans le traitement des troubles génito-urinaires postopératoires.

→La fonction clitoridienne paraît donc avoir deux commandes nerveuses: i) *autonome*, par le nerf caverneux, projection antéro-inférieure de la BNV, destinée aux corps caverneux et par le nerf spongieux, branche inférieure terminale de la BNV, destinée aux bulbes vestibulaires ; ii) *somatique*, par le nerf dorsal du clitoris et ses communications avec le NC. L'influx parasympathique cholinergique/nitrergique véhiculé par la BNV pourrait être responsable de la tumescence clitoridienne par relaxation des fibres musculaires lisses des sinus caverneux et augmentation de la pression artérielle intra-caverneuse. De même, l'engorgement des petites lèvres, correspondant à l'augmentation du flux sanguin dans les bulbes vestibulaires, pourrait être commandé par le parasympathique. L'influx sympathique inhibiteur serait alors supporté par des fibres adrénergiques empruntant les même voies nerveuse et impliquant des récepteurs α -adrénergiques responsables de la contraction des fibres musculaires lisses induites par la noradrénaline. Le NC ne contenant pas de fibre sensitive (CGRP+), la sensibilité épicroitique pourrait être exclusivement supportée par le somatique infra-lévatorien via le nerf dorsal du clitoris, branche du nerf pudendal. Les fibres sensibles retrouvées dans le nerf spongieux, coexistant avec des fibres adrénergiques et cholinergiques, pourraient être impliquées dans la sensibilité autonome à la distension des glandes périnéales ou de la muqueuse des petites lèvres. Par analogie à la commande de l'émission séminale par le sympathique, les fibres adrénergiques du nerf spongieux pourraient être responsables de la vidange des glandes périnéales associée à la lubrification génitale. Il s'agirait alors de nerfs sensori-moteurs à stimulation antidromique et à fonction efférente.

Neural Supply to the Clitoris: Immunohistochemical Study with Three-Dimensional Reconstruction of Cavernous Nerve, Spongious Nerve, and Dorsal Clitoris Nerve in Human Fetus

David Moszkowicz, MD,^{*†} Bayan Alsaid, MD,^{*} Thomas Bessedé, MD,^{*} Mazen Zaitouna, MD,^{*} Christophe Penna, MD,^{†‡} Gérard Benoit, MD,^{*} and Frédérique Peschaud, MD^{*†‡}

^{*}Laboratory of Experimental Surgery, EA 4122, Faculty of Medicine, Bicêtre-Paris 11 University, Le Kremlin-Bicêtre, France; [†]Department of Surgery Assistance-Publique-Hôpitaux de Paris, Ambroise Paré Hospital, Boulogne, France; [‡]University PIFO UVSQ, Guyancourt, France

DOI: 10.1111/j.1743-6109.2010.02182.x

ABSTRACT

Introduction. Little detailed information is available concerning autonomic and somatic nerve supply to the clitoris, potentially causing difficulties for nerve preservation during pelvic and perineal surgery.

Aim. To identify the location and type (nitroergic, adrenergic, cholinergic and sensory) of nerve fibers in the clitoris and to provide a three-dimensional (3D) representation of their structural relationship in the human female fetus.

Methods. Serial transverse sections were obtained from five human female fetuses (18–31 weeks of gestation) and subjected to histological and immunohistochemical investigations; digitized serial sections were used to construct a 3D representation of the pelvis.

Main Outcome Measures. Pelvic-perineal nerve location and type were evaluated qualitatively.

Results. The female neurovascular bundle (NVB) is the antero-inferior terminal portion of the inferior hypogastric plexus that runs along the postero-lateral then lateral face of the vagina and is rich in nNOS-positive fibers. The cavernous nerve (CN) is a thin ventrocaudal collateral projection of the NVB, and this projection does not strictly follow the NVB course. The CN runs along the lateral surface of the vagina and urethra and penetrates the homolateral clitoral crus. The CN provides adrenergic, cholinergic, and nitroergic innervation to the clitoris, but not sensory innervation. The spongious nerve (SN) is the terminal and main projection of the NVB and provides nitroergic innervation to the vestibular bulbs. The dorsal clitoris nerve (DCN), somatic branch of the pudendal nerve, runs along the superior surface of the clitoral crus and body and has a segmental proerectile nitroergic activity related to communicating branches with the CN.

Conclusions. “Computer-assisted anatomic dissection” allowed the identification of the precise location and distribution of the autonomic and somatic neural supply to female erectile bodies, providing an anatomical basis for nerve-sparing surgical techniques, and participating to the understanding of neurogenic female sexual dysfunction.

Moszkowicz D, Alsaid B, Bessedé T, Zaitouna M, Penna C, Benoit G, and Peschaud F. Neural supply to the clitoris: Immunohistochemical study with 3D reconstruction of cavernous nerve, spongious nerve and dorsal clitoris nerve in human fetus. J Sex Med 2011;8:1112–1122.

Key Words. Anatomy; Cavernous Nerve; Computer-Assisted Anatomic Dissection; Dorsal Clitoris Nerve; Female Neurogenic Sexual Dysfunction; Neurovascular Bundle; Spongious Nerve

Introduction

Sexual dysfunction remains a major cause of postoperative morbidity after pelvic surgery [1]. With the aim of improving postoperative functional results, “nerve-sparing” surgical techniques have been described for each part of the pelvis: posterior with proctectomy [2], middle with hysterectomy [3] and anterior with prostatectomy [4]. Nerve preservation techniques are supported by anatomical data concerning pelvic and perineal innervation [5]. There are two distinct compartments in the lower pelvis, separated by the levator ani muscle, and innervated by two nerve pathways [6]. The supralelevator pathway consists of autonomic nerves, including the inferior hypogastric plexus (IHP) and its efferents. The infralevator pathway is comprised of somatic nerves, including the pudendal nerve (PN) with its terminal branches. Although numerous studies have investigated the neurovascular bundle (NVB) and cavernous nerve (CN) in men [7–9], the autonomic innervation of erectile bodies in women remains poorly understood [10]. Female clitoral neuroanatomy is microscopic and difficult to define by classical anatomical methods of dissection [11] and, other than male/female anatomic parallelism, the concept of female NVB has not been clearly demonstrated. Furthermore, there is a great variability in the quality and validity of the neuroanatomical descriptions available. Immunostaining methods allow specific detection of biologically active substances within the nervous fibers and tissues and can be used to assess the type of nerve fibers. The combination of three-dimensional (3D) reconstruction and immunohistochemical staining provides a useful approach for identifying the peripheral innervations of female deep pelvic organs and for obtaining anatomic data that can be exploited surgically [12,13]. The computer-assisted anatomic dissection technique has helped provide a detailed knowledge of nerve types, allowing a good understanding of the pathophysiology and functional consequences of pelvic surgery [14,15].

We report a study that aims to identify the precise location and nature of the clitoral nerve supply in the human female fetus and to provide a 3D representation of the female NVB and branches and their relationship to pelvic anatomic structures.

Methods

Fetal Material

This work involved a defined protocol that required, and received, examination and approval

by the French Biomedicine Agency. The fetal preparations were obtained from miscarriages or legal abortions and were authorized for scientific use by the parents. There was no abandon of the body and manipulations were such that skin integrity was preserved during organ removal. The fetuses were devoid of maceration, or macroscopic abnormalities, as could be determined by the pathologists on macroscopic examination.

We studied five female fetuses after between 18 and 31 weeks of gestation, with a crown-rump length “CRL” of between 140 and 310 mm. The gestational age of each fetus was determined from the CRL, corrected by the first-trimester ultrasound CRL measurement and confirmed at autopsy by assessment of organ maturation [16].

Macroscopic Dissection

The entire pelvis, from sacrum to pubic arch, was removed en bloc and the clitoris was divided close to the posterior contact with the vulva skin to preserve skin integrity. Organs were fixed in 10% paraformaldehyde for 48 hours and serial transversal cross-sections were cut at 4 mm intervals through the whole anatomic piece. The slices were embedded in paraffin and series of 5- μ m-thick sections were prepared every 50–150 μ m. These sections (between 150 and 250 sections from each fetus) were whole-mounted on Superfrost glass slides (Menzel-Glaser, Braunschweig, Germany).

Histological Examination

Pelvic and perineal structures were investigated by conventional staining with hematein-eosin-phloxine (HE) and immunohistochemistry using relevant polyclonal antibodies for labeling neural structures in pelvic tissues (Table 1) as previously described [14]. Briefly, after removal of paraffin and rehydration, antigen retrieval was performed if necessary by microwave retrieval with citrate buffer pH = 6.0. The avidin biotin peroxidase procedure was performed with a Vector ABC Elite kit (antirabbit immunoglobulin G [IgG] biotinylated secondary antibodies followed by the avidin-biotin complex; ref. PK6100, Vector Lab, Burlingame, CA, USA). The DAB detection kit (DAB, ref. SK-4100, Vector Lab) was used for chromogenic detection. To confirm the specificity of the reagents, negative control slides were prepared for each antibody (diluted primary antibody was replaced with diluents). To eliminate false-negative results, positive control tissue sections were prepared and treated with IgG at equivalent dilutions (Table 1).

Table 1 Primary polyclonal antisera

Antigen	Dilution	Incubation time	Incubation temperature	Antigen retrieval	Positive control	Species	Provider	Code
P-S100	1/400	30 minutes	Room	No	No	Rabbit	Dako, Glostrup, Denmark	Z0311
TH	1/750	12 hours	4°C	Citrate buffer	Human adrenal gland	Rabbit	Abcam, Cambridge, MA, USA	ab1112
VACht	1/2,000	12 hours	4°C	Citrate buffer	Human colon	Rat	Sigma, Chicago, IL, USA	V5387
nNOS	1/200	12 hours	4°C	No	Human male cavernous nerve	Rabbit	Cayman, Ann Arbor, MI, USA	160870
PMP 22	1/100	12 hours	4°C	No	Sciatic nerve	Rabbit	Abcam, Cambridge, MA, USA	ab61220
CGRP	1/200	12 hours	4°C	Citrate buffer	Human thyroid	Rabbit	ARP; ARP American Research Products, Belmont, MA, USA	03-16008

P-S100 = protein S100; TH = tyrosine hydroxylase; VACht = vesicular acetylcholine transporter; nNOS = neural nitric oxide synthase; PMP22 = peripheral myelin protein 22; CGRP = calcitonin gene-related peptide.

All the immunohistochemical detections and basic colorations were performed manually by the authors.

Neuronal Immunolabeling (Anti-Cow Protein S100)

PS100 is a general immunolabeling marker for all nerves; it specifically identifies the nucleus and cytoplasm of Schwann cells in formalin-fixed paraffin-embedded nerve tissue [17].

Autonomic Nervous System Immunolabeling

Cholinergic Fibers (Anti-Rat Vesicular Acetylcholine Transporter [VACht]). VACht mRNA is present in all principal cholinergic neurons known in the nervous system and its corresponding immunostain is considered to be a specific marker for cholinergic neurons and fibers [18].

Adrenergic Fibers (Anti-Rat Tyrosine Hydroxylase [TH]). TH is involved in the conversion of phenylalanine to dopamine (in the catecholamine biosynthetic pathway). It is used as a marker for adrenergic neurons and fibers [19].

Somatic Nervous System Immunolabeling: Peripheral Myelin Protein of Myelin Sheath (Anti-Human PMP22)

PMP 22 is a 22 kDa glycoprotein expressed in compact myelin of the peripheral nervous system [20,21].

Immunolabeling Nitroergic Nerve Fibers: Neural Isoform of Nitric Oxide Synthase (nNOS)

The physiological response to sexual arousal in female is mediated by cGMP/NO via genital smooth muscle relaxation [22,23]. The consequences of NO synthesis, cGMP production, regulated by NO-type 5 phosphodiesterase, include vascular engorgement of the clitoris and the anterior wall of the vagina [24]. Three types of NOS isoforms: inducible, endothelial, and neural (n) have been identified [25] and are generated in human clitoris and vagina, and are distributed in nerve bundles, and the vascular and sinusoidal endothelium [26–28].

Immunolabeling Sensory Nerve Fibers: Calcitonin Gene-Related Peptide (CGRP)

CGRP is present in thyroid C-cells [29] and within sensory system nerves; it is considered to be a neuromarker of sensory nerve fibers [26,30].

3D Reconstruction

Serial two-dimensional sections, stained and immunolabeled for nerve fibers and for neurotransmitters, were used for 3D reconstructions.

Analysis of sections stained with HE under appropriately high magnifications (×4 to ×20) allowed us to distinguish various anatomical structures. HE-stained sections were considered to be the reference sections. The subsequent section, treated with anti-S100, revealed pelvic-perineal nerves. By comparing HE-stained sections with anti-S100-labeled and sections treated with anti-VAcHT, anti-TH, anti-PMP22, anti-CGRP and anti-nNOS, we were able to distinguish the nature of nerve fibers: autonomic (cholinergic or adrenergic) or somatic; sensory and erectile. The interval between the sections was negligible (5 μm) and they were thus considered to be superimposable. All sections were digitized by direct scanning at 4,800 dots/inch resolution, and then images were stacked and aligned with Adobe Photoshop image processing software. Pelvic anatomical structures and nerve fibers were manually outlined in all histological sections; a 3D analysis of location, course, and distribution of nerve fibers was performed in *x*- and *y*-axes as an animated motion picture with Surfdriver software for Windows (WinSurf 4.3, Scott Lozanoff, University of Hawaii, Manoa, HI, USA).

Results

Clitoral Anatomy

The clitoris is positioned deep to the labia minora, inferior to the pubic arch. It consists of the junction of erectile bodies: posteriorly paired vestibular bulbs (VBs) and, anteriorly, crura that take an inferior concave shape and join distally to form a single corpora. The urethra and vagina form the midline of a pyramidal structure: the pyramid apex is the clitoral body and bulbs form the lateral margin of the pyramid base beneath the skin of the labia minora (Figure 3).

Clitoris Neural Supply

Table 2 summarizes the distribution of neurotransmitters in the clitoris. Figure 1 shows

schematic representations of microscopic images from Figures 2 to 4.

Somatic Nerve Pathway from the Infralevator Compartment: The Dorsal Clitoris Nerve (DCN)

The DCN is a somatic branch of the PN in the perineum. It ascends along the ischiopubic ramus periostum. Where the two clitoral crura meet to become the clitoral body, the DCN passes to its superior surface. It remains a large trunk until it joins the distal clitoris, branching all along its path giving two to three branches that course along 2 and 10 o'clock positions laterally to each side of both crus and of the body like a "crab claw." The DNC, like somatic nerves, is PMP 22 positive. It contains a mixed association of TH- and VAcHT-positive fibers. Sensory fibers (CGRP+) are found in its distal part.

Autonomic Nerve Pathways from the Supralevator Compartment

NVB (Figures 5 and 6). The most caudal part of the IHP is situated along the vaginal dorso-lateral border and rectal ventrolateral border. The more the levator ani muscle approaches the rectum, the more the IHP fibers are pushed into a small triangular space bordered by the levator ani muscle laterally, the rectum dorsally and the vagina ventrally. IHP gives four main terminal efferences at its anteroinferior angle. Anteriorly, the fibers reach the bladder and urethral sphincter. Posteromedially, fibers course to the posterior vaginal and anterior rectal walls. Postero-inferiorly, the fibers project to the posterior rectal wall and smooth anal sphincter, forming the inferior rectal plexus (IRP). Anteroinferiorly, although number of nerves has diminished, the IHP branches still consist of thick fibers forming a neural bundle that associates with the vaginal pedicle, constituting a NVB. The NVB contains both nNOS-negative fibers and nNOS-positive fibers that are densely clustered around the vaginal pedicle. Furthermore, the NVB contains VAcHT- and TH-positive fibers and rare

Table 2 Summary of neurotransmitter distribution in the neural pathways to the clitoris

	Nerve S100	Somatic (myelin sheat) PMP22	Sympathetic TH	Parasympathetic		Sensory CGRP
				VAcHT	nNOS	
NVB	+	-	Mixed	Mixed	Dense periarterial clustering	+
CN	+	-	++	+++	100%	0
SN	+	-	Mixed	Mixed	++	+
DCN	+	+	++	+++	Segmental	Distal

TH = tyrosine hydroxylase; VAcHT = vesicular acetylcholine transporter; nNOS = neural nitric oxide synthase; CGRP = calcitonin gene-related peptide; NVB = neurovascular bundle; CN = cavernous nerve; SN = spongious nerve; DCN = dorsal clitoris nerve.

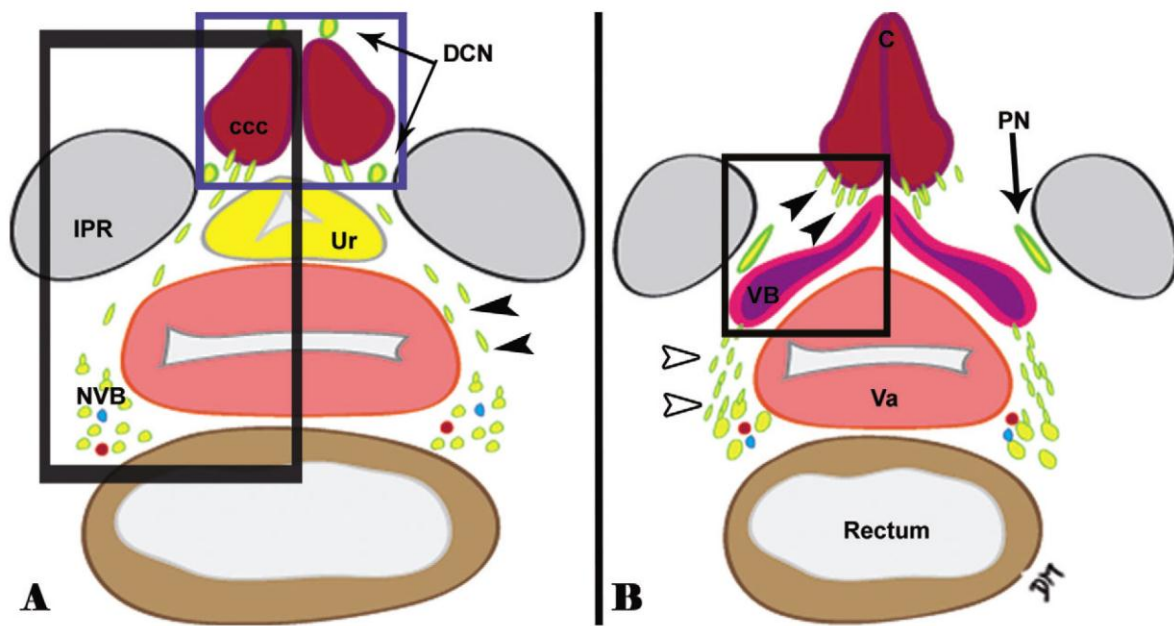


Figure 1 Schematic representation of perineal innervation at the level of the corporis cavernosum clitoridis (ccc, left) and vestibular bulbs (VBs, right). The cavernous nerve (black arrowheads) branches from the neurovascular bundle (NVB) and courses between the ischiopubic ramus (IPR) and urethra (Ur). The spongious nerve (white arrowheads) is the terminal projection of the NVB, destined for the VB. The dorsal clitoris nerve (DCN) originates from the pudendal nerve (PN). The left black square corresponds to Figure 2, the left blue square to Figure 3 and the right black square to Figure 4. Va = vagina.




Figure 2 Serial transverse sections (5- μ m thick) from a 19-week-old female fetus (perineal level) scanned at an optical resolution of 4,800 dpi. Microscopic aspect of the anterior perineal neural supply showing nervous fibers and ganglia of the spongious nerve (square in the S100-labeled image), the somatic dorsal clitoris nerve (arrowhead in PMP22-labeled image) and the whole of the proerectile cavernous nerve (arrowheads in the nNOS-labeled image). All the nerves contain immuno-stained fibers with the anti-VACHT or anti-TH antibodies but cholinergic fibers are mostly in the cavernous nerve (CN). IPR = ischiopubic ramus, Ur = urethra, Va = vagina, ccc = corpus cavernosum clitoridis.

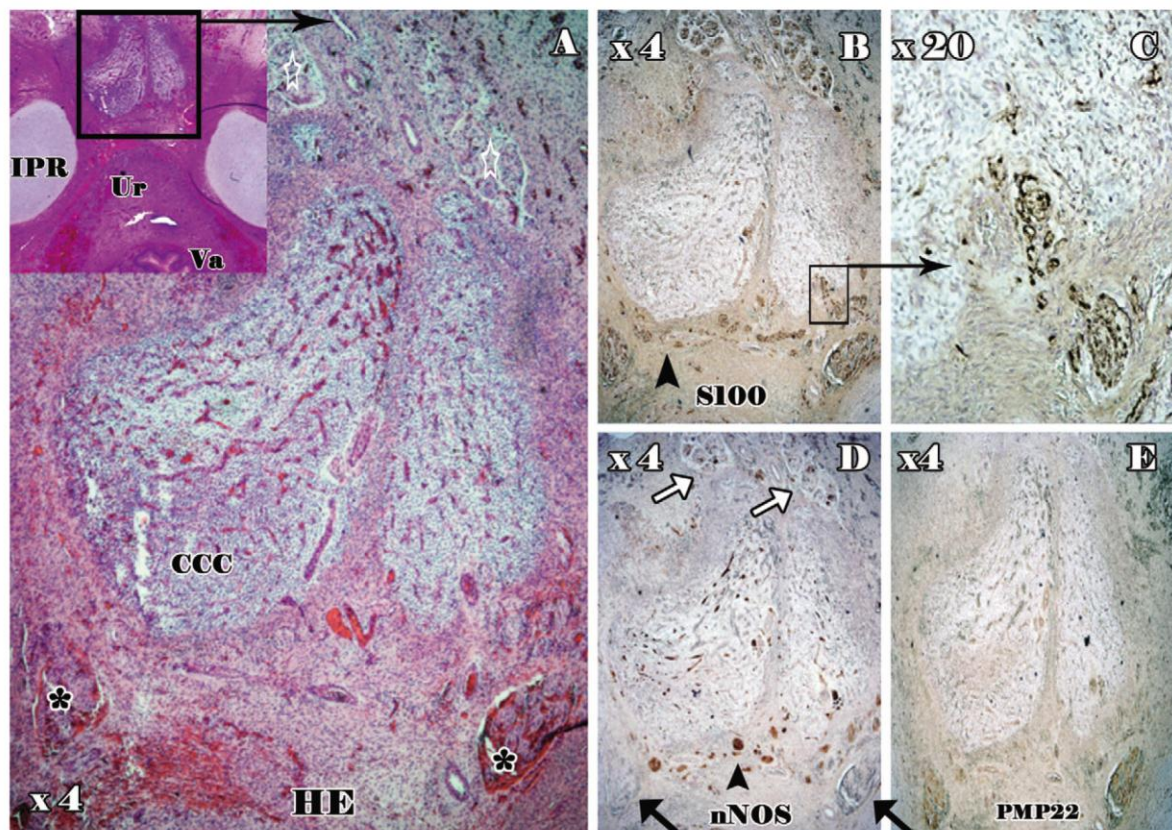


Figure 3 Serial transverse sections (5- μ m thick) from a 19-week-old female fetus through the clitoral crus (ccc). The reference section stained with HE was scanned at an optical resolution of 4,800 dpi (Figure 3A, square) and is shown at $\times 4$ magnification, centered on the clitoris. The proximal (black asterisk) and distal (white stars) portions of the dorsal clitoris nerve are visible. Fibers of the cavernous nerve (arrowhead) in Figure 3B ($\times 4$ magnification), are immunolabeled with anti-S100, and penetrate the posterior aspect of the clitoral crus (Figure 3C, $\times 20$). Figure 3D ($\times 4$): cavernous nerve (CN) fibers are totally nNOS-positive (arrowhead) although proximal portion of the DCN is nNOS-negative (black arrows) and the distal portion of the DCN is nNOS-positive (white arrows). The DCN is somatic and PMP22-positive although the cavernous nerve (CN) is autonomic and PMP22-negative (Figure 3E, $\times 4$). Other abbreviations: Va = vagina, Ur = urethra, IPR = ischiopubic ramus.

(CGRP-positive) sensory fibers. These autonomic fibers are PMP 22-negative.

The NVB heads caudally and ventrally along the dorso-lateral then lateral vaginal wall and passes through the pelvic floor, from the suprallevator to infralelevator space. It then gives out its last three collateral branches: anterior to urethral sphincter (urethral plexus [UP]), anterolateral to the clitoris corpora cavernosa (CN) and posterolateral to VBs ("spongy nerve" [SN]).

CN (Figures 2–6). The CN originates from ganglion cell clusters on the posterior side of the inferior margin of the future interpubic disk at the recto-vaginal angle. After leaving the UP towards the urethral sphincter, the CN forms the last anterolateral projection of the NVB. It is a microscopic network, composed of numerous fibers, and takes

an antero-caudal path. It courses along the lateral vaginal wall and the medial aspect of the levator ani covered by the endopelvic fascia. It then courses between the ischiopubic ramus on the medial side and urethral striated sphincter on the lateral side where it coexists with the DNC. Thus, coursing at 1 and 11 o'clock at the anterolateral urethral walls, it does not exactly follow the path of the NVB. Finally, it reaches posterior and posterolateral faces of the homolateral clitoral crus. The CN is an autonomic structure (PMP22-negative) in which there are both cholinergic (VACHT+) fibers and fewer adrenergic (TH+). All CN fibers are nNOS positive, but are not sensory.

Distal Caverno-Pudendal Communication (Figures 3 and 6). The DCN has a segmental nNOS activity. Its proximal portion, branching from the PN and

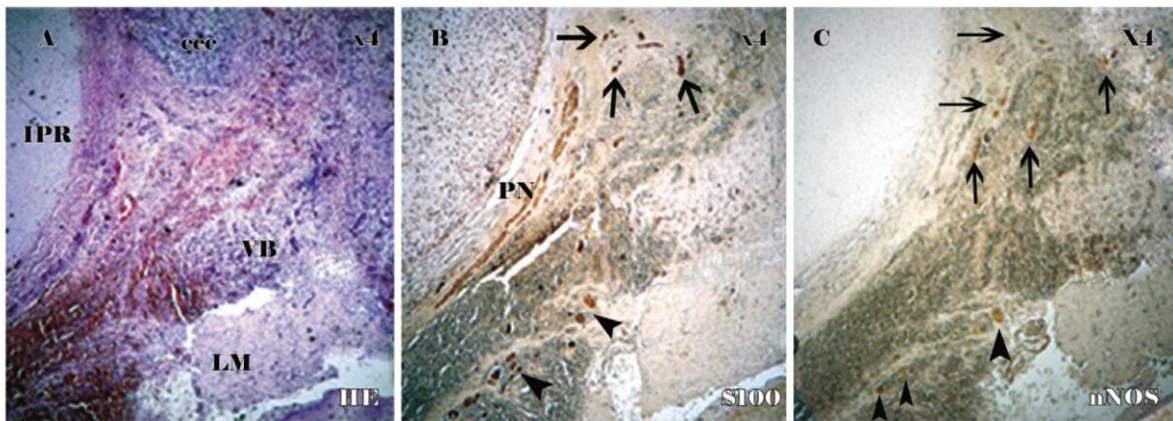


Figure 4 Microscopic image ($\times 4$) of serial transverse sections ($5\text{-}\mu\text{m}$ thick) from a 19-week-old female fetus. The reference section stained with HE (Figure 4A) is through the left vestibular bulb (VB), clitoris corpus cavernosum (ccc) and labia minor (LM). The clitoris neural supply is immunolabeled with anti-S100 (Figure 4B) and anti-nNOS (Figure 4C). The terminal portions of spongy nerve fibers (arrowheads) are neural nitric oxide synthase (nNOS+) or nNOS- and reach the posterior face of the VB; the cavernous nerve fibers (arrows) are all nNOS+ and reach the posterior face of the ccc. The pudendal nerve (PN) terminates at the medial side of the ischiopubic ramus (IPR) and gives rise to the dorsal clitoris nerve that is nNOS- in its proximal portion.

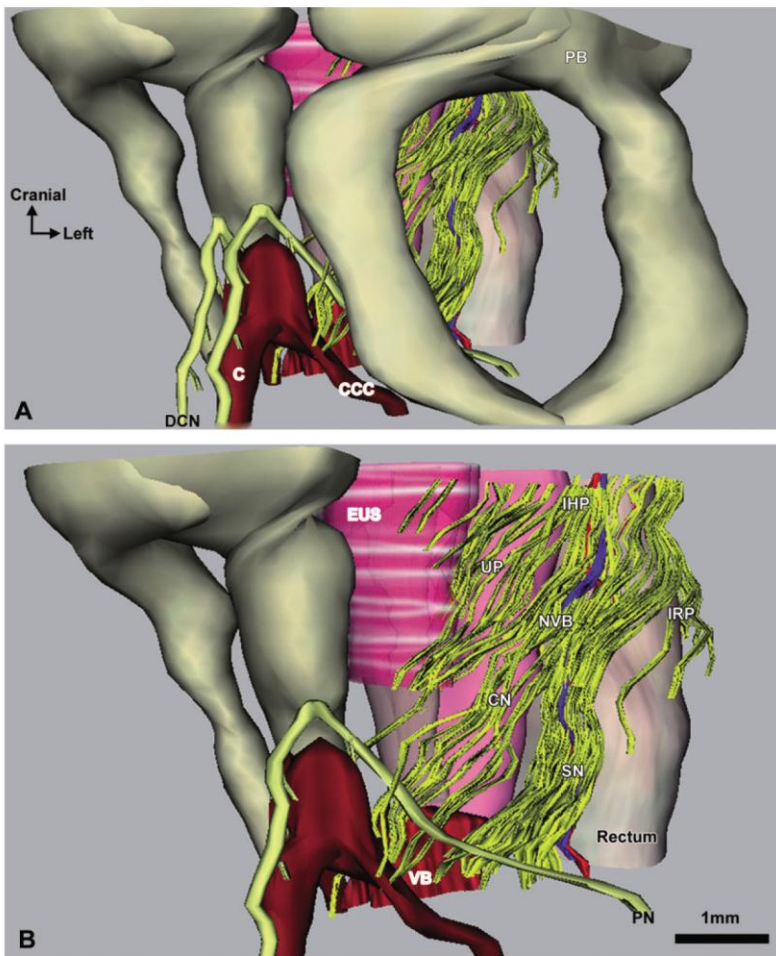


Figure 5 Computer assisted three-dimensional reconstruction of a 19-week-old female fetal pelvis and perineum. Anterolateral view of the pelvic and perineal organs (A) with left coxal bone and right innervation complete transparency (B). The neurovascular bundle (NVB) originates from the inferior hypogastric plexus (IHP) and successively gives three major projections: the urethral plexus (UP) for the urethral sphincter, the cavernous nerve (CN) for the corpus cavernosum, and the spongy nerve (SN) for vestibular bulbs (VB). DNC = dorsal clitoris nerve, PB = pubic bone, PN = pudendal nerve, C = clitoris body, EUS = external urethral sphincter, IRP = inferior rectal plexus.

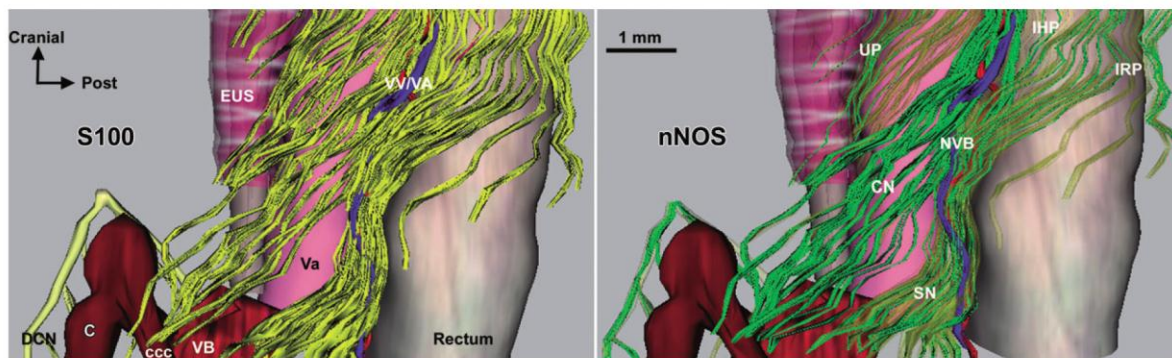


Figure 6 Computer-assisted three-dimensional reconstruction of a 19-week-old female fetal pelvis and perineum, lateral view without bones and without left clitoral crus. Nerve fibers of neurovascular bundle (NVB) immunolabeled with anti-S100 (in yellow) join the vaginal artery and vein (VA/VV) at the vaginorectal angle. Nitroergic fibers (nNOS-positive, in green, with yellow fibers transparent) are mostly clustered around the vaginal pedicle in the NVB. The cavernous nerve (CN) is totally nNOS-positive, whereas the spongiosus nerve (SN), inferior rectal plexus (IRP), and urethral plexus (UP) contain both nNOS-positive and nNOS-negative fibers. The distal portion of the dorsal clitoris nerve (DCN) is nNOS-positive. VB = vestibular bulb, CCC = clitoris corpus cavernosum, Va = vagina, EUS = external urethral sphincter, IHP = inferior hypogastric plexus; nNOS = neural nitric oxide synthase.

joining the clitoral crus on each side is nNOS-negative although its most distal portion, beyond its top, is nNOS-positive. Our 3D reconstruction displays the communication between the somatic DCN and terminal portion of the autonomic CN fibers.

“SN” (Figures 2 and 4–6). After having branched from the CN, the NVB continues largely intact. The most distal—terminal—and main projection of the NVB, or “postero-lateral” projection, continues at 2 and 10 o’clock at the anterolateral rectal wall and changes its path from superoinferior to posteroanterior before reaching VB on each side. Its origin is thus posteroinferior to the CN origin and its pathway is more posterior and medial. The “SN” contains both nNOS-positive + and nNOS-negative fibers, adrenergic (TH+) and cholinergic (VACHT+) fibers and few sensory fibers (CGRP+). The SN is PMP22-negative.

Discussion

We report a detailed description of the location and nerve types within the female fetal NVB from its origin from the IHP, along vagina posterolateral wall, the collateral branches, UP and CN, and ending as the so-called “SN.”

After eight weeks of gestation (Carnegie stage 23), intrapelvic innervation is mainly mature, stable and comparable with that of the adult [31]. The NVB anatomic layout does not undergo fundamental changes during growth in fetal and post

fetal periods [32] but fetus clitoral position is not in its final position in adult as the clitoris moves up during female development [11], potentially impacting on DCN anatomy. The female fetus is thus a good anatomic and physiological model for studies of pelvic-perineal innervation.

Our 3D reconstruction demonstrates that below the parietal peritoneum, fibers serving female sexual and continence organs are bundled in a NVB with the vaginal pedicle. We found a clear concentration of nerve bundles at 2 and 10 o’clock positions around the anterior rectum and at 5 and 7 o’clock around the posterior vaginal wall. Some authors report the existence of female NVB [33], “vaginal plexus” [28], or “uterovaginal plexus” [34] but ours is the first complete immunohistochemical study with 3D reconstruction of IHP terminal branches with focus on NVB and collateral branches. Most NVB terminal fibers converge on the VB. By analogy with the male corpus spongiosum, we propose that these fibers be called the “SN.”

Clitoral erectile function was found to have two nerve controls. The first is autonomic. The CC receives neural supply from the proerectile (nNOS+) CN that is an anteroinferior collateral projection of the NVB. VB receive neural supply from the SN, an inferior terminal projection of the NVB, which contains proerectile fibers. The second neural control is somatic, through the DCN, which takes over erectile activity for the distal clitoris after the branching of communicating nerve fibers that reach CN fibers. Cholinergic/

nitrergic parasympathetic impulses contained in the NVB and CN may induce clitoral tumescence because of the relaxation of the smooth muscle of the cavernous sinuses and increased intracavernous arterial blood flow. VIPergic associated nerves, releasing vasoactive intestinal peptide (VIP), would help to dilate the clitoral arterial supply [35].

Similarly, engorgement of labia minora, which depends on increasing blood flow in the VB, might be commanded by the SN parasympathetic impulses. Sympathetic inhibitory input would be conveyed by coexisting adrenergic nerve fibers, involving α -adrenergic receptors and norepinephrine induced smooth muscle contraction [22].

As was found in male fetuses, the female CN contains no sensory fibers [9]. The sensory function of the clitoris may be exclusively supported by the infraleatory somatic nervous system, through PN branches, including the DCN. Sensory fibers originating from the NVB and found in the SN that coexist with adrenergic and cholinergic fibers may be autonomic sensory fibers connected to perineal glands, with distension sensitivity or connected to labia minora mucosa.

In men, semen emission is dependent on sympathetic neural activity. By analogy, it is possible that, in women, the adrenergic fibers found in the SN are responsible for perineal gland smooth muscle contractions involved in genital secretions during arousal. Female "ejaculation," when occurring, may correspond to emptying the content of major vestibular glands, as a consequence of orgasmic striated perineal muscle contractions, under somatic control [36]. Thus, these would be "sensorimotor" nerves that may be stimulated antidromically and have an efferent function.

The existence of distal caverno-pudendal communications, as demonstrated by our study, has been mentioned previously in both female and male subjects [28,37]. Most descriptions suggest that the CN sends fibers to join the DCN and that the CN projects nNOS-positive branches to the DCN to transform its immunoreactivity from nNOS-negative to nNOS-positive [37,38]. These communications might partly explain the heterogeneity of sexual function recovery after pelvic surgery with or without pelvic nerve preservation [39] and could play a role in nerve plasticity [40].

Intact sex steroids, autonomic/somatic nerves, and arterial inflow/perfusion pressure to women's genital organs play fundamental roles in maintaining women's sexual function [34,41,42].

Thus, disruption of neural integrity is likely to interfere with normal sexual functioning, although psychological and relationship factors play important roles as well [43]. In fact, clitoral innervation courses through a region that serves as a crossroads for digestive, urological, and gynecologic surgery. In each of these specialties, both resection and reconstructive surgery should preserve clitoral innervation, proximally, within the NVB, and distally, within the CN and SN. The technique of clitoridoplastie aims to create the best cosmetic aspect to ensure normal development of sexual identity. It recently included a mobilization of the glans with its NVB [44]. Two parallel incisions of Buck's fascia made at 2 and 10-o'clock positions might ensure nerve preservation despite an important symmetric reduction of the length and diameter of the corpora cavernosa, as well as the glans volume. Female incontinence surgery is associated with various rates of postoperative sexual dysfunction, and the rate correlates with the circumferential extent of dissection. It has been hypothesized that it may result from both neuronal and vascular disorders, which encourage analytic micromorphological studies [45]. With minor periurethral dissections, sub-urethral slings provide 85% of postoperative sexual satisfaction, without significant difference between *trans*-vaginal and *trans*-obturator tapes [46]. Implantation of an artificial urethral sphincter requires a larger dissection on the pathway of clitoral innervation, but sexual disorders that it could generate have never been investigated. At last, to provide a genital sensitivity after a sex reassignment surgery in transsexual female-to-male patients, microsurgical coaptation of the nerves from donor flap to erogenous pelvic recipient nerves should be preferred to nonerogenous nerves such as saphenous, femoral, ilioinguinal, or iliohypogastric [47]. Therefore in these phalloplasties, precise location of the recipient nerves has to be determined.

Conclusions

This study provides the first anatomic reconstruction of the female NVB and components travelling toward erectile bodies, including, for the corpus cavernosum, the CN, and, for VB (or "clitoral bulbs"), a nerve plexus we name the "SN." Both nerves would be implicated in clitoral and labial engorgement and tumescence during sexual arousal. However, these data were obtained in fetal tissues and further anatomical studies in adult are

required, considering that anatomical relationship, as well nervous apparatus, could change anatomical relationship during puberty and menopause. A thorough understanding of the neuroanatomy and physiology of clitoral arousal, would be particularly helpful for the strategic design of female pelvic surgery, including nerve-sparing techniques, as well as for medical therapies of various types of arousal disorders, and particularly postoperative sexual dysfunction. The role of central neuropeptides within the spinal cord also requires clarification [48,49]. In animal studies, type 5 phosphodiesterase inhibitors, for example sildenafil, promote clitoral smooth muscle relaxation and consequently increased clitoral and vaginal blood flow and lubrication [50]. However, the clinical value of these experimental findings remains unclear, and they are the subject of continuing work to develop pleasure-triggers to treat female sexual dysfunction.

Acknowledgments

We thank the Association Recherche Oncologie Digestive (A.R.O.L.D Boulogne) for support in the form of a grant. We thank Dr. Sophie Patrier (Genetics and medical embryology, Trousseau Hospital, Paris, France) and Dr. Jeannine Quillard (Pathology, Bichêtre Hospital, Le Kremlin-Bicêtre, France) for scientific collaboration.

Corresponding Author: Frédérique Peschaud, MD, Laboratoire de Chirurgie Expérimentale, EA 4122, Faculté de médecine Paris 11-Sud, 63 rue Gabriel Péri, Le Kremlin-Bicêtre 94270, France. Tel: +33149095589; Fax: +33149095869; E-mail: mjpeschaud@gmail.com

Conflict of Interest: None of the authors has any financial or personal relationship with other people or organizations that might have influenced the present work.

Statement of Authorship

Category 1

(a) Conception and Design

David Moszkowicz; Bayan Alsaïd; Gérard Benoit; Frédérique Peschaud

(b) Acquisition of Data

David Moszkowicz; Bayan Alsaïd; Mazen Zaitouna

(c) Analysis and Interpretation of Data

David Moszkowicz; Bayan Alsaïd; Frédérique Peschaud

Category 2

(a) Drafting the Article

David Moszkowicz; Bayan Alsaïd; Frédérique Peschaud

(b) Revising It for Intellectual Content

David Moszkowicz; Bayan Alsaïd; Thomas Bessedé; Gérard Benoit; Frédérique Peschaud; Christophe Penna

Category 3

(a) Final Approval of the Completed Article

David Moszkowicz; Bayan Alsaïd; Thomas Bessedé; Mazen Zaitouna; Christophe Penna, Gérard Benoit; Frédérique Peschaud

References

- Nesbakken A, Nygaard K, Bull-Njaa T, Carlsen E, Eri LM. Bladder and sexual dysfunction after mesorectal excision for rectal cancer. *Br J Surg* 2000;87:206–10.
- Liang JT, Lai HS, Lee PH. Laparoscopic pelvic autonomic nerve-preserving surgery for patients with lower rectal cancer after chemoradiation therapy. *Ann Surg Oncol* 2007;14:1285–7.
- Trimbos JB, Maas CP, Deruiter MC, Peters AA, Kenter GG. A nerve-sparing radical hysterectomy: Guidelines and feasibility in Western patients. *Int J Gynecol Cancer* 2001;11:180–6.
- Gillitzer R, Thuroff JW, Neisius A, Wollner J, Hampel C. Robot-assisted ascending-descending laparoscopic nerve-sparing prostatectomy. *BJU Int* 2009;104:128–53.
- Mauroy B, Demondion X, Bizet B, Claret A, Mestdagh P, Hurt C. The female inferior hypogastric (= pelvic) plexus: Anatomical and radiological description of the plexus and its afferences—Applications to pelvic surgery. *Surg Radiol Anat* 2007;29:55–66.
- Benoit G, Droupy S, Quillard J, Paradis V, Giuliano F. Supra and infralevator neurovascular pathways to the penile corpora cavernosa. *J Anat* 1999;195:605–15.
- Walsh PC, Lepor H, Eggleston JC. Radical prostatectomy with preservation of sexual function: Anatomical and pathological considerations. *Prostate* 1983;4:473–85.
- Costello AJ, Brooks M, Cole OJ. Anatomical studies of the neurovascular bundle and cavernosal nerves. *BJU Int* 2004;94:1071–6.
- Alsaïd B, Karam I, Bessedé T, Abd-alsamad I, Uhl JF, Delmas V, Benoit G, Droupy S. Tridimensional computer-assisted anatomic dissection of posterolateral prostatic neurovascular bundles. *Eur Urol* 2010;58:281–7.
- Munarriz R, Kim NN, Goldstein I, Traish AM. Biology of female sexual function. *Urol Clin North Am* 2002;29:685–93.
- O'Connell HE, Sanjeevan KV, Hutson JM. Anatomy of the clitoris. *J Urol* 2005;174:1189–95.
- Karam I, Droupy S, Abd-alsamad I, Uhl JF, Benoit G, Delmas V. Innervation of the female human urethral sphincter: 3D reconstruction of immunohistochemical studies in the fetus. *Eur Urol* 2005;47:627–33.
- Karam I, Droupy S, Abd-alsamad I, Korbage A, Uhl JF, Benoit G, Delmas V. The precise location and nature of the nerves to the male human urethra: Histological and immunohistochemical studies with three-dimensional reconstruction. *Eur Urol* 2005;48:858–64.
- Alsaïd B, Bessedé T, Karam I, Abd-alsamad I, Uhl JF, Benoit G, Droupy S, Delmas V. Coexistence of adrenergic and cholinergic nerves in the inferior hypogastric plexus: Anatomical and immunohistochemical study with 3D reconstruction in human male fetus. *J Anat* 2009;214:645–54.
- Moszkowicz D, Alsaïd B, Bessedé T, Penna C, Nordlinger B, Benoit G, Peschaud F. Where does pelvic nerve injury occur during rectal surgery for cancer. *Colorectal Dis* 2010 Aug 16 [Epub ahead of print] doi: 10.1111/j.1463-1318.2010.02384.x.

- 16 Hern WM. Correlation of fetal age and measurements between 10 and 26 weeks of gestation. *Obstet Gynecol* 1984;63:26–32.
- 17 Aigner F, Zbar AP, Ludwikowski B, Kreczy A, Kovacs P, Fritsch H. The rectogenital septum: Morphology, function, and clinical relevance. *Dis Colon Rectum* 2004;47:131–40.
- 18 Weihe E, Tao-Cheng JH, Schafer MK, Erickson JD, Eiden LE. Visualization of the vesicular acetylcholine transporter in cholinergic nerve terminals and its targeting to a specific population of small synaptic vesicles. *Proc Natl Acad Sci U S A* 1996;93:3547–52.
- 19 Butler-Manuel SA, Buttery LD, A'Hern RP, Polak JM, Barton DP. Pelvic nerve plexus trauma at radical and simple hysterectomy: A quantitative study of nerve types in the uterine supporting ligaments. *J Soc Gynecol Investig* 2002;9:47–56.
- 20 Snipes GJ, Suter U, Welcher AA, Shooter EM. Characterization of a novel peripheral nervous system myelin protein (PMP-22/SR13). *J Cell Biol* 1992;117:225–38.
- 21 Bremer J, Baumann F, Tiberi C, Wessig C, Fischer H, Schwarz P, Steele AD, Toyka KV, Nave KA, Weis J, Aguzzi A. Axonal prion protein is required for peripheral myelin maintenance. *Nat Neurosci* 2010;13:310–8.
- 22 Munarriz R, Kim SW, Kim NN, Traish A, Goldstein I. A review of the physiology and pharmacology of peripheral (vaginal and clitoral) female genital arousal in the animal model. *J Urol* 2003;170:S40–4. discussion S44–5.
- 23 D'Amati G, di Gioia CR, Bologna M, Giordano D, Giorgi M, Dolci S, Jannini EA. Type 5 phosphodiesterase expression in the human vagina. *Urology* 2002;60:191–5.
- 24 Uckert S, Ehlers V, Nuser V, Oelke M, Kauffels W, Scheller F, Jonas J. In vitro functional responses of isolated human vaginal tissue to selective phosphodiesterase inhibitors. *World J Urol* 2005;23:398–404.
- 25 Moncada S, Rees DD, Schulz R, Palmer RM. Development and mechanism of a specific supersensitivity to nitrovasodilators after inhibition of vascular nitric oxide synthesis in vivo. *Proc Natl Acad Sci U S A* 1991;88:2166–70.
- 26 Hoyle CH, Stones RW, Robson T, Whitley K, Burnstock G. Innervation of vasculature and microvasculature of the human vagina by NOS and neuropeptide-containing nerves. *J Anat* 1996;188(Pt 3):633–44.
- 27 Burnett AL, Calvin DC, Silver RI, Peppas DS, Docimo SG. Immunohistochemical description of nitric oxide synthase isoforms in human clitoris. *J Urol* 1997;158:75–8.
- 28 Yucel S, De Souza A Jr, Baskin LS. Neuroanatomy of the human female lower urogenital tract. *J Urol* 2004;172:191–5.
- 29 Grunditz T, Ekman R, Hakanson R, Rerup C, Sundler F, Uddman R. Calcitonin gene-related peptide in thyroid nerve fibers and C cells: Effects on thyroid hormone secretion and response to hypercalcemia. *Endocrinology* 1986;119:2313–24.
- 30 Suzuki N, Hardebo JE, Owman C. Origins and pathways of cerebrovascular nerves storing substance P and calcitonin gene-related peptide in rat. *Neuroscience* 1989;31:427–38.
- 31 Arango-Toro O, Domenech-Mateu JM. Development of the pelvic plexus in human embryos and fetuses and its relationship with the pelvic viscera. *Eur J Morphol* 1993;31:193–208.
- 32 Fritsch H. Topography of the pelvic autonomic nerves in human fetuses between 21 and 29 weeks of gestation. *Anat Embryol (Berl)* 1989;180:57–64.
- 33 Baader B, Herrmann M. Topography of the pelvic autonomic nervous system and its potential impact on surgical intervention in the pelvis. *Clin Anat* 2003;16:119–30.
- 34 Berman JR, Adhikari SP, Goldstein I. Anatomy and physiology of female sexual function and dysfunction: Classification, evaluation and treatment options. *Eur Urol* 2000;38:20–9.
- 35 Salonia A, Giraldi A, Chivers ML, Georgiadis JR, Levin R, Maravilla KR, McCarthy MM. Physiology of women's sexual function: Basic knowledge and new findings. *J Sex Med* 2010;7:2637–60.
- 36 Hines TM. The G-spot: A modern gynecologic myth. *Am J Obstet Gynecol* 2001;185:359–62.
- 37 Yucel S, Baskin LS. Identification of communicating branches among the dorsal, perineal and cavernous nerves of the penis. *J Urol* 2003;170:153–8.
- 38 Martin-Alguacil N, Pfaff DW, Shelley DN, Schober JM. Clitoral sexual arousal: An immunocytochemical and innervation study of the clitoris. *BJU Int* 2008;101:1407–13.
- 39 Lange MM, Marijnen CA, Maas CP, Putter H, Rutten HJ, Stiggelbout AM, Meershoek-Klein Kranenburg E, van de Velde CJ. Risk factors for sexual dysfunction after rectal cancer treatment. *Eur J Cancer* 2009;45:1578–88.
- 40 Colombel M, Droupy S, Paradis V, Lassau JP, Benoit G. Caverno-pudendal nervous communicating branches in the penile hilum. *Surg Radiol Anat* 1999;21:273–6.
- 41 Nappi R, Salonia A, Traish AM, van Lusen RH, Vardi Y, Kodiglu A, Goldstein I. Clinical biologic pathophysiologies of women's sexual dysfunction. *J Sex Med* 2005;2:4–25.
- 42 Traish AM, Botchevar E, Kim NN. Biochemical factors modulating female genital sexual arousal physiology. *J Sex Med* 2010;7:2925–46.
- 43 Rowland DL. Neurobiology of sexual response in men and women. *CNS Spectr* 2006;11:6–12.
- 44 Acimi S. Clitoroplasty: A variant of the technique. *Urology* 2008;72:669–71.
- 45 Caruso S, Rugolo S, Bandiera S, Mirabella D, Cavallaro A, Cianci A. Clitoral blood flow changes after surgery for stress urinary incontinence: Pilot study on TVT versus TOT procedures. *Urology* 2007;70:554–7.
- 46 Pace G, Vicentini C. Female sexual function evaluation of the tension-free vaginal tape (TVT) and transobturator suburethral tape (TOT) incontinence surgery: Results of a prospective study. *J Sex Med* 2008;5:387–93.
- 47 Selvaggi G, Monstrey S, Ceulemans P, T'Sjoen G, De Cuypere G, Hoebeke P. Genital sensitivity after sex reassignment surgery in transsexual patients. *Ann Plast Surg* 2007;58:427–33.
- 48 Gelez H, Poirier S, Facchinetti P, Allers KA, Wayman C, Bernabé J, Alexandre L, Giuliano F. Neuroanatomical evidence for a role of central melanocortin-4 receptors and oxytocin in the efferent control of the rodent clitoris and vagina. *J Sex Med* 2010;7:2056–67.
- 49 Wilson LA, Wayman CP, Jackson VM. Neuropeptide modulation of a lumbar spinal reflex: Potential implications for female sexual function. *J Sex Med* 2009;6:947–57.
- 50 Chivers ML, Rosen RC. Phosphodiesterase type 5 inhibitors and female sexual response: Faulty protocols or paradigms. *J Sex Med* 2010;7:858–72.

Article 4 : Innervation sympathique - adrénérique et parasymphatique - nitregerique du sphincter anal interne : analyse 3D [68].

Moszkowicz D, Peschaud F, Bessede T, Zaitouna M, Benoit G, Alsaïd B. Internal anal sphincter parasympathetic-nitregeric and sympathetic-adrenergic innervation: a 3D morphologic and functional analysis. *Dis Colon Rectum*. 2012 Apr; 55(4) :473-81.

IF 2011 : **3,132**

Résumé

Objectifs l'organisation et la fonction de l'innervation du sphincter anal interne (SAI) sont peu connues. De plus, la fonction sphinctérienne est souvent altérée après proctectomie pour cancer. Notre objectif était d'identifier l'anatomie topographique et structurelle (nitregerique, adrénérique, cholinergique) de l'innervation autonome destinée au sphincter anal interne et d'analyser ses rapports avec les viscères pelviens en utilisant la technique de Dissection Anatomique Assistée par Ordinateur (DAAO): prélèvement anatomique en bloc, dissection immunohistochimique des nefs pelvi-périnéaux et reconstruction tridimensionnelle (3D).

Matériel et méthodes: des coupes sériées de 5µm d'épaisseur ont été effectuées tous les 50 à 150 µm sur le bassin de 14 fœtus humains (7 masculins, 7 féminins, 15-31 SG), obtenus après autorisation d'autopsie scientifique par l'agence de la Biomédecine et consentement écrit des parents. Les coupes ont été traitées manuellement par l'Hémaroxyline-Eosine puis immunomarquées pour détecter les fibres nerveuses (anticorps anti-protéine S-100), les fibres somatiques (anticorps anti-PMP22), les fibres autonomes adrénériques (anticorps anti-TH) et cholinergiques (anticorps anti-VACHT), et les fibres érectiles (anticorps anti-nNOS) ainsi que l'actine lisse des sphincters (anticorps anti-SMA). Les lames ont ensuite été numérisées par un

scanner de haute résolution optique et les images bidimensionnelles ont été réalignées et reconstruites manuellement en trois dimensions puis traitées par un logiciel d'animation.

Résultats: *Anatomie morphologique* : le plexus hypogastrique inférieur est une lame nerveuse épaisse et fenêtrée localisée entre les viscères pelviens et la paroi pelvienne latérale. De son bord inférieur, situé au bord postérolatéral du vagin et de la prostate et au bord antérolatéral du rectum, naissent des efférences terminales : antérieures, formant la bandelette neurovasculaire, pour le périnée uro-génital; médiales, pour les parois vaginales et rectales et la prostate ; postéro-inférieures, pour la paroi rectale postéro-latérale et le sphincter anal interne, formant le plexus rectal inférieur (PRI). Le PRI est composé de ganglions et de fibres nerveuses microscopiques qui traversent le plancher pelvien et atteignent le sphincter anal interne où elles entrent en rapport étroit avec les fibres musculaires lisses sphinctériennes.

Anatomie fonctionnelle : le PRI contient des fibres cholinergiques (VAcHT+) et adrénrgiques (TH+). Parmi les fibres cholinergiques, on trouve des fibres nitrergiques (nNOS+) et non-nitrergiques (nNOS-). Les fibres intra-sphinctériennes issues du PRI sont surtout cholinergiques, mais aussi adrénrgiques-sympathiques. Les fibres nerveuses cholinergiques-nitrergiques sont dispersées de façon circonférentielle dans le SAI, participant à la relaxation sphinctérienne.

Conclusion: notre étude a permis l'identification de la distribution de l'innervation autonome du SAI. Elle contribue à la compréhension de la dysfonction sphinctérienne neurogène postopératoire. Ces nouvelles connaissances peuvent être à la base des techniques chirurgicales de préservation de l'innervation autonome à destinée génito-urinaire en permettant l'implantation peropératoire précise d'électrodes de neurostimulation. La cartographie 3D des neurotransmetteurs pelvi-périnéaux permettra la sélection de molécules

pharmacologiques utiles au traitement des troubles primitifs et postopératoires de la continence et de l'exonération.

→ Le système nerveux parasympathique commande la relaxation du sphincter anal interne via la stimulation de récepteurs muscariniques et l'activation de la nNOS permettant la libération de NO. Nous avons ici montré que le substratum anatomique en est le plexus rectal inférieur, dont certaines fibres sont simultanément nitrergiques et cholinergiques. De même, le PRI contient des fibres sympathiques-adrénergiques, probablement responsables du tonus sympathique de repos par libération de noradrénaline. Ce neurotransmetteur permet la contraction du sphincter anal interne en réponse à la stimulation de récepteurs α 1-adrénergiques et sa relaxation, en réponse à la stimulation de récepteurs β -adrénergiques.

→ L'incontinence observée après proctectomie, faisant partie du syndrome de résection antérieure, pourrait être due à la lésion directe du sphincter par étirement lors de la dilatation anale nécessaire à l'anastomose mécanique circulaire trans-suturale, comme à la blessure de la commande nerveuse autonome sympathique, inévitable lors de la section rectale. Les caractéristiques manométriques du néorectum confectionné avec un réservoir colique dénervé par sa dissection pourraient également expliquer les mauvais résultats fonctionnels post-opératoires. La perte de fonction du tonus parasympathique inhibiteur pourrait également être à l'origine de contractions anarchiques médiées par l'acétylcholine et responsables des impériosités parfois observées.

Internal Anal Sphincter Parasympathetic-Nitrergic and Sympathetic-Adrenergic Innervation: A 3-Dimensional Morphological and Functional Analysis

David Moszkowicz, M.D.^{1,2} • Frédérique Peschaud, M.D., Ph.D.^{1,2,3}

Thomas Bessede, M.D.¹ • Gérard Benoit, M.D.¹ • Bayan Alsaïd, M.D., Ph.D.^{1,4}

1 Laboratory of Experimental Surgery, Faculty of Medicine, Paris-Sud 11 University, Le Kremlin-Bicêtre, France

2 Department of Surgery Assistance-Publique-Hôpitaux de Paris, Ambroise Paré Hospital, Boulogne-Billancourt, France

3 University UVSQ-PIFO, Guyancourt, France

4 Laboratory of Anatomy, Faculty of Medicine, University of Damascus, Damascus, Syria

BACKGROUND: Little detailed information is available concerning morphological and functional autonomic nerve supply to the internal anal sphincter. However, denervation of the sphincter potentially affects anal function after rectal surgery for cancer.

OBJECTIVE: The aim of this study was to identify the location and type (nitrergic, adrenergic, and cholinergic) of nerve fibers in the internal anal sphincter and to provide a 3-dimensional representation of their structural relationship in the human fetus.

MATERIALS AND METHODS: serial transverse sections were obtained from 14 human fetuses (7 male, 7 female, 15–31 weeks of gestation) and were studied histologically and immunohistochemically; digitized serial sections were used to construct a 3-dimensional representation of the pelvis.

MAIN OUTCOMES MEASURES: The location and type of internal anal sphincter nerves were assessed qualitatively.

RESULTS: Posteroinferior fibers originating from the inferior hypogastric plexus posteroinferior angle projected to the posterolateral and posterior rectal wall and internal anal sphincter, forming the inferior rectal plexus. The inferior rectal plexus contained vesicular acetylcholine transporter-positive (cholinergic), tyrosine hydroxylase-positive (adrenergic/sympathetic), and neural nitric oxide synthase-positive (nitrergic) fibers. The intrasphincteric vesicular acetylcholine transporter-positive fibers included both neural nitric oxide synthase-negative fibers and neural nitric oxide synthase-positive fibers (nitrergic-parasympathetic).

LIMITATIONS: The study focused on topographic and functional anatomy, so that quantitative data were not obtained. A small number of fetal specimens were available.

CONCLUSIONS: We report the precise location and distribution of the autonomic neural supply to the internal anal sphincter. This description contributes to the understanding of neurogenic postoperative sphincteric dysfunction. Three-dimensional cartography of pelvic-perineal neurotransmitters provides an anatomical and physiological basis for the selection and development of pharmacological agents to be used in the treatment of primary or postoperative continence and evacuation disorders.

Funding/Support: This work was supported by a grant from the Association Recherche Oncologie Digestive (A.R.O.L.D Boulogne).

Financial Disclosures: None of the authors has any financial or personal relationship that might have influenced the present work.

Correspondence: David Moszkowicz, M.D., Laboratoire de chirurgie expérimentale EA 4122 Faculté de Médecine, Université Paris-Sud 11; 63 avenue Gabriel Péri, 94270, Le Kremlin Bicêtre, France. E-mail: drmoszko@gmail.com

Dis Colon Rectum 2012; 55: 473–481
DOI: 10.1097/DCR.0b013e318245190e
©The ASCRS 2012

DISEASES OF THE COLON & RECTUM VOLUME 55: 4 (2012)

KEY WORDS: Anal sphincter; Anterior resection syndrome; Autonomic nervous system; Colorectal cancer; Nervous control of intestinal functions; Nitric oxide; Pelvic nerves; Total mesorectal excision.

473

Pelvic neuroanatomy is complex to define by classical anatomical methods of dissection, and there is substantial inconsistency in the quality and validity of available neuroanatomical descriptions. Immunostaining methods allow specific detection of biologically active substances within the nervous fibers and tissues and can be used to identify nerve fiber types. Computer-assisted anatomic dissection, involving the combination of 3-dimensional (3D) reconstruction and immunohistochemical staining, is a useful approach for identifying the peripheral innervations of deep pelvic organs and for obtaining anatomic data that can be exploited clinically.¹ This technique has helped provide a detailed description of nerve types, allowing a good understanding of the pathophysiology and functional consequences of pelvic surgery.² Autonomic, as well as somatic, innervation is involved in the regulation of defecation and is the object of much physiopathological and therapeutic interest.³ Nitric oxide (NO), an inhibitory neurotransmitter widely distributed in the gastrointestinal tract, is involved in nonadrenergic, noncholinergic intestinal and sphincter relaxation.^{4–6} Nevertheless, the organization and topographical distribution of neurotransmitters within the autonomic neural supply to the internal anal sphincter (IAS) remains unclear, although denervation potentially affects anal function after rectal surgery for cancer. We report an investigation of the precise location and functional nature of the IAS autonomic innervation; we provide a 3D representation of the terminal branches of the inferior hypogastric plexus and their relationship to pelvic-perineal anatomic structures.

MATERIALS AND METHODS

Fetal Material

This work involved a defined protocol that required, and received, examination and approval by the French Biomedicine Agency. The fetal preparations were obtained from miscarriages or legal abortions and were authorized for scientific use by the parents. The fetuses were devoid of maceration or macroscopic abnormalities as could be determined by the pathologists on macroscopic examination. We studied 14 fetuses, 7 male and 7 female, with a crown-rump length (CRL) of 110 to 310 mm. All fetuses studied had a gestational age between 15 and 31 weeks. The gesta-

tional age of each fetus was determined from the CRL, corrected according to the first-trimester ultrasound CRL measurement, and confirmed at autopsy by assessment of organ maturation.⁷

Macroscopic Dissection

The entire pelvis, from sacrum to pubic arch, was removed en bloc. Organs were fixed in 10% paraformaldehyde for 48 hours and serial transverse cross sections were cut at 4-mm intervals through the whole anatomic piece. The slices were embedded in paraffin and series of 5- μ m-thick sections were prepared every 50 to 150 μ m. These sections (between 150 and 250 from each fetus) were whole-mounted on Superfrost glass slides.

Histological Examination

Pelvic and perineal structures were investigated by conventional staining with hematin-eosin-phloxine (HE) and immunohistochemistry with the use of relevant polyclonal antibodies for labeling neural structures in pelvic tissues (Table 1) as previously described.⁸ In brief, after removal of paraffin and rehydration, antigen retrieval was performed if necessary by microwave retrieval with citrate buffer (pH = 6.0). A Vector ABC Elite kit (anti-rabbit IgG biotinylated secondary antibodies followed by the avidin-biotin complex; ref. PK6100, Vector Laboratories, Burlingame, CA) was used for the avidin-biotin-peroxidase procedure and a DAB detection kit (DAB, ref. SK-4100, Vector Laboratories, Burlingame, CA) was used for chromogenic detection. To confirm the specificity of the reagents, negative control slides were prepared for each antibody (diluted primary antibody was replaced with diluents). To eliminate false-negative results, positive-control tissue sections were prepared and treated with primary antibodies at equivalent dilutions, as outlined in Table 1. All the immunohistochemical experiments and standard staining were performed manually by the authors.

Immunolabeling of Nerve Fibers: Anti-protein S100 Antibody. PS100 is a general immunolabeling marker for all nerves; it particularly identifies the nucleus and cytoplasm of Schwann cells in formalin-fixed paraffin-embedded nerve tissue.^{9,10}

TABLE 1. Primary polyclonal antisera (from rabbit)

Antigen	Dilution	Incubation time	Incubation temperature	Antigen retrieval	Positive control	Provider	Code
P-S100	1/400	30 min	Room	No	Human sciatic nerve	Dako, Glostrup, Denmark	Z0311
TH	1/750	12 h	4°C	Citrate buffer	Human adrenal gland	abcam, Cambridge, MA	ab112
VAcHT	1/2000	12 h	4°C	Citrate buffer	Human colon	Sigma, St Louis, MO	V5387
nNOS	1/200	12 h	4°C	No	Human male cavernous nerve	Cayman, Ann Arbor, MI	160870
SMA	1/150	10 min	Room	No	Human colon	abcam, Cambridge, MA	ab15267

P-S100 = protein-S100; TH = tyrosine hydroxylase; VAcHT = vesicular acetylcholine transporter; nNOS = neural nitric oxide synthase; SMA = smooth muscle actin.

Cholinergic Fibers Immunolabeling: Anti-VACHT Antibody.

Vesicular acetylcholine transporter (VACHT) mRNA is present in all known principal cholinergic neurons in the nervous system, and VACHT immunostaining is considered to be a specific marker for cholinergic neurons and fibers.¹¹

Adrenergic Fibers Immunolabeling: Anti-TH Antibody.

Tyrosine hydroxylase (TH) is involved in the conversion of tyrosine to dopamine (in the catecholamine biosynthetic pathway). It is used as a marker for adrenergic neurons and fibers.¹²

Nitric Fibers Immunolabeling: Anti-nNOS Antibody.

NO is the major neurotransmitter mediating neurogenic relaxation of the human IAS.⁵ Three types of nitric oxide synthase (NOS) isoforms, inducible (i), endothelial (e), and neural (n), have been identified.¹³ The basal IAS tone is largely controlled by eNOS in the mucosa, whereas the rectoanal inhibitory reflex (RAIR) is controlled by nNOS.¹⁴ Significant nNOS gene expression has been described in both smooth muscle cells and myenteric neurons of the opossum IAS, and confirmed by reverse transcriptase-polymerase chain reaction.¹⁵ Endogenous NO inhibits small intestine and colonic motility and contraction frequency in rats.¹⁶

Smooth Muscle Fibers of the IAS Immunolabeling: Anti- α -SMA Antibody. α -smooth muscle actin (SMA).¹⁷**Three-Dimensional Reconstruction**

Serial 2D sections, stained and immunolabeled for nerve fibers and for neurotransmitters, were used for 3D reconstructions. Analysis of sections stained with HE under appropriately high magnifications ($\times 4$ to $\times 20$) allowed various anatomical structures to be distinguished. HE-stained sections were considered to be the reference sections. The subsequent section, treated with anti-S100, revealed pelvic-perineal nerves. By comparing HE-stained sections and anti-S100-labeled sections with sections treated with anti-VACHT, anti-TH, and anti-nNOS, we were able to distinguish the nature of the nerve fibers: autonomic (cholinergic or adrenergic) and nitric. The intervals between the sections were negligible ($5 \mu\text{m}$) and they were therefore considered to be superimposable. All sections were digitized by direct scanning at $4800 \text{ dots inch}^{-1}$ resolution, and images were stacked and aligned with Adobe Photoshop image-processing software. Pelvic anatomical structures and nerve fibers were manually outlined in all histological sections; a 3D investigation of location, course and distribution of nerve fibers was performed in x and y axes as an animated motion picture with Surfdriver software for Windows (WinSurf 4.3).

RESULTS**Morphological Neuroanatomy**

The inferior hypogastric plexus appeared as a small, thick, fenestrated plate composed of nerve fibers and ganglion cells positioned between the connective tissue of the rectal visceral fascia medially and the connective tissue of the pelvic wall laterally. The number and density of the nerve fibers were variable, but they were present, on both sides, in all male and female fetuses. The most caudal part of the inferior hypogastric plexus was along the vaginal/prostatic dorsolateral border and rectal ventrolateral border. There were terminal efferents at the inferior aspect of the inferior hypogastric plexus: to the anterior, the fibers reached the bladder and smooth urethral sphincter; medially, transversal fibers led to the posterior vaginal/prostatic walls and anterior rectal wall; and posteroinferiorly, fibers headed to the posterolateral and posterior rectal wall and IAS (Figs. 1–3). These last fibers formed the inferior rectal plexus. The inferior rectal plexus was a microscopic network, composed of numerous fibers of small caliber that took a postero-caudal path passing through the pelvic floor, from the supralevator to infralevator space. These nerve fibers (positive for anti-S100 antibody labeling) terminated after intermingling with the smooth muscle fibers of the internal sphincter (positive for anti-SMA antibody labeling) (Fig. 4).

Functional Neuroanatomy

On each side, fibers and ganglia of the inferior hypogastric plexus were both positive with cholinergic immunolabeling (anti-VACHT) and adrenergic immunolabeling (anti-TH). Posteroinferior branches of the inferior hypogastric plexus forming the inferior rectal plexus contained cholinergic (VACHT-positive) and adrenergic (TH-positive) fibers. The VACHT-positive fibers included both nonnitric (nNOS-negative) fibers and nitric (nNOS-positive) fibers (Figs. 1 and 2). Intrasphincteric innervation found in transverse sections through the IAS consisted mostly of VACHT-positive fibers, but there were also TH-positive fibers originating from the inferior rectal plexus. IAS nitric fibers were dispersed among cholinergic fibers around the whole circumference (Figs. 2 and 4).

DISCUSSION

We report here the first detailed description with 3D reconstruction of the location and nerve types of the human autonomic innervation of the IAS from its origin in the inferior hypogastric plexus, along the rectum wall, to its intrasphincteric ending. After 8 weeks of gestation (Carnegie stage II3), intrapelvic innervation is mostly mature, stable, and comparable to that of the adult.¹⁸ This anatomic

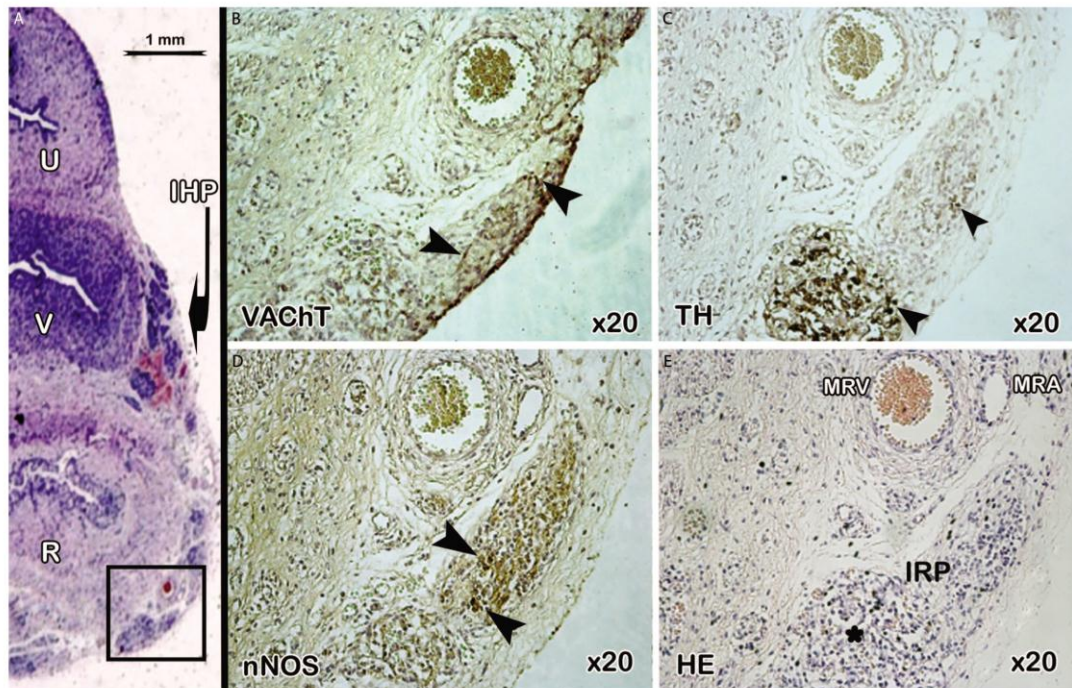


FIGURE 1. Application of multiple immunocytochemical markers of autonomic nerves to the inferior rectal plexus. Serial transverse sections ($5\ \mu\text{m}$ thick) from a 18-week-old female fetus. A, The reference section stained with HE was scanned at an optical resolution of 4800 dpi showing the microscopic aspect of the fibers (black arrowheads) and ganglia (black star, in HE magnification (E)) of the distal inferior hypogastric plexus on the anterolateral rectal wall, and is shown at $\times 20$ magnification (HE (E)), centered on the IRP (black square). The IRP contains fibers showing immunolabeling with the anti-VACht (B) or anti-TH (C) antibodies. Some of the VACht-positive fibers are nNOS-positive and some nNOS-negative (D). HE = hematin-eosin-phloxine; IRP = inferior rectal plexus; VACht = vesicular acetylcholine transporter; TH = tyrosine hydroxylase; nNOS = neuronal nitric oxide synthase; U = urethra; V = vagina; R = rectum; MRV = middle rectal vein; MRA = middle rectal artery.

layout does not undergo any fundamental changes during growth in the fetal and postfetal periods.¹⁹ The fetus is thus a good anatomic and physiological model for studies of pelvic-perineal innervation.^{8,20} Even if reconstructions based on adult cadaver specimens should have a higher clinical value, important limitations exist while using the adult cadaveric sample.¹ The specimen's size affects the easy manipulation of the immunostained sections, and treatment of the adult images is more complex and time consuming. The immunolabeling was less specific in the adult specimens, probably because of the difficulty in controlling the cadaveric postmortal conditions. Finally, including the surrounding bones in the case of extended specimens necessitates sectioning with an autopsy saw, which could destroy the adjacent tissues and affect the determination of anatomic landmarks, or require a decalcification step, tending to reduce the quality of immunohistochemical studies.

The IAS has been reported to receive its parasympathetic nerve supply from the sacral outflow (pelvic

splanchnic nerves) and its sympathetic supply from both the thoracolumbar outflow (sacral splanchnic nerves) and hypogastric nerves.^{21,22} Here, we show that the sphincter autonomic neural command was specifically supplied by the inferior rectal plexus, originating from the inferior angle of the inferior hypogastric plexus, the integrative center of parasympathetic and sympathetic pelvic innervations.

In general, it is accepted that the parasympathetic system has an inhibitory effect on the tone of the IAS causing relaxation mediated via muscarinic receptors and nNOS activation leading to NO release.³ O'Kelly et al⁵ argued, by superfusion organ bath techniques, the role of NO in the neurogenic relaxation of the human IAS. They also found, by using cryostat sections stained for NOS immunoreactivity, that NOS positively stains axons ramifying into and throughout the IAS where they laid in close proximity to smooth muscle cells, concluding that NO mediates the RAIR.²³ Here, we confirm the parasympathetic nature of these nerve fibers, which are both nitroergic and cholinergic

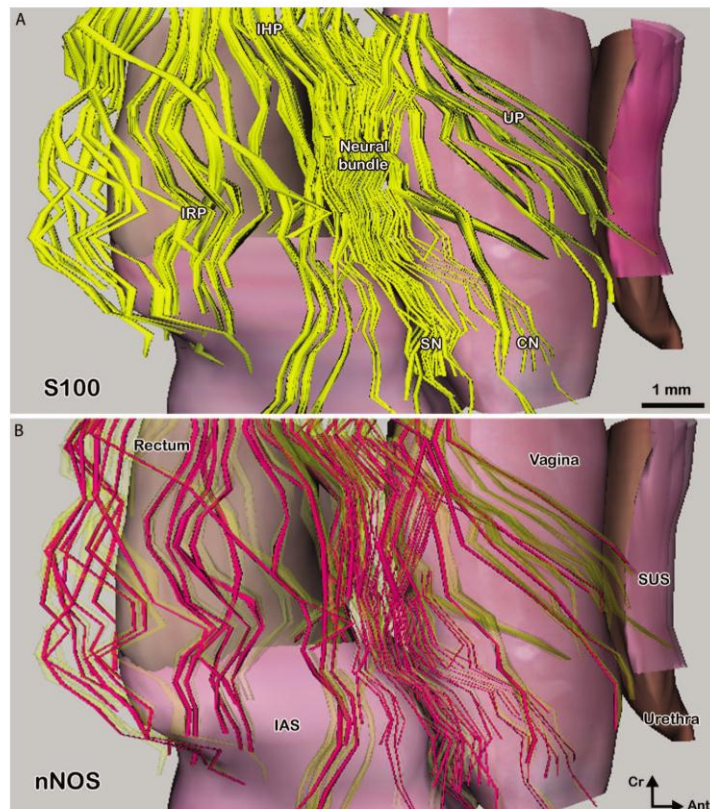


FIGURE 2. Computer-assisted 3D reconstruction of a 20-week-old female fetal pelvis and autonomic innervation (lateral view). Nerve fibers of the neural bundle immunolabeled with anti-S100 (in yellow, A) originate from the inferior hypogastric plexus (IHP) and give 3 major projections successively: the urethral plexus (UP) for the smooth urethral sphincter (SUS), the cavernous nerve (CN) for the corpus cavernosum and the spongiosus nerve (SN) for vestibular bulbs (VB). Fibers of the inferior rectal plexus (IRP) originating from the inferior hypogastric plexus posteroinferior angle reach the internal anal sphincter (IAS) on both sides. The inferior rectal plexus contains both nitrergic and nonnitrergic fibers (nNOS-positive, in magenta, with yellow fibers transparent, B). Ant = anterior; Cr = cranial.

and probably mediate IAS relaxation.^{24,25} The enteric nervous system runs intramurally in the gastrointestinal tract, and is composed of the myenteric plexus and the submucosal plexus. It causes relaxation of the IAS during defecation, mainly via NO, but also via nonadrenergic, noncholinergic neurotransmitters like vasoactive intestinal peptide, carbon monoxide, and ATP.^{26,27}

The inferior rectal plexus was found also to contain sympathetic-adrenergic nerve fibers (TH-positive), probably responsible for the tonic excitatory sympathetic discharge to the IAS at rest^{22,28} and for the release of noradrenaline, which has a dual role in the IAS: eliciting both contraction (in response to α_1 -adrenoreceptors stimulation) and relaxation (in response to stimulation of β -adrenoreceptors).³

A characteristic believed to be common to chronic anal fissures is a high resting anal canal pressure due to

hypertonicity of the IAS. A pharmacological approach to the treatment of anal fissures (“chemical sphincterotomy”) by NO donors, for example, glyceryl trinitrate, or alternative agents that show a similar effect via membrane calcium channels, muscarinic receptors, and α_1 -adrenoreceptor antagonist or β_3 -adrenoreceptor agonist, is a possible alternative to surgical sphincterotomy.^{29,30} By contrast, α_1 -adrenoreceptor agonists, such as topical phenylephrine, induces contraction of the IAS and may be beneficial in the treatment of fecal incontinence.³

Locally advanced cancer of the middle or lower rectum is usually treated by preoperative chemoradiotherapy followed by radical surgery, according to the principles of total mesorectal excision with sphincter preservation.³¹ Fibers of the inferior rectal plexus are inevitably sectioned during mesorectal division, at a point along the pararectal inferior rectal plexus pathway, before penetrating the IAS.

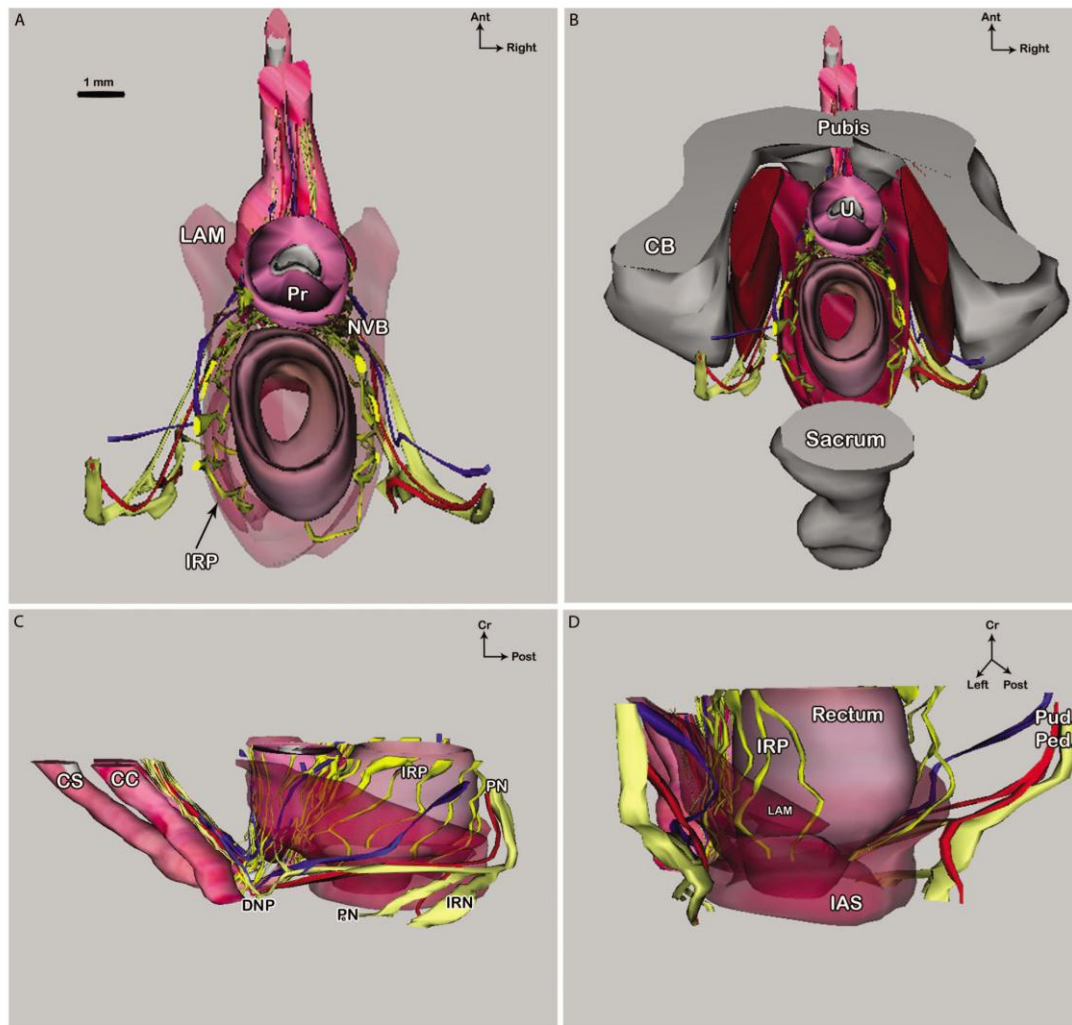


FIGURE 3. Computer-assisted 3D reconstruction from transverse immunolabeled histological sections of a 15-week-old male fetus. A, Superior view of intrapelvic organs with transparency of the levator ani muscle (LAM). The male neurovascular bundle (NVB, with autonomic nerve fibers in bright yellow, arteries in red, and veins in blue) travels at the prostate (Pr) posterolateral aspect and rectum anterolateral aspect. Fibers of the inferior rectal plexus (IRP) originating from the inferior hypogastric plexus posteroinferior angle reach the internal anal sphincter (IAS) on both sides. B, Same view with representation of the coxal bones (CB) with parietal pelvic muscles and sacrum. C, Lateral view: the pudendal nerve (PN, with somatic nerves in light yellow) gives collateral branches: inferior rectal nerve (IRN) and perineal nerve (PeN) providing somatic innervation to the perineum. The PN terminal branch, the dorsal nerve of the penis (DNP), reaches the Penis corporis cavernosum (CC). D, Posterior view. CS = corpus spongiosum; Pud. Ped. = pudendal pedicle.

The long-term functional results of such procedures are poor in many patients, especially in cases of low anastomosis. Frequent stools, urgency, clustering, and fecal incontinence comprise the “anterior resection syndrome.”³² Continence disorders may be due to intraoperative direct injury to the IAS (rectosphincteric incontinence) or its autonomic nerve supply (neurogenic incontinence).³³

Direct injury to the IAS and intramural sympathetic-adrenergic innervation by stretching may be partially responsible for anal hypotonia in patients who have a low stapled transanal circular anastomosis.³⁴ Denervation of the remnant sigmoid colon during its mobilization in low sphincter-saving resections may contribute to the postoperative motility characteristics of the neorectum (less

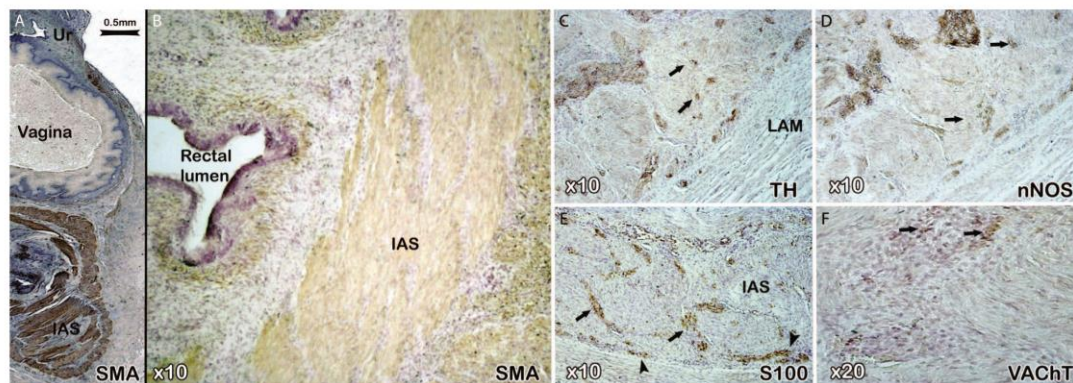


FIGURE 4. Internal anal sphincter intrinsic innervation. Serial transverse sections (5 μ m thick) from a 20-week-old female fetus through the internal anal sphincter (IAS), immunolabeled with anti-smooth muscle actin (SMA; A and B), scanned at an optical resolution of 4800 dpi (A) and shown at $\times 10$ to $\times 20$ magnifications. Fibers of the inferior rectal plexus (arrowheads) were immunolabeled with anti-S100 (S100; E), and penetrated the IAS (intrasphincteric fibers are shown by arrows). Some of the inferior rectal plexus fibers are adrenergic (TH-positive; C) and some cholinergic (VAcHT-positive; F) fibers are nitrergic (nNOS-positive; D). VAcHT = vesicular acetylcholine transporter; TH = tyrosine hydroxylase; nNOS = neuronal nitric oxide synthase; LAM = levator ani muscle.

propagation of contractions, augmented spastic contractions, and reduced colonic transit time) and to the defecatory function of patients.³⁵ The increase in mobility is probably a result of myenteric plexus sympathetic denervation and destruction of an inhibitory α -sympathetic pathway contributing to the anterior resection syndrome.³⁶ The RAIR requires an intact network of interstitial Cajal cells—pacemaker cells of the gastrointestinal tract that can spontaneously generate electrical currents—in the IAS. Both loss of nitrergic innervation and deficiency of interstitial Cajal cells lead to impaired anal relaxation and may play an important role in this particular type of rectal evacuation disorder.³⁷ However, the RAIR may be abolished only temporarily after restorative rectal resection,³⁸ and, in the long term, may be restored by regeneration of intramural neurons across the anastomosis.³⁹

Although most IAS intrinsic autonomic innervation is unavoidably cut during rectal division, upstream supplying nerve fibers running to and from the inferior hypogastric plexus must be preserved during rectal mobilization. Intraoperative neuromonitoring is increasingly used in surgery; it has been introduced to assist pelvic autonomic nerve preservation, which theoretically avoids postoperative disturbances of genitourinary and digestive function.⁴⁰ Stimulation of parasympathetic pelvic nerves with monitoring of intravesical pressure seems to be predictive of postoperative bladder function.⁴¹ Similarly, intermittent bipolar electric stimulation of the inferior hypogastric plexus with simultaneous observation of electromyographic signals of the IAS appears to be possible in animal models.⁴² By describing the terminal fibers of the inferior hypogastric plexus, our study has improved the descrip-

tion of topographic and functional anatomical data. This should help the development and validation of these procedures in humans, allowing electrophysiologically confirmed intraoperative nerve preservation.

CONCLUSIONS

Our 3D reconstruction demonstrates that below the parietal peritoneum, autonomic nerve fibers serving anal function originate from the postero-inferior angle of the inferior hypogastric plexus and carry both sympathetic and parasympathetic/nitrergic or nonnitrergic impulses to the IAS. A clear understanding of the neuroanatomy and physiology of the IAS will facilitate the strategic design of pelvic surgery, including nerve-sparing and stimulation techniques, and may help establish medical therapies of anal tone disorders, in particular, anal fissure, anal incontinence, and anterior resection syndrome. However, these data were obtained in fetal tissues, and further anatomical studies, especially in adults, providing qualitative and quantitative information about the role of peripheral and central neuropeptides will be conducted for a better understanding of pelvic-perineal neuroanatomy and physiology.

REFERENCES

1. Alsaïd B, Bessedé T, Diallo D, et al. Computer-assisted anatomic dissection (CAAD): evolution, methodology and application intra-pelvic innervation study [published online ahead of print July 21, 2011]. *Surg Radiol Anat*. doi: 10.1007/s00276-011-0855-1.
2. Moszkowicz D, Alsaïd B, Bessedé T, et al. Where does pelvic nerve injury occur during rectal surgery for cancer? *Colorectal Dis*. 2011;13:1326–1334.

3. Mills K, Chess-Williams R. Pharmacology of the internal anal sphincter and its relevance to faecal incontinence. *Auton Autacoid Pharmacol.* 2009;29:85–95.
4. Sanders KM, Ward SM. Nitric oxide as a mediator of nonadrenergic noncholinergic neurotransmission. *Am J Physiol.* 1992; 262:G379–G392.
5. O'Kelly T, Brading A, Mortensen N. Nerve mediated relaxation of the human internal anal sphincter: the role of nitric oxide. *Gut.* 1993;34:689–693.
6. Opazo A, Lecea B, Gil V, Jimenez M, Clave P, Gallego D. Specific and complementary roles for nitric oxide and ATP in the inhibitory motor pathways to rat internal anal sphincter. *Neurogastroenterol Motil.* 2011;23:e11–e25.
7. Hern WM. Correlation of fetal age and measurements between 10 and 26 weeks of gestation. *Obstet Gynecol.* 1984;63:26–32.
8. Moszkowicz D, Alsaïd B, Bessedé T, et al. Neural supply to the clitoris: immunohistochemical study with three-dimensional reconstruction of cavernous nerve, spongiosus nerve, and dorsal clitoris nerve in human fetus. *J Sex Med.* 2011;8:1112–1122.
9. Alsaïd B, Bessedé T, Diallo D, et al. Division of autonomic nerves within the neurovascular bundles distally into corpora cavernosa and corpus spongiosum components: immunohistochemical confirmation with three-dimensional reconstruction. *Eur Urol.* 2011;59:902–909.
10. Aigner F, Zbar AP, Ludwikowski B, Kreczy A, Kovacs P, Fritsch H. The rectogenital septum: morphology, function, and clinical relevance. *Dis Colon Rectum.* 2004;47:131–140.
11. Weihe E, Tao-Cheng JH, Schafer MK, Erickson JD, Eiden LE. Visualization of the vesicular acetylcholine transporter in cholinergic nerve terminals and its targeting to a specific population of small synaptic vesicles. *Proc Natl Acad Sci USA.* 1996;93:3547–3552.
12. Butler-Manuel SA, Buttery LD, A'Hern RP, Polak JM, Barton DP. Pelvic nerve plexus trauma at radical and simple hysterectomy: a quantitative study of nerve types in the uterine supporting ligaments. *J Soc Gynecol Investig.* 2002;9:47–56.
13. Moncada S, Rees DD, Schulz R, Palmer RM. Development and mechanism of a specific supersensitivity to nitrovasodilators after inhibition of vascular nitric oxide synthesis in vivo. *Proc Natl Acad Sci USA.* 1991;88:2166–2170.
14. Terauchi A, Kobayashi D, Mashimo H. Distinct roles of nitric oxide synthases and interstitial cells of Cajal in rectoanal relaxation. *Am J Physiol Gastrointest Liver Physiol.* 2005;289:G291–G299.
15. Chakder S, Bandyopadhyay A, Rattan S. Neuronal NOS gene expression in gastrointestinal myenteric neurons and smooth muscle cells. *Am J Physiol.* 1997;273:C1868–C1875.
16. Meile T, Glatzle J, Habermann FM, Kreis ME, Zittel TT. Nitric oxide synthase inhibition results in immediate postoperative recovery of gastric, small intestinal and colonic motility in awake rats. *Int J Colorectal Dis.* 2006;21:121–129.
17. Kobayashi M, Inoue K, Warabi E, Minami T, Kodama T. A simple method of isolating mouse aortic endothelial cells. *J Atheroscler Thromb.* 2005;12:138–142.
18. Arango-Toro O, Domenech-Mateu JM. Development of the pelvic plexus in human embryos and fetuses and its relationship with the pelvic viscera. *Eur J Morphol.* 1993;31:193–208.
19. Fritsch H. Topography of the pelvic autonomic nerves in human fetuses between 21–29 weeks of gestation. *Anat Embryol (Berl).* 1989;180:57–64.
20. Moszkowicz D, Alsaïd B, Bessedé T, Penna C, Benoit G, Peschard F. Female pelvic autonomic neuroanatomy based on conventional macroscopic and computer-assisted anatomic dissections. *Surg Radiol Anat.* 2011;33:397–404.
21. Shibamoto T, Chakder S, Rattan S. Role of hypogastric nerve activity in opossum internal anal sphincter function: influence of surgical and chemical denervation. *J Pharmacol Exp Ther.* 1994;271:277–284.
22. Mizutani M, Neyra T, Ono K, Yamasato T, Tokunaga A. Histochemical study of the lumbar colonic nerve supply to the internal anal sphincter and its physiological role in dogs. *Brain Res.* 1992;598:45–50.
23. O'Kelly TJ, Davies JR, Brading AF, Mortensen NJ. Distribution of nitric oxide synthase containing neurons in the rectal myenteric plexus and anal canal: morphologic evidence that nitric oxide mediates the rectoanal inhibitory reflex. *Dis Colon Rectum.* 1994;37:350–357.
24. Shafik A, El-Sibai O, Ahmed I. Parasympathetic extrinsic reflex: role in defecation mechanism. *World J Surg.* 2002;26:737–741.
25. Radomirov R, Ivancheva C, Brading AF, Itzev D, Rakovska A, Negrev N. Ascending and descending reflex motor activity of recto-anal region-cholinergic and nitrergic implications in a rat model. *Brain Res Bull.* 2009;79:147–155.
26. Jones OM, Brading AF, Mortensen NJ. Role of nitric oxide in anorectal function of normal and neuronal nitric oxide synthase knockout mice: a novel approach to anorectal disease. *Dis Colon Rectum.* 2003;46:963–970.
27. Rattan S, Regan RF, Patel CA, De Godoy MA. Nitric oxide not carbon monoxide mediates nonadrenergic noncholinergic relaxation in the murine internal anal sphincter. *Gastroenterology.* 2005;129:1954–1966.
28. Frenckner B, Ihre T. Influence of autonomic nerves on the internal and sphincter in man. *Gut.* 1976;17:306–312.
29. Bhardwaj R, Vaizey CJ, Boulos PB, Hoyle CH. Neuromyogenic properties of the internal anal sphincter: therapeutic rationale for anal fissures. *Gut.* 2000;46:861–868.
30. Banwait KS, Rattan S. Role of nitric oxide in beta3-adrenoceptor activation on basal tone of internal anal sphincter. *Am J Physiol Gastrointest Liver Physiol.* 2003;285:G547–G555.
31. Gerard JP, Conroy T, Bonnetain F, et al. Preoperative radiotherapy with or without concurrent fluorouracil and leucovorin in T3–4 rectal cancers: results of FFCD 9203. *J Clin Oncol.* 2006;24:4620–4625.
32. Bretagnol F, Troubat H, Laurent C, Zerbib F, Saric J, Rullier E. Long-term functional results after sphincter-saving resection for rectal cancer. *Gastroenterol Clin Biol.* 2004;28:155–159.
33. Otto IC, Ito K, Ye C, et al. Causes of rectal incontinence after sphincter-preserving operations for rectal cancer. *Dis Colon Rectum.* 1996;39:1423–1427.
34. Horgan PG, O'Connell PR, Shinkwin CA, Kirwan WO. Effect of anterior resection on anal sphincter function. *Br J Surg.* 1989;76:783–786.
35. Koda K, Saito N, Seike K, Shimizu K, Kosugi C, Miyazaki M. Denervation of the neorectum as a potential cause of defecatory disorder following low anterior resection for rectal cancer. *Dis Colon Rectum.* 2005;48:210–217.
36. Lee WY, Takahashi T, Pappas T, Mantyh CR, Ludwig KA. Surgical autonomic denervation results in altered colonic motility: an explanation for low anterior resection syndrome? *Surgery.* 2008;143:778–783.

37. Cobine CA, Hennig GW, Bayguinov YR, Hatton WJ, Ward SM, Keef KD. Interstitial cells of Cajal in the cynomolgus monkey rectoanal region and their relationship to sympathetic and nitrergic nerves. *Am J Physiol Gastrointest Liver Physiol.* 2010;298:G643–G656.
38. Schuster MM, Hendrix TR, Mendeloff AI. The internal anal sphincter response: manometric studies on its normal physiology, neural pathways, and alteration in bowel disorders. *J Clin Invest.* 1963;42:196–207.
39. Lane RH, Parks AG. Function of the anal sphincters following colo-anal anastomosis. *Br J Surg.* 1977;64:596–599.
40. Kneist W, Kauff DW, Rahimi Nedjat RK, et al. Intraoperative pelvic nerve stimulation performed under continuous electromyography of the internal anal sphincter. *Int J Colorectal Dis.* 25: 1325–1331.
41. Kneist W, Junginger T. Validity of pelvic autonomic nerve stimulation with intraoperative monitoring of bladder function following total mesorectal excision for rectal cancer. *Dis Colon Rectum.* 2005;48:262–269.
42. Kneist W, Kauff DW, Koch KP, et al. Selective pelvic autonomic nerve stimulation with simultaneous intraoperative monitoring of internal anal sphincter and bladder innervation. *Eur Surg Res.* 46: 133–138.

The American Society of Colon and Rectal Surgeons'

SAN ANTONIO




JUNE 2–6, 2012



ANNUAL SCIENTIFIC MEETING

Henry B. Gonzalez Convention Center & Grand Hyatt Hotel

SAN ANTONIO, TEXAS

Copyright © The American Society of Colon & Rectal Surgeons, Inc. Unauthorized reproduction of this article is prohibited.

Article 5 : Communications intra pelviennes autonomiques-somatiques: dissection anatomique assistée par ordinateur chez le fœtus humain [69].

Moszkowicz D*, Alsaïd B*, Peschaud F, Bessede T, Zaitouna M, Karam I, Droupy S, Benoit G. Autonomic-somatic communications in the human pelvis: computer-assisted anatomic dissection in male and female fetuses. *Journal of Anatomy*. 2011 Nov; 219(5):565-73.

* Contribution équivalente

IF 2010 : **2,37**

Résumé

Objectifs : la continence sphinctérienne et la fonction sexuelle requièrent l'activité coordonnée de voies nerveuses somatiques supra-lévatoriennes et autonomes infra-lévatoriennes qui communiquent à différents niveaux lors de leur trajet intra-pelvien. Cependant, les techniques de dissection macroscopique classiques sont limitées pour l'analyse morpho-fonctionnelle des fibres nerveuses de petit calibre. L'objectif de cette étude était d'identifier la topographie et la nature de ces communications autonomiques-somatiques par l'association d'immunomarquages neurales spécifiques et de la reconstruction 3D.

Matériel et méthodes: nous avons étudié 14 pelvis fœtaux humains normaux (7 filles, 7 garçons, entre 15 et 31 semaines de gestation), par la technique de Dissection Anatomique Assistée par Ordinateur avec immunomarquages pan-nerveux, nitrergique et de la gaine de myéline. Nous avons déterminé la localisation et la distribution des voies nerveuses supra- et infra-lévatoriennes et représenté leur topographie et leurs rapports en 3D.

Résultats: ces 2 voies nerveuses apportaient une innervation double à cinq cibles : le sphincter anal, les muscles élévateurs de l’anus, le sphincter urétral, le corps spongieux/bulbes vestibulaires, les corps caverneux et les muscles striés du périnée. Ces deux voies communiquaient à trois niveaux : proximal/supra-lévatorien, entre le nerf pudendal et le plexus hypogastrique inférieur, intermédiaire/intra-lévatorien et distal infra-lévatorien. Le nerf dorsal (ND) du pénis/clitoris présentait une activité nitrergique segmentaire. Le ND proximal était nNOS-négatif, alors que sa portion distale était nNOS-positive. La communication distale impliquait les fibres autonomes nitrergiques du nerf caverneux et des fibres somatiques nitrergiques du ND qui se croisaient en distalité, formant un “X allongé”.

Conclusion: les structures pelviennes impliquées dans la continence sphinctérienne et la fonction sexuelle reçoivent une innervation double autonome supra-lévatorienne et somatiques infra-lévatorienne. Nous avons pu décrire des communications proximales, intermédiaires et distales entre ces deux voies. La communication distale entre le nerf caverneux et le nerf dorsal du pénis/clitoris serait impliquée dans le transfert de l’activité nitrergique érectile en distalité dans les deux sexes. Ces structures, importantes pour l’érection et la tumescence clitoridienne, doivent être préservée par le chirurgien, notamment au cours des reconstructions du périnée uro-génital.

- L'organisation de l'innervation génitale semble donc être tout à fait superposable entre les 2 sexes. Le PHI se projette en distalité vers les corps érectiles en formant une bandelette nerveuse donnant une branche collatérale caverneuse, et une branche terminale spongieuse. La description de la fonction, de l'origine, du trajet et de la terminaison du nerf caverneux et du nerf spongieux et de leurs rapports avec le viscère de l'étage moyen du pelvis nous a permis d'actualiser les connaissances anatomiques et notamment le concept de « bandelette neurovasculaire postéro-latérale prostatique » décrit par Walsh et al. en 1982 [70].
- L'oxyde nitrique synthétisé par la nNOS est un facteur clé de l'expression de protéines impliquée dans la neuroplasticité cérébrale. La synthèse de NO répond à un influx calcique activant les récepteurs NMDA post-synaptiques à l'origine de la mise en œuvre de la voie du cGMP, de PKG et d'ERK activant la synthèse de protéines nucléaires impliquées dans la plasticité synaptique [71]. Par extrapolation au système nerveux végétatif, les communications nerveuses exprimant la nNOS pourraient servir de support au phénomène de plasticité et de régénération nerveuse post-lésionnelle [72].
- La section bilatérale des nerfs caverneux chez le rat supprime l'érection du corps du pénis du rat mais pas l'érection du gland [40], ce qui tend à confirmer la description du relai distal nitroergique de l'activité érectile par les communications autonomiques-somatiques. L'amélioration de la fonction sexuelle observée grâce à la neuromodulation trans-sacrée, pourrait avoir ces communications proximales et distales comme substratum anatomique.

Autonomic-somatic communications in the human pelvis: computer-assisted anatomic dissection in male and female fetuses

Bayan Alsaid,^{1,2*} David Moszkowicz,^{1*} Frédérique Peschard,¹ Thomas Bessede,¹ Mazen Zaitouna,^{1,2} Ibrahim Karam,¹ Stéphane Droupy¹ and Gérard Benoit¹

¹Laboratory of Experimental Surgery, EA 4122, Faculty of Medicine, University of Paris-Sud 11, Le Kremlin-Bicêtre, France

²Laboratory of Anatomy, Faculty of Medicine, University of Damascus, Damascus, Syria

Abstract

Sphincter continence and sexual function require co-ordinated activity of autonomic and somatic neural pathways, which communicate at several levels in the human pelvis. However, classical dissection approaches are only of limited value for the determination and examination of thin nerve fibres belonging to autonomic supralelevator and somatic infralevator pathways. In this study, we aimed to identify the location and nature of communications between these two pathways by combining specific neuronal immunohistochemical staining and three-dimensional reconstruction imaging. We studied 14 normal human fetal pelvic specimens (seven male and seven female, 15–31 weeks' gestation) by three-dimensional computer-assisted anatomic dissection (CAAD) with neural, nitrergic and myelin sheath markers. We determined the precise location and distribution of both the supra- and infralevator neural pathways, for which we provide a three-dimensional presentation. We found that the two pathways crossed each other distally in an X-shaped area in two spatial planes. They yielded dual innervation to five targets: the anal sphincter, levator ani muscles, urethral sphincter, corpus spongiosum and perineal muscles, and corpora cavernosa. The two pathways communicated at three levels: proximal supralelevator, intermediary intralelevator and distal infralevator. The dorsal penis/clitoris nerve (DN) had segmental nitrergic activity. The proximal DN was nNOS-negative, whereas the distal DN was nNOS-positive. Distal communication was found to involve interaction of the autonomic nitrergic cavernous nerves with somatic nitrergic branches of the DN, with nitrergic activity carried in the distal part of the nerve. In conclusion, the pelvic structures responsible for sphincter continence and sexual function receive dual innervation from the autonomic supralelevator and the somatic infralevator pathways. These two pathways displayed proximal, intermediate and distal communication. The distal communication between the CN and branches of the DN extended nitrergic activity to the distal part of the cavernous bodies in fetuses of both sexes. These structures are important for erectile function, and care should therefore be taken to conserve this communication during reconstructive surgery.

Key words: cavernous nerves; computer-assisted anatomic dissection; inferior hypogastric (pelvic) plexus; nitrergic nerve; pudendal nerve; spongious nerves; supra and infralevator pathways communications.

Introduction

Urination, defecation and sexual function are under the control of the somatic and autonomic nerve pathways,

which involve reflex loops supported by neural loops surrounding the levator ani muscles (LAM). Classically, two distinct compartments in the lower pelvis are recognised, separated by the LAM, and innervated by two nerve pathways (Benoit et al. 1999). The supralelevator pathway mostly involves autonomic nerves: the superior hypogastric plexus (SHP) with hypogastric nerves (HN), the pelvic splanchnic nerves (PSN) and the inferior hypogastric (pelvic) plexus (IHP) with its terminal projections. This plexus has been the subject of various anatomical descriptions, which have tended to adopt a systematic approach to the complex distal branches (Fritsch, 1989; Colleselli

Correspondence

Dr Bayan Alsaid, Laboratoire de chirurgie expérimentale, EA 4122, Faculté de Médecine, 63 rue Gabriel Péri, 94270 Le Kremlin-Bicêtre, France. E: drbayan@gmail.com

*Equivalent contribution.

Accepted for publication 1 July 2011

Article published online 22 July 2011

et al. 1998; Baader & Herrmann, 2003; Mauroy et al. 2007a; Alsaïd et al. 2011; Moszkowicz et al. 2011a). The infralevator pathway consists of somatic nerves: the pudendal nerve (PN) and its terminal branches. There is less debate about the distribution of nerves in the somatic system than in the autonomic system, but various descriptions of the somatic innervation of the LAM have been reported (Roberts et al. 1988; Narayan et al. 1995; Wallner et al. 2008).

The dorsal penis/clitoris nerve (DN) has been shown to contain autonomic nerve fibres, suggesting that there may be communicating branches at several levels of the pelvis and perineum (Yucel et al. 2004; Martin-Alguacil et al. 2008a). Many descriptions of the pathways followed by these communicating branches have been published, based on gross anatomical investigations and the microdissection of IHP terminal branches and PN branches in adult specimens (Paick et al. 1993; Colombel et al. 1999; Moszkowicz et al. 2011b). More recently, specific neuronal immunohistochemical staining and three-dimensional reconstruction imaging techniques have facilitated efforts to determine the topography and nature of these branches in fetal specimens (Yucel & Baskin, 2003).

The existence of these autonomic-somatic communicating branches suggests possible plasticity in the supply of nerves for clitoris/penis erection, bladder and urethral and anal sphincter contraction/relaxation. This plasticity is of potential clinical interest for the rehabilitation of postoperative uro-genital and digestive dysfunctions and their pharmacological treatment.

The aim of this study was to improve the anatomical description of the infra- and supralelevator pathway branches and the autonomic-somatic communications of these branches, by performing an immunohistochemical analysis with three-dimensional reconstruction.

Materials and methods

This work was carried out according to a specific protocol submitted to and approved by the French Biomedicine Agency. The fetal specimens were obtained from miscarried fetuses or fetuses aborted legally, and authorisation for the scientific use of this material was obtained from the parents. The fetuses had no maceration or macroscopic abnormalities on macroscopic pathology examination.

We studied 14 fetuses, seven male and seven female, with a crown-rump length (CRL) of 110–310 mm. All fetuses studied had a gestational age between 15 and 31 weeks. The gestational age of each fetus was determined from the CRL and fetal heel-to-toe length, corrected for the first-trimester ultrasound CRL measurement, and was confirmed, on *post mortem* examination, by estimating organ maturation (Hern, 1984).

The entire pelvis, from the sacrum to the pubic arch, was removed *en bloc*. Organs were fixed by incubation in formalin (10% formaldehyde) for 48 h. We then cut the tissue into transverse slices at 4-mm intervals. The tissue slices were placed in baskets, processed and embedded in cardboard moulds filled with paraffin. We then cut series of 5- μ m-thick sections at 50–150- μ m intervals with a sliding microtome. In total, we obtained 150–320 sections for each fetus.

We investigated intrapelvic and perineal innervation by conventional histological [haematoxylin-eosin (HE)] and immunohistochemical staining of neural structures, as previously described (Alsaïd et al. 2009). All immunohistochemical and histological staining procedures were performed manually by the authors. Briefly, the neuronal markers used were detected with polyclonal antibodies against protein S100, the neural isoform of nitric oxide synthase (nNOS) and peripheral myelin protein (PMP 22) (Table 1). The nNOS is generated in human erectile bodies and is mostly found in the cavernous tissue of the clitoris and the penis, particularly in the pro-erectile nerve bundles and vascular and sinusoidal endothelium (Burnett et al. 1992; Hoyle et al. 1996; Martin-Alguacil et al. 2008b). The nNOS antiserum used recognises a peptide of 155 kDa on Western blots of mouse brain (quality control data supplied by the manufacturer) (Baizer & Broussard, 2010). PMP 22 is a 22-kDa glycoprotein produced by myelinating Schwann cells in the compact myelin of the somatic peripheral nervous system (Snipes et al. 1992; Bremer et al. 2010). The avidin-biotin-peroxidase detection procedure was carried out with the Vectastain ABC kit (ref. PK6100; Vector Laboratories, Burlingame, CA, USA). Chromogenic detection was performed with the DAB detection kit (DAB, ref. SK-4100; Vector Laboratories). As a control for all immunohistochemical analyses, we used non-immune serum or IgG at an equivalent dilution.

Serial stained and immunolabelled two-dimensional sections were used for three-dimensional reconstructions. Analyses of HE-stained sections under appropriately high magnification ($\times 4$ to $\times 40$) made it possible to identify the various anatomical structures (organs, bones and fascia). Subsequent sections, treated with an antibody against S100, were used to identify pelvic-perineal nerves and communicating branches. By comparing HE-stained sections with sections stained with antibodies against S100, PMP22 and nNOS, we were able to determine the nature of the nerve fibres identified: somatic or autonomic and

Table 1 Primary polyclonal antisera.

Antigen	Dilution	Incubation time	Incubation temperature	Antigen retrieval	Positive control	Species	Provider	Code
S-100	1/400	30 min	Room	No	Human sciatic nerve	Rabbit	Dako; DK	Z0311
nNOS	1/200	12 h	4 °C	No	Human adult cavernous nerve	Rabbit	Cayman; USA	160870
PMP22	1/100	12 h	4 °C	No	Human sciatic nerve	Rabbit	Abcam; USA	Ab61220

nitroergic (erectile). The sections were taken at almost the same level, with a negligible interval between sections (5 μm). The computer system comprised a personal laptop computer (Windows XP) equipped with the Epson Perfection V750 digitisation system, SILVERFAST AI digitisation software, ADOBE PHOTOSHOP image processing software and SURFDRIVER software for Windows (WINSURF image reconstruction software, version 4.3). All the sections were digitised by direct scanning at a resolution of 4800 dots per inch (dpi), and then the images were then stacked and aligned. The brightness and contrast of histological tissue images were adjusted in ADOBE PHOTOSHOP. The pelvic anatomical structures and nerve fibres were outlined manually on all histological sections. A three-dimensional analysis of the location, course and distribution of the nerve fibres was then carried out along the *x*- and *y*-axes to generate a movie.

Results

Supralelevator pathway

The IHP acted as a four-sided integration centre for the autonomic supralelevator pathway. It received two groups of afferent branches: the HN from the SHP and the PSN from two to four sacral roots. The upper part of the IHP put out branches to the upper part of the rectum and the neck of the bladder. The lower part of the IHP gave rise to efferent branches running in three distal directions: postero-inferior, lateral and antero-inferior (Fig. 1B).

The postero-inferior branches travelled toward the rectal wall and the smooth anal sphincter. Fibres in lateral directions branched out toward the LAM. Nerve fibres from the IHP converged anteriorly and distally to form the neurovascular bundles (NVB) with the adjacent vessels. The NVB descended at the 4–5 and 7–8 o'clock positions to the prostate in males or to the vagina in females. Some NVB nerve fibres branched medially to innervate the seminal complex (prostate, seminal vesicles and vas deferens) or the vaginal wall. More caudally, the NVB gave rise to nerve fibres following three major projections: an anterior projection for the urethral sphincter complex, an antero-lateral projection [cavernous nerves (CN)] travelling anterolaterally to the prostate/vagina to reach the corpora cavernosa, and a postero-lateral projection [spongious nerves (SN)] continuing posterolaterally to the prostate/vagina to innervate the corpus spongiosum.

Efferent distal branches from the lower part of the IHP tended to radiate out in five main directions: (1) internal anal sphincter; (2) LAM; (3) bladder neck and internal urethral sphincter; (4) seminal complex/vagina and corpus spongiosum; and (5) corpora cavernosa (Fig. 1C,D).

Infralelevator pathway

The PN and its branches were involved in the infralelevator pathways. The PN originated at the sacral plexus. It passed between the piriformis and coccygeus muscles and crossed the spine of the ischium, subsequently following the same

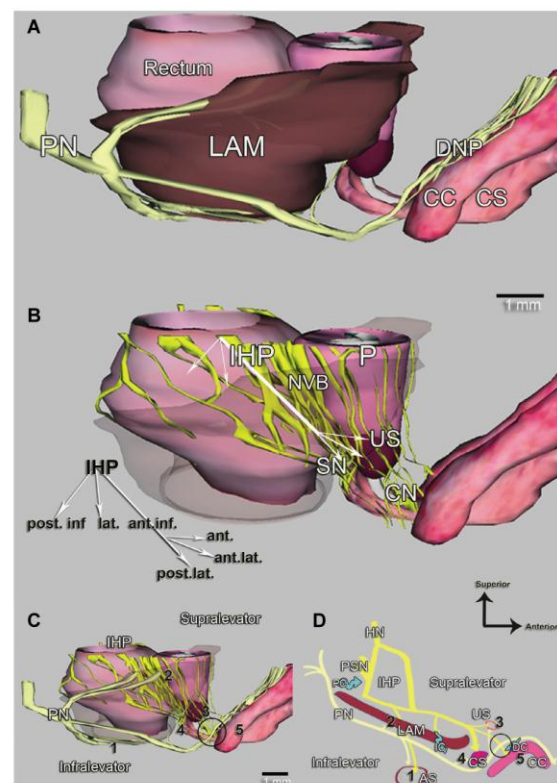


Fig. 1 (A,B) Three-dimensional computer-assisted anatomic dissection from transverse immunolabelled histological sections of a 15-week-old male fetus. (A) Lateral view of intrapelvic organs showing the infralelevator neural pathways of the pudendal nerve (PN) behind the levator ani muscles (LAM) and its terminal branch [dorsal nerve of the penis (DNP)]. (B) Same view with transparency of the LAM, showing the distal distribution of the inferior hypogastric (pelvic) plexus (IHP), in three directions: postero-inferior for the anal sphincter, lateral for the LAM, and antero-inferior for the neurovascular bundles (NVB), which travel posterolaterally to the prostate (P), nerve fibres from the NVB forming three projections: anterior for the urethral sphincter (US), antero-lateral cavernous nerve (CN) for the corpora cavernosa (CC) and postero-lateral spongious nerves (SN) for the corpus spongiosum (CS). (C) Same lateral view with the two pathways, supra- and infralelevator. (D) Schematic diagram of the supra- and infralelevator pathways. These two pathways ensure the dual innervation of five targets: (1) anal sphincter (AS); (2) LAM; (3) urethral sphincter (US); (4) CS and perineal muscles; and (5) CC. Communications between the two pathways occurred at three levels (blue arrow in D): proximal communication, intralelevator communication (IC) and distal communication (DC). The two pathways crossed distally in an X-shaped area in two spatial planes (cycle in C,D).

course as the internal pudendal vessels in the pudendal canal (Alcock's canal).

The LAM received branches from the infralelevator pathway. These branches left the PN at the level of spine of the ischium, before entering the pudendal canal. The PN gave off the inferior rectal nerves, two sets of which (posterior

and lateral) penetrated the external anal sphincter. The external urethral sphincter also received different branches of the PN arising just before its penetration of the urogenital diaphragm. Terminal branches of the PN were grouped together in two nerves: the perineal nerve to the perineal muscles and the dorsal nerve of the penis/clitoris (Fig. 1A).

Branches from the PN extended in five main directions: (1) external anal sphincter; (2) LAM; (3) external urethral sphincter; (4) bulbospongiosus muscles and corpus spongiosum/vestibule; and (5) ischiocavernosus muscles and corpora cavernosa of the penis/clitoris (Fig. 1C,D).

The supralelevator-autonomic and infralevator-somatic pathways displayed proximal, intermediate and distal connections.

Proximal communications

Some fibres branched out from the PN just after its separation from the sacral plexus and before it reached the course of the infralevator pathway, joining the supralelevator branches of the IHP via the lateral face of its posterior portion and intermingling with them. These branches constituted proximal communications between the infra and supralelevator pathways. The number and density of these fibres were variable, but they were consistently present, on both sides, in both male and female fetuses (Fig. 2). These

somatic (PMP 22-positive) fibres were non-nitroergic (nNOS-negative) in both sexes and on both sides.

Intermediate communications

Lateral fibres from the IHP travelled laterally to the parietal pelvic fascia, entering the LAM and continuing distally between the iliococcygeus and the pubococcygeus muscles. Most of these fibres dispersed in the LAM, but we were able to follow some, with great care, to more distal positions. They split off from the inferior border of the LAM and continued in the direction of the pudendal pedicles (Fig. 3). This situation was observed in two male subjects, with a 50- μ m interval between sections used. The observed fibres were autonomic (PMP 22-negative) and non-nitroergic (nNOS-negative).

Distal communications

The distal communications occurred at the level of the penile/clitoral root. The supralelevator CN travelled along the antero-lateral surface of the urethral sphincter to reach the medial surface of the crural bodies. They then dispersed in the penile/clitoral hilum accompanying the cavernous arteries. The CN were strongly nitroergic (nNOS+) and their autonomic non-myelinated nature was confirmed by a lack of staining for myelin (PMP22-) (Fig. 4).


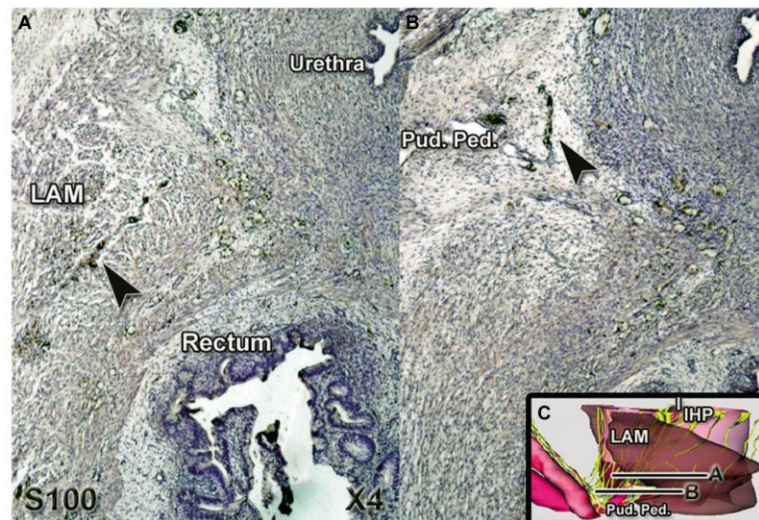


Fig. 2 Serial transverse sections of 21-week-old female (A,B) and 20-week-old male (C,D) fetuses, at 150- μ m intervals, immuno-stained with antibody against S100 and scanned at an optical resolution of 4800 dpi, showing the microscopic ($\times 4$) appearance of the nerve fibres (frame in A,B). (E) Three-dimensional computer-assisted anatomical dissection from transverse immuno-labelled histological sections of the male fetus showing the two levels of section in (C,D). Nerve fibres leave the pudendal nerve (PN) (A,C arrowhead) to reach the inferior hypogastric (pelvic) plexus (IHP) via the lateral face of its posterior portion (B,D arrowhead) (SN, sciatic nerve).

Fig. 3 (A,B) Microscopic appearance ($\times 4$) of serial transverse sections of 15-week-old male fetus ($50\text{-}\mu\text{m}$ intervals) at the level of membranous urethra, immuno-stained with antibody against S100. (C) Three-dimensional computer-assisted anatomic dissection showing the two levels of section in (A,B). Nerve fibres from the inferior hypogastric (pelvic) plexus (IHP) travelled distally in the levator ani muscles; some fibres (arrowhead in A) cross the lower border of the muscle in the direction of the pudendal pedicle (Pud. Ped.) (arrowhead in B).



The infralevator PN became the dorsal nerve (DN) of the penis or clitoris after it had crossed the urogenital diaphragm and reached the crural bodies. The somatic DN (PMP22+) had segmental nNOS activity (Fig. 5). Its proximal portion, branching off from the PN, was nNOS-negative. However, a weak nNOS signal was obtained for the most distal portion, beyond the top. Dorsal nerve branches on the dorsal side of the corpora cavernosa distal to the pubic arch were positive for the marker of nitrergic activity.

Two to three nerve fibres branching from the DN that were found to be PMP22+, confirming their somatic nature, displayed strong nitrergic activity (nNOS +) in both sexes (Fig. 4). The change in the nitrergic nature of the DN related to these retrograde branches: the DN became nNOS-positive when the CN interacted with DN branches (Fig. 6).

With our three-dimensional reconstruction, it was possible to represent the supra- and infralevator pathways on both sides of the LAM and their relations. The infralevator PN pierced the urogenital perineal diaphragm and ascended to reach the cavernous bodies, whereas the supralevator CN, when dispersing in the penile/clitoral hilum, tended to follow a descending course. An X-shaped area, in two spatial planes, in which the two pathways crossed was noted (Fig. 1C,D). Distal communication between the somatic DN branches and the autonomic CN occurred at this cross-over point, with the DN carrying nitrergic activity distally (Fig. 6).

Discussion

This study provides information about the dual innervation of pelvic structures by the autonomic supralevator and somatic infralevator pathways and the communications between these pathways, based on the computer-assisted

anatomic dissection (CAAD) of both male and female human fetuses.

At the end of the 8 weeks of gestation (Carnegie stage 23), the neuro-anatomical topography of the fetus resembles that in adults (Fritsch, 1989; Arango-Toro & Domenech-Mateu, 1993; Alsaïd et al. 2011). Moreover, the immunohistochemical characteristics of the penile dorsal nerve in fetal specimens were consistent with the results obtained for adults (Yucel & Baskin, 2003). The fetus is considered an anatomically and physiologically good experimental model for studies of pelvic-perineal innervation.

We have previously described the concept of the supra- and infralevator pathways (Benoit et al. 1999), with the IHP and its efferences ensuring the autonomic innervation of the anatomical structures above the LAM. The PN and its branches are located below the pelvic diaphragm and supply the somatic impulse toward the perineum and the external genital structures. Interaction between the two systems ensures a normal micturition/defecation-continenence cycle and normal sexual function. The efferences from the IHP have been the subject of various descriptions based on anatomic dissection (Baader & Herrmann, 2003; Costello et al. 2004; Mauroy et al. 2007b). However, we subdivided the distal branches of the lower part of the IHP into three directions: postero-inferior for the rectum and anal sphincter, lateral for the LAM, and antero-inferior for the prostate/vagina, the urethral sphincter and the erectile bodies.

The PN gives off the inferior rectal nerve, which extends to the external anal sphincter muscle, the perineal nerve, which extends to the perineal muscles (bulbospongiosus muscles and ischiocavernosus muscle), and the dorsal nerve of the clitoris/penis. Somatic innervation of the external urethral sphincter has been reported before, with some authors claiming that this innervation is generated by a supralevator somatic branch (Karam et al. 2005) that may

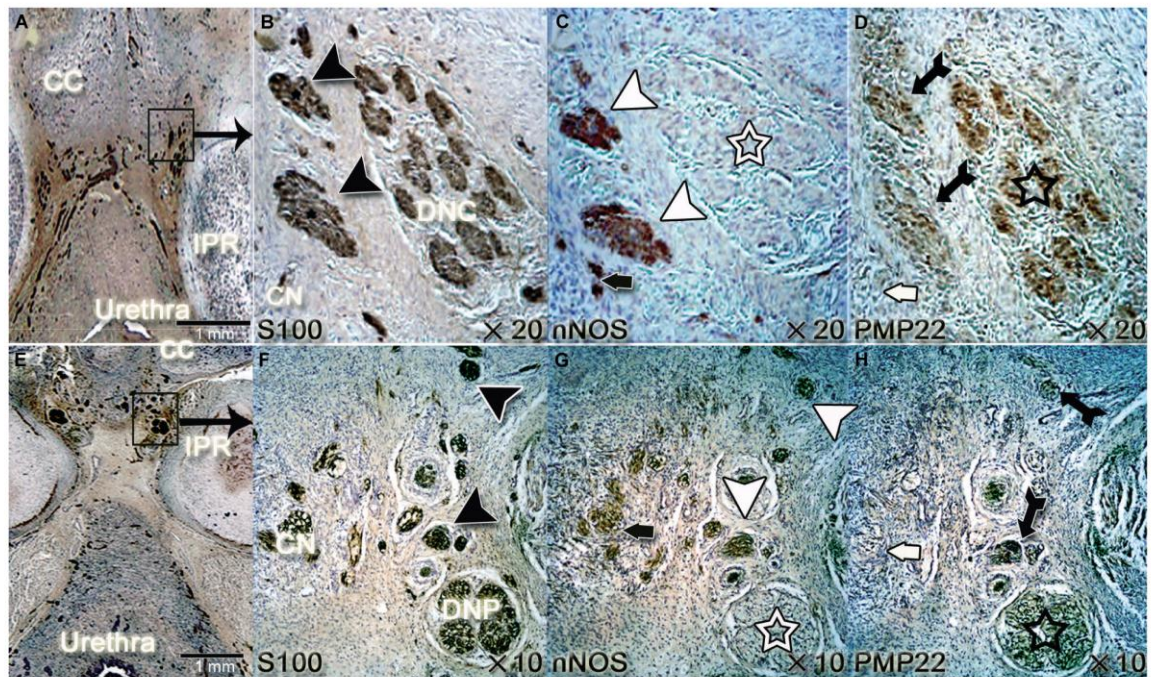


Fig. 4 (A,E) Transverse sections at the level of ischiopubic root (IPR), showing the clitoris and the penile hilum in 26-week-old female and 20-week-old-male fetuses, respectively. Sections immunostained with antibody against S100 and scanned at an optical resolution of 4800 dpi. Microscopic appearance of the dorsal nerve of the clitoris (DNC) in B (from inset in A) and dorsal nerve of the penis (DNP) in F (from inset in E) and their surrounding nerve fibres, treated with an antibody against nitric oxide synthase (anti-nNOS) (in C and G) and an antibody against the myelin sheath (anti-PMP22) (in D and H). At the proximal part of the corpora cavernosa (CC) in both sexes, nerve fibres branching from the DN (back arrow in B, F) had strong nitric activity (white arrowhead in C, G) in both sexes. The proximal portion of the DN had no nitric activity at this level (white star in C, G). These branches were somatic (PMP22+, black arrow in D,H) and had the same somatic nature as DN (PMP22+, black star in D,H). The cavernous nerves (CN) directed to the corpora cavernosa (CC) were strongly nitric (black bold arrow in C,G) and autonomic and non-myelinated in nature (PMP22-, white bold arrow in D,H).

originate from the sacral plexus. Others have reported this somatic innervation results from the PN crossing the urogenital diaphragm or from perineal branches of the PN (Junemann et al. 1987; Narayan et al. 1995). The somatic system is easier to describe than the autonomic system, but several studies on cadavers have yielded conflicting results concerning the innervation of the LAM by branches of the PN (Roberts et al. 1988; Shafik et al. 1995; Barber et al. 2002) or by the levator ani nerve (LAN) (Wallner et al. 2008), which arises directly from the sacral plexus.

Dual autonomic supralelevator and somatic infralevator innervation occurred in five directions, playing a role in urination, defecation and sexual function. Innervation of the anal sphincter, the urethral sphincters and the LAM is responsible for micturition-continenence and defecation cycles. Innervation of the other two structures is of importance in ejaculation/orgasm (seminal complex, vagina, corpus spongiosum and bulbospongiosus muscles) and in erection (corpora cavernosa and ischiocavernosus muscles) functions. This description of this dual innervation improves our understanding of the reflex loops around the LAM and

demonstrates the importance of autonomic nerve fibre preservation during surgical procedures, as these fibres play an important role in pelvic functional cycles.

Autonomic-somatic communications were found to occur between the supralelevator-autonomic and the infralevator-somatic pathways at several levels. Proximal communication between the supra- and infralevator pathways has been reported before (Arango-Toro & Domenech-Mateu, 1993; Benoit et al. 1999) and our description of some fibres of the PN joining the supralelevator course of the IHP and intermingling with it are consistent with these previous studies.

There have been reports of intermediate intralelevator communication. Wallner et al. (2008) reported a somatic communicating nerve branch between the LAN and the PN in more than half the hemi-pelvises studied. In our study, the LAN was not identified distinctly. The only branches identified in relation to the sacral plexus were the proximal infra-supralelevator communication between the PN and the IHP. No distinct pathway was observed when these communicating branches, which intermingle with the autonomic plexus, were followed. We observed some nerve fibres branching off from the IHP

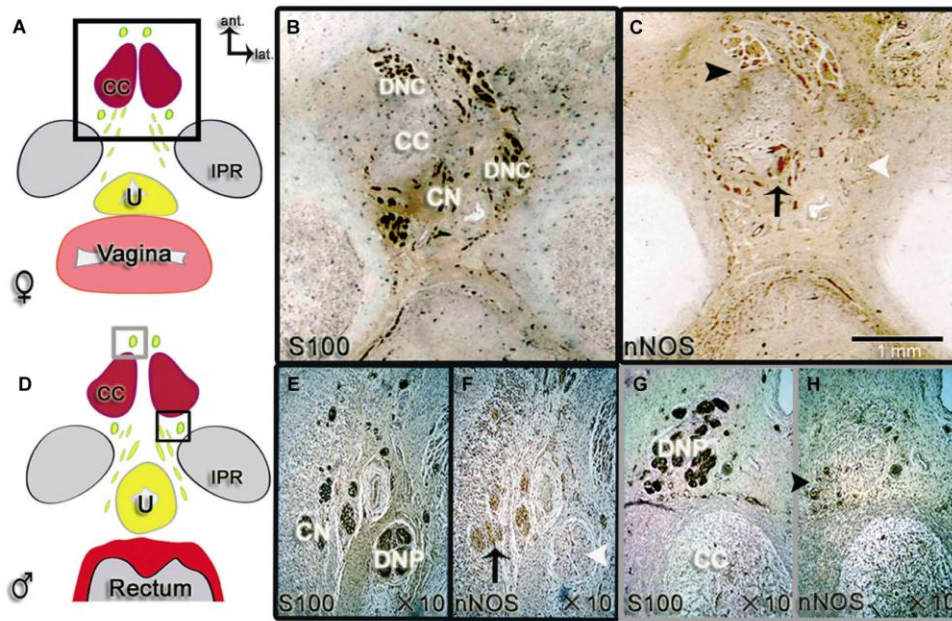


Fig. 5 (A,D) Schematic diagrams of pelvic transverse sections at the ischio-pubic root (IPR) in female and male fetuses, (B,C) Serial transverse sections of 26-week-old female fetuses at the level of the clitoris hilum (frame in A) immuno-stained with antibody against S100 in (B) and antibody against nNOS in (C) and scanned at an optical resolution of 4800 dpi. (E–H) Microscopic appearance ($\times 10$) of the dorsal nerve of the penis (DNP) in 20-week-old-male fetuses; proximal portion near the penile hilum (black frame in D) and distal portion in the penis (grey frame in D), immuno-stained with antibody against S100 in (E,G) and antibody against nNOS in (F,H). The cavernous nerves (CN) travel antero-lateral to the urethra (U) and reach the corpora cavernosa (CC). CN gave a positive signal with anti-nNOS antibodies in both sexes (black arrow in C,F), The somatic dorsal nerve of the clitoris (DNC) and the DNP had segmental nitregeric activity and their proximal portions were negative for nNOS (white arrowhead in C,F), with parietal anti-nNOS staining observed in the distal portions (black arrowhead in C,H).

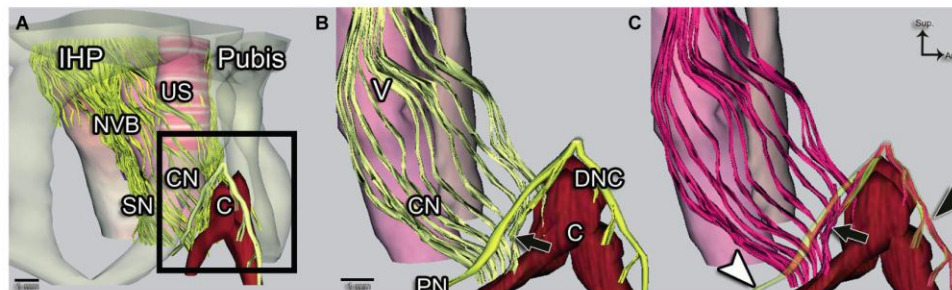


Fig. 6 (A) Computer-assisted anatomical dissection (CAAD) of the pelvic structure with pubis transparency in a 26-week-old female fetus, shown in antero-lateral view. (B) Zoomed view (frame in A) without the bone. (C) Same view with nerve fibre transparency, with nitregeric nerve fibres shown in pink. The distal branches from the inferior hypogastric (pelvic) plexus (IHP) formed the neurovascular bundles (NVB). Some nerve fibres converged in an anterior position to innervate the urethral sphincter (US). The NVB continued its postero-lateral course to the vagina, to reach the corpus spongiosum vestibular bulb via the spongious nerves (SN). The cavernous nerves (CN) travelled anterolaterally to the vagina (V) and reached the corpora cavernosa of the clitoris (C). All the CN fibres were nitregeric. The pudendal nerve (PN) became the dorsal nerve of the clitoris (DNC), which had segmental nitregeric activity, with a non-nitregeric proximal portion (white arrowhead in C) and a nitregeric distal portion (black arrowhead in C). The change in the nitregeric nature of the DN related to the DNC branches (black arrow in B,C), which interacted with the nitregeric CN and carried the nitregeric activity to the DN. This interaction occurred in the X-shaped region of communication between the infra- and supraleator pathways.

toward the LAM and travelling laterally to the pelvic fascia. Most were dispersed in the lower part of the muscle, but some followed an intralevator course to the emergence of the

pudendal pedicle. These fibres were very fine and were observed in only two subjects. These fibres were considered to constitute intermediate communications between the

autonomic supralelevator and the somatic infralevator pathways, partly accounting for the autonomic innervation of the proximal part of corpora cavernosa. Given the small number of subjects concerned, further studies are required to determine the occurrence of the intralelevator communications and to clarify their nature.

Various reports have considered the distal communicating branches between the cavernous and dorsal nerves and their potential importance in erectile function. In a previous dissection study (Colombel et al. 1999), we identified communicating branches from the CN that joined the DN at an acute angle but did not determine their nature. Paick et al. (1993) also reported that the CN sent connecting branches to the DN or completely merged into the DN. They suggested that the DN acts as a 'carrier' of the CN to the distal corpora cavernosa and glans. More recently, Yucel & Baskin (Yucel & Baskin, 2003; Yucel et al. 2004) demonstrated segmental nitrergic activity of the DN in both sexes. They used three-dimensional reconstruction to identify branches from the cavernous nerve joining the dorsal nerve of the penis and sending out nNOS-positive fibres in males. In females, they put forward an explanation for the loss of nNOS positivity in the dorsal nerve fibres of the clitoris proximal to the clitoral body hilum, involving possible communication between nNOS-immunoreactive CN and the distal dorsal nerve of the clitoris. In our study, based on similar methods, we confirmed the occurrence of segmental nitrergic activity in both sexes. This conversion was related to the interaction between the CN and the DN in the hilum of the penis/clitoris. We also highlighted the existence of some somatic nitrergic DN branches carrying the nitrergic reaction from the CN to the distal part of the DN. These observations are consistent with the description of the DN as a carrier of autonomic nitrergic activity to the distal part of the cavernous tissues (Paick et al. 1993; Yucel & Baskin, 2003; Yucel et al. 2004). The nerves in the corpora cavernosa are known to extend from the CN. However, we observed that the distribution of the CN was limited to the penile/clitoris root and the proximal part of the corporeal bodies, with the DN supporting innervation to more distal areas. The DN is considered to be the nerve conferring sensitivity on the external genital organs, the glans skin in particular. The DN is not considered an autonomic nerve, but it contains autonomic nerve fibres supplying distal nitrergic reactivity, highlighting the importance of the DN in erection physiology.

This hypothesis has significant implications for surgery and improves our understanding of erectile dysfunction after pelvic surgery, radical prostatectomy in particular. It suggests possible plasticity in the supply of nerves for penis erection. The notion of segmental DN nitrergic activity is important during sex reassignment surgery and reconstruction of the external genital. In clitoroplasty or phalloplasty, the mobilisation of the glans with its NVB (Acimi, 2008) should respect the course of the antero-lateral cavernous

nerve. In transsexual female-to-male surgery, the precise location of the recipient nerves must be determined distally to the X-shaped area of communication, to preserve nitrergic activity in the distal part of the erectile bodies.

Sacral neuromodulation (SNM) has recently shown clinically important benefit for the sexual function of both genders, mainly in individuals with lower urinary tract symptoms (Pauls et al. 2007; Lombardi et al. 2008). The mechanism by which SNM works is not completely known (Bernstein & Peters, 2005) but one potential explanation is its action on the parasympathetic system that influences both detrusor contraction and erectile function through somatic spinal loops (Leng & Chancellor, 2005). Autonomic manifestations of sexual function improvement might involve the distal caverno-pudendal nitrergic communications.

Conclusion

The pelvic structures responsible for sphincter control and sexual function receive dual innervation from the autonomic supralelevator and the somatic infralevator pathways. These two pathways display proximal, intermediate and distal communications. The CN and branches from the DN communicate distally in an X-shaped region in which these pathways cross each other in two spatial planes. This interaction carries nitrergic activity to the distal part of the cavernous bodies in both sexes and is important for erectile function. The existence of these autonomic-somatic communicating branches suggests possible plasticity of the nervous supply of potential clinical interest for the prevention of postoperative urogenital and digestive dysfunctions and for pharmacological and rehabilitation treatments for these dysfunctions. However, these data were obtained in fetal tissues and further anatomical studies in adult are required, considering that anatomical relationship, as well nervous apparatus, could change anatomical relationships during puberty.

References

- Acimi S (2008) Clitoroplasty: a variant of the technique. *Urology* **72**, 669–671.
- Alsaid B, Bessedé T, Karam I, et al. (2009) Coexistence of adrenergic and cholinergic nerves in the inferior hypogastric plexus: anatomical and immunohistochemical study with 3D reconstruction in human male fetus. *J Anat* **214**, 645–654.
- Alsaid B, Bessedé T, Diallo D, et al. (2011) Division of autonomic nerves within the neurovascular bundles distally into corpora cavernosa and corpus spongiosum components: immunohistochemical confirmation with three-dimensional reconstruction. *Eur Urol* **59**, 902–909.
- Arango-Toro O, Domenech-Mateu JM (1993) Development of the pelvic plexus in human embryos and fetuses and its relationship with the pelvic viscera. *Eur J Morphol* **31**, 193–208.

- Baader B, Herrmann M** (2003) Topography of the pelvic autonomic nervous system and its potential impact on surgical intervention in the pelvis. *Clin Anat* **16**, 119–130.
- Baizer JS, Broussard DM** (2010) Expression of calcium-binding proteins and nNOS in the human vestibular and precerebellar brainstem. *J Comp Neurol* **518**, 872–895.
- Barber MD, Bremer RE, Thor KB, et al.** (2002) Innervation of the female levator ani muscles. *Am J Obstet Gynecol* **187**, 64–71.
- Benoit G, Droupy S, Quillard J, et al.** (1999) Supra and infralevator neurovascular pathways to the penile corpora cavernosa. *J Anat* **195** (Pt 4), 605–615.
- Bernstein AJ, Peters KM** (2005) Expanding indications for neuromodulation. *Urol Clin North Am* **32**, 59–63.
- Bremer J, Baumann F, Tiberi C, et al.** (2010) Axonal prion protein is required for peripheral myelin maintenance. *Nat Neurosci* **13**, 310–318.
- Burnett AL, Lowenstein CJ, Brecht DS, et al.** (1992) Nitric oxide: a physiologic mediator of penile erection. *Science* **257**, 401–403.
- Colleselli K, Stenzl A, Eder R, et al.** (1998) The female urethral sphincter: a morphological and topographical study. *J Urol* **160**, 49–54.
- Colombel M, Droupy S, Paradis V, et al.** (1999) Caverno-pudendal nervous communicating branches in the penile hilum. *Surg Radiol Anat* **21**, 273–276.
- Costello AJ, Brooks M, Cole OJ** (2004) Anatomical studies of the neurovascular bundle and cavernosal nerves. *Br J Urol Int* **94**, 1071–1076.
- Fritsch H** (1989) Topography of the pelvic autonomic nerves in human fetuses between 21–29 weeks of gestation. *Anat Embryol (Berl)* **180**, 57–64.
- Hern WM** (1984) Correlation of fetal age and measurements between 10 and 26 weeks of gestation. *Obstet Gynecol* **63**, 26–32.
- Hoyle CH, Stones RW, Robson T, et al.** (1996) Innervation of vasculature and microvasculature of the human vagina by NOS and neuropeptide-containing nerves. *J Anat* **188** (Pt 3), 633–644.
- Junemann KP, Schmidt RA, Melchior H, et al.** (1987) Neuroanatomy and clinical significance of the external urethral sphincter. *Urol Int* **42**, 132–136.
- Karam I, Moudouni S, Droupy S, et al.** (2005) The structure and innervation of the male urethra: histological and immunohistochemical studies with three-dimensional reconstruction. *J Anat* **206**, 395–403.
- Leng WW, Chancellor MB** (2005) How sacral nerve stimulation neuromodulation works. *Urol Clin North Am* **32**, 11–18.
- Lombardi G, Mondaini N, Giubilei G, et al.** (2008) Sacral neuromodulation for lower urinary tract dysfunction and impact on erectile function. *J Sex Med* **5**, 2135–2140.
- Martin-Alguacil N, Pfaff DW, Shelley DN, et al.** (2008a) Clitoral sexual arousal: an immunocytochemical and innervation study of the clitoris. *BJU Int* **101**, 1407–1413.
- Martin-Alguacil N, Schober J, Kow LM, et al.** (2008b) Oestrogen receptor expression and neuronal nitric oxide synthase in the clitoris and preputial gland structures of mice. *Br J Urol Int* **102**, 1719–1723.
- Mauroy B, Bizet B, Bonnal JL, et al.** (2007a) Systematization of the vesical and uterovaginal efferences of the female inferior hypogastric plexus (pelvic): applications to pelvic surgery on women patients. *Surg Radiol Anat* **29**, 209–217.
- Mauroy B, Demondion X, Bizet B, et al.** (2007b) The female inferior hypogastric (= pelvic) plexus: anatomical and radiological description of the plexus and its afferences – applications to pelvic surgery. *Surg Radiol Anat* **29**, 55–66.
- Moszkowicz D, Alsaïd B, Bessedé T, et al.** (2011a) Female pelvic autonomic neuroanatomy based on conventional macroscopic and computer-assisted anatomic dissections. *Surg Radiol Anat* **33**, 397–404.
- Moszkowicz D, Alsaïd B, Bessedé T, et al.** (2011b) Neural supply to the clitoris: immunohistochemical study with three-dimensional reconstruction of cavernous nerve, spongiosus nerve, and dorsal clitoris nerve in human fetus. *J Sex Med* **8**, 1112–1122.
- Narayan P, Konety B, Aslam K, et al.** (1995) Neuroanatomy of the external urethral sphincter: implications for urinary continence preservation during radical prostate surgery. *J Urol* **153**, 337–341.
- Paick JS, Donatucci CF, Lue TF** (1993) Anatomy of cavernous nerves distal to prostate: microdissection study in adult male cadavers. *Urology* **42**, 145–149.
- Pauls RN, Marinkovic SP, Silva WA, et al.** (2007) Effects of sacral neuromodulation on female sexual function. *Int Urogynecol J Pelvic Floor Dysfunct* **18**, 391–395.
- Roberts WH, Harrison CWS, Mitchell DAJ, et al.** (1988) The levator ani muscle and the nerve supply of its puborectalis component. *Clin Anat* **1**, 267–283.
- Shafik A, el-Sherif M, Youssef A, et al.** (1995) Surgical anatomy of the pudendal nerve and its clinical implications. *Clin Anat* **8**, 110–115.
- Snipes GJ, Suter U, Welcher AA, et al.** (1992) Characterization of a novel peripheral nervous system myelin protein (PMP-22/SR13). *J Cell Biol* **117**, 225–238.
- Wallner C, van Wissen J, Maas CP, et al.** (2008) The contribution of the levator ani nerve and the pudendal nerve to the innervation of the levator ani muscles; a study in human fetuses. *Eur Urol* **54**, 1136–1142.
- Yucel S, Baskin LS** (2003) Identification of communicating branches among the dorsal, perineal and cavernous nerves of the penis. *J Urol* **170**, 153–158.
- Yucel S, De Souza A Jr, Baskin LS** (2004) Neuroanatomy of the human female lower urogenital tract. *J Urol* **172**, 191–195.

Article 6 : Préservation de l'innervation à destinée génitale de la femme au cours de l'exérèse totale du mésorectum : quel plan de dissection antérieur ? [4]

Peschaud F, **Moszkowicz D**, Alsaïd B, Bessède T, Penna C, Benoit G. Preservation of genital innervation in women during total mesorectal excision: which anterior plane? *World J Surg* 2012;36(1): 201-207.

IF 2011: **2,362**

Résumé

Objectifs: chez l'homme, la dysfonction érectile liée aux blessures des structures nerveuses autonomes après exérèse totale du mésorectum (ETM) est une cause majeure de morbidité post-opératoire. Cependant, chez la femme, l'innervation des corps érectiles est moins connue et les caractéristiques du plan de dissection antérolatérale du rectum au cours de l'ETM doit être précisé. L'existence d'un septum recto-vaginal (SRV) et sa structures demeurent le sujet de controverses. L'objectif de cette étude était donc d'identifier le septum recto-vaginal chez le fœtus humain féminin et le sujet adulte afin de définir ses rapports avec les fibres nerveuses destinées aux corps érectiles.

Matériel et méthodes: dissections macroscopiques, études histochimiques et immunohistochimiques avec reconstruction 3D réalisées chez 6 sujets adultes frais et 6 fœtus de sexe féminin.

Résultats: Le SRV était clairement définissable chez tous les adultes. Il se composait de multiples feuillets de tissu conjonctif associés à des fibres musculaires lisses issues des parois utérine et vaginale. Les fibres nerveuses issues de la partie distale du PHI et responsables de la fonction sexuelle convergent vers le diaphragme uro-génital. Elles sont regroupées et associées aux pédicules vasculaires vaginaux longs pour former les bandelettes neuro-vasculaires (BNV), situées à 2 et 10 heures sur la face antérolatérale du rectum, véhiculant des fibres sympathiques, parasympathiques, nitreurgiques et sensibles. Ces troncs neurovasculaires regroupant l'ensemble des fibres nerveuses érectiles destinées au périnée (cholinergiques et nNOS +) peuvent être lésés lors de la dissection antérolatérale du rectum. Ces BNV envoient des fibres nerveuses destinées à la paroi postérieure du vagin, qui se situent en avant du septum rectovaginal (SRV). Trois efférences principales sont issues des BNV à hauteur du bas rectum : le plexus urétral, destiné au sphincter urétral, le nerf caveux, destiné aux corps caveux du clitoris et le nerf spongieux, destiné aux bulbes vestibulaires. La dissection antérolatérale du rectum devrait donc, si les conditions carcinologiques le permettent, passer dans un plan situé entre le prolongement latéral postérieur du SRV en arrière et la face postérieure de la BNV en avant. En effet, une lésion tronculaire des BNV au cours de cette dissection, où convergent l'ensemble des fibres destinées à l'innervation des corps érectiles et du sphincter urétral, pourrait conduire à une dysfonction multiple avec trouble de la continence, de la tumescence clitoridienne et de la sécrétion génitale.

Conclusions: afin de réduire le risque de dysfonction sexuelle après ETM pour cancer, si les conditions carcinologiques le permettent, il convient de respecter un plan de dissection au contact du mésorectum antérieur, en arrière de l'extension postérieure du SRV, respectant l'innervation autonome à génito-urinaire.

Preservation of Genital Innervation in Women During Total Mesorectal Excision: Which Anterior Plane?

Frédérique Peschaud · David Moszkowicz ·
Bayan Alsaïd · Thomas Bessede · Christophe Penna ·
Gérard Benoit

Published online: 6 October 2011
© Société Internationale de Chirurgie 2011

Abstract

Background Erectile dysfunction, principally related to injury of the autonomic nerve fibers in men, is a major cause of postoperative morbidity after anterolateral dissection during total mesorectal excision (TME) for rectal adenocarcinoma. However, the autonomic innervation of erectile bodies is less known in women, and the anterolateral plane of dissection during TME remains unclear. The existence of the rectovaginal septum (RVS) is controversial. The purpose of the present study was to identify the RVS in the human fetus and adult female by dissection, immunohistochemistry, and three-dimensional reconstruction, and to define its relationship with erectile nerve fibers so as to determine the anterolateral plane of dissection during TME, which could reduce postoperative sexual dysfunction in women.

Method Macroscopic dissection, histologic studies, and immunohistochemistry examination with 3D reconstruction

were performed in six fresh female adult cadavers and six female fetuses.

Results The RVS was clearly definable in all adult specimens. It was composed of multiple connective tissue, with smooth muscle fibers originating from the uterus and the vagina. It is closely applied to the vagina and has a relationship with the neurovascular bundles (NVBs) that contain erectile fibers intended for the clitoris. The NVBs are situated anteriorly to the posterior extension of rectovaginal septum. This posterior extension protects the NVBs during the anterior and anterolateral dissection for removal of rectal cancer.

Conclusions To reduce the risk of postoperative sexual dysfunction in women undergoing TME for rectal cancer, we recommend careful dissection to the anterior mesorectum to develop a plane of dissection behind the posterior extension of the RVS if oncologically reasonable.

F. Peschaud · D. Moszkowicz · B. Alsaïd · T. Bessede ·
G. Benoit
Laboratory of Experimental Surgery, EA 4122, Faculty of
Medicine, Paris Sud-11 University, 78, rue du Général Leclerc,
94275 Le Kremlin-Bicêtre, France

F. Peschaud · C. Penna
Department of Surgery Assistance Publique, Hôpitaux de Paris,
Ambroise Paré Hospital, 9 avenue Charles-de-Gaulle, 92
Boulogne-Billancourt, France

F. Peschaud · C. Penna
University of Versailles Sain-Quentin-en-Yvelines (UVSQ), 55
avenue de Paris, 78035 Versailles, France

F. Peschaud (✉)
Service de Chirurgie Oncologique et Digestive, Hôpital
Ambroise Paré, 9 Avenue Charles de Gaulle, 92100 Boulogne,
France
e-mail: frederique.peschaud@apr.aphp.fr

Introduction

Sexual dysfunction remains a major cause of postoperative morbidity after prostatectomy with total mesorectal excision (TME) for rectal adenocarcinoma [1, 2]. Erectile dysfunction is principally related to injury of the nerve fibers of the inferior hypogastric (pelvic) plexus (IHP) during anterolateral dissection [3]. The neurovascular bundles (NVBs) and their relationship with rectal fascia and Denonvilliers' fascia have been widely studied in men [4–6] to determine the best approach to rectal dissection during TME. Accordingly, nerve-sparing surgical techniques have been described in men to improve postoperative functional results after TME [7, 8].

The current description of the surgical technique is supported by anatomical data of pelvic and perineal

innervation [9–12]. However, the autonomic innervation of erectile bodies is less known in women, and the existence of the rectovaginal septum (RVS; the equivalent of Denonvilliers' fascia in men) [13] is controversial. Consequently, the anterior and anterolateral plane of dissection during TME in women remains unclear.

Pelvi-perineal innervation is microscopic and difficult to define by classical anatomical methods of dissection. However, specific biologically active substances within the nerve fibers and tissues can be detected by immunohistochemical methods and used to determine the nature of nerve fibers and their relationship with the anatomic structures. Three-dimensional (3D) reconstruction of serial immunolabeled histologic sections thus constitutes an interesting tool with which to identify the peripheral innervations of female deep pelvic organs and to obtain usable surgical anatomic data [14–17].

The purpose of the present study was to identify the RVS in the human fetus and adult female, and to define its relationship with the neurovascular bundles by dissection, immunohistochemistry, and 3D reconstruction so as to determine the anterior plane of dissection during TME, thereby reducing postoperative sexual dysfunction in women.

Methods

Specimens

Fetal specimen

This work involved a defined protocol that required and received examination and approval by the French Biomedicine Agency. We studied the pelvic portion of six normal female fetuses between 25 and 31 weeks of gestation. Specimens were fixed in formalin, cut into blocks, and embedded in paraffin to obtain a series of 5 μm sections at 50–200 μm intervals.

Adult fresh cadaveric specimens

Six adult female cadavers (age range at death: 77–89 years) were dissected at the Anatomy Laboratory of the Saint-Pères School of Medicine, University Paris V. Although the exact cause of death was unknown, macroscopic examination showed that the pelvis was free from visible tumors and had not been subject to surgical intervention. All the intrapelvic organs and their surrounding tissues were removed in a single block. Specimens included the rectum, the uterus, the vagina, the bladder and urethra, and the inferior hypogastric plexus (IHP) with afferent and efferent fibers. Tissues were cut into transverse sections after formalin fixation, and each transverse section was divided into multiple blocks (two to

four portions) with standard and/or mega-cassettes for embedding in paraffin. We then cut series of 5 μm sections at intervals of 200–250 μm . Two of the six specimens were cut midsagittally and examined.

Histologic and immunohistochemistry examination

The pelvic autonomic nerves were investigated by conventional histologic staining methods (hematoxylin/eosin [H&E], and Masson trichrome stain, which was intended to distinguish the fascial connective tissue) and immunohistochemical staining of the neural structures as previously described [14, 15]. The following immunomarkers were used: protein S-100 for nerve fibers, vesicular acetylcholine transporter (VAcHT) for cholinergic fibers, tyrosine hydroxylase (TH) for adrenergic-sympathetic fibers, calcitonin gene-related peptide (CGRP) for sensory nerve fibers, smooth muscle actin (SMA) for smooth muscles fibers, and neural nitric oxide synthase (nNOS) for nitrergic erectile nerve fibers [18–21].

Three-dimensional (3D) reconstruction of the female fetus

Serial 2D sections, stained and immunolabeled for nerve fibers and for neurotransmitters, were used to perform the 3D reconstructions. Analysis of sections stained with H&E and Masson trichrome under appropriately high magnifications ($\times 4$ – $\times 20$) allowed us to distinguish various anatomical structures. The H&E-stained sections were considered to be the reference sections. The subsequent section, treated with anti-S100, revealed pelvic-perineal nerves. By comparing H&E-stained sections and anti-S100-labeled sections, as well as those treated with anti-VAcHT, anti-TH, anti-PMP22, anti-CGRP, and anti-nNOS, we were able to distinguish the nature of nerve fibers: autonomic (cholinergic or adrenergic) or somatic; sensory and erectile. All sections were digitized by direct scanning at 4,800 dots-inch⁻¹ resolution, and then images were stacked and aligned with Adobe Photoshop image processing software. Pelvic anatomical structures and nerve fibers were outlined manually in all histological sections and reconstructed in 3D using Surfdriver software for Windows (WinSurf 4.3).

Results

Recto-vaginal septum (RVS)

Macroscopic dissection of midsagittal sections in the adult (Fig. 1a)

The RVS was found cranially from below the recto-uterine pouch in all female cadavers examined. This structure was independent of the peritoneum of the recto-uterine pouch.

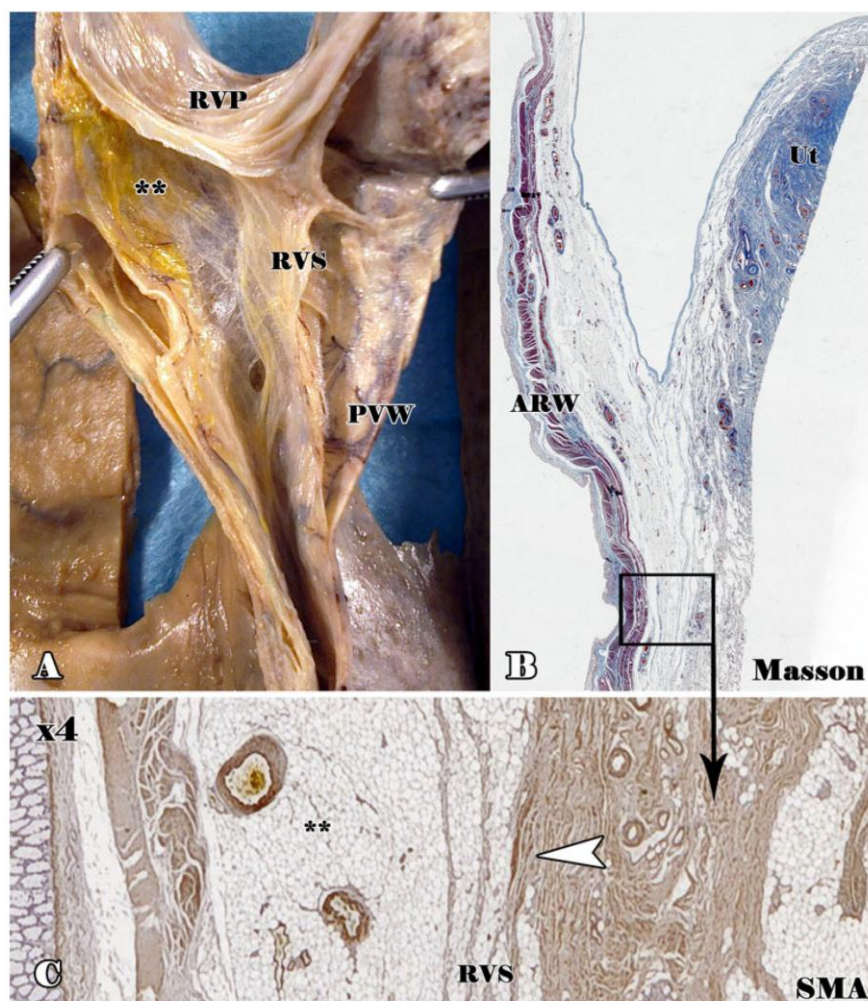


Fig. 1 Adult recto-vaginal septum (RVS). Macroscopic dissection of midsagittal section of a 78-year-old adult cadaver showing the RVS, stained with Masson trichrome (**b**), located at the posterior vaginal wall (PVW) and anterior rectal wall (ARW). The RVS contains smooth

muscle fibers (immunolabeled with anti-smooth muscle actin (SMA), **c** black square, $\times 4$ magnification) originating from the vagina and uterus (U; white arrowhead). RUP recto-uterine pouch; bold asterisks anterior mesorectum

It was easily separated from the fascia propria of the rectum, which surrounds the anterior rectal wall and its mesorectum. There was strong connective tissue between the RVS and the anterior fascia propria, but at the level of the lower rectum, the anterior mesorectum was very thin and the fascia propria of the rectum was attached to the RVS.

Histologic examination (Figs. 1b,c; 2; 3a)

The RVS was clearly definable in all specimens. Histologically, it was composed of multiple connective tissue layers that were closely applied to the vagina and contained smooth muscle fibers from the vagina and the inferior segment of the uterus. Ventrocranially, it formed an

incomplete anatomic partition between the posterior and the middle compartments. However, there was no layer of smooth muscular fibers laterally at any level, and the RSV had no definable lateral edge. The multiple connective tissue layers were separated laterally and made a “Y” shaped extension that joined the lateral vaginal wall anteriorly and the fascia propria of the rectum posteriorly.

Recto-vaginal septum and neurovascular bundles: relationship (Figs. 4, 5)

The inferior hypogastric plexus (IHP) was located on the pelvic side wall, stretched from the lateral surface of the rectum, passed the cervix and the vaginal fornix laterally, and

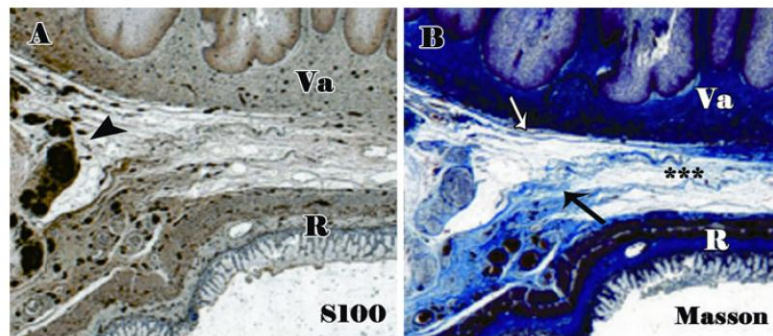


Fig. 2 Fetal RVS and neurovascular bundle (NVB). Histologic 5- μ m-thick transverse sections of a 26-week-old female fetus scanned at an optical resolution of 4,800 dpi. The RVS (asterisks) is composed medially of multiple connective tissue (Masson trichrome staining,

bold asterisks, **b**) and forming laterally anterior (white arrow) and posterior (black arrow) extensions in the form of a “Y,” where the neurovascular bundle is situated (black arrowhead S100 immunolabeling; **a**). Va vagina; R rectum

extended to the lateral vaginal wall and the base of the bladder. It contained a mixed association of TH, VACHT, CGRP, and nNOS-positive fibers. The anteroinferior part of the IHP converged in a caudal direction and reached down to the pelvic floor. The closer the levator ani muscle was to the rectum, the more the distal plexus was pushed into a small triangular space bordered by the levator ani muscle laterally, the rectum dorsally, and the vagina ventrally. These antero-inferior fibers were gathered in neural bundles forming NVBs with the vaginal pedicle. The NVBs were situated at the 2 o’clock and 10 o’clock positions around the anterior rectum and at the 5 o’clock and 7 o’clock positions around the posterior vaginal wall. These bundles then formed two major perineal projections: an anterior projection for the urethral sphincter complex and an inferior projection for the perineal erectile bodies. The NVBs contained nNOS-positive fibers, which were densely clustered around the vaginal pedicle. Furthermore, the NVBs contained VACHT- and TH-positive fibers and occasional sensory fibers (CGRP-positive).

The last four collateral branches of the NVBs were: medial to the posterior vaginal wall, anterior to the urethral sphincter (urethral plexus), anterolateral to the clitoris corpora cavernosa (cavernous nerve), and posterolateral to the clitoris bulbs (spongious nerve).

The trunk of the NVBs was situated between the anterolateral and posterolateral extension of the RVS—i.e., between “the two arms of the elongated Y,” and all the nerves of the NVBs were scattered in the loose connective tissue. Posterolateral extension of the RVS separated the NVBs from the rectal fascia.

Discussion

The rectovaginal septum (RVS), which corresponds to Denonvilliers’ fascia in men, is composed of multiple

connective tissue layers and smooth muscle fibers originating from the uterus and vaginal muscular walls. It is closely applied to the vagina and has relationship with the neurovascular bundles giving rise to vaginal and perineal efferent fibers. Injury to the NVBs during TME may lead to severe sexual dysfunction because sympathetic, parasympathetic, and erectile efferent fibers intermingle at this level.

The existence of the RVS in women is controversial. Some authors claim that there is no fascial layer between the posterior vaginal wall and the anterior rectal wall [22–24]. However, macroscopic and microscopic studies in the fetus have shown dense collagen tissue and multiple layers of connective tissue between the rectal and vaginal wall from 25 weeks of gestation [25]. Furthermore, smooth muscle fibers inserted between several layers of connective tissue have been described in the adult and form an independent anatomic structure between the anterior genital compartment and the posterior visceral compartment in the female [26]. This structure presents the RVS and it is the equivalent of Denonvilliers’ fascia described in men as a prostate-peritoneal aponeurosis.

According to our macroscopic findings, the RVS is closely applied to the posterior vaginal wall. Indeed, we observed that the smooth muscle fibers, situated between the dense collagen tissue, originate from the uterus and the vaginal wall, in contrast to observations by Aigner et al. and Ludwikowski et al. [26, 27]. To Aigner et al. [26], the septum originated from the longitudinal muscle layer of the ventral rectal wall. These smooth muscle fibers are present only between the rectum and the vagina. Therefore, the RVS (smooth muscle fibers and connective tissue) is a structure that can be easily seen medially. On the other hand, it does not exist laterally as such. It gives an anterior and posterior extension in the form of a “Y.” We also noted that the posterolateral extension joins behind the

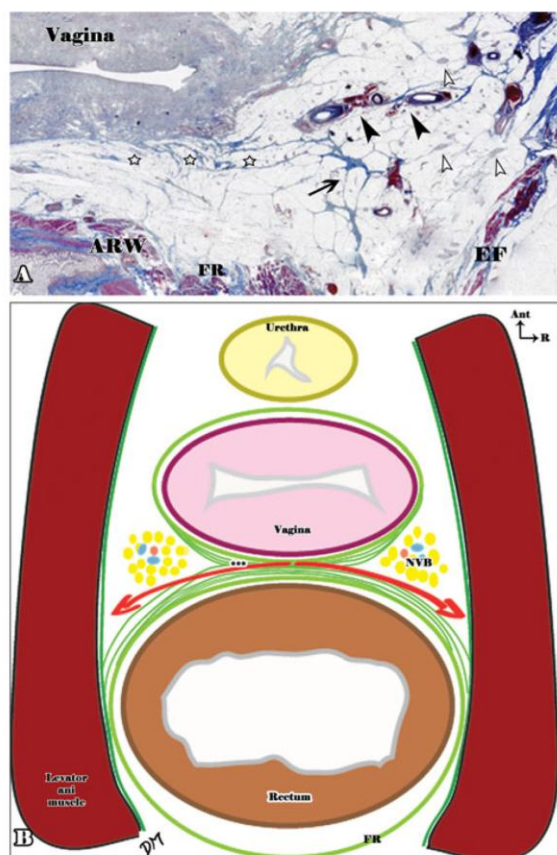


Fig. 3 Anterolateral plane of surgical rectal dissection. **a** Histologic transverse sections of a 80-year-old adult cadaver stained with Masson trichrome showing the RVS (white stars) with its posterior extension (black arrow), in relation to the vaginal pedicle (black arrowheads) and the neural bundle (white arrowheads). **b** Manual illustration of a transverse section of the neurovascular bundle (NVB) between the rectum and the vagina, showing its relationship with the RVS (bold asterisks). Red arrows show the ideal anterolateral plane of surgical dissection, behind the rectovaginal septum posterior extension, in order to avoid a potential NVB injury

fascia propria of the rectum that coats the anterior mesorectum, in contrast to observations of Zhai et al. [28], who concluded that the posterior layer of the rectovaginal septum was the fascia propria itself. The anterolateral extension joins anteriorly the lateral side of the vagina. This finding is different from the traditional description of Denonvilliers' fascia in men, where the fascia is composed of two layers, anterior and posterior, and that the posterior layer is the fascia propria of the rectum [29–32].

In our study, we did not observe any attachment of the RVS to the peritoneum of the recto-uterine pouch, in contrast to the observations of Zhai et al. [28]. The septum is gradually thinner and finally disappears at the level of the

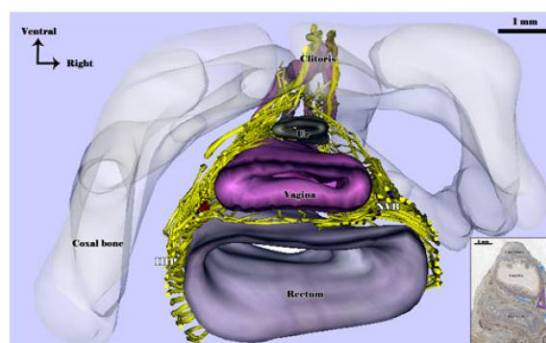


Fig. 4 Morphologic and functional systematization of the NVB. Histologic 5- μ m-thick transverse sections of a 30-week-old female fetus scanned at an optical resolution of 4,800 dpi, stained with hematoxylin/eosin (**a**) and immunolabeled with anti-S100 antibody (**b**), anti-TH (**c**), anti-nNOS (**d**), and anti-VaChT (**e**). Neurovascular bundles consist of nerve fibers and vaginal blood vessels scattered throughout the posterior and anterior extension of the RVS in a triangularly shaped space. LAM levator ani muscle; PM piriform muscle; PN pudendal nerve

perineal body [33]. At the lowest level of the rectum, the posterior vaginal wall and the anterior rectal wall are side by side and attached to the lowest part of the rectum. Three-dimensional reconstruction of the fascia (RVS) was not possible, because it is not a cylinder structure that can be outlined.

The neurovascular bundles were initially described by Walsh et al. [34] in men. We previously demonstrated by immunohistochemistry and 3D reconstruction that fibers supplying sexual organs were bundled in neurovascular bundles with the vaginal pedicle below the parietal peritoneum. These nerve bundles, originating from the IHP, contained sympathetic, parasympathetic, and erectile nerve fibers. Their terminal branches were the urethral plexus, the cavernous nerve for the clitoris corpora cavernosa, and the spongiosus nerve for the clitoris spongiosus bulbs [18]. In the present study, these NVBs are confirmed to be located at the 2 o'clock and 10 o'clock positions around the anterior rectum but are found anteriorly to the posterolateral extension of the RVS. This extension protects the NVB during anterior dissection of the rectum. A triangular zone can be described between the two lateral (posterior and anterior) extensions of RVS where the NVBs are situated.

Previous data have shown that erectile dysfunction in men after TME is a result of parasympathetic nerve damage [35–38]. However, female sexual dysfunction after pelvic surgery has largely been neglected in the colorectal literature. In our study the two key steps during TME for rectal cancer in women during which the NVBs or their branches are at risk of injury are the anterior and anterolateral dissections.

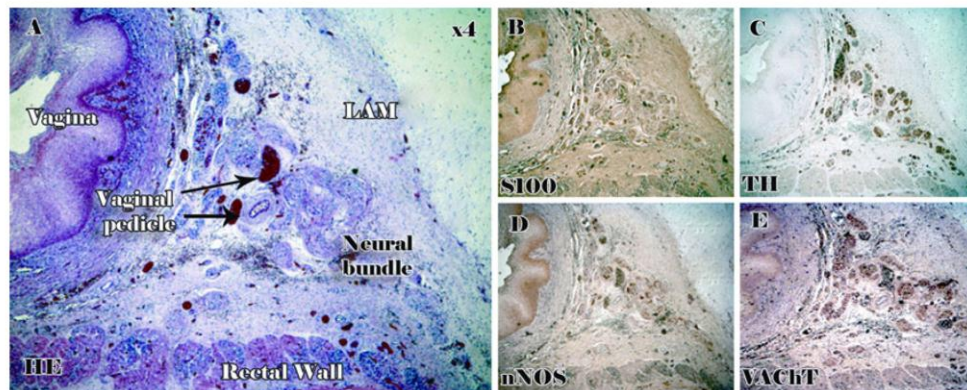


Fig. 5 Three-dimensional (3D) view of fetus intrapelvic organs with pelvic nerves. Superior infraperitoneal 3D view of a 30-week-old female fetus: intrapelvic organs with immunolabeled pelvic nerves showing the position of the inferior hypogastric plexus (IHP) on the lateral aspects of the rectum. From the IHP, efferent branches rise in distal directions: postero-inferior for the rectal wall, lateral for the levator ani muscles, and antero-inferior to form the NVBs. Some fibers from the NVBs branch medially to innervate the posterior

vaginal wall. More caudally, the bundle puts out fibers in three major projections: an anterior projection for the urethral sphincter complex, an anterolateral projection (the cavernous nerve) that travels anterolaterally to the vagina to reach the corpora cavernosa, and a posterolateral projection (the spongiosus nerve) that continues posterolaterally to the vagina to innervate the corpus spongiosum. In inset, blue arrows show the directions of the IHP and NVB main terminal efferences. *Ur* urethra

The NVBs, which are the erectile nervous trunks, give out a few nitrergic vasoactive branches for the posterior vaginal wall, which then run in front of the RVS and are probably responsible for vaginal lubrication. If the RVS is removed during TME, these nerves can be injured, resulting in sexual dysfunction such as vaginal dryness.

During anterolateral dissection, the NVBs can be hurt. Indeed, they lie in front of the posterolateral extension of RVS and are protected by this extension. Thus, if the posterolateral extension of the RVS is preserved during anterior resection of the rectum, the NVBs could also be preserved. This therefore defines an anterior plane of dissection between the RVS anteriorly and the fascia propria of the rectum posteriorly. Injury to the NVBs seems to be most likely when surgeons choose the surgical plane in front of the RVS, because the surgical plane easily shifts ventrolaterally toward the trunk of NVBs.

There is some dispute as to whether the best plane for performing TME for rectal cancer is in front of or behind the RVS [3, 35, 36, 39]. Heald et al. [39, 40] described Denonvilliers' fascia in men as constituting the anterior surface of the rectum, lying on the rectal side of the plane in which TME surgery is conducted. So, TME should resect Denonvilliers' fascia. Lindsey and colleagues recommend a mesorectal plane of dissection along the proper rectal fascia immediately behind Denonvilliers' fascia in men [3, 35, 36]. Our study confirms that the anterior dissection plane in women with rectal cancer is probably behind the RVS. Indeed, the NVB with erectile fibers for

the clitoris runs directly in front of the posterolateral borders of the RVS. Damage at this level can therefore give rise to severe sexual dysfunction.

In contrast, when the rectal tumor is anterior, making it necessary to increase the circumferential resection margin, the RVS can be removed, but the dissection plane should return as soon as possible to the fascia propria of the rectum laterally to reduce the risk of injury to the NVBs.

Conclusions

In women, the NVBs containing erectile fibers intended for the clitoris are situated anteriorly to the posterior extension of the RVS, which is the equivalent of Denonvilliers' fascia in men. This posterior extension protects the NVBs during the anterior dissection for removal of rectal cancer.

We therefore recommend careful dissection to the anterior mesorectum to develop a plane of dissection behind the posterior extension of the RVS if oncologically reasonable. If the rectal tumor is anterior, and if it is necessary to remove the vaginal wall partially and thus remove the RVS, the plane of dissection should join as soon as possible the posterior extension of the RVS to avoid lesions of the NVBs.

Acknowledgments This study was supported by grants from the A.R.O.L.D Association.

Conflicts of interest None of the authors has any financial or personal relationship that might have influenced this study.

References

- Nesbakken A, Nygaard K, Bull-Njaa T et al (2000) Bladder and sexual dysfunction after mesorectal excision for rectal cancer. *Br J Surg* 87:206–210
- Liang JT, Lai HS, Lee PH (2007) Laparoscopic pelvic autonomic nerve-preserving surgery for patients with lower rectal cancer after chemoradiation therapy. *Ann Surg Oncol* 14:1285–1287
- Lindsey I, Mortensen NJ (2002) Iatrogenic impotence and rectal dissection. *Br J Surg* 89:1493–1494
- Costello AJ, Brooks M, Cole OJ (2004) Anatomical studies of the neurovascular bundle and cavernosal nerves. *BJU Int* 94:1071–1076
- Walsh PC, Donker PJ (1982) Impotence following radical prostatectomy: insight into etiology and prevention. *J Urol* 128:492–497
- Alsaid B, Bessede T, Diallo D et al (2011) Division of autonomic nerves within the neurovascular bundles distally into corpora cavernosa and corpus spongiosum components: immunohistochemical confirmation with three-dimensional reconstruction. *Eur Urol* 59:902–909
- Fazio VW, Fletcher J, Montague D (1980) Prospective study of the effect of resection of the rectum on male sexual function. *World J Surg* 4:149–152. doi:10.1007/BF02393562
- Kneist W, Junginger T (2007) Male urogenital function after confirmed nerve-sparing total mesorectal excision with dissection in front of Denonvilliers' fascia. *World J Surg* 31:1321–1328. doi:10.1007/s00268-007-9008-4
- Hida J, Yasutomi M, Maruyama T et al (1999) High ligation of the inferior mesenteric artery with hypogastric nerve preservation in rectal cancer surgery. *Surg Today* 29:482–483
- Maeda K, Maruta M, Utsumi T et al (2002) Does perifascial rectal excision (i.e. TME) when combined with the autonomic nerve-sparing technique interfere with operative radicality? *Colorectal Dis* 4:233–239
- Havenga K, DeRuiter MC, Enker WE et al (1996) Anatomical basis of autonomic nerve-preserving total mesorectal excision for rectal cancer. *Br J Surg* 83:384–388
- Clausen N, Wolloscheck T, Konerding MA (2008) How to optimize autonomic nerve preservation in total mesorectal excision: clinical topography and morphology of pelvic nerves and fasciae. *World J Surg* 32:1768–1775. doi:10.1007/s00268-008-9625-6
- Denonvilliers CP (1836) *Anatomie du perinee*. *Bull Mem Soc Anat Paris* 2:105–106
- Alsaid B, Bessede T, Karam I et al (2009) Coexistence of adrenergic and cholinergic nerves in the inferior hypogastric plexus: anatomical and immunohistochemical study with 3D reconstruction in human male fetus. *J Anat* 214:645–654
- Moszkowicz D, Alsaid B, Bessede T et al (2011) Female pelvic autonomic neuroanatomy based on conventional macroscopic and computer-assisted anatomic dissections. *Surg Radiol Anat* 33:397–404
- Benoit G, Cailleaux F, Quillard J et al (1991) Computer assisted anatomical reconstruction: a prostate model. *Surg Radiol Anat* 13:45–47
- Alsaid B, Bessede T, Diallo D et al. (2011) Computer-assisted anatomic dissection (CAAD): evolution, methodology and application intra-pelvic innervation study. *Surg Radiol Anat* July 21 [Epub ahead of print]
- Moszkowicz D, Alsaid B, Bessede T et al (2011) Neural supply to the clitoris: immunohistochemical study with three-dimensional reconstruction of cavernous nerve, spongiosus nerve, and dorsal clitoris nerve in human fetus. *J Sex Med* 8:1112–1122
- Munarriz R, Kim NN, Goldstein I et al (2002) Biology of female sexual function. *Urol Clin North Am* 29:685–693
- Yucel S, De Souza A, Baskin LS Jr (2004) Neuroanatomy of the human female lower urogenital tract. *J Urol* 172:191–195
- Uckert S, Ehlers V, Nuser V et al (2005) In vitro functional responses of isolated human vaginal tissue to selective phosphodiesterase inhibitors. *World J Urol* 23:398–404
- Tobin CE, Rumery RE (1948) A method for staining collagenous tissue in gross anatomical sections. *Anat Rec* 101:281–289
- Ricci JV, Lisa JR, Kron WL et al (1947) The relationship of the vagina to adjacent organs in reconstructive surgery; a histologic study. *Am J Surg* 74:387–410
- Kleeman SD, Westermann C, Karram MM (2005) Rectoceles and the anatomy of the posteriorovaginal wall: revisited. *Am J Obstet Gynecol* 193:2050–2055
- Church JM, Raudkivi PJ, Hill GL (1987) The surgical anatomy of the rectum—a review with particular relevance to the hazards of rectal mobilisation. *Int J Colorectal Dis* 2:158–166
- Aigner F, Zbar AP, Ludwikowski B et al (2004) The rectogenital septum: morphology, function, and clinical relevance. *Dis Colon Rectum* 47:131–140
- Ludwikowski B, Hayward IO, Fritsch H (2002) Rectovaginal fascia: an important structure in pelvic visceral surgery? About its development, structure, and function. *J Pediatr Surg* 37:634–638
- Zhai LD, Liu J, Li YS et al (2009) Denonvilliers' fascia in women and its relationship with the fascia propria of the rectum examined by successive slices of celloidin-embedded pelvic viscera. *Dis Colon Rectum* 52:1564–1571
- Diop M, Parratte B, Tatu L et al (2003) "Mesorectum": the surgical value of an anatomical approach. *Surg Radiol Anat* 25:290–304
- Nano M, Levi AC, Borghi F et al (1998) Observations on surgical anatomy for rectal cancer surgery. *Hepatogastroenterology* 45:717–726
- Chapuis P, Bokey L, Fahrner M et al (2002) Mobilization of the rectum: anatomic concepts and the bookshelf revisited. *Dis Colon Rectum* 45:1–8 discussion 8–9
- van Ophoven A, Roth S (1997) The anatomy and embryological origins of the fascia of Denonvilliers: a medico-historical debate. *J Urol* 157:3–9
- Bisset IP, Chau KY, Hill GL (2000) Extrafascial excision of the rectum: surgical anatomy of the fascia propria. *Dis Colon Rectum* 43:903–910
- Walsh PC, Lepor H, Eggleston JC (1983) Radical prostatectomy with preservation of sexual function: anatomical and pathological considerations. *Prostate* 4:473–485
- Lindsey I, Warren BF, Mortensen NJ (2005) Denonvilliers' fascia lies anterior to the fascia propria and rectal dissection plane in total mesorectal excision. *Dis Colon Rectum* 48:37–42
- Lindsey I, Guy RJ, Warren BF et al (2000) Anatomy of Denonvilliers' fascia and pelvic nerves, impotence, and implications for the colorectal surgeon. *Br J Surg* 87:1288–1299
- Akasu T, Sugihara K, Moriya Y (2009) Male urinary and sexual functions after mesorectal excision alone or in combination with extended lateral pelvic lymph node dissection for rectal cancer. *Ann Surg Oncol* 16:2779–2786
- Celentano V, Fabbrocile G, Luglio G et al (2010) Prospective study of sexual dysfunction in men with rectal cancer: feasibility and results of nerve sparing surgery. *Int J Colorectal Dis* 25:1441–1445
- Heald RJ, Husband EM, Ryall RD (1982) The mesorectum in rectal cancer surgery—the clue to pelvic recurrence? *Br J Surg* 69:613–616
- Heald RJ (1988) The "Holy Plane" of rectal surgery. *J R Soc Med* 81:503–508

Erratum to: Preservation of Genital Innervation in Women During Total Mesorectal Excision: Which Anterior Plane?

Frédérique Peschaud · David Moszkowicz ·
Bayan Alsaïd · Thomas Bessede · Christophe Penna ·
Gérard Benoit

Published online: 9 December 2011
© Société Internationale de Chirurgie 2011

Erratum to: World J Surg
DOI 10.1007/s00268-011-1313-2

In the original article the captions for Figs. 4 and 5 are transposed. Following are the figures with their correct corresponding captions:

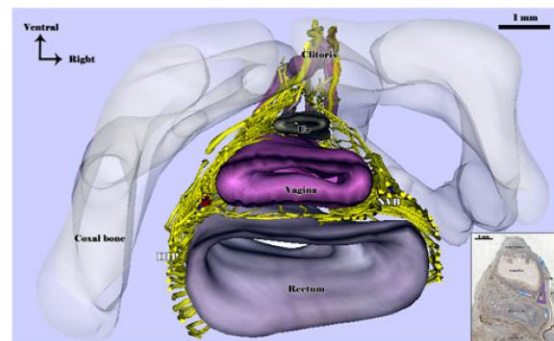


Fig. 4 Three-dimensional (3D) view of fetus intrapelvic organs with pelvic nerves. Superior infraperitoneal 3D view of a 30-week-old female fetus: intrapelvic organs with immunolabeled pelvic nerves showing the position of the inferior hypogastric plexus (IHP) on the lateral aspects of the rectum. From the IHP, efferent branches rise in distal directions: postero-inferior for the rectal wall, lateral for the levator ani muscles, and antero-inferior to form the NVBs. Some fibers from the NVBs branch medially to innervate the posterior vaginal wall. More caudally, the bundle puts out fibers in three major projections: an anterior projection for the urethral sphincter complex, an anterolateral projection (the cavernous nerve) that travels anterolaterally to the vagina to reach the corpora cavernosa, and a posterolateral projection (the spongious nerve) that continues posterolaterally to the vagina to innervate the corpus spongiosum. In *inset*, blue arrows show the directions of the IHP and NVB main terminal efferences. *Ur* urethra

The online version of the original article can be found under doi:10.1007/s00268-011-1313-2.

F. Peschaud · D. Moszkowicz · B. Alsaïd · T. Bessede ·
G. Benoit
Laboratory of Experimental Surgery, EA 4122, Faculty of
Medicine, Paris Sud-11 University, 78, rue du Général Leclerc,
94275 Le Kremlin-Bicêtre, France

F. Peschaud · C. Penna
Department of Surgery Assistance Publique, Hôpitaux de Paris,
Ambroise Paré Hospital, 9 avenue Charles-de-Gaulle,
92 Boulogne-Billancourt, France

F. Peschaud · C. Penna
University of Versailles Sain-Quentin-en-Yvelines (UVSQ),
55 avenue de Paris, 78035 Versailles, France

F. Peschaud (✉)
Service de Chirurgie Oncologique et Digestive, Hôpital
Ambroise Paré, 9 Avenue Charles de Gaulle,
92100 Boulogne, France
e-mail: frederique.peschaud@apr.aphp.fr

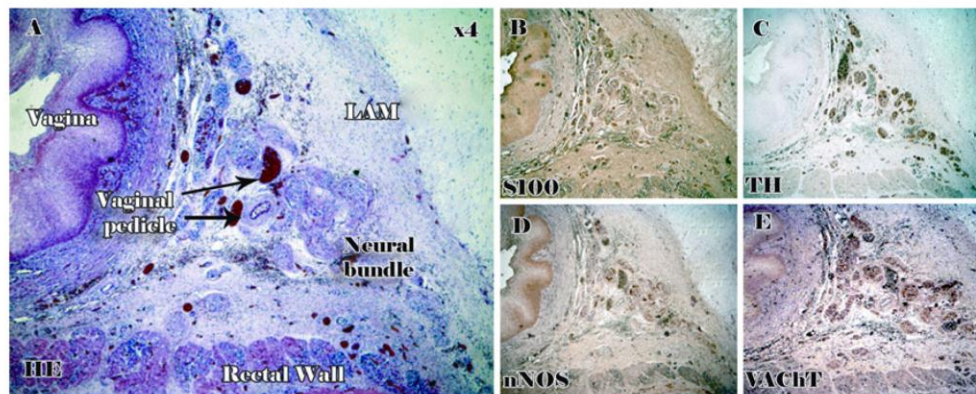


Fig. 5 Morphologic and functional systematization of the NVB. Histologic 5- μ m-thick transverse sections of a 30-week-old female fetus scanned at an optical resolution of 4,800 dpi, stained with hematoxylin/eosin (a) and immunolabeled with anti-S100 antibody (b), anti-TH (c), anti-nNOS (d), and anti-VAcHT (e). Neurovascular

bundles consist of nerve fibers and vaginal blood vessels scattered throughout the posterior and anterior extension of the RVS in a triangularly shaped space. LAM levator ani muscle; PM piriform muscle; PN pudendal nerve

IV. Conclusions et perspectives

La fonction sexuelle peut être altérée chez les femmes traitées pour un cancer, notamment colorectal [73, 74]. Les différentes composantes de la réponse sexuelle peuvent être concernées et la genèse de ces troubles est souvent multifactorielle et fréquemment iatrogène, impliquant la radiothérapie et la chirurgie pelviennes qui peuvent être à l'origine de lésions peu réversibles de l'innervation pelvi-périnéale.

Notre travail anatomique a permis d'améliorer la compréhension de la physiopathologie de certains troubles fonctionnels post-opératoire en chirurgie pelvienne. Cela a pu conduire, à l'occasion d'une collaboration au sein du laboratoire, à la description d'une zone particulièrement à risque de blessure nerveuse lors de la proctectomie pour cancer, située à la face antérolatérale du bas rectum, en rapport avec le septum recto-génital, correspondant à la position de la bandelette neurovasculaire devant être préservée par le chirurgien.

Nos résultats anatomiques et physiologiques devront être confirmés par des travaux de recherche fondamentale et corrélés à la pratique clinique par des travaux de recherche clinique.

Le projet de recherche s'articulera autour de deux axes principaux :

1- Recherche expérimentale chez le fœtus humain et le petit rongeur

- a. Cartographie immunohistochimique des autres neurotransmetteurs pelviens et périnéaux impliqués dans la fonction sexuelle de la femme, avec reconstruction 3D assistée par ordinateur : VIP, ocytocine, neuropeptide Y et sérotonine notamment.
- b. Cartographie des neurotransmetteurs exprimés par les branches afférentes au plexus hypogastrique inférieur

- i. par transport axonal rétrograde de la forme neurale de la nitric oxide synthase (nNOS) et du virus de la pseudo-rage afin de préciser le rôle du système nerveux parasympathique crânial dans la fonction érectile en déterminant l'origine et le trajet dans le système nerveux central des fibres parasympathiques contenues dans les nerfs hypogastriques.
 - ii. par analyse moléculaire du contenu en neurotransmetteurs des nerfs splanchniques pelviens après capture microscopique LASER sur coupe histologique de pelvis de fœtus humain de sexe féminin (niveau d'expression des ARN messagers correspondants à la nNOS et au VIP). Nous aurons recours à la RT-PCR en employant les amorces spécifiques des neurotransmetteurs et au Western Blot pour préciser l'expression protéique des médiateurs.
- c. Travail électrophysiologique de neurostimulation peropératoire du PHI chez la femelle du rat avec détection doppler de la tumescence clitoridienne afin de confirmer les résultats anatomiques et physiologiques obtenus (travail en cours, dirigé par le Dr Bessède).

2- Recherche appliquée

- a. Etude anatomopathologique sur pièce opératoire d'exérèse des viscères pelviens (travail en cours, dirigé par le Dr Peschaud).
- b. Corrélation des résultats anatomo-pathologiques obtenus à l'administration de questionnaires d'évaluation de la fonction sexuelle et d'explorations fonctionnelles pré- et post-opératoires chez la femme adulte.
- c. Etude clinique d'évaluation de techniques chirurgicales de préservation nerveuse modifiées, par cœlioscopie et laparotomie.

- d. Mise en place d'un protocole de neurostimulation peropératoire permettant le développement de techniques chirurgicales de préservation nerveuse confirmée par électrophysiologie avec détection électromyographique génitale, comme cela a déjà été fait par détections anale et urinaire [75-77].

3- Recherche en pédagogie médicale

La valeur pédagogique des images 3D obtenues grâce à notre technique reste à démontrer auprès d'étudiants en anatomie et de chirurgiens en formation, en la comparant aux méthodes classiques (mais néanmoins indispensables) d'enseignement (résultats soumis).

V. Références bibliographiques

1. Hendren SK, O'Connor BI, Liu M et al. Prevalence of male and female sexual dysfunction is high following surgery for rectal cancer. *Ann Surg* 2005;242:212-23.
2. Daniels IR, Woodward S, Taylor FG, Raja A, Toomey P. Female urogenital dysfunction following total mesorectal excision for rectal cancer. *World J Surg Oncol* 2006;4:6.
3. da Silva GM, Hull T, Roberts PL et al. The effect of colorectal surgery in female sexual function, body image, self-esteem and general health: a prospective study. *Ann Surg* 2008;248:266-72.
4. Peschard F, Moszkowicz D, Alsaïd B, Bessedé T, Penna C, Benoit G. Preservation of genital innervation in women during total mesorectal excision: which anterior plane? *World J Surg* 2012;36:201-7.
5. Rosen R, Brown C, Heiman J et al. The Female Sexual Function Index (FSFI): a multidimensional self-report instrument for the assessment of female sexual function. *J Sex Marital Ther* 2000;26:191-208.
6. Robert R, Labat JJ, Riant T, Louppe JM, Hamel O. [The pudendal nerve: clinical and therapeutic morphogenesis, anatomy, and physiopathology]. *Neurochirurgie* 2009;55:463-9.
7. Benoit G, Droupy S, Quillard J, Paradis V, Giuliano F. Supra and infralevator neurovascular pathways to the penile corpora cavernosa. *J Anat* 1999;195 (Pt 4):605-15.
8. Connell K, Guess MK, La Combe J et al. Evaluation of the role of pudendal nerve integrity in female sexual function using noninvasive techniques. *Am J Obstet Gynecol* 2005;192:1712-7.
9. Schraffordt SE, Tjandra JJ, Eizenberg N, Dwyer PL. Anatomy of the pudendal nerve and its terminal branches: a cadaver study. *ANZ J Surg* 2004;74:23-6.
10. Shafik A, Doss S. Surgical anatomy of the somatic terminal innervation to the anal and urethral sphincters: role in anal and urethral surgery. *J Urol* 1999;161:85-9.
11. Baqué P (2008) *Manuel pratique d'anatomie*, Ellipses, Paris.
12. Mauroy B, Demondion X, Bizet B, Claret A, Mestdagh P, Hurt C. The female inferior hypogastric (= pelvic) plexus: anatomical and radiological description of the plexus and its afferences--applications to pelvic surgery. *Surg Radiol Anat* 2007;29:55-66.
13. Munarriz R, Kim NN, Goldstein I, Traish AM. Biology of female sexual function. *Urol Clin North Am* 2002;29:685-93.
14. Giuliano F, Pfaus J, Srilatha B et al. Experimental models for the study of female and male sexual function. *J Sex Med* 2010;7:2970-95.
15. Brenman JE, Chao DS, Gee SH et al. Interaction of nitric oxide synthase with the postsynaptic density protein PSD-95 and alpha1-syntrophin mediated by PDZ domains. *Cell* 1996;84:757-67.
16. Luo CX, Zhu DY. Research progress on neurobiology of neuronal nitric oxide synthase. *Neurosci Bull* 2011;27:23-35.
17. Bredt DS. Endogenous nitric oxide synthesis: biological functions and pathophysiology. *Free Radic Res* 1999;31:577-96.
18. Christopherson KS, Bredt DS. Nitric oxide in excitable tissues: physiological roles and disease. *J Clin Invest* 1997;100:2424-9.
19. Musicki B, Liu T, Lagoda GA, Bivalacqua TJ, Strong TD, Burnett AL. Endothelial nitric oxide synthase regulation in female genital tract structures. *J Sex Med* 2009;6 Suppl 3:247-53.

20. Burnett AL, Lowenstein CJ, Bredt DS, Chang TS, Snyder SH. Nitric oxide: a physiologic mediator of penile erection. *Science* 1992;257:401-3.
21. O'Kelly T, Brading A, Mortensen N. Nerve mediated relaxation of the human internal anal sphincter: the role of nitric oxide. *Gut* 1993;34:689-93.
22. Chivers ML, Rosen RC. Phosphodiesterase type 5 inhibitors and female sexual response: faulty protocols or paradigms? *J Sex Med* 2010;7:858-72.
23. Rowland DL. Neurobiology of sexual response in men and women. *CNS Spectr* 2006;11:6-12.
24. Levin RJ. The physiology of sexual function in women. *Clin Obstet Gynaecol* 1980;7:213-52.
25. Burnett AL, Tillman SL, Chang TS et al. Immunohistochemical localization of nitric oxide synthase in the autonomic innervation of the human penis. *J Urol* 1993;150:73-6.
26. Burnett AL, Calvin DC, Silver RI, Peppas DS, Docimo SG. Immunohistochemical description of nitric oxide synthase isoforms in human clitoris. *J Urol* 1997;158:75-8.
27. Yucel S, De Souza A, Jr., Baskin LS. Neuroanatomy of the human female lower urogenital tract. *J Urol* 2004;172:191-5.
28. Martin-Alguacil N, Schober J, Kow LM, Pfaff D. Oestrogen receptor expression and neuronal nitric oxide synthase in the clitoris and preputial gland structures of mice. *BJU Int* 2008;102:1719-23.
29. Al-Hijji J, Larsson B, Batra S. Nitric oxide synthase in the rabbit uterus and vagina: hormonal regulation and functional significance. *Biol Reprod* 2000;62:1387-92.
30. Martin-Alguacil N, Pfaff DW, Shelley DN, Schober JM. Clitoral sexual arousal: an immunocytochemical and innervation study of the clitoris. *BJU Int* 2008;101:1407-13.
31. Uckert S, Ehlers V, Nuser V et al. In vitro functional responses of isolated human vaginal tissue to selective phosphodiesterase inhibitors. *World J Urol* 2005;23:398-404.
32. Munarriz R, Kim SW, Kim NN, Traish A, Goldstein I. A review of the physiology and pharmacology of peripheral (vaginal and clitoral) female genital arousal in the animal model. *J Urol* 2003;170:S40-4; discussion S44-5.
33. Blank MA, Gu J, Allen JM et al. The regional distribution of NPY-, PHM-, and VIP-containing nerves in the human female genital tract. *Int J Fertil* 1986;31:218-22.
34. Hoyle CH, Stones RW, Robson T, Whitley K, Burnstock G. Innervation of vasculature and microvasculature of the human vagina by NOS and neuropeptide-containing nerves. *J Anat* 1996;188 (Pt 3):633-44.
35. Aughton KL, Hamilton-Smith K, Gupta J, Morton JS, Wayman CP, Jackson VM. Pharmacological profiling of neuropeptides on rabbit vaginal wall and vaginal artery smooth muscle in vitro. *Br J Pharmacol* 2008;155:236-43.
36. Salonia A, Giraldi A, Chivers ML et al. Physiology of Women's Sexual Function: Basic Knowledge and New Findings. *J Sex Med*
37. Gelez H, Poirier S, Facchinetti P et al. Neuroanatomical evidence for a role of central melanocortin-4 receptors and oxytocin in the efferent control of the rodent clitoris and vagina. *J Sex Med* 7:2056-67.
38. Giuliano F, Rampin O, Allard J. Neurophysiology and pharmacology of female genital sexual response. *J Sex Marital Ther* 2002;28 Suppl 1:101-21.
39. Komisaruk BR, Sansone G. Neural pathways mediating vaginal function: the vagus nerves and spinal cord oxytocin. *Scand J Psychol* 2003;44:241-50.
40. Tajkarimi K, Burnett AL. The role of genital nerve afferents in the physiology of the sexual response and pelvic floor function. *J Sex Med* 2011;8:1299-312.

41. Nappi R, Salonia A, Traish AM et al. Clinical biologic pathophysiologies of women's sexual dysfunction. *J Sex Med* 2005;2:4-25.
42. de Lorig F, de Jonge WJ, Wedel T, Vanderwinden JM, Benninga MA, Boeckxstaens GE. Interstitial cells of Cajal are involved in the afferent limb of the rectoanal inhibitory reflex. *Gut* 2005;54:1107-13.
43. Sanders KM, Ward SM. Nitric oxide as a mediator of nonadrenergic noncholinergic neurotransmission. *Am J Physiol* 1992;262:G379-92.
44. O'Kelly TJ, Davies JR, Brading AF, Mortensen NJ. Distribution of nitric oxide synthase containing neurons in the rectal myenteric plexus and anal canal. Morphologic evidence that nitric oxide mediates the rectoanal inhibitory reflex. *Dis Colon Rectum* 1994;37:350-7.
45. Uhl JF, Plaisant O, Ami O, Delmas V. [3D modeling in the field of morphology: methods, interest and results]. *Morphologie* 2006;90:5-20.
46. Benoit G, Cailleaux F, Quillard J et al. Computer assisted anatomical reconstruction: a prostate model. *Surg Radiol Anat* 1991;13:45-7.
47. Alsaid B, Bessede T, Diallo D et al. Computer-assisted anatomic dissection (CAAD): evolution, methodology and application in intra-pelvic innervation study. *Surg Radiol Anat* 2011;
48. Clausen N, Wolloscheck T, Konerding MA. How to optimize autonomic nerve preservation in total mesorectal excision: clinical topography and morphology of pelvic nerves and fasciae. *World J Surg* 2008;32:1768-75.
49. Moszkowicz D, Alsaid B, Bessede T et al. Where does pelvic nerve injury occur during rectal surgery for cancer? *Colorectal Dis* 2011;13:1326-34.
50. Heald RJ, Husband EM, Ryall RD. The mesorectum in rectal cancer surgery--the clue to pelvic recurrence? *Br J Surg* 1982;69:613-6.
51. MacFarlane JK, Ryall RD, Heald RJ. Mesorectal excision for rectal cancer. *Lancet* 1993;341:457-60.
52. Maas CP, Moriya Y, Steup WH, Kiebert GM, Kranenburg WM, van de Velde CJ. Radical and nerve-preserving surgery for rectal cancer in The Netherlands: a prospective study on morbidity and functional outcome. *Br J Surg* 1998;85:92-7.
53. Carlsen E, Schlichting E, Guldvog I, Johnson E, Heald RJ. Effect of the introduction of total mesorectal excision for the treatment of rectal cancer. *Br J Surg* 1998;85:526-9.
54. Alves A, Panis Y, Mathieu P, Kwiatkowski F, Slim K, Manton G. Mortality and morbidity after surgery of mid and low rectal cancer. Results of a French prospective multicentric study. *Gastroenterol Clin Biol* 2005;29:509-14.
55. Lange MM, Maas CP, Marijnen CA et al. Urinary dysfunction after rectal cancer treatment is mainly caused by surgery. *Br J Surg* 2008;95:1020-8.
56. Kneist W, Heintz A, Junginger T. Major urinary dysfunction after mesorectal excision for rectal carcinoma. *Br J Surg* 2005;92:230-4.
57. Eveno C, Lamblin A, Mariette C, Pocard M. Sexual and urinary dysfunction after proctectomy for rectal cancer. *J Visc Surg* 2010;147:e21-30.
58. Pocard M, Zinzindohoue F, Haab F, Caplin S, Parc R, Turet E. A prospective study of sexual and urinary function before and after total mesorectal excision with autonomic nerve preservation for rectal cancer. *Surgery* 2002;131:368-72.
59. Lindsey I, Mortensen NJ. Iatrogenic impotence and rectal dissection. *Br J Surg* 2002;89:1493-4.
60. Baader B, Herrmann M. Topography of the pelvic autonomic nervous system and its potential impact on surgical intervention in the pelvis. *Clin Anat* 2003;16:119-30.

61. Kneist W, Kauff DW, Gockel I et al. Total mesorectal excision with intraoperative assessment of internal anal sphincter innervation provides new insights into neurogenic incontinence. *J Am Coll Surg* 2012;214:306-12.
62. Bissett IP, Hill GL. Extrafascial excision of the rectum for cancer: a technique for the avoidance of the complications of rectal mobilization. *Semin Surg Oncol* 2000;18:207-15.
63. Burnett AL, Goldstein I, Andersson KE et al. Future sexual medicine physiological treatment targets. *J Sex Med* 2010;7:3269-304.
64. Lindsey I, George B, Kettlewell M, Mortensen N. Randomized, double-blind, placebo-controlled trial of sildenafil (Viagra) for erectile dysfunction after rectal excision for cancer and inflammatory bowel disease. *Dis Colon Rectum* 2002;45:727-32.
65. Sandner P, Hutter J, Tinel H, Ziegelbauer K, Bischoff E. PDE5 inhibitors beyond erectile dysfunction. *Int J Impot Res* 2007;19:533-43.
66. Moszkowicz D, Alsaïd B, Bessedé T, Penna C, Benoit G, Peschaud F. Female pelvic autonomic neuroanatomy based on conventional macroscopic and computer-assisted anatomic dissections. *Surg Radiol Anat* 2011;33:397-404.
67. Moszkowicz D, Alsaïd B, Bessedé T et al. Neural supply to the clitoris: immunohistochemical study with three-dimensional reconstruction of cavernous nerve, spongious nerve, and dorsal clitoris nerve in human fetus. *J Sex Med* 2011;8:1112-22.
68. Moszkowicz D, Peschaud F, Bessedé T, Benoit G, Alsaïd B. Internal anal sphincter parasympathetic-nitrergic and sympathetic-adrenergic innervation: a 3-dimensional morphological and functional analysis. *Dis Colon Rectum* 2012;55:473-81.
69. Alsaïd B, Moszkowicz D, Peschaud F et al. Autonomic-somatic communications in the human pelvis: computer-assisted anatomic dissection in male and female fetuses. *J Anat* 2011;219:565-73.
70. Alsaïd B, Bessedé T, Diallo D et al. Division of autonomic nerves within the neurovascular bundles distally into corpora cavernosa and corpus spongiosum components: immunohistochemical confirmation with three-dimensional reconstruction. *Eur Urol* 2011;59:902-9.
71. Gallo EF, Iadecola C. Neuronal nitric oxide contributes to neuroplasticity-associated protein expression through cGMP, protein kinase G, and extracellular signal-regulated kinase. *J Neurosci* 2011;31:6947-55.
72. Colombel M, Droupy S, Paradis V, Lassau JP, Benoit G. Caverno-pudendal nervous communicating branches in the penile hilum. *Surg Radiol Anat* 1999;21:273-6.
73. Desimone M, Spriggs E, Gass JS, Carson SA, Krychman ML, Dizon DS. Sexual Dysfunction in Female Cancer Survivors. *Am J Clin Oncol* 2012;
74. Den Oudsten BL, Traa MJ, Thong MS et al. Higher prevalence of sexual dysfunction in colon and rectal cancer survivors compared with the normative population: A population-based study. *Eur J Cancer* 2012;
75. Kneist W, Kauff DW, Rahimi Nedjat RK et al. Intraoperative pelvic nerve stimulation performed under continuous electromyography of the internal anal sphincter. *Int J Colorectal Dis* 25:1325-31.
76. Kneist W, Kauff DW, Koch KP et al. Selective pelvic autonomic nerve stimulation with simultaneous intraoperative monitoring of internal anal sphincter and bladder innervation. *Eur Surg Res* 46:133-8.
77. Kneist W, Junginger T. Validity of pelvic autonomic nerve stimulation with intraoperative monitoring of bladder function following total mesorectal excision for rectal cancer. *Dis Colon Rectum* 2005;48:262-9.

Étude anatomique et immunohistochimique de l'innervation pelvipérinéale de la femme avec reconstruction 3D. Peut-on encore diminuer les séquelles sexuelles et urinaires de la dissection rectale pour cancer ?

Female pelvic-perineal innervation: anatomical and immunohistochemical study with 3D reconstruction. Can we still reduce sexual and urinary dysfunctions after rectal dissection for cancer ?

D Moszkowicz [1], B Alsaïd [1], G Benoit [1], F Peschaud [1,2,3]

1. Laboratoire de chirurgie expérimentale EA 4122 - Faculté de Médecine, Université Bicêtre-Paris 11 - 94270 Le Kremlin-Bicêtre
2. Département de Chirurgie, Hôpital Ambroise Paré (AP-HP), Boulogne-Billancourt, France
3. Université PIFO, Saint-Quentin-en-Yvelines, France

Mots clés

- ◆ Bandelette neuro-vasculaire
- ◆ Cancer du rectum
- ◆ Clitoris
- ◆ Dissection Anatomique Assistée par Ordinateur
- ◆ Dysfonction sexuelle neurogène de la femme
- ◆ Nerf caverneux du clitoris
- ◆ Nerf spongieux
- ◆ Proctectomie

Résumé

Introduction. Le traitement de l'adénocarcinome rectal implique l'exérèse extrafasciale du mésorectum associée à la préservation de l'innervation autonome à destinée génito-urinaire. Les dysfonctions urinaires et sexuelles sont néanmoins fréquentes au décours de cette chirurgie, particulièrement si la tumeur est antérieure, si elle est fixée ou si le pelvis est étroit. Une meilleure connaissance de l'anatomie de l'innervation pelvipérinéale pourrait contribuer à améliorer les résultats des techniques chirurgicales de préservation nerveuse.

Matériel et méthodes. Afin d'identifier la localisation et la fonction (nitroergique, sympathique-adrénergique, parasympathique-cholinergique et sensitive) des fibres nerveuses destinées au clitoris et au sphincter urétral, des coupes sériées du petit bassin de sept fœtus humains féminins (de 18 à 32 semaines de gestation) ont été traitées par techniques histologiques et immunohistochimiques, numérisées puis reconstruites en 3 dimensions et animées.

Résultats. Les structures nerveuses afférentes au plexus hypogastrique inférieur (PHI) - nerfs splanchniques pelviens (NSP), nerfs splanchniques sacraux (NSS) et nerfs hypogastriques (NH) - sont richement interconnectées et véhiculent de façon mixte l'influx sympathique et parasympathique pelvien. Ces structures sont facilement identifiables (pour les NH) ou situées à distance du plan de l'exérèse rectale (pour les NSP, NSS) et sont donc peu à risque lors de la dissection rectale postérieure. Les fibres nerveuses issues de la partie distale du PHI et responsables de la fonction sexuelle convergent vers le diaphragme uro-génital. Elles sont regroupées et associées aux pédicules vasculaires vaginaux longs pour former les bandelettes neuro-vasculaires (BNV), situées à 2 et 10 heures sur la face antérolatérale du rectum, véhiculant des fibres sympathiques, parasympathiques, nitroergiques et sensibles. Ces troncs neurovasculaires regroupant l'ensemble des fibres nerveuses érectiles destinées au périnée (cholinergiques et nNOS+) peuvent être lésés lors de la dissection antérolatérale du rectum. Ces BNV envoient des fibres nerveuses destinées à la paroi postérieure du vagin, qui se situent en avant du septum recto-vaginal (SRV). Trois efférences principales sont issues des BNV à hauteur du bas rectum : le plexus urétral, destiné au sphincter urétral, le nerf caverneux, destiné aux corps caverneux du clitoris et le nerf spongieux, destiné aux bulbes vestibulaires. La dissection antérolatérale du rectum devrait donc, si les conditions carcinologiques le permettent, passer dans un plan situé entre le prolongement latéral postérieur du SRV en arrière et la face postérieure de la BNV en avant. En effet, une lésion tronculaire des BNV au cours de cette dissection, où convergent l'ensemble des fibres destinées à l'innervation des corps érectiles et du sphincter urétral, pourrait conduire à une dysfonction multiple avec trouble de la continence, de la tumescence clitoridienne et de la sécrétion génitale.

Conclusions. Notre « Dissection anatomique assistée par ordinateur » a permis de préciser la distribution et la fonction des fibres nerveuses autonomes destinées aux organes génitaux et à l'urètre. Cela a permis d'approfondir la connaissance des bases anatomiques et physiologiques utiles au développement des techniques chirurgicales de préservation nerveuse, participant ainsi à une meilleure compréhension des dysfonctions sexuelles et urinaires neurogènes postopératoires.

Correspondance :

Dr Frédérique Peschaud (MCU-PH)
Service de Chirurgie Oncologique et digestive, Hôpital Ambroise Paré, 9 Avenue Charles de Gaulle, 92100 Boulogne, France. E-mail: frederique.peschaud@apr.aphp.fr

Disponible en ligne sur www.bium.univ-paris5.fr/acad-chirurgie
1634-0647 - © 2011 Académie nationale de chirurgie. Tous droits réservés.

Keywords

- ◆ Cavernous nerve of clitoris
- ◆ Clitoris
- ◆ Computer-Assisted Anatomic Dissection
- ◆ Female neurogenic sexual dysfunction
- ◆ Neurovascular bundle
- ◆ Proctectomy
- ◆ Rectal cancer
- ◆ Spongy Nerve

Abstract

Introduction. Optimal treatment of rectal adenocarcinoma involves total mesorectal excision with nerve-preserving dissection. Urinary and sexual dysfunction is still frequent following these procedures, particularly when the tumour is located anterolaterally, when it is fixed and when the pelvis is narrow. Improved knowledge of pelvic nerve anatomy may help to optimize surgical nerve preservation.

Methods. To identify the location and function (nitroergic, sympathetic-adrenergic, parasympathetic-cholinergic and sensitive) of genitals and urethral sphincter neural supply, serial transverse sections were obtained from seven human female fetuses (18-32 weeks of gestation) and subjected to histological and immunohistochemical investigations; digitized serial sections were used to construct a 3D animated representation of the pelvis.

Results. Inferior hypogastric plexus (IHP) afferences - pelvic splanchnic nerves (PSN), sacral splanchnic nerves (SSN) and hypogastric nerves (HN) - are widely interconnected and support a mixed sympathetic and parasympathetic neural impulse. These nerve structures are easily recognized (as HN) or are located from afar the dissection plane (PSN, SSN) and are at low risk of injury during posterior rectal dissection. Nerve efferences originating from the IHP distal part convey the sexual erectile impulse and converge to the pelvic floor. They are grouped with the vaginal pedicles, forming a neurovascular bundle (NVB), located at 2 and 10 o'clock at the rectum anterolateral wall, conveying sympathetic, parasympathetic, nitroergic (cholinergic-nNOS+) and sensitive fibers. These neurovascular trunks can be injured during rectal anterolateral dissection. These NVBs send nerve branches to the vagina posterior wall, that course at the anterior side of the rectovaginal septum (RVS). Three main efferences originate from the NVB at the low rectum level: the urethral plexus, for the urethral sphincter, the cavernous nerve, for the corpora cavernosa of clitoris, and the spongy nerve, for the vestibular bulbs. The NVBs are situated anteriorly to the posterior extension of rectovaginal septum and, if oncologically reasonable, a careful dissection to the anterior mesorectum to develop a dissection behind the posterior extension of rectovaginal septum would be preferable. In fact, multiple dysfunctions affecting urinary continence, clitoral tumescence and genital secretion could result from a NVB injury.

Conclusions. "Computer-assisted anatomic dissection" allowed the identification of the precise function and distribution of the autonomic neural supply to the female genitals and urethra, providing an anatomical basis for nerve-sparing surgical techniques, and participating to the understanding of postoperative neurogenic sexual and urinary dysfunctions.

La proctectomie avec exérèse totale du mésorectum (ETM) et préservation nerveuse est la chirurgie de référence du cancer du rectum (1). Cette chirurgie est associée à des séquelles urinaires et sexuelles dans 10 à 70 % des cas liées, notamment, à des lésions iatrogènes des nerfs pelvi-périnéaux (2). Ces nerfs peuvent être lésés en plusieurs endroits - plexus hypogastrique supérieur (PHS), nerfs hypogastriques (NH), plexus hypogastriques inférieurs (PHI) et branches efférentes - car leur identification précise peut être difficile en raison de leur taille et de leur proximité avec les organes pelviens (3). La connaissance approfondie de cette innervation pelvienne est donc nécessaire pour la prise en charge des cancers du rectum.

La réponse sexuelle est régulée par les systèmes nerveux somatique et autonome, périphérique et central. Au niveau périphérique, la réponse sexuelle dépend de l'activation, par le système autonome, de mécanismes de contrôle neuromusculaires et vasoactifs impliqués dans la congestion des corps érectiles et de la muqueuse vaginale et dans la lubrification vaginale (4). De plus, un arc réflexe d'afférences génitales passant par les nerfs somatiques pudendaux contrôle la contraction orgasmique des muscles striés du périnée. L'oxyde nitrique (NO) est le principal médiateur physiologique de la fonction érectile, et son enzyme de synthèse, la NO synthétase (NOS), est exprimée dans le tissu caverneux du clitoris et du vagin humains, dans les nerfs du système nerveux autonome et dans les endothéliums vasculaires et sinusoidaux (5, 6). La rupture de l'intégrité des commandes nerveuses mais aussi hormonales et vasculaires de la réponse sexuelle sont donc susceptibles d'interférer avec la fonction sexuelle, bien que des facteurs psychologiques et relationnels puissent y jouer des rôles importants (7).

La majorité des travaux s'intéressant aux séquelles sexuelles après proctectomie sont réalisés chez l'homme et très peu de travaux concernent exclusivement les femmes chez qui l'anatomie de l'innervation pelvipérinéale est mal connue (8). La réduction de ces séquelles fonctionnelles postopératoires nécessite une meilleure compréhension de l'anatomie nerveuse pelvi-périnéale, qui peut être éclaircie par de nouvelles techniques d'étude. En effet, l'anatomie topographique de l'innervation pelvienne est classiquement étudiée par dissection macroscopique des nerfs sur sujet frais ou formolés et la dissection de l'environnement adipeux et osseux des structu-

res nerveuses présentent le risque de détruire les nerfs ou de perturber leur organisation spatiale. L'utilisation combinée d'un prélèvement macroscopique en bloc et de méthodes immunohistochimiques permet de respecter l'intégrité des nerfs et de détecter les neurotransmetteurs au sein des tissus nerveux. Ces techniques permettent d'obtenir des renseignements précis sur le trajet, le type de fibres et leurs rapports anatomiques. De plus à partir de ces coupes histologiques immunomarquées et des techniques de traitement d'images en 3D par ordinateur, il est possible de reconstruire, de visualiser dans l'espace, et d'animer les structures anatomiques afin de réaliser une Dissection Anatomique Assistée par Ordinateur (DAAO) (9, 10).

Pour contribuer à améliorer les résultats fonctionnels sexuels de la chirurgie d'exérèse rectale pour cancer chez la femme, les objectifs de ce travail étaient d'étudier l'anatomie topographique et structurelle de l'innervation pelvi-périnéale chez le fœtus féminin en utilisant la technique de Dissection Anatomique Assistée par Ordinateur (DAAO) et de compléter cette étude par une étude du septum recto-vaginal sur sujet anatomique adulte afin d'améliorer la compréhension des déterminants anatomiques et physiologiques des dysfonctions sexuelles et urinaires survenant après proctectomie.

Matériel et méthode

Des coupes sériées de 5 µm d'épaisseur ont été effectuées tous les 50 à 150 µm sur le bassin de sept fœtus humains de sexe féminin entre 18 et 32 semaines de gestation. Les coupes ont été traitées manuellement par l'Hématoxyline-Eosine et le trichrome de Masson puis immunomarquées pour détecter les fibres nerveuses (anticorps anti-protéine S-100), les fibres somatiques (anticorps anti-PMP22), les fibres autonomes adrénergiques (anticorps anti-TH, *tyrosin hydroxylase*) et cholinergiques (anticorps anti-VACHT, *vesicular acetylcholine transporter*), les fibres sensibles (anticorps anti-CGRP, *calcitonin gene related peptid*) et les fibres érectiles (anticorps anti-nNOS, *neural nitric oxide synthase*) ainsi que l'actine lisse des sphincters. Les lames ont ensuite été numérisées par un scanner de haute résolution optique et les images bidimensionnelles ont été reconstruites manuellement en trois dimensions par contournage des structures anatomiques (logiciel Surfdriver

pour Windows, Winsurf) puis traitées par un logiciel d'animation.

Les organes pelviens de six sujets adultes de sexe féminin (77-89 ans) ont été prélevés en bloc puis sectionnés dans le sens sagittal et les coupes histologiques ont été traitées par le trichrome de Masson pour identifier les fibres conjonctives des fascias, l'anticorps anti-protéine S100 pour identifier les fibres nerveuses et l'anticorps anti-actine lisse pour identifier les fibres musculaires lisses des fascias.

Résultats

Branches afférentes du plexus hypogastrique inférieur

Les structures nerveuses afférentes du plexus hypogastrique inférieur (PHI) - nerfs splanchniques pelviens (NSP), nerfs splanchniques sacraux (NSS) et nerfs hypogastriques (NH) - sont richement interconnectées et véhiculent de façon mixte l'influx sympathique-adrénergique (TH positif) et parasymphatique-cholinergique (VACHT positif) pelvien (tableau 1).

Branches efférentes du plexus hypogastrique inférieur - Rapports avec le septum recto-vaginal

Les fibres nerveuses issues de la partie distale du PHI et responsables de la continence urinaire et de la fonction sexuelle convergent vers le diaphragme pelvien. Elles sont regroupées et associées au pédicule vasculaire vaginal long pour former la bandelette neurovasculaire (BNV) constituée de fibres nerveuses adrénériques (TH+), cholinergiques (VACHT+), sensibles (CGRP+) et nitreurgiques (nNOS+) et située à 2 et 10 heures sur la face antérolatérale du rectum. Ce tronc neurovasculaire regroupe l'ensemble des fibres nerveuses érectiles destinées au périnée.

Trois efférences principales sont issues de cette BNV à hauteur du bas rectum : le plexus urétral, destiné au sphincter urétral, le nerf caveux, destiné aux corps caveux du clitoris et le « nerf spongieux », destiné aux bulbes vestibulaires du clitoris (vidéo 1). Ces plexus nerveux sont riches en fibres nitreurgiques-cholinergiques (nNOS+) (tableau 1).

Le septum rectovaginal (SRV, équivalent masculin du fascia de Denonvilliers) est une structure mixte contenant des fibres conjonctives et des fibres musculaires lisses issues de l'utérus et du vagin. Latéralement, il émet deux extensions, antérieure qui fusionne avec le fascia vaginal et postérieure qui fusionne avec le fascia viscéral rectal, en forme de « Y allongé ». La BNV envoie des fibres nerveuses destinées à la paroi postérieure du vagin qui se situent en avant du SRV sur la ligne médiane. Latéralement, le tronc de la BNV se situe en avant de l'extension postérieure du SRV.

Discussion

Anatomie appliquée à la technique chirurgicale de résection rectale et aux résultats fonctionnels sexuels et urinaires postopératoires

Notre étude a permis de discuter la conception classique de l'innervation intra-pelvienne de la femme et des zones à risque de blessure nerveuse (11). Les structures classiquement considérées comme purement sympathiques ou parasymphatiques ne véhiculent pas qu'un seul type d'influx et sont, par ailleurs, richement interconnectées. De plus, certaines struc-

	Sympathique	Parasympathique	Sensitif	
	TH	VACHT	nNOS	CGRP
NH	+++	+	+	+
TS	+++	++	++	+
NSP	mixte	mixte	?	+
BNV	mixte	mixte	Dense Regroupement péri-artériel	+
NC	++	+++	100 %	0
NS	mixte	mixte	++	+

Tableau 1. Résumé de la répartition des neurotransmetteurs pelvipérinéaux.

NH : nerf hypogastrique ; TS : tronc sympathique ; NSP : nerf splanchnique pelvien ; BNV : bandelette neurovasculaire, NC : nerf caveux ; NS : « nerf spongieux » ; NDC : nerf dorsal du clitoris ; TH : anti-tyrosine hydroxylase ; VACHT : anti-transporteur vésiculaire de l'acétylcholine ; nNOS : neural Nitric Oxide Synthase ; CGRP : Calcitonin Gene Related Peptid.

tures sont apparues comme situées à distance du plan de l'exérèse rectale et d'autres comme beaucoup plus exposées lors de la dissection du rectum.

Ligature de l'artère mésentérique inférieure et dissection rectale postérieure

La préservation du plexus mésentérique inférieur lors de la ligature de l'artère mésentérique inférieure et la préservation des nerfs hypogastriques par clivage rétrorectal en avant du fascia préhypogastrique (12) sont bien connues des chirurgiens. Notre étude immunohistochimique a permis de mettre en évidence, au sein du plexus hypogastrique supérieur (PHS) et du nerf hypogastrique (NH), la coexistence de fibres cholinergiques (VACHT+) et adrénériques (TH+). Classiquement, ces nerfs sont considérés comme purement sympathiques (adrénériques) (9, 13). La présence des fibres cholinergiques au sein des NH peut avoir plusieurs explications. Dans un travail récent de notre équipe, l'origine des fibres cholinergiques cheminant dans le NH était attribuée à trois sources possibles : des fibres du nerf vague (X) parasymphatiques qui seraient transmises aux NH par les plexus coeliaque, mésentérique et hypogastrique supérieur ; des fibres ascendantes issues des nerfs splanchniques pelviens *via* le plexus hypogastrique inférieur (PHI) ; des fibres pré-ganglionnaires sympathiques issues des nerfs splanchniques lombaires ou thoraciques traversant les ganglions mésentériques pour rejoindre les plexus hypogastriques supérieur et inférieur (9). Ainsi, les fibres cholinergiques du NH sont soit des fibres sympathiques pré-ganglionnaires soit des fibres parasymphatiques. Nos résultats sont en faveur de cette dernière hypothèse, puisque ces mêmes fibres sont simultanément cholinergiques et nNOS positives et ont donc un effet de relaxation musculaire lisse, phénomène attribué au système nerveux autonome parasymphatique. Au vu de nos résultats immunohistochimiques, le traumatisme chirurgical des NH, structures classiquement considérées comme purement sympathiques responsables de l'éjaculation, pourrait être responsable d'insuffisance érectile, ce qui est corroboré par les résultats d'études cliniques (14).

Nous avons montré la coexistence, dans le tronc sympathique paravertébrale (TS), d'un contingent mixte de fibres adrénériques (anticorps anti-TH) sympathiques, mais aussi de fibres cholinergiques (anticorps anti-VACHT) et nNOS positives (anticorps anti-nNOS) parasymphatiques. De même, les nerfs splanchniques pelviens véhiculent une innervation mixte adrénérique et cholinergique. Cependant, la topographie de ces structures nerveuses, en dehors de curages ganglionnaires latéraux extensifs, les rend peu vulnérables au traumatisme chirurgical lors de l'exérèse totale du mésorectum.

Dissection rectale antérolatérale

Nous devons à Walsh la description originelle aujourd'hui précisée, notamment par notre équipe, de la bandelette neurovasculaire latéro-prostatique (10, 15, 16). À l'occasion de nos travaux, destinés à comprendre les déterminants anatomiques de séquelles sexuelles de la chirurgie rectale pour cancer chez la femme, nous avons pu mettre en évidence une concentration de fibres nerveuses à la face antérolatérale du rectum et postérolatérale du vagin à l'origine de l'innervation des corps érectiles et du sphincter urétral de la femme. L'existence de cette bandelette nerveuse, appelée parfois « plexus vaginal » (17), a déjà été évoquée mais sans systématisation morphologique ni fonctionnelle. Elle est souvent assimilée au seul nerf caverneux. Au cours de cette étude, nous avons pu décrire précisément cette BNV qui se distribue en fait dans trois directions principales, formant le plexus urétral (PU), le nerf caverneux (NC) et le « nerf spongieux » (NS) (18). La majorité des fibres de la BNV, après le départ du NC, convergent vers les bulbes vestibulaires (BV, ou bulbes du clitoris), équivalent du corps spongieux de l'homme. Ainsi nous avons proposé de regrouper sous le terme de « nerf spongieux » l'ensemble des fibres nerveuses destinées à ces BV. D'autre part, l'existence de communications entre le nerf dorsal du clitoris (NDC) et le nerf caverneux (NC) a été mise en évidence dans nos travaux et a déjà été évoquée et discutée dans la littérature, chez la femme comme chez l'homme (17, 19, 20). Ces communications pourraient expliquer la conservation de la fonction érectile après prostatectomie radicale sans préservation nerveuse (21) et être impliquées dans les phénomènes de plasticité nerveuse observés après lésion nerveuse (19). L'innervation des corps érectiles de la femme, corps caverneux (CC) et bulbes vestibulaires (BV) qui composent tous deux le clitoris (22), dépend donc d'une double commande : commande autonome, par le nerf caverneux (NC) pour les corps caverneux (CC) et par le nerf spongieux (NS) pour les bulbes vestibulaires (BV), tous deux riches en fibres érectiles nNOS positives ; commande somatique, par le nerf dorsal du clitoris (NDC), branche du nerf pudendal, qui prend le relai de l'activité érectile du clitoris distal par l'intermédiaire de branches communicantes issues du NDC. L'influx cholinergique/parasymphatique et nitregergique contenu dans la BNV et dans le NC devrait être responsable du phénomène de tumescence clitoridienne par vasodilatation et augmentation de la pression intra-caverneuse. Nous avons par ailleurs constaté que le NC ne contient pas de fibre sensitive, comme cela avait été remarqué chez l'homme (10). La fonction sensitive du clitoris pourrait donc être supportée par le système nerveux somatique sensitif véhiculé par les branches terminales du nerf pudendal (NDC, nerf périméal). Les fibres sensibles contenues dans la BNV et dans le NS, qui coexistent avec des fibres cholinergiques et adrénérgiques, pourraient être des fibres sensibles autonomes dirigées vers les bulbes vestibulaires et/ou jouant un rôle dans la sensibilité à la distension des glandes périméales.

Ainsi, notre étude chez le fœtus a permis de mettre en évidence des zones semblant particulièrement exposées lors de la dissection du rectum sous péritonéal. Lors de l'ouverture du fond du cul de sac rectovaginal (Douglas) sur la ligne médiane, la partie proximale du septum rectovaginal (SRV) n'apparaît pas comme une structure indépendante individualisable, car il s'agit plutôt de fines couches de tissu conjonctif et musculaire lisse. Le clivage entre la face postérieure du vagin et la face antérieure du rectum devrait se faire en arrière du SRV à condition d'obtenir une marge de résection circonférentielle antérieure suffisante. En effet, cette dissection respecterait les fibres nerveuses destinées à la paroi vaginale postérieure et situées en avant de ce septum. Parmi ces fibres, certaines sont nNOS positives, intervenant probablement dans la vasomotricité de la paroi vaginale et jouant ainsi un rôle dans la lubrification vaginale (5).

En poursuivant cette dissection latéralement et vers le bas, à

hauteur du moyen rectum puis du bas rectum, les bandelettes neurovasculaires (BNV) sont plus exposées, car situées à 2 et 10 heures à la face antérieure du rectum. Il semble exister un plan de dissection permettant de préserver la BNV, entre le prolongement latéral du septum rectovaginal (SRV) fusionné au fascia viscéral rectal et le bord postérieur de la BNV. Il conviendrait donc, lors de la dissection antérolatérale du rectum, de rejoindre aussi directement que possible la face antérieure du rectum, dans un plan situé entre le prolongement latéral du SRV en arrière et la face postérieure de la BNV en avant, afin de ne pas étendre la dissection vers le tronc de la BNV. En effet, une lésion tronculaire de la BNV au cours de cette dissection, où convergent l'ensemble des fibres destinées à l'innervation des corps érectiles et du sphincter urétral, pourrait conduire à une dysfonction multiple avec trouble de la continence, de la tumescence clitoridienne et de la lubrification vulvaire car, à ce niveau, les efférences sympathiques et parasymphatiques coexistent. De plus, cette innervation est terminale, à la différence des afférences du PHI qui sont richement interconnectées. En effet, le NC, dernière collatérale de la BNV, est érectile pur à dominance parasymphatique et sa blessure à son origine occasionnera inévitablement une « dysfonction érectile » postopératoire.

Intérêts pédagogiques de la technique de Dissection Anatomique Assistée par Ordinateur (DAAO)

La reconstruction en trois dimensions de coupes histologiques immunomarquées permet de déterminer, au sein de fibres nerveuses de très petit calibre (25 µm de diamètre), la localisation et la nature des neurotransmetteurs et des récepteurs. Ainsi, cette méthode de DAAO développée dans le laboratoire et utilisée ici est une méthode fiable de recherche en anatomie. Le potentiel pédagogique de cette technique semble très étendu (23) :

- enseignement de l'anatomie en 3D, à l'aide de films d'animations représentant les structures anatomiques, que l'on peut virtuellement visualiser sous toutes leurs faces, « disséquer » ou rendre transparentes. Le corolaire direct de cet enseignement est la réalisation en temps réel de schémas anatomiques sur tablette graphique qui pourraient remplacer le dessin à la craie sur tableau noir ;
- enseignement de la technique chirurgicale, qui pourrait aussi être complété en simulant la résection d'organe et en insistant sur les rapports anatomiques importants (illustrations des techniques de préservation nerveuse) ;
- stockage des données obtenues permettant leur réutilisation de façon illimitée et leur compilation pour la création d'atlas électroniques interactifs et de sites internet consacrés.

Conclusion

Notre étude a permis de développer un premier modèle anatomo-physiologique et pédagogique d'innervation du pelvis et du périnée du fœtus féminin. Ce modèle est techniquement accessible et les données anatomiques obtenues sont fiables grâce à une maturité nerveuse acquise précocement au cours de la gestation. Le concept de bandelette neurovasculaire de la femme a ainsi été précisé avec systématisation morphologique et fonctionnelle. Cela a permis d'approfondir la connaissance des bases anatomiques et physiologiques, utiles au développement des techniques chirurgicales de préservation nerveuse et participant ainsi à une meilleure compréhension des dysfonctions sexuelles et urinaires neurogènes postopératoires.

Questions

Questions du Docteur Frédéric Bargy

Question 1

Quelle est l'origine des fœtus utilisés dans l'étude et leurs termes respectifs ?

Réponse

Cette étude a été réalisée sur des pièces anatomiques issues de fœtus de sexe féminin issus du service de fœtopathologie de l'hôpital Trousseau, après validation par l'Agence de Biomédecine. Un formulaire de consentement pour autopsie de fœtus était systématiquement signé par les parents, autorisant de pratiquer des examens à visée scientifique comportant des prélèvements qui seraient conservés dans un but de recherche.

Tous les fœtus avaient entre 18 et 32 semaines de gestation et leur anatomie était ainsi comparable à l'anatomie définitive de l'adulte.

Question 2

Avez-vous observé les lames pelviennes et quels rapports avez-vous retrouvé avec les plexus hypogastriques inférieurs ?

Réponse

Les coupes colorées avec le trichrome de Masson (identifiant les fibres conjonctives des fascias) sur les fœtus les plus âgés ne nous ont pas permis d'identifier les classiques lames sagittales du pelvis. Les plexus hypogastriques inférieurs ne semblent pas posséder des réelles tuniques conjonctives et sont appliqués au contact direct des fascias viscéraux pelviens.

Question 3

Quelles structures conjonctives avez-vous mis en évidence sur le trajet du nerf pudendal ?

Réponse

L'autopsie fœtale implique la parfaite restauration de l'intégrité tégumentaire. Ainsi, nos prélèvements n'ont pas emporté le nerf pudendal au cours de son trajet dans la fosse ischio-rectale. Néanmoins, nous avons pu étudier sa portion terminale (le nerf dorsal du clitoris).

Question 4

Avez-vous retrouvé des fibres végétatives destinées vers les muscles ischio-caverneux et bulbo spongieux ?

Réponse

Nous avons pu mettre en évidence des fibres autonomes issues du plexus hypogastrique inférieur au sein du muscle élévateur de l'anus et semblant se diriger vers le périnée urogénital (publication en cours). Leur rôle exact n'est pas encore connu.

Question du Docteur Yves Laburthe-Tolra

La reconstitution du chevelu plexique périviscéral suppose des contourages très fins, non superposés, très difficiles à réaliser, comme je l'ai expérimenté manuellement avec les logiciels qui existaient il y a 3 ans. Nous avons, avec le Pr Patrick Barbet, eu l'occasion de présenter à l'Académie, en 2008, les résultats de nos travaux sur les 100 cas d'embryons jeunes examinés par une technique voisine, à l'Hôpital Saint Vincent de Paul, à Paris, au niveau des membres supérieurs. Les résultats présentés ce jour résultent-ils d'une meilleure performance, de l'opérateur et du matériel ?

Réponse

Nous avons utilisé la dernière génération de tablette graphique avec écran intégré et un matériel informatique optimal (écran large, mémoire vive importante) permettant d'obtenir un contourage précis. Grâce à la dernière version du logiciel de contourage (*Surfdriver*), il a été possible de faire des contourages pour 16 structures différentes sur le même objet, le nombre d'objets disponibles étant illimité. Néanmoins, les plus récents logiciels de contourage automatique permettraient théoriquement d'optimiser cette étape de contourage mais leur utilisation est encore difficile.

Commentaires du Professeur Michel Malafosse

J'exprime toutes mes félicitations à l'auteur de ce travail d'anatomie magnifique : vit-on jamais aussi parfaitement le

« chevelu » des nerfs du bas pelvis ? Mais il est juste que le chirurgien donne son point de vue : il ne lui est guère possible qu'il puisse imaginer de les voir au cours de l'acte opératoire aussi parfaitement, quoique le souci de les préserver reste sa préoccupation permanente.

Dans l'exérèse rectale pour maladie inflammatoire, cette préservation est essentielle compte-tenu de la bénignité histologique de la maladie à traiter et du jeune âge fréquent des patients concernés ; on y parvient très habituellement car, après avoir repéré ces nerfs sous le promontoire, on les suit, et dès qu'ils deviennent de repérage incertain il ne faut plus vouloir les disséquer, d'autant que le tissu cellulaire périrectal est souvent modifié par l'inflammation : l'exérèse doit alors être poursuivie en « mordant » sur la paroi rectale musculuse (je rappelle que la recto-colite et la maladie de Crohn sont des maladies de la seule muqueuse) autant que de besoin et aussi bas dans le pelvis qu'il est nécessaire. À cette condition on peut dire que les séquelles fonctionnelles génito-urinaires sont quasi-inexistantes.

Le problème est évidemment tout différent dans la chirurgie du cancer du rectum, car le but à atteindre est ici de faire une exérèse « carcinologique », c'est-à-dire en passant au large de la zone tumorale et sans l'ouvrir : du respect de ce principe dépend le pronostic tant local que vital. C'est dire qu'on ne saurait faire l'ablation d'un cancer rectal invasif qu'en réalisant l'exérèse totale du mésorectum sans l'ouvrir à aucun endroit, selon la technique décrite par HEALD ; cette technique nécessite une dissection aussi patiente que possible des nerfs, fondée sur une connaissance parfaite de leur anatomie : c'est dire tout l'intérêt pour le chirurgien du travail que vient de nous présenter D. Moszkowicz, l'anatomiste ! Mais le chirurgien doit malheureusement le rappeler : la marge de « sécurité » de l'exérèse en largeur prime ; donc, en regard de la zone tumorale qu'on peut à présent bien repérer par les moyens d'imagerie du rectum, ce serait une faute de ne pas sacrifier les nerfs pelviens, si cela est nécessaire à la préservation du pronostic vital qui passe d'abord par le souci d'éviter au maximum les récidives locales. Le travail de D. Moszkowicz, par la minutie de sa description, contribue à atteindre ce but.

Références

1. MacFarlane JK, Ryall RD, Heald RJ. Mesorectal excision for rectal cancer. *Lancet* 1993 ; 341 : 457-60.
2. Lange MM, Maas CP, Marijnen CA, Wiggers T, Rutten HJ, et al; Cooperative Clinical Investigators of the Dutch Total Mesorectal Excision Trial. Urinary dysfunction after rectal cancer treatment is mainly caused by surgery. *Br J Surg* 2008 ; 95 : 1020-8.
3. Bissett IP, Hill GL. Extrafascial excision of the rectum for cancer: a technique for the avoidance of the complications of rectal mobilization. *Semin Surg Oncol* 2000 ; 18 : 207-15.
4. Salonia A, Giraldi A, Chivers ML, Georgiadis JR, Levin R, et al. Physiology of Women's Sexual Function: Basic Knowledge and New Findings. *J Sex Med* 2010 May 11.
5. Hoyle CH, Stones RW, Robson T, Whitley K, Burnstock G. Innervation of vasculature and microvasculature of the human vagina by NOS and neuropeptide-containing nerves. *J Anat* 1996 ; 188 (Pt 3) : 633-44.
6. Martin-Alguacil N, Pfaff DW, Shelley DN, Schober JM. Clitoral sexual arousal: an immunocytochemical and innervation study of the clitoris. *BJU Int* 2008 ; 101 : 1407-13.
7. Nappi R, Salonia A, Traish AM, van Lunsen RH, Vardi Y, et al. Clinical biologic pathophysiology of women's sexual dysfunction. *J Sex Med* 2005 ; 2 : 4-25.
8. Lindsey I, Mortensen NJ. Iatrogenic impotence and rectal dissection. *Br J Surg* 2002 ; 89 : 1493-4.
9. Alsaïd B, Bessedé T, Karam I, Abd-alsamad I, Uhl JF, et al. Coexistence of adrenergic and cholinergic nerves in the inferior hypogastric plexus: anatomical and immunohistochemical study with 3D reconstruction in human male fetus. *J Anat* 2009 ; 214 : 645-54.
10. Alsaïd B, Karam I, Bessedé T, Abdalsamad I, Uhl JF, et al. Tridimensional Computer-Assisted Anatomic Dissection of Posterolateral

- ral Prostatic Neurovascular Bundles. *Eur Urol* 2010 ; 58 : 281-7.
11. Moszkowicz D, Alsaïd B, Bessède T, Penna C, Nordlinger B, et al. Where does pelvic nerve injury occur during rectal surgery for cancer? *Colorectal Dis* 2010 Aug 16.
 12. Kinugasa Y, Murakami G, Suzuki D, Sugihara K. Histological identification of fascial structures posterolateral to the rectum. *Br J Surg* 2007 ; 94 : 620-6.
 13. Butler-Manuel SA, BATTERY LD, A'Hern RP, Polak JM, Barton DP. Pelvic nerve plexus trauma at radical and simple hysterectomy: a quantitative study of nerve types in the uterine supporting ligaments. *J Soc Gynecol Investig* 2002 ; 9 : 47-56.
 14. Hojo K, Vernava AM, 3rd, Sugihara K, Katumata K. Preservation of urine voiding and sexual function after rectal cancer surgery. *Dis Colon Rectum* 1991 ; 34 : 532-9.
 15. Walsh PC, Lepor H, Eggleston JC. Radical prostatectomy with preservation of sexual function: anatomical and pathological considerations. *Prostate* 1983 ; 4 : 473-85.
 16. Alsaïd B, Bessède T, Diallo D, Moszkowicz D, Karam I, et al. Division of Autonomic Nerves Within the Neurovascular Bundles Distally into Corpora Cavernosa and Corpus Spongiosum Components: Immunohistochemical Confirmation with Three-Dimensional Reconstruction. *Eur Urol* 2011 ; 59 : 902-9.
 17. Yucel S, De Souza A Jr, Baskin LS. Neuroanatomy of the human female lower urogenital tract. *J Urol* 2004 ; 172 : 191-5.
 18. Moszkowicz D, Alsaïd B, Bessède T, Zaitouna M, Penna C, et al. Neural supply to the clitoris: immunohistochemical study with three-dimensional reconstruction of cavernous nerve, spongiosus nerve, and dorsal clitoris nerve in human fetus. *J Sex Med* 2011 ; 8 : 1112-22.
 19. Colombel M, Droupy S, Paradis V, Lassau JP, Benoit G. Cavernopudendal nervous communicating branches in the penile hilum. *Surg Radiol Anat* 1999 ; 21 : 273-6.
 20. Yucel S, Baskin LS. Identification of communicating branches among the dorsal, perineal and cavernous nerves of the penis. *J Urol* 2003 ; 170 : 153-8.
 21. Pontes JE, Huben R, Wolf R. Sexual function after radical prostatectomy. *Prostate* 1986 ; 8 : 123-6.
 22. O'Connell HE, Sanjeevan KV, Hutson JM. Anatomy of the clitoris. *J Urol* 2005 ; 174 : 1189-95.
 23. Moszkowicz D, Alsaïd B, Bessède T, Penna C, Benoit G, Peschaud F. Female pelvic autonomic neuroanatomy based on conventional macroscopic and computer-assisted anatomic dissections. *Surg Radiol Anat* 2011 Janv 12.

Video 1. Séquence animée présentant la reconstruction 3D du pelvis et du périnée d'un fœtus féminin de 19 semaines de gestation avec immunomarquage neuronal par l'anticorps anti-protéine S100 et l'anticorps anti-nNOS. Les branches terminales du plexus hypogastrique inférieur (innervation autonome, nerf spongiosus et nerf caverneux) et du nerf pudendal (innervation somatique, nerf dorsal du clitoris) destinées notamment aux corps érectiles (corps caverneux du clitoris, bulbes vestibulaires) véhiculent une innervation érectile nitrergique (nNOS positive, fibres en magenta). Tableau 1. Résumé de la répartition des neurotransmetteurs pelvipérinéaux.

Voir la vidéo à http://www2.biusante.parisdescartes.fr/acad-chir/?ti_xxx=2011x10x2

◆ **Résumé de la thèse** : l'innervation pelvi-périnéale de la femme est assurée par des efférences du plexus hypogastrique inférieur qui est le centre d'intégration sympathique et parasympathique du pelvis. Au sein des branches efférentes de ce plexus, nous avons mis en évidence la coexistence de neurotransmetteurs cholinergiques, adrénergiques et sensitifs mais aussi l'abondance de fibres nerveuses contenant la forme neurale de l'enzyme de synthèse de l'oxyde nitrique, notamment dans les fibres destinées aux organes érectiles du périnée, au sphincter urétral et au sphincter anal lisses, où ce neurotransmetteur participe à la commande de la relaxation musculaire lisse. Ces structures doivent être respectées par le chirurgien pour prévenir les dysfonctions sexuelles et sphinctériennes post-opératoires.

◆ **Mots clés** : anatomie, innervation pelvienne, cancer du rectum, dysfonction sexuelle neurogène de la femme, nerf caverneux, nerf spongieux, nerf dorsal du clitoris, oxyde nitrique synthétase, plexus rectal inférieur, proctectomie.

◆ **Laboratoire d'accueil** : Laboratoire de Chirurgie Expérimentale, UPRES EA 4122, Université Paris-Sud 11, Faculté de Médecine, 63 avenue Gabriel Péri, 94270, Le Kremlin-Bicêtre, France ; Directeur : Professeur Gérard Benoît

PÔLE : SCIENCES CHIRURGICALES

UNIVERSITÉ PARIS-SUD 11

UFR «FACULTÉ DE PHARMACIE DE CHATENAY-MALABRY »

5, rue Jean Baptiste Clément

92296 CHÂTENAY-MALABRY Cedex