



**HAL**  
open science

# INTERACTIONS FRONTO-PARIETALES: DYNAMIQUE ET ORGANISATION DES RESEAUX CEREBRAUX DE L'ATTENTION SPATIALE

Michel Thiébaud

► **To cite this version:**

Michel Thiébaud. INTERACTIONS FRONTO-PARIETALES: DYNAMIQUE ET ORGANISATION DES RESEAUX CEREBRAUX DE L'ATTENTION SPATIALE. Neurosciences. Université Pierre et Marie Curie - Paris VI, 2007. Français. NNT : 2007PA066719 . tel-00803106

**HAL Id: tel-00803106**

**<https://theses.hal.science/tel-00803106>**

Submitted on 21 Mar 2013

**HAL** is a multi-disciplinary open access archive for the deposit and dissemination of scientific research documents, whether they are published or not. The documents may come from teaching and research institutions in France or abroad, or from public or private research centers.

L'archive ouverte pluridisciplinaire **HAL**, est destinée au dépôt et à la diffusion de documents scientifiques de niveau recherche, publiés ou non, émanant des établissements d'enseignement et de recherche français ou étrangers, des laboratoires publics ou privés.

THESE DE DOCTORAT DE L'UNIVERSITE

PIERRE ET MARIE CURIE

PARIS VI

Spécialité

Neurosciences

Présentée par

Michel THIEBAUT DE SCHOTTEN

Née le 20 janvier 1981 à Lisieux

Pour obtenir le grade de

DOCTEUR DE L'UNIVERSITE PIERRE ET MARIE CURIE

**INTERACTIONS FRONTO-PARIETALES  
DYNAMIQUE ET ORGANISATION DES RESEAUX  
CEREBRAUX DE L'ATTENTION**

Thèse dirigée par les **Dr. Paolo BARTOLOMEO** et **Richard LEVY**

Soutenue le 20 Septembre 2007

Devant le jury composé de :

<i>Président du jury :</i>	Pr. Richard LEVY
<i>Rapporteurs :</i>	Pr. Sylvie CHOKRON
	Pr. Angela SIRIGU
<i>Examineurs :</i>	Dr. Marco CATANI
	Pr. Fabrizio DORICCHI
	Pr. Etienne KOECHLIN

## **Financement**

Allocation de recherche du Ministère de l'Éducation Nationale, de la Recherche et de la Technologie (2005-2007).

## Remerciements

Merci à mes parents de m'avoir mis au monde et entretenu jusqu'à ce que le ministère de la recherche prenne le relais. Merci surtout à vous pour les principes et les conseils que je garde de votre éducation qui jouent pour beaucoup aujourd'hui dans ma vie.

Merci au Ministère de l'Education Nationale de la Recherche et du Développement et l'Ecole doctorale Cerveau Cognition Comportement pour l'argent qui m'a été confié pour ma recherche, j'espère en avoir fait bon usage.

Merci à Paolo et Richard, mes deux directeurs, de vous démenner pour faire de moi un bon chercheur épanoui. Ce ne doit pas être tous les jours facile. Merci aussi pour le temps que vous avez passé à corriger ce document.

Merci à Marco d'accepter de prendre le relais, ma formation est loin d'être finie et j'ai encore beaucoup à apprendre (bon courage !)

Merci à mes proches parce qu'ils sont proches.

Merci à mon adorable collègue de bureau, Emmanuelle, pour une année de DEA et trois années de thèse inoubliables en sa compagnie.

Merci à l'équipe technique qui a éclairé mon esprit pratique : Stéphane, Eric, Jérôme, Romain.

Merci le CENIR, de mettre à ma disposition trois supers ordinateurs le week-end.

Merci les patients pour leur patience justement, ce qu'ils m'ont appris du monde et le bon travail que nous avons fait ensemble.

Merci à mon groupe de musique, ChromatiZme, le CD n'est pas prêt et ne sera pas présent dans le matériel supplémentaire... ce n'est pas grave je crois que la patience des lecteurs de la thèse se serait arrêtée au titre n°1 de toute façon.

Merci à Bruno Dubois, pour les discrètes petites touches qu'il place souvent pour faciliter ma vie professionnelle.

Merci à Hugues pour la neurochirurgie, la science et le bourbon.

Merci à mes rapporteurs d'avoir accepté d'évaluer ma thèse, c'est long, c'est rébarbatif probablement, mais c'est très important pour moi.

Merci à Mathias pour m'avoir souvent guidé quel que soit le domaine.

Merci au Moose Head, le bar d'en bas de chez moi pour son air climatisé, ses sourires chaleureux et les litres de Beamish qui m'ont été offerts (et je pense à quelqu'un en particulier).

Merci à tous mes collègues qui sont devenu des amis, pour leurs conseils avisés, leur écoute.

Merci à Trent Reznor pour cette chanson « Something I can never have » que j'ai écouté 614 fois sur mon ordinateur en pensant à ma thèse... entre autre.

Merci aux chercheurs extérieurs qui ont guidé ma réflexion et ma méthode N.Geschwind, M. Mesulam, F. Doricchi, M. Husain, J. Schmahmann, D. Pandya, D. Jones, M. Catani, D. Le Bihan. Ils ne le savent pas, mais leurs papiers ont tout changé pour moi.

Merci à Marie Jeanne & George Brassens et la Cabane D'auvergne (le pavé gourmand !) pour m'avoir accompagné les soirs où il fallait penser à autre chose.

Merci à ceux qui savent pourquoi je dis merci : Igor, Mathilde, Gilles, Estelle, Christophe, Vieran.

Merci à ceux que je n'aime pas, ne changez rien, vous êtes parfaits.

Merci à ceux que je n'ai pas remerciés par mégarde et qui se reconnaissent à cette dernière ligne.

## **Publications**

**Urbanski M., Thiebaut de Schotten M., Rodrigo S., Catani M., Oppenheim C., Touzé E., Chokron S., Méder J.F., Lévy R., Dubois B., Bartolomeo P.** Brain network for spatial awareness: Evidence from diffusion tensor tractography. JNNP (submitted)

**Volle E, Kinkingnéhun S, Pochon JB, Mondon K, Thiebaut de Schotten M, Renie L, du Boisgucheneuc F, Duffau H, Samson Y, Dubois B, Levy R.** The functional architecture of the posterior and lateral prefrontal cortex in humans. Journal of neuroscience (submitted)

**Thiebaut de Schotten M, Kinkingnéhun S, Delmaire C, Lehericy S, Duffau H, Thivard L, Volle E, Levy R, Dubois B, Bartolomeo P.** Visualization of disconnection syndromes in humans Cortex (under review).

**Duffau H, Thiebaut de Schotten M, Mandonnet E.** White matter functional connectivity as an additional landmark for dominant temporal lobectomy JNNP (2007, in press)

**Bartolomeo P, Thiebaut de Schotten M, Doricchi F.** Left Unilateral neglect as a disconnection syndrome. Cerebral Cortex (2007, in press).

**Thiebaut de Schotten M, Bartolomeo P.** Neuro-anatomy of space processing. Medecine science (2006).

**Thiebaut de Schotten M, Urbanski M, Duffau H, Volle E, Levy R, Dubois B, Bartolomeo P.** Direct evidence for a parietal-frontal pathway subserving spatial awareness. Science (2005).

# Sommaire

## Résumé

**I – ATTENTION : DEFINITION DU CONCEPT.....p.13**

**II - LE SYNDROME DE NEGLIGENCE SPATIALE  
UNILATERALE : UN MODELE LESIONNEL POUR L'ETUDE  
DE L'ATTENTION..... p.15**

- 1. DESCRIPTION CLINIQUE..... p.16**
- 2. MISE EN EVIDENCE DE LA NSU : LES TESTS  
NEUROPSYCHOLOGIQUES..... p.18**
- 3. BASES COGNITIVES DE LA NSU..... p.22**
- a) NSU et représentation mentale..... p.24**
- b) NSU et orientation de l'attention..... p.29**
- 4. NSU ET CONSCIENCE ..... p.35**

**III - INVESTIGATION DES BASES NEURALES DE LA NSU  
AU MOYEN DE LA TECHNIQUE DE STIMULATION  
ELECTRIQUE PER-OPERATOIRE (IES) .....p.38**

- 1. BASES NEUROANATOMIQUES DE LA NSU ..... p.42**
- a) Cortex pariétal..... p.42**
- b) Autres localisations moins fréquentes..... p.43**
- c) Fibres de la substance blanche : une issue possible du débat..... p.44**
- 2. PRINCIPES ET FONCTIONNEMENT DU TENSEUR DE DIFFUSION (DTI).  
..... p.45**
- a) Limites de l'imagerie par résonance magnétique (IRM) anatomique conventionnelle.  
..... p.45**
- b) L'imagerie par tenseur de diffusion (DTI) ..... p.46**
- b.1) Le tenseur de diffusion et l'ellipsoïde de diffusion ..... p.46**
- b.2) Visualisation 2d du tenseur de diffusion..... p.49**
- b.3) Visualisation 3d du tenseur de diffusion..... p.50**
- 3. LA TECHNIQUE IES (INTRA-OPERATIVE ELECTRICAL  
STIMULATIONS) ..... p.52**
- 4. APPLICATION..... p.53**
- 5. DISCUSSION..... p.72**

**IV - DE LA DISCONDUCTION A LA  
DISCONNEXION.....p.75**

1. PRINCIPES ET DEFINITIONS.....p.75
2. LA NEGLIGENCE SPATIALE UNILATERALE : UN SYNDROME DE DISCONNEXION ? .....p.78

**V – MISE EN EVIDENCE DES SYNDROMES DE DISCONNEXION.....p.112**

**VI – DISCUSSION GENERALE : DE LA DISCONNEXION A L'HODOLOGIE..... p.133**

1. L'IMPORTANCE DES VOIES DE CONNEXION DE LA SUBSTANCE BLANCHE.....p.133
2. LA NEGLIGENCE SPATIALE UNILATERALE .....p.136
3. PERSPECTIVES : VERS UNE APPROCHE HODOLOGIQUE DE LA NSU ET DE L'ATTENTION SPATIALE..... p.138

**Références ..... p.144**

**ANNEXE 1 LA BATTERIE PARIETALE..... p. 155**

**ANNEXE 2 WHITE MATTER FUNCTIONAL CONNECTIVITY AS AN ADDITIONAL LANDMARK FOR DOMINANT TEMPORAL LOBECTOMY..... p. 184**

**ANNEXE 3 LES CHEMINS TORDUS..... p. 188**



## INDEX DES FIGURES

<b>Figure 1</b> <i>Empédocle, gravure sur bois, H. Schedel (484 ? -424)</i> .....	<b>p. 13</b>
<b>Figure 2</b> <i>Exemple de copie de dessin et de bissection de ligne chez un patient négligent</i> .....	<b>p. 17</b>
<b>Figure 3</b> <i>Exemple de copie réalisée par une patiente présentant une négligence centrée sur la scène (le dernier arbre à gauche est manquant) et sur l'objet (la partie gauche de la maison et celle du sapin sont manquantes)</i> .....	<b>p. 19</b>
<b>Figure 4</b> <i>Le barrage de traits (Albert, 1973)</i> .....	<b>p. 20</b>
<b>Figure 5</b> <i>Le barrage de lettres (Mesulam, 1985)</i> .....	<b>p. 20</b>
<b>Figure 6</b> <i>Le barrage de cloches (Gauthier et al., 1989)</i> .....	<b>p. 21</b>
<b>Figure 7</b> <i>Illustration de la performance des patients en fonction de la longueur des lignes à bissecter</i> .....	<b>p. 22</b>
<b>Figure 8</b> <i>Les figures enchevêtrées de Gainotti et al. (1991)</i> .....	<b>p. 22</b>
<b>Figure 9</b> <i>Photographie de la « Piazza del Duomo » à Milan</i> .....	<b>p. 24</b>
<b>Figure 10</b> <i>Dessin de papillon réalisé de mémoire par un patient négligent. Yeux fermés (Chokron et al., 2004)</i> .....	<b>p. 28</b>
<b>Figure 11</b> <i>Dessin de papillon réalisé de mémoire par un patient négligent. Yeux ouverts (Chokron et al., 2004)</i> .....	<b>p. 28</b>
<b>Figure 12</b> <i>Régions cérébrales activées lors de tâches impliquant l'orientation endogène (blanc) ou exogène (pointillés gris) de l'attention (d'après Corbetta et Shulman, 2002)</i> ..	<b>p. 32</b>
<b>Figure 13</b> <i>Illustration du paradigme de Posner et al. (1984)</i> .....	<b>p. 33</b>
<b>Figure 14</b> <i>Exemple tiré de l'expérience de Marshall et Halligan (1988)</i> .....	<b>p. 35</b>
<b>Figure 15</b> <i>Maximum de recouvrement des lésions des patients qui présentent un syndrome de NSU décrits Vallar (Vallar, 2001) et Mort &amp; collaborateur (Mort et al., 2003)</i> .....	<b>p. 39</b>
<b>Figure 16</b> <i>Illustration de la correspondance entre le résultat neuro-anatomique mis en évidence par Karnath &amp; coll. (Karnath et al., 2001) et l'hypothèse cognitive décrite par Milner &amp; Goodale (Milner and Goodale, 1995)</i> .....	<b>p. 40</b>
<b>Figure 17</b> <i>Score en détection des macaques après la résection (Gaffan and Hornak, 1997)</i> ..	<b>p. 41</b>
<b>Figure 18</b> <i>IRM T1 haute définition</i> .....	<b>p. 46</b>
<b>Figure 19</b> <i>Cartes de diffusion de la même coupe axiale mesurées suivant deux orientations différentes</i> .....	<b>p. 47</b>
<b>Figure 20</b> <i>Ellipsoïde 3d de diffusion</i> .....	<b>p. 48</b>
<b>Figure 21</b> <i>Une IRM conventionnelle (image pondérée en T1) recalée sur une carte anisotropique et une carte d'orientation</i> .....	<b>p. 49</b>
<b>Figure 22</b> <i>Groupe d'axones myélinisés qui forment ensemble un faisceau</i> .....	<b>p. 51</b>
<b>Figure 23</b> <i>La technique IES</i> .....	<b>p. 53</b>
<b>Figure 24</b> <i>Ancienne description des faisceaux supérieurs d'association chez l'homme par Nieuwenhuys (Nieuwenhuys et al., 1988b)</i> .....	<b>p. 66</b>
<b>Figure 25</b> <i>Nouvelle description des faisceaux supérieurs d'association chez le macaque par Schmammann &amp; Pandya (Schmammann and Pandya, 2006)</i> .....	<b>p. 66</b>
<b>Figure 26</b> <i>Meta analyse de l'activation fonctionnelle durant l'orientation de l'attention vers des cibles inattendues (Corbetta and Shulman, 2002)</i> .....	<b>p. 73</b>
<b>Figure 27</b> <i>Les réseaux fronto pariétaux d'orientation de l'attention</i> .....	<b>p. 74</b>
<b>Figure 28</b> <i>Historique des bases neurales du langage dans l'hémisphère gauche</i> ..	<b>p. 76</b>
<b>Figure 29</b> <i>Reconstruction en DTI du faisceau arqué suivant une approche de double région d'intérêt</i> .....	<b>p. 78</b>

<b>Figure 30</b> <i>Illustration du faisceau longitudinal supérieur (branche 3 en vert et branche 2) et du faisceau occipito-frontal inférieur.....</i>	<b>p. 111</b>
<b>Figure 31</b> <i>Exemple de diagramme produit par Freud (Freud, 1891).....</i>	<b>p. 134</b>
<b>Figure 32</b> <i>Illustration en DTI de quelques exemples des faisceaux d'association, de projection ou commissuraux (Catani and ffytche, 2005).....</i>	<b>p. 136</b>
<b>Figure 33</b> <i>Les syndromes de disconnexion classiques et plus récents d'après Catani et ffytche (2005).....</i>	<b>p. 137</b>
<b>Figure 34</b> <i>Modèle d'étude des corrélations clinico-pathologiques.....</i>	<b>p. 138</b>
<b>Figure 35</b> <i>Vue globale latérale et médiane des frontières cytoarchitectoniques du cerveau humain (Economo, 1925).....</i>	<b>p. 155</b>

## **Résumé**

### **INTERACTIONS FRONTO-PARIETALES: DYNAMIQUE ET ORGANISATION DES RESEAUX CEREBRAUX DE L'ATTENTION SPATIALE**

L'attention spatiale est une famille de processus cognitifs qui nous permet d'interagir de façon efficace avec notre environnement, en sélectionnant les stimuli importants et en inhibant les distracteurs. La négligence spatiale unilatérale (NSU) est une condition neurologique qui résulte de lésions de l'hémisphère cérébral droit chez l'homme. Le signe principal de cette pathologie est un manque sévère de la distribution de l'attention dans l'hémiespace gauche. Les travaux de cette thèse mettent en évidence à partir de la NSU qu'une distribution équilibrée de l'attention spatiale nécessite la préservation des chemins de connexions reliant le lobe pariétal au lobe frontal. La seconde partie de cette thèse porte sur l'anatomie de ces connexions, sur une réflexion sur la pertinence de l'étude des grandes voies de connexion (approche hodologique) dans les neurosciences cognitives et des conséquences des disconnexions dans les syndromes neurologiques.

### **FRONTO-PARIETAL INTERACTIONS: DYNAMIC FUNCTIONING AND ORGANISATION OF THE BRAIN NETWORKS OF SPATIAL ATTENTION**

Spatial attention refers to a family of cognitive processes which allow us to interact efficiently with our environment, by selecting relevant stimuli and inhibiting distractors. Unilateral spatial neglect (USN) is a dramatic neurological condition resulting from damage to the right hemisphere of the human brain. USN is mainly characterized by a severe lack of attention for left, contralesional stimuli. This thesis uses USN to demonstrate that a normal distribution of spatial attention needs unimpaired pathways linking the parietal to the frontal lobe. The second part of this thesis deals with the connective anatomy of long-range brain pathways, the relevance of the study of these pathways to cognitive neuroscience (hodological approach), and the consequences of white-matter disconnections in neurological syndromes.

## I – ATTENTION : DEFINITION DU CONCEPT



*Fig. 1 : Empédocle, gravure sur bois, H. Schedel (484 ? -424) Empédocle d'Agrigente (Sicile) que Platon désigne par l'expression "les muses de Sicile" a été considéré comme un véritable mage, guérisseur des âmes et du corps. Porte-parole des démocrates de sa cité, il lutte contre la tyrannie avant d'être exilé et de se réfugier dans le Péloponnèse. Une légende affirme qu'il se serait précipité dans le cratère de l'Etna. La philosophie d'Empédocle se trouve exposée en deux longs poèmes : De la nature et Les purifications. Inspirée par l'école pythagoricienne, sa doctrine articule les quatre racines des choses : le feu, l'air, l'eau et la terre. Toutes les choses sont un mélange adéquatement dosé de ces quatre éléments. Son poème de la nature est riche en observations biologiques et médicales (en particulier sur le fœtus) et Galien en fera le fondateur de l'école italienne de médecine.*

Il y a près de 25 siècles, Empédocle raisonna sur la nature de dieu et la relia au concept d'un cercle dont le centre est partout et la circonférence nulle part. L'omniprésence qu'Empédocle envisage par là sous-entend une conscience absolue de tout : rien n'est ignoré, laissé pour compte, aucune étroite et spécifique focalisation n'est possible, tous les événements sont enregistrés en parallèle, toute chose possède un accès direct et instantané à l'action et le global serait comparable au focal. Quiconque inférieur à une entité montrant une telle omniprésence montrera le besoin de choisir lequel de tous ces événements mentaux ou extérieurs aura un accès préférentiel aux portes exigües de la conscience et de l'action.

« Attention » est un terme générique qui est utilisé dans le domaine des Sciences Cognitives pour désigner tout l'éventail des processus qui permettent la gestion de ces choix. Plus précisément, l'attention implique une attribution préférentielle de nos ressources de traitement limitées et de nos possibilités de réponses à des événements qui ont acquis une pertinence comportementale (Mesulam, 1999). D'un point de vue neuronal, l'attention se réfère aux modulations réversibles lors de ce type de sélections : l'intensité et la durée des réponses neuronales à ce type d'évènements (Muller et al., 2003).

## **II - LE SYNDROME DE NEGLIGENCE SPATIALE UNILATERALE : UN MODELE LESIONNEL POUR L'ETUDE DE L'ATTENTION**

### *Résumé*

*Les patients cérébro-lésés droits montrent fréquemment des signes de négligence spatiale unilatérale (Azouvi et al., 2002). Ce syndrome reflète un sévère trouble de l'attention spatiale et concerne environ la moitié des patients porteurs d'une lésion hémisphérique droite (Azouvi et al., 2002), soit plusieurs milliers de cas par an en France. Les patients atteints de cette pathologie se comportent en ignorant la moitié gauche du monde (Bartolomeo and Chokron, 2001). Ils ne mangent pas ce qui se trouve dans la moitié gauche de leur assiette, ne se rasent pas la partie gauche du visage et ne répondent pas quand ils sont interrogés du côté gauche. Cette pathologie rend en effet impossible toute activité qui demande de l'attention, comme la conduite automobile ou plus simplement faire ses courses au supermarché. Il s'agit donc d'un modèle lésionnel idéal pour l'étude des processus attentionnels.*

La Négligence Spatiale Unilatérale (NSU) est un syndrome neurologique se manifestant fréquemment après une lésion de l'hémisphère cérébral non dominant pour le langage (voir pour revue (Bartolomeo and Chokron, 2001)). On estime qu'environ 85% des patients porteurs d'une lésion hémisphérique droite présentent en phase subaiguë des signes de NSU qui détermineront dans 36% des cas une NSU modérée à sévère (Azouvi et al., 2002). Ce syndrome est caractérisé par une difficulté voire une impossibilité à détecter, s'orienter vers et identifier des événements situés dans l'hémiespace gauche, indépendamment de la présence d'un déficit sensoriel ou moteur élémentaire (Heilman and Valenstein, 1979). Les patients se comportent comme si la partie gauche de leur espace corporel et/ou extra-corporel n'existait plus.

Le syndrome de NSU a donné lieu à de nombreuses recherches depuis ces 30 dernières années et reste à l'origine de nombreux débats encore actuellement tant sur le plan théorique que sur le plan neuroanatomique.

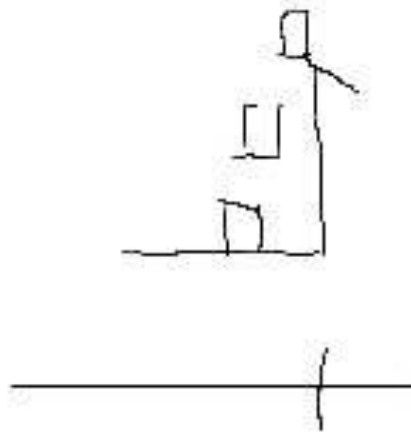
L'intérêt pour la NSU provient des questions théoriques qu'elle pose sur des activités cognitives aussi complexes que la représentation mentale, l'attention et la conscience de l'espace et sur leurs localisation et fonctionnement dans le cerveau.

Sur le plan de la santé publique, la NSU pose des problèmes importants, du fait qu'elle aggrave le handicap en gênant la rééducation motrice (Appelros et al., 2002; Denes et al., 1982; Jehkonen et al., 2000). La réhabilitation sociale de ces patients est également compromise, du fait de la réduction d'autonomie déterminée par la NSU (par exemple, ces patients ne peuvent plus conduire une voiture).

La compréhension des mécanismes de la NSU est importante pour fournir aux cliniciens des outils adaptés de diagnostic et de traitement (rééducation). La recherche sur la NSU peut en outre contribuer à une meilleure compréhension des mécanismes cérébraux du traitement de l'espace et des corrélats neuronaux de la conscience perceptive.

## **1. DESCRIPTION CLINIQUE**

En phase aiguë, les patients négligents présentent typiquement une déviation de la tête et des yeux vers la droite et ne peuvent prêter attention aux événements du côté gauche. Ils peuvent ne manger que ce qui se trouve à droite dans leur assiette, ne se raser ou se maquiller que la partie droite du visage, ne lire que l'extrémité droite des journaux ou des livres (dyslexie de l'héminégligence). Ainsi, les patients héminégligents agissent comme s'ils ignoraient la moitié gauche de l'espace: En dessinant de mémoire ou en copie une fleur ou une maison, ils omettent les détails de gauche. Ils déplacent vers la droite le milieu subjectif d'une ligne horizontale lors d'une tâche de bissection (voir Figure 2)



*Fig. 2 : Exemple de copie de dessin et de bissection de ligne chez un patient négligent.*

Certains patients vont apprendre à compenser leur NSU dans la vie quotidienne et dans les tests alors que d'autres vont présenter une chronicité pouvant aller à plusieurs années après l'accident vasculaire, ce qui rend d'autant plus importante la question de trouver des moyens de rééducation adaptés pour ces patients dont l'évolution de la NSU est moins favorable.

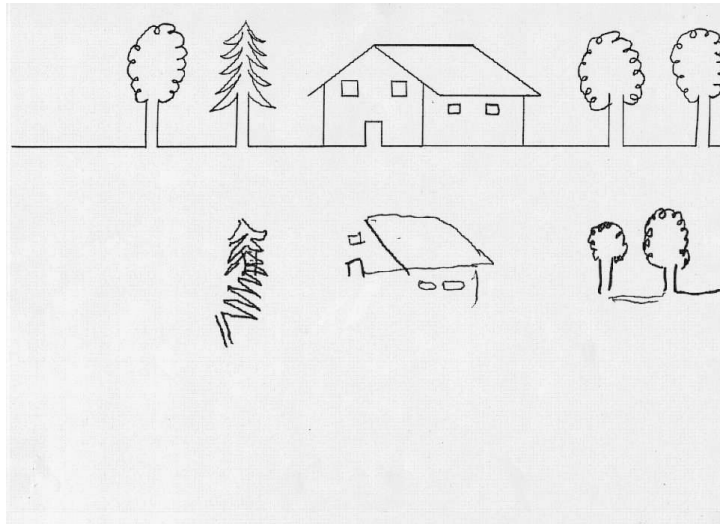


## 2. MISE EN EVIDENCE DE LA NSU : LES TESTS NEUROPSYCHOLOGIQUES

Parfois, les patients ne présentent pas de signes cliniques évidents de NSU en phase subaiguë, et la NSU peut donc passer inaperçue si on ne fait pas de tests spécifiques sur lesquels repose le diagnostic. Ces tests standardisés sont simples (papier/crayon) et peuvent être administrés au lit du patient, en prenant garde de maintenir centrée la feuille de test par rapport au tronc du patient. Deux batteries validées sont souvent utilisées pour évaluer la NSU : La Behavioural Inattention Test comportant une série de tests conventionnels et neuf tests dits « comportementaux » (Halligan et al., 1991a) et la Batterie d'Evaluation de la Négligence Spatiale Unilatérale du GEREN, de langue française, validée sur une population de 206 patients permettant une évaluation à la fois du niveau de déficit mais également de ses conséquences fonctionnelles (Azouvi et al., 2002); pour les données normatives, voir (Rousseaux et al., 2001). Cette batterie comporte des tests visuo-peceptifs (*cf.* par exemple le test des figures enchevêtrées), visuo-graphiques (*cf.* par exemple la copie de dessin) ainsi que l'échelle Catherine Bergego (ECB), questionnaire en 10 items d'auto-évaluation de la NSU par le patient et par le thérapeute, permettant ainsi d'apprécier l'importance de l'anosognosie associée à la NSU (Bergego et al., 1995).

### **COPIE DE DESSIN** (Gainotti et al., 1972)

Les patients négligents omettent ou distordent les éléments situés sur la gauche de la feuille (NSU centrée sur la scène, ou « scene-based »). Certains patients présentent un phénomène de NSU centrée sur l'objet (« object-based ») dans laquelle tous les éléments sont présents mais la partie gauche d'un item peut être manquante (Gainotti et al., 1972); (Marshall and Halligan, 1993); (Walker, 1995) (voir figure 3). Enfin certains patients peuvent aussi déplacer certains éléments situés à gauche sur le modèle du côté droit lors de la copie (allochirie : (Critchley, 1953); (Halligan et al., 1992)).



*Fig. 3 : Exemple de copie réalisée par une patiente présentant une négligence centrée sur la scène (le dernier arbre à gauche est manquant) et sur l'objet (la partie gauche de la maison et celle du sapin sont manquantes).*

### **TESTS DE BARRAGE**

Les patients doivent cocher ou entourer des traits (Albert, 1973) (voir figure 4), des lettres (Mesulam, 1985) (voir figure 5), des formes (Gauthier et al., 1989); (Halligan et al., 1991a) (voir figure 6). En général, ils débutent l'exploration du côté droit et omettent les éléments situés à gauche.




Fig. 4




Fig. 5


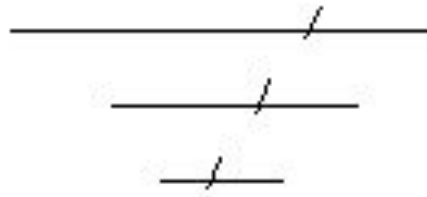


Fig. 6

*Fig 4-6 : Exemples de performances de deux patientes lors des tests de barrage. Dans le barrage de traits (Albert, 1973) (Fig. 4), le sujet doit cocher tous les traits qu'il voit. Ici la patiente commence par cocher un trait à l'extrémité droite (flèche) puis poursuit uniquement le test sur la moitié droite de la feuille. Dans le barrage de lettres (Mesulam, 1985) (Fig. 5), le sujet doit entourer tous les « A » répartis de façon symétrique entre la moitié gauche et la moitié droite de la feuille. La même patiente n'est parvenue qu'à entourer les A à l'extrémité droite de la feuille. Dans le barrage de cloches (Fig. 6) (Gauthier et al., 1989), le sujet doit entourer toutes les cloches réparties parmi des distracteurs visuels de façon symétrique. Ici une autre patiente parvient à franchir la ligne médiane mais l'extrémité gauche de la feuille n'est pas explorée.*

### **BISSECTION de LIGNES**

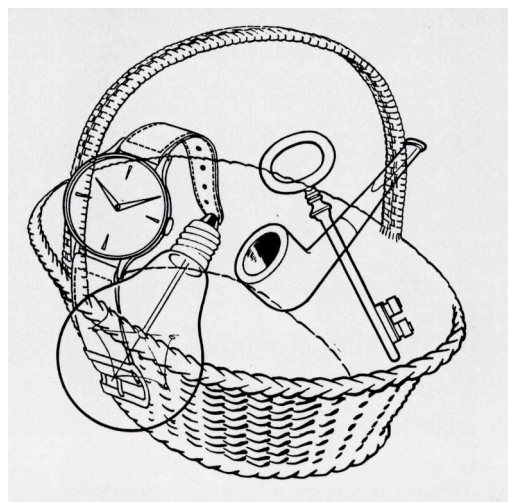
Quand on demande aux patients d'indiquer le milieu de lignes horizontales de différentes longueurs, ils dévient vers la droite le milieu subjectif (Schenkenberg et al., 1980) particulièrement pour les lignes longues. Paradoxalement, le milieu subjectif des lignes courtes est dévié à gauche (« cross-over effect », (Marshall and Halligan, 1989) (voir figure 7).



*Fig. 7 : Illustration de la performance des patients en fonction de la longueur des lignes à bissecter. Pour les lignes longues, les patients déplacent le milieu subjectif vers la droite de façon importante. Pour les lignes courtes, le milieu subjectif est plutôt déplacé à gauche.*

**FIGURES ENCHEVÊTRÉES** (Gainotti et al., 1991)

Les patients doivent dénommer différents dessins d'objets qui sont en partie superposés (2 à gauche, 1 central et 2 à droite) (voir figure 8). Certains patients omettent les items de gauche, ou font des erreurs de reconnaissance en se focalisant sur les détails de droite des objets situés dans l'espace gauche. Souvent, même sans omission, on observe quand même une nette tendance des patients à dénommer en premier les items situés à droite.



*Fig. 8 : Exemple du test des figures enchevêtrées de Gainotti et al. (1991). Les réponses des patients sont notées dans l'ordre de production.*

Du fait que la NSU peut se manifester dans l'espace représentationnel (cf. 1, section III.), d'autres épreuves en permettent une évaluation plus spécifique : comme par exemple, les dessins de mémoire ou les épreuves reposant sur l'évocation mentale d'un espace, notamment

l'évocation mentale de la carte de France (Rode et al., 1995); pour une revue des différents types d'épreuves d'évaluation voir (Gainotti et al., 1989).

### 3. BASES COGNITIVES DE LA NSU

Beaucoup de dissociations dans les manifestations de la NSU ont été décrites. En effet, les patients peuvent montrer une NSU dans l'espace proche et non dans l'espace lointain (Halligan et al., 1991a) ou l'inverse (Cowey et al., 1994). Par exemple, certains patients peuvent dévier vers la droite le milieu subjectif d'une ligne présentée sur une feuille (espace péri-personnel) alors qu'ils pointeront correctement le milieu d'une ligne présentée au loin (espace extra-personnel) (Halligan et al., 1991a). Les patients peuvent montrer une NSU dans certains tests et non à d'autres (Halligan and Marshall, 1992) voire des patterns opposés de NSU (gauche/droite) en fonction de la tâche (Costello and Warrington, 1987) ; (Halligan and Marshall, 1998);(Humphreys and Riddoch, 1994). La NSU peut se manifester non seulement dans l'espace visuel mais également auditif (Bisiach et al., 1984) ; (De Renzi et al., 1989), tactile (Bisiach et al., 1985); (Chedru, 1976) ou imaginé (Bisiach and Luzzatti, 1978; Bisiach et al., 1981) ou encore engager des représentations centrées sur le corps et/ou sur l'objet. Ces multiples dissociations ont conduit à voir la NSU comme un déficit très hétérogène (voir par exemple, (Chatterjee, 1998); (Stone et al., 1998); (Vallar, 1994) voire comme une « entité sans signification » (Halligan and Marshall, 1992).

Bien qu'initialement la NSU ait été considérée comme liée à des déficits sensoriels primaires comme l'hémianopsie latérale homonyme gauche (Bender, 1952), tous les patients négligents n'ont pas forcément de déficit du champ visuel, de même que tous les patients hémianopsiques ne sont pas forcément hémignégligents (Gainotti, 1968); (Làdavas, 1987); (McFie et al., 1950). De plus, de nombreuses études ont montré une préservation chez certains patients de traitements implicites dans le champ visuel négligé pouvant aller jusqu'à un haut niveau (Barton et al., 1998); (Berti et al., 1992); (D'Erme et al., 1993); (Halligan et al., 2003); (Ishiai et al., 1996); (Karnath and Hartje, 1987); (Làdavas et al., 1997a); (Marshall and Halligan, 1988); (McGlinchey-Berroth et al., 1993); (Volpe et al., 1979).

Des déficits sous-jacents de plus haut niveau ont été envisagés, tels que la difficulté à construire ou à explorer une représentation interne de l'espace (théories « représentationnelles », cf. 1., section III) ou des difficultés à orienter l'attention dans l'espace (théories « attentionnelles », cf. 2., section III) ou une disconnexion à l'intérieur d'un vaste réseau impliqué dans la conscience et l'attention spatiale (cf. 3., section III).

### a) NSU et représentation mentale

L'imagerie mentale correspond à la faculté par laquelle nous pouvons visualiser un stimulus de mémoire (Bartolomeo, 2002). Cette capacité du cerveau à produire des images mentales permet la création de nouvelles représentations, essentielle à la mise en œuvre des processus cognitifs les plus complexes. En élaborant des images mentales nous pouvons créer des cartes représentationnelles, attribuant une dimension spatiale aux objets - dimension qui peut être sélectivement endommagée dans la NSU. Parmi les premières descriptions de patients présentant un déficit au niveau des représentations spatiales, on trouve (Bisiach and Luzzatti, 1978) qui ont introduit le terme de NSU représentationnelle. Ces deux auteurs demandent à leurs patients de décrire une place familière, la place de la Cathédrale à Milan (Piazza del Duomo, voir figure 9), selon deux perspectives diamétralement opposées.



*Fig. 9 : Photographie de la « Piazza del Duomo » à Milan. Dans l'expérience de Bisiach et Luzzatti (1978), les patients devaient s'imaginer sur la place et décrire tout ce qu'ils « voyaient » soit en faisant face à la cathédrale soit en faisant dos à la cathédrale.*

Pour chaque point de vue, les patients rapportent les items situés à droite et peu d'items, voire aucun, à gauche. Selon Bisiach et Luzzatti, ce comportement reflèterait l'existence d'une représentation spatiale analogique et symétrique dans les deux hémisphères cérébraux qui serait partiellement détruite dans la NSU représentationnelle. Les patients auraient perdu la moitié gauche d'une représentation cognitive de l'espace. D'autres auteurs proposent en revanche que le déficit ne se situerait pas au niveau de la représentation mais plutôt au niveau

de l'exploration de cette représentation (Bartolomeo et al., 2005). La carte mentale serait intacte, mais les patients ne seraient pas capables d'explorer la partie gauche de leurs images mentales.

Suite aux descriptions de Bisiach et Luzzatti, de nombreux cas de dissociation entre NSU représentationnelle et perceptive ont été rapportés (Beschlin et al., 2000); (Guariglia et al., 1993); (Ortigue et al., 2001). La question est alors de savoir si la NSU représentationnelle est une entité à part entière ou si elle fait partie intégrante de la NSU perceptive.

Guariglia et al. (1993) rapportent le cas d'un patient qui ne montre pas de signe de NSU personnelle, extra personnelle ou péri personnelle, mais présente de sévères problèmes dans la récupération d'items du côté gauche (des deux points de vue opposés) de places familières. Ce patient a des performances normales pour les tâches requérant la génération et la manipulation d'images d'objets. Beschlin et al. (2000) rapportent le cas remarquable d'un patient présentant une sévère NSU personnelle droite ainsi qu'une NSU perceptive droite, alors qu'une NSU représentationnelle se manifeste du côté gauche. Ortigue et al. (2001) décrivent également le cas d'une NSU représentationnelle, sans NSU perceptive. Le patient omet systématiquement les items situés à gauche lors des tâches d'imagerie. Ce pattern de performance suggère une dissociation entre imagerie mentale et perception dans la NSU.

Néanmoins, certains auteurs proposent une hypothèse alternative remettant en cause la dissociation de ces deux déficits. Bartolomeo et al. (Bartolomeo et al., 1994; Bartolomeo et al., 2005) suggèrent que l'occurrence d'une NSU représentationnelle sans NSU perceptive peut se manifester au décours de la maladie. Les patients montreraient originellement une association entre NSU représentationnelle et visuelle, puis grâce aux stratégies compensatoires perceptives (appries en rééducation ou hors rééducation), ils récupéreraient uniquement de leur déficit perceptif. Cette explication peut être prise en compte pour le patient de Guariglia et al. (1993) qui a été testé pour la première fois seize mois après l'accident vasculaire cérébral, et pour la patiente M.N. de Coslett (Coslett, 1997) évaluée deux ans après son accident vasculaire cérébral. Un cas semble aller à l'encontre de la position de Bartolomeo et al. (1994 ; 2005): Beschlin et al. ((Beschlin et al., 1997) rapportent un patient avec un large infarctus pariétal droit sans signe évident de NSU perceptive immédiatement après l'accident vasculaire cérébral mais présentant une NSU limitée à l'imagerie visuelle. L'altération est extrêmement sévère lorsque le patient est évalué par la description de places familières et de la carte d'Italie. Le cas de NSU représentationnelle pure décrit par Ortigue et al. (2001) semble également être en contradiction avec cette hypothèse, puisque le patient manifeste une NSU représentationnelle apparemment isolée en phase aiguë.

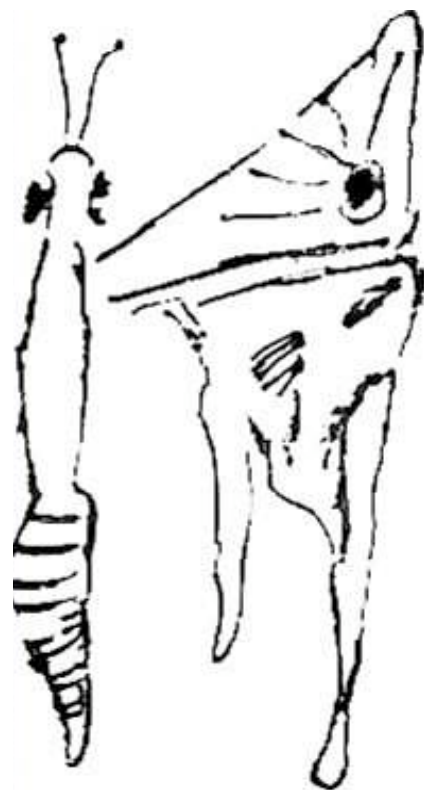

L'un des problèmes de la mise en évidence de la NSU représentationnelle pourrait être dû à la non spécificité et sensibilité des épreuves. En effet, de nombreux tests utilisés pour évaluer un déficit perceptif sont standardisés et permettent un consensus dans l'interprétation des résultats, alors que les principales épreuves évaluant un déficit représentationnel font appel aux processus d'évocation, en demandant aux patients de décrire de mémoire des lieux familiers. Plusieurs points sont critiquables : 1) malgré l'instruction de s'imaginer la scène « comme si elle se trouvait devant leurs yeux », les patients peuvent simplement produire une liste d'items provenant de leur mémoire sémantique verbale ; D'ailleurs, il semble que le déficit ne soit observable que si une composante spatiale est en jeu. (Della Sala et al., 2004) ont mis en évidence des troubles de la mémoire de travail visuo-spatiale dans la NSU représentationnelle. Quant à Rode et al. (2004), ils montrent clairement chez un patient présentant une NSU représentationnelle gauche durable que le déficit n'est présent que dans la condition où il doit imaginer mentalement l'espace à explorer mais disparaît dans la condition où il doit évoquer le nom de villes sans consigne d'imagination. 2) ce type d'épreuve est influencé par le niveau socio-culturel, ce qui implique une importante variabilité inter et intra individuelle. Afin de pallier à ces critiques, récemment Bartolomeo et al. (2005) ont créé une tâche géographique sur la carte de France basée sur des temps de réaction et permettant ainsi une mesure plus contrôlée de l'imagerie mentale. Cette étude montre que seuls deux patients présentent une NSU représentationnelle en plus d'une NSU perceptivo. Les patients étaient capables d'imaginer des items à gauche mais ils présentaient un ralentissement du temps de réponse pour ces mêmes items par rapport aux items de droite. La dissociation entre les temps de réponse et la précision de la réponse suggère que le côté gauche de leur carte mentale n'est pas perdu, mais seulement « exploré » moins efficacement. D'autres types de test permettant d'évaluer l'imagerie mentale sont les épreuves papier/crayon. Il est demandé aux patients de réaliser des dessins de mémoire. Les deux patients décrits par Bisiach et Luzzatti (1978) présentaient également une NSU gauche lors de la réalisation de dessins. Cependant, le feedback visuel présent dans ces tâches papier/crayon influence l'expression de la NSU. Ainsi, en comparant les performances de patients lors de la réalisation de dessins de mémoire les yeux ouverts vs fermés, Chedru (1976) puis Anderson (Anderson, 1993) remarquent alors que les patients omettent moins de détails à gauche dans la condition « yeux fermés ». D'autres auteurs (Chokron et al., 2004); (Halligan and Marshall, 1994) confirment ces résultats : les dessins réalisés avec les yeux fermés permettraient l'évaluation réelle de l'imagerie mentale alors que la présence d'un feedback visuel dans la condition « yeux ouverts » accentuerait les signes de NSU (voir figures 10 et 11). Lorsque les

patients commencent à dessiner à droite, leur attention est capturée par ces éléments déjà présents et empêche l'exploration vers le côté gauche (Chokron *et al.*, 2004).



*Fig. 10*



*Fig. 11*

*Fig. 10-11 : Exemples de dessins de papillon réalisés de mémoire par un patient négligent.  
Yeux fermés (Fig. 10) et Yeux ouverts (Fig. 11) (Chokron et al., 2004).*

La NSU représentationnelle reste à l'heure actuelle un déficit d'interprétation difficile et constitue un défi à la fois pour la rééducation des patients et pour une meilleure compréhension des liens qui existent entre l'imagerie mentale et la perception visuelle.

## **b) NSU et orientation de l'attention**

Les théories attentionnelles de la NSU reposent sur des observations cliniques basiques comme la présence de « l'attraction magnétique » du regard vers le côté ipsilésionnel (le fait que ces patients tendent à regarder vers la droite dès qu'une scène visuelle se présente à leurs yeux, (Gainotti et al., 1991) et l'impossibilité apparente des stimuli présentés du côté opposé à la lésion cérébrale à capturer l'attention des patients. Il existe de nombreux résultats indiquant que la NSU résulte d'une association de plusieurs désordres de l'orientation de l'attention dans l'espace (Bartolomeo and Chokron, 2002b); (Heilman and Van Den Abell, 1980); (Mesulam, 1981).

### ***MODELES ANATOMO-CLINIQUES DE L'ATTENTION SPATIALE***

La NSU est plus fréquente, plus sévère et plus durable après une lésion touchant l'hémisphère droit qu'après une lésion touchant l'hémisphère gauche (Beis et al., 2004) ; (Stone et al., 1991). Cette asymétrie a encouragé l'émergence de modèles anatomo-cliniques du contrôle de l'orientation de l'attention par les hémisphères cérébraux et a été également reproduite par certains modèles mathématiques de simulation du comportement hémiparétique.

**Le modèle de Heilman** (Heilman and Valenstein, 1979; Heilman et al., 1983b; Heilman et al., 1985; Heilman et al., 1993a) suppose que chaque hémisphère cérébral contrôle les niveaux attentionnel et intentionnel de l'hémiespace controlatéral avec toutefois une compétence supplémentaire de l'hémisphère droit pour activer les systèmes attentionnels droit et gauche alors que l'hémisphère gauche ne pourrait activer que le système attentionnel controlatéral. Le niveau attentionnel et le niveau intentionnel mettraient en jeu des réseaux distincts : 1/ un réseau postérieur qui gérerait l'attention spatiale via le thalamus qui filtre les informations sensorielles vers le cortex et les régions associatives, et 2/ un réseau antérieur qui gèrerait l'intention via des boucles cortico-sous-corticales passant par le thalamus et les noyaux gris centraux. Une lésion hémisphérique gauche ne déterminerait pas une NSU sévère puisque l'hémisphère droit serait capable de compenser en partie l'orientation de l'attention

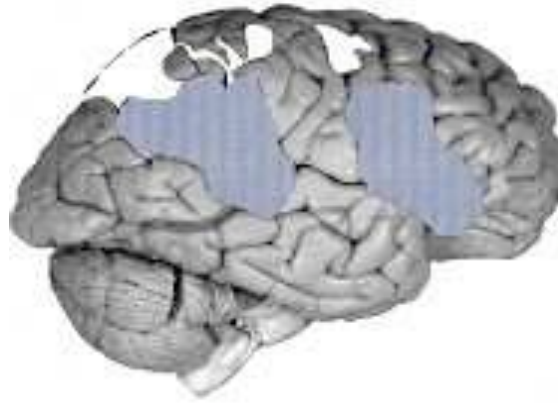
vers la droite alors que l'hémisphère gauche ne pourrait pas prendre le relais en cas de lésion hémisphérique droite pour orienter l'attention vers la gauche.

**Le modèle de Kinsbourne** (Kinsbourne, 1970, 1987, 1993) suppose que l'activation d'un hémisphère a pour conséquence l'apparition d'un biais attentionnel controlatéral. Les deux hémisphères s'inhiberaient réciproquement par l'intermédiaire du corps calleux. En condition physiologique, le vecteur attentionnel de l'hémisphère gauche serait plus puissant que celui de l'hémisphère droit du fait de la prépondérance de l'activité langagière chez l'homme. Ainsi, une lésion hémisphérique gauche diminuerait l'importance du vecteur attentionnel et permettrait une sorte de rééquilibre en diminuant également l'inhibition exercée sur l'hémisphère droit. De ce fait, une lésion gauche ne donnerait pas ou peu de signes de NSU droite. En revanche, une lésion hémisphérique droite aurait pour conséquence de rendre encore plus puissant le biais attentionnel physiologique vers la droite, en libérant l'hémisphère gauche des inhibitions exercées par l'hémisphère droit. Selon Kinsbourne, il faudrait donc parler plus d'« hyperattention droite » que de NSU gauche (mais voir (Bartolomeo and Chokron, 1999), pour des résultats qui vont à l'encontre de ce modèle)

**Le modèle de Mesulam** (Mesulam, 1981, 2002) suppose un circuit attentionnel impliquant trois régions interconnectées. Ces régions sont sous l'influence d'un système réticulé ascendant activateur permettant un niveau d'éveil et de vigilance suffisants et sont connectées à la fois à des structures sous-corticales comme le colliculus supérieur, le pulvinar et le striatum mais aussi à un ensemble d'aires situées dans le cortex pré-moteur, pré-frontal latéral, orbito-frontal, temporal latéral supérieur, para-hippocampique et insulaire. Mesulam décrit 1/ un composant pariétal postérieur (comprenant le sillon intra-pariétal, une partie des lobules pariétal supérieur, inférieur et temporo-médial supérieur) permettant la création d'une représentation mentale dynamique d'évènements saillants dans des coordonnées multiples et le calcul des stratégies de mouvements attentionnels ; 2/ le composant frontal centré sur le champ oculomoteur frontal, les cortex pré-moteur et préfrontal permettant la conversion de plans et d'intentions en séquences motrices qui dirigent le foyer attentionnel ; 3/ le gyrus cingulaire permettant l'identification de la pertinence motivationnelle des stimuli. Mesulam ajoute également une dominance de l'hémisphère droit pour contrôler bilatéralement la distribution attentionnelle alors que l'hémisphère gauche n'aurait de compétence que pour un contrôle controlatéral et postule que le volume et l'activité des aires dévouées aux processus attentionnels soient plus importants dans l'hémisphère droit que dans l'hémisphère gauche.

## ***BASES NEURALES DE L'ATTENTION***

De nombreuses études mettent en évidence la ségrégation des aires cérébrales sous-tendant les différentes fonctions attentionnelles et leur réseau en imagerie fonctionnelle (voir figure 12), (Corbetta and Shulman, 2002). La préparation et l'application d'une sélection « top down » (dépendante des attentes du sujet) des stimuli et des réponses incluent une partie du cortex intrapariétal et le cortex frontal supérieur (notamment le champ oculomoteur frontal): ce système dorsal, bilatéral, correspondrait à l'orientation volontaire de l'attention. Un autre système, ventral et latéralisé du côté droit, est impliqué dans une sélection « bottom up » (guidée par le stimulus). Il inclut le cortex temporo-pariétal et le cortex frontal inférieur (Corbetta et Shulman, 2002). Ce second système, automatique, est spécialisé dans la détection des stimuli pertinents pour le comportement, particulièrement quand ils sont saillants ou inattendus. Les aires cérébrales de ce réseau ventral recouvrent en majorité les régions corticales qui, quand elles sont lésées, provoquent le syndrome de NSU (Corbetta et Shulman, 2002).



*Fig. 12. Régions cérébrales activées lors de tâches impliquant l'orientation endogène (blanc) ou exogène (pointillés gris) de l'attention (d'après Corbetta et Shulman, 2002). Le réseau exogène est latéralisé à droite.*

### ***ATTENTION EXOGÈNE VERSUS ENDOGÈNE ET NSU***

**Le modèle de Posner** (Posner, 1980; Posner and Petersen, 1990), issu de la psychologie cognitive, spécifie trois processus essentiels à la mise en jeu de l'orientation de l'attention visuo-spatiale qui peuvent être étudiés au moyen du paradigme d'indication spatiale (Posner and Petersen, 1990; Posner et al., 1982; Posner, 1984; Posner et al., 1984). Trois carrés sont placés au centre de l'écran : un au milieu, un à gauche et un à droite. La consigne donnée au sujet est de détecter le plus rapidement possible une cible (ex : une astérisque) qui apparaît dans l'un des deux carrés latéraux. Des indices (épaississement du contour d'un carré périphérique, ou flèche centrale indiquant un des carrés latéraux) peuvent être présentés avant l'apparition de la cible. On distingue des indices valides, qui indiquent le bon côté d'apparition de la cible, et des indices non valides qui indiquent le carré opposé (voir figure 13).

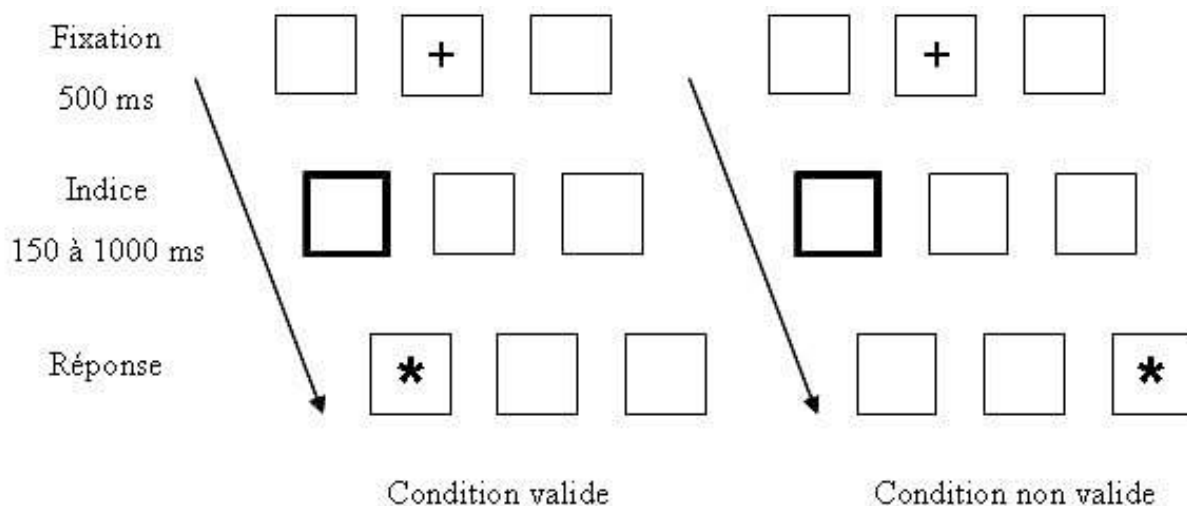


Fig. 13 : Illustration du paradigme de Posner et al. (1984). Après avoir fixé le carré central, un indice (épaississement du contour) apparaît dans un des carrés latéraux pour une durée variable de temps. Ensuite apparaît une cible (astérisque) dans le même carré que l'indice (condition valide) ou dans le carré opposé (condition non valide). Le sujet doit appuyer le plus rapidement possible sur un bouton dès qu'il voit la cible.

La proportion des indices valides et non valides peut être manipulée : soit les indices ne sont pas informatifs car la cible apparaîtra autant de fois du même côté que du côté opposé (condition 50-50%), soit le sujet a tout intérêt à traiter la localisation de l'indice car elle lui indiquera dans la majorité des essais la localisation de la cible (condition 80-20%). Le temps entre l'apparition de l'indice et celle de la cible peut être plus ou moins long (par ex., de 150 à 1000 ms). Ce paradigme permet de séparer les processus d'orientation automatique de l'attention (attention exogène) des processus d'orientation volontaire (attention endogène) : en effet, dans la condition avec indices non informatifs, le sujet n'a pas d'intérêt particulier à traiter volontairement l'indice alors que si les indices sont informatifs, le sujet doit engager volontairement son attention sur l'indice pour répondre plus rapidement à la cible. En réalité dans cette dernière condition, la mise en jeu exogène de l'attention n'est pas totalement absente du simple fait de l'apparition des carrés et de l'indice mais elle atteint son maximum au bout de 150-200 ms de délai indice/cible ; après ce délai, l'attention exogène est supplantée par l'attention endogène, liée aux stratégies du sujet et qui demande donc plus de temps pour se mettre en place. Chez les patients, plusieurs études montrent que l'attention endogène vers le côté négligé est relativement préservée, bien que ralentie (Bartolomeo and Chokron, 2002b; Bartolomeo et al., 2001) alors que l'orientation exogène est gravement perturbée, ce qui a pour effet l'absence de capture automatique de l'attention du côté négligé (Bartolomeo et al.,



1999); (Natale et al., 2005). Selon les travaux de Posner et collaborateurs, l'engagement de l'attention vers une localisation spatiale dépendrait du pulvinar alors que le mouvement de l'attention vers un nouvel emplacement dépendrait du colliculus supérieur. De plus, les patients négligents présentent un déficit de désengagement à droite (le désengagement de l'attention serait sous-tendu par le lobe pariétal postérieur) : une fois leur attention engagée sur une cible du côté non négligé (à droite), ils montrent des difficultés de réorientation de l'attention vers la gauche (Bartolomeo et Chokron, 2002; Bartolomeo *et al.*, 2001; Posner *et al.*, 1984).

Ce déficit d'orientation automatique vers le côté négligé pourrait expliquer les comportements de déviation en bissection chez ces patients non pas comme le résultat d'une compression de l'espace vers la droite (Halligan and Marshall, 1991b) mais plutôt comme la conséquence d'un déséquilibre attentionnel automatique (Bartolomeo et al., 2004). En effet, Bartolomeo et al. (2004) ont montré que les patients dévient vers la droite que lorsqu'il existe des stimuli distracteurs ipsilésionnels alors que leurs performances ne diffèrent pas de celles des témoins lorsqu'aucun stimulus n'est présenté dans l'hémiespace droit. En effet, les stimuli ipsilésionnels attirent automatiquement l'attention vers l'hémiespace droit indépendamment de leur pertinence pour la tâche (Corben et al., 2001) en augmentant ainsi le déséquilibre attentionnel en défaveur de l'hémiespace gauche (Bartolomeo *et al.*, 2004).

Au vu de la correspondance entre les aires dévolues à l'attention exogène et les régions lésées causant la NSU et à l'instar des données cognitives, il semble essentiel de considérer le déficit d'orientation automatique de l'attention à gauche chez ces patients comme l'un des facteurs principaux causant le syndrome de NSU.


Les troubles de l'attention sélective spatiale ne sont pas exclusifs dans la NSU puisqu'il existe également des troubles de l'attention sélective non latéralisés (« attentional blink », (Husain et al., 1997). Chez les sujets normaux, la capacité à détecter un second objet apparaissant moins de 400 ms après la présentation d'un premier objet est altérée. Chez les patients négligents, ce temps est multiplié par trois, ce qui démontre que le déficit d'orientation de l'attention dans la NSU n'est pas uniquement spatial mais également temporel. D'autre part, il existe également des troubles de l'attention soutenue (Hjaltason et al., 1996) ; (Robertson et al., 1995), un déficit fréquent de la mémoire de travail visuo-spatiale (Della Sala *et al.*, 2004) ainsi qu'un déficit de remapping spatial du fait du dysfonctionnement du lobe pariétal qui conduit à des difficultés à guider les saccades à travers l'espace après qu'un objet à droite ou à gauche ait été fixé (Husain and Rorden, 2003b; Husain et al., 2001; Pisella and Mattingley, 2004).

L'association de ces différents troubles dans la NSU est importante à prendre en considération pour la compréhension du syndrome et les bases futures de rééducation.

#### 4. NSU ET CONSCIENCE

Les patients négligents semblent se comporter comme si une partie du monde n'existait plus. Cependant, dans certains cas, on a pu mettre en évidence des signes de « connaissance implicite » des stimuli négligés (voir par exemple : (Berti and Rizzolatti, 1992; Marshall and Halligan, 1988); (Volpe et al., 1979). Certains patients semblent même capables d'éviter des obstacles qu'ils assurent ne pas voir (McIntosh et al., 2004b; McIntosh et al., 2004a).

En 1988, Marshall et Halligan ont décrit une patiente qui était incapable de décrire la différence entre deux dessins de maisons identiques, sauf que dans l'un des deux des flammes sortaient de la partie gauche de la maison (voir figure 14), mais préférait la maison sans flamme quand on lui demandait dans laquelle elle préférerait vivre.



*Fig. 14 : Exemple tiré de l'expérience de Marshall et Halligan (1988). Les maisons sont présentées l'une au dessus de l'autre.*

De même, malgré l'incapacité des patients à identifier de manière explicite les mots ou les images présents dans leur hémichamp négligé, la performance de certains d'entre eux s'améliore considérablement lorsqu'on leur demande de porter des jugements ou d'identifier par choix forcés les cibles présentées dans le champ négligé (D'Erme et al., 1993).

Des signes semblables de « perception implicite » peuvent se retrouver dans les tâches de localisation de cibles latéralisées (gauche ou droite) ou bilatérales (gauche et droite). Dans une étude menée chez des sujets négligents et des sujets sains, Marzi et al. (Marzi et al., 1996) ont montré que les 2 groupes de sujets répondaient plus rapidement quand les cibles étaient présentes des deux cotés par rapport à quand elles étaient présentées en condition unilatérale (« redundancy target effect »). Cet effet est présent chez les patients aussi bien dans les essais où leur perception des 2 cibles était correcte que dans les essais où ils avaient négligé la cible de gauche. Néanmoins, une autre étude a montré que des patients négligents étaient aussi lents à détecter les cibles en condition unilatérale gauche qu'en condition bilatérale (Vuilleumier and Rafal, 1999).

Un traitement implicite a été observé également lors des paradigmes d'amorçage dont l'amorce, non perçue consciemment, a un effet sur le traitement du stimulus suivant. Quand deux images, par exemple, sont présentées simultanément à droite et à gauche du champ visuel, les patients négligents nient voir celle de gauche et aucune perception ne semble se réaliser. Cependant, si on leur demande de réaliser une tâche de catégorisation ou de décision lexicale sur un mot central lié sémantiquement ou non à l'image qui le précède (l'amorce), le même effet d'amorçage présent chez les normaux peut se produire chez les patients : ils répondent mieux et plus vite à la cible quand celle-ci est précédée par une autre image de la même catégorie (ex : une rose et une marguerite). Cet effet - dit d'amorçage-, est présent, voire supérieur (Schweinberger and Stief, 2001), quand l'amorce n'est pas perçue consciemment par le patient (Berti and Rizzolatti, 1992); (Làdavas et al., 1993); (McGlinchey-Berroth et al., 1993) Ces études d'amorçage chez les patients négligents suggèrent donc fortement un traitement inconscient de l'image du niveau perceptif jusqu'au très haut niveau du traitement sémantique (McGlinchey-Berroth et al., 1993).

Les dissociations entre traitement explicite et implicite du stimulus négligé ne semblent toutefois être présentes que chez une minorité des patients. Pour la plupart des patients négligents, la destinée du stimulus négligé semble être l'oubli complet (D'Erme *et al.*, 1993).

Souvent les patients négligents ne sont pas conscients de leur déficits moteur, sensoriels ou cognitifs (anosognosie : (Babinski, 1914, 1918). Il est important de lever l'anosognosie pour l'efficacité de la rééducation. Ce déficit de conscience peut également concerner l'hémicorps

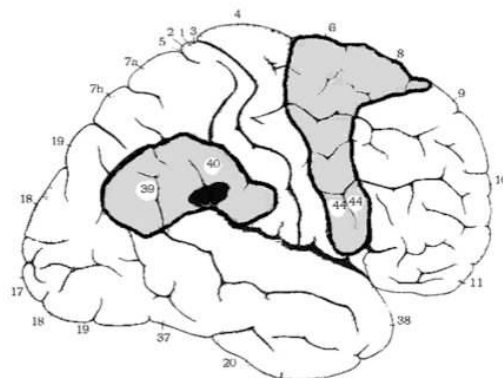
gauche des patients (hémiasomatognosie, qui est associée à l'anosognosie dans le syndrome d'Anton-Babinski) et entraîner des chutes ou des contusions lorsque les patients se cognent sur les obstacles situés du côté gauche. On assiste parfois même à des phénomènes de rejet, de déni d'appartenance de leur jambe ou de leur main gauche (misoplégie : (Critchley, 1953). L'anosognosie pour l'hémiplégie semble associée aux lésions des aires prémotrices (BA 6 et BA 44), de l'aire motrice BA 4 et du cortex somatosensoriel de l'hémisphère droit (Berti et al., 2005).

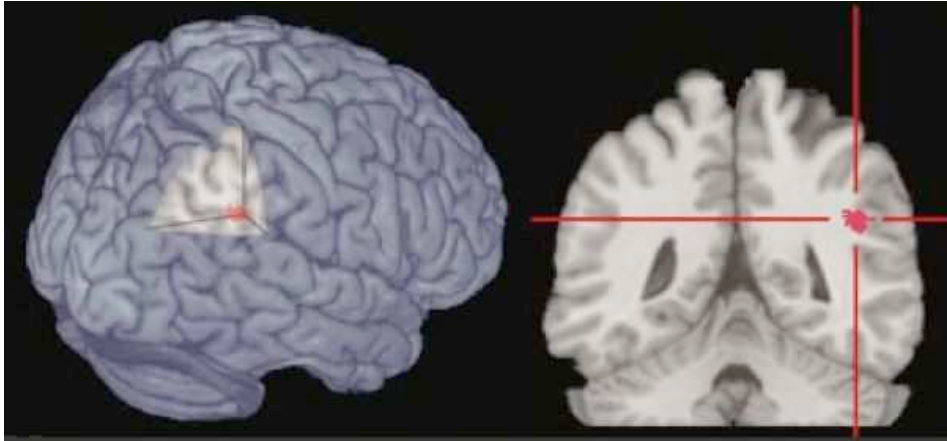
### III - INVESTIGATION DES BASES NEURALES DE LA NSU AU MOYEN DE LA TECHNIQUE DE STIMULATION ELECTRIQUE PER-OPERATOIRE (IES)

#### *Résumé des bases neuroanatomiques de la NSU*

*La recherche scientifique sur le syndrome de NSU est très importante en Sciences Cognitives pour comprendre les mécanismes cérébraux dévolus à la conscience de l'espace. D'un point de vue clinique, la recherche sur la NSU peut améliorer les diagnostics en 1) perfectionnant les tests visuospatiaux, 2) clarifiant les pronostiques des patients selon le type de difficultés qu'ils présentent, 3) permettant le développement de stratégies rationnelles de rééducation. Cependant, bien que le phénomène de NSU soit exploré depuis plusieurs décades, les bases neurales de ce syndrome sont toujours controversées.*

*À ce jour, la stratégie habituelle employée pour identifier le corrélat lésionnel de la NSU s'est toujours réduite à la superposition de lésion (Bates et al., 2003a). Les lésions dessinées à partir des images acquises par résonance magnétique (IRM) ou scanner (CT scans) des lésions cérébrales de patients qui ont souffert d'une attaque cérébrale, qu'ils présentent ou non un syndrome de NSU, sont superposées. La zone de recouvrement maximal des lésions des patients avec NSU non ou peu touchée par les lésions des patients épargnés est considérée comme la base neurale de ce syndrome. Ces études (Vallar, 2001; Mort et al., 2003) ont généralement indiqué le lobule pariétal inférieur comme le site de recouvrement maximal (figure 15).*





*Fig. 15 : La figure du haut illustre le recouvrement maximal des lésions des patients qui présentent un syndrome de NSU décrit par Vallar(Vallar, 2001). La figure du bas correspond au maximum de recouvrement mis en évidence par Mort & collaborateur(Mort et al., 2003) pour ce même syndrome.*

*Cependant une étude plus récente insista davantage sur le rôle crucial d'une lésion des parties moyenne et rostrale du gyrus temporal supérieur dans le comportement négligeant jusqu'à exclure l'importance des lésions qui touchent la jonction temporo-pariétale (Karnath et al., 2001; Karnath et al., 2004). Ce résultat est en complet accord avec la prédiction de Miller et Goodale sur une lésion de la voie ventrale du « What » comme prédicteur du syndrome de NSU(Milner and Goodale, 1995)(figure 16).*

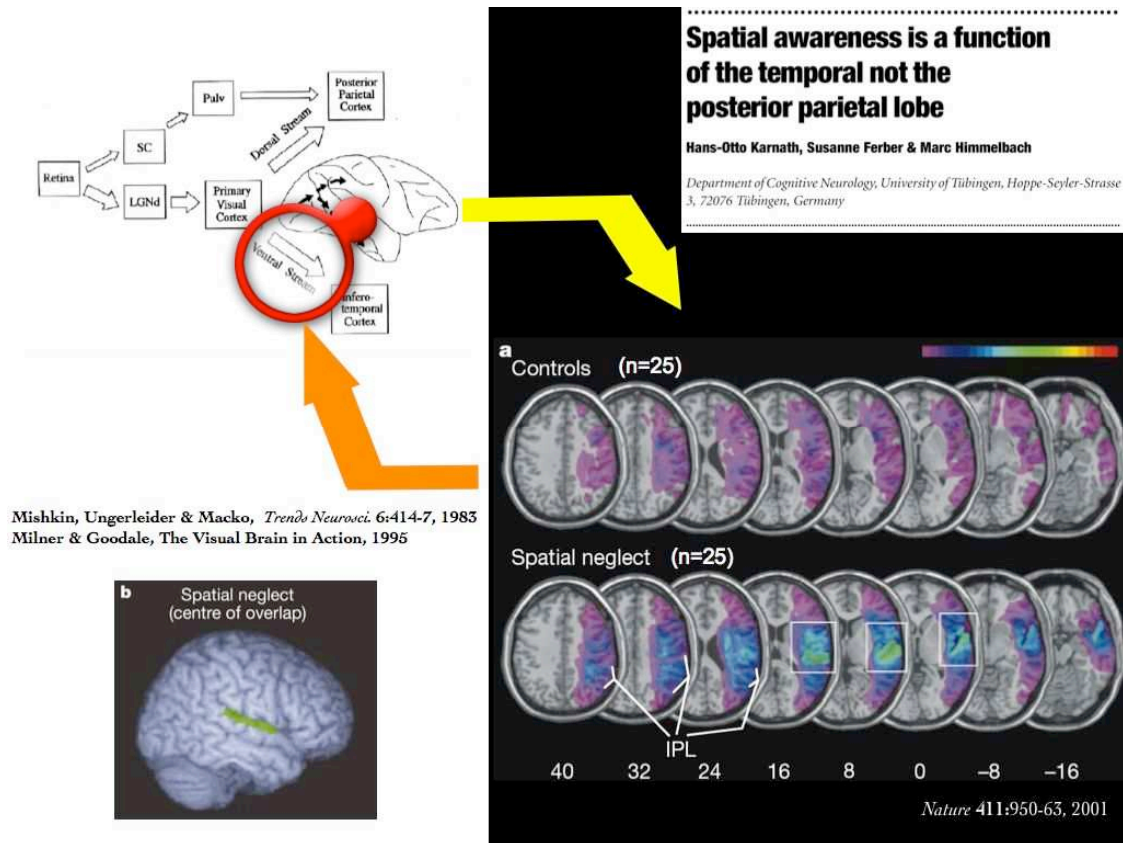


Fig. 16 : Illustration de la correspondance entre le résultat neuro-anatomique mis en évidence par Karnath & coll. (Karnath et al., 2001) et l'hypothèse cognitive décrite par Milner & Goodale (Milner and Goodale, 1995) expliquant le syndrome de NSU comme la conséquence d'une lésion de la voie visuelle ventrale du « what » (Mishkin et al., 1983).

L'idée d'une implication des circuits d'association dans ce syndrome a cependant reçu moins d'attention (Leibovitch et al., 1998; Doricchi and Tomaiuolo, 2003), malgré les travaux défendant l'hypothèse d'une disconnexion fronto-pariétale chez l'animal (Gaffan and Hornak, 1997; Burcham et al., 1997) (voir figure 17).

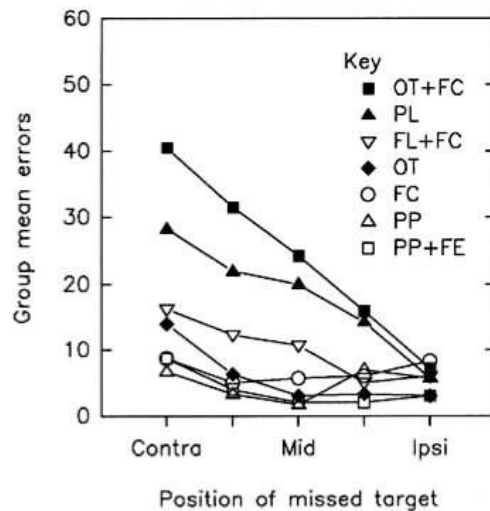


Fig. 17 : Dans cette figure de Gaffan et Hornak (Gaffan and Hornak, 1997) on peut observer le score d'omissions dans une tâche de recherche de cibles des macaques après la résection (OT, tractus optique ; FC, résection de la commissure antérieure ; PL, leucotomie pariétale ; FL, lobectomie frontale ; PP, ablation du cortex pariétal postérieur ; FE, ablation de la frontal eye field). En l'absence de déficits neuro-visuels, c'est la leucotomie pariétale qui entraîne le plus d'omissions controlatérales chez le macaque.

Cependant, la méthode de superposition de lésions utilisée dans les études chez les êtres humains comporte plusieurs limites (Godefroy et al., 1998). Premièrement elles montrent une faiblesse de résolution spatiale due aux difficultés de délimitation des lésions vasculaires aggravée par le fait que ces lésions sont soit directement dessinées sur un « template » (Karnath et al., 2001; Karnath et al., 2004) soit normalisées sur un cerveau standard. Cette procédure ne peut qu'approximer l'organisation spatiale réelle des individus. Deuxièmement, les lésions vasculaires peuvent entraîner des problèmes d'irradiation des territoires vasculaires alentours non pris en compte dans la segmentation. Troisièmement, dans le cas de lésions multiples (très fréquentes dans les cas étudiés de négligence) une région de superposition est identifiée comme cruciale dans le syndrome de négligence alors que le déficit résulte en fait de la co-occurrence de certaines lésions. Plus généralement, la superposition de lésion tend vers une vue très phrénologique des relations anatomo-fonctionnelles, dans laquelle chaque région du cerveau est dévolue à ou cruciale pour une fonction particulière. Beaucoup de preuves venant des sciences cognitives suggèrent à la place que le cerveau est une mosaïque de régions très interactives fonctionnellement. En d'autres termes, la fonction d'une région cérébrale donnée ne se révèle que par son



*interaction avec d'autres régions, sous la forme d'un réseau fonctionnel.*

## **1. BASES NEUROANATOMIQUES DE LA NSU**

### **a) Cortex pariétal**

Brain (1941) a le premier souligné l'importance des régions pariétales postérieures à l'origine du tableau d'agnosie spatiale unilatérale. Par la suite, (Hécaen et al., 1956) ont montré, dans une étude radio-anatomique, l'importance de la région pariéto-occipito-temporale droite à l'origine du syndrome apraxico-agnosique (chez des patients ayant subi une exérèse chirurgicale de cette région du fait d'une épilepsie rebelle). Cette région a par la suite été confirmée sur une population plus importante de 179 patients (Hécaen et al., 1972) ainsi que par les premières études en imagerie cérébrale par (Heilman et al., 1983b) et par (Vallar and Perani, 1986). La NSU est retrouvée le plus fréquemment après lésion du lobule pariétal inférieur, plus particulièrement dans sa portion à la jonction avec le lobe temporal et plus rarement la portion dorso-latérale du lobe frontal de l'hémisphère droit (voir pour revue (Vallar, 2001).

Le sillon intrapariétal sépare le lobule pariétal supérieur (dont la lésion engendrerait plutôt des comportements de type ataxie optique : (Perenin and Vighetto, 1988) et le lobule pariétal inférieur (dont la lésion engendrerait des comportements de NSU: (Jeannerod et al., 1994), et des difficultés de manipulation d'objets : (Binkofski et al., 1999). De nombreuses aires ont été identifiées dans le sillon intrapariétal chez le singe (LIP : aire intrapariétale latérale ; AIP : aire intrapariétale antérieure ; MIP : aire intrapariétale médiane ; VIP : aire intrapariétale ventrale). L'implication du LIP dans la conscience visuo-spatiale gauche a été postulée chez l'homme (Vallar, 2001; Marshall et al., 2002) à partir notamment des travaux réalisés sur le singe chez qui les neurones du LIP sont dévolus à une représentation de saillance des objets ayant une pertinence pour le comportement de l'animal et dont l'activité est corrélée aux déplacements de l'attention dans l'espace dans des tâches requérant la détection perceptive ou la mémoire spatiale (Gottlieb et al., 1998; Gottlieb, 2002). Ils sont également impliqués dans les mouvements de saccades du fait des projections massives avec les colliculi supérieurs et le champ oculo-moteur frontal. Le rôle de ces neurones pourrait également expliquer que des traitements comme la stimulation calorique vestibulaire ou la vibration des muscles de la nuque à gauche puissent diminuer transitoirement la NSU. La plupart des neurones du LIP encodent la localisation des stimuli en coordonnées rétinotopiques mais leur activité est

modulée par des informations sur les variables posturales comme la position et le mouvement des yeux, de la tête, du bras (Andersen et al., 1997; Duhamel et al., 1997) ce qui permet une localisation spatiale précise dans divers cadres de références et peut expliquer que la NSU puisse se manifester simultanément par rapport à ces cadres (Driver and Mattingley, 1998); (Gottlieb, 2002); (Pouget and Driver, 2000).

Ce rôle intégratif multi-modal du cortex pariétal est favorisé par la présence de nombreux neurones ayant des champs récepteurs bimodaux (auditivo-visuel au niveau du LIP et plutôt visuo-tactile au niveau du VIP), ce qui pourrait expliquer le fait que la NSU puisse concerner plusieurs modalités sensorielles. De plus, les fortes connexions du lobe pariétal avec les systèmes moteurs, pré-moteurs ainsi que les aires extra-striées lui confèrent un rôle clef pour une orientation motrice et perceptive coordonnées vers des cibles.

Cette localisation pariétale a été précisée par la suite à partir d'études utilisant la méthode de superpositions de lésions (Bates et al., 2003b; Frank et al., 1997; Rorden and Karnath, 2004) au gyrus angulaire et à la partie médiane du lobe temporal (Mort et al., 2003). Cette dernière région, assez inattendue, reste cohérente avec les résultats en imagerie fonctionnelle qui rapportent une activation de cette aire temporale lors de l'encodage d'une localisation spatiale ou de la récupération en mémoire de cette localisation (Epstein et al., 1999).

## **b) Autres localisations moins fréquentes**

Des cas de NSU ont été rapportés également après des lésions dans différents territoires perfusés par l'artère cérébrale moyenne :

- le lobe frontal inférieur (Husain and Kennard, 1997).
- les ganglions de la base (Damasio et al., 1980; Ferro et al., 1987; Heilman et al., 1982; Karnath et al., 2002a; Karnath et al., 2005).
- le thalamus (Cambier et al., 1980; Rafal and Posner, 1987; Schott et al., 1981; Watson and Heilman, 1979).
- le gyrus cingulaire, bien que de façon rare (Heilman et al., 1983a) du fait de son implication dans des tâches de déplacements de l'attention, d'exploration oculomotrice et de recherche manuelle chez les sujets normaux (Nobre et al., 1997; Gitelman et al., 1999; Kim et al., 1999).

Des cas de NSU après accident vasculaire touchant l'artère cérébrale postérieure ont également été rapportés, notamment lorsque des régions plus antérieures du lobe occipital sont également lésées (Cals et al., 2002; Doricchi and Angelelli, 1999).

Enfin, certaines études ont valorisé plutôt les lésions touchant le gyrus temporal supérieur (GTS) droit du moins chez les patients n'ayant pas d'hémianopsie latérale homonyme gauche associée. Ce résultat suggère que cette région, comparable à son homologue gauche dévolue au langage, soit responsable de la conscience de l'espace chez l'homme (Karnath et al., 2001; Karnath et al., 2002b; Karnath et al., 2004a; Karnath et al., 2004b) d'autant qu'elle reçoit de nombreuses afférences multimodales sensorielles (Jones and Powell, 1970). Le GTS est également connecté à un réseau anatomique cortico-sous-cortical avec le putamen, le noyau caudé et le pulvinar qui, quand ils sont lésés, génèrent aussi le syndrome d'héminégligence mais le rôle d'une lésion du cortex temporal supérieur dans la NSU est contesté par d'autres études (Marshall et al., 2002; Mort et al., 2003; Doricchi and Tomaiuolo, 2003; Hommet et al., 2004; Thiebaut de Schotten et al., 2005).

### **c) Fibres de la substance blanche : une issue possible du débat**

En effet, il semble qu'une combinaison de lésions du cortex pariétal inférieur à des disconnexions sous-corticales pariéto-frontales (Doricchi and Tomaiuolo, 2003; Gaffan and Hornak, 1997) ou à la fois pariéto-frontales et pariéto-temporales (Leibovitch et al., 1998) soient les causes les plus fréquentes d'observation du syndrome de NSU. Chez le singe, Gaffan et Hornak (1997) ont observé une NSU plus sévère avec des lésions incluant la substance blanche qu'avec des lésions confinées à la substance grise. Déjà (Geschwind, 1965b) avait proposé que la NSU puisse résulter d'une disconnexion entre les aires visuelles et somatosensorielles hémisphériques droite, et l'hémisphère gauche, dominant pour le langage.

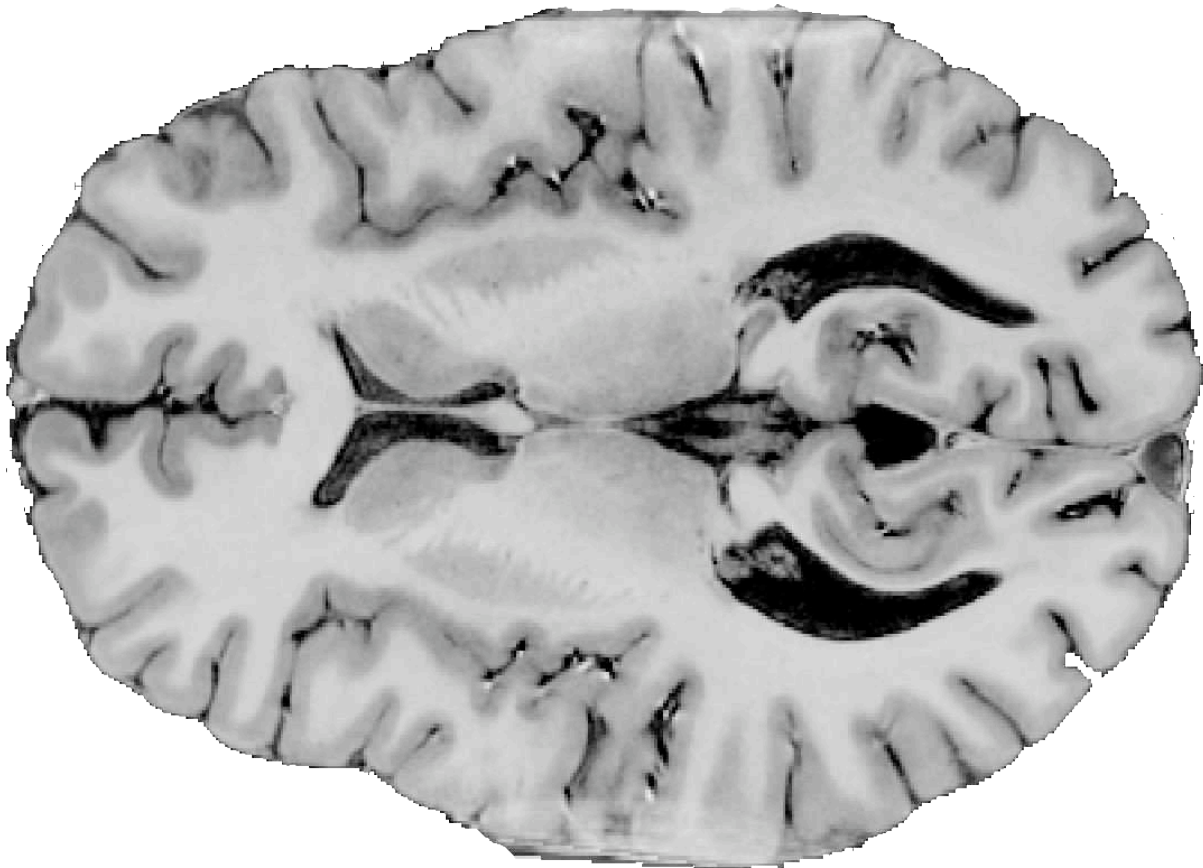
Certaines études ont confirmé l'implication de la substance blanche sous-corticale dans le déterminisme du comportement d'héminégligence en rapportant des cas de patients porteurs de lésions touchant les fibres inter-hémisphériques du corps calleux (Heilman and Adams, 2003; Ishiai et al., 2001; Kashiwagi et al., 1990). Cependant, plus récemment, il semble qu'une lésion des fibres d'association intra-hémisphériques soit principalement invoquée (Mort et al., 2003; Doricchi and Tomaiuolo, 2003). Elle concerne des fibres d'association pariéto-frontales dénommées en fonction des études comme le faisceau longitudinal supérieur droit (Doricchi and Tomaiuolo, 2003) qui interconnecte le lobule pariétal inférieur au gyrus frontal inférieur et au gyrus temporal supérieur (Catani et al., 2002; Catani et al., 2005) ou le faisceau occipito-frontal supérieur droit, une autre voie de communication pariéto-frontale (Thiebaut de Schotten et al., 2005; Nieuwenhuys et al., 1988a). Thiebaut de Schotten et al.

(2005) ont mesuré les erreurs de déviation vers la droite dans une tâche de bissection de lignes au cours de stimulations électriques (inactivations transitoires) lors de la résection d'un gliome chez deux patients gauchers (l'un situé sur la partie caudale du lobe temporal droit, l'autre sur le lobe pariétal inférieur droit). Diverses régions corticales et sous-corticales dans la substance blanche ont été stimulées afin de minimiser les dégâts de l'exérèse. L'inactivation de deux structures corticales déterminait une déviation : il s'agissait du gyrus supra-marginal (la partie antérieure du lobule pariétal inférieur) et de la partie caudale du GTS. En revanche, l'inactivation d'une partie plus antérieure du GTS ainsi que du champ oculomoteur frontal, ne provoquait pas de déviation significative. Toutefois, les déviations les plus massives (de l'ordre de 30% de la longueur de l'hémisegment de droite de la ligne) étaient observées lors de l'inactivation de la substance blanche au fond du lobule pariétal inférieur. Grâce à une technique innovante d'imagerie cérébrale, le tracking de fibres, cette zone a été identifiée comme une portion du faisceau longitudinal supérieur.

## **2. PRINCIPES ET FONCTIONNEMENT DU TENSEUR DE DIFFUSION (DTI).**

### **a) Limites de l'imagerie par résonance magnétique (IRM) anatomique conventionnelle.**

L'IRM est une technique d'imagerie qui détecte le signal des protons des molécules d'eau. Les images résultantes reflètent donc la densité d'eau contenue dans les tissus. Les images obtenues par résonance magnétique sont composées de plusieurs éléments individuels (voxels : volume à 3 dimensions) d'intensité variable. Dès lors qu'on observe une IRM, deux paramètres sont à prendre en compte : la résolution spatiale et le contraste. Les IRM modernes possèdent une résolution de 1 à 3 millimètres (voir parfois moins) et révèlent de subtils détails de l'anatomie cérébrale. Le contraste, lui est créé par la différence d'intensité des voxels entre les différentes régions du cerveau. Conventionnellement, les contrastes en résonance magnétique sont principalement basés sur la différence de temps de relaxation de l'eau contenue dans les tissus ( $T_1$  &  $T_2$ ) et permettent de mettre en évidence différentes régions cérébrales comme le cortex, la substance grise profonde et la substance blanche (voir figure 18). Malheureusement, les IRM conventionnelles ne réussissent pas à offrir un bon contraste de la substance blanche qui généralement semble homogène quelle que soit la qualité de la résolution spatiale de l'acquisition, ce qui bien évidemment n'est pas le cas.



*Fig. 18 : IRM T1 haute définition ( $500\mu\text{m} \times 500\mu\text{m} \times 500\mu\text{m}$ ), le cortex et la substance grise profonde sont bien distincts cependant la substance blanche semble homogène.*

## **b) L'imagerie par tenseur de diffusion (DTI)**

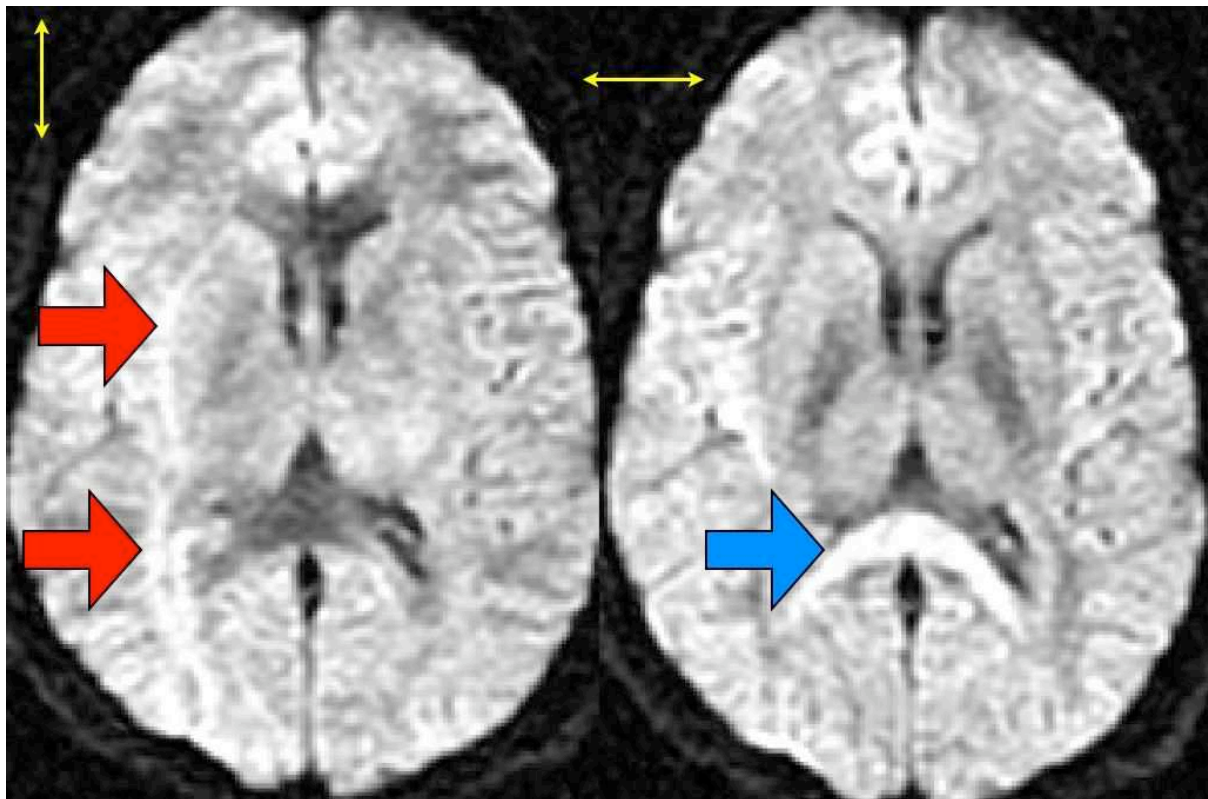
### **b.1) Le tenseur de diffusion et l'ellipsoïde de diffusion**

L'IRM peut être utilisée également non pas pour mesurer la densité d'eau contenue dans les tissus mais pour estimer localement les propriétés chimiques et physiques de l'eau : précisément deux propriétés importantes 1) la diffusion et 2) le flux moléculaire.

La diffusion est le reflet du mouvement thermique Brownien. Cette propriété peut être comprise facilement si l'on imagine l'évolution d'une tache d'encre sur un papier buvard. Généralement cette évolution donne un cercle (distribution Gaussienne) qui grossit petit à petit. Plus la diffusion est rapide plus le diamètre du cercle va être important. C'est ainsi qu'on peut estimer l'étendue de la diffusion, et comme l'étendue de la diffusion est équivalente dans toutes les directions, la diffusion est appelée isotropique. Imaginons maintenant que le papier que nous utilisons, issu d'une fabrication spéciale, est composé de

fibres verticales très serrées et horizontales très espacées. La tache que nous obtiendrons alors aura une forme ovale allongée sur l'axe horizontal. La diffusion est dans ce cas définie comme anisotrope. Le même processus se produit dans le cerveau où l'eau a tendance à diffuser préférentiellement le long des axones. Si de l'encre était injectée à l'intérieur de la substance blanche cérébrale, la forme de sa distribution serait allongée le long des faisceaux de fibres et plus sphérique ou isotropique (équivalente dans toutes les directions) dans la substance grise à cause du manque d'alignement des fibres.

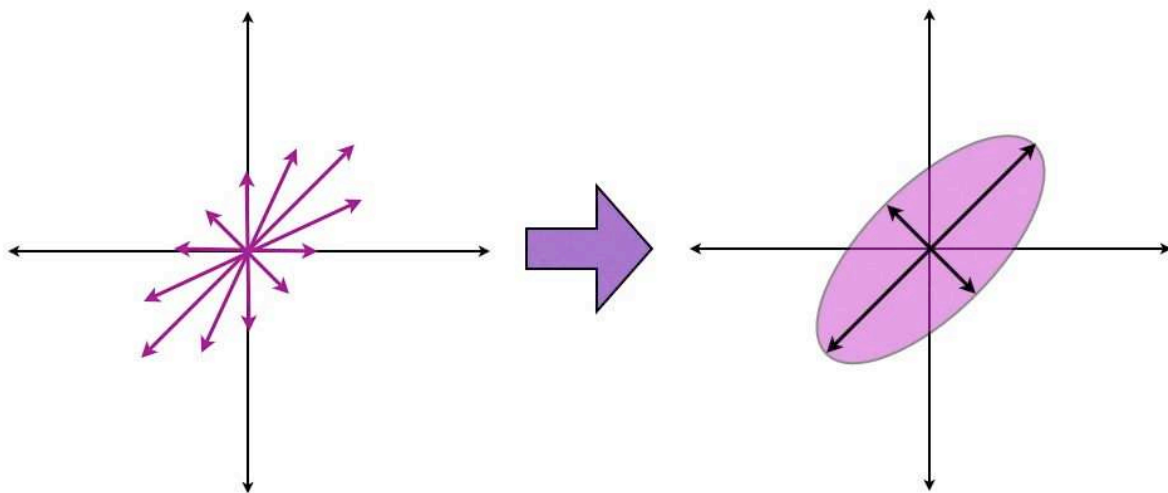
L'une des formidables possibilités de l'estimation de la diffusion par l'IRM est que l'étendue de la diffusion peut être mesurée le long d'un axe pré-déterminé (voir figure 19)



*Fig. 19 : Cartes de diffusion de la même coupe axiale mesurées suivant deux orientations différentes (flèches jaunes). Dans ces images, l'intensité représente l'étendue de la diffusion. Par exemple, le faisceau occipito-frontal inférieur (indiqué par les flèches rouges) a une constante de diffusion élevée quand l'image est acquise le long de l'axe vertical (première image) mais un faible niveau de diffusion quand l'image est acquise sur l'axe horizontal (seconde image). Le phénomène inverse se produit pour le corps calleux (indiqué par la flèche jaune).*

En regardant ces images, on voit clairement que la diffusion de l'eau dans le cerveau est anisotrope et que l'étendue de cette diffusion dépend de l'orientation de cette mesure particulièrement dans la substance blanche.

L'étendue de l'anisotropie de la diffusion de l'eau peut être analysée plus précisément en mesurant la constante de diffusion sur plusieurs axes. Due à la complexité de la cyto-architecture sous-jacente (sans compter le bruitage de l'image) parfois la mesure peut amener à un modèle d'anisotropie très complexe. Cependant, lorsque la cyto-architecture est homogène à l'intérieur d'un voxel (généralement  $3 \times 3 \times 3$ ), l'importance de la diffusion (la tache d'encre si nous reprenons la métaphore) peut être décrite par une ellipsoïde très simple (voir figure 20).

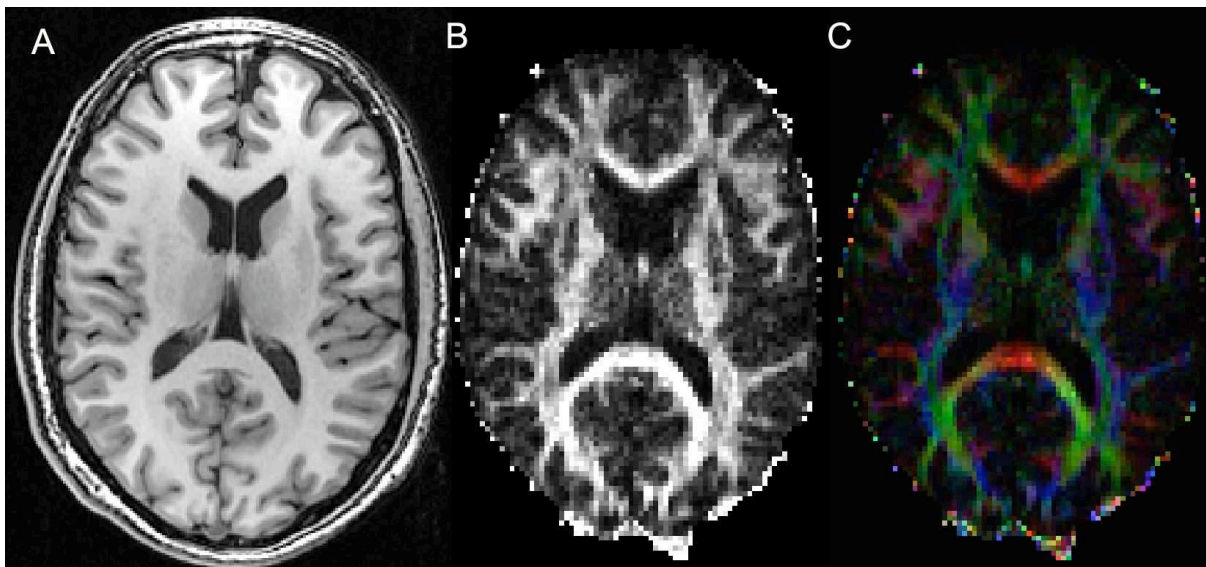


*Fig. 20 : En utilisant une estimation de la diffusion suivant plusieurs axes (à gauche les flèches violettes représentent l'intensité des constantes de diffusion selon les différents axes mesurés) le processus de diffusion peut être étudié plus en détail. En tenseur de diffusion, cette mesure est représenté par une ellipsoïde 3d (ou ovale sur cette représentation 2d).*

Le tenseur de diffusion est donc une technique dans laquelle la diffusion est mesurée suivant une série de directions spatiales. La forme et la direction de l'ellipsoïde sont déterminées dans chaque voxel de l'image à partir de l'intensité de la diffusion selon chacun des axes de mesure.

## b.2) Visualisation 2d du tenseur de diffusion

Comme l'acquisition est faite sur au moins 6 directions, l'information doit être réduite en différentes images pour pouvoir être appréciée visuellement. Il est bien entendu impossible de voir les 6 paramètres (au minimum) dans une seule image, c'est pourquoi deux types de représentation sont généralement employés. L'une d'elle est appelée carte anisotropiques (anisotropie fractionnelle) (FA maps) et l'autre cartes d'orientation (ou RGB maps). Les cartes anisotropiques donnent des informations sur l'étendue (anisotropie) de l'ellipsoïde de diffusion (Figure 21B). Dans ce type de cartes, la substance blanche paraît plus claire (plus anisotrope) que la substance grise. Cette approche met bien en évidence les différentes aires du cerveau afférentées (ou efferentées) par des structures de substance blanche cohérentes. Il est postulé que les facteurs comme la densité axonale, la myélinisation et l'homogénéité de l'orientation axonale affectent le degré de diffusion anisotrope. Dans les cartes d'orientation (cartes RGB, voir figure 21C) l'angle de l'axe le plus long de l'ellipsoïde est représenté par 3 couleurs principales (rouge, vert, bleu).



*Fig. 21 : Exemple de (A) une IRM conventionnelle (image pondérée en T1) recalée sur (B) une carte anisotropique et (C) une carte d'orientation. Pour la carte codée en couleur (carte d'orientation), l'intensité est proportionnelle à l'intensité de l'anisotropie et les différentes couleurs rouge, vert, bleu représentent les fibres qui vont respectivement de la droite vers la gauche (et inversement), du rostral au caudal (id.), et du haut vers le bas (id.).*



### b.3) Visualisation 3d du tenseur de diffusion

Avec les approches chimiques, le traceur suit la totalité des projections axonales. Avec la DTI, un tel suivi des axones n'est pas possible parce que nous ne pouvons estimer que les informations de la diffusion d'un voxel à l'autre. Bien entendu de nombreux axones peuvent entrer dans un voxel et en sortir. Il faut donc prendre en compte le fait que l'information de certaines trajectoires spécifiques va dégénérer dans ce pixel. Cependant, si de nombreux axones forment un large faisceau et si ce faisceau est suffisamment large pour contenir plusieurs voxels dans son diamètre, alors un rendu 3d de ce faisceau peut-être reconstruit en se basant sur la DTI simplement en connectant les informations d'un voxel à l'autre (voir figure 22).

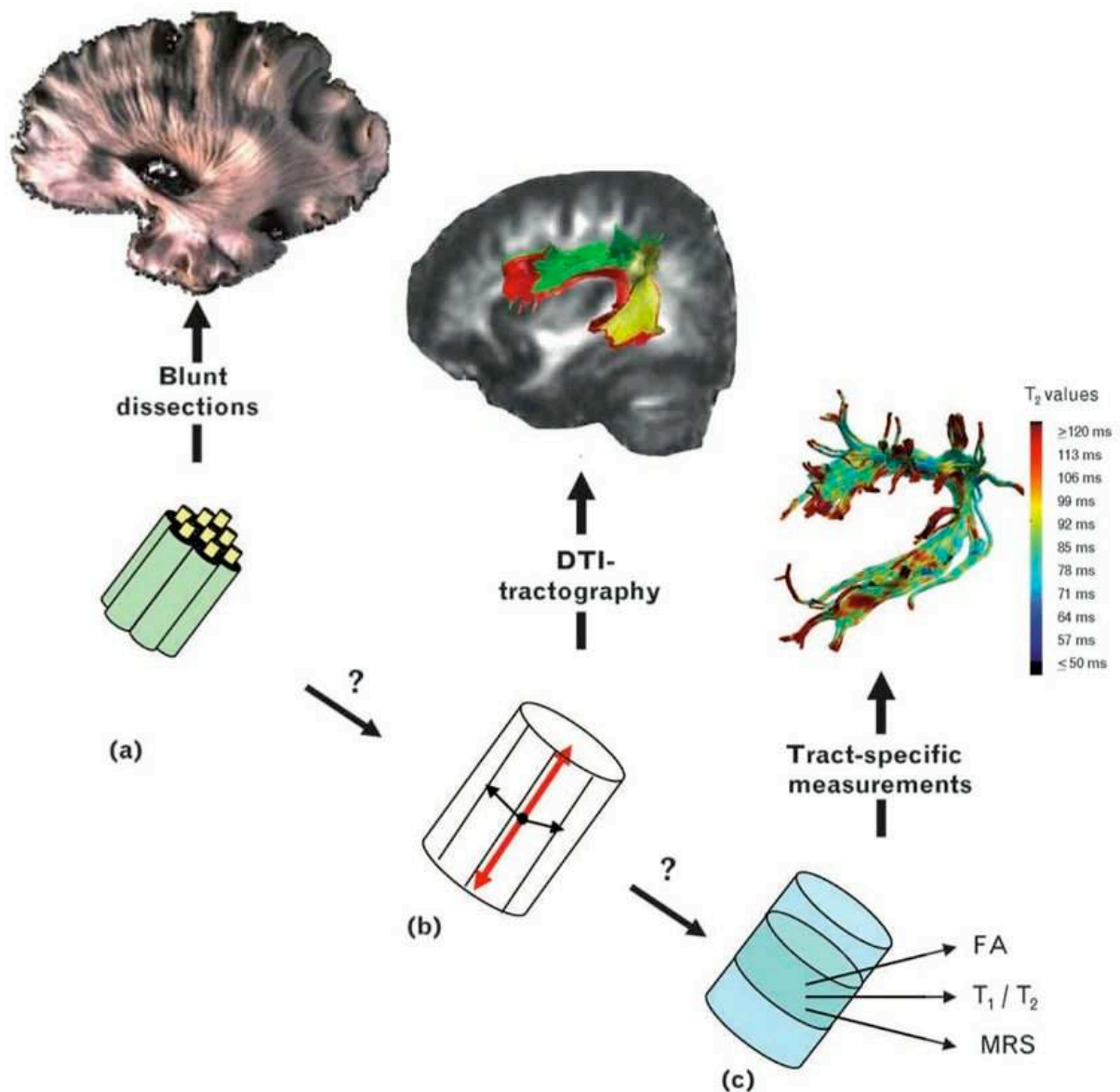
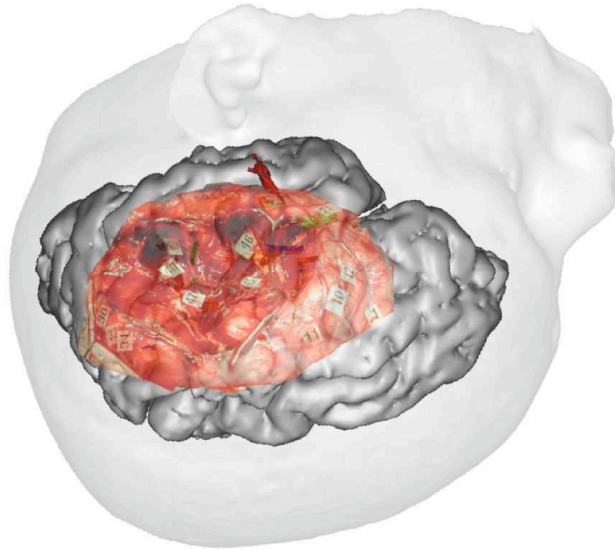


Fig. 22 : Groupe d'axones myélinisés qui forment ensemble un faisceau. Ces axones parallèles peuvent être visualisés en dissection post-mortem (a). Le tenseur de diffusion en revanche permet d'effectuer une dissection virtuelle in-vivo (b). La combinaison d'autres techniques avec cette méthode de dissection in vivo se présente comme le nouvel objectif technique à réaliser (c) (Catani, 2006).

### **3. LA TECHNIQUE IES (INTRA-OPERATIVE ELECTRICAL STIMULATIONS)**

La prescription d'un traitement neurochirurgical de lésions localisées dans le système nerveux central dépend directement du risque de déficit neurologique encouru en phase post-opératoire. La détection des structures peri-lésionnelles fonctionnelles est alors nécessaire. Cependant il faut prendre en compte les différences majeures inter-individuelles anatomo-fonctionnelles (Herholz et al., 1996; Ojemann et al., 1989b; Uematsu et al., 1992). D'autant plus que ces lésions peuvent induire un effet de masse et/ou une réorganisation fonctionnelle (Seitz et al., 1995; Wunderlich et al., 1998). Bien que les récentes avancées technologiques en neuroimagerie permettent une investigation fonctionnelle non invasive (PETscan, IRM fonctionnelle et Magneto Encephalographie) qui commence à être reconnue pour la cartographie sensori-motrice des fonctions (Nyberg et al., 1996; Rezai et al., 1996; Yousry et al., 1995), ces techniques manquent toujours de précision pour des investigations sur des fonctions cognitives plus complexes (le PETscan montre une sensibilité de 71%, Herholz et al., 1997) De plus, elles ne donnent pas d'informations en temps réel durant la neurochirurgie et n'ont pas d'accès à la valeur fonctionnelle des fibres de substance blanche dont il est aussi nécessaire de définir les limites fonctionnelles avant la résection afin d'éviter les séquelles neurologiques. Ces techniques, somme toute, permettent la détection de toutes les aires impliquées dans la réalisation d'une tâche, mais pas des structures essentielles de ces réseaux. La plus précise des méthodes prescrites à ce jour dans ce cas se trouve être la stimulation directe intra opératoire (IES) du système nerveux. Grâce à leur identification en direct en salle d'opération, cette technique permet de préserver les réseaux essentiels de la motricité, du langage, de la mémoire voire même de la conscience de l'espace (Berger et al., 1990; Black and Ronner, 1987; Burchiel et al., 1989; Danks et al., 1998; Herholz et al., 1997; King and Schell, 1987; LeRoux et al., 1991; Ojemann and Dodrill, 1985; Ojemann et al., 1996; Thiebaut de Schotten et al., 2005). Cette technique permet d'accéder à une cartographie au niveau cortical (Berger et al., 1990; Ebeling et al., 1989; Ebeling et al., 1992; Haglund et al., 1993; Ojemann et al., 1989a; Walsh et al., 1992) et sous-cortical (Berger and Ojemann, 1992; Skirboll et al., 1996) au niveau cérébral, mais également au niveau bulbaire (Morota et al., 1996; Strauss et al., 1993). Elle dispose d'une résolution temporelle exacte et d'une résolution spatiale de l'ordre de 5mm<sup>2</sup> (voir figure 23).



*Fig. 23 : La technique IES : sur cette figure se trouve la photographie de la cavité opératoire projetée sur la reconstruction 3d du cerveau du patient. L'ensemble de la surface corticale et sous corticale accessible a été stimulé et chaque étiquette correspond à une fonction cognitive altérée lors de la stimulation.*

#### **4. APPLICATION**

*Grâce à cette technique, nous avons pu 1) Eviter les signes de négligence post opératoire chez des patients après resection d'une tumeur localisée dans le carrefour sylvien droit 2) Verifier directement les hypothèse sur les bases neuroanatomique de l'héminégligence.*

REPORTS

24. B. Morales, S. Y. Choi, A. Kirkwood, *J. Neurosci.* **22**, 8084 (2002).  
 25. G. D. Mower, *Brain Res. Dev. Brain Res.* **58**, 151 (1991).  
 26. T. K. Hensch et al., *Science* **282**, 1504 (1998).  
 27. Z. J. Huang et al., *Cell* **98**, 739 (1999).  
 28. N. Mataga, Y. Mizuguchi, T. K. Hensch, *Neuron* **44**, 1031 (2004).  
 29. E. J. Bradbury et al., *Nature* **416**, 636 (2002).  
 30. T. Pizzorusso et al., *Science* **298**, 1248 (2002).  
 31. M. Fagiolini, T. K. Hensch, *Nature* **404**, 183 (2000).  
 32. M. Fagiolini et al., *Science* **303**, 1681 (2004).  
 33. S. Taha, J. L. Hanover, A. J. Silva, M. P. Stryker, *Neuron* **36**, 483 (2002).  
 34. M. Simonen et al., *Neuron* **38**, 201 (2003).  
 35. B. Zheng et al., *Neuron* **38**, 213 (2003).  
 36. J. DeFelipe, E. G. Jones, *J. Neurosci.* **5**, 3246 (1985).  
 37. P. Somogyi, I. Soltesz, *Neuroscience* **19**, 1051 (1986).  
 38. A. Rebsam, I. Seif, P. Gaspar, *J. Neurosci.* **25**, 706 (2005).  
 39. We thank N. Tian for providing dark-reared mice. This work was supported by grants from NIH to S.M.S. and A.W.M. and from the McKnight Founda-

tion to S.M.S. S.M.S. is a member of the Kavli Institute of Neuroscience at Yale.

**Supporting Online Material**  
[www.sciencemag.org/cgi/content/full/309/5744/2222/DC1](http://www.sciencemag.org/cgi/content/full/309/5744/2222/DC1)  
 Materials and Methods  
 Figs. S1 to S3  
 References

3 May 2005; accepted 26 August 2005  
 10.1126/science.1114362

## Direct Evidence for a Parietal-Frontal Pathway Subserving Spatial Awareness in Humans

Michel Thiebaut de Schotten,<sup>1</sup> Marika Urbanski,<sup>1</sup> Hugues Duffau,<sup>2</sup> Emmanuelle Volle,<sup>1,3</sup> Richard Lévy,<sup>1,4</sup> Bruno Dubois,<sup>1,4</sup> Paolo Bartolomeo<sup>1,4\*</sup>

Intraoperative electrical stimulation, which temporarily inactivates restricted regions during brain surgery, can map cognitive functions in humans with spatiotemporal resolution unmatched by other methods. Using this technique, we found that stimulation of the right inferior parietal lobule or the caudal superior temporal gyrus, but not of its rostral portion, determined rightward deviations on line bisection. However, the strongest shifts occurred with subcortical stimulation. Fiber tracking identified the stimulated site as a section of the superior occipitofrontal fasciculus, a poorly known parietal-frontal pathway. These findings suggest that parietal-frontal communication is necessary for the symmetrical processing of the visual scene.

Left unilateral neglect is a neurological condition resulting from right hemisphere damage (1, 2). Neglect patients ignore left-sided events in everyday life (3) and have a poor functional outcome. They typically bisect horizontal lines to the right of the true center (2, 4), perhaps because they perceive the left half of the line as being shorter or less salient than the right half (5, 6). The study of unilateral neglect is important if we are to understand the mechanisms of spatial cognition, but its anatomical correlates are controversial. Most studies implicate the inferior parietal lobule (IPL) (7, 8), consistent with the known role of posterior parietal cortex in spatial attention (9, 10) and perceptual salience (11). Others implicate the rostral superior temporal gyrus (rSTG) (12), suggesting a segregation of spatial awareness in the ventral cortical visual stream (13, 14). The underlying subcortical association circuits have received less attention (15).

We used intraoperative direct electrical stimulation (16) to study line bisection performance. During brain surgery for tumor resection, it is common clinical practice to awaken patients in order to assess the functional role of

restricted brain regions (the brain has no receptors for pain), so that the surgeon can maximize the extent of the exeresis without provoking cognitive impairment. Patients perform cognitive tasks, such as counting or figure naming, while the surgeon temporarily inactivates restricted regions (~5 mm) around the tumor by means of electrical stimuli (16). If the patient stops talking or produces incorrect responses, the surgeon avoids removing the stimulated region.

CAL, a 27-year-old woman, and SB, a 28-year-old man, both left-handed, underwent surgical resection of a low-grade glioma (WHO II). In CAL, the glioma was centered on the caudal part of the right temporal lobe (17). CAL showed a rightward deviation upon stimulation of two cortical sites: the supra-marginal gyrus (SMG), the rostral subdivision of the IPL, and the caudal portion of the superior temporal gyrus (cSTG) (Fig. 1) (table S2). There was no deviation during stimulation of the rSTG or of the frontal eye field.

In SB, the glioma was centered on the right inferior parietal lobule (17). SB showed a rightward deviation remarkably identical in amplitude to that shown by CAL (Fig. 2) (table S2) upon stimulation of the SMG. SB also deviated rightward during cSTG stimulation, again consistent with CAL's performance. Stimulation of other neighboring areas ("control 1" in Fig. 2B) did not determine pathological shifts. During tumor resection, subcortical regions on the floor of the surgical cavity were stimulated.

SB showed a large rightward deviation upon stimulation of the restricted region labeled as 42 in Fig. 2A, but not of neighboring cortical or subcortical areas ("control 2" in Fig. 2B). Stimulation of region 42 was repeated after additional excavation of the surgical cavity, causing even greater deviations ("O-FF 2" in Fig. 2B). Again, stimulation of neighboring subcortical sites had no effect on line bisection performance. Still further extension of the resection into the depth of the angular gyrus caused SB to deviate rightward even during stimulation of neighboring regions, or in the absence of any stimulation ("control 3" in Fig. 2B). As a consequence, the neurosurgeon decided to stop the exeresis at this level. Five days after surgery, SB accurately bisected 20-cm lines ("day +5" in Fig. 2B) and showed no signs of neglect (table S1).

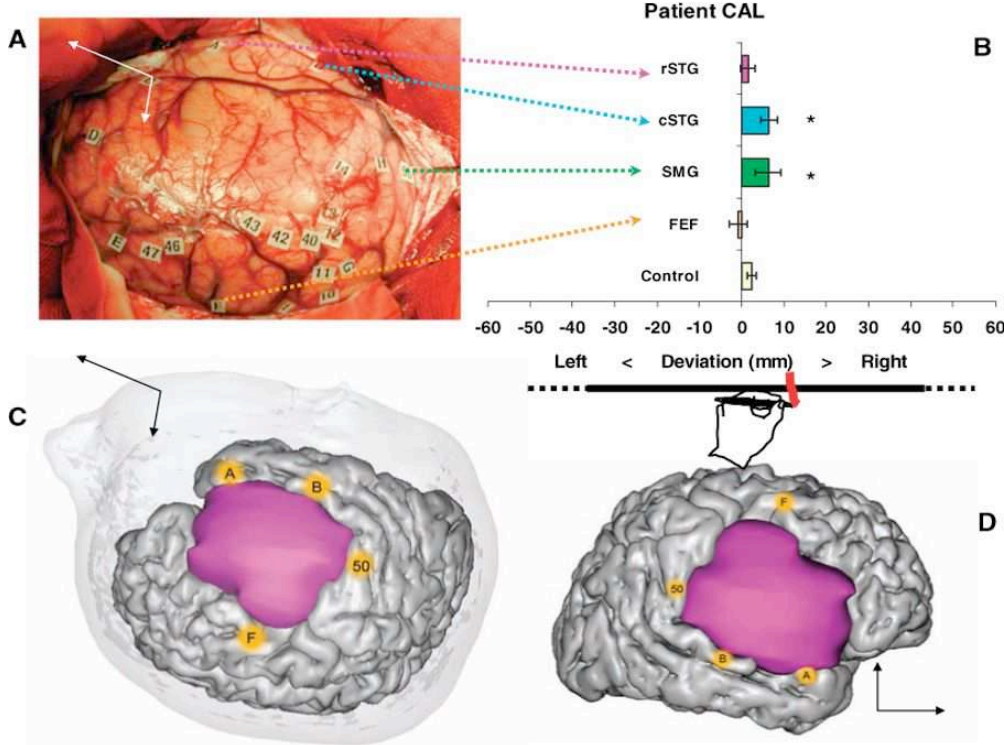
Using diffusion tensor magnetic resonance tractography (18) on postoperative magnetic resonance imaging (MRI) scans and diffusion tensor imaging (DTI) scans, we were able to precisely map the course of long association fibers in the white matter of this patient (19). The region labeled as 42 in Fig. 2A, whose inactivation had produced the maximal rightward shifts on line bisection, corresponded exactly to a portion of the superior occipitofrontal fasciculus (18, 20) that connects the parietal to the frontal lobe (21) (Fig. 2, C and D) (figs. S1 and S2). The stimulated region was both distinct and remote from other corticocortical pathways, such as the optic radiations or the parietal-temporal connections.

Our findings demonstrate that the SMG, the cSTG, and a poorly known parietal-frontal pathway, the superior occipitofrontal fasciculus (18, 20), but not the rSTG, are critical to the symmetrical processing of the visual scene in humans (22). These results provide evidence relevant to the debate about the lesional correlates of neglect, based until now on the relatively imprecise lesion-overlapping method in stroke patients, and support the proposal that damage to the temporal-parietal junction (7, 8, 23) and the underlying white matter (15) is a crucial antecedent of left neglect. As a consequence, there is no need to postulate a segregation of spatial awareness, specific to humans, in the rostral part of the right STG (14).

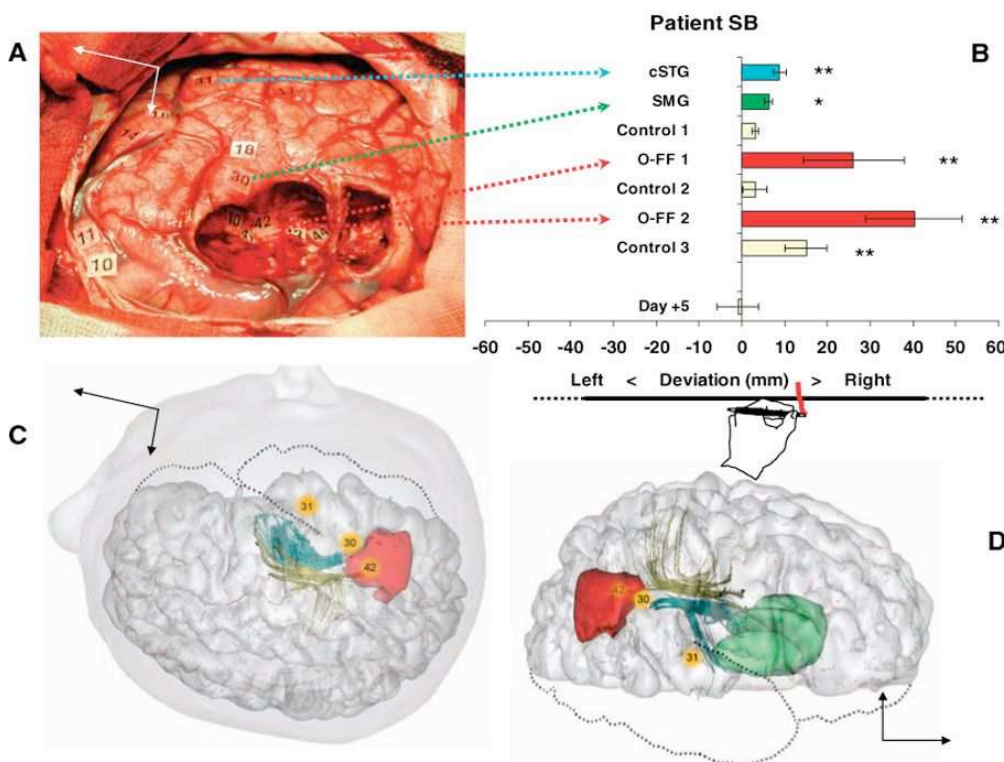
We observed the maximal deviation upon inactivation of the superior occipitofrontal fasciculus in the depth of the IPL. This result specifies the precise anatomical locus of the parietal-frontal pathway in which neglect

<sup>1</sup>INSERM Unit 610, <sup>2</sup>Department of Neurosurgery, <sup>3</sup>Department of Neuroimaging, <sup>4</sup>Department of Neurology, Assistance Publique-Hôpitaux de Paris, Hôpital de la Salpêtrière, 75013 Paris, France.

\*To whom correspondence should be addressed. E-mail: paolo.bartolomeo@chups.jussieu.fr



**B** Fig. 1. Performance of patient CAL. (A) The surgical field. (B) Mean deviation (in millimeters) with 95% confidence intervals during stimulation of the rostral part of the superior temporal gyrus (rSTG, label A;  $n = 4$ ), of the caudal part of the STG (cSTG, label B;  $n = 2$ ), of the supramarginal gyrus (SMG, label 50;  $n = 4$ ), of the frontal eye field (FEF, label F;  $n = 5$ ), and of control neighboring regions (superior frontal gyrus, medial frontal gyrus, precentral gyrus, postcentral gyrus, and tumor,  $n = 16$ ). \* $P < 0.05$  (two-tailed) as compared to controls' performance (32). (C) Three-dimensional reconstruction of the tumor mass (in purple) and of the stimulated regions (in yellow). (D) Lateral view.



**B** Fig. 2. Performance of patient SB. (A) The surgical field. (B) Mean deviation (in millimeters) with 95% confidence intervals during stimulation of the caudal part of the STG (cSTG, label 31;  $n = 6$ ), of the supramarginal gyrus (SMG, label 30;  $n = 4$ ), of the superior occipitofrontal fasciculus (label 42) during (O-FF 1;  $n = 4$ ) and after tumor resection (O-FF 2,  $n = 4$ ), and of control neighboring regions (postcentral gyrus, lateral occipital gyri, and tumor) before resection (control 1,  $n = 27$ ), during resection (control 2,  $n = 38$ ), and after resection (control 3,  $n = 12$ ). Performance 5 days after surgery is also shown (day +5). \* $P < 0.05$ , \*\* $P < 0.01$  (both two-tailed) as compared to controls' performance (32). (C) Three-dimensional reconstruction of the surgical resection (in red) and of the stimulated regions (in yellow), showing their relationships with the superior occipitofrontal fasciculus (in yellow) and the superior longitudinal fasciculus (in blue) (18). The head of the caudate nucleus and the putamen are shown in green. (D) Lateral view.

## REPORTS

patients' lesions overlap (15). Our findings are similar to those obtained in nonhuman primates. Monkeys showed persistent signs of neglect after unilateral section of the white matter between the fundus of the intraparietal sulcus and the lateral ventricle (24). The greater effect of subcortical inactivation, as compared to cortical inactivation, is consistent with the idea that symmetrical space processing requires the integrity of a parietal-frontal network (1, 15). Damage to restricted regions of the white matter can cause the dysfunction of large-scale neurocognitive networks. According to an influential model (1), signs of left neglect result from impairment of a right-hemisphere network, including prefrontal, parietal, and cingulate components. The parietal component of the network could be especially important for the perceptual salience of extrapersonal objects, whereas the frontal component might be implicated in the production of an appropriate response to behaviorally relevant stimuli (1), in the online retention of spatial information (1, 25), or in the focusing of attention on salient items through reciprocal connections to more posterior regions (20).

Models of line bisection postulate a competition between the relative salience of the two lateral segments (6). The bisection mark is drawn at the point of subjective equality between the two segments (5). Bisection-related tasks activate the IPL in humans (26). Transcranial magnetic stimulation over the right posterior parietal cortex, but not over the STG, was found to bias the comparison of the lengths of the component segments of pretransected lines in a direction coherent with rightward shifts in line bisection (27). In the monkey, regions adjacent to the intraparietal sulcus, such as the lateral intraparietal area, are related to visual perceptual salience (11) and can reinforce the stimulus attentional priority (10). Parietal inactivation may thus bias the perceptual decision by modulating the salience of the line segments (6).

The assessment of spatial cognition during intraoperative stimulation offers the double opportunity of preserving spatial processing functions during brain surgery and of pinpointing the neurocognitive systems devoted to spatial processing in humans. Spatial awareness is dependent not only on the cortical areas of the temporal-parietal junction, but also on a larger parietal-frontal network communicating via the superior occipitofrontal fasciculus.

### References and Notes

- M. M. Mesulam, *Philos. Trans. R. Soc. London Ser. B* **354**, 1325 (1999).
- P. Azouvi et al., *J. Neurol. Neurosurg. Psychiatry* **73**, 160 (2002).
- P. Bartolomeo, S. Chokron, *Neurosci. Biobehav. Rev.* **26**, 217 (2002).
- T. Schenkenberg, D. C. Bradford, E. T. Ajax, *Neurology* **30**, 509 (1980).
- J. C. Marshall, P. W. Halligan, *Cognit. Neuropsychol.* **7**, 107 (1990).
- B. Anderson, *Brain* **119**, 841 (1996).
- G. Vallar, *Neuroimage* **14**, S52 (2001).
- D. J. Mort et al., *Brain* **126**, 1986 (2003).

- M. Corbetta, G. L. Shulman, *Nat. Rev. Neurosci.* **3**, 201 (2002).
- J. W. Bisley, M. E. Goldberg, *Science* **299**, 81 (2003).
- J. P. Gottlieb, M. Kusunoki, M. E. Goldberg, *Nature* **391**, 481 (1998).
- H. O. Karnath, M. Fruhmann Berger, W. Kuker, C. Rorden, *Cereb. Cortex* **14**, 1164 (2004).
- A. D. Milner, M. A. Goodale, *The Visual Brain in Action* (Oxford Univ. Press, Oxford, 1995).
- H. O. Karnath, *Nat. Rev. Neurosci.* **2**, 568 (2001).
- F. Doricchi, F. Tomaiuolo, *Neuroreport* **14**, 2239 (2003).
- H. Duffau et al., *Brain* **128**, 797 (2005).
- CAL and SB attended clinical observation because of epileptic seizures. They showed no abnormality on preoperative neurological and neuropsychological examination, consistent with the slowly infiltrative character of low-grade gliomas, whose clinical presentation rarely includes signs of focal brain disease other than epilepsy. In particular, there were no signs of neglect on paper-and-pencil tests (table S1). Intraoperative electrical stimulation was well tolerated, and the patients reported no abnormal visual sensations. They bisected horizontal lines with their left, dominant hand during brain surgery (28). Eight healthy left-handed subjects (mean age, 31 years; SD, 5.3; range, 26 to 38) served as controls. They performed 30 line bisections each, with the same test material and in a body position similar to that of the patients. Our patients' baseline performance was well within the range of the controls' performance (mean  $\pm$  SD, 0.28  $\pm$  2.39 mm) as well as that of 10 strongly left-handed normal individuals tested in another study (29) (mean  $\pm$  SD,  $-1.50 \pm 3.66$  mm). In an unselected population of 204 patients with right brain damage (2), 5 of the 10 patients with the strongest left-handedness deviated rightward on 20-cm lines as compared to controls (29), a frequency of impairment similar to that showed by right-handed patients (2).
- M. Catani, R. J. Howard, S. Pajevic, D. K. Jones, *Neuroimage* **17**, 77 (2002).
- The neurosurgeon stopped the resection after stimulation of the region labeled as 42 (Fig. 2A). As a consequence, region 42 corresponded to the deepest point on the floor of the rostral-superior part of the surgical cavity, and was thus easily identified on postoperative anatomical MRI scans. The white matter tract underlying region 42 was identified by overlapping the MRI scans with the DTI scans (fig. S1) (Fig. 2, C and D).
- M. Petrides, D. N. Pandya, in *Principles of Frontal Lobe Function*, D. T. Stuss, R. T. Knight, Eds. (Oxford Univ. Press, Oxford, 2002), pp. 31–50.
- The superior occipitofrontal fasciculus is a poorly known long association pathway. It terminates

rostrally in the lateral prefrontal cortex of the inferior and middle frontal gyri (18). Its caudal terminations are less known (18, 30), but despite its name, derived from early descriptions (37), the superior occipitofrontal fasciculus seems to terminate caudally in the superior parietal gyrus (18) and in the intraparietal sulcus [(30), p. 367].

- We used line bisection because it is an easy task for patients to perform and allows repeated assessments in the time scale required by intraoperative testing. Bisection of centrally presented 20-cm lines correlates positively and significantly with cancellation tests and is a good predictor of clinical neglect as assessed by standardized scales (2, 28).
- C. Rorden, M. Fruhmann Berger, H.-O. Karnath, *Cognit. Brain Res.*, published online 19 February 2005 (10.1016/j.cogbrainres.2004.10.022).
- D. Gaffan, J. Hornak, *Brain* **120**, 1647 (1997).
- M. Husain, C. Rorden, *Nat. Rev. Neurosci.* **4**, 26 (2003).
- G. R. Fink, J. C. Marshall, P. H. Weiss, I. Toni, K. Zilles, *Neuropsychologia* **40**, 119 (2002).
- A. Ellison, I. Schindler, L. L. Pattison, A. D. Milner, *Brain* **127**, 2307 (2004).
- See supporting data on Science Online.
- M. Rousseaux et al., *Rev. Neurol. (Paris)* **157**, 1385 (2001).
- R. Nieuwenhuis, J. Voogd, C. van Huijzen, *The Human Central Nervous System: A Synopsis and Atlas* (Springer-Verlag, New York, 1988).
- M. J. Déjerine, *Anatomie des Centres Nerveux* (Rueff, Paris, 1895).
- J. R. Crawford, P. H. Garthwaite, *Neuropsychologia* **40**, 1196 (2002).
- We thank the patients for their cooperation; P. Gatignol for help with intraoperative testing; J. Chiras and the Department of Neuroradiology of the Salpêtrière Hospital for MRI acquisitions; S. Kinkingnehun, C. Delmaire, J. B. Pochon, L. Thivard, and the staff of BrainVISA software for technical support for image analysis; and P. Azouvi and the members of the Groupe d'Etude sur la Rééducation et l'Évaluation de la Négligence (GEREN) for permission to use data from GEREN studies (2, 29).

### Supporting Online Material

www.sciencemag.org/cgi/content/full/309/5744/2226/DC1

Materials and Methods

SOM Text

Tables S1 and S2

Figs. S1 and S2

References

17 June 2005; accepted 26 August 2005  
10.1126/science.1116251

# Breakdown of Cortical Effective Connectivity During Sleep

Marcello Massimini,<sup>1,2</sup> Fabio Ferrarelli,<sup>1</sup> Reto Huber,<sup>1</sup> Steve K. Esser,<sup>1</sup> Harpreet Singh,<sup>1</sup> Giulio Tononi<sup>1\*</sup>

When we fall asleep, consciousness fades yet the brain remains active. Why is this so? To investigate whether changes in cortical information transmission play a role, we used transcranial magnetic stimulation together with high-density electroencephalography and asked how the activation of one cortical area (the premotor area) is transmitted to the rest of the brain. During quiet wakefulness, an initial response (~15 milliseconds) at the stimulation site was followed by a sequence of waves that moved to connected cortical areas several centimeters away. During non-rapid eye movement sleep, the initial response was stronger but was rapidly extinguished and did not propagate beyond the stimulation site. Thus, the fading of consciousness during certain stages of sleep may be related to a breakdown in cortical effective connectivity.

When awakened early in the night from non-rapid eye movement (NREM) sleep, people often report little or no conscious experience

(1). It was first thought that this fading of consciousness was due to the brain shutting down. However, although brain metabolism is re-



## Supporting Online Material for

### Direct Evidence for a Parietal-Frontal Pathway Subserving Spatial Awareness in Humans

Michel Thiebaut de Schotten, Marika Urbanski, Hugues Duffau, Emmanuelle Volle, Richard Lévy, Bruno Dubois, Paolo Bartolomeo\*

\*To whom correspondence should be addressed. E-mail:  
paolo.bartolomeo@chups.jussieu.fr

Published 30 September 2005, *Science* **309**, 2226 (2005)  
DOI: 10.1126/science.1116251

#### **This PDF file includes:**

Materials and Methods

Tables S1 and S2

Figs. S1 and S2

References



## Supporting Online Material

**Participants.** CAL and SB attended clinical observation because of epileptic seizures. They showed no abnormality on pre-operative neurological and neuropsychological examination. In particular, there were no signs of neglect on paper-and-pencil tests (*S1*) (see Table S1). Eight healthy left-handed subjects (mean age, 31 years; SD, 5.3, range 26-38) served as controls. They performed 30 line bisections each, with the same test material and in a similar body position as the patients.

**Surgical procedure.** Patients were placed in a semidecubitus position on their left side and used their left, dominant hand to perform line bisection tasks. Intraoperative cortico-subcortical mapping was performed under local anesthesia using the technique of direct intraoperative electrical stimulation (*S2*). A bipolar electrode with 5-mm spaced tips delivering a biphasic current with parameters non-deleterious for the CNS (pulse frequency of 60 Hz, single pulse phase duration of 1 ms, amplitude from 2 to 8 mA) was applied to the brain of awake patients. In addition to line bisection, sensori-motor and language functions were assessed (counting and naming). In order to perform a successful tumour removal while sparing functional areas, all resections were pursued until functional pathways were encountered around the surgical cavity, then these were followed according to functional boundaries. These procedures allow the surgeon to minimize the residual morbidity while increasing the quality of the resection, and thereby to improve patient survival by minimizing the anaplastic transformation of low-grade gliomas (*S2*).

**Line bisection task.** Twenty-cm long, 1-mm thick black lines were centered on a horizontal A4 sheet (one line per sheet) (*S3*, *S4*), and presented aligned to the subjects' eye-axis, in central position with respect to the patient's sagittal head plane. Subjects were instructed to mark with a pencil the center of each line. Patients and examiners were blind concerning the stimulated sites. One examiner said "go" just before presenting each line, upon which the surgeon immediately started the stimulation. After each bisection, another examiner assessed the accuracy of the bisection mark by overlapping the test sheet with a transparency indicating 5% and 10% deviations. When a deviation greater than 5% occurred, the examiner said "yes", and the neurosurgeon put a numbered label on the stimulated area. Patients kept bisecting lines without further stimulation until their performance reverted to normality. During the surgical intervention, CAL performed a total of 31 line bisections; SB performed 106 line bisections.

**Data analysis.** For each trial, we calculated the deviation in mm from the true center of the line, with leftward errors scored as negative deviations and rightward errors scored as positive deviations. Patients' bisection performance for each stimulated site was compared to controls' using a significance test for comparing an individual case with small control samples (S5).

**Diffusion tensor analysis.** Diffusion tensor imaging (DTI) was performed using echo-planar imaging at 1.5 T (General Electric) with standard head coil for signal reception. DTI axial slices were obtained using the following parameters: repetition time, 10s; echo time, 88ms; flip angle, 90°; matrix, 128 × 128; field of view; 380 × 380mm<sup>2</sup>, slice thickness, 3mm; no gap (3mm isotropic voxels); acquisition time, 320s. Four averages were used with signal averaging in the scanner buffer. Diffusion weighting was performed along six independent directions, with a b-value of 900 s/mm<sup>2</sup>. High-resolution 3-D anatomical images were used for display and anatomical localization (110 axial contiguous inversion recovery three dimensional fast SPGR images, 1.5mm thick; TI, 400ms; FOV, 240 × 240mm<sup>2</sup>; matrix size, 256 × 256). BrainVisa, a software platform for visualization and analysis of multi-modality brain data (<http://brainvisa.info/>), was used to visualize the anisotropy data, define the regions of interest, track fibres and register T1-weighted MRI with DTI.

**Supplementary discussion.** It has been claimed (*S6*) that line bisection is not a specific task for neglect, because neglect patients (as assessed by cancellation tests) would often perform normally on this task. In this study (*S6*), however, the lines were presented with their right extremity aligned with the right margin of the sheet. This procedure likely resulted in an underestimation of pathological performance on line bisection, because it is well known that displacing the lines towards the right side decreases patients' rightward errors (*S7*). Dissociations between line bisection and cancellation tests may occur (*S8*), and suggest that these tasks recruit different processes or strategies, depending perhaps on the different number of objects that compete for attention, e.g. two segments meeting in an imaginary midpoint target for line bisection, or several physical targets for target cancellation. However, in a study (*S3*) with greater statistical power, which employed centrally placed, 20-cm lines, line bisection performance correlated positively and significantly with cancellation tests and clinical scales of neglect. Thus, in conditions similar to those of the present study, line bisection performance did capture significant aspects of neglect behavior.

**Table S1. Patients' demographical details and their performance on the neglect battery.**

Patient	Gender / Age / Education (years of schooling)	Time between test and surgery	Line Bisection % deviation	Line cancellation max 30 / 30	Bells cancellation max 15 / 15	Letter cancellation max 30 / 30	Overlapping figures max 10 / 10	Landscape drawing max 6
CAL	F / 27 / 12	Day before surgery	0.00	30 / 30	15 / 15	30 / 29	10/10	6
		114 days after surgery	-1.63	30 / 30	14 / 15	29 / 30	10/10	6
SB	M / 29 / 12	Day before surgery	+0.04	30 / 30	15 / 14	30 / 30	10/10	6
		5 days after surgery	-1.00	28 / 25	13 / 12	28 / 29	10/10	6
		51 days after surgery	-0.03	30 / 30	14 / 15	29 / 30	10/10	6

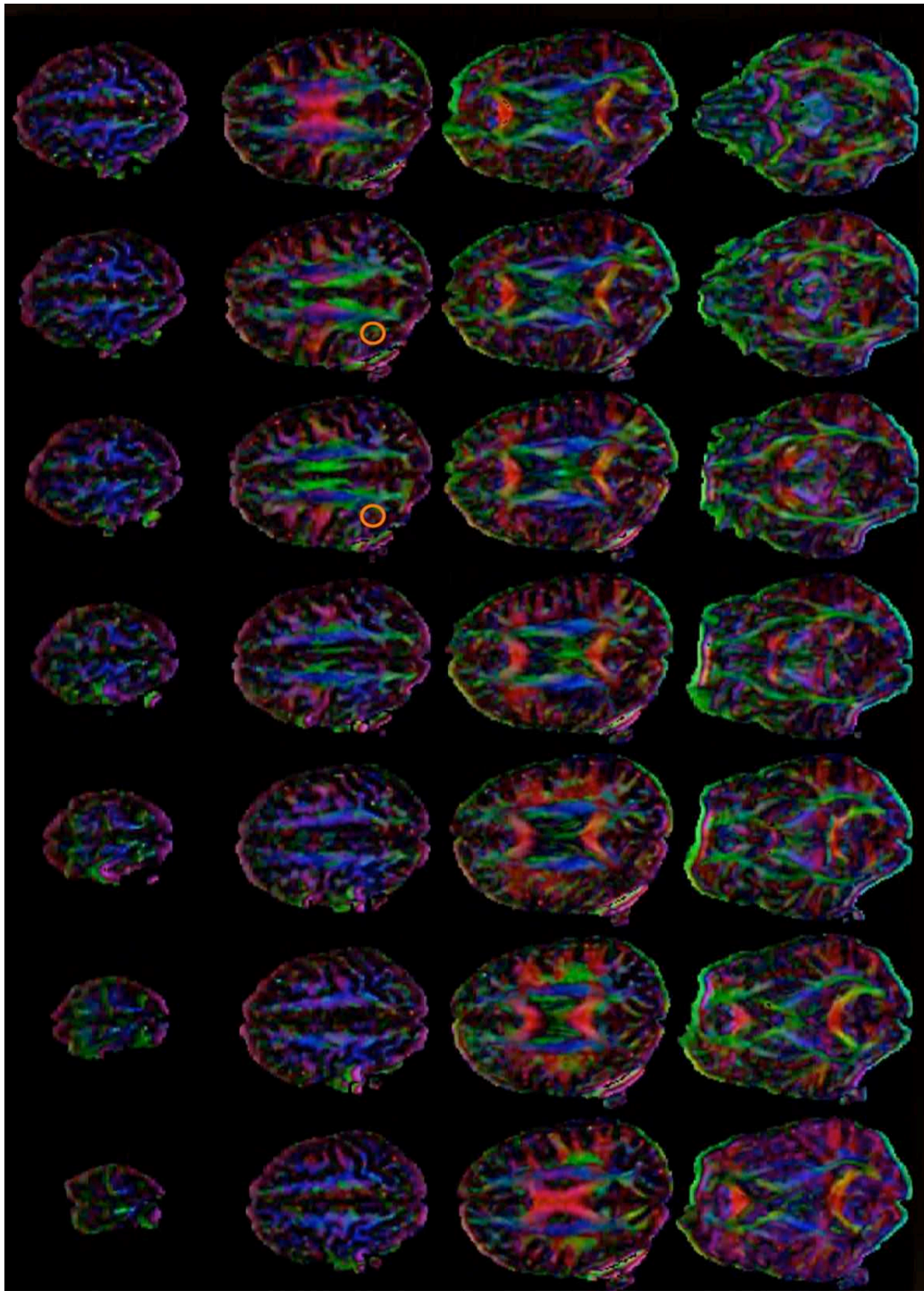
See (S1) for detailed test description. For line bisection, + indicates rightward deviation and - indicates leftward deviation. For the cancellation tests and the overlapping figures test, left / right correct responses are reported. The landscape drawing, consisting of a central house with two trees on each side, was scored by assigning 2 points to the house and 1 point to each tree completely copied.

**Table S2. Intraoperative bisection task: Talairach coordinates (S9) of the stimulated sites and patients' performance**

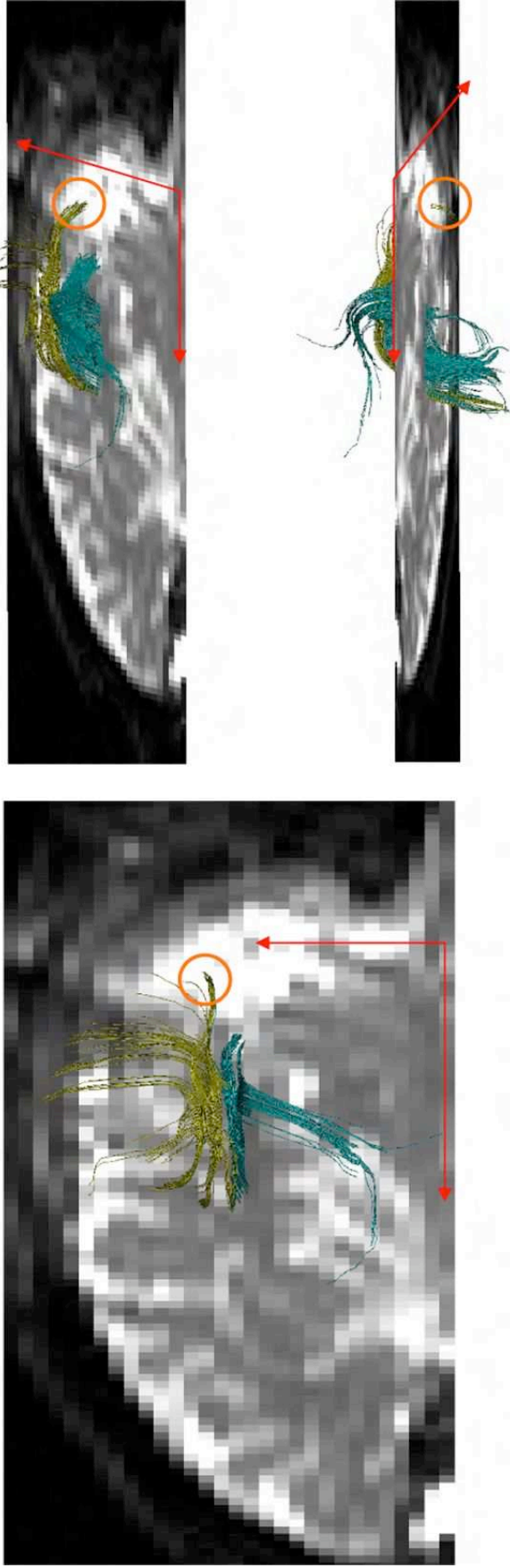
Patient	Talairach coordinates			Anatomical area*	Mean deviation (mm)**	SD (mm)
	X	y	z			
CAL	60	22	-15	rSTG	+1.50	1.29
	71	-21	13	cSTG	+6.50	2.12
	70	-22	32	SMG	+6.25	2.22
	17	2	75	FEF	-0.80	1.92
SB	71	-23	15	cSTG	+8.83	1.86
	67	-40	37	SMG	+6.25	0.96
	39	-52	39	O-FF1	+26.13	1.41
				O-FF2	+40.25	11.62

\*rSTG, rostral superior temporal gyrus; cSTG, caudal superior temporal gyrus; SMG, supra-marginal gyrus; FEF, frontal eye field; O-FF, superior occipito-frontal fasciculus

\*\* + indicates rightward deviation and - indicates leftward deviation.



**Fig. S1.** Orientation colored coding of the post-operative DTI maps for patient SB, illustrated on axial slices. Fiber directions of the right-left, rostral-caudal, and superior-inferior orientations were coded in red, green, and blue, respectively. The orange circle corresponds to region 42 in Fig. 2A.



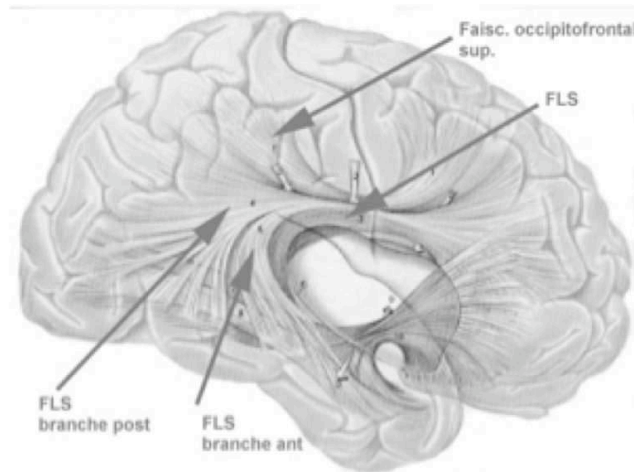
**Fig. S2.** Additional 3D reconstructions of the superior occipito-frontal fasciculus (in yellow) and of the superior longitudinal fasciculus (in blue) for patient SB. The orange circle corresponds to region 42 in Fig. 2A.

## References and Notes

- S1. P. Bartolomeo, S. Chokron, *Neuropsychologia* **37**, 881 (1999).
- S2. H. Duffau *et al.*, *Brain* **128**, 797 (April 1, 2005).
- S3. P. Azouvi *et al.*, *Journal of Neurology, Neurosurgery and Psychiatry* **73**, 160 (2002).
- S4. M. Rousseaux *et al.*, *Revue Neurologique* **157**, 1385 (2001).
- S5. J. R. Crawford, P. H. Garthwaite, *Neuropsychologia* **40**, 1196 (2002).
- S6. S. Ferber, H. O. Karnath, *Journal of Clinical and Experimental Neuropsychology* **23**, 599 (Oct, 2001).
- S7. T. Schenkenberg, D. C. Bradford, E. T. Ajax, *Neurology* **30**, 509 (1980).
- S8. P. W. Halligan, J. C. Marshall, *Cortex* **28**, 525 (1992).
- S9. J. Talairach, P. Tournoux, *Co-planar stereotaxic atlas of the human brain: an approach to medical cerebral imaging* (Thieme Medical Publishers, Stuttgart ; New York, 1988), pp. viii, 122.

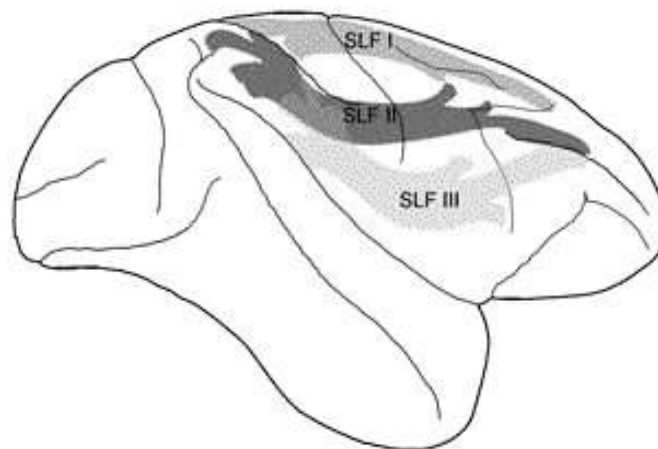


Avec la mise à jour des connaissances scientifiques sur l'organisation générale des grands faisceaux de substance blanche, la labellisation utilisée dans l'article précédent à partir d'anciennes références (Bossy, 1991; Nieuwenhuys et al., 1988b) est devenue obsolète (voir figure 24).



*Fig. 24 : Ancienne description des faisceaux supérieurs d'association chez l'homme par Nieuwenhuys (Nieuwenhuys et al., 1988b)*

Le faisceau occipito-frontal supérieur que nous avons décrit ne correspond plus à la classification scientifique moderne des faisceaux d'association. Le faisceau que nous avons stimulé lors de l'opération porte désormais le nom de faisceau longitudinal supérieur II (voir figure 25) comme l'explique la lettre de correction que nous avons soumise au magazine Science.



*Fig. 25 : Nouvelle description des faisceaux supérieurs d'association chez le macaque par Schmammann & Pandya (Schmammann and Pandya, 2006)*

## **Brain pathways for spatial awareness**

M. Thiebaut de Schotten, M. Urbanski, H. Duffau, E. Volle, R. Lévy, B. Dubois, & P. Bartolomeo

In a recently published study (*1*), we employed a neuroimaging method, diffusion tensor imaging tractography, to identify a fronto-parietal pathway important for spatial awareness. Based on the available literature (see, e.g., ref. (*2*)), we labelled this pathway as “superior occipito-frontal fasciculus”. However, further evidence from our laboratory (Fig. 1) led us to reconsider this labelling. We are now convinced that the pathway likely corresponds to the human homologous of the second branch of the superior longitudinal fasciculus (SLF II), described in the monkey brain by Schmahmann and Pandya (*3*). In the monkey, the SLF II originates in the caudal inferior parietal lobe (corresponding to the human angular gyrus) and the occipito-parietal area and projects to the dorsolateral prefrontal cortex. We would like to underline that this modification does not hamper the main point of our article (*1*), that damage to the fronto-parietal pathways is important to produce neglect. On the contrary, it renders our results even more consistent with the data reported by Doricchi and Tomaiuolo (*4*), which demonstrated that damage to the SLF in human patients with vascular lesions correlates with the presence of spatial neglect. Future studies on the implication of white matter pathways in human cognition would greatly benefit from a stereotaxic atlas of the white matter tracts in the human brain.

### References

1. M. Thiebaut de Schotten *et al.*, *Science* **309**, 2226 (2005).
2. J. Talairach, P. Tournoux, *Co-planar stereotaxic atlas of the human brain: an approach to medical cerebral imaging* (Thieme Medical Publishers, Stuttgart; New York, 1988).
3. J. D. Schmahmann, D. N. Pandya, *Fiber Pathways of the Brain* (Oxford University Press, New York, 2006).
4. F. Doricchi, F. Tomaiuolo, *NeuroReport* **14**, 2239 (2003).

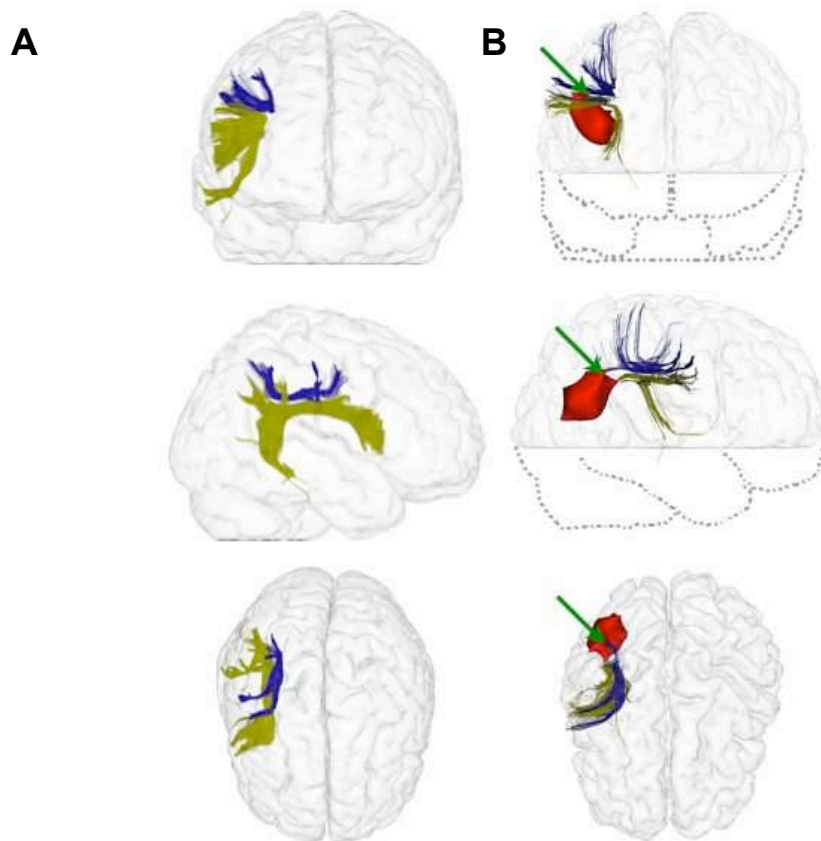


Figure 1. (A) Frontal lateral and top view of the three-dimensional reconstruction of the surgical resection (in red) and of the subcortical stimulated region (green arrow) in one neurosurgical patient(Thiebaut de Schotten et al., 2005), showing their relationships with the SLF II (in blue) and the arcuate fasciculus (including its long segment and its anterior segment also named as SLFIII in yellow) (B) Frontal lateral and top view of the three-dimensional reconstruction of the SLF II (in blue), the arcuate fasciculus (anterior segment/SLF III and long segment in yellow) in the referential space (Montreal Neurological Institute <http://www.mni.mcgill.ca>). Reconstructions were performed using BrainVisa 3.0.2 (<http://brainvisa.info/>).

## **Mapping of visuo-spatial functions during brain surgery: a new tool to prevent unilateral spatial neglect**

Paolo Bartolomeo<sup>a,b</sup>, Michel Thiebaut de Schotten,<sup>a</sup> & Hugues Duffau,<sup>c</sup>

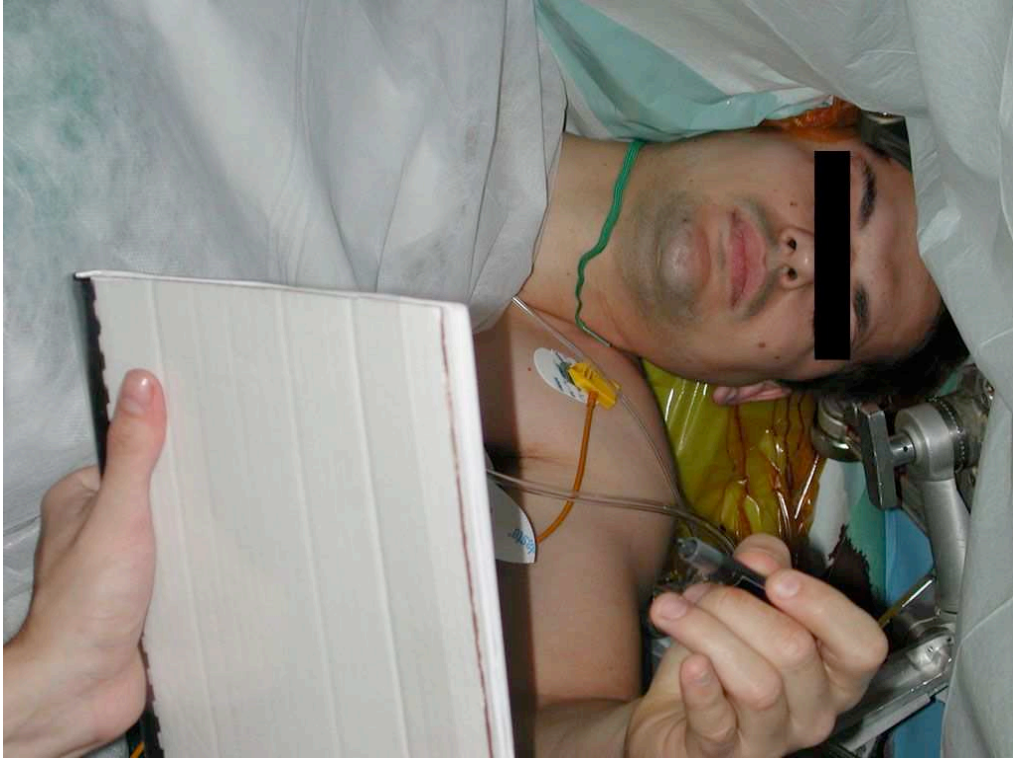*<sup>a</sup>INSERM Unit 610, Hôpital de la Salpêtrière, Paris, France; <sup>b</sup>Department of Neurology, AP-HP, Hôpital de la Salpêtrière, Paris, France; <sup>c</sup>Department of Neurosurgery, AP-HP, Hôpital de la Salpêtrière, Paris, France*

In the past decade, major advances in intraoperative functional mapping have dramatically improved the results of brain surgery. When removing a brain tumour, it is common clinical practice to awaken the patient, and temporarily inactivate small (~5mm) brain regions with electrical stimuli, while the patient performs functional tasks. If the patient produces incorrect responses, the surgeon leaves the region intact, to preserve the patient's functional abilities<sup>1</sup>. This procedure allows the surgeon to minimize the residual morbidity while increasing the quality of the resection, and thereby to improve patient survival. However, although sensorimotor and cognitive functions such as language, memory or calculation have been extensively mapped intraoperatively, visuo-spatial functions have received less attention. Unilateral spatial neglect (USN) is a dramatic neurological condition resulting from damage affecting the temporo-parietal or frontal cortex, or the thalamus or the basal ganglia of the right hemisphere<sup>2</sup>. Neglect patients behave as if the left part of the world did not exist<sup>3</sup>. Their functional recovery is poor, with major clinical and social consequences. USN typically results from vascular strokes, but other aetiologies are possible. For example, a case of USN was reported after right inferior parietal cortectomy for intractable epilepsy<sup>4</sup>. Although this particular patient recovered from neglect after 2 years, other neurosurgical patients risk to suffer from chronic USN as a result of more extensive, cortico-subcortical resections, as required especially in cerebral gliomas. In order to prevent the occurrence of USN in these patients, we propose to assess visuo-spatial functions intraoperatively, by asking patients to bisect 20-cm horizontal lines (Fig. 1). If the patient shifts the subjective centre more than ~6.5mm rightward<sup>2</sup>, then the neurosurgeon leaves the inactivated area untouched. Using this

procedure, our group was able to avoid postoperative USN in two patients who underwent resection of low-grade glioma in the right temporo-parietal region<sup>5</sup>. On line bisection, they significantly deviated rightward upon inactivation of the supra-marginal and caudal superior temporal cortices, and of the superior occipito-frontal fasciculus. These regions were accordingly spared by the resection, and no USN was observed a few days after surgery. Visuo-spatial functions should be assessed systematically during surgery involving the temporo-parietal region, even when language is not concerned, by using the simple, safe, well-tolerated, and cost-effective procedure of line bisection. Such a strategy can prevent postoperative USN, and consequently allow patients to resume the tasks of a normal socio-professional life, such as driving.

## References

1. Duffau H. Lessons from brain mapping in surgery for low-grade glioma: insights into associations between tumour and brain plasticity. *Lancet Neurology* 2005;**4**(8):476-86.
2. Azouvi P, Samuel C, Louis-Dreyfus A, et al. Sensitivity of clinical and behavioural tests of spatial neglect after right hemisphere stroke. *Journal of Neurology, Neurosurgery and Psychiatry* 2002;**73**(2):160-166.
3. Bartolomeo P, Chokron S. Orienting of attention in left unilateral neglect. *Neuroscience and Biobehavioral Reviews* 2002;**26**(2):217-234.
4. Hommet C, Bardet F, de Toffol B, et al. Unilateral spatial neglect following right inferior parietal cortectomy. *Epilepsy and Behavior* 2004;**5**(3):416-9.
5. Thiebaut de Schotten M, Urbanski M, Duffau H, et al. Direct evidence for a parietal-frontal pathway subserving spatial awareness in humans. *Science* 2005;**309**(5744):2226-2228.



*Figure 1: Line bisection during brain surgery. The photograph illustrates simplicity and feasibility of the task. Under test conditions, the 20-cm line (not shown in the figure) is presented aligned to the subjects' eye-axis, in central position with respect to the patient's sagittal head plane.*

### 3. DISCUSSION

Ces résultats mis en évidence durant les opérations chirurgicales abondent dans le sens des modèles de négligence qui postulent que cette pathologie résulte d'un dommage causé sur un réseau très largement distribué dans l'hémisphère droit (Mesulam, 1999; Heilman et al., 1993b) incluant des composantes préfrontales, pariétales et cingulaires. D'un côté, la composante pariétale pourrait être particulièrement importante dans la saillance perceptive d'objets extra-personnels et de l'autre la composante frontale pourrait être impliquée dans la production d'une réponse appropriée à un stimulus considéré comme pertinent, dans la rétention d'informations spatiales et dans l'orientation de l'attention sur des objets saillants de par ses connections réciproques avec les régions plus postérieures. Dans la bissection de ligne, l'inactivation du cortex pariétal pourrait alors modifier la saillance des deux segments. Le centre subjectif de la ligne est alors déplacé vers le côté du segment subjectivement alors considéré comme plus saillant parce qu'il paraît alors plus long qu'il n'est réellement.

La saillance relative des deux segments de la ligne pourrait aussi être influencée par l'attention spatiale. L'attention peut être dirigée vers un objet dans l'espace quand elle est capturée par un stimulus (« bottom up » on parlera alors d'attention exogène) ou plus volontairement (« top down » ou attention endogène Bartolomeo, 2000). Les patients avec une NSU gauche montre une capture exogène de l'attention altérée à gauche et donc un biais conséquent de capture exogène vers la droite, avec une orientation endogène de l'attention relativement épargnée (Bartolomeo and Chokron, 2002a). Dans la bissection de ligne, la comparaison perceptive nécessaire entre les deux segments est implicite et donc devrait ne recruter que des processus exogènes (Fink et al., 2002). Si la balance de l'attention exogène est déséquilibrée chez les patients alors la déviation dans la bissection de ligne penchera du côté où le poids de cette capture exogène est le plus important. La neuro-imagerie met également en évidence un réseau dans l'hémisphère droit spécialement dévolu à la détection des stimulus inattendus, une fonction typique de l'attention exogène. Ce réseau inclut le lobule pariétal inférieur, les gyri frontaux inférieur et moyen et l'operculum frontal.

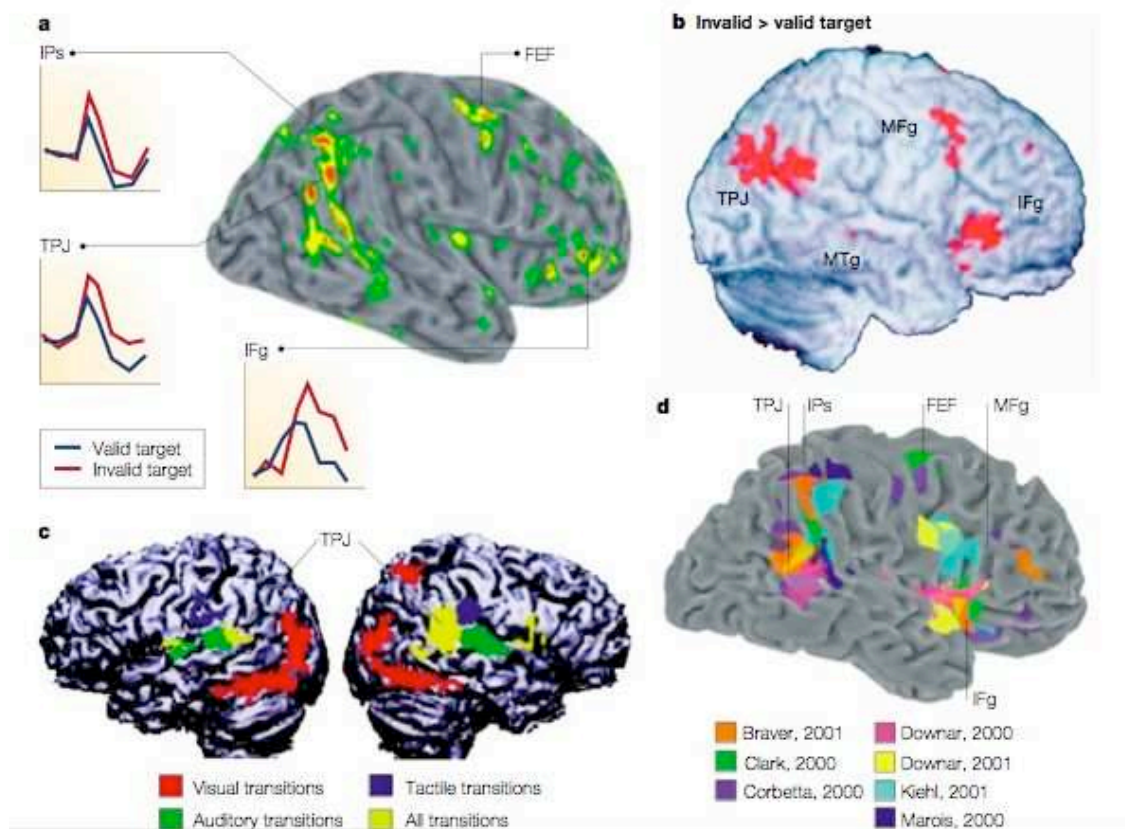
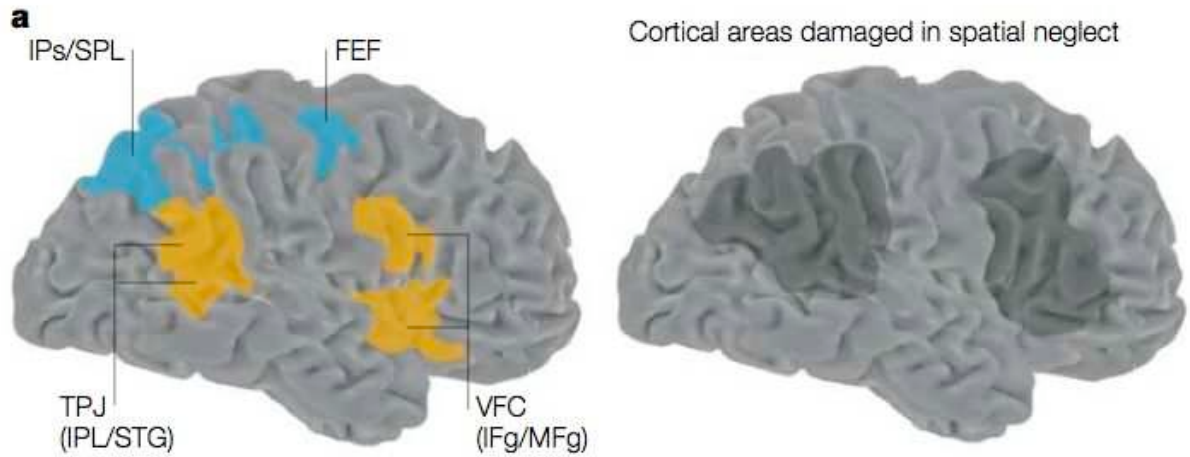


Fig. 26. (a) Réorientation spatiale vers des cibles inattendues (Corbetta and Shulman, 2002). Les graphiques montrent que la réponse hémodynamique est plus forte et plus soutenue pour les cibles inattendues. FEF, frontal eye field ; IFg, inferior frontal gyrus ; IPa, intraparietal sulcus ; TPJ, temporo-parietal junction. (b) Activation similaire d'une autre étude pour la réorientation spatiale vers des cibles inattendues. MFG, middle frontal gyrus ; MTg, middle temporal gyrus (Arrington et al., 2000). (c) Détection de cible à faible fréquence d'apparition (Downar et al., 2000) (d) Meta analyse d'étude en IRMf pour la détection de cibles à faible fréquence d'apparition indépendamment de la modalité de réponse.

Un réseau plus dorsal et bilatéral cette fois-ci, incluant le lobe pariétal supérieur et la frontal eye field serait, lui, dévolu à l'attention endogène. Par ailleurs, les lésions corticales le plus souvent associées avec la négligence gauche se superposent précisément sur le réseau de l'attention exogène (voir figure 26) cohérent avec le déficit exogène mis en évidence chez ces patients (Bartolomeo and Chokron, 2002a; Corbetta and Shulman, 2002; voir figure 27).



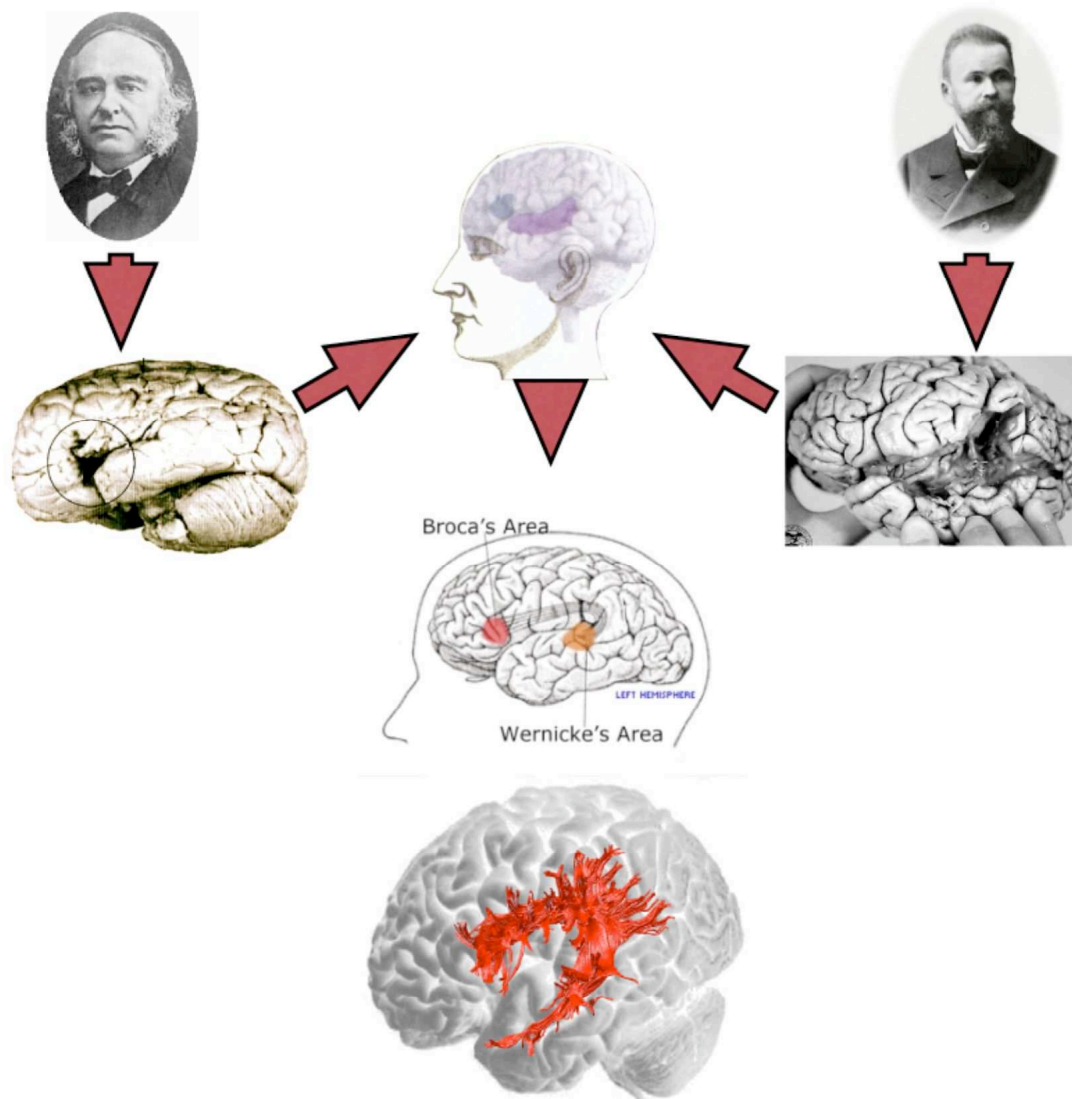


*Fig. 27 : Dans cette figure (Corbetta and Shulman, 2002) se trouvent a) les réseaux fronto-pariétaux dorsal (en bleu ; orientation endogène de l'attention ; IPs/SPL, sillon intrapariétal et lobule pariétal supérieur ; FEF, frontal eye field) et ventral (en orange ; orientation vers un stimulus inattendu/capture exogène de l'attention ; TPJ, jonction temporo-pariétale ; IPL/STG, lobule pariétal inférieur et gyrus temporal supérieur) et leur relation anatomiques avec b) les régions endommagées chez les patients NSU.*

## **IV - DE LA DISCONDUCTION A LA DISCONNEXION**

### **1. PRINCIPES ET DEFINITIONS**

Jusqu'alors la substance blanche avait déjà été impliquée dans des syndromes de conduction tels que, lors d'une lésion (du dommage) du faisceau arqué gauche (Déjerine, 1895), l'aphasie de conduction (Benson et al., 1973). Ces patients sont capables de comprendre (Wernicke, 1874) de parler (Broca, 1861) mais pas de répéter ce qu'un interlocuteur peut leur dire (Benson et al., 1973)(voir figure 28 pour une illustration).

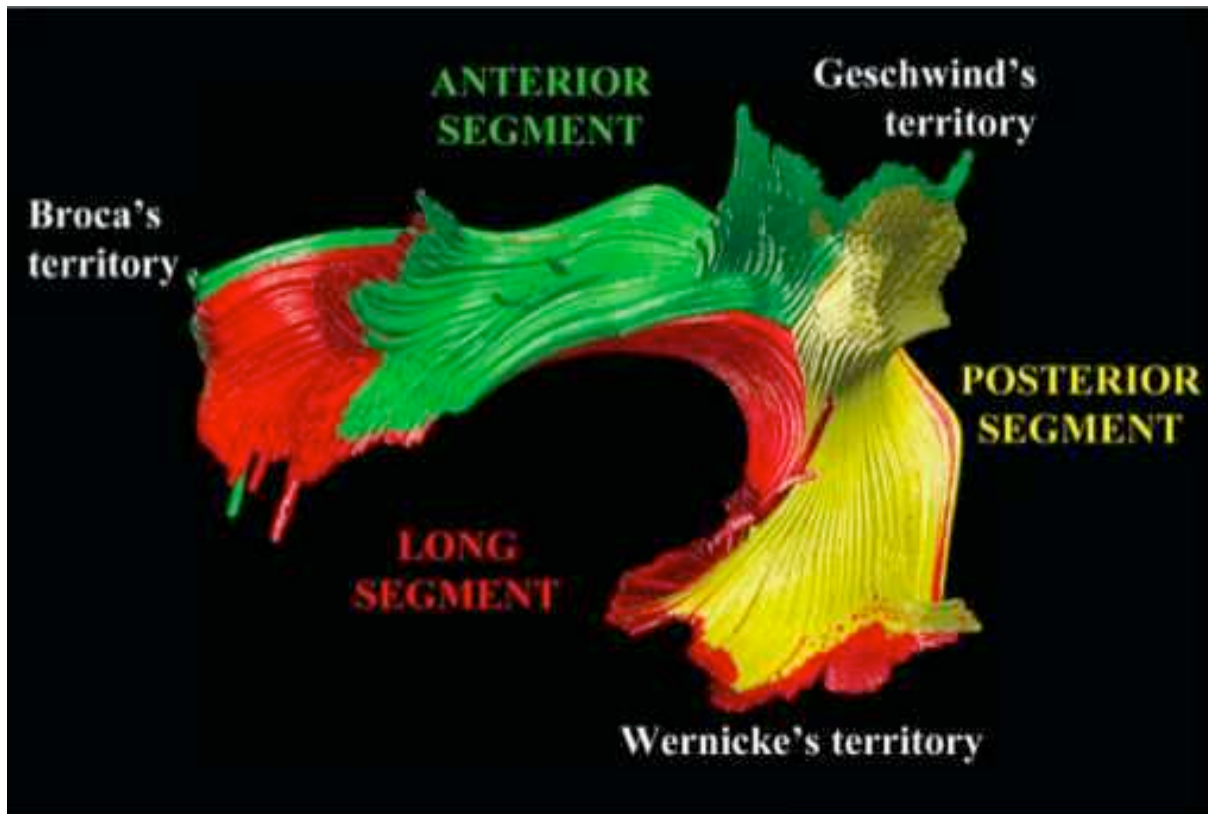


*Fig. 28: Dans cette figure est illustré en résumé l'historique des bases neurales du langage dans l'hémisphère gauche 1) selon les modèles lésionnels découverts par P. Broca (Broca, 1861) en haut à gauche et C. Wernicke (Wernicke, 1874) en haut à droite et 2) leur connectivité anatomique mis en évidence de façon anatomique (Déjerine, 1895) et en imagerie (Catani et al., 2002)*

Il s'agit donc d'une disconduction « per se » puisque ces aires du langage restent fonctionnelles indépendamment de leur connexion. Cependant la tâche de répétition nécessite un échange entre ces deux aires qui assument une fonction différente. On dit alors que ces aires fonctionnent sur un principe de sommation (Godefroy et al., 1998).

Ce n'est pas le cas de la négligence puisque dès que la communication entre les aires frontales et pariétales est interrompue, le syndrome de négligence devient très sévère (Thiebaut de Schotten et al., 2005). En d'autres termes, c'est précisément en l'absence de possibilité d'interaction entre ces deux aires que la fonction devient déficitaire. Ce système semble donc fonctionner sur un principe d'association (Godefroy et al., 1998).

Il est à noter cependant que cliniquement les patients qui présentent une aphasie de conduction, associent souvent ce syndrome à un trouble de la mémoire de travail verbale. En effet une troisième composante anatomique pariétale (l'aire de Geschwind (Geschwind, 1965b; Catani et al., 2005) rentre en jeu dans ce modèle anatomique du langage (voir figure 29) et semblerait fonctionner sur un principe d'association avec les aires de Broca et Wernicke.



*Fig. 29 : Reconstruction en DTI du faisceau arqué suivant une approche de double région d'intérêt. Le territoire de Broca est connecté directement et indirectement dans le cerveau moyen. Le chemin direct (long segment en rouge) correspond à la description classique du faisceau arqué et passe médialement dans la figure. Le chemin indirect passe de façon plus latérale, il est composé 1) du segment antérieur (en vert) qui connecte le cortex pariétal inférieur (territoire de Geschwind) et le territoire de Broca 2) du segment postérieur (en jaune) qui connecte les aires de Geschwind et Wernicke.*

## 2. LA NEGLIGENCE SPATIALE UNILATERALE : UN SYNDROME DE DISCONNEXION ?

Cerebral Cortex Advance Access published January 31, 2007

Cerebral Cortex  
doi:10.1093/cercor/bhl181

### Left Unilateral Neglect as a Disconnection Syndrome

Paolo Bartolomeo<sup>1,2,3</sup>, Michel Thiebaut de Schotten<sup>1,3</sup> and Fabrizio Doricchi<sup>4,5</sup>

<sup>1</sup>INSERM Unit 610, Hôpital de la Salpêtrière, F-75013 Paris, France, <sup>2</sup>Department of Neurology, Assistance Publique - Hôpitaux de Paris (AP-HP), Hôpital de la Salpêtrière, Paris, France, <sup>3</sup>Université Pierre et Marie Curie-Paris 6, Paris, France, <sup>4</sup>Centro Ricerche di Neuropsicologia, Fondazione Santa Lucia—Istituto di Ricovero e Cura a Carattere Scientifico, 00179 Roma, Italy and <sup>5</sup>Dipartimento di Psicologia 39, Università degli Studi di Roma "La Sapienza," Roma, Italy

Unilateral spatial neglect is a disabling neurological condition that typically results from right hemisphere damage. Neglect patients are unable to take into account information coming from the left side of space. The study of neglect is important for understanding the brain mechanisms of spatial cognition, but its anatomical correlates are currently the object of intense debate. We propose a reappraisal of the contribution of disconnection factors to the pathophysiology of neglect based on a review of animal and patient studies. These indicate that damage to the long-range white matter pathways connecting parietal and frontal areas within the right hemisphere may constitute a crucial antecedent of neglect. Thus, neglect would not result from the dysfunction of a single cortical region but from the disruption of large networks made up of distant cortical regions. In this perspective, we also reexamined the possible contribution to neglect of interhemispheric disconnection. The reviewed evidence, often present in previous studies but frequently overlooked, is consistent with the existence of distributed cortical networks for orienting of attention in the normal brain, has implications for theories of neglect and normal spatial processing, opens perspectives for research on brain-behavior relationships, and suggests new possibilities for patient diagnosis and rehabilitation.

**Keywords:** attention, brain lesions, perceptual disorders, spatial cognition, white matter fiber pathways

No wonder Lashley thought the whole brain was involved in mental tasks. It was not the whole brain, but a widely dispersed network of quite localized neural areas  
Michael I. Posner (2005, p. 239)

#### Introduction

Patients with right hemisphere damage often show signs of left unilateral neglect, an inability to take into account information coming from the left side of space (Mesulam 1985; Heilman et al. 1993; Bartolomeo and Chokron 2001, 2002; Vallar 2001; Parton et al. 2004). Neglect patients do not eat from the left part of their dish, they bump with their wheelchair into obstacles situated on their left, and when questioned from the left side they may either fail to answer or respond to a right-sided bystander. When presented with bilateral stimuli, they may immediately look toward the rightmost stimulus, as if their attention were "magnetically" attracted (Gainotti et al. 1991). On visuo-spatial testing, they omit targets on the left in search tasks, deviate rightward when bisecting horizontal lines, and do not copy the left part of drawings. This neurological condition is a significant source of handicap and disability for patients and entails a poor functional outcome. A better understanding of neglect is thus required both on clinical grounds, for purposes

of diagnosis and rehabilitation, and in order to comprehend the brain mechanisms of attention and spatial processing. Unfortunately, however, despite decades of research there are still important disagreements on the interpretation of the neglect syndrome, even on basic matters such as its lesional basis. This question constitutes the specific focus of the present review.

Most studies devoted to the anatomical correlates of neglect indicate the temporal-parietal junction (TPJ) and the inferior parietal lobule (IPL) (Vallar 2001; Mort et al. 2003), consistent with the known role of posterior parietal cortex in spatial attention (Colby and Goldberg 1999; Gitelman et al. 1999; Corbetta and Shulman 2002). In contrast with this view, another line of findings implicated more rostral portions of the superior temporal gyrus (Karnath et al. 2001, 2004), emphasizing the role of the ventral visual stream in spatial awareness originally hypothesized by Milner and Goodale (1995). In addition, damage to several other brain structures has been reported to determine neglect, including the thalamus, the basal ganglia, and the dorsolateral prefrontal cortex (Vallar 2001; Karnath et al. 2002).

However, at variance with interpretations of neglect stressing the role of damage to local brain modules, it has long been proposed that attentional spatial processes that may be disrupted in neglect do not result from the activity of single-brain areas but rather emerge from the interaction of large-scale networks (Mesulam 1981; Heilman et al. 1993). If so, then damage to the connections making up these networks is expected to impair their integrated functioning and consequently to bring about signs of neglect. Consistent with this prediction, here we review accumulating evidence that long-lasting signs of left unilateral neglect may also result from the important influence of intra- and interhemispheric disconnection.

#### Intrahemispheric Disconnection

##### *Frontoparietal Networks of Spatial Attention*

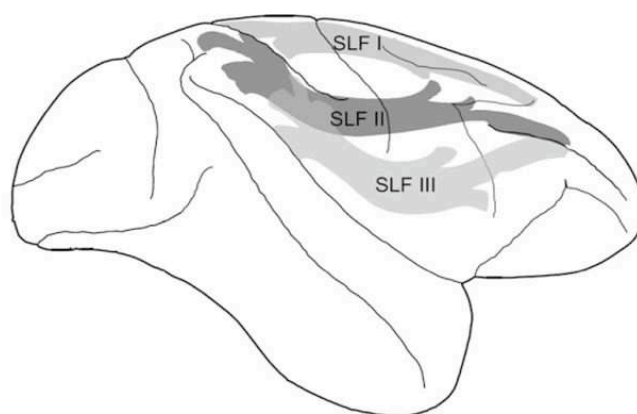
Within each hemisphere, large-scale cortical networks coordinate the operations of spatial attention (Mesulam 1981; Posner and Petersen 1990; LaBerge 2000; Corbetta and Shulman 2002). Important components of these networks include the dorsolateral prefrontal cortex and the posterior parietal cortex. Physiological studies indicate that these 2 structures show interdependence of neural activity. During memory-guided saccades, cooling of parietal neurons engenders changes in neural activity in prefrontal neurons, and vice versa (Chafee and Goldman-Rakic 2000). Not surprisingly, in the monkey, these 2 structures are directly and extensively interconnected (Selemon and Goldman-Rakic 1988; Morecraft et al. 1993). Several distinct frontoparietal long-range pathways have been identified (Petrides and Pandya 2002; Schmahmann and Pandya 2006).

These pathways include the arcuate fasciculus (AF), the superior longitudinal fasciculus (SLF), and the frontooccipital fasciculus (FOF). The AF links the caudal portions of the temporal lobe, at the junction with the parietal lobe, with the dorsal portions of the areas 8, 46, and 6 in the frontal lobe (Schmahmann and Pandya 2006). Within the SLF, 3 distinct branches can be identified on the basis of cortical terminations and course (Fig. 1; Petrides and Pandya 2002; Schmahmann and Pandya 2006). The SLF I links the superior parietal region and the adjacent medial parietal cortex with the supplementary and premotor areas in the frontal lobe. The SLF II originates in the caudal inferior parietal lobe (corresponding to the human angular gyrus) and the occipitoparietal area and projects to the dorsolateral prefrontal cortex. The SLF III connects the rostral portion of the inferior parietal lobe (homologous to the human supramarginal gyrus) with the ventral premotor area 6, the adjacent area 44, the frontal operculum, and the area 46. The FOF links the medial preoccipital area PO, the lateral-dorsal occipital area DP, the medial parietal area PGm, the caudal cingulate gyrus, and the caudal IPL to the dorsal premotor (area 6) and the dorsal prefrontal cortices (areas 8, 9, and 46) (Schmahmann and Pandya 2006). Rizzolatti and Matelli (2003) proposed to dissociate the dorsal cortical visual stream (see Mishkin et al. 1983; Milner and Goodale 1995) into 2 components, a dorsodorsal stream, which controls actions "on line" and whose damage leads to optic ataxia, and a ventrodorsal stream, implicated in space perception and action understanding. In this framework, FOF and SLF II may be considered to connect, respectively, the dorsodorsal and the ventrodorsal cortical networks (Schmahmann and Pandya 2006). Although it is not a frontoparietal pathway, the inferior longitudinal fasciculus (ILF) may also be relevant here because its lesion has been implicated in neglect (Leibovitch et al. 1998; Bird et al. 2006). In the monkey, the ILF originates in the ventral lateral and ventral preoccipital areas and runs in the depth of the temporal lobe to terminate in the superior temporal sulcus, the inferior temporal gyrus, and other temporal areas; moreover, it connects the caudal part of the cingulate gyrus, the IPL, and the superior temporal gyrus (STG) to the parahippocampal gyrus (Schmahmann and Pandya 2006).

Diffusion tensor imaging (DTI), a new technique to map the course of white matter tracts in the living human brain (Basser et al. 1994), has demonstrated a similar organization of frontoparietal pathways in humans (Catani et al. 2002; Makris et al. 2005; Rushworth et al. 2005), although the identification of the cortical terminations remains uncertain due to the technical limitations of the DTI method.

### **Frontoparietal Disconnection and Spatial Neglect**

How is visuospatial processing affected by damage to these frontoparietal networks? In a groundbreaking study in the monkey, Gaffan and Hornak (1997) showed that severe neglect may arise after a unilateral section of the white matter between the fundus of the intraparietal sulcus and the lateral ventricle, interrupting long-range communication pathways between the parietal and the frontal lobes. When showed several horizontally arranged stimuli, neglect monkeys often omitted to respond to targets contralateral to the lesion, choosing instead an ipsilateral distractor. Interestingly, in this study monkeys demonstrated little, if any, contralateral neglect after isolated ablations of the frontal cortex and the posterior parietal cortex or even after



**Figure 1.** Schematic depiction of the 3 branches of the SLF in the monkey brain according to Schmahmann and Pandya (2006).

a combined lesion of both of these structures. The monkeys with neglect also had clear impairments in everyday activities such as visual searching for food in free vision in the home cage. When offered 2 handfuls of food by an observer, they failed to find the food in the observer's hand that was contralateral to the monkey's lesion. This was in marked contrast to the monkeys with hemianopia alone that had efficient visual searching which compensated for their hemianopia in free vision (Gaffan D, personal communication, 2006). Thus, disconnection really proved crucial to observe neglect in monkeys in this study (for analogous results obtained in rodents, see Burcham et al. 1997; Reep et al. 2004).

Importantly, analogous findings were reported in different studies in human patients. Using computed tomography scans and single photon emission computed tomography, Leibovitch et al. (1998) investigated the anatomical correlates of neglect in a large sample of right brain-damaged patients not selected for the presence or absence of concomitant visual field defects. These authors found that the main correlate of chronic neglect was the combined lesion involvement and hypofunctioning of fibers connecting the parietal and temporal lobes (ILF), as well as those linking the parietal and frontal lobes (SLF), loaded in the white matter beneath the TPJ.

More recently, Doricchi and Tomaiuolo (2003) made a further step and disentangled the contribution of SLF and ILF disconnection to spatial neglect. In their study, lesion overlap was mapped in a sample of chronic neglect patients without visual field defects. Patients were further divided in 2 subgroups based on whether the lesion involved or spared the basal ganglia. In both subgroups, areas of maximal lesion overlap were found in the SLF beneath the rostral sector of the supramarginal gyrus. This finding revealed that, in humans, damage limited to frontoparietal connections in the SLF is sufficient to contribute to the development of chronic neglect. The authors concluded that while "a brain damage affecting circumscribed portions of the IPL could... disrupt only a subset of those different spatial abilities that, with different emphasis and by different authors, are currently considered to be specifically defective in neglect patients, ... disconnection of the parietal-frontal spatial attentional network... might render neglect more persistent by extensively compromising the sensory-motor mapping of the contralesional space even in those patients who, suffering only partial damage of the functionally

heterogeneous IPL-TPJ area, would otherwise show more selective (and perhaps transitory) parietal related spatial deficits" (p. 2242).

More compelling and direct evidence stressing the importance of frontoparietal disconnection in neglect came from a recent study employing intraoperative electrical stimulation in human patients (Thiebaut de Schotten et al. 2005). During brain surgery for resection of low-grade gliomas, neurosurgeons often awaken patients in order to assess the functional role of restricted brain regions so that the extent of the excision can be maximized without provoking cognitive impairments. Patients perform cognitive tasks, such as counting or naming, while the surgeon temporarily inactivates restricted regions around the tumor, using electrical stimuli. If the patient stops talking or produces incorrect responses, the surgeon avoids removing the stimulated region. This technique allows researchers to map cognitive functions in humans with unrivaled spatiotemporal resolution (~5 mm by 4 s). Thiebaut de Schotten et al. (2005) asked 2 patients with gliomas in the right temporoparietal region to mark the midpoint of 20-cm horizontal lines (a typical neglect task; Azouvi et al. 2002) while being stimulated. Electrical stimulation of the right IPL or the caudal STG, but not of its more rostral portions, determined rightward deviations on line bisection.

However, the strongest shifts occurred when one of the patients was stimulated subcortically. Fiber tracking using DTI identified the stimulated site as the likely human homologue of the SLF II (in the original article, which was published before the atlas of Schmahmann and Pandya became available, the pathway was incorrectly labeled as FOF; this, however, does not hamper the main point made by Thiebaut de Schotten and co-workers that damage to the frontoparietal pathways is important to produce neglect), consistent with the postulated role of this pathway in space perception (Rizzolatti and Matelli 2003; Schmahmann and Pandya 2006). Thus, there is a remarkable consistency between the behavioral consequences of frontoparietal disconnection in humans and monkeys, despite the fact that different behavioral tests were used: line bisection (Thiebaut de Schotten et al. 2005) or target cancellation (Doricchi and Tomaiuolo 2003) in humans and target search in monkeys (Gaffan and Hornak 1997). This convergence of results strongly suggests a similar organization of space-processing mechanisms across the 2 species. The demonstration of the role of frontoparietal disconnections in neglect supports models of neglect postulating an impairment of large-scale right hemisphere networks (Mesulam 1999), including prefrontal, parietal, and cingulate components. The parietal component could determine the perceptual salience of extrapersonal objects, whereas the frontal component might be implicated in the production of an appropriate response to behaviorally relevant stimuli (Mesulam 1999), in the online retention of spatial information (Husain and Rorden 2003) or in the focusing of attention on salient items through reciprocal connections to more posterior regions (Petrides and Pandya 2002). We also note that, as a consequence of frontoparietal disconnection, inaccurate or slowed communication between posterior and anterior brain regions, whether coupled or not with a general deficit in responding to unattended stimuli, might delay the information transfer from sensory-related areas to response-related regions to the point of exceeding an elapse of time after which this information is no longer useful for affecting behavior (Bartolomeo and Chokron 2002).

### **Reappraisal of Previous Lesion Overlap Studies**

To explore the consistency of the above reviewed results with previous evidence from vascular patients, we plotted on a standardized brain the subcortical lesions of the stroke patients with neglect from the lesion overlapping studies that contained sufficient details (Doricchi and Tomaiuolo 2003; Mort et al. 2003; Karnath et al. 2004; Corbetta et al. 2005). Long-range connections were visualized using fiber tracking (Thiebaut de Schotten et al. 2006) (see Supplementary Material). Most interestingly, neglect patients' lesions invariably overlapped at or near the subcortical long-range pathways linking the parietal to the frontal lobes (Fig. 2). The same meta-analysis revealed the presence of an important lesion overlap in the white matter frontoparietal connections in the study by Karnath et al. (2004). This overlap shows striking resemblance with the lesion overlap documented by Doricchi and Tomaiuolo (2003) in the same area, indicating that in the sample of patients studied by Karnath et al. (2004), lesion overlap in the STG was not selective and that neglect could have been due to frontoparietal disconnection rather than STG damage.

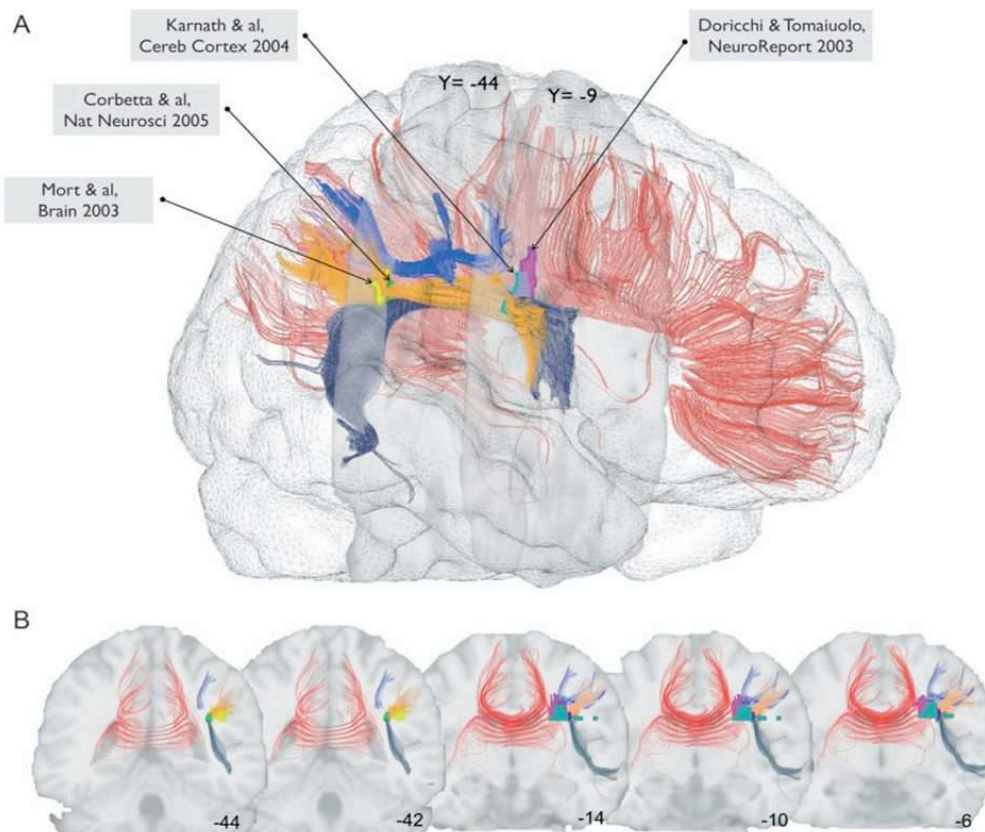
### **Further Evidence on Frontoparietal Disconnection in Neglect**

In a recent group study on 52 right brain-damaged patients with vascular lesions, Committeri et al. (2007) investigated the anatomical correlates of personal neglect (i.e., neglect concerning the patient's own body) and extrapersonal neglect (concerning the space external to the patient's body). Committeri et al. concluded that personal neglect is due to lesion involvement of the supramarginal gyrus in the parietal lobe, whereas extrapersonal neglect results from damage of more ventral areas including the STG and the inferior frontal gyrus (IFG).

In a first series of comparisons, the authors made voxel-by-voxel subtractions between 1) patients with extrapersonal neglect (whether isolated or in combination with personal neglect) versus patients with pure personal neglect or no neglect at all; 2) patients with personal neglect (whether isolated or in combination with extrapersonal neglect) versus patients with pure extrapersonal neglect or no neglect. The results of these subtractions are reported in their Figure 2. In the first row of axial slices, a distinct area of overlap is clearly present in the white matter of the axial slice  $z = +28$ . We found that this spot is perfectly centered on the SLF on the matching Talairach template and is only 9 mm caudal and 1 mm superior to the maximum lesion overlap previously found by Doricchi and Tomaiuolo (2003) in a group of patients showing extrapersonal neglect on both line-bisection and multiple-item cancellation tasks (see Supplementary Fig. 2).

In a second series of subtractions, Committeri et al. compared patients with pure extrapersonal neglect or pure personal neglect with patients without neglect. Also in this case, a similar maximum lesion overlap on the SLF was found in patients with pure extrapersonal neglect (see the axial slice  $z = +28$  in the third row of their Fig. 2). These anatomical findings went probably unnoticed because for the quantitative analysis, Committeri et al. considered the percentage of white matter damaged within 3 ample regions of interest: the centrum semiovale, the supralenticular and sublenticular corona radiata, and the external and internal capsulae. They found that the white matter immediately dorsal (supralenticular corona radiata and centrum semiovale) and ventral (sublenticular corona radiata) to





**Figure 2.** Lateral view (A) and coronal sections (B) of a normalized brain showing a 3-dimensional reconstruction of white matter pathways (red, corpus callosum; dark blue, AF; orange, SLF III; blue, SLF II) and the maximum overlap of neglect patients' subcortical lesions from 4 studies (pink, Doricchi and Tomaiuolo 2003; yellow, Mort et al. 2003; light blue, Karnath et al. 2004; green, Corbetta et al. 2005). See Supplementary Material for methods.

the insula was significantly more damaged in patients with extrapersonal neglect and that the white matter underlying the supramarginal gyrus was more damaged in patients with personal neglect. However, with respect to a more precise anatomical localization of these areas, the higher spatial resolution provided by voxel-by-voxel subtractions reported in their Figure 2 is instructive and unequivocal in indicating specific damage of white matter fasciculi linking parietal and frontal areas in patients with extrapersonal neglect. With reference to the distinct branches of the SLF identified in the monkey by Schmahmann and Pandya (2006) (see Supplementary Fig. 1 and Supplementary Material), we found that the maximum lesion overlap found by Committeri et al. locates itself at the boundary between the likely human homologous of SLF II and SLF III (see Supplementary Fig. 2). Thus, the involvement of dorsal SLF underneath the central sulcus documented by Doricchi and Tomaiuolo (2003) cannot be merely attributed to the presence of concomitant and undetected personal neglect that, as proposed by Committeri et al. in the discussion section, would have shifted the lesion overlap dorsally with respect to more ventral areas which, in their proposal, would subservise awareness of the extrapersonal space.

In a third analysis of their data, Committeri et al. used voxel-based lesion-symptom mapping (VLSM; see Bates et al. 2003). For each voxel, patients were divided into 2 groups according to whether or not their lesion affected that voxel. Scores for

extrapersonal and personal neglect were then compared for these 2 groups, yielding a *t*-statistics for each voxel and a corresponding *t*-test-based statistical map for the entire voxel-based brain volume. Also in this case, white matter involvement was present for extrapersonal neglect in fibers feeding the frontal eye field (first row of their Fig. 4, sagittal slice  $x = +36$ ; a more ventral white matter involvement is evident in axial slice  $z = +20$ ) as well as for personal neglect (second row of their Fig. 4, axial slice  $z = +32$  and sagittal slice  $z = +36$ ). VLSM analysis also allows researchers to evaluate the similarity between the *t*-test-based statistical maps by calculating the correlations between the *t*-scores of personal and extrapersonal neglect for each voxel (Bates et al. 2003). A positive correlation for one voxel suggests that this voxel performs a core function common to both types of deficit (Bates et al. 2003). Committeri et al. obtained a strong positive correlation of 0.84 (reflecting 70% of overlap in the variance) for the IFG (see Husain and Kennard 1996), the posterior insular-opercular temporal-parietal cortex, and most importantly, the white matter underlying the central sulcus (see Doricchi and Tomaiuolo 2003). Therefore, also the VLSM analysis demonstrated that this region of the white matter is implicated in a core function for spatial awareness, as originally suggested by the results of Doricchi and Tomaiuolo (2003) and Thiebaut de Schotten et al. (2005).

In support of this interpretation, another recent VLSM study on 80 stroke patients (Verdon et al. 2006) found that damage to

frontoparietal white matter fibers, which the authors identified with the pathway described by Thiebaut de Schotten et al. (Thiebaut de Schotten et al. 2005), correlated with the presence of generalized and severe neglect.

#### Relation to Spatial Working Memory Impairment

A cognitive function that could be particularly sensitive to frontoparietal disconnection is the building up and maintenance of memory for inspected spatial locations. In a series of studies, Husain et al. (2001) showed that neglect in cancellation tasks is significantly increased by the failure to remember the location of already canceled items. In a study addressing the anatomical correlates of poor spatial working memory (SWM) in neglect patients, Malhotra et al. (2005) concluded that "...a deficit in SWM would not be expected in all neglect patients, but it would be anticipated to occur in those who have damage to critical areas in the right parietal and frontal lobe that support SWM performance. ... lesion locations associated with the poorest SWM performance among neglect patients were *in right parietal white matter* and... the right insula. Damage to both these sites would be consistent with deafferentation and/or loss of cortical regions known to support SWM based on functional neuroimaging evidence" (Malhotra et al. 2005, p. 434, our italics). This conclusion clearly suggests the possibility that a lesion of the white matter can disrupt the whole frontoparietal network subserving SWM capacities.

#### Other Intrahemispheric Pathways

A recent anatomical investigation suggests that frontoparietal disconnection due to middle cerebral artery infarctions might not be the only type of intrahemispheric disconnection related to neglect. Bird et al. (2006) showed that in patients with infarctions in the territory of the right posterior cerebral artery, disconnection of white matter fiber tracts between the parahippocampal gyrus and the angular gyrus was correlated with left neglect. Interestingly, the authors also noted that when this type of intrahemispheric disconnection was coupled with lesions of the splenium of the corpus callosum (producing interhemispheric disconnection, see Interhemispheric Interactions and Disconnection below), neglect tended to be more severe.

#### Intrahemispheric Disconnection and Neglect: Discussion

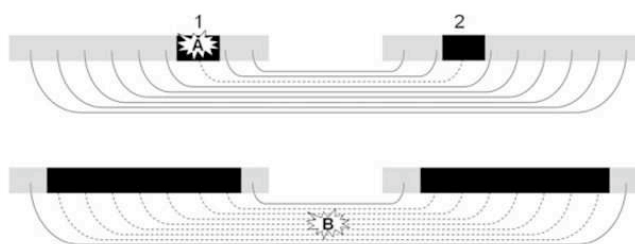
##### Disconnection and Cortical Deactivation

Despite the abundant evidence reviewed above, an apparent challenge to the role of subcortical disconnection in the pathogenesis of neglect comes from a number of investigations on the correlation between levels of cortical perfusion and the presence of neglect in the acute, or hyperacute, poststroke phase. Using perfusion weighting imaging, based on estimates of arrival and clearance of a bolus of contrast indicating the level of functional activity in otherwise structurally spared cortical areas, Hillis et al. (2002) investigated the functional correlates of neglect and aphasia due to hyperacute (within 48 h from stroke) subcortical infarction. They found that, independent of the lesion localization (corona radiata or caudate/capsular structures), neglect was only present in patients who had associated cortical hypoperfusion and absent in those having no cortical hypoperfusion. Importantly, though only tested in aphasic patients, pharmacological or surgical intervention re-

storing cortical perfusion led to substantial improvement of cognitive impairments and prevented the development of cortical infarcts. This study shows that a lesion in the white matter does not necessarily cause neglect; however, no precise mapping of white matter lesions was made, thus leaving unexplored the relationship between lesion location and extent, cortical hypoperfusion and neglect. Notwithstanding this limitation, the findings by Hillis et al. (2002) are relevant in that they confirm that a subcortical disruption of frontoparietal connections, whether resulting from vascular damage (Doricchi and Tomaiuolo 2003), surgical section (Gaffan and Hornak 1997), or temporary/functional lesions (Thiebaut de Schotten et al. 2005), might cause neglect by reducing functional activity in the entire cortical-subcortical frontoparietal network connected by these pathways.

Following the terminology recently proposed by Catani and ffytche (2005), the present pathophysiological interpretation of the neglect syndrome emphasizes the combined role of "topological" factors, related to dysfunction of cortical specialized areas, and "hodological" factors, related to dysfunction of connecting pathways among the same areas. Furthermore, we propose that disconnection might produce more of a deficit than cortical damage/dysfunction alone through several, not mutually exclusive, mechanisms: 1) Damage to the tightly packed fibers of the white matter may result quantitatively more disrupting than damage to equivalent cortical volumes, by impairing the functioning of larger cortical areas (Fig. 3). 2) Brain networks are composed of cortical modules interacting with each other. Disturbed communication between modules might thus produce not only cortical hypofunctioning but also hyper- or inadequate functioning of several cortical areas, resulting in a more severe disintegration of complex functions than the deficit relative to lesion to isolated modules (Catani and ffytche 2005). 3) Cortical lesions may leave the possibility for other cortical areas to functionally compensate for the deficit, through the phenomena of brain plasticity (see, e.g., Duffau 2005); on the other hand, white matter damage, which provokes the dysfunction of a whole network of connected areas, might render compensation more difficult to obtain.

It remains to be seen whether frontoparietal disconnection is sufficient to produce signs of neglect, as suggested by some of the results reviewed here, or whether concomitant cortical damage is necessary. A prediction resulting from the first hypothesis is that patients with relatively pure white matter



**Figure 3.** White matter lesions may cause more severe deficits than equivalent cortical lesions. Gray areas: functionally normal cortex. Black rectangles: dysfunctional cortical regions. Dashed pathways: dysfunctional white matter tracts. Lesion A to the cortical gray matter impairs cortical functions both 1) locally, through topological mechanisms, and 2) distally, through hodological mechanisms (see Catani and ffytche 2005). Lesion B, of equivalent volume but affecting the tightly packed white matter tracts, may impair the integrated functioning of larger cortical regions, thus resulting in a more severe deficit.

damage, resulting for example from multiple sclerosis or cerebral autosomal dominant arteriopathy with subcortical infarcts and leukoencephalopathy (CADASIL), may show signs of neglect. To the best of our knowledge, in the literature there are only a case report (Graff-Radford and Rizzo 1987) and a group study (Gilad et al. 2006) describing the possible occurrence of left neglect in patients with multiple sclerosis. Together with reports of patients with lesions of vascular origin, which affected primarily or exclusively the posterior limb of the right internal capsule (Healton et al. 1982; Ferro and Kertesz 1984; Ferro et al. 1987), this evidence does suggest the possibility of a purely disconnection basis of neglect. The apparently rare occurrence of neglect in diseases selectively affecting the white matter may depend on the frequently bilateral hemispheric involvement in these diseases, which may prevent unilateral neglect to occur (see the discussion on interhemispheric interactions in Neglect, Orienting of Attention and Interhemispheric Interactions: Callosal or Collicular? below), but probably also on the relative lack of interest for neglect of clinicians whom these patients are referred to. Signs of neglect may easily pass undetected without proper testing, as confirmed by the substantial lack of neglect literature before the mid-twentieth century. Only a systematic assessment of neglect in patients with selective damage of the white matter can shed light on this issue.

#### *Perspectives for Neglect Research*

The above reviewed evidence suggests that there are at least 2 long-range pathways linking the parietal to the frontal lobes whose dysfunction could be implicated in neglect (see Fig. 1). As previously mentioned, the inactivation of the SLF II in the right hemisphere causes rightward deviation on line-bisection tasks (Thiebaut de Schotten et al. 2005). Lesion of the more ventrally located SLF III in the right hemisphere correlates with rightward deviation on line-bisection and left omissions on visual search tasks (Doricchi and Tomaiuolo 2003). Although the combined lesion of these pathways might well generally disrupt the right hemisphere attentional networks (Corbetta et al. 2005), thus giving rise to generalized left neglect, future studies might be able to correlate selective lesions of one of these 2 pathways with particular patterns of functional deactivation in the cortex and behavioral dissociations in neglect symptoms. For example, the identification of white matter pathways disrupted in a particular patient, and the cortical areas consequently hypoactive even if undamaged (Corbetta et al. 2005), might help detailing the anatomical correlates of the many dissociations of performance described in neglect patients (near vs. far, perceptual vs. imaginal, etc.). Until now, the neural correlates of neglect dissociations have proved difficult to assess, perhaps because only gray matter lesions were considered. These considerations might prove important for patient diagnosis because a particular form of disconnection might have greater predictive value than the localization of gray matter lesions concerning the patients' deficits and disabilities. The demonstration of anatomically intact but functionally inactivated areas might also open perspectives for treatments (whether pharmacological or rehabilitative), aimed at restoring normal neural activity in these areas.

#### *Implications for Theories of Neglect*

The role of damage to different sectors of the cerebral networks linking the parietal and frontal lobes in the pathogenesis of unilateral neglect is currently a matter of intense debate.

One thesis proposes that the higher frequency, severity, and duration of left neglect after right brain damage, compared with right neglect after left brain damage, are due to the different competence of the 2 hemispheres in dealing with the left and the right side of space. According to this theory, the left hemisphere is able to represent only the right hemispace, whereas the right hemisphere is endowed with sensory-motor representations of both sides of space. Therefore, the higher frequency of neglect following right hemisphere damage is linked to the limited capacity of the left hemisphere in dealing with the left hemispace; conversely, the lower frequency of neglect after left hemisphere damage depends on the ability of the right hemisphere to deal with the whole horizontal space (Heilman et al. 1993; Mesulam 1999).

A second theory based on neuroimaging studies (Corbetta and Shulman 2002) holds that what is lateralized in the right hemisphere is not the sensory-motor representation of both hemispaces but, rather, a network including the IPL, the posterior part of the STG, the inferior and middle frontal gyri, and the frontal operculum, especially concerned with the detection of novel unexpected stimuli (such as those appearing at an unexpected spatial location following the presentation of an invalid spatial cue). This right hemisphere network triggers reorienting of attentional resources in dorsal bilateral networks including the superior parietal lobule and the frontal eye field (Corbetta et al. 2005). At variance with the previous hypothesis, Corbetta and co-workers surmise that each hemisphere is endowed with a dorsal network guiding endogenous orienting in the contralateral space and that the higher frequency of neglect following right hemisphere damage is due to the disruption of the alerting ventral network lateralized in the right hemisphere (Corbetta and Shulman 2002). A precise reconstruction of the section of the SLF damaged by the lesion causing neglect might therefore constitute a crucial test of these 2 hypotheses. Frontoparietal disconnection in the right hemisphere may disrupt the function of one or both of these networks or impair the integrated functioning of the 2 networks (Doricchi and Tomaiuolo 2003; Mort et al. 2003; Corbetta et al. 2005). For instance, showing that a selective lesion of SLF II, connecting the dorsal network, is sufficient to produce neglect signs would favor the first hypothesis, whereas linking neglect to a selective damage to the SLF III or the AF, connecting the ventral network, would be consistent with the theory of Corbetta and co-workers.

However, more complex anatomical-functional scenarios consistent with the heterogeneity of the neglect syndrome can be envisaged. For example, selective lesions of the different sectors of the SLF could be associated with different types of neglect or the presence of different neglect signs (e.g., behavioral dissociations in the performance of different tasks as, e.g., line bisection vs. multiple-item cancellation). We strongly argue that such a differential approach to the study of neglect syndrome could be by far more fruitful, from both clinical and theoretical standpoints, than trying to attribute neglect to the main influence of disruption of a single anatomical-functional brain module.

#### **Interhemispheric Interactions and Disconnection**

##### ***Neglect, Orienting of Attention and Interhemispheric Interactions: Callosal or Collicular?***

Patients with left neglect typically show an asymmetry of attentional orienting, whereby orienting to right-sided objects

is easier and faster than orienting to left-sided objects (for review, see Bartolomeo and Chokron 2002). Thus, it has been suggested that left neglect essentially results from a rightward attentional bias (Kinsbourne 1970), from a deficit in disengaging attention from the right side to reorient it to the left side (Posner et al. 1984; Morrow and Ratcliff 1988), or from a deficit in orienting attention to the left contralesional hemispace (Heilman and Valenstein 1979). A well-articulated account of neglect based on orienting of attention is the opponent processor model (Kinsbourne 1970, 1977, 1987, 1993). According to this hypothesis, each hemisphere shifts attention toward the contralateral hemispace by inhibiting the other hemisphere. Moreover, in the normal brain there is a tendency to rightward orienting supported by the left hemisphere, which has a stronger orienting tendency than the right hemisphere. Right hemisphere lesions, by disinhibiting the left hemisphere, exaggerate this physiological rightward bias, thus giving rise to left neglect. Left neglect does not reflect an attentional deficit but an attentional bias consisting of enhanced attention toward the right. The verbal interaction between patient and examiner would further enhance left neglect by further activating the already disinhibited left hemisphere. Furthermore, left neglect patients would suffer from an abnormally tight focus of attention, which would deprive them of the possibility of a more general overview of the visual scene (Kinsbourne 1993). Right neglect would rarely be observed because much larger lesions of the left hemisphere are needed to overcome its stronger tendency to rightward orienting and because the verbal exchanges with the examiner would now work in the opposite direction, activating the left hemisphere and minimizing right neglect. Evidence supporting the opponent processor model came from the pioneering report of a patient who showed a severe left neglect following a first right-sided parietal infarct but abruptly recovered from neglect 10 days later, when he suffered from a second infarct in the dorsolateral frontal cortex of the left hemisphere (Vuilleumier et al. 1996). However, conclusive anatomical inferences from this case report seem not easy because the patient was studied in the acute phase of the disease, when transient phenomena of neural depression in areas remote from the lesion can occur (diaschisis; Meyer et al. 1993). As noted by the authors, the second stroke induced a tonic leftward deviation of head and gaze: this occurrence might have contributed to minimizing left neglect signs, similarly to the effects of vestibular or optokinetic stimulations (see Gainotti 1993; Vallar et al. 1997; Chokron and Bartolomeo 1999).

According to the opponent-processing model, increasing severity of neglect should result from an increasingly stronger bias toward the right, reflecting increasing disinhibition of the left hemisphere. Thus, response times to right-sided targets should become progressively faster as neglect increases in severity across patients. Contrary to this prediction, a group study of patients with varying degrees of neglect on paper-and-pencil tests demonstrated that not only patients' response times to left targets but also those to right targets increased with increasing neglect (Bartolomeo and Chokron 1999b). However, the 2 regression lines were not parallel. With increasing neglect, responses to left targets increased more steeply than those to right targets. Thus, a rightward attentional bias is present in patients with left neglect, together with left hypoattention. However, the rightward bias is one of the defective, and not enhanced, attention.

Full understanding of the interactions between the opponent processors in the 2 hemispheres requires the identification of neural mechanisms and pathways mediating such interactions. Mutually inhibitory interhemispheric interactions would intuitively appear to implicate the callosal connections; however, also the superior colliculi (SC), which mutually inhibit one another, are plausible candidates (Kinsbourne 1987). In the cat, lesion of one SC produces contralateral neglect, which can be reversed by lesion to the contralateral SC or by section of the intertectal commissure (Sprague 1966).

A more recent study (Rushmore et al. 2006) showed that ablation or cooling of the posterior parietal cortex induced contralateral neglect, which corresponded to decreased metabolic activity (as measured by 2-deoxyglucose uptake) of the ipsilateral SC and increased activity of the contralateral SC, but not of the contralateral parietal cortex; cooling of the opposite parietal cortex or SC restored orienting reactions to the previously neglected stimuli; and, correspondingly, collicular activity reverted to symmetry.

Weddell (2004) reported a possible human analogue of the Sprague effect (see also Zihl and von Cramon 1979). In a patient with a midbrain tumor, right frontal damage resulting from a surgical procedure provoked signs of left neglect, which disappeared abruptly 7 months later, when the tumor extended into the left SC. Most of the retinal afferents to the SC come from the contralateral eye. Thus, patching the right eye should decrease the visual input to the left SC, thereby decreasing its inhibition on the right SC. Consistent with the collicular hypothesis, neglect patients were found to show some improvement during the period when the patch was worn (Butter and Kirsch 1992). However, another study, contrasting monocular eye patching with patching of the 2 right visual hemifields that decreases the visual input to the left hemisphere, found an improvement of neglect only in the hemifield-patching group (Beis et al. 1999). Thus, a corticosubcortical system including both cortical and subcortical systems (respectively, the frontoparietal regions and the SC) might constitute the neural basis for the opponent processor model.

Results from transcranial magnetic stimulation (TMS) and functional magnetic resonance imaging (fMRI) studies in humans are also relevant for the opponent processor model. Oliveri et al. (1999) studied the effects of temporary inactivation by TMS of parietal and frontal sites in the intact hemisphere upon contralateral tactile extinction to bilateral simultaneous in right- and left brain-damaged patients. In right brain-damaged patients, TMS over the intact left frontal site significantly reduced extinction as compared with controls, whereas the same effect was not observed upon stimulation of the homologous site in the intact right hemisphere of left brain-damaged patients. These results are in keeping with the idea that TMS reduces inhibition from the stimulated to the unstimulated hemisphere and that mutual inhibition between the 2 hemispheres is asymmetrical, with more prominent inhibition directed from the left to the right hemisphere. Without excluding the possible contribution of subcortical mechanisms, the authors argued that TMS effects on extinction of tactile digit stimuli could have been well mediated by callosal fibers connecting "hand representations of associative parietal and frontal areas" as these connections "are more powerful and widespread than those between the primary hand motor and sensory areas" (p. 1737). As far as tactile modality is concerned, the authors further argued that this callosal mechanism might be particularly plausible because subcortical

mechanisms as the Sprague effect “seem to be valid especially for the visual system” (p. 1737).

A recent fMRI investigation (Corbetta et al. 2005) explored 11 stroke patients with left neglect who, in keeping with previous overlap studies (Doricchi and Tomaiuolo 2003; Mort et al. 2003), showed a maximal lesion overlap in the white matter beneath the IPL (see their Fig. 2 and the present Fig. 2). Four weeks after the stroke, when performing a response time task to lateralized stimuli, neglect patients had decreased activation of structurally intact frontoparietal regions in the right hemisphere (especially the intraparietal sulcus, the superior parietal lobule, and the dorsolateral prefrontal cortex), coupled with robust activation of the homologous regions in the left hemisphere. Thirty-nine weeks after lesion onset, recovery of neglect signs was paralleled by the disappearance of the imbalance between the 2 superior parietal lobules. According to the authors, this pattern of results suggests that lesions of the right TPJ determine a functional imbalance of the superior parietal lobules, which are structures important to attentional orienting. Consistent with the many previous findings and interpretations of neglect summarized in the present review, Corbetta et al. concluded that their results “rule out the possibility that neglect results form the critical dysfunction of one brain area” (p. 1608).

In conclusion, the reviewed evidence indicates that insight in the anatomical basis of the dynamic interplay between homologous structures in the 2 halves of the brain is of importance for the diagnosis and treatment of neglect and for the understanding of the mechanisms of spontaneous recovery or relevant clinical changes during the transition from the acute to the postacute and chronic phase.

### *Confabulations and Implicit Processing*

Four decades ago, in his seminal review of disconnection syndromes, Geschwind (Geschwind 1965) suggested that some neglect signs reflected the activity of the left hemisphere being deprived of information from the right hemisphere. In Geschwind's view, the left hemisphere is dominant not only for language but also for cognition in general; thus, if the right visual and somesthetic cortex are isolated from the left hemisphere, “[t]he left side of the body and of space is then ‘lost’. The patient will then respond in many instances by using [a] technique of confabulatory completion” (p. 600). These confabulatory responses would be the result of an isolated left hemisphere, with no access to the left-sided information processed by the right hemisphere. In other words, interhemispheric disconnection would produce a deafferentation of the left hemisphere, degrading the information coming from the left part of space, processed by the right hemisphere. To address the “vexing problem of why a left parietal lesion less often produces neglect of half space than does a right parietal lesion” (p. 601), Geschwind further proposed that “disease may simply aggravate the normal disadvantage of the right hemisphere in being further away and responding less well to stimuli” (p. 601), thus anticipating the above reviewed hypothesis later developed by Kinsbourne (see Neglect, Orienting of Attention and Interhemispheric Interactions: Callosal or Collicular? above).

Although the idea of a generally dominant left hemisphere is no longer accepted, other aspects of Geschwind's proposal might help interpreting patterns of performance later described in split-brain patients and neglect patients. Following surgical

section of the corpus callosum, it has been reported that the left hemisphere sometime provides post hoc confabulatory verbal explanations of actions performed by the right hemisphere (Gazzaniga and Baynes 2000). In a well-known example (see Gazzaniga and Baynes 2000), a split-brain patient was shown tachistoscopically the pictures of a snow scene in the left visual field/right hemisphere and a rooster claw in the right field/left hemisphere. When the patient was presented with multiple pictures and asked to use each hand to choose those matching the bilateral displays, his right hand chose the picture of a rooster, and his left hand, driven by the right hemisphere, appropriately chose a shovel as a match for the snow scene. At debriefing, however, the patient, whose left hemisphere had not seen the snow scene, confabulated that the shovel was needed to clean out the chicken house.

Right brain-damaged patients with left-sided extinction or neglect may show remarkable implicit processing without overt verbal recognition of stimuli tachistoscopically presented in the left hemifield. Patients can perform better than chance when forced to make same/different judgments or to select in a multiple choice the identity of a nonexplicitly detected item (Volpe et al. 1979) and can show implicit semantic processing of the stimulus presented in the neglected hemifield (McGlinchey-Berroth et al. 1993; Berti et al. 1994), although only a minority of neglect patients may show such effects (D'Erme et al. 1993). One may also wonder whether any interhemispheric disconnection factors may contribute to the implicit processing and the confabulations concerning the neglected left side of visual stimuli presented in free vision. For example, in an often-cited case report (Marshall and Halligan 1988), patient P.S. was unable to tell the difference between 2 vertically arranged houses, one of which had its left side on fire. However, when asked in which of the 2 she would live, P.S. consistently chose the house that was not burning. In Geschwind's view, this behavior could be accounted for by postulating 1) an inability of the left hemisphere to access left-sided information (the fire), with consequent lack of verbal acknowledgment of the difference between the 2 houses; 2) some residual (right hemisphere-based?) knowledge of this difference, either resulting in the appropriate behavioral choice or causing misinterpretation of the difference and resulting in a choice consistent with the misinterpretation. A further prediction coming from this hypothesis is that, if patients are asked “why” they prefer the nonburning house, their left hemisphere should either admit ignorance or produce confabulatory responses. In the case of P.S., no comments about her choices are available, except that she deemed “silly” the task of choosing between 2 “identical” houses. However, other studies provide this information and report a variety of responses at debriefing. For instance, a patient described by Manning and Kartsounis (1993) chose the non-burning house confabulating that it had an extra fireplace, consistent with Geschwind's hypothesis. Another patient described by Bisiach and Rusconi (1990) consistently chose the “burning” house, considering it more “spacious” on the burning side, where the contour of the flames actually enlarged the shape of the house, an example of choice based on an implicit misinterpretation of the difference. In a group of 13 neglect patients (Doricchi et al. 1997), responses motivating correct implicit choices of the “non-burning house” were equally distributed into two categories: 1) “there is no specific reason for my choice, the 2 houses are the same anyway,” suggesting complete uncoupling of verbal output from

implicit processing; 2) "the house I chose is 'better', 'bigger', or 'works better,'" suggesting, in this case, approximation of verbal output to implicit processing. Unfortunately, hypotheses on the functional and anatomical basis of the different examples of dissociation between explicit and implicit processing remain highly speculative because no related empirical evidence is currently available. Geschwind's proposal of confabulatory responses resulting from an isolated left hemisphere indicates, however, possible ways to afford this fascinating puzzle.

### **Extinction**

An important clinical phenomenon that has been interpreted in terms of interhemispheric disconnection is extinction after unilateral brain damage. Extinction refers to the failure of verbally reporting the most contralesional of a pair of simultaneous stimuli while maintaining an intact or largely preserved ability of reporting the same contralesional stimulus when presented alone. Extinction can occur both within and between different sensory modalities. It is often clinically detected in the recovery phase of neglect, though it can doubly dissociate from it. Marzi and co-workers (Smania et al. 1996) argued that right brain-damaged patients with extinction might suffer a partial interhemispheric disconnection syndrome, "whereby the information on the stimulus presented to the damaged right hemisphere cannot be efficiently integrated with that available to the left hemisphere" subserving the verbal response or mastering the task of deciding about the number of stimuli presented ("1" or "2"). These authors studied a right brain-damaged patient in whom disruption of interhemispheric transfer of visual information was demonstrated by recording of evoked potentials (Smania et al. 1996). In this patient, extinction of contralesional visual stimuli on double simultaneous presentation dropped dramatically when, instead of a verbal response (saying "2"), a motor response with no preferential triggering by one hemisphere (e.g., moving the eyes upward) or a response requiring bilateral muscular control (e.g., lowering the chin) was required to report double stimuli. According to the authors, when 2 stimuli are simultaneously presented to a right brain-damaged patient, the one perceived directly by the intact left hemisphere (dominating the verbal response) has stronger central representation, thus masking the weaker callosal input coming from the damaged hemisphere. In case of unilateral presentation to the damaged right hemisphere, the same callosal input triggers normal verbal recognition because no other stimulus competes for response in the left hemisphere. Impaired verbal report of stimuli arriving at the right hemisphere when simultaneously presented with stimuli to the left hemisphere was documented in a split-brain patient (Reuter-Lorenz et al. 1995). In line with the hypothesis that weak or impaired access to the responding hemisphere can modulate extinction and neglect phenomena, Corballis et al. (2005) recently described a callosotomized patient showing striking neglect for stimuli presented to the right hemisphere when these had to be reported verbally (i.e., by the left hemisphere). Neglect, however, disappeared when nonverbal responses were required, and the report was no more under the control of the left hemisphere. Thus, callosal damage might contribute, at least in some cases, to the appearance of split-brain-like confabulations or extinction of stimuli presented to the damaged hemisphere.

### **Anatomical Evidence Supporting the Influence of Interhemispheric Disconnection on Neglect**

From an anatomical standpoint, the hypothesis of a contribution of interhemispheric disconnection to some of the behavioral features characterizing neglect has received empirical support from studies in animals and humans. Watson et al. (1984) found that on several behavioral measures (i.e., responses to auditory, visual, and somesthetic stimuli, circling behavior, and asymmetric orienting), postoperative neglect was more severe in monkeys that underwent callosotomy prior to ablation of the frontal arcuate gyrus as compared with monkeys that underwent only equivalent cortical ablation. Gaffan and Hornak (1997) showed that monkeys with combined resection of the right optic tract (causing complete left hemianopia) and the corpus callosum (causing complete interhemispheric forebrain disconnection) showed more severe neglect than monkeys undergoing section of frontoparietal connections (also causing substantial neglect, see Frontoparietal Disconnection and Spatial Neglect above) or resection of the parietal and/or prefrontal cortex (causing very mild and transitory neglect). The authors argued that severe neglect in monkeys with combined optic tract-callosal disconnection depended on the impossibility of the intact attentional frontoparietal system of the blind hemisphere to receive visual information gathered by the seeing hemisphere and to build up an adaptive compensatory mnemonic representation of the space contralateral to the blind hemisphere. In keeping with the proposal of Gaffan and Hornak, the defective integration of visual input from the intact left hemisphere with damaged mechanisms of space representation in the right hemisphere appears to produce erroneous compensation of the visual field defect in patients with neglect and concomitant hemianopia. This is revealed by horizontal distance-reproduction tasks forcing patients to set distance end points toward the attended or the otherwise spontaneously unattended hemispace (Bisiach et al. 1996; Doricchi and Angelelli 1999; Nico et al. 1999; Doricchi et al. 2005). In these tasks, the combination of neglect and hemianopia leads to marked and paradoxical hypometric distance reproductions in the ipsilesional direction (probably as a consequence of saccadic undershooting made in order to keep the endpoint from falling into the blind hemifield) and hypermetric responses in the contralesional direction (as a consequence of saccadic overshooting made to shift the blind hemifield away and bring the endpoint position into the seeing hemifield moving contralesionally; Ishiai 2002). Also in keeping with the findings of Gaffan and Hornak, the greater severity of neglect symptoms in patients with concomitant neglect and hemianopia, as compared with those with neglect unaccompanied by hemianopia, is well documented by studies from several laboratories and can be particularly evident in tasks requiring parallel processing of stimuli extending along the horizontal space such as, for example, the line-bisection task (D'Erme et al. 1987; Binder et al. 1992; Harvey et al. 1995; Bartolomeo and Chokron 1999a; Harvey and Milner 1999; Doricchi et al. 2005).

Results analogous to those obtained by Gaffan and Hornak with hemianopic-callosotomized monkeys were recently reported in human patients by Park et al. 2006, who found that among "...the various combinations of occipital plus adjacent lesions, only occipital injury together with complete injury to the splenium of the corpus callosum significantly contributed to the frequency and severity" of spatial neglect (p. 60). Park et al.

further observed that in their group of patients with unilateral damage in the territory of the posterior cerebral artery, visual field defects per se did not predict the severity of neglect. We notice, however, that the absence of a significant correlation between hemianopia and severity of neglect only reconfirms the well-established double dissociation between visual neglect and hemianopia (McFie et al. 1950; Gainotti 1968) and is not surprising to be found in a group of unselected right brain-damaged patients. In such an unselected group including hemianopic patients both with and without neglect, the compensatory leftward attentional bias of pure hemianopic patients (Fuchs 1920; D'Erme et al. 1987; Barton and Black 1998) will tend to cancel out the relationship between presence of hemianopia and severity of neglect that is observed when only patients with neglect are considered (Halligan et al. 1990; Gaffan and Hornak 1997; Doricchi and Angelelli 1999).

Finally, it is worth emphasizing that in patients with neglect, the influence of interhemispheric disconnection might be at work independently from the presence of concomitant visual field defect. Kashiwagi et al. (1990) described a patient who demonstrated left neglect signs after callosal infarction, with magnetic resonance imaging showing no lesion in the right hemisphere. This patient had neglect when performing paper-and-pencil tasks with his right hand but not when using his left hand (see also the already mentioned study by Corballis et al. 2005). More recently, the above reviewed lesion overlapping study by Doricchi and Tomaiuolo (2003) found that damage to callosal radiation can be a lesional correlate of chronic neglect unaccompanied by hemianopia.

In conclusion, though interhemispheric disconnection might not be a sufficient cause of neglect per se, as also suggested by the fact that split-brain patients do not systematically show signs of left neglect (Plourde and Sperry 1984; Gazzaniga and Baynes 2000), it could still explain some neglect-related phenomena. In this sense, the confabulations produced by split-brain patients and those generated by neglect patients might have at least partially superimposed functional causes, with the left hemisphere being totally deprived of right hemisphere processing in the first case or being provided with incompletely processed right hemisphere information in the second case.

## Conclusion

A wealth of data from cognitive neurosciences indicate that the brain is a mosaic of functionally interconnected areas. The anatomical basis of these functional links begins now to be explored in detail (Mesulam 2005). Recent developments in neuroimaging techniques, such as DTI and fiber-tracking techniques, permit to map in vivo the white matter pathways, both in normal individuals (Catani et al. 2002) and in neurological patients (Thiebaut de Schotten et al. 2005). These new and exciting developments are likely to change our way of looking at brain-behavior relationships, for example, by giving the possibility of directly testing the disconnection hypotheses put forward by Geschwind (1965) 40 years ago (Catani and ffytche 2005), and more specifically, the interhemispheric disconnection hypothesis of neglect as well as the frontoparietal disconnection hypothesis reviewed here. Full consideration of the pathways of communication between functional regions of the brain will help avoid the risk of interpreting in a localist, "phrenological" way, patterns of performance which reflect instead the complexity of multiple, highly interactive processes.

## Supplementary Material

Supplementary Material can be found at <http://www.cercor.oxfordjournals.org/>.

## Notes

We thank Francesco Tomaiuolo and Maurizio Corbetta for providing us with details about their anatomical data, Marco Catani for very helpful discussion, and Serge Kinkingnéhun and Cyril Poupon for help with neuroimaging processing. The Nuclear Magnetic Resonance database is the property of the Commissariat à l'Énergie Atomique, Service Hospitalier Frédéric Joliot, Unité de Neuro-imagerie Anatomofonctionnelle and can be provided on demand to [cpoupon@shfjcea.fr](mailto:cpoupon@shfjcea.fr). *Conflict of Interest* None declared.

Address correspondence to Paolo Bartolomeo (Email: [paolo.bartolomeo@chups.jussieu.fr](mailto:paolo.bartolomeo@chups.jussieu.fr)) or to Fabrizio Doricchi (Email: [fabrizio.doricchi@uniroma1.it](mailto:fabrizio.doricchi@uniroma1.it)).

## References

- Azouvi P, Samuel C, Louis-Dreyfus A, Bernati T, Bartolomeo P, Beis J-M, Chokron S, Leclercq M, Marchal F, Martin Y et al. 2002. Sensitivity of clinical and behavioural tests of spatial neglect after right hemisphere stroke. *J Neurol Neurosurg Psychiatry*. 73(2):160-166.
- Bartolomeo P, Chokron S. 1999a. Egocentric frame of reference: its role in spatial bias after right hemisphere lesions. *Neuropsychologia*. 37(8):881-894.
- Bartolomeo P, Chokron S. 1999b. Left unilateral neglect or right hyperattention? *Neurology*. 53(9):2023-2027.
- Bartolomeo P, Chokron S. 2001. Levels of impairment in unilateral neglect. In: Boller F, Grafman J, editors. *Handbook of neuropsychology*. 2nd ed. Amsterdam (The Netherlands): Elsevier Science Publishers. p. 67-98.
- Bartolomeo P, Chokron S. 2002. Orienting of attention in left unilateral neglect. *Neurosci Biobehav Rev*. 26(2):217-234.
- Barton JJ, Black SE. 1998. Line bisection in hemianopia. *J Neurol Neurosurg Psychiatry*. 64(5):660-662.
- Basser PJ, Mattiello J, LeBihan D. 1994. Estimation of the effective self-diffusion tensor from the NMR spin echo. *J Magn Reson B*. 103(3):247-254.
- Bates E, Wilson SM, Saygin AP, Dick F, Sereno MI, Knight RT, Dronkers NF. 2003. Voxel-based lesion-symptom mapping. *Nat Neurosci*. 6(5):448-450.
- Beis J-M, Andre J-M, Baumgarten A, Challier B. 1999. Eye patching in unilateral spatial neglect: efficacy of two methods. *Arch Phys Med Rehabil*. 80(1):71-76.
- Berti A, Frassinetti F, Umiltà C. 1994. Nonconscious reading? Evidence from neglect dyslexia. *Cortex*. 30:181-197.
- Binder J, Marshall R, Lazar R, Benjamin J, Mohr JP. 1992. Distinct syndromes of hemineglect. *Arch Neurol*. 49(11):1187-1194.
- Bird CM, Malhotra P, Parton A, Coulthard E, Rushworth MF, Husain M. 2006. Visual neglect following right posterior cerebral artery infarction. *Journal of Neurology, Neurosurgery and Psychiatry*. 77: 1008-1012.
- Bisiach E, Pizzamiglio L, Nico D, Antonucci G. 1996. Beyond unilateral neglect. *Brain*. 119:851-857.
- Bisiach E, Rusconi ML. 1990. Break-down of perceptual awareness in unilateral neglect. *Cortex*. 26(4):643-649.
- Burcham KJ, Corwin JV, Stoll ML, Reep RL. 1997. Disconnection of medial agranular and posterior parietal cortex produces multimodal neglect in rats. *Behav Brain Res*. 86(1):41-47.
- Butter CM, Kirsch N. 1992. Combined and separate effects of eye patching and visual stimulation on unilateral neglect following stroke. *Arch Phys Med Rehabil*. 73(12):1133-1139.
- Catani M, ffytche DH. 2005. The rises and falls of disconnection syndromes. *Brain*. 128(Pt 10):2224-2239.
- Catani M, Howard RJ, Pajevic S, Jones DK. 2002. Virtual in vivo interactive dissection of white matter fasciculi in the human brain. *Neuroimage*. 17(1):77-94.
- Chafee MV, Goldman-Rakic PS. 2000. Inactivation of parietal and prefrontal cortex reveals interdependence of neural activity

- during memory-guided saccades. *J Neurophysiol.* 83(3):1550-1566.
- Chokron S, Bartolomeo P. 1999. Réduire expérimentalement la négligence spatiale unilatérale: revue de la littérature et implications théoriques. *Rev Neuropsychol.* 9(2-3):129-165.
- Colby CL, Goldberg ME. 1999. Space and attention in parietal cortex. *Annu Rev Neurosci.* 22:319-349.
- Committeri G, Pitzalis S, Galati G, Patria F, Pelle G, Sabatini U, Castriota-Scanderbeg A, Piccardi L, Guariglia C, Pizzamiglio L. 2007. Neural bases of personal and extrapersonal neglect in humans. *Brain.* 130(2):431-441.
- Corballis MC, Corballis PM, Fabri M, Paggi A, Manzoni T. 2005. Now you see it, now you don't: variable hemineglect in a commissurotomy man. *Cogn Brain Res.* 25(2):521-530.
- Corbetta M, Kincade MJ, Lewis C, Snyder AZ, Sapir A. 2005. Neural basis and recovery of spatial attention deficits in spatial neglect. *Nat Neurosci.* 8(11):1603-1610.
- Corbetta M, Shulman GL. 2002. Control of goal-directed and stimulus-driven attention in the brain. *Nat Rev Neurosci.* 3(3):201-215.
- D'Erme P, De Bonis C, Gainotti G. 1987. Influenza dell'emi-inattenzione e dell'emianopsia sui compiti di bisezione di linee nei pazienti cerebrolesi [Influence of unilateral neglect and hemianopia on line bisection performance in brain-damaged patients]. *Arch Psicol Neurol Psichiatr.* 48:165-189.
- D'Erme P, Robertson IH, Bartolomeo P, Daniele A. 1993. Unilateral neglect: the fate of the extinguished visual stimuli. *Behav Neurol.* 6:143-150.
- Doricchi F, Angelelli P. 1999. Misrepresentation of horizontal space in left unilateral neglect: role of hemianopia. *Neurology.* 52(9):1845-1852.
- Doricchi F, Guariglia P, Figliozzi F, Silvetti M, Bruno G, Gasparini M. 2005. Causes of cross-over in unilateral neglect: between-group comparisons, within-patient dissociations and eye movements. *Brain.* 128(Pt 6):1386-1406.
- Doricchi F, Incoccia C, Galati G. 1997. Influence of figure-ground contrast on the implicit and explicit processing of line drawings in patients with left unilateral neglect. *Cogn Neuropsychol.* 14:573-594.
- Doricchi F, Tomaiuolo F. 2003. The anatomy of neglect without hemianopia: a key role for parietal-frontal disconnection? *Neuroreport.* 14(17):2239-2243.
- Duffau H. 2005. Lessons from brain mapping in surgery for low-grade glioma: insights into associations between tumour and brain plasticity. *Lancet Neurol.* 4(8):476-486.
- Ferro JM, Kertesz A. 1984. Posterior internal capsule infarction associated with neglect. *Arch Neurol.* 41(4):422-424.
- Ferro JM, Kertesz A, Black SE. 1987. Subcortical neglect: quantitation, anatomy, and recovery. *Neurology.* 37(9):1487-1492.
- Fuchs W. 1920. Untersuchung über das Sehen der Hemianopiker und Hemiamblyopiker. *Z Psychol Physiol Sinnersorg.* 84:67-169.
- Gaffan D, Hornak J. 1997. Visual neglect in the monkey. Representation and disconnection. *Brain.* 120(Pt 9):1647-1657.
- Gainotti G. 1968. [Les manifestations de négligence et d'inattention pour l'hémi-espace]. *Cortex.* 4:64-91.
- Gainotti G. 1993. The role of spontaneous eye movements in orienting attention and in unilateral neglect. In: Robertson IH, Marshall JC, editors. *Unilateral neglect: clinical and experimental studies.* Hove (UK): Lawrence Erlbaum Associates. p. 107-122.
- Gainotti G, D'Erme P, Bartolomeo P. 1991. Early orientation of attention toward the half space ipsilateral to the lesion in patients with unilateral brain damage. *J Neurol Neurosurg Psychiatry.* 54:1082-1089.
- Gazzaniga MS, Baynes K. 2000. Consciousness, introspection, and the split-brain: the two minds/one body problem. In: Gazzaniga MS, editor. *The new cognitive neurosciences.* Cambridge (MA): MIT Press. p. 1355-1363.
- Geschwind N. 1965. Disconnexion syndromes in animals and man—part II. *Brain.* 88:585-644.
- Gilad R, Sadeh M, Boaz M, Lampl Y. 2006. Visual spatial neglect in multiple sclerosis. *Cortex.* 42(8):1138-1142.
- Gitelman DR, Nobre AC, Parrish TB, LaBar KS, Kim Y-H, Meyer JR, Mesulam MM. 1999. A large-scale distributed network for covert spatial attention: further anatomical delineation based on stringent behavioural and cognitive controls. *Brain.* 122(6):1093-1106.
- Graff-Radford NR, Rizzo M. 1987. Neglect in a patient with multiple sclerosis. *Eur Neurol.* 26(2):100-103.
- Halligan PW, Marshall JC, Wade DT. 1990. Do visual field deficits exacerbate visuo-spatial neglect? *J Neurol Neurosurg Psychiatry.* 53(6):487-491.
- Harvey M, Milner AD. 1999. Residual perceptual distortion in 'recovered' hemispatial neglect. *Neuropsychologia.* 37(6):745-750.
- Harvey M, Milner AD, Roberts RC. 1995. An investigation of hemispatial neglect using the landmark task. *Brain Cogn.* 27:59-78.
- Healton EB, Navarro C, Bressman S, Brust JC. 1982. Subcortical neglect. *Neurology.* 32(7):776-778.
- Heilman KM, Valenstein E. 1979. Mechanisms underlying hemispatial neglect. *Ann Neurol.* 5:166-170.
- Heilman KM, Watson RT, Valenstein E. 1993. Neglect and related disorders. In: Heilman KM, Valenstein E, editors. *Clinical neuropsychology.* 3rd ed. New York (NY): Oxford University Press. p. 279-336.
- Hillis AE, Wityk RJ, Barker PB, Beauchamp NJ, Gailloud P, Murphy K, Cooper O, Metter EJ. 2002. Subcortical aphasia and neglect in acute stroke: the role of cortical hypoperfusion. *Brain.* 125(Pt 5):1094-1104.
- Husain M, Kennard C. 1996. Visual neglect associated with frontal lobe infarction. *J Neurol.* 243(9):652-657.
- Husain M, Mannan S, Hodgson T, Wojciulik E, Driver J, Kennard C. 2001. Impaired spatial working memory across saccades contributes to abnormal search in parietal neglect. *Brain.* 124(Pt 5):941-952.
- Husain M, Rorden C. 2003. Non-spatially lateralized mechanisms in hemispatial neglect. *Nat Rev Neurosci.* 4(1):26-36.
- Ishiai S. 2002. Perceptual and motor interaction in unilateral spatial neglect. In: Karnath HO, Milner D, Vallar G, editors. *The cognitive and neural bases of spatial neglect.* Oxford: Oxford University Press. p. 181-193.
- Karnath H-O, Ferber S, Himmelbach M. 2001. Spatial awareness is a function of the temporal not the posterior parietal lobe. *Nature.* 411(6840):950-963.
- Karnath H-O, Fruhmann Berger M, Kuker W, Rorden C. 2004. The anatomy of spatial neglect based on voxelwise statistical analysis: a study of 140 patients. *Cereb Cortex.* 14(10):1164-1172.
- Karnath H-O, Himmelbach M, Rorden C. 2002. The subcortical anatomy of human spatial neglect: putamen, caudate nucleus and pulvinar. *Brain.* 125(2):350-360.
- Kashiwagi A, Kashiwagi T, Nishikawa T, Tanabe H, Okuda J. 1990. Hemispatial neglect in a patient with callosal infarction. *Brain.* 113(Pt 4):1005-1023.
- Kinsbourne M. 1970. A model for the mechanism of unilateral neglect of space. *Trans Am Neurol Assoc.* 95:143-146.
- Kinsbourne M. 1977. Hemi-neglect and hemisphere rivalry. In: Weinstein EA, Friedland RP, editors. *Hemi-inattention and hemisphere specialization.* New York: Raven Press. p. 41-49.
- Kinsbourne M. 1987. Mechanisms of unilateral neglect. In: Jeannerod M, editor. *Neurophysiological and neuropsychological aspects of spatial neglect.* Amsterdam (The Netherlands): Elsevier Science Publishers. p. 69-86.
- Kinsbourne M. 1993. Orientational bias model of unilateral neglect: evidence from attentional gradients within hemispace. In: Robertson IH, Marshall JC, editors. *Unilateral neglect: clinical and experimental studies.* Hove (UK): Lawrence Erlbaum Associates. p. 63-86.
- LaBerge D. 2000. Networks of attention. In: Gazzaniga MS, editor. *The new cognitive neurosciences.* Cambridge (MA): MIT Press. p. 711-724.
- Leibovitch FS, Black SE, Caldwell CB, Ebert PL, Ehrlich LE, Szalai JP. 1998. Brain-behavior correlations in hemispatial neglect using CT and SPECT: the Sunnybrook Stroke Study. *Neurology.* 50(4):901-908.
- Makris N, Kennedy DN, McInerney S, Sorensen AG, Wang R, Caviness VS Jr, Pandya DN. 2005. Segmentation of subcomponents within the superior longitudinal fascicle in humans: a quantitative, in vivo, DT-MRI study. *Cereb Cortex.* 15(6):854-869.



- Malhotra P, Jager HR, Parton A, Greenwood R, Playford ED, Brown MM, Driver J, Husain M. 2005. Spatial working memory capacity in unilateral neglect. *Brain*. 128(Pt 2):424-435.
- Manning L, Kartsounis LD. 1993. Confabulations related to tacit awareness in visual neglect. *Behav Neurol*. 6:211-213.
- Marshall JC, Halligan PW. 1988. Blindsight and insight into visuo-spatial neglect. *Nature*. 336:766-767.
- McFie J, Piercy MF, Zangwill OL. 1950. Visual spatial agnosia associated with lesions of the right hemisphere. *Brain*. 73:167-190.
- McGlinchey-Berroth R, Milberg W, Verfaellie M, Alexander M, Kiduff PT. 1993. Semantic processing in the neglected visual field: evidence from a lexical decision task. *Cogn Neuropsychol*. 10:79-108.
- Mesulam MM. 1981. A cortical network for directed attention and unilateral neglect. *Ann Neurol*. 10:309-325.
- Mesulam MM. 1985. Attention, confusional states and neglect. In: Mesulam MM, editor. *Principles of behavioral neurology*. Philadelphia (PA): F.A. Davis. p. 125-168.
- Mesulam MM. 1999. Spatial attention and neglect: parietal, frontal and cingulate contributions to the mental representation and attentional targeting of salient extrapersonal events. *Philos Trans R Soc Lond B Biol Sci*. 354(1387):1325-1346.
- Mesulam MM. 2005. Imaging connectivity in the human cerebral cortex: the next frontier? *Ann Neurol*. 57(1):5-7.
- Meyer JS, Obara K, Muramatsu K. 1993. Diaschisis. *Neurol Res*. 15(6):362-366.
- Milner AD, Goodale MA. 1995. *The visual brain in action*. Oxford: Oxford University Press.
- Mishkin M, Ungerleider LG, Macko KA. 1983. Object vision and spatial vision: two cortical pathways. *Trends Neurosci*. 6:414-417.
- Morecraft RJ, Geula C, Mesulam MM. 1993. Architecture of connectivity within a cingulo-fronto-parietal neurocognitive network for directed attention. *Arch Neurol*. 50(3):279-284.
- Morrow LA, Ratcliff G. 1988. The disengagement of covert attention and the neglect syndrome. *Psychobiology*. 16(3):261-269.
- Mort DJ, Malhotra P, Mannan SK, Rorden C, Pambakian A, Kennard C, Husain M. 2003. The anatomy of visual neglect. *Brain*. 126(Pt 9):1986-1997.
- Nico D, Galati G, Incoccia C. 1999. The endpoints' task: an analysis of length reproduction in unilateral neglect. *Neuropsychologia*. 37(10):1181-1188.
- Oliveri M, Rossini PM, Traversa R, Cicinelli P, Filippi MM, Pasqualetti P, Tomaiuolo F, Caltagirone C. 1999. Left frontal transcranial magnetic stimulation reduces contralesional extinction in patients with unilateral right brain damage. *Brain*. 122(Pt 9):1731-1739.
- Park KC, Lee BH, Kim EJ, Shin MH, Choi KM, Yoon SS, Kwon SU, Chung CS, Lee KH, Heilman KM et al. 2006. Deafferentation-disconnection neglect induced by posterior cerebral artery infarction. *Neurology*. 66(1):56-61.
- Parton A, Malhotra P, Husain M. 2004. Hemispatial neglect. *J Neurol Neurosurg Psychiatry*. 75(1):13-21.
- Petrides M, Pandya DN. 2002. Association pathways of the prefrontal cortex and functional observations. In: Stuss DT, Knight RT, editors. *Principles of frontal lobe function*. Oxford: Oxford University Press. p. 31-50.
- Plourde G, Sperry RW. 1984. Left hemisphere involvement in left spatial neglect from right-sided lesions. *Brain*. 107(Pt 1):95-106.
- Posner MI. 2005. How I got here. In: Mayr U, Awh E, Keele SW, editors. *Developing individuality in the human brain: a tribute to Michael I. Posner*. Washington (DC): American Psychological Association. p. 328.
- Posner MI, Petersen SE. 1990. The attention system of human brain. *Annu Rev Neurosci*. 13:25-42.
- Posner MI, Walker JA, Friedrich EJ, Rafal RD. 1984. Effects of parietal injury on covert orienting of attention. *J Neurosci*. 4:1863-1874.
- Reep RL, Corwin JV, Cheatwood JL, Van Vleet TM, Heilman KM, Watson RT. 2004. A rodent model for investigating the neurobiology of contralateral neglect. *Cogn Behav Neurol*. 17(4):191-194.
- Reuter-Lorenz PA, Nozawa G, Gazzaniga MS, Hughes HC. 1995. Fate of neglected targets: a chronometric analysis of redundant target effects in the bisected brain. *J Exp Psychol Hum Percept Perform*. 21(2):211-230.
- Rizzolatti G, Matelli M. 2003. Two different streams form the dorsal visual system: anatomy and functions. *Exp Brain Res*. 153(2):146-157.
- Rushmore RJ, Valero-Cabre A, Lomber SG, Hilgetag CC, Payne BR. 2006. Functional circuitry underlying visual neglect. *Brain*. 129(Pt 7):1803-1821.
- Rushworth MFS, Behrens TEJ, Johansen-Berg H. 2006. Connection patterns distinguish 3 regions of human parietal cortex. *Cerebral Cortex*. 16:1418-1430.
- Schmahmann JD, Pandya DN. 2006. *Fiber pathways of the brain*. New York: Oxford University Press. 450 p.
- Selemon LD, Goldman-Rakic PS. 1988. Common cortical and subcortical targets of the dorsolateral prefrontal and posterior parietal cortices in the rhesus monkey: evidence for a distributed neural network subserving spatially guided behavior. *J Neurosci*. 8(11):4049-4068.
- Smania N, Martini MC, Prior M, Marzi CA. 1996. Input and response determinants of visual extinction: a case study. *Cortex*. 32:567-591.
- Sprague JM. 1966. Interaction of cortex and superior colliculus in mediation of visually guided behavior in the cat. *Science*. 153(743):1544-1547.
- Thiebaut de Schotten M, Kinkingnéhun SR, Delmaire C, Lévy R, Volle E, Dubois B, Lehericy S, Duffau H, Bartolomeo P. 2006. OVER-TRACK: A new tool to visualize the white matter organization in Talairach space. *Neuroimage*. 31(Supplement 1):S110.
- Thiebaut de Schotten M, Urbanski M, Duffau H, Volle E, Lévy R, Dubois B, Bartolomeo P. 2005. Direct evidence for a parietal-frontal pathway subserving spatial awareness in humans. *Science*. 309(5744):2226-2228.
- Vallar G. 2001. Extrapersonal visual unilateral spatial neglect and its neuroanatomy. *Neuroimage*. 14(1 Pt 2):S52-S58.
- Vallar G, Guariglia C, Rusconi ML. 1997. Modulation of the neglect syndrome by sensory stimulation. In: Thier P, Karnath HO, editors. *Parietal lobe contributions to orientation in 3D-space*. Heidelberg (Germany): Springer-Verlag. p. 555-578.
- Verdon V, Lovblad K-O, Hauert C-A, Vuilleumier P. Neuroanatomical basis of hemispatial neglect components using Voxel-based Lesion Symptom Mapping. 2nd Meeting of the European Societies of Neuropsychology; 2006 October 18-20; Toulouse, France. p 277.
- Volpe BT, Ledoux JE, Gazzaniga MS. 1979. Information processing of visual stimuli in an "extinguished" field. *Nature*. 282(5740):722-724.
- Vuilleumier P, Hester D, Assal G, Regli F. 1996. Unilateral spatial neglect recovery after sequential strokes. *Neurology*. 46:184-189.
- Watson RT, Valenstein E, Day AL, Heilman KM. 1984. The effect of corpus callosum lesions on unilateral neglect in monkeys. *Neurology*. 34(6):812-815.
- Weddell RA. 2004. Subcortical modulation of spatial attention including evidence that the Sprague effect extends to man. *Brain Cogn*. 55(3):497-506.
- Zihl J, von Cramon D. 1979. Collicular function in human vision. *Exp Brain Res*. 35(3):419-424.

**Overlap Region of Interest (ROI).** Data from the original overlapping maps were used to define the maximum overlap described by Doricchi and Tomaiuolo (Doricchi and Tomaiuolo 2003) (see Table 1 for MNI coordinates). The subcortical maximum lesion overlaps of the Karnath et al study (Karnath et al. 2004, Fig. 2) were manually drawn on the same Montreal Neurological Institute (MNI) template using MRICro 1.40 (Rorden and Brett 2000) (<http://www.sph.sc.edu/comd/rorden/mricro.html>). For the remaining studies (Mort et al. 2003; Corbetta et al. 2005), the maximum overlap was manually drawn in MRICro, using the MNI coordinates reported in the studies for the lesion overlaps correlated to spatial neglect. Supplementary Table 1 reports the MNI coordinates of the centroids of the subcortical maximum overlap areas in these studies.

**DTI acquisition.** Diffusion-weighted magnetic resonance imaging data were acquired from a healthy 41-year-old male right-handed volunteer, using DTI at 1.5T. Diffusion parameters were TR/TE/angle: 12.5s/66.2ms/90°, voxel size: 1.88x1.88x2 mm<sup>3</sup>, b-value: 700 s/mm<sup>2</sup>, 41 directions and 1 B0 image. Data were acquired with NMR pulse sequences, reconstructed with NMR reconstructor package and post processed with AIMS/Anatomist/BrainVisa software, available at <http://brainvisa.info>.

**Tractography.** Diffusion image analysis was performed using tensor diffusion imaging and deterministic fiber algorithm using Brainvisa 3.0.2 (<http://brainvisa.info/>). Fiber tracking was performed using two manually drawn ROIs: (1) a global ROI based on previously published methods (Catani et al. 2005) and (2) caudal selective ROIs (Thiebaut de Schotten et al. 2006), which allowed us to differentiate the single fasciculi (Supplementary Figure 1).

**Bundle normalization and visualization.** EPI B0 image was normalized with default parameters to the EPI template space provided by statistical parametric mapping software (SPM2, Wellcome Department of Cognitive Neurology, Institute of Neurology, London, UK,

<http://www.fil.ion.ucl.ac.uk/spm/>), in association with MATLAB version 7 (The Mathworks, Inc., MA, USA). The resulting deformation matrix was applied to the fiber bundles (Thiebaut de Schotten et al. 2006). The maximum overlaps and the normalized bundles were visualized using Anatomist 3.0.2 (<http://brainvisa.info>).

### **References**

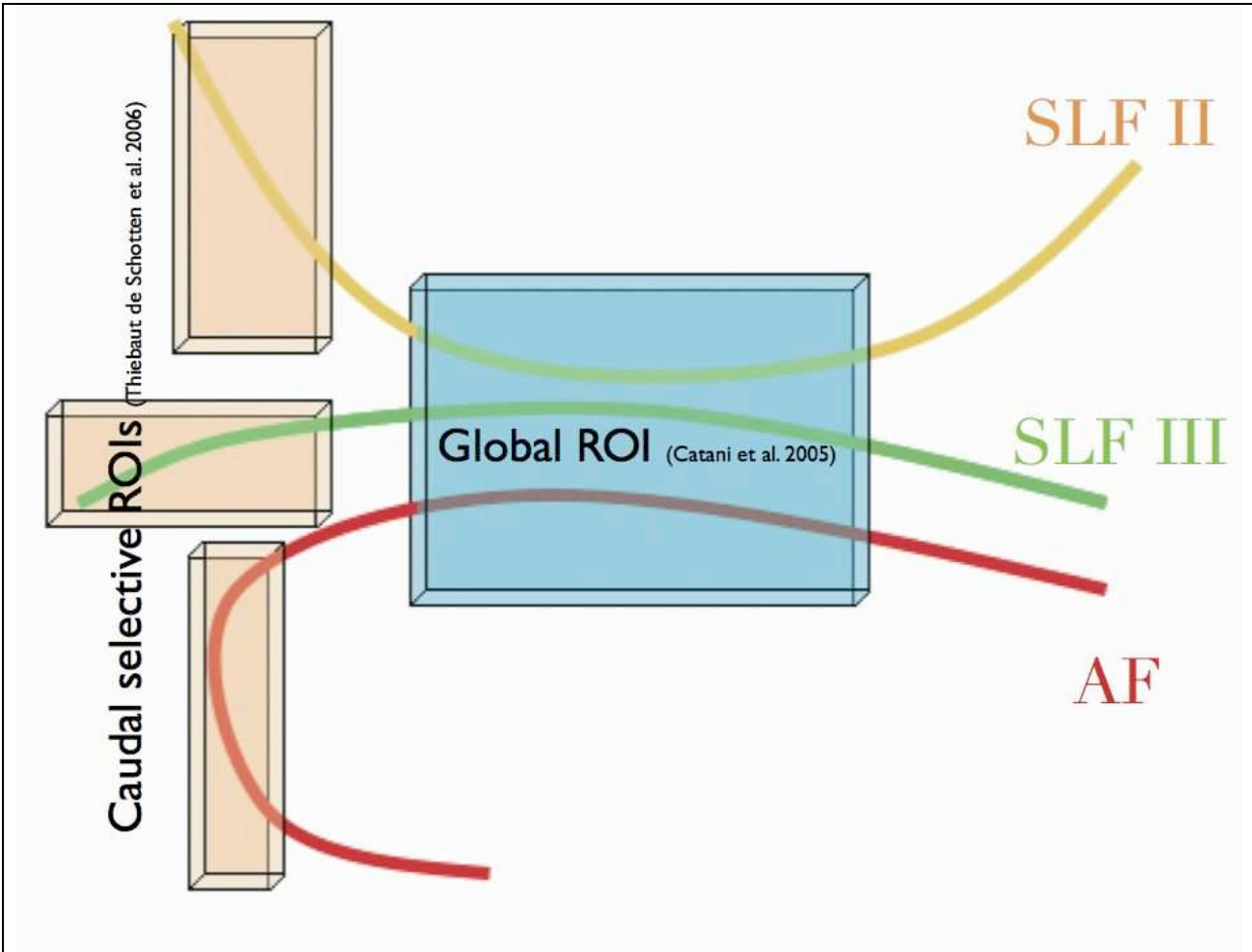
- Catani M, Jones DK, ffytche DH. 2005. Perisylvian language networks of the human brain. *Annals of Neurology* 57(1):8-16.
- Committeri G, Pitzalis S, Galati G, Patria F, Pelle G, Sabatini U, Castriota-Scanderbeg A, Piccardi L, Guariglia C, Pizzamiglio L. 2006. Neural bases of personal and extrapersonal neglect in humans. *Brain*.
- Corbetta M, Kincade MJ, Lewis C, Snyder AZ, Sapir A. 2005. Neural basis and recovery of spatial attention deficits in spatial neglect. *Nature Neuroscience* 8(11):1603-1610.
- Doricchi F, Tomaiuolo F. 2003. The anatomy of neglect without hemianopia: a key role for parietal-frontal disconnection? *NeuroReport* 14(17):2239-2243.
- Karnath H-O, Fruhmann Berger M, Kuker W, Rorden C. 2004. The anatomy of spatial neglect based on voxelwise statistical analysis: a study of 140 patients. *Cerebral Cortex* 14(10):1164-1172.
- Mort DJ, Malhotra P, Mannan SK, Rorden C, Pambakian A, Kennard C, Husain M. 2003. The anatomy of visual neglect. *Brain* 126(Pt 9):1986-1997.
- Rorden C, Brett M. 2000. Stereotaxic display of brain lesions. *Behavioural Neurology* 12(4):191-200.
- Thiebaut de Schotten M, Kinkingnéhun SR, Delmaire C, Lévy R, Volle E, Dubois B, Lehericy S, Duffau H, Bartolomeo P. 2006. OVER-TRACK: A new tool to visualize the white matter organization in Talairach space. *Neuroimage* 31(Supplement 1).

***Supplementary Table 1***

	<i>MNI coordinates</i>		
	<i>x</i>	<i>y</i>	<i>z</i>
(Corbetta et al. 2005)	37	-44	23
(Doricchi and Tomaiuolo 2003)	35	-12	27
	26	-10	35
(Karnath et al. 2004)	26	-5	24
	41	-12	24
(Mort et al. 2003)	46	-44	29

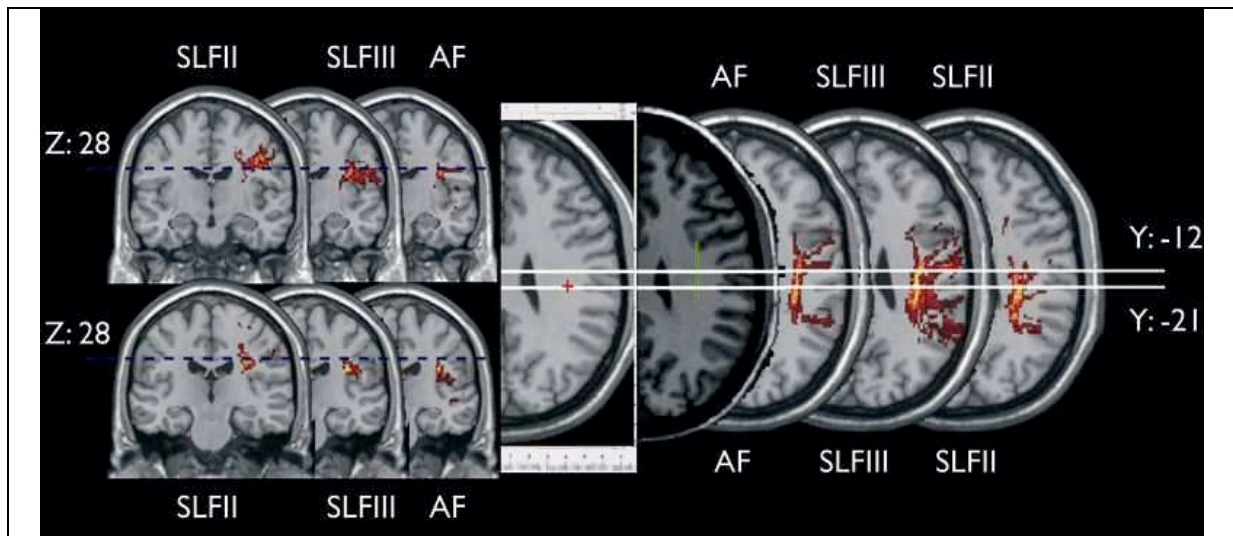
Coordinates of the centroids of the subcortical maximum overlap areas

Supplementary Figure 1



ROIs used to track the SLF II, the SLF III and the AF.

## Supplementary Figure 2



The red cross indicates the subcortical maximum lesion overlap found in patients with extrapersonal neglect by Committeri et al. (Committeri et al. 2006, Fig. 2, first row, axial slice Z = +28)). The lesion overlap described in patients with extrapersonal neglect by Doricchi and Tomaiuolo (Doricchi and Tomaiuolo 2003) is indicated in green. The matching MNI templates showing the trajectories of SLF II, III and AF are also shown.

## **Brain networks of spatial awareness: evidence from diffusion tensor imaging tractography**

Urbanski M, PhD <sup>1,2,8</sup>, Thiebaut de Schotten M, MA <sup>1,3,8</sup>, Rodrigo S, MD <sup>4</sup>, Catani M, MD <sup>5</sup>, Oppenheim C, MD, PhD <sup>4</sup>, Touzé E, MD, PhD <sup>6</sup>, Chokron S, PhD <sup>2</sup>, Méder J-F, MD <sup>4</sup>, Lévy R, MD, PhD <sup>1,3,7,8</sup>, Dubois B, MD, PhD <sup>1,3,7,8</sup> & Bartolomeo P, MD, PhD <sup>1,3,7,8</sup>

<sup>1</sup> *INSERM Unit 610, Hôpital de la Salpêtrière, Paris, France*

<sup>2</sup> *ERT TREAT VISION, CNRS UMR 5105 Paris & Grenoble, France*

<sup>3</sup> *Université Pierre et Marie Curie-Paris6, Paris, France*

<sup>4</sup> *Department of Neuroradiology, Hôpital Sainte-Anne, Paris, France*

<sup>5</sup> *Institute of Psychiatry, King's College London, United Kingdom*

<sup>6</sup> *Department of Neurology, Hôpital Sainte-Anne, Paris, France*

<sup>7</sup> *Department of Neurology, AP-HP, IFR 70, Hôpital de la Salpêtrière, Paris, France*

<sup>8</sup> *IFR70, Hôpital de la Salpêtrière, Paris, France*

Correspondence to: Marika Urbanski or Paolo Bartolomeo, Inserm U610, G.H. Pitié Salpêtrière, 47 boulevard de l'Hôpital, 75013 PARIS, FRANCE, E-mail: marika.urbanski@gmail.com or paolo.bartolomeo@gmail.com Telephone: +33 1 42 16 00 96, Fax: +33 1 42 16 41 95.

Number of references, 50; number of tables, 1; number of figures, 3.

Word count: Title, 88 characters; Summary, 248 words; Text, 2317 words.

Running title: Brain networks of spatial awareness

Disclosure: the authors report no conflict of interest.

Search terms: [ 207 ] Neglect, [ 208 ] Attention, [ 120 ] MRI

## **Abstract**

**Background.** Left unilateral neglect, a dramatic condition which impairs awareness of left-sided events, has been classically reported after right hemisphere cortical lesions involving the temporo-parietal junction (TPJ) or the superior temporal gyrus (STG). More recently, the importance of the involvement of long-range white matter tracts has been stressed, consistent with the idea that awareness of events occurring in space depends on the coordinated activity of anatomically distributed brain regions. Damage to the superior longitudinal fasciculus (SLF), linking parietal to frontal cortical regions, or to the inferior longitudinal fasciculus (ILF), connecting more ventral networks in the temporal lobe, have been described in neglect patients. **Methods.** Four right-handed patients with right-hemisphere strokes were submitted to a high-definition anatomical MRI with diffusion tensor imaging (DTI) sequences and to a paper-and-pencil neglect battery. We used DTI tractography to visualize the SLF, the ILF and the inferior fronto-occipital fasciculus (IFOF), a pathway running in the depth of the temporal lobe, not hitherto associated with neglect. **Results.** Two patients with cortical involvement of the STG and STG/TPJ, but intact and symmetrical fasciculi, showed no signs of neglect. The two remaining patients had white matter damage involving the SLF and the IFOF, and demonstrated signs of left neglect. **Conclusions.** Cortical damage to the TPJ or STG may not be sufficient to produce visual neglect. SLF involvement can determine neglect through dysfunction of fronto-parietal networks important for spatial attention. IFOF disconnection may contribute to neglect by impairing the top-down modulation of visual areas from frontal cortex.



## *Introduction*

Left visual neglect is a frequent consequence of right hemisphere lesions<sup>1</sup>. Neglect patients behave as if the left part of the world did not exist anymore, and have poor functional outcome. Despite decades of research on this syndrome the precise localization of the lesions determining neglect remains controversial. In stroke patients, lesions often overlap on the inferior parietal lobule (IPL), at the junction with the temporal lobe<sup>2, 3</sup>. Conflicting evidence, however, indicates lesions of the middle and rostral parts of superior temporal gyrus (STG)<sup>4, 5</sup>, but not the temporo-parietal junction (TPJ)<sup>6</sup>. Signs of neglect can also occur after lesions of the ventrolateral frontal lobe<sup>7, 8</sup>, of the medial temporal lobe<sup>3</sup>, of the occipital lobe and the corpus callosum<sup>9</sup>, or after damage to two major rostro-caudal brain pathways, the superior<sup>10, 11</sup> and inferior<sup>12</sup> longitudinal fasciculi. Thus, rather than damage to single cortical modules, dysfunction of large cortical networks<sup>13, 14</sup> can be the crucial antecedent of neglect<sup>10, 11, 15-18</sup>.

Diffusion tensor imaging (DTI) tractography can be used to track the long-range white matter pathways<sup>19</sup> and then explore, in a standardized brain space, their relationships with the lesions found in stroke patients with standard, anatomical MRI. A recent meta-analysis<sup>17</sup> of previous lesion overlapping studies demonstrated that the subcortical lesions of neglect patients invariably overlapped at or near the SLF. Disconnection between cortical modules might thus be a general mechanism of neglect<sup>15</sup>. This possibility is also consistent with the results of monkey studies<sup>20, 21</sup>, rodent studies<sup>22</sup> and of computer simulations of attention<sup>23</sup>. Here we describe four patients with strokes in the right hemisphere, two of whom showed signs of extrapersonal neglect on paper-and-pencil tests. We used DTI tractography to directly visualize the SLF, the ILF and the inferior fronto-occipital fasciculus (IFOF), a pathway running in the depth of the temporal lobe, not hitherto associated with neglect.

## *Methods*

### **Patients**

Four right-handed patients with a vascular stroke in the right hemisphere gave written informed consent to participate to this study, which was approved by the ethics committee of the Hôtel-Dieu Hospital in Paris, France. Their demographic and clinical details are reported in Table 1.

Table 1: Demographical and clinical data

Patient	Clinical diagnosis of Neglect	Visual Field	Gender / age / education (years of schooling)	Onset of illness (days)	Line bisection (% deviation)	Line cancellation (max 30 / 30)	Bells cancellation (max 15 / 15)	Letter cancellation (max 30 / 30)	Overlapping figures (max 10 / 10)	Landscape drawing (max 6)
Case 1	NO	normal	F / 45 / 14	9	-3.10	30 / 30	15 / 15	29 / 30	10 / 10	6
Case 2	NO	normal	M / 60 / 14	5	4.80	30 / 30	15 / 15	28 / 29	10 / 10	6
Case 3	YES	Left extinction	F / 59 / 10	9	15.70*	29 / 30	0 / 6*	0 / 13*	6 / 10*	4.5*
Case 4	YES	Left hemianopia	F / 80 / 17	729	1.00	30 / 30	1 / 15*	9 / 28*	9 / 10*	3.5*

\* Pathological score<sup>37, 50</sup>

For the line bisection test, we calculated the cumulated percentage of deviation from the true centre of all the lines (rightward deviation carried a positive sign, leftward deviation carried a negative sign). For each cancellation tests and the overlapping figures test, we reported the number of items cancelled (or identified) on each half of the page or of the central figure (number on the left / number on the right). For the landscape copy, we assigned 2 points to the complete copy of the house and 1 point to the complete copy of each tree, 0.5 point to item whose only right half was copied and 0 point to item completely omitted.

## Neglect battery

Patients underwent a paper-and-pencil neglect battery<sup>24</sup> including a line bisection test consisting in eight lines horizontally disposed in a vertical A4 sheet in a fixed random order (three 60 mm samples, three 100 mm samples and two 180 mm samples)<sup>25</sup>; three cancellation tests in which patients were asked to cancel stimuli of various kind: 1/ lines<sup>26</sup>, 2/ As among other letters<sup>27</sup>, 3/ silhouettes of bells among other objects<sup>28</sup>; an overlapping figures task<sup>29</sup> in which patients were requested to identify five patterns of overlapping linear drawings of common objects (one central and a pair of objects over each of its sides); a copy of a linear drawing representing a central house and four trees (a pair of trees over each of its side) presented on a horizontal A4 sheet<sup>29</sup>.

## MRI acquisition

MRI data were acquired using echo-planar imaging at 1.5T (General Electric) with a standard head coil for signal reception. DTI axial slices were obtained using the following parameters: repetition time, 6575ms; echo time, 74.3ms; flip angle, 90°; matrix, 128 x 128 ; slice thickness, 4mm with no gap; FOV, 28 cm; acquisition time, 250s . One average was used with

signal averaging in the scanner buffer. Diffusion weighting was performed along 36 independent directions, with a b-value of 700s/mm<sup>2</sup>. High-resolution 3-D anatomical images were used for display and anatomical localization (114 axial contiguous inversion recovery three dimensional fast SPGR images, 1.2mm thick; inversion time, 450ms; flip angle, 15°; matrix, 256 x 256; FOV, 28cm; acquisition time, 370s).

## **Diffusion Tensor Data Analysis**

Data were analysed on an independent workstation (Linux PC, kubuntu 6.06 LTS). Raw diffusion-weighted data were corrected for geometric distortion secondary to eddy currents using a registration technique based upon the geometric model of distortions<sup>30</sup>. Brainvisa 3.0.2 (<http://brainvisa.info/>) software was used to calculate diffusion tensors and anisotropy data, define the ROIs and perform fiber tracking.

## **Tractography**

Fiber tracking of the superior longitudinal fasciculus (SLF), inferior longitudinal fasciculus (ILF) and the inferior fronto-occipital fasciculus (IFOF) was performed using previously described ROIs<sup>31</sup>. A “two regions of interest” approach was used for each fasciculus tracking. The procedure<sup>32</sup> consisted in defining a second ROI, at a distance from the first ROI, such that it contained at least a section of the desired fasciculus but did not contain any fibers of the undesired fasciculus that passed through the first ROI. Fiber tracking was performed using a Diffusion Tensor model with a likelihood algorithm. Pathways were traced out until the fractional anisotropy of the tensor fell below an arbitrary threshold of 0.20.

For the SLF, a single ROI was used to visualise the entire arcuate fasciculus, then a two-ROI approach was used to visualise subcomponents of the SLF<sup>33</sup>. For the two-ROI approach, the first ROI was placed in the white matter underlying Broca territory and the second ROI was drawn caudally including the white matter under the Geschwind and the Wernicke territory<sup>33</sup>. For the ILF, the first ROI was drawn in the occipital white matter and the second ROI was placed in the white matter underlying the rostral temporal regions<sup>34</sup>. For the IFOF, the first ROI was placed in the occipital white matter and the second ROI was drawn rostrally in the white matter of the anterior floor of the external capsule<sup>31</sup>.

DTI and high-resolution 3-D anatomical images were registered using Brainvisa 3.0.2. The derived tracts were displayed using Anatomist 3.0.2 (<http://brainvisa.info/>).

To explore more in details in the present patients the possible involvement of the SLF<sup>10, 11, 17</sup>, we also projected their lesions to the normalized white matter percentage maps of the SLF

(ranging from 0 to 50%) based on DTI tractography of 16 normal subjects<sup>35</sup>.

## Results

Cases 1 and 2 demonstrated no signs of neglect on paper-and-pencil tests; cases 3 and 4 had signs of left neglect in three or more of six tests of the neglect battery (Table 1).

Case 1 showed left motor deficit, left somatosensory extinction and dysarthria as a consequence of an ischemic stroke in the territory of the right middle cerebral artery, affecting both the inferior parietal and the superior temporal cortices (Fig. 1, case 1), either of which has been considered as the crucial lesional correlate of neglect<sup>2, 6</sup>. The lesion involved the posterior part of the insula, the STG (gray matter and underlying white matter), the angular and supramarginal gyri (gray matter and underlying white matter), and the posterior part of the middle temporo-occipital gyrus. Despite the localization of the cortical lesion, nine days after clinical onset case 1 displayed no signs of extinction or neglect on neuropsychological testing. The tractography reconstruction of long range white matter pathways showed intact and bilateral representation of the SLF, IFOF and ILF (Fig. 2 and 3, case 1).

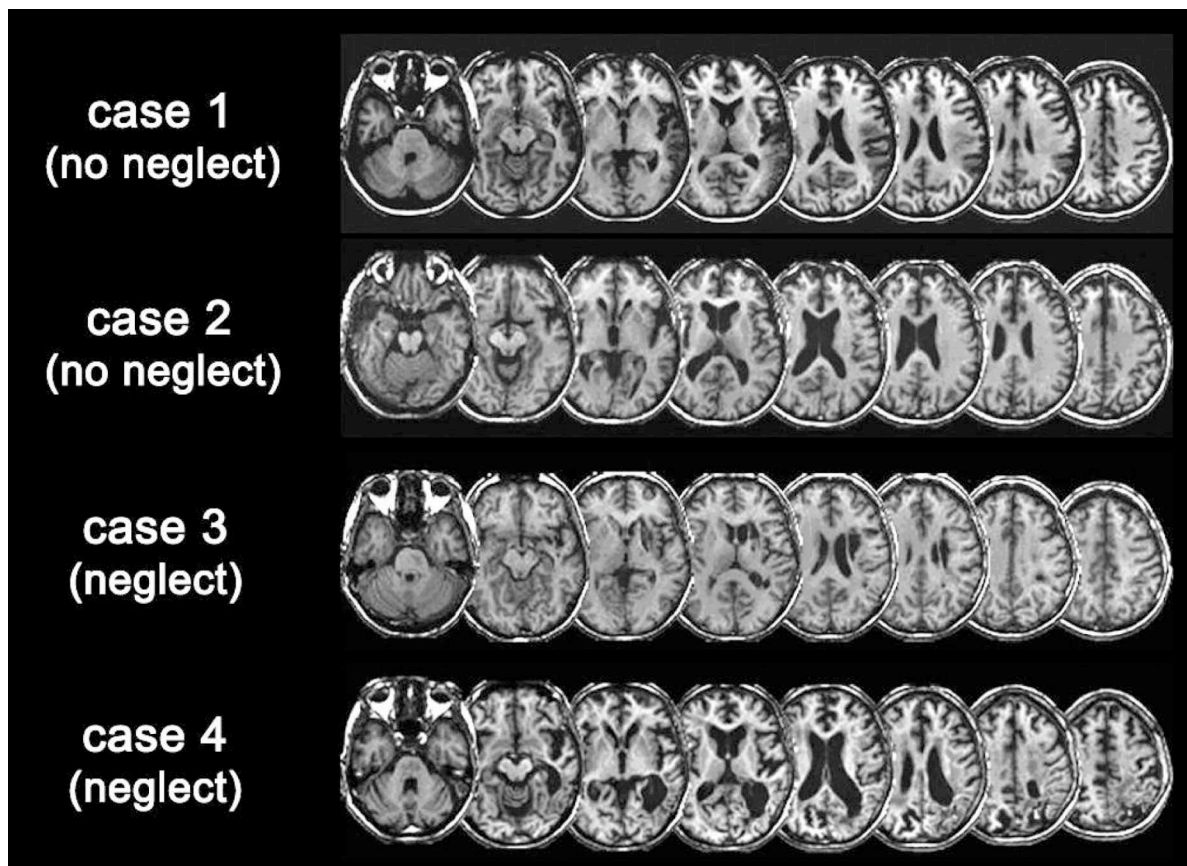


Figure 1: MRI axial slices of the lesions in the right hemisphere for the four patients (neurological convention: left hemisphere is on the left side).

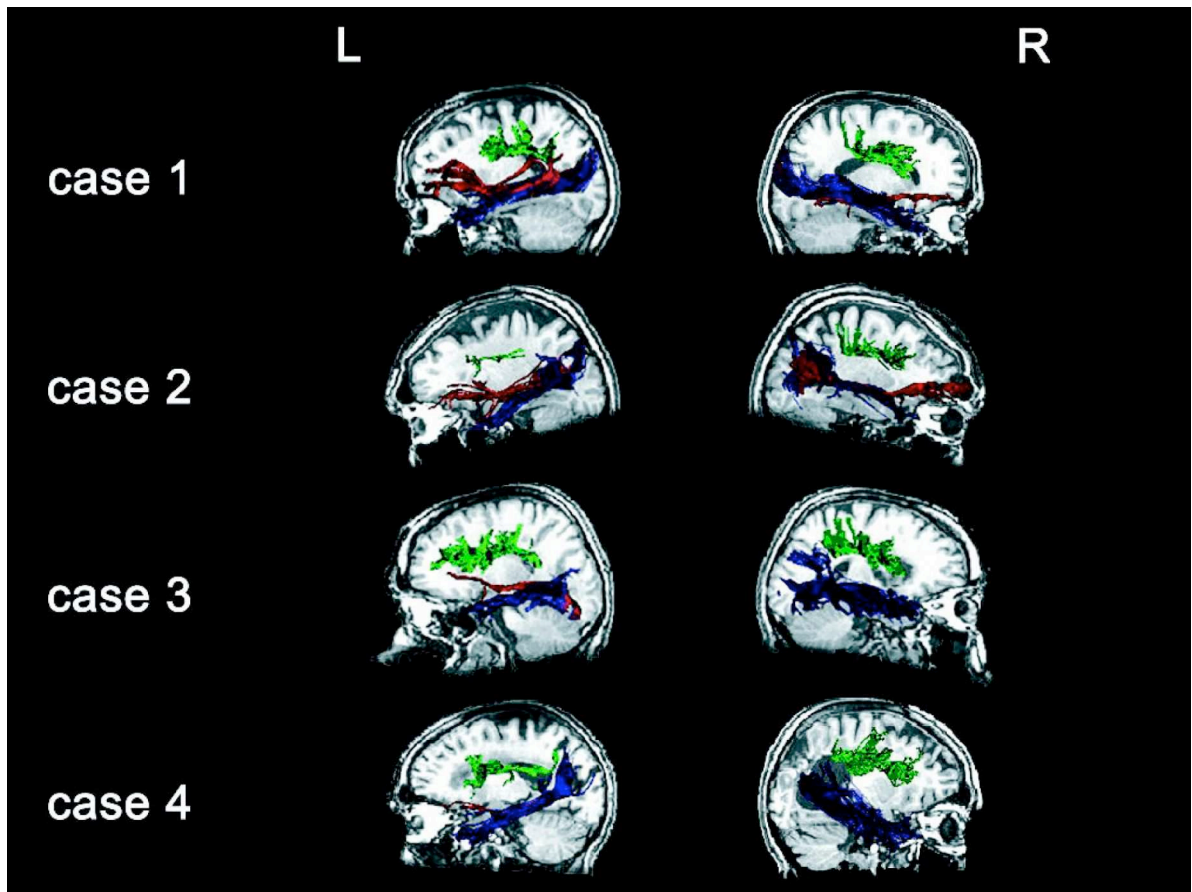


Figure 2: Sagittal lateral views (left hemisphere, L; right hemisphere, R) of the DTI tractography of the **SLF** (in green), the **ILF** (in blue) and the **IFOF** (in red) for the four patients studied. For each hemisphere, the three fasciculi are displayed on a sagittal MRI slice in the extended acpc referential.

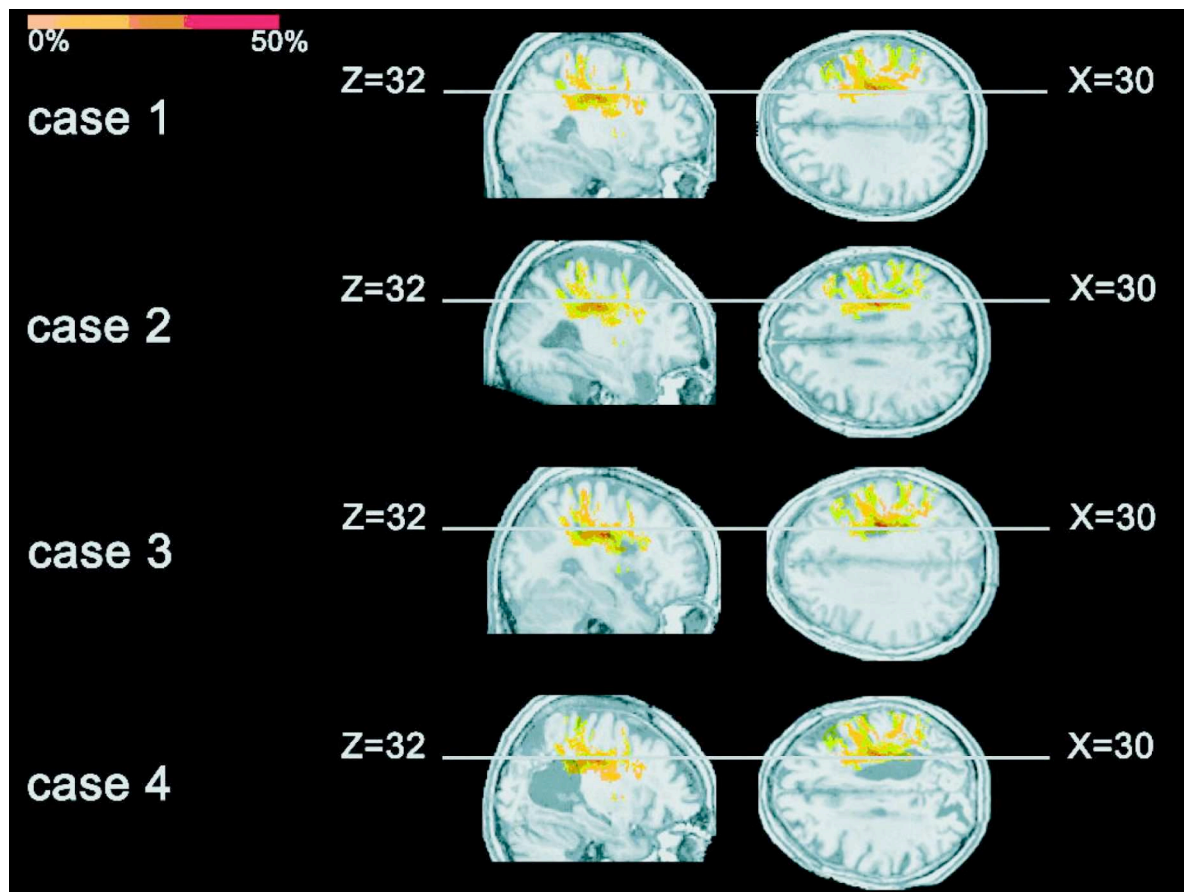


Figure 3: Patients' lesions projections to the normalized percentage maps of the SLF localization in 16 normal subjects<sup>36</sup> in the MNI referential space (<http://www.mni.mcgill.ca>). An axial (Z=32) and a sagittal (X=30) MRI slices are shown (neurological convention: left hemisphere is on the left side).

Case 2 was admitted to hospital with dysarthria, left upper limb motor deficit, and extinction for left visual and tactile stimuli. Five days later, a mild motor deficit persisted. Orientation in time and space was normal and there were no more signs of visual field deficit, sensory extinction or left neglect. MRI demonstrated a right hemispheric lesion involving the posterior part of the insula, the whole temporal pole and the superior, middle and inferior temporal gyri (Fig. 1, case 2). The tractography reconstruction showed intact and bilateral representation of the SLF, IFOF and ILF (Fig. 2 and 3, case 2).

Case 3 was admitted to hospital with left hemiparesis predominant in the arm, left Babinski sign, rightward deviation of the head, signs of left neglect and anosognosia. Nine days later, case 3 still had left visual and tactile extinction, signs of severe left neglect and anosognosia. When describing from memory of a map of France<sup>36</sup>, she produced 8 items on the left side and 7 items on the right side, thus showing no evidence of imaginal neglect<sup>37</sup>. MRI (Fig. 1,

case 3) demonstrated a right hemispheric lesion involving the subinsular and temporal stem white matter, the body of the caudate nucleus, the lenticular nucleus, the middle part of the corona radiata, the angular and supra-marginal gyri (gray matter and underlying white matter). The tractography reconstruction showed intact and bilateral representation of the ILF, partial involvement of the right SLF (Fig. 2 and 3, case 3) and complete disconnection of the right IFOF (Fig.2, case 3).

Case 4 had a right hemorrhagic occipital-parietal stroke, which resulted in left homonymous hemianopia. Two years after clinical onset, she had left hemiparesis and signs of left neglect. She was anosognosic and did not explore the left hemispace to compensate for her hemianopia. Neuropsychological examination revealed no deficit of memory or language. MRI showed a right hemispheric lesion involving the inferior and superior parietal lobules (gray matter and underlying white matter), the precuneus, the cuneus, the middle temporo-occipital gyrus and the posterior part of the inferior temporal gyrus. The tractography reconstruction showed intact and bilateral representation of the ILF, partial involvement of the right SLF (Fig. 2 and 3, case 4) and complete lesion of the right IFOF (Fig. 2, case 4).

## *Discussion*

We used DTI-tractography to show direct evidence of a disconnection mechanism involving the major rostro-caudal white matter pathways in neglect patients with vascular lesions. Previous studies demonstrating white-matter disconnection in neglect patients had relied on anatomical<sup>10, 12, 38</sup> or functional<sup>18</sup> MRI, and inferred the site of tract lesion either from general anatomical knowledge<sup>10</sup>, or from DTI in normal subjects<sup>12</sup>. Compared to previous attempts using MRI or CT scans the use of DTI tractography allowed us to identify more precisely the white matter pathways that were damaged in neglect patients.

The present results confirm the importance of a right-hemisphere fronto-parietal network, connected by the SLF, for visuospatial awareness<sup>10, 11</sup>. Moreover, our findings extend and precise the anatomical localization of those previous results, by demonstrating that (1) the partial interruption of the SLF combined with complete damaged to the IFOF can be associated with chronic visual neglect, and (2) temporal lesions sparing the SLF and IFOF, but encroaching upon the IPL and the STG, two areas previously indicated as the critical cortical loci for spatial awareness<sup>2, 5, 6</sup>, do not necessarily provoke chronic visual neglect, as shown by case 1's normal performance on visuospatial tests and consistent with results obtained in monkey<sup>20</sup>.

Our results offer a way to solve the controversy concerning the neural bases of neglect in

humans, by confirming that neglect can be associated to lesions in the temporal lobe<sup>5, 6, 12</sup>. However, our study and previous reports<sup>12</sup> suggest that neglect in patients with temporal lesions may result from the lesion extending into the deep white matter connecting occipital to frontal lobe through the IFOF. After its discovery<sup>39</sup>, the IFOF was demonstrated in post-mortem dissections<sup>40</sup> and in virtual *in vivo* DTI-tractography reconstructions<sup>31</sup>. The IFOF connects the lateral and medial orbitofrontal cortex to the occipital lobe. At least in humans, it represents the only direct connections between occipital and frontal lobes<sup>19</sup>. The function of the IFOF is at present unknown. The inferior-lateral portions of the frontal lobe, a projection site of the IFOF, have been identified as the typical lesional site for frontal neglect<sup>8</sup>. Frontal neglect, perhaps less common than neglect resulting from lesions to more posterior parts of the brain<sup>3</sup>, might have specific characters, such as a dependency on the presence of right-sided distracters to be elicited<sup>41</sup>. Both the neglect patients we reported showed little asymmetry of performance on the Albert line cancellation test, where there are no distracters, whereas they omitted most contralateral targets on the bells test and the letter cancellation test, where a target/distracter discrimination is required. Thus, they showed a pattern of neglect similar to that of a patient with a predominantly frontal lesion<sup>41</sup>. Patients with lesions in the inferior and precentral frontal gyri and the underlying white matter may show impaired performance on cancellation tasks but accurately bisect horizontal lines<sup>42</sup>, as did the present patients with IFOF disconnection. IFOF disconnection may deafferent the ventral frontal cortex from more posterior sources of visual input, related, for example, to object identification. In the monkey, neuron populations in the lateral prefrontal cortex respond both to the location and to the identity of previously presented visual objects, thus allowing the integration of "what" and "where" information<sup>43</sup>. Regions in the human ventrolateral prefrontal cortex, which constitute a projection site for the IFOF, show lateral selectivity in the short-time retention of spatial information<sup>44</sup> and may be important to resolve perceptual ambiguity<sup>45</sup>. Damage to these regions in the right hemisphere may bias rightwards the mental reconstruction of a number line<sup>46</sup>. Furthermore, the right ventrolateral prefrontal cortex is a cortical endpoint of the ventral spatial attentional network, which is important for the response to previously unattended targets, and whose dysfunction leads to neglect behavior<sup>18</sup>. The right ventrolateral prefrontal cortex may represent a site of functional interaction between the dorsal and the ventral attentional networks<sup>18</sup>. We propose that the ventral prefrontal cortex represents a convergence zone of three streams of visual processing: (1) the occipito-temporal stream, dedicated to object processing<sup>47, 48</sup>, through the IFOF and the uncinate fasciculus<sup>31</sup>, (2) the ventral parieto-frontal attentional network<sup>18</sup>, presumably connected by the human homologue



of the SLF III<sup>49</sup>, and (3) the dorsal parieto-temporal attentional network<sup>18</sup>, linked by the human homologue of the SLF II<sup>11, 49</sup>. After damage to the IFOF, its frontal projection sites are likely to be deprived of the direct visual input from the contralateral space. IFOF disconnection can also impair frontal top-down influences on extrastriatal visual areas, thus leading to poor attentional processing of left-sided stimuli. Both mechanisms can contribute to the development of impaired visuospatial awareness for stimuli contralateral to the disconnection.

However, we do not know yet whether an isolated lesion of the IFOF is enough to cause neglect, even if an IFOF localization could be consistent with previously reported cases of neglect in patients with posterior cerebral artery strokes<sup>12</sup>. Also it is unclear whether involvement of different tracts is associated with different clinical profiles. Future studies on larger cohorts are needed to shed light on this matter.

## **References**

1. Azouvi P, Samuel C, Louis-Dreyfus A, et al. Sensitivity of clinical and behavioural tests of spatial neglect after right hemisphere stroke. *Journal of Neurology, Neurosurgery and Psychiatry* 2002;73:160-166.
2. Vallar G. Extrapersonal visual unilateral spatial neglect and its neuroanatomy. *Neuroimage* 2001;14:S52-S58.
3. Mort DJ, Malhotra P, Mannan SK, et al. The anatomy of visual neglect. *Brain* 2003;126:1986-1997.
4. Committeri G, Pitzalis S, Galati G, et al. Neural bases of personal and extrapersonal neglect in humans. *Brain* 2007;130:431-441.
5. Karnath H-O, Fruhmann Berger M, Kuker W, Rorden C. The anatomy of spatial neglect based on voxelwise statistical analysis: a study of 140 patients. *Cerebral Cortex* 2004;14:1164-1172.
6. Karnath H-O, Ferber S, Himmelbach M. Spatial awareness is a function of the temporal not the posterior parietal lobe. *Nature* 2001;411:950-963.
7. Heilman KM, Valenstein E. Frontal lobe neglect in man. *Neurology* 1972;22:660-664.
8. Husain M, Kennard C. Visual neglect associated with frontal lobe infarction. *Journal of Neurology* 1996;243:652-657.
9. Park KC, Lee BH, Kim EJ, et al. Deafferentation-disconnection neglect induced by posterior cerebral artery infarction. *Neurology* 2006;66:56-61.
10. Doricchi F, Tomaiuolo F. The anatomy of neglect without hemianopia: a key role for parietal-frontal disconnection? *NeuroReport* 2003;14:2239-2243.
11. Thiebaut de Schotten M, Urbanski M, Duffau H, et al. Direct evidence for a parietal-frontal pathway subserving spatial awareness in humans. *Science* 2005;309:2226-2228.
12. Bird CM, Malhotra P, Parton A, Coulthard E, Rushworth MF, Husain M. Visual neglect following right posterior cerebral artery infarction. *Journal of Neurology, Neurosurgery and Psychiatry* 2006;77:1008-1012.
13. Mesulam MM. A cortical network for directed attention and unilateral neglect. *Annals of Neurology* 1981;10:309-325.
14. Heilman KM, Watson RT, Valenstein E. Neglect and related disorders. In: Heilman KM, Valenstein E, eds. *Clinical Neuropsychology*, 3rd ed. New York: Oxford University Press, 1993: 279-336.
15. Bartolomeo P. A parieto-frontal network for spatial awareness in the right hemisphere

of the human brain. *Archives of Neurology* 2006;63:1238-1241.

16. Gaffan D. Widespread Cortical Networks Underlie Memory and Attention. *Science* 2005;309:2172-2173.
17. Bartolomeo P, Thiebaut de Schotten M, Doricchi F. Left unilateral neglect as a disconnection syndrome. *Cerebral Cortex* 2007;doi: 10.1093/cercor/bhl1181.
18. He BJ, Snyder AZ, Vincent JL, Epstein A, Shulman GL, Corbetta M. Breakdown of functional connectivity in frontoparietal networks underlies behavioral deficits in spatial neglect. *Neuron* 2007;53:905-918.
19. Catani M. Diffusion tensor magnetic resonance imaging tractography in cognitive disorders. *Current Opinion in Neurology* 2006;19:599-606.
20. Gaffan D, Hornak J. Visual neglect in the monkey. Representation and disconnection. *Brain* 1997;120:1647-1657.
21. Buschman TJ, Miller EK. Top-Down Versus Bottom-Up Control of Attention in the Prefrontal and Posterior Parietal Cortices. *Science* 2007;315:1860-1862.
22. Reep RL, Corwin JV, Cheatwood JL, Van Vleet TM, Heilman KM, Watson RT. A rodent model for investigating the neurobiology of contralateral neglect. *Cognitive and Behavioral Neurology* 2004;17:191-194.
23. Di Ferdinando A, Parisi D, Bartolomeo P. Modeling orienting behavior and extinction with "ecological" neural networks. *Journal of Cognitive Neuroscience* 2007;19.
24. Bartolomeo P, Chokron S. Egocentric frame of reference: Its role in spatial bias after right hemisphere lesions. *Neuropsychologia* 1999;37:881-894.
25. D'Erme P, De Bonis C, Gainotti G. Influenza dell'emi-inattenzione e dell'emianopsia sui compiti di bisezione di linee nei pazienti cerebrolesi [Influence of unilateral neglect and hemianopia on line bisection performance in brain-damaged patients]. *Archivio di Psicologia, Neurologia e Psichiatria* 1987;48:165-189.
26. Albert ML. A simple test of visual neglect. *Neurology* 1973;23:658-664.
27. Mesulam MM. Attention, confusional states and neglect. In: Mesulam MM, ed. *Principles of Behavioral Neurology*. Philadelphia (PA): F.A. Davis, 1985: 125-168.
28. Gauthier L, Dehaut F, Joanette Y. The bells test: A quantitative and qualitative test for visual neglect. *International Journal of Clinical Neuropsychology* 1989;11:49-53.
29. Gainotti G, D'Erme P, Bartolomeo P. Early orientation of attention toward the half space ipsilateral to the lesion in patients with unilateral brain damage. *Journal of Neurology, Neurosurgery and Psychiatry* 1991;54:1082-1089.
30. Mangin JF, Poupon C, Clark C, Le Bihan D, Bloch I. Distortion correction and robust

- tensor estimation for MR diffusion imaging. *Medical Image Analysis* 2002;6:191-198.
31. Catani M, Howard RJ, Pajevic S, Jones DK. Virtual in vivo interactive dissection of white matter fasciculi in the human brain. *Neuroimage* 2002;17:77-94.
  32. Basser PJ, Pierpaoli C. A simplified method to measure the diffusion tensor from seven MR images. *Magnetic Resonance in Medicine* 1998;39:928-934.
  33. Catani M, Jones DK, ffytche DH. Perisylvian language networks of the human brain. *Annals of Neurology* 2005;57:8-16.
  34. Catani M, Jones DK, Donato R, Ffytche DH. Occipito-temporal connections in the human brain. *Brain* 2003;126:2093-2107.
  35. Thiebaut de Schotten M, Kinkingnéhun SR, Delmaire C, et al. Visualization of disconnection syndromes in humans. submitted.
  36. Rode G, Perenin MT. Temporary remission of representational hemineglect through vestibular stimulation. *NeuroReport* 1994;5:869-872.
  37. Bartolomeo P, D'Erme P, Gainotti G. The relationship between visuospatial and representational neglect. *Neurology* 1994;44:1710-1714.
  38. Leibovitch FS, Black SE, Caldwell CB, Ebert PL, Ehrlich LE, Szalai JP. Brain-behavior correlations in hemispatial neglect using CT and SPECT: the Sunnybrook Stroke Study. *Neurology* 1998;50:901-908.
  39. Curran EJ. A new association fiber tract in the cerebrum. *Journal of Comparative Neurology and Psychology* 1909;19:645-662.
  40. Crosby EC, Humphrey T, Lauer EW. *Correlative Anatomy of the Nervous System*. New York: Macmillian Co., 1962.
  41. Husain M, Kennard C. Distractor-dependent frontal neglect. *Neuropsychologia* 1997;35:829-841.
  42. Binder J, Marshall R, Lazar R, Benjamin J, Mohr JP. Distinct syndromes of hemineglect. *Archives of Neurology* 1992;49:1187-1194.
  43. Rao SC, Rainer G, Miller EK. Integration of what and where in the primate prefrontal cortex. *Science* 1997;276:821-824.
  44. Rizzuto DS, Mamelak AN, Sutherling WW, Fineman I, Andersen RA. Spatial selectivity in human ventrolateral prefrontal cortex. *Nature Neuroscience* 2005;8:415-417.
  45. Sterzer P, Kleinschmidt A. A neural basis for inference in perceptual ambiguity. *Proceedings of the National Academy of Sciences of the United States of America* 2007;104:323-328.
  46. Doricchi F, Guariglia P, Gasparini M, Tomaiuolo F. Dissociation between physical

and mental number line bisection in right hemisphere brain damage. *Nature Neuroscience* 2005;8:1663-1665.

47. Mishkin M, Ungerleider LG, Macko KA. Object vision and spatial vision: Two cortical pathways. *Trends in Neurosciences* 1983;6:414-417.

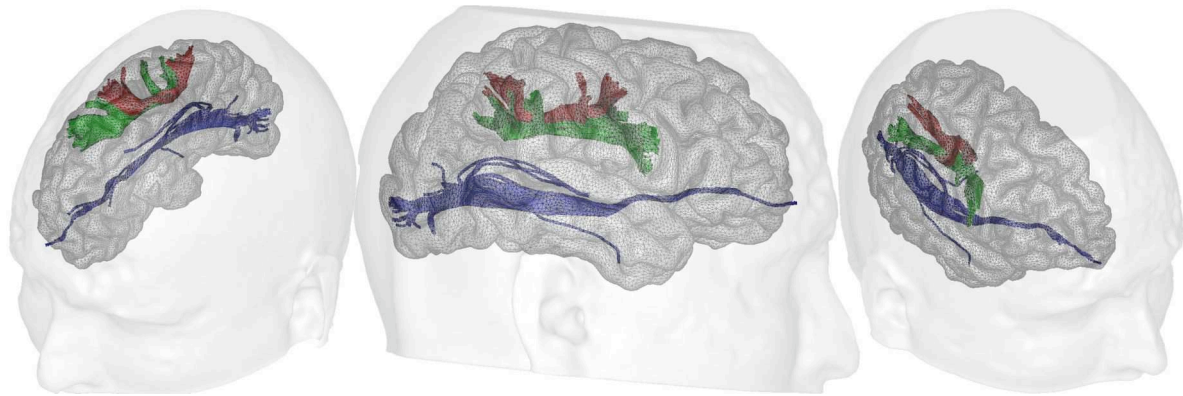
48. Milner AD, Goodale MA. *The Visual Brain in Action*. Oxford: Oxford University Press, 1995.

49. Schmahmann JD, Pandya DN. *Fiber Pathways of the Brain*. New York: Oxford University Press, 2006.

50. Rousseaux M, Beis JM, Pradat-Diehl P, et al. Normalisation d'une batterie de dépistage de la négligence spatiale. Etude de l'effet de l'âge, du niveau d'éducation, du sexe, de la main et de la latéralité [Presenting a battery for assessing spatial neglect. Norms and effects of age, educational level, sex, hand and laterality]. *Revue Neurologique* 2001;157:1385-1401.

### **3. Discussion**

Nous avons vu dans les deux articles précédents que tous les résultats anatomiques de la littérature convergent vers une explication de l'héminégligence comme la conséquence d'une disconnexion fronto-parietale (faisceau longitudinal supérieur) et/ou d'une disconnexion occipito-frontale (faisceau occipito-frontal inférieur, voir figure 30).



*Fig. 30 : Illustration du faisceau longitudinal supérieur (branche 3 en vert et branche 2 en rouge) et du faisceau occipito-frontal inférieur (en bleu).*

Ces résultats mettent à jour une faiblesse des connaissances des réseaux de substance blanche dans le cerveau humain et les conséquences cognitives de leur lésion. C'est pourquoi il est nécessaire de développer de nouvelles méthodes permettant d'étudier précisément les disconnexions.

# V – MISE EN EVIDENCE DES SYNDROMES DE DISCONNEXION

*Article soumis à Cortex*

## **Visualization of disconnection syndromes in humans**

Michel Thiebaut de Schotten<sup>1,2,7</sup>, Serge Kinkingnéhun<sup>1,6</sup>, Christine Delmaire<sup>2,4,6</sup>, Stéphane Lehéricy<sup>1,4,6</sup>, Hugues Duffau<sup>3,6</sup>, Lionel Thivard<sup>2,5</sup>, Emmanuelle Volle<sup>1,2,4,7</sup>, Richard Levy<sup>1,2,5,7</sup>, Bruno Dubois<sup>1,2,5,7</sup>, Paolo Bartolomeo<sup>1,2,5,7</sup>

<sup>1</sup>*INSERM Unit 610, Hôpital de la Salpêtrière, Paris, France*

<sup>2</sup>*Université Pierre et Marie Curie-Paris6, Paris, France*

<sup>3</sup>*Department of Neurosurgery, Hôpital Gui de Chauliac, CHU Montpellier, Montpellier, France*

<sup>4</sup>*Department of Neuroradiology, AP-HP, Hôpital de la Salpêtrière, Paris, France*

<sup>5</sup>*Department of Neurology, AP-HP, Hôpital de la Salpêtrière, Paris, France*

<sup>6</sup>*IFR49, SHFJ, Orsay, France*

<sup>7</sup>*IFR70, Hôpital de la Salpêtrière, Paris, France*

Correspondence to: Michel Thiebaut de Schotten or Paolo Bartolomeo, Inserm U610, G.H. Pitié Salpêtrière, 47 boulevard de l'Hôpital, 75013 PARIS, FRANCE, E-mail: michel.thiebaut@gmail.com or paolo.bartolomeo@gmail.com Telephone: +33 1 42 16 00 95, Fax: +33 1 42 16 41 95, Inserm U610, G.H. Pitié Salpêtrière, 47 boulevard de l'Hôpital, 75013 PARIS, FRANCE.

Number of references, 43; number of tables, 1; number of figures, 6.

Word count: Title, 45 characters; abstract, 200; text, 3597 words

Running title: Visualization of disconnection syndromes

## ***Abstract***

Knowledge of the relationship between structure and function is essential to explore the architecture of cognition. Cognitive processes require the coordinated activity of large-scale brain networks consisting of distant cortical regions, connected by long-range white matter tracts. Despite decades of connectional tracing studies in monkey, the backwardness of human anatomy makes it difficult to draw conclusions from lesion studies and functional neuroimaging when brain connectivity is at issue. We propose an approach to clinico-anatomical correlation, based on a standardised atlas of white matter tracts derived from diffusion tensor imaging tractography. We mapped the course and cortical projections of three rostro-caudal association pathways in the Montreal Neurological Institute space. For each voxel we defined the probability of finding fibres belonging to individual tracts. To test the utility of this method the averaged map was then used to localise the overlapping lesion derived from a group of patients with brain damage and neglect. Our study provides a general approach for establishing anatomo-functional correlations by identifying the cortical areas connected in normal subjects, or disconnected by white matter lesions. This method will help researchers and clinicians to identify the neural bases of cognitive abilities and the behavioural consequences of brain lesions.

**Key Words:** White matter, long-range connections, anatomo-clinical correlations, diffusion tensor imaging tractography.



## **Introduction**

Research on the neural correlates of human behaviour has recently witnessed an enormous expansion thanks to the increasingly precise descriptions of patterns of performance of patients with focal brain lesions and to the development of neuroimaging techniques, such as positron emission tomography and magnetic resonance imaging, used to study normal subjects while performing cognitive tasks. It is currently and widely accepted that cognitive abilities are not related to single cortical areas, but to distributed cortical networks, often including brain structures remote from each other and connected by long-range association bundles in the cerebral white matter (Catani and ffytche, 2005; Geschwind, 1965a, 1965b; Mesulam, 1990). Thus, knowledge of the organization of these pathways is essential to make inferences about structure/function relationships in the human brain (Mesulam, 2004). For example, models of language implicate the left arcuate fasciculus (AF; Benson et al., 1973), whose damaging typically results in conduction aphasia (Kempler et al., 1988; Naeser et al., 1982; Schmahmann and Pandya, 2006), whereas its temporary electrical inactivation during neurosurgery induces anomia errors (Duffau et al., 2002). Damage to the superior longitudinal fasciculus (SLF) in the right hemisphere is correlated with left unilateral neglect (Doricchi and Tomaiuolo, 2003), a disabling condition entailing the lack of awareness of events occurring in the left contralesional, side (Bartolomeo and Chokron, 2001; Heilman et al., 1993; Mesulam, 1999; Parton et al., 2004) and temporary inactivation during brain surgery of this same parieto-frontal pathway also induced signs of left neglect (Thiebaut de Schotten et al., 2005).

The course and projections of the SLF are well known in the monkey (Schmahmann and Pandya, 2006), but the terminations of its components in the human brain can only be extrapolated from the data available from non-human primates (Makris et al., 2005)

Until recently, the study of white matter organization in humans was based on neuropathological examination of post-mortem brain tissue (Bossy, 1991; Déjerine, 1895; Nieuwenhuys et al., 1988), but it has now received new momentum from the utilization of diffusion tensor imaging (DTI; Basser et al., 1994). DTI reflects the diffusion in space of water in the living brain. Water tends to diffuse preferentially along the axonal fibres, allowing for inference of the pathway followed by the fibres (Basser et al., 1994; Mori et al., 2005). Using this method, long-range pathways of superior associative fibres have been

visualized in human individuals (Catani et al., 2002) or small groups of subjects (Catani et al., 2005; Makris et al., 2005).

DTI is well adapted for a general description of subcortical white matter architecture in the human brain (Catani et al., 2005; Jones et al., 2002; Xu et al., 2002), but current work based on this approach has several limitations: (1) the correspondance with normalised space is difficult to establish (Catani et al., 2002; Catani et al., 2005; Mori et al., 2005; Wakana et al., 2004) (2) the variability in brain anatomy between individuals (Brett et al., 2002) may render difficult to decide whether a particular bundle is lesioned or not in an individual patient; (3) accurate estimates of the fasciculus size are not easy to obtain (Kinoshita et al., 2005); (4) cortical projections cannot be visualized, because specificity is often lost for tracts that run parallel to (or are merged with) one another (Basser et al., 2000; Wakana et al., 2004); (5) bundles tend to spread near the cortical projection site (Bossy, 1991; Déjerine, 1895; Nieuwenhuys et al., 1988), which also renders their visualization difficult or impossible using DTI. In addition, when evaluating the white matter lesions of brain-damaged patients, white matter damage typically perturbs the anisotropy signal, thus rendering difficult to reconstruct the fasciculi in traditional DTI approaches and consequently to decide whether a particular bundle is lesioned or not in an individual patient.

To address these issues, following previous attempts (Ciccarelli et al., 2003; Mori et al., 2002; Newton et al., 2006; Parker et al., 2005; Xu et al., 2002), we developed a method to localize the course and projections of long-range white matter pathways in the human brain. Using this method, we aim at the construction of an atlas of the human white matter in MNI space. Here, we applied this method to the mapping of three major caudal-rostral associative bundles. We normalized directly the image of the voxels concerned by the track of the long-range association fibres in the native space of each participant's brain (Davatzikos, 1998). We subsequently overlapped them in order to define the probability to find these specific fibres in each voxel of the MNI space. This approach permitted us to obtain a more precise estimate of the cortical projections of each fasciculus, and consequently a more complete visualization of the networks connected by each pathway. Using this method, we identified the trajectories and cortical projections of the AF and of two components of the SLF in each hemisphere of the standard human brain defined by the MNI space. Importantly, this method can be used in clinico-anatomical correlation studies where tracts can not be visualized, thus allowing the researcher to take into account possible hodological mechanisms of deficit (Catani and ffytche, 2005) In this sense, the present method permit to visualize and identify the white matter pathways damaged in disconnection syndromes. As an example, we provided a re-

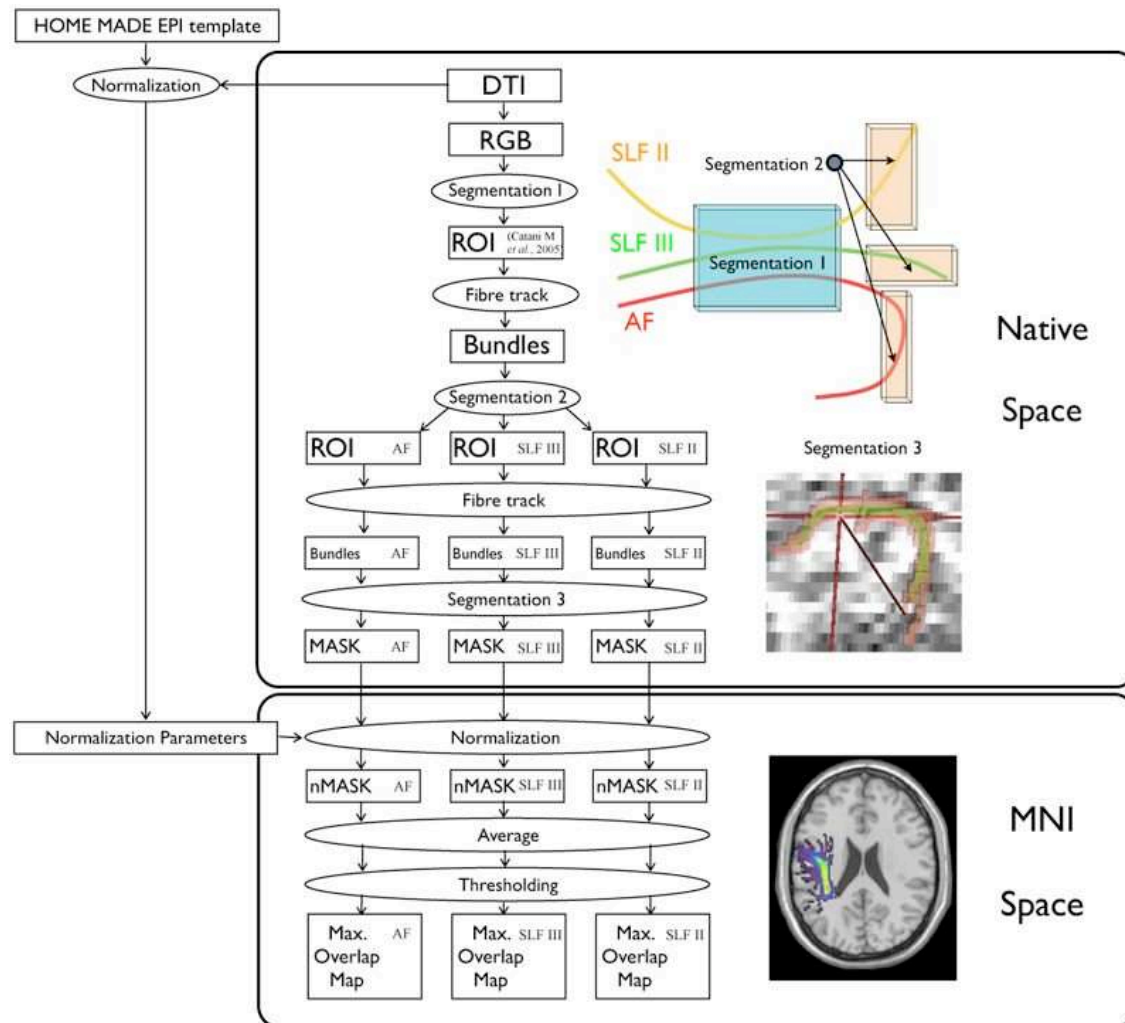
analysis of a previous lesion overlapping study, which permitted the identification of the white matter bundles typically damaged in patients with left unilateral neglect, a neurological syndrome resulting from right brain damage.

### ***Material and methods***

#### **Subjects and Data Acquisition**

Twenty-four right-handed subjects (twelve males and twelve females; mean age,  $28.0 \pm 7.0$  years; range, 18-42 years) gave written informed consent to participate to the study, which was approved by the local ethics committee. No subject had radiological signs of cerebral lesions on conventional MRI. MRI data were acquired using echo-planar imaging at 1.5 T (General Electric, Milwaukee, WI) with a standard head coil for signal reception. DTI axial slices were obtained using the following parameters: repetition time, 10s; echo time, 88ms; flip angle,  $90^\circ$ ; matrix,  $128 \times 128$ ; field of view,  $380 \times 380\text{mm}^2$ ; slice thickness, 3mm with no gap; in plane pixel size,  $3 \times 3 \text{mm}^2$  (isotropic voxels); acquisition time, 320s and 30 slices (not including the cerebellum). Four averages were used with signal averaging in the scanner buffer. Diffusion weighting was performed along six independent directions, with a b-value of  $900 \text{ s/mm}^2$ .

## Tractography : Definition of the regions of interest (ROI)



*Fig. 1. Procedure used to build maps of percentage overlap for the AF, the SLF III and the SLF II. See methods for keys and details.*

Fibre tracking was performed using two manually drawn ROIs in the native space: (1) a global ROI based on a previously published method (Catani et al., 2005) and (2) selective ROIs, which permitted us to differentiate the fasciculi (Figure 1).

Raw diffusion-weighted data were corrected for geometric distortion secondary to eddy currents using a registration technique based upon the geometric model of distortions (Mangin et al., 2002). Brainvisa 3.0.2 (<http://brainvisa.info/>) software was used to calculate diffusion tensors and anisotropy data, to define the ROIs and to perform fibre tracking. Fibre tracking was performed using the following steps: first, we defined a large ROI including all superior frontal, parietal and temporal associative fibres, as illustrated on a RGB map, whose colour referential indicated the main diffusion directions (Catani et al., 2005). Fibres passing through this ROI were reconstructed into three dimensional bundles. Second, we created a

virtual dissociation of this package of bundles in both hemispheres using an atlas of fibres (Bossy, 1991) and previous descriptions (Catani et al., 2005). We separated the fibres into three fasciculi presenting a convexity directed (1) upward: the AF (Bossy, 1991; Catani et al., 2002; Catani et al., 2005; Déjerine, 1895); (2) downward: the SLF II (Schmahmann and Pandya, 2006); (3) mesially: the SLF III (Bossy, 1991; Catani et al., 2005). In order to track these three fasciculi individually, three ROIs per hemisphere were created directly on the fibres of interest at the level of the caudal part of their convexity. Only bundles having more than 20 mm of length were kept in order to remove artefacts and to preserve long and valid fibres.

### **DTI template creation**

We created a homemade template using statistical parametric mapping software (SPM2, Welcome Department of Cognitive Neurology, Institute of Neurology, London, UK, <http://www.fil.ion.ucl.ac.uk/spm/>), in association with MATLAB version 6.5 (The Mathworks, Inc., MA, USA). The DTI images with no diffusion gradient (EPI T<sub>2</sub>-weighted images obtained for b=0) of all subjects were used to build the template. Images were spatially normalized to the standard EPI template provided in SPM2 using the default parameters of SPM2. The normalized EPI images were visually checked for misregistration (anterior and posterior commissure coordinates). Misregistered images were excluded from the analysis (n = 1). Then we averaged and smoothed (Filter Width at Half Maximum isotropic Gaussian kernel: 12 mm) the 21 normalized EPI images to create an EPI template (Thivard et al., 2005).

### **Spatial normalization and superposition of fibers**

Three stages were necessary to draw the percentage overlap maps of the long-range connections: (1) the elaboration of an individual mask for each fasciculus; (2) the spatial normalization of the masks to the homemade template, which approximates the space defined by Talairach and Tournoux (Talairach and Tournoux, 1988) to the MNI space; (3) the averaging of the normalized masks for each fasciculus (see Figure 1).

First, a three dimensional mask was created for each fasciculus using DTI images in the native space. This mask included all voxels crossed by fibres of the fasciculus of interest. Then, we normalized all DTI images as previously described using our homemade EPI template and applied the deformation matrix to the three dimensional masks of each fasciculus. The normalized EPI images were again visually checked for misregistration. Misregistered images, i.e., those with incorrect values of anterior and posterior commissure coordinates (n = 2), were excluded from the analysis. The EPI deformation field was applied to the fasciculi masks. Normalized masks were transformed to binary images with the voxels

inside the masks having a value of 1 and the other voxels of the images set to 0. For each hemisphere, we averaged the masks of each of the three fasciculi (AF, SLF III and SLF II) for all subjects. The resulting maps showed for each voxel the percentage of subjects having a fibre passing through it using Brainvisa. The final maps displayed the percentage of fasciculus overlap for each voxel (range, 0% - 50%).

### **Visualization of cortical projections**

The final map was finally projected on the surface of a normalized brain without any thresholding. Then the texture of the sulci and the cortical map of the fasciculi projections were projected on inflated normalized brain using Brainvisa 3.0.2. This offers the opportunity to estimate the projections of the three pathways explored.

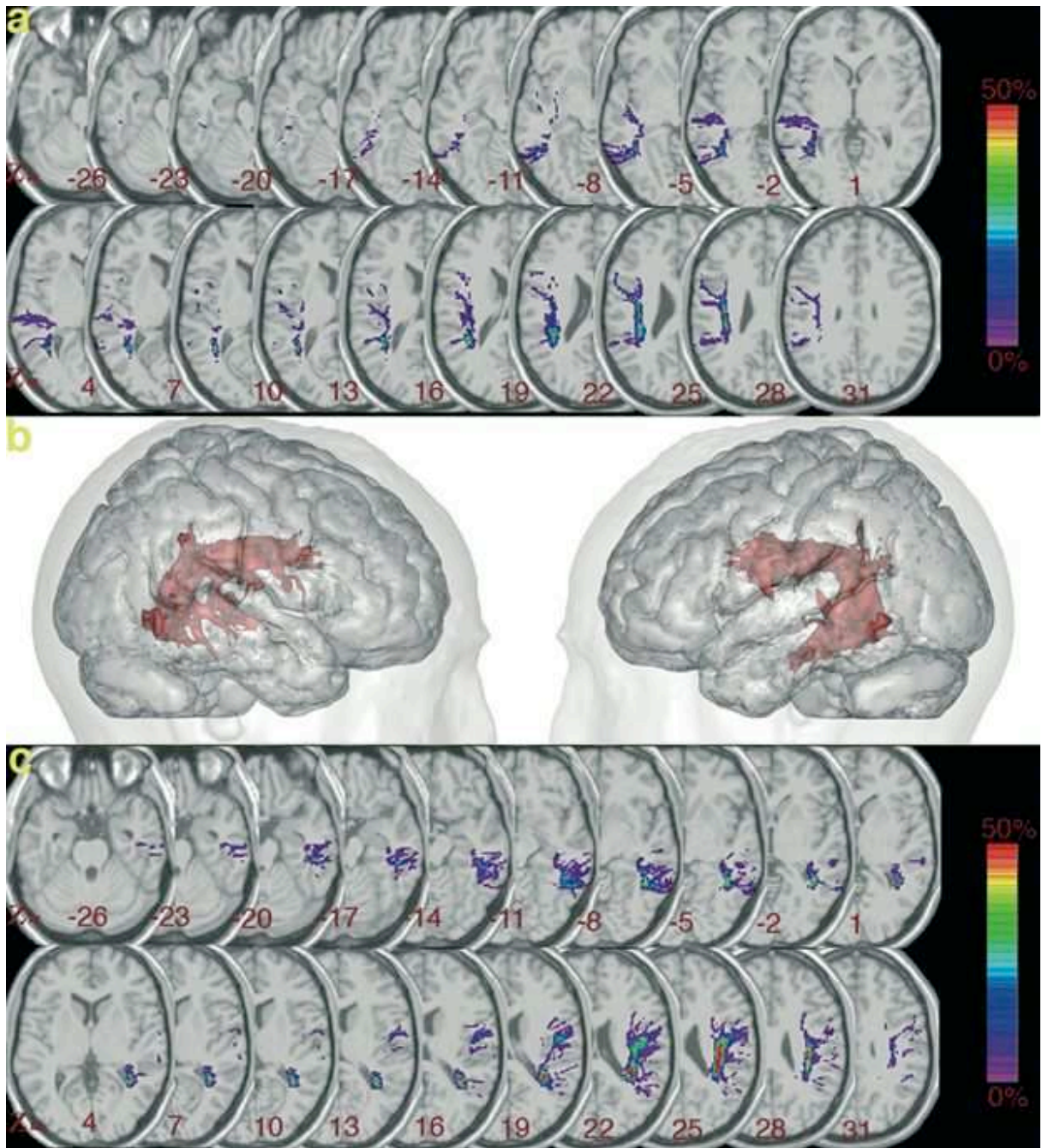
## **Visualization of disconnection results**

Thanks to this approach, neuro-imaging results can be projected to the normalized white matter maps. This offers the possibility to take into consideration the possible damage to long-range white matter pathways in studies based on anatomical images which do not allow the direct visualization of these pathways. As an example, we provide a re-analysis of the results of a study (Doricchi and Tomaiuolo, 2003), which investigated the anatomical correlates of spatial neglect. In the original study, the Talairach atlas (Talairach and Tournoux, 1988) was used to match the patients' lesions with normal anatomical structures, and neglect patients' lesions were found to overlap on the SLF, thus suggesting an important role for fronto-parietal disconnection in left neglect (Bartolomeo, 2006; Bartolomeo et al., 2007; Thiebaut de Schotten et al., 2005). Doricchi and Tomaiuolo kindly provided us with their original data, consisting of the maximum lesion overlap (as detected by T1-weighted MRI scans) of 21 patients with unilateral right hemisphere damage and signs of left neglect on tasks of line bisection and letter cancellation, in the absence of homonymous hemianopia. Patients' lesions were overlaid to create a map defining for each voxel of the MNI space the percentage of neglect patients whose lesion affected that voxel. We plotted the statistical map lesions on the full mask (without any threshold) of the three normalized fasciculi, AF, SLF III and SLF II. A lesioned voxel was considered to correlate with neglect if it was damaged in at least 80% of the neglect patients, and to be independent of neglect if it was lesioned in less than 5% of the patients. A chi-square test on the number of voxels implicated or not in full mask overlap of each fasciculus was performed to discriminate the relative contribution to neglect of damage to that fasciculus.

## **Results**

Following the terminology proposed by Schmahmann and Pandya (2006), we describe in a ventral-to-dorsal direction the AF, the SLF III and the SLF II.

## The arcuate fasciculus

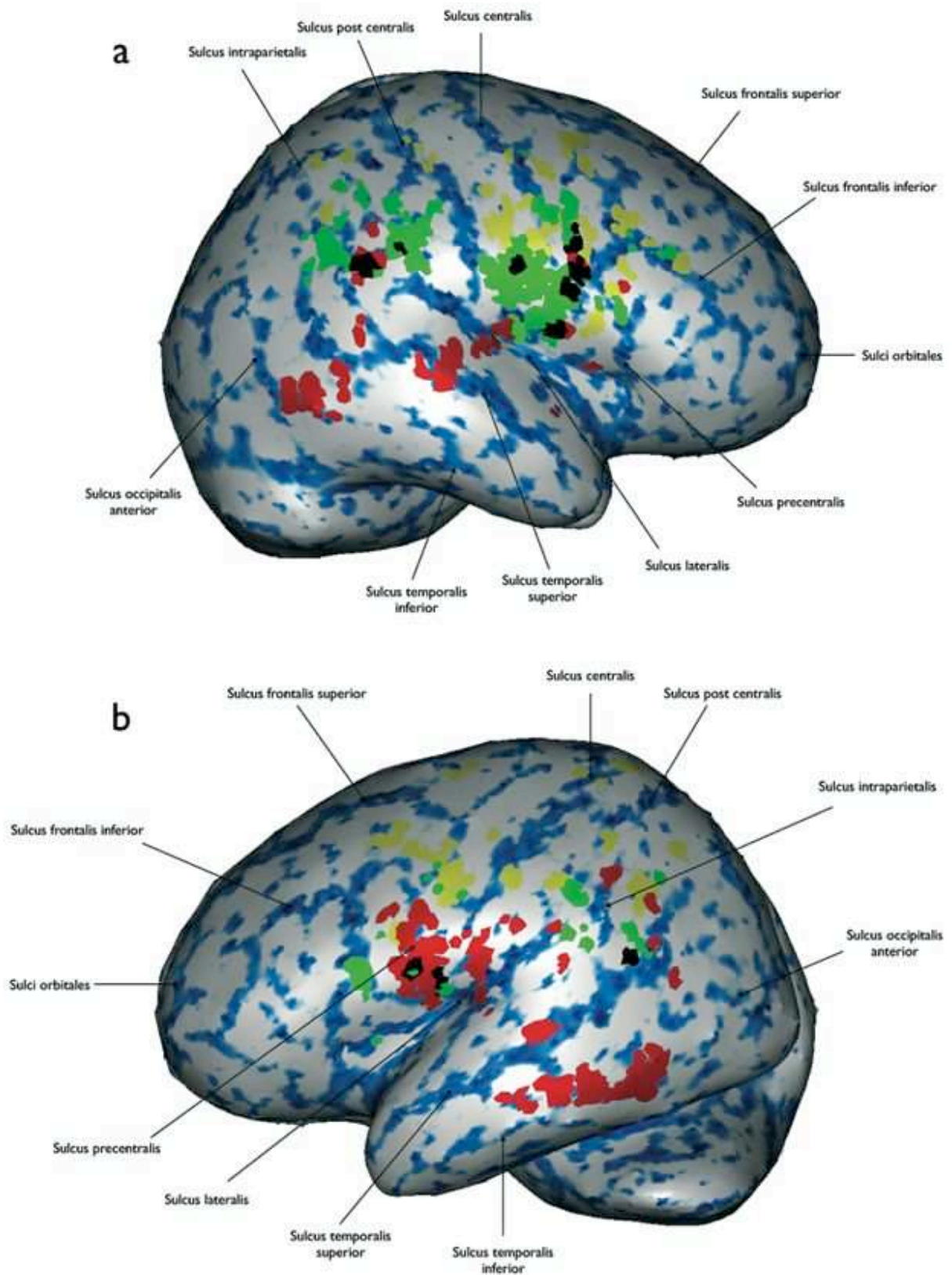


*Fig. 2. Probabilistic maps (in percentage of overlapping) for the AF in (a) the right hemisphere and (c) the left hemisphere in different axial sections of the MNI space. (b) 3-D reconstruction.*

Figure 2 shows the percentage of overlap of the fasciculi and a 3-D visualization of the full overlap of the AF for the right hemisphere (12 normalized fasciculi) and for the left hemisphere (14 normalized fasciculi). For both hemispheres, the tracks originated in the median and superior temporal gyri (Brodmann areas [BA] 21, 22, 41 and 42), coursed around

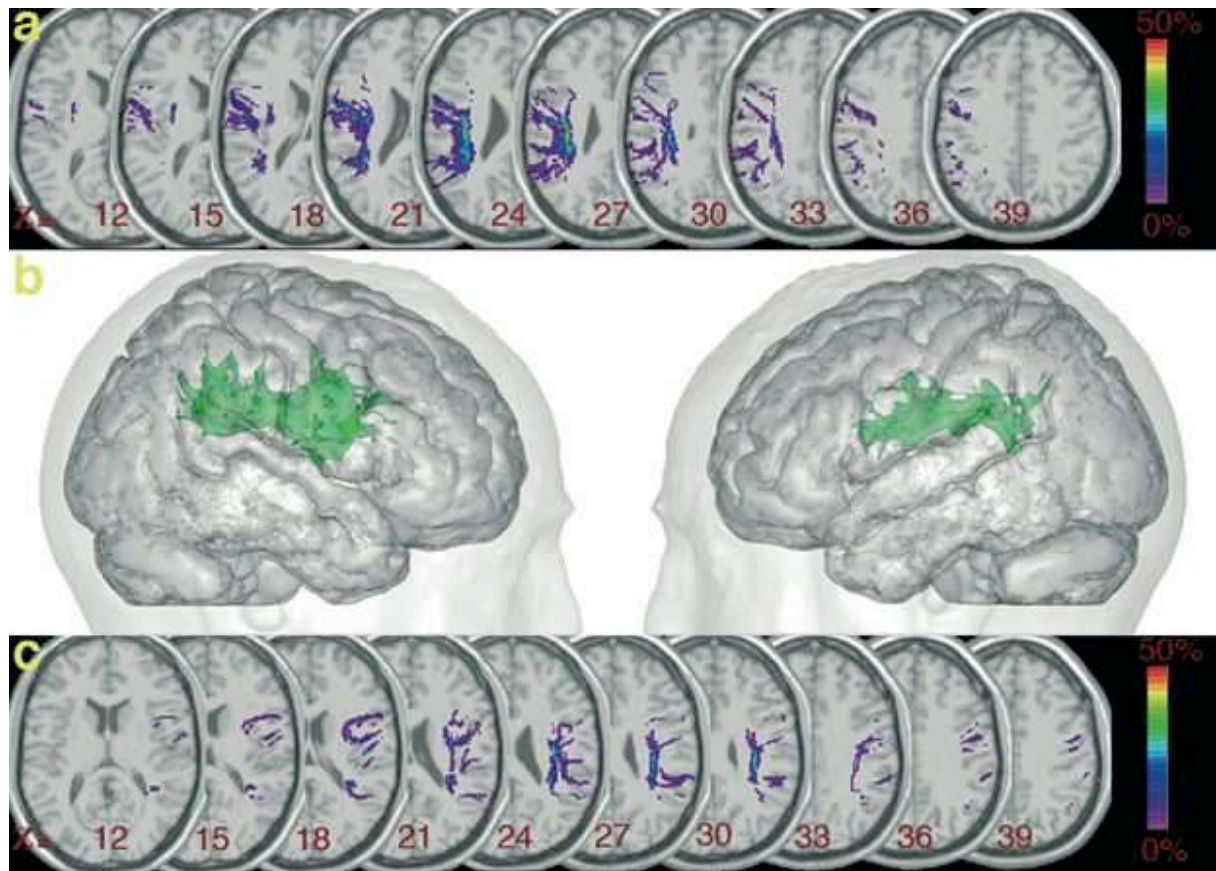


the supramarginal gyrus and ended in the rolandic operculum, the posterior part of the inferior frontal gyrus (BA 44, see also figure 3) (“originate” and “end” are only descriptive terms because fibre tracking is blind to fibre direction).



*Fig. 3. Cortical projections of the mapped fasciculi for the right hemisphere (a) and the left hemisphere (b) on a normalized, inflated brain. Red, AF; green, SLF III; yellow, SLF II.*

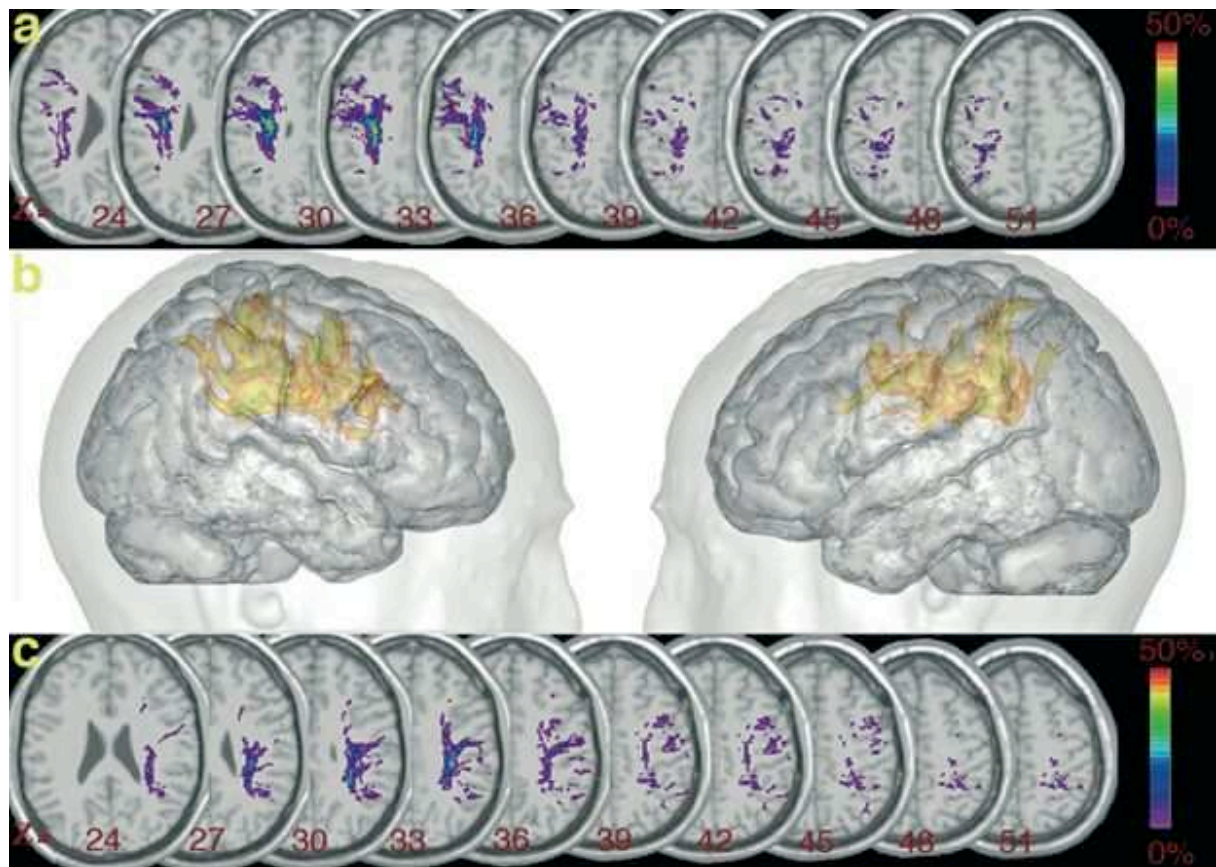
### The superior longitudinal fasciculus III



*Fig. 4. Probabilistic maps (in percentage of overlapping) for the SLF III in (a) the right hemisphere and (c) the left hemisphere in different axial sections of the MNI space. (b) 3-D reconstruction.*

The SLF III was described in the monkey by Schmahmann and Pandya (2006). Figure 4 shows the percentage of overlap of the fasciculi and a 3-D full overlap visualization for the right hemisphere (16 normalized fasciculi) and for the left hemisphere (15 normalized fasciculi). In the left hemisphere, the SLF III originated mainly in the superior temporal gyrus and in the supramarginal gyrus (BA 22 and 40) and terminated in the rolandic operculum and the inferior frontal operculum (BA 44 and 45). In the right hemisphere, the track originated mainly in the supramarginal and angular gyri (BA 39 and 40) and terminated in the precentral gyrus, the rolandic operculum and the inferior frontal operculum (BA 44, 45 and the inferior part of BA 6) (see Figure 3).

### The superior longitudinal fasciculus II



*Fig. 5. Probabilistic maps (in percentage of overlapping) for the SLF II in (a) the right hemisphere and (c) the left hemisphere in different axial sections of the MNI space. (b) 3-D reconstruction.*

Figure 5 shows the percentage of SLF II overlap and the 3D full overlap visualization of the SLF II for the right hemisphere (19 normalized fasciculi) and for the left hemisphere (19

normalized fasciculi). For both hemispheres, the caudal terminations of the SLF II were in the inferior and superior parietal lobules, and mainly in the angular gyrus (BA 39), including the intraparietal sulcus (IPS). The rostral terminations were observed in the middle and superior frontal gyri (BA 9, 8, 46 and 6) (see also figure 3).

### **Analysis of white matter damage in left unilateral neglect**

The re-analysis of a previous lesion overlapping study of left neglect (Doricchi and Tomaiuolo, 2003), which we provide as an example of application of our approach, demonstrated a different implication in unilateral neglect for the three fascicles (Table 1 and Fig. 6; chi-square value, 6961.05; d.f., 2;  $P < 0.0001$ ).

	AF	SLF III	SLF II
<5%	5866	6	23
>80%	370	631	1792

Table 1. Number of voxels for each of the three fascicles implicated, respectively, in <5% and >80% of patients with left neglect from a previous lesion overlap study (Doricchi and Tomaiuolo, 2003).

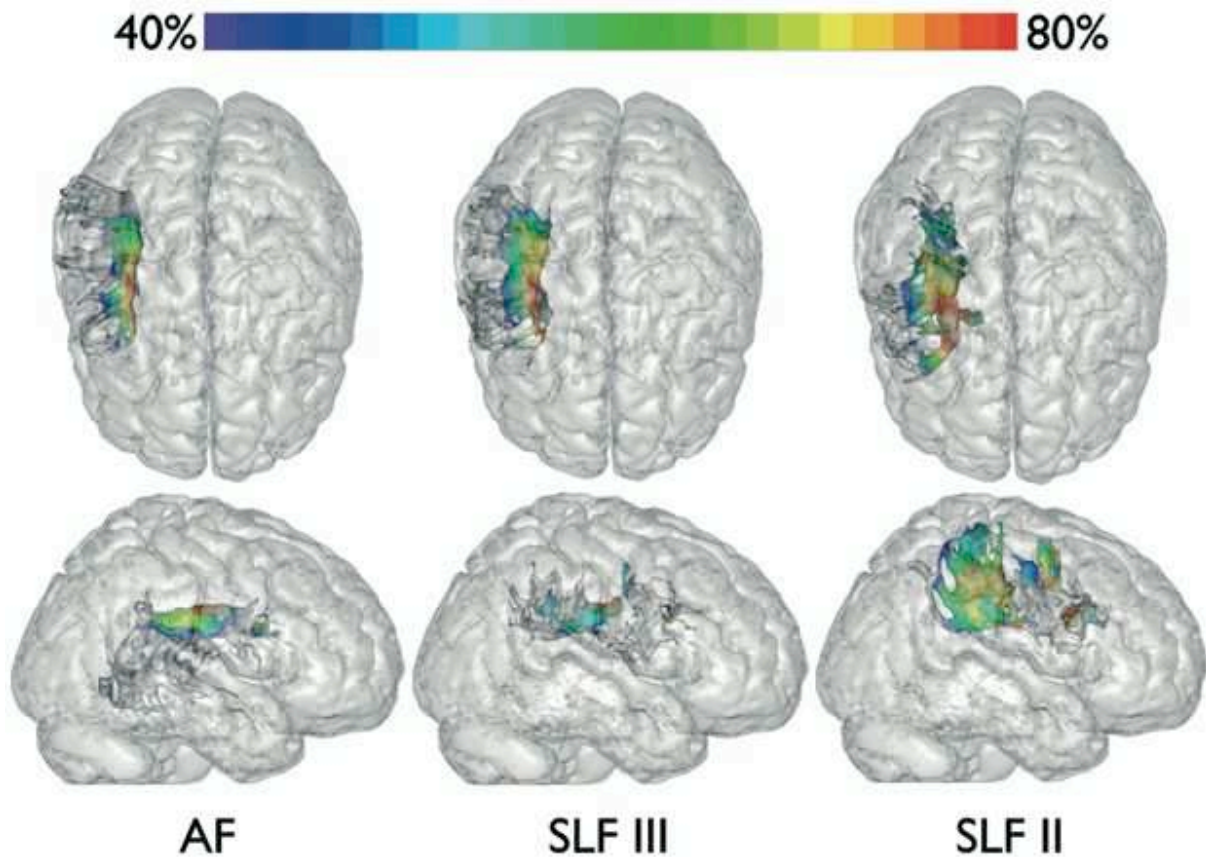


Fig. 6. Percentage lesion overlaps of patients with left neglect from a previous study (Doricchi and Tomaiuolo, 2003), plotted on the three long-range pathways in MNI space.

Post-hoc tests showed a difference between the AF and each of the two components of the SLF (chi-square value, 4028.11; d.f., 1;  $P < 0.0001$ ). The SLF III and the SLF II did not differ between themselves (chi-square value,  $<1$ ). Thus, in this patient series unilateral neglect was related to damage to the right SLF III and II, but not to the AF. The present analysis permitted us to refine the original interpretation of the results as showing a link between neglect and fronto-parietal disconnection (Doricchi and Tomaiuolo, 2003) by identifying precisely the critical branches of the SLF whose damage brought about neglect signs.

## ***Discussion***

The concept of disconnection syndromes, introduced during 19<sup>th</sup> century and reinvented by the charismatic work of Norman Geschwind (1965a, 1965b), has been central in the development of cognitive neurosciences. The advent of functional neuroimaging, with its focus on cortical modules, has weakened the interest on the connection systems in the brain. A partial reversal of this trend has been initiated with the advent of diffusion tensor imaging and tractography (Catani and ffytche, 2005), but knowledge on the real connectivity of the human brain and its relationship to normal and impaired cognition remains enigmatic (Mesulam, 2004). Our approach aims at a better localization of brain lesions in neurological patients or foci of metabolic activation in neuroimaging studies on normal individuals, despite the vast inter-subject variability in brain anatomy, and taking into proper consideration the long-range white matter pathways in the brain.

The present approach is notably different from previous tracking studies (Catani et al., 2002; Catani et al., 2005; Mori et al., 2005; Wakana et al., 2004), because we first tracked the fibre bundles in the subjects' native space and then normalized the resulting tracks into a standard space. In this way, we were able to work in the native DTI space, and not in a space reconstructed and interpolated by normalization. Although we acknowledge the limit of using only 6 directions for the DTI acquisition, the identification of the probability of presence for each voxel of the MNI space of three long-range fasciculi in each hemisphere of the living human brain constitute a first step towards the construction of a white matter atlas in the MNI space. Moreover, we presented a possibility of estimating the location of the cortical endpoints of the fibre tracks mapped onto the cortical surface.

Our description of the AF is consistent with previous studies (Catani et al., 2002; Catani et al., 2005; Déjerine, 1895), showing that the AF originates in prefrontal cortex (Broca's area) and premotor cortex and projects caudally to the superior and middle temporal gyri, including Wernicke's area. Somewhat unexpectedly, some cortical projections of the AF were found to terminate in the inferotemporal regions. Other DTI studies did not find this result, perhaps because of considerable inter-subject variability coupled with normalization and averaging procedures (Catani et al., 2005; Jones et al., 2002). Inferotemporal terminations similar to those found in the present study were, however, detected by Catani et al in their description of the human AF using DTI (Catani et al., 2002; Bossy, 1991).

Our description of the SLF III corresponds to the third parieto-frontal parallel pathway described by Schmahmann & Pandya (2006). Consistent with the monkey data (Schmahmann and Pandya, 2006), the caudal projections of the SLF III are mainly located in the supra-marginal gyrus, while the rostral projections are in the rolandic and the inferior frontal operculum, including, for the right hemisphere, the inferior part of BA 6. The SLF II runs dorsally to the SLF III and links the middle and superior frontal gyri to the IPS, the supra-marginal gyrus and especially the angular gyrus of the parietal lobe, again consistent with monkey results (Schmahmann and Pandya, 2006). Temporary electrical inactivation of the right SLF II in a human patient (Thiebaut de Schotten et al., 2005) provoked dramatic rightward deviations in line bisection, a typical sign of left neglect (Schenkenberg et al., 1980). In line bisection, the subjective centre of the line is drawn at the point of subjective equality between the two line segments (Marshall and Halligan, 1990), whose relative salience may compete with each other (Anderson, 1996). In left neglect, salience would be rendered asymmetrical by the lesion, thus provoking rightward bisection errors (Anderson, 1996). In the monkey, regions of the IPS such as the lateral intraparietal area are important for visual salience (Gottlieb et al., 1998) and orienting of attention (Wardak et al., 2004). The present demonstration that the SLF II projects to the IPS nicely complements these data, and suggests a similar organization of the neural mechanisms of space processing in humans and in monkeys.

The present approach may offer the opportunity to re-examine previously published results obtained with lesion overlapping in stroke patients or fMRI. As an example, the maximum lesion overlap on the SLF in neglect patients (Doricchi and Tomaiuolo, 2003). We demonstrated a joint implication of the SLF III and of the SLF II, consistent with neurosurgical stimulation data (Thiebaut de Schotten et al., 2005) and suggesting the possibility that both of these parieto-frontal pathways may be important to spatial cognition. Thus, the present approach permitted to take into consideration those hodological factors (Catani and ffytche, 2005) which, in addition to topological factors resulting from cortical damage or deafferentation, may lead to neglect behavior (Bartolomeo et al., 2007). This should not be taken to imply that disconnection alone can cause neglect, or that the SLF is the only pathway implicated. Further work is necessary to disentangle the contributions of different lesional sites on different forms of neglect.

In vivo functional anatomy in humans, combining hodological, functional imaging and clinical evidence, is a major challenge of cognitive neuroscience (ffytche and Catani, 2005; Mesulam, 2004). We obtained maps detailing the course, location, projection and size of long-



range association fasciculi in the MNI space. Our results confirm and extend the reconstructions of the stem portions of the fasciculi based on RGB maps (Makris et al., 2005), for which the cortical projection sites could only be extrapolated from the monkey data. These maps will help clinicians and researchers to better define the location of subcortical brain lesions and their anatomical relationship with association pathways. Future results obtained with this method are likely to bring attention to the functional role of cortico-cortical association pathways in defining the architecture of the large brain networks which shape human sensory-motor and cognitive processes.

## **Acknowledgements**

We thank the participants for their cooperation, Fabrizio Doricchi and Francesco Tomaiuolo for providing us with details about their anatomical data, J. Chiras and the Department of Neuroradiology of the Salpêtrière Hospital for MRI acquisitions and the staff of BrainVISA software for technical support for image analysis.

## References

- Anderson, B., 1996. A mathematical model of line bisection behaviour in neglect. *Brain* 119, 841-850.
- Bartolomeo, P., 2006. A parietofrontal network for spatial awareness in the right hemisphere of the human brain. *Arch Neurol* 63, 1238-1241.
- Bartolomeo, P., Chokron, S., 2001. Levels of impairment in unilateral neglect. In: Boller, F., Grafman, J. (Eds.), *Handbook of Neuropsychology*. Elsevier Science Publishers, Amsterdam, pp. 67-98.
- Bartolomeo, P., Thiebaut de Schotten, M., Doricchi, F., 2007. Left Unilateral Neglect as a Disconnection Syndrome. *Cereb Cortex* (in press).
- Basser, P.J., Mattiello, J., LeBihan, D., 1994. Estimation of the effective self-diffusion tensor from the NMR spin echo. *J Magn Reson B* 103, 247-254.
- Basser, P.J., Pajevic, S., Pierpaoli, C., Duda, J., Aldroubi, A., 2000. In vivo fiber tractography using DT-MRI data. *Magn Reson Med* 44, 625-632.
- Benson, D.F., Sheremata, W.A., Bouchard, R., Segarra, J.M., Price, D., Geschwind, N., 1973. Conduction aphasia. A clinicopathological study. *Arch Neurol* 28, 339-346.
- Bossy, J., 1991. *Les hémisphères cérébraux*. Berlin: Springer, Berlin: Springer.
- Brett, M., Johnsrude, I.S., Owen, A.M., 2002. The problem of functional localization in the human brain. *Nat Rev Neurosci* 3, 243-249.
- Catani, M., ffytche, D.H., 2005. The rises and falls of disconnection syndromes. *Brain* 128, 2224-2239.
- Catani, M., Howard, R.J., Pajevic, S., Jones, D.K., 2002. Virtual in vivo interactive dissection of white matter fasciculi in the human brain. *Neuroimage* 17, 77-94.
- Catani, M., Jones, D.K., ffytche, D.H., 2005. Perisylvian language networks of the human brain. *Ann Neurol* 57, 8-16.
- Ciccarelli, O., Toosy, A.T., Parker, G.J., Wheeler-Kingshott, C.A., Barker, G.J., Miller, D.H., Thompson, A.J., 2003. Diffusion tractography based group mapping of major white-matter pathways in the human brain. *Neuroimage* 19, 1545-1555.
- Davatzikos, C., 1998. Mapping image data to stereotaxic spaces: applications to brain mapping. *Hum Brain Mapp* 6, 334-338.
- Doricchi, F., Tomaiuolo, F., 2003. The anatomy of neglect without hemianopia: a key role for parietal-frontal disconnection? *NeuroReport* 14, 2239-2243.

- Duffau, H., Capelle, L., Sichez, N., Denvil, D., Lopes, M., Sichez, J.P., Bitar, A., Fohanno, D., 2002. Intraoperative mapping of the subcortical language pathways using direct stimulations. An anatomo-functional study. *Brain* 125, 199-214.
- Déjerine, M.J., 1895. *Anatomie des Centres Nerveux*. Rueff et Cie, Paris.
- ffytche, D.H., Catani, M., 2005. Beyond localization: from hodology to function. *Philos Trans R Soc Lond B Biol Sci* 360, 767-779.
- Geschwind, N., 1965a. Disconnexion syndromes in animals and man - Part I. *Brain* 88, 237-294.
- Geschwind, N., 1965b. Disconnexion syndromes in animals and man - Part II. *Brain* 88, 585-644.
- Gottlieb, J.P., Kusunoki, M., Goldberg, M.E., 1998. The representation of visual salience in monkey parietal cortex. *Nature* 391, 481-484.
- Heilman, K.M., Watson, R.T., Valenstein, E., 1993. Neglect and related disorders. In: Heilman, K.M., Valenstein, E. (Eds.), *Clinical Neuropsychology*. Oxford University Press, New York, pp. 279-336.
- Jones, D.K., Griffin, L.D., Alexander, D.C., Catani, M., Horsfield, M.A., Howard, R., Williams, S.C., 2002. Spatial normalization and averaging of diffusion tensor MRI data sets. *Neuroimage* 17, 592-617.
- Kempler, D., Metter, E.J., Jackson, C.A., Hanson, W.R., Riege, W.H., Mazziotta, J.C., Phelps, M.E., 1988. Disconnection and cerebral metabolism. The case of conduction aphasia. *Arch Neurol* 45, 275-279.
- Kinoshita, M., Yamada, K., Hashimoto, N., Kato, A., Izumoto, S., Baba, T., Maruno, M., Nishimura, T., Yoshimine, T., 2005. Fiber-tracking does not accurately estimate size of fiber bundle in pathological condition: initial neurosurgical experience using neuronavigation and subcortical white matter stimulation. *Neuroimage* 25, 424-429.
- Makris, N., Kennedy, D.N., McInerney, S., Sorensen, A.G., Wang, R., Caviness, V.S., Jr., Pandya, D.N., 2005. Segmentation of subcomponents within the superior longitudinal fascicle in humans: a quantitative, in vivo, DT-MRI study. *Cereb Cortex* 15, 854-869.
- Mangin, J.F., Poupon, C., Clark, C., Le Bihan, D., Bloch, I., 2002. Distortion correction and robust tensor estimation for MR diffusion imaging. *Med Image Anal* 6, 191-198.
- Marshall, J.C., Halligan, P.W., 1990. Line bisection in a case of visual neglect: Psychophysical studies with implications of theory. *Cognitive Neuropsychology* 7, 107-130.

- Mesulam, M.-M., 2004. Imaging connectivity in the human cerebral cortex: The next frontier? *Annals of Neurology* 57, 5-7.
- Mesulam, M.M., 1990. Large-scale neurocognitive networks and distributed processing for attention, language, and memory. *Ann Neurol* 28, 597-613.
- Mesulam, M.M., 1999. Spatial attention and neglect: parietal, frontal and cingulate contributions to the mental representation and attentional targeting of salient extrapersonal events. *Philosophical Transactions of the Royal Society of London B* 354, 1325-1346.
- Mori, S., Kaufmann, W.E., Davatzikos, C., Stieltjes, B., Amodei, L., Fredericksen, K., Pearlson, G.D., Melhem, E.R., Solaiyappan, M., Raymond, G.V., Moser, H.W., van Zijl, P.C., 2002. Imaging cortical association tracts in the human brain using diffusion-tensor-based axonal tracking. *Magn Reson Med* 47, 215-223.
- Mori, S., Wakana, S., Nage-Poetscher, L.M., van Zijl, P.C.M., 2005. *MRI Atlas of Human White Matter*. ELSEVIER, Amsterdam, The Netherlands.
- Naeser, M.A., Alexander, M.P., Helm-Estabrooks, N., Levine, H.L., Laughlin, S.A., Geschwind, N., 1982. Aphasia with predominantly subcortical lesion sites: description of three capsular/putaminal aphasia syndromes. *Arch Neurol* 39, 2-14.
- Newton, J.M., Ward, N.S., Parker, G.J., Deichmann, R., Alexander, D.C., Friston, K.J., Frackowiak, R.S., 2006. Non-invasive mapping of corticofugal fibres from multiple motor areas--relevance to stroke recovery. *Brain* 129, 1844-1858.
- Nieuwenhuys, R., Voogd, J., Huijzen, C.v., 1988. *The human central nervous system: a synopsis and atlas*. Springer-Verlag, Berlin; New York.
- Parker, G.J., Luzzi, S., Alexander, D.C., Wheeler-Kingshott, C.A., Ciccarelli, O., Lambon Ralph, M.A., 2005. Lateralization of ventral and dorsal auditory-language pathways in the human brain. *Neuroimage* 24, 656-666.
- Parton, A., Malhotra, P., Husain, M., 2004. Hemispatial neglect. *J Neurol Neurosurg Psychiatry* 75, 13-21.
- Schenkenberg, T., Bradford, D.C., Ajax, E.T., 1980. Line bisection and unilateral visual neglect in patients with neurologic impairment. *Neurology* 30, 509-517.
- Schmahmann, J.D., Pandya, D.N., 2006. *Fiber pathways of the brain*. Oxford University Press, New York.
- Talairach, J., Tournoux, P., 1988. *Co-planar stereotaxic atlas of the human brain: an approach to medical cerebral imaging*. Thieme Medical Publishers, Stuttgart; New York.

- Thiebaut de Schotten, M., Urbanski, M., Duffau, H., Volle, E., Lévy, R., Dubois, B., Bartolomeo, P., 2005. Direct evidence for a parietal-frontal pathway subserving spatial awareness in humans. *Science* 309, 2226-2228.
- Thivard, L., Adam, C., Hasboun, D., Clemenceau, S., Dezamis, E., Lehericy, S., Dormont, D., Chiras, J., Baulac, M., Dupont, S., 2005. Interictal diffusion MRI in partial epilepsies explored with intracerebral electrodes. *Brain*.
- Wakana, S., Jiang, H., Nagae-Poetscher, L.M., van Zijl, P.C., Mori, S., 2004. Fiber tract-based atlas of human white matter anatomy. *Radiology* 230, 77-87.
- Wardak, C., Olivier, E., Duhamel, J.R., 2004. A deficit in covert attention after parietal cortex inactivation in the monkey. *Neuron* 42, 501-508.
- Xu, D., Mori, S., Solaiyappan, M., van Zijl, P.C., Davatzikos, C., 2002. A framework for callosal fiber distribution analysis. *Neuroimage* 17, 1131-1143.

# **VI – DISCUSSION GENERALE : DE LA DISCONNEXION A L'HODOLOGIE**

## **1. L'IMPORTANCE DES VOIES DE CONNEXION DE LA SUBSTANCE BLANCHE**

Rien ne définit mieux la fonction d'un neurone que ses connexions (Mesulam, 2005). Les informations circulent, les virus se propagent, les décharges épileptiques diffusent le long de ces connexions. Privé de ses connexions un neurone meurt dans des conditions d'apoptose (Duvall et al., 1985; Kerr et al., 1972). La mort neuronale dans la sclérose latérale amyotrophique, la dégénérescence neurofibrillaire dans la maladie d'Alzheimer, l'atrophie dans la dégénérescence olivopontocerebelleuse progressent le long des connections neuronales.

Une fois l'âge adulte atteint, les connexions deviennent plus importantes que les gènes ou les molécules. Par exemple, bien qu'ils aient des fonctions complètement différentes, il est tout à fait reconnu que les gènes et les protéines des neurones auditifs et visuels du cortex cérébral sont très similaires. Ce qui détermine finalement leur grande différence dans leur fonction ne se trouve pas être leur profil moléculaire mais plutôt leur connectivité.

Mais pourquoi nous intéresser à la connectivité à l'âge de l'imagerie fonctionnelle ? A une époque où des aimants dont la puissance croit de façon exponentielle promettent de détecter l'emplacement de même la plus discrète des pensées ? N'est-il pas nécessaire de localiser les aires corticales dévolues à la déception, la colère, l'introspection, l'empathie, l'orientation de l'attention ? Devons nous réellement nous intéresser également à leurs connexions ? La réponse est « oui », principalement parce que la fonction d'un système complexe ne peut pas être déduite juste par l'inventaire de ses composantes : la relation entre ses composantes introduit des attributs qui ne sont pas contenus dans la liste de ses éléments constitutifs « le tout est différent de la somme des parties »(Koffka, 1935).. Dans le cas du système nerveux, l'unité composée de cette architecture reliée qui permet au « tout de dépasser la somme de ses parties » est appelée réseau à grande échelle. Les détails du fonctionnement de ces réseaux à grande échelle nécessitent d'élaborer des techniques pour comprendre les modèles de connectivité.

Si le cortex cérébral avait été organisé sous la forme d'une chaîne de travail, où chaque station ajoute un nouvel ingrédient et fait suivre sa production à la station suivante, les connexions devraient avoir été inférées depuis longtemps à partir d'expériences précises et subtiles réalisées en imagerie fonctionnelle. Mais la réalité est bien plus complexe. Les connexions qui associent différentes aires cérébrales ne suivent pas une hiérarchie stricte. Il existe des connexions proactives et rétroactives, des nœuds de convergence, des traitements parallèles où deux aires corticales peuvent communiquer entre elles via différents chemins directs ou indirects (Catani et al., 2005). Si l'on regarde bien cette architecture, une aire cérébrale peut à la fois être au début, au milieu et à la fin d'un processus cognitif.

Cette distribution des connexions est complexe mais pas chaotique car elle obéit à des contraintes phylogénétiques établies.

La connectivité du cerveau humain devint une aire favorite de recherche durant la seconde partie du XIXe siècle. Charcot, Wernicke, Lichtheim et Freud, entre autres, publièrent des diagrammes élaborés décrivant les voies d'association corticales impliquées dans l'aphasie et des pathologies analogues (Freud, 1891; Lichtheim, 1885; Wernicke, 1874).

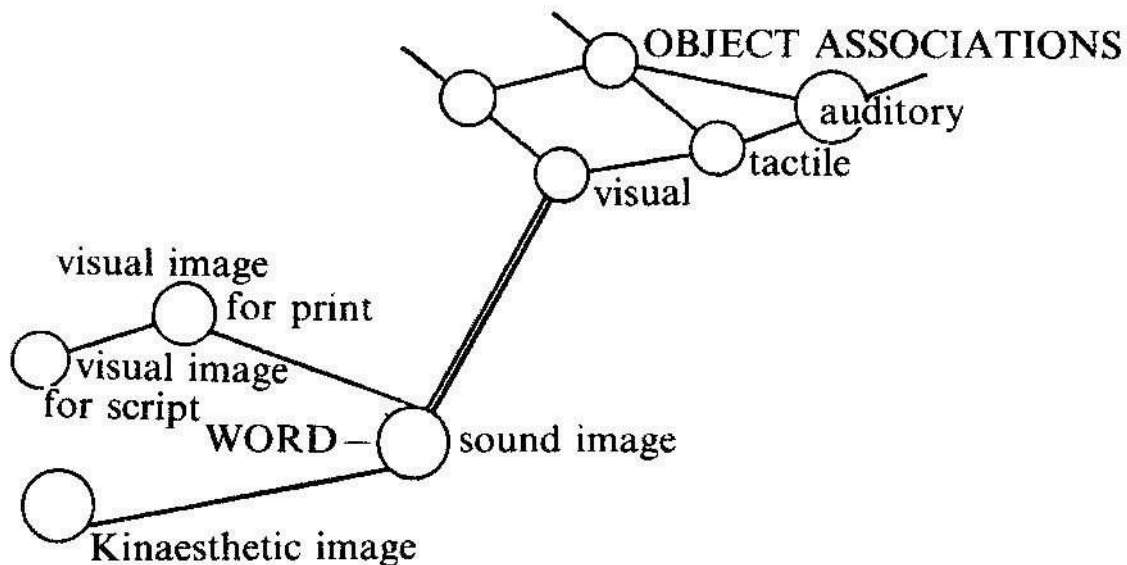


Fig. 31 : Exemple de diagramme produit par Freud (Freud, 1891)

Après la première et la seconde guerre mondiale, l'anglais est devenu le langage dominant en science et la littérature française et allemande sur la connectivité a été oubliée déclenchant une stagnation de la neurologie comportementale. Ce champ de recherche a été repris par le charismatique Norman Geschwind en 1965 dans ses articles qui revisitent la littérature classique sur la connectivité. Il explique, avec une vue plus contemporaine, les syndromes d'apraxie, d'aphasie d'agnosie et d'héminégligence comme la conséquence de

l'interruption de voies spécifiques connectant une région du cortex à une autre (Geschwind, 1965a, 1965b). Son travail peut être considéré comme très audacieux : en effet ses explications étaient basées sur des prédictions concernant la connectivité cérébrale et non des faits.

Depuis que cette recherche a repris, les études de la substance blanche ont émergé en première ligne de la clinique contemporaine et la recherche fondamentale en Neurosciences. Le développement du tenseur de diffusion et des outils de tractographie a permis la visualisation de l'organisation des fibres de substance blanche avec une précision qui n'avait encore jamais été atteinte *in vivo*. Nous sommes donc à l'aube d'un immense champ de recherche sur les nombreux longs faisceaux de substance blanche (voir figure 32) dont le coût phylogénétique justifie leur rôle déterminant dans la réalisation des fonctions cognitives.

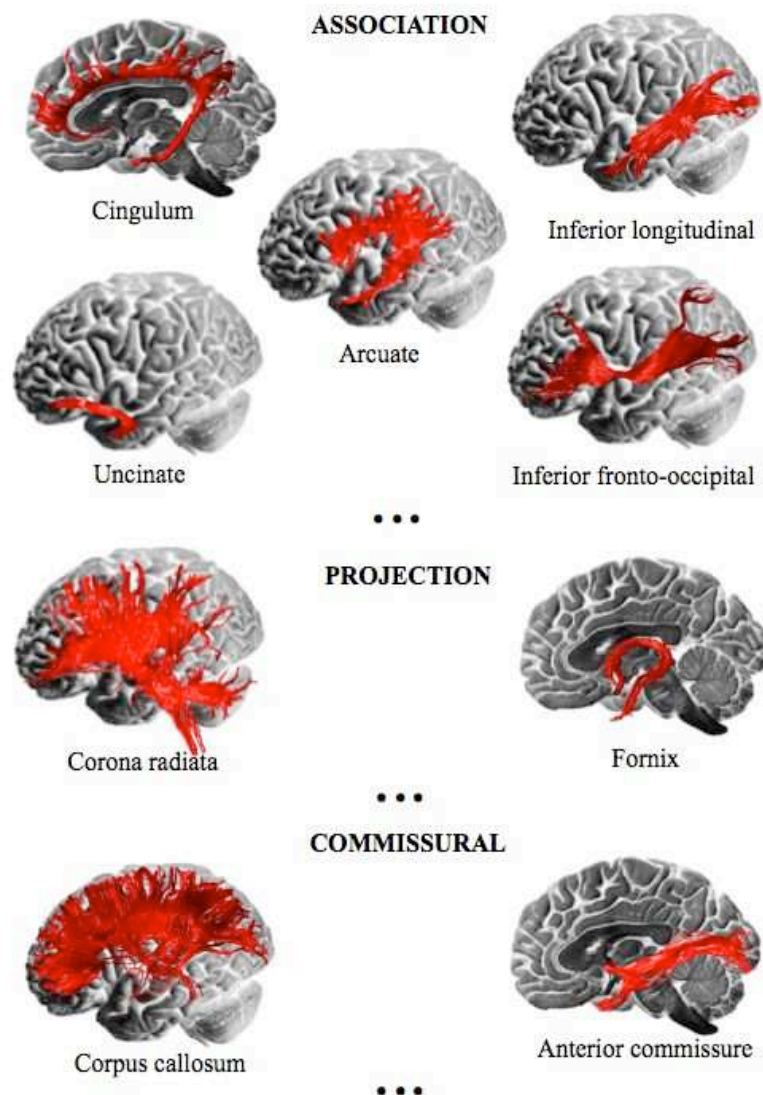


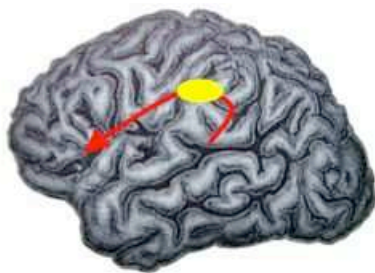
Fig 32 : Illustration en DTI de quelques exemples des faisceaux d'association, de projection ou commissuraux (Catani and ffytche, 2005).



## **2. LA NEGLIGENCE SPATIALE UNILATERALE**

Au terme de cette thèse, en utilisant le syndrome de NSU comme modèle de perturbation des réseaux de l'attention spatiale décrit comme frontaux-pariétaux dans la littérature (voir figure 26), nous avons démontré que la disconnexion des faisceaux reliant les aires frontales aux aires pariétales dans l'hémisphère droit (faisceaux longitudinaux supérieurs, Schmahmann and Pandya, 2006; Thiebaut de Schotten et al., 2006; Schmahmann et al., 2007; Thiebaut de Schotten et al., submitted) conduisait à un trouble sévère de l'attention dans l'hémi-espace gauche corroborant les résultats déjà obtenus chez le macaque (Gaffan and Hornak, 1997; Gaffan, 2005).

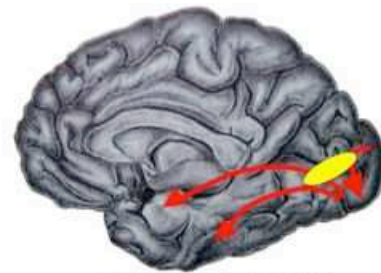
La NSU peut donc désormais être apparentée à la famille des grands syndromes de disconnexion (voir figure 33).



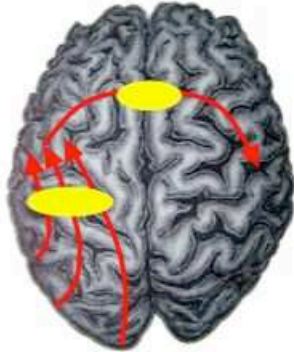
CONDUCTION APHASIA



Carl Wernicke



VISUAL AGNOSIA



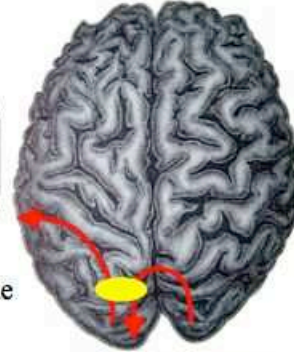
APRAXIA



Hugo Liepmann

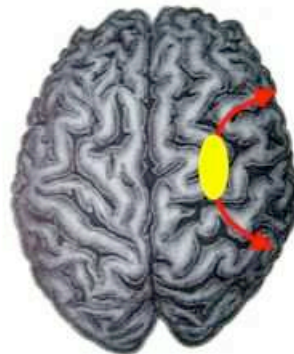

Jules Déjérine



PURE ALEXIA

(Catani and ffytche, Brain 2005)



NEGLECT

(Gaffan & Hornak, Brain 1997  
Leibovitch et al., Neurology 1998  
Doricchi & Tomaiuolo, NeuroReport 2003  
Thiebaut de Schotten et al., Science 2005  
Bartolomeo et al, Cerebral Cortex 2007  
Corbetta et al Neuron 2007)

Fig. 33 :Les syndromes de disconnexion classiques et plus récents d'après Catani et ffytche (2005).

Nous avons également mis en évidence qu'une autre disconnexion du faisceau reliant cette fois-ci les aires occipitales aux aires frontales dans l'hémisphère droit (faisceau occipito-frontal (Catani et al., 2002; Urbanski et al., submitted)) pouvait amener également à un trouble sévère de l'attention. Ces deux disconnexions (fronto-pariétale et fronto-occipitale) mènent donc à un syndrome de négligence, mais les raisons sous-jacentes de ce même comportement pathologique en apparence nous amèneront probablement à découvrir des dissociations déterminantes dans la compréhension de l'organisation de l'enchaînement des traitements cognitifs mis en jeu lors des processus attentionnels.

En effet, la NSU reste un sujet très controversé, que ce soit sur ses mécanismes ou sur ses bases neurales. Derrière son importance clinique, son étude nous permet de mieux comprendre les mécanismes de l'attention. La recherche sur ses mécanismes fonctionnels semble évoluer vers une description des dissociations dans les performances des patients isolant ainsi les signes de déficit (Doricchi et al., 2005) et leurs modes d'interaction (Husain and Rorden, 2003a). Désormais, la haute résolution des techniques d'imagerie apporte de nouvelles données pertinentes pour débattre des bases anatomiques de la négligence (Bird et al., 2006). Ce débat semble désormais porter davantage sur de larges réseaux étendus plutôt que de petits modules isolés (Thiebaut de Schotten et al., 2005; Bartolomeo, 2006; He et al., 2007). En d'autres termes, l'écart séparant les modèles fonctionnels de la négligence et les descriptions anatomiques semble se réduire (Corbetta et al., 2005; Bartolomeo, 2006; He et al., 2007).

### **3. PERSPECTIVES : VERS UNE APPROCHE HODOLOGIQUE DE LA NSU ET DE L'ATTENTION SPATIALE**

Dans le modèle décrit par Catani & ffytche (2005) (résumé dans la figure 34) les territoires corticaux sont simplifiés à deux aires ou sous-régions spécialisées qui respectent des frontières cytoarchitectoniques (pour une vue globale de ces territoires voir figure 35 (Economo and Koskinas, 1925)). Il n'est pas clair encore à ce jour si différentes régions spécialisées sont anatomiquement distinctes (par exemple les aires V1, V2, V3 du lobe occipital) ou si elles se recouvrent (comme dans le cas de la ségrégation rostro-caudale des territoires de Broca). Par contre, nous connaissons un grand nombre de territoires dévolus à des fonctions globales, comme le langage, les praxies, la vision ou encore l'attention.

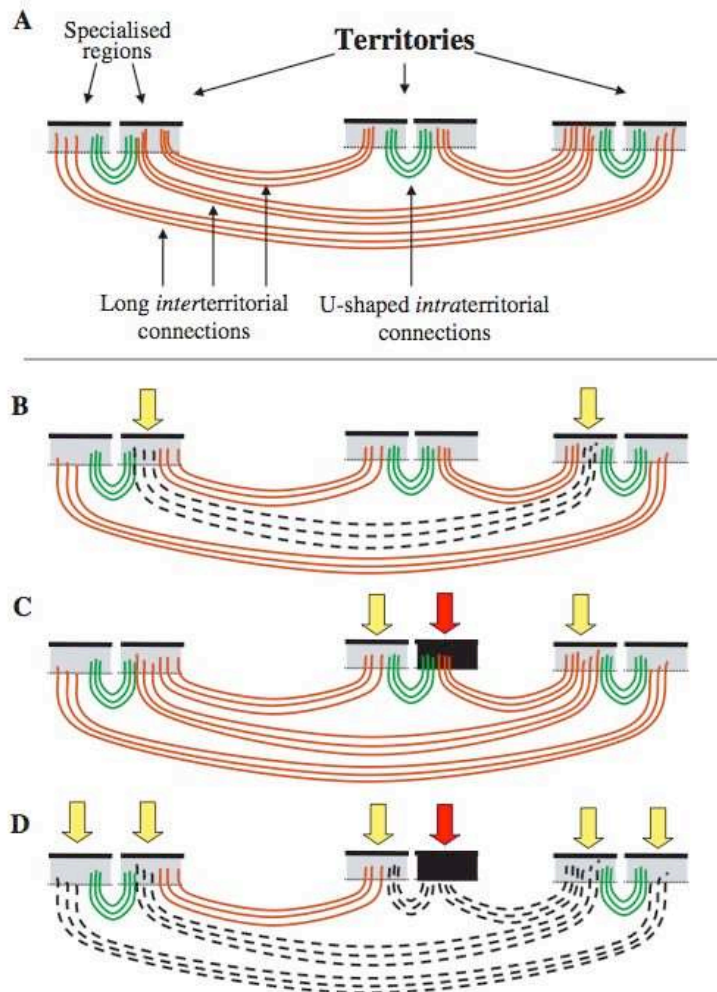


Fig. 34 : Modèle d'étude des corrélations clinico-pathologiques (A) Vue contemporaine du cortex et de ses connexions. Des aires différentes et spécialisées du cortex (les rectangles gris) sont connectées par des fibres en U (en vert) pour former des territoires étendus, eux mêmes connectés par de longues fibres inter-territoriales (en orange). (B) La conséquence d'une pathologie de la substance blanche. Le faisceau hachuré est aussi bien hyper ou hypo fonctionnel. Les flèches jaunes indiquent une dysfonction des régions corticales, dans ce cas suivant un mécanisme hodologique. (C) La conséquence d'une pathologie corticale. La région en noir du cortex est hyper ou hypo fonctionnelle. La flèche rouge indique une dysfonction du cortex suivant un mécanisme topologique. Pour certaines tâches cognitives, des régions corticales distantes peuvent manifester un dysfonctionnement suivant un mécanisme hodologique secondaire (les flèches jaunes). (D) La conséquence de la combinaison d'une pathologie corticale et de la substance blanche. La région en noir et les faisceaux hachurés sont hyper ou hypo fonctionnels. Les flèches jaunes indiquent les régions corticales de projection affectées par un mécanisme hodologique alors que les flèches rouges indiquent une région manifestant une dysfonction topologique.

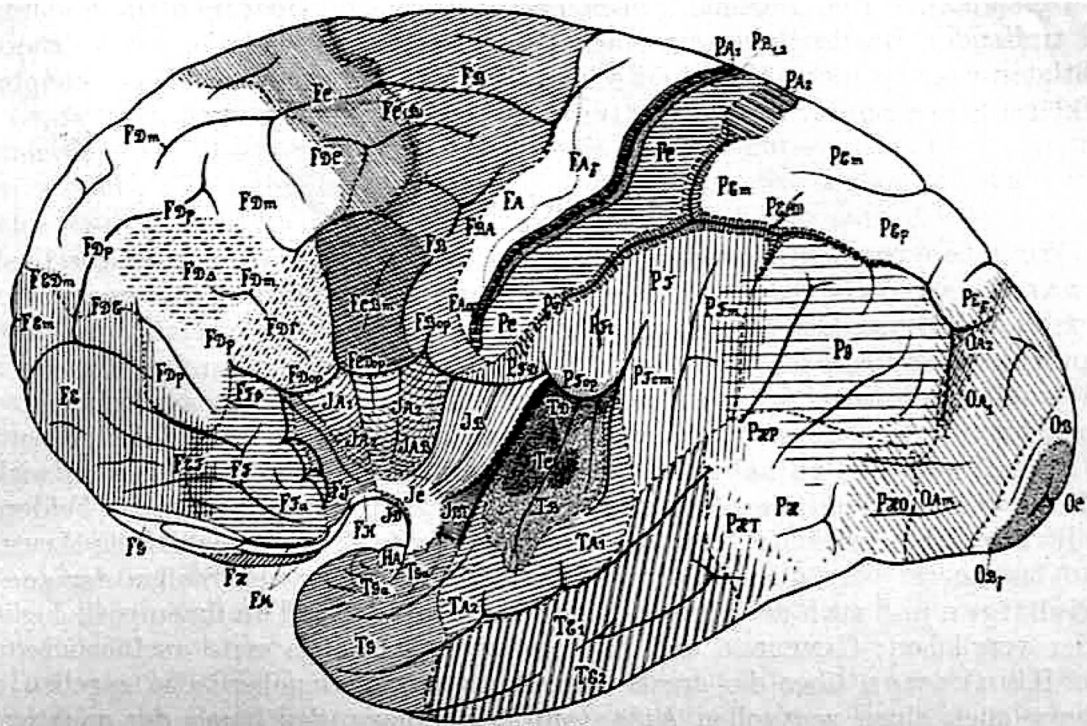


Abb. 19.

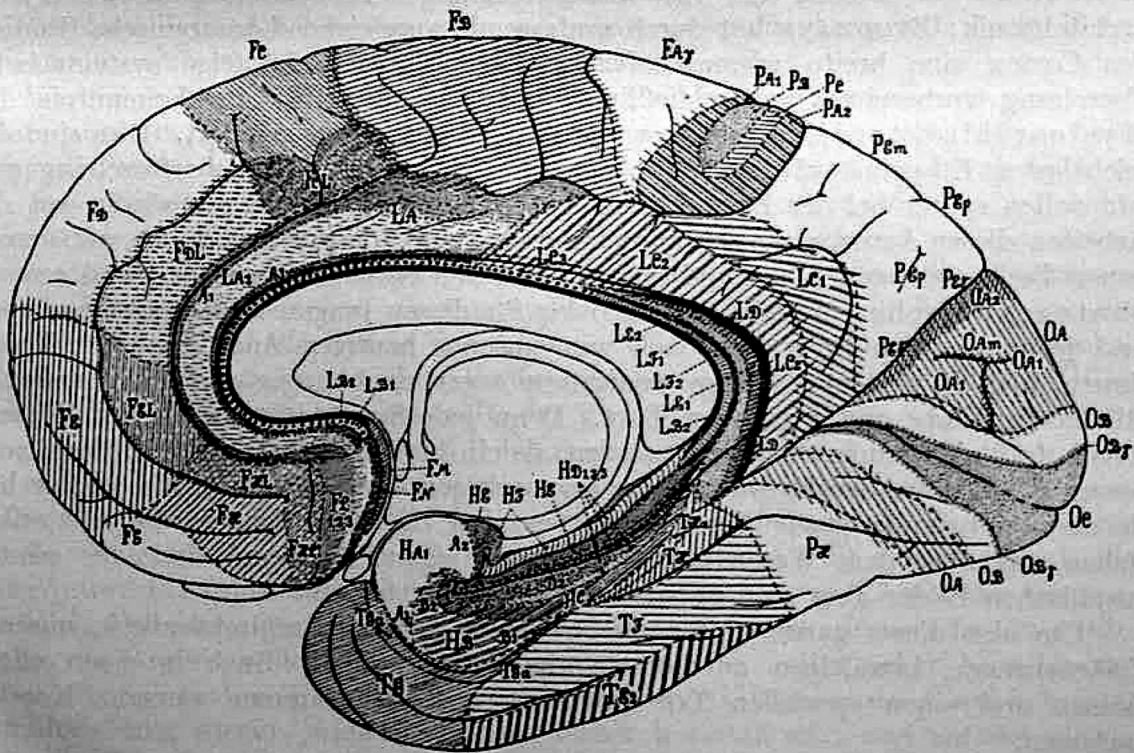


Abb. 20.

Fig. 35 : Vue globale latérale et médiane des frontières cytoarchitectoniques du cerveau humain (Economo, 1925)

Les connexions intraterritoriales sont majoritairement les connexions en U, mais les régions corticales voisines à l'intérieur d'un même territoire peuvent également connecter leurs frontières par des fibres intracorticales (non représentées dans la figure 34). Les investigations en tractographie suggèrent que les territoires en revanche sont connectés par de multiples fibres d'association organisées en parallèle (Catani et al., 2005). Bien que les détails anatomiques de ces connexions interterritoriales doivent encore être démontrés, des données existent déjà et suggèrent que des régions spécialisées spécifiques dans différents territoires sont connectées en parallèle (Ffytche and Catani, 2005; Catani et al., 2005).

Quelles sont les conséquences fonctionnelles des pathologies dans ce nouveau modèle ? Selon cette nouvelle terminologie, un mécanisme topologique (du grec *topos* = place) réfère généralement à une dysfonction du cortex indépendamment du fait qu'il s'agisse d'un déficit, d'une hyperfonction ou de la combinaison des deux. Les dysfonctions qui peuvent être reliées à une approche topologique vont des déficits dus à la perte d'une région corticale spécialisée, c'est le cas lors de la prosopagnosie pour des lésions de régions spécialisées pour les visages dans le gyrus fusiforme (Sergent et al., 1992), à des symptômes positifs spécifiques, comme des hallucinations de visages liés à l'hyperexcitabilité et l'activité spontanée des aires du cortex dévolues à la perception des visages (Ffytche et al., 1998). Un mécanisme hodologique (du grec *hodos* = voie ou chemin) se réfère généralement à une dysfonction due à des voies de connexion, que ce soit une disconnexion, une hyperconnexion ou la combinaison des deux. Les dysfonctions hodologiques peuvent être illustrées par les syndromes de disconnexion classiques comme l'aphasie de conduction due à des lésions sous-corticales pures (Naeser et al., 1982) ou encore la combinaison d'une hyperconnectivité fronto-frontale avec des disconnexions entre le lobe frontal et d'autres régions (Courchesne and Pierce, 2005b, 2005a) qui pourrait être la base neurale de l'autisme.

Malgré l'accumulation des preuves en faveur d'une hypothèse disconnective de l'héminégligence relatée dans cette thèse, cette conclusion est encore remise en cause dans de nombreuses investigations utilisant une approche de corrélations entre les niveaux de perfusion corticale et la présence de négligence en phases aiguë, hyperaiguë ou encore subaiguë. Comme précisé dans la revue de *Cerebral Cortex* (Bartolomeo et al, 2007) en utilisant l'imagerie pondérée par la perfusion, indiquant le niveau d'activité fonctionnelle des régions corticales épargnées de toute lésion, Hillis et ses collaborateurs (2002) ont étudié le corrélat fonctionnel de l'héminégligence et de l'aphasie en période hyperaiguë (dans les 24 heures qui suivent l'accident vasculaire cérébral sous-cortical). Ces auteurs ont mis en

évidence qu'indépendamment de la localisation de la lésion (corona radiata ou les structures caudée ou capsulaire), le syndrome d'héminégligence était seulement présent chez les patients associant une hypoperfusion corticale à leur lésion sous-corticale. Cette étude suggère qu'une lésion dans la substance blanche ne cause pas nécessairement l'héminégligence. Malheureusement, aucune reconstruction de la substance blanche n'a été effectuée dans cette étude, ce qui laisse inconnue la relation entre l'emplacement et l'étendue de la lésion de la substance blanche, l'hypoperfusion corticale et l'héminégligence. Malgré cette limitation, les résultats de Hillis et ses collaborateurs confirment en un sens, qu'une perturbation sous-corticale des échanges fronto-pariétaux peut causer l'héminégligence en réduisant l'activité fonctionnelle des régions fronto-pariétales.

Un second point à prendre prudemment en considération concerne l'approche des corrélations anatomo-cliniques de l'héminégligence (en d'autres termes les statistiques utilisant les superposition de lésions) dans la substance grise et la substance blanche. Husain et Nachev (2007) mettent en évidence que la validité de l'approche en superposition de lésions peut être biaisée par l'inhomogénéité dans l'étendue ou la distribution des lésions vasculaires. Cette limitation suggère que les inférences sur l'anatomie de la NSU utilisant cette méthode doivent être prudemment estimées en comparant des patients avec ou sans NSU souffrant d'une lésion de volume comparable et confère à l'approche neurochirurgicale des stimulations per-opératoire des substances grises et blanche un intérêt majeur (Thiebaut de Schotten et al, 2005). Les résultats de ces études (voir aussi Gharabaghi et al., 2006) semblent également remettre en question l'idée que la taille des lésion « per se » pourrait être l'une des causes directes de troubles sévères de l'attention entraînant l'héminégligence.

Dans la revue de *Cerebral Cortex* (Bartolomeo et al, 2007), nous nous proposons de donner différents scénarios anatomo-fonctionnels qui peuvent être cohérents avec l'hétérogénéité du syndrome de négligence. De multiples systèmes de cartographie sensori-moteurs seraient dévolus aux processus de distribution de l'attention dans l'espace et sa représentation (Rizzolatti, 1997). L'idée générale serait que des disconnexions anatomiques différentes (= section d'un faisceau de substance blanche) des réseaux de substance grise peuvent être associées avec différents signes de négligence. Comme suggéré précédemment, la variabilité inter-patients dans la composition symptomatologique du syndrome peut résulter de la destruction sélective de différents secteurs de la substance blanche, de la localisation précise de la disconnexion à différents points le long du même fasciculus jusqu'à des

disconnexions accompagnées d'une lésion de différents modules de substance grise. Si l'on suit la terminologie récemment proposée par Catani et ffytche (2005), cette approche souligne un rôle combiné de facteurs topologiques, relié à la dysfonction d'aires corticales spécialisées, et des facteurs hodologiques, reliés à la dysfonction des voies de connexion entre ces aires. Nous proposons donc que la disconnexion puisse produire davantage de déficit qu'un dommage ou qu'une dysfonction corticale. Le dommage des fibres de la substance blanche peut entraîner davantage de troubles en perturbant le fonctionnement de larges réseaux corticaux (Bartolomeo et al., 2007) et en limitant la récupération et la plasticité (He et al., 2007).

Un second point à prendre en considération dans l'étude de la NSU dans les recherches anatomo-cliniques futures concerne les tâches d'évaluation de la NSU. Clairement, il est impossible de considérer la NSU comme le syndrome résultant d'une collection de symptômes homogènes. Il faut donc étudier la NSU plus en détail et chercher l'origine des dissociations que l'on trouve lors de l'évaluation des patients. Binder et al. (1992) mets en évidence pour la première fois que les déficits dans la bissection de ligne extrapersonnelle sont dissociables des déficits dans les tâches de barrage (see also Halligan and Marshall, 1992). Anatomiquement, l'échec aux tâches de bissection est corrélé au dommage des aires postérieures occipito-pariétales, alors que l'échec aux tâches de barrage semble être plus fréquent pour les dommages du cortex frontal et des ganglions de la base. Ce résultat a été confirmé par Doricchi et Angelelli (1999), par Azouvi et al. (2002) dans une importante cohorte de patients, par Verdon et al. (2006) en utilisant l'approche VLSM, et sont également soutenus par les résultats en imagerie fonctionnelle (Fink et al., 2002). Ce type de dissociations est un exemple clair de la richesse du syndrome de négligence et par là même, des différents éléments composant les processus de distribution de l'attention spatiale à prendre en considération.

En conclusion, nous pouvons dire que l'étude des corrélats anatomiques de la négligence spatiale unilatérale semble entrer dans une nouvelle vague très prometteuse. En effet, les opinions très contradictoires sur la localisation corticale des lésions qui provoquent les troubles attentionnels manifestés dans ce syndrome sont progressivement remplacées. Désormais l'idée générale la plus défendue est qu'une lacune générale de vigilance dans l'hémiespace controlésionnel est une conséquence de la destruction de larges réseaux corticaux et de leurs connexions.



## References

- ALBERT ML. A simple test of visual neglect. *Neurology*, 23: 658-664, 1973.
- ANDERSEN RA, SNYDER LH, BRADLEY DC, and XING J. Multimodal representation of space in the posterior parietal cortex and its use in planning movements. *Annual Review of Neuroscience*, 20: 303-30, 1997.
- ANDERSON B. Spared awareness for the left side of internal visual images in patients with left-sided extrapersonal neglect. *Neurology*, 43: 213-216, 1993.
- APPELROS P, KARLSSON GG, SEIGER A, and NYDEVIK I. Neglect and anosognosia after first-ever stroke: incidence and relationship to disability. *J Rehabil Med*, 34: 215-20, 2002.
- ARRINGTON CM, CARR TH, MAYER AR, and RAO SM. Neural mechanisms of visual attention: object-based selection of a region in space. *J Cogn Neurosci*, 12 Suppl 2: 106-17, 2000.
- AZOUVI P, SAMUEL C, LOUIS-DREYFUS A, BERNATI T, BARTOLOMEO P, BEIS J-M, CHOKRON S, LECLERCQ M, MARCHAL F, MARTIN Y, DE MONTETY G, OLIVIER S, PERENNOU D, PRADAT-DIEHL P, PRAIRIAL C, RODE G, SIEROFF E, WIART L, and ROUSSEAU M. Sensitivity of clinical and behavioural tests of spatial neglect after right hemisphere stroke. *Journal of Neurology, Neurosurgery and Psychiatry*, 73: 160-166, 2002.
- BABINSKI J. Contribution à l'étude des troubles mentaux dans l'hémiplégie organique (anosognosie). *Revue Neurologique*, 21: 845-8, 1914.
- BABINSKI J. Anosognosie. *Revue Neurologique*, 31: 365-7, 1918.
- BARTOLOMEO P. Orienting of attention in unilateral neglect. *Neurological Sciences*: S132, 2000.
- BARTOLOMEO P. The relationship between visual perception and visual mental imagery: a reappraisal of the neuropsychological evidence. *Cortex*, 38: 357-378, 2002.
- BARTOLOMEO P. A parieto-frontal network for spatial awareness in the right hemisphere of the human brain. *Archives of Neurology*, 63: 1238-1241, 2006.
- BARTOLOMEO P, BACHOUD-LÉVI A-C, AZOUVI P, and CHOKRON S. Time to imagine space: a chronometric exploration of representational neglect. *Neuropsychologia*, 43: 1249-1257, 2005.
- BARTOLOMEO P and CHOKRON S. Left unilateral neglect or right hyperattention? *Neurology*, 53: 2023-2027, 1999.
- BARTOLOMEO P and CHOKRON S. Levels of impairment in unilateral neglect. In Boller F. and Grafman J. (Eds.), *Handbook of Neuropsychology*. Amsterdam: Elsevier Science Publishers, 2001, pp. 67-98.
- BARTOLOMEO P and CHOKRON S. Orienting of attention in left unilateral neglect. *Neuroscience and Biobehavioral Reviews*, 26: 217-234, 2002a.
- BARTOLOMEO P and CHOKRON S. Orienting of attention in left unilateral neglect. *Neuroscience and Biobehavioral Reviews*, 26: 217-234, 2002b.
- BARTOLOMEO P, CHOKRON S, and SIÉROFF E. Facilitation instead of inhibition for repeated right-sided events in left neglect. *NeuroReport*, 10: 3353-3357, 1999.
- BARTOLOMEO P, D'ERME P, and GAINOTTI G. The relationship between visuospatial and representational neglect. *Neurology*, 44: 1710-1714, 1994.
- BARTOLOMEO P, SIÉROFF E, DECAIX C, and CHOKRON S. Modulating the attentional bias in unilateral neglect: The effects of the strategic set. *Experimental Brain Research*, 137: 424-431, 2001.
- BARTOLOMEO P, THIEBAUT DE SCHOTTEN M, and DORICCHI F. Left Unilateral Neglect as a Disconnection Syndrome. *Cereb Cortex*, 2007.

- BARTOLOMEO P, URBANSKI M, CHOKRON S, CHAINAY H, MORONI C, SIÉROFF E, BELIN C, and HALLIGAN P. Neglected attention in apparent spatial compression. *Neuropsychologia*, 42: 49-61, 2004.
- BARTON JJ, BEHRMANN M, and BLACK S. Ocular search during line bisection. The effects of hemi-neglect and hemianopia. *Brain*, 121: 1117-31, 1998.
- BATES E, WILSON SM, SAYGIN AP, DICK F, SERENO MI, KNIGHT RT, and DRONKERS NF. Voxel-based lesion-symptom mapping. *Nature Neuroscience*, 6: 448-50, 2003a.
- BATES E, WILSON SM, SAYGIN AP, DICK F, SERENS MI, KNIGHT RT, and DRONKERS NF. Voxel-based lesion-symptom mapping. *Nature Neuroscience*, 6: 448-50, 2003b.
- BEIS J-M, KELLER C, MORIN N, BARTOLOMEO P, BERNATI T, CHOKRON S, LECLERCQ M, LOUIS-DREYFUS A, MARCHAL F, MARTIN Y, PERRENOU D, PRADAT-DIEHL P, PRAIRIAL C, RODE G, ROUSSEAU M, SAMUEL C, SIEROFF E, WIART L, and AZOUVI P. Right spatial neglect after left hemisphere stroke: qualitative and quantitative study. *Neurology*, 63: 1600-5, 2004.
- BENDER MB. *Disorders in perception*. Springfield, Ill.: Thomas, 1952.
- BENSON DF, SHEREMATA WA, BOUCHARD R, SEGARRA JM, PRICE D, and GESCHWIND N. Conduction aphasia. A clinicopathological study. *Arch Neurol*, 28: 339-46, 1973.
- BERGEGO C, AZOUVI P, SAMUEL C, and AL. E. Validation d'une échelle d'évaluation fonctionnelle de l'héminégligence dans la vie quotidienne: l'échelle CB. *Ann Readapt Med Phys*, 38: 183-9, 1995.
- BERGER MS and OJEMANN GA. Intraoperative brain mapping techniques in neuro-oncology. *Stereotact Funct Neurosurg*, 58: 153-61, 1992.
- BERGER MS, OJEMANN GA, and LETTICH E. Neurophysiological monitoring during astrocytoma surgery. *Neurosurg Clin N Am*, 1: 65-80, 1990.
- BERTI A, ALLPORT A, DRIVER J, DIENES Z, OXBURY JM, and OXBURY S. Levels of processing for visual stimuli in an "extinguished" field. *Neuropsychologia*, 30: 403-15, 1992.
- BERTI A, BOTTINI G, GANDOLA M, PIA L, SMANIA N, STRACCIARI A, CASTIGLIONI I, VALLAR G, and PAULESU E. Shared cortical anatomy for motor awareness and motor control. *Science*, 309: 488-91, 2005.
- BERTI A and RIZZOLATTI G. Visual processing without awareness: evidence from unilateral neglect. *Journal of Cognitive Neuroscience*, 4: 345-351, 1992.
- BESCHIN N, BASSO A, and DELLA SALA S. Perceiving left and imagining right: dissociation in neglect. *Cortex*, 36: 401-414, 2000.
- BESCHIN N, COCCHINI G, DELLA SALA S, and LOGIE R. What the eyes perceive, the brain ignores: A case of pure unilateral representational neglect. *Cortex*, 33: 3-26, 1997.
- BINDER J, MARSHALL R, LAZAR R, BENJAMIN J, and MOHR JP. Distinct syndromes of hemineglect. *Archives of Neurology*, 49: 1187-1194, 1992.
- BINKOFSKI F, BUCCINO G, STEPHAN KM, RIZZOLATTI G, SEITZ RJ, and FREUND HJ. A parieto-premotor network for object manipulation: evidence from neuroimaging. *Experimental Brain Research*, 128: 210-3, 1999.
- BIRD CM, MALHOTRA P, PARTON A, COULTHARD E, RUSHWORTH MF, and HUSAIN M. Visual neglect after right posterior cerebral artery infarction. *J Neurol Neurosurg Psychiatry*, 77: 1008-12, 2006.
- BISIACH E, CAPITANI E, LUZZATTI C, and PERANI D. Brain and conscious representation of outside reality. *Neuropsychologia*, 19: 543-551, 1981.
- BISIACH E, CAPITANI E, and PORTA E. Two basic properties of space representation in the brain: Evidence from unilateral neglect. *Journal of Neurology, Neurosurgery and Psychiatry*, 48: 141-144, 1985.
- BISIACH E, CORNACCHIA L, STERZI R, and VALLAR G. Disorders of perceived auditory lateralization after lesions of the right hemisphere. *Brain*, 107: 37-52, 1984.

- BISIACH E and LUZZATTI C. Unilateral neglect of representational space. *Cortex*, 14: 129-133, 1978.
- BLACK PM and RONNER SF. Cortical mapping for defining the limits of tumor resection. *Neurosurgery*, 20: 914-9, 1987.
- BOLLER F and GRAFMAN J. *Handbook of Neuropsychology*, 2001.
- BOSSY J. *Les hémisphères cérébraux*. Berlin: Springer: Berlin: Springer, 1991.
- BRAIN WR. Visual disorientation with special reference to lesion of the right cerebral hemisphere. *Brain*, 64: 2446-72, 1941.
- BROCA P. Perte de la parole, ramollissement chronique et destruction partielle du lobe antérieur gauche. *Bull Soc Anthropol*, 2: 235-238, 1861.
- BURCHAM KJ, CORWIN JV, STOLL ML, and REEP RL. Disconnection of medial agranular and posterior parietal cortex produces multimodal neglect in rats. *Behavioral Brain Research*, 86: 41-47, 1997.
- BURCHIEL KJ, CLARKE H, OJEMANN GA, DACEY RG, and WINN HR. Use of stimulation mapping and corticography in the excision of arteriovenous malformations in sensorimotor and language-related neocortex. *Neurosurgery*, 24: 322-7, 1989.
- CALS N, DEVUYST G, AFSAR N, KARAPANAYIOTIDES T, and BOUGOUSSLAWSKY J. Pure superficial posterior cerebral artery territory infarction in the Lausanne Stroke Registry. *Journal of Neurology, Neurosurgery and Psychiatry*, 249: 855-61, 2002.
- CAMBIER J, ELGHOZI D, and STRUBE E. Lésions du thalamus droit avec syndrome de l'hémisphère mineur. Discussion du concept de négligence thalamique. *Revue Neurologique*, 136: 105-16, 1980.
- CATANI M. Diffusion tensor magnetic resonance imaging tractography in cognitive disorders. *Curr Opin Neurol*, 19: 599-606, 2006.
- CATANI M and FFYTCHÉ DH. The rises and falls of disconnection syndromes. *Brain*, 128: 2224-2239, 2005.
- CATANI M, HOWARD RJ, PAJEVIC S, and JONES DK. Virtual in vivo interactive dissection of white matter fasciculi in the human brain. *Neuroimage*, 17: 77-94, 2002.
- CATANI M, JONES DK, and FFYTCHÉ DH. Perisylvian language networks of the human brain. *Annals of Neurology*, 57: 8-16, 2005.
- CHATTERJEE A. Motor minds and mental models in neglect [Review]. *Brain and Cognition*, 37: 339-349, 1998.
- CHEDRU F. Space representation in unilateral spatial neglect. *Journal of Neurology, Neurosurgery and Psychiatry*, 39: 1057-1061, 1976.
- CHOKRON S, COLLIOT P, and BARTOLOMEO P. The role of vision on spatial representations. *Cortex*, 40: 281-290, 2004.
- CORBEN LA, MATTINGLEY JB, and BRADSHAW JL. A kinematic analysis of distractor interference effects during visually guided action in spatial neglect. *Journal of the International Neuropsychological Society*, 7: 334-43, 2001.
- CORBETTA M, KINCADE MJ, LEWIS C, SNYDER AZ, and SAPIR A. Neural basis and recovery of spatial attention deficits in spatial neglect. *Nature Neuroscience*, 8: 1603-1610, 2005.
- CORBETTA M and SHULMAN GL. Control of goal-directed and stimulus-driven attention in the brain. *Nature Reviews Neuroscience*, 3: 201-215, 2002.
- COSLETT HB. Neglect in vision and visual imagery: A double dissociation. *Brain*, 120: 1163-1171, 1997.
- COSTELLO AD and WARRINGTON EK. The dissociation of visuospatial neglect and neglect dyslexia. *Journal of Neurology, Neurosurgery and Psychiatry*, 50: 1110-6, 1987.
- COURCHESNE E and PIERCE K. Brain overgrowth in autism during a critical time in development: implications for frontal pyramidal neuron and interneuron development and connectivity. *Int J Dev Neurosci*, 23: 153-70, 2005a.

- COURCHESNE E and PIERCE K. Why the frontal cortex in autism might be talking only to itself: local over-connectivity but long-distance disconnection. *Curr Opin Neurobiol*, 15: 225-30, 2005b.
- COWEY A, SMALL M, and ELLIS S. Left visuo-spatial neglect can be worse in far than in near space. *Neuropsychologia*, 32: 1059-1066, 1994.
- CRITCHLEY M. *The parietal lobes*. New York: Hafner, 1953.
- D'ERME P, ROBERTSON IH, BARTOLOMEO P, and DANIELE A. Unilateral neglect: The fate of the extinguished visual stimuli. *Behavioural Neurology*, 6: 143-150, 1993.
- DAMASIO AR, DAMASIO H, and CHUI HC. Neglect following damage to frontal lobe or basal ganglia. *Neuropsychologia*, 18: 123-32, 1980.
- DANKS RA, ROGERS M, AGLIO LS, GUGINO LD, and BLACK PM. Patient tolerance of craniotomy performed with the patient under local anesthesia and monitored conscious sedation. *Neurosurgery*, 42: 28-34; discussion 34-6, 1998.
- DE RENZI E, GENTILINI M, and BARBIERI C. Auditory neglect. *Journal of Neurology, Neurosurgery and Psychiatry*, 52: 613-617, 1989.
- DEJERINE MJ. *Anatomie des Centres Nerveux*. Paris: Rueff et Cie, 1895.
- DELLA SALA S, LOGIE R, BESCHIN N, and DENIS M. Preserved visuo-spatial transformations in representational neglect. *Neuropsychologia*, 42: 1358-64, 2004.
- DENES G, SEMENZA C, STOPPA E, and LIS A. Unilateral spatial neglect and recovery from hemiplegia: A follow-up study. *Brain*, 105: 543-552, 1982.
- DORICCHI F and ANGELELLI P. Misrepresentation of horizontal space in left unilateral neglect: role of hemianopia. *Neurology*, 52: 1845-1852, 1999.
- DORICCHI F, GUARIGLIA P, GASPARINI M, and TOMAIUOLO F. Dissociation between physical and mental number line bisection in right hemisphere brain damage. *Nat Neurosci*, 8: 1663-5, 2005.
- DORICCHI F and TOMAIUOLO F. The anatomy of neglect without hemianopia: a key role for parietal-frontal disconnection? *NeuroReport*, 14: 2239-2243, 2003.
- DOWNAR J, CRAWLEY AP, MIKULIS DJ, and DAVIS KD. A multimodal cortical network for the detection of changes in the sensory environment. *Nat Neurosci*, 3: 277-83, 2000.
- DRIVER J and MATTINGLEY JB. Parietal neglect and visual awareness. *Nature Neuroscience*, 1: 17-22, 1998.
- DUHAMEL JR, BREMMER F, BENHAMED S, and GRAF W. Spatial invariance of visual receptive fields in parietal cortex neurons. *Nature*, 389: 845-8, 1997.
- DUVALL E, WYLLIE AH, and MORRIS RG. Macrophage recognition of cells undergoing programmed cell death (apoptosis). *Immunology*, 56: 351-8, 1985.
- EBELING U, SCHMID UD, and REULEN HJ. Tumour-surgery within the central motor strip: surgical results with the aid of electrical motor cortex stimulation. *Acta Neurochir (Wien)*, 101: 100-7, 1989.
- EBELING U, SCHMID UD, YING H, and REULEN HJ. Safe surgery of lesions near the motor cortex using intra-operative mapping techniques: a report on 50 patients. *Acta Neurochir (Wien)*, 119: 23-8, 1992.
- ECONOMO C and KOSKINAS GN. *Die Cytoarchitektonik der Des Erwachsenen Menschen*. Wien.Hirnrinde: Springer, 1925.
- EPSTEIN R, HARRIS A, STANLEY D, and KANSWISHER N. The parahippocampal place area: recognition, navigation, or encoding? *Neuron*, 23: 115-25, 1999.
- FERRO JM, KERTESZ A, and BLACK SE. Subcortical neglect: quantitation, anatomy, and recovery. *Neurology*, 37: 1487-92, 1987.
- FFYTCH DH and CATANI M. Beyond localization: from hodology to function. *Philos Trans R Soc Lond B Biol Sci*, 360: 767-79, 2005.

- FFYTCHÉ DH, HOWARD RJ, BRAMMER MJ, DAVID A, WOODRUFF P, and WILLIAMS S. The anatomy of conscious vision: an fMRI study of visual hallucinations. *Nat Neurosci*, 1: 738-42, 1998.
- FINK GR, MARSHALL JC, WEISS PH, TONI I, and ZILLES K. Task instructions influence the cognitive strategies involved in line bisection judgements: evidence from modulated neural mechanisms revealed by fMRI. *Neuropsychologia*, 40: 119-130, 2002.
- FRANK RJ, DAMASIO H, and GRABOWSKI TJ. Brainvox: an interactive, multimodal visualization and analysis system for neuroanatomical imaging. *Neuroimage*, 5: 13-30, 1997.
- FREUD S. *Auffassung der Aphasien*. Leipzig: Deuticke, 1891.
- GAFFAN D. NEUROSCIENCE: Widespread Cortical Networks Underlie Memory and Attention. *Science*, 309: 2172-2173, 2005.
- GAFFAN D and HORNAK J. Visual neglect in the monkey. Representation and disconnection. *Brain*, 120: 1647-1657, 1997.
- GAINOTTI G. Les manifestations de négligence et d'inattention pour l'hémi-espace. *Cortex*, 4: 64-91, 1968.
- GAINOTTI G, D'ERME P, and BARTOLOMEO P. Early orientation of attention toward the half space ipsilateral to the lesion in patients with unilateral brain damage. *Journal of Neurology, Neurosurgery and Psychiatry*, 54: 1082-1089, 1991.
- GAINOTTI G, D'ERME P, and DE BONIS C. Clinical aspects and mechanisms of visuo-spatial neglect. *Revue Neurologique (Paris)*, 145: 626-34, 1989.
- GAINOTTI G, MESSERLI P, and TISSOT R. Qualitative analysis of unilateral spatial neglect in relation to the laterality of cerebral lesions. *Journal of Neurology, Neurosurgery and Psychiatry*, 35: 545-550, 1972.
- GAUTHIER L, DEHAUT F, and JOANETTE Y. The bells test: A quantitative and qualitative test for visual neglect. *International Journal of Clinical Neuropsychology*, 11: 49-53, 1989.
- GESCHWIND N. Disconnexion syndromes in animals and man - Part I. *Brain*, 88: 237-294, 1965a.
- GESCHWIND N. Disconnexion syndromes in animals and man - Part II. *Brain*, 88: 585-644, 1965b.
- GITELMAN DR, NOBRE AC, PARRISH TB, LABAR KS, KIM YH, MEYER JR, and MESULAM MM. A large-scale distributed network for covert spatial attention: further anatomical delineation based on stringent behavioural and cognitive controls. *Brain*, 122: 1093-106, 1999.
- GODEFROY O, DUHAMEL A, LECLERC X, SAINT MICHEL T, HENON H, and LEYS D. Brain-behaviour relationships. Some models and related statistical procedures for the study of brain-damaged patients. *Brain*, 121 (Pt 8): 1545-1556, 1998.
- GOTTLIEB JP. Parietal mechanisms of target representation. *Current Opinion in Neurobiology*, 12: 134-40, 2002.
- GOTTLIEB JP, KUSUNOKI M, and GOLDBERG ME. The representation of visual salience in monkey parietal cortex. *Nature*, 391: 481-484, 1998.
- GUARIGLIA C, PADOVANI A, PANTANO P, and PIZZAMIGLIO L. Unilateral neglect restricted to visual imagery. *Nature*, 364: 235-237, 1993.
- HAGLUND MM, OJEMANN GA, and BLASDEL GG. Optical imaging of bipolar cortical stimulation. *J Neurosurg*, 78: 785-93, 1993.
- HALLIGAN PW, COCKBURN J, and WILSON BA. The behavioural assessment of visual neglect. *Neuropsychological Rehabilitation*, 1: 5-32, 1991a.
- HALLIGAN PW, FINK GR, MARSHALL JC, and VALLAR G. Spatial cognition: evidence from visual neglect. *Trends in Cognitive Sciences*, 7: 125-133, 2003.

- HALLIGAN PW and MARSHALL JC. Spatial compression in visual neglect: A case study. *Cortex*, 27: 623-629, 1991b.
- HALLIGAN PW and MARSHALL JC. Left visuospatial neglect: A meaningless entity? *Cortex*, 28: 525-535, 1992.
- HALLIGAN PW and MARSHALL JC. Completion in visuo-spatial neglect: A case study. *Cortex*, 30: 685-694, 1994.
- HALLIGAN PW and MARSHALL JC. Visuospatial neglect: the ultimate deconstruction? *Brain and Cognition*, 37: 419-38, 1998.
- HALLIGAN PW, MARSHALL JC, and WADE DT. Left on the right: Allochiria in a case of left visuo-spatial neglect. *Journal of Neurology, Neurosurgery and Psychiatry*, 55: 717-719, 1992.
- HE BJ, SNYDER AZ, VINCENT JL, EPSTEIN A, SHULMAN GL, and CORBETTA M. Breakdown of functional connectivity in frontoparietal networks underlies behavioral deficits in spatial neglect. *Neuron*, 53: 905-18, 2007.
- HEALTON EB, NAVARRO C, BRESSMAN S, and BRUST JC. Subcortical neglect. *Neurology*, 32: 776-8, 1982.
- HÉCAEN H, PENFIELD W, BERTRAND C, and MALMO R. The syndrome of apractognosia due to lesions of the minor cerebral hemisphere. *Arch Neurol Psychiatry*, 75: 400-34, 1956.
- HÉCAEN H, TZORTZIS C, and MASURE MC. Disorders of spatial orientation on the route-finding test associated with unilateral cortical lesions. *Perception*, 1: 325-30, 1972.
- HEILMAN KM and ADAMS DJ. Callosal neglect. *Archives of Neurology*, 60: 276-279, 2003.
- HEILMAN KM, BOWERS D, VALENSTEIN E, and WATSON RT. Disorders of visual attention. *Baillieres Clinical Neurology*, 2: 389-413, 1993a.
- HEILMAN KM and VALENSTEIN E. Mechanisms underlying hemispatial neglect. *Annals of Neurology*, 5: 166-170, 1979.
- HEILMAN KM and VAN DEN ABELL T. Right hemisphere dominance for attention: the mechanism underlying hemispheric asymmetries of inattention (neglect). *Neurology*, 30: 327-30, 1980.
- HEILMAN KM, WATSON RT, BOWERS D, and VALENSTEIN E. Right hemisphere dominance for attention. *Revue Neurologique*, 139: 15-7, 1983a.
- HEILMAN KM, WATSON RT, and VALENSTEIN E. Neglect and related disorders. In Heilman K.M. and Valenstein E. (Eds.), *Clinical Neuropsychology*. New York: Oxford University Press, 1985, pp. 279-336.
- HEILMAN KM, WATSON RT, and VALENSTEIN E. Neglect and related disorders. In Heilman K.M. and Valenstein E. (Eds.), *Clinical Neuropsychology*. New York: Oxford University Press, 1993b, pp. 279-336.
- HEILMAN KM, WATSON RT, VALENSTEIN E, and DAMASIO AR. Localisation of lesion in neglect. In Kertesz A. (Ed.) *Localization in neuropsychology*. New York: Academic Press, 1983b, pp. 471-92.
- HERHOLZ K, REULEN HJ, VON STOCKHAUSEN HM, THIEL A, ILMBERGER J, KESSLER J, EISNER W, YOUSRY TA, and HEISS WD. Preoperative activation and intraoperative stimulation of language-related areas in patients with glioma. *Neurosurgery*, 41: 1253-60; discussion 1260-2, 1997.
- HERHOLZ K, THIEL A, WIENHARD K, PIETRZYK U, VON STOCKHAUSEN HM, KARBE H, KESSLER J, BRUCKBAUER T, HALBER M, and HEISS WD. Individual functional anatomy of verb generation. *Neuroimage*, 3: 185-94, 1996.
- HILLIS AE, WITYK RJ, BARKER PB, BEAUCHAMP NJ, GAILLOUD P, MURPHY K, COOPER O, and METTER EJ. Subcortical aphasia and neglect in acute stroke: the role of cortical hypoperfusion. *Brain*, 125: 1094-1104, 2002.

- HJALTASON H, TEGNER R, THAM K, LEVANDER M, and ERICSON K. Sustained attention and awareness of disability in chronic neglect. *Neuropsychologia*, 34: 1229-33, 1996.
- HOMMET C, BARDET F, DE TOFFOL B, PERRIER D, BIRABEN A, VIGNAL JP, SCARABIN JM, CORBINEAU M, and CHAUVEL P. Unilateral spatial neglect following right inferior parietal cortectomy. *Epilepsy and Behavior*, 5: 416-9, 2004.
- HUMPHREYS GW and RIDDOCH MJ. Attention to within-object and between-object spatial representations: Multiple sites for visual selection. *Cognitive Neuropsychology*, 11: 207-241, 1994.
- HUSAIN M and KENNARD C. Distractor-dependent frontal neglect. *Neuropsychologia*, 35: 829-41, 1997.
- HUSAIN M, MANNAN SK, HODGSON T, WOJCIULIK E, DRIVER J, and KENNARD C. Impaired spatial working memory across saccades contributes to abnormal search in parietal neglect. *Brain*, 124: 941-52, 2001.
- HUSAIN M and NACHEV P. Space and the parietal cortex. *Trends Cogn Sci*, 11: 30-6, 2007.
- HUSAIN M and RORDEN C. Non-spatially lateralized mechanisms in hemispatial neglect. *Nat Rev Neurosci*, 4: 26-36, 2003a.
- HUSAIN M and RORDEN C. Non-spatially lateralized mechanisms in hemispatial neglect. *Nature Reviews Neuroscience*, 4: 26-36, 2003b.
- HUSAIN M, SHAPIRO K, MARTIN J, and KENNARD C. Abnormal temporal dynamics of visual attention in spatial neglect patients. *Nature*, 385: 154-6, 1997.
- ISHIAI S, KOYAMA Y, and FURUYA T. Conflict and integration of spatial attention between disconnected hemispheres. *Journal of Neurology, Neurosurgery and Psychiatry*, 71: 472-77, 2001.
- ISHIAI S, SEKI K, KOYAMA Y, and GONO S. Ineffective leftward search in line bisection and mechanisms of left unilateral spatial neglect. *Journal of Neurology*, 243: 381-387, 1996.
- JEANNEROD M, DECETY J, and MICHEL F. Impairment of grasping movements following a bilateral posterior parietal lesion. *Neuropsychologia*, 32: 369-80, 1994.
- JEHKONEN M, AHONEN JP, DASTIDAR P, KOIVISTO AM, LAIPPALA P, VILKKI J, and MOLNAR G. Visual neglect as a predictor of functional outcome one year after stroke. *Acta Neurol Scand*, 101: 195-201, 2000.
- JONES EG and POWELL TP. An anatomical study of converging sensory pathways within the cerebral cortex of the monkey. *Brain*, 93: 793-820, 1970.
- KARNATH H-O and HARTJE W. Residual information processing in the neglected visual half-field. *Journal of Neurology*, 234: 180-184, 1987.
- KARNATH HO, FERBER S, and HIMMELBACH M. Spatial awareness is a function of the temporal not the posterior parietal lobe. *Nature*, 411: 950-963, 2001.
- KARNATH HO, FRUHMANN BERGER M, KUKER W, and RORDEN C. The anatomy of spatial neglect based on voxelwise statistical analysis: a study of 140 patients. *Cerebral Cortex*, 14: 1164-1172, 2004.
- KARNATH HO, FRUHMANN BERGER M, KUKER W, and RORDEN C. The anatomy of spatial neglect based on voxelwise statistical analysis: a study of 140 patients. *Cerebral Cortex*, 14: 1164-1172, 2004a.
- KARNATH HO, FRUHMANN BERGER M, ZOPF R, and KUKER W. Using SPM normalization for lesion analysis in spatial neglect. *Brain*, 127: E10; author reply E11, 2004b.
- KARNATH HO, HIMMELBACH M, and RORDEN C. The subcortical anatomy of human spatial neglect: putamen, caudate nucleus and pulvinar. *Brain*, 125: 350-60, 2002a.
- KARNATH HO, MILNER D, and VALLAR G. *The Cognitive and Neural Bases of Spatial Neglect*. Oxford: Oxford University Press, 2002b.

- KARNATH HO, ZOPF R, JOHANNSEN L, FRUHMANN BERGER M, NÄGELE T, and KLOSE U. Normalized perfusion MRI to identify common areas of dysfunction: patients with basal ganglia neglect. *Brain*, 128: 2462-9, 2005.
- KASHIWAGI A, KASHIWAGI T, NISHIKAWA T, TANABE H, and OKUDA J. Hemispatial neglect in a patient with callosal infarction. *Brain*, 113: 1005-1023, 1990.
- KERR JF, WYLLIE AH, and CURRIE AR. Apoptosis: a basic biological phenomenon with wide-ranging implications in tissue kinetics. *Br J Cancer*, 26: 239-57, 1972.
- KIM YH, GITELMAN DR, NOBRE AC, PARRISH TB, LABAR KS, and MESULAM MM. The large-scale neural network for spatial attention displays multifunctional overlap but differential asymmetry. *Neuroimage*, 9: 269-77, 1999.
- KING RB and SCHELL GR. Cortical localization and monitoring during cerebral operations. *J Neurosurg*, 67: 210-9, 1987.
- KINSBOURNE M. A model for the mechanism of unilateral neglect of space. *Transactions of the American Neurological Association*, 95: 143-6, 1970.
- KINSBOURNE M. Mechanisms of unilateral neglect. In Jeannerod M. (Ed.) *Neurophysiological and Neuropsychological Aspects of Spatial Neglect*. Amsterdam: Elsevier Science Publishers, 1987, pp. 69-86.
- KINSBOURNE M. Orientational bias model of unilateral neglect: Evidence from attentional gradients within hemispace. In Robertson I.H. and Marshall J.C. (Eds.), *Unilateral Neglect: Clinical and Experimental Studies*. Hove (UK): Lawrence Erlbaum Associates, 1993, pp. 63-86.
- KOFFKA K. *Principles of Gestalt Psychology*, 1935.
- LÁDAVAS E. Is the hemispatial deficit produced by right parietal lobe damage associated with retinal or gravitational coordinates? *Brain*, 110: 167-80, 1987.
- LÁDAVAS E, PALADINI R, and CUBELLI R. Implicit associative priming in a patient with left visual neglect. *Neuropsychologia*, 31: 1307-20, 1993.
- LÁDAVAS E, ZELONI G, ZACCARA G, and GANGEMI P. Eye movements and orienting of attention in patients with visual neglect. *Journal of Cognitive Neuroscience*, 9: 67-74, 1997a.
- LEIBOVITCH FS, BLACK SE, CALDWELL CB, EBERT PL, EHRLICH LE, and SZALAI JP. Brain-behavior correlations in hemispatial neglect using CT and SPECT: the Sunnybrook Stroke Study. *Neurology*, 50: 901-908, 1998.
- LEROUX PD, BERGER MS, HAGLUND MM, PILCHER WH, and OJEMANN GA. Resection of intrinsic tumors from nondominant face motor cortex using stimulation mapping: report of two cases. *Surg Neurol*, 36: 44-8, 1991.
- LICHTHEIM L. Über Aphasie. *Deutsches Archiv für Klinische Medecin*, 36, 1885.
- MARSHALL JC, FINK GR, HALLIGAN PW, and VALLAR G. Spatial awareness: a function of the posterior parietal lobe? *Cortex*, 38: 253-7; discussion 258-60, 2002.
- MARSHALL JC and HALLIGAN PW. Blindsight and insight into visuo-spatial neglect. *Nature*, 336: 766-767, 1988.
- MARSHALL JC and HALLIGAN PW. When right goes left: An investigation of line bisection in a case of visual neglect. *Cortex*, 25: 503-515, 1989.
- MARSHALL JC and HALLIGAN PW. Visuo-spatial neglect: a new copying test to assess perceptual parsing. *Journal of Neurology*, 240: 37-40, 1993.
- MARZI CA, SMANIA N, MARTINI MC, GAMBINA G, TOMELLERI G, PALAMARA A, ALESSANDRINI F, and PRIOR M. Implicit redundant-targets effect in visual extinction. *Neuropsychologia*, 34: 9-22, 1996.
- McFIE J, PIERCY MF, and ZANGWILL OL. Visual spatial agnosia associated with lesions of the right hemisphere. *Brain*, 73: 167-190, 1950.



- MCGLINCHEY-BERROTH R, MILBERG W, VERFAELLIE M, ALEXANDER M, and KIDUFF PT. Semantic processing in the neglected visual field: Evidence from a lexical decision task. *Cognitive Neuropsychology*, 10: 79-108, 1993.
- MCINTOSH RD, McCLEMENTS KI, DIJKERMAN HC, BIRCHALL D, and MILNER AD. Preserved obstacle avoidance during reaching in patients with left visual neglect. *Neuropsychologia*, 42: 1107-17, 2004a.
- MCINTOSH RD, McCLEMENTS KI, SCHINDLER I, CASSIDY TP, BIRCHALL D, and MILNER AD. Avoidance of obstacles in the absence of visual awareness. *Proceedings: Biological Sciences*, 271: 15-20, 2004b.
- MESULAM MM. A cortical network for directed attention and unilateral neglect. *Annals of Neurology*, 10: 309-325, 1981.
- MESULAM MM. *Principles of Behavioral Neurology*. Philadelphia (PA): F.A. Davis, 1985.
- MESULAM MM. Spatial attention and neglect: parietal, frontal and cingulate contributions to the mental representation and attentional targeting of salient extrapersonal events. *Philosophical Transactions of the Royal Society of London B*, 354: 1325-1346, 1999.
- MESULAM MM. Functional anatomy of attention and neglect: from neurons to networks. In Karnath H.O., Milner A.D., and Vallar G. (Eds.), *The cognitive and neural bases of spatial neglect*. Oxford: Oxford University Press, 2002, pp. 33-45.
- MILNER AD and GOODALE MA. *The Visual Brain in Action*. Oxford: Oxford University Press, 1995.
- MISHKIN M, UNGERLEIDER LG, and MACKO KA. Object vision and spatial vision: Two cortical pathways. *Trends in Neurosciences*, 6: 414-417, 1983.
- MOROTA N, DELETIS V, LEE M, and EPSTEIN FJ. Functional anatomic relationship between brain-stem tumors and cranial motor nuclei. *Neurosurgery*, 39: 787-93; discussion 793-4, 1996.
- MORT DJ, MALHOTRA P, MANNAN SK, RORDEN C, PAMBAKIAN A, KENNARD C, and HUSAIN M. The anatomy of visual neglect. *Brain*, 126: 1986-1997, 2003.
- MULLER NG, BARTELT OA, DONNER TH, VILLRINGER A, and BRANDT SA. A physiological correlate of the "Zoom Lens" of visual attention. *J Neurosci*, 23: 3561-5, 2003.
- NAESER MA, ALEXANDER MP, HELM-ESTABROOKS N, LEVINE HL, LAUGHLIN SA, and GESCHWIND N. Aphasia with predominantly subcortical lesion sites: description of three capsular/putaminal aphasia syndromes. *Arch Neurol*, 39: 2-14, 1982.
- NATALE E, POSTERARO L, PRIOR M, and MARZI CA. What kind of visual spatial attention is impaired in neglect? *Neuropsychologia*, 43: 1072-85, 2005.
- NIEUWENHUYS R, VOOGD J, and HUIJZEN C. *The human central nervous system: a synopsis and atlas*. Berlin; New York: Springer-Verlag, 1988a.
- NIEUWENHUYS R, VOOGD J, and HUIJZEN CV. *The human central nervous system: a synopsis and atlas*. Berlin; New York: Springer-Verlag, 1988b.
- NOBRE AC, SEBESTYEN GN, GITELMAN DR, MESULAM MM, FRACKOWIAK RS, and FRITH CD. Functional localization of the system for visuospatial attention using positron emission tomography. *Brain*, 120: 515-33, 1997.
- NYBERG G, ANDERSSON J, ANTONI G, LILJA A, PELLETTIERI L, VALIND S, and LANGSTROM B. Activation PET scanning in pretreatment evaluation of patients with cerebral tumours or vascular lesions in or close to the sensorimotor cortex. *Acta Neurochir (Wien)*, 138: 684-94, 1996.
- OJEMANN G, OJEMANN J, LETTICH E, and BERGER M. Cortical language localization in left, dominant hemisphere. An electrical stimulation mapping investigation in 117 patients. *J Neurosurg*, 71: 316-26, 1989a.

- OJEMANN G, OJEMANN J, LETTICH E, and BERGER M. Cortical language localization in left, dominant hemisphere. An electrical stimulation mapping investigation in 117 patients. *Journal of Neurosurgery*, 71: 316-326, 1989b.
- OJEMANN GA and DODRILL CB. Verbal memory deficits after left temporal lobectomy for epilepsy. Mechanism and intraoperative prediction. *J Neurosurg*, 62: 101-7, 1985.
- OJEMANN JG, MILLER JW, and SILBERGELD DL. Preserved function in brain invaded by tumor. *Neurosurgery*, 39: 253-8; discussion 258-9, 1996.
- ORTIGUE S, VIAUD-DELMON I, ANNONI JM, LANDIS T, MICHEL C, BLANKE O, VUILLEUMIER P, and MAYER E. Pure representational neglect after right thalamic lesion. *Annals of Neurology*, 50: 401-404, 2001.
- PERENIN MT and VIGHETTO A. Optic ataxia: a specific disruption in visuomotor mechanisms. I. Different aspects of the deficit in reaching for objects. *Brain*, 111: 643-674, 1988.
- PISELLA L and MATTINGLEY JB. The contribution of spatial remapping impairments to unilateral visual neglect. *Neuroscience and Biobehavioral Reviews*, 28: 181-200, 2004.
- POSNER MI. Orienting of attention. *The Quarterly Journal of Experimental Psychology*, 32: 3-25, 1980.
- POSNER MI. *Attention and Performance X*. Netherland, 1984.
- POSNER MI, COHEN Y, and RAFAL RD. Neural systems control of spatial orienting. *Philosophical Transactions of the Royal Society of London B*, 298: 187-198, 1982.
- POSNER MI and PETERSEN SE. The attention system of human brain. *Annual Review of Neuroscience*, 13: 25-42, 1990.
- POSNER MI, WALKER JA, FRIEDRICH FJ, and RAFAL RD. Effects of parietal injury on covert orienting of attention. *Journal of Neuroscience*, 4: 1863-1874, 1984.
- POUGET A and DRIVER J. Relating unilateral neglect to the neural coding of space. *Current Opinion in Neurobiology*, 10: 242-9, 2000.
- RAFAL RD and POSNER MI. Deficits in human visual spatial attention following thalamic lesions. *Proceedings of the National Academy of Sciences of the United States of America*, 84: 7349-53, 1987.
- REZAI AR, HUND M, KRONBERG E, ZONENSHAYN M, CAPPELL J, RIBARY U, KALL B, LLINAS R, and KELLY PJ. The interactive use of magnetoencephalography in stereotactic image-guided neurosurgery. *Neurosurgery*, 39: 92-102, 1996.
- ROBERTSON IH, TEGNER R, THAM K, LO A, and NIMMO-SMITH I. Sustained attention training for unilateral neglect: theoretical and rehabilitation implications. *Journal of Clinical and Experimental Neuropsychology*, 17: 416-30, 1995.
- RODE G, PERENIN MT, and BOISSON D. Neglect of the representational space: demonstration by mental evocation of the map of France. *Revue Neurologique (Paris)*, 151: 161-4, 1995.
- RODE G, ROSSETTI Y, PERENIN MT, and BOISSON D. Geographic information has to be spatialized to be neglected: a representational neglect case. *Cortex*, 40: 391-7, 2004.
- RORDEN C and KARNATH HO. Using human brain lesions to infer function: a relic from a past era in the fMRI age? *Nature Reviews Neuroscience*, 5: 813-9, 2004.
- ROUSSEAU M, BEIS J-M, PRADAT-DIEHL P, MARTIN Y, BARTOLOMEO P, BERNATI T, CHOKRON S, LECLERCQ M, LOUIS-DREYFUS A, MARCHAL F, PERENNOU D, PRAIRIAL C, RODE G, SAMUEL C, SIEROFF E, WIART L, and AZOUVI P. Presenting a battery for assessing spatial neglect. Norms and effects of age, educational level, sex, hand and laterality. *Revue Neurologique (Paris)*, 157: 1385-400, 2001.
- SCHENKENBERG T, BRADFORD DC, and AJAX ET. Line bisection and unilateral visual neglect in patients with neurologic impairment. *Neurology*, 30: 509-517, 1980.

- SCHMAHMANN JD and PANDYA DN. *Fiber Pathways of the Brain*. New York: Oxford University Press, 2006.
- SCHMAHMANN JD, PANDYA DN, WANG R, DAI G, D'ARCEUIL HE, DE CRESPIGNY AJ, and WEDEEN VJ. Association fibre pathways of the brain: parallel observations from diffusion spectrum imaging and autoradiography. *Brain*, 130: 630-53, 2007.
- SCHOTT B, LAURENT B, MAUGUIERE F, and CHAZOT G. Motor negligence in a case of right thalamic hematoma. *Revue Neurologique*, 137: 447-55, 1981.
- SCHWEINBERGER SR and STIEF V. Implicit perception in patients with visual neglect: lexical specificity in repetition priming. *Neuropsychologia*, 39: 420-9, 2001.
- SEITZ RJ, HUANG Y, KNORR U, TELLMANN L, HERZOG H, and FREUND HJ. Large-scale plasticity of the human motor cortex. *Neuroreport*, 6: 742-4, 1995.
- SERGENT J, OHTA S, and MACDONALD B. Functional neuroanatomy of face and object processing. A positron emission tomography study. *Brain*, 115 Pt 1: 15-36, 1992.
- SKIRBOLL SS, OJEMANN GA, BERGER MS, LETTICH E, and WINN HR. Functional cortex and subcortical white matter located within gliomas. *Neurosurgery*, 38: 678-84; discussion 684-5, 1996.
- STONE SP, HALLIGAN PW, MARSHALL JC, and GREENWOOD RJ. Unilateral neglect: a common but heterogeneous syndrome. *Neurology*, 50: 1902-5, 1998.
- STONE SP, WILSON BA, WROOT A, HALLIGAN P, LANGE LS, MARSHALL JC, and GREENWOOD RJ. The assessment of visuo-spatial neglect after acute stroke. *Journal of Neurology Neurosurgery and Psychiatry*, 54: 345-50, 1991.
- STRAUSS C, ROMSTOCK J, NIMSKY C, and FAHLBUSCH R. Intraoperative identification of motor areas of the rhomboid fossa using direct stimulation. *J Neurosurg*, 79: 393-9, 1993.
- THIEBAUT DE SCHOTTEN M, KINKINGNÉHUN SR, DELMAIRE C, LÉVY R, VOLLE E, DUBOIS B, LEHÉRICY S, DUFFAU H, and BARTOLOMEO P. OVER-TRACK: A new tool to visualize the white matter organization in Talairach space. *Neuroimage*, 31, 2006.
- THIEBAUT DE SCHOTTEN M, KINKINGNÉHUN SR, DELMAIRE C, THIVARD L, LÉVY R, VOLLE E, DUFFAU H, DUBOIS B, LEHÉRICY S, and BARTOLOMEO P. Visualization of disconnection syndromes in humans. submitted.
- THIEBAUT DE SCHOTTEN M, URBANSKI M, DUFFAU H, VOLLE E, LÉVY R, DUBOIS B, and BARTOLOMEO P. Direct evidence for a parietal-frontal pathway subserving spatial awareness in humans. *Science*, 309: 2226-2228, 2005.
- UEMATSU S, LESSER R, FISHER RS, GORDON B, HARA K, KRAUSS GL, VINING EP, and WEBBER RW. Motor and sensory cortex in humans: topography studied with chronic subdural stimulation. *Neurosurgery*, 31: 59-71; discussion 71-2, 1992.
- URBANSKI M, THIEBAUT DE SCHOTTEN M, RODRIGO S, CATANI M, OPPENHEIM C, TOUZÉ E, CHOKRON S, MÉDER JF, LEVY R, DUBOIS B, and BARTOLOMEO P. Brain networks of spatial awareness: evidence from diffusion tensor imaging tractography. submitted.
- VALLAR G. Left spatial hemineglect: An unmanageable explosion of dissociations? No. *Neuropsychological Rehabilitation*, 4: 209-212, 1994.
- VALLAR G. Extrapersonal visual unilateral spatial neglect and its neuroanatomy. *Neuroimage*, 14: S52-S58, 2001.
- VALLAR G and PERANI D. The anatomy of unilateral neglect after right-hemisphere stroke lesions. A clinical/CT-scan correlation study in man. *Neuropsychologia*, 24: 609-22, 1986.
- VOLPE BT, LEDOUX JE, and GAZZANIGA MS. Information processing of visual stimuli in an "extinguished" field. *Nature*, 282: 722-4, 1979.
- VUILLEUMIER P and RAFAL RD. Both means more than two: localizing and counting in patients with visuospatial neglect. *Nature Neuroscience*, 2: 783-784, 1999.

- WALKER R. Spatial and object-based neglect. *Neurocase*, 1: 371-383, 1995.
- WALSH AR, SCHMIDT RH, and MARSH HT. Cortical mapping and local anaesthetic resection as an aid to surgery of low and intermediate grade gliomas. *Br J Neurosurg*, 6: 119-24, 1992.
- WATSON RT and HEILMAN KM. Thalamic neglect. *Neurology*, 29: 690-4, 1979.
- WERNICKE C. *Der aphasische Symptomencomplex*, 1874.
- WUNDERLICH G, KNORR U, HERZOG H, KIWIT JC, FREUND HJ, and SEITZ RJ. Precentral glioma location determines the displacement of cortical hand representation. *Neurosurgery*, 42: 18-26; discussion 26-7, 1998.
- YOUSRY TA, SCHMID UD, JASSOY AG, SCHMIDT D, EISNER WE, REULEN HJ, REISER MF, and LISSNER J. Topography of the cortical motor hand area: prospective study with functional MR imaging and direct motor mapping at surgery. *Radiology*, 195: 23-9, 1995.

## ANNEXE 1 LA BATTERIE PARIETALE

Conçue durant ma thèse avec l'aide de Bruno Dubois, Laurent Cohen & Paolo Bartolomeo.

### BATTERIE PARIETALE ACP

Date :

#### INFORMATIONS GENERALES

NOM :

Prénom :

SEXE :

Latéralisation :

Date de Naissance :

Main utilisée lors du bilan :

Niveau Culturel :

#### PATHOLOGIE

Date de l'accident neurologique :

Etiologie :

#### TROUBLES MOTEURS

(modérée=difficultés motrices légères\_sévère=incapacité à faire des mouvements distinct\_massive=complète paralysie de l'hémicorps)

##### DROITE

- 0 Pas d'hémiplégie
- 1 Hémiplégie modérée
- 2 Hémiplégie sévère
- 3 Hémiplégie massive

##### GAUCHE

- 0 Pas d'hémiplégie
- 1 Hémiplégie modérée
- 2 Hémiplégie sévère
- 3 Hémiplégie massive

#### **Score d'anosognosie /3**

Dans la vie de tous les jours, avez-vous une plainte particulière, quelque chose qui vous gêne régulièrement (à adapter selon la situation)

- 1 = légère (anasodiasphorie)
- 2 = Moyenne (consent si l'on insiste)
- 3 = Sévère (Déni complet)

#### **Score de déviation de la tête et des yeux /3**

- 1 = légère (Légère déviation du regard)
- 2 = Moyenne (déviation du regard accompagnée de la déviation de la tête)
- 3 = Sévère (déviation sévère du regard, de la tête et du corps)

NOTES :

## QUESTIONNAIRE DE LATERALITE :

(entourer G, D, ou bien les deux)

Quelle main utilisez vous pour ...

- Ecrire G / D
- Dessiner G / D
- Lancer G / D
- Couper avec des ciseaux G / D
- Vous servir d'une brosse à dents G / D
- Couper avec un couteau sans fourchette (du pain ..) G / D
- Manger avec une cuillère G / D
- Tenir une pelle (main au bout du manche) G / D
- Allumer une allumette (de quelle main tenez-vous l'allumette ?) G / D
- Ouvrir une boîte (couvercle) G / D

## **BALINT**

### • ATAXIE OPTIQUE

#### - **Préhension périphérique**


*Regardez mon nez ... allez attraper mon crayon...*

POSITION DU CRAYON	Main Droite	Main Gauche
En haut à gauche (pour l'examineur)	/1	/1
En bas à gauche	/1	/1
En haut à droite	/1	/1
En bas à droite	/1	/1

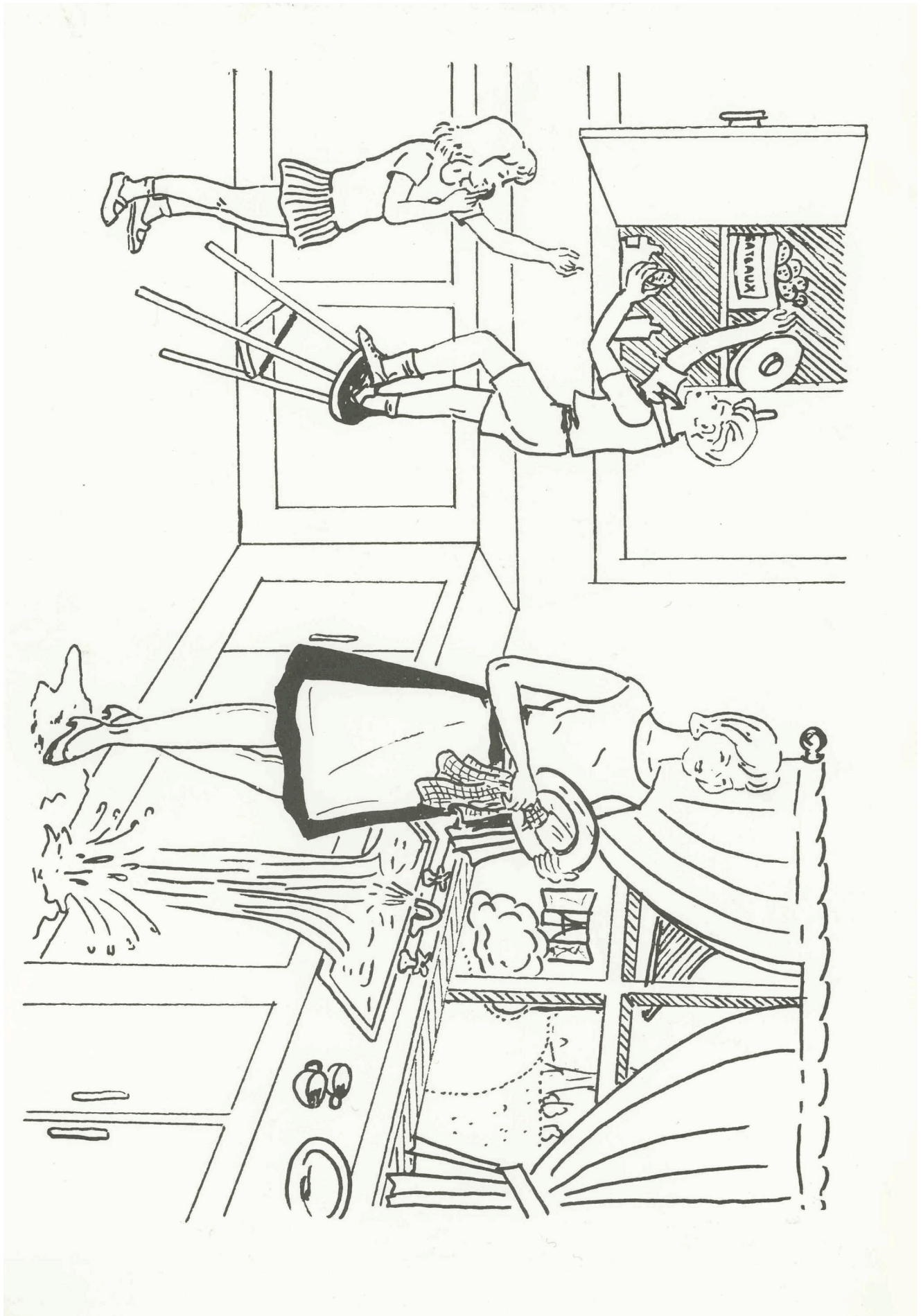
#### - **Faites un point au milieu de chaque rond (feuille suivante)**

### • SIMULTAGNOSIE

#### - Description du cookie theft (BDAE)










- **Comptage de points**

Présentez pendant deux secondes chacun des carrés suivants et demandez d'estimer le nombre approximatif de points.



- **APRAXIE DU REGARD**

- **Vision périphérique**

*Regardez mon nez ... allez regarder mon crayon...*

POSITION DU CRAYON	
En haut à gauche	/1
En bas à gauche	/1
En haut à droite	/1
En bas à droite	/1

## **NEGLIGENCE**

- **BATTERIE DU GEREN**

- **Troubles du champ visuel**

Regardez mon nez... vous voyez mes deux mains ? Laquelle a bougé ? (répéter 3 fois la stimulation seulement si le patient présente une difficulté de type extinction ou cécité)

*(NB : extinction quand un des stimuli bilatéraux n'est pas perçu alors que les stimuli unilatéraux ont été perçus QSG=quadrant supérieur Gauche QSD=quadrant supérieur droit EG= équateur gauche QIG=quadrant inférieur gauche...)*

		1 <sup>ère</sup> stimulation	2 <sup>ème</sup> stimulation	3 <sup>ème</sup> stimulation
☞	☞			
	QSG-QSD			
	☞			
	EG			
	QIG-QID			
☞	☞			
☞				
	ED			
	☞			
	QSG			
	☞			
	QIG			
☞	☞			
	QSG-QSD			
☞	☞			
	EG-ED			
	QID			
☞				
	QIG-QID			
☞	☞			
☞				
	QSD			
☞	☞			
	EG-ED			
		GAUCHE	DROITE	
	Erreurs 1 Stim			
	Erreurs 2 Stim			
	Erreurs totales			
	QSG	QIG	QSD	OID
Erreurs totales				

Noter E pour Extinction et C pour cécité pour les 4 quadrant visuels du patient ci-dessous.

Gauche du patient    Droite du patient


**- Troubles sensitifs**

Fermez les yeux... mettez vos main sur vos cuisses... Vous allez me dire où je vous ai touché... (Répéter 3 fois la stimulation seulement en cas de difficulté du patient)

	STIMULATION TACTILE (très discrète !)		
Yeux Fermés			
	1 <sup>ère</sup> stimulation	2 <sup>ème</sup> stimulation	3 <sup>ème</sup> stimulation
Joue D – Joue G			
Main G			
Pied D – Pied G			
Main D			
Joue G			
Pied G			
Joue D – Joue G			
Main D – Main G			
Pied D			
Pied D – Pied G			
Joue D			
Main D – Main G			
	GAUCHE	DROITE	
Erreurs 1 Stim			
Erreurs 2 Stim			
Erreurs Totales			

**- Troubles Auditifs**

Les yeux fermés en tapant à côté de l'oreille gauche et droite du patient son pouce et son index. (Stimulation gauche, droite et gauche-droite, répéter 3 fois si difficultés du patient)

Stimulation auditive			
	/1	/1	/1
Gauche			
Droite			
Gauche/droite			

### - Négligence motrice

#### 1 - Faire asseoir sur un fauteuil

- Place symétriquement les deux bras sur les bras du fauteuil ou sur les cuisses 0
- Les place asymétriquement mais corrige spontanément. 1
- Laisse pendre le bras mais corrige sur ordre (ou latence > 60s) 2

#### 2 - Gesticulation spontanée (à coter seulement si la gesticulation est suffisante du côté sain)

- Gesticule symétriquement 0
- Gesticule un peu de la main malade 1
- Ne gesticule pas de la main malade 2

#### 3 - Réaction d'évitement. Instruction : défendez vous dès que le pinçon devient trop fort

- Retire immédiatement le bras 0
- Retire le bras avec retard (évaluer le retard) 1

#### 4 - Haut les mains

- Met la main malade en position normale 0
- Ebauche l'élévation de la main malade 1
- Elève la main seulement sur ordre 2

#### 5 - Hypométrie doigt-nez

- Mouvement complet du doigt sans mouvement de la tête 0
- Mouvement de la tête de moins de 5 cm 1
- Mouvement de la tête de plus de 5 cm 2

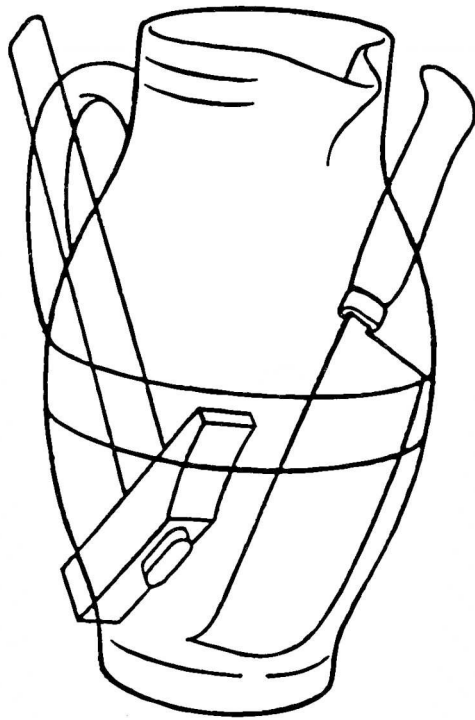
#### 6 - Viser pour tirer un coup de fusil

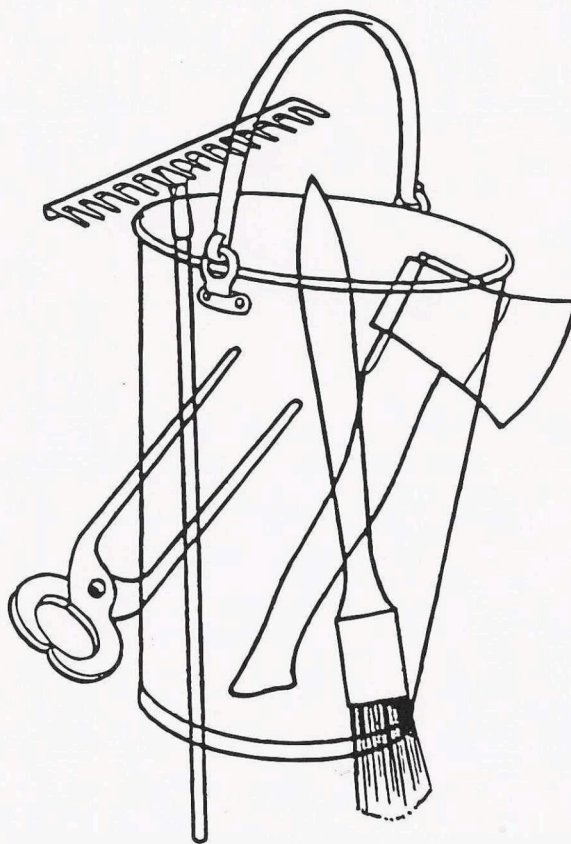
- Met la main malade en position normale 0
- Ebauche l'élévation de la main malade 1
- N'élève la main gauche que sur ordre 2


#### 7 - Lancer une boulette de papier vers l'épaule et essayer de l'attraper au vol

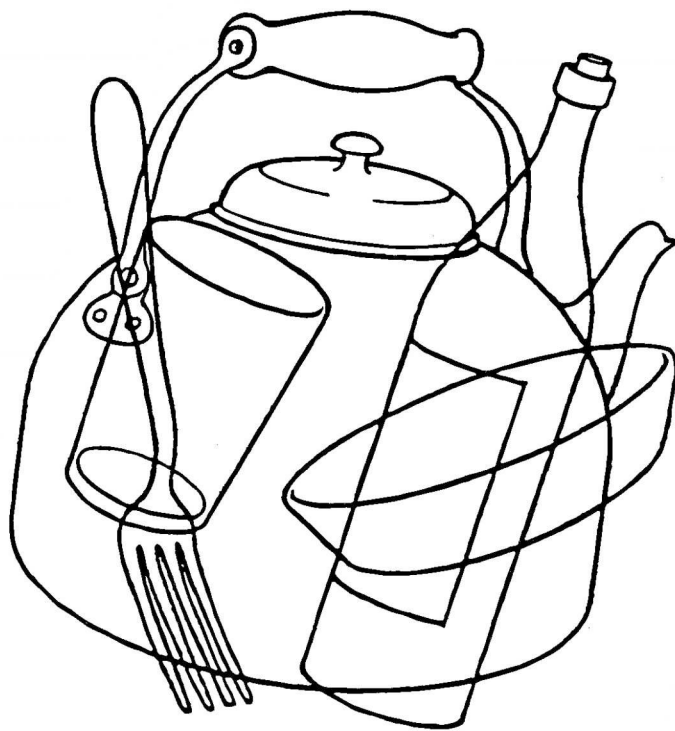

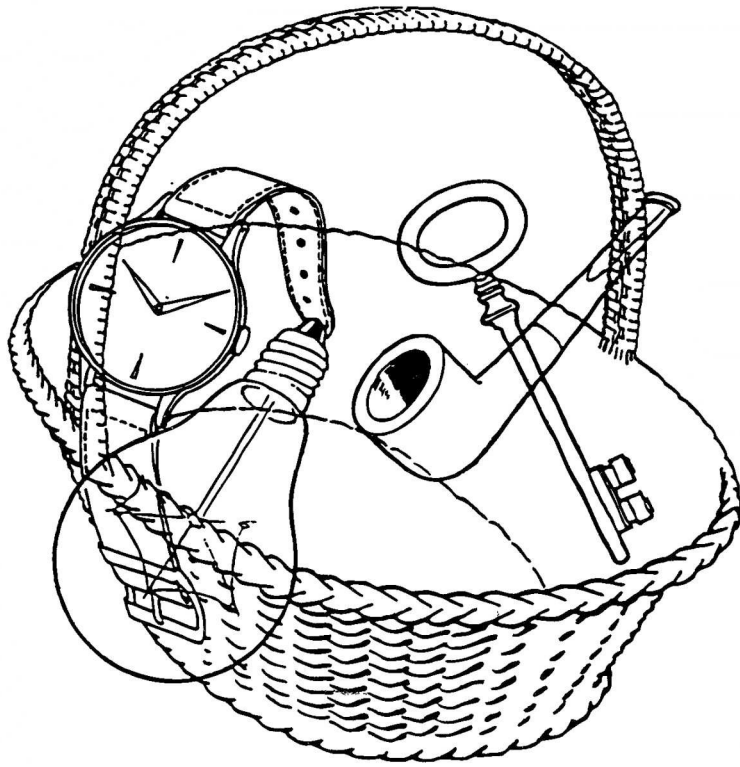


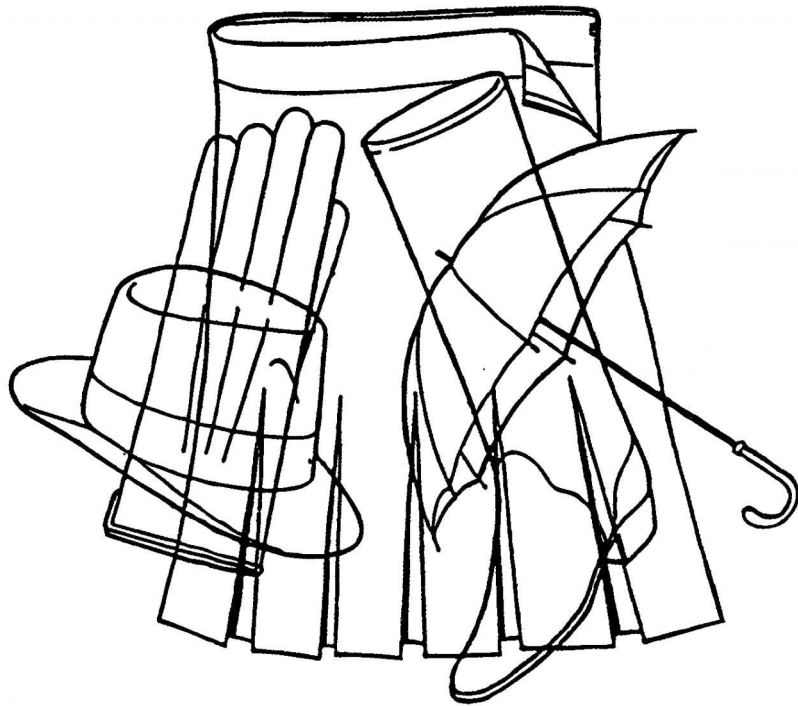












Lecture (le neuropsychologue écrit ce que lit le patient) :

**Il est 7h25, Robert boit son café. Il met sa veste et se rend au parking de l'immeuble. Une mauvaise surprise l'attend : son pneu avant gauche est crevé. Il change de roue et roule vers la porte d'Orléans. A 8H05 , il prend la bretelle de l'autoroute A6 qui mène à Orly.**

### **MEMOIRE**

Administrer deux essais à chaque niveau. Arrêter après deux échecs consécutifs au même niveau.

- CORSI

Pointage ordre direct					
Item	Essais I	R/E	Essais II	R/E	2 1 0 ?
2-6			8-4		
2-7-5			8-1-6		
3-2-8-4			2-6-1-5		
5-3-4-6-1			3-5-1-7-2		
1-7-2-8-5-4			7-3-6-1-4-8		
8-2-5-3-4-1-6			4-2-6-8-3-7-5		
7-5-6-3-8-7-4-2			1-6-7-4-2-8-5-3		

Pointage ordre indirect					
Item	Essais I	R/E	Essais II	R/E	2 1 0 ?
3-6			7-4		
6-8-5			3-1-8		
8-4-1-6			5-2-4-1		
4-6-8-5-2			8-1-6-3-7		
7-1-8-3-6-2			3-8-1-7-5-4		
1-5-2-7-4-3-8			6-7-4-3-1-5-2		

- VERBAL

Ordre direct					
Item	Essais I	R/E	Essais II	R/E	2 1 0 ?
6-2-9			3-7-5		
5-4-1-7			8-3-9-6		
3-6-9-2-5			6-9-4-7-1		
9-1-8-4-2-7			6-3-5-4-8-2		
1-2-8-5-3-4-6			2-8-1-4-8-7-5		
3-8-2-9-5-1-7-4			5-9-1-8-2-6-4-7		

Ordre indirect					
Item	Essais I	R/E	Essais II	R/E	2 1 0 ?
5-1			3-8		
4-9-3			5-2-6		
3-8-1-4			1-7-9-5		
6-2-9-7-2			4-8-5-2-7		
7-1-5-2-8-6			8-3-1-9-6-4		
4-7-3-9-1-2-8			8-1-2-9-3-6-5		



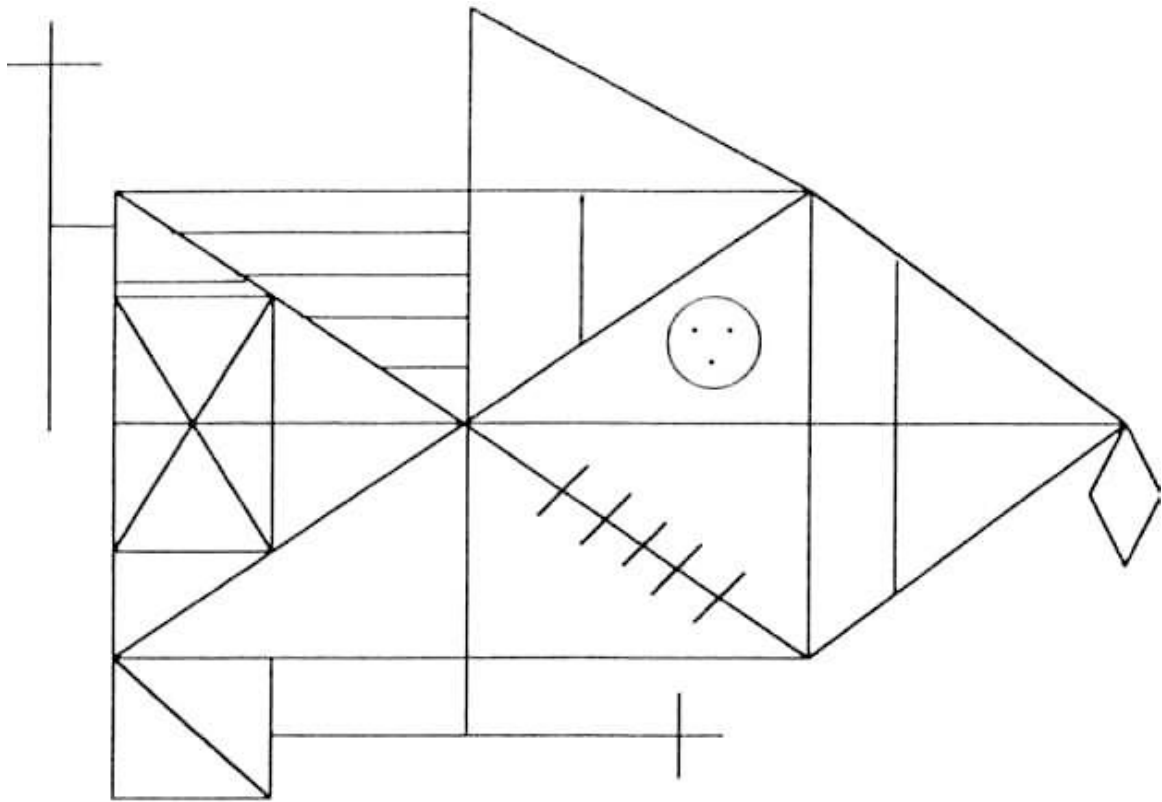
## PRAXIE

- VERSION COURTE DE LA BREP  
(Sur imitation pour les dessins)

	Score (sur 2)	Imitations Gestes	Score (sur 2)
Faire au revoir (Ordre)		NS8	
Boire de la soupe à la cuillère (Ordre)		NS9	
Ecrire avec un crayon (Ordre)		NS10	
Se brosser les dents (Ordre)		NS16	
Répondre au téléphone (Ordre)		NS19	
Se peigner les cheveux (Ordre)		NS22	
NS1		NS23	
NS3		NS25	

## APRAXIE CONSTRUCTIVE

- FIGURE REY COPIE



Montrez moi mon nez ...

/1

- **INDISTINCTION DROITE/GAUCHE ET PARTIES DU CORPS**

**Montrez moi votre ...**

Partie du corps	Partie désignée	Côté désigné
main gauche		
Cou		
coude droit		
cuisse gauche		
cheville droite		
Ventre		
oreille gauche		
épaule droite		
Nez		
poignet gauche		
Bouche		
genou droit		

**Montrez moi MON / MA**

Partie du corps	Partie désignée	Côté désigné
main gauche		
cou		
coude droit		
cuisse gauche		
cheville droite		
ventre		
oreille gauche		
épaule droite		
nez		
poignet gauche		
bouche		
genou droit		

- **AGNOSIE DIGITALE**

- Dénomination et désignation sur la main du patient et sur celle de l'examineur

Montrez moi votre...

Partie du Corps	Doigt désigné	Score	/5
Index		/1	
Auriculaire		/1	
Annulaire		/1	
Pouce		/1	
Majeur		/1	

En pointant les doigts du sujet lui demander :  
Comment s'appelle ce doigt ?

Partie du Corps	Doigt désigné	Score	/5
Index		/1	
Auriculaire		/1	
Annulaire		/1	
Pouce		/1	
Majeur		/1	

- **ACALCULIE**

- Arithmétique oralement  
Faire résoudre mentalement


Résoudre	Score	/7	Résoudre	Score	/7	Résoudre	Score	/6
7-6	/1		7+6	/1		7x6	/1	
4-2	/1		4+2	/1		4x2	/1	
9-2	/1		9+2	/1		9x2	/1	
8-7	/1		8+7	/1		8x7	/1	
5-4	/1		5+4	/1		5x4	/1	
25-7	/1		25+7	/1		3x13	/1	
35-11	/1		35+11	/1				

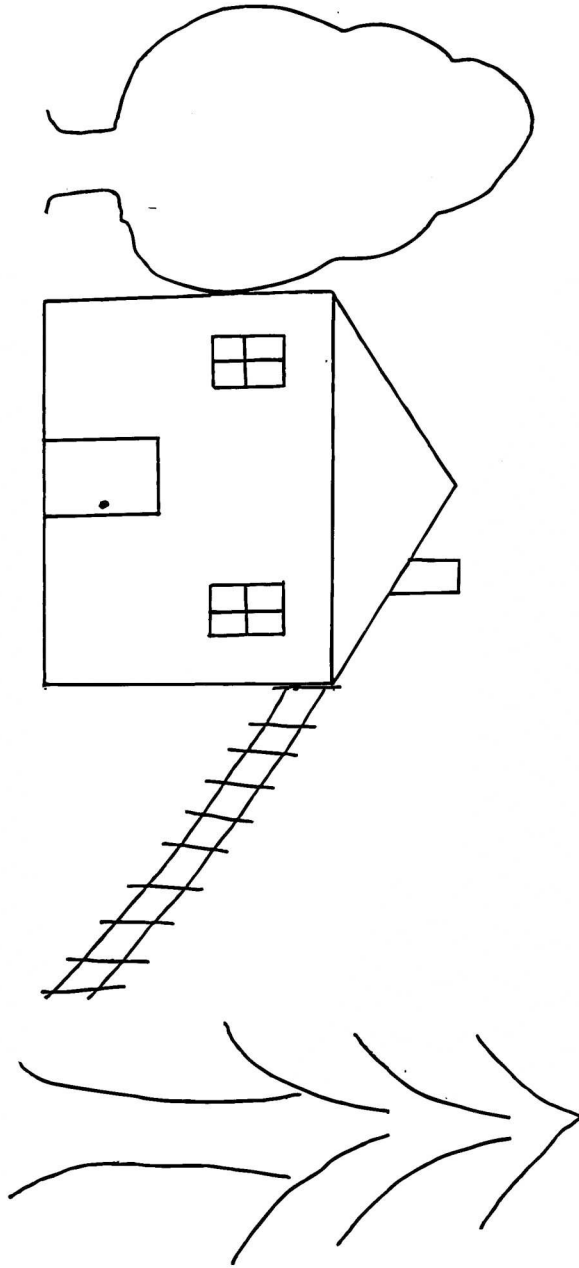
- **AGRAPHIE**

-Dictée d'une phrase

Les clients mécontents ont attendu longtemps devant la porte du magasin.









## ANNEXE 2

*Article sous presse dans JNNP*

### WHITE MATTER FUNCTIONAL CONNECTIVITY AS AN ADDITIONAL LANDMARK FOR DOMINANT TEMPORAL LOBECTOMY

Hugues Duffau<sup>1,2,3</sup>, M.D., Ph.D., Michel Thiebaut de Schotten<sup>4,5,6</sup>, Ph.D.,  
and Emmanuel Mandonnet, M.D, Ph.D.<sup>2,7</sup>

<sup>1</sup>Department of Neurosurgery, Hôpital Gui de Chauliac, Montpellier, France

<sup>2</sup>INSERM U678, Hôpital de la Salpêtrière, Paris, France

<sup>3</sup>Laboratoire de la Cognition et du Comportement, FRE 2987 (CNRS/ Université de Paris V René Descartes), Institut de Psychologie, Boulogne Billancourt, France

<sup>4</sup>INSERM Unit 610, Hôpital de la Salpêtrière, Paris, France

<sup>5</sup>Université Pierre et Marie Curie-Paris 6, Paris, France

<sup>6</sup>IFR 70, Hôpital de la Salpêtrière, Paris, France

<sup>7</sup>Department of Neurosurgery, Hôpital Lariboisière, Paris, France

**Corresponding Author:** Hugues Duffau, M.D., Ph.D.,

Department of Neurosurgery, Hôpital Gui de Chauliac, CHU de Montpellier

80 avenue Augustin Fliche, 34295 Montpellier Cedex 5, France

Phone: 33 (0)4 67 33 02 90 Fax: 33 (0)4 67 33 75 57

Email: h-duffau@chu-montpellier.fr

**Key words:** Temporal lobectomy, Anatomic-functional connectivity, Subcortical mapping, Inferior occipito-temporal fasciculus, Arcuate fasciculus, Optic radiations

**Word count:** 1821

## **Abstract**

Dominant temporal lobectomy is classically performed according to two criteria: a perfect knowledge of the temporo-mesial microsurgical anatomy, and cortical landmarks laterally. However, the functional anatomy of the subcortical white matter tracts is less taken into account, despite the risk to induce a permanent deficit (especially aphasia) if damaged. Even if Klinger's technique allows to dissect fibers on cadaveric specimen, the exact 3D geometry of these fasciculi remains poorly described. Tractography, based on diffusion tensor imaging (DTI), is a powerful tool to build 3D images of several fasciculi, helping neurosurgeon to create a mental representation of their relationships. Moreover, intraoperative subcortical electrostimulation enables to map the function of these pathways. Here, we review the recent findings about the white matter anatomo-functional connectivity of dominant temporal lobe, based on combined anatomical data provided by DTI and functional information provided by intraoperative stimulation. Then, we discuss their implications for temporal lobectomy, by using white matter functional connectivity as an additional landmark.

## **Introduction**

Since many decades, neurosurgeons perform temporal lobectomy in the dominant hemisphere, preserving the anterior part of the superior temporal gyrus as well as the mid part of the middle temporal gyrus, while resecting the anterior and mid part of the inferior temporal gyrus without any functional consequences, especially on language [1]. This usual view has been challenged since a major interindividual anatomo-functional variability for language has been demonstrated at the level of the lateral temporal cortex, using both intraoperative electrostimulation [2] and functional neuroimaging [3]. Indeed, the anterior part of the superior temporal gyrus and the mid part of the middle temporal gyrus may be involved in language. When evidenced intraoperatively, these areas have to be preserved [2]. In addition, temporo-basal areas can also play a role in language, even if their resection does not systematically cause definitive deficit [4].

Thus, preoperative as well as intraoperative cortical mapping techniques have been introduced in order to tailor the cortical resection of the dominant temporal lobe according to functional boundaries, initially for epilepsy surgery [2], and then for glioma surgery [5]. However, because glioma spread along white matter fasciculi, intraoperative subcortical stimulation has been proposed, about ten years ago, in order to stop the resection as close as possible to eloquent subcortical pathways [6]. Similarly, in epilepsy surgery, the resection of cortical foci is often associated with a disconnection of white matter tracts [1]. However, functional damage during this disconnection must be avoided, in order to preserve the quality of life [7].

Thus, the aim of this paper is not to describe the well known anatomical landmarks of a temporo-mesial lobectomy [8, 9], and neither to detail the limbic connectivity of temporo-mesial structures involved in memory processing. We will rather attempt to describe additional and reliable landmarks given by functional white matter pathways (with special emphasis on language), in order to make the resection of the dominant temporal lobe more reproducible and safer, not only for glioma surgery, but also for corticectomies in epilepsy surgery.

## **Tractography Method**

### **Subject and Acquisition parameters**

One single right-handed subject (36 years old) gave written informed consent to participate in the study, which was approved by the local ethics committee. No subject had radiological

signs of cerebral lesions on conventional MRI. MRI data were acquired using echo-planar imaging at 1.5 T (General Electric Healthcare Signa) with a standard head coil for signal reception. DTI axial slices were obtained using the following parameters: repetition time, 19s; echo time, 93ms; flip angle, 90°; voxel size, 1,88\*1,88\*2 mm (isotropic voxels); Diffusion weighting was performed along two hundreds independent directions, with a b-value of 3000 s/mm<sup>2</sup>.

### **Image processing**

Raw diffusion-weighted data were corrected for geometric distortion secondary to eddy currents using a registration technique based upon the geometric model of distortions (Mangin et al., 2002a). Brainvisa 3.0.2 (<http://brainvisa.info/>) software was used to calculate diffusion tensors and anisotropy data, to define the ROIs and to perform fibre tracking using likelihood algorithm (Mangin et al., 2002b) on diffusion tensor model with a fractional anisotropic threshold of 0.2 and a maximum angle of 45°

### **Methodological advances in subcortical mapping**

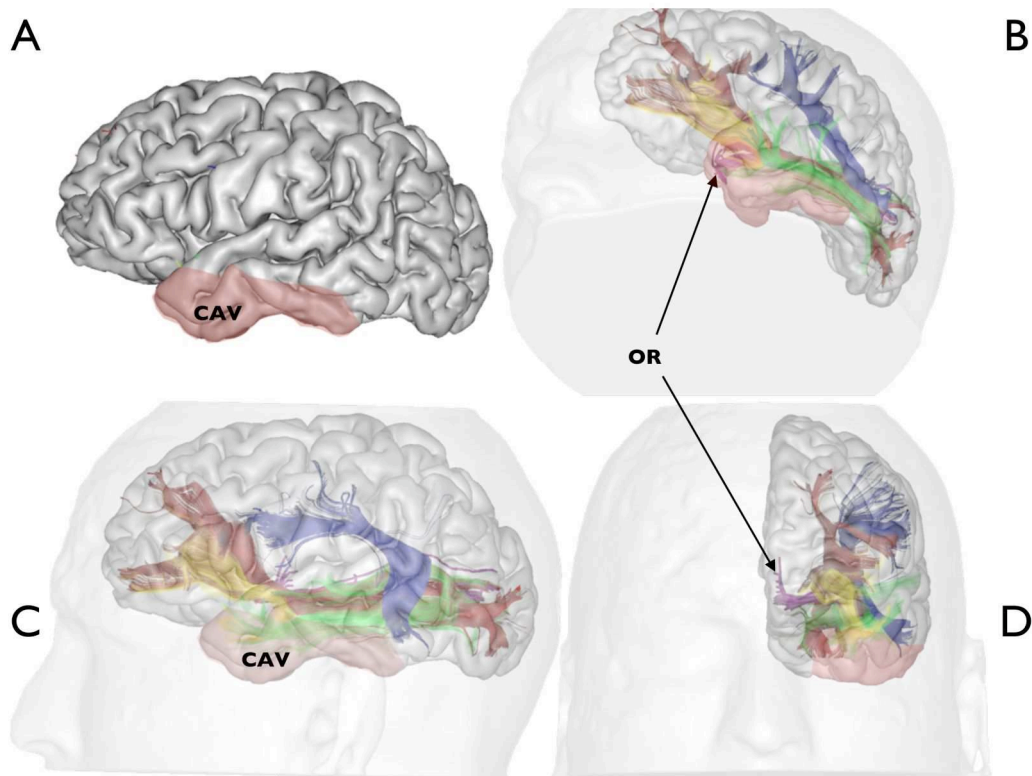
Recent developments of diffusion tensor imaging (DTI) have enabled the non invasive study of white matter bundles, in particular those thought to be involved in language [10]. However, DTI gives only anatomical information, and cannot provide details regarding the function sustained by the fibers.

Interestingly, during brain surgery for resection of a tumor invading both cortical and subcortical structures, it is now a common clinical practice to awaken patients in order to assess the functional role of restricted brain regions, so that the surgeon can maximise the extent of the resection without generating neither motor, sensory nor cognitive (especially language) impairments. Patients continuously perform functional tasks, while the surgeon temporarily inactivates localized regions within the grey or white matter around the lesion, using electrical stimulations. If the patient stops speaking or produces wrong responses, the surgeon does not remove the stimulated region. Indeed, it has been demonstrated that resection too close to structures that are considered as eloquent on the basis of electrical mapping, induced postoperative deficit [5]. Therefore, intraoperative electrostimulation is able to identify, with a great accuracy (5 mm) and reproducibility, the structures that are essential for the brain function, not only at cortical but also at subcortical levels [11].

Moreover, combining the precise functional disturbances elicited by stimulations with the anatomical data provided by pre- and post-operative magnetic resonance imaging (in

particular DTI), has enabled to perform reliable anatomo-functional correlations, especially with regard to the subcortical pathways [12-14]. In comparison to the voxel-based lesion – symptom mapping, which analyzes the relationship between tissue damage and behavior in patients with a neurological deficit [15], electrical mapping offers the possibility to study the relationship between brain and behavior in subjects with no or only very slight neurological disorder – since stimulation generates the effects of a transient virtual lesion [15].

On the basis of this methodological progress, it is now possible to integrate the better knowledge of the subcortical connectivity in the surgical planning of temporal lobectomy within the dominant hemisphere. To this end, we will study successively the different fasciculi which will be encountered during a resection of the temporal lobe, from anterior to posterior (Fig 1).



### Figure Legend

Fig. 1: The Fiber tracking of the arcuate fasciculus (blue), inferior longitudinal fasciculus (green), inferior fronto-occipital fasciculus (red), uncinate (yellow), optic radiation (OR) was performed using the ROIs described by Catani et al. [23] A “two regions of interest” approach was used for each fasciculus tracking. The procedure, described by Basser et al. [34], consisted in defining a second ROI, at a distance from the first ROI, such that it contained at least a section of the desired fasciculus but did not contain any fibres of the undesired fasciculus that passed through the first ROI. DTI and high-resolution 3-D anatomical images (B, C, D) was registered using Brainvisa 3.0.2. The displaying of derived tracts was performed using Anatomist 3.0.2 (<http://brainvisa.info>).

We have drawn a virtual resection cavity (CAV) according to essential subcortical pathways (inferior fronto-occipital fasciculus and arcuate fasciculus), while removing the "non essential" tracts (uncinate, inferior longitudinal fasciculus and anterior part of the OR). By reporting this cavity on the 3-D surface reconstruction (A), we have obtained a resection similar to those classically reported in the literature - according to cortical boundaries.

### White matter (functional) landmarks in temporal lobectomy

### **Uncinate fasciculus**

This pathway connects the anterior part of the temporal pole, the uncus, amygdale and hippocampal gyrus to the orbital and polar frontal cortex [16]. A reduced left-greater-than right asymmetry of uncinate fasciculus has been linked to schizophrenia by in vivo DTI study [17, 18], although post-mortem studies failed to confirm this hypothesis [19]. Moreover, this tract is regularly sectioned in epilepsy surgery, without inducing major personality disorders. Thus, to the present date, the functional role of the dominant uncinate fasciculus remains speculative, and its resection is widely admitted.

### **Inferior longitudinal fasciculus**

This tract, first described by K.F. Burdach in 1822, connects the anterior part of the temporal lobe to the occipital lobe, and runs laterally and inferiorly to the lateral wall of the temporal horn. Recent DTI studies [20] have demonstrated the existence of both a direct and indirect pathway (constituted by U-shaped fibers of the occipito-temporal projection system). Interestingly, while the inferior longitudinal fasciculus was supposed to play a role in emotional processing – likely through a wide network also involving the uncinate fasciculus – , a recent brain stimulation study has demonstrated that this tract was not essential for cognitive function, especially for language [21]. As a consequence, its disconnection or resection can be performed with no ecological consequence on the quality of life, even in the dominant hemisphere, as for the uncinate fasciculus. These findings are in accordance with the classical view concerning the temporal lobectomy, i.e. that it is possible to remove the inferior temporal gyrus and the fusiform gyrus (in addition to the temporal pole), without generating permanent deficit. Interestingly, some studies have also proposed that this resection might be performed very posteriorly, even if the existence of cortical eloquent areas have been suspected – namely that language disturbances have been elicited by cortical electrostimulation at the level of the so-called postero-basal temporal areas [4].

### **Inferior occipito-frontal fasciculus**

This tract comes from the occipital lobe and postero-lateral temporal areas, then runs laterally and superiorly to the lateral wall of the temporal horn, and continues antero-superiorly to the orbito-frontal and dorso-lateral prefrontal cortices via the anterior floor of the external capsule under the insular lobe [22, 23]. Recently, using intraoperative subcortical mapping, it has been demonstrated that direct electrostimulation of this pathway induced semantic paraphasias (i.e. errors with regard to the meaning of the word target) with a high reproducibility [24]. These observations have provided strong arguments in favour of the fact that the inferior occipito-frontal fasciculus was a subcortical pathway underlying the “ventral

stream”, crucial for language semantic processing, and able to compensate the inferior longitudinal fasciculus – thus explaining why this latter can be removed without deficit [21]. As a consequence, the inferior occipito-frontal fasciculus has absolutely to be preserved at the end of surgical resection in the depth of the dominant temporal lobe [24]. Interestingly, in the anterior floor of the external capsule, this pathway is located immediately medially and above the uncinate fasciculus [22]. Therefore, since the uncinate fasciculus can be resected, the inferior occipito-frontal fasciculus represents the postero-superior and deep limit of the resection of the temporal pole, at the level of the “pli falciforme de Broca”. More posteriorly, the temporal part of this pathway represents the supero-mesial and deep boundary of the resection, above the roof of the temporal horn of the ventricle [24]. Indeed, the roof of the ventricle is a good anatomical landmark to distinct the inferior lateral fasciculus (below) and the inferior occipito-temporal fasciculus (above).

Finally, it is worth noting that, since this tract connects the frontal lobe to the postero-lateral temporal cortex, the posterior limit of the resection at the cortical level (superior and middle temporal cortices) depends on the individual distribution of the language sites detected using brain mapping techniques. However, the subcortical postero-lateral boundary of the resection has also to be determined. The temporal part of the arcuate fasciculus may represent this limit.

### **Superior longitudinal fasciculus**

The superior longitudinal fasciculus (or arcuate fasciculus) is a fiber tract stemming from the caudal part of the posterior and superior temporal cortex (mainly Wernicke’s area) that arches around the insula and projects forward to end within the frontal lobe (mainly prefrontal and premotor gyri, especially Broca’s area) [25]. With regard to functional aspects, Wernicke and then later Geschwind postulated that lesions of this tract would produce conduction aphasia. Recently, the different parts of the arcuate fasciculus have been identified using intraoperative subcortical stimulations, by eliciting reproducible phonemic paraphasias, namely disorders that affect the phonological form of the words [26]. As a consequence, it is mandatory to preserve this pathway, which subserves the “dorsal phonological stream”. Thus, the anterior wall of the temporal part of the arcuate fasciculus, running vertically at the outer surface of the ventricle, represents the subcortical postero-lateral boundary of the resection [26].

### **Optic radiations**



The optic pathways are located just medially and above the inferior longitudinal fasciculus, whereas the inferior occipito-frontal fasciculus runs medially and above them [22, 27-29]. Interestingly, it was recently demonstrated that it was possible to identify these visual tracts intraoperatively, by eliciting transient shadow during their direct electrostimulation [26]. It is very important to preserve the optic radiations at this level, to avoid a permanent postoperative hemianopsia, a deficit which prevents to lead a normal life (e.g. for driving) – conversely to a single quadrantanopsia, frequently induced following a temporal lobectomy, but which has no ecological consequence on the quality of life. As a consequence, this tract has to represent the postero-superior and deep limit of a temporal lobectomy.

Finally, in the depth, the pyramidal pathway [30], running within the posterior limb of the internal capsule, and easily detectable using intraoperative stimulation, has to be preserved: this tract constitutes the most posterior mesial boundary of the resection.

## **Conclusion**

The better knowledge of the anatomo-functional organization of the subcortical pathways may provide additional and reliable landmarks to perform temporal lobectomy in the dominant hemisphere. Indeed, while it is currently well-known that slow-growing lesion may induce functional cortical reshaping, due to cerebral plasticity mechanisms [31], such reorganization is negligible within the white matter [6]. As a consequence, the subcortical landmarks here detailed are very reproducible, and can be useful to optimize the benefit/risk ratio of temporal lobectomy, that is to perform a large resection of pathological tissue (during glioma as well as epilepsy surgery) without postoperative impairment of language function. Intraoperative stimulation is still the gold standard to map these functional pathways, but in a near future, intraoperative MRI combined with pre-operative DTI could allow their intraoperative identification with a great accuracy [32, 33].

## **Acknowledgements**

NMR database is the property of CEA SHFJ/UNAF and can be provided on demand to cpoupon@shfj.cea.fr. Data were acquired with NMR pulse sequences, reconstructed with NMR reconstructor package and post-processed with AIMS/Anatomist/BrainVisa software, freely available at <http://brainvisa.info>.

## References

1. Spencer, D.D., Spencer, S.S., Mattson, R.H., et al., Access to the posterior medial temporal lobe structures in the surgical treatment of temporal lobe epilepsy. *Neurosurgery*, 1984. 15(5): p. 667-71.
2. Ojemann, G., Ojemann, J., Lettich, E., et al., Cortical language localization in left, dominant hemisphere. An electrical stimulation mapping investigation in 117 patients. *J Neurosurg*, 1989. 71(3): p. 316-26.
3. Vigneau, M., Beaucousin, V., Herve, P.Y., et al., Meta-analyzing left hemisphere language areas: phonology, semantics, and sentence processing. *Neuroimage*, 2006. 30(4): p. 1414-32.
4. Luders, H., Lesser, R.P., Hahn, J., et al., Basal temporal language area. *Brain*, 1991. 114 (Pt 2): p. 743-54.
5. Haglund, M.M., Berger, M.S., Shamseldin, M., et al., Cortical localization of temporal lobe language sites in patients with gliomas. *Neurosurgery*, 1994. 34(4): p. 567-76; discussion 576.
6. Duffau, H., Intraoperative cortico-subcortical stimulations in surgery of low-grade gliomas. *Expert Rev Neurother*, 2005. 5(4): p. 473-85.
7. Smith, J.R., VanderGriff, A., and Fountas, K., Temporal lobotomy in the surgical management of epilepsy: technical report. *Neurosurgery*, 2004. 54(6): p. 1531-4; discussion 1534-6.
8. Sindou, M. and Guenot, M., Surgical anatomy of the temporal lobe for epilepsy surgery. *Adv Tech Stand Neurosurg*, 2003. 28: p. 315-43.
9. Wen, H.T., Rhoton, A.L., Jr., de Oliveira, E., et al., Microsurgical anatomy of the temporal lobe: part 1: mesial temporal lobe anatomy and its vascular relationships as applied to amygdalohippocampectomy. *Neurosurgery*, 1999. 45(3): p. 549-91; discussion 591-2.
10. Catani, M., Jones, D.K., and ffytche, D.H., Perisylvian language networks of the human brain. *Ann Neurol*, 2005. 57(1): p. 8-16.
11. Duffau, H., Lessons from brain mapping in surgery for low-grade glioma: insights into associations between tumour and brain plasticity. *Lancet Neurol*, 2005. 4(8): p. 476-86.
12. Kamada, K., Todo, T., Masutani, Y., et al., Visualization of the frontotemporal language fibers by tractography combined with functional magnetic resonance imaging and magnetoencephalography. *J Neurosurg*, 2007. 106(1): p. 90-8.
13. Thiebaut de Schotten, M., Urbanski, M., Duffau, H., et al., Direct evidence for a parietal-frontal pathway subserving spatial awareness in humans. *Science*, 2005. 309(5744): p. 2226-8.
14. Henry, R.G., Berman, J.I., Nagarajan, S.S., et al., Subcortical pathways serving cortical language sites: initial experience with diffusion tensor imaging fiber tracking combined with intraoperative language mapping. *Neuroimage*, 2004. 21(2): p. 616-22.
15. Bates, E., Wilson, S.M., Saygin, A.P., et al., Voxel-based lesion-symptom mapping. *Nat Neurosci*, 2003. 6(5): p. 448-50.
16. Crosby, E.C., Humphrey, T., and E.W., L., Correlative Anatomy of the Nervous System. 1962, New York: MacMillian.

17. Burns, J., Job, D., Bastin, M.E., et al., Structural disconnectivity in schizophrenia: a diffusion tensor magnetic resonance imaging study. *Br J Psychiatry*, 2003. 182: p. 439-43.
18. Kubicki, M., Westin, C.F., Maier, S.E., et al., Uncinate fasciculus findings in schizophrenia: a magnetic resonance diffusion tensor imaging study. *Am J Psychiatry*, 2002. 159(5): p. 813-20.
19. Highley, J.R., Walker, M.A., Esiri, M.M., et al., Asymmetry of the uncinate fasciculus: a post-mortem study of normal subjects and patients with schizophrenia. *Cereb Cortex*, 2002. 12(11): p. 1218-24.
20. Catani, M., Jones, D.K., Donato, R., et al., Occipito-temporal connections in the human brain. *Brain*, 2003. 126(Pt 9): p. 2093-107.
21. Mandonnet, E., Nouet, A., Gatignol, P., et al., Does the left inferior longitudinal fasciculus play a role in language? A brain stimulation study. *Brain*, 2007. 130(Pt 3): p. 623-9.
22. Kier, E.L., Staib, L.H., Davis, L.M., et al., MR imaging of the temporal stem: anatomic dissection tractography of the uncinate fasciculus, inferior occipitofrontal fasciculus, and Meyer's loop of the optic radiation. *AJNR Am J Neuroradiol*, 2004. 25(5): p. 677-91.
23. Catani, M., Howard, R.J., Pajevic, S., et al., Virtual in vivo interactive dissection of white matter fasciculi in the human brain. *Neuroimage*, 2002. 17(1): p. 77-94.
24. Duffau, H., Gatignol, P., Mandonnet, E., et al., New insights into the anatomo-functional connectivity of the semantic system: a study using cortico-subcortical electrostimulations. *Brain*, 2005. 128(Pt 4): p. 797-810.
25. Nieuwenhuys, R., Voogd, J., and van Huijzen, C., The human central nervous system. 1988, Berlin: Springer-Verlag.
26. Duffau, H., Capelle, L., Sichez, N., et al., Intraoperative mapping of the subcortical language pathways using direct stimulations. An anatomo-functional study. *Brain*, 2002. 125(Pt 1): p. 199-214.
27. Sincoff, E.H., Tan, Y., and Abdulrauf, S.I., White matter fiber dissection of the optic radiations of the temporal lobe and implications for surgical approaches to the temporal horn. *J Neurosurg*, 2004. 101(5): p. 739-46.
28. Rubino, P.A., Rhoton, A.L., Jr., Tong, X., et al., Three-dimensional relationships of the optic radiation. *Neurosurgery*, 2005. 57(4 Suppl): p. 219-27; discussion 219-27.
29. Ebeling, U. and Reulen, H.J., Neurosurgical topography of the optic radiation in the temporal lobe. *Acta Neurochir (Wien)*, 1988. 92(1-4): p. 29-36.
30. Ebeling, U. and Reulen, H.J., Subcortical topography and proportions of the pyramidal tract. *Acta Neurochir (Wien)*, 1992. 118(3-4): p. 164-71.
31. Desmurget, M., Bonnetblanc, F., and Duffau, H., Contrasting acute and slow-growing lesions: a new door to brain plasticity. *Brain*, 2006.
32. Nimsky, C., Ganslandt, O., and Fahlbusch, R., Implementation of fiber tract navigation. *Neurosurgery*, 2006. 58(4 Suppl 2): p. ONS-292-303; discussion ONS-303-4.
33. Nimsky, C., Ganslandt, O., Merhof, D., et al., Intraoperative visualization of the pyramidal tract by diffusion-tensor-imaging-based fiber tracking. *Neuroimage*, 2006. 30(4): p. 1219-29.
34. Basser, P.J. Fiber-Tractography via diffusion tensor MRI (DT-MRI). in Sixth Annual Meeting of the International Society for Magnetic Resonance in Medicine. 1998: ISMRM.



**ANNEXE 3 LES CHEMINS TORDUS**

