



HAL
open science

Neuropsychological aspects of right temporal lobe epilepsy : visual memory and perception

Ilona Wisniewski

► **To cite this version:**

Ilona Wisniewski. Neuropsychological aspects of right temporal lobe epilepsy : visual memory and perception. *Neurons and Cognition [q-bio.NC]*. Université de Strasbourg, 2012. English. NNT : 2012STRAJ090 . tel-00865637

HAL Id: tel-00865637

<https://theses.hal.science/tel-00865637v1>

Submitted on 24 Sep 2013

HAL is a multi-disciplinary open access archive for the deposit and dissemination of scientific research documents, whether they are published or not. The documents may come from teaching and research institutions in France or abroad, or from public or private research centers.

L'archive ouverte pluridisciplinaire **HAL**, est destinée au dépôt et à la diffusion de documents scientifiques de niveau recherche, publiés ou non, émanant des établissements d'enseignement et de recherche français ou étrangers, des laboratoires publics ou privés.



UNIVERSITÉ DE STRASBOURG



Ecole Doctorale
des Sciences
de la Vie
et de la Santé
STRASBOURG

**ÉCOLE DOCTORALE DES SCIENCES DE LA VIE ET DE LA
SANTÉ**

Laboratoire d'imagerie et de neurosciences cognitives (CNRS, UMR 7237, IFR 037)

THÈSE présentée par :

Ilona WISNIEWSKI

Soutenance prévue le: **15 novembre 2012**

Pour obtenir le grade de : **Docteur de l'université de Strasbourg**

Discipline/S spécialité : **Neurosciences/Neuropsychologie**

**NEUROPSYCHOLOGICAL ASPECTS OF
RIGHT TEMPORAL LOBE EPILEPSY:
VISUAL MEMORY AND PERCEPTION**

THÈSE dirigée par :

Mme MANNING, Lilianne

Professeur, Université de Strasbourg

RAPPORTEURS :

M ROSENOW Felix

Professeur, Université de Giessen et Marburg

M BENGNER Thomas

Docteur, Université de Berlin

EXAMINATEUR :

Mme GIERSCH Anne

Docteur, Université de Strasbourg

Für meine Eltern und Jeff

Acknowledgements

I offer my deepest gratitude to Pr. Lilianne Manning to whom I am indebted for introducing me to cognitive neuropsychology, and whose enthusiasm for this discipline encouraged me to pursue this thesis. I am grateful for her guidance, discussions, and the effort which she has invested.

My sincere acknowledgements also go to the medical director of the Kork Epilepsy Centre, Pr. Dr. Bernhard J. Steinhoff for his endless support and kind advice.

I am grateful to the committee members, Dr. Anne Giersch, Pr. Dr. Felix Rosenow and Dr. Thomas Bengner for offering their precious time to officially review this thesis.

I wish to warmly thank my colleague Dr. Anne-Sophie Wendling for her comments and complicity.

I would also like to acknowledge the former psychology intern Celina Westermann who collected half of the control subjects' data for the parallel versions of the DMS-48.

I thank the clinical staff at the Kork Epilepsy Centre for their help and guidance in the medical field.

I would also like to thank Dr. Olivier Després for his friendly introductions to statistics.

I owe to my parents-in-law Dr. Philipp and Kathleen Turner-Hubbard for their encouragements, and for English revisions of the manuscript.

Thanks to my friends and compatriots: Ania, Ula, Marc-Antoine, Yolanda and Ewa for being there for me the last years.

Last, but not least, this thesis would not have been possible without the endless help and support of my wonderful parents Krystyna and Piotr Wisniewski, as well as my husband Dr. Jeffrey T. Hubbard, to whom every page is dedicated.

Résumé en Français

Aspects neuropsychologiques de l'épilepsie du lobe temporal droit :

La perception et la mémoire visuelle

L'intention de cette thèse était dans un premier temps d'avancer des connaissances sur les procédures diagnostiques qui permettent d'examiner des déficits de la mémoire visuelle dans un contexte de chirurgie d'épilepsie. Dans un deuxième volet, l'étude des caractéristiques des capacités perceptives visuelles dans un cas d'épilepsie du lobe temporal (ELT) a été menée, avant et après traitement chirurgical.

La forme la plus fréquente des épilepsies pharmacorésistantes émerge du lobe temporal (LT) mésial. Pour ces patients, des procédures chirurgicales qui visent à contrôler des crises peuvent être une alternative de traitement. Ils impliquent généralement la résection de l'hippocampe et des structures méso-temporales annexes localisées dans un hémisphère cérébrale (Engel, 2001). Cependant, le LT a une relevance particulière pour l'acquisition, la consolidation, le stockage et la récupération de la mémoire à long-terme. Donc, l'oubli accéléré est présent dans un pourcentage non négligeable des patients et, le cas échéant, il est handicapant (Mameniskiene et al., 2006).

Dans la pratique clinique, des neuropsychologues qui se spécialisent dans l'identification des déficits mnésiques chez des patients ELT ont un double objectif. Le premier objectif est de latéraliser et de localiser la zone dysfonctionnelle avant l'opération, et ainsi d'apporter un outil diagnostique aux autres techniques médicales. Cela est réalisé pour répondre au deuxième objectif, de pronostiquer le résultat cognitif postopératoire (Helmstaedter et al., 2003, Witt et al., 2009). L'approche diagnostique de la zone dysfonctionnelle, se base sur l'examen des dissociations entre les performances aux stimuli verbaux versus non-verbaux utilisés dans la tâche mnésique (Baker et al., 2004). Ce concept de la « spécificité au matériel » a été introduit par Milner (Milner, 1971). Il suppose que des lésions du LT de l'hémisphère gauche, typiquement spécialisée dans le langage, provoquerait des déficits de la mémoire verbale. En revanche, l'atteinte du lobe temporal droit, aurait pour impact des déficits de la mémoire non-verbale (généralement, visuelle ou visuo-spatiale). Il est intéressant de noter que des déficits de la mémoire

visuelle, ont été trouvés de façon moins systématique que des troubles du versant verbal et ainsi l'hypothèse de la « spécificité au matériel » a été mise en question (Barr et al., 1997, Vaz, 2004, Vannucci, 2007). Parmi les hypothèses explicatives, il a été suggéré que des controverses pouvaient résulter de la méthodologie des tests utilisés et du manque d'aptitude à examiner la mémoire visuelle (Vaz, 2004).

(1) Dans la première étude, nous avons ainsi considéré la validité de quatre tests visuo-spatiaux comme méthode d'identification des dysfonctions du LT méstral droit chez des patients souffrant d'une ELT.

Nous avons examiné quatre-vingt candidats pré-chirurgicaux qui étaient homogènes au niveau de leurs caractéristiques démographiques et cliniques, l'âge, durée d'éducation, âge au début des crises, durée de la maladie, nombre des médicaments antiépileptiques et fréquence des crises. La batterie des tests utilisée contenait le « Corsi Block-Tapping Test » (Wechsler, 1991), « Diagnosticum für Cerebralschädigung » (DCS) (Weidlich et al., 2001) un apprentissage du chemin « Verbaler und Visueller Merkfähigkeitstest » (VVM) (Schelling et al., 2001), et la « Figure Complexe de Rey-Osterrieth » (ROCF) (Rey et al., 1944).

La sensibilité, spécificité et les courbes receiver operating characteristics (ROC) ont été calculés à partir des données normées. Il en résulte que la capacité de latéraliser la zone dysfonctionnelle avec ces tests est faible. Cela même lors des contrôles statistiques supplémentaires des pathologies structurales et des anomalies intercritiques. En revanche, une analyse avec le Mann Whitney ranksum test a montré que les patients ELT droit ont une tendance à échouer à un nombre plus élevé de tests que le groupe ELT gauche. En outre, des calculs additionnels montrent des corrélations entre des mesures aux tests de mémoire visuelle et plusieurs autres domaines cognitives, comme le raisonnement non verbal, la vitesse de traitement, l'attention, la visuoconstruction et des fonctions exécutives comme la planification visuelle.

(2) Le deuxième volet s'inscrit directement dans la thématique du premier, tentant d'avancer des connaissances sur des procédures diagnostiques de la mémoire visuelle. Il a été suggéré que des outils psychométriques de reproduction, avec des demandes élevées sur des fonctions attentionnelles et visuoconstructives, soient prédestinés à l'échec, dans

des populations où le profil cognitif global est faible (McConley et al., 2008). D'autre part, des études cliniques ont rapporté que des tests de reconnaissance visuelle sont plus sensibles pour examiner le LT droit que les tests de reproduction (Bengner et al., 2010, Smith et al., 2011). A présent, des neuropsychologues cliniciens dans le domaine de l'épilepsie continuent à chercher des méthodes valides pour détecter des dysfonctions du LT droit ainsi que des tâches parallèles qui permettraient un suivi du profil mnésique postopératoire.

Ainsi, nous nous sommes intéressés à une tâche qui auparavant s'est avérée utile dans la détection des déficits mnésiques associés au « mild cognitive impairment » dans la maladie d'Alzheimer, le « Delayed Matching to Sample task » (DMS-48) (Barbeau et al., 2004), un test de reconnaissance visuelle simple qui contrôle l'attention et la verbalisation des items.

Dans la deuxième étude, le DMS-48 et une batterie complète neuropsychologique, contenant une variété de tests standards verbaux et non-verbaux, connue de la première publication ont été administrés à un groupe de 48 patients avec des ELT mésiales. Par la suite, deux versions parallèles du DMS-48 ont été développées, et des données normatives étaient obtenues dans une population de 172 volontaires sains. L'utilisation de ces versions parallèles a en conséquence permis d'évaluer un groupe de patients ELT lors du suivi postopératoire. Nos analyses démontrent des différences très significatives entre les ELT gauches et droites uniquement pour le DMS-48, mais pour aucune autre mesure. Les deux versions parallèles se sont avérées être des outils statistiquement comparables à la tâche originale et ont ainsi pu être administrés aux groupes qui ont tous subi des résections des structures temporo-mésiales. La comparaison des performances pré- et postopératoires démontre des scores stables pour toutes les mesures visuelles, pendant que la performance aux tâches de la mémoire verbale a diminué chez le groupe des patients ELT gauche.

(3) Le dernier volet de cette thèse concerne l'étude d'un cas d'ELT droite qui a des implications sur les connaissances de la perception et l'imagerie visuelle. Il a été suggéré que la perception visuelle et l'imagerie qui est la capacité de générer une représentation perceptuelle à partir de la mémoire, reposent sur les mêmes substrats neuronaux (Kosslyn, 1980, Kosslyn et al., 1997, Cichy et al., 2011). Cependant, des dissociations sélectives pour l'imagerie et la perception étaient observées, ainsi que des dissociations entre la modalité espace et objet (Behrmann et al., 1994, Bartolomeo et al., 1998). Les troubles de la perception et l'imagerie ont été rapportés dans une seule étude de groupe existante sur

les troubles cognitifs des épilepsies du lobe occipital (Piazzini et al., 2009). Chez les patients ELT, la question sur l'existence d'un trouble de la perception visuelle est controversée, car la perception est généralement préservée (Helmstaedter et al., 2001, Grant et al., 2008, Carvajal et al., 2009). Par contre, des déficits légers peuvent devenir évidents dans un contexte de laboratoire avec des « techniques spécialisées ».

Le cas unique que nous avons étudié a souffert d'une ELT avec une sclérose hippocampique et un début de crise dans la région temporo-occipitale droite. Un examen pré-chirurgical exhaustif nous a permis, de clarifier ces déficits de la mémoire visuelle, de reconnaissance des objets visuelles, et l'imagerie visuelle des capacités de perception et l'imagerie spatiale bien préservées. Après une lobectomie temporale droite, la patiente était sans crise et un an après l'opération ses scores cognitifs étaient dans la norme pour la perception visuelle et l'imagerie. Nos résultats suggèrent que la reconnaissance et l'imagerie visuelle des objets sont soutenues par des régions corticales à proximité de la voie ventrale temporo-occipitale et que les modalités spatiales de perception et d'imagerie, se situent à l'extérieur de la voie ventrale, suivant l'hypothèse des deux voies de Mishkin and Ungerleider (1982). En outre, les capacités de mémoire visuelle faibles ne se sont pas améliorées après l'opération, constituant ainsi un déficit structurel permanent. En revanche, les déficits chroniques du système visuel qui étaient présents pendant l'examen préopératoire ont récupérés. Ces données mettent en évidence que la capacité de l'activité paroxystique non-lésionnelle est à l'origine des dysfonctionnements cognitifs qui peuvent être réversibles avec un contrôle adéquat des crises.

En conclusion, ce travail de thèse a démontré (1) que les tests visuo-spatiaux utilisés dans la pratique du diagnostic préopératoire ont une validité de latéralisation faible et qu'ils sont fort dépendant aux autres fonctions cognitives qui peuvent être atteintes dans l'ELT gauches et droites (Wisniewski et al., 2012b). (2) La deuxième étude a montré qu'un test de reconnaissance visuelle (DMS-48) qui limite l'engagement d'autres fonctions cognitives, peut réussir à latéraliser des patients ELT. Un développement successif des versions parallèles et une validation pour des populations postopératoires ont montré une meilleure adaptation à la pratique clinique que les tests examinés dans la première étude (Wisniewski et al., soumis). (3) Dans la troisième partie, il a été démontré sur un cas unique que la reconnaissance visuelle des objets et l'imagerie sont soutenues par des régions corticales anatomiquement proches de la voie temporo-occipitale ventrale et que la

perception ainsi que l'imagerie visuelle de l'espace pourraient être soutenues par des mécanismes en dehors de cette voie. Par ailleurs, ces résultats indiquent que l'activité proximale non lésionnelle dans le LT postérieur peut causer des déficits chroniques du système visuel, qui peuvent être réversible avec un contrôle des crises réussi (Wisniewski et al., 2012a).

Dans le cadre des perspectives, les deux premiers volets peuvent servir de référence pour des futurs développements des outils psychométriques dans la visée d'une meilleure prise en charge des patients ELT. Par ailleurs, des corrélations avec biomarqueurs et une application aux études d'imagerie fonctionnelle pourraient être réalisées. La troisième partie, ouvre une piste de recherche sur la signification des désordres de la perception visuelle sur la cognition et la qualité de vie des patients.

- Baker GA, Goldstein LH (2004) The dos and don'ts of neuropsychological assessment in epilepsy. *Epilepsy & Behav* 5 Suppl 1:77-80.
- Barbeau E, Didic M, Tramon E, Felician O, Joubert S, Sontheimer A, Ceccaldi M, Poncet M (2004) Evaluation of visual recognition memory in MCI patients. *Neurology* 62:1317-1322.
- Barr WB, Chelune GJ, Hermann BP, Loring DW, Perrine K, Strauss E, Trenerry MR, Westerveld M (1997) The use of figural reproduction tests as measures of nonverbal memory in epilepsy surgery candidates. *J Int Neuropsychol Soc* 3:435-443.
- Bartolomeo P, Bachoud-Levi AC, De Gelder B, Denes G, Dalla Barba G, Brugieres P, Degos J-D (1998) Multiple-domain dissociation between impaired visual perception and preserved mental imagery in a patient with bilateral extrastriate lesions *Neuropsychologia* 36:239-249.
- Behrmann M, Moscovitch M, Winocur G (1994) Intact visual imagery and impaired visual perception in a patient with visual agnosia. *J Exp Psychol Hum Percept Perform* 20:1068-1087.
- Bengner T, Malina T (2010) Long-term face memory as a measure of right temporal lobe function in TLE: the Alsterdorfer Faces Test. *Epilepsy Res* 89:142-147.
- Carvajal F, Rubio S, Martin P, Serrano JM, Garcia-Sola R (2009) Perception and recall of faces and facial expressions following temporal lobectomy. *Epilepsy & Behav* 14:60-65.
- Cichy RM, Heinzle J, Haynes JD (2011) Imagery and Perception Share Cortical Representations of Content and Location. *Cereb Cortex*.
- Engel J, Jr. (2001) Mesial temporal lobe epilepsy: what have we learned? *Neuroscientist* 7:340-352.
- Grant AC, Donnelly KM, Chubb C, Barr WB, Kuzniecky R, Devinsky O (2008) Temporal lobe epilepsy does not impair visual perception. *Epilepsia* 49:710-713.
- Helmstaedter C, Kurthen M (2001) Memory and epilepsy: characteristics, course, and influence of drugs and surgery. *Curr Opin Neurol* 14:211-216.

- Helmstaedter C, Kurthen M, Lux S, Reuber M, Elger CE (2003) Chronic epilepsy and cognition: a longitudinal study in temporal lobe epilepsy. *Ann Neurol* 54:425-432.
- Kosslyn SM (1980) *Image and mind*. Cambridge, United States of America: Harvard University Press.
- Kosslyn SM, Thompson WL, Alpert NM (1997) Neural systems shared by visual imagery and visual perception: a positron emission tomography study. *NeuroImage* 320-334.
- Mameniskiene R, Jatuzis D, Kaubrys G, Budrys V (2006) The decay of memory between delayed and long-term recall in patients with temporal lobe epilepsy. *Epilepsy & Behav* 8:278-288.
- McConley R, Martin R, Palmer CA, Kuzniecky R, Knowlton R, Faught E (2008) Rey Osterrieth complex figure test spatial and figural scoring: relations to seizure focus and hippocampal pathology in patients with temporal lobe epilepsy. *Epilepsy & Behav* 13:174-177.
- Milner B (1971) Interhemispheric differences in the localization of psychological processes in man. *British medical bulletin* 27:272-277.
- Piazzini A, Saetti C, Turner K, Fiorino A, Canger R, Canevini MP (2009) Visuo-perceptive impairment in adult patients with occipital lobe epilepsies. *Epilepsy & Behav* 15:256-259.
- Rey A, Osterrieth P-A (1944) L'examen psychologique dans les cas d'encéphalopathie traumatique. In: *Le test de copie d'une figure complexe : Contribution à l'étude de la perception et de la mémoire*, vol. 112, pp 286-340: *Arch Psychol*
- Schelling D, Schächtele B (2001) *Verbaler und Visueller Merkfähigkeitstest (VVM)*. Frankfurt, Germany: Swets & Zeitlinger
- Smith ML, Bigel M, Miller LA (2011) Visual paired-associate learning: in search of material-specific effects in adult patients who have undergone temporal lobectomy. *Epilepsy & Behav* 20:326-330.
- Vannucci M (2007) Visual memory deficits in temporal lobe epilepsy: toward a multifactorial approach. *Clin EEG Neurosci* 38:18-24.
- Vaz SA (2004) Nonverbal memory functioning following right anterior temporal lobectomy: a meta-analytic review. *Seizure* 13:446-452.
- Wechsler D (1991) *Hamburger Wechsler Intelligenztest für Erwachsene Revision*. Bern, Switzerland: Huber Verlag
- Weidlich S, Lamberti G (2001) *DCS: Diagnosticum für Cerebralschädigung. Ein visueller Lern- und Gedächtnistest*. Göttingen, Germany: Huber Verlag.
- Wisniewski I, Staack AM, Bilic S, Steinhoff BJ, Manning L (2012a) Visuo-perceptual and visuospatial abilities prior to and after anterior temporal lobectomy: a case study. *Epilepsy & Behav* 23:74-78.
- Wisniewski I, Wendling AS, Manning L, Steinhoff BJ (2012b) Visuo-spatial memory tests in right temporal lobe epilepsy foci: clinical validity. *Epilepsy & Behav* 23:254-260.
- Wisniewski I, Wendling AS, Westermann C, Manning L, Steinhoff BJ (soumis) The importance of the DMS-48 as a visual recognition memory task for cognitive epilepsy evaluation.
- Witt JA, Helmstaedter C (2009) [Neuropsychology in epilepsy]. *Fortschr Neurol Psychiatr* 77:691-698.

Abstract

The aim of the present thesis was to advance the knowledge of diagnostic procedures for lateralizing visual memory deficits and to study the characteristics of perception in temporal lobe epilepsy (TLE), before and after surgical treatment.

The first publication examined the appropriateness of four routinely used learning and reproduction visuo-spatial memory tests as an identification method for right mesial temporal lobe (TL) dysfunctions in a sample of 80 patients with unilateral TLE. Various statistical methods illustrate the tests poor capacity to lateralize the functional deficit zone, even when epilepsy-related clinical factors such as presence of cortical malformation or contralateral interictal epileptiform discharges (IEDs) were controlled. Importantly for furthering neuropsychological practice, cognitive factors were identified that correlate with the visuo-spatial memory measures.

The second study is built upon the results of the first, aiming to validate a new test paradigm for lateralizing right hippocampal dysfunctions. The Delayed Matching to Sample (DMS-48) task was previously shown to successfully measure visual recognition memory deficits in early Alzheimer's Disease, thus we assessed 48 mesial TLE patients preoperatively with the original DMS-48 task, and 33 postoperatively with two parallel versions that we had developed and standardized in 172 healthy controls. Our analysis suggests that the DMS-48 and its parallel versions were able to lateralize the epileptic onset zone both pre- and postsurgically. Additionally, the postoperative scores did not change concerning the preoperative performance.

The third section expands from the topic of visual memory to visual perception, attempting to disentangle deficits in visual memory, visual object recognition and visual imagery from well-preserved spatial capacities in a TLE patient who presented right hippocampal sclerosis and a seizure onset pattern in the right temporo-occipital area. One-year after a right temporal lobectomy, the patient became seizure-free, with recovery of visual perception and imagery. This single case study suggests that visual object recognition and visual imagery are sustained by cortical areas located in proximity to the temporo-occipital ventral pathway, and that perception and imagery for space is subserved by mechanisms

which are anatomically close, and outside the ventral path. Furthermore, the results seem to indicate that nonlesional paroxysmal activity in the posterior temporal lobe can cause chronic dysfunctions of the visual system and those may be reversible with effective seizure control.

Table of Contents

| | |
|---------------------------------------------------------------------------------------------------------------------------------|-----------|
| Acknowledgements | 3 |
| Résumé en Français | 4 |
| Abstract in English | 10 |
| Table of Contents | 12 |
| List of Abbreviations | 13 |
| List of Figures/Tables | 15 |
| General Introduction..... | 17 |
| Part I: Theoretical Background | 19 |
| <i>Chapter 1- Epilepsies: classification and treatment</i> | <i>20</i> |
| 1.1 Epilepsies..... | 21 |
| 1.2 Classification | 24 |
| 1.3 Mesial temporal lobe epilepsy | 26 |
| 1.4 Pharmacotherapy | 28 |
| 1.5 Epilepsy surgery | 30 |
| <i>Chapter 2- Visual memory and perception</i> | <i>39</i> |
| 2.1 The visual perceptive system..... | 40 |
| 2.2 Memory | 47 |
| 2.3 Visual memory impairment in temporal lobe epilepsy | 60 |
| Part II: Research Projects | 70 |
| Experimental Introduction..... | 71 |
| <i>Chapter 3- Visuo-spatial memory tests in right temporal lobe epilepsy foci: clinical validity.....</i> | <i>73</i> |
| <i>Chapter 4- The importance of the DMS-48 as a visual recognition memory task for cognitive epilepsy evaluation</i> | <i>81</i> |
| <i>Chapter 5- Visuo-perceptual and visuospatial abilities prior to and after anterior temporal lobectomy: A case study.....</i> | <i>97</i> |
| Conclusions and Perspectives..... | 103 |
| References | 107 |

List of Abbreviations

| | |
|----------------|----------------------------------------------------------------|
| AEDs | Antiepileptic Drugs |
| ALF | Accelerated Long-term Forgetting |
| 2/3 ATL | Two-thirds Anterior Temporal Lobectomy |
| AUC | Area Under the Curve |
| BFRT | Benton Facial Recognition Test |
| DCS | Diagnosticum für Cerebralschädigung |
| DMS-48 | Delayed Matching to Sample |
| EEG | Electroencephalogram |
| ERPs | Event-Related Potentials |
| fMRI | Functional Magnetic Resonance Imaging |
| IEDs | Interictal Epileptiform Discharges |
| ILAE | International League Against Epilepsy |
| ISAP | Intracarotid Sodium Amobarbital Procedure |
| LEA | Lateral Entorhinal Cortex |
| LTM | Long-Term Memory |
| LTP | Long-Term Potentiation |
| MCI | Mild Cognitive Impairment |
| MEA | Medial Entorhinal Area |
| MNI | Montreal Neurological Institute |
| MRI | Magnetic Resonance Imagery |
| MTLE-HS | Mesial Temporal Lobe Epilepsies due to Hippocampal Sclerosis |
| MWT-B | Mehrfachwahl-Wortschatz-Intelligenztest |
| PEGV | Protocole d'Evaluation des Gnosies Visuelles Montréal-Toulouse |
| PET | Positron Emission Tomography |
| PRC | Perirhinal Cortices |
| ROC | Receiver Operating Characteristic |
| ROCF | Rey-Osterrieth-Complex-Figure |
| sAHE | Selective Amygdalohippocampectomy |
| STM | Short-Term Memory |
| TL | Temporal Lobe |
| TLE | Temporal Lobe Epilepsy |

Introductory materials

| | |
|----------------|--------------------------------------------|
| TMT | Trail Making Test |
| TPR+AHE | Temporal Pole Resection, combined with AHE |
| VerbM | Verbal Memory |
| VisM | Visual/Visuospatial Memory |
| VLMT | Verbaler Lern und Merkfähigkeitstest |
| VOSP | Visual Object & Space Perception battery |
| VVM | Verbaler und Visueller Merkfähigkeitstest |
| WAIS | Wechsler Adult Intelligence Scale |
| WM | Working Memory |
| WMS-R | Wechsler Memory Scale-Revised |
| WRMT | Warrington Recognition Memory Test |

Index of Figures/Tables

Chapter 1

- Figure 1: Egyptian papyrus
- Figure 2: Neuropathological cut with hippocampal sclerosis on the right side
- Figure 3: EEG reflecting a right MTLE-HS seizure.
- Figure 4: Coronal slice (1.5 Tesla) revealing sclerosis of the right hippocampus
- Figure 5: TLE surgery procedures
- Figure 6: Morphological and functional factors influencing cognition in epilepsy
- Table 1: Classification and terminology and the newly proposed terminology and concepts
- Table 2: Overview of cognitive side effects of antiepileptic medication

Chapter 2

- Figure 7: Representation of the two-stream hypothesis
- Figure 8: The Canonical-Unusual View Matches
- Figure 9: Degraded PEGV
- Figure 10: Long-term memory subsystems
- Figure 11: Diagram of the hierarchically organized memory systems
- Figure 12: A coronal slice of the brain
- Figure 13: Proposed functional organization of the visual medial TL memory system
- Figure 14: A revised cognitive model of forgetting

Study 1

- Figure 1a: Effects of contralateral IEDs on ROCF-reproduction
- Figure 1b: Effects of contralateral IEDs on DCS
- Figure 2a: ROC curve for VisM
- Figure 2b: ROC curve for VerbM
- Table 1: Demographic and clinical characteristics
- Table 2: Sensitivity and specificity of VerbM and VisM tests for TLE sample
- Table 3: AUC and the cut-off parameters for memory

Study 2

- Table 1: Preoperative demographic and clinical characteristics
- Table 2: Control subjects characteristics
- Table 3: Postoperative demographic and clinical characteristics
- Table 4: Outcome for neuropsychological tests
- Table 5: Classification function for DMS-48 Set 1 and Set 2
- Table 6: Normative values for the DMS-48-3 months and DMS-48-12 months parallel versions
- Figure 1: Mean patient and control performance for Set 1 and Set 2

Study 3

Figure 1: CB's 1-year postoperative MRI inversion-recovery slice

Figure 2: Two examples of CB's copying and drawing from memory

Figure 3: Schema proposed to represent CB's structural deficits and postoperative functional changes

Table 1: CB's pre- and postoperative neuropsychological test results

General Introduction

In mesial temporal lobe epilepsy (TLE) which is a common form of drug-resistant epilepsies, dysfunctions in a variety of cognitive skills may be associated, especially concerning memory. Surgical resections of hippocampal structures can be successful at eliminating seizures; however, they may also have further memory deficits as a consequence. Neuropsychological assessments aim to localize or lateralize epilepsy associated cognitive impairment and the prediction of risk of postoperative cognitive loss. When focal memory deficits become apparent on the examination they are often material-specific, with well-established deficits for left sided lesions and less constantly observed difficulties in visual memory for right TLE. Furthermore, minor difficulties in visual perception may be associated.

The general aim of this thesis was to examine visual memory and perception in mesial TLE. In the first part, we investigated whether neuropsychological visual memory diagnostic tools could be ameliorated, with respect to localizing epilepsy-associated dysfunctions. The second part, aimed to advance knowledge on the characteristics of visual perception, imagery and memory in a pathology that affects cognition through the interaction of structural and functional factors.

This thesis is composed of five chapters. The first two chapters comprise the theoretical background. Specifically, chapter 1 discusses the epilepsies and their subsequent classification systems, introducing the concept of mesial TLE. In addition, conservative treatment options such as pharmacotherapy and commonly associated cognitive side effects are presented. This is followed by an overview of epilepsy surgery, and the medical and neuropsychological examinations required for this procedure. Chapter 2 focuses on the cognitive aspects, perception and memory, with attention given to their associated neuroanatomy. More precisely, visual memory and epilepsy associated factors that may have an impact on TLE are examined, and a review of studies aiming to lateralize with specific tests is provided. The final three chapters comprise the experimental sections. Chapter 3 evaluates four established visuo-spatial memory tests in regards to their lateralizing ability in mesial TLE patients. This comparison includes control of epilepsy-related clinical factors, in an attempt to lateralize by combining several tasks and a

correlation analysis with other cognitive functions. Chapter 4 is a study that aims to validate an alternative visual memory paradigm by means of a visual recognition task the “Delayed Matching to Sample (DMS-48)”. This study includes a preoperative evaluation of epileptic patients, followed by two postoperative follow-up measures using parallel versions specifically designed and normed for this purpose. The final project, in Chapter 5, expands upon this idea integrating visual memory with the concepts of visual perception. In this publication, we demonstrate the pre- and postoperative neuropsychological profiles of a single case with mesial TLE, who displayed a seizure pattern in the right temporo-occipital area. This study specifically aims to determine the neuronal basis of visual perception and imagery, followed by a discussion of how structural and functional epilepsy-related factors affect memory in the visual system.

Part I:

Theoretical background

Chapter 1

Epilepsies: classification and treatment

1.1 Epilepsies

The first chapter is devoted to epilepsies. After a historical introduction, an overview of the classification systems aims to situate mesial temporal lobe epilepsy within the context of other epileptic syndromes. This is followed by an outline of treatment options, including pharmacotherapy and epilepsy surgery. Finally, the discipline of neuropsychology is discussed, including its historical appearance in epileptology and importance in caring for patients with this specific epilepsy disorder.

1.1.1 Generalities

Epilepsies are a heterogeneous group of syndromes defined by recurrent seizures whose pathophysiology results from excessive paroxysmal discharges of cerebral neurons (Gastaut, 1973). Affecting over 50 million people worldwide, with a prevalence of 0.5-4%, epilepsy is one of the most common medical and social disorders, though the incidence rate is higher in developing countries. Furthermore, epilepsies occur in all ages and both genders (World Health Organization, 2009). Seizures can last anywhere from seconds to minutes and can range from a brief loss of consciousness, an automatic motor movement or behavior, to severe convulsions of the whole body. These are the clinical manifestations for disequilibrium between excitatory and inhibitory neurotransmitters that can be the physiologic cause for cognitive impairment and a variety of associated chronic psychological and psychiatric disorders (Lee, 2010). Seizures may appear at random moments or intervals and can be highly limiting to a person's quality of life and social integration. From an outside observer, the clinical effects of a seizure that affects the full body can be impressive and alarming. Therefore, epilepsy has received a lot of public attention and has often been misunderstood and stigmatized throughout time. Indeed, the history of epilepsy reflects this perception.

1.1.2 Historical introduction

The history of epilepsy can be traced back as far as medical records exist. The first such evidence comes from an ancient Egyptian papyrus (1650-1570 BCE), describing symptoms and treatments of “nesejet”, a disease that was most likely epilepsy (Figure 1). The hieroglyphic symbols include the “snail” [𓏏], an ideogram for deity and the “beating man” [𓏏] which represents danger, demons and death (Schneble, 2003).




Figure 1. Egyptian papyrus. From Schneble (2003).

During the Greek epoch, the practice of medicine predominated by magic and religion was disrupted with the appearance of a naturalistic approach personified by Hippocrates. In the 4th century BCE, Hippocrates writes “On the sacred disease”, a monography in which he explains the clinical characteristics of “epilepsis”, a term derived from the Greek verb *επιλαμβάνειν* (epilambanein: being overwhelmed by surprise) (Schneble, 2005).

Although having the reputation of being a “holy disease”, epilepsy had a natural physical cause that Hippocrates localized in the brain. By the 3rd century BCE in the Roman Empire, the ideas of Hippocrates had taken traction with Galen, a man who attempted the first classification system for different types of seizures (Hillebrand, 2007).

During medieval times, the syndrome etiology was reattributed to a demonic possession or a lunatic dependency. Most medical advances from antiquity were banned in exchange for exorcism, isolation and persecution. Few asylums for epilepsy patients existed, the first in the beginning of the 16th century being a benedict abbey close to Rufach in Alsace. During the renaissance, around the year 1600, the concept of an organic cause was reconsidered. In the 18th century, P. Pinel established modern psychiatry, which helped liberate epilepsy

patients from hand and foot chains; his student E. Esquirol segregated epileptic from psychiatric patients in separate institutions. At that time, the prevailing thought was to attribute the symptoms of epilepsy as a type of “insanity”. This mindset continued until the 19th century when John Hughlings Jackson first conceptualized epilepsies as neurological disorders with underlying neuropathological mechanisms (Bennett, 1992).

Medical consciousness for epilepsy continued to develop. For example, in 1892 the “Therapy and Care Centre for Epileptic Children” was founded in Kork. Just over a hundred years ago, in 1909 during a congress in Budapest, the International League Against Epilepsy (ILAE) was established in order to count the number of epileptic patients and to develop treatment plans. The beginning of the 20th century was also the advent of more widely industrialized pharmaceutical-based medical treatments, which allowed the first antiepileptic drugs, Bromides (Locock, 1857) and Phenobarbital (Hauptmann, 1912) to be created. Finally, in 1929 the basis for the clinical diagnosis of the disease was developed by Berger, who established the technique of the electroencephalogram (EEG), thus allowing clinicians to register electrophysiological neuronal changes (Berger, 1929).

1.2 Classification

Diagnostic procedures in epilepsy are primarily based on the seizure semiology and routine EEG that provides important information for treatment. A wide range of epilepsy syndromes and seizure types have been identified and standardized by the Commission on Classification and Terminology of the International League Against Epilepsy (ILAE), attributing specific terminology and a classification system composed of epileptic seizures (1981) and epileptic syndromes (1989). Though widely still considered to be valid, since 2001 several attempts have been made to update the concepts from 1981 and 1989 (Engel, 2001b, 2006). Currently, new proposals of terminology and classification are being considered (Berg et al., 2010) and are regarded as the basis for reforms under discussion at numerous institutions globally (e.g. Panayiotopoulos, 2011, 2012).

1.2.1 Epileptic seizure types after the ILAE classification of 1981

The first ILAE seizure classification (1981) was based on seizure semiology and the presence of ictal and interictal EEG patterns. Seizures based on these criteria are divided primarily into two major categories:

Focal (or partial): EEG manifestations that reflect local neuronal activation. Furthermore, partial seizures can be categorized depending on the degree of consciousness.

-*Simple partial seizures*: consciousness is not impaired,

-*Complex partial seizures*: consciousness is impaired,

-*Secondary generalization*: partial seizures may evolve into generalized motor seizures.

Generalized seizures: The EEG reflects activity in both hemispheres and typically involves a loss of consciousness. Generalized seizures may be non-convulsive or convulsive and can vary in their degree of severity. Generalized seizures are defined as absence seizures, atypical absence seizures, myoclonic seizures, clonic seizures, tonic seizures, tonic-clonic seizures and atonic seizures.

1.2.2 Epileptic syndromes after the ILAE classification of 1989

The ILAE proposal for a classification (1989) introduced the concept of epileptic syndromes:

(1) Localization-related (focal, local, partial) epilepsies and syndromes; (2) Generalized epilepsies and syndromes; (3) Epilepsies and syndromes of an undetermined pathophysiology (whether focal or generalized); or (4) Special syndromes.

These syndromes can be further divided into a second axis, according to their etiology, in (1) idiopathic epilepsies, which are generally age related, (2) cryptogenic epilepsies, where no lesion can be detected though is suspected, and (3) symptomatic epilepsies that originate from structural lesions. After the proposed classification scheme from 2001 (Engel, 2001b), focal epilepsies may be “idiopathic” separated from “symptomatic or probably symptomatic” epilepsies. However, the focal pathophysiology does not necessarily exclude at least some genetic roots as was previously suspected in the 1980s.

1.2.3 Newly proposed terminology and concepts

In an attempt to update the classification from 1981/1989, ILAE has proposed changes in the methodology to which clinicians are currently in the process of adjusting. With this approach the hierarchical organization described above is being abandoned and exchanged for a more flexible multidimensional approach justified by the accumulation of progressive scientific techniques and advances in neuroimager, neurophysiology and genetics. An abbreviated overview is displayed in table 1.

| Table 1. Classification and Terminology and the Newly proposed Terminology and Concepts (1981, 1989, Berg et al., 2010, Berg et al., 2011) | |
|---------------------------------------------------------------------------------------------------------------------------------------------------|---------------------------------------------------------------------------------------------------------------------------------------------------------------------------------------------------------------------------|
| | Revised concept |
| Focal seizures | Originate at some point within networks of one hemisphere |
| Generalized seizures | Conceptualized as originating at some point within and rapidly engaging bilaterally distributed networks, not necessarily starting from both hemispheres |
| Focal and generalized epilepsies | Abandoned as overarching categories, since many syndromes include both seizure types |
| Idiopathic, symptomatic and cryptogenic epilepsies | Genetic: a direct result of a known or presumed genetic defect Structural/metabolic: another distinct structural or metabolic condition Unknown: the nature of the underlying cause is unknown |
| Complex partial and simple partial seizures | No specific classification is recommended. Seizures should be described accurately according to their semiologic features without trying to fit them into artificial categories |

Adapted from Berg and Scheffer (2011)

1.3 Mesial temporal lobe epilepsy

The ILAE Commission (1989) distinguishes focal epilepsies based upon the anatomical structures involved. Temporal lobe epilepsies (TLE) are characterized by seizures that originate from the mesial (medial) and/or neocortical structures and can be caused by tumours, infectious and vascular diseases, malformations and dysplasia, as well as injuries to the area. The most common forms however, comprising two-thirds of all TLE, are mesial temporal lobe epilepsies due to hippocampal sclerosis (MTLE-HS). Recently, the ILAE commission published a report that considered MTLE-HS as a syndromic entity (Engel, 2001a). Hippocampal sclerosis or atrophy is associated with the loss of hippocampal cells. (For more detailed information on the hippocampus structure and formation, see chapter 2). Figure 2, displays a neuropathological cut with unilateral Ammons horn sclerosis.

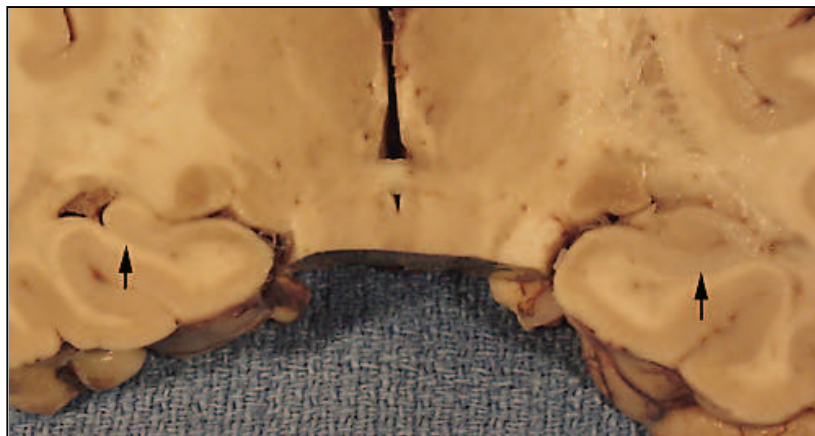

Figure 2. Neuropathological cut with hippocampal sclerosis on the right side. From Argamanolis, www.neuropathology-web.org.

As a consequence, the reduction of hippocampal cells induces changes in synaptic organization, predisposing the remaining neurons to hypersynchronous discharges that then engage an epileptic network, spreading to the neocortex and manifesting as clinically observable seizures (Wieser, 2004).

It has been suggested that MTLE-HS is a subtype of a larger mesial TLE syndrome underlined by a heterogeneity of epileptic networks involving other mesial temporal lobe structures, such as the amygdala, enthorinal cortex and extratemporal structures (Wieser,

2004). Patients with MTLE-HS often have a history of complicated febrile seizures in early childhood, or perinatal trauma, hypoxia or infections, and these seizures mainly occur between 4 and 16 years, often after a latent period (Williamson et al., 1993). The clinical manifestations may vary and generally include as a first symptom an aura (e.g. an ascending epigastric aura, mental hallucinations and illusions of déjà-vu, language impairment). Simple focal seizures that last only a few seconds may be the only incident, but often precipitate complex focal seizures with a gradual loss of consciousness, orolimentary automatisms, staring, motor restlessness, vocalisation, dystonic posturing, hypersalivation and unforced head deviation, or generalization into tonic-clonic seizures (Engel et al., 1997).

The pathogenesis of hippocampal sclerosis and the role that repetitive seizure activity has in this process remains uncertain. For example, febrile convulsions have been discussed as possible causes for a hippocampal sclerosis; however, the inverse could prove true as pre-existing hippocampal defects could predispose one to febrile convulsions (for review see, Lado et al., 2002).

Mesial TLE affects the neuronal network that has an effect on the patient's cognition, specifically memory dysfunction. Similarly, in mesial TLE a patient's quality of life may be reduced due to psychiatric conditions such as psychosis or personality disorders. Previously, it has been shown that psychiatric comorbidities found in mesial TLE can be explained by neuronal network dysfunction linked to the epileptogenic focus but also with the side-effects of antiepileptic drugs (AEDs) (Schmitz et al., 2011).

1.4 Pharmacotherapy

1.4.1 Treatment

Pharmacotherapy is the basis of every epilepsy treatment and one AED is usually administered once the diagnosis of epilepsy by two unprovoked seizures has been established (Schmitz et al., 2005). Although, it may be justified to start treatment even after a first seizure, if a pre-disposition for recurrence is apparent due to EEG or imaging (Fisher et al., 2005).

There were two periods for the advancement of AEDs. The first began in the 20th century and lasted until the 1970's. During this period, bromides, phenobarbital, phenytoin, carbamazepine, valproic acid, ethosuximide and primidone were commercialized and prescribed throughout the 1980's. In the 1990's, the new group of AEDs developed as initial treatment including, vigabatrin, gabapentin, lamotrigine, oxcarbazepine, felbamate, tiagabine, topiramate, zonisamide and levetiracetam (Estler et al., 2007).

The ILAE has investigated treatment guidelines for clinicians based on a meta-analysis of published drug research and were unable to conclusively determine the most ideal form of treatment. Thus, the choice of the AED needs to be adapted to each individual patient where an equilibrium exists between the maximum effectiveness for seizure control in conjunction with the minimum amount changes for the patient's quality of life (Glauser et al., 2006).

1.4.2 Side effects

For TLE and other partial syndromes, carbamazepine, gabapentin, lamotrigine, levetiracetam, oxcarbazepine, topiramate, valproic acid, zonisamide and from older drugs, phenobarbital, phenytoin and primidone, are usually prescribed, though they can cause negative side effects such as fatigue, drowsiness, confusion, mood changes, depression, agitation, restlessness, double vision, nausea and cognitive side effects (Asadi-Pooya et al., 2009). AEDs affect the same excitatory and inhibitory mechanisms that are also responsible for neurocognitive processes, and thus side effects are likely to appear with

intake of medication. For polytherapies, it is acknowledged that they should be avoided, since multiple substances augment the risk for cognitive side effects (Jokeit et al., 2005). Generally these dysfunctions are reversible through reduction of these medications (Meador et al., 2011). Extensive reviews and book chapters exist that cover a variety of associated cognitive profiles of newer and older antiepileptic drugs concerning behavioral changes, psychopathology, processing speed (mental and motor), concentration or attention, executive functions, language and memory (Vermeulen et al., 1995, Motamedi et al., 2003, Asadi-Pooya et al., 2009, Lyseng-Williamson, 2011, Mayer, 2011, Zhang et al., 2011). The major findings for common monotherapies are summarized in table 2.

| Table 2. Overview of cognitive side effects of antiepileptic medication | |
|---------------------------------------------------------------------------------------------------------------------------------|-------------------------------------------------------------------------------------------------------------------------------------------------------------------------------------------------------------------------------------------------------------------------------------------------------------------------------------------------------------|
| <i>Old group</i> | |
| Bromides Limited neuropsychological data. High risk for negative side effects, especially slowing of processing speed | Phenobarbital Highest rate of side effects for socio-emotional functions. Can cause aggressiveness, hyperactivity, disturbance of sleep and social cognition |
| Carbamazepine Side effects are low, generally concerning psychomotor and mental speed | Valproate Can cause reversible slowing in processing speed and regression of IQ. Severe changes in vigilance can be informant of a valproate encephalopathy |
| Phenytoin Only mild sedative effects and rare behavioral changes | |
| <i>New group</i> | |
| Oxcarbazepine Rare side effects, slowing of mental and psychomotor speed | Lamotrigine Cognitive functions are generally not affected, rare slowing of psychomotor and mental speed |
| Levetiracetam Rare side effects, risk for aggressive tendencies for patients with behavioral difficulties | Topiramate Compared to the other drugs, it has the highest risk for cognitive side effects. Cognitive consequences can be severe for mental speed, memory, reduction of word finding and word fluency. In particular cases, patients become aphasic or mutistic. Possible are also psychiatric consequences, e.g. anxiety, aggression, depression |
| Zonisamide Few empirical data. Possible reduction of verbal memory and verbal fluency. Mood problems may occur | |

Adapted after Mayer (2011)

1.5 Epilepsy surgery

Although all patients with diagnosed epilepsy are generally treated with one or more AEDs, approximately one third continue to have drug-resistant (or refractory) epilepsy (Kwan et al., 2010). For patient groups where drug-resistance is established and who suffer from symptomatic location-related syndromes such as MTLE-HS, surgery is a frequent treatment alternative; such patients comprise the largest group in surgical series (Engel, 2001a). Unilateral temporal lobe (TL) surgery, aims to resect the epileptic focus and as a consequence control functional disturbances. Currently, seizure outcome is assessed according to the “Engel” or “Wieser” classification system and can be achieved in 60-70% of the patients (e.g., Gleissner et al., 2002, Wisniewski et al., 2011). In this context, cognitive and behavioural disturbances that may follow a surgical treatment have to be controlled (Lee, 2010).

1.5.1 Medical technical examination in epilepsy surgery

1.5.1.1 Historical introduction

The first attempts to treat epilepsy through surgical procedures can be traced back to antiquity. However, the first modern epilepsy surgery resembling contemporary methods was a craniotomy performed to alleviate motor seizures, which took place in 1886 in London, by the surgeon Sir Victor Horsley, after a recommendation by JH Jackson. Surgeries in the United-States followed in the early 20th century, beginning with Benjamin Dudley. These treatments were primarily focused on patients with posttraumatic lesions, and it was not until the development of the EEG and application to humans that clinicians were able to localize seizures, culminating in its first application to epilepsy surgery in 1935, in Breslau, Germany by Foerster and Altenburger. Further development came in particular from the Montreal Neurological Institute (MNI), where Wilder Penfield, who was visiting Foerster in Breslau at the time as a Rockefeller foundation scholar, and Herbert Jasper, developed diagnostic and surgical techniques through promotion of the EEG-based identification of TL foci and treatment via TL resection (for more details, Meador et al., 1989).

1.5.1.2 Presurgical evaluation of epilepsy

Epilepsy surgery requires an extensive presurgical evaluation in order to determine and resect the *epileptogenic zone* (Rosenow et al., 2001), a term used to describe the area responsible for the generation of seizures. This evaluation consists of separate techniques: a Video-EEG, Magnetic Resonance Imagery (MRI), and neurological and neuropsychological examinations, which together provide coherent information as to which subareas constitute the epileptogenic zone.

- The epileptogenic lesion* is the lesion seen by the MRI causing the epileptic seizures,
- The ictal symptomatogenic zone* is the region of the cortex reflecting seizure semiology,
- The ictal onset area* is the seizure onset as defined by the EEG,
- The irritative zone* is the area that produces interictal epileptiform discharges (IEDs),
- The functional deficit zone* is the brain region that is functionally abnormal in the interictal period and is reflected during the neuropsychological and neurological examination.

EEG

During the Video-EEG examination surface electrodes are placed according to the 10-20 system. The EEG analysis consists of epileptic activity during the seizure (ictal) and also between clinically observable episodes (interictal).

In unilateral MTLE-HS the typical interictal EEG abnormalities are represented by sharp-waves, spikes and Theta-Delta-slowing over the temporal anterior and basal region ipsilateral to the lesion. Some rare contra-lateral EEG-abnormalities can also be observed.

A typical MTLE-HS electrical seizure pattern is characterized by an initial flattening over the ipsilateral anterior and middle temporal electrodes followed by a rhythmical recruiting of Theta- or sharp-wave discharges of the same topography (Figure 3). The propagation pattern is typically seen over the ipsilateral fronto-central region. The secondary ictal implication of the contralateral TL is not rare and is not necessarily associated with worse prognosis for surgery outcome (Surges et al., 2012).

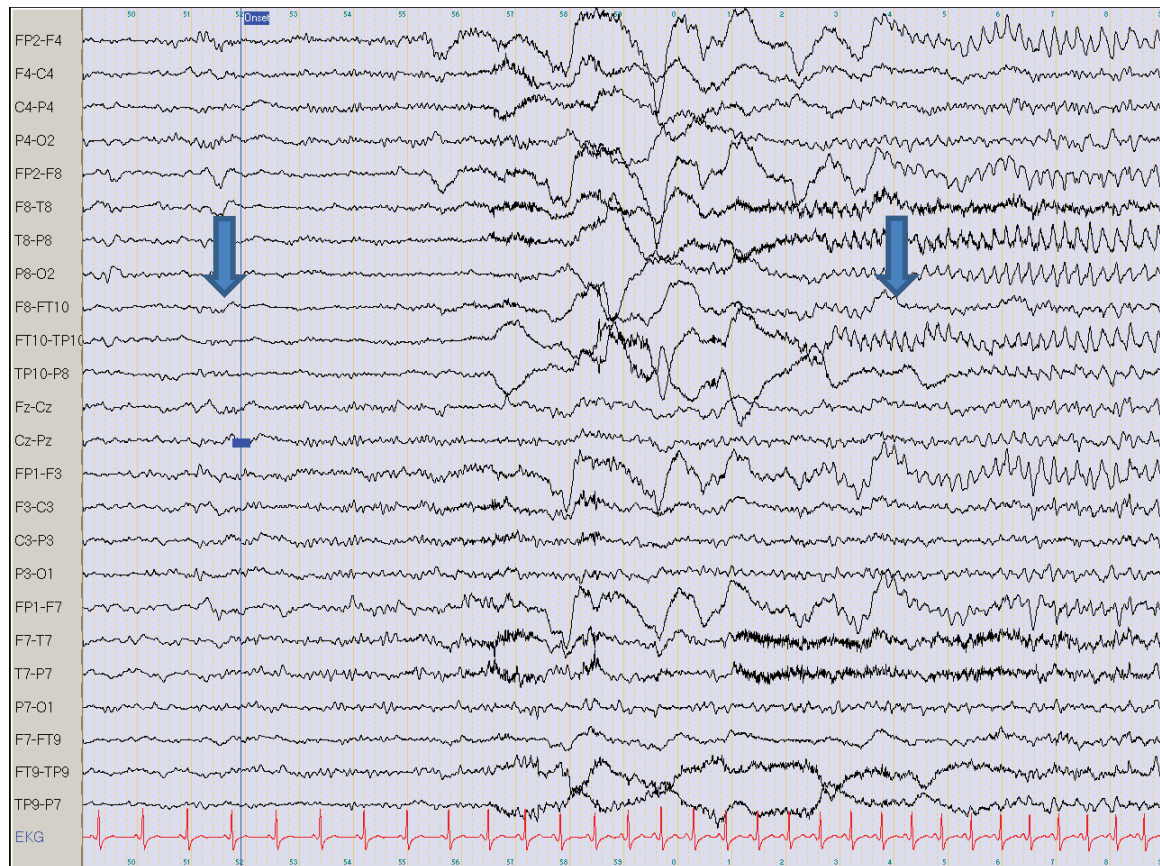


Figure 3. EEG reflecting a right MTLE-HS seizure. From the Kork Epilepsy Centre. Illustrated by the electrodes, F8-FT10 and FT10-TP10 flattening, which indicates the seizure onset (first arrow), followed by artifacts and then, a rhythmic seizure pattern (second arrow).

In certain cases, an invasive EEG diagnostic is performed with intracranial electrodes if the surface electrodes are unable to detect the epileptogenic zone, but the patient is still considered as likely to profit from a surgery. None of the patients included in this thesis underwent invasive diagnostics.

MRI

MRI scans are recommended for patients with seizures due to the information about the aetiology that they provide. If tailored specifically for presurgical epilepsy diagnostics, they should include a specific protocol of volumetric 1mm isotropic T1, T2 and FLAIR images. T2 and FLAIR should be obtained in at least two dimensions, including coronal 2-3 mm slices angled to the hippocampi. During the MRI a typical mesial TLE patient will display hyperintensity on the T2-weighted sequence, a sign of hippocampal sclerosis or atrophy of the hippocampal structures (Knake et al., 2011). Additionally, lesions in the neocortex are frequently present (Kim et al., 2010). In this thesis, all patients presented

with hippocampal sclerosis, and a subgroup presented additional blurring of the cortical gray-white matter junction, or additional focal cortical thickening (Figure 4).

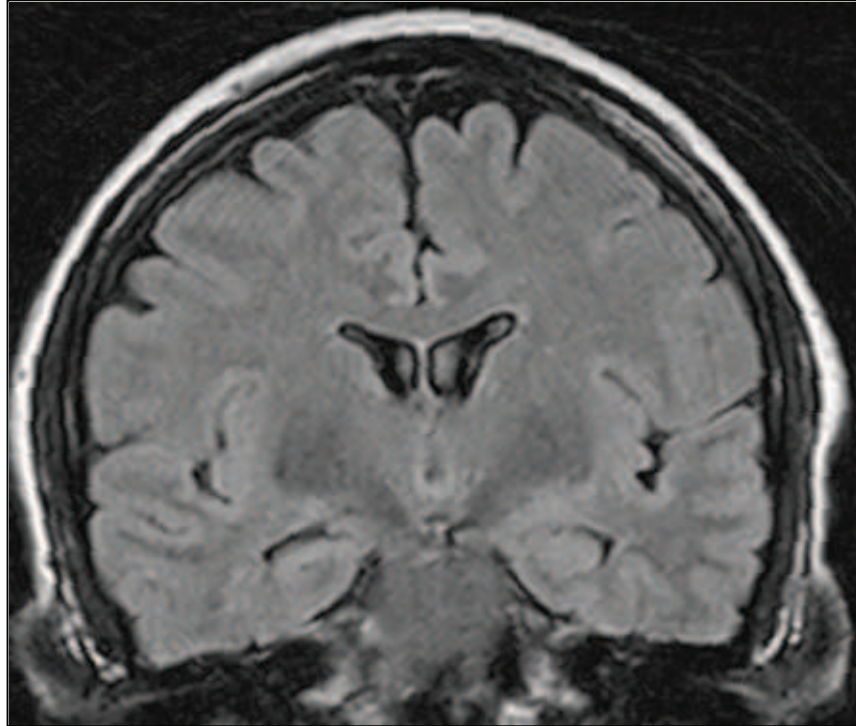


Figure 4. Coronal slice (1.5 Tesla) revealing sclerosis of the right hippocampus, as well as white matter blurring of the right temporal pole and the amygdala.

fMRI

Although the Wada test and electrocortical stimulation are still in use, patients diagnosed at the Kork Epilepsy Centre routinely undergo a non-invasive examination of their language areas via the functional magnetic resonance imaging (fMRI). The purpose of the fMRI is to measure cerebrovascular changes that occur in response to cognitive stimulation, and in this context may also focus specifically on centres of the brain responsible for memory function.

In more than 90% of the population language function is linked to the left hemisphere; to the frontal lobe for speech production and the posterior TL structures for comprehension. However, in patients with TLE and specifically left TLE, bilateral and right-sided language dominance is more frequent (about 20%, due to language reorganization in response to the pathology). Diagnosis of language function is important for coordinating with other

examinations, such as the patient's neuropsychological profile and for interpretation of the presence or absence of speech in the semiology of seizures (Labudda et al., 2011).

1.5.1.3 Surgery procedures

Once a preoperative epilepsy diagnosis has been performed, the aim of curative surgery is to remove the epileptogenic zone responsible for the seizures (Chabardes et al., 2011). For TLE patients that receive care at the Kork Epilepsy Centre, surgeries are mainly performed at the University Hospital in Freiburg where the neurosurgeon principally has the option of three epilepsy surgeries (Figure 5). The two-thirds anterior temporal lobe resection (2/3 ATL) is the standard procedure, which, in addition to the resection of the amygdala and hippocampus, includes a removal of a piece of the lateral temporal lobe approximately 5cm in size (Hufnagel, 2008). Moreover, other patient-adapted surgeries may be performed when further lesions to the neocortex are not present. The selective amygdalo-hippocampectomy (sAHE) consists of several variants that allow the surgeon to remove 3 cm of the anterior part of the hippocampus and the amygdala via different approaches, e.g., the horn of the lateral ventricle (Yasargil, 1967) or the middle temporal gyrus (Niemeyer, 1958). The third technique is a tailored amygdalohippocampectomy following ablation of the temporal pole (temporal pole resection, combined with amygdalohippocampectomy; TPR+AHE) (Helmstaedter et al., 2008).

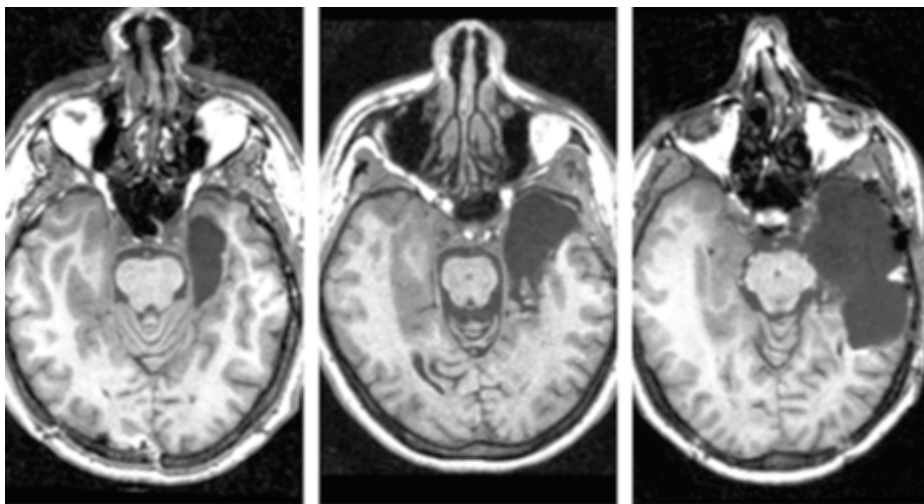


Figure 5. TLE surgery procedures. From left to right, sAHE: selective amygdalohippocampectomy, TPR+AHE: temporal pole resection with amygdalohippocampectomy and 2/3 TLR: 2/3 temporal lobe resection. From, Helmstaedter et al. (2008)

1.5.2 Neuropsychology and epilepsy surgery

1.5.2.1 Historical introduction

The psychologist Brenda Milner performed pioneering work on the topics of memory and hemispheric specialisation that enabled the field of neuropsychology to flourish in the domain of epilepsy surgery.

In her autobiography she recounts that after completing graduate school and studying memory with F.C. Barlett in Cambridge, she began her doctoral thesis in 1950 under the supervision of Donald O. Hebb, the founder of cognitive psychobiology at McGill University in Montreal (Milner, 1996). Together, they worked at the Montreal Neurological Institute (MNI) in collaboration with Wilder Penfield, surgeon and medical director, studying the behavioural effects of brain lesions, following the principle that analysis of disordered brain functions could allow them to gain insight into the functioning of the normal brain (Craik, 1943), as Milner knew from K.J.W. Craik, her tutor at Cambridge University. Her dissertation from 1952 focused on complex perceptual tasks and the identification of mild visuoperceptive deficits in patients with right TL lesions (Milner, 1996). Fascinated by this burgeoning field, which was mostly untouched, she continued at the MNI as a postdoctoral fellow, investigating the effects of TL lesions on cognition, this time concentrating specifically on memory.

During this period, Penfield was already well-known for experimental procedures involving stimulation of the exposed cortex in conscious patients, and having performed some of the first TLE surgeries, routine removals of the anterior hippocampus and parahippocampal gyrus, in conjunction with the amygdala (Penfield et al., 1952). Under normal circumstances these unilateral resections rarely caused prominent memory difficulties, however, Milner described two cases PB and FC of severe memory loss following unilateral TL surgery that most likely occurred due to an undetected sclerosis of the contralateral hippocampus (Milner et al., 1955). The extent of the damage to memory function from bilateral medial TL lesions became apparent soon after Milner and Penfield presented at the American Neurological Association in 1955, where neurosurgeon William Scoville came upon their work. He had performed surgeries, including bilateral resections of the medial TL structures. He invited Milner to examine his patients that all showed a

certain degree of memory difficulties postoperatively. One patient, HM presented an extreme loss of recent memory (Scoville et al., 1957). This man, Henry Gustav Molaison (1926-2008) (Bendict, 2008), who had suffered from intractable epilepsy since childhood, profited postoperatively from a reduction of seizures. Tragically however, from the date of surgery he lost all capacity to form new explicit long-term memories, while his short-term memory and acquisition of motor skills remained intact. HM still serves today as the most studied patient in brain science and his case informed numerous developments on memory research, based on the defining principle of the existence of multiple memory systems. The maturation of clinical neuropsychology in the field of epileptology continued, with three major epilepsy centres involved contemporaneously with its development, including the University of Illinois, the University of London/Guy's Maudsley Hospital, in addition to Milner and her collaborators at MNI, who continued to carefully investigate brain function in the hopes of preventing postoperative cognitive morbidity (Loring, 2010).

1.5.2.2 The neuropsychological assessment

Presently the neuropsychological diagnosis represents a significant portion of the analysis of risk for a patient considering epilepsy surgery. Through evaluation of the patient's cognitive strengths and weaknesses, the neuropsychological tests allow clinicians to localize and lateralize the seizure focus by reflecting the dysfunctional zone (Rosenow et al., 2001).

Lateralizing memory deficits is based on the core concept of material-specificity of memory, whereby the left mesial TL is supposed to mediate memory for verbal material and the right-sided hippocampal complex, is responsible for non-verbal memory, more specifically visual/figural and spatial materials. Deficits corresponding to left mesial TLE would therefore correspond to verbal, and deficits associated with the right mesial TLE would result in visual memory deficits. Once the dysfunction, is localised, it is equally as important to determine if any specific cognitive changes may occur in the patient's cognitive capacities postoperatively. In order to address this, a preoperative baseline assessment must be followed by postoperative testing using parallel versions of these tests. These measurements ideally involve a comprehensive examination covering the major cognitive domains of intelligence, attention, language, visual-spatial, visuomotor, and particularly in the case of TLE, learning and memory processes (Lee, 2010).

The particularity of examining TLE patients comes from the complications that can arise from various interacting factors specific to epilepsy, comprised of two dynamic groups (illustrated by Figure 6). The first, which consists of *morphological factors*, is generally due to a lesion in the medial TL that existed prior to surgery or resulted after a resection. Such structural damage is likely to induce deficits in episodic long-term memory. The second, called *functional factors*, adds to the cognitive impairment of the patient and it encompasses, effects due to AEDs, IEDs, the type and frequency of the seizures, whether there is spreading to other lobes, and any existing psychiatric comorbidities. Functional deficits generally affect attention and/or executive functions, and in contrast to deficits that may be caused by morphological factors, are largely reversible if attempts at controlling the seizures are successful (Elger et al., 2004).

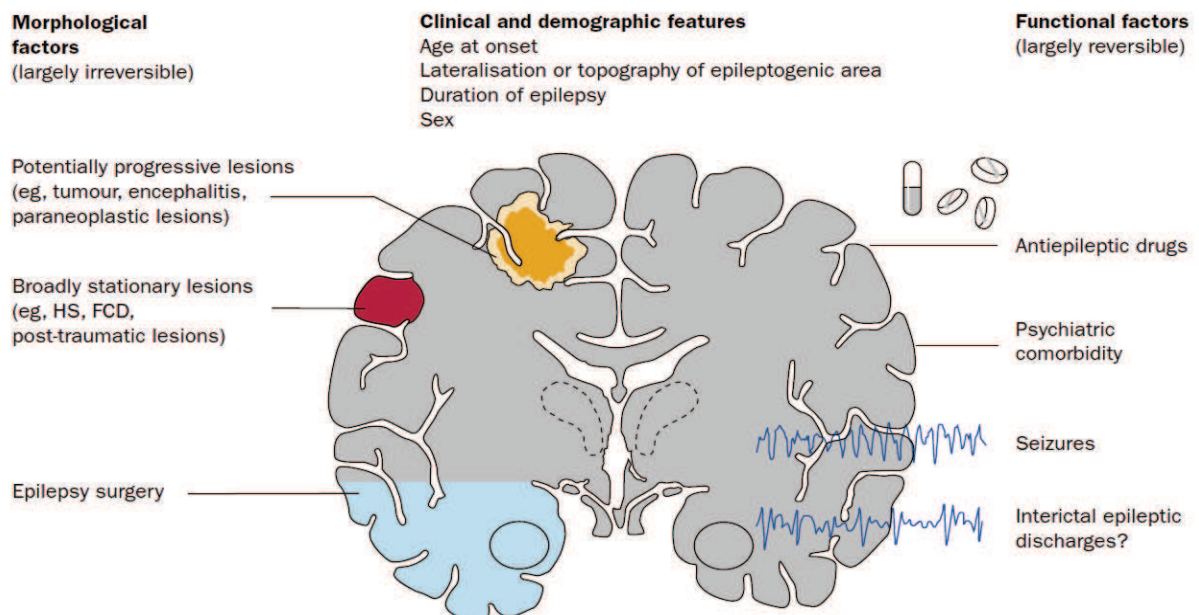


Figure 6. Morphological and functional factors influencing cognition in epilepsy. From Elger et al. (2004)

Neuropsychologists must therefore consider the patient's history, drug intake and medical examinations when interpreting the results of neuropsychological tests, which in turn are required to show validity for localizing epileptic foci (Baker et al., 2004). There is need for the availability of psychometrical sensitive and specific tools. In German-speaking

epilepsy centers, only 25% of tests used are evidence-based (Witt et al., 2009) and attempts to standardize diagnostic tools are presently still ongoing (Brueckner et al., 2010).

In essence, MTLE-HS is an epileptic syndrome that is highly pharmaco-resistant and for which surgery is a viable option if the epileptogenic zone can be coherently detected. Impairment to the TL can chronically affect cognitive processes, specifically, memory, language, perception, attention and executive functions. Thus, neuropsychological examinations play an integral role in modern epileptology.

Chapter 2

Visual memory and perception

The localization of deficits of visual memory and perception as a consequence of right temporal lobe epilepsy (TLE) is matter of discussion within the field of neuropsychology. The following comprises two parts that describe visual memory and perception. It begins with a discussion of cognitive, neuroanatomical, and physiological models within the healthy brain, before characterizing these functions in populations affected by mesial TLE.

2.1 The visual perceptive system

One of the most important aspects of our existence is the interpretation and interaction with the world around. In our everyday lives we encounter objects of various sizes and shapes, which reflect differing amounts of visible light that in turn enters the eye via the lens, creating an image on the retina, a membrane in the posterior chamber that converts electromagnetic radiance into specific neuronal signals. These signals travel, via the optic nerve, to different parts of the brain, arriving first at the lateral geniculate nucleus of the thalamus, and eventually making their way to the primary and secondary visual cortices. Situated in the occipital pole, the primary visual cortex (striate cortex or V1) is the first cortical projection point and reorients the inverted retinal image. Directly beneath area V1 lies the secondary visual cortex (extrastriate cortex or V2), followed from both sides by V3, an area responsible for higher cortical processing and releasing two separate streams, which carry out further information processing (Fahle, 2008).

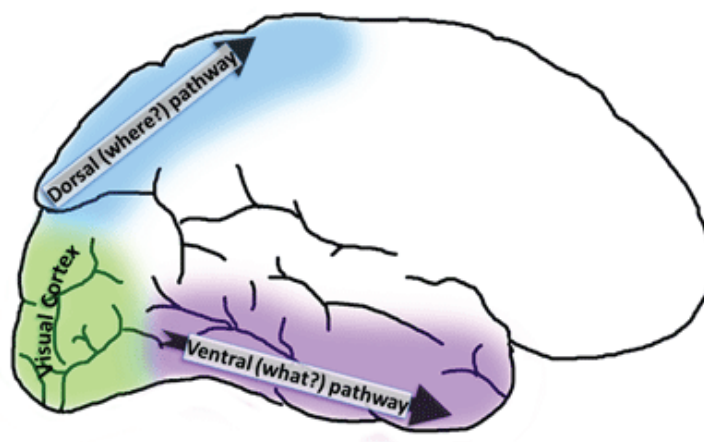


Figure 7. Representation of the two-stream hypothesis

According to the “two-stream hypothesis” of Mishkin & Ungerleider (1982), both ventral and dorsal streams exist as anatomical and physiological subsystems of the visual cortex (Figure 7). The dorsal, or “where” stream, is thought to be predominantly involved in visuo-spatial perception skills and extends from V1 into the parietal lobe, interconnecting with the ventral pathway that departs from the striate cortex at the temporo-occipital junction (V2, V3, V4, to the inferior temporal lobe). This ventral or “what” pathway, is implicated in object recognition and form identification (Ungerleider et al., 1994). Due to multiple connections with parts of the temporal lobe (TL) responsible for memory consolidation, the percept can be matched to contents stored in the cortex.

Cognitive psychologists often refer to visual object perception as a “bottom-up” process. However, a “top-down” process also exists wherein the percept is “run backwards” and found in the memory store. The visual top-process corresponds to “visual mental imagery” (Farah, 1984). Physical trauma to the posterior part of the brain can cause deficits in either of these processes, with perception specific damage referred to as “visual agnosia”. In subsequent sections, these deficits will be discussed more explicitly, followed by a chapter section focusing on the characteristics of perception in TLE.

2.1.1 Agnosia

Distinct lesions in the “where” and “what” systems are known to cause specific dysfunctions in perceptive skills. For example, a dysfunction of the dorsal visual system, extending from the occipital towards the parietal lobe, provokes visuo-spatial perception deficits. Conversely, lesions in the ventral visual system at the temporo-occipital junction cause various forms of visual object recognition disorders or visual agnosias (Bauer et al., 2003). Indeed, “There is amazing diversity to the ways in which object recognition can break down” (Farah, 2004) (p.1). Different agnosia subtypes are classified according to the taxonomy of Lissauer (1890) who distinguished between “apperceptive agnosias”, caused by an impairment of visual perception, and “associative agnosias” where the perception is relatively spared, yet recognition impairment persists at higher processing levels. In reality this distinction is not as dichotomous as it seems, however Lissauer’s classification is still applied for organizational reasons (Farah, 2004).

Most forms of agnosia cause clinically significant impairments, meaning those that are evident in the patient's everyday life. For example in "visual form agnosia", simple shapes, numbers, and letters cannot be recognized (Benson et al., 1969). Intriguingly, while a single object configuration may be relatively spared, the difficulty may arise when a person is presented several objects simultaneously in "dorsal simultagnosia". In "ventral simultagnosia", the perception and recognition are spared though only for one object at any time (Kinsbourne et al., 1963). Additionally, there are highly specialised deficits, such as prosopagnosia, a selective deficit for the recognition of well-known faces, wherein other visual recognition processes may remain unaffected (Damasio et al., 1982).

However, a subgroup of patients presents deficits in visual recognition that do not disturb their everyday life as seen in other agnosia types. This visual agnosia is detected in a clinical "laboratory" setting, where visual stimuli are presented to the subjects in "unconventional or unusual views" versus the "conventional or usual or canonical view" (Figure 8), or are visually degraded versus the complete image (Figure 9). If the patient fails to recognise the unconventional view, but succeeds with the conventional view, a case of "perceptual categorization" deficit might be present (Warrington et al., 1973). In 1999, Davidoff & Warrington described a patient, RK, with an infarction in the temporo-parieto-occipital region of the right hemisphere, who showed only slight deficits in object recognition when the object was presented from a conventional view. Thus there were no indications of early visual processing or recognition problems. However, his "access to the (semantic) representation" was undermined when the percept varied in presentation (unconventional view). Hence, the authors hypothesized that a subcortical route existed, where visual information passes from the right hemisphere to the semantic object recognition system in the left hemisphere (Davidoff et al., 1999).



Figure 8. The Canonical-Unusual View Matches (Manning, 2000)

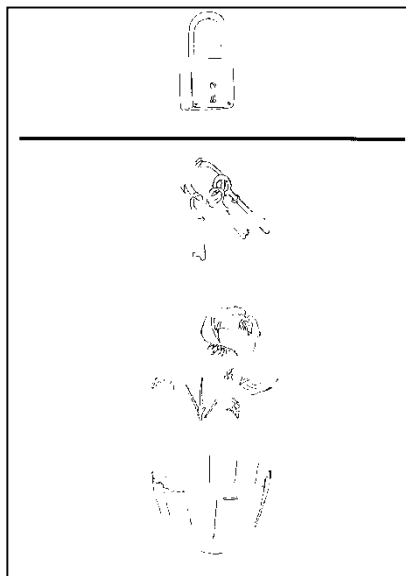


Figure 9. Degraded PEGV. Adaptated after Agniel et al. (1987)

2.1.2 Mental imagery

Mental imagery allows the subjects to vividly generate a cognitive representation of objects, scenes or locations from memory without implicating the eye (Farah, 2000). Due to the similarities of visual imagery and perception, it has long been suggested that they rely on the same cortical representations (Kosslyn, 1980). With the advent of positron emission tomography (PET) and functional magnetic resonance imaging (fMRI), it was discovered that the visual cortices of the occipital lobe are implicated in both processes, thus proving that perception and imagery share the same neural substrates (e.g. Kosslyn et al., 1997, Cichy et al., 2011).

In most cases of damage to the visual cortices, patients present deficits in mental imagery as well as defects in visual perception. However, studies of brain-lesioned single-cases have reported some dissociation. There is evidence of selective impairments of visual imagery where the perception was spared (Farah, 1988), and inversely where a deficiency was observed in perception though visual imagery was preserved (Behrmann et al., 1992, Behrmann et al., 1994, Bartolomeo et al., 1998). These cases support the view that mental imagery and perception, even if they are closely intertwined, are two distinct functional processes.

Like perception, imagery can be divided according to the different kinds of stimuli. Based on evidence from brain damaged patients, it has been suggested that visual imagery for forms, faces, objects and colours involves the ventral, occipito-temporal stream, while spatial imagery might require the dorsal occipito-parietal stream (Farah et al., 1988, Palermo et al., 2010). Recently, an fMRI study demonstrated that imagery for space and objects can be represented by different brain structures. Hence, overlapping activations were found for both vision and imagery in the ventral temporo-occipital pathway when recognizing objects. For the location of objects, the representations were also shared, situated in cortical regions lateral to the ventral-path (Cichy et al., 2011).

Numerous experiments were performed involving patients with focal brain lesions in the temporo-occipital pathway, where both left and right-sided lesions are known to cause disturbances in mental imagery. However, the majority of reported cases involve lesions within the left hemisphere (for review see, Farah, 2000, Bartolomeo, 2002). Additionally,

functional neuroimaging studies have tended to the left hemisphere as the basis for visual imagery. For example, Esposito et al. (1997) showed the left inferior TL as the most reliably activated area, extending into the occipital association cortex. However this finding is complemented by Bartolomeo (2008), who reported that visual mental imagery requires more distributed networks within several brain areas, providing top-down input from frontal and parietal regions to the TL (Mechelli et al., 2004).

2.1.3 Visual perception and temporal lobe epilepsy

There is evidence of visuoperceptive impairment in adults suffering from occipital lobe epilepsy (Piazzini et al., 2009). Concerning TLE there is ongoing debate of whether deficits in visual perception are caused by the disease. In assessing H.M., it was revealed that even in the presence of extraordinary memory impairment, perceptual functions were preserved (Scoville et al., 1957). Currently, in preoperative epilepsy diagnostics, little interest is given to studying perception as the majority of researchers agree that visual perception is generally preserved in patients with unilateral mesial TLE (Helmstaedter et al., 2001a, Grant et al., 2008, Carvajal et al., 2009). Nevertheless, deficits can be observed in certain cases, especially, through the use of specific test methodology. Milner found in patients who had received an anterior temporal lobectomy (ATL), that perceptual deficits persisted when using rapidly presented stimuli, or required the discrimination of small differences in the contours (Milner, 1958, Milner, 1968). Concurrently, Kimura found that by using a tachistoscope to produce an extremely brief exposure to the stimuli, perception impairment existed between overlapping nonsense objects and groups of dots. This perceptual impairment was present for right TLE patients in both, the pre- and postoperative group. However, the differences were slight when compared to the deficits in visual memory and could only be detected with a “special technique” of perceptually demanding tasks (Kimura, 1963). Furthermore, the importance of the posterior temporal cortex for visual object recognition becomes apparent when studying faces and their dissociation. In a milestone paper, Milner demonstrated the presence of a facial recognition impairment in the group that received ALT, on the right, but not on the left side (Milner, 1968). More recently, she was unable to reproduce these findings in patients who had received selective amygdalohippocampectomy (sAHE) and the authors therefore

concluded that the right medial TL structures must be necessary for retention but not for the perception of faces (Crane et al., 2002).

In order to further examine the relationship between visual memory and perception in TLE, combining neuropsychological and electrophysiological methodologies has been useful. For visual perception to take place, neuronal networks synchronize and corresponding gamma and theta waveform activity can then be observed on the EEG (Demiralp et al., 2007). It has been acknowledged that children with centro-temporal spikes present significant deficits in higher functions of spatial perception and orientation. In a single case report of a child with occipito-temporal complex sharp-waves, it was shown that this electrophysiological pattern was the cause of major deficits in visual perception (Eriksson et al., 2003, Volk-Kernstock et al., 2006). An additional study, involving event-related potentials (ERPs), showed that healthy hippocampi respond differently between nonsense and real objects. In contrast, ERPs measured outside of the hippocampus proper, within other mesial TL structures, did not differ depending on the stimulus type, thus underlying the importance of the hippocampal structures in object recognition (Vannucci et al., 2003).

To our knowledge there is only one study referring to the implication of hippocampal structures in visual perception: the remaining studies described above indicated instead that if perceptive impairment appears in TLE, it is a consequence of a dysfunction of neocortical temporal structures.

2.2 Memory

Memory is a fundamental process for the constitution of human consciousness. All types of stimuli that establish an experience can be stored and retrieved at a later point in time; however, they are not a static imprint and have a tendency to become forgotten or overwritten with time. These stimuli are diverse, and can be verbal, such as the trace of a conversation, or the recall of a book that was read. They can also be nonverbal, for example, one might remember complex visual scenes, or objects distributed over space and time. Since the 1960s, the term *memory* no longer refers to a unitary phenomenon but has been replaced by conceptualizations characterizing memory information processing based on time, the content and different participating processes.

2.2.1 Classification by temporal direction

In 1968, Atkinson & Shiffrin proposed a hierarchical two-component memory system wherein short-term memory (STM) was considered a “gateway” with information being held for approximately one minute, before it was transferred into more permanent long-term memory (LTM) storage. Subsequently, this model was further validated with evidence from double-dissociations on brain-lesioned case studies. Milner noticed that although patients with damage to the hippocampi had difficulties remembering new material, their capacity to immediately repeat a sequence of numerical digits was preserved (Milner, 1966). Shortly thereafter, Shallice & Warrinton (1970) observed patients with an inverted distortion, able to encode and store new verbal material, but an impairment of short-term memory due to left perisylvian lesions. Later, the two-component memory system added a third store involving external stimuli, which pass through a verbal or nonverbal perceptual system (sensory memory). This model was revised by Baddeley & Hitch (1974) who introduced the concept of working memory (WM) emphasizing the importance of cognitive processing between the short-term and long-term memory storage, and included an attention controller, the central executive, and two subsidiary systems (the phonological loop and visuospatial sketchpad) for holding verbal and visuo-spatial information, respectively. In subsequent years, a fourth component was introduced, the

episodic buffer, responsible for binding verbal and visuo-spatial information (Baddeley, 2000).

Luck & Hollingworth (2008) focused on a model specifically for visual memory and propose a concept of “visual STM”. This model is based upon the theory of a WM that can be divided into verbal and visual modalities. Placing the emphasis on the perceptive domain, the authors use the term STM instead of WM. Visual STM derives thus from a perceptive system (visual sensory memory) and its capacity for processing depends on the stimulus complexity, ranging from 3-4 simple objects and 1-2 complex items (Luck et al., 1997). This performance is limited compared to the verbal modality, which is rather dependent on stimulus quantity, where the storage can contain approximately 7 (± 2) digits (Miller, 1956). Arguments for their independence had already been given by Scarborough (1972), who showed that verbal and visual STM items do not interfere with one another. Similarly no interference exists between certain spatial and object memory tasks, suggesting that further qualitative differences exist in visual memory (Hyun et al., 2007).

Although the cooperation of various brain regions, including the frontal lobe, seems to be required in order to keep an image in memory over a short period of time (Liebe et al., 2012), functional distinction is accepted and has been validated by neuroimaging studies. For example, an fMRI experiment has located specific spatial STM representation in the inferior intra-parietal sulcus (IPS) and specific STM for objects in the IPS and the lateral occipital complex (Xu et al., 2006).

LTM is theoretically unlimited concerning its capacity. For patients with brain disorders, it can be further divided into anterograde memory, which concerns recollection of information after the onset of the disease, and remote memory that involves recalling information from before this onset. There are several LTM subsystems predicated upon the study of patients with brain lesions, and these can be classified according to their content.

2.2.2 Classification by content

To classify the different memory components, there are two dominant dichotomies in memory literature (Squire et al., 1998, Tulving, 2005). The first taxonomy, advanced by Squire & Zola (1998) is based on a biological perspective aiming to explain memory patterns in amnesia in order to associate them with specific cerebral regions (Squire, 2004). The diagram presented below (Figure 10) makes its main distinction between explicit (or declarative) and implicit (or non-declarative) memory. Knowledge about facts and biographical events are situated under declarative memory, whereas the non-declarative group englobes forms of memory that are considered to be automatically processed.

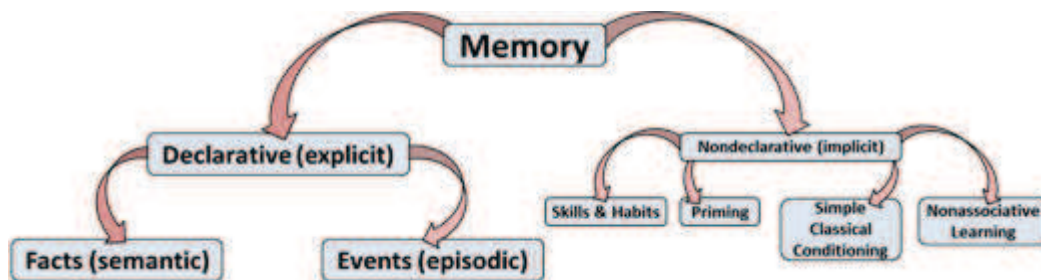


Figure 10. Long-term memory subsystems, from Squire and Zola-Morgan (1991)

This model has been criticized because although it reflects different memory contents, the formation of the model results from studying dissociations in a collection of amnesic patient case studies, and it does not describe the organization of the memory system (Cubelli, 2010).

The taxonomy by Tulving (2005) distinguishes five memory systems organized hierarchically, reflecting their phylo- and ontogenetical development (Figure 11). The initial classification model, as proposed by Tulving (1972), at first suggested a division into two subsystems: episodic and semantic memory. Episodic memory refers to information about personal episodes or events that can be placed within a spatial and temporal context. This type of memory is assessed in the ‘laboratory’ setting with list-learning, short story or visual recognition paradigms. The second subsystem, semantic memory, refers to a person’s generic knowledge of the world. Later, a third component

referring to automatized motor, sensori-motor or cognitive tasks, was added (Tulving, 1983). In the most recent proposal, two further components were supposed. Priming refers to the re-identification of previously perceived stimuli and the perceptual memory system is a pre-semantic processing stage that relies on familiarity judgements (Tulving, 2002, 2005).

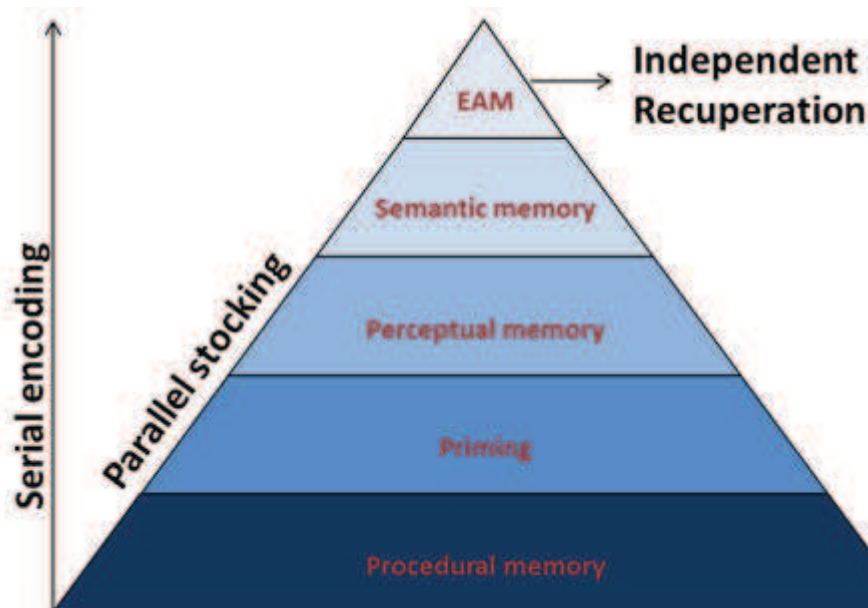


Figure 11. Diagram of the hierarchically organized memory systems. Adapted from Tulving (2002, 2005)

Tulving (1985) attempts to connect memory to consciousness, attributing a level of consciousness to the 3 original sub-systems. Procedural memory is unconscious and situated at an 'anoetic' level. Semantic memory is 'noetic', concerning conscious general knowledge about the world. Finally, episodic-autobiographical memory (EAM) is context-specific with respect to time and place. The 'autonoetic' consciousness is considered an attribute of human self-reflection, allowing mental time-travel and re-experiencing of the episode. Another characteristic is visual mental imagery and emotional aspects.

A subsequent important point in Tulving's model is the functional SPI (serial, parallel, and independent) dimension. It suggests the encoding of memory in a serial successive manner. For example, whereas in the view of Squire (1992) semantic memory would result from episodic traces in which the context has disappeared, Tulving suggests that autonoetic

consciousness emerges from a noetic base. The information is then stocked in parallel in these different systems and can be recuperated independently.

2.2.3 Memory processes

As mentioned above, memory processes are characterized by encoding, followed by a consolidation phase in order to allow stocking, and finally recuperation at a later time point. Encoding is dependent on STM and WM processes and their respective capacities. The acquisition of information can be intentional or incidental, the later of which is less effortful. During the consolidation phase neuronal structural changes occur that transmit information into the LTM store. Meanwhile, interference shortly after the encoding period has a detrimental effect on the material (for review, see Dewar et al., 2010). Ultimately, what allows a clinician to evaluate the memory performance in the clinical setting are diverse retrieval conditions that can be differentiated into free recall, recall with cues, or recognition paradigms.

2.2.4 Neuroanatomy of the temporal lobe

The formation, consolidation and recuperation of the memory system, require diverse brain regions and their interaction via nervous connections. According to Tulving (2005), each memory system and process engages specific brain structures. In essence, procedural memory involves subcortical and cortical motor-related structures; priming requires the neocortical association cortex, and perceptual memory, the sensory cortex. For the formation of episodic and semantic memories, a set of structures and connections is required, summarized as the limbic system.

The limbic system is constructed around the medial TL and is composed of a system of anatomically and functionally interconnected structures including the “hippocampal complex”, which encompasses several parts. The “hippocampus proper” refers to the cell fields (CA1-CA4) of the hippocampus and the dentate gyrus, the “hippocampal region” denotes the hippocampus as a whole and the first part of the parahippocampal gyrus, the

subiculum, and the “hippocampal formation” incorporates the hippocampal region and the entorhinal cortex (Figure 12).

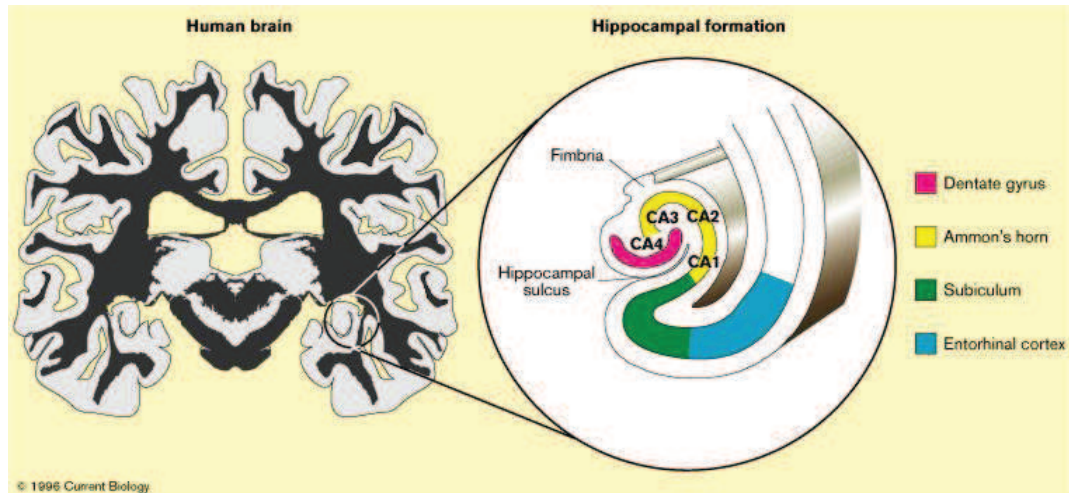


Figure 12. From left to right. A coronal slice of the brain, with enlarged hippocampal formation and its topographical divisions. From (Parkin, 1999)

In conjunction with the adjacent perirhinal and parahippocampal cortices, the hippocampal complex is linked to the amygdala, the fornix, the mammillary bodies, the anterior dorso-medial thalamic nucleus, and parts of the frontal lobe (Squire et al., 1991, Markowitsch, 2000, Squire et al., 2004). With this interconnection, the hippocampal complex is capable of binding together a range of emotional and sensory aspects to form a memory trace.

2.2.5 Visual memory pathways

Episodic memories may be material-specific with the hippocampus receiving verbal information from the language centres in the left hemisphere and visual input from the ventral and dorsal pathways. For visual memory the interaction of two parallel pathways is assumed (Figure 13).

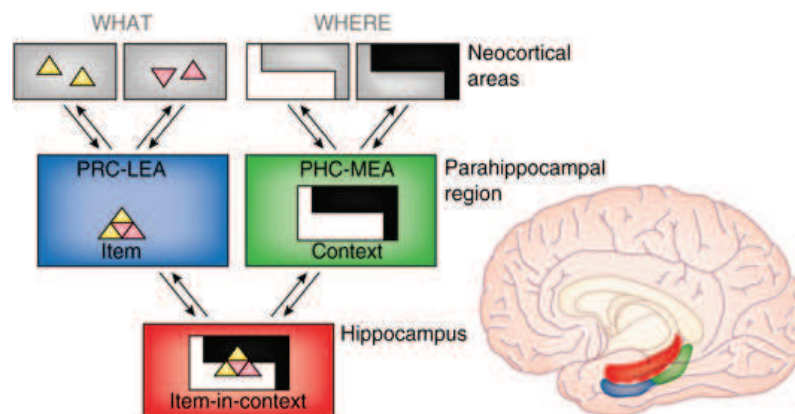


Figure 13. Proposed functional organization of the visual medial TL memory system. From (Eichenbaum et al., 2007)

The first visual path connects the ventral visual pathway (regarding the object features of “what”) important for object recognition, to the perirhinal cortices (PRC), before projecting into the lateral entorhinal cortex (LEA) and reaching the hippocampus proper. The parahippocampal complex (PHC) is part of a second path, receiving information containing spatial information from the dorsal visual stream (regarding the object features “where”) and projecting via the medial entorhinal area (MEA) into the hippocampus, which is more involved with contextual processing of information (Eichenbaum et al., 2007).

Further different recuperation processes, such as recall versus recognition can also be comprehended based upon their neuroanatomical organization. The recuperation of visual memory involves two other localizable memory circuits, depending on the retrieval process. The first, specifically for recalling events, requires in addition to the medial TL, the prefrontal cortex, which would induce a top-down mechanism and cue out information from the inferior TL (Lee et al., 2000, Takahashi et al., 2002). This anatomical relay was

recently shown in a study where synchronized theta, beta and gamma bands appear when attention and working memory processes are activated in the prefrontal cortex in order to communicate with the hippocampal complex and the visual cortices (Benchenane et al., 2011). The second process underlying recognition memory was derived from electrophysiological measures in monkeys (Murray et al., 1993). This recognition involves material stored in the inferior temporal neocortex being recuperated via “backward fiber projections”. The brain regions identified were the anterior inferior temporal cortex, located at the end of the ventral pathways, responsible for object recognition, and the perirhinal cortex. A number of studies pointing to the importance of the PRC as a storage area for visual representation have accumulated since (for review, see Murray et al., 2007). As these findings point to the importance of the PRC, there is debate about the involvement of the hippocampus and adjacent structures in recognition memory. Barbeau provided neuropsychological evidence of two cases showing a double dissociation. One patient had selective damage to the hippocampus and consequently impaired recall of visual memory while his recognition memory was spared. Inversely, the second patient had a spared hippocampus and damage to the temporal pole, entorhinal, and perirhinal structures. Thus he had deficits in visual recognition memory, however, his recall performance was inversely preserved (Barbeau et al., 2010). Notwithstanding the impressive double dissociation, it is important to notice that prior to that, Squire et al. (2007) had reviewed this topic and concluded that even though the PRC have an important role in processing visual memory, the clinical reality of patients with hippocampal lesions is that they have similarly impaired recognition versus recall performances. In this context, it is important to recall the different memory sub-processes, and the importance of the hippocampal complex in memory consolidation.

2.2.6 Memory consolidation

In the traditional two-store model of memory after Atkinson & Shiffrin (1968), the formation of new memories is supposed to result from a transfer beginning at the STM, where information is held for some seconds and after being actively maintained in the consciousness, is transferred into the LTM store. Emerging evidence from behavioural and pharmacological findings, however, suggests that this passage is not instantaneous, but acts as a midway consolidation stage to solidify the memory trace. Dewar, Cowan and Della

Salla (2010) reviewed the subject and proposed a cognitive concept that assumes an “intermediate memory/consolidation stage” in the dual STM/LTM memory model (Figure 14).

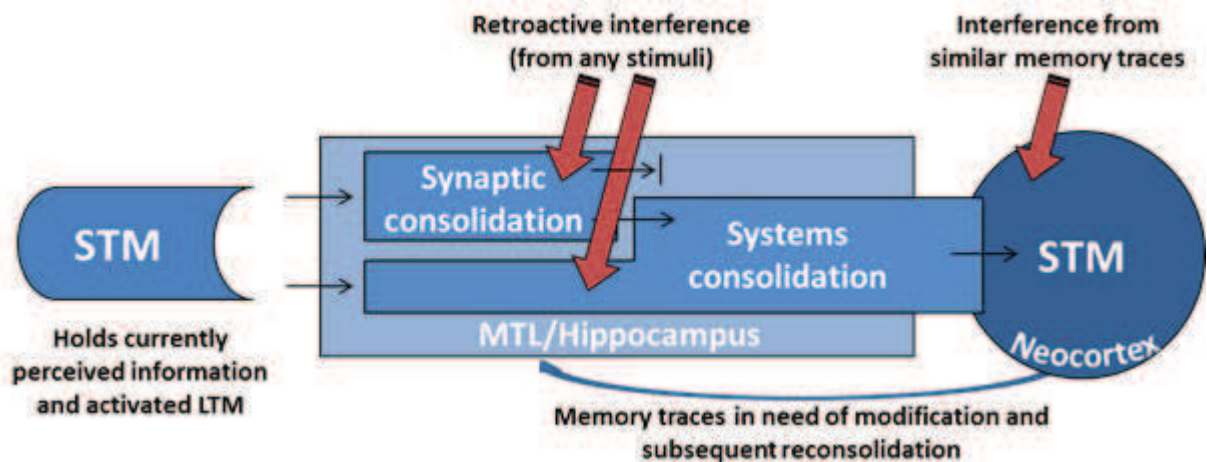


Figure 14. A revised cognitive model of forgetting. Adapted after Dewar et al. (2010)

The existence of two consolidation processes has been suggested. The first is the “synaptic consolidation” process, which refers to long-term potentiation (LTP), an increased post synaptic long-lasting excitability within the hippocampus (Bliss et al., 1973). This type of consolidation is identifiable in all species and allows information held in the STM to become rapidly “bound” into a memory trace that is resistant for minutes to hours from interfering stimuli (Dudai et al., 2004). In the clinical context of epilepsy, which aims to lateralize or localize the dysfunctional zone, the recuperation is generally measured after 30 minutes to several hours (Lee et al., 2005). Therefore, in the routine clinical setting, it is not known whether the trace is gradually forgotten afterwards or whether it can be further processed by “system consolidation”, thus enabling formation of stable memory traces. This stabilization extends from hours to years and depends on not only the utility of the memories, but also the presence of interfering factors with biological adjustments (e.g. sleep) that need to occur for the consolidation to take place (for review, see Stickgold et al., 2007).

The cortical structures involved in system consolidation are the mesial TL surrounding the hippocampus, and the neocortex. Two leading models hypothesize on the respective implication of the neurobiological basis for the formation of stable LTM. The “standard theory of consolidation” (Alvarez et al., 1994, Squire et al., 1995) supposes that sensory information that was processed in the neocortex is being ‘bound’ by the hippocampal complex. Of important note is that the contribution of the hippocampus would diminish with progressing consolidation, leaving stable and permanent mnesic traces solitary in the neocortex. This view is based on the concept of declarative memory and does not distinguish the nature of episodic from semantic memory, unlike Tulving’s model, which considers them to be separate experiences (Tulving, 1989). Therefore in the standard theory of consolidation, knowledge about the world results from declarative traces in which the context has disappeared (Squire, 1992). An alternative model proposed by Nadel and Moscovitch (1997) assumes that the hippocampal complex is necessary for the recuperation of episodic memory for the entirety of a person’s lifetime, and that with increasing recall and reconsolidation, the number of connections or traces with the hippocampus are being multiplied. The second theory considers contextually charged episodic memory and semantic information as separate experiences, involving disparate neuronal networks. The hippocampal complex is therefore implicated in contextualized episodic memory, and the neocortical temporo-anterior areas sustaining context-free semantic memory where verbal and visual information overlap (Menon et al., 2002, Giovagnoli et al., 2005, Lambon Ralph et al., 2007).

2.2.7 Forgetting

The consequences of impaired system consolidation can be comprehended in the phenomenon of accelerated long-term forgetting (ALF) which has been described in various patients that suffered from TLE. These patients had normal performances on neuropsychological tests with standard recall delays, and yet showed disproportionate ALF after delays extending over days or weeks and deficits in their remote memory (for reviews, Mayes et al., 2003, Bell et al., 2007, Butler et al., 2008, Butler et al., 2010).

ALF can affect both verbal and nonverbal material, as shown by two group studies (Mameniskiene et al., 2006, Butler et al., 2010). However, lateralization effects that

pointed to the epileptogenic zone were to our knowledge found only in groups of TLE patients with left seizure foci for verbal material (Blake et al., 2000, Jokeit et al., 2001). In this context, long-term forgetting of verbal versus visual material does not follow the same function. Accordingly, Erdelyi (2010) studied normal subjects, showing that recall performance on tasks for pictorial stimuli may be enhanced with a series of effortful retrieval, and thus achieve opposite performance to the Ebbinghaus' classical verbal curve with forgetting that declines over time.

ALF might occur in patients with mesial TLE but also without structural lesions to the hippocampus (view, Butler et al., 2010). Research has especially focused on seizures as important underlying pathophysiology. Hence, Jokeit (2001) performed a word-position association-learning test every 24 hours during EEG monitoring and demonstrated no difference in retention between patients with left- and right sided TLE on seizure-free days. However, patients with left- but not right-sided TLE exhibited impaired retention of word position if a seizure had occurred during the preceding 24-hour interval. Inversely, Wilkinson (2012) found that patients with right lateralized seizure-onsets whose verbal recall was normal at the 1 hour delay had ALF after 6 weeks. This ALF was not associated with the underlying hippocampal lesion, but with the frequency of epileptic seizures. Other factors influencing ALF are high doses of anticonvulsant medication, but also mood disorders, anxiety and sleep quality (view, Butler et al., 2010).

ALF has important clinical implications, as it occurs more widely than in isolated cases and could be an explanation for the performance of patients that have a mismatch between subjective and objective memory performance. These patients often complain about memory difficulties, but demonstrate normal performances on the standard memory tests (Butler et al., 2009, Witt et al., 2012). Conversely, for lateralizing the dysfunction zone in patients with mesial TLE, standard memory tests are usually sufficient, because they typically reveal the impairment after about 30 minutes. Furthermore, with patients that already perform at the bottom, no significant additional forgetting that would help with lateralizing decisions is detectable after weekly intervals (Bell et al., 2005, Muhlert et al., 2011).

2.2.8 Functional hemispheric specialisation

The brain consists of two cerebral hemispheres that communicate through the corpus callosum. Each side is composed of comparable structures, though there is structural and functional lateralization of motor and cognitive capacities. The most established concepts involve motor movement, in that control of the right body half requires engagement of the left hemisphere and vice versa for the left half. In 95% of right-handed humans, language is processed in the left hemisphere. This is slightly less in left-handed subjects, where approximately 70% have their language areas situated in the left hemisphere. Thus, the left hemisphere is termed the “dominant” cerebral side (Young et al., 2008). Both language and laterality are particularly sensitive to shift, as a consequence of neuronal plasticity phenomena, into the contralateral hemisphere. This is the case when function is disturbed due to imbalance caused by malformations, acute lesions or epileptic activity at a young age (Mayer, 2011). In certain children or particularly rare cases of adults, who have undergone hemispherectomies due to catastrophic epilepsies, the maintenance of intellectual capacity and functional plasticity is possible with only one hemisphere (Steinhoff et al., 2009).

2.2.8.1 Evidence from split-brain patients

The focus on isolated hemispheric specialisation debuted with the neuropsychological work on “split-brain” patients who had received surgical dissection of the corpus callosum in order to relieve their drug-resistant epilepsy. With the purpose of investigating cognitive functions, Michael Gazzaniga has worked with these specific patients since 1961 and has provided insight into the organization of brain functions within the hemisphere. In his experiments, patients were asked to fixate a point in space during presentation of flashed stimuli occurring either to the left or right visual hemifield, allowing him to address each hemisphere respectively. He found that a separated left hemisphere was sufficient for all aspects of language, whereas patients with only right hemispheres still showed rudimentary language processing. In terms of visual information, both detached half-fields, satisfactorily, fulfilled their function in most experiments (Gazzaniga, 1970). However, there was proof that the right-hemisphere superiorly treated visual assignments. The ability to copy geometric patterns was higher with the left as opposed to the right hand and that

the perception of spatial patterns seemed to preferentially involve the right hemisphere (Gazzaniga et al., 1965).

Concerning memory, relatively mild impairment follows the disconnection (Gazzaniga, 1970). In 1971, Milner assessed seven commissurotomy patients with a delayed-matching to sample test, where tactile nonsense figures made out of wire had to be matched (Milner, 1971). The authors found that patients failed to memorize the stimuli when they were touched only with the right hand and thereby activating the left hemisphere. These findings coincided with the framework of the theory of material-specificity for memory.

2.3 Visual memory impairment in temporal lobe epilepsy

2.3.1 Introduction

In the 1960's the concept of material-specificity was based upon postoperative studies of patients with unilateral TL resections who did not present severe amnesia as seen in the cases with bilateral hippocampal lesions, but showed double dissociations of verbal and nonverbal memory performances. Meyer and Yates (1955) were among the first to report that an anterior temporal lobectomy (ATL) induced milder memory deficits. Those were material-specific depending on whether the operation was carried out in the left speech dominant or the right non-dominant hemisphere. Thus, ATL in the left speech dominant hemisphere impaired learning and recall of verbal material, in opposition to right temporal resections, which had no effect on verbal memory but impaired retention of visual material. Indeed, Blakemore & Falconer from the Maudsley Hospital in London, showed deficits for an auditory paired-associative learning test in a pre- and postoperative study (Blakemore et al., 1967). At about the same time, Milner and Teuber (1968) reported that verbal memory deficits can also occur when the material is presented as a written word.

The first study measuring perception, recognition, and recall of visual and auditory patterns, was realized by one of Milner's students who showed deficits associated with lesions to the right TL (Kimura, 1961). In 1968, Milner discovered robust deficits for facial recognition and memory in right TLE patients (Milner, 1968, Milner, 2003 republished). In the following years, studies from pre- and postoperative patient groups were continuously being published, containing new findings and test methods that gradually became established as pre- and postoperative assessment tools.

2.3.2 Visual memory and the concept of material-specificity

At present, the model of material-specificity is the principal paradigm for pre- and postoperative cognitive measures in the context of epilepsy surgery. However, this requires that the judgement of right hemispheric dysfunctions results from a dissociation of verbal and visual memory skills. Therefore, visual memory should be regarded in comparison with verbal memory (Lee et al., 2000). As reported by (Saling, 2009), the material-specificity model follows two structural assumptions. The first, emphasizes that “verbal and non-verbal memory are unitary and internally homogenous constructs” (p. 571), meaning that either task, e.g. face recognition or visuospatial memory correlate, can be substituted with the other, and still represent the same module of visual memory. Equally, this hypothesis claims that the same brain lesions cannot affect two differentially unrelated visual memory tests differently. The second postulation is the “laterality/independence assumption” (p.571), which assumes that verbal and visual memory is sustained exclusively by a unilateral TL structure and is absent on the contralateral side.

Although the model of material-specificity is still a valid concept, evidence from neuropsychological studies is accumulating, suggesting a different clinical reality. This is because visual memory deficits due to right TL damage are not as frequently reported, neither pre- nor postoperatively (for review see, Barr, 1997, Vaz, 2004, Vannucci, 2007, Sherman et al., 2011).

2.3.3 Evidence from Wada and fMRI

The intracarotid sodium amobarbital procedure (ISAP) or Wada test involves the injection of sodium amytal into one of the cerebral hemispheres, leaving it thus anaesthetized for a limited amount of time. The test was first developed for studying the lateralization of language functions and was applied to the assessment of material-specific short-term memory to identify presurgical patients that could be at risk for global amnesia (Wada et al., 1960, Milner et al., 1962).

There are two theories concerning risk for deficits following a temporal lobectomy. The traditional model, called the “functional reserve” hypothesis, suggests that postsurgical

memory depends on the functional reserve of the contralateral TL. The “functional adequacy” hypothesis supposes that the postsurgical outcome would depend on the functional adequacy of the tissue resected, as reflected by preoperative neuropsychological memory scores, histologic cell densities and MRI volumetric measures (Chelune, 1995). The Wada test, is considered valid to predict loss of verbal material after left sided surgery, whereas there is generally no prediction for visual material among right TLE patients (e.g. Kneebone et al., 1995, Chiaravalloti et al., 2001, Yu et al., 2010).

Functional magnetic resonance imaging (fMRI) is a critical tool for studying the functional anatomy of the various memory processes. Some studies succeeded in showing material-specific activations in the right TL for visual material and the left TL for verbal (e.g. Golby et al., 2001, Golby et al., 2002, Powell et al., 2008). Others however showed a similar implication of left and right TL structures for visual memory (e.g. Glikmann-Johnston et al., 2008). The findings concerning the prediction of TL resections are comparable to investigations with the Wada test, in that there is an evident prediction of postoperative drop for verbal memory performance after left ATL. However, activation within the right hippocampus is still a less predictive method to determine the outcome of visual memory (Powell et al., 2008, Bonelli et al., 2010).

2.3.4 The factorial approach to visual memory

There are a significant number of clinical studies that have examined the factors affecting memory tests in TLE patients. Vannucci (2007) proposed that investigations of visual memory should be structured according to the hypothesis that multiple factors can have dynamic interactions and influence visual memory test performance. It is therefore pertinent to discuss and review these factors, which can differ individually in every patient. In epileptology those which are most referred to are functional and structural factors in addition to demographic and clinical variables as described by Elger et al. (2004). Furthermore, it is important to focus on the first assumption of the material-specificity model, that test quality does not influence performance, by comparing the effects of different test sub-processes.

2.3.4.1 Structural factors

Studies attempting to validate hippocampal volume and verbal memory show strong relationships between the two, though they are less consistent for visual memory (Sawrie et al., 2001, Mechanic-Hamilton et al., 2009). Other authors have questioned the implication of the hippocampal structures and measured the effects of neocortical defects on visual recognition memory. Hence, Baxendale (1997) showed that additional cortical dysplasia causes worse performances on the “Warrington Recognition Memory Test For Faces” (RMF), regardless of the side of lesion. Interesting information can also be derived from comparisons of pre- versus postoperative data and the effect of different surgery designs. Based on the available body of literature, it seems that verbal memory tends to significantly drop after left-sided surgery, whereas again the findings for right TLE resections are less consistent (for review see, Barr, 1997, Vaz, 2004, Vannucci, 2007, Sherman et al., 2011). A recent review assessing the reliable change index or standardized regression-based change estimate, instead of simple Analysis of Variance designs, reported that drops in visual memory following surgery are a reality in about 20% of the patients versus 44% for verbal memory for the left sided group (Sherman et al., 2011). In terms of the differential involvement of mesial versus lateral structures, Helmstaedter et al. (2008) compared the effects of selective amygdalohippocampectomy (sAHE) versus temporal pole resection with amygdalohippocampectomy (TPR+AHE) in seizure-free patients and found a double-dissociation concerning material-specificity. Verbal memory outcome was most affected after the sAHE procedure, suggesting that connections along the temporal stem between the temporal and frontal lobe are essential. In regards to figural memory, patients with TPR+AHE had the worst outcomes, which in agreement with Baxendale (1997) shows the importance of temporal neocortical structures for visual memory.

2.3.4.2 Functional factors

Ictal seizure activity and interictal epileptiform discharges

Interictal epileptiform discharges (IEDs) and ictal discharges are generated by different populations of neurons involving different cellular networks (Janszky et al., 2003). A seizure begins when a certain number of neurons synchronously depolarize. This depolarization shift lasts longer than a normal excitatory postsynaptic potential (100-200

ms vs. 10-16 ms) and corresponds to a train of action potentials that are conducted away from the soma along the axon of the neuron. This is followed by a large hyperpolarization, which serves to limit the duration of interictal paroxysms, and appears as an IED on the EEG. Therefore, IEDs have an inhibitory function versus the excitatory function of seizures (Holmes et al., 2006). Both these mechanisms are capable of causing cognitive impairment.

IEDs impact cognition in several ways, though most often affecting transient cognitive functions, such as attention for visual stimuli that forms the basis of higher cognitive processes (Aldenkamp et al., 2004b). Childhood epilepsies that are heavily impacted by centrotemporal spikes are sufficient to induce severe learning and memory impairment (Baglietto et al., 2001). In adults with TLE, it is acknowledged that IEDs alone are not enough to cause impairment, and are rather supplementary factors to ictal discharges (Aldenkamp et al., 2004a). However, it is important to note that in combination with seizures, IEDs have been found to significantly impair test performance on attention and visual learning in a postoperative patient sample, as reported by our group (Wisniewski et al., 2011). It is, though, possible that the neuropsychological disturbances attributed to IEDs are simply reflecting the severity of the underlying seizure disorders.

It is well established that focal epileptiform EEG discharges result in focal deficits, whereas generalized seizures can cause global cognitive impairment (Wilkus et al., 1976). As previously mentioned in Chapter 1, even if a focal seizure beginning in the mesial TL does not result in a secondary generalization, there is a high probability that it will propagate to the frontal and contralateral TL (Surges et al., 2012). Consequently, TLE patients may, in addition, have deficits in attention and executive functions (Helmstaedter et al., 2001a, Helmstaedter et al., 2003, McDonald et al., 2005, Wang et al., 2010). However, these auxiliary disturbances can be reversed with successful seizure control (Elger et al., 2004).

2.3.4.3 Demographical and clinical factors

Age at onset, duration of disease

Extensive clinical work has shown that severe focal deficits in childhood will remain in adulthood. However, within the context of neurocognition, it is possible that dysfunctions

in a specific area can be altered with the progression of brain development, (e.g. deficits in perception of the form or mental rotation can have negative effects on other higher order processes, such as calculation). It is therefore plausible that cognitive functions due to acquired early dysfunctions in childhood differ from deficits that are a consequence of irritational processes in adulthood (Mayer, 2011 (p.46-47)).

Unfortunately, neuropsychological studies covering the life-span of epileptic patients do not currently exist. Nevertheless, Helmstaedter et al. (2009a) recently published a large study of 1165 patients with chronic TLE contrasted with a healthy control group recruited over a period of 20 years, and calculated age-related regression, though only for verbal memory tasks. They found that patients did not sufficiently develop the ability to efficiently learn in childhood and adolescence, although the age-associated decline was parallel and not accelerated between the patients and the controls (Helmstaedter et al., 2009a). In a separate fMRI-based study, researchers demonstrated that for both verbal and nonverbal material, a longer duration of the disease was associated with a reduction of activity in both temporal lobes, though was more profound on the ipsilateral side to the seizure focus (Cheung et al., 2006). This change in metabolism is associated with shifts in the plasticity of cognitive functions, especially for language. For example, Wada test protocols or fMRI measures show that left TLE patients with chronic seizures display atypical language lateralization (Helmstaedter et al., 2004, Hamberger et al., 2011). Furthermore, adaptive functional brain reorganization for memory has been observed, specifically with early onset of the disease, in fMRI studies. A brain with mesial TLE can recruit structures contralateral to the epileptic focus, allowing the patient in certain cases to maintain functionally preserved memory (Janszky et al., 2004, Janszky et al., 2005, Figueiredo et al., 2008).

Gender

The literature indicates that healthy men and women process episodic memory differently. Generally speaking, women have an advantage in verbal and men in visual or visuospatial tasks (Herlitz et al., 2002). These changes in performance are associated with higher hippocampal activation on the left for women and on the right for men, during material specific fMRI tasks. Differences of functional recruitment of the two hemispheres need to be considered for TLE patients as well as for healthy control subjects (Banks et al., 2012). In a pre- and postoperative study, Helmstaedter et al. (2004) addressed specifically the

question of gender differences and showed that women had an advantage for verbal memory processing. With respect to figural memory, measured with the “Diagnosticum für Cerebralschädigung” (DCS-R) (Helmstaedter et al., 1991), no significant differences were found regarding left versus right TLE patients; however, when compared to men, women had poorer scores, regardless of the side of their lesions.

General cognitive functioning

An additional factor influencing memory test outcome is that mesial TLE is associated with lower general cognitive capacities across all domains: language, executive functions, motor speed and visuoconstructional skills, which can be expressed in terms of IQ and correlate with the age of disease onset (Hermann et al., 1997, Oyegbile et al., 2004, Helmstaedter, 2005). Helmstaedter (2005) found that 30% of patients from his centre showed an IQ score below 85. When he compared 31 mesial TLE patients with their siblings, 36% of the patients versus 7% of their siblings had an IQ of less than 85. Furthermore, the cognitive reserve hypothesis might be applicable to chronic TLE since patients with more years of education prior to the onset of epilepsy display a better overall mental status (Akman et al., 2003, Oyegbile et al., 2004).

2.3.4.4 Test validity

The term “validity” refers to the degree to which the intent of the test measurement is in accordance with the results (Franzen, 2000). Tests designed to assess localized memory deficits can create a confluence with other cognitive functions, thus requiring interactions with additional brain structures. For example, a free recall for a set of abstract patterns, without cuing the subject, raises the demands on working-memory based recall strategies (Baddeley, 2000). More specifically concerning visual memory, a person might be asked to reproduce visually abstract patterns, and a task that will additionally involve the motor and visuoconstructive skills (Barr et al., 1997). Within this context, two specific recuperation processes are distinguished based upon their auxiliary cognitive demands. Principle among these are recognition tasks, judged as “simpler” inasmuch as they require only that the subject decides whether a given stimulus was previously presented. There are a diverse number of test paradigms using recall, reproduction, or recognition memory tasks, any of which have the possibility of influencing the specific measurement of memory and

ultimately simulating failure. This is exemplified by cases in which minute details of a memory are encoded and stored; however, the capacity for its retrieval, specifically regarding relevant information, may be insufficient. This is especially true for a visual memory task that has high demands on other functions (Luck et al., 2008).

In 1997, Barr grouped tasks routinely used in clinical practice into “figural reproduction” and “figural learning”. In two studies, he was able to isolate and examine the two test groups’ respective validities, with the first involving reproduction, and the second including a learning curve, free recall and recognition trial (Barr, 1997, Barr et al., 1997). As a result of the publication, involving multiple medical centres, Barr and others concluded that figural reproduction tests, such as the Wechsler Memory Scale (WMS) or Rey-Osterrieth-Complex-Figure test (ROCF) were not appropriate for preoperative lateralization diagnostics (Loring et al., 1988, Barr et al., 1997, Raspall et al., 2005, Frank et al., 2008, Schouten et al., 2009, Tudesco Ide et al., 2010). Furthermore, additional figural reproduction measures including “Benton Visual Retention Test” (BVRT) had no diagnostic utility. An earlier study by Helmstaedter et al. (1995) found that although figural reproduction difficulties for the BVRT were highly evident in right TLE patients, these patients succeeded in compensating with verbalization strategies.

Consequently, learning tasks, the nonverbal pendants of verbal list learning models, were suggested by Barr et al. (1997) as more appropriate tools for assessment. However, through examination of previous test validation studies, a number of difficulties and controversies continue to arise. The “Brief Visuospatial Memory Test-Revised” (BVMT-R), is a figural learning task requiring the retention of geometric designs to be reproduced via drawing immediately following each trial. Once an interval of 30 minutes has passed, a delayed recall is asked, followed by a recognition trial. This test was reported as being unable to discriminate between the left and right preoperative TLE patients (Barr et al., 2004). The “Diagnosticum für Cerebralschädigung” (DCS) is a complex figure list learning and recall task where the subject is required to construct a variety of objects using wooden sticks. Although it was shown to be a sensitive instrument for right mesial TL dysfunction (Helmstaedter et al., 1991, Gleissner et al., 1998), more precise examination of their study on 28 pre- and post-surgical candidates, shows that Gleissner et al. (1998) did not compare right and left TL epilepsies to one another. In addition, further investigations of this test failed to show any lateralizing effects (Gleissner et al., 2002, Lutz et al., 2004).

Moreover, there do not seem to be differences concerning the diagnostic utility of spatial versus pictorial stimuli. However, one exception is the “Brown Location Test”, which requires the subject to learn the spatial location of dots. One study found that right TLE patients who received ATL performed significantly worse (Brown et al., 2010), whereas other spatial tasks, such as the “Ruff-Light Trail Learning Test”, showed that left TLE patients scored worse (Araujo et al., 2009). Concerning, the “Verbaler und Visueller Merkfähigkeits-test” (VVM), known as the VVM-path which requires the subject to reproduce a trail, to date only one abstract has been published indicating sensitivity for right TL dysfunction (Quiske et al., 2000). Furthermore, there exists the Corsi-Block-Tapping task a spatial task that does not pass a statistical trend for lateralization (Tudesco Ide et al., 2010).

Snitz et al. (1996) identified an important confounding variable for visual memory tests; overall cognitive performance, and specifically visual-perceptive processing, were positively correlated with test failure in both groups of TLE patients. Within this framework, Jones-Gotman reported that while right TLE patients have difficulties learning and recalling the “Abstract Design List” (ADL), they succeed in remembering the information they have learned (Jones-Gotman et al., 1997). Since learning and recalling visual material seems to be difficult for left TLE patients as well, recent evidence suggests that performance on recognition trials is better in left TLE patients, specifically with the “Visual Paired-Associate Learning”, which uses pairs of abstract designs (Smith et al., 2011), and the “Biber Figure Learning Test-Extended” (BFLT-E), which is sensitive to visuoconstruction (Glosser et al., 2002).

The category of recognition memory tasks most commonly includes face stimuli, in forced-choice patterns. Frequently, findings are reported for the “Warrington Recognition Memory Test For Faces” (RMF) given its widespread use. However, its diagnostic utility for preoperative epilepsy patients is controversial due to data showing it to be non-sensitive, with material-specific deficits appearing only for postoperative groups (Hermann, 1995, Baxendale, 1997). The advantage of this test is that the correlation with IQ levels is low, and completely encompasses the visuoconstructional skills (Testa et al., 2004). Comparable results were reported for the “Wechsler Memory Scale-III (WMS-III) Faces Subtest” and the “Graduate Hospital Facial Memory Test” (FMT), both of which can differentiate the side of a hippocampal lesion in a postoperative group (Chiaravalloti et al.,

2004). Recently, psychologists at the Epilepsy Centre in Hamburg, Germany, developed the “Alsterdorfer Faces Test” based upon the principles of recognition. Using this test, they observed that performance in right TLE patients in comparison with the left TLE group dropped significantly, but only when the assessment took place 24 hours after the encoding session. This means that measuring accelerated forgetting may be helpful with the diagnosis (Bengner et al., 2006, Bengner et al., 2010). Surprisingly, these conclusions are contrary to the initial experiments of Milner (1968). Milner indicated that her right TLE group, though performing worse on immediate and delayed facial recognition than controls, did not show accelerated forgetting on the task. Additionally, these differences were due to healthy participants achieving better results on the delay because of their increased ability to reconsolidate and recode visual representations (Milner, 1968). However, two recognition memory tasks, both demanding the immediate recognition with different stimuli, the “Three-Dimensional Objects” for visuospatial memory (Hampstead et al., 2010) and the colored photographs of doors from the “Doors and People Tests” (Morris et al., 1995) were shown to lateralize right TLE dysfunctions.

In summary, visual memory performance in TLE depends on several interacting clinical and demographic factors, such as the structural pathology of the brain, the ictal seizure activity propagation patterns, their frequency, the presence of IEDs, the age at onset and duration of the disease, gender, and the overall effects of the antiepileptic drugs either with mono- or polytherapy. This dynamically affects the general cognitive functioning of the patient and their capacity to process memory tasks. Clinical studies tend to acknowledge visual recognition memory tasks as more useful for assessment than figural reproduction or figural learning tasks. Concerning the validity of established memory tests to lateralize epileptogenic foci, publications exist that generally focus on a single task but do not compare several tasks within a patient group.

Part II:

Research Projects

Experimental Introduction

The following three chapters encompass the experimental work that was performed at the Kork Epilepsy Centre. Healthy control data was collected in the surrounding geographic area. The experiments are separated into three distinct articles.

Chapter 3

Visuo-spatial memory tests in right temporal lobe epilepsy foci: clinical validity.
Wisniewski I, Wendling AS, Manning L, Steinhoff BJ. *Epilepsy & Behavior* 2012, 23(3):254-60.

This study compared four established learning and reproduction visuo-spatial memory tests in the same patient population in order to inspect their validity for identifying right mesial temporal lobe dysfunction. Clinical, demographic variables and cognitive factors were considered.

Chapter 4

The importance of the DMS-48 as a visual recognition memory task for cognitive epilepsy evaluation.

Wisniewski I, Wendling AS, Westermann C, Manning L, Steinhoff BJ. *In submission*.

The aim of this study was to develop a new testing paradigm for lateralizing right hippocampal dysfunction during preoperative evaluations as well as for postoperative follow-ups. The first part applied the Delayed Matching to Sample (DMS-48) task, previously established in the detection of mild cognitive impairment in early onset Alzheimer's disease. Additionally, normative values of 172 healthy control subjects were collected using two parallel versions designed by the authors for use in the neuropsychological battery in epilepsy patients. The third part applied these new parallel versions to patient populations that had received surgery 3 or 12 months prior.

Chapter 5


Visuoperceptual and visuospatial abilities prior to and after anterior temporal lobectomy: a case study.

Wisniewski I, Staack AM, Bilic S, Manning L. *Epilepsy & Behavior* 2012, 23(1):74-8.

The third experimental study involved an extensive neuropsychological case study of a patient with right hippocampal sclerosis that presented a seizure onset pattern in the right temporo-occipital area preoperatively, which subsided following an ATL. The evaluation sought to study the relationship of visual memory, perception, and imagery for objects and space with temporal lobe dysfunction, and in what way these functions can be affected by surgical procedures.

Chapter 3

Visuo-spatial memory tests in right temporal lobe epilepsy foci: clinical validity



Visuo-spatial memory tests in right temporal lobe epilepsy foci: Clinical validity

Ilona Wisniewski^{a,b}, Anne-Sophie Wendling^a, Lilianne Manning^b, Bernhard J. Steinhoff^{a,*}

^a Epilepsiezentrum Kork, Germany

^b Laboratory of Imaging and Cognitive Neurosciences (CNRS, UMR 7237, IFR 037) and University of Strasbourg, France

ARTICLE INFO

Article history:

Received 15 August 2011

Revised 9 November 2011

Accepted 13 December 2011

Available online 16 February 2012

Keywords:

Epilepsy
Temporal lobe
Memory
Tests
Lateralization
Sensitivity

ABSTRACT

Objective: To examine the appropriateness of visual memory tests as an identification method for right mesial temporal lobe dysfunctions in an epilepsy patient group and to study the relationship and possible overlap with non-memory cognitive domains and demographic variables.

Methods: Eighty preoperative candidates with mesial temporal lobe epilepsy (TLE) were examined using the “Corsi Block-Tapping Test”, “Diagnosticum für Cerebralschädigung” (DCS), the path subtest of the “Verbaler und Visueller Merkfähigkeitstest” (VVM), and the Rey-Osterrieth Complex Figure Test (ROCF). Factorial analyses were performed on raw scores to determine the effect of epilepsy-related variables, interictal epileptiform discharges (IEDs) and presence of cortical dysgenesis, on visual and verbal memory parameters. Sensitivity, specificity and Receiver Operating Characteristic (ROC) curves were calculated based on normative data. Furthermore, Spearman correlations between memory and non-memory cognitive tasks were performed.

Results: The scores for test sensitivity and specificity and the ROC curves illustrate the tests' poor capacity to lateralize the functional deficit zone even when epilepsy-related factors, such as cortical dysgenesis or presence of contralateral IEDs were controlled. Significant correlations were found between the visual memory measures and nonverbal reasoning, processing speed, attentional flexibility, and visual planning.

Conclusion: These neuropsychological tests are not sensitive enough to lateralize the epileptogenic focus in temporal lobe epilepsy patients since in addition to learning and consolidation processes, they measure additional cognitive domains. These results have implications for clinical neuropsychologists, in terms of test choice and the interpretation in the context of presurgical diagnostics.

© 2011 Elsevier Inc. All rights reserved.

1. Introduction

The most common form of drug-resistant epilepsies emerges from the mesial temporal lobe (TL) and two thirds of surgical procedures performed to eliminate seizures consist of resectioning hippocampal or medial temporal structures [1]. Since Scoville and Milner's pioneering work [2] that reported severe memory loss in a patient who underwent a bilateral temporal lobectomy, neuropsychologists who specialize in identifying memory deficits have become indispensable in most epilepsy centers. Currently, neuropsychological assessments provide accessory diagnostic information, despite the use of more and more advanced neuroimaging technology. This is particularly the case regarding the localization and lateralization of epilepsy-associated cognitive impairment and prediction of risk for postoperative cognitive loss [3,4]. When focal deficits become manifest during the neuropsychological examination, they usually reflect dysfunctions caused at least partially by epileptic activity. If there is concordance between neuropsychological findings and the results of other

diagnostic techniques such as EEG or MRI, this gives confidence for precise localization of the epileptogenic zone and a favorable postoperative outcome. Conversely, discordance between neuropsychological results and other diagnostic approaches usually indicates that further considerations are required given the potential of consequences for the patient's postoperative quality of life and seizure [5]. The established neuropsychological approach is to lateralize and localize the functional deficit zone via examination of material-specific dissociations between performances on verbal and non-verbal tasks, such as visual/visuo-spatial tests [6]. The concept of material-specific memory impairment has been influential for TL epileptology, since it was introduced [7]. It supposes that if language dominance is located in the left hemisphere, left TL regions are specialized in verbal memory (VerbM) and the right TL in visual/visuo-spatial memory (VisM). Interestingly, VisM deficits as a consequence of right-sided lesions have been reported less consistently in the last few decades than VerbM deficits in left temporal lobe epilepsy (TLE) cases and thus the theory of material-specificity has been questioned [8,9]. It was proposed that VisM may be dependent on both right and left mesial TL integrity, which was supported by quantitative hippocampal studies as well as some fMRI experiments [10,11]. However, several authors continue to support the theory of material-

* Corresponding author at: Epilepsiezentrum Kork, Landstrasse 1, 77694 Kehl-Kork, Germany. Fax: +49 7851842555.

E-mail address: bsteinhoff@epilepsiezentrum.de (B.J. Steinhoff).

specificity. For example Coleshill et al. [12] and Golby et al. [13] reported that the results of electrical stimulation of the hippocampus and of fMRI studies, respectively, favored the concept of material-specificity.

The controversy may arise from methodological issues. There is a strong suspicion indicating that the measures being utilized may not adequately assess VisM function in epilepsy patients [14]. For example, Helmstaedter et al. [15], postulated that left hemisphere verbalization strategies can be a confounding factor when evaluating right TL structures. Equally, sporadic studies have shown that memory test performance can be influenced by constructional abilities [14], as well as attention factors and executive functions [16]. Impairment of the above-mentioned functions is a common consequence of TLE disorders [17]. Another bias can be the several interacting variables that characterize the cognitive profile in TLE such as the underlying structural damage, seizure frequency, antiepileptic drugs (AEDs), interictal epileptiform discharges (IEDs) and duration of epilepsy [18–20]. Moreover, an association between an early onset of epilepsy with lower cognitive functioning is well-known [21]. However, little is understood about test deviations due to IQ variations that occur in the normative range. Recently, Witt and Helmstaedter [4] reported that only 25% of tests used in German-speaking epilepsy centers were evidence-based and therefore promote the accumulation of knowledge on already established tests. In order to contribute to this discussion, we sought to compare VisM tests in the same patient group to evaluate their validity in assessing visuo-spatial memory function in right TLE patients from an anatomic–clinical perspective. Since lateralization of epileptic foci is based on the dissociation with VerbM, these measures were equally included in our analysis. The four VisM measurements that are routinely and pragmatically used in our epilepsy center comprised the “Diagnosticum für Cerebralschädigung” (DCS) [22], the “Rey-Osterrieth Complex Figure Test” (ROCF) [23], a visuo-spatial subtest of the broader “Verbaler und Visueller Merkfähigkeitstest” (VVM), known as the VVM-path [24] and a subtest from the “Wechsler Memory Scale-Revised” (WMS-R) [25], the Corsi Block-Tapping Test. VerbM was assessed with the VLMT [26] and VVM-building [24]. We compared these tests’ capacity to identify right versus left mesial TL dysfunctions in a patient group, who, according to the presurgical diagnostic work-up, had a clear diagnosis of unilateral TLE. More precisely, we aimed to study the sensitivity and specificity for each test. In addition, we expected non-memory cognitive domains such as processing speed, visual planning, IQ, and the age at epilepsy onset/duration of disease, to correlate with memory performance and thus affect the test validity and we therefore measured the impact of these variables on the test procedures. Finally, epilepsy-related factors were hypothesized to influence neuropsychological outcome.

2. Methods

2.1. Patients

The cohort was composed of 80 symptomatic TLE patients who underwent preoperative diagnostics at the Kork Epilepsy Centre, Germany. Criteria for inclusion were unilateral hippocampal atrophy/sclerosis on 1.5 Tesla MRI scans; though some patients presented with additional unilateral white matter blurring or dysplasia to the temporal pole (for distribution view Table 1). The MRI results were given by our neuroradiologists and confirmed by a second investigator. A further point was a seizure onset in the TL of the same hemisphere, identified using a prolonged video EEG. Presence of contralateral IEDs was taken into account for the analyses and classified as follows. (A) Patients without IEDs contralateral to the seizure onset. (B) Patients with less than 10% of contralateral IEDs and group (C) had 10–30% of contralateral IEDs. The cohort included 38 patients with left TLE and 42 with right TLE. All patients were native German speakers with an IQ > 80. A subset

Table 1
Demographic and clinical characteristics.

| N = 80 | lTLE | rTLE | Student-t/chi square |
|-------------------------------|------------------------------------|------------------------------------|-----------------------|
| Gender (male/female), n | 19/19 | 10/32 | p = 0.01 ^a |
| Age (years) | $\mu = 42.97$ ($\sigma = 10.44$) | $\mu = 42.04$ ($\sigma = 11.96$) | n.s. ^b |
| Age (years) at epilepsy onset | $\mu = 17.45$ ($\sigma = 16.07$) | $\mu = 17.78$ ($\sigma = 12.95$) | n.s. ^b |
| Duration of disease (years) | $\mu = 25.94$ ($\sigma = 15.07$) | $\mu = 23.45$ ($\sigma = 13.53$) | n.s. ^b |
| Monthly seizure frequency | $\mu = 6.75$ ($\sigma = 6.37$) | $\mu = 7.78$ ($\sigma = 6.53$) | n.s. ^b |
| Lesion | | | |
| HS/A | 16 | 18 | |
| HS/A + WMB | 12 | 8 | |
| HS/A + TPD | 10 | 16 | |
| IEDs A/B/C, n | 18/12/8 | 19/16/7 | |
| Drugs | $\mu = 1.4$ ($\sigma = 0.74$) | $\mu = 1.5$ ($\sigma = 0.55$) | n.s. ^b |
| Years of education | $\mu = 12.91$ ($\sigma = 1.74$) | $\mu = 12.42$ ($\sigma = 2.2$) | n.s. ^b |

lTLE: patients with left temporal lobe epilepsy; rTLE: patients with right temporal lobe epilepsy; μ : mean; σ : standard deviation; HS/A: hippocampal sclerosis/atrophy; HS/A + WMB: hippocampal sclerosis/atrophy + white matter blurring; HS/A + TPD: hippocampal sclerosis/atrophy + temporal pole dysplasia.

^a Chi-square.

^b Student t-test.

of the left TLE cohort (n = 36) was controlled for language lateralization via fMRI. None of the included patients showed atypical language lateralization. For the remaining 44 patients, all were right handed, and no fMRI examination was available. In these cases, the presence or absence of postictal speech was controlled. In all of the left TLE patients, a sustained postictal dysphasic period had been documented between the termination of the seizure and the onset of speech. Conversely, the right TLE group showed no difficulties. The demographic and clinical characteristics controlled for variation between the two patient subgroups (left vs. right) are presented in Table 1.

2.2. Neuropsychological assessment

Testing was performed under stable medical conditions, meaning that at least 12 h had passed since the last seizure. All patients received the full cognitive battery used for preoperative surgery assessment at the Kork Epilepsy Centre, Germany. Assessment was performed during several days within a period of approximately 1 week with no more than one memory test given at each session. In addition to the memory tests described below, additional cognitive domains were collected for analysis. Intellectual capacity was measured using premorbid verbal IQ estimation, specifically the MWT-B [27] and a tool for nonverbal intelligence, the Raven’s Progressive Matrices [28]. To determine processing speed and attention, several tests were presented: the Trail Making Test A and B/A which reflects processing speed and attentional flexibility [29], as well as two subtests of the Attention Test Battery [TAP 1.7; 30], the subtests Go/No-go and Incompatibility, which assess selective attention and the aptitude to suppress inadequate reactions to irrelevant stimuli. Furthermore, the concept of visual planning/visuoconstruction was elucidated using the Labyrinth-Test [31], which requires the subject to predict an exit path. To examine more precisely the patient’s visuoconstructive capacities, the Block Design test from the revised version of the Wechsler Adult Intelligence Scale [WAIS-R; 32] and the copy of the ROCF were administered.

2.2.1. VisM tests

2.2.1.1. “Diagnosticum für Cerebralschädigung” (DCS). The most commonly used measurement is based on a concept from Gestalt psychology,

involving the interaction of selective attention and shape perception as a condition for memory performance. Normative data are available for three distinctive age groups (19–39 ($n = 199$), 40–59 ($n = 82$), 60–79 ($n = 49$)), and for three education levels. The patient is shown nine hand-drawn geometric figures in succession, composed of five black lines on a white background. The examinees are then told to memorize and reproduce as many as they can with five wooden sticks, after all figures are presented. The learning period ends either when the subject has reproduced all nine items or after the sixth learning trial has been carried out. The primary variable (DCS 1–6) represents the total number of figures correctly produced during trials 1 to 6, and reflects figure recall.

2.2.1.2. “Rey-Osterrieth Complex Figure Test” (ROCF). This test was originally developed as a way to differentiate between difficulties with perception and memory. It begins with copying the figure. The subject is not told to memorize, but to draw it completely and avoid any missing parts. The patient starts using only one colored pencil, and after a few elements, he/she is given two additional, different colors. This is followed by an immediate recall using only one pencil. Scores were determined using the Osterrieth procedure [33], which divides the figure into 18 possible elements and provides norms based on a mixed sample between 4 and 60 years from different, not closer specified social backgrounds. The first variable (ROCF-copy) reflects visuo-constructive skills and the second variable (ROCF-reproduction) represents the immediate figure reproduction.

2.2.1.3. “Verbaler und Visueller Merkfähigkeitstest” (VVM): VVM-path. The VVM-path involves recalling a sketched path superimposed over a street map, both immediately following presentation and again after 2 h. The more closely the paths resemble the original, the higher the point-value. Thus, the variables used for analysis assess the performance of the acquisition (VVM-path T1) and the consolidation processes of visuo-spatial long-term memory (VVM-path T2). Normative data exist for four age groups (15–19 ($n = 256$), 20–29 ($n = 343$), 30–59 ($n = 277$), 60–75 ($n = 34$)), and four education levels. No effect of gender was found.

2.2.1.4. “Corsi Block-Tapping Test” from WMS-R. This test is designed to assess the memory span. Normative data included 30 subjects per age group (15–19, 20–25, 26–34, 35–44, 45–54, 55–64, 65–74). The task begins with the examiner tapping a specific sequence of blocks and asking the examinee to mimic the pattern, which increases in length with each correctly completed trial. It concludes when the examinee fails to complete the same sequence twice. The total number of points received for each subset was taken as variables for spatial short-term memory (Corsi-forward).

2.2.2. VerbM tests

2.2.2.1. “Verbaler Lern und Merkfähigkeitstest” (VLMT). The German equivalent of the RAVLT has normative data for three age groups (15–29 ($n = 139$), 30–49 ($n = 89$), >49 ($n = 53$)). The norms were not controlled for years of education and gender. A list of fifteen semantically independent nouns is read aloud by the examiner, each trial followed by a free recall test (VLMT Dg1–Dg5). In a further test phase a second list of 15 nouns is read once for interference. The direct recall of list B is instantly followed by a free recall of list A without further presentation of the list. After an interval of thirty minutes the subject is requested again to recall the words from list A (VLMT Dg7).

2.2.2.2. “Verbaler und Visueller Merkfähigkeitstest” (VVM): VVM-building. During the VVM-building, the examinee is asked to read a short story under time limit and to answer questions concerning the content shortly after presentation (VVM-building T1) and again after 2 h (VVM-building T2). Normative data are the same as for VVM-path.

2.3. Statistical analysis

Statistical analysis was achieved using Statistica (Statsoft®, version 8.0). The possible effect of the secondary variable gender on memory was controlled for using one-way ANOVA that did not show significant differences. Equally, the effect of side of hippocampal atrophy/sclerosis (left and right) on the “additional cognitive domains” (described above), was controlled using several one-way analyses of variance. These analyses showed no significant differences. For all the aforementioned tests, except for measures of reaction time (i.e., TAP 1.7 and Trail Making Test), the higher the score, the better the performance. For the VerbM and VisM parameters, factorial ANOVAs were calculated with the side of hippocampal atrophy/sclerosis (left vs. right TLE), extent of pathology (hippocampal sclerosis/atrophy vs. additional temporal pole abnormalities), and IEDs (groups A, B, C) as the independent variables and the memory test scores as dependent variables. $p < 0.05$ was taken as statistically significant. $p < 0.1$ was taken as a trend. Since the factorial ANOVA showed no significant effects, the hypothesis was deconstructed for each independent variable using several one-way ANOVAs. In order to analyze the sensitivity and specificity of the memory parameters (Corsi-forward, Rey-reproduction, VVM-path T1 and T2, DCS 1–6, VVM-building T1 and T2, VLMT Dg1–5, VLMT Dg7) the normative percentage values were transformed to binary values. For every patient the score of 16 was used, after the usual recommendations for clinical neuropsychologists [34]. A value <16 indicated test failure and >16 indicated preservation. Furthermore, sensitivity for the VisM was obtained by dividing the number of right TLE patients with deficient scores by the total number of right TLE patients. Specificity was calculated by dividing the number of left TLE patients with preserved score by the total number of left TLE patients. The percentage of correctly classified patients was obtained by adding the sum of left TLE patients with preserved score to the sum of right TLE patient with a deficient score and dividing it by the total number of assessed patients. (To obtain numbers for VerbM tests, substitute left by right TLE and vice versa, in the description above.) A ROC curve, the sensitivity plotted in function of the specificity rate for different cut-off parameters based on the normative values was obtained with MedCal®. The areas under the curve (AUC) measure how well the memory test parameters can distinguish between left and right TLE. To determine whether multiple test failures were related to the side of lesion a Mann–Whitney U test was performed. With side of lesion as the independent (grouping) variable, the number of tests failed (ranked 1–5) was the dependent variable.

Spearman correlations were calculated using Statistica between the VerbM and VisM test variables, and between memory variables and the following functions: IQ, visual planning, processing speed/attention and the clinical and demographic variables. The probability significance was accounted for using a Bonferroni adjustment, yielding a new value of $p < 0.006$.

3. Results

3.1. ANOVA: Effects of side of hippocampal atrophy/sclerosis (right versus left TLE), presence or absence of contralateral IEDs to the side of lesion, and the extent of pathology (hippocampal sclerosis/atrophy vs. additional temporal pole abnormalities)

No interaction effects were obtained for the side of hippocampal atrophy/sclerosis, presence or absence of contralateral IEDs to the side of lesion, and the extent of pathology. Therefore, several one-way ANOVAs were performed, with the following group-differences.

Only one effect for the variable hippocampal atrophy/sclerosis was found for VLMT Dg1–Dg5 ($F = 4, 83, p = 0.03$); and VLMT Dg7 ($F = 8, 83, p = 0.003$). LTE patients learned significantly less words than RTE patients and showed a decrease in the delayed recall, independently from the other variables. No effects for the side of hippocampal lesion

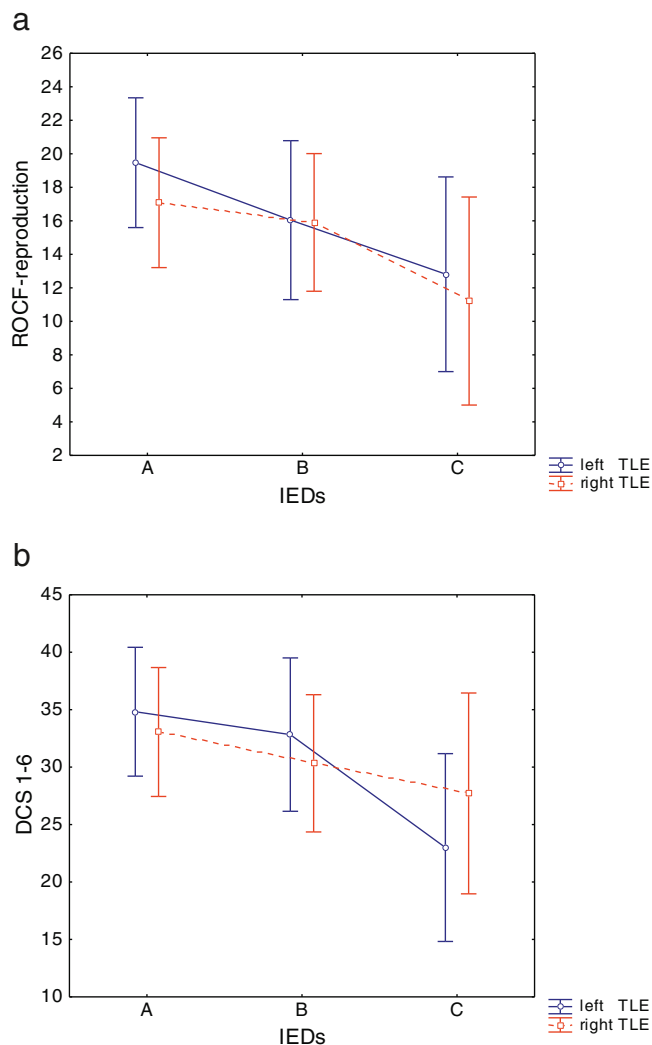


Fig. 1. a. Effects of contralateral IEDs on ROCF-reproduction. b. Effects of contralateral IEDs on DCS 1–6. The graphs represent (A) patients without IEDs contralateral to the seizure onset; (B) patients with less than 10% of contralateral IEDs (C) patients with 10–30% of contralateral IEDs.

were found for the VisM parameters and for VVM-building T1 and T2. The extent of pathology showed a trend for Corsi-forward ($F=2, 59, p=0.059$). Patients with additional damage to the temporal pole tended to perform worse on the Corsi-forward than the other groups. The contralateral presence of IEDs did not influence the VerbM measures. For the VisM test, a main effect was found for ROCF-reproduction ($F=3.07, p=0.05$) and a trend for DCS 1–6 ($F=2.84, p=0.06$). The performance on the tasks decreased in patients with presence of IEDs contralateral to TL, no difference depending on the side of lesion was obtained (Figs. 1a and b).

3.2. Sensitivity and specificity of the memory parameters and Receiver Operating Characteristic (ROC) curve

The scores for test sensitivity and specificity based on the recommended normative values as well as the percentage of correctly classified patients (Table 2) illustrate the test's poor capacity to lateralize the epileptic zone.

For VisM, chi-square calculation did not show any significant differences except for Corsi-forward that classified 62.5% of patients correctly. For VerbM, the VLMT Dg7 reached significance. The ROC curves for VisM are presented in Fig. 2a and for VerbM in Fig. 2b respectively. VLMT Dg7 reached the largest AUC, and the other AUC calculations and the cut-off parameters reflecting the highest concordance of sensitivity and specificity in this specific ROC curve are presented in Table 3.

3.3. Multiple test failures

The Mann–Whitney *U* test indicated that there was a trend for RTLE patients to fail multiple VisM tests ($U=628.5, p<0.10$).

3.4. Correlations: VisM and other parameters

Correlations between the memory parameters and other cognitive domains, as well as demographic variables, are shown in Table 4. All VerbM measures, except the 30-minute delayed word list recall VLMT Dg7, correlated positively with the verbal and nonverbal IQ estimation. VVM-building T1 and T2 correlated negatively with the processing speed from the Go/No go measure. All VisM parameters correlated positively with the domain visual planning/construction and the nonverbal IQ. Only VVM-path T1 correlated additionally with the verbal IQ. Negative correlations with the Trail Making Test

Table 2
Sensitivity and specificity of VerbM and VisM tests for TLE sample (N=80).

| Test | Side | Preserved, n | Deficient, n | Sensitivity | Specificity | % Classified | Chi-square |
|---------------|------|--------------|--------------|-------------|-------------|--------------|-----------------|
| DCS 1–6 | L | 21 | 17 | 50 | 55.3 | 52.5 | $p=0.64$ (n.s.) |
| | R | 21 | 21 | | | | |
| ROCF-rep. | L | 22 | 16 | 45.2 | 57.9 | 56.3 | $p=0.26$ (n.s.) |
| | R | 19 | 23 | | | | |
| VVM path-T1 | L | 30 | 8 | 64.3 | 79 | 56.3 | $p=0.15$ (n.s.) |
| | R | 27 | 15 | | | | |
| VVM path-T2 | L | 23 | 15 | 59.5 | 60.5 | 50 | $p=0.92$ (n.s.) |
| | R | 25 | 17 | | | | |
| Corsi-forward | L | 25 | 13 | 40.5 | 65.8 | 62.5 | $p=0.02^*$ |
| | R | 17 | 25 | | | | |
| VVM build-T1 | L | 16 | 22 | 57.8 | 47.6 | 52.5 | $p=0.26$ (n.s.) |
| | R | 20 | 22 | | | | |
| VVM build-T2 | L | 13 | 25 | 65.7 | 47.6 | 56.2 | $p=0.22$ (n.s.) |
| | R | 20 | 22 | | | | |
| VLMT Dg1–5 | L | 27 | 11 | 28.9 | 80.9 | 56.2 | $p=0.29$ (n.s.) |
| | R | 34 | 8 | | | | |
| VLMT Dg7 | L | 21 | 17 | 44.7 | 86 | 66.2 | $p=0.002^*$ |
| | R | 36 | 6 | | | | |

Presented are preserved and deficient effective numbers for the tasks. L stands for the left and R for the right hemisphere. n.s. stands for not significant chi-square measures.
* Significant at $p<0.05$.

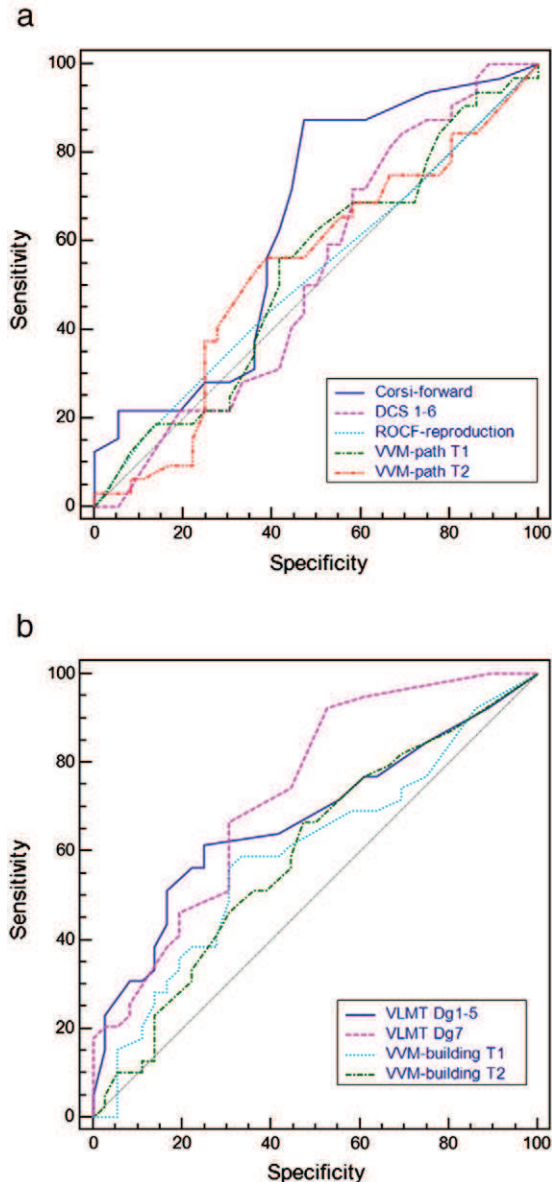


Fig. 2. a. ROC curve for VisM. b. ROC curve for VerbM. The ROC curves reflect the sensitivity specificity ratio for the VisM tests.

were obtained for Corsi-forward and DCS 1–6. The duration of epilepsy correlated negatively with only VVM-path T2.

3.5. Correlations: VisM and VerbM

The short-term memory measure Corsi-forward was uniquely correlated to the VVM-path T1. Other VisM tests showed positive inter-correlations. VerbM measures were correlated as well (Table 5). DCS 1–6 was strongly correlated with all VerbM measures and VVM-path T1 was correlated to the verbal encoding parameters (VLMT Dg1–5, VVM-building T1).

4. Discussion

This study simultaneously assessed VisM and VerbM test validity in the same patient sample. Since there is no consensus concerning the lateralizing capacity of the neuropsychological tests that address VisM in right TLE for the time being [35,36], these results have implications for clinical neuropsychologists, for test choice and interpretation in the context of presurgical diagnostics.

In accordance with the literature, the VerbM measures “VLMT Dg1–5/Dg7” were significantly lower in left TLE patients [35,37,38], and the “VVM-building T1/T2” did not show any differences between the patient groups. Strong negative correlations were found between processing speed and the recall, thus we hypothesize that this time constraint measure does not adequately assess a patient population that might present reduced reaction times [39]. Sensitivity and specificity outcomes were not significant for learning trial “VLMT Dg1–5”, although a significant main effect of the raw scores existed, possibly reflecting a bias in the normative data. An ANOVA did not show any significant effects for VisM and a statistical comparison of sensitivity and specificity only showed an effect for “Corsi-forward” from the WMS-R. Furthermore when a ROC curve analysis based on normative scores was performed, the results showed poor AUCs for VisM and for the “VVM-building T1/T2”. The cut off scores based on the ROC analysis varied from the commonly accepted percentile score of 16. This can be informative for clinical interpretation, but is not crucial in tests with low AUCs. At least two studies have shown the revised form of the DCS (DCS-R) to be a sensitive instrument for right mesial TL dysfunction [40,41]. However, in their study of 28 pre- and post-surgical candidates, Gleissner et al. [40] did not compare right and left TL epilepsies to each other. Conversely, more recent comparisons of pre- and postsurgical patients were consistent with our findings and did not show any effects for the DCS-R with regard to its lateralizing effect [35,37]. More precisely, Gleissner et al. [37] found the DCS-R memory performance to be slightly impaired in both preoperative groups (left and right), with no apparent side-specific postoperative differences. For the ROCF the results are broadly coherent with several studies that used diverse scoring systems. Overall, no lateralizing effect was found for the quantitative 36-point system that we and others used [36,42–47]. Nevertheless, the findings of Loring et al. [45], which were then verified by Frank et al. [43], showed that the use of a qualitative scoring system revealed that right TLE patients are more likely to commit a higher number of spatial-relational errors than patients with left-sided foci.

In our sample, the “VVM-path T1” showed good specificity (79%), though with a two-hour delay, the left TLE patient group showed accelerated forgetting (60.5%). Our results suggest a poorer lateralizing validity contrary to the only published sensitivity and specificity study by Quiske et al. [48] who classified 75% of patients (vs. our 56.3%) correctly. Nonetheless, these authors did not find an effect related to the lesion side when a t-test was performed on the raw scores. Concerning the Corsi Block-Tapping Test, raw scores did not differ in regards to seizure-onset location. This absence of effect is consistent with a previous group study of 80 pre-surgical candidates [35], as well as a transcranial magnetic stimulation study of the temporal lobes that failed to find a lateralizing effect for a computerized Corsi Block Test [49]. However, other authors reported a statistical trend ($p = 0.06$) in a smaller group of 39 mesial TLE patients [36].

Table 3
AUC and the cut-off parameters for memory.

| | AUC | Cut-off score |
|-------------------|-------|---------------|
| VerbM | | |
| VLMT Dg1–5 | 0.673 | 35 |
| VLMT Dg7 | 0.736 | 10 |
| VVM-building T1 | 0.597 | 18 |
| VVM-building T2 | 0.596 | 9 |
| VisM | | |
| Corsi-forward | 0.640 | 10 |
| DCS 1–6 | 0.517 | 25 |
| ROCF-reproduction | 0.535 | 16 |
| VVM-path T1 | 0.542 | 23 |
| VVM-path T2 | 0.544 | 29 |

AUC represents area under the curve.

Table 4
Spearman correlations of memory vs. other cognitive domains/demographics.

| | Visual planning/construction | | IQ | | | Processing speed/attention | | Demographics |
|-----------------|------------------------------|-----------|--------|--------|--------|----------------------------|----------|--------------|
| | Labyrinth | ROCF-copy | Cubes | MWT-B | Raven | Trail | Go/No go | Duration |
| DCS 1–6 | | | 0.331* | | 0.439* | –0.395* | | |
| ROCF-rep. | 0.364* | 0.378* | | | 0.496* | | | |
| VVM-path T1 | | 0.394* | 0.394* | 0.348* | 0.396* | | | |
| VVM-path T2 | | 0.413* | 0.451* | | 0.414* | | | –0.294* |
| Corsi-forward | | | 0.381* | | 0.377* | –0.349* | | |
| VLMT Dg1–5 | | | | 0.337* | 0.531* | | | |
| VLMT Dg7 | | | | | | | | |
| VVM-building T1 | | | | 0.420* | 0.517* | | –0.417* | |
| VVM-building T2 | | | | 0.390* | 0.396* | | –0.336* | |

* $p < 0.006$ following Bonferroni adjustment.

Memory damage in TLE can reflect interacting factors, the first of which being the extent of the structural damage. For example, additional cortical dysgenesis to the hippocampal lesion was previously found to significantly lower scores of the Warrington Recognition Memory Test for Faces [50], a test that was proven sensitive for lateralizing right temporal epileptic foci [14]. In our study, the additional damage to the temporal pole, white matter blurring or dysplasia, showed an effect with only one task, the Corsi Block-Tapping test. We hypothesize that the absence of effect for the other tasks is due to poor VisM test validity, since the Corsi-Block-Tapping test achieved the best classification rates. Secondly, in addition to structural lesions, the paroxysmal activity can lead to metabolic disturbances [51,52]. IEDs are known to have an inhibitory function on mental processes and can cause additional cognitive impairment [53,54]. In the present study, no dissociation for VisM was observed between patients who had only a unilateral presence of IEDs, nevertheless contralateral IEDs had a degrading effect on the ROCF and DCS performance for both left and right TLE patients. Therefore, these results favor the hypothesis of a bi-lateral distribution of VisM in the temporal lobes or an absence of test validity.

Neuropsychological diagnoses in clinical practice take into account the patients' overall cognitive performance, rather than focusing solely on the memory domain [6]. We therefore correlated memory parameters to other cognitive domains and demographics in order to study test characteristics and how other factors might influence the diagnosis.

We expected an association of early onset of epilepsy with lower cognitive functioning [21], though the only variable to correlate was "VVM-path T2". All VisM, but not VerbM, parameters were correlated with the visuo-spatial construction/planning skills. The short-term memory measure "Corsi-forward" showed a relationship with the Block Design task (WAIS-R), which requires visuo-spatial construction/planning skills [32], and the TMT, an indicator for processing speed and mental flexibility. These findings coincide with Sanchez-Cubillo et al [16], who showed that low TMT scores correlated with lower performance on the Corsi

Block-Tapping Test in a sample of healthy adults. Performance on the "ROCF-reproduction" showed a strong positive relationship to the "ROCF-copy" and the Labyrinth test. This outcome is not surprising, since the "ROCF" has been known since the 1940s to reflect complex visual cognitive functions as well as organizational and planning abilities, which overlap with the memory measure [23]. Similarly, the "DCS 1–6" learning performance correlated with the cubes as well as processing speed/attention. Notably, this test is based on a concept from Gestalt psychology involving a mixture of complex cognitive skills, such as selective attention and the perception of shapes as a condition for figural learning and reproduction [22]. Although only patients with preserved intellectual functions were included ($IQ > 80$), variation on the Raven's Progressive Matrices was observed for all tests except the verbal accelerated forgetting measure "VLMT Dg7". These findings suggest that lower performance on the Raven's Progressive Matrices is likely to affect the memory outcome. As for the intercorrelation of the VerbM and VisM tasks, it appears that the DCS 1–6 was strongly correlated with all VerbM measures; this could reflect the test's outcome responsiveness to verbalization techniques. It can be assumed that both VisM and VerbM tests measure similar concepts, since they are correlated in each group, verbal versus non verbal, respectively.

In essence, the ROCF, the VVM-path and the DCS were invalid instruments for lateralizing epileptic foci in our patient cohort, even when epilepsy-related factors, such as the extent of the structural lesion or presence of contralateral IEDs, were controlled. The classification rate of the Corsi Block-Tapping Test, reached significance with 62.5%, and showed the best AUC in the ROC curve. When all the test failures were considered, right TLE patients however tended to fail more tests than left TLE patients. We found no evidence disproving models that account for the hypotheses of bilateral distribution of VisM [8,10,11], however we showed that tests used to validate this model have fundamental problems, and can exist equally for VerbM, such as the VVM-building where a correlation was shown with other cognitive domains that tend to be impaired in epilepsy patients. Thus, we recommend that these tests should be interpreted with

Table 5
Spearman correlations of VisM versus VerbM tests.

| | DCS 1–6 | ROCF-rep | VVM-path T1 | VVM-path T2 | Corsi-forward | VLMT Dg1–5 | VLMT Dg7 | VVM-building T1 | VVM-building T2 |
|-----------------|---------|----------|-------------|-------------|---------------|------------|----------|-----------------|-----------------|
| DCS 1–6 | | 0.434* | 0.406* | 0.395* | | 0.424* | 0.356* | 0.405* | 0.372* |
| ROCF-rep. | 0.434* | | 0.352* | 0.396* | | | | | |
| VVM-path T1 | 0.406* | 0.352* | | 0.736* | 0.336* | 0.363* | | 0.344* | |
| VVM-path T2 | 0.395* | 0.396* | | | | | | | |
| Corsi-forward | | | 0.336* | | | | | | |
| VLMT Dg1–5 | 0.424* | | 0.363* | | | | 0.748* | 0.405* | 0.372* |
| VLMT Dg7 | 0.356* | | | | | 0.748* | | 0.382* | 0.388* |
| VVM-building T1 | 0.405* | | 0.344* | | | 0.405* | 0.382* | | 0.883* |
| VVM-building T2 | 0.372* | | | | | 0.372* | 0.388* | 0.883* | |

* $p < 0.006$ following Bonferroni adjustment.

caution in clinical practice. Further examination and re-evaluation of the current clinical method should be considered, emphasizing the development of new tools that reduce the demand of nonverbal reasoning visual planning and construction.

References

- [1] Engel Jr J. Mesial temporal lobe epilepsy: what have we learned? *Neuroscientist* 2001;7:340–52.
- [2] Scoville WB, Milner B. Loss of recent memory after bilateral hippocampal lesions. *J Neurol Neurosurg Psychiatry* 1957;20:11–21.
- [3] Helmstaedter C, Kurthen M, Lux S, Reuber M, Elger CE. Chronic epilepsy and cognition: a longitudinal study in temporal lobe epilepsy. *Ann Neurol* 2003;54:425–32.
- [4] Witt JA, Helmstaedter C. Neuropsychology in epilepsy. *Fortschr Neurol Psychiatr* 2009;77:691–8.
- [5] Lee GP. American Academy of Clinical Neuropsychology. *Neuropsychology of epilepsy and epilepsy surgery*. Oxford, U.K.: Oxford University Press; 2010.
- [6] Baker GA, Goldstein LH. The dos and don'ts of neuropsychological assessment in epilepsy. *Epilepsy Behav* 2004;5(Suppl 1):S77–80.
- [7] Milner B. Amnesia following operation on the temporal lobes. In: Whitty CMW, Zangwill OL, editors. *Amnesia*. London, U.K.: Butterworths; 1966. p. 109–33.
- [8] Raspall T, Donate M, Boget T, et al. Neuropsychological tests with lateralizing value in patients with temporal lobe epilepsy: reconsidering material-specific theory. *Seizure* 2005;14:569–76.
- [9] Saling MM. Verbal memory in mesial temporal lobe epilepsy: beyond material specificity. *Brain* 2009;132:570–82.
- [10] Glikmann-Johnston Y, Saling MM, Chen J, et al. Structural and functional correlates of unilateral mesial temporal lobe spatial memory impairment. *Brain* 2008;131:3006–18.
- [11] Kennepohl S, Sziklas V, Garver KE, Wagner DD, Jones-Gotman M. Memory and the medial temporal lobe: hemispheric specialization reconsidered. *Neuroimage* 2007;36:969–78.
- [12] Coleshill SG, Binnie CD, Morris RG, et al. Material-specific recognition memory deficits elicited by unilateral hippocampal electrical stimulation. *J Neurosci* 2004;24:1612–6.
- [13] Golby AJ, Poldrack RA, Brewer JB, et al. Material-specific lateralization in the medial temporal lobe and prefrontal cortex during memory encoding. *Brain* 2001;124:1841–54.
- [14] Vaz SA. Nonverbal memory functioning following right anterior temporal lobectomy: a meta-analytic review. *Seizure* 2004;13:446–52.
- [15] Helmstaedter C, Pohl C, Elger CE. Relations between verbal and nonverbal memory performance: evidence of confounding effects particularly in patients with right temporal lobe epilepsy. *Cortex* 1995;31:345–55.
- [16] Sanchez-Cubillo I, Perianez JA, Adrover-Roig D, et al. Construct validity of the Trail Making Test: role of task-switching, working memory, inhibition/interference control, and visuomotor abilities. *J Int Neuropsychol Soc* 2009;15:438–50.
- [17] Helmstaedter C. Effects of chronic temporal lobe epilepsy on memory functions. In: Arzimanoglou A, Aldenkamp A, Cross H, Lassonde M, Moshe SL, Schmitz B, editors. *Cognitive dysfunction in children with temporal lobe epilepsy*. Progress in epileptic disorders series. London, U.K.: John Libbey; 2005. p. 13–30.
- [18] Aldenkamp A, Arends J. The relative influence of epileptic EEG discharges, short nonconvulsive seizures, and type of epilepsy on cognitive function. *Epilepsia* 2004;45:54–63.
- [19] Hoppe C, Elger CE, Helmstaedter C. Long-term memory impairment in patients with focal epilepsy. *Epilepsia* 2007;48(Suppl 9):26–9.
- [20] Jokeit H, Ebner A. Long term effects of refractory temporal lobe epilepsy on cognitive abilities: a cross sectional study. *J Neurol Neurosurg Psychiatry* 1999;67:44–50.
- [21] Cormack F, Cross JH, Isaacs E, et al. The development of intellectual abilities in pediatric temporal lobe epilepsy. *Epilepsia* 2007;48:201–4.
- [22] Weidlich S, Lamberti G. DCS: Diagnostikum für Cerebralschädigung. Ein visueller Lern- und Gedächtnistest. 4th ed. Göttingen, Germany: Huber Verlag; 2001.
- [23] Rey A, Osterrieth P-A. L'examen psychologique dans les cas d'encéphalopathie traumatique. Le test de copie d'une figure complexe: Contribution à l'étude de la perception et de la mémoire. *Arch Psycho*; 1944. p. 286–340.
- [24] Schelling D, Schächtele B. *Verbal- und Visueller Merkfähigkeitstest (VVM)*. Frankfurt, Germany: Swets & Zeitlinger; 2001.
- [25] Härting C, Markowitsch HJ, Neufeld H, Calabrese P, Deisinger K, Kessler J. *Wechsler Memory Scale-Revised (WMS-R)*. (German Version)Göttingen, Germany: Hogrefe Verlag; 2000.
- [26] Helmstaedter C, Lendt M, Lux S. VLMT: Verbaler Lern- und Merkfähigkeitstest. Göttingen, Germany: Beltz Test GmbH; 2001.
- [27] Lehrl S. *Mehrfachwahl-Wortschatz-Intelligenztest: Manual mit Block MWT-B*. 4th ed. Bahlingen, Germany: Spitta; 1999.
- [28] Raven JC, Court JH. *Manual for Raven's progressive matrices and vocabulary scales. Section 1: general overview*. San Antonio, USA: Harcourt Assessment; 2003.
- [29] Tombaugh TN. Trail Making Test A and B: normative data stratified by age and education. *Arch Clin Neuropsychol* 2004;19:203–14.
- [30] Zimmerman P, Fimm B. *Testbatterie zur Aufmerksamkeitsprüfung (TAP)*. Würselen, Germany: Psytest; 1992.
- [31] Chapuis P. *Labyrinth-test*. Bern, Switzerland: Huber Verlag; 1959.
- [32] Wechsler D. *Hamburger Wechsler Intelligenztest für Erwachsene Revision*. Bern, Switzerland: Huber Verlag; 1991.
- [33] Rey A. *Manuel du test de copie d'une figure complexe de A. Rey*. Paris, France: Les Editions du Centre de Psychologie Appliquée; 1959.
- [34] Hartje W, Poek K. *Klinische Neuropsychologie*. Stuttgart, Germany: Thieme Verlag; 2006.
- [35] Lutz MT, Clusmann H, Elger CE, Schramm J, Helmstaedter C. Neuropsychological outcome after selective amygdalohippocampectomy with transsylvian versus transcortical approach: a randomized prospective clinical trial of surgery for temporal lobe epilepsy. *Epilepsia* 2004;45:809–16.
- [36] Tudesco Ide S, Vaz LJ, Mantoan MA, et al. Assessment of working memory in patients with mesial temporal lobe epilepsy associated with unilateral hippocampal sclerosis. *Epilepsy Behav* 2010;18:223–8.
- [37] Gleissner U, Helmstaedter C, Schramm J, Elger CE. Memory outcome after selective amygdalohippocampectomy: a study in 140 patients with temporal lobe epilepsy. *Epilepsia* 2002;43:87–95.
- [38] White JR, Matchinsky D, Beniak TE, et al. Predictors of postoperative memory function after left anterior temporal lobectomy. *Epilepsy Behav* 2002;3:383–9.
- [39] McDonald CR, Delis DC, Norman MA, Wetter SR, Tecoma ES, Iragui VJ. Response inhibition and set shifting in patients with frontal lobe epilepsy or temporal lobe epilepsy. *Epilepsy Behav* 2005;7:438–46.
- [40] Gleissner U, Helmstaedter C, Elger CE. Right hippocampal contribution to visual memory: a presurgical and postsurgical study in patients with temporal lobe epilepsy. *J Neurol Neurosurg Psychiatry* 1998;65:665–9.
- [41] Helmstaedter C, Pohl C, Elger CE. Eine modifizierte Version des Diagnosticums für Cerebralschäden (DCS) zur Diagnostik räumlich-visueller Gedächtnisdefizite bei Patienten mit Temporallappenepilepsie. In: Scheffner D, editor. *Epilepsie*, 90. Reinbeck, Germany: Einhorn-PressVerlag; 1991. p. 272–9.
- [42] Barr WB, Chelune GJ, Hermann BP, et al. The use of figural reproduction tests as measures of nonverbal memory in epilepsy surgery candidates. *J Int Neuropsychol Soc* 1997;3:435–43.
- [43] Frank J, Landeira-Fernandez J. Comparison between two scoring systems of the Rey-Osterrieth Complex Figure in left and right temporal lobe epileptic patients. *Arch Clin Neuropsychol* 2008;23:839–45.
- [44] Giovagnoli AR, Erbetta A, Villani F, Avanzini G. Semantic memory in partial epilepsy: verbal and non-verbal deficits and neuroanatomical relationships. *Neuropsychologia* 2005;43:1482–92.
- [45] Loring DW, Lee GP, Meador KJ. Revising the Rey-Osterrieth: rating right hemisphere recall. *Arch Clin Neuropsychol* 1988;3:239–47.
- [46] McConley R, Martin R, Palmer CA, Kuzniemy R, Knowlton R, Faught E. Rey Osterrieth complex figure test spatial and figural scoring: relations to seizure focus and hippocampal pathology in patients with temporal lobe epilepsy. *Epilepsy Behav* 2008;13:174–7.
- [47] Schouten D, Hendriksen JG, Aldenkamp AP. Performance of children with epilepsy on the Rey-Osterrieth complex figure test: is there an effect of localization or lateralization? *Epilepsy Res* 2009;83:184–9.
- [48] Quiske A, Germann J, Wohlfahrt R, Schulze-Bonhage A. Spezifität und Sensitivität des verbalen und visuellen Merkfähigkeitstests. *Epilepsieblätter* 2000;13:15.
- [49] Duzel E, Hufnagel A, Helmstaedter C, Elger C. Verbal working memory components can be selectively influenced by transcranial magnetic stimulation in patients with left temporal lobe epilepsy. *Neuropsychologia* 1996;34:775–83.
- [50] Baxendale SA. The role of the hippocampus in recognition memory. *Neuropsychologia* 1997;35:591–8.
- [51] Henry TR, Votaw JR. The role of positron emission tomography with [¹⁸F]fluorodeoxyglucose in the evaluation of the epilepsies. *Neuroimaging Clin N Am* 2004;14:517–35 (ix).
- [52] Mueller SG, Laxer KD, Cashdollar N, Flenniken DL, Matson GB, Weiner MW. Identification of abnormal neuronal metabolism outside the seizure focus in temporal lobe epilepsy. *Epilepsia* 2004;45:355–66.
- [53] Aldenkamp AP, Arends J. Effects of epileptiform EEG discharges on cognitive function: is the concept of "transient cognitive impairment" still valid? *Epilepsy Behav* 2004;5(Suppl 1):S25–34.
- [54] Holmes GL, Lenck-Santini PP. Role of interictal epileptiform abnormalities in cognitive impairment. *Epilepsy Behav* 2006;8:504–15.

Chapter 4

The importance of the DMS-48 as a visual recognition memory task for cognitive epilepsy evaluation

The importance of the DMS-48 as a visual recognition memory task for cognitive epilepsy evaluation

Ilona Wisniewski^{1,2}, Anne-Sophie Wendling¹, Celina Westermann¹, Lilianne Manning² and Bernhard J. Steinhoff¹

¹Epilepsiezentrum Kork, Germany

²Laboratory of Imaging and Cognitive Neurosciences (CNRS, UMR 7237, IFR 037) and University of Strasbourg, France

Abstract

Currently no consensus exists regarding the lateralizing validity of established visual memory tests in pre-surgical epilepsy diagnostics. The Delayed Matching to Sample (DMS-48) task was previously shown to successfully assess visual recognition memory deficits in early Alzheimer Disease, thus we determined that this task was applicable for lateralisation of hippocampal regions and parallel versions for evaluation of postoperative memory outcome. Forty-eight preoperative mesial temporal lobe epilepsy (TLE) patients were given a full neuropsychological battery containing a variety of standard verbal and figural learning and reproduction memory tests, in addition to the DMS-48. Furthermore, to eliminate practice effects post-operatively, two parallel versions of the DMS-48 were developed and normalised in 172 healthy controls. Using these parallel versions allowed a group of TLE patients to be assessed postoperatively. Our analysis revealed highly significant differences between the left and right mesial temporal lobe for both the DMS-48 and the parallel versions, but not for any of the other visual memory tasks we studied. The two parallel versions administered to the control group were found to be comparable tools to the original task, and could thus be utilized for the follow up. Postoperatively, all visual memory measures remained stable, while performance on verbal memory tasks diminished in left TLE patients. The present findings suggest that clinical usefulness is high for both the DMS-48 and its parallel versions for pre- and postsurgical cognitive epilepsy evaluation, by lateralising the epileptic onset zone and controlling postoperative changes.

Introduction

Clinical neuropsychologists aim to evaluate epilepsy-associated functional deficits, particularly in the context of epilepsy surgery, in order to predict the risk of postoperative cognitive loss (Lee, 2010). Particular attention is given to material-specific memory assessment, since the surgical procedure in temporal lobe epilepsy (TLE) patients involves the removal either of the left or the right hippocampal region. The theoretical concept of material-specificity is widely recognized in the field of cognitive neuropsychology and proposes that memory is formed by processing perceptual information from adjacent cortical areas in the hippocampus and surrounding structures (Milner, 1972). Assuming usual hemispheric dominance for language, the temporal lobe (TL) of the left hemisphere is responsible for verbal memory, whereas the right TL structures are involved in non-verbal (visual memory) function. Consequently, selective deficits in either the verbal or the visual modality would permit lateralization of the dysfunctional zone in their respective hemispheres (Milner, 1972, Helmstaedter et al., 2001a). Associated deficits in verbal memory with left TLE are frequent (e.g., Milner, 1958, Sass et al., 1994, Jokeit et al., 1999) and further decline after surgical removal of unilateral dominant hippocampal structures, is commonly reported (e.g., Gleissner et al., 2002, Martin et al., 2002, White et al., 2002, Lutz et al., 2004). Remarkably, visual memory deficits due to right TL damage are not as frequently reported, neither pre- nor postoperatively (for review see, Barr, 1997, Vaz, 2004, Vannucci, 2007, Sherman et al., 2011). Several studies have addressed these variations in visual memory and proposed that methodological constraints of some neuropsychology tests are an underlying cause, specifically, that difficulties in visual memory may be compensated by the use of verbalization strategies (Helmstaedter et al., 1995, Silverberg et al., 2005). Additionally, the attentional performance of TLE patients can be lowered by functional factors, such as ictal and interictal discharges and as a consequence of antiepileptic drugs (AEDs) (Jokeit et al., 1999, Aldenkamp et al., 2004a, Aldenkamp et al., 2004b, Hoppe et al., 2007, Wisniewski et al., 2011). Thus, tests that are difficult, with high demands on attentional or visuoconstructional abilities, are at risk for failure due to the patients overall cognitive condition (McConley et al., 2008).

Barr et al. (1997) suggested that figural learning tests which include a learning phase with a recall or recognition trial, may show higher sensitivity to dysfunctions of the right TL than figural tests that require reproduction. Recent studies have reported that visual recognition memory tests are sensitive for right TL dysfunctions (Bengner et al., 2010, Smith et al., 2011). Presently, clinicians continue to search for methods that are able to

detect material-specific deficits and there is currently, to the best of our knowledge, a lack of parallel versions for the tests, which are given to measure postoperative decline. The interest of parallel versions would be the reduction of possible practice effects (Bengner et al., 2010). Thus, we considered the utility of the Delayed Matching to Sample task (DMS-48) (Barbeau et al., 2004a), a simple visual recognition memory task that controls for attention and verbalization of items. Previously, the DMS-48 was found to detect mild cognitive impairment (MCI) in an elderly population by Barbeau et al. (2004a), who interpreted this finding in terms of the presence of neurofibrillary tangles in the hippocampal regions.

In the present study, we addressed the efficacy of including the DMS-48 for lateralization of memory dysfunction, in a group of preoperative TLE patients. Further, we determined that for perisurgical diagnostics there was a need for additional tasks. Therefore, our second study involved the development of two parallel versions of the DMS-48 and collection of normative data for clinical use in postoperative follow-ups. Finally, we used these parallel versions to inspect postoperative functional changes in a patient sample.

2. Methods

2.1. Subjects

2.1.1. Preoperative group

Our preoperative cohort consisted of 48 patients with medically intractable TLE undergoing preoperative surgery evaluation at the Kork Epilepsy Centre, Germany. All patients had a unilateral seizure onset determined via surface ictal and interictal EEG, with an ipsilateral hippocampal atrophy/sclerosis identified following a 1.5 Tesla MRI scan, and typical language lateralization during the fMRI examination. In addition, all patients were German native speakers with an IQ of at least 85 points. Demographic and clinical characteristics of the patient cohort are summarized in Table 1. The subgroups left versus right TLE were controlled for gender, age, age at epilepsy onset, mean duration of epilepsy, number of antiepileptic drugs, IQ, and monthly seizure frequency.

Table 1. Preoperative demographic and clinical characteristics

| N=48 | lTLE | rTLE | Statistics |
|---------------------------------------------|------------------------------|------------------------------|------------|
| Gender (male/female), <i>n</i> | 11/14 | 7/16 | n.s. |
| Age (years) | $\mu=44.5$ ($\sigma=10.6$) | $\mu=42.4$ ($\sigma=10.6$) | n.s. |
| Age (years) at epilepsy onset | $\mu=17.7$ ($\sigma=19.1$) | $\mu=21.04$ ($\sigma=15$) | n.s. |
| Duration of disease (years) | $\mu=26.8$ ($\sigma=14.8$) | $\mu=19.7$ ($\sigma=12.6$) | n.s. |
| Monthly seizure frequency | $\mu=6.1$ ($\sigma=6.5$) | $\mu=6.2$ ($\sigma=5.9$) | n.s. |
| Lesion | | | |
| HS/A | 10 | 7 | |
| HS/A + WMB | 8 | 8 | |
| HS/A + TPD | 7 | 8 | |
| Antiepileptic medication | $\mu=1.3$ ($\sigma=0.7$) | $\mu=1.3$ ($\sigma=0.7$) | n.s. |
| Years of education | $\mu=12.9$ ($\sigma=1.7$) | $\mu=12.7$ ($\sigma=2$) | n.s. |
| IQ (MWT-B, Lehl, 1999) | $\mu=102$ ($\sigma=12.5$) | $\mu=107$ ($\sigma=14$) | n.s. |

lTLE: patients with left temporal lobe epilepsy; rTLE: patients with right temporal lobe epilepsy; μ : mean; σ : standard deviation; Lesion subgroups, HS/A: hippocampal sclerosis/atrophy; HS/A + WMB: hippocampal sclerosis/atrophy + white matter blurring; HS/A + TPD: hippocampal sclerosis/atrophy + temporal pole dysplasia. No significant differences for gender, age, age at epilepsy onset, mean duration of epilepsy, number of drug therapy, IQ, or monthly seizure frequency, years of education; controlled via chi-square test or the one-way analysis of variance (ANOVA) ($p>0.05$).

2.1.2. Control subjects for standardization of parallel versions of the DMS-48

One hundred seventy-two healthy control subjects were recruited from areas in close geographical proximity to the epilepsy centre via newsletter. Four distinct age groups were considered: 18-29, 30-39, 40-49 and 50-59 years. In order to have a representative population sample, each age group was controlled for an even distribution of socio-economic professions (physical labour, technical skills, and academics). All participants gave written informed consent. The demographic characteristics, controlled for subject homogeneity, are presented in table 2.

Table 2. Control subject characteristics

| N=172 | Group 1 | Group 2 | Statistics |
|---------------------------------------|-------------------------------|-------------------------------|------------|
| N | 85 | 87 | |
| Gender (male/female), <i>n</i> | 32/53 | 38/59 | n.s.** |
| Age (years) | $\mu=38.2$ ($\sigma=12.75$) | $\mu=38.8$ ($\sigma=12.14$) | n.s.* |
| Years of education | $\mu=13.2$ ($\sigma=2.1$) | $\mu=13.5$ ($\sigma=2$) | n.s.* |

μ : mean; σ : standard deviation. No significant differences for gender, age and years of education; controlled via the chi-square test or one-way ANOVA ($p>0.05$). ** analysis was performed via the chi-squared test, * analysis was performed using one-way analysis of variance

2.1.3. Postoperative group

For the postoperative follow-up a subset of 22 TLE patients were drawn from the preoperative sample, after undergoing epilepsy surgery. They subsequently returned to the Kork Epilepsy Centre for two postoperative follow-up cognitive assessments. Since not all patients were available for assessment at 3-month and one-year follow-ups, the data was analysed separately for each occasion. The clinical and appropriate demographic characteristics of these patients are presented in table 3.

Table 3. Postoperative demographic and clinical characteristics

| 3-month postoperative | | | Statistics |
|---------------------------------------|-----------------------------|------------------------------|------------|
| N=16 | lTLE | rTLE | |
| Gender (male/female), <i>n</i> | 3/5 | 2/6 | n.s. |
| Age (years) | $\mu=43.8$ ($\sigma=9.8$) | $\mu=43.1$ ($\sigma=9.8$) | n.s. |
| Age (years) at epilepsy onset | $\mu=8.8$ ($\sigma=6.1$) | $\mu=15.3$ ($\sigma=9.7$) | n.s. |
| Duration of disease (years) | $\mu=35$ ($\sigma=7.7$) | $\mu=35$ ($\sigma=12.7$) | n.s. |
| Type of surgery | | | |
| saAHE | 2 | 1 | |
| TPR+AHE | 3 | 0 | |
| 2/3 TLR | 3 | 7 | |
| Drugs | $\mu=2$ ($\sigma=0.7$) | $\mu=1.4$ ($\sigma=0.9$) | n.s. |
| IQ (MWT-B, Lehrl, 1999) | $\mu=100$ ($\sigma=12$) | $\mu=101$ ($\sigma=13$) | n.s. |
| Years of education | $\mu=12$ ($\sigma=1.8$) | $\mu=12.7$ ($\sigma=2.5$) | n.s. |
| Seizure free/persistence | 6/4 | 6/3 | n.s. |
| 12-month postoperative | | | Statistics |
| N=17 | lTLE | rTLE | |
| Gender (male/female), <i>n</i> | 3/6 | 3/5 | n.s. |
| Age (years) | $\mu=41.1$ ($\sigma=9.2$) | $\mu=43.6$ ($\sigma=10.5$) | n.s. |
| Age (years) at epilepsy onset | $\mu=10$ ($\sigma=5.8$) | $\mu=22$ ($\sigma=14$) | $p=0.03$ |
| Duration of disease (years) | $\mu=31$ ($\sigma=11$) | $\mu=22.3$ ($\sigma=16.2$) | n.s. |
| Type of surgery | | | |
| saAHE | 2 | 1 | |
| TPR+AHE | 3 | 0 | |
| 2/3 TLR | 4 | 7 | |
| Drugs | $\mu=1$ ($\sigma=0.5$) | $\mu=1$ ($\sigma=0.6$) | n.s. |
| IQ (MWT-B, Lehrl, 1999) | $\mu=95$ ($\sigma=5$) | $\mu=109$ ($\sigma=19$) | $p=0.05$ |
| Years of education | $\mu=11.8$ ($\sigma=1.4$) | $\mu=13.4$ ($\sigma=3$) | n.s. |
| Seizure free/persistence | 5/4 | 4/4 | n.s. |

lTLE: patients with left temporal lobe epilepsy; rTLE: patients with right temporal lobe epilepsy; μ : mean; σ : standard deviation; Type of surgery subgroups, saAHE: selective amygdalohippocampectomy, TPR+AHE: temporal pole resection with amygdalohippocampectomy, 2/3 TLR: 2/3 temporal lobe resection. Comparable characteristics for the 3-month postoperative follow-up, controlled via the chi-square test and one-way analysis of variance (ANOVA) ($p>0.05$). For the 12-month postoperative follow-up, age at epilepsy onset and IQ is significantly higher for the rTLE group.

2.2. Procedure

2.2.1. Preoperative procedure

Patients received a complete cognitive battery, under stable medical conditions (at least 12 hours after their last seizure). Assessment was performed during several days within a period of approximately one week with no more than one memory test given at each session. In addition to the DMS-48, other neuropsychological tests were considered for analysis.

DMS-48

For a detailed description of this computerized forced-choice task, see, Barbeau et al. (2004a). Briefly summarised, during an implicit encoding phase, subjects are not told to memorise, but instead are asked to examine 48 consecutive pictures of concrete and abstract objects and decide if the items contain more or less than 3 colours (controlling for attention and verbalization). During this time, the subjects are unaware that their memory is being tested, until they are asked during the immediate recognition trial to detect the previously seen items from a paired distractor (Set 1). One hour later, a second recognition trial with a new set of distractors is presented (Set 2). The subject's performance is expressed in percentage of correct answers. Normative values exist for 8 age groups (20-29, 30-39, 40-49, 50-59, 60-96, 70-79, 80-89, and 90-99). For normative data, see, Barbeau et al. (2004b).

Other neuropsychological tests

To control for attention, the Trail Making Test (TMT) (Tombaugh, 2004) was presented. Visual perception and visuoconstruction were assessed with the Picture Completion and the Block Design task from the revised version of the Wechsler Adult Intelligence Scale (WAIS) (Aster et al., 2006) and the copy of the Rey-Osterrieth Complex Figure Test (ROCF) (Rey, 1959). As additional memory measures, the six learning trials of the Diagnostikum für Cerebralschädigung (DCS) (Weidlich et al., 2001); the ROCF immediate recall (Rey, 1959); the immediate reproduction of the museum subtest of the Verbaler und Visueller Merkfähigkeitstest (VVM-path) (Schelling et al., 2001); the verbal memory list learning paradigm and the recall after 30 minutes Verbaler Lern und Merkfähigkeitstest (VLMT-A, German version of the Rey Auditory Verbal Learning Test) (Helmstaedter et al., 2001b) and the immediate and 2 hour delayed recall, story learning task, VVM-building (Schelling et al., 2001) were utilized.

2.2.2. Standardization of the parallel versions

The two parallel versions (DMS-48 3-month and 12-month) were designed with new stimuli using a commercially available clip art program (Printmaster 2.0 ®, Encore Inc.), based on the same principle as the original DMS-48 (Barbeau et al., 2004a) with permission of E. Barbeau. Subjects were assessed using Set 1 and Set 2 for either the 3-month or the 12-month version.

2.2.3. Postoperative procedure

Nineteen patients were assessed using the DMS-48 3-month version 90 days postoperatively. Sixteen patients were available for the one year postoperative control, and were examined with the DMS-48 12-month version. For all other verbal and visual memory tests, existing parallel versions were used as well.

For the 3 month follow up, the MCG-Figure (Loring et al., 2003), DCS Neu (unpublished), VVM-path and building (form C) (Schelling et al., 2001) and VLMT-C (Helmstaedter et al., 2001b) were taken. Furthermore, The Taylor Figure (Strauss et al., 1990), VVM-path and building (form D) (Schelling et al., 2001), DCS parallel (Weidlich et al., 2001), and VLMT-D (Helmstaedter et al., 2001b) were also used.

2.3. Statistical analysis

2.3.1. Preoperative group

All statistical analyses were done using Statistica (Statsoft ®, version 8.0). The lateralisation effect (left and right TLE) on the test scores was calculated using a repeated measures ANOVA, with time at examination for Set 1 and Set 2 as within effect, and the lateralization of epilepsy (left versus right) as between effect. Further to compare the DMS-48 to other memory measures one-way ANOVAs were performed for each parameter respectively. To analyse the sensitivity and specificity of the DMS-48, we transformed the raw scores for the immediate and 1h delayed recall into percentages and calculated the mean and standard deviation in order to compare the left and right TLE group with the normative data from Barbeau et al. (2004b) that is expressed only in percentages (with standard deviation). The receiver operating characteristics (ROC) curve could not be applied to calculate the appropriate cut off score due to the low data variability in the DMS-48. Therefore, in accordance with the usual recommendations for clinical neuropsychologists (Hartje et al., 2006), one standard deviation below the mean was set as deficient score. Sensitivity was obtained by dividing the number of right TLE

patients with deficient scores by the total number of right TLE patients. Specificity was calculated by dividing the number of left TLE patients with preserved score by the total number of left TLE patients. The percentage of correctly classified patients was obtained by adding the sum of left TLE patients with preserved score to the sum of right TLE patient with a deficient score and dividing it by the total number of assessed patients.

2.3.2 Control for standardization

To determine normative values, raw scores for each set were transformed into percentages, and means and standard deviations were calculated. The effects of age group, education level and gender on the two sets of raw scores were examined using a repeated measures MANOVA. To screen for inter-rater reliability, the effect of two examiners on the performances of two separate age groups (18-29 and 30-39 years, respectively) were controlled using a one-way ANOVA. $P < 0.05$ was taken as statistically significant and $p < 0.1$ was taken as a trend. The Newmans-Keuls post-hoc test was used for further results.

2.3.3 Postoperative group

For the DMS-48 3-month group, a repeated measures ANOVA was used for DMS-48 Set 1 and Set 2 and other visual and verbal memory variables, with the lateralization of epilepsy (left versus right TLE) taken as the independent variable and the time of assessment before and after surgery as within effect. For the DMS-48 12-month group, a repeated measures ANCOVA was performed, with IQ and age at epilepsy onset controlled for covariance. The Newmans-Keuls post-hoc test was used for both versions.

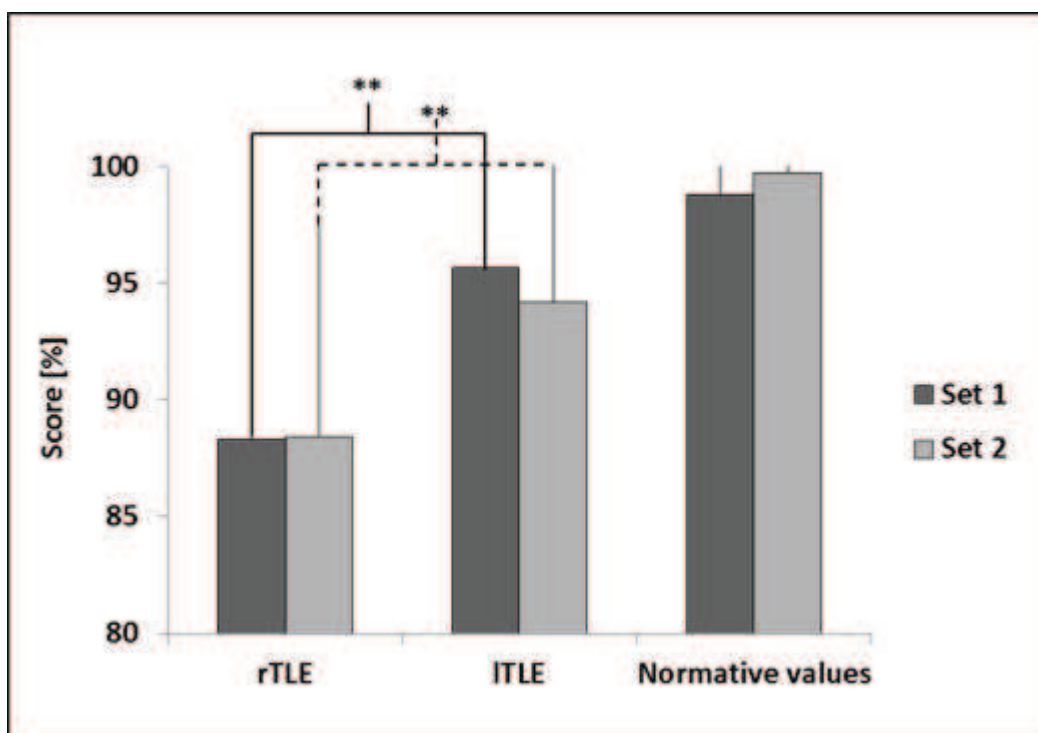
3. Results

3.1. DMS-48 in preoperative mesial TLE patients

3.1.1. Raw score differences

The repeated measures ANOVA showed no significant differences between Set 1 and Set 2 for the DMS-48. The variable lateralization of epilepsy (right versus left TLE) had a highly significant effect for the DMS-48: Sets 1 and Set 2 ($F=9.6$, $p=0.003$) (Figure 1, for further illustration).

Figure 1. Mean patient and control performance for Set 1 and Set 2



Patient performance on DMS-48 (left temporal lobe epilepsy (ITLE) and right temporal lobe epilepsy (rTLE)) versus the normative values for Set 1 and Set 2. Data are expressed as mean percentages (score). Asterisks represent the intergroup significance for raw scores. rTLE group scores are significantly lower.

When one-way ANOVAs were performed, no effects were observed for attention measures, visual perception or visuoconstruction. Other visual memory tests, the ROCF, DCS and the VVM-path, as well as the verbal memory parameters did not differentiate between left and right TLE patients (table 4).

Table 4. Outcome for neuropsychological tests

| N=48 | ITLE | rTLE | One-way ANOVA |
|-----------------------|--------------------|--------------------|-------------------------|
| | μ (σ) | μ (σ) | |
| <u>Visual Memory</u> | | | |
| ROCF recall | 17 (9.1) | 13.4 (6.6) | F=2.3, p=0.13 |
| DCS | 32.4 (12) | 29.8 (12.6) | F=0.5, p=0.48 |
| VVM-path | 19 (7) | 18.1 (7.2) | F=1.5, p=0.7 |
| DMS-48 (Set 1) | 45.9 (2.4) | 42.8 (4.6) | F=8.4, p=0.005** |
| DMS-48 (Set 2) | 45.2 (2.8) | 42.1 (4.3) | F=8.1, p=0.006** |
| <u>Verbal Memory</u> | | | |
| VVM-building T1 | 6.9 (4.8) | 9 (4.8) | F=2.2, p=0.14 |
| VVM-building T2 | 5.1 (4.4) | 6.9 (3.5) | F=2.2, p=0.14 |
| VLMT Dg1-Dg5 | 46.6 (7.4) | 48.3 (8.8) | F=0.5, p=0.47 |
| VLMT Dg 7 | 8.1 (3) | 9 (3.1) | F=0.8, p=0.35 |

Raw score mean (μ), standard deviation (σ) and one-way ANOVA calculation for visual and verbal memory tests in comparison for the patients with left temporal lobe epilepsy (ITLE) and patients with right temporal

lobe epilepsy (rTLE). DMS-48 is the only test to reach significance. Asterisks represent the intergroup significance for raw scores.

3.1.2. Classification function, based on normative values

Analysis with the Chi-square test indicated a significant distribution of preserved and deficient performance in TLE patients for Set 1, but not for Set 2. Sixty-nine percent of the patients were lateralized correctly as left or right TLE for Set 1 versus 65% for Set 2. Sensitivity, Specificity and related data are shown in table 5.

Table 5. Classification function for DMS-48 Set 1 and Set 2

| Test | Lateralization | Preserved, n | Deficient, n | Sensitivity | Specificity | % classified | X ² |
|-------------------|----------------|--------------|--------------|-------------|-------------|--------------|----------------|
| Set 1- 1 σ | L | 17 | 8 | 70 | 68 | 69 | p=0.009 |
| | R | 7 | 16 | | | | |
| Set 2- 1 σ | L | 14 | 11 | 74 | 56 | 65 | (n.s.) |
| | R | 6 | 17 | | | | |

Preserved and deficient effective numbers for Set 1 and Set 2. Cut-off score is one standard deviation below the mean. L=left and R=hemisphere. Distribution is significant using the chi-square test (df-1) function and indicates preservation and deficiency for L and R respectively.

3.2. Standardization of two parallel versions for the postoperative follow-up

The standardized control subject performances, for Set 1 and Set 2, with different age groups for the 3- and 12-month version are represented in table 6. The normative values for the original test version that we used for the preoperative assessment are published in (Barbeau et al., 2004b).

Table 6. Normative values for the DMS-48-3 months and DMS-48-12 months parallel versions

DMS-48 3-month

| Age | 18-29 | | 30-39 | | 40-49 | | 50-59 | |
|-------|----------------|-----------------|----------------|-----------------|----------------|-----------------|----------------|-----------------|
| | % (σ) | RW (σ) | % (σ) | RW (σ) | % (σ) | RW (σ) | % (σ) | RW (σ) |
| Set 1 | 99 (2) | 47 (1) | 99 (2) | 47 (1) | 99 (2) | 47(1) | 98 (3) | 47 (1) |
| Set 2 | 98 (2) | 47 (1) | 98 (2) | 47 (1) | 98 (2) | 47 (1) | 96 (4) | 46 (2) |
| n | 24 | | 20 | | 20 | | 21 | |

DMS-48 12-month

| Age | 18-29 | | 30-39 | | 40-49 | | 50-59 | |
|-------|----------------|-----------------|----------------|-----------------|----------------|-----------------|----------------|-----------------|
| | % (σ) | RW (σ) | % (σ) | RW (σ) | % (σ) | RW (σ) | % (σ) | RW (σ) |
| Set 1 | 98 (2) | 47 (1) | 99 (2) | 47 (1) | 99 (2) | 47 (1) | 98 (3) | 47 (1) |
| Set 2 | 99 (2) | 47 (1) | 98 (2) | 47 (1) | 99 (2) | 47 (1) | 98 (30) | 46 (2) |
| n | 22 | | 20 | | 23 | | 21 | |

Normative values for two parallel versions. Mean performance in percentages and standard deviation (% (σ),) for different age groups and the raw score mean and standard deviation RW (σ).

The performance on the two parallel versions did not differ depending on the participant's gender or level of education. For the 3-month version, the age group did not have an effect on Set 1 and only for Set 2 a trend close to significance was found ($F=2.62$, $p=0.06$). Post-hoc analysis using the Newman-Keuls test showed a trend for decline in recognition performance between the age group 50-60 years with both 30-39 years ($p=0.06$), and 40-49 years ($p=0.1$), respectively. For the 12-month version, an interaction effect was found between the age group and the time of examination ($F=3.02$, $p=0.03$). The Newman-Keuls post-hoc test revealed that the age group 18-29 scored significantly better after the one hour delay ($p=0.02$). No significant differences, depending on inter-raters were found.

3.3. Postoperative follow-up

3.3.1. 3-month follow-up

No significant effects were found for the time of examination for Set 1 or Set 2. The patients' test performance after surgery did not differ from the preoperative results on Set 1 or Set 2. Furthermore, no interaction effects were found for either parameter. The lateralization of epilepsy (left versus right TLE) had an impact on the DMS-48 3-month for Set 1 ($F=6.6$, $p=0.02$) and Set 2 ($F=6$, $p=0.03$). Newman-Keuls post-hoc test showed the right TLE sample scoring significantly lower than the left TLE group for Set 1 ($p=0.02$) and Set 2 ($p=0.03$). No effects were found for the visual memory parameters, ROCF recall, DCS and VVM-path. For verbal memory a trend to significance was found for the interaction lateralization of epilepsy x time of examination for VVM-building T1 ($F=4.5$, $p=0.057$) and a highly significant effect for T2 ($F=14$, $p=0.003$). Post-hoc analysis using Newman-Keuls test showed that left TLE patients performed worse after surgery than before and performed poorer overall as compared to the right TLE group after surgery. An additional interaction effect between lateralization of epilepsy x time of examination was found for the other verbal memory measures VLMT Dg1-Dg 5 ($F=9.2$, $p=0.009$) and Dg 7 ($F=16$, $p=0.001$). Post-hoc analysis showed that left TLE groups performed worse after surgery than before and worse than the right TLE group as well.

3.3.2. 12-month follow-up

MANOVA with IQ and age of epilepsy onset taken as covariants showed no effects for the time of examination for Set 1 or Set 2. The side of epilepsy (left versus right TLE) had an effect for Set 1 ($F=17$, $p=0.001$) and Set 2 ($F=19$, $p=0.001$). Newman-Keuls post-hoc test showed right TLE patients to perform worse than left TLE patients on Set 1 ($p=0.002$) and

Set 2 ($p=0.002$). No effects were found for visual memory, except and interaction effect between lateralization of lesion x time at examination for the ROCF. Newman-Keuls post-hoc test, showed that the right TLE group scores were significantly lower than the left TLE group, but only before surgery ($F=6.2$, $p=0.03$). No effects were measured for the VVM-building task. Word list learning was significantly lower after surgery in the left than right TLE group (VLMT Dg1-5: $F=5$, $p=0.04$).

3.4. Discussion

In these studies, we aimed primarily to investigate the efficiency of the DMS-48 test to detect lateralization of visual recognition memory dysfunction. Furthermore, we developed alternative versions of this test for use in neuropsychological postoperative follow-ups by collecting control subject data and comparing test criteria of the original to these parallel versions. Finally, we assessed a patient sample after surgery in order to examine any possible functional changes.

Contrary to our expectations, the verbal memory measures were not sensitive enough to discriminate lateralization of our patient sample of 48 preoperative candidates. Although verbal memory deficits for left TLE patients are consistently found in the literature, (e.g., Milner, 1958, Sass et al., 1994, Jokeit et al., 1999) and the VLMT specifically has been shown as a valid method compared to other verbal memory measures, a possible absence of a lateralizing effect between left and right TLE patients has been previously reported in a small patient group (Helmstaedter et al., 2009b).

In relation to visual memory, only the DMS-48 Sets 1 and 2 showed highly significant differences. As anticipated, the DMS-48, a visual recognition memory test that detected MCI in a group with neurological changes affecting the parahippocampal region (Barbeau et al., 2004a) showed validity in the context of preoperative neuropsychology diagnosis. These findings demonstrate the role of the non-language-dominant hippocampal region for visual recognition memory. The absence of group differences for figural reproduction tests, such as VVM-path and ROCF, or the figural learning test, DCS, are consistent with several prior studies where these same types of tests failed to lateralize the seizure onset zone (Barr et al., 1997, Gleissner et al., 2002, Giovagnoli et al., 2005, Frank et al., 2008, McConley et al., 2008). Reviewing the literature for recognition memory, several tests

seem to be useful in clinical context. The Doors and People Test (Baddeley et al., 1994), was previously validated for differentiating between verbal and visual memory deficits after a temporal lobectomy (Morris et al., 1995). Recently Smith et al. (2011) showed that a visual paired associative learning task was able to underline material-specific deficits in right TLE for the recognition condition, but not for learning or the recall trials. Visual recognition tasks used in cognitive epilepsy assessments commonly contain photographs of faces as stimuli. The Warrington Face Recognition Memory Test (WRMT) (Warrington, 1984) and the Denman Recognition Test (Denman, 1984) are based on a similar forced choice design as the DMS-48, measuring immediate face recognition specifically. More precisely the Denman Recognition Memory task was found to discriminate left versus right TLE patients in a large preoperative patient sample (Barr et al., 1997). However, for the WRMT, two studies rated the preoperative clinical utility as low, though postoperative differences between the groups reached significance (Hermann, 1995). We propose that the reason why the DMS-48 successfully assesses visual memory difficulties could be that this recognition format encompasses motor and visuoconstructive skills, because the patient is not required to reproduce the stimuli. Furthermore, this test does not depend on the level of education and thus can be judged as not particularly challenging the intellectual skills of the patient. Equally, the DMS-48 controls attention during encoding, since the subjects are asked to focus on colors. Therefore the DMS-48 would not penalize patients with attentional difficulties that are commonly impaired in TLE patients due to interictal discharges or side effects of medication (Aldenkamp et al., 2004b). Further, the color count could inhibit verbalization and thus would not allow the right TLE patients to boost their memory performance.

Furthermore, concerning forgetting over time, during validation studies of the Alsterdorfer Faces test, another computerized forced choice task, Bengner et al. (2007), found a dissociation between the immediate and 24-hour long-term face recall. In their study only the long-term recall was able to distinguish left from right TLE patients. Against these assumptions, though concordant with the study of Barbeau et al. (2004a), where DMS-48 Sets 1 and 2 distinguished MCI patients from patients with Parkinson's disease and healthy controls, our results showed no decline in the performance between patients for the one-hour delayed recall. This suggests that the immediate recall of the DMS-48 is sufficient for the detection of visual recognition memory deficits.

To our knowledge, recognition memory tests are usually not available in parallel versions that provide normative data, thus not allowing an assessment of the patients postoperatively or during other repeated follow-up appointments that measure the patient's progression. Therefore, we developed two versions of the DMS-48 with new stimuli and assessed a control group in order to develop a test with comparable values to the DMS-48. The results showed that the parallel versions are comparable to the original DMS-48. As in Barbeau et al. (2004b), the inter-rater fidelity was stable and neither gender nor, the education level had an influence on the performance in the healthy control group. Normally these are confounding factors that may influence memory test outcome in a clinical assessment, however, in regards to the DMS-48 these seem to be absent (Helmstaedter et al., 2004, Cormack et al., 2007). Concerning age, test performance was not affected, except a trend towards decline on Set 2, evident only in the 3-month version for the 50-59 year old group. In regards to the DMS-48 12-month version, the youngest group profited from the one-hour delayed recall. This reflects another memory tendency that was found for visual recognition memory tests that the performance can increase with the repeated presentation of visual stimuli (Erdelyi, 2010).


As for the postoperative patient sample, right TLE patients continued to show significantly lower effects on only the DMS-48 and the sensitivity effect remained for both parallel versions. The parallel versions of other visual memory tests failed to lateralize deficits in right TLE. Furthermore, none of the visual memory tests showed a postoperative decline in performance for either patient group. However, a clear postoperative change was found for verbal learning and was even more pronounced for delayed recall, in left TLE patients. These findings are concordant with previous cognitive outcome studies of epilepsy surgery, where verbal memory deficits were commonly observed after left TLE surgery (e.g., Milner, 1958, Sass et al., 1994, Jokeit et al., 1999). Concerning visual memory, the risk for postoperative loss is considered half as compared to verbal memory, and in addition, there is no additional risk for memory loss depending on the side of surgery, for review see, (Barr, 1997, Vaz, 2004, Vannucci, 2007, Sherman et al., 2011).

It has been previously suggested that absence of lateralizing effects of visual memory tests can be attributed to several functional factors such as seizures and medication effects that can diminish differences between left and right TLE patients (Helmstaedter et al., 2003). In addition, visual memory would be distributed differently than verbal memory, specifically

that hippocampal structures sustain visual memory bilaterally (Golby et al., 2002, Kennepohl et al., 2007), or that visual memory is situated on areas expanding more broadly over the neocortex than verbal memory (Helmstaedter et al., 2008). Since our study showed validity for the DMS-48 in pre- and postoperative patients, but not for other more frequently used tests, we suggest that this lack of lateralization effect can equally be attributed to different test methodologies.

Chapter 5

Visuoperceptual and visuospatial abilities prior to and after anterior temporal lobectomy: A case study



Case Report

Visuoperceptual and visuospatial abilities prior to and after anterior temporal lobectomy: A case study

Ilona Wisniewski^{a,b}, Anke M. Staack^a, Sofia Bilic^a, Bernhard J. Steinhoff^a, Lilianne Manning^{b,*}^a Epilepsiezentrum Kork, Kehl-Kork, Germany^b Laboratory of Imaging and Cognitive Neurosciences (CNRS, UMR 7237, IFR 037) and University of Strasbourg, France

ARTICLE INFO

Article history:

Received 14 September 2011

Revised 8 October 2011

Accepted 10 October 2011

Available online 22 November 2011

Keywords:

Temporal lobe epilepsy surgery

Visual perception

Mental imagery

Visual object recognition

Spatial perception

ABSTRACT

We describe a patient who presented with temporal lobe epilepsy and a seizure onset pattern in the right temporo-occipital area. Structural MRI revealed sclerosis in the right hippocampus. A comprehensive presurgical neuropsychological assessment allowed us to disentangle deficits in visual object recognition and visual imagery from well-preserved spatial capacities. Following a right temporal lobectomy, the patient remained seizure free, and 1 year postsurgery, the patient's scores on object recognition and imagery were in the normal range. Our findings suggest that visual object recognition and visual imagery are sustained by cortical areas located in proximity to the temporo-occipital ventral pathway and that perceptual and imagery spatial processing is subserved as well by anatomically close mechanisms. Furthermore, the results seem to indicate that nonlesional paroxysmal activity in the posterior temporal lobe can cause chronic dysfunctions of the visual system and that it may be reversible with effective seizure control.

© 2011 Elsevier Inc. All rights reserved.

1. Introduction

Mishkin and Ungerleider [1] proposed, in relation to visual perception, the two-stream hypothesis. According to this theory, there are two pathways, dorsal and ventral, with the former extending into the parietal lobe and sustaining visuospatial perception, and the latter spreading over the temporo-occipital junction to the inferior temporal lobe and supporting visual object recognition [2]. Moreover, it has been suggested that impairments in perception and imagery can occur concurrently and rely on the same neural substrate [3–5]. However, dissociations in single-case studies have been documented: selective impairment of imagery [6] and selective impairment in recognition for objects and space [7,8].

Studies examining visual perception in adults with occipital lobe epilepsies (OLEs) are rare. Interesting results have been reported; for example, Piazzini et al. [9] observed significant dysfunction in naming objects, recognizing famous faces, and visual object imagery in an OLE group compared with a control group. Most authors agree that visual perception is generally preserved in temporal lobe epilepsy (TLE) [10–12]. However, more than 40 years ago, Milner observed mild facial perception disorders in right TLE, and because these patients rarely seemed aware of their deficit, it was elicited by means of “special techniques” [13].

In TLE the major neuropathological substrate is hippocampal sclerosis [14]. In healthy subjects, the hippocampus supports acquisition and

long-term consolidation of episodic autobiographical memory regardless of the age of recollections [15]. Conversely, concept-based knowledge or semantic memory is independent of hippocampal structures, and involves the lateral temporal lobe regions [15–17]. Deficits in semantic memory per se, in which the memory trace itself is degraded, can be differentiated from a selective impairment in accessing semantic memory from vision, previously observed in patients with damage to posterior brain regions [18]. The “laboratory” episodic memory deficits that are normally observed in TLE are frequently material specific, because under normal healthy conditions, the left temporal lobe processes verbal material, and the right temporal lobe, nonverbal stimuli [19]. TLE causes usually irreversible memory impairment. Additionally, medication, interictal discharges, and the propagation of seizures can lead to widespread auxiliary metabolic disturbances, including damage to the bilateral temporal and ipsilateral extratemporal regions [20,21]. Thus, functional changes in extratemporal cognitive functions such as attention and executive functions can occur and also recover after successful seizure control [22–25].

In the present study, we examined a candidate for right TLE surgery with temporo-occipital seizure propagation. The administration of a detailed neuropsychological protocol before and after epilepsy surgery was aimed at evaluating visual perception, imagery, and semantic memory, as well as functional changes that can result from successful seizure control.

2. Case presentation

C.B. is a right-handed female, retired factory worker, with 9 years of education, who had had intractable epilepsy since the age of 7. At

* Corresponding author at: Department of Psychology, UDS, 12, rue Goethe, 67000 Strasbourg, France.

E-mail address: manning@unistra.fr (L. Manning).

age 49 she underwent her first examination at the Kork Epilepsy Centre and was identified only at this point as a possible surgery candidate. She therefore underwent a preoperative neuropsychological assessment. During this period, she was experiencing dyscognitive focal seizures almost daily (during a 3-day video/EEG monitoring session, a total of seven seizures were recorded). Interictal epileptiform discharges (IEDs) with a posterior temporal accentuation were regularly observed on the surface EEG. Additionally, the EEG showed seizure onset in the right temporal occipital area that, after 15 seconds, persisted approximately 2 minutes with, as evidenced with right temporo-occipital electrode recordings. Field extension of the epileptiform activity was also observed to the right temporal anterior and frontal areas, as well as the left occipital lobe. Brain imaging with a 1.5-T Magnetom (Siemens, Erlangen) revealed sclerosis of the right hippocampus, as well as gray–white matter blurring of the right temporal pole and the amygdala.

Functional MRI showed language representation in the left hemisphere. Light myopia and astigmatism were corrected by glasses, and the preoperative ophthalmological perimetrical examination did not reveal any pathological findings. Six months after the preoperative data were collected, C.B. underwent a right anterior temporal lobectomy with resection of the hippocampus, the amygdala, and an approximately 2.5×2.0×1.5-cm area of the anterior temporal lobe (Fig. 1). One year after surgery she remained free of seizures and showed only a single discrete IED on the routine 20-minute EEG examination.

3. Methods

3.1. Neuropsychological assessment

During both the pre- and postoperative cognitive assessments, C.B. was on the same anticonvulsant therapy (levetiracetam 2500 mg and lamotrigine 100 mg). Preoperatively, she was examined more than 12 hours after her last seizure and she gave written informed consent. Four female, age ($\mu=52.25$, $\sigma=2.21$)- and education ($\mu=9$, $\sigma<1$)-matched control subjects underwent identical neuropsychological examinations for the experimental tasks that were not standardized.

3.2. Test material

The standard diagnostic test battery included measures of intelligence, the Mehrfachwahl-Wortschatz-Intelligenztest (MWT-B) [26],

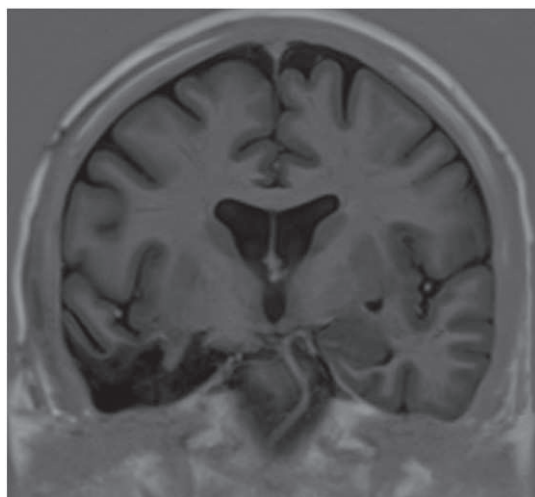


Fig. 1. C.B.'s 1-year postoperative MRI inversion–recovery coronal slice.

and attentional performance and information processing speed, Aufmerksamkeits-Belastungstest (Test d2) [27]. Visual naming was tested with the Boston Naming Test [28], and language fluency with the L-P-S Leistungsprüfsystem (LPS-6) [29]. Measures of executive functions required visual support: Tower of Hanoi [30], Labyrinth Test [31], Trail Making Test [32]. Verbal memory was evaluated with the German version of the Rey Auditory Verbal Learning Test [33], and visuospatial memory was evaluated with a variety of items: Diagnosticum für Cerebralschädigung [34], Rey–Osterrieth Complex Figure Test [35], Benton Facial Recognition Test (BFRT) [36], Delayed Matching to Sample Test 48 [37], Visueller Merkfähigkeitstest [38].

Visual access to semantics was tested with the Naming Categories Test [39,40], in which knowledge and naming of items belonging to nine categories were probed with 152 canonical black-and-white line drawings, and with the Written Word–Picture Version of the Pyramids and Palm Trees [41]. The verbal version was presented in German.

Visuo-perceptual capacities were assessed using the Picture Completion Test, which measures perception of missing details from the Wechsler Adult Intelligence Scale III (WAIS-III) [42], as well as the four subtests from the Visual Object & Space Perception Battery (VOSP: Incomplete Letters, Object Decision Test, Progressive Silhouette Test, and Silhouette Test); the Canonical–Unusual View Matches [39]; and the Same–Different Object and Category Pair Finding Test [39,43]. These tests are described in detail elsewhere [39]. In the Same–Different Object Test, the examinee has to decide if the two object halves shown on one card belong to the same object or to two different objects. In a second subtest, Category Pair Finding, one object half is presented on a separate card and the subject has to find its respective category. Finally, figures from the Functional and Category Pair Finding Test from a specific test battery (Protocole d'Evaluation Des Gnosies Visuelles Montréal-Toulouse [PEGV]) were presented [based on 44]. The figures were degraded in the Microsoft Paint Program and a target had to be matched with its pair. The first assessment used degraded stimuli followed by a presentation of non-degraded functional pictures.

Facial perception was probed with the BRFT [36].

Visual imagery was comprehensively tested with the Heads Test [18] and Animal Tails Test [see (6,45), for detailed description] and by asking the patient to draw from memory and then to make a copy from a model.

Spatial perception and spatial imagery were assessed with the WAIS-III Spatial Construction Cubes Test; three subtests of the Spatial Section of the VOSP (Dot Counting, Dot Centre, and Cube Analysis); the Judgement of Line Orientation Test [36]; the Manikin Test [adapted from 46]; and two tailor-made tests (created by one of the authors, I.W.). In addition, we used the Block Rotation task, which asks the examinee to indicate which color should be on top after a block is rotated a given number of times (up to 9), and is designed to measure the ability to mentally rotate. Finally the patient was administered the Rotated Letters task in which 10 three-dimensional light gray capital letters must be named after they are presented from several diverse angles.

3.3. Statistic analysis

For statistical comparisons, a modified *t* test was used to test differences between the two examination times [47]. $P<0.05$ was taken as statistically significant, whereas $P<0.1$ was taken as a trend.

4. Results

The standard assessment showed an average level of intelligence and pre- to postoperative stable attentional performance and information processing speed. Language fluency and spontaneous

expression were preserved at both times of examination. Executive functions showed a preoperative pattern of dysfunction for tasks that required visual support. Postoperatively, executive function improved and reached an average range. Memory for verbal material was preserved before surgery, but dropped postoperatively. Encoding for figural contents was nearly impossible on both occasions.

Table 1 lists the pre- and postoperative results for the tests examining visual access to semantics as well as visual perception and visual imagery. Preoperatively, C.B. showed slight difficulties in Naming

Categories because, on the one hand, she made only one error when naming Means of Transport. On the other hand, the three errors in the Fruits and Vegetables category were not related to a more general living category deficit as she named 100% of the animal exemplars with which she was presented. Her visual recognition was deemed impaired as naming after definition was errorless. No selective impairment was detected for a given category. A general object recognition deficit was corroborated by difficulties in the Object section of the Visual Perception subtests of the VOSP. Her scores were not transient, as repetition of the VOSP 2 weeks later revealed the same pattern of performance. Further testing with the Canonical–Unusual View Matches and the Same–Different Object Test showed lower performance in perceptual categorization compared with controls; however, differences reached only a statistical trend. Her performance on the Category Pair–Finding Test was clearly deficient and an indication that recognition and additional categorization were altered and more difficult than object recognition, and impaired performance in attributing degraded stimuli to their function or category supports this idea. The picture version of the Pyramid and Palm Trees showed revealed deficits in accessing semantics from vision. The spared performance before and after surgery on the Non-degraded PEGV and the Canonical–Unusual View Matches and the successful access to semantics through verbal information suggest that general semantic object knowledge was preserved. Additionally, a perception deficit was detected for facial processing. Concerning visual imagery, C.B. was unable to imagine animals in their entities or draw from memory (see Fig. 2), which led us to the conclusion that there were simultaneous deficits in perception and the imagery of objects. Conversely, spatial ability, measured with subtests from the VOSP and WAIS and the Judgement of Line Orientation Test, was spared, as was imagery of space assessed with mental rotation tasks, such as the Manikin Test and Block Rotation and Rotated Letter tasks.

Postoperatively, all tasks that measured visual access to semantics showed improvement when compared with preoperative performance. When measured against scores of the control subjects, only the Degraded PEGV showed a significant deviation. Similarly, visual imagery task scores normalized, as did her performance on the facial perception task. Finally, her performance on spatial ability tests and spatial imagery remained preserved and stable.

5. Discussion

The relationship between visual perception and visual imagery in a case with unusual EEG characteristics in this specific type of epilepsy was studied. EEG analysis of a patient with structural impairment of right hippocampal structures showed seizure propagation to the temporo-occipital pathway. The initial assessment revealed severe visual anterograde memory impairment and deficits in visual object recognition. Nevertheless, C.B.'s skill in everyday activities such as recognition of items in the supermarket was spared. Coherent with this observation, her performance on basic perception tasks, such as the Perceptual Screening Test from the VOSP, was preserved and her performance on the visuospatial section of the VOSP was very good. Furthermore, she was good at recognizing typically presented objects in the PEGV and Canonical–Unusual View Matches, and in reproducing the object directly from a model. However, the capacity for more detailed examination of the recognition of an unusual point of view or a degraded image tended to be lower in C.B. than in controls. Categorization of visually presented stimuli was also more difficult than categorization of verbally presented items; in particular, there was significant difficulty when degraded images had to be categorized. This indicates that she had trouble accessing semantic memory from vision, which indicates a deficit in high-level visual processing, comparable to a perceptual categorization deficit only demonstrable with experimental tasks [43,48]. In C.B.'s case it was not the general semantic knowledge per se that was compromised,

Table 1
C.B.'s pre- and postoperative neuropsychological test results.

| | Preoperative | Postoperative |
|------------------------------------------------------|-------------------------------------|-------------------------------------|
| <i>Visual access to semantics</i> | | |
| Naming categories | | |
| Body parts | 20/20 | |
| Clothing | 15/15 | |
| Furniture | 14/14 | |
| Animals | 18/19 | |
| Actions | 17/17 | |
| Kitchen objects | 20/20 | |
| Means of transport | 12/13 | |
| Fruit and vegetable | 9/12 | |
| Kitchen objects | 22/22 | |
| Boston Naming Test | | |
| Visual Presentation) | 37/50 (impaired) | 47/50 (preserved) |
| Naming after Verbal Definition | 47/50 | 47/50 |
| Picture Completion: WAIS-III | 8/25 (impaired) | 18/25 (preserved) |
| VOSP: Object Perception | | |
| Incomplete Letters | 17/20 (Pr = 11.5) | 18/20 (Pr = 26) |
| Silhouette Test | 16/30 (Pr = 7) | 24/30 (Pr = 55.8–68.8) |
| Object Decision Test | 12/20 (Pr = 1.2) | 18/20 (Pr = 39.5–57.8) |
| Progressive Silhouette Test | 16 (Pr = 2.3) | |
| Canonical–Unusual View | | |
| Matches | 14/20 $t(3) = -1.845, P = 0.08$ | 17/20 $t(3) = -0.543, P = 0.313$ |
| Same–Different Object Test | | |
| | 57/70 $t(3) = -1.71, P = 0.09$ | 68/70 $t(3) = 0.327, P = 0.382$ |
| Category Pair Finding Test | | |
| | 47/70 $t(3) = -7.791, P = 0.002$ | 67/70 $t(3) = 0.304, P = 0.391$ |
| Degraded Functional and Category Pair Finding (PEGV) | | |
| | 12/20 $t(3) = -4.472, P = 0.01$ | 17/20 $t(3) = -3.041; P = 0.03$ |
| Pyramids and Palm Trees | | |
| Written word | 49/52 $t(3) = 0, P = 0.5$ | 50/52 $t(3) = 0.28, P = 0.39$ |
| Visual | 44/52 $t(3) = -1.610, P = 0.1$ | 48/52 $t(3) = -0.179, P = 0.435$ |
| <i>Knowledge about the world</i> | | |
| Famous Scenes Test | | |
| | 3/10 $t(3) = -6.708, P = 0.003$ | 3/10 $t(3) = -6.708, P = 0.003$ |
| <i>Facial perception</i> | | |
| BFRT | | |
| | 19/27 (Pr = 8–11) | 23/27 (Pr = 72–85) |
| <i>Visual imagery</i> | | |
| Heads Test | | |
| | 27/30 $t(3) = -4.919, P = 0.008$ | 30/30 $t(3) = -1.32, P = 0.13$ |
| Animal Tails Test | | |
| Auditory | 7/14 $t(3) = -5.884, P = 0.005$ | 10/14 $t(3) = -3.060, P = 0.027$ |
| Masked | 9/14 $t(3) = -8.497, P = 0.002$ | 14/14 $t(3) = 0.447, P = 0.343$ |
| Unmasked | 14/14 | |
| <i>Spatial perception and spatial imagery</i> | | |
| Cube copying: WIE | 30/51 (preserved) | 30/51 (preserved) |
| VOSP: Space Perception | Subtests achieved (4/4) | Subtests achieved (3/4) |
| Judgment of Line Orientation | 21/30 (Pr = 22) | 22/30 (Pr = 22) |
| Manikin Test | 16/16 $t(3) = 0.706, P = 0.266$ | 16/16 |
| Block Rotation | 9/9 | 9/9 |
| Rotated Letters | 10/10 | 10/10 |

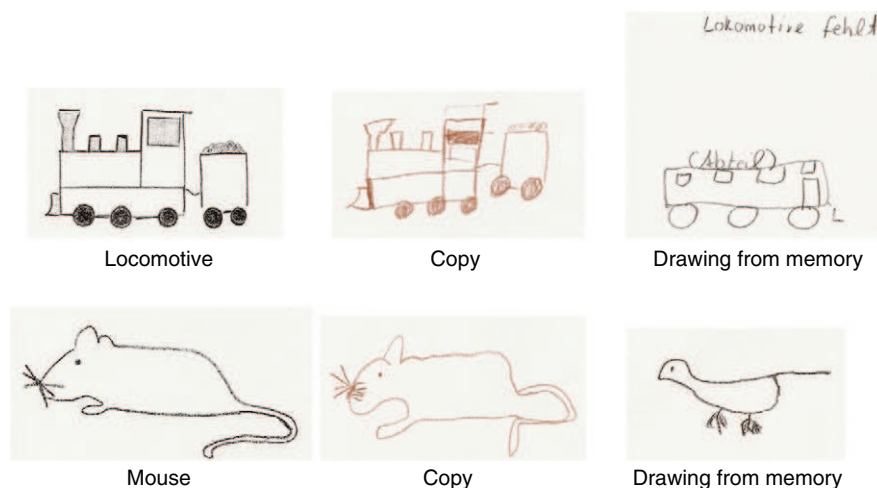

Fig. 2. Two examples of C.B.'s copying and drawing from memory.

as the normal view of objects could be categorized in the PEGV [44] and semantic attribution from verbal stimuli in the Pyramids and Palm Trees was spared. In addition, no category-specific impairment was detected. These results are consistent with studies that have found the majority of distortions of semantic memory in left TLE rather than right TLE [49,50] or anterior temporal atrophy [51].

In terms of mental imagery, C.B. also had problems with her ability to generate and revisualize a representation from the memory store, such as imagining and drawing visual details about objects and living things. However, her performance on spatial processing in either recognition or imagery was remarkably normal and she processed with no delay or hesitation. Thus, under the well-established two-stream hypothesis [2], it can be assumed that the impaired recognition of objects might have been caused by epileptic activity in the ventral path and that intact spatial capacities were possibly due to the unaffected dorsal stream that underlies spatial processing. As for the imagery domain for objects, the simultaneous inhibition and recovery in this patient are coherent with the argument favoring either shared neural representations or topographical closeness of these areas to the ventral pathway. Prior studies in brain areas responsible for perception and imagery have indicated that although some case studies report possible dissociations [6–8], neuroimaging techniques, such as PET [5] and functional MRI [52], generally show that perception and imagery for common objects share, at least partially, similar cerebral mechanisms. The fact that the spatial domain was preserved suggests that similar to perception, two different neuronal networks underlie visual and spatial imagery. Our findings are in line with a prior case

study that observed the inverse pattern of performance, a deficit for recognition and imagery of space and preserved visual object recognition and imagery [53]. More recently, in a PET study, occipitoparietal cortical areas were found to be involved in spatial imaging as well as in visual perception [54].

This is the first case, to the best of our knowledge, to discuss the recovery of visual imagery after successful epileptic surgery. We observed that C.B.'s visual access to semantics and visual imagery seemed to improve similarly to her executive functions. This alludes to the theoretical model of executive functions that has previously been characterized in epilepsy surgery. Impairment of executive functions is not uncommon in TLE, as the physiopathology involved is thought to be a result of the propagation of seizures from the temporal to the frontal lobes [55,56]. Recovery after anterior temporal lobectomy is common [24,25,57], implying that cognitive deficits caused by seizures can be reversed [57,58]. We therefore suggest, with caution, that in patients with TLE, the “bottom-up” and “top-down” mechanisms involved in visual perception could be affected and recover in a manner similar to executive functions.

Finally, the structural hippocampal lesion in C.B.'s right temporal lobe caused irreversible episodic memory damage and the memory degradation progressed even further into the verbal domain following ablation of the mesial temporal lobe structures. This finding, although not routine [23,58–60], has been described [61]. We suggest that interaction between a structural lesion and paroxysmal activity is responsible for this aspect of the cognitive profile in TLE [22]. C.B.'s structural deficits and postoperative functional changes are schematically illustrated in Fig. 3.

This study shows how structural and functional factors interact with one another and may be disentangled with specialized testing tools. In this case, unusual nonlesional electrophysiological disruptions affected extratemporal lobe functions such as object recognition and imagery, and we characterized these difficulties to determine their possible occurrence during the neuropsychological evaluation for right temporal lobe epilepsy. We observed that postoperative cognitive profile changes could have implications for the clinical prognosis, as it was demonstrated that these specific extratemporal lobe functions can recover with successful seizure control.

References

- [1] Mishkin M, Ungerleider LG. Contribution of striate inputs to the visuospatial functions of parieto-preoccipital cortex in monkeys. *Behav Brain Res* 1982;6:57–77.
- [2] Ungerleider LG, Haxby JV. 'What' and 'where' in the human brain. *Curr Opin Neurobiol* 1994;4:157–65.
- [3] Kosslyn SM. *Image and mind*. Cambridge: Harvard Univ. Press; 1980.

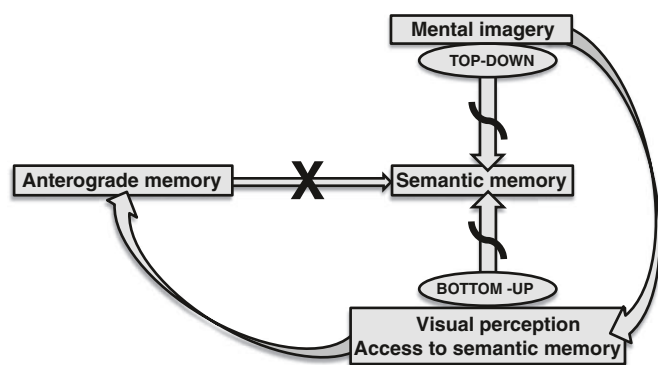


Fig. 3. Schema proposed to represent C.B.'s structural deficits (marked with an 'X') and postoperative functional changes (marked with curved lines).

- [4] Cichy RM, Heinze J, Haynes JD. Imagery and perception share cortical representations of content and location. *Cereb Cortex* June 2011 Epub 10.
- [5] Kosslyn SM, Thompson WL, Alpert NM. Neural systems shared by visual imagery and visual perception: a positron emission tomography study. *Neuroimage* 1997;6:320–34.
- [6] Farah MJ. Is visual imagery really visual? Overlooked evidence from neuropsychology. *Psychol Rev* 1988;95:307–17.
- [7] Bartolomeo P, Bachoud-Levi AC, De Gelder B, et al. Multiple-domain dissociation between impaired visual perception and preserved mental imagery in a patient with bilateral extrastriate lesions. *Neuropsychologia* 1998;36:239–49.
- [8] Behrmann M, Moscovitch M, Winocur G. Intact visual imagery and impaired visual perception in a patient with visual agnosia. *J Exp Psychol Hum Percept Perform* 1994;20:1068–87.
- [9] Piazzini A, Saetti C, Turner K, Fiorino A, Canger R, Canevini MP. Visuoperceptive impairment in adult patients with occipital lobe epilepsies. *Epilepsy Behav* 2009;15:256–9.
- [10] Carvajal F, Rubio S, Martin P, Serrano JM, Garcia-Sola R. Perception and recall of faces and facial expressions following temporal lobectomy. *Epilepsy Behav* 2009;14:60–5.
- [11] Grant AC, Donnelly KM, Chubb C, Barr WB, Kuzniecky R, Devinsky O. Temporal lobe epilepsy does not impair visual perception. *Epilepsia* 2008;49:710–3.
- [12] Helmstaedter C, Kurthen M. Memory and epilepsy: characteristics, course, and influence of drugs and surgery. *Curr Opin Neurol* 2001;14:211–6.
- [13] Milner B. Visual recognition and recall after right temporal-lobe excision in man. *Epilepsy Behav* 2003;4:799–812.
- [14] Blumcke I, Thom M, Wiestler OD. Ammon's horn sclerosis: a maldevelopmental disorder associated with temporal lobe epilepsy. *Brain Pathol* 2002;12:199–211.
- [15] Nadel L, Moscovitch M. Memory consolidation, retrograde amnesia and the hippocampal complex. *Curr Opin Neurobiol* 1997;7:217–27.
- [16] Saumier D, Chertkow H. Semantic memory. *Curr Neurol Neurosci Rep* 2002;2:516–22.
- [17] Tulving E. Episodic and semantic memory. In: Tulving E, Donaldson W, editors. *Organization of memory*. New York: Academic Press; 1972. p. 381–403.
- [18] Riddoch J, Humphrey G, Colheart M, Punnell E. Semantic system or systems? Neuropsychological evidence re-examined. *Cogn Neuropsychol* 1988;3:–25.
- [19] Bonelli SB, Powell RH, Yogarajah M, et al. Imaging memory in temporal lobe epilepsy: predicting the effects of temporal lobe resection. *Brain* 2010;133:1186–99.
- [20] Henry TR, Votaw JR. The role of positron emission tomography with [¹⁸F] fluorodeoxyglucose in the evaluation of the epilepsies. *Neuroimaging Clin N Am* 2004;14:517–35 ix.
- [21] Mueller SG, Laxer KD, Cashdollar N, Flenniken DL, Matson GB, Weiner MW. Identification of abnormal neuronal metabolism outside the seizure focus in temporal lobe epilepsy. *Epilepsia* 2004;45:355–66.
- [22] Elger CE, Helmstaedter C, Kurthen M. Chronic epilepsy and cognition. *Lancet Neurol* 2004;3:663–72.
- [23] Gleissner U, Helmstaedter C, Schramm J, Elger CE. Memory outcome after selective amygdalohippocampectomy: a study in 140 patients with temporal lobe epilepsy. *Epilepsia* 2002;43:87–95.
- [24] Kim CH, Lee SA, Yoo HJ, Kang JK, Lee JK. Executive performance on the Wisconsin Card Sorting Test in mesial temporal lobe epilepsy. *Eur Neurol* 2007;57:39–46.
- [25] Piazzini A, Turner K, Chifari R, Morabito A, Canger R, Canevini MP. Attention and psychomotor speed decline in patients with temporal lobe epilepsy: a longitudinal study. *Epilepsy Res* 2006;72:89–96.
- [26] Lehl S. Mehrfachwahl-Wortschatz-Intelligenztest: Manual mit Block MWT-B4th ed. Bathlingen: Spitta; 1999.
- [27] Brickenkamp R. Aufmerksamkeits-Belastungstest (Test d2). 9th ed. Göttingen: Hogrefe Verlag; 2002.
- [28] Kaplan E, Goodglass H, Weintraub S. Boston Naming Test. 2nd ed. Philadelphia: Lippincott Williams & Wilkins; 1983.
- [29] Horn W. L-P-S Leistungsprüfsystem (LPS-6). 2nd ed. Göttingen: Hogrefe Verlag; 1983.
- [30] Botermans. Turm von Hanoi mit 4 Scheiben Munich: Denkspiele der Welt; 1998.
- [31] Chapuis P. Labyrinth-Test. Bern: Huber Verlag; 1959.
- [32] Tombaugh TN. Trail Making Test A and B: normative data stratified by age and education. *Arch Clin Neuropsychol* 2004;19:203–14.
- [33] Helmstaedter C, Lendt M, Lux S. VLMT: Verbaler Lern- und Merkfähigkeitstest. Göttingen: Beltz Test GmbH; 2001.
- [34] Weidlich S, Lamberti G. DCS: Diagnosticum für Cerebralschädigung. Ein visueller Lern- und Gedächtnistest 4th ed. Göttingen: Huber Verlag; 2001.
- [35] Rey A. Manuel du test de copie d'une figure complexe de A. Rey. Paris: Les Editions du Centre de Psychologie Appliquée; 1959.
- [36] Benton AL. Der Benton Test. Bern: Huber Verlag; 1961.
- [37] Barbeau E, Didic M, Tramoni E, et al. Evaluation of visual recognition memory in MCI patients. *Neurology* 2004;62:1317–22.
- [38] Schelling D, Schächtele B. Verbaler und Visueller Merkfähigkeitstest (VVM). Frankfurt: Swets & Zeitlinger; 2001.
- [39] Manning L. Loss of visual imagery and defective recognition of parts of wholes in optic aphasia. *Neurocase* 2000;6:111–28.
- [40] Snodgrass JG, Vanderwart M. A standardized set of 260 pictures: norms for name agreement, image agreement, familiarity, and visual complexity. *J Exp Psychol Hum Learn* 1980;6:174–215.
- [41] Howard D, Patterson K. The Pyramids and Palm Trees Test. San Antonio, TX: Pearson; 1992.
- [42] Aster M, Neubauer A, Horn R. Mosaiktest aus: Wechsler Intelligenztest für Erwachsene (WIE): Deutschsprachige Bearbeitung und Adaptation des WAIS-III von David Wechsler. Frankfurt: Harcourt Test Services; 2006.
- [43] Davidoff J, Warrington EK. The bare bones of object recognition: implications from a case of object recognition impairment. *Neuropsychologia* 1999;37:279–92.
- [44] Agniel A, Joannette Y, Doyon B, Duchain C. Protocole d'évaluation des gnosies visuelles. Protocole Montréal-Toulouse module, 2. Montréal: Laboratoire Th Alajouanine, Centre de recherche du Centre Hospitalier Côte-des-Neiges; 1987.
- [45] Campbell R, Manning L. Optic aphasia: a case with spared action naming and associated disorders. *Brain Lang* 1996;53:183–221.
- [46] Ratcliff G. Spatial thought, mental rotation and the right cerebral hemisphere. *Neuropsychologia* 1979;17:49–54.
- [47] Crawford JR, Garthwaite PH. Investigation of the single case in neuropsychology: confidence limits on the abnormality of test scores and test score differences. *Neuropsychologia* 2002;40:1196–208.
- [48] Warrington EK, Taylor AM. The contribution of the right parietal lobe to object recognition. *Cortex* 1973;9:152–64.
- [49] Giovagnoli AR, Erbetta A, Villani F, Avanzini G. Semantic memory in partial epilepsy: verbal and non-verbal deficits and neuroanatomical relationships. *Neuropsychologia* 2005;43:1482–92.
- [50] Voltzenlogel V, Despres O, Vignal JP, Steinhoff BJ, Kehrli P, Manning L. Remote memory in temporal lobe epilepsy. *Epilepsia* 2006;47:1329–36.
- [51] Lambon Ralph MA, Lowe C, Rogers TT. Neural basis of category-specific semantic deficits for living things: evidence from semantic dementia, HSVE and a neural network model. *Brain* 2007;130:1127–37.
- [52] Ganis G, Thompson WL, Kosslyn SM. Brain areas underlying visual mental imagery and visual perception: an fMRI study. *Brain Res Cogn Brain Res* 2004;20:226–41.
- [53] Luzzatti C, Vecchi T, Agazzi D, Cesa-Bianchi M, Vergani C. A neurological dissociation between preserved visual and impaired spatial processing in mental imagery. *Cortex* 1998;34:461–9.
- [54] Vanlierde A, De Volder AG, Wanet-Defalque MC, Veraart C. Occipito-parietal cortex activation during visuo-spatial imagery in early blind humans. *Neuroimage* 2003;19:698–709.
- [55] McDonald CR, Delis DC, Norman MA, Wetter SR, Tecoma ES, Iragui VJ. Response inhibition and set shifting in patients with frontal lobe epilepsy or temporal lobe epilepsy. *Epilepsy Behav* 2005;7:438–46.
- [56] Wang XQ, Lang SY, Hong LU, Lin MA, Yan-ling MA, Yang F. Changes in extratemporal integrity and cognition in temporal lobe epilepsy: a diffusion tensor imaging study. *Neurol India* 2010;58:891–9.
- [57] Helmstaedter C. Effects of chronic temporal lobe epilepsy on memory functions. In: Arzimanoglou A, Aldenkamp A, Cross H, Lassonde M, Moshe SL, Schmitz B, editors. *Cognitive dysfunction in children with temporal lobe epilepsy*. Progress in Epileptic Disorders series. London: John Libbey; 2005. p. 13–30.
- [58] Helmstaedter C, Loer B, Wohlfahrt R, et al. The effects of cognitive rehabilitation on memory outcome after temporal lobe epilepsy surgery. *Epilepsy Behav* 2008;12:402–9.
- [59] Lutz MT, Clusmann H, Elger CE, Schramm J, Helmstaedter C. Neuropsychological outcome after selective amygdalohippocampectomy with transsylvian versus transcortical approach: a randomized prospective clinical trial of surgery for temporal lobe epilepsy. *Epilepsia* 2004;45:809–16.
- [60] White JR, Matchinsky D, Beniak TE, et al. Predictors of postoperative memory function after left anterior temporal lobectomy. *Epilepsy Behav* 2002;3:383–9.
- [61] Martin RC, Kretzmer T, Palmer C, et al. Risk to verbal memory following anterior temporal lobectomy in patients with severe left-sided hippocampal sclerosis. *Arch Neurol* 2002;59:1895–901.

Conclusions and Perspectives

Conclusions and perspectives

(i) “Visuo-spatial memory tests in right temporal lobe epilepsy foci: clinical validity“, aimed to assess the lateralizing validity of five visual figural reproduction and learning memory tests (DCS, VVM, ROCF, and the Corsi-Block-Tapping test) in a patient sample of eighty preoperative candidates with mesial TLE. The analysis showed that even when epilepsy related factors, such as the extent of the structural lesion or presence of contralateral IEDs were controlled, the visual memory tests were invalid instruments for lateralizing epileptic foci in our patient sample. However, when all test failures were considered, right TLE patients tended to fail more often than those in the left TLE group. An additional argument in favour of the theory of material-specificity is that one of the two tests used to assess verbal memory was shown to be an efficient instrument to lateralize, whereas the second indicated comparable failure to the visual tests. This suggests that success or failure may depend on a specific test instrument. Since neuropsychological diagnoses in clinical practice take into account the patient’s overall cognitive performance, additional correlation analysis was performed, which showed relationships with other cognitive domains that tend to be impaired in epilepsy patients. This study pointed to the fundamental problems that can exist for not only visual, but also verbal test methodology in the context of presurgical diagnostics. These results have strong implications for clinical psychologists regarding choice and interpretation of these tests depending on the patient’s individual cognitive situation. The immediate consequence of this study was to emphasize development of a new visual memory tool that would reduce the impact on other cognitive domains, such as demands on nonverbal reasoning, visual planning, and construction.

(ii) Pursuant to this, the second research project, “The importance of the DMS-48 as a visual recognition memory task for cognitive epilepsy evaluation“, introduced a delayed matching to sample task, based on visual recognition, previously successful in identifying mesial TL lesions in an MCI population. Hence, the DMS-48 was applied as an additional measure, to the figural learning and reproduction tests described in the first study. As the results indicated the lateralizing ability of the DMS-48, two parallel versions of the test were developed and standardized with an age and education matched control group.

The DMS-48 was the only visual memory test that continued to distinguish between, left and right medial TLE patients, while there was not material-specificity for the groups, when assessed with other tools not controlling for verbalization and additional intellectual skills. Thus, the principal paradigm of the theory of material-specificity, postulating that unilateral hemispheric dysfunctions result in a dissociation of verbal and visual memory skills, was not disproven, however the assumption that emphasizes the internally homogenous modularity of verbal and visual memory, suggesting that tasks with different methodology can be substituted with one another, was invalidated. We therefore propose that newly developed neuropsychological tools that aim to lateralize memory dysfunction should be validated for epilepsy patients. Specifically, since this population may have supplementary functional deficits to the structural lesions. Prior mapping with fMRI paradigms of brain regions activated by certain stimuli and requiring specific skills could help ameliorate test validity.

Although, the patient sample differed pre- and postoperatively regarding the DMS-48 and its parallel versions, and in addition verbal memory dropped for left sided resections, the right TLE group did not change, suggesting that right TLE patients do not bear any postoperative risk in loss of visual memory. In order to explore this question, we advocate for cross-validation of this test with an increased patient sample size and including biomarkers such as advanced MRI analysis and postoperative histology.

(iii) The third experiment, “Visuoperceptual and visuospatial abilities prior to and after anterior temporal lobectomy: a case study”, showed that ictal epileptic propagation pattern to the posterior temporal and occipital lobes along the ventral visual pathway, associated with right hippocampal sclerosis, can cause deficits in accessing semantic memory from vision and visual imagery for objects while the perception and imagery for spaces may be spared. This suggests that two different neuronal networks underlie imagery for objects and for space, with the later, being situated in the dorsal visual stream. Additionally, since these deficits recuperated after successful surgery, we conclude that impairment in visual “top-down” and “bottom-up mechanisms” is not associated with structural issues such as the mesio-temporal lesion, but is related to more posterior functional temporo-occipital disturbances, similar to deficits in executive functions after ictal propagation to the frontal lobe.

Conclusions and perspectives

Since the perceptive and executive difficulties arrested at the same time as the seizure activity, it would be difficult to measure the occurrence of perceptive disturbances in epilepsy patients with rare disturbances to the visual pathways, with and without impairment to executive functions, thus, implicating the frontal lobes. Application of techniques such as fMRI could also be appropriate procedures to map in selected cases. Finally, the significance of disturbances in visual perception on the patient's quality of life and other cognitive functions, remains relevant to explore.

References

- (1981) Proposal for revised clinical and electroencephalographic classification of epileptic seizures. From the Commission on Classification and Terminology of the International League Against Epilepsy. *Epilepsia* 22:489-501.
- (1989) Proposal for revised classification of epilepsies and epileptic syndromes. Commission on Classification and Terminology of the International League Against Epilepsy. *Epilepsia* 30:389-399.
- Agniel A, Joannette Y, Doyon B, Duchain C (1987) Protocole d'évaluation des gnosies visuelles. Protocole Montréal-Toulouse module 2. Montréal, Canada: Laboratoire Th Alajouanine. Centre de recherche du Centre Hospitalier Côte-des-Neiges
- Akman CI, Hu Y, Fu DD, Holmes GL (2003) The influence of cognitive reserve on seizure-induced injury. *Epilepsy & Behav* 4:435-440.
- Aldenkamp A, Arends J (2004a) The relative influence of epileptic EEG discharges, short nonconvulsive seizures, and type of epilepsy on cognitive function. *Epilepsia* 45:54-63.
- Aldenkamp AP, Arends J (2004b) Effects of epileptiform EEG discharges on cognitive function: is the concept of "transient cognitive impairment" still valid? *Epilepsy & Behav*: 5 Suppl 1:25-34.
- Alvarez P, Squire LR (1994) Memory consolidation and the medial temporal lobe: a simple network model. *Proc Natl Acad Sci U S A* 91:7041-7045.
- Araujo GC, Schwarze NJ, White DA (2009) Lateralizing seizure focus in presurgical patients with temporal lobe epilepsy: utility of the Ruff-Light Trail Learning Test. *Epilepsy & Behavior* 15:496-499.
- Asadi-Pooya A, Sperling M (2009) Antiepileptic drugs: A clinicians manual. pp 15-69 New York, USA: Oxford University Press.
- Aster M, Neubauer A, Horn R (2006) Mosaiktest aus: Wechsler Intelligenztest für Erwachsene (WIE). Deutschsprachige Bearbeitung und Adaptation des WAIS-III von David Wechsler. Frankfurt, Germany: Harcourt Test Services.
- Atkinson RC, Shiffrin RM (1968) Human memory: a proposed system and its control processes. In: *The Psychology of Learning and Motivation: Advances in Research and Theory*, vol. 2 (Spence, K. W., ed), pp 89-195 New York: Academic Press.
- Baddeley A (2000) The episodic buffer: a new component of working memory? *Trends in Cognitive Sciences* 4:417-423.
- Baddeley AD (1974) Working Memory. In: *Recent Advances in Learning and Motivation*, vol. 8 (Bower, G. A., ed), pp 47-89 New York: University Press.
- Baddeley AD, Emslie H, Nino-Smith I (1994) *Doors and People: A test of visual and verbal recall and recognition* Bury St. Edmunds, England: Thames Valley Test Company.
- Baglietto MG, Battaglia FM, Nobili L, Tortorelli S, De Negri E, Calevo MG, Veneselli E, De Negri M (2001) Neuropsychological disorders related to interictal epileptic discharges during sleep in benign epilepsy of childhood with centrotemporal or Rolandic spikes. *Developmental medicine and child neurology* 43:407-412.
- Baker GA, Goldstein LH (2004) The dos and don'ts of neuropsychological assessment in epilepsy. *Epilepsy & Behav*: 5 Suppl 1:77-80.

References

- Banks SJ, Jones-Gotman M, Ladowski D, Sziklas V (2012) Sex differences in the medial temporal lobe during encoding and recognition of pseudowords and abstract designs. *NeuroImage* 59:1888-1895.
- Barbeau E, Didic M, Tramon E, Felician O, Joubert S, Sontheimer A, Ceccaldi M, Poncet M (2004a) Evaluation of visual recognition memory in MCI patients. *Neurology* 62:1317-1322.
- Barbeau E, Tramon E, Joubert S, Didic M, Poncet M (2004b) Evaluation de la memoire de reconnaissance visuelle: normalisation d'une nouvelle epreuve en choix force et utilite en neuropsychologie clinique. In: *Les troubles de la memoire dans la maladie d'Alzheimer* (Ergis, A. M. et al., eds), pp 85-101 Marseille, France: Editions Solal.
- Barbeau EJ, Pariente J, Felician O, Puel M (2010) Visual recognition memory: A double anatomo-functional dissociation. *Hippocampus* 21: 923-34.
- Barr W, Morrison C, Zaroff C, Devinsky O (2004) Use of the Brief Visuospatial Memory Test-Revised (BVMT-R) in neuropsychological evaluation of epilepsy surgery candidates. *Epilepsy & Behav* 5:175-179.
- Barr WB (1997) Examining the right temporal lobe's role in nonverbal memory. *Brain Cogn* 35:26-41.
- Barr WB, Chelune GJ, Hermann BP, Loring DW, Perrine K, Strauss E, Trenerry MR, Westerveld M (1997) The use of figural reproduction tests as measures of nonverbal memory in epilepsy surgery candidates. *J Int Neuropsychol Soc* 3:435-443.
- Bartolomeo P (2002) The Relationship Between Visual Perception and Visual Mental Imagery: A Reappraisal of the Neuropsychological Evidence. *Cortex* 38:357-378.
- Bartolomeo P (2008) The neural correlates of visual mental imagery: an ongoing debate. *Cortex* 44:107-108.
- Bartolomeo P, Bachoud-Levi AC, De Gelder B, Denes G, Dalla Barba G, Brugieres P, Degos J-D (1998) Multiple-domain dissociation between impaired visual perception and preserved mental imagery in a patient with bilateral extrastriate lesions *Neuropsychologia* 36:239-249.
- Bauer RM, Demery JA (2003) Agnosia. In: *Clinical neuropsychology* (Heilman, K. M. and Valenstein, E., eds), pp 236-295 Oxford: Oxford University Press.
- Baxendale SA (1997) The role of the hippocampus in recognition memory. *Neuropsychologia* 35:591-598.
- Behrmann M, Moscovitch M, Winocur G (1994) Intact visual imagery and impaired visual perception in a patient with visual agnosia. *J Exp Psychol Hum Percept Perform* 20:1068-1087.
- Behrmann M, Winocur G, Moscovitch M (1992) Dissociation between mental imagery and object recognition in a brain-damaged patient. *Nature* 359:636-637.
- Bell BD, Fine J, Dow C, Seidenberg M, Hermann BP (2005) Temporal lobe epilepsy and the selective reminding test: the conventional 30-minute delay suffices. *Psychological Assessment* 17:103-109.
- Bell BD, Giovagnoli AR (2007) Recent innovative studies of memory in temporal lobe epilepsy. *Neuropsychol Rev* 17:455-476.
- Benchenane K, Tiesinga PH, Battaglia FP (2011) Oscillations in the prefrontal cortex: a gateway to memory and attention. *Curr Opin Neurobiol* 21:475-485.
- Bendict C (2008) H. M., an Unforgettable Amnesiac, Dies at 82. In: *The New York Times* New York, USA.
- Bengner T, Malina T (2007) Dissociation of short- and long-term face memory: evidence from long-term recency effects in temporal lobe epilepsy. *Brain Cogn* 64:189-200.

References

- Bengner T, Malina T (2010) Long-term face memory as a measure of right temporal lobe function in TLE: the Alsterdorfer Faces Test. *Epilepsy Res* 89:142-147.
- Bengner T, Malina T, Lindenau M, Voges B, Goebell E, Stodieck S (2006) Face memory in MRI-positive and MRI-negative temporal lobe epilepsy. *Epilepsia* 47:1904-1914.
- Bennett TL (1992) *The Neuropsychology of epilepsy*. New York: Plenum Press.
- Benson DF, Greenberg JP (1969) Visual form agnosia. A specific defect in visual discrimination. *Arch Neurol* 20:82-89.
- Berg AT, Berkovic SF, Brodie MJ, Buchhalter J, Cross JH, van Emde Boas W, Engel J, French J, Glauser TA, Mathern GW, Moshe SL, Nordli D, Plouin P, Scheffer IE (2010) Revised terminology and concepts for organization of seizures and epilepsies: report of the ILAE Commission on Classification and Terminology, 2005-2009. *Epilepsia* 51:676-685.
- Berg AT, Scheffer IE (2011) New concepts in classification of the epilepsies: entering the 21st century. *Epilepsia* 52:1058-1062.
- Berger H (1929) Ueber das Elektrekephalogramm. *Arch Psychiatr Nervenkr* 97:6-26.
- Blake RV, Wroe SJ, Breen EK, McCarthy RA (2000) Accelerated forgetting in patients with epilepsy: evidence for an impairment in memory consolidation. *Brain* 123:472-483.
- Blakemore CB, Falconer MA (1967) Long-term effects of anterior temporal lobectomy on certain cognitive functions. *J Neurol Neurosurg Psychiatry* 30:364-367.
- Bliss TV, Gardner-Medwin AR (1973) Long-lasting potentiation of synaptic transmission in the dentate area of the unanaesthetized rabbit following stimulation of the perforant path. *The Journal of Physiology* 232:357-374.
- Bonelli SB, Powell RH, Yogarajah M, Samson RS, Symms MR, Thompson PJ, Koepp MJ, Duncan JS (2010) Imaging memory in temporal lobe epilepsy: predicting the effects of temporal lobe resection. *Brain* 133:1186-1199.
- Brown FC, Tuttle E, Westerveld M, Ferraro FR, Chmielowiec T, Vandemore M, Gibson-Beverly G, Bemus L, Roth RM, Blumenfeld H, Spencer DD, Spencer SS (2010) Visual memory in patients after anterior right temporal lobectomy and adult normative data for the Brown Location Test. *Epilepsy & Behav* 17:215-220.
- Brueckner K, Lutz M (2010) Standards in der neuropsychologischen prae- und postchirurgischen Epilepsiediagnostik. *Zeitschrift fuer Epileptologie* 23:64-65.
- Butler C, Muhlert N, Zeman A (2010) Accelerated long-term forgetting. In: *Forgetting, Current issues in memory*, pp 215-237 East Sussex Eng. New York: Psychology Press.
- Butler CR, Bhaduri A, Acosta-Cabronero J, Nestor PJ, Kapur N, Graham KS, Hodges JR, Zeman AZ (2009) Transient epileptic amnesia: regional brain atrophy and its relationship to memory deficits. *Brain* 132:357-368.
- Butler CR, Zeman AZ (2008) Recent insights into the impairment of memory in epilepsy: transient epileptic amnesia, accelerated long-term forgetting and remote memory impairment. *Brain* 131:2243-2263.
- Carvajal F, Rubio S, Martin P, Serrano JM, Garcia-Sola R (2009) Perception and recall of faces and facial expressions following temporal lobectomy. *Epilepsy & Behav* 14:60-65.
- Chabardes S, Prabhu S, Tanriverdi T (2011) Surgery for temporal lobe epilepsy: pros, cons and comparison between different procedures. In: *The mesial temporal lobe epilepsies*, vol. 9 (Rosenow, F. et al., eds), pp 245-262 Montrouge, France: John Libbey Eurotext.

References

- Chelune GJ (1995) Hippocampal adequacy versus functional reserve: predicting memory functions following temporal lobectomy. *Arch Clin Neuropsychol* 10:413-432.
- Cheung MC, Chan AS, Chan YL, Lam JM, Lam W (2006) Effects of illness duration on memory processing of patients with temporal lobe epilepsy. *Epilepsia* 47:1320-1328.
- Chiaravalloti ND, Glosser G (2001) Material-specific memory changes after anterior temporal lobectomy as predicted by the intracarotid amobarbital test. *Epilepsia* 42:902-911.
- Chiaravalloti ND, Tulskey DS, Glosser G (2004) Validation of the WMS-III Facial Memory subtest with the Graduate Hospital Facial Memory Test in a sample of right and left anterior temporal lobectomy patients. *J Clin Exp Neuropsychol* 26:484-497.
- Cichy RM, Heinzle J, Haynes JD (2011) Imagery and Perception Share Cortical Representations of Content and Location. *Cereb Cortex* 22:372-380.
- Cormack F, Cross JH, Isaacs E, Harkness W, Wright I, Vargha-Khadem F, Baldeweg T (2007) The development of intellectual abilities in pediatric temporal lobe epilepsy. *Epilepsia* 48:201-204.
- Craik KJW (1943) *The nature of explanation*. Cambridge Eng: University Press.
- Crane J, Milner B (2002) Do I know you? Face perception and memory in patients with selective amygdalo-hippocampectomy. *Neuropsychologia* 40:530-538.
- Cubelli R (2010) A new taxonomy of memory and forgetting. In: *Forgetting*, vol. 1 (Della Sala, S., ed), pp 35-47 New York: Psychology Press.
- D'Esposito M, Detre JA, Aguirre GK, Stallcup M, Alsop DC, Tippet LJ, Farah MJ (1997) A functional MRI study of mental image generation. *Neuropsychologia* 35:725-730.
- Damasio AR, Damasio H, Van Hoesen GW (1982) Prosopagnosia: anatomic basis and behavioral mechanisms. *Neurology* 32:331-341.
- Davidoff J, Warrington EK (1999) The bare bones of object recognition: implications from a case of object recognition impairment. *Neuropsychologia* 37:279-292.
- Demiralp T, Bayraktaroglu Z, Lenz D, Junge S, Busch NA, Maess B, Ergen M, Herrmann CS (2007) Gamma amplitudes are coupled to theta phase in human EEG during visual perception. *Int J Psychophysiol* 64:24-30.
- Denman SB (1984) Denman Neuropsychology Memory Scale. This test may be ordered from Sidney B. Denman, 1040 Fort Sumter Drive Charleston, SC 29412, USA.
- Dewar M, Cowan N, Della Sala S (2010) Forgetting due to retroactive interference in amnesia. In: *Forgetting, Current issues in memory*, pp 185-209 East Sussex Eng. New York: Psychology Press.
- Dudai Y, Eisenberg M (2004) Rites of passage of the engram: reconsolidation and the lingering consolidation hypothesis. *Neuron* 44:93-100.
- Eichenbaum H, Yonelinas AP, Ranganath C (2007) The medial temporal lobe and recognition memory. *Annual Review of Neuroscience* 30:123-152.
- Elger CE, Helmstaedter C, Kurthen M (2004) Chronic epilepsy and cognition. *Lancet Neurol* 3:663-672.
- Engel J, Jr. (2001a) Mesial temporal lobe epilepsy: what have we learned? *Neuroscientist* 7:340-352.
- Engel J, Jr. (2001b) A proposed diagnostic scheme for people with epileptic seizures and with epilepsy: report of the ILAE Task Force on Classification and Terminology. *Epilepsia* 42:796-803.
- Engel J, Jr. (2006) Report of the ILAE classification core group. *Epilepsia* 47:1558-1568.

References

- Engel JJ, Williamson PD, Wieser HG (1997) Mesial temporal lobe epilepsy. In: *Epilepsy: A comprehensive Textbook* (Engel, J. J. and T.A., P., eds), pp 2417-2426 Philadelphia: Lippincott-Raven.
- Erdelyi MH (2010) The ups and downs of memory. *The American psychologist* 65:623-633.
- Eriksson K, Kylliainen A, Hirvonen K, Nieminen P, Koivikko M (2003) Visual agnosia in a child with non-lesional occipito-temporal CSWS. *Brain & Development* 25:262-267.
- Estler C-J, Schmidt H (2007) *Pharmakologie und Toxikologie: Fuer Studium und Praxis*. Miesbach, Germany: Schattauer.
- Fahle M (2008) Visuelles System und visuelle Wahrnehmung. In: *Handbuch der Neuro- und Biopsychologie* (Gauggel, S. and Herrmann, M., eds), pp 359-374 Goettingen: Hogrefe.
- Farah MJ (1984) The neurological basis of mental imagery: a componential analysis. *Cognition* 18:245-272.
- Farah MJ (1988) Is visual imagery really visual? Overlooked evidence from neuropsychology. *Psychological Review* 95:307-317.
- Farah MJ (2000) *The cognitive neuroscience of vision*. Malden, Mass., USA: Blackwell Publishers.
- Farah MJ (2004) *Visual agnosia*. Cambridge, United States of America: MIT Press.
- Farah MJ, Hammond KM, Levine DN, Calvanio R (1988) Visual and spatial mental imagery: dissociable systems of representation. *Cognitive Psychology* 20:439-462.
- Figueiredo P, Santana I, Teixeira J, Cunha C, Machado E, Sales F, Almeida E, Castelo-Branco M (2008) Adaptive visual memory reorganization in right medial temporal lobe epilepsy. *Epilepsia* 49:1395-1408.
- Fisher RS, van Emde Boas W, Blume W, Elger C, Genton P, Lee P, Engel J, Jr. (2005) Epileptic seizures and epilepsy: definitions proposed by the International League Against Epilepsy (ILAE) and the International Bureau for Epilepsy (IBE). *Epilepsia* 46:470-472.
- Frank J, Landeira-Fernandez J (2008) Comparison between two scoring systems of the Rey-Osterrieth Complex Figure in left and right temporal lobe epileptic patients. *Archives of clinical neuropsychology* 23:839-845.
- Franzen MD (2000) *Reliability and validity in neuropsychological assessment*. New York: Kluwer Academic/Plenum Publishers.
- Gastaut H (1973) *Dictionary of epilepsy*. Geneva: World Health Organization.
- Gazzaniga MS (1970) *The bisected brain*. New York,: Appleton-Century-Crofts.
- Gazzaniga MS, Bogen JE, Sperry RW (1965) Observations on visual perception after disconnection of the cerebral hemispheres in man. *Brain* 88:221-236.
- Giovagnoli AR, Erbetta A, Villani F, Avanzini G (2005) Semantic memory in partial epilepsy: verbal and non-verbal deficits and neuroanatomical relationships. *Neuropsychologia* 43:1482-1492.
- Glauser T, Ben-Menachem E, Bourgeois B, Cnaan A, Chadwick D, Guerreiro C, Kalviainen R, Mattson R, Perucca E, Tomson T (2006) ILAE treatment guidelines: evidence-based analysis of antiepileptic drug efficacy and effectiveness as initial monotherapy for epileptic seizures and syndromes. *Epilepsia* 47:1094-1120.
- Gleissner U, Helmstaedter C, Elger CE (1998) Right hippocampal contribution to visual memory: a presurgical and postsurgical study in patients with temporal lobe epilepsy. *Journal of Neurology, Neurosurgery, and Psychiatry* 65:665-669.

References

- Gleissner U, Helmstaedter C, Schramm J, Elger CE (2002) Memory outcome after selective amygdalohippocampectomy: a study in 140 patients with temporal lobe epilepsy. *Epilepsia* 43:87-95.
- Glikmann-Johnston Y, Saling MM, Chen J, Cooper KA, Beare RJ, Reutens DC (2008) Structural and functional correlates of unilateral mesial temporal lobe spatial memory impairment. *Brain* 131:3006-3018.
- Glosser G, Cole L, Khatri U, DellaPietra L, Kaplan E (2002) Assessing nonverbal memory with the Biber Figure Learning Test-Extended in temporal lobe epilepsy patients. *Arch Clin Neuropsychol* 17:25-35.
- Golby AJ, Poldrack RA, Brewer JB, Spencer D, Desmond JE, Aron AP, Gabrieli JD (2001) Material-specific lateralization in the medial temporal lobe and prefrontal cortex during memory encoding. *Brain* 124:1841-1854.
- Golby AJ, Poldrack RA, Illes J, Chen D, Desmond JE, Gabrieli JD (2002) Memory lateralization in medial temporal lobe epilepsy assessed by functional MRI. *Epilepsia* 43:855-863.
- Grant AC, Donnelly KM, Chubb C, Barr WB, Kuzniecky R, Devinsky O (2008) Temporal lobe epilepsy does not impair visual perception. *Epilepsia* 49:710-713.
- Hamberger MJ, Cole J (2011) Language organization and reorganization in epilepsy. *Neuropsychol Rev* 21:240-251.
- Hampstead BM, Lacey S, Ali S, Phillips PA, Stringer AY, Sathian K (2010) Use of complex three-dimensional objects to assess visuospatial memory in healthy individuals and patients with unilateral amygdalohippocampectomy. *Epilepsy & Behav* 18:54-60.
- Hartje W, Poeck K (2006) *Klinische Neuropsychologie*. Stuttgart, Germany: Thieme Verlag.
- Hauptmann A (1912) Luminal bei Epilepsie. *59*:107-109.
- Helmstaedter C (2005) Effects of chronic temporal lobe epilepsy on memory functions. In: *Cognitive dysfunction in children with temporal lobe epilepsy* (Arzimanoglou, A. et al., eds), pp 13-30 London, U.K.: John Libbey, Progress in Epileptic Disorders Series.
- Helmstaedter C, Brosch T, Kurthen M, Elger CE (2004) The impact of sex and language dominance on material-specific memory before and after left temporal lobe surgery. *Brain* 127:1518-1525.
- Helmstaedter C, Elger CE (2009a) Chronic temporal lobe epilepsy: a neurodevelopmental or progressively dementing disease? *Brain* 132:2822-2830.
- Helmstaedter C, Kurthen M (2001a) Memory and epilepsy: characteristics, course, and influence of drugs and surgery. *Curr Opin Neurol* 14:211-216.
- Helmstaedter C, Kurthen M, Lux S, Reuber M, Elger CE (2003) Chronic epilepsy and cognition: a longitudinal study in temporal lobe epilepsy. *Ann Neurol* 54:425-432.
- Helmstaedter C, Lendt M, Lux S (2001b) VLMT: Verbaler Lern- und Merkfähigkeitstest. Göttingen, Germany: Beltz Test GmbH.
- Helmstaedter C, Pohl C, Elger CE (1991) Eine modifizierte Version des Diagnosticums für Cerebralschäden (DCS) zur Diagnostik räumlich-visueller Gedächtnisdefizite bei Patienten mit Temporallappenepilepsie. In: *Epilepsie* 90 (Scheffner, D., ed), pp 272-279 Reinbeck, Germany: Einhorn-PressVerlag.
- Helmstaedter C, Pohl C, Elger CE (1995) Relations between verbal and nonverbal memory performance: evidence of confounding effects particularly in patients with right temporal lobe epilepsy. *Cortex* 31:345-355.
- Helmstaedter C, Richter S, Roske S, Oltmanns F, Schramm J, Lehmann TN (2008) Differential effects of temporal pole resection with amygdalohippocampectomy

- versus selective amygdalohippocampectomy on material-specific memory in patients with mesial temporal lobe epilepsy. *Epilepsia* 49:88-97.
- Helmstaedter C, Wietzke J, Lutz MT (2009b) Unique and shared validity of the "Wechsler logical memory test", the "California verbal learning test", and the "verbal learning and memory test" in patients with epilepsy. *Epilepsy Res* 87:203-212.
- Herlitz A, Yonker JE (2002) Sex differences in episodic memory: the influence of intelligence. *J Clin Exp Neuropsychol* 24:107-114.
- Hermann BP, Connel, B., Barr, W.B., Wyler, A.R. (1995) The utility of the warrington recognition memory test for temporal lobe epilepsy: pre- and postoperative results. *Journal of Epilepsy* 8:139-145.
- Hermann BP, Seidenberg M, Schoenfeld J, Davies K (1997) Neuropsychological characteristics of the syndrome of mesial temporal lobe epilepsy. *Arch Neurol* 54:369-376.
- Hillebrand B (2007) *Geschichte der Epilepsien*. Norderstedt, Germany: Verlag fuer Akademische Texte.
- Holmes GL, Lenck-Santini PP (2006) Role of interictal epileptiform abnormalities in cognitive impairment. *Epilepsy & Behav* 8:504-515.
- Hoppe C, Elger CE, Helmstaedter C (2007) Long-term memory impairment in patients with focal epilepsy. *Epilepsia* 48 Suppl 9:26-29.
- Hufnagel A (2008) *Operative Epilepsiebehandlung*. pp 1-2 Berlin: Informationszentrum Epilepsie (ize) der Dt. Gesellschaft für Epileptologie e.V.
- Hyun JS, Luck SJ (2007) Visual working memory as the substrate for mental rotation. *Psychonomic Bulletin & Review* 14:154-158.
- Janszky J, Jokeit H, Kontopoulou K, Mertens M, Ebner A, Pohlmann-Eden B, Woermann FG (2005) Functional MRI predicts memory performance after right mesiotemporal epilepsy surgery. *Epilepsia* 46:244-250.
- Janszky J, Ollech I, Jokeit H, Kontopoulou K, Mertens M, Pohlmann-Eden B, Ebner A, Woermann FG (2004) Epileptic activity influences the lateralization of mesiotemporal fMRI activity. *Neurology* 63:1813-1817.
- Janszky J, Schulz R, Hoppe M, Ebner A (2003) Spikes on the postoperative EEG are related to preoperative spike frequency and postoperative seizures. *Epilepsy Res* 57:153-158.
- Jokeit H, Daamen M, Zang H, Janszky J, Ebner A (2001) Seizures accelerate forgetting in patients with left-sided temporal lobe epilepsy. *Neurology* 57:125-126.
- Jokeit H, Ebner A (1999) Long term effects of refractory temporal lobe epilepsy on cognitive abilities: a cross sectional study. *Journal of Neurology, Neurosurgery, and Psychiatry* 67:44-50.
- Jokeit H, Kramer G, Ebner A (2005) Do antiepileptic drugs accelerate forgetting? *Epilepsy & Behav* 6:430-432.
- Jones-Gotman M, Zatorre RJ, Olivier A, Andermann F, Cendes F, Staunton H, McMackin D, Siegel AM, Wieser HG (1997) Learning and retention of words and designs following excision from medial or lateral temporal-lobe structures. *Neuropsychologia* 35:963-973.
- Kennepohl S, Sziklas V, Garver KE, Wagner DD, Jones-Gotman M (2007) Memory and the medial temporal lobe: hemispheric specialization reconsidered. *NeuroImage* 36:969-978.
- Kim DW, Lee SK, Nam H, Chu K, Chung CK, Lee SY, Choe G, Kim HK (2010) Epilepsy with dual pathology: surgical treatment of cortical dysplasia accompanied by hippocampal sclerosis. *Epilepsia* 51:1429-1435.

References

- Kimura D (1961) Some effects of temporal-lobe damage on auditory perception. *Canadian Journal of Psychology* 15:156-165.
- Kimura D (1963) Right temporal-lobe damage. Perception of unfamiliar stimuli after damage. *Arch Neurol* 8:264-271.
- Kinsbourne M, Warrington EK (1963) The Localizing Significance of Limited Simultaneous Visual Form Perception. *Brain* 86:697-702.
- Knake S, Wehner W, Grant E (2011) Structural imaging of mesial temporal lobe epilepsy. In: *The mesial temporal lobe epilepsies*, vol. 9 (Rosenow, F. et al., eds), pp 165-174 Montrouge, France: John Libbey Eurotext.
- Kneebone AC, Chelune GJ, Dinner DS, Naugle RI, Awad IA (1995) Intracarotid amobarbital procedure as a predictor of material-specific memory change after anterior temporal lobectomy. *Epilepsia* 36:857-865.
- Kosslyn SM (1980) *Image and mind*. Cambridge, United States of America: Harvard University Press.
- Kosslyn SM, Thompson WL, Alpert NM (1997) Neural systems shared by visual imagery and visual perception: a positron emission tomography study. *NeuroImage* 320-334.
- Kwan P, Brodie MJ (2010) Definition of refractory epilepsy: defining the indefinable? *Lancet Neurol* 9:27-29.
- Labudda K, Woermann FG (2011) The role of cognitive fMRI in mesial temporal lobe epilepsy. In: *The mesial temporal lobe epilepsies*, vol. 9 (Rosenow, F. et al., eds), pp 175-188 Montrouge, France: John Libbey Eurotext.
- Lado FA, Laureta EC, Moshe SL (2002) Seizure-induced hippocampal damage in the mature and immature brain. *Epileptic Disord* 4:83-97.
- Lambon Ralph MA, Lowe C, Rogers TT (2007) Neural basis of category-specific semantic deficits for living things: evidence from semantic dementia, HSVE and a neural network model. *Brain* 130:1127-1137.
- Lee AC, Buckley MJ, Pegman SJ, Spiers H, Scahill VL, Gaffan D, Bussey TJ, Davies RR, Kapur N, Hodges JR, Graham KS (2005) Specialization in the medial temporal lobe for processing of objects and scenes. *Hippocampus* 15:782-797.
- Lee AC, Robbins TW, Owen AM (2000) Episodic memory meets working memory in the frontal lobe: functional neuroimaging studies of encoding and retrieval. *Critical Reviews in Neurobiology* 14:165-197.
- Lee GP (2010) *Neuropsychology of epilepsy and epilepsy surgery*. Oxford, U.K.: Oxford University Press.
- Lehrl S (1999) *Mehrfachwahl-Wortschatz-Intelligenztest: Manual mit Block MWT-B*. Bahlingen, Germany: Spitta.
- Liebe S, Hoerzer GM, Logothetis NK, Rainer G (2012) Theta coupling between V4 and prefrontal cortex predicts visual short-term memory performance. *Nature Neuroscience* 15:456-462.
- Lissauer H (1890) Ein Fall von Seelenblindheit nebst einem Beitrage zur Theorie der selben *Archiv fuer Psychiatrie und Nervenkrankheiten* 21:222-270.
- Locock C (1857) Discussion of paper by E. H. Sieveking: analysis of 52 cases of epilepsy observed by the author. *Lancet* i:525.
- Loring DW (2010) History of neuropsychology through epilepsy eyes. *Arch Clin Neuropsychol* 25:259-273.
- Loring DW, Lee GP, Meador KJ (1988) Revising the Rey-Osterrieth: rating right hemisphere recall. *Archives of clinical neuropsychology : the official journal of the National Academy of Neuropsychologists* 3:239-247.

References

- Loring DW, Meador KJ (2003) The Medical College of Georgia (MCG) Complex Figures: Four forms for follow-up. . In: Rey-Osterrieth handbook((Eds.), J. K. E. K., ed) Odessa: Psychological Assessment Resources.
- Luck SJ, Hollingworth AR (2008) Visual memory. New York: Oxford University Press.
- Luck SJ, Vogel EK (1997) The capacity of visual working memory for features and conjunctions. *Nature* 390:279-281.
- Lutz MT, Clusmann H, Elger CE, Schramm J, Helmstaedter C (2004) Neuropsychological outcome after selective amygdalohippocampectomy with transsylvian versus transcortical approach: a randomized prospective clinical trial of surgery for temporal lobe epilepsy. *Epilepsia* 45:809-816.
- Lyseng-Williamson KA (2011) Spotlight on levetiracetam in epilepsy. *CNS Drugs* 25:901-905.
- Mameniskiene R, Jatuzis D, Kaubrys G, Budrys V (2006) The decay of memory between delayed and long-term recall in patients with temporal lobe epilepsy. *Epilepsy Behav* 8:278-288.
- Manning L (2000) Loss of visual imagery and defective recognition of parts of wholes in optic aphasia. *Neurocase* 6:111-128.
- Markowitsch HJ (2000) The anatomical bases of memory. In: The new cognitive neurosciences (Gazzaniga, M. S., ed) Cambridge, MA: MIT Press.
- Martin RC, Kretzmer T, Palmer C, Sawrie S, Knowlton R, Faught E, Morawetz R, Kuzniecky R (2002) Risk to verbal memory following anterior temporal lobectomy in patients with severe left-sided hippocampal sclerosis. *Arch Neurol* 59:1895-1901.
- Mayer H (2011) Neuropsychologie der Epilepsien. Goettingen, Germany: Hogrefe.
- Mayer V, Yates AJ (1955) Intellectual changes following temporal lobectomy for psychomotor epilepsy; preliminary communication. *J Neurol Neurosurg Psychiatry* 18:44-52.
- Mayes AR, Isaac CL, Holdstock JS, Cariga P, Gummer A, Roberts N (2003) Long-term amnesia: a review and detailed illustrative case study. *Cortex* 39:567-603.
- McConley R, Martin R, Palmer CA, Kuzniecky R, Knowlton R, Faught E (2008) Rey Osterrieth complex figure test spatial and figural scoring: relations to seizure focus and hippocampal pathology in patients with temporal lobe epilepsy. *Epilepsy & Behav* 13:174-177.
- McDonald CR, Delis DC, Norman MA, Wetter SR, Tecoma ES, Iragui VJ (2005) Response inhibition and set shifting in patients with frontal lobe epilepsy or temporal lobe epilepsy. *Epilepsy & Behav* 7:438-446.
- Meador KJ, Bromley RL, Leeman BA, Baker GA (2011) Cognitive and neurodevelopmental effects of antiepileptic drugs. *Epilepsy & Behav* 22:9-16.
- Meador KJ, Loring DW, Flanigin HF (1989) History of epilepsy surgery. *Journal of Epilepsy* 2:21-25.
- Mechanic-Hamilton D, Korczykowski M, Yushkevich PA, Lawler K, Pluta J, Glynn S, Tracy JJ, Wolf RL, Sperling MR, French JA, Detre JA (2009) Hippocampal volumetry and functional MRI of memory in temporal lobe epilepsy. *Epilepsy & Behav* 16:128-138.
- Mechelli A, Price CJ, Friston KJ, Ishai A (2004) Where bottom-up meets top-down: neuronal interactions during perception and imagery. *Cereb Cortex* 14:1256-1265.
- Menon V, Boyett-Anderson JM, Schatzberg AF, Reiss AL (2002) Relating semantic and episodic memory systems. *Brain Res Cogn Brain Res* 13:261-265.
- Miller GA (1956) The magical number seven plus or minus two: some limits on our capacity for processing information. *Psychol Rev* 63:81-97.

References

- Milner B (1958) Psychological defects produced by temporal lobe excision. *Res Publ Assoc Res Nerv Ment Dis* 36:244-257.
- Milner B (1966) Amnesia following operation on the temporal lobes. In: *Amnesia*(Whitty, C. M. W. and Zangwill, O. L., eds), pp 109–133 London, U.K.: Butterworths.
- Milner B (1968) Visual recognition and recall after right temporal-lobe excision in man. *Neuropsychologia* 6:191-209.
- Milner B (1971) Interhemispheric differences in the localization of psychological processes in man. *British Medical Bulletin* 27:272-277.
- Milner B (1972) Disorders of learning and memory after temporal lobe lesions in man. *Clin Neurosurg* 19:421-446.
- Milner B (1996) Brenda Milner. In: *The history of neuroscience in autobiography, vol. 2* (Squire, L. R. and Society for Neuroscience., eds), pp 276-305 Washington DC: Society for Neuroscience.
- Milner B (2003) Visual recognition and recall after right temporal-lobe excision in man. *Epilepsy & Behav* 4:799-812.
- Milner B, Penfield W (1955) The effect of hippocampal lesions on recent memory. *Trans Am Neurol Assoc* 30:42-48.
- Milner B, Ranch C, Rasmussen T (1962) Study of short-term memory after intracarotid injection of sodium amytal. *Trans Am Neurol Assoc* 87:224-226.
- Milner B, Taylor L, Sperry RW (1968) Lateralized suppression of dichotically presented digits after commissural section in man. *Science* 161:184-186.
- Mishkin M, Ungerleider LG (1982) Contribution of striate inputs to the visuospatial functions of parieto-preoccipital cortex in monkeys. *Behav Brain Res* 6:57-77.
- Morris RG, Abrahams S, Polkey E, Baddeley AD (1995) Doors and People: Visual and verbal memory after unilateral temporal lobectomy. *Neuropsychology* 9:464-469.
- Motamedi G, Meador K (2003) Epilepsy and cognition. *Epilepsy & Behav* 4 (Suppl 2):25-38.
- Muhlert N, Grunewald RA, Hunkin NM, Reuber M, Howell S, Reynders H, Isaac CL (2011) Accelerated long-term forgetting in temporal lobe but not idiopathic generalised epilepsy. *Neuropsychologia* 49:2417-2426.
- Murray EA, Bussey TJ, Saksida LM (2007) Visual perception and memory: a new view of medial temporal lobe function in primates and rodents. *Annual Review of Neuroscience* 30:99-122.
- Murray EA, Gaffan D, Mishkin M (1993) Neural substrates of visual stimulus-stimulus association in rhesus monkeys. *J Neurosci* 13:4549-4561.
- Nadel L, Moscovitch M (1997) Memory consolidation, retrograde amnesia and the hippocampal complex. *Curr Opin Neurobiol* 7:217-227.
- Niemeyer P (1958) The transventricular amygdala-hippocampectomy in temporal lobe epilepsy. In: *Temporal lobe epilepsy*(Baldwin, M. and Bailey, P., eds), pp 461-482 Springfield Charles C Thomas.
- Oyegbile TO, Dow C, Jones J, Bell B, Rutecki P, Sheth R, Seidenberg M, Hermann BP (2004) The nature and course of neuropsychological morbidity in chronic temporal lobe epilepsy. *Neurology* 62:1736-1742.
- Palermo L, Nori R, Piccardi L, Giusberti F, Guariglia C (2010) Environment and object mental images in patients with representational neglect: two case reports. *J Int Neuropsychol Soc* 16:921-932.
- Panayiotopoulos CP (2011) The new ILAE report on terminology and concepts for organization of epileptic seizures: a clinician's critical view and contribution. *Epilepsia* 52:2155-2160.

- Panayiotopoulos CP (2012) The new ILAE report on terminology and concepts for the organization of epilepsies: Critical review and contribution. *Epilepsia* 53:399-404.
- Parkin AJ (1999) Human memory. *Current Biology* : CB 9:R582-585.
- Penfield W, Baldwin M (1952) Temporal lobe seizures and the technic of subtotal temporal lobectomy. *Annals of Surgery* 136:625-634.
- Piazzini A, Saetti C, Turner K, Fiorino A, Canger R, Canevini MP (2009) Visuo-perceptive impairment in adult patients with occipital lobe epilepsies. *Epilepsy & Behav* 15:256-259.
- Powell HW, Richardson MP, Symms MR, Boulby PA, Thompson PJ, Duncan JS, Koeppe MJ (2008) Preoperative fMRI predicts memory decline following anterior temporal lobe resection. *J Neurol Neurosurg Psychiatry* 79:686-693.
- Quiske A, Germann J, Wohlfahrt R, Schulze-Bonhage A (2000) Spezifität und Sensitivität des verbalen und visuellen Merkfähigkeitstests. *Epilepsieblätter* 13:15-15.
- Raspall T, Donate M, Boget T, Carreno M, Donaire A, Agudo R, Bargallo N, Rumia J, Setoain X, Pintor L, Salamero M (2005) Neuropsychological tests with lateralizing value in patients with temporal lobe epilepsy: reconsidering material-specific theory. *Seizure* 14:569-576.
- Rey A (1959) Manuel du test de copie d'une figure complexe de A. Rey. Paris, France: Les Editions du Centre de Psychologie Appliquée.
- Rey A, Osterrieth P-A (1944) L'examen psychologique dans les cas d'encéphalopathie traumatique. In: *Le test de copie d'une figure complexe : Contribution à l'étude de la perception et de la mémoire*, vol. 112, pp 286-340: Arch Psychol
- Rosenow F, Lüders H (2001) Presurgical evaluation of epilepsy. *Brain* 124:1683-1700.
- Saling MM (2009) Verbal memory in mesial temporal lobe epilepsy: beyond material specificity. *Brain* 132:570-582.
- Sass KJ, Westerveld M, Buchanan CP, Spencer SS, Kim JH, Spencer DD (1994) Degree of hippocampal neuron loss determines severity of verbal memory decrease after left anteromesiotemporal lobectomy. *Epilepsia* 35:1179-1186.
- Sawrie SM, Martin RC, Knowlton R, Faught E, Gilliam F, Kuzniecky R (2001) Relationships among hippocampal volumetry, proton magnetic resonance spectroscopy, and verbal memory in temporal lobe epilepsy. *Epilepsia* 42:1403-1407.
- Scarborough DL (1972) Stimulus modality effects on forgetting in short-term memory. *Journal of Experimental Psychology* 95:285-289.
- Schelling D, Schächtele B (2001) *Verbaler und Visueller Merkfähigkeitstest (VVM)*. Frankfurt, Germany: Swets & Zeitlinger
- Schmitz B, Mula M, Trimble M (2011) Cognitive and psychiatric symptoms and their treatment in temporal lobe epilepsy: the role of mesiotemporal structures. In: *The mesial temporal lobe epilepsies*, vol. 9 (Rosenow, F. et al., eds), pp 71-92 Montrouge, France: John Libbey Eurotext.
- Schmitz B, Steinhoff BJ (2005) *Epilepsien*. Stuttgart, Germany: Georg Thieme Verlag.
- Schneble HJ (2003) *Heillos, heilig, heilbar*. Berlin: Walter de Gruyter GMBH.
- Schneble HJ (2005) *Epilepsie*. Muenchen: Beck.
- Schouten D, Hendriksen JG, Aldenkamp AP (2009) Performance of children with epilepsy on the Rey-Osterrieth complex figure test: is there an effect of localization or lateralization? *Epilepsy Research* 83:184-189.
- Scoville WB, Milner B (1957) Loss of recent memory after bilateral hippocampal lesions. *J Neurol Neurosurg Psychiatry* 20:11-21.

References

- Shallice T, Warrington EK (1970) Independent functioning of verbal memory stores: a neuropsychological study. *The Quarterly Journal of Experimental Psychology* 22:261-273.
- Sherman EM, Wiebe S, Fay-McClymont TB, Tellez-Zenteno J, Metcalfe A, Hernandez-Ronquillo L, Hader WJ, Jette N (2011) Neuropsychological outcomes after epilepsy surgery: systematic review and pooled estimates. *Epilepsia* 52:857-869.
- Silverberg N, Buchanan L (2005) Verbal mediation and memory for novel figural designs: a dual interference study. *Brain Cogn* 57:198-209.
- Smith ML, Bigel M, Miller LA (2011) Visual paired-associate learning: in search of material-specific effects in adult patients who have undergone temporal lobectomy. *Epilepsy & Behav* 20:326-330.
- Snitz BE, Roman DD, Beniak TE (1996) Efficacy of the Continuous Visual Memory Test in lateralizing temporal lobe dysfunction in chronic complex-partial epilepsy. *J Clin Exp Neuropsychol* 18:747-754.
- Squire LR (1992) Declarative and Nondeclarative Memory: Multiple Brain Systems Supporting Learning and Memory. *J Cogn Neurosci* 4:232-243.
- Squire LR (2004) Memory systems of the brain: a brief history and current perspective. *Neurobiology of Learning and Memory* 82:171-177.
- Squire LR, Alvarez P (1995) Retrograde amnesia and memory consolidation: a neurobiological perspective. *Curr Opin Neurobiol* 5:169-177.
- Squire LR, Stark CE, Clark RE (2004) The medial temporal lobe. *Annual Review of Neuroscience* 27:279-306.
- Squire LR, Wixted JT, Clark RE (2007) Recognition memory and the medial temporal lobe: a new perspective. *Nature Reviews Neuroscience* 8:872-883.
- Squire LR, Zola-Morgan S (1991) The medial temporal lobe memory system. *Science* 253:1380-1386.
- Squire LR, Zola SM (1998) Episodic memory, semantic memory, and amnesia. *Hippocampus* 8:205-211.
- Steinhoff BJ, Staack AM, Bilic S, Kraus U, Schulze-Bonhage A, Zentner J (2009) Functional hemispherectomy in adults with intractable epilepsy syndromes: a report of 4 cases. *Epileptic Disord* 11:251-257.
- Stickgold R, Walker MP (2007) Sleep-dependent memory consolidation and reconsolidation. *Sleep Medicine* 8:331-343.
- Strauss E, Spreen (1990) A comparison of the Rey and Taylor Figures. *Archives of Clinical Neuropsychology* 5:417-420.
- Surges R, Kurthen M, Elger C (2012) Das EEG in der praeoperativen Epilepsiediagnostik. In: *Klinische Elektroenzephalographie* (Zschocke, S. and Hansen, H.-C., eds), pp 239-245 Berlin: Springer Verlag.
- Takahashi E, Miyashita Y (2002) Neuronal representation of visual long-term memory and its top-down executive processing. In: *Neuropsychology of memory* (Squire, L. G. and Schacter, D. L., eds), pp 301-310 New York: The Guilford Press.
- Testa SM, Schefft BK, Privitera MD, Yeh HS (2004) Warrington's recognition memory for faces: interpretive strategy and diagnostic utility in temporal lobe epilepsy. *Epilepsy & Behav* 5:236-243.
- Tombaugh TN (2004) Trail Making Test A and B: normative data stratified by age and education. *Archives of clinical neuropsychology* 19:203-214.
- Tudisco Ide S, Vaz LJ, Mantoan MA, Belzunces E, Noffs MH, Caboclo LO, Yacubian EM, Sakamoto AC, Bueno OF (2010) Assessment of working memory in patients with mesial temporal lobe epilepsy associated with unilateral hippocampal sclerosis. *Epilepsy & Behav* 18:223-228.

References

- Tulving E (1972) Episodic and semantic memory. In: Organization of memory (Tulving, E. and Donaldson, W., eds), pp 381–403 New York, United States of America: Academic Press.
- Tulving E (1983) Elements of episodic memory. Oxford, England: Clarendon Press.
- Tulving E (1985) Memory and consciousness. *Canadian Psychology* 1-12.
- Tulving E (1989) Memory: Performance, knowledge, and experience. *European Journal of Cognitive Psychology* 1:3-26.
- Tulving E (2002) Episodic memory: from mind to brain. *Annual Review of Psychology* 53:1-25.
- Tulving E (2005) Episodic memory and auto-noesis: Uniquely human? . In: The missing link in cognition: Self-knowing consciousness in man and animals (Terrase, H. S. and Metcalfe, J., eds), pp 3-56 New York: Oxford University Press.
- Ungerleider LG, Haxby JV (1994) 'What' and 'where' in the human brain. *Curr Opin Neurobiol* 4:157-165.
- Vannucci M (2007) Visual memory deficits in temporal lobe epilepsy: toward a multifactorial approach. *Clin EEG Neurosci* 38:18-24.
- Vannucci M, Dietl T, Pezer N, Viggiano MP, Helmstaedter C, Schaller C, Elger CE, Grunwald T (2003) Hippocampal function and visual object processing in temporal lobe epilepsy. *Neuroreport* 14:1489-1492.
- Vaz SA (2004) Nonverbal memory functioning following right anterior temporal lobectomy: a meta-analytic review. *Seizure* 13:446-452.
- Vermeulen J, Aldenkamp AP (1995) Cognitive side-effects of chronic antiepileptic drug treatment: a review of 25 years of research. *Epilepsy Res* 22:65-95.
- Volkl-Kernstock S, Willinger U, Feucht M (2006) Spatial perception and spatial memory in children with benign childhood epilepsy with centro-temporal spikes (BCECTS). *Epilepsy Res* 72:39-48.
- Wada J, Rassmussen T (1960) Intracarotid injection of sodium amytal for the lateralization of cerebral speech dominance: experimental and clinical observations. *J Neurosurg* 17:266-282.
- Wang XQ, Lang SY, Hong LU, Lin MA, Yan-ling MA, Yang F (2010) Changes in extratemporal integrity and cognition in temporal lobe epilepsy: a diffusion tensor imaging study. *Neurol India* 58:891-899.
- Warrington EK (1984) Recognition Memory Test. Berkshire: NFER-Nelson.
- Warrington EK, Taylor AM (1973) The contribution of the right parietal lobe to object recognition. *Cortex* 9:152-164.
- Wechsler D (1991) Hamburger Wechsler Intelligenztest für Erwachsene Revision. Bern, Switzerland: Huber Verlag
- Weidlich S, Lamberti G (2001) DCS: Diagnosticum für Cerebralschädigung. Ein visueller Lern- und Gedächtnistest. Göttingen, Germany: Huber Verlag.
- White JR, Matchinsky D, Beniak TE, Arndt RC, Walczak T, Leppik IE, Rarick J, Roman DD, Gummit RJ (2002) Predictors of postoperative memory function after left anterior temporal lobectomy. *Epilepsy & Behav* 3:383-389.
- Wieser HG (2004) ILAE Commission Report. Mesial temporal lobe epilepsy with hippocampal sclerosis. *Epilepsia* 45:695-714.
- Wilkinson H, Holdstock JS, Baker G, Herbert A, Clague F, Downes JJ (2012) Long-term accelerated forgetting of verbal and non-verbal information in temporal lobe epilepsy. *Cortex* 48:317-332.
- Wilkus RJ, Dodrill CB (1976) Neuropsychological correlates of the electroencephalogram in epileptics: I. Topographic distribution and average rate of epileptiform activity. *Epilepsia* 17:89-100.

References

- Williamson PD, French JA, Thadani VM, Kim JH, Novelly RA, Spencer SS, Spencer DD, Mattson RH (1993) Characteristics of medial temporal lobe epilepsy: II. Interictal and ictal scalp electroencephalography, neuropsychological testing, neuroimaging, surgical results, and pathology. *Ann Neurol* 34:781-787.
- Wisniewski I, Staack AM, Bilic S, Steinhoff BJ, Manning L (2012a) Visuo-perceptual and visuospatial abilities prior to and after anterior temporal lobectomy: a case study. *Epilepsy Behav* 23:74-78.
- Wisniewski I, Wendling AS, Manning L, Steinhoff BJ (2012b) Visuo-spatial memory tests in right temporal lobe epilepsy foci: clinical validity. *Epilepsy Behav* 23:254-260.
- Wisniewski I, Wendling AS, Steinhoff BJ (2011) Impact of side of lesion, seizure outcome and interictal epileptiform discharges on attention and memory after surgery in temporal lobe epilepsy. *Epileptic Disord* 13:27-35.
- Wisniewski I, Wendling AS, Westermann C, Manning L, Steinhoff BJ (unpublished) The importance of the DMS-48 as a visual recognition memory task for cognitive epilepsy evaluation.
- Witt JA, Glockner C, Helmstaedter C (2012) Extended retention intervals can help to bridge the gap between subjective and objective memory impairment. *Seizure* 21:134-140.
- Witt JA, Helmstaedter C (2009) [Neuropsychology in epilepsy]. *Fortschr Neurol Psychiatr* 77:691-698.
- World Health Organization W (2009) Epilepsy.
- Xu Y, Chun MM (2006) Dissociable neural mechanisms supporting visual short-term memory for objects. *Nature* 440:91-95.
- Yasargil M (1967) Development of diagnosis and surgical therapy of cerebrovascular diseases *Schweizerische Medizinische Wochenschrift* 97:1734-1736.
- Young PA, Young PH, Tolbert DL (2008) Basic clinical neuroscience. Philadelphia: Wolters Kluwer Health/Lippincott Williams & Wilkins.
- Yu HY, Shih YH, Su TP, Shan IK, Yiu CH, Lin YY, Kwan SY, Chen C, Yen DJ (2010) The Wada memory test and prediction of outcome after anterior temporal lobectomy. *Journal of Clinical Neuroscience* 17:857-861.
- Zhang LL, Zeng LN, Li YP (2011) Side effects of phenobarbital in epilepsy: a systematic review. *Epileptic Disord* 13:349-365.