



**HAL**  
open science

# Ocular toxoplasmosis: immunopathology and virulence: the influence of parasite virulence on the clinical, biological, and immunological characteristics of ocular toxoplasmosis (OT) in the Old and New World

Ligia Alejandra de La Torre Cifuentes

## ► To cite this version:

Ligia Alejandra de La Torre Cifuentes. Ocular toxoplasmosis: immunopathology and virulence: the influence of parasite virulence on the clinical, biological, and immunological characteristics of ocular toxoplasmosis (OT) in the Old and New World. Human health and pathology. Université de Strasbourg; Universidad del Quindío (Armenia, Colombie), 2013. English. NNT: 2013STRAJ043 . tel-01037947

**HAL Id: tel-01037947**

**<https://theses.hal.science/tel-01037947>**

Submitted on 23 Jul 2014

**HAL** is a multi-disciplinary open access archive for the deposit and dissemination of scientific research documents, whether they are published or not. The documents may come from teaching and research institutions in France or abroad, or from public or private research centers.

L'archive ouverte pluridisciplinaire **HAL**, est destinée au dépôt et à la diffusion de documents scientifiques de niveau recherche, publiés ou non, émanant des établissements d'enseignement et de recherche français ou étrangers, des laboratoires publics ou privés.



Discipline:

**Life and Health Sciences (ED 414)**

Co-Tutoring Doctoral Thesis

**“Ocular Toxoplasmosis: Immunopathology and Virulence”**

**The influence of parasite virulence on the clinical, biological, and immunological characteristics of ocular toxoplasmosis (OT) in the Old and New World**

**Ligia Alejandra DE LA TORRE CIFUENTES**

Public Defense: 18<sup>th</sup> September 2013

Strasbourg, France

Director from France:

**Ermanno CANDOLFI**, MD, PhD.  
Institut de Parasitologie et de Pathologie  
Tropicale  
de la Faculté de Médecine  
Université de Strasbourg, France

Director from Colombia:

**Jorge GOMEZ-MARIN**, MD, PhD.  
GEPAMOL Group  
Centro de Investigaciones Biomédicas  
Universidad del Quindío, Armenia,  
Colombia

**Joint PhD Program : Université de Strasbourg (France)  
and  
Universidad del Quindío (Colombia)**

**JURY MEMBERS:**

Jury President: Pr Laurent GAUCHER

**External jury members:**

**Europe**

**Pr Isabelle VILLENA**

Laboratoire de Parasitologie-Mycologie,  
Centre National de Référence de la Toxoplasmose,  
Centre de Ressources Biologiques Toxoplasma,  
Hôpital Maison Blanche, 45 rue Cognacq-Jay; 51092 Reims Cédex

**Pr Hervé PELLOUX**

UMR 5163, LAPM, Centre National de la Recherche Scientifique  
38041 Grenoble, France

**South America**

**Pr GONZÁLEZ John Mario, rapporteur externe**

Profesor Asociado, Facultad de Medicina,  
Universidad de los Andes,  
Carrera 1 No. 18A-10, edificio Q, piso 8,  
Bogotá D.C., Colombia  
Téléfono: +57 (1) 3394949 ext 3718. Lab ext. 3900  
Fax: +57 (1) 3324281

**Pr GONZALEZ Angel, rapporteur externe**

Universidad de Antioquia, Grupo de Micología Médica y Experimental  
(CIB-UdeA-UPB), Corporación para Investigaciones Biológicas (CIB),  
Medellín, Colombia

**Internal jury members:**

**Europe**

**Pr Laurent GAUCHER**

Service d'Ophtalmologie,  
Nouvel Hôpital Civil CHU de Strasbourg,  
Strasbourg, France

**South America**

**Pr. Juan Carlos SEPÚLVEDA-ARIAS**

Facultad de Ciencias de la Salud,  
Universidad Tecnológica de Pereira,  
Pereira, Risaralda, Colombia

## **DEDICATION**

To my daughters, Andrea and Gabriela, for their unconditional support and for giving me the inspiration to continue always looking ahead. For sharing with me good and bad moments; for their tenderness, for their fortitude, and for their endless love.

To my brother, Diego Francisco, for his love.

To my parents, for their care, for being there constantly, for their life example, for their amazing and infinite love.

## **ACKNOWLEDGEMENTS**

*To my mentors, Ermanno Candolfi and Jorge Enrique Gomez, for trusting me, for their advice, for their open-handedness, and for their absolute support.*

*To Quindio University and Strasbourg University, for giving me this wonderful opportunity. To Madame Florentz, for her aid.*

*To my friends, Julie and Esterina, for sharing with me the best moments inside and outside the lab, and for demonstrating to me the real value of friendship.*

*To all the people in the CIB and IPPTS, for the magnificent work environment.*

*To our patients.*

## **ABSTRACTS**

**(English, Spanish, and French)**

## ABSTRACT

**Introduction:** Ocular involvement, mainly retinochoroiditis, is one of the most severe sequelae of *Toxoplasma gondii* infection. However, the pathophysiological mechanisms of retinal destruction are poorly understood. Several studies suggested a more frequent and more severe ocular involvement in South American infections compared with European infections, probably due to different *T. gondii* strains (Type I/III, and atypical vs. Type II).

**Objective:** To compare the clinical characteristics and biological and immunological responses in a single study and using the same parameters, in Colombian and French patients with active ocular toxoplasmosis (OT), as well as to study the local cytokinome in aqueous humor of these patients and correlate it with the clinical features.

**Materials and methods:** We prospectively collected and compared the clinical features of patients with active OT, evaluated at the Department of Ophthalmology of Strasbourg University Hospital and of Quindio University Health-Center. Results of biological tests in the collected aqueous humor samples were compared between Colombian and French patients: the pattern of protein recognition by immunoblotting (IB); the relative diagnostic sensitivities of IB and Polymerase Chain Reaction (PCR); and the cytokine and chemokine profiles.

**Results:** We found that Colombian and French OT patients presented not only different clinical characteristics but also biological characteristics, and that more virulent South American strains might be responsible for these differences, due to a disruption of the protective effects of interferon gamma (IFN- $\gamma$ ). Retinal lesions were 50% greater in Colombian patients. Macular localization leading to visual impairment was observed in 56% of Colombian cases, compared with 13% of French patients. Moreover, more vitreous inflammation and vasculitis were observed in Colombian patients. However, cytokine assays of the aqueous humor showed upregulation of inflammatory responses in European patients, notably IL-17, which we did not observe in Colombian patients. In a mouse model, intraocular tachyzoite injection of type II and atypical *T. gondii* strains resulted in differences in parasite multiplication and pathology similar to those observed in human infections. Production of IL-17 and other inflammatory markers, like IL-6, MCP-1, and the Th17 transcription factor ROR $\gamma$ t was observed upon infection with the type II PRU strain, but was much less with the atypical LEF strain. In a previous work, the cytokine and mRNA patterns showed an upregulation of Th1 responses, notably IFN- $\gamma$  production, in French patients, and anti-IL-17A antibody markedly diminished clinical damage and retinal inflammation, and also diminished parasite proliferation. In contrast to these previous findings in French patients, the cytokinome of aqueous humor of OT Colombian patients



showed a downregulation of Th1 and Th17 responses and an upregulation of the Th2 response. Correlation between the clinical characteristics of Colombian patients with active OT and the levels of cytokines in aqueous humor (AH) showed that local production of cytokines differed between patients with OT, and particular cytokine levels were related to more severe clinical characteristics. Some cytokines were related to a higher number of recurrences.

**Conclusion:** There are clinical and biological differences between Colombian and French patients with OT. There seem to be strain-specific differences in IL-17 and IFN- $\gamma$  induction, which play an important role in the pathogenesis of this disease. These differences should be considered when thinking in perspectives of any possible immune-modulatory treatment in OT.

**KEYWORDS:** Ocular toxoplasmosis, *Toxoplasma gondii*, strains, cytokines, aqueous humor.

## RESUMEN

**Introducción:** El compromiso ocular, principalmente la retinocorioiditis, es uno de las secuelas más severas de la infección por *Toxoplasma gondii*. Sin embargo, los mecanismos fisiopatológicos de la destrucción retiniana no son bien entendidos. Algunos estudios sugieren un compromiso más frecuente y más severo en las infecciones en Sur América, comparadas con las infecciones en Europa, probablemente debido a las diferentes cepas de *T. gondii* (Tipos I/III y atípicas vs. Tipo II).

**Objetivo:** comparar las características clínicas, biológicas, y las respuestas inmunes, en un único estudio y usando los mismos parámetros, en pacientes colombianos y franceses con toxoplasmosis ocular (TO) activa; así como también estudiar el citoquinoma local en el humor acuoso de éstos pacientes y correlacionarlo con los hallazgos clínicos.

**Materiales y métodos:** Recolectamos consecutivamente y comparamos los hallazgos clínicos de los pacientes con TO activa, que consultaron al departamento de Oftalmología del Hospital Universitario de Estrasburgo y al Centro de Salud de la Universidad del Quindío. Los resultados de los exámenes biológicos en humor acuso (HA) fueron comparados entre los pacientes colombianos y franceses: el patrón de reconocimiento de proteínas por inmunobloting (IB), las sensibilidades diagnósticas relativas de IB, la prueba de reacción en cadena de la polimerasa (PCR), y el perfil de citoquinas y quimioquinas.

**Resultados:** Los pacientes colombianos y franceses con TO activa presentaron no solo diferencias clínicas sino también biológicas. Las cepas suramericanas, más virulentas, pueden jugar un papel crucial en estas diferencias, debido a la disrupción de los efectos protectores del IFN- $\gamma$ . Las lesiones retinianas fueron 50% más grandes en los pacientes colombianos, la localización macular, que lleva a compromiso visual, fue observada en 56% de los casos, comparado con el 13% en los franceses. Adicionalmente, se observó mayor inflamación vítrea y vasculitis en los pacientes colombianos. Sin embargo, los resultados de citoquinas en humor acuoso mostraron aumento de la respuesta inflamatoria en los pacientes europeos, notablemente IL-17, lo cual no se observó en los pacientes colombianos. En modelo murino, la patología mostró diferencias similares a las encontradas en la infección en humanos entre las cepas de *T. gondii* tipo II y atípicas. La producción de IL-17 y otros marcadores inflamatorios, como IL-6, MCP-1 y el factor de transcripción de Th17, ROR $\gamma$ t, fueron observados luego de la infección con cepas tipo II PRU, pero mucho menos con cepas atípicas LEF. En trabajos previos, los patrones de citoquinas y mRNA mostraron elevación de la respuesta Th1, principalmente producción de IFN- $\gamma$ , en pacientes

franceses, y los anticuerpos anti IL-17A disminuyeron notablemente el daño clínico y la inflamación retiniana, así como también la proliferación parasitaria. El citoquinoma en humor acuoso de los pacientes colombianos con TO activa, mostró disminución de la respuesta Th1 y Th17, contrario a los pacientes franceses, y aumento en la respuesta Th2. La correlación entre las características clínicas en los pacientes colombianos con TO activa y los niveles de citoquinas en HA, mostraron que la producción local de citoquinas difiere entre los pacientes con TO y los niveles de ciertas citoquinas se encontraron relacionados con características clínicas más severas, así como con las recurrencias. Trabajos preliminares nos han permitido iniciar un modelo de éstas afecciones oculares empleando una cepa de tipo II y una cepa atípica suramericana de *T.gondii*, además de evaluar la posibilidad de efectuar futuros tratamientos intraoculares dirigidos por transfección *in vivo*.

**Conclusión:** existen diferencias clínicas y biológicas, entre los pacientes colombianos y franceses con TO. Parece haber diferencias específicas de cada cepa en particular en la inducción de IL-17 e IFN- $\gamma$ , que juegan un papel importante en la patogénesis de la enfermedad. Estas diferencias deben ser consideradas cuando se piensa en posibles perspectivas con tratamientos inmunomoduladores en TO.

**PALABRAS CLAVE:** Toxoplasmosis ocular, *Toxoplasma gondii*, cepas, citoquinas, humor acuoso.

## RÉSUMÉ

**Résultats:** Nous avons sélectionné des patients atteints d'une TO biologiquement confirmée et avons exploré les différences cliniques et biologiques de deux groupes de patients, l'un en France, l'autre en Colombie. Dans notre hypothèse de départ, les souches sud-américaines, seraient plus virulentes et elles pourraient jouer un rôle crucial dans la sévérité et l'évolution de la TO. Nous avons constaté, chez les patients colombiens, de plus grandes lésions de la rétine et une plus grande proportion de lésions maculaires, dans un contexte inflammatoire vitréen plus sévère. Le cytoquinome oculaire confirme une forte réponse inflammatoire chez les patients européens centrée sur l'IL-17, mais cette réponse Th17 est absente chez les sujets colombiens. L'IL-6 et l'IL-13 sont au contraire fortement augmentées chez ces derniers. Nous avons également démontré que certaines cytokines étaient associées à certaines caractéristiques cliniques comme la sévérité de l'inflammation ou la récurrence. Des travaux préliminaires nous ont permis de débiter une modélisation de ces affections oculaires en employant une souche de type II et une souche atypique de *T. gondii*. Nous avons aussi évalué la possibilité d'effectuer des traitements ciblés en intraoculaires par transfection *in vivo*.

**Conclusion:** Nous avons constaté des différences cliniques et biologiques entre les patients colombien et français. Il semble y avoir une régulation souche dépendante de la production d'IFN- $\gamma$  et d'IL-17. Ces différences pourraient contribuer à expliquer la plus grande sévérité des toxoplasmoses oculaires en Colombie. En se basant sur nos résultats nous pouvons envisager d'explorer des traitements immunomodulateurs plus ciblés.

**Mots clés:** *Toxoplasma gondii*, toxoplasmosse oculaire, souches, cytokines, humeur aqueuse.

## TABLE OF CONTENTS

<b>List of abbreviations</b>	xv
<b>List of figures</b>	xix
<b>List of tables</b>	xxii
<b>INTRODUCTION</b>	1
<b>I- The parasite</b>	4
<b>A. <i>T. gondii</i></b>	5
i. Discovery and history of <i>T. gondii</i>	5
ii. Parasite transmission and life cycle	7
1. Tachyzoites, bradyzoites, and tissue cysts	9
2. Asexual cycle	10
3. Sexual cycle	13
4. <i>T. gondii</i> proteins involved in gliding motility and host cell attachment, invasion, and egress	14
a. Resident surface proteins and lipids	14
b. Transient surface proteins: MICs	15
c. Rhoptry neck proteins: RONS	16
d. Rhoptry bulb proteins	17
5. <i>T. gondii</i> proteins involved in development and stage differentiation	17
a. Dense granules	17
b. Cytoskeleton	18
6. Cyst formation and parasite tissue burden	18
7. Population structure and genotype differences	19
<b>B. Virulence</b>	21
i. Introduction	21
ii. Definition of virulence in <i>T. gondii</i>	23
iii. <i>T. gondii</i> genetic diversity	24
iv. <i>T. gondii</i> development and virulence	25
v. Modulation of virulence in an obligatory parasite	26
vi. <i>T. gondii</i> virulence factors in host cell	27
vii. Rhoptry kinases and pseudokinases of the ROP2 family	27
viii. Additional factors	30
<b>II- The disease</b>	31
<b>A. General aspects</b>	32

i.	General epidemiology – worldwide occurrence and course of the disease	32
ii.	Congenital toxoplasmosis	34
iii.	Infection in immunocompromised patients	36
<b>B.</b>	<b>Ocular toxoplasmosis</b>	38
i.	Physiopathology/Immunopathology	38
ii.	Immunology of OT – ocular immune response and specificity in South America	41
1.	The importance of intraocular-cytokine dissection analysis in the local response to <i>T. gondii</i> infection	41
2.	Cytokines in innate immune responses to <i>T. gondii</i>	43
3.	Cytokines in adaptive immune responses to <i>T. gondii</i>	46
a.	The importance of the equilibrium between Th1/Th2/Th17/Treg responses: maintaining counterbalance in <i>T. gondii</i> infection control	47
b.	The innate immune response is required to activate the acquired immune response: Th1 type cytokine response. The dual role of IL-12: immune protection connected with IFN- $\gamma$ production vs. pathological role once dysregulated	50
c.	Treg type cytokines. Regulatory role of IL-10: avoiding tissue damage when levels are sufficient vs. promoting tissue destruction when insufficiently produced	52
d.	Pro-inflammatory cytokines/chemokines and their counterbalance. TGF- $\beta$ protective function antagonized by IL-6. Inflammatory and pathological effects of IL-12 and IL-18 beyond the eye	54
e.	Th17 and its activators. TGF- $\beta$ acting together with IL-6	56
iii.	Epidemiology	58
iv.	Clinical presentation	59
1.	Symptoms	59
2.	Ocular features	60
v.	Diagnosis	66
vi.	Therapy	68
<b>III-</b>	<b>Personal work</b>	70
<b>A.</b>	<b>Objectives</b>	71
i.	Determination of the severity: clinical and biological comparison of French and Colombian patients	71
ii.	Cytokinome analysis in Colombian patients: is OT immune response related to strain virulence?	71

iii.	Modeling OT: preliminary results and perspectives	72
<b>B.</b>	<b>Papers</b>	72
	<b>ARTICLE 1. Prevention of retinochoroiditis in congenital toxoplasmosis – Europe versus South America</b>	73
i.	Introduction	74
ii.	Article	75
iii.	Conclusions and perspectives	79
	<b>ARTICLE 2. Severe South American ocular toxoplasmosis is associated with decreased IFN-<math>\gamma</math>/IL-17A and increased IL-6/IL-13 intraocular levels</b>	80
i.	Introduction	81
ii.	Article	82
iii.	Conclusions and perspectives	94
	<b>ARTICLE 3. Cytokine milieu is linked to clinical characteristics in Colombian patients presenting an active ocular toxoplasmosis</b>	95
i.	Introduction	96
ii.	Article	97
iii.	Conclusions and perspectives	124
	<b>ARTICLE 4. New clinical and experimental insights into Old World and neotropical ocular toxoplasmosis</b>	125
i.	Introduction	126
ii.	Article	126
iii.	Conclusions and perspectives	136
<b>IV-</b>	<b>General discussion</b>	137
<b>A.</b>	<b>Influence of virulence on differences in the pathogenesis and outcome of OT in Europe and South America</b>	141
<b>B.</b>	<b>Molecular mechanisms underlying T. gondii strains: GRA15, ROP16, ROP18, ROP5 (influence on STAT 3/STAT 6, NF<math>\kappa</math><math>\beta</math>, and IRGs)</b>	144
i.	What is known in mouse models?	144
ii.	What have we found in the human intraocular response to T. gondii?	146
iii.	Intraocular cytokine profile in Old and New World patients suffering from active OT and its potential explanation	147
iv.	Intraocular cytokine profile in Colombian patients suffering from active OT versus control cataract patients, and the possible explanation	150
<b>V-</b>	<b>General conclusions</b>	161
<b>VI-</b>	<b>General perspectives</b>	164
<b>VII-</b>	<b>References</b>	174



## LIST OF ABBREVIATIONS

AC:	Anterior Chamber
ABCA4:	ATP-binding cassette transporter gene
AH:	Aqueous Humor
AIDS:	Acquired Immunodeficiency Syndrome
AMA-1:	Apical Membrane Antigen 1
APC:	Antigen Presenting Cells
AT:	Amazonian Toxoplasmosis
BSA:	Bovine Serum Albumin
CCR5:	C-C Chemokine Receptor Type 5
CD:	Cluster Differentiation
CME:	Cystoid Macular Edema
CNS:	Central Nervous System
CNVMs:	Choroidal Neovascular Membranes
COL2A1:	Type II Collagen
CT:	Computed Tomography
CXCR:	Chemokine Receptor
DAPI:	Diamidino-2-Phenylindole staining
DCs:	Dendritic Cells
DG:	Dense Granules
DNA:	Deoxyribonucleic Acid
EAU:	Experimental Autoimmune Uveitis
ELISA:	Enzyme-Linked Immunosorbent Assay
FGF:	Fibroblast Growth Factor
FHUS:	Fuchs Heterochromic Uveitis Syndrome
GATA-3:	Trans-acting T-cell-specific transcription factor
GBPs:	Guanylate-Binding Proteins
GC:	Ganglion Cells
gm:	Grams

GPI:	Glycosylphosphatidylinositol
GRA1:	Granule Recombinant Antigen 1
GTP:	Guanosine Triphosphate
HG12:	Haplogroup 12
HIV:	Human Immunodeficiency Virus
HOSTs:	Host Organelle-Sequestering Tubulo Structures
IB:	Immunoblotting
ICAM-1:	Intercellular Adhesion Molecule 1
IELs:	Intraepithelial Lymphocytes
IFN:	Interferon
IgG:	Immunoglobulin G
IgM:	Immunoglobulin M
IL:	Interleukin
IL-R:	Interleukin Receptor
iNOS:	Inducible Nitric Oxide
IOP:	Intra Ocular Pressure
IP-10:	Interferon-induced Protein 10
IRG:	Immunity-related GTPases
IU:	Intermediate Uveitis
Kg:	Kilograms
KO:	Knockout
LEF:	RMS (Reims) – 1994 Virulent <i>Toxoplasma</i> Strain
LPL:	Lamina Propria Lymphocytes
MAP:	Mitogen-Activated Protein
MAR:	Microneme Adhesive Repeat
MCP:	Monocyte Chemoattractant Protein
MCSF:	Macrophage Colony-Stimulating Factor
MICs.:	Micronemal Proteins
MIP-1:	Macrophage Inflammatory Protein 1
mg:	Milligrams

MORN:	Membrane Occupation and Recognition Nexus Protein
mRNA:	Messenger Ribonucleic Acid
MyD88:	Myeloid Differentiation Primary Response Gene 88
M2AP:	Microneme 2 Associated Protein
NF $\kappa$ B:	Nuclear Factor Kappa B
NK:	Natural Killer cells
NO:	Nitric Oxide
NTP:	Nucleoside Triphosphate
OT:	Ocular Toxoplasmosis
PBS:	Phosphate Buffered Saline
PCR:	Polymerase Chain Reaction
PDGF:	Platelet-Derived Growth Factor
PFA:	Paraformaldehyde
PMNs:	Polymorphonuclear Leukocytes
PRU:	Prugniaud <i>Toxoplasma</i> Strain
PV:	Parasitophorous Vacuole
PVM:	Parasitophorous Vacuole Membrane
P2X7-R:	Purinergic receptor P2X purinoceptor 7
p30:	Protein 30
p47:	Protein 47
p65:	Protein 65
RNA:	Ribonucleic Acid
ROM:	Rhomboid Protease
RONs:	Rhoptry Neck Proteins
ROP:	Rhoptry Protein
ROR:	Related Orphan Receptor
ROS:	Reactive Oxygen Species
RPE:	Retinal Pigment Epithelium
SAG:	Surface Antigen
SA:	South America

siRNA:	Small Interfering RNA
SRS9:	Bradyzoite-Specific Surface Antigen
STAT:	Signal Transducers and Activators of Transcription
SYROCOT:	Systematic Review on Congenital Toxoplasmosis
<i>T. gondii</i> :	<i>Toxoplasma gondii</i>
TGF- $\beta$ :	Transforming Growth Factor Beta
TgMIC:	<i>Toxoplasma gondii</i> Micronemal Protein
TgMIC2-AP:	<i>Toxoplasma gondii</i> Micronemal Protein 2 Adhesive Protein
TgPhIL1:	<i>Toxoplasma gondii</i> Photosensitized Iodonaphthaline Labeling 1
TgRON:	<i>Toxoplasma gondii</i> Rhoptry Neck Proteins
TgSub1:	<i>Toxoplasma gondii</i> Subtilisin Protease 1
Th:	T Helper Cells
TLR:	Toll-Like Receptor
T lympho- cytes:	Thymus-Derived Lymphocytes
TNF:	Tumor Necrosis Factor
TRAP:	Thrombospondin-Related Anonymous Protein
Treg:	Regulatory T cells
TLR:	Toll-Like Receptors
Tyk:	Tyrosine Kinase
VEGF:	Vascular Endothelial Growth Factor

## LIST OF FIGURES

This list does not include the figures in the articles.

- Figure 1.** *Life cycle of Toxoplasma gondii.* **8**
- Figure 2.** *Sexual and asexual cycle of Toxoplasma gondii.* **11**
- Figure 3.** *Characteristic toxoplasmic retinochoroidal damage: atrophic retinochoroidal scar (caused by tissue destruction and necrosis), with hyperpigmented borders (due to the alteration on RPE).* **39**
- Figure 4.** *Cytokine network in adaptive immune response to Toxoplasma. Cytokines are crucial in cellular differentiation, inhibition, and activation of the different types of T cells.* **58**
- Figure 5.** *Active toxoplasmic lesions. a: Primary lesion: creamy-white retinochoroidal lesion without concomitant hyperpigmented scar (blue arrow). b: Recurrent lesion: creamy-white active lesion (blue arrow) with accompanying hyperpigmented old scar (red arrow).* **60**
- Figure 6.** *Toxoplasmic retinochoroidal scars located in different places of the retina. a: Macular atrophic retinochoroidal scar with hyperpigmented borders and a size of approximately 2 disc diameters (dd) (blue arrow). b: Peripheral atrophic retinal scar with a size of about 3 dd, and another hyperpigmented peripheral scar of about 0.5 dd. The sizes of the lesions are compared with the size of the optic disc.* **61**
- Figure 7.** *Additional findings in OT. Vitreous haze (vitritis). Active peripapillar inflammation with vitreous opacity. Details of the retina are* **61**

*not clearly observed because of the vitreous haze.*

**Figure 8.** *Additional findings. a: Neuroretinitis and papillitis due to ocular toxoplasmosis b: Active retinochoroiditis with perivascular sheathing.* **62**

**Figure 9.** *Retinal detachment as a complication of ocular toxoplasmosis.* **62**

**Figure 10.** *Bilateral macular compromise. Chorioretinal scars with an atrophic center and hyperpigmented borders.* **64**

**Figure 11.** *Bilateral macular compromise. Extensive tissue destruction. Retinal tissue has been completely destructed, leading to visualization of the sclera in necrotic areas of the retinochoroidal scars.* **64**

**Figure 12.** *Bilateral compromise. a,b: Extensive chorioretinal scars. b: Optic nerve atrophy.* **65**

**Figure 13.** *Bilateral macular compromise. Extensive and multiple chorioretinal scars.* **65**

**Figure 14.** *Bilateral, extensive, multiple, chorioretinal scars, both central and peripheral.* **66**

**Figure 15.** *Unilateral macular lesions in different patients.* **66**

**Figure 16.** *Influence of virulence on the pathogenesis of OT. Different clinical outcomes in OT in Europe and South America.* **142**

**Figure 17.** *Differences in the local immune response between*

<i>European and South American patients. Toxoplasma strains, parasitic load, protein recognition (IB), and cytokine/chemokine patterns were different between the populations.</i>	<b>143</b>
<b>Figure 18.</b> <i>Strain modulation of cytokine network in immune response to Toxoplasma and virulence. Cytokine modulation of Type I, II, and III Toxoplasma strains and their virulence in a mouse model. Comparison of cytokines present in AH of Colombian and French patients.</i>	<b>147</b>
<b>Figure 19.</b> <i>Proposed dynamics of a Type I/III and atypical (South American) ocular infection, in contrast to a Type II (European) ocular infection. Influence of virulence on intraocular immune response.</i>	<b>156</b>
<b>Figure 20.</b> <i>Local production of IL-17 in a mouse model of OT. Eyes infected with PRU and LEF Toxoplasma strains. IL-17 is present in a progressive pattern (Days 1, 3, and 7) from the outer Ganglion Cells (GC) to the inner layers Retinal Pigmented Epithelium (RPE) of the retina with PRU and LEF strains.</i>	<b>170</b>
<b>Figure 21.</b> <i>Possible resident producer cells of IL-17A in a mouse model of ocular toxoplasmosis (OT).</i>	<b>171</b>
<b>Figure 22.</b> <i>In vivo siRNA delivery to the vitreous in a mouse model of ocular toxoplasmosis (OT). Sticky siRNA + in vivo jetPEI (24 hours). Preliminary results in the first step of siRNA delivery to the vitreous in a mouse model of OT. Transfected cells can be seen in the vitreous, which seem to be monocytes. There is probably one lymphocyte in the retina.</i>	<b>173</b>

## LIST OF TABLES

This list does not include the tables in the articles.

<b>Table 1.</b> Hypothesis of the implications of infecting strains in the main differences in intraocular cytokine levels in AH samples of patients with active OT from Europe and South America.	157
--	-----



## INTRODUCTION

Toxoplasmosis is caused by a ubiquitous apicomplexan parasite of warm-blooded animals, and is one of the more common parasitic zoonoses worldwide (Elmore *et al.*, 2010). Felids are the key animal species in the life cycle of this parasite because they are the hosts that can excrete the environmentally resistant stage, the oocyst. Humans become infected congenitally or postnatally. Acquired infection could be due to ingestion of tissue cysts from undercooked meat, consuming food or drink contaminated with oocysts, or by accidentally ingesting oocysts from the environment (Elmore *et al.*, 2010). However, only a small percentage of exposed adult humans or other animals develop clinical signs of disease. In pregnant women, the infection may be transmitted to the fetus and result in a severe infection and in immunocompromised hosts, a latent infection may be activated and cause clinical disease (Dubey and Jones, 2008). It is unknown whether the severity of toxoplasmosis in immunocompetent hosts is due to the parasite strain, host variability, or other factors. Recently, attention has been focused on genetic variability among *Toxoplasma gondii* isolates from sick and apparently healthy hosts (Dubey and Jones, 2008), but also on virulence differences among *T. gondii* strains (Lehmann *et al.*, 2006).

Ocular toxoplasmosis (OT) is the most common cause of posterior uveitis (Holland, 2003). It can cause visual impairment and blindness (Holland, 2003; de-la-Torre, López-Castillo *et al.*, 2009). It affects patient's quality of life (de-la-Torre *et al.*, 2011) and produces irreversible sequelae (Holland, 2003). Although OT is a typical recurrent disease, we still do not know how to avoid recurrences or why they occur (de-la-Torre, Rios-Cadauid *et al.*, 2009). There is no ideal treatment and the treatments being applied have controversial efficacy (Stanford and Gilbert, 2009; de-la-Torre, Stanford *et al.*, 2011).

Considering these circumstances, the main challenges we have today are to really understand the immunopathology of OT (Garweg and Candolfi, 2009),

to find out how to limit the damage, avoid sequelae, and prevent recurrences, and to develop a new treatment based on immunomodulation that should be more efficient than the current antibiotic-based one. Thus, it is essential to look for immune-based interventions supported by a better clinical and pathophysiological understanding that can lead to more effective strategies to prevent and treat OT. Treatments with cytokines or anti-cytokines could be considered, if we obtain a better understanding of the nature of the immune response. Several studies have shown that Th2 involvement in OT is important in the humoral response, and that Th1 plays an important role in limitation of parasite proliferation (Gaddi and Yap, 2007; Amadi-Obi *et al.*, 2007). The role of Th17, at least in ocular infection by Type II strains, is probably related to development of retinal lesions (Sauer *et al.*, 2012).

Confirmation of the differences in the clinical picture between Colombian and French patients suffering active OT, with higher severity in Colombian patients, the differences in the biological and immunological responses, and the different infecting strains in the Old and New World are an important input in the field of this neglected disease. Particularly for me, working in a South American country and seeing daily severe cases of OT in my uveitis clinic that seriously compromise the quality of life of our patients, this work inspires me to continue investigating this fascinating field where too much remains to be elucidated.

## I- THE PARASITE

## **A. *T. gondii***

### **i. Discovery and history of *T. gondii***

It has been more than 100 years since *T. gondii* was initially described by Charles Nicolle and Louis Manceaux in 1908, while conducting *Leishmania* research at the Pasteur Institute in Tunis. They described a blood-borne unicellular parasite in the tissues of a small hamster-like rodent named *Ctenodoactylus gundi*. In parallel (1908), in Brazil, Alfonso Splendore identified the same protozoan in rabbit tissues (Weiss and Dubey, 2009). One year later, Nicole and Manceaux named the parasite in accordance with its morphology (toxо: arc or bow; plasma: life) and the animal in which it was discovered (the gundi). In retrospect, the correct name should be *T. gundii* (Dubey, 2008). The parasite was first found in laboratory animals. For the next 30 years, *T. gondii*-like organisms were found in several other hosts, mainly avian species (Dubey, 2002), although viable *T. gondii* was first isolated by Sabin and Olitsky (1937) and proven to be identical with to human isolate of *T. gondii* (Dubey, 2008).

Regarding studies of the complex protection against *T. gondii*, which involves innate and specific immunity, in the 1940s, humoral antibodies were found to kill extracellular but not intracellular tachyzoites (Sabin, 1948; Sabin *et al.*, 1937). In the next 50 years, protective immunity was found to be mediated largely by immune lymphoid cells (Frenkel, 1967; Suzuki *et al.*, 1988; Gazzinelli *et al.*, 1991; Dubey, 2008).

The question of why some hosts develop clinical toxoplasmosis whereas most remain asymptomatic is unknown. During the 1980s and 1990s, methods were developed to recognize genetic differences among *T. gondii* isolates from humans and animals (Pfefferkorn *et al.*, 1980; Darde *et al.*, 1998; Tibayrene *et al.*, 1991; Sibley *et al.*, 1992; Howe *et al.*, 1995; Dubey, 2008).

Mapping of *T. gondii* genes was achieved recently (Khan *et al.*, 2005), and undoubtedly will help in the search for better antigens for diagnosis and protection, and mechanism of disease. Until recently, *T. gondii* was considered clonal, with very little genetic variability (Howe *et al.*, 1995). Lehmann *et al.* (2006) performed the first in-depth study of genetic variability among more than 275 *T. gondii* isolates obtained worldwide from one host (free-range chicken) and in one laboratory (Dubey *et al.*, 2002). They found geographic differences, with some isolates being confined to Brazil, whereas others were distributed worldwide. Phenotypically, *T. gondii* isolates from asymptomatic chickens from Brazil were mouse virulent (Dubey *et al.*, 2002). This point is of interest because according to Dubey (2008), there is no non-pathogenic strain of *T. gondii* and virulence in mice may have no clinical relevance with respect to disease in humans and farm animals. *T. gondii* can cause several clinical syndromes including encephalitis, chorioretinitis, congenital infection, and neonatal mortality (Weiss and Dubey, 2009). Fifteen years after the description of *T. gondii* by Nicolle and Manceaux, a fatal case of toxoplasmosis in a child was reported by Janků (Weiss and Dubey, 2009).

In 1939, Wolf, Cowen, and Paige were the first to demonstrate the medical importance of *T. gondii* by conclusively identifying it as a cause of human disease in tissues of a congenitally infected infant in New York City, USA (Dubey, 2009). Its veterinary importance became known when in 1957, it was found to cause abortion storms in sheep in Australia (Hartley *et al.*, 1957; Tenter *et al.*, 2000; Dubey, 2008). The discovery of a *T. gondii*-specific antibody test, the Sabin-Feldman dye test, in 1948 led to the recognition that *T. gondii* is a common parasite of warm-blooded hosts with a worldwide distribution. Its life cycle was not discovered until 1970, when it was found that felids were its definitive host and an environmentally resistant stage (oocyst) was excreted in feces of infected cats (Dubey, 2008). The recent discovery of its common infection in certain marine wildlife (sea otters) indicates

contamination of our seas with *T. gondii* oocysts washed from land (Dubey, 2008).

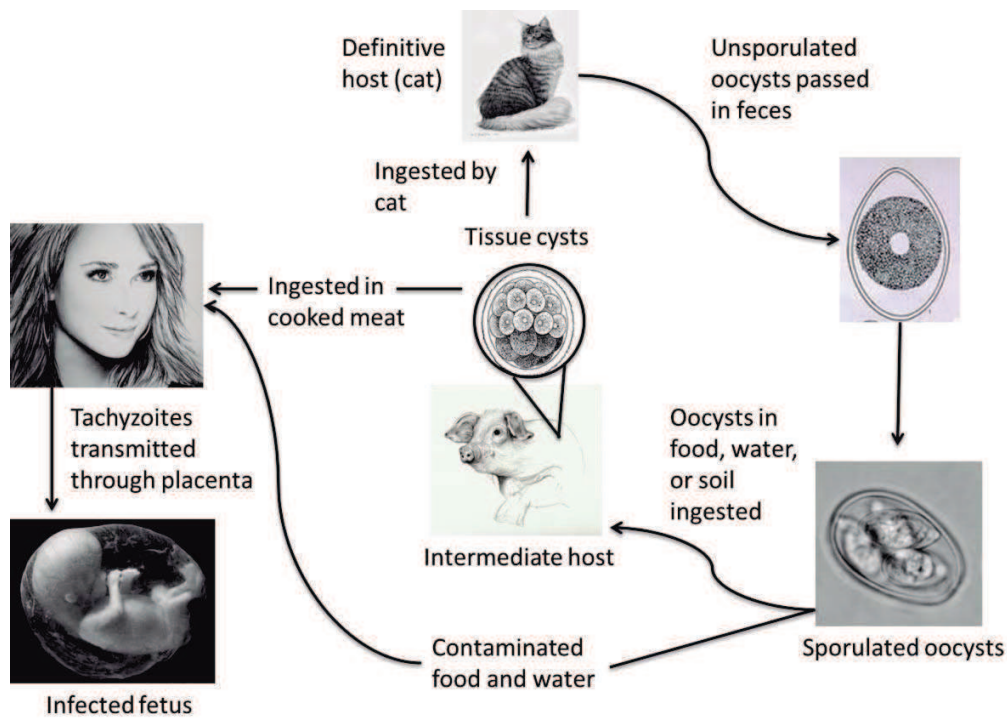
## ii. Parasite transmission and life cycle

*T. gondii*, an obligate intracellular parasite, is a facultatively heteroxenous, polyxenous protozoa that has developed several potential routes of transmission within and between different host species (Tenter *et al.*, 2000). This cosmopolitan parasite infects the majority of warm-blooded animals including humans. Felids are its definitive hosts, in which the parasite completes the sexual cycle, representing the main reservoir of infection, by excreting oocysts, which are the environmentally resistant stage. The parasite propagates by the use of an asexual cycle in other mammals and in birds.

Nearly one-third of the human population has been exposed to this parasite (Halonen and Weiss, 2013). Transmission to humans occurs through ingestion of tissue cysts from undercooked meat, by accidentally consuming food or drink contaminated with oocysts, or by accidentally ingesting oocysts from the environment (Elmore *et al.*, 2010).

Serological surveys indicate that *T. gondii* infections are common in wild carnivores, including pigs, bears, felids, fox, raccoons, and skunks. Clinical and subclinical toxoplasmosis have been reported for wild cervids, ungulates, marsupials, monkeys, and marine mammals. Southern sea otter populations have been severely impacted by *Toxoplasma* infections (Hill *et al.*, 2005).

In the life cycle of *T. gondii*, there are three different infectious stages: tachyzoites, which facilitate expansion during acute infection; bradyzoites, which maintain chronic infection; and sporozoites, which are disseminated in the environment within oocysts (Dubey, 1998) (**Figure 1**).



**Figure 1. Life cycle of *Toxoplasma gondii*.** Modified from: Dubey JP, Lindsay DS, Speer CA. Structures of *Toxoplasma gondii* tachyzoites, bradyzoites, and sporozoites and biology and development of tissue cysts. *Clin Microbiol Rev.* 1998 Apr;11(2):267-99.

All three stages are haploid; tachyzoites and bradyzoites divide asexually, while sporozoites are the product of meiosis. Sexual development only occurs within enterocytes of the feline gut, ultimately yielding diploid oocysts, which undergo meiosis after shedding (**Figure 1**).

Understanding the adaptations of these stages for various steps in the life cycle provides a support for considering the unique population structure of *T. gondii*.



## 1. Tachyzoites, bradyzoites, and tissue cysts

Humans and animals become infected mainly by ingesting bradyzoites or oocysts. After ingestion, both bradyzoites and sporozoites convert to tachyzoites inside tissues. The conversion of tachyzoites to bradyzoites and bradyzoites to tachyzoites is of biological and clinical significance because bradyzoites are less susceptible to chemotherapy, and reactivation of bradyzoites to tachyzoites is considered the cause of fatal toxoplasmosis in acquired immunodeficiency syndrome (AIDS) patients. Of all the methods currently available to assess stage conversion of *T. gondii*, feeding infective stages to cats is the most reliable method. Felidae, the definitive hosts of *T. gondii*, excrete oocysts 3–10 days after ingesting tissue cysts/bradyzoites,  $\geq$  18 days after ingesting oocysts, and  $\geq$  13 days after ingesting tachyzoites (Dubey, 1998).

*Tachyzoites.* The tachyzoite is the stage that Nicolle and Manceaux found in the gundi. This stage has also been called the trophozoite, the proliferative form, the feeding form, and the endozoite. It divides into two by a specialized process called endodyogeny (Dubey, 2008).

*Bradyzoites and tissue cysts.* The term “bradyzoite” was proposed by Frenkel (1973) to describe the stage encysted in tissues. Bradyzoites are also called cystozoites. Dubey and Beattie (1988) proposed that cysts should be called tissue cysts to avoid confusion with oocysts and pseudocysts. Jacobs, Remington, and Melton (1960a) first provided a biological characterization of cysts when they found that the cyst wall was destroyed by pepsin or trypsin, but the cystic organisms were resistant to digestion by gastric juices (pepsin-HCl), whereas tachyzoites were destroyed immediately. Thus, tissue cysts were shown to be important in the life cycle of *T. gondii* because

carnivorous hosts can become infected by ingesting infected meat (Dubey, 2008).

Bradyzoites and tissue cysts are an integral part of the life cycle of *T. gondii*, independent of immunity. There are no strains of *T. gondii* in nature that do not form tissue cysts. Tissue cysts develop and remain intracellular, and bradyzoites differ from tachyzoites with respect to location of the nucleus (central in tachyzoites, terminal in bradyzoites), amylopectin granule (numerous in bradyzoites, absent or few in tachyzoites), contents of rhoptries (honeycomb in tachyzoites, electron dense in older bradyzoites). Asexual and sexual stages are morphologically different from tachyzoites and bradyzoites, which also occur in the cat intestine (Dubey, 2008).

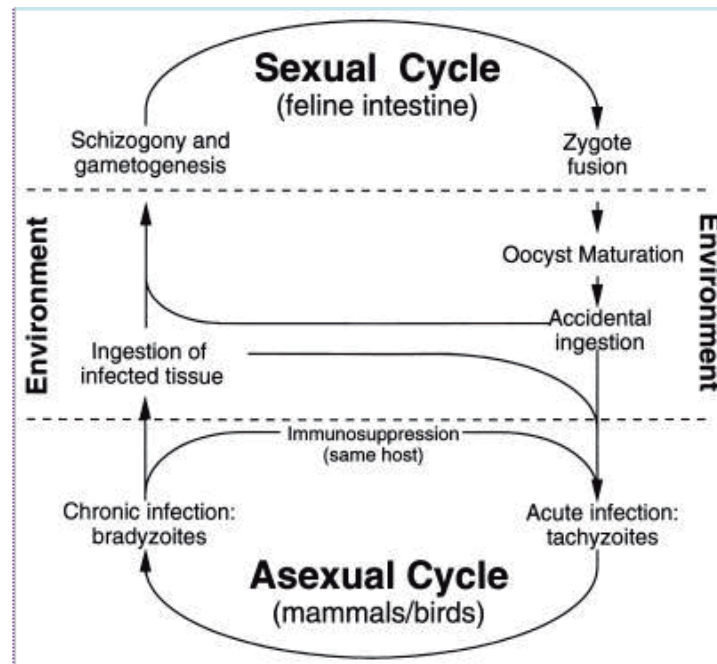
## **2. Asexual cycle**

*Toxoplasma* is capable of infecting and replicating within virtually any nucleated mammalian or avian cell (Black and Boothroyd, 2000). Its life cycle is divided between feline and non-feline infections, which are correlated with sexual and asexual replication, respectively (**Figure 2**).

Tachyzoites multiply very quickly in a wide variety of nucleated host cells during the acute phase of infection. Parasite invasion is driven by actin-based motility, generating a parasitophorous vacuole (PV) derived from invagination of the host cell plasma membrane and secretion of parasite proteins (Dubey, 1998; Bradley and Sibley, 2007).

Within the PV, tachyzoites divide every 6–9 hours by a process called endodyogeny, in which daughter cells form internally within the mother cell (Dubey, 1998; Morrissette and Sibley, 2002). Rupture of the host cell leads to emergence of parasites that infect new host cells. Infection evokes strong

innate and adaptive immune responses that control parasite replication but do not eliminate the infection. In response to environmental stress, tachyzoites convert into a semidormant stage known as bradyzoites, which are contained within tissue cysts (Dubey *et al.*, 1976; Dubey, 1998).



**Figure 2. Sexual and asexual cycle of *Toxoplasma gondii*.** From: Black MW, Boothroyd JC. Lytic cycle of *Toxoplasma gondii*. *Microbiol Mol Biol Rev.* 2000 Sep;64(3):607-23.

Tissue cysts form in a variety of cells, especially long-lived differentiated cells such as neurons and muscle cells, thus assuring long-term infection (Dubey, 1997). Histological evidence suggests that cysts turnover slowly *in vivo*, releasing bradyzoites into the surrounding tissue (Frenkel *et al.*, 1987; Dubey, 1998). The subsequent inflammatory and cellular immune responses contain the infection, although cyst rupture also gives rise to daughter cysts. Following cyst rupture, conversion to tachyzoites can result in reactivation of latent infection, for example, in immunocompromised mice (Suzuki *et al.*, 1988; Dubey, 1998). Similarly, reactivation of latent infection results in

toxoplasmic encephalitis, an important cause of opportunistic disease in immunodeficient patients (i.e., AIDS, transplant, and chemotherapy patients) (Dubey, 1998; Montoya and Liesenfeld, 2004; Sibley *et al.*, 2009).

If first contracted during pregnancy, *T. gondii* may be transmitted vertically by tachyzoites that are passed to the fetus via the placenta. Horizontal transmission of *T. gondii* may involve three life-cycle stages, i.e., ingesting infectious oocysts from the environment, drinking contaminated water (Dubey, 2004; López-Castillo *et al.*, 2005; Balasundaram *et al.*, 2010; Ekman *et al.*, 2012), or ingesting tissue cysts or tachyzoites that are contained in meat or primary offal (viscera) of many different animals (Balasundaram *et al.*, 2010; Gómez-Marín *et al.*, 2012). Transmission may also occur via tachyzoites contained in blood products, tissue transplants, or unpasteurized milk. However, it is not known which of these routes is more important epidemiologically.

In the past, the consumption of raw or undercooked meat, in particular of pigs and sheep, was regarded as a major route of transmission to humans. However, recent studies showed that the prevalence of *T. gondii* in meat-producing animals decreased considerably over the past 20 years in areas with intensive farm management. For example, in several countries of the European Union, prevalences of *T. gondii* in fattening pigs are now < 1%. Considering these data, it is unlikely that pork is still a major source of infection for humans in these countries. However, it is likely that the major routes of transmission are different in human populations with differences in culture and eating habits. In the Americas, recent outbreaks of acute toxoplasmosis in humans have been associated with oocyst contamination of the environment. Therefore, future epidemiological studies on *T. gondii* infections should consider the role of oocysts as potential sources of infection

for humans, and methods to monitor these are currently being developed (Tenter *et al.*, 2000).

### **3. Sexual cycle**

The sexual cycle of *T. gondii* starts when a domestic cat or any other member of the Felidae family ingests any of the infectious stages (tachyzoites, bradyzoites, or sporozoites). The parasite then infects the epithelial cells of the ileum, and initiates asexual development in a series of different morphological schizont stages (stages A to E) that show particular division characteristics. Gamete formation is likely initiated by merozoites released from stage D schizonts approximately 2 days post infection of the cat. The female macrogamete contains abundant organelles while the male microgamont harbors up to 21 microgametes. The male microgametes have a top end perforatorium organelle and flagella, which they employ to swim, penetrate, and fertilize mature female macrogametes to form zygotes. A number of layers of cyst wall are subsequently formed around the parasite, infected epithelial cells split, and oocysts are released into the intestinal lumen. Oocysts are excreted following defecation, and after that, sporulation occurs in the environment. Within 1 to 5 days post excretion, sporulated oocysts, containing two sporocysts harboring four sporozoites each, are ready to start a new cycle (Dubey *et al.*, 1998).

The oocyst is the infectious stage subsequent to sexual recombination of the parasites (Dubey, 1998; Dubey *et al.*, 1997). This stage is very resistant to all kind of disinfectants (Dubey *et al.*, 1997), tremendously infective, and more pathogenic in mice compared with bradyzoites (Dubey, 1998). Oocysts may persist for years in the soil (Dubey, 2004), as well as in water (de Moura *et al.*, 2006), and possibly also in other free-living microorganisms

(Winiecka-Krusnell *et al.*, 2009). Thus, oocysts are probably widespread in nature where domestic and wild cats ramble (Dubey, 2004).

#### **4. *T. gondii* proteins involved in gliding motility and host cell attachment, invasion, and egress**

##### **a. Resident surface proteins and lipids**

Diverse surface proteins have been found to be involved in virulence, such as GPI lipid, P30, SAG1, and SAG3 (Striepen *et al.*, 1997; Boothroyd *et al.*, 1998; Dzierszynski *et al.*, 2000; Lekutis *et al.*, 2001). Some of them are differentially expressed during the life cycle but their role is still poorly understood. The only data gathered so far suggest a contribution to host cell attachment before invasion and to modulating the immune defense of the host (Boothroyd *et al.*, 1998; Dubremetz and Lebrun, 2012). When purified and injected into mice, GPI lipid elicits a strong TNF response, mediated by interaction with TLR2 and TLR4, suggesting a significant effect on the immune response (Debierre-Grockiego *et al.*, 2003; Debierre-Grockiego *et al.*, 2007; Dubremetz and Lebrun, 2012).

A group of transmembrane proteases named rhomboids, some of which are located on the parasite surface, have the particularity of cleaving within the transmembrane domain of proteins. One of them, called ROM4, acts on the microneme protein AMA1 (Buguliskis *et al.*, 2010), and has been shown to be needed for invasion, as interfering with this cleavage inhibits invasion (Parussini *et al.*, 2012). ROM4 also controls indirectly the intracellular proliferation of tachyzoites (Santos *et al.*, 2011; Dubremetz and Lebrun, 2012).

## **b. Transient surface proteins: MICs**

Most MIC proteins are transiently expressed adhesins, i.e., surface proteins involved in binding specific ligands expressed on the surface of putative target cells, these ligands being either peptide sequences or glycans. In addition, at least one of them (thrombospondin-related anonymous protein, TRAP) is also a transmembrane protein connected to a unique actomyosin-based gliding motility motor located underneath the plasma membrane of the parasite (Opitz and Soldati, 2002; Dubremetz and Lebrun, 2012). In *T. gondii*, the TRAP ortholog TgMIC2 also proved to be essential for motility (Jewett and Sibley, 2004), due to its role in transducing the actomyosin motor power through the parasite membrane (Huynh and Carruthers, 2006; Dubremetz and Lebrun, 2012). The TgMIC2 companion TgMIC2-AP was itself found to play a significant role, as its deletion led to an 80% reduction in invasion capability, most likely due to a trafficking defect of the TgMIC2 protein to the parasite surface in the absence of TgM2-AP (Huynh *et al.*, 2003).

Other microneme proteins have also been shown to modulate the infectivity of *T. gondii*. Soluble TgMIC1 protein is one of them, the deletion of which induces a 50% decrease in invasion, but only a slight decrease in virulence *in vivo* (Cerede *et al.*, 2005; Dubremetz and Lebrun, 2012). TgMIC1 was shown to bind sialylated carbohydrates specifically through a microneme adhesive repeat (MAR) domain structure (Blumenschein *et al.*, 2007), suggesting that its effect on invasion is probably through helping in the binding step preceding moving junction formation, like most of the adhesins found on the invasive stages (zoites) or in micronemes. The TgMIC3 protein is unessential for invasion *in vitro*, and a mutant without TgMIC3 has also a slight defect in virulence *in vivo*, but what is interesting is that MIC1 and MIC3 double deletion parasites fully lose virulence *in vivo*, although they do not show such a spectacular phenotype *in vitro* where they behave like the single TgMIC1 knockout (Cerede *et al.*, 2005; Dubremetz and Lebrun, 2012). The reason for

this discrepancy between *in vitro* and *in vivo* results is not known, but could arise from either differences in invasion depending on cell type in mouse tissues, or from involvement of the MIC proteins in the immune response, such as described below for ROP proteins. MIC6 and MIC4 are involved in a complex with MIC1, MIC6 being the transmembrane escort that ensures targeting of its companion MIC1 to the micronemes, whereas MIC4 is also needed for the association between MIC6 and MIC1 (Reiss *et al.*, 2001; Dubremetz and Lebrun, 2012). MIC8 is a transmembrane microneme protein that was initially thought to act as an escort for MIC3, but was later proven not to be; it was shown to be essential for invasion by taking part in the signalling cascade leading to rhoptry exocytosis (Kessler *et al.*, 2008).

Apical membrane antigen 1 (**AMA-1**) is a microneme protein that was discovered in *Plasmodium* sp. 30 years ago and found in *T. gondii* more recently. It is conserved in all Apicomplexa, and was shown recently to be an important component of the moving junction during invasion (Alexander *et al.*, 2005). In addition, it probably contributes to intracellular tachyzoite multiplication (Santos *et al.*, 2011).

Another group of microneme proteins, perforins (pore-forming proteins), also affect intracellular development. The microneme protease TgSub1, which cleaves TgMIC2, MIC4, and M2AP after their translocation on the parasite surface, can be ablated without blocking parasite development. However, motility and invasion are strongly reduced, and virulence in mice is also considerably reduced (Dubremetz and Lebrun, 2012; Lagal *et al.*, 2010).

### **c. Rhoptry neck proteins: RONS**

RONS contribute to the formation of the Apicomplexa parasite structure that drives host cell invasion, the moving junction (Alexander *et al.*, 2005; Lebrun *et al.*, 2005). One of them, named TgRON8, can be deleted without



interrupting parasite development, yet deletion leads to decreased invasion and decreased virulence in mice (Straub *et al.*, 2011; Dubremetz and Lebrun, 2012).

#### **d. Rhoptry bulb proteins**

**Rhoptry bulb proteins** could act on host cell gene expression control rather than invasion. Toxofilin, which appears to modify the cortical actin skeleton of the host cell during invasion, may facilitate invasion (Lodoen *et al.*, 2010; Delorme-Walker *et al.*, 2012; Dubremetz and Lebrun, 2012).

### **5. *T. gondii* proteins involved in development and stage differentiation**

#### **a. Dense granules**

More than 20 proteins have been identified in *T. gondii* dense granules (DG), which are exocytosed during or after host cell invasion, to be targeted to either the vacuolar space, the parasitophorous vacuole membrane (PVM), or the cytosol of the cell. Their function is not clearly established, except for those with obvious enzymatic activities, such as the NTPases. Several of these are involved in specialized PV membranous structures such as the tubulovesicular network, or the host organelle-sequestering tubulo structures (HOSTs; Coppens *et al.*, 2006; Travier *et al.*, 2008).

Among DG proteins, only GRA1 is suggested to be essential, as its coding gene could not be deleted. Nevertheless, some morphological changes could be observed in the vacuole, small changes at *in vitro* development occur when GRA2 (Mercier *et al.*, 1998) and GRA3 (Craver and Knoll, 2007) are deleted, virulence in mice is significantly attenuated. By contrast, GRA5 (Mercier *et al.*, 2001) or GRA14 (Rome *et al.*, 2008) deletion does not affect

virulence in mice. The GRA7 protein, which has been shown to be involved in the sequestration of host cell lysosomes into the PV (HOSTS; Coppens *et al.*, 2006), is required for *in vitro* development in low-nutrient conditions, but no data have been reported on its contribution *in vivo*. GRA15, recently described, is an effector of the immune response (Dubremetz and Lebrun, 2012).

### **b. Cytoskeleton**

The cytoskeleton is a major element of parasite shape and of gliding motility. *T. gondii* tachyzoites have a refined subplasmalemmal cytoskeleton that comprises a system of flattened vesicles underneath the plasmalemma, together with subpellicular microtubules extending from an apical ring that forms near the centriole at an early stage of endodyogeny. The protein **MORN1**, despite its participation in the biogenesis of the cytoskeleton of tachyzoites in building of the posterior end of the cytoskeleton, has been shown to be unnecessary. Parasites without MORN1 are nevertheless partly impaired in the last step of endodyogeny, with a negative impact on the production of infective parasites and resulting in decreased proliferation *in vitro* and attenuated virulence in mice (Heaslip *et al.*, 2010; Dubremetz and Lebrun, 2012). **TgPHIL1**, a protein associated with the apical part of the inner complex, can be deleted, but the resulting parasites have a growth defect *in vitro* that translates into reduced proliferation and dissemination during mouse infection (Barkhuff *et al.*, 2011; Dubremetz and Lebrun, 2012).

## **6. Cyst formation and parasite tissue burden**

As acute infections by virulent strains in mice ordinarily lead to death, excluding, in this way, the possibility of a chronic phase characterized by cyst formation, the occurrence of this phase is generally considered a negative marker of virulence. Yet, cysts are necessary for transmission to both

intermediate and definitive hosts, and parasite factors modulating the ability to make cysts must consequently be considered as contributing to virulence. Bradyzoite-specific surface proteins are such virulence factors, as ablation of a cluster of genes coding for bradyzoite-specific **SAG2**-related proteins decreased the cyst numbers and persistence, impairing transmission (Saeij *et al.*, 2008; Dubremetz and Lebrun, 2012). Ablation of the SRS9 gene coding a major bradyzoite protein related to **SAG1** also induced a decrease in persistence of brain cysts, but it also led to an earlier reactivation in the intestine upon immunosuppression, suggesting organ-specific consequences for persistence, which might be associated with the immune response (Kim *et al.*, 2007; Dubremetz and Lebrun, 2012).

## 7. Population structure and genotype differences

It is essential to consider the contribution of genetic variation among parasites to patterns of disease transmission and clinical manifestations. Focusing on the geographic component of this variation, it has been shown that most genotypes are locale-specific, but some are found across continents and are closely related to each other, indicating a recent radiation of a pandemic genotype. Furthermore, the geographic structure of *T. gondii* is extraordinary in having one population that is found on all continents except South America (SA), whereas other populations are generally confined to SA, and yet another population is found worldwide (Lehmann *et al.*, 2006). There is an unusual global population structure: in North America and Europe, isolated strains fall predominantly into four largely clonal lineages, but in SA, there is great genetic diversity and the North American clonal lineages are rarely found (Minot *et al.*, 2012). Type II, followed by HG12, Type III, and Type I strains, are the dominant clonotypes in North America and Europe, whereas clonality is largely absent in SA (Minot *et al.*, 2012).

An additional issue has emerged recently when comparative clinical series were analyzed between continents. A comparative prospective cohort study of congenitally infected children in Brazil and Europe found that Brazilian children presented eye lesions that were larger, more numerous, and more likely to affect the part of the retina responsible for central vision, compared with their counterparts in Europe (Gilbert *et al.*, 2008). Additionally, parasite genotyping indicates that a different parasite strain is responsible for disease in Europe and in SA (Gómez-Marín, 2009).

Differences between strains may be an explanation for the high incidence and rate of complications in South American children compared with those in Europe (Gómez-Marín, 2009). Previous and recent comparative data (Garweg *et al.*, 2005; Dodds *et al.*, 2008) found significant differences in immunological response between South American and European patients with OT. These results support the notion that South American patients should be treated differently to the standard European protocols (Sauer *et al.*, 2011). In recent studies, cytokine assays of aqueous humor (AH) showed upregulation of inflammatory responses in European patients, notably IL-17, which we did not observe in Colombian patients. In a newly established mouse model of intraocular tachyzoite injection (Sauer *et al.*, 2012), parasite multiplication and pathology showed similar differences between Type II and atypical *T. gondii* strains as in human infections. There seem to be strain-specific differences in IL-17 and IFN- $\gamma$  induction, and this could play an important role in the pathogenesis of this disease. These differences should be considered when thinking in perspectives of any possible immune-modulatory treatment in OT.

Serotyping of *T. gondii* in chronically infected pregnant women showed the predominance of Type II in the Old World and Types I and III in the New World. Homogenous genotype II results were found in Europe and Type I or

III were only found in Colombia (Peyron *et al.*, 2006). Serotypes from immunocompetent individuals with various clinical presentations (including active toxoplasmic retinochoroiditis, pulmonary involvement, and altered general status, secondary to severe primary infection) and those from human immunodeficiency virus (HIV)-infected patients differed according to geographical origin, with a homogeneous distribution of serotype II in Europe and of serotypes I and III in SA, independent of the clinical presentation of the disease (Morisset *et al.*, 2008).

An atypical multilocus genotype with one allele found only for isolates of French Guiana has been seen in severe acquired toxoplasmosis in immunocompetent adult patients in this region. This newly described form of toxoplasmosis, “Amazonian toxoplasmosis” (AT), is characterized by severe cases and atypical strains linked to a neotropical forest-based cycle, leading to disseminated toxoplasmosis with a possible trend toward life-threatening pneumonia. These atypical *T. gondii* strains, which are unrelated to archetypal clonal lineages (I, II, and III), have been reported more frequently over the last decade in areas other than Europe and North America (Carme *et al.*, 2002; Carme *et al.*, 2009; Demar *et al.*, 2012). Genetic variation between *Toxoplasma* strains determines differences in virulence, modulation of host signaling pathways, growth, dissemination, and disease severity in mice and likely in humans (Minot *et al.*, 2012).

## **B. Virulence**

### **i. Introduction**

*T. gondii* is a common parasite of animals and humans and can cause grave opportunistic infections. However, the majority of infections are asymptomatic, possibly because the organism has co-evolved with its many vertebrate hosts

and has developed multiple strategies to persist asymptotically for the lifetime of the host (Hunter and Sibley, 2012).

*Toxoplasma* virulence is dependent on factors involved in either parasite-host cell interaction or host immune response. It is fundamentally defined in the mouse but little is known concerning human infection. The genetic dependence of virulence is a growing field that is benefiting from the recent development of research of the population structure of *T. gondii* (Dubremetz and Lebrun, 2012).

Over the past two decades, infection studies in the mouse, combined with forward genetic approaches aimed at disentangling the molecular basis of infection, have discovered that *T. gondii* virulence is mediated, in part, by secretion of effector proteins into the host cell during invasion. These virulence factors neutralize innate immunity and promote survival of the parasite (Hunter and Sibley, 2012).

*T. gondii* has long been considered a mild pathogen, compared with a fatal pest such as *Plasmodium falciparum* (Dubremetz and Lebrun, 2012). Except being considered a serious concern for pregnancy in a very limited number of countries such as France and Austria, it was mostly looked upon as a commensal in the human host, and producing essentially asymptomatic infection. With the AIDS epidemics, the concept of “opportunistic pathogen” emerged, and this parasite took an important place, leading to increasing medical and scientific interest (Dubremetz and Lebrun, 2012). The way in which the organism was viewed also changed with the turn of the 21<sup>st</sup> century, when *T. gondii* strains were capable of killing healthy humans in South American tropical areas (Darde *et al.*, 1998). Additionally, while the chronic phase of the infection has been considered so far as completely innocuous, some authors are now suggesting that the existence of cysts in the brain

could be involved with mental disorders such as schizophrenia (Torrey and Yolken, 2003).

## **ii. Definition of virulence in *T. gondii***

*T. gondii* virulence has been defined by the number of tachyzoites needed to finally kill a mouse subsequent to an intraperitoneal injection. The lethal dose 100 (LD100), defined as the number of tachyzoites needed to kill 100% of BALB/c mouse, is the index most widely used to define the degree of virulence of a given strain. This can vary widely, from a high virulence, i.e., one to ten tachyzoites, to low virulence (> 1,000 tachyzoites). This definition has been very helpful for studying the *T. gondii*-mouse interaction, and is still extensively accepted. This topic is less apparent while analyzing other hosts, in particular man, where the criteria are not so simple to define and analyze (Dubremetz and Lebrun, 2012). In this case, some stages in pathology have been described, partially in relation to organ localization (eye, lung, and brain) or to septicemia, even though the association with specific virulence factors has not been recognized so far, and the epidemiological data obtained up to now are just linked to parasite strain differences (Boothroyd and Grigg, 2002).

*T. gondii* virulence definition is complicated by the fact that this parasite is ubiquitous, as it is able to infect a large variety of hosts. Within this host range, susceptibility to infection and acute disease is extremely variable, as mice can die in a few days and rats may be fully refractory, showing that not only parasitic factors, but also host factors are involved in virulence (Dubremetz and Lebrun, 2012).

Most of the virulence studies have been done on mouse models and consequently, *T. gondii* virulence is generally defined with respect to mouse infection, leading to much vagueness when defining virulence in other hosts, especially humans, which may be different to that in rodents. Up to recently,

the main parameters measured when defining virulence has been the rate of multiplication of the parasite, and the effect on a variety of aspects of the immune response, depending on the *T. gondii* strain and on the mouse strain used, leading to a simplistic consideration in which mice would die from septicemia or as consequence of an immunopathological reaction. This is an ambiguity since the parasitic factors involved in these phenomena, apart from the well-known immune-dominant surface protein named SAG1, were once considered crucial but, like many others, were eventually proved not to be essential (Rachinel *et al.*, 2004).

Within the last decade, significant advances have been made in the field, due to two major breakthroughs. The first was completion of sequencing of the *T. gondii* genome, allowing for an accurate analysis of the function of individual genes involved in the infection through classical and molecular genetics. Secondly, the precise dissection of the host cell response to infection through extensive transcriptomic analysis was made possible with microarray technology (Dubremetz and Lebrun, 2012).

### **iii. *T. gondii* genetic diversity**

The enormous host variety for *T. gondii* asexual development, in combination with the strict restriction of the sexual process to Felidae, associated with the domestication of sheep and cat, has led to a significant bias in the genetic diversity of this parasite in the human environment, which is dominated by the clonal expansion of three genotypes (classically named I, II, and III). These genotypes have with very different virulence to mice, and are derived from two founding ancestors and two crosses in the recent history (Sibley and Ajioka, 2008). The majority of virulence studies have, up to now, dealt with these three genotypes, both experimentally in animals and in the course of the study of human infections. This aspect is being slowly corrected by sampling wilder areas of the world, leading to the discovery of new strains with unexpected



virulence features in humans (Darde *et al.*, 1998). Additionally, the complexity of the genetic diversity has been perceived by showing that the population structure of *T. gondii* throughout the world is far more diverse than expected (Su *et al.*, 2012). That way, the understanding of virulence is likely to advance notably with the study of new parasites.

#### **iv. *T. gondii* development and virulence**

The wide range of infected cells and tissues, resulting from the facultative heteroxenous life cycle of *T. gondii*, impacts on the concept of virulence for this parasite (Dubremetz and Lebrun, 2012). In the cat, most of the primary infection is located in enterocytes (Dubey *et al.*, 1970), whereas in the intermediate hosts, the nucleated blood cells, neurons, and myocytes are the major targets. In the cat, the primary infection seems to be self-limiting, just as for gut coccidia, whereas in humans and other warm-blooded vertebrates, it depends on the host and is most likely controlled by the immune response (Dubey *et al.*, 1988; Dubremetz and Lebrun, 2012).

As a result, the primary infection is self-curing in cats, and no modulation through virulence parameters has been defined until now. The cat can also behave as an intermediate host through encystment of the parasite in different organs during primary infection (Dubey *et al.*, 1970; Dubremetz and Lebrun, 2012). In intermediate host infection, the first line is in relation to cell invasion and intracellular development, whereas the second concerns host cell and control of host responses. Invasion is a complex process that has been extensively studied but is not completely understood. So far, it seems that the main element in the process are motility and recognition processes through surface interactions between the parasite and host cell, followed by PV development and parasite entry (Besteiro *et al.*, 2011; Dubremetz and Lebrun, 2012). These events basically involve parasite surface molecules, in concert with exocytosis of apical organelle contents, associated with the

gliding motility system. Intracellular development, followed by escape of offspring parasites to invade new host cells or encystment to avoid the immune response, are important parameters of virulence, since they determine the capacity of the parasite to proliferate within the host, or to propagate the disease to a new host. Therefore, factors that act on the multiplication rate are likely to be virulence factors (Dubremetz and Lebrun, 2012). Modulation of the host or host cell responses is the other way in which parasite virulence is expressed, which has gained considerable interest in recent years and is now the major field of investigation regarding genetic analysis of virulence in *T. gondii*. It works by either modulating host cell transcription of immunity-related signaling factors, or by interfering directly with primary immune response intracellular effectors (Dubremetz and Lebrun, 2012).

#### **v. Modulation of virulence in an obligatory parasite**

Contrary to a large amount of pathogens that can survive or proliferate outside their host, obligatory parasites have to reside in their host to complete their life cycle. Hence, in these parasites, virulence cannot be defined by the absolute ability to infect, but only by the gradation of the disease. Thus, the products of genes crucial for host invasion cannot be considered virulence factors, since their absence obstructs parasite survival (Dubremetz and Lebrun, 2012). Yet, the notion of essentiality in this area is being challenged in an increasing number of cases where genes that were believed to be absolutely required for infection were experimentally proven to be not essential (Rachinel *et al.*, 2004; Pernas and Boothroyd, 2010). Therefore, virulence factors will be defined as gene products that influence the severity of the disease but are not essential to parasite transmission and survival (Dubremetz and Lebrun, 2012).

#### **vi. *T. gondii* virulence factors in host cell**

*T. gondii* effectors modify the host cell in a variety of ways, leading either to better trophic conditions for the parasite, to intracellular resistance against innate immune defense, or to modulation of the host immune system homeostasis to regulate the secondary response. A large number of these factors are secreted during invasion and are translocated into the host cell cytosol where they interfere with host cell functions. This characteristic of *T. gondii* virulence has recently gained importance due to the discovery of the properties of a family of ROPs, the first member of which was named ROP2 (Sadak *et al.*, 1988). The family was later shown to encompass more than 40 members (Peixoto *et al.*, 2010). This discovery came through both protein characterization (El Hajj *et al.*, 2006; El Hajj *et al.*, 2007) and reverse genetic analysis of *T. gondii* virulence in mice (Saeij *et al.*, 2006; Taylor *et al.*, 2006).

Modulation of host cell transcription by *T. gondii* infection has been demonstrated. The parasite translocates exocytosed proteins directly into the cytosol of the host cell during invasion, and translocation of a rhoptry phosphatase into the host cell nucleus has been demonstrated by microarrays (Gilbert *et al.*, 2007; Blader *et al.*, 2001). *T. gondii* virulence factors are polymorphic and are responsible for genetic modulation of virulence. Variants have been identified that interfere with the severity of infection (Dubremetz and Lebrun, 2012).

#### **vii. Rhoptry kinases and pseudokinases of the ROP2 family**

Kinase homologs are among over 40 genes that encode ROPs in the *T. gondii* genome, and were the first ones to be described. Later on, genomic and proteomic investigations showed that some members of the family were true kinases, and they were translocated into the host cell at invasion. Genetic studies have revised the chromosome loci responsible for

*T. gondii* virulence in mice and genes encoding members of this family. The interference of these proteins with parasite infection concerns fundamentally the modulation of inflammation at various levels, depending on the ROP protein concerned, leading to very important differences in virulence between strains, as genetic variation among these proteins has emerged as a major effector in the outcome of infection (Dubremetz and Lebrun, 2012).

These proteins are able to act in two main ways. The first one is the activation of antigen presenting cells (APCs) through TLRs, leading to NF $\kappa$ B activation and nuclear translocation to activate the transcription of pro-inflammatory cytokines such as IL-12 and IL-18, which will in turn trigger the production of interferon gamma (IFN- $\gamma$ ) by T lymphocytes and NK cells. In the second way, infected cells activated by IFN- $\gamma$  can manipulate interferon-regulated GTPases (p47 immunity-related GTPases or IRGs, and p65 guanylate-binding proteins or GBPs) capable of destroying the otherwise invulnerable PV (Butcher *et al.*, 2005; Martens *et al.*, 2005), and virulent parasites will interfere with this second line of defense. In the first case, the pathology will be driven by overinflammation, whereas in the second one, it will occur from unrestricted proliferation of the parasite (Melo *et al.*, 2011).

The kinase **ROP16** has been shown to phosphorylate STAT3/6, which suppresses NF $\kappa$ B phosphorylation and consequently decreases inflammation (Yamamoto *et al.*, 2009; Ong *et al.*, 2009). It is not clear yet how this function is related to virulence, and ROP16 also alters the transcription of many other genes lacking STAT transcription factor-binding elements. Additionally, recent works have shown that ROP16 can also interfere with GBP binding to the PVM (Virreira *et al.*, 2011).

The kinase **ROP18** acts after the IFN- $\gamma$  cascade has been triggered, and protects the PVM against destruction by blocking IRG-dependent killing

through inactivation of the IRG proteins, by phosphorylation of the nucleotide-binding site (Fentress *et al.*, 2010; Steinfeldt *et al.*, 2010). This effect requires the simultaneous expression of a virulent **ROP5** allele, which may act by allowing access of ROP18 to the IRG phosphorylation site (Niedelman *et al.*, 2012). The kinase **ROP38** is suggested to modulate a MAP kinase also involved in IL-12 production, leading also to an inflammation defect (Peixoto *et al.*, 2010).

The pseudokinase **ROP5**, despite lacking enzyme activity, is also an allele-specific strong modulator of acute virulence (Reese *et al.*, 2011). Its effect appears to be the inhibition of IRGα6 coating on the PVM by interfering with oligomerization of this GTPase (Niedelman *et al.*, 2012), in addition to allowing the effect of ROP18 mentioned above. The genetics of *T. gondii* virulence in mice is strongly biased toward variations in these recently discovered effectors, as at least three of them (ROPs 5, 16, and 18) were recognized during genetic crosses and mapping of major virulence genes in the progeny (Saeij *et al.*, 2006; Taylor *et al.*, 2006; Dubremetz and Lebrun, 2012).

The connection between some of these factors and the IRG proteins that are widely expressed in mice but not in humans may be biologically significant, as mice are a natural host in the parasite life cycle whereas humans are not (Dubremetz and Lebrun, 2012). This, consecutively confines the possible impact of these virulence factors in the human disease: certainly, neither ROP18 nor ROP5 has any effect on IFN-γ-mediated killing of *T. gondii* in human cells (Dubremetz and Lebrun, 2012; Niedelman *et al.*, 2012). ROP5 controlled virulence by blocking IFN-γ, and directly regulated activity of ROP18 *in vitro*, and both proteins were necessary to avoid IRG recruitment and clearance in macrophages (Behnke *et al.*, 2012).

### viii. Additional factors

The **GRA15** protein shows specific genetic variation among *T. gondii* strains, and the Type II GRA15 is involved in the activation of NF $\kappa$ B signaling far more than Type I or III, resulting in a significant change in the immune response pattern of the host (Rosowski *et al.*, 2011; Dubremetz and Lebrun, 2012). Although how GRA15 acts is unclear, it has also been shown to play a part in interfering with mouse GBP binding to the PVM (Virreira *et al.*, 2011; Dubremetz and Lebrun, 2012).

The **cyclophilin** secreted by the parasite from DG has also been suggested to play a part in immunoregulation (Aliberti *et al.*, 2003), by inducing IL-12 production through molecular mimicry of the chemokine CCR5. The actin-regulating protein **profilin** has been shown to activate the host immune response through TLR11 binding, and might therefore be involved in virulence; however, it has also been described as essential for parasite development through its role in motility, and cannot in fact be considered a virulence factor (Plattner *et al.*, 2008; Dubremetz and Lebrun, 2012).

*T. gondii* proteins involved in gliding motility, host cell attachment, invasion, and egress including resident surface proteins and lipids (SAG1), transient surface proteins (MICs), RONs, and rhoptry bulb proteins, which are mentioned above in the description of the parasite, also play an important role in virulence. Moreover, DG (GRAs 5, 7, 14, and 15) and the cytoskeleton (the proteins MORN1 and TgPHIL1) are *T. gondii* virulence factors in development and stage differentiation, as well as cyst formation and parasite tissue burden (Dubremetz and Lebrun, 2012).

## **II- THE DISEASE**

## A. General aspects

### i. General epidemiology – worldwide occurrence and course of the disease

The prevalence of *T. gondii* infection differs greatly, with high rates in Latin America, parts of Eastern/Central Europe, the Middle East, and parts of Southeast Asia and Africa, and lower rates in many European countries and the United States (Pappas *et al.*, 2009). *T. gondii* infects around one-third of the world's population, but among this big proportion it rarely causes clinically significant disease (Montoya and Liesenfeld, 2004). Yet, certain individuals are at high risk for severe or life-threatening toxoplasmosis. Individuals at risk for toxoplasmosis include fetuses, newborns, and immunologically impaired patients.

Congenital toxoplasmosis is frequently a subclinical infection. Among immunodeficient persons, toxoplasmosis most frequently occurs in those with defects of T cell-mediated immunity, such as those with hematological malignancies, bone marrow and solid organ transplants, or AIDS. In most immunocompetent individuals, primary or chronic (latent) *T. gondii* infection is asymptomatic. A small percentage of these patients eventually develop retinochoroiditis, lymphadenitis, or, rarely, myocarditis and polymyositis (Montoya and Liesenfeld, 2004).

From a clinical point of view, toxoplasmosis has several **forms of presentation**; they differ depending on multifactorial elements related to the host, parasite, and environment, such as disease course, predominant localization of the infection in the body, grade of compromise, host immune response, form of acquisition, infecting parasite strain, among others. **Acute toxoplasmosis**, which is characterized by the rapid reproduction of tachyzoites in cells of different tissues of the host body, is usually a



self-limited disease. This form of disease presents symptoms like malaise, fever, fatigue, headache, and cervical lymphadenopathy (Flegr, 2013). In susceptible individuals, it can be accompanied also by transient psychiatric symptoms, and in immunocompromised subjects it can even have a fatal outcome.

In some individuals, acute toxoplasmosis can develop into a **chronic** course. Thus, the symptoms of acute toxoplasmosis could persist or periodically return for many years. In most cases, the activated immune system causes transition of acute toxoplasmosis into **latent** toxoplasmosis. In this stage of infection, tissue cysts with slowly reproducing bradyzoites are formed, and they survive in diverse tissues of the body, including the brain and the eye, for many years or until the end of the life of the host (Flegr, 2013). The presence of these cysts induces local inflammation in the infected tissues, and the bradyzoites release various antigens and other molecules, for example, dopamine, into surrounding tissues in the brain. The presence of living parasites protects the host against new infection; however, after an **immunosuppression** process (AIDS or immunosuppression in oncological or transplantation patients), the latent toxoplasmosis quickly passes into a new, severe acute phase. Without radical and rapid treatment, the patient usually develops extended retinal damage or even dies of encephalitis (Luft and Remington, 1992).

In the case of infection of a woman immediately before **pregnancy** or in the first trimester of pregnancy, the infection is transmitted from mother to fetus in about 10% of cases, resulting in either abortion or serious malformations of the fetus, including hydrocephalus and microcephalus. If the infection of the mother occurs in the third trimester, the probability of infection of the fetus is much higher, 50–60%. The resulting symptoms of congenital toxoplasmosis

can sometimes cause intracranial calcifications or ophthalmological defects such as retinochoroiditis (Desmonts and Couvreur, 1974).

Humans can acquire *Toxoplasma* infection by eating tissue cysts in undercooked or raw meat from an infected intermediate host, or by ingestion of oocytes with, for example, unwashed vegetables or drinking water contaminated with the feces of an infected cat. Acute toxoplasmosis resulting from the infection by oocytes usually has a worse course than acute toxoplasmosis acquired from tissue cysts (Dubey, 2004; Flegr, 2013).

## **ii. Congenital toxoplasmosis**

Based on serological studies, it is estimated that the incidence of primary maternal *T. gondii* infection during pregnancy ranges from about 1–310 cases per 10,000 pregnancies in different populations in Europe, Asia, Australia, and the Americas. The incidence of prenatal *T. gondii* infection within the same or similar populations has been estimated to range from about 1–120 cases per 10,000 births (Desmonts and Couvreur, 1974; Glasner *et al.*, 1992; McCannel *et al.*, 1996; de-la-Torre *et al.*, 2009).

About 10–20% of pregnant women infected with *T. gondii* become symptomatic (Montoya and Remington, 1996). The most common signs of infection are lymphadenopathy and fever. If the mother was infected prior to pregnancy, there is virtually no risk of fetal infection, as long as she remains immunocompetent (Montoya and Remington, 1996). When a mother is infected with *T. gondii* during pregnancy, the parasite may be disseminated hematogenously to the placenta. When this occurs, infection may be transmitted to the fetus transplacentally or during vaginal delivery (Gras *et al.*, 2005; Thiébaud *et al.*, 2007).

Congenital toxoplasmosis is generally the result of a primary infection during pregnancy. The clinical manifestation of the infant will depend on the gestational week when the mother acquired the infection and is characterized by a broad spectrum of symptoms at birth, including varying degrees of neurological, ophthalmological, and systemic involvement (Gómez-Marín *et al.*, 2011). If the mother acquired the infection in the first trimester and it was not treated, the risk of infection to the fetus is around 14–17%, and toxoplasmosis in the infant is generally severe. If the mother was infected in the third trimester and it was untreated, the risk of fetal infection is approximately 59–65%, and involvement is mild or not apparent at birth. These different rates of transmission are most likely related to placental blood flow, the virulence and amount of *T. gondii* acquired, and the immunological ability of the mother to restrict parasitemia (Gómez-Marín *et al.*, 2011).

The most significant manifestation of toxoplasmosis in the fetus is encephalomyelitis, which may have severe results. Approximately 10% of prenatal *T. gondii* infections result in abortion or neonatal death. In approximately 67–80% of prenatally infected infants, the infection is subclinical and can be diagnosed using only serological and other laboratory methods. Although these infants appear healthy at birth, they may develop clinical symptoms and deficiencies later in life (Gómez-Marín *et al.*, 2011).

Recent reports indicate that congenital toxoplasmosis is more often symptomatic in South America than in Europe. This was demonstrated when cohorts of congenitally infected children from different continents were compared (SYROCOT, 2007). The greater severity of South American cases was an unexpected result of the Systematic Review on Congenital Toxoplasmosis SYROCOT international collaborative study (SYROCOT, 2007). Additionally, a comparative prospective cohort study of congenitally infected children in Brazil and Europe found that Brazilian children had eye

lesions that were larger, more numerous, and more likely to affect the part of the retina responsible for central vision, compared with their counterparts in Europe (Gilbert *et al.*, 2008). The authors of the study suggested that the increased frequency and severity of ocular disease in Brazil compared with Europe was due to exposure to more virulent strains of *T. gondii* in Brazil (Gilbert *et al.*, 2008). Importantly, parasite genotyping studies indicated that current markers were not useful for indicating clinical outcome, but they clearly showed a different parasite population between Europe and SA (Gómez-Marín, 2009; Gómez-Marín *et al.*, 2011). Congenital toxoplasmosis caused by atypical genotypes is more severe than that caused by typical genotypes (Lindsay and Dubey, 2011).

In Colombia, there is a high lethality rate in prenatally untreated congenital infected children (25%). Interestingly, a significant correlation was identified between mean rainfall at the city and the incidence of markers for congenital infection (Gómez-Marín *et al.*, 2011).

### **iii. Infection in immunocompromised patients**

Generally, the incidence of the infection varies by population group and geographic location. For example, the cultural habits of a population may affect the acquisition of *T. gondii* infection from ingested tissue cysts in undercooked or uncooked meat (Hill and Dubey, 2002).

Seropositivity rates in the United States have been reported to be between 10% and 15%, although sources vary, and higher infection rates have been estimated (Jones *et al.*, 2007; Kaplan *et al.*, 2009). *T. gondii* seropositivity rates among patients with HIV infection vary from 10–45% in the United States.

Most cases of toxoplasmosis in immunocompromised patients are a consequence of latent infection and reactivation. In patients with AIDS, *T. gondii* tissue cysts can reactivate with CD4 counts of less than 200 cells/ $\mu$ L; with counts of less than 100 cells/ $\mu$ L, development of clinical disease is more possible (Luft and Remington, 1992). Without adequate prophylaxis or restoration of immune function, patients with CD4 counts of less than 100 cells/ $\mu$ L who are positive for *T. gondii* IgG antibodies have a 30% risk of eventually developing reactivation disease (Porter and Sande, 1992).

While toxoplasmosis in immunocompromised patients could manifest as retinochoroiditis, reactivation in these individuals is characteristically presented in the Central Nervous System (CNS), with brain involvement being common. Toxoplasmic encephalitis and brain abscess present most commonly as headache, but focal neurological deficits and seizures are also common. With substantial disease, patients may also exhibit the signs and symptoms of elevated intracranial pressure. Cerebral toxoplasmosis is generally identified on computed tomography (CT) scan as multiple ring-enhancing lesions; however, solitary lesions may be seen, and negative CT or magnetic resonance imaging (MRI) scans should not rule out the diagnosis of CNS toxoplasmosis (Torok *et al.*, 2009).

Apart from CNS toxoplasmosis, other conditions commonly identified in immunocompromised patients include toxoplasmic pneumonitis, myocarditis, and disseminated toxoplasmosis. Toxoplasmic pneumonitis typically exhibits characteristic symptoms of an infectious pulmonary process, including fever, dyspnea, and cough. Chest radiography is often nonspecific, but findings may have an appearance similar to that of *Pneumocystis (carinii) jirovecii* pneumonia. Diagnosis is established via bronchoalveolar lavage. Most patients with extra-CNS manifestations of toxoplasmosis will also be noted to

have CNS lesions when appropriate radiographic studies have been performed (Hofman *et al.*, 1993).

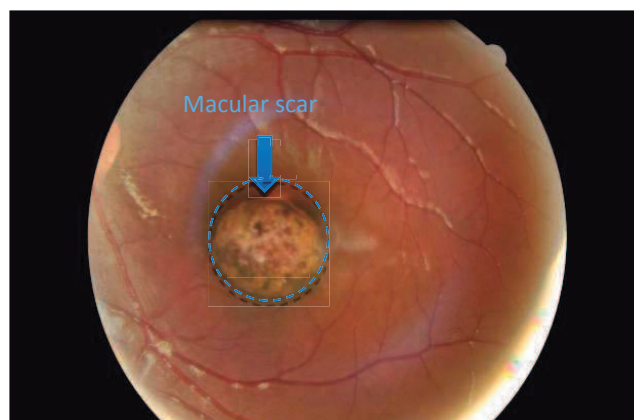
## **B. Ocular toxoplasmosis**

### **i. Physiopathology/Immunopathology**

Studies in murine models and in humans have led to helpful insights into the pathogenesis of ocular toxoplasmosis (Gazzinelli *et al.*, 1994). In mice, after the inoculation of *Toxoplasma* tachyzoites the majority of them develop minor uveitis and retinal vasculitis (Gazzinelli *et al.*, 1994). The uveitis is characterized by an infiltration of CD4+ lymphocytes and macrophages into the retina and by the expression of TNF- $\alpha$  and IFN- $\gamma$  messenger ribonucleic acid (mRNA) in retinal lymphocytes (Gazzinelli *et al.*, 1994). Generally, the inflammation becomes destructive, with retinochoroidal damage and alteration of the retinal pigment epithelium (RPE) (**Figure 3**). Parasites have rarely been detected *in situ* in these mice (Gazzinelli *et al.*, 1994). In humans, the lymphocytes of patients with OT react not only to *T. gondii* antigens but also retinal antigens (Nussenblatt *et al.*, 1989).

The opposite situation has also been observed. Cytokine and lymphocyte depletion have been detected in the model of toxoplasmic retinochoroiditis in the mouse. Treating mice with anti-CD4 or anti-CD8 antibodies provokes an increase in the number of ocular cysts, whereas treatment with anti-IFN- $\gamma$  or anti-TNF- $\alpha$  antibodies produces lesions containing tachyzoites (Nussenblatt *et al.*, 1989). The histopathological features of mice treated with antibodies to produce immunodepression are similar to those in the lesions of immune-depressed patients (Pivetti-Pezzi *et al.*, 1994). These patients develop multiple lesions characterized by retinal necrosis and marked inflammation of the retina, vitreous humor, and subjacent choroid (Pivetti-Pezzi *et al.*, 1994). The model supports the conclusion that

retinochoroiditis in immunocompetent subjects must be considered independently of cases arising in immunodepressed patients. Overall, the results of murine and human OT studies indicate that although parasite-mediated host cell lysis is an important cause of tissue destruction in OT, hypersensitivity and inflammation aggravate the process in otherwise immunocompetent persons (Garweg and Candolfi, 2009).



**Figure 3.** Characteristic toxoplasmic retinochoroidal damage: atrophic retinochoroidal scar (caused by tissue destruction and necrosis), with hyperpigmented borders (due to the alteration of Pigmented Retinal Epithelium (RPE)).

In one study of local cytokine concentrations in 27 patients with OT, no correlation was found with age, sex, or region of origin of the patient, time from symptom onset to the obtainment of samples, the degree of uveal inflammation, or the etiology of the infection (acquired or congenital; Lahmar *et al.*, 2009). However, a characteristic local cytokine profile in human OT compared with other causes of uveitis was observed.

Predominantly high levels of IFN- $\gamma$ , IL-6, and MIP-1 were often detected in samples from patients with OT and in samples from those with viral uveitis, whereas IL-17 was frequently detected in samples from patients with OT and in samples from those with intermediate uveitis (IU; Lahmar *et al.*, 2009). This

profile particularly included IL-17A overexpression. In another prospective study in French patients, it was found that Th1 (IL-2 and IFN- $\gamma$ ) and Th2 (IL-13) cytokines, as well as inflammatory (IL-6, IL-17, and MCP-1) and downregulating cytokines (IL-10) were upregulated in AH of patients with confirmed OT (Sauer *et al.*, 2012).

In contrast, TNF- $\alpha$  was not upregulated. Additionally, the strong upregulation of IL-17 was confirmed. All other cytokines and chemokines were below the detection limit (Lahmar *et al.*, 2009). As these studies were done in patients infected by the relatively benign Type II strain, predominant in Europe and North America, which induces IL-17 production in mouse models, it would be of interest to analyze the inflammatory cytokines in South American patients infected with more virulent strains, causing more severe clinical disease.

A higher frequency of some polymorphisms in cytokine genes in patients with OT, compared with people infected but without ocular manifestations, has been reported (Cordeiro *et al.*, 2008; de Albuquerque *et al.*, 2009). Specific IL-1, IL-10, and IFN- $\gamma$  alleles were particularly found in patients with OT (Cordeiro *et al.*, 2008; de Albuquerque *et al.*, 2009). No such association was found with TNF- $\alpha$  gene polymorphisms (Cordeiro *et al.*, 2008). Another study in Brazil found that genotypes related to a lower production of IL-6 were associated with the occurrence of toxoplasmic retinochoroiditis (Cordeiro *et al.*, 2013).

According to the host susceptibility and to the parasite virulence, there is an ocular response that leads to retinal damage or parasite control, with a balance between both, resulting in survival of the host and parasite (Denkers, 2003). The innate and adaptive immune responses both have diverse humoral and cellular elements, which produce acute and chronic responses in which cytokines/chemokines play an important role (Dupont *et al.*, 2012).



## **ii. Immunology of OT – ocular Immune response and specificity in South America**

### **1. The importance of intraocular cytokine dissection analysis in the local response to *T. gondii* infection**

As we already mentioned, *T. gondii* infection is an important cause of ocular disease, both in immunocompetent and in immunocompromised patients. In general, toxoplasmosis is either clinically asymptomatic or associated with only mild clinical symptoms. Nevertheless, the parasite persists in the host CNS and in the retina, establishing latent infection (Nishanth *et al.*, 2010). Thus, fetuses and immunocompromised individuals might undergo life-threatening toxoplasmosis due to the inability to prevent parasite-induced tissue necrosis (Nishanth *et al.*, 2010).

The parasite-mediated lysis of host cells is a consequence of unsuccessful immune control of replication of the tachyzoites. A possible role for immune hypersensitivity reactions in facilitating some specific pathological alterations in toxoplasmosis has been proposed (Gaddi and Yap, 2007). While parasite-mediated host cell destruction may be the main cause of tissue damage in immunodeficiency conditions, hypersensitivity and inflammatory reactions could cause severe injury in otherwise immunocompetent populations (Gaddi and Yap, 2007).

It is not difficult to understand why fetuses and immune-suppressed individuals cannot control the parasite damage. Nevertheless, the reason why important tissue destruction is observed in some immune-competent individuals remains to be elucidated. Possible explanations for this are infection by a virulent strain, ingestion of high parasite load, and the kind of

infectious source, containing oocysts or tissue cysts. However, the reason why huge differences exist in terms of ocular compromise between these otherwise healthy patients infected with virulent strains remains to be clarified (Dupont *et al.*, 2012).

In some regions of the southern hemisphere, otherwise healthy individuals may present with severe toxoplasmosis, with pulmonary involvement and splenomegaly (Carme *et al.*, 2002). Certain unusual strains of *T. gondii* may also be related to an augmented incidence of ocular infection in SA (Grigg *et al.*, 2001). Since clinically distinguishing between congenitally transmitted and acquired toxoplasmosis is difficult, it is uncertain what proportion of disease in patient subpopulations is caused by immunodeficiency or “anergy” resulting from exposure of the fetal immune system to *Toxoplasma* antigens, versus damage caused by hypersensitivity reactions subsequent to excessive immune reactivity (Gaddi and Yap, 2007).

Cell-mediated immunity to *T. gondii* antigens includes innate acute inflammatory responses and antigen-specific adaptive immunity (Denkers and Gazinelli, 1998; Cai *et al.*, 2000). Since cytokines are important signaling molecules involved in cellular communication, they are crucial to the development and functioning of both innate and adaptive immune responses. Some cytokines may play a significant role in immune protection but could also be pathological when dysregulated (Gaddi and Yap, 2007). They are regularly secreted by immune cells that have encountered a pathogen, thereby activating and recruiting additional immune cells to increase the organism’s response to the pathogen.

Recent and emerging concepts on the role of cytokines in the immune response to *T. gondii* have revealed their influence on host protection and their role in mediating along with regulating pathological hypersensitivity

reactions in experimental mouse models (Gaddi and Yap, 2007; Munoz *et al.*, 2011). Nevertheless, little is known about the role of cytokines in the human intraocular response to *T. gondii*, as immune responses in humans have not been investigated in detail (Munoz *et al.*, 2011).

In chronically infected individuals, the immune response appears to be strictly activation site-specific, since, with respect to activation markers and the production of T1 group cytokines, the systemic cellular response to soluble *Toxoplasma* antigen does not differ between patients with either ocular or asymptomatic toxoplasmosis (Fatoohi *et al.*, 2006; Garweg and Candolfi, 2009).

It is essential to analyze the lymphokine repertoires of eye-infiltrating T cells during OT and expand beyond the classical Th1/Th2 type cytokines, as well as analyze the influence of parasite genotype or host genetic polymorphisms on tilting the balancing between pro-inflammatory versus anti-inflammatory cytokine production (Gaddi and Yap, 2007).

## **2. Cytokines in innate immune responses to *T. gondii***

After the challenge with *T. gondii*, monocytes, macrophages, neutrophils, and DCs are recruited to the place of infection, and all of these cells are involved in recognizing and fighting this parasite (Del Rio *et al.*, 2001; Mordue et Sibley, 2003; Liu *et al.*, 2006; Dunay *et al.*, 2008; Dunay *et al.*, 2010; Tait *et al.*, 2010; Dupont *et al.*, 2012). Yet, questions persist about their precise roles in regulating infection. One of the most critical functions of the innate immune response to *T. gondii* is the capability to sense the pathogen and produce IL-12, which activates NK cells and T cells to produce IFN- $\gamma$  (Gazzinelli *et al.*, 1993; Gazzinelli *et al.*, 1994; Hunter *et al.*, 1994; Dupont *et al.*, 2012).

IFN- $\gamma$  is the main mediator involved in fighting *T. gondii* and stimulates numerous intracellular machineries to destroy the parasite and inhibit its reproduction. This Th1 immune response, characterized by the production of IL-12 and IFN- $\gamma$ , is typical of infection with several intracellular pathogens (Dupont et al., 2012). Mice deficient in either IL-12 or IFN- $\gamma$  that are infected with *T. gondii* develop acute disease and present a failure to control parasite load (Gazzinelli et al., 1994; Hunter et al., 1994; Suzuki et al., 1988; Dupont et al., 2012).

The first step necessary for innate production of IL-12 during *T. gondii* infection is recognition of the parasite by the host. Innate immune receptors called TLRs, which are present in APCs, play a role in this process. The adapter molecule myeloid differentiation primary response gene 88 (MyD88) is important for most TLR signaling, as well as IL-1R/IL-18R signaling (Sukhumavasi et al., 2008). There is considerable evidence that MyD88 is required for innate sensing of *T. gondii* and IL-12 responses, and for prolonged resistance to the pathogen (LaRosa et al., 2008; Sukhumavasi et al., 2008).

Thus, mice deficient in MyD88, which is required for downstream signaling from most TLRs, are acutely predisposed to toxoplasmosis (Scanga et al., 2002). Particular TLRs such as 2, 4, 9, and 11 are involved in the immune response to *Toxoplasma*. TLR11 reacts to a profilin-like molecule conserved among protozoan parasites (Yarovinsky et al., 2005; Jenkins et al., 2010), whereas TLRs 2 and 4 recognize GPIs on the surface of the parasite (Debierre-Grockiego et al., 2007). Moreover, subsequent to oral infection with *T. gondii*, bacterial antigens translocate from the gut, and TLRs 2, 4, and 9 respond to these microbial offenses, contributing to progress of the Th1 immune response (Benson et al., 2009).

The CD8 $\alpha$ <sup>+</sup> subset of DCs are the most relevant sources of IL-12 (Reise Sousa *et al.*, 1997; Dupont *et al.*, 2012), and the transcription factor Batf3 is important in this process, as shown in Batf3 KO mice (Mashayekhi *et al.*, 2011). Neutrophils, which are another source of IL-12 during toxoplasmosis (Bliss *et al.*, 1999a; Bliss *et al.*, 1999b; Bliss *et al.*, 2000), have the chemokine receptor CXCR2, which is necessary, in a mouse model, for neutrophil recruitment to the site of infection (Del Rio *et al.*, 2001). These cells are also involved in other effector mechanisms that directly destroy parasites, including phagocytosis, the release of reactive chemical species, and the formation of extracellular traps (Nakao and Konishi, 1991; Konishi and Nakao, 1992; Chtanova *et al.*, 2008; Abi Abdallah *et al.*, 2012).

Monocytes are also required for resistance during toxoplasmosis, as mice deficient in the chemokine receptor CCR2 (CCR2 KO), which is necessary for monocyte recruitment to the place of infection, show increased susceptibility when challenged (Dunay *et al.*, 2010; Robben *et al.*, 2005; Benevides *et al.*, 2008). After *T. gondii* challenge, inflammatory monocytes produce IL-12 *in vitro* and *in vivo*; yet, it is not clear whether they are a crucial source of this cytokine (Mordue and Sibley, 2003; Robben *et al.*, 2005; Aldebert *et al.*, 2007; Benevides *et al.*, 2008; Dunay *et al.*, 2010; Whitmarsh *et al.*, 2011; Dupont *et al.*, 2012). It has also been suggested that these cells contribute to the direct control of *T. gondii* through the generation of nitric oxide (NO), which inhibits parasite replication (Dunay *et al.*, 2010).

In response to soluble *Toxoplasma* antigens, monocytes additionally produce IL-1 (Gazzinelli *et al.*, 1995). It increases anti-parasitic effector mechanisms in macrophages and astrocytes *in vitro* (Hammouda *et al.*, 1995; Halonen *et al.*, 1998). The production of IFN- $\gamma$  from innate and adaptive sources could be

stimulated by IL-1 acting in synergism with IL-12 (Hunter *et al.*, 1995; Shibuya *et al.*, 1998).

NK cells are active in acute as well as in chronic infection, although their activity is less significant in the chronic stage (Dupont *et al.*, 2012). Even if these cells produce IFN- $\gamma$ , and also IL-10, IL-12, and TNF- $\alpha$ , they could only provide a limited mechanism of resistance through their capacity to produce IFN- $\gamma$ , in mice that lack T cells (Hunter *et al.*, 1994; Dupont *et al.*, 2012). Human and murine NK cells can also be cytotoxic for cells infected with *T. gondii* (Hauser Jr and Tsai, 1986; Subauste *et al.*, 1992). In addition, it has been proposed that NK cells are infected with *T. gondii* after the lysis of infected cells, which may promote dissemination of the parasite (Persson *et al.*, 2009). NK cells can also act to promote adaptive immune responses. Hence, in the absence of CD4<sup>+</sup> T cells, they can provide help to the CD8<sup>+</sup> T cell response (Combe *et al.*, 2005; Dupont *et al.*, 2012). Production of IFN- $\gamma$  by NK cells has been associated with the improvement of CD4<sup>+</sup> T cell responses (Goldszmid *et al.*, 2007; Dupont *et al.*, 2012).

The parasite signals and circumstances that stimulate the innate immune response, leading to predominant production of IL-12, IL-23, or IL-27 by innate immune cells, remain unknown. For example, commensal bacteria in the gut may influence and favor the IL-23-IL-17 axis at the expense of IL-12- or IL-27-dominated responses (McKenzie *et al.*, 2006).

### **3. Cytokines in adaptive immune responses to *T. gondii***

The significance of adaptive immune responses for human defense against *T. gondii* during infection is confirmed by the augmented vulnerability of patients with primary or acquired defects in T cell function (Dupont *et al.*, 2012). Mice with deficiencies in B cells, CD4<sup>+</sup> T cells, or CD8<sup>+</sup> T cells survive the acute stage of infection, but finally show increased susceptibility to *T. gondii*

(Denkers *et al.*, 1997; Kang *et al.*, 2000; Johnson and Sayles, 2002; Dupont *et al.*, 2012). Diverse cytokines are characteristic of different T cell populations that participate in adaptive immunity.

Although toxoplasmosis is characterized by a strong protective Th1 response, additional IL-4-producing Th2 cells develop and contribute to optimal control of the parasite and survival in toxoplasmosis (Nishanth *et al.*, 2010). Experimental studies with mice have shown that control of *T. gondii* in both acute and chronic infection is critically dependent on IFN- $\gamma$ -producing CD4+ and CD8+ T cells. Likewise, IL-4, B cells, and antibodies contribute to the control of *T. gondii* in the CNS (Nishanth *et al.*, 2010).

**a. The importance of the equilibrium between Th1/Th2/Th17/Treg responses: maintaining counterbalance in *T. gondii* infection control**

The two sets of cytokines, Th1 (IFN- $\gamma$ , IL-2, and IL-12) and Th2 (IL-4, IL-6, and IL-10), represent two polar reactions of the immune system. The Th1 group of cytokines is involved mostly in cellular responses, while the Th2 group is associated primarily with humoral ones. In OT, the pathogenic roles of the cytokines produced by Th1 and Th17 cells and the protective and homeostatic roles of IL-10, IL-27, and TGF- $\beta$  in reducing the host's hypersensitivity response to *T. gondii* have been only incompletely clarified (Gaddi and Yap, 2007; Garweg and Candolfi, 2009).

In the investigation of immunoregulatory cytokines in ocular fluid samples from patients with infectious uveitis, including viral infections and toxoplasma chorioretinitis, even though a number of cytokines (IL-6, IL-10, and IFN- $\gamma$ ) were detected in samples of human ocular fluid, a single role for either a Th1 or Th2 response in the pathogenesis of clinical uveitis could not be established (Ongkosuwito *et al.*, 1998). Indirect evidence for a protective role of IFN- $\gamma$  in OT has been found using a synthetic polymeric complex of

polyinosinic and polycytidylic acids, which is a strong inducer of IFN- $\gamma$  (Garweg and Candolfi, 2009). Prophylactic use of this polymer postpones the progress of lesions in the retina of *Toxoplasma*-infected eyes, but it does not completely suppress the disease (O'Connor, 1983; Garweg and Candolfi, 2009).

In a mouse model study, IFN- $\gamma$  was reported to regulate the ocular distribution and load of *T. gondii* (Norose *et al.*, 2003). In humans, higher levels of IFN- $\gamma$  and 10-fold higher numerical densities of activated CD25+ T cells have been reported in blood cultures derived from *Toxoplasma*-infected patients than in those from healthy controls after stimulation with soluble *Toxoplasma* antigen. No differences were detected between patients with either ocular or asymptomatic toxoplasmosis. Chronic infection with *Toxoplasma* therefore seems to be connected with a continued stimulation of IFN- $\gamma$  production (Garweg and Candolfi, 2009). This variable might influence the recurrence pattern (Fatoohi *et al.*, 2006; Garweg and Candolfi, 2009).

Mutant mice lacking CD25+ and CD4+ Treg cells spontaneously develop autoimmune uveoretinitis (Takeuchi *et al.*, 2004). Therefore, the clear activation of CD25+ Treg cells that is associated with OT in wild-type mice could protect the host against autoimmunity in this infection. The numerical densities of CD4+ and CD25+ Treg cells are increased in the eyes of mice with experimental autoimmune uveitis (EAU) during resolution of the first attack. During reactivation of the disease, the response is weaker and corresponds with lower levels of IL-10 in the AH (Ke *et al.*, 2008). In murine OT, results demonstrate that IL-10 is important in the regulation of inflammation during acute OT (Lu *et al.*, 2003).

In mice chronically infected with *T. gondii*, there were modifications to elements of immune privilege, with upregulation of major histocompatibility



complex class I, and increase of the intraocular RNA levels for TGF- $\beta$ , TNF- $\alpha$ , and IL-6, while those for IL-1- $\alpha$  were low. IL-6 appeared to play a role in controlling parasite quantity and inflammation (Lyons *et al.*, 2001).

*In vitro Toxoplasma* studies have shown that human RPE cells respond to infection by secreting IL-1 $\beta$ , IL-6, granulocyte macrophage colony-stimulating factor (MCSF), and intercellular adhesion molecule 1 (ICAM-1). These molecules could have an important immunoregulatory function in the pathophysiological processes that are related to OT. TGF- $\beta$ , in contrast, promotes the replication of *T. gondii* (Nagineeni *et al.*, 1996).

In a murine model of acquired OT, focal ocular inflammation, with involvement of the RPE, was observed 2 weeks after inoculation with an avirulent strain of *T. gondii*. By the fourth week, the ocular inflammatory response had abated and ocular cysts were rarely observed. In many of the retinal lesions, no parasitic DNA could be detected. These findings indicate that the formation of retinal lesions was instigated by the inflammatory response to the infection, not by the parasite itself. Treatment of the mice with monoclonal antibodies against T cells (CD4+ and CD8+) or cytokines (IFN- $\gamma$  or TNF- $\alpha$ ) caused a marked increase in the number of retinal lesions. These lesions were more frequently associated with the presence of parasites, along with a severe inflammatory response (Gazzinelli *et al.*, 1994).

In human OT, the levels of IL-6 are significantly elevated in the AH, but not in the serum, indicating that the raised levels of IL-6 found in the AH of uveitis patients did not result from serum leakage, but from local production (Murray *et al.*, 1990). Intraocular levels of IL-6 were reported to be higher in patients with toxoplasmic retinochoroiditis than in those with acute retinal necrosis. In OT patients, intraocular levels of IFN- $\gamma$  and IL-10 were elevated in about half of the cases; IL-2 was infrequently detected in both patient groups. A different

role for either Th1 or Th2 cells in the pathogenesis of either OT or acute retinal necrosis could not be confirmed (Ongkosuwito *et al.*, 1998).

In cases of clinically established retinal vasculitis and vitritis, which are the hallmarks of active OT, a disproportion in the IL-17/IL-27 axis seems to be a precondition for inflammatory and tissue hypersensitivity reactions. This imbalance has a tendency to be more prominent in patients who have been infected with *Toxoplasma* postnatally than in those with congenital infection. Treg cells may thus play an essential role in ocular inflammation, and their dysregulation or failure could contribute to the severity of OT and its relapse (Garweg and Candolfi, 2009). These factors could partially account for the long-suspected, but still unconfirmed, autoimmune characteristics of recurrent OT (Garweg and Candolfi, 2009). Similar immunoregulatory phenomena have been reported in the inflammatory states associated with organ transplantation and overt autoimmune disease (Afzali *et al.*, 2007).

**b. The innate immune response is required to activate the acquired immune response: Th1-type cytokine response. The dual role of IL-12: immune protection connected with IFN- $\gamma$  production vs. pathological role once dysregulated**

The production of IFN- $\gamma$  by innate type NK cells and adaptive CD4 and CD8 T lymphocytes is critical to host defense (Suzuki *et al.*, 1988; Gaddi and Yap, 2007). IL-12, which is composed of the IL-12 p40 and IL-12 p35 subunits, has been recognized as crucial for early IFN- $\gamma$  production and appropriate differentiation of Th1 lymphocytes during the immune response to *Toxoplasma* (Gazzinelli *et al.*, 1994; Yap *et al.*, 2000; Gaddi and Yap, 2007). In the absence of the IL-12 p40 gene or the IL-12 receptor-associated signal transducers Tyk2 and STAT-4, IFN- $\gamma$  production is severely decreased, generating vulnerability to acute *Toxoplasma* infection (Yap and Sher, 1999; Cai *et al.*, 2000; Shaw *et al.*, 2003; Gaddi and Yap, 2007).

In contrast, IL-23, although an IL-12-associated cytokine composed of the shared IL-12 p40 subunit and a unique p19 subunit, is not needed for mouse immunity to *T. gondii* infection (Lieberman *et al.*, 2004; Gaddi and Yap, 2007). Hence, IL-12 p40 secretion by innate type DCs and via an MyD88-dependent recognition mechanism is fundamental and may be sufficient for initiating IFN- $\gamma$ -mediated immunity to *Toxoplasma*. Adjunct cytokines such as IL-18 and IL-23 could, instead, have a pathogenic function (Mordue *et al.*, 2001; Gaddi and Yap, 2007).

Experimental studies with mice have revealed that control of *T. gondii* in both acute and chronic toxoplasmosis is critically dependent on IFN- $\gamma$ -producing CD4 and CD8 T cells (Gazzinelli *et al.*, 1992; Denkers and Gazzinelli, 1998; Suzuki *et al.*, 1988; Nishanth *et al.*, 2010). Additional to a direct protective role, CD4 T cells may act as helper T cells (for B cell immunoglobulin class switching and CD8 T cell differentiation); however, in particular circumstances, they may in fact aggravate disease (Gaddi and Yap, 2007). A study of ocular toxoplasmosis in CD4- and CD8-deficient genetic backgrounds also indicated that the inflammatory response in the eye is mediated primarily by CD4 T cells, whereas CD8 T cells may be more important in limiting parasite replication (Lu *et al.*, 2004, Gaddi and Yap, 2007).

Therefore, in the immune-competent host, CD4 T cells may play a predominant role in stimulating tissue inflammatory responses associated with toxoplasmic encephalitis and chorioretinitis. An immunopathogenic role of CD4 T cells is additionally reinforced by studies using per oral *T. gondii* infection of mice, which showed subsequent tissue inflammation and destruction in the small intestine (Liesenfeld *et al.*, 1996; Gaddi and Yap, 2007). Likewise, lymphocytes isolated from the small intestine of infected

susceptible mice expressed amplified levels of IFN- $\gamma$  and TNF- $\alpha$ , suggesting that dysregulated secretion of these cytokines by intestinal CD4 T cells could be the fundamental pathogenic mechanism. Certainly, late antibody deactivation of IFN- $\gamma$  or TNF- $\alpha$  or chemical inactivation of inducible nitric oxide (iNOS), an enzyme activated synergistically by IFN- $\gamma$  and TNF- $\alpha$ , was sufficient to avoid intestinal necrosis (Liesefeld *et al.*, 1999).

**c. Treg type cytokines. Regulatory role of IL-10: avoiding tissue damage when levels are sufficient vs. promoting tissue destruction when insufficiently produced**

The regulatory mechanisms preventing tissue destruction by limiting Th1 type hypersensitivity responses have been shown in toxoplasmic ileitis mouse models with different susceptibilities to *T. gondii* infection (C57BL/6 vs. Balb/c strain mice) (Gazzinelli *et al.*, 1996). IL-10 has been revealed to be the main immune regulatory tool in avoiding Th1-mediated hypersensitivity ileitis in resistant Balb/c mice infected per orally with *T. gondii*. The role of IL-10 was previously shown to be critical in downregulating systemic IFN- $\gamma$  responses in C57BL/6 mice following intraperitoneal *Toxoplasma* infection (Gazzinelli *et al.*, 1996).

IL-10-deficient C57BL/6 mice displayed elevated circulating IL-12 levels and consequently increased IFN- $\gamma$  and TNF- $\alpha$  responses and intense hepatic inflammation and tissue necrosis. Transitory reduction of CD4 T cells or functional loss of innate IL-12 secretion by DCs was sufficient to save IL-10-deficient mice, which suggests that IL-10 acts in a host-protective manner primarily by controlling IL-12-driven pathogenic effects mediated by CD4 T cells (Gazzinelli *et al.*, 1996).

IL-10 is a cytokine produced by DCs, macrophages, B cells, and certain T cell subsets, including Th2 cells and Treg cells (Moore *et al.*, 2001; Levings *et al.*,

2002; Gaddi and Yap, 2007). The main regulatory effect of IL-10 on immune responses, which is typically inhibitory, is believed to be facilitated indirectly by affecting the costimulatory activity and cytokine responses of DCs and macrophages. Although IL-10 is produced by myeloid cells in response to bacterial and fungal pathogens, the IL-10-inducing capacity of *T. gondii* remains not well described.

A study has reported that upon injection of mice with high doses of the virulent RH strain, resident peritoneal macrophages seemed to respond fast by producing IL-10 (Bliss *et al.*, 2000). Another study has likewise reported that B-2 type B cells may be a possible source of immunoregulatory IL-10 (Mun *et al.*, 2003). Yet, the pathogen recognition mechanism and signaling pathways that regulate innate IL-10 production in response to *T. gondii* infection and the functional role of IL-10 in the immune response to this parasite remain to be clarified. CD4 T cells may be the most significant source of immunoregulatory IL-10 during *T. gondii* infection (Roers *et al.*, 2004). Pre-mediated deletion of the IL-10 gene in CD4 T cells is sufficient to confer susceptibility to per oral *T. gondii* infection, despite the preserved ability of innate cellular components to produce IL-10 in response to bacterial lipopolysaccharide (Roers *et al.*, 2004).

The crucial significance of CD4-derived IL-10 in preventing immunopathology during toxoplasmosis raises the question of whether the pathogenic CD4 cell (producer of IFN- $\gamma$  and TNF- $\alpha$ ) and the regulatory CD4 cell (producer of IL-10) are different cells or are in fact the same cell type (Gaddi and Yap, 2007). Some studies indicate that CD4 Th1 cells can synthesize antagonistic cytokines in response to *T. gondii* infection, and that a significant portion of IFN- $\gamma$ -producing cells are also IL-10 producers, whereas cells that produce only IL-10 and not IFN- $\gamma$  are rare (Jankovic *et al.*, 2002). Whether this is also the case *in vivo* remains to be determined. This issue leads to significant questions, such as how the timing and magnitude of IFN- $\gamma$  versus IL-10

production are controlled upon the encounter of Th1 cells with infected APCs (Gaddi and Yap, 2007). Simultaneous production of antagonistic IL-10 and IFN- $\gamma$  may lead to failed or abortive activation of macrophage effector function (Gaddi and Yap, 2007).

A negative feedback mechanism for improving effector cell activation and pathogen clearance, while preventing excessive DC innate cytokine production and Th1 hypersensitivity has been proposed. Upon re-encounter with *T. gondii*-infected cells, Th1 cells first produce IFN- $\gamma$  that functions in a paracrine manner not only to activate effector cells but also to induce costimulatory activity of APCs for reactivating IL-10 gene expression in the same Th1 cell population (Gaddi and Yap, 2007).

**d. Pro-inflammatory cytokines/chemokines and their counterbalance. TGF- $\beta$  protective function, antagonized by IL-6. Inflammatory and pathological effects of IL-12 and IL-18 beyond the eye**

Both IL-12 and IL-18 appear to contribute to the severe inflammatory ileitis associated with oral *T. gondii* infection. While IL-18 seems to play a greater role in provoking intestinal necrosis and inflammation, it appears that IL-12 is crucial in controlling parasite load and replication (Vossenkamper *et al.*, 2004).

Pro-inflammatory cytokines such as IFN- $\gamma$  and TNF- $\alpha$  are secreted by the lamina propria lymphocytes (LPLs or CD4 T cells of the lamina propria) after oral infection with *T. gondii* cysts (Liesenfeld *et al.*, 1996; Liesenfeld, 2002). LPLs also generate pro-inflammatory chemokines such as MCP-1, MCP-3, and interferon-induced protein (IP) 10 (Mennechet *et al.*, 2002).

NK cells have also been involved in immunopathology, since they are early producers of IFN- $\gamma$  (Khan *et al.*, 2006). Their recruitment to places of *T. gondii* infection appears to be partially mediated by the presence of the chemokine receptor CCR5 on their surface (Khan *et al.*, 2006). NK T cells have also been implicated as both mediators of resistance and pathology to *T. gondii*. However, with their exceptional cytokine repertoire, they may also be considered immunoregulatory cells. NK T cells have a special cytokine range, which comprises both Th1 (IFN- $\gamma$ ) and Th2 cytokines (IL-4 and IL-10). NK T ligand activates a change from a Th1 cytokine profile to a Th2 cytokine profile, including IL-4, IL-10, and IL-13 (Ronet *et al.*, 2005). Because of their ability to produce Th2 cytokines, particularly IL-10, NK T cells may be involved as immunomodulators of pathology (Ronet *et al.*, 2005).

Besides IL-10, another significant regulatory cytokine connected to the regulation of intestinal immunopathology is TGF- $\beta$ . TGF- $\beta$  production by intraepithelial lymphocytes (IELs) has been proposed to be critical in the regulation of the pathogenic LPL responses that occur during per oral infections (Okamoto *et al.*, 1995). TGF- $\beta$  regulation of tissue inflammation and immunity might extend outside the gastrointestinal system, as TGF- $\beta$  has been identified as a main mediator of the immune-privileged state in the CNS and the eye (Okamoto *et al.*, 1995), where latent *T. gondii* resides and frequently becomes reactivated. TGF- $\beta$  present in the eye microenvironment may condition APCs to produce the anti-inflammatory cytokine IL-10, thereby reducing NK- and CD4 Th1-mediated pro-inflammatory reactions (Okamoto *et al.*, 1995).

Interestingly, IL-10-deficient mice infected intracamerally with *T. gondii* presented significant necrosis while transgenic overexpression of IL-10 markedly decreased ocular tissue destruction (Lu *et al.*, 2003). Hence, in *T. gondii* infection, TGF- $\beta$  alone is not sufficient for preserving immune privilege;

further downregulatory actions of IL-10 are required. It is feasible that innate responses to the parasite result in the production of inflammatory cytokines, such as IL-6, which antagonizes TGF- $\beta$  and eliminates the immune privilege previously functioning in the eye and CNS (Ohta *et al.*, 2000; Gaddi and Yap, 2007).

#### **e. Th17 and its activators. TGF- $\beta$ acting together with IL-6**

Although TGF- $\beta$  has been typically considered an immunoregulatory cytokine that prevents T cell stimulation directly and indirectly promotes tolerogenic or suppressive immune responses (Gaddi and Yap, 2007), relatively recent experiments have demonstrated an unexpected function for TGF- $\beta$ , acting together with IL-6 and other inflammatory cytokines, in driving the differentiation of Th17 cells (Veldhoen *et al.*, 2006; Gaddi and Yap, 2007). Th17 lymphocytes are currently recognized to be the most important pathogenic mediators of organ-specific autoimmune diseases, comprising rheumatoid arthritis, allergic encephalomyelitis, and inflammatory bowel disease (Cua *et al.*, 2003; Langrish *et al.*, 2005; Gaddi and Yap, 2007).

The *in vivo* growth and development of Th17 cells also requires IL-23, besides the inductive effects of TGF- $\beta$  and IL-6 (Liang *et al.*, 2006). In contrast to Th1 cells, which secrete IFN- $\gamma$  and are marked by expression of the transcription factor T-bet, Th17 cells differentiate via the action of ROR $\gamma$ t (Ivanov *et al.*, 2006) and produce a different set of pro-inflammatory and anti-microbial cytokines, including, IL-6, TNF- $\alpha$ , and IL-22, a member of the IL-10 cytokine family that is coexpressed by Th17 cells and cooperatively with IL-22 enhances expression of antimicrobial peptides (Liang *et al.*, 2006).

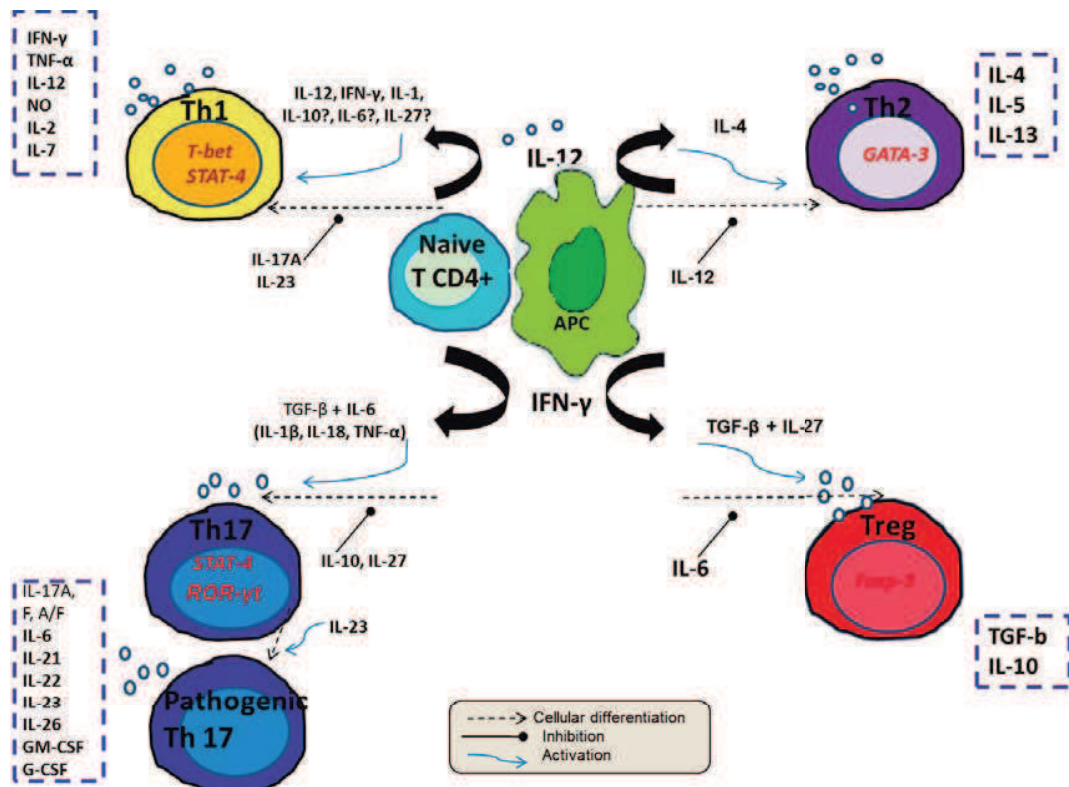
IL-17/IL17 receptor signaling has been associated with stimulating the maturation, migration, and partial activation of neutrophils (Kolls and Linden, 2004). Thus, IL-17 has been implicated in host resistance to extracellular



bacterial pathogens, such as *Klebsiella pneumoniae* (Happel *et al.*, 2005). Knowing the link between neutrophils and IL-17, the response of these cells to per oral *T. gondii* infection of mice deficient in the IL-17 receptor was investigated (Kelly *et al.*, 2005). The deficiency in neutrophil recruitment to the ilea and peritoneal cavities of IL-17 receptor-deficient infected mice seemed to lead to increased mortality, suggesting that IL-17-mediated responses may exert both protective and pathogenic effects.

The possible pathogenic role of Th17 cells in chronic toxoplasmosis in the brain of IL-27 receptor-deficient mice was shown in a mouse model of CNS inflammation during *Toxoplasma* encephalitis. Extremely high Th17 responses, associated with inflammation of the brain, were found. IL-27 was shown to suppress Th17 differentiation of naïve CD4 T cells driven by TGF- $\beta$  and IL-6. Hence, IL-27, a cytokine produced by APCs, can act as an endogenous suppressor of the Th17 response to parasite antigens during *T. gondii* infection. A previous study similarly showed a role of IL-27 in inhibiting Th cell production of IL-2. Thus, IL-27 production during *T. gondii* infection could counteract the immunoregulatory effects of IL-10 and TGF- $\beta$  in preventing T cell responses in general, and Th17 responses in particular (Stumhofer *et al.*, 2006).

Although our knowledge of the complex cytokine network in the adaptive immune response is increasing each day, much more has to be elucidated to truly understand it (**Figure 4**). Our newly improved understanding of the varied cytokine roles and their protective and pathogenic tissue responses, require further studies.



**Figure 4.** Cytokine network in the adaptive immune response to *Toxoplasma*. Cytokines are crucial in cellular differentiation, inhibition, and activation of the different T cell types. Modified from: Sauer *et al.*, 2012; Jones *et al.*, *Parasite Immunol* 2006; and Gaddi *et al.*, *Immunol Cell Biol* 2007.

### iii. Epidemiology

The epidemiology of OT was recently reviewed (Petersen *et al.*, 2012). This disease is responsible for 30–50% of posterior uveitis cases in immunocompetent individuals, and in some countries it is one of the most important causes of visual impairment (Arevalo *et al.*, 2010). OT has been reported to generate a significant impact on patients' quality of life, especially when patients have bilateral lesions and a high number of recurrences (de-la-Torre *et al.*, 2011).

From reports of clinical series of uveitis, it seems that OT is more common in SA, Central America, the Caribbean, and parts of tropical Africa compared

with Europe and Northern America, and is quite rare in China (Petersen *et al.*, 2012). OT in SA is more severe than on other continents, probably due to the presence of extremely virulent genotypes of the parasite (Sauer *et al.*, 2011).

Few studies have reported the prevalence of toxoplasmic chorioretinal scars in the general population through funduscopic screening. In the United States, in 842 residents of Maryland, 5 (0.6%) presented chorioretinal scars consistent with *Toxoplasma* lesions (Smith and Ganley, 1972). Another study in the south of Brazil found a prevalence of 17.7% (Glasner *et al.*, 1992). In Colombia, an intermediate prevalence (6%) was found (de-la-Torre *et al.*, 2007). Besides, in military personnel in Colombia, characteristic toxoplasmic chorioretinal lesions were found in four soldiers who operated in the jungle (0.8%) and in one urban soldier (0.19%; Gómez-Marín *et al.*, 2012).

In Colombia it is estimated that 5.5% of the population have retinochoroidal scars after a non-congenital infection and 20% of these persons have reduced visual capacity, while 0.5% of the population have scars from congenital infection (de-la-Torre *et al.*, 2007). The incidence of OT (new cases by year) has been estimated in Colombia (Quindío region) to be three new episodes by 100,000 inhabitants per year (de-la-Torre *et al.*, 2009), while in British-born patients, it was estimated to be 0.4 cases per 100,000 population and the lifetime risk of disease was estimated to be 18 cases per 100,000 population (Gilbert *et al.*, 1999).

#### **iv. Clinical presentation**

##### **1. Symptoms**

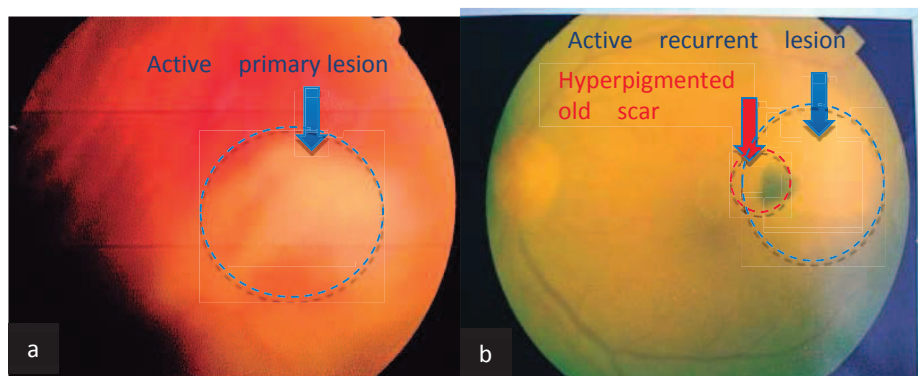
Although OT could be asymptomatic, especially if there is a peripheral chorioretinal lesion, the most common symptoms during the active phase are blurred vision, floaters, photophobia, and ocular pain (Gilbert *et al.*, 1999;

Bosch-Driessen *et al.*, 2002; de-la-Torre *et al.*, 2009). Floaters could remain, although less intense, in the chronic phase. Scotomas might be a complaint, particularly if there are central lesions.

## 2. Ocular features

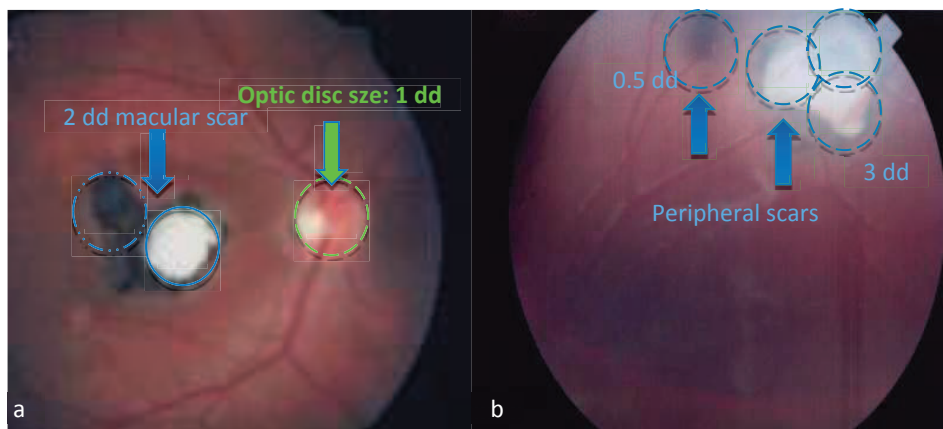
The most frequent distinguishing findings in OT are focal necrotizing retinochoroiditis associated with vitreous inflammation, frequently concomitant with adjacent old scars indicative of recurrent attacks in satellite positions (70–80% of cases seen at first consultation; de-la-Torre *et al.*, 2009; Gilbert *et al.*, 1999; Bosch-Driessen *et al.*, 2002). The clinical picture is typically characterized by 8- to 16-week active periods of intraocular inflammation. Clinically, OT can be classified as follows (**Figure 5**):

- Primary, if there is an active creamy-white focal retinal lesion without associated pigmented retinochoroidal scars in either eye; and
- Recurrent, if an active retinochoroidal lesion occurs in the presence of old pigmented retinochoroidal scars in either eye.

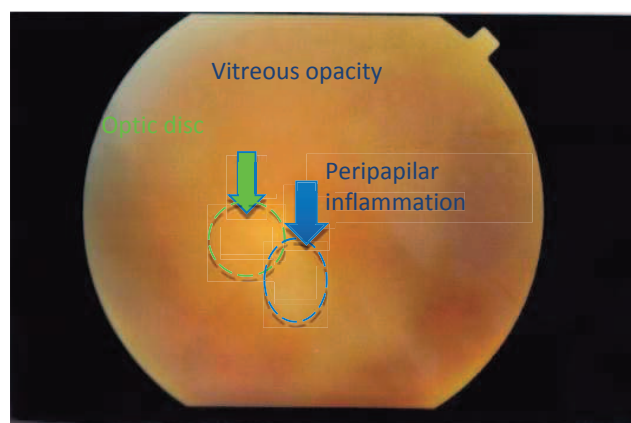


**Figure 5.** Active toxoplasmic lesions. *a*: Primary lesion, a creamy-white retinochoroidal lesion without concomitant hyperpigmented scar (blue arrow). *b*: Recurrent lesion, a creamy-white active lesion (blue arrow) with accompanying hyperpigmented old scar (red arrow).

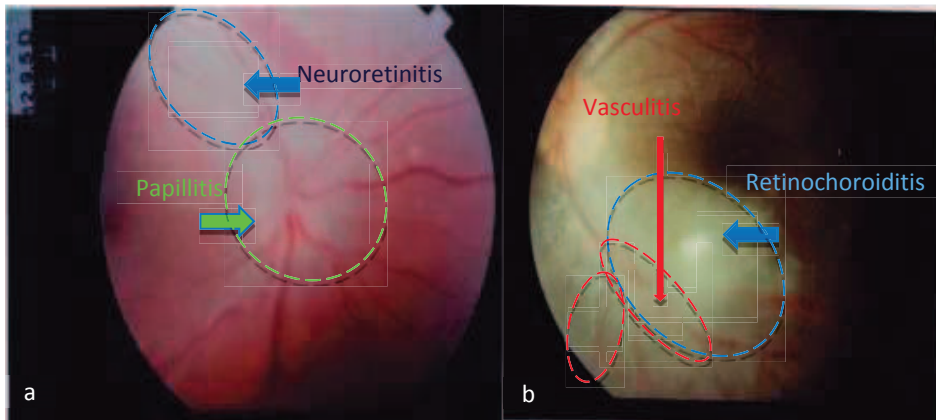
According to their size, lesions might be described in millimeters or in optic disc diameters. In relation to their location, central lesions are defined as lesions situated within the large vascular arcades, and peripheral ones are situated outside of the large vascular arcades (**Figure 6**). Additional findings are vitritis, anterior uveitis, vasculitis, and papillitis (**Figures 7 and 8**).



**Figure 6.** Toxoplasmic retinochoroidal scars located in different parts of the retina. a: Macular atrophic retinochoroidal scar with hyperpigmented borders and a size of approximately 2 disc diameters (dd) (blue arrow). The size of the lesion is described according to the optic disc size, which is one disc diameter = 1dd (green arrow). b: Peripheral atrophic retinal scar with a size of about 3 dd, and a hyperpigmented peripheral scar of about 0.5 dd. The sizes of the lesions are compared with the size of the optic disc.

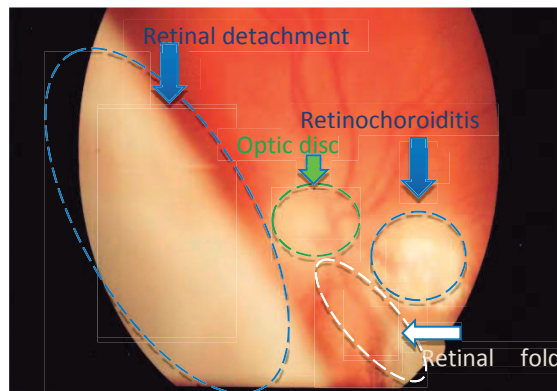


**Figure 7.** Additional findings in OT: vitreous haze (vitritis) and active peripapillary inflammation with vitreous opacity. Details of the retina are not clearly observed because of the vitreous haze.



**Figure 8.** Additional findings in ocular toxoplasmosis (OT): neuroretinitis, papillitis, and retinochoroiditis. a. Neuroretinitis and papillitis due to OT. b. Active retinochoroiditis with perivascular sheathing.

The most frequent complications after resolution of inflammation are strabismus, posterior synechiae, ocular hypertension, cataracts, and cystoid macular edema (CME; Gilbert *et al.*, 1999; Bosch-Driessen *et al.*, 2002; de-la-Torre *et al.*, 2009). Further complications are epiretinal membranes, chorioretinal neovascularization, and retinal detachment (**Figure 9**).



**Figure 9.** OT complication: retinal detachment.

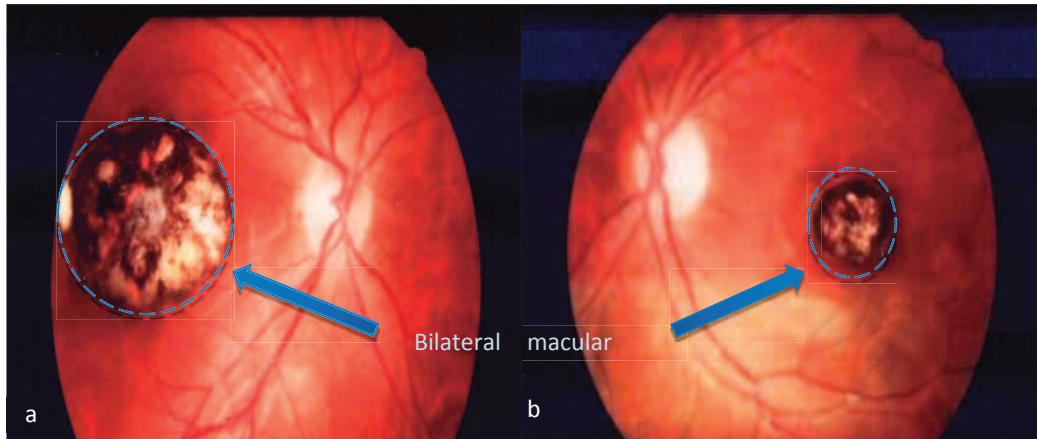
There are no differences in gender distribution of the disease or the age of presentation (Gilbert *et al.*, 1999; Bosch-Driessen *et al.*, 2002; de-la-Torre *et*

*et al.*, 2009). The causes of visual loss include location of toxoplasmic lesion in the macular area and retinal detachment (Gilbert *et al.*, 1999; Bosch-Driessen *et al.*, 2002; de-la-Torre *et al.*, 2009). Definitive unilateral blindness can be 24–37% (Gilbert *et al.*, 1999; Bosch-Driessen *et al.*, 2002; de-la-Torre *et al.*, 2009). Complications like granulomatous iritis, high intraocular pressure, retinal vasculitis and vascular occlusions, rhegmatogenous and serous retinal detachments, and diverse forms of secondary pigmentary retinopathies might disguise the original toxoplasmic lesion and make the correct diagnosis difficult (Gilbert *et al.*, 1999; Bosch-Driessen *et al.*, 2002; de-la-Torre *et al.*, 2009).

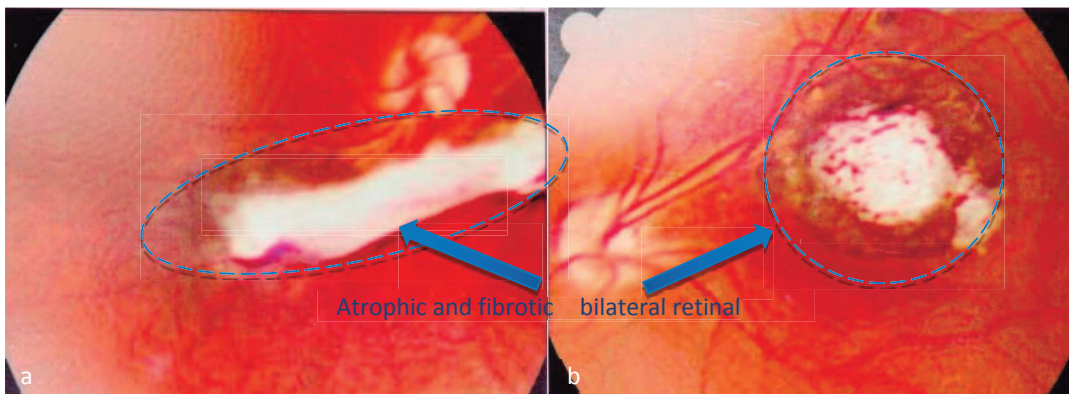
OT is characterized by recurrences that cause further visual loss and thus seriously affect quality of life (de-la-Torre *et al.*, 2009). The risk of a recurrence is highest soon after an episode, and then declines as the patient continues to remain recurrence-free (clustering) (de-la-Torre *et al.*, 2009). The frequency of recurrence in OT in Colombia was found to be two episodes every 11 years, with recurrences clustering soon after an active attack (de-la-Torre *et al.*, 2009). Previous use of systemic steroids without antibiotics or subconjunctival injection of steroids is related to a higher index of recurrences. Additional factors related to more frequent episodes of recurrences are still to be identified (de-la-Torre *et al.*, 2009).

Some differences between South American and European clinical case series have been observed in terms of the rate of congenital transmission, probability of symptoms in congenital form (Gilbert *et al.*, 2008), levels of ocular inflammation (Dodds *et al.*, 2008), and levels of intraocular specific antibodies (Garweg *et al.*, 2004). A comparative prospective cohort study of congenitally infected children in Brazil and Europe found that compared with their counterparts in Europe, Brazilian children displayed eye lesions that were larger, more numerous, and more likely to affect the part of the retina

responsible for central vision (Gilbert *et al.*, 2008). Figures 10 to 15 show images from Colombian patients with OT.

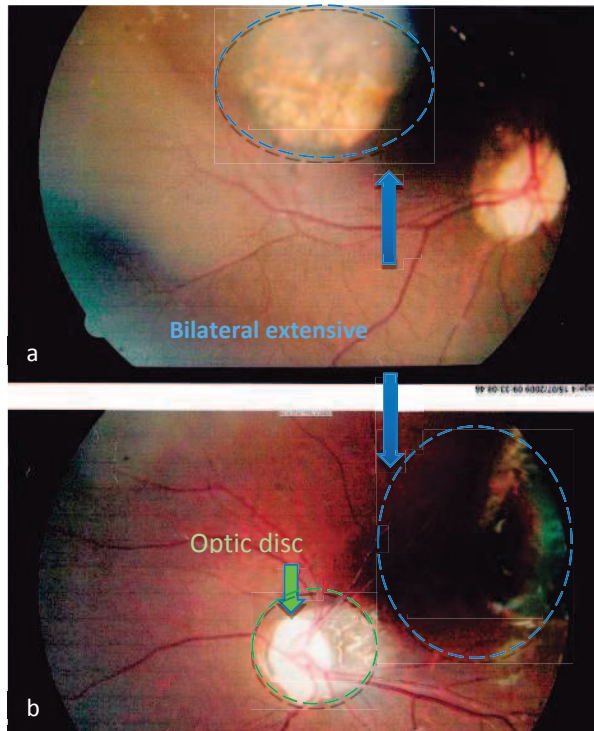


**Figure 10.** Bilateral macular compromise: chorioretinal scars with atrophic center and hyperpigmented borders.

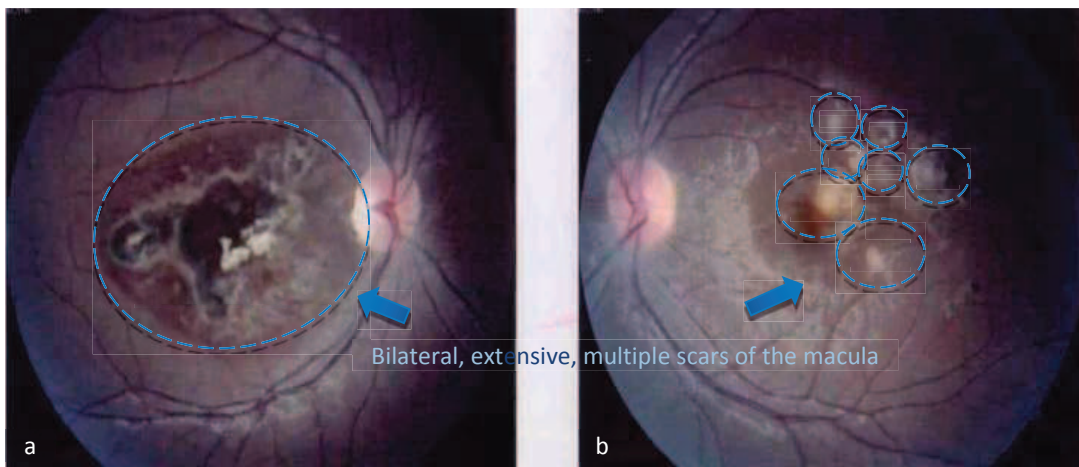


**Figure 11.** Bilateral macular compromise: extensive tissue destruction. Retinal tissue has been completely destroyed, leading to visualization of the sclera in the necrotic areas of the retinochoroidal scars.

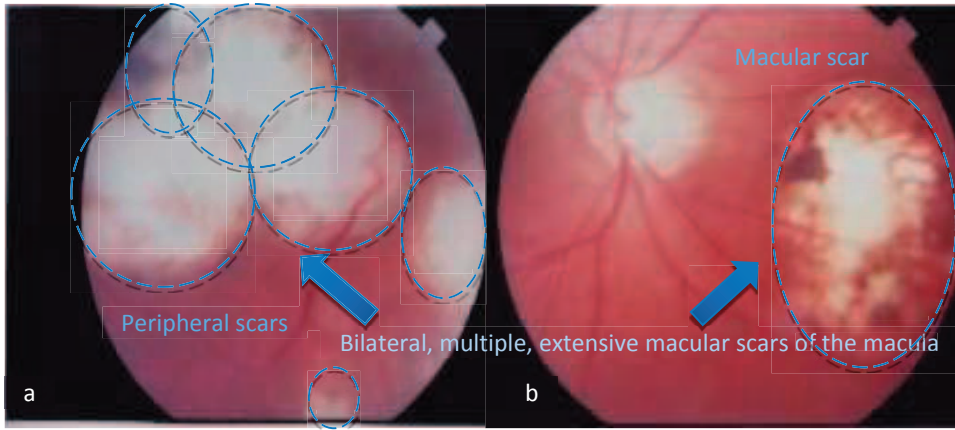




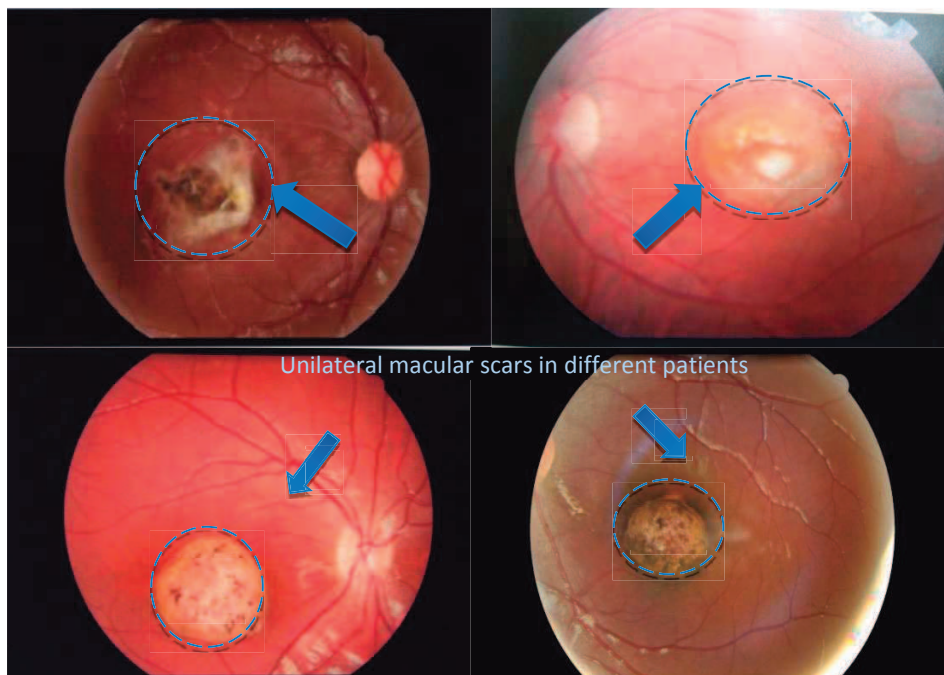
**Figure 12.** Bilateral compromise: extensive chorioretinal scars and optic nerve atrophy. a, b: Extensive chorioretinal scars. b: Optic nerve atrophy.



**Figure 13.** Bilateral macular compromise: multiple extensive chorioretinal scars.



**Figure 14.** Bilateral, multiple, extensive scars of the macula, both central and peripheral.



**Figure 15.** Unilateral macular lesions in different patients.

## v. Diagnosis

The clinical manifestations of OT are usually highly characteristic, but some other ocular infections such as herpes, cytomegalovirus, or autoimmune diseases can give occasionally similar lesions. Up to 21% of hyperpigmented retinochoroidal lesions are not toxoplasmic (Talabani *et al.*, 2009).

Likewise, occasional atypical presentation of OT can misguide the diagnosis to other causes, retarding the initiation of specific therapy. Serological tests on peripheral blood are necessary, but they are insufficient to confirm the diagnosis. Patients with OT always register positive for *Toxoplasma*-specific IgG; therefore, a negative result should indicate to the clinician another etiology. However, a positive test is not a confirmation for this etiology (Villard *et al.*, 2003; Talabani *et al.*, 2009). *Toxoplasma*-specific immunoglobulin M (IgM) can be detected in the serum, which may be indicative of a recently acquired infection. The parasite itself has been detected in the peripheral blood both of patients with OT and of control individuals (Garweg *et al.*, 2011).

In immunocompetent individuals, *Toxoplasma* DNA can be amplified within samples of AH in maximally 30–40% of clinically diagnosed cases (Villard *et al.*, 2003; Talabani *et al.*, 2009; Garweg *et al.*, 2011). The low DNA amplification rates could be due to the low parasitic load in the AH (even in cases of acute infection), the small amount of sample that is available for analysis, and/or an early degradation of *Toxoplasma* DNA. As an alternative to the AH, the vitreous humor can be analyzed when available (Garweg *et al.*, 2011).

Clinical and serological criteria in typical forms can be enough for the diagnosis. Typical lesions during active episodes in recurrent forms of OT consist of a creamy-white focal retinal lesion combined with hyperpigmented retinochoroidal scars in either eye, together with a serum sample positive for *Toxoplasma*-specific IgG. If the patient responds to appropriate anti-*Toxoplasma* therapy, no further laboratory analyses are needed. If serum samples are positive for *Toxoplasma*-specific IgM, this indicates that ocular involvement is the consequence of a recently acquired (primary) infection. Sampling of intraocular fluids is not required in either instance (Garweg *et al.*, 2011).

If the lesions are not typical, paired samples of AH and serum should be collected and analyzed in parallel. Positive investigation of these samples may face technical difficulties, since none of the commercially available ELISA, PCR, and immunoblotting tests are standardized for testing ocular fluid samples, nor are they routinely applied in most commercial laboratories. A referral to specialized diagnostic centers should be considered. At these centers, support in clinical interpretation of outcomes may also be available (Garweg *et al.*, 2011). Local IgG production can be detected by using the ELISA technique (Goldmann-Witmer coefficient). If no local specific IgG production is detected, or if the blood-retinal barrier is severely compromised, immunoblotting analysis of the serum and AH (as a more sensitive alternative) and PCR analysis of the latter to detect parasitic DNA can be performed. Using this strategy, a laboratory confirmation of the diagnosis can be achieved in 85% of cases (Villard *et al.*, 2003; Garweg *et al.*, 2011).

#### **vi. Therapy**

A recent review analyzed the current evidence for OT treatment (de-la-Torre *et al.*, 2011). Even though a Cochrane meta-analysis concluded that there was uncertainty about the effectiveness of antibiotic treatment (Gilbert *et al.*, 2002), and while in Europe and the United States some ophthalmologists consider it unnecessary to use antibiotics in peripheral small lesions, it seems that OT in some regions with the presence of virulent strains, such as SA, should be always treated with antibiotics (de-la-Torre *et al.*, 2009).

The classic therapy for OT consists of pyrimethamine and sulfadiazine plus corticosteroids. In this therapy, an initial dose of 75–100 mg of pyrimethamine is given daily for 2 days, followed by a 25–50 mg dose daily. Sulfadiazine, 2–4 g, is given daily for 2 days, followed by a 500 mg–1 g dose every 6 h as well as 5 mg of folinic acid daily for 4–6 weeks. Oral prednisolone (1 mg/kg daily)

is given from the third day of therapy and tapered over 2–6 weeks (de-la-Torre *et al.*, 2011). A good response with resolution of inflammation and establishment of the characteristic hyperpigmentation of the lesion can be observed after 4–6 weeks of treatment. Folinic acid should also be administered to protect against leukopenia and thrombocytopenia (de-la-Torre *et al.*, 2011).

An alternative antibiotic therapy is the combination of trimethoprim (80 mg)/sulfamethoxazole (400 mg) every 12 h plus oral prednisone (1 mg/kg, started after 3 days; Gilbert *et al.*, 2002). When there is not a good response to systemic antibiotics, intravitreal clindamycin injection and dexamethasone are an alternative treatment for toxoplasmosis retinochoroiditis (Soheilian *et al.*, 2005). Intravitreal drug administration bypasses ocular barriers and thereby delivers a high drug concentration directly to intraocular tissues, avoiding systemic exposure and its risk of complications (Soheilian *et al.*, 2005).

### III- PERSONAL WORK

## **A. Objectives**

### **i. Determination of the severity: clinical and biological comparison of French and Colombian patients**

Knowing the particular geographical distribution of *T. gondii* around the world, with evident differences of strains in South America and Europe (Lehman, *et al.*, 2006), our purpose was to analyze the clinical features in Colombian and French patients with OT and correlate them with the biological and immune responses. Several studies suggested a more frequent and more severe ocular involvement in South American infections compared with European infections, due to different *T. gondii* strains (Type I/III and atypical vs. Type II) (Gilbert, *et al.*, 2009; Vasconcelos-Santos, *et al.* 2009). Thus, we aimed to compare the clinical characteristics and biological and immune responses, in a single study and using the same parameters, in Colombian and French patients with active OT.

### **ii. Cytokinome analysis in Colombian patients: is OT immune response related to strain virulence?**

One of the possible explanations for the dissimilar clinical features in Colombian and French patients with OT is infection with diverse strains with different virulence. Thus, we wanted to correlate these features with the infecting strain and with the immune response, since the local cytokinome in the AH of these patients could give us clues for understanding the physiopathological mechanisms of OT, and could lead to insights for novel and better therapies.

### **iii. Modeling OT: preliminary results and perspectives**

There exist long discussions on whether inflammation in immune-privileged tissues is controlled locally by endogenous mechanisms in the local tissue or indirectly through the intervention of T cells that regulate autoreactive T cells (Lee *et al.*, 2011). Thus, it is of interest to study the local immune response in the eye infected with *T. gondii* and to contrast these results with the systemic response.

It has been reported that local IL-17A production plays an important role in the pathology of OT (Sauer *et al.*, 2012). Hence, we aimed to investigate the main intraocular source of this cytokine and the kinetics of its production. We show here preliminary data from our personal works.

We also want to propose to open the future possibility of the use of siRNA delivery into the vitreous in an animal model of OT, with the purpose of blocking the transcription factors required for the production of IL-17 (ROR $\gamma$ T) or other cytokines such as IL-6/IL-13 (GATA-3). In this preliminary work, we aimed to investigate if it would be possible to obtain the same results as therapy with intraocular monoclonal antibodies with siRNA, which could be considered a future alternative in the treatment of OT. However, even more, we aimed to expand this possibility to the use of siRNA delivery in the vitreous; thus, we explored another future prospect to modulate the local immune response in OT.

## **B. Papers**



## **ARTICLE 1**

**PREVENTION OF RETINOCHOROIDITIS IN  
CONGENITAL TOXOPLASMOSIS – EUROPE VERSUS  
SOUTH AMERICA** (published in *Pediatr Infect Dis J.* 2011  
Jul;30(7):601-3)

## **i. Introduction**

The cases we observed and the clinical practice in children with congenital toxoplasmosis in SA and Europe are evidently not the same on the two continents (Ajzenberg, 2011). Thus, here we have conducted a literature review, in order to discuss the importance of screening and therapy for congenital toxoplasmosis.

The serologies achieved throughout the screening during pregnancy lead to an early diagnosis and treatment of the mothers with primary infection, probably limiting the incidence of congenital toxoplasmosis (Chene and Thiébaud, 2009; McLeod *et al.*, 2009). This massive screen gives us the possibility of making a prompt detection and opportune treatment of the cases, in order to avoid severe sequelae (Freeman *et al.*, 2008; McAuley, 2008; McLeod *et al.*, 2009), and to diminish the societal cost of congenital toxoplasmosis (Stillwaggon *et al.*, 2011). Less time between diagnosis and treatment *in utero* improves outcomes (McLeod *et al.*, 2009). In addition, superior outcomes seem to be related to treatment of infected children during their first year of life (McLeod *et al.*, 2009). In spite of antenatal and postnatal therapy, chorioretinitis can occur at any age, with a prevalence of > 20% at 10 years of age. Long-term ophthalmological follow-up remains essential (Kieffer *et al.*, 2013).

In general, there is a good prognosis of congenital toxoplasmosis in Europe, and there is a low risk of late ocular manifestation on this continent (Faucher *et al.*, 2011; Peyron *et al.*, 2011). The opposite situation is seen in SA, where the pathology is more severe. Here, prenatal and postnatal follow-up are poor. This situation, combined with the presence of more virulent *Toxoplasma* strains, leads to more frequent neurological and visual impairment, and there is a high lethality rate in prenatally untreated children (25%) (Gómez-Marín *et*

*al.*, 2011). Thus, it is crucial to implement rigorous prenatal screening in this part of the world (Gómez-Marín *et al.*, 2011).

## **ii. Article**

# Prevention of Retinochoroiditis in Congenital Toxoplasmosis

## *Europe Versus South America*

Arnaud Sauer, MD,\*† Alejandra de la Torre, MD,‡ Jorge Gomez-Marin, MD, PhD,‡  
Tristan Bourcier, MD, PhD,\* Justus Garweg, MD, PhD,§ Claude Speeg-Schatz, MD, PhD,\*  
and Ermanno Candolfi, MD, PhD†

Congenital toxoplasmosis is suspected when seroconversion occurs in a pregnant woman, and it is confirmed by one or more biologic tests (polymerase chain reaction on amniotic fluid or neonatal serodiagnosis). The methods used are diagnostic in more than 95% of cases at birth and in 100% of cases by the age of 9 months.<sup>1</sup> Ocular lesions represent the most frequent complication of congenital toxoplasmosis, independent of any treatment.<sup>2</sup> The risk of toxoplasmic retinochoroiditis is highly unpredictable, however, mainly because the pathophysiology is poorly understood.<sup>3</sup> By school age, 10% to 20% of children with congenital toxoplasmosis have one or more retinochoroidal lesions, but more than 90% of them have normal vision in both eyes; bilateral blindness is very rare.<sup>4–6</sup> This article focuses on the controversy surrounding the effectiveness of screening and treatment for children with congenital toxoplasmosis.

### THE EUROPEAN POINT OF VIEW

#### Antenatal Treatment

For more than 30 years, the presumed effectiveness of retinochoroiditis prevention through specific antenatal and postnatal anti-*Toxoplasma* treatment has been an important justification for antenatal and neonatal *Toxoplasma* screening programs in Europe, the United States, and South America. In a French study, however, delayed antenatal treatment did not demonstrate an increased risk for retinochoroiditis at 6 years of age, although the study was not designed to answer this question, ie, benefits were not compared with a control group of untreated women.<sup>6</sup> A recent meta-analysis of all cohort studies of children with congenital toxoplasmosis found no evidence that antenatal treatment reduced the risk of retinochoroiditis after 4 years of follow-up.<sup>4</sup> Available data suggest that maternal treatment does not prevent transplacental transmission.<sup>2,4,7</sup> These data also challenge the rationale for antenatal screening to prevent retinochoroiditis.<sup>6,7</sup> However, a recent study has established that prenatal follow-up and treatment have an important clinical benefit in severe neurologic disease.<sup>8</sup> Thus, fetal ultrasound examination for detection of neurologic disorders and treatment of these severely affected babies are fully justified.<sup>4,8</sup>

#### Postnatal Treatment and Follow-up

Freeman et al<sup>4</sup> showed that the presence of fetal ultrasound abnormalities was associated with a markedly increased risk of retinochoroiditis, and that all children with intracranial abnormalities developed retinochoroiditis. Moreover, children with nonocular manifestations of congenital toxoplasmosis (notably neurologic sequelae, lymphadenopathy, or hepatosplenomegaly) detected before 4 months of age had more than twice the risk of having retinochoroiditis detected at birth or later in childhood compared with children who had no such manifestations. In contrast, children with no signs of retinochoroiditis at 4 months of age had a low risk of developing retinochoroiditis by the age of 4 years, regardless of other clinical manifestations.

Freeman et al<sup>4,9</sup> also examined the effect of delayed postnatal treatment and found no evidence of harm. They postulated that postnatal treatment is probably less effective than antenatal treatment, because treatment is likely to be most effective when given soon after maternal seroconversion, before the parasite forms bradyzoite cysts that are impenetrable to antibiotics. Doubts as to the benefits of postnatal treatment are also reflected by variations in clinical practice. In the Danish National Screening Program, treatment was given for only 3 months instead of the

Accepted for publication January 13, 2011.

From the \*Service d'Ophtalmologie, Hôpitaux Universitaires de Strasbourg, Strasbourg Cedex, France; †Institut de Parasitologie et Pathologie Tropicale, Faculté de Médecine de l'Université de Strasbourg, Hôpitaux Universitaires de Strasbourg, Strasbourg Cedex, France; ‡Grupo de Parasitología Molecular (GEPAMOL) Universidad del Quindío, Armenia, Quindío, Colombia, South America; and §Swiss Eye Institute, University of Bern, Bern, Switzerland.

Address for correspondence: Arnaud Sauer, MD, Service d'Ophtalmologie, Hôpitaux Universitaires de Strasbourg, Nouvel Hôpital Civil, BP 426, 67091 Strasbourg Cedex, France. E-mail: arnaud.sauer@chru-strasbourg.fr.

Copyright © 2011 by Lippincott Williams & Wilkins

ISSN: 0891-3668/11/3007-0001

DOI: 10.1097/INF.0b013e3182129e70

standard 1-year course, and practitioners participating in another cohort study could not be persuaded to treat infected infants at all.<sup>4</sup>

Currently, all children with congenital toxoplasmosis identified by antenatal or neonatal screening are treated postnatally and followed throughout childhood. However, the need for regular ophthalmic examinations throughout childhood is also controversial. All relevant studies show that children with normal ophthalmoscopy in early infancy have a low risk of retinochoroiditis.<sup>4,5,10</sup> Pediatricians should also be aware that postnatal treatment has no defensible evidence base and carries a considerable risk of adverse effects, leading to treatment interruption in 14% to 58% of cases.<sup>2,10,11</sup> In one study, infected and uninfected children born to *Toxoplasma*-infected mothers had no detectable differences in a range of developmental outcomes at the age 3 to 4 years, but the parents of infected children were significantly more anxious. Part of this anxiety may be due to parents' concerns about their child's vision, a fear that is reinforced by repeated examinations.<sup>12</sup>

Recent studies provide an evidence base for an alternative strategy, in which postnatal treatment and follow-up are tailored to the prognosis. Freeman et al<sup>4</sup> suggest that 9 in 10 infected children, who are at lower risk of retinochoroiditis (normal fundus examination, no clinical manifestations, and normal fetal ultrasound) could be offered a short course (3 months) or no postnatal treatment. In addition, instead of regular fundus examination, parents could be advised to consult whether their child develops eye problems, and visual acuity could be tested during routine school-based screening at 3 to 4 years of age. Before this age, ophthalmic examination at birth is advisable, along with yearly examinations if the fundus remains normal. Although many ophthalmologists are not convinced of the benefits of yearly ophthalmoscopy, some centers repeat the examinations at 6-month intervals.<sup>10</sup> Children at a high risk of ocular toxoplasmosis, that is, those who have fetal ultrasound abnormalities and postnatal clinical manifestations or retinal scars, should be routinely treated for probably 1 year and examined up to 4 times a year. These recommendations may apply to regions where *Toxoplasma gondii* type 2 strains predominate (Europe and North America), but not to areas where more virulent strains circulate (mainly central and South America), as mentioned below.<sup>4</sup>

It has to be, nevertheless, admitted that most cases of acute ocular toxoplasmosis, including those diagnosed during childhood, may be due to infection acquired after birth.<sup>13</sup> Does this imply that we should screen the entire population to prevent retinochoroiditis?

## Conclusions for Europe

Diagnosis of congenital toxoplasmosis deserves to be confirmed biologically. The effectiveness of postnatal treatment and follow-up should be evaluated systematically, ideally in a randomized, controlled clinical trial. Regular follow-up and treatment are likely to be most beneficial to children with early clinical manifestations and/or retinochoroiditis, who have a high risk of recurrent lesions and associated functional damage. The other 90% of children, who are at a low risk of ocular toxoplasmosis, may live in peace until the age of 4, because all the European cohorts have only been followed up to 4 years of age. Furthermore, studies performed in North America have demonstrated that more than 70% of congenitally infected babies develop new chorioretinal lesion commonly diagnosed after the first decade.<sup>14,15</sup> But after the age of 4, corresponding to a correct language development, diagnosis will be made on ocular complaints such as floaters or decreased vision described by the patients. Thus, a systematic screening for congenital ocular toxoplasmosis by fundus examination during childhood period should not be the rule.

## THE SOUTH AMERICA COUNTERPART

### Treatment and Follow-up Are Justified by the Severity of Ocular Symptoms

Congenital toxoplasmosis in South America is more symptomatic than in Europe as demonstrated by 2 different reports comparing cohorts of congenitally infected children from different continents. The higher severity of South American cases was an unexpected result of the Systematic Review on Congenital Toxoplasmosis (SYROCOT) international collaborative study.<sup>7</sup> For that analysis, 25 cohorts of infected mothers from Europe, North America, and South America, identified during prenatal screening, were selected. The risk of ocular lesions was much higher among Colombian and Brazilian children (47% [18/38]) than among European children (14% [79/550]); the crude risk of intracranial lesions was also much higher among children in South America (53% [20/38]) than among those in Europe (9% [49/550]).<sup>7</sup> Additionally, a comparative prospective cohort study of congenitally infected children in Brazil and Europe found that Brazilian children had eye lesions that were larger, more numerous, and more likely to affect the part of the retina responsible for central vision, compared with their counterparts in Europe. More children developed retinochoroiditis sooner in Brazil than in Europe, and retinochoroidal lesion recurred at an earlier age in Brazil than in Europe.<sup>16</sup> By 4 years of age, the probability of a second lesion among children with a first lesion was 43% in Brazil compared with 29% in Europe, and the risk of multiple recurrences was also greater in Brazil.<sup>16</sup> Moreover, a recent report about 178 congenitally infected children in the Southeastern region of Brazil, found a high rate of early retinochoroidal involvement (80%) and 47% of them had active lesions during the first 3 months of life.<sup>16</sup> Brazil is not the only nation that is now reporting the clinical characteristics of the congenital ocular disease in South America. A study in Colombia found that toxoplasmosis was the second commonest cause of congenital blindness.<sup>17</sup> Additionally, a frequency of 0.6% of congenital toxoplasmosis in the Quindio region<sup>18</sup> and a high ocular involvement in 36% of congenitally infected children<sup>19</sup> has been reported. Moreover, in a retrospective study of uveitis in 693 Colombian patients in which 417 (60.1%) had a specific diagnosis, toxoplasmosis (acquired or congenital) was the most frequent cause with 276 cases (39.8%), followed by idiopathic uveitis and toxocariasis.<sup>20</sup> In addition, the incidence of ocular toxoplasmosis is higher in the Quindio region of Colombia, with 3 new episodes per 100,000 inhabitants per year,<sup>21</sup> as compared with that reported in England with 0.8 per 100,000 inhabitants.<sup>22</sup> Importantly, the impact of parasite genotyping indicates that current markers are not useful to indicate clinical outcome, but they clearly show a different parasite population between Europe and South America.<sup>23</sup> Differences between strains may be an explanation for the high incidence and rate of complications in South America compared with that observed in Europe. Also, the absence of systematic follow-up of pregnant women may explain the severity of the disease in South America. Other factors that may be playing a role are prenatal treatment which is practiced in Europe but not in South America, infectious form of the parasite, genetics of the host, and size of parasite inoculum during primary infection.

Current Colombian practice guidelines, based on expert consensus for congenitally infected children,<sup>24</sup> recommend postnatal treatment for symptomatic children, for at least 1 year. For asymptomatic children, pyrimethamine-sulfadiazine treatment for 1 year is recommended and a fundus eye examination every 6 months, together with neurologic (cerebral tomography) and audiologic examination. After the first year, the eye fundus examination is recommended once a year for asymptomatic children. For children at a high risk of ocular toxoplasmosis, ie, those who have

fetal ultrasound abnormalities and postnatal clinical manifestations such as retinal scars, an eye examination in every 6 months is advised.<sup>25</sup>

### Conclusions for South America

The available clinical studies show that congenital (and also noncongenital) ocular toxoplasmosis differs significantly between South America and Europe. Data from other continents are lacking, but it is evident that clinical and public health decisions should be taken differently for South America. In South America, it is urgent to implement a program of preventive measures. The main risk factors for pregnant women have been identified and potential effective public health measures should take these into account<sup>25</sup>; moreover, clinical trials to evaluate potential vaccine candidates deserve prioritization.<sup>26</sup> In addition to preventive measures and vaccines, prenatal screening and treatment ought to be implemented immediately, notably given that severe disease can be decreased by such intervention.<sup>8</sup>

### REFERENCES

- Pinon JM, Dumon H, Chemla C, et al. Strategy for diagnosis of congenital toxoplasmosis: evaluation of methods comparing mothers and newborns and standard methods for postnatal detection of immunoglobulin G, M, and A antibodies. *J Clin Microbiol*. 2001;39:2267–2271.
- Stanford MR, Gilbert RE. Treating ocular toxoplasmosis: current evidence. *Mem Inst Oswaldo Cruz*. 2009;104:312–315.
- Garweg JG, Candolfi E. Immunopathology in ocular toxoplasmosis: facts and clues. *Mem Inst Oswaldo Cruz*. 2009;104:211–220.
- Freeman K, Tan HK, Prusa A, et al. Predictors of retinochoroiditis in children with congenital toxoplasmosis: European, prospective cohort study. *Pediatrics*. 2008;121:1215–1222.
- Tan HK, Schmidt D, Stanford M, et al. European Multicentre Study on Congenital Toxoplasmosis (EMSCOT). Risk of visual impairment in children with congenital toxoplasmic retinochoroiditis. *Am J Ophthalmol*. 2007;144:648–653.
- Wallon M, Kodjikian L, Binquet C, et al. Long-term ocular prognosis in 327 children with congenital toxoplasmosis. *Pediatrics*. 2004;113:1567–1572.
- SYROCOT (Systematic Review on Congenital Toxoplasmosis) study group, Thiébaud R, Leproust S, et al. Effectiveness of prenatal treatment for congenital toxoplasmosis: a meta-analysis of individual patients' data. *Lancet*. 2007;369:115–122.
- Cortina-Borja M, Tan HK, Wallon M, et al. European Multicentre Study on Congenital Toxoplasmosis (EMSCOT). Prenatal treatment for serious neurological sequelae of congenital toxoplasmosis: an observational prospective cohort study. *PLoS Med*. 2010;12:7.
- Pfaff AW, Candolfi E. New insights in toxoplasmosis immunology during pregnancy. Perspective for vaccine prevention. *Parassitologia*. 2008;50:55–58.
- Gilbert RE, Peckham CS. Congenital toxoplasmosis in the United Kingdom: to screen or not to screen? *J Med Screen*. 2002;9:135–141.
- Daveluy A, Haramburu F, Bricout H, et al. Review of data related to side effects of drugs used in congenital toxoplasmosis. Bordeaux, France: EUROTOXO, A European Consensus on the State of the Science; 2005.
- Freeman K, Salt A, Prusa A, et al. European Multicentre Study on Congenital Toxoplasmosis. Association between congenital toxoplasmosis and parent-reported developmental outcomes, concerns, and impairments, in 3 year old children. *BMC Pediatr*. 2005;5:23.
- Stanford MR, Tan HK, Gilbert RE. Toxoplasmic retinochoroiditis presenting in childhood: clinical findings in a UK survey. *Br J Ophthalmol*. 2006;90:1464–1467.
- Phan L, Kasza K, Jalbrzikowski J, et al. Toxoplasmosis Study Group. Longitudinal study of new eye lesions in children with toxoplasmosis who were not treated during the first year of life. *Am J Ophthalmol*. 2008;146:375–384.
- Phan L, Kasza K, Jalbrzikowski J, et al. Toxoplasmosis Study Group. Longitudinal study of new eye lesions in treated congenital toxoplasmosis. *Ophthalmology*. 2008;115:553–559.
- Vasconcelos-Santos DV, Machado Azevedo DO, Campos WR, et al. UFMG Congenital Toxoplasmosis Brazilian Group. Congenital toxoplasmosis in southeastern Brazil: results of early ophthalmologic examination of a large cohort of neonates. *Ophthalmology*. 2009;116:2199–2205.
- de-la-Torre A, Gonzalez G, Diaz-Ramirez J, et al. Screening by ophthalmoscopy for toxoplasma retinochoroiditis in Colombia. *Am J Ophthalmol*. 2007;143:354–356.
- de-la-Torre A, López-Castillo CA, Rueda JC, et al. Clinical patterns of uveitis in two ophthalmology centres in Bogota, Colombia. *Clin Experiment Ophthalmol*. 2009;37:458–466.
- Gomez-Marin JE, Gonzalez MM, Montoya MT, et al. A newborn screening programme for congenital toxoplasmosis in the setting of a country with less income. *Arch Dis Child*. 2007;92:88.
- Gomez-Marin JE, delaTorre A. Positive benefit of postnatal treatment in congenital toxoplasmosis. *Arch Dis Child*. 2007;92:88–89.
- de-la-Torre A, Lopez-Castillo C, Gomez-Marin JE. Incidence and clinical characteristics in a Colombian cohort of ocular toxoplasmosis. *Eye*. 2009;23:1090–1093.
- Gilbert RE, Dunn DT, Lightman S, et al. Incidence of symptomatic toxoplasma eye disease: aetiology and public health implications. *Epidemiol Infect*. 1999;123:283–289.
- Morisset S, Peyron F, Lobry J, et al. Serotyping of *Toxoplasma gondii*: striking homogeneous pattern between acute and asymptomatic infections within Europe and South America. *Microbes Infect*. 2008;10:742–747.
- Gomez Marin JE, Ruiz B, Silva P, et al. Guía de práctica clínica para toxoplasmosis durante el embarazo y toxoplasmosis congénita en Colombia. *Infectio*. 2007;11:129–141.
- Lopez CA, Diaz J, Gomez Marin JE. Factores de Riesgo en mujeres embarazadas, infectadas por *Toxoplasma gondii* en Armenia-Colombia. *Rev Salud Publica*. 2005;7:180–190.
- Siachoque H, Guzman F, Burgos J, et al. *Toxoplasma gondii*: immunogenicity and protection by P30 peptides in a murine model. *Exp Parasitol*. 2006;114:62–65.

### **iii. Conclusions and perspectives**

*T. gondii* causes more severe ocular damage in congenitally infected children in SA compared with Europe. The obvious dissimilarities in the frequency, size, and multiplicity of retinochoroidal lesions could be due to infection with more virulent genotypes of the parasite (Gilbert *et al.*, 2008).

It is clear that clinical and public health decisions should be taken differently in South America than in Europe. While in Europe the majority of children are at a low risk of OT, and would not require regular follow-up and treatment until the age of 4 years (Freeman *et al.*, 2005), in some countries of SA, such as Colombia, it is imperative to implement a program of preventive actions and to employ effective public health measures, taking into account the critical risk factors for gestational and congenital infection. Clinical trials to evaluate potential vaccine candidates merit prioritization (Siachoque *et al.*, 2006). Besides preventive measures and vaccines, prenatal screening and treatment have to be implemented immediately in South American countries, especially since severe disease can be reduced by this action (Cortina-Borja *et al.*, 2010).

## **ARTICLE 2**

### **SEVERE SOUTH AMERICAN OCULAR TOXOPLASMOSIS IS ASSOCIATED WITH DECREASED IFN- $\gamma$ /IL-17A AND INCREASED IL-6/IL-13 INTRAOCULAR LEVELS**

(published in Plos Neglected Tropical Diseases 2013 Nov  
21;7(11):e2541)



## **i. Introduction**

Infection with *T. gondii* is a prominent cause of visual impairment in several countries, being responsible for 30–50% of uveitis cases in otherwise healthy persons (Arevalo *et al.*, 2010). Ocular compromise is a possible problem with both acquired and congenital toxoplasmosis. There exists a disparity in levels and harshness of this infection, which are greater in South America than in Europe (Gilbert *et al.*, 2008). Certain differences between South American and European clinical case series were detected in terms of congenital transmission rates, probability of symptoms in congenital OT (Thiébaud *et al.*, 2007; Gilbert *et al.*, 2008), severity of ocular inflammation (Dodds *et al.*, 2008), and intraocular specific antibody levels (Garweg *et al.*, 2004). Still, no comparative clinical and biological studies have been conducted yet in patients from both continents with laboratory-confirmed OT.

The population structure of *T. gondii* in North America and Europe includes three highly predominant clonal lineages (Types I, II, and III). They are significantly dissimilar in virulence in the mouse model. The majority of human and animal infections are produced by Type II strains. On the contrary, heterogeneous atypical genotypes of *T. gondii* are linked to severe infections in humans in South America (Carme *et al.*, 2009; Su *et al.*, 2012). *Toxoplasma* strains show great genetic variation in this region, which might somewhat explain the reason why congenital toxoplasmosis is more severe in South America than in Europe (Sauer *et al.*, 2011; Thiébaud *et al.*, 2007; McLeod *et al.*, 2012). A comparative prospective cohort study of congenital OT in Brazil and Europe found that Brazilian children exhibited eye lesions that were bigger, more numerous, and more likely to affect the macula (Gilbert *et al.*, 2008). Circumstantial medical cases have been also described, for instance, severe atypical bilateral retinochoroiditis in a Brazilian patient, produced by an extremely divergent, non-archetypal *T. gondii* strain (Bottos *et al.*, 2009).

Due to the significantly diverse population configuration of *T. gondii* in Europe and SA, it is appropriate to investigate the repercussions of this diversity on human pathogenesis (Garweg and Candolfi, 2009). Thus, we conducted a multicenter case series study with the aim of comparing the diverse clinical features among Colombian and French populations, collecting equal data and implementing the same laboratory assays in patients with biologically confirmed OT. We correlated the clinical and immunological findings to results of *Toxoplasma* strain genotyping and peptide-based strain serotyping.

## **ii. Article**

# Severe South American Ocular Toxoplasmosis Is Associated with Decreased Ifn- $\gamma$ /Il-17a and Increased Il-6/Il-13 Intraocular Levels

Alejandra de-la-Torre<sup>1,2,3</sup>, Arnaud Sauer<sup>2,4</sup>, Alexander W. Pfaff<sup>2</sup>, Tristan Bourcier<sup>4</sup>, Julie Brunet<sup>2</sup>, Claude Speeg-Schatz<sup>4</sup>, Laurent Ballonzoli<sup>4</sup>, Odile Villard<sup>2</sup>, Daniel Ajzenberg<sup>5</sup>, Natarajan Sundar<sup>6</sup>, Michael E. Grigg<sup>6</sup>, Jorge E. Gomez-Marin<sup>1,9</sup>, Ermanno Candolfi<sup>2,9\*</sup>

**1** GEPAMOL, Centro de Investigaciones Biomédicas, Universidad del Quindío, Armenia, Colombia, **2** Institut de Parasitologie et Pathologie Tropicale, Fédération de Médecine Translationnelle, Université de Strasbourg, Strasbourg, France, **3** Universidad del Rosario, Escuela de Medicina y Ciencias de la Salud, Departamento de Inmunología, Bogotá, Colombia, **4** Service d'Ophtalmologie, Hôpitaux Universitaires de Strasbourg, Strasbourg, France, **5** Centre National de Référence (CNR) Toxoplasmose/Toxoplasma Biological Resource Center (BRC), Centre Hospitalier-Universitaire Dupuytren, Limoges, France and INSERM UMR 1094, Neuroépidémiologie Tropicale, Laboratoire de Parasitologie-Mycologie, Faculté de Médecine, Université de Limoges, Limoges, France, **6** Laboratory of Parasitic Diseases, National Institutes of Health, National Institute of Allergy and Infectious Diseases (NIAID), Bethesda, Maryland, United States of America

## Abstract

In a cross sectional study, 19 French and 23 Colombian cases of confirmed active ocular toxoplasmosis (OT) were evaluated. The objective was to compare clinical, parasitological and immunological responses and relate them to the infecting strains. A complete ocular examination was performed in each patient. The infecting strain was characterized by genotyping when intraocular *Toxoplasma* DNA was detectable, as well as by peptide-specific serotyping for each patient. To characterize the immune response, we assessed *Toxoplasma* protein recognition patterns by intraocular antibodies and the intraocular profile of cytokines, chemokines and growth factors. Significant differences were found for size of active lesions, unilateral macular involvement, unilateral visual impairment, vitreous inflammation, synechiae, and vasculitis, with higher values observed throughout for Colombian patients. Multilocus PCR-DNA sequence genotyping was only successful in three Colombian patients revealing one type I and two atypical strains. The Colombian OT patients possessed heterogeneous atypical serotypes whereas the French were uniformly reactive to type II strain peptides. The protein patterns recognized by intraocular antibodies and the cytokine patterns were strikingly different between the two populations. Intraocular IFN- $\gamma$  and IL-17 expression was lower, while higher levels of IL-13 and IL-6 were detected in aqueous humor of Colombian patients. Our results are consistent with the hypothesis that South American strains may cause more severe OT due to an inhibition of the protective effect of IFN- $\gamma$ .

**Citation:** de-la-Torre A, Sauer A, Pfaff AW, Bourcier T, Brunet J, et al. (2013) Severe South American Ocular Toxoplasmosis Is Associated with Decreased Ifn- $\gamma$ /Il-17a and Increased Il-6/Il-13 Intraocular Levels. *PLoS Negl Trop Dis* 7(11): e2541. doi:10.1371/journal.pntd.0002541

**Editor:** Armando Jardim, McGill University, Canada

**Received:** May 2, 2013; **Accepted:** October 2, 2013; **Published:** November 21, 2013

This is an open-access article, free of all copyright, and may be freely reproduced, distributed, transmitted, modified, built upon, or otherwise used by anyone for any lawful purpose. The work is made available under the Creative Commons CC0 public domain dedication.

**Funding:** This work was supported by Colciencias, Grant 111345921861, the Ecos Nord Program, the Intramural Research Program of the National Institutes of Health and NIAID and the Fondation Nationale pour la Recherche, Grant Retinal Physiopathology DPR20121125433. We would like to thank the Universidad del Quindío, Hôpitaux Universitaires de Strasbourg for the PHRC grant 2007-3964, and Université de Strasbourg for additional financial support. The funders had no role in study design, data collection and analysis, decision to publish, or preparation of the manuscript.

**Competing Interests:** The authors have declared that no competing interests exist.

\* E-mail: candolfi@unistra.fr

These authors contributed equally to this work.

## Introduction

Infection with the protozoan parasite *Toxoplasma gondii* is a leading cause of visual impairment in numerous countries, being responsible for 30 to 50% of uveitis cases in immunocompetent individuals [1]. Ocular toxoplasmosis (OT) is a potential complication of both acquired and congenital toxoplasmosis [2]. The incidence of ocular toxoplasmosis has been estimated in Colombia (Quindío region) to be of three new episodes by 100 000 inhabitants by year [3], while in British-born patients it has been estimated to be 0.4 cases per 100,000 population per year and the lifetime risk of disease to be 18 cases per 100,000 population [4].

In a Colombian study, 5.5% of the population in the province of Quindío exhibited retinochoroidal scars resulting from a

postnatally acquired infection, with 20% of this group presenting reduced visual capacity. [3,5]. In a retrospective study on uveitis conducted in 693 Colombian patients, 417 of whom had a definitive diagnosis, toxoplasmosis was the most frequent cause with 276 cases (39.8%) followed by idiopathic uveitis and toxocariasis [6].

Some differences between South American and European clinical case series were observed in terms of congenital transmission rates, probability of symptoms in congenital OT [7,8], severity of ocular inflammation [9] and intraocular specific antibody levels [10]. However, no comparative clinical and biological studies have been performed yet in patients from both continents with laboratory-confirmed OT.

The population structure of *T. gondii* in North America and Europe includes three highly prevalent clonal lineages, Types I

## Author Summary

Ocular toxoplasmosis (OT), due to protozoan parasite *Toxoplasma gondii*, is a potential complication of both acquired and congenital infection, leading to visual impairment in numerous countries and being responsible for 30 to 50% of uveitis cases in immunocompetent individuals. In this study we confirmed the presence of more severe ocular toxoplasmosis in a tropical setting of Colombia, when compared to France. The main hypothesis for these clinical differences is based on the idea that severe disease in humans may result from poor host adaptation to neotropical zoonotic strains of *T. gondii*. Indeed, our results are consistent with the hypothesis that South American strains may cause more severe OT due to an inhibition of the intraocular protective immune response.

(haplogroup 1, Clade A), II (Haplogroup 2, Clade D), and III (haplogroup 3, Clade, C) which differ greatly in virulence in the mouse model. The vast majority of human and animal infections are caused by the relatively avirulent Type II strains. In contrast, heterogeneous atypical genotypes of *T. gondii* are associated with severe infections in humans in South America. They belong to various haplogroups: 4, 5, 8 10 and 15, Clade F [11,12][13]. The high genetic diversity of *Toxoplasma* strains in the tropical zone of the Americas may partly explain why congenital toxoplasmosis is more symptomatic in South America than Europe, as was demonstrated in cohorts of congenitally infected children from different continents [8,14,15]. A comparative prospective cohort study of congenitally infected children in Brazil and Europe found that Brazilian children displayed eye lesions that were larger, more numerous, and more likely to affect the central part of the retina responsible for acute vision [7]. Anecdotal clinical cases were also reported in the literature, such as a severe atypical bilateral retinochoroiditis in a Brazilian patient, caused by a highly divergent, non-archetypal *T. gondii* strain [16].

Given the markedly different population structure of *T. gondii* in Europe and South America, it is relevant to study the implications of this diversity on human pathogenesis [17]. Therefore, we conducted a multicenter case series study in order to compare the different clinical and immunological characteristics between Colombian and French patients, collecting the same data and performing the same laboratory assays in patients with biologically confirmed OT. The findings were related to *Toxoplasma* strain genotyping and peptide-based strain serotyping in our patients.

## Materials and Methods

### Study population

We collected data from consecutive patients who consulted at the Departments of Ophthalmology at Strasbourg University Hospital (France) and Quindío University Health Center (Armenia, Colombia) between August 2008 and August 2010. Both departments were tertiary-level centers able to perform anterior chamber paracentesis. For both patient populations, a complete ocular examination was conducted, including best-corrected Snellen visual acuity, slit-lamp biomicroscopy, tonometry, and indirect ophthalmoscopy. The clinical diagnosis of OT was based on criteria previously described by G. Holland [6,18]. Screened patients with clinically suspected OT and seropositive for anti-*Toxoplasma* immunoglobulin G (IgG) antibodies were subsequently

submitted to biological investigations to assess the local presence of *Toxoplasma* DNA and/or the intraocular antibody synthesis [19] to confirm OT.

### Ethics statement

Ethics Committee/Institutional Review Board (IRB) approval were obtained from Hôpitaux Universitaires de Strasbourg (PHRC 2007/3964) and Quindío University (ACT 14, 2008/23-06). Written informed consent was obtained from all subjects.

### Clinical evaluation criteria

We analyzed the clinical characteristics of 19 French and 23 Colombian patients with active uveitis and biologically confirmed OT. Patients who were immunocompromised, suffered from other ocular infections, or received local or systemic anti-*Toxoplasma* treatment for active uveitis, were excluded. An assessment of the inflammation level and anatomic classification of uveitis was carried out according to the criteria proposed by the International Uveitis Study Group (IUSG) [20]. The size of the retinochoroidal lesions was measured in disc-diameters (dd).

### Sample collection and biological OT diagnosis

Paired samples of aqueous humor and serum were obtained from each subject at the time of clinical diagnosis for laboratory analysis. The Colombian samples were stored locally at  $-80^{\circ}\text{C}$  and then shipped together on dry ice to Strasbourg for laboratory analysis. Aqueous humor samples (100–150  $\mu\text{L}$ ) were collected through anterior chamber paracentesis and stored, along with serum samples, at  $-80^{\circ}\text{C}$  until analysis. The diagnosis of OT was first confirmed by real-time PCR detection of *Toxoplasma* DNA [21]. Positive PCR results were quantified using a standard curve with serial 10-fold dilutions from a calibrated suspension of *T. gondii* RH-Strain DNA. For PCR negative patients, immunoblot (IB) was performed in order to detect intraocular synthesis of *Toxoplasma*-specific antibodies (LDBIO Diagnosis, Lyon, France). If both PCR and IB were inconclusive, a modified Goldmann-Witmer test was used to prove intraocular specific antibody synthesis [22].

### Cytokine-Chemokine Profile measurement in aqueous humor

The Bio-Plex Human 27-Plex Cytokine Panel assay (Bio-Rad, Marne-la-Coquette, France) was used according to the manufacturer's recommendations to measure cytokine and chemokine levels in aqueous humor. The assay plate layout consisted in a standard series in duplicate (1 to 32 000 pg/mL), four blank wells and 20  $\mu\text{L}$  duplicates of AqH samples, diluted to 50  $\mu\text{L}$  with BioPlex Human serum diluent [23]. A set of *Toxoplasma* seropositive cataract patients were used as control, 9 Colombian and 10 French. Data were analyzed with Bio-Plex Manager TM software V1.1.

### *Toxoplasma* strain genotyping analysis

DNA extraction for genotyping analysis was performed directly on ocular fluid samples and indirectly on infected cell cultures for six reference strains. GT1, PTG, and CTG strains were selected as reference Types I, II, and III strains, respectively. TgCtCo02, TgCtCo05, and TgCtCo07 strains were selected as reference Colombian strains [24,25]. *T. gondii* DNA samples were subjected to genotyping analysis with 15 microsatellite markers in a multiplex PCR assay, as described elsewhere [26].

### Toxoplasma strain serotyping analysis

Serotyping of *Toxoplasma* infections was performed using 5 polymorphic synthetic peptides derived from the *T. gondii* dense granule proteins (GRA), GRA6 and GRA7. This test detects the presence of strain specific antibodies raised against Type II or non-Type II GRA6/7 alleles in patients infected with Type II or non-Type II (NE-II) parasites respectively, as previously described [14,27]. Briefly, the ELISA results presented are an optical density (OD) index obtained by dividing the OD value at 405 nm for each of the 5 serotyping peptides by the mean of the OD readings for the 2 control peptides. Threshold values are determined by averaging the normalized OD ratio from 100 seronegative French samples and adding 2 standard deviations, above which normalized values are considered positive. Obtained results are divided in four populations depending on their reactivity to the 5 peptides: I/III, ATYP, no reactivity (NR), and II [28]. I/III, ATYP and NR are considered as NE-II [14]. Sera from pregnant women, tested *Toxoplasma* seropositive in our laboratories, were used to assess the *Toxoplasma* serotype in a larger population from each country, 45 serum samples from Colombia and 100 from France.

### Statistical analysis

Mann-Whitney test followed by Dunn's Multiple Comparison test was applied for comparison of clinical and laboratory characteristics for French and Colombian patients with confirmed active ocular toxoplasmosis (P values < 0.05 were considered statistically significant; Stata software, College Station (Tx) USA). Fisher's exact test was used to compare diagnostic performances of IB and PCR as well as the serotype prevalence. Wilcoxon matched-pairs signed rank test was performed to compare IB patterns. Mann-Whitney test was used to compare intraocular parasite loads (P values < 0.05 were considered statistically significant). Kruskal-Wallis test followed by Dunn's Multiple Comparison test were applied for comparison of cytokine and chemokine levels in aqueous humor between control and OT populations in both countries (P values < 0.05 were considered statistically significant) (GraphPad Prism, La Jolla, CA, USA).

## Results

### Clinical characteristics

The clinical findings for OT patients are summarized in Tables 1 and S1. Statistically significant differences between groups were found for eight parameters, being higher in Colombian patients in all cases: i) time between consultation and anterior chamber

paracentesis (p = 0.02); ii) size of active lesions (p = 0.04); iii) unilateral macular involvement (p = 0.001); iv) unilateral visual impairment (p = 0.04); v) vitreous inflammation (p = 0.00001); vi) percentage of patients with synechiae (p = 0.04); vii) vasculitis (p = 0.04) and viii) bilateral involvement (p = 0.04). In addition, there was a trend towards higher values for the Colombian patients regarding the number of lesions, number of recurrences, and intraocular pressure (IOP), although these differences were not statistically significant. We conducted a stratified analysis in order to exclude the influence of time before anterior chamber paracentesis as a possible cause of the differences in clinical findings. We compared early (< 20 days after symptom onset) and late consultations (> 20 days after symptom onset). As shown in Table 2 and supplementary figure 1, most significant clinical differences between the populations were also visible when comparing only the early-consultant groups.

### Detection of *Toxoplasma* DNA in aqueous humor and strain genotyping analysis

In Colombians, aqueous humor samples revealed the presence of *T. gondii* DNA in 11 out of 23 samples (47.8%). In French patients, *T. gondii* DNA could be detected in aqueous humor samples of 7 out of 19 patients (36.8%). This difference was not statistically significant. In contrast, parasite loads in aqueous humor were significantly higher in Colombian patients, 4.53 parasites  $\pm$  2 per 100  $\mu$ L versus 0.35  $\pm$  0.13 parasites per 100  $\mu$ L (p = 0.0006) (Figure 1). Aqueous humor samples from all French patients and 14 Colombian patients had an insufficient amount of *T. gondii* DNA for genotyping analysis. Only 9 Colombian ocular fluid samples were submitted for multilocus PCR-DNA sequence genotyping analysis. Six had unsuccessful PCR amplification for all 15 tested markers due to low *T. gondii* DNA concentration. The genotype of one clinical sample (case COL-#6) was closely related to a Type I strain, but harboring unique alleles at three MS loci, M102, N83 and AA, using 15 amplified markers (Table 3). Of note, the genotype of a reference Colombian isolate (TgCtCo07) collected from a cat in 2005 was also Type I-like, suggesting that Type I-like strains may not be uncommon in animals and humans in Colombia. The genotypes of the other two clinical samples (cases COL-#26 and COL-#38) could not be fully determined, with only four and five successfully amplified markers, respectively. However, the results of the amplified markers showed that both genotypes were different from the Type II or III strains, which are common in North America and Europe. They present a majority of Type I alleles (case COL-#26), like TgCtCo07 but distinct at the N61 marker, and a combination of

**Table 1.** Comparative clinical and laboratory characteristics for French and Colombian patients with confirmed active ocular toxoplasmosis (all cases).

CLINICAL CHARACTERISTICS	FRANCE (n = 19)			COLOMBIA (n = 23)			P-value
	Mean/n(%)*	Median	(Range)	Mean/n(%)*	Median	(Range)	
Age at consultation	45.22	44.5	(16–77)	38.3	37	(20–86)	0.23
Evolution time (days)	15	6	(1–150)	46	15	(4–240)	<b>0.02</b>
Macular involvement	2 (10.53%)	N.A.	N.A.	13 (56.52%)	N.A.	N.A.	<b>0.001</b>
Vitreous inflammation Level(+)**	0.95	2	(0–1)	2.41	2	(0–4)	<b>0.00001</b>
Synechia	2 (5.26%)	N.A.	N.A.	11 (47.8%)	N.A.	N.A.	<b>0.04</b>

Mann and Whitney test followed by Bonferroni-Dunn's Multiple Comparison test was applied (P values < 0.05 were considered statistically significant)

\*Percentages take into account only the patients with available information

\*\*Measured according to Standardization Uveitis Nomenclature (SUN)

N.A. = Not applicable (for categorical variables)

doi:10.1371/journal.pntd.0002541.t001

**Table 2.** Comparative clinical and laboratory characteristics for French and Colombian patients with confirmed active ocular toxoplasmosis, stratified by evolution time before consultation.

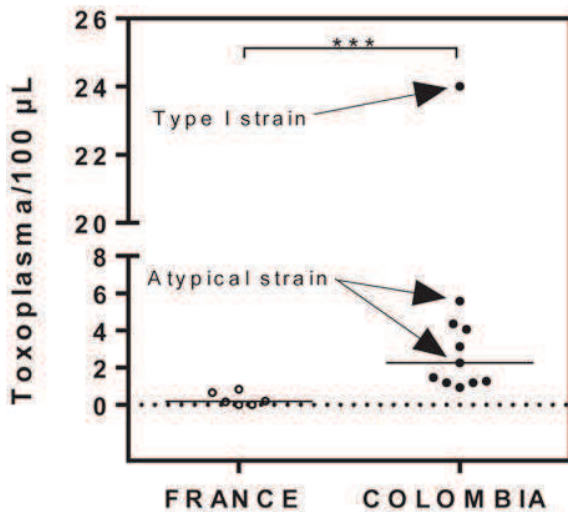
CLINICAL CHARACTERISTICS	EARLY CONSULTATION						P-value
	FRANCE (n = 15)			COLOMBIA (n = 12)			
	Mean/n(%)*	Median	(Range)	Mean/n(%)*	Median	(Range)	
Age at consultation	44.64	44.5	(16–74)	31.33	24	(20–82)	<b>0.05</b>
Macular involvement	2 (13.33%)	N.A.	N.A.	7(58.33%)	N.A.	N.A.	<b>0.01</b>
Vitreous inflammation Level(+)	0.93	2	(0–1)	2.58	2	(0–4)	<b>0</b>
Strabismus	0 (0%)	N.A.	N.A.	3 (25%)	N.A.	N.A.	<b>0.04</b>
Synechia	0.13	N.A.	N.A.	0.5	N.A.	N.A.	<b>0.03</b>
	LATE CONSULTATION						P-value
	FRANCE (n = 4)			COLOMBIA (n = 11)			
	Mean/n(%)*	Median	(Range)	Mean/n(%)*	Median	(Range)	
Age at consultation	47.25	45.5	(821–77)	45.9	43	(27–86)	0.9
Macular involvement	0(0%)	N.A.	N.A.	6(54.54%)	N.A.	N.A.	0.06
Vitreous inflammation Level(+)	1	2	(1–1)	2.23	2	(0–4)	0.11
Strabismus	0(0%)	N.A.	N.A.	0(0%)	N.A.	N.A.	0.39
Synechia	0	N.A.	N.A.	0.45	N.A.	N.A.	0.11

Mann and Whitney test followed by Bonferroni-Dunn's Multiple Comparison test was applied (P values<0.05 were considered statistically significant)

\*Percentages take into account only the patients with available information

N.A. = Not applicable (for categorical variables)

doi:10.1371/journal.pntd.0002541.t002



**Figure 1. Parasite load in PCR positive patients.** Aqueous humor was obtained from French and Colombian OT patients, DNA extracted, and the number of parasites per mL aqueous humor determined by quantitative PCR using *Toxoplasma*-specific primers. The Mann and Whitney test was significant ( $P=0.0002$ ). doi:10.1371/journal.pntd.0002541.g001

Type I, III, and atypical alleles (case COL-#38), like TgCtCo02 and TgCtCo05, but again distinct at the N60 and N82 genetic markers.

**Detection of intraocular anti-*Toxoplasma* antibodies**

IB detected local antibody production in 19/23 Colombian (82.6%) and 13/19 French (68.4%) patients (not significant).

However, a significant difference was observed in number of bands and their recognition pattern of *Toxoplasma* proteins ( $p<0.0001$ ) (Figure 2). Specific proteins were recognized in 3.3% to 63.3% of Colombian patients and 3.8% to 53.8% of French patients. Colombian patients recognized most frequently a 62 kDa protein, observed in 63.3% of patients. In French patients, the most frequently detected protein was at 34.2 kDa, found in 53.8% of patients.

***Toxoplasma* strain serotyping analysis**

As the amount of aqueous humor was insufficient for *Toxoplasma* strain typing using an ELISA peptide-based assay, we decided to serotype these patients using their sera. Ten OT patients from each center were assessed, all from the early consultation group. Among the Colombian patients, no Type II serotype was detected. We found 4 I/III, one atypical and 5 non reactive (NR) serotypes (Table 4). In contrast, all tested French OT patients showed Type II serotypes except one patient with an atypical serotype. These patterns were significantly different between the two groups ( $p<0.0001$ ). The two cases COL#26 and COL#38, found as suspected Type I and Type I/III by genotyping, were serotyped as NR and type I/III, respectively (Table 4).

To test if certain *T. gondii* strains are associated with OT, we determined the overall distribution of serotypes in infected non-OT control populations from both countries. Among the 45 Colombian control patients, only 6 subjects (13.3%) had a type II whereas 39 (86.6%) had NE-II serotypes, which were subdivided in 6 NR, 29 type I/III and 4 atypical serotypes. Of 100 French control patients, we found 64 (64%) type II, and 36 (36%) with NE-II; 10 NR, 2 type I/III and 24 atypical serotypes. No statistically significant differences were observed between the control and OT groups in Colombian patients, however we found a significant difference

**Table 3. Genotyping results of *T. gondii* DNA from 6 reference strains and 9 Colombian human ocular fluid samples with 15 microsatellite markers in a single multiplex PCR assay.**

Type <sup>a</sup>	Isolate <sup>b</sup>	Origin (Host) <sup>c</sup>	Microsatellite markers <sup>d</sup>														
			TUB2	W35	TgM-A	B18	B17	M33	IV.1	XI.1	M48	M102	N60	N82	AA	N61	N83
I	GT1 (Reference)	USA (Goat)	291	248	209	160	342	169	274	358	209	168	145	119	265	87	306
II	PTG (Reference)	USA (Sheep)	289	242	207	158	336	169	274	356	215	174	142	111	265	91	310
III	CTG (Reference)	USA (Cat)	289	242	205	160	336	165	278	356	215	190	147	111	269	89	312
Atypical	TgCtCo02 (Reference)	Colombia (Cat)	291	248	205	160	342	167	274	358	209	166	142	123	291	89	306
Atypical	TgCtCo05 (Reference)	Colombia (Cat)	291	242	205	160	336	165	276	356	223	166	142	121	279	87	304
I	TgCtCo07 (Reference)	Colombia (Cat)	291	248	209	160	342	169	274	358	209	166	147	127	265	87	306
ND	COL-# 15)	Colombia (Human, AH)	NA	NA	NA	NA	NA	NA	NA	NA	NA	NA	NA	NA	NA	NA	NA
ND	COL-#2)	Colombia (Human, AH)	NA	NA	NA	NA	NA	NA	NA	NA	NA	NA	NA	NA	NA	NA	NA
I	COL-#6)	Colombia (Human, AH)	291	248	209	160	342	169	274	358	209	166	145	117	269	87	306
ND	COL-# 1)	Colombia (Human, AH)	NA	NA	NA	NA	NA	NA	NA	NA	NA	NA	NA	NA	NA	NA	NA
ND	COL-#24)	Colombia (Human, AH)	NA	NA	NA	NA	NA	NA	NA	NA	NA	NA	NA	NA	NA	NA	NA
ND	COL-#25)	Colombia (Human, AH)	NA	NA	NA	NA	NA	NA	NA	NA	NA	NA	NA	NA	NA	NA	NA
ND	COL-#26)	Colombia (Human, AH)	NA	NA	209	160	NA	NA	NA	NA	NA	NA	NA	127	NA	89	NA
ND	COL-#38)	Colombia (Human, AH)	NA	242	205	NA	342	NA	NA	NA	NA	NA	140	117	NA	NA	NA
ND	COL-#41)	Colombia (Human, AH)	NA	NA	NA	NA	NA	NA	NA	NA	NA	NA	NA	NA	NA	NA	NA

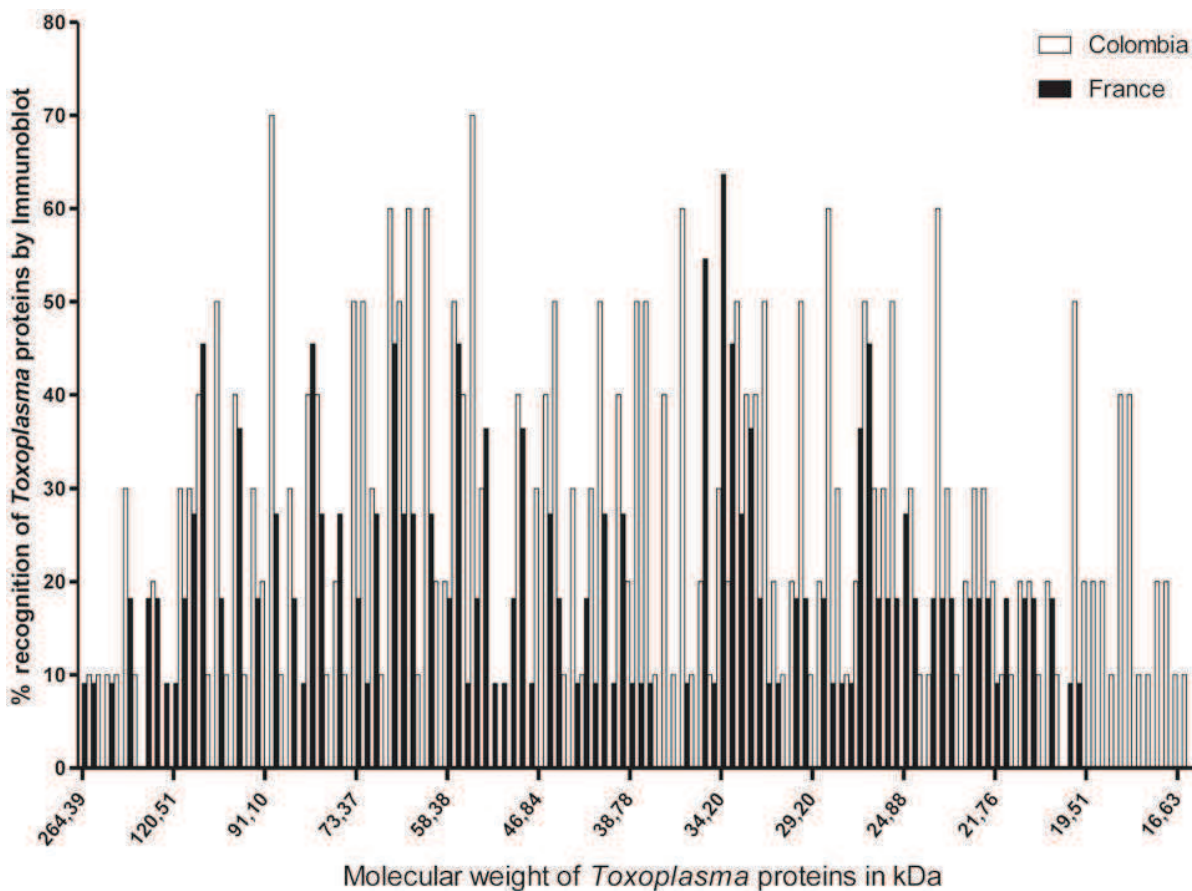
<sup>a</sup>ND, Not Determined.

<sup>b</sup>PTG is a clone of the ME49 strain; CTG is also known as CEP or C strain. GT1, PTG, and CTG are reference type I, II, and III strains, respectively. TgCtCo02, TgCtCo05, and TgCtCo07 are reference strains isolated from cats in Colombia. All DNA samples from reference strains were kindly provided by Chunlei Su and Jitender Dubey.

<sup>c</sup>AH, Aqueous Humor; VH, Vitreous Humor.

<sup>d</sup>NA, Not Amplified

doi:10.1371/journal.pntd.0002541.t003



**Figure 2. Differences in pattern recognition by immunoblotting between Colombian and French patients.** Aqueous humor samples were tested against *Toxoplasma* proteins, as detailed in the *Materials and methods* section. The percentage of French or Colombian patients recognizing the different *Toxoplasma* proteins is given. A Wilcoxon matched-pairs signed rank test was performed to compare IB patterns ( $p < 0.0001$ ).

doi:10.1371/journal.pntd.0002541.g002

( $P = 0.02$ ) between the French control and OT populations, with respect to the proportion of the two types, II and NE-II.

### Ocular cytokine and chemokine pattern

Cytokines patterns in aqueous humor of OT patients were compared to cataract controls (Figure 3 and Table S2 in Text S1). Several immune mediators were augmented in French, as well as in Colombian patients. In French patients, the Th1 type cytokines IFN- $\gamma$ , IL-2 and IL-15 were expressed in all patients. This Th1 immune response was associated to a Th17 response with increased IL-17 production. Additionally, we observed a large proinflammatory response with increased levels of IL-6, IL-1 $\beta$ , IL-8, MIP-1 $\beta$ , MCP-1 and G-CSF. These patients also possessed a corresponding anti-inflammatory response was based on the presence of IL-4, IL-10, and IL-1RA. In contrast, Colombian patients had lower expression of major proinflammatory immune modulators, including IFN- $\gamma$ , IL-15, IL-17, IL-2, IL-10, MIP-1 $\beta$ , GM-CSF and G-CSF, with the exception of elevated TNF- $\alpha$  and IL-6 levels. These patients also had elevated levels of the counterregulating Th2-type cytokine IL-13.

### Discussion

Previously published studies found differences between South American and European clinical case series on adult patients in

terms of frequency of serological markers in OT [8], probability of symptoms in congenital infection [7], as well as inflammation levels and IOP [9]. However, these were mostly retrospective evaluations of multiple studies. Their main limitation is their inclusion of patients with “suspected” OT, rather than biologically confirmed cases. While the ocular signs of toxoplasmic retinochoroiditis are highly suggestive of this disease, they may be mimicked by other infections [22], while in some cases, the symptoms may be atypical [19,29]. Therefore, we strengthened our evaluation by inclusion of biologically confirmed OT cases only, as well as by comparing the same bio-clinical data from two different populations of OT patients, located in South America and Europe in a cross sectional study. Among the 17 criteria analyzed in the two populations, the following were significantly higher in Colombian patients: macular involvement, vitreous inflammation, strabismus, bilateral involvement and synechiae. Our findings confirm and expand the data from the retrospective study of Dodds *et al.* from patients with biologically unconfirmed OT which found elevated IOP, increased presence of synechiae, AC cells, flare, and vitreous humor haze [9]. In our study, one key difference between the two patient populations was the date of consultation, as Colombian patients consulted later than the French. However, when our analysis was stratified regarding this aspect, the observed clinical differences remained significant.



**Table 4.** Distribution of Toxoplasma serotypes among Colombian and French OT patients (OT-CO# and OT-FR#) were assessed for antibodies reacting to 5 strain-specific GRA6 and GRA7 polymorphic peptides derived from Type II or Type I/III parasites.

PATIENTS								
Colombia								
	6I/III***	D6I/III****	6II	D6II	7II	SAG1*****	Serotype	Conclusion
OT-CO1	1.6←	1.2	1.3	1.2	1.0	7.3←	I/III	NE-II
OT-CO2	7.6←	1.3	4.1←	1.3	0.9	25.2←	ATYP	NE-II
OT-CO3*	0.1	0.8	1.1	1.0	0.9	8.3←	NR	NE-II
OT-CO4	1.6←	1.1	1.1	1.4	1.1	2.7←	I/III	NE-II
OT-CO5**	1.7←	1.5←	1.3	1.1	1.0	25.0←	I/III	NE-II
OT-CO6	1.0	0.9	1.1	1.0	0.6	4.6←	NR	NE-II
OT-CO7	5.5←	1.0	1.0	1.0	1.0	8.5←	I/III	NE-II
OT-CO8	1.3	1.0	1.1	0.6	1.0	26.6←	NR	NE-II
OT-CO9	0.8	0.8	0.7	1.0	0.6	6.0←	NR	NE-II
OT-CO10	1.2	1.3	1.2	1.0	1.0	20.9←	NR	NE-II
France								
OT-FR1	1.4	1.3	3.3←	2.0←	11.6←	26.0←	II	II
OT-FR2	1.2	1.1	2.0←	2.1←	1.5←	25.4←	II	II
OT-FR3	0.6	0.6	0.8	0.8	4.2	13.7←	II	II
OT-FR4	1.1	1.2	2.5←	3.0←	4.4←	21.4←	II	II
OT-FR5	0.0	1.2	1.6←	1.2	10.7←	4.5←	II	II
OT-FR6	1.0	1.0	1.5←	1.6←	2.3←	10.5←	II	II
OT-FR7	1.1	1.2	1.4	1.6←	1.3	6.4←	II	II
OT-FR8	1.1	1.4	3.2←	3.2←	2.4←	17.6←	II	II
OT-FR9	ND	ND	ND	ND	ND	ND	ND	ND
OT-FR10	2.4←	1.1	1.1	1.1	3.1←	8.1←	ATYP	NE-II

Peptide names were abbreviated as follows: “6” denoting peptides from GRA6; “7” from GRA7; “I/III” or “II” for the strain bearing the peptide allele; and “d” indicating a truncated diagnostic peptide. Reactivity at SAG1 served as a positive control to indicate the presence of anti-Toxoplasma antibodies. Type I/III infections produce antibodies that react with 1 or both 6-I/III and d6I/III peptides, Type II infections react with at least 1 of the 6-II, d6-II and 7-II peptides, Atypical (ATYP) infections identify strain-specific antibodies that react with both I/III and II peptides, or do not react (nonreactive “NR”) with any of the allele-specific peptides. For the purposes of statistical analyses, patients were classified as possessing either a Type II serotype or NE-II serotype (for all other reactivities). Fischer’s exact test was applied for comparison between population and difference was highly significant (P<0.0001)

\*found with a majority of Type I alleles by genotyping; case COL#26

\*\*found with a combination of Type I, III, and atypical alleles by genotyping : case COL#38

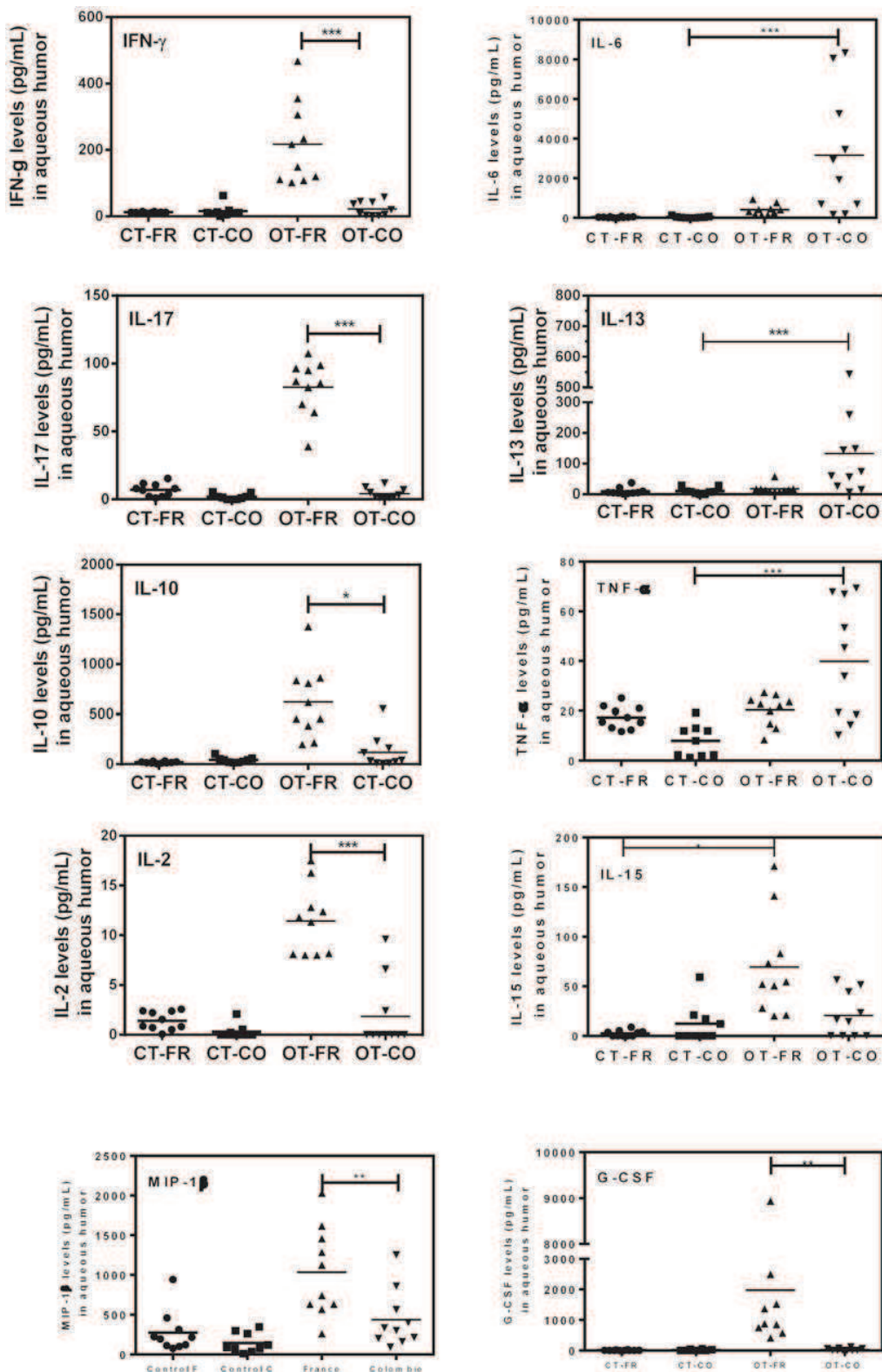
\*\*\*6I/III refers to the C-terminal peptide from the Dense Granule protein GRA6 (peptide “CLHPERVNVFDY”)

\*\*\*\*D” stands for a delimited version of the 6I/III peptide, by truncation of the terminal Y amino acid, used to confirm specificity

\*\*\*\*\*SAG1 is a recombinant protein used to confirm seropositivity among the patient samples received for serotyping

←Positive reactivity by ELISA-based assay (cut-off value = 1.4)

doi:10.1371/journal.pntd.0002541.t004



**Figure 3. Cytokine and chemokine levels (pg/mL) in aqueous humor for French and Colombian patients.** Aqueous humor samples were tested for ocular cytokines and chemokines as detailed in *Material and methods* section, for Colombian (OT-CO; n=10) and French ocular toxoplasmosis patients (OT-FR; n=10). They were compared to cataract control groups from Colombia (CT-CO; n=9) and France (CT-FR; n=10). Kruskal-Wallis test followed by Dunn's Multiple Comparison test were applied for comparison between populations (significant for P<0.05). doi:10.1371/journal.pntd.0002541.g003

The main hypothesis for these clinical differences is based on the idea that severe disease in humans may result from poor host adaptation to neotropical zoonotic strains of *T. gondii* [11]. Our study accumulated some clues supporting this hypothesis.

Central strain-specific parasite virulence factors in human infections were revealed in the last years [30]. Their role in the presence of more virulent parasite genotypes in South America [11,12] is not yet thoroughly studied. These strains are rarely found in Europe [31] where Type II genotypes predominate, including in OT patients [32]. In the three Colombian OT patients where we could detect *Toxoplasma* DNA, we found one Type I and two atypical strains. The fact that no patient of the French group had a sufficient ocular parasite load for genotyping clearly shows the difference in ocular virulence. Additionally, we noticed that intraocular antibodies responses showed major differences in *Toxoplasma* antigen recognition by an immunoblotting assay. Even if this could be partly due to better detection of *Toxoplasma* Type I antigens used in this assay by Colombian patients, other, host immune specific factors are certainly crucial such as local antibodies, whose exact role and function should be explored.

Our serotyping assay confirmed that Colombian and French patients recognize different strain-specific epitopes. Colombian OT patients recognized a heterogeneous pattern of strain specific peptides, but none of them were from type II strains. The French OT patients recognized only Type II strain specific peptides, confirming the reliability of this test in a geographic region with predominant type II strains infections [33]. The corresponding control populations presented the same serological pattern for Colombia, but a slightly different pattern for France, where some sera were non reactive to Type II antigens. The difference may be due to the unequal sample sizes, so this point needs further investigation using more samples and equilibrated OT and control population. However, these data indicate that type II and non-type II strains are able to cause ocular pathology, but with a markedly different clinical picture. Concerning the Colombian strains, current serotyping techniques might be not sensitive enough to distinguish the highly variable strains.

When we looked at the patients' local immunological reaction, we observed clearly different cytokine signatures. In French patients, the host-parasite relationship seems to be equilibrated between protection and inflammation. The protective effect of IFN- $\gamma$  is balanced by anti-inflammatory cytokines such as IL-2 and IL-10. The role of IL-17 is controversial. We have previously observed an early pathologic and parasite promoting role for IL-17 in French patients and in an animal model infected by a Type II *Toxoplasma* strain [34]. In the intraocular ocular environment, IL-17 would attract neutrophils [35] and, accompanied by IL-15 and MIP-1 $\beta$ /CCL4, activates and attracts NK cells [36] and monocytes [37]. All these innate immune cells might cause retinal inflammation, but then permit to control *Toxoplasma* proliferation [38,39]. As our recent findings implicate IL-27 and the Treg subset in counterbalancing deleterious inflammatory Th17 type responses [34], the corresponding mediators deserve to be examined more closely in future studies.

In contrast, in the clinically more severe Colombian cases, IFN- $\gamma$  and other major immunomodulators such as IL-17 were barely detectable, while IL-6 and IL-13 were enhanced. Virulent strains encode virulence factors able to modulate multiple immune host cell signaling pathways through polymorphic effectors secreted into the host cells such as ROP16 and GRA15 [38,40]. The presence of *Toxoplasma* effector proteins from virulent strains could explain the down-regulation of ocular IFN- $\gamma$ , leading to higher ocular parasite loads in Colombian patients. The IL-17

down-regulation remains to be explained, but decreased levels of IL-17 and other immune modulators, including proangiogenic factors, could lead to a defect in the migration of leukocytes to the eyes and be another explanation for impaired control of parasites in the context of virulent South American infections. IL-6 could also antagonize the anti-microbial properties of IFN- $\gamma$  by sustained activation of STAT3, a potent inhibitor of IL-12 and IFN- $\gamma$  [41]. Down-regulation of IFN- $\gamma$  and its anti-*Toxoplasma* activity was also observed for IL-13 in human fibroblasts [42]. It is important to note here that Type I strains express a ROP16 allele associated with prolonged activation of STAT3 and STAT6 signaling, which may in part contribute to the increased IL-13 levels, whereas Type II strains activate this pathway only transiently, allowing the establishment of an inflammatory reaction [43]. This may constitute the fundamental basis for the differential cytokine response observed in our study.

The theory of local T cell exhaustion may be also of interest in the settings of Colombian patients. Immune exhaustion is characterized by the modification of the CD8+ functions by reducing their polyfunctionality and their efficacy [44]. Indeed, high *Toxoplasma* loads associated with a decreased IFN- $\gamma$  and IL-15 production and enhancement of TNF- $\alpha$  could be one aspect of this loss of CD8+ T cell polyfunctionality. In contrast, in French patients, elevated IL-15 is critical for homeostasis of memory CD8 T cells, and may lead to a better control of parasite proliferation and subsequent parasite latency in the retina.

Taken together, our results indicate that virulent strains observed in South America may suppress host-protective pathways, opening the way to multiplication and cytolytic activity of the parasite in retinal tissues including blood vessels. The presence of TNF- $\alpha$  in most of these patients could also contribute by enhancing an ongoing immunopathological retinal process [45]. In contrast, in French patients, the cytokine environment may lead to the encystation of the parasite in the retinal tissues, leading to subsequent recurrences.

Of course, for ethical reasons, we were only able to take one time-point. Our results represent thus a snapshot of a developing immune response. Additionally, a multifactorial origin of the observed clinical and biological differences could not be excluded. In our study, the source of contamination may have been drinking water collected from surface water sources (*i.e.*, rivers, lakes) [46,47,48,49]. The more common macular involvement in Colombian patients is often associated with congenital toxoplasmosis [6,15,50,51]. Even if we studied adult populations, we cannot exclude a congenital origin of infection in some Colombian patients. Moreover, acute toxoplasmosis was only diagnosed in 2 Colombian and 1 French case. The remaining population was considered to exhibit chronic toxoplasmosis. Finally, individual susceptibility was previously related to variations in various genes encoding immune response players, such as IFN- $\gamma$ , IL-1 $\alpha$ , IL-10, TLR-9 or ABCA4, COL2A1, and P2X $_7$ -R [52,53,54,55]. These genetically susceptible patients are possibly less able to cope with a more virulent strain. Further investigations with larger cohorts including an evaluation of their immunological response and their individual susceptibility to *Toxoplasma* are needed to address these topics.

## Supporting Information

**Text S1 Checklist S1.** Strobe checklist for a cross sectional study, including 19 French and 23 Colombian cases of confirmed active ocular toxoplasmosis. Clinical, parasitological and immunological responses are compared and correlated to the infecting strains. **Figure S1.** Fundus examination in a patient with

bilateral-extensive-multiple, central and peripheral, chorio-retinal scars (white circled lesions) in a Colombian patient suffering from a severe ocular toxoplasmosis; A : right eye; B : left eye. **Table S1.** Complete data of all clinical and laboratory characteristics. Mann and Whitney test followed by Bonferroni-Dunn's Multiple Comparison test was applied (P values<0.05 were considered statistically significant). **Table S2.** Intraocular cytokines, chemokines and growth factors in aqueous humor of Cataract Control patients from France (CT-CO) and Colombia (CT-FR) and from Ocular toxoplasmosis patients from France (OT-FR) and Colombia (OT-CO). Levels of these immune mediators are expressed as mean and standard deviation, median and range (min-max) in pg/mL. Statistical differences between CT and OT and between OT from France versus OT from Colombia were calculated using a Kruskal-Wallis test followed by Dunn's Multiple Comparison test. Significant differences between populations (P<0.05) were highlighted by tinting the spaces. Description of

major general functions of cytokines and chemokines are issued from "Commins SP et al., *J Allerg Clin Immunol*, 2010; Banchereau J. et al., *Nature Immunology*, 2012". (DOCX)

## Acknowledgments

We are grateful to Chunlei Su (University of Tennessee, USA) and Jitender Dubey (United States Department of Agriculture, USA) for kindly providing DNA samples from reference *T. gondii* strains.

## Author Contributions

Conceived and designed the experiments: AdIT AS JEGM EC TB DA MEG. Performed the experiments: AdIT AS AWP JB OV DA NS. Analyzed the data: AdIT AS AWP DA MEG JEGM EC. Contributed reagents/materials/analysis tools: AdIT AS TB CSS LB. Wrote the paper: AdIT AWP JEGM EC.

## References

- Arevalo JF, Belfort R, Jr., Muccioli C, Espinoza JV (2010) Ocular toxoplasmosis in the developing world. *Int Ophthalmol Clin* 50: 57–69.
- Gilbert RE, Stanford MR (2000) Is ocular toxoplasmosis caused by prenatal or postnatal infection? *Br J Ophthalmol* 84: 224–226.
- de-la-Torre A, Lopez-Castillo CA, Gomez-Marin JE (2009) Incidence and clinical characteristics in a Colombian cohort of ocular toxoplasmosis. *Eye (Lond)* 23: 1090–1093.
- Gilbert RE, Dunn DT, Lightman S, Murray PI, Pavesio CE, et al. (1999) Incidence of symptomatic *Toxoplasma* eye disease: aetiology and public health implications. *Epidemiol Infect* 123: 283–289.
- de-la-Torre A, Gonzalez G, Diaz-Ramirez J, Gomez-Marin JE (2007) Screening by ophthalmoscopy for *Toxoplasma* retinochoroiditis in Colombia. *Am J Ophthalmol* 143: 354–356.
- de-la-Torre A, Lopez-Castillo CA, Rueda JC, Mantilla RD, Gomez-Marin JE, et al. (2009) Clinical patterns of uveitis in two ophthalmology centres in Bogota, Colombia. *Clin Experiment Ophthalmol* 37: 458–466.
- Gilbert RE, Freeman K, Lago EG, Bahia-Oliveira LM, Tan HK, et al. (2008) Ocular sequelae of congenital toxoplasmosis in Brazil compared with Europe. *PLoS Negl Trop Dis* 2: e277.
- Thiebaut R, Leproust S, Chene G, Gilbert R (2007) Effectiveness of prenatal treatment for congenital toxoplasmosis: a meta-analysis of individual patients' data. *Lancet* 369: 115–122.
- Dodds EM, Holland GN, Stanford MR, Yu F, Siu WO, et al. (2008) Intraocular inflammation associated with ocular toxoplasmosis: relationships at initial examination. *Am J Ophthalmol* 146: 856–865 e852.
- Garweg JG, Garweg SD, Flueckiger F, Jacquier P, Boehnke M (2004) Aqueous humor and serum immunoblotting for immunoglobulin types G, A, M, and E in cases of human ocular toxoplasmosis. *J Clin Microbiol* 42: 4593–4598.
- Carme B, Demar M, Ajzenberg D, Darde ML (2009) Severe acquired toxoplasmosis caused by wild cycle of *Toxoplasma gondii*, French Guiana. *Emerg Infect Dis* 15: 656–658.
- Su C, Khan A, Zhou P, Majumdar D, Ajzenberg D, et al. (2012) Globally diverse *Toxoplasma gondii* isolates comprise six major clades originating from a small number of distinct ancestral lineages. *Proc Natl Acad Sci U S A* 109: 5844–5849.
- Su C, Khan A, Zhou P, Majumdar D, Ajzenberg D, et al. Globally diverse *Toxoplasma gondii* isolates comprise six major clades originating from a small number of distinct ancestral lineages. *Proc Natl Acad Sci U S A* 109: 5844–5849.
- McLeod R, Boyer KM, Lee D, Mui E, Wroblewski K, et al. (2012) Prematurity and Severity Are Associated With *Toxoplasma gondii* Alleles (NCCCTS, 1981–2009). *Clin Infect Dis*.
- Sauer A, de la Torre A, Gomez-Marin J, Bourcier T, Garweg J, et al. (2011) Prevention of retinochoroiditis in congenital toxoplasmosis: Europe versus South America. *Pediatr Infect Dis J* 30: 601–603.
- Bottos J, Miller RH, Belfort RN, Macedo AC, Belfort R, Jr., et al. (2009) Bilateral retinochoroiditis caused by an atypical strain of *Toxoplasma gondii*. *Br J Ophthalmol* 93: 1546–1550.
- Garweg JG, Candolfi E (2009) Immunopathology in ocular toxoplasmosis: facts and clues. *Mem Inst Oswaldo Cruz* 104: 211–220.
- Holland GN (2004) Ocular toxoplasmosis: a global reassessment. Part II: disease manifestations and management. *Am J Ophthalmol* 137: 1–17.
- Garweg JG, de Groot-Mijnes JD, Montoya JG (2011) Diagnostic approach to ocular toxoplasmosis. *Ocul Immunol Inflamm* 19: 255–261.
- Deschenes J, Murray PI, Rao NA, Nussenblatt RB (2008) International Uveitis Study Group (IUSG): clinical classification of uveitis. *Ocul Immunol Inflamm* 16: 1–2.
- Reischl U, Bretagne S, Krüger D, Ernault P, Costa J (2003) Comparison of two DNA targets for the diagnosis of Toxoplasmosis by real-time PCR using fluorescence resonance energy transfer hybridization probes. *BMC Infect Dis* 3: 1–9.
- Villard O, Filisetti D, Roch-Deries F, Garweg J, Flament J, et al. (2003) Comparison of enzyme-linked immunosorbent assay, immunoblotting, and PCR for diagnosis of toxoplasmic chorioretinitis. *J Clin Microbiol* 41: 3537–3541.
- Lahmar I, Abou-Bacar A, Abdelrahman T, Guinard M, Babba H, et al. (2009) Cytokine profiles in toxoplasmic and viral uveitis. *J Infect Dis* 199: 1239–1249.
- Dubey JP, Su C, Cortes JA, Sundar N, Gomez-Marin JE, et al. (2006) Prevalence of *Toxoplasma gondii* in cats from Colombia, South America and genetic characterization of *T. gondii* isolates. *Vet Parasitol* 141: 42–47.
- Dubey JP, Velmurugan GV, Rajendran C, Yabsley MJ, Thomas NJ, et al. (2011) Genetic characterisation of *Toxoplasma gondii* in wildlife from North America revealed widespread and high prevalence of the fourth clonal type. *Int J Parasitol* 41: 1139–1147.
- Ajzenberg D, Collinet F, Mercier A, Vignoles P, Darde ML (2010) Genotyping of *Toxoplasma gondii* isolates with 15 microsatellite markers in a single multiplex PCR assay. *J Clin Microbiol* 48: 4641–4645.
- Kong JT, Grigg ME, Uyetake L, Parmley S, Boothroyd JC (2003) Serotyping of *Toxoplasma gondii* infections in humans using synthetic peptides. *J Infect Dis* 187: 1484–1495.
- Shobab L, Pleyer U, Johnsen J, Metzner S, James ER, et al. (2013) *Toxoplasma* Serotype Is Associated With Development of Ocular Toxoplasmosis. *J Infect Dis* 208 (9): 1520–1528.
- Fardeau C, Romand S, Rao NA, Cassoux N, Bettembourg O, et al. (2002) Diagnosis of toxoplasmic retinochoroiditis with atypical clinical features. *Am J Ophthalmol* 134: 196–203.
- Sibley LD, Khan A, Ajioka JW, Rosenthal BM (2009) Genetic diversity of *Toxoplasma gondii* in animals and humans. *Philos Trans R Soc Lond B Biol Sci* 364: 2749–2761.
- Elbez-Rubinstein A, Ajzenberg D, Darde ML, Cohen R, Dumetre A, et al. (2009) Congenital toxoplasmosis and reinfection during pregnancy: case report, strain characterization, experimental model of reinfection, and review. *J Infect Dis* 199: 280–285.
- Fekkar A, Ajzenberg D, Bodaghi B, Touafek F, Le Hoang P, et al. (2011) Direct genotyping of *Toxoplasma gondii* in ocular fluid samples from 20 patients with ocular toxoplasmosis: predominance of type II in France. *J Clin Microbiol* 49(4):1513–7.
- Sibley LD, Ajioka JW (2008) Population structure of *Toxoplasma gondii*: clonal expansion driven by infrequent recombination and selective sweeps. *Annu Rev Microbiol* 62: 329–351.
- Sauer A, Pfaff AW, Rochet E, Villard O, Creuzot-Garcher C, et al. (2012) IL-17A as an effective target for anti-inflammatory and anti-parasitic treatment of toxoplasmic uveitis. *J Infect Dis* in press.
- Cua DJ, Tato CM (2010) Innate IL-17-producing cells: the sentinels of the immune system. *Nat Rev Immunol* 10: 479–489.
- Schulthess J, Meresse B, Ramiro-Puig E, Montcuquet N, Darce S, et al. (2012) Interleukin-15-dependent NKp46+ innate lymphoid cells control intestinal inflammation by recruiting inflammatory monocytes. *Immunity* 37: 108–121.
- Bennouna S, Bliss SK, Curiel TJ, Denkers EY (2003) Cross-talk in the innate immune system: neutrophils instruct recruitment and activation of dendritic cells during microbial infection. *J Immunol* 171: 6052–6058.
- Hunter CA, Sibley LD (2012) Modulation of innate immunity by *Toxoplasma gondii* virulence effectors. *Nat Rev Microbiol* 10: 766–778.
- Kelly MN, Kolls JK, Happel K, Schwartzman JD, Schwarzenberger P, et al. (2005) Interleukin-17/interleukin-17 receptor-mediated signaling is important for generation of an optimal polymorphonuclear response against *Toxoplasma gondii* infection. *Infect Immun* 73: 617–621.

40. Melo MB, Jensen KD, Saeij JP (2011) *Toxoplasma gondii* effectors are master regulators of the inflammatory response. *Trends Parasitol* 27: 487–495.
41. Whitmarsh RJ, Gray CM, Gregg B, Christian DA, May MJ, et al. (2011) A critical role for SOCS3 in innate resistance to *Toxoplasma gondii*. *Cell Host Microbe* 10: 224–236.
42. Chaves AC, Ceravolo IP, Gomes JA, Zani CL, Romanha AJ, et al. (2001) IL-4 and IL-13 regulate the induction of indoleamine 2,3-dioxygenase activity and the control of *Toxoplasma gondii* replication in human fibroblasts activated with IFN-gamma. *Eur J Immunol* 31: 333–344.
43. Denkers EY, Bzik DJ, Fox BA, Butcher BA (2012) An inside job: hacking into Janus kinase/signal transducer and activator of transcription signaling cascades by the intracellular protozoan *Toxoplasma gondii*. *Infect Immun* 80: 476–482.
44. Gigley JP, Bhadra R, Moretto MM, Khan IA (2012) T cell exhaustion in protozoan disease. *Trends Parasitol* 28: 377–384.
45. Egan CE, Cohen SB, Denkers EY (2010) Insights into inflammatory bowel disease using *Toxoplasma gondii* as an infectious trigger. *Immunol Cell Biol* 90: 668–675.
46. Balasundaram MB, Andavar R, Palaniswamy M, Venkatapathy N (2010) Outbreak of acquired ocular toxoplasmosis involving 248 patients. *Arch Ophthalmol* 128: 28–32.
47. Burnett AJ, Shortt SG, Isaac-Renton J, King A, Werker D, et al. (1998) Multiple cases of acquired toxoplasmosis retinitis presenting in an outbreak. *Ophthalmology* 105: 1032–1037.
48. Lopez-Castillo CA, Diaz-Ramirez J, Gomez-Marin JE (2005) [Risk factors for *Toxoplasma gondii* infection in pregnant women in Armenia, Colombia]. *Rev Salud Publica (Bogota)* 7: 180–190.
49. Vaudoaux JD, Muccioli C, James ER, Silveira C, Magargal SL, et al. (2010) Identification of an atypical strain of *Toxoplasma gondii* as the cause of a waterborne outbreak of toxoplasmosis in Santa Isabel do Ivaí, Brazil. *J Infect Dis* 202: 1226–1233.
50. Gomez-Marin JE, de-la-Torre A, Angel-Muller E, Rubio J, Arenas J, et al. (2011) First Colombian multicentric newborn screening for congenital toxoplasmosis. *PLoS Negl Trop Dis* 5: e1195.
51. Gomez-Marin JE, Gonzalez MM, Montoya MT, Giraldo A, Castaño JC (2007) A newborn screening programme for congenital toxoplasmosis in the setting of a country with less income. *Arch Dis Child* 92: 88.
52. Albuquerque MC, Aleixo AL, Benchimol EI, Leandro AC, das Neves LB, et al. (2009) The IFN-gamma +874T/A gene polymorphism is associated with retinochoroiditis toxoplasmosis susceptibility. *Mem Inst Oswaldo Cruz* 104: 451–455.
53. Cordeiro CA, Moreira PR, Andrade MS, Dutra WO, Campos WR, et al. (2008) Interleukin-10 gene polymorphism (-1082G/A) is associated with toxoplasmic retinochoroiditis. *Invest Ophthalmol Vis Sci* 49: 1979–1982.
54. Cordeiro CA, Moreira PR, Costa GC, Dutra WO, Campos WR, et al. (2008) TNF-alpha gene polymorphism (-308G/A) and toxoplasmic retinochoroiditis. *Br J Ophthalmol* 92: 986–988.
55. Peixoto-Rangel AL, Miller EN, Castellucci L, Jamieson SE, Peixe RG, et al. (2009) Candidate gene analysis of ocular toxoplasmosis in Brazil: evidence for a role for toll-like receptor 9 (TLR9). *Mem Inst Oswaldo Cruz* 104: 1187–1190.

### iii. Conclusions and perspectives

-Clinical presentation of OT in Colombian and French patients differed significantly, being more severe for Colombian patients. Significant differences were found for the size of active lesions, unilateral macular involvement, unilateral visual impairment, vitreous inflammation, synechiae, and vasculitis, with higher values observed for the Colombian patients.

-The Colombian OT patients possessed heterogeneous atypical serotypes, whereas the French patients were uniformly reactive to Type II strain peptides.

-The protein patterns recognized by intraocular antibodies and the cytokine patterns were strikingly different between the two populations.

-Intraocular expression of IFN- $\gamma$  and IL-17 was lower, while higher levels of IL-13 and IL-6 were detected in AH of Colombian patients. Our results are consistent with the hypothesis that South American strains may be responsible for more severe OT due to inhibition of the protective effect of IFN- $\gamma$ .

-IL-17 has an important role in the induction of inflammation in murine and human OT that is probably related to the infecting strains of *T. gondii*.

-Our results are consistent with the hypothesis that South American strains may be responsible for more severe OT due to inhibition of the intraocular protective immune response.

-It would be important to study if there are genetically susceptible patients, who are probably less competent to handle a more virulent strain. Further investigations with larger cohorts including an evaluation of their immunological response and their individual susceptibility to *Toxoplasma*, are needed to address these topics.

**ARTICLE 3**

**CYTOKINE MILIEU IS LINKED TO CLINICAL  
CHARACTERISTICS IN COLOMBIAN PATIENTS  
PRESENTING AN ACTIVE OCULAR TOXOPLASMOSIS**

(submitted to Cytokine, Manuscript Number:  
CYTO13-551R1)

## **i. Introduction**

OT severity differs significantly among patients (de-la-Torre *et al.*, 2009). Study of the cytokine profile of the AH shed light on the pathogenesis of ocular disease for further origins of infectious uveitis (Lacomba *et al.*, 2000; Ooi, Galatowicz, Calder *et al.*, 2006; Ooi, Galatowicz *et al.*, 2006), but the exact role of cytokines in toxoplasmic uveitis remains to be clarified (Garweg and Candolfi, 2009; Lahmar *et al.*, 2009; Sauer *et al.*, 2012).

Cytokines have diverse functions, depending on the local immunological environment (Lacomba *et al.*, 2000; Ooi *et al.*, 2006; Ooi *et al.*, 2006). Consequently, an ocular cytokine map or “cytokinome” will contribute to a superior understanding of the physiopathology of particular kinds of uveitis and of different outcomes in the same infectious uveitis, as occur in OT, giving us support for novel targeted therapy (Ooi *et al.*, 2006; Lahmar *et al.*, 2009; Sauer *et al.*, 2012).

Few studies have been conducted on the OT cytokine profile. In 27 French patients, a specific local cytokine profile for OT was obtained, which was different from that for other causes of uveitis (Lahmar *et al.*, 2009). However, there was no correlation with clinical features. Nevertheless, elevated levels of IFN- $\gamma$ , IL-6, and MIP-1 $\beta$  were regularly identified in samples from patients with OT, as well as viral uveitis, while IL-17 was frequently detected in AH from patients with OT and in samples from those with intermediate, but not viral uveitis (Lahmar *et al.*, 2009). Another prospective study using AH samples from French patients revealed enhanced Th1 (IL-2 and IFN- $\gamma$ ) and Th2 (IL-13) cytokines, as well as inflammatory (IL-6, IL-17, and MCP-1) and downregulating (IL-10) immune mediators. In contrast, TNF- $\alpha$  was not upregulated (Sauer *et al.*, 2012).



However, these results are particular to European and North American patients, where infection by Type II strains prevail (Sibley and Ajioka, 2008). It would be relevant to evaluate the inflammatory cytokines in South American patients, as they are frequently infected by more virulent strains and present more a severe clinical picture (Gilbert *et al.*, 2008; de-la-Torre *et al.*, 2009; Sauer *et al.*, 2011). Hence, the present study aimed to analyze the local cytokine profiles in Colombian patients with active OT, and to correlate them with the individual clinical features, along with the type of infecting strain, as determined by serotyping.

## **ii. Article**

## **Ocular cytokinome is linked to clinical characteristics in ocular toxoplasmosis**

Alejandra de-la-Torre<sup>1,2,3\*</sup>, Jorge E. Gomez-Marin<sup>1</sup>, Alexander W. Pfaff<sup>2</sup>, Michael E. Grigg<sup>4</sup>, Odile Villard<sup>2</sup>, Ermanno Candolfi<sup>2</sup>

<sup>1</sup> GEPAMOL, Centro de Investigaciones Biomédicas, Facultad de Ciencias de la Salud, Universidad del Quindío, Avenida Bolívar 12N, Armenia, Colombia

<sup>2</sup> Institut de Parasitologie et Pathologie Tropicale, Fédération de Médecine Translationnelle de Strasbourg, Université de Strasbourg, France

<sup>3</sup> Universidad del Rosario, Escuela de Medicina y Ciencias de la Salud, Departamento de Inmunología, Bogotá, Colombia

<sup>4</sup> Laboratory of Parasitic Diseases, National Institutes of Health, National Institute of Allergy and Infectious Diseases (NIAID), Bethesda, Maryland, USA.

**\*Corresponding author:** Jorge E. Gomez. Universidad del Quindio. E-mail : gepamol2@uniquindio.edu.co

## Abstract

**Purpose:** to determine the cytokine levels in aqueous humor (AH) of Colombian patients with active ocular toxoplasmosis (OT), and to correlate them with their clinical characteristics.

**Methods:** 27 cytokines /chemokines were assayed in 15 AH samples (nine patients with diagnosis of OT biologically -confirmed and six controls that underwent cataract surgery). Correlations were assessed between cytokine/chemokine levels, type of inflammatory response (Th1, Th2, Th17, Treg), and clinical characteristics.

**Results:** Th2 predominant response was related to more severe clinical features. The presence of VEGF and IL-5 was related to higher number of recurrences. Growth factors (VEGF, FGF, PDGF- $\beta$ ), were related to higher number of lesions. Patients infected by not-type-II strains had a particular intraocular cytokine-pattern.

**Conclusions:** Th2 response was related to more severe clinical characteristics in patients infected by non-type-II strains. IL-5 and VEGF were associated with recurrences. We correlate for the first time, specific cytokine-patterns with clinical characteristics and with the infecting *Toxoplasma* strain.

**Key words:** *Toxoplasma gondii*, uveitis, Th2, Colombia, intraocular cytokines.

## 1. INTRODUCTION

Ocular toxoplasmosis (OT) is the most common cause of posterior uveitis and, in some countries, it is one of the most important causes of visual impairment [1]. The severity of the disease varies greatly between patients [1]. OT is characterized by necrotizing retinopathy, which is triggered by the activation of dormant organisms within the retina [2]. For other causes of infectious uveitis, the cytokine profile analysis in aqueous humor elucidated the pathogenesis of the ocular disease [3, 4, 5] but the precise role of cytokines in toxoplasmic uveitis remains to be determined [6, 7]. Cytokines can be pro or anti-inflammatory, synergistic, antagonistic, pleiotropic, redundant, and interactive, depending on the local immunological environment [3, 4, 5]. Therefore, an ocular cytokine mapping or cytokinome will contribute to a better understanding of the physiopathology of specific forms of uveitis and of different outcomes in a same infectious uveitis, as occurs in OT, providing guidance for new targeted treatment [4, 6, 7]. A study on the ocular cytokinome in 27 immunocompetent french patients with OT found no correlation with age, sex or region of origin of the patient; neither with time from symptom onset to the obtainment of samples; degree of uveal inflammation; or the etiology of the infection (primary acquired or congenital). However, a specific local cytokine-profile for ocular toxoplasmosis was observed, distinct from other causes of uveitis [6]. Particularly high levels of IFN- $\gamma$ , IL-6, and MIP-1 $\beta$  were frequently detected in samples from patients with ocular toxoplasmosis, as well as viral uveitis, whereas IL-17 was frequently detected in samples from patients with ocular toxoplasmosis and in samples from those with intermediate, but not viral uveitis [6]. Another prospective study using aqueous humor (AH) samples from French patients revealed enhanced Th1 (IL-2, IFN- $\gamma$ ) and Th2 (IL-13) cytokines, as well as inflammatory (IL-6, IL-17, MCP-1) and down-regulating (IL-10) immune mediators. In contrast, TNF- $\alpha$  was not up-regulated [7]. However, these results are representative for European (and North American) patients, where Type II strains predominate [8, 9]. We recently found that cytokine patterns were strikingly different between the French and Colombian patients with ocular toxoplasmosis [10]. Intraocular IFN- $\gamma$  and IL-17 expression was lower, while higher levels of IL-13

and IL-6 were found in aqueous humor samples from Colombian patients [10]. These results are consistent with the hypothesis that South American strains may cause more severe OT due to an inhibition of the protective effect of IFN- $\gamma$  [10]. Thus, our present work aimed to study the local cytokine profiles in Colombian patients with active OT, and to correlate them with the individual clinical manifestations, as well as with the type of infecting strain determined by serotyping.

## 2. MATERIALS AND METHODS

**2.1. Patients and controls.** We prospectively collected all consecutive patients who consulted the Quindío University Health-Center (Armenia, Colombia) between August 2008 and August 2010. This consultation is a tertiary-level center able to perform anterior chamber paracentesis. A complete ocular examination was conducted, including best-corrected Snellen visual acuity, slit-lamp biomicroscopy, tonometry, and indirect ophthalmoscopy. The clinical diagnosis of active OT was confirmed by biological tests on AH samples as previously described [11, 12]. Screened patients with clinically suspected OT and positive for anti-*Toxoplasma* immunoglobulin G (IgG) antibodies in serum were subsequently diagnosed as confirmed OT when positive for *Toxoplasma* DNA by polymerase chain reaction (PCR) or for presence of specific local antibodies against *T. gondii* by immunoblot in aqueous humor compared with immunoblot patterns in serum [12]. Six aqueous humor samples were used as controls from patients that underwent cataract surgery, in which OT was discarded by serological and molecular tests in AH, as described previously [11, 12]. The study followed the tenets of the Declaration of Helsinki. All participants and controls were asked to participate voluntarily in the study. If they accepted then they signed an informed consent according to the Colombian legislation for research with humans (resolution 008430 of 1993 by the ministry of health). The University of Quindio Institutional Review Board approved the study (act number 14, 23 June 2008). Immunocompromised patients were not included. Recurrences information was extracted for all known recurrences, even if the episode was not observed by us, from the referring physician and by clinical

chart annotations as we described previously [13]. An assessment of the inflammation level and anatomic classification of uveitis were carried out according to the criteria proposed by the International Uveitis Study Group (IUSG) [14]. The size of the retinochoroidal lesions was measured in disc-diameters (dd). Inflammation was defined according to the number of cells in vitreous examination. In correlation analysis, the number of cells and the levels of particular cytokines were evaluated. For qualitative analysis purposes, a higher inflammation was defined if there were  $\geq 3+$  cells in vitreous examination, and moderate or lower inflammation if there were 2+ or fewer cells, considering the number of vitreous cells visualized in 3 mm x 1mm slit beam, according to the Standardization of Uveitis Nomenclature (SUN) grading system [14].

**2.2 Cytokine measurement in aqueous humor.** In order to prevent changes in the level of cytokines or increase due to multiple freeze - thawing cycles, samples were immediately stored and maintained at  $-80^{\circ}\text{C}$  until analysis. The Bio-Plex Pro Human 27-plex Panel assay (Bio-Rad) was used to measure cytokine and chemokine levels in 50  $\mu\text{l}$  of the supernatants of aqueous humor of infected and control patients, according to the manufacturer's recommendations. All measurements were done in duplicate. Concentrations were calculated using standard curves of known concentrations and levels of cytokines expressed in pg/ml for each cytokine. Data were analyzed with Bio-Plex Manager TM software V1.1.

**2.3 Serotyping of *Toxoplasma* infections.** Polymorphic synthetic peptides derived from the *T. gondii* dense granule proteins (GRA), GRA6 and GRA7 were used to detect the presence of strain specific antibodies against Type II or not-Type II GRA6/7 alleles in serum of patients, as previously described [15].

**2.4 Statistical analysis.** Differences in proportions among groups were compared by the Fisher's exact test and for non-parametric data, differences of means between two groups were analyzed by a Kruskal Wallis test, with the software Epi-Info™ version 3.5.1 (CDC, Atlanta, USA). The statistical significance of the

relationship between clinical features and cytokine profiles was studied by Spearman's non-parametric correlation-test. Correlation between cytokine levels and serotyping results was analyzed by Kruskal Wallis tests, using the statistical package software SPSS version 14 (SPSS Inc. Chicago, USA).

### 3. RESULTS

**3.1. Clinical and laboratory characteristics of Colombian patients with ocular toxoplasmosis:** During the period of study, 42 patients with clinical symptoms of OT underwent laboratory analysis: 20 cases (47.6%) were confirmed as OT, 13 (30.9%) were conclusively discarded as toxoplasmosis, and 9 (21.4%) had an inconclusive diagnosis. Aqueous humor samples analyzed by PCR revealed the presence of *T. gondii* DNA in 11 out of 19 samples (57.8%) and presence of local antibodies by immunoblot was found in 10 of 11 patients (34.8%). One patient was positive simultaneously by PCR and immunoblot assays. Median number of inflammatory cells in aqueous humor from OT patients was 2.5 (range 0-4), of 1.5 (range 0-4) in non-OT patients and of 2.5 (range 0-4) in patients with inconclusive diagnosis. Median number of recurrences was of 1.0 (range 0-9) in OT patients, of 1.5 (range 0-6) in non-OT and of 1.5 (range 0-4) in patients with inconclusive diagnosis. Mean number of lesions (actives and non-actives) was of 2 (range 1-6) in OT patients, of 2 (range 1-6) in non OT patients and of 1 (range of 1-5) in patients with inconclusive diagnosis.

**3.2. Cytokine profiles in OT patients vs. controls.** Only 9 of 20 cases (45%) with confirmed OT could be analyzed for cytokines in aqueous humor due to low amount of sample that remained after laboratory diagnosis. Non- statistically significant differences existed between patients where the measurement of cytokines in AH could be made and those where it was not possible, in age (median age: 25 years, range 20-82 vs 42 years, range 20-86;  $p=0.07$ ) or gender distribution (% males 72 vs 44;  $p= 0.36$ ). Also not statistically significant differences were found in clinical characteristics (Table 1). All patients received indications to begin treatment after aqueous humor sampling.

The pattern of expression of intraocular immune modulators was heterogeneous in OT patients with high inter-individual variations compared to cataract patients (**Figures 1 to 5**). However, levels of the pro-inflammatory chemokines/chemokines IL-8, IP-10, MCP-1, MIP-1 $\alpha$ , MIP-1 $\beta$ , PDGF-bb, and RANTES (**Figure 1**), as well as the growth factors, GM-CSF, G-CSF, FGF, (**Figure 2**) were significantly higher in OT patients than in cataract controls. Some Th1 cytokines were also present at higher levels, such as IFN- $\gamma$  followed by TNF- $\alpha$ , and IL-7 (**Figure 3**), but not IL-17. However, in active OT patients, we found higher levels of the Th17 activators (IL-1 $\beta$  and IL-6) and of the Th17 inhibitor (IL-1RA), than in cataract controls (**Figure 4**). Interestingly, the Th2 response was elevated in OT patients, mainly characterized by higher levels of IL-4, and IL-13, as well as Treg response as distinguished by IL-10 (**Figure 5**). IL10 was predominant over IFN  $\gamma$  as determined by the IFN  $\gamma$ /IL10 ratio of each patient (mean  $\pm$  SD ratio for the OT patients: 0.28 $\pm$ 0.17).

**3.2 Clinical data correlate with cytokine profiles.** **Table 2** summarizes the statistically significant correlations between clinical characteristics and cytokine levels. The age was positively correlated with IL-12, TNF- $\alpha$ , IL-7, IL-4, IL-17, IL-1b and IL-1RA levels. The number of active lesions was positively correlated with VEGF, FGF, PDGF-bb, IL-12, and IL-13 levels. The size of active lesions was positively correlated with IFN- $\gamma$ , TNF- $\alpha$ , IL-7, IL-4, IL-13, IP-10, IL-1b, IL1RA, MIP-1a, MIP-1 $\beta$ , RANTES and FGF. The size of inactive lesions was negatively correlated with FGF. The number of inactive lesions was positively correlated with VEGF. Vitreous inflammation was positively correlated with TNF- $\alpha$  and IFN- $\gamma$  levels. The total number of recurrences was positively correlated with IL-5 and VEGF. Finally, the number of scars was positively correlated with VEGF levels.

We draw a cytokine profile for each OT patient (see examples in **Figure 6**). Although there are inter-individual variations, it is interesting to observe that there are some patterns: chemokines and growth factors were predominant in all patients; MCP-1, IP-10 and IL-6 had high levels; IL-17 and IFN- $\alpha$  had extremely low levels and expression of IL-12 was related with higher inflammation level.



**3.3 Cytokine profile and Toxoplasma serotyping.** Four out of nine patients showed Type I/III serotypes, and 5 out of 9 patients exhibit non-Type I/III serotypes. We compared median cytokine levels between OT patients infected by I/III strains versus -infected by non- I/III strains. Significant higher levels were found for some cytokines in OT patients infected by I/III strains: IL-12, IL-13, IL-17, IL-1 $\beta$ , IL-5, IL-7, IL-1ra, IL-4, G-CSF, PDGF-bb and TNF- $\alpha$  (**Table 3**). No significant correlation was found between serotype and the level of inflammation (median level of inflammatory cells of 2.5 in I/III strain infected patients versus 1 in not- I/III strain infected patients,  $p= 0.3$ ) or other clinical characteristics (bilateral lesions, papillitis, number of recurrences, number of lesions, vasculitis, or synechiae).

#### 4. DISCUSSION

The immune response in eye is customized in an autonomous manner to the general expression patterns in other tissues, thus the retina is known to have an endogenous immune system coordinated by microglia and dendritic cells as well as perivascular macrophages from three different retinal layers of cells: epithelial pigmentary, choroids and retina [16]. Retinal endothelial cells expressed relatively high levels of transcripts involved in the immune response, including cell adhesion molecules, cytokines, chemokines, receptors, and enzymes involved in synthesizing inflammatory proteins [17]. Retinal pigmentary endothelial (RPE) cells, a monolayer of epithelial cells between retinal and choroidal tissue also possess a variety of immunological functions [17]. The intraocular milieu of cytokines generated by these different retinal layers can be measured by new techniques that simultaneously measure more than 20 cytokine levels in small volumes of biological samples, that enable to determine complex interactions and to identify cytokines that play essential roles in the inflamed eye [3, 4, 5, 6, 7]. Abnormal aqueous humor concentrations of cytokines have been reported for different types of uveitis, and diverse cytokine profiles may be characteristic of specific diseases [4, 5, 6]. In consequence, cytokine profile patterns may serve as diagnostic and prognostic monitoring tools for the clinician [18]. Cytokine analysis

of aqueous humor may also be useful to understand the immunopathogenic mechanisms of infectious uveitis [4]. Our intention was exactly to look into the eye, because things happen there. Immunological response to *Toxoplasma* is specific to the eye [2]. This is clearly observable with the production of antibodies that do not increase in sera and rise in the aqueous humor during an ocular toxoplasmosis [11].

We look for the local immune response that causes or accompanies different types of lesions. To achieve this goal, we determined the levels of cytokines in aqueous humor from nine Colombian patients with ocular toxoplasmosis, by using the same recruitment criteria and the same methodology used in our previous work [6, 7, 10]. The main limitation of others studies is the inclusion of patients with presumed OT, rather than biologically confirmed cases [19]. While the ocular signs of toxoplasmic retinochoroiditis are highly suggestive of this disease, they may be mimicked by other infections [11] and symptoms may be atypical in some cases [20]. We demonstrated that, in our series of cases, 30% of retinochoroiditis were not due to toxoplasmosis.

We recently report a more severe ocular infection in South America that was correlated with the infecting *Toxoplasma* strain [10]. Here, we confirm that the cytokine pattern observed in Colombian OT patients is completely different to the pattern reported in French patients [6, 7, 10]. The severity of ocular toxoplasmic infection due to predominant Th2 response in Colombian patients is confirmed by the association between high IL13 and IL4 levels and higher size and number of lesions. Although IFN  $\gamma$  and TNF  $\alpha$  had higher levels compared to cataract controls, they never reach the levels described in previous studies in French patients [10]. Additionally, we calculate the IFN  $\gamma$ /IL10 ratio that indicated a predominance of IL10 over IFN  $\gamma$ . The lower Th1 response in Colombian patients can be explained by a specific modulation of the immune response by South American strains. Strains of the types I and III inhibit NF $\kappa$ B pathway (resulting in reduced IFN- $\gamma$  production) whereas type II strains induce it [21]. In support of this, local cytokine profiles of patients infected with I/III strains were significantly

different to those infected with non-I/III strain. The heterogeneous clinical and cytokine aspect observed in Colombian patients can be explained by the more heterogeneous parasite population of *T. gondii* infecting people in Colombia [10, 22] compared to the very homogeneous infection in France by type II strains [23]. However, it is needed to refine the serotyping methods in order to differentiate more precisely the type of infecting strain. Genotyping method for virulent alleles of *Toxoplasma* ROP18 identified an association between infection by a parasite with the virulent allele of ROP18 and a higher inflammatory reaction in ocular toxoplasmosis, whereas the serotyping method was not able to identify this [24]. Therefore it would be important to obtain a better serotyping method to determine the infecting strain.

We found a positive correlation between age and levels of IL-4 and TNF- $\alpha$ . Aging in humans was related with progressive decline in T cell numbers and increased production of TNF- $\alpha$  [25]. Also it has been previously reported a positive correlation between age and an increased secretion of IL-4, reflecting an age-dependent accumulation of memory T cells [26, 27]. Other association that we found was between high VEGF levels and higher number of inactive lesions, higher number of recurrences and higher number of scars. VEGF increased expression of hypoxia-inducible factor 1-alpha in an *in vitro* model of *Toxoplasma* infection [28]. This can contribute to the formation of choroidal neovascular-membranes that are frequently observed in Colombian patients with ocular toxoplasmosis [1].

Interferon gamma-induced protein 10 (IP-10) is secreted by monocytes, endothelial cells and fibroblasts [29] and was positively correlated with size of active lesions. IP-10 plays a role for chemoattraction of monocytes/macrophages, T cells, NK cells, and DC and promotes T cell adhesion to endothelial cells [29]. Thus, if there are more T cells adhesion to endothelial cells, there are more chemoattraction of monocytes and a higher vitreous inflammation and higher size of lesions. The positive correlation that we found between size of active lesions and other cytokines (IFN- $\gamma$ , TNF- $\alpha$ , IL-7, IL-1b, IL-1ra) can be explained by their pro-inflammatory effect, counterbalanced by a predominant IL-4 and IL10 response, as

revealed by the lower IFN  $\gamma$ /IL10 ratios. Additionally, bigger active lesions were correlated with chemokine RANTES, as well as with angiogenic and wound healing factor FGF, which is not surprising, considering that with bigger lesions it is expected to exist more presence of inflammatory and antigenic factors.

The number of recurrences was related with IL-5. This cytokine has an important role in the induction of a Th2 response and antibody production by enhancing specific IgA production [30]. Presence of specific IgA has been described as predictor of recurrences in ocular toxoplasmosis [31]. This correlation of recurrences with higher levels of IL-5 and VEGF will need of studies in the mouse model in order to determine if their inhibition would reduce recurrences or reactivation of eye infection [2].

High levels of IL-6, IL-10, IL-12p70, and MCP-1 were found associated with more inflammation. Particularly, IL-6 is a major proinflammatory cytokine in uveitis and elevated intraocular levels were found in AH of patients with uveitis of diverse origins, including ocular toxoplasmosis, viral uveitis, Fuchs heterochromic uveitis syndrome (FHUS), and inflammatory bowel disease [31-37]. IL-6 can enhance the progression of the parasite by activation of STAT-3, which is an inhibitor of IL-12, a key cytokine that induce protective response against *Toxoplasma* infection [38]. STAT3 appears to be a key target of *T. gondii* virulence factors [38]. Further investigations are needed to study the role of intraocular IL-6 and his counter-balance by IL-12 in human OT.

The role of IL-9 and IL-10 and of the cell subset producing them, require further investigation in the pathogenesis of uveitis. IL-10 can be associated not only with the Th2 response [39]. IL-10 is an immunomodulatory cytokine produced by various cell types, including Treg cells, B cells, and monocytes [39]. Recent studies identified IL-10 production in cells that otherwise show Th1 and Th17 phenotypes [40]. In the present study, higher levels of IL-9 were associated with higher anatomical compromise (involvement of anterior and posterior pole), and higher levels of IL-10 were associated with higher vitreous inflammation.

IL-15, IFN- $\gamma$ , and TNF- $\alpha$ , were associated with the presence of papillitis, as well as IL-4, IL-5 and eotaxin. In contrast, IL-4 and IL-12 were not detected in patients with tuberculous uveitis [37] while in our patients higher levels of IL-12 were positively correlated with higher number of active retinochoroidal lesions.

In conclusion, for the first time it was found that there are significant correlates of specific cytokine patterns with clinical characteristics in OT, such as inflammation, recurrences and the infecting *T. gondii* strain. These results will help to build new working hypothesis about the differences in therapeutic response and prognosis in OT and to test immunomodulatory options for the treatment of this important ocular infection.

### **Funding**

This work was supported by Colciencias [grant 111345921861], the Ecos Nord Program, Fondation pour la Recherche Médicale, and the Intramural Research Program of the National Institutes of Health and NIAID.

### **Acknowledgments**

We would like to thank the Universidad del Quindío, Hôpitaux Universitaires de Strasbourg for the PHRC grant 2007-3964, and Université de Strasbourg for additional financial support.

All authors declare no conflicts of interest, and no financial interest.

## REFERENCES

1. de-la-Torre A, López-Castillo CA, Gómez-Marín JE. Incidence and clinical characteristics in a Colombian cohort of ocular toxoplasmosis. *Eye (Lond)* 2009; 23(5):1090-1093.
2. Pfaff A, de-la-Torre A, Rochet E, Brunet J, Sabou M, Sauer A, Bourcier T, Gomez-Marín JE, Candolfi E. New clinical and experimental insights into Old World and neotropical ocular toxoplasmosis. *Int J Parasitol* 2013; doi: 10.1016/j.ijpara.2013.09.007
3. Lacombe MS, Martin CM, Chamond C, Galena JMG, Omar M, Esterez C. Aqueous and serum interferon gamma, interleukin (IL-2, IL-4 and IL-10) in patients with uveitis. *Arch Ophthalmol* 2000; 118:768-772.
4. Ooi KG, Galatowicz G, Calder VL, Lightman SL. Cytokines and chemokines in uveitis: is there a correlation with clinical phenotype? *Clin Med Res* 2006; 4(4):294-309.
5. Ang M, Cheung G, Vania M, Chen J, Yang H, Li J, Chee SP. Aqueous cytokine and chemokine analysis in uveitis associated with tuberculosis. *Mol Vis* 2012; 18:565-573.
6. Lahmar I, Abou-Bacar A, Abdelrahman T, Guinard M, Babba H, Ben Yahia S, Kairallah M, Speeg-Schatz C, Bourcier T, Sauer A, Villard O, Pfaff AW, Mousli M, Garweg JG, Candolfi E. Cytokine profiles in toxoplasmic and viral uveitis. *J Infect Dis* 2009; 199(8):1239-1249.
7. Sauer A, Pfaff AW, Villard O, *et al.* Interleukin 17A as an Effective Target for Anti-inflammatory and Antiparasitic Treatment of Toxoplasmic Uveitis. *J Infect Dis* 2012; 206(8):1319-1329.
8. Sibley LD, Ajioka JW. Population structure of *Toxoplasma gondii*: clonal expansion driven by infrequent recombination and selective sweeps. *Annu Rev Microbiol* 2008; 62:329-351.
9. Gilbert RE, Freeman K, Lago EG, Bahia-Oliveira LM, Tan HK, Wallon M, Buffolano W, Stanford MR, Petersen E; European Multicentre Study on

- Congenital Toxoplasmosis (EMSCOT). Ocular sequelae of congenital toxoplasmosis in Brazil compared with Europe. *PLoS Negl Trop Dis* 2008; 13: 2(8):e277.
10. de-la-Torre A, Sauer A, Bourcier T, Speeg-Schatz C, Ballonzoli L, Ajzenberg D, Sundar N, Grigg ME, Villard O, Brunet J, Pfaff A, Gomez-Marín J, Candolfi E. Severe Southamerican ocular toxoplasmosis is associated with decreased IFN- $\gamma$ /IL-17A and increased IL-6/IL-13 intraocular levels. *PLoS Neglected Trop Dis* 2013; 7(11): e2541. doi: 10.1371/journal.pntd.0002541
  11. Garweg JG, de Groot-Mijnes JD, Montoya JG. Diagnostic approach to ocular toxoplasmosis. *Ocul Immunol Inflamm* 2011; 19(4):255-261.
  12. Villard O, Cimon B, Franck J, Fricker-Hidalgo H, Godineau N, Houze S, Paris L, Pelloux H, Villena I, Candolfi E. Evaluation of the usefulness of six commercial agglutination assays for serologic diagnosis of toxoplasmosis. Network from the French National Reference Center for Toxoplasmosis. *Diagn Microbiol Infect Dis* 2012; 73(3):231-235.
  13. de-la-Torre A, Rios-Cadavid AC, Cardozo-García CM, Gomez-Marín JE. Frequency and factors associated with recurrences of ocular toxoplasmosis in a referral centre in Colombia. *Br J Ophthalmol*. 2009; 93(8):1001-1004.
  14. Deschenes J, Murray PI, Rao NA, Nussenblatt RB. International Uveitis Study Group (IUSG): clinical classification of uveitis. *Ocul Immunol Inflamm* 2008; 16(1):1-2.
  15. Kong JT, Grigg ME, Uyetake L, Parmley S, Boothroyd JC. Serotyping of *Toxoplasma gondii* infections in humans using synthetic peptides. *J Infect Dis* 2003; 187(9):1484-1495.
  16. Stein-Streilein J. Immune regulation and the eye. *Trends Immunol*. 2008; 29(11):548-554. doi: 10.1016/j.it.2008.08.002
  17. Bharadwaj AS, Appukuttan B, Wilmarth PA, Pan Y, Stempel AJ, Chipps TJ, Benedetti EE, Zamora DO, Choi D, David LL, Smith JR. Role of the retinal vascular endothelial cell in ocular disease. *Prog Retin Eye Res*. 2013; 32:102-80.

18. Fisson S, Ouakrim H, Touitou V, Baudet S, Ben Abdelwahed R, Donnou S, Miloudi A, Galand C, Bodaghi B, Lehoang P, Brissard M, Le Garff-Tavernier M, Fridman WH, Sautès-Fridman C, Cassoux N, Merle-Béral H. Cytokine profile in human eyes: contribution of a new cytokine combination for differential diagnosis between intraocular lymphoma or uveitis. *PLoS One*. 2013;8(2):e52385. doi: 10.1371/journal.pone.0052385.
19. Dutra MS, Béla SR, Peixoto-Rangel AL, Fakiola M, Cruz AG, Gazzinelli A, Quites HF, Bahia-Oliveira LM, Peixe RG, Campos WR, Higino-Rocha AC, Miller NE, Blackwell JM, Antonelli LR, Gazzinelli RT. Association of a NOD2 gene polymorphism and T-helper 17 cells with presumed ocular toxoplasmosis. *J Infect Dis*. 2013; 207 (1): 152-63. doi: 10.1093/infdis/jis640.
20. Dodds EM, Holland GN, Stanford MR, Yu F, Siu WO, Shah KH, Ten Dam-van Loon N, Muccioli C, Hovakimyan A, Barisani-Asenbauer T International Ocular Toxoplasmosis Research Group. Intraocular inflammation associated with ocular toxoplasmosis: relationships at initial examination. *Am J Ophthalmol* 2008; 146(6): 856-865.
21. Rosowski EE, Lu D, Julien L, Rodda L, Gaiser RA, Jensen KD, Saeij JP Strain-specific activation of the NF-kappaB pathway by GRA15, a novel *Toxoplasma gondii* dense granule protein. *J Exp Med* 2011; 208:195–212.
22. Gallego C, Saavedra C, Gómez Marín JE Direct genotyping of animal and human isolates of *Toxoplasma gondii* from Colombia (South America). *Acta Tropica* 2006; 97: 161-167
23. Fekkar A, Ajzenberg D, Bodaghi B, Touafek F, Le Hoang P, Delmas J, Robert PY, Dardé ML, Mazier D, Paris L. Direct genotyping of *Toxoplasma gondii* in ocular fluid samples from 20 patients with ocular toxoplasmosis: predominance of type II in France. *J Clin Microbiol* 2011; 49(4): 1513-1537.
24. Sánchez V, de-la-Torre A, Gómez Marín JE. Characterization of ROP18 alleles in human toxoplasmosis. *Parasitol Int* 2013; doi: 10.1016/j.parint.2013.10.012.



25. Gupta S, Chiplunkar S, Kim C, Yel L, Gollapudi S. Effect of age on molecular signaling of TNF-alpha-induced apoptosis in human lymphocytes. *Mech Ageing Dev* 2003; 124(4):503-509.
26. Nolan Y, Maher FO, Martin DS, Clarke RM, Brady MT, Bolton AE, Mills KH, Lynch MA. Role of interleukin-4 in regulation of age-related inflammatory changes in the hippocampus. *J Biol Chem* 2005; 280(10):9354-9362.
27. Li SP, Miller RA. Age-associated decline in IL-4 production by murine T lymphocytes in extended culture. *Cell Immunol* 1993; 151(1):187-195.
28. Spear W, Chan D, Coppens I, Johnson RS, Giaccia A, Blader IJ. The host cell transcription factor hypoxia-inducible factor 1 is required for *Toxoplasma gondii* growth and survival at physiological oxygen levels. *Cell Microbiol* 2006; 8(2):339–352.
29. Moser B, Loetscher P. Lymphocyte traffic control by chemokines. *Nat. Immunol.* 2001; 2(2):123–128
30. Takatsu K, Kouro T, Nagai Y. Interleukin 5 in the link between the innate and acquired immune response. *Adv Immunol.* 2009;101:191-236. doi: 10.1016/S0065-2776(08)01006-7.
31. Gómez Marín JE, Montoya MT, Castaño JC, Alvarado F, Duque AM, Chemla C, Aubert D, Bonhomme A, Pinon JM. Frequency of specific anti-*Toxoplasma gondii* IgM, IgA and IgE in Colombian patients with acute and chronic ocular toxoplasmosis. *Mem Inst Oswaldo Cruz* 2000; 95(1):89-94
32. Iyer JV, Connolly J, Agrawal R, Yeo TK, Lee B, Au B, Teoh SC. Cytokine analysis of aqueous humor in HIV patients with cytomegalovirus retinitis. *Cytokine.* 2013; 64(2):541-7. doi: 10.1016/j.cyto.2013.08.006.
33. Takase H, Futagami Y, Yoshida T, Mochizuki M, Kamoi K, Sugita S, Imai Y. Cytokine profile in aqueous humor and sera of patients with infectious or noninfectious uveitis. *Invest Ophthalmol Vis Sci* 2006; 47:1557-1561.
34. van Kooij B, Rothova A, Rijkers GT, deGroot Mijnes J. Distinct cytokine and chemokine profiles in the aqueous humor of patients with uveitis and cystoid macular edema. *Am J Ophthalmol* 2006; 142:192-194.

35. Yoshimura T, Sonoda KH, Ohguro N, et al. Involvement of Th17 cells and the effect of anti-IL-6 therapy in autoimmune uveitis. *Rheumatology* 2009; 48: 347-355.
36. El-Asrar AMA, Struyf S, Kangavea D, Al-Obeidana SS, Opdenakkerb G, Geboesch K, Van Damme J Cytokine profiles in aqueous humor of patients with different clinical entities of endogenous uveitis. *Clin Immunol* 2011; 139:177-184.
37. Perez VL, Papaliodis GN, Chu D, Anzaar F, Christen W, Foster CS. Elevated levels of interleukin 6 in the vitreous fluid of patients with pars planitis and posterior uveitis: the Massachusetts eye & ear experience and review of previous studies. *Ocul Immunol Inflamm* 2004; 12:193-201.
38. Saeij JP, Coller S, Boyle JP, Jerome ME, White MW, Boothroyd JC. *Toxoplasma* co-opts host gene expression by injection of a polymorphic kinase homologue. *Nature* 2007; 445: 324-327.
39. O'Garra A, Vieira PL, Vieira P, Goldfeld AE. IL-10-producing and naturally-occurring CD4+ Tregs: limiting collateral damage. *J Clin Invest* 2004; 114:1372-1378.
40. Damsker JM, Hansen AM, Caspi RR. Th1 and Th17 cells: adversaries and collaborators. *Ann N Y Acad Sci* 2010; 1183: 211-221.

**Table 1.** Comparison of clinical characteristics in patients with ocular toxoplasmosis where cytokine analysis was performed versus those where it was not possible due to low amount of aqueous humor (AH) sample

	Median (range) or percent (n/N) in patients where cytokine analysis was not possible	Median (range) or percent (n/N) in patients with cytokine analysis	P-value
<b>Age of first clinical episode</b>	38.3 (16-85)	20 (16-52)	0.09
<b>Number of scars</b>	1 (0-4)	2.5 (0-4)	0.3
<b>Number of inflammatory cells in vitreous humor</b>	2.5 (1-4)	2 (0.5-4)	0.71
<b>Mean size of scars in disk diameters</b>	0.12 (0-1)	0.5 (0-2.5)	0.12
<b>Number of lesions</b>	2.5 (1-3)	2.0 (1-6)	0.9
<b>Number of recurrences episodes</b>	1 (0-9)	1.5 (0-3)	0.71
<b>Bilateral involvement</b>	11.1% (1/9)	22.2% (2/9)	1.0
<b>IgM anti-Toxoplasma positive test</b>	9.0% (1/11)	11.1% (1/9)	1.0
<b>Positive PCR in AH for Toxoplasma DNA</b>	60% (6/10)	55% (5/9)	1.0
<b>IgG anti Toxoplasma (UI/ml)</b>	201 (90-421)	194 (97-301)	0.56

**Table 2. Spearman's correlation of clinical characteristics and levels of intraocular cytokines (pg/ml) in patients with active OT**

Cytokine	Age	Size active lesions DD	Size inactive lesions DD	Number of inactive lesions	High vitreous Inflammation	Number of recurrences	Number of scars
IL-12	,727(*)	NS	NS	NS	NS	NS	NS
IFN-g	NS	,676(*)	NS	NS	,709(*)	NS	NS
TNF-a	,803(**)	,725(*)	NS	NS	,688(*)	NS	NS
IL2	NS	NS	NS	NS	NS	NS	NS
IL-7	,668(*)	,780(*)	NS	NS	NS	NS	NS
IL-15	NS	NS	NS	NS	NS	NS	NS
IL-4	,840(**)	,728(*)	NS	NS	NS	NS	NS
IL-10	NS	NS	NS	NS	NS	NS	NS
IL-13	NS	,759(*)	NS	NS	NS	NS	NS
IL-5	NS	NS	NS	NS	NS	,685(*)	NS
IL-9	NS	NS	NS	NS	NS	NS	NS
IP-10	NS	,690(*)	NS	NS	NS	NS	NS
EOTAXIN	NS	NS	NS	NS	NS	NS	NS
IL-17	,785(*)	NS	NS	NS	NS	NS	NS
IL-1b	,762(*)	,811(**)	NS	NS	NS	NS	NS
IL1-ra	,679(*)	,809(**)	NS	NS	NS	NS	NS
IL-6	NS	NS	NS	NS	NS	NS	NS
IL-8	NS	NS	NS	NS	NS	NS	NS
MCP-1	NS	NS	NS	NS	NS	NS	NS
MIP-1 <sup>a</sup>	NS	,845(**)	NS	NS	NS	NS	NS
MIP-1b	NS	,725(*)	NS	NS	NS	NS	NS
G-CSF	NS	NS	NS	NS	NS	NS	NS
GM-CSF	NS	NS	NS	NS	NS	NS	NS
PDGF-bb	NS	NS	NS	NS	NS	NS	NS
VEGF	NS	NS	NS	,720(*)	NS	,747(*)	,720(*)
RANTES	NS	,772(*)	NS	NS	NS	NS	NS
FGF	NS	,690(*)	-,707(*)	NS	NS	NS	NS

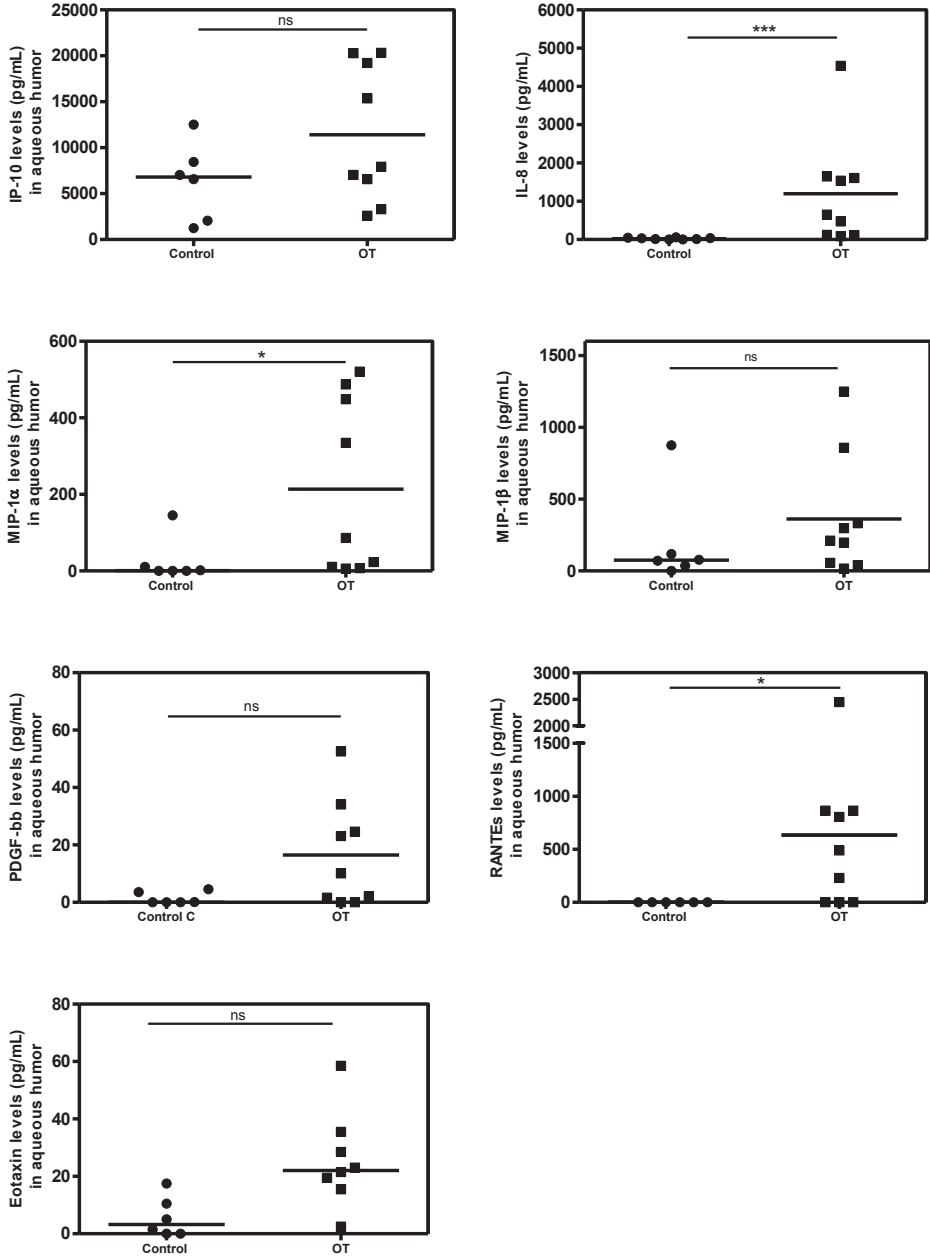
NS: Non significant correlation. Level of significance (two tailed): \*:  $1-\alpha = 0,9$  (90%). \*\*:  $1-\alpha = 0,95$  (95%). \*\*\*:  $1-\alpha = 0,99$  (99%).

**Table 3. Cytokines with significant different levels according to infecting *T. gondii* strain in Colombian patients with active OT**

Cytokine Group	Cytokine	Serotype		P-value (Kruskal-Wallis)
		I/III	No I/II	
		Cytokine median (range) pg/ml N: 4	Cytokine median (range) pg/ml N: 5	
Th1	TNF-a	67,3 (33,8-69,3)	14,3 (9,3-53,3)	0,05
	IL-7	21,4 (9,4-23,9)	3,4 (2,4-14,4)	0,03
	IL-12	63,4 (13,9-460,9)	8,9 (0-31,4)	0,05
Th17	IL-17	5,9 (0-11,9)	0 (0-0)	0,03
Th17 activators	IL-1b	76,9 (21,9-80,9)	14,9 (6,4-56,9)	0,05
Th17 inhibitors	IL1-ra	122,55 (62,3-170,3)	8,3 (7,3-87,3)	0,04
Th2	IL-4	31,5 (12,5-36,5)	5,5 (3,5-23,5)	0,05
	IL-5	50,5 (8,5-66,5)	6,5 (0,5-50,5)	0,05
	IL-13	166,5 (59,5-543,5)	48,5 (7,5-143,5)	0,05
Growth Factors	G-CSF	95,55 (45,3-140,8)	29,8 (0-61,8)	0,05
Chemokines	PDGF-bb	29,35 (23-52,6)	4,6 (0-10,1)	0,01

Figure 1

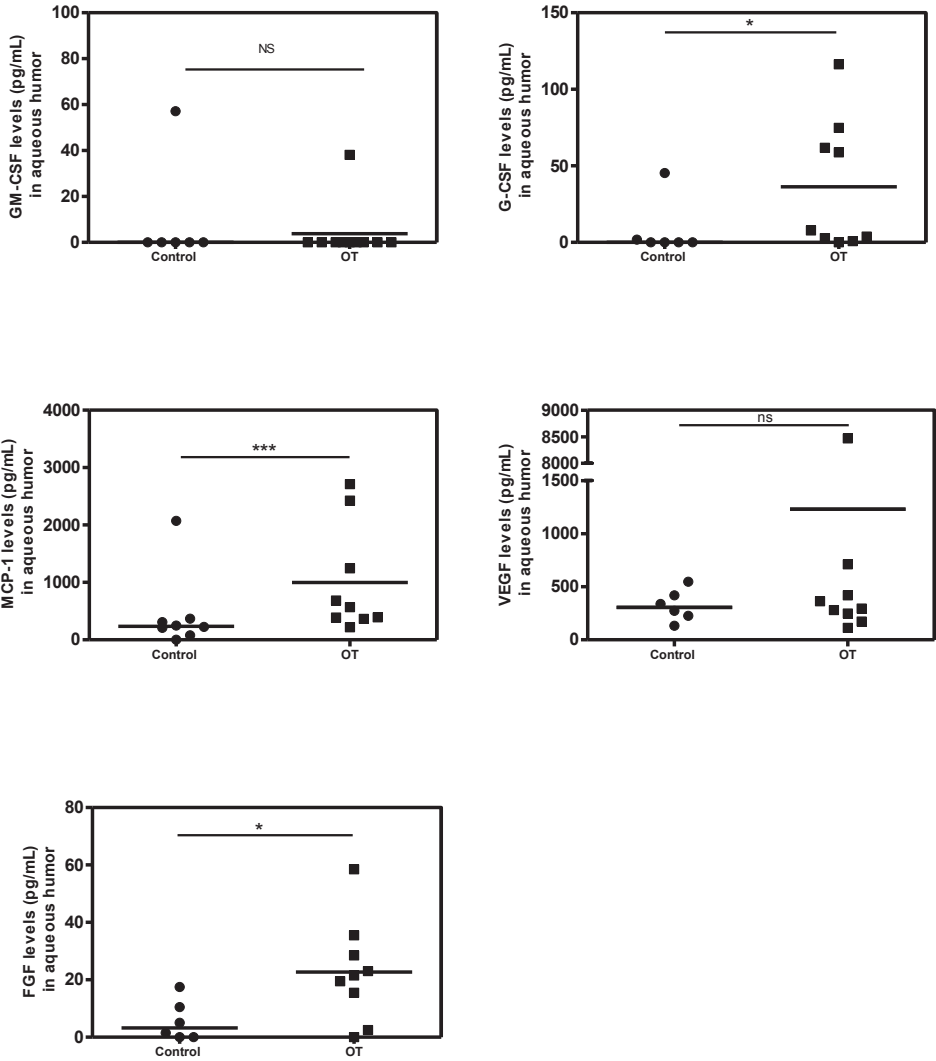
Figure 1. Chemokines in AH of Colombian Patients (n=9) with OT vs Cataract controls (n=6)



Important expression of intraocular chemokines in active OT patients.  
Level of significance: \*:  $1-\alpha = 0.9$  (90%). \*\*:  $1-\alpha = 0.95$  (95%). \*\*\*:  $1-\alpha = 0.99$  (99%).

Figure 2

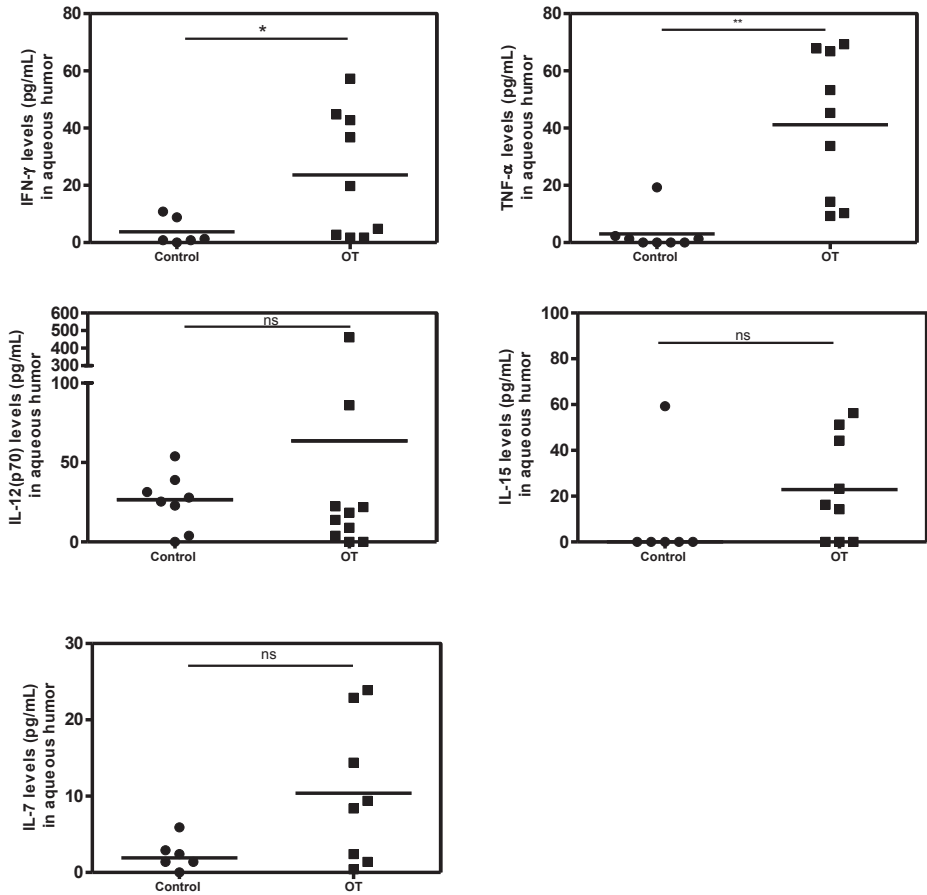
Figure 2. Proinflammatory Growth Factors, angiogenesis and wound healing factors in AH of Colombian Patients (n=9) with OT vs Cataract controls (n=6)



Higher levels of the pro-inflammatory growth factors in active OT patients compared to cataract controls. Level of significance: \*: 1- $\alpha$  = 0.9 (90%). \*\*: 1- $\alpha$  = 0.95 (95%). \*\*\*: 1- $\alpha$  = 0.99 (99%).

Figure 3

Figure 3. Th1 Cytokine profile in AH of Colombian Patients (n=9) with OT vs cataract controls (n=6)

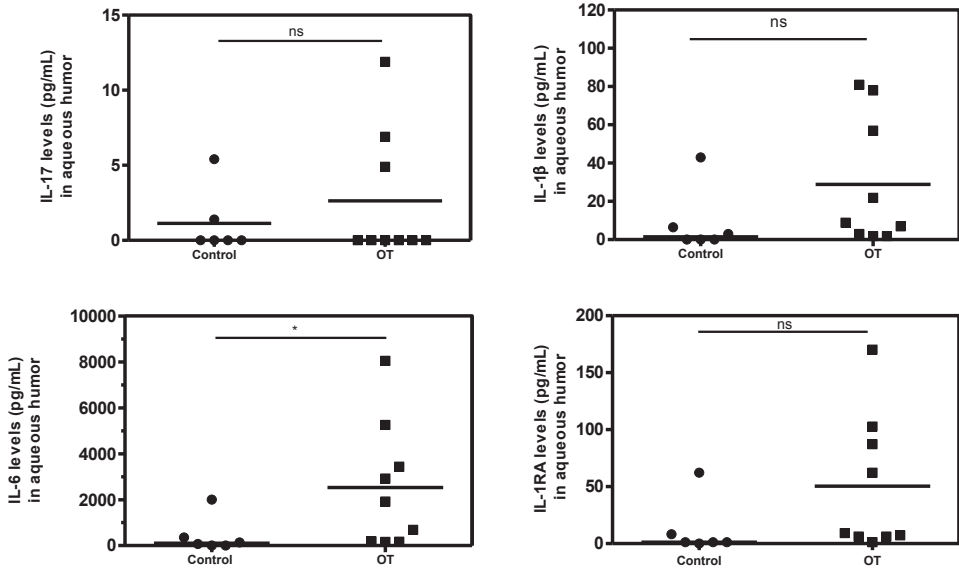


Higher levels of Th1 cytokines in active OT patients compared to controls. Level of significance: \*:  $1-\alpha = 0.9$  (90%). \*\*:  $1-\alpha = 0.95$  (95%). \*\*\*:  $1-\alpha = 0.99$  (99%).



Figure 4

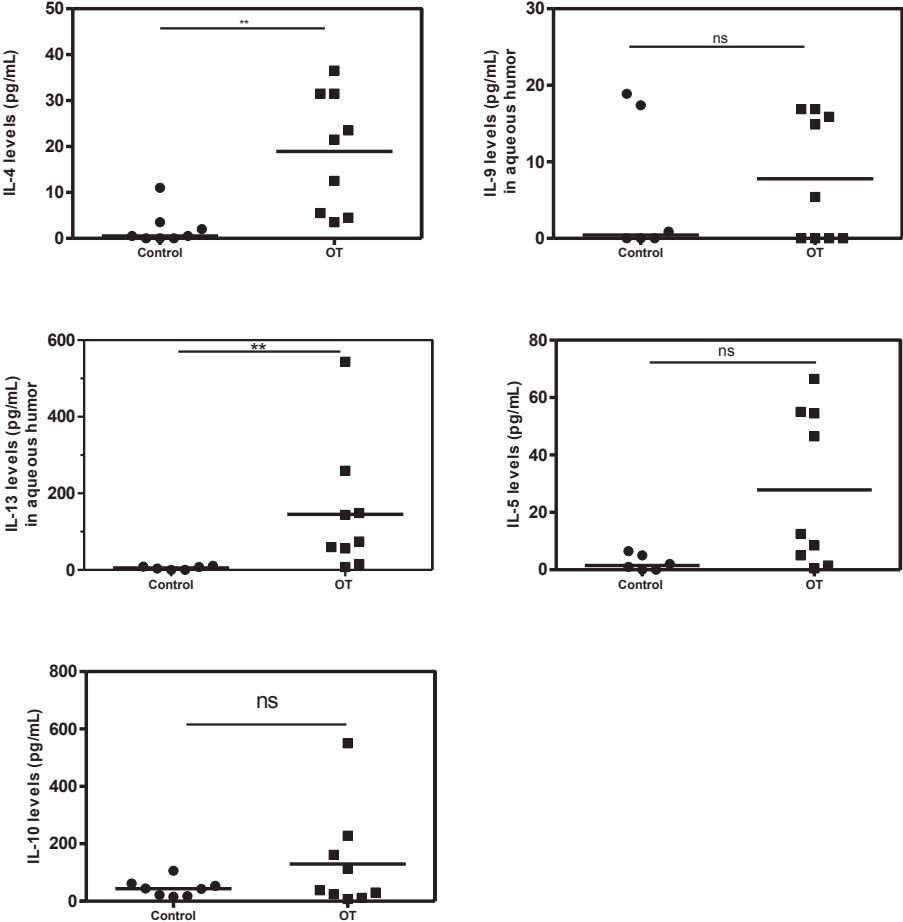
Figure 4. Th17 Cytokine profile in AH of Colombian Patients (n=9) with OT vs cataract controls (n=6)



Counter-balance of Th17 activators (IL-1β and IL-6), and Th17 inhibitor (IL-1RA) in active OT patients, compared to controls in which the expression of these factors is low or there are not expression. Level of significance: \*: 1-α = 0.9 (90%). \*\*: 1- α= 0.95 (95%).\*\*\*: 1- α= 0.99 (99%).

Figure 5

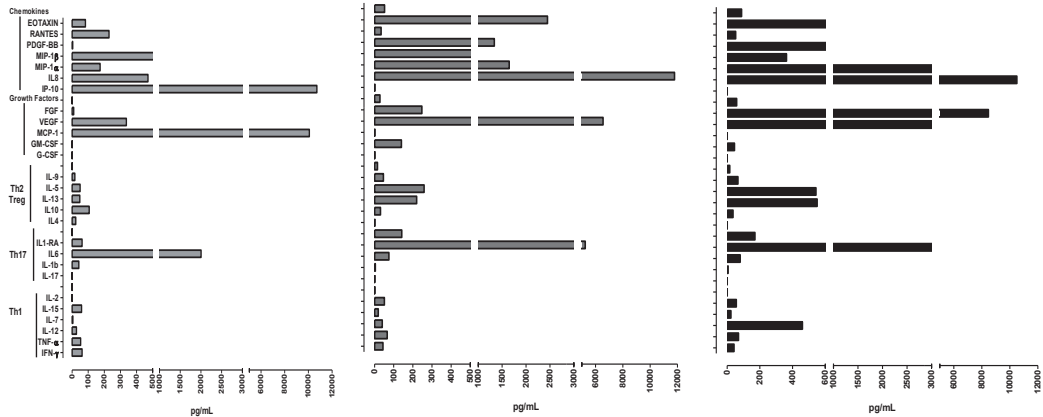
Figure 5. Th2 and Treg Cytokine Profile in AH of Colombian Patients (n=9) with OT vs Cataract controls (n=6)



Prominent Th2 response in active OT patients. Level of significance: \*:  $1-\alpha = 0.9$  (90%). \*\*:  $1-\alpha = 0.95$  (95%). \*\*\*:  $1-\alpha = 0.99$  (99%).

Figure 6

Figure 6. Examples of individual typical cytokine-profiles patterns in AH of patients with active OT



Female, 25 years old.  
 Panuveitis, one active lesions  
 2dd, two inactive lesions 0,5 dd,  
 3+ a/c cells, 4+ vitreous cells.  
 Two recurrences, papillitis, CME.  
 Serotype: No I/III.

Female, 27 years old.  
 Panuveitis, one peripheral active  
 lesion, 1dd, 1+ a/h cells, 2+  
 vitreous cells.  
 No recurrences, acquired  
 infection.  
 Serotype: I/III.

Male, 82 years old.  
 Panuveitis, four active lesions  
 3dd, two inactive lesions 2dd, 2+  
 a/h cells, 4+ vitreous cells.  
 Two recurrences, macular  
 involvement, cataract, synechia,  
 vasculitis, papillitis, retinal  
 detachment.  
 Serotype: Atypical strain

### **iii. Conclusions and perspectives**

-We found specific intraocular cytokine patterns in OT patients from South American, which are different from those described in European OT patients.

-This heterogeneity in infection characteristics allowed us, for the first time, to correlate clinical characteristics, such as inflammation or recurrences with the infecting *T. gondii* strain and with specific cytokine patterns.

-A major Th2 response was related to more severe clinical features in Colombian patients with active OT.

-Although IL-17 levels were low compared with those reported in European patients, its presence in Colombian patients was related to a higher number of recurrences, along with VEGF and IL-5.

-VEGF and other growth factors (FGF, PDGF- $\beta$ ) could play an important role in the pathogenesis of OT in Colombian patients. They were related to a higher number of active and inactive lesions in our patients.

-The association with IL-5 is of interest and will be addressed in subsequent studies in a mouse model in order to determine if inhibition of this cytokine could reduce recurrences or reactivation of eye infection.

**ARTICLE 4**

**NEW CLINICAL AND EXPERIMENTAL INSIGHTS INTO  
OLD WORLD AND NEOTROPICAL OCULAR  
TOXOPLASMOSIS**

(published in Int J Parasitol. 2013 Nov 4;pii:  
S0020-7519(13)00255-5)

## **i. Introduction**

In this article, we summarize the main aspects of OT in Europe and SA, regarding epidemiology, clinical appearance, and immunological features. Concerning epidemiology, OT is more common in SA, Central America, the Caribbean, and some parts of tropical Africa compared with Europe and Northern America, and it is very unusual in China. Ocular infection in SA is more severe than on other continents due to the existence of particularly virulent genotypes of the parasite (Petersen *et al.*, 2012). It has been reported that disease characteristics also differ in diverse areas of the world, for example, Europe, North America, and SA (Dodds *et al.*, 2008). This situation evidently has significant consequences for therapy approaches (Sauer *et al.*, 2011).

Evaluation of cohorts of congenitally infected children from different continents showed that congenital toxoplasmosis was more frequently symptomatic in SA than in Europe; diverse studies found that 50–65% of the children developed ocular lesions (Thiébaud *et al.*, 2007; Gilbert *et al.*, 2008). Moreover, lesions were larger, more numerous, more recurrent, and more likely to impair vision. In Colombia, the lethality rate in congenitally infected children with lack of prenatal therapy is as high as 25% (Gómez-Marín *et al.*, 2011).


## **ii. Article**



Contents lists available at ScienceDirect

International Journal for Parasitology

journal homepage: www.elsevier.com/locate/ijpara



Invited Review

New clinical and experimental insights into Old World and neotropical ocular toxoplasmosis

Alexander W. Pfaff<sup>a,\*</sup>, Alejandra de-la-Torre<sup>a,b,1</sup>, Elise Rochet<sup>a</sup>, Julie Brunet<sup>a</sup>, Marcela Sabou<sup>a</sup>, Arnaud Sauer<sup>c</sup>, Tristan Bourcier<sup>c</sup>, Jorge E. Gomez-Marin<sup>b</sup>, Ermanno Candolfi<sup>a,\*</sup>

<sup>a</sup> Institut de Parasitologie et Pathologie Tropicale, Fédération de Médecine Translationnelle, Université de Strasbourg, 3 rue Koeberlé, 67000 Strasbourg, France

<sup>b</sup> GEPAMOL, Centro de Investigaciones Biomédicas, Universidad del Quindío, Avenida Bolívar 12N, Armenia, Colombia

<sup>c</sup> Service d’Ophtalmologie, Centre Hospitalier Universitaire, 1 place de l’Hôpital, 67000 Strasbourg, France

ARTICLE INFO

Article history:

Received 11 July 2013  
 Received in revised form 20 September 2013  
 Accepted 22 September 2013  
 Available online xxx

Keywords:

*Toxoplasma gondii*  
 Ocular toxoplasmosis  
 Parasite strains  
 South America  
 Human studies  
 Mouse models  
 Inflammation

ABSTRACT

Retinal lesions or other ocular manifestations are serious consequences of infection with the protozoan parasite *Toxoplasma gondii*. Whilst classically considered a consequence of congenital transmission, recent screening studies estimated that 2% of *T. gondii* seropositive persons in Europe and North America have retinal lesions, most of them persisting unnoticed. The situation is more dramatic in South America, probably due to the predominance of virulent strains. Some of these strains seem to exhibit ocular or neuronal tropism and are responsible for severe ocular lesions. Despite the medical importance, the physiopathological mechanisms have only recently begun to be elucidated. The particular immune-privileged situation in the eye has to be considered. Studies on French patients showed low or undetectable ocular parasite loads, but a clear Th1/Th17 type immune reaction. Suitable mouse models have appeared in the last few years. Using such a model, IL-17A proved to impair parasite control and induce pathology. In contrast, in South American patients, the parasite seems to be much less efficiently controlled through a Th2 type or suppressive immune response that favors parasite replication. Finally, several host genetic markers controlling immune response factors have been associated with ocular involvement of *T. gondii* infection, mainly in South America.

© 2013 Published by Elsevier Ltd. on behalf of Australian Society for Parasitology Inc.

1. Introduction

While the apicomplexan parasite *Toxoplasma gondii* infects approximately one-third of the world’s population, transmission frequency is very variable, owing to temperature and humidity variation, as well as local eating habits (Montoya and Liesenfeld, 2004). Following a multiplication phase, where the parasites disseminate throughout the body, the host’s immune system takes control and eliminates most of the parasites, mainly by cellular, IFN- $\gamma$  driven Th1 type responses (Pifer and Yarovinsky, 2011). However, *T. gondii* persists in cysts, mostly in muscles and the CNS. These cysts can reactivate when immunity weakens. Consequently, reactivation of cerebral cysts was a major cause of mortality in AIDS patients before the introduction of effective anti-viral therapies. The retina has also been identified as the location of dormant cyst forms in mice (Lahmar et al., 2010). Until recently, the presence of *T. gondii* in eye tissues was not considered to be a threat to health in immunocompetent persons, with the notable

exception of congenital infection. However, thorough investigation of *T. gondii* seropositive individuals revealed a non-negligible prevalence of retinal lesions, with a life-long risk of recurrence, i.e. the appearance of new lesions (Delair et al., 2008). Despite this apparent medical importance, the physiopathology is still not well understood, which also thus far prevented the introduction of an efficient treatment (Holland, 2004). This review summarises the current knowledge, the active fields of research and the ideal therapeutic strategy.

2. Epidemiology

Toxoplasmic retinochoroiditis is the commonest form of posterior uveitis in many countries. Prevalence and incidence of ocular symptoms after infection depend on socio-economic factors and the circulating parasite genotypes (Holland, 2003; Furtado et al., 2013). Ocular toxoplasmosis (OT) is more common in South and central America, the Caribbean and parts of tropical Africa, compared with Europe and Northern America, and is quite rare in China. Ocular disease in South America is more severe than in other continents due to the presence of extremely virulent genotypes of the parasite (Petersen et al., 2012). The results obtained in a

\* Corresponding authors. Tel.: +33 3 69 55 14 45; fax: +33 3 68 85 38 09.

E-mail addresses: pfaff@unistra.fr (A.W. Pfaff), candolfi@unistra.fr (E. Candolfi).

<sup>1</sup> Present address: Universidad del Rosario, Escuela de Medicina y Ciencias de la Salud, Departamento de Inmunología, Bogotá, Colombia

study comparing OT in Europe, North America and South America suggest that disease characteristics also vary in different areas of the world (Dodds et al., 2008), which obviously has fundamental consequences for treatment strategies (Sauer et al., 2011).

### 2.1. Europe and North America

There are few studies on the prevalence of OT. It is usually estimated through funduscopic screening by discovering chorioretinal scars, suspected to be toxoplasmic, in the general population, as the concerned individuals are often unaware of the presence of scars. A large retrospective study in a United States (US) medical center identified OT as the most common form of posterior uveitis in the 1990s (Rodriguez et al., 1996), which was confirmed for various countries. Generally, it is estimated that approximately 2% of *T. gondii* seropositive persons will develop retinal lesions (Holland, 2003). This led to the estimation that in 2009, 1,075,242 persons became infected in the US, resulting in 21,505 new cases of retinal lesions, of which 4,839 were symptomatic (Jones and Holland, 2010).

In Europe, Gilbert et al. (1999) placed the incidence of symptomatic OT at 0.8/100,000 persons per year, and the lifetime risk (to 60 years of age) at 18/100,000 British born individuals. *Toxoplasma gondii* infection was the main cause of posterior uveitis in 1,064 consecutive patients at a national uveitis referral center in Italy between 2002 and 2008, accounting for 6.9% of all uveitis cases (Cimino et al., 2010). A French multi-center study showed that retinal toxoplasmic lesions could more often attribute to acquired than to congenital infection (Delair et al., 2008). In Germany, a survey of 1,916 patients seen in a similar setting and almost concurrently, also found OT to be the most frequent diagnosis in patients with posterior uveitis and the cause of 4.2% of uveitis cases (Jakob et al., 2009). Acquired infections also may be complicated by recurrent retinochoroiditis, with recurrences being most common close to the time of acquisition (Delair et al., 2011).

The incidence of congenital infections varies with the geographical origin, in parallel with overall seroprevalence. A large retrospective study in the US estimated the number at approximately one in 10,000 live births (Guerina et al., 1994), whereas three in 10,000 live births were observed in France (Villena et al., 2010). A prospective cohort study on European children with confirmed congenital toxoplasmosis found retinal lesions in one of six of these children, who received treatment for at least 1 year, after the first 4 years of life (Tan et al., 2007). Curiously, some North American studies found retinal lesions in more than 70% of congenitally infected and untreated, and 58% of treated children (Mets et al., 1996; Phan et al., 2008). These discrepancies might be due to referral bias or divergent criteria for proven toxoplasmic lesions. In any case, even in countries with low *T. gondii* seroprevalence, such as the Netherlands, congenital toxoplasmosis causes considerable morbidity, with retinal lesions playing an important part (Havelaar et al., 2007).

### 2.2. South America

The enormous impact of toxoplasmosis on public health is best demonstrated by the incidence numbers of congenital OT. The estimated number of one case of congenital toxoplasmosis in 770 live births in Brazil (Vasconcelos-Santos et al., 2009) is 5–15-fold higher than what is seen in Europe and North America. A comparative prospective cohort study of congenitally infected children in Brazil and Europe showed that Brazilian children were at a five-times higher risk than European children of developing eye lesions. Two-thirds of Brazilian children infected with congenital toxoplasmosis had eye lesions by 4 years of age compared with one in six in Europe (Gilbert et al., 2008).

The burden of OT in South America is impressive not only in congenitally infected children, but also in adolescents and adults, most of whom have presumably acquired infection postnatally (Ajzenberg, 2011). Population-based studies of this age group showed that the prevalence of OT is higher in South America compared with North America. Initial studies found an OT prevalence as high as 17.7% in the Erechim region in southern Brazil (Glasner et al., 1992). However, the situation within South America seems to be much more heterogeneous than in Europe or North America. A survey of university students and employees in the Colombian town of Armenia (Quindio region) diagnosed OT in 6% of the study group, 20% of which had visual impairment. (De-la-Torre et al., 2007). The prevalence of congenital toxoplasmosis in this region was estimated at 0.5%. Although the academic study group might not be altogether representative of the overall population, this study suggests a predominance of postnatally acquired OT. The incidence of OT has been estimated to be three new episodes per 100,000 inhabitants per year (De-la-Torre et al., 2009), compared with 0.4 cases per 100,000 persons in British-born patients (Gilbert et al., 1999). Additionally, striking differences are seen even within Colombia. In military personnel operating in the jungle, *T. gondii* seropositivity was significantly higher than in those serving in Bogota, after only 1 year of service (80% versus 45%), but characteristic toxoplasmic chorioretinal lesions were only found in four soldiers that operated in the jungle (0.8%) and in one urban soldier (0.19%) (Gomez-Marin et al., 2012). Consequently, *T. gondii* strain distribution and OT frequency may vary considerably.

Assuming that half of the 41 million inhabitants of Colombia are chronically infected with *T. gondii*, we can estimate that 1 million people live with retinochoroidal scars and at least 200,000 suffer from unilateral legal blindness due to this infection in this country. If we transpose this scenario to the whole population living in tropical parts of South America, especially in Brazil, we have to become aware that the neglected tropical disease OT is in fact a leading cause of blindness in South America (De-la-Torre et al., 2007; Ajzenberg, 2011).

Some studies estimated the proportion of seropositive patients who will eventually develop retinal lesions. In Southern Brazil, 383 persons were reexamined to determine the rates of seroconversion and the incidence of toxoplasmic retinal lesions in individuals who were seronegative for *T. gondii* infection. In this series, 11 (8.3%) of 131 individuals who were seropositive without ocular lesions in 1990 were found to have typical lesions by 1997 (Silveira et al., 2001). The above-mentioned Colombian study (De-la-Torre et al., 2007) suggests that 11% of people with acquired infection develop ocular lesions.

## 3. Clinical appearance

### 3.1. Europe and North America

In young children, OT may be asymptomatic. Children who are able to vocalise may complain of decreased vision or ocular pain, while parents may note leukocoria or strabismus. Adults often present with floaters, which may be associated with altered vision. The 'classic' sign of infection includes retinal scars, white-appearing lesions in the active phase often associated with vitritis (Holland, 2000, 2004; Butler et al., 2013). Depending on the size and thickness of involved retina, the overlying vitreous and subjacent choroid are variably involved. Spontaneous resolution of active retinochoroiditis is the rule in immunocompetent patients, resulting in an atrophic, well-defined scar. Complications may include fibrous bands, secondary serous or rhegmatogenous retinal detachments, optic neuritis and neuropathy, cataracts, increased intraocular pres-



sure during active infection, and choroidal neovascular membranes (Vasconcelos-Santos, 2012; Butler et al., 2013).

Interestingly, Bosch-Driessen et al. (2002) found a significantly increased likelihood of macular lesions (i.e. 46% versus 16%), as well as bilateral disease (i.e. 85% versus 28%), in congenital versus post-natal infections, respectively. Mets et al. (1996) reported macular involvement in 55% and bilateral involvement in 51% of 94 patients with confirmed congenital OT. Congenital infections are not necessarily more severe than postnatal cases, but given the higher incidence of macula involvement, congenital infection carries an increased risk of legal blindness (Bosch-Driessen et al., 2002; Holland, 2004; Butler et al., 2013). Recently, Holland (2009) reported an unadjusted rate of recurrence of 0.2 episodes/year in a cohort of 143 Dutch patients followed for up to 41 years. They noted the recurrence risk decreased with increasing disease-free intervals and increasing age at first clinical episode (Holland, 2009). Recurrences of active retinochoroiditis have been reported to occur in 79% of 76 patients followed for over 5 years, predominantly along the scar border (Bosch-Driessen et al., 2002). In immunocompromised patients, recurrence is the rule in the absence of long-term anti-parasitic therapy (Pivetti-Pezzi et al., 1994; Hodge et al., 1998).

Recurrences in untreated congenital toxoplasmosis occur during teenage years. Manifestations at birth are less severe and recurrences are fewer in those who were treated promptly, early in the course of their disease in utero and in the first year of life. European studies suggested that up to 9% of children with retinal lesions due to congenital toxoplasmosis have significant bilateral vision impairment (Tan et al., 2007).

### 3.2. South America

Ocular disease in South America is not only more frequent but also more severe than in Europe and North America. Congenital toxoplasmosis caused by atypical genotypes is often more severe than that caused by the canonical strains (Dodds et al., 2008; Lindsay and Dubey, 2011). Comparison of cohorts of congenitally infected children from different continents showed that congenital toxoplasmosis is more often symptomatic in South America than in Europe, with different studies showing that approximately 50% of children will develop ocular lesions during the first year of life (Thiebaut et al., 2007; Gilbert et al., 2008). Additionally, lesions are larger, more numerous, more recurrent and more likely to impair vision. In Colombia, the lethality rate in congenitally infected children in the absence of prenatal treatment is as high as 25% (Gomez-Marin et al., 2011).

Recurrences in OT patients have been reported to have a frequency of two episodes each 11 years in a Colombian study, with recurrences clustering soon after an active attack (De-la-Torre et al., 2009). Regarding all of these elements, it becomes evident that quality of life in South American OT patients is significantly affected, especially if they have bilateral lesions and frequent recurrences (De-la-Torre et al., 2011).

## 4. Immunological aspects

### 4.1. Ocular immune response

Given the immune privileged ocular environment, we first outline the principal particularities of specific immunological features in the eye. Crucially, this system controls the development of anti-retinal immune reactions in multiple ways, well beyond a simple physical separation of the ocular compartment (Streilein, 2003). It has long been realised that the intraocular environment diminishes cellular activation (Streilein, 1993). Retinal pigmented epithelial (RPE) cells have been shown to secrete TGF- $\beta$  and other

immunosuppressive mediators (Sugita et al., 2006) and to inhibit T-cell development in a contact-dependent manner (Sugita et al., 2008). This explains, at least in part, the absence of peripheral T-cell reactivity against antigens encountered within the eye. Additionally, this efficient exclusion of anti-ocular T-cell responses has another downside: the increased likelihood of these hidden antigens to induce autoimmune reactions. Indeed when, for example through pathogen-induced injury, the blood-retinal barrier is breached, T-cells might encounter these 'unknown' antigens which suddenly appear in the periphery, as 'non-self' and initiate a detrimental reaction cascade (Caspi, 2006). Many systemic human autoimmune diseases affect the eye, demonstrating the vulnerability of this organ to pathological self-attack (Barisani-Asenbauer et al., 2012). This condition has been modelled by the inducible mouse disease, experimental autoimmune uveitis, and thoroughly immunologically characterised (Horai and Caspi, 2011). Interestingly, while a Th17 response seems to be responsible for pathology upon retinal antigen administration, injection of antigen-pulsed dendritic cells induces a Th1-driven uveitis (Caspi, 2008). Further studies showed that the cytokines IL-17A and IL-17F activate RPE cells and compromise their barrier function (Chen et al., 2011). This very likely leads to an enhanced influx of inflammatory cells and retinal damage, and demonstrated again the detrimental role of an ocular Th17 type reaction during inflammatory processes.

The retina also possesses specialised cell types which often assume dual functions: preserving the structural and functional integrity of this organ and maintaining the metabolic homeostasis of the fragile neurons. The RPE cells are certainly the best known example, as indicated above. Moreover CD-40 stimulated RPE cells eliminate *T. gondii* through an autophagic process (Van Grol et al., 2013). However, the diverse types of glial cells also actively participate in the immune equilibrium. Muller cells, which span the entire thickness of the retina, have been identified as guardians of neuron integrity in the healthy and diseased retina (Bringmann et al., 2006). When infected with *T. gondii* in vitro, Muller cells secrete a large panel of immune mediators (Knight et al., 2006). However, it is not yet known whether this activation is protective or detrimental to the adjacent neuronal cells. As a self-protective mechanism, CD40-associated autophagy was recently described to protect against photoreceptor degeneration (Chen et al., 2013).

### 4.2. Studies on human OT

Due to the very limited access to ocular tissue, pathophysiological studies on humans are rare. Some post-mortem examinations described histopathological features (Butler et al., 2013), but immunological investigations usually looked at immune mediators in the peripheral blood or genetic markers (see below). Therefore, we assessed cytokine concentrations in aqueous humor, taken by puncture at the same time as the diagnosis, as ocular fluids are the most reliable samples to test for the presence of *Toxoplasma* DNA and/or local specific antibody production (Villard et al., 2003). This allowed the study of the local immune response to *Toxoplasma* in biologically confirmed OT cases. Furthermore, the BioPlex<sup>®</sup> technology allowed the simultaneous evaluation of more than 20 markers in the small available volumes. Interestingly, our retrospective study of patients with toxoplasmic, viral and intermediate uveitis showed a marked expression of IL-17A in the aqueous humor of most patients with OT, but not viral uveitis (Lahmar et al., 2009). It was also observed that Th1 cytokines (IL-2, IFN- $\gamma$ ) as well as inflammatory (IL-6, IL-17, MCP-1) and downregulating cytokines (IL-10) were strongly upregulated in aqueous humor of patients with confirmed OT. The Th2 cytokine IL-13 was only weakly upregulated. Interestingly, TNF- $\alpha$  levels remained unchanged (Lahmar et al., 2009; Sauer et al., 2012). This inflammatory pattern implicating a Th17 type response and the self-limiting nature of inflamma-

tion is similar to the previously described autoimmune diseases, which indicates the direction of further investigation. However, it has to be kept in mind that there is no evidence of an autoimmune component in the development of OT, and treatment strategies have to consider the infectious nature of this condition.

As the epidemiology and clinical course of South American infections are so different, a study to compare the cytokinome as well as the clinical characteristics of French and Colombian OT patients has been conducted. Colombian patients show a more suppressive immune reaction with lowered IFN- $\gamma$  and IL-17A levels associated with drastically higher local parasite proliferation. Paradoxically, IL-6 levels are significantly elevated in OT patients (De-la-Torre et al., 2013).

#### 4.3. Modeling physiopathology in animals

Thorough insight into the parasitological and immunological dynamics of retinal infection requires adapted animal models, especially in the mouse. Great progress towards establishment of such models was made in recent years, which will increase our understanding of the immunological mechanisms regulating parasite proliferation and the cellular actors involved in the immune response, as well as the formation of retinal lesions. In the longer term, this modelling will allow the development of new therapeutic tools through the identification of specific targets.

The first described animal models used oral or i.p. infection of adult or pregnant mice in order to mimic natural infection, which identified the roles of some key cytokines (Jones et al., 2006). The majority of mice developed minor uveitis and retinal vasculitis. The uveitis is characterised by an infiltration of CD4+ lymphocytes and macrophages into the retina and by IFN- $\gamma$  and TNF- $\alpha$  transcription in retinal lymphocytes. Chemokines such as CXCL10 are important in this protective response (Norose et al., 2011). Parasites have rarely been detected in situ in these mice. Treating mice with anti-CD4+ or anti-CD8+ antibodies provoked an increase in ocular cyst numbers, whereas treatment with anti-IFN- $\gamma$  or anti-TNF- $\alpha$  antibodies produced lesions containing tachyzoites (Gazzinelli et al., 1994; Pavesio et al., 1995; Gormley et al., 1999; Sauer et al., 2009). A recent publication confirmed the up-regulation of IL-17A in the retina and the pivotal role of IFN- $\gamma$  using knockout (KO) mice (Kikumura et al., 2012). Of note, the histopathological characteristics of KO mice or mice treated with neutralising antibodies resemble those seen in immunodepressed patients, rather than the normal course of infection in immunocompetent individuals. The main problem with this infection protocol is the inconsistent rate and slow kinetics of lesion formation, making detailed immunological studies difficult to interpret. Moreover, these experiments could not distinguish between systemic and local effects of cytokines.

Several injection routes close to the eye were tested but proved less than ideal. Subconjunctival injection in guinea pigs did not result in any retinal effects (Skorich et al., 1988). The injection via the right carotid in cats reproduced chorioretinitis lesions. However, this model induced vasculitis and rather non-reproducible ocular lesions (Davidson et al., 1993; Sauer et al., 2009). The eye drop instillation technique was also tested, showing the same pattern of infection as intravitreal infection, with a lower inflammatory infiltrate and the advantage of not causing mechanical damage (Tedesco et al., 2005).

The model of OT using intravitreal tachyzoite injection reproduces key features of the human disease with much higher success rates than systemic infection. It has already proven its effectiveness in a non-human primates (Holland et al., 1988) and rabbits (Garweg et al., 1998). This intravitreal injection in the rabbit model was also combined with a previous systemic infection to test the hypothesis of an autoimmune component in OT. However, their results did not

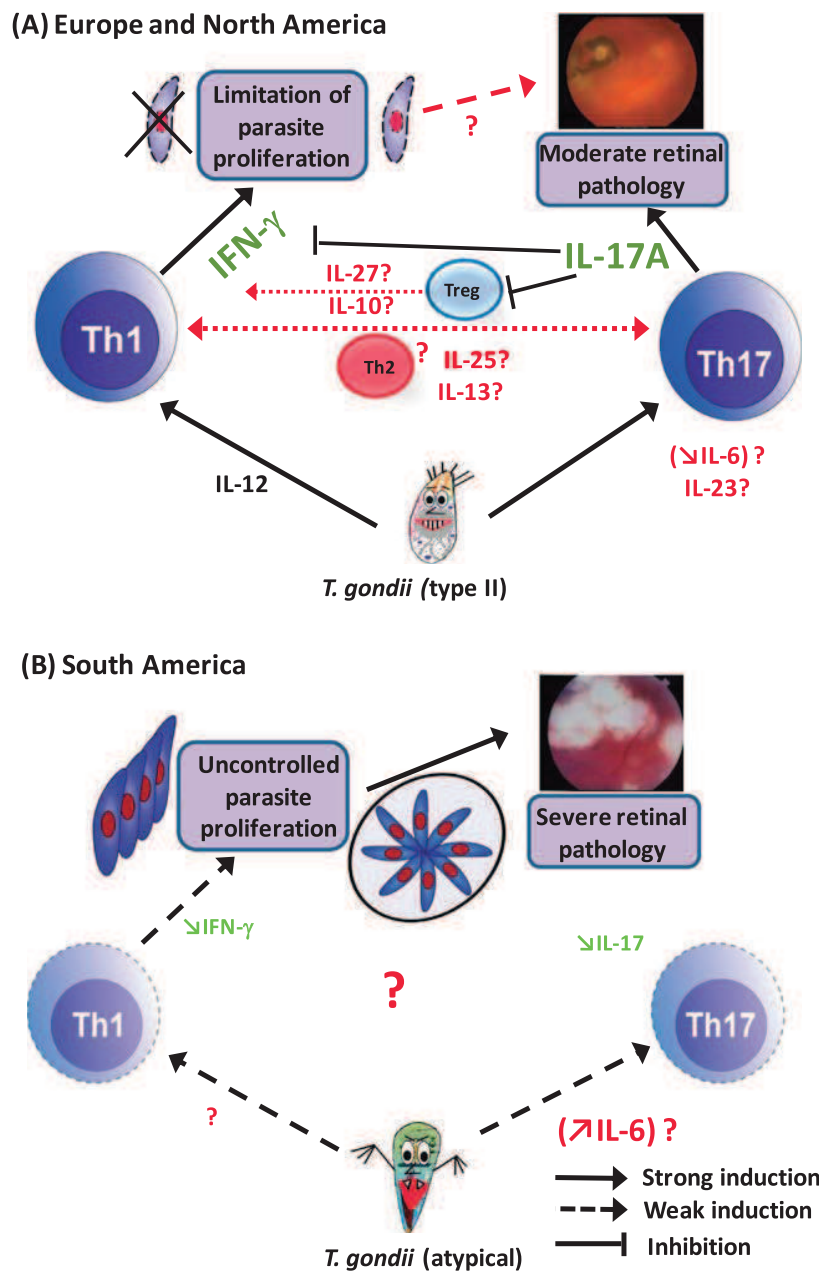
indicate the stimulation of a reaction against retinal antigens by *T. gondii* presence in the eye (Garweg et al., 2009). More recently, intravitreal injection has been introduced in the mouse model (Lu et al., 2005; Charles et al., 2007). The use of very fine (30 Gauge) needles allows modelling of the characteristics of human OT with little or no post-injection lesions. This model was used to test the role of SAG1 in ocular infection, and to demonstrate that immune suppressing properties of retinal cells are induced by local *T. gondii* infection (Charles et al., 2007, 2010; Mimura et al., 2012). We employed simultaneous intravitreal injection of parasites and neutralising antibodies to characterise the intraocular cytokinome following *T. gondii* infection in more detail. We demonstrated that IL-17A was indeed responsible for the retinal pathology, but also for enhanced retinal parasite proliferation, partly by suppression of the protective cytokine IFN- $\gamma$  (Sauer et al., 2012). Additionally, our recently adapted protocol of systemic infection and intravitreal challenge as an approximate model of OT recurrence will soon permit novel insights in this aspect of OT.

In mouse experiments aimed at the pathological and immunological dynamics of congenital infection, we observed retinal lesions in some eyes 4 weeks after birth. Interestingly, infection rate and parasite load in the eye were always inferior to the brain. We also demonstrated that neonatal infection constitutes a valid and more efficient model for congenital infection (Sauer et al., 2009; Lahmar et al., 2010). Finally, we used the recurrence model in neonatally infected mice to demonstrate a shift from a pathological Th17 type response upon primary infection to a more benign Th1/Th2/Treg response in re-challenged animals following neonatal infection (Sauer et al., 2013). We have to keep in mind, however, that nearly all of these experiments were done with a canonical type II strain of *T. gondii*. The use of atypical strains could shed light on the particular mechanisms at play in South American infections.

#### 4.4. Immunology: outlook

The striking difference between European/North American and South American forms of toxoplasmosis initiated considerable research activity to elucidate physiopathological mechanisms. The few existing immunological studies on OT patients allow us to outline the specific immune response pattern in European and North American patients, in comparison with their South American counterparts (Fig. 1). Further, more detailed studies are necessary, especially in the more heterogeneous South American setting, to investigate more subtle differences such as recurrences and severity of disease.

Beyond pure correlation, the introduction and continuous refinement of suitable animal models gradually opens the way for a thorough mechanistic comprehension of retinal infection and inflammation. This is mainly true for the role of the IL-17 dependent inflammatory response and its relation to the protective IFN- $\gamma$  driven response (Fig. 1). Many questions remain open to investigation. Th2 cytokines might have a more important role than previously thought in local antibody production, as well as by their immune regulatory properties. Moreover, the regulation of the Th17 type response is central to our understanding of the inflammatory process and should be more thoroughly investigated, for example the role of IL-6 which is involved in Th17 cell polarisation, but was paradoxically shown to protect against retinal pathology (Lyons et al., 2001). Even if this study used systemic infection and IL-6 KO mice, thus making it difficult to distinguish between local and systemic effects of IL-6, it illustrates the complexity of intraocular inflammation and demonstrates the need to study this process in detail in the process of developing therapeutic intervention. It seems to be clear that a future immune-based intervention will have to take into account the profound geographical differences in OT.



**Fig. 1.** Proposed scheme of pathology and immune response of ocular toxoplasmosis (OT), according to the data known to date. (A) The type II *Toxoplasma gondii* strain, predominating in Europe and North America, induces both Th1 and Th17 type responses. It seems that IL-17A is responsible for retinal pathology, as well as for suppression of a protective IFN- $\gamma$  driven response, as neutralisation of this cytokine reverses, at least partially, both effects. This pathological process is usually self-limiting with time, leading to moderate retinal pathology and relatively small lesions. Regulatory T (Treg) cells and perhaps Th2 cells seem to be suppressed by IL-17A, but many details (drawn in red) remain to be elucidated, namely the induction and regulation of IL-17A production (around IL-6 and IL-23), the possible involvement of other IL-17 family members and the exact role of Th2 and/or Treg cells in the interaction between IL-17A and IFN- $\gamma$ . (B) The atypical and highly variable strains observed in South America, in contrast, induce very little production of both IFN- $\gamma$  and IL-17A. Curiously, IL-6 is up-regulated in patients. The relative absence of IFN- $\gamma$  allows uncontrolled parasite replication, which results in severe pathology with numerous, larger lesions. Much less is known about the immunological regulation of this process than in type II infection.

463 **5. Immunogenetics**

464 **5.1. Parasite factors**

465 The highly variable clinical expression leads to the question of  
466 the respective roles of host or parasite genetic factors. The three  
467 canonical European and North American strain types I, II and III  
468 show clear differences in mouse virulence. In contrast, humans  
469 are generally less susceptible to *Toxoplasma* infection, and differ-  
470 ences between strains are often less clear-cut. However, some

*Toxoplasma* outbreaks with unusually severe ocular pathology, 471  
e.g. in Canada in 1994–95 (Burnett et al., 1998), have been associ- 472  
ated with the mouse-virulent type I parasite. Even more than the 473  
differences among the classical genotypes, the discovery of highly 474  
variable and often pathogenic strains in South America (Grigg 475  
et al., 2001) elicited research with associations between the parasite 476  
genome and ocular pathology. 477

A major obstacle for parasite genotyping is the small quantity of 478  
parasites isolated from patients, which often does not allow PCR 479  
amplification and sequencing of a sufficient number of loci. Grigg 480

et al. (2001) performed PCR restriction fragment length polymorphism (RFLP) assays for SAG3 (p43) and SAG4 (p18), two single-copy surface antigen genes. Together with strategies for SAG1, SAG2 and B1, multilocus RFLP analyses were performed on PCR-amplified parasite DNA present in 12 clinical specimens from OT patients. Most samples (8/12) were not infected by type II or type III strains. Only one type III and three type II strains were identified, all from immunosuppressed patients. In six otherwise healthy adults and in one immunosuppressed patient, the SAG1 allele associated with type I was amplified. Of 12 samples, three possessed true type I strains; five of 12 had new recombinant genotypes with alleles typical of type I or III strains at all loci examined (Grigg et al., 2001). In Poland, samples taken from peripheral blood of 73 patients with OT identified only type I strains as determined by sequencing *Toxoplasma* non-transcribed spacer 2 (NTR). However, as only one allele was analysed, this result is unlikely to reflect the real genotype in all infections (Switaj et al., 2006). Another multilocus typing study on Brazilian OT patients revealed highly divergent genotypes, mostly of a I/III genotype (Khan et al., 2006). In contrast, direct genotyping of *T. gondii* strains from aqueous or vitreous humor of 20 French OT patients showed a predominance of type II strains, but in this case, multiple microsatellite alleles were analysed (Fekkar et al., 2011). In Colombia, SAG2 genotyping data in humans and animals also suggested a predominance of the type I allele (Gallego et al., 2006). A major breakthrough was the development of serotyping techniques to overcome the problem of insufficient parasite numbers for PCR-based genotyping (Kong et al., 2003). This allowed a comparative study between European and South American infection using large cohorts, which confirmed the homogeneous distribution of serotype II in Europe and of serotypes I/III in South America (Morisset et al., 2008). Of note, these serotype results are based on a few and probably still not very accurate markers. These presumed type I or I/III strains will, in the future, be more precisely characterised. Altogether, these data strongly suggest the existence of distinct European/North American and South American *Toxoplasma* populations. Additionally, it is important to keep in mind that, with the increase in worldwide travel and trade, *T. gondii* can appear in human cases in locations far from its origin. This may explain reports of very severe cases in North America and Europe (Masur et al., 1978; Pomares et al., 2011).

Now that the tools are available, it would be interesting to elucidate the apparent differences in pathology between strains. For example, some of these non-archetypical strains exhibit CNS or ocular tropism, whereas others do not, as seen in local outbreaks with high incidence of retinal affection, or its total absence (de Moura et al., 2006). Mouse studies have shown that monocytes

and dendritic cells function as shuttles to transport tachyzoites into the brain, but this has to date only been shown for the canonical strains. Interestingly, RH, but also South American strains are able to migrate through human retinal vascular endothelium as free tachyzoites (Furtado et al., 2012). As for multiplication, avirulent strains show a preference for microglia over astrocytes whereas the virulent strain infects both types of cells with equal efficiency (Fischer et al., 1997). Strain-specific differences in *Toxoplasma* in the modulation of retinal host cell transcription have been identified previously (Knight et al., 2005). Therefore, there is experimental evidence that preferential invasion of nervous and retinal cells may depend of the infecting strain type.

### 5.2. Host genetic factors

Genetic linkage studies to identify host susceptibility markers are difficult to conduct, due to the low number of cases in Europe and North America. Chances are much better in Brazilian regions with a very high prevalence of OT, and nearly all genetic studies were undertaken in these regions. Obviously, genes coding for known immune mediators or their promoter regions were checked for association with clinically apparent OT. A polymorphism of the extracellular pattern recognition receptor TLR9 was associated with toxoplasmic retinochoroiditis in patients originating from the state of Rio de Janeiro, Brazil (Peixoto-Rangel et al., 2009). Recently, another study found an association with the intracellular pattern recognition receptor NOD2 in patients from the same region, as well as from the Belo Horizonte region, Brazil (Dutra et al., 2013).

In recent years, genes coding for immunological factors known to influence the course of *Toxoplasma* infection and the respective promoter regions have been compared between OT patients and controls in endemic Brazilian regions. Thus, the IFN- $\gamma$  +874T/A gene polymorphism correlated with OT (Albuquerque et al., 2009). While it was not detailed whether this polymorphism changed IFN- $\gamma$  expression levels, a series of studies from Belo Horizonte University made quantitative assessments. A polymorphism in the IL-1 gene which leads to higher levels of the corresponding protein was positively correlated with recurrence, but not overall OT frequency (Cordeiro et al., 2008c). In contrast, for a polymorphism in the IL-6 promoter (-174 G/C), the variant which leads to lower IL-6 production was associated with enhanced OT frequency (Cordeiro et al., 2013). In another study, the genotypes related with low IL-10 production (-1082 G/A polymorphism) were associated with the occurrence of OT (Cordeiro et al., 2008a). Interestingly, the TNF- $\alpha$  (-308 G/A) polymorphism, which was shown to influence a variety of inflammatory and infectious diseases, could not be

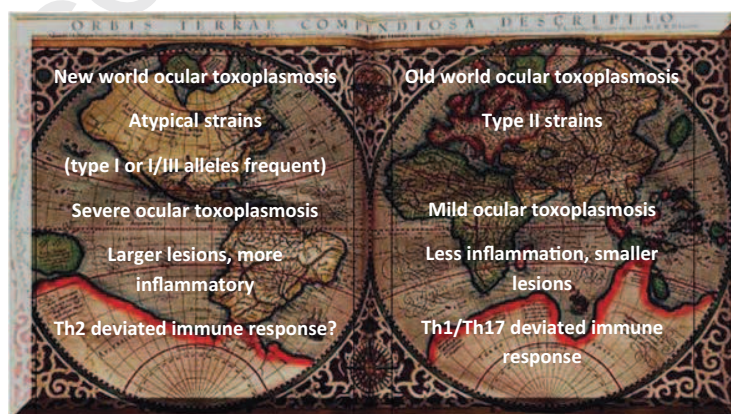


Fig. 2. Geographical divergence of clinical human ocular toxoplasmosis.

573 correlated with frequency of OT occurrence or recurrence (Cordeiro  
574 et al., 2008b). This result corresponds with our observations in hu-  
575 man (Lahmar et al., 2009; Sauer et al., 2012) and murine studies  
576 (Sauer et al., 2013), which also did not show a change in TNF- $\alpha$   
577 expression.

578 Jamieson and colleagues looked, in a large multi-center study,  
579 at cohorts of mother–child duos in Europe and parent–child trios  
580 in North America to identify factors associated with the develop-  
581 ment or not of ocular disease following congenital infection. Poly-  
582 morphisms in *COL2A1* and *ABCA4* coding for retinal proteins known  
583 for their involvement in genetic retinal disorders indeed correlated  
584 with OT expression (Jamieson et al., 2008). Such association was  
585 also found, in the North American cohort, for polymorphisms in  
586 the gene coding for P2X(7) (Jamieson et al., 2010), a receptor  
587 protein known to participate in inflammasome activation.

588 Together, despite searching only for a restricted numbers of fac-  
589 tors, these association studies demonstrate the importance of key  
590 immune factors in human OT development and validate results  
591 obtained from the above outlined mouse studies.

## 592 6. Retinal latency

593 *Toxoplasma gondii* remains latent in the retina within cysts. A  
594 remarkable feature of retinal cysts is the nearly complete absence  
595 of inflammation in the surrounding tissue, except during recur-  
596 rences, as stated by us and other investigators. The mechanisms  
597 which allow its survival and long-term persistence by triggering  
598 the down-regulation of a major inflammatory response are still  
599 unknown. A clue might be the fact that the intracellular presence  
600 of *Toxoplasma* results in efficient dysregulation of the cell cycle  
601 (Brunet et al., 2008) and, more generally, the intracellular machin-  
602 ery and transcriptional changes. Targeting regulatory cascades  
603 controlling chromatin structure to subvert host cell function allows  
604 the parasite to simultaneously down-regulate transcription of sev-  
605 eral host genes. Transcriptional initiation of many genes requires  
606 changes in chromatin structure surrounding the promoter. The  
607 most common mechanisms to induce epigenetic changes and  
608 control gene expression are DNA methylation and histone modifi-  
609 cations by chromatin-remodeling complexes and histone-modify-  
610 ing enzymes. In the last few years, evidence has accumulated  
611 that histone modifications and chromatin remodeling are key  
612 targets for pathogen manipulation during infection (Gomez-Diaz  
613 et al., 2012).

614 The ability of *T. gondii* to establish chronic infection depends  
615 especially on various immune evasion strategies. The parasite has  
616 developed epigenetic mechanisms by which it can render the  
617 host's immune responses inactive and undergo latency. *Toxoplasma*  
618 *gondii* prevents overinduction of pro-inflammatory cytokine pro-  
619 duction, a response that enables host survival and allows establish-  
620 ment of persistent infection in the host. Long-term transcriptional  
621 silencing by chromatin remodeling of IFN- $\gamma$ -regulated promoters  
622 was found to have an important role in suppression of a host's  
623 immune response to *T. gondii* infection (Lang et al., 2012). *Toxo-*  
624 *plasma gondii* regulates both inflammatory cytokines such as  
625 TNF- $\alpha$  (Leng et al., 2009), as well as anti-inflammatory mediators  
626 such as IL-10 (Leng and Denkers, 2009), to optimise its  
627 environment.

628 Histone modification and chromatin remodeling by *T. gondii*  
629 infection is an emerging field of study and future work will deter-  
630 mine how epigenetic regulation of gene expression by *T. gondii*  
631 secreted proteins could be a general mechanism to enhance intra-  
632 cellular survival and reservoir persistence in immune privileged  
633 organs, thus maximising its chances of transmission. Finally, this  
634 could lead to identification of new potential targets for future  
635 development of novel therapeutic intervention strategies.

## 7. Perspectives

636 Obviously, OT is not the same disease in Europe and in South  
637 America (Fig. 2), with crucial consequences for treatment strate-  
638 gies. The geographical mapping of OT is beginning to take shape.  
639 However, there are still considerable discrepancies between some  
640 studies, maybe due to the evolution of diagnostic tools. Compar-  
641 ative studies should be undertaken, using the same criteria in diag-  
642 nosis and strain typing.

643 Concerning more fundamental research, there are still very few  
644 data on the differential infection and proliferation capacity of the  
645 different *T. gondii* strains in various retinal cell types. These differ-  
646 ential mechanisms are certainly a major factor determining strain-  
647 specific virulence. A special focus should be on the molecular  
648 mechanisms allowing parasite persistence in retinal cells and the  
649 influence of host genetic diversity on primary pathology and recur-  
650 rence. It is certain that an important part of the answer will be  
651 found at the epigenetic level. Finally, from a medical point of view,  
652 the reason for ocular tropism of certain strains is of primordial  
653 interest, as it could direct prevention and treatment in a more tar-  
654 geted way. Clearly, the actual approach of a monotherapy using  
655 steroids is far from ideal (Garweg and Stanford, 2013). More gener-  
656 ally, elucidating strain-dependent involvement of the IL-6–IL-23–  
657 IL-17 inflammatory cascade should result in targeted treatment  
658 according to the infecting strain, the patient's genetic disposition  
659 and the severity of the lesions.  
660

## Acknowledgments

661 We want to thank Gabriela Castaño-De-la-Torre for the *Toxo-*  
662 *plasma* drawings. Our work has been supported in France by the  
663 Fondation de Recherche Médicale (Retinal Physiopathology pro-  
664 gram, Grant DPR20121125433) and the Programme Hospitalier  
665 de Recherche Clinique (Grant PHRC 2007-3964); in Colombia by  
666 Colciencias (Grants 111345921861 and 111351929258). Further  
667 support came from the French-Colombian exchange program  
668 ECOS-Nord (Grant C10S01). E.R. has received a Berthe Fouassier  
669 Ph.D. scholarship of the Fondation de France (Grants 12165 and  
670 2012-32622).  
671

## References

- 672  
673 Aizenberg, D., 2011. Unresolved questions about the most successful known  
674 parasite. *Expert Rev. Anti Infect. Ther.* 9, 169–171.  
675 Albuquerque, M.C., Aleixo, A.L., Benchimol, E.I., Leandro, A.C., das Neves, L.B.,  
676 Vicente, R.T., Bonecini-Almeida Mda, G., Amendoeira, M.R., 2009. The IFN-  
677 gamma +874T/A gene polymorphism is associated with retinochoroiditis  
678 toxoplasmosis susceptibility. *Mem. Inst. Oswaldo Cruz* 104, 451–455.  
679 Barisani-Asenbauer, T., Maca, S.M., Mejdoubi, L., Emminger, W., Machold, K., Auer,  
680 H., 2012. Uveitis- a rare disease often associated with systemic diseases and  
681 infections- a systematic review of 2619 patients. *Orphanet J Rare Dis.* 7, 57.  
682 Bosch-Driessen, L.E., Berendschot, T.T., Ongkosuwito, J.V., Rothova, A., 2002. Ocular  
683 toxoplasmosis: clinical features and prognosis of 154 patients. *Ophthalmology*  
684 109, 869–878.  
685 Bringmann, A., Pannicke, T., Grosche, J., Francke, M., Wiedemann, P., Skatchkov, S.N.,  
686 Osborne, N.N., Reichenbach, A., 2006. Muller cells in the healthy and diseased  
687 retina. *Prog. Retin. Eye Res.* 25, 397–424.  
688 Brunet, J., Pfaff, A.W., Abidi, A., Unoki, M., Nakamura, Y., Guinard, M., Klein, J.P.,  
689 Candolfi, E., Mousli, M., 2008. *Toxoplasma gondii* exploits UHRF1 and induces  
690 host cell cycle arrest at G2 to enable its proliferation. *Cell. Microbiol.* 10, 908–  
691 920.  
692 Burnett, A.J., Shortt, S.G., Isaac-Renton, J., King, A., Werker, D., Bowie, W.R., 1998.  
693 Multiple cases of acquired toxoplasmosis retinitis presenting in an outbreak.  
694 *Ophthalmology* 105, 1032–1037.  
695 Butler, N.J., Furtado, J.M., Winthrop, K.L., Smith, J.R., 2013. Ocular toxoplasmosis II:  
696 clinical features, pathology and management. *Clin. Exp. Ophthalmol.* 41, 95–  
697 108.  
698 Caspi, R., 2008. Autoimmunity in the immune privileged eye: pathogenic and  
699 regulatory T cells. *Immunol. Res.* 42, 41–50.  
700 Caspi, R.R., 2006. Ocular autoimmunity: the price of privilege? *Immunol. Rev.* 213,  
701 23–35.

- Charles, E., Callegan, M.C., Blader, I.J., 2007. The SAG1 *Toxoplasma gondii* surface protein is not required for acute ocular toxoplasmosis in mice. *Infect. Immun.* 75, 2079–2083.
- Charles, E., Joshi, S., Ash, J.D., Fox, B.A., Farris, A.D., Bzik, D.J., Lang, M.L., Blader, I.J., 2010. CD4 T-cell suppression by cells from *Toxoplasma gondii*-infected retinas is mediated by surface protein PD-L1. *Infect. Immun.* 78, 3484–3492.
- Chen, Y., Yang, P., Li, F., Kijlstra, A., 2011. The effects of Th17 cytokines on the inflammatory mediator production and barrier function of ARPE-19 cells. *PLoS ONE* 6, e18139.
- Chen, Y., Sawada, O., Kohno, H., Le, Y.Z., Subauste, C., Maeda, T., Maeda, A., 2013. Autophagy protects the retina from light-induced degeneration. *J. Biol. Chem.* 288, 7506–7518.
- Cimino, L., Aldigeri, R., Salvarani, C., Zotti, C.A., Boiardi, L., Parmeggiani, M., Casali, B., Cappuccini, L., 2010. The causes of uveitis in a referral centre of Northern Italy. *Int. Ophthalmol.* 30, 521–529.
- Cordeiro, C.A., Moreira, P.R., Andrade, M.S., Dutra, W.O., Campos, W.R., Orefice, F., Teixeira, A.L., 2008a. Interleukin-10 gene polymorphism (–1082G/A) is associated with toxoplasmic retinochoroiditis. *Invest. Ophthalmol. Vis. Sci.* 49, 1979–1982.
- Cordeiro, C.A., Moreira, P.R., Costa, G.C., Dutra, W.O., Campos, W.R., Orefice, F., Teixeira, A.L., 2008b. TNF-alpha gene polymorphism (–308G/A) and toxoplasmic retinochoroiditis. *Br. J. Ophthalmol.* 92, 986–988.
- Cordeiro, C.A., Moreira, P.R., Costa, G.C., Dutra, W.O., Campos, W.R., Orefice, F., Teixeira, A.L., 2008c. Interleukin-1 gene polymorphisms and toxoplasmic retinochoroiditis. *Mol. Vis.* 14, 1845–1849.
- Cordeiro, C.A., Moreira, P.R., Bessa, T.F., Costa, G.C., Dutra, W.O., Campos, W.R., Orefice, F., Young, L.H., Teixeira, A.L., 2013. Interleukin-6 gene polymorphism (–174 G/C) is associated with toxoplasmic retinochoroiditis. *Acta Ophthalmol.* 91, e311–314.
- Davidson, M.G., Lappin, M.R., English, R.V., Tompkins, M.B., 1993. A feline model of ocular toxoplasmosis. *Invest. Ophthalmol. Vis. Sci.* 34, 3653–3660.
- De-la-Torre, A., Gonzalez, G., Diaz-Ramirez, J., Gomez-Marín, J.E., 2007. Screening by ophthalmoscopy for *Toxoplasma* retinochoroiditis in Colombia. *Am. J. Ophthalmol.* 143, 354–356.
- De-la-Torre, A., Rios-Cadavid, A.C., Cardozo-Garcia, C.M., Gomez-Marín, J.E., 2009. Frequency and factors associated with recurrences of ocular toxoplasmosis in a referral centre in Colombia. *Br. J. Ophthalmol.* 93, 1001–1004.
- De-la-Torre, A., Gonzalez-Lopez, G., Montoya-Gutierrez, J.M., Marin-Arango, V., Gomez-Marín, J.E., 2011. Quality of life assessment in ocular toxoplasmosis in a Colombian population. *Ocul. Immunol. Inflamm.* 19, 262–266.
- De-la-Torre, A., Sauer, A., Pfaff, A.W., Bourcier, T., Brunet, J., Speeg-Schatz, C., Ballonzoli, L., Villard, O., Aizenberg, D., Sundar, N., Grigg, M.E., Gomez-Marín, J.E., Candolfi, E., 2013. Severe South American ocular toxoplasmosis is associated with decreased IFN-gamma/IL-17A and increased IL-6/IL-13 intraocular levels. *PLoS Negl. Trop. Dis.* (in press).
- de Moura, L., Bahia-Oliveira, L.M., Wada, M.Y., Jones, J.L., Tuboi, S.H., Carmo, E.H., Ramalho, W.M., Camargo, N.J., Trevisan, R., Graca, R.M., da Silva, A.J., Moura, I., Dubey, J.P., Garrett, D.O., 2006. Waterborne toxoplasmosis, Brazil, from field to gene. *Emerg. Infect. Dis.* 12, 326–329.
- Delair, E., Monnet, D., Grabar, S., Dupuy-Camet, J., Yera, H., Brezin, A.P., 2008. Respective roles of acquired and congenital infections in presumed ocular toxoplasmosis. *Am. J. Ophthalmol.* 146, 851–855.
- Delair, E., Latkany, P., Noble, A.G., Rabiah, P., McLeod, R., Brezin, A., 2011. Clinical manifestations of ocular toxoplasmosis. *Ocul. Immunol. Inflamm.* 19, 91–102.
- Dodds, E.M., Holland, G.N., Stanford, M.R., Yu, F., Siu, W.O., Shah, K.H., Ten Dam-van Loon, N., Muccioli, C., Hovakimyan, A., Barisani-Asenbauer, T., 2008. Intraocular inflammation associated with ocular toxoplasmosis: relationships at initial examination. *Am. J. Ophthalmol.* 146 (856–865), e852.
- Dutra, M.S., Bela, S.R., Peixoto-Rangel, A.L., Fakiola, M., Cruz, A.G., Gazzinelli, A., Quites, H.F., Bahia-Oliveira, L.M., Peixe, R.G., Campos, W.R., Higino-Rocha, A.C., Miller, N.E., Blackwell, J.M., Antonelli, L.R., Gazzinelli, R.T., 2013. Association of a NOD2 Gene Polymorphism and T-Helper 17 Cells With Presumed Ocular Toxoplasmosis. *J. Infect. Dis.* 207, 152–163.
- Fekkar, A., Aizenberg, D., Bodaghi, B., Touafek, F., Le Hoang, P., Delmas, J., Robert, P.Y., Darde, M.L., Mazier, D., Paris, L., 2011. Direct genotyping of *Toxoplasma gondii* in ocular fluid samples from 20 patients with ocular toxoplasmosis: predominance of type II in France. *J. Clin. Microbiol.* 49, 1513–1517.
- Fischer, H.G., Nitzgen, B., Reichmann, G., Gross, U., Hadding, U., 1997. Host cells of *Toxoplasma gondii* encystation in infected primary culture from mouse brain. *Parasitol. Res.* 83, 637–641.
- Furtado, J.M., Bharadwaj, A.S., Chipps, T.J., Pan, Y., Ashander, L.M., Smith, J.R., 2012. *Toxoplasma gondii* tachyzoites cross retinal endothelium assisted by intercellular adhesion molecule-1 in vitro. *Immunol. Cell Biol.* 90, 912–915.
- Furtado, J.M., Winthrop, K.L., Butler, N.J., Smith, J.R., 2013. Ocular toxoplasmosis I: parasitology, epidemiology and public health. *Clin. Exp. Ophthalmol.* 41, 82–94.
- Gallego, C., Saavedra-Matiz, C., Gomez-Marín, J.E., 2006. Direct genotyping of animal and human isolates of *Toxoplasma gondii* from Colombia (South America). *Acta Trop.* 97, 161–167.
- Garweg, J.G., Kuenzli, H., Boehnke, M., 1998. Experimental ocular toxoplasmosis in naive and primed rabbits. *Ophthalmologica* 212, 136–141.
- Garweg, J.G., de Kozak, Y., Goldenberg, B., Boehnke, M., 2009. Anti-retinal autoantibodies in experimental ocular and systemic toxoplasmosis. *Graefes Arch. Clin. Exp. Ophthalmol.* 248, 573–584.
- Garweg, J.G., Stanford, M.R., 2013. Therapy for Ocular Toxoplasmosis – the Future. *Ocul. Immunol. Inflamm.* 21, 300–305.
- Gazzinelli, R.T., Brezin, A., Li, Q., Nussenblatt, R.B., Chan, C.C., 1994. *Toxoplasma gondii*: acquired ocular toxoplasmosis in the murine model, protective role of TNF-alpha and IFN-gamma. *Exp. Parasitol.* 78, 217–229.
- Gilbert, R.E., Dunn, D.T., Lightman, S., Murray, P.I., Pavesio, C.E., Gormley, P.D., Masters, J., Parker, S.P., Stanford, M.R., 1999. Incidence of symptomatic *Toxoplasma* eye disease: aetiology and public health implications. *Epidemiol. Infect.* 123, 283–289.
- Gilbert, R.E., Freeman, K., Lago, E.G., Bahia-Oliveira, L.M., Tan, H.K., Wallon, M., Buffolano, W., Stanford, M.R., Petersen, E., 2008. Ocular sequelae of congenital toxoplasmosis in Brazil compared with Europe. *PLoS Negl. Trop. Dis.* 2, e277.
- Glasner, P.D., Silveira, C., Kruszon-Moran, D., Martins, M.C., Burnier Junior, M., Silveira, S., Camargo, M.E., Nussenblatt, R.B., Kaslow, R.A., Belfort Junior, R., 1992. An unusually high prevalence of ocular toxoplasmosis in southern Brazil. *Am. J. Ophthalmol.* 114, 136–144.
- Gomez-Diaz, E., Jorda, M., Peinado, M.A., Rivero, A., 2012. Epigenetics of host-pathogen interactions: the road ahead and the road behind. *PLoS Pathog.* 8, e1003007.
- Gomez-Marín, J.E., De-la-Torre, A., Angel-Muller, E., Rubio, J., Arenas, J., Osorio, E., Nunez, L., Pinzon, L., Mendez-Cordoba, L.C., Bustos, A., De-la-Hoz, I., Silva, P., Beltran, M., Chacon, L., Marrugo, M., Manjarres, C., Baquero, H., Lora, F., Torres, E., Zuluaga, O.E., Estrada, M., Moscote, L., Silva, M.T., Rivera, R., Molina, A., Najera, S., Sanabria, A., Ramirez, M.L., Alarcon, C., Restrepo, N., Falla, A., Rodriguez, T., Castano, G., 2011. First Colombian multicentric newborn screening for congenital toxoplasmosis. *PLoS Negl. Trop. Dis.* 5, e1195.
- Gomez-Marín, J.E., De-la-Torre, A., Barrios, P., Cardona, N., Alvarez, C., Herrera, C., 2012. Toxoplasmosis in military personnel involved in jungle operations. *Acta Trop.* 122, 46–51.
- Gormley, P.D., Pavesio, C.E., Luthert, P., Lightman, S., 1999. Retinochoroiditis is induced by oral administration of *Toxoplasma gondii* cysts in the hamster model. *Exp. Eye Res.* 68, 657–661.
- Grigg, M.E., Ganatra, J., Boothroyd, J.C., Margolis, T.P., 2001. Unusual abundance of atypical strains associated with human ocular toxoplasmosis. *J. Infect. Dis.* 184, 633–639.
- Guerina, N.G., Hsu, H.W., Meissner, H.C., Maguire, J.H., Lynfield, R., Stechenberg, B., Abrams, I., Pasternack, M.S., Hoff, R., Eaton, R.B., et al., 1994. Neonatal serologic screening and early treatment for congenital *Toxoplasma gondii* infection. The New England Regional Toxoplasma Working Group. *N. Engl. J. Med.* 330, 1858–1863.
- Havelaar, A.H., Kemmeren, J.M., Kortbeek, L.M., 2007. Disease burden of congenital toxoplasmosis. *Clin. Infect. Dis.* 44, 1467–1474.
- Hodge, W.G., Seiff, S.R., Margolis, T.P., 1998. Ocular opportunistic infection incidences among patients who are HIV positive compared to patients who are HIV negative. *Ophthalmology* 105, 895–900.
- Holland, G.N., O'Connor, G.R., Diaz, R.F., Minasi, P., Wara, W.M., 1988. Ocular toxoplasmosis in immunosuppressed nonhuman primates. *Invest. Ophthalmol. Vis. Sci.* 29, 835–842.
- Holland, G.N., 2000. Ocular toxoplasmosis: new directions for clinical investigation. *Ocul. Immunol. Inflamm.* 8, 1–7.
- Holland, G.N., 2003. Ocular toxoplasmosis: a global reassessment. Part I: epidemiology and course of disease. *Am. J. Ophthalmol.* 136, 973–988.
- Holland, G.N., 2004. Ocular toxoplasmosis: a global reassessment. Part II: disease manifestations and management. *Am. J. Ophthalmol.* 137, 1–17.
- Holland, G.N., 2009. Ocular toxoplasmosis: the influence of patient age. *Mem. Inst. Oswaldo Cruz* 104, 351–357.
- Horai, R., Caspi, R.R., 2011. Cytokines in autoimmune uveitis. *J. Interferon Cytokine Res.* 31, 733–744.
- Jakob, E., Reuland, M.S., Mackensen, F., Harsch, N., Fleckenstein, M., Lorenz, H.M., Max, R., Becker, M.D., 2009. Uveitis subtypes in a german interdisciplinary uveitis center—analysis of 1916 patients. *J. Rheumatol.* 36, 127–136.
- Jamieson, S.E., de Roubaix, L.A., Cortina-Borja, M., Tan, H.K., Mui, E.J., Cordell, H.J., Kirisits, M.J., Miller, E.N., Peacock, C.S., Hargrave, A.C., Coyne, J.J., Boyer, K., Bessieres, M.H., Buffolano, W., Ferret, N., Franck, J., Kieffer, F., Meier, P., Nowakowska, D.E., Paul, M., Peyron, F., Stray-Pedersen, B., Prusa, A.R., Thulliez, P., Wallon, M., Petersen, E., McLeod, R., Gilbert, R.E., Blackwell, J.M., 2008. Genetic and epigenetic factors at COL2A1 and ABCA4 influence clinical outcome in congenital toxoplasmosis. *PLoS ONE* 3, e2285.
- Jamieson, S.E., Peixoto-Rangel, A.L., Hargrave, A.C., Roubaix, L.A., Mui, E.J., Boulter, N.R., Miller, E.N., Fuller, S.J., Wiley, J.S., Castellucci, L., Boyer, K., Peixe, R.G., Kirisits, M.J., Elias Lde, S., Coyne, J.J., Correa-Oliveira, R., Sautter, M., Smith, N.C., Lees, M.P., Swisher, C.N., Heydemann, P., Noble, A.G., Patel, D., Bardo, D., Burrows, D., McLone, D., Roizen, N., Withers, S., Bahia-Oliveira, L.M., McLeod, R., Blackwell, J.M., 2010. Evidence for associations between the purinergic receptor P2X(7) (P2RX7) and toxoplasmosis. *Genes Immun.* 11, 374–383.
- Jones, J.L., Holland, G.N., 2010. Annual burden of ocular toxoplasmosis in the US. *Am. J. Trop. Med. Hyg.* 82, 464–465.
- Jones, L.A., Alexander, J., Roberts, C.W., 2006. Ocular toxoplasmosis: in the storm of the eye. *Parasite Immunol.* 28, 635–642.
- Khan, A., Jordan, C., Muccioli, C., Vallochi, A.L., Rizzo, L.V., Belfort Jr., R., Vitor, R.W., Silveira, C., Sibley, L.D., 2006. Genetic divergence of *Toxoplasma gondii* strains associated with ocular toxoplasmosis, Brazil. *Emerg. Infect. Dis.* 12, 942–949.
- Kikumura, A., Ishikawa, T., Norose, K., 2012. Kinetic analysis of cytokines, chemokines, chemokine receptors and adhesion molecules in murine ocular toxoplasmosis. *Br. J. Ophthalmol.* 96, 1259–1267.
- Knight, B.C., Brunton, C.L., Modi, N.C., Wallace, G.R., Stanford, M.R., 2005. The effect of *Toxoplasma gondii* infection on expression of chemokines by rat retinal vascular endothelial cells. *J. Neuroimmunol.* 160, 41–47.

- 874 Knight, B.C., Kissane, S., Falciani, F., Salmon, M., Stanford, M.R., Wallace, G.R., 2006.  
875 Expression analysis of immune response genes of Muller cells infected with  
876 *Toxoplasma gondii*. J. Neuroimmunol. 179, 126–131.
- 877 Lahmar, I., Abou-Bacar, A., Abdelrahman, T., Guinard, M., Babba, H., Ben Yahia, S.,  
878 Kairallah, M., Speeg-Schatz, C., Bourcier, T., Sauer, A., Villard, O., Pfaff, A.W.,  
879 Mousli, M., Garweg, J.G., Candolfi, E., 2009. Cytokine profiles in toxoplasmic and  
880 viral uveitis. J. Infect. Dis. 199, 1239–1249.
- 881 Lahmar, I., Guinard, M., Sauer, A., Marcellin, L., Abdelrahman, T., Roux, M., Mousli,  
882 M., Moussa, A., Babba, H., Pfaff, A.W., Candolfi, E., 2010. Murine neonatal  
883 infection provides an efficient model for congenital ocular toxoplasmosis. Exp.  
884 Parasitol. 124, 190–196.
- 885 Lang, C., Hildebrandt, A., Brand, F., Opitz, L., Dihazi, H., Luder, C.G., 2012. Impaired  
886 chromatin remodelling at STAT1-regulated promoters leads to global  
887 unresponsiveness of *Toxoplasma gondii*-infected macrophages to IFN- $\gamma$ .  
888 PLoS Pathog. 8, e1002483.
- 889 Leng, J., Butcher, B.A., Egan, C.E., Abi Abdallah, D.S., Denkers, E.Y., 2009. *Toxoplasma*  
890 *gondii* prevents chromatin remodeling initiated by TLR-triggered macrophage  
891 activation. J. Immunol. 182, 489–497.
- 892 Leng, J., Denkers, E.Y., 2009. *Toxoplasma gondii* inhibits covalent modification of  
893 histone H3 at the IL-10 promoter in infected macrophages. PLoS ONE 4, e7589.
- 894 Lindsay, D.S., Dubey, J.P., 2011. *Toxoplasma gondii*: the changing paradigm of  
895 congenital toxoplasmosis. Parasitology, 1–3.
- 896 Lu, F., Huang, S., Hu, M.S., Kasper, L.H., 2005. Experimental ocular toxoplasmosis in  
897 genetically susceptible and resistant mice. Infect. Immun. 73, 5160–5165.
- 898 Lyons, R.E., Anthony, J.P., Ferguson, D.J., Byrne, N., Alexander, J., Roberts, F., Roberts,  
899 C.W., 2001. Immunological studies of chronic ocular toxoplasmosis: up-  
900 regulation of major histocompatibility complex class I and transforming  
901 growth factor beta and a protective role for interleukin-6. Infect. Immun. 69,  
902 2589–2595.
- 903 Masur, H., Jones, T.C., Lempert, J.A., Cherubini, T.D., 1978. Outbreak of toxoplasmosis  
904 in a family and documentation of acquired retinochoroiditis. Am. J. Med. 64,  
905 396–402.
- 906 Mets, M.B., Holfels, E., Boyer, K.M., Swisher, C.N., Roizen, N., Stein, L., Stein, M.,  
907 Hopkins, J., Withers, S., Mack, D., Luciano, R., Patel, D., Remington, J.S., Meier, P.,  
908 McLeod, R., 1996. Eye manifestations of congenital toxoplasmosis. Am. J.  
909 Ophthalmol. 122, 309–324.
- 910 Mimura, K.K., Tedesco, R.C., Calabrese, K.S., Gil, C.D., Oliani, S.M., 2012. The  
911 involvement of anti-inflammatory protein, annexin A1, in ocular toxoplasmosis.  
912 Mol. Vis. 18, 1583–1593.
- 913 Montoya, J.G., Liesenfeld, O., 2004. Toxoplasmosis. Lancet 363, 1965–1976.
- 914 Morisset, S., Peyron, F., Lobry, J.R., Garweg, J., Ferrandiz, J., Musset, K., Gomez-Marin,  
915 J.E., de la Torre, A., Demar, M., Carme, B., Mercier, C., Garin, J.F., Cesbron-Delauw,  
916 M.F., 2008. Serotyping of *Toxoplasma gondii*: striking homogeneous pattern  
917 between symptomatic and asymptomatic infections within Europe and South  
918 America. Microbes Infect. 10, 742–747.
- 919 Norose, K., Kikumura, A., Luster, A.D., Hunter, C.A., Harris, T.H., 2011. CXCL10 is  
920 required to maintain T-cell populations and to control parasite replication  
921 during chronic ocular toxoplasmosis. Invest. Ophthalmol. Vis. Sci. 52, 389–398.
- 922 Pavesio, C.E., Chiappino, M.L., Gormley, P., Setzer, P.Y., Nichols, B.A., 1995. Acquired  
923 retinochoroiditis in hamsters inoculated with ME 49 strain *Toxoplasma*. Invest.  
924 Ophthalmol. Vis. Sci. 36, 2166–2175.
- 925 Peixoto-Rangel, A.L., Miller, E.N., Castellucci, L., Jamieson, S.E., Peixe, R.G., Elias Lde,  
926 S., Correia-Oliveira, R., Bahia-Oliveira, L.M., Blackwell, J.M., 2009. Candidate gene  
927 analysis of ocular toxoplasmosis in Brazil: evidence for a role for toll-like  
928 receptor 9 (TLR9). Mem. Inst. Oswaldo Cruz 104, 1187–1190.
- 929 Petersen, E., Kijlstra, A., Stanford, M., 2012. Epidemiology of ocular toxoplasmosis.  
930 Ocul. Immunol. Inflamm. 20, 68–75.
- 931 Phan, L., Kasza, K., Jalbrzikowski, J., Noble, A.G., Latkany, P., Kuo, A., Mieler, W.,  
932 Meyers, S., Rabiah, P., Boyer, K., Swisher, C., Mets, M., Roizen, N., Cezar, S.,  
933 Sautter, M., Remington, J., Meier, P., McLeod, R., 2008. Longitudinal study of new  
934 eye lesions in children with toxoplasmosis who were not treated during the  
935 first year of life. Am. J. Ophthalmol. 146, 375–384.
- 936 Pifer, R., Yarovinsky, F., 2011. Innate responses to *Toxoplasma gondii* in mice and  
937 humans. Trends Parasitol. 27, 388–393.
- 938 Pivetti-Pezzi, P., Accorinti, M., Tamburi, S., Ciapparani, V., Abdulaziz, M.A., 1994.  
939 Clinical features of toxoplasmic retinochoroiditis in patients with acquired  
940 immunodeficiency syndrome. Ann. Ophthalmol. 26, 73–84.
- Pomares, C., Ajzenberg, D., Bornard, L., Bernardin, G., Hasseine, L., Darde, M.L.,  
Marty, P., 2011. Toxoplasmosis and horse meat, France. Emerg. Infect. Dis. 17,  
1327–1328.
- Rodriguez, A., Calonge, M., Pedroza-Seres, M., Akova, Y.A., Messmer, E.M., D'Amico,  
D.J., Foster, C.S., 1996. Referral patterns of uveitis in a tertiary eye care center.  
Arch. Ophthalmol. 114, 593–599.
- Sauer, A., Lahmar, I., Scholler, M., Villard, O., Speeg-Schatz, C., Brunet, J., Pfaff, A.,  
Bourcier, T., Candolfi, E., 2009. Development of murine models of ocular  
toxoplasmosis and preliminary results of ocular inflammatory transcriptome. J.  
Fr. Ophthalmol. 32, 742–749.
- Sauer, A., de la Torre, A., Gomez-Marin, J., Bourcier, T., Garweg, J., Speeg-Schatz, C.,  
Candolfi, E., 2011. Prevention of retinochoroiditis in congenital toxoplasmosis:  
Europe versus South America. Pediatr. Infect. Dis. J. 30, 601–603.
- Sauer, A., Pfaff, A.W., Villard, O., Creuzot-Garcher, C., Dalle, F., Chiquet, C., Pelloux,  
H., Speeg-Schatz, C., Gaucher, D., Prevost, G., Bourcier, T., Candolfi, E., 2012.  
Interleukin 17A as an effective target for anti-inflammatory and antiparasitic  
treatment of toxoplasmic uveitis. J. Infect. Dis. 206, 1319–1329.
- Sauer, A., Rochet, E., Lahmar, I., Brunet, J., Sabou, M., Bourcier, T., Candolfi, E., Pfaff,  
A.W., 2013. The local immune response to intraocular *Toxoplasma* re-challenge:  
less pathology and better parasite control through Treg/Th1/Th2 induction. Int.  
J. Parasitol. 43, 721–728.
- Silveira, C., Belfort Jr., R., Muccioli, C., Abreu, M.T., Martins, M.C., Victora, C.,  
Nussenblatt, R.B., Holland, G.N., 2001. A follow-up study of *Toxoplasma gondii*  
infection in southern Brazil. Am. J. Ophthalmol. 131, 351–354.
- Skorich, D.N., Chiappino, M.L., Nichols, B.A., 1988. Invasion of the guinea pig  
conjunctiva by *Toxoplasma gondii*. Invest. Ophthalmol. Vis. Sci. 29, 1871–1880.
- Streilein, J.W., 1993. Immune privilege as the result of local tissue barriers and  
immunosuppressive microenvironments. Curr. Opin. Immunol. 5, 428–432.
- Streilein, J.W., 2003. Ocular immune privilege: the eye takes a dim but practical  
view of immunity and inflammation. J. Leukoc. Biol. 74, 179–185.
- Sugita, S., Futagami, Y., Smith, S.B., Naggar, H., Mochizuki, M., 2006. Retinal and  
ciliary body pigment epithelium suppress activation of T lymphocytes via  
transforming growth factor beta. Exp. Eye Res. 83, 1459–1471.
- Sugita, S., Horie, S., Nakamura, O., Futagami, Y., Takase, H., Keino, H., Aburatani, H.,  
Katunuma, N., Ishidoh, K., Yamamoto, Y., Mochizuki, M., 2008. Retinal pigment  
epithelium-derived CTLA-2alpha induces TGFbeta-producing T regulatory cells.  
J. Immunol. 181, 7525–7536.
- Switaj, K., Master, A., Borkowski, P.K., Skrzypczak, M., Wojciechowicz, J.,  
Zaborowski, P., 2006. Association of ocular toxoplasmosis with type 1  
*Toxoplasma gondii* strains: direct genotyping from peripheral blood samples. J.  
Clin. Microbiol. 44, 4262–4264.
- Tan, H.K., Schmidt, D., Stanford, M., Tear-Fahnehjelm, K., Ferret, N., Salt, A., Gilbert,  
R., 2007. Risk of visual impairment in children with congenital toxoplasmic  
retinochoroiditis. Am. J. Ophthalmol. 144, 648–653.
- Tedesco, R.C., Smith, R.L., Corte-Real, S., Calabrese, K.S., 2005. Ocular toxoplasmosis  
in mice: comparison of two routes of infection. Parasitology 131, 303–307.
- Thiebaut, R., Leproust, S., Chene, G., Gilbert, R., 2007. Effectiveness of prenatal  
treatment for congenital toxoplasmosis: a meta-analysis of individual patients'  
data. Lancet 369, 115–122.
- Van Grol, J., Muniz-Feliciano, L., Portillo, J.A., Bonilha, V.L., Subauste, C.S., 2013. CD40  
induces anti-*Toxoplasma gondii* activity in nonhematopoietic cells dependent on  
autophagy proteins. Infect. Immun. 81, 2002–2011.
- Vasconcelos-Santos, D.V., Machado Azevedo, D.O., Campos, W.R., Orefice, F.,  
Queiroz-Andrade, G.M., Carellos, E.V., Castro Romanelli, R.M., Januario, J.N.,  
Resende, L.M., Martins-Filho, O.A., de Aguiar Vasconcelos Carneiro, A.C., Almeida  
Vitor, R.W., Caiaffa, W.T., 2009. Congenital toxoplasmosis in southeastern  
Brazil: results of early ophthalmologic examination of a large cohort of  
neonates. Ophthalmology 116 (1199–2205), e2191.
- Vasconcelos-Santos, D.V., 2012. Ocular manifestations of systemic disease:  
toxoplasmosis. Curr. Opin. Ophthalmol. 23, 543–550.
- Villard, O., Filisetti, D., Roch-Deries, F., Garweg, J., Flament, J., Candolfi, E., 2003.  
Comparison of enzyme-linked immunosorbent assay, immunoblotting, and PCR  
for diagnosis of toxoplasmic chorioretinitis. J. Clin. Microbiol. 41, 3537–3541.
- Villena, I., Ancelle, T., Delmas, C., Garcia, P., Brezin, A.P., Thulliez, P., Wallon, M., King,  
L., Goulet, V., 2010. Congenital toxoplasmosis in France in 2007: first results  
from a national surveillance system. Euro. Surveill., 15.

### **iii. Conclusions and perspectives**

- Occurrence and severity of OT are more significant in SA than in Europe.
- In classic European infections, the Th17 type response is detrimental.
- Host and parasite genetic factors are essential for the variability of disease.
- Comparison of studies should be undertaken, using the same criteria in diagnosis and strain typing.
- There are still very few data on the differential infection and proliferation capacity of the different *T. gondii* strains in various retinal cell types.
- These differences are certainly a major factor in determining strain-specific virulence.
- A special focus should be on the molecular mechanisms that allow parasite persistence in retinal cells, and why reactivation is more frequent in some patients than in others.
- An important part of the answer will be found at the epigenetic level.
- From a medical point of view, the reason for ocular tropism of certain strains is of primordial interest, as it could direct prevention and treatment in a more targeted way.
- Elucidating strain-dependent involvement of the IL-6-IL-23-IL-17 inflammatory cascade should result in targeted treatment according to the infecting strain, the patient's genetic disposition, and the severity of the lesions.



## **IV- GENERAL DISCUSSION**

Although certain differences between South American and European clinical case series have been detected in terms of congenital transmission rates, probability of symptoms in congenital OT (Thiébaud *et al.*, 2007; Gilbert *et al.*, 2008), severity of ocular inflammation (Dodds *et al.*, 2008), and intraocular specific antibody levels (Garweg *et al.*, 2004), no comparative clinical and biological studies have been performed yet in patients from both continents with laboratory-confirmed OT. These previous studies were mostly retrospective and their main limitation is the inclusion of patients with “suspected” OT, rather than biologically confirmed cases. Even though the ocular signs of toxoplasmic retinochoroiditis are highly suggestive of this disease, they may be mimicked by other infections (Villard *et al.*, 2003). Furthermore, in some cases the symptoms may be atypical (Fardeau *et al.*, 2002; Garweg *et al.*, 2011). Therefore, we strengthened our evaluation by including biologically confirmed OT cases only, as well as by comparing the same bio-clinical data in a prospective study from two different populations (SA and Europe) suffering from biologically confirmed OT.

Among the 17 criteria analyzed in the two populations, the following were significantly higher in Colombian patients: macular involvement; vitreous inflammation; strabismus; bilateral involvement; and synechiae. Our findings confirm and expand the data from one retrospective study in patients with diagnosed OT, which found elevated IOP, increased presence of synechiae, AC cells, flare, and vitreous humor haze (Dodds *et al.*, 2008). The main theory for these clinical differences is founded on the idea that severe disease in humans could be the end result of reduced host adaptation to neotropical zoonotic strains of *T. gondii* (Carme *et al.*, 2009). Our study gathered certain indications that support this theory.

The role of strain-specific virulence factors of the parasite genotypes in SA in humans has not been carefully investigated so far. Virulent strains are not

frequently found in Europe (Elbez-Rubinstein *et al.*, 2009), where Type II genotypes are the most common within OT patients (Fekkar *et al.*, 2011).

In the three Colombian OT patients in which we could detect *Toxoplasma* DNA, we found one Type I and two atypical strains. The fact that no patient of the French group had a sufficient ocular parasite load for genotyping clearly shows the difference in ocular virulence. Moreover, intraocular antibody responses evaluated by an immunoblotting assay revealed important differences in *Toxoplasma* antigen recognition. Even if this could be partially due to better recognition by Colombian patients of the *Toxoplasma* Type I antigens used in this assay, additional host immune-specific elements are definitely essential in the intra ocular immune-response.

We confirmed by a serotyping assay that Colombian patients recognized different epitopes to French patients. Colombian OT patients recognized a heterogeneous pattern of strain-specific peptides, but none of them were from a Type II strain. The French OT patients recognized only Type II strain-specific peptides, confirming the reliability of this test in a geographic region with predominantly Type II strains infections (Sibley and Ajioka, 2008). The corresponding non-infected populations presented the same serological pattern in Colombia, but a slightly different pattern in France, where some sera were not reactive to Type II antigens. This interesting point needs additional investigation with further OT and control samples. However, these data indicate that Type II and non-Type II strains are able to cause ocular pathology, but with a different clinical picture.

The local immune response has been analyzed in several studies in mouse models, which have shown that Th2 involvement in OT is important in the humoral response, Th1 participation plays an important role in limitation of parasite proliferation (Gaddi and Yap, 2007; Amadi-Obi *et al.*, 2007), and the

role of Th17, at least in ocular infection by Type II strains, is probably related to retinal lesion development (Sauer *et al.*, 2012). Nevertheless, until now there are very few studies in humans that analyze the local immune response in OT (Garweg *et al.*, 2004; Lahmar *et al.*, 2009).

Looking at the local immunological reaction, we evidently detected different characteristics in the cytokine response. In French patients, the host-parasite relationship appeared to be equilibrated between protection and inflammation. The protective effect of IFN- $\gamma$  was balanced by anti-inflammatory cytokines such as IL-2 and IL-10. The role of IL-17 is controversial. We have previously observed an early pathological and parasite-promoting role for IL-17 in French patients and in an animal model infected by a Type II *Toxoplasma* strain (Sauer *et al.*, 2012). In an angiogenic VEGF/PDGF intraocular ocular environment, IL-17 attracts neutrophils (Cua and Tato, 2010) and, accompanied by IL-15 and MIP-1 $\beta$ /CCL4, it activates and attracts NK cells (Schulthess *et al.*, 2012) and monocytes (Bennouna *et al.*, 2003). All these innate immune cells can then control *Toxoplasma* proliferation (Kelly *et al.*, 2005; Hunter and Sibley, 2012). As our recent findings implicate IL-27 and the Treg subset in counterbalancing deleterious inflammatory Th17 type responses (Sauer *et al.*, 2012), the corresponding mediators deserve to be examined more closely in future studies.

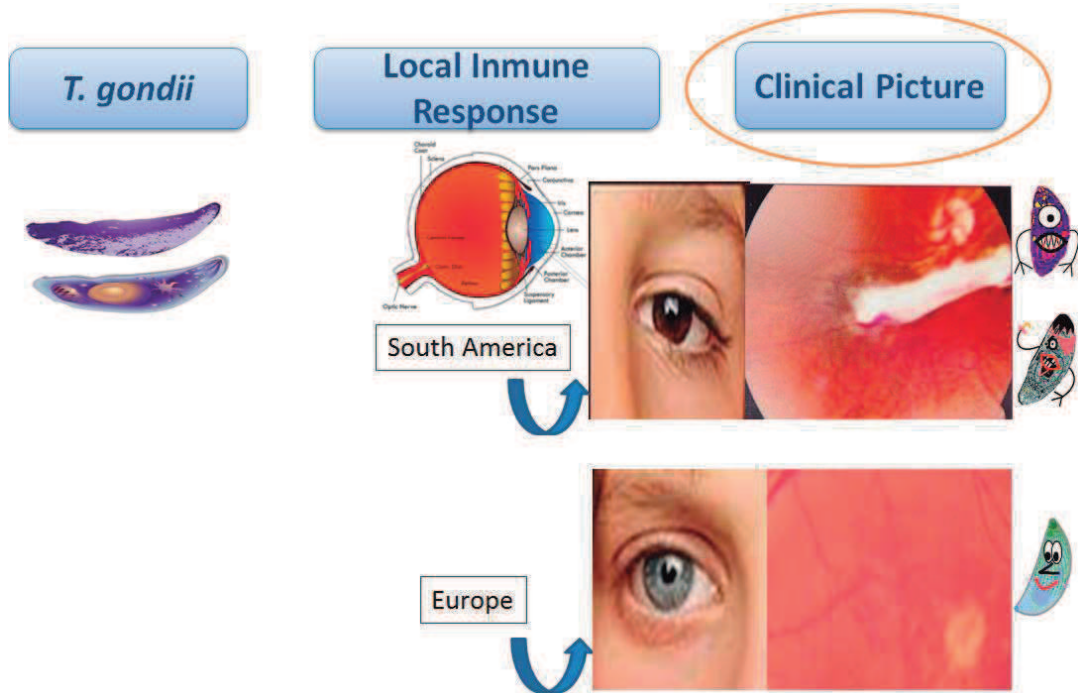
In contrast, in the clinically more severe Colombian cases, levels of IFN- $\gamma$  and other major immunomodulators such as IL-17 were lowered, while levels of IL-6 and IL-13 were enhanced. Virulent strains encode virulence factors that are able to modulate multiple immune host cell signaling pathways through polymorphic effectors secreted into the host cells, such as ROP16 and GRA15 (Kelly *et al.*, 2005; Hunter and Sibley, 2012).

The presence of *Toxoplasma* effector proteins from virulent strains could explain the downregulation of ocular IFN- $\gamma$ , leading to higher ocular parasite loads in Colombian patients. The IL-17 downregulation remains to be explained, but decreased levels of IL-17 and other immune modulators, including proangiogenic factors, could lead to a defect in the migration of leukocytes to the eyes and could be another explanation for impaired control of parasites in the context of virulent South American infections. IL-6 could also antagonize the anti-microbial properties of IFN- $\gamma$  by sustained activation of STAT3, a potent inhibitor of IL-12 and IFN- $\gamma$  (Whitmarsh *et al.*, 2011). Downregulation of IFN- $\gamma$  and its anti-*Toxoplasma* activity was also observed for IL-13 in human fibroblasts (Chaves *et al.*, 2001). It is important to note here that Type II strains express a null ROP16 allele, which is associated with prolonged activation of STAT3 and STAT6 signaling (Denkers *et al.*, 2012). This may, in part, contribute to the increased IL-13. In contrast, because Type I strains do not activate this pathway as effectively, this may be a pivotal basis for the differential cytokine responses observed.

#### **A. Influence of virulence on differences in the pathogenesis and outcome of OT in Europe and South America (Figure 16)**

The three highly predominant clonal parasite lineages (Types I, II, and III) are significantly dissimilar in virulence in the mouse model (Saeij *et al.*, 2005). The majority of human and animal infections are produced by Type II strains (Howe, 1997). On the contrary, heterogeneous atypical genotypes of *T. gondii* are linked to severe infections in humans in South America (Carme *et al.*, 2009; Su *et al.*, 2012). *Toxoplasma* strains present great genetic variety in this world region, which might somewhat explain why congenital toxoplasmosis is more severe in South America than Europe, as was revealed in diverse studies (Sauer *et al.*, 2011; McLeod *et al.*, 2012). A comparative prospective cohort study of congenital OT in Brazil and Europe found that Brazilian

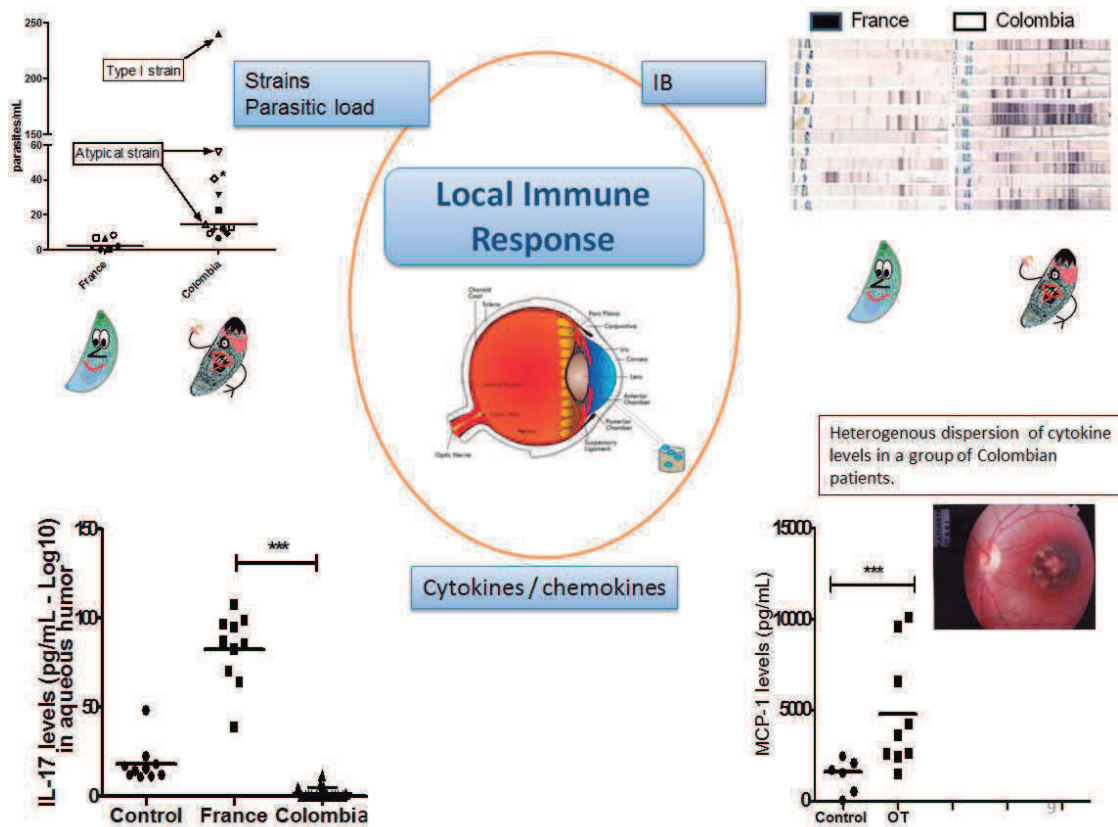
children presented eye lesions that were bigger, more numerous, and more likely to affect the macula (Gilbert *et al.*, 2008). Circumstantial medical cases have been also described, for instance, severe atypical bilateral retinochoroiditis in a Brazilian patient, produced by an extremely divergent, non-archetypal *T. gondii* strain (Bottos *et al.*, 2009).



**Figure 16.** Influence of virulence on the pathogenesis and outcome of OT: different clinical outcomes in OT between Europe and South America.

Due to the significantly diverse population configuration of *T. gondii* in Europe and SA, it is appropriate to investigate the repercussions of this diversity on human pathogenesis (Garweg and Candolfi, 2009). On this point, our comparison of the diverse clinical features between Colombian and French populations, by collecting equal data and implementing the same laboratory assays in patients with biologically confirmed OT, allowed us to correlate the

clinical and immunological findings to results of *Toxoplasma* strain genotyping and peptide-based strain serotyping. Differences in the local immune response between Europe and SA are shown in **Figure 17**.



**Figure 17.** Differences in the local Immune response between European and South American patients.

*Toxoplasma* strains, parasitic load, protein recognition (IB), and cytokine/chemokine patterns were different between the populations.

## **B. Molecular mechanisms underlying *T. gondii* strains: GRA15, ROP16, ROP18, ROP5 (influence on STAT 3/STAT 6, NF $\kappa$ B, and IRGs)**

### **i. What is known in mouse models?**

The requisite for producing a lifelong chronic infection, as by *T. gondii*, is the cautious regulation of immune activation and host cell effector machinery. This successful parasite neutralizes the immune response of the host, and in certain cases incites it, through the use of particular parasite effector proteins. *Toxoplasma* effectors are major controllers of the pro-inflammatory response, which provokes many of the toxoplasmaicidal mechanisms of the host (Melo *et al.*, 2011). The mixture of these effectors existing in certain *Toxoplasma* strains probably works to preserve an ideal parasite burden in different hosts to guarantee parasite transmission (Melo *et al.*, 2011).

*Toxoplasma* strains modulate host cell signaling pathways (Melo *et al.*, 2011). The parasite needs to secrete various proteins from specialized secretory organelles known as DG and rhoptries (Melo *et al.*, 2011). Initially, infection with a Type I strain (RH) does not trigger pro-inflammatory reactions (Melo *et al.*, 2011). The Type I strain allele of GRA15 results in a truncated and non-functional protein, allowing a “silent” infection without activation of NF $\kappa$ B (Melo *et al.*, 2011; Rosowski *et al.*, 2011). Instead, ROP16<sub>I</sub> triggers continuous activation of STAT3 and STAT6, reducing the production of IL-12, IL-1b, and IL-6 (Melo *et al.*, 2011; Saeij *et al.*, 2007).

In addition to the capacity to decrease pro-inflammatory cytokine secretion, Type I strains express ROP5 alleles related to high virulence (Behnke *et al.*, 2011; Reese *et al.*, 2011) and ROP18<sub>I</sub>, which phosphorylates IRGs, blocking their recruitment to the PV that is necessary for parasite destruction, allowing free parasite progress (Fentress *et al.*, 2010; Steinfeldt *et al.*, 2010).



Preserved parasite proteins secreted by infected cells, profilin and cyclophilin-18, are recognized by DCs via TLR11 and CCR5, respectively, leading to late NF $\kappa$ B activation and production of IL-12, which sequentially activates NK and T cells to produce IFN- $\gamma$  (Yarovinsky *et al.*, 2005; Melo *et al.*, 2011).

Nevertheless, Type I strains also avoid activation of DCs (Tait *et al.*, 2010), and by the time the pro-inflammatory reaction is active, host survival is affected because of an uninhibited parasite load. Type II strains are very effective in activating an early response. These strains express the active form of GRA15, which activates NF $\kappa$ B in infected cells (Rosowski *et al.*, 2011), and a less functional form of ROP16, which leads to a brief activation of STAT3/6 (Saeij *et al.*, 2007). Therefore, there is a substantial production of pro-inflammatory cytokines early after infection.

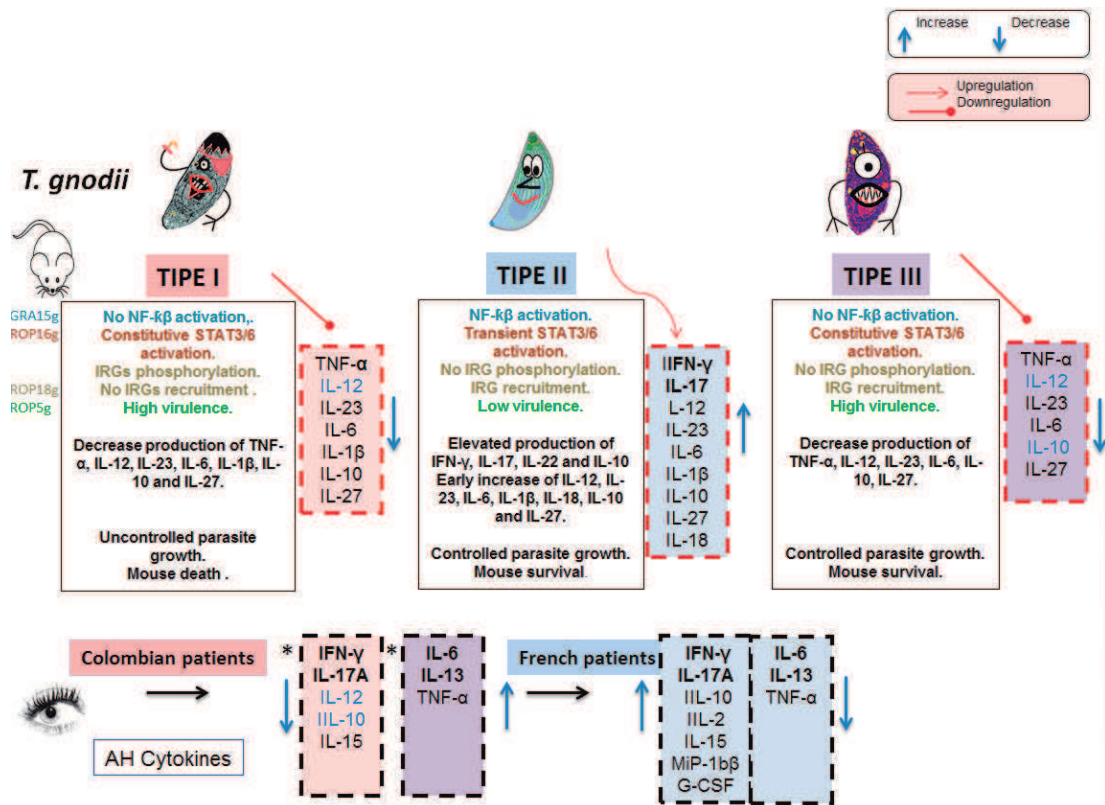
The environment induced by the parasite modulates the activation of some T cell subtypes, mostly guiding the response to a Th1 type (Denkers and Gazzinelli, 1998). Parts of the Th17 reaction to *Toxoplasma* appear to have contrary effects on host survival; an IL-23-motivated IL-22 response by CD4+ T cells mostly has a negative influence (Muñoz *et al.*, 2009), whereas signaling by the IL-17 receptor could be favorable, by dropping parasite burden (Kelly *et al.*, 2005).

Intracellular parasite growth is orderly because of the expression of an avirulent form of ROP18, which does not block the recruitment of IRGs to the PV (Fentress *et al.*, 2010; Steinfeldt *et al.*, 2010; Melo *et al.*, 2011). Type II strains also express ROP5 alleles associated with low virulence (Melo *et al.*, 2011). However, susceptible animals die due to severe ileitis. Similar to Type I, Type III-secreted GRA15 and ROP16 do not activate NF $\kappa$ B and induce a continuous activation of STAT3/6, respectively, controlling the early secretion

of pro-inflammatory cytokines (Melo *et al.*, 2011; Rosowski *et al.*, 2011). Yet, these strains express an inactive ROP18, being incapable of eluding intracellular killing mediated by IRGs. In this situation, late secretion of IL-12 by DCs activates a Th1 type reaction that is enough to regulate parasite burden and lead to cyst development, leading to a chronic infection (Melo *et al.*, 2011).

## **ii. What have we found in the human intraocular response to *T. gondii*?**

While there was an important advance in the last decade in understanding how *T. gondii* modulates immune responses in the mouse model, little is known regarding the role of strain-specific virulence factors in other hosts (Melo *et al.*, 2011). Here is one of the most important points in our work. We are studying the local immune response in the eye in humans infected by different parasite strains, and for the first time, we can hypothesize the underlying molecular mechanisms in humans by correlating these mechanisms with those found in the mouse model (**Figure 18**).



**Figure 18.** Strain modulation of the cytokine network in the immune response to *Toxoplasma* and virulence. Modulation of cytokines by Type I, II, and III *Toxoplasma* strains and their virulence in a mouse model. Comparison between cytokines present in AH of Colombian and French patients. Modified from: Melo MB, Jensen KD, Saeij JP. 2011. *Toxoplasma gondii* effectors are master regulators of the inflammatory response. *Trends Parasitol.* 27: 487e495.

### iii. Intraocular cytokine profile in Old and New World patients suffering from active OT and its potential explanation

When we studied the patients' local immunological reaction, one of the main purposes in the present doctoral thesis, we observed clearly different cytokine signatures. In French patients, the host-parasite relationship seemed to be equilibrated between protection and inflammation. The protective effect of IFN- $\gamma$  was balanced by anti-inflammatory cytokines such as IL-2 and IL-10. We have previously observed an early pathological and parasite-promoting

role for IL-17 in French patients and in an animal model infected by a Type II *Toxoplasma* strain (Lahmar *et al.* 2009; Sauer *et al.*, 2012). This IL-17 role was not observed in Colombian patients infected by atypical and Type I strains. Thus, the role of IL-17 seems to be controversial, depending on the infecting strain.

IL-17 attracts neutrophils (Cua and Tato, 2010), and it activates and attracts NK cells (Schulthess *et al.*, 2012) and monocytes (Bennouna *et al.*, 2003). All these innate immune cells can then control *Toxoplasma* proliferation (Kelly *et al.*, 2005; Hunter and Sibley, 2012). As our recent findings implicate IL-27 and the Treg subset in counterbalancing deleterious inflammatory Th17 type responses (Sauer *et al.*, 2012), it could be interesting to study the corresponding mediators in further studies.

Levels of IFN- $\gamma$  and other major immunomodulators such as IL-17 were lowered, in the more severe Colombian cases of OT, while levels of IL-6 and IL-13 were enhanced. Virulent strains encode virulence factors that are able to modulate multiple immune host cell signaling pathways through polymorphic effectors secreted into the host cells, such as ROP16 and GRA15 (Melo *et al.*, 2011; Hunter and Sibley, 2012).

The downregulation of ocular IFN- $\gamma$ , leading to higher ocular parasite loads in Colombian patients, could be explained by the presence of *Toxoplasma* effector proteins from virulent strains. The IL-17 downregulation remains to be explained, but decreased levels of IL-17 and other immune modulators, including proangiogenic factors, could lead to a defect in the migration of leukocytes to the eyes and could be another explanation for impaired control of parasites in the virulent South American infections. IL-6 could also antagonize the anti-microbial properties of IFN- $\gamma$  by sustained activation of STAT3, a potent inhibitor of IL-12 and IFN- $\gamma$  (Suzuki *et al.*, 1988).

Downregulation of IFN- $\gamma$  and its anti-*Toxoplasma* activity was also observed for IL-13 in human fibroblasts (Chaves *et al.*, 2001).

The null expression of ROP 16 allele in Type II strains, which is associated with prolonged activation of STAT3 and STAT6 signaling, may, partially, contribute to the increased IL-13. Type II strains do not activate this pathway as effectively, and this could contribute to the differential cytokine responses observed (Butcher *et al.*, 2001) (**Figure 19**).

The theory of local T cell exhaustion may also be of interest in the context of Colombian patients. Immune exhaustion is characterized by the modification of CD8+ T cell functions by reducing their polyfunctionality and their efficacy (Gigley *et al.*, 2012). Indeed, high *Toxoplasma* loads associated with a decreased IFN- $\gamma$  and IL-15 production and enhancement of TNF- $\alpha$  could be one aspect of this loss of CD8+ T cell polyfunctionality. In contrast, in French patients, elevated IL-15 is critical for homeostasis of memory CD8+ T cells, and may lead to a better control of parasite proliferation and subsequent parasite latency in the retina.

Taken together, our results indicate that virulent strains observed in South America may suppress host-protective pathways, opening the way to multiplication and cytolytic activity of the parasite in retinal tissues including blood vessels. The presence of TNF- $\alpha$  in most of these patients could also contribute by enhancing an ongoing immunopathological retinal process (Egan *et al.*, 2010).

Of course, a multifactorial origin of the observed clinical and biological differences could not be excluded. In our study, the source of contamination may have been drinking water collected from surface water sources (i.e.,

rivers and lakes; Burnett *et al.*, 1998; Lopez-Castillo *et al.*, 2005; Balasundaram *et al.*, 2010; Vaudaux *et al.*, 2010).

Commonly, macular involvement in Colombian patients is often associated with congenital toxoplasmosis (Gómez-Marín *et al.*, 2007; de-la-Torre *et al.*, 2009; Sauer *et al.*, 2011; Gómez-Marín *et al.*, 2011). Even though we studied adult populations, we cannot exclude a congenital origin of infection in some Colombian patients. Moreover, acute toxoplasmosis was only diagnosed in two Colombian cases and one French case. The remaining population was considered to exhibit chronic toxoplasmosis.

Finally, individual susceptibility was previously related to variations in several genes encoding immune response players, such as IFN- $\gamma$ , IL-1 $\alpha$ , IL-10, TLR9, ABCA4, COL2A1, and P2X<sub>7</sub>-R (Cordeiro *et al.*, 2008; Cordeiro *et al.*, 2008; de Albuquerque *et al.*, 2009; Peixoto-Rangel *et al.*, 2009). Genetically susceptible patients are possibly less able to cope with a more virulent strain. Further investigations with larger cohorts including an evaluation of their immunological response and their individual susceptibility to *Toxoplasma*, are needed to address these topics.

#### **iv. Intraocular cytokine profile in Colombian patients suffering from active OT versus control cataract patients, and the possible explanation**

We determined the levels of cytokines in AH from nine Colombian patients with OT, by using the same recruitment criteria and the same methodology to analyze cytokines as in previous studies (Lahmar *et al.*, 2009; Sauer *et al.*, 2012). We and others reported more severe ocular infection in South American patients compared with European and North American patients (Dodds *et al.*, 2008; Sauer *et al.*, 2011). In our study, we showed that the cytokine pattern observed in Colombian OT patients completely differed from

the pattern previously reported in French patients (Lahmar *et al.*, 2009; Sauer *et al.*, 2012).

The major differences were lower IFN- $\gamma$  and IL-17 levels, but there were also increased levels of TNF- $\alpha$ , IL-6, and IL-13 in Colombian patients, as well as a large inter-individual variation. These observations could be related to the nature of the infecting *Toxoplasma* strain. Serotyping in our study showed frequent recognition of Type I/III-specific peptides in Colombian patients, whereas French patients were nearly exclusively infected by Type II strains (Fekkar *et al.*, 2011). Thus, the lower Th1 response in Colombian patients compared with French patients can be explained by specific modulation of the immune response by South American strains. Strains of Types I and III were shown to inhibit the NF $\kappa$ B pathway (resulting in reduced IFN- $\gamma$  production), whereas Type II strains induced it (Rosowski *et al.*, 2011). In support of this, local cytokine profiles of Colombian OT patients infected with Type I/III strains versus non-Type I/III strains were significantly different. Moreover, the heterogeneous clinical and cytokine aspects observed in Colombian patients, and also wildlife (Gallego *et al.*, 2006) were possibly related to diverse infections with Types I and III and highly variable atypical *T. gondii* strains, whereas the nearly uniform Type II infections in 18 French patients resulted in more homogenous cytokine patterns (Lahmar *et al.*, 2009; Sauer *et al.*, 2012).

However, the serotyping methods need to be refined in order to differentiate more precisely the type of infecting strain in one particular patient. The positive correlation between age and IL-12 level could be linked to more prolonged antigen exposure with increasing age, leading to a greater stimulation of APCs, macrophages, PMNs, DCs, and B cells. *T. gondii* induces secretion of IL-12 directly and rapidly by both human and mouse APCs (Gazzinelli, Wysocka M *et al.*, 1994; Robben *et al.*, 2004; Denkers *et al.*, 2012). IL-12 has been shown to be fundamental both in mice and in

humans to control a protective response against *T. gondii*. The parasite simultaneously triggers the secretion of protective cytokines (IFN- $\gamma$  and IL-12) and paradoxically suppresses the same type of response (Gaddi and Yap, 2007; Denkers *et al.*, 2012). This dual capacity of the parasite could be advantageous and permit the establishment of a stable host-parasite interaction. Failure to successfully adjust these responses could be causative of the host's bad control of the parasite observed in patients infected by a virulent strain (Vallochi *et al.*, 2008). Binomial IL-12 and IFN- $\gamma$  production is critical to resistance to *T. gondii* infection in mice, and this intricate mechanism involving simultaneous activation of different signaling pathways could be required for induction and control of IL-12 during acute infection with *T. gondii*.

Much remains to be learned about the mechanisms involved and their relevance to parasite-host interactions during natural infection in humans. The rise in IL-13 levels in older patients with OT could be related to downregulation of TNF- $\alpha$  production by this cytokine, and inhibition of Th1 cells in Colombian patients (Robben *et al.*, 2004). We found that in our patients, IL-12 was not only related to age but also to the number of active lesions and the total number of lesions (active and inactive). This could be explained by the fact that in the presence of more numerous lesions, higher phagocytic activity it could be expected and consequently, increased IL-12 production (Robben *et al.*, 2004).

IL-13 is also related to the number of active lesions and the total number of lesions, indicating a predominant Th2 response, which activates the local production of antibodies by the influence of IL-13 on B lymphocytes (McKenzie *et al.*, 1993). The consequence of increased expression of VEGF is the involvement of Bruch's membrane accompanied by secondary inflammation due to the infection by *T. gondii*, which results in the formation of



choroidal neovascular membranes (CNVMs; Spear *et al.*, 2006). Similar to CNVM secondary to age-related macular degeneration, *T. gondii* ocular infection increases expression of hypoxia-inducible factor 1 alpha in tissue culture, along with VEGF (Spear *et al.*, 2006). We found a relationship between VEGF and other growth factors (FGF and PDGF-bb), resulting in a higher number of active lesions and higher VEGF, and higher total number of lesions (active and inactive). This could be explained by the increased expression of hypoxia-inducible factor 1 alpha along with VEGF produced by *T. gondii* ocular infection. This also contributes to neovascular disease and to the formation of CNVMs in OT.

Vitreous inflammation in our patients was correlated with interferon gamma-induced protein 10 (IP-10), which is secreted by monocytes, endothelial cells, and fibroblasts (Medoff *et al.*, 2002). This plays a role in the chemoattraction of monocytes/macrophages, T cells, NK cells, and DCs (Medoff *et al.*, 2002). IP-10 promotes T cell adhesion to endothelial cells (Taub 1993). Thus, if there are more T cells adhering to endothelial cells, there is more chemoattraction of monocytes and higher vitreous inflammation. We also found high levels of IP-10 associated with extended anatomical involvement (anterior and posterior poles simultaneously). Similar findings have been described in patients with IU and CME active disease (Valentincic *et al.*, 2011). Vitreous inflammation in our patients was also correlated with IFN- $\gamma$  and TNF- $\alpha$ , as well as with other cytokines and growth factors, which are pro-inflammatory. The relationship we found between the size of lesions and IP-10 and MIP-1, including its subunits (a, and b), could be because a bigger size of lesions could result in more macrophage activation, more T cell adhesion to endothelial cells, more transmigration of monocytes and T cells to the vitreous, and consequently higher vitreous inflammation.

The number of recurrences in our patients was mainly related to IL-5. Previous studies in mice have shown that IL-5 may play a role in the production of IL-12 in *T. gondii* infection (Zhang et al., 1999). IL-5, a product of both Th2 and mast cells, has been shown to have an important role in the induction of a Th2 response and antibody production by B cells, but also in enhancing IgA production, by inducing maturation but not class switching of surface IgA-positive B cells into IgA-secreting cells (Matsumoto, 1989). The presence of IgA has been described in OT patients with active and inactive lesions (Nickdel *et al.*, 2001).

Although IL-17 levels were low in South American patients compared with European patients, the presence of IL-17 was related to a higher number of recurrences, as well as VEGF and IL-5. The association with IL-5 is of interest and will be addressed in future studies in a mouse model, in order to determine if inhibition of this cytokine could reduce recurrences or reactivation of eye infection (Garweg and Candolfi, 2009; Sauer *et al.*, 2012).

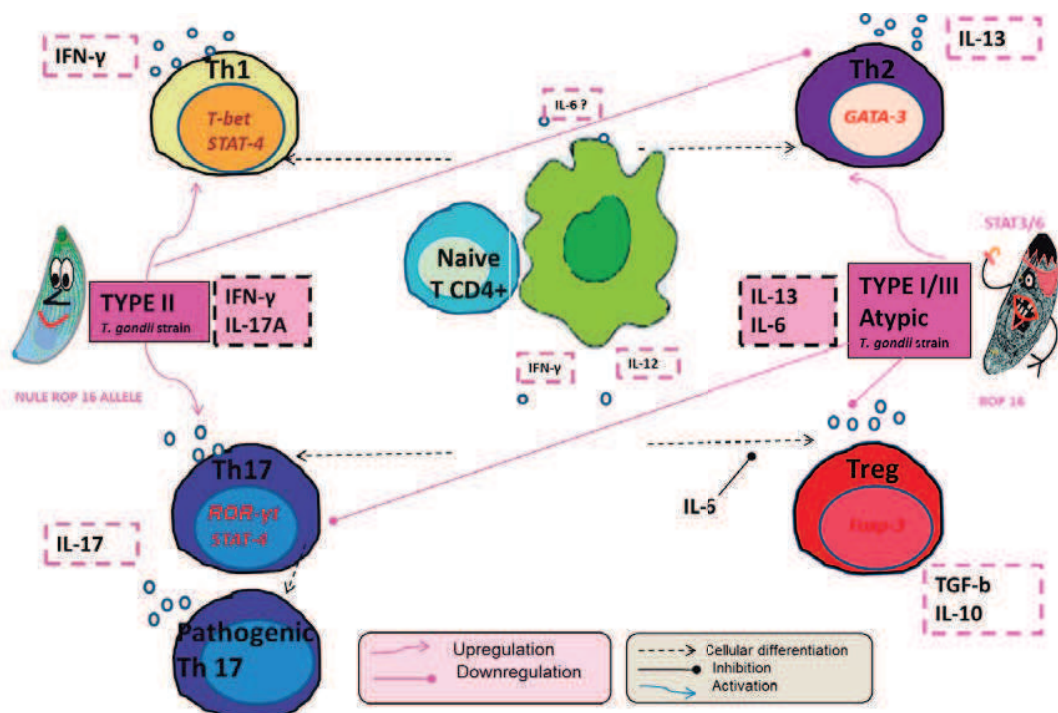
Previous work on IU found a tendency towards Th1 polarization in panuveitis compared with anterior uveitis (Valentincic *et al.*, 2011). In our patients, Th1 polarity was not detected even in patients with a large uveal tract compromise; instead, we found an important Th2 response characterized by high levels of IL-4 and IL-13. Production of IL-5 was elevated in OT patients compared with controls, with the presence of two groups of patients, one with more elevated IL-5 levels, a higher grade of inflammation, and the presence of papillitis. Papillar inflammation in our patients was also correlated with the presence of IL-4. The relationship between IL-5, IL-4, and inflammation could be associated with the B cell activation that, at the same time, leads to T cell activation, enhancing the inflammatory response as we previously mentioned.

We found elevated levels in the AH of IL-6, IL-10, IL-12p70, and MCP-1 in patients with OT compared with controls. The correlation between IL-12p70 and MCP-1 with the inflammation in OT has already been discussed. IL-6 is a major pro-inflammatory cytokine in uveitis and elevated intraocular levels were found in the AH of patients with uveitis of diverse origins, including OT, viral uveitis, Fuchs heterochromic uveitis syndrome (FHUS), and inflammatory bowel disease (Ongkosuwito *et al.*, 1998; Akpek *et al.*, 1999; Perez *et al.*, 2004; Van Kooij *et al.*, 2006; Lahmar *et al.*, 2009; El-Asrar *et al.*, 2011). The presence of IL-6 could enhance progression of the parasite by activation of STAT3, which is an inhibitor of IL-12 (El-Asrar *et al.*, 2011). STAT3 appears to be a key target of *T. gondii* virulence factors. Further investigations are needed to study the role of intraocular IL-6 in OT, and the counterbalance with the presence of IL-12 in human OT.

Studies in autoimmune uveitis have revealed that Th1 and Th17 cells can both be pathogenic effectors; however, paradoxically, some cytokines produced by these subsets can also be protective, depending on their timing and cellular source (Perez *et al.*, 2004). Thus, the roles of IL-9, IL-10, and of the cell subset producing them require further investigation in the pathogenesis of uveitis. IL-10 can be associated not only with the Th2 response. It is an immunomodulatory cytokine produced by various cell types, including Treg cells, B cells, and monocytes (Mosser, 2008). Recent studies identified IL-10 production in cells that otherwise showed Th1 and Th17 phenotypes (Whitmarsh *et al.*, 2011). In the present study, higher levels of IL-9 were associated with higher anatomical compromise in terms of inflammation (involvement of anterior and posterior poles), and higher levels of IL-10 were associated with higher vitreous inflammation. In other infectious uveitis, for instance, presumed tuberculous uveitis, both Th1 and Th17 cells were involved and clinical disease activity was significantly correlated with the levels of IL-15, IFN- $\gamma$ , TNF- $\alpha$ , and IP-10 (Damsker *et al.*, 2010). Likewise, we

found a remarkable expression of IP-10 in patients that was related to higher inflammation. IL-15, IFN- $\gamma$ , and TNF- $\alpha$  were associated with the presence of papillitis, as well as IL-4, IL-5, and eotaxin. In contrast, in patients with tuberculous uveitis IL-4 and IL-12 were not detected (Damsker *et al.*, 2010), while in our patients higher levels of IL-12 were positively correlated with a higher number of active retinochoroidal lesions. Altogether, our results and those from other studies do not support a separate role for either the Th1 or Th2 response in the pathogenesis of clinical uveitis (O'Garra *et al.*, 2004).

In conclusion, we showed specific intraocular cytokine patterns in OT patients in a particular South American setting that are different from those reported in European infections. This heterogeneous infection setting enabled us, for the first time, to correlate clinical characteristics, such as inflammation and recurrences with the infecting *T. gondii* strain and with specific cytokine patterns.



**Figure 19.** Proposed dynamics of a Type I/III and atypical (South American) ocular infection in contrast with a Type II (European) ocular infection and the influence of virulence on intraocular immune response.

In **Table 1**, we hypothesize the implications of infecting strains for the main differences in intraocular cytokine levels in AH samples of patients with active OT from Europe and South America.

**Table 1. Hypothesis on the implications of infecting strains for the main differences in intraocular cytokine levels in AH samples of patients with active OT from Europe and South America.**

<b>Clue</b>	<b>Hypothesis</b>
<b><i>In Colombian patients, usually infected by virulent strains, IL-12 was diminished comparing with levels in French patients.</i></b>	Type I/III and atypical strains downregulate IL-12 in Colombian OT patients.
<b><i>Greater parasite load in the AH of Colombian patients compared with French patients.</i></b>	There is uncontrolled parasite growth related to downregulation of IL-12 and IFN- $\gamma$ in Colombian OT patients infected with virulent strains.
<b><i>IL-10 was lower in Colombian patients and higher in French patients.</i></b>	Type I strains downregulate IL-10 in Colombian patients, leading to a lack of regulatory response and higher inflammation in these patients.
<b><i>IFN-<math>\gamma</math> was higher in French patients compared with</i></b>	Type II strains that infect French patients upregulate IFN- $\gamma$ , leading to more protection and less inflammation in these patients, as well as better control of parasite

<b>Colombian patients, in whom IFN-<math>\gamma</math> was very low.</b>	growth.
<b>IL-17 was elevated in French patients and very low in Colombian patients.</b>	<p>Type II strains upregulate IL-17 in French patients and virulent strains downregulate IL-17 in Colombian patients. Decreased levels of IL-17 could lead to a defect in the migration of leukocytes to the eyes, since in an angiogenic VEGF/PDGF intraocular ocular environment, IL-17 would attract neutrophils.</p> <p>This could be another explanation for impaired control of parasites in the context of virulent South American infections. IL-17 has an important role in the induction of inflammation in murine and human OT that is probably related to the infecting strains of <i>T. gondii</i>.</p>
<b>IL-6 and IL-13 were higher in Colombian patients compared with French patients.</b>	<p>IL-6 could also antagonize the anti-microbial properties of IFN-<math>\gamma</math> by sustained activation of STAT3, a potent inhibitor of IL-12 and IFN-<math>\gamma</math>. Type II strains express a null ROP16 allele, which is associated with prolonged activation of STAT3 and STAT6 signaling. This may, in part, contribute to the increased IL-13. In contrast, because Type I strains do not activate this pathway as effectively, this may be a pivotal basis for the differential cytokine responses observed.</p>
<b>IFN-<math>\gamma</math> and IL-15 were lower and TNF-<math>\alpha</math> was elevated in Colombian patients compared with French patients.</b>	<p>High <i>Toxoplasma</i> loads associated with decreased IFN-<math>\gamma</math> and IL-15 production and enhancement of TNF-<math>\alpha</math> could be explained by theory of “local T cell exhaustion”, characterized by the alteration of CD8+ T cell functions by reducing their polyfunctionality and efficacy.</p>
<b>Presence of elevated TNF-<math>\alpha</math> in Colombian</b>	<p>This could contribute to enhancing an ongoing immunopathological retinal process observed in South</p>

<b><i>patients and low levels in French patients.</i></b>	American patients, in which the host protective pathways are suppressed, opening the way to multiplication and cytolytic activity of the parasite in retinal tissues including blood vessels.
---	---

Certainly, there is a multifactorial origin of the observed clinical and biological differences between patients from South America, and Europe. Drinking water collected from surface water sources (i.e., rivers and lakes; Gómez-Marín *et al.*, 2007; Vaudaux *et al.*, 2010; Gómez-Marín *et al.*, 2011; de-la-Torre *et al.*, 2013 submitted), congenital origin of infection (de-la-Torre *et al.*, 2013 submitted) and individual susceptibility related to variations in different genes encoding immune response players, such as IFN- $\gamma$ , IL-1 $\beta$ , IL-10, TLR-9, ABCA4, COL2A1, and P2X<sub>7</sub>-R (Cordeiro *et al.*, 2008; Peixoto-Rangel *et al.*, 2009; Albuquerque *et al.*, 2009), are some of the factors which determine individuals' immunological response and susceptibility to *Toxoplasma*.

One additional point that deserves to be considered is the probability of eventually having to face severe OT cases in European patients, as a probable consequence of the globalization of markets with exchange of food products between South America, North America, and Europe (Bastiaan *et al.*, 2009). This may result from consumption of meat, fruits, and vegetables contaminated with oocysts of Type I and III and atypical parasites. It is also postulated that global warming may lead to an increase in incidence of the infection in some areas of the world (Meerburg *et al.*, 2009).

The scenario we intend to demonstrate in our work may induce the required determination to continue establishing significant correlations between *Toxoplasma* infection and disease outcome. Here, we see that different strains of *Toxoplasma* produce different kinds and severity of infection in

humans, specifically in OT. Thinking about the present and also the future, there is a necessity for non-invasive resources for distinguishing the type of strain responsible for the disease (Boothroyd, 2009). Detecting the parasite by PCR is definitive but acquiring parasite material from the patient is difficult in all but the most acute cases (Boothroyd, 2009). Instead, serological means have been attempted where strain-specific peptides are used to look for the presence of specific antibodies (Peyron *et al.*, 2006; Sousa, 2009).

In the present work, we used both methods (PCR of AH samples and serotyping with strain-specific peptides). While this methodology is still under development, it has been shown to be workable in a few studies of humans where the strain type was known (Peyron *et al.*, 2006; Sousa *et al.*, 2009; Boothroyd, 2009).



## **V. GENERAL CONCLUSIONS**

-Clinical presentation of OT in South American and European patients differed significantly, being more severe for South American patients. Significant differences were found in the size of active lesions, unilateral macular involvement, unilateral visual impairment, vitreous inflammation, synechiae, and vasculitis, with higher values observed for the Colombian patients.

-The Colombian OT patients possessed heterogeneous atypical serotypes whereas the French patients were uniformly reactive to Type II strain peptides.

-The protein patterns recognized by intraocular antibodies and the cytokine patterns were strikingly different between the two populations.

-The parasitic load in the AH was higher in Colombian patients than in French patients.

-We found specific intraocular cytokine patterns in OT patients in the specific South American background that are different from those described in European OT patients.

-This heterogeneous infection scenario allowed us, for the first time, to correlate clinical characteristics, such as inflammation and recurrences with the infecting *T. gondii* strain and with specific cytokine patterns.

-A major Th2 response was related to more severe clinical features in Colombian patients with active OT.

-Although IL-17 levels were low in Colombian patients compared with that reported in European patients, the presence of IL-17 in Colombian patients was related to a higher number of recurrences, along with VEGF and IL-5.

-VEGF and other growth factors (FGF and PDGF-bb) could play an important role in the pathogenesis of OT in Colombian patients. They were related to a higher number of active and inactive lesions in our patients.

-The association with IL-5 is of interest and will be investigated in subsequent studies in a mouse model in order to determine if inhibition of this cytokine could reduce recurrences or reactivation of eye infection.

-Elucidating strain-dependent involvement of the IL-6-IL-23-IL-17 inflammatory cascade should result in targeted treatment according to the infecting strain, the patient's genetic disposition, and severity of the lesions.

-The correlation of the clinical pictures' differences between Colombian and French patients suffering from active OT (with greater severity in Colombian patients), the differences in the biological and immune response, and the different infecting strains in the Old and New World, makes an important contribution to the study field of this neglected disease. In this work, we confirmed the presence of more severe OT in the tropical setting of Colombia compared with France. The main hypothesis for these clinical differences is based on the idea that severe disease in humans may result from poor host adaptation to neotropical zoonotic strains of *T. gondii*. Indeed, our results are consistent with the hypothesis that South American strains may be responsible for more severe OT due to inhibition of the intraocular protective immune response.

-Particularly for me, working in a South American country, and seeing daily severe cases of OT in my uveitis clinic that seriously compromise the quality of life of our patients, this work inspires me to continue investigating this fascinating disease for which too much remains to be clarified.

## **VI- GENERAL PESPRACTIVES**

-Although there are still significant discrepancies among selected studies, perhaps due to the evolution of diagnostic tools, the geographic mapping of OT is starting to take form. Matched studies ought to be carried out, using the same criteria in diagnosis and strain typing.

-Evidently, the current therapy approach with antibiotics and/or antiparasitic medications as well as steroids is not ideal, considering that they do not prevent recurrences and in some cases, they do not stabilize vision (de-laTorre *et al.*, 2011). An ideal therapeutic approach includes the strain of the parasite, localization of the lesion, and severity of the inflammatory response as a basis for therapeutic decision making. New treatments targeting aspects of the parasite's physiology are very encouraging (de-laTorre *et al.*, 2011). Taking into account our results, it would be of interest to develop in the future "individualized" therapies that take into account the parasite type-strain, specific molecular targets and the susceptibility of the specific host.

- In order to achieve specific targeted treatment according to the infecting strain, the genetic characteristics of the patient, and the severity of the lesions, it is necessary to elucidate strain-dependent activation of inflammatory cascades, like IL-6, IL-23, IL-17, and other pathways.

-There exist long discussions on whether inflammation in immune-privileged tissues is controlled locally by endogenous mechanisms in the local tissue or indirectly through the intervention of T cells that regulate autoreactive T cells (Lee *et al.*, 2011). It is of interest to investigate if the local immune response in the eye infected with *T. gondii* could be different to the systemic response. In terms of cytokine regulation by diverse strains of *T. gondii*, one of the most evident differences we found in the local immune response was the opposite reactions in the production of IL-17. Thus, we have started to identify the main intraocular sources of this cytokine and evaluate the kinetics of its production. In this regard, we obtained preliminary data from our personal works, and the

following paper is in preparation: “**Resident cells of the retina are early producers of IL-17 in acute ocular toxoplasmosis in a C57BL/6 mouse model**”. The following paragraphs present the abstract of this paper, along with some discussion, conclusions, and perspectives on this topic.

### **A. Abstract**

**Purpose:** To evaluate the local production of IL-17 in a C57BL/6 mouse model of acute ocular toxoplasmosis (OT).

**Materials and Methods:** Immunofluorescent antibodies anti-IL-17, anti- $\gamma\delta$ , anti-NK, anti-CD45, anti-GFAP, were used in eye cryocuts, in order to evaluate the expression of IL-17 in acute OT, and to identify the cells that produced IL-17 in the retina of C57BL/6 mice intraocularly infected with different strains of *Toxoplasma gondii* (virulent LEF and avirulent PRU).

**Results:** We found that in the retina of C57BL/6 mice intraocularly infected with different strains of *T. gondii*, IL-17 was expressed in early stages of the infection. Using anti-IL-17A antibodies, we observed that this cytokine was present in a progressive pattern from day 0 to day 7. We observed that after the first days of infection, there was soft fluorescent staining in the ganglion layer, but then, this staining became more visible and moved from the external into the internal layers, reaching a complete compromise of retinal tissue on day 7. When comparing the astrocyte staining (GFAP) in *T. gondii*-infected mice with the staining of IL-17 in eyes infected with *T. gondii*, we observed the same pattern. There were no differences between PRU and LEF strains in triggering different type of sources of this cytokine. Virulent and avirulent strains triggered the same resident cells of the retina to produce IL-17.

**Conclusion:** IL-17 is locally produced in the eye in the acute phase of OT. Astrocytes and microglial cells could be the resident cells that produce IL-17 in the retina in the early stages, independently of the infecting strain.

**Keywords:** ocular toxoplasmosis, interleukin-17, cytokine, astrocytes, microglia, retina.

There exist long discussions on whether inflammation in immune-privileged tissues is controlled locally by endogenous mechanisms in the target tissue or indirectly through the intervention of T cells that regulate autoreactive T lymphocytes (Lee *et al.*, 2011). One study in C57BL/6 mice showed that retinal microglia and ganglion cells constitutively expressed IL-27, whereas photoreceptor cells expressed IL-27 receptors and produced the anti-inflammatory cytokine IL-10 in response to IL-27 stimulation (Lee *et al.*, 2011). The same study showed that suppression of inflammatory responses in the immune-privileged retina was orchestrated in part by anti-inflammatory molecules produced by neuroretinal cells in response to IL-27 signaling, while IL-10-producing T cells appeared to play marginal roles in controlling the severity or duration of inflammation in the CNS (Lee *et al.*, 2011).

It has been also suggested that the retinal astrocyte cells (RACs) in EAU-susceptible mice contribute to the reactivation of pathogenic T cells in the eye, leading to intraocular inflammation and tissue damage (Jiang *et al.*, 2008). Concerning OT, it was observed more than 30 years ago that peripheral lymphocytes were unresponsive to *T. gondii* antigens over a period of several months following asymptomatic primary infection (Johnson, 1981; Gaddi and Yap, 2007). This concept needs to be re-examined using current knowledge and methodologies in cytokine and lymphocyte biology. Likewise, the lymphokine repertoires of eye-infiltrating T cells during OT (Gaddi and

Yap 2007; Feron *et al.*, 2001) need to be defined and expanded further than the classical Th1/Th2 type cytokines.

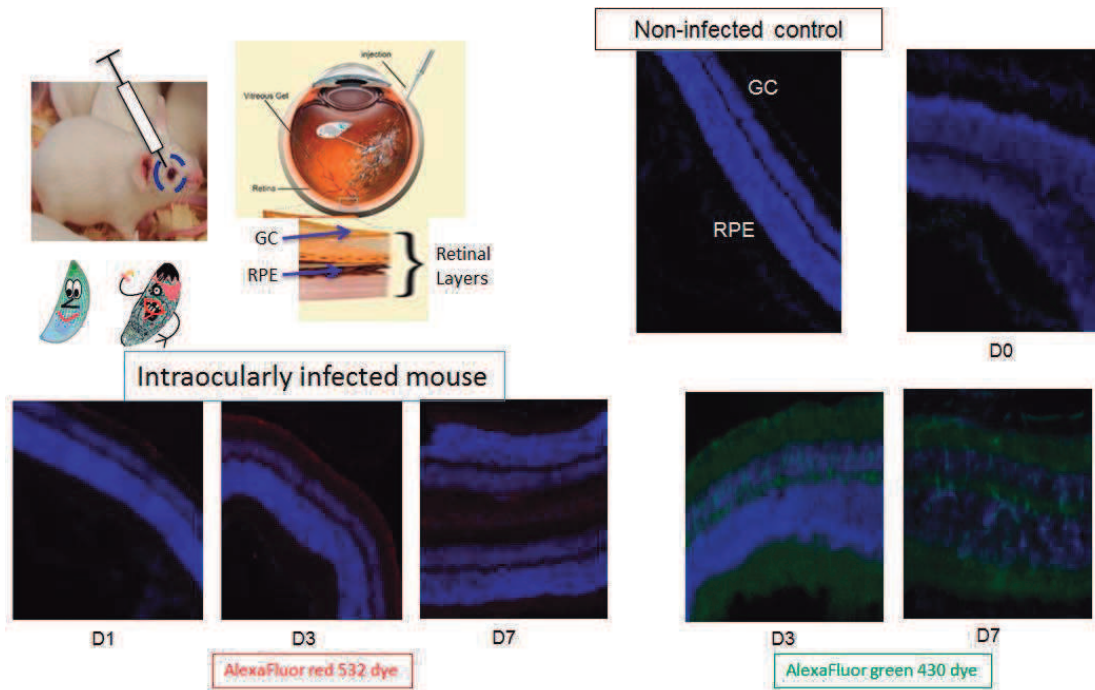
Recent advances in our understanding of the molecular substructures of innate recognition of *T. gondii* (Aliberti *et al.*, 2003; Yarovinsky *et al.*, 2005) led us to study the influence of parasite genotype or host genetic polymorphisms in orienting the response toward pro-inflammatory versus anti-inflammatory cytokine production (Gaddi and Yap 2007). Local IL-17A production by resident cells has been proposed to play an essential role in the pathology of OT (Sauer *et al.*, 2012), but until now there is no confirmation of what these specific cells are.

We performed immunocytochemistry in 32 infected eyes with different strains of *T. gondii* (16 with the PRU strain and 16 with the LEF strain). Parasite-infected eyes were harvested and fixed for 30 minutes at room temperature in 3% paraformaldehyde (3% PFA) in PBS for 10 minutes. Eyes were then placed in increasing concentrations of sucrose (10–30%) in PBS at room temperature, followed by overnight incubation at 4°C in PBS containing 30% sucrose. The cryoprotected eyes were then embedded in Tissue-Teck OCT compound (Sakura Fintek, Torrance, California) and were rapidly frozen in liquid nitrogen. Then 15-µm thick sections were prepared with a cryostat. Sections were placed on glass slides, incubated briefly in ice-cold methanol, and then stored at -20°C until used. Immunofluorescence of the retina was blocked with 20 mM glycine for 20 minutes. Then glycine was washed with PBS (3 x 5 minutes). Primary antibodies were added (1/100 in PBS + 1% BSA), 150 µL of the mix for each slide. We used GFAP, vimentin, and CD45 antibodies. Then the slides were incubated for 2 hours at room temperature in a wet box. Then they were washed with PBS (3 x 5 minutes). Conjugated secondary antibodies were diluted 1/50 (Abs anti-rabbit, AlexaFluor green 430 dye, and red 532 dye), and incubated 45 minutes, at room temperature in the dark. Then the slides were washed with PBS (4 x 5 minutes). DAPI (150



μL) staining was performed for a few seconds. The slides were then washed with PBS. Assembly was performed; 30 μL Moviol was added to each slide, which was then covered with a cap-slip. After 30 minutes, the slides were stored at 4°C in the dark. Immunofluorescence staining by anti-IL-17, anti-GFAP, and anti-CD45 was observed on a Leica SR5 confocal microscope and evaluated using Leica LAS imaging analysis software.

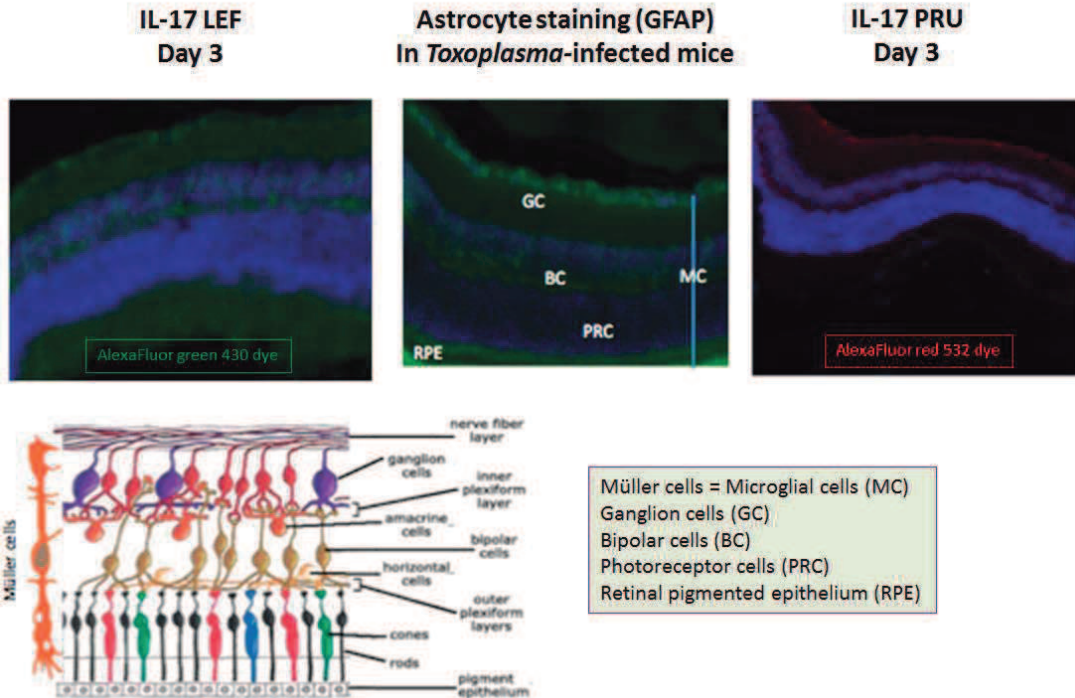
We found that in the retina of C57BL/6 mice intraocularly infected with different strains of *T. gondii*, IL-17A was expressed in early stages of the infection. Using anti-IL-17A antibody, we observed that this cytokine was present in a progressive pattern from day 0 to day 7. After the first days of infection, there was soft fluorescent staining in the ganglion layer, but later, this staining became more visible and moved from the external into the internal layers, reaching a complete compromise of retinal tissue on day 7 (**Figure 20**). The same pattern was observed when comparing the astrocyte staining (GFAP) in *T. gondii*-infected mice with the staining of IL-17 in eyes infected with *T. gondii*. As shown in **Figure 21**, we observed co-localization of IL-17 and proteins of specific cell types.



**Figure 20.** Local production of IL-17 in a mouse model of OT.

Eyes were infected with PRU and LEF strains. IL-17 was present in a progressive pattern (days 1, 3, and 7) from the outer (GC) to the inner layers (RPE) of the retina with PRU and LEF strains.

Possible resident producer cells of IL-17 in a mouse model of OT in early stages of infection



**Figure 21.** Possible resident producer cells of IL-17A in a mouse model of OT.

When comparing the astrocyte staining (GFAP) in *Toxoplasma gondii*-infected mice with the IL-17A staining, we observed a similar pattern. That indicated that astrocytes and microglial cells (Müller cells) were the resident cells producing IL-17.

In this study, we investigated intraocular producer cells of IL-17 and examined whether the secretion of this cytokine was mediated locally by neuroretinal cells or by regulatory T cells. We showed that microglia cells in the neuroretina constitutively secreted IL-17 and that IL-17 expression was upregulated during acute OT.

## B. Conclusions and perspectives

-Beyond the traditional Th1/Th2 types, cytokine/chemokine secretion and kinetics have to be carefully dissected considering not only the lymphokine ranges of T cells that infiltrate the eye during OT, but also the

cytokines/chemokines produced by intraocular resident cells.

-In view of the immunoprivilege of the eye, this dissection could give us important clues to the immunopathology of OT.

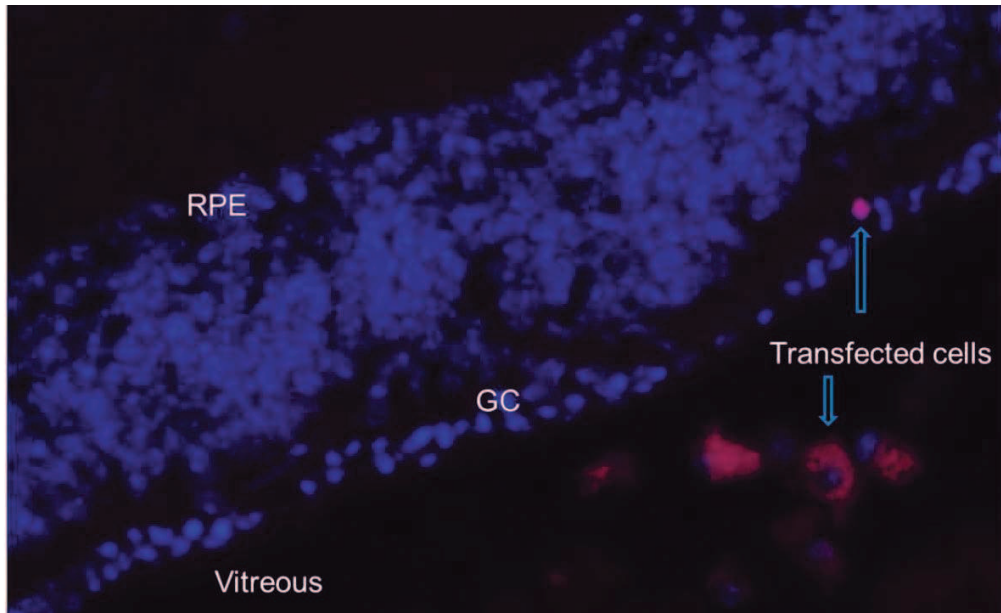
-IL-17 is constitutively produced by resident cells of the retina and is upregulated in the acute phase of OT. Astrocytes and microglial cells could be the resident cells that produce IL-17 in the retina in early stages of the infection, independently of the infecting *Toxoplasma* strain.

-It would be important to study if there are genetically susceptible patients who are probably less able to handle a virulent strain. Further investigations with larger cohorts including an evaluation of their immunological response and their individual susceptibility to *Toxoplasma* are needed to address these topics. In this regard, we are initiating a new research study: “**Gene Polymorphisms in Immune Response of Ocular Toxoplasmosis**” (Code 111056934589, Concourse No: 569/2012, *Colciencias*).

-Neutralization of certain cytokine pathways *in situ* could be an effective means to control pathology without interfering with anti-parasitic mechanisms. We could name this therapy “Immunomodulation in OT”.

- **We started to work with siRNA delivery into the vitreous in an animal model of OT**, with the purpose of evaluating the best conditions for transfecting cells in the retina. We performed *in vivo* injection into the vitreous of fluorescently labeled siRNAs (in C57BL6 mice previously intraocularly infected with different *Toxoplasma* strains) using different technologies from Polyplus. In the preliminary experiments, we observed cells transfected with a non-specific siRNA in the vitreous and retina of C57BL6 mice intraocularly

infected with *T. gondii*. JetPEI, cationic lipid, cationic siRNA Z30, and siRNA+ IC4 gave the best results (**Figure 22**).



**Figure 22.** In vivo siRNA delivery into the vitreous, in a mouse model of ocular toxoplasmosis (OT).

*Preliminary results in the first step of siRNA delivery into the vitreous in a mouse model of OT.*

*The image was taken 24 hours after Injection of sticky siRNA + jetPEI. We can see here transfected cells in the vitreous. Most of these seem to be monocytes, and probably one is a lymphocyte in the retina.*

## VII- REFERENCES

1. Abi Abdallah DS, Lin C, Ball CJ, King MR, Duhamel GE, Denkers EY. 2012. *Toxoplasma gondii* triggers release of human and mouse neutrophil extracellular traps. *Infect Immun.* 80(2): 768-77.
2. Afzali B, Lombardi G, Lechler RI, Lord GM. 2007. The role of T helper and autoimmune disease. *Clin Exp Immunol.* 148: 32-46.
3. Ajzenberg D. 2011. Unresolved questions about the most successful known parasite. *Expert Rev Anti Infect Ther.* 9(2): 169-71.
4. Akpek EK, Maca SM, Christen WG, Foster CS. 1999. Elevated vitreous interleukin-10 level is not diagnostic of intraocular central nervous system lymphoma. *Ophthalmology.* 106: 2291-5.
5. Albuquerque MC, Aleixo AL, Benchimol EI, Leandro AC, das Neves LB, *et al.* 2009. The IFN-gamma +874T/A gene polymorphism is associated with retinochoroiditis toxoplasmosis susceptibility. *Mem Inst Oswaldo Cruz.* 104: 451-55.
6. Aldebert D, Durand F, Mercier C, Brenier-Pinchart MP, Cesbron-Delauw MF, Pelloux H. 2007. *Toxoplasma gondii* triggers secretion of interleukin-12 but low level of interleukin-10 from the THP-1 human monocytic cell line. *Cytokine.* 37(3): 206-11.
7. Aliberti J, Valenzuela JG, Carruthers VB, Hieny S, Andersen J, *et al.* 2003. Molecular mimicry of a CCR5 binding-domain in the microbial activation of dendritic cells. *Nat Immunol.* 4: 485-90.
8. Amadi-Obi A, Yu CR, Liu X, Mahdi RM, Clarke GL, *et al.* 2007. TH17 cells contribute to uveitis and scleritis and are expanded by IL-2 and inhibited by IL-27/STAT1. *Nat Med.* 13(6):711-8.
9. Arevalo JF, Belfort R Jr, Muccioli C, Espinoza JV. 2010. Ocular toxoplasmosis in the developing world. *Int Ophthalmol Clin.* 50: 57-69.
10. Balasundaram MB, Andavar R, Palaniswamy M, Venkatapathy N. 2010. Outbreak of acquired ocular toxoplasmosis involving 248 patients. *Arch Ophthalmol.* 128(1): 28-32.

11. Barkhuff WD, Gilk SD, Whitmarsh R, Tilley LD, Hunter C, Ward GE. 2011. Targeted disruption of TgPhIL1 in *Toxoplasma gondii* results in altered parasite morphology and fitness. *PLoS One*. 6: e23977.
12. Behnke MS, Fentress SJ, Mashayekhi M, Li LX, Taylor GA, Sibley LD. 2012. The polymorphic pseudokinase ROP5 controls virulence in *Toxoplasma gondii* by regulating the active kinase ROP18. *PLoS Pathog*. 8(11): e1002992.
13. Behnke MS, Khan A, Wootton JC, Dubey JP, Tang K, Sibley LD. 2011. Virulence differences in *Toxoplasma* mediated by amplification of a family of polymorphic pseudokinases. *Proc Natl Acad Sci U S A*. 108(23):9631-6.
14. Bastiaan G. Meerburg, Aize Kijlstra. 2009. Changing climate—changing pathogens: *Toxoplasma gondii* in North-Western Europe. *Parasitol Res*. June; 105(1): 17–24.
15. Benevides L, Milanezi CM, Yamauchi LM, Benjamim CF, Silva JS, Silva NM. 2008. CCR2 receptor is essential to activate microbicidal mechanisms to control *Toxoplasma gondii* infection in the central nervous system. *Am J Pathol*. 173(3): 741-51.
16. Bennouna S, Bliss SK, Curiel TJ, Denkers EY. 2003. Cross-talk in the innate immune system: neutrophils instruct recruitment and activation of dendritic cells during microbial infection. *J Immunol*. 171: 6052-58.
17. Benson A, Pifer R, Behrendt CL, Hooper LV, Yarovinsky F. 2009. Gut commensal bacteria direct a protective immune response against *Toxoplasma gondii*. *Cell Host Microbe*. 6(2): 187-96.
18. Besteiro S, Dubremetz JF, Lebrun M. 2011. The moving junction of apicomplexan parasites: a key structure for invasion, *Cell Microbiol*. 13: 797-805.
19. Black MW and Boothroyd JC. 2000. Lytic cycle of *Toxoplasma gondii*. *Microbiol Mol Biol Rev*. 64(3): 607-23.



20. Blader IJ, Manger ID, Boothroyd JC. 2001. Microarray analysis reveals previously unknown changes in *Toxoplasma gondii*-infected human cells, *J Biol Chem.* 276: 24223-31.
21. Bliss SK, Butcher BA, Denkers EY. 2000. Rapid recruitment of neutrophils containing prestored IL-12 during microbial infection. *J Immunol.* 165: 4515-21.
22. Bliss SK, Marshall AJ, Zhang Y, Denkers EY. 1999a. Human polymorphonuclear leukocytes produce IL-12, TNF- $\alpha$ , and the chemokines macrophage-inflammatory protein-1  $\alpha$  and -1 $\beta$  in response to *Toxoplasma gondii* antigens. *J Immunol.* 162(12): 7369-75.
23. Bliss SK, Zhang Y, Denkers EY. 1999b. Murine neutrophil stimulation by *Toxoplasma gondii* antigen drives high-level production of IFN- $\gamma$ -independent IL-12. *J Immunol.* 163(4): 2081-8.
24. Blumenschein TM, Friedrich N, Childs RA, Saouros S, Carpenter EP, *et al.* 2007. Atomic resolution insight into host cell recognition by *Toxoplasma gondii*. *Embo J.* 26: 2808-20.
25. Boothroyd JC. 2009. *Toxoplasma gondii*: 25 years and 25 major advances for the field *Int J Parasitol.* Author manuscript; available in PMC 2010 August 1. Published in final edited form as: *Int J Parasitol.* 39(8): 935–946.
26. Boothroyd JC and Grigg ME. 2002. Population biology of *Toxoplasma gondii* and its relevance to human infection: do different strains cause different disease? *Curr Opin Microbiol.* 5: 438-42.
27. Boothroyd JC, Hehl A, Knoll LJ, Manger ID. 1988. The surface of *Toxoplasma*: more and less. *Int J Parasitol.* 28(1): 3-9.
28. Bottos J, Miller RH, Belfort RN, Macedo AC; UNIFESP Toxoplasmosis Group, Belfort R Jr, Grigg ME. 2009. Bilateral retinochoroiditis caused by an atypical strain of *Toxoplasma gondii*. *Br J Ophthalmol.* 93(11):1546-50.
29. Bosch-Driessen L, Berendscho T, Ongkosuwito JV, Rothova A. 2002. Ocular toxoplasmosis: clinical features and prognosis of 154 patients. *Ophthalmology.* 109: 869-78.

30. Bradley PJ and Sibley LD. 2007. Rhoptries: an arsenal of secreted virulence factors. *Curr Opin Microbiol.* 10(6): 582-7.
31. Buguliskis JS, Brossier F, Shuman J, Sibley LD. 2010. Rhomboid 4 (ROM4) affects the processing of surface adhesins and facilitates host cell invasion by *Toxoplasma gondii*. *PLoS Pathog.* 6: e1000858.
32. Burnett AJ, Shortt SG, Isaac-Renton J, King A, Werker D, *et al.* 1998. Multiple cases of acquired toxoplasmosis retinitis presenting in an outbreak. *Ophthalmology.* 105: 1032-37.
33. Butcher BA, Fox BA, Rommereim LM, Kim SG, Maurer KJ, *et al.* 2011. *Toxoplasma gondii* rhoptry kinase ROP16 activates STAT3 and STAT6 resulting in cytokine inhibition and arginase-1-dependent growth control. *PLoS Pathog.* 7(9): e1002236.
34. Butcher BA, Greene RI, Henry SC, Annecharico KL, Weinberg JB, *et al.* 2005. GTPases regulate *Toxoplasma gondii* survival in activated macrophages. *Infect Immun.* 73: 3278-86.
35. Cai G, Radzanowski T, Villegas EN, Kastelein R, Hunter CA. 2000. Identification of STAT4-dependent and independent mechanisms of resistance to *Toxoplasma gondii*. *J Immunol.* 165: 2619-27.
36. Carne B, Bissuel F, Ajzenberg D, Bouyne R, Aznar C, *et al.* 2002. Severe acquired toxoplasmosis in immunocompetent adult patients in French Guiana. *J Clin Microbiol.* 40: 4037-44.
37. Carne B, Demar M, Ajzenberg D, Dardé ML. 2009. Severe acquired toxoplasmosis caused by wild cycle of *Toxoplasma gondii*, French Guiana. *Emerg Infect Dis.* 15(4): 656-8.
38. Cerede O, Dubremetz JF, Soete M, Deslee D, Vial H, *et al.* 2005. Synergistic role of micronemal proteins in *Toxoplasma gondii* virulence. *J Exp Med.* 201: 453e463.
39. Chaves AC, Ceravolo IP, Gomes JA, Zani CL, Romanha AJ, *et al.* 2001. IL-4 and IL-13 regulate the induction of indoleamine 2,3-dioxygenase

- activity and the control of *Toxoplasma gondii* replication in human fibroblasts activated with IFN-gamma. *Eur J Immunol.* 31: 333-44.
40. Chêne G, Thiébaud R. 2009 Options for clinical trials of pre and post-natal treatments for congenital toxoplasmosis. *Mem Inst Oswaldo Cruz.* 104(2):299-304.PMID: 19430657.
41. Chtanova T, Schaeffer M, Han SJ, van Dooren GG, Nollmann M, *et al.* 2008. Dynamics of neutrophil migration in lymph nodes during infection. *Immunity.* 29(3): 487-96.
42. Combe CL, Curiel TJ, Moretto MM, Khan IA. 2005. NK cells help to induce CD8(+)-T-cell immunity against *Toxoplasma gondii* in the absence of CD4(+) T cells. *Infect Immun.* 73(8): 4913-21.
43. Coppens I, Dunn JD, Romano JD, Pypaert M, Zhang H, *et al.* 2006. *Toxoplasma gondii* sequesters lysosomes from mammalian hosts in the vacuolar space. *Cell.* 125: 261e274.
44. Cordeiro CA, Moreira PR, Andrade MS, Dutra WO, Campos WR, *et al.* 2008. Interleukin-10 gene polymorphism (-1082G/A) is associated with toxoplasmic retinochoroiditis. *Invest Ophthalmol Vis Sci.* 49: 1979-82.
45. Cordeiro CA, Moreira PR, Bessa TF, Costa GC, Dutra WO, *et al.* 2013. Interleukin-6 gene polymorphism (-174 G/C) is associated with toxoplasmic retinochoroiditis. *Acta Ophthalmol.* 91(4):e311-4.
46. Cordeiro CA, Moreira PR, Costa GC, Dutra WO, Campos WR, *et al.* 2008. TNF-alpha gene polymorphism (-308G/A) and toxoplasmic retinochoroiditis. *Br J Ophthalmol.* 92: 986-8.
47. Cordeiro CA, Moreira PR, Costa GC, Dutra WO, Campos WR, Orefice F, Teixeira AL. 2008. Interleukin-1 gene polymorphisms and toxoplasmic retinochoroiditis. *Mol Vis.* 14:1845-9.
48. Cortina-Borja M, Tan HK, Wallon M, Paul M, Prusa A, Buffolano W, Malm G, Salt A, Freeman K, Petersen E, Gilbert RE; European Multicentre Study on Congenital Toxoplasmosis (EMSCOT). 2010. Prenatal treatment

- for serious neurological sequelae of congenital toxoplasmosis: an observational prospective cohort study. *PLoS Med.* 12;7(10).
49. Craver P and Knoll JL. 2007. Increased efficiency of homologous recombination in *Toxoplasma gondii* dense granule protein 3 demonstrates that GRA3 is not necessary in cell culture but does contribute to virulence, *Mol Biochem Parasitol.* 153: 149e157.
50. Cua DJ, Sherlock J, Chen Y, Murphy CA, Joyce B, *et al.* 2003. Interleukin-23 rather than interleukin-12 is the critical cytokine for autoimmune inflammation of the brain. *Nature.* 421: 744-8.
51. Cua DJ and Tato CM. 2010. Innate IL-17-producing cells: the sentinels of the immune system. *Nat Rev Immunol.* 10: 479-89.
52. Alexander DL, Mital J, Ward GE, Bradley P, Boothroyd JC. 2005. Identification of the moving junction complex of *Toxoplasma gondii*: a collaboration between distinct secretory organelles. *PLoS Pathog.* 1: e17.
53. Damsker JM, Hansen AM, Caspi RR. 2010. Th1 and Th17 cells: adversaries and collaborators. *Ann N Y Acad Sci.* 1183: 211-21.
54. Darde ML, Villena I, Pinon JM, Beguinot I. 1998. Severe toxoplasmosis caused by a *Toxoplasma gondii* strain with a new isoenzyme type acquired in French Guyana. *J Clin Microbiol.* 36: 324.
55. de Albuquerque MC, do Couto Aleixo ALQ, Benchimol EI, Leandro ACCS, das Neves LB, Vicente RT, Bonecini-Almeida MG, Amendoeira MRR. 2009. The IFN-g +874T/A gene polymorphism is associated with retinochoroiditis toxoplasmosis susceptibility. *Mem Inst Oswaldo Cruz.* 104: 451-5.
56. de Moura L, Bahia-Oliveira LM, Wada MY, Jones JL, Tuboi SH, *et al.* 2006. Waterborne toxoplasmosis, Brazil, from field to gene. *Emerg Infect Dis.* 12(2): 326-9.
57. Debierre-Grockiego F, Campos MA, Azzouz N, Schmidt J, Bieker U, *et al.* 2007. Activation of TLR2 and TLR4 by glycosylphosphatidylinositols derived from *Toxoplasma gondii*. *J Immunol.* 179(2): 1129-1137.

58. Debieire-Grockiego F, Azzouz N, Schmidt J, Dubremetz JF, Geyer H, et al. 2003. Roles of glycosylphosphatidylinositols of *Toxoplasma gondii*. Induction of tumor necrosis factor-alpha production in macrophages. *J Biol Chem*. 278: 32987e32993.
59. Del Rio L, Bennouna S, Salinas J, Denkers EY. 2001. CXCR2 deficiency confers impaired neutrophil recruitment and increased susceptibility during *Toxoplasma gondii* infection. *J Immunol*. 167(11): 6503-9.
60. de-la-Torre A, González G, Díaz-Ramírez J, Gómez-Marín JE. 2007. Screening by ophthalmoscopy for *Toxoplasma* retinochoroiditis in Colombia. *Am J Ophthalmol*. 143: 354-6.
61. de-la-Torre A, González-López G, Montoya-Gutiérrez JM, Marín-Arango V, Gómez-Marín JE. 2011. Quality of life assessment in ocular toxoplasmosis in a Colombian population. *Ocul Immunol Inflamm*. 19(4): 262-6.
62. de-la-Torre A, López-Castillo CA, Gómez-Marín JE. 2009. Incidence and clinical characteristics in a Colombian cohort of ocular toxoplasmosis. *Eye (Lond)*. 23(5): 1090-3.
63. de-la-Torre A, Lopez-Castillo CA, Rueda JC, Mantilla RD, Gómez-Marín JE, et al. 2009. Clinical patterns of uveitis in two ophthalmology centres in Bogota, Colombia. *Clin Experiment Ophthalmol*. 37: 458-66.
64. de-la-Torre A, Rios-Cadavid AC, Cardozo-García CM, Gómez-Marín JE. 2009. Frequency and factors associated with recurrences of ocular toxoplasmosis in a referral centre in Colombia. *Br J Ophthalmol*. 93(8): 1001-4.
65. de-la-Torre A, Stanford M, Curi A, Jaffe GJ, Gómez-Marín JE. 2011. Therapy for ocular toxoplasmosis. Review. *Ocul Immunol Inflamm*. Oct 19(5): 314-20.
66. Delorme-Walker, Abrivard M, Lagal V, Anderson K, Perazzi A, Gonzalez V, et al. 2012. Toxofilin upregulates the host cortical actin cytoskeleton dynamics facilitating *Toxoplasma* invasion, *J Cell Sci* 125(Pt 18): 4333-42.

67. Demar M, Hommel D, Djossou F, Peneau C, Boukhari R, Louvel D, Bourbigot AM, Nasser V, Ajzenberg D, Darde ML, Carme B. 2012. Acute toxoplasmoses in immunocompetent patients hospitalized in an intensive care unit in French Guiana. *Clin Microbiol Infect.* 18(7): E221-31.
68. Denkers EY. 2003. From cells to signaling cascades: manipulation of innate immunity by *Toxoplasma gondii*. *FEMS Immunol Med Microbiol.* 5;39(3):193-203.
69. Denkers EY and Gazzinelli RT. 1998. Regulation and function of T-cell-mediated immunity during *Toxoplasma gondii* infection. *Clin Microbiol Rev.* 11: 569-88.
70. Denkers EY, Schneider AG, Cohen SB, Butcher BA. 2012. Phagocyte responses to protozoan infection and how *Toxoplasma gondii* meets the challenge. *PLoS Pathog.* 8(8): e1002794.
71. Denkers EY, Yap G, Scharon-Kersten T, Charest H, Butcher BA, Caspar P, Heiny S, Sher A. 1997. Perforin-mediated cytotoxicity plays a limited role in host resistance to *Toxoplasma gondii*. *J Immunol.* 159(4): 1903-8.
72. Desmonts G and Couvreur J. 1974. Congenital toxoplasmosis. A prospective study of 378 pregnancies. *N Engl J Med.* 290(20): 1110-6.
73. Dodds EM, Holland GN, Stanford MR, Yu F, Siu WO, Shah KH, Ten Dam-van Loon N, Muccioli C, Hovakimyan A, Barisani-Asenbauer T. 2008. International Ocular Toxoplasmosis Research Group. Intraocular inflammation associated with ocular toxoplasmosis: relationships at initial examination. *Am J Ophthalmol.* 146(6): 856-65.
74. Dubey JP and Beattie CP. 1998. *Toxoplasmosis of animals and man.* CRC Press. Boca Raton, Florida. CRC Press pp.1-120.
75. Dubey JP, Miller NL, Frenkel JK. 1970. *Toxoplasma gondii* life cycle in cats, *J Am Vet Med Assoc.* 157: 1767e1770.
76. Dubey JP, Lindsay DS, Speer CA. 1998. Structures of *Toxoplasma gondii* tachyzoites, bradyzoites, and sporozoites and biology and development of tissue cysts. *Clin Microbiol Rev.* 11(2): 267-99.

77. Dubey JP and Jones JL. 2008. *Toxoplasma gondii* infection in humans and animals in the United States. *Int J Parasitol.* 38(11): 1257-78.
78. Dubey JP, Speer CA, Shen SK, Kwok OC, Blixt JA. 1997. Oocyst-induced murine toxoplasmosis: life cycle, pathogenicity, and stage conversion in mice fed *Toxoplasma gondii* oocysts. *J Parasitol.* 83(5): 870-82.
79. Dubey JP. 1998. Advances in the life cycle of *Toxoplasma gondii*. *Int J Parasitol.* 28(7): 1019-24.
80. Dubey JP. 1997. Bradyzoite-induced murine toxoplasmosis: stage conversion, pathogenesis, and tissue cyst formation in mice fed bradyzoites of different strains of *Toxoplasma gondii*. *J Eukaryot Microbiol.* 44(6): 592-602.
81. Dubey JP. 2009. History of the discovery of the life cycle of *Toxoplasma gondii*. *Int J Parasitol.* 39(8): 877-82.
82. Dubey JP. 2008. The history of *Toxoplasma gondii* – the first 100 years. *J Eukaryot Microbiol.* 55(6): 467-75.
83. Dubey JP. 2004. Toxoplasmosis – a waterborne zoonosis. *Vet Parasitol.* 126(1-2): 57-72.
84. Dubey JP. 2002. A review of toxoplasmosis in wild birds. *Vet Parasitol.* 106(2):121-53.
85. Dubey JP, Frenkel JK. 1976. Feline toxoplasmosis from acutely infected mice and the development of *Toxoplasma* cysts. *J Protozool.* 23(4):537-46.
86. Dubremetz JF, Lebrun M. 2012. Virulence factors of *Toxoplasma gondii*. *Microbes Infect.* pii: S1286-4579(12)00222-5.
87. Dunay IR, Damatta RA, Fux B, Presti R, Greco S, Colonna M, Sibley LD. 2008. Gr1 (+) inflammatory monocytes are required for mucosal resistance to the pathogen *Toxoplasma gondii*. *Immunity.* 29(2): 306-17.
88. Dunay IR, Fuchs A, Sibley LD. 2010. Inflammatory monocytes but not neutrophils are necessary to control infection with *Toxoplasma gondii* in mice. *Infect Immun.* 78(4): 1564-70.

89. Dupont CD, Christian DA, Hunter CA. 2012. Immune response and immunopathology during toxoplasmosis. *Semin Immunopathol.* 34(6): 793-813.
90. Dzierszinski F, Mortuaire M, Cesbron-Delauw MF, Tomavo S. 2000. Targeted disruption of the glycosylphosphatidylinositol-anchored surface antigen SAG3 gene in *Toxoplasma gondii* decreases host cell adhesion and drastically reduces virulence in mice, *Mol. Microbiol.* 37: 574-82.
91. Egan CE, Cohen SB, Denkers EY. 2010. Insights into inflammatory bowel disease using *Toxoplasma gondii* as an infectious trigger. *Immunol Cell Biol.* 90: 668-75.
92. Ekman CC, Chiossi MF, Meireles LR, Andrade Júnior HF, Figueiredo WM, Marciano MA, Luna EJ. 2012. Case-control study of an outbreak of acute toxoplasmosis in an industrial plant in the state of São Paulo, Brazil. *Rev Inst Med Trop Sao Paulo.* 54(5): 239-44.
93. El Hajj H, Demey E, Poncet J, Lebrun M, Wu B, Galeotti N, Fourmaux MN, Mercereau-Puijalon O, Vial H, Labesse G, Dubremetz JF. 2006. The ROP2 family of *Toxoplasma gondii* rhoptry proteins: proteomic and genomic characterization and molecular modeling, *Proteomics* 6: 5773-84.
94. El Hajj H, Lebrun M, Arold ST, Vial H, Labesse G, Dubremetz JF. 2007. ROP18 is a rhoptry kinase controlling the intracellular proliferation of *Toxoplasma gondii*, *PLoS Pathog.* 3: e14.
95. El-Asrar AMA, Struyfb S, Kangavea D, Al-Obeidana SS, Opdenakkerb G, Geboesch K, Van Damme J. 2011. Cytokine profiles in aqueous humor of patients with different clinical entities of endogenous uveitis. *Clin Immunol.* 139: 177-84.
96. Elbez-Rubinstein A, Ajzenberg D, Dardé ML, Cohen R, Dumètre A, Yera H, Gondon E, Janaud JC, Thulliez P. 2009. Congenital toxoplasmosis and reinfection during pregnancy: case report, strain characterization, experimental model of reinfection, and review. *J Infect Dis.* 199 (2):280-5.



97. Elmore SA, Jones JL, Conrad PA, Patton S, Lindsay DS, Dubey JP. 2010. *Toxoplasma gondii*: epidemiology, feline clinical aspects, and prevention. *Trends Parasitol.* 26(4): 190-6.
98. Fardeau C, Romand S, Rao NA, Cassoux N, Bettembourg O, Thulliez P, Lehoang P. 2002. Diagnosis of toxoplasmic retinochoroiditis with atypical clinical features. *Am J Ophthalmol.* 134(2):196-203.
99. Fatoohi F, Cozon GJ, Wallon M, Kodjikian L, Peyron F. 2006. Systemic T cell response to *Toxoplasma gondii* antigen in patients with ocular toxoplasmosis. *Jpn J Ophthalmol.* 50:103-10.
100. Faucher B, Garcia-Meric P, Franck J, Minodier P, Francois P, Gonnet S, L'ollivier C, Piarroux R. 2012. Long-term ocular outcome in congenital toxoplasmosis: a prospective cohort of treated children. *J Infect.* 64(1):104-9.
101. Fekkar A, Ajzenberg D, Bodaghi B, Touafek F, Le Hoang P, et al. 2011. Direct genotyping of *Toxoplasma gondii* in ocular fluid samples from 20 patients with ocular toxoplasmosis: predominance of type II in France. *J Clin Microbiol.* 49(4):1513-7.
102. Fentress SJ, Behnke MS, Dunay IR, Mashayekhi M, Rommereim LM, et al. 2010. Phosphorylation of immunity-related GTPases by a *Toxoplasma gondii*-secreted kinase promotes macrophage survival and virulence. *Cell Host Microbe.* 8: 484e495.
103. Feron EJ, Klaren VN, Wierenga EA, Verjans GM, Kijlstra A. 2001. Characterization of *Toxoplasma gondii*-specific T cells recovered from vitreous fluid of patients with ocular toxoplasmosis. *Invest Ophthalmol Vis Sci.* 42: 3228-32.
104. Flegr J. 2013. How and why *Toxoplasma* makes us crazy. *Trends Parasitol.* 29(4): 156-63.
105. Freeman K, Salt A, Prusa A, Malm G, Ferret N, Buffolano W, Schmidt D, Tan HK, Gilbert RE. European Multicentre Study on Congenital

- Toxoplasmosis. 2005. Association between congenital toxoplasmosis and parent-reported developmental outcomes, concerns, and impairments, in 3 year old children. *BMC Pediatr.* 13;5:23.
106. Freeman K, Tan HK, Prusa A, Petersen E, Buffolano W, Malm G, Cortina-Borja M, Gilbert R; European Multicentre Study on Congenital Toxoplasmosis. 2008. Predictors of retinochoroiditis in children with congenital toxoplasmosis: European, prospective cohort study. *Pediatrics.* 121(5):e1215-22.
  107. Frenkel JK. 1967. Adoptive immunity to intracellular infection. *J Immunol.* 98(6):1309-19.
  108. Frenkel JK, Escajadillo A. 1987. Cyst rupture as a pathogenic mechanism of toxoplasmic encephalitis. *Am J Trop Med Hyg.* 36(3):517-22.
  109. Gaddi PJ and Yap GS. 2007. Cytokine regulation of immunopathology in Toxoplasmosis. *Immunology and Cell Biology.* 85: 155-9.
  110. Gallego C, Saavedra C, Gómez Marín JE. 2006. Direct genotyping of animal and human isolates of *Toxoplasma gondii* from Colombia (South America). *Acta Tropica.* 97: 161-7.
  111. Garweg JG and Candolfi E. 2009. Immunopathology in ocular toxoplasmosis: facts and clues. *Mem Inst Oswaldo Cruz, Rio de Janeiro.* 104(2): 211-20.
  112. Garweg JG, de Groot-Mijnes JD, Montoya JG. 2011. Diagnostic approach to ocular toxoplasmosis. *Ocul Immunol Inflamm.* 19: 255-61.
  113. Garweg JG, Garweg SD, Flueckiger F, Jacquier P, Boehnke M. 2004. Aqueous humor and serum immunoblotting for immunoglobulin types G, A, M, and E in cases of human ocular toxoplasmosis. *J Clin Microbiol.* 42: 4593-8.
  114. Garweg JG, Ventura AC, Halberstadt M, Silveira C, Muccioli C, Belfort RJ, Jacquier P. 2005. Specific antibody levels in the aqueous humor and

- serum of two distinct populations of patients with ocular toxoplasmosis. *Int J Med Microbiol.* 295(4): 287-95.
115. Gazzinelli RT, Bala S, Stevens R, Baseler M, Wahl L, Kovacs J, Sher A. 1995. HIV infection suppresses type 1 lymphokine and IL-12 responses to *Toxoplasma gondii* but fails to inhibit the synthesis of other parasite-induced monokines. *J Immunol.* 155(3): 1565-74.
  116. Gazzinelli RT, Brezin A, Qian L, Nussenblatt RB, Chan CC. 1994. *Toxoplasma gondii*: acquired ocular toxoplasmosis in the murine model, protective role of TNF- $\alpha$  and IFN- $\lambda$  *Exp Parasitol.* 78: 217-29.
  117. Gazzinelli RT, Hakim FT, Hieny S, Shearer GM, Sher A. 1991. Synergistic role of CD4<sup>+</sup> and CD8<sup>+</sup> T lymphocytes in IFN-gamma production and protective immunity induced by an attenuated *Toxoplasma gondii* vaccine. *J Immunol.* 146(1):286-92.
  118. Gazzinelli RT, Hieny S, Wynn TA, Wolf S, Sher A. 1993. Interleukin 12 is required for the T-lymphocyte-independent induction of interferon gamma by an intracellular parasite and induces resistance in T-cell-deficient hosts. *Proc Natl Acad Sci USA.* 90(13): 6115-19.
  119. Gazzinelli RT, Wysocka M, Hayashi S, Denkers EY, Hieny S, Caspar P, Trinchieri G, Sher A. 1994. Parasite-induced IL-12 stimulates early IFN-gamma synthesis and resistance during acute infection with *Toxoplasma gondii*. *J Immunol.* 153(6): 2533-43.
  120. Gazzinelli RT, Wysocka M, Hieny S, Schariton-Kersten T, Cheever A, Kuhn R *et al.* 1996. In the absence of endogenous IL-10, mice acutely infected with *Toxoplasma gondii* succumb to a lethal immune response dependent on CD4<sup>+</sup> T cells and accompanied by overproduction of IL-12, IFN-gamma and TNF-alpha. *J Immunol.* 157: 798-805.
  121. Gazzinelli RT, Xu Y, Hieny S, Cheever A, Sher A. 1992. Simultaneous depletion of CD4<sup>+</sup> and CD8<sup>+</sup> T lymphocytes is required to reactivate chronic infection with *Toxoplasma gondii*. *J Immunol.* 149:175-80.

122. Gigley JP, Bhadra R, Moretto MM, Khan IA. 2012. T cell exhaustion in protozoan disease. *Trends Parasitol.* 28: 377-84.
123. Gilbert LA, Ravindran S, Turetzky J.M, Boothroyd JC, Bradley PJ. 2007. *Toxoplasma gondii* targets a protein phosphatase 2C to the nuclei of infected host cells, *Eukaryot Cell.* 6: 73e83.
124. Gilbert RE, Dunn DT, Lightman S, Murray PI, Pavesio CE, *et al.* 1999. Incidence of symptomatic toxoplasma eye disease: aetiology and public health implications. *Epidemiol Infect.* 123: 283-89.
125. Gilbert RE, Freeman K, Lago EG, Bahia-Oliveira LM, Tan HK, Wallon M, Buffolano W, Stanford MR, Petersen E, for The European Multicentre Study on Congenital Toxoplasmosis (EMSCOT). 2008. Ocular sequelae of congenital toxoplasmosis in Brazil compared with Europe. *PLoS Negl Trop Dis.* 2: e277.
126. Gilbert RE, See SE, Jones LV, Stanford MS. 2002. Antibiotics versus control for toxoplasma retinochoroiditis. *Cochrane Database Syst Rev.* 1: CD002218.
127. Glasner PD, Silveira C, Kruszon-Moran D, *et al.* 1992. An unusually high prevalence of ocular toxoplasmosis in southern Brazil. *Am J Ophthalmol.* 114: 136-44.
128. Goldszmid RS, Bafica A, Jankovic D, Feng CG, Caspar P, Winkler-Pickett R, Trinchieri G, Sher A. 2007. TAP-1 indirectly regulates CD4+ T cell priming in *Toxoplasma gondii* infection by controlling NK cell IFN-gamma production. *J Exp Med.* 204: 2591-602.
129. Gómez-Marín JE, de-la-Torre A, Angel-Muller E, Rubio J, Arenas J, *et al.* 2011. First Colombian multicentric newborn screening for congenital toxoplasmosis. *PLoS Negl Trop Dis.* 5: e1195.
130. Gómez-Marín JE, de-la-Torre A, Barrios P, Cardona N, Álvarez C, Herrera C. 2012. Toxoplasmosis in military personnel involved in jungle operations. *Acta Trop.* 122: 46-51.

131. Gómez-Marín JE, Gonzalez MM, Montoya MT, Giraldo A, Castaño JC. 2007. A newborn screening programme for congenital toxoplasmosis in the setting of a country with less income. *Arch Dis Child*. 92: 88.
132. Gómez-Marín JE. 2009. Toxoplasma strain nomenclature. *J Infect Dis*. 200: 1012.
133. Gras L, Wallon M, Pollak A, Cortina-Borja M, Evengard B, *et al*. 2005. Association between prenatal treatment and clinical manifestations of congenital toxoplasmosis in infancy: a cohort study in 13 European centres. *Acta Paediatr*. 94(12): 1721-31.
134. Grigg ME, Ganatra J, Boothroyd JC, Margolis TP. 2001. Unusual abundance of atypical strains associated with human ocular toxoplasmosis. *J Infect Dis*. 184: 633-9.
135. Halonen SK, Chiu F, Weiss LM. 1998. Effect of cytokines on growth of *Toxoplasma gondii* in murine astrocytes. *Infect Immun*. 66(10): 4989-93.
136. Halonen SK and Weiss LM. 2013. Toxoplasmosis. *Handb Clin Neurol*. 114:125-45.
137. Hammouda NA, Rashwan EA, Hussien ED, Abo el-Naga I, Fathy FM. 1995. Measurement of respiratory burst of TNF and IL-1 cytokine activated murine peritoneal macrophages challenged with *Toxoplasma gondii*. *J Egypt Soc Parasitol*. 25(3): 683-91.
138. Happel KI, Dubin PJ, Zheng M, Ghilardi N, Lockhart C, *et al*. 2005. Divergent roles of IL-23 and IL-12 in host defense against *Klebsiella pneumoniae*. *J Exp Med*. 202: 761-9.
139. Hartley WJ and Marshall SC. 1957. Toxoplasmosis as a cause of ovine perinatal mortality. *N Z Vet J*. 5 (4):119-124.
140. Hauser WE Jr and Tsai V. 1986. Acute toxoplasma infection of mice induces spleen NK cells that are cytotoxic for *T. gondii* in vitro. *J Immunol*. 136(1): 313-9.

141. Heaslip AT, Dzierszynski F, Stein B, Hu K. 2010. TgMORN1 is a key organizer for the basal complex of *Toxoplasma gondii*, PLoS Pathog 6: e1000754.
142. Hill D and Dubey JP. 2002. *Toxoplasma gondii*: transmission, diagnosis and prevention. Clin Microbiol Infect. Oct;8(10):634-40.
143. Hill DE, Chirukandoth S, Dubey JP. 2005. Biology and epidemiology of *Toxoplasma gondii* in man and animals. Anim Health Res Rev. 6(1): 41-61.
144. Hofman P, Bernard E, Michiels JF, Thyss A, Le Fichoux Y, Loubière R. 1993. Extracerebral toxoplasmosis in the acquired immunodeficiency syndrome (AIDS). Pathol Res Pract. 189(8): 894-901.
145. Holland GN. 2003. Ocular toxoplasmosis: a global reassessment. Part I: epidemiology and course of disease. Am J Ophthalmol. 136(6): 973-88.
146. Howe DK, Honoré S, Derouin F, Sibley LD. 1997. Determination of genotypes of *Toxoplasma gondii* strains isolated from patients with toxoplasmosis. J Clin Microbiol. 35(6):1411-4.
147. Howe DK, Sibley LD. 1995. *Toxoplasma gondii* comprises three clonal lineages: correlation of parasite genotype with human disease. J Infect Dis. 172(6):1561-6.
148. Hunter CA, Chizzonite R, Remington JS. 1995. IL-1 beta is required for IL-12 to induce production of IFN-gamma by NK cells. A role for IL-1 beta in the T cell-independent mechanism of resistance against intracellular pathogens. J Immunol. 155(9): 4347-54.
149. Hunter CA and Sibley LD. 2012. Modulation of innate immunity by *Toxoplasma gondii* virulence effectors. Nat Rev Microbiol. 10(11): 766-78.
150. Hunter CA, Subauste CS, Van Cleave VH, Remington JS. 1994. Production of gamma interferon by natural killer cells from *Toxoplasma gondii*-infected SCID mice: regulation by interleukin-10, interleukin-12, and tumor necrosis factor alpha. Infect Immun. 62(7): 2818-24.

151. Huynh MH, Carruthers VB. 2006. Toxoplasma MIC2 is a major determinant of invasion and virulence. *PLoS Pathog.* 2: e84.
152. Huynh MH, Rabenau KE, Harper JM, Beatty WL, Sibley LD, Carruthers VB. 2003. Rapid invasion of host cells by Toxoplasma requires secretion of the MIC2-M2AP adhesive protein complex. *Embo J.* 22: 2082e2090.
153. Ivanov II, McKenzie BS, Zhou L, Tadokoro CE, Lepelley A, Lafaille JJ *et al.* 2006. The orphan nuclear receptor ROR $\gamma$  directs the differentiation program of proinflammatory IL-17<sup>+</sup> T helper cells. *Cell.* 126: 1121-33.
154. Jankovic D, Kullberg MC, Hieny S, Caspar P, Collazo CM, Sher A. 2002. In the absence of IL-12, CD4<sup>+</sup> T cell responses to intracellular pathogens fail to default to a Th2 pattern and are host protective in an IL-10<sup>-/-</sup> setting. *Immunity.* 16: 429-39.
155. Jenkins MC, Tuo W, Feng X, Cao L, Murphy C, Fetterer R. 2010. *Neospora caninum*: cloning and expression of a gene coding for cytokine-inducing profilin. *Exp Parasitol.* 125(4): 357-62.
156. Jewett TJ and Sibley LD. 2004. The toxoplasma proteins MIC2 and M2AP form a hexameric complex necessary for intracellular survival. *J Biol Chem.* 279: 9362e9369.
157. Jiang G, Ke Y, Sun D, Han G, Kaplan HJ, Shao H. 2008. Reactivation of uveitogenic T cells by retinal astrocytes derived from experimental autoimmune uveitis-prone B10RIII mice. *Invest Ophthalmol Vis Sci.* 49(1): 282-9.
158. Johnson Jr WD. 1981. Chronological development of cellular immunity in human toxoplasmosis. *Infect Immun.* 33: 948-9.
159. Johnson LL and Sayles PC. 2002. Deficient humoral responses underlie susceptibility to *Toxoplasma gondii* in CD4-deficient mice. *Infect Immun.* 70(1): 185-91.

160. Jones JL, Kruszon-Moran D, Sanders-Lewis K, Wilson M. 2007. Toxoplasma gondii infection in the United States, 1999-2004, decline from the prior decade. *Am J Trop Med Hyg.* 77(3): 405-10.
161. Kang H, Remington JS, Suzuki Y. 2000. Decreased resistance of B cell-deficient mice to infection with Toxoplasma gondii despite unimpaired expression of IFN-gamma, TNF-alpha, and inducible nitric oxide synthase. *J Immunol.* 164(5): 2629-34.
162. Kaplan JE, Benson C, Holmes KH, Brooks JT, Pau A, Masur H. 2009. Guidelines for prevention and treatment of opportunistic infections in HIV-infected adults and adolescents: recommendations from CDC, the National Institutes of Health, and the HIV Medicine Association of the Infectious Diseases Society of America. *MMWR Recomm Rep.* 58: 1-207.
163. Ke Y, Jiang G, Sun D, Kaplan HJ, Shao H. 2008. Ocular regulatory T cells distinguish monophasic from recurrent autoimmune uveitis. *Invest Ophthalmol Vis Sci.* 49(9): 3999-4007.
164. Kelly MN, Kolls JK, Happel K, Schwartzman JD, Schwarzenberger P, Combe C *et al.* 2005. Interleukin-17/interleukin-17 receptor-mediated signaling is important for generation of an optimal polymorphonuclear response against Toxoplasma gondii infection. *Infect Immun.* 73: 617-21.
165. Kessler H, Herm-Gotz A, Hegge S, Rauch M, Soldati-Favre D, Frischknecht F, Meissner M. 2008. Microneme protein 8ea new essential invasion factor in Toxoplasma gondii, *J Cell Sci.* 121: 947e956.
166. Khan A, Taylor S, Su C, Mackey AJ, Boyle J, Cole R, *et al.* 2005. Composite genome map and recombination parameters derived from three archetypal lineages of Toxoplasma gondii. *Nucleic Acids Res.* 33(9):2980-92.
167. Khan IA, Thomas SY, Moretto MM, *et al.* 2006. CCR5 is essential for NK cell trafficking and host survival following Toxoplasma gondii infection. *PLoS Pathog.* 2(6):e49.



168. Kieffer F, Wallon M. 2013. Congenital toxoplasmosis. *Handb Clin Neurol.* 112:1099-101.
169. Kim SK, Karasov A, Boothroyd JC. 2007. Bradyzoite-specific surface antigen SRS9 plays a role in maintaining *Toxoplasma gondii* persistence in the brain and in host control of parasite replication in the intestine, *Infect Immun.* 75: 1626e1634.
170. Kolls JK and Linden A. 2004. Interleukin-17 family members and inflammation. *Immunity.* 21: 467-76.
171. Konishi E and Nakao M. 1992. Naturally occurring immunoglobulin M antibodies: enhancement of phagocytic and microbicidal activities of human neutrophils against *Toxoplasma gondii*. *Parasitology.* 104(Pt 3): 427-32.
172. Lacombe MS, Martin CM, Chamond RR, Galera JM, Omar M, Estevez EC. 2000. Aqueous and serum interferon gamma, interleukin (IL) 2, IL-4, and IL-10 in patients with uveitis. *Arch Ophthalmol.* 118(6):768-72.
173. Lagal V, Binder EM, Huynh MH, Kafsack BF, Harris PK, Diez R, Chen D, Cole RN, Carruthers VB, Kim K. 2010. *Toxoplasma gondii* protease TgSUB1 is required for cell surface processing of micronemal adhesive complexes and efficient adhesion of tachyzoites. *Cell Microbiol.* 12: 1792e1808.
174. Lahmar I, Abou-Bacar A, Abdelrahman T, Guinard M, Babba H, Ben Yahia S, Kairallah M, Speeg-Schatz C, Bourcier T, Sauer A, Villard O, Pfaff AW, Mousli M, Garweg JG, Candolfi E. 2009. Cytokine profiles in toxoplasmic and viral uveitis. *J Infect Dis.* 199(8): 1239-49.
175. Langrish CL, Chen Y, Blumenschein WM, Mattson J, Basham B, Sedgwick JD, *et al.* 2005. IL-23 drives a pathogenic T cell population that induces autoimmune inflammation. *J Exp Med.* 201: 233-40.
176. LaRosa DF, Stumhofer JS, Gelman AE, Rahman AH, Taylor DK, Hunter CA, Turka LA. 2008. T cell expression of MyD88 is required for

- resistance to *Toxoplasma gondii*. *Proc Natl Acad Sci U S A*. 105(10): 3855-60.
177. Lebrun M, Michelin A, El Hajj H, Poncet J, Bradley PJ, Vial H, Dubremetz JF. 2005. The rhoptry neck protein RON4 re-localizes at the moving junction during *Toxoplasma gondii* invasion. *Cell Microbiol*. 7: 1823e1833.
178. Lee YS, Amadi-Obi A, Yu CR, and Egwuagu CE. 2011. Retinal cells suppress intraocular inflammation (uveitis) through production of interleukin-27 and interleukin-10. *Immunology*. 132(4): 492-502.
179. Lehmann T, Marcet PL, Graham DH, Dahl ER, Dubey JP. 2006. Globalization and the population structure of *Toxoplasma gondii*. *Proc Natl Acad Sci U S A*. 103(30): 11423-8.
180. Lekutis C, Ferguson DJ, Grigg ME, Camps M, Boothroyd JC. 2001. Surface antigens of *Toxoplasma gondii*: variations on a theme. *Int J Parasitol*. 31: 1285e1292.
181. Levings MK, Bacchetta R, Schulz U, Roncarolo MG. The role of IL-10 and TGF-beta in the differentiation and effector function of T regulatory cells. *Int Arch Allergy Immunol*. 129: 263-76.
182. Liang SC, Tan XY, Luxenberg DP, Karim R, Dunussi-Joannopoulos K, Collins M, *et al*. 2006. Interleukin (IL)-22 and IL-17 are coexpressed by Th17 cells and cooperatively enhance expression of antimicrobial peptides. *J Exp Med*. 203: 2271-9.
183. Lieberman LA, Cardillo F, Owyang AM, Rennick DM, Cua DJ, Kastelein RA, *et al*. 2004. IL-23 provides a limited mechanism of resistance to acute toxoplasmosis in the absence of IL-12. *J Immunol*. 173: 1887-93.
184. Liesenfeld O, Kang H, Park D, Nguyen TA, Parkhe CV, Watanabe H *et al*. 1999. TNF-alpha, nitric oxide and IFN-gamma are all critical for development of necrosis in the small intestine and early mortality in

- genetically susceptible mice infected per orally with *Toxoplasma gondii*. *Parasite Immunol.* 21: 365-76.
185. Liesenfeld O, Kosek J, Remington JS, Suzuki Y. 1996. Association of CD4+ T cell-dependent, interferon-gamma-mediated necrosis of the small intestine with genetic susceptibility of mice to per oral infection with *Toxoplasma gondii*. *J Exp Med.* 184: 597-607.
  186. Liesenfeld O. 2002. Oral infection of C57BL/6 mice with *Toxoplasma gondii*: a new model of inflammatory bowel disease? *J Infect Dis.* 185 (Suppl 1): S96–101.
  187. Lindsay DS and Dubey JP. 2011. *Toxoplasma gondii*: the changing paradigm of congenital toxoplasmosis. *Parasitology.* 9:1-3.
  188. Liu CH, Fan YT, Dias A, Esper L, Corn RA, Bafica A, Machado FS, Aliberti J. 2006. Cutting edge: dendritic cells are essential for in vivo IL-12 production and development of resistance against *Toxoplasma gondii* infection in mice. *J Immunol.* 177(1): 31-3.
  189. Lodoen MB, Gerke C, Boothroyd JC. 2010. A highly sensitive FRET-based approach reveals secretion of the actin-binding protein toxofilin during *Toxoplasma gondii* infection. *Cell Microbiol.* 12: 55e66.
  190. Lopez-Castillo CA, Diaz-Ramirez J, Gómez-Marín JE. 2005. Risk factors for *Toxoplasma gondii* infection in pregnant women in Armenia, Colombia. *Rev Salud Pública, Bogotá.* 7: 180-90.
  191. Lu F, Huang S, Kasper LH. 2004. CD4+ T cells in the pathogenesis of murine ocular toxoplasmosis. *Infect Immun.* 72: 4966-72.
  192. Lu F, Huang S, Kasper LH. 2003. Interleukin-10 and pathogenesis of murine ocular toxoplasmosis. *Infect Immun.* 71(12): 7159-63.
  193. Luft BJ and Remington JS. 1992. Toxoplasmic encephalitis in AIDS. *Clin Infect Dis.* 15(2): 211-22.
  194. Lyons RE, Anthony JP, Ferguson DJ, Byrne N, Alexander J, Roberts F, Roberts CW. 2001. Immunological studies of chronic ocular toxoplasmosis: up-regulation of major histocompatibility complex class I

- and transforming growth factor beta and a protective role for interleukin-6. *Infect Immun.* 69: 2589-95.
195. Martens S, Parvanova I, Zerrahn J, Griffiths G, Schell G, Reichmann G, Howard J. 2005. Disruption of *Toxoplasma gondii* parasitophorous vacuoles by the mouse p47-resistance GTPases. *PLoS Pathog.* 1: e24.
196. Mashayekhi M, Sandau MM, Dunay IR, Frickel EM, Khan A, Goldszmid RS, Sher A, Ploegh HL, Murphy TL, Sibley LD, Murphy KM. 2011. CD8alpha(+) dendritic cells are the critical source of interleukin-12 that controls acute infection by *Toxoplasma gondii* tachyzoites. *Immunity.* 35(2): 249-59.
197. Matsumoto R, Matsumoto M, Mita S, Hitoshi Y, Ando M, et al. 1989. Interleukin-5 induces maturation but not class switching of surface IgA-positive B cells into IgA-secreting cells. *Immunology.* 66(1): 32–38.
198. McAuley JB. 2008. Toxoplasmosis in children. *Pediatr Infect Dis J.* 27(2):161-2.
199. McCannel CA, Holland GN, Helm CJ, Cornell PJ, Winston JV, Rimmer TG. 1996. Causes of uveitis in the general practice of ophthalmology. UCLA Community-Based Uveitis Study Group. *Am J Ophthalmol.* 121(1): 35-46.
200. McKenzie AN, Culpepper JA, de Waal Malefyt R, Brière F, Punnonen J, Aversa G, Sato A, et al. 1993. Interleukin 13, a T-cell-derived cytokine that regulates human monocyte and B-cell function. *Proc Natl Acad Sci U S A.* 90(8): 3735-9.
201. McKenzie BS, Kastelein RA, Cua DJ. 2006. Understanding the IL-23-IL-17 immune pathway. *Trends Immunol.* 27: 17-23.
202. McLeod R, Kieffer F, Sautter M, Hosten T, Pelloux H. 2009. Why prevent, diagnose and treat congenital toxoplasmosis? *Mem Inst Oswaldo Cruz.* 104 (2):320-44.

203. McLeod R, Boyer KM, Lee D, Mui E, Wroblewski K, Karrison T, Noble AG, Withers S, Swisher CN, Heydemann PT, Sautter M, Babiarz J, Rabiah P, Meier P, Grigg ME; Toxoplasmosis Study Group. 2012. Prematurity and severity are associated with *Toxoplasma gondii* alleles (NCCCTS, 1981-2009). *Clin Infect Dis.* 54(11):1595-605.
204. Medoff BD, Sauty A, Tager AM, Maclean JA, Smith RN, Mathew A, Dufour JH, *et al.* 2002. IFN-gamma-inducible protein 10 (CXCL10) contributes to airway hyperreactivity and airway inflammation in a mouse model of asthma. *J Immunol.* 168(10): 5278-86.
205. Melo MB, Jensen KD, Saeij JP. 2011. *Toxoplasma gondii* effectors are master regulators of the inflammatory response. *Trends Parasitol.* 27: 487e495.
206. Mennechet FJ, Kasper LH, Rachinel N, Li W, Vandewalle A, Buzoni-Gatel D. 2002. Lamina propria CD4+ T lymphocytes synergize with murine intestinal epithelial cells to enhance proinflammatory response against an intracellular pathogen. *J Immunol.* 168: 2988-96.
207. Mercier C, Howe DK, Mordue D, Lingnau M, Sibley LD. 1998. Targeted disruption of the GRA2 locus in *Toxoplasma gondii* decreases acute virulence in mice. *Infect Immun.* 66: 4176e4182.
208. Mercier C, Rauscher B, Lecordier L, Deslee D, Dubremetz JF, Cesbron-Delauw MF. 2001. Lack of expression of the dense granule protein GRA5 does not affect the development of *Toxoplasma* tachyzoites. *Mol Biochem Parasitol.* 116: 247e251.
209. Minot S, Melo MB, Li F, Lu D, Niedelman W, Levine SS, *et al.* 2012. Admixture and recombination among *Toxoplasma gondii* lineages explain global genome diversity. *Proc Natl Acad Sci U S A.* 109(33): 13458-63.
210. Montoya JG and Liesenfeld O. 2004. Toxoplasmosis. *Lancet.* 363(9425): 1965-76.
211. Montoya JG and Remington JS. 1996. Toxoplasmic chorioretinitis in the setting of acute acquired toxoplasmosis. *Clin Infect Dis.* 23(2): 277-82.

212. Moore KW, de Waal Malefyt R, Coffman RL, O'Garra A. 2001. Interleukin-10 and the interleukin-10 receptor. *Annu Rev Immunol.* 19: 683-765.
213. Mordue DG, Monroy F, La Regina M, Dinarello CA, Sibley LD. 2001. Acute toxoplasmosis leads to lethal overproduction of Th1 cytokines. *J Immunol.* 167: 4574-84.
214. Mordue DG and Sibley LD. 2003. A novel population of Gr-1+-activated macrophages induced during acute toxoplasmosis. *J Leukoc Biol.* 74(6): 1015-25
215. Morisset S, Peyron F, Lobry JR, Garweg J, Ferrandiz J et al. 2008. Serotyping of *Toxoplasma gondii*: striking homogeneous pattern between symptomatic and asymptomatic infections within Europe and South America. *Microbes Infect.* 10(7): 742-7.
216. Morrissette NS and Sibley LD. 2002. Disruption of microtubules uncouples budding and nuclear division in *Toxoplasma gondii*. *J Cell Sci.* 115(Pt 5): 1017-25.
217. Mosser DM, Zhang X. 2008. Interleukin-10: new perspectives on an old cytokine. *Immunol Rev.* 226:205-18.
218. Mun HS, Aosai F, Chen M, Piao LX, Norose K, Iwakura Y, *et al.* 2003. Pathogenicity of *Toxoplasma gondii* through B-2 cell-mediated downregulation of host defense responses. *Microbiol Immunol.* 47: 533-42.
219. Munoz M, Liesenfeld O, Heimesaat MM. 2011. Immunology of *Toxoplasma gondii*. *Immunol Rev.* 240(1): 269-85.
220. Muñoz M, Heimesaat MM, Danker K, Struck D, Lohmann U, et al. 2009. Interleukin (IL)-23 mediates *Toxoplasma gondii*-induced immunopathology in the gut via matrixmetalloproteinase-2 and IL-22 but independent of IL-17. *J Exp Med.* 206(13):3047-59.

221. Murray PI, Hoekzema R, van Haren MA, de Hon FD, Kijlstra A. 1990. Aqueous humor interleukin-6 levels in uveitis. *Invest Ophthalmol Vis Sci.* 31: 917-920.
222. Nagineni CN, Pardhasaradhi K, Martins MC, Detrick B, Hooks JJ. 1996. Mechanisms of interferon-induced inhibition of *Toxoplasma gondii* replication in human retinal pigment epithelial cells. *Infect Immun.* 64: 4188-96.
223. Nakao M and Konishi E. 1991. Proliferation of *Toxoplasma gondii* in human neutrophils in vitro. *Parasitology.* 103(Pt 1): 23-7.
224. Nickdel MB, Roberts F, Brombacher F, Alexander J, Roberts CW. 2001. Counter-protective role for interleukin-5 during acute *Toxoplasma gondii* Infection. *Infect Immun.* 69(2): 1044-52.
225. Niedelman W, Gold DA, Rosowski EE, Sprockholt JK, Lim D, Farid Arenas A, Melo MB, Spooner E, Yaffe MB, Saeij JP. 2012. The rhoptry proteins ROP18 and ROP5 mediate *Toxoplasma gondii* evasion of the Murine, but not the human, interferon-gamma response. *PLoS Pathog.* 8: e1002784.
226. Nishanth G, Sakowicz-Burkiewicz M, Händel U, *et al.* 2010. Protective *Toxoplasma gondii*-specific T-cell responses require T-cell-specific expression of protein kinase C-theta. *Infect Immun.* 78(8): 3454-64.
227. Norose K, Mun HS, Aosai F, Chen M, Piao LX, Kobayashi M, Iwakura Y, Yano A. 2003. IFN-gamma-regulated *Toxoplasma gondii* distribution and load in the murine eye. *Invest Ophthalmol Vis Sci.* 44: 4375-81.
228. Nussenblatt RB, Mittal KK, Fuhman S, Sharma SD, Palestine AG. 1989. Lymphocyte proliferative responses of patients with ocular toxoplasmosis to parasite and retinal antigens. *Am J Ophthalmol.* 107: 632-41.
229. O'Connor GR. 1983. Factors related to the initiation and recurrence of uveitis. XL Edward Jackson memorial lecture. *Am J Ophthalmol.* 96: 577-99.

230. O'Garra A, Vieira PL, Vieira P, Goldfeld AE. 2004. IL-10-producing and naturally-occurring CD4<sup>+</sup> Tregs: limiting collateral damage. *J Clin Invest.*114: 1372-8.
231. Ohta K, Yamagami S, Taylor AW, Streilein JW. 2000. IL-6 antagonizes TGF-beta and abolishes immune privilege in eyes with endotoxin-induced uveitis. *Invest Ophthalmol Vis Sci.* 41: 2591-9.
232. Ooi KG, Galatowicz G, Calder VL, Lightman SL. 2006. Cytokines and chemokines in uveitis: is there a correlation with clinical phenotype? *Clin Med Res.* 4(4):294-309. Review.
233. Ooi KG, Galatowicz G, Towler HM, Lightman SL, Calder VL. 2006. Multiplex cytokine detection versus ELISA for aqueous humor: IL-5, IL-10, and IFN-gamma profiles in uveitis. *Invest Ophthalmol Vis Sci.*47(1):272-7.
234. Okamoto S, Hara Y, Streilein JW. 1995. Induction of anterior chamber-associated immune deviation with lymphoreticular allogeneic cells. *Transplantation.* 59: 377-81.
235. Ong YC, Reese ML, Boothroyd JC. 2009. Toxoplasma rhoptry protein 16 (ROP16) subverts host function by direct tyrosine phosphorylation of STAT6, *J Biol Chem.* 285: 28731e28740.
236. Ongkosuwito JV, Feron EJ, van Doornik CE, Van der Lelij A, Hoyng CB, La Heij EC, *et al.* 1998. Analysis of immunoregulatory cytokines in ocular fluid samples from patients with uveitis. *Invest Ophthalmol Vis Sci.* 39: 2659-65.
237. Opitz C and Soldati D. 2002. 'The glideosome': a dynamic complex powering gliding motion and host cell invasion by *Toxoplasma gondii*. *Mol Microbiol.* 45: 597-604.
238. Pappas G, Roussos N, Falagas ME. 2009. Toxoplasmosis snapshots: global status of *Toxoplasma gondii* seroprevalence and implications for pregnancy and congenital toxoplasmosis. *Int J Parasitol.* 39: 1385-94.
239. Parussini F, Tang Q, Moin SM, Mital J, Urban S, Ward GE. 2012. Intramembrane proteolysis of *Toxoplasma* apical membrane antigen 1



- facilitates host-cell invasion but is dispensable for replication. *Proc Natl Acad Sci U S A.* 109: 7463-8.
240. Peixoto L, Chen F, Harb OS, Davis PH, Beiting DP, *et al.* 2010. Integrative genomic approaches highlight a family of parasite-specific kinases that regulate host responses. *Cell Host Microbe.* 8: 208-18.
241. Peixoto-Rangel AL, Miller EN, Castellucci L, Jamieson SE, Peixe RG, *et al.* 2009. Candidate gene analysis of ocular toxoplasmosis in Brazil: evidence for a role for toll-like receptor 9 (TLR9). *Mem Inst Oswaldo Cruz.* 104: 1187-90.
242. Perez VL, Papaliodis GN, Chu D, Anzaar F, Christen W, Foster CS. 2004. Elevated levels of interleukin 6 in the vitreous fluid of patients with pars planitis and posterior uveitis: the Massachusetts eye & ear experience and review of previous studies. *Ocul Immunol Inflamm.* 12: 193-201.
243. Pernas L, Boothroyd J.C. 2010. Association of host mitochondria with the parasitophorous vacuole during *Toxoplasma* infection is not dependent on rhoptry proteins ROP2/8. *Int J Parasitol.* 40: 1367e1371.
244. Persson CM, Lambert H, Vutova PP, Dellacasa-Lindberg I, Nederby J, Yagita H, *et al.* 2009. Transmission of *Toxoplasma gondii* from infected dendritic cells to natural killer cells. *Infect Immun.* 77(3): 970-6.
245. Petersen E, Kijlstra A, Stanford M. 2012. Epidemiology of ocular toxoplasmosis. *Ocul Immunol Inflamm.* 20: 68-75.
246. Peyron F, Lobry JR, Musset K, Ferrandiz J, Gomez-Marin JE, *et al.* 2006. Serotyping of *Toxoplasma gondii* in chronically infected pregnant women: predominance of type II in Europe and types I and III in Colombia (South America). *Microbes Infect.* 8(9-10): 2333-40.
247. Peyron F, Garweg JG, Wallon M, Descloux E, Rolland M, Barth J. 2011. Long-term impact of treated congenital toxoplasmosis on quality of life and visual performance. *Pediatr Infect Dis J.* 30(7):597-600

248. Pfefferkorn LC, Pfefferkorn ER. 1980. *Toxoplasma gondii*: genetic recombination between drug resistant mutants. *Exp Parasitol.* 50(3):305-16.
249. Pivetti-Pezzi P, Accorinti M, Tambori S, Ciapparoni V, Ahmed-Adulaziz M. 1994. Clinical features of toxoplasmic retinochoroiditis in patients with acquired immunodeficiency syndrome. *Ann Ophthalmol.* 26: 73-84.
250. Plattner F, Yarovinsky F, Romero S, Didry D, Carlier MF, *et al.* 2008. *Toxoplasma* profilin is essential for host cell invasion and TLR11-dependent induction of an interleukin-12 response. *Cell Host Microbe* 3: 77e87.
251. Porter SB and Sande MA. 1992. Toxoplasmosis of the central nervous system in the acquired immunodeficiency syndrome. *N Engl J Med.* 327(23): 1643-8.
252. Petersen E, Kijlstra A, Stanford M. 2012. Epidemiology of ocular toxoplasmosis. *Ocul Immunol Inflamm.* 20: 68-75.
253. Pivetti-Pezzi P, Accorinti M, Tambori S, Ciapparoni V, Ahmed-Adulaziz M. 1994. Clinical features of toxoplasmic retinochoroiditis in patients with acquired immunodeficiency syndrome. *Ann Ophthalmol.* 26: 73-84.
254. Plattner F, Yarovinsky F, Romero S, Didry D, Carlier MF, *et al.* 2008. *Toxoplasma* profilin is essential for host cell invasion and TLR11-dependent induction of an interleukin-12 response. *Cell Host Microbe.* 3: 77-87.
255. Rachinel N, Buzoni-Gatel D, Dutta C, Mennechet FJ, Luangsay S, *et al.* 2004. The induction of acute ileitis by a single microbial antigen of *Toxoplasma gondii*. *J Immunol.* 173: 2725-35.
256. Reese ML, Zeiner GM, Saeij JP, Boothroyd JC, Boyle JP. 2011. Polymorphic family of injected pseudokinases is paramount in *Toxoplasma* virulence. *Proc Natl Acad Sci U S A.* 108: 9625-30.

257. Reise Sousa C, Hieny S, Scharton-Kersten T, Jankovic D, Charest H, *et al.* 1997. In vivo microbial stimulation induces rapid CD40 ligand independent production of interleukin 12 by dendritic cells and their redistribution to T cell areas. *J Exp Med.* 186(11): 1819-29.
258. Reiss M, Viebig N, Brecht S, Fourmaux MN, Soete M, *et al.* 2001. Identification and characterization of an escorter for two secretory adhesins in *Toxoplasma gondii*. *J Cell Biol.* 152: 563-78.
259. Robben PM, LaRegina M, Kuziel WA, Sibley LD. 2005. Recruitment of Gr-1+ monocytes is essential for control of acute toxoplasmosis. *J Exp Med.* 201(11): 1761-9.
260. Robben PM, Mordue DG, Truscott SM, Takeda K, Akira S, Sibley LD. 2004. Production of IL-12 by macrophages infected with *Toxoplasma gondii* depends on the parasite genotype. *J Immunol.* 172(6): 3686-94.
261. Roers A, Siewe L, Strittmatter E, Deckert M, Schluter D, *et al.* 2004. T cell-specific inactivation of the interleukin 10 gene in mice results in enhanced T cell responses but normal innate responses to lipopolysaccharide or skin irritation. *J Exp Med.* 200: 1289-97.
262. Rome ME, Beck JR, Turetzky JM, Webster P, Bradley PJ. 2008. Intervacuolar transport and unique topology of GRA14, a novel dense granule protein in *Toxoplasma gondii*. *Infect Immun.* 76: 4865-75.
263. Ronet C, Darche S, Leite de Moraes M, Miyake S, Yamamura T, *et al.* 2005. NKT cells are critical for the initiation of an inflammatory bowel response against *Toxoplasma gondii*. *J Immunol.* 175: 899-908.
264. Rosowski EE, Lu D, Julien L, Rodda L, Gaiser RA, *et al.* 2011. Strain-specific activation of the NF-kappaB pathway by GRA15, a novel *Toxoplasma gondii* dense granule protein. *J Exp Med.* 208: 195-212.
265. Sabin AB, Olitsky PK. 1937. *Toxoplasma* and obligate intracellular parasitism. *Science.* 85(2205):336-8.

266. Sadak A, Taghy Z, Fortier B, Dubremetz JF. 1988. Characterization of a family of rhoptry proteins of *Toxoplasma gondii*. *Mol Biochem Parasitol.* 29: 203-11.
267. Saeij JP, Arrizabalaga G, Boothroyd JC. 2008. A cluster of four surface antigen genes specifically expressed in bradyzoites, SAG2CDXY, plays an important role in *Toxoplasma gondii* persistence. *Infect Immun.* 76: 2402-10.
268. Saeij JP, Boyle JP, Boothroyd JC. 2005. Differences among the three major strains of *Toxoplasma gondii* and their specific interactions with the infected host. *Trends Parasitol.* 10:476-81.
269. Saeij JP, Boyle JP, Collier S, Taylor S, Sibley LD, *et al.* 2006. Polymorphic secreted kinases are key virulence factors in toxoplasmosis. *Science.* 314: 1780-3.
270. Saeij JP, Collier S, Boyle JP, Jerome ME, White MW, Boothroyd JC. 2007. *Toxoplasma* co-opts host gene expression by injection of a polymorphic kinase homologue. *Nature.* 445(7125):324-7.
271. Santos JM, Ferguson DJ, Blackman MJ, Soldati-Favre D. 2011. Intramembrane cleavage of AMA1 triggers *Toxoplasma* to switch from an invasive to a replicative mode. *Science.* 331: 473-7.
272. Sauer A, de la Torre A, Gómez-Marín J, Bourcier T, Garweg J, *et al.* 2011. Prevention of retinochoroiditis in congenital toxoplasmosis: Europe versus South America. *Pediatr Infect Dis J.* 30: 601-3.
273. Sauer A, Pfaff AW, Villard O, Creuzot-Garcher C, Dalle F, *et al.* 2012. Interleukin 17A as an effective target for anti-inflammatory and antiparasitic treatment of toxoplasmic uveitis. *J Infect Dis.* 206(8): 1319-29.
274. Scanga CA, Aliberti J, Jankovic D, Tilloy F, Bennouna S, *et al.* 2002. Cutting edge: MyD88 is required for resistance to *Toxoplasma gondii* infection and regulates parasite-induced IL-12 production by dendritic cells. *J Immunol.* 168(12): 5997-6001.

275. Schulthess J, Meresse B, Ramiro-Puig E, Montcuquet N, Darche S, *et al.* 2012. Interleukin-15-dependent NKp46+ innate lymphoid cells control intestinal inflammation by recruiting inflammatory monocytes. *Immunity* 37: 108-21.
276. Shaw MH, Boyartchuk V, Wong S, Karaghiosoff M, Ragimbeau J, *et al.* 2003. A natural mutation in the Tyk2 pseudokinase domain underlies altered susceptibility of B10.Q/J mice to infection and autoimmunity. *Proc Natl Acad Sci U S A.* 100: 11594-9.
277. Shibuya K, Robinson D, Zonin F, Hartley SB, Macatonia SE, *et al.* 1998. IL-1 alpha and TNF-alpha are required for IL-12-induced development of Th1 cells producing high levels of IFN-gamma in BALB/c but not C57BL/6 mice. *J Immunol.* 160(4): 1708-16.
278. Siachoque H, Guzman F, Burgos J, Patarroyo ME, Gomez Marin JE. 2006. *Toxoplasma gondii*: immunogenicity and protection by P30 peptides in a murine model. *Exp Parasitol.* 114(1):62-5.
279. Sibley LD and Ajioka JW. 2008. Population structure of *Toxoplasma gondii*: clonal expansion driven by infrequent recombination and selective sweeps. *Annu Rev Microbiol.* 62: 329-51.
280. Sibley LD, Khan A, Ajioka JW, Rosenthal BM. 2009. Genetic diversity of *Toxoplasma gondii* in animals and humans. *Philos Trans R Soc Lond B Biol Sci.* 364(1530): 2749-61.
281. Sibley LD, LeBlanc AJ, Pfefferkorn ER, Boothroyd JC. 1992. Generation of a restriction fragment length polymorphism linkage map for *Toxoplasma gondii*. *Genetics.* 132(4):1003-15.
282. Smith RE and Ganley JP. 1972. Ophthalmic survey of a community 1. Abnormalities of the ocular fundus. *Am J Ophthalmol.* 74: 1126-30.
283. Soheilian M, Sadoughi MM, Ghajarnia M, Dehghan MH, Yazdani S, *et al.* 2005. Prospective randomized trial of trimethoprim/sulfamethoxazole versus pyrimethamine and sulfadiazine in the treatment of ocular toxoplasmosis. *Ophthalmology.* 11: 1876-82.

284. Sousa S, Ajzenberg D, Marle M, et al. 2009. Selection of Polymorphic Peptides from GRA6 and GRA7 Sequences of *Toxoplasma gondii* Strains To Be Used in Serotyping. *Clin Vaccine Immunol.* 16(8): 1158–1169.
285. Spear W, Chan D, Coppens I, Johnson RS, Giaccia A, Blader IJ. 2006. The host cell transcription factor hypoxia-inducible factor 1 is required for *Toxoplasma gondii* growth and survival at physiological oxygen levels. *Cell Μικροβιολ.* 8(2): 339-52.
286. Stanford MR and Gilbert RE. 2009. Treating ocular toxoplasmosis: current evidence. *Mem Inst Oswaldo Cruz.* 104(2): 312-5.
287. Steinfeldt T, Konen-Waisman S, Tong L, Pawlowski N, Lamkemeyer T, et al. 2010. Phosphorylation of mouse immunity related GTPase (IRG) resistance proteins is an evasion strategy for virulent *Toxoplasma gondii*, *PLoS Biol.* 8: e1000576.
288. Stillwaggon E, Carrier CS, Sautter M, McLeod R. 2011. Maternal serologic screening to prevent congenital toxoplasmosis: a decision-analytic economic model. *PLoS Negl Trop Dis.* 5(9):e1333.
289. Straub KW, Peng ED, Hajagos BE, Tyler JS, Bradley PJ. 2011. The moving junction protein RON8 facilitates firm attachment and host cell invasion in *Toxoplasma gondii*. *PLoS Pathog.* 7: e1002007.
290. Striepen B, Zinecker CF, Damm JB, Melgers PA, Gerwig GJ, et al. 1997. Molecular structure of the “low molecular weight antigen” of *Toxoplasma gondii*: a glucose alpha 1-4 N-acetylgalactosamine makes free glycosylphosphatidylinositols highly immunogenic. *J Mol Biol.* 266: 797-813.
291. Stumhofer JS, Laurence A, Wilson EH, Huang E, Tato CM, et al. 2006. Interleukin 27 negatively regulates the development of interleukin 17-producing T helper cells during chronic inflammation of the central nervous system. *Nat Immunol.* 7: 937-45.
292. Su C, Khan A, Zhou P, Majumdar D, Ajzenberg D, et al. 2012. Globally diverse *Toxoplasma gondii* isolates comprise six major clades

- originating from a small number of distinct ancestral lineages. *Proc Natl Acad Sci U S A*. 109: 5844-9.
293. Subauste CS, Dawson L, Remington JS. 1992. Human lymphokine activated killer cells are cytotoxic against cells infected with *Toxoplasma gondii*. *J Exp Med*. 176(6): 1511-9.
294. Sukhumavasi W, Egan CE, Warren AL, Taylor GA, Fox BA, *et al*. 2008. TLR adaptor MyD88 is essential for pathogen control during oral *Toxoplasma gondii* infection but not adaptive immunity induced by a vaccine strain of the parasite. *J Immunol*. 181(5): 3464-73.
295. Suzuki Y, Orellana MA, Schreiber RD, Remington JS. 1988. Interferon-gamma: the major mediator of resistance against *Toxoplasma gondii*. *Science*. 240: 516-8.
296. SYROCOT. 2007. Effectiveness of prenatal treatment for congenital toxoplasmosis: a metaanalysis of individual patient's data. *Lancet*. 369: 115-22.
297. Taub DD, Lloyd AR, Conlon K, Wang JM, Ortaldo JR, Harada A, Matsushima K, Kelvin DJ, Oppenheim JJ. 1993. Recombinant human interferon-inducible protein 10 is a chemoattractant for human monocytes and T lymphocytes and promotes T cell adhesion to endothelial cells. *J Exp Med*. 177(6):1809-14.
298. Tait ED, Jordan KA, Dupont CD, Harris TH, Gregg B, *et al*. 2010. Virulence of *Toxoplasma gondii* is associated with distinct dendritic cell responses and reduced numbers of activated CD8+ T cells. *J Immunol*. 185(3): 1502-12.
299. Takeuchi M, Keino H, Kezuka T, Usui M, Taguchi O. 2004. Immune responses to retinal self-antigens in CD25(+)CD4(+) regulatory T-cell-depleted mice. *Invest Ophthalmol Vis Sci*. 45: 1879-86.
300. Talabani H, Asseraf M, Yera H, Delair E, Ancelle T, *et al*. 2009. Contributions of immunoblotting, real-time PCR, and the

- Goldmann-Witmer coefficient to diagnosis of atypical toxoplasmic retinochoroiditis. *J Clin Microbiol.* 47: 2131-5.
301. Taylor GA, Barragan A, Su C, Fux B, Fentress SJ, *et al.* 2006. A secreted serine-threonine kinase determines virulence in the eukaryotic pathogen *Toxoplasma gondii*. *Science* 314: 1776e1780.
302. Tenter AM, Heckeroth AR, Weiss LM. 2000. *Toxoplasma gondii*: from animals to humans *International Journal for Parasitology.* *Int J Parasitol.* 31(2):217-20.
303. Thiébaud R, Leproust S, Chêne G, Gilbert R. 2007. Effectiveness of prenatal treatment for congenital toxoplasmosis: a meta-analysis of individual patients' data. *Lancet.* 369(9556): 115-22.
304. Tibayrenc M, Kjellberg F, Arnaud J, Oury B, Brenière SF, Dardé ML, Ayala FJ. 1991. Are eukaryotic microorganisms clonal or sexual? A population genetics vantage. *Proc Natl Acad Sci U S A.* 15;88(12):5129-33.
305. Torok E, Moran E, Cooke F. 2009. *Toxoplasmosis.* *Oxford Handbook of Infectious Diseases and Microbiology.* New York: Oxford University Press. Vol 1 p.567.
306. Torrey EF, Yolken RH. 2003. *Toxoplasma gondii* and schizophrenia, *Emerg Infect Dis.* 9: 1375-80.
307. Travier L, Mondragon R, Dubremetz JF, Musset K, Mondragon M, *et al.* 2008. Functional domains of the *Toxoplasma* GRA2 protein in the formation of the membranous nanotubular network of the parasitophorous vacuole. *Int J Parasitol.* 38: 757-73.
308. Valentincic NV, de Groot-Mijnes JD, Kraut A, Korosec P, Hawlina M, Rothova A. 2011. Intraocular and serum cytokine profiles in patients with intermediate uveitis. *Mol Vis.* 17: 2003-10.
309. Vallochi AL, Goldberg AC, Falcai A, Ramasawmy R, Kalil J, *et al.* 2008. Molecular markers of susceptibility to ocular toxoplasmosis, host and guest behaving badly. *Clin Ophthalmol.* 2(4): 837-48.



310. Van Kooij B, Rothova A, Rijkers GT, deGroot Mijnes J. 2006. Distinct cytokine and chemokine profiles in the aqueous humor of patients with uveitis and cystoid macular edema. *Am J Ophthalmol.* 142: 192-4.
311. Vasconcelos-Santos DV, Machado Azevedo DO, Campos WR, Oréfica F, Queiroz-Andrade GM, Carellos EV, Castro Romanelli RM, Januário JN, Resende LM, Martins-Filho OA, de Aguiar Vasconcelos Carneiro AC, Almeida Vitor RW, Caiaffa WT; UFMG Congenital Toxoplasmosis Brazilian Group. 2009. Congenital toxoplasmosis in southeastern Brazil: results of early ophthalmologic examination of a large cohort of neonates. *Ophthalmology.* 116(11):2199-205.
312. Vaudaux JD, Muccioli C, James ER, Silveira C, Magargal SL, *et al.* 2010. Identification of an atypical strain of *Toxoplasma gondii* as the cause of a waterborne outbreak of toxoplasmosis in Santa Isabel do Ivaí, Brazil. *J Infect Dis.* 202: 1226-33.
313. Veldhoen M, Hocking RJ, Atkins CJ, Locksley RM, Stockinger B. 2006. TGF-beta in the context of an inflammatory cytokine milieu supports de novo differentiation of IL-17-producing T cells. *Immunity.* 24: 179-89.
314. Villard O, Filisetti D, Roch-Deries F, Garweg J, Flament J, Candolfi E. 2003. Comparison of enzyme-linked immunosorbent assay, immunoblotting, and PCR for diagnosis of toxoplasmic chorioretinitis. *J Clin Microbiol.* 41: 3537-41.
315. Virreira Winter S, Niedelman W, Jensen KD, Rosowski EE, Julien L, *et al.* 2011. Determinants of GBP recruitment to *Toxoplasma gondii* vacuoles and the parasitic factors that control it. *PLoS One.* 6: e24434.
316. Vossenkämper A, Struck D, Alvarado-Esquivel C, Went T, Takeda K, *et al.* 2004. Both IL-12 and IL-18 contribute to small intestinal Th1-type immunopathology following oral infection with *Toxoplasma gondii*, but IL-12 is dominant over IL-18 in parasite control. *Eur J Immunol.* 34: 3197-207.

317. Niedelman W, Gold DA, Rosowski EE, Sprokholt JK, Lim D, *et al.* 2012. The rhoptry proteins ROP18 and ROP5 mediate *Toxoplasma gondii* evasion of the murine, but not the human, interferon-gamma response. *PLoS Pathog.* 8: e1002784.
318. Weiss LM and Dubey JP. 2009. Toxoplasmosis: a history of clinical observations. *Int J Parasitol.* 39(8): 895-901.
319. Whitmarsh RJ, Gray CM, Gregg B, Christian DA, May MJ, *et al.* 2011. A critical role for SOCS3 in innate resistance to *Toxoplasma gondii*. *Cell Host Microbe.* 10(3): 224-36.
320. Winiiecka-Krusnell J, Dellacasa-Lindberg I, Dubey JP, Barragan A. 2009. *Toxoplasma gondii*: uptake and survival of oocysts in free living amoebae. *Exp Parasitol.* 121(2): 124-31.
321. Yamamoto M, Standley DM, Takashima S, Saiga H, Okuyama M, *et al.* 2009. A single polymorphic amino acid on *Toxoplasma gondii* kinase ROP16 determines the direct and strain-specific activation of Stat3. *J Exp Med.* 206: 2747-60.
322. Yap G, Pesin M, Sher A. 2000. Cutting edge: IL-12 is required for the maintenance of IFN-gamma production in T cells mediating chronic resistance to the intracellular pathogen, *Toxoplasma gondii*. *J Immunol.* 165: 628-31.
323. Yap GS, Sher A. 1999. Cell-mediated immunity to *Toxoplasma gondii*: initiation, regulation and effector function. *Immunobiology.* 201: 240-7.
324. Yarovinsky F, Zhang D, Andersen JF, Bannenberg GL, Serhan CN, *et al.* 2005. TLR11 activation of dendritic cells by a protozoan profilin-like protein. *Science.* 308(5728): 1626-9.
325. Zhang Y and Denkers EY. 1999. Protective role for interleukin-5 during chronic *Toxoplasma gondii* infection. *Infect Immun.* 67(9): 4383-92.