



HAL
open science

Electrical brain stimulation and human insular connectivity

Talal Almashaikhi

► **To cite this version:**

Talal Almashaikhi. Electrical brain stimulation and human insular connectivity. Neurobiology. Université Claude Bernard - Lyon I, 2013. English. NNT : 2013LYO10174 . tel-01167874

HAL Id: tel-01167874

<https://theses.hal.science/tel-01167874>

Submitted on 24 Jun 2015

HAL is a multi-disciplinary open access archive for the deposit and dissemination of scientific research documents, whether they are published or not. The documents may come from teaching and research institutions in France or abroad, or from public or private research centers.

L'archive ouverte pluridisciplinaire **HAL**, est destinée au dépôt et à la diffusion de documents scientifiques de niveau recherche, publiés ou non, émanant des établissements d'enseignement et de recherche français ou étrangers, des laboratoires publics ou privés.

THESE DE L'UNIVERSITE DE LYON

Délivrée par

L'UNIVERSITE CLAUDE BERNARD LYON 1

ECOLE DOCTORALE NEUROSCIENCES COGNITIVES

DIPLOME DE DOCTORAT

(Arrêté du 7 août 2006)

Soutenue publiquement le

27 septembre 2013

Par

ALMASHAIKHI Talal

TITRE:

Electrical Brain Stimulation and Human Insular Connectivity

Directeur de thèse:

Mr. le Pr Philippe Ryvlin

JURY:

Mr. le Pr Pierre Thomas (Rapporteur)

Mr. le Pr Edouard Hirsch (Rapporteur)

Mr. le Pr Marc Guenot (Evaluateur)

Mr. le Pr Patrick Mertens (Evaluateur)

Mr. le Pr Philippe Ryvlin (Directeur de thèse)

UNIVERSITE CLAUDE BERNARD - LYON 1

Président de l'Université

M. François-Noël GILLY

Vice-président du Conseil d'Administration

M. le Professeur Hamda BEN HADID

Vice-président du Conseil des Etudes et de la Vie
Universitaire

M. le Professeur Philippe LALLE

Vice-président du Conseil Scientifique

M. le Professeur Germain GILLET

Secrétaire Général

M. Alain HELLEU

COMPOSANTES SANTE

Faculté de Médecine Lyon Est – Claude Bernard

Directeur : M. le Professeur J. ETIENNE

Faculté de Médecine et de Maïeutique Lyon Sud – Charles
Mérieux

Administrateur provisoire : M. le Professeur G.
KIRKORIAN

UFR d'Odontologie

Directeur : M. le Professeur D. BOURGEOIS

Institut des Sciences Pharmaceutiques et Biologiques

Directeur: Mme la Professeure C.
VINCIGUERRA.

Institut des Sciences et Techniques de la Réadaptation

Directeur : M. le Professeur Y. MATILLON

Département de formation et Centre de Recherche en
Biologie Humaine

Directeur : M. le Professeur P. FARGE

COMPOSANTES ET DEPARTEMENTS DE SCIENCES ET TECHNOLOGIE

Faculté des Sciences et Technologies

Directeur : M. le Professeur F. De MARCHI

Département Biologie

Directeur : M. le Professeur F. FLEURY

Département Chimie Biochimie

Directeur : Mme le Professeur H. PARROT

Département GEP	Directeur : M. N. SIAUVE
Département Informatique	Directeur : M. le Professeur S. AKKOUCHE
Département Mathématiques	Directeur : M. le Professeur A. GOLDMAN
Département Mécanique	Directeur : M. le Professeur H. BEN HADID
Département Physique	Directeur : Mme S. FLECK
Département Sciences de la Terre	Directeur : Mme la Professeure I. DANIEL
UFR Sciences et Techniques des Activités Physiques et Sportives	Directeur : M. C. COLLIGNON
Observatoire de Lyon	Directeur : M. B. GUIDERDONI
Polytech Lyon	Directeur : M. P. FOURNIER
Ecole Supérieure de Chimie Physique Electronique	Directeur : M. G. PIGNAULT
Institut Universitaire de Technologie de Lyon 1	Directeur : M. C. VITON
Institut Universitaire de Formation des Maîtres	Directeur : M. R. BERNARD
Institut de Science Financière et d'Assurances	Directeur: Mme la Professeure V. MAUME-DESCHAMPS

“The doubter is a true man of science; he doubts only himself and his interpretations, but he believes in science”

Claude Bernard

To all the people in my life, without your support and motivation I could not reach this point.

Acknowledgments:

In this short list I would like to pass my big appreciation and thanks to all whom participated or helped in my project or even were indirectly involved in pushing me forward and without whom I would not achieve this work.

1. To **all patients** involved in this study and to **all their families**; you are the source of our knowledge, thank you for your patience and hope we did all the best we could for you to get better.

2. **My family**: First of all; my mother and my late father who passed away during the period of preparation for this work. Thanks to my brothers and sisters for their unlimited support. My dearest wife and my three lovely kids, I would not have enough words to thank you, I think you suffered the most due to my frequent absences and being busy most of the time.

3. **The government of the Sultanate of Oman** represented by the Sultan Qaboos university and its hospital, the cultural attaché at the Omani embassy in London, and the Omani embassy in Paris. They sponsored my stay in France and were the unstoppable thrust and power for my study.

4. **Professor Philippe Ryvlin**: He is the person responsible for having me here in France and the director of my thesis and the mentor throughout my study. Dear professor, you opened a door for me through whom I gained access to the epilepsy world, which will be a major part of my research and work for the future, thank you.

5. **Professor Philippe Kahane** and **Dr Michel Magnin**: Thank you both for taking part in the committee following my thesis progress. Professor Kahane, I cannot find enough words to thank you; mainly through you and the others in our department I learnt epilepsy.

6. The **staff of EFN** at the HFME: On the top is **Professor Alexis Arzimanoglou**, thank you for taking me in and thank you for all the knowledge you passed to me. A big thank to all the

staff of EFN; doctors and nurses and supporting team, especially **Dr Karine Ostrowsky Coste** for her contribution to my work in insula.

7. The staff of the **research unit DYCOG**: Thanks to **Professor Oliver Bertrand, Dr Julien Junge, Romain Bouet, Karim Jerbi, Sarang Dalal, and Pierre-Emmanuel Aguera**. Thank you all for the great help I got during all the phases of my work, especially in relation to the analysis software; ELAN.

8. The **neurosurgery unit** at the neurology hospital: My thanks go to **Professor Marc Guenot**, who did all the implantations for our patients with epilepsy. Thank you dear professor for your great care of our patients and the superior quality of work.

9. The **neurology and epilepsy unit** at the neurology hospital: Thanks to **Dr Sylvain Rheims** for his input and ideas in relation to my publications in the insula. It was a great pleasure learning from you dear Sylvain.

10. **Micromed France**: Thank you **Jean-Luc Magnon and Franck Siguret** for your big involvement in the software we use for the registration of intracerebral EEG and for all the associated work. Thank you Franck for the huge effort you made for the continuity of our work.

11. Last but not least, I would like to show my deepest appreciation and thanks to **professors Pierre Thomas and Edouard Hirsch** for participating in the evaluation of my current work and for taking part of the jury. Thank you for your time and efforts. And thanks to the other members in the jury; **Professors Marc Guenot and Patrick Mertens**, deeply appreciating your time and input.

RESUME en français

Objectifs: Le cortex insulaire est le cinquième lobe du cerveau en charge de l'intégration de nombreuses fonctions cognitives, sous-tendues par une organisation cytoarchitectonique et une connectivité aussi riche que complexe. Ce travail vise à évaluer la connectivité fonctionnelle insulaire du cerveau humain par le biais de stimulation électrique intra-cérébrale et de potentiels évoqués cortico-corticaux (PECC) réalisés chez des patients explorés en stéréoelectroencéphalographie (SEEG) pour une épilepsie partielle réfractaire.

Dispositif expérimental: Nous avons développé un protocole automatisé permettant de stimuler successivement l'ensemble des bipoles d'enregistrement intracérébraux (deux plots contigus d'une même électrode) disponibles chez les patients explorés en SEEG. Deux séries de 20 stimulations monophasiques d'une durée unitaire de 1 ms et d'une intensité de 1 mA, étaient délivrés à une fréquence de 0,2 Hz au niveau de chaque bipole (105 en moyenne, produisant un total d'environ 11.000 PECC par patient). Un premier travail a consisté dans la mise au point d'une méthode fiable d'analyse statistique objective des PECC significatifs, en complément de l'analyse visuelle, sur un échantillon de 33017 enregistrements chez trois patients. . L'analyse a porté sur les quatre fenêtres temporelles post-stimulation suivantes: 10-100 ms, 100-300 ms, 300-500 ms, 500-1000 ms. La seconde partie de notre thèse a appliqué ces méthodes à l'étude des connections intra-insulaires sur un échantillon de 10 patients présentant au moins deux électrodes intra-insulaires. La dernière partie de notre travail s'est intéressé aux efférences insulaires sur un échantillon de 11 patients.

Résultats: L'analyse visuelle des 33017 enregistrements a révélé un PECC dans 21% des segments 10-100 ms, 14% des segments 100-300 ms, 3% des segments 300-500 ms, et seulement 1% des segments 500-1000 ms. L'analyse statistique avait une sensibilité variant de 91% à 97%, en fonction de la fenêtre temporelle étudiée, et une spécificité de 97 à 98%. Les faux négatifs reflétaient des PECCs de très faible amplitude et/ou la présence d'une ligne de base très bruitée. L'étude des connections intra-insulaires a révélé une riche connectivité réciproque entre les cinq gyri insulaires, avec des PECC présents dans 74% des connections testées, et une latence moyenne de 26 ± 3 ms. La seule exception était l'absence de connection entre les gyri antérieur et postérieur courts, ainsi qu'entre les insulas droite et gauche. L'étude des efférences insulaires a mis en évidence une connectivité avec de nombreuses structures, 193 des 578 connections testées (33%) ayant produit des PECCs significatifs, notamment au niveau des opercules périsylvians (59%), mais aussi du cortex pericentral (38%), des structures temporales mésiales et latérales (24%, 28%), du cortex pariétal latérale (26%), et du cortex orbitaire (25%). Le pattern de connectivité variait en fonction du gyrus insulaire stimulé.

Conclusion: L'étude des PECC apporte des éléments de connectivité fonctionnelle de résolution spatiale et temporelle inégalée, complémentaires de ceux découlant des techniques de neuroimagerie. La gestion complexe du volume de données à gérer pour chaque patient peut être résolu par des procédures d'analyse statistiques automatisée de sensibilité et spécificité satisfaisante. Le pattern des connections intra- et extra-insulaires révélé par cette approche permet une meilleure compréhension de la physiologie de l'insula chez l'Homme et des modalités de propagations des décharges épileptiques impliquant ce lobe.

RESUME en anglais

Objectives: The insular cortex is the fifth lobe of the brain and is in charge of the integration of many cognitive functions, underpinned by a rich cytoarchitectonic organization and a complex connectivity. Our work aims to evaluate the insular functional connectivity of the human brain using intracerebral electrical stimulation and recording of cortico-cortical evoked potentials (CCEPs) in patients investigated with stereoelectroencephalography (SEEG) for refractory partial epilepsy.

Experimental design: We first developed an automated protocol to stimulate successively all intracerebral recorded bipoles (two contiguous leads of the same electrode) available in patients undergoing SEEG. Two sets of 20 monophasic stimulation of 1 ms duration and 1 mA intensity were delivered at a frequency of 0.2 Hz at each bipole (105 on average, producing a total of about 11,000 recordings per patient). We then develop a reliable and objective statistical method to detect significant CCEPs as a complement to visual analysis, and validate this approach on a sample of 33017 recordings in three patients. The analysis was performed over four distinct post-stimulus epochs: 10-100 ms, 100-300 ms, 300-500 ms, 500-1000 ms. In the second part of our thesis, we applied these methods to the study of intra-insular connections on a sample of 10 patients with at least two intra-insular electrodes. The last part of our work used the same approach to investigate insular efferents in a sample of 11 patients.

Results: Visual analysis of 33017 records revealed CCEPs in 21% of 10-100 ms epochs, 14% of 100-300 ms epochs, 3% of 300-500 ms epochs, and only 1% of 500-1000 ms epochs. Statistical analysis had a sensitivity ranging from 91% to 97%, depending on the epochs, and a specificity of 97-98%. False negative findings reflected CCEPs of very low amplitude and/or the presence of a very noisy baseline. The study of intra-insular connections revealed a

rich reciprocal connectivity between the five insular gyri, with CCEPs recorded in 74% of tested connections and an average latency of 26 ± 3 ms. The only exception was the lack of connection between the anterior and posterior short gyri, as well as between the right and left insulae. The study of insular efferent also showed connectivity with many other cortical structures, with 193 of the 578 tested connections (33%) showing significant CCEPs, particularly over the perisylvian structures (59%), and to a lesser degree with the pericentral cortex (38%), mesial and lateral temporal structures (24, 28%), lateral parietal cortex (26%) and orbito-frontal cortex (25%). The pattern of connectivity varied according to the insular gyrus stimulated.

Conclusion: The study of CCEPs provides novel and important findings regarding the human brain functional connectivity, with unmatched spatial and temporal resolutions as compared to neuroimaging techniques. The complex management of large volume of data in each patient can be solved by automated statistical analysis procedures with satisfactory sensitivity and specificity. The pattern of connections within and outside the insula revealed by this approach provides a better understanding of the physiology of the Human insula as well as of the propagation of epileptic discharges involving this lobe.

DISCIPLINE

Neurosciences

MOTS-CLES

Français: stimulation électrique du cerveau, insula, connectivité fonctionnelle, potentiel évoqué, humaine

Anglais : Electrical brain stimulation, insula, functional connectivity, evoked potential, human

INTITULE ET ADRESSE DE L'U.F.R. OU DU LABORATOIRE :

TIGER et DYCOG- CRNL

INSERM U1028, CNRS UMR5292

Service de neurologie fonctionnelle et epileptologie,

Hôpital neurologique,

59 Boulevard Pinel,

69677 Lyon

Table of Contents:	Page
Abbreviations list	16
Chapter I Introduction	18
Chapter II Background	
Part one: Electrical brain stimulation (EBS)	23
1. Introduction	
2. EBS history and development	
3. EBS mechanisms and physiology	
4. EBS uses :	
4.1 EBS and functional connectivity study	
4.1.1 Connectivity of mesial temporal structures	
4.1.2 Connectivity of temporal neocortex	
4.1.3 Connectivity of the frontal cortex	
4.1.4 Connectivity of the thalamic medial pulvinar nucleus	
4.2 EBS and epileptogenicity study	
5. EBS parameters	
6. EBS analysis	
7. EBS advantages	
8. EBS limitations	
9. Summary	
Part two: Human insular cortex	46
1. Introduction	
2. Insula in history	
3. Insular development	
4. Insular gross anatomy	
5. Insular cytoarchitecture	
5.1 Cytoarchitecture and connectivity	
5.2 Cytoarchitecture differences	
5.2.1 Males to females differences	
5.2.2 Differences across species	
5.2.3 Differences between human's and monkey's insula	
5.3 Von Economo neurons (VEN)	
6. Insular connectivity pattern	
6.1 Intra-insular connectivity	
6.2 Extra-insular connectivity (efferent/afferent)	
6.2.1 Macaque insular structural connectivity	
6.2.2 Human insular connectivity	
6.3 Region specific connectivity	
6.3.1 Insulo-limbic connectivity	
6.3.2 Insulo-temporal neocortical connectivity	
6.3.3 Insulo-IFG and premotor cortex connectivity	
6.3.4 Insulo-primary somatosensory cortex connectivity	
6.3.5 Insulo-inferior and superior parietal lobule connectivity	
6.3.6 Insulo-thalamic connectivity	

- 6.4 Interhemispheric insular connectivity
- 6.5 Lateralization of insular connections
- 6.6 Transferring macaque's connectivity studies into human
- 7. Insular functions
 - 7.1 Anterior insula functional specialization
 - 7.2 Posterior insula functional specialization
 - 7.3 Detailed examples of insular functions
- 8. Insular cortex and EBS
 - 8.1 Insular connectivity in the context of EBS studies
- 9. Insular epilepsy
- 10. Summary

Chapter III: Personal work

Part one: Introduction	77
Part two: Method	78
1. Patients	
2. Stereotaxic implantation of depth electrodes	
3. Brain stimulation and CCEP recordings	
4. Data analysis	
Part three: EBS induced responses analysis	97
1. Introduction	
2. Article (Intra-cerebral evoked potentials analysis)	
Part four: Intra-insular connectivity	116
1. Introduction	
2. Article (Intra-insular functional connectivity in human)	
3. Additional unpublished findings	
Part five: Insular efferent connections	148
1. Introduction	
2. Article (Functional connectivity of insular efferences)	
Discussion	182
Conclusion and future directions	192
References	194

Abbreviations list:

ALG: anterior long gyrus

ASG: anterior short gyrus

BT: basal temporal

CCEP: corticocortical evoked potential

CEP: cortical evoked potential

DR: delayed response

DTI: diffusion tensor imaging

EBS: electrical Brain stimulation

ECoG: electrocorticography

EP: evoked potential

ER: early response

EZ: epileptogenic zone

fMRI: functional MRI

HRP: horseradish peroxidase

icEEG: intracerebral EEG

IFG: inferior frontal gyrus

LMCx: lateral motor cortex

LPSTG: left posterior superior temporal gyrus

MEG: magnetoencephalography

MMCx: medial motor cortex

MRI: magnetic resonance imaging

MSG: middle short gyrus

OFC: orbitofrontal cortex

PEP: PuM-evoked potential

PET: positron emission tomography

PLG: posterior long gyrus

PSG: posterior short gyrus

PuM: thalamic medial pulvinar nucleus

SI: suprasylvian parietal cortex

SII: parietal opercular cortex

SMA: supplementary motor area

SPES: single pulse electrical stimulation

SR: stable response

TAA: tritiated amino acid

TP junction: temporoparietal junction

VEN: von Economo neurons

Chapter I: Introduction

Chapter I: Introduction:

The Island of Reil, or the insular cortex, is named after Dr. Johann Christian Reil and has been the focus of many recent studies (Craig 2010). It is completely covered by the operculum (frontal, parietal and temporal) in the depth of the sylvian fissure. Anatomically it is made up of anterior and posterior parts separated by the central insular sulcus. The anterior insula includes anterior, middle and posterior short gyri (ASG, MSG, PSG), and the posterior insula includes anterior and the posterior long gyri (ALG, PLG) (Ture et al, 1999). Two (Brodmann 1909), three (von Economo and Koskinas 1925; Mesulam and Mufson, 1982a) or more (Rose 1928, Kurth et al., 2010b) cytoarchitecturally distinguishable cortical areas have been described in the insula, depending on the pattern of granulation, lamination, and myelination.

Human and animal studies attributed a variety of functions to the insular cortex; sensory, motor, cognitive, and affective (Augustine, 1985; Mesulam and Mufson, 1985; Craig et al., 2000; Brooks et al., 2005; Mutschler et al., 2009; Ackermann and Riecker, 2010; Small, 2010; Kurth et al., 2010a; Cauda et al., 2011; Pugnaghi et al., 2011; Stephani et al., 2011; Nieuwenhuys, 2012). It is involved in disorders like the epilepsy (Isnard et al., 2004; Ryvlin et al., 2006), and autism spectrum disorder (Ebisch et al., 2010). Paraesthesias or warmth, feelings of pharyngo-laryngeal constriction and dysphonic or dysarthric speech were described as typical of seizures that started from the insular cortex (Isnard et al., 2004).

To function normally as a multimodal functional hub, the insula depends on its vast network of connections, either within the insula (Mesulam and Mufson, 1985) or with other cortical areas (Mesulam and Mufson, 1985; Cerliani et al., 2011). The intra-insular connectivity is thought to take part in the middle regions of the insula (Cloutman et al., 2011) and is mainly

directed from anterior to posterior (Mesulam and Mufson, 1982b). While the insular connectivity with other cortical regions is believed to have two complementary networks; an anterior network which connects the anterior insula with regions responsible for cognition and social interaction, and a posterior network which connects the posterior insula with regions responsible for sensorimotor input (Mesulam and Mufson, 1982b; Mufson and Mesulam, 1982; Cauda et al., 2011; Cloutman et al., 2011).

Our knowledge about this complex connectivity network comes from either animal tracer studies (Mesulam and Mufson, 1985, Friedman et al., 1986) or human imaging studies (Cauda et al., 2011; Cerliani et al., 2011; Cloutman et al., 2012; Jakab et al., 2011). In addition to imaging studies, human brain functional connectivity could be studied using electrical brain stimulation (EBS) during intracerebral EEG (icEEG) investigation of epilepsy. A method used frequently to examine normal cortical functions (Stephani et al., 2011) and to test for cortical hyperexcitability in epilepsy (Valentin et al., 2002). EBS was used to explore functional connectivity between brain regions such as the mesial temporal structures (Brazier 1964; Buser and Bancaud 1983; Rutecki et al 1989; Wilson et al., 1990; Catenoix et al., 2005; Lacruz et al. 2007), temporal neocortex including language areas (Matsumoto et al. 2004), frontal cortex (Buser et al., 1992, Lacruz et al. 2007), motor system (Matsumoto et al. 2007), and thalamic medial pulvinar nucleus (Rosenberg et al., 2009), but not that of the insula.

Here in Lyon, the epilepsy team has already used the EBS in the study of human brain connectivity (Catenoix et al.; 2005; Rosenberg et al., 2009; Catenoix et al., 2011). So, benefiting from the recent technological advances in stimulation techniques and signal analysis; we decided to revisit the topic and apply it on human insular functional connectivity. This current work includes 11 patients undergoing icEEG as part of their epilepsy pre-surgical evaluation at the epilepsy unit in the Hôpital Femme Mère Enfant in Lyon. We use parameters

of stimulation similar to those already tested in the past, and proved not to produce any clinical manifestation, nor to provoke any seizure (Gordon et al., 1990). We analyze our data using the ELAN software developed by the DYCOG laboratory of Lyon Neuroscience Research Centre (Aguera et al, 2011).

The main aims of this work, are first to establish a valid stimulation technique for the study of human brain functional connectivity and the analysis procedure to go with it. The second aim is to study human insular cortex functional connectivity at two levels; both intra-insular and efferent connections. Chapter two is devoted to the literature review of electrical brain stimulation (EBS) and insular cortex. The third chapter is covering personal work including three original scientific articles: 1) Intra-cerebral evoked potential analysis; 2) Intra-insular functional connectivity in human; and 3) Functional connectivity of insular efferences.

Chapter II: Background

Chapter II: Background:

Part one: Electrical brain stimulation (EBS)

1. Introduction:

Electrical brain stimulation (EBS) is a commonly used clinical tool in surgical evaluation of patients with refractory epilepsy and brain tumors resection. It involves sending electrical discharges into cortical regions of interest, to either provoke a seizure or test a function related to these regions, which helps to avoid major post-surgical sensorimotor or cognitive impairments. In addition, this technique allows obtaining data to study brain connectivity beyond limitations of other techniques, such as post mortem dissections, diffusion tensor imaging, and functional magnetic resonance imaging.

This part is dedicated to EBS with special attention to its uses in the study of human brain epileptogenicity and functional connectivity.

2. EBS history and development:

Ever since the pioneering work by Todd, Ferrier and Jackson in the 19th century (Reynolds, 2004), changes in electrical activity of human brain have been considered to play a major role in epilepsy mechanisms. Penfield used EBS in awake patients undergoing epilepsy surgery and discovered that temporal and sylvian regions are responsible for oral automatisms, and frontal areas for eye movement, head rotation, motor arrest and vocalization. He described also the motor and somatosensory homunculi; carrying his name today (Penfield and Boldrey, 1937), plus many other cortical areas (Penfield and Jasper, 1954).

Later to Penfield, EBS was used by various teams, where they follow different protocols for either normal function localization or seizure onset zone localization or brain connectivity

study. These protocols included single pulse (Valentin et al., 2002, 2005b, 2005a), paired pulse (Wilson et al., 1998), and repetitive (trains of pulses) stimulation (Buser and Bancaud, 1983; Kahane et al., 1993, 2004).

3. EBS mechanisms and physiology:

Mechanisms of action of EBS are not well understood, but the commonly accepted idea is that the primary targets of EBS are (large myelinated) axons, and not cell bodies (Holsheimer et al., 2000). The generator mechanism of post EBS evoked potentials also not precisely known; two possible mechanisms are hypothesized; orthodromic activation (feed forward transmission to the recorded area), or antidromic activation (feed back transmission from the stimulated area). The delivered electrical charge could pass directly from the stimulated area to the recorded area, or have a relay through third-region mediation. This last point has important implications for functional connectivity studies with EBS as we cannot completely exclude possible indirect connectivity between two studied regions. This is also complicated by the non-physiological nature of stimuli which may activate pathways in an unusual way; resulting in a potential indeterminacy in assessing true directionality of anatomo-functional connections identified with this technique.

The post EBS evoked potentials (EPs) are usually polyphasic in character; with its first peak being considered as the normal physiological response of the cortex (Valentin et al., 2002; Matsumoto et al., 2004). This first peak, named N1 (Matsumoto et al., 2004) or early response (Valentin et al., 2002), is the one used by many authors to measure the functional connectivity. The latency of this peak is depending on the distance between two studied regions and its amplitude is variable according to the strength of the delivered stimulus (Valentin et al., 2002). The Kings college group classified responses to EBS into four types; early, delayed, repetitive and stable responses (Valentin et al., 2002, 2005a,b; Flanagan et al., 2009), details of each in the following text.

4. EBS uses:

In addition to testing normal cortical functions (Penfield and Jasper, 1954, Afif et al., 2010a, Stephani et al., 2011), EBS was used to estimate functional connectivity (Brazier, 1964; Buser et al., 1968; Buser and Bancaud, 1983; Rutecki et al., 1989; Matsumoto et al., 2004; Catenoix et al., 2005; Matsumoto et al., 2007; Lacruz et al., 2007; Rosenberg et al., 2009) and to identify the epileptogenic area by either searching for after-discharge thresholds (Cherlow et al., 1977; Engel et al., 1981), abnormal brain responses (Valentin et al., 2002, 2005a,b; Flanagan et al., 2009), eliciting auras (Schulz et al., 1997) or complete seizures (Munari et al., 1993; David et al., 2008). In the subsections 4.1 and 4.2 we cover the use of EBS in functional connectivity and epileptogenicity studies respectively with details of some works in the area. The use of EBS in testing cortical functions is beyond the interest of this work and not detailed below.

4.1. EBS and functional connectivity study:

4.1.1 Connectivity of mesial temporal structures:

Estimation of cortical connectivity is performed by the detection of sites showing post EBS responses and the measurement of the first peak latency. In 1989, Rutecki et al. studied the neural pathways between the hippocampus and the entorhinal cortex intraoperatively in 31 patients undergoing anterior temporal lobectomy. Stimulation was delivered into platinum disc electrodes over the entorhinal and hippocampal surfaces. Rectangular pulses of 100 μ sec duration, 1 to 12 mA in intensity, were delivered at 0.1 to 20 Hz. In 29 of the patients, entorhinal stimulation evoked a characteristic positive-negative potential in the hippocampus. The entorhinal-evoked hippocampal response closely resembled, or was identical to, the spontaneously occurring hippocampal interictal spike discharge. In patients with hippocampal sclerosis, the evoked responses were of simple morphology and long latency (mean peak at

21.9 msec). In patients in whom the hippocampus was histologically normal, the evoked responses were of greater complexity and shorter latency (mean 11.8 msec) (Figure II.1). Overall, stimulation of the entorhinal cortex evoked responses at different hippocampal recording sites, while Stimulation of the hippocampus evoked a potential in the entorhinal cortex, amygdala, insula, and lateral temporal cortex.

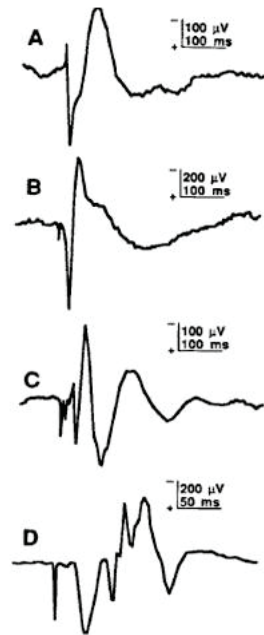


Figure II.1: Examples of simple and complex hippocampal potentials evoked by entorhinal stimulation (Rutecki et al. 1989). A and B: Simple responses that consisted of a positive-negative waveform. Both of these patients had hippocampal sclerosis. Stimulus intensity was 8 mA. C and D: Complex responses in patients with a ganglioglioma and histologically normal hippocampus. These evoked potentials consisted of multiple components. Note the different time scale in D. Stimulus intensities were 12 and 8 mA for C and D, respectively.

Wilson et al. (1990) studied connections in the human mesial temporal lobe using a different technique than Rutecki et al. (1989). They used brief, single pulses of electrical stimulation to evoke field potential responses in limbic structures of 74 epileptic patients undergoing icEEG. Stimulation consisted of biphasic; rectangular pulses of 100 μs/phase duration were delivered at a rate of 0.1 Hz or less, with currents ranging from 0.25 to 5.0 mA. Studied areas included amygdala, entorhinal cortex, presubiculum, the anterior, middle and posterior levels of hippocampus and the middle and posterior levels of parahippocampal gyrus (Figure II.2).

Interestingly, response probabilities across sites were not found to differ significantly between non-epileptogenic vs. identified epileptogenic regions (Figure II.3). Mean onset latencies ranged from 4.4 ms in the perforant pathway connecting entorhinal cortex to anterior hippocampus to 24.8 ms in the pathway connecting the amygdala and middle hippocampus. Stimulation of presubiculum and entorhinal cortex was most effective in evoking widespread responses in adjacent limbic recording sites, whereas posterior parahippocampal gyrus appeared functionally separated from other limbic sites. Stimulation did not evoke responses in any sites in contralateral hippocampal formation; in marked contrast to the anatomical and physiological evidence in lower animals for strong contralateral connections between subfields of the hippocampus via the hippocampal commissure (Pandya and Rosene, 1985).

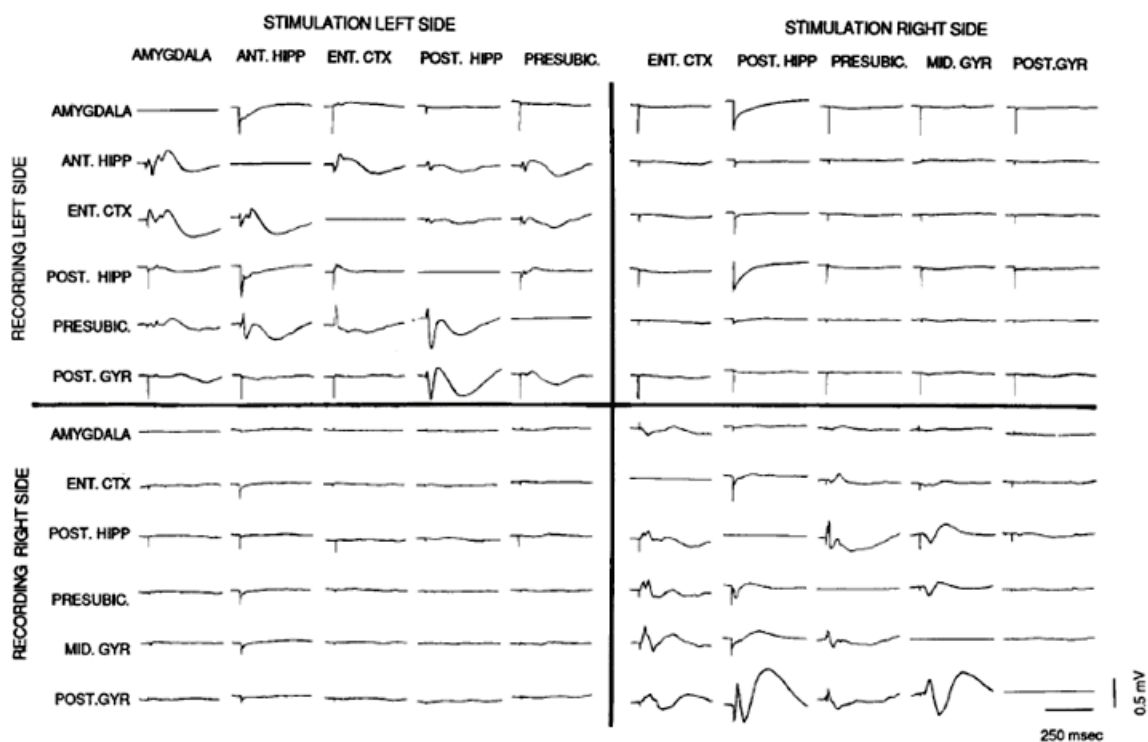


Figure II.2: Field potential matrix for one patient (Wilson et al., 1990) showing distribution of responses evoked in adjacent depth electrodes. Structures labeled at the top of each column are stimulation sites used to evoke responses in recording sites indicated to the left of each row. Straight lines indicate local responses were not recorded in this patient. Note that all clear responses are recorded ipsilateral to site of stimulation; contralateral deflections are stimulus artifact. Each record is the average of 20 stimulations using a current strength of 5.0 mV which occurs 50 ms after the start of the sweep. All derivations are bipolar to insure origin of response is local.

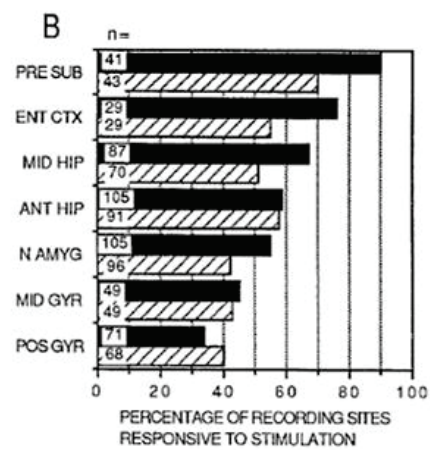
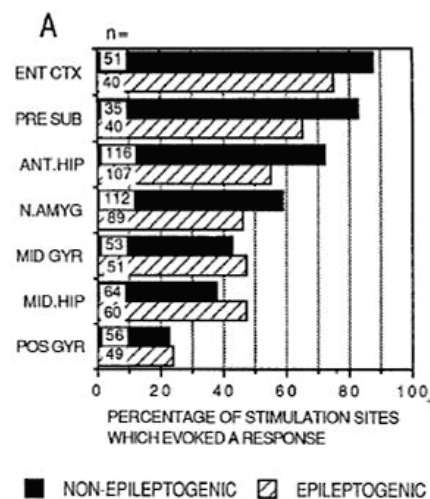


Figure II.3: Limbic response is unaffected by stimulation in epileptogenic vs. nonepileptogenic sites (Wilson et al., 1990). A Each site is ranked according to the percentage of stimulation sites from non-epileptogenic temporal lobes which were effective in evoking responses elsewhere. Total number of sites stimulated in each structure are labeled on each histogram (N =). Black columns represent non-epileptogenic sites, diagonal columns represent epileptogenic sites. B Each site is ranked according to the percentage of recording sites from nonepileptogenic temporal lobes which were responsive to stimulation of other limbic electrode sites. Total number of recording sites in each structure are labeled on each histogram (N =). Black columns represent non-epileptogenic sites, diagonal columns represent epileptogenic sites. None of the structures differed significantly on the basis of epilepsy in either effectiveness (A) or responsiveness (B).

The hippocampal connectivity was revisited again in 2005 by Catenox et al. (Figure II.4). They studied the connectivity of this structure with the orbitofrontal cortex (OFC) for better understanding of the pathways involved in seizure propagation. The study involved 3 epileptic patients undergoing an icEEG. Bipolar electrical stimulation was applied in the hippocampus, consisting of two series of 25 pulses of 1 ms duration, 0.2 Hz frequency, and 3

mA intensity. These stimulations evoked reproducible responses in the OFC in all 3 patients, with a mean latency of the first peak of 222 ms (range: 185–258 ms). Those results confirmed for the first time the functional connectivity between the hippocampus and the OFC in human, and highlighted the potential role of the OFC in the propagation of mesial temporal lobe seizures.

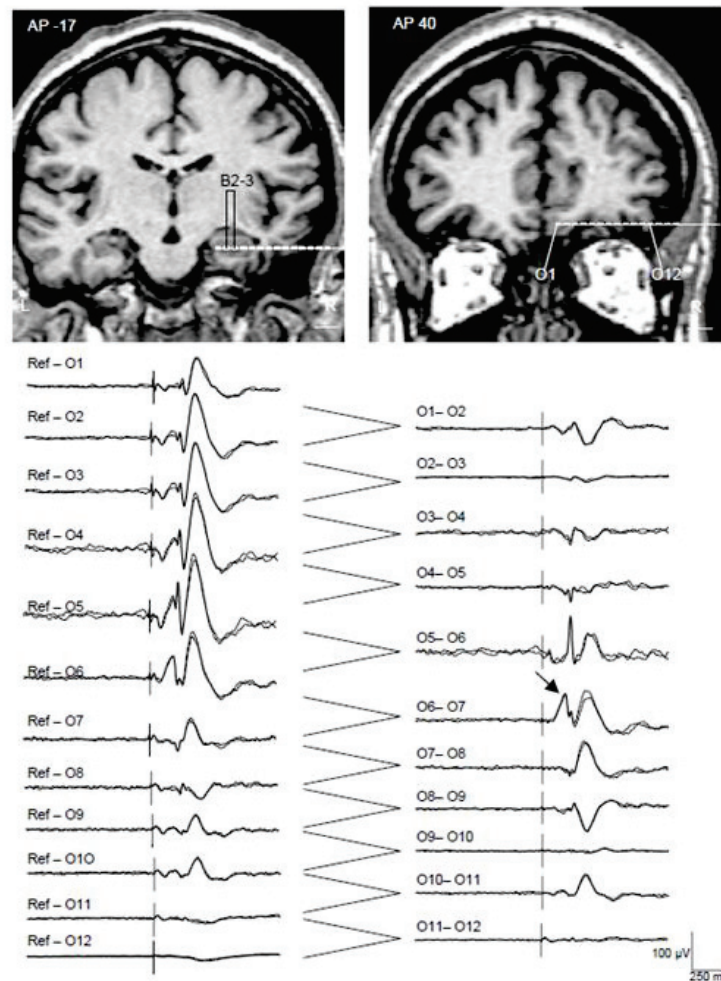


Figure II.4: Evoked potentials recorded in OFC following ipsilateral hippocampal stimulations in one patient (Catenoux et al., 2005). Top, localization of electrode contacts used in the hippocampus (left) and ipsilateral OFC (right) on stereotactic coronal MRI sections. Antero-posterior (AP) levels are referred to the posterior commissure. L and R, left and right hemispheres; scale, 10 mm. Bottom, averaged evoked OFC potentials in referential (left) and bipolar (right) montages following ipsilateral hippocampal stimulations. The averages of the two series of stimulations are superimposed showing the reproducibility of the responses. Positive polarity is upward. Latency of the first peak was measured on bipolar montage (arrow).

In 2011, Catenoix et al. expanded the study of hippocampal connectivity to involve this time its projections within and outside the temporal lobe (Figure II.5). A similar EBS protocol of the previous study (Catenoix et al, 2005) was used on seven patients investigated by depth electrodes for refractory epilepsy. Stimulations were delivered in a total of 36 hippocampal stimulations sites with reproducible EPs recorded in several brain regions with variable latencies, amplitudes and morphologies. Within the temporal lobe, EPs were present in the amygdala, entorhinal cortex, temporal pole and temporal neocortex. EPs were also observed in the frontal lobe, anterior cingulate gyrus and orbito- frontal cortex, midcingulate and posterior cingulate gyrus, insula and thalamic pulvinar nucleus. This widespread hippocampal connectivity supports its role in memory and behavioral processes and provides some clues to potential pathways of propagation of mesial temporal lobe seizure, via various structures.

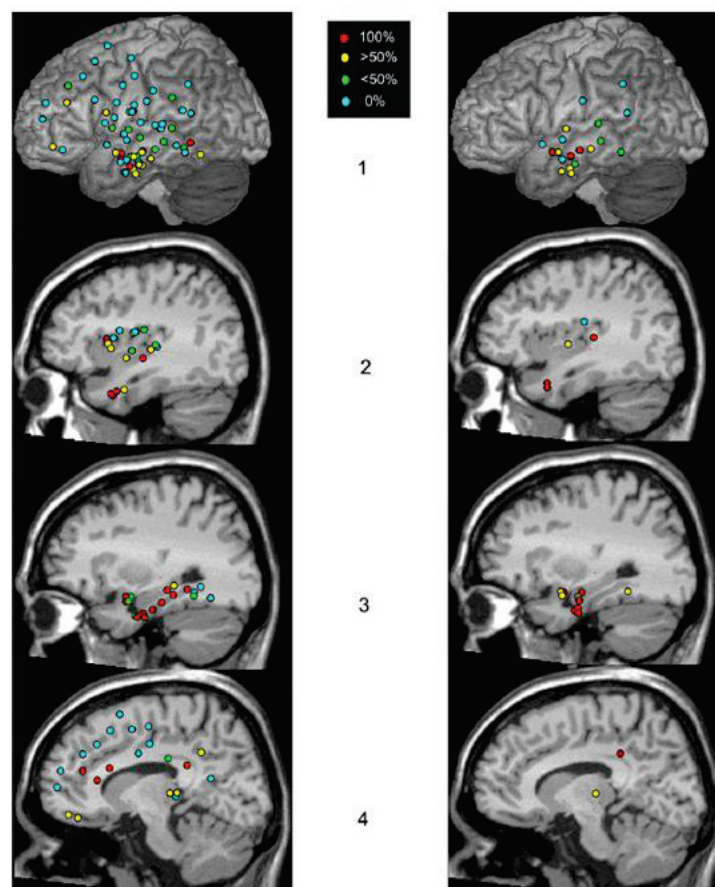


Figure II.5: Overview of global hippocampal connectivity (Catenoix et al., 2011). Representation of the distribution and response rates of EPs obtained after anterior (left column) and posterior (right column) hippocampal stimulation. The colored circles correspond to the percentage of contact pairs showing EPs after hippocampal stimulation: red = 100%, yellow > 50%, green < 50%, blue = 0%. MNI slices on temporal neocortex, dorso-

lateral frontal cortex, fronto-parietal operculum, temporo-parietal junction (1), insula and temporal pole (2), mesio-temporal structures (3), medial frontal cortex, cingulate gyrus and pulvinar (4).

4.1.2 Connectivity of temporal neocortex:

A joined American-Japanese team introduced the use of EBS in patients with subdural electrodes; a technique which they named ‘corticocortical evoked potentials’ (CCEPs). Using this EBS technique, Matsumoto et al. (2004) were able to describe for the first time the inter-areal connections in vivo in the human language system (Figure II.6). The study involved eight patients with epilepsy (age 13–42 years) undergoing invasive monitoring for epilepsy surgery. The electrical stimulus used for this purpose consisted of a constant current square wave pulse of 0.3 ms duration, which was given at a frequency of 1 Hz in a bipolar fashion with intensity ranging from 10–12 mA. Stimulation at the anterior language area elicited CCEPs in the lateral temporo-parietal area (seven of eight patients) in the middle and posterior part of the superior temporal gyrus, the adjacent part of the middle temporal gyrus and the supramarginal gyrus. Stimulation of the posterior language area produced CCEPs in the anterior language (three of four patients) as well as in the basal temporal area (one of two patients). This study revealed a bidirectional connection between Broca’s and Wernicke’s areas probably through the arcuate fasciculus and/or the cortico-subcortico-cortical pathway. The responses in this study were described to consist of an early (N1) and a late (N2) negative potential (Figure II.7). In which the N1 peak was visually identified as a first negative deflection that was clearly distinguishable from the stimulus artifact, and it is the one used to measure connectivity.

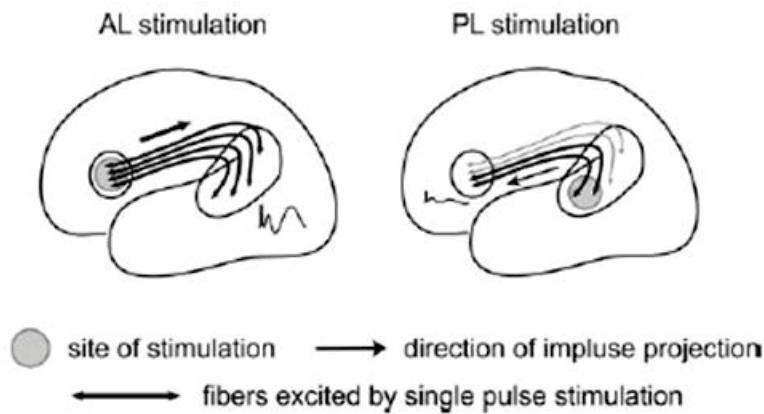


Figure II.6: Schematic illustration of presumed connections between the anterior and posterior language areas (Matsumoto et al., 2004). The grey circle denotes the site of stimulation. Arrows indicate the direction of impulse projection evoked by single pulse stimulation. The excited fibers are shown as thick black lines, and those not excited as thin grey lines. Waveforms show representative CCEPs. AL = anterior language area; PL = posterior language area.

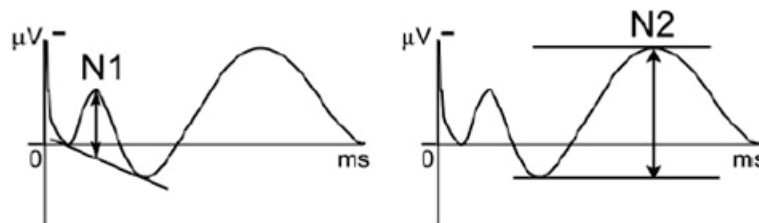


Figure II.7: Post EBS evoked potentials (Matsumoto et al., 2004). Both N1 and N2 are indicated.

Using the same CCEP technique, Koubeissi et al (2012) studied the role of the basal temporal (BT) cortex in language processing, by investigated the connectivity between perisylvian cortex and both BT areas. They recorded corticocortical evoked potentials (CCEPs) in 8 patients with subdural electrodes implanted for surgical evaluation of intractable epilepsy. Posterior language area stimulation elicited CCEPs in ipsilateral BT cortex in 3/4 patients with left hemispheric grids. CCEPs were recorded in bilateral BT cortices in 3/4 patients with strips upon stimulation of the left posterior superior temporal gyrus (LPSTG), and in the LPSTG in the fourth patient upon stimulation of either BT area. According to the authors, the role of BT cortex in language processing may be bilaterally distributed and related to linking visual information with phonological representations stored in the LPSTG.

4.1.3 Connectivity of the frontal cortex:

At King's college (London), Valentin et al. (2002) introduced the use of EBS in their implanted epileptic patients (either with subdural or depth electrodes), they called it single pulse electrical stimulation (SPES). A technique they used for both epileptogenicity studies as well as the study of human brain functional connectivity.

In 2007, this team investigated the connections between human temporal and frontal cortices in 51 patients assessed for surgery for treatment of epilepsy (Lacruz et al., 2007). EBS of monophasic single pulses of 1 ms duration and current intensity ranging between 4 and 8 mA was delivered in bipolar fashion every 8 or 10 s. EP responses to each pulse were recorded by the electrodes not used for stimulation (Figure II.8). The studied regions were medial temporal, entorhinal, lateral temporal, medial frontal, lateral frontal and orbital frontal cortices.

Connections between intralobar temporal and frontal regions (Figures II.9, and II.10) were common (43–95%). Connections from temporal to ipsilateral frontal regions were relatively uncommon (0–25% of hemispheres). Connections from frontal to ipsilateral temporal cortices were more common, particularly from orbital to ipsilateral medial temporal regions (40%). Contralateral temporal connections were rare (< 9%) whereas contralateral frontal connections were frequent and faster, particularly from medial frontal to contralateral medial frontal (61%) and orbital frontal cortices (57%), and between both orbital cortices (67%). Orbital cortex receives profuse connections from the ipsilateral medial (78%) and lateral (88%) frontal cortices, and from the contralateral medial (57%) and orbital (67%) frontal cortices. No differences were found between epileptogenic and non-epileptogenic hemispheres, the same finding of Wilson et al. (1990).

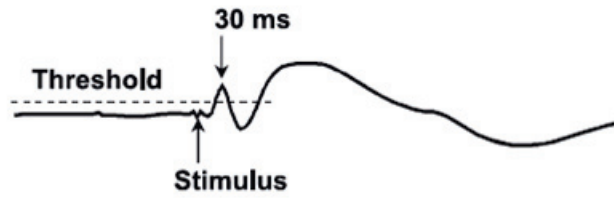


Figure II.8: Example of the studied EPs (Lacruz et al., 2007).

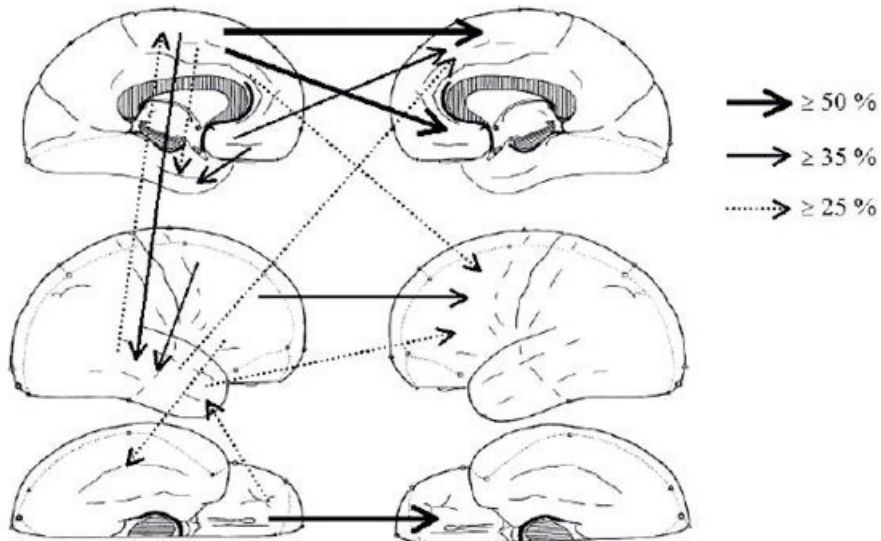


Figure II.9: Most common ipsilateral and contralateral interlobar connections (Lacruz et al., 2007). Ipsilateral connections are shown by arrows on the brain drawn on the left side of the figure whereas contralateral connections are shown by arrows between both brains.

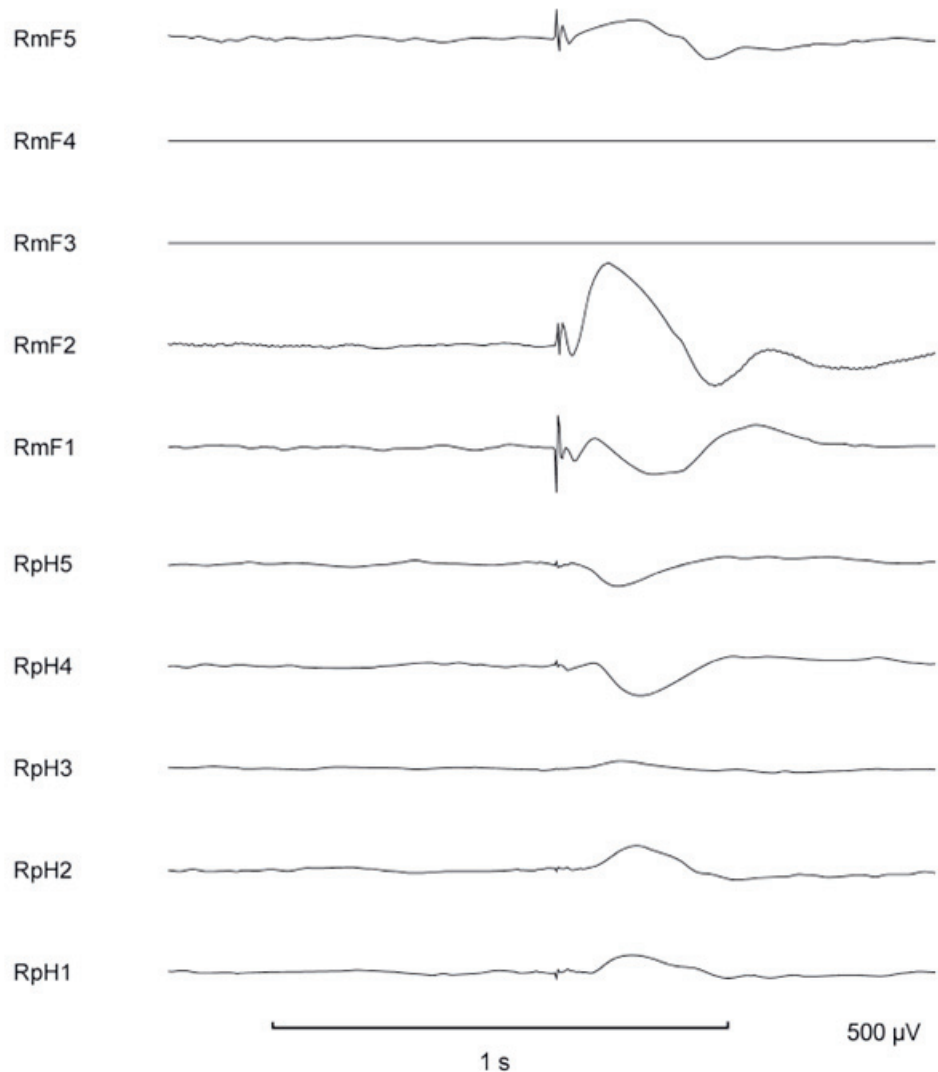


Figure II.10: Example of connections between frontal and ipsilateral temporal structures evoked by SPES (Lacruz et al., 2007). The average of 18 stimulations is used. When stimulating electrodes 3 and 4 of the right medial frontal bundle (RmF3-4), there is a response in the ipsilateral temporal lobe at RpH1-4, suggesting the presence of functional connections between both lobes. The flat horizontal lines show the stimulating electrodes. Recordings are shown as common reference to the average of each bundle of electrodes. RmF, right medial frontal; RpH, right posterior hippocampus.

After their work in the connectivity of the language system (Matsumoto et al. 2004), Matsumoto et al. (2007) used their CCEP technique to investigate the organization of the motor system. The knowledge about such system is important to understand the rapid spread of epileptic discharges through the network underlying ictal motor manifestation. The authors investigated the connections between the lateral motor cortex (LMCx; sensorimotor ‘SM’ and lateral premotor areas) and the medial motor cortex (MMCx; supplementary motor area proper ‘SMA’, pre-SMA and foot SM). Seven patients were included in the study. EBS was

delivered to MMCx (7 patients) and LMCx (4 patients). Short-latency CCEPs were observed when stimulating MMCx and recording from LMCx (mean latency: 21.6 ms, range: 9–47 ms) and vice versa when stimulating LMCx and recording from MMCx (mean latency: 29.4 ms, range: 11–57 ms). In this study, the team focused on the analysis of the N1 potential since not all the responses showed a clear N2 peak, and N1 was clearly established as a connectivity measure. The same team (Matsumoto et al., 2012) investigated the parieto-frontal network using the same technique in a group of six patients with epilepsy and one with brain tumor. Tracking the connections from the parietal stimulus site to the frontal site where the maximum CCEP was recorded, was characterized by: 1) mirror symmetry across the central sulcus (the more caudal the parietal stimulus site, the more rostral the frontal response site, and vice versa), 2) preserved dorso-ventral organization of the predominant circuits (dorsal parietal to dorsal frontal and ventral parietal to ventral frontal areas), and 3) projections to more than one frontal cortical sites (predominant and additional circuits) in 56% of the explored connections.

4.1.4 Connectivity of the thalamic medial pulvinar nucleus:

The reciprocal functional connectivity between thalamic medial pulvinar nucleus (PuM) and cortex was assessed by Rosenberg et al. (2009) using intracerebral-evoked responses obtained after PuM and cortical electrical stimulation in 7 epileptic patients undergoing icEEG (Figure II.11). Square pulses of current were applied in bipolar fashion; they consisted of 2 series of 25 pulses of 1 ms duration and 3 mA intensity, delivered at a frequency of 0.2 Hz. Cortical-evoked potentials (CEPs) to PuM stimulation were recorded from all explored cortical regions, except striate cortex, anterior cingulate, and postcentral gyrus. Percentages of cortical contacts pairs responding to PuM stimulation (CEPs response rate) ranged from 80% in temporal neocortex, temporoparietal (TP) junction, insula, and frontoparietal opercular cortex

to 34% in mesial temporal regions. Reciprocally, PuM-evoked potentials (PEPs) response rates were 14% after cortical stimulation in insula and frontoparietal opercular cortex, 67% in the TP junction, 76% in temporal neocortex, and 80% in mesial temporal regions.

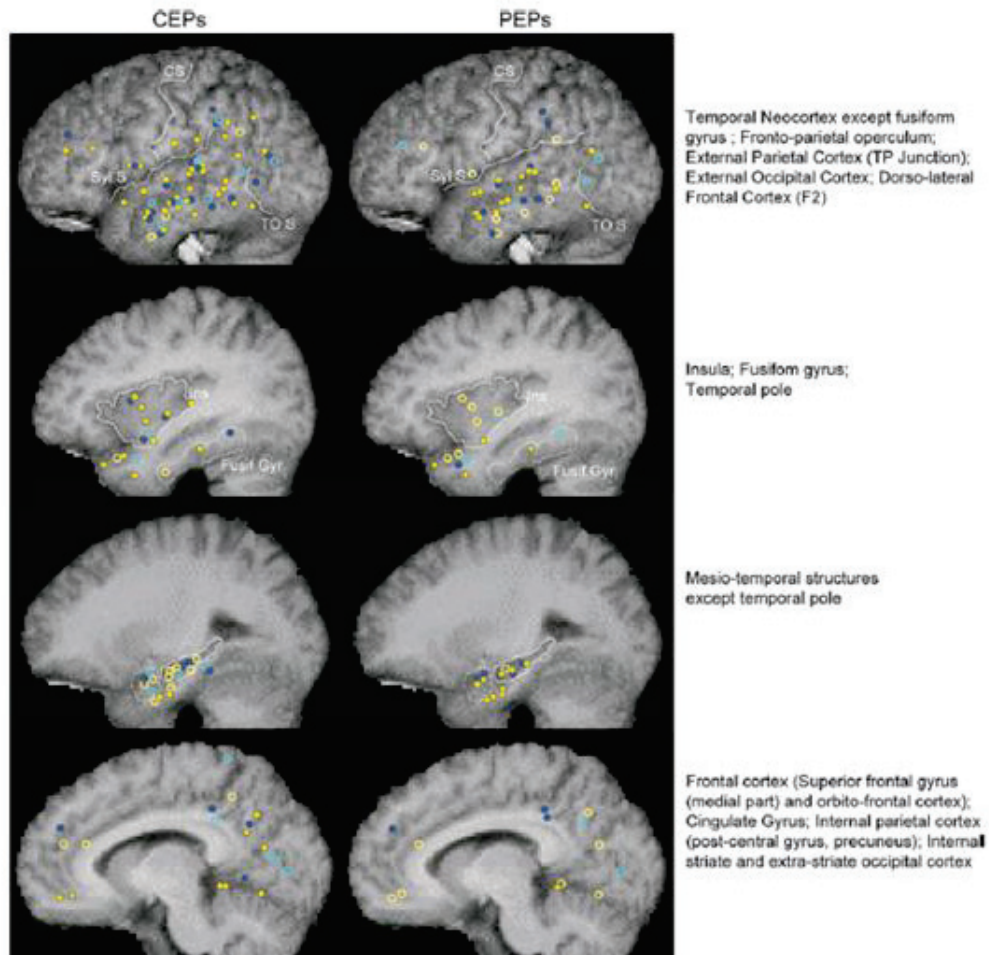


Figure II.11: Overview of global PuM--cortex connectivity (Rosenberg et al., 2009). Left column: filled circles were plotted when at least one of the contact pairs exploring a given cerebral structure exhibited a CEPs response after PuM stimulation; empty circles: absence of CEP; yellow circle: CEP in patients with thalamic contact pair located in the posterior part of PuM; blue circle: CEP in patients with thalamic contact pair located in the anterior part of PuM. Right column: filled circles were drawn when stimulation through at least one of the contact pairs localized in a given cerebral structure evoked a PEP response; empty circles: absence of PEP; yellow circle: PEP in patients with thalamic contact pair located in the posterior part of PuM (patients 1--4); blue circle: PEP in patients with thalamic contact pair located in the anterior part of PuM (patients 5--7). CS, central sulcus; Sylv S, sylvian scissure; TOS, temporooccipital scissure; Ins, insula; Fusif Gyr, fusiform gyrus. CEP, cortical evoked potential; PEP, PuM evoked potential.

4.2. EBS and epileptogenicity study:

Valentin et al (2002) investigated the in vivo cortical excitability in the human brain using the SPES. Their study included 45 patients suffering from temporal lobe epilepsy, with implanted subdural or intracerebral electrodes for pre-surgical assessment. SPES was performed in bipolar fashion of 0.3 or 1 ms duration, a current intensity of 1 to 8 mA, and every 10s. Monophasic pulses were chosen in order to increase the localizing accuracy of electrical stimulation. By comparing cortical responses in areas where seizure onset occurred, with responses recorded elsewhere, the authors distinguished two main types of responses (Figure II.12): 1) ‘early responses’, spikes and/or slow waves starting within 100 ms after the stimulus which were observed in most regions in all patients, and seem to be a normal response of the cortex to single pulse stimulation; 2) ‘delayed responses’, spikes or sharp waves occurring between 100 ms and 1 s after stimulation which were seen in some regions in 27 patients., their distribution was significantly associated with the regions where seizure onset occurred. According to the authors the presence of delayed responses can identify regions of hyperexcitable cortex in the human brain.

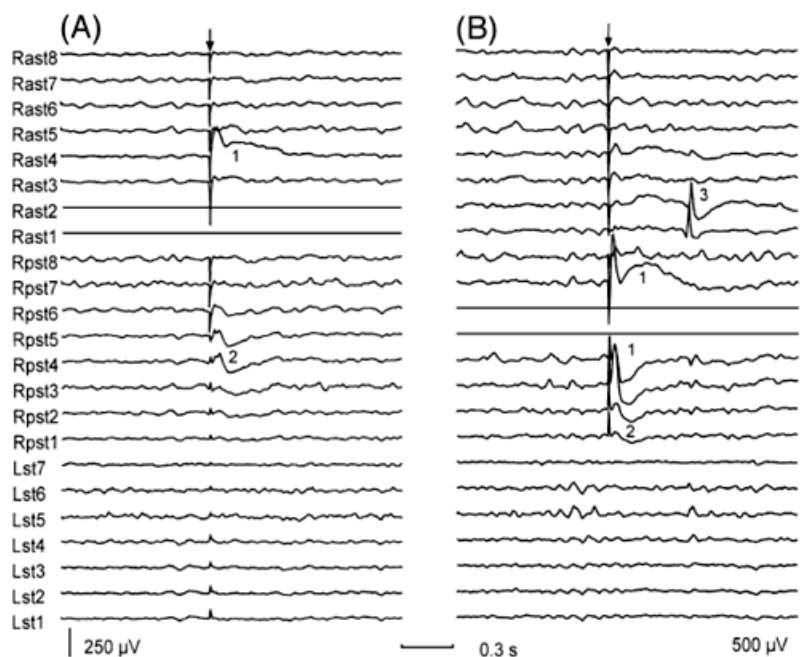


Figure II.12: Early and delayed responses evoked by SPES (Valentin et al., 2002). The patient showed focal seizures starting at electrode 1 of the right anterior subtemporal strip (Rast1). (A) Early responses seen when stimulating the deepest electrodes of the right anterior

subtemporal region (Rast1, Rast2, shown as $\bar{}$ at traces). (B) Early and delayed responses during stimulation through electrodes located at the right posterior subtemporal region (Rpst4, Rpst5). Inserted numbers indicate different response types: (1) early responses seen at electrodes located close to the stimulating electrodes; (2) early responses seen at electrodes located >3 cm away from the stimulating electrodes; and (3) delayed responses seen with a latency of >100 ms. The arrows indicate the stimulation artifact. Both recordings have similar time calibration but different gain. Abbreviations: Lst = left subtemporal strip; Rast = right anterior subtemporal strip; Rpst = right posterior subtemporal strip

Valentin et al (2005a) used again the SPES to evaluate the human brain epileptogenicity, but in the frontal lobe this time. SPES (1-millisecond pulses, 4 to 8 mA, 0.1 Hz) has been used in 30 patients with intracranial electrodes in the frontal lobes. In addition to the above mentioned two types of responses i.e. early and delayed responses, the authors described a second type of late responses. This was labeled as repetitive response (Figure II.13), and it is made of two or more consecutive sharp-and-slow-wave complexes, each resembling the initial early response. Frontal late responses were associated with neuropathologic abnormalities, and complete resection of abnormal SPES areas was associated with good postsurgical seizure outcome. This last observation was confirmed with another study (Valentin et al., 2005b) of abnormal responses to SPES during chronic intracranial recordings in 40 consecutive patients who were thereafter operated on because of refractory epilepsy and had a follow-up period of at least 12 months. Surgical outcome was significantly better when areas with abnormal responses to SPES were completely resected compared with partial or no removal of abnormal SPES areas ($p=0.006$). Neuropathological examination showed structural abnormalities in the abnormal SPES areas in 26 of the 29 patients in whom these regions were resected, despite the absence of clear MRI abnormalities in nine patients.

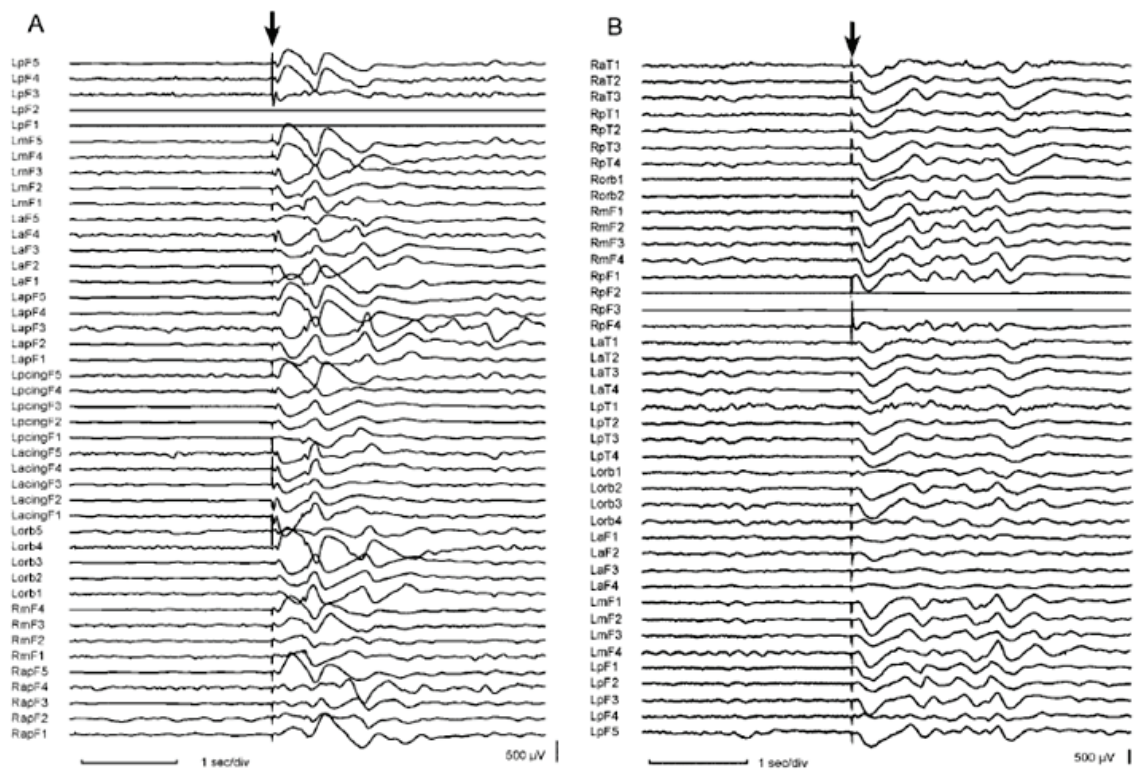


Figure II.13: Widespread repetitive responses evoked by SPES in the frontal lobe (Valentin et al., 2005a). (A) Bilateral repetitive responses with similar morphology and distribution to the first early response. Stimulation was performed through electrodes 1 and 2 of the left posterior frontal electrode bundle (LpF1 and 2). Recordings have been displayed in common average reference. (B) Bilateral repetitive responses with similar distribution but lower amplitude than the first early response. Stimulation was performed through electrodes 2 and 3 of the right posterior frontal electrode bundle (RpF 2 and 3). Recordings have been displayed in common reference to Pz. Both recordings have similar time calibration but different gain.

All of the above studies by the King's college group were conducted in adult patients. So, to test the usefulness of SPES on the pediatric population; Flanagan et al (2009) studied this in a group of 35 children. The stimulation data was examined for associations between response type, ictal onset zone, lesion boundary, and seizure outcome. The authors identified cortical responses to SPES that were similar to those reported in adults. When late responses (delayed and repetitive) were present in an area, removal of this entire area was associated with good outcome. In addition to previously mentioned responses, Flanagan et al. described a new type of responses, called Stable responses (SRs). They consist of a small spike or sharp wave, most often superimposed on the slow wave of an early response (ER). SRs had a latency ≥ 100 ms. In contrast to delayed responses (DRs), however, SRs have a fixed latency (typically with a

variation in latency of less than 20 ms). Furthermore, when present during the stimulation of a particular site, SRs arise after most or all stimuli. In this respect they resemble ERs, except that the latency is typically ≥ 100 ms. There was no clear relationship between the location of the SRs and the location of the stimulating electrodes.

The other form of EBS; the cortico-cortical evoked potential (CCEP) was used also to study human brain epileptogenicity. Iwasaki et al. (2010) studied this in a group of ten patients undergoing intracranial recordings with subdural electrodes for epilepsy surgery. They measured amplitudes, latencies, and stimulus thresholds of CCEPs near ictal onset zones (iCCEPs), and compared with adjacent neocortex not associated with ictal EEG (nCCEP). CCEP amplitude and latency measurements were made with each stimulation site, using graded stimulation intensities. The first negative (N1) iCCEP amplitude was higher than that of nCCEP in seven of the eight patients. There was no significant difference seen in latency changes or stimulus threshold. According to the authors, this accentuated CCEP amplitudes near ictal onset zones could reflect an increased excitability of the cortex associated with the epileptogenic zone in some patients with neocortical epilepsy.

5. EBS parameters:

In their study of 1990, Gordon et al. tried to define the safe parameters for electrical cortical stimulation in human. This was done by examining the light microscopic histology at a total of 11 sites of direct subdural electrical stimulation, taken as part of anterior temporal lobectomies in 3 patients. Stimulations had been done through 3.175 mm diameter electrodes, with 0.3 msec square wave pulses of alternating polarity at 50 pulses/sec. In 2 patients, one site each had been used as a common reference for stimulation, receiving over 251 stimulation trials, most of 2-5 sec duration, at currents of 12.5-15.0 mA, 1 day prior to resection. The maximum charge per phase was 4.0-4.4 pC; the maximum charge density was

52-57 pC per geometric cm² per pulse at the electrode surfaces. Comparison of hematoxylin and eosin, periodic acid-Schiff, and cresyl violet-stained material from the electrode sites with that from other regions did not show any histologic abnormalities attributable to the electrical stimulation. So the authors came to a conclusion that the relatively brief and intermittent periods utilized for human stimulation testing do not appear to cause structural damage at the light microscopic level at the above mentioned charge densities.

Though monophasic pulses are more efficient to initiate action potentials (Merrill et al, 2005), it should be kept in mind that monophasic pulses induce more tissue damage than biphasic pulses, and should thus be avoided for long periods of stimulation, and to be used only with previously mentioned protocols (SPES and CCEP). Add to this, it is always preferable to use bipolar stimulation; to reduce the risk of false positive by having a more focal current flow that is confined between the two stimulation electrodes (Nathan, 1993). Another important parameter is the shape of the current pulses; where a fast-rising rectangular pulse of depolarizing negative current is mostly preferred, being the most efficient waveform for extracellular stimulation (Yeomans, 1990). In addition to those parameters, the electrical field produced by EBS depends also on the pulse duration, frequency, and current intensity as could be noted from all above mentioned studies.

6. EBS analysis:

The very early EBS studies (Brazier, 1964; Buser and Bancaud, 1983) used only the direct visual analysis (i.e. simple visualization of resulting responses without further statistical confirmation) in the assessment of EPs. This type of analysis has its inherent limitations, especially when testing epileptic brains full of discharges and when dealing with huge amount of stimulation data requiring allot of time. Taking the advantage of the technological improvement, more recent studies used sophisticated statistical analysis in conjunction with the traditional simple visual analysis of responses. Valentin et al. (2002, 2005a, b) used the

method of comparing the 1000 ms post-stimulus with the 1000 ms pre-stimulus baseline. They observed that delayed responses often resembled spontaneous interictal discharges and were not seen after every stimulus, so the association between stimulation and delayed responses was established by comparing the occurrence of spikes during one second before and one second after each stimulation. It was assumed that spikes were related to stimulation if the number of stimuli showing spikes during the following second was greater than the number of stimuli showing spikes during the previous second with $P < 0.05$ (one-tailed sign test).

Other authors tried to analyze the EPs in the time-frequency domain (Van't Klooster, 2011), a quantitative way of analysis to enhance EBS specificity and clinical use. Time-frequency analysis could give a global view to responses including higher frequencies not detected by the simple visual analysis. Van't Klooster et al. (2011) recorded EBS data at a 2048-Hz sampling rate from 13 patients. The single pulse electrical stimulation (10 stimuli, 1 ms, 8 mA, 0.2 Hz) was performed in bipolar fashion. The time-frequency analysis based on Morlet wavelet transformation was performed in a (-1 s: 1 s) time interval around the stimulus and a frequency range of 10–520 Hz. Significant ($P = 0.05$) changes in power spectra averaged for 10 epochs were computed, resulting in event-related spectral perturbation images. In these images, time-frequency analysis of single pulse-evoked responses included the following range of values: 10–80 Hz for spikes, 80–250 Hz for ripples and 250–520 Hz for fast ripples. Sensitivity, specificity and predictive value of time-frequency single pulse-evoked responses in the three frequency ranges were compared with seizure onset zone and post-surgical outcome. The authors believe this technique could be greatly helpful in epileptic zone delineation in the future and faster than the routinely used visual assessment of events.

7. EBS advantages:

EBS offers a list of advantages making it a suitable test for studying human brain connectivity in vivo, in comparison to other techniques. These advantages are: 1) EBS studies are relatively easy to perform; it does not require patient's cooperation, and the chance of provoking seizures is extremely low (Matsumoto et al., 2004a, b). It can be scheduled and does not require long-term monitoring and it is not painful; 2) in comparison to PET and fMRI studies, the EBS study provides a direct neuronal response to the stimulation and more localized cortical stimulation with better temporal resolution (Selimbeyoglu and Parvizi, 2010); 3) in contrast to the DTI study, this technique is capable of providing the direction of connectivity, at least electrophysiologically, by stimulating both ends of connection; 4) EBS makes it possible to separate between pathological and normal zones from each other in a given patient within certain limits; 5) EBS gives accurate and reliable data on the distribution not only of the cortical eloquent areas, but also of the functional white matter bundles and deep grey nuclei (unlike fMRI and DTI) (Mandonnet et al., 2010).

8. EBS limitations:

EBS technique suffers from certain limitations including: 1) though it has a good spatial resolution, the delivered current can diffuse over the cortex and give unwanted results (Mandonnet et al., 2010); 2) EBS can be only applied to a patient population, so projecting data collected from patients with various etiologies and sites of seizure onset to a normal population shall be done with caution; 3) in the same line of the previous point, the choice of electrode placements is guided by patient's suspected epileptogenic zone, as a result, not all patients have electrodes placed in exactly the same sites. Still, in case of large number of patients and limited number of electrode implantation protocols, a significant proportion of patients may have electrodes placed in broadly similar areas; 4) EBS is a non-physiological stimulus of the brain, and we are still very limited in understanding how it functions, and how much similarity it has to the natural neural pulses; 5) any slight technical approximation can

result in false negatives, e.g. intensity of stimulation that is too low, lasts too short or is performed during a transient post-epileptic refractory phase may lead to an erroneous negative result; 6) the clinical use of EBS is compromised by the subjective visual analysis in the time domain and the use of statistics.

9. Summary:

Electrical brain stimulation (EBS) is an interesting investigation tool for both clinical and research purposes. It could be used either directly during brain surgeries or during pre-surgical work up for patients with refractory epilepsies. We use EBS to test for normal cortical functions, test for epileptogenicity or to study the human brain functional connectivity. Since the sixties many teams used EBS to study the functional connectivity of different brain regions except the insular cortex, leaving the way for further work in this interesting field.

Part two: Human insular cortex

1. Introduction

Insula was first described by Reil (1809) and named 'Island of Reil' after him. Streeter (1912) and Kodam (1926) identified it as being the first cortex to differentiate and develop in the fetus. It is found in the depth of the sylvian fissure hidden by other cerebral lobes behind the temporo-parieto-frontal opercula (Varnavas & Grand, 1999; Ture et al., 2000; Naidich et al., 2004; Afif et al., 2007).

It is a multifunctional region, where a wide range of functions take place e.g. language production and grammatical processing (Isnard et al., 2004; Afif et al., 2010), pain modulation (Ostrowsky et al., 2000; Mazzola et al., 2006; Afif et al., 2008), visceral sensory processing (Ostrowsky et al., 2000; Isnard et al., 2004), and auditory processing (Manes et al., 1999; Bamiou et al., 2003). icEEG recordings, have implicated the insular cortex in seizure generation and propagation (Isnard et al., 2000, 2004; Ryvlin et al., 2006).

This multi-functionality is reflected on an anatomical organization characterized by a wide spectrum of connections and a heterogeneous cytoarchitecture (Mesulam and Mufson, 1985). The primate insula is interconnected with several cortical regions, and demonstrates abundant intransular connections (Pandya et al. 1981; Mesulam and Mufson 1982, 1985; Friedman et al., 1986; Augustine 1996).

2. Insula in history:

The Island of Reil, or the insular cortex, is named after Dr. Johann Christian Reil, but an earlier description has existed at least since 1543, when Vesalius made simplistic sketches of the area based on his dissections (Saunders and O'Malley, 1982). The first illustration of the

insula was published in 1641, in the ‘Institutiones Anatomicae’ of Casper Bartholin (Bartholin 1641). Later to that, Vicq d’Azyr described it as ‘the convolutions situated between the Sylvian fissure and the corpus striatum’ (Vicq d’Azyr 1786). In 1861, Broca identified the motor speech centre as the left frontal operculum, and disproved the role of the insula by comparing post-mortem findings in the brains of aphasic patients with normals. Eberstaller (1887) gave the earliest and most complete morphological outline of the insula. This was followed by a group of most important works in the study of insular cytoarchitecture and anatomy early in the twentieth century e.g. Brodmann 1909; Rose 1928; von Economo 1929 etc. A rebirth of the interest in the insula was crowned by the great work of Mesulam and Mufson (1982, 1985) which forms the cornerstone of most of today’s work in the insula.

3. Insular development

Embryological studies have shown that human insula displays slower development than the surrounding neocortex. Being attached to the underlying structures and with the faster growth of other lobes; the insula becomes covered in an enclosed space (Sylvian fissure), making it the ‘hidden fifth lobe’ of the brain (Cunningham, 1891; Lockard, 1948; Afif et al., 2007). The surface of the insula remains smooth up to the middle of the fifth month of development. Only at about 19 weeks, the insula enlarges, and the separation between the anterior and the posterior portion becomes visible (Cunningham 1891). All gyri and sulci appear by 40-44 weeks of development and the newborn insula presents an almost adult appearance (Cunningham 1891).

4. Insular gross anatomy

Brodmann, defined five lobes of the brain, the fifth being the insular lobe (Brodmann 1909), giving it areas number 13 and 16. Von Economo described in a comprehensive way the gyral and sulcal patterns of the insula (von Economo, 1929). Human’s insula is found in the depth

of the Sylvian fissure (Figure II.14), and covered by the operculum. A central insular sulcus divides the surface of the insula into two portions; the larger anterior insula and the smaller posterior insula (Figure II.15). The anterior insula is made of three short insular gyri (anterior, middle and posterior) (ASG, MSG, and PSG). The posterior insula is made of the anterior and posterior long insular gyri (ALG and PLG). The main arterial supply of the insula stems from the middle cerebral artery, with predominance from the M2 segment. The insular arteries principally supply the insular cortex, the capsula extrema and sporadically the claustrum and the capsula externa (Varnavas and Grand, 1999; Ture et al., 2000).

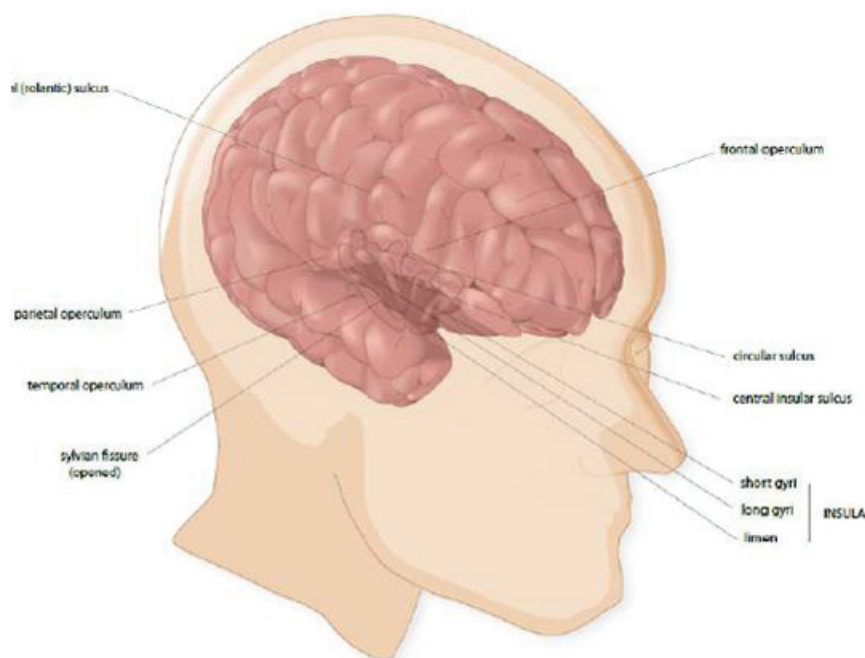


Figure II.14: The insular cortex is encased within the brain at the depths of the Sylvian fissure (Nguyen et al., 2009).

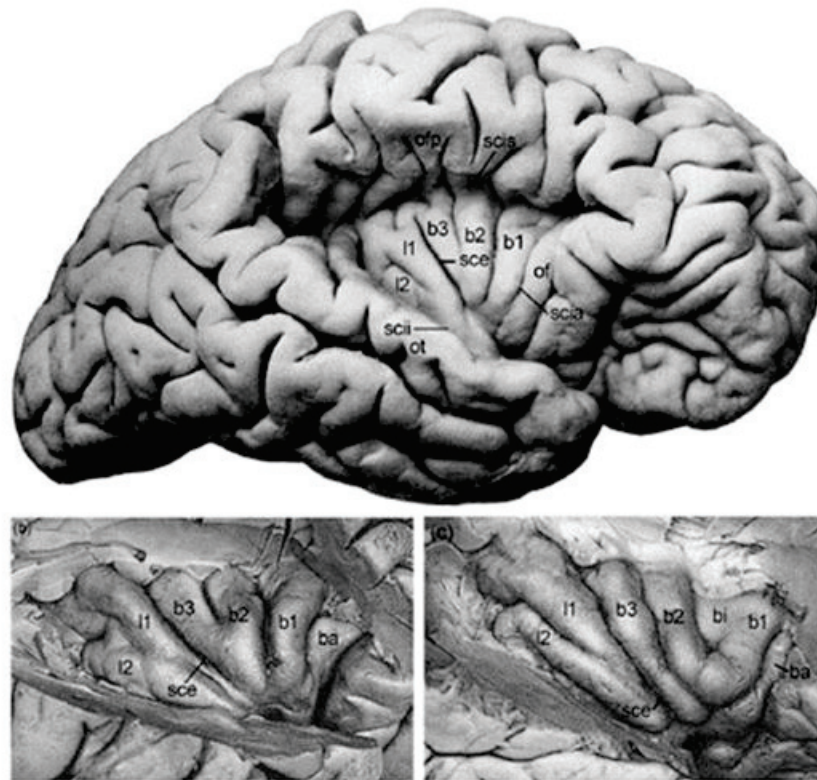


Figure (II.15): Insular gross anatomy (Nieuwenhuys, 2012). ba, gyrus brevis accessorius; bi, gyrus brevis intermedius; b1, b2, b3, gyrus brevis primus -secundus, -tertius; l, gyrus longus; I1, I2, gyrus longus primus, -secundus; of, operculum orbitofrontale; ofp, operculum frontoparietale; ot, operculum temporale; sce, sulcus centralis insulae; scia, scii, scis, sulcus circularis insulae, pars anterior, -pars inferior, -pars superior.

5. Insular cytoarchitecture:

The insula is part of a large mesocortical (paralimbic) domain with transitory architectonic characteristics between allo- and isocortex (Mesulam and Mufson 1982a). But its cytoarchitectonic structure is a matter of debate as there is a large variation in the literature regarding the cytoarchitecture of the insula. Two school of thoughts exist in relation to this issue (Nieuwenhuys, 2012); the first is postulating an anterior to posterior arrangement of the insula, with an anterior agranular and posterior granular areas separated by the central insular sulcus, mimicking the transition observed around the rolandic sulcus (Brodmann, 1909; Von Economo, 1925; Baily and Von Bonin, 1951). The second proposes a complex concentric aspect of arrangement around the apex of the insula, where the central insular sulcus plays no

important role (Rose, 1928; Brockhaus, 1940). This view is in line with the tripartation (agranular, dysgranular and granular) of the macaque insula reported by Mesulam and Mufson (1985). A recent postmortem study of human insula supported this hypothesis (Morel et al., 2013). The cytoarchitectonic/probabilistic maps of Kurth et al. (2010b) indicated the existence of three different zones in the posterior insula, adding more light to our understanding of the complex nature of this lobe in human (Figures II.16 and II.17).

In Monkeys, the agranular sector lacks identifiable aggregates of granule cells and displays a relatively simple laminar arrangement consisting of three cellular strata. The middle dysgranular sector contains five to six cortical layers with variable granulation. The granular sector occupies a posterior-dorsal wedge of the insula and made of six layers. Layers 2 and 4 are both granular and fully demarcated from adjoining laminae. The human insula shows a remarkable similarity in overall plan and contains agranular, dysgranular, and granular sectors (Mesulam and Mufson, 1985).

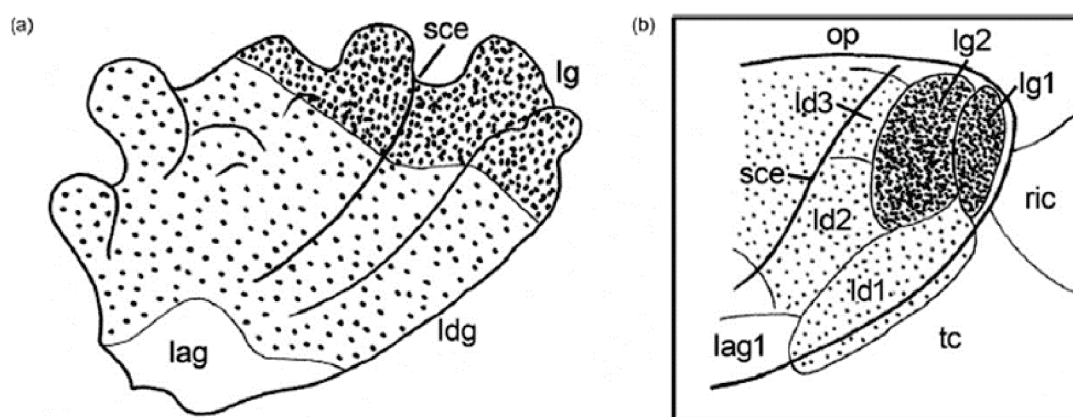


Figure II.16: Two examples of recent insular cytoarchitecture studies (Nieuwenhuys, 2012). (a) Subdivision according to Bonthuis et al. (2005). lag, agranular cortex; ldg, dysgranular cortex; lg, granular cortex. (b) Subdivision of the posterior insular region according to Kurth et al. (2010a). lg1, lg2, granular areas; ld1–3, dysgranular areas; lag1, agranular area; op, operculum parietale; ric, retroinsular cortex; sce, sulcus centralis insulae; tc, temporal cortex.

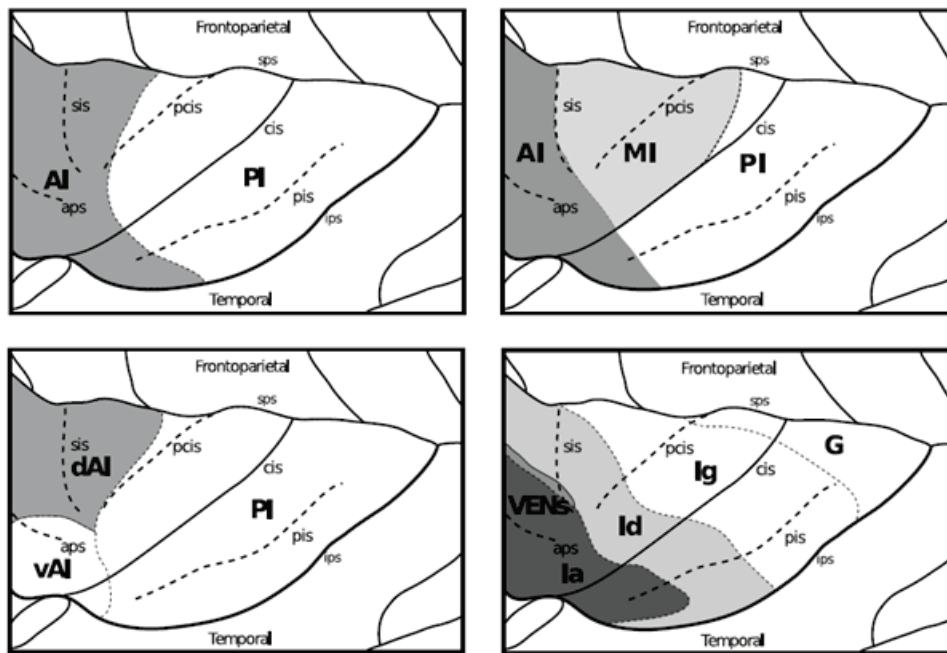


Figure II.17: Correspondence between insular anatomy and various subdivision approaches and imaging methods (Jakab et al., 2011). Top left: clustering based on similarities of structural connectivity (DTI), 2-way clustering. Top right: clustering based on similarities of structural connectivity (DTI), 3-way clustering. Bottom left: three systems of functional connectivity identified using fMRI (schematic drawing based on the paper by Deen et al. 2011). Bottom right: major cytoarchitectural domains of the human insula (Gallay et al., 2011). aps anterior periinsular sulcus, sis short insular sulcus, pcis precentral insular sulcus, cis central insular sulcus, pis postcentral insular sulcus, sps superior periinsular sulcus, ips inferior periinsular sulcus, AI, PI anterior, posterior insula, MI dorsomedial insula (in 3-way clustering), vAI ventro-anterior insula, dAI dorsoanterior insula, Ia agranular, Id dysgranular, Ig granular insula, G hypergranular subdivision, VENS von Economo neurons.

5.1 Cytoarchitecture and connectivity:

Interestingly, insular cytoarchitecture determines its connectivity pattern (Figures II.18 and II.19) i.e. there is preferential interconnectivity and concordance between the cytoarchitectonics of regions that are connected to the insula and the architecture of the insular cortex (Vogt and Vogt 1903). The agranular part of the orbitofrontal cortex is preferentially linked to the agranular part of the insula and the granular orbitofrontal cortex is preferentially linked to the granular insula. Several animal studies suggest a gradual rather than abrupt variation in connectivity: the gradient of increasingly more complex architecture spanning from agranular to granular territories (von Economo, 1927; Mesulam and Mufson, 1982a; Mesulam and Mufson, 1985; Friedman et al., 1986) appears to be related to the

gradual change in connectivity patterns, as reported by tracer-injection studies (Amaral and Price, 1984; Friedman et al., 1986; Chikama et al., 1997). On other hand, human studies were divided in opinion; Kurth et al. (2010b) claims the presence of clear boundaries between granular and dysgranular insular regions, while Cereliani et al. (2011) was in favor of a gradual pattern as in the case of the animals.

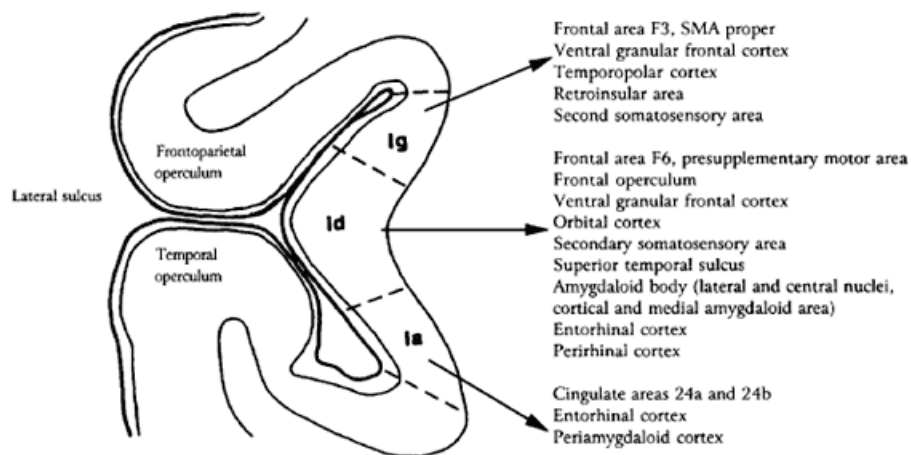


Figure II.18: Efferent insular projections from specific cytoarchitectural areas of the insular cortex (Augustine, 1996)

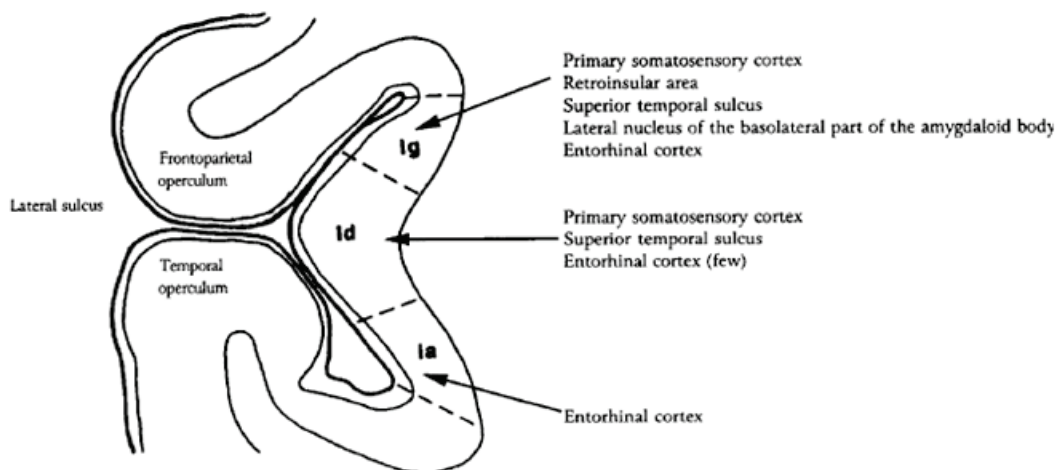


Figure II.19: Afferent projections to specific cytoarchitectural areas of the insular cortex (Augustine, 1996).

5.2 Cytoarchitecture differences:

5.2.1 Males to females differences:

At cellular level a difference was found between the female and male insulae; where the male insula is thought to be more complex with a different pattern of dendritic complexity across the insular gyri, whereas the complexity of basilar dendrites remain relatively stable in females (Anderson et al., 2009). This difference is not limited to the insula, where several differences between the brains of males and females have been well documented. For example, the female cortex is often thicker than the male cortex (Luders et al. 2005) with different gray/white matter ratios (Allen et al. 2003). Structural and chemical sexual dimorphisms have also been noted in the hippocampus (Madeira and Lieberman 1995), amygdala, medial paralimbic cortex (Goldstein et al. 2001), and prefrontal cortex (Bixio et al. 1995), all structures closely linked to emotions and, potentially, along with the insula, to interoception. Indeed, studies with emotional or interoceptive components have found sex differences in the activation of the insula and related limbic structures (Naliboff et al. 2003).

5.2.2 Differences across species:

In a comparative study across various species (primates and non primates), Butti and Hof (2010) concluded that it is not possible to identify a general model of organization for the mammalian insular cortex. The reason being the insula shows substantial variability in shape, extent, and gyral and sulcal patterns, as well as differences in laminar organization, cellular specialization, and structural associations with the Claustrum. But this can be looked at with a less effect when comparing between the human and the macaque insulae due to their multiple similarities (Mesulam and Mufson 1985).

5.2.3 Differences between human's and monkey's insula:

The major difference is that dysgranular domain in average represents half the anatomical territory in the human insula, versus a third in the monkey. The granular are reduced, and agranular increased (by about twofold) in the human insula compared to monkeys. The particular increase in dysgranular domain in the human insula has to be related to the large expansion of multimodal, associative cortex and their interactions with the insula. Attention should be paid also to the recent presumption of Craig (2009, 2010b, 2011) that the human anterior insula has no clear homologue in the rhesus monkey.

5.3 Von Economo neurons (VEN):

The von Economo neurons (VEN) are large bipolar neurons located in frontoinsular and anterior cingulate cortex in great apes and humans, but not other primates (Allman et al. 2010). The majority of VENs were found in the anterior insula, and some of the dysgranular areas. No obvious lateralization was found in the distribution of VENs, since similar distributions were observed in left and right hemispheres.

The VENs are proposed to be important in a neural circuitry underlying social awareness (Allman et al., 2005). Loss of VENs has been found in fronto-temporal dementia and several neuropsychiatric disorders including autism, and schizophrenia (Simms et al., 2009; Seeley, 2010; Butti et al., 2013; Santos et al., 2011).

6. Insular connectivity pattern (Figures II.20 and II.21):

Neural connectivity is heavily implicated in determining the functional specialization of a region, governing the nature and flow of information to and from an area (Behrens and Johansen-Berg, 2005; Plaut, 2002). We observe this in the insular cortex which is characterized by a wide range of anatomical connections (Mesulam and Mufson, 1985;

Augustine 1985; Augustine 1996; Nieuwenhuys 2012) to execute the long list of associated functions.

The two main sources of our knowledge about insular connectivity are tracer injection studies in monkeys e.g. Mesulam and Mufson 1982; Mufson and Mesulam 1982; Friedman et al., 1986; and Chikima et al., 1997, plus the imaging studies in human e.g. Deen et al., 2011; Cerliani et al., 2011; Cauda et al., 2011; Jakab et al., 2011; Cloutman et al., 2011; and Touroutoglou et al., 2012. Insular connections can be divided into two main groups; the intra-insular connections and the extra-insular connections (efferent/afferent), most of which are reciprocal and topographically organized (Aggleton et al., 1980).

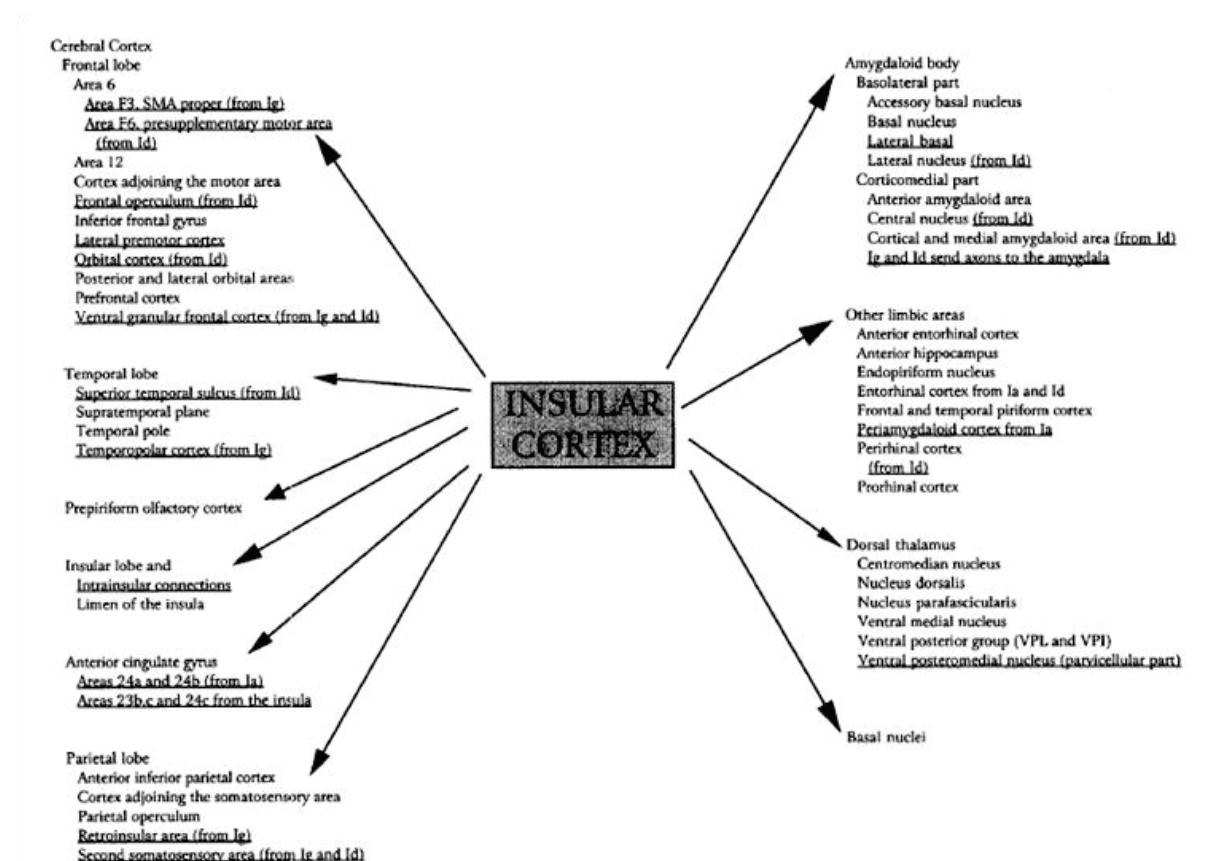


Figure II.20: Efferent insular projections (Augustine, 1996)

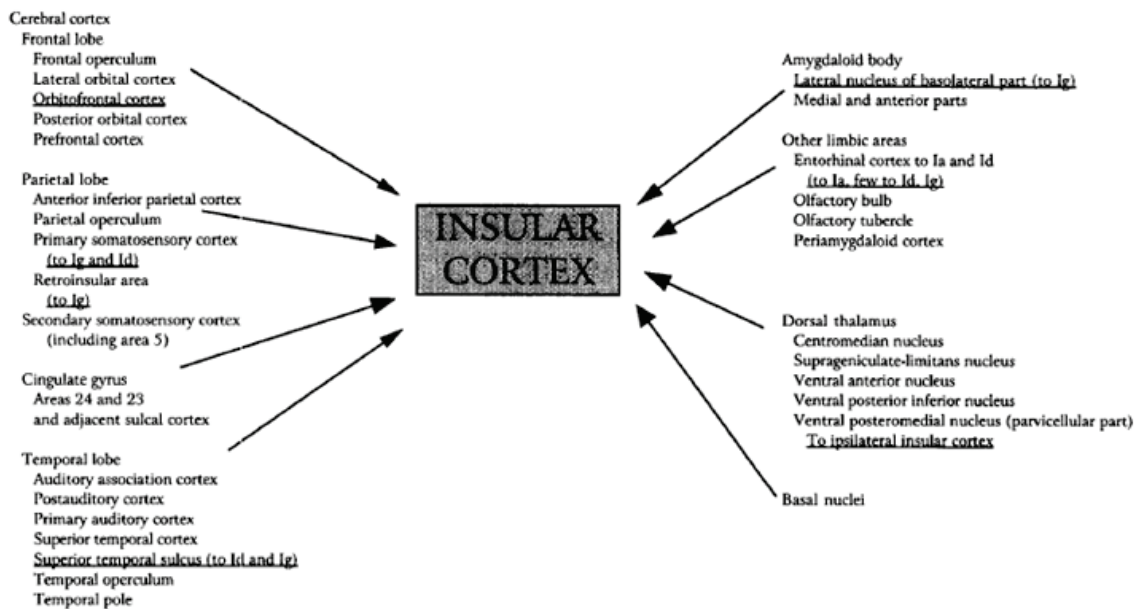


Figure II.21: Afferents to the insula (Augustine, 1996).

6.1. Intra-insular connectivity:

There are abundant intransular connections in the animal's brains (Pandya et al. 1981; Mesulam and Mufson 1982b, 1985; Mufson and Mesulam 1982; Augustine 1996). Horseradish Peroxidase (HRP) injections into the macaque insula revealed intra-insular connections within 1 mm of the injection site and on all sides. Dorsal injections often resulted in anterograde and retrograde label several millimeters ventrally or vice versa but confined to the same coronal plane (Friedman et al., 1986). For the human, Kurth et al. (2010b) proposed the presence of intransular connections looking to the fact that functional categories overlap in the anterior dorsal insula. In their tractography study, Cloutman et al. (2011) found that the anterior and posterior insular regions have strong within-subregion connectivity, and anterior–posterior interconnectivity does exist in the transitional area (particularly between PSG and ALG). In a recent resting state functional MRI in healthy human adults, Touroutoglou et al. (2012) found that within the insula itself, the right dorsal anterior insula signal correlated with signal fluctuations in the bilateral mid and posterior insular regions.

These connections occur predominantly from the anterior to the posterior sectors. They provide a potential pathway for conveying olfactory and gustatory information into the posterior insula (Mufson and Mesulam 1982). Intra-insular connectivity is abnormally reduced in pathologies like the autism spectrum disorder. A reduction not limited to the insula, but it involving the network responsible for emotional and interoceptive awareness in patients with autism (Ebisch et al., 2010).

6.2. Extra-insular connectivity (efferent/afferent):

6.2.1 Macaque insular structural connectivity (Figure II.22):

In macaques, the insula projects to primary and secondary sensory cortices (Mesulam and Mufson, 1982b; Mufson and Mesulam, 1982; Friedman et al., 1986), to premotor regions (Luppino et al., 1993), to the posterior parietal lobule (Andersen et al., 1990; Rozzi et al., 2006) as well as to higher-order association areas in the prefrontal lobe (Petrides and Pandya, 1999). The insula, especially its anterior portion, also has extensive connections with the amygdaloid complex (Mufson et al., 1981) as well as with other limbic and paralimbic regions in the frontal and temporal lobes (Mesulam and Mufson, 1985). Insular projections were found to both limbic and motor compartments of the striatum (Chikama et al., 1997) to autonomic nuclei in the brainstem and several thalamic nuclei (Mesulam and Mufson, 1985).

In two consecutive studies, Mesulam and Mufson (Mufson and Mesulam, 1982; Mesulam and Mufson, 1982) studied extensively the insular afferent and efferent using axonal transport methods (tracer injection with HRP and TAA). The horseradish peroxidase (HRP) is used to trace anterograde projections while the tritiated amino acid (TAA) is basically a retrograde tracing agent. Their study on the afferent projections concluded that injections of horseradish peroxidase (HRP) in the insula revealed labeled neurons in the prefrontal cortex, the lateral orbital region, the frontoparietal operculum, the cingulate gyms and adjacent medial cortex, the prepiriform olfactory cortex, the temporal pole, the cortex of the superior temporal sulcus,

the rhinal cortex, the supratemporal plane, and the posterior parietal lobe. Tritiated amino acid (TAA) injections in some of the cortical regions which contained retrogradely labeled neurons confirmed projections to the insula from prefrontal granular cortex, orbital frontal cortex, prepiriform cortex, temporal pole, rhinal cortex, cingulate gyrus, frontal operculum, and parietal cortex. Mesulam and Mufson study on the efferent insular projections revealed that this cortex sends neural efferents to cortical areas from which it receives reciprocal afferent projections. This study showed that the cortical areas connected with the granular sector of the insula are also granular in architecture whereas virtually all the connections of the agranular insula arise from agranular, or dysgranular areas. Thus and as previously described, there is a correspondence between the architecture of insular sectors and the areas with which they have connections. The insula is heavily interconnected with temporopolar and lateral orbital areas. Furthermore, many cortical connections of the lateral orbital cortex are quite similar to those of the insula. These common connectivity patterns support the conclusion, based on architectonic observations, that the insulo-orbito-temporopolar component of the paralimbic brain should be considered as an integrated unit of cerebral organization.

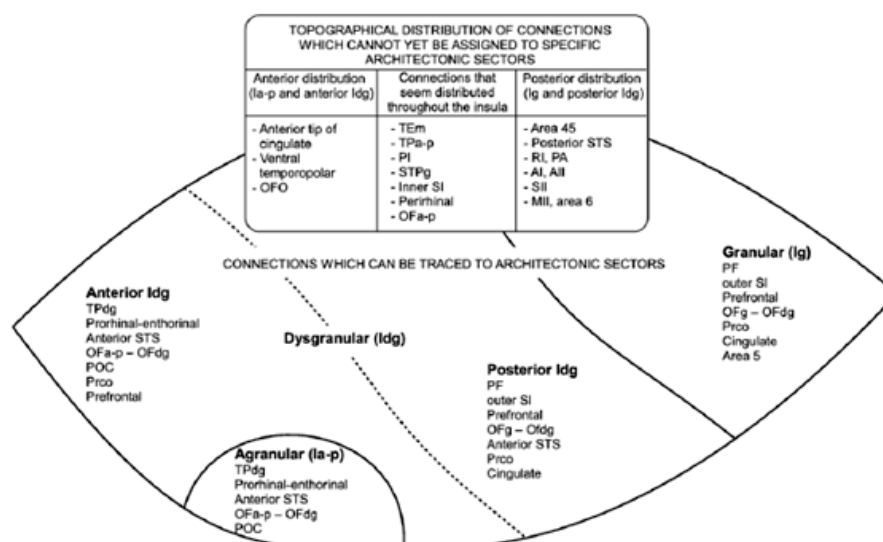


Figure II.22: Macaque insular connections (Mesulam and Mufson, 1982b)

6.2.2. Human insular connectivity:

In humans, to our knowledge, there have been no postmortem tracer studies of insula connectivity. Most of the available imaging studies (both structural and functional) agreed that the pattern of insular connectivity is almost identical to that of the macaque (Cerliani et al., 2011; Deen et al., 2011, Cauda et al., 2011). This insulo-cortical connectivity is divided into an anterior network dealing with affective and cognitive processing, a posterior network dealing with sensory-discriminative processing of noxious and somatosensory stimuli, and a middle territory of a mixed nature between the two other networks (Cauda et al., 2011).

Human insular structural connectivity (tractography studies):

Using the probabilistic tractography, Cerliani et al. (2011) demonstrated that (Figure II.23): 1) the cortical regions receiving most of the projections from the anterior insula included the orbitofrontal cortex (OFC), pars orbitalis and several locations in pars triangularis of the inferior frontal gyrus (IFG), and the dorsal part of the temporal pole; 2) the amygdala is connected prevalently with the anterior insula and specifically with the most ventral and anterior insular territory around the limen; 3) most of the tractography samples from the posterior dorsal insula reached the parietal lobe, including SI, SII, and the posterior parietal lobule as well as posterior regions of the temporal lobe in the superior temporal gyrus, the superior temporal sulcus, and the middle temporal gyrus; 4) regions in the frontal lobe that were mostly connected with the posterior dorsal insula included cortical territories in the premotor cortex, in pars triangularis and pars opercularis of the IFG as well as in the left dorsolateral prefrontal cortex; 5) cortical regions receiving the largest amount of samples from middle insular territories were located mostly in the lateral and middle premotor cortices as well as in regions of the temporal and parietal lobe adjacent to those reached by the

posterior dorsal insula. Several territories in the IFG and OFC were also mostly reached by samples from the middle insula.

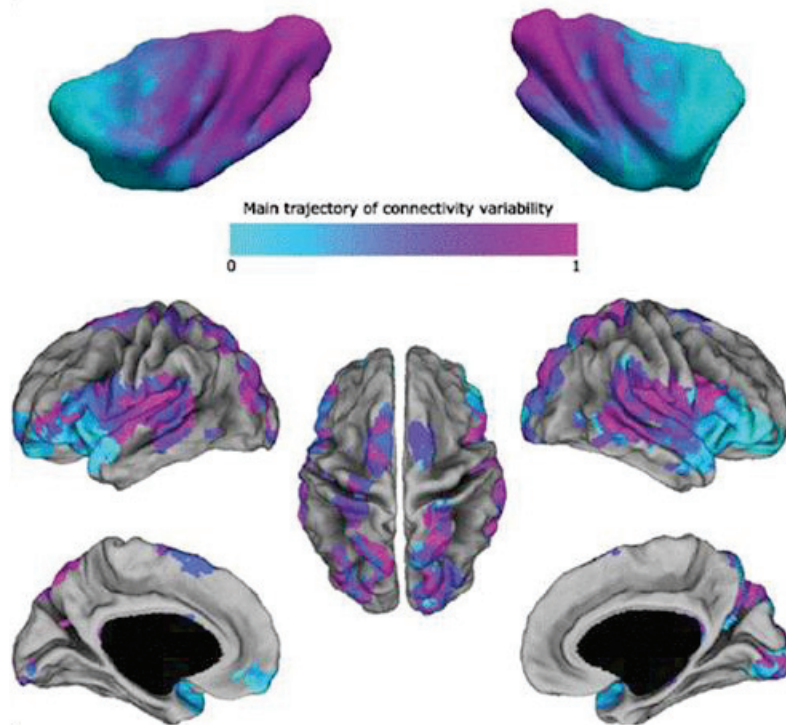


Figure II.23: Human insular connectivity pattern as tested by probabilistic tractography (Cerliani et al., 2011). Blue color, anterior insula; purple color, posterior insula. We notice the wide spread connectivity of the insula, and the specificity of connectivity of the two parts of the insula.

In a more recent tractography study, Cloutman et al. (2011) reached to similar findings of Cerliani et al. (2011). According to Cloutman the structural connectivity of the human insula (Figure II.24) is organized in to two complementary neural networks connected via a dual route architecture: 1) an anterior network connecting anterior-most insular areas with orbital/inferior frontal and temporal regions via an exclusively ventral pathway; and 2) a posterior network involving connectivity between the posterior-most insular areas and predominantly posterior temporal regions via dorsal and ventral pathways. A transitional area involving the dorsal-middle region of the insula was also found which demonstrated a graduated pattern of anterior– posterior hybrid connectivity between frontal and temporal areas.

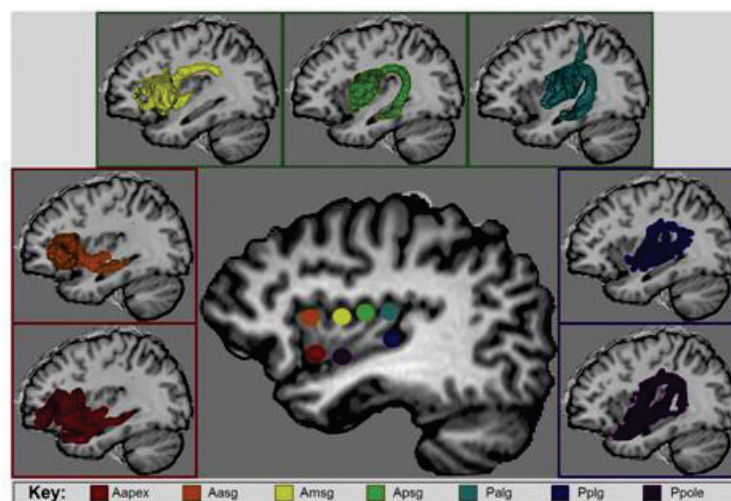


Figure II.24: (Cloutman et al., 2012) Location of the seven insular areas used as seed regions for probabilistic tracking (center), and examples of fiber pathways found for each tractographic region in the anterior (left), posterior (right), and transitional (top) networks derived from current tracking results. Abbreviations: Aapex = anterior apex (red), Aasg = anterior anterior short gyrus (orange), Amsg = anterior middle short gyrus (yellow), Apsg = anterior posterior short gyrus (green), Palg = posterior anterior long gyrus (teal), Pplg = posterior posterior long gyrus (blue), Ppole = posterior pole (purple).

Human insular functional connectivity (resting-stat functional MRI):

Two good examples of this type of method are Cauda et al. (2011) and Deen et al. (2011), (Figures II.25 and II.26). According to Cauda et al. there are two major complementary networks involving the ventral-anterior and dorsal-posterior insula. One network links the anterior insula to the middle and inferior temporal cortex and anterior cingulate cortex, and is primarily related to limbic regions which play a role in emotional aspects. The second links the middle-posterior insula to premotor, sensorimotor, supplementary motor and middle posterior cingulate cortices, indicating a role for the insula in sensorimotor integration. Deen et al. were in agreement with Cauda's findings, they found that posterior insula is functionally connected to primary and secondary motor and somatosensory cortices. While the ventral anterior insula was most strongly correlated with pregenual anterior cingulate cortex and the dorsal anterior insula was found to be functionally connected to dorsal part of the anterior cingulate cortex.

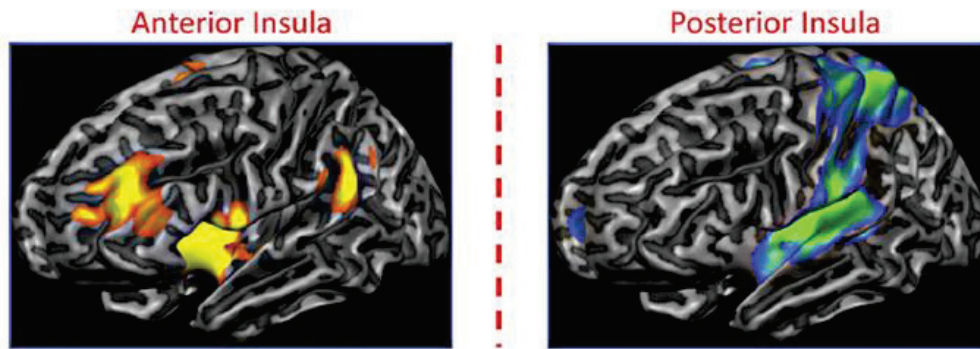


Figure II. 25: Anterior and posterior insular connectivity pattern as proven by resting stat MRI (Cauda et al., 2011)

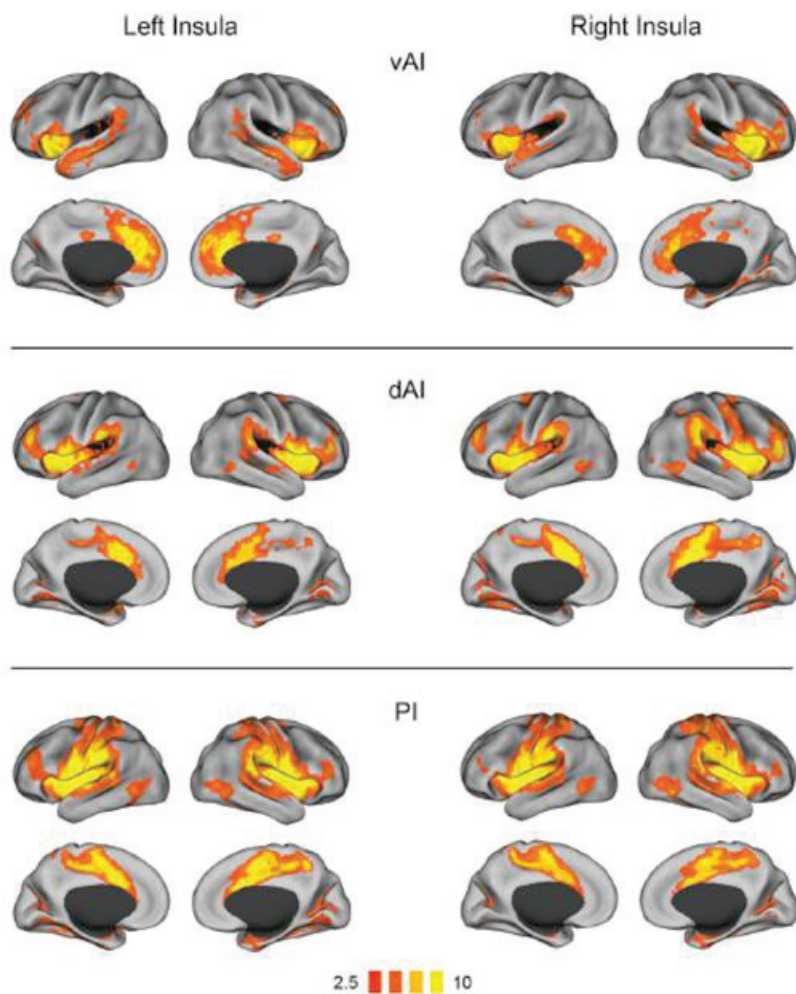


Figure II.26: Functional connectivity of insular subregions (Deen et al., 2011): ventral anterior insula (vAI), dorsal anterior insula (dAI), and posterior insula (PI). Connectivity

maps for left hemisphere seeds are shown on the left; maps for right hemisphere seeds are on the right.

This correspondence between the structural and functional methods results should be analyzed with caution. The reason is that the functional-structural connectivity relationship between these two methodologies may not be a simple one-to-one mapping (Damoiseaux and Greicius, 2009; Zhang et al., 2010). These functional correlations may result from indirect structural connections via shared brain regions (Damoiseaux and Greicius, 2009). A good example of this is the finding in rsfMRI (Cauda et al., 2011; Deen et al., 2011) of an existing connectivity between the insula and the anterior cingulate cortex, a finding not supported by the tractography studies (Cerliani et al., 2011; Cloutman et al., 2011).

6.3. Region specific connectivity:

In this subsection we look very briefly in to the specific pattern of cortical regions connectivity with the insula.

6.3.1. Insulo-limbic Connectivity:

Anatomical studies have consistently found that the insular cortex has extensive limbic (entorhinal, perirhinal, posterior orbitofrontal, temporopolar, cingulate and amygdaloid complex) and paralimbic connections concentrated mostly in its anteroventral territories (Augustine 1985; Mesulam and Mufson, 1985). The amygdala, entorhinal cortex, and hippocampus are mainly connected to the most rostral ventral insular field, corresponding to the agranular insula (Mufson et al., 1981; Cerliani et al., 2011).

6.3.2. Insulo-temporal neocortical connectivity:

Fibers destined for the insular lobe arise from the temporal lobe, including the primary auditory, auditory association, and postauditory cortex, superior temporal cortex, and the temporal operculum (Augustine 1985).

6.3.3. Insulo-IFG and premotor cortex connectivity:

In human, the inferior frontal gyrus (IFG) and adjacent ventral premotor cortex have their maximum connection probability to the dorsal part of the middle insula in the territory of the middle and posterior short gyri (Cerliani et al., 2011). Macaque studies showed evidence for moderate anatomical connections between dysgranular and granular insula and the macaque homologue of inferior frontal gyrus (Mesulam and Mufson, 1982b).

6.3.4. Insulo-Primary somatosensory cortex connectivity:

Tracer injection studies in macaques have shown that SI is strongly reciprocally connected with the insula and especially with posterior territories spanning the granular and adjacent dysgranular fields (Friedman et al., 1986; Mesulam and Mufson, 1982b). Similar connectivity pattern was found in the human, with projections to the postcentral gyrus, mostly originating in the middle and caudal insular cortex (Cerliani et al., 2011).

6.3.5. Insulo-Inferior and superior parietal lobule connectivity:

In macaque, insular projections to the inferior parietal lobule concentrated mainly in the granular insula and to a lesser extent in the adjacent dysgranular fields (Mesulam and Mufson, 1982b). In human, the posterior dorsal part of the insula has the maximum connection probability with both parietal lobules (Cerliani et al., 2011).

6.3.6. Insulo-thalamic connectivity:

The insula receives fibers from the centromedian (CM), ventral anterior (VA), suprageniculatae-limitans, and ventral posterior inferior (VPI) nuclei, and the parvicellular part of the ventral posteromedial nucleus (VPMpc) (Augustine 1985). The insula sends fibers to the ventral medial and centromedian nuclei, and to the ventral posterior group (VPL and VPI).

6.4. Interhemispheric insular connectivity:

The evidence of interhemispheric insular connectivity is limited. Using EBS in rats, Zhang and Oppenheimer (2000) suggested that the two insulae may communicate with each other to integrate and balance cardiovascular function between hemispheres. In the human brain this connectivity is shown in few tractography studies of the autistic spectrum disorder patients (Ebisch et al., 2010, Anderson et al., 2011).

6.5. Lateralization of insular connections:

Away from the anterior and posterior differences of insular connections, differences were also reported between the left and the right insulae. Actually, insular lobes of the two sides have slightly different developmental sequences: the right lobe ceases growth earlier than the left, whereas the left lobe has a larger surface than the right, especially in humans (Carpenter, 1991). Cauda et al. (2011) and Craig (2002, 2005, 2008) reported that the insulae of the two sides have different patterns of functional connectivity. In his tractography study, Jakab et al. (2011) found that connections of the anterior insula have larger leftward representation relative to the total insular gray matter volume. Supporting the idea that the right insula is acting as a pivotal region in the attentional systems of the brain (Sridharan et al., 2008; Nelson et al., 2010), and the left insula is vital in the cardiovascular functions (Zhang & Oppenheimer, 2000).

6.6. Transferring macaque's connectivity studies in to human:

The relevance of macaque studies to human insular connectivity is suggested by the similarities observed in the gyration, cytoarchitecture, and functional anatomy of the insula between the two species. Some authors suggested that the human insula has a plan of

organization virtually identical to that of the rhesus monkey (Mesulam and Mufson, 1982a). Interestingly, both display an anterior-posterior pattern evolving from agranular to granular cortices through a transitional dysgranular area. They also share a similar trajectory of connectivity, which follows the cytoarchitecture pattern between connected zones (Cerliani et al., 2011). However, some differences were reported between the two species. For instance, the human and not the macaque insula is characterized by the presence of the Von Economo neurons (VEN) (Allman et al., 2005; Butti and Hof 2010), this is a group of specialized neurons in some portions of the anterior insula and the cingulate, the function of which is thought to be the fast conduction of high mental functions between those two regions. Some authors suggested that the human anterior insula is a newly developed region with no macaque equivalent (Craig 2009). So, all animal data shall be interpreted with caution in relation to its similarities and differences with the human insular connectivity pattern.

7. Insular functions:

Our knowledge regarding the functions of the insula are derived from animal experiments, clinical reports, stimulation studies and more recently functional neuroimaging experiments. They all confirm the essential role of the insula in the integration between major functional systems being part of the paralimbic structures (the function of paralimbic areas is the integration between extrapersonal stimuli and the internal milieu). Over the years, a lot of different roles have been attributed to this lobe, though it forms only 2% of the total cortical surface area. Here is a list of functions and disorders which had been associated with the insula (further details in the Brain Structure and Function 2010 special issue about the insula):

1) Functions: Auditory, vestibular, somatosensory, pain and temperature perception, viscerosensation, taste, olfaction, visceromotor control, somatomotor control, motor plasticity, speech production, cognitive control, bodily awareness, self-recognition, individual emotions, and social emotions.

2) Dysfunction: Schizophrenia, conduct disorder, frontotemporal dementia, and drug addiction.

7.1. Anterior insula functional specialization:

Craig has argued that the sense of the physiological condition of the body, i.e. the “interoception”, which is associated with autonomic control, is engendered in the right anterior insula and might present the basis for our awareness of the “feeling self” (Craig 2002, 2009). He suggested that this area might represent a polymodal integration zone involved in all human feelings and thus may contain a representation of ‘me’ as a feeling entity, engendering the fundamental phenomenon of human subjective awareness (Craig 2010). In a patient who underwent surgical exploration of the insula, olfactory sensations, and changes in gastrointestinal motility were reported only when the anterior insular cortex was stimulated (Penfield and Faulk, 1955). Gustatory function also appears to be concentrated in the anterior insula.

7.2 Posterior insula functional specialization:

In contrast to the olfactory-gustatory-autonomic functions of the anterior insula, the posterior insula appears specialized for auditory-somesthetic-skeletomotor tasks. Actually, there is a convergence of somatosensory and auditory information in this portion of the insula. Such multimodal convergence may occur directly without intervening relays in modality specific association areas. The posterior insula is in a unique position to receive information in all five sensory modalities: gustatory, olfactory, auditory, somesthetic and, to a lesser extent, visual.

Kurth et al., (2010a) performed meta-analyses of 1,768 functional neuroimaging experiments. The analysis revealed four functionally distinct regions on the human insula (Figure II.27), which map to the social-emotional, the sensorimotor, the olfacto-gustatory, and the cognitive network of the brain. Sensorimotor tasks activated the mid-posterior and social-emotional

tasks the anterior-ventral insula. In the central insula activation by olfacto-gustatory stimuli was found, and cognitive tasks elicited activation in the anterior- dorsal region. They found that all tested functions overlapped on the anterior-dorsal insula (Figure II.28), such overlap might constitute a correlate for a functional integration between different functional systems.

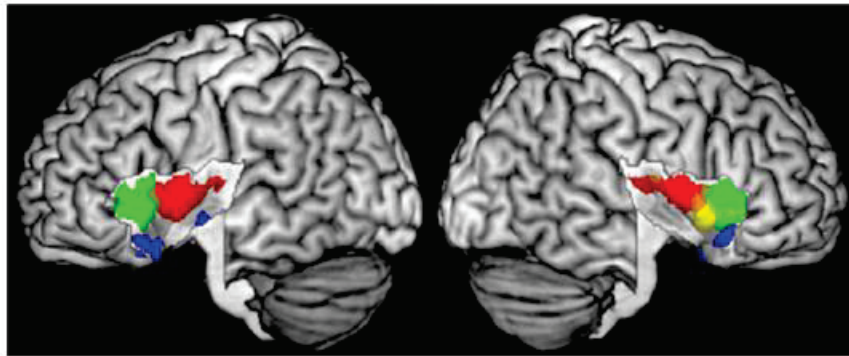


Figure II.27: Functional differentiation of the insula by functional domains (Kurth et al., 2010a). Red, sensorimotor; green, cognitive; yellow, chemical sensory; blue, social-emotional.

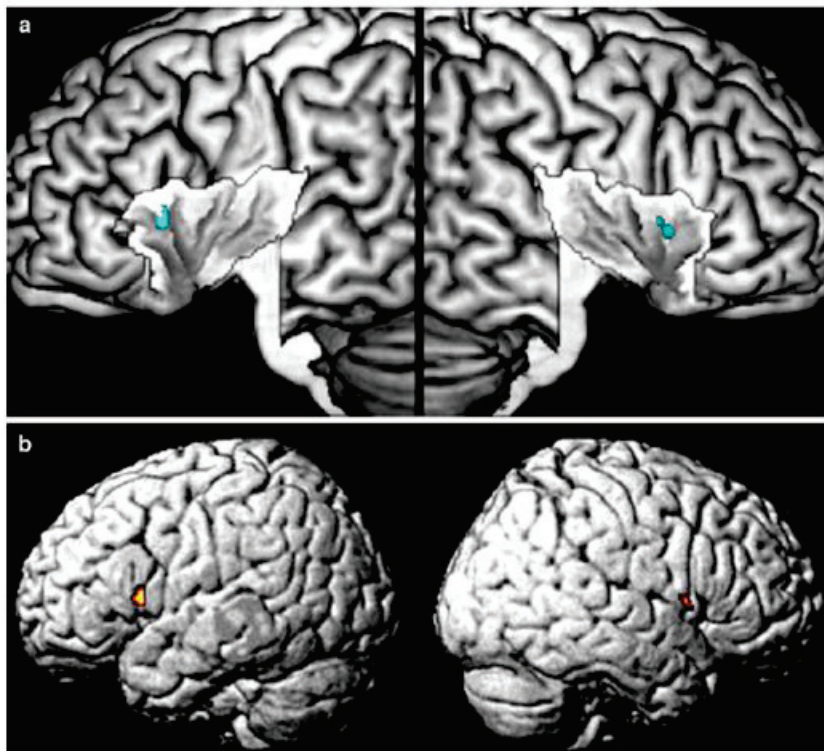


Figure II.28: Overlap of all functional categories (Kurth et al., 2010a). a. All overlap on the anterior-dorsal part of the insula indicating functional integration between them. b. Throughout the whole brain the anterior-dorsal insula was the only region that participated in the processing of all categories.

7.3. Detailed examples of insular functions:

With its very long list of supposed functions, we thought to give only two good examples of well studied insular functions; language and pain.

Insula and language:

The insula has been, as a matter of fact, considered a language area for the past decades (Augustine 1996). Many studies reported an involvement of the left anterior insula in overt language production tasks and specifically in the motor control of speech (Duffau et al., 2000; Ackermann and Riecker, 2004, 2010). Deficits in speech coordination are associated with lesions (Dronkers, 1996) and hypometabolism (Nestor et al., 2003) in the short gyri of the insula. Also, the left anterior insula is involved in detecting pure rhythmic aspects of speech production (Geiser et al., 2008).

EBS studies (Ostrowsky et al., 2000; Isnard & Mauguiere, 2005) suggested that the insula is involved in speech disturbances, including slurred speech and speech arrest. Other studies involving EBS of the insular cortex during surgical procedures suggest that the dominant insula may still be involved in language (Duffau et al., 2001, 2009). Numerous functional imaging studies have demonstrated the activation of the anterior insula during language-based tasks (Wise et al., 1999; Riecker et al., 2000, 2005).

Insula and pain (Figure II.29):

The insula participates in both the lateral and medial pain system (Craig, 2002). Functional imaging studies provided evidence for a linear representation of objective intensity for noxious heat and graded innocuous cool as well as stimulus localization in the contralateral posterior insula (Craig et al., 2000; Hua le et al., 2005). EBS studies showed that electrical stimulation in and around the insula produces perception of pain (Ostrowsky et al., 2002; Frot

and Mauguiere, 2003; Afif et al., 2008) in the same manner that lesions do e.g. after a stroke involving the operculo-insula region (Bowsher et al., 2004).

Ostrowsky et al. (2002) found the representation of 15 painful insular responses to EBS in 14 patients to be located in the upper posterior insular cortex, predominantly in the right hemisphere. In addition, they found somatosensory responses and especially sensation of non-painful warmth to be more frequently located in the lower posterior insula. And a somatotopic distribution of painful responses to EBS of the posterior insula was demonstrated with responses in the upper limbs being more dorsal compared to those in the lower limbs and painful responses in the face being more rostral to those in the limbs (Mazzola et al. 2006).

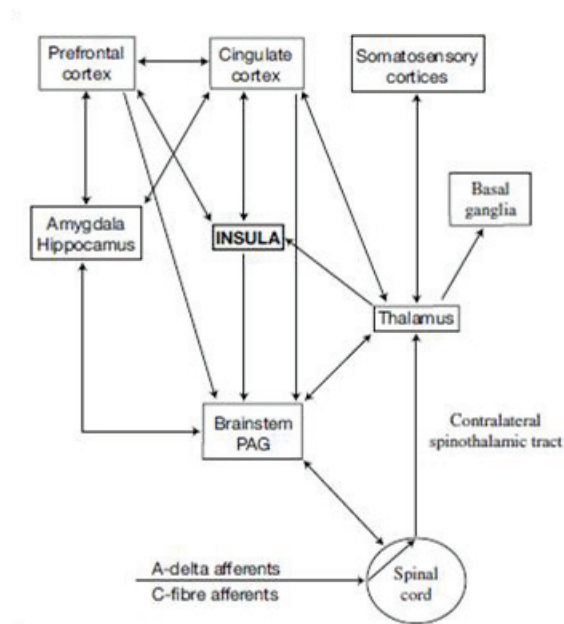


Figure II.29: Schematic diagram showing some of the main anatomical components of human nociceptive processing in the brain and possible functional connectivity (PAG, periaqueductal grey matter) (Shelley and Trimble, 2004). Insula plays a central role in this system.

8. Insular cortex and EBS:

Since the time of Penfield, EBS studies investigated either insular functions or its involvement in epilepsy, but none explored insular connectivity. During the period from 1945 to 1953 the Penfield team in MNI was using EBS during intra-operative investigations on awake patients undergoing surgical intervention for epilepsy and brain tumors. This allowed them to obtain visceral responses in approximately 40% of insular stimulations, while another 40% of responses resulted in a variety of sensory symptoms. They also described motor and gustative phenomena on insular stimulation (Penfield and Jasper, 1954; Penfield and Faulk, 1955).

It wasn't possible till late in the nineties to investigate the insular cortex with EBS in the context of icEEG for epilepsy pre-surgical evaluation. This improvement in the stereotactic implantation of intracerebral electrodes allowed the epilepsy team in Lyon to realize the majority of work in this regard. In the year 2000 Ostrowsky et al. suggested that the topographic organization of the human insula is divided in to two different cortical networks, a visceral network extending to the temporomesial structures and a somesthetic network reaching the opercular cortex. These networks are disturbed with stimulation of the anterior or the posterior insula, respectively. In their paper of 2002, Ostrowsky et al. described the representation of pain and somatic sensation in the human insula, where both overlap in the posterior insula. In the same field of pain and somatic sensations; Mazzola et al. (2006) compared EBS induced clinical manifestations in different cortical areas: the suprasylvian parietal cortex (SI), the parietal opercular cortex (SII) and the insular region. Somatosensory manifestations accounted for 93.5% of responses obtained from SI, while sensory phenomena represented 64% of all responses obtained from insular cortex stimulation. Moreover, these authors underlined that non-somatosensory symptoms were more frequently observed from the insular region with respect to SI and SII cortex.

Isnard et al. (2000, 2004, and 2009) looked at the insular involvement in the temporal lobe epilepsy, they described five different categories of clinical responses on stimulating the insula with EBS (Isnard et al., 2004): somatosensory (43% of all responses), viscerosensitive (22%), auditory (10%), dysarthria (6%) and others (10% including olfactogustatory in 2%). In addition, they provided a characterization of the clinical symptomatology in insular seizures. According to the authors, the most frequent initial subjective manifestation was a sensation of laryngeal constriction or paresthesiae, often unpleasant, affecting large cutaneous territories. Ryvlin et al. (2006) suggested that the anterosuperior portion of the insula might play a pivotal role in generating nocturnal hypermotor seizures in some patients with nonlesional drug-resistant epilepsy suggesting nocturnal frontal lobe epilepsy (NFLE) or autosomal dominant nocturnal frontal lobe epilepsy (ADNFLE).

The team in Grenoble studied the anatomofunctional organization of the insular cortex using EBS (Afif et al., 2010a). The stimulation from within the insular cortex evoked 83 responses in the 25 studied patients, without evidence of afterdischarge in the insular or extrainsular regions. They classified the principal responses as sensory (paresthesias and localized warm sensations), motor, pain, auditory, oropharyngeal, speech disturbances (including speech arrest and reduced voice intensity) and neurovegetative phenomena, such as facial reddening, generalized sensations of warmth or cold, hypogastric sensations, anxiety attacks, respiratory accelerations, sensations of rotation, and nausea. The same team implicated the insular middle short gyrus in speech production (Afif et al., 2010b).

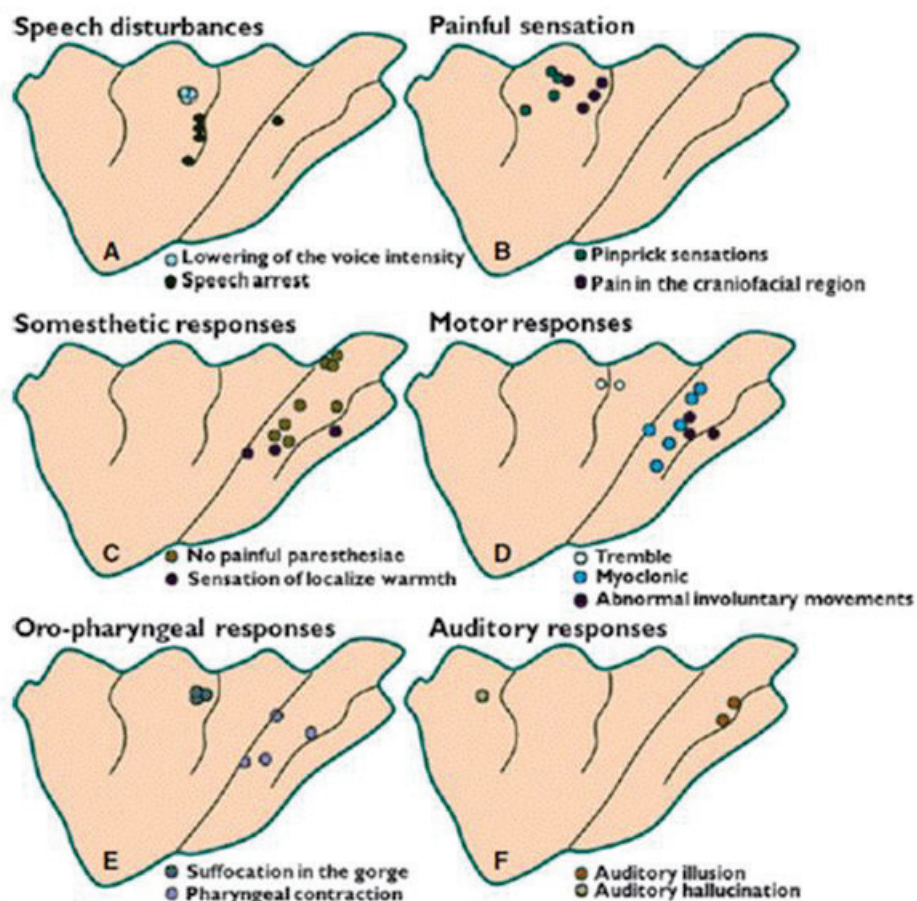


Figure II.30: Insular sites responding to electrical stimulation (Afif et al., 2010a). The sites corresponding to clinical responses were first located on each patient's individual diagram before being transferred onto the insular template. (A) Speech disturbances; (B) pain; (C) somesthetic responses; (D) motor responses; (E) oropharyngeal responses; (F) auditory responses.

Two other interesting works studied the functional topography of the insula using the EBS. The first came from Cleveland (Stephani et al., 2010); they induced two main categories of symptoms: visceral/internal sensations (44%) and somatosensations (56%), and they concluded that somatosensory/visceral symptoms were restricted to the posterior insula while the anterior insula did not show reproducible clear clinical responses to EBS (Figure II.31). The other came from the team in Milan (Pugnagi et al., 2011); they performed a total of 341 electrical bipolar stimulations. The most frequently induced symptom was a somatosensory manifestation (70%), (Figure II.32) mainly tingling and electric sensation involving the contralateral face and arm. Motor responses represented the 8% of the total amount, as well as

auditory phenomena. Language dysfunction accounted for 2% of responses. Autonomic and gustatory phenomena represented respectively 1% of responses.

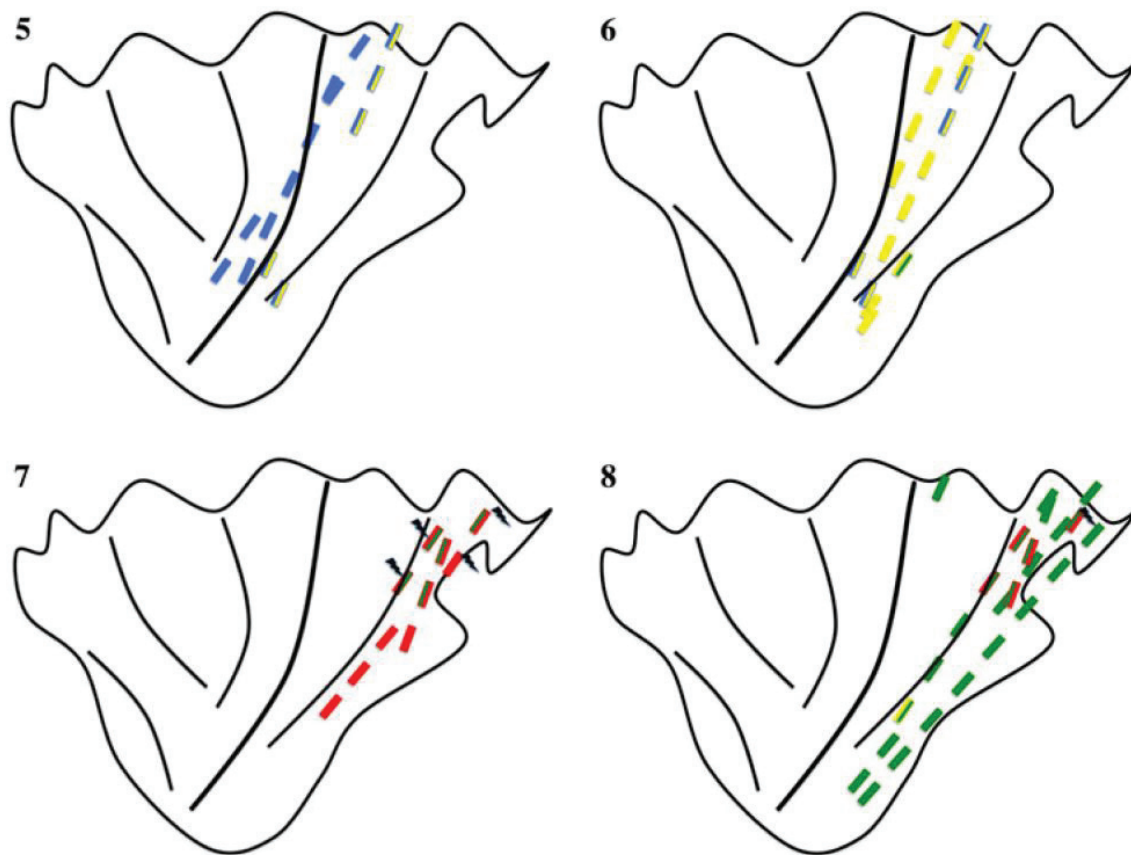


Figure II.31: The color-coded pictograms of the insula include the localizations of those electrode contacts that evoked clinical responses with EBS (Stephani et al., 2011). The responses were grouped into gustatory responses (5), viscerosensory responses (6), responses of warmth or pain (7) and into general somatosensory responses (8). The following color code is applied: blue gustation, yellow viscerosensation, red thermosensation, red with mark pain, green somatosensation. Composite color bars indicate qualitatively inconsistent or ambiguous symptoms after stimulation

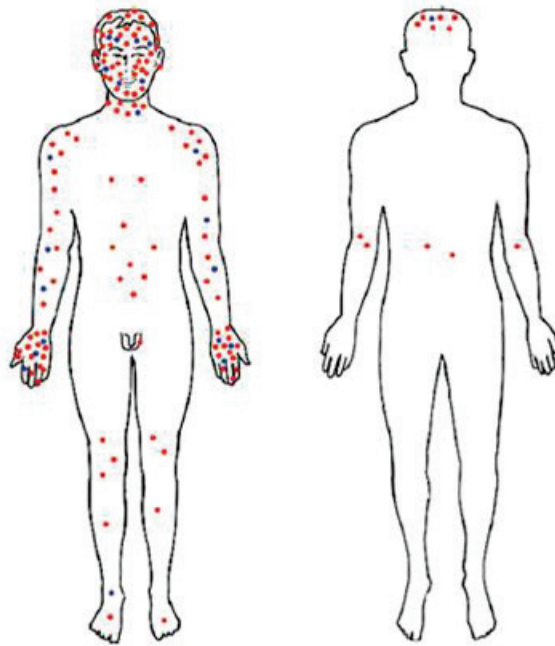


Figure II.32: Representation of body regions involved by somatosensory manifestation induced by insular cortex stimulations in high frequencies stimulations; 50 Hz (red dot) and low frequencies stimulation; 1 Hz (blue dot) (Pugnagi et al., 2011). Each dot represents one stimulation; responses involving more than one body region are represented with one dot for every region.

8.1. Insular connectivity in the context of EBS studies:

As we noted above, EBS has been used to study the connectivity of various brain regions such as the mesial temporal structures (Brazier 1964; Buser and Bancaud 1983; Rutecki et al 1989; Wilson et al., 1990; Catenoix et al., 2005; Lacruz et al. 2007), temporal neocortex including language areas (Matsumoto et al. 2004), frontal cortex (Buser et al., 1992, Lacruz et al. 2007), motor system (Matsumoto et al. 2007), and thalamic medial pulvinar nucleus (Rosenberg et al., 2009), but not that of the insula, making it a very interesting future target for EBS.

9. Insular epilepsy:

The idea that seizures generated in the insular lobe may present like temporal lobe seizures or that the insular lobe involvement in the genesis of some of the symptoms observed in the temporo-mesial seizures had been discussed since the mid twenty century, by Guillaume and Mazar (1949) and Penfield and Jasper (1954).

The more recent invasive studies (icEEG) showed that seizures starting at the insula could form part of various possible epileptic networks: insulo-temporal epileptic network (Isnard et al, 2000, 2004), insulo-parietal network (Isnard et al, 2004, 2011) and insulo-frontal network (Ryvlin et al, 2006). Different symptoms could strongly suggest insular involvement especially if in the following sequence: a sensation of laryngeal constriction and paresthesiae, often unpleasant, affecting large cutaneous territories, followed by dysarthric speech and focal motor convulsion symptoms (Isnard et al., 2004). Ictal signs arising from the insula occur in full consciousness. Seizures arising from the temporal lobe always invade the insular region, but in approximately 10% of cases, the seizures originate in the insular cortex itself (Isnard et al., 2004).

10. Summary:

The human insular cortex is a complex region, variable at its cellular structure, its functions and connectivity pattern. The majority of our knowledge about its functional and structural connectivity comes from either animal tracers or human imaging studies. Being a commonly investigated region with intracerebral EEG gives us the possibility to test its functional connectivity with electrical brain stimulation. A technique previously used to study connectivity of other regions but not that of the insula, opening the door for future contribution in the area.

Chapter III: Personal Work

Chapter III: Personal Work:

Part one: Introduction

The data for this work was collected from a group of 20 children admitted at the epilepsy and sleep unit at the child and mother hospital in Lyon (HFME) from 01/2009 to 12/2010. Children underwent icEEG as part of the pre-surgical evaluation of their drug resistant partial epilepsy. In our practice we use electrical stimulation in conjunction with the icEEG for the demarcation of normal and pathological cortical areas to avoid unwanted damage during epileptic surgery. Supported by the existing evidence of the possible use of EBS in human brain connectivity study e.g. Catenoix et al., 2005; Lacruz et al., 2007; Rosenberg et al., 2009, we decided to revisit this topic and to examine the insular functional connectivity.

Prior to studying the connectivity in the targeted region, we went into a prolonged process of standardization and verification of our EBS analysis technique (01/2011 to 03/2012). And since we deliver EBS and record it from all the implanted electrodes in all the studied patients, we ended with a huge amount of data concerning many cortical regions. We focused our efforts on the insular cortex, studying both its internal and external (efferent and afferent) connectivity patterns. Remaining data are still available for possible future use, either the connectivity of other regions or the study of human brain epileptogenicity.

Three articles were the result of this work; the first of which is treating electrical brain stimulation (EBS) and the analysis of resulting cortico-cortical evoked potentials (CCEPs), the second and the third articles were about the use of EBS in the study of Intra-insular and insular efferent connections respectively.

Part Two: Method

In this part of the work we discuss the used method in general and cover some of the areas not mentioned in detail in the individual articles to follow.

1. Patients:

Out of the twenty patients received EBS only eleven of them had insular electrodes and whom we mention below their clinical details. The first article includes patients 1, 11 and 2 in order, the second article includes patients 1 to 10, and the last article includes all of the eleven patients in same order mentioned here.

Patient 1 (A.N.):

History:

A.N. is an 11 years old right-handed girl with no past medical, personal or family history. First seizure was at the age of 8 years; with a de déjà-vu sensation followed by loss of conciseness and prolonged sleep after that. At time of hospitalization her seizure was described as following: warm feeling in the palate, followed by respiratory difficulty and abdominal pain which was more or less ascending in nature, after that she complains of left hand paresthesiae including the two feet also, and terminating by headache.

Complementary examinations:

Scalp EEG: right temporal anomalies.

MRI: a suspicion of hyper-signal on FLAIR of both the hippocampus and the amygdala on the right side.

FDG-PET: hypometabolism of the right temporal pole.

icEEG: An epileptic zone involving the right mesial temporal structures.

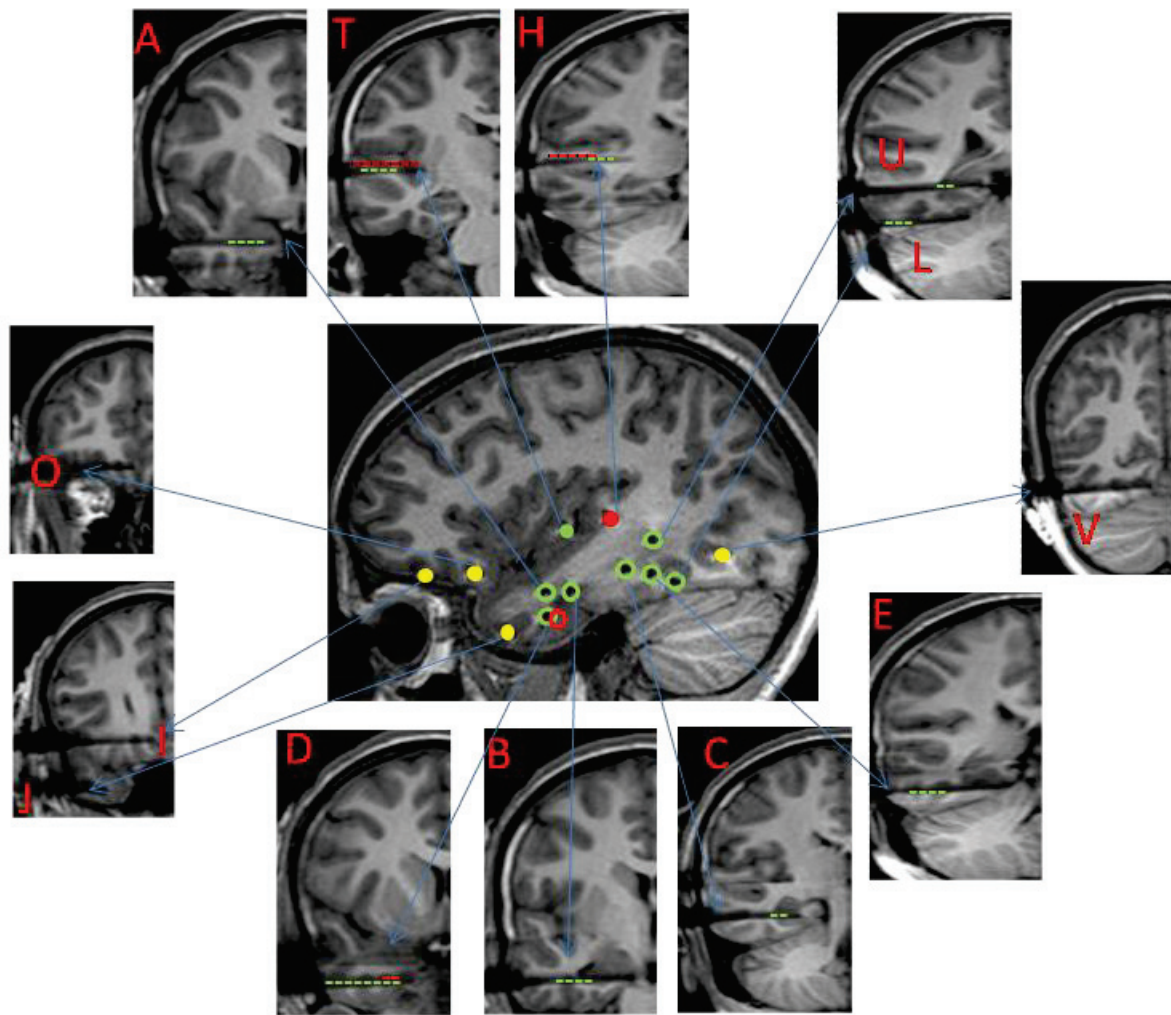


Figure III.1: Patient 1 MRI with electrodes in place (Right hemisphere). Central sagittal image: each insular electrode is represented by a unique colored solid circle; non-insular electrodes are represented by empty circles with the color of each of the insular electrode they are responding to. Yellow solid circles are for non responding electrodes. Peripheral coronal images: a cross-section of each electrode with its name and its responding contacts (responses are indicated by color coded dotted lines, representing the color of the corresponding stimulated insular electrode).

Patient 2 (A.T.):

History:

A.T. is a 9 years old right-handed boy with no past medical, personal or family history. First seizure was at the age of 8 years; in a febrile context, during which he developed a convulsive status epilepticus followed by a prolonged coma. His EEG at that time showed a right sided slowing. At time of hospitalization his seizure was described as following: an inaugural cry

followed by deviation of the angle of the mouth to the right, then the child fall down followed by secondary generalization. The child is having a post-ictal aphasia and headache.

Complementary examinations:

MRI: Bilateral hippocampal atrophy, more pronounced in the right side.

icEEG: An epileptic zone involving both the hippocampi.

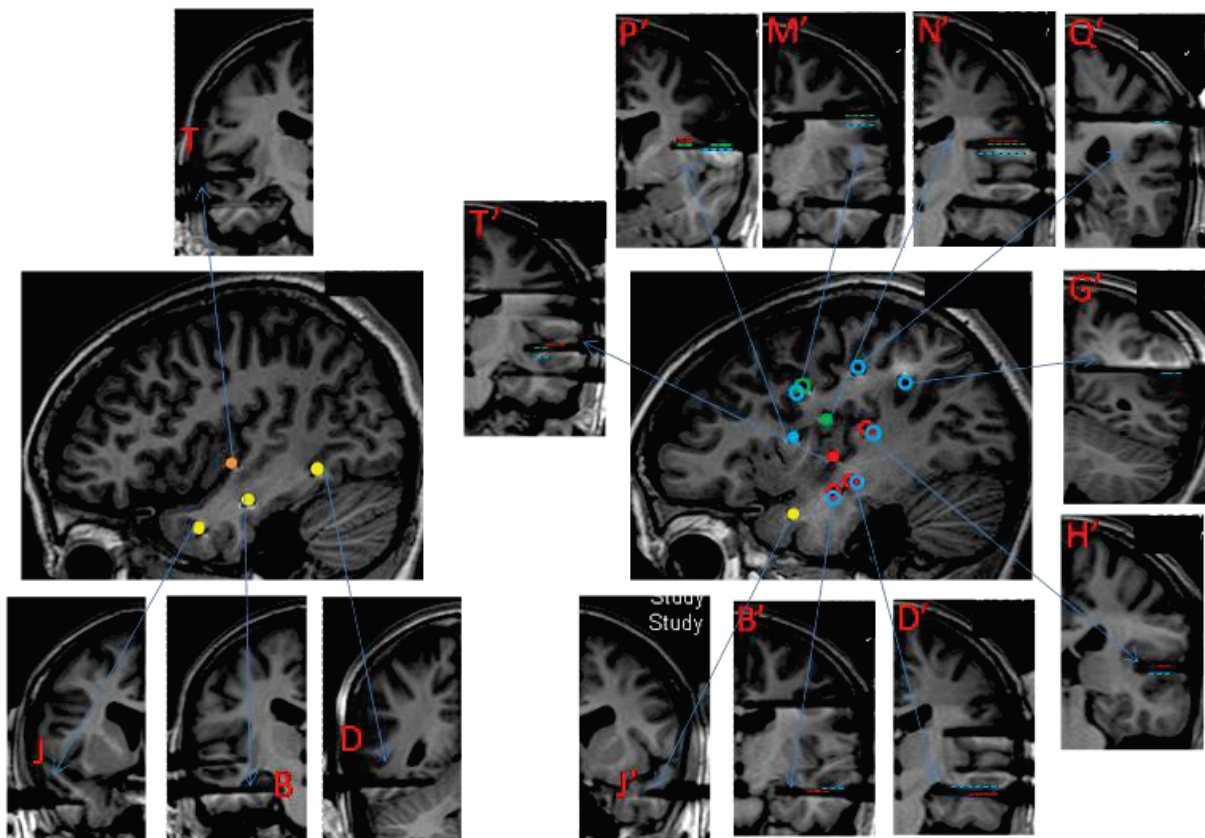


Figure III.2: Patient 2 MRI with electrodes in place (Left and Right hemispheres). Central sagittal image: each insular electrode is represented by a unique colored solid circle; non-insular electrodes are represented by empty circles with the color of each of the insular electrode they are responding to. Yellow solid circles are for non responding electrodes. Peripheral coronal images: a cross-section of each electrode with its name and its responding contacts (responses are indicated by color coded dotted lines, representing the color of the corresponding stimulated insular electrode).

Patient 3 (C.R.):

History:

C.R. is an 11 years old right-handed girl with no past medical, personal or family history.

First seizure was at the age of 7 years. At time of hospitalization her seizure was described as

following: a tingling sensation in front of and inside the right ear, followed by right arm elevation to the back with painful sensation in the whole arm. In post-ictal the child is mildly dysarthric and the right arm is hypotonic.

Complementary examinations:

MRI: bilateral hippocampal dysgenesis.

icEEG: An epileptic zone involving the left insula.

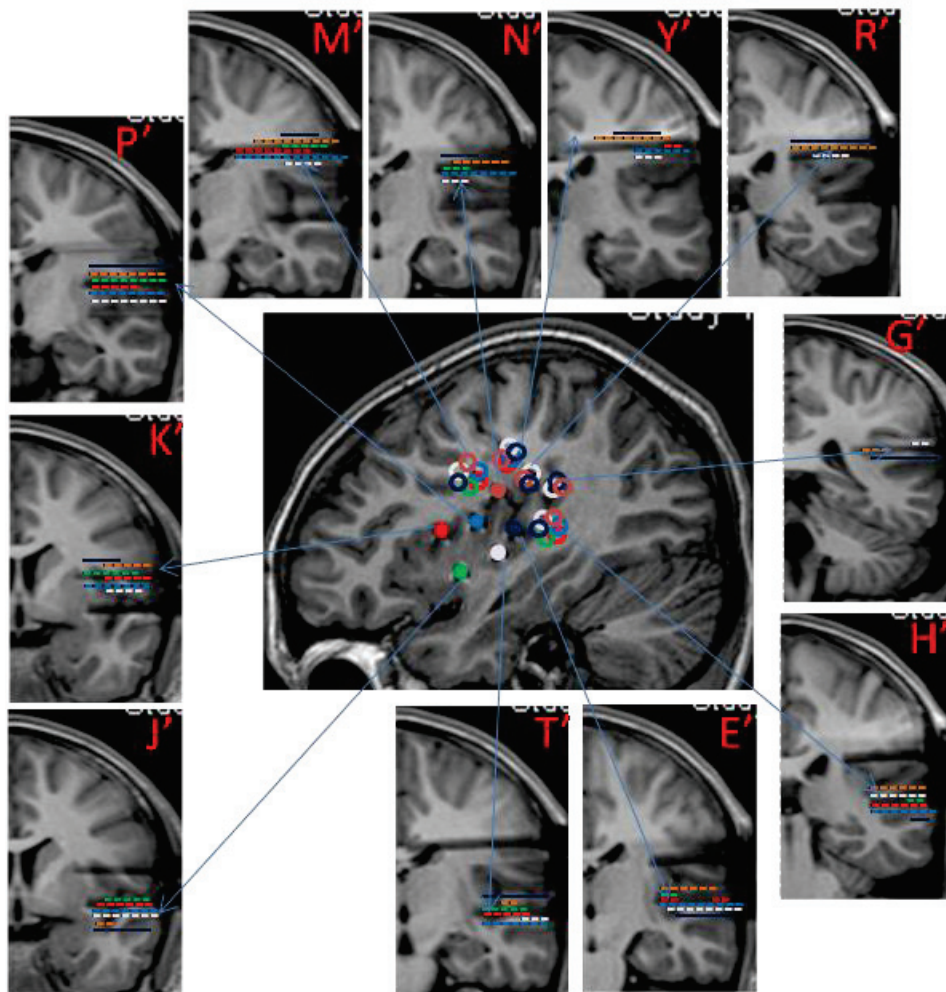


Figure III.3: Patient 3 MRI with electrodes in place. (Left hemisphere). Central sagittal image: each insular electrode is represented by a unique colored solid circle; non-insular electrodes are represented by empty circles with the color of each of the insular electrode they are responding to. Yellow solid circles are for non responding electrodes. Peripheral coronal images: a cross-section of each electrode with its name and its responding contacts (responses are indicated by color coded dotted lines, representing the color of the corresponding stimulated insular electrode).

Patient 4 (R.R.):

History:

R.R. is a 10 years old ambidextrous boy with no past medical, personal or family history. First seizure was at the age of 7 years. At time of hospitalization his seizure was described as following: a paresthesiae in the tongue and the inner wall of the mouth, followed by a forceful closure of the mouth and an inability to talk, then a dystonic posturing of both upper and lower limbs.

Complementary examinations:

MRI: Normal.

FDG-PET: left peri-sylvian hypometabolism.

MEG: left peri-sylvian focus.

icEEG: An epileptic zone involving the left third frontal gyrus.

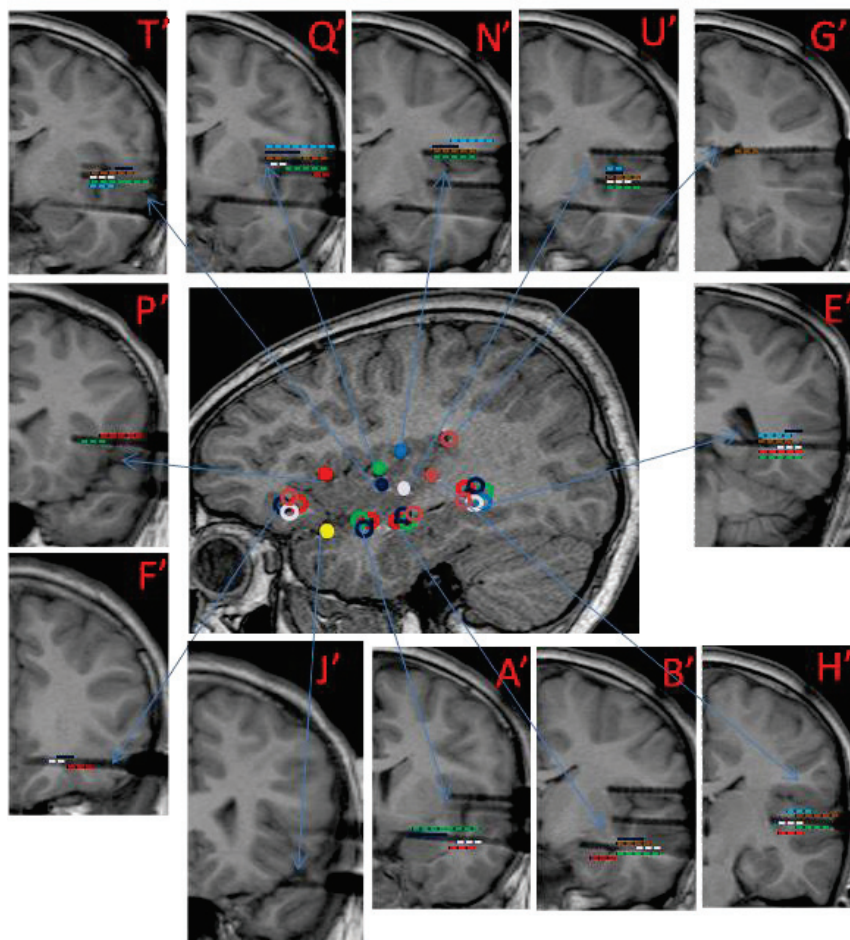


Figure III.4: Patient 4 MRI with electrodes in place (Left hemisphere). Central sagittal image: each insular electrode is represented by a unique colored solid circle; non-insular electrodes are represented by empty circles with the color of each of the insular electrode they are responding to. Yellow solid circles are for non responding electrodes. Peripheral coronal images: a cross-section of each electrode with its name and its responding contacts (responses are indicated by color coded dotted lines, representing the color of the corresponding stimulated insular electrode).

Patient 5 (A.B.):

History:

A.B. is a 17 years old right-handed young lady, history of partial epilepsy in the mother (cryptogenic). First seizure was at the age of four months. At time of hospitalization she had hypermotor seizures at bed time.

Complementary examinations:

MRI: Left temporo-orbitofrontal dysplasia.

FDG-PET: left peri-sylvian hypometabolism.

MEG: left peri-sylvian focus.

icEEG: An epileptic zone involving the left orbito-frontal region.

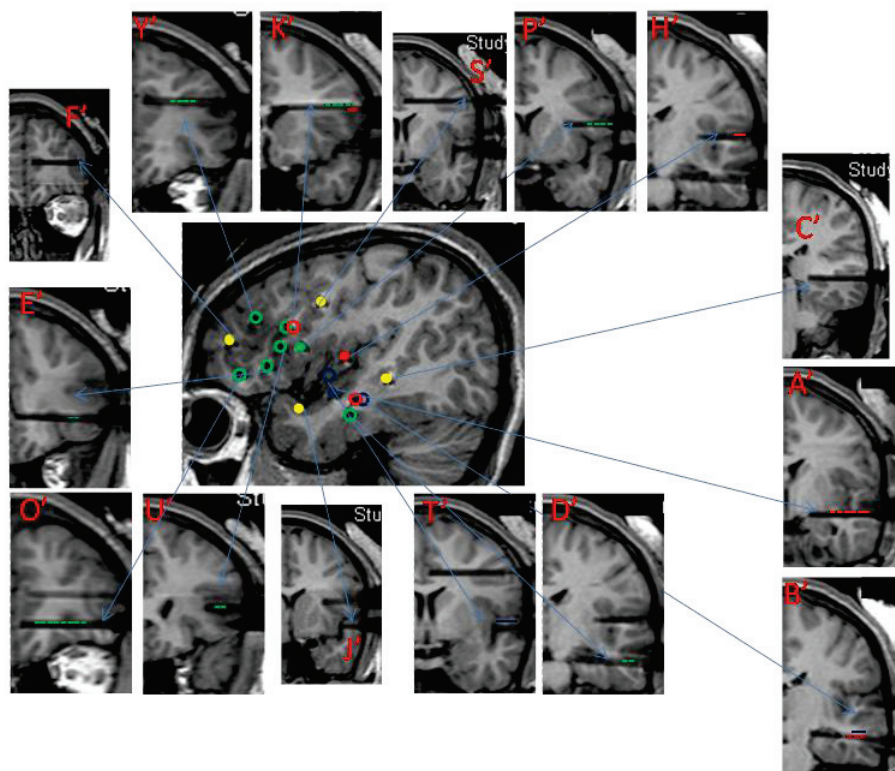


Figure III.5: Patient 5 MRI with electrodes in place (Left hemisphere). Central sagittal image: each insular electrode is represented by a unique colored solid circle; non-insular electrodes are represented by empty circles with the color of each of the insular electrode they are responding to. Yellow solid circles are for non responding electrodes. Peripheral coronal images: a cross-section of each electrode with its name and its responding contacts (responses are indicated by color coded dotted lines, representing the color of the corresponding stimulated insular electrode).

Patient 6 (F.C.):

History:

F.C. is a 12 years old right-handed boy, who was born preterm, and with a family history of epilepsy. First seizure was at the age seven years. Seizures are happening as following: the child hears unusual sounds around him, followed by staring and verbal and motor automatisms, he sleeps in post-ictal stat, with no deficit.

Complementary examinations:

MRI: Multiple bilateral tubers.

icEEG: An epileptic zone involving the right temporal pole.

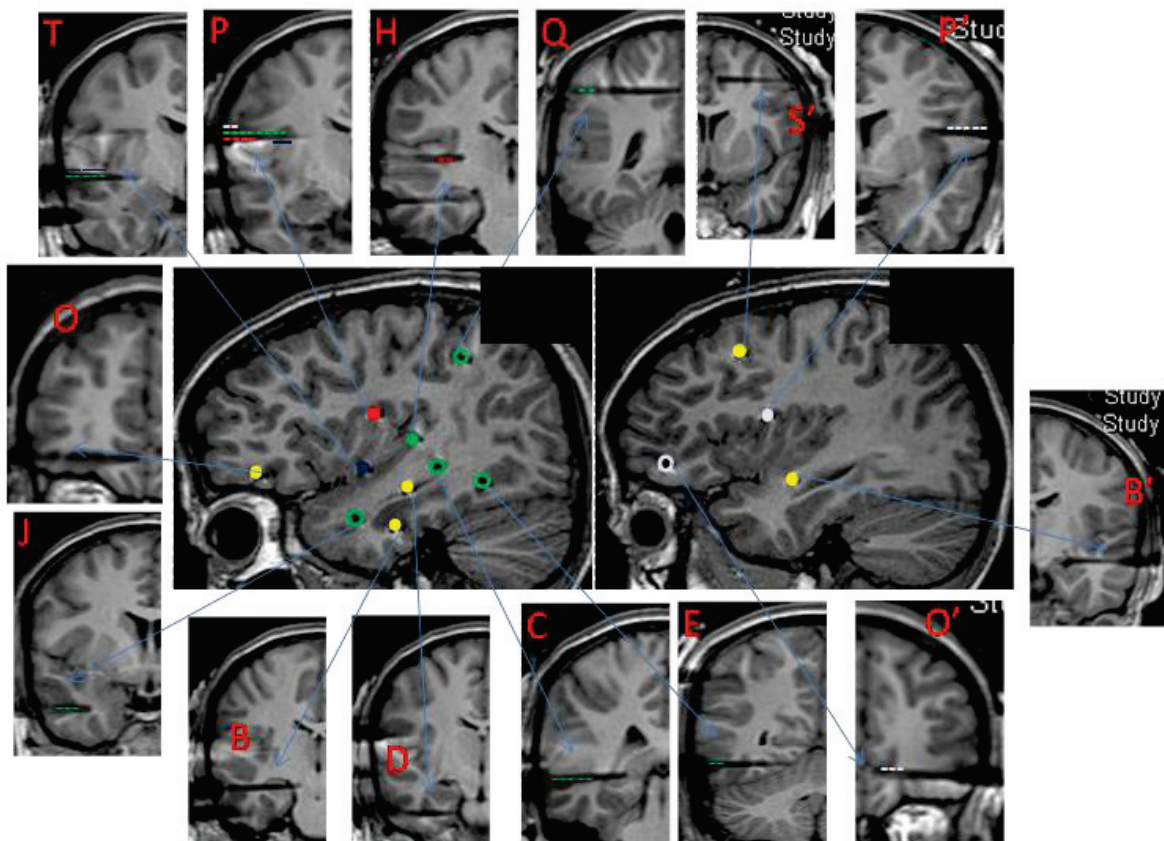


Figure III.6: Patient 6 MRI with electrodes in place (Left and right hemispheres). Central sagittal image: each insular electrode is represented by a unique colored solid circle; non-insular electrodes are represented by empty circles with the color of each of the insular electrode they are responding to. Yellow solid circles are for non responding electrodes. Peripheral coronal images: a cross-section of each electrode with its name and its responding contacts (responses are indicated by color coded dotted lines, representing the color of the corresponding stimulated insular electrode).

Patient 7 (P.T.K.):

History:

P.T. K. is a 13 years old right-handed boy, a history of febrile convulsion (right sided hemi-convulsion and a short lasting deficit after that) at the age of 11 months, and family history of epilepsy. First spontaneous seizure was at the age five years. Seizures are happening as following: an ascending epigastric sensation, followed by loss of consciousness, staring, oroalimentary automatisms, fisting with the right hand, and ending by a post-ictal speech trouble and sleep.

Complementary examinations:

MRI: left hippocampal atrophy.

FDG-PET: left mesial temporal hypometabolism.

icEEG: An epileptic zone involving the left mesial temporal structures.

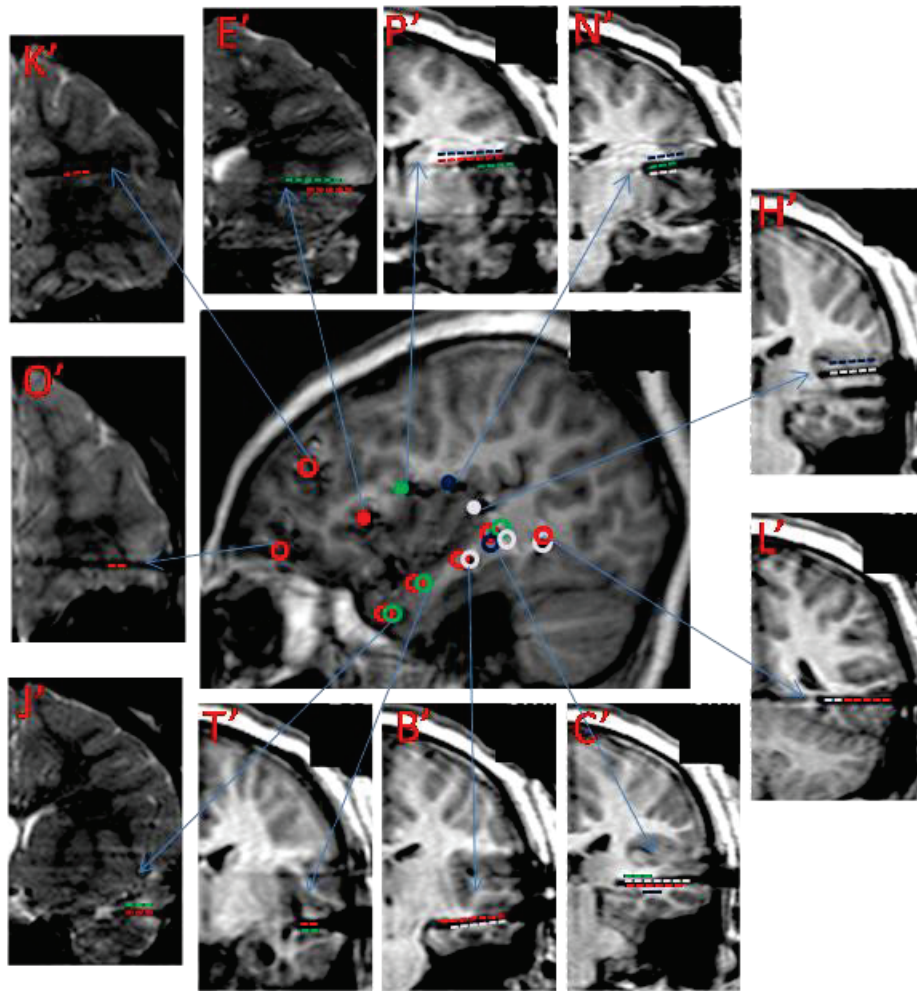


Figure III.7: Patient 7 MRI with electrodes in place (Left hemisphere). Central sagittal image: each insular electrode is represented by a unique colored solid circle; non-insular electrodes are represented by empty circles with the color of each of the insular electrode they are responding to. Yellow solid circles are for non responding electrodes. Peripheral coronal images: a cross-section of each electrode with its name and its responding contacts (responses are indicated by color coded dotted lines, representing the color of the corresponding stimulated insular electrode).

Patient 8 (I.L.):

History:

I.L. is a 14 years old right-handed girl, no past medical, personal or family history. First spontaneous seizure was at the age eight years (right parietal porencephalic cyst treated surgically with uncapping, but not successful). Seizures are described as following: left arm paresthesiae followed by right occulo-cephalic deviation, chewing and verbal automatism.

Complementary examinations:

MRI: right parietal porencephalic cyst.

icEEG: An epileptic zone involving the right lateral parietal surface.

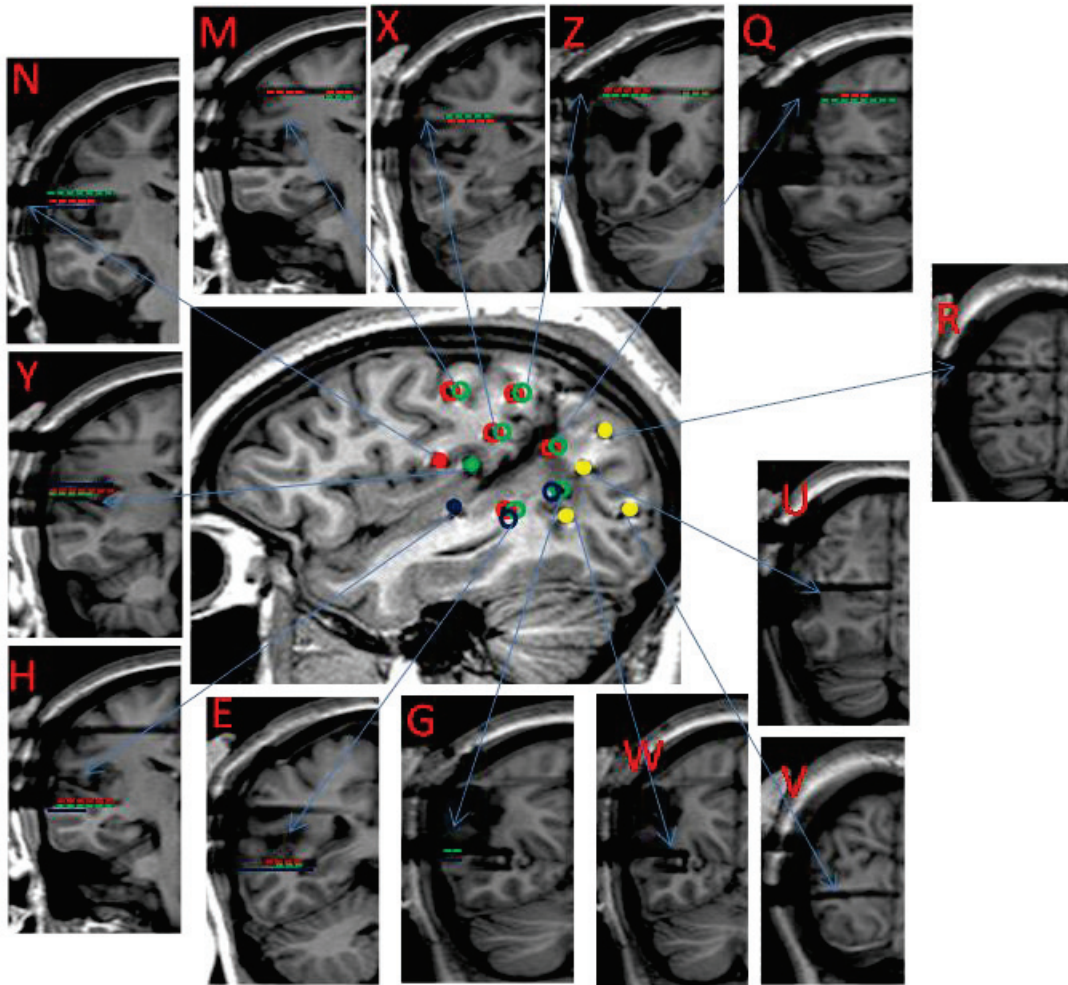


Figure III.8: Patient 8 MRI with electrodes in place (right hemisphere). Central sagittal image: each insular electrode is represented by a unique colored solid circle; non-insular electrodes are represented by empty circles with the color of each of the insular electrode they are responding to. Yellow solid circles are for non responding electrodes. Peripheral coronal images: a cross-section of each electrode with its name and its responding contacts (responses are indicated by color coded dotted lines, representing the color of the corresponding stimulated insular electrode).

Patient 9 (F.D.):

History:

F.D. is a 14 years old right-handed boy, no past medical, personal or family history. First spontaneous seizure was at the age of one year. He is presenting with hypermotor seizures.

Complementary examinations:

MRI: Left frontal dysplasia.

icEEG: An epileptic zone involving the left frontal cortex.

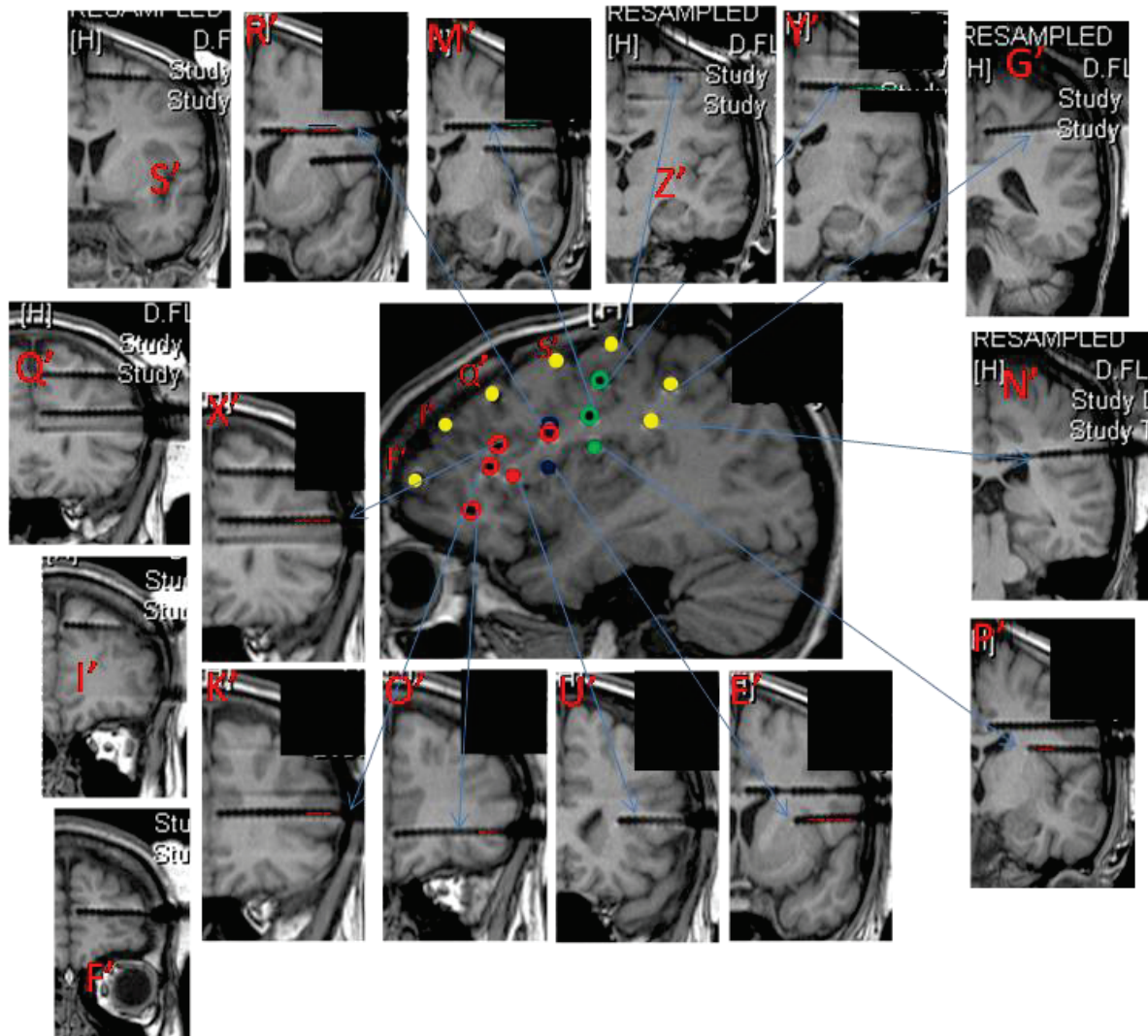


Figure III.9: Patient 9 MRI with electrodes in place (left hemisphere). Central sagittal image: each insular electrode is represented by a unique colored solid circle; non-insular electrodes are represented by empty circles with the color of each of the insular electrode they are responding to. Yellow solid circles are for non responding electrodes. Peripheral coronal images: a cross-section of each electrode with its name and its responding contacts (responses are indicated by color coded dotted lines, representing the color of the corresponding stimulated insular electrode).

Patient 10 (M.B.):

History:

M.B. is a 14 years old right-handed girl, no past medical, personal or family history. First spontaneous seizure was at the age of two years. Seizures are described as following:

elevation of the right arm followed by the right leg, associated with slow head deviation to the left ending by a post-ictal sleep.

Complementary examinations:

MRI: Normal.

icEEG: An epileptic zone involving the right lateral temporal cortex.

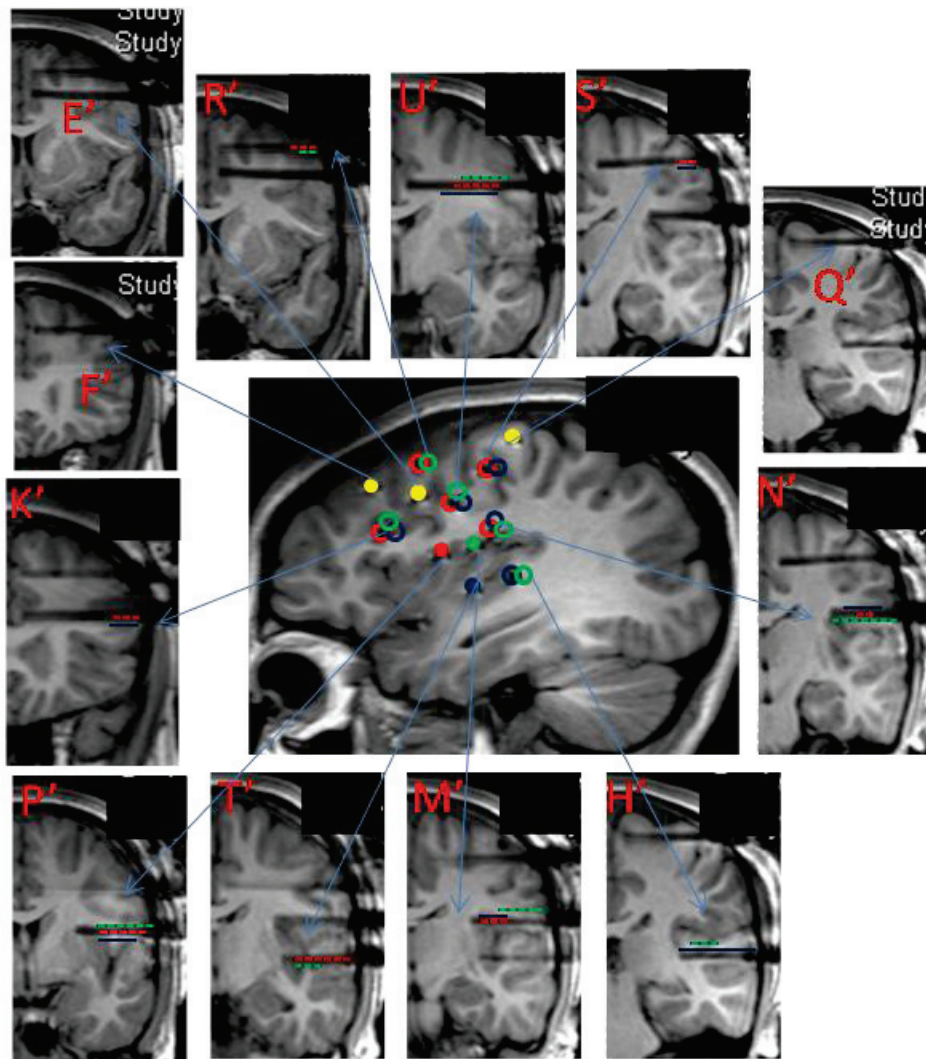


Figure III.10: Patient 10 MRI with electrodes in place (right hemisphere). Central sagittal image: each insular electrode is represented by a unique colored solid circle; non-insular electrodes are represented by empty circles with the color of each of the insular electrode they are responding to. Yellow solid circles are for non responding electrodes. Peripheral coronal images: a cross-section of each electrode with its name and its responding contacts (responses are indicated by color coded dotted lines, representing the color of the corresponding stimulated insular electrode).

Patient 11 (M.B.):

History:

M.B. is an 11 years old right-handed girl, no past medical, personal or family history. First spontaneous seizure was at the age of six years described as hypotonic fall to the left side. Seizures during hospitalization are described as following: the child is complaining that the left arm is moving without actually detected movement, and then the child falls to her left side.

Complementary examinations:

MRI: Right parietal lesion.

FDG-PET: Right inferior parietal hypometabolism.

icEEG: An epileptic zone involving the right post-central gyrus.

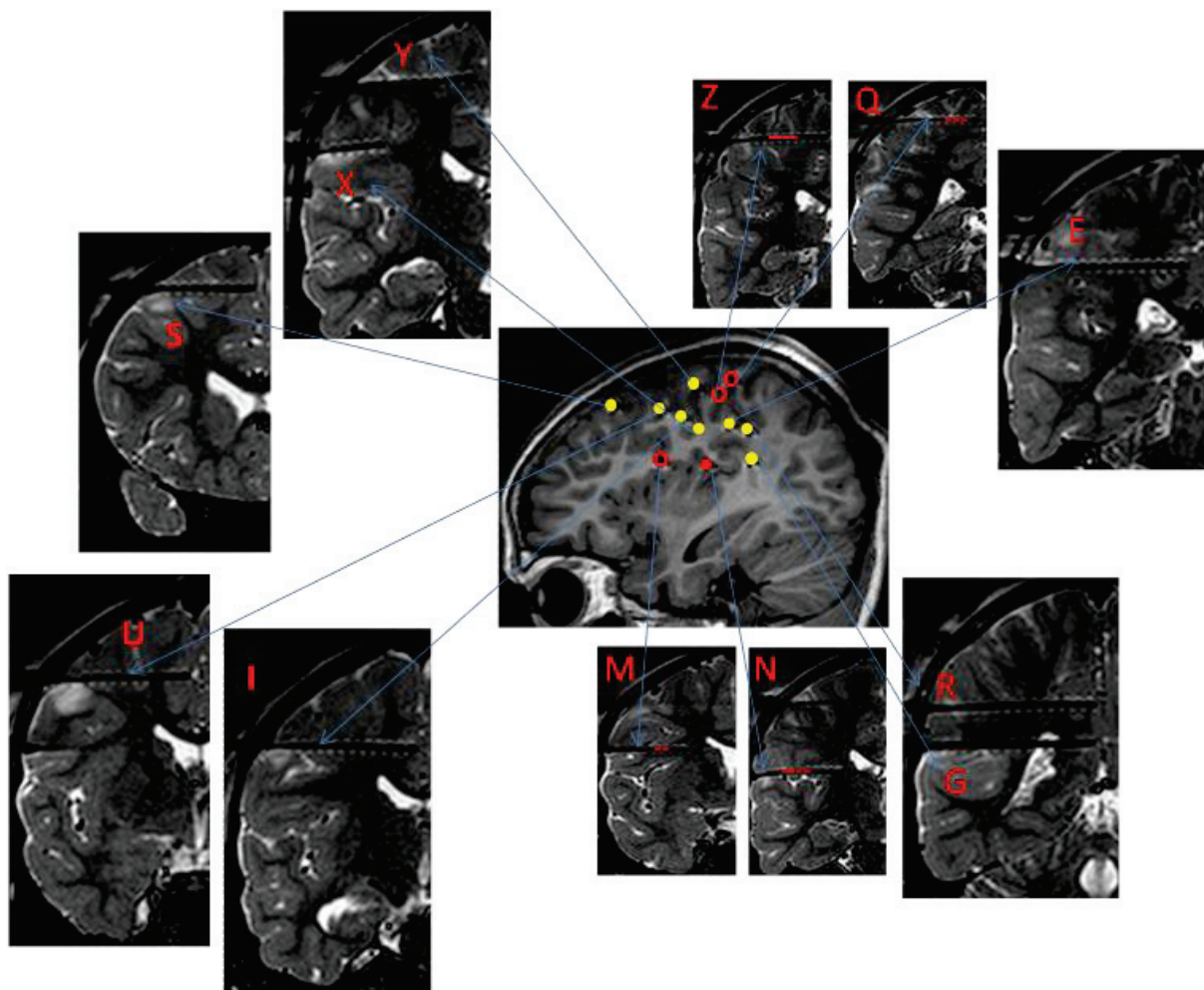


Figure III.11: Patient 11 MRI with electrodes in place (right hemisphere). Central sagittal image: each insular electrode is represented by a unique colored solid circle; non-insular

electrodes are represented by empty circles with the color of each of the insular electrode they are responding to. Yellow solid circles are for non responding electrodes. Peripheral coronal images: a cross-section of each electrode with its name and its responding contacts (responses are indicated by color coded dotted lines, representing the color of the corresponding stimulated insular electrode).

Patient	Age/gender	Epilepsy duration (years)	MRI findings	SOZ determined by SEEG	Seizure Propagation	Number and lateralization of depth electrodes	Number and lateralization of insular electrodes
1	11/F	3	R hippocampal sclerosis	R mesial temporal	R mesial temporal	13R	2R
2	9/M	4	Bilateral hippocampal atrophy	Bilateral hippocampi	L operculo-insular	10L, 4R	3L, 1R
3	11/F	3	Bilateral hippocampal dysgenesis	L insula	L F3 and T1	11L	6L
4	10/M	3	Normal	L third frontal gyrus	L third frontal gyrus	12L	6L
5	17/F	16	L Temporo-orbitofrontal dysplasia	L orbitofrontal	L temporal pole	15L	3L
6	12/M	5	Multiple bilateral tubers	R temporal pole	R neocortical temporal insula	10R, 4L	3R, 1L
7	13/M	8	L hippocampal atrophy	L mesial temporal		11L	4L
8	14/F	7	R parietal porencephalic cyst	R lateral parietal	R lateral parietal	13R	3R
9	14/M	13	L frontal dysplasia	L frontal mesial	L lateral frontal	16L	3L
10	14/F	12	Normal	R lateral temporal	R lateral temporal	12L	3L
11	11/F	5	R parietal lesion	R post central gyrus	R post central gyrus	12R	1R

Table III.1: Patients characteristics. F, female; M, male; L, left; R, Right.

2. Stereotaxic implantation of depth electrodes:

IcEEG was performed according to the technique described by Talairach and Bancaud (1973), a procedure used routinely in our department (Guenot et al., 2001). The brain regions to be investigated were determined for each patient, based on individual presurgical data, and most likely origin of seizure onset.

Electrodes were implanted perpendicular to the mid-sagittal plane with the patient's head fixed in the Talairach's stereotactic frame, providing Talairach's coordinates for each electrode in relation to the anterior commissure/posterior commissure plane. The exact location of each electrode and recording lead was further verified with a post-implantation MRI (Examples in the previous section).

3. Brain stimulation and CCEP recordings

Intracerebral CCEP recordings were performed using a video-EEG monitoring system (Micromed, Treviso, Italy) that allowed to simultaneously recording up to 128 contacts at a sampling rate of 1024 Hz. We performed 0.2Hz stimulations at least four days following electrodes implantation, once the patient has fully recovered from the surgical procedure. When EBS was delivered to one contact, CCEPs were recorded from all other contacts, in a way that all contacts of one patient are stimulated and used to record CCEPs also. Contacts sampling gray matter only were used. We used bipolar stimulation of adjacent contacts from the same electrode, known to deliver current within 5 mm around the stimulated bipole (Nathan et al., 1993). Electrical stimulation was delivered using a current-regulated neurostimulator (Micromed, Treviso, Italy), with parameters ensuring patient safety and effective generation of CCEPs (Gordon et al., 1990; Catenoix et al., 2005; Catenoix et al., 2011). We used monophasic pulse of 1 ms width and 1 mA intensity resulting in an electrical charge of 1 μC . The latter was delivered over a contact surface of 0.05 cm^2 (0.8 mm diameter

X 2 mm length X π), resulting in a total charge density of 20 $\mu\text{C}/\text{cm}^2/\text{phase}$, thus significantly lower than the maximum safe value of 60 $\mu\text{C}/\text{cm}^2/\text{phase}$ (Gordon et al. 1990). Two consecutive series of 20 pulses were delivered at each pair of contacts. During the stimulation, the child was able to continue his/her normal activity. No seizures were induced by this type of stimulation.

4. Data analysis:

EEG data were analyzed with the software package for electrophysiological analysis (ELAN-pack) developed at the DYCOG laboratory of Lyon Neuroscience Research Centre (CRNL, Lyon, France) (Aguera et al., 2011). ELAN is a freely available software package which provides a wide range of signal analysis tools for electrophysiological data including scalp electroencephalography (EEG), magnetoencephalography (MEG), intracranial EEG, and local field potentials (LFPs).

We first performed an automatic detection of the pulse artifact generated on the stimulated contacts, and systematically verified the accuracy of the generated marker. We used the stimulation marker for averaging each block of 20 consecutive pulse stimulations, and then calculated grand averages from the two blocks. Both visual and statistical analyses were used to conclude on the presence of significant CCEPs over each recording contact. CCEPs were first selected on the basis of visual analysis if detected and found comparable in each of the two consecutive series. Statistical analysis of the selected CCEPs was then performed using the non-parametric statistical function of ELAN-pack for single trails (Wilcoxon test), with significance set at $p < 0.001$. In brief, this statistical analysis compared each time point of the post-stimulation period to the 1000 ms pre-stimulation baseline, providing a curve, superimposed on the CCEP, illustrating the p-value associated with each component of the CCEP (examples of CCEPs in the articles). The first 10 ms post-stimulation were not evaluated due to the presence of residual stimulation-induced artifact. CCEPs were considered significant when they reached the statistical threshold of $p \leq 0.001$ during at least 5

consecutive ms. The latency of the first peak of each significant potential was measured on the grand average of the two series.

Part three: EBS analysis

1. Introduction:

As it was discussed in the background of this work, EBS was used either to study epileptogenicity (Valentin et al., 2002, 2005a,b; Flanagan et al., 2009; van't Klooster et al., 2011) or to study cortical connectivity (Brazier, 1964; Buser et al., 1968; Rutecki et al., 1989; Wilson et al., 1990; Buser et al., 1992; Matsumoto et al., 2004; Catenoix et al., 2005; Lacruz et al., 2007; Matsumoto et al., 2007; Rosenberg et al., 2009; Catenoix et al., 2011). The only issue with these previous works is that most of the analysis based on the direct visual observation of the resulting EPs. This visual analysis has its own limitations and difficulties e.g. interobserver variability, inter-ictal tracing full of epileptic discharges. Few authors proposed the use of statistical analysis to overcome these limitations e.g. Valentin et al. (2002) proposed a cumulative evaluation of the responses after 10 stimuli in a statistical way, i.e. in relation to the occurrence of pre-stimulus spontaneous spikes (Valentin et al., 2002), this helped them to verify if the recorded response is induced by the EBS or part of an ongoing epileptic activity.

In this work we implemented a form of automatic EBS i.e. it can be scheduled to run automatically without the need for the intervention of the examiner, at the same time the patient is free to continue his/her normal activity and it was not painful. To overcome the limitations of doing visual analysis alone we used the stat function incorporated in the ELAN software. This study involved the analysis of CCEPs from 33017 recording sites of three patients (Patients 1, 11, and 2 in the list). The result of this study helped us to plan our analysis technique for the other two coming studies about the insular connectivity.

The main results are summarized below:

- 1) Best response rate and best correspondence between visual and statistical analysis were observed in the early 100ms post-stimulation.
- 2) The statistical test is highly sensitive and specific for responses detection with best results in the early 300 ms.
- 3) The main reason for visual/statistic discordance is the combination of a noisy background tracing and small (though clear) responses.
- 4) The parameters used here are thought to be the most suitable for this type of studies.
- 5) Responses are of variable forms but mainly consist of two early peaks and may be followed by a slow wave or a sinusoidal repetitive prolonged wave form.

2. Article: (in preparation for submission to clinical neurophysiology journal)

« Intra-cerebral evoked potentials analysis »

Talal Almashaikhi, Sylvain Rheims, Julien Jung, Karine Ostrowsky-Coste, Alexandra

Montavont, Marc Guénot, Olivier Bertrand, Philippe Ryvlin

Intra-cerebral evoked potentials analysis

Talal Almashaikhi,^{1,3,6} Sylvain Rheims,^{1,2} Julien Jung,⁵ Karine Ostrowsky-Coste,^{1,3} Alexandra Montavont,^{1,2,3} Marc Guénot,⁴ Olivier Bertrand,⁵ Philippe Ryvlin^{1,2,3}

¹TIGER, Lyon's Research Neuroscience Centre, CRNL INSERM U1028, CNRS 5292, UCBLyon 1, CH Le Vinatier - Bâtiment 452, 95 bd Pinel, 69675 Bron Cedex, France

²Department of Functional Neurology and Epileptology, Hospices Civils de Lyon, 59 Boulevard Pinel, 69003 Lyon, France

³Department of Pediatric Epilepsy, Sleep and Neurophysiology, Hospices Civils de Lyon, 59 Boulevard Pinel, 69003 Lyon, France

⁴Department of Functional Neurosurgery, Hospices Civils de Lyon, 59 Boulevard Pinel, 69003 Lyon, France

⁵DYCOG, Lyon's Research Neuroscience Centre, CRNL INSERM U1028, CNRS 5292, UCBLyon 1, CH Le Vinatier - Bâtiment 452, 95 bdPinel, 69675 Bron Cedex, France

⁶Department of Clinical Physiology, Neurophysiology division, Sultan Qaboos University Hospital, P.O. Box 38, PC 123, Al Khod, Muscat, Oman

*Corresponding Author. Reprint requests should be sent to: Pr Philippe Ryvlin, Unité 301, Hôpital Neurologique, 59 bd Pinel, 69003, Lyon. Email: ryvlin@cermep.fr.

Short title: evoked potential analysis

Keywords: intracerebral EEG, cortico-cortical evoked potential, statistical analysis, Intracerebral electrical stimulation

Abstract:

Direct electrical stimulation of the brain in patients with refractory partial epilepsy undergoing intracerebral EEG (icEEG) investigation allows to record cortico-cortical evoked potentials (CCEPs) which might inform on both the epileptogenicity and the functional connectivity of the tested brain regions. Development of this field requires objective and time-effective methods to analyze the large volume of collected data. We studied three patients undergoing icEEG using low-frequency (0.2 Hz), low intensity (1 mA), 1 ms duration bipolar stimulations performed over all relevant recorded bipoles, resulting in the stimulation of more than 314 brain sites, and recording of 33017 traces. Visual detection of CCEPs was used as a gold standard. Statistical analysis of each trace was performed using non parametric test, with a significance threshold set at $p \leq 0.001$. Findings from visual and statistical analysis were compared for four post-stimulus epochs: 10-100 ms, 100-300 ms, 300-500 ms, and ≥ 500 ms. Visual analysis detected CCEPs in respectively 21%, 14%, 3% and 1% of these four epochs. Statistical analysis demonstrated 91% to 97% sensitivity, depending on the epoch studied, and 97 to 98% specificity. False negative statistical findings primarily reflected small amplitude CCEP and noisy baseline. Statistical analysis of CCEPs appears an appropriate surrogate to time-consuming and subjective visual analysis for investigating large scale icEEG data.

Introduction:

Intracerebral electrical stimulation (ICES) is routinely performed in patients with refractory epilepsy undergoing intracerebral EEG (icEEG) recordings, with the view to delineate a potentially resectable epileptogenic zone. ICES can help assessing the epileptogenicity and functionality of the implanted brain regions. This procedure might include 50Hz, 1Hz, 0.2Hz

or 0.1Hz stimulations, each of which aiming at different purposes. 50Hz and 1Hz stimulations are used to trigger ictal signs or symptoms, epileptic discharges, and full-blown seizures, suggesting the epileptogenicity of the stimulated cortex (Buser et al., 1968; Gombi et al., 1976; Munari et al., 1993; Kahane et al., 1993; Wilson & Engel, 1993; Wilson et al., 1998; Kahane et al., 2004; Matsumoto et al., 2005). These high and low frequency stimulations can also be used to localize eloquent cortex by either interrupting normal function (e.g. speech arrest elicited by 50Hz stimulation of language areas), or generating specific signs (e.g. time-locked clonic movements triggered by 1Hz stimulation of the motor cortex or pyramidal tract). More recently, 0.2Hz and 0.1Hz have been developed to trigger abnormal cortical evoked responses (i.e. delayed to more than 100 msec or repetitive) that are suggestive of an underlying epileptogenic cortex (Valentin et al., 2002, 2005a,b; Flanagan et al., 2009; van't Klooster et al., 2011).

In addition to their primary clinical objective, 0.2Hz and 0.1Hz stimulations allow to generate highly reproducible early responses at distant recording sites, thought to be physiological and to reflect brain connectivity (Brazier, 1964; Buser et al., 1968; Rutecki et al., 1989; Wilson et al., 1990; Buser et al., 1992; Matsumoto et al., 2004; Catenoix et al., 2005; Lacruz et al., 2007; Matsumoto et al., 2007; Rosenberg et al., 2009; Catenoix et al., 2011). This methodology offers a unique approach to the functional anatomy of the human brain, with high temporal and spatial resolution, providing complementary data to those obtained with diffusion tensor imaging and functional MRI. The opportunity to record such cortico-cortical evoked responses (CCEP) is rapidly expanding due to the worldwide development of icEEG and increased stimulating and recording capacities with modern EEG systems. Using 128 channel system, one can theoretically test up to 16.000 potential intracerebral connections by stimulating each of the 128 icEEG leads and looking for responses at all other recorded sites. This figure rises to 65.000 testable connections for the more recently available 256 channel systems.

The detection and analysis of CCEPs at such a large scale represents a major challenge, and one of the main current limitations of this investigation. Visual analysis is both time consuming and subjective, raising the problems of inter-observer variability and applicability. The automatic detection of specific waveform templates is hampered by the large variation in latency, duration, amplitude and waveform of CCEPs as a function of the exact location of both the stimulating and recording bipoles in any given structure (Alarcon et al., 1997). Statistical methods have been developed in order to compare the frequency of pre- and post-stimulus spikes (Valentin et al., 2002).

In the current study we have implemented and tested the reliability of another statistical method for detecting significant CCEPs in the context of large scale brain connectivity data analysis.

Method:

Patients

Three patients with drug resistant partial epilepsy contemplating epilepsy surgery, and undergoing icEEG, were included in this study.

Stereotactic implantation of depth electrodes

IcEEG was performed according to the technique described by Talairach and Bancaud (1973), a procedure used routinely in our hospital (Guenot et al., 2001). The brain regions to be investigated were determined for each patient, based on individual presurgical data, and most likely origin of seizure onset. In general, about one third of electrodes target the most likely zone of seizure onset, whereas the remaining electrodes will probe alternative but less likely hypothesis, or will help to define the borders of the epileptogenic zone. As a result, a significant number of recording leads are not affected by the epileptic process.

Electrodes were implanted perpendicular to the mid-sagittal plane with the patient's head fixed in the Talairach stereotactic frame. The location of the electrode contacts was subsequently reported on a stereotaxic scheme for each patient and defined by their coordinates in relation to the anterior commissure/posterior commissure plane. The exact location of each electrode was later verified with a post-implantation MRI.

Twelve to fourteen semirigid intracerebral electrodes were implanted per patient, either unilaterally (n=2) or bilaterally (n=1). Each electrode was 0.8 mm in diameter and included 5, 12 or 15 leads 2 mm in length, 1.5 mm apart (Dixi, Besançon, France), depending on the target region. No morbidity was related to cerebral electrode implantation.

Brain stimulation and CCEP recordings

Intracerebral recordings were performed using a video-EEG monitoring system (Micromed, Treviso, Italy) that allowed to record simultaneously up to 128 contacts at a sampling rate of 1024 Hz.

We performed 0.2Hz stimulations at least four days following electrodes implantation, once the patient has fully recovered from the surgical procedure. We used bipolar stimulation of adjacent contacts from the same electrode, known to deliver current within 5 mm around the stimulated bipole (Nathan et al., 1993). Electrical stimulation was delivered using a current-regulated neurostimulator (Micromed, Treviso, Italy), with parameters ensuring patient safety and effective generation of EPs (Gordon et al., 1990; Catenoix et al., 2005; Catenoix et al., 2011). We used monophasic pulse of 1 ms width and 1 mA intensity resulting in an electrical charge of 1 μC . The latter was delivered over a contact surface of 0.05 cm^2 (0.8 mm diameter X 2 mm length X π), resulting in a total charge density of 20 $\mu\text{C}/\text{cm}^2/\text{phase}$, thus significantly lower than the maximum safe value of 60 $\mu\text{C}/\text{cm}^2/\text{phase}$ (Gordon et al. 1990). Two consecutive series of 20 pulses were delivered at each pair of adjacent contacts. The number of stimulated bipoles varied among patients according to the selection of recordings leads. For

example, if all 10 leads of an electrode were recorded, nine bipoles would be stimulated (1-2 to 9-10). If some intermediate leads were not recorded due to their location in the white matter, we would not stimulate across these missing leads (e.g. if lead #4 not recorded, stimulated bipoles would include 1-2, 2-3, and then 5-6 to 9-10, but not 3-5). This resulted in a mean number of 105 stimulated bipoles per patient.

Data analysis

EEG data were analyzed with the software package for electrophysiological analysis (ELAN-pack) developed at the DYCOG laboratory of Lyon Neuroscience Research Centre (CRNL, Lyon, France) (Aguera et al., 2011). We first performed an automatic detection of the pulse artifact generated on the stimulated contacts. We then used the stimulation marker for averaging each block of 20 consecutive pulse stimulations, and calculating grand averages from the two blocks.

All recorded data following each stimulated bipole were analyzed by one investigator (TA) using two methodologies, performed during sessions separated by at least six months.

The first session consisted in a strictly visual and thus subjective analysis. The presence of CCEP was considered if a potential could be clearly distinguished from the baseline background noise, and appeared similar on the two 20 trials averages.

The second session incorporated a more objective analysis, performed using the non parametric statistical function of ELAN-pack for single trails. Each time point of the post-stimulation period was compared to the 1000 ms pre-stimulation baseline, using 5 ms and 50 ms duration sliding windows and a statistical significance of $p \leq 0.001$. Results were presented as a curve, overlaying the grand average, that crossed the horizontal axis when $p \leq 0.001$.

The presence or absence of CCEP as delineated by the visual and statistical analyses, were separately reported for four post-stimulus epochs: 10-100 ms, 100-300 ms, 300-500 ms, and >500 ms. Visually-detected CCEPs that spanned over two consecutive time-windows were allocated to that displaying their peak, selectively. We did not investigate the first 10 ms due to the usual presence of stimulus-induced artefact hampering any reliable analysis of this early post-stimulus period.

For the purpose of this study, we arbitrarily considered visual analysis as our gold standard, and defined: 1) true positive as significant statistical findings associated with a visually detectable CCEP, 2) false positive as significant statistical findings not associated with a visually detectable CCEP, 3) false negative as lack of significant statistical finding associated with a visually detectable CCEP, and 4) true negative as lack of significant statistical finding with no visually detectable CCEP.

We calculated the rate of true and false positive and negative findings for each time-window and investigated the potential reasons for discordance between visual and statistical analyses by investigating in more details a sub-sample of recordings. The two following situations were examined: 1) recordings with a visually detectable but not statistically significant CCEP: 2) recordings with a statistically significant but not visually detectable CCEP. Five samples of these two situations were randomly chosen for each of the four time-windows, resulting in a total of 40 recordings. For each of these recordings, we construct and examined a graph consisting in three overlapping curves, including the two 20 trials averages and associated p-value (Figure 1). In most cases, this allowed to understand the primary reason why either the visual or statistical analysis failed to demonstrate a CCEP detected by the other method. When judged necessary, we also went back to the raw data to search for intermittent EEG artifacts or epileptic abnormalities which could explain our findings.

We further investigated the impact of decreasing the number of stimuli from 40 to 20 on statistical findings. We hypothesized that this reduction could decrease the proportion of both true and false positive, and randomly selected a sub-sample of recordings with statistically significant findings with or without associated visually detectable CCEP. Twenty-five recordings reflecting these two situations were analyzed for each of the four time-windows, resulting in a total of 200 samples.

Results:

A total number of 33017 recordings, and 132068 epochs, were examined in the three patients. Visual analysis detected a total of 12733 CCEPs, including 6982 (21.1%) between 10 and 100 ms, 4453 (13.5%) between 100 and 300 ms, 1037 (3.1%) between 300 and 500 ms, and 261 (0.8%) between 500 and 1000 ms post-stimulus (Table1). CCEPs were frequently polyphasic, with the majority of responses detected after 100 ms following an earlier CCEP that occurred within the first 100 ms.

The 5 ms duration sliding window allowed to detect twice more significant CCEPs than that lasting 50 ms, and was thus used for all further analyses. Our statistical method detected 11895 of the 12733 visually detected CCEPs (93% sensitivity), including 91% of those observed between 10-100 ms post-stimulus, and 96% to 97% of those observed in the three later epochs (table 1). False positive were detected in 2798 of the 119335 recording samples with no visually detectable CCEP (2.3%), including 1.8% in the 10-100 ms period, and 2.4 to 2.7% for the other three epochs, translating into specificity ranging from 97 to 98% (table 1). The overall negative predictive value of statistical analysis was 99%, varying between 97% and 100% depending on the epochs. Its positive predictive value was much more variable, varying from 24% for the latest epoch (>500 ms) to 93% for the earliest one (10-100 ms).

The analysis of the sample of 40 recordings displaying discordant visual and statistical findings revealed that false negative statistical data resulted from low signal to noise ratio either due to very low amplitude CCEPs, lack of stable baseline, or a combination of both. Most false positive statistical findings corresponded to the detection of CCEPs which visually-detected peak was observed in the previous or next epoch, resulting in empirically ascribing this CCEP to a single epoch for visual analysis whereas it truly extended to another one as delineated by statistical analysis.

Reducing the number of averaged stimuli from 40 to 20 dramatically reduced the sensitivity of statistical analysis by around 50%, while decreasing the proportion of false positives by 20%.

Discussion:

This study aimed at validating an objective statistical analysis of CCEPs which automatic implementation would enable time-efficient and reliable analysis of large scale data. Our findings suggest that this is indeed feasible, with an overall sensitivity of 93% and specificity of 98%.

The continuing worldwide development of intracerebral EEG investigations in patients suffering from refractory partial epilepsy, together with the technological advances of video-EEG recording systems, offer major opportunities to further investigate CCEPs with the view to better delineate the epileptogenic zone to be resected and to gain knowledge into the functional connectivity of the Human brain. Physiological CCEPs remain the only method to directly test the functional connectivity between two brain regions. Indeed, diffusion tensor imaging and tractography delineate the presence of anatomic connections without inferring on their functionality or directionality (Catani et al. 2002, Cerliani et al., 2011; Cloutman et al., 2011), whereas functional MRI only provides indirect evidence of such functionality by showing correlated activity between different cortical regions (Cauda et al., 2011; Deen et al.,

2011). Furthermore, physiological CCEPs can be reliably elicited using safe stimulating parameters ensuring a total charge density well below the maximum safe value of 60 $\mu\text{C}/\text{cm}^2/\text{phase}$ (Gordon et al. 1990). Using such parameters (1 ms pulse duration, 1 mA intensity) and 0.2 Hz frequency, we never elicited an ictal discharge in a series of 20 patients stimulated over a mean number of 105 cortical sites. The only sign and symptom which could result from this stimulation were brief painless clonic movement when stimulating the pyramidal tract. Accordingly, we could run a stimulation program, developed through our digital neurostimulator, that allowed the automatic successive stimulation of each of the relevant recorded bipole over a period of about six hours (200 seconds per bipole), without significant staff intervention. This protocol generates an average of 11.000 recordings per patient, one fourth of which will show CCEP. Visual analysis of such data is highly time-consuming, stressing the need for reliable methods enabling the automatic detection of CCEPs.

The statistical analysis used in our study is based on a classic non parametric method implemented in the software ELAN-pack, whereby the post-stimulus EEG signal is compared to that of the pre-stimulus baseline according to various user-selected settings (duration of sliding window, statistical threshold). Several empirical parameters were tested in this validation study, suggesting that 5 ms duration sliding window and 40 averaged stimuli were more appropriate than 50 ms duration sliding window and 20 averaged stimuli. In contrast with scalp-recorded evoked potentials induced by peripheral sensory stimulation, CCEPs demonstrate large variations in terms of waveforms, latency and amplitude as a function of the exact position of the stimulating and recording bipoles, hampering their automatic detection by waveform recognition algorithms (Alarcon et al., 1997).

We used visual analysis as a gold standard given the excellent reliability of this method to detect CCEP. As previously reported, CCEPs, including those of small amplitude, demonstrated very high level of reproducibility between the two consecutive series of 20

stimuli each, making their visual detection straightforward. This statement does not apply to the first 10 ms post-stimulus where the distinction between early occurring CCEP and stimulation induced artefact. Analysis of CCEPs was segmented into four post-stimulus epochs according to prior observations suggesting that physiological CCEPs primarily occur during the first 100 ms (most often peaking between 15 and 40 ms), while epileptiform CCEPs are more likely to occur after 100 ms (Valentin et al., 2002).

Accordingly, the proportion of recordings displaying visually detected CCEPs decreased from 21% for the 10-100 ms epochs, to 14%, 3% and 1% for the next three epochs, respectively. Sensitivity and specificity of statistical analysis remained comparable for the four epochs, with values equal or above 96% in all instances but for the sensitivity during the first 100 ms which was 91%. This lower sensitivity primarily reflected small amplitude CCEPs, often located adjacent to CCEP of greater amplitude in the same anatomical region. Thus, this sub-optimal, yet high sensitivity appears unlikely to compromise the description and understanding of regional brain connectivity through CCEPs. Similarly, false positive generated by statistical analysis most often corresponded to true CCEPs covering several epochs but which visual detection was empirically ascribed to the single epoch displaying their peak. This occurred more frequently in the latest post-stimulus epochs, due to the fact the CCEPs usually peaked during the earliest epochs.

Overall, the statistical method developed and tested in this study appears appropriate for investigating large scale CCEP data without the need to rely on time-consuming visual analysis. While the method used for validating this approach has relied on the visual display of p-value data, future development will allow performing fully automatic extraction of significant CCEPs.

References

Aguera PE, Jerbi K, Caclin A, Bertrand O (2011): ELAN: A software package for analysis and visualization of MEG, EEG, and LFP signals. *Comput Intell Neurosci* 2011: 158970

Alarcon G, Garcia Seoane JJ, Binnie CD, Martin Miguel MC, Juler J, Polkey CE, Elwes RD, Ortiz Blasco JM. 1997. Origin and propagation of interictal discharges in the acute electrocorticogram. Implications for pathophysiology and surgical treatment of temporal lobe epilepsy. *Brain* 120(12):2259.

Brazier MA. 1964. Evoked responses recorded from the depths of the human brain. *Annals of the New York Academy of Sciences* 112(1):33-59.

Buser P, Bancaud J, Chauvel P. 1992. Callosal transfer between mesial frontal areas in frontal lobe epilepsies. *Adv Neurol* 57:589-604.

Buser P, Bancaud J, Talairach J, Szikla G. 1968. Interconnexions amygdalohippocampiques chez l'homme. Etude physiologique au cours d'explorations stereotaxiques. *Rev Neurol* 119(3):283-8.

Catani M, Howard RJ, Pajevic S, Jones DK. 2002. Virtual in vivo interactive dissection of white matter fasciculi in the human brain. *Neuroimage* 17(1):77-94.

Catenoix H, Magnin M, Guenot M, Isnard J, Manguiere F, Ryvlin P. 2005. Hippocampal-orbitofrontal connectivity in human: an electrical stimulation study. *Clinical neurophysiology* 116(8):1779-84.

Catenoix H, Magnin M, Manguiere F, Ryvlin P. 2011. Evoked potential study of hippocampal efferent projections in the human brain. *Clinical Neurophysiology*.

Cauda F, D'Agata F, Sacco K, Duca S, Geminiani G, Vercelli A. 2011. Functional connectivity of the insula in the resting brain. *Neuroimage* 55(1):8-23.

Cerliani L, Thomas RM, Jbabdi S, Siero JC, Nanetti L, Crippa A, Gazzola V, D'Arceuil H, Keyzers C (2011): Probabilistic tractography recovers a rostrocaudal trajectory of connectivity variability in the human insular cortex. *Hum Brain Mapp*.33: 2005-2034.

Cloutman LL, Binney RJ, Drakesmith M, Parker GJ, Ralph MA (2011): The variation of function across the human insula mirrors its patterns of structural connectivity: Evidence from in vivo probabilistic tractography. *NeuroImage* 59: 3514-3521.

Deen B, Pitskel NB, Pelphrey KA. 2011. Three systems of insular functional connectivity identified with cluster analysis. *Cereb Cortex* 21(7):1498-506.

Flanagan D, Valentin A, Garcia Seoane JJ, Alarcon G, Boyd SG. 2009. Single-pulse electrical stimulation helps to identify epileptogenic cortex in children. *Epilepsia* 50(7):1793-803.

Gombi R, Velok G, Hullay J. 1976. The value of electrostimulation in epileptic focus localization. *Acta neurochirurgica*(23 Suppl):15.

Gordon B, Lesser RP, Rance NE, Hart Jr J, Webber R, Uematsu S, Fisher RS. 1990. Parameters for direct cortical electrical stimulation in the human: histopathologic confirmation. *Electroencephalography and clinical neurophysiology* 75(5):371-7.

Guenot M, Isnard J, Ryvlin P, Fischer C, Ostrowsky K, Mauguiere F, Sindou M. 2001. Neurophysiological monitoring for epilepsy surgery: the Talairach SEEG method. *Stereotactic and functional neurosurgery* 77(1-4):29-32.

Kahane P, Tassi L, Francionne S, Hoffmann D, Lo Russo G, Munari C (1993): Manifestations électrocliniques induites par la stimulation électrique intracérébrale par chocs dans les épilepsies temporales. *ClinNeurophysiol*22: 305-326.

Kahane P, Minotti L, Hoffmann D, et al (2004): Invasive EEG in the definition of the seizure onset zone: depth electrodes. In: Rosenow F, Lüders HO, editor. *Handbook of Clinical*

Neurophysiology, Vol.3.Presurgical assessment of the epilepsies with clinical neurophysiology and functional imaging. Amsterdam: Elsevier BV. p 109-133.

Lacruz ME, Garcia Seoane JJ, Valentin A, Selway R, Alarcon G. 2007. Frontal and temporal functional connections of the living human brain. *Eur J Neurosci* 26(5):1357-70.

Matsumoto R, Nair DR, LaPresto E, Bingaman W, Shibasaki H, Luders HO (2007): Functional connectivity in human cortical motor system: a cortico-cortical evoked potential study. *Brain* 130: 181-197.

Matsumoto R, Kinoshita M, Taki J, Hitomi T, Mikuni N, Shibasaki H, Fukuyama H, Hashimoto N, Ikeda A (2005): In vivo epileptogenicity of focal cortical dysplasia: A direct cortical paired stimulation study. *Epilepsia* 46: 1744-1789.

Matsumoto R, Nair DR, LaPresto E, Najm I, Bingaman W, Shibasaki H, Luders HO (2004): Functional connectivity in the human language system: a cortico-cortical evoked potential study. *Brain* 127: 2316-2330.

Munari C, Kahane P, Tassi L, Francione S, Hoffmann D, Lo RG, Benabid AL (1993):Intracerebral low frequency electrical stimulation: a new tool for the definition of the "epileptogenic area". *Actaneurochirurgica.Supplementum* 58: 181-185.

Nathan SS, Sinha SR, Gordon B, Lesser RP, Thakor NV (1993): Determination of current density distributions generated by electrical stimulation of the human cerebral cortex. *Electroencephalography and clinical neurophysiology* 86: 183-192.

Rosenberg DS, Mauguiere F, Catenoix H, Faillenot I, Magnin M (2009): Reciprocal thalamocortical connectivity of the medial pulvinar: a depth stimulation and evoked potential study in human brain. *Cerebral Cortex* 19: 1462-1473.

Rutecki PA, Grossman RG, Armstrong D, Irish-Loewen S (1989): Electrophysiological connections between the hippocampus and entorhinal cortex in patients with complex partial seizures. *Journal of neurosurgery* 70: 667-675.

Talairach J, Bancaud J (1973): Stereotaxic approach to epilepsy. Methodology of anatomic-functional stereotaxic investigations. *ProgNeurolSurg* 5: 297-354.

Valentin A, Alarcon G, Garcia-Seoane JJ, Lacruz ME, Nayak SD, Honavar M, Selway RP, Binnie CD, Polkey CE (2005a): Single-pulse electrical stimulation identifies epileptogenic frontal cortex in the human brain. *Neurology* 65: 426-435.

Valentin A, Alarcon G, Honavar M, Garcia Seoane JJ, Selway RP, Polkey CE, Binnie CD(2005b): Single pulse electrical stimulation for identification of structural abnormalities and prediction of seizure outcome after epilepsy surgery: a prospective study. *Lancet Neurol* 4: 718-726.

Valentin A, Anderson M, Alarcon G, Seoane JJ, Selway R, Binnie CD, Polkey CE (2002): Responses to single pulse electrical stimulation identify epileptogenesis in the human brain in vivo. *Brain* 125: 1709-1718.

van't Klooster MA, Zijlmans M, Leijten FS, Ferrier CH, van Putten MJ, Huiskamp GJ (2011): Time--frequency analysis of single pulse electrical stimulation to assist delineation of epileptogenic cortex. *Brain* 134: 2855-2866.

Wilson CL, Engel J, Jr. 1993. Electrical stimulation of the human epileptic limbic cortex. *Adv Neurol* 63:103-13. Wise RJ, Greene J, Buchel C, Scott SK. 1999. Brain regions involved in articulation. *Lancet* 353(9158):1057-61.

Wilson CL, Isokawa M, Babb TL, Crandall PH (1990) Functional connections in the human temporal lobe. *Experimental brain research* 82: 279-292.

Wilson CL, Khan SU, Engel Jr J, Isokawa M, Babb TL, Behnke EJ. 1998. Paired pulse suppression and facilitation in human epileptogenic hippocampal formation. *Epilepsy research* 31(3):211-30.

	Epoch post-stimulus				
	10-100 ms (N=33017)	100-300 ms (N=33017)	300-500 ms (N=33017)	> 500 ms (N=33017)	All epochs (N=132068)
No CCEP (true negative)	25576 (77%)	27804 (84%)	31208 (95%)	31949 (97%)	116537 (88%)
CCEP only detected by statistical analysis (false positive)	459 (1%)	760 (2%)	772 (2%)	807 (2%)	2798 (2%)
CCEP only detected by visual analysis (false negative)	637 (2%)	152 (0.5%)	38 (0.1%)	11 (0.03%)	838 (1%)
CCEP detected by visual and statistical analysis (true positive)	6345 (19%)	4301 (13%)	999 (3%)	250 (1%)	11895 (9%)
Sensitivity of statistical analysis	91%	97%	96%	96%	93%
Specificity of statistical analysis	98%	97%	98%	98%	98%
Positive predictive value of statistical analysis	93%	85%	56%	24%	81%
Negative predictive value of statistical analysis	98%	99%	100%	100%	99%

Table 1: Visual and statistical analysis of 33017 post-stimulation recordings.

Figures

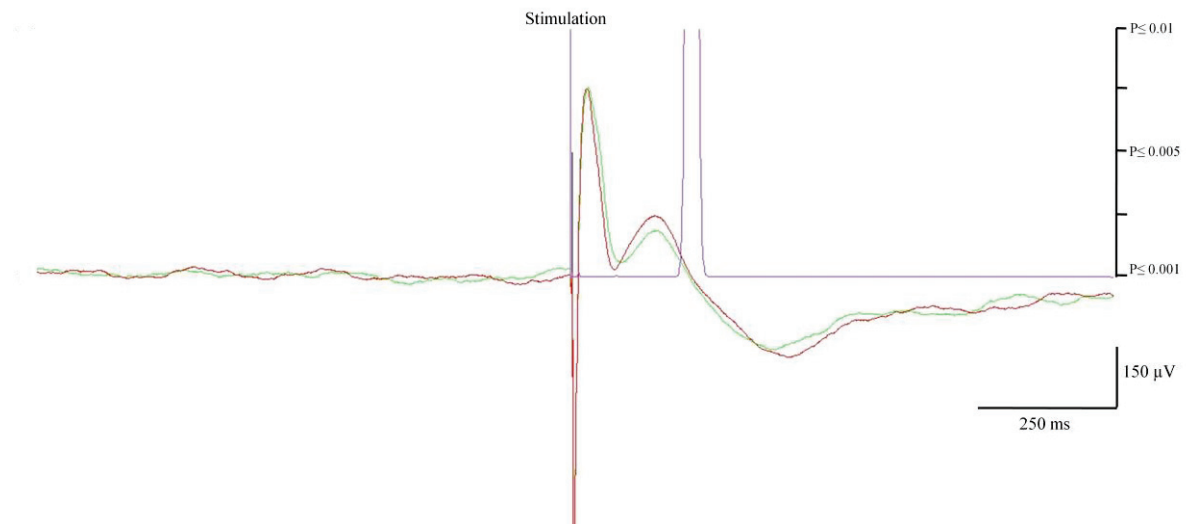


Figure 1: Example of CCEP graph. Negative polarity is upward. The green and red color superimposed curves are the average of two 20-trials showing similar N1 and N2 peaks. The purple curve represents the p statistic which value is < 0.001 threshold (i.e. significant response) when reaching the abscissa.

Part four: Intra-insular connectivity

1. Introduction:

The human insular cortex is a multimodal region with a complex network of connections. Most of our knowledge about this connectivity is either from the animal literature (Mesulam and Mufson, 1985) or from the human imaging studies (Cerliani et al., 2011; Cauda et al., 2011). Up to this date there is no single electrophysiological study reporting the human insular functional connectivity.

In this article we report for the first time the human in-vivo intra-insular functional connectivity at both gyral and functional levels. Ten patients were involved (those are patients one to ten in the list). The idea beyond this study is to have an in-depth look to how the various insular parts are connected to each other for a better understanding of its function.

The main results can be summarized as following:

- 1) Statistically significant evoked potentials were recorded in 74% of tested connections, with an average latency of 26 ± 3 ms.
- 2) All gyri were interconnected, except the anterior and posterior short gyri.
- 3) Most intra-insular connections were reciprocal, showing no clear anterior to posterior directionality.
- 4) No connection was observed between the right and left insulae.
- 5) Human insula is characterized by rich reciprocal connections within and between its mid and posterior aspects, in particular throughout the regions underlying sensorimotor integration.

2. Article: (Accepted for publication at the human brain mapping journal)

« Intra-insular functional connectivity in Human »

Talal Almashaikhi, Sylvain Rheims, Karine Ostrowsky-Coste, Alexandra Montavont, Julien Jung, Julitta de Bellescize, Alexis Arzimanoglou, Pascal Keo Kosal, Marc Guénot, Olivier Bertrand, Philippe Ryvlin



talal almashaikhi <talalalmashaikhi@gmail.com>

HBM-13-0212.R2, Accept Manuscript, Human Brain Mapping.

hbmjll@uthscsa.edu <hbmjll@uthscsa.edu>

Tue, Jun 25, 2013 at 4:41 PM

To: talalalmashaikhi@gmail.com, sylvain.rheims@chu-lyon.fr, karine.ostrowsky-coste@chu-lyon.fr, alexandra.montavont@chu-lyon.fr, julien.jung@inserm.fr, julitta.debellescize@chu-lyon.fr, aarzmanoglou@orange.fr, pascale.keo.kosal@chu-lyon.fr, marc.guenot@chu-lyon.fr, olivier.bertrand@inserm.fr, ryvlin@cermep.fr

Date:25-Jun-2013

Dear Prof. Ryvlin:

RE: HBM-13-0212.R2, Intra-insular functional connectivity in Human

I am pleased to inform you that your manuscript has been reviewed and accepted for publication in Human Brain Mapping.

If all of your final accepted files have NOT been submitted in either .doc or .rtf format for the text/tables and either .tif or .eps format for the figures, you may receive a request to provide new files.

Your article cannot be published until the publisher has received the appropriate signed license agreement. Within the next few days the corresponding author will receive an email from Wiley's Author Services system which will ask them to log in and will present them with the appropriate license for completion.

You may contact Rebecca Strauss if you have any questions about this process at hbm@wiley.com

If you wish to submit artwork to be considered for the cover of the issue in which your article will appear, please contact hbmeic@uthscsa.edu for instructions.

To ensure that your digital graphics are suitable for print purposes, please go to RapidInspector™ at <http://rapidinspector.cadmus.com/wi/index.jsp>. This free, stand-alone software application will help you to inspect and verify illustrations right on your computer.

Thank you for your support of Human Brain Mapping. I look forward to seeing more of your work in the future.

Sincerely,

Dr. Jack Lancaster

Editor-in-Chief, Human Brain Mappinghbmjll@uthscsa.edu

Human Brain Mapping is participating in the PEER project, which aims to monitor the effects of systematic self-archiving (author deposit in repositories) over time. PEER is supported by the EC eContentplus programme

(http://ec.europa.eu/information_society/activities/econtentplus/index_en.htm).

As your manuscript has been accepted for publication you may be eligible to participate in the PEER project. If you are based in the European Union, your manuscript will be archived by Wiley-Blackwell on your behalf, as part of this project. For further information please visit the PEER project website at <http://www.peerproject.eu/> .

Intra-insular functional connectivity in Human

Talal Almashaikhi,^{1,4,6} Sylvain Rheims,^{1,3} Karine Ostrowsky-Coste,⁴ Alexandra Montavont,^{1,3,4} Julien Jung,⁴ Julitta de Bellescize,⁴ Alexis Arzimanoglou,^{1,4} Pascal Keo Kosal,⁴ Marc Guénot,⁵ Olivier Bertrand,² Philippe Ryvlin^{1,3,4*}

¹TIGER and ²LDYCOG, Lyon's Neuroscience Research Centre, INSERM U1028, CNRS 5292, UCB Lyon 1, Lyon, France

³Department of Functional Neurology and Epileptology, ⁴Pediatric Epilepsy Department, and

⁵Department of Functional Neurosurgery, Hospices Civils de Lyon, Lyon, France

⁶Department of Clinical Physiology, Neurophysiology division, Sultan Qaboos University Hospital, Muscat, Oman

*Corresponding Author. Reprint requests should be sent to: Pr Philippe Ryvlin, Unité 301, Hôpital Neurologique, 59 bd Pinel, 69003, Lyon. Email: ryvlin@cermep.fr.

Short title: Human intra-insular connectivity

Keywords: insular, functional connectivity, intra-cranial electrical stimulation, evoked potential, human

Figures: 4, Tables: 2

Abstract

Objectives: The anatomical organization of the insular cortex is characterized by its rich and heterogeneous cytoarchitecture and its wide network of connections. However, only limited knowledge is available regarding the intra-insular connections subserving the complex integrative role of the insular cortex. The aim of this study was to analyze the functional connectivity within and across insular sub-regions, at both gyral and functional levels

Experimental design: We performed intra-cerebral electrical stimulation in ten patients with refractory epilepsy investigated with depth electrodes, 38 of which were inserted in the insula. Bipolar electrical stimulation, consisting of two series of 20 pulses of 1 ms duration, 0.2 Hz frequency, and 1 mA intensity, were delivered at each insular contact. For each stimulated insular anatomical region, we calculated a rate of connectivity, reflecting the proportion of other insular contacts showing significant evoked potentials.

Results: Statistically significant evoked potentials were recorded in 74% of tested connections, with an average latency of 26 ± 3 ms. All insular gyri were interconnected, except the anterior and posterior short gyri. Most connections were reciprocal, showing no clear anterior to posterior directionality. No connection was observed between the right and left insulae.

Conclusion: These findings point to specific features of Human insula connectivity as compared to non-Human primates, and remain consistent with the complex integration role devoted to the Human insula in many cognitive domains.

Introduction

The insula is a functionally complex region providing multimodal integration and involved in various verbal and non-verbal activities, including speech motor control (Bohland and

Guenther, 2006), emotional processing (Calder et al., 2000; Adolphs et al., 2003; Wicker et al., 2003), pain perception (Ostrowsky et al., 2002; Alkire et al., 2004; Mazzola et al., 2006), somatosensory integration (Burton et al., 1993), auditory processing (Bieser, 1998) as well as taste and olfactory perceptions (Yaxley et al., 1990; Kurth et al., 2010; Small, 2010; Stephani et al., 2011).

The anatomical organization of the insular cortex is characterized by its rich and heterogeneous cytoarchitecture (Mesulam and Mufson, 1985) and its wide network of connections (Augustine, 1996). However, only limited knowledge is available regarding the intra-insular connections subserving the complex integrative role of the insular cortex. The non-human primate insula demonstrates abundant bi-directional intra-insular connections, with stronger connectivity from anterior to posterior regions (Mesulam and Mufson, 1982b; Seltzer and Pandya, 1991), providing a potential pathway for conveying olfactory and gustatory information into the posterior insula (Mesulam and Mufson, 1982b). In human, a single in vivo probabilistic tractography has suggested strong within-subregion structural connectivity in both anterior and posterior insular regions (Cloutman et al. 2011).

Human cerebral functional connectivity can be studied in patients with refractory epilepsy undergoing intracerebral EEG (icEEG) investigation, by applying electrical stimulation to cortical areas and recording evoked potentials (EP) in distant connected structures (Brazier, 1964; Buser and Bancaud, 1983; Rutecki et al., 1989; Wilson et al., 1990; Buser et al., 1992; Matsumoto et al., 2004; Catenoix et al., 2005; Lacruz et al., 2007; Matsumoto et al., 2007; Rosenberg et al., 2009; Catenoix et al., 2011). This approach offers a high level of temporal and spatial resolution for mapping brain connectivity, providing complementary findings to those depicted by currently available neuroimaging methods. Taking advantage of clinical icEEG investigations of the insula, we applied this method to analyze the functional connectivity within and across insular sub-regions, at both gyral and functional levels.

Materials and Methods

Patients

Ten patients with drug resistant partial epilepsy contemplating epilepsy surgery and undergoing icEEG were included in this study. Inclusion criteria included the presence of at least two different electrodes inserted within the same insula, in order to look at EP in at least one insular electrode while stimulating another. Exclusion criteria included the presence of any morphological abnormality of the insula. All patients gave their informed consent to participate in this study.

Stereotaxic implantation of depth electrodes

IcEEG was performed according to the technique described by Talairach and Bancaud (1973), a procedure used routinely in our department (Guenot et al., 2001). The brain regions to be investigated were determined for each patient, based on individual presurgical data, and most likely origin of seizure onset. In general, about one third of electrodes target the most likely zone of seizure onset, whereas the remaining electrodes probe alternative but less likely hypothesis, or help to define the borders of the epileptogenic zone. As a result, a significant number of recording contacts are not affected by the epileptic process. This is particularly true for the insula, which is often investigated due to its potential to mimic temporal or frontal lobe seizures (Isnard et al., 2001, Isnard et al., 2004, Ryvlin et al., 2006), but eventually found not to be affected in the majority of cases.

Electrodes were implanted perpendicular to the mid-sagittal plane with the patient's head fixed in the Talairach's stereotactic frame, providing Talairach's coordinates for each electrode in relation to the anterior commissure/posterior commissure plane. The exact location of each electrode and recording lead was further verified with a post-implantation

MRI. The two deepest contacts of the electrodes targeting the insula were located within that structure, while the next more lateral contact was located either in the sylvian fissure or within the deepest portion of the adjacent operculum (temporal, frontal or parietal). For the purpose of illustrating our findings on a single template, we used the above information to position the insular leads inserted in our ten patients onto a T1-MRI sagittal slice of the insula derived from a normal subject.

Eleven to sixteen semirigid intracerebral electrodes were implanted per patient, either unilaterally (n=8) or bilaterally (n=2). Each electrode was 0.8 mm in diameter and included 5, 12 or 15 contacts 2 mm in length, 1.5 mm apart (Dixi, Besançon, France), depending on the target region. No morbidity was related to cerebral electrode implantation.

Brain stimulation and EP recordings

Intracerebral EP recordings were performed using a video-EEG monitoring system (Micromed, Treviso, Italy) that allowed to simultaneously recording up to 128 contacts at a sampling rate of 1024 Hz. As part of the clinical icEEG investigation, electrical brain stimulation is systematically performed to assess the epileptogenicity and functionality of the implanted brain regions. This procedure includes 50Hz, 1Hz and 0.2Hz stimulations, with 50Hz and 1Hz aiming at triggering ictal signs, epileptic discharge, or full-blown seizure (Munari et al., 1993; Kahane et al., 1993; Kahane et al., 2004), while 0.2Hz are used to trigger abnormal cortical evoked responses (i.e. delayed to more than 100 ms or repetitive) suggestive of an underlying epileptogenic cortex (Valentin et al., 2002; 2005a; 2005b; van't Klooster et al., 2011). In addition to their clinical utility, 0.2Hz stimulations also allow to measure physiological early responses, referred to as evoked potentials (EPs) in this study, and reflecting brain connectivity (Brazier, 1964; Buser and Bancaud, 1983; Rutecki et al., 1989; Wilson et al., 1990; Buser et al., 1992; Matsumoto et al., 2004; Catenoix et al., 2005; Lacruz et al., 2007; Matsumoto et al., 2007; Rosenberg et al., 2009; Catenoix et al., 2011).

We performed 0.2Hz stimulations at least four days following electrodes implantation, once the patient has fully recovered from the surgical procedure. We used bipolar stimulation of adjacent contacts from the same electrode, known to deliver current within 5 mm around the stimulated bipole (Nathan et al., 1993). Electrical stimulation was delivered using a current-regulated neurostimulator (Micromed, Treviso, Italy), with parameters ensuring patient safety and effective generation of EPs (Gordon et al., 1990; Catenoix et al., 2005; Catenoix et al., 2011). We used monophasic pulse of 1 ms width and 1 mA intensity resulting in an electrical charge of 1 μC . The latter was delivered over a contact surface of 0.05 cm^2 (0.8 mm diameter X 2 mm length X π), resulting in a total charge density of 20 $\mu\text{C}/\text{cm}^2/\text{phase}$, thus significantly lower than the maximum safe value of 60 $\mu\text{C}/\text{cm}^2/\text{phase}$ (Gordon et al. 1990). Two consecutive series of 20 pulses were delivered at each pair of contacts.

Data analysis

EEG data were analyzed with the software package for electrophysiological analysis (ELAN-pack) developed at the DYCOG laboratory of Lyon Neuroscience Research Centre (CRNL, Lyon, France) (Aguera et al., 2011). We first performed an automatic detection of the pulse artifact generated on the stimulated contacts, and systematically verified the accuracy of the generated marker. Thanks to the very reproducible shape and amplitude of artifacts, as well as the associated high signal to noise ratio, this procedure did not suffer from false positive or negative detection. We used the stimulation marker for averaging each block of 20 consecutive pulse stimulations, and then calculated grand averages from the two blocks. Both visual and statistical analyses were used to conclude on the presence of significant EPs over each recording contact. EPs were first selected on the basis of visual analysis if detected and found comparable in each of the two consecutive series. Statistical analysis of the selected EPs was then performed using the non-parametric statistical function of ELAN-pack for single trails (Wilcoxon test), with significance set at $p < 0.001$. In brief, this statistical analysis compared each time point of the post-stimulation period to the 1000 ms pre-

stimulation baseline, providing a curve, superimposed on the EP, illustrating the p-value associated with each component of the EP. The first 10 ms post-stimulation were not evaluated due to the presence of residual stimulation-induced artifact. EPs were considered significant when they reached the statistical threshold of $p \leq 0.001$ during at least 5 consecutive ms. The latency of the first peak of each significant potential was measured on the grand average of the two series.

Insular regions targeted by intracerebral electrodes were divided into those involved at seizure onset, those invaded during seizure propagation, and those not affected by the epileptic discharge.

For each stimulated insular anatomical region, we calculated a rate of connectivity, reflecting the proportion of other insular contacts showing significant EPs. This analysis was performed at the gyral level, considering the three short and two long gyri as five distinct anatomical regions, and at a functional level, distinguishing the social-emotional, cognitive, chemical sensory and sensorimotor insular sub-regions as identified in a recent functional neuroimaging meta-analysis of the human insula (Kurth et al. 2010).

Results

A total number of 38 electrodes were implanted into 12 insulae (two patients had bilateral implantation), with 29 electrodes placed in the left insula (76 %) and 9 in the right (24 %). The gyral location of these electrodes was as followed: three electrodes in the ASG, four in the MSG, seven in the PSG, 10 in the ALG, and 14 in the PLG. In terms of functional areas, three electrodes sampled the cognitive, four the chemical sensory, and 26 the sensorimotor subregions of the insula, whereas no electrode was placed in its social emotional portion (five other electrodes fell out of the functional areas determined by Kurth et al., 2010).

Stimulations were performed at all 38 insular electrodes, giving rise to significant EPs on other insular contacts in 74% of the 110 tested connections. Recorded EPs typically corresponded to biphasic early responses, with an average \pm SD latency of the first peak of 26 ± 3 ms (range 20 to 31 ms) (Figure.1).

The epileptogenic zone was located in the temporal lobe in five patients, frontal lobe in three, parietal lobe in one and in the insula in one. In this patient, four of the six insular electrodes were involved at seizure onset, while the other two were only affected during seizure propagation. Another two patients with a temporal or a frontal epileptogenic zone had one of their insular electrodes affected by seizure propagation. The proportion, morphology, and latency of EPs triggered or recorded at each insular contact were comparable for those involved at seizure onset, those affected during seizure propagation, and those not affected by the epileptic discharge. Thus, further results pooled data triggered and recorded at all insular contacts.

Gyral connectivity

Connectivity between the different insular gyri is described in table I and figures 2 and 3, and summarized below. The ASG demonstrated limited connectivity (30%, N=20), with most of its connections targeting the adjacent MSG and being unidirectional from anterior to posterior. The MSG showed a 67% rate of connectivity (N=24), distributed over all other gyri, with most connections being reciprocal. The PSG showed the highest rate of connectivity (88%, N=40), primarily targeting the MSG and the two long gyri with reciprocal connections. ALG showed a 71% rate of connectivity (N=52), mostly with the adjacent PSG and PLG. All connections with PSG were reciprocal, while nearly half of those with PLG were unidirectional. Among the latter, half were anterior to posterior, while the other half

were posterior to anterior. PLG showed a 75% rate of connectivity (N=60), which qualitative pattern was similar to that described for ALG.

Latencies of the earliest EP varied from 21 ± 1 ms for connections between the anterior short and long gyri, to 34 ± 1 ms for connections between the middle short and posterior long gyri (see table I).

Intra-gyral connectivity could only be tested across a limited number of connections within the PSG (N=4) and the PLG (N=8), showing 100% connectivity rate in these two gyri.

Functional connectivity

Connectivity between the different functional areas of the insula is described in table II and figure 4 and summarized below. The cognitive subregion had a low rate of unidirectional anterior to posterior connectivity with sensorimotor areas (29%) (N=7). In contrast, the chemical sensory and sensorimotor areas demonstrated a 63% rate of reciprocal connectivity (N=8). Only two connections could be tested between the cognitive and chemical sensory areas, showing bidirectional connectivity. Connectivity within the same functional subregion could only be assessed within the sensorimotor area where 93% of connections proved functional (N=44).

Latencies of the earliest EP were 25 ± 3 ms for connections between the cognitive and chemical sensory regions, 28 ± 5 ms for connections between the chemical sensory and sensorimotor regions, and 27 ± 3 ms for connections within the sensorimotor area (see table II).

Contralateral connectivity

Two patients had bilateral insular implantation, both of whom had three electrodes on one side and a single electrode on the opposite side. In one patient, contralateral electrode had an

exact counterpart in the opposite insula, located in the same portion of the PLG. However, no EP could be recorded over the 12 potential interhemispheric connections tested in these patients.

Discussion

This study provides the first human electrophysiological data exploring intra-insular functional connectivity, offering clues to the complex integrative role of the insular cortex.

Our knowledge of intra-insular connectivity primarily relies on data from non-human primates (Mesulam and Mufson, 1982b; Seltzer and Pandya, 1991). The relevance of these to human insular connectivity is suggested by the similarities observed in the gyration, cytoarchitecture, and functional anatomy of the insula between the two species, leading some authors to suggest that the human insula has a plan of organization virtually identical to that of the rhesus monkey (Mesulam and Mufson, 1982a). Both display an anterior-posterior pattern evolving from agranular to granular cortices through a transitional dysgranular area and a similar pattern of connectivity with extra-insular regions, primarily governed by the cytoarchitectonic features of the connected brain regions (Cerliani et al., 2011). In line with the above observations, a recent *in vivo* tractography study reported an anterior-posterior connectivity predominating over the transitional area of the human insula, particularly between the posterior short and anterior long gyri (Cloutman et al., 2011). However, whether intra-insular functional connectivity overlaps with these structural data remained to be determined. So far, only indirect evidence of intra-insular functional connectivity in human is available, based on the pattern of insular activation observed in a meta-analysis of 1,768 functional neuroimaging experiments (Kurth et al., 2010).

Our study used direct electrical stimulation of the human insula and associated EPs to assess intra-insular functional connectivity. This method has been used to study the connectivity of various brain regions such as the mesial temporal structures (Brazier, 1964; Buser and

Bancaud, 1983; Rutecki et al., 1989; Wilson et al., 1990; Catenoix et al., 2005; Lacruz et al., 2007; Catenoix et al., 2011), temporal neocortex including language areas (Matsumoto et al., 2004), frontal cortex (Buser et al., 1992;Lacruz et al., 2007), motor system (Matsumoto et al.,2007), and thalamic medial pulvinar nucleus (Rosenberg et al., 2009). Based on this method, we showed that the human insula was characterized by rich connections between various insular gyri which can be summarized as follows: 1) all gyri were interconnected, except the anterior and posterior short gyri for which limited sample size hampers any firm conclusion; 2) most intra-insular connections proved reciprocal, in contrast with the anterior-posterior preferential direction described in the macaque monkey (Mesulam et al., 1982b; Seltzer and Pandya, 1991).

This latter finding raises the possibility that the human insula might have specific functional characteristics, but could also reflect differences between structural and functional methods on one hand, and non-human and human studies on the other hand. Indeed, divergences between human neuroimaging functional and structural connectivity data have been reported in other brain regions (Damoiseaux and Greicius, 2009; Zhang et al., 2010). The anterograde transport methods used in monkeys has offered the possibility to clearly determine the directionality of connections within the insular cortex of non-human primates (Mesulam et al., 1982b), an information not assessable with in vivo tractography in Human. Whether connection directionality can be reliably tested by intra-cerebral electrical stimulation studies remains disputed. Indeed, such stimulation is thought to primarily trigger action potentials within bypassing axons with both orthodromic and antidromic propagation (Wilson et al., 1990; Zhang and Oppenheimer, 2000; Matsumoto et al., 2004). While this mechanism might well occur, it remains that 14% of the connections observed in our study were unidirectional, demonstrating that bidirectional stimulation of the same axons is not a generalized feature of cortico-cortical EPs. Furthermore, some insular contacts showed bidirectional connectivity with one insular region and unidirectional connectivity with another (see figure 3). Finally,

latencies of reciprocal EPs usually differ between the two directions, supporting the view that distinct neurons are stimulated to produce EPs of varying latency.

While our data suggest a more reciprocal intra-insular connectivity pattern than that described in monkeys, some anterior to posterior preferential direction was observed for connections in the anterior short gyrus and cognitive subregion. However, only a few electrodes were available in those regions, with very low connectivity rates, hampering any robust conclusion regarding this finding.

The morphology of EPs recorded in our series was consistent with those observed in the above studies. Latencies of the first detectable peak were consistent with the average values found in previous studies, typically ranging between 20 and 30 ms (Matsumoto et al., 2004; 2007). However, 10 to 20 ms latencies were reported for short distance EPs recorded within the motor and language brain regions (Matsumoto et al., 2004; 2007), in line with the observation that EPs latency increases with the distance between the stimulating and recording electrodes (Matsumoto et al., 2012). Thus, latencies of intra-insular EPs could be considered excessive according to the relatively short distance of the tested connections. One possibility could be that we failed at detecting earlier EPs occurring during the first 10 ms post-stimulation, due to stimulus-induced artifact. Another hypothesis would be that unlike the motor and language networks that require fast processing monosynaptic pathways, the more integrative role of the insula is subtended by slower polysynaptic connections.

This hypothesis is consistent with the greater connectivity rate observed within the insula as compared to other brain regions assessed using the same methodology (Wilson et al., 1990; Lacruz et al., 2007), as well as with the dense connections observed between the insular cortex and many cortical and subcortical regions (Mesulam and Mufson, 1985; Buttner-Ennever and Gerrits, 2004; Brooks et al., 2005; Pritchard and Norgren, 2004). The Human insula is thought to ensure a complex integration role in many cognitive domains such as emotional processing (Calder et al., 2000; Adolphs et al., 2003; Wicker et al., 2003),

somatosensory and pain integration (Burton et al.,1993; Ostrowsky et al., 2002; Alkire et al, 2004, Mazzola et al., 2006), taste and olfaction (Yaxley et al.,1990; Kurth et al., 2010; Small, 2010; Stephani et al., 2011), and auditory and speech processing (Bieser, 1998; Bohland and Guenther, 2006). Specifically, we observed dense functional connectivity within the sensorimotor portion of the insula, a region thought to provide a primary interoceptive representation of the physiological condition of the body which is then associated with input from multiple other sources in the mid-insula (Craig, 2010). Rich bidirectional connectivity between cortical areas that receive sensory afferents from different sources might underlie the build-up of complex representation of sensory environment.

On the other hand, the low connectivity pattern observed between the anterior short gyrus or cognitive subregion of the insula and the other insular regions is surprising. Indeed, it has been proposed that multimodal sensory information converge to the most anterior portion of the insula in a way that would contribute to self-recognition and emotional awareness (Craig, 2009). Conversely, other authors view that the anterior insula as an anatomically and functionally distinct structure from the remainder of the insula (Nelson et al., 2010). In any event, our study suffers from clear undersampling of the most anterior portion of the insula, and further data will be needed to conclude on this issue.

Some other limitations need to be acknowledged. Firstly, icEEG based studies of functional connectivity are necessarily performed in patients with epilepsy which brain connections might be altered, especially within the epileptogenic zone. In fact, no difference between the EPs recorded from contacts included in the epileptic network and those recorded from non-epileptic tissue was observed, as previously described by others (Wilson et al., 1990; Lacruz et al., 2007). Furthermore, the insula was not part of the epileptogenic zone in nine out of our ten patients, with the majority of tested contacts not even affected by the epileptic discharge during its propagation. Thus, we believe that our main findings are likely to apply to healthy individuals. A second issue relates to the sampling limitations of electrodes implanted

orthogonally in the insula, with vascular constraints hampering access to the ventral portion of the anterior insula, leaving this region unexplored by our study. In addition, the clinical profiles of our patients resulted in greater need for exploring the posterior short and long gyri rather than the anterior and middle short gyri, leading to less robust findings for these latter structures.

We failed to detect contralateral EPs to insular stimulation, even though we could test 12 potential connections in two patients, including one pair of electrodes placed in a very homologous position within both insulae. This negative finding is in contrast with evidence of structural and functional connections between the two insulae in Human (Ebisch et al., 2010, Anderson et al., 2011). While most likely reflecting insufficient insular sampling, our findings also suggest that the density of connections between the two insulae is much lower than that observed within each insula.

Overall, electrically-induced cortico-cortical EPs demonstrate that the Human insula is characterized by rich reciprocal connections within and between its mid and posterior aspects, in particular throughout the regions underlying sensorimotor integration. Further studies should confirm these findings in larger population and look at their relation to the insular afferents and efferents as delineated by the same electrophysiological method.

References:

Adolphs R, Tranel D, Damasio AR (2003): Dissociable neural systems for recognizing emotions. *Brain and cognition* 52: 61-69.

Aguera PE, Jerbi K, Caclin A, Bertrand O (2011): ELAN: A software package for analysis and visualization of MEG, EEG, and LFP signals. *Comput Intell Neurosci* 2011: 158970

Alkire MT, White NS, Hsieh R, Haier RJ (2004): Dissociable brain activation responses to 5-Hz electrical pain stimulation: A high-field functional magnetic resonance imaging study. *Anesthesiology* 100: 939-946.

Anderson JS, Druzgal TJ, Froehlich A, DuBray MB, Lange N, Alexander AL, Abildskov T, Nielsen JA, Cariello AN, Cooperrider JR, Bigler ED, Lainhart JE (2010): Decreased interhemispheric functional connectivity in autism. *Cerebral Cortex* 21: 1134-1146.

Augustine JR. (1996): Circuitry and functional aspects of the insular lobe in primates including humans. *Brain Research Reviews* 22: 229-244.

Bieser, A (1998): Processing of twitter-call fundamental frequencies in insula and auditory cortex of squirrel monkeys. *Experimental Brain Research* 122: 139–148.

Bohland JW, Guenther FH (2006): An fMRI investigation of syllable sequence production. *Neuroimage* 32: 821-841.

Brazier MA (1964): Evoked responses recorded from the depths of the human brain. *Annals of the New York Academy of Sciences* 112: 33-59.

Brooks JC, Zambreanu L, Godinez A, Craig AD, Tracey I (2005): Somatotopic organisation of the human insula to painful heat studied with high resolution functional imaging. *Neuroimage* 27: 201-209.

Burton H, Videen TO, Raichle ME (1993): Tactile-vibration-activated foci in insular and parietal-opercular cortex studied with positron emission tomography: mapping the second somatosensory area in humans. *Somatosensory & motor research* 10: 297-308.

Buser P, Bancaud J (1983): Unilateral connections between amygdala and hippocampus in man. A study of epileptic patients with depth electrodes. *Electroencephalography and clinical neurophysiology* 55: 1-12.

Buser P, Bancaud J, Chauvel P (1992): Callosal transfer between mesial frontal areas in frontal lobe epilepsies. *AdvNeurol* 57: 589-604.

Büttner-Ennever, J. A., & Gerrits, N. M (2004): Vestibular system. In G. Paxinos & J. K. Mai, editor. *The human nervous system*. Amsterdam: Elsevier. p 1212–1240.

Calder AJ, Keane J, Manes F, Antoun N, Young AW (2000): Impaired recognition and experience of disgust following brain injury. *Nature neuroscience* 3: 1077-1078.

Catenoix H, Magnin M, Guenot M, Isnard J, Mauguiere F, Ryvlin P (2005): Hippocampal-orbitofrontal connectivity in human: an electrical stimulation study. *Clinical neurophysiology* 116: 1779-1784.

Catenoix H, Magnin M, Mauguiere F, Ryvlin P (2011): Evoked potential study of hippocampal efferent projections in the human brain. *Clinical Neurophysiology* 122: 2488-2497.

Cerliani L, Thomas RM, Jbabdi S, Siero JC, Nanetti L, Crippa A, Gazzola V, D'Arceuil H, Keysers C (2011): Probabilistic tractography recovers a rostrocaudal trajectory of connectivity variability in the human insular cortex. *Hum Brain Mapp.*33: 2005-2034.

Cloutman LL, Binney RJ, Drakesmith M, Parker GJ, Ralph MA (2011): The variation of function across the human insula mirrors its patterns of structural connectivity: Evidence from in vivo probabilistic tractography. *NeuroImage* 59: 3514-3521.

Craig AD (2009): How do you feel—now? The anterior insula and human awareness. *Nat Rev Neurosci.*10: 59-70.

Craig AD (2010): The sentient self. *Brain structure and function* 214: 563-577.

Damoiseaux JS, Greicius MD (2009): Greater than the sum of its parts: a review of studies combining structural connectivity and resting-state functional connectivity. *Brain Structure and Function* 213: 525-533.

Ebisch SJH, Gallese V, Willems RM, Mantini D, Groen WB, Romani GL, Buitelaar JK, Bekkering H (2010): Altered intrinsic functional connectivity of anterior and posterior insula regions in high-functioning participants with autism spectrum disorder. *Hum Brain Mapp* 32: 1013-28.

Gordon B, Lesser RP, Rance NE, Hart Jr J, Webber R, Uematsu S, Fisher RS (1990): Parameters for direct cortical electrical stimulation in the human: histopathologic confirmation. *Electroencephalography and clinical neurophysiology* 75: 371-377.

Guenot M, Isnard J, Ryvlin P, Fischer C, Ostrowsky K, Mauguiere F, Sindou M (2001): Neurophysiological monitoring for epilepsy surgery: the Talairach SEEG method. *Stereotactic and functional neurosurgery* 77: 29-32.

Isnard J, Guenot M, Ostrowsky K, Sindou M, Mauguiere F (2001): The role of the insular cortex in temporal lobe epilepsy. *Annals of neurology* 48: 614-623.

Isnard J, Guenot M, Sindou M, Mauguiere F (2004): Clinical Manifestations of Insular Lobe Seizures: A Stereo-electroencephalographic Study. *Epilepsia* 45: 1079-1090.

Kahane P, Tassi L, Francionne S, Hoffmann D, Lo Russo G, Munari C (1993): Manifestations électrocliniques induites par la stimulation électrique intracérébrale par chocs dans les épilepsies temporales. *ClinNeurophysiol* 22: 305-326.

Kahane P, Minotti L, Hoffmann D, et al (2004): Invasive EEG in the definition of the seizure onset zone: depth electrodes. In: Rosenow F, Lüders HO, editor. *Handbook of Clinical Neurophysiology, Vol.3. Presurgical assessment of the epilepsies with clinical neurophysiology and functional imaging*. Amsterdam: Elsevier BV. p 109-133.

Kurth F, Zilles K, Fox PT, Laird AR, Eickhoff SB (2010): A link between the systems: functional differentiation and integration within the human insula revealed by meta-analysis. *Brain Structure and Function* 214: 519-534.

Lacruz ME, Garcia Seoane JJ, Valentin A, Selway R, Alarcon G (2007): Frontal and temporal functional connections of the living human brain. *Eur J Neurosci* 26: 1357-1370.

Matsumoto R, Nair DR, Ikeda A, Fumuro T, Lapresto E, Mikuni N, Bigaman W, Miamoto S, Fukuyama H, Takahashi R, Najm I, Shibasaki H, Luders HO (2012): Parieto-frontal network in Human studied by cortico-cortical evoked potential. *Hum Brain Mapp.* 33: 2856-2872.

Matsumoto R, Nair DR, LaPresto E, Bingaman W, Shibasaki H, Luders HO (2007): Functional connectivity in human cortical motor system: a cortico-cortical evoked potential study. *Brain* 130: 181-197.

Matsumoto R, Nair DR, LaPresto E, Najm I, Bingaman W, Shibasaki H, Luders HO (2004): Functional connectivity in the human language system: a cortico-cortical evoked potential study. *Brain* 127: 2316-2330.

Mazzola L, Isnard J, Mauguiere F (2006): Somatosensory and pain responses to stimulation of the second somatosensory area (SII) in humans. A comparison with SI and insular responses. *Cerebral Cortex* 16: 960-968.

MesulamMM, Mufson EJ (1985): The insula of Reil in man and monkey. In A. Peters & E.G. Jones, editor. *Association and auditory cortices*. New York: Plenum p 179-226.

Mesulam MM, Mufson EJ (1982a): Insula of the old world monkey. I. Architectonics in the insulo-orbito-temporal component of the paralimbic brain. *J Comp Neurol* 212: 1-22.

Mesulam M, Mufson EJ (1982b): Insula of the old world monkey. III: Efferent cortical output and comments on function. *The Journal of comparative neurology* 212: 38-52.

Munari C, Kahane P, Tassi L, Francione S, Hoffmann D, Lo RG, Benabid AL (1993): Intracerebral low frequency electrical stimulation: a new tool for the definition of the "epileptogenic area". *Actaneurochirurgica.Supplementum* 58: 181-185.

Nathan SS, Sinha SR, Gordon B, Lesser RP, Thakor NV (1993): Determination of current density distributions generated by electrical stimulation of the human cerebral cortex. *Electroencephalography and clinical neurophysiology* 86: 183-192.

Nelson SM, Dosenbach NU, Cohen AL, Wheeler ME, Schlaggar BL, Petersen SE (2010): Role of the anterior insula in task-level control and focal attention. *Brain Structure and Function* 214: 669-680.

Ostrowsky K, Magnin M, Ryvlin P, Isnard J, Guenot M, Mauguiere F (2002): Representation of pain and somatic sensation in the human insula: a study of responses to direct electrical cortical stimulation. *Cerebral Cortex* 12: 376-385.

Pritchard, T. C., & Norgren, R (2004): Gustatory system. In G. Paxinos & J. K. Mai, editor. *The human nervous system*. Amsterdam: Elsevier. p 1171–1196.

Rosenberg DS, Mauguiere F, Catenoix H, Faillenot I, Magnin M (2009): Reciprocal thalamocortical connectivity of the medial pulvinar: a depth stimulation and evoked potential study in human brain. *Cerebral Cortex* 19: 1462-1473.

Rutecki PA, Grossman RG, Armstrong D, Irish-Loewen S (1989): Electrophysiological connections between the hippocampus and entorhinal cortex in patients with complex partial seizures. *Journal of neurosurgery* 70: 667-675.

Ryvlin P, Minotti L, Demarquay G, Hirsch E, Arzimanoglou A, Hoffman D, Guenot M, Picard F, Rheims S, Kahane P (2006): Nocturnal hypermotor seizures, suggesting frontal lobe epilepsy, can originate in the insula. *Epilepsia* 47: 755-765.

Seltzer B, Pandya DN (1991): Post-rolandic cortical projections of the superior temporal sulcus in the rhesus monkey. *The Journal of comparative neurology* 312: 625-640.

Small DM (2010): Taste representation in the human insula. *Brain Structure and Function* 214: 551-561.

Stephani C, Fernandez-Baca Vaca G, Maciunas R, Koubeissi M, Luders HO (2011): Functional neuroanatomy of the insular lobe. *Brain Structure and Function* 216: 137-149.

Talairach J, Bancaud J (1973): Stereotaxic approach to epilepsy. Methodology of anatomofunctional stereotaxic investigations. *ProgNeuroSurg* 5: 297-354.

Valentin A, Alarcon G, Garcia-Seoane JJ, Lacruz ME, Nayak SD, Honavar M, Selway RP, Binnie CD, Polkey CE (2005a): Single-pulse electrical stimulation identifies epileptogenic frontal cortex in the human brain. *Neurology* 65: 426-435.

Valentin A, Alarcon G, Honavar M, Garcia Seoane JJ, Selway RP, Polkey CE, Binnie CD(2005b): Single pulse electrical stimulation for identification of structural abnormalities and prediction of seizure outcome after epilepsy surgery: a prospective study. *Lancet Neurol* 4: 718-726.

Valentin A, Anderson M, Alarcon G, Seoane JJ, Selway R, Binnie CD, Polkey CE (2002): Responses to single pulse electrical stimulation identify epileptogenesis in the human brain in vivo. *Brain* 125: 1709-1718.

van't Klooster MA, Zijlmans M, Leijten FS, Ferrier CH, van Putten MJ, Huiskamp GJ (2011): Time--frequency analysis of single pulse electrical stimulation to assist delineation of epileptogenic cortex. *Brain* 134: 2855-2866.

Wicker B, Keysers C, Plailly J, Royet JP, Gallese V, Rizzolatti G (2003): Both of Us Disgusted in My Insula: The Common Neural Basis of Seeing and Feeling Disgust. *Neuron* 40: 655-664.

Wilson CL, Isokawa M, Babb TL, Crandall PH (1990) Functional connections in the human temporal lobe. *Experimental brain research* 82: 279-292.

Yaxley S, Rolls ET, Sienkiewicz ZJ (1990): Gustatory responses of single neurons in the insula of the macaque monkey. *Journal of Neurophysiology* 63: 689-700.

Zhang D, Snyder AZ, Shimony JS, Fox MD, Raichle ME (2010): Noninvasive functional and structural connectivity mapping of the human thalamocortical system. *Cerebral cortex* 20: 1187-1194.

Zhang ZH, Oppenheimer SM (2000): Electrophysiological evidence for reciprocal insulo-insular connectivity of baroreceptor-related neurons. *Brain research* 863: 25-41.

Tables:

		Recorded leads				
		Anterior short gyrus	Middle short gyrus	Posterior short gyrus	Anterior long gyrus	Posterior long gyrus
Stimulated leads	Anterior short gyrus	–	100% (N=2) 24±7	0 (N=2)	33% (N=3) 21±1	33% (N=3) 28±1
	Middle short gyrus	50% (N=2) 24±5	–	100% (N=2) 30±1	50% (N=4) 26±5	75% (N=4) 34±1
	Posterior short gyrus	0 (N=2)	100% (N=2) 29±4	100% (N=4) 30±5	100% (N=6) 25±3	100% (N=10) 28±4
	Anterior long gyrus	0 (N=3)	50% (N=4) 26±1	100% (N=6) 27±5	–	77% (N=13) 27±2
	Posterior long gyrus	0 (N=3)	50% (N=4) 27±5	90% (N=10) 28±3	77% (N=13) 26±5	100% (N=8) 28±2

Table I. Connectivity across and within the five insular gyri. For each tested connection: 1) top number represents connectivity rate (responding connections/total tested connections); 2) middle number in brackets (N) is the number of connections tested; 3) bottom number is the mean latency in ms ± SD. Empty cells: no tested connection.

		Recorded leads		
		Cognitive	Chemical sensory	Sensory-motor
Stimulated leads	Cognitive	–	100% (N=2) 25±3	29% (N=7) 27±4
	Chemical sensory	50% (N=2) 26±2	–	63% (N=8) 28±5
	Sensory-motor	0 (N=7)	63% (N=8) 28±2	93% (N=44) 27±3

Table II. Connectivity across and within main insular functional subregions. For each tested connection: 1) top number represents connectivity rate (responding connections/total tested connections); 2) middle number in brackets (N) is the number of connections tested; 3) bottom number is the mean latency in ms ± SD. Empty cells: no tested connection.

Figures

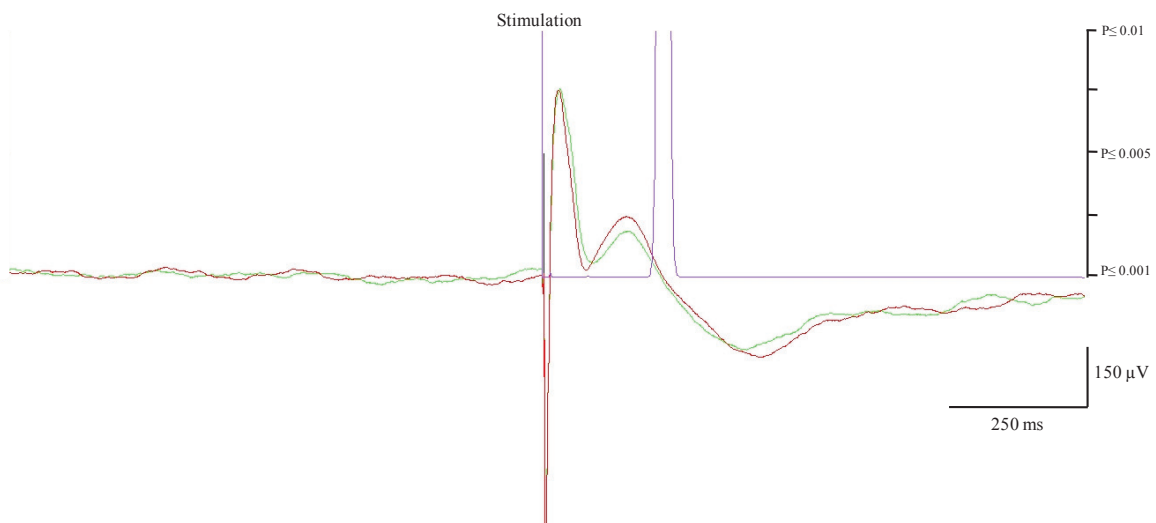


Figure 1. Illustration of evoked potential recorded after insular stimulation. Negative polarity is upward. The green and red color superimposed curves are the average of two 20-trials showing similar N1 and N2 peaks. The purple curve represents the p statistic which value is < 0.001 threshold (i.e. significant response) when reaching the abscissa.

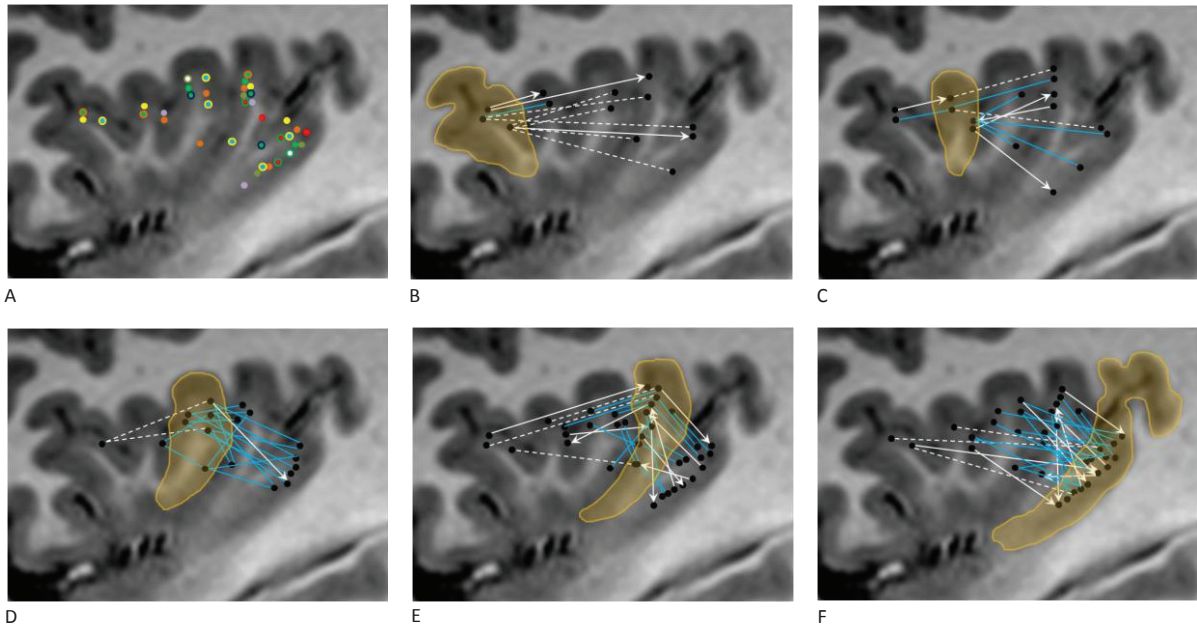


Figure 2. Electrodes location and Gyrus connectivity pattern. A: Electrodes location in all 10 patients; different color is used for each patient, B: Anterior short gyrus connectivity, C: Middle short gyrus connectivity, D: Posterior short gyrus connectivity, E: Anterior long gyrus connectivity. F: Posterior long gyrus connectivity. For graphs B to F, gyrus of interest is encircled and highlighted, blue solid lines indicate bidirectional connectivity, white solid arrows indicate unidirectional connectivity and dotted white lines indicate lack of detectable connection.

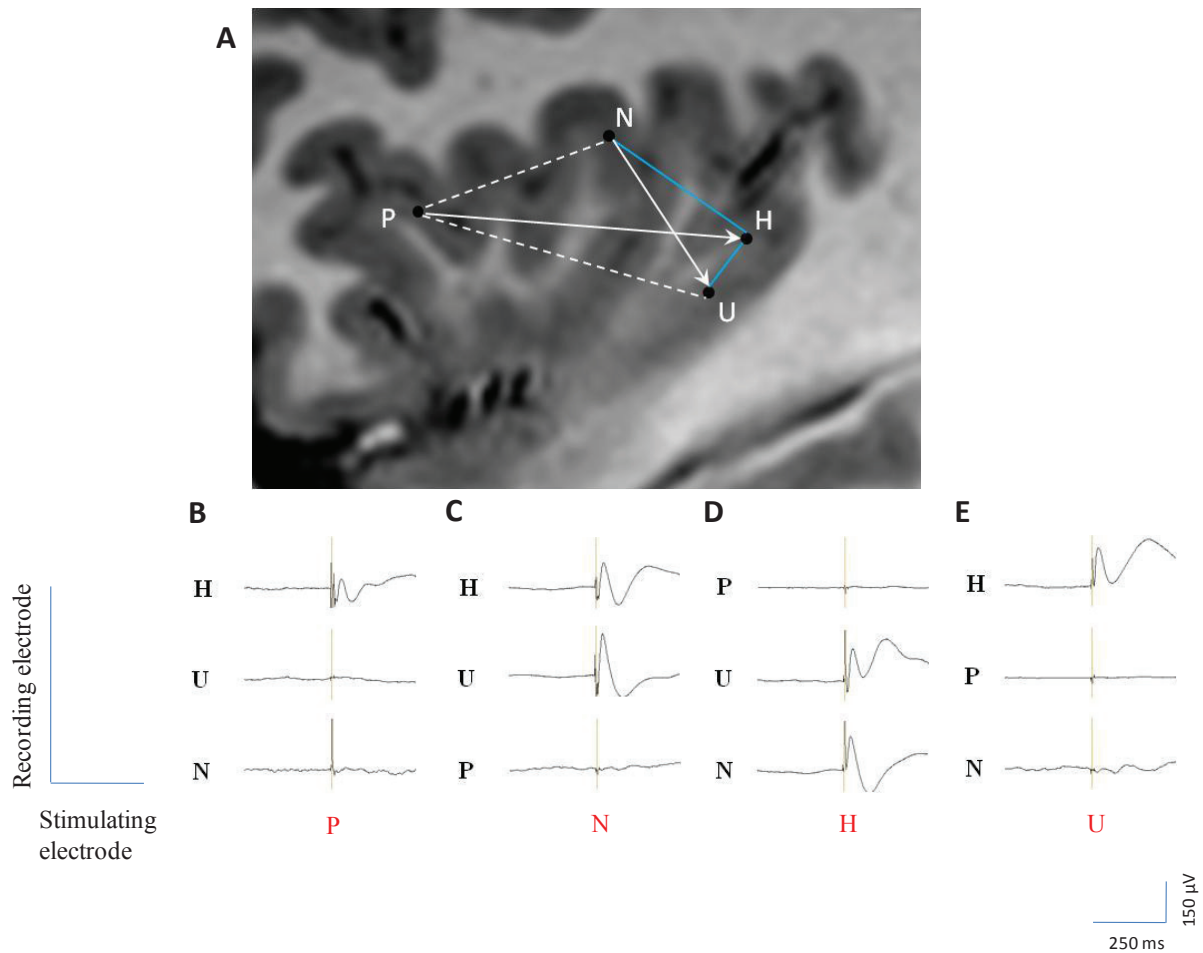


Figure 3. Illustration of the various patterns of connectivity in one patient: A) Connectivity between four insular leads located within the anterior short (P), posterior short (N), and posterior long (H, U) gyri. Blue solid lines indicate bidirectional connectivity, white solid arrows indicate unidirectional connectivity and dotted white lines indicate lack of detectable connection. B to E) EPs evoked by stimulating P, N, H and U leads, respectively: B) the stimulation of P (anterior short gyrus) generate EPs only over H (posterior long gyrus), which are not reciprocal; C) the stimulation of N (posterior short gyrus) generate EPs over H and U (posterior long gyrus), only one of which is reciprocal (H); D) the stimulation of U (posterior long gyrus) generate EPs only over H, which are reciprocal; and E) the stimulation of H (posterior long gyrus) generate EPs over N (posterior short gyrus) and U (posterior long gyrus), both of which are reciprocal.

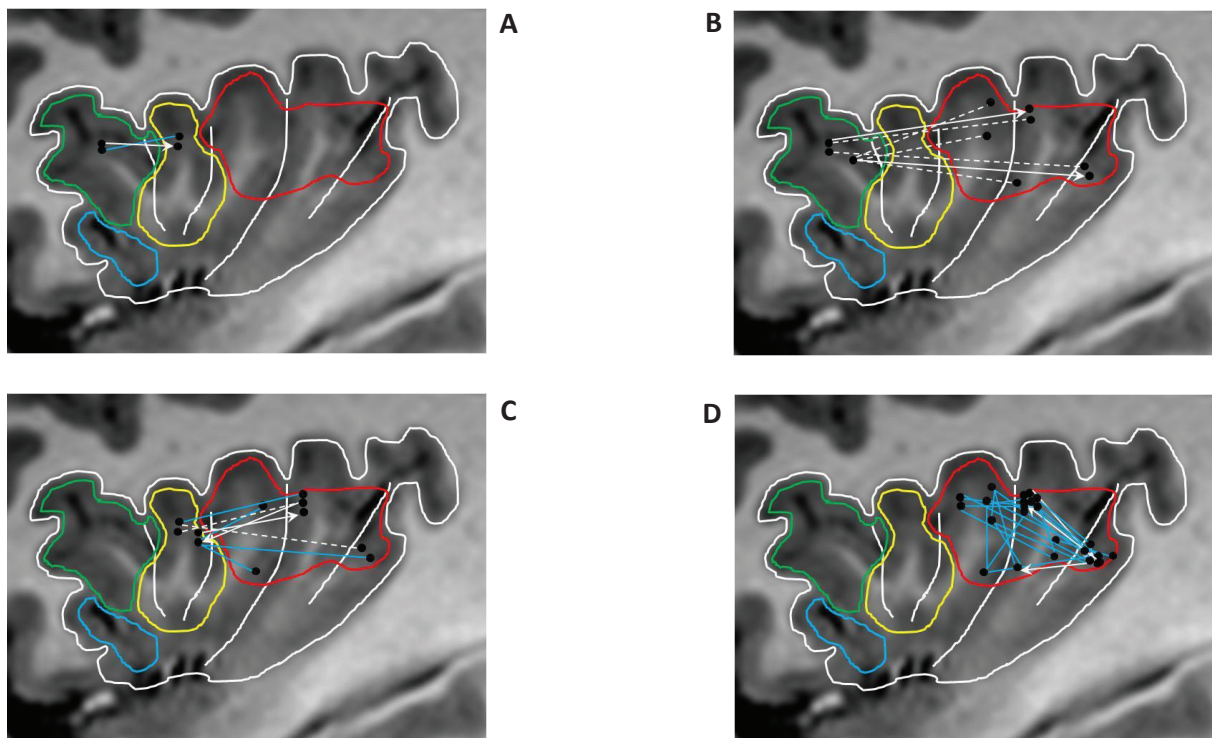


Figure 4. Connectivity across and within main insular functional subregions. A: Connectivity between cognitive and chemical sensory regions; B: Connectivity between cognitive and sensorimotor regions; C: Connectivity between chemical sensory and sensorimotor regions; D: Connectivity within sensorimotor region. Functional regions as delineated by Kurth et al. 2010: social-emotional (blue), cognitive (green), chemical sensory (yellow), sensorimotor (red). For graphs A to D, blue lines indicate bidirectional connectivity, white arrows indicate unidirectional connectivity and dotted white lines indicate lack of detectable connection.

3. Additional unpublished findings:

In addition to looking at intra-insular connectivity at both gyral and functional divisions, we studied also the connectivity pattern at cytoarchitectonic level, distinguishing the agranular, dysgranular, and granular aspects of the insula. The borders of these three cytoarchitectonic areas were defined according to data derived from previous studies (Rose, 1928; Brockhaus, 1940; Bonthius et al., 2005; Kurth et al., 2010a). Specifically, the border between the granular and dysgranular areas was that delineated by Kurth et al. (2010a), whereas the anterior limit of the dysgranular insula was defined according to the classical work of Rose (1928), Brockhaus (1940) and Bonthius et al. (2005). The granular area comprised the dorsal part of the anterior and posterior long gyri (ALG and PLG), the dysgranular area included the ventral part of the anterior and posterior long gyri, as well as the dorsal part of the middle and the posterior short gyri (MSG and PSG), and the agranular area comprised the ventral part of the middle and the anterior short gyri (MSG and ASG) (Rose, 1928; Brockhaus, 1940; Bonthius et al, 2005; Kurth et al., 2010a).

Cytoarchitectonic connectivity findings:

Connectivity between the different insular cytoarchitectonic areas is described in table III.2 and fig. III.12 and summarized below. Agranular regions had no connectivity with dysgranular areas (N=8), and very low bi-directional connectivity with granular areas (20%) (N=10). Conversely, dysgranular and granular areas were highly connected to each other, with an 81% connectivity rate (N=32), mostly bidirectional with a slight predominance of granular to dysgranular connections.

There was also a high rate of connectivity within each cytoarchitectonic sub-regions, which varied from 75% within the agranular cortex (N=4), to 93% within the dysgranular regions (N=50), and 100% within the granular areas (N=2).

Conclusion:

Connectivity was primarily observed within insular regions sharing the same cytoarchitectonic characteristics, as well as between the granular and dysgranular cortices. In contrast, no connection was observed between the agranular and dysgranular areas, and only a few between the agranular and granular regions

		Recorded leads		
		Agranular	Dysgranular	Granular
Stimulated leads	Agranular	75% (N=4) 24±5	0 (N=4)	20% (N=5) 26±6
	Dysgranular	0 (N=4)	93% (N=50) 28±3	75% (N=16) 26±7
	Granular	20% (N=5) 25±6	88% (N=16) 26±4	100% (N=2) 28±2

Table III.2: Cytoarchitectonic area connectivity. For each tested connection: 1) top number represents connectivity rate (responding connections/total tested connections); 2) middle number in brackets (N) is the number of connections tested; 3) bottom number is the mean latency in msec ± SD. Empty cells: no tested connections.

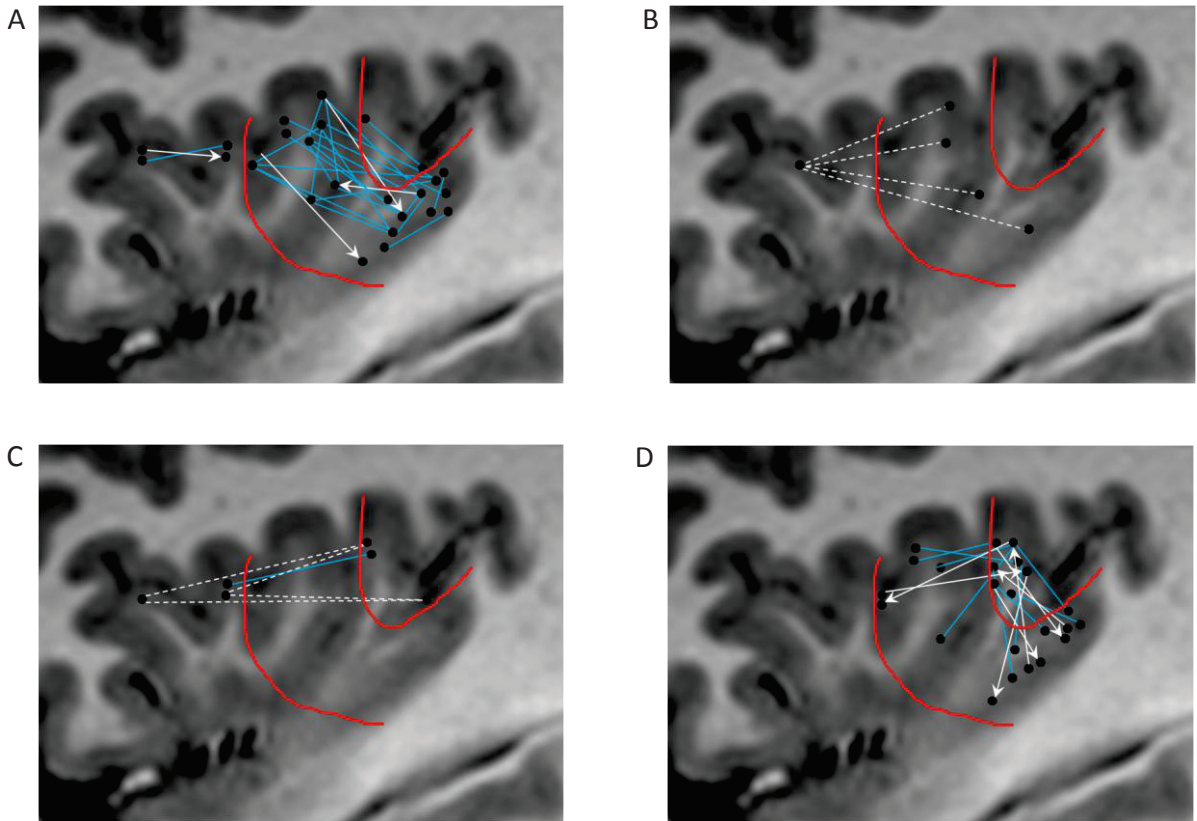


Figure III.12: Cytoarchitectonic connectivity pattern. A: Connectivity within each of the three cytoarchitectonic areas; B: Connectivity between agranular and dysgranular regions; C: Connectivity between agranular and granular regions; D: Connectivity between agranular and granular regions. Blue solid lines indicate bidirectional connectivity, white solid arrows indicate unidirectional connectivity and dotted white lines indicate lack of detectable connection.

Part five: Insular efferent connections

1. Introduction:

Macaque tract tracing studies showed reciprocal connections between insula and nearby medial temporal, temporopolar, and orbitofrontal cortex, as well as the cingulate gyrus and lateral prefrontal areas (Mesulam and Mufson 1982b; Mufson and Mesulam 1982). Anterior insula is connected to anterior cingulate gyrus, while posterior insula is also connected with middle cingulate, around supplementary motor area (Mesulam and Mufson 1982b; Mufson and Mesulam 1982). In human, tractography seeds from the anterior insula were mainly found in limbic and paralimbic regions and in anterior parts of the inferior frontal gyrus, while seeds from caudal insular territories mostly reached parietal and posterior temporal cortices (Cerliani et al., 2011)

As an extension of the previous paper on intra-insular functional connectivity we looked into the pattern of insular connectivity with other cortical regions. Using the same previously mentioned technique we examined insular connectivity with the rest of the cortex in eleven patients (patients 1 to 11 in the list). The major results of this study can be summarized as following:

- 1) Highly reproducible EPs were elicited in 33% of tested connections with an average latency of 33 ± 5 ms, 93% of positive connections were reciprocal.
- 2) Limited interhemispheric connectivity; observed only between the insula and the opposite parietal operculum.
- 3) No difference in the connectivity pattern of the epileptic and the normal cortices.
- 5) Best observed connectivity was with the operculum (frontal, parietal, temporal).
- 6) Limited connectivity with mesial temporal structures, the non-opercular temporal neocortex and the orbitofrontal cortex.
- 7) No observed connectivity with the mesial frontal cortex or the cingulate gyrus.

8) An anterior posterior trend of connectivity was observed; the anterior most gyrus was projecting preferentially to hippocampus and orbito-frontal cortex while the posterior most gyri were projecting in preference to the precentral cortex, parietal operculum and the parietal lobe.

2. Article: (Submitted at human brain mapping journal)

« **Functional connectivity of insular efferences** »

Talal Almashaikhi, Sylvain Rheims, Julien Jung, Karine Ostrowsky-Coste, Alexandra Montavont, Alexis Arzimanoglou, Julitta De Bellescize, Pascal Keo Kosal, Marc Guénot, Olivier Bertrand, Philippe Ryvlin

Functional connectivity of insular efferences

Talal Almashaikhi,^{1,4,6} Sylvain Rheims,^{1,3} Julien Jung,⁴ Karine Ostrowsky-Coste,⁴ Alexandra Montavont,^{1,3,4} Julitta de Bellescize,⁴ Alexis Arzimanoglou,^{1,4} Pascale Keo Kosal,⁴ Marc Guénot,⁵ Olivier Bertrand,² Philippe Ryvlin^{1,3,4*}

¹TIGER and ²DYCOG, Lyon's Neuroscience Research Centre, INSERM U1028, CNRS 5292, UCB Lyon 1, Lyon, France

³Department of Functional Neurology and Epileptology, ⁴Pediatric Epilepsy Department, and

⁵Department of Functional Neurosurgery, Hospices Civils de Lyon, Lyon, France

⁶Department of Clinical Physiology, Neurophysiology division, Sultan Qaboos University Hospital, Muscat, Oman

*Corresponding Author. Reprint requests should be sent to: Pr Philippe Ryvlin, Unité 301, Hôpital Neurologique, 59 bd Pinel, 69003, Lyon. Email: ryvlin@cermep.fr.

Short title: Human insular efferent connections

Keywords: insular, functional connectivity, intra-cranial electrical stimulation, evoked potential, human

Figures: 5, Tables: 3 (including one supplementary table)

Abstract

Objectives: The aim of our study was to explore the functional connectivity between the insula and other cortical regions, in human, using cortico-cortical evoked potentials (CCEPs).

Experimental design: We performed intra-cerebral electrical stimulation in eleven patients with refractory epilepsy investigated with depth electrodes, including 39 targeting the insula. Electrical stimulation consisted of two series of 20 pulses of 1 ms duration, 0.2 Hz frequency, and 1 mA intensity delivered at each of the 39 insular bipoles. Rates of connectivity were reported whenever a non-insular cortical region was tested by at least ten stimulating/recording electrode pairs in three or more patients.

Results: Significant CCEPs were elicited in 193 of the 578 (33%) tested connections, with an average latency of 33 ± 5 ms. The highest connectivity rates were observed with the nearby perisylvian structures (59%), followed by the pericentral cortex (38%), the temporal neocortex (28%), the lateral parietal cortex (26%), the orbitofrontal cortex (25%), the mesial temporal structures (24%), the dorsolateral frontal cortex (15%), the temporal pole (14%), and the mesial parietal cortex (11%). No connectivity was detected in the mesial frontal cortex or cingulate gyrus. The pattern of connectivity also differed between the five insular gyri, with greater connectivity rate for the posterior short gyrus (49%), than for the middle short (29%), and two long gyri (28% and 33%).

Conclusion: The Human insula is characterized by a rich and complex connectivity that varies as a function of the insular gyrus and appears to partly differ from the efferences described in non-human primates.

Introduction

Our knowledge of insular connectivity in primates primarily derives from macaque tracer injection data and human neuroimaging studies. In macaques, the insula has reciprocal connections with nearby medial temporal, temporopolar and orbitofrontal cortex, as well as with the anterior cingulate gyrus and lateral prefrontal areas (Mesulam and Mufson 1982; Mufson and Mesulam 1982). Differences exist in the topographic distribution of projections from and into the sub regions of the macaque's insula, whereby its anterior aspect is extensively connected with the amygdala, orbitofrontal cortex, anterior cingulate gyrus, temporal pole, and entorhinal cortex, while its posterior part is preferentially connected to the premotor cortex, first and second somatosensory cortices, superior temporal sulcus, and posterior cingulate gyrus (Mesulam and Mufson 1985, Augustine 1986). This organization is consistent with the anterior to posterior cytoarchitectonic gradient of the insula, progressively shifting from agranular, to dysgranular and granular cortices (Mesulam and Mufson 1982).

Similarly, resting state functional connectivity measures in Human have identified an anterior and a posterior insular functional network (Cauda et al. 2011). The former links the anterior insula to the middle and inferior temporal cortex as well as to the anterior cingulate gyrus, and is responsible for emotional salience and cognitive control. The posterior network links the middle-posterior insula to premotor, sensorimotor, supplementary motor and middle-posterior cingulate cortices, and primarily supports verbal, auditory and motor processing. Probabilistic tractography and structural connectivity mapping are also in agreement with this bipartition of the human insula (Cloutman et al., 2011) and rostrocaudal trajectory of connectivity reflecting cytoarchitecture (Cerliani et al., 2011).

However, the above findings do not provide details about the functionality and latency of the identified connections. Such information can be obtained by generating cortico-cortical evoked potentials (CCEPs) through low-frequency electrical brain stimulation (EBS) in

patients undergoing intracerebral EEG investigation (icEEG) for refractory partial epilepsy (Catenoix et al. 2005, 2011). Investigating the insula is of particular interest in patients with epilepsy, since this region might be the site of seizure onset, mimicking temporal or frontal lobe epilepsy through its propagation pathways (Ryvlin and Kahane, 2005; Ryvlin et al. 2006a, Ryvlin 2006). So far, however, EBS was primarily applied to the insula using high frequency stimulation to trigger signs or symptoms informing on its functional role, but not on its connectivity (Ostrowsky et al., 2000; 2002; Afif et al., 2010a; 2010b; Stephani et al., 2011; Pugnaghi et al., 2011). Recently, we have examined the intra-insular connectivity using low-frequency EBS, and described reciprocal connections between most of the five insular gyri (Almashaikhi et al., in press). In the current study we used the same technique to examine the functional efferences of the Human insula.

Materials and Methods

Patients

The study included eleven patients with drug-resistant partial epilepsy undergoing icEEG as part of pre-surgical assessment of their epilepsy, including the ten patients previously reported in a CCEP study of intransular connectivity (Almashaiki et al. in press). All patients had a morphologically normal insula on MRI. Extra insular cortical lesions were observed in four patients, including a left temporo-frontal cortical dysplasia, a right frontal cortical dysplasia, a right parietal porencephalic cyst, and two tubers (right temporal pole and left frontal) in a patient with a minor form of tuberous sclerosis. Another four patients demonstrated hippocampal atrophy or malrotation, which were bilateral in half of them. All patients and caregivers gave their informed consent to participate to this study.

Stereotactic implantation of depth electrodes

IcEEG was performed according to the technique described by [Talairach and Bancaud \(1973\)](#), a procedure used routinely in our department ([Guenot et al., 2001](#)). The brain regions to be investigated were determined for each patient, based on individual presurgical data, and most likely origin of seizure onset. Electrodes were implanted perpendicular to the mid-sagittal plane with the patient's head fixed in the Talairach's stereotactic frame, providing Talairach's coordinates for each electrode in relation to the anterior commissure/posterior commissure plane. Eleven to sixteen semirigid intracerebral electrodes were implanted per patient, including at least one which targeted the insula ipsilateral to the putative ictal onset zone in all patients. Two patients had bilateral implantation. Each electrode was 0.8 mm in diameter and included 5, 12 or 15 contacts 2 mm in length, 1.5 mm apart (Dixi, Besançon, France), depending on the target region.

A total of 39 insular electrodes were placed in the eleven patients, including ten in the right insula and 29 in the left insula. The median number of insular electrodes per patient was 3 (range 1-6). Three electrodes explored the anterior short gyrus (ASG), four the middle short gyrus (MSG), seven the posterior short gyrus (PSG), 11 the anterior long gyrus (ALG), and 14 the posterior long gyrus (PLG). Apart from these 39 insular electrodes, 5-13 electrodes were implanted in each patient (median = 10) (see supplementary table 1). A single electrode could sample different structures along its course in the cortex, while the same brain region could be sampled by several electrodes in the same patient. The investigated brain regions included the hippocampus (n=12 electrodes), the entorhinal cortex (n=3 electrodes), the amygdala (n=3 electrodes), the parahippocampus (n=2 electrodes), the temporal neocortex (n=56 electrodes), the orbitofrontal cortex (n=8 electrodes), the mesial frontal cortex (n=10 electrodes), the dorsolateral frontal cortex (n=26 electrodes), the frontal operculum (n=20 electrodes), the parietal operculum (n=8 electrodes), the parietal lobe (n=19 electrodes) and

the occipital lobe (n=3 electrodes). The exact location of each electrode and recording lead was further verified with a post-implantation MRI in all patients.

Seizure onset zone (table 1)

The seizure onset zone (SOZ) was defined by icEEG recordings as the epileptogenic cortex which shows the first clear ictal EEG change and needs to be resected to produce seizure freedom. Areas of secondary spread were also identified on icEEG recordings as the cortical regions recruited during the course of the ictal discharge but which were not involved at seizure onset.

The insula was part of the SOZ in one patient (#3) and included in the area of secondary spread in two others (#2, #7). In patient #3, seizures originated within the left insula (PSG, ALG and PLG) and then spread to the ipsilateral third frontal gyrus and first temporal gyrus. In patients #2 and #7, seizures initiated within the mesial temporal structures and then spread to the ipsilateral insula (PSG, ALG and PLG for patient #2; PLG for patient #7).

The SOZ of the eight other patients was frontal in three (#4, #5, #9), parietal in two (#8, #11), and temporal in three (one mesial temporal (#1), one temporo-polar (#6), and one lateral temporal (#10)).

For further analysis, recorded contacts were divided into those located in the epileptogenic zone (epileptic contacts), and those located elsewhere (non-epileptic contacts).

Brain stimulation and CCEP recordings

EBS is routinely and systematically performed in our patients undergoing icEEG as part of the clinical investigation to assess the epileptogenicity and functionality of the implanted brain regions. Stimulations at 50Hz and 1Hz aim at triggering ictal signs, epileptic discharges,

or full-blown seizures (Munari et al., 1993; Kahane et al., 1993; Kahane et al., 2004), whereas 0.2Hz are used to trigger abnormal cortical evoked responses (i.e. delayed to more than 100 msec or repetitive) suggestive of an underlying epileptogenic cortex (Valentin et al., 2002; 2005a; 2005b; van't Klooster et al., 2011). In addition to their clinical utility, 0.2Hz stimulations also allow to measure physiological early responses, referred to as cortico-cortical evoked potentials (CCEPs) in this study, and reflecting brain connectivity (Brazier, 1964; Buser and Bancaud, 1983; Rutecki et al., 1989; Wilson et al., 1990; Buser et al., 1992; Matsumoto et al., 2004; Catenoix et al., 2005; Lacruz et al., 2007; Matsumoto et al., 2007; Rosenberg et al., 2009; Catenoix et al., 2011). We performed 0.2Hz stimulations at least four days following electrodes implantation, once the patient has fully recovered from the surgical procedure.

We used bipolar stimulation of adjacent contacts from the same electrode, known to deliver current within 5 mm around the stimulated bipole (Nathan et al., 1993). Electrical stimulation was delivered using a current-regulated neurostimulator (Micromed, Treviso, Italy), with parameters ensuring patient safety and effective generation of CCEPs ([Gordon et al., 1990](#); Catenoix et al., 2005; Catenoix et al., 2011). We used monophasic pulse of 1 ms width and 1 mA intensity resulting in an electrical charge of 1 μC . The latter was delivered over a contact surface of 0.05 cm^2 (0.8 mm diameter X 2 mm length X π), resulting in a total charge density of 20 $\mu\text{C}/\text{cm}^2/\text{phase}$, thus significantly lower than the maximum safe value of 60 $\mu\text{C}/\text{cm}^2/\text{phase}$ (Gordon et al. 1990). Two consecutive series of 20 pulses were delivered at each pair of contacts. Intracerebral recordings were performed using a video-EEG monitoring system (Micromed, Treviso, Italy) that allowed to simultaneously recording 128 contacts at a sampling rate of 1024 Hz.

Data analysis

EEG data were analyzed with the software package for electrophysiological analysis (ELAN-pack) developed at the DYCOG laboratory of Lyon Neuroscience Research Centre (CRNL, Lyon, France) (Aguera et al., 2011). We first performed an automatic detection of the pulse artifact generated on the stimulated contacts, and systematically verified the accuracy of the generated marker. Thanks to the very reproducible shape and amplitude of artifacts, as well as the associated high signal to noise ratio, this procedure did not suffer from false positive or negative detection. We used the stimulation marker for averaging each block of 20 consecutive pulse stimulations, and then calculated grand averages from the two blocks. Both visual and statistical analyses were used to conclude on the presence of significant CCEPs over each recording contact. CCEPs were first selected on the basis of visual analysis if detected and found comparable in each of the two consecutive series. Statistical analysis of the selected CCEPs was then performed using the non-parametric statistical function of ELAN-pack for single trails (Wilcoxon test), with significance set at $p < 0.001$. In brief, this statistical analysis used a sliding window of 5 ms duration to compare each consecutive periods of the post-stimulation period to the 1000 ms pre-stimulation baseline, providing a curve, superimposed on the CCEP, illustrating the p-value associated with each component of the CCEP. The first 10 ms post-stimulation were not evaluated due to the presence of residual stimulation-induced artifact. CCEPs were considered significant when they reached the statistical threshold of $p \leq 0.001$. The latency of the first peak of each significant potential was measured on the grand average of the two series.

For each stimulated insular anatomical region, we analyzed the number of non-insular contacts showing significant CCEPs, and the latency of the earliest detected peak. This was done for epileptic and non-epileptic contacts separately. For each identified insular efferent region, we searched for reciprocal connection by analyzing insular CCEPs elicited by stimulating this efferent region. These analyses were performed at the gyral level, considering the three short (ASG, MSG and PSG) and two long gyri (ALG and PLG) as five distinct

anatomical regions. The reason for choosing this segmentation were the following: (i) different functional parcellation of the insula have been proposed, considering either two, three or four distinct sub regions, making it difficult to rely on an objective and uniform functional framework; (ii) conversely, the division of the insula into its five gyri allows avoiding any ambiguity and an easy reconstruction of findings into the various functional parcellation previously identified; and (iii) gyral findings can be directly used for better understanding the propagation of epileptic discharges involving the insula, given that implantation of depth electrodes in patients undergoing SEEG is currently based on the identification of anatomical gyri, rather than functional regions.

Once a non-epileptic non-insular contact showed significant CCEPs after an insular stimulation in at least one patient, it was considered that the two regions were connected. Given the cortical sampling variability across patients, we could not determine whether the absence of visualized CCEP between a specific insular region and a specific extra-insular cortical region reflected the absence of functional connection or the limited sampling within the insular cortex and/or the non-insular region. In this context, connectivity was analyzed using the following empirical rules: (i) when a connection between an insular gyrus and a non-insular region was sampled by ≥ 10 stimulation/recording electrode pairs in at least three different patients: a rate of connectivity was calculated, the presence of at least one significant CCEP in a non-epileptic non insular region was considered as reflecting a functional connectivity between the two tested structures, while the lack of CCEP in all tested connections was considered as reflecting the lack of functional connectivity between the two structures; (ii) when a connection between an insular gyrus and a non-insular region was sampled by < 10 stimulation/recording electrode pairs or in less than three different patients: rate of connectivity was not calculated, the presence of at least one significant CCEP in a non-epileptic non insular region was still considered as reflecting a functional connectivity

between the two tested structures, but no conclusion was drawn from the lack of CCEP in all tested connections.

The global connectivity rates of the five insular gyri were compared to each other using chi-2 statistic.

Results

An overview of insular connectivity is shown in figures 1 to 5 while detailed characteristics of CCEPs (presence, rate, latency, reciprocity) are provided in table 2.

A total of 578 electrode pairs were tested. Significant CCEPs were elicited in 193 of these 578 tested connections (TC) (33%). Recorded CCEPs typically corresponded to biphasic early responses, with average \pm SD latency for first peak of 33 ± 5 ms (range 24 to 44 ms). 179 of these 193 connections were reciprocal (93%). Only one of the 32 interhemispheric TC in two patients (#2, #6) elicited a significant CCEP, specifically by stimulating the left MSG and recording from the right parietal operculum.

The proportion, morphology, and latency of CCEPs triggered at each insular contact were comparable for those involved at seizure onset, those affected during seizure propagation, and those not affected by the epileptic discharge. Thus, further results pooled data triggered at all insular contacts.

The highest occurrence of CCEPs was observed in the opercular regions (59%, n=188 TC), with comparable rates for the temporal (60%, n=84 TC), frontal (55%, n=75 TC), and parietal operculum (69%, n=29 TC). The overall insular connectivity was lower with the other brain regions (21%, n=390 TC), including the pericentral cortex (pre- and postcentral gyri, 38%, n=39 TC), non-opercular temporal neocortex (2nd, 3rd and 4th temporal gyri, 28%, n=81 TC), lateral parietal cortex (superior and inferior lobules, 26%, n=43 TC), orbitofrontal cortex (25% n=24 TC), mesial temporal structures (amygdala, hippocampus, entorhinal cortex and

parahippocampal gyrus, 24%, n=58 TC), non-opercular lateral frontal cortex (1st and 2nd frontal gyri and frontal pole, 15%, n=47 TC), temporal pole (14%, n=22), and mesial parietal cortex (11%, n=28 TC). Furthermore, no CCEP could be elicited in the mesial frontal cortex (n=31 tested connections), including the SMA, pre-SMA, anterior and mid cingulate gyrus.

The connectivity rates of the five insular gyri showed significantly greater rate for the PSG (49%, n=84 TC), than for the MSG (29%, n=66 TC, $p<0.025$), the ALG (28%, n=178, $p<0.01$), and the PLG (33%, n=202, $p<0.025$), but not than for the ASG (38%, n=48 TC). No other significant difference was observed between ASG, MSG, ALG and PLG. As detailed below, connectivity patterns varied across the five insular gyri, though this was not statistically tested due to too low sample size in many regions and unbalanced number of TC between insular gyri, and to avoid performing a meaningless number of statistical comparisons.

Anterior short gyrus (ASG, figure 1, table 2):

A total of 48 connections were tested between the ASG and non-insular regions. Functional connectivity was observed between the ASG and the hippocampus (all 3 TC) and orbitofrontal cortex (all 3 TC). CCEPs were also observed in the frontal operculum, temporal pole, temporal operculum, lateral temporal neocortex and dorsolateral frontal cortex. All connections were reciprocal.

Middle short gyrus (MSG, figure 2, table 2):

A total of 66 connections were tested between the MSG and non-insular regions. High rate connectivity was observed with the frontal operculum (67%, n=12 TC). CCEPs were also recorded in the temporal and parietal operculum, as well with the hippocampus, the temporal pole and the primary motor cortex. Stimulation of the MSG did not elicit any CCEP in the

dorsolateral frontal cortex (n=11 TC), nor in the orbitofrontal cortex (n=3 TC). Most connections were reciprocal (89%).

Posterior short gyrus (PSG, figure 3, table 2):

A total of 84 connections were tested between the PSG and non-insular regions. PSG was connected with the frontal (71%, n=14 TC), and temporal operculum (67%, n=18 TC). Connectivity was also observed with the parietal operculum, lateral temporal, frontal dorsolateral and lateral parietal cortex, precentral region, orbitofrontal cortex and amygdala, but not with the other temporolimbic regions (n=8 TC). 95% of connections were reciprocal.

Anterior long gyrus (ALG, figure 4, table 2):

A total of 178 connections were tested between the ALG and non-insular regions. Connections were again observed within the perisylvian region, but with a gradient showing higher rate of connectivity with the parietal (6 out of 8 TC) and frontal operculum (58%, n=19 TC), than with the 1st temporal gyrus (33%, n=21 TC). CCEPs were also elicited in the precentral gyrus (60%, n=10 TC), lateral temporal neocortex (24%, n=25 TC), lateral parietal cortex (21%, n=14 TC), hippocampus (20%, n=10 TC), as well as in the orbitofrontal cortex, 1st frontal gyrus, postcentral gyrus, mesial parietal cortex, amygdala, and entorhinal cortex. No connection was observed with the temporal pole (n=6 TC) and cingulate gyrus (n=8 TC). 88% of connections were reciprocal.

Posterior long gyrus (PLG, figure 5, table 2):

A total of 202 connections were tested between the PLG and non-insular regions. PLG was connected to the perisylvian region, with higher connectivity rate with the temporal (75%, n=32 TC) and parietal operculum (7 out of 9 TC), than with the frontal operculum (35%, n=23 TC). CCEPs were also observed in the lateral parietal cortex (38%, n=16 TC), lateral temporal cortex (26%, n=34 TC), and hippocampus (14%, n=14 TC), as well as in the

temporal pole, amygdala, entorhinal cortex, orbitofrontal cortex, dorsolateral frontal cortex, pre- and postcentral gyri, and mesial parietal cortex. No connection was observed with the cingulate gyrus (n=6 TC). 89% of connections were reciprocal.

Overall ASG showed the lowest connectivity rate with the perisylvian region (40%, n=15 TC), but the highest rate with non opercular regions (36%, n=33 TC), especially with the orbitofrontal cortex and the mesial temporal structures. MSG was characterized by very low connectivity rate with non opercular regions (9%, n=43 TC). PSG had among the higher connectivity rates with both opercular (71%, n=38 TC) and non opercular regions (30%, n=46 TC), primarily with frontal and temporal lateral neocortex. ALG showed intermediate connectivity with both opercular (50%, n=48 TC) and non opercular regions (21%, n=117 TC), with the latter concentrating on the mesial temporal structures, the precentral cortex, and to a lower extent, the parietal lobe. PLG also demonstrated intermediate connectivity rate with the perisylvian region (61%, n=64 TC) and other brain regions (20%, n=138 TC), in particular with lateral, and to a lesser degree mesial, parietal regions.

Discussion

Tracer injections in macaques have delineated a complex and rich pattern of connectivity of the insula, which has been largely confirmed by human neuroimaging studies (Mesulam and Mufson, 1982; Mufson and Mesulam, 1982; Deen et al., 2011; Cauda et al., 2011; Cerliani et al., 2011; Cloutman et al., 2011). However, details about the functionality, reciprocity and latency of the identified connections in Human remain largely unknown. Our study provides the first electrophysiological data on the efferent functional connectivity of the human Insula.

Using electrical brain stimulation and CCEP recordings, we observed dense functional efferent connectivity which main characteristics can be summarized as follows: (i) the highest connectivity rate (59%) was with the nearby perisylvian cortex (frontal, parietal and temporal operculum), (ii) the highest long distance connectivity rates were with the pericentral region

(41%), followed by the amygdala (36%), posterior hippocampus (33%), and lateral temporal neocortex (30%), (iii) most other testable connections associated with CCEPs had connectivity rates between 14% and 26%, and included the dorsolateral and orbital frontal cortex, the temporal pole, entorhinal cortex and anterior hippocampus, and the mesial and lateral parietal cortex, (iv) no connection was demonstrated with the cingulate gyrus (23 TC), mesial premotor cortex (17 TC), and 4th and 5th temporal gyri apart from the entorhinal cortex (8 TC), occipital lobe (8 TC), and frontal pole (6 TC), v) most connections were reciprocal (93%), irrespective of the brain regions connected, (vi) the posterior short gyrus of the insula showed higher connectivity rate than most other insular gyri (except the anterior short) (vii) possible differences in the pattern of connectivity of the five insular gyri were also noted, but could not be statistically tested according to the sampling issue discussed below.

Indeed, several limitations of CCEPs interpretation deserve attention. Such studies are necessarily performed in patients with epilepsy, in whom the impact of seizures and interictal EEG discharges on brain connectivity remains a matter of debate (Meador and Hermann, 2010). However, no difference between the early latency EPs (< 100 msec) recorded from contacts included in the epileptic network and those recorded from nonepileptic tissue was observed in previous CCEP studies (Lacruz et al., 2007; Wilson et al., 1990; Almashaikhi et al. in press), nor in this series. In addition, the insula was not part of the epileptogenic zone in 10 out of 11 patients, and was affected by the epileptic discharge during its propagation in only two other patients. Similarly, the majority of tested connections were not included within the epileptic network. Overall, we believe that our main findings are likely to apply to healthy individuals, though this cannot be firmly demonstrated. At least, the reported data are relevant to the understanding of propagation pathways of epileptic discharge originating in the insula. Other limitations are the small number of patients studied and the limited spatial sampling of intracerebral EEG investigations, both of which hamper any firm conclusion regarding lack of connection between the insula or one of its gyri and extra-insular cortical region. Indeed, the

absence of visualized CCEP could either reflect the true absence of functional connection or lack of recording contact in the appropriate efferent target. Our criteria of testing a connection by at least ten electrode pairs in three or more patients to conclude on the presence or absence of functional connectivity might be too liberal, even though we did not observe one instance where a functional connection would be present in less than 10% of TC. A greater concern is the selective sampling of one or several sub regions within some of the cortical structures investigated, reflecting both the clinical practice and vascular constraint of SEEG. For instance, electrodes are not being placed in the anterior and inferior part of the insula, due to the vicinity of sylvian vessels. Another example is the anterior cingulate gyrus which pregenual aspect was the only portion targeted by depth electrodes, a limitation that might account for the lack of observed connectivity between the insula and this gyrus. Finally, the set of TC varied between each insular gyrus, which could account for part of the differences observed in connectivity rates.

Tracer injection studies in macaques as well as Human neuroimaging studies have enabled to develop a framework whereby the connectivity between the insula and other brain regions has been divided into two complementary networks, one involving the anterior insula which plays a role in emotional aspects through connections with the amygdala, entorhinal cortex, orbitofrontal cortex and anterior cingulate cortex, and another involving the posterior insula which is primarily involved in sensorimotor integration with predominant connections with the premotor cortex, first and second somatosensory cortices, superior temporal sulcus, and posterior cingulate gyrus (Mesulam and Mufson, 1982; Mufson and Mesulam, 1982; Deen et al., 2011; Cauda et al., 2011; Cerliani et al., 2011; Cloutman et al., 2011). A parcellation of the Human insula into three functionally distinct regions has also been proposed by several authors, based on cytoarchitectonic, DTI and functional MRI studies (Jakab et al. 2011; Deen et al. 2011; Gallay et al. 2011), while an activation-likelihood-estimation meta-analysis of

1,768 functional neuroimaging experiments concluded on the presence of four functionally distinct regions, mapping to the social-emotional, the sensorimotor, the olfacto-gustatory, and the cognitive network of the brain (Kurth et al. 2010).

According to the above studies, the anterior insula usually includes the first or first two short gyri of the insula, with or without the most anterior aspect of the long gyri. In monkeys, the anterior insula shows dense connections to limbic areas, including the amygdala, entorhinal cortex, temporal pole, orbitofrontal cortex and anterior cingulate gyrus (Mesulam and Mufson, 1982; Mufson and Mesulam, 1982; Mesulam and Mufson 1985). Functional imaging studies in human showed that the anterior insula is most strongly correlated with the regions responsible for emotional processing and cognitive control (Deen et al., 2011). This view is supported by structural imaging studies which indicate that the cortical regions receiving most of the projections from the anterior insula constitute a ventrally-based network including the orbitofrontal cortex, the frontal operculum, the temporal pole, and the amygdala (Cerliani et al., 2011), and forming part of a key emotional salience and cognitive control network associated with the implementation of goal-directed behavior (Cloutman et al. 2011). For reasons explained above, our own findings regarding the anterior insula is limited to its dorsal and dysgranular part. Nevertheless, we could confirm ASG connectivity with the anterior fronto-temporal brain regions, including the temporal pole and orbitofrontal cortex, as well as with the hippocampus, in line with a previous CCEPs study of hippocampal connectivity performed by our group on a different set of patients (Catenoix et al. 2011). However, this pattern was partly different for the MSG which had the lowest connectivity rate with non-opercular brain regions (i.e. 9% as compared to 36% for the ASG) and was not connected to the orbitofrontal cortex. Conversely we observed a few connections between the MSG and both the precentral cortex and the parietal operculum, not previously identified as efferent targets of the anterior insula. Furthermore, ASG showed the lowest connectivity rate with the perisylvian region (40%), as compared to all four other insular gyri (66%), in line with its

lower rate of intra-insular connectivity (Almashaikhi et al. in press). Thus, all above findings are in favor of a subdivision of the dorsal anterior insula into two distinct functional components centered around the ASG and MSG, respectively. We failed to identify CCEPs in the anterior cingulate cortex, in contrast with the classic view that the anterior insula is connected with this structure with which it shares specialized neurons (von Economo neurons) thought to play a role in social awareness (Allman et al., 2005; 2010). As previously mentioned, this might reflect our restricted sampling of the pregenual aspect of the anterior cingulate. It might also points to truly different insula to cingulate connectivity between macaque and Human since several tractography studies also failed to detect connections between the ASG and the anterior cingulate cortex (Cerliani et al., 2011; Cloutman et al., 2011). We also failed to detect connection between the anterior insula and both the amygdala and entorhinal cortex, but this finding remains unreliable according to the very small number of tested connections (n=3).

The posterior insula, which usually includes the posterior short gyrus and dorsal aspect of the two long gyri, is connected with the orbitofrontal, mid and posterior cingulate, mesial and lateral premotor and somatosensory cortices, as well as with the temporal operculum and the amygdala in macaque (Mufson et al. 1981; Mesulam and Mufson 1982; Mufson and Mesulam 1982). In Human, the posterior insula was found to be functionally connected to primary and secondary motor and somatosensory cortices supporting its role in processing somatosensory stimuli with affective or motivational significance (Deen et al., 2011). Tractography samples from the posterior dorsal insula reached the parietal lobe, the posterior part of temporal operculum, and extrastriate regions of the occipital cortex (Cerliani et al., 2011; Cloutman et al., 2011). CCEPs obtained in our study partly confirmed these findings, by showing consistent connectivity of the posterior insula with the motor and sensory cortex, the parietal lobe (including the parietal operculum), and the temporal operculum, but also to a lesser

degree with the frontal dorsolateral, orbitofrontal, lateral temporal and entorhinal cortices, the temporal pole and the hippocampus. Conversely, no connection was observed with the occipital lobe, mesial frontal cortex or mid and posterior cingulate gyri, a finding hampered by the small number of tested connections with each of these regions. Furthermore, some differences were observed between the different gyri constitutive of the posterior insula, with the PSG and PLG showing greater connectivity with the temporal operculum than the ALG (72% vs. 33%), while the PSG and ALG showed higher connectivity rates with the precentral cortex than the PLG (60% vs. 14%). Connectivity rates with the frontal operculum also decreased from the PSG (71%) to the ALG (58%) and PLG (35%). The greater overall connectivity of the PSG is consistent with its higher rate of intra-insular connectivity (Almashaikhi et al. in press), as well as its proposed role of a transitional and integrative area (Craig, 2010).

We found limited connectivity between the insula and contralateral brain regions, specifically with the parietal operculum. This paucity of contralateral connections is in line with our previous observation of lack of inter-insular CCEPs in two patients who underwent bilateral implantation of the insula (patients #2 and 6 of this series) (Almashaikhi et al. in press). The interhemispheric connection observed in the present study might play a role in the sensorimotor function of the insula and also account for contralateral propagation of insular seizures.

Overall, electrically induced corticocortical EPs demonstrate that the human insula is characterized by rich reciprocal connections with several brain regions, most of which are in line with previously identified functional networks in macaques and neuroimaging studies in Human. However, although differences were observed in the pattern of connectivity of the

different subdivisions of the insula, a larger than previously reported redundancy was noted, consistent with the rich intra-insular connectivity recently reported (Almashaikhi et al. in press). From an epilepsy point of view, this suggests that propagation of insular seizures might be more diverse and complex than what has been suggested on the basis of a few observations (Ryvlin et al. 2006b; Ryvlin 2006). The main unexpected finding was the lack of detected connection between the insula and the cingulate gyrus as well as with the SMA and pre-SMA. This negative finding might just reflect the sample limitations of our series, justifying further studies in larger population.

References :

Afif A, Mertens P (2010b): Description of sulcal organization of the insular cortex. *Surg Radiol Anat* 32: 491-498.

Afif A, Minotti L, Kahane P, Hoffmann D (2010a): Anatomofunctional organization of the insular cortex: a study using intracerebral electrical stimulation in epileptic patients. *Epilepsia* 51:2305-2315.

Aguera PE, Jerbi K, Caclin A, Bertrand O (2011): ELAN: A software package for analysis and visualization of MEG, EEG, and LFP signals. *Comput Intell Neurosci* 2011:158970.

Allman JM, Tetreault NA, Hakeem AY, Manaye KF, Semendeferi K, Erwin JM, Park S, Goubert V, Hof PR (2010): The von Economo neurons in frontoinsular and anterior cingulate cortex in great apes and humans. *Brain Structure and Function* 214:495-517.

Allman JM, Watson KK, Tetreault NA, Hakeem AY (2005): Intuition and autism: a possible role for Von Economo neurons. *Trends in cognitive sciences* 9:367-373.

Almashaikhi T, Rheims S, Ostrowsky-Coste K, Montavont A, Jung J, De Bellescize J, Arzimanoglou A, Keo Kosal P, Guénot M, Bertrand O, Ryvlin P: Intra-insular Functional Connectivity in Human. *Hum Brain Mapp* (in press).

Augustine JR (1996): Circuitry and functional aspects of the insular lobe in primates including humans. *Brain Research Reviews* 22:229-244.

Brazier MA (1964): Evoked responses recorded from the depths of the human brain. *Annals of the New York Academy of Sciences* 112:33-59.

Buser P, Bancaud J (1983): Unilateral connections between amygdala and hippocampus in man. A study of epileptic patients with depth electrodes. *Electroencephalography and clinical neurophysiology* 55: 1-12.

Buser P, Bancaud J, Chauvel P (1992): Callosal transfer between mesial frontal areas in frontal lobe epilepsies. *Adv Neurol* 57:589-604.

Catenoix H, Magnin M, Guénot M, Isnard J, Mauguier F, Ryvlin P (2005): Hippocampal-orbitofrontal connectivity in human: an electrical stimulation study. *Clinical neurophysiology* 116:1779-1784.

Catenoix H, Magnin M, Mauguier F, Ryvlin P (2011): Evoked potential study of hippocampal efferent projections in the human brain. *Clinical Neurophysiology* 122: 2488-2497.

Cauda F, D'Agata F, Sacco K, Duca S, Geminiani G, Vercelli A (2011): Functional connectivity of the insula in the resting brain. *Neuroimage* 55:8-23.

Cerliani L, Thomas RM, Jbabdi S, Siero JC, Nanetti L, Crippa A, Gazzola V, D'Arceuil H, Keysers C (2011): Probabilistic tractography recovers a rostrocaudal trajectory of connectivity variability in the human insular cortex. [Hum Brain Mapp](#) 33: 2005-2034.

Cloutman LL, Binney RJ, Drakesmith M, Parker GJ, Ralph MA (2011): The variation of function across the human insula mirrors its patterns of structural connectivity: Evidence from in vivo probabilistic tractography. *NeuroImage* 59: 3514-3521.

Craig AD (2010): The sentient self. *Brain Struct Funct* 214:563–577.

Deen B, Pitskel NB, Pelphrey KA (2011): Three systems of insular functional connectivity identified with cluster analysis. *Cereb Cortex* 21:1498-1506.

Gallay Ds, Gallay MN, Jeanmonod D, Rouiller EM, Morel A (2011): The insula of Reil revisited: multiarchitectonic organization in macaque monkeys. *Cereb Cortex* 22: 175-190.

Gordon B, Lesser RP, Rance NE, Hart Jr J, Webber R, Uematsu S, Fisher RS (1990): Parameters for direct cortical electrical stimulation in the human: histopathologic confirmation. *Electroencephalography and clinical neurophysiology* 75:371-377.

Guenot M, Isnard J, Ryvlin P, Fischer C, Ostrowsky K, Mauguiere F, Sindou M (2001): Neurophysiological monitoring for epilepsy surgery: the Talairach SEEG method. *Stereotactic and Functional Neurosurgery* 77:29-32.

Jakab A, Molnar PP, Bogner P, Beres M, Berenyi EL (2011): Connectivity-based parcellation reveals interhemispheric differences in the insula. *Brain Topogr* 25:264-271.

Kahane P, Tassi L, Francionne S, Hoffmann D, Lo Russo G, Munari C (1993): Manifestations électrocliniques induites par la stimulation électrique intracérébrale par chocs dans les épilepsies temporales. *Clin Neurophysiol* 22: 305-326.

Kahane P, Minotti L, Hoffmann D (2004): Invasive EEG in the definition of the seizure onset zone: depth electrodes. In: Rosenow F, Lüders HO, editor. *Handbook of Clinical Neurophysiology, Vol.3. Presurgical assessment of the epilepsies with clinical neurophysiology and functional imaging*. Amsterdam: Elsevier BV. p 109-133.

Kurth F, Zilles K, Fox PT, Laird AR, Eickhoff SB (2010): A link between the systems: functional differentiation and integration within the human insula revealed by meta-analysis. *Brain Structure and Function* 214:519-34.

Lacruz ME, Garcia Seoane JJ, Valentin A, Selway R, Alarcon G (2007): Frontal and temporal functional connections of the living human brain. *Eur J Neurosci* 26:1357-1370.

Matsumoto R, Nair DR, LaPresto E, Bingaman W, Shibasaki H, Luders HO (2007): Functional connectivity in human cortical motor system: a cortico-cortical evoked potential study. *Brain* 130: 181-197.

Matsumoto R, Nair DR, LaPresto E, Najm I, Bingaman W, Shibasaki H, Luders HO (2004): Functional connectivity in the human language system: a cortico-cortical evoked potential study. *Brain* 127: 2316-2330.

Meador KJ, Hermann B (2010): How localized is localization-related epilepsy?. *Neurology* 75: 386-387.

Mesulam MM (1985): The insula of Reil in man and monkey: architectonics, connectivity and function. *Cerebral cortex*, vol 4, Association and auditory cortices: 179-226.

Mesulam M, Mufson EJ (1982): Insula of the old world monkey. III: Efferent cortical output and comments on function. *The Journal of comparative neurology* 212: 38-52.

Mufson EJ, Mesulam MM (1982): Insula of the old world monkey. II: Afferent cortical input and comments on the claustrum. *J Comp Neurol* 212: 23-37.

Mufson EJ, Mesulam MM, Pandya DN (1981): Insular interconnections with the amygdale in the rhesus monkey. *Neuroscience* 6:1231-1248.

Munari C, Kahane P, Tassi L, Francione S, Hoffmann D, Lo RG, Benabid AL (1993): Intracerebral low frequency electrical stimulation: a new tool for the definition of the "epileptogenic area". *Acta Neurochirurgica Supplementum* 58: 181-185.

Nathan SS, Sinha SR, Gordon B, Lesser RP, Thakor NV (1993): Determination of current density distributions generated by electrical stimulation of the human cerebral cortex. *Electroencephalography and clinical neurophysiology* 86: 183-192.

Ostrowsky K, Isnard J, Ryvlin P, Guenot M, Fischer C, Mauguier F (2000): Functional mapping of the insular cortex: clinical implication in temporal lobe epilepsy. *Epilepsia* 41:681-686.

Ostrowsky K, Magnin M, Ryvlin P, Isnard J, Guenot M, Mauguière F (2002): Representation of pain and somatic sensation in the human insula: a study of responses to direct electrical cortical stimulation. *Cereb Cortex* 12:376-385.

Pugnaghi M, Meletti S, Castana L, Francione S, Nobili L, Mai R, Tassi L (2011): Features of somatosensory manifestations induced by intracranial electrical stimulations of the human insula. *Clinical Neurophysiology* 122:2049-2058.

Rosenberg DS, Mauguier F, Catenoix H, Faillenot I, Magnin M (2009): Reciprocal thalamocortical connectivity of the medial pulvinar: a depth stimulation and evoked potential study in human brain. *Cerebral Cortex* 19: 1462-1473.

Rutecki PA, Grossman RG, Armstrong D, Irish-Loewen S (1989): Electrophysiological connections between the hippocampus and entorhinal cortex in patients with complex partial seizures. *Journal of neurosurgery* 70: 667-675.

Ryvlin P, Kahane P (2005): The hidden causes of surgery-resistant temporal lobe epilepsy: extratemporal or temporal plus? *Curr Opin Neurol* 18: 125-127.

Ryvlin P (2006): Avoid falling into the depths of the insular trap. *Epileptic Disord* 8 (Suppl 2): 37-56.

Ryvlin P, Minotti L, Demarquay G, Hirsch E, Arzimanoglou A, Hoffman D, Guénot M, Picard F, Rheims S, Kahane P (2006b): Nocturnal hypermotor seizures, suggesting frontal lobe epilepsy, can originate in the insula. *Epilepsia* 47: 755-765.

Ryvlin P, Rheims S, Risse G (2006a): Nocturnal frontal lobe epilepsy. *Epilepsia* 47 (Suppl 2): 83-86.

Stephani C, Fernandez-Baca Vaca G, Maciunas R, Koubeissi M, Luders HO (2011): Functional neuroanatomy of the insular lobe. *Brain Structure and Function* 216: 137-149.

Talairach J, Bancaud J (1973): Stereotaxic approach to epilepsy. Methodology of anatomofunctional stereotaxic investigations. *ProgNeurolSurg* 5: 297-354.

Valentin A, Alarcon G, Garcia-Seoane JJ, Lacruz ME, Nayak SD, Honavar M, Selway RP, Binnie CD, Polkey CE (2005a): Single-pulse electrical stimulation identifies epileptogenic frontal cortex in the human brain. *Neurology* 65: 426-435.

Valentin A, Alarcon G, Honavar M, Garcia Seoane JJ, Selway RP, Polkey CE, Binnie CD (2005b): Single pulse electrical stimulation for identification of structural abnormalities and prediction of seizure outcome after epilepsy surgery: a prospective study. *Lancet Neurol* 4: 718-726.

Valentin A, Anderson M, Alarcon G, Seoane JJ, Selway R, Binnie CD, Polkey CE (2002): Responses to single pulse electrical stimulation identify epileptogenesis in the human brain in vivo. *Brain* 125: 1709-1718.

van't Klooster MA, Zijlmans M, Leijten FS, Ferrier CH, van Putten MJ, Huiskamp GJ (2011): Time--frequency analysis of single pulse electrical stimulation to assist delineation of epileptogenic cortex. *Brain* 134: 2855-2866.

Wilson CL, Isokawa M, Babb TL, Crandall PH (1990): Functional connections in the human temporal lobe. *Experimental brain research* 82: 279-292.

Tables

Table 1: Epileptogenic zone as determined by SEEG

Patient #	SOZ determined by SEEG	# of electrodes	Lobes investigated
1	Right mesial temporal	13	Front. (M, L), Temp. (M,L), Occ.
2	Bilateral hippocampi	14	Front. (M, L), Pariet. (M,L), Temp. (M,L),
3	Left insula	11	Front. (M, L), Pariet. (M, L), Temp. (L),
4	Left third frontal gyrus	12	Front. (M, L), Pariet. (L), Temp. (M,L),
5	Left orbitofrontal	15	Front. (M, L), Temp. (M,L),
6	Right temporal pole	14	Front. (M, L), Pariet. (M,L), Temp. (M,L),
7	Left mesial temporal	11	Front. (M, L), Pariet. (L), Temp. (M,L),
8	Right lateral parietal	13	Front. (M, L), Pariet. (M,L), Temp. (L), Occ.
9	Left frontal mesial	16	Front. (M, L), Pariet. (M,L)
10	Right lateral temporal	12	Front. (M, L), Pariet. (L), Temp. (L),
11	Right post central gyrus	12	Front. (M, L), Pariet. (M,L)

Table 2: Connectivity pattern of the insula.

		Insular gyri					Entire insula	Reciprocity
		ASG	MSG	PSG	ALG	PLG		
Amygdala		0/1	0/1	1/2 28 ms	2/3 25±3 ms	1/4 30 ms	4/11 (36%) 28±3 ms	100%
Hippoc.	Ant	2/2 34±22 ms	0/2	0/4	1/6 40±5 ms	1/9 37 ms	4/23 (17%) 37±3 ms	100%
	Post	1/1 32 ms	1/2 29 ms		1/4 45 ms	1/5 35 ms	4/12 (33%) 35±7 ms	100%
Entorhinal cortex			0/1		1/3 32 ms	1/4 37 ms	2/8 35±4 ms	100%
Temporal pole		1/2 49 ms	1/2 36 ms	0/3	0/6	1/9 32 ms	3/22 (14%) 39±9 ms	100%
5 th tempor. gyrus				0/1	0/1	0/2	0/4	
4 th tempor. gyrus					0/2	0/2	0/4	
3 rd tempor. gyrus		1/1 41 ms	1/2 30 ms		3/7 35±13 ms	1/10 (10%) 31 ms	6/20 (30%) 34±4 ms	83%
2 nd tempor. gyrus		2/5 30±2 ms	0/5	4/9 39±2 ms	3/16 (19%) 50 ms	8/22 (36%) 25±2 ms	17/57 (30%) 36±1 ms	94%
1st tempor. gyrus (Temporal operculum)	Ant	1/3 37 ms	4/5 32±7 ms	8/12 (67%) 26±6 ms	3/11 (27%) 35±5 ms	14/17 (82%) 25±2 ms	30/48 (63%) 31±5 ms	87%
	Post	1/2 30 ms	1/3 20 ms	4/6 33±14 ms	4/10 (40%) 26±3 ms	10/15 (67%) 28±3 ms	20/36 (56%) 27±5 ms	95%
Orbito-frontal		3/3 33±5 ms	0/3	1/3 40 ms	1/7 40 ms	1/8 65 ms	6/24 (25%) 44±14 ms	100%
Frontal pole		0/1	0/2		0/2	0/1	0/6	
3rd frontal gyrus (front. operculum)		4/7 28±8 ms	8/12 (67%) 29±4 ms	10/14 (71%) 29±4 ms	11/19 (58%) 35±5 ms	8/23 (35%) 26±3 ms	41/75 (55%) 29±3 ms	85%
2nd frontal gyrus		2/4 35±3 ms	0/6	2/2 30±1 ms	0/8	0/5	4/25 (16%) 32±3 ms	100%
1st frontal gyrus		0/3	0/3	1/3 35 ms	1/5 28 ms	1/2 30 ms	3/16 (19%) 31±4 ms	100%
Pre-SMA & SMA		0/1	0/2	0/4	0/6	0/4	0/17	
Cingulate gyrus	Ant	0/1	0/2	0/1	0/3	0/3	0/10	
	Mid	0/1	0/1		0/2		0/4	
	Post	0/1	0/1	0/1	0/3	0/3	0/9	
Precentral gyrus		0/3	1/4 24 ms	3/5 33 ms	6/10 (60%) 30±7 ms	1/7 24±3 ms	11/29 (38%) 27±5 ms	83%
Postcentral gyrus					2/6 23±2 ms	2/4 25±3 ms	4/10 (40%) 24±1 ms	100%
Parietal operculum		0/3	2/3 36±11 ms	5/6 27±3 ms	6/8 27±2 ms	7/9 26±5 ms	20/29 (69%) 43±27 ms	95%
Lateral parietal (sup & inf lobule)		0/2	0/3	2/8 38±2 ms	3/14 (21%) 28± 7 ms	6/16 (38%) 27± 3 ms	11/43 (26%) 30± 1 ms	92%
Mesial parietal		0/1	0/1		1/13 22 ms	2/13 24±2 ms	3/28 (11%) 23±1 ms	67%
Occipital lobe					0/3	0/5	0/8	
Total opercular regions		6/15 (40%)	15/23 (65%)	27/38 (71%)	24/48 (50%)	39/64 (61%)	111/188 (59%)	91%
Total other regions		12/33 (36%)	4/43 (9%)	14/46 (30%)	25/130 (21%)	27/138 (20%)	82/390 (21%)	94%
Total		18/48 (38%)	19/66 (29%)	41/84 (49%)	49/178 (28%)	66/202 (33%)	193/578 (33%) 33±5 ms	93%
Reciprocity		100%	89%	95%	88%	89%		

For each tested connection, numerator corresponds to the number of significant CCEPs and denominator the number of connections tested for that region. Corresponding % are provided in brackets only for sites where at least ten connections were tested in three patients or more.

Bottom number is the mean latency in ms \pm SD (if ≥ 2 CCEPs recorded). Empty cells correspond to regions where no connection was tested. ASG, MSG and PSG (anterior, middle and posterior short gyri), ALG and PLG (anterior and posterior long gyri)

Patient #		1	2	3	4	5	6	7	8	9	10	11	Total electrodes	Total patients	
Side of the electrodes		Right	Left	Right	Left	Left	Left	Right	Left	Left	Right	Left	Left	Right	
Insula	ASG					1			1		1			3	3
	MSG				1		1		1		1			4	4
	PSG		1		2	2			1			1		7	5
	ALG	1	1		1	1	1	1		1	1	1	1	11	11
	PLG	1	1	1	2	2	1	2		1	2		1	14	9
Amygdala		1				1	1							3	3
Hippocampus	Anterior	1	1	1		1	1	1	1	1				8	6
	Posterior	1					1	1		1				4	4
Entorhinal cortex		1					1	1						3	3
Temporal pole		1	1	1		1	1	1		1				7	6
5th temporal gyrus	Anterior		1											1	1
	Posterior			1										1	1
4th temporal gyrus	Anterior	2												2	1
	Posterior													0	0
3rd temporal gyrus	Anterior	1					1	1						3	3
	Posterior	2		1				1		1				5	4
2nd temporal gyrus	Anterior	2	2	1		2	2	1	1	1				12	6
	Posterior	2				1	1	1		1				6	5
1st temporal gyrus (temporal operculum)	Anterior	1	1		3	2	1	1		1		1		11	8
	Posterior	1	1		1	1	1	1		1	2		1	10	9
Orbito-frontal		2				1	1	1	1	1		1		8	6
Frontal pole							1					1		2	2
3rd frontal gyrus (frontal operculum)			1		3	2	4	1	1	2	1	3	2	20	9
2nd frontal gyrus	Anterior						1			1		2	1	5	4
	Posterior						1					1	1	3	3
1st frontal gyrus	Anterior											2		2	1
	Posterior								1			1	2	4	3
Pre-supplementary motor area							1					2		3	2
Supplementary motor are								1			1	1	1	4	4
Cingulate gyrus	Anterior						1		1			1		3	3
	Middle											1		2	2
	Posterior		1							1	1			3	3
Precentral gyrus			1		1					1	3	2	2	10	6
Postcentral gyrus										2			4	6	2
Parietal operculum			1		1	1			1	1	1	1	1	8	8
Lateral parietal (sup/inf lobule, supramarginalis gyrus)			2		2	1		1		3	1		4	14	5
Mesial parietal				1				1		5	1		5	13	5
Occipital lobe		1								2				3	2
TOTAL *		21	15	6	14	17	23	16	6	16	16	20	17	14	201

Supplementary table 1: Electrodes location. The number of electrodes sampling each anatomical region is indicated. Note: each electrode may sample more than one anatomical structure.

Figures

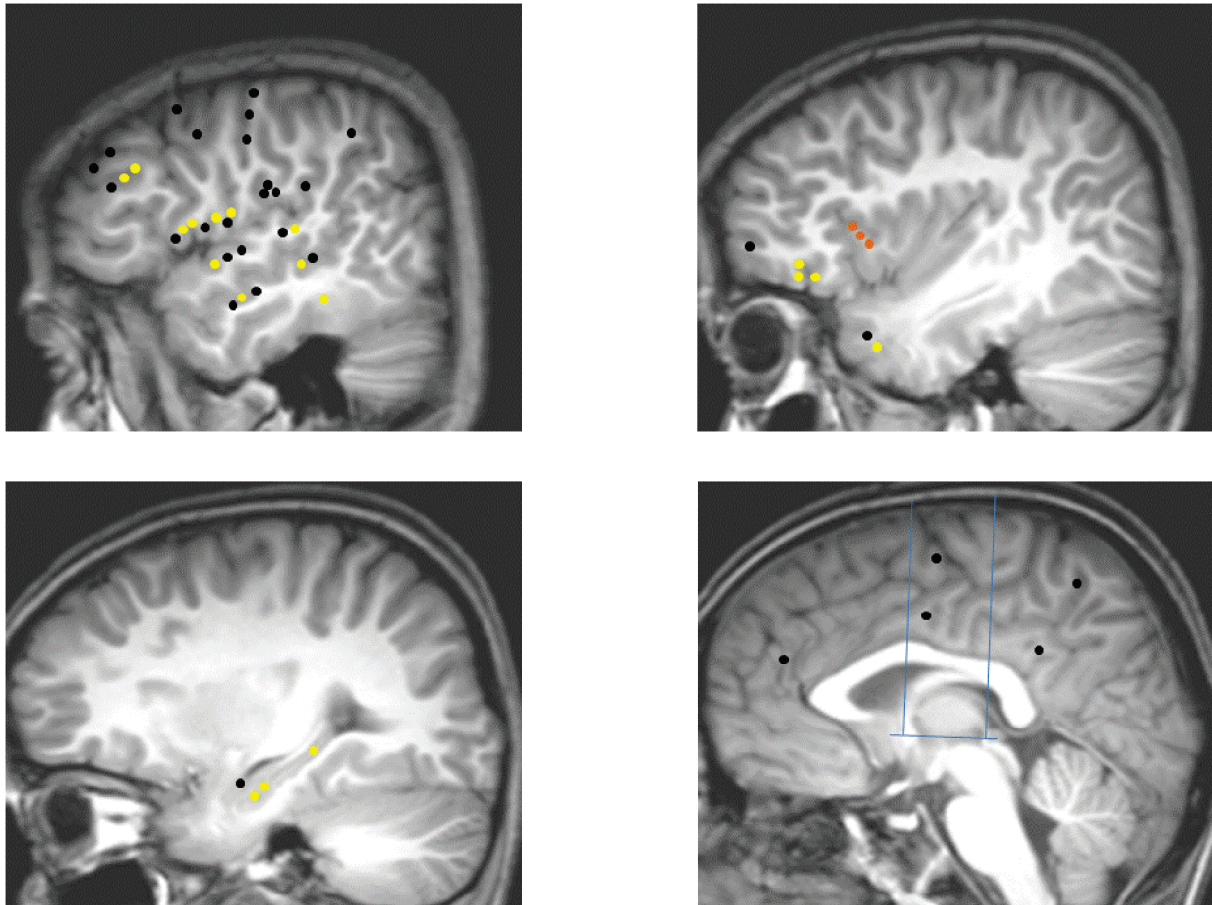


Figure 1. ASG connectivity pattern: Upper left: Temporal neocortex, dorso-lateral frontal cortex, fronto-parietal operculum, temporo-parietal junction; Upper right: Insula, temporal pole, frontal pole and the fronto-orbital cortex; Lower left: mesio-temporal structures; Lower right: medial frontal, parietal and occipital cortices, cingulate gyrus. Yellow dots: connections demonstrating significant CCEPs; Black dots: connections without significant CCEP; Orange dots: ASG electrodes.

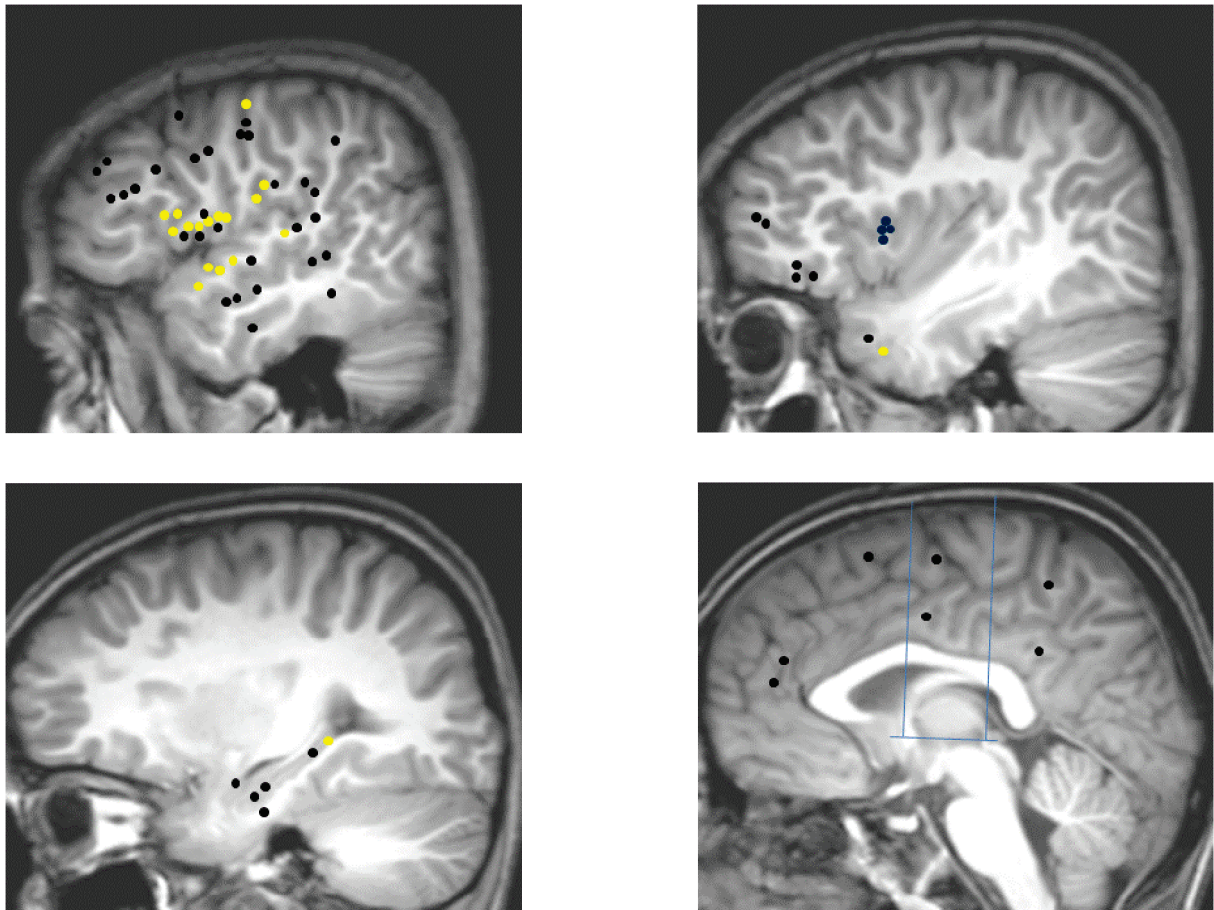


Figure 2. MSG connectivity pattern: Upper left: Temporal neocortex, dorso-lateral frontal cortex, fronto-parietal operculum, temporo-parietal junction; Upper right: Insula, temporal pole, frontal pole and the fronto-orbital cortex; Lower left: mesio-temporal structures; Lower right: medial frontal, parietal and occipital cortices, cingulate gyrus. Yellow dots: connections demonstrating significant CCEPs; Black dots: connections without significant CCEP; Blue dots: MSG electrodes.

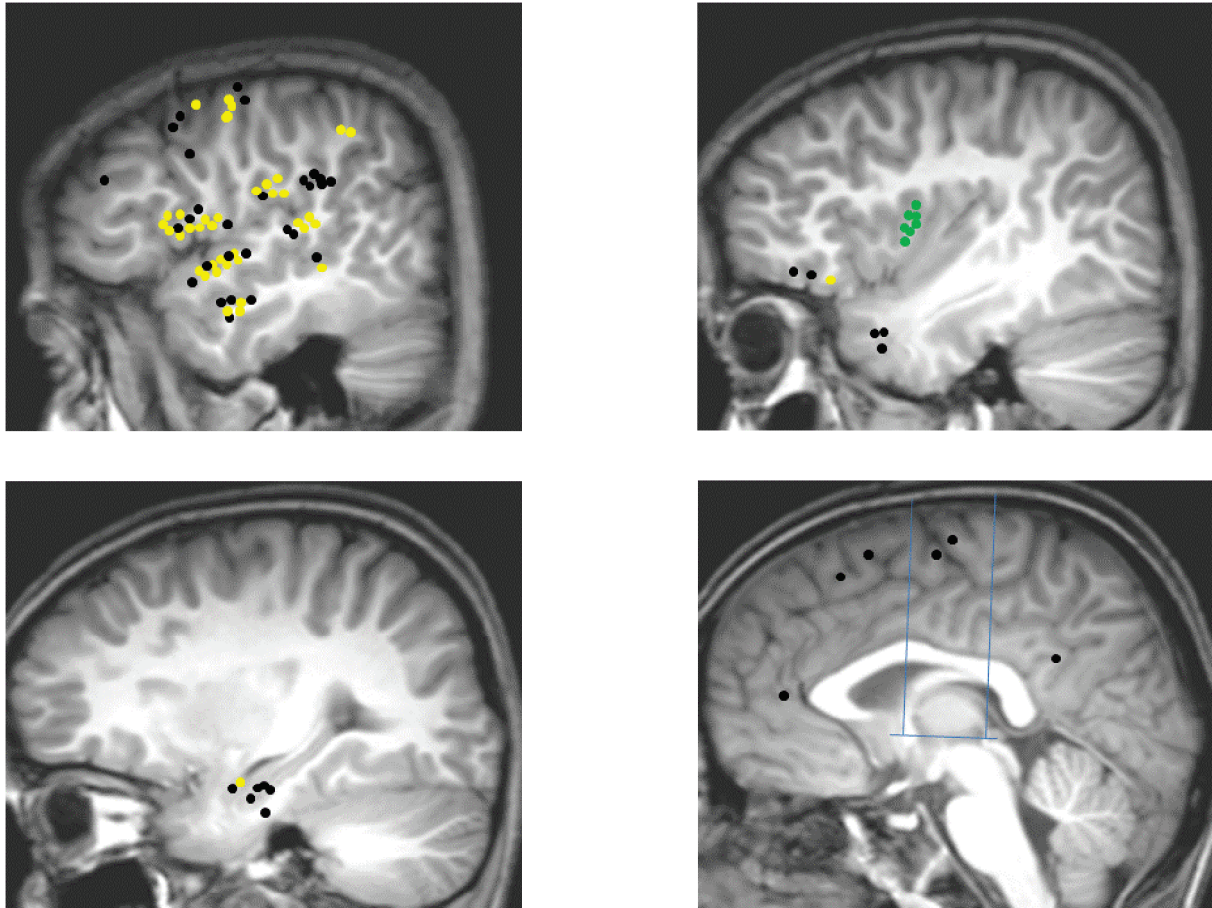


Figure 3. PSG connectivity pattern: Upper left: Temporal neocortex, dorso-lateral frontal cortex, fronto-parietal operculum, temporo-parietal junction; Upper right: Insula, temporal pole, frontal pole and the fronto-orbital cortex; Lower left: mesio-temporal structures; Lower right: medial frontal, parietal and occipital cortices, cingulate gyrus. Yellow dots: connections demonstrating significant CCEPs; Black dots: connections without significant CCEP; Green dots: PSG electrodes.

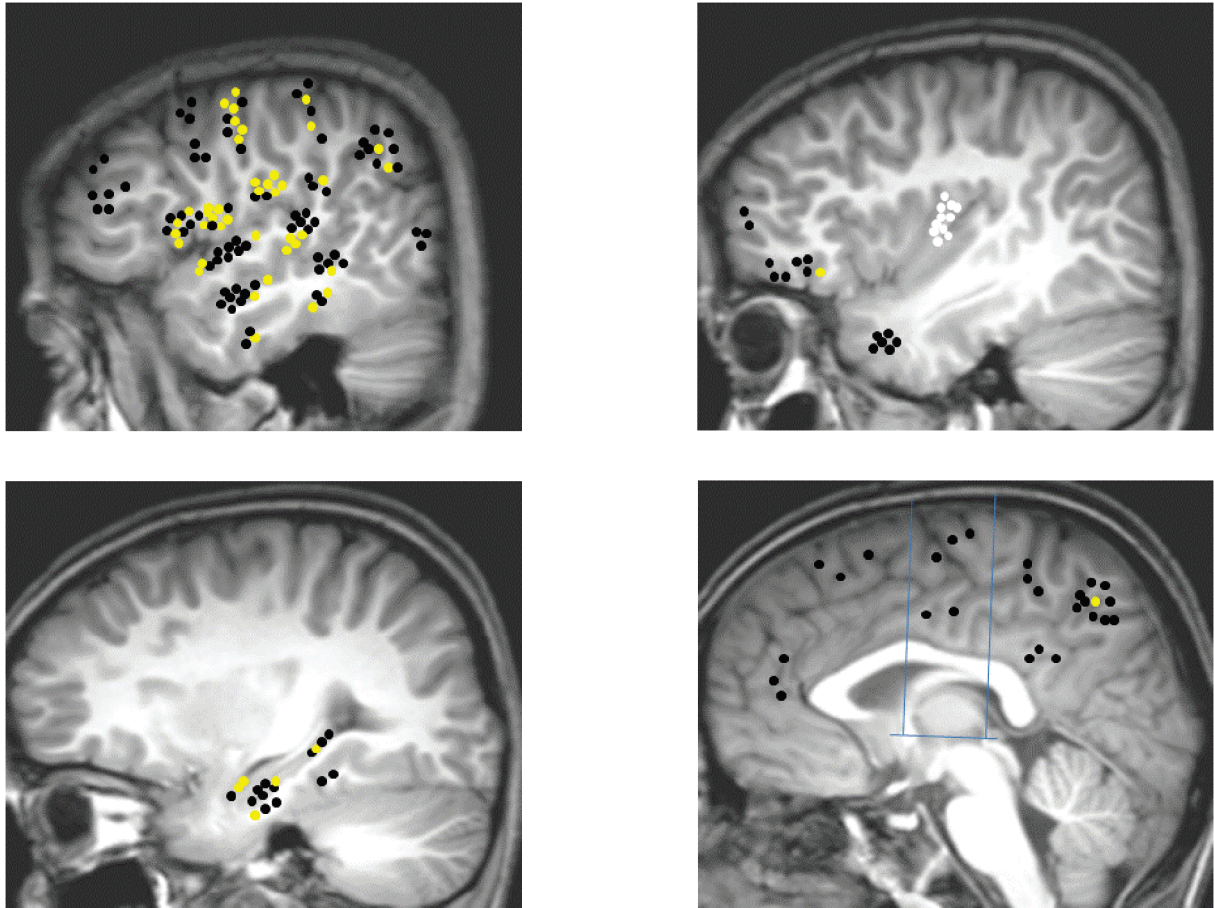


Figure 4. ALG connectivity pattern: Upper left: Temporal neocortex, dorso-lateral frontal cortex, fronto-parietal operculum, temporo-parietal junction; Upper right: Insula, temporal pole, frontal pole and the fronto-orbital cortex; Lower left: mesio-temporal structures; Lower right: medial frontal, parietal and occipital cortices, cingulate gyrus. Yellow dots: connections demonstrating significant CCEPs; Black dots: connections without significant CCEP; White dots: ALG electrodes.

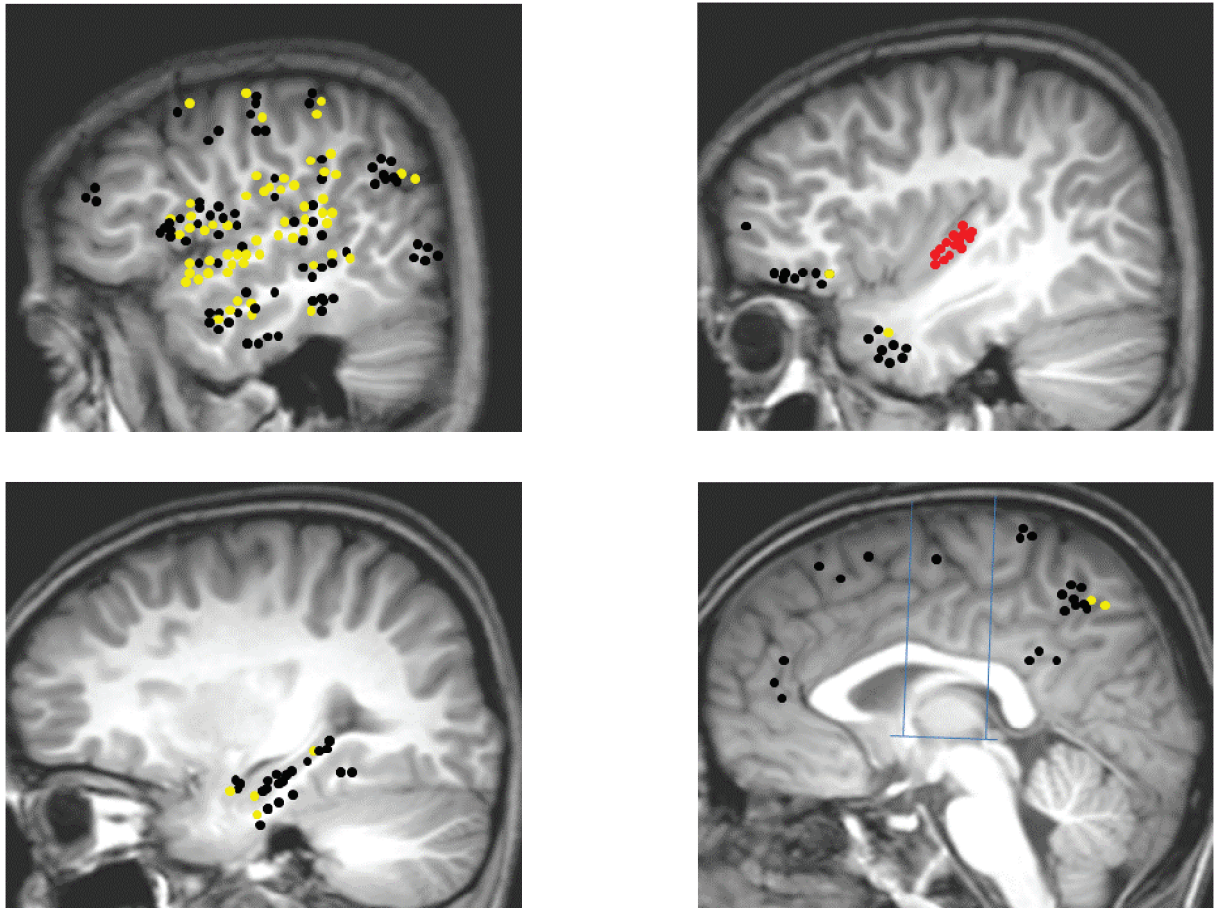


Figure 5. PLG connectivity pattern: Upper left: Temporal neocortex, dorso-lateral frontal cortex, fronto-parietal operculum, temporo-parietal junction; Upper right: Insula, temporal pole, frontal pole and the fronto-orbital cortex; Lower left: mesio-temporal structures; Lower right: medial frontal, parietal and occipital cortices, cingulate gyrus. Yellow dots: connections demonstrating significant CCEPs; Black dots: connections without significant CCEP; Red dots: PLG electrodes.

Discussion:

In the current work we demonstrated for the first time the in-vivo human insular functional connectivity using the electrical brain stimulation (EBS). The work was in three main phases: 1) application of EBS into a group of eleven patients undergoing intra-cerebral EEG (icEEG) for the pre-surgical evaluation of their refractory focal epilepsy; 2) collection of data and development of analysis technique for the resulting evoked potentials (EPs); 3) application of the analysis technique to study both intra-insular and insular efferent connections.

EBS is a non-physiological process which involves sending an electrical discharge into a specific site in the human brain and recording its effect in the form of EPs at nearby or distant sites. The exact mechanism of this procedure is not known, and it is harmless when performed in the previously documented limits (Gordon et al., 1990). Though it is applicable only during invasive pre-surgical evaluations of intractable epilepsy patients, it provides a unique opportunity to map both normal and pathological cortices (Valentine et al., 2002, 2005 a, b) and to track in vivo cortical networks (Matsumoto et al., 2004; Catenoix et al., 2005; Lacruz et al., 2007). EBS has advantages over other connectivity study methods; compared to fMRI studies, the EBS study provides direct neuronal responses to the stimulation and more localized cortical stimulation with better temporal resolution. In contrast to the DTI study, this technique is capable of providing the direction of connectivity, at least electrophysiologically, by stimulating both ends of connection. The EBS study, however, cannot identify the actual anatomical pathway of the circuit, and in this regard it may well be regarded as ‘functional tractography’ as compared with ‘anatomical fiber tractography’ by DTI (Matsumoto et al., 2007).

We developed a stimulation technique which delivers electrical discharges automatically into all the available grey matter contacts without the need for the intervention of the examiner.

The EBS we used sent monophasic negative pulses of 1ms duration and 1 mA intensity every five seconds to two adjacent contacts of the same electrode. In addition to being safe to the patient, those stimulation parameters proved their usefulness in studying human brain functional connectivity in previous studies (Wilson et al., 1990; Catenoix et al., 2005). In our study, resulting EPs were usually consisting of a sharp wave followed by one slow wave or a group of slow and sharp waves. We only used the first post-stimulation peak for the determination of the presence or absence of a connection between two sites. In their multiple articles, Valentin et al. (2002, 2005a, b, 2009) labeled this as the early responses and consider it the normal physiological cortical responses to EBS. A parameter they used to study the tempo-frontal connectivity in a group of patients (Lacruz et al., 2007). The same type of responses was used by other teams for measuring cortical connectivity (Matsumoto et al., 2004; Catenoix et al., 2005; Rosenberg et al., 2009) using both depth electrodes and grids.

In our first study we went into a long procedure of verification and analysis of the EBS induced potentials. This study aimed at validating an objective statistical analysis of EPs which automatic implementation would enable time-efficient and reliable analysis of large scale data. The main findings of this study were as following: 1) the majority of recorded responses were in the first 100 ms; 2) the used statistical test was good in detecting most of the EPs with both high sensitivity 93% and specificity 98%.

The visual analysis of evoked potentials has its own limitations especially with epileptic regions where the morphology and topography of delayed responses (Valentin et al.; 2005) are often similar to those of spontaneous epileptiform discharges, and can be practically impossible to identify them in the context of continuous spiking. For such reason, Valentin et al. (2002) have implemented the use of a statistical analysis in addition to the used visual analysis. This statistical analysis compares the spikes both one second before and after the stimulation to tell the difference between induced activity and the ongoing pathological one.

The statistical analysis used in our study is based on a classic non parametric method implemented in the software ELAN-pack, whereby the post-stimulus EEG signal is compared to that of the pre-stimulus baseline according to various user-selected settings (duration of sliding window, statistical threshold). Several empirical parameters were tested in this validation study, suggesting that 5 ms duration sliding window and 40 averaged stimuli were more appropriate than 50 ms duration sliding window and 20 averaged stimuli. Analysis of EPs was segmented into four post-stimulus epochs according to prior observations suggesting that physiological EPs primarily occur during the first 100 ms (most often peaking between 15 and 40 ms), while epileptiform EPs are more likely to occur after 100 ms (Valentin et al., 2002).

After confirming the reliability of our implemented EPs analysis method, we used it in exploring the functional connectivity of the insular region. Prior to discussing the second and third paper about insular connectivity and for important methodologic and conceptual reasons, a distinction needs to be made between anatomic and functional connectivity (Fingelkurts and Kahkonen 2005). Anatomic connectivity could be studied either in postmortem with tract tracing or in-vivo using DTI. Tracer injection studies are rarely used to study human insular cortex and mostly used in macaques and other animals, while DTI reveals similarly oriented myelinated axonal processes but not necessarily effective connections between brain areas (Catani et al. 2002). Functional connectivity is a characterization of temporally related and spatially disparate neurophysiological events (Friston et al. 1993; Lee et al. 2003). EBS measures cortical responses to electrophysiological changes making it a suitable tool to study functional connectivity. EBS recordings offer a spatial resolution of typically 1 cm interelectrode distance and a temporal resolution in the order of tens to hundreds of milliseconds, a resolution not offered by resting state functional MRI for example. Interestingly, the presence of functional connectivity between two sites is not always supported by a direct structural connectivity and they could be connected through a third party

site. This is supported by some divergences found between human neuroimaging functional and structural connectivity data in many brain regions (Damoiseaux and Greicius, 2009; Zhang et al., 2010).

Our main findings about the human intra-insular functional connectivity were the following:

- 1) all insular gyri were interconnected, with the exception of anterior and posterior short gyri;
- 2) most of tested connections were reciprocal with no clear anterior to posterior directionality and a latency averaging at 26 ± 3 ms;
- 3) rich reciprocal connections within and between mid and posterior insula especially the regions underlying sensorimotor integration;
- 4) no interhemispheric connections between the two insulae.

Intra-insular connectivity is rarely covered in the literature, with evidence of structural connectivity in the macaque's insula mainly antero-posteriorly directed (Mesulam and Mufson, 1982b). While the evidence in the human is limited to results from imaging studies, indicating structural and functional connectivity taking place in the middle region of the insula (Kurth et al., 2010a; Cloutman et al., 2011). Our findings were mostly in agreement with those previous studies, but two main issues need to be explored further: 1) directionality of the intra-insular connections; and 2) the absence of inter-insular connections. Though there was an anterior to posterior trend of connectivity for the ASG but this is a region sampled with low number of electrodes and little conclusion can be drawn. We believe that connection directionality can be determined using EBS as in tracer injection studies, which is not the case of tractographies. Some other authors suggested that due possible contamination of bypassing axons, EBS may lose its ability to determine directionality (Wilson et al., 1990; Zhang and Oppenheimer, 2000; Matsumoto et al., 2004). Interestingly in our study 14% of the connections were unidirectional plus latencies of reciprocal EPs were different for the two directions, in favor of the EBS possibility to determine directionality and not only sending electrical discharges in the two directions of an axon. Zhang and Oppenheimer (2000) suggested that the two insulae in the rat are connected for the normal regulation of

cardiovascular functions. On the other hand the evidence from human studies is indicating the absence or the reduction of such connections in diseases like autism (Ebisch et al., 2010, Anderson et al., 2011). Though we examined 12 potential connections in two patients, all tested negative for inter-insular connectivity. Insufficient insular sampling is a possible reason, but we believe that inter-insular connectivity is limited in comparison with the rich intra-insular connectivity.

By applying Kurth's et al., (2010a) functional division of the insula to our results we found that the sensorimotor portion of the insula is heavily interconnected. This portion is thought to receive connections from various insular and extra-insular regions and is playing a major role in our interaction with the outer world (Craig, 2010). It is also thought to be strongly connected to more anterior insular regions which are responsible for self-recognition and emotional awareness (Craig, 2009). This was not the case with our study where the anterior short gyrus or cognitive subregion of the insula were poorly connected to other insular regions. The undersampling of this region in our study could be a confounding factor for such contradicting result.

In our study about the insular efferent connections we observed the following: 1) highly reproducible EPs were elicited in 33% of tested connections with an average latency of 33 ± 5 ms, 93% of positive connections were reciprocal; 2) limited interhemispheric connectivity; observed only between the insula and the opposite parietal operculum; 3) no difference in the connectivity pattern of the epileptic and the normal cortices; 4) best observed connectivity was with the operculum (frontal, parietal, temporal); 5) limited connectivity with mesial temporal structures, the non-opercular temporal neocortex and the orbitofrontal cortex; 6) no observed connectivity with the mesial frontal cortex or the cingulate gyrus; 7) an anterior posterior trend of connectivity was observed; the anterior most gyrus was projecting preferentially to hippocampus and orbito-frontal cortex while the posterior most gyri were projecting in preference to the precentral cortex, parietal operculum and the parietal lobe.

In monkeys, the anterior insula shows dense connections to limbic areas like the amygdala and entorhinal cortices as well as to the temporal pole, the orbitofrontal cortex and the anterior cingulate gyrus (Mesulam and Mufson, 1982b; Mufson and Mesulam, 1982; Mesulam and Mufson 1985). Functional imaging studies in human showed that the anterior insula is most strongly correlated with the regions responsible for emotional processing and cognitive control (Deen et al., 2011). A view supported by structural imaging studies which indicated that the cortical regions receiving most of the projections from the anterior insula included the orbitofrontal cortex, the frontal operculum, the temporal pole, and the amygdala (Cerliani et al., 2011). Cloutman et al (2011), using in vivo probabilistic tractography associated the anterior insula with a ventrally-based network involving orbital/inferior frontal and anterior/polar temporal regions, forming part of a key emotional salience and cognitive control network associated with the implementation of goal-directed behavior. As well as it showed strong frontal connectivity to orbitofrontal and frontal opercular regions, and connections with several anterior temporal areas and the posterior middle temporal gyrus. In our study the anterior insula (ASG, MSG, and PSG) was connected to both frontal and temporal lateral neocortex, as well as the opercular cortex, the orbito-frontal cortex, the hippocampus and the amygdala. Few connections were found also with the primary motor cortex. Interestingly there was a special pattern of connectivity at gyral level, as we notice in the case of the ASG which was connected to neither the parietal operculum nor the primary motor cortex.

On the other hand, the macaque posterior insula is connected with the orbitofrontal cortices, premotor cortex, somatosensory cortices, temporal operculum, mid and posterior cingulate cortices, the amygdala, and around supplementary motor area (SMA) (Mufson et al. 1981; Mesulam and Mufson 1982b; Mufson and Mesulam 1982). Deen et al. (2011) found that the posterior insula is functionally connected to primary and secondary motor and somatosensory cortices and is generally involved in processing somatosensory stimuli with affective or

motivational significance. Tractography samples from the posterior dorsal insula reached the parietal lobe, the posterior part of temporal operculum, and extrastriate regions of the occipital cortex (Cerliani et al., 2011); findings confirmed by Cloutman et al (2011) using similar technique. The posterior insula (ALG, and PLG) in our current study was connected to the lateral frontal and temporal neocortex, the mesial temporal structures including the entorhinal cortex, the opercular cortex, the orbito-frontal cortex as well as the peri-central cortex and the parietal lobe. Interestingly, this part of the insula was connected to both the supramarginal gyrus and the primary sensory cortex, a finding not evoked in testing the anterior insula.

Our findings were in line with the insular connectivity pattern from both macaque and human studies. Both anterior and posterior insula were connected to the hippocampus, confirming the insulo-hippocampic connectivity recently described by Catenoix et al. (2011) using EBS. Both amygdala and entorhinal cortex were connected to the posterior insula, though they were believed to preferentially connect with the anterior insula in the macaque (Mesulam and Mufson 1985, Augustine 1986). We showed that the insular connectivity to the frontal lobe was as previously described, with the anterior insula being preferentially connected to the orbito-frontal cortex and the posterior insula to the central cortex. None of the mesial frontal structures was connected to the insula including the SMA, in contradiction with previous studies (Mesulam and Mufson 1982b; Mufson and Mesulam 1982; Vogt and Pandya 1987; Luppino et al., 1993). These studies found the posterior insula to be connected with middle cingulate, and around the supplementary motor area. We failed to detect any connections with the anterior, middle or posterior parts of the cingulate gyrus. The anterior cingulate cortex is believed to be connected with the anterior most part of the insula and to share with it and with the orbitofrontal cortex the presence of the specialized neurons (von Economo neurons) which are thought to play a role in social awareness (Allman et al., 2005; 2010). In our case the anterior most gyrus (ASG) was strongly connected with the orbitofrontal cortex but not the anterior cingulate cortex. This finding of non-connectivity between the anterior insula and the

anterior cingulate cortex is supported by the tractography studies which failed to detect any structural connections between those two regions (Cerliani et al., 2011; Cloutman et al., 2011).

Thus, the insula acts as a multimodal center for variable functions e.g. gustatory, visceral sensation, visceral motor responses, processing of vestibular function, attention, pain, and emotion (Penfield and Faulk, 1955; Craig, 2002, 2003). The dorsal posterior insula is functionally connected to sensory areas, bringing visceral sensation to the posterior network, whereas the ventral anterior is mostly connected to the limbic system, bringing emotional aspects to the anterior network. So, the insula integrates interoception and exteroception with emotion and memory giving the perception of self and of how the self feels (Bonthius et al., 2005; Craig, 2010).

It should be emphasized that the connectivity patterns reported above should be regarded as the lower limit of the real functional connectivity. The presence of early responses provides evidence of connections between the stimulated insular region and the areas where they are recorded. On the other hand, absence of those responses does not imply lack of functional connection. There might be significant loss of neuronal impulses due to polysynaptic pathways, which may render responses undetectable by the used recording technique.

The morphology and the average latencies of the first detectable EPs peak in our studies were consistent with those observed in previous studies (Matsumoto et al., 2004, 2007). Latencies were typically ranging between 20 and 30 ms. Matsumoto et al. (2012) reported an increase in the latency with the increasing distance between the stimulating and the recording electrodes, an observation we failed to show either at the intra-insular or extra-insular levels. We shall keep in mind also that the spatial distribution of the observed EPs depended on the extent of electrode coverage determined solely by clinical considerations.

Comparing our findings with macaque's findings need to be done with caution even at the presence of many similarities between the human and the macaque insulae. The human insula is enlarged in size relative to that in the macaque (Mesulam and Mufson, 1982a), but the same authors suggested that the human insula has a plan of organization virtually identical to that of the rhesus monkey. Recent functional neuroimaging techniques, resting state analysis, and diffusion tensor imaging in humans show striking similarities with anatomical connectivity reported for the primate. Both display an anterior-posterior pattern evolving from agranular to granular cortices through a transitional dysgranular area and a similar pattern of connectivity with extra-insular regions, primarily governed by the cytoarchitectonic features of the connected brain regions (Cerliani et al., 2011). Tract tracing studies in macaque showed that the insula is connected to the primary and secondary somatosensory areas, to orbitofrontal, prefrontal and motor cortex, superior temporal gyrus, temporal pole, frontal operculum, parietal operculum, primary auditory and auditory association cortices, visual association cortex, olfactory bulb, anterior cingulate cortex, amygdaloid body, hippocampus and entorhinal cortex (Flynn et al., 1999). Most of these connections are reciprocal and topographically organized (Aggleton et al., 1980). Our results are in agreement with the primate data.

Our studies suffered from a group of limitations, and these are: 1) all stimulations were carried out in epileptic patients and the results may not be transferable to healthy individuals. In our current study we found no differences between epileptogenic and non-epileptogenic hemispheres as previously described by others (Wilson et al., 1990; Lacruz et al., 2007), which suggests that projection patterns between regions are broadly preserved in patients with epilepsy. This is not surprising, as most of the functional connections studied appear to be underpinned by axonal pathways whereas epilepsy is primarily a cortical disorder. Nevertheless, given that it has been claimed that long-term epilepsy induces substantial re-

wiring of brain connections, differences may have been masked by heterogeneities in the patient population and it cannot be ruled out that the epileptic condition of the patients could modify the evoked responses, by increasing or decreasing the neuronal excitability in the stimulated or recorded areas; 2) the number of patients studied is still very small and individual functional anatomy may have influenced the results disproportionately. Add to that the choice of electrode placements was driven by the likely candidate sites for the origin of the patients' seizures. Consequently, not all patients had electrodes placed in exactly the same sites; 3) the thickness of the insular cortex varies according to different regions, but on average is about 3 mm, therefore, the number of contacts located inside the insular cortex can generally be one or two (since the length of a contact is 2 mm and the inter-leads distance is 1.5 mm), limiting the number of sampling contacts; 4) even with stimulation applied between 2 adjacent contacts separated by 1.5 mm, one issue concerns the volume of cerebral tissue effectively excited by stimulation. This point is particularly critical to decide whether the physiological effects of our insular stimuli were limited to insula itself or may have involved adjacent structures or fibers; 5) last issue relates to the sampling limitations of electrodes implanted orthogonally in the insula, with vascular constraints hampering access to the ventral portion of the anterior insula, leaving this region unexplored by our study.

Conclusion and Future directions

The current work permitted us to characterize the pattern of human insular functional connectivity and for the first time using the electrical brain stimulation. A complex connectivity was observed at both intra-insular and extra-insular levels and is reciprocal in the majority of cases. This will add to our global understanding of the involvement of this strategic cortex in many of the functions and pathologies it is involved with.

In comparison to imaging studies, EBS has remained rarely used because it can be applied only in epileptic patients whose presurgical evaluation necessitates intracerebral electrodes implantation. Furthermore, the spatial sampling is limited to brain areas suspected to be involved in seizures onset or propagation and thus varies from one patient to the other. However, such depth stimulations and recordings provide a unique opportunity to map in vivo the functional connections that may exist between given cerebral regions (Brazier 1964; Catenoix et al. 2005; Lacruz et al., 2007; Rosenberg et al., 2009). Using a new automatic EBS technique we were able to demonstrate the possibility of studying the functional connectivity of human brain without side effects on the patients and without special intervention from the examiner. The statistical test we implemented was both highly sensitive and specific.

The insular functional connectivity whether within this complex region or with other cortical region was a reflection of the functional complexity of this region. Most of our findings were in agreement with the present literature in primates and human imaging studies. At intra-insular level we found that all insular gyri were interconnected, with the exception of least sampled anterior and posterior short gyri. Most of these connections were reciprocal with no clear anterior to posterior directionality and a latency averaging at 26 ± 3 ms. The highest concentration of reciprocal connections was within and between mid and posterior insula especially the regions underlying sensorimotor integration. We failed to demonstrate any interhemispheric connections between the two insulae.

The insular efferent connections mostly reciprocal and with a latency averaging at 33 ± 5 ms. The interhemispheric connectivity was not absent but limited to a single positive connection between the insula and the opposite parietal operculum. The insula was strongly connected to its surrounding operculum (frontal, parietal, temporal), where the posterior most gyri showed a preference for connection with the parietal operculum. The anterior most gyrus was projecting preferentially to hippocampus and orbito-frontal cortex while the posterior most gyri were projecting in preference to the precentral cortex, and the parietal lobe. We failed to demonstrate any connectivity with mesial frontal structures or the cingulate gyrus

We believe this area shall be investigated again in a larger population size and may be using a multimodality technique e.g. tractography plus EBS in studying the connectivity pattern between lateral and mesial frontal cortices (Swann et.al, 2012). Another possible future task is to use all the remaining data we have to analyze connectivity of other regions not covered in this study. Our technique was to send automatic pulses to all grey matter leads and not only the insula, leaving us with a wealth of interesting data.

There is a near future project to study the insular afferent connections in complement to our current study in insular efferent connections. This may shade light on certain patterns and findings not detected with our examination of the efferent connections. Another area which we did not cover in our study is the results of EBS in the pathological regions and to compare that with the findings from the King's college group (Valentin et al., 2002, 2005a, b; Flangan et al. 2009). Data from such pathological regions could be submitted to different analytic tests like time frequency analysis (van 't Klooster et al., 2011) and compare them to normal regions, which may help in developing an automatic technique for epileptic region detection.

References:

Ackermann H, Riecker A (2004): The contribution of the insula to motor aspects of speech production: a review and a hypothesis. *Brain Lang* 89:320-328.

Ackermann H, Riecker A (2010): The contribution (s) of the insula to speech production: a review of the clinical and functional imaging literature. *Brain Structure and Function* 214:419-433.

Adolphs R, Tranel D, Damasio AR (2003): Dissociable neural systems for recognizing emotions. *Brain and cognition* 52: 61-69.

Afif A, Bouvier R, Buenerd A, Trouillas J, Mertens P (2007): Development of the human fetal insular cortex: study of the gyration from 13 to 28 gestational weeks. *Brain Structure and Function* 212:335-346.

Afif A, Hoffmann D, Minotti L, Benabid AL, Kahane P (2008): Middle short gyrus of the insula implicated in pain processing. *Pain* 138:546-555.

Afif A, Mertens P (2010b): Description of sulcal organization of the insular cortex. *Surg Radiol Anat* 32:491-498.

Afif A, Minotti L, Kahane P, Hoffmann D (2010a): Anatomofunctional organization of the insular cortex: a study using intracerebral electrical stimulation in epileptic patients. *Epilepsia* 51:2305-2315.

Aggleton JP, Burton MJ, Passingham RE (1980) : Cortical and subcortical afferents to the amygdala of the rhesus monkey (*Macaca mulatta*). *Brain Res* 190:347-368.

Aguera PE, Jerbi K, Caclin A, Bertrand O (2011): ELAN: A software package for analysis and visualization of MEG, EEG, and LFP signals. *Comput Intell Neurosci* 2011: 158970

Alarcon G, Garcia Seoane JJ, Binnie CD, Martin Miguel MC, Juler J, Polkey CE, Elwes RD, Ortiz Blasco JM (1997): Origin and propagation of interictal discharges in the acute electrocorticogram. Implications for pathophysiology and surgical treatment of temporal lobe epilepsy. *Brain* 120:2259.

Alkire MT, White NS, Hsieh R, Haier RJ (2004): Dissociable brain activation responses to 5-Hz electrical pain stimulation: A high-field functional magnetic resonance imaging study. *Anesthesiology* 100: 939-946.

Allen JS, Damasio H, Grabowski TJ, Bruss J, Zhang W (2003) : Sexual dimorphism and asymmetries in the gray-white composition of the human cerebrum. *Neuroimage* 18:880-894.

Allman JM, Tetreault NA, Hakeem AY, Manaye KF, Semendeferi K, Erwin JM, Park S, Goubert V, Hof PR (2010): The von Economo neurons in frontoinsular and anterior cingulate cortex in great apes and humans. *Brain Structure and Function* 214:495-517.

Allman JM, Watson KK, Tetreault NA, Hakeem AY (2005): Intuition and autism: a possible role for Von Economo neurons. *Trends in cognitive sciences* 9:367-373.

Amaral DG, Price JL (1984) : Amygdalo-cortical projections in the monkey (*Macaca fascicularis*). *J Comp Neurol* 230:465-496.

Andersen RA, Asanuma C, Essick G, Siegel RM (1990) : Corticocortical connections of anatomically and physiologically defined subdivisions within the inferior parietal lobule. *J Comp Neurol* 296:65-113.

Anderson JS, Druzgal TJ, Froehlich A, DuBray MB, Lange N, Alexander AL, Abildskov T, Nielsen JA, Cariello AN, Cooperrider JR, Bigler ED, Lainhart JE (2010): Decreased interhemispheric functional connectivity in autism. *Cerebral Cortex* 21: 1134-1146.

Anderson JS, Nielsen JA, Froehlich AL, DuBray MB, Druzgal TJ, Cariello AN, Cooperrider JR, Zielinski BA, Ravichandran C, Fletcher PT and others (2011) : Functional connectivity magnetic resonance imaging classification of autism. *Brain* 134:3742-3754.

Anderson K, Bones B, Robinson B, Hass C, Lee H, Ford K, Roberts TA, Jacobs B (2009): The morphology of supragranular pyramidal neurons in the human insular cortex: a quantitative Golgi study. *Cerebral Cortex* 19:2131-2144.

Augustine JR, others (1985): The insular lobe in primates including humans. *Neurological research* 7:2.

Augustine JR (1996): Circuitry and functional aspects of the insular lobe in primates including humans. *Brain Research Reviews* 22:229-244.

Baily, P. & von Bonin, G. (1951). *The isocortex of man*. Urbana: University of Illinois Press.

Bamiou DE, Musiek FE, Luxon LM. 2003. The insula (Island of Reil) and its role in auditory processing. *Brain research reviews* 42:143-154.

Bartholin C (1641) *Institutiones Anatomicae ab auctoris filio Thoma Bartholino*,. Hack, Leiden.

Behrens TE, Johansen-Berg H (2005) : Relating connectional architecture to grey matter function using diffusion imaging. *Philos Trans R Soc Lond B Biol Sci* 360:903-911.

Bieser, A (1998): Processing of twitter-call fundamental frequencies in insula and auditory cortex of squirrel monkeys. *Experimental Brain Research* 122: 139–148.

Bixo M, Backstrom T, Winblad B, Andersson A (1995) : Estradiol and testosterone in specific regions of the human female brain in different endocrine states. *J Steroid Biochem Mol Biol* 55:297-303.

Bohland JW, Guenther FH (2006): An fMRI investigation of syllable sequence production. *Neuroimage* 32: 821-841.

Bonthius DJ, Solodkin A, Van Hoesen GW (2005): Pathology of the insular cortex in Alzheimer disease depends on cortical architecture. *Journal of Neuropathology & Experimental Neurology* 64:910.

Bowsher D, Brooks J, Enevoldson P (2004) : Central representation of somatic sensations in the parietal operculum (SII) and insula. *Eur Neurol* 52:211-225.

Brazier MA (1964): Evoked responses recorded from the depths of the human brain. *Annals of the New York Academy of Sciences* 112:33-59.

Brockhaus H (1940): Die Cyto-und Myeloarchitektonik des Cortex claustralis und des Claustrum beim Menschen. *J. Psychol. Neurol* 49:249-348.

Brodman K. 1909. *Vergleichende lokalisationslehre der grobhirnrinde*. Barth, Leipzig.

Brooks JC, Zambreanu L, Godinez A, Craig AD, Tracey I, others (2005): Somatotopic organisation of the human insula to painful heat studied with high resolution functional imaging. *Neuroimage* 27: 201.

Burton H, Videen TO, Raichle ME (1993): Tactile-vibration-activated foci in insular and parietal-opercular cortex studied with positron emission tomography: mapping the second somatosensory area in humans. *Somatosensory & motor research* 10: 297-308.

Buser P, Bancaud J (1983): Unilateral connections between amygdala and hippocampus in man. A study of epileptic patients with depth electrodes. *Electroencephalography and clinical neurophysiology* 55: 1-12.

Buser P, Bancaud J, Chauvel P (1992): Callosal transfer between mesial frontal areas in frontal lobe epilepsies. *Adv Neurol* 57:589-604.

Buser P, Bancaud J, Talairach J, Szikla G (1968): Interconnexions amygdalohippocampiques chez l'homme. Etude physiologique au cours d'explorations stereotaxiques. *Rev Neurol* 119:283-288.

Buser P, Bancaud J (1983): Unilateral connections between amygdala and hippocampus in man. A study of epileptic patients with depth electrodes. *Electroencephalography and clinical neurophysiology* 55:1-12.

Buser P, Talairach J, Bancaud J (1968): [Evoked potentials, paroxysmal responses to peripheral and epileptogenic zone stimulations]. *Rev Neurol (Paris)* 118:514.

Butti C, Hof PR (2010) The insular cortex: a comparative perspective. *Brain Structure and Function* 214:477-493.

Butti C, Santos M, Uppal N, Hof PR (2013): Von Economo neurons: clinical and evolutionary perspectives. *Cortex* 49:312-326.

Büttner-Ennever, J. A., & Gerrits, N. M (2004): Vestibular system. In G. Paxinos & J. K. Mai, editor. *The human nervous system*. Amsterdam: Elsevier. p 1212–1240.

Calder AJ, Keane J, Manes F, Antoun N, Young AW (2000): Impaired recognition and experience of disgust following brain injury. *Nature neuroscience* 3: 1077-1078.

Catani M, Howard RJ, Pajevic S, Jones DK (2002) : Virtual in vivo interactive dissection of white matter fasciculi in the human brain. *Neuroimage* 17:77-94.

Catenoix H, Magnin M, Guenot M, Isnard J, Mauguiere F, Ryvlin P (2005): Hippocampal-orbitofrontal connectivity in human: an electrical stimulation study. *Clinical neurophysiology* 116:1779-1784.

Catenoix H, Magnin M, Mauguiere F, Ryvlin P (2011): Evoked potential study of hippocampal efferent projections in the human brain. *Clinical Neurophysiology*.

Cauda F, D'Agata F, Sacco K, Duca S, Geminiani G, Vercelli A (2011): Functional connectivity of the insula in the resting brain. *Neuroimage* 55:8-23.

Cerliani L, Thomas RM, Jbabdi S, Siero JC, Nanetti L, Crippa A, Gazzola V, D'Arceuil H, Keysers C (2011): Probabilistic tractography recovers a rostrocaudal trajectory of connectivity variability in the human insular cortex. *Hum Brain Mapp*.33: 2005-2034.

Cherlow DG, Dymond AM, Crandall PH, Walter RD, Serafetinides EA (1977): Evoked response and after-discharge thresholds to electrical stimulation in temporal lobe epileptics. *Archives of neurology* 34:527.

Chikama M, McFarland NR, Amaral DG, Haber SN (1997): Insular cortical projections to functional regions of the striatum correlate with cortical cytoarchitectonic organization in the primate. *The Journal of neuroscience* 17:9686-9705.

Cloutman LL, Binney RJ, Drakesmith M, Parker GJ, Ralph MA (2011): The variation of function across the human insula mirrors its patterns of structural connectivity: Evidence from in vivo probabilistic tractography. *NeuroImage* 59: 3514-3521.

Craig AD (2009): How do you feel—now? The anterior insula and human awareness. *Nat Rev Neurosci*.10: 59-70.

Craig AD (2010): The sentient self. *Brain structure and function* 214: 563-577.

Craig AD, Chen K, Bandy D, Reiman EM, others (2000): Thermosensory activation of insular cortex. *Nature neuroscience* 3:184-90.

Craig AD (2002) : How do you feel? Interoception: the sense of the physiological condition of the body. *Nat Rev Neurosci* 3:655-666.

Craig AD (2005) : Forebrain emotional asymmetry: a neuroanatomical basis? *Trends Cogn Sci* 9:566-571.

Craig AD (2010a): Once an island, now the focus of attention. *Brain Structure and Function* 214:395-396.

Craig AD (2010b): The sentient self. *Brain structure and function* 214:563-577.

Craig AD (2011) : Significance of the insula for the evolution of human awareness of feelings from the body. *Ann N Y Acad Sci* 1225:72-82.

Cunningham DJ (1891): The development of the gyri and sulci on the surface of the island of Reil of the human brain. *Transactions of the Royal Academy of Medicine in Ireland* 9:469-480.

Damoiseaux JS, Greicius MD (2009): Greater than the sum of its parts: a review of studies combining structural connectivity and resting-state functional connectivity. *Brain Structure and Function* 213:525-533.

David O, Wozniak A, Minotti L, Kahane P (2008): Preictal short-term plasticity induced by intracerebral 1 Hz stimulation. *Neuroimage* 39:1633-1646.

de Economo CF, Koskinas GR (1925): *Die cytoarchitektonik der hirnrinde der erwachsenen menschen*: Springer.

Deen B, Pitskel NB, Pelphrey KA (2011): Three systems of insular functional connectivity identified with cluster analysis. *Cereb Cortex* 21:1498-1506.

Dronkers NF (1996) : A new brain region for coordinating speech articulation. *Nature* 384(6605):159-161.

Duffau H, Bauchet L, Lehericy S, Capelle L (2001) : Functional compensation of the left dominant insula for language. *Neuroreport* 12:2159-2163.

Duffau H, Capelle L, Lopes M, Faillot T, Sichez JP, Fohanno D (2000) The insular lobe: physiopathological and surgical considerations. *Neurosurgery* 47:801.

Duffau H, Gatignol P, Moritz-Gasser S, Mandonnet E (2009) : Is the left uncinate fasciculus essential for language? A cerebral stimulation study. *J Neurol* 256:382-389.

Ebisch SJ, Gallese V, Willems RM, Mantini D, Groen WB, Romani GL, Buitelaar JK, Bekkering H (2011): Altered intrinsic functional connectivity of anterior and posterior insula regions in high-functioning participants with autism spectrum disorder. *Human brain mapping* 32:1013-1028.

Engel J, Jr., Rausch R, Lieb JP, Kuhl DE, Crandall PH (1981) Correlation of criteria used for localizing epileptic foci in patients considered for surgical therapy of epilepsy. *Ann Neurol* 9:215-224.

Fingelkurts AA, Fingelkurts AA, Kahkonen S (2005) : Functional connectivity in the brain--is it an elusive concept? *Neurosci Biobehav Rev* 28:827-836.

Flanagan D, Valentin A, Garcia Seoane JJ, Alarcon G, Boyd SG (2009) : Single-pulse electrical stimulation helps to identify epileptogenic cortex in children. *Epilepsia* 50:1793-1803.

Flynn MC, Plata-Salaman CR, French-Mullen JM (1999) Neuropeptide Y-related compounds and feeding. *Physiol Behav* 65:901-905.

Friedman DP, Murray EA, O'Neill JB, Mishkin M (1986): Cortical connections of the somatosensory fields of the lateral sulcus of macaques: evidence for a corticolimbic pathway for touch. *The Journal of comparative neurology* 252:323-347.

Friston KJ, Frith CD, Liddle PF, Frackowiak RS (1993) : Functional connectivity: the principal-component analysis of large (PET) data sets. *J Cereb Blood Flow Metab* 13:5-14.

Frot M, Mauguiere F (2003) : Dual representation of pain in the operculo-insular cortex in humans. *Brain* 126:438-450.

Geiser E, Zaehle T, Jancke L, Meyer M (2008) : The neural correlate of speech rhythm as evidenced by metrical speech processing. *J Cogn Neurosci* 20:541-552.

Goldstein JM, Seidman LJ, Horton NJ, Makris N, Kennedy DN, Caviness VS, Jr., Faraone SV, Tsuang MT (2001) : Normal sexual dimorphism of the adult human brain assessed by in vivo magnetic resonance imaging. *Cereb Cortex* 11:490-497.

Gombi R, Velok G, Hully J (1976): Stereotactic diagnosis of epilepsy by electrical stimulation. *Acta medica Academiae Scientiarum Hungaricae* 33:111.

Gombi R, Velok G, Hully J (1976): The value of electrostimulation in epileptic focus localization. *Acta neurochirurgica*(23 Suppl):15.

Gordon B, Lesser RP, Rance NE, Hart Jr J, Webber R, Uematsu S, Fisher RS (1990): Parameters for direct cortical electrical stimulation in the human: histopathologic confirmation. *Electroencephalography and clinical neurophysiology* 75:371-377.

Guenot M, Isnard J, Ryvlin P, Fischer C, Ostrowsky K, Mauguiere F, Sindou M (2001): Neurophysiological monitoring for epilepsy surgery: the Talairach SEEG method. *Stereotactic and functional neurosurgery* 77:29-32.

Guillaume MMJ, Mazars G. (1949) Cing cas de foyers epileptogenes insulaires operes. *Soc Francaise de Neurol* 766-769.

Guillaume MMJ, Mazars G. (1949) Techniques de resection de l'insula dans les epilepsies insulaires. *Rev Neurol* 81:900-903.

Holsheimer J, Demeulemeester H, Nuttin B, De Sutter P (2000): Identification of the target neuronal elements in electrical deep brain stimulation. *European Journal of Neuroscience* 12:4573-4577.

Hua LH, Strigo IA, Baxter LC, Johnson SC, Craig AD, others (2005): Anteroposterior somatotopy of innocuous cooling activation focus in human dorsal posterior insular cortex. *American Journal of Physiology-Regulatory, Integrative and Comparative Physiology* 289:R319-325.

Isnard J, Guenot M, Ostrowsky K, Sindou M, Mauguiere F (2000): The role of the insular cortex in temporal lobe epilepsy. *Annals of neurology* 48:614-623.

Isnard J, Guenot M, Ostrowsky K, Sindou M, Mauguiere F (2001): The role of the insular cortex in temporal lobe epilepsy. *Annals of neurology* 48: 614-623.

Isnard J, Guenot M, Sindou M, Mauguiere F (2004): Clinical Manifestations of Insular Lobe Seizures: A Stereo-electroencephalographic Study. *Epilepsia* 45:1079-1090.

Isnard J, Guenot M, Sindou M, Mauguiere F (2004): Clinical Manifestations of Insular Lobe Seizures: A Stereo-electroencephalographic Study. *Epilepsia* 45: 1079-1090.

Isnard J, Magnin M, Jung J, Mauguiere F, Garcia-Larrea L (2011): Does the insula tell our brain that we are in pain? *Pain*.

Isnard J, Mauguiere F (2005) : [The insula in partial epilepsy]. *Rev Neurol (Paris)* 161:17-26.

Isnard J (2009) : [Insular epilepsy: A model of cryptic epilepsy. The Lyon experience]. *Rev Neurol (Paris)* 165:746-749.

Iwasaki M, Enatsu R, Matsumoto R, Novak E, Thankappan B, Piao Z, O'Connor R T, Horning K, Bingaman W, Nair D (2010): Accentuated cortico-cortical evoked potentials in neocortical epilepsy in areas of ictal onset. *Epileptic disorders* 12:292-302.

Jakab A, Molnar PP, Bogner P, Beres M, Berenyi EL (2011): Connectivity-based parcellation reveals interhemispheric differences in the insula. *Brain Topography*:1-8.

Kahane P, Tassi L, Francionne S, Hoffmann D, Lo Russo G, Munari C (1993): Manifestations électrocliniques induites par la stimulation électrique intracérébrale par chocs dans les épilepsies temporales. *ClinNeurophysiol* 22: 305-326.

Kahane P, Minotti L, Hoffmann D, et al (2004): Invasive EEG in the definition of the seizure onset zone: depth electrodes. In: Rosenow F, Lüders HO, editor. *Handbook of Clinical Neurophysiology, Vol.3.Presurgical assessment of the epilepsies with clinical neurophysiology and functional imaging*. Amsterdam: Elsevier BV. p 109-133.

Koubeissi MZ, Lesser RP, Sinai A, Gaillard WD, Franaszczuk PJ, Crone NE (2012) : Connectivity between perisylvian and bilateral basal temporal cortices. *Cereb Cortex* 22:918-925.

Kurth F, Eickhoff SB, Schleicher A, Hoemke L, Zilles K, Amunts K (2010b): Cytoarchitecture and probabilistic maps of the human posterior insular cortex. *Cerebral Cortex* 20:1448-1461.

Kurth F, Zilles K, Fox PT, Laird AR, Eickhoff SB (2010a): A link between the systems: functional differentiation and integration within the human insula revealed by meta-analysis. *Brain Structure and Function* 214:519-534.

Lacruz ME, Garcia Seoane JJ, Valentin A, Selway R, Alarcon G (2007): Frontal and temporal functional connections of the living human brain. *Eur J Neurosci* 26:1357-1370.

Lee L, Harrison LM, Mechelli A (2003) : A report of the functional connectivity workshop, Dusseldorf 2002. *Neuroimage* 19:457-465.

Lockhard, I (1948): Certain developmental relations and fiber connections of the triangular gyrus in primates. *Journal of Comparative Neurology*, 89: 349-386.

Luders E, Narr KL, Thompson PM, Rex DE, Jancke L, Toga AW (2006) : Hemispheric asymmetries in cortical thickness. *Cereb Cortex* 16:1232-1238.

Luppino G, Matelli M, Camarda R, Rizzolatti G (1993) : Corticocortical connections of area F3 (SMA-proper) and area F6 (pre-SMA) in the macaque monkey. *J Comp Neurol* 338:114-140.

Madeira MD, Lieberman AR (1995) : Sexual dimorphism in the mammalian limbic system. *Prog Neurobiol* 45:275-333.

Mandonnet E, Winkler PA, Duffau H (2010): Direct electrical stimulation as an input gate into brain functional networks: principles, advantages and limitations. *Acta neurochirurgica* 152:185-193.

Manes F, Paradiso S, Robinson RG (1999) : Neuropsychiatric effects of insular stroke. *J Nerv Ment Dis* 187:707-712.

Matsumoto R, Nair DR, Ikeda A, Fumuro T, Lapresto E, Mikuni N, Bigaman W, Miamoto S, Fukuyama H, Takahashi R, Najm I, Shibasaki H, Luders HO (2012): Parieto-frontal network in Human studied by cortico-cortical evoked potential. *Hum Brain Mapp.* 33: 2856-2872.

Matsumoto R, Nair DR, LaPresto E, Bingaman W, Shibasaki H, Luders HO (2007): Functional connectivity in human cortical motor system: a cortico-cortical evoked potential study. *Brain* 130: 181-197.

Matsumoto R, Kinoshita M, Taki J, Hitomi T, Mikuni N, Shibasaki H, Fukuyama H, Hashimoto N, Ikeda A (2005): In vivo epileptogenicity of focal cortical dysplasia: A direct cortical paired stimulation study. *Epilepsia* 46: 1744-1789.

- Matsumoto R, Nair DR, LaPresto E, Najm I, Bingaman W, Shibasaki H, Luders HO (2004): Functional connectivity in the human language system: a cortico-cortical evoked potential study. *Brain* 127: 2316-2330.
- Mazzola L, Isnard J, Mauguiere F (2006): Somatosensory and pain responses to stimulation of the second somatosensory area (SII) in humans. A comparison with SI and insular responses. *Cerebral Cortex* 16: 960-968.
- Merrill DR, Bikson M, Jefferys JG (2005): Electrical stimulation of excitable tissue: design of efficacious and safe protocols. *Journal of neuroscience methods* 141:171-198.
- MESILAM MM (1985): The insula of Reil in man and monkey: architectonics, connectivity and function. *Cerebral cortex*, vol 4, Association and auditory cortices:179-226.
- Mesulam M, Mufson EJ (1982b): Insula of the old world monkey. III: Efferent cortical output and comments on function. *The Journal of comparative neurology* 212: 38-52.
- Mesulam MM, Mufson EJ (1982a): Insula of the old world monkey. I. Architectonics in the insulo-orbito-temporal component of the paralimbic brain. *J Comp Neurol* 212: 1-22.
- MesulamMM, Mufson EJ (1985): The insula of Reil in man and monkey. In A. Peters & E.G. Jones, editor. *Association and auditory cortices*. New York: Plenum p 179-226.
- Morel A, Gallay MN, Baechler A, Wyss M, Gallay DS (2013) : The human insula: Architectonic organization and postmortem MRI registration. *Neuroscience* 236:117-135.
- Mufson EJ, Mesulam MM, Pandya DN (1981): Insular interconnections with the amygdala in the rhesus monkey. *Neuroscience* 6:1231-1248.
- Mufson EJ, Mesulam MM (1982): Insula of the old world monkey. II: Afferent cortical input and comments on the claustrum. *J Comp Neurol* 212:23-37.

Munari C, Kahane P, Tassi L, Francione S, Hoffmann D, Lo RG, Benabid AL (1993): Intracerebral low frequency electrical stimulation: a new tool for the definition of the "epileptogenic area". *Actaneurochirurgica. Supplementum* 58: 181-185.

Mutschler I, Wieckhorst B, Kowalevski S, Derix J, Wentlandt J, Schulze-Bonhage A, Ball T (2009): Functional organization of the human anterior insular cortex. *Neuroscience letters* 457:66-70.

Naidich TP, Kang E, Fatterpekar GM, Delman BN, Gultekin SH, Wolfe D, Ortiz O, Yousry I, Weismann M, Yousry TA (2004): The insula: anatomic study and MR imaging display at 1.5 T. *American journal of neuroradiology* 25:222-232.

Naliboff BD, Berman S, Chang L, Derbyshire SW, Suyenobu B, Vogt BA, Mandelkern M, Mayer EA (2003): Sex-related differences in IBS patients: central processing of visceral stimuli. *Gastroenterology* 124:1738-1747.

Nathan SS, Sinha SR, Gordon B, Lesser RP, Thakor NV (1993): Determination of current density distributions generated by electrical stimulation of the human cerebral cortex. *Electroencephalography and clinical neurophysiology* 86: 183-192.

Nelson SM, Dosenbach NU, Cohen AL, Wheeler ME, Schlaggar BL, Petersen SE (2010): Role of the anterior insula in task-level control and focal attention. *Brain Structure and Function* 214: 669-680.

Nestor PJ, Graham NL, Fryer TD, Williams GB, Patterson K, Hodges JR (2003): Progressive non-fluent aphasia is associated with hypometabolism centred on the left anterior insula. *Brain* 126:2406-18.

Nguyen DK, Nguyen DB, Malak R, Leroux JM, Carmant L, Saint-Hilaire JM, Giard N, Cossette P, Bouthillier A (2009): Revisiting the role of the insula in refractory partial epilepsy. *Epilepsia* 50:510-20.

Nieuwenhuys R (2012): The insular cortex A review. *Progress in brain research* 195:123.

Ongur D, Ferry AT, Price JL (2003): Architectonic subdivision of the human orbital and medial prefrontal cortex. *The Journal of Comparative Neurology* 460:425-49.

Ostrowsky K, Isnard J, Ryvlin P, Guenot M, Fischer C, Mauguiere F (2000): Functional mapping of the insular cortex: clinical implication in temporal lobe epilepsy. *Epilepsia* 41:681-686.

Ostrowsky K, Magnin M, Ryvlin P, Isnard J, Guenot M, Mauguiere F (2002): Representation of pain and somatic sensation in the human insula: a study of responses to direct electrical cortical stimulation. *Cerebral Cortex* 12: 376-385.

Ostrowsky K, Magnin M, Ryvlin P, Isnard J, Guenot M, Mauguiere F (2002): Representation of pain and somatic sensation in the human insula: a study of responses to direct electrical cortical stimulation. *Cerebral Cortex* 12:376-385.

Pandya DN, Hoesen GW, Mesulam MM (1981): Efferent connections of the cingulate gyrus in the rhesus monkey. *Experimental Brain Research* 42:319-330.

Pandya DN, Rosene DL (1985) Some observations on trajectories and topography of commissural fibers. In: Reeves AG (ed) *Epilepsy and the corpus callosum*. Plenum Press, New York, pp 21-40.

Penfield W, Boldrey E (1937): Somatic motor and sensory representation in the cerebral cortex of man as studied by electrical stimulation. *Brain: A journal of neurology*.

Penfield W, Faulk Jr ME, others (1955): The insula; further observations on its function. *Brain: a journal of neurology* 78:445.

Penfield W, Jasper H (1954): Epilepsy and the functional anatomy of the human brain. .

Petrides M, Pandya DN (1999) : Dorsolateral prefrontal cortex: comparative cytoarchitectonic analysis in the human and the macaque brain and corticocortical connection patterns. Eur J Neurosci 11:1011-1036.

Plaut DC (2002) : Graded modality-specific specialisation in semantics: A computational account of optic aphasia. Cogn Neuropsychol 19:603-639.

Pritchard, T. C., &Norgren, R (2004): Gustatory system. In G. Paxinos& J. K. Mai, editor. The human nervous system. Amsterdam: Elsevier. p 1171–1196.

Pugnaghi M, Meletti S, Castana L, Francione S, Nobili L, Mai R, Tassi L (2011): Features of somatosensory manifestations induced by intracranial electrical stimulations of the human insula. Clinical Neurophysiology.

Reil JC (1809): Untersuchungen uber den Bau des grossen Gehirns im Menschen. Arch Physiol (Halle) 9:136-208.

Reynolds EH (2004): Todd, Faraday, and the electrical basis of epilepsy. Epilepsia 45:985-992.

Riecker A, Ackermann H, Wildgruber D, Meyer J, Dogil G, Haider H, Grodd W (2000) : Articulatory/phonetic sequencing at the level of the anterior perisylvian cortex: a functional magnetic resonance imaging (fMRI) study. Brain Lang 75:259-276.

Riecker A, Mathiak K, Wildgruber D, Erb M, Hertrich I, Grodd W, Ackermann H (2005) : fMRI reveals two distinct cerebral networks subserving speech motor control. Neurology 64:700-706.

Rose M (1928): Die Inselrinde des menschen und der tiere. J Psychol Neurol 37:467-624.

Rosenberg DS, Mauguiere F, Catenoix H, Faillenot I, Magnin M (2009): Reciprocal thalamocortical connectivity of the medial pulvinar: a depth stimulation and evoked potential study in human brain. *Cerebral Cortex* 19: 1462-1473.

Rozzi S, Calzavara R, Belmalih A, Borra E, Gregoriou GG, Matelli M, Luppino G (2006) : Cortical connections of the inferior parietal cortical convexity of the macaque monkey. *Cereb Cortex* 16:1389-1417.

Rutecki PA, Grossman RG, Armstrong D, Irish-Loewen S (1989): Electrophysiological connections between the hippocampus and entorhinal cortex in patients with complex partial seizures. *Journal of neurosurgery* 70: 667-675.

Ryvlin P, Minotti L, Demarquay G, Hirsch E, Arzimanoglou A, Hoffman D, Guenot M, Picard F, Rheims S, Kahane P (2006): Nocturnal hypermotor seizures, suggesting frontal lobe epilepsy, can originate in the insula. *Epilepsia* 47: 755-765.

Santos M, Uppal N, Butti C, Wicinski B, Schmeiller J, Giannakopoulos P, et al. von Economo neurons in autism (2011): A stereologic study of the frontoinsular cortex in children. *Brain Research*, 1380: 206-217.

Saunders JB de CM, O'Malley CD (1982) *The anatomical drawings of Andreas Vesalius: De Humani Corporis Fabrica, Epitome, Tabulae Sex*. Bonanza Books, New York, pp 190-195.

Schulz R, Luders HO, Tuxhorn I, Ebner A, Holthausen H, Hoppe M, Noachtar S, Pannek H, May T, Wolf P (1997) : Localization of epileptic auras induced on stimulation by subdural electrodes. *Epilepsia* 38:1321-1329.

Seeley WW (2010) : Anterior insula degeneration in frontotemporal dementia. *Brain Struct Funct* 214:465-475.

Selimbeyoglu A, Parvizi J (2010): Electrical stimulation of the human brain: perceptual and behavioral phenomena reported in the old and new literature. *Frontiers in Human Neuroscience* 4.

Seltzer B, Pandya DN (1991): Post-rolandic cortical projections of the superior temporal sulcus in the rhesus monkey. *The Journal of comparative neurology* 312: 625-640.

Simms ML, Kemper TL, Timbie CM, Bauman ML, Blatt GJ (2009): The anterior cingulate cortex in autism: heterogeneity of qualitative and quantitative cytoarchitectonic features suggests possible subgroups. *Acta Neuropathol* 118:673-684.

Small DM (2010): Taste representation in the human insula. *Brain Structure and Function* 214: 551-561.

Sridharan D, Levitin DJ, Menon V (2008): A critical role for the right fronto-insular cortex in switching between central-executive and default-mode networks. *Proceedings of the National Academy of Sciences* 105:12569.

Stephani C, Fernandez-Baca Vaca G, Maciunas R, Koubeissi M, Luders HO (2011): Functional neuroanatomy of the insular lobe. *Brain Structure and Function* 216: 137-149.

Swann NC, Cai W, Conner CR, Pieters TA, Claffey MP, George JS, Aron AR, Tandon N (2012): Roles for the pre-supplementary motor area and the right inferior frontal gyrus stopping action electrophysiological responses and functional and structural connectivity. *Neuroimage*. 59: 2860-2870

Talairach J, Bancaud J (1973): Stereotaxic approach to epilepsy. Methodology of anatomic-functional stereotaxic investigations. *ProgNeurolSurg* 5: 297-354.

Touroutoglou A, Hollenbeck M, Dickerson BC, Barrett LF (2012): Dissociable large-scale networks anchored in the right anterior insula subserved affective experience and attention. *NeuroImage*.

Ture U, Yasargil DC, Al-Mefty O, Yasargil MG (1999) : Topographic anatomy of the insular region. *J Neurosurg* 90(4):720-33. Vogt BA, Pandya DN. 1987. Cingulate cortex of the rhesus monkey: II. Cortical afferents. *J Comp Neurol* 262:271-289.

Ture U, Yasargil MG, Friedman AH, Al-Mefty O (2000): Fiber dissection technique: lateral aspect of the brain. *Neurosurgery* 47:417.

Valentin A, Alarcon G, Garcia-Seoane JJ, Lacruz ME, Nayak SD, Honavar M, Selway RP, Binnie CD, Polkey CE (2005a): Single-pulse electrical stimulation identifies epileptogenic frontal cortex in the human brain. *Neurology* 65: 426-435.

Valentin A, Alarcon G, Honavar M, Garcia Seoane JJ, Selway RP, Polkey CE, Binnie CD(2005b): Single pulse electrical stimulation for identification of structural abnormalities and prediction of seizure outcome after epilepsy surgery: a prospective study. *Lancet Neurol* 4: 718-726.

Valentin A, Anderson M, Alarcon G, Seoane JJ, Selway R, Binnie CD, Polkey CE (2002): Responses to single pulse electrical stimulation identify epileptogenesis in the human brain in vivo. *Brain* 125: 1709-1718.

van't Klooster MA, Zijlmans M, Leijten FS, Ferrier CH, van Putten MJ, Huiskamp GJ (2011): Time--frequency analysis of single pulse electrical stimulation to assist delineation of epileptogenic cortex. *Brain* 134: 2855-2866.

Varnavas GG, Grand W (1999): The insular cortex: morphological and vascular anatomic characteristics. *Neurosurgery* 44:127.

Vogt, O, and Vogt, C (1903): Zur anatomischen Gliederung des cortex cerebri, *J. Psychol. Neurol.*, 2: 160-180.

Wicker B, Keysers C, Plailly J, Royet JP, Gallese V, Rizzolatti G (2003): Both of Us Disgusted in My Insula: The Common Neural Basis of Seeing and Feeling Disgust. *Neuron* 40: 655-664.

Wilson CL, Engel J, Jr (1993) : Electrical stimulation of the human epileptic limbic cortex. *Adv Neurol* 63:103-13. Wise RJ, Greene J, Buchel C, Scott SK. 1999. Brain regions involved in articulation. *Lancet* 353:1057-1061.

Wilson CL, Isokawa M, Babb TL, Crandall PH (1990) Functional connections in the human temporal lobe. *Experimental brain research* 82: 279-292.

Wilson CL, Khan SU, Engel Jr J, Isokawa M, Babb TL, Behnke EJ (1998): Paired pulse suppression and facilitation in human epileptogenic hippocampal formation. *Epilepsy research* 31:211-230.

Yaxley S, Rolls ET, Sienkiewicz ZJ (1990): Gustatory responses of single neurons in the insula of the macaque monkey. *Journal of Neurophysiology* 63: 689-700.

Yeomans JS (1990) : "Temporal summation decay" in hypothalamic self-stimulation: threshold changes at long intrapair intervals due to axonal subnormal periods. *Behav Neurosci* 104:991-999.

Zhang D, Snyder AZ, Shimony JS, Fox MD, Raichle ME (2010): Noninvasive functional and structural connectivity mapping of the human thalamocortical system. *Cerebral cortex* 20: 1187-1194.

Zhang ZH, Oppenheimer SM (2000): Electrophysiological evidence for reciprocal insulo-insular connectivity of baroreceptor-related neurons. *Brain research* 863: 25-41.