



**HAL**  
open science

# Caractéristiques et traitements des cicatrices myocardiques responsables d'arythmie ventriculaire

Frédéric Sacher

► **To cite this version:**

Frédéric Sacher. Caractéristiques et traitements des cicatrices myocardiques responsables d'arythmie ventriculaire. Biologie cellulaire. Université de Bordeaux, 2014. Français. NNT : 2014BORD0032 . tel-01179660

**HAL Id: tel-01179660**

**<https://theses.hal.science/tel-01179660>**

Submitted on 23 Jul 2015

**HAL** is a multi-disciplinary open access archive for the deposit and dissemination of scientific research documents, whether they are published or not. The documents may come from teaching and research institutions in France or abroad, or from public or private research centers.

L'archive ouverte pluridisciplinaire **HAL**, est destinée au dépôt et à la diffusion de documents scientifiques de niveau recherche, publiés ou non, émanant des établissements d'enseignement et de recherche français ou étrangers, des laboratoires publics ou privés.



Année 2014

THÈSE  
pour le  
DOCTORAT DE L'UNIVERSITÉ BORDEAUX

Ecole doctorale: Sciences de la Vie et de la Santé  
Mention: Sciences, Technologie, Santé  
Option: Biologie Cellulaire et Physiopathologie

Présentée et soutenue publiquement

*Le 20 mars 2014*

***Par Frédéric Sacher***

*Né le 24 janvier 1975 à Châteauroux*

**CARACTERISTIQUES ET TRAITEMENTS DES  
CICATRICES MYOCARDIQUES RESPONSABLES  
D'ARYTHMIE VENTRICULAIRE**

**Membres du Jury**

Mr. le Professeur Roger MARTHAN Président

Mr. le Professeur Dominique BABUTY Rapporteur

Mr. le Professeur Dominique LACROIX Rapporteur

Mr. le Professeur Christian DE CHILLOU Examineur

Mr. le Docteur Olivier BERNUS Examineur

Mr. le Docteur Philippe MAURY Examineur

Mr. le Professeur Pierre JAIS Directeur de Thèse

## **Remerciements**

### **M. le Pr JAÏS, directeur de thèse**

Tu es à l'origine du développement du programme d'ablation de TV et tu as eu une place prépondérante dans l'essor de ce laboratoire animal. Ta gentillesse, ta compétence et ta disponibilité malgré ton emploi du temps très chargé m'ont permis de réaliser cette thèse. Il est toujours très stimulant de discuter et d'échanger avec toi.

### **Mr le Pr Marthan, président du Jury**

Directeur de l'école doctorale et de l'unité INSERM 1045 au sein de laquelle j'ai eu le plaisir de réaliser ma thèse, vous me faites l'honneur de juger cette thèse et je vous en remercie.

### **Mr le Pr Babuty, rapporteur**

Témoin de ma formation médicale tourangelle en temps qu'étudiant en médecine, tu as toujours été présent. En PCEM2, j'avais eu la chance de faire mon travail pour le mémoire de C1 de physiologie dans le service de rythmologie où tu étais PH sur la mesure non invasive du faisceau de His grâce à l'ECG haute amplification. Je te remercie de juger ce travail

### **Mr le Pr Lacroix, rapporteur**

Tu m'as initié à l'ablation des TV lors de mes 6 mois à Lille. Ta rigueur intellectuelle et ton engagement dans la formation sont un exemple. Je te remercie de participer à ce jury et en suis très honoré.

### **Mr le Pr De Chillou, examinateur**

Tu es probablement un des électrophysiologistes français qui a fait le plus pour la connaissance des mécanismes des tachycardies ventriculaires et de leur ablation. C'est un véritable honneur de te compter parmi les membres de ce jury.

### **Mr le Dr Bernus, examinateur**

C'est toujours un réel plaisir de venir sur le site de l'IHU pour faire les manipulations animales et pouvoir discuter de projet en commun. Ta connaissance de l'électrophysiologie expérimentale m'a permis de découvrir un autre pan de la rythmologie. En tant que directeur scientifique de l'IHU, tu as monté une belle équipe scientifique, ne reste plus que le versant footballistique (-35)

### **Mr Le Dr Maury, examinateur**

C'est toujours un plaisir d'échanger avec toi, tu as toujours plein d'idées et d'avis pertinents sur les différents dossiers que nous pouvons échanger. Ton dynamisme est un exemple. Malgré d'autres impératifs, tu t'es débrouillé pour être présent pour juger cette thèse et je t'en remercie.

Je remercie également Michel Haissaguerre sans qui rien de tout cela n'aurait été possible. Votre enthousiasme, votre gentillesse et votre simplicité font mon admiration. Le flot continu de vos idées ainsi que votre dynamisme pour innover sont une source continue de motivation. Votre disponibilité me procure un enrichissement permanent et m'a permis de découvrir l'électrophysiologie.

Bien évidemment Nicolas et Arnaud qui pendant que j'étais à l'IHU ont assuré la prise en charge des patients. Il est toujours très agréable de discuter ensemble et d'échanger même lorsqu'on n'est pas d'accord Nicolas.

Egalement Meleze qui a été ma CCA et dont la pugnacité et l'habileté technique force le respect,

Philippe, Pierre, Sylvain et Adlane avec qui il est toujours passionnant d'échanger,

A l'équipe des soins intensifs, qui sont toujours là lorsqu'on a besoin d'eux,

Toute l'équipe paramédicale du 3<sup>e</sup> actuelle et passée, aux secrétaires (particulièrement Laurence pour son aide) et l'équipe de la salle de KT,

Bien sur Delphine Vieillot pour sa présence, sa bonne humeur et son implication lors des expérimentations animales,

Toute l'équipe du LIRYC, nous n'attendons plus qu'une équipe de foot pour challenger celle de rythmologie clinique.

**A mes parents et mes sœurs,**

Pour m'avoir toujours entouré de leur affection.

**A ma femme Agathe,**

Pour sa patience et son amour.

**A mes 3 magnifiques enfants Victor, Juliette et Adan**

Pour la joie qu'ils nous procurent.





## Résumé

L'ablation par radiofréquence percutanée est un des traitements des tachycardies ventriculaires (TV). Bien que salvateur chez certains patients avec myocardiopathie (MCP), les taux de succès rapportés varient de 53 à 67% dans les centres entraînés.

Le but de ce travail est d'essayer de mieux comprendre le substrat des arythmies ventriculaires et d'en améliorer le traitement. Pour cela, nous avons étudié le substrat des patients adressés pour ablation de TV (sur MCP ischémique, sur MCP dilatée à coronaires saines avec cicatrices sous épiscopardiques, chez les patients avec assistance ventriculaire gauche et chez un patient avec syndrome de Brugada). Nous avons également évalué et proposé des outils/attitudes thérapeutiques pour essayer d'améliorer le traitement des TV.

Nous avons mis en évidence des particularités électrophysiologiques pour chacun de ces substrats qui permettent d'optimiser et d'adapter la cartographie et l'ablation chez ces patients. Par ailleurs, nous avons montré l'intérêt : (1) de nouvelles technologies pour améliorer l'efficacité de l'ablation ; (2) des approches épiscopardiques ou d'alcoolisation intra coronaire, chez certains patients sélectionnés, qui permettent d'éliminer le substrat et (3) de l'imagerie cardiaque pour mieux identifier le substrat et diminuer les risques per procédure.

La connaissance du substrat spécifique à chaque pathologie, une information sur la force du contact entre le cathéter et le tissu, l'imagerie cardiaque (scanner et IRM), une approche épiscopardique chez certains patients et l'homogénéisation de la cicatrice myocardique permettent d'être plus efficace lors de l'ablation des TV.

## Mots clés

Tachycardie Ventriculaire ; Ablation par cathéter ; Imagerie par Résonance Magnétique cardiaque ; Myocardiopathie

## Laboratoire

INSERM 1045 -Centre de Recherche Cardio-Thoracique de Bordeaux – CRCTB (Pr Marthan)

Au sein du département de L'Institut de Rythmologie et de modélisation Cardiaque (IHU LIRYC ; Pr Haissaguerre)

## Summary

Radiofrequency (RF) catheter ablation is a recognized treatment for ventricular tachycardia (VT) in patients with structural heart disease. Even if it can be life saving, success rate remains around 53 to 67%.

We aimed to better characterized VT substrate in patients with ischemic cardiomyopathy (CMP), non ischemic CMP with subepicardial scar, left ventricular assist device and Brugada syndrome. We also evaluate the efficacy of new technologies (such as contact force), specific approaches (epicardial access, intra coronary alcohol ablation), systematic use of cardiac imaging and new end-points for VT ablation.

We demonstrated that each substrate had specific electrophysiological properties that help optimizing the mapping and the ablation in these patients. We also showed the interest of (1) new technologies to improve RF lesion formation; (2) specific approaches in selected patients to eradicate the VT substrate; and (3) cardiac imaging to help identifying the substrate and preventing complications. Finally using local abnormal ventricular potential elimination as an end-point for VT ablation is feasible and associated with lower mortality during follow-up when achieved.

Knowledge of substrate specificities, use of contact force, cardiac imaging, epicardial access in selected patients and scar homogenization improve VT ablation efficacy and/or safety.

## Title

Characterization and treatment of myocardial scar leading to ventricular arrhythmia

## Key words

Ventricular Tachycardia ; Catheter Ablation ; Cardiac Magnetic Resonance Imaging ; Structural Heart Disease

# SOMMAIRE

Liste des abréviations .....	p. 9
Liste des publications scientifiques en rapport avec la thèse .....	p. 10
Liste des présentations orales et affichées en rapport avec la thèse .....	p. 14

## I – Préambule

A) Historique .....	p. 22
B) Substrat des tachycardies ventriculaires .....	p. 24
1) <i>Histologie</i>	
2) <i>Système Nerveux Autonome</i>	
C) Relation substrat/électrogrammes .....	p. 26
1) <i>Amplitude des EGM</i>	
2) <i>Fragmentation des EGM</i>	
3) <i>Potentiels tardifs</i>	
4) <i>Doubles Potentiels</i>	
D) Techniques de cartographie .....	p. 28
1) <i>Cartographie d'activation</i>	
2) <i>Cartographie par entraînement</i>	
3) <i>Cartographie du substrat</i>	
E) Apport de l'imagerie pour l'ablation des tachycardies ventriculaires .....	p. 36
1) <i>Echographie</i>	
2) <i>Imagerie par Résonnance Magnétique</i>	
3) <i>Scanner</i>	
4) <i>Autres techniques d'imagerie</i>	
F) Références .....	p. 39

## II- Objectifs

## III- Première partie : Etat des lieux de l'ablation des tachycardies ventriculaires dans un centre tertiaire

A) Ventricular Tachycardia Ablation: Evolution of Patients and Procedures Over 8 Years .....	p. 47
1) <i>Etude</i> .....	p. 47
2) <i>Implications</i> .....	p. 48
3) <i>Manuscrit</i> .....	p. 49
B) Références .....	p. 59

## IV- Deuxième partie : Caractéristiques des cicatrices myocardiques responsables d'arythmie ventriculaire

<b>A) Electrophysiologic characterization of local abnormal ventricular activities in post infarction ventricular tachycardia with respect to their anatomic location.....</b>	<b>p. 60</b>
1) <i>Etude</i> .....	<i>p. 60</i>
2) <i>Implications</i> .....	<i>p. 61</i>
3) <i>Manuscrit</i> .....	<i>p. 62</i>
<b>B) Non-ischemic cardiomyopathy with subepicardial scar: a specific entity requiring a specific approach. ....</b>	<b>p. 70</b>
1) <i>Etude</i> .....	<i>p. 70</i>
2) <i>Implications</i> .....	<i>p. 70</i>
3) <i>Manuscrit</i> .....	<i>p. 72</i>
<b>C) Characteristics of VT Ablation in Patients with Continuous Flow Left Ventricular Assist Devices .....</b>	<b>p. 91</b>
1) <i>Etude</i> .....	<i>p. 91</i>
2) <i>Implications</i> .....	<i>p. 92</i>
3) <i>Manuscrit</i> .....	<i>p. 93</i>
<b>D) Insight into the mechanism of Brugada syndrome: Epicardial substrate and modification during ajmaline testing .....</b>	<b>p. 108</b>
1) <i>Etude</i> .....	<i>p. 108</i>
2) <i>Implications</i> .....	<i>p. 108</i>
3) <i>Manuscrit</i> .....	<i>p. 109</i>
<b>E) Références .....</b>	<b>p. 112</b>

## V- Troisième partie : Approche thérapeutique des arythmies ventriculaires sur cicatrices myocardiques

<b>A) Comparison of Ventricular Radiofrequency Lesions in Sheep Using Standard Irrigated Tip Catheter versus Catheter Ablation Enabling Direct Visualization .....</b>	<b>p. 114</b>
1) <i>Etude</i> .....	<i>p. 114</i>
2) <i>Implications</i> .....	<i>p. 115</i>
3) <i>Manuscrit</i> .....	<i>p. 116</i>
<b>B) Endocardial Versus Epicardial Ventricular Radiofrequency Ablation Utility of In Vivo Contact Force Assessment .....</b>	<b>p. 121</b>
1) <i>Etude</i> .....	<i>p. 121</i>
2) <i>Implications</i> .....	<i>p. 122</i>
3) <i>Manuscrit</i> .....	<i>p. 123</i>
<b>C) Characterization of Contact Force During Endocardial and Epicardial Ventricular Mapping .....</b>	<b>p. 131</b>
1) <i>Etude</i> .....	<i>p. 131</i>
2) <i>Implications</i> .....	<i>p. 132</i>
3) <i>Manuscrit</i> .....	<i>p. 133</i>

<b>D) Transcoronary ethanol ventricular tachycardia ablation in the modern electrophysiology era .....</b>	<b>p. 168</b>
1) <i>Etude</i> .....	p. 168
2) <i>Implications</i> .....	p. 169
3) <i>Manuscrit</i> .....	p. 170
<b>E) Epicardial Ventricular Tachycardia Ablation: A Multicenter Safety Study .....</b>	<b>p. 177</b>
1) <i>Etude</i> .....	p. 177
2) <i>Implications</i> .....	p. 178
3) <i>Manuscrit</i> .....	p. 179
<b>F) Multimodality Imaging to Improve the Safety and Efficacy of Epicardial Ablation of Scar-Related Ventricular Tachycardia .....</b>	<b>p. 186</b>
1) <i>Etude</i> .....	p. 186
2) <i>Implications</i> .....	p. 186
3) <i>Manuscrit</i> .....	p. 187
<b>G) Steam Pop during radiofrequency ablation: Imaging features on Magnetic Resonance Imaging and Multi-Detector Computed Tomography .....</b>	<b>p. 189</b>
1) <i>Etude</i> .....	p. 189
2) <i>Implications</i> .....	p. 189
3) <i>Manuscrit</i> .....	p. 190
<b>H) Endocardial Ablation to Eliminate Epicardial Arrhythmia Substrate in Scar-Related Ventricular Tachycardia .....</b>	<b>p. 196</b>
1) <i>Etude</i> .....	p. 196
2) <i>Implications</i> .....	p. 197
3) <i>Manuscrit</i> .....	p. 198
<b>I) Complete Substrate Ablation of Scar-Related Ventricular Tachycardia Reduces Cardiac Mortality in Patients with Implantable Cardioverter-Defibrillators .....</b>	<b>p. 229</b>
1) <i>Etude</i> .....	p. 229
2) <i>Implications</i> .....	p. 229
3) <i>Manuscrit</i> .....	p. 231
<b>J) Références .....</b>	<b>p. 265</b>

## VI- Conclusion

## Liste des Abréviations

CI : Confidence Interval

DAVD : Dysplasie Arythmogène du Ventricule Droit

EGM : Electrogramme

Epi : Epicardique

Endo : Endocardique

FEVG : Fraction d'éjection ventriculaire gauche

HR : Hazard Ratio

IdM : Infarctus du Myocarde

IRM : Imagerie par Résonance Magnétique

LAVA : Local Abnormal Ventricular Activity (potentiels ventriculaires anormaux témoignant d'un trouble de conduction myocardique local)

MIBI : MethoxyIsoButylIsonitrile ( Technetium (99mTc) sestamibi)

MIBG : MétalodoBenzylGuanidine

PET Scan : Tomographie par Émission de Positrons

PPI : Post-Pacing Interval = cycle de retour après stimulation

PPI-TCL : Post Pacing Interval –Tachycardia Cycle Length = durée du cycle de retour après entraînement à laquelle est soustrait le cycle de la tachycardie.

TCL : Tachycardia Cycle Length = cycle de la tachycardie

TV : Tachycardie Ventriculaire

VD : Ventricule Droit

VG : Ventricule Gauche

## Liste des publications scientifiques en rapport avec la thèse

### 2014

Maury P, Baratto F, Zeppenfeld K, Klein G, Delacretaz E, **Sacher F**, Pruvot E, Brigadeau F, Rollin A, Andronache M, Maccabelli G, Gawrysiak M, Brenner R, Forclaz A, Schlaepfer J, Lacroix D, Duparc A, Mondoly P, Bouisset F, Delay M, Hocini M, Derval N, Sadoul N, Magnin-Poull I, Klug D, Haïssaguerre M, Jaïs P, Della Bella P, De Chillou C.  
Radio-frequency ablation as primary management of well-tolerated sustained monomorphic ventricular tachycardia in patients with structural heart disease and left ventricular ejection fraction over 30%.  
Eur Heart J. 2014 Feb 16.

Komatsu Y, Daly M, **Sacher F**, Cochet H, Denis A, Derval N, Jesel L, Zellerhoff S, Lim HS, Jadidi A, Nault I, Shah A, Roten L, Pascale P, Scherr D, Aurillac-Lavignolle V, Hocini M, Haïssaguerre M, Jaïs P.  
Endocardial Ablation to Eliminate Epicardial Arrhythmia Substrate in Scar-Related Ventricular Tachycardia.  
J Am Coll Cardiol. 2014 Jan 17. doi: 10.1016/j.jacc.2013.10.087.

### 2013

Cochet H, Dubois R, **Sacher F**, Derval N, Sermesant M, Hocini M, Montaudon M, Haïssaguerre M, Laurent F, Jaïs P.  
Cardiac Arrhythmias: Multimodal Assessment Integrating Body Surface ECG Mapping into Cardiac Imaging.  
Radiology. 2013 Dec 3:131331.

Komatsu Y, **Sacher F**, Cochet H, Jais P  
Multimodality imaging to improve the safety and efficacy of epicardial ablation of scar-related ventricular tachycardia  
J Cardiovasc Electrophysiol 2013;12:1426-7

Komatsu Y, Daly M, **Sacher F**, Derval N, Pascale P, Roten L, Scherr D, Jadidi A, Ramoul K, Denis A, Jesel L, Zellerhoff S, Lim HS, Shah A, Cochet H, Hocini M, Haïssaguerre M, Jaïs P.  
Electrophysiologic characterization of local abnormal ventricular activities in postinfarction ventricular tachycardia with respect to their anatomic location.  
Heart Rhythm. 2013;10(11):1630-7.

Wright M, Harks E, Deladi S, Fokkenrood S, Zuo F, VAN Dusschoten A, Kolen AF, Belt H, **Sacher F**, Hocini M, Haïssaguerre M, Jaïs P.  
Visualizing intramyocardial steam formation with a radiofrequency ablation catheter incorporating near-field ultrasound.  
J Cardiovasc Electrophysiol. 2013;24(12):1403-9.

**Sacher F**, Jesel L, Jais P, Haïssaguerre M.

Insight into the mechanism of Brugada syndrome: Epicardial substrate and modification during ajmaline testing.

Heart Rhythm. 2013 May 31. pii: S1547-5271(13)00616-4. doi:

Komatsu Y, Cochet H, Jadidi A, **Sacher F**, Shah A, Derval N, Scherr D, Pascale P, Roten L, Denis A, Ramoul K, Miyazaki S, Daly M, Riffaud M, Sermesant M, Relan J, Ayache N, Kim S, Montaudon M, Laurent F, Hocini M, Haïssaguerre M, Jaïs P.

Regional myocardial wall thinning at multidetector computed tomography correlates to arrhythmogenic substrate in postinfarction ventricular tachycardia: assessment of structural and electrical substrate.

Circ Arrhythm Electrophysiol. 2013;6(2):342-50

**Sacher F**, Wright M, Derval N, Denis A, Ramoul K, Roten L, Pascale P, Bordachar P, Ritter P, Hocini M, Dos Santos P, Haïssaguerre M, Jais P.

Endocardial versus epicardial ventricular radiofrequency ablation: utility of in vivo contact force assessment.

Circ Arrhythm Electrophysiol. 2013;6(1):144-50

Cochet H, Komatsu Y, **Sacher F**, Jadidi AS, Scherr D, Riffaud M, Derval N, Shah A, Roten L, Pascale P, Relan J, Sermesant M, Ayache N, Montaudon M, Laurent F, Hocini M, Haïssaguerre M, Jaïs P.

Integration of merged delayed-enhanced magnetic resonance imaging and multidetector computed tomography for the guidance of ventricular tachycardia ablation: a pilot study.

J Cardiovasc Electrophysiol. 2013;24(4):419-26

## 2012

Roten L, Derval N, Pascale P, Jais P, Coste P, **Sacher F**.

What next after failed septal ventricular tachycardia ablation?

Indian Pacing Electrophysiol J. 2012 ;12(4):180-5.

de Chillou C, Magnin-Poull I, Andronache M, **Sacher F**, Groben L, Abdelaal A, Muresan L, Jarmouni S, Schwartz J, Jaïs P, Aliot E.

Showing up channels for postinfarct ventricular tachycardia ablation.

Pacing Clin Electrophysiol. 2012 ;35(7):897-904.

**Sacher F**, Derval N, Jadidi A, Scherr D, Hocini M, Haïssaguerre M, Dos Santos P, Jais P.

Comparison of ventricular radiofrequency lesions in sheep using standard irrigated tip catheter versus catheter ablation enabling direct visualization.

J Cardiovasc Electrophysiol. 2012 ;23(8):869-73

Jaïs P, Maury P, Khairy P, **Sacher F**, Nault I, Komatsu Y, Hocini M, Forclaz A, Jadidi AS,

Weerasoorya R, Shah A, Derval N, Cochet H, Knecht S, Miyazaki S, Linton N, Rivard L, Wright



M, Wilton SB, Scherr D, Pascale P, Roten L, Pederson M, Bordachar P, Laurent F, Kim SJ, Ritter P, Clementy J, Haïssaguerre M.

Elimination of local abnormal ventricular activities: a new end point for substrate modification in patients with scar-related ventricular tachycardia.

Circulation. 2012 May 8;125(18):2184-96.

## 2011

Francis J, **Sacher F**.

Transcoronary ethanol ablation for ventricular tachycardia.

Indian Pacing Electrophysiol J. 2011 Nov;11(6):159-60.

Tokuda M, Sobieszczyk P, Eisenhauer AC, Kojodjojo P, Inada K, Koplan BA, Michaud GF, John RM, Epstein LM, **Sacher F**, Stevenson WG, Tedrow UB.

Transcoronary ethanol ablation for recurrent ventricular tachycardia after failed catheter ablation: an update.

Circ Arrhythm Electrophysiol. 2011 Dec 1;4(6):889-96.

## 2010

**Sacher F**, Roberts-Thomson K, Maury P, Tedrow U, Nault I, Steven D, Hocini M, Koplan B, Leroux L, Derval N, Seiler J, Wright MJ, Epstein L, Haissaguerre M, Jais P, Stevenson WG

Epicardial ventricular tachycardia ablation a multicenter stafey study

J Am Coll Cardiol 2010;21:2366-72

Wright M, Harks E, Deladi S, Suijver F, Barley M, Van Dusschoten A, Fokkenrood S, Zuo F, **Sacher F**, Hocini M, Haissaguerre M, Jais P

Real-time lesion assessment using a novel combined ultrasound and radiofrequency ablation catheter

Heart Rhythm 2010;

## 2009

**Sacher F**, Derval N, Hocini M, Jais P, Ploux S, Bordachar P, Ritter P, Clémenty J, Haissaguerre M

Extrasystoles ventriculaires sur cœur « apparemment » sain

Archives of cardiovascular diseases supp 2009 ;2 :116-121

Weerasooriya R, Jais P, **Sacher F**, Knecht S, Wright M, Lellouch N, Nault I, Matsuo S, Hocini M, Clementy J, Haissaguerre M.

Utility of the lateral fluoroscopic view for subxiphoid pericardial access.

Circ Arrhythm Electrophysiol. 2009 Aug;2(4):e15-7.

Knecht S, **Sacher F**, Wright M, Hocini M, Nogami A, Arentz T, Petit B, Franck R, De Chillou C, Lamaison D, Farré J, Lavergne T, Verbeet T, Nault I, Matsuo S, Leroux L, Weerasooriya R, Cauchemez B, Lellouche N, Derval N, Narayan SM, Jaïs P, Clementy J, Haïssaguerre M.  
Long-term follow-up of idiopathic ventricular fibrillation ablation: a multicenter study.  
J Am Coll Cardiol. 2009 Aug 4;54(6):522-8.

Raymond JM, **Sacher F**, Winslow R, Tedrow U, Stevenson WG.

Catheter ablation for scar-related ventricular tachycardias.

Curr Probl Cardiol. 2009 May;34(5):225-70.

Massoure PL, Jais P, **Sacher F**, Haïssaguerre M.

Tachycardia-Induced Right Ventricular Cardiomyopathy: Epicardial Radiofrequency Ablation of an Unusual and Unexpected Ventricular Tachycardia.

J Cardiovasc Electrophysiol. 2009 Jan 16.

## 2008

**Sacher F**, Tedrow UB, Field ME, Raymond JM, Koplan BA, Epstein LM, and Stevenson WG

Ventricular Tachycardia Ablation: Evolution of Patients and Procedures Over 8 Years

Circ Arrhythmia Electrophysiol. 2008;1:153-161

**Sacher F**, Sobieszczyk P, Tedrow U, Eisenhauer AC, Field ME, Selwyn A, Raymond JM, Koplan B, Epstein LM, Stevenson WG.

Transcoronary Ethanol Ventricular Tachycardia Ablation in the Modern Electrophysiology Era  
Heart Rhythm 2008 Jan;5(1):62-8.

## Liste des présentations orales et affichées en rapport avec la thèse

### Heart Rhythm Society (San Francisco) : mai 2014

**Frederic Sacher**, MD, Laurence Jéssel, MD, Claire Borni-Duval, MD, Antoine Benard, MD, Yhsou Delmas, MD, Antoine Deplagne, MD, Frédéric Lavainne, MD, Jean-Baptiste Gourraud, MD, Cécile Vigneau, MD, Atman Haddj-Elmrabet, MD, Philippe Mabo, MD, Julien Ott, MD, Arnaud Denis, MD, Dorothée Bazin-kara, MD, Sébastien Buffler, MD, Han Lim, MD, Sylvain Reuter, MD, Pierre Bories, MD, Adrien Keller, MD, Bruno Seigneuric, MD, Adlane Zemmoura, MD, Philippe Maury, MD, Thierry Hannedouche, MD, Jean-Philippe Bourdenx, MD, Michel Haissaguerre, MD and Christian Combe, MD. Implantable Loop Recorder to Characterize Cardiac Arrhythmias in Hemodialysis Patients. **MP03-01**

**Frederic Sacher**, MD, Cyrille Casset, Eng., sylvain Ploux, MD, Sana Amraoui, MD, Arnaud Denis, MD, Han S. Lim, MBBS, Pierre Bordachar, MD, Nicolas Derval, MD, Benjamin Berte, MD, Adlane Zemmoura, MD, Saagar N. Mahida, MBChB, Kyungmoo Ryu, PhD, Seigo Yamashita, MD, Meleze Hocini, MD, Philippe Ritter, MD, Michel Haissaguerre, MD and Pierre Jais, MD. Electrical and Hemodynamic Effects of Cardiac Resynchronization Therapy: Epicardial Versus Endocardial Left Ventricular Stimulation. **PO02-184**.

**Frederic Sacher**, MD, Frederic Casassus, MD, Cyrille Casset, Eng., Han S. Lim, MBBS, Lionel Leroux, MD, PhD, Nicolas Derval, MD, Arnaud Denis, MD, Seigo Yamashita, MD, Benjamin Berte, MD, Saagar N. Mahida, MBChB, Meleze Hocini, MD, Michel Haissaguerre, MD and Pierre Jais, MD. Intracoronary temperature monitoring to prevent coronary artery damage during epicardial VT ablation. **PO02-207**.

Benjamin Berte, MD, **Frederic Sacher**, MD, Hubert Cochet, MD, Saagar N. Mahida, MBChB, Seigo Yamashita, MD, Han S. Lim, MBBS, Arnaud Denis, MD, Nicolas Derval, MD, Meleze Hocini, MD, Michel Haissaguerre, MD, Pierre Jais, MD. An Intramural Focus of a Septal Ventricular Tachycardia: Pitfalls and Solutions. **PO01-204**

Benjamin Berte, MD, **Frederic Sacher**, MD, Hubert Cochet, MD, Saagar N. Mahida, MBChB, Seigo Yamashita, MD, Han S. Lim, MBBS, Arnaud Denis, MD, Sana Amraoui, MD, Nicolas Derval, MD, Meleze Hocini, MD, Michel Haissaguerre, PhD and Pierre Jais, MD. Non-Ischemic Cardiomyopathy with Subepicardial Scar: a Specific Entity Requiring a Specific Approach. **PO03-126**.

Gijsbert FL. Kapel, MD, **Frederic Sacher**, MD, Adrianus P. Wijnmaalen, MD, PhD, Jean-Benoit Thambo, MD, Nicolas Derval, MD, Martin J. Schalij, MD, PhD, Zakaria Jalal, MD and Katja Zeppenfeld, MD, PhD. The Value of Reported Risk Factors to Predict the Substrate for Ventricular Tachycardia in Repaired Tetralogy of Fallot. **PO04-201**.

Hubert Cochet, MD, PhD, **Frederic Sacher**, MD, Nicolas Derval, MD, Arnaud Denis, MD, Sana Amraoui, MD, Seigo Yamashita, MD, Benjamin Berte, MD, Han S. Lim, MBBS, Saagar Mahida, MD, Michel Montaudon, MD, PhD, Francois Laurent, MD, Meleze Hocini, MD, Michel Haissaguerre, PhD and Pierre Jais, MD. Left Phrenic Nerve on Cardiac Multi-Detector Computed Tomography: Detection Rate and Anatomical Variability. **PO05-124**.

Benjamin Berte, MD, **Frederic Sacher**, MD, Saagar N. Mahida, MBChB, Han S. Lim, MBBS, Seigo Yamashita, MD, Arnaud Denis, MD, Sana Amraoui, MD, Nicolas Derval, MD, Meleze Hocini, MD, Michel Haissaguerre, MD and Pierre Jais, MD. Lessons from Redo VT Ablations: Safety and Efficacy. **AB30-04**

Yuki Komatsu, MD, Jean-Philippe Maury, MD, **Frederic Sacher**, MD, Matthew G. Daly, MBChB, Stephan Zellerhoff, MD, Han Lim, MBBS, Laurence Jesel, MD, Anne Rollin, MD, Alexandre Duparc, MD, Pierre Mondoly, MD, Valerie Aurillac-Lavignolle, RN, Amir Jadidi, MD, Laurent Roten, MD, Patrizio Pascale, MD, Daniel Scherr, MD, Khaled Ramoul, MD, Arnaud Denis, MD, Ashok J. Shah, MD, MBBS, Hubert Cochet, MD, Nicolas Derval, MD, Meleze Hocini, MD, Michel Haissaguerre, PhD and Pierre Jais, MD. Impact of Complete Substrate Ablation for Ventricular Tachycardia Ablation on Cardiac Mortality in Patients with Implantable Cardioverter Defibrillator. **AB09-03**

Marie Sadron, MD, Philippe Maury, MD, **Frederic Sacher**, MD, David Hamon, MD, Patrizio Pascale, MD, Alexandre Duparc, MD, Pierre Mondoly, MD, Anne Rollin, MD, Nicolas Derval, MD, Christelle Cardin, MD, Pierre Jais, MD, Meleze Hocini, MD, Marc Delay, MD, Nicolas Lellouche, MD and Michel Haissaguerre. - Premature ventricular beat-induced cardiomyopathy: Characteristics and prognosis factor for recovery after radio-frequency ablation. **AB30-02**

Mikael Hanninen, MD, FRCP, Hubert Cochet, MD, PhD, Benjamin Berte, MD, Nicolas Derval, MD, **Frederic Sacher**, MD, Meleze Hocini, MD, Seigo Yamashita, MD, Han S. Lim, MBBS, Saagar N. Mahida, MBChB, Arnaud Denis, MD, Sana Amraoui, MD, Michel Haissaguerre, PhD and Pierre Jais, MD. LAVA does not always fall within the scar border zone in non-ischemic VT substrates. **AB09-05**

Nicolas Derval, MD, Yuki Komatsu, MD, **Frederic Sacher**, MD, Sylvain Ploux, MD, Arnaud Denis, MD, Hubert Cochet, MD, PhD, Laurence Jesel, MD, Han S. Lim, MBBS, Benjamin Berte, MD, Saagar Mahida, MD, Seigo Yamashita, MD, Sana Amraoui, MD, Adlane Zemmoura, MD, Philippe Ritter, MD, Meleze Hocini, MD, Michel Haissaguerre, PhD, Pierre Jais, MD and Pierre Bordachar, MD. Characterization of different LV activation patterns between heart failure patients with narrow QRS, nonspecific intraventricular conduction disturbance and left bundle branch block. **MP02-02**

Hubert Cochet, MD, PhD, Yuki Komatsu, MD, Amir Jadidi, MD, **Frederic Sacher**, MD, Nicolas Derval, MD, Arnaud Denis, MD, Sana Amraoui, MD, Maxime Sermesant, PhD, Seigo Yamashita, MD, Benjamin Berte, MD, Han S. Lim, MBBS, Saagar Mahida, MD, Bruno Quesson, PhD, Olivier Bernus, PhD, Michel Montaudon, MD, PhD, Francois Laurent, MD, Meleze Hocini, MD, Michel Haissaguerre, PhD and Pierre Jais, MD. Mapping and Quantification of Right Ventricular Fat with Multi-Detector Computed Tomography in Arrhythmogenic Right Ventricular Cardiomyopathy. **PO01-211**

Seigo Yamashita, MD, Hubert Cochet, MD, Benjamin Berte, MD, Han S. Lim, MBBS, Saagar N. Mahida, MBChB, Yuki Komatsu, MD, Sana Amraoui, MD, Arnaud Denis, MD, Nicolas Derval, MD, **Frédéric Sacher**, MD, Méléze Hocini, MD, Michel Haïssaguerre, MD and Pierre Jaïs, MD. Role of high resolution imaging integration for epicardial ventricular tachycardia ablation. **PO02-144.**

Seigo Yamashita, MD, Hubert Cochet, MD, Benjamin Berte, MD, Han S. Lim, MBBS, Saagar N. Mahida, MBChB, Yuki Komatsu, MD, Sana Amraoui, MD, Arnaud Denis, MD, Nicolas Derval, MD, **Frédéric Sacher**, MD, Méléze Hocini, MD, Michel Haïssaguerre, MD and Pierre Jaïs, MD. Impact of image integration on clinical outcome after VT ablation in ischemic cardiomyopathy patients. **PO03-124**.

Benjamin Berte, MD, valentin meillet, Eng., Remi Dubois, Eng., Hubert Cochet, MD, **Frederic Sacher**, MD, Carole Pomier, No Degree, Saagar N. Mahida, MBChB, Seigo Yamashita, MD, Han S. Lim, MBBS, Arnaud Denis, MD, Sana Amraoui, MD, Nicolas Derval, MD, Meleze Hocini, MD, Michel Haissaguerre, PhD and Pierre Jais, MD. New Non-Invasive Mapping of Ventricular Tachycardia: a Feasibility Pilot-Study. **PO03-127**.

Seigo Yamashita, MD, Hubert Cochet, MD, Benjamin Berte, MD, Han Lim, MD, Saagar Mahida, MD, Yuki Komatsu, MD, Sana Amraoui, MD, Arnaud Denis, MD, Nicolas Derval, MD, **Frédéric Sacher**, MD, Méléze Hocini, MD, Michel Haïssaguerre, MD and Pierre Jaïs, MD. Relationship between structural and electrical substrate in 92 consecutive patients referred for scar-related VT ablation with real-time image integration. **PO03-129**.

Mikael Hanninen, MD, FRCP, Hubert Cochet, MD, PhD, Benjamin Berte, MD, Nicolas Derval, MD, **Frederic Sacher**, MD, Meleze Hocini, MD, Seigo Yamashita, MD, Han S. Lim, MBBS, Saagar N. Mahida, MBChB, Arnaud Denis, MD, Sana Amraoui, MD, Michel Haissaguerre, PhD and Pierre Jais, MD. LAVA distribution is predictable and differs by VT substrate. **PO04-126**.

#### **Europace (Athènes) : du 23 au 26 juin 2013**

P Maury, M Sadron, **F Sacher**, A Duparc, P Mondoly, N Derval, A Rollin, C Cardin, P Pascale, M Hocini, P Jais, M Haissaguerre. Premature ventricular beat induced cardiomyopathy characteristics and prognosis after radiofrequency ablation. **Poster session 4 – P1119**

#### **Heart Rhythm Society (Denver) : du 8 au 11 mai 2013**

**F Sacher**, T Reichlin, E Zado, M Field, J Gonzales, K Bhasin, K Ellenbogen, F Picard, L Barandon, P Ritter, J Calderon, N Derval, A Denis, R Shepard, J Coffey, F Garcia, M Hocini, U Tedrow, S Dukkupati, M Haissaguerre, A d'Avila, W Stevenson, F Marchlinski, P Jais. Characteristics of VT ablation in patients with continuous flow left ventricular assist devices. **Heart Rhythm 2013, 10,5S: P002-154**

P Jais, **F Sacher**, Y Komatsu, A Shah, N Derval, A Denis, M Hocini, M Daly, S Zellerhoff, H Cochet, F Laurent, M Montaudon, M Haissaguerre. Long term outcome of scar related VT ablation with the endpoint of LAVA elimination. **Heart Rhythm 2013, 10,5S: P004-146**

L Jesel, **F Sacher**, Y Komatsu, M Daly, W Ambri, N Derval, K Ramoul, A Denis, S Zellerhoff, M Hocini, M Haissaguerre, P Jais. Characterization of contact force in different regions of the endocardium and epicardium during substrate mapping for VT ablation. **Heart Rhythm 2013, 10,5S: P003-158**

Z Jalal, **F Sacher**, P Bordachar, H Cochet, N Derval, S Ploux, M Haissaguerre, JB Thambo, P Jais. Characterization of right ventricular activation in patients with tetralogy of Fallot and right bundle branch block. **Heart Rhythm 2013, 10,5S: P003-181**

Y Komatsu, **F Sacher**, H Cochet, M Daly, L Jesel, N Derval, A Jadidi, A Shah, I Nault, P Pascale, L Roten, D Scherr, A Denis, K Ramoul, S Zellerhoff, M Hocini, M Haissaguerre, P Jais. Predictors of difficult elimination of local abnormal ventricular activities in ischemic and non ischemic ventricular tachycardia. **Heart Rhythm 2013, 10,5S: P003-161**

N Derval, Y Komatsu, **F Sacher**, A Denis, S Ploux, H Cochet, P Pascale, L Roten, K Ramoul, D Scherr, M Daly, L Jesel, S Amraoui, A Zemmoura, P Ritter, M Hocini, M Haissaguerre, P Jais, P Bordachar. Characterization of different LV activation patterns between heart failure patients with narrow QRS, non specific intraventricular conduction disturbance and left bundle branch block. **Heart Rhythm 2013, 10,5S: P002-21**

H Cochet, Y Komatsu, A Jadidi, A Denis, **F Sacher**, N Derval, K Ramoul, M Daly, L Jesel, S Zellerhoff, J Relan, M Sermesant, N Ayache, M Montaudon, F Laurent, M Hocini, M Haissaguerre, P Jais. Automatic myocardial fat quantification at contrast-enhanced cardiac MDCT in arrhythmogenic right ventricular cardiomyopathy: initial validation vs controls. **Heart Rhythm 2013, 10,5S: P003-152**

Y Komatsu, A Jadidi, H Cochet, **F Sacher**, A Denis, P Pascale, L Roten, D Scherr, M Daly, K Ramoul, A Shah, H Lehrmann, R Weber, J Schiebeling-Romer, G Pache, T Arentz, J Relan, M Sermesant, N Ayache, F Laurent, N Derval, M Hocini, M Haissaguerre, P Jais. CT scan segmentation of myocardial hypodensity to guide ventricular tachycardia ablation in arrhythmogenic right ventricular cardiomyopathy. **Heart Rhythm 2013, 10,5S: P003-156**

Y Komatsu, M Daly, **F Sacher**, N Derval, H Cochet, A Jadidi, P Pascale, L Roten, D Scherr, A Denis, K Ramoul, L Jesel, S Zellerhoff, A Shah, M Hocini, M Haissaguerre, P Jais. Electrophysiologic characteristics of local abnormal ventricular activities in ischemic and non-ischemic ventricular tachycardia depend on scar location. **Heart Rhythm 2013, 10,5S: P003-157**

P Jais, Y Komatsu, **F Sacher**, A Denis, N Derval, M Daly, L Jesel, S Zellerhoff, J Relan, M Montaudon, F Laurent, M Hocini, M Haissaguerre, H Cochet. Image integration to guide mapping and ablation of scar related ventricular tachycardia: preliminary results in 58 consecutive patients. **Heart Rhythm 2013, 10,5S: P005-148**

### **Heart Rhythm Society 2012 (Boston)**

**F. Sacher**, H. Cochet, Z. Jalal, J. Relan, M. de Guillebon, N. Derval, P. Pascale, L. Roten, D. Scherr, X. Iriart, A. Denis, W. Ambri,, M. Hocini, M. Sermesant, M. Montaudon, N. Ayache, M. Haïssaguerre, F. Laurent, J.B. Thambo, P. Jaïs. Discrepancies between unipolar and bipolar voltage mapping for scar assessment in the right ventricle: insights from high resolution magnetic resonance imaging. **Heart Rhythm 2012, 9,5S: AB 34-04**

**F. Sacher**, F. Didelot, P. Thomas, N. Derval, M. Hocini, P. Dos Santos, M. Haïssaguerre, P. Jaïs. Endocardial vs epicardial ventricular ablation. Utility of in contact force assessment. **Heart Rhythm 2012, 9,5S: PO2-162**

H. Cochet, **F. Sacher**, N. Derval, A. Shah, Y. Komatsu, D. Scherr, L. Roten, P. Pascale, M. Zakaria Jalal, M. de Guillebon, J.B. Thambo, J. Relan, M. Sermesant, N. Ayache, M.

Montaudon, F. Laurent, M. Hocini, M. Haïssaguerre, P. Jaïs. Detection of right ventricular isthmuses after tof repair: head to head comparison between high-resolution delayed enhancement MRI and invasive contact mapping. **Heart Rhythm 2012, 9,5S: AB42-03**

H. Cochet, **F Sacher**, N. Derval, A. Shah, Y. Komatsu, D. Scherr, L. Roten, P. Pascale, M. Zakaria Jalal, M. de Guillebon, J.B. Thambo, J. Relan, M. Sermesant, N. Ayache, M. Montaudon, F. Laurent, M. Hocini, M. Haïssaguerre, P. Jaïs. Right ventricular scar-related isthmus size at delayed-enhancement MRI correlates to apparent conduction velocity during sinus rhythm at contact mapping. **Heart Rhythm 2012, 9,5S: PO05-157**

Y. Komatsu, H. Cochet, A.S. Jadidi, D. Scherr, **F. Sacher**, N. Derval, A. Shah, L. Roten, P. Pascale, S. Miyazaki, M. Sermesant, J. Relan, M. Montaudon, F. Laurent, S.J.Kim, M. Hocini, M. Haïssaguerre, P. Jaïs. Myocardial wall thinning correlates with sites of local abnormal ventricular activities in ischemic patients undergoing catheter ablation for ventricular tachycardia: a computed tomography study using image integration. **Heart Rhythm 2012, 9,5S: PO3-156**

A. Denis, H. Cochet, **F. Sacher**, Y. Komatsu, D. Scherr, L. Roten, P. Pascale, K. Ramoul, N. Derval, M. Montaudon, F. Laurent, M. Hocini, M. Haïssaguerre, P. Jaïs. Is high resolution delayed enhancement MRI able to identify af ablation lesions and completeness? **Heart Rhythm 2012, 9,5S:PO04-116**

A. Denis, **F. Sacher**, N. Derval, P. Jaïs, M. Hocini, M. de Guillebon, A. Zemmoura, S. Ploux, P. Bordachar, P. Lemetayer, J. Clementy, M. Haïssaguerre. Diagnostic values of isoproterenol test compared to exercise test in arrhythmogenic right ventricular cardiomyopathy (ARVC). **Heart Rhythm 2012, 9,5S:PO04-149**

H. Cochet, Y. Komatsu, A. Sherwan Jadidi, D. Scherr, M. Riffaud, **F. Sacher**, N. Derval, A. Shah, L. Roten, P. Pascale, P. Pascale, J. Relan, M. Sermesant, N. Ayache, M. Montaudon, F. Laurent, M. Hocini, M. Haïssaguerre, P. Jaïs. Multimodal guidance of ventricular tachycardia ablation using fused delayed-enhanced magnetic resonance imaging and multi-detector computed tomography. **Heart Rhythm 2012, 9,5S: AB01-02**

#### **Heart Rhythm Society 2011 (San Francisco) : du 4 au 7 mai 2011**

Jais P, **Sacher F**, Maury P, Jadidi A, Nault I, Hocini M, Derval N, Wilton S, Forclaz A, Miyazaki S, Knecht S, Shah A, Bordachar P, Ritter P, Haïssaguerre M. Large clinical experience of VT ablation with the end point of LAVA elimination. **Heart Rhythm 2011,8,5S:AB16-6**

Denis A, **Sacher F**, Derval N, Jais P, Hocini M, Knecht S, Ritter P, Bordachar P, Ploux S, De Guillebon M, Whinnett Z, Le Metayer P, Clémenty J, Haïssaguerre M. Diagnostic value of the Isoproterenol test in arrhythmogenic right ventricular cardiomyopathy. **Heart Rhythm 2011,8,5S:AB40-4**

Jadidi A, Cochet H, **Sacher F**, Kim S, Sermesant M, Relan J, Derval N, Miyazaki S, Shah A, Scherr D, Wilton S, Pascale P, Roten L, Pedersen M, Knecht S, Bordachar P, Ritter P, Hocini M, Montaudon M, Laurent F, Ayache N, Haïssaguerre M, Jais P. Ventricular scar imaging at MRI correlates to critical isthmuses of ventricular tachycardia circuits and sites of slow

conduction during sinus rhythm – Utility of integrating MR-data into 3D mapping systems. **Heart Rhythm 2011,8,5S:AB41-4**

Jadidi, **Sacher F**, Shah A, Nault I, Forclaz A, Miyazaki S, Scherr D, Pascale P, Roten L, Wilton S, Pedersen M, Bordachar P, Ritter P, Kim S, Derval N, Knecht S, Hocini M, Haissaguerre M, Jais P. Novel high density mapping catheter facilitates identification of arrhythmogenic substrate and critical isthmuses during endo epicardial VT ablation – clinical implications for VT ablation. **Heart Rhythm 2011,8,5S:PO1-71**

Cochet H, Jadidi A, **Sacher F**, Derval N, Sermesant M, Relan J, Kim S, Bordachar P, Ritter P, Hocini M, Montaudon M, Laurent F, Ayache N, Haissaguerre M, Jais P. Ventricular scar at cardiac CT correlates to critical isthmuses of ventricular tachycardia circuits and sites of slow conduction during sinus rhythm – evidence for clinical use of CT integration into 3D mapping systems. **Heart Rhythm 2011,8,5S:PO1-77**

Maury JP, Della Bella P, Delacretaz E, **Sacher F**, Maccabelli G, Brenner R, Rollin A, Duparc A, Mondoly P, Jais P. Late outcome of radiofrequency ablation for monomorphic sustained ventricular tachycardia in patients with underlying heart disease without implantation of a defibrillator. **Heart Rhythm 2011,8,5S:PO2-152**

Jadidi A, **Sacher F**, Scherr D, Wilton S, Pedersen M, Miyazaki S, Shah A, Roten L, Pascale P, Bordachar P, Ritter P, Knecht S, Derval N, Hocini M, Haissaguerre M, Jais P. Combined endo and epicardial approach for ablation ventricular tachycardia in ARVC longterm follow-up results. **Heart Rhythm 2011,8,5S:PO5-143**

#### **Heart Rhythm Society 2010 (Denver) : du 12 au 15 mai 2010**

Jadidi A, Hocini M, Wright M, Shah A, Liu X, Linton N, Forclaz A, Miyazaki S, Nault I, Rivard L, Xhaet O, Derval N, **Sacher F**, Jais P, Narayan S, Haissaguerre M. Exploring the arrhythmogenic substrate in idiopathic VF. **Heart Rhythm 2010,7,S282:P04-71**

Nault I, **Sacher F**, Deplagne A, Lellouche N, Derval N, Rivard L, Forclaz A, Jadidi A, Miyazaki S, Liu X, Linton N, Xhaet O, Shah A, Hocini M, Haissaguerre M, Jais P. Is systematic epicardial mapping useful during the index ablation for ventricular tachycardia? **Heart Rhythm 2010,7,S283:P04-73**

#### **XXes Journées Européennes de la SFC (Paris) 13-16 janvier 2010**

**Sacher F**, Derval N, Nault I, Wright M, Deplagne A, Ritter P, Hocini M, Bordachar P, Ploux S, Léonard O, Clémenty J, Haissaguerre M, Jais P. Unipolar vs Bipolar pacing for ventricular tachycardia pace-mapping : does it make a difference ? **Abstract 199**

**Sacher F**, Maury P, Tedrow U, Nault I, Deplagne A, Bordachar P, Derval N, Hocini M, Ritter P, Ploux S, Duparc A, Wright M, Clémenty J, Haissaguerre M, Stevenson W, Jais P. Epicardial VT ablation: a multicentre safety study. **Abstract 229**

#### **Heart Rhythm Society 2009 (Boston) : du 13 au 16 mai 2009**



**Sacher F**, Steven D, Maury P, Tedrow U, Nault I, Roberts-Thomson K, Hocini M, Haïssaguerre M, Jaïs P, Stevenson W. Epiardial VT ablation: a multicenter safety study. **Heart Rhythm** 2009,5S,S66:AB31-1

Knecht S, **Sacher F**, Wright M, Hocini M, Nogami A, Arentz T, Petit B, Frank R, De Chillou C, Lamaison D, Farré J, Lavernege T, Verbeet T, Nault I, Matsuo S, Weerasooriya R, Cauchemez B, Lellouche N, Derval N, Narayan S, Jaïs P, Clémenty J, Haïssaguerre M. Long-term outcome is excellent after catheter ablation of idiopathic ventricular fibrillation. **Heart Rhythm** 2009,5S,S66:AB31-2

**Sacher F**, Maury P, Nault I, Wright M, Lellouche N, Derval N, Ploux S, Hocini M, Bordachar P, Deplagne A, Ritter P, Clémenty J, Haïssaguerre M, Jaïs P. Prevalence of epicardial scar in patients referred for ventricular tachycardia ablation. **Heart Rhythm** 2009,5S,S175:PO02-101

Nault I, Maury P, **Sacher F**, Lellouche N, Deplagne A, Knecht S, Wright M, Matsuo S, Forclaz A, Miyazaki S, Jadidi A, Derval N, Weerasooriya R, Ploux S, Bordachar P, Ritter P, Clémenty J, Hocini M, Haïssaguerre M, Jaïs P. Characterization of late ventricular potentials as ventricular tachycardia substrate and impact of ablation. **Heart Rhythm** 2009,5S,S227:PO03-67

**Sacher F**, Jaïs P, Wright M, Nault I, Hocini M, Derval N, Bordachar P, Deplagne A, Ritter P, Ploux S, Clémenty J, Haïssaguerre M. Comparison of ventricular epicardial vs. endocardial RF ablation in a sheep model. **Heart Rhythm** 2009,5S,S227:PO03-68

Nault I, Maury P, **Sacher F**, Lellouche N, Deplagne A, Knecht S, Weerasooriya R, Wright M, Matsuo S, Derval N, Jadidi A, Forclaz A, Miyazaki S, Ploux S, Ritter P, Bordachar P, Hocini M, Clémenty J, Haïssaguerre M, Jaïs P. Long term follow-up after catheter ablation of ventricular tachycardia aiming at elimination of late ventricular potentials. **Heart Rhythm** 2009,5S,S290:PO04-68

Szumowski LJ, Derejko P, Orczykowski M, **Sacher F**, Hocini M, Przybylski A, Bodalski R, Zakrzewska J, Kepski R, Szufiadowicz E, Sanders P, Haïssaguerre M, Walczak F. Ventricular arrhythmia originating from Purkinje fibers in patients after myocardial infarction - long term follow-up. **Heart Rhythm** 2009,5S,S428:PO06-102

#### **Cardiostim** : Juin 2008

**Sacher F**, Malchano Z, Rothe C, Nault I, Matsuo S, Knecht S, Hocini M, Lim KT, Wright M, Lellouche N, Clémenty J, Haïssaguerre M, Robinson D, Jais P. What happens at the tissue interface during RF ablation ? Direct in vivo visualization with the Iris catheter. **Europace** 2008;10:178P\_16

**Sacher F**, Tedrow U, Field M, Seiler J, Raymond J-M, Koplan B, Epstein L, Stevenson W. Ventricular tachycardia ablation: evolution of substrate, procedure and outcome. **Europace** 2008;10:234L\_4

**Heart Rhythm Society 2008 (San Francisco) : du 14 au 17 mai 2008**

**Sacher F**, Malchano Z, Rothe C, Matsuo S, Hocini M, Nault I, Knecht S, Wright M, Lim KT, Lellouche N, Haissaguerre M, Robinson D, Jais P. Direct visualization of radiofrequency lesions formation: in vivo evaluation of the iris catheter in a porcine model. **Heart Rhythm 2008,5S;S66:AB32-2**

**Sacher F**, Derval N, Jesel L, Wolpert C, Hocini M, Knecht S, Yli-Mayry S, Nault I, Lacroix D, Lim KT, Jais P, O'Neill M, Wright M, Matsuo S, De Roy L, Lellouche N, Aizawa Y, Clémenty J, Leenhardt A, Haissaguerre M. Initiation of ventricular arrhythmia in idiopathic ventricular fibrillation associated with early repolarization syndrome. **Heart Rhythm 2008,5S;S150:PO1-136**

**Sacher F**, Raymond JM, Tedrow U, Stevenson W. Unipolar vs bipolar pacing for VT pace-mapping : does it make a difference ? **Heart Rhythm 2008,5S;S229:PO3-56**

**Sacher F, Jais P**, Tedrow U, Seiler J, Hocini M, Haissaguerre M, Stevenson W. Safety and feasibility of epicardial VT ablation with open irrigated RF catheters. **Heart Rhythm 2008,5S;S371:PO6-39**

**Sacher F**, Tedrow U, Field M, Seiler F, Raymond JM, Koplan B, Epstein L, Stevenson W. Ventricular tachycardia ablation : evolution of substrate, procedure and outcome. **Heart Rhythm 2008,5S;S372:PO6-41**

**Journées Européennes de la SFC, 2008**

**Sacher F**, Raymond JM, Tedrow U, Jais P, Hocini M, Koplan B, Clémenty J, Epstein L, Haissaguerre M, Stevenson W. Ablation des tachycardies ventriculaires : récurrence et mortalité à long terme en fonction du substrat

**American Heart Association annual session, 2007**

**Sacher F**, Sobieszczyk P, Tedrow U, Eisenhauer AC, Field ME, Selwyn A, Raymond JM, Koplan B, Epstein LM, Stevenson WG. Is There An Indication For Transcoronary Ethanol VT Ablation In 2007?

## I – Préambule

### A) Historique

Les tachycardies ventriculaires (TV) sur myocardopathie ischémique peuvent survenir à la phase aiguë de l'infarctus du myocarde (IdM) mais elles apparaissent le plus souvent après un intervalle libre de plusieurs années<sup>1</sup>. On estime que 2 à 5% des patients ayant fait un infarctus transmural feront une TV au cours du suivi. Toutefois avant l'ère de la revascularisation coronaire, ce risque était beaucoup plus important et peu de thérapeutique disponible : Amiodarone disponible à partir de 1968 en France mais 1985 aux Etats-Unis, défibrillateur implantable à partir de 1980<sup>2</sup> mais élargissement de l'utilisation au cours des années 90. Avant cette époque, outre l'utilisation de bêtabloquants et d'anti-arythmiques plus ou moins délétères, seule l'ablation chirurgicale était pratiquée. La première ablation de TV chirurgicale par résection d'anévrysme a été rapportée par Couch<sup>3</sup> en 1959. Il faut attendre 1983 pour la première ablation percutanée de TV par fulguration<sup>4</sup> et 1991 pour les premières ablations de TV par RF<sup>5,6</sup> puis 2001 pour l'ablation de TV par RF avec cathéters irrigués<sup>7</sup>. Toutefois, jusque dans les années 90, c'est grâce à la cartographie per chirurgical que nous avons pu le mieux comprendre les mécanismes des TV sur myocardopathie et qu'elles ont pu être traitées<sup>8-16,17,18</sup>. C'est finalement le développement des systèmes de cartographie électro-anatomique tridimensionnelle qui a permis l'essor de ce type de procédure par voie percutanée depuis le début des années 2000.

Alors qu'auparavant seuls les patients les plus sévères avec anévrysmes ventriculaires étaient proposés à l'ablation, les indications se sont très nettement élargies. La plupart des patients adressés pour ablation de TV ont déjà un défibrillateur et ont recours à l'ablation pour des chocs itératifs. Actuellement, l'indication d'ablation est posée de plus en plus tôt car des études récentes estiment que les chocs délivrés par le défibrillateur pourraient augmenter la mortalité<sup>19</sup>.

Les indications reconnues par la dernière conférence de consensus<sup>20</sup> sont reprises dans le tableau.

**Tableau : Indication des ablations de tachycardies ventriculaires en 2014<sup>20</sup>**

Patients avec myocardopathie	Patients avec cœur sain	Contre-indication à l'ablation
Ablation recommandée si :	Ablation recommandée si :	1- en cas de thrombus mobile (éventuellement ablation épiscopordique) 2- si ESV ou TVNS asymptomatiques et ne provoquant pas de dysfonction ventriculaire 3- si TV liée à une cause réversible (hyperkaliémie ischémie, ...)
1- TV soutenue symptomatique qui récidive malgré les AA ou lorsque les AA ne sont pas tolérés ou désirés. 2- pour contrôler les orages rythmiques ou TV incessantes en l'absence de cause curable 3- patients avec ESV, TVNS ou TV fréquentes qui induisent une dysfonction ventriculaire 4- TV due à une réentrée de branche à branche ou un circuit inter fasciculaire 5- TV polymorphes soutenues ou FV récidivantes malgré les AA quand il y a une ESV initiatrice accessible à l'ablation	1- TV monomorphe responsable de symptôme sévère 2- TV monomorphe si AA inefficaces, mal tolérés ou non désirés 3- TV polymorphes ou FV récidivantes (orage rythmique) réfractaires aux AA avec ESV initiatrices identifiées	
Ablation devrait être considérée si :	1- patients avec un ou plusieurs épisodes de TV monomorphe soutenue malgré un AA de classe 1 ou 3 2- patients avec TV monomorphe soutenue liée à une cicatrice d'IdM avec FEVG>30%, en alternative à l'amiodarone 3- patients avec TV monomorphe soutenue tolérée sur cicatrice d'IdM avec FEVG>35% même en l'absence d'AA	
1- patients avec un ou plusieurs épisodes de TV monomorphe soutenue malgré un AA de classe 1 ou 3 2- patients avec TV monomorphe soutenue liée à une cicatrice d'IdM avec FEVG>30%, en alternative à l'amiodarone 3- patients avec TV monomorphe soutenue tolérée sur cicatrice d'IdM avec FEVG>35% même en l'absence d'AA		

## B) Substrat des tachycardies ventriculaires sur cardiopathie ischémique

Il existe classiquement 3 mécanismes pour la genèse des arythmies et donc des TV (automaticité, activité déclenchée, réentrée). L'automaticité et l'activité déclenchée donnent des TV focales ou multifocales. Nous n'aborderons dans cette thèse que la réentrée car il s'agit du mécanisme le plus fréquent chez les patients avec myocardopathie. Pour comprendre le substrat de ces réentrées, il faut garder en mémoire qu'elle nécessite pour exister : (1) un bloc unidirectionnel et (2) que la longueur d'onde de l'influx électrique (vitesse de conduction x période réfractaire) soit plus courte que le circuit de la réentrée.

### 1) Histologie

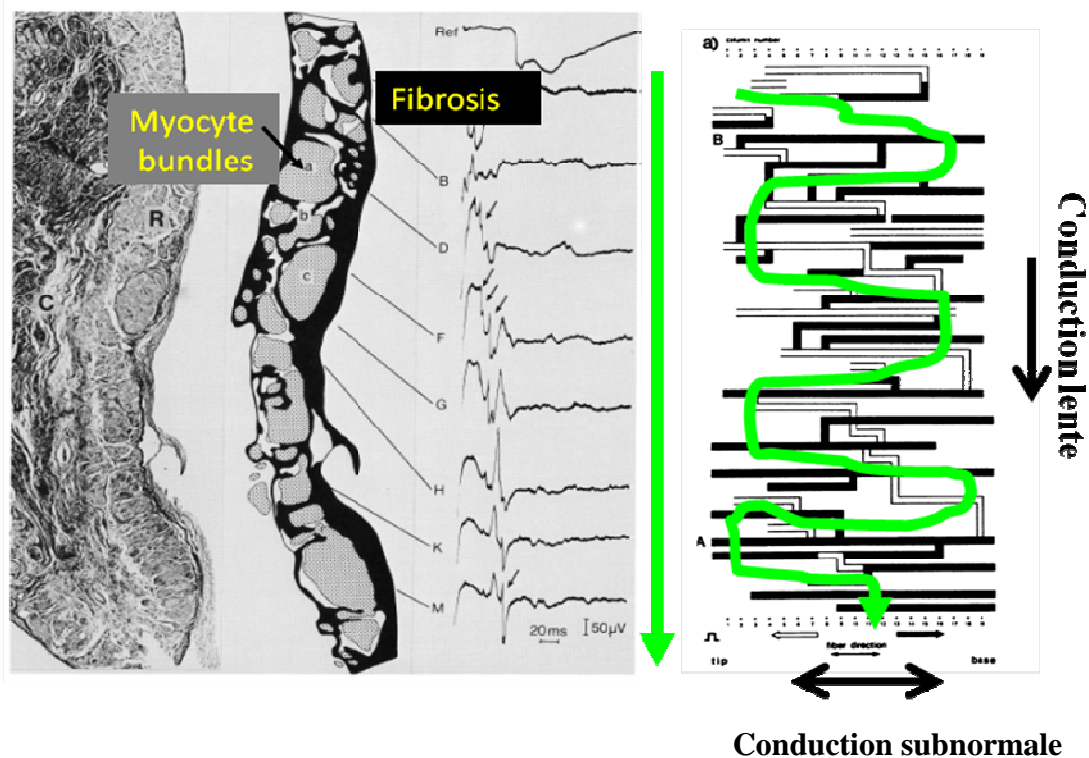
Après un infarctus du myocarde, du tissu conjonctif est retrouvé entre les îlots de myocytes survivants à l'intérieur de la zone infarctée où la fibrose est importante<sup>21</sup>. Les myocytes survivants peuvent être connectés entre eux pour former de véritables chemins de conduction de l'influx électrique à l'intérieur de la cicatrice. En 1993, de Bakker et coll.<sup>22</sup> ont démontré que le ralentissement de la conduction à l'intérieur de la cicatrice d'infarctus était lié à la présence de tissu fibreux entre les amas de myocytes survivants. Ils ont également montré que les vitesses de conduction étaient très inhomogènes dans ces zones avec une conduction quasiment normale dans le sens des fibres alors qu'à l'opposé, la conduction transversale était très ralentie, engendrant une activation en zigzag (**figure 1**). La présence de fibrose à l'intérieur de la cicatrice d'infarctus engendre une perte de couplage électrique transversale entre les myocytes survivants et comme les connexions termino-terminales des myocytes sont peu affectées dans la zone cicatricielle<sup>23</sup>, l'influx électrique se propage de façon longitudinale à travers ces faisceaux de myocytes. Ils forment des zones d'activation préférentielles protégées par la fibrose appelées chenaux « channel » que l'on peut traduire par isthme lorsqu'ils sont le siège de blocs unidirectionnels et donc du développement d'arythmie ventriculaire par réentrée.

Sur les coupes histologiques, ces faisceaux de myocytes peuvent ne pas mesurer plus de 0.1 à 0.2 mm<sup>21</sup>. Toutefois, la taille des isthmes responsables de TV chez l'homme a été mesurée, lors de cartographie électro-anatomique à  $16 \pm 8$  mm de large (de 6 à 30 mm) et  $31 \pm 7$  mm de long<sup>24</sup>.

Il est intéressant de constater que le délai entre l'infarctus et l'apparition de TV est généralement long (plusieurs années)<sup>1</sup>. Il existe donc pendant cette période un remodelage myocardique pour arriver à la création de ces chenaux et qu'ils acquièrent les propriétés électrophysiologiques leur permettant de soutenir un circuit de tachycardie. Sur des cœurs ischémiques ou avec insuffisance cardiaque, il a été montré que des fibroblastes pouvaient se différencier en myofibroblastes. Ces derniers favoriseraient le couplage électrique entre les myocytes survivants et les fibroblastes grâce aux « gap junctions » ce qui augmenterait la susceptibilité de développer des arythmies réentrantes<sup>25</sup>. Des études chez le chien ont montré que la fibrose liée à l'infarctus altère la taille et la forme des myocytes ainsi que leur interconnexion. Ces phénomènes entraînent un ralentissement de la conduction, des blocs de conduction et donc le potentiel pour des circuits réentrants<sup>26</sup>. Il existe également une modification des canaux ioniques de ces cellules due à l'altération des protéines constituant ces canaux et un remodelage des connections (connexine 43) intercellulaires<sup>27</sup>.

**Figure 1: Activation en zig-zag dans la zone infarctée<sup>22</sup>.**

A gauche, coupe perpendiculaire à la direction des fibres de l'endocarde d'un muscle papillaire réséqué (C=fibrose ; R= îlot de myocytes survivants). A droite représentation schématique de la propagation de l'influx électrique dans la cicatrice. La vitesse de conduction dans le sens des fibres (à l'horizontal) est normale alors que dans le sens transversal (vertical) la conduction est très ralentie.



## 2) Système nerveux autonome

Le remodelage du système nerveux autonome après un infarctus se caractérise par une hétérogénéité de la repousse nerveuse cardiaque et une surreprésentation du système nerveux sympathique cardiaque<sup>28-30</sup>. Ce remodelage neuronal après infarctus du myocarde résulte du relargage local immédiat de NGF (Nerve Growth Factor) suivi d'une augmentation de l'expression du NGF et la GAP 43 (Growth Associated Protein 43) dans la zone infarctée. Ces NGF et GAP43 sont transportés à retro vers le ganglion stellaire qui à son tour induit la repousse nerveuse essentiellement dans les zones non infarctées du ventricule gauche. Zhou et al<sup>31</sup> ont montré que chez des chiens avec infarctus chronique et innervation cardiaque majorée, des décharges sympathiques spontanées provoquaient des arythmies ventriculaires. L'importance du remodelage du système nerveux autonome dans la survenue des arythmies ventriculaires chez les patients avec cardiopathie est également supportée par l'efficacité clinique des bêtabloquants et de la sédation pour la prévention de ces arythmies ou pour contrôler un orage rythmique. De plus études chez l'homme ont montré que la dénervation sympathique cardiaque gauche ou bilatérale permettait de contrôler les orages rythmiques<sup>32</sup>.

### C) Relation Substrat/ Electrogrammes (EGM)

La précision des électrogrammes (EGM) enregistrés en mode unipolaire est théoriquement meilleure qu'en mode bipolaire pour définir l'activation de l'activité électrique cardiaque. Toutefois ce sont les enregistrements bipolaires qui sont toujours utilisés pour cartographier les arythmies réentrantes. Le signal à distance est plus atténué avec les enregistrements bipolaires, ils sont donc plus précis pour analyser les signaux locaux. Nous ne traiterons ici que des signaux bipolaires.

#### 1) Amplitude des EGM

L'équipe de Philadelphie a montré que les EGM bipolaires enregistrés dans les zones de cicatrices en rythme sinusal étaient typiquement inférieurs à 1,5 mV et que des signaux inférieurs à 0.5 mV représentaient souvent la zone la plus fibrotique de la cicatrice (dense scar). Ces valeurs sont maintenant utilisées par la plupart des électrophysiologistes.

## 2) Fragmentation des EGM

Les EGM à l'intérieur des cicatrices myocardiques sont souvent plus tardifs et fragmentés<sup>33-35</sup> avec multiples composantes représentant chacune une activation non synchrone des différentes fibres musculaires survivantes à l'intérieur de la cicatrice<sup>36</sup>. En utilisant une simulation d'un modèle de microfibre<sup>37</sup>, il a également été montré que l'augmentation de la densité et de la longueur du tissu collagène diminuait les vitesses de conduction jusqu'à 75% et augmentait le nombre de déflexions des potentiels fragmentés (jusqu'à 14 déflexions). A l'inverse, la conduction lente induite par les bloqueurs des canaux sodiques réduit de façon uniforme les vitesses de conduction et ne résulte donc pas en une fragmentation des EGM.

## 3) Potentiels tardifs

Hsia et coll.<sup>38</sup> ont étudié la relation entre les potentiels tardifs et le substrat endocardique des TV réentrantes. Il a montré une incidence importante des potentiels tardifs enregistrés près de l'isthme (89%) par rapport aux sites d'entrée (57%) ou de sortie (20%) de la zone cicatricielle de l'isthme. Les potentiels étaient d'autant plus tardifs qu'ils étaient situés aux sites d'entrée de la TV dans l'infarctus ( $218 \pm 27$  ms) ou dans l'isthme ( $194 \text{ ms} \pm 40$  ms par rapport aux potentiels tardifs enregistrés aux sites de sortie de la tachycardie ventriculaire ( $131 \pm 29$  ms). De la même façon, Harada et coll.<sup>39</sup> ont montré un long délai de conduction sur l'électrocardiogramme de surface entre l'artéfact de stimulation et le début du QRS de surface quand on stimule dans la zone retrouvant ces potentiels tardifs. Il a également trouvé une prévalence plus importante de potentiels tardifs au niveau central ou proximal du circuit de réentrée par rapport aux sorties ou au circuit externe. La capacité des potentiels tardifs à démasquer de façon efficace ces isthmes responsables des tachycardies est cependant limitée. En fait, Harada et coll.<sup>39</sup> ont démontré que les potentiels tardifs étaient aussi fréquents dans la cicatrice mais en dehors des circuits de la tachycardie ventriculaire. De la même façon, la présence de potentiels tardifs n'était pas corrélée aux potentiels mid-diastoliques enregistrés pendant les TV qui sont pathognomoniques de l'isthme.

## 4) Doubles Potentiels

Les doubles potentiels suggèrent la présence de bloc de conduction locale et même de lignes de bloc lorsque ces potentiels sont enregistrés sur une distance assez importante. Ils sont également fréquemment retrouvés dans les zones infarctées. Ils sont le témoin de la présence de



fibres de myocytes survivants et électriquement connectés au tissu environnant mais avec une conduction excessivement lente entre les deux structures.

Alors que Cassidy et al.<sup>8</sup> ne retrouvaient pas d'aspect d'EGM en rythme sinusal prédictif du site d'origine des TV sur myocardopathie ischémique, Zeppenfeld et al.<sup>40</sup> ont montré qu'un EGM ayant une amplitude inférieure à 1 mV, une durée supérieure ou égale à 40 ms et au moins quatre déflexions, avait une sensibilité de 86% et une spécificité de 94% pour prédire les sites d'ablation efficace des TV. Par ailleurs, nous avons récemment montré que l'élimination de toutes les activités ventriculaires locales anormales (potentiels tardifs, fragmentés, doubles potentiels) permettait lorsqu'on y arrivait, d'avoir un meilleur taux de succès<sup>41</sup>.

## D) Techniques de cartographie

### *1) Cartographie d'activation*

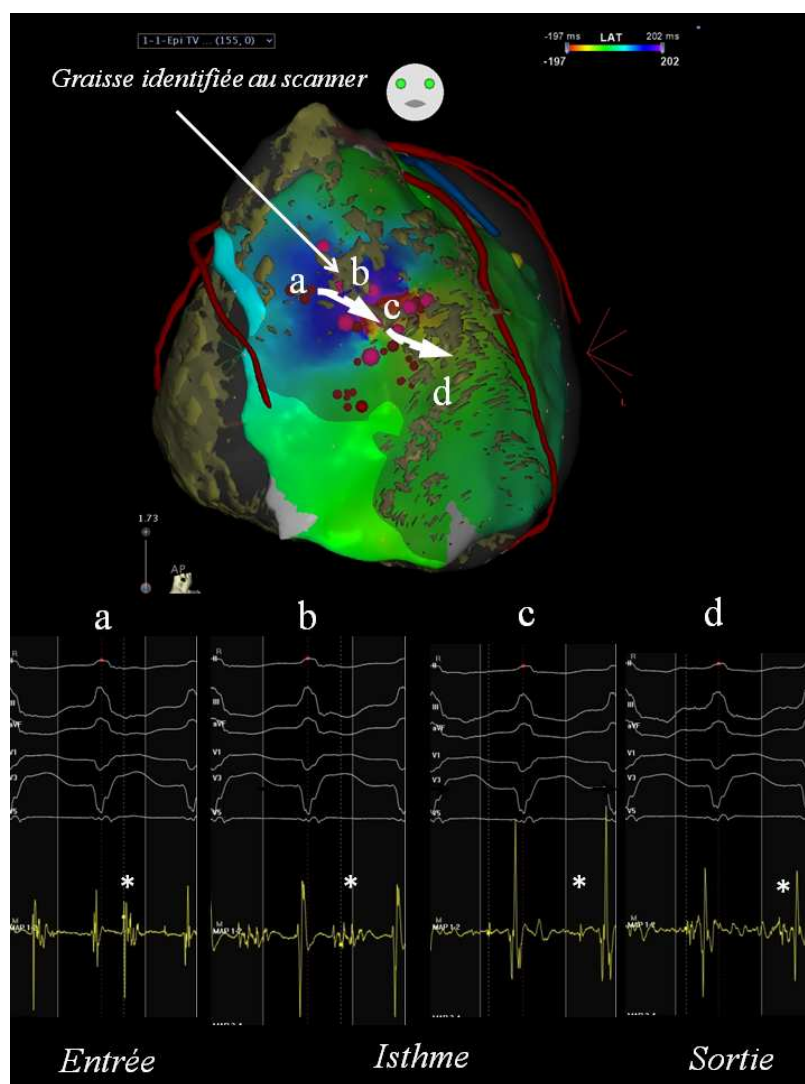
Cette méthode n'est utilisable que lorsque la TV est inductible et suffisamment bien tolérée pour être respectée pendant quelques minutes à dizaines de minutes. Elle est, le plus souvent, utilisée de manière limitée dans la zone d'intérêt (cicatrice) pour localiser des potentiels mid-diastoliques et associée à des manœuvres d'entraînement pour s'assurer que l'on se trouve bien dans le circuit de la TV. Cette cartographie d'activation peut être réalisée point par point avec un cathéter quadripolaire en le déplaçant d'un point à l'autre mais également avec des cathéters multipolaires, ce qui permet d'obtenir une carte détaillée plus rapidement. Généralement, en cartographie de contact, on utilise l'enregistrement bipolaire, ce qui permet de diminuer les signaux farfield. On va alors chercher des potentiels sur l'ensemble du cycle. Typiquement ceux qui précède le début du QRS par moins de 30% du cycle de la TV sont nommés pré-systoliques. Lorsqu'ils surviennent plus précocement, on parle de potentiels mid-diastoliques (**figure 2**).

Dans les TV macro-réentrantes qui sont les plus fréquentes sur les cicatrices myocardiques il n'y a pas de point le plus précoce ou le plus tardif mais une activité continue.

Plusieurs facteurs peuvent limiter ce type de cartographie. Outre l'absence de TV inductible ou bien tolérée, l'activation locale peut parfois être difficile à identifier quand les potentiels sont

fragmentés ou dédoublés. Il est parfois difficile de savoir quelle est l'activation locale de l'activation farfield. De plus, l'activation locale dans l'isthme est souvent de faible amplitude et peut parfois ne pas être visualisée sur le système de recueil lorsque l'amplification utilisée est faible ou que le niveau de bruit est élevé (**figure3**). Enfin si une partie du circuit est intramurale ou épicardique et que l'on ne cartographie que l'endocarde, on peut la manquer.


**Figure 2 : Exemple de carte d'activation avec les EGMs correspondants**



Carte d'activation épicardique réalisée avec système CARTO 3 (Biosense Webster). Sur cette carte, ont été intégrées l'infiltration graisseuse myocardique ainsi que les coronaires à partir des images du scanner. L'activation est représentée par un code couleur. Les EGM en TV montrent : (a) un potentiel (\*) après le QRS de surface témoin de l'entrée dans la cicatrice, (b) un potentiel fragmenté mid-diastolique (\*) correspondant au milieu de l'isthme où la conduction est la plus lente, (c) un potentiel plus fin (\*) et se rapprochant du QRS suivant et donc de la sortie et enfin (d) un potentiel pré-systolique (\*) correspondant au site d'émergence de la TV. A noter que le potentiel le plus ample est en fait un potentiel far-field correspondant à la dépolarisation autour de la cicatrice.

**Figure 3. Recueil dans la zone cicatricielle où le potentiel local est beaucoup moins volté que le potentiel farfield.**

L'amplitude du potentiel d'intérêt est égale au niveau du bruit lorsque le système de cartographie électro-anatomique (3D system) est en marche. Il n'est donc pas visible par contre lorsqu'on éteint le système il devient apparent si le gain est suffisant.



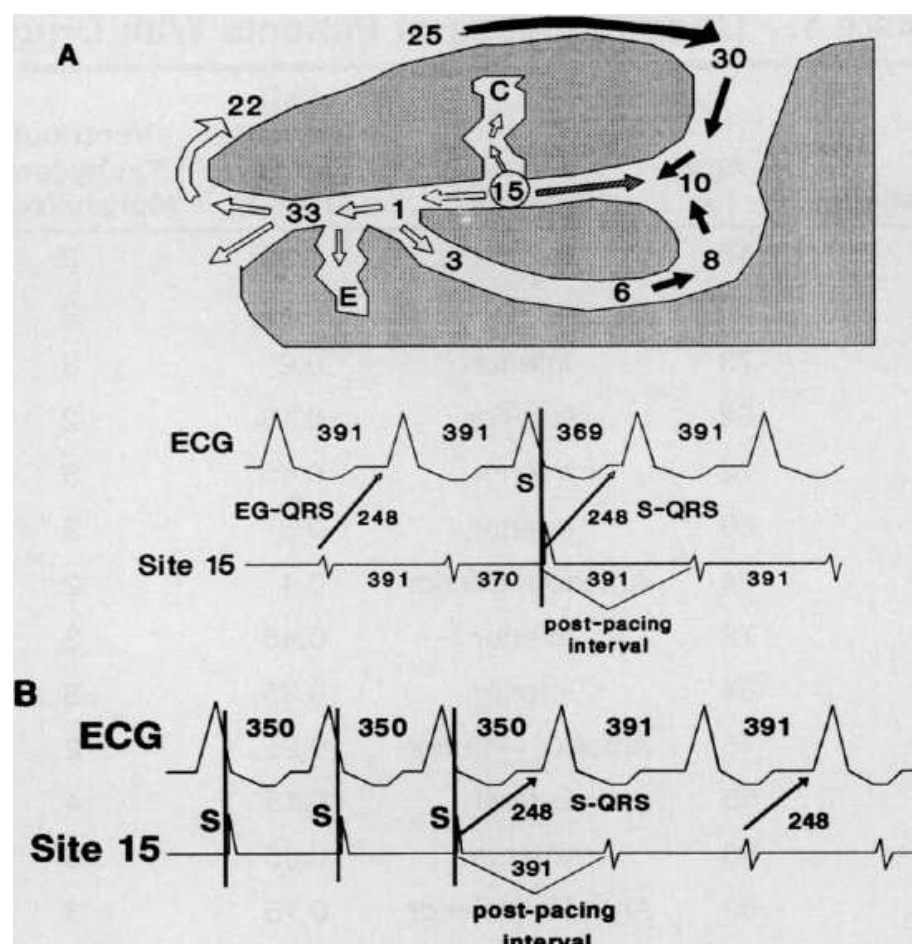
## 2) Cartographie par entrainement

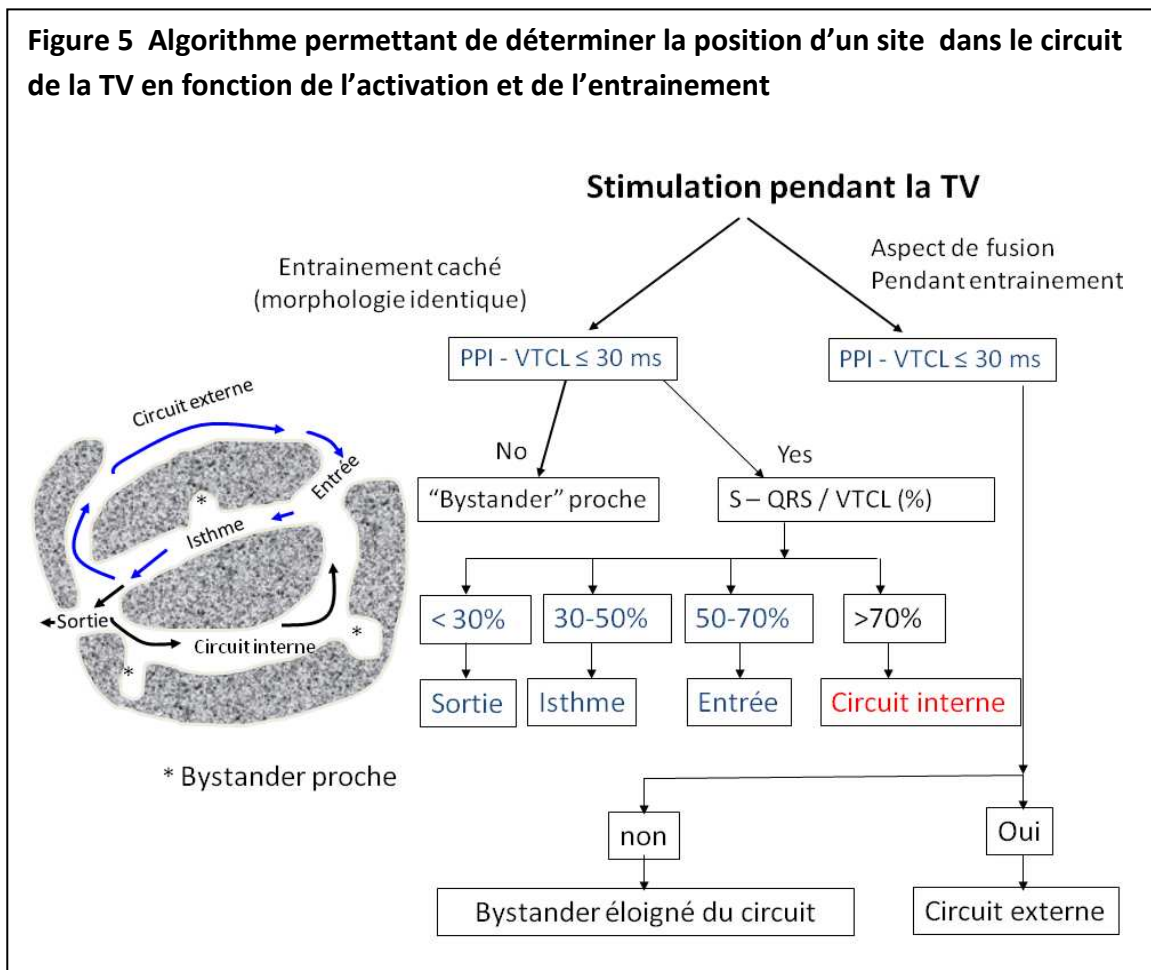
L'entrainement est particulièrement utile lors de la cartographie de tachycardie réentrante afin de distinguer les sites appartenant aux circuits des sites dits « bystander » en dehors du circuit<sup>43</sup>. La **figure 4** résume le trajet de l'influx électrique dans une tachycardie réentrante. L'idée est de stimuler en un site d'intérêt un peu plus rapidement que le cycle de la tachycardie ( $\approx 30\text{ms}$ ) afin de la capturer. Une fois la TV capturée, on arrête de stimuler et on mesure le cycle de retour (PPI=postpacing interval). Lorsqu'on soustrait à ce PPI le cycle de la tachycardie (PPI-TCL), on obtient une valeur qui lorsqu'elle est  $\leq 30\text{ms}$  est généralement considérée comme témoin d'un site de stimulation dans le circuit de la tachycardie. Lorsque la stimulation est réalisée dans l'isthme, la morphologie des complexes entrainés est identique à celle de la TV (entrainement caché), il n'y a pas d'aspect de fusion. Cela témoigne d'un acheminement de l'influx électrique hors de la cicatrice par le même point de sortie qu'en TV. Cela sera aussi le cas si on stimule au point de sortie de la TV mais là, l'intervalle entre l'artéfact de stimulation et le QRS sera très court. La stimulation d'une région bystander dans la cicatrice mais avec un influx émergent par la même sortie aura également la même morphologie mais le cycle de retour sera long avec un  $\text{PPI-TCL} > 30\text{ms}$  (**figure 5**). Lorsque l'on se trouve à l'entrée du circuit, on

obtiendra une fusion progressive avec modification de l'aspect ECG par rapport à la tachycardie mais le cycle de retour sera court (PPI-TCL<30ms). Par contre lorsqu'on stimule à l'extérieur de la cicatrice non seulement la morphologie changera mais le cycle de retour sera long si l'on est en dehors du circuit. Le but de l'ablation en TV est de cibler l'isthme <sup>44-46</sup>.

**Figure 4 : Représentation d'un circuit de TV avec ECG et EGM enregistré au site 15 <sup>43</sup>**

La stimulation au site 15 (isthme du circuit de TV) pendant la TV (cycle 391ms) engendre une activation orthodromique vers le site 1 puis la sortie de la cicatrice (site 33) qui correspond au début du QRS. La stimulation (panel B) anticipe la tachycardie (stimulation 40ms plus rapide: 350ms) et continue de la recycler tant que dure la stimulation (aspect ECG identique = entraînement caché). A l'arrêt de la stimulation, le cycle de retour (PPI) est de 391ms, c'est-à-dire le cycle de la tachycardie montrant que le site de stimulation se situe dans le circuit de la TV





### 3) Cartographie du substrat

La majorité des patients adressés pour ablation de TV sur myocardopathie ont plusieurs morphologies de TV qui ne peuvent pas toutes être cartographiées. Dans l'étude multicentrique Thermocool, Stevenson et al. ont montré que 31% des patients n'avaient que des TV non cartographiables et 38% des TV cartographiables et non cartographiables<sup>47</sup>. La cartographie du substrat permet de faire la majorité de l'ablation si ce n'est toute l'ablation en rythme sinusal ce qui permet de très nettement diminuer le risque de complication hémodynamique.

Les techniques de cartographie du substrat ont évolué à travers le temps et peuvent être différentes d'un centre à l'autre. Au début, il s'agissait d'identifier la cicatrice d'infarctus responsable de la TV. Le chirurgien faisait alors une résection sous endocardique chirurgicale de cette cicatrice<sup>15</sup>. Toutefois lorsqu'il s'est agi d'ablation endocavitaire, il a fallu limiter la zone à

traiter et identifier cette zone infarctée (pas de visualisation directe de la zone comme pour le chirurgien). Il y a alors eu de nombreux travaux sur l'aspect des électrogrammes endocavitaires permettant de repérer les zones d'intérêt. Au début des années 2000, les systèmes de cartographie tridimensionnelle se sont développés permettant de réaliser des cartes du voltage endocardique. Les études initiales sur la faisabilité de l'ablation des TV sur myocardopathie basée sur le voltage ont non seulement montré l'utilité de cette stratégie dans les TV post infarctus mais également chez des patients avec myocardopathie non ischémique. Les limites de voltage  $<1.5\text{mV}$  pour des régions cicatricielles et  $<0.5\text{mV}$  pour de la cicatrice dense<sup>33, 34</sup> ont alors été adoptées dans tous les laboratoires d'électrophysiologie.

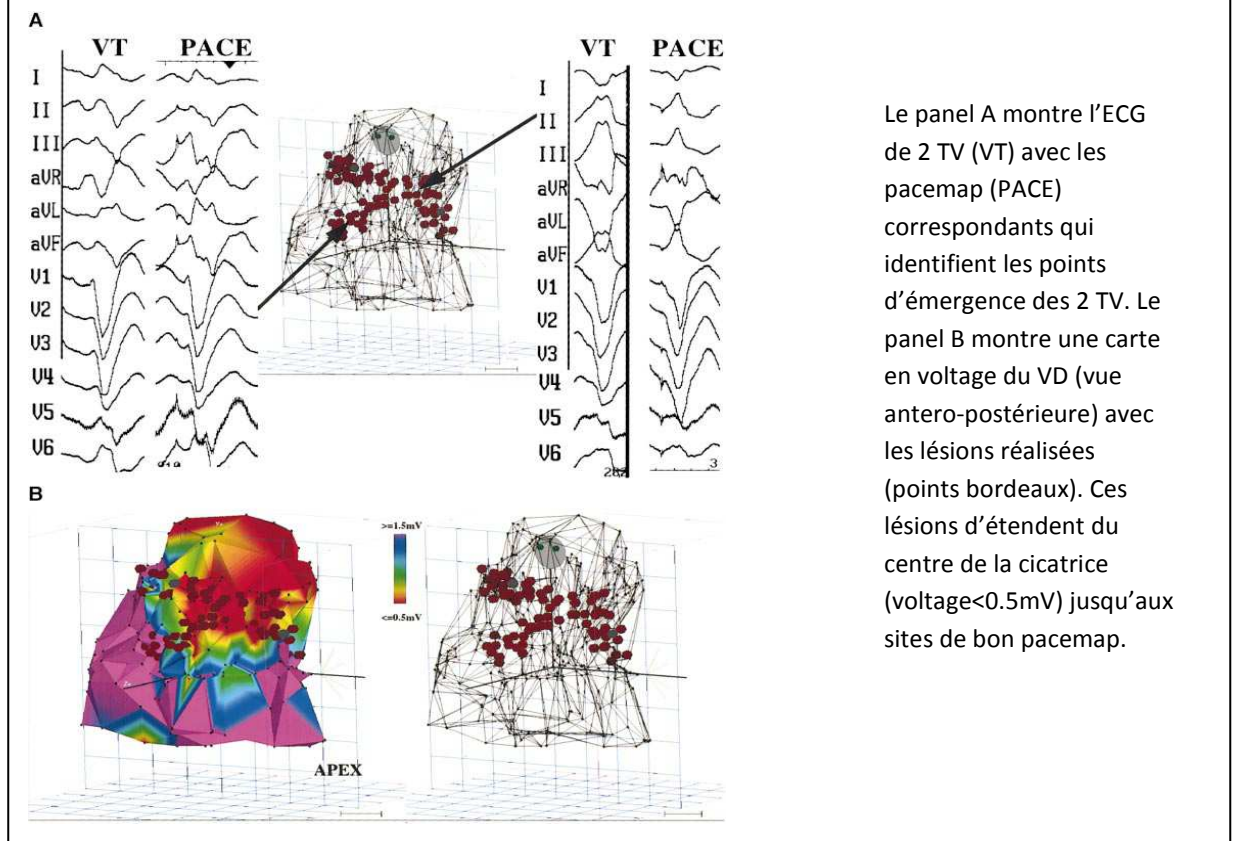
Chez les patients avec TV sur cicatrice myocardique, la zone de bas voltage ( $<1.5\text{mV}$ ) est souvent étendue et l'ablation complète de cette zone voir son encerclement par application de radiofréquence n'est généralement pas réalisable ni même souhaitable. Différentes stratégies pour éliminer le substrat des TV ont été rapportées. La première est la topo-stimulation ou pacemapping dans la zone bordante de la cicatrice pour identifier les zones de sortie de la TV<sup>34</sup>. Des lésions linéaires sont alors réalisées dans ces zones de sortie puis l'ablation est complétée vers l'intérieur de la cicatrice ou se situe généralement l'isthme de la TV (**figure 6**). D'autres types de lésions ont été proposés par exemple parallèle à la zone bordante dans la zone de bas voltage pour couper le chemin de sortie de l'influx électrique<sup>48</sup> (**figure 7**).

Même si ces stratégies peuvent être efficaces, leur limite réside dans le fait qu'il ne cible qu'une TV et qu'il faille la morphologie de cette dernière pour guider le pacemapping. Beaucoup de centres d'électrophysiologie ont proposés leur propre stratégie par exemple en ciblant les potentiels tardifs isolés<sup>49, 50</sup> qui sont souvent présents dans l'isthme des TV mais qui ne sont pas très spécifiques. Le groupe de Boston a proposé de stimuler dans la cicatrice pour identifier les zones non excitables qui correspondent à de la fibrose et qui peuvent donc démasquer des isthmes<sup>51</sup> (**figure 8**). Ils proposent ainsi de relier ces zones entre elles ou à un obstacle anatomique afin de bloquer ces isthmes potentiels. Une autre façon d'identifier un isthme potentiel est de jouer sur les limites de la carte de voltage car Arenal et al. ont montré qu'un isthme peut être identifié comme une zone de très bas voltage encadrée par du tissu mieux volté au sein de la cicatrice<sup>52, 53</sup> (**figure 9**). Plus récemment, nous avons proposés d'éliminer tous les potentiels anormaux dans la cicatrice et avons montré que lorsqu'on y arrivait, le devenir des patients était meilleur (réduction de la mortalité ou récurrence de TV, HR : 0.49; 0.26–0.95;



$p=0.035$ )<sup>41</sup>. Enfin de Chillou et al.<sup>54</sup> ont utilisé le pacemap pour identifier les isthmes potentiels dans la cicatrice (**figure 10**).

**Figure 6: Schéma d'ablation linéaire proposé par Marchlinski et al.<sup>34</sup>**



**Figure 7: Carte Electroanatomique en voltage chez un patient avec large cicatrice antéro-septo-apicale<sup>48</sup>**

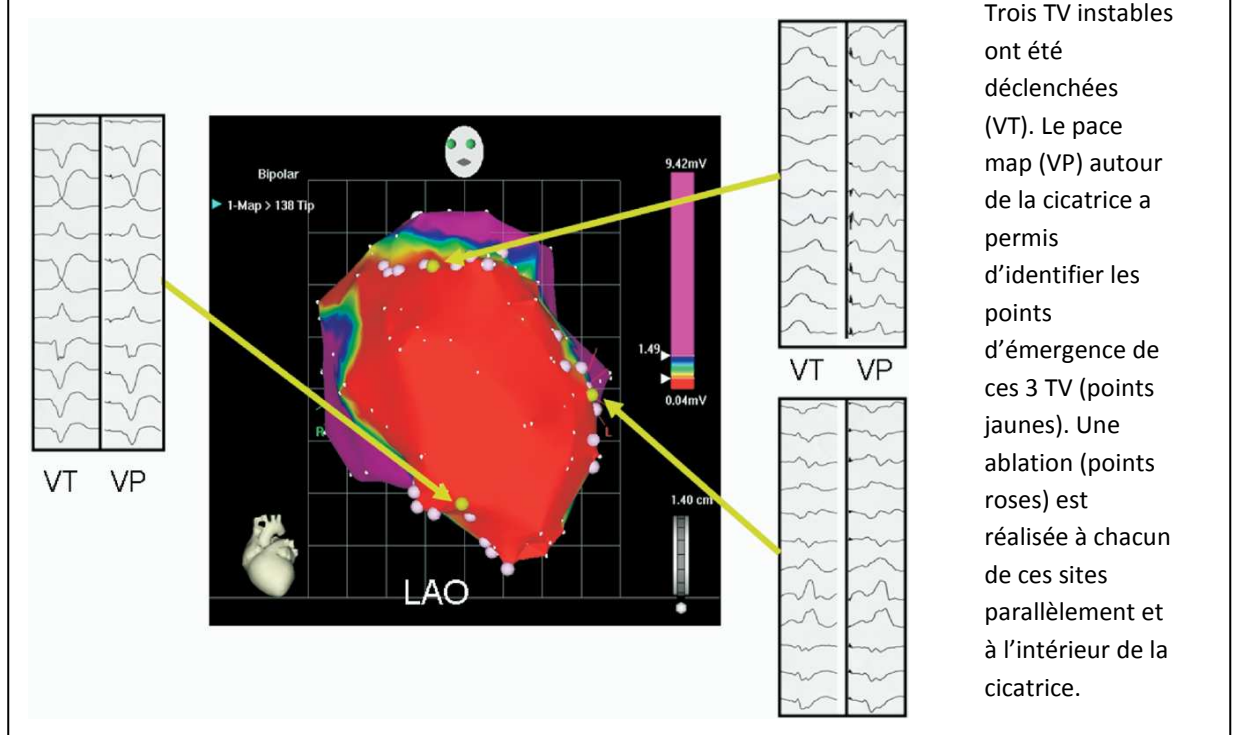
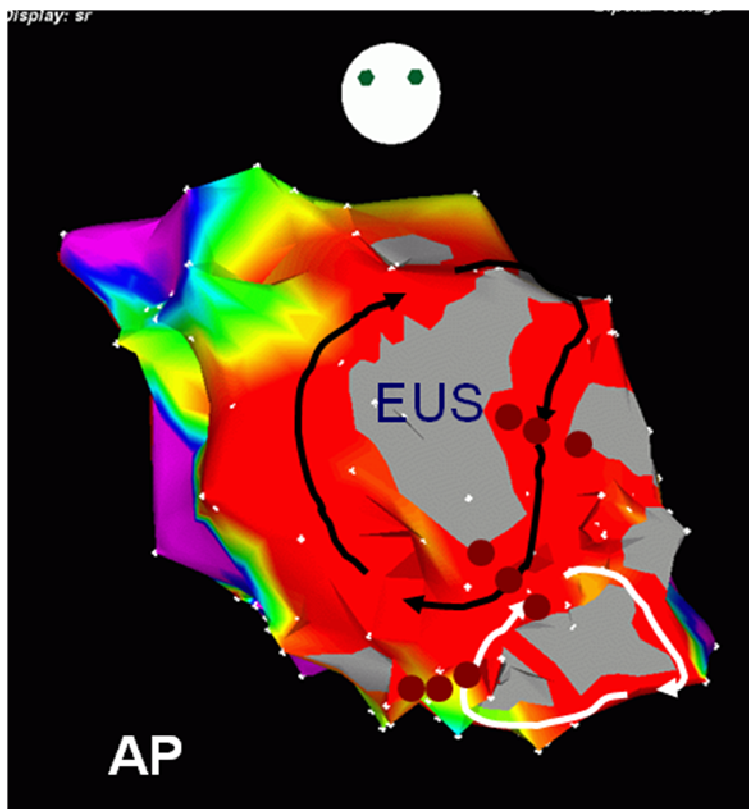


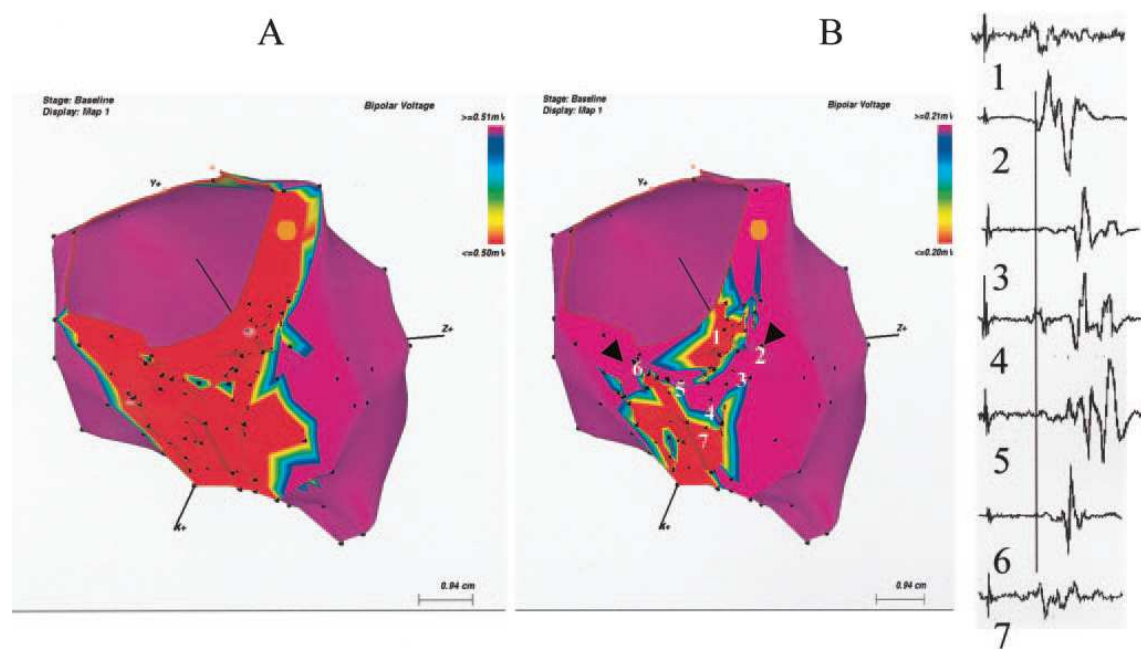
Figure 8: Identification des zones non excitables<sup>51</sup>



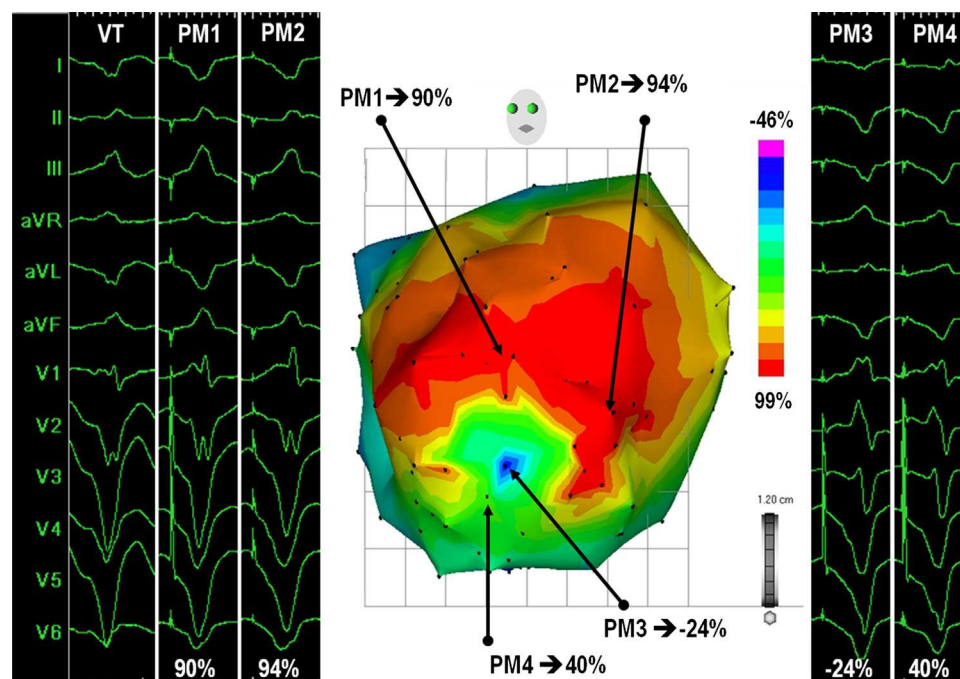
Carte électroanatomique en voltage du VG. La zone grise (EUS) représente la zone non stimuable malgré des stimulations à 10mA pendant 2ms. Cela démasque des chenaux qui sont alors coupés par application de radiofréquence (points bordeaux)

Figure 9: Cartes en voltage montrant l'effet de modification du voltage sur l'identification d'isthme potentiel<sup>52</sup>

Vue de la face inférieure du VG avec cicatrice définie à 0,5mV (panel A) puis 0,2mV (panel B). A 0,2mV, un isthme apparaît. A droite sont représentés les EGM enregistrés dans cet isthme.





**Figure 10: Pacemap pour identifier les isthmes en rythme sinusal<sup>54</sup>**

Exemple de carte de pacemapping chez un patient avec infarctus antérieur. L'ECG 12 dérivations en TV (VT) ainsi que les ECG résultant de 4 pacemap (PM 1 à 4) sont représentés avec leur localisation sur une reconstruction 3D du cœur (CARTO3, Biosense Webster). Le codage couleur représente le pourcentage de correspondance entre le pacemap local et l'aspect 12 dérivations de la TV.

Ces différentes stratégies d'ablation du substrat n'ont jamais été directement comparées entre elles et les taux de récurrence de TV avec l'une ou l'autre technique sont similaires dans la littérature. L'ablation du substrat aboutit en général à une diminution très nette du nombre d'épisodes de TV et donc de choc chez les porteurs de défibrillateur<sup>34, 41, 47, 49, 52, 55, 56</sup>. C'est une approche largement utilisée dans l'ablation de TV pour les patients avec TV non cartographiables mais également pour les patients avec TV cartographiables chez lesquels on associe les techniques de cartographie d'activation et d'entraînement.

### E) Apport de l'imagerie pour l'ablation des tachycardies ventriculaires

Récemment les techniques d'imagerie se sont développées en électrophysiologie interventionnelle. Elles ont un rôle crucial avant, pendant et après la procédure. Elles vont permettre non seulement d'identifier la cardiopathie sous-jacente mais également d'identifier le substrat arythmogène et éventuellement de s'assurer de l'efficacité de la procédure et de l'absence de complication.

#### 1) Echographie

L'échocardiographie transthoracique est bien sûr largement utilisée avant l'ablation afin d'évaluer la fonction ventriculaire gauche et la cardiopathie sous-jacente. Elle sert aussi avec injection de contraste à éliminer un thrombus intra-ventriculaire gauche en cas d'anévrisme ou de cardiopathie très dilatée.

L'échographie transoesophagienne permet essentiellement d'éliminer un thrombus intra-auriculaire gauche et pour certaines équipes, réaliser un cathétérisme transeptal. Lorsque l'on retrouve une athéromatose importante de la crosse aortique, elle peut également influencer sur la voie d'abord en préférant la voie transeptale à la voie rétrograde aortique.

Enfin, certaines équipes utilisent également l'échographie intracardiaque pour guider leur cathéter, faire la ponction transeptale et éventuellement intégrer l'anatomie cardiaque dans le système de navigation (CartoSound , Biosense Webster).

## *2) Imagerie par résonance magnétique*

Une IRM, lorsqu'elle est faisable, permet d'aider au diagnostic de la cardiopathie sous-jacente lorsqu'elle n'est pas connue. Elle permet également d'identifier la cicatrice et de voir si cette dernière est endocardique, épicaudique, intramurale, voire transmurale<sup>57</sup>. Toutes ces informations peuvent être importées dans les systèmes de cartographie actuels. Par ailleurs, dans une étude prospective incluant 48 patients avec cardiopathie ischémique, la taille de l'infarctus et sa masse à l'IRM ont été identifiés comme prédicteurs d'inductibilité de tachycardie ventriculaire<sup>58</sup>. Il a également été montré que l'hétérogénéité de la zone bordante d'un infarctus était également prédictive d'inductibilité<sup>59</sup> et un facteur de risque de mortalité chez les patients avec myocardiopathie ischémique<sup>60</sup>. Dans un modèle animal d'infarctus du myocarde, le rehaussement tardif haute résolution à l'IRM avait une très bonne corrélation avec les isthmes des TV situés en bordure de la cicatrice<sup>61</sup>. Pour résumer, ces résultats suggèrent que le risque augmente avec la taille de l'infarctus<sup>58</sup>, la complexité géométrique de la cicatrice<sup>62</sup>, et son hétérogénéité<sup>59, 60, 63</sup>. S'ils sont prometteurs, ces résultats sont issus d'études animales ou de séries cliniques de petite taille, et comprenant exclusivement des patients ischémiques.

Toutefois l'IRM est maintenant régulièrement utilisée lors des ablations de tachycardie ventriculaire pour améliorer l'identification des zones anormales.

### *3) Scanner cardiaque*

Les gros avantages du scanner par rapport à l'IRM sont une meilleure résolution spatiale et la possibilité de l'utiliser chez les porteurs de défibrillateur. Il permet non seulement d'avoir une idée précise de l'anatomie cardiaque (coronaires, nerf phrénique) si on doit avoir un accès épicardique, mais également d'identifier le substrat sous-jacent. Il permet d'identifier les zones d'amincissement cardiaque. On peut ensuite importer et fusionner ces zones dans le système de cartographie tridimensionnelle pour mieux cibler la zone cicatricielle <sup>64</sup>.

### *4) Autres techniques d'imagerie*

D'autres méthodes d'imagerie ont été rapportées. L'angiographie rotationnelle<sup>65</sup> permet d'avoir une anatomie précise de la cavité à explorer. Les scintigraphies au MIBI/MIBG<sup>66, 67</sup> permettent d'avoir une information sur la dénervation adrénergique. Il devient possible d'intégrer ces informations sur les plateformes de cartographie et donc d'avoir une information fonctionnelle en plus des éléments anatomiques. Enfin le PET-scan apporte non seulement des données utiles sur les zones de cicatrice lors de sarcoïdose cardiaque mais, il pourrait également être utile chez les patients avec myocardiopathie qui sont porteurs de défibrillateur afin d'identifier les zones cicatricielles et d'avoir une meilleure caractérisation tissulaire voir des informations sur le métabolisme tissulaire<sup>68-70</sup>. Ces informations pourraient ensuite être intégrées dans les systèmes de cartographie.

**F) Références**

1. Sacher F, Tedrow U, Field ME, Raymond JM, Koplan B, Epstein L, Stevenson WG. Ventricular Tachycardia Ablation: Evolution of Patients and Procedures Over 8 Years. *Circ Arrhythm Electrophysiol.* 2008; 1: 153-161.
2. Mirowski M, Reid PR, Mower MM, Watkins L, Gott VL, Schauble JF, Langer A, Heilman MS, Kolenik SA, Fischell RE, Weisfeldt ML. Termination of malignant ventricular arrhythmias with an implanted automatic defibrillator in human beings. *N Engl J Med.* 1980; 303: 322-324.
3. COUCH OA, Jr. Cardiac aneurysm with ventricular tachycardia and subsequent excision of aneurysm; case report. *Circulation.* 1959; 20: 251-253.
4. Hartzler GO. Electrode catheter ablation of refractory focal ventricular tachycardia. *J Am Coll Cardiol.* 1983; 2: 1107-1113.
5. Kuck KH, Schluter M, Geiger M, Siebels J. Successful catheter ablation of human ventricular tachycardia with radiofrequency current guided by an endocardial map of the area of slow conduction. *Pacing Clin Electrophysiol.* 1991; 14: 1060-1071.
6. Morady F, Harvey M, Kalbfleisch SJ, el-Atassi R, Calkins H, Langberg JJ. Radiofrequency catheter ablation of ventricular tachycardia in patients with coronary artery disease. *Circulation.* 1993; 87: 363-372.
7. Soejima K, Delacretaz E, Suzuki M, Brunckhorst CB, Maisel WH, Friedman PL, Stevenson WG. Saline-cooled versus standard radiofrequency catheter ablation for infarct-related ventricular tachycardias. *Circulation.* 2001; 103: 1858-1862.
8. Cassidy DM, Vassallo JA, Buxton AE, Doherty JU, Marchlinski FE, Josephson ME. The value of catheter mapping during sinus rhythm to localize site of origin of ventricular tachycardia. *Circulation.* 1984; 69: 1103-1110.
9. Buxton AE, Marchlinski FE, Doherty JU, Cassidy DM, Vassallo JA, Flores BT, Josephson ME. Repetitive, monomorphic ventricular tachycardia: clinical and electrophysiologic characteristics in patients with and patients without organic heart disease. *Am J Cardiol.* 1984; 54: 997-1002.
10. Vassallo JA, Cassidy D, Simson MB, Buxton AE, Marchlinski FE, Josephson ME. Relation of late potentials to site of origin of ventricular tachycardia associated with coronary heart disease. *Am J Cardiol.* 1985; 55: 985-989.
11. Cassidy DM, Vassallo JA, Buxton AE, Doherty JU, Marchlinski FE, Josephson ME. Catheter mapping during sinus rhythm: relation of local electrogram duration to ventricular tachycardia cycle length. *Am J Cardiol.* 1985; 55: 713-716.
12. Vassallo JA, Cassidy DM, Marchlinski FE, Miller JM, Buxton AE, Josephson ME. Abnormalities of endocardial activation pattern in patients with previous healed myocardial infarction and ventricular tachycardia. *Am J Cardiol.* 1986; 58: 479-484.

13. Kienzle MG, Doherty JU, Cassidy D, Buxton AE, Marchlinski FE, Waxman HL, Josephson ME. Electrophysiologic sequelae of chronic myocardial infarction: local refractoriness and electrographic characteristics of the left ventricle. *Am J Cardiol.* 1986; 58: 63-69.
14. Josephson ME, Horowitz LN, Farshidi A. Continuous local electrical activity. A mechanism of recurrent ventricular tachycardia. *Circulation.* 1978; 57: 659-665.
15. Miller JM, Kienzle MG, Harken AH, Josephson ME. Subendocardial resection for ventricular tachycardia: predictors of surgical success. *Circulation.* 1984; 70: 624-631.
16. Miller JM, Kienzle MG, Harken AH, Josephson ME. Morphologically distinct sustained ventricular tachycardias in coronary artery disease: significance and surgical results. *J Am Coll Cardiol.* 1984; 4: 1073-1079.
17. Lacroix D, Klug D, Warembourg H, Logier R, Kacet S, Lekieffre J. Value of mapping in surgical treatment of ventricular tachycardia. *Arch Mal Coeur Vaiss.* 1996; 89 Spec No 1: 109-113.
18. Lacroix D, Klug D, Grandmougin D, Jarwe M, Kouakam C, Kacet S. Ventricular tachycardia originating from the posteroseptal process of the left ventricle with inferior wall healed myocardial infarction. *Am J Cardiol.* 1999; 84: 181-186.
19. Poole JE, Johnson GW, Hellkamp AS, Anderson J, Callans DJ, Raitt MH, Reddy RK, Marchlinski FE, Yee R, Guarnieri T, Talajic M, Wilber DJ, Fishbein DP, Packer DL, Mark DB, Lee KL, Bardy GH. Prognostic importance of defibrillator shocks in patients with heart failure. *N Engl J Med.* 2008; 359: 1009-1017.
20. Aliot EM, Stevenson WG, Almendral-Garrote JM, Bogun F, Calkins CH, Delacretaz E, Bella PD, Hindricks G, Jais P, Josephson ME, Kautzner J, Kay GN, Kuck KH, Lerman BB, Marchlinski F, Reddy V, Schalij MJ, Schilling R, Soejima K, Wilber D, European Heart Rhythm Association, European Society of Cardiology, Heart Rhythm Society. EHRA/HRS Expert Consensus on Catheter Ablation of Ventricular Arrhythmias: developed in a partnership with the European Heart Rhythm Association (EHRA), a Registered Branch of the European Society of Cardiology (ESC), and the Heart Rhythm Society (HRS); in collaboration with the American College of Cardiology (ACC) and the American Heart Association (AHA). *Europace.* 2009; 11: 771-817.
21. Fenoglio JJ, Jr, Pham TD, Harken AH, Horowitz LN, Josephson ME, Wit AL. Recurrent sustained ventricular tachycardia: structure and ultrastructure of subendocardial regions in which tachycardia originates. *Circulation.* 1983; 68: 518-533.
22. de Bakker JM, van Capelle FJ, Janse MJ, Tasseron S, Vermeulen JT, de Jonge N, Lahpor JR. Slow conduction in the infarcted human heart. 'Zigzag' course of activation. *Circulation.* 1993; 88: 915-926.
23. Luke RA, Saffitz JE. Remodeling of ventricular conduction pathways in healed canine infarct border zones. *J Clin Invest.* 1991; 87: 1594-1602.
24. de Chillou C, Lacroix D, Klug D, Magnin-Poull I, Marquie C, Messier M, Andronache M, Kouakam C, Sadoul N, Chen J, Aliot E, Kacet S. Isthmus characteristics of reentrant ventricular tachycardia after myocardial infarction. *Circulation.* 2002; 105: 726-731.

25. Zlochiver S, Munoz V, Vikstrom KL, Taffet SM, Berenfeld O, Jalife J. Electrotonic myofibroblast-to-myocyte coupling increases propensity to reentrant arrhythmias in two-dimensional cardiac monolayers. *Biophys J*. 2008; 95: 4469-4480.
26. Janse MJ, Wit AL. Electrophysiological mechanisms of ventricular arrhythmias resulting from myocardial ischemia and infarction. *Physiol Rev*. 1989; 69: 1049-1169.
27. Peters NS, Coromilas J, Severs NJ, Wit AL. Disturbed connexin43 gap junction distribution correlates with the location of reentrant circuits in the epicardial border zone of healing canine infarcts that cause ventricular tachycardia. *Circulation*. 1997; 95: 988-996.
28. Cao JM, Chen LS, KenKnight BH, Ohara T, Lee MH, Tsai J, Lai WW, Karagueuzian HS, Wolf PL, Fishbein MC, Chen PS. Nerve sprouting and sudden cardiac death. *Circ Res*. 2000; 86: 816-821.
29. Cao JM, Fishbein MC, Han JB, Lai WW, Lai AC, Wu TJ, Czer L, Wolf PL, Denton TA, Shintaku IP, Chen PS, Chen LS. Relationship between regional cardiac hyperinnervation and ventricular arrhythmia. *Circulation*. 2000; 101: 1960-1969.
30. Ajjola OA, Yagishita D, Patel KJ, Vaseghi M, Zhou W, Yamakawa K, So E, Lux RL, Mahajan A, Shivkumar K. Focal myocardial infarction induces global remodeling of cardiac sympathetic innervation: neural remodeling in a spatial context. *Am J Physiol Heart Circ Physiol*. 2013; 305: H1031-40.
31. Zhou S, Jung BC, Tan AY, Trang VQ, Gholmieh G, Han SW, Lin SF, Fishbein MC, Chen PS, Chen LS. Spontaneous stellate ganglion nerve activity and ventricular arrhythmia in a canine model of sudden death. *Heart Rhythm*. 2008; 5: 131-139.
32. Vaseghi M, Rn Msn Np JG, Kanaan C, Ajjola OA, Marmureanu A, Mahajan A, Shivkumar K. Cardiac sympathetic denervation in patients with refractory ventricular arrhythmias or electrical storm: Intermediate and long-term follow-up. *Heart Rhythm*. 2013; .
33. Callans DJ, Ren JF, Michele J, Marchlinski FE, Dillon SM. Electroanatomic left ventricular mapping in the porcine model of healed anterior myocardial infarction. Correlation with intracardiac echocardiography and pathological analysis. *Circulation*. 1999; 100: 1744-1750.
34. Marchlinski FE, Callans DJ, Gottlieb CD, Zado E. Linear ablation lesions for control of unmappable ventricular tachycardia in patients with ischemic and nonischemic cardiomyopathy. *Circulation*. 2000; 101: 1288-1296.
35. Wroblewski D, Houghtaling C, Josephson ME, Ruskin JN, Reddy VY. Use of electrogram characteristics during sinus rhythm to delineate the endocardial scar in a porcine model of healed myocardial infarction. *J Cardiovasc Electrophysiol*. 2003; 14: 524-529.
36. Gardner PI, Ursell PC, Fenoglio JJ, Jr, Wit AL. Electrophysiologic and anatomic basis for fractionated electrograms recorded from healed myocardial infarcts. *Circulation*. 1985; 72: 596-611.
37. Jacquemet V, Henriquez CS. Genesis of complex fractionated atrial electrograms in zones of slow conduction: a computer model of microfibrosis. *Heart Rhythm*. 2009; 6: 803-810.

38. Hsia HH, Lin D, Sauer WH, Callans DJ, Marchlinski FE. Relationship of late potentials to the ventricular tachycardia circuit defined by entrainment. *J Interv Card Electrophysiol.* 2009; 26: 21-29.
39. Harada T, Stevenson WG, Kocovic DZ, Friedman PL. Catheter ablation of ventricular tachycardia after myocardial infarction: relation of endocardial sinus rhythm late potentials to the reentry circuit. *J Am Coll Cardiol.* 1997; 30: 1015-1023.
40. Zeppenfeld K, Kies P, Wijffels MC, Bootsma M, van Erven L, Schalij MJ. Identification of successful catheter ablation sites in patients with ventricular tachycardia based on electrogram characteristics during sinus rhythm. *Heart Rhythm.* 2005; 2: 940-950.
41. Jais P, Maury P, Khairy P, Sacher F, Nault I, Komatsu Y, Hocini M, Forclaz A, Jadidi AS, Weerasoorya R, Shah A, Derval N, Cochet H, Knecht S, Miyazaki S, Linton N, Rivard L, Wright M, Wilton SB, Scherr D, Pascale P, Roten L, Pederson M, Bordachar P, Laurent F, Kim SJ, Ritter P, Clementy J, Haissaguerre M. Elimination of local abnormal ventricular activities: a new end point for substrate modification in patients with scar-related ventricular tachycardia. *Circulation.* 2012; 125: 2184-2196.
42. de Bakker JM, van Capelle FJ, Janse MJ, Wilde AA, Coronel R, Becker AE, Dingemans KP, van Hemel NM, Hauer RN. Reentry as a cause of ventricular tachycardia in patients with chronic ischemic heart disease: electrophysiologic and anatomic correlation. *Circulation.* 1988; 77: 589-606.
43. Stevenson WG, Khan H, Sager P, Saxon LA, Middlekauff HR, Natterson PD, Wiener I. Identification of reentry circuit sites during catheter mapping and radiofrequency ablation of ventricular tachycardia late after myocardial infarction. *Circulation.* 1993; 88: 1647-1670.
44. Bogun F, Bahu M, Knight BP, Weiss R, Paladino W, Harvey M, Goyal R, Daoud E, Man KC, Strickberger SA, Morady F. Comparison of effective and ineffective target sites that demonstrate concealed entrainment in patients with coronary artery disease undergoing radiofrequency ablation of ventricular tachycardia. *Circulation.* 1997; 95: 183-190.
45. El-Shalakany A, Hadjis T, Papageorgiou P, Monahan K, Epstein L, Josephson ME. Entrainment/mapping criteria for the prediction of termination of ventricular tachycardia by single radiofrequency lesion in patients with coronary artery disease. *Circulation.* 1999; 99: 2283-2289.
46. Bogun F, Kim HM, Han J, Tamirissa K, Tschopp D, Reich S, Elmouchi D, Igic P, Lemola K, Good E, Oral H, Chugh A, Pelosi F, Morady F. Comparison of mapping criteria for hemodynamically tolerated, postinfarction ventricular tachycardia. *Heart Rhythm.* 2006; 3: 20-26.
47. Stevenson WG, Wilber DJ, Natale A, Jackman WM, Marchlinski FE, Talbert T, Gonzalez MD, Worley SJ, Daoud EG, Hwang C, Schuger C, Bump TE, Jazayeri M, Tomassoni GF, Kopelman HA, Soejima K, Nakagawa H, Multicenter Thermocool VT Ablation Trial Investigators. Irrigated radiofrequency catheter ablation guided by electroanatomic mapping for recurrent ventricular tachycardia after myocardial infarction: the multicenter thermocool ventricular tachycardia ablation trial. *Circulation.* 2008; 118: 2773-2782.



48. Oza S, Wilber DJ. Substrate-based endocardial ablation of postinfarction ventricular tachycardia. *Heart Rhythm*. 2006; 3: 607-609.
49. Arenal A, Glez-Torrecilla E, Ortiz M, Villacastin J, Fdez-Portales J, Sousa E, del Castillo S, Perez de Isla L, Jimenez J, Almendral J. Ablation of electrograms with an isolated, delayed component as treatment of unmappable monomorphic ventricular tachycardias in patients with structural heart disease. *J Am Coll Cardiol*. 2003; 41: 81-92.
50. Bogun F, Good E, Reich S, Elmouchi D, Igic P, Lemola K, Tschopp D, Jongnarangsin K, Oral H, Chugh A, Pelosi F, Morady F. Isolated potentials during sinus rhythm and pace-mapping within scars as guides for ablation of post-infarction ventricular tachycardia. *J Am Coll Cardiol*. 2006; 47: 2013-2019.
51. Soejima K, Stevenson WG, Maisel WH, Sapp JL, Epstein LM. Electrically unexcitable scar mapping based on pacing threshold for identification of the reentry circuit isthmus: feasibility for guiding ventricular tachycardia ablation. *Circulation*. 2002; 106: 1678-1683.
52. Arenal A, del Castillo S, Gonzalez-Torrecilla E, Atienza F, Ortiz M, Jimenez J, Puchol A, Garcia J, Almendral J. Tachycardia-related channel in the scar tissue in patients with sustained monomorphic ventricular tachycardias: influence of the voltage scar definition. *Circulation*. 2004; 110: 2568-2574.
53. Hsia HH, Lin D, Sauer WH, Callans DJ, Marchlinski FE. Anatomic characterization of endocardial substrate for hemodynamically stable reentrant ventricular tachycardia: identification of endocardial conducting channels. *Heart Rhythm*. 2006; 3: 503-512.
54. de Chillou C, Groben L, Magnin-Poull I, Andronache M, Magdi Abbas M, Zhang N, Abdelaal A, Ammar S, Sellal JM, Schwartz J, Brembilla-Perrot B, Aliot E, Marchlinski FE. Localizing the Critical Isthmus of Post-Infarct Ventricular Tachycardia: The Value of Pace Mapping during Sinus Rhythm. *Heart Rhythm*. 2013; .
55. Kottkamp H, Wetzel U, Schirdewahn P, Dorszewski A, Gerds-Li JH, Carbucicchio C, Kobza R, Hindricks G. Catheter ablation of ventricular tachycardia in remote myocardial infarction: substrate description guiding placement of individual linear lesions targeting noninducibility. *J Cardiovasc Electrophysiol*. 2003; 14: 675-681.
56. Soejima K, Suzuki M, Maisel WH, Brunckhorst CB, Delacretaz E, Blier L, Tung S, Khan H, Stevenson WG. Catheter ablation in patients with multiple and unstable ventricular tachycardias after myocardial infarction: short ablation lines guided by reentry circuit isthmuses and sinus rhythm mapping. *Circulation*. 2001; 104: 664-669.
57. Codreanu A, Odille F, Aliot E, Marie PY, Magnin-Poull I, Andronache M, Mandry D, Djaballah W, Regent D, Felblinger J, de Chillou C. Electroanatomic characterization of post-infarct scars comparison with 3-dimensional myocardial scar reconstruction based on magnetic resonance imaging. *J Am Coll Cardiol*. 2008; 52: 839-842.
58. Bello D, Fieno DS, Kim RJ, Pereles FS, Passman R, Song G, Kadish AH, Goldberger JJ. Infarct morphology identifies patients with substrate for sustained ventricular tachycardia. *J Am Coll Cardiol*. 2005; 45: 1104-1108.



59. Schmidt A, Azevedo CF, Cheng A, Gupta SN, Bluemke DA, Foo TK, Gerstenblith G, Weiss RG, Marban E, Tomaselli GF, Lima JA, Wu KC. Infarct tissue heterogeneity by magnetic resonance imaging identifies enhanced cardiac arrhythmia susceptibility in patients with left ventricular dysfunction. *Circulation*. 2007; 115: 2006-2014.
60. Yan AT, Shayne AJ, Brown KA, Gupta SN, Chan CW, Luu TM, Di Carli MF, Reynolds HG, Stevenson WG, Kwong RY. Characterization of the peri-infarct zone by contrast-enhanced cardiac magnetic resonance imaging is a powerful predictor of post-myocardial infarction mortality. *Circulation*. 2006; 114: 32-39.
61. Ashikaga H, Sasano T, Dong J, Zviman MM, Evers R, Hopenfeld B, Castro V, Helm RH, Dickfeld T, Nazarian S, Donahue JK, Berger RD, Calkins H, Abraham MR, Marban E, Lardo AC, McVeigh ER, Halperin HR. Magnetic resonance-based anatomical analysis of scar-related ventricular tachycardia: implications for catheter ablation. *Circ Res*. 2007; 101: 939-947.
62. Ciaccio EJ, Ashikaga H, Kaba RA, Cervantes D, Hopenfeld B, Wit AL, Peters NS, McVeigh ER, Garan H, Coromilas J. Model of reentrant ventricular tachycardia based on infarct border zone geometry predicts reentrant circuit features as determined by activation mapping. *Heart Rhythm*. 2007; 4: 1034-1045.
63. Roes SD, Borleffs CJ, van der Geest RJ, Westenberg JJ, Marsan NA, Kaandorp TA, Reiber JH, Zeppenfeld K, Lamb HJ, de Roos A, Schalij MJ, Bax JJ. Infarct tissue heterogeneity assessed with contrast-enhanced MRI predicts spontaneous ventricular arrhythmia in patients with ischemic cardiomyopathy and implantable cardioverter-defibrillator. *Circ Cardiovasc Imaging*. 2009; 2: 183-190.
64. Komatsu Y, Cochet H, Jadidi A, Sacher F, Shah A, Derval N, Scherr D, Pascale P, Roten L, Denis A, Ramoul K, Miyazaki S, Daly M, Riffaud M, Sermesant M, Relan J, Ayache N, Kim S, Montaudon M, Laurent F, Hocini M, Haissaguerre M, Jais P. Regional myocardial wall thinning at multidetector computed tomography correlates to arrhythmogenic substrate in postinfarction ventricular tachycardia: assessment of structural and electrical substrate. *Circ Arrhythm Electrophysiol*. 2013; 6: 342-350.
65. Orlov MV, Ansari MM, Akrivakis ST, Jadidi A, Nijhof N, Natan SR, Wylie JV, Hicks A, Armstrong J, Jais P. First experience with rotational angiography of the right ventricle to guide ventricular tachycardia ablation. *Heart Rhythm*. 2011; 8: 207-211.
66. Simula S, Lakka T, Laitinen T, Remes J, Kettunen R, Kuikka J, Hartikainen J. Cardiac adrenergic denervation in patients with non-Q-wave versus Q-wave myocardial infarction. *Eur J Nucl Med*. 2000; 27: 816-821.
67. Simula S, Lakka T, Kuikka J, Laitinen T, Remes J, Kettunen R, Hartikainen J. Cardiac adrenergic innervation within the first 3 months after acute myocardial infarction. *Clin Physiol*. 2000; 20: 366-373.
68. Fahmy TS, Wazni OM, Jaber WA, Walimbe V, Di Biase L, Elayi CS, DiFilippo FP, Young RB, Patel D, Riedlbauchova L, Corrado A, Burkhardt JD, Schweikert RA, Arruda M, Natale A. Integration of positron emission tomography/computed tomography with electroanatomical

mapping: a novel approach for ablation of scar-related ventricular tachycardia. *Heart Rhythm*. 2008; 5: 1538-1545.

69. Tian J, Smith MF, Chinnadurai P, Dilsizian V, Turgeman A, Abbo A, Gajera K, Xu C, Plotnick D, Peters R, Saba M, Shorofsky S, Dickfeld T. Clinical Application of PET/CT Fusion Imaging for Three-Dimensional Myocardial Scar and Left Ventricular Anatomy during Ventricular Tachycardia Ablation. *J Cardiovasc Electrophysiol*. 2008; .

70. Dickfeld T, Kocher C. The role of integrated PET-CT scar maps for guiding ventricular tachycardia ablations. *Curr Cardiol Rep*. 2008; 10: 149-157.

## II- Objectifs

Le but de cette thèse était d'essayer de mieux comprendre le substrat des arythmies ventriculaires et d'en améliorer le traitement. Elle se compose de 3 parties. Dans la première, nous dressons un état des lieux de l'ablation de TV. Dans la deuxième, nous décrivons le substrat responsable d'arythmie ventriculaire dans différents types de pathologies (mycardiopathie ischémique, mycardiopathie dilatée à coronaires saines, patients porteurs d'assistance ventriculaire gauche et syndrome de Brugada). Enfin dans la troisième partie, nous avons évalué et proposé des outils/attitudes thérapeutiques pour essayer d'améliorer le traitement des tachycardies ventriculaires.

La **première partie** dresse un état des lieux de l'ablation de TV dans un centre tertiaire. L'objectif est de montrer l'évolution (1) des patients adressés pour ce traitement, (2) des caractéristiques de leur arythmie et (3) des procédures d'ablation. Nous avons également étudié leur devenir pour identifier des facteurs prédictifs de mortalité.

La **deuxième partie** vise à mieux comprendre les caractéristiques des cicatrices myocardiques responsables d'arythmie ventriculaire grâce à l'imagerie et aux explorations électrophysiologiques chez différents types de patients. Le premier de ces travaux consiste à identifier les caractéristiques électrophysiologiques des potentiels ventriculaires anormaux en fonction de leur répartition dans le myocarde chez des patients aux antécédents d'infarctus du myocarde. Les 3 travaux suivants ont pour but de décrire le substrat et le mécanisme des arythmies ventriculaires chez (1) les patients avec cicatrices limitées à la partie sous épicaudique du myocarde, (2) les patients avec assistance ventriculaire gauche à débit continu et (3) les patients avec syndrome de Brugada.

Enfin la **troisième partie** se concentre sur les approches thérapeutiques qui permettent de traiter ces tachycardies ventriculaires. Les trois premiers travaux ont pour but d'évaluer de nouvelles technologies qui pourraient améliorer les procédures d'ablation (visualisation endoscopique en temps réel du substrat et de la formation des lésions, information sur la force du contact entre le cathéter et le myocarde). Les quatrième et cinquième travaux visent à évaluer l'efficacité et la sécurité de deux approches moins répandues (ablation par alcoolisation intra coronaire et ablation par voie épicaudique). Les sixième et septième manuscrits évaluent l'intérêt de l'imagerie (scanner/IRM cardiaque) pour mieux comprendre et éviter les complications de l'ablation des TV. Le huitième travail consiste à évaluer la faisabilité d'une approche novatrice dans l'ablation du substrat des TV qui est de cibler les potentiels endocardiques pour éliminer les potentiels épicaudiques en regard. Enfin le dernier travail vise à évaluer le devenir des patients (en termes de mortalité) ayant eu une ablation de TV avec comme critère de succès l'élimination de tous les potentiels ventriculaires anormaux.

### III- Première partie : Etat des lieux de l'ablation des tachycardies ventriculaires dans un centre tertiaire

#### A) Ventricular Tachycardia Ablation: Evolution of Patients and Procedures Over 8 Years

Publié: Circ Arrhythmia Electrophysiol. 2008;1:153-161

##### 1) Etude

Depuis le début des années 2000, il existe une augmentation continue du nombre d'ablation par radiofréquence (RF)(essentiellement liée à l'ablation de FA) et de centres les pratiquant. Toutefois l'ablation des tachycardies ventriculaires (TV) s'est également développée. Le but de ce travail a été d'étudier l'évolution des patients adressés pour ablation de TV et des techniques d'ablation mais également de préciser le devenir de ces patients. Nous avons donc analysé les dossiers de tous les patients adressés pour ablation de TV entre 1999 et 2006 au Brigham & Women's Hospital de Boston.

Le nombre de patients adressés pour ablation de TV a cru régulièrement pendant cette période. Les patients avec cardiopathie dilatée non ischémique représentent la principale cause de cette augmentation en passant de 27% à 35% ( $p=0.06$ ) des ablations de TV. Parallèlement, le nombre d'abord épiscardique est passé de 7% à 12% ( $p=0.04$ ) des procédures. Chez les patients avec cardiopathies ischémiques, il est également intéressant de noter qu'il existe souvent une longue période entre l'infarctus du myocarde et l'ablation de TV ( $10 \pm 8$  ans). Par ailleurs, l'indication d'ablation de TV est souvent retenue en dernier recours (origine rythmique: 29% des indications pour les cardiopathies ischémiques et 22% pour les cardiopathies dilatées à coronaires saines).

Un système de cartographie 3D était utilisé dans 78% des cas. Les taux de succès aigus étaient meilleurs chez les patients sans cardiopathie (83%) puis chez les patients avec cardiopathie ischémique (65%) et enfin le succès était moindre chez les patients avec cardiopathie dilatée à coronaire saine (51%). Par contre le taux de mortalité était supérieur chez les patients avec cardiopathie ischémique (35%) vs patients avec cardiopathie dilatée à coronaires saines (17%) au cours d'un suivi moyen de  $3 \pm 2$  ans. Les facteurs prédictifs de mortalité en analyse multivariée étaient un âge  $>62$  ans (HR=

2.6 (1.5-4.3) ;  $p < 0.001$ ), une fraction d'éjection ventriculaire gauche  $< 30\%$  (HR=1.5 (1.2-1.8) ;  $p < 0.001$ ) et les patients avec assistance hémodynamique (HR=4.3 (1.9-10) ;  $p < 0.001$ ).

Les taux de complication durant la procédure sont également différents en fonction de l'étiologie de la TV. Alors que le taux est très faible chez les patients sans cardiopathie (2.7%), il augmente chez les patients avec myocardopathie à coronaires saines (6.2%) et est 2 fois plus important chez les patients avec myocardopathie ischémique (11.5%).

## *2) Implications*

Le nombre de patient adressé pour ablation de TV ne cesse de croître. Le nombre absolu de patient avec myocardopathie ischémique est à peu près stable par contre il y a de plus en plus de patients avec myocardopathie dilatée à coronaires saines. Cela pose des problèmes de diagnostic étiologique et d'identification des zones à cibler car les substrats sont plus souvent épicaudiques. L'IRM est devenue un outil de choix pour avancer sur l'étiologie de ces myocardopathies dilatées. Elle est également très utile en cas d'ablation pour anticiper la voie d'abord (épicaudique) et la zone à cibler. Nous réalisons maintenant systématiquement une IRM cardiaque avant implantation d'un défibrillateur chez ces patients.

Le taux de mortalité chez les patients avec myocardopathie ischémique reste significatif malgré l'absence de récurrence après ablation de TV. Il est évoqué la possibilité que ces patients soient adressés trop tard dans l'évolution de leur pathologie<sup>1</sup>. D'autant que le délai médian entre l'infarctus et l'ablation est de 9 ans. Certaines études montrent que le devenir est meilleur lorsque l'ablation est réalisée après le premier épisode de TV<sup>2</sup>, d'autant que de plus en plus d'étude montre que les chocs du défibrillateur peuvent aggraver la mortalité<sup>3,4,5</sup>. Il est primordial que les patients aient un suivi régulier après infarctus du myocarde avec correction des facteurs de risque et traitements optimaux (IEC) pour diminuer le remodelage tissulaire.

# Circulation

## Arrhythmia and Electrophysiology

JOURNAL OF THE AMERICAN HEART ASSOCIATION

American Heart  
Association   
*Learn and Live*

### **Ventricular Tachycardia Ablation: Evolution of Patients and Procedures Over 8 Years**

Frédéric Sacher, Usha B. Tedrow, Michael E. Field, Jean-Marc Raymond, Bruce A. Koplan, Laurence M. Epstein and William G. Stevenson

*Circ Arrhythmia Electrophysiol* 2008;1;153-161; originally published online Jun 6, 2008;

DOI: 10.1161/CIRCEP.108.769471

Circulation: Arrhythmia and Electrophysiology is published by the American Heart Association, 7272 Greenville Avenue, Dallas, TX 75214

Copyright © 2008 American Heart Association. All rights reserved. Print ISSN: 1941-3149. Online ISSN: 1941-3084

The online version of this article, along with updated information and services, is located on the World Wide Web at:

<http://circep.ahajournals.org/cgi/content/full/1/3/153>

Subscriptions: Information about subscribing to *Circulation: Arrhythmia and Electrophysiology* is online at

<http://circep.ahajournals.org/subscriptions/>

Permissions: Permissions & Rights Desk, Lippincott Williams & Wilkins, a division of Wolters Kluwer Health, 351 West Camden Street, Baltimore, MD 21202-2436. Phone: 410-528-4050. Fax: 410-528-8550. E-mail:

[journalpermissions@lww.com](mailto:journalpermissions@lww.com)

Reprints: Information about reprints can be found online at

<http://www.lww.com/reprints>

## Ventricular Tachycardia Ablation Evolution of Patients and Procedures Over 8 Years

Frédéric Sacher, MD; Usha B. Tedrow, MD; Michael E. Field, MD; Jean-Marc Raymond, MD;  
Bruce A. Koplman, MD; Laurence M. Epstein, MD; William G. Stevenson, MD

**Background**—Evolving management of coronary artery disease, heart failure, and the use of implantable cardioverter-defibrillators impacts the characteristics of patients with recurrent ventricular tachycardia (VT). We investigated the substrate, procedure, and outcome evolution of all patients referred for VT ablation during the past 8 years.

**Methods and Results**—From 1999 to 2006, 493 consecutive patients (358 male,  $57 \pm 16$  years) underwent 623 VT ablations: 131 had no structural heart disease (SHD), 213 had ischemic cardiomyopathies (ICMP), and 149 had nonischemic cardiomyopathies (NICMP). Although the main substrate is ICMP, the proportion of NICMP has increased from 27% to 35% ( $P=0.06$ ) from 1999–2002 to the 2003–2006. The procedure abolished or modified inducible VTs in  $\geq 75\%$  of patients in all groups, but abolition of all monomorphic VTs was achieved in 125 (83%) patients without SHD, 180 (65%) with ICMP, and 99 (51%) with NICMP ( $P<0.0001$ ). During a mean follow-up of  $3.3 \pm 2.4$  years, no deaths occurred in patients without SHD, but 75 patients (35%) with ICMP and 26 patients (17%) with NICMP died after a median of 13 months. Multivariate Cox regression analysis found that age, ejection fraction, and need for preprocedural mechanical hemodynamic support predicted mortality.

**Conclusions**—The substrate causing VT in patients requiring ablation is evolving and determines the long-term outcome. In the setting of a normal heart, VT ablation is associated with a low risk of subsequent mortality, with no deaths occurring during a mean follow-up of  $>3$  years. In contrast, in patients with SHD and recurrent VT, VT ablation can be helpful to suppress drug refractory VT, but long-term mortality remains significant. (*Circ Arrhythmia Electrophysiol.* 2008;1:153-161.)

**Key Words:** tachycardia ■ catheter ablation ■ mortality ■ ventricles

Evolving management of coronary syndromes and heart failure therapies in nonischemic and ischemic diseases impact the substrate causing ventricular tachycardia (VT) with structural heart disease (SHD). The predominant strategy for treating VT remains palliative, using antiarrhythmic drugs (AADs) and implantable cardioverter-defibrillators (ICDs). Even though ICDs improve survival and reduce sudden death in high-risk patients with SHD,<sup>1–3</sup> 10% to 20% of patients with ICDs experience “electrical storm” with repeated device therapies.<sup>4,5</sup> Although AADs reduce the frequency of VT episodes, efficacy has been disappointing<sup>6,7</sup> and side effects are an important problem.<sup>8</sup> Radiofrequency (RF) catheter ablation is an option to control recurrent VT. Often it is used as a sole therapy in patients without SHD or in combination with an ICD and antiarrhythmic therapy in scar-related VT associated with SHD. Several investigators reported ablation outcomes for series of patients selected for having one predominant morphology of VT. Other studies reporting RF catheter ablation for VT considered only patients with one under-

lying cause, relatively small numbers of patients, or short follow-up periods.

**Editorial see p 147**  
**Clinical Perspective see p 161**

The objectives of this study were to evaluate the evolution of the substrate associated with VT, the procedural evolution, and the long-term mortality of all patients with VT ablation during the last 8 years.

### Methods

#### Study Population

From January 1999 to December 2006, 493 consecutive patients (358 [73%] male,  $57 \pm 16$  years) underwent 623 VT ablations at our institution. One hundred thirty-one had no SHD, 213 had ischemic cardiomyopathy (ICMP) with coronary artery disease defined as history of prior myocardial infarction or documented obstructive coronary artery disease, and 149 had a nonischemic cardiomyopathy (NICMP) (Table 1). Approximately 53% of these patients have also been reported in smaller cohorts investigating specific mapping and ablation methods.<sup>9–19</sup> In all patients, at least one episode of VT

Received January 28, 2008; accepted May 1, 2008.

From Brigham and Women's Hospital, Harvard Medical School, Boston, Mass.

Guest Editor for this article was Douglas P. Zipes, MD.

Correspondence to William G. Stevenson, Cardiac Arrhythmia Department, Cardiovascular Division, Brigham and Women's Hospital, 75 Francis Street, Boston, MA 02115. E-mail frederic.sacher@chu-bordeaux.fr

© 2008 American Heart Association, Inc.

*Circ Arrhythmia Electrophysiol* is available at <http://circep.ahajournals.org>

DOI: 10.1161/CIRCEP.108.769471



**Table 1. Characteristics of Patients With Ventricular Tachycardia (VT) Ablation Depending on the Substrate**

	No SHD	ICMP	NICMP	P Value Between ICMP and NICMP	Overall P Value
Demographic (n=493)	n=131	n=213	n=149		
Age, y	46±14	67±11	52±15	<0.001	<0.001
Sex (male), n (%)	55 (42)	188 (88)	115 (77)	0.006	<0.001
LVEF, %	61±5	28±13	39±16	<0.001	<0.001
No. of failed AAD	2±1	3±1	3±1	NS	<0.001
Procedure (n=623)	n=150	n=278	n=195		
No. of patients with a prior ablation, n (%)	58 (39)	128 (46)	117 (60)	0.02	<0.001
No. of VT before ablation					
None during the last month, n (%)	23 (15)	6 (2)	20 (10)	<0.001	<0.001
>1 during the last month but not the week preceding ablation, n (%)	70 (47)	30 (11)	48 (25)	<0.001	<0.001
>1 VT in the week preceding ablation/arrhythmic storm, n (%)	57 (38)/11 (7)	242 (87)/81 (29)	127 (65)/43 (22)	<0.001/NS	<0.001/ <0.001
Acute results				0.001	<0.001
Success, n (%)	108 (72)	180 (65)	99 (51)		
Indeterminant, n (%)	17 (11)	79 (28)	54 (28)		
Failure, n (%)	25 (17)	19 (7)	42 (21)		
Radiofrequency time, min	13±10	33±22	26±21	NS	<0.001
Fluoroscopy time, min	35±23	46±26	48±29	NS	<0.001
Complications, n (%)	4 (2.7)	32 (11.5)	12 (6.2)	0.03	0.002

SHD indicates structural heart disease; ICMP, ischemic cardiomyopathies; NICMP, non-ICMP; LVEF, left ventricular ejection fraction; AAD, antiarrhythmic drugs.

(sustained or nonsustained) was recorded during monitoring by using Holter, ICD log, or 12-lead ECG. VT was continuous and incessant, or very frequent, meeting a commonly used definition of electrical storm<sup>5</sup> with more than 3 separate VT episodes in the 24 hours before ablation in 136 (22%) patients. Patients failed a mean of 3±1 AADs. Amiodarone was used before ablation in 14% in the group without SHD, in 84% in the group with ICMP, and in 59% in patients with NICMP. A prior ablation had been attempted in 49% of patients (mean of 1.5±0.7 previous ablations for the group). An ICD had been implanted previously in 87% of patients with ICMP and in 69% of patients with NICMP, and these were biventricular pacing devices in 13% and 12% of cases, respectively.

Written informed consent was obtained from all patients. Procedures and review of medical records were conducted under protocols approved by the institutional human subject protection committee.

### VT ablation

The methods used for mapping and ablation were those reported previously<sup>10,11,20</sup> but did evolve from 1999 to 2006. Ventricular mapping was performed with 7 or 8F steerable catheters with either an 8-, 4-, or 3.5-mm electrode tip (Navi Star or Thermo-Cool, Biosense Webster Inc, Diamond Bar, CA). Bipolar electrograms were recorded on the electroanatomic mapping system (filtered at 10 to 400 Hz) (CARTO, Biosense Webster) and a separate digital system (filtered at 30 to 500 Hz; Prucka Engineering Inc). Pace mapping and entrainment mapping used unipolar pacing from the distal electrode with an initial current strength of 10 mA and pulse width of 2 ms.

If VT was not incessant, the ventricle of interest (right, left or both) was mapped during sinus or paced rhythm to identify areas with abnormal electrograms and low-voltage (<1.5 mV) consistent with scar.<sup>10,11,21,22</sup> If abnormal areas were present, the mapping catheter was placed at an abnormal site that had pace-mapping characteristics of an exit or potential isthmus site, and VT initiated to assess the electrograms during VT, entrainment mapping, and potential RF ablation during VT to assess VT termination as previously described.<sup>10,11</sup> If VT was stable, mapping continued

during VT. If the circuit could not be identified, ablation was performed through the presumptive exit based on voltage mapping combined with pace mapping. In patients without SHD, a focal source for the arrhythmia was sought from a combination of activation mapping and pace mapping.

Ablation lesions were created with RF current with a maximum power of 50 W (EP Technologies Inc or Stockert, Biosense Webster Inc) by using various types of catheter ablation over the study period (4-mm or 8-mm standard tip, internally or externally irrigated tip catheters).

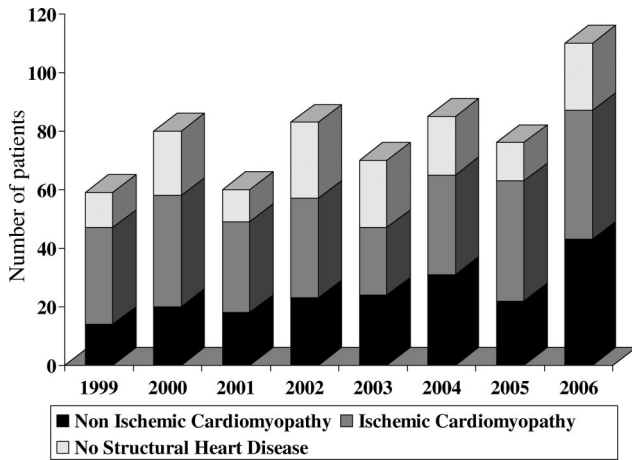
The acute outcome of the ablation procedure was defined as follows: success—no monomorphic VT was inducible (including VTs that had not been observed to occur spontaneously, often referred to as nonclinical); indeterminant—monomorphic VT was inducible but was different and usually faster than VTs induced at the beginning of the procedure, suggesting that the arrhythmia substrate has been modified, or the acute outcome could not be reliably determined because of the inability to reliably induce the arrhythmia, but no arrhythmia was provokable after ablation (particularly in patients without SHD); and failure—VT inducible at the beginning of the procedure remained present or inducible.

After ablation, AADs were reduced or discontinued depending on the substrate and the acute success of the procedure. We report only the major complications (resulting in long-term disability, requiring intervention, or prolonging hospital stay) including the life-threatening complications (with immediate or short-term risk of death).

### Data Collection and Follow-Up

Data were collected from a centralized system that contained complete records of all patients treated and followed at the Brigham and Women's Hospital. These records provide a detailed history and diagnosis for all patients, including ablation report, emergency department visits, and outpatient visits, as well as data recorded during inpatient care. Patients local to the hospital were followed up in Brigham and Women's Hospital clinics. Referring cardiologists were contacted for clinical follow-up of their patients. Mortality was assessed from the social security death index queried in October 2007.





**Figure 1.** Frequency of the different ventricular tachycardia substrates from 1999 to 2006.

**Statistical Analysis**

Baseline characteristics of the patients were compared with the  $\chi^2$  test for the categorical variables and with a *t* test for the quantitative variable depending on the substrate. The event-free survival was graphically displayed according to the method of Kaplan and Meier, with unadjusted comparisons of mortality by the log-rank test. Univariate and multivariate Cox proportional hazards regression analyses were used to evaluate the contribution of cardiomyopathy type (ischemic or nonischemic), age, left ventricular ejection fraction (LVEF), acute outcome, complications related to the procedure, hemodynamic support, AADs, and number of VTs induced to mortality. A 2-sided  $\alpha$  value <0.05 was considered statistically significant. The authors had full access to the data, and take full responsibility for the integrity of the data.

**Results**

**Substrate and Clinical Presentation**

Our idiopathic VT (no SHD) population was composed of 78 patients with typical right ventricular (RV) outflow tract VT, 12 with left ventricular (LV) outflow tract VT, 10 fascicular VT, 8 RV VT outside the outflow tract, 14 LV other than

outflow tract or fascicular VT, and 9 epicardial VTs. Although the main substrate for VT due to SHD is ICMP, there has been a trend for an increasing proportion of NICMP from 27% to 35% ( $P=0.06$ ) from 1999–2002 to 2003–2006 period (Figure 1).

Patients with ICMP had a mean of  $2.2 \pm 0.9$  coronary vessels diseased. Their last myocardial infarction occurred  $10 \pm 8.3$  years (median 9 years) before ablation. One hundred eight (51%) patients with ICMP had prior coronary artery bypass surgery, and 70 (33%) had prior percutaneous coronary intervention before ablation. Only 61 (29%) patients had not had a revascularization procedure, 31% during 1999–2002 versus 26% during 2003–2006 ( $P=NS$ ). In ICMP, the predominant scar region was the inferior wall, but the proportion of patients with septal scars increased over time (Table 2).

NICMP substrates during this 8-year period, were idiopathic dilated cardiomyopathy (n=106; 54%), valvular heart disease (37; 19%), congenital heart disease (14; 7%), arrhythmogenic RV dysplasia (30; 15%), and sarcoidosis (8; 4%). Their mean LVEF was  $39 \pm 16\%$ . In NICMP, the septum, inferior and lateral wall as well as perivalvular areas, and epicardium were almost equally involved with sites of low-voltage scar giving rise to VT (Table 2). In the 106 patients with idiopathic dilated cardiomyopathy, 46 patients had a predominant basal scar, 10 patients had a predominant apical scar, 21 patients had scar involving the mid left ventricle, and 16 patients had no scar. Accurate data on base versus apex location were not available in the 13 remaining patients.

Most of the patients with SHD (288; 80%) had an ICD before referral VT ablation and were referred for recurrent ICD therapies. In the 74 remaining patients with SHD and no ICD at presentation, 19 were referred for frequent recurrent nonsustained VT, 43 because of stable sustained VT and 12 because of VT causing syncope. In the 131 patients without SHD, 51 patients were referred for frequent recurrent non-

**Table 2. Evolution of the Patients Undergoing Ventricular Tachycardia Ablation Between 1999–2002 and 2003–2006 According to Substrate**

	Ischemic Cardiomyopathy			Idiopathic Dilated Cardiomyopathy		
	1999–2002	2003–2006	<i>P</i>	1999–2002	2003–2006	<i>P</i>
Demographic, n (%)	136 (48)	142 (42)		36 (13)	70 (21)	
Age, y	68 ± 11	65 ± 11	0.02	52 ± 16	58 ± 14	NS
Sex (male), n (%)	116 (85)	132 (93)	0.03	30 (83)	55 (79)	NS
LVEF, %	29 ± 12	28 ± 13	NS	30 ± 11	32 ± 12	NS
Scar area						
Procedure with voltage map	132	134		31	66	
Inferior scar, n (%)	96 (73)	80 (60)	0.02	10 (32)	16 (24)	NS
Anterior scar, n (%)	30 (23)	40 (30)	NS	2 (6)	11 (16)	NS
Septal scar, n (%)	43 (33)	66 (49)	0.004	7 (23)	18 (27)	NS
Lateral scar, n (%)	31 (23)	38 (28)	NS	2 (6)	12 (18)	NS
Apex, n (%)	35 (27)	45 (34)	NS	7 (23)	8 (12)	NS
LV outflow tract, n (%)	4 (3)	1 (0.7)	NS	7 (23)	14 (21)	NS
Epicardial ablation, n (%)	7 (5)	13 (9)	NS	8 (26)	18 (27)	NS

LVEF indicates left ventricular ejection fraction; LV, left ventricle.

**Table 3. Complications During the 48 Hours After Ventricular Tachycardia Ablation**

	No SHD n=4 (2.7%)	ICMP n=32 (11.5%)	NICMP n=12 (6.2%)	No. (%) n=48 (7.7%)
Major life-threatening complications				23 (3.7)
Tamponade-cardiac perforation	2	3	3	8 (1.3)
Cardiogenic shock	0	5	2	7 (1.1)
Acute respiratory distress	0	2	2	4 (0.6)
Pulmonary embolism	0	1	1	2 (0.3)
Stroke	0	2	0	2 (0.3)
Other major complications				25 (4)
Transient ischemic event	1	2	0	3 (0.5)
Other embolic event	0	1	1	2 (0.3)
Atrioventricular block	1	3	1	5 (0.8)
Local vascular complication	0	7	2	9 (1.4)
Groin hematoma (requiring blood transfusion)	0	5	0	5 (0.8)
Phrenic nerve injury	0	1	0	1 (0.2)

SHD indicates structural heart disease; ICMP, ischemic cardiomyopathies; NICMP, non-ICMP.

sustained VT, 55 for stable sustained VT, and 25 because of VT leading to syncope.

### VT Characteristics and Procedure

Of the 623 VT ablation procedures, we had detailed data on VT characteristics available in 587 (94%) (139 [93%] for no SHD, 268 [96%] for ICMP and 180 [92%] for NICMP). A mean of  $2.2 \pm 1.7$  monomorphic VTs per procedure was induced. Of the 587 procedures, unstable VTs (requiring termination for hemodynamic compromise) alone were present in 131 (22%), stable VTs (monomorphic hemodynamically well tolerated) alone were seen in 183 (31%), and both were present in 273 (47%) procedures.

There were several electrophysiological differences according to the underlying heart disease. At the time of the procedure, patients with no SHD often had only premature ventricular contractions or nonsustained inducible VT (80 patients; 58%), compared with 6 (2%) and 24 (13%) of ICMP and NICMP patients, respectively ( $P < 0.001$ ). Very slow ( $< 150$  bpm) and very fast ( $> 200$  bpm VTs) ventricular contractions were more common in patients with SHD.

In 2003–2006, 78% of the VT ablations in patients with SHD were performed using a combination of substrate mapping, pace mapping, entrainment mapping, and activation mapping. Of note, epicardial ablations increased from 7% to 12% of procedures ( $P = 0.04$ ) from 1999–2002 to 2003–2006 period. Mechanical hemodynamic support (intraaortic balloon pump or assist device) was used in 21 procedures.

Procedural outcomes are shown in Table 1. VTs were abolished (success) or modified in 83% of patients without SHD, in 83% of ICMP, and in 79% of NICMP patients. Acute success, with the abolition of all monomorphic VTs, was achieved most often in patients with no SHD, followed by patients with ICMP and NICMP. None of the patients without SHD was receiving amiodarone at discharge, whereas 33% of patients in the ICMP group and 18% of patients in the

NICMP group were receiving amiodarone at the time of hospital discharge.

Of the 623 procedures, 48 (7.7%) patients had adverse events during or within 48 hours after the procedure (Table 3). Life-threatening complications were seen in 2 (1.3%) patients without SHD, in 13 patients with ICMP (4.7%), and in 8 patients with NICMP (4.1%).

### Outcome

Mean follow-up for the entire group was  $3.3 \pm 2.4$  years. No deaths occurred in non-SHD patients during a mean follow-up of  $4.2 \pm 2.2$  years in this group. In contrast, 75 patients (35%) with ICMP and 26 patients (17%) with NICMP died after a median of 13 months (5 patients within 1 week). Kaplan-Meier curves of survival are displayed in Figure 2. Eight patients (3.8%) with ICMP and 13 patients (8.7%) with NICMP underwent heart transplantation 3.3 months (median) after VT ablation.

In univariable Cox proportional hazards analysis, age and LVEF were among the predictors of mortality (Table 4). ICMP had a 2-fold (95% CI, 1.3 to 3.2) increased risk of mortality compared with NICMP. Other univariable risk factors for mortality were complications related to the procedure, the number of failed AADs, and the number of VTs induced during the procedure. This increased risk was explained by older age and lower ejection fractions among these patients. Age, LVEF, and mechanical hemodynamic support were independent predictors of mortality in a multivariable model (Table 4). For every year of age, there was a 4.3% mortality increase, and for every percent of ejection fraction increase, there was a 3.3% mortality decrease. Those patients requiring mechanical support pre- or periprocedurally had a 4-fold greater independent risk of mortality, with worse prognosis than those suffering a major procedural complication. Arrhythmic storm and incessant VT were not predictors of mortality in this population.

Unadjusted Survival after VT ablation

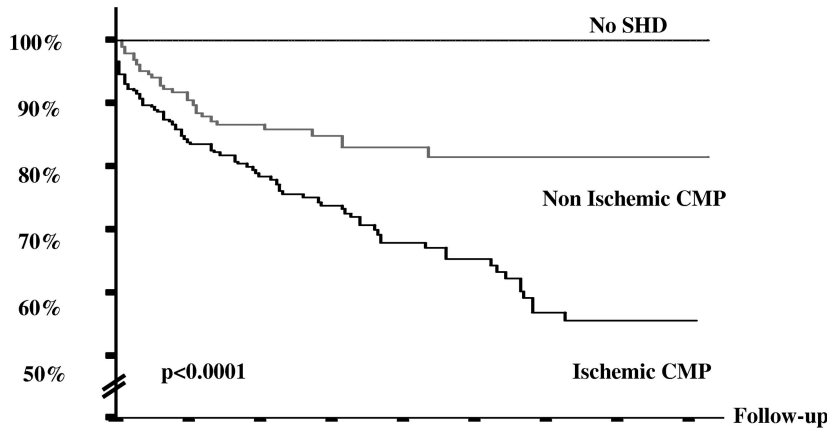


Figure 2. Kaplan-Meier curves of survival after ventricular tachycardia (VT) ablation depending on the substrate. SHD indicates structural heart disease; CMP, cardiomyopathy.

Number of patients alive	0	1	2	3	4	5	6	7	8	(years)
No SHD	131	117	105	89	70	53	35	16	5	
Non Ischemic CMP	149	113	88	68	45	32	17	11	3	
Ischemic CMP	213	158	113	89	67	51	30	16	5	

VT recurred after a median of 1 month in 29% of ICMP and in 39% of NICMP patients, and arrhythmic outcome was not available for 30 of these procedures (6%). Data for recurrent VT during late follow-up were not reliably obtainable for the patients without SHD because of the referral nature of the population.

Discussion

Main Findings

During a mean follow-up of  $3.3 \pm 2.4$  years, no deaths were seen after VT ablation in patients without SHD and long-term mortality was 35% for ICMP and 17% for NICMP. Age, LVEF, and necessity for mechanical hemodynamic support during the procedure were independent risk factors for mortality. During VT ablation, patients without SHD more often had only inducible premature ventricular contractions, whereas patients with ICMP and NICMP had sustained VTs that could be very slow or very fast. A

combination of substrate mapping, pace mapping, activation mapping, and entrainment was predominantly used especially in patients with SHD. Although the main substrate for VT ablation is ICMP (especially with inferior scar, late after myocardial infarction), the proportion of patients with NICMP is increasing. These patients have more variable scar locations (Table 1).

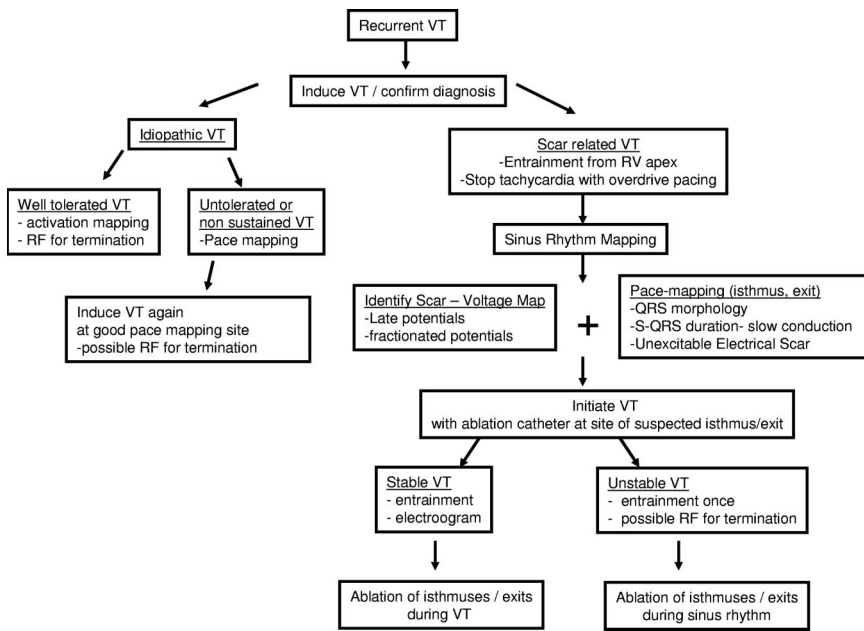
Long-Term Outcome and Predictors of Mortality

VT in normal hearts (so called idiopathic VT) is generally thought to be benign, based on small historical series. In our study, there was no death with a follow-up of  $4.2 \pm 2.2$  years in this sizable observational group. For patients with SHD, VT ablation is a palliative therapy that can reduce the number of ICD shocks.<sup>23</sup> However, the presence of shocks may indicate more severe disease.<sup>24</sup> This concern is consistent with the mortality rate of 35% at 3 years in the ICMP group. Mortality was somewhat better in the NICMP group (18% at

Table 4. Predictive Factors of Mortality in Patients With Cardiomyopathy Undergoing Ventricular Tachycardia (VT) Ablation

	Unadjusted			Adjusted		
	Hazard Ratio	95% CI	P	Hazard Ratio	95% CI	P
Age >62 y	2.508	1.622–3.877	<0.0001	2.573	1.543–4.292	0.0003
LVEF <30%	2.212	1.477–3.314	0.0001	1.477	1.246–1.750	<0.0001
ICMP	2.054	1.315–3.209	<0.0001	0.935	0.562–1.555	NS
Complications	1.956	1.419–2.698	<0.0001	1.584	0.902–2.783	NS
Mechanical hemodynamic support	3.352	1.687–6.660	<0.0006	4.333	1.874–10.016	<0.0001
No. of failed AAD	1.213	1.019–1.444	0.03	1.089	0.885–1.340	NS
No. of VT induced	1.184	1.060–1.321	0.0027	1.106	0.980–1.248	NS
Prior failed ablation	1.240	0.834–1.843	NS			

LVEF indicates left ventricular ejection fraction; ICMP, ischemic cardiomyopathies; AAD, antiarrhythmic drugs. Cutoff value for age and LVEF were the median.



**Figure 3.** Approach to mapping and ablation of ventricular tachycardias (VTs) performed in our center. RF indicates radiofrequency.

3 years), likely related, at least in part, to younger age and generally better LV function in the NICMP patients.

Arrhythmic storm has been shown to predict mortality in NICMP and ICMP.<sup>25,26</sup> In our study, patients with incessant VT or electrical storm had similar outcomes to those with less frequent VT. It is possible that ablation improved outcome for patients with electrical storm or incessant VT,<sup>27</sup> such that their prognosis was then similar to those with intermittent VT. There are also, however, substantial selection biases that influence our results. The sickest patients may not have been thought appropriate for VT ablation and not been referred. The nature and provocative factors for electrical storm also varies among different studies. In our population, ablation was not performed in patients with a secondary cause of arrhythmic storm (such as ischemia and metabolic disorders), whereas in the study of Exner et al,<sup>26</sup> 65.4% of arrhythmic storms were attributed to 1 or more of these secondary causes.

**Procedure**

In patients with SHD, a combined approach (substrate mapping, pace mapping, and activation mapping) was usually used (Figure 3). When VT is stable, substrate mapping during sinus rhythm can be used to identify regions for further evaluation during VT, minimizing the time spent in VT. Brief entrainment is often possible, even for unstable VTs, to confirm the location of a reentry circuit, potentially allowing ablation with a smaller number of RF lesions than when ablation is guided only by substrate mapping.<sup>10</sup>

Of note, the characteristics of VT, specifically the VT cycle length, were different depending on the substrate. Patients without SHD more often have only premature ventricular contractions at that time of the procedure with more difficulty inducing VT, possibly consistent with the nonreentrant mechanisms thought to be common in this population. Patients with ICMP have slower VT (cycle length > 400 ms) than those with NICMP probably because

of the substantial extent of scar with slow conduction after myocardial infarction.

In patients with SHD, acute success with abolition of all inducible VTs (59%) was similar to previous reports (averaging respectively 38% to 75%).<sup>28-30</sup> Despite the evolution of therapy, the acute procedural outcome is failure in 13% of our patients at our referral center and modified substrate (still inducible VT but different from those initially inducible) in 28% of procedures.

In the multicenter study of Calkins et al<sup>28</sup> (using an internally irrigated catheter for ablation of mappable VT ablation in ICMP), ablation of all mappable VTs was achieved acutely in 75% of patients with an 8% risk of major complication. We observed roughly similar acute success rate and complication rates in a more diverse population of patients with SHD, including patients with unstable VTs. Both studies demonstrate that major complications are not negligible in this particularly sick population.

Failure may be the result of inaccurate mapping, inadequate lesion creation, or to the presence of deep intramyocardial or epicardial arrhythmia substrate. Concerning the first item, many studies have been published in the last 10 years that have improved our ability to interpret electrograms and identify components of reentry circuits using entrainment and characterize entrainment.<sup>10-12,31,32</sup> and to better define the substrate based on low-voltage areas, unexcitable electric scar, and electrograms.<sup>33-35</sup> Concerning inadequate lesion formation, progresses have been made by using larger ablation electrodes and cooled-tip electrodes that increase lesion size.<sup>36</sup> However, even with irrigated tip catheters ventricular lesions may not be transmural. It is clear that epicardial approaches are required for some patients.<sup>13,37</sup>

Deep intramural circuits or foci may still be difficult to eliminate with available approaches. New technologies, such as needle-irrigated RF ablation, that allows deliver energy directly inside the myocardium, that are under investigation



will be of interest in this regard<sup>38,39</sup> and systems for improved catheter navigation seem promising.<sup>40</sup>

### Substrate

In ICMP, there was often a substantial latency between infarction and the VT ablation because of occurrence of multiple, refractory VTs, with a median delay between the last myocardial infarction and VT ablation of 9 years. This observation suggests a role for continued late remodeling occurring after myocardial infarction. The recent observation from the Multicenter Automatic Defibrillator Implantation Trial-II that appropriate ICD therapy for VT or VF predicts increased mortality also suggests that arrhythmias are a marker for disease severity and possibly remodeling.<sup>24</sup> Thus, the occurrence of frequent VT, resulting in referral for VT ablation may be a marker of a more advanced or malignant disease consistent with mortality rates in our post MI patients of 16%, 24%, and 35% at 1, 2, and 3 years after ablation.

There has been an increase in the proportion of patients with NICMP and VT compared with ICMP over the last 8 years. It is possible that more aggressive reperfusion strategies for acute myocardial infarction result in smaller infarcts and reduce the number of infarct survivors that eventually need VT ablation. It is also possible that more NICMP patients with VT are surviving because of a better medical therapy and a greater use of ICDs in that population. Changes in referral patterns may also be responsible for this trend. The recognition that ablation of these VTs can be challenging may lead to earlier referral to a tertiary center.

### Clinical Implication

VT ablation may be considered as a reasonable first- or second-line therapy in patients with idiopathic VT that is symptomatic or sufficiently frequent to raise concern about causing depressed ventricular function. In patients with SHD, ablation can be useful to prevent or reduce recurrent episodes of VT, usually as an adjunctive therapy to an ICD. The risks are greater, and mortality remains significant after ablation in these patients with recurrent, drug refractory VT. Attention to optimizing treatment of the underlying disease, as well as controlling VT recurrences, seems prudent. A recent study suggested that outcomes may be better in patients undergoing ablation after initial presentation with VT.<sup>41</sup> Further studies are needed to help define the role of ablation as the patient population and technologies continue to evolve.

### Limitations

(1) Our findings are based on a retrospective observational analysis. Although we adjusted for potentially confounding difference, we cannot exclude that other factors have contributed to our findings. (2) Being a referral center for VT ablation, our population is selected and may be skewed toward a sicker VT ablation population, consistent with the relatively high proportion of patients who had prior ablation attempts. It is possible that long-term mortality would be better for ablation performed before failure of multiple antiarrhythmic medications. (3) Although our findings of no mortality in patients without SHD are reassuring, it should be appreciated that some myopathic processes, such as sarcoid-

osis and arrhythmogenic RV dysplasia can be subtle in their clinical manifestations and may escape detection. A careful search for underlying disease is warranted in these patients. (4) Patients without SHD often stop seeing their referring cardiologist during late follow-up, such that clinical follow-up for VT recurrences was not available for 71% of our patients without SHD. Use of the social security death index allowed mortality to be obtained for all patients. In SHD patients, follow-up was based on reports of ICD interrogations, which may have been incomplete. (5) Most of our SHD patients had ICDs that undoubtedly extend survival in this patient population. The impact of an ablation strategy on mortality either with or without an ICD cannot be assessed from our data. (6) The ablation and mapping technology used in an individual patient was influenced by its availability and uncontrolled patient and physician factors. We did not, therefore, attempt to compare different ablation technologies overall in this population.

### Conclusions

In this large observational series, the proportion of patients with NICMP compared with ICMP with VT requiring ablation is increasing. Procedures targeting these substrates have evolved through the last 8 years with availability of epicardial mapping and common use of a combination of substrate mapping, pace mapping, and activation mapping.

In the setting of a normal heart, prognosis is excellent, with no deaths occurring over a mean follow-up >3 years. For patients with recurrent VT due to SHD, ablation is a palliative option, which suppresses or decreases drug refractory VT episodes, whereas long-term mortality remains significant.

### Disclosures

We report for Dr Frederic Sacher an educational grant from Biosense Webster (modest). When these patients were studied, Dr Tedrow received research funding from Boston Scientific and Medtronic (modest) and received speaking honoraria from Boston Scientific (modest), Medtronic (modest), and St Jude Medical Inc (modest). Dr Bruce Koplan received speaking honoraria from Boston Scientific (modest), Medtronic (modest), and St Jude Medical Inc (modest). Dr Laurence Epstein was a consultant to Biosense Webster (modest) and received speaking honoraria from Boston Scientific (modest), Medtronic (modest), St Jude Medical Inc (modest), and Biosense Webster (modest). Dr William Stevenson was a consultant to Biosense Webster (modest) and received speaking honoraria from Boston Scientific (modest), Medtronic (Modest), St Jude Medical Inc (modest), and Biosense Webster (modest).

### Funding sources

F.S. was supported by a grant from the French Federation of Cardiology.

### References

1. A comparison of antiarrhythmic-drug therapy with implantable defibrillators in patients resuscitated from near-fatal ventricular arrhythmias. The Antiarrhythmics Versus Implantable Defibrillators (AVID) Investigators. *N Engl J Med.* 1997;337:1576–1583.
2. Moss AJ, Zareba W, Hall WJ, Klein H, Wilber DJ, Cannom DS, Daubert JP, Higgins SL, Brown MW, Andrews ML, Multicenter Automatic Defibrillator Implantation Trial II Investigators. Prophylactic implantation of

- a defibrillator in patients with myocardial infarction and reduced ejection fraction. *N Engl J Med*. 2002;346:877–883.
3. Bardy GH, Lee KL, Mark DB, Poole JE, Packer DL, Boineau R, Domanski M, Troutman C, Anderson J, Johnson G, McNulty SE, Clapp-Channing N, Davidson-Ray LD, Fraulo ES, Fishbein DP, Luceri RM, Ip JH, Sudden Cardiac Death in Heart Failure Trial (SCD-HeFT) Investigators. Amiodarone or an implantable cardioverter-defibrillator for congestive heart failure. *N Engl J Med*. 2005;352:225–237.
  4. Villacastin J, Almendral J, Arenal A, Albertos J, Ormaetxe J, Peinado R, Bueno H, Merino JL, Pastor A, Medina O, Tercedor L, Jimenez F, Delcan JL. Incidence and clinical significance of multiple consecutive, appropriate, high-energy discharges in patients with implanted cardioverter-defibrillators. *Circulation*. 1996;93:753–762.
  5. Credner SC, Klingenhoben T, Mauss O, Sticherling C, Hohnloser SH. Electrical storm in patients with transvenous implantable cardioverter-defibrillators: incidence, management and prognostic implications. *J Am Coll Cardiol*. 1998;32:1909–1915.
  6. Roberts SA, Viana MA, Nazari J, Bauman JL. Invasive and noninvasive methods to predict the long-term efficacy of amiodarone: a compilation of clinical observations using meta-analysis. *Pacing Clin Electrophysiol*. 1994;17:1590–1602.
  7. Haverkamp W, Martinez-Rubio A, Hief C, Lammers A, Muhlenkamp S, Wichter T, Breithardt G, Borggrefe M. Efficacy and safety of d,l-sotalol in patients with ventricular tachycardia and in survivors of cardiac arrest. *J Am Coll Cardiol*. 1997;30:487–495.
  8. Preliminary report: effect of encainide and flecainide on mortality in a randomized trial of arrhythmia suppression after myocardial infarction. The Cardiac Arrhythmia Suppression Trial (CAST) Investigators. *N Engl J Med*. 1989;321:406–412.
  9. Soejima K, Delacretaz E, Suzuki M, Bruckhorst CB, Maisel WH, Friedman PL, Stevenson WG. Saline-cooled versus standard radiofrequency catheter ablation for infarct-related ventricular tachycardias. *Circulation*. 2001;103:1858–1862.
  10. Soejima K, Suzuki M, Maisel WH, Bruckhorst CB, Delacretaz E, Blier L, Tung S, Khan H, Stevenson WG. Catheter ablation in patients with multiple and unstable ventricular tachycardias after myocardial infarction: short ablation lines guided by reentry circuit isthmuses and sinus rhythm mapping. *Circulation*. 2001;104:664–669.
  11. Soejima K, Stevenson WG, Maisel WH, Sapp JL, Epstein LM. Electrically unexcitable scar mapping based on pacing threshold for identification of the reentry circuit isthmus: feasibility for guiding ventricular tachycardia ablation. *Circulation*. 2002;106:1678–1683.
  12. Tung S, Soejima K, Maisel WH, Suzuki M, Epstein L, Stevenson WG. Recognition of far-field electrograms during entrainment mapping of ventricular tachycardia. *J Am Coll Cardiol*. 2003;42:110–115.
  13. Soejima K, Stevenson WG, Sapp JL, Selwyn AP, Couper G, Epstein LM. Endocardial and epicardial radiofrequency ablation of ventricular tachycardia associated with dilated cardiomyopathy: the importance of low-voltage scars. *J Am Coll Cardiol*. 2004;43:1834–1842.
  14. Soejima K, Couper G, Cooper JM, Sapp JL, Epstein LM, Stevenson WG. Subxiphoid surgical approach for epicardial catheter-based mapping and ablation in patients with prior cardiac surgery or difficult pericardial access. *Circulation*. 2004;110:1197–1201.
  15. Lopera G, Stevenson WG, Soejima K, Maisel WH, Koplan B, Sapp JL, Satti SD, Epstein LM. Identification and ablation of three types of ventricular tachycardia involving the his-purkinje system in patients with heart disease. *J Cardiovasc Electrophysiol*. 2004;15:52–58.
  16. Bruckhorst CB, Delacretaz E, Soejima K, Maisel WH, Friedman PL, Stevenson WG. Identification of the ventricular tachycardia isthmus after infarction by pace mapping. *Circulation*. 2004;110:652–659.
  17. Koplan BA, Soejima K, Baughman K, Epstein LM, Stevenson WG. Refractory ventricular tachycardia secondary to cardiac sarcoid: electrophysiologic characteristics, mapping, and ablation. *Heart Rhythm*. 2006;3:924–929.
  18. Zeppenfeld K, Schalij MJ, Bartelings MM, Tedrow UB, Koplan BA, Soejima K, Stevenson WG. Catheter ablation of ventricular tachycardia after repair of congenital heart disease: electroanatomic identification of the critical right ventricular isthmus. *Circulation*. 2007;116:2241–2252.
  19. Eckart RE, Hruczkowski TW, Tedrow UB, Koplan BA, Epstein LM, Stevenson WG. Sustained ventricular tachycardia associated with corrective valve surgery. *Circulation*. 2007;116:2005–2011.
  20. Stevenson WG, Friedman PL, Kocovic D, Sager PT, Saxon LA, Pavri B. Radiofrequency catheter ablation of ventricular tachycardia after myocardial infarction. *Circulation*. 1998;98:308–314.
  21. Marchlinski FE, Callans DJ, Gottlieb CD, Zado E. Linear ablation lesions for control of unmappable ventricular tachycardia in patients with ischemic and nonischemic cardiomyopathy. *Circulation*. 2000;101:1288–1296.
  22. Hsia HH, Callans DJ, Marchlinski FE. Characterization of endocardial electrophysiological substrate in patients with nonischemic cardiomyopathy and monomorphic ventricular tachycardia. *Circulation*. 2003;108:704–710.
  23. Strickberger SA, Man KC, Daoud EG, Goyal R, Brinkman K, Hasse C, Bogun F, Knight BP, Weiss R, Bahu M, Morady F. A prospective evaluation of catheter ablation of ventricular tachycardia as adjuvant therapy in patients with coronary artery disease and an implantable cardioverter-defibrillator. *Circulation*. 1997;96:1525–1531.
  24. Moss AJ, Greenberg H, Case RB, Zareba W, Hall WJ, Brown MW, Daubert JP, McNitt S, Andrews ML, Elkin AD, Multicenter Automatic Defibrillator Implantation Trial-II (MADIT-II) Research Group. Long-term clinical course of patients after termination of ventricular tachyarrhythmia by an implanted defibrillator. *Circulation*. 2004;110:3760–3765.
  25. Bansch D, Bocker D, Brunn J, Weber M, Breithardt G, Block M. Clusters of ventricular tachycardias signify impaired survival in patients with idiopathic dilated cardiomyopathy and implantable cardioverter defibrillators. *J Am Coll Cardiol*. 2000;36:566–573.
  26. Exner DV, Pinski SL, Wyse DG, Renfro EG, Follmann D, Gold M, Beckman KJ, Coromilas J, Lancaster S, Hallstrom AP, AVID Investigators. Antiarrhythmics versus implantable defibrillators. Electrical storm presages nonsudden death: the antiarrhythmics versus implantable defibrillators (AVID) trial. *Circulation*. 2001;103:2066–2071.
  27. Carbucicchio C, Santamaria M, Trevisi N, Maccabelli G, Giraldo F, Fassini G, Riva S, Moltrasio M, Cireddu M, Veglia F, Della Bella P. Catheter ablation for the treatment of electrical storm in patients with implantable cardioverter-defibrillators: short- and long-term outcomes in a prospective single-center study. *Circulation*. 2008;117:462–469.
  28. Calkins H, Epstein A, Packer D, Arria AM, Hummel J, Gilligan DM, Trusso J, Carlson M, Luceri R, Kopelman H, Wilber D, Wharton JM, Stevenson W, Cooled RF Multicenter Investigators Group. Catheter ablation of ventricular tachycardia in patients with structural heart disease using cooled radiofrequency energy: results of a prospective multicenter study. *J Am Coll Cardiol*. 2000;35:1905–1914.
  29. O'Donnell D, Bourke JP, Anilkumar R, Simeonidou E, Furniss SS. Radiofrequency ablation for post infarction ventricular tachycardia: report of a single centre experience of 112 cases. *Eur Heart J*. 2002;23:1699–1705.
  30. Della Bella P, Riva S, Fassini G, Giraldo F, Berti M, Klersy C, Trevisi N. Incidence and significance of pleomorphism in patients with postmyocardial infarction ventricular tachycardia: acute and long-term outcome of radiofrequency catheter ablation. *Eur Heart J*. 2004;25:1127–1138.
  31. Bogun F, Kim HM, Han J, Tamirisa K, Tschopp D, Reich S, Elmouchi D, Igic P, Lemola K, Good E, Oral H, Chugh A, Pelosi F, Morady F. Comparison of mapping criteria for hemodynamically tolerated, postinfarction ventricular tachycardia. *Heart Rhythm*. 2006;3:20–26.
  32. de Chillou C, Lacroix D, Klug D, Magnin-Poull I, Marquie C, Messier M, Andronache M, Koukam C, Sadoul N, Chen J, Aliot E, Kacet S. Isthmus characteristics of reentrant ventricular tachycardia after myocardial infarction. *Circulation*. 2002;105:726–731.
  33. Bogun F, Good E, Reich S, Elmouchi D, Igic P, Lemola K, Tschopp D, Jongnarangsin K, Oral H, Chugh A, Pelosi F, Morady F. Isolated potentials during sinus rhythm and pace-mapping within scars as guides for ablation of post-infarction ventricular tachycardia. *J Am Coll Cardiol*. 2006;47:2013–2019.
  34. Arenal A, Glez-Torrecilla E, Ortiz M, Villacastin J, Fdez-Portales J, Sousa E, del Castillo S, Perez de Isla L, Jimenez J, Almendral J. Ablation of electrograms with an isolated, delayed component as treatment of unmappable monomorphic ventricular tachycardias in patients with structural heart disease. *J Am Coll Cardiol*. 2003;41:81–92.
  35. Arenal A, del Castillo S, Gonzalez-Torrecilla E, Atienza F, Ortiz M, Jimenez J, Puchol A, Garcia J, Almendral J. Tachycardia-related channel in the scar tissue in patients with sustained monomorphic ventricular tachycardias: influence of the voltage scar definition. *Circulation*. 2004;110:2568–2574.
  36. Nakagawa H, Yamanashi WS, Pitha JV, Arruda M, Wang X, Ohtomo K, Beckman KJ, McClelland JH, Lazzara R, Jackman WM. Comparison of in vivo tissue temperature profile and lesion geometry for radiofrequency ablation with a saline-irrigated electrode versus tem-

- perature control in a canine thigh muscle preparation. *Circulation*. 1995;91:2264–2273.
37. Sosa E, Scanavacca M, d'Avila A, Oliveira F, Ramires JA. Nonsurgical transthoracic epicardial catheter ablation to treat recurrent ventricular tachycardia occurring late after myocardial infarction. *J Am Coll Cardiol*. 2000;35:1442–1449.
  38. Sapp JL, Cooper JM, Zei P, Stevenson WG. Large radiofrequency ablation lesions can be created with a retractable infusion-needle catheter. *J Cardiovasc Electrophysiol*. 2006;17:657–661.
  39. Thiagalingam A, Pouliopoulos J, Barry MA, Boyd AC, Eipper V, Yung T, Ross DL, Kovoov P. Cooled needle catheter ablation creates deeper and wider lesions than irrigated tip catheter ablation. *J Cardiovasc Electrophysiol*. 2005;16:508–515.
  40. Ray IB, Dukkipati S, Houghtaling C, McPherson CD, Kastelein N, Ruskin JN, Reddy VY. Initial experience with a novel remote-guided magnetic catheter navigation system for left ventricular scar mapping and ablation in a porcine model of healed myocardial infarction. *J Cardiovasc Electrophysiol*. 2007;18:520–525.
  41. Reddy VY, Reynolds MR, Neuzil P, Richardson AW, Taborsky M, Jongnarangsin K, Kralovec S, Sediva L, Ruskin JN, Josephson ME. Prophylactic catheter ablation for the prevention of defibrillator therapy. *N Engl J Med*. 2007;357:2657–2665.

### CLINICAL PERSPECTIVE

Ventricular tachycardia (VT) ablation may be considered as a reasonable first-line therapy in patients with idiopathic VT that is symptomatic or sufficiently frequent to raise concern about causing depressed ventricular function. In these patients, prognosis is excellent after ablation, with no deaths occurring over a mean follow-up 3 years. In patients with SHD, ablation can be useful to prevent or reduce recurrent episodes of VT, usually as adjunctive therapy to an ICD. Complications rate and mortality (35% for ischemic cardiomyopathy and 17% for nonischemic cardiomyopathy, with a  $3.3 \pm 2.4$ -yr follow-up) remain higher in this population. Age, LVEF, and necessity for mechanical hemodynamic support during the procedure were independent risk factors for mortality in this large observational studies. Attention to optimizing treatment of the underlying disease, as well as controlling VT recurrences, seems prudent. A recent study suggested that outcomes may be better in patients undergoing ablation after initial presentation with VT (Reddy V et al. *N Engl J Med*. 2007;357:2657–2665). Further studies are needed to help define the role of ablation, as the patient population and technologies continue to evolve.

## **B) Références**

1. Marchlinski FE. Ventricular tachycardia ablation: moving beyond treatment of last resort. *Circ Arrhythm Electrophysiol.* 2008; 1: 147-149.
2. Reddy VY, Reynolds MR, Neuzil P, Richardson AW, Taborsky M, Jongnarangsin K, Kralovec S, Sediva L, Ruskin JN, Josephson ME. Prophylactic catheter ablation for the prevention of defibrillator therapy. *N Engl J Med.* 2007; 357: 2657-2665.
3. Poole JE, Johnson GW, Hellkamp AS, Anderson J, Callans DJ, Raitt MH, Reddy RK, Marchlinski FE, Yee R, Guarnieri T, Talajic M, Wilber DJ, Fishbein DP, Packer DL, Mark DB, Lee KL, Bardy GH. Prognostic importance of defibrillator shocks in patients with heart failure. *N Engl J Med.* 2008; 359: 1009-1017.
4. Sweeney MO. Point: implantable cardioverter-defibrillator shocks for ventricular tachyarrhythmias increase mortality. *Heart Rhythm.* 2012; 9: 985-987.
5. Sweeney MO. There are lots of things about implantable cardioverter-defibrillators that should be eliminated: shocks are a good start. *Heart Rhythm.* 2012; 9: 2075-2076.



## IV- Deuxième partie : Caractéristiques des cicatrices myocardiques responsables d'arythmie ventriculaire

Le développement de l'imagerie cardiaque et des systèmes de cartographie nous aide à mieux corréliser les signaux électriques enregistrés dans la cicatrice à l'anatomie. Le premier travail à consister à identifier les caractéristiques des potentiels ventriculaires anormaux (LAVA) en fonction de leur localisation anatomique. Les 3 autres travaux de ce chapitre ont consisté à caractériser le substrat (1) des patients avec cardiopathie dilatée à coronaires saines ayant une cicatrice prédominante sur le versant épicaudique, (2) des patients porteurs d'une assistance ventriculaire gauche à flux continu et (3) d'un patient avec syndrome de Brugada.

### A) Electrophysiologic characterization of local abnormal ventricular activities in post infarction ventricular tachycardia with respect to their anatomic location

Publié: Heart Rhythm. 2013;10(11):1630-7

#### 1) Etude

L'ablation des TV ciblant le substrat s'est développée ces dernières années. Différentes méthodes ont été rapportées<sup>1-7</sup>. Récemment, nous avons montré que l'élimination complète des potentiels ventriculaires anormaux (LAVA) était associée à un meilleur devenir des patients<sup>8</sup>. Le terme LAVA permet de regrouper l'ensemble des potentiels anormaux ventriculaires antérieurement décrits (doubles, tardifs, isolés, fragmentés). Ces LAVA sont définis comme des électrogrammes de haute-fréquence distinct du signal ventriculaire "far-field" survenant le plus souvent après ce dernier en rythme sinusal mais parfois masqués à l'intérieur. Ils peuvent avoir plusieurs composantes séparées par des signaux de faible amplitude ou une ligne iso-électrique. Le but de ce travail est de mieux décrire ces potentiels ventriculaires anormaux en fonction de leur localisation chez les patients avec TV post infarctus du myocarde.

Sur un total de 31 patients avec cartographie du substrat, nous avons analysé 1104 sites avec LAVA enregistrés sur l'endocarde (n=839) ou sur l'épicarde (n=265). Les caractéristiques identifiées sont les suivantes. Ces potentiels sont plus tardifs lorsqu'ils se

situent sur l'épicaarde vs l'endocarde ou sur la paroi latérale vs septale. Alors qu'on s'attend à les trouver dans la cicatrice définie par une zone avec voltage  $<1,5\text{mV}$ , 3% de ces LAVA sont retrouvés dans des zones avec voltage  $>1,5\text{mV}$ . Il existe un continuum dans le délai de survenue des LAVA, 28% surviennent avant la fin du QRS de surface (34% sur le versant endocardique mais seulement 9% sur le versant épicaardique). La durée des LAVA est plus importante chez les patients avec infarctus les plus anciens et au centre de la cicatrice (par rapport à la zone bordante).

## *2) Implications*

Lors de la cartographie du substrat, il ne faut pas uniquement repérer les zones de bas voltage ( $<1,5\text{mV}$ ) et les potentiels tardifs. Il est important de regarder les signaux et d'annoter ces LAVA même en zone dite "normale". Il est parfois nécessaire d'utiliser des extrastimuli pour éventuellement démasquer ces LAVA tout particulièrement en cas de cicatrice septale où ils surviennent volontiers avant la fin du QRS de surface. Ceci est aussi vrai chez les patients stimulo-dépendant chez qui il faut parfois stimuler d'autres sites pour démasquer ces potentiels anormaux. Enfin chez les patients avec infarctus récents, il faut s'attendre à avoir des LAVA moins tardifs (en fonction du territoire de l'infarctus) et moins fragmentés que chez les patients avec infarctus anciens.

# Electrophysiologic characterization of local abnormal ventricular activities in postinfarction ventricular tachycardia with respect to their anatomic location

Yuki Komatsu, MD, Matthew Daly, MBChB, Frédéric Sacher, MD, Nicolas Derval, MD, Patrizio Pascale, MD, Laurent Roten, MD, Daniel Scherr, MD, Amir Jadidi, MD, Khaled Ramoul, MD, Arnaud Denis, MD, Laurence Jesel, MD, Stephan Zellerhoff, MD, Han S Lim, MBBS, Ashok Shah, MD, Hubert Cochet, MD, Mëlèze Hocini, MD, Michel Haïssaguerre, MD, Pierre Jaïs, MD

From the Department of Cardiac Electrophysiology, Hôpital Cardiologique du Haut-Lévêque, Université Victor Segalen Bordeaux II, Institut LYRIC, Equipex MUSIC, Bordeaux, France.

**BACKGROUND** Local abnormal ventricular activities (LAVA) in patients with scar-related ventricular tachycardia (VT) may appear at any time during or after the far-field electrogram. Although they may be separated from the far-field signal by an isoelectric line and extend beyond the end of surface QRS, they may also appear fused or buried within the QRS.

**OBJECTIVE** The purpose of this study was to characterize LAVA in postinfarction VT patients with respect to their anatomic locations.

**METHODS** Thirty-one patients with postinfarction VT underwent mapping/ablation during sinus rhythm with a three-dimensional electroanatomic mapping system. From a total of 18,270 electrograms reviewed in all study subjects, 1104 LAVA (endocardium 839, epicardium 265) were identified and analyzed.

**RESULTS** The interval from onset of QRS complex to ventricular electrogram (EGM onset) on the endocardium was significantly shorter than the epicardium ( $P < .001$ ). EGM onset was shortest in the septal endocardium and longest in the inferior and lateral epicardium. There was a significant positive correlation between EGM onset and LAVA lateness as estimated by the interval from surface QRS onset to LAVA ( $r = 0.52$ ,  $P < .001$ ). LAVA were more

frequently detected after the QRS complex in the epicardium (241/265 [91%]) than in the endocardium (551/839 [66%],  $P < .001$ ). Only 43% of endocardial septal LAVA were detected after the QRS complex.

**CONCLUSION** Lateness of LAVA is affected to a large extent by their locations. The chance of detecting late LAVA increases when electrogram onset is later. Substrate-based approach targeting delayed signals relative to the QRS complex may miss critical the arrhythmogenic substrate, particularly in the septum and other early-to-activate regions.

**KEYWORDS** Catheter ablation; Ventricular tachycardia; Mapping; Three-dimensional mapping; Postmyocardial infarction; Local abnormal ventricular activities

**ABBREVIATIONS** 3D-EAM = three-dimensional electroanatomic mapping; ICD = implantable cardioverter-defibrillator; LAVA = local abnormal ventricular activities; LV = left ventricle; RV = right ventricle; VT = ventricular tachycardia

(Heart Rhythm 2013;10:1630–1637) © 2013 Heart Rhythm Society. All rights reserved.

## Introduction

Catheter ablation of scar-related ventricular tachycardia (VT) has been widely adopted for the management of patients requiring frequent therapy from their implantable cardioverter-defibrillator (ICD).<sup>1,2</sup> A substrate-based approach is attractive because poor hemodynamic tolerance during VT, multiple VT morphologies, or noninducibility can render the VT unmappable.<sup>3,4</sup> We reported that complete elimination of local

abnormal ventricular activities (LAVA) is associated with superior survival free from recurrent VT during long-term follow-up.<sup>5</sup> LAVA are generated by poorly coupled viable fibers within the scar.<sup>5–7</sup> LAVA may appear at any time during or after the far-field ventricular electrogram in sinus rhythm. That is, LAVA may be separated from the far-field signal by an isoelectric line and extend beyond the end of the surface QRS, but LAVA may also appear fused or buried within the QRS. The lateness of local activation is thought to be due to local conduction delay in abnormal myocardial tissue where conduction is slowed by fibrosis.<sup>6,7</sup>

In theory, the left ventricular (LV) areas first excited in sinus rhythm are the endocardial septum below the attachment of the mitral valve.<sup>8</sup> The wave of excitation spreads from endocardium to epicardium. Epicardial posterobasal is the last region to

This study was supported in part by a grant from Fondation Leducq (09 CVD 03). **Address reprint requests and correspondence:** Dr. Yuki Komatsu, Department of Cardiac Electrophysiology, Hôpital Cardiologique du Haut-Lévêque, the Université Victor Segalen Bordeaux II, Avenue de Magellan, 33604 Bordeaux-Pessac, France. E-mail address: yk.komat@gmail.com.

be activated.<sup>8</sup> We hypothesized that LAVA characteristics would be affected not only by local conduction delay but also by their anatomic locations because the wavefront reaches the scar margin at different times according to their locations. This study was undertaken to test this hypothesis by assessing the detailed characteristics of LAVA with respect to their anatomic locations in patients with postinfarction VT.

## Methods

### Study population

This study enrolled 31 postinfarction patients (Table 1) undergoing VT ablation using a three-dimensional electro-anatomic mapping (3D-EAM) system from November 2009 to January 2013. All patients had episodes of repetitive, sustained VT resistant to antiarrhythmic drug therapy requiring external cardioversion or ICD therapy. Three patients had undergone a prior unsuccessful ablation procedure. The mean age of infarction, which was defined as the time from first infarction to the ablation procedure, was  $180 \pm 95$  months. Two patients had a left bundle branch block, and three had a right bundle branch block. Twelve patients had a nonspecific LV conduction disturbance, which are defined as QRS duration  $> 110$  ms but not meeting the criteria of left or right bundle branch block.<sup>9</sup> Written informed consent was obtained in all patients.

### Electrophysiologic study

All antiarrhythmic drugs except amiodarone were discontinued for at least five half-lives before ablation, provided the stability of arrhythmia allowed it. ICD therapies were turned off, and the device programmed to a surveillance-only mode. A 6Fr steerable quadripolar or decapolar catheter (Xtrem, Sorin, Montreux, France; Dynamic, Bard Electrophysiology, Lowell,

MA) was inserted from the right femoral vein and placed at the right ventricular (RV) apex or into the coronary sinus. The LV endocardium was accessed by transseptal or retrograde transaortic approach. Pericardial access was obtained if a previous endocardial ablation had failed, if an epicardial substrate was suspected (based on VT morphology on surface ECG), or minimal or no endocardial scar. Pericardial access was obtained by a subxiphoid puncture. Electroanatomic mapping was performed during sinus rhythm using CARTO (Biosense Webster, Diamond Bar, CA) or NavX (St. Jude Medical, St. Paul, MN). Mapping was performed with an ablation catheter (Thermocool, Biosense Webster) and/or a multipolar high-density mapping catheter (PentaRay, Biosense Webster). PentaRay is an irrigated catheter with five splines, each with four poles of 1-mm electrode size and 4-4-4 mm interelectrode spacing. Bipolar signals were filtered from 30 to 250 Hz. We used the following voltage criteria: peak-to-peak bipolar amplitude  $< 1.5$  mV defined the low-voltage zone, amplitude of 0.5–1.5 mV the scar border zone, and amplitude  $< 0.5$  mV dense scar.<sup>4</sup>

### Definition of LAVA

As we previously reported,<sup>5</sup> LAVA during sinus rhythm were defined as electrograms with the following features: (1) sharp, high-frequency ventricular potentials distinct from the far-field ventricular electrogram, (2) occurring any time during or (most frequently) after the far-field ventricular electrogram during sinus rhythm, and (3) sometimes displaying double or multiple high-frequency signals separated by very-low-amplitude signals or an isoelectric interval. LAVA have no quantitative definition because LAVA sometimes appear to be short duration and high amplitude ( $> 1.5$  mV). The key feature to confirm the presence of LAVA and to distinguish them from far-field potential is to demonstrate their poorly coupled nature to the rest of the myocardium. When LAVA appear fused with the far-field ventricular potential, ventricular pacing maneuvers were performed to distinguish them from far-field ventricular electrogram. RV pacing sometimes unmasked LAVA that were not obvious during sinus rhythm (Figure 1). Importantly, programmed stimulation could increase the delay of LAVA from far-field ventricular potential (Figure 1), based on the conduction properties of LAVA, that is, they are usually poorly coupled to the rest of the myocardium.

### Radiofrequency ablation

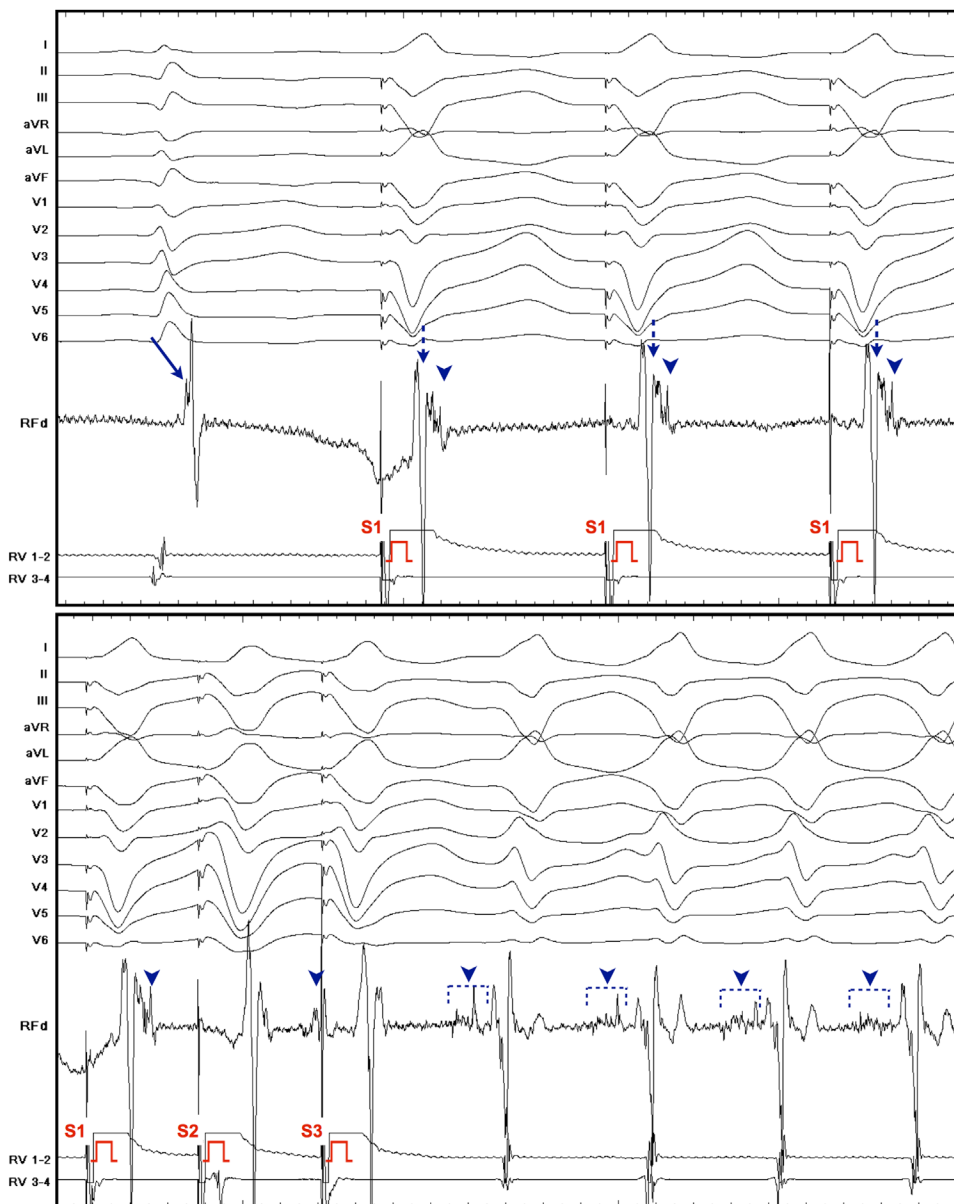
To test inducibility, programmed ventricular stimulation was performed from the RV apex at basic drive cycle length 600 and 400 ms with up to triple extrastimuli decrementally to 200 ms or ventricular refractoriness, whichever occurred first. When VT was inducible and hemodynamically tolerated, ablation was guided by conventional activation and entrainment mapping.<sup>10</sup> After restoration of sinus rhythm, further ablation targeting LAVA was performed. In patients with noninducible or poorly tolerated VT, ablation of LAVA during sinus rhythm was performed. All areas displaying

**Table 1** Patient characteristics (n = 31)

Age (years)	60 $\pm$ 10
Male	30 (97%)
Hypertension	20 (65%)
Diabetes mellitus	5 (16%)
LVEF (%)	30.4 $\pm$ 9.9
LVEF $\leq$ 30%	17 (55%)
QRS width in sinus rhythm (ms)	129 $\pm$ 36
Conduction disturbance	
Left bundle branch block	2 (6%)
Right bundle branch block	3 (10%)
Nonspecific left ventricular conduction disturbance	12 (39%)
QRS $\leq$ 110 ms	14 (45%)
Previous ablation	3 (10%)
Implantable cardioverter-defibrillator	26 (84%)
Medications	
Amiodarone	27 (87%)
Beta-blocker	29 (94%)
Statin	26 (84%)
Angiotensin-converting enzyme inhibitor/ angiotensin receptor blocker	26 (84%)

Data are given as mean  $\pm$  SD or n (%).

LVEF = left ventricular ejection fraction.



**Figure 1** Local abnormal ventricular activities (LAVA) unmasked by ventricular pacing maneuvers. The local ventricular electrogram in sinus rhythm with far-field ventricular potential fused with abnormal sharp signal (*arrow*). Pacing from the right ventricle (RV) (decoupled the LAVA (*arrowhead*) from the far-field potential (*dotted arrow*)). Programmed RV stimulation increased the delay from the far-field potential. Ventricular tachycardia (VT) was induced after the stimulation (S3). LAVA became a presystolic fragmented potential during VT, which was associated with the slow conducting channel of this VT reentrant circuit.

LAVA were delineated and labeled on the 3D-EAM. Ablation was performed with a 3.5-mm open-irrigation catheter (Thermocool, Biosense Webster) with a power of 25–50 W endocardially and 25–35 W epicardially. Radiofrequency energy was delivered until elimination of LAVA was achieved.

Where LAVA appeared to follow a distinct activation sequence, the earliest signals were targeted first,<sup>5</sup> based on the hypothesis that the conducting channels of the VT reentrant circuit have interconnecting pathways, with orthodromic activation from the edge to the inside of the scar.<sup>11</sup> This ablation approach was performed for the purpose of a potential reduction of radiofrequency delivery by “disconnecting” the entire slow conducting channel from the rest of the ventricle instead of starting ablation at the latest signal and having to ablate the entire channel. If both endocardial and epicardial LAVA were detected, ablation was first performed endocardially, aiming to abolish the potentials

transmurally, followed by epicardial ablation if required. Following ablation, areas previously displaying LAVA were remapped. In the presence of residual LAVA, radiofrequency ablation was continued. VT inducibility was reassessed by programmed stimulation using the same protocol, unless the original VT was hemodynamically unstable. The goal and ideal end-point of ablation was complete elimination of all identified LAVA.

### Analysis of LAVA characteristics

The location of LAVA was documented on the 3D-EAM and segmented into seven regions: endocardial (septum, anterior, apex, inferior/lateral), and epicardial (anterior, apex, and inferior/lateral). As shown in [Figure 2](#), the analysis of LAVA characteristics included (1) the amplitude of the signal (in mV), which were automatically obtained in 3D-EAM as peak-to-peak bipolar amplitude; (2) the interval from the



onset of the QRS complex on surface ECG to the onset of ventricular electrogram ([EGM onset] in ms); (3) the duration from onset of ventricular electrogram to end of LAVA ([EGM duration] in ms); (4) the interval from onset of QRS complex to end of LAVA ([LAVA lateness] in ms); (5) whether LAVA was clearly separated by an isoelectric interval; and (6) whether LAVA was detected after the end of the QRS complex. All measurements were obtained from the LAVA in sinus rhythm.

### Statistical analysis

Categorical variables are expressed as number and percentage, and were compared using Pearson's  $\chi^2$  test or Fisher exact test, as appropriate. Continuous data for normally distributed variables are expressed as mean  $\pm$  SD and compared by Student *t* test. Variables of LAVA characteristics were expressed as median [25, 75th percentiles] and compared using Mann-Whitney *U* test or Kruskal-Wallis test because these were non-normally distributed variables. Spearman rank correlation coefficients were calculated between LAVA lateness and EGM onset. All tests were two tailed, and  $P < .05$  was considered significant.

## Results

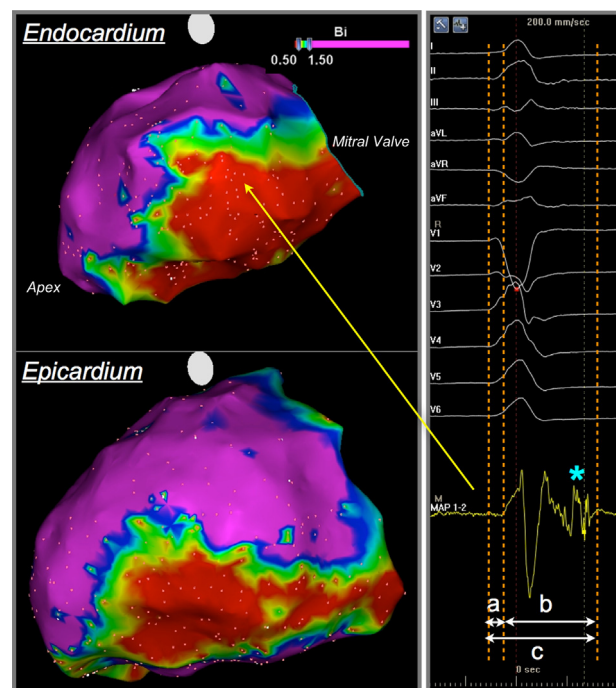
### Mapping data

Detailed LV endocardial mapping was performed in 30 patients and epicardial mapping in 14 patients. One patient did not undergo endocardial mapping because of intracardiac thrombus. The endocardium and epicardium were mapped with  $410 \pm 233$  and  $426 \pm 245$  points/map, respectively. Endocardial and epicardial low-voltage areas (bipolar voltage  $< 1.5$  mV) were identified in all patients. Eighteen patients had anterior infarction and 13 had inferior infarction. Fourteen of the anterior infarction patients and three of the inferior infarction patients had septal low-voltage area with the presence of septal LAVA. Three patients had the low-voltage area located at the anteroseptum and the inferior wall.

From a total of 18,270 electrograms mapped and reviewed in all study subjects, 1104 LAVA (endocardium 839, epicardium 265) were identified. Mapping data of 14 patients with septal scar and 17 patients without septal scar are summarized in Table 2. Endocardial and epicardial low voltage were not significantly different between patients with and without septal scar (endocardium:  $106 \pm 61$  cm<sup>2</sup> vs.  $88 \pm 45$  cm<sup>2</sup>,  $P = .37$ ; epicardium:  $78 \pm 24$  cm<sup>2</sup> vs.  $92 \pm 45$  cm<sup>2</sup>,  $P = .57$ ). There was no significant difference in LAVA density between patients with and those without septal scar (endocardium:  $0.32 \pm 0.15$  points/cm<sup>2</sup> vs.  $0.35 \pm 0.23$  points/cm<sup>2</sup>,  $P = .73$ ; epicardium:  $0.18 \pm 0.07$  points/cm<sup>2</sup> vs.  $0.25 \pm 0.14$  points/cm<sup>2</sup>,  $P = .23$ ).

### Characteristics of endocardial and epicardial LAVA

The characteristics of 1104 LAVA (839 endocardial, 265 epicardial) were analyzed. There were clear differences in LAVA characteristics between the endocardium and epicardium. EGM onset on the endocardium was significantly



**Figure 2** Assessment of local abnormal ventricular activities (LAVA) characteristics. Electroanatomic mapping was performed during sinus rhythm. A peak-to-peak bipolar amplitude  $< 1.5$  mV was defined as low-voltage zone, an amplitude 0.5–1.5 mV as border zone, and amplitude  $< 0.5$  mV as dense scar. Detailed assessment of LAVA characteristics was undertaken on the following points: interval from onset of surface QRS to onset of electrogram (EGM onset: *a*); electrogram duration (EGM duration: *b*); and interval from onset of surface QRS to end of LAVA (LAVA lateness: *c*). We also assessed signal amplitude (peak-to-peak bipolar amplitude), whether or not fractionated components (*asterisk*) were separated by an isoelectric line from the far-field signal, and whether or not fractionated components (*asterisk*) lasted beyond the QRS complex.

earlier than on the epicardium (7.0 ms [ $-3.0$  ms, 19.0 ms] vs. 29.0 ms [19.0 ms, 38.0 ms],  $P < .001$ ). LAVA lateness on the endocardium was much shorter than on the epicardium (146 ms [123 ms, 185 ms] vs. 168 ms [149 ms, 218 ms],  $P < .001$ ). Endocardial LAVA amplitude was significantly lower compared to the epicardial LAVA (0.34 mV [0.18 mV, 0.67 mV] vs. 0.40 mV [0.23 mV, 0.65 mV],  $P = .024$ ).

We found a continuum of lateness of LAVA with substantial number of LAVA occurring before the end of QRS complex. LAVA may occur any time during or after the QRS complex in sinus rhythm. Figure 3 shows number of LAVA plotted against an interval from the end of QRS complex to the end of LAVA, demonstrating the wide range over which they were detected (endocardial LAVA: 17 ms [ $-11$  ms, 49 ms], epicardial LAVA: 60 ms [41 ms, 100 ms]). An interval  $> 0$  ms means that LAVA were detected after QRS end, which traditionally has been defined as “late potential.” Epicardial LAVA (241/265 [91%]) were more frequently detected after the QRS complex than endocardial LAVA (551/839 [66%]).

### LAVA characteristics with regard to anatomic location

All LAVA were further assessed according to their anatomic locations. Endocardial LAVA were located septally in 207,

**Table 2** Mapping data of patients with and without septal scar

	All patients (n = 31)	Patients with septal scar (n = 14)	Patients without septal scar (n = 17)	P value
Earliest activation before QRS onset (ms)	-4.8 ± 8.0	-3.4 ± 6.8	-5.9 ± 8.8	.40
Mapping points per map (points/map)				
Endocardium	410 ± 233	425 ± 227	397 ± 246	.75
Epicardium	426 ± 245	559 ± 403	373 ± 146	.43
Low-voltage area (<1.5 mV) (cm <sup>2</sup> )				
Endocardium	97 ± 53	106 ± 61	88 ± 45	.37
Epicardium	88 ± 40	78 ± 24	92 ± 45	.57
Dense scar area (<0.5 mV) (cm <sup>2</sup> )				
Endocardium	55 ± 44	60 ± 49	50 ± 41	.57
Epicardium	49 ± 32	42 ± 28	52 ± 34	.59
LAVA density in low voltage (<1.5 mV) (points/cm <sup>2</sup> )				
Endocardium	0.34 ± 0.19	0.32 ± 0.15	0.35 ± 0.23	.73
Epicardium	0.23 ± 0.13	0.18 ± 0.07	0.25 ± 0.14	.23

Data are given as mean ± SD.

LAVA = Local abnormal ventricular activities.

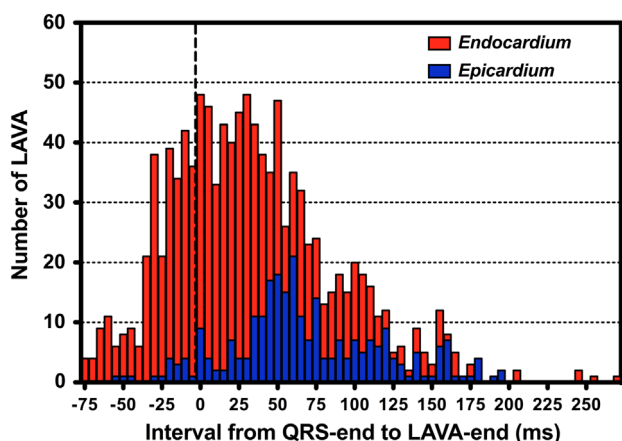
anteriorly in 103, apically in 254, and inferior/laterally in 275. Epicardial LAVA were located anteriorly in 59, apically in 101, and inferior/laterally in 105. Figure 4 shows the 3D-EAM of patients who displayed both septal and inferolateral substrates. The activation timing of local electrograms was different according to their locations. There was a significant difference in EGM onset between regions ( $P < .001$  for both endocardial and epicardial regions; Figure 5A). Endocardial septal LAVA had the earliest EGM onset among all endocardial and epicardial regions (-2 ms [-10 ms, 5 ms]). The epicardial inferior/lateral LAVA had the latest EGM onset (35 ms [28 ms, 44 ms]). EGM duration was significantly different among endocardial regions ( $P < .001$ ) but not among epicardial regions ( $P = .82$ ; Figure 5B). The median of EGM duration in the endocardial septal LAVA was shortest among all endocardial and epicardial regions (124 ms [98 ms, 144 ms]). A significant difference in LAVA lateness was found between regions ( $P < .001$  for endocardial regions,  $P = .022$  for epicardial regions; Figure 5C). Only 3% of endocardial septal LAVA were clearly separated

by an isoelectric line from far-field ventricular potential (Figure 5D), whereas LAVA in other regions had a higher incidence. The vast majority of epicardial LAVA were detected after the end of surface QRS (anterior 80%, apex 91%, inferior/lateral 97%). On the endocardium, 64% of anterior LAVA, 69% of apex LAVA, 81% of inferior/lateral LAVA, and only 43% septal LAVA were detected after the QRS (Figure 5E).

Figure 6 shows a scatter plot of LAVA lateness vs. EGM onset of all LAVA. There was a significant positive correlation between EGM onset and LAVA lateness in both the endocardium ( $r = 0.47$ ,  $P < .001$ ) and epicardium ( $r = 0.58$ ,  $P < .001$ ). This correlation held true regardless of whether patients had conduction disturbance ( $r = 0.56$ ,  $P < .001$ ) or QRS width  $\leq 110$  ms ( $r = 0.52$ ,  $P < .001$ ).

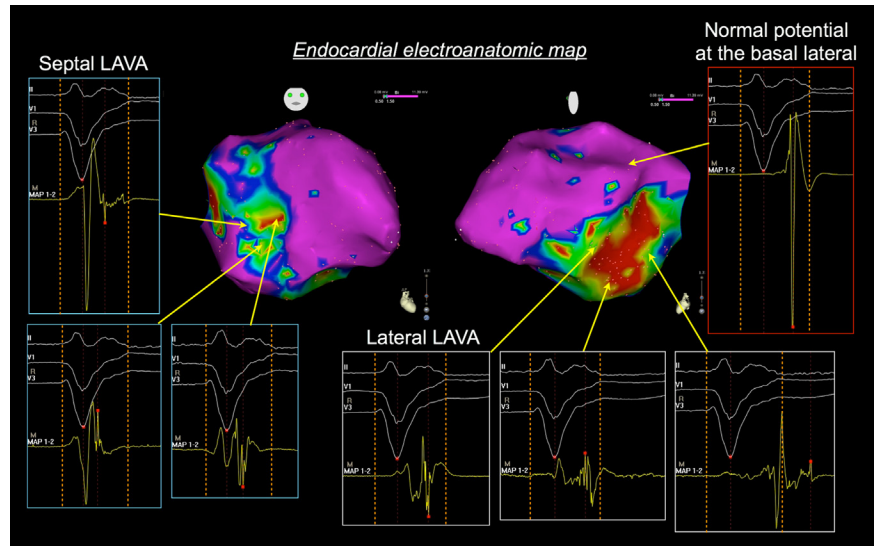
**LAVA delay and low voltage**

The distribution of LAVA in dense scar, border zone, normal voltage was 64%, 33%, and 3% on the endocardium, and 59%, 37%, and 4% on the epicardium, respectively. LAVA with normal voltage were usually located near the border of low-voltage area (not farther than 20 mm). There was no significant difference in EGM onset between dense scar and border zone on both endocardium and epicardium (endocardium: 7.0 ms [-2.0 ms, 17.0 ms] vs. 6.0 ms [-4.5 ms, 21.0 ms],  $P = .49$ ; epicardium: 30.0 ms [18.5 ms, 37.0 ms] vs. 26.0 ms [19.0 ms, 39.0 ms],  $P = .62$ ). However, LAVA lateness in the dense scar was much later than the border zone on both endocardium and epicardium (endocardium: 154 ms [130 ms, 193 ms] vs. 135 ms [117 ms, 161 ms],  $P < .001$ ; epicardium: 182 ms [151 ms, 232 ms] vs. 160 ms [146 ms, 193 ms];  $P = .002$ ). EGM duration in the dense scar was also significantly longer than the border zone on both endocardium and epicardium (endocardium: 148 ms [124 ms, 180 ms] vs. 128 ms [107 ms, 154 ms],  $P < .001$ ; epicardium: 152 ms [130 ms, 192 ms] vs. 136 ms [121 ms, 160 ms],  $P = .001$ ). The very delayed LAVA (LAVA lateness >200 ms) were almost exclusively located within low-voltage area (23% in border zone, 76% in dense scar).



**Figure 3** Endocardial and epicardial local abnormal ventricular activities (LAVA) histogram. Number of LAVA plotted against interval from end of QRS complex (QRS end) to end of LAVA (LAVA end). Bin size was 5 ms.

**Figure 4** Different timing of local electrograms according to their locations. This patient with ischemic cardiomyopathy had both septal and lateral scar. The timing of the far-field signal of septal local abnormal ventricular activities (LAVA) was earlier than that of lateral LAVA. The simple, high-amplitude electrogram was found at the basal lateral region, with activation timing later than the septal LAVA.

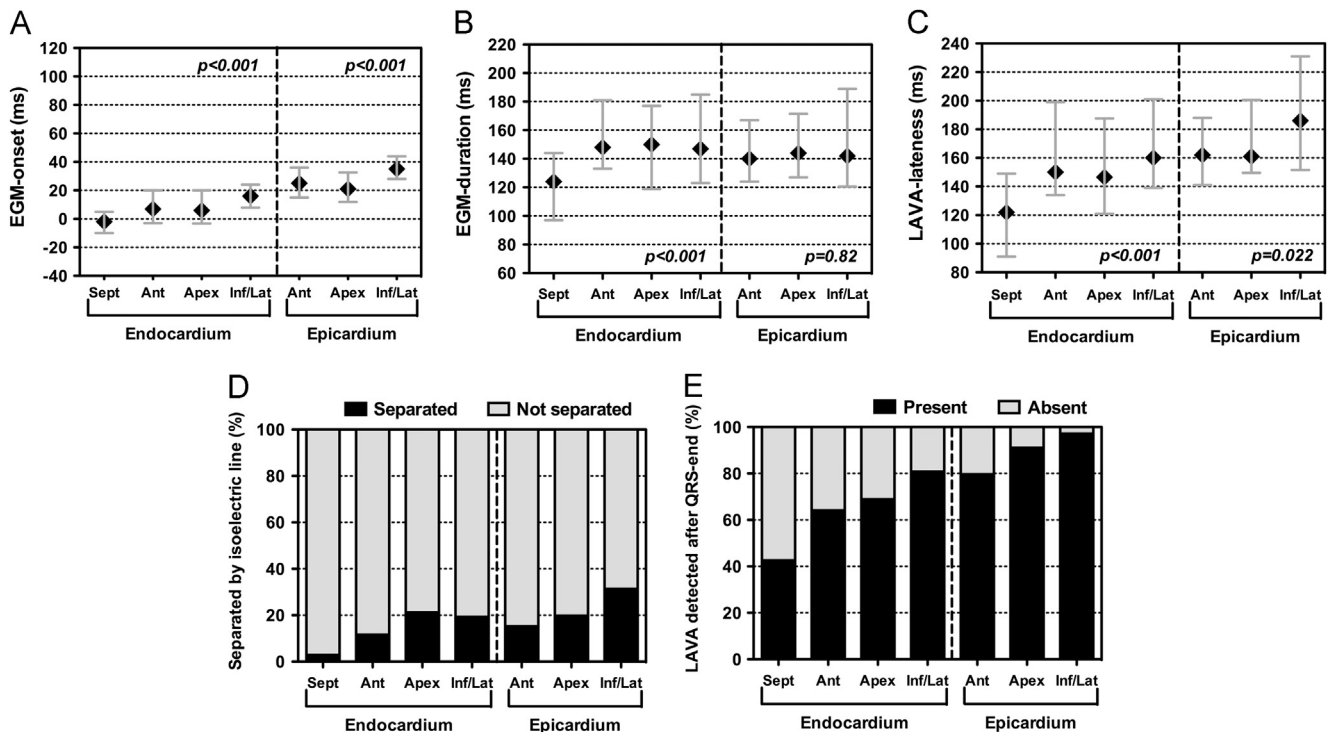


**Relation between clinical characteristics and LAVA characteristics**

The maximal EGM duration did not significantly correlate with LV ejection fraction ( $r = -0.29, P = .11$ ) or baseline QRS width ( $r = 0.27, P = .15$ ). The maximal EGM duration was similar between patients taking and those not taking amiodarone (193 ms [155 ms, 261 ms] vs. 180 ms [124 ms, 245 ms],  $P = .41$ ). There was a significant correlation between maximal EGM duration and infarct age ( $r = 0.50, P = .008$ ), whereas infarct age did not correlate with EGM onset ( $r = 0.14, P = .50$ ).

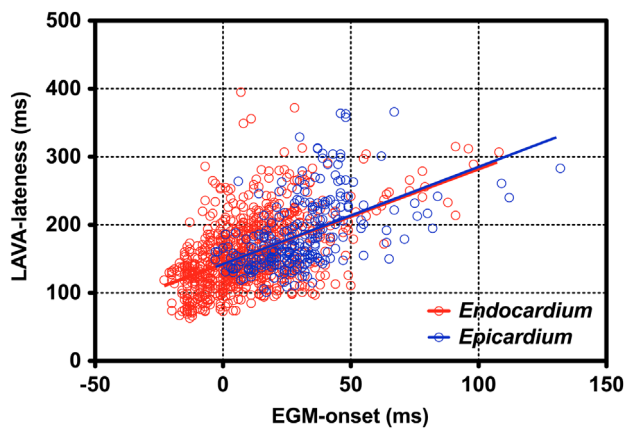
**Ablation results**

Radiofrequency ablation targeting LAVA was performed in all patients. Mean procedure and radiofrequency times were  $275 \pm 76$  minutes and  $39 \pm 22$  minutes, respectively. In 13 patients (42%), complete elimination of all identified LAVA could not be achieved. Two patients had epicardial LAVA that were located close to the coronary arteries and/or phrenic nerve. Cardiac tamponade occurred during one procedure, preventing complete LAVA elimination. In 10 patients, LAVA could not be abolished despite extensive ablation. Of these, eight had scar involving septum. Two patients with septal scar underwent



**Figure 5** Comparison of local abnormal ventricular activities (LAVA) characteristics among seven segments. A significant difference was found in EGM onset (A), EGM duration among endocardial regions (B), and LAVA latency among regions (C). Only 3% of septal LAVA were separated by an isoelectric line from the far-field ventricular potential (D). Only 43% of septal LAVA were detected after the QRS complex (E).





**Figure 6** Correlation between electrogram (EGM) onset and local abnormal ventricular activities (LAVA) latency. A scatter plot of all LAVA (endocardium 839, epicardium 265) is shown. There was a significant positive correlation between EGM onset and LAVA latency in both endocardium and epicardium.

ablation from the RV septum, but their septal LAVA still persisted after the ablation. During median follow-up time 11 months, 22 patients (71%) were free from both death and ICD therapies (antitachycardia pacing, shock, or both).

## Discussion

This is the first study demonstrating the different characteristics of LAVA with regard to their anatomic locations. The main findings are that LAVA delay is determined primarily by the following three parameters: (1) LAVA location in endocardium vs. epicardium; (2) anatomic location of the scar (i.e., septal vs. inferior and lateral); and (3) local conduction disturbances around and within the scar.

### Factors determining LAVA latency

The targets of substrate-based ablation are surviving myocardial bundles within the fibrotic scar. Their signals are frequently assimilated to potentials occurring after the surface QRS, producing what have traditionally been called “late potentials.” However, we observed a continuum of “lateness” and many LAVA occurring before the end of the surface QRS. The timing of near-field and far-field electrograms around and within the scar was influenced by their anatomic location. It is intuitive that given two scars of identical electrical properties, the one struck later by an activation front would hold a higher proportion of late signals. This is because the local near-field abnormal activation usually occurs after the far-field signal. Therefore, our hypothesis was that late LAVA would be more likely to occur in late-activating regions of the ventricle and vice versa. We assessed LAVA according to location and timing of the local far-field electrogram. A previous study had demonstrated underrepresentation of late potentials as assessed by signal-averaged electrogram in anterior infarction compared with inferior infarction, which might be explained by the different timing of the electrogram onset.<sup>12</sup>

We found that the timing of electrogram onset was significantly different between endocardial and epicardial regions.

Our observation is in line with a prior study using the isolated human heart.<sup>8</sup> An excitation wavefront reaches a great part of the LV endocardium in 30 ms except at the posterobasal area and spreads toward the epicardium. The last LV region to be excited is the posterobasal epicardium. The present study found that the latency of LAVA correlated well to the timing of the electrogram onset. In consequence, the chance of detecting late LAVA increases when electrogram onset is later. Therefore, it is not surprising that the majority of epicardial LAVA are detected after the QRS complex. In contrast, delayed LAVA are less likely to be found in the endocardial septum, which is activated earlier, at least 30 ms earlier than the basal inferolateral region.

Interestingly, only 3% of septal LAVA were separated from the far-field ventricular potential by an isoelectric line. Septal VT substrate may be located in the subendocardium or intramural myocardium, whereas full-thickness scar is less common.<sup>13</sup> This makes the vector of depolarization potentially more complex. This may explain the relative paucity of LAVA separated from the far-field signal by an isoelectric line as well as the lower incidence of delayed LAVA. Our findings suggest that patients with septal scar may frequently require ventricular pacing maneuvers to decouple the nondelayed LAVA from the far-field ventricular electrogram.

We should emphasize that the timing of LAVA is also affected by local conduction delay. LAVA occurring very late after the far-field potential as a result of reduced conduction velocity in surviving fibers were more likely to be found in the dense scar area. This finding is consistent with previous studies in which the regions responsible for generating delayed abnormal signals usually are those classified as being in the inner channel of reentrant circuits, which often disperse in the dense scar rather than in the scar border zone.<sup>11,14,15</sup> Most of the very delayed LAVA were identified in the dense scar even though the timing of far-field electrogram onset was comparable to that in the scar border zone. In addition, older infarct age, which allows postinfarct remodeling by collagenous fiber deposition in the scar,<sup>6,16</sup> was associated with greater duration of local abnormal signal. However, infarct age did not correlate with the timing of far-field electrogram onset. These observations suggest that the latency of LAVA can be affected by poor local conduction depending on the severity of fibrosis and infarct architecture, which may contribute to delay in propagation after the activation wavefront reaches the scar margin.

### Clinical implications

So-called “late potentials,” which usually are defined as potentials recorded after the end of surface QRS, have been proposed as a target of substrate-based ablation.<sup>11,14,15,17–19</sup> In prior studies, late potentials could not be found in between 3% and 29% of postinfarction VT patients.<sup>17–20</sup> In 4 patients (13%) in this study, all LAVA were buried within the QRS complex and would not have been identified using the previous definitions. Furthermore, more than half of septal

LAVA did not extend beyond the end of the QRS complex and fell short of “late potential” criteria.

Although very delayed abnormal signals may have high specificity for prediction of critical isthmus of VT,<sup>15</sup> critical sites for generation and perpetuation of VT may not necessarily have late potentials. A prior study reported that late potentials during sinus rhythm were absent in 29% of central VT reentrant circuits and in 46% of VT termination sites.<sup>20</sup> Although application of an arbitrary cutoff such as the end of the surface QRS appears simple and is reasonably specific, it may miss a critical arrhythmia substrate.

LAVA within the same scar may show a distinct activation sequence, which increases the likelihood of a critical isthmus of a reentrant circuit. It may be possible to eliminate the circuit by targeting the earliest LAVA. However, we should keep in mind that different directions of wavefront propagation can change the characteristics of LAVA, that is, the presence or absence of local abnormal delayed potentials at critical sites of the reentrant circuit may depend on the direction of activation during mapping.<sup>21</sup>

### Study limitations

Because substrate mapping during paced rhythm was not systematically performed, LAVA characteristics during pacing rhythm could not be assessed. We focused on the assessment of LAVA characteristics during sinus rhythm in these study subjects. However, it remains speculative whether or not pacing at sites with normal electrograms in sinus rhythm brings out LAVA. The characteristics of LAVA during both sinus rhythm and paced rhythm in the same procedure merit further evaluation.

The activation map during sinus rhythm may look subtly different from patient to patient depending on conduction disturbance. However, the overall pattern of LV depolarization was not be changed—from the septum to inferior and lateral, from endocardium to epicardium. Importantly, a positive correlation between electrogram onset and lateness of LAVA held true regardless of the presence of conduction disturbance.

Finally, it was difficult to measure the amplitude of both LAVA and far-field components separately when they were completely fused each other. The amplitude of LAVA electrograms in the scar border zone as well as normal voltage area might be overestimated because they were more likely to be early-coupled LAVA fused with far-field signal. Detailed mapping with pacing maneuvers may be warranted, especially at the border of the low-voltage area.

### Conclusion

The lateness of LAVA is determined to a large extent by when the activation wavefront reaches the scar margin as well as poor conduction at the edge of and within the scar. Substrate-based ablation strategy that only targets signals that are late compared to the QRS complex may miss critical arrhythmogenic substrate, particularly in the septum and other early-to-activate regions.

### References

- Natale A, Raviele A, Al-Ahmad A, et al. Venice Chart International Consensus document on ventricular tachycardia/ventricular fibrillation ablation. *J Cardiovasc Electrophysiol* 2010;21:339–379.
- Aliot EM, Stevenson WG, Almendral-Garrote JM, et al. EHRA/HRS expert consensus on catheter ablation of ventricular arrhythmias. *Heart Rhythm* 2009;6:886–933.
- Stevenson WG, Wilber DJ, Natale A, et al. Multicenter Thermocool VT Ablation Trial Investigators. Irrigated radiofrequency catheter ablation guided by electro-anatomic mapping for recurrent ventricular tachycardia after myocardial infarction: the Multicenter Thermocool Ventricular Tachycardia Ablation Trial. *Circulation* 2008;118:2773–2782.
- Marchlinski FE, Callans DJ, Gottlieb CD, Zado E. Linear ablation lesions for control of unmappable ventricular tachycardia in patients with ischemic and nonischemic cardiomyopathy. *Circulation* 2000;101:1288–1296.
- Jais P, Maury P, Khairy P, et al. Elimination of local abnormal ventricular activities: a new end point for substrate modification in patients with scar-related ventricular tachycardia. *Circulation* 2012;125:2184–2196.
- Gardner PI, Ursell PC, Fenoglio JJ Jr, Wit AL. Electrophysiologic and anatomic basis for fractionated electrograms recorded from healed myocardial infarcts. *Circulation* 1985;72:596–611.
- de Bakker JM, van Capelle FJ, Janse MJ, et al. Slow conduction in the infarcted human heart “zigzag” course of activation. *Circulation* 1993;88:915–926.
- Durrer D, van Dam RT, Freud GE, Janse MJ, Meijler FL, Arzbaeher RC. Total excitation of the isolated human heart. *Circulation* 1970;41:899–912.
- Surawicz B, Childers R, Deal BJ, et al. AHA/ACCF/HRS recommendations for the standardization and interpretation of the electrocardiogram: part III: intra-ventricular conduction disturbances: a scientific statement from the American Heart Association Electrocardiography and Arrhythmias Committee, Council on Clinical Cardiology; the American College of Cardiology Foundation; and the Heart Rhythm Society. Endorsed by the International Society for Computerized Electrocardiology. *J Am Coll Cardiol* 2009;53:976–981.
- Stevenson WG, Khan H, Sager P, et al. Identification of reentry circuit sites during catheter mapping and radiofrequency ablation of ventricular tachycardia late after myocardial infarction. *Circulation* 1993;88:1647–1670.
- Arenal A, del Castillo S, Gonzalez-Torrecilla E, et al. Tachycardia-related channel in the scar tissue in patients with sustained monomorphic ventricular tachycardias: influence of the voltage scar definition. *Circulation* 2004;110:2568–2574.
- Benchimol-Barbosa PR, Muniz RT. Ventricular late potential duration correlates to the time of onset of electrical transients during ventricular activation in subjects post-acute myocardial infarction. *Int J Cardiol* 2008;129:285–287.
- Yoshida K, Yokokawa M, Desjardins B, et al. Septal involvement in patients with post-infarction ventricular tachycardia: implications for mapping and radio-frequency ablation. *J Am Coll Cardiol* 2011;58:2491–2500.
- Arenal A, Glez-Torrecilla E, Ortiz M, et al. Ablation of electrograms with an isolated, delayed component as treatment of unmappable monomorphic ventricular tachycardias in patients with structural heart disease. *J Am Coll Cardiol* 2003;41:81–92.
- Bogun F, Good E, Reich S, et al. Isolated potentials during sinus rhythm and pace-mapping within scars as guides for ablation of post-infarction ventricular tachycardia. *J Am Coll Cardiol* 2006;47:2013–2019.
- Bogun F, Krishnan S, Siddiqui M, et al. Electrogram characteristics in postinfarction ventricular tachycardia: effect of infarct age. *J Am Coll Cardiol* 2005;46:667–674.
- Nakahara S, Tung R, Ramirez RJ, et al. Characterization of the arrhythmogenic substrate in ischemic and nonischemic cardiomyopathy implications for catheter ablation of hemodynamically unstable ventricular tachycardia. *J Am Coll Cardiol* 2010;55:2355–2365.
- Vergara P, Trevisi N, Ricco A, et al. Late potentials abolition as an additional technique for reduction of arrhythmia recurrence in scar related ventricular tachycardia ablation. *J Cardiovasc Electrophysiol* 2012;23:621–627.
- Arenal A, Hernández J, Calvo D, et al. Safety, long-term results, and predictors of recurrence after complete endocardial ventricular tachycardia substrate ablation in patients with previous myocardial infarction. *Am J Cardiol* 2013;111:499–505.
- Harada T, Stevenson WG, Kocovic DZ, Friedman PL. Catheter ablation of ventricular tachycardia after myocardial infarction: relation of endocardial sinus rhythm late potentials to the reentry circuit. *J Am Coll Cardiol* 1997;30:1015–1023.
- Brunckhorst CB, Stevenson WG, Jackman WM, et al. Ventricular mapping during atrial and ventricular pacing. Relationship of multipotential electrograms to ventricular tachycardia reentry circuits after myocardial infarction. *Eur Heart J* 2002;23:1131–1138.

**B) Non-ischemic cardiomyopathy with subepicardial scar: a specific entity requiring a specific approach**

*En cours d'écriture: soumission Circulation Arrhythmia & Electrophysiology*

*1) Etude*

Parmi les patients avec cardiopathie dilatée à coronaires saines adressés pour ablation de TV, nous avons étudié tous les patients avec cicatrice sous-épicaudique. Treize patients (12 hommes, 49 ±19 ans) sur 105 (12%) remplissaient ce critère. Trois patients avaient une histoire authentifiée de myocardite tandis que les dix autres avaient une histoire clinique compatible avec une imagerie cardiaque évocatrice d'une séquelle de myocardite (zones de rehaussement tardif à IRM) et/ou amincissement au scanner cardiaque en territoire latéral ou infero-latéral). Dans 35% des cas des potentiels ventriculaires locaux anormaux (LAVA) se trouvaient dans des zones avec voltage >1,5mV sur la carte automatique. La réalisation d'une carte manuelle prenant en compte le voltage des LAVA permettait un chevauchement de 74% avec la zone de réhaussement tardif à l'IRM. Les tentatives d'ablation endocardique en regard du site épicaudique optimal n'ont quasiment jamais permis de faire disparaître les potentiels épicaudiques anormaux. Il a toujours fallu faire l'ablation sur le versant épicaudique pour être efficace.

*2) Implications*

Comme montré dans le travail de la première partie, le nombre de patients adressés pour ablation de TV et porteur de cardiopathie non ischémiques est en augmentation. Il n'est pas rare que les seuls examens à visée diagnostique chez ces patients soient une coronarographie et une échographie cardiaque alors que le spectre des étiologies potentielles est vaste. La mise en évidence de son étiologie peut avoir un impact thérapeutique direct si l'on envisage une ablation de TV. En effet, la stratégie sera différente si une cicatrice est retrouvée à l'IRM ou pas, si elle est septale ou sous épicaudique. De plus cela peut orienter vers certaines étiologies nécessitant un traitement spécifique (sarcoidose cardiaque à la phase aiguë) ou vers des pathologies familiales (laminopathies) à dépister.

Ce substrat particulier sous épicaudique est important à reconnaître car une ablation épicaudique d'emblée est justifiée compte tenu de l'inefficacité de l'ablation endocardique. De plus, il est important de ne pas regarder que les couleurs codant pour le voltage sur la

carte électro-anatomique car des sites pathologiques peuvent se trouver dans la zone considérée "normale"  $>1.5\text{mV}$ . Si l'on veut avoir une idée réelle de la cicatrice sur le système de cartographie, il faut soit taggé les potentiels anormaux sur la carte soit faire une carte en voltage manuelle en déplaçant la fenêtre d'intérêt sur ces potentiels uniquement.

Enfin les isthmes de ces TV se trouvant généralement sur la face latérale du VG, il est important de bien identifier le trajet du nerf phrénique (scanner cardiaque + stimulation haute intensité avant ablation) et des artères coronaires (scanner cardiaque + coronarographie pour s'assurer de la fusion correcte de l'imagerie) avant l'ablation dans cette zone.

**Non-ischemic cardiomyopathy with subepicardial scar:  
a specific entity requiring a specific approach.**

B Berte, F Sacher, H Cochet, S Mahida, S Yamashita, H Lim, A Denis,  
N Derval, M Hocini, M Haïssaguerre, P Jaïs.

**From:** Bordeaux University Hospital and LIRYC, L'Institut de rythmologie et modélisation  
cardiaque, Université de Bordeaux, F33000, Bordeaux, France

**Running Title:** *Berte et al.* Subepicardial VT ablation.

**Total word count:**

**Address:**

Dr. Frédéric Sacher

Hôpital Cardiologique du Haut-Lévêque

33604 Bordeaux-Pessac,

France

Telephone: 33-5-57656471; Fax: 33-5-57656509

Email: frederic.sacher@chu-bordeaux.fr

## **Abstract**

### **Introduction:**

Non-ischemic cardiomyopathy (NICM) is a growing part of VT ablation. The purpose of this study is to further characterize the substrate in a subset of NICM patients with subepicardial scar using a combination of imaging and electroanatomic map (EAM).

### **Methods:**

All NICM patients referred for VT ablation with subepicardial scar were included. Delayed enhancement MRI (DE-MRI) and/or multidetector CT (MDCT) data were merged within the EAM map. A combined endo- and epicardial approach was used with bipolar standard voltage cut-offs (0.5/1.5mV). The voltage map was manually adapted to measure nearfield LAVA amplitude when LAVA were presents (manual map).

### **Results:**

Thirteen patients (12M, 49 ±14ans) meet the inclusion criteria. Few epicardial voltage areas <1.5mV were found in automatic maps and 35% of LAVA were present in epicardial areas >1.5mV. Manual epicardial voltage maps of nearfield LAVA allow having 97% of LAVA within the voltage area <1.5mV. Nearfield low voltage area correlated well with gray zone area on DE-MRI (74% overlap). All LAVA were found within 10 mm of DE-MRI scar. In these patients, 11/13patients had normal bipolar endocardial map. In these patients, attempt to ablate from the endocardium failed to eliminate epicardial LAVA.

### **Conclusion:**

In patients with NICM and subepicardial scar only, automatic voltage mapping may miss or minimize the electrical VT substrate. Nearfield voltage mapping is highly correlated to MRI substrate and may be superior in this condition. Epicardial access is required to successfully ablate the VT.

**Key words:** VT ablation; epicardial substrate, cardiac MRI

## **Background**

In recent years, RF catheter ablation has been established as an effective treatment strategy for management of patients with drug-refractory, scar-related ventricular tachycardia (VT) in the context of ischemic heart disease (ICM). VT ablation is also emerging as a potentially effective strategy for the treatment of recurrent VT in patients with non-ischemic cardiomyopathy (NICM) <sup>1</sup>. However, the arrhythmogenic substrate and the optimal ablation strategy for patients with NICM are less clearly defined and outcome of VT ablation in NICM is worse compared to ICM <sup>2,3</sup>. In contrast to patients with ICM, in whom the scar is typically subendocardial or transmural, patients with NICM have heterogeneous substrate depending on the etiology. Some of them present with basal scar other with septal scar (laminopathy, cardiac sarcoidosis). Epicardial scar is more frequent in this settings and epicardial approach is often required <sup>4,5</sup>.

The purpose of the present study is to determine the specific characteristics of subepicardial scar using delayed enhancement magnetic resonance imaging (DE-MRI), multi-detector computed tomography (MDCT), local EGM (automatic voltage mapping and manual adjustment) and LAVA characteristics in order to further characterise the arrhythmogenic substrate and to determine the optimal ablation strategy in these subset of patients with NICM.

## **Methods**

### *Patient selection*

All patients with NICM and subepicardial scar (**Figure 1**) referred for VT ablation were included in the study. The study was approved by the institutional review board



### *MRI/MDCT imaging*

DE-MRI was performed prior to ablation using a 1.5 T clinical scanner equipped with a 32-channel cardiac coil (Avanto, Siemens Medical Solutions, Erlangen, Germany). This 3 Dimensional, inversion-recovery- prepared, ECG-gated, respiration-navigated gradient-echo pulse sequence with fat saturation was initiated 15 minutes after intravenous injection of 0.2 mmol/kg gadoterate meglumine. Contrast-enhanced, ECG-gated cardiac MDCT was performed immediately following MRI study using a 64-slice CT scanner (SOMATOM Definition, Siemens Medical Solutions, Forchheim, Germany). Identical body positions were used for CT and MRI. Images were acquired during an expiratory breath hold with tube current modulation set on end-diastole. CT angiographic images were acquired during the injection of a 120 mL bolus of iomeprol 400 mg I/mL (Bracco, Milan, Italy) at a rate of 4 mL/s, and reconstructed at the same phase as the one used for DE imaging. Anatomical structures (left atrium, LV endocardium, LV epicardium, coronary sinus, coronary artery, phrenic nerve course) as well as LV wall thinning (<5mm) were identified on MDCT for importation and merge in the 3D system. Even if it works better in patients with ischemic cardiomyopathy<sup>6</sup>, wall thinning <5mm was used as a surrogate for scar identification.

### *Electrophysiology study and ablation technique*

Endocardial and epicardial substrate maps were performed in all patients. Automatic peak-to-peak voltage measurement of the EAM system was used. Delayed enhancement on MRI and wall thinning <5mm on MDCT images were merged<sup>7</sup> with the electroanatomical maps (endocardial and/or epicardial) within the 3D system (CARTO 3, Biosense Webster or Velocity, Saint Jude Medical). Epicardial approach was gained before transseptal puncture, before heparin administration and a steerable sheath (Agilis small curve, Saint Jude Medical) was used. Epicardial mapping was performed using a 20 electrode mapping catheter (Pentaray

NAV, Biosense Webster) and/or an ablation catheter (Navistar Thermocool, Biosense Webster). An ablation catheter (Navistar Thermocool, Biosense Webster) was used for endocardial mapping after obtaining retrograde or transseptal access. When transseptal access was performed, a steerable sheath (Agilis large curve, Saint Jude Medical) was used. High-density substrate mapping and pacemapping was performed in the region of interest. If VT was tolerated, activation and entrainment mapping was performed. Endocardial and epicardial ablations were performed with an irrigated-tip catheter (Navistar® Thermocool®). Substrate-based LAVA ablation during sinus rhythm was performed. The end point of the procedures was complete LAVA elimination, except if complications such as phrenic nerve injury or coronary injury were expected because of unfavourable anatomical location. Correlation between scar size on imaging and low voltage area was measured as percentage of area overlap.

#### *Voltage map analysis*

Firstable the voltage maps were set up with standard voltage range (0.5 – 1.5mV). In order to further investigate optimal settings, the EAMs were analysed off-line. We set up voltage map with different settings of unipolar (7.95mV on epi<sup>5</sup>, 8.3 mV on endo<sup>8</sup>) and bipolar (1mV<sup>4</sup>, 1.5 mV<sup>9</sup>, 1.8mV<sup>5</sup>) voltage (**Figure 2**). We also revised all epicardial map points of all EAM maps and changed the window of interest to the near-field signal on the CARTO system and changed the calipers amplitude to the near-field signal on the NAVx system (**Figure 3**) to obtain a map of the LAVA voltage.

#### *Prevention of complications*

We used the left atrium with the pulmonary veins and the left atrial appendage as well as the coronary sinus to obtain accurate merge of imaging segmentation on the EAM. When ablation was needed close to coronary artery based on MDCT segmentation, a coronary angiography

was performed to ascertain the good merge. A distance <5mm from the coronary artery held RF delivery. Concerning phrenic nerve, his course is highly variable but often lies on the lateral LV wall. On top of the phrenic nerve segmentation from MDCT (**Figure 1**), we performed a periprocedural pacemap of the phrenic nerve and tagged its course on the EAM substrate map. Before any ablation in this area, pacing at 10mA and 2ms was performed to ensure the absence of phrenic capture.

### *Statistical analysis*

For statistical analysis we used SPSS 16 software. Continuous variables are summarized by mean  $\pm$  SD or median and interquartile range (IQR; 25th–75th percentile), depending on the normality of distribution, as assessed by normal probability and quartile plots. Categorical variables are represented by frequencies and percentages. Two group comparisons were measured with paired Student *t* test.

## **Results**

### *Population*

A subepicardial scar was observed in 13 (12 male, mean age  $49\pm 13$  yrs) from 105 patients (12%) with NICM referred for VT ablation. Coronary angiography in all patients demonstrated normal coronary arteries. Ten patients had an ICD implanted. Three patients had been hospitalized for severe acute myocarditis ( $3 \pm 1$  years earlier). In the 10 other patients, the clinical history as well as imaging showing subepicardial scar in lateral of inferolateral LV wall were favoring this etiology. Baseline patient characteristics are summarized in **Table 1**.

### *MRI characteristics*

DE-MRI data were obtained in 8 patients before ICD implantation who did not have an ICD in situ. Non-transmural subepicardial scar was seen in all patients with a mean surface area of  $31 \text{ cm}^2 \pm 12 \text{ cm}^2$ . Scar was seen in lateral and inferolateral regions of the left. MRI characteristics are shown in **table 2**.

### *MDCT characteristics*

MDCT data were obtained in 9 patients. Wall thinning was seen in 8 patients: six patients showed lateral wall thinning, two patients showed inferolateral wall thinning and one patient did not show wall thinning. We encountered a mean surface area of  $17 \text{ cm}^2 \pm 13 \text{ cm}^2$  when a wall thickness cut-off  $< 5 \text{ mm}$  was used. An example of wall thinning and anatomical isthmus is shown in **figure 4**.

### *Combined epicardial and endocardial approach*

A combined epicardial and endocardial approach was used for VT ablation in 12 out of the 13 patients. In the remaining patient, a previous endocardial procedure (normal endocardial voltage map) resulted in a tamponade managed surgically. One year after, he experienced arrhythmic storm. An attempt at percutaneous subxyphoid approach failed and a surgical epicardial approach was performed.

### *EGM characteristics*

EGM characteristics are shown in **Table 2**. With automatic EAM peak-to-peak voltage mapping, we found a large amount of LAVA in the normal epicardial bipolar peak-to-peak voltage EGM region within the area of scar detected on MRI (median 35% [32%, 41%] of LAVA in normal voltage area) (**Figures 3 & 5**). All LAVA appear in or within 10mm of the

MRI scar. Furthermore, LAVA were closely coupled to the far field EGM in the border zone, and late with low amplitude in the centre of the scar.

#### *Retrospective correlation of EAM and MRI data*

Despite the identification of scar on MRI and wall thinning on MDCT, we identified amplitudes >1.5 mV of peak-to-peak bipolar in the corresponding regions in the EAM (far-field EGM). In order to further investigate these discrepant findings, the EAMs were analysed off-line. Manual re-analysis demonstrated that the automatic EAM map was inaccurate as it measured the far-field ventricular signal as opposed to the near-field LAVA signal, which is often of smaller amplitude. We tried all different bipolar and unipolar endocardial and epicardial cut-offs without improvement of scar visualisation (**figure 2**). The near-field signal voltage map (**figure 5**), was more accurate to delineate the scar on MRI than the different unipolar or bipolar cut-offs used. We had a significantly better correlation between scar on MRI, LAVA and the low voltage area with the near field voltage mapping than with the automatic mapping: Few voltage abnormalities were found in automatic maps and LAVA were found in normal voltage regions (median 35% [32%, 41%] of LAVA in normal voltage area). Manual maps of near field LAVA gave better scar delineation and correlation ( $p < 0.05$ ) between low voltage area and location of LAVA (median 3% [0%, 9%] of LAVA in normal voltage area) (**figure 5**). Near field low voltage area correlated well with gray zone area on DE-MRI (mean 29 cm<sup>2</sup> vs 31cm<sup>2</sup>). Wall thinning on MDCT underestimated near field low voltage area: (mean 17cm<sup>2</sup> vs 29 cm<sup>2</sup>). All LAVA were found within 10 mm of DE-MRI scar.

#### *RF ablation*

Attempt at ablating epicardial LAVA from the endocardium in the absence of endocardial LAVA on the opposite site was not successful. Therefore, epicardial ablation was needed in

all patients. Mean total RF time was  $28 \pm 13$  minutes ( $22 \pm 9$  min. on the epicardium using 20 to 30 watts) and mean procedure time was  $296 \pm 90$  min.

### *Complications*

Incomplete LAVA elimination was accepted because of coronary artery proximity ( $<5\text{mm}$ ) in 3 patients. In these 3 patients, endocardial ablation in regard of the epicardial site was attempted but failed to get rid of the epicardial LAVA. In 2 patients, saline infusion in the pericardium was performed to prevent phrenic nerve injury during ablation. However in one other patient, a phrenic nerve palsy which recovered within 6 months occurred.

### **Discussion**

We demonstrate that a subgroup of patients with non-ischemic cardiomyopathy with a subepicardial scar distribution have distinct scar characteristics with apparently normal bipolar voltage EGM. This substrate accounts for 12% of our NICM VT ablations. Near field LAVA signals correlated well with delayed enhancement area on MRI. It raises the question of spatial resolution of EGM recorded by catheter ablation. In the presence of a small scar the surrounding tissue is recorded by the mapping catheter and then display voltage  $>1.5\text{mV}$  even in area of scar.

As described by our group <sup>10</sup>, targeting epicardial LAVA from endocardium was ineffective at sites where neither endocardial LAVA nor wall thinning were present. In these patients, an epicardial approach was required in all patients.

The results of the present study demonstrate the importance of pre-ablation imaging with MRI/MDCT in order to get a clear view of the location of the scar. We routinely perform a systematic MRI/MDCT acquisition before each ICD implantation. We observed a strong correlation between epicardial LAVA sites and subepicardial scar on DE MRI but underestimation of the wall thinning area was observed with MDCT.

Manually corrected EAM maps to near-field voltages of LAVA provided a more accurate delineation of the scar. MRI/MDCT helps to further differentiate epicardial low voltage regions of epicardial fat around the coronaries and to prevent potential complications with visualisation of the coronaries and the phrenic nerve, in order to adapt the treatment strategy.

This substrate is suggestive of myocarditis sequellae as shown by the clinical history of the patients (hospitalization for severe acute myocarditis 2, 3 and 5 years prior to ablation) and the imaging data.



## References

1. Aliot EM, Stevenson WG, Almendral-Garrote JM, et al. EHRA/HRS Expert Consensus on Catheter Ablation of Ventricular Arrhythmias: developed in a partnership with the European Heart Rhythm Association (EHRA), a Registered Branch of the European Society of Cardiology (ESC), and the Heart Rhythm Society (HRS); in collaboration with the American College of Cardiology (ACC) and the American Heart Association (AHA). *Heart rhythm : the official journal of the Heart Rhythm Society* 2009;6:886-933.
2. Tokuda M, Tedrow UB, Kojodjojo P, et al. Catheter ablation of ventricular tachycardia in nonischemic heart disease. *Circulation Arrhythmia and electrophysiology* 2012;5:992-1000.
3. Dinov B, Fiedler L, Schonbauer R, et al. Outcomes in Catheter Ablation of Ventricular Tachycardia in Dilated Non-Ischemic Cardiomyopathy in Comparison to Ischemic Cardiomyopathy: Results from the Prospective HEart Centre of LeiPzig VT (HELP - VT) Study. *Circulation* 2013.
4. Cano O, Hutchinson M, Lin D, et al. Electroanatomic substrate and ablation outcome for suspected epicardial ventricular tachycardia in left ventricular nonischemic cardiomyopathy. *Journal of the American College of Cardiology* 2009;54:799-808.
5. Piers SR, van Huls van Taxis CF, Tao Q, et al. Epicardial substrate mapping for ventricular tachycardia ablation in patients with non-ischaemic cardiomyopathy: a new algorithm to differentiate between scar and viable myocardium developed by simultaneous integration of computed tomography and contrast-enhanced magnetic resonance imaging. *European heart journal* 2013;34:586-96.
6. Komatsu Y, Cochet H, Jadidi A, et al. Regional myocardial wall thinning at multidetector computed tomography correlates to arrhythmogenic substrate in postinfarction ventricular tachycardia: assessment of structural and electrical substrate. *Circulation Arrhythmia and electrophysiology* 2013;6:342-50.
7. Cochet H, Komatsu Y, Sacher F, et al. Integration of merged delayed-enhanced magnetic resonance imaging and multidetector computed tomography for the guidance of ventricular tachycardia ablation: a pilot study. *Journal of cardiovascular electrophysiology* 2013;24:419-26.
8. Hutchinson MD, Gerstenfeld EP, Desjardins B, et al. Endocardial unipolar voltage mapping to detect epicardial ventricular tachycardia substrate in patients with nonischemic left ventricular cardiomyopathy. *Circulation Arrhythmia and electrophysiology* 2011;4:49-55.
9. Marchlinski FE, Callans DJ, Gottlieb CD, Zado E. Linear ablation lesions for control of unmappable ventricular tachycardia in patients with ischemic and nonischemic cardiomyopathy. *Circulation*. 2000 Mar 21;101(11):1288-96.
10. Komatsu Y, Daly M, Sacher F, Cochet H, Denis A, Derval N, Jesel L, Zellerhoff S, Lim HS, Jadidi A, Nault I, Shah A, Roten L, Pascale P, Scherr D, Aurillac-Lavignolle V, Hocini M, Haïssaguerre M, Jaïs P. Endocardial Ablation to Eliminate Epicardial Arrhythmia Substrate in Scar-Related Ventricular Tachycardia. *J Am Coll Cardiol*. 2014 Jan 17. pii: S0735-1097(14)00173-9. doi: 10.1016

## Tables

**Table 1.** Population characteristics with imaging results

**Table 2.** Mapping characteristics.

## Figures

**Figure 1: Cardiac MRI and electroanatomic map of a 34 yo patients with acute myocarditis 2 years ago referred for VT ablation.**

The top panel displays the cardiac MRI of the patients which reveals a subepicardial infero-lateral delayed enhancement area (arrows) with preserved subendocardium. The middle panel shows the epicardial voltage map (CARTO 3, Biosense Webster) with standard voltage settings (0.5-1.5 mV). The MRI scar (semitransparent green) and the phrenic nerve (green) course are merged on the 3D system. Of note there is almost no voltage <1.5mV on the voltage map. EGMs at the scar border are showing closed coupled abnormal potential with different voltages. The map is inaccurate because the voltage is annotated on the farfield V and not the near field LAVA. The bottom panel shows the endocardial voltage map with the merged MRI scar of the same patient. The EGM at the opposite site of one epicardial LAVA displays normal voltage without LAVA.

**Figure 2: Different reference values for unipolar and bipolar voltage (endocardial and epicardial) with automatic mapping versus manual adaptation.**

**Figure 3: Automatic EAM mapping compared to manual correction of bipolar peak-to-peak near-field voltage**

A. EAM automatic voltage measurement and LAVA annotation. Few zones of low voltages and most LAVA in zones of normal bipolar voltage. Patient 1 with CARTO system and patient 2 with NAVx system.

B. Manual voltage mapping of nearfield LAVA signal. Better delineation of the low voltage area. Almost all LAVA inside this zone. Same voltage scale gives the impression of a channel inside the scar.

C. CARTO system: Manual mapping by changing the window of interest to the LAVA signal (patient 1).

D. NAVx system: Manual adaptation of voltage caliper to the LAVA signal (patient 2).

**Figure 4: Advantages of periprocedural MDCT, MRI and coronary angiography.**

**Figure 5. Correlation between low voltage area, LAVA and scar on DE-MRI.**

**Table 1.** Population characteristics with imaging results

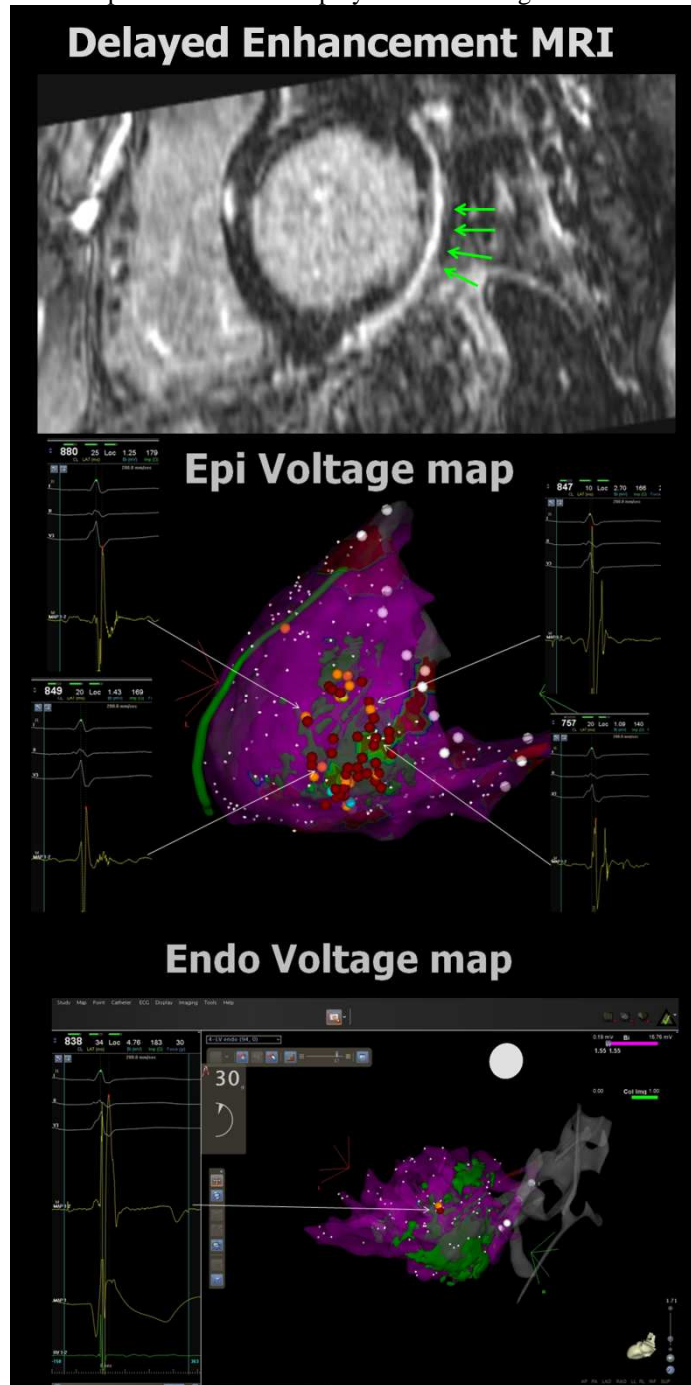
Patient	age	M/F	EF	ICD	med	side effects	CT image	wall thinning on MDCT	scar area on DE-MRI	location of scar on imaging
1	57	M	40%	1	amio		NA	NA	SCAR 22.2cm <sup>2</sup> GZ 27.3cm <sup>2</sup>	inferolateral and high lateral
2	55	M	40%	1	amio-sotalol	hyperthyroid	wall thinning lateral	<5mm 50 cm <sup>2</sup>	NA	lateral
3	71	M	20%	CRT-D	amio	hyperthyroid	NA	NA	NA	NA
4	58	M	25%	1	BB		wall thinning lateral	<5mm 56 cm <sup>2</sup>	SCAR 51.7cm <sup>2</sup> GZ 87.2cm <sup>2</sup>	apical and lateral
5	55	M	?	1	BB		NA	NA	NA	NA
6	41	F	?	1	amio	hyperthyroid	wall thinning lateral	<3mm 69cm <sup>2</sup> and <5mm 142cm <sup>2</sup>	NA	lateral LV and postero lat RV
7	34	M	45%	1	BB		wall thinning lateral	<5mm 14cm <sup>2</sup>	SCAR 28cm <sup>2</sup> GZ 34cm <sup>2</sup>	laterobasal scar
8	33	M	55%	0	amio		wall thinning lateral	<5mm 12cm <sup>2</sup>	SCAR 39cm <sup>2</sup> GZ 52cm <sup>2</sup>	lateral and apical
9	72	M	45%	1	amio	hyperthyroid	wall thinning inferolateral	<5mm 30 cm <sup>2</sup>	NA	lateral
10	31	M	?	1	BB		wall thinning lateral	<5mm 15 cm <sup>2</sup>	NA	lateral basal and apical
11	42	M	45%	0 (schizophrenic)	amio		no wall thinning	<2mm 1cm <sup>2</sup> and <5mm 6cm <sup>2</sup>	SCAR 33cm <sup>2</sup> GZ 65cm <sup>2</sup>	latero basal
12	55	M	54%	0	BB		wall thinning inferolateral	<5mm 21cm <sup>2</sup>	SCAR 26cm <sup>2</sup> GZ 42cm <sup>2</sup>	inferolateral
13	38	M	60%	1	sotalol		NA	NA	NA	NA

**Table 2. Mapping characteristics.**

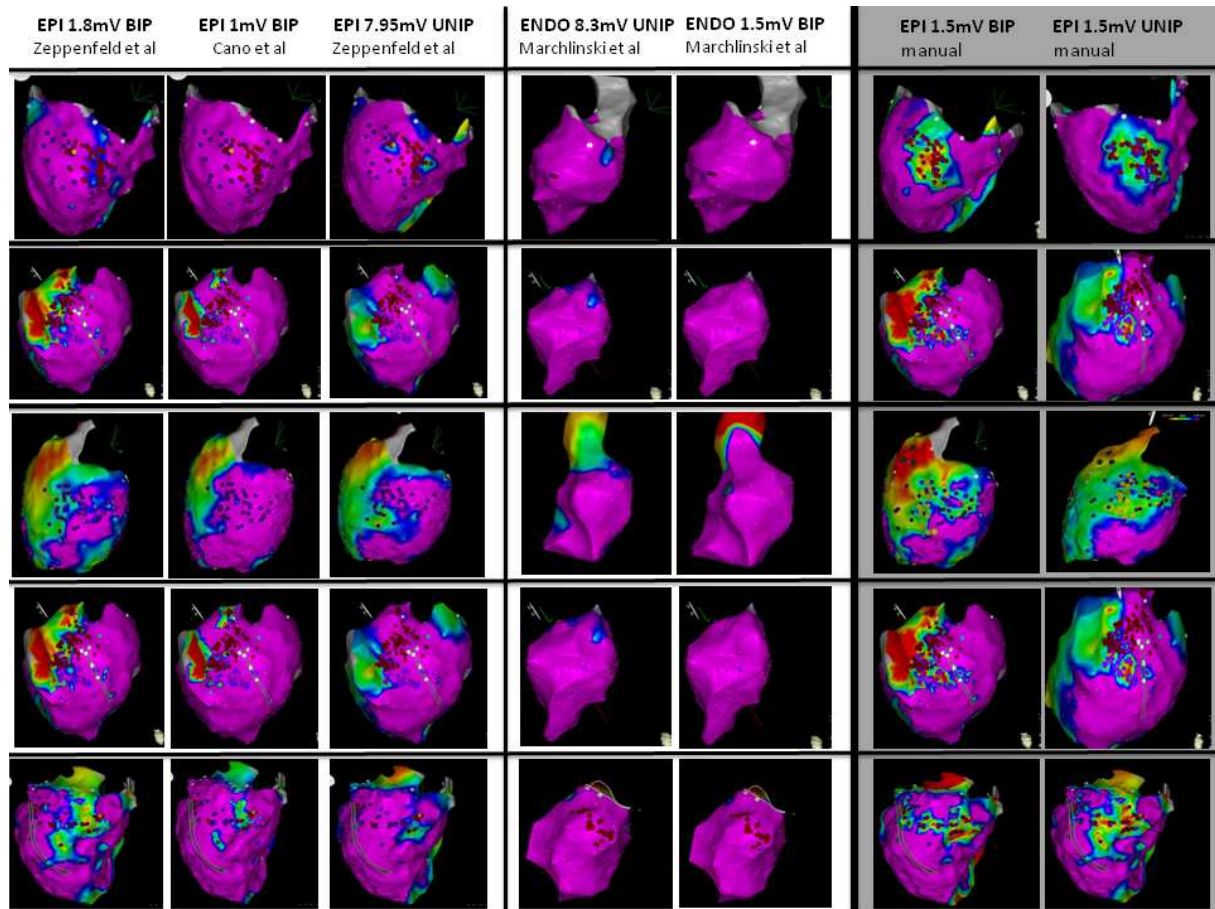
<b>Patient</b>	<b>EAM system</b>	<b>map points ENDO</b>	<b>map points EPI</b>	<b>low voltage area, ENDO (cm<sup>2</sup>)</b>	<b>low voltage area, EPI (cm<sup>2</sup>)</b>	<b>EPI location of LAVA</b>
1	CARTO 3	155	109	11	25	inferolateral
2	CARTO 3	213	114	0	19	lateral
3	CARTO 3	0	149	0	16	inferolateral
4	EnSite NavX	270	935	5	10	inferolateral basal-apical
5	EnSite NavX	234	855	12	26	high lateral
6	CARTO 3	90	368	9	15	Inferolateral and apical
7	CARTO 3	90	259	1	18	latero basal
8	EnSite NavX	317	1385	2	5	Inferolateral and apical
9	EnSite NavX	253	626	12	33	inferolateral basal-apical
10	CARTO 3	105	524	0	39	lateral basal-apical
11	CARTO 3	165	581	0	27	lateral
12	CARTO 3	446	1334	0	28	inferolateral
13	CARTO 3	140	665	0	30	inferolateral

**Figure 1: Cardiac MRI and electroanatomic map of a 34 yo patients with acute myocarditis 2 years ago referred for VT ablation.**

The top panel displays the cardiac MRI of the patients which reveals a subepicardial infero-lateral delayed enhancement area (arrows) with preserved subendocardium. The middle panel shows the epicardial voltage map (CARTO 3, Biosense Webster) with standard voltage settings (0.5-1.5 mV). The MRI scar (semitransparent green) and the phrenic nerve (green) course are merged on the 3D system. Of note there is almost no voltage <1.5mV on the voltage map. EGMs at the scar border are showing closed coupled abnormal potential with different voltages. The map is inaccurate because the voltage is annotated on the farfield V and not the near field LAVA. The bottom panel shows the endocardial voltage map with the merged MRI scar of the same patient. The EGM at the opposite site of one epicardial LAVA displays normal voltage without LAVA.



**Figure 2: Different reference values for unipolar and bipolar voltage (endocardial and epicardial) with automatic mapping versus manual adaptation.**



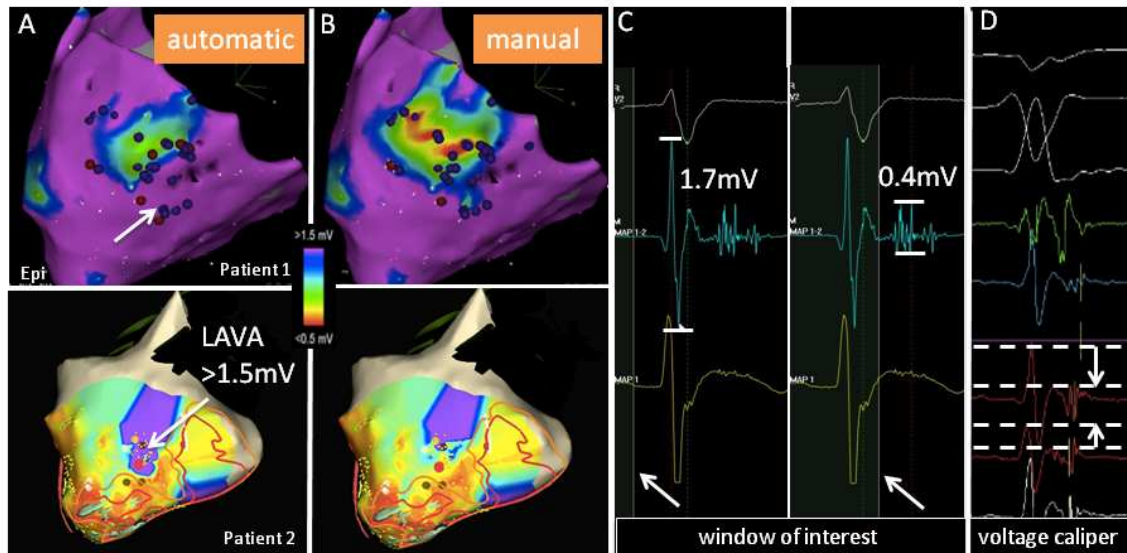
**Figure 3: Automatic EAM mapping compared to manual correction of bipolar peak-to-peak near-field voltage**

A. EAM automatic voltage measurement and LAVA annotation. Few zones of low voltages and most LAVA in zones of normal bipolar voltage. Patient 1 with CARTO system and patient 2 with NAVx system.

B. Manual voltage mapping of nearfield LAVA signal. Better delineation of the low voltage area. Almost all LAVA inside this zone. Same voltage scale gives the impression of a channel inside the scar.

C. CARTO system: Manual mapping by changing the window of interest to the LAVA signal (patient 1).

D. NAVx system: Manual adaptation of voltage caliper to the LAVA signal (patient 2).



A. EAM automatic voltage measurement and LAVA annotation. Few zones of low voltages and most LAVA in zones of normal bipolar voltage. Patient 1 with CARTO system and patient 2 with NAVx system.

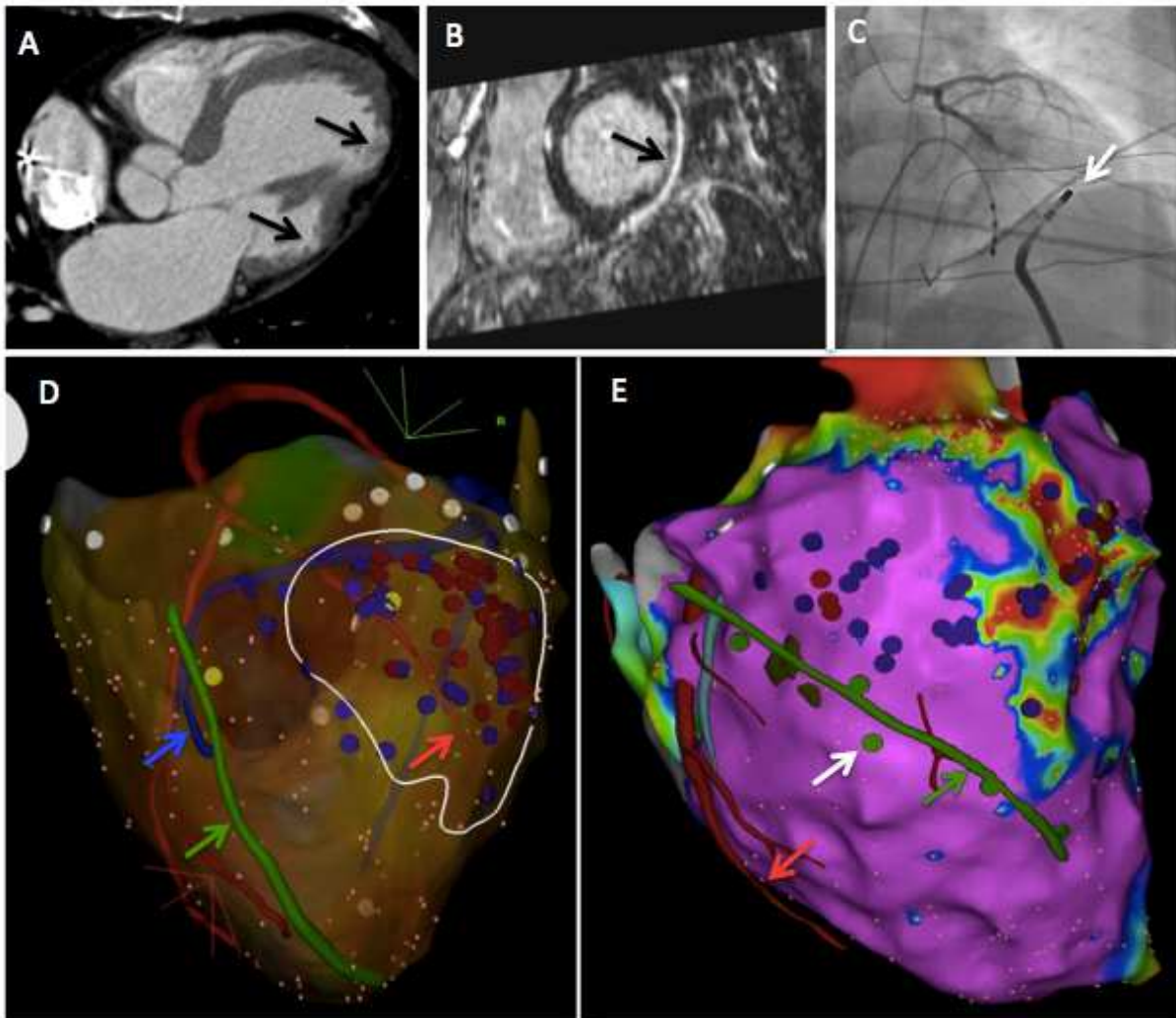
B. Manual voltage mapping of nearfield LAVA signal. Better delineation of the low voltage area. Almost all LAVA inside this zone. Same voltage scale gives the impression of a channel inside the scar.

C. CARTO system: Manual mapping by changing the window of interest to the LAVA signal (patient 1).

D. NAVx system: Manual adaptation of voltage caliper to the LAVA signal (patient 2).

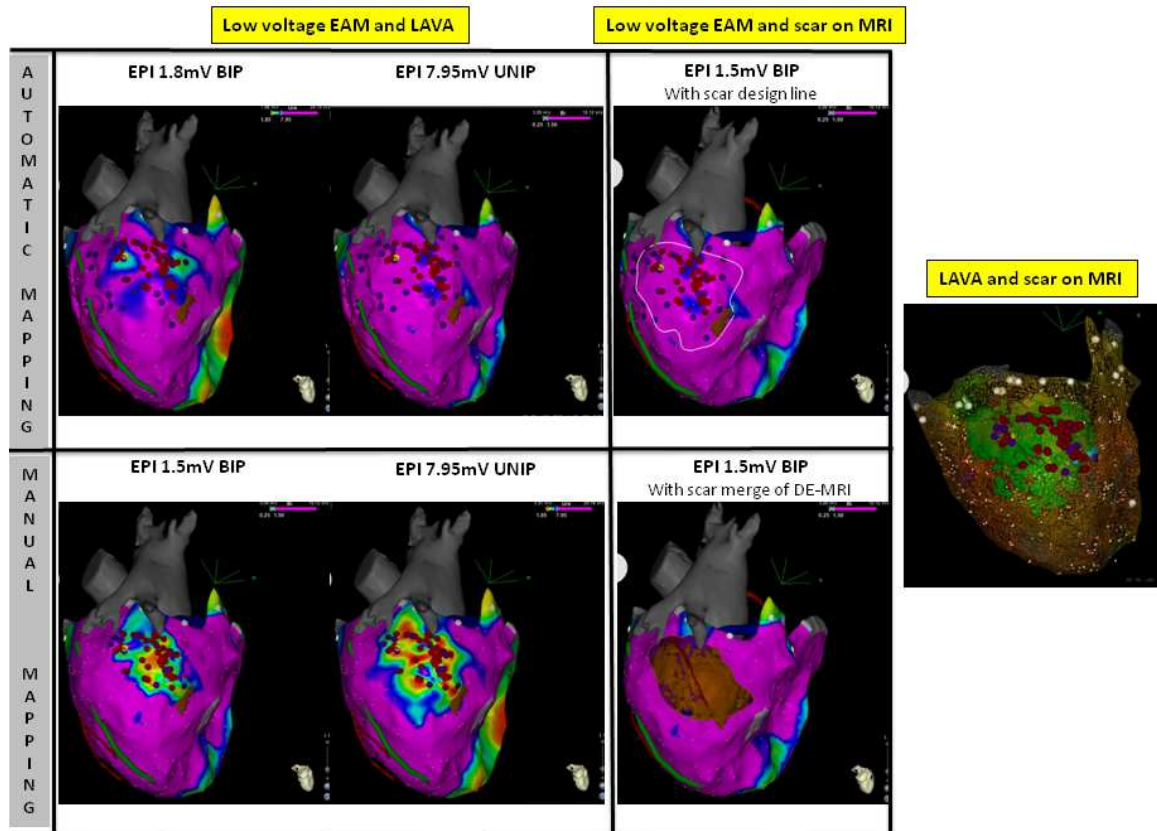


**Figure 4: Advantages of periprocedural MDCT, MRI and coronary angiography.**



**A.** MDCT shows 2 zones of focal wall thinning (black arrows) and anatomical isthmus in between.  
**B.** DE-MRI shows subepicardial scar by delayed enhancement without transmural enhancement (black arrow).  
**C.** Coronary angiogram prior to ablation on a good ablation spot shows the ablation catheter pushing the coronary artery (white arrow). No ablation is performed at that site.  
**D.** Image merge into EAM system. MDCT segmentation of coronaries (red arrow), phrenic nerve (green arrow) and CS (blue arrow). Ablation if >5mm distance from coronaries.  
**E.** Image merge into EAM system. MDCT segmentation of phrenic nerve. Phrenic capture by pacemapping with 20mA output (green dots): good correlation with segmentation.

**Figure 5. Correlation between low voltage area, LAVA and scar on DE-MRI.**



### **C) Characteristics of VT Ablation in Patients with Continuous Flow Left Ventricular Assist Devices**

En cours d'écriture: soumission Heart Rhythm

#### *1) Etude*

Le but de cette étude est d'étudier les caractéristiques des TV chez les patients implantés avec assistance ventriculaire gauche à flux continu (Heart Mate 2, Thoratec) bénéficiant d'une ablation de TV. Nous avons inclus tous les patients avec Heart Mate 2 et ablation de TV de 8 centres d'électrophysiologie. Vingt-deux patients (18 hommes,  $57 \pm 11$  ans) ont été inclus. Ils avaient bénéficié d'une assistance pour insuffisance cardiaque progressive (n=13) ou en phase aiguë d'un choc cardiogénique (n=9). L'origine de la myocardopathie était ischémique chez 13 patients (59%) et non ischémique chez 9 (41%). Chez 17 patients (77%), l'assistance a été implantée en attente d'une transplantation cardiaque. La fraction d'éjection moyenne et le diamètre télodiastolique moyen avant implantation était de  $17 \pm 9\%$  et  $67 \pm 9\text{mm}$ . Vingt patients avaient un défibrillateur avant implantation et 2 l'ont eu après. Trois patients ont nécessité un changement de défibrillateur après l'implantation de l'assistance du à des interférences empêchant l'interrogation du défibrillateur (Atlas, St Jude Medical n=1; Paradym, Sorin Group n=2).

Les TV sont survenues  $2,6 \pm 4,5$  mois (0 jour à 510 jours) après l'implantation de l'assistance. Un orage rythmique est survenu chez 14 patients, lesquels avaient déjà tous fait au moins un épisode de TV avant l'implantation de l'assistance. Les symptômes pendant les TV étaient essentiellement liés aux chocs du défibrillateur (n=12), certains ont ressentis des sensations de malaises avec hypotension (n=6) ou une fatigue avec palpitations (n=4).

L'ablation a été réalisée dans le mois suivant l'implantation de l'assistance chez 8 patients pour des TV incessantes. Une approche transeptale a été utilisée chez 12 (retrograde aortique chez les autres). Les TV ont été cartographiées avec utilisation du système electro-anatomique CARTO 3 (Biosense Webster). Après la réalisation d'une carte en voltage, 58 TV déclenchées chez les 22 patients ont pu être cartographiées au moins partiellement grâce au support hémodynamique de l'assistance. Seulement 4 des 58 TV (7%) étaient liées à la canule de l'assistance mais pour 3 des 4 patients cette canule était implantée dans une cicatrice de nécrose antérieure. L'ablation a été réalisée  $9 \pm 6$  mois après

l'implantation de l'assistance chez ces 4 patients. Chez les 6 patients sans TV avant l'implantation de l'assistance les TV ont commencé  $6 \pm 3$  mois après l'implantation.

Pendant le suivi, 6 patients ont été transplantés et 8 sont décédés. Concernant les 8 autres patients, 6 n'ont plus fait d'arythmie  $5 \pm 6$  mois après l'ablation et chez les 6 autres le nombre de TV a chuté drastiquement. Chez un patient avec récurrence de TV, le changement de la vitesse de la turbine de 9400 à 9000 tours /min a permis d'annihiler toute récurrence.

## *2) Implications*

Les systèmes d'assistance ventriculaire gauche à débit continu sont de plus en plus implantés pas seulement en attente d'une greffe cardiaque mais également en thérapie définitive car le patient peut vivre presque normalement avec. Nous sommes ainsi amenés à en voir de plus en plus. Les arythmies ventriculaires ne sont pas rares et même si elles sont beaucoup mieux tolérées que chez les patients sans assistance, elles posent des problèmes. Les patients avec défibrillateur vont recevoir des chocs qui sont douloureux chez un patient qui ne syncope pas et peuvent même être traumatisants s'ils sont récidivants. Si les arythmies ne sont pas traitées, elles vont perdurer et entraîner une défaillance ventriculaire droite plus ou moins rapide (assistance mono ventriculaire).

L'ablation chez ces patients est faisable l'assistance permettant la cartographie en TV. L'ablation est également efficace et n'entraîne pas d'excès de risque. Quelques précautions sont cependant nécessaires. Il faut éviter d'implanter des défibrillateurs SORIN et le défibrillateur Atlas (St Jude Medical) car ces derniers peuvent être non interrogeables (interférences). Par contre les systèmes de cartographie ne pose pas de problème particulier. Il faut préférer une voie transeptale même si la voie rétrograde aortique est possible après ETO pour éliminer un thrombus dans la racine aortique (cusps ne s'ouvrent plus ou mal). En ce qui concerne le mécanisme des TV, il s'agit essentiellement de TV liées au substrat sous jacent (myocardiopathie) et non pas liées à l'implantation de la canule même si cela a été décrit. Les mécanismes par lequel des TV surviennent juste après l'implantation de l'assistance sont probablement liés au changement de tension pariétale et donc d'étirement de la cicatrice.

## **Characteristics of VT Ablation in Patients with Continuous Flow Left Ventricular Assist Devices**

Frederic Sacher<sup>1</sup>, MD, Tobias Reichlin<sup>2</sup>, MD, Erica Zado<sup>3</sup>, PA, Michael E. Field<sup>4</sup>, MD, Juan Viles Gonzales<sup>5</sup>, MD, Kabir Bhasin<sup>6</sup>, MD, Kenneth Ellenbogen<sup>7</sup>, MD, Philippe Maury<sup>8</sup>, MD, Francois Picard<sup>1</sup>, MD, Laurent Barandon<sup>1</sup>, MD, Philippe Ritter<sup>1</sup>, MD, Joachim Calderon<sup>1</sup>, MD, Nicolas Derval<sup>1</sup>, MD, Arnaud Denis<sup>1</sup>, MD, Richard Shepard<sup>7</sup>, MD, James O. Coffey<sup>5</sup>, MD, Fermin Garcia<sup>3</sup>, MD, Meleze Hocini<sup>1</sup>, MD, Usha Tedrow<sup>2</sup>, MD, Srinivas R. Dukkupati<sup>6</sup>, MD, Michel Haissaguerre<sup>1</sup>, MD, Andre d'Avila<sup>6</sup>, MD, William G. Stevenson<sup>2</sup>, MD, Francis E. Marchlinski<sup>3</sup>, MD and Pierre Jais<sup>1</sup>, MD.

*1) Hôpital Cardiologique du Haut Leveque / LIRYC / Université Bordeaux , Bordeaux, France, 2) Brigham and Women Hospital, Boston, MA, 3) University of Pennsylvania, Philadelphia, PA, 4) University of Wisconsin, Madison, WI, 5) University of Miami, Miami, FL, 6) Mount Sinai Hospital, New York, NY, 7) Virginia Commonwealth University School of Medicine, Richmond, VA 8) CHU de Toulouse, France*

### **Address:**

Dr. Frédéric Sacher

Hôpital Cardiologique du Haut-Lévêque

33604 Bordeaux-Pessac,

France

Telephone: 33-5-57656471; Fax: 33-5-57656509

Email: frederic.sacher@chu-bordeaux.fr

## **Abstract:**

Left ventricular assist devices (LVAD) are increasingly used as a bridge to cardiac transplant or as destination therapy. Patients concerned by LVAD therapy are at high risk for ventricular arrhythmias. This study describes VT characteristics and ablation in these patients.

## **Methods**

All patients from 8 tertiary EP centers with a Heart Mate 2 (HM2) LVAD who underwent ventricular arrhythmia (VA) catheter ablation were included.

## **Results**

Twenty-two patients (18 m, age  $57 \pm 11$  years) underwent 24 ablation procedures with 3D electroanatomic system. Their underlying structural heart disease was ischemic (n=13) and non ischemic (n=9) with a mean left ventricular ejection fraction of  $17 \pm 9\%$ . Fifty-eight VT (cycle length: 280-740ms, arrhythmic storm in 14) and 2 ventricular fibrillation trigger were targeted (12 transeptal, 10 retrograde aortic approaches). Eight patients required VT ablation <1 month after LVAD implantation due to intractable VT. Only 4/58 (7%) of the targeted ventricular arrhythmias were related to the HM2 cannula site with ablation performed  $9 \pm 6$  months after HM2 placement. In the remaining pts in whom VT was not related to the cannula, ablation was performed  $3 \pm 4$  months after LVAD placement. In the 7 pts without VT prior to HM2 implantation, VT began to occur  $6 \pm 2.5$  months after implantation. At 12 months, 6 pts were transplanted and 8 died. Of the remaining 8 pts, 6 were arrhythmia free. In 1 pt with VT recurrence, change of turbine speed from 9400 to 9000 rpm extinguished VT.

## **Conclusion**

Catheter ablation of VT among LVAD recipients is feasible and safe. Intrinsic myocardial scar, rather than the apical cannula, appears to be the dominant substrate.

**Key words:** Ventricular Tachycardia ; Catheter ablation, Left Ventricular Assist Device

## **Introduction**

Left ventricular assist device (LVAD) therapy has extended the survival of patients with advanced heart failure as a bridge to transplantation<sup>1</sup> or as destination therapy<sup>2</sup> with improved quality of life. Postoperative ventricular tachyarrhythmia events (VTEs) occur in up to 35% of the patients within 30 days<sup>3,4</sup>, with a resultant mean drop of  $1.4 \pm 0.6$  L/min in LVAD flow output<sup>5</sup>. Despite the long-held belief that recipients of LVAD are unaffected by VTE, the crude mortality rate is as high as 52% for patients with VTE occurring within 1 week postoperatively<sup>6</sup>. A concomitant implantable cardioverter- defibrillator (ICD) during VAD support has been associated with a significant mortality reduction (hazard ratio 0.55; 95% confidence interval 0.32-0.94;  $p = 0.028$ ) with a 25% incidence of appropriate ICD therapy in this population<sup>7</sup>.

According to 2006 American College of Cardiology/American Heart Association Task Force/European Society of Cardiology Committee guidelines, catheter ablation for ventricular tachycardia is indicated for patients receiving ICD shocks not manageable by reprogramming or drug therapy and symptomatic patients with drug-resistant monomorphic ventricular tachyarrhythmia (VT) or who are drug-intolerant and prefer ablative therapy<sup>8</sup>. Prior literature on catheter ablation for VT in the VAD population demonstrated feasibility in this population<sup>9-11</sup>. However the electrophysiologic (EP) characteristics and outcomes associated with catheter ablation for VT in patients with Heart Mate 2 device (Thoratec) have not yet been evaluated in a multicentric series.

## **Methods**

Patients were recruited in 8 electrophysiology centers. All patients with ventricular tachycardia/fibrillation (VT/VF) ablation after LVAD implantation (Heart Mate 2, Thoratec) (*Figure 1*) were included in this retrospective study. Data were collected from medical chart, electrophysiological procedure (EP) report, 3D mapping system, Implantable Cardioverter-Defibrillator (ICD) log.

### ***Ablation procedure***

Patients were referred for VT/VF ablation because of refractory recurrent ventricular arrhythmias. Transesophageal echocardiography was performed prior ablation in patients with



an AF history or if a retrograde aortic approach was planned to rule out left atrial appendage or aortic root thrombus. Femoral venous and arterial accesses were obtained for endocardial access and hemodynamic monitoring. A 3D mapping system (Carto 3, Biosense Webster) was used to perform substrate mapping. Programmed stimulation was then performed to induce and map VT. Irrigated tip catheters were used in all for ablation.

### ***Statistical analysis***

Categorical variables are described as numbers with corresponding percentages. Continuous variables were described as mean  $\pm$  SD.

## **Results**

### ***Population***

Twenty-two patients (18 male,  $57 \pm 11$  yo) with LVAD (Heart Mate 2, Thoratec) underwent VT/VF ablation in 8 EP centers between 2009 and 2012 (**Table**). They were implanted with an LVAD because of progressive heart failure (n=13) or acute cardiogenic shock (n=9) in the setting of ischemic cardiomyopathy (CMP) (n=13, 59%) or dilated CMP (n=9, 41%). In 17 (77%) patients, the LVAD implantation was considered as a bridge to cardiac transplant. Mean turbine speed was  $8700 \pm 1500$  rpm (7800-9800).

An ICD was present in 20 patients including 2 with post LVAD implantation. Two patients did not have an ICD at the time of their ablation. Of note, 3 patients required ICD replacement (Atlas, St Jude Medical n=1; Paradym, Sorin Group n=2) after LVAD implantation because of interference that prevented any possibility of device interrogation.

Mean LVEF was  $17 \pm 9\%$  with a mean LV end diastolic diameter before LVAD of  $67 \pm 9$ mm that shortens to  $56 \pm 13$ mm (p=0.001) 1 months after LVAD implantation.

### ***Ventricular Arrhythmias Characteristics***

Before LVAD implantation, 6 patients experienced arrhythmic storm, 10 others at least one VT/VF episode and 6 never had any VT/VF. Among the 22 patients with VT ablation, VT/VF occurred  $2.6 \pm 4.5$  months (0 days to 510 days) after LVAD implantation. Arrhythmic storm occurred in 14 patients post LVAD implantation. All of them had at least one VT episode

before LVAD implantation. Symptoms during ventricular arrhythmias were mainly related to ICD shocks (n=12), dizziness/hypotension (n=6) and asthenia/palpitation (n=4).

### ***Ablation***

Eight pts required VT ablation < 1 month after LVAD implantation due to intractable VT. These patients have more often arrhythmic storm episode before LVAD implantation (5/8; 63%). Transeptal approach was used for 12 procedures and retro-aortic approach in the remaining 10. No pericardial access was attempted. Electro-anatomic system (CARTO 3, Biosense Webster) was used in all but one case (**Figure 2**). In 2 patients, interferences between LVAD and the CARTO system prevent from mapping the whole LV (transient loss of catheter visualization in some area). Mean scar surface was  $44 \pm 26 \text{ cm}^2$ . Fifty-eight VTs (CL 280-740ms) and 2 VF triggers were targeted during 24 procedures. LVAD support allowed VT activation mapping (**Figure 3**).

Only 4/58 (7%) of the targeted ventricular arrhythmias were related to the HM2 cannula site (**Figure 4**) with ablation performed  $9 \pm 6$  months after HM2 placement. The substrate was anterior myocardial infarction in 3 of the 4 patients with VT anchored by the cannula. In the remaining patients in whom VT was not related to the cannula, ablation was performed  $2 \pm 3$  months after LVAD placement. In the 6 pts with no VT prior to HM2 implantation, VT began to occur  $6 \pm 2.5$  months after implantation.

Acute success (absence of VT inducibility) was present in 18/20 procedures in which it was attempted. Mean RF duration was  $16 \pm 8$  min.

### ***Complications***

A patient with VT ablation for arrhythmic storm developed cardiogenic shock with acidosis and another patient had groin hematoma following ablation.

### ***Outcome***

During follow-up, 6 pts were transplanted and 8 died (septic shock n=2, massive stroke n=2, hemolysis n=1, turned off LVAD n =1, terminal heart failure n=1, Sudden death n=1). Of the remaining 8 pts, 6 are arrhythmia free  $5 \pm 6$  months after their last ablation. In 1 pt with VT recurrence, change of turbine speed from 9400 to 9000 rpm extinguished VT.

## **Discussion**

The main substrate for VT in patients referred for VT ablation after HM2 implantation is their underlying scar but rarely the cannula (7%). Whereas some studies speculated that these VA could be linked to the cannula<sup>3,9</sup> other are more concordant with our findings<sup>10,11</sup>. Cantillon et al.<sup>10</sup> found that 75% of VT were coming from the intrinsic scar vs 14% from the cannula area. They also found some microentrant/focal mechanisms (7%) and bundle branch reentry (3.5%). In our study, 3/4 patients with VT coming from the cannula area had the cannula inserted within or close an antero-apical scar that could also explain the reentry. Another possible mechanism is the suction from the cannula<sup>12</sup>, as it occurred in one of our patients in whom change of turbine speed from 9400 to 9000 rpm extinguished VT.

Patients having VT at the early phase post LVAD implantation (<1 month), have all a history of VT before implantation. It has then been proposed to perform surgical VT ablation during LVAD implantation<sup>13</sup> to prevent post implantation VA that alter the pronostic<sup>14</sup>. It allowed significant decrease of postoperative resource use and complications. However it means that VT circuit or at least scar should be clearly identified before LVAD implantation to guide the surgeon during the procedure.

### **Access to the Left Ventricle and other Technical Considerations**

As peripheral pulse is not pulsatile with continuous flow device, it is crucial to monitor invasive arterial blood pressure; peripheric automatic system may be misleading. In case of retrograde aortic access, it is important to keep in mind that there is no or little flow going through the aortic valve. It may then be more difficult to cross the valve because of the absence of opening. It can be facilitating by transiently decreasing the LVAD flow. Moreover there is a risk of thrombus in the aortic root even if these patients are fully anticoagulated for the LVAD. Nevertheless we find reasonable to perform transesophageal echocardiography before getting retrograde aortic access. For transeptal access, a steerable sheath is extremely helpful to map the whole LV.

### **Interferences**

As previously reported<sup>15-17</sup>, LVAD interferences could prevent from ICD interrogation and programming (Atlas, St Jude Medical n=1; Paradym, Sorin Group n=2). Concerning 3D

electroanatomic system, in 2 patients, ablation catheter could not be visualized in areas (inferior apical LV wall) close to the device.

### **Conclusions**

Patients with arrhythmic storm before LVAD implantation are at high risk to develop VT after implantation. Catheter ablation of VT is effective and safe among LVAD recipients even within 1 month post implantation. Intrinsic myocardial scar, rather than the apical cannula, appears to be the dominant substrate. Mid-term prognostic of these patients remains poor with a high mortality rate.

## References

1. Bank AJ, Mir SH, Nguyen DQ, Bolman RM, 3rd, Shumway SJ, Miller LW, Kaiser DR, Ormaza SM, Park SJ. Effects of left ventricular assist devices on outcomes in patients undergoing heart transplantation. *Ann Thorac Surg.* 2000; 69: 1369-74; discussion 1375.
2. Rose EA, Gelijns AC, Moskowitz AJ, Heitjan DF, Stevenson LW, Dembitsky W, Long JW, Ascheim DD, Tierney AR, Levitan RG, Watson JT, Meier P, Ronan NS, Shapiro PA, Lazar RM, Miller LW, Gupta L, Frazier OH, Desvigne-Nickens P, Oz MC, Poirier VL, Randomized Evaluation of Mechanical Assistance for the Treatment of Congestive Heart Failure (REMATCH) Study Group. Long-term use of a left ventricular assist device for end-stage heart failure. *N Engl J Med.* 2001; 345: 1435-1443.
3. Ziv O, Dizon J, Thosani A, Naka Y, Magnano AR, Garan H. Effects of left ventricular assist device therapy on ventricular arrhythmias. *J Am Coll Cardiol.* 2005; 45: 1428-1434.
4. Refaat M, Chemaly E, Lebeche D, Gwathmey JK, Hajjar RJ. Ventricular arrhythmias after left ventricular assist device implantation. *Pacing Clin Electrophysiol.* 2008; 31: 1246-1252.
5. Oz MC, Rose EA, Slater J, Kuiper JJ, Catanese KA, Levin HR. Malignant ventricular arrhythmias are well tolerated in patients receiving long-term left ventricular assist devices. *J Am Coll Cardiol.* 1994; 24: 1688-1691.
6. Bedi M, Kormos R, Winowich S, McNamara DM, Mathier MA, Murali S. Ventricular arrhythmias during left ventricular assist device support. *Am J Cardiol.* 2007; 99: 1151-1153.
7. Cantillon DJ, Tarakji KG, Kumbhani DJ, Smedira NG, Starling RC, Wilkoff BL. Improved survival among ventricular assist device recipients with a concomitant implantable cardioverter-defibrillator. *Heart Rhythm.* 2010; 7: 466-471.
8. European Heart Rhythm Association, Heart Rhythm Society, Zipes DP, Camm AJ, Borggrefe M, Buxton AE, Chaitman B, Fromer M, Gregoratos G, Klein G, Moss AJ, Myerburg RJ, Priori SG, Quinones MA, Roden DM, Silka MJ, Tracy C, Smith SC, Jr, Jacobs AK, Adams CD, Antman EM, Anderson JL, Hunt SA, Halperin JL, Nishimura R, Ornato JP, Page RL, Riegel B, Priori SG, Blanc JJ, Budaj A, Camm AJ, Dean V, Deckers JW, Despres C, Dickstein K, Lekakis J, McGregor K, Metra M, Morais J, Osterspey A, Tamargo JL, Zamorano JL, American College of Cardiology, American Heart Association Task Force, European Society of Cardiology Committee for Practice Guidelines. ACC/AHA/ESC 2006 guidelines for management of patients with ventricular arrhythmias and the prevention of sudden cardiac death: a report of the American College of Cardiology/American Heart Association Task Force and the European Society of Cardiology Committee for Practice Guidelines (Writing Committee to Develop Guidelines for Management of Patients With Ventricular Arrhythmias and the Prevention of Sudden Cardiac Death). *J Am Coll Cardiol.* 2006; 48: e247-346.
9. Dandamudi G, Ghumman WS, Das MK, Miller JM. Endocardial catheter ablation of ventricular tachycardia in patients with ventricular assist devices. *Heart Rhythm.* 2007; 4: 1165-1169.

10. Cantillon DJ, Bianco C, Wazni OM, Kanj M, Smedira NG, Wilkoff BL, Starling RC, Saliba WI. Electrophysiologic characteristics and catheter ablation of ventricular tachyarrhythmias among patients with heart failure on ventricular assist device support. *Heart Rhythm*. 2012; 9: 859-864.
11. Herweg B, Ilercil A, Kristof-Kuteyeva O, Rinde-Hoffman D, Caldeira C, Mangar D, Karlnosky R, Barold SS. Clinical observations and outcome of ventricular tachycardia ablation in patients with left ventricular assist devices. *Pacing Clin Electrophysiol*. 2012; 35: 1377-1383.
12. Vollkron M, Voigtl P, Ta J, Wieselthaler G, Schima H. Suction events during left ventricular support and ventricular arrhythmias. *J Heart Lung Transplant*. 2007; 26: 819-825.
13. Mulloy DP, Bhamidipati CM, Stone ML, Ailawadi G, Bergin JD, Mahapatra S, Kern JA. Cryoablation during left ventricular assist device implantation reduces postoperative ventricular tachyarrhythmias. *J Thorac Cardiovasc Surg*. 2013; 145: 1207-1213.
14. Brenyo A, Rao M, Koneru S, Hallinan W, Shah S, Massey HT, Chen L, Polonsky B, McNitt S, Huang DT, Goldenberg I, Aktas M. Risk of mortality for ventricular arrhythmia in ambulatory LVAD patients. *J Cardiovasc Electrophysiol*. 2012; 23: 515-520.
15. Rohit M, Charles JL, Sai-Sudhakar C, Hasan AK, Chan D. A device-device interaction between a Thoratec Heartmate II left ventricular assist device and a St. Jude Atlas (V-193) implantable cardioverter defibrillator. *J Cardiovasc Electrophysiol*. 2007; 18: E27; author reply E28.
16. Matthews JC, Betley D, Morady F, Pelosi F, Jr. Adverse interaction between a left ventricular assist device and an implantable cardioverter defibrillator. *J Cardiovasc Electrophysiol*. 2007; 18: 1107-1108.
17. Boudghene-Stambouli F, Boule S, Goeminne C, Botcherby E, Marquie C, Kouakam C, Guedon-Moreau L, Schurtz G, de Groote P, Lamblin N, Fertin M, Robin E, Brigadeau F, Klug D, Lacroix D, Meurice J, Wissocque L, Vincentelli A, Kacet S. Clinical implications of left ventricular assist device implantation in patients with an implantable cardioverter-defibrillator. *J Interv Card Electrophysiol*. 2013; .

## **Table and Figures**

**Table:** *Clinical characteristics of the population*

**Figure 1:** *Heart Mate 2 device (Thoratec)*

**Figure 2:** *Bipolar voltage map (Carto 3) of a patient implanted with a Heart Mate 2 device (Green) implanted for progressive heart failure in the context of ischemic CMP (panel A). Note that the whole heart is displaying voltage <0.5mV. On panel B is displayed a unipolar voltage map of a patient with dilated CMP. HM2 device image (green) is imported into Carto 3 from the CT scan.*

**Figure 3:** *Programmed stimulation in a patient with LVAD and dilated CMP. Arterial Pressure line is displayed (BP4). Note the little systolo-diastolic variation during baseline rhythm. When a fast VT is induced (cycle length 272ms) the systolo-diastolic variation disappears but arterial pressure remains around 70 mmHg and the patient is asymptomatic which allows fast VT mapping*

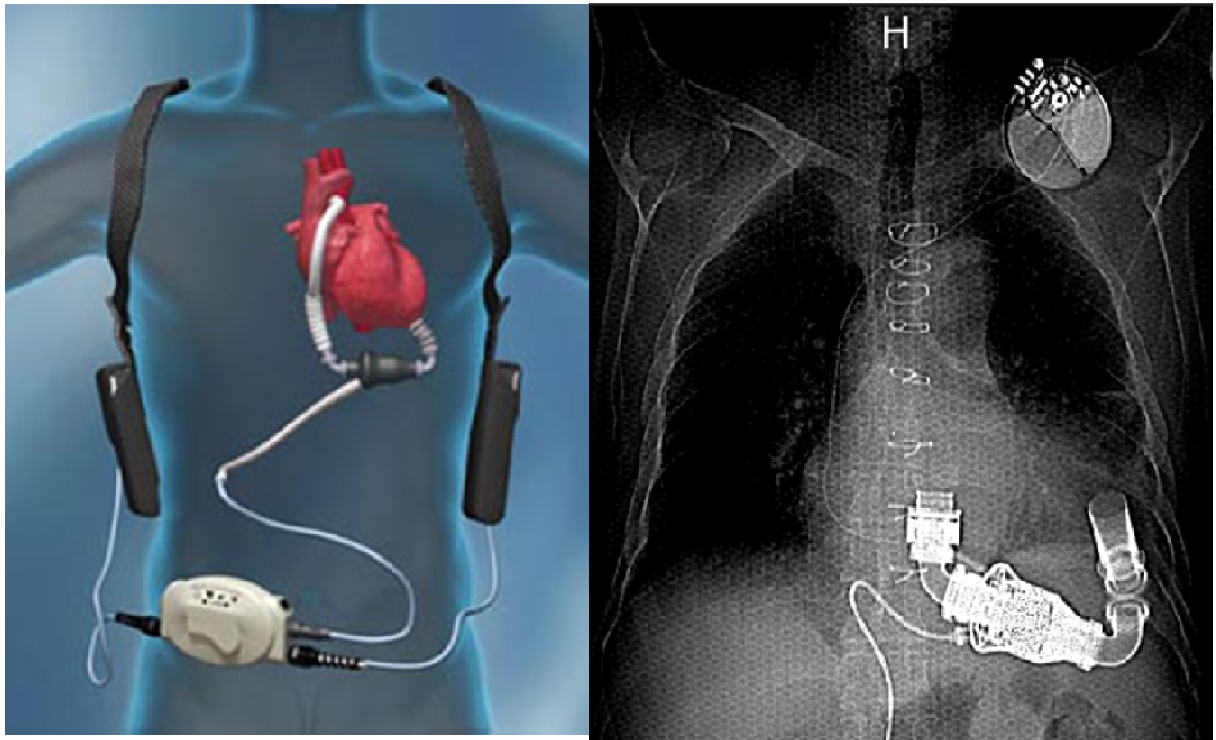
**Figure 4:** *Activation map (Carto 3) of a VT that was anchored on the cannula in a 55 yo woman with a prior anterior myocardial infarction.*



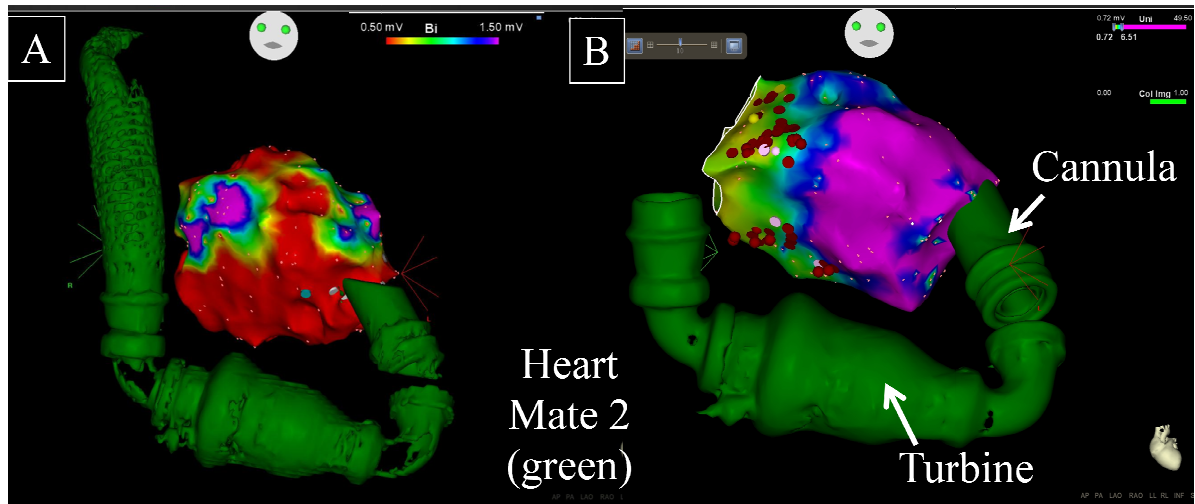
**Table:** *Clinical characteristics of the population*

	<i>n = 22</i>
<i>Sex, male (n, %)</i>	<i>18 (82%)</i>
<i>Age , y</i>	<i>57 ±11</i>
<i>LVEF pre LVAD impl.</i>	<i>17 ±9%</i>
<i>LVEDD (mm)</i>	<i>67 ±9</i>
<i>Ischemic CMP</i>	<i>13 (59%)</i>
<i>ICD</i>	<i>20 (91%%)</i>
<i>CRT</i>	<i>12/20 (60%)</i>
<i>VT/VF preLVAD</i>	<i>16 (73%)</i>

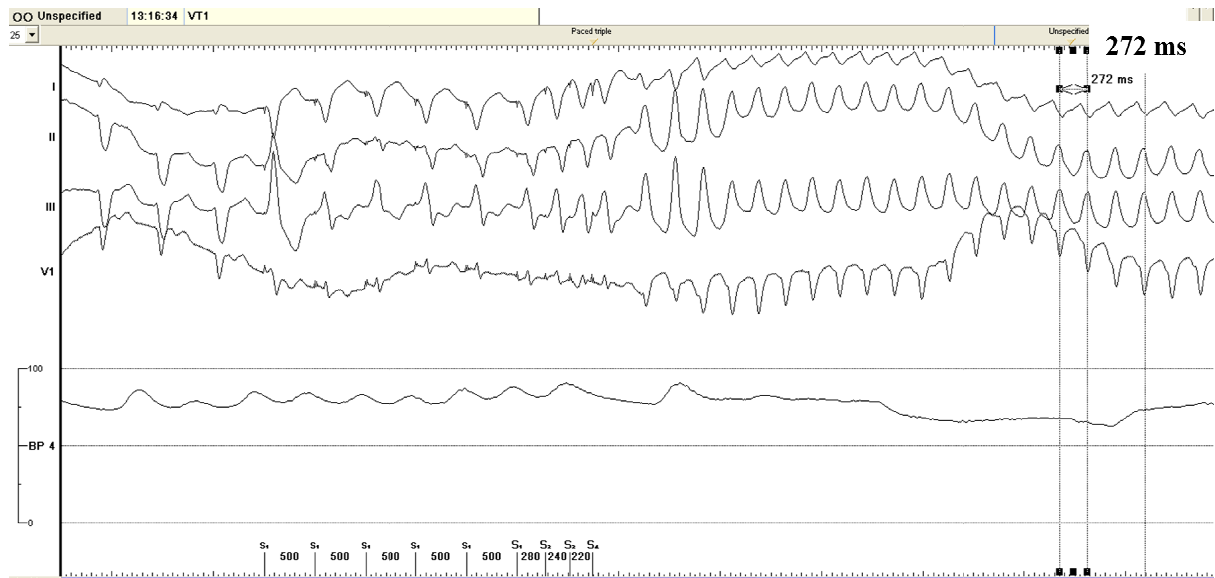
**Figure 1:** Heart Mate 2 device (Thoratec)



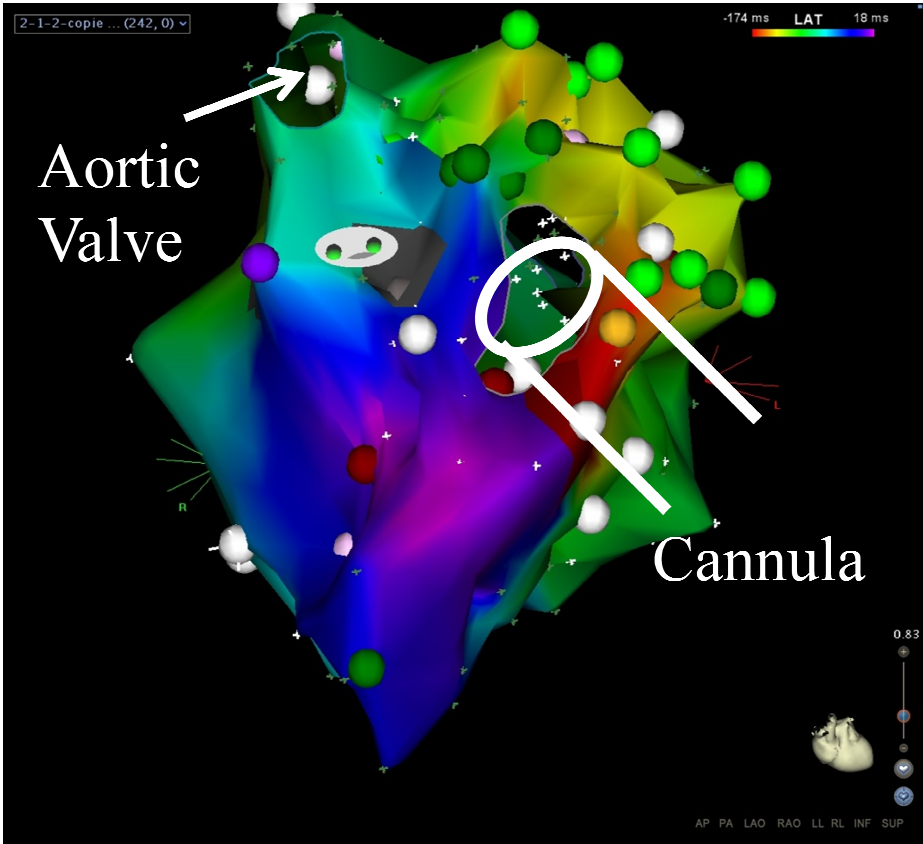
**Figure 2:** Bipolar voltage map (Carto 3) of a patient implanted with a Heart Mate 2 device (Green) implanted for progressive heart failure in the context of ischemic CMP (panel A). Note that the whole heart is displaying voltage  $<0.5\text{mV}$ . On panel B is displayed a unipolar voltage map of a patient with dilated CMP. HM2 device image (green) is imported into Carto 3 from the CT scan.



**Figure 3:** Programmed stimulation in a patient with LVAD and dilated CMP. Arterial Pressure line is displayed (BP4). Note the little systolo-diastolic variation during baseline rhythm. When a fast VT is induced (cycle length 272ms) the systolo-diastolic variation disappears but arterial pressure remains around 70 mmHg and the patient is asymptomatic which allows fast VT mapping



**Figure 4:** Activation map (Carto 3) of a VT that was anchored on the cannula in a 55 yo woman with a prior anterior myocardial infarction.



**D) Insight into the mechanism of Brugada syndrome: Epicardial substrate and modification during ajmaline testing**

Accepté: Heart Rhythm. 2013 May 31. pii: S1547-5271(13)00616-4. doi:

*1) Etude*

Ce cas montre que les patients avec syndrome de Brugada ont un substrat électrique essentiellement épicardique car les signaux bipolaires endocardiques en regard de la zone épicardique sont normaux. Chez notre patient qui n'avait pas l'aspect de Brugada à l'état de base, le test à l'ajmaline va démasquer cet aspect ECG ce qui est classique. L'apparition de cet aspect ECG va être comtemporain d'un retard des potentiels présents dans la zone anormale épicardique. Cet élément est très en faveur d'un mécanisme impliquant un problème de dépolarisation.

*2) Implications*

Il s'agit d'un cas qui nous semble crucial pour la compréhension des mécanismes du syndrome de Brugada chez l'homme. Ce retard localisé des potentiels épicardiques anormaux sous ajmaline n'avait jamais été identifié jusqu'à présent. Il apporte un élément de plus au débat sur le mécanisme repolarisation (essentiellement montrée sur des modèles expérimentaux<sup>9,10</sup> vs dépolarisation (arguments liées aux études cliniques<sup>11-14</sup>). De plus, ce cas montre comment identifier le substrat dans le syndrome de Brugada en vue d'une ablation.

## IMAGE

# Insight into the mechanism of Brugada syndrome: Epicardial substrate and modification during ajmaline testing

Frédéric Sacher, MD, Laurence Jesel, MD, Pierre Jais, MD, Michel Haïssaguerre, MD

From the Bordeaux University Hospital and LIRYC, L'Institut de rythmologie et modélisation cardiaque, Université de Bordeaux, Bordeaux-Pessac, France.

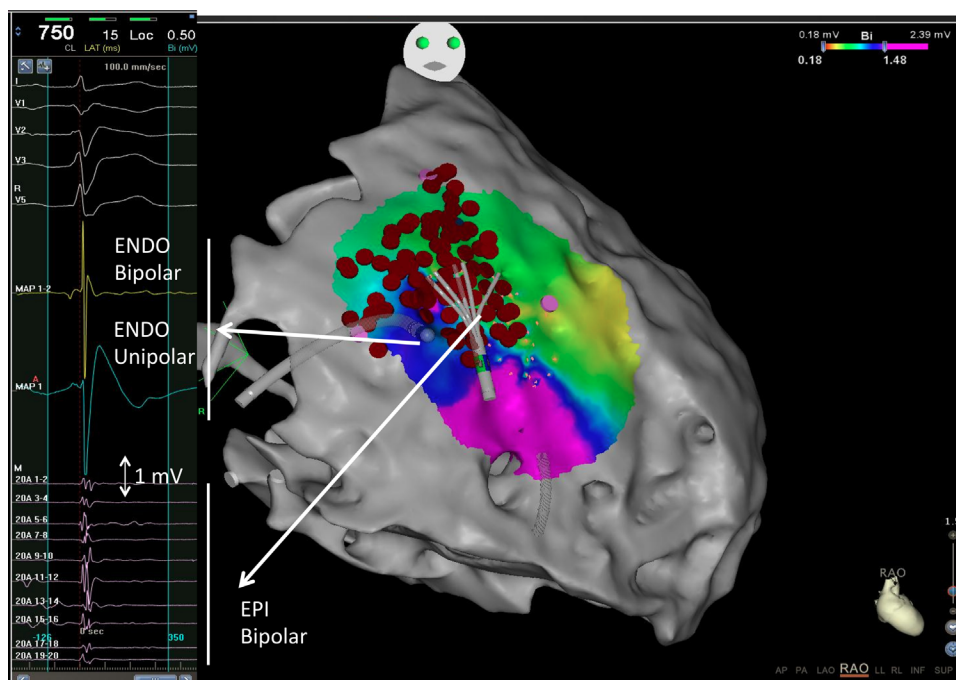


Figure 1

A 32-year-old man with Brugada syndrome and previous aborted sudden cardiac death was referred for ventricular fibrillation (VF) ablation owing to multiple VF recurrences ( $n = 7$ ). In the absence of clearly defined premature ventricular contractions serving as triggers,<sup>1</sup> a decision was

**KEYWORDS** Brugada syndrome; Ablation; Ventricular Fibrillation; Sudden cardiac death

**ABBREVIATIONS** ECG = electrocardiogram; EGM = electrogram; VF = ventricular fibrillation (Heart Rhythm 2013;0:1-3)

Dr Sacher has received speaking honorarium from Biosense Webster, St Jude Medical, and Sorin Group and research grant from Medtronic and Sanofi-Aventis. Dr Jais has received consulting fees and speaking honorarium from Biosense Webster and St Jude Medical. Dr Haïssaguerre has received consulting fees and speaking honorarium from Biosense Webster. **Address reprint requests and correspondence:** Dr Frédéric Sacher, Hôpital Cardiologique du Haut-Lévêque, 33604 Bordeaux-Pessac, France. E-mail address: frederic.sacher@chu-bordeaux.fr.

made to perform a combined epicardial and endocardial approach for substrate ablation.<sup>2,3</sup> After femoral venous access, a percutaneous subxyphoid pericardial approach was performed. An epicardial voltage map (CARTO 3, Biosense Webster, Diamond Bar, CA) was then acquired by using a multipolar mapping catheter (Pentaray, Biosense Webster) in conjunction with an irrigated-tip ablation catheter (Smartouch, Biosense Webster). An area of fragmented and low-voltage ( $< 1$  mV) electrograms (EGMs) ( $19 \text{ cm}^2$ ) was identified at the lower anterolateral part of the right ventricular outflow tract (Figure 1). In this area, epicardial EGMs had lower amplitude and fragmented potentials compared to the corresponding endocardial area and the surrounding epicardium. In the absence of type 1 Brugada pattern at baseline electrocardiogram (ECG) (Figure 2A), we performed an ajmaline challenge with the Pentaray lying over the area of abnormal epicardial EGMs (Figure 1). A half



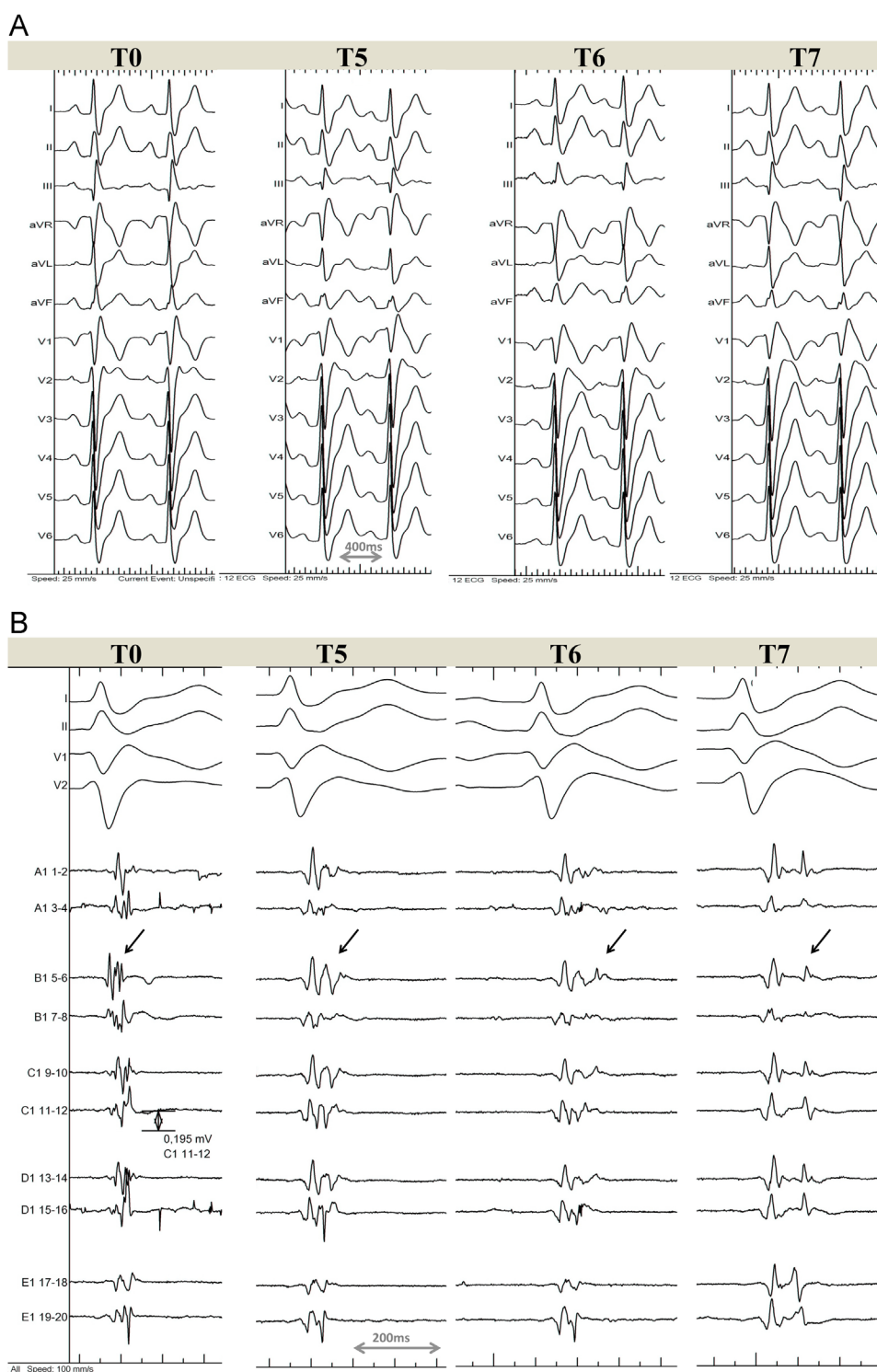

Figure 2

dose of ajmaline (60 mg over 5 minutes) was administered in consideration of the patient's weight (125 kg) and recent VF episodes. The results of the ajmaline test are displayed in Figure 2. At T5 (5 minutes after the start of ajmaline infusion), the ajmaline infusion was complete but the typical type 1 Brugada pattern on ECG increased until T7 (2 minutes after the end of ajmaline infusion). Fragmented and low-

voltage EGMs were seen to split progressively on Pentaray (Figure 2B) during apparition of the type 1 Brugada ECG pattern. The maximal delay of epicardial potentials (compared to baseline) was 82 ms. Within 30 minutes, the type 1 Brugada pattern decreased and epicardial EGMs returned to baseline (data not shown). We then targeted and eliminated all local abnormal epicardial potentials over this area

(red dots on Figure 1) with 30 minutes of radiofrequency application.

This image newly illustrates modification of the epicardial right ventricular outflow tract substrate during an ajmaline challenge inducing the type 1 Brugada pattern. Together with the area of low-voltage and fragmented potentials, similar to that described by Nademanee et al,<sup>3</sup> this finding is in favor of a depolarization substrate. The mechanism of Brugada syndrome has traditionally been proposed to be exclusively linked to repolarization abnormalities (phase 2 reentry).<sup>4</sup> However, recent studies in humans showed the evidence of depolarization abnormalities.<sup>3,5,6</sup> As spontaneous VF did not occur during the procedure, we cannot be certain of the mechanism responsible for its initiation. We can speculate that depolarization is an important component but a mixed mechanism involving repolarization cannot be excluded. Phase 2 reentry could be responsible for premature ventricular contractions but would need the depolarization substrate to initiate VF. As this abnormal depolarization substrate seems to develop over time, it could explain why VF occurs generally during adulthood in contrast to other channelopathies such as long QT and catecholaminergic polymorphic ventricular tachycardia.

## Acknowledgments

We thank Dr Lim for reviewing the manuscript and Dr Derval for technical assistance for preparing images.

## References

1. Haissaguerre M, Extramiana F, Hocini M, et al. Mapping and ablation of ventricular fibrillation associated with long-QT and Brugada syndromes. *Circulation* 2003;108:925–928.
2. Morita H, Zipes DP, Morita ST, Lopshire JC, Wu J. Epicardial ablation eliminates ventricular arrhythmias in an experimental model of Brugada syndrome. *Heart Rhythm* 2009;6:665–671.
3. Nademanee K, Veerakul G, Chandanamattha P, et al. Prevention of ventricular fibrillation episodes in Brugada syndrome by catheter ablation over the anterior right ventricular outflow tract epicardium. *Circulation* 2011;123:1270–1279.
4. Yan GX, Antzelevitch C. Cellular basis for the Brugada syndrome and other mechanisms of arrhythmogenesis associated with ST-segment elevation. *Circulation* 1999;100:1660–1666.
5. Lambiase PD, Ahmed AK, Ciaccio EJ, et al. High-density substrate mapping in Brugada syndrome: combined role of conduction and repolarization heterogeneities in arrhythmogenesis. *Circulation* 2009;120:106–117,1–4.
6. Hoogendijk MG, Opthof T, Postema PG, Wilde AA, De Bakker JM, Coronel R. The Brugada ECG pattern: a marker of channelopathy, structural heart disease, or neither? Toward a unifying mechanism of the Brugada syndrome. *Circ Arrhythm Electrophysiol* 2010;3:283–290.

## E) Références

1. Marchlinski FE, Callans DJ, Gottlieb CD, Zado E. Linear ablation lesions for control of unmappable ventricular tachycardia in patients with ischemic and nonischemic cardiomyopathy. *Circulation*. 2000; 101: 1288-1296.
2. Oza S, Wilber DJ. Substrate-based endocardial ablation of postinfarction ventricular tachycardia. *Heart Rhythm*. 2006; 3: 607-609.
3. Soejima K, Stevenson WG, Maisel WH, Sapp JL, Epstein LM. Electrically unexcitable scar mapping based on pacing threshold for identification of the reentry circuit isthmus: feasibility for guiding ventricular tachycardia ablation. *Circulation*. 2002; 106: 1678-1683.
4. Arenal A, del Castillo S, Gonzalez-Torrecilla E, Atienza F, Ortiz M, Jimenez J, Puchol A, Garcia J, Almendral J. Tachycardia-related channel in the scar tissue in patients with sustained monomorphic ventricular tachycardias: influence of the voltage scar definition. *Circulation*. 2004; 110: 2568-2574.
5. Arenal A, Glez-Torrecilla E, Ortiz M, Villacastin J, Fdez-Portales J, Sousa E, del Castillo S, Perez de Isla L, Jimenez J, Almendral J. Ablation of electrograms with an isolated, delayed component as treatment of unmappable monomorphic ventricular tachycardias in patients with structural heart disease. *J Am Coll Cardiol*. 2003; 41: 81-92.
6. Bogun F, Good E, Reich S, Elmouchi D, Igic P, Lemola K, Tschopp D, Jongnarangsin K, Oral H, Chugh A, Pelosi F, Morady F. Isolated potentials during sinus rhythm and pace-mapping within scars as guides for ablation of post-infarction ventricular tachycardia. *J Am Coll Cardiol*. 2006; 47: 2013-2019.
7. de Chillou C, Groben L, Magnin-Poull I, Andronache M, Magdi Abbas M, Zhang N, Abdelaal A, Ammar S, Sellal JM, Schwartz J, Brembilla-Perrot B, Aliot E, Marchlinski FE. Localizing the Critical Isthmus of Post-Infarct Ventricular Tachycardia: The Value of Pace Mapping during Sinus Rhythm. *Heart Rhythm*. 2013; .
8. Jais P, Maury P, Khairy P, Sacher F, Nault I, Komatsu Y, Hocini M, Forclaz A, Jadidi AS, Weerasoorya R, Shah A, Derval N, Cochet H, Knecht S, Miyazaki S, Linton N, Rivard L, Wright M, Wilton SB, Scherr D, Pascale P, Roten L, Pederson M, Bordachar P, Laurent F, Kim SJ, Ritter P, Clementy J, Haissaguerre M. Elimination of local abnormal ventricular activities: a new end point for substrate modification in patients with scar-related ventricular tachycardia. *Circulation*. 2012; 125: 2184-2196.
9. Yan GX, Antzelevitch C. Cellular basis for the Brugada syndrome and other mechanisms of arrhythmogenesis associated with ST-segment elevation. *Circulation*. 1999; 100: 1660-1666.
10. Di Diego JM, Cordeiro JM, Goodrow RJ, Fish JM, Zygmunt AC, Perez GJ, Scornik FS, Antzelevitch C. Ionic and cellular basis for the predominance of the Brugada syndrome phenotype in males. *Circulation*. 2002; 106: 2004-2011.

11. Lambiase PD, Ahmed AK, Ciaccio EJ, Brugada R, Lizotte E, Chaubey S, Ben-Simon R, Chow AW, Lowe MD, McKenna WJ. High-density substrate mapping in Brugada syndrome: combined role of conduction and repolarization heterogeneities in arrhythmogenesis. *Circulation*. 2009; 120: 106-17, 1-4.
12. Postema PG, van Dessel PF, de Bakker JM, Dekker LR, Linnenbank AC, Hoogendijk MG, Coronel R, Tijssen JG, Wilde AA, Tan HL. Slow and discontinuous conduction conspire in Brugada syndrome: a right ventricular mapping and stimulation study. *Circ Arrhythm Electrophysiol*. 2008; 1: 379-386.
13. Coronel R, Casini S, Koopmann TT, Wilms-Schopman FJ, Verkerk AO, de Groot JR, Bhuiyan Z, Bezzina CR, Veldkamp MW, Linnenbank AC, van der Wal AC, Tan HL, Brugada P, Wilde AA, de Bakker JM. Right ventricular fibrosis and conduction delay in a patient with clinical signs of Brugada syndrome: a combined electrophysiological, genetic, histopathologic, and computational study. *Circulation*. 2005; 112: 2769-2777.
14. Nademanee K, Veerakul G, Chandanamattha P, Chaothawee L, Ariyachaipanich A, Jirasirojanakorn K, Likittanasombat K, Bhuripanyo K, Ngarmukos T. Prevention of ventricular fibrillation episodes in Brugada syndrome by catheter ablation over the anterior right ventricular outflow tract epicardium. *Circulation*. 2011; 123: 1270-1279.

## V- Troisième partie : Approche thérapeutique des arythmies ventriculaires sur cicatrices myocardiques

### A) Comparison of Ventricular Radiofrequency Lesions in Sheep Using Standard Irrigated Tip Catheter versus Catheter Ablation Enabling Direct Visualization

Publié: J Cardiovasc Electrophysiol. 2012 ;23(8):869-73

#### 1) Etude

Malgré les progrès actuels de l'ablation par RF, l'évaluation en temps réel des lésions créées n'est pas directement possible. Ceci est responsable d'une part des échecs de ces procédures (absence de véritable lésion). Une start-up américaine (Voyage Medical, Redwood, CA) a développé un cathéter d'ablation avec système d'endoscopie intégré (cathéter IRIS) qui permet de visualiser la lésion créée par le cathéter en temps-réel. Nous avons évalué l'intérêt éventuel de ce type de technologie par rapport aux cathéters standards de RF. Pour ce faire, nous avons réalisé des lésions de RF in vivo dans des ventricules de moutons avec le nouveau système (cathéter IRIS, Voyage Medical) et un cathéter utilisé quotidiennement en clinique (Thermocool, Biosense Webster, CA). Les lésions ont ensuite été comparées lors de la nécropsie.

Sur un total de 160 lésions de RF réalisées (80 avec chaque cathéter), le monitoring visuel direct a permis de diminuer la puissance délivrée de  $30 \pm 2$  Watts avec le cathéter classique à  $21 \pm 4$ W avec le cathéter IRIS ( $p < 0.001$ ). Le plus intéressant est que lorsqu'on réalise des applications avec le cathéter classique, il n'y a pas de lésion identifiable à la nécropsie dans 22% des cas vs 1% avec le cathéter IRIS (1 application pour laquelle aucune lésion n'a été retrouvée mais déplacement du cathéter après 8 secondes). Enfin la visualisation en temps réel nous a permis d'identifier les différentes étapes de la formation des lésions de RF (blanchiment, puis microbulle voir brunissement et macrobulle avant un pop). Ces informations permettent ainsi de monitorer la puissance en temps réel pour obtenir une lésion optimale et éviter la survenue de pop (explosion intra-tissulaire liée à un échauffement cellulaire lors du tir de RF).

## *2) Implications*

Premièrement, le taux d'applications de RF ne résultant pas en une lésion peut atteindre 20% lors des procédures d'ablation. Ce chiffre peut certainement expliquer une partie des récives et plaident en faveur du développement de nouvelles technologies pour mieux appréhender la lésion que l'on crée.

Deuxièmement, la visualisation en temps réel de la formation de la lésion permet: 1) de s'assurer du contact entre le cathéter et le tissu, 2) d'adapter la puissance en fonction des caractéristiques de la lésion (pas de modification de couleur du tissu ou au contraire apparition d'un brunissement ou de macro bulles) pour optimiser la lésion tout en évitant les complications.

Toutefois il reste des limites à ce nouvel outil qui sont sa maniabilité et le fait qu'il faille être perpendiculaire au tissu afin de pouvoir visualiser et délivrer correctement la RF.

# Comparison of Ventricular Radiofrequency Lesions in Sheep Using Standard Irrigated Tip Catheter versus Catheter Ablation Enabling Direct Visualization

FREDERIC SACHER, M.D.,<sup>\*,†,‡</sup> NICOLAS DERVAL, M.D.,<sup>\*,†,‡</sup> AMIR JADIDI, M.D.,<sup>†</sup>  
 DANIEL SCHERR, M.D.,<sup>‡</sup> MELEZE HOCINI, M.D.,<sup>\*,†,‡</sup> MICHEL HAISSAGUERRE, M.D.,<sup>\*,†,‡</sup>  
 PIERRE DOS SANTOS, M.D., PH.D.,<sup>\*,†,‡</sup> and PIERRE JAIS, M.D.,<sup>\*,†,‡</sup>

From the <sup>\*</sup>University of Bordeaux, Centre de Recherche Cardio-Thoracique de Bordeaux, Bordeaux, France; <sup>†</sup>INSERM, Centre de Recherche Cardio-Thoracique de Bordeaux, Bordeaux, France; and <sup>‡</sup>Bordeaux University Hospital, F-33000 Bordeaux, France

**Comparison of Ventricular Radiofrequency Lesions in Sheep.** *Introduction:* In vivo assessment of RF ablation lesions is limited. Improved feedback could affect procedural outcome. A novel catheter, IRIS™ Cardiac Ablation Catheter (IRIS), enabling direct tissue visualization during ablation, was compared to a 3.5 mm open-irrigated tip ThermoCool™ Catheter (THERM) for endocardial ventricular RF ablation in sheep.

*Methods:* Sixteen anesthetized sheep (6 ± 1 years old, 60 ± 10 kg) underwent ventricular RF applications with either the THERM (Biosense Webster) or IRIS (Voyage Medical) ablation catheter. In the THERM group, RF was delivered (30 W, 60 seconds) when electrode contact was achieved as assessed by recording high-amplitude electrogram, tactile feedback, and x-ray. In the IRIS group, direct visualization was used to confirm tissue contact and to guide energy delivery (10–25 W for 60 seconds) depending on visual feedback during lesion formation.

*Results:* A total of 160 RF applications were delivered (80 with THERM; 80 with IRIS). Average power delivery was significantly higher in the THERM group than in the IRIS group (30 ± 2 W [25–30 W] for 57 ± 14 seconds vs 21 ± 4 W [10–25 W] for 57 ± 27 seconds; P < 0.001). At necropsy, 62/80 (78%) lesions created with THERM were identified versus 79/80 (99%) with IRIS (P < 0.001). The lesion dimensions were not significantly different between THERM and IRIS.

*Conclusion:* Despite best efforts using standard clinical assessments of catheter contact, 22% of RF applications in the ventricles using a standard open-irrigated catheter could not be identified on necropsy. In vivo assessment of catheter contact by direct visualization of the tissue undergoing RF ablation with the IRIS™ catheter was more reliable by allowing creation of 99% prescribed target lesions without significant complications. (*J Cardiovasc Electrophysiol*, Vol. 23, pp. 869-873, August 2012)

*catheter ablation, IRIS catheter, ventricle: irrigated tip catheter ablation*

## Introduction

Real-time assessment of lesion formation during radiofrequency (RF) ablation is met with certain limitations. Better feedback could improve lesion formation, which may then affect acute and chronic procedure-related outcomes. A novel catheter enabling direct tissue visualization (IRIS™ cardiac ablation catheter, Voyage Medical, Redwood City, CA, USA)

(IRIS group) (Fig. 1)<sup>1</sup> during ablation was compared to a 3.5 mm open-irrigated tip catheter (Thermocool™ catheter, Biosense Webster, Diamond Bar, CA, USA) (THERM group) for endocardial ventricular RF ablation efficacy in ovine.

## Methods

### Animal Preparation

The experimental protocols were handled in compliance with the Guiding Principles in the Use and Care of Animals published by the National Institute of Health (NIH Publication No. 85-23, Revised 1996).

Sheep were sedated with an intramuscular injection of 20 mg/kg ketamine hydrochloride and anesthetized with sodium pentobarbital (10 mg/kg). A 5F catheter was placed in the internal jugular vein for infusion of drugs and fluids. Anesthesia was maintained using continuous intravenous infusion of ketamine (500 mg/h) and pentobarbital. Slow intravenous infusion of saline was used to maintain hydration throughout the procedure. The trachea was intubated through a midline cervical incision and continuous artificial ventilation (Siemens Servo B, Berlin, Germany) was provided using room air supplemented with oxygen. A bolus of 5,000 IU of heparin was infused prior to catheter introduction.

French Society and French Federation of Cardiology provided an unrestricted grant. Plateforme de Technologie et d'Innovation Biomédicale hosted this animal study.


Dr. Sacher reports consulting fees from Voyage Medical and Sorin Group, and speaker honorarium from Biosense Webster. Dr. Jais reports consulting fees from Voyage Medical, Biosense Webster, and Saint Jude Medical. Dr. Haissaguerre reports consulting fees from Biosense Webster. Other authors: No disclosures.

Address for correspondence: Dr. Frédéric Sacher, M.D., Hôpital Cardiologique du Haut-Lévêque, 33604 Bordeaux-Pessac, France. Fax: +33-55-765-6509; Email: frederic.sacher@chu-bordeaux.fr

Manuscript received 20 November 2011; Revised manuscript received 6 March 2012; Accepted for publication 7 March 2012.

doi: 10.1111/j.1540-8167.2012.02338.x





**Figure 1.** IRIS™ cardiac ablation catheter.

Access to the right ventricle (RV) was obtained via femoral vein using a long sheath (steerable for THERM [Agilis, St. Jude Medical] and nonsteerable for IRIS). The left ventricle (LV) was accessed via retrograde aortic approach using a short sheath placed in the femoral artery.

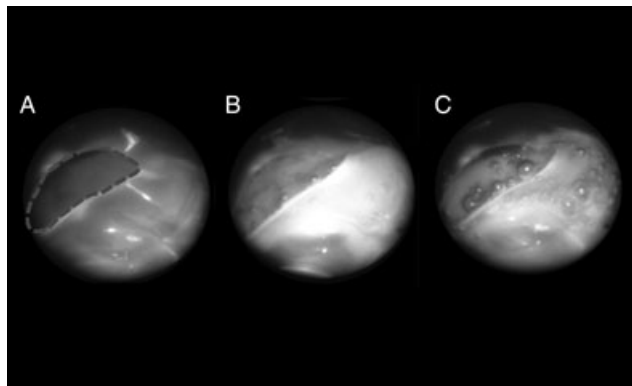
#### Description of the IRIS Catheter

The catheter is made of a 12F shaft (total insertable length of 93 cm) with a multidirectional steerable distal segment to facilitate navigation. Its distal end comprised a self-deploying distal silicone hood over a nitinol structure (Fig. 1). The hood diameter is 7 mm with a central aperture on the hood face of 3 mm, where positive-pressure saline irrigation exits the hood to clear blood from the field of view in front of the hood. The catheter contains a separate flexible illumination bundle and fiberscope that when used in conjunction with an endoscopy camera and illumination source allows collection of high-resolution, full-color video signals from the catheter. These video signals are displayed on a monitor in the lab and recorded by an external system for digital archive and review. The IRIS catheter also includes a RF electrode located in the proximal aspect of the hood. This electrode conducts RF energy to the tissue via the conductive saline within the hood without direct physical contact of a metallic electrode to the myocardium. The saline irrigation, in addition to clearing the field of view of blood and providing cooling at the tissue interface, also acts as an ionic bridge or “virtual electrode” for the current to be coupled to the tissue.<sup>2,3</sup> This catheter also incorporates 4 microelectrodes on the hood face and 8 on the outside surface of the hood to record bipolar electrogram information and allow localization of the catheter on an impedance-based 3-D mapping and navigation system, respectively.

#### Study Design

A total of 160 RF lesions were applied in 16 female sheep ( $6 \pm 1$  years old,  $60 \pm 10$  kg) by 2 electrophysiologists (PJ and FS). Only one type of catheter was used for all lesions delivered in each individual animal.

In the THERM group, 80 ventricular RF applications (40 in the RV, 40 in the LV) were delivered when electrode contact was achieved, as assessed by recording of high amplitude potentials, tactile feed-back, and stable catheter position on fluoroscopy. The power was restricted to 30 W for 60 seconds at each site, with the irrigation flow rate titrated to maintain target temperature between 39 and 43 °C. Impedance was



**Figure 2.** Semiology of lesion formation. This figure shows direct visualization of a lesion formation with the IRIS catheter. Panel A shows the normal endocardial tissue before any ablation. The dashed circle represents the hood aperture. The caricatural sequence starts with progressive tissue blanching followed by the appearance of microbubbles (panel B) and in the case of overheating, outgassing (panel C), and/or browning of the tissue.

monitored throughout the application. Comparison of the local ventricular electrogram (EGM) amplitude before and after each application was performed and an amplitude reduction by > 50% was considered to represent a good lesion. This group was the control group.

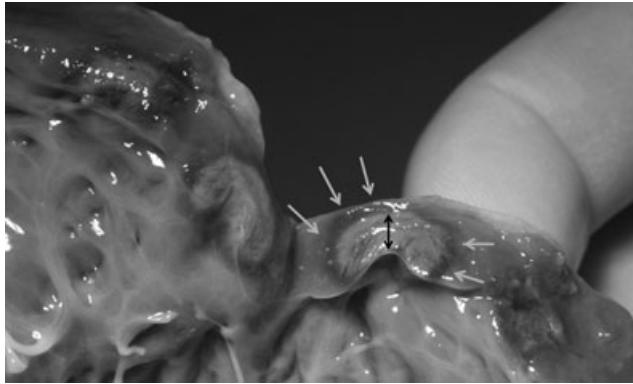
In the IRIS group, RF applications ( $n = 80$ –40 in the RV, 40 in the LV) were delivered when the electrode contact was achieved as assessed by direct visualization (movie in Supporting Information). RF delivery was initiated at 10 W and the power increased up to 25 W for 60 seconds maximum, depending on the visual feedback during lesion formation, as described below. During RF delivery under direct visualization, we visualized the endocardium “blanching,” or turning white, as tissue heating occurred. If the tissue did not blanch after 5–10 seconds of RF delivery, the power was progressively increased until blanching occurred. RF power was reduced or terminated when outgassing (i.e., large amount of microbubbles and steam formation<sup>4</sup>) or macrobubble formation was observed in the visual field during RF delivery (Fig. 2).

Each lesion set was delivered from apical to basal locations in the ventricles starting randomly from the RV or the LV. In the case of a steam pop or sustained polymorphic ventricular tachycardia (VT)/ventricular fibrillation (VF) requiring defibrillation, the RF application was terminated before the completion of 60 seconds and the actual duration of application was noted. Location, average power, maximum power, and impedance drop were also noted for each ablation lesion.

#### Necropsy

After completion of the lesion sets, each sheep was sacrificed and the heart explanted. Gross anatomical examination was performed immediately to identify and measure each lesion. These measurements were unblinded to the catheter used. The epicardium was analyzed before the endocardium to assess transmural. Endocardial expressions of the lesions were identified and measured in terms of their width, length, and then depth (Fig. 3). Lesions that were transmural were noted. Lesions in situ involving the lung and/or mediastinum were also examined.





**Figure 3.** Photos taken during necropsy. After having measuring length and width the lesion was sliced in the middle and the depth was measured (black arrow) without taking into account the inflammation (red collar: white arrows).

### Statistical Analysis

All continuous variables were reported as mean  $\pm$  SD and compared by Student's *t*-test. Categorical data were presented as numbers (percentages) and compared using the chi-square test. Statistical significance was established at  $P < 0.05$ .

## Results

### In Vivo RF Lesion Monitoring

A total of 160 RF applications were performed (80 THERM: 40 LV–40 RV and 80 IRIS: 40 LV–40 RV). RF parameters are reported in Table 1. Mean power delivery was statistically higher in the THERM group when compared with the IRIS group ( $30 \pm 2$  vs  $21 \pm 4$  W;  $P < 0.001$ ) due to the strategy adopted for the RF application, as well as the fact that the design of the IRIS catheter allows delivering energy directly to the tissue without the heat sink effect of the circulating blood. Whereas 30 W limit was reached for almost all RF applications in the THERM group, the minimum and maximum powers were 10 and 25 W in the IRIS group. The percentage of impedance drop, 10 seconds after RF start, was  $13 \pm 8\%$  in the THERM group; 47 of 80 (59%) applications resulted in a mean impedance drop  $\geq 10\%$  after 10 seconds of RF application. For 37 of 80 (46%) applications, the EGM reduced by at least 50%. EGM reduction was more frequent when a lesion was found at necropsy (35/62–56%) compared to the absence of lesion (2/18–11%). The mean impedance drop at 10 seconds in the IRIS group was  $16 \pm 7\%$  ( $P = \text{NS}$  compared to THERM). EGM recordings were not available with our initial version of the IRIS catheter. However, tissue blanching was observed for all RF deliveries with a predictable sequence: (1) tissue blanching; (2) microbubbles at the aperture in the hood if power continues to be increased and then, if power is not titrated down; (3) outgassing and/or tissue browning suggestive of overheating (Fig. 2). At the onset of moderate to vigorous microbubble formation, the power was titrated down to avoid tissue overheating and discoloration. Despite the technological differences, mean pump flow rate was similar to the 2 catheters during ablation ( $25 \pm 11$  mL/min for THERM vs  $25 \pm 3$  mL/min for IRIS,  $P = \text{NS}$ ). However, during the mapping period, a con-

tinuous infusion rate of 8–15 mL/min (vs 2 mL/min in the THERM) was necessary in the IRIS group to visualize the endocardium.

### Safety

No thrombus was visualized during mapping or ablation with the IRIS catheter. No thrombus was noticed in the THERM group. A lower incidence of steam pops was observed in the IRIS group (2/80, 2.5% both in the same animal) compared to the THERM group (6/80, 7.5% in 3 different animals) ( $P < 0.001$ ). There was no difference in terms of VF induction during ablation with 3(3.8%) and 2(2.5%) applications responsible for VF induction in the THERM versus IRIS group, respectively. There was no case of tamponade in any of the specimens.

### Lesion Examination

At necropsy, 62 of 80 (78%) applications were identified in the THERM group versus 79 of 80 (99%) in the IRIS group ( $P < 0.001$ ). With reference to the only missing lesion in the IRIS group, the catheter lost contact from the target site 15 seconds after the onset of RF application, so little energy was deposited at this site. Despite lower mean power delivery, more lesions were identified in the IRIS group when compared to the THERM group, and were of similar size (Table 1). The mean lesion depth was also similar between the 2 groups ( $4.7 \pm 2.1$  mm vs  $4.3 \pm 1.7$ ; THERM vs IRIS groups;  $P = \text{NS}$ ) despite lower IRIS power delivery. In the IRIS group, the lesion morphology visualized in vivo during ablation matched with that observed at necropsy (Fig. 4).

## Discussion

This study, for the first time, quantifies that a high number of conventional RF deliveries are not associated with any identifiable lesions. This is probably due to complete lack of catheter contact (despite trying to establish it effectively using indirect means) or possibly suboptimal contact such as the one obtained when the catheter is sliding against the tissue. The lack of direct monitoring capability for acute lesion formation is, in fact, a significant limitation. The direct visualization ablation tool studied here allows visualization of lesion formation at the surface of the tissue. As a consequence, it improves acute lesion formation compared to standard ablation (99% vs 78% identifiable lesions at necropsy). It allows for confirming and monitoring catheter/tissue contact, catheter stability and lesion formation during RF delivery. Moreover a “visual” semiology of lesion formation has been reliably identified with the IRIS catheter. The caricatural sequence starts with progressive tissue blanching followed by the appearance of microbubbles and in the case of overheating, outgassing and/or browning of the tissue (Fig. 2).

### Contact

Standard tools (high amplitude potentials, tactile feedback, and fluoroscopy) do not reliably assess catheter/tissue contact, resulting in the absence of lesion formation in more than 20% RF applications in the THERM group. The potential reasons are that (1) the contact may not be enough to ensure a good lesion, (2) catheters excursion may result in a sweeping motion over a large portion of the endocardium

**TABLE 1**  
Radiofrequency Application Characteristics and Lesion Size Depending on the Catheter

		THERM Group	IRIS Group	P-Value
RF parameters	Number of RF applications	80	80	
	Power (W)	30 ± 2	21 ± 4	P < 0.001
	RF duration (seconds)	57 ± 14	57 ± 27	NS
	Mean pump flow rate during ablation (mL/min)	25 ± 11	25 ± 3	NS
	Percentage of impedance drop at 10 seconds	13 ± 8%	16 ± 7%	NS
	Steam pop	6 (7.5%)	2 (2.5%)	NS
	Charring	0 (0%)	0 (0%)	NS
Necropsy	Number of lesions	62 (78%)	79 (99%)	P < 0.001
	Lesion depth (mm)	4.7 ± 2.1	4.3 ± 1.7	NS
	Lesion width (mm)	5.3 ± 1.7	4.9 ± 1.7	NS
	Lesion length (mm)	7.7 ± 2.1	7.8 ± 3.8	NS
	Transmurality	17 (21%)	33 (41%)	P = 0.03

in areas of high cardiac motion, and (3) the catheter may move and imperceptibly lose the tissue-contact during RF application.

This new technology allows the ability to ascertain good contact between the catheter tip and the tissue without any calibration or reliance on standard methods. Moreover, it also ensures catheter stability throughout the application (catheter microdisplacement due to cardiac motion can be clearly and continuously visualized—see the movie in Supporting Information). In the absence of complete contact with the tissue, the blood enters the visual field immediately disallowing visualization of the endocardium. Visualization potential relies heavily on manual preservation of a fine balance between the catheter-tissue forces such that they should be adequate for both the tissue visualization and ablation and the maintenance of catheter stability. If too much force is applied, the catheter has a tendency to slip away from the desired location with cardiac motion. The need for fine balance was found to be particularly important at sites with excessive cardiac motion. Other systems have been developed to measure the amplitude and direction of contact force. The “Tacticath” system from Endosense has 3 sensing optical fibers embedded that allow measurement of both the magnitude and direction of the catheter contact force.<sup>5</sup> The “Smart Touch” system from

Biosense Webster displays the same type of information using a transmitter coil and a precision spring at the tip of the catheter with sensors receiving transmitter coils location signal and micromovements of the spring to establish amplitude and direction of the contact force. Despite giving important additional information about catheter/tissue contact compared to standard catheters, these 2 systems do not allow direct visual monitoring and confirmation of lesion formation.

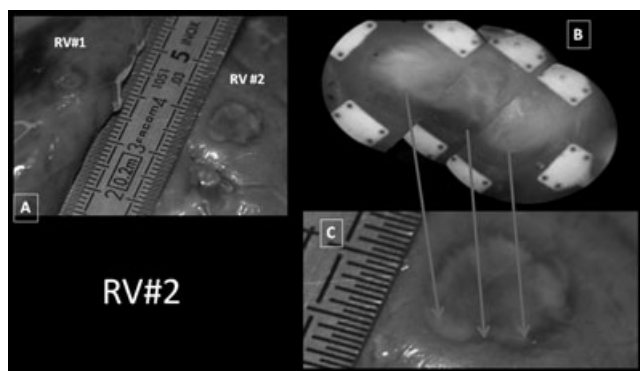
Another obstacle in the process of good lesion formation is the loss of RF energy into the surrounding blood pool during RF application. The IRIS catheter delivers RF energy directly toward the tissue through a virtual electrode. This curtails the amount of RF current that goes to the blood when compared with the conventional RF catheter,<sup>3</sup> allowing more efficient delivery of energy into the tissue. RF current is delivered through a saline irrigation volume within the hood, which isolates this virtual electrode from the lower impedance blood pool during ablation and directs the energy into the tissue. Interestingly, bench data (supplemental file) showed that with 30 ± 2 W RF deliveries with THERM catheter, lesions sizes were similar to those resulting from 21 ± 4 W delivered with the IRIS catheter which concurs with our in vivo observations.

#### Visualization of Lesion Formation

In addition to tissue-contact feedback, this system allows for optimization of energy delivery. It allows the use of the highest possible energy while minimizing complications like steam pop and char formation. In our initial experience, outgassing or tissue discoloration (“browning”) of the tissue were seen before pop occurred. Reducing the power at this stage prevented pops from occurring. However, some limitations with monitoring do exist. While myocardial blanching is recognizable by endoscopic visualization, it is important to note that it represents the phenomenon of the tissue-surface. Surface blanching does not ensure transmural necrosis. However, just being able to ensure lesion contiguity on the tissue surface based on visual inspection can be a big step forward allowing identification of gaps in the lesion.<sup>2</sup>

#### Safety

Although a large clinical experience is necessary, the virtual electrode has the potential to greatly reduce untoward events like steam pop, formation of thrombus, and char on the ablation catheter. The latter may help reduce the incidence of



**Figure 4.** Correlation between in vivo endocardial visualization (panel B) and necropsy (panel A and C). Panel A shows the endocardium of the right ventricle displaying the first (RV#1) and the second (RV#2) lesion performed. Panel C is a zoom of RV#2. The image on panel B depicts the same lesion visualized by the IRIS catheter. Panel B is made of 3 screen shots that represent the different areas of this lesion (small field of view) that match with necropsy (arrows).

embolic events secondary to catheter ablation. On the other hand, because the formation of virtual electrode requires a constant flush of saline (8–15 mL/min during mapping and 25 mL/min during ablation), fluid overload may be of some concern for long procedures.

### Limitations

Due to the different technical characteristics of the 2 catheters, the pathology was not blinded and may have introduced a measurement bias despite using the same criteria for all lesions measurement. Another limitation is the absence of microscopic analysis that prevents from comparing the quality of the lesions made by the different catheters.

### Conclusions

Despite best efforts using standard clinical assessments of catheter contact, 22% of RF applications in the ventricles using a standard open-irrigated catheter could not be identified on necropsy. In vivo assessment of catheter contact by direct visualization of the tissue undergoing RF ablation with the IRIS™ Catheter was more reliable by allowing creation of 99% prescribed target lesions without significant complications.

*Acknowledgments:* The authors wish to thank Bryan Wylie, Leslie Oley, and Dave Robinson, employees of Voyage Medical, for their support in the animal lab, figures preparation, and movie edits.

### References

1. Ahmed H, Neuzil P, Skoda J, Petru J, Sediva L, Kralovec S, Reddy VY: Initial clinical experience with a novel visualization and virtual

electrode radiofrequency ablation catheter to treat atrial flutter. *Heart Rhythm* 2011;8:361-367.

2. Sacher F, Oley L, Wylie B, Jais P: Direct visualization of radiofrequency lesion formation and gap in humans. *Heart Rhythm* 2011; 2011 Apr 22 [Epub ahead of print].
3. Chik WW, Barry MA, Malchano Z, Wylie B, Pouliopoulos J, Huang K, Lu J, Thavapalachandran S, Robinson D, Saadat V, Thomas SP, Ross DL, Kovoor P, Thiagalingam A: In vivo evaluation of virtual electrode mapping and ablation utilizing a direct endocardial visualization ablation catheter. *J Cardiovasc Electrophysiol* 2012;23:88-95
4. Wood, MA, Shaffer, KM, Ellenbogen, AL, Ownby, ED: Microbubbles during radiofrequency catheter ablation: Composition and formation. *Heart Rhythm* 2005 2;397-403
5. Yokoyama K, Nakagawa H, Shah DC, Lambert H, Leo G, Aeby N, Ikeda A, Pitha JV, Sharma T, Lazzara R, Jackman WM: Novel contact force sensor incorporated in irrigated radiofrequency ablation catheter predicts lesion size and incidence of steam pop and thrombus. *Circ Arrhythm Electrophysiol* 2008;1:354-362.

### Supporting Information

Additional Supporting Information may be found in the online version of this article:

**Movie:** Direct visualization of catheter ablation with the IRIS Catheter

**Supplemental file:** Evaluation of the IRIS Ablation Catheter compared to the ThermoCool Irrigated Radiofrequency Catheter in an in vitro Porcine Cardiac Tissue Ablation Model.

Please note: Wiley-Blackwell is not responsible for the content or functionality of any supporting materials supplied by the authors. Any queries (other than missing material) should be directed to the corresponding author for the article.

## B) Endocardial Versus Epicardial Ventricular Radiofrequency Ablation Utility of In Vivo Contact Force Assessment

Publié: Circ Arrhythm Electrophysiol. 2013;6(1):144-50

### 1) Etude

Afin d'améliorer les lésions réalisées lors de l'ablation par RF (manquante dans 20% des cas cf article précédent), différents systèmes permettant d'appréhender le contact entre le cathéter et le tissu ont été développés. Ils ne permettent pas à proprement parler de monitorer la création de lésion mais il s'agit d'une aide pour s'assurer que le cathéter reste en contact pendant les applications. Il y a eu plusieurs études dans la fibrillation atriale qui ont montré que le contact était un déterminant important de la taille de la lésion<sup>1</sup> mais également des récurrences à 3 et 6 mois<sup>2</sup>. Par ailleurs la plupart des études visant à déterminer la relation contact/taille de lésion ont été réalisées ex-vivo ou dans l'oreillette.

Le but de notre étude a été d'évaluer le contact utilisé in vivo lors de l'ablation par RF dans les ventricules sur le versant endocardique et épicardique (différences liées à l'absence de sang circulant, convexité de la paroi, graisse épicardique) et de corrélérer ces informations sur le contact à la taille des lésions retrouvées lors de la nécropsie. Nous avons donc comparé les lésions d'un groupe témoin (lésions réalisées avec un cathéter classique (Thermocool, Biosense Webster) avec des paramètres standards (30 watts, température 42°C pendant 1 minute) avec un groupe dans lequel les lésions ont été réalisées avec un cathéter irrigué avec information sur le contact (Tacticath, Endosense) (mêmes paramètres mais contact >10grammes requis). La mesure du contact était évaluée par effet Bragg<sup>3</sup>.

Pour cette étude nous avons réalisé 160 lésions (80 épiscopiques et 80 endocardiques) avec chaque cathéter chez 20 moutons.

Lors de l'ablation endocardique, 22% des applications de RF ne donnent pas de RF alors que lorsqu'on a une information sur le contact seulement 2% des applications n'engendrent pas de lésion.

Les forces de contact entre le cathéter et le tissu sont plus importantes lors d'une ablation endocardique (39 ±18 g) vs épiscopique (21 ±14g; p<0.001) essentiellement liées à la force axiale. Alors que l'aire sous la courbe du contact en fonction du temps (Force Time Integral) était supérieure lors des applications de RF endocardiques, les lésions épiscopiques étaient

plus volumineuses ( $231 \pm 182 \text{mm}^3$  vs  $209 \pm 131 \text{mm}^3$ ;  $p=0.02$ ) dues à l'absence de deperdition énergétique délivrée liée au sang circulant.

## *2) Implications*

La force du contact entre le cathéter de radiofréquence et le tissu est un déterminant majeur des lésions réalisées mais également du risque de perforation. L'apport de cette information sur le cathéter d'ablation est une aide supplémentaire pour s'assurer de la qualité et de la durabilité dans le temps des lésions réalisées.<sup>2</sup>. Le point le plus important de ce travail a été de montrer que 1 lésion sur 5 réalisées dans le ventricule par des opérateurs expérimentés n'aboutit à aucune lésion visible lorsqu'on n'a pas d'information sur le contact. L'autre point important est la morphologie des lésions qui sont différentes lorsqu'on les réalise sur le versant endocardique vs épicardique.

Les lésions épicardiques sont généralement plus étendues et moins profondes car la force axiale est moins importante (lésion moins profonde) et le cathéter glisse sur l'épicaarde (mouvement d'essuie glace) pendant l'application de radiofréquence (lésion plus étendue)<sup>1</sup>.

## Endocardial Versus Epicardial Ventricular Radiofrequency Ablation: Utility of In Vivo Contact Force Assessment

Frederic Sacher, Matthew Wright, Nicolas Derval, Arnaud Denis, Khaled Ramoul, Laurent Roten, Patrizio Pascale, Pierre Bordachar, Philippe Ritter, Meleze Hocini, Pierre Dos Santos, Michel Haissaguerre and Pierre Jais

*Circ Arrhythm Electrophysiol.* 2013;6:144-150; originally published online February 7, 2013;  
doi: 10.1161/CIRCEP.111.974501

*Circulation: Arrhythmia and Electrophysiology* is published by the American Heart Association, 7272 Greenville Avenue, Dallas, TX 75231

Copyright © 2013 American Heart Association, Inc. All rights reserved.

Print ISSN: 1941-3149. Online ISSN: 1941-3084

The online version of this article, along with updated information and services, is located on the World Wide Web at:

<http://circep.ahajournals.org/content/6/1/144>

**Permissions:** Requests for permissions to reproduce figures, tables, or portions of articles originally published in *Circulation: Arrhythmia and Electrophysiology* can be obtained via RightsLink, a service of the Copyright Clearance Center, not the Editorial Office. Once the online version of the published article for which permission is being requested is located, click Request Permissions in the middle column of the Web page under Services. Further information about this process is available in the [Permissions and Rights Question and Answer](#) document.

**Reprints:** Information about reprints can be found online at:  
<http://www.lww.com/reprints>

**Subscriptions:** Information about subscribing to *Circulation: Arrhythmia and Electrophysiology* is online at:  
<http://circep.ahajournals.org/subscriptions/>



## Endocardial Versus Epicardial Ventricular Radiofrequency Ablation

### Utility of In Vivo Contact Force Assessment

Frederic Sacher, MD; Matthew Wright, MRCP, PhD; Nicolas Derval, MD; Arnaud Denis, MD; Khaled Ramoul, MD; Laurent Roten, MD; Patrizio Pascale, MD; Pierre Bordachar, MD; Philippe Ritter, MD; Meleze Hocini, MD; Pierre Dos Santos, MD, PhD; Michel Haissaguerre, MD; Pierre Jais, MD

**Background**—Contact force (CF) is an important determinant of lesion formation for atrial endocardial radiofrequency ablation. There are minimal published data on CF and ventricular lesion formation. We studied the impact of CF on lesion formation using an ovine model both endocardially and epicardially.

**Methods and Results**—Twenty sheep received 160 epicardial and 160 endocardial ventricular radiofrequency applications using either a 3.5-mm irrigated-tip catheter (Thermocool, Biosense-Webster, n=160) or a 3.5 irrigated-tip catheter with CF assessment (Tacticath, Endosense, n=160), via percutaneous access. Power was delivered at 30 watts for 60 seconds, when either catheter/tissue contact was felt to be good or when  $CF > 10$  g with Tacticath. After completion of all lesions, acute dimensions were taken at pathology. Identifiable lesion formation from radiofrequency application was improved with the aid of CF information, from 78% to 98% on the endocardium ( $P < 0.001$ ) and from 90% to 100% on the epicardium ( $P = 0.02$ ). The mean total force was greater on the endocardium ( $39 \pm 18$  g versus  $21 \pm 14$  g for the epicardium;  $P < 0.001$ ) mainly because of axial force. Despite the force–time integral being greater endocardially, epicardial lesions were larger ( $231 \pm 182$  mm<sup>3</sup> versus  $209 \pm 131$  mm<sup>3</sup>;  $P = 0.02$ ) probably because of the absence of the heat sink effect of the circulating blood and covered a greater area ( $41 \pm 27$  mm<sup>2</sup> versus  $29 \pm 17$  mm<sup>2</sup>;  $P = 0.03$ ) because of catheter orientation.

**Conclusions**—In the absence of CF feedback, 22% of endocardial radiofrequency applications that are thought to have good contact did not result in lesion formation. Epicardial ablation is associated with larger lesions. (*Circ Arrhythm Electrophysiol.* 2013;6:144-150.)

**Key Words:** ablation ■ contact force ■ endocardium ■ epicardial ■ ventricular tachycardia

Contact force (CF) is an important determinant of lesion formation for endocardial atrial catheter ablation.<sup>1</sup> However, little is known about its impact on ventricular radiofrequency (RF) ablation (particularly epicardial ablation). We investigated ventricular lesion formation after RF ablation on the epicardium (EPI) and endocardially (ENDO) in a sheep model using standard irrigated-tip catheter versus a CF-sensing catheter.

#### Clinical Perspective on p 150

#### Methods

#### Animal Preparation

The experimental protocols were handled in compliance with the Guiding Principles in the Use and Care of Animals published by the National Institutes of Health (NIH Publication No. 85-23, Revised 1996).

Twenty-two sheep ( $6 \pm 1$  years,  $55 \pm 10$  kg) were sedated with an intramuscular injection of 20 mg/kg ketamine hydrochloride and anaesthetized with sodium pentobarbital (10 mg/kg). Slow intravenous infusion of saline maintained hydration throughout surgery, and anesthesia was maintained using continuous intravenous infusion of ketamine (500 mg/hour) and pentobarbital (150 mg/hour). The trachea was intubated through a midline cervical incision for connection to a respirator (Siemens Servo B, Berlin, Germany). Sheep were then ventilated using room air supplemented with oxygen. An intravenous access was placed in the internal jugular vein for infusion of drugs and fluids. Arterial blood gases were monitored periodically (Radiometer, Copenhagen, Denmark), and ventilatory parameters were adjusted to maintain blood gases within physiological ranges.

Access to the right ventricle (RV) was performed via femoral vein and a long steerable 8.5 Fr sheath (Agilis, St Jude Medical) was inserted. The left ventricle (LV) was accessed via a retrograde aortic approach, and a short 7 or 8 Fr sheath was placed in the femoral artery. Epicardial access was performed with a tuohy needle (Braun, Germany) via a subxyphoid approach, as previously described.<sup>2,3</sup> A 8.5 Fr Agilis (St Jude Medical) sheath was used to manipulate the

Received May 22, 2012; accepted December 18, 2012.

From the University of Bordeaux, LIRYC (F.S., N.D., A.D., K.R., L.R., P.P., P.B., P.R., M.H., P.D.S., M.H., P.J.), INSERM, Centre de recherche Cardio-Thoracique de Bordeaux (F.S., N.D., A.D., P.B., P.R., M.H., P.D.S., M.H., P.J.), Bordeaux University Hospital, Bordeaux, France (F.S., N.D., A.D., K.R., L.R., P.P., P.B., P.R., M.H., P.D.S., M.H., P.J.); and St. Thomas' Hospital & Kings College London, London, UK (M.W.).

Correspondence to Frédéric Sacher, MD, Hôpital Cardiologique du Haut-Lévêque, 33604 Bordeaux-Pessac, France. E-mail frederic.sacher@chu-bordeaux.fr  
© 2013 American Heart Association, Inc.

*Circ Arrhythm Electrophysiol* is available at <http://circep.ahajournals.org>

DOI: 10.1161/CIRCEP.111.974501

ablation catheter in the pericardium. Intrapericardial fluid was drained continuously with a vacuum system connected to the epicardial sheath.

Two sheep were excluded from this study: one because of an epicardial access problem, and the second one because of intractable ventricular fibrillation that could not be converted by several direct current shocks after the initial endocardial LV lesion.

## CF Measurement

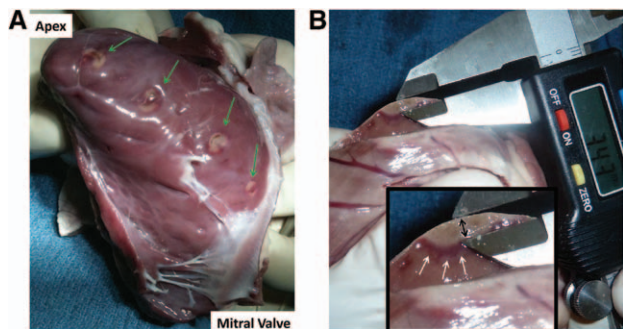
The Tactiath catheter (Endosense, Switzerland) displays CF information due to a force sensor incorporated into its distal part between the second and third electrode. The force sensor consisted of a deformable body and 3 optical fibers to measure microdeformations that correlate with force applied to the catheter tip. Infrared laser light is emitted through the proximal end of the 3 optical fibers. The light is reflected by fiber Bragg gratings on the deformable body at the distal end of the optical fibers, near the tip of the catheter. Applying CF to the tip of the catheter produces a microdeformation of the deformable body, causing the fiber Bragg gratings to either stretch or compress, which changes the wave length of the reflected light. The change of wave length is proportional to the CF applied to the tip. By monitoring the wave length of the reflected light in the 3 fibers, the system is able to calculate and display the vector of the CF (magnitude and angle).

## Ablation

Two operators (F.S. and P.J.) performed both endocardial and epicardial ablation of the RV and LV with a 3.5-mm open irrigated-tip catheter (Thermocool, Biosense Webster, Diamond Car, CA; THERM group) or a 3.5-mm open irrigated-tip catheter enabling CF information (Tactiath, Endosense, Switzerland; Tactiath group). In each sheep, a mean of 16 RF applications were performed (4 at the ENDO of the LV, 4 at the ENDO of the RV; 4 at the EPI of the RV and 4 at the EPI of the LV, going from apical to basal for each series of 4; Figure 1A). Epicardial lesions were performed anteriorly and endocardial lesions were performed inferiorly to give separation between the lesions at pathology, ensuring a perfect match between RF applications and lesions found at necropsy in the absence of electroanatomic system. The order of RF application (RV versus LV, ENDO versus EPI) was randomized for each animal.

RF was delivered when electrode contact was achieved as assessed by recording high-amplitude potentials, tactile feedback, and fluoroscopy, or when  $CF > 10$  g (when possible) for the Tactiath group. Energy was delivered in power control mode at 30 W for 60 seconds, with a flow rate titrated to obtain a target temperature between 39 to 43°C.

Impedance was recorded and the percentage of impedance drop at 10 seconds was calculated. Impedance was taken before RF delivery (baseline impedance) and 10 seconds after RF start (impedance t10). Difference of local ventricular bipolar amplitude before and after each application was measured with the caliper function of the



**Figure 1.** **A**, Represents 4 endocardial lesions performed on the inferior wall of the left ventricle. **B**, Endocardial and epicardial lesions were then sliced in the middle and the depth was measured (black arrow) without taking into account the inflammation (red collar: white arrows).

Labsystem Pro (Bard). A cutoff value of 50% amplitude reduction was arbitrarily chosen to identify a presumed effective lesion. In the Tactiath group, CF as well as force–time integral (FTI; area under the curve of CF for the duration of RF delivery)<sup>4</sup> were monitored continuously.

In case of steam pop or sustained polymorphic ventricular tachycardia/ventricular fibrillation requiring defibrillation, RF was stopped immediately and the RF duration was noted.

## Necropsy

After completion of the lesion set, the sheep was euthanized and the heart explanted. In situ lesions on lung or mediastinum were examined. Gross anatomic examination was performed immediately to identify and measure lesions. Measurements were performed with a micrometer ( $\pm 0.1$  mm). Inflammation (red collar; Figure 1B) was excluded from the lesion size. In case of RF application on epicardial fat, the myocardial lesion sizes were not included in the analysis.

Lesions volume was calculated according to the formula of Yokoyama et al.<sup>6</sup> The maximum depth (a), maximum diameter (b), depth at the maximum diameter (c), and surface diameter (d) of the lesion were measured. Lesion volume was calculated as follows:  $\text{volume} = (1/6) \times (A \times B^2 + C \times D^2) / 2$ .<sup>5,6</sup>

## Statistical Analysis

Quantitative variables were expressed as mean  $\pm$  standard deviation. We compared characteristics of RF applications/lesions performed with the 2 types of catheters (Thermocool and Tactiath) on the endocardium, and then on the EPI. We also compared all RF applications/lesions performed on the endocardium (whatever catheter used) to those performed on the EPI. Comparisons of quantitative variables between groups were performed using linear mixed models, where correlations between animal values were handled through the unstructured covariance matrix of random effects through autocorrelated error structures. Comparison of the number of lesions found at necropsy and transmuralities of the lesions between groups were performed using marginal logistic regression models. Bivariate correlation between axial force and lesion depth, lateral force and lesion depth/surface area/volume were performed with the Pearson test. A value  $P < 0.05$  was considered statistically significant.

## Results

A total of 320 RF applications were performed (80 on the endocardium and 80 on the EPI with each catheter). There were no differences in terms of actual power delivery, RF duration, and irrigation rate, according to either catheter or ventricular surface (Table 1). CF achieved was greater ENDO with a total CF of  $39 \pm 18$  g versus  $21 \pm 14$  g epicardially ( $P < 0.001$ ) and a FTI of  $2338 \pm 1076$  g second versus  $1163 \pm 705$  g second. This was mainly because of axial force ( $28 \pm 19$  g versus  $11 \pm 9$  g;  $P = 0.005$ ), although lateral force was also higher ENDO ( $22 \pm 12$  g versus  $16 \pm 10$  g;  $P = 0.008$ ). Of note, catheter orientation was mainly parallel to the tissue epicardially, whereas, ENDO, it was predominantly perpendicular to the tissue.

Mean impedance drop at 10 seconds was lower on the endocardium ( $12 \pm 7\%$ ) versus EPI ( $17 \pm 10\%$ ;  $P < 0.001$ ), as well as the percentage of applications with an impedance drop  $> 10\%$  at 10 seconds ( $54\%$  versus  $71\%$ ;  $P = 0.004$ ). No difference was found, between EPI and ENDO, in terms of electrogram (EGM) decrease.

Steam pops occurred 13 times in 4 sheep (ENDO=7 and EPI=6) during RF application, predominantly with the thermocool catheter (12 versus 1 with Tactiath). When the



**Table 1. Electrophysiological Parameters During Ablation and Lesion Characteristics at Necropsy Depending Site of Ablation**

		THERM Group		Tacticath Group		P Value		
		ENDO	EPI	ENDO	EPI	ENDO THERM vs ENDO Tacticath	EPI THERM vs EPI Tacticath	ENDO vs EPI Tacticath
RF parameters	No. of RF applications	80	80	80	80	-	-	-
	Power (W)	30±2	30±1	30±2	30±1	NS	NS	NS
	RF duration (s)	57±14	55±13	59±5	58±7	NS	NS	NS
	Mean pump flow rate during ablation (mL/min)	25±11	23±11	25±14	21±15	NS	NS	NS
	Percentage of Impedance drop at 10 s (%)	13±8	18±10	10±6	14±9	<i>P</i> <0.001	<i>P</i> =0.009	<i>P</i> <0.001
Contact force data	Total force (g)	-	-	39±18	21±14	-	-	<i>P</i> <0.001
	Axial force (g)	-	-	28±19	11±9	-	-	<i>P</i> =0.005
	Lateral force (g)	-	-	22±12	16±10	-	-	<i>P</i> =0.008
	Force time integral (g s)	-	-	2338±1076	1163±705	-	-	<i>P</i> <0.001
Necropsy	No. of lesions	62 (78%)	61/68 (90%) [12 on fat]	78 (98%)	72/72 (100%) [8 on fat]	<i>P</i> =0.007	<i>P</i> =0.02	NS
	Lesion depth (mm)	4.7±2.1	4.1±1.6	4.4±1.4	4.0±1.4	NS	NS	NS
	Lesion width (mm)	5.3±1.7	6.3±1.9	5.1±1.6	5.9±1.9	NS	NS	NS
	Lesion length (mm)	7.7±2.2	8.4±2.6	7.2±1.9	8.1±2.7	NS	NS	<i>P</i> <0.001
	Volume (mm <sup>3</sup> )	229±147	249±183	209±131	231±182	NS	NS	<i>P</i> =0.02

ENDO indicates endocardium; EPI, epicardium; RF, radiofrequency; and THERM, Thermocool.

steam pop occurred with the Tacticath catheter, the total force was 60 g and FTI 3300 g second.

Thirteen applications (ENDO=5 and EPI=8) in 6 sheep induced ventricular tachycardia/ventricular fibrillation that required external cardioversion.

### Necropsy

A total of 293 RF applications were identified at necropsy (92%). On the endocardium, 62 ventricular lesions were identified on 80 RF (78%) applications in the THERM group, whereas 78 of 80 (98%) were identified in the Tacticath group (*P*=0.007; Table 1). Epicardially, 20 ablation sites were identified on fat, and therefore were not included in the analysis (12 in the THERM group and 8 in the Tacticath group). Sixty-one of 68 (90%) RF applications in the THERM group versus 72 of 72 (100%) in the Tacticath group (*P*=0.02) were identified. Of note, when local fat thickness was ≤1 mm, 6 myocardial lesions out of 7 RF applications could be identified. Maximal myocardial lesion depth was 2 mm. But when fat thickness was >1 mm, no myocardial lesion could be identified (maximal CF 16 g).

A 50% decrease in electrogram amplitude (before and after RF applications) was in favor of lesions found at necropsy: 156 of 159 (98%) versus 80 of 114 (70%) in the absence of EGM amplitude decrease (*P*<0.001). However, lesion sizes were not statistically different depending on this decrease or on the impedance drop.

Lesions were larger epicardially (231±182 mm<sup>3</sup> versus 209±131 mm<sup>3</sup>; *P*=0.02) and covered a greater area (41±27 mm<sup>2</sup> versus 29±17 mm<sup>2</sup>; *P*=0.03). There was a trend toward deeper lesions, when applications were performed ENDO (4.6±1.7 mm versus EPI: 4.1±1.5 mm; *P*=NS), with a weak correlation (*r*=0.19; *P*=0.03) between axial force and lesion depth, but not between lateral force and lesion depth, surface area, or volume. There was no difference in achieving transmural lesions between EPI and ENDO RF delivery (ENDO: 23% of transmural lesion versus EPI: 13%; *P*=NS) nor depending on the catheter used. Transmural lesions were mainly found in the RV (n=40) or at the left ventricular apex (n=17), where ventricular wall are thinner. Endocardial LV lesions were larger than RV endocardial ones, despite identical RF settings (irrigated-tip catheter, 30 W for 60 seconds), but with a trend to higher CF (mainly because of axial force) and FTI (Table 2).

In the CF group alone, the mean total CF and FTI were higher in RF applications with lesions found at necropsy, than those where no lesion was identified (33±18 g versus 7±0.5 g; *P*<0.001 and 1941±1068 g second versus 404±32 g second; *P*<0.001). The relationships between CF, FTI, and lesion depth/volume are reported in Figure 2. On the endocardium, the mean lesion depth and size increase with the FTI (Figure 2A). However, this visual correlation was not present on the EPI (Figure 2B), where a FTI between 1000 and 2500 g second resulted in the same lesion volume on average. The maximal total CF and FTI for RF applications not resulting in

**Table 2. Contact Force Information and Lesion Size Depending on RF Application Site**

		Endocardium			Epicardium		
		RV	LV	P Value	RV	LV	P Value
CF data	Total force (g)	36±15	43±20	NS	20±12	22±10	NS
	Axial force (g)	23±16	34±21	0.006	10±9	11±9	NS
	Lateral force (g)	24±12	20±13	NS	15±10	16±10	NS
Necropsy	Force time integral (g s)	2133±881	2549±1220	NS	1063±724	1240±649	NS
	Lesion depth (mm)	4.0±1.4	5.0±2.0	0.001	3.6±1.3	4.5±1.6	0.02
	Volume (mm <sup>3</sup> )	179±134	249±136	0.003	221±178	261±186	NS

LV indicates left ventricle; and RV, right ventricle.

lesions at necropsy were 7 g and 439 g second. The minimal total CF and FTI for RF applications resulting in lesions at necropsy were 10 g/609 g second on the endocardium and 5 g/273 g second on the EPI.

Of note, in 3 sheep (2 with Thermocool, 1 with Tactiath), pulmonary lesions facing the epicardial RF ablation site were identified (Figure 3). For the Tactiath patient, the force was not directed toward the heart.

### Discussion

This study provides a number of unique insights into acute ventricular lesion formation:

1. Even with experienced operators a fifth of ventricular endocardial RF applications do not result in lesion formation when fluoroscopy, tactile feedback, and EGM amplitude are used to assess contact.
2. The addition of CF information dramatically decreases the number of RF applications that do not result in lesion formation.
3. Absence of circulating blood on the EPI (no heat sink effect) allows creating larger lesion on the EPI. Lower axial CF achieved epicardially associated with parallel catheter orientation alters the lesion geometry to being broad and shallow. These changes in geometry could have important implications for ventricular tachycardia ablation.

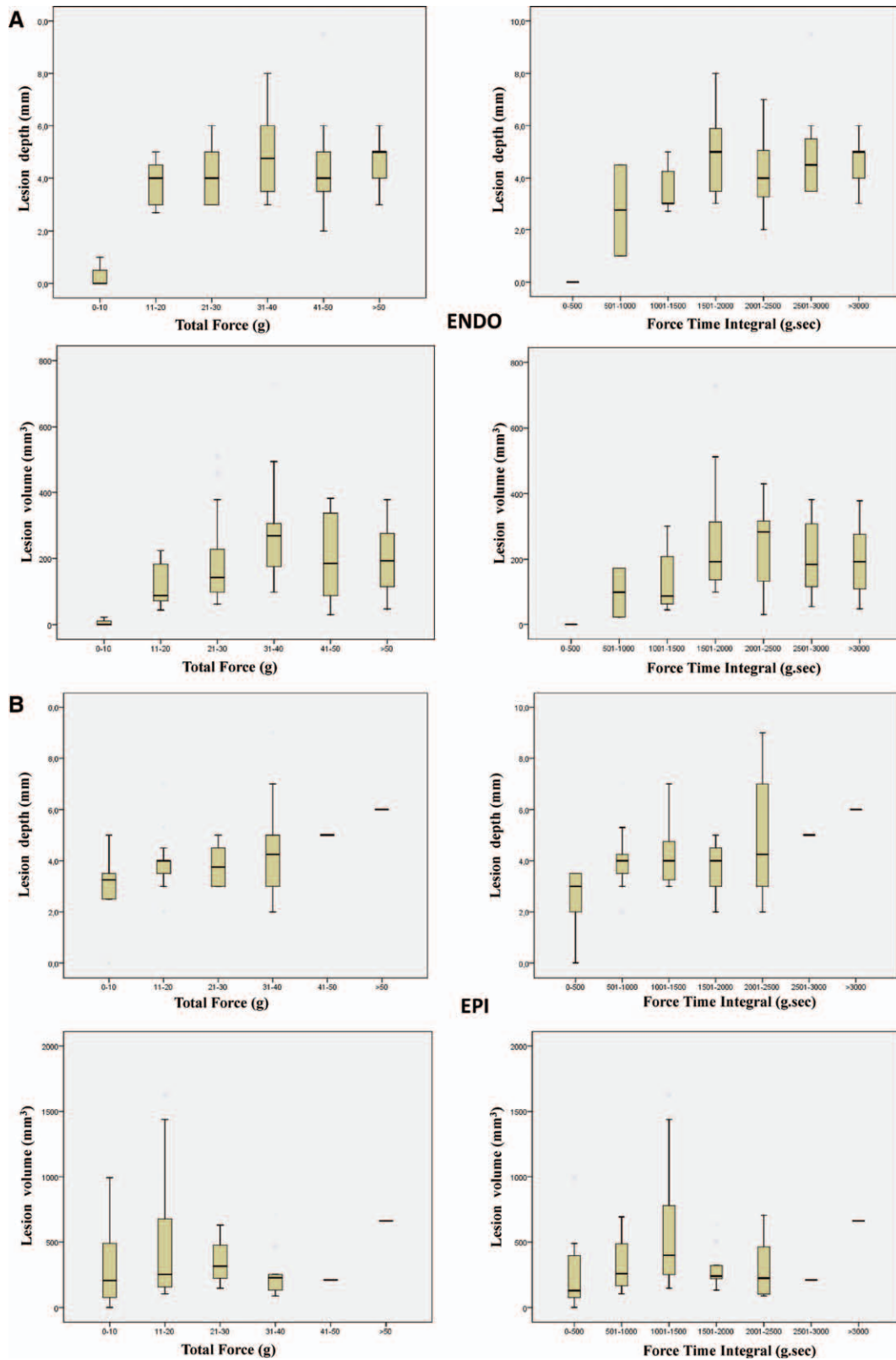
### Lesion Formation

In the Thermocool group, 22% of RF applications did not result in lesion formation. This was despite the impression of being in good contact based on tactile feedback, fluoroscopy, and high-amplitude electrograms. The 2 RF applications with CF information (Tactiath group), which did not result in lesion at necropsy, had a low CF <10 g and a FTI <500 g second because of catheter instability or displacement meaning that the amount of energy received to the tissue was too low to create lesion. Interestingly in the Toccata study,<sup>1</sup> 12% of RF applications (operator blinded to CF information) were performed with a CF <5 g. In an oral communication, showing the 12-months follow-up of the atrial fibrillation population of this Toccata study, all patients with a mean CF <10 g during RF applications experienced atrial fibrillation recurrence. CF feedback seems less crucial in the pericardial space because this is a virtual space, so in the absence of fluid, the catheter is in contact with the tissue.

Whereas a CF <10 g resulted in the absence of lesion on the endocardium, this was not the case on the EPI. On the EPI, limitation of RF efficacy by fat occurred for 20 of 160 RF applications. However, these 20 applications could be identified on epicardial fat. A limited myocardial lesion could even be identified when local fat thickness was <1 mm, but in these cases, the maximal lesion depth seen was 2 mm.

The mean impedance drop during the first 10 seconds was more important during ablation on the EPI versus endocardium whatever the catheter used (Thermocool  $P < 0.001$  and Tactiath  $P < 0.001$ ), but was not able to predict lesion size. A decrease  $\geq 10\%$  of impedance during the first 10 seconds of RF application was not able to predict lesion at necropsy, neither was the decrease  $> 50\%$  of the electrogram. Yokoyama et al<sup>6</sup> emphasized that the magnitude of impedance decrease during RF applications increased significantly with increasing CF. However, at the same CF, there was no difference in the magnitude of impedance decrease between 30 and 50 W, whereas these applications resulted in different lesion volume. We also reported a poor correlation between impedance drop and lesion depth.<sup>7</sup> Concerning the EGM amplitude, although a reduction of electrogram amplitude was in favor of lesion formation, 2% of applications with lesion found at necropsy did not have a EGM amplitude reduction  $> 50\%$ . This may be because of the fact that RF applications were performed in healthy ventricular myocardium, whereas spatial resolution of the catheter allows recording of normal tissue activities outside the lesion. Looking at CF information, total force was much higher when ablation was performed on the endocardium (39±18 versus 21±14g) predominantly because of an increased axial force, whereas on the EPI, lateral force was superior to axial force (Table 1). Whereas the catheter tip was mainly oriented parallel on the EPI because of its constraint from the parietal pericardium, this was not the case on the endocardium. The electrode orientation has previously been shown to influence lesion characteristics in a bench model.<sup>8</sup> In atrium, optimal CF has been evaluated around 20 g.<sup>6,9-11</sup> Concerning safety, minimal forces to perforate ventricles mechanically (without RF delivery) are higher than for atria (131 g [RA], 159 g [LA], 168 g [RV], and 227 g [LV])<sup>12</sup>; however, the force required to perforate when RF is delivered can be as low as 77 g in the atrium.<sup>13</sup>

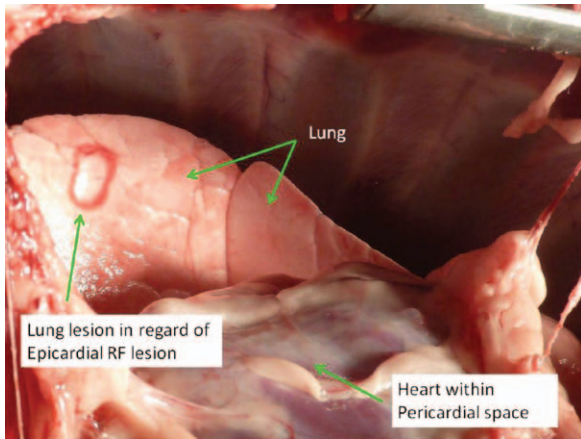
Whereas it has been shown that CF was correlated with lesion volume,<sup>6</sup> it seems that a parameter coupling instantaneous total force and application duration (FTI)<sup>4</sup> was more accurate to predict lesion size. This was visually verified



**Figure 2.** Mean lesion depth and volume of lesions performed with the TactiCath catheter depending on contact force (CF) and force-time integral (FTI) applied on the endocardium (A) vs epicardium (B).

for endocardial ventricular applications in this study, but not for epicardial ones. Moreover, in the TactiCath group, FTI was twice lower when applications were performed on the EPI compared with the endocardium, however, lesions volume

were larger on the EPI ( $231 \pm 182 \text{ mm}^3$  versus  $209 \pm 131 \text{ mm}^3$ ;  $P=0.02$ ; Table 1). This was possibly because of the absence of the heat sink effect of circulating blood on the EPI, where energy stays locally.



**Figure 3.** Lung lesion because of radiofrequency (RF) delivered on the epicardium with the catheter not well applied toward the heart.

On the ventricular endocardium, as earlier demonstrated for the atria, a total force <10 g or a FTI <500 g second results in no lesion being identifiable. However, optimal CF for ablation seems to be higher than for atria, based on Figure 2A. A total force of 30 to 40 g and a FTI between 2000 and 2500 g second seem to create optimal lesion.

On the epicardial side, CF information may not be as useful as ENDO, CF <10 g or an FTI <500 were enough to create lesion and there was no clear difference of lesion depth or volume using 11 to 20, 21 to 30, or 31 to 40 g of force. Moreover, it was infrequent to obtain a force >40 g on the pericardium, when the catheter lay on the ventricles in the absence of adhesions. CF >40 g was obtained mainly when catheter faced the concavity of the pericardial space. Applying energy when the force is not directed toward the heart may result in lung lesion (Figure 3). It is particularly important that the vector of force is pointing toward the myocardium and not the lung, to prevent/minimize pulmonary lesions.

### Limitations

Because of the design of the study, the operators were not blinded to the catheter type. To ensure recognition of the different ablation site at necropsy, a systematic approach was performed. Lesions characteristics, if RF had been applied at different sites, may have been different because of differing loads on the catheter dependent on the angle at which the catheter tip makes contact with the tissue.<sup>8</sup> Other variables such as electrode surface area in contact with the tissue and local blood flow known to effect lesion formation could not be controlled. Prevalence of ventricular arrhythmias during RF application is much higher in animal model compared with patients.

### Conclusions

More than 20% of endocardial ventricular RF applications are not associated with tissue lesion in the absence of CF information with experienced operators. Epicardial ablation is associated with wider and larger lesions, whereas endocardial ablation results in deeper lesions.

### Acknowledgments

We thank Dr Antoine Benard, CHU de Bordeaux, pôle de santé publique, France, for his assistance concerning statistical analysis. We are grateful to Philippe Thomas and Fabrice Didelot from Biotronik, France, for their technical support.

### Sources of Funding

This study was supported by an unrestricted grant: “Bourse de rythmologie Sanofi-Aventis” of the French Federation of Cardiology. Tactiath catheters were provided by Biotronik, France. Matthew Wright acknowledges financial support from the Department of Health via the National Institute for Health Research (NIHR) comprehensive Biomedical Research Center award to Guy’s & St Thomas’ NHS Foundation Trust in partnership with King’s College London and King’s College Hospital NHS Foundation Trust.

### Disclosures

Dr Sacher received speaking honorarium from Biosense Webster and Biotronik. Drs Jais and Haissaguerre receive consulting fees from Biosense Webster. Tactiath catheters were given by Biotronik, France.

### References

1. Kuck KH, Reddy VY, Schmidt B, Natale A, Neuzil P, Saoudi N, Kautzner J, Herrera C, Hindricks G, Jais P, Nakagawa H, Lambert H, Shah DC. A novel radiofrequency ablation catheter using contact force sensing: Toccata study. *Heart Rhythm*. 2012;9:18–23.
2. Sosa E, Scanavacca M, d’Avila A, Pilleggi F. A new technique to perform epicardial mapping in the electrophysiology laboratory. *J Cardiovasc Electrophysiol*. 1996;7:531–536.
3. Weerasooriya R, Jais P, Sacher F, Knecht S, Wright M, Lellouch N, Nault I, Matsuo S, Hocini M, Clementy J, Haissaguerre M. Utility of the lateral fluoroscopic view for subxiphoid pericardial access. *Circ Arrhythm Electrophysiol*. 2009;2:e15–e17.
4. Shah DC, Lambert H, Nakagawa H, Langenkamp A, Aeby N, Leo G. Area under the real-time contact force curve (force-time integral) predicts radiofrequency lesion size in an *in vitro* contractile model. *J Cardiovasc Electrophysiol*. 2010;21:1038–1043.
5. Wittkamp FH, Nakagawa H, Foresti S, Aoyama H, Jackman WM. Saline-irrigated radiofrequency ablation electrode with external cooling. *J Cardiovasc Electrophysiol*. 2005;16:323–328.
6. Yokoyama K, Nakagawa H, Shah DC, Lambert H, Leo G, Aeby N, Ikeda A, Pitha JV, Sharma T, Lazzara R, Jackman WM. Novel contact force sensor incorporated in irrigated radiofrequency ablation catheter predicts lesion size and incidence of steam pop and thrombus. *Circ Arrhythm Electrophysiol*. 2008;1:354–362.
7. Wright M, Harks E, Deladi S, Suijver F, Barley M, van Dusschoten A, Fokkenrood S, Zuo F, Sacher F, Hocini M, Haissaguerre M, Jais P. Real-time lesion assessment using a novel combined ultrasound and radiofrequency ablation catheter. *Heart Rhythm*. 2011;8:304–312.
8. Wood MA, Goldberg SM, Parvez B, Pathak V, Holland K, Ellenbogen AL, Han FT, Alexander D, Lau M, Reshko L, Goel A. Effect of electrode orientation on lesion sizes produced by irrigated radiofrequency ablation catheters. *J Cardiovasc Electrophysiol*. 2009;20:1262–1268.
9. Okumura Y, Johnson SB, Bunch TJ, Henz BD, O’Brien CJ, Packer DL. A systematic analysis of *in vivo* contact forces on virtual catheter tip/tissue surface contact during cardiac mapping and intervention. *J Cardiovasc Electrophysiol*. 2008;19:632–640.
10. Di Biase L, Natale A, Barrett C, Tan C, Elayi CS, Ching CK, Wang P, Al-Ahmad A, Arruda M, Burkhardt JD, Wisnoskey BJ, Chowdhury P, De Marco S, Armaganijan L, Litwak KN, Schweikert RA, Cummings JE. Relationship between catheter forces, lesion characteristics, “popping,” and char formation: experience with robotic navigation system. *J Cardiovasc Electrophysiol*. 2009;20:436–440.
11. Thiagalingam A, D’Avila A, Foley L, Guerrero JL, Lambert H, Leo G, Ruskin JN, Reddy VY. Importance of catheter contact force during irrigated radiofrequency ablation: evaluation in a porcine *ex vivo* model using a force-sensing catheter. *J Cardiovasc Electrophysiol*. 2010;21:806–811.

12. Shah D, Lambert H, Langenkamp A, Vanenkov Y, Leo G, Gentil-Baron P, Walpoth B. Catheter tip force required for mechanical perforation of porcine cardiac chambers. *Europace*. 2011;13:277–283.
13. Perna F, Heist EK, Danik SB, Barrett CD, Ruskin JN, Mansour M. Assessment of catheter tip contact force resulting in cardiac perforation in swine atria using force sensing technology. *Circ Arrhythm Electrophysiol*. 2011;4:218–224.

### CLINICAL PERSPECTIVE

Although radiofrequency (RF) catheter ablation is well established, the operator has minimal information to guide actual lesion formation. This is of more importance for ventricular tachycardia than for simple supra ventricular tachycardia ablations, where the effect of ablation is immediately apparent, for example, loss of delta wave. This study demonstrates that even in experienced hands, 20% of lesion deliveries do not result in any myocardial lesions being formed. Contact force feedback dramatically improved the ablation results on the ventricular endocardium and epicardium, and a contact force threshold was defined for effective lesion formation. In addition, the vector of the catheter force (axial versus lateral) critically influenced lesion geometry and depth. The force–time integral (FTI) throughout RF application correlates to lesion volume in the atria, and this was also the case in the ventricle especially with endocardial lesions. Interestingly, epicardial RF applications required less contact force for similar lesion size, possibly due to less convective cooling on the epicardial surface. These data suggest that contact force feedback can dramatically increase the efficiency of lesion delivery for the operator. Although we are still unable to visualize lesion formation in real-time, the addition of contact force as another surrogate of lesion formation is an important step forward for catheter ablations.



## C) Characterization of Contact Force During Endocardial and Epicardial Ventricular Mapping

En révision (R2): Circulation Arrhythmia and Electrophysiology

### 1) Etude

Cette étude vise à décrire la force du contact utilisée lors de la cartographie des ventricules des patients adressés pour ablation de TV. Nous avons décrit ce contact sur le versant endocardique mais également épicaudique. Nous avons également comparé la cartographie par voie transeptale et rétrograde aortique. La force du contact était évaluée avec un cathéter Smartouch (Biosense Webster). L'opérateur était en aveugle des informations de contact pendant la cartographie (mais pas pendant l'ablation). Un total de 8979 points de cartographie avec information sur l'orientation et la force du contact ont été analysés. Ils provenaient de 13 cartes épicaudiques, 12 cartes endocardiques ventriculaires gauches (6 réalisée par voie transeptale, 6 par voie rétrograde aortique) et 12 cartes endocardiques ventriculaires droites réalisées chez 21 patients.

Sur le versant épicaudique, la médiane de la force du contact était de 8 grammes (4-13g) avec un vecteur orienté vers la paroi dans 46% des cas. Lorsque ce vecteur n'était pas orienté vers le myocarde mais vers le péricarde, la force du contact était supérieure 16 grammes (10-24g) [ $p < 0.001$ ]. Lors de la cartographie endocardique (VG et VD), le contact était correctement orienté (vers le myocarde) dans 94% des cas. La force du contact était supérieure par rapport à l'épicaudique: 15 grammes (8-25g) pour le VG et 13 grammes (7-22g) pour le VD. Lors de la cartographie endocardique VG, la force du contact était supérieure lors de l'accès transeptal avec utilisation d'une gaine défléctable (16 grammes (8-27g)) par rapport à l'accès rétrograde aortique (14 grammes (8-22g);  $p < 0.001$ ). De plus, la force du contact avec un accès rétrograde aortique était moins bon pour le septum et la région basale antérieure.

## *2) Implications*

Lors de la cartographie épicardique mais plus encore lors de l'ablation il est primordial de s'assurer que le cathéter pointe bien vers le myocarde et non vers le péricarde. Sinon les lésions thérapeutiques de radiofréquence myocardiques seront moindres mais en plus il existe un risque de lésion non voulue d'organes extracardiaques (poumon)<sup>4</sup>. Compte-tenu des différences de force du contact en fonction des zones endocardiques VG ciblées, il peut être intéressant de privilégier une voie d'abord par rapport à l'autre (transeptale ou rétrograde aortique).

Disclaimer: The manuscript and its contents are confidential,  
intended for journal review purposes only, and not to be further  
disclosed.

URL: <http://circep-submit.aha-journals.org>

Title: Characterization of Contact Force During Endocardial and  
Epicardial Ventricular Mapping

Manuscript number: CIRCAE/2013/001219

Author(s): Laurence Jesel, Hôpital Cardiologique du Haut-Lévêque &  
Université Victor Segalen Bordeaux II

Frédéric Sacher, Hôpital Cardiologique du Haut-Lévêque & Université  
Victor Segalen Bordeaux II, LIRYC Institute

Yuki Komatsu, Hôpital Cardiologique du Haut-Lévêque and Université  
Victor Segalen Bordeaux II

Matthew Daly, Hôpital Cardiologique du Haut-Lévêque & Université  
Victor Segalen Bordeaux II, LIRYC Institute

Stephan Zellerhoff, CHU / Université de Bordeaux - Institut LIRYC /  
INSERM U1045



Han Lim, University of Adelaide & Royal Adelaide Hospital

Nicolas Derval, Hôpital Cardiologique du Haut-Lévêque & Université

Victor Segalen Bordeaux II, LIRYC Institute

Arnaud Denis, Hôpital Cardiologique du Haut-Lévêque & Université

Victor Segalen Bordeaux II, LIRYC Institute

Wislane Ambri, Biosense Webster

Khaled Ramoul, Hôpital Cardiologique du Haut-Lévêque & Université

Victor Segalen Bordeaux II, LIRYC Institute

Valérie Aurillac, Department of Cardiac Electrophysiology, Hôpital

Cardiologique du Haut-Lévêque

Mélèze Hocini, Hôpital Cardiologique du Haut-Lévêque & Université

Victor Segalen Bordeaux II, LIRYC Institute

Michel Haïssaguerre, Hôpital cardiologique du Haut-Lévêque

Pierre Jais, Hôpital Cardiologique Haut Lévêque

Disclaimer: The manuscript and its contents are confidential, intended for journal review purposes only, and not to be further disseminated.

# Characterization of Contact Force During Endocardial and Epicardial Ventricular Mapping

## SHORT TITLE: Contact Force During Ventricular Mapping

**Authors:** Laurence Jesel, MD; Frédéric Sacher, MD; Yuki Komatsu, MD; Matthew Daly MD, Stephan Zellerhoff MD, Han S. Lim, MBBS, PhD Nicolas Derval, MD, Arnaud Denis, MD, Wislane Ambri, Meng, Khaled Ramoul, MD, Valérie Aurillac, Méléze Hocini, MD, Michel Haïssaguerre, MD, Pierre Jaïs, MD

**Authors' institution:** Department of Cardiac Electrophysiology, Hôpital Cardiologique du Haut-Lévêque and Université Victor Segalen Bordeaux II, Bordeaux, France

**CORRESPONDENCE:** Laurence Jesel, MD

Department of Cardiac Electrophysiology, Hôpital Cardiologique du Haut-Lévêque, Avenue de Magellan, 33604 Bordeaux-Pessac, France.

Phone number: +33 5 57 65 65 65 or +33 3 69 55 09 48

Fax number: +33 5 57 65 65 09

Email: [laurence.jesel@chru-strasbourg.fr](mailto:laurence.jesel@chru-strasbourg.fr)

**WORD COUNT:** 4123 words

Subject codes: (22) Ablation/ICD/surgery, (106) Electrophysiology

## ABSTRACT

**Background:** The optimal contact force (CF) for ventricular mapping and ablation remains unvalidated. We assessed CF in different endocardial and epicardial regions during ventricular tachycardia (VT) substrate mapping using a CF-sensing catheter (Smartouch, Biosense-Webster) and compared the trans-septal (TS) versus retro-aortic approach (RAo).

**Methods and results:** In total, 8979 mapping points with CF and force vector orientation (VO) were recorded in 21 patients, comprising 13 epicardial, 12 left ventricular (LV) (6 TS, 6 RAo) and 12 right ventricular (RV) endocardial maps. VO was defined as 'adequate' when the vector was directed towards the myocardium. During epicardial mapping, 46% of the points showed an 'adequate' VO and a median CF of 8 (4-13) g, however with significant differences among the 8 regions. When VO was 'inadequate', median CF was higher at 16 (10-24) g ( $p < 0.0001$ ). During LV and RV endocardial mapping, 94% of VO were 'adequate'. Median CF of 'adequate' VO in the LV and RV endocardium were higher than in the epicardium (15 (8-25) and 13 (7-22) g vs. 8 (4-13) g respectively; both  $p < 0.001$ ). Median LV CF with TS approach was higher than RAo, with regional variation. CF in the apico-inferior and apico-septal

regions was higher with TS approach ( $p < 0.001$ ).

**Conclusions:** Ventricular mapping demonstrates important regional variations in CF but in general, CF is higher endocardially than epicardially where poor catheter orientation is associated with higher CF. A TS approach may lead to improved contact. Use of CF may optimize safety and efficacy during VT substrate mapping and ablation.

**Key words:** ventricular tachycardia, epicardium, endocardium, mapping, catheter ablation

Disclaimer: The manuscript and its contents are confidential, intended for journal review purposes only, and not to be further disclosed.

## ***Introduction***

Ablation of scar-related ventricular tachycardia (VT) often relies on a substrate-based approach. Electroanatomic mapping is commonly performed to identify low voltage regions and local abnormal ventricular activities (LAVA) (1-3). During substrate mapping, poor tissue contact may lead to gaps in the electro-anatomical 'shell' or may mislabel a normal region as a low voltage scar area. Substrate detection may be impacted and LAVA may be more difficult to identify. Unfortunately, several indicators of contact during mapping and ablation, including observation of catheter movement during fluoroscopy, catheter impedance and ST changes in the unipolar signal during ablation, have limited efficacy (4,5).

The contact force catheter allows assessment of real time contact force at the tip of the catheter. The contact force observed during endocardial and epicardial ventricular mapping and ablation has not been yet reported.

This study aimed to assess the contact force (CF) in different endocardial and epicardial regions during ventricular tachycardia (VT) substrate mapping using a CF catheter (Smartouch, Biosense Webster) and to compare trans-septal and retro-aortic approaches.

## **Methods**

### **Study population.**

CF was assessed in a total of 37 ventricular chambers in 21 patients (18 males, age 53±15) referred to our center for ventricular tachycardia ablation, using a three-dimensional electroanatomic mapping system and CF catheter. Seven patients presented with ischemic cardiomyopathy, 9 with arrhythmogenic right ventricular cardiomyopathy, 1 with myocarditis and 1 with Brugada syndrome. Three patients had no structural heart disease. The study was approved by our local institutional review committee. Written informed consent was obtained for all patients.

### **Left and right ventricular and pericardial accesses.**

Substrate mapping and ablation were performed under conscious sedation and supplementary analgesia (Sufentanil or remifentanil) under supervision of an anesthesiologist for the pericardial approach.

Vascular sheaths were inserted into the right femoral vein, right femoral artery, and/or subxyphoid area under local anesthesia (bupivacaine). A 6-French steerable

quadripolar or decapolar catheter (2-5-2mm, Xtrem, ELA Medical, Montrouge, France) was positioned in the right ventricular (RV) apex or coronary sinus.

Retrograde access to the left ventricle (LV) was obtained through the right femoral artery in 6 patients. The LV endocardium was accessed by trans-septal puncture using a long curve steerable sheath (Agilis, St. Jude Medical) and BRK Needle, (St. Jude Medical) in 6 patients. The access to RV was obtained through the right femoral vein using a medium curve sheath (Agilis, St. Jude Medical).

Pericardial access was obtained in patients in whom an epicardial substrate was suspected based on the clinical VT morphology on surface ECG, the nature of the underlying heart disease or the preprocedural MRI suggesting subepicardial substrate. Pericardial access, as described by Sosa et al. (6,7) was modified so as to access the pericardial space through an anterior puncture to prevent intra-abdominal route, as previously described (3). The pericardial puncture was guided by a 90° left lateral fluoroscopic projection. A steerable sheath (Agilis, St. Jude Medical) was then introduced in the pericardial space to provide catheter stability and maneuverability.



## **Contact force catheter**

All procedures were performed with an irrigated CF catheter (Thermocool SmartTouch, Biosense-Webster, Inc., Diamond Bar, CA, USA) and the CARTO 3 mapping system (Biosense-Webster, Diamond Bar, California). The catheter uses a 3.5 mm irrigated tip electrode with location sensors at the tip that are connected by a precision spring to the shaft, housing micro-sensors to detect small movements of the catheter.

Before mapping, the catheter was calibrated whilst floating free in the right atrium to set the baseline value. The force was measured in real time in grams. The direction of the force was displayed as an arrow vector on the tip of the catheter image on the CARTO 3 system. Contact force (CF) for each acquired point was recorded along with the voltage and local activation time.

## **Mapping**

Two experienced operators performed endocardial and epicardial ventricular mapping blinded to CF information. During RF delivery, CF and force vector orientation (VO) were carefully monitored. Electroanatomical maps were constructed

by manually tracing the wall surface with the roving catheter. When the operator judged the position and contact as stable (at least 2.5 seconds), the point was acquired on the CARTO system. Low voltage and scar were defined by bipolar voltage of 0.5-1.5 mV and  $<0.5$  mV respectively (2).

Thirteen epicardial, twelve left ventricular endocardial maps (6 with trans-septal and 6 with retroaortic approach) and twelve right ventricular endocardial maps were constructed in the 21 patients. 4,155 epicardial, 2629 LV and 2195 RV endocardial mapping points were recorded in sinus rhythm.

The CF and VO were assessed among the following regions: anterior, left ventricle, inferior, right ventricle for the epicardium and anterior, lateral, inferior and septal for LV endocardium. Each region was divided into basal and apical segments. RV endocardial regions were apical, septal, inferior, free wall, RV outflow tract. (Fig.2,4, 7). VO was defined as 'adequate' epicardially when the vector was pointing inwards the myocardium and 'adequate' endocardially when pointing outwards the myocardium (Fig. 1). Each point was assigned to one of the different regions, the CF was registered and the vector was assessed as 'adequate' or not. In normal healthy regions, the voltage of each point was recorded.

## **Statistical analysis.**

Continuous variables are expressed as mean $\pm$ SD or median and interquartile range (IQR; 25<sup>th</sup>-75<sup>th</sup> percentile), depending on the normality of the distribution, as assessed by normal probability and quartile plots. Categorical variables are represented by percentages. Continuous variables were compared using nonparametric Kruskal-Wallis test. Comparison of the CF between regions and between LV accesses were assessed with a Wilcoxon two-sample test. Categorical variables were compared using the chi-square test. A ROC curve analysis was done to find the minimal contact for which a normal EGM (>1.5 mV) could be expected.

A p-value of <0.05 was considered statistically significant.

Statistical analysis testing was performed with SAS software version 9.2 (SAS

Institute, Cary, NC).

## **Results**

### **Patient characteristics**

Twenty one patients aged  $53 \pm 15$  years were included. 18 (82 %) were male and 17 (81%) had a previously implanted ICD. An underlying structural heart disease was

present in 18 patients, ischemic in 7 (39%), ARVC in 9 (50%), Brugada syndrome in 1 (5.5%) and myocarditis in 1 (5.5%). Patient characteristics are summarized in table 1.

A total of 8979 points were analyzed corresponding to 13 epicardial maps (4.155 points), 12 left ventricular endocardial maps (2.629 points) and 12 right ventricular endocardial maps (2.195 points). Six left ventricular endocardial maps were performed with a transseptal approach (TS) and six with a retroaortic approach (RAo).

### **Epicardial contact force**

Out of 4.155 analyzed points, 46% showed 'adequate' VO, ie. pointing inwards the myocardium. The median CF observed epicardially in case of 'adequate' VO was 8 g (4-13). CF was significantly greater (16 g (10-24),  $p < 0.0001$ ) when the VO was not 'adequate'. There was a significant difference in CF between different regions in the epicardium ( $p < 0.0001$ ). It was lower in the four apical regions. There was also a significant regional difference in the percentage of 'adequate' VO ( $p < 0.0001$ ). In the 4 apical regions, more than half of the vectors were not pointing inwards the

myocardium. In apical and basal left ventricular region, only 20% and 31% of VO were 'adequate' (Fig.2).

### **Left endocardial contact force**

During endocardial LV mapping, 92% of VO were 'adequate.' Median CF was greater than in the epicardium (15 g (8-25) vs 8 g (4-13);  $p < 0.001$ ). Overall, the median CF using a TS approach was higher than with a RAO approach (16 g (8-27) vs 14 g (8-22),  $p < 0.001$ ). High CF ( $> 40$ g) was recorded in 7% of TS points and 4% of RAO points. With TS,  $CF > 20$  g was recorded in 41% of the points and in 30% with RAO approach ( $p < 0.001$ ) (Fig. 3).

There was a significant difference in CF within the 8 segments of the LV using a trans-septal approach ( $p < 0.001$ ). CF was lower in the basal septum and basal anterior regions compared to other regions (Fig. 4).

There was also a significant difference in CF within the 8 segments of the LV using a retroaortic approach ( $p < 0.001$ ). CF was lower in the septum and basal anterior regions (Fig. 4). Highest contact was observed in basal lateral and basal inferior regions.

When comparing the impact of approach on CF by region, a significant difference was observed in apico-inferior and apico-septal region in favor of a trans-septal approach ( $p < 0.0001$  for both regions) (Fig.5).

### **Right endocardial contact force**

During endocardial RV mapping, 95% of VO were 'adequate'. Median CF was lower than in the LV endocardium and greater than in the epicardium (13 g (7-22) vs. 15g (8-25) ( $p < 0.0001$ ) vs. 8 g (4-13) ( $p < 0.0001$ ) respectively).

There was a significant difference in CF within the 5 regions of the RV endocardium ( $p < 0.0001$ ). CF was lower in the septal and apical regions and the highest CF was observed on the free wall (Fig. 6).

### **Potential amplitude according to the contact in the endocardium and the epicardium**

In the endocardium, the bipolar signal amplitude in healthy regions of the ventricles increased with CF. No further significant increase was observed after 15 g (Fig. 7).

Based on ROC curve, the best cut-off value for CF to obtain a signal amplitude > 1.5 mV in the endocardium was 11 g (sensitivity 68% and specificity 72%).

In the epicardium, the bipolar signal amplitude of healthy regions increased progressively with CF. No further significant increase was noted after 10 g (Fig. 7).

The best cut-off value to obtain a normal potential in the epicardium was 6 g (sensitivity 60% and specificity 58%).

### ***Discussion***

This study provides new insights into the characterization of contact force during endocardial and epicardial ventricular mapping:

- Important regional differences exist in CF according to the mapped region of the ventricle but as a rule, endocardial contact is higher than epicardial.
- During epicardial mapping, catheter orientation can be inadequately directed away from the myocardium in almost half of the mapping points, and this inadequate orientation is frequently associated with higher CF.
- During LV endocardial mapping, trans-septal approach is associated with higher CF than the retro-aortic approach, particularly in the apico-inferior and



apico-septal regions.

### **Epicardial contact**

Inadequate vector orientation in the epicardium may potentially decrease ablation efficacy and increase risks, by causing extra-cardiac lesions. The pericardial space is virtual, allowing to maintain the catheter in contact with the myocardium. Applying significant force to the catheter appears to direct the vector to the concavity of the pericardial space, potentially tenting the parietal pericardium. In an animal study, our group showed, (albeit with another contact catheter), that the total force was much higher when ablation was performed on the endocardium because of an increased axial force. On contrary, in the pericardial space, the lateral component of the force was more important (8). This could also explain the tendency for epicardial lesions to be shallower and wider than endocardial lesions. In that paper (8), we also showed that a CF of less than 10 g in the epicardium was sufficient to create a lesion and there was no clear difference in lesion depth or volume with increased CF. In addition, extracardiac lesions were also observed, particularly on lungs, when the force was not directed towards the myocardium. These data suggest that, in the pericardial

space, the force orientation may be more important, for both safety and efficacy, than the amount of applied force.

Mapping healthy epicardium, bipolar signal amplitude increased significantly with CF but not after 10g. The best cut-off value to have a normal EGM ( $>1.5$  mV) was 6 g. A small number of points of the curve may be altered because of the presence of fat which led to a smaller potential amplitude (9). Mizuno et al (10) have calculated a best CF cut-off value to obtain systolo-diastolic contact in the epicardium at 8 g, which is in the same range as our data. They also described that bipolar signal amplitude increased with respect to CF from weak ( $<3$ g) to modest (3-10g) and moderate (10-20) but not for strong forces ( $>20$ g).

When analyzing regional differences of CF in the epicardium, apical segments and the whole lateral region (LV) showed lower contact when VO was adequate and fewer 'adequate' VO. This could be explained by an anterior pericardial puncture. The steerable sheath is therefore important to stabilize and correct the orientation of the catheter.

## LV endocardial mapping

During LV endocardial mapping, most VO were 'adequate.' Here, the VO information seems to be less important, as the catheter may move freely within the cavity. The median CF of 15 g was significantly greater than in the epicardium. Our group (8) already showed a much higher CF ( $39 \pm 18$ g) from the endocardium in a sheep model because of increased axial force compared to the epicardium where lateral force was more predominant.

Mizuno H. et al reported (10) a mean CF during LV endocardium mapping of  $10.5 \pm 9.2$  g using a retro-aortic approach alone whereas, by combining it with trans-septal approach, the CF significantly increased to  $13.9 \pm 10.2$  g. We also reported an overall force of 16 g with trans-septal versus 14 g with retro-aortic route. The difference, although statistically significant, is quite modest. With a trans-septal route, 41% of the mapping points displayed a  $CF > 20$ g versus 30% with a retro-aortic approach.

When comparing regions with both approaches, basal anterior and basal septum LV appeared to have lower overall CF. As recently demonstrated in the left atrium (11), LV anatomy mapping can be more challenging in certain areas. No data are available yet on the relationship between CF and VT recurrence or LAVA elimination.

Tilz et al (oral communication AHA 2011) showed dividing the left ventricle in 11 regions and using retro-aortic approach, that the highest CF was in basal-inferior and basal-lateral areas, which is concordant with our findings.

When comparing the effect on CF of the two approaches by region, there is a significant difference in apical septum and apical inferior region in favor of a trans-septal approach.

To reach the septum and the anterior region of the LV by a retro-aortic route, the catheter needs 2 curves, which probably results in less contact. Tortuosity of the aorto-ileo-femoral arteries may also have an impact on CF. With a trans-septal approach, a steerable sheath may stabilize the catheter and increase CF. Shah et al. (12) showed on a porcine heart model that time to LV perforation was shorter when a sheath was used because of a greater contact. A large proportion of VT patients have ischemic cardiomyopathy with cardiovascular risk factors. Manipulation of an ablation catheter in the aorta or peripheral arteries may be hazardous in this setting. A trans-septal puncture is not without risk (13), however, and ultimately the approach must be tailored to the patient.

Okumura et al (14) and more recently Mizuno et al (10) reported the relationship between the catheter contact and the electrogram amplitude. When analyzing electrograms according to contact, we did not find any improvement in EGM amplitude after 15 g in the endocardium. We found 11g as a cut-off contact value to expect a normal EGM (>1.5 mV). Similarly, Mizuno et al. (10) found no improvement of EGM amplitude with strong force (>20g), whereas a weak CF resulted in low signal amplitude and a cut-off value for good systolo-diastolic contact in the LV endocardium of 8 g was calculated.

### **RV endocardial mapping**

RV endocardial mapping characteristics were similar to the LV with mostly 'adequate' VO and a greater CF compared with the epicardium. Overall CF in the RV was lower than in the LV but the difference, although statistically significant, was quite modest. There were significant differences in CF within the 5 RV regions. Surprisingly, in the apex, a lower CF of 9 g was observed. In clinical practice, the apex is usually easily accessible and a higher CF would be expected. This may be partially explained by the careful attention of the operator in relation to the risk of perforation, especially with

the use of a steerable sheath (12). The highest CF was observed in the free wall. The greater proportion of ARVC (9/12) in our cohort could explain this result with the free wall being one of the main regions of interest for mapping and ablation. The use of a sheath may also increase the CF in this region. A lower CF is usually expected in the basal free wall and posterior RVOT but in our study, the segmentation to 5 RV regions was unable to differentiate these regions. Notably, no data on regional CF in the RV has been reported in the literature.

### **Study limitations**

This paper describes CF and VO during ventricular endocardial and epicardial mapping only. Epicardial fat may decrease signal amplitude in spite of good contact, and this may have a modest effect on our cut-off value for CF required to identify a normal EGM in the epicardium. As the operators were blind to CF data during mapping, the catheter stability was assessed on classical parameters.

### **Conclusion**

Ventricular mapping demonstrates important regional variations in CF but in general,

CF is higher endocardially than epicardially where poor catheter orientation is associated with higher CF. Endocardially lower CF is observed in the basal septum and basal anterior regions. However, a trans-septal approach may lead to improved contact, particularly in the apico-septal and inferior regions. Use of CF catheter may optimize safety and efficacy during VT substrate mapping and ablation.

### **Disclosures**

Dr Sacher received speaking honorarium and consulting fees from St Jude Medical, Biosense Webster, Biotronik, Sorin Group, Medtronic.

Pr Jais received speaking honorarium and consulting fees from St Jude Medical, Biosense Webster.

### **REFERENCES**

1. Stevenson WG, Khan H, Sager P et al. Identification of reentry circuit sites during catheter mapping and radiofrequency ablation of ventricular tachycardia late after myocardial infarction. *Circulation* 1993;88:1647-70.

2. Marchlinski FE, Callans DJ, Gottlieb CD, Zado E. Linear ablation lesions for control of unmappable ventricular tachycardia in patients with ischemic and nonischemic cardiomyopathy. *Circulation* 2000;101:1288-96.
3. Jais P, Maury P, Khairy P et al. Elimination of local abnormal ventricular activities: a new end point for substrate modification in patients with scar-related ventricular tachycardia. *Circulation* 2012;125:2184-96.
4. Wittkamp FH, Nakagawa H. RF catheter ablation: Lessons on lesions. *Pacing and clinical electrophysiology : PACE* 2006;29:1285-97.
5. Zheng X, Walcott GP, Hall JA et al. Electrode impedance: an indicator of electrode-tissue contact and lesion dimensions during linear ablation. *Journal of interventional cardiac electrophysiology : an international journal of arrhythmias and pacing* 2000;4:645-54.
6. Sosa E, Scanavacca M, d'Avila A, Pilleggi F. A new technique to perform epicardial mapping in the electrophysiology laboratory. *Journal of cardiovascular electrophysiology* 1996;7:531-6.
7. Sosa E, Scanavacca M. Epicardial mapping and ablation techniques to control ventricular tachycardia. *Journal of cardiovascular electrophysiology*



2005;16:449-52.

8. Sacher F, Wright M, Derval N et al. Endocardial versus epicardial ventricular radiofrequency ablation: utility of in vivo contact force assessment. *Circulation Arrhythmia and electrophysiology* 2013;6:144-50.
9. Desjardins B, Morady F, Bogun F. Effect of epicardial fat on electroanatomical mapping and epicardial catheter ablation. *Journal of the American College of Cardiology* 2010;56:1320-7.
10. Mizuno H, Vergara P, Maccabelli G et al. Contact Force Monitoring for Cardiac Mapping in Patients with Ventricular Tachycardia. *Journal of cardiovascular electrophysiology* 2012.
11. Kumar S, Morton JB, Lee J et al. Prospective characterization of catheter-tissue contact force at different anatomic sites during antral pulmonary vein isolation. *Circulation Arrhythmia and electrophysiology* 2012;5:1124-9.
12. Shah D, Lambert H, Langenkamp A et al. Catheter tip force required for mechanical perforation of porcine cardiac chambers. *Europace : European pacing, arrhythmias, and cardiac electrophysiology : journal of the working*

groups on cardiac pacing, arrhythmias, and cardiac cellular electrophysiology of the European Society of Cardiology 2011;13:277-83.

13. Tzeis S, Andrikopoulos G, Deisenhofer I, Ho SY, Theodorakis G. Transseptal catheterization: considerations and caveats. Pacing and clinical electrophysiology : PACE 2010;33:231-42.

14. Okumura Y, Johnson SB, Bunch TJ, Henz BD, O'Brien CJ, Packer DL. A systematical analysis of in vivo contact forces on virtual catheter tip/tissue surface contact during cardiac mapping and intervention. Journal of cardiovascular electrophysiology 2008;19:632-40.

Disclaimer: The manuscript and its contents are confidential, intended for journal review purposes only, and not to be further disseminated.

**Table 1 : patients characteristics**

Patient	Chamber analysed	Gender	Age (yrs)	Cardiomyopathy	EF (%)	ICD
1	LV RAo, RV, EPI	F	39	ARVC	45	1
2	LV TS, EPI	M	64	CAD	20	1
3	LV RAo, RV, EPI	M	72	CAD	23	1
4	LV TS, EPI	M	72	CAD	25	1
5	LV RAo, EPI	M	57	CAD	30	1
6	RV, EPI	M	45	ARVC	45	1
7	RV, EPI	F	48	ARVC	48	1
8	LV RAo, EPI	M	32	MYOCARDITIS	45	1
9	RV, EPI	M	67	ARVC	65	1
10	LV TS, RV, EPI	M	60	ARVC	60	0
11	RV, EPI	M	28	ARVC	60	1
12	RV, EPI	M	60	ARVC	61	1
13	LV TS, EPI	M	53	CAD	49	1
14	LV TS	M	73	CAD	30	1
15	LV TS	M	62	CAD	25	1
16	LV RAo	F	61	NO	60	0
17	LV RAo	M	37	NO	65	0
18	RV	M	60	NO	64	1
19	RV	M	15	ARVC	62	0
20	RV	M	57	ARVC	65	1
21	RV	M	51	SB	65	1

**Figure 1:** A: example of 'inadequate' epicardial point with VO pointing outwards the myocardium. B: example of 'adequate' endocardial point with VO pointing outwards the myocardium (VO: vector orientation)

**Figure 2:** A. Contact force (CF) in the 8 regions of the epicardium when vector orientation is 'adequate', B. Percentage of 'adequate' vectors in the 8 regions of epicardium. (AA: apicoanterior, BA: basal anterior, ALV: apical left ventricle, BLV: basal left ventricle, AI: apicoinferior, BI: basal inferior, ARV: apical right ventricle, BRV: basal right ventricle. VO: vector orientation)

**Figure 3:** Percentage (%) of endocardial left ventricular points with CF > 20 g according to the LV approach, \*  $p < 0,001$  (TS: transseptal, RAo: retroaortic)

**Figure 4:** Contact force in the 8 regions of the left ventricle endocardium with transseptal approach (A) and retroaortic approach (B). (AA: apicoanterior, BA: basal anterior, AL: apicolateral BL: basal lateral, AI: apicoinferior, BI: basal inferior, AS: apical septum, BS: basal septum; TS transseptal, RAo retroaortic)

**Figure 5:** Comparison of contact force in the 8 regions of the left ventricle endocardium using either transseptal (TS) or retroaortic approach (RAo); \*  $p < 0,001$ ;

AA: apicoanterior, BA: basal anterior, AL: apicolateral BL: basal lateral, AI:

apicoinferior, BI: basal inferior, AS: apical septum, BS: basal septum.

**Figure 6:** Contact force (g) in the 5 regions of the right ventricle endocardium. ( A:

apex, S: septum, I: inferior, F: free wall, R: right ventricle outflow tract)

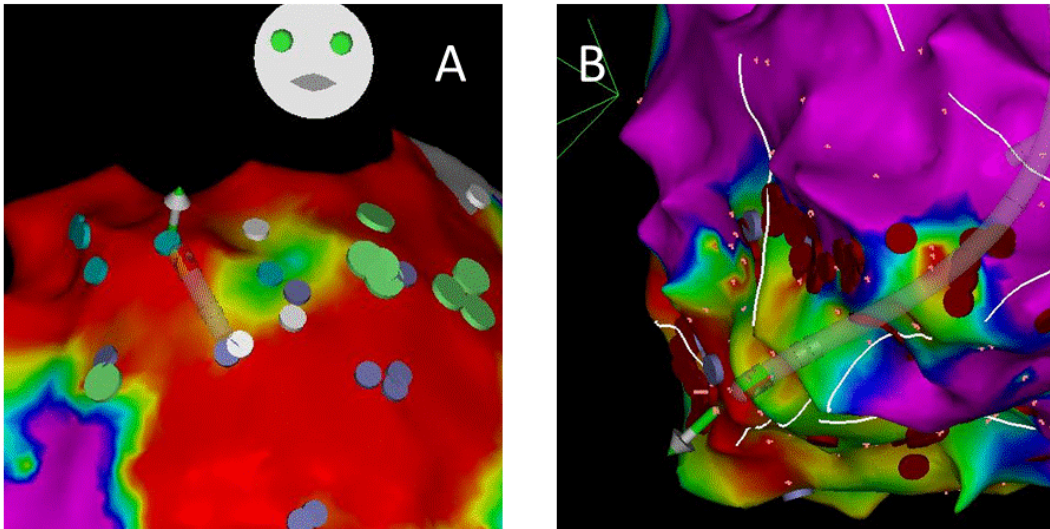
**Figure 7:** Bipolar signal amplitude in healthy regions of the ventricular endocardium

and the epicardium according to the contact force. (ENDO: endocardium (black);

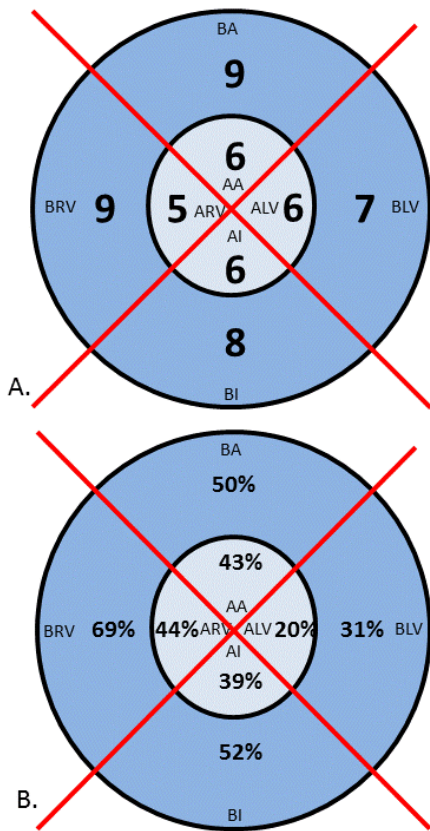
EPI: epicardium (white)).

Disclaimer: The manuscript and its contents are confidential, intended for journal review purposes only, and not to be further disclosed.

**Figure 1:** A: example of 'inadequate' epicardial point with VO pointing outwards the myocardium. B: example of 'adequate' endocardial point with VO pointing outwards the myocardium (VO: vector orientation)



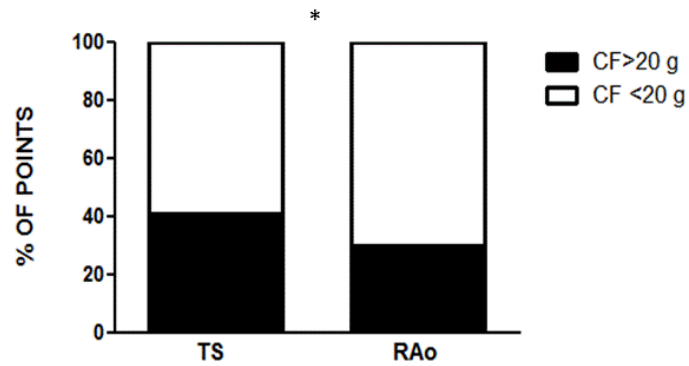
**Figure 2:** A. Contact force (CF) in the 8 regions of the epicardium when vector orientation is 'adequate', B. Percentage of 'adequate' vectors in the 8 regions of epicardium. (AA: apicoanterior, BA: basal anterior, ALV: apical left ventricle, BLV: basal left ventricle, AI: apicoinferior, BI: basal inferior, ARV: apical right ventricle, BRV: basal right ventricle. VO: vector orientation)



EPICARDIAL REGIONS	CF when VO is adequate (g)	Percentage of adequate vectors (%)	CF when VO is inadequate (g)
AA	6 (4-12)	43	13 (10-21)
BA	9 (5-14)	50	14 (9-22)
ALV	6 (4-16)	20	19 (12-27)
BLV	7 (4-15)	31	20 (14-26)
AI	6 (4-10)	39	17 (11-25)
BI	8 (5-13)	52	17 (11-25)
ARV	5 (3-13)	44	13 (9-19)
BRV	9 (4-12)	69	12 (9-17)

**Figure 3:** Percentage (%) of endocardial left ventricular points with CF > 20 g

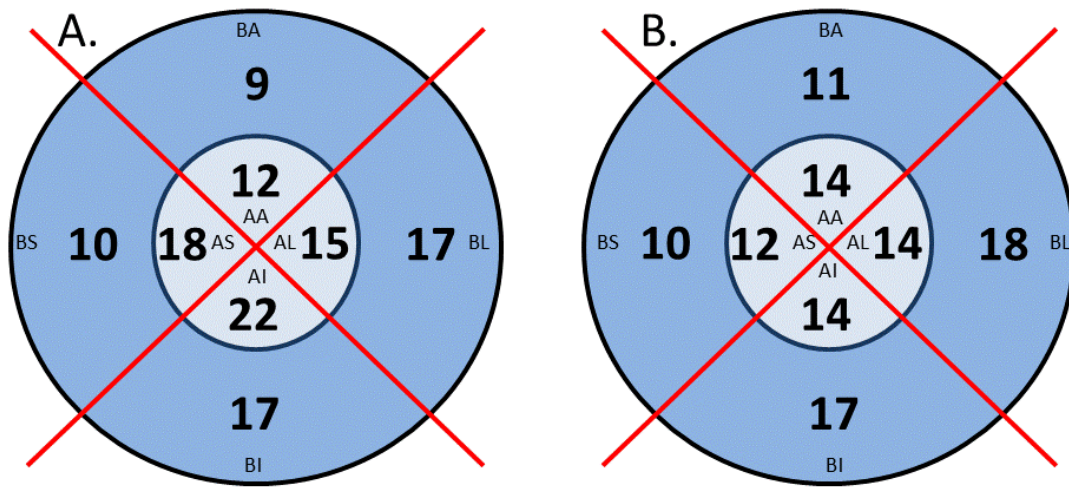
according to the LV approach, \*  $p < 0,001$  (TS: transseptal, RAo: retroaortic)



Disc  
confide  
only



**Figure 4:** Contact force in the 8 regions of the left ventricle endocardium with transseptal approach (A) and retroaortic approach (B). (AA: apicoanterior, BA: basal anterior, AL: apicolateral BL: basal lateral, AI: apicoinferior, BI: basal inferior, AS: apical septum, BS: basal septum; TS transseptal, RAo retroaortic)



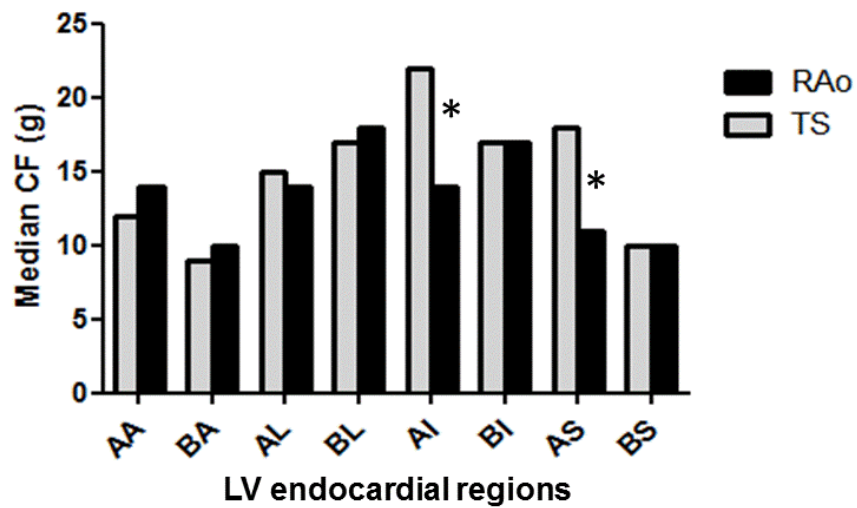
LV ENDOCARDIAL REGIONS	CF with TS (g)	CF with RAo (g)	p
AA	12 (5-20)	14 (6-20)	0.68
BA	9 (5-18)	11 (7-15)	0.52
AL	15 (9-27)	14 (7-25)	0.50
BL	17 (9-27)	18 (11-30)	0.33
AI	22 (11-31)	14 (8-21)	0.0001
BI	17 (9-27)	17 (9-24)	0.54
AS	18 (10-29)	12 (6-19)	0.0001
BS	10 (5-18)	10 (7-19)	0.35

**Figure 5:** Comparison of contact force in the 8 regions of the left ventricle

endocardium using either transeptal (TS) or retroaortic approach (RAo); \*  $p < 0,001$ ;

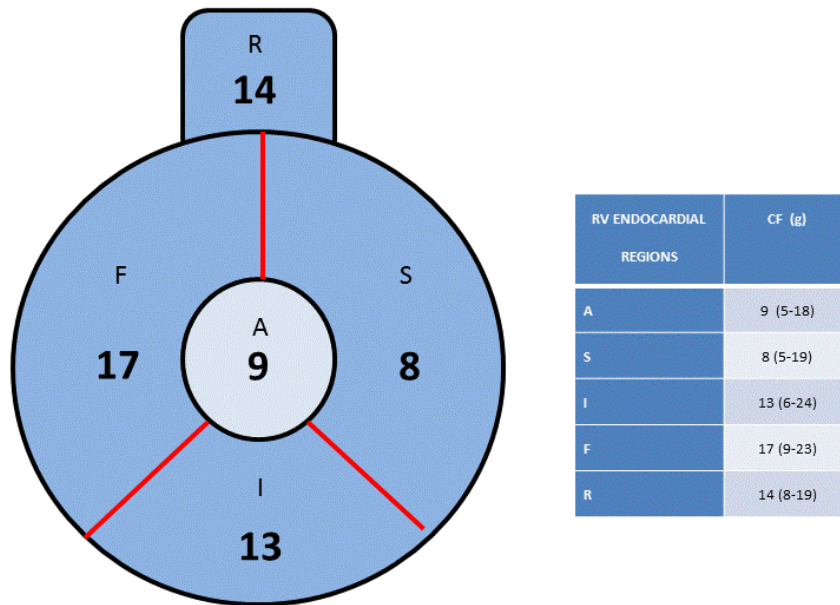
AA: apicoanterior, BA: basal anterior, AL: apicolateral BL: basal lateral, AI:

apicoinferior, BI: basal inferior, AS: apical septum, BS: basal septum.



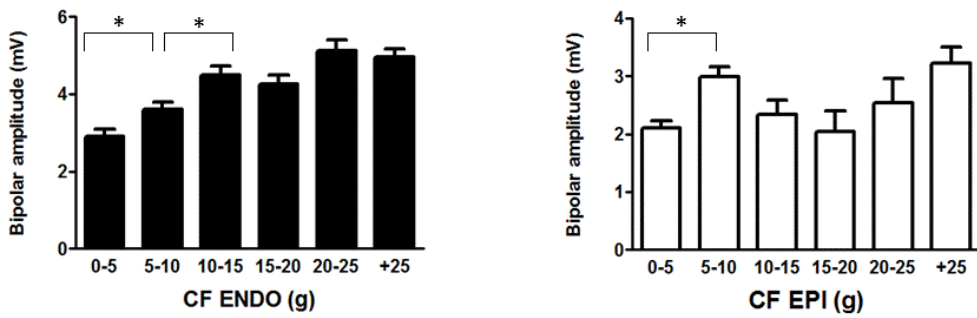
**Figure 6:** Contact force (g) in the 5 regions of the right ventricle endocardium. ( A:

apex, S: septum, I: inferior, F: free wall, R: right ventricle outflow tract)



Disclaimer:  
confidential, an-  
only, an-

**Figure 7:** Bipolar signal amplitude in healthy regions of the ventricular endocardium and the epicardium according to the contact force. (ENDO: endocardium (black); EPI: epicardium (white)).



Disclaimer:  
confidential, an-  
only, an-

## **D) Transcoronary ethanol ventricular tachycardia ablation in the modern electrophysiology**

Publié: Heart Rhythm 2008 Jan;5(1):62-8.

### *1) Etude*

Chez certains patients, l'ablation par RF tant endocardique qu'épicardique ne permet pas d'atteindre la partie critique du circuit de TV. Au début des années 90, alors que la technologie de l'ablation percutanée par RF en était à ses balbutiements (pas de cathéter irrigué, pas de système de navigation 3D, pas d'accès épicaire percutané), certains électrophysiologistes ont utilisé l'injection d'éthanol intra-coronaire afin d'éliminer les tachycardies ventriculaires<sup>5-8</sup>. Avec le développement technologique des années 2000, cette approche n'était plus réellement utilisée. Cependant malgré les outils technologiques en notre possession, il est parfois difficile d'atteindre des sites dans la profondeur du myocarde ventriculaire et plus particulièrement dans le septum. Ce travail s'intéresse aux ablations de TV par alcoolisation intra-coronaire réalisées entre 2000 et 2007 au Brigham and Women's Hospital de Boston.

Tout d'abord ces procédures représentent 1.4% (9 patients, 55 ±9 ans, FEVG= 23 ±8%) des ablations de TV réalisées dans ce centre. Elles ont toutes étaient réalisées par un angioplasticien habitué à l'alcoolisation septale (mycardiopathies hypertrophiques). Cet angioplasticien était assisté d'un électrophysiologiste. Les patients avaient une mycardiopathie ischémique (n=6) ou dilatée à coronaires saines (n=3), une cicatrice septale pour la majorité (n=7) et au moins un échec d'ablation par RF (2.2 ±0.8). La TV ciblée (TV clinique) a été éliminée chez 8/9 patients. A 2 ans, 4/6 patients n'avaient pas récidivé. Par contre, 3 patients étaient décédés témoignant du caractère sévère de la mycardiopathie sous jacente.

## *2) Implications*

Cette approche n'est qu'exceptionnellement nécessaire et ne se conçoit qu'après échec médicamenteux et de l'ablation par RF pour traiter des TV récidivantes. Toutefois cette étude montre qu'elle reste une option, à l'heure actuelle, chez les patients avec un isthme responsable de la TV ancré dans la profondeur du myocarde en particulier septal. Les indications doivent être évaluées minutieusement car il s'agit de créer une nécrose myocardique chez des patients ayant déjà une altération du myocarde. Par ailleurs, il existe un risque de bloc atrio-ventriculaire complet lorsqu'on cible une première septale mais ces patients sont déjà implantés d'un défibrillateur.

# Transcoronary ethanol ventricular tachycardia ablation in the modern electrophysiology era

Frédéric Sacher, MD, Piotr Sobieszczyk, MD, Usha Tedrow, MD, Andrew C. Eisenhauer, MD, Michael E. Field, MD, Andrew Selwyn, MD, Jean-Marc Raymond, MD, Bruce Koplan, MD, Laurence M. Epstein, MD, William G. Stevenson, MD, FHRS

*From the Brigham and Women's Hospital, Harvard Medical School, Boston.*

**BACKGROUND** Radiofrequency catheter ablation for ventricular tachycardia (VT) may be unsuccessful when critical portions of the circuit cannot be interrupted with either endocardial or epicardial radiofrequency application.

**OBJECTIVE** We sought to investigate whether transcoronary ethanol ablation (TCEA) can be used as a therapy for patients with VT who have failed medications and radiofrequency ablation in the modern era.

**METHODS** Nine patients (7 men,  $55 \pm 9$  years old, left ventricular ejection fraction  $23\% \pm 8\%$ ,  $2.2 \pm 0.8$  failed VT ablations) with at least 1 unsuccessful attempt at radiofrequency catheter ablation for symptomatic VT at our institution between 2000 and May 2007 underwent TCEA. The majority of patients had an ischemic cardiomyopathy (67%), and all patients had VT due to scar-related reentry. In the 7 patients with VT involving a septal scar, a septal perforator artery was a suitable target in 5 patients, whereas in

the remaining patients, a distal branch of the circumflex and the conus branch of the right coronary artery were targeted. In the 2 patients in whom VT involved an inferior scar, a branch of the posterior descending artery was targeted.

**RESULTS** Acute success was obtained in 56% of patients (89% for clinical targeted VT). During a mean follow-up of  $29 \pm 23$  months, 3 deaths occurred and 67% of the patients were free of recurrence.

**CONCLUSION** TCEA may represent an option in patients with refractory VT in whom radiofrequency ablation fails, especially in cases of septal scar in which failure is thought to be caused by inability to provide adequate lesion depth.

**KEYWORDS** Ventricular tachycardia; Ablation; Transcoronary ethanol ablation

(Heart Rhythm 2008;5:62–68) © 2008 Heart Rhythm Society. All rights reserved.

## Introduction

Endocardial radiofrequency (RF) catheter ablation (RFCA) has been shown to be a successful therapy for drug resistant ventricular tachycardia (VT) related to a subendocardial circuit.<sup>1–3</sup> However, up to 5% to 15% of VT circuits are located epicardially or intramurally<sup>4,5</sup> and are therefore not accessible using this approach. A nonsurgical subxiphoid technique to access the pericardial space<sup>4–6</sup> has been developed to target epicardial circuits, but deep intramural circuits remain challenging to eliminate and the percutaneous epicardial approach is difficult and sometimes not possible in cases of prior cardiac surgery.<sup>7</sup>

Intracoronary injection of ethanol has been shown to be an effective alternative ablative technique for the treatment of refractory VT in the early 1990s, both experimentally<sup>8,9</sup> and clinically.<sup>10–13</sup> Since then, technology for mapping and ablation has improved (irrigated-tip catheters, electroanatomical mapping) and ablation is now considered in a

broader population of patients. However, despite these advances, there are a number of patients in whom VT cannot be eliminated with an endocardial or epicardial RFCA approach. We reviewed all transcoronary ethanol ablation (TCEA) performed between 2000 and May 2007 to determine the efficacy and safety of such a procedure in the modern electrophysiology era.

## Methods

### Patient selection

Patients who had undergone at least 1 unsuccessful attempt at RFCA for symptomatic monomorphic VT at Brigham and Women's Hospital between 2000 and May 2007 were considered for TCEA. Patients had to have an area of scar with frequent monomorphic VT coming from this area. All patients had given written informed consent.

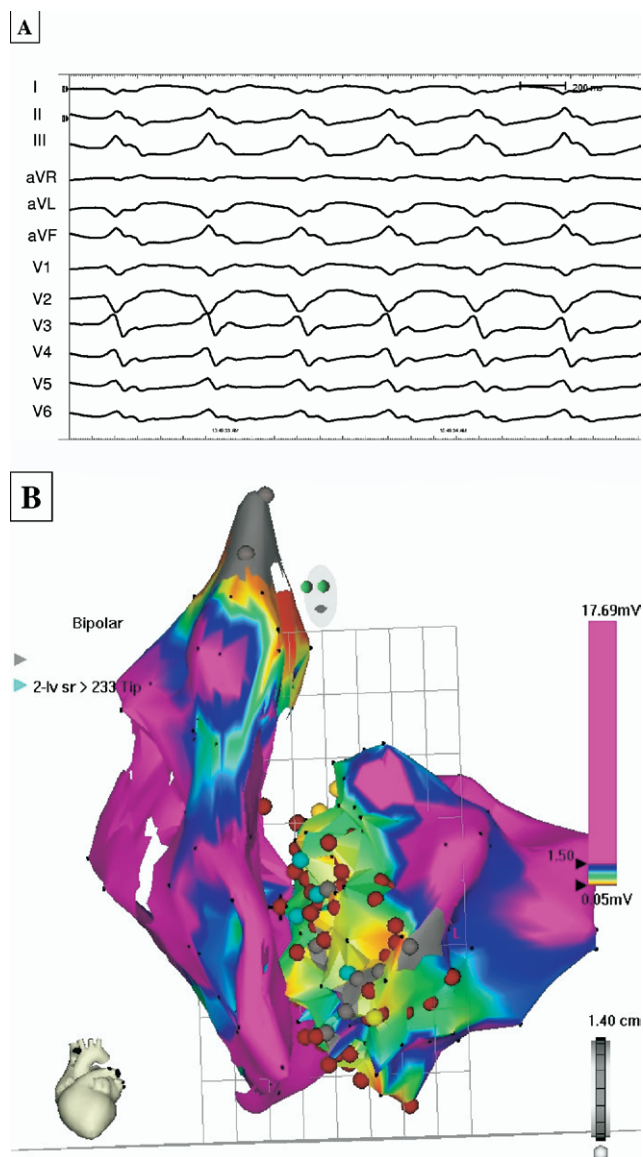
### Procedure

#### Preprocedural investigations

Transthoracic echocardiography was performed before the procedure in all patients to assess left ventricular (LV) function, localize areas of previous infarction, and exclude the presence of LV thrombus. To predict the likely target location for ablation, we used a combination of (1) mor-

Dr. Sacher is supported by a grant from the French Federation of Cardiology. **Address reprint requests and correspondence:** Dr. Frédéric Sacher, Cardiac Arrhythmia Unit, Cardiovascular Division, Brigham and Women's Hospital, 75 Francis Street, Boston, Massachusetts 02115. E-mail address: frederic.sacher@chu-bordeaux.fr. (Received July 23, 2007; accepted September 12, 2007)





**Figure 1** A: Twelve-lead ECG of the targeted VT. Note the inferior axis with the LBBB and the transition in V2-V3 in favor of a superoseptobasal exit for the VT. B: Left anterior oblique view of a voltage map of the right and left ventricle (in the same patient) localizing the scar in the septum. RF attempts (dark red dot) were not effective. ECG = electrocardiogram; LBBB = left bundle branch block; RF = radiofrequency; VT = ventricular tachycardia.

phological analysis of electrocardiogram (ECG) characteristics during VT<sup>14</sup> (Figure 1A), (2) location of previous myocardial infarction or scar from noninvasive imaging data and low voltage areas on electroanatomical mapping (Figure 1B), and (3) data such as pace mapping and entrainment from previous endocardial VT mapping.

### Transcatheter ethanol ablation

All patients were studied in the electrophysiology laboratory in the postabsorptive state, and all antiarrhythmic drugs had been discontinued with the exception of amiodarone.

In all patients, at least 1 quadripolar electrode catheter was positioned via a 6F femoral venous sheath in right

ventricular apex. In patients without incessant VT, programmed stimulation using up to 3 extrastimuli from 2 right ventricular sites was performed for VT induction.

The operators for all procedures included both an electrophysiologist and an interventional cardiologist trained in the technique of transcatheter ethanol ablation for hypertrophic cardiomyopathy.

Once clinical VT was induced, attempts were made to terminate the tachycardia by overdrive pacing or, if necessary, cardioversion. Selective coronary angiography was then performed via a 6F femoral arterial sheath. Patients were heparinized, and the activated clotting time was maintained at >250 seconds. The ostium of the relevant coronary artery was selectively intubated using an angioplasty wire (Graphix Intermediate, Boston Scientific Corporation, Natick, Massachusetts) (Figure 2A). An 8-mm over-the-wire balloon sized to be slightly larger than the angiographic diameter of the target vessel (HighSail, Guidant Corporation, Santa Clara, California) was deployed in the ostium of the target branch vessel and fully inflated to prevent backwash of ethanol into other coronary vessels and verified using contrast injection after guidewire removal. In 2 patients, a sonography contrast agent (Optison, Amersham Health, Buckinghamshire, England) was injected in the targeted coronary artery and its territory verified by echocardiography (Figure 2B). Next the VT was reinduced, and with the balloon fully inflated, iced saline was injected (2 to 3 ml) via the central lumen in an attempt to terminate VT. If the VT stopped during iced saline infusion (Figure 2C), the artery was defined as suitable for ethanol injection. If the VT continued, another branch was targeted. Sites that were deemed feasible were those in which VT termination had occurred with iced saline injection without associated complication, such as PR prolongation or atrioventricular block, and that were within an arterial branch thought to be sufficiently distal and unlikely to cause significant collateral ventricular damage. Once an appropriate target site had been identified, 1 ml of sterile absolute alcohol was injected with the balloon inflated for 10 minutes. After deflation of the balloon, contrast was injected to assess target vessel patency. If perfusion was present, additional ethanol was infused and the balloon inflation maintained for 10 minutes after that infusion. This could be repeated up to a maximum of 5 ml of ethanol in 1 artery.

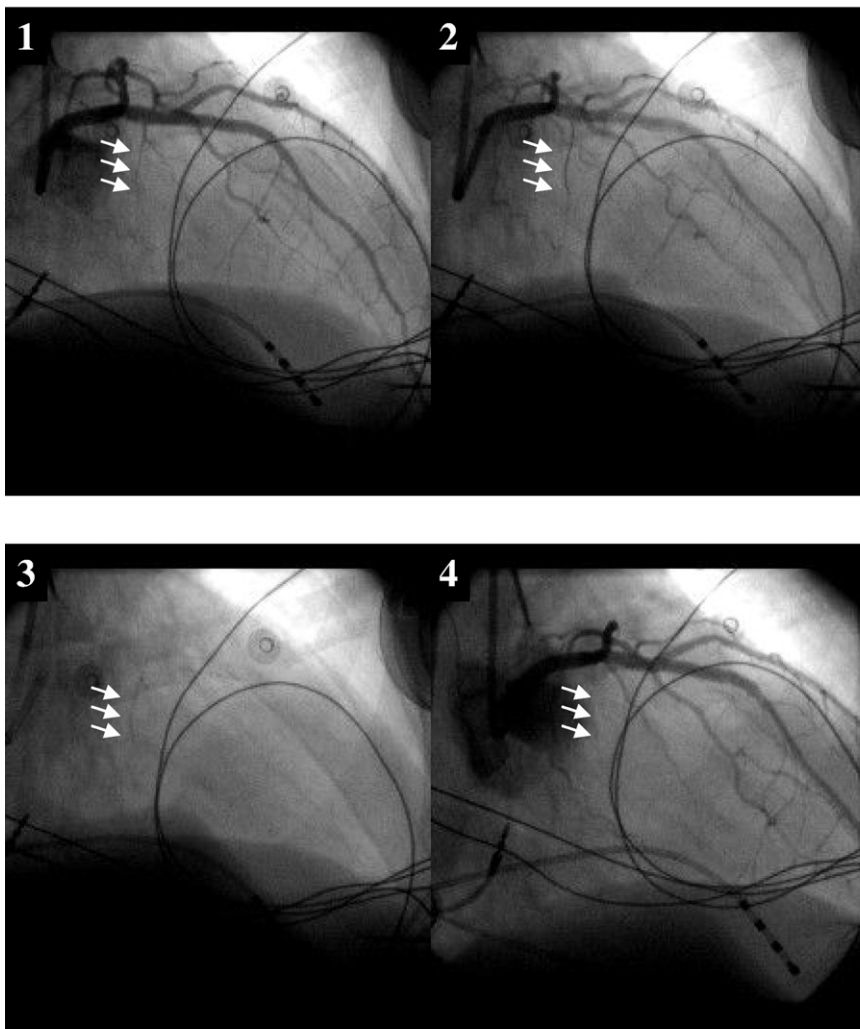
### End points

The primary end point was an acutely successful ablation defined as termination of VT during chemical ablation followed by failure of inducibility at the end of the case using the pacing techniques described above. Secondary end points included all-cause mortality obtained by the chart review and social security death index and recurrent VT during the follow-up period based on hospital admission and implantable-cardioverter defibrillator (ICD) interrogation performed at routine follow-up visits.

Serum creatine kinase MB (CPK-MB) and/or troponin I was measured 12 hours after each procedure, and transtho-



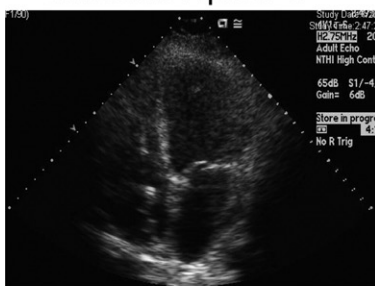
## Panel A



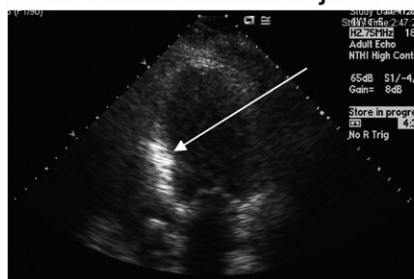
**Figure 2 A:** (1) Coronary angiograms before any injection showing the potential target. After having placed the guidewire in the first septal perforator (2), the balloon was inflated to occlude the vessel (3) before any ethanol was injected to be sure there would not be any ethanol back-flush. (4) Coronary angiogram after ethanol injection: the branch of the first septal perforator is occluded. **B:** Injection of echocontrast agent in the septal to localize the area vascularized by this branch. Note the enhancement after ethanol injection. **C:** During iced saline infusion, the ventricular tachycardia terminates without any premature ventricular contraction. Note the biventricular paced rhythm after ventricular tachycardia termination: the patient had heart block before the procedure.

## Panel B

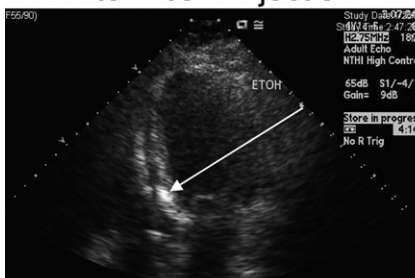
### Baseline Apical 4



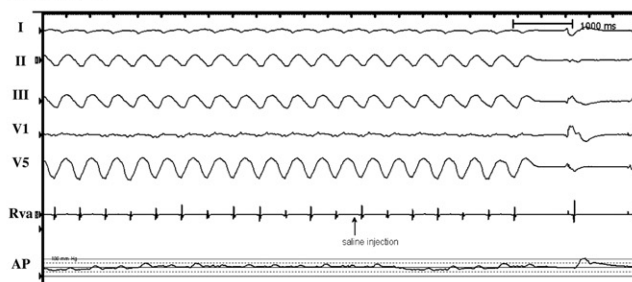
### After Echocontrast Injection



### After ETOH injection



## Panel C



racic echocardiography was performed within 5 days after the procedure.

### Statistical analysis

Demographic and electrophysiological data are presented as mean and standard deviation. Data given in parentheses are minimal and maximal values. LV ejection fraction (LVEF) values before and after the procedure were compared with a paired *t* test.

## Results

### Patient characteristics

A total of 9 consecutive patients (7 male,  $55 \pm 9$  years old, mean LVEF  $23\% \pm 8\%$ ) had transcatheter ethanol ablation at our institution from 2000 to May 2007. During the same period of time, a total of 632 RFCA for VT were performed. In all patients selected for TCEA, a mean of  $4.6 \pm 1.3$  antiarrhythmic drugs and  $2.2 \pm 0.8$  RFCA procedures (3 had epicardial ablation) before TCEA had failed.

Six patients had ischemic heart disease with remote ( $>6$  months) myocardial infarction, and 3 had idiopathic dilated cardiomyopathy (iDCM). Clinical patient characteristics are summarized in Table 1. All patients had an ICD in situ at presentation.

### VT characteristics and artery location

Targeted clinical VT (mean cycle length  $436 \pm 83$  ms) had right bundle branch block morphology (2 left superior, 1 right inferior axis) in 3 patients, LBBB morphology in 5 patients (1 right superior, 3 left superior axis, 1 with a  $+10^\circ$  axis) and indeterminate in 1 patient. There were a mean of  $2.9 \pm 1.2$  VTs inducible during the procedure. All patients had an electroanatomical voltage map (CARTO, Biosense Webster Diamond Bar, CA) of the right ventricle ( $n = 4$ ) and/or left ventricle ( $n = 9$ ) before TCEA. Left ventricular septal and inferior scars were predominant (Table 1).

The targeted coronary arteries (Table 2) were (1) one or more septal perforators in 5 patients, (2) a distal branch of the posterior descending artery (PDA) in 2 (one via a saphenous graft), (3) a distal branch of the native circumflex in 1, and (4) the conus branch from the right coronary artery in 1. In 2 patients, the initially chosen branch artery could not be reached so an adjacent one was cannulated. Because of transient heart block during iced saline infusion, another artery was targeted in patient 7.

### Intracoronary artery alcohol ablation

Absolute ethanol (96%) was injected intracoronary (1 to 8 ml per patient with a mean of  $3.4 \pm 2.6$  ml and a median of 2.3 ml). In 5 patients, injection was followed by ST elevation with a mean maximal ST elevation of  $0.16 \pm 0.30$  mV. Mean CPK-MB and Troponin I 12 hours after the procedure were  $111 \pm 102$  ng/ml (normal reference value 30 to 293 ng/ml) and  $22.8 \pm 13.0$  ng/ml (10.0 to 38.5 ng/ml). LVEF postprocedure was not significantly different from baseline LVEF ( $22\% \pm 8\%$  vs.  $23\% \pm 8\%$  respectively,  $P = .65$ ). Acute success (no inducible monomorphic VT) was

obtained in 5 patients. Three patients had inducible monomorphic VT that was different from the VT targeted for transcatheter ablation (modified substrate). In only 1 patient, the targeted VT remained inducible (failure).

Three patients had complications: 2 had transient severe hypotension after ethanol injection (with a total amount of 6 ml and 5 ml of ethanol). One patient had bilateral groin hematomas that required blood transfusion.

### Follow-up

During a mean follow-up of  $29 \pm 23$  months, 4 patients remained free of all VT and 1 patient had recurrence but with a dramatic decrease in VT episodes (from 5 episodes the week before the procedure to  $<2$  per year after). Of the remaining patients, 3 patients died of refractory heart failure (mean LVEF  $17\% \pm 7\%$ )  $27 \pm 25$  days after the procedure (with 1 patient continuing to have frequent episodes of VT). Another patient had a heart transplant 1 month after the procedure because of recurrent frequent VT.

## Discussion

This series represents the largest to date of the use of TCEA in patients with refractory VT after failed RF. The cytotoxic effect of ethanol has been used elsewhere therapeutically to destroy renal tumors,<sup>15,16</sup> to ablate the AV node,<sup>10,17</sup> and to reduce septal thickness in patients with hypertrophic cardiomyopathy. Case reports and animal studies have reported its use in treatment of VT previously.<sup>10,11,13,18–20</sup> This approach was first described experimentally by Inoue et al.<sup>8</sup> They reported that ethanol at volume of 0.4 to 2 ml produced transmural necrosis in  $>80\%$  of dogs. In humans, postmortem and posttransplant heart examination have revealed a near transmural dense infarction and a minimal layer of surviving subendocardium with a complete disruption of the arterial wall integrity of the injected coronary branch.<sup>11,19</sup>

Our study shows that TCEA offers a potential therapy for refractory VT in the modern electrophysiology era. At a large VT referral center, the need for such a procedure is infrequent (1.4%). In those cases in which it constitutes the only remaining option before cardiac transplant, it may be performed with a moderate degree of efficacy. This procedure may be most applicable in patients in whom the VT circuits are deep intramyocardial (as may occur in patients with VT involving the septum).

Before injecting pure ethanol in the coronary artery (with an irreversible effect), proving the relationship between the artery branch and a critical aspect of the VT circuit with a reversible maneuver such as cold saline injection or interruption of intracoronary blood flow with balloon inflation is mandatory. Brugada et al. terminated tachycardia by interrupting blood flow to the suspected arrhythmogenic area<sup>21</sup> or used cold saline to interrupt tachycardia.<sup>22</sup> Friedman et al.<sup>23</sup> injected antiarrhythmic drugs in the targeted coronary artery branch during VT.

The use of myocardial contrast echocardiography, utilized in 2 of our patients, can also help to delineate the target

**Table 1** Population characteristics before transcatheter ethanol ablation

Patients	Age, gender	LVEF (%)	Type of CMP	Scar location	VT frequency	Number of previous ablation attempt	Epicardial ablation	Failed AAD
1	59 F	10	CAD	Septum	>1/week	3	0	5
2	57 M	15	CAD	Septum	Incessant	1	0	5
3	63 F	25	iDCM	Septum, LVOT	2/month	2	1	5
4	51 M	20	CAD	Septum	>1/week	2	0	5
5	51 M	35	CAD	Inferior wall	>1/week	2	1	3
6	47 M	25	CAD	Inferior wall, Septum	>2/month	1	0	3
7	63 M	34	iDCM	Septum	.>2/month	3	0	5
8	48 M	20	iDCM	Inferior wall	Arrhythmic storm	3	1	5
9	76 M	20	CAD	Septal and right and left inferior wall	Arrhythmic storm	3	0	3

AAD = anti-arrhythmic drug; CAD = coronary artery disease; CMP = cardiomyopathy; iDCM = idiopathic dilated cardiomyopathy; LVEF = left ventricular ejection fraction; LVOT = Left ventricular outflow tract; VT = ventricular tachycardia.

area supplied by the branch vessel to ensure that the infarction will be selective.<sup>24</sup> Another elegant way to verify electrophysiologically that the putative target branch supplies the VT circuit is to place a dedicated electrophysiology catheter (Pathfinder mapping catheter, Cardima, Inc., Fremont, California)<sup>19</sup> or a high-torque floppy angioplasty guidewire connected to a single channel of a conventional electrophysiology amplifier<sup>20</sup> in the suspected artery. This technique allows for mapping of diastolic potentials and performance of entrainment mapping and pace mapping from inside the coronary artery. Critical isthmuses may then be identified as for standard endocardial VT procedure.<sup>25</sup> However, there is the potential for electrical noise and artifact with these types of recordings that may obscure the low voltage potentials characteristic of scar-related VTs.

## Safety

The use of angioplasty guidewires in percutaneous revascularization of coronary artery stenosis is not without risk. It is important that, as in the present study, the coronary artery cannulation and infusion procedure be performed by an experienced coronary interventionist. The risk of coronary artery perforation has been reported at 0.4% in the context of angioplasty in complex coronary artery disease.<sup>26</sup>

The development of permanent AV block after intracoronary alcohol injection is a well-recognized complication,<sup>11,22</sup> even after prior iced saline injection. This complication did not arise in any patient in the present study, although we had 1 patient with transient AV block after iced saline injection in a first septal perforator, which led us to change our targeted artery.

The use of intracoronary alcohol injection has the potential to cause ventricular myocardial damage leading to worsening of symptoms of heart failure.<sup>19</sup> Although global LVEF was not significantly different before and after the procedure in our patients, which was also the case in the series published by Kay et al,<sup>11</sup> this does not exclude an adverse impact on ventricular function. To reduce adverse effects, the target areas chosen are thought to be scar or infarct areas that likely contain small bundles of surviving

myocardium within dense scar or at border zones that do not contribute substantially to contractility. Ablation of areas containing Purkinje fibers could theoretically also aggravate ventricular dysfunction by increasing mechanical dyssynchrony. We also used subselective coronary cannulation of relatively small branches (discussed later). Despite these precautions, there was a substantial mortality rate of 33% during follow-up. Use of this procedure in the sickest patients, in whom other therapies are failing, likely contributes to the high mortality rate. The 3 patients who died had low ejection fractions with recurrent episodes of congestive heart failure before the procedure. In this setting, the increasing number of VT may have been a marker of terminal cardiac failure. But it is also possible that ethanol infusion may have adversely modified the substrate or contributed to further depression of ventricular function.

The amount of ethanol to optimize the efficacy/safety ratio is not known. One study<sup>20</sup> empirically used 1 ml of ethanol without assessing artery occlusion; all 5 patients with ethanol infusion were alive but their mean EF was 46%. Furthermore, whether sufficient ethanol to produce total occlusion of the targeted artery, as is performed for hypertrophic cardiomyopathy ethanol ablation, and was pursued in our series, is required remains uncertain. Based on our and prior studies,  $\leq 2$  ml per branch is often used<sup>11,27,28</sup> (median 2.25 ml in our series). Because of the concern for potential myocardial damage, we used highly selective intracoronary ethanol injection in the smallest arterial branch in which iced saline injection resulted in VT termination. We also used balloon occlusion to prevent reflux, and injected the smallest amount of ethanol that occluded the targeted artery. It is possible that highly selective injections will not ablate sufficient tissue to control the arrhythmia in some patients, especially if the branch is too distal and is not the only supply to the critical reentry circuit isthmus.

When to perform a transcatheter ethanol ablation?

With the efficacy and safety of modern RFCA, and the potential for myocardial injury, we believe that TCEA

**Table 2** Transcatheter ethanol ablation characteristics and patient outcome

Patients	Number of inducible VT	Targeted VTCL (ms)	Morphology and axis of the targeted VT	Number of branches tried with saline	Number of unreachable branch	Coronary artery injected	Total amount of ethanol (ml)	Acute outcome	Recurrence of clinical VT	Vital status
1	3	480	RBBB/left superior axis	2	0	First and second septal perforators	3 ml × 2 arteries	Modified substrate	Yes	Dead
2	3	570	LBBB/inferior axis	2	0	Septal perforators × 2	1 ml and 2 ml	Success	No	Dead
3	3	530	RBBB/left superior axis	2	0	First septal perforator	1	Modified substrate	No	Dead
4	2	450	LBBB/right superior axis	2	0	Two distal septal perforators	4 ml × 2 arteries	Success	No	Alive
5	5	325	LBBB/left superior axis	1	0	First septal perforator	2	Success	No	Alive
6	1	450	LBBB/+10° axis	1	0	Left circumflex branch	3	Success	No	Alive
7	4	395	Undetermined/inferior axis	2	1	Conal branch from the RCA	4	Failure	Yes	Alive
8	2	340	RBBB/superior axis	2	1	Posterolateral branch distal to the PDA	5	Modified substrate	No but frequent other VT leading to cardiac transplant	Alive
9	3	380	LBBB/superior axis	1	0	Distal PDA via a saphenous graft	2	Success	No	Alive

LBBB = left bundle branch block; PDA = posterior descending artery; RCA = right coronary artery; RBBB = right bundle branch block; VT = ventricular tachycardia; VTCL = ventricular tachycardia cycle length.

should be a last resort for control of recurrent VT in patients who have failed antiarrhythmic drug therapy and RFCA. In the case of failed endocardial VT ablation, subxiphoid pericardial access for epicardial VT ablation should be considered, but may fail to eliminate intramural arrhythmia foci, a concern particularly in the septum. Epicardial access may be difficult, or not easily attainable in patients with previous cardiac surgery.<sup>7</sup> In patients with low EF who are not candidates for cardiac transplantation, TCEA may be the only remaining tool for controlling symptoms after failed RF ablation even if it does not improve the prognosis.

Other methods to deal with difficult ablation targets are in development. Direct intramyocardial ethanol<sup>29,30</sup> injection with a needle has been reported in animals but was limited by lesion depth and safety. Currently under development is an irrigated needle that via the endocardium can be plunged into the myocardial wall to allow RF delivery directly in the area of interest.<sup>31</sup>

**Limitations**

This is a retrospective study of an evolving technique (use of myocardial contrast imaging only in 2 patients, various amount of ethanol used). The study was conducted at a large VT referral center, introducing referral biases such that the population is highly selected.

**Conclusion**

In the modern catheter ablation era, TCEA is rarely used (1.4%). This procedure is associated with a moderate degree of efficacy with potential complications. In this sick patient population, the mortality was 33% during a mean follow-up of 29 ± 23 months. However in VTs refractory to endocardial and/or epicardial ablation, it may be a life-saving consideration for deep intramural and/or septal VTs.

**References**

- O'Callaghan PA, Poloniecki J, Sosa-Suarez G, et al. Long-term clinical outcome of patients with prior myocardial infarction after palliative radiofrequency catheter ablation for frequent ventricular tachycardia. *Am J Cardiol* 2001;87:975-9; A4.
- Borger van der Burg AE, de Groot NM, van Erven L, et al. Long-term follow-up after radiofrequency catheter ablation of ventricular tachycardia: a successful approach? *J Cardiovasc Electrophysiol* 2002;13:417-423.
- Segal OR, Chow AW, Markides V, et al. Long-term results after ablation of infarct-related ventricular tachycardia. *Heart Rhythm* 2005;2:474-482.
- Sosa E, Scanavacca M, D'Avila A, et al. Endocardial and epicardial ablation guided by nonsurgical transthoracic epicardial mapping to treat recurrent ventricular tachycardia. *J Cardiovasc Electrophysiol* 1998;9:229-239.
- Sosa E, Scanavacca M, d'Avila A, et al. Nonsurgical transthoracic epicardial catheter ablation to treat recurrent ventricular tachycardia occurring late after myocardial infarction. *J Am Coll Cardiol* 2000;35:1442-1449.
- Schweikert RA, Saliba WJ, Tomassoni G, et al. Percutaneous pericardial instrumentation for endo-epicardial mapping of previously failed ablations. *Circulation* 2003;108:1329-1335.
- Soejima K, Couper G, Cooper JM, et al. Subxiphoid surgical approach for epicardial catheter-based mapping and ablation in patients with prior cardiac surgery or difficult pericardial access. *Circulation* 2004;110:1197-1201.
- Inoue H, Waller BF, Zipes DP. Intracoronary ethyl alcohol or phenol injection ablates aconitine-induced ventricular tachycardia in dogs. *J Am Coll Cardiol* 1987;10:1342-1349.
- Haines DE, Wayne JG, DiMarco JP. Intracoronary ethanol ablation in swine: effects of ethanol concentration on lesion formation and response to programmed ventricular stimulation. *J Cardiovasc Electrophysiol* 1994;5:422-431.
- Brugada P, de Swart H, Smeets J, et al. Transcatheter chemical ablation of atrioventricular conduction. *Circulation* 1990;81:757-761.



11. Kay GN, Epstein AE, Bubien RS, et al. Intracoronary ethanol ablation for the treatment of recurrent sustained ventricular tachycardia. *J Am Coll Cardiol* 1992;19:159–168.
12. Nellens P, Gurosoy S, Andries E, et al. Transcoronary chemical ablation of arrhythmias. *Pacing Clin Electrophysiol* 1992;15:1368–1373.
13. Okishige K, Andrews TC, Friedman PL. Suppression of incessant polymorphic ventricular tachycardia by selective intracoronary ethanol infusion. *Pacing Clin Electrophysiol* 1991;14:188–195.
14. Josephson ME, Callans DJ. Using the twelve-lead electrocardiogram to localize the site of origin of ventricular tachycardia. *Heart Rhythm* 2005;2:443–446.
15. Ellman BA, Parkhill BJ, Curry TS 3rd, et al. Ablation of renal tumors with absolute ethanol: a new technique. *Radiology* 1981;141:619–626.
16. Ellman BA, Parkhill BJ, Marcus PB, et al. Renal ablation with absolute ethanol. Mechanism of action. *Invest Radiol* 1984;19:416–423.
17. Kay GN, Bubien RS, Dailey SM, et al. A prospective evaluation of intracoronary ethanol ablation of the atrioventricular conduction system. *J Am Coll Cardiol* 1991;17:1634–1640.
18. Delacretaz E, Seiler J, Tanner H, et al. Ablation of ventricular tachycardia: neither inside nor out, thus back to alcohol. *Heart Rhythm* 2006;3:1230–1231.
19. Ramana RK, Wilber DJ, Leya F. Ethanol septal ablation for refractory ventricular tachycardia. *J Invasive Cardiol* 2007;19:E142–E145.
20. Segal OR, Wong T, Chow AW, et al. Intra-coronary guidewire mapping—a novel technique to guide ablation of human ventricular tachycardia. *J Interv Card Electrophysiol* 2007;18:143–154.
21. Brugada P, de Swart H, Smeets JL, et al. Termination of tachycardias by interrupting blood flow to the arrhythmogenic area. *Am J Cardiol* 1988;62:387–392.
22. Brugada P, de Swart H, Smeets JL, et al. Transcoronary chemical ablation of ventricular tachycardia. *Circulation* 1989;79:475–482.
23. Friedman PL, Selwyn AP, Edelman E, et al. Effect of selective intracoronary antiarrhythmic drug administration in sustained ventricular tachycardia. *Am J Cardiol* 1989;64:475–480.
24. Nagueh SF, Lakkis NM, He ZX, et al. Role of myocardial contrast echocardiography during nonsurgical septal reduction therapy for hypertrophic obstructive cardiomyopathy. *J Am Coll Cardiol* 1998;32:225–229.
25. Delacretaz E, Stevenson WG. Catheter ablation of ventricular tachycardia in patients with coronary heart disease: part I: mapping. *Pacing Clin Electrophysiol* 2001;24:1261–1277.
26. Gunning MG, Williams IL, Jewitt DE, et al. Coronary artery perforation during percutaneous intervention: incidence and outcome. *Heart* 2002;88:495–498.
27. Veselka J, Duchonova R, Prochazkova S, et al. Effects of varying ethanol dosing in percutaneous septal ablation for obstructive hypertrophic cardiomyopathy on early hemodynamic changes. *Am J Cardiol* 2005;95:675–678.
28. Veselka J, Duchonova R, Palenickova J, et al. Impact of ethanol dosing on the long-term outcome of alcohol septal ablation for obstructive hypertrophic cardiomyopathy: a single-center prospective, and randomized study. *Circ J* 2006;70:1550–1552.
29. Weismuller P, Mayer U, Richter P, et al. Chemical ablation by subendocardial injection of ethanol via catheter—preliminary results in the pig heart. *Eur Heart J* 1991;12:1234–1239.
30. Kurita A, Mitani H, Kato R, et al. Efficacy of direct injection of ethanol into the myocardium to control aconitine-induced ventricular tachycardia in anesthetized dogs. *Jpn Heart J* 1996;37:611–625.
31. Sapp JL, Cooper JM, Zei P, et al. Large radiofrequency ablation lesions can be created with a retractable infusion-needle catheter. *J Cardiovasc Electrophysiol* 2006;17:657–661.

## E) Epicardial Ventricular Tachycardia Ablation: A Multicenter Safety Study

Publié: J Am Coll Cardiol 2010;21:2366-72

### 1) Etude

Le taux de succès des ablations par RF des TV chez les patients avec myocardopathie est évalué entre 53 et 67%<sup>9-11</sup>. Une des causes d'échec est la présence de circuits intramuraux ou sous épicaudiques.

Certains types de myocardopathies (dilatée à coronaires saines, maladie de Chagas, dysplasie arythmogène du ventricule droit) ont un substrat à prépondérance épicaudique<sup>12-14</sup> et nécessite donc un abord épicaudique. Aucune étude n'avait rapporté de façon systématique les complications de ce type de procédure. Nous avons donc colligé les dossiers des patients avec ablation de TV ayant eu un abord épicaudique dans 3 centres tertiaires d'électrophysiologie (Brigham and Women's Hospital à Boston, le CHU de Bordeaux et le CHU de Toulouse).

Sur 913 ablations de TV réalisées entre 2001 et 2007, un abord épicaudique a été réalisé dans 156 procédures. Cela concernait 134 patients (109 hommes, 56 ±15 ans) qui avaient une myocardopathie ischémique (n=51), une myocardopathie dilatée à coronaires saines (n=39), une dysplasie arythmogène du ventricule droit (n=14) ou un autre substrat (n=30).

L'accès épicaudique a été obtenu par voie sous xyphoïdienne percutanée (n=136), par voie sous xyphoïdienne chirurgicale (n=14) ou pendant chirurgie cardiaque à coeur ouvert (n=6). La voie sous xyphoïdienne percutanée a échoué chez 15 patients: 11 avaient un antécédent de chirurgie cardiaque, 2 un antécédent de péricardite et 1 des patches de défibrillateur épicaudique. Une ablation épicaudique a été réalisée dans 121 des 156 procédures avec accès épicaudique. Il a été possible de refaire un accès percutané sous xyphoïdien lors d'une nouvelle procédure à la suite de récurrence pour 19 patients. Nous avons eu un échec chez une patiente avec réaction péricardique majeure après la première ablation épicaudique.

Huit (5%) complications majeures sont survenues pendant la procédure. Sept saignements épicaudiques importants (>80cm<sup>3</sup>) et une sténose coronaire. Durant un suivi moyen de 2 ans, 3 complications majeures retardées ont été observées: une péricardite majeure, une tamponnade retardée (3 semaines) et une occlusion coronaire 2 semaines après la procédure.

Cette étude montre un risque de complication majeure de 7% lié à l'abord épicardique (5% per procédure et 2% après la sortie de l'hôpital).

## *2) Implications*

Cette étude nous permet d'avoir une idée sur le pourcentage de risque lié à l'abord épicardique. Connaître ces risques est important pour informer le patient mais également pour les éviter. En particulier, il est indispensable de bien identifier le réseau coronaire avant de faire l'ablation sur le versant épicardique. D'autres complications non retrouvées dans cette étude doivent être prévenues: la lésion du nerf phrénique lorsque l'ablation épicardique a lieu sur la paroi latérale VG, les saignements intra-abdominaux si la ponction est trop profonde et lèse un vaisseau infradiaphragmatique.

Cette étude montre également que la sélection des patients est primordiale car les échecs d'accès épicardique étaient essentiellement liés à un antécédent de chirurgie cardiaque. Chez ces patients, nous ne réalisons pas d'abord épicardique par voie percutanée. Lorsque l'abord est indispensable, nous demandons aux chirurgiens de faire un mini abord qui lui permet en plus de lever les adhérences.

QUARTERLY FOCUS ISSUE: HEART RHYTHM DISORDERS

## Epicardial Ventricular Tachycardia Ablation

### A Multicenter Safety Study

Frédéric Sacher, MD,\*† Kurt Roberts-Thomson, MBBS, PhD,† Philippe Maury, MD,‡ Usha Tedrow, MD,† Isabelle Nault, MD,\* Daniel Steven, MD,† Meleze Hocini, MD,\* Bruce Koplan, MD,† Lionel Leroux, MD,\* Nicolas Derval, MD,\* Jens Seiler, MD,† Matthew J. Wright, MBBS, PhD,\* Laurence Epstein, MD,† Michel Haissaguerre, MD,\* Pierre Jais, MD,\* William G. Stevenson, MD†

*Bordeaux-Pessac, France; Boston, Massachusetts; and Toulouse, France*

<b>Objectives</b>	The aim of this study was to perform a systematic evaluation of safety and midterm complications after epicardial ventricular tachycardia (VT) ablation.
<b>Background</b>	Epicardial VT ablation is increasingly performed, but there is limited information about its safety and midterm complications.
<b>Methods</b>	All patients undergoing VT ablation at 3 tertiary care centers between 2001 and 2007 were included in this study. Of 913 VT ablations, 156 procedures (17%) involved epicardial mapping and/or ablation. These were performed in 134 patients (109 men; mean age $56 \pm 15$ years) after a previous VT ablation in 115 (86%). The underlying substrates were ischemic cardiomyopathy in 51 patients, nonischemic cardiomyopathy in 39 patients, arrhythmogenic right ventricular cardiomyopathy in 14 patients, and other types of cardiomyopathy in 30 patients.
<b>Results</b>	Epicardial access was obtained via percutaneous subxiphoid puncture in 136 procedures, by a surgical subxiphoid approach in 14, and during open-heart surgery in 6. Epicardial ablation (mean radiofrequency duration: $13 \pm 12$ min; median: 10 min) was performed in 121 of 156 procedures (78%). Twenty patients subsequently required repeat procedures, and the epicardium could be reaccessed in all but 1 patient. A total of 8 (5%) major complications related to pericardial access were observed acutely: 7 epicardial bleeding ( $>80$ cm <sup>3</sup> ) and 1 coronary stenosis. After a mean follow-up period of $23 \pm 21$ months, 3 delayed complications related to pericardial access were noted: 1 major pericardial inflammatory reaction, 1 delayed tamponade, and 1 coronary occlusion 2 weeks after the procedure.
<b>Conclusions</b>	VT ablation required epicardial ablation in 121 of 913 procedures (13%), with a risk of 5% and 2% of acute and delayed major complications related to epicardial access. (J Am Coll Cardiol 2010;55:2366-72) © 2010 by the American College of Cardiology Foundation

Radiofrequency (RF) catheter ablation of ventricular tachycardia (VT) in patients with structural heart disease remains a challenging task, with reported success rates not exceeding 53% to 67% from multicenter or large series ( $n > 200$ ) (1-3). One possible limitation of conventional endocardial

ablation techniques is that some re-entry circuits may lie deep in the subendocardium or in the epicardium, areas impossible to access with current endocardial ablation techniques. Epicardial substrate seems of particular importance for VT ablation in the setting of nonischemic cardiomyopathy (CMP) (4) or arrhythmogenic right ventricular cardiomyopathy (ARVC) but also in patients with ischemic CMP (2,5).

See page 2373

Since 1996 (6), many centers have reported their experiences (4,7-10) with epicardial ablation, but safety and midterm complications have not been systematically assessed in clinical practice.

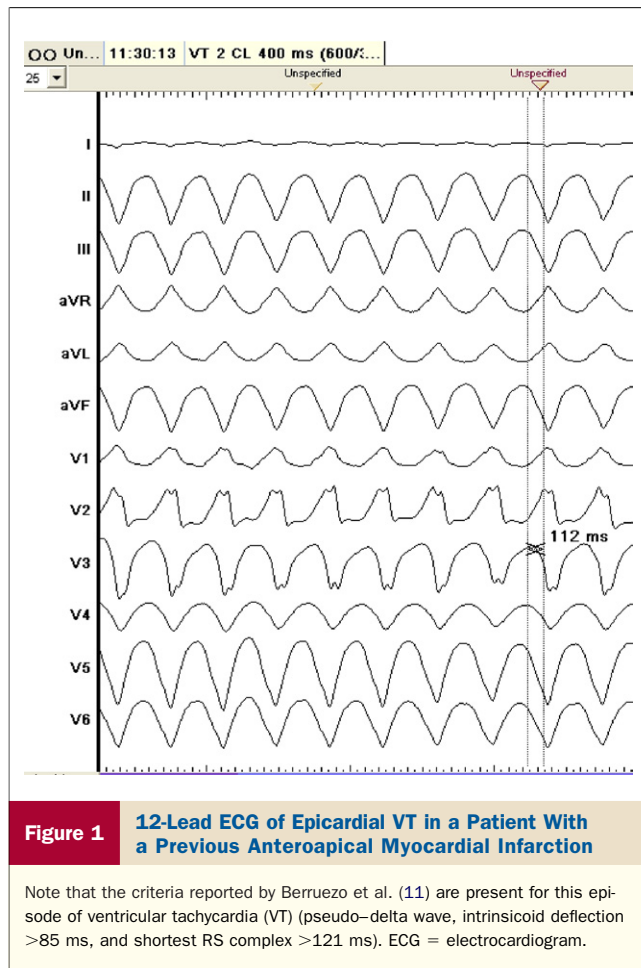
#### Methods

**Population and substrate.** All patients undergoing VT ablation at 3 tertiary care electrophysiology centers between

From the \*Université Bordeaux II, Hôpital Cardiologique du Haut-Lévêque, Bordeaux-Pessac, France; †Brigham and Women's Hospital, Harvard Medical School, Boston, Massachusetts; and the ‡CHU Ranguéil, Toulouse, France. Dr. Sacher received an unrestricted research grant from the French Federation of Cardiology. Dr. Roberts-Thomson is the recipient of a Postgraduate Research Scholarship (grant ID 489417) from the National Health and Medical Research Council of Australia and the AstraZeneca Fellowship in Medical Research from the Royal Australian College of Physicians. Dr. Tedrow has received research grants from Biosense Webster and Boston Scientific and speaking honoraria from Medtronic and Boston Scientific. Dr. Seiler has received a research grant from St. Jude Medical. Dr. Epstein has received honoraria for speaking, research, and consulting from Boston Scientific, Medtronic, and St. Jude Medical. Dr. Haissaguerre has received consulting fees from Biosense Webster. Dr. Jais has received honoraria for speaking, research, and consulting from Biosense Webster and St. Jude Medical.

Manuscript received July 4, 2009; revised manuscript received October 2, 2009, accepted October 18, 2009.





2001 and 2007 were included in this study. Of 913 VT ablations, 156 (17%) involved epicardial mapping and/or ablation. They were performed in 134 patients (109 men; mean age  $56 \pm 15$  years), after previous failed VT ablation in 115 (86%) or because the epicardium was thought to be a likely source on the basis of the characteristics of VT in the remaining patients (Figs. 1 and 2) (11). The underlying substrates were ischemic CMP in 51 patients (38%), non-ischemic CMP in 39 (29%), ARVC in 14 (10%), and other types of CMP (valvular, sarcoidosis, noncompaction of the left ventricle, isolated left ventricular diverticulum) in 13 (10%); 17 patients (13%) had no structural heart disease (Table 1). All patients had failed therapy with 1 or more antiarrhythmic drugs.

**Procedure.** With patients under conscious sedation, the pericardium was mainly accessed via a percutaneous subxiphoid puncture, as previously described (6), using an epidural needle (Tuohy bevel, 18 gauge,  $1.3 \times 80$  or 150 mm; Braun, Kronberg, Germany) originally developed to perform epidural access. The needle has a smoothly curved distal end, intended to facilitate entry into a potential space, and hopefully decreases the likelihood of a traumatic myocardial puncture. Percutaneous subxiphoid epicardial access was performed before heparin infusion in patients with international normalized ratios <2.0.

In cases of previous cardiac surgery or difficult pericardial access, a surgical subxiphoid (9) (Fig. 3) or lateral thoracotomy approach was performed under general anesthesia. When cardiac surgery was indicated for concomitant valvular or ischemic heart disease, ablation was performed during open-chest surgery.

The ablation protocols differed among centers and evolved during the course of the study. Different types of ablation catheters were used in the pericardium (4- and 8-mm solid tip, internally and externally irrigated-tip catheters, and cryocatheters). RF ablation parameters used in the pericardium differed depending on the type of catheter and the center. After 2006, externally irrigated-tip catheters (3.5-mm tip, ThermoCool, NaviStar or not; Biosense Webster, Diamond Bar, California) were used at all 3 centers for epicardial RF ablation. Catheter irrigation during epicardial mapping was set at 0 or 1 ml/min. During epicardial ablation, power ranged from 20 to 50 W, with irrigation of 10 to 30 ml/min. Intrapericardial fluid was drained by aspiration from the access sheath periodically after RF ablation lesions or continuously with a vacuum system connected to the epicardial sheath, which was 0.5- to 1-F larger than the ablation catheter.

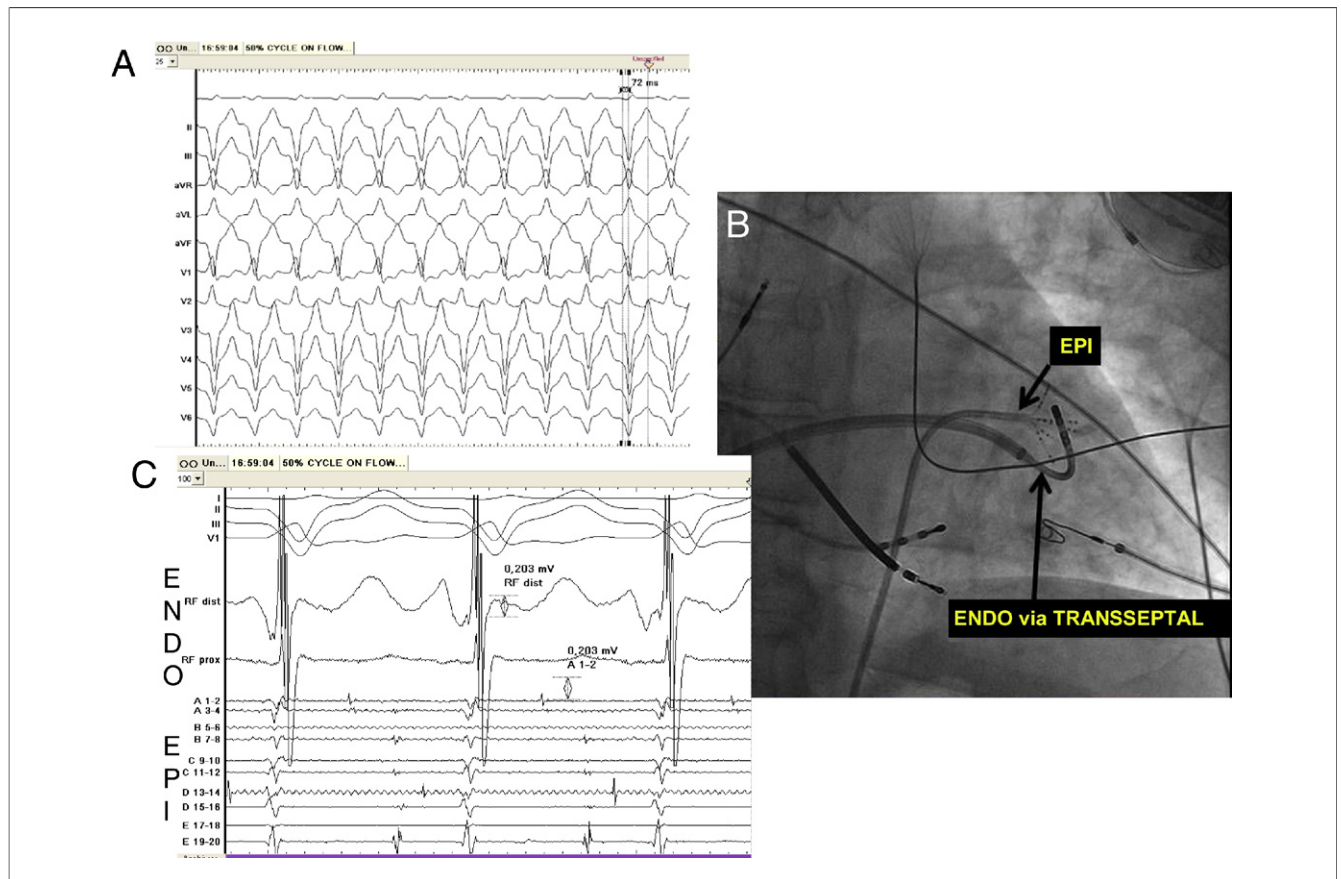
Before ablation on the left ventricular epicardium, coronary angiography was performed to confirm the absence of a coronary artery at the ablation site. High-output (10 mA or greater) pacing was also performed before ablation on the lateral left ventricular wall to exclude close proximity to the left phrenic nerve (12). From pericardial access to pericardial sheath removal, a catheter or a guidewire was always present, protruding from the sheath, because of concern that the sharp edge of a pericardial sheath might predispose to laceration of adjacent tissue or vessels. The pericardial sheath was removed at the end of the ablation in the absence of pericardial bleeding.

Echocardiography was performed within 24 h after the procedure and/or at discharge to assess pericardial fluid. Use of nonsteroidal anti-inflammatory drugs was left to the physician's discretion.

**Data collection.** Data were collected from a centralized system containing complete records of all patients treated and followed at the different centers. These records provided detailed histories and diagnoses for all patients, ablation reports, emergency department visits and outpatient visits, as well as data recorded during inpatient care. Patients local to the hospital were followed up in the ablation center. For the other patients, referring cardiologists were contacted for clinical follow-up and echocardiographic data of their patients. Mortality was assessed from the Social Security Death Index for American patients or by direct phone calls to referring physicians for European patients.

**Abbreviations and Acronyms**

- ARVC** = arrhythmogenic right ventricular cardiomyopathy
- CMP** = cardiomyopathy
- RCA** = right coronary artery
- RF** = radiofrequency
- RV** = right ventricular



**Figure 2** VT in a 61-Year-Old Man With Mild Ischemic Cardiomyopathy (LVEF: 50%)

(A) Twelve-lead electrocardiographic morphology of ventricular tachycardia (VT), which does not appear epicardial (EPI) in origin (relatively short QRS complex, no pseudo-delta wave, intrinsicoid deflection in lead V<sub>2</sub> <85 ms). However, no optimal spot could be found in the endocardium (normal endocardial voltage). (B) Fluoroscopy (postero-anterior view) of the catheter's position in C. Ablation catheter is in the endocardium while the PentaRay catheter (Biosense Webster) is on the epicardial side of the same area. (C) Endocardial (ENDO) and epicardial mapping demonstrates that the critical portion of the circuit is epicardial (50% of the VT cycle length is recorded on the PentaRay catheter, whereas electrograms recorded on the ablation catheter [using the same amplification], at the corresponding endocardial spot, are normal). LVEF = left ventricular ejection fraction.

**Statistical analysis.** Continuous variables are expressed as mean ± SD or medians when indicated. Complication and right ventricular (RV) puncture rates of the first 78 procedures compared with the following 78 were compared using Fisher exact tests. A p value <0.05 was considered statistically significant.

**Results**

**Procedure.** A total of 115 patients underwent only 1 effective epicardial access (percutaneous, surgical, or via

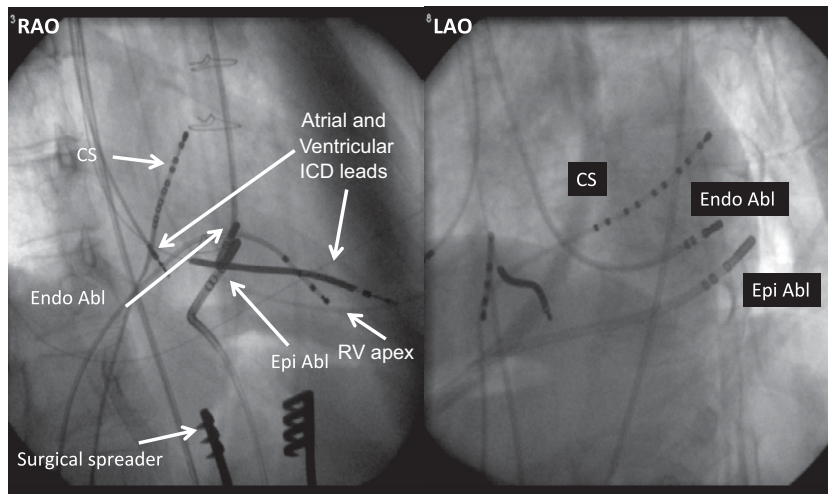
thoracotomy). Sixteen patients had 2 epicardial procedures and 3 patients had 3 epicardial procedures with successful percutaneous subxiphoid access. However, in 1 other patient, repeat access failed 3 months after the initial epicardial procedure, but she had experienced a dramatic pericardial reaction after the initial procedure.

The percutaneous subxiphoid approach was successful in accessing the pericardial space in 136 procedures and failed in 15 (10%). The reasons for these 15 failures (in 15 different

**Table 1** Baseline Characteristics of the Population Depending on the Substrate

	Ischemic CMP (n = 51)	Idiopathic Dilated CMP (n = 39)	ARVC (n = 14)	No CMP (n = 17)	Other CMP (n = 13)	All Patients (n = 134)
Percentage of epicardial access compared with the global population of VT ablation (n = 722)	16%	35%	41%	6%	18%	19%
Age (yrs)	63 ± 11	59 ± 15	42 ± 13	48 ± 14	53 ± 13	56 ± 15
Men	48 (94%)	32 (82%)	9 (64%)	10 (59%)	10 (77%)	109 (81%)
Left ventricular ejection fraction (%)	31 ± 11	33 ± 12	59 ± 9	61 ± 9	44 ± 11	40 ± 17
Patients with previous endocardial VT ablation	46 (90%)	33 (85%)	9 (64%)	15 (88%)	12 (92%)	115 (86%)
Patients with epicardial mapping and ablation	42 (82%)	36 (92%)	14 (100%)	12 (71%)	9 (69%)	113 (84%)

ARVC = arrhythmogenic right ventricular cardiomyopathy; CMP = cardiomyopathy; VT = ventricular tachycardia.



**Figure 3** Fluoroscopic View During VT Ablation With Surgical Subxiphoid Access

(Left) Right anterior oblique (RAO) view with an ablation catheter on the site of interest on the endocardial side (Endo Abl) via a retrograde aortic approach. Another catheter (Epi Abl) is placed on the epicardial side of the same spot and has been introduced via surgical approach. Note the surgical spreader (bottom). (Right) Left anterior oblique (LAO) view of the same site. CS = coronary sinus catheter; ICD = implantable cardioverter-defibrillator; RV apex = catheter placed at the apex of the right ventricle; VT = ventricular tachycardia.

patients) were histories of cardiac surgery in 11 patients, an implantable cardioverter-defibrillator epicardial patch in 1 patient, and histories of pericarditis in 2 patients (including the patient with a failed repeat procedure). For the remaining procedure, the patient had experienced a myocardial infarction several years before the procedure, and no clear reason for pericardial adhesions or failed access was identified.

Concerning the 15 patients from these procedures (with failed percutaneous epicardial access), the surgical subxiphoid approach was then performed successfully in 9 patients. No further epicardial attempt was performed in 5 patients, who were not counted further in the study (although no complications were noted during follow-up, they did experience VT recurrence). The remaining patient with failed access had previously successful percutaneous subxiphoid pericardial access and was included in this group for her first procedure but not counted for her second (failed) procedure.

A total of 14 surgical subxiphoid pericardial windows and 6 thoracotomy procedures were performed for access. Epicardial RF or cryoablation was delivered in 121 of 156 procedures (78%) (Table 1). Cryoablation was used in 11 procedures (7%) because of adjacent coronary arteries ( $n = 5$ ) or during open-chest surgery ( $n = 6$ ). In the 35 remaining procedures, no energy was delivered to the epicardium. In 33 procedures, the endocardium was finally thought to be a better target than the epicardium. In the last 2 procedures, no ablation was performed, because of the closeness of the proximal part of the left anterior descending coronary artery.

Total endocardial and epicardial RF ablation time was  $22 \pm 16$  min. In the 110 procedures with epicardial RF

ablation, mean epicardial RF duration was  $13 \pm 12$  min (median 10 min). Maximal power varied from 20 to 50 W (median 30 W). Externally irrigated-tip catheters were used for epicardial ablation in 99 of 156 procedures (63%).

**Complications.** Major complications (Table 2) were observed acutely or before discharge in 14 of 156 procedures (9%). Eight were related to epicardial approach (5%): 7 epicardial bleeding ( $>80$  cm<sup>3</sup>) because of RV puncture in 4 cases (bleeding stopped spontaneously or after reversal of heparin anticoagulation; no patient required blood transfusion or surgery) and 1 asymptomatic coronary stenosis in a procedure with cryoablation close to a posterolateral ventricular branch of the right coronary artery (RCA). At this ablation site, cryoablation was attempted because of proximity to the coronary artery. Angiography performed after the 4-min cryoapplication showed a 50% to 60% stenosis. Follow-up stress testing with single photon-emission computed tomographic perfusion imaging showed that scar presumably existed before the ablation and was unrelated to the coronary stenosis.

Six complications were related to endocardial ablation: pulmonary embolism in 2 patients (in patients with both venous and arterial femoral access in addition to pericardial puncture), an audible steam pop with pericardial effusion during endocardial ablation in 1 patient (using 35 W with an irrigated-tip catheter in the RV outflow tract in a patient with ARVC), cardiogenic shock in 1 patient, infranodal atrioventricular block in 1 patient (in a patient with idiopathic dilated CMP and epicardial VT as well as multiple VTs from the left Purkinje network), and bilateral groin hematomas requiring blood transfusion in 1 patient (Table 2).



**Table 2** Acute and Delayed Major and Minor Complications Related to Epicardial and Endocardial VT Ablation

		Complications Related to Epicardial Approach		Other Complications	
<b>Major complications</b>					
Acute	Intrapericardial bleeding (>80 cm <sup>3</sup> )	7 (4.5%)		Pulmonary embolism	2 (1.3%)
	Coronary artery stenosis	1 (0.6%)		Endocardial pop with pericardial effusion	1 (0.6%)
				Cardiogenic shock	1 (0.6%)
				Infranodal AV block	1 (0.6%)
				Bilateral groin hematoma requiring blood transfusion	1 (0.6%)
Delayed (>48 h)	Major pericardial reaction	1 (0.6%)			
	Delayed tamponade	1 (0.6%)			
	Myocardial infarction	1 (0.6%)			
Total		11 (7%)			6 (4%)
<b>Minor complications</b>					
	RV puncture without consequence	23/136 percutaneous approach (17%)		Femoral dissection	1 (0.6%)
	Pleural catheterization with guidewire	2 /136 (1.5%)			
	Chest pain	Almost all patients			

AV = atrioventricular; RV = right ventricular; VT = ventricular tachycardia.

Minor complications (Table 2) related to epicardial access were also noted: RV puncture without significant bleeding (<80 cm<sup>3</sup>) in 23 procedures (17% of percutaneous subxiphoid access), inadvertent entry of the guidewire into the pleural space without pneumothorax or complication in 2 procedures (Fig. 3), and chest pain after almost all procedures (related to pericardial inflammation), usually requiring treatment with nonsteroidal anti-inflammatory drugs. One minor complication related to endocardial procedure was also noted (a femoral artery dissection that did not require therapy).

To evaluate a possible learning-curve effect on the complication rate, the population was divided into 2 groups (group 1: procedures performed during the first half of the study [initial experience or learning curve] vs. group 2: procedures performed during the second half of the study). No difference was found in terms of major complications related or not to pericardial access (3 of 78 during the first period vs. 5 of 78 during the second period, p = NS), but a trend toward more RV punctures (without consequence) during the first part of the study was observed (16 of 68 [24%] vs. 7 of 68 [10%] with percutaneous subxiphoid puncture, p = 0.07).

**Follow-up.** After a mean follow-up period of 23 ± 21 months, 3 of 134 patients (2%) had undergone heart transplantation, and 118 of 134 (88%) were still alive. Freedom from VT recurrence was achieved in 95 of 134 patients (71%). Three delayed complications (2%) related to pericardial access were noted: 1 major pericardial inflammatory reaction, 1 delayed tamponade 10 days after the procedure in a patient with a suprathreshold international normalized ratio of 11, and 1 acute inferior myocardial infarction 2 weeks after the procedure. This patient had ARVC with epicardial RV free wall ablation, without preceding coronary angiography, which was not routinely performed before ablation on the RV epicardial free wall. Emergency coronary angiography showed RCA occlusion at

the site of the ablation, with an unusual RCA anatomy (the marginal branch of the RCA supplying the posterior descending artery).

No constrictive pericarditis or phrenic nerve injuries were reported in any patient.

## Discussion

In this multicenter study, VT ablation required epicardial ablation in 121 of 913 procedures (13%). The overall risk for acute (5%) and delayed (2%) major complications related to epicardial access and ablation seems justified by the absence of alternative treatments in this population. However, these results must be interpreted in the context of the procedures being performed in selected patients and at experienced centers with acute surgical backup; widespread application of epicardial access and ablation should progress with caution.

Consistent with prior reports, the highest prevalence of epicardial VT substrate was observed in patient groups with diagnoses of ARVC (41%) and nonischemic dilated CMPs (35%), followed by patients with ischemic heart disease (Table 1). Even if these prevalences may be overestimated because of the referral nature of the population (patients with epicardial substrate more often referred by other centers that are not familiar with this technique), the proportion of epicardial VT substrate in ARVC (13) and nonischemic dilated CMPs (4) is higher compared with other substrates.

Although all cardiologists are trained to perform pericardial puncture for tamponade, accessing the pericardium in the absence of pericardial fluid is more challenging. A specific technique has been described by Sosa et al. (6) and adopted with some variation by electrophysiologists performing such procedures. To prevent major complications, some precautions are necessary. First, patient selection is important. Despite a study by Sosa et al. (14) demonstrating

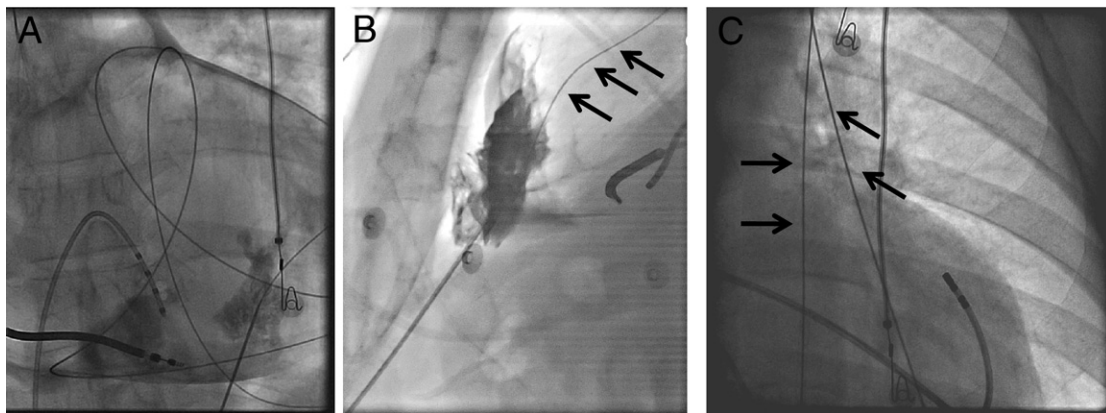
that access can be achieved in some patients who have had prior cardiac surgery, adhesions may prevent access or limit mapping, RV puncture may be more likely when a potential pericardial space is not encountered, and coronary artery bypass grafts may be at risk in some cases. In our study, percutaneous subxiphoid pericardial access and/or mapping failed in 11 of 13 patients (85%) with previous cardiac surgery. When access was finally obtained in 2 patients, mapping was limited to the inferior wall.

Second, puncture is facilitated by the use of a Tuohy needle to limit the risk for myocardial injury. Use of contrast medium to confirm entry in the pericardial space and the introduction of a long guidewire, inserted to sufficient length to cross multiple cardiac chambers along the cardiac silhouette and thus exclude the possibility that it has been inserted into a cardiac chamber, are mandatory before introducing the sheath. This ensures that myocardial perforation or laceration with a large sheath does not occur (Fig. 4). In this study, 20% of RV punctures occurred during percutaneous subxiphoid pericardial access, but only 4 (3%) resulted in significant bleeding. One of these 4 patients had received heparin after transeptal access performed before epicardial access, but there was no additional anticoagulation risk noted for the other 3 patients. Concerning the 3 patients with pericardial bleeding but without RV puncture, myocardial injury was thought by the operator to be unlikely. In 1 of these patients, contrast medium injection showed a coronary vein shadow, leading to a suspicion of inadvertent coronary vein puncture. Moreover, to avoid myocardial wall injury by the sharp edges of a sheath, it seems reasonable that intrapericardial sheaths should always contain either a guidewire and dilator or a catheter and should not be left empty in the pericardial space.

The timing of the epicardial procedure relative to the endocardial procedure is also an important issue. It seems reasonable to perform epicardial access before systemic anticoagulation because of the possibility of bleeding complications. Even though in this study, bleeding always stopped spontaneously or after heparin reversal, caution is warranted, and on-site surgical backup is advised.

Initially, solid-tip catheters were used for epicardial ablation, but power delivery was limited because of the absence of cooling from blood flow that is present during endocardial ablation (15). Although externally irrigated-tip catheters were initially avoided at some centers because of the need for intrapericardial fluid infusion, this type of catheter was subsequently used for epicardial ablation in 63% of our procedures, with periodic intrapericardial fluid drainage and careful monitoring of arterial pressure and motion of the cardiac silhouette on fluoroscopy (every 15 to 20 min). At 1 center, fluid was drained continuously with a vacuum system connected to the epicardial sheath during mapping and ablation. These investigators also believed that this approach improved contact between the catheter tip and the myocardium.

Because of the risk for coronary artery lesions in the case of RF application to a vessel, it seemed reasonable to perform coronary angiography before energy delivery to the epicardium. Because coronary vessels are usually absent from the RV free wall, we did not systematically perform coronary artery angiography at this site. However, even in the absence of coronary artery lesions in such cases in our study, it could be useful to perform coronary angiography even at this site, especially when the catheter position is doubtful or close to the septal area.



**Figure 4** Pericardial Access and Complications

(A) Normal pericardial access: posteroanterior view of the heart with a guidewire introduced through percutaneous subxiphoid access into the pericardium. This appearance is typical of a guidewire correctly placed into the pericardial space. (B) Right ventricular puncture: lateral projection with the Tuohy needle in the **right bottom corner** with a guidewire (**arrows**) that does not loop into the pericardium but goes into the right ventricle and the pulmonary artery. The contrast staining in the anterior mediastinum indicates that this has been a difficult pericardial catheterization. Furthermore, this compounds the problem by impairing the visualization of the Tuohy needle. (C) Pleural puncture: lateral view with the guidewire (**arrows**) in the pleural cavity.

It is not clear whether epicardial ablation may create pericardial adherences, but d'Avila et al. (16) suggested infusing intrapericardial corticosteroids at the end of the procedure to limit this potential risk. In our series, 20 patients had redo epicardial procedures a median of 3 months after the previous epicardial ablation, with no access or mapping issues, except for 1 patient in whom it was impossible to reaccess the pericardium. This patient had experienced a dramatic pericardial reaction after the initial epicardial procedure. No case of constrictive pericarditis was noted after a mean follow-up period of almost 2 years. Whether the follow-up was too short to develop this complication is uncertain, but it would be unlikely that the risk for constrictive pericarditis after epicardial ablation exceeds the risk after cardiac surgery, for which it has been estimated to be 0.2% to 0.3% (17).

Chest pain during the procedure is obviously an issue and requires powerful analgesia such as fentanyl or sufentanyl in the absence of general anesthesia. Residual chest pain is also frequent after the procedure, and nonsteroidal anti-inflammatory drugs are usually prescribed for 1 week.

Our study points out some complications of epicardial mapping and ablation, but other complications have been reported, such as abdominal bleeding after diaphragmatic vessel injury (8), increased defibrillation threshold due to air in the pericardium (18), and phrenic nerve injury (12). Other complications not yet reported may also be anticipated, such as lung or mediastinal lesions.

**Study limitations.** The study cohort consisted of a highly selected group of patients with a variety of diagnoses and underlying arrhythmia substrates. The majority of the patients had failed prior endocardial ablation attempts. This reflected the nature of the referral practice at these 3 tertiary care electrophysiology centers. It is important to note that these findings may not be applicable to less experienced operators or centers. Percutaneous subxiphoid pericardial access for mapping and/or ablation was started routinely at different times at the different centers (in 2000 at Brigham and Women's Hospital, in 2004 at Bordeaux University Hospital, and in 2005 at Toulouse University Hospital), but the pericardial puncture technique itself remained the same over the years. The numbers of procedures performed at the different centers over the study period differed (104 patients at Brigham and Women's Hospital, 38 patients at Bordeaux University Hospital, and 14 patients at Toulouse University Hospital). Because of the retrospective nature of the study, the exact number of RV punctures may be slightly different from reality (on the basis of the report).

## Conclusions

VT ablation required epicardial ablation in 121 of 913 procedures (13%). The risks for acute (5%) and delayed (2%) major complications related to epicardial access seem justified by the absence of a therapeutic alternative for this population.

**Reprint requests and correspondence:** Dr. Frédéric Sacher, Hôpital Cardiologique du Haut-Lévêque, 33604 Bordeaux-Mérignac, France. E-mail: frederic.sacher@chu-bordeaux.fr.

## REFERENCES

1. Calkins H, Epstein A, Packer D, et al., Cooled RF Multi Center Investigators Group. Catheter ablation of ventricular tachycardia in patients with structural heart disease using cooled radiofrequency energy: results of a prospective multicenter study. *J Am Coll Cardiol* 2000;35:1905–14.
2. Sacher F, Tedrow U, Field ME, et al. Ventricular tachycardia ablation: evolution of patients and procedures over 8 years. *Circ Arrhythm Electrophysiol* 2008;1:153–61.
3. Stevenson WG, Wilber DJ, Natale A, et al., Multicenter ThermoCool VT Ablation Trial Investigators. Irrigated radiofrequency catheter ablation guided by electroanatomic mapping for recurrent ventricular tachycardia after myocardial infarction: the Multicenter ThermoCool Ventricular Tachycardia Ablation trial. *Circulation* 2008;118:2773–82.
4. Soejima K, Stevenson WG, Sapp JL, Selwyn AP, Couper G, Epstein LM. Endocardial and epicardial radiofrequency ablation of ventricular tachycardia associated with dilated cardiomyopathy: the importance of low-voltage scars. *J Am Coll Cardiol* 2004;43:1834–42.
5. Sosa E, Scanavacca M, d'Avila A, Oliveira F, Ramires JA. Nonsurgical transthoracic epicardial catheter ablation to treat recurrent ventricular tachycardia occurring late after myocardial infarction. *J Am Coll Cardiol* 2000;35:1442–9.
6. Sosa E, Scanavacca M, d'Avila A, Pilleggi F. A new technique to perform epicardial mapping in the electrophysiology laboratory. *J Cardiovasc Electrophysiol* 1996;7:531–6.
7. Brugada J, Berruezo A, Cuesta A, et al. Nonsurgical transthoracic epicardial radiofrequency ablation: an alternative in incessant ventricular tachycardia. *J Am Coll Cardiol* 2003;41:2036–43.
8. Sosa E, Scanavacca M. Epicardial mapping and ablation techniques to control ventricular tachycardia. *J Cardiovasc Electrophysiol* 2005;16:449–52.
9. Soejima K, Couper G, Cooper JM, Sapp JL, Epstein LM, Stevenson WG. Subxiphoid surgical approach for epicardial catheter-based mapping and ablation in patients with prior cardiac surgery or difficult pericardial access. *Circulation* 2004;110:1197–201.
10. Aryana A, d'Avila A, Heist EK, et al. Remote magnetic navigation to guide endocardial and epicardial catheter mapping of scar-related ventricular tachycardia. *Circulation* 2007;115:1191–200.
11. Berruezo A, Mont L, Nava S, Chueca E, Bartholomay E, Brugada J. Electrocardiographic recognition of the epicardial origin of ventricular tachycardias. *Circulation* 2004;109:1842–7.
12. Fan R, Cano O, Ho SY, et al. Characterization of the phrenic nerve course within the epicardial substrate of patients with nonischemic cardiomyopathy and ventricular tachycardia. *Heart Rhythm* 2009;6:59–64.
13. Garcia FC, Bazan V, Zado ES, Ren JF, Marchlinski FE. Epicardial substrate and outcome with epicardial ablation of ventricular tachycardia in arrhythmogenic right ventricular cardiomyopathy/dysplasia. *Circulation* 2009;120:366–75.
14. Sosa E, Scanavacca M, D'Avila A, Antonio J, Ramires F. Nonsurgical transthoracic epicardial approach in patients with ventricular tachycardia and previous cardiac surgery. *J Interv Card Electrophysiol* 2004;10:281–8.
15. d'Avila A, Houghtaling C, Gutierrez P, et al. Catheter ablation of ventricular epicardial tissue: a comparison of standard and cooled-tip radiofrequency energy. *Circulation* 2004;109:2363–9.
16. d'Avila A, Neuzil P, Thiagalingam A, et al. Experimental efficacy of pericardial instillation of anti-inflammatory agents during percutaneous epicardial catheter ablation to prevent postprocedure pericarditis. *J Cardiovasc Electrophysiol* 2007;18:1178–83.
17. Cimino JJ, Kogan AD. Constrictive pericarditis after cardiac surgery. *Am Heart J* 1989;118:1292–301.
18. Yamada T, McElderry HT, Platonov M, Doppalapudi H, Kay GN. Aspirated air in the pericardial space during epicardial catheterization may elevate the defibrillation threshold. *Int J Cardiol* 2009;135:e34–5.

**Key Words:** epicardial VT ablation ■ safety ■ complications.

## **F) Multimodality Imaging to Improve the Safety and Efficacy of Epicardial Ablation of Scar-Related Ventricular Tachycardia**

Publié: J Cardiovasc Electrophysiol 2013;12:1426-7

### *1) Etude*

Il s'agit d'un cas mais qui illustre parfaitement l'intérêt de l'imagerie pour améliorer l'efficacité mais également la sécurité de l'ablation par RF des TV. Tout d'abord, l'IRM cardiaque nous a permis d'identifier une cicatrice limitée en zone sous épocardique ce qui nous a conduit à réaliser une procédure en planifiant un abord épocardique. Ensuite l'intégration de la zone de rehaussement tardif identifiée à l'IRM dans le système de cartographie a permis de localiser précisément la zone pathologique. Ensuite l'implémentation des données du scanner dans le même modèle, nous permet d'identifier le réseau coronaire et le nerf phrénique. Lors de la cartographie d'activation en TV, l'isthme a été identifié en regard d'une coronaire ce qu'a confirmé la coronarographie. Une tentative d'ablation endocavitaire en regard de cet isthme (potentiels endocardiques normaux) s'est révélée infructueuse. Nous avons donc réalisé l'ablation un peu à distance de cette coronaire (5mm) en essayant d'éliminer tous les potentiels anormaux (LAVA) adjacents.

### *2) Implications*

Ce travail montre que l'identification des zones de cicatrices avant l'ablation est cruciale pour planifier au mieux sa procédure. L'idéal est la réalisation d'une IRM cardiaque qui est souvent contre-indiquée chez les patients porteurs de défibrillateur ce qui concerne la plupart de nos patients adressés pour ablation de TV. Nous réalisons donc maintenant systématiquement une IRM cardiaque avant implantation d'un défibrillateur chez les patients avec myocardopathie.

Le 2<sup>e</sup> point important est l'intérêt d'identifier les coronaires et le nerf phrénique si on prévoit de faire une ablation épocardique. Dans notre cas, l'application de radiofréquence à l'aveugle sur notre meilleur site épocardique aurait très certainement conduit à une sténose voir thrombose coronaire à plus ou moins brève échéance.



# Multimodality Imaging to Improve the Safety and Efficacy of Epicardial Ablation of Scar-Related Ventricular Tachycardia

YUKI KOMATSU, M.D., FRÉDÉRIC SACHER, M.D., HUBERT COCHET, M.D., and  
PIERRE JAÏS, M.D.

From the Department of Cardiac Electrophysiology, Hôpital Cardiologique du Haut-Lévêque and the Université Victor Segalen Bordeaux II, Bordeaux, France

*catheter ablation, epicardial ablation, magnetic resonance imaging, ventricular tachycardia*

A 41-year-old man with mild left ventricular dysfunction postmyocarditis was referred for catheter ablation of sustained ventricular tachycardia (VT). Contrast-enhanced magnetic resonance imaging (MRI) showed subepicardial basal-lateral delayed-enhancement (Fig. 1, left lower panel). Cardiac geometry, including coronary arteries and phrenic nerves, was acquired from multidetector computed tomography (MDCT). Both MRI- and MDCT-derived images were segmented and integrated with a 3-dimensional electroanatomic map. The epicardial regions of low voltage and delayed activation corresponded to the subepicardial basal-lateral delayed enhancement on MRI (Fig. 1A,B). The region of and around delayed enhancement harbored all local abnormal ventricular activities (LAVA) (Fig. 1A,B, green dots). The diaphragm was captured by high-intensity pacing along the phrenic nerve segmentation (Fig. 1A,B, yellow dots). Coronary angiography (online movie, Fig. 1C) found our ablating catheter at the site recording LAVA (Fig. 1A and B, pink dot; Fig. 1D) displacing the same left circumflex branch overlaid on our segmented imaging, which implies highly

accurate multimodal image registration. During induced VT, a mid-diastolic potential was found between two coronary artery branches (Fig. 1A,B, white dot). Radiofrequency energy was delivered here, immediately terminating the VT without complication. However, complete LAVA elimination was unwarranted alongside the arteries.

The present case highlights the utility of multimodality image integration with navigation system for visualizing a potential arrhythmogenic substrate as well as anatomical structures, and illustrates the importance of coronary angiography when target in the proximity of coronary vessels as demonstrated by high-resolution merged imaging.

## Supporting Information

Additional Supporting information may be found in the online version of this article at the publisher's website:

Online movie.

---

J Cardiovasc Electrophysiol, Vol. 24, pp. 1426-1427, December 2013.

Dr. Jais reports honoraria relevant to this topic from Biosense Webster, and also St. Jude Medical, for whom he serves as consultant/on advisory board. Other authors: No disclosures.

Address for correspondence: Yuki Komatsu, M.D. Department of Cardiac Electrophysiology, Hôpital Cardiologique du Haut-Lévêque, the Université Victor Segalen Bordeaux II, Avenue de Magellan, 33604 Bordeaux, France. Fax: +33 5 57 65 65 09; E-mail: yk.komat@gmail.com

Manuscript received 23 June 2013; Accepted for publication 8 July 2013.

doi: 10.1111/jce.12248



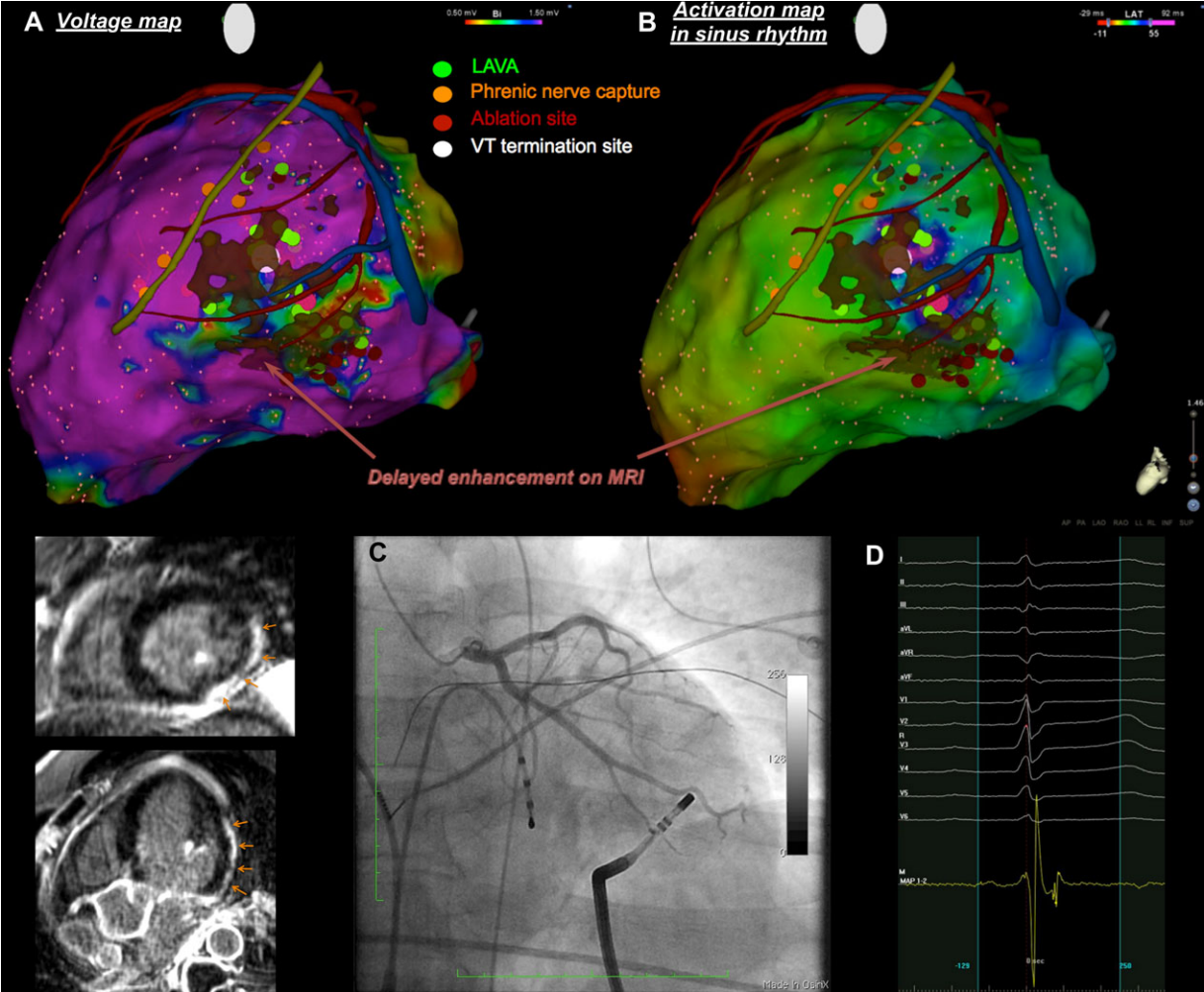


Figure 1.

## **G) Steam Pop during radiofrequency ablation: Imaging features on Magnetic Resonance Imaging and Multi-Detector Computed Tomography**

Accepté : Circulation Arrhythmia and Electrophysiology

### *1) Etude*

Il est parfois difficile de connaître l'effet d'une application de RF sur le myocarde. Dans ce cas d'ablation d'extrasystole ventriculaire, 2 sites seulement ont été ciblés avec sur un de ces 2 sites la survenue d'un pop (explosion intra-tissulaire liée à un échauffement cellulaire lors du tir de RF). La réalisation d'un scanner et d'une IRM cardiaque, le lendemain de la procédure a permis de mettre en évidence ces lésions de RF.

Sur les images IRM, les 2 sites avec et sans pop n'étaient pas différents seules les séquences ciné retrouvaient une communication avec le cavité cardiaque pour le site du pop. Sur le scanner, une zone hyperdense intense communicant avec le VG, entourée d'une zone hypodense (oedème myocardique ou nécrose tissulaire) a été identifiée sur le site du pop. Alors que sur l'autre site, seul l'aspect hypodense existait. La lésion du pop n'étant pas transmurale, il n'y avait pas de communication avec l'espace péricardique et donc pas d'épanchement.

### *2) Implications*

Il est utile de comprendre ce que l'ablation donne au niveau tissulaire (taille des lésions). Malgré l'utilisation de paramètres standard avec un bon contact 20 grammes, la lésion est loin d'être transmurale ce qui peut poser des problèmes pour atteindre des foyers profonds. Par ailleurs, l'imagerie nous a permis de voir l'étendue du pop qui est loin d'être un phénomène anodin. Non seulement il peut être responsable de perforation cardiaque mais lorsqu'il est ouvert sur les cavités cardiaques comme c'est le cas chez notre patiente cela signifie qu'il y a eu perte de substance qui est partie dans la circulation avec les risques emboliques inhérents.

Disclaimer: The manuscript and its contents are confidential,  
intended for journal review purposes only, and not to be further  
disclosed.

URL: <http://circep-submit.aha-journals.org>

Title: Steam pop during radiofrequency ablation: imaging features on  
magnetic resonance imaging and multi-detector computed tomography

Manuscript number: CIRCAE/2013/001418

Author(s): Hubert Cochet, CHU / Université de Bordeaux - IHU Liryc /  
INSERM U1045

Frédéric Sacher, Hôpital Cardiologique du Haut-Lévêque & Université  
Victor Segalen Bordeaux II, LIRYC Institute

Arnaud Chaumeil, Clinique du Pont de chaume

Pierre Jais, Hôpital Cardiologique Haut Lévêque

# **Steam Pop during Radiofrequency Ablation: Imaging Features on Magnetic Resonance Imaging and Multi-Detector Computed Tomography**

**Running title:** *Cochet et al.; Imaging features of steam pop on MRI and MDCT*

Hubert Cochet, MD, PhD<sup>1,3</sup>; Frederic Sacher, MD<sup>2,3</sup>; Arnaud Chaumeil, MD<sup>4</sup>; Pierre Jais, MD<sup>2,3</sup>

<sup>1</sup>Department of cardiovascular imaging, <sup>2</sup>Department of cardiac pacing and electrophysiology, CHU / Université de Bordeaux, Pessac, France; <sup>3</sup>L'Institut de Rythmologie et de Modélisation Cardiaque LIRYC, CHU / Université de Bordeaux / INSERM U1045, Pessac; <sup>4</sup>Department of cardiology, Clinique du Pont de Chaume, Montauban, France

## **Correspondence:**

Dr. Hubert Cochet

Département d'imagerie cardiovasculaire

Hôpital cardiologique Haut Lévêque

CHU Bordeaux, 33604 Pessac

France

Tel: +33557656542

Fax: +33557656880

E-mail: [hcochet@wanadoo.fr](mailto:hcochet@wanadoo.fr)

**Journal Subject Codes:** [22] Ablation/ICD/surgery, Diagnostic testing:[30] CT and MRI

**Key words:** ablation, imaging

A 48 year-old woman was referred to catheter ablation for symptomatic premature ventricular contraction (PVC). Left ventricular endocardial mapping was performed via a retrograde aortic approach using a three-dimensional electro-anatomical mapping system (Carto3, Biosense Webster, Diamond Bar, CA). PVCs were only present during exertion. No PVC was present at baseline. Isoproterenol infusion was started and initiated PVCs when heart rate was around 100 bpm. PVC origin was identified at the infero-septal region mainly based on pacemapping. Radiofrequency ablation was performed using a 3.5mm open-irrigation catheter that enables contact force monitoring (Smartouch, Biosense Webster). On a mid-ventricular site (site 1), radiofrequency was delivered during 2 min (35 W, contact force 20g) resulting in successful termination of the ectopic. Unfortunately isoproterenol infusion unmasked a second morphology close to the previous one, possibly due to a change of exit site. After a combination of pacemapping and activation mapping a more basal site was targeted (site 2). Radiofrequency was delivered during 74 seconds at the power of 40 W with a mean contact force of 35g and was interrupted because of a steam pop. The patient remained asymptomatic and no pericardial effusion was seen on immediate two-dimensional echocardiography. No more PVC was seen 30 minutes after ablation despite isoproterenol infusion.

On day one, magnetic resonance imaging was performed on a 1.5 Tesla scanner (Avanto, Siemens Medical Systems, Erlangen, Germany). T2 weighted imaging showed a large area of myocardial edema extending in the whole septum, beyond ablation sites (A). Delayed-enhanced imaging was performed at high spatial resolution (1.25x1.25x2.5mm) using a free breathing method initially developed for atrial imaging. Both ablation sites exhibited a peripheral enhancement surrounding a “No Reflow – like” dark core, suggesting myocardial and microvascular necrosis (B). No difference was observed between the sites with or without steam

pop. Cine imaging showed myocardial swelling on site 1 (without steam pop) (online Movie 1). On site 2 (with steam pop), an intra-myocardial bright area was seen on the inferior septum at end-systole, communicating with left ventricular blood pool (online Movie 2). ECG-gated contrast-enhanced multi-detector computed tomography was performed on a 64-slice scanner (Somatom Definition, Siemens Medical Systems, Forchheim, Germany). On site 1 (without steam pop) myocardial hypodensity was seen, suggesting either myocardial edema or tissue necrosis. On site 2 (with steam pop) an area of intense enhancement communicating with intra-ventricular blood pool was seen, surrounded by myocardial hypodensity. This pattern suggested that steam pop had induced an intra-myocardial hematoma communicating with the ventricular cavity. Myocardial swelling was seen on both ablation sites. None of the ablation lesions were transmural. The transmuralities of lesions with and without steam pop were similar, indicating that steam pop had only damaged sub-endocardial myocardial layers.

Steam pop refers to the audible sound produced by intra-myocardial explosion when tissue temperature reaches 100°C, leading to the production of gas<sup>1</sup>. It is a potentially severe complication of radiofrequency ablation as it has been associated with cardiac perforation<sup>2</sup> and ventricular septal defect<sup>3</sup>. The present case is to our knowledge the first to report on imaging features of a steam pop lesion on magnetic resonance imaging and computed tomography. The site of steam pop appears as an intra-myocardial hematoma communicating with the ventricular cavity. However, it does not translate into increased lesion transmuralities. Additional studies are required to define the potential role of systematic imaging after steam pop.

**Funding Sources:** This research is supported by grants from Fondation Leducq (09 CVD 03), European Union Seventh Framework Program (FP7/2007-2013; Grant Agreement HEALTH-F2-2010-261057, EUTRAF), and Agence Nationale de la Recherche (Grant ANR-10-IAHU-04).

**Conflict of Interest Disclosures:** None

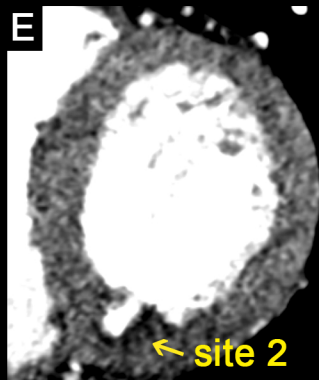
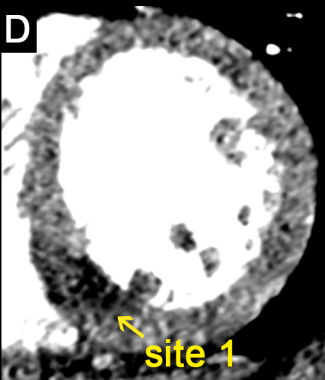
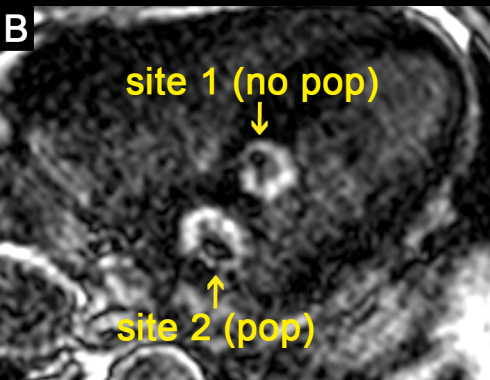
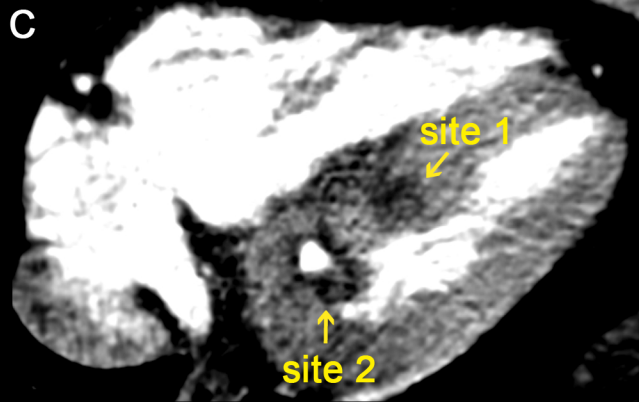
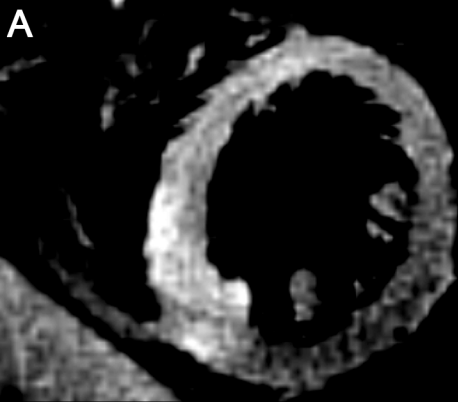**References:**

1. Nakagawa H, Yamanashi WS, Pitha JV, Arruda M, Wang X, Ohtomo K, Beckman KJ, McClelland JH, Lazzara R, Jackman WM. Comparison of in vivo tissue temperature profile and lesion geometry for radiofrequency ablation with a saline-irrigated electrode versus temperature control in a canine thigh muscle preparation. *Circulation*. 1995;91:2264–2273.
2. Tokuda M, Kojodjojo P, Epstein LM, Koplán BA, Michaud GF, Tedrow UB, Stevenson WG, John RM. Outcomes of cardiac perforation complicating catheter ablation of ventricular arrhythmias. *Circ Arrhythm Electrophysiol*. 2011;4:660–666.
3. Schönbauer R, Sommer P, Misfeld M, Dinov B, Fiedler L, Huo Y, Gaspar T, Breithardt OA, Hindricks G, Arya A. Relevant ventricular septal defect caused by steam pop during ablation of premature ventricular contraction. *Circulation*. 2013;127:e843-e844.

**Figure Legend:**

**Figure:** Imaging features on day one after steam pop. T2 weighted magnetic resonance imaging in short axis shows diffuse septal edema extending beyond ablation sites (A). Late gadolinium enhancement in trans-axial plane shows a peripheral enhancement surrounding a “No Reflow – like” dark core on both ablation sites (with or without steam pop) (B). ECG-gated contrast-enhanced multi-detector computed tomography shows myocardial hypodensity on site 1 (without steam pop) (C, D). On site 2 (with steam pop) an area of intense enhancement communicating with intra-ventricular blood pool is seen, surrounded by myocardial hypodensity (C, E). This pattern suggests that steam pop has induced an intra-myocardial hematoma communicating with the ventricular cavity. Myocardial swelling is seen on both ablation sites. None of the ablation lesions are transmural. The transmuralities of lesions with and without steam pop were similar, indicating that steam pop has only damaged sub-endocardial myocardial layers.





## **H) Endocardial Ablation to Eliminate Epicardial Arrhythmia Substrate in Scar-Related Ventricular Tachycardia**

Accepté: J Am Coll Cardiol. 2014 Jan 17. doi: 10.1016/j.jacc.2013.10.087.

### *1) Etude*

L'application de RF sur le versant épicardique du myocarde expose à certaines complications (lésion nerf phrénique, des coronaires, saignement, douleur) et limitations (présence de graisse limitant l'efficacité des lésions). On a, par ailleurs, beaucoup plus de recul et d'expérience avec l'ablation endocardique qui n'a pas ces risques.

Cette étude a inclus 46 patients avec des potentiels ventriculaires anormaux (LAVA) épicardiques. Le substrat était un myocardiopathie ischémique (n=20), une myocardiopathie dilatée à coronaires saines (n=15) ou une dysplasie arythmogène du ventricule droit (DAVD) (n= 15). Un total de 173 sites avec application de RF endocardique ciblant des LAVA épicardiques ont été analysés. Cette approche a été efficace sur 48/173 (28%) sites et essentiellement dans la DAVD (26/63sites; 40%). L'efficacité chez les patients avec myocardiopathie ischémique est moindre (20/71sites; 28%), et cette approche s'avère peu efficace chez les patients avec myocardiopathie dilatée à coronaires saines (3/39 sites; 8%). Les facteurs de succès de cette approche sont (1) l'épaisseur myocardique (VD vs VG; site d'ablation dans une zone d'amincissement (<5mm) au scanner), (2) la présence de LAVA endocardique en regard du site épicardique, (3) une diminution du voltage endocardique unipolaire en regard du site epicardique, (4) la présence de LAVA épicardique de faible amplitude (<0,5mV) et retardé après le QRS. Chez 4/18 patients avec myocardiopathie ischémique et 2/15 DAVD, tous les LAVA épicardiques ont pu être éliminés par ablation endocardique.

Enfin les patients avec élimination complète des LAVA (endo + épi) avaient un meilleur devenir (moins de récurrence de TV/décès) que les autres: 25/32 (78%) vs 6/14 (43%) sans récurrence ni décès (p=0.024).

## *2) Implication*

Cette étude montre que l'on peut cibler les LAVA épocardiques par l'ablation du site en regard lorsqu'ils se situent dans le VD ou dans une zone amincie du VG (<5mm) ou lorsqu'il existe également des LAVA sur le site endocardique en regard. Dans les autres cas, l'efficacité est très aléatoire et il vaut certainement mieux réaliser d'emblée l'ablation sur le versant épocardique lorsque l'isthme de la TV se situe à cet endroit. De plus si le myocarde n'est pas aminci et qu'il n'y a pas de potentiel anormal en endocardique, l'ablation risque de détruire du myocarde sain. De plus, cette approche permet de monitorer la transmuralité des lésions et de diminuer/éviter l'ablation sur le versant épocardique malgré un substrat épocardique chez certains.

# Accepted Manuscript



Endocardial Ablation to Eliminate Epicardial Arrhythmia Substrate in Scar-Related Ventricular Tachycardia

Yuki Komatsu, MD Matthew Daly, MBChB Frédéric Sacher, MD Hubert Cochet, MD Arnaud Denis, MD Nicolas Derval, MD Laurence Jesel, MD Stephan Zellerhoff, MD Han S. Lim, MBBS Amir Jadidi, MD Isabelle Nault, MD Ashok Shah, MD Laurent Roten, MD Patrizio Pascale, MD Daniel Scherr, MD Valerie Aurillac-Lavignolle, BSc Méléze Hocini, MD Michel Haïssaguerre, MD Pierre Jaïs, MD

PII: S0735-1097(14)00173-9

DOI: [10.1016/j.jacc.2013.10.087](https://doi.org/10.1016/j.jacc.2013.10.087)

Reference: JAC 19729

To appear in: *Journal of the American College of Cardiology*

Received Date: 20 July 2013

Revised Date: 3 September 2013

Accepted Date: 7 October 2013

Please cite this article as: Komatsu Y, Daly M, Sacher F, Cochet H, Denis A, Derval N, Jesel L, Zellerhoff S, Lim HS, Jadidi A, Nault I, Shah A, Roten L, Pascale P, Scherr D, Aurillac-Lavignolle V, Hocini M, Haïssaguerre M, Jaïs P, Endocardial Ablation to Eliminate Epicardial Arrhythmia Substrate in Scar-Related Ventricular Tachycardia, *Journal of the American College of Cardiology* (2014), doi: 10.1016/j.jacc.2013.10.087.

This is a PDF file of an unedited manuscript that has been accepted for publication. As a service to our customers we are providing this early version of the manuscript. The manuscript will undergo copyediting, typesetting, and review of the resulting proof before it is published in its final form. Please note that during the production process errors may be discovered which could affect the content, and all legal disclaimers that apply to the journal pertain.

**Endocardial Ablation to Eliminate Epicardial Arrhythmia Substrate in Scar-Related Ventricular Tachycardia**

Yuki Komatsu, MD, Matthew Daly, MBChB, Frédéric Sacher, MD, Hubert Cochet, MD, Arnaud Denis, MD, Nicolas Derval, MD, Laurence Jesel, MD, Stephan Zellerhoff, MD, Han S Lim, MBBS, Amir Jadidi, MD, Isabelle Nault, MD, Ashok Shah, MD, Laurent Roten, MD, Patrizio Pascale, MD, Daniel Scherr, MD, Valerie Aurillac-Lavignolle, BSc, Mélèze Hocini, MD, Michel Haïssaguerre, MD, Pierre Jaïs, MD.

From the Department of Cardiac Electrophysiology, Hôpital Cardiologique du Haut-Lévêque, Université Victor Segalen Bordeaux II, Institut LYRIC, Equipex MUSIC, Bordeaux, France.

**SHORT RUNNING TITLE:** Endocardial ablation for epicardial VT substrate

**DISCLOSURE:** none

**SOURCE OF FUNDING:** This research was supported by Leducq Foundation grant number: 09 CVD 03

**ADDRESS for CORRESPONDENCE:**

Yuki Komatsu, MD.

Department of Cardiac Electrophysiology, Hôpital Cardiologique du Haut-Lévêque and the Université Victor Segalen Bordeaux II, Bordeaux, France.

Address: Avenue de Magellan, 33604 Bordeaux-Pessac, France.

Phone number: +33 5 57 65 65 65

Fax number: +33 5 57 65 65 09

e-mail: yk.komat@gmail.com

## STRUCTURED ABSTRACT

**Objectives:** We evaluated the feasibility and safety of epicardial substrate elimination using endocardial radiofrequency (RF) delivery in patients with scar-related ventricular tachycardia (VT).

**Background:** Epicardial RF delivery is limited by fat or associated with bleeding, extra-cardiac damages, coronary vessels and phrenic nerve injury. Alternative ablation approaches may be desirable.

**Methods:** Forty-six patients (18 ischemic cardiomyopathy [ICM], 13 non-ischemic dilated cardiomyopathy [NICM], 15 arrhythmogenic right ventricular cardiomyopathy [ARVC]) with sustained VT underwent combined endo- and epicardial mapping. All patients received endocardial ablation targeting local abnormal ventricular activities in the endocardium (Endo-LAVA) and epicardium (Epi-LAVA), followed by epicardial ablation if needed.

**Results:** From a total of 173 endocardial ablations targeting Epi-LAVA at the facing site, 48 (28%) applications (ICM: 20/71 [28%], NICM: 3/39 [8%], ARVC: 25/63 [40%]) successfully eliminated the Epi-LAVA. Presence of Endo-LAVA, most delayed and low bipolar amplitude of Epi-LAVA, low unipolar amplitude in the facing endocardium, and Epi-LAVA within a wall thinning area at CT scan were associated with successful ablation. Endocardial ablation could abolish all Epi-LAVA in 4 ICM and 2 ARVC patients, whereas all patients with NICM required epicardial ablation. Endocardial ablation was able to eliminate Epi-LAVA at least partially in 15 (83%) ICM, 2 (13%) NICM, and 11 (73%) ARVC patients, contributing to a potential reduction in epicardial RF applications. Pericardial bleeding occurred in 4 patients with epicardial ablation.

**Conclusions:** Elimination of Epi-LAVA using endocardial RF delivery is feasible and may be used first to reduce the risk of epicardial ablation.

**KEY WORDS:** arrhythmia, ventricular tachycardia, ablation, epicardium, local abnormal ventricular activities

## ABBREVIATIONS:

ARVC = arrhythmogenic right ventricular cardiomyopathy

ICD = implantable cardioverter defibrillator

ICM = ischemic cardiomyopathy

LAVA = local abnormal ventricular activities

LV = left ventricle

MDCT = multi-detector computed tomography

NICM = non-ischemic dilated cardiomyopathy

RF = radiofrequency

VT = ventricular tachycardia

## INTRODUCTION

Since the first description of epicardial ventricular tachycardia ablation using percutaneous subxiphoid access in 1996 (1), epicardial mapping and ablation have been widely performed for the treatment of scar-related ventricular tachycardia (VT). Combined endo- and epicardial ablation has been used to achieve improved outcomes, not only in the setting of non-ischemic dilated cardiomyopathy (NICM) (2,3) and arrhythmogenic right ventricular cardiomyopathy (ARVC) (4-6), but also in ischemic cardiomyopathy (ICM) (7,8). Regions of critically slow conduction necessary for reentry can lie deep in the subendocardial layer or in the epicardial myocardium, and can be recorded as local abnormal ventricular activities (LAVA) from the pericardial space. Complete elimination of both endocardial LAVA (Endo-LAVA) and epicardial LAVA (Epi-LAVA), if present, is associated with superior survival from recurrent VT during long-term follow-up (9).

Endocardial ablation is usually effective in eliminating most endocardial substrate but epicardial lesions are thought to be required for epicardial targets. Epicardial radiofrequency (RF) ablation has potential risks, however, such as pericardial bleeding, and injury of coronary vessels or the phrenic nerve (10-12). Epicardial ablation, particularly if contact force is not directed toward the heart, can result in extra-cardiac damage such as pulmonary lesions (13). Furthermore, epicardial fat can significantly reduce ablation lesion depth (14). One fourth of the epicardial surface is covered by >4mm of fat, which is predominantly present at the left ventricular (LV) superior wall and right ventricular (RV) anterior wall (15). An epicardial fat layer >7mm and substrate in close proximity to the coronary arteries are associated with epicardial ablation failure (15), highlighting the need for alternative ablation approaches.

The objective of this study was to evaluate the feasibility and safety of of Epi-LAVA elimination using endocardial RF delivery in patients with scar-related VT due to ICM,



NICM, and ARVC. The secondary objective was to assess variables which might be predictive of successful Epi-LAVA elimination endocardially, including clinical and electrophysiologic parameters and anatomical information as assessed by contrast-enhanced multidetector computed tomography (MDCT).

## METHODS

### Patient selection

This study enrolled consecutive patients who underwent combined endo- and epicardial mapping/ablation of scar-related sustained VT using a 3-dimensional electroanatomic mapping system between April 2009 and March 2013 at our center. All patients had episodes of repetitive sustained VT, resistant to anti-arrhythmic drug therapy, requiring external cardioversion or therapy from an implantable cardioverter defibrillator (ICD). ICM was diagnosed on the basis of significant coronary artery disease (>75% stenosis), documented myocardial infarction, and/or Q waves in the 12-lead electrocardiogram (ECG) with regional wall motion abnormality. The diagnosis of NICM was based on a left ventricular ejection fraction of <50% in the absence of coronary artery disease, documented myocardial infarction or focal wall motion abnormality. Patients diagnosed as ARVC fulfilled 2010 task force criteria (16). We excluded other causes of sustained VT, such as cardiac sarcoidosis, congenital heart disease, long-lasting hypertensive heart disease, valvular heart disease, and toxin-related cardiomyopathy. Written informed consent was obtained in all patients.

### Electrophysiologic study

All anti-arrhythmic drugs except amiodarone were discontinued for at least 5 half-lives before ablation if the stability of arrhythmia allowed it. ICD therapies were turned off and the device programmed to a surveillance-only mode. A 6-French steerable quadripolar or decapolar catheter (Xtrem, ELA medical, Montrouge, France; or Dynamic, BARD Electrophysiology, MA, USA) was inserted from the right femoral vein and placed into the

distal coronary sinus or at the RV apex. The LV endocardium was accessed by transseptal or retrograde transaortic approach. Pericardial access was obtained through a subxiphoid and anterior puncture under left lateral fluoroscopic guidance in all patients. The indications for epicardial access were previous failed endocardial ablation, minimal or no endocardial scar, suspected epicardial substrate based on VT morphology (17,18) or the type of cardiomyopathy (NICM and ARVC). A steerable sheath (Agilis, St-Jude Medical, St.Paul, Minnesota, USA) was introduced into the pericardial space. Continuous aspiration was then connected to the sheath. Systemic heparinization was maintained throughout the procedure with a target activated clotting time  $\geq 200$ sec after establishment of pericardial access and transseptal puncture. Both endo- and epicardial mapping were performed with a multipolar high-density mapping catheter (PentaRay, Biosense Webster, Diamond Bar, California, USA) in all patients. Although PentaRay allows high-density mapping in both endo- and epicardium, it may produce mechanical ectopics when used endocardially. In this situation, we used a 4-mm tip mapping catheter (Navistar-Thermocool, Biosense Webster) to complete mapping. Electrograms were filtered at 30 to 250 Hz (bipolar) and 1 to 240 Hz (unipolar). Electroanatomical mapping was performed during sinus rhythm using Carto (Biosense Webster) or NavX (St.Jude Medical).

#### MDCT image processing and registration

Our strategy for MDCT image acquisition and registration with 3-dimensional electroanatomic map is provided in the supplemental material and is as previously described (19). Contrast-enhanced MDCT was performed on a 64-slice CT scanner (SOMATOM Definition, Siemens Medical Solutions, Forchheim, Germany) 1-3 days before the procedure in 21 patients. Three-dimensional surface meshes of the endocardium, epicardium, coronary arteries, coronary sinus, and LV myocardial wall thinning (defined as areas with end-diastolic wall thickness  $< 5$ mm) were generated from MDCT data using CardioviZ3D software (INRIA,

Sophia Antipolis, France). A cut-off of 5mm for significant LV wall thinning was based on a previous report describing the reference values of wall thicknesses by MDCT in a healthy population (20). MDCT data were imported into 3-dimensional navigation systems and were integrated with the electroanatomic maps. Whether Epi-LAVA were located inside or outside of the LV wall thinning segmentation was assessed.

#### Definition of LAVA and low-voltage zone

As previously described (9,21), LAVA were defined as electrograms from poorly coupled surviving myocardial fibers with the following features: (i) sharp, high-frequency ventricular potentials distinct from the far-field ventricular electrogram, (ii) occurring anytime during or, more frequently, after the far-field ventricular electrogram during sinus rhythm, (iii) sometimes displaying double or multiple high-frequency signals separated by very low-amplitude signals or an isoelectric interval. When LAVA occur within the QRS and are fused with the far-field ventricular potential, ventricular pacing with extra systole is performed to differentiate them from far-field ventricular potential. LAVA are delayed and distinguished from the far-field potential by the pacing maneuver, due to poor coupling of the muscle bundle generating the LAVA signal.

We employed the following voltage criteria: a peak-to-peak bipolar amplitude of  $<1.5\text{mV}$  defined the bipolar low-voltage zone (22); a unipolar amplitude of  $<8.3\text{mV}$  in the LV, and  $<5.5\text{mV}$  in the RV defined the low unipolar voltage zone (23,24).

#### Radiofrequency ablation

After completion of endo- and epicardial mapping, VT inducibility was tested by programmed ventricular stimulation from RV apex at basic drive cycle length 600 and 400 ms with up to triple extrastimuli decrementally to 200 ms or ventricular refractoriness. When hemodynamically tolerated VT was inducible, ablation was guided by conventional activation and entrainment mapping (25). The critical sites of VT were defined as the sites

where pre-systolic or mid-diastolic electrograms were present and either radiofrequency ablation or mechanical manipulation by the catheter terminated the VT, followed by non-inducibility of the VT that was reproducibly inducible before. After termination of VT, further ablation targeting LAVA during sinus rhythm was performed. In patients with non-inducible or poorly tolerated VT, ablation of LAVA was performed in sinus rhythm. Radiofrequency energy was delivered with a 3.5mm open-irrigation catheter (NaviStar-Thermocool) with a power of 30-50W endocardially. When ablating epicardially or in the RV endocardium, power ranged from 25 to 35W.

If LAVA were detected on both endo- and epicardium, our strategy was always to start ablation endocardially, aiming at elimination of both Endo- and Epi-LAVA. If LAVA were detected epicardially in the absence of Endo-LAVA, endocardial ablation was performed at the facing site aiming to abolish the potentials transmurally. During endocardial ablation at the facing site of Epi-LAVA, careful monitoring of transmural response and elimination of Epi-LAVA was possible using a multipolar high-density mapping catheter (PentaRay, Biosense Webster) which was placed at Epi-LAVA sites and stabilized by a steerable sheath (Agilis, St-Jude Medical) (Figure 1). This strategy was repeated at adjacent sites as needed to achieve complete Epi-LAVA elimination. After endocardial ablation, epicardial mapping of areas previously displaying LAVA was performed and used to guide further ablation as indicated by Epi-LAVA persistence. Re-mapping allowed us to classify patients as having complete or incomplete Epi-LAVA elimination after endocardial ablation.

The goal and ideal procedural end point was complete elimination of all identified LAVA. Induction of VT was repeated with programmed stimulation using the same protocol as pre-ablation. In patients with hemodynamically unstable VT, VT-inducibility was not retested post-ablation.

Follow-up

After ablation, ICD therapies were reprogrammed with active VT and ventricular fibrillation zones. Patients were monitored at least 48h in-hospital before discharge. Patients were followed every 3 months to assess VT recurrences. Recurrence of VT after hospital discharge was assessed by ICD interrogation at each visit, and careful interview, ECG, and a Holter monitoring for the patients without ICD. Any sustained VT during follow-up, whether symptomatic, treated by ICD or not, was considered a recurrence of VT.

#### Statistical analysis

Categorical variables were expressed as numbers and percentages, and were compared using Pearson's chi-square test or Fisher's exact test, as appropriate. Continuous data for normally distributed variables were expressed as mean $\pm$ standard deviation and compared by Student t-test. Non-normally distributed variables were expressed as median [25, 75th percentiles] and compared using Mann-Whitney U-test or Kruskal-Wallis test. No corrections were made for multiple observations within individuals. Statistical calculations were performed using SPSS version 21.0 (IBM, SPSS, Chicago, Illinois, USA). All tests were 2-tailed, and a p-value of  $<0.05$  was considered statistically significant.

## RESULTS

#### Study population

During the study period, a total of 51 patients (20 ICM, 15 NICM, 16 ARVC) underwent combined endo- and epicardial mapping with a 3-dimensional navigation system. The 46 (18 ICM, 13 NICM, 15 ARVC) patients who demonstrated evidence of Epi-LAVA comprised this study cohort (Table 1). Four patients had previously failed ablation (range 1 to 3). No patient had previous cardiac surgery. Pericardial access was obtained percutaneously in all. For LV endocardial access (ICM and NICM patients), a retrograde approach was used in 7 patients and a transseptal approach in 24 patients.

#### Prevalence of abnormal regions

Endo- and epicardium were mapped with  $420\pm 271$  and  $572\pm 379$  points per map, respectively. In ICM and NICM, the locations of epicardial low-voltage region (bipolar voltage  $< 1.5\text{mV}$ ) with presence of Epi-LAVA were the following: the apex in 15 (13 ICM, 2 NICM), anterior in 13 (10 ICM, 3 NICM), inferior in 15 (8 ICM, 7 NICM), and lateral in 18 (5 ICM, 13 NICM). In ARVC, epicardial low-voltage regions with Epi-LAVA were identified apically in 3, anteriorly in 9, inferiorly in 9, and laterally in 11. An endocardial low-voltage area was identified in all (100%) patients with ICM, 9 (69%) patients with NICM, and 13 (87%) patients with ARVC. The endo- and epicardial bipolar low-voltage area was  $80.2 [62.9, 124.3] \text{ cm}^2$  and  $77.7 [45.4, 111.4] \text{ cm}^2$  in ICM;  $11.7 [3.2, 29.6] \text{ cm}^2$  and  $45.2 [39.2, 53.6] \text{ cm}^2$  in NICM; and  $32.5 [11.1, 55.7] \text{ cm}^2$  and  $110.6 [55.0, 139.0] \text{ cm}^2$  in ARVC. Contrast-enhanced MDCT was performed in 21 patients (12 ICM and 9 NICM). A wall thinning region was identified in all ICM and 7 NICM patients. In all patients, high resolution wall thinning segmentation was successfully integrated with 3-dimensional electroanatomic mapping, and its location corresponded to the electrophysiologic scar.

#### Endocardial ablation at the facing site of Epi-LAVA

There was no significant artifactual interference on the multielectrode catheter placed on the epicardium during ablation from the endocardial site, which enabled monitoring of the transmural response in the target Epi-LAVA (Figure 1). A total of 173 endocardial ablations of Epi-LAVA monitored by multielectrode catheter during the RF energy delivery were analyzed. Of these, 79 (46%) were targeted from sites with no Endo-LAVA. Among 173 Epi-LAVA sites, 48 (28%) applications successfully eliminated the facing Epi-LAVA. Successful ablation was most frequently achieved in ARVC (25 of 63 applications [40%]), followed by ICM (20 of 71 applications [28%]). In NICM, only 3 of 39 applications (8%) successfully eliminated the Epi-LAVA at the facing site. Figure 2 shows Epi-LAVA and VT reentry circuit eliminated by ablation at the facing endocardial site in a patient with ARVC. In total, 39 VTs

(18 in ICM, 9 in NICM, 12 in ARVC) were hemodynamically tolerated and mapped using conventional activation and entrainment mapping approaches. Of these, 23 (7 in ICM, 7 in NICM, 9 in ARVC) VTs had the critical site of VT reentrant circuit identified in the epicardium. Endocardial ablation at the facing site of the epicardial critical isthmus was performed leading to successful termination of 5 VTs (2 [28%] ICM, 0 [0%] NICM, 3 [33%] ARVC).

Table 2 shows predictors of successful Epi-LAVA elimination endocardially. There were no significant differences in RF time, average temperature, average impedance, and power between successful and unsuccessful ablation. Endo-LAVA at the ablation site was more frequently present in the success site (32/48 [67%] vs. 62/125 [50%],  $p=0.044$ ). The most delayed Epi-LAVA were more frequently eliminated; that is, the duration from the onset of ventricular electrogram to the end of Epi-LAVA (EGM-duration) was significantly longer in the successful site than unsuccessful sites (143 [116, 186] ms vs. 110 [86, 140] ms,  $p<0.001$ ). Bipolar amplitude of Epi-LAVA was significantly lower at successful ablation sites (0.26 [0.21, 0.34] mV vs. 0.71 [0.34, 1.24] mV,  $p<0.001$ ). Bipolar and unipolar amplitude of the facing endocardial ablation site was also lower at successful ablation sites (0.35 [0.21, 0.61] mV vs. 0.54 [0.22, 1.03] mV,  $p=0.041$ ; and 2.52 [2.02, 2.96] mV vs. 4.51 [3.38, 5.51] mV,  $p<0.001$ , respectively).

The relationship between the impact of endocardial ablation on Epi-LAVA at the facing site and LV wall thinning seen on MDCT was assessed in 95 RF applications in the 21 patients. Of these, 72 (76%) Epi-LAVA (ICM: 59/67 [88%], NICM: 13/28 [46%]) were located within the wall thinning area, and the remaining 23 were outside. None of the 23 Epi-LAVA outside the wall thinning segmentation could be eliminated transmurally from the endocardium, whereas 23 (32%) of 72 Epi-LAVA within the wall thinning could be eliminated ( $p=0.002$ ).



***Overall outcome of endocardial ablation of Epi-LAVA***

In 4 of 18 patients with ICM and 2 of 15 patients with ARVC, endocardial ablation could abolish all Epi-LAVA. These patients achieved complete elimination of both Endo- and Epi-LAVA using only endocardial ablation. In contrast, all patients with NICM required epicardial ablation. Incomplete Epi-LAVA elimination after endocardial ablation occurred in 22 patients (11 ICM, 2 NICM, 9 ARVC). Therefore, endocardial ablation had an impact on Epi-LAVA in 15 (83%) ICM, 2 (13%) NICM, and 11 (73%) ARVC patients, contributing to a potential reduction in epicardial RF applications.

Table 3 shows the characteristics of patients with complete, partial, and no elimination of Epi-LAVA by endocardial ablation. Patients with no impact of endocardial ablation on Epi-LAVA had smallest low-voltage area in both endo- and epicardium. The presence of Endo-LAVA was associated with a greater impact of endocardial ablation on Epi-LAVA. In all patients with complete elimination of Epi-LAVA endocardially (6/6 [100%]) and most of patients with partial elimination (15/22 [68%]), all Epi-LAVA corresponded with low endocardial unipolar voltage, compared to 3/18 (17%) patients with no elimination.

In 8 (7 ICM and 1 NICM) of 21 patients undergoing MDCT, all identified Epi-LAVA were located within the LV wall thinning segmentation. In all of these, endocardial ablation had an impact on Epi-LAVA (complete elimination in 2 and partial elimination in 6). The remaining 13 patients had presence of Epi-LAVA which were located outside the wall thinning (Figure 3). None of these attained complete elimination of Epi-LAVA endocardially; 4 had partial impact of endocardial ablation on Epi-LAVA and 9 had no impact.

**Procedural and follow-up results**

Mean procedure and RF time were  $310 \pm 65$  min and  $34 \pm 14$  min, respectively. Mean RF time on the epicardium was  $12.5 \pm 11.7$  min. All identified LAVA were completely eliminated in 32

(70%) patients (13/18 [72%] ICM, 7/13 [54%] NICM, 12/15 [80%] ARVC). As shown in Figure 4, complete elimination of all Endo- and Epi-LAVA was more likely to be achieved in patients with impact of endocardial ablation on Epi-LAVA than those without (23/28 [72%] versus 9/18 [50%],  $p=0.021$ ). In 14 patients, complete elimination of LAVA could not be achieved. Of these, 6 (1 ICM, 4 NICM, 1 ARVC) patients had epicardial LAVA which were located close to the coronary arteries or phrenic nerve. In the remaining 8 patients, LAVA could not be abolished despite extensive ablation. Pericardial bleeding occurred in 4 patients. Three of them were managed conservatively, but one patient required surgical intervention. Pericardial bleeding only occurred in patients who received epicardial RF delivery. There was neither phrenic nerve palsy, injury of coronary vessels, hepatic injury nor intraabdominal bleeding.

One patient with ICM died of severe heart failure with recurrence of VT storm 48 hours after the ablation procedure. One patient with ICM died of a noncardiac cause 5 months after the intervention. After a median follow-up period of 11 months, 31 (67%) patients were free from both death and VT recurrence. Patients who achieved complete elimination of Endo- and Epi-LAVA were more frequently free from VT recurrence and death (25/32 [78%] vs. 6/14 [43%],  $p=0.024$ ). Of 6 patients in whom endocardial ablation abolished all Epi-LAVA, 5 patients were free from VT recurrence and death, and 1 patient experienced VT recurrence. Three patients underwent redo procedures, two of whom had LAVA successfully eliminated during the initial procedure and the other had persistent LAVA. The repeat epicardial procedure with percutaneous subxiphoid access was successfully performed in all patients. Both patients who achieved complete LAVA elimination at the index procedure had LAVA recovery. Repeat ablation eliminated all LAVA.

## DISCUSSION

This study describes the feasibility and safety of a novel approach for modification of

subepicardial VT substrate from endocardial ablation and demonstrates the following:

- Endocardial RF was associated with Epi-LAVA elimination at the facing site in 28% of applications, and complete or incomplete elimination was achieved in 61% of patients overall, thereby reducing the need for epicardial ablation.
- The underlying structural heart disease was a major determinant of success, as only 8% of endocardial applications eliminated the facing Epi-LAVA in NICM, compared to 28% in ICM and 40% in ARVC.
- The electrophysiological characteristics of the targeted region were also important; most delayed and lowest bipolar amplitude Epi-LAVA were more prone to complete elimination. Similarly low unipolar amplitude in the facing endocardium was associated with greater success.
- Endocardial ablation was more likely to eliminate epicardial substrate when delivered in a thin walled region of the LV (<5mm at MDCT).

These findings indicate that epicardial scar homogenization by complete elimination of poorly coupled bundles through endocardial ablation is more readily achieved within the most severe scars.

#### Elimination of epicardial LAVA by endocardial transmural lesion

Recurrent VT originating from the subepicardium is thought to be an important reason for failure of endocardial ablation (26-30). Elimination of epicardial arrhythmia substrate using endocardial ablation is conventionally thought to be impractical as transmural ventricular lesions are probably rare using the current ablation technology. Endocardial substrate-based ablation targeting delayed and fragmented local potentials has been reported, but never used while monitoring the epicardial facing site. In this study, the multielectrode mapping catheter placed epicardially was used not only for high-density mapping but also as a landmark of the target Epi-LAVA location, guiding the operator to the facing endocardial site exactly. It also

enables online monitoring of the impact of endocardial ablation on Epi-LAVA.

Both low bipolar amplitude of the target Epi-LAVA and low unipolar amplitude at the facing endocardial region were strongly associated with the successful elimination of Epi-LAVA transmurally. These findings may indicate that transmural Epi-LAVA elimination is more feasible in regions of wall thinning. Where Epi-LAVA are located outside the wall thinning area, it seems to be difficult to penetrate deep enough into the myocardium to disrupt the intramural or subepicardial circuits. We found that the negative predictive value for elimination of Epi-LAVA from the endocardium outside the LV wall thinning areas was 100%. These findings allow the operator to avoid ineffective RF energy applications on the endocardium. In patients with NICM, Epi-LAVA elimination from the facing endocardial site is more difficult. This may be explained by our finding of a lower proportion of Epi-LAVA within the wall thinning segmentation in NICM than in ICM. This ablation technique yields maximal benefit in patients with ARVC. A prior study of in vivo lesion assessment has demonstrated that transmural lesions are more likely to be attained in the RV; not unexpected as the ventricular wall here is thinner compared to the LV (13).

#### Impact of elimination of endocardial LAVA on epicardial substrate

Even if endocardial ablation cannot eliminate the Epi-LAVA at the facing site transmurally, a subset of epicardial scar had no LAVA anymore after complete elimination of Endo-LAVA. The presence of Endo-LAVA was significantly associated with the impact of endocardial ablation on Epi-LAVA, suggesting the presence of the interconnecting channels between endo- and epicardial LAVA regions. This phenomenon is less common in NICM compared to ICM. This is consistent with the known characteristics of scar in different types of structural heart disease; that is, arrhythmia substrates in NICM are located predominantly intramurally or subepicardially with the minimal subendocardial substrate (3), whereas the ischemic scar usually progresses from the subendocardium to the epicardium within the territory of the

culprit coronary arteries.

### ***Clinical implications***

Epicardial mapping and ablation might conventionally be started directly prior to endocardial attempt if epicardial substrate is thought to be responsible for VT perpetuation. However, our findings show that some epicardial ablations can be avoided if endocardial ablation is performed first. Elimination of Epi-LAVA endocardially can diminish the need for epicardial RF energy delivery, increasing the safety of ablation. Furthermore, the present technique has possibility to improve the efficacy of ablation as it may eliminate subepicardial surviving fibers which could have been impossible to eradicate from the epicardium because of the existence of epicardial fat and coronary vessels.

The present study provides a valuable clue suggesting the anatomical and electrophysiological characteristics which predict the impact of endocardial ablation on epicardial arrhythmia substrate modification. This approach is less useful if Epi-LAVA are located outside the LV wall thinning area as imaged by contrast-enhanced MDCT, if there is no substrate at the corresponding endocardial region, or if the unipolar voltage of corresponding endocardial region is normal. Also, it is less effective for substrate in NICM. Further development of alternative approaches is warranted to improve the efficacy of ablation in these less favorable situations.

### ***Limitations***

Although this ablation technique was performed in consecutive patients prospectively, RF parameters, such as ablation time and power, were not systematically standardized in each RF energy application for the purpose of this study. Moreover, we did not deliver higher power or longer RF selectively at healthier regions with normal-voltage and non-thinned sites in an attempt to make a deeper lesion. Although our data provided no justification for high power output or prolonged ablation delivery, we cannot rule out the possibility that this more

aggressive strategy might be associated with a higher rate of Epi-LAVA elimination.

However, extensive endocardial ablation to get rid of Epi-LAVA may increase the risk for complications such as volume overload, steam pop or cardiac perforation, and thromboembolic events.

## CONCLUSIONS

Elimination of epicardial LAVA from endocardial ablation is feasible and has maximum benefit in patients with arrhythmogenic right ventricular cardiomyopathy and ischemic cardiomyopathy where epicardial substrate is located in a thin myocardial wall. This novel approach has the potential to reduce or obviate the need for epicardial radiofrequency energy delivery, and therefore could be performed prior to epicardial ablation for the modification of epicardial arrhythmia substrate.

## REFERENCES

1. Sosa E, Scanavacca M, d'Avila A, Pilleggi F. A new technique to perform epicardial mapping in the electrophysiology laboratory. *J Cardiovasc Electrophysiol.*1996;7:531-536.
2. Maury P, Escourrou G, Guilbeau C, Duparc A, Hebrard A, Delay M. Histopathologic effects of endocardial and epicardial percutaneous radio- frequency catheter ablation in dilated nonischemic cardiomyopathy. *Pacing Clin Electrophysiol.*2008;31:1218-1222.
3. Cano O, Hutchinson M, Lin D, et al. Electroanatomic substrate and ablation outcome for suspected epicardial ventricular tachycardia in left ventricular nonischemic cardiomyopathy. *J Am Coll Cardiol.*2009;54:799-808.
4. Bai R, Di Biase L, Shivkumar K, et al. Ablation of ventricular arrhythmias in arrhythmogenic right ventricular dysplasia/cardiomyopathy: arrhythmia-free survival after endo-epicardial substrate based mapping and ablation. *Circ Arrhythm Electrophysiol.*2011;4:478-485.
5. Philips B, Madhavan S, James C, et al. Outcomes of catheter ablation of ventricular tachycardia in arrhythmogenic right ventricular dysplasia/cardiomyopathy. *Circ Arrhythm Electrophysiol.*2012;5:499-505.
6. Garcia FC, Bazan V, Zado ES, Ren JF, Marchlinski FE. Epicardial substrate and outcome with epicardial ablation of ventricular tachycardia in arrhythmogenic right ventricular cardiomyopathy/dysplasia. *Circulation.*2009;120:366-375.
7. Tung R, Michowitz Y, Yu R, et al. Epicardial ablation of ventricular tachycardia: An institutional experience of safety and efficacy. *Heart Rhythm.*2013;10:490-8.
8. Di Biase L, Santangeli P, Burkhardt DJ, et al. Endo-epicardial homogenization of the scar versus limited substrate ablation for the treatment of electrical storms in patients with ischemic cardiomyopathy. *J Am Coll Cardiol.*2012;60:132-141.



9. Jaïs P, Maury P, Khairy P, et al. Elimination of local abnormal ventricular activities: a new end point for substrate modification in patients with scar-related ventricular tachycardia. *Circulation*.2012;125:2184-96.
10. Aliot EM, Stevenson WG, Almendral-Garrote JM, et al. EHRA/HRS expert consensus on catheter ablation of ventricular arrhythmias: developed in a partnership with the European Heart Rhythm Association (EHRA), a registered branch of the European Society of Cardiology (ESC), and the Heart Rhythm Society (HRS); in collaboration with the American College of Cardiology (ACC) and the American Heart Association (AHA). *Heart Rhythm*.2009;6:886-993.
11. Della Bella P, Brugada J, Zeppenfeld K, et al. Epicardial ablation for ventricular tachycardia: a European multicenter study. *Circ Arrhythm Electrophysiol*.2011;4:653-659.
12. Sacher F, Roberts-Thomson K, Maury P, et al. Epicardial ventricular tachycardia ablation a multicenter safety study *J Am Coll Cardiol*.2010;55:2366-2372.
13. Sacher F, Wright M, Derval N, et al. Endocardial versus epicardial ventricular radiofrequency ablation: utility of in vivo contact force assessment. *Circ Arrhythm Electrophysiol*.2013;6:144-50.
14. D'Avila A, Houghtaling C, Gutierrez P. Catheter ablation of ventricular epicardial tissue: a comparison of standard and cooled-tip radiofrequency Energy. *Circulation*.2004;109:2363-9.
15. van Huls van Taxis CF, Wijnmaalen AP, Piers SR, van der Geest RJ, Schalij MJ, Zeppenfeld K. Real-time integration of MDCT-derived coronary anatomy and epicardial fat: impact on epicardial electroanatomic mapping and ablation for ventricular arrhythmias. *JACC Cardiovasc Imaging*.2013;6:42-52.
16. Marcus FI, McKenna WJ, Sherrill D, et al. Diagnosis of arrhythmogenic right ventricular

cardiomyopathy/dys- plasia: proposed modification of the task force criteria.

*Circulation*.2010;121:1533-1541.

17. Berruezo A, Mont L, Nava S, Chueca E, Bartholomay E, Brugada J. Electrocardiographic recognition of the epicardial origin of ventricular tachycardias.  
*Circulation*.2004;109:1842-7.
18. Vallès E, Bazan V, Marchlinski FE. ECG criteria to identify epicardial ventricular tachycardia in nonischemic cardiomyopathy. *Circ Arrhythm Electrophysiol*.2010;3:63-71.
19. Komatsu Y, Cochet H, Jadidi A, et al. Regional Myocardial Wall Thinning at Multi-Detector Computed Tomography Correlates to Arrhythmogenic Substrate in Post-Infarction Ventricular Tachycardia: Assessment of Structural and Electrical Substrate.  
*Circ Arrhythm Electrophysiol*.2013;6:342-350.
20. Stolzmann P, Scheffel H, Leschka S, et al. Reference values for quantitative left ventricular and left atrial measurements in cardiac computed tomography. *Eur Radiol*.2008;18:1625-1634.
21. Komatsu Y, Daly M, Sacher F, et al. Electrophysiologic Characterization of Local Abnormal Ventricular Activities in Post-Infarction Ventricular Tachycardia with Respect to Their Anatomical Location. *Heart Rhythm*.2013;(in press).
22. Marchlinski FE, Callans DJ, Gottlieb CD, Zado E. Linear ablation lesions for control of unmappable ventricular tachycardia in patients with ischemic and nonischemic cardiomyopathy. *Circulation*.2000;101:1288-96.
23. Hutchinson MD, Gerstenfeld EP, Desjardins B, et al. Endocardial unipolar voltage mapping to detect epicardial ventricular tachycardia substrate in patients with nonischemic left ventricular cardiomyopathy. *Circ Arrhythm Electrophysiol*.2011;4:49-55.
24. Polin GM, Haqqani H, Tzou W, et al. Endocardial unipolar voltage mapping to identify epicardial substrate in arrhythmogenic right ventricular cardiomyopathy/dysplasia. *Heart*

- Rhythm*.2011;8:76-83.
25. Stevenson WG, Khan H, Sager P, et al. Identification of reentry circuit sites during catheter mapping and radiofrequency ablation of ventricular tachycardia late after myocardial infarction. *Circulation*.1993;88:1647-1670.
  26. Kaltenbrunner W, Cardinal R, Dubuc M, et al. Epicardial and endocardial mapping of ventricular tachycardia in patients with myocardial infarction: is the origin of the tachycardia always subendocardially localized? *Circulation*.1991;84:1058-71.
  27. Blanchard SM, Walcott GP, Wharton JM, Ideker RE. Why is catheter ablation less successful than surgery for treating ventricular tachycardia that results from coronary artery disease? *Pacing Clin Electrophysiol*.1994;17:2315-24.
  28. Trappe HJ, Klein H, Auricchio A, et al. Catheter ablation of ventricular tachycardia: role of the underlying etiology and the site of energy delivery. *Pacing Clin Electrophysiol*.1992;15:411-24.
  29. Kottkamp H, Hindricks G, Chen X, et al. Radiofrequency catheter ablation of sustained ventricular tachycardia in idiopathic dilated cardiomyopathy. *Circulation*.1995;92:1159-68.
  30. Schweikert RA, Saliba WI, Tomassoni G, et al. Percutaneous pericardial instrumentation for endo-epicardial mapping of previously failed ablations. *Circulation*.2003;108:1329-35.

**FIGURE LEGENDS****Figure 1. Endocardial ablation eliminates the epicardial LAVA at the facing site in a patient with ICM**

**A.** The multielectrode catheter (PentaRayNav) lying epicardially displayed LAVA (\*). Endocardial ablation catheter placed at the facing site to the epicardial PentaRayNav by a transseptal approach also showed abnormal sharp signals. **B.** Endocardial ablation eliminated epicardial LAVA after increasing their delay.

**Figure 2. Epicardial VT reentry circuit eliminated by ablation at the facing endocardial site in a patient with ARVC**

**A.** VT which was hemodynamically tolerated was mapped in both endo and epicardium in an ARVC patient. The isochronal map during VT showed the critical isthmus of the VT reentrant circuit at the epicardial basal postero-lateral region. The local electrograms at the critical isthmus displayed fractionated signals covering almost the entire cycle length of the VT (**a,b,c,d**). However, the critical isthmus was close to the right coronary artery rendering radiofrequency ablation at the region unwarranted. **B.** The multielectrode catheter (PentaRayNav) was placed at the epicardial slow conducting region. The ablation catheter was put at the endocardial region facing the epicardial PentaRanNav. **C.** The epicardial PentaRayNav displayed fractionated pre-systolic potentials, while the endocardial ablation catheter showed fewer fractionated potentials activating later compared to the fractionated signals at the facing epicardial site. **D.** Radiofrequency energy application on the endocardial region terminated the VT after prolongation of VT cycle length. **E.** After termination of VT, LAVA were identified at the epicardial critical isthmus of the VT reentrant circuit (\*). Endocardial ablation at the facing site was continued in sinus rhythm, and eliminated the epicardial LAVA completely.

**Figure 3. Endo- and epicardial voltage map with wall thinning segmentation in a patient with ICM**

**A.** Endocardial bipolar voltage map shows low-voltage with the presence of LAVA (light blue dots) at the basal postero-lateral LV. A peak-to-peak bipolar amplitude  $<1.5\text{mV}$  is defined as low-voltage and  $<0.5\text{mV}$  as dense scar. **B.** Endocardial unipolar voltage map is shown. A unipolar amplitude of  $<8.3\text{mV}$  is defined as abnormal voltage. **C.** Epicardial bipolar voltage map merged with the MDCT model shows the location of low-voltage area and LAVA corresponding to the wall thinning segmentation (white area). Endocardial ablation successfully eliminated the postero-lateral LAVA (**in blue box**) which had the following characteristics: low bipolar amplitude, location within the wall thinning segmentation, opposite endocardial low unipolar voltage, and presence of LAVA at the opposite endocardium. On the contrary, epicardial LAVA located mid-anteriorly (**in red box**) could not be eliminated by endocardial ablation and needed to be ablated epicardially. They were of higher bipolar voltage ( $>1.5\text{mV}$ ), located outside the wall thinning segmentation, and opposite endocardium with higher unipolar amplitude.

**Figure 4. Patient flow chart and procedure outcome**

Endo=endocardium; Epi=epicardium; LAVA=local abnormal ventricular activities.

<b>Table 1. Characteristics of study population</b>	
<b>Variables</b>	<b>N=46</b>
<b>Age</b>	52±16
<b>Male/Female</b>	42/4
<b>Underlying structural heart disease</b>	
<b>ICM</b>	18
<b>NICM</b>	13
<b>ARVC</b>	15
<b>Hypertension</b>	18 (39%)
<b>LV ejection fraction</b>	38±14
<b>ICD</b>	41 (89%)
<b>NYHA class III</b>	5 (11%)
<b>Medications</b>	
<b>Amiodarone</b>	36 (78%)
<b>Beta-blocker</b>	43 (93%)
<b>Prior failed ablation procedure</b>	4 (9%)
<b>No. of VT morphology</b>	2.0 [1.0, 3.0]
Data are presented as mean±SD, median [quartiles] or n (%). ARVC=arrhythmogenic right ventricular cardiomyopathy; ICD=implantable cardioverter-defibrillator; ICM=ischemic cardiomyopathy; LV=left ventricular; NICM=non-ischemic dilated cardiomyopathy; VT=ventricular tachycardia.	

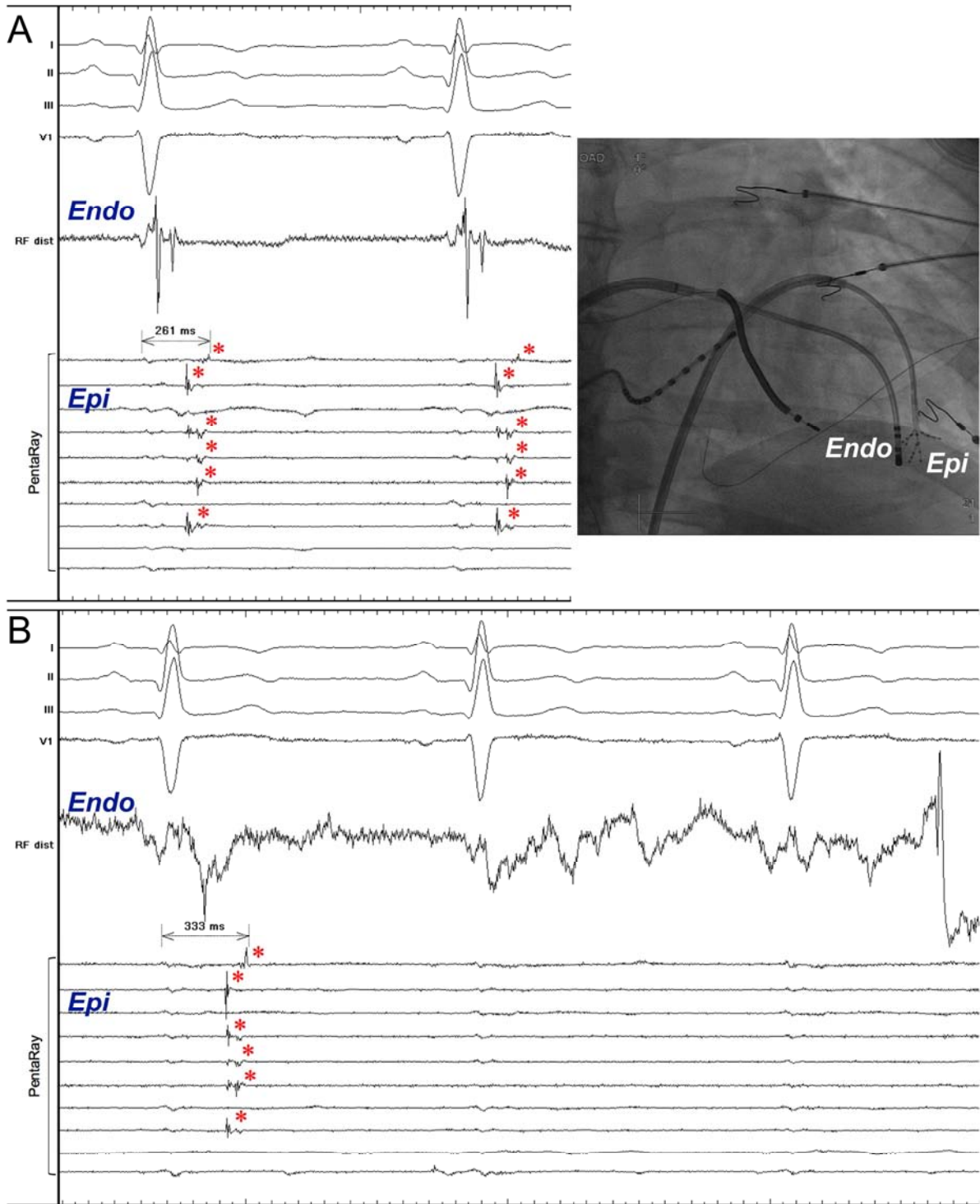
	<b>Success n=48</b>	<b>Failure n=125</b>	<b>p Value</b>
<b>RF parameters</b>			
<b>RF time, sec</b>	68 [56, 88]	65 [55, 87]	0.60
<b>Average temperature, °C</b>	38 [36, 40]	39 [37, 40]	0.36
<b>Average impedance, Ω</b>	140 [130, 155]	143 [130, 165]	0.25
<b>Power, W</b>	35 [30, 36]	35 [30, 38]	0.37
<b>Electrophysiological parameters</b>			
<b>Presence of opposite Endo-LAVA</b>	32 (67%)	62 (50%)	<b>0.044</b>
<b>EGM-duration of the target Epi-LAVA, ms</b>	143 [116, 186]	110 [86, 140]	<b>&lt;0.001</b>
<b>EGM-duration of opposite Endo-LAVA, ms</b>	110 [96, 131]	114 [95, 138]	0.66
<b>Bipolar amplitude of the target Epi-LAVA, mV</b>	0.26 [0.21, 0.34]	0.71 [0.34, 1.24]	<b>&lt;0.001</b>
<b>Bipolar amplitude of opposite endocardium, mV</b>	0.35 [0.21, 0.61]	0.54 [0.22, 1.03]	<b>0.041</b>
<b>Unipolar amplitude of opposite endocardium, mV</b>	2.52 [2.02, 2.96]	4.51 [3.38, 5.51]	<b>&lt;0.001</b>
Data are presented as median [quartiles] or n (%).			

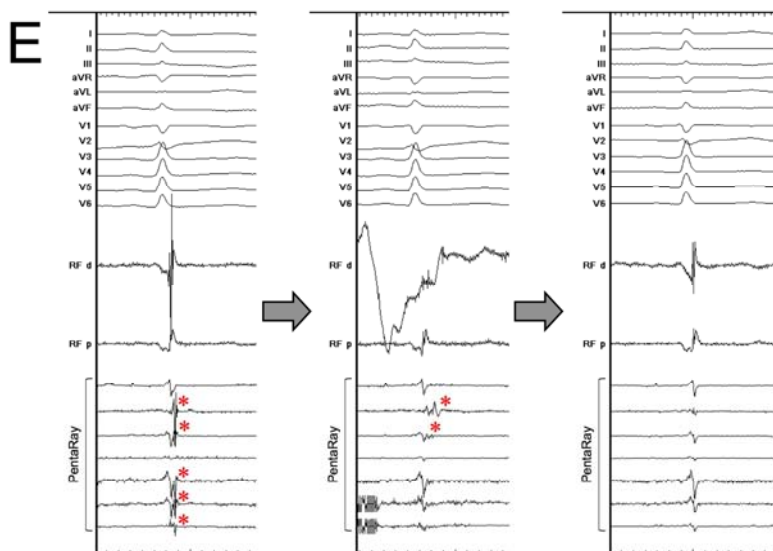
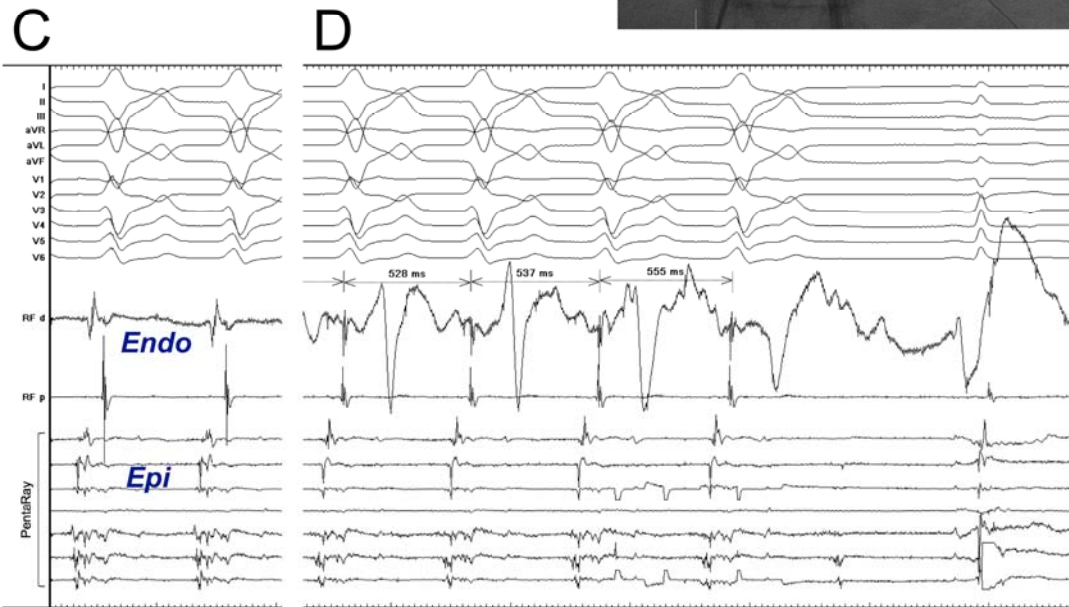
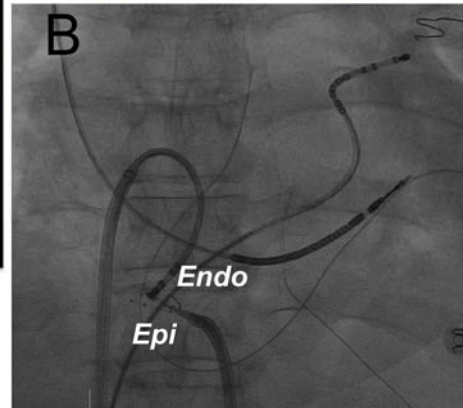
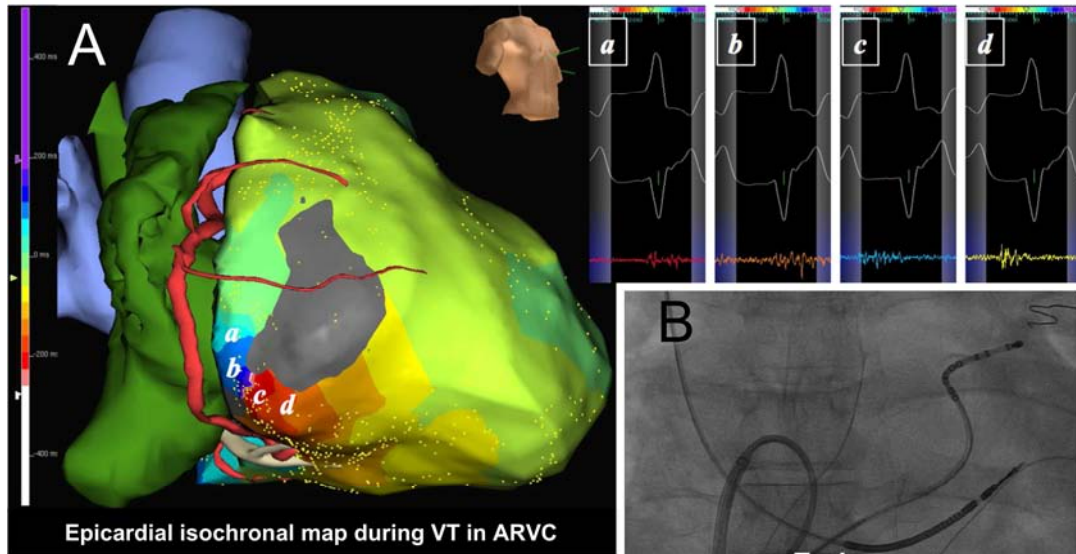
**Table 3. Patients with complete, partial, and no elimination of Epi-LAVA endocardially**

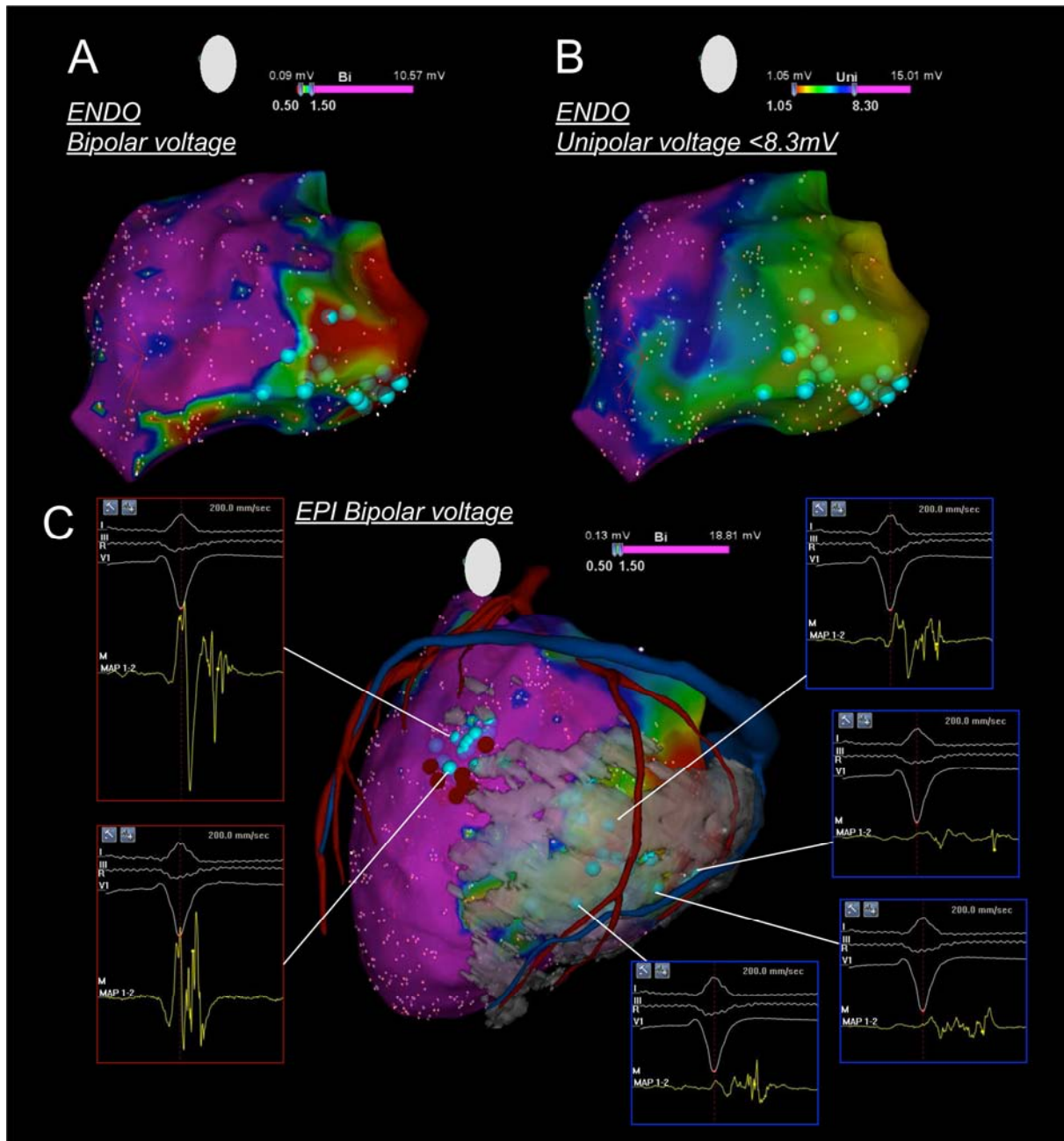
	<b>Complete elimination of Epi-LAVA endocardially (n=6)</b>	<b>Partial elimination of Epi-LAVA endocardially (n=22)</b>	<b>No impact of endocardial ablation on Epi-LAVA (n=18)</b>	<b>p Value</b>
<b>Age</b>	56±15	53±16	50±16	0.65
<b>Male</b>	6 (100%)	19 (86%)	17 (94%)	0.63
<b>LV ejection fraction</b>	36±17	39±16	38±9	0.86
<b>Medications</b>				
<b>Amiodarone</b>	5 (83%)	17 (77%)	13 (72%)	0.38
<b>Beta-blocker</b>	6 (100%)	20 (91%)	17 (94%)	0.61
<b>Underlying structural heart disease</b>				
<b>ICM</b>	4 (67%)	11 (50%)	3 (17%)	<b>0.002</b>
<b>NICM</b>	0 (0%)	2 (9%)	11 (61%)	
<b>ARVC</b>	2 (33%)	9 (41%)	4 (22%)	
<b>No. of VT morphology</b>	1.5 [0.8, 4.0]	1.5 [0, 3.0]	2.0 [1.0, 2.3]	0.82
<b>Endo total low-voltage area, cm<sup>2</sup></b>	65.0 [47.5, 107.8]	59.1 [40.4, 86.7]	12.6 [5.1, 40.1]	<b>0.010</b>
<b>Epi total low-voltage area, cm<sup>2</sup></b>	97.9 [43.3, 120.2]	101.0 [49.4, 117.8]	47.6 [39.8, 68.0]	<b>0.030</b>
<b>Presence of Endo-LAVA</b>	6 (100%)	18 (82%)	7 (39%)	<b>0.003</b>
<b>Amplitude of Epi-LAVA, mV</b>	0.37 [0.33, 0.45]	0.39 [0.24, 0.74]	0.67 [0.43, 1.31]	<b>0.041</b>
<b>Duration of Epi-LAVA, ms</b>	156 [121,195]	139 [116, 163]	108 [90, 149]	<b>0.044</b>
<b>All Epi-LAVA within abnormal endocardial unipolar voltage zone</b>	6 (100%)	15 (68%)	3 (17%)	<b>&lt;0.001</b>

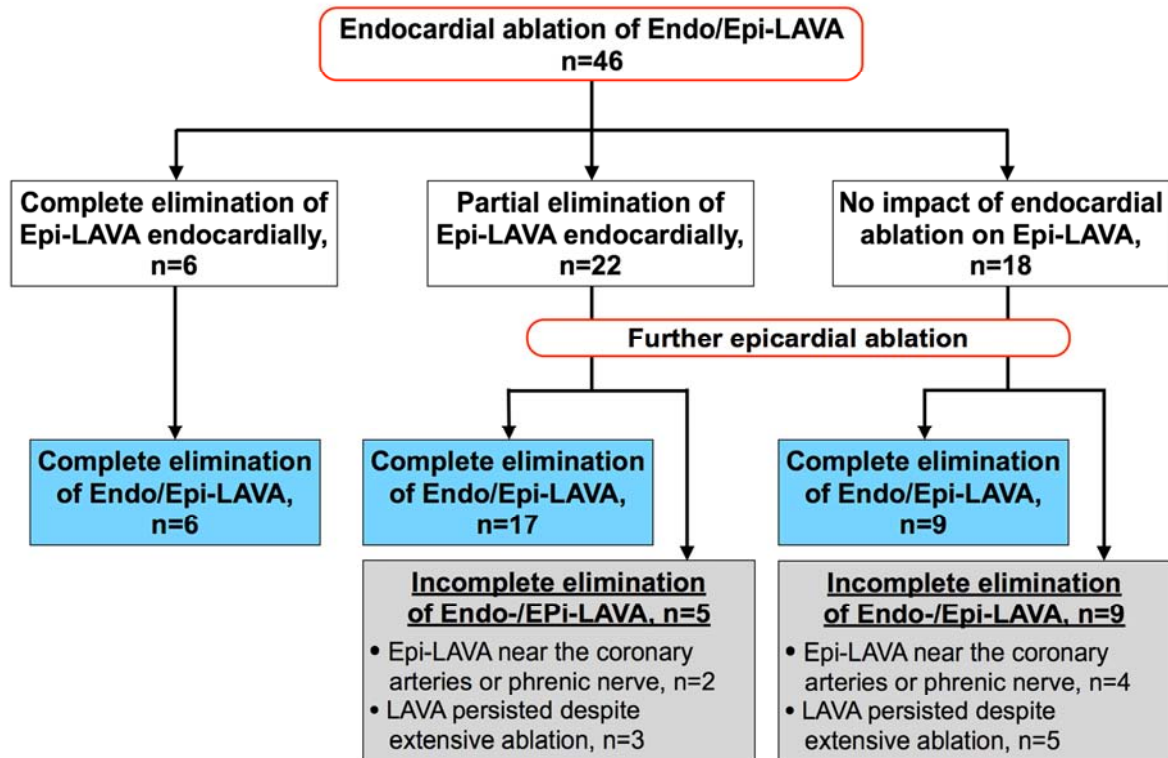
Data are presented as mean±SD, median [quartiles] or n (%).











## SUPPLEMENTAL MATERIAL

### *MDCT image acquisition and segmentation*

Contrast-enhanced multidetector computed tomography (MDCT) was performed on a 64-slice CT scanner (SOMATOM Definition, Siemens Medical Solutions, Forchheim, Germany) 1-3 days prior to the procedure. CT angiographic images were acquired during an injection of 120mL bolus of iodinated contrast agent at a rate of 4mL/s. Image was acquired during an expiratory breath hold with tube current modulation set on end-diastole. Acquisition parameters were slice thickness of 0.6mm, tube voltage of 120kVp, maximum tube current of 850mAs, and gantry rotation time of 330ms.

Trans-axial MDCT images comprising the whole heart volume were imported in DICOM format to a local database using the OsiriX3.6.1 software platform (OsiriX foundation, Geneva, Switzerland). The epicardium was manually contoured on short axis images. The endocardium and coronary vessels were segmented using automatic region growth segmentation and automatic vessel analysis. Wall thinning segmentation was automatically derived from endo- and epicardial contours. Segmented images were loaded in CardioviZ3D (INRIA, Sophia Antipolis, France). Using this software, 3-dimensional surface meshes of the endocardium, epicardium, coronary arteries, coronary sinus, and LV myocardial wall thinning (defined as areas with end-diastolic wall thickness < 5mm) were generated.

### *Three-dimensional registration of MDCT model*

Segmented images were imported into 3-dimensional navigation systems. Identifiable anatomic reference points (coronary sinus, aortic root, LV apex, and mitral annulus [3, 6, 9, and 12 o'clock]) were acquired on the electroanatomic map. They were used as landmarks for alignment and orientation of the electroanatomic map and MDCT models. The decapolar catheter, which was placed in the coronary sinus as distally as possible (distal electrodes in the great cardiac vein), served as a stable spatial reference as well as a discreet anatomic boundary for guidance of 3-dimensional registration. This could be monitored throughout the procedure. After initial alignment using these fixed reference points as landmarks, registration using CartoMerge software (Biosense Webster) was performed when using Carto. When using NavX, after primary registration, the registered model was refined using additional fiducial points, judiciously placed in stepwise fashion to further align both surfaces at sites of local mismatch.



## I) Complete Substrate Ablation of Scar-Related Ventricular Tachycardia Reduces Cardiac Mortality in Patients with Implantable Cardioverter-Defibrillators

*En révision: Circulation*

### 1) Etude

Récemment nous avons proposé une nouvelle stratégie d'ablation de TV ciblant le substrat dans le but d'éliminer tous les potentiels ventriculaires anormaux (LAVA). Le but de cette étude est d'évaluer l'impact de cette stratégie sur la mortalité.

Tous les patients adressés pour ablation de TV guidée par les LAVA sur myocardopathie ischémique ou dilatée à coronaires saines entre janvier 2006 et mars 2013 au CHU de Bordeaux et de Toulouse ont été inclus. Sur les 195 patients (65 ±11ans; myocardopathie ischémique n=144 / myocardopathie dilatée à coronaires saines n =51) inclus, l'élimination complète des LAVA a pu être réalisée chez 121(62%) et la non inductibilité chez 133 (68%). La non inductibilité était retrouvée chez 64% des patients avec élimination incomplète des LAVA alors que 12% des patients avec élimination complète des LAVA restaient inductibles.

Les patients avec élimination incomplète des LAVA ont reçu plus de choc électrique par leur défibrillateur (36% vs 10%;  $p<0,001$ ). La mortalité était plus importante chez les patients avec choc électrique (40% vs 12%) mais pas chez ceux qui n'avaient que de la stimulation anti-tachycardique (20% vs 22%).

En analyse multivariée, l'élimination incomplète des LAVA est associée à un taux de récurrence de TV (HR=3 [CI:1,9-4,8]; $p<0,001$ ) et de mortalité supérieur (HR=2,8 [CI:1,6-5,0];  $p=0,001$ ). La persistance d'inductibilité est associée à un risque de récurrence de TV (HR=1,9 [CI:1,2-3,0]; $p=0,004$ ) mais pas à une surmortalité.

### 2) Implications

La dernière conférence d'expert a évoqué l'absence de critère de succès per procédure robuste pour l'ablation des TV<sup>15</sup>. Cette étude montre qu'il est pertinent en terme de survie de choisir comme critère de succès l'élimination des LAVA. Ce critère est associé à une diminution nette des récurrences de TV et à une moindre mortalité.

La non inductibilité, critère le plus souvent utilisé, est particulièrement pertinent pour cibler une TV clinique et la cartographier si possible mais il n'est pas rare qu'on induise des TV mal tolérées, multiples ou que les patients ne soient pas inductibles en début de procédure. Cette non inductibilité est associée à une diminution des récurrences de TV mais pas à une moindre mortalité. Enfin de plus en plus d'études<sup>16, 17</sup> montrent que la survenue de choc électrique itératif est probablement délétère et qu'il vaut mieux privilégier la stimulation anti-tachycardique qui est moins traumatisante pour le patient et pas associée à une surmortalité comme la survenue de choc.



Disclaimer: The manuscript and its contents are confidential, intended for journal review purposes only, and not to be further disclosed.

URL: <http://circ-submit.aha-journals.org>

Title: Complete Substrate Ablation of Scar-Related Ventricular Tachycardia Reduces Cardiac Mortality in Patients with Implantable Cardioverter-Defibrillators

Manuscript number: CIRCULATIONAHA/2014/009284

Author(s): Yuki Komatsu, Hôpital Cardiologique du Haut-Lévêque, the Université Victor Segalen Bordeaux II, Institut LYRIC, Bordeaux, France

Philippe Maury, University Hospital Ranguel

Frédéric Sacher, Hôpital Cardiologique du Haut-Lévêque & Université Victor Segalen Bordeaux II, LIRYC Institute

Paul Khairy, Montreal Heart Institute

Matthew Daly, Hôpital Cardiologique du Haut-Lévêque & Université Victor Segalen Bordeaux II, LIRYC Institute

Han Lim, University of Adelaide & Royal Adelaide Hospital

Stephan Zellerhoff, CHU / Université de Bordeaux - Institut LIRYC /  
INSERM U1045

Laurence Jesel, Hôpital Cardiologique du Haut-Lévêque & Université  
Victor Segalen Bordeaux II

Anne Rollin, Hospital Rangueil, CHU Toulouse, Toulouse, France  
alexandre DUPARC, University Hospital of Rangueil

Pierre Mondoly, University Hospital Rangueil

Laurent Roten, Hôpital Cardiologique du Haut-Lévêque & Université  
Victor Segalen Bordeaux II, LIRYC Institute, Bordeaux, France

Patrizio Pascale, Hôpital Cardiologique du Haut-Lévêque & Université  
Victor Segalen Bordeaux II, LIRY Institute, Bordeaux, France

Daniel Scherr, Hôpital Cardiologique du Haut-Lévêque & Université  
Victor Segalen Bordeaux II, LIRYC Institute, Bordeaux, France

Khaled Ramoul, Hôpital Cardiologique du Haut-Lévêque & Université  
Victor Segalen Bordeaux II, LIRYC Institute

Valérie Aurillac, Department of Cardiac Electrophysiology, Hôpital  
Cardiologique du Haut-Lévêque

Ashok Shah, Hôpital Cardiologique du Haut-Lévêque & Université  
Victor Segalen Bordeaux II, LIRYC Institute

Arnaud Denis, Hôpital Cardiologique du Haut-Lévêque & Université  
Victor Segalen Bordeaux II, LIRYC Institute

Hubert Cochet, CHU / Université de Bordeaux - IHU Liryc / INSERM U1045

Nicolas Derval, Hôpital Cardiologique du Haut-Lévêque & Université  
Victor Segalen Bordeaux II, LIRYC Institute

Mélèze Hocini, Hôpital Cardiologique du Haut-Lévêque & Université  
Victor Segalen Bordeaux II, LIRYC Institute

Michel Haïssaguerre, Hôpital cardiologique du Haut-Lévêque

Pierre Jais, Hôpital Cardiologique Haut Lévêque

Disclaimer: The manuscript and its contents are confidential, intended for journal review purposes only, and not to be further disclosed.

# Complete Substrate Ablation of Scar-Related Ventricular Tachycardia Reduces Cardiac Mortality in Patients with Implantable Cardioverter-Defibrillators

*Komatsu et al.* VT substrate ablation and mortality

Yuki Komatsu, MD;<sup>1</sup> Philippe Maury, MD;<sup>2</sup> Frédéric Sacher, MD;<sup>1</sup> Paul Khairy, MD, PhD;<sup>3</sup> Matthew Daly, MBChB;<sup>1</sup> Han S Lim, MBBS;<sup>1</sup> Stephan Zellerhoff, MD;<sup>1</sup> Laurence Jesel, MD;<sup>1</sup> Anne Rollin, MD;<sup>2</sup> Alexandre Duparc, MD;<sup>2</sup> Pierre Mondoly, MD;<sup>2</sup> Laurent Roten, MD;<sup>1</sup> Patrizio Pascale, MD;<sup>1</sup> Daniel Scherr, MD;<sup>1</sup> Khaled Ramoul, MD;<sup>1</sup> Valerie Aurillac-Lavignolle, BSc;<sup>1</sup> Ashok Shah, MD;<sup>1</sup> Arnaud Denis, MD;<sup>1</sup> Hubert Cochet, MD;<sup>1</sup> Nicolas Derval, MD;<sup>1</sup> Méléze Hocini, MD;<sup>1</sup> Michel Haïssaguerre, MD;<sup>1</sup> Pierre Jaïs, MD.<sup>1</sup>

<sup>1</sup> *Hôpital Cardiologique du Haut-Lévêque, the Université Victor Segalen Bordeaux II, Institut LYRIC, Bordeaux, France.*

<sup>2</sup> *Hospital Rangueil, CHU Toulouse, Toulouse, France.*

<sup>3</sup> *Montreal Heart Institute, Université de Montréal, Montreal, Canada.*

**CORRESPONDENCE:** Yuki Komatsu, MD.  
Hôpital Cardiologique du Haut-Lévêque, Bordeaux, France.  
Address: Avenue de Magellan, 33604 Bordeaux-Pessac, France.  
Phone number: +33 5 57 65 65 65  
Fax number: +33 5 57 65 65 09  
e-mail: yk.komat@gmail.com

**WORD COUNT:** 6864 words

**JOURNAL SUBJECT CODE:** 22

## ABSTRACT

**Background:** An electrophysiologically (EP)-guided substrate-based approach to ventricular tachycardia (VT) ablation targeting complete elimination of local abnormal ventricular activities (LAVA) was recently described. Its impact on mortality remains unknown.

**Methods and Results:** A total of 195 patients (65±11 years) with ischemic or dilated cardiomyopathy and implantable cardioverter-defibrillators (ICD) underwent VT ablation at two institutions using the EP-guided substrate-based approach and were followed for a median of 23 months. Complete LAVA elimination and non-inducibility of any VT were achieved post-ablation in 121 (62%) and 133 (68%) patients, respectively, with both acute procedural outcomes obtained in 95 (49%) patients. In multivariate analyses, incomplete LAVA elimination was associated with a significantly higher risk of recurrent VT [hazard ratio (HR) 3.031, 95% confidence interval (CI) 1.915-4.798],  $p<0.001$ ] and mortality [HR 2.779, 95% CI (1.562-4.947),  $p=0.001$ ]. In contrast, failure to achieve the non-inducibility outcome post-ablation was independently associated with recurrent VT [HR 1.937, 95% CI (1.229-3.055),  $p=0.004$ ] but not mortality. Patients with incomplete LAVA elimination experienced a higher rate of ICD shocks (36% versus 10%,  $p<0.001$ ). Ventricular tachycardia recurrences were more frequent in patients who subsequently died (60% versus 34%). Higher mortality was associated with ICD shocks (40% versus 12%) but not with anti-tachycardia pacing (20% versus 22%).

**Conclusions:** Complete LAVA elimination as a procedural outcome for EP-guided substrate ablation is associated with markedly reduced rates of recurrent VT and mortality. It may be hypothesized that the lower mortality is driven by a reduction in appropriate ICD shocks.

## ***INTRODUCTION***

Patients with ischemic (ICM) and non-ischemic dilated cardiomyopathy (NICM) are at increased risk for fatal ventricular arrhythmias and cardiac mortality. While risk of sudden death due to malignant ventricular tachycardia (VT) is mitigated by implantable cardioverter defibrillators (ICD), recurrent VT leading to frequent ICD discharges may increase mortality and hospitalizations for congestive heart failure, and reduce quality of life.<sup>1-7</sup> Catheter ablation more effectively controls incessant VT or electrical storms than optimal pharmacological therapy.<sup>8,9</sup> Randomized prospective studies previously demonstrated the effectiveness and safety of VT ablation in the setting of ICM.<sup>10,11</sup> While these studies have not conclusively demonstrated a mortality reduction, the Substrate Mapping and Ablation in Sinus Rhythm to Halt Ventricular Tachycardia (SMASH-VT) trial reported a trend toward improved survival with VT ablation.<sup>10</sup> Successful VT ablation might lower mortality by reducing the hemodynamic compromise associated with recurrent VT or by reducing the shock burden. Recent studies have suggested that achieving non-inducibility of any VT as an acute procedural outcome is associated with reduced mortality.<sup>8,12-15</sup> However, other studies have failed to confirm these results.<sup>16-18</sup>

We previously reported that an electrophysiological (EP) substrate-based approach with the procedural endpoint of complete elimination of local abnormal ventricular activities (LAVA) yields superior survival free from recurrent VT at long-term follow-up.<sup>19</sup> This strategy aims to abolish all surviving bundles in the scar that could serve as a slow conducting isthmus for a reentrant VT circuit. Importantly, this approach does not rely exclusively on VT inducibility as a procedural endpoint. The current study sought to assess whether the acute procedural outcome of EP substrate ablation with the endpoint of complete LAVA elimination is associated with a mortality reduction in ICD recipients with ICM or NICM. We further explored the relationship between non-inducibility and ICD therapies on subsequent mortality.

## ***METHODS***

### ***Patient population***

Patients with ICM or NICM who underwent catheter ablation of sustained VT from January 2006 to March 2013 were recruited from 2 institutions. All patients were required to have ICD or CRT-D devices in order to optimize ascertainment of VT recurrences and to assess the relationship between VT recurrences, ICD therapies, and clinical outcomes. All enrolled patients had episodes of repetitive sustained VT that required either external cardioversion or ICD therapy. The diagnosis of NICM was based on a left ventricular ejection fraction (LVEF) <50% in the absence of coronary artery disease, documented myocardial infarction, or focal wall motion abnormality. Patients were excluded if they had acute ongoing cardiac ischemia, bundle branch reentrant VT, or other likely causes of cardiomyopathy than ICM or NICM, such as arrhythmogenic right ventricular cardiomyopathy, cardiac sarcoidosis, congenital heart disease, primary valvular disease, or toxin-related cardiomyopathy. Written informed consent was obtained in all patients.

### ***Electrophysiological study***

During the EP study, ICD therapies were turned off and the device programmed to a surveillance-only mode. Mapping and ablation was performed under conscious sedation using midazolam and morphine at the start of the procedure and sufentanil 0.05 to 0.2 mg during pericardial access. Six-French steerable quadripolar or decapolar catheters (2-5-2mm, Xtrem, ELA medical, Montrouge, France; or Dynamic, BARD Electrophysiology, MA, USA) were placed at the right ventricular (RV) apex or distal coronary sinus. The left ventricular (LV) endocardium was accessed by a transseptal or retrograde transaortic approach. Epicardial mapping was performed if a previous endocardial ablation had failed, if an epicardial substrate was suspected (based on pre-acquired contrast-enhanced cardiac magnetic resonance imaging or VT morphology on surface ECG), or in cases of minimal or no endocardial scar. Pericardial access was obtained via a subxiphoid puncture under fluoroscopic guidance. Systemic heparinization was maintained throughout the procedure following pericardial access and transseptal puncture. Electroanatomical mapping was performed in



sinus or paced rhythm using CARTO (Biosense-Webster, Diamond Bar, California) or NavX (Ensite NavX, St Jude Medical, St. Paul, Minnesota) at the operator's discretion. Bipolar signals were filtered from 30 to 250 Hz. Detailed LV endocardial and epicardial substrate mapping was undertaken to identify and localize regions displaying LAVA.

Once electroanatomic maps were acquired, an attempt was made to induce VT pre-ablation. Programmed ventricular stimulation was performed from the RV apex at basic drive cycle lengths of 600 and 400ms with up to triple extrastimuli decrementing down to 200ms or to ventricular refractoriness, whichever occurred first.

### ***Radiofrequency ablation***

When VT was inducible and hemodynamically tolerated, ablation was initially guided by conventional activation and entrainment mapping.<sup>20</sup> After restoration of sinus rhythm, further ablation targeting LAVA in sinus rhythm was performed. In patients with non-inducible or poorly tolerated VT, LAVA were ablated during sinus or paced rhythm.

As previously reported,<sup>19,21</sup> LAVA were defined as electrograms with the following features: (i) sharp, high-frequency ventricular potentials distinct from the far-field ventricular electrogram, (ii) occurring anytime during or most frequently after the far-field ventricular electrogram in sinus or paced rhythm, (iii) sometimes displaying double or multiple high-frequency signals separated by very low-amplitude signals or an isoelectric interval. In case of ambiguity, e.g., suspected fusion of LAVA with the far-field ventricular potential within the QRS complex, ventricular pacing was used to unmask LAVA signals by demonstrating their poorly coupled nature.

Details of the EP substrate ablation technique have been described previously.<sup>19</sup>

Radiofrequency energy was delivered with a 3.5 mm open-irrigation catheter (Thermocool, Biosense Webster) with a power of 30-50W endocardially, and 25-35W epicardially (temperature limit of 43°C, irrigation flow rate of 20-30ml/min). If both endo- and epicardial LAVA were detected, ablation was performed initially on the endocardial side aiming at elimination of both endocardial and epicardial LAVA, followed by subsequent epicardial ablation if needed.<sup>22</sup> During

endocardial ablation, careful monitoring for elimination of epicardial LAVA was performed using a multipolar mapping catheter (PentaRay, Biosense-Webster, Diamond Bar, CA) placed at epicardial LAVA regions and stabilized by a steerable sheath (Agilis, St.Jude Medical, St Paul, MN).<sup>22</sup> Where LAVA could be discerned to follow a distinct activation sequence, the earliest-coupled LAVA were targeted first. This approach aimed to disconnect the entire slow conducting channel by using fewer radiofrequency deliveries instead of initiating ablation at the latest signal and proceeding to ablate the entire channel.<sup>19,21,23</sup> Following ablation, areas previously displaying LAVA were carefully remapped. If residual LAVA were identified, ablation was conducted with the objective of completely eliminating all identified LAVA.

### ***Acute procedural outcome***

Response categories to catheter ablation of LAVA were predefined as ineffective, delayed effect, abolition, or dissociation. Acute procedural success was defined as complete elimination of LAVA, confirmed by abolition or dissociation at all identified LAVA sites. Causes of acute failure (incomplete LAVA elimination) were recorded and defined as follows: (i) epicardial LAVA were located in close proximity to the coronary vessels and/or phrenic nerve, (ii) LAVA were within the vicinity of the His bundle, (iii) pericardial adhesions prohibited access to a particular pericardial site, (iv) LAVA persisted despite extensive ablation and the procedure ended in the interest of patient safety, and (v) severe complication resulted in acute premature termination of the procedure.

Programmed ventricular stimulation to test VT inducibility was repeated using the same protocol as pre-ablation induction, except in the most unstable patients in the interest of safety. VT inducibility was considered positive if induction of sustained monomorphic VT persisted >30 seconds or a hemodynamically unstable VT required termination by ventricular burst pacing or external cardioversion, irrespective of its morphology.

### ***Follow-up***

After the procedure, patients were monitored at least 48 hours in-hospital. ICD therapies were reprogrammed with VT and ventricular fibrillation zones. Patients were followed every 3 months or

in the event of symptoms. Arrhythmia logs from ICD or CRT-D devices were interrogated at each visit. Primary end points were VT recurrence as detected by ICD interrogation and all-cause mortality. VT recurrence was defined as sustained VT treated by anti-tachycardia pacing or shock or any sustained VT detected in the ICD monitoring zone.

### ***Statistical analysis***

Categorical variables were expressed as numbers and percentages, and were compared using chi-square or Fisher's exact tests, as appropriate. Continuous data were expressed as mean±standard deviation or as median [25, 75th percentiles]. Continuous data were compared by unpaired Student t-tests and Mann-Whitney U-tests for normally and non-normally distributed variables, respectively. The concordance between complete LAVA elimination and non-inducibility as procedural outcomes was assessed by the  $\kappa$  agreement test. Univariate logistic regression analyses were performed to identify factors associated with incomplete LAVA elimination and failure to obtain non-inducibility of any VT after ablation. Univariate logistic regression analysis was also performed to assess associations between VT recurrence, ICD shocks, and anti-tachycardia pacing during follow-up on subsequent mortality. Odds ratios (OR) with corresponding 95% confidence intervals (CI) and two-sided p-values were presented. Freedom from VT recurrence and death was estimated by the Kaplan-Meier method and compared by the log-rank test. Univariate Cox proportional hazards models were used to identify pre- and intra-procedural factors associated with VT recurrence and all-cause death. Variables with p-values<0.1 in univariate analyses were entered into an automated forward multivariate Cox regression model, from which hazard ratios (HR) and 95% confidence CIs were derived.

All tests were 2-tailed and p-values <0.05 were considered statistically significant. All statistical analyses were performed with the SPSS statistical software (version 21.0, SPSS, Inc., Chicago, IL, USA).

## **RESULTS**

### ***Study population***

The study population consisted of 195 patients (ICM=144, NICM=51), mean age  $65\pm 11$  years, 92% male. Baseline characteristics are summarized in **Table 1**. The LVEF was  $31.8\pm 10.7\%$  and 28% of patients had New York Heart Association (NYHA) functional class III or IV symptoms. Prior ablation attempts were unsuccessful in 60 (31%) patients. The vast majority of patients (89%) had previously implanted ICD or CRT-D devices, with ICDs implanted prior to discharge in the remaining 11%. One hundred patients (51%) presented with electrical storm, which was defined as more than 3 ICD interventions in 24 hours. At admission, 146 (75%) patients were on amiodarone therapy. Most received both beta-blockers and angiotensin-converting-enzyme inhibitors or angiotensin-receptor blockers.

### ***Procedural results***

A combined endo- and epicardial approach was used in 79 (41%) patients. Before ablation, 165 patients (85%) had either inducible or spontaneous sustained VT with an average of  $1.9\pm 1.7$  morphologies. In the remaining 30 (15%) patients, VT could not be induced at baseline despite clinical documentation. In 81 (42%) patients, VT was poorly tolerated hemodynamically and required immediate termination by ventricular burst pacing or external electrical cardioversion. LAVA were detected in 188 (96%) patients. Radiofrequency ablation targeting LAVA was performed endocardially in all but 2 patients who had intracardiac thrombus (and, therefore, underwent an epicardial-only approach). Epicardial ablation was undertaken in 58 patients. Epicardial mapping was performed without RF ablation due to absence of epicardial LAVA in 14 patients. In an additional 7 patients, endocardial ablation alone eliminated all epicardial LAVA. The mean procedural duration was  $219\pm 87$  minutes, with an average RF duration of  $28\pm 15$  minutes.

LAVA were completely eliminated in 121 (62%) patients. Eight patients had epicardial LAVA in close proximity to the coronary arteries and/or phrenic nerve, 1 patient had LAVA close to the His bundle and, in 56 (29%) patients, LAVA could not be abolished despite extensive

ablation. In 20 of these patients, epicardial LAVA persisted despite epicardial RF delivery, with further epicardial RF delivery thought to be unwarranted to prevent collateral damage. Thirty-six had endocardial LAVA that remained after extensive ablation, and the procedure was discontinued in the interest of patient safety. One patient did not achieve LAVA elimination due to acute cardiac tamponade.

At the end of the ablation procedure, non-inducibility of any VT was achieved in 133 (68%) patients. In the remaining 62 (32%) patients, 2 had persistent inducibility of the presumptive clinical VT and 32 achieved elimination of all clinically documented VTs with persistent inducibility of non-documented VTs. In 28 patients, VT inducibility was not re-tested to avoid aggravating a fragile hemodynamic status. In the 167 patients in whom VT inducibility was tested, there was a fair concordance between complete LAVA elimination and absence of any inducible VT ( $\kappa=0.261$ ,  $p<0.001$ ). VT non-inducibility was obtained in 64% of patients with incomplete LAVA elimination, whereas 12% of patients with complete LAVA elimination failed to obtain non-inducibility.

### ***Complications and 1-month mortality***

One patient died of intraprocedural electromechanical dissociation. Five patients had pericardial tamponade, including one with late tamponade occurring after anticoagulation was initiated for atrial fibrillation, and one with right ventricular perforation requiring surgical repair. Two patients experienced transient cerebrovascular ischemic attacks. One patient developed complete AV block. No patient had phrenic nerve palsy, coronary vessel injury, hepatic injury, or intraabdominal bleeding. The 1-month mortality in the 194 procedural survivors was 5% (10 patients), due to uncontrollable ventricular arrhythmias in 5, refractory heart failure in 3, acute myocardial infarction leading to cardiac arrest in 1, and sepsis in 1 patient.

### ***Predictors of acute procedural failure***

Clinical and procedural variables associated with incomplete elimination of LAVA and persistent VT inducibility are shown in **Figure 1**. History of NICM (OR 2.322,  $p=0.011$ ), presence of septal substrate (OR 2.328,  $p=0.006$ ), renal insufficiency (OR 2.174,  $p=0.022$ ), and NYHA class IIIorIV

(OR 3.622,  $p < 0.001$ ) were associated with incomplete LAVA elimination. The following variables were associated with persistent VT inducibility: LVEF  $\leq 30\%$  (OR 2.099,  $p = 0.023$ ), NYHA class III or IV (OR 2.590,  $p = 0.004$ ), renal insufficiency (OR 2.011,  $p = 0.042$ ), hemodynamically unstable VT (OR 2.015,  $p = 0.025$ ), and number of VT morphologies induced during the procedure (OR 1.309,  $p = 0.004$ ). VT termination by ablation before substrate-targeted ablation was associated with non-inducibility (OR 0.498,  $p = 0.031$ ).

### ***VT recurrence and mortality during follow-up***

All but one patient who died during the procedure were included in survival analyses. No patient was lost to follow-up. Eighty (41%) patients had VT recurrence during a median follow-up of 23 [7, 38] months, corresponding to an average survival of 9.0 months (95% CI 6.1 to 11.9 months) without recurrent VT. Overall, 38 (19%) patients received an appropriate ICD shock, and 42 (22%) received only anti-tachycardia pacing attempts. Patients with complete LAVA elimination exhibited a significantly lower rate of VT recurrence than those without (28% vs. 63%, log-rank  $p < 0.001$ ; **Figure 2A**). Patients with non-inducibility post-ablation also exhibited a lower VT recurrence rate than those who failed to achieve non-inducibility (32% vs. 61%, log-rank  $p < 0.001$ ; **Figure 2B**). Pre- and intra-procedural factors associated with VT recurrence are shown in **Table 2**. In multivariate analyses, NICM (HR 1.636,  $p = 0.047$ ), cumulative number of prior procedures (HR 1.668,  $p = 0.001$ ), failure to obtain VT non-inducibility (HR 1.937,  $p = 0.004$ ) and incomplete elimination of LAVA (HR 3.031,  $p < 0.001$ ) were independently associated with recurrent VT.

During follow-up, 55 (28%) patients died, 44 from cardiac causes (uncontrollable ventricular arrhythmia leading to cardiac arrest or refractory heart failure). Eleven patients died of non-cardiac cause (pneumonia, sepsis, and cancer). All-cause mortality was significantly lower in patients with complete LAVA elimination (16% vs. 49%, log-rank  $p < 0.001$ ; **Figure 3A**). Patients who were non-inducible post-ablation also had a lower mortality rate than those who failed to achieve non-inducibility (20% vs. 46%, log-rank  $p < 0.001$ ; **Figure 3B**). In multivariate Cox regression analyses (**Table 2**), factors independently associated with all-cause mortality were age

(HR 1.562 per 10 year increment,  $p=0.002$ ), NICM (HR 2.637,  $p=0.001$ ), electrical storm (HR 2.054,  $p=0.028$ ), NYHA class III or IV (HR 2.590,  $p=0.001$ ), and incomplete LAVA elimination (HR 2.779,  $p=0.001$ ). Failure to obtain VT non-inducibility was not independently associated with mortality.

### ***Combined endpoint of LAVA elimination and non-inducibility***

In further subgroup analyses, patients who achieved both non-inducibility and complete LAVA elimination had a lower incidence of recurrent VT or all-cause death than those with non-inducibility but incomplete LAVA elimination (33% vs. 74%, log-rank  $p<0.001$ ; **Figure 4**). All-cause mortality was lowest (15%) in patients who achieved the combined endpoint of non-inducibility and complete LAVA elimination, compared to 34% in non-inducible patients without complete LAVA elimination, and 46% in those who failed to achieve non-inducibility ( $p<0.001$ , **Table 3**). The incidence of non-cardiac mortality was comparable regardless of procedural outcome.

### ***Relationship between VT recurrence and subsequent cardiac mortality***

VT recurred more frequently in patients who subsequently died (60% vs. 34%; OR 2.936,  $p=0.001$ ; **Figure 5**). Higher mortality was associated with having received ICD shock (40% vs. 12%; OR 3.261 [1 ICD shock vs. no shock],  $p=0.033$ ) but not with anti-tachycardia pacing (20% vs. 22%). Risk was further increased by multiple ICD shocks (OR 6.989 [multiple ICD shocks vs. no shock],  $p<0.001$ ). Among patients who experienced VT recurrence, ICD shocks were associated with a 4-fold higher risk of death compared to anti-tachycardia pacing alone (OR 3.875,  $p=0.005$ ).

There was an increased rate of ICD shocks in patients with incomplete compared to complete LAVA elimination (10% vs. 36%,  $p<0.001$ ). As shown in **Table 3**, the prevalence of ICD shocks was lowest (8%) in patients who achieved the combined end-point of non-inducibility and complete LAVA elimination, compared to 26% in non-inducible patients without complete LAVA elimination, and 33% in those who failed to achieve non-inducibility ( $p<0.001$ ). A non-significant trend toward a lower prevalence of anti-tachycardia pacing without ICD shocks was observed in



patients achieving this combined endpoint ( $p=0.072$ ). Patients with both non-inducibility and complete LAVA elimination were more likely to discontinue amiodarone during follow-up (41%), compared to non-inducible patients without complete LAVA elimination (26%), and those who failed to achieve non-inducibility (21%) ( $p=0.025$ ).

## ***DISCUSSION***

### ***Main findings***

This study examined a large population of ICD patients undergoing EP-guided substrate ablation of scar-related VT in the setting of ICM and NICM at two institutions. We evaluated whether complete substrate ablation as indicated by complete LAVA elimination would be associated with a cardiac mortality benefit. The main findings are summarized as follows:

- Complete LAVA elimination was achieved in 62% of patients and was associated with reduced mortality as well as better VT-free survival during follow-up.
- In a multivariate Cox regression model, incomplete LAVA elimination was the strongest predictor of mortality with almost 3-fold increased probability.
- Patients who achieved the combined endpoint of complete LAVA elimination and non-inducibility had a significantly lower cardiac mortality with higher rate of amiodarone discontinuation than those with non-inducibility but incomplete LAVA elimination.
- VT recurrence requiring ICD shock was strongly associated with subsequent mortality. Its risk was further increased by the occurrence of multiple ICD shocks (represented by the 7-fold increase in cardiac mortality).
- Anti-tachycardia pacing without ICD shocks was not associated with mortality risk

### ***Acute procedural outcome and cardiac mortality***

Irrespective of the ablation strategy, non-inducibility of VT remains the targeted procedural endpoint of most if not all centers. Recognized limitations of relying on non-inducibility as a procedural endpoint include the lack of VT inducibility in a subset of patients at the beginning of

the procedure despite clinical documentation, thereby obscuring its relevance. The degree of sedation, the intensity of the induction protocol, and pacing site(s) may all influence the results of inducibility testing. Inducibility may not be tested post ablation in the interest of patient safety. Furthermore, whether the goal should be non-inducibility of any VT, or whether absence of clinical VT but persistent inducibility of non-clinical VT is a reasonable goal, is the subject of ongoing controversy.<sup>8,13,15</sup> Despite these limitations, we observed that failure to obtain VT non-inducibility was associated with less favorable outcomes. Our results are consistent with a recent report that found that partial success and failure to attain non-inducibility of the presumed clinical VT were strongly associated with poor long-term outcomes in patients with NICM or ICM.<sup>15</sup> Persistent inducibility of non-clinical (usually rapid VT or ventricular fibrillation) after VT substrate ablation may reflect more advanced and complex arrhythmia substrates, which may be less amenable to radiofrequency ablation. In our analysis, however, non-inducibility was associated with recurrent VT or cardiac death in univariate analysis but was not an independent predictor of outcome. Indeed, a considerable proportion of patients who achieved non-inducibility subsequently experienced VT recurrences and died of uncontrollable ventricular arrhythmias and/or severe refractory heart failure.

In light of the numerous limitations of non-inducibility and its imperfect correlation with long-term outcome, our study provides important insights regarding the value of an EP substrate-based approach using a potentially more objective and reliable acute procedural outcome criterion. As such, this is the first study to report a favorable association between complete LAVA elimination and mortality. Since the VT substrate often has complex scar architecture, ventricular arrhythmias that a patient can potentially develop may not be limited to "clinical" or "inducible" VTs, particularly when long-term outcomes are considered. Therefore, our strategy of a substrate-based approach with the endpoint of complete elimination of LAVA aims at abolishing all potential VT isthmuses in the complex scar architecture, as opposed to relying exclusively on VT inducibility. Incomplete LAVA elimination was associated not only with a higher VT recurrence rate but also a 3-fold higher cardiac mortality rate in multivariate analyses. Furthermore, complete

LAVA elimination enhanced the prognostic benefit in patients with non-inducible VT. Those who achieved the combined endpoint of complete LAVA elimination and VT non-inducibility exhibited significantly lower cardiac mortality compared to those with non-inducibility but incomplete LAVA elimination.

### ***Pre-procedural factors associated with difficult-to-eliminate LAVA***

The inability to completely eliminate LAVA in patients with NICM and septal VT substrates may be due, in part, to intramural substrates seated deep within the subepicardial layer or interventricular septum and most often preserved wall thickness. Scar in NICM has a more patchy, non-transmural distribution with a predilection for the subepicardial peri-valvular region,<sup>24-27</sup> often with coronary vessels or the phrenic nerve in close proximity. Previous studies have demonstrated that a septal VT substrate can involve the intramural myocardium in both ICM and NICM, as evidenced by electroanatomic mapping and magnetic resonance imaging.<sup>28,29</sup> Alternative ablation techniques such as transcatheter ethanol ablation<sup>30,31</sup> or bipolar radiofrequency ablation<sup>32</sup> may be helpful, though these conditions remain less amenable to complete substrate modification. A higher NYHA functional class is also associated with incomplete LAVA elimination. In patients with severe heart failure, the procedure is occasionally discontinued earlier in order to avoid aggravating a fragile hemodynamic status. In these less favorable conditions, invasive hemodynamic support using a percutaneous left ventricular assist device can allow for lengthier more stable procedures albeit at the cost of more intensive post-operative care.<sup>33,34</sup>

### ***VT recurrence and subsequent cardiac mortality in ICD patients***

Although ICDs are lifesaving, several studies have reported worse outcomes following shocks,<sup>1-6</sup> with some authors suggesting that associated myocardial injury results in increased mortality.<sup>35</sup> The associations between VT recurrence, ICD shocks, and subsequent cardiac mortality identified in our study are consistent with previous reports. These results underscore the importance of improving VT ablation outcomes despite concomitant ICD therapy. In this regard, achieving both complete LAVA elimination and non-inducibility was associated with a markedly lower incidence of VT

recurrence and ICD shocks, superior to VT non-inducibility with persistent LAVA. While cause and effect cannot be definitively established from such an observational study, our results suggest that the mortality benefit associated with complete LAVA elimination is likely driven by the decreased incidence of VTs requiring ICD shocks. This is supported by the observation that ICD shocks for recurrent VT were associated with a 4-fold higher mortality risk than anti-tachycardia pacing alone and that multiple ICD shocks conferred a higher risk.<sup>1-6</sup> These results are in line with previous studies suggesting that shock burden is associated with an increased hazard for death, but not anti-tachycardia pacing.<sup>6</sup> Our findings support the practice of considering repeat procedures to suppress recurrent VT that trigger ICD shocks,<sup>36</sup> since prior ablation failure did not preclude subsequent successful ablation.

Antiarrhythmic drugs are often used to reduce the likelihood of VT recurrence and ICD shocks. However, these drugs are associated with potential adverse side effects. It is well-known that amiodarone has non-cardiac toxicities that can be associated with increased mortality in patients with NYHA class III heart failure and without ICDs.<sup>37</sup> Moreover, proarrhythmia, possible increased defibrillation thresholds, and slowing the VT cycle length to below the detection window may result in deleterious effects. In the present study, the amiodarone discontinuation rate was significantly higher in patients who achieved the combined endpoint of LAVA elimination and non-inducibility, which may have contributed to the better outcomes observed.

### ***Study limitations***

This study is not randomized and, hence, subject to the limitations inherent to observational studies. While every effort was made to adjust for baseline imbalances and relevant variables, multivariate analyses cannot control for unmeasured or unknown confounders. As discussed above, the drawbacks regarding VT inducibility as a procedural outcome are well established. In our study, 28 (14%) patients did not undergo VT inducibility testing post ablation for safety reasons and were, therefore, considered to have not achieved the VT inducibility endpoint. Since patients who did not undergo VT inducibility testing may have differed systematically from those in whom VT

inducibility was verified, sensitivity analyses were performed in the subgroup of patients (N=167) in whom VT inducibility was tested. All multivariate associations between VT inducibility, LAVA elimination, VT recurrence, and mortality remained robust. In the absence of a contemporary control group, this study was not designed to test the hypothesis that complete LAVA elimination as an intention-to-treat strategy yields superior outcomes to “standard” VT ablation that relies exclusively on VT non-inducibility. In light of the major reductions observed in VT recurrence and mortality rates, randomized trials are warranted to confirm the incremental benefit of a complete substrate modification approach.

### ***Conclusions***

Ablation of scar-related VT guided by an EP substrate approach with the endpoint of VT non-inducibility and LAVA elimination allows for a high survival free from recurrent VT. When this combined endpoint is reached, VT recurrence and mortality rates are substantially lower, reflecting in part the reduced incidence of ICD shocks. In light of these favorable results, this study provides the grounds for pursuing a randomized study to more definitively determine whether this substrate homogenization approach confers a mortality benefit in ICD recipients.

**DISCLOSURE:** none

### **SOURCES OF FUNDING:**

This study was supported by a grant from Fondation Leducq (09 CVD 03)

## REFERENCES

1. Pacifico A, Ferlic LL, Cedillo-Salazar FR, Nasir N, Doyle TK, Henry PD. Shocks as predictors of survival in patients with implantable cardioverter- defibrillators. *J Am Coll Cardiol.*1999;34:204–210.
2. Bänsch D, Böcker D, Brunn J, MD, Weber M, Breithardt G, Block M. Clusters of ventricular tachycardias signify impaired survival in patients with idiopathic dilated cardiomyopathy and implantable cardioverter defibrillators. *J Am Coll Cardiol.* 2000;36:566–573.
3. Mitchell LB, Pineda A, Titus JL, MD, Bartosch PM, Benditt DG. Sudden death in patients with implantable cardioverter defibrillators: the importance of post-shock electromechanical dissociation. *J Am Coll Cardiol.*2002;39:1323–1328.
4. Poole JE, Johnson GW, Hellkamp AS, Anderson J, Callans DJ, Raitt MH, Reddy RK, Marchlinski FE, Yee R, Guarnieri T, Talajic M, Wilber DJ, Fishbein DP, Packer DL, Mark DB, Lee KL, Bardy GH. Prognostic importance of defibrillator shocks in patients with heart failure. *N Engl J Med.*2008;359:1009–17.
5. Moss AJ, Greenberg H, Case RB, Zareba W, Hall WJ, Brown MW, Daubert JP, McNitt S, Andrews ML, Elkin AD; Multicenter Automatic Defibrillator Implantation Trial-II (MADIT-II) Research Group. Long-term clinical course of patients after termination of ventricular tachyarrhythmia by an implanted defibrillator. *Circulation.*2004;110:3760-5.
6. Larsen GK, Evans J, Lambert WE, Chen Y, Raitt MH. Shocks burden and increased mortality in implantable cardioverter-defibrillator patients. *Heart Rhythm.*2011;8:1881-6.
7. Sears SF, Hauf JD, Kirian K, Hazelton G, Conti JB. Posttraumatic stress and the implantable cardioverter-defibrillator patient: what the electrophysiologist needs to know. *Circ Arrhythm Electrophysiol.*2011;4:242–250.
8. Carbucicchio C, Santamaria M, Trevisi N, Maccabelli G, Giraldi F, Fassini G, Riva S, Moltrasio M, Cireddu M, Veglia F, Della Bella P. Catheter ablation for the treatment of

- electrical storm in patients with implantable cardioverter-defibrillators: short- and long-term outcomes in a prospective single-center study. *Circulation*.2008;117:462–69.
9. Di Biase L, Santangeli P, Burkhardt DJ, Bai R, Mohanty P, Carbucicchio C, Dello Russo A, Casella M, Mohanty S, Pump A, Hongo R, Beheiry S, Pelarqonio G, Santerelli P, Zucchetti M, Horton R, Sanchez JE, Elayi CS, Lakkireddy D, Tondo C, Natale A. Endo-Epicardial homogenization of the scar versus limited substrate ablation for the treatment of electrical storms in patients with ischemic cardiomyopathy. *J Am Coll Cardiol*.2012;60:132-141.
  10. Reddy VY, Reynolds MR, Neuzil P, Richardson AW, Taborsky M, Jongnarangsin K, Kralovec S, Sediva L, Ruskin JN, Josephson ME. Prophylactic catheter ablation for the prevention of defibrillator therapy. *N Engl J Med*.2007;357:2657–65.
  11. Kuck KH, Schaumann A, Eckardt L, Willems S, Ventura R, Delacrétaç E, Pitschner HF, Kautzner J, Schumacher B, Hansen PS; VTACH study group. Catheter ablation of stable ventricular tachycardia before defibrillator implantation in patients with coronary heart disease (VTACH): a multicentre randomised controlled trial. *Lancet*.2010;375:31–40.
  12. Sauer WH, Zado E, Gerstenfeld EP, Marchlinski FE, Callans DJ. Incidence and predictors of mortality following ablation of ventricular tachycardia in patients with an implantable cardioverter-defibrillator. *Heart Rhythm*.2010;7:9–14.
  13. Della Bella P, Barratto F, Tsiachris D, Trevisi N, Vergara P, Bisceglia C, Petracca F, Carbucicchio C, Benussi S, Maisano F, Alfieri O, Pappalardo F, Zangrillo A, Maccabelli G. Management of ventricular tachycardia in the setting of a dedicated unit for the treatment of complex ventricular arrhythmias: long-term outcome after ablation. *Circulation*. 2013;127:1359–1368.
  14. Tokuda M, Kojodjojo P, Tung S, Tedrow UB, Nof E, Inada K, Koplan BA, Michaud GF, John RM, Epstein LM, Stevenson WG. Acute failure of catheter ablation for ventricular



- tachycardia due to structural heart disease: causes and significance. *J Am Heart Assoc.* 2013;2:e000072 doi: 10.1161/JAHA.113.000072.
15. Dinov B, Fiedler L, Schönbauer R, Bollmann A, Rolf S, Piorkowski C, Hindricks G, Arya A. Outcomes in Catheter Ablation of Ventricular Tachycardia in Dilated Non-Ischemic Cardiomyopathy in Comparison to Ischemic Cardiomyopathy: Results from the Prospective HEart Centre of LeiPzig VT (HELP - VT) Study. *Circulation.* 2013 (in press).
  16. Calkins H, Epstein A, Packer D, Arria AM, Hummel J, Gilligan DM, Trusso J, Carlson M, Luceri R, Kopelman H, Wilber D, Wharton JM, Stevenson W. Catheter ablation of ventricular tachycardia in patients with structural heart disease using cooled radiofrequency energy: results of a prospective multicenter study. Cooled RF Multi Center Investigators Group. *J Am Coll Cardiol.*2000;35:1905–1914.
  17. Stevenson WG, Wilber DJ, Natale A, Jackman WM, Marchlinski FE, Talbert T, Gonzalez MD, Worley SJ, Daoud EG, Hwang C, Schuger C, Bump TE, Jazayeri M, Tomassoni GF, Kopelman HA, Soejima K, Nakagawa H; Multicenter Thermocool VT Ablation Trial Investigators. Irrigated radiofrequency catheter ablation guided by electroanatomic mapping for recurrent ventricular tachycardia after myocardial infarction: the multicenter thermocool ventricular tachycardia ablation trial. *Circulation.*2008;118:2773-82.
  18. Tanner H, Hindricks G, Volkmer M, Furniss S, K€uhlkamp V, Lacroix D, DE Chillou C, Almendral J, Caponi D, Kuck KH, Kottkamp H. Catheter ablation of recurrent scar-related ventricular tachycardia using electroanatomical mapping and irrigated ablation technology: results of the prospective multicenter Euro-VT-study. *J Cardiovasc Electrophysiol.* 2010;21:47-53.
  19. Jaïs P, Maury P, Khairy P, Sacher F, Nault I, Komatsu Y, Hocini M, Forclaz A, Jadidi AS, Weerasooryia R, Shah A, Derval N, Cochet H, Knecht S, Miyazaki S, Linton N, Rivard L, Wright M, Wilton SB, Scherr D, Pascale P, Roten L, Pederson M, Bordachar P, Laurent F, Kim SJ, Ritter P, Clementy J, Haïssaguerre M. Elimination of local abnormal ventricular

- activities: a new end point for substrate modification in patients with scar-related ventricular tachycardia. *Circulation*.2012;125:2184-96.
20. Stevenson WG, Khan H, Sager P, Saxon LA, Middlekauff HR, Natterson PD, Wiener I. Identification of reentry circuit sites during catheter mapping and radiofrequency ablation of ventricular tachycardia late after myocardial infarction. *Circulation*.1993;88:1647-1670.
21. Komatsu Y, Daly M, Sacher F, Derval N, Pascale P, Roten L, Scherr D, Jadidi A, Ramoul K, Denis A, Jesel L, Zellerhoff S, Lim HS, Shah A, Cochet H, Hocini M, Haïssaguerre M, Jaïs P. Electrophysiologic characterization of local abnormal ventricular activities in postinfarction ventricular tachycardia with respect to their anatomic location. *Heart Rhythm*. 2013;10:1630-7.
22. Komatsu Y, Daly M, Sacher F, Cochet H, Denis A, Derval N, Jesel L, Zellerhoff S, Lim HS, Jadidi A, Nault I, Shah A, Roten L, Pascale P, Scherr D, Aurillac-Lavignolle V, Hocini M, Haïssaguerre M, Jaïs P. Endocardial ablation to eliminate epicardial arrhythmia substrate in scar-related ventricular tachycardia. *J Am Coll Cardiol*.2014 (in press).
23. Tung R, Mathuria NS, Nagel R, Mandapati R, Buch EF, Bradfield JS, Vaseghi M, Boyle NG, Shivkumar K. Impact of local ablation on interconnected channels within ventricular scar: mechanistic implications for substrate modification. *Circ Arrhythm Electrophysiol*. 2013;6:1131-8.
24. Cano O, Hutchinson M, Lin D, Garcia F, Zado E, Bala R, Riley M, Cooper J, Dixit S, Gerstenfeld E, Callans D, Marchlinski FE. Electroanatomic substrate and ablation outcome for suspected epicardial ventricular tachycardia in left ventricular nonischemic cardiomyopathy. *J Am Coll Cardiol*.2009;54:799-808.
25. Bogun FM, Desjardins B, Good E, Gupta S, Crawford T, Oral H, Ebinger M, Pelosi F, Chugh A, Jongnarangsin K, Morady F. Delayed-enhanced magnetic resonance imaging in nonischemic cardiomyopathy: utility for identifying the ventricular arrhythmia substrate. *J Am Coll Cardiol*.2009;53:1138-45.

26. Hsia HH, Callans DJ, Marchlinski FE. Characterization of endocardial electrophysiological substrate in patients with nonischemic cardiomyopathy and monomorphic ventricular tachycardia. *Circulation*.2003;108:704-10.
27. Nakahara S, Tung R, Ramirez RJ, Michowitz Y, Vaseghi M, Buch E, Gima J, Wiener I, Mahajan A, Boyle NG, Shivkumar K. Characterization of the arrhythmogenic substrate in ischemic and nonischemic cardiomyopathy implications for catheter ablation of hemodynamically unstable ventricular tachycardia. *J Am Coll Cardiol*.2010;55:2355-65.
28. Haqqani HM, Tschabrunn CM, Tzou WS, Dixit S, Cooper JM, Riley MP, Lin D, Hutchinson MD, Garcia FC, Bala R, Verdino RJ, Callans DJ, Gerstenfeld EP, Zado ES, Marchlinski FE. Isolated septal substrate for ventricular tachycardia in nonischemic dilated cardiomyopathy: incidence, characterization, and implications. *Heart Rhythm*.2011;8:1169-1176.
29. Yoshida K, Yokokawa M, Desjardins B, Good E, Oral H, Chugh A, Pelosi F, Morady F, Bogun F. Septal involvement in patients with post-infarction ventricular tachycardia: implications for mapping and radiofrequency ablation. *J Am Coll Cardiol*.2011;58:2491-500.
30. Sacher F, Sobieszczyk P, Tedrow U, Eisenhauer AC, Field ME, Selwyn A, Raymond JM, Koplan B, Epstein LM, Stevenson WG. Transcoronary ethanol ventricular tachycardia ablation in the modern electrophysiology era. *Heart Rhythm*.2008;5:62-68.
31. Kay GN, Epstein AE, Bubien RS, Anderson PG, Dailey SM, & Plumb VJ. Intracoronary ethanol ablation for the treatment of recurrent sustained ventricular tachycardia. *J Am Coll Cardiol*.1992;19:159-168.
32. Koruth JS, Dukkipati S, Miller MA, Neuzil P, d'Avila A, Reddy VY. Bipolar irrigated radiofrequency ablation: a therapeutic option for refractory intramural atrial and ventricular tachycardia circuits. *Heart Rhythm*.2012;9:1932-41.

33. Miller MA, Dukkipati SR, Mittnacht AJ, Chinitz JS, Belliveau L, Koruth JS, Gomes JA, d'Avila A, Reddy VY. Activation and entrainment mapping of hemodynamically unstable ventricular tachycardia using a percutaneous left ventricular assist device. *J Am Coll Cardiol.*2011;58:1363-1371.
34. Sjauw KD, Konorza T, Erbel R, Danna PL, Viecca M, Minden HH, Butter C, Engström T, Hassager C, Machado FP, Pedrazzini G, Wagner DR, Schamberger R, Kerber S, Mathey DG, Schofer J, Engström AE, Henriques JP. Supported high-risk percutaneous coronary intervention with the Impella 2.5 device the Europella registry. *J Am Coll Cardiol.* 2009;54:2430–4.
35. Tereshchenko LG, Faddis MN, Fetics BJ, Zelik KE, Efimov IR, Berger RD. Transient local injury current in right ventricular electrogram after implantable cardioverter-defibrillator shock predicts heart failure progression. *J Am Coll Cardiol.*2009;54:822-828.
36. Kosmidou I, Inada K, Seiler J, Koplán B, Stevenson WG, Tedrow UB. Role of repeat procedures for catheter ablation of postinfarction ventricular tachycardia. *Heart Rhythm.*2011;8:1516-1522.
37. Packer DL, Prutkin JM, Hellkamp AS, Mitchell LB, Bernstein RC, Wood F, Boehmer JP, Carlson MD, Frantz RP, McNulty SE, Rogers JG, Anderson J, Johnson GW, Walsh MN, Poole JE, Mark DB, Lee KL, Bardy GH. Impact of implantable cardioverter-defibrillator, amiodarone, and placebo on the mode of death in stable patients with heart failure: analysis from the sudden cardiac death in heart failure trial. *Circulation.* 2009;120:2170–2176.

## FIGURE LEGENDS

**Figure 1.** Factors associated with acute procedural failure as defined by incomplete LAVA elimination or failure to obtain VT non-inducibility.

**Figure 2.** Kaplan-Meyer curves plotting freedom from VT according to acute procedural result.

**Figure 3.** Kaplan-Meyer curves of survival from all-cause death according to acute procedural result.

**Figure 4.** Kaplan-Meyer curves of freedom from VT recurrence or all-cause death among three groups.

**Figure 5.** Relation between ICD therapies and subsequent mortality.

Disclaimer: The manuscript and its contents are confidential, intended for journal review purposes only, and not to be further disclosed.

**Table 1. Patient characteristics**

	<b>n=195</b>
<b>Age</b>	65±11
<b>Male</b>	179 (92%)
<b>Number of previous procedure</b>	0.41±0.72 (range 0-4)
<b>Underlying heart disease</b>	
<b>Ischemic cardiomyopathy</b>	144 (74%)
<b>Non-ischemic dilated cardiomyopathy</b>	51 (26%)
<b>Hypertension</b>	99 (51%)
<b>Diabetes mellitus</b>	36 (19%)
<b>Medication pre-ablation</b>	
<b>Amiodarone</b>	146 (75%)
<b>Beta-blocker</b>	187 (96%)
<b>Sotalol</b>	14 (7%)
<b>Statin</b>	136 (70%)
<b>ACE-I/ARB</b>	158 (81%)
<b>Electrical storm</b>	100 (51%)
<b>ICD</b>	
<b>ICD pre-ablation</b>	174 (89%)
<b>ICD implanted post-ablation</b>	21 (11%)
<b>LVEF, %</b>	31.8±10.7
<b>LVEF≤30%</b>	112 (57%)
<b>NYHA class</b>	
<b>NYHA I or II</b>	140 (72%)
<b>NYHA III or IV</b>	55 (28%)
<b>Renal insufficiency</b>	48 (25%)

Data are presented as n (%) or mean±SD. ACEI=angiotensin-converting enzyme inhibitor; ARB=angiotensin receptor blocker; ICD=implantable cardioverter-defibrillator; LVEF=left ventricular ejection fraction; NYHA=New York Heart Association.

Table 2. Cox regression analysis for VT recurrence and mortality

	VT recurrence				Mortality			
	Univariate		Multivariate		Univariate		Multivariate	
	HR (95%CI)	P	HR (95%CI)	P	HR (95%CI)	P	HR (95%CI)	P
<b><i>Pre-procedural factors</i></b>								
Age, per 10-year ↑	1.119 (0.908-1.378)	0.292	—	—	<b>1.469 (1.123-1.920)</b>	<b>0.005</b>	<b>1.562 (1.175-2.077)</b>	<b>0.002</b>
Male	0.998 (0.434-2.297)	0.997	—	—	0.685 (0.292-1.606)	0.384	—	—
NICM	<b>1.915 (1.194-3.072)</b>	<b>0.007</b>	<b>1.636 (1.006-2.661)</b>	<b>0.047</b>	<b>2.564 (1.478-4.446)</b>	<b>0.001</b>	<b>2.637 (1.475-4.715)</b>	<b>0.001</b>
No. of prior procedure	<b>1.587 (1.163-2.164)</b>	<b>0.004</b>	<b>1.668 (1.227-2.268)</b>	<b>0.001</b>	0.978 (0.647-1.479)	0.917	—	—
Hypertension	1.107 (0.713-1.718)	0.652	—	—	1.250 (0.733-2.132)	0.413	—	—
Diabetes mellitus	1.312 (0.767-2.246)	0.321	—	—	1.600 (0.871-2.938)	0.130	—	—
Electrical storm	1.191 (0.767-1.848)	0.436	—	—	<b>3.107 (1.666-5.796)</b>	<b>&lt;0.001</b>	<b>2.054 (1.080-3.906)</b>	<b>0.028</b>
LVEF≤30%	1.213 (0.776-1.896)	0.397	—	—	<b>1.884 (1.060-3.350)</b>	<b>0.031</b>	—	—
NYHA IIIorIV	<b>1.859 (1.169-2.954)</b>	<b>0.009</b>	—	—	<b>3.856 (2.262-6.572)</b>	<b>&lt;0.001</b>	<b>2.590 (1.505-4.456)</b>	<b>0.001</b>
Renal insufficiency	<b>1.750 (1.089-2.813)</b>	<b>0.021</b>	—	—	<b>2.388 (1.396-4.083)</b>	<b>0.001</b>	—	—
<b><i>Intra-procedural factors</i></b>								
Epicardial access	1.127 (0.724-1.756)	0.596	—	—	0.776 (0.449-1.339)	0.362	—	—
Hemodynamically-unstable VT	1.343 (0.865-2.083)	0.188	—	—	1.025 (0.601-1.748)	0.928	—	—
Septal substrate	<b>1.917 (1.235-2.975)</b>	<b>0.004</b>	—	—	<b>1.883 (1.109-3.196)</b>	<b>0.019</b>	—	—
No. of VTmorphologies	1.109 (0.980-1.255)	0.100	—	—	<b>1.150 (1.011-1.309)</b>	<b>0.034</b>	—	—
VT termination	1.099 (0.704-1.714)	0.679	—	—	1.034 (0.608-1.759)	0.903	—	—
Failure to obtain VT non-inducibility	<b>2.333 (1.500-3.628)</b>	<b>&lt;0.001</b>	<b>1.937 (1.229-3.055)</b>	<b>0.004</b>	<b>2.670 (1.572-4.534)</b>	<b>&lt;0.001</b>	—	—
Incomplete LAVA elimination	<b>3.279 (2.100-5.118)</b>	<b>&lt;0.001</b>	<b>3.031 (1.915-4.798)</b>	<b>&lt;0.001</b>	<b>3.788 (2.171-6.611)</b>	<b>&lt;0.001</b>	<b>2.779 (1.562-4.947)</b>	<b>0.001</b>
Procedure time, min	1.012 (0.987-1.038)	0.349	—	—	0.995 (0.962-1.029)	0.764	—	—
RF time, min	1.006 (0.858-1.180)	0.939	—	—	1.063 (0.871-1.299)	0.546	—	—

LAVA=local abnormal ventricular activities; LVEF=left ventricular ejection fraction; NICM=non-ischemic dilated cardiomyopathy; NYHA=New York Heart Association.



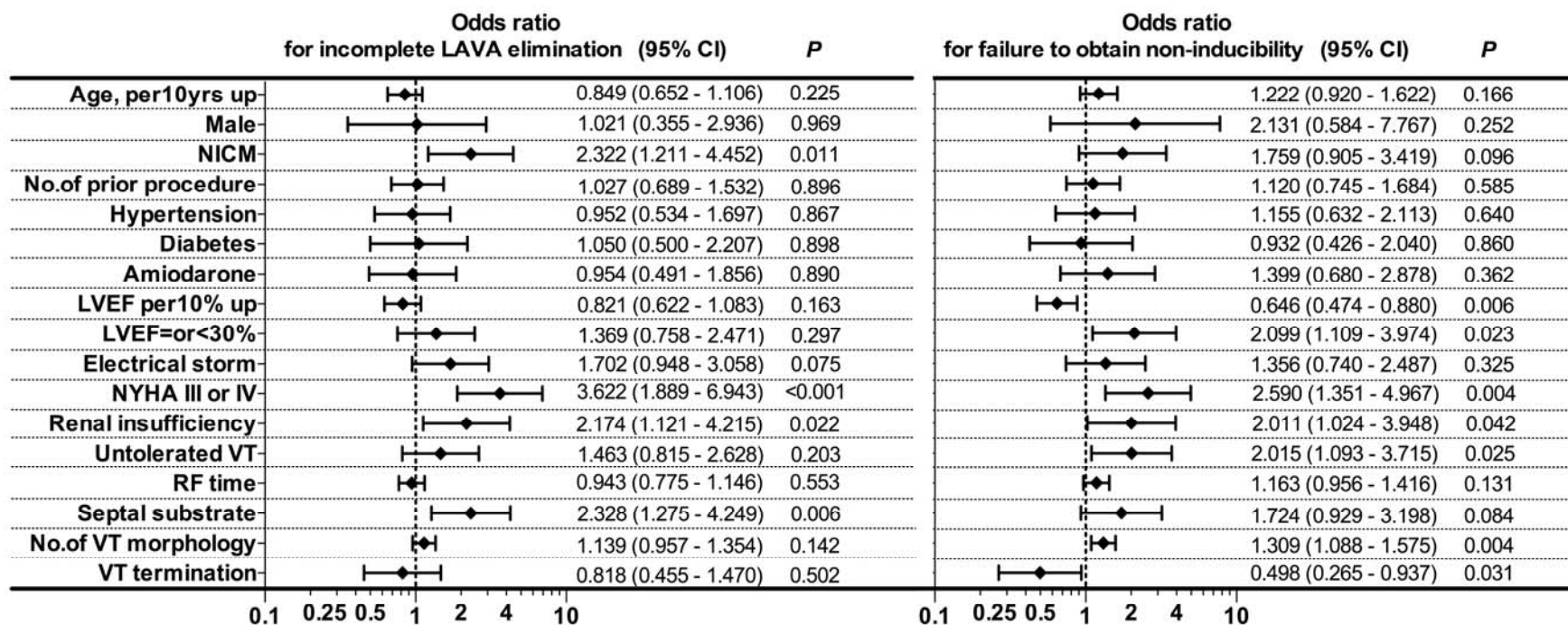
**Table 3. Procedural outcome and follow-up**

	<b>Non-inducibility + complete LAVA elimination (n=95)</b>	<b>Non-inducibility + incomplete LAVA elimination (n=38)</b>	<b>Failure to obtain non- inducibility (n=61)</b>	<b><i>P</i></b>
<b>All cause mortality</b>	14 (15%)	13 (34%)	28 (46%)	<0.001
<b>Cardiac mortality</b>	9 (10%)	12 (32%)	23 (38%)	<0.001
<b>Non-cardiac mortality</b>	5 (5%)	1 (3%)	5 (8%)	0.493
<b>One month mortality</b>	0 (0%)	4 (10%)	6 (10%)	0.006
<b>VT recurrence</b>	22 (23%)	21 (55%)	37 (61%)	<0.001
<b>ICD therapy</b>				
<b>At least one ICD shock</b>	8 (8%)	10 (26%)	20 (33%)	<0.001
<b>Multiple ICD shocks</b>	3 (3%)	6 (16%)	14 (23%)	0.001
<b>ATP without ICD shocks</b>	14 (15%)	11 (29%)	17 (28%)	0.072
<b>Medication during follow-up</b>				
<b>Amiodarone</b>	36 (38%)	20 (53%)	43 (71%)	<0.001
<b>Discontinuation of amiodarone</b>	39 (41%)	10 (26%)	13 (21%)	0.025
<b>Beta-blocker</b>	91 (96%)	36 (95%)	60 (98%)	0.583
<b>Sotalol</b>	6 (6%)	3 (8%)	3 (5%)	0.834

ATP=antitachycardia pacing; ICD=implantable cardioverter-defibrillator; LAVA=local abnormal ventricular activities.

Confidential,  
do not disseminate further

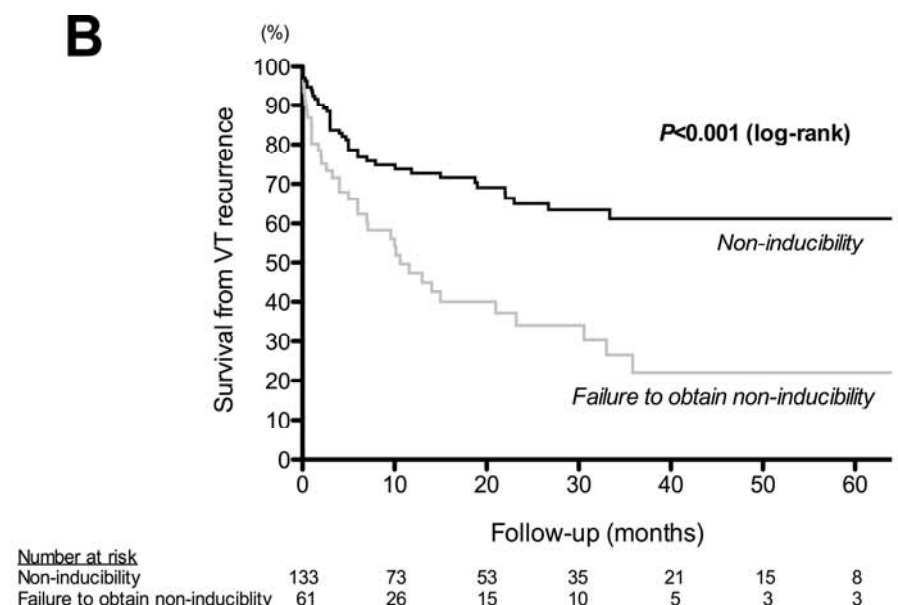
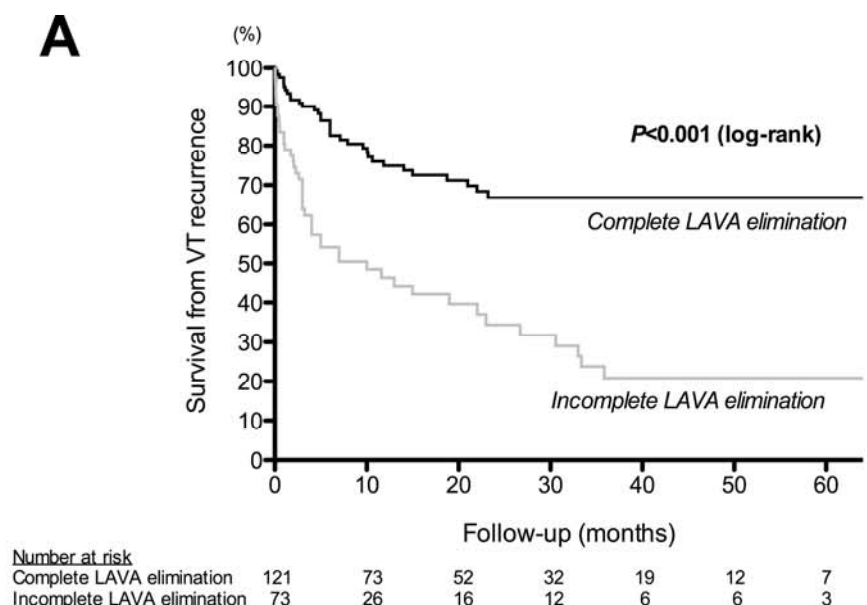
Figure 1



Disclaimer: This document is intended for journal use only.

Confidential,  
do not disseminate further

Figure 2

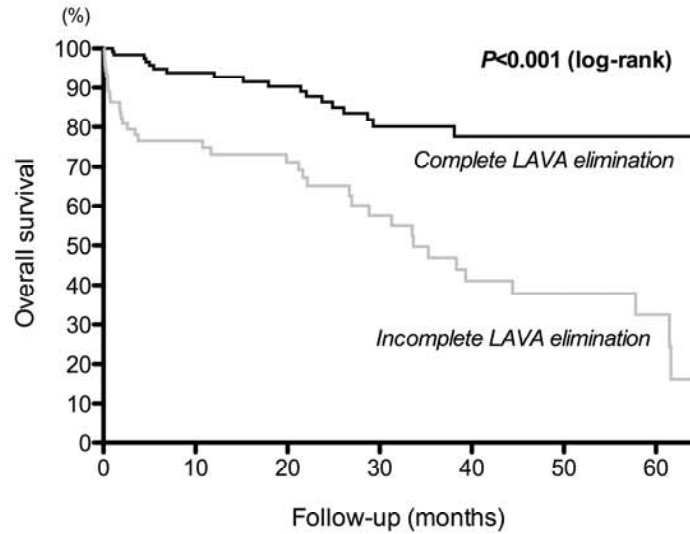


Disclaimer: The manuscript is intended for journal review

confidential,  
to be further

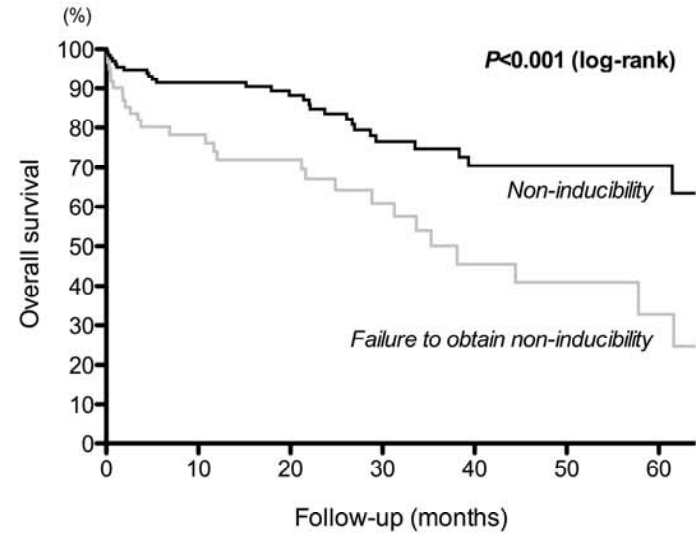
Figure 3

**A**



Number at risk		0	10	20	30	40	50	60
Complete LAVA elimination	121	89	71	46	29	18	11	
Incomplete LAVA elimination	73	46	38	23	15	11	5	

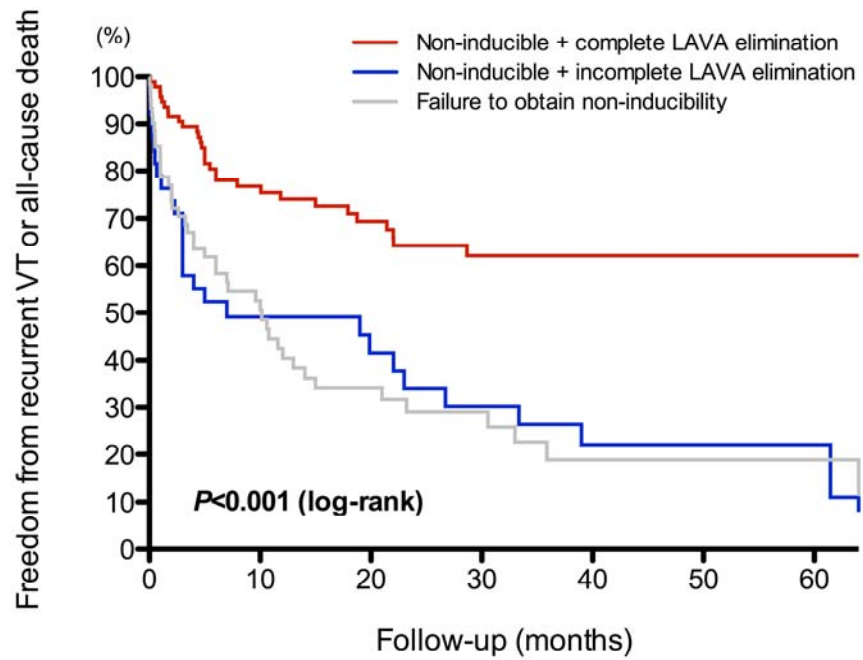
**B**



Number at risk		0	10	20	30	40	50	60
Non-inducibility	133	96	78	50	33	23	11	
Failure to obtain non-inducibility	61	39	31	19	11	6	5	

Disclaimer: The  
intended for journal

Figure 4



Number at risk


	0	10	20	30	40	50	60
Non-inducible + complete elimination	95	58	42	27	16	11	7
Non-inducible + incomplete elimination	38	16	12	9	6	5	2
Failure to obtain non-inducibility	61	26	15	10	5	3	3

Disclaimer: This document is intended for journal use only.

Confidential, not to be further distributed.

Confidential,  
do not disseminate further

Figure 5



Disclaimer: The manuscript is intended for journal review only.

## J) Références

1. Kuck KH, Reddy VY, Schmidt B, Natale A, Neuzil P, Saoudi N, Kautzner J, Herrera C, Hindricks G, Jais P, Nakagawa H, Lambert H, Shah DC. A novel radiofrequency ablation catheter using contact force sensing: Toccata study. *Heart Rhythm*. 2012; 9: 18-23.
2. Neuzil P, Reddy VY, Kautzner J, Petru J, Wichterle D, Shah D, Lambert H, Yulzari A, Wissner E, Kuck KH. Electrical reconnection after pulmonary vein isolation is contingent on contact force during initial treatment: results from the EFFICAS I study. *Circ Arrhythm Electrophysiol*. 2013; 6: 327-333.
3. Yokoyama K, Nakagawa H, Shah DC, Lambert H, Leo G, Aeby N, Ikeda A, Pitha JV, Sharma T, Lazzara R, Jackman WM. Novel contact force sensor incorporated in irrigated radiofrequency ablation catheter predicts lesion size and incidence of steam pop and thrombus. *Circ Arrhythm Electrophysiol*. 2008; 1: 354-362.
4. Sacher F, Wright M, Derval N, Denis A, Ramoul K, Roten L, Pascale P, Bordachar P, Ritter P, Hocini M, Dos Santos P, Haissaguerre M, Jais P. Endocardial versus epicardial ventricular radiofrequency ablation: utility of in vivo contact force assessment. *Circ Arrhythm Electrophysiol*. 2013; 6: 144-150.
5. Inoue H, Waller BF, Zipes DP. Intracoronary ethyl alcohol or phenol injection ablates aconitine-induced ventricular tachycardia in dogs. *J Am Coll Cardiol*. 1987; 10: 1342-1349.
6. Haines DE, Wayne JG, DiMarco JP. Intracoronary ethanol ablation in swine: effects of ethanol concentration on lesion formation and response to programmed ventricular stimulation. *J Cardiovasc Electrophysiol*. 1994; 5: 422-431.
7. Brugada P, de Swart H, Smeets JL, Wellens HJ. Transcoronary chemical ablation of ventricular tachycardia. *Circulation*. 1989; 79: 475-482.
8. Kay GN, Epstein AE, Bubien RS, Anderson PG, Dailey SM, Plumb VJ. Intracoronary ethanol ablation for the treatment of recurrent sustained ventricular tachycardia. *J Am Coll Cardiol*. 1992; 19: 159-168.
9. Calkins H, Epstein A, Packer D, Arria AM, Hummel J, Gilligan DM, Trusso J, Carlson M, Luceri R, Kopelman H, Wilber D, Wharton JM, Stevenson W. Catheter ablation of ventricular tachycardia in patients with structural heart disease using cooled radiofrequency energy: results of a prospective multicenter study. Cooled RF Multi Center Investigators Group. *J Am Coll Cardiol*. 2000; 35: 1905-1914.
10. Sacher F, Tedrow U, Field ME, Raymond JM, Koplan B, Epstein L, Stevenson WG. Ventricular Tachycardia Ablation: Evolution of Patients and Procedures Over 8 Years. *Circ Arrhythm Electrophysiol*. 2008; 1: 153-161.



11. Stevenson WG, Wilber DJ, Natale A, Jackman WM, Marchlinski FE, Talbert T, Gonzalez MD, Worley SJ, Daoud EG, Hwang C, Schuger C, Bump TE, Jazayeri M, Tomassoni GF, Kopelman HA, Soejima K, Nakagawa H, Multicenter Thermocool VT Ablation Trial Investigators. Irrigated radiofrequency catheter ablation guided by electroanatomic mapping for recurrent ventricular tachycardia after myocardial infarction: the multicenter thermocool ventricular tachycardia ablation trial. *Circulation*. 2008; 118: 2773-2782.
12. Sosa E, Scanavacca M, D'Avila A, Bellotti G, Pilleggi F. Radiofrequency catheter ablation of ventricular tachycardia guided by nonsurgical epicardial mapping in chronic Chagasic heart disease. *Pacing Clin Electrophysiol*. 1999; 22: 128-130.
13. Soejima K, Stevenson WG, Sapp JL, Selwyn AP, Couper G, Epstein LM. Endocardial and epicardial radiofrequency ablation of ventricular tachycardia associated with dilated cardiomyopathy: the importance of low-voltage scars. *J Am Coll Cardiol*. 2004; 43: 1834-1842.
14. Garcia F.C., Sussman J.S., Bala R., Toca F.M., Lin D., Dixit S., Marchlinski FE. Epicardial ablation to eliminate ventricular tachycardia associated with right ventricular cardiomyopathy: Characterization of the substrate. *Heart Rhythm*. 2006; 3: S4-S5.
15. Aliot EM, Stevenson WG, Almendral-Garrote JM, Bogun F, Calkins CH, Delacretaz E, Bella PD, Hindricks G, Jais P, Josephson ME, Kautzner J, Kay GN, Kuck KH, Lerman BB, Marchlinski F, Reddy V, Schaliq MJ, Schilling R, Soejima K, Wilber D, European Heart Rhythm Association, European Society of Cardiology, Heart Rhythm Society. EHRA/HRS Expert Consensus on Catheter Ablation of Ventricular Arrhythmias: developed in a partnership with the European Heart Rhythm Association (EHRA), a Registered Branch of the European Society of Cardiology (ESC), and the Heart Rhythm Society (HRS); in collaboration with the American College of Cardiology (ACC) and the American Heart Association (AHA). *Europace*. 2009; 11: 771-817.
16. Poole JE, Johnson GW, Hellkamp AS, Anderson J, Callans DJ, Raitt MH, Reddy RK, Marchlinski FE, Yee R, Guarnieri T, Talajic M, Wilber DJ, Fishbein DP, Packer DL, Mark DB, Lee KL, Bardy GH. Prognostic importance of defibrillator shocks in patients with heart failure. *N Engl J Med*. 2008; 359: 1009-1017.
17. Sweeney MO. Point: implantable cardioverter-defibrillator shocks for ventricular tachyarrhythmias increase mortality. *Heart Rhythm*. 2012; 9: 985-987.

## VI- Conclusion

Le nombre d'ablation de TV croît régulièrement avec une évolution en ce qui concerne le substrat des patients adressés: augmentation de la proportion de myocardopathie dilatée à coronaires saines. Le corolaire est l'augmentation des procédures avec abord épicaudique ces dernières années. Les patients sont référés tardivement dans l'histoire de leur myocardopathie (médiane 9 ans après un infarctus du myocarde) et souvent en dernier recours (orage rythmique dans 29% des cas pour les myocardopathies ischémiques et 22% pour les myocardopathies dilatées à coronaires saines). Malgré des taux de succès estimés à 65% pour les patients avec myocardopathie ischémique et 51% pour les patients avec myocardopathie dilatée à coronaires saines, la mortalité après 3 ans de suivi moyen est importante (35% et 17% respectivement). Ces éléments nous incitent à tenter d'intervenir plus tôt dans l'évolution de l'arythmie, particulièrement dans les myocardopathies ischémiques.

Notre volet sur la caractérisation du substrat, nous a permis de montrer que, chez les patients avec antécédent d'infarctus du myocarde, les caractéristiques (fragmentés, tardifs, doubles) des potentiels ventriculaires anormaux (LAVA) sont liées à leur localisation dans le myocarde et dans la cicatrice. Ainsi certains LAVA «cibles de l'ablation» peuvent être mal identifiés lors de la cartographie du substrat car précoces (particulièrement dans le septum, en zone bordante de cicatrice ou lors d'infarctus récent). En cas de doute, la stimulation ventriculaire (au mieux près du site) avec extrastimuli peut permettre de les démasquer. Nous avons également montré que chez les patients avec myocardopathie dilatée à coronaires saines avec substrat sous épicaudique adressés pour ablation de TV, l'étiologie de cette myocardopathie est très vraisemblablement une séquelle de myocardite. Lorsqu'un tel substrat est identifié chez un patient adressé pour ablation de TV, une approche épicaudique semble justifiée d'emblée car l'ablation endocardique est inefficace. La cartographie du substrat retrouve souvent des potentiels ventriculaires farfield >1,5mV. Si l'on se réfère uniquement au codage couleur habituel du voltage (0,5mv-1,5mV), les LAVA se trouvent dans des zones de voltage normal (>1,5mV). De plus, les isthmes des TV se situent très fréquemment sur la paroi latérale du VG potentiellement proche de structures sensibles (artères coronaires, nerf phrénique). Ces structures doivent être clairement identifiées avant l'application de radiofréquence pour ne pas les léser. Concernant les patients avec assistance ventriculaire gauche à flux continu, la survenue de TV est problématique (choc du défibrillateur ou altération ventriculaire droite si TV respectée). L'ablation est faisable et sûre dans ce contexte. Le circuit des TV est essentiellement lié aux cicatrices myocardiques à l'origine de la myocardopathie et non à l'implantation de la canule. Enfin nous avons montré chez un patient avec syndrome de Brugada, qu'il existait des potentiels ventriculaires anormaux précoces uniquement épicaudique en regard de la base de

l'infundibulum pulmonaire. La perfusion d'ajmaline en même temps qu'elle augmente l'aspect de Brugada sur l'ECG de surface retarde ces potentiels. Cette observation ajoute un élément en faveur de l'hypothèse d'un problème de dépolarisation dans le Brugada.

Enfin nous avons pu montrer, dans la troisième partie, l'intérêt de nouvelles technologies (visualisation de la création de la lésion en temps réel, mesure de la force du contact) pour améliorer l'efficacité des applications de radiofréquence (RF): 22% des applications de RF ne correspondent à aucune lésion avec la technologie habituelle. Ces nouvelles technologies nous ont également permis de voir que les lésions réalisées dans l'endocarde et sur l'épicarde n'ont pas la même morphologie due aux différences de contact exercé par le cathéter sur le tissu : les lésions endocardiques sont plus profondes mais moins larges que celles réalisées sur l'épicarde. Par ailleurs, nous avons pu montrer que l'alcoolisation intra-coronaire gardait une place (limitée) pour détruire un circuit profond inaccessible à l'ablation par radiofréquence. L'approche épiscopique par contre est de plus en plus utilisée pour l'ablation des TV après échec d'ablation endocardique mais également chez les patients avec dysplasie arythmogène du ventricule droit ou myocardiopathie dilatée à coronaires saines. Cette approche comporte ses propres risques (7% de risque majeur) mais utilisée chez des patients bien sélectionnés, elle permet d'atteindre la partie du circuit de TV qui n'était pas accessible depuis l'endocarde. Il est important de bien connaître ses risques potentiels afin de les éviter. Pour diminuer les risques inhérents à l'ablation en particulier épiscopique, l'apport de l'imagerie (IRM et scanner cardiaque) est très important (anatomie des coronaires, du nerf phrénique...). Cette même imagerie après l'ablation peut également nous aider à mieux comprendre les lésions réalisées pendant l'ablation et visualiser les conséquences d'application pathologique (pop). Nous avons également montré que l'ablation depuis l'endocarde pouvait éliminer des LAVA sur le versant épiscopique si la paroi était fine (ventricule droit, zone d'amincissement au scanner <5mm), s'il existait des LAVA endocardiques en regard du site épiscopique ciblé et si l'amplitude en unipolaire sur le versant endocavitaire du site était basse. Si ces conditions ne sont pas remplies, cette approche n'est pas efficace et peut même être délétère si la cicatrice est uniquement sous épiscopique. Enfin l'élimination complète des LAVA comme critère de succès d'une ablation de TV est faisable dans 62% des procédures vs 68% pour la non inductibilité. L'élimination incomplète des LAVA est associée à un taux de récurrence de TV (HR=3 [CI:1,9-4,8]; p<0,001) et de mortalité supérieur (HR=2,8 [CI:1,6-5,0]; p=0.001). Alors que la persistance d'inductibilité est associée à un risque de récurrence de TV (HR=1,9 [CI:1,2-3,0]; p=0,004) mais pas à une surmortalité.

