



HAL
open science

Presentation, optimization and result of new methods of infiltration and neurolysis under CT guidance in the management of pain

Adrian Kastler

► **To cite this version:**

Adrian Kastler. Presentation, optimization and result of new methods of infiltration and neurolysis under CT guidance in the management of pain. Imaging. Université de Franche-Comté, 2014. English. NNT : 2014BESA3017 . tel-01230122

HAL Id: tel-01230122

<https://theses.hal.science/tel-01230122>

Submitted on 17 Nov 2015

HAL is a multi-disciplinary open access archive for the deposit and dissemination of scientific research documents, whether they are published or not. The documents may come from teaching and research institutions in France or abroad, or from public or private research centers.

L'archive ouverte pluridisciplinaire **HAL**, est destinée au dépôt et à la diffusion de documents scientifiques de niveau recherche, publiés ou non, émanant des établissements d'enseignement et de recherche français ou étrangers, des laboratoires publics ou privés.

UNIVERSITE DE FRANCHE COMTE

ÉCOLE DOCTORALE « ENVIRONNEMENTS-SANTÉ »

Année 2014

THESE

Pour obtenir le grade de

Docteur de l'Université de Franche-Comté

Spécialité : Innovation Technologique

Présentée et soutenue publiquement

Le 12 décembre 2014

Par

Adrian KASTLER

**'Presentation, optimization and results of new methods of
infiltration and neurolysis under CT guidance in the
management of pain.**

Directeur de thèse : Laurent TAVERNIER

Nicolas AMORETTI, Docteur, HDR à L'Université de Nice

Rapporteur

Fabrice-Guy BARRAL, Professeur à L'Université de St Etienne

Rapporteur

Alexis KELEKIS, Professeur à l'Université d'Athènes, Grèce

Examineur

Philippe PEREIRA, Professeur à l'Université de Heidelberg, Allemagne

Examineur

Laurent TAVERNIER, Professeur à l'Université de Franche-Comté

Directeur

Cette thèse est dédiée à mon Père, le Professeur Bruno KASTLER.

Il est mon véritable Maître, mon Mentor, mon Soutien et avant tout il est celui de qui je m'inspire. Il m'a donné envie de faire ce métier, il m'a apporté son regard et son expérience sur la discipline. Tous les jours j'essaie d'appliquer ce qu'il m'a enseigné et transmis ; il y a évidemment l'application de ses techniques innovantes et inédites : tous les patients que, modestement j'essaie de soulager au quotidien, bénéficient directement de l'ensemble des techniques qu'il a mis au point et qu'il continue à me transmettre. Mais au delà de l'aspect technique, il m'a appris à écouter, observer, et répondre aux attentes des patients qui, bien souvent, viennent chercher autre chose que le seul geste technique : je suis intimement convaincu que l'efficacité de nos techniques ne peut être que renforcé par une prise en charge globale et attentive du patient. Ce sont les gens comme toi qui rendent la noblesse à notre métier et qui aident à oublier toute la médiocrité qui peut l'entourer.

Papa, je suis si fier de toi, cette thèse est le fruit de notre collaboration, qui m'est si chère mais surtout le résultat de tant d'années de travail que tu as dédié et à tes patients et à la recherche perpétuelle de nouvelles solutions à leur apporter.

Merci pour tout ce que tu m'apportes.

Merci encore et toujours.

A ma mère, merci Maman, je sais que si j'en suis la aujourd'hui, c'est aussi grâce à toi. Merci pour ton éternel soutien dans les moments difficiles, et ta disponibilité au quotidien. Enfin, j'aimerais souligner que, même si nos activités quotidiennes paraissent éloignées, elles se rejoignent très étroitement dans cette activité de prise en charge de la douleur, et si j'apporte autant d'importance à la prise en charge globale des patients et surtout à leur écoute, ce n'est sûrement pas anodin. Je pense, qu'ayant une mère Psychiatre, cela doit jouer un rôle dans la conception de mon activité. Merci pour cela.

A Tif, Flo, Gagou, Thibault, Guillaume, Alex, Ali, Mehri et Goli, : merci d'être toujours là quand il faut, vous donnez un réel sens au mot FAMILLE.

Mention spéciale à Guigui : si content de te voir rejoindre le club de la radio après tant d'effort. BRAVO, et Flounch : si FIER de te voir si bien progresser dans un monde si différent: You're up next ! Enfin Titi : big sis', merci pour ton regard bienveillant depuis tout petit !

Enfin, Andia et Shirine, les deux femmes de ma vie. Vous donnez un sens à ma vie et sans vous, elle n'aurait que peu d'intérêt. Merci de rendre le quotidien aussi plaisant, merci pour tout le soutien. Je n'ai pas de mot pour exprimer l'importance et le rôle si primordial que vous avez dans ma vie.

Je vous aime si fort.

Une page de remerciements ne pourrait se conclure sans remercier les patients que modestement nous essayons de soulager. Cette thèse leur est ainsi également dédiée, pour leur courage et leur optimisme.

Table Of Content

I - Introduction , p.1

II - Pain Historical facts , p.5

A - History of Pain , p.6

B - History of Interventional Pain Management , p.7

III - Definition and Concept of PAIN , p.9

A - Definition, p.10

i - IASP definition

ii - Acute pain definition :

ii - Chronic Pain definition

B - Physiopathology of Pain , p.11

1 - Pain Due to an Excess of Nociperception

2 - Neurogenic Pain

3 - Hysterical Pain

C - Neurophysiological basis to chronic pain : the biopsychosocial model , p.12

IV - Review of Existing Pain procedures .14

A – Neural Blocks, p.15

1.Definition

2. Local Anesthetic Agents

a) *Physiopathology*

b) *Toxicity*

c) *Frequently used local anesthetic agents*

B-Corticosteroid Infiltration, p22

1-Pathophysiology

2-Side effects

3-Corticosteroid agent description and Frequently used Corticosteroid agents

C - Neurolysis, p.26

1-Chemical Neurolysis :

2-Physical Neurolysis

V - Imaging Guiding Modalities: p.32

A - Fluoroscopy p.33

B - Cone Beam CT/Angiographic computed tomography p.34

C - Ultrasound p.35

D - CT Guidance p.36

E - MRI Guidance P.38

VI - Review of existing indications of pain interventional techniques, p.41

A - Abdominal and Pelvic Pain, p.42

B - Lumbar Pain "Low back Pain" p.44

C - Thoracic Spine Pain p.46

D - Head and Neck Pain, p47

1- Head

2 - Cervical

VII - Clinical Applications of modified existing techniques p, 51

A- Inguinal/Groin Pain p.53

1 - Part I : Radiofrequency Neurolysis in the Management of Inguinal Neuralgia : Preliminary Study. p.54

2 - Part II : Radiofrequency neurolysis versus local nerve infiltrations in 41 patients with refractory chronic inguinal neuralgia. p.69

B - Head, and Neck p.85

1) Neck : Stellate Ganglion, p.84

CT-guided Stellate Ganglion Blockade vs. Radiofrequency Neurolysis in the Management of Refractory type I Complex Regional Pain Syndrome of the Upper Limb, p.85

2) Head, p.101

a) Sphenopalatine Ganglion, p.101

Alcohol percutaneous neurolysis of the sphenopalatine ganglion in the management of refractory cranio facial pain p.102

b) Greater Occipital Nerve, p.121

2 - A simplified CT guided approach for greater occipital nerve infiltration in the management of Occipital Neuralgia p.122

VIII : Unidirectional Radiofrequency Probe Experiments: Future perspectives,

p.137

A - Introduction, *p.138*

B - Radiofrequency Principle, *p.139*

C - RF equipment *p.140*

D - Illustrations of possible applications of Unipolar Probe, *p.141*

E - Feasibility of Mass production Partially Insulated RF probe, *p.142*

IX : Conclusion, *p.147*

X : References, *p.152*

XI : Résumé long, *p.166*

I - Introduction

Albert Schweitzer, physician, well known humanitarian, and 1952 Peace Nobel prize laureate stated, *"We must all die. But that I can save him from days of torture, that is what I feel is my great and ever new privilege. Pain is a more terrible lord of mankind than even death itself"* [1]. This statement shows how Albert Schweitzer had, in his time, already identified the most important elements of the concept of pain : the 'horrible' nature of pain and the obligation any physician has to try to relieve it.

The definition of pain has evolved over the years, it differs depending on the dictionary used : it is defined as a physical or mental suffering (Larousse dictionary), a painful sensation in some part of the body (Robert), a physical suffering, or a suffering which is to the soul what physical suffering is to the body (Littre). However, the internationally recognized definition of pain to date is this defined by The International Association for the Study of Pain (IASP) which has adopted Merskey's definition of pain [2]: Pain is an unpleasant sensory and emotional experience, associated with a real or virtual tissue damage or described in terms of such a damage. With this definition, pain is no longer defined from the perspective of the physician, but from that of the patient. To date, literature is replete with numerous descriptions of the concept and treatment of pain. Chronic pain, which is defined as a pain that has lasted for more than 6 months, has been recognized as a multifactorial and multidimensional disorder with many possible etiologies including sensory and effective components. F. Bourreau had perfectly and accurately defined the concept of chronic pain, in 1988 [3]: *"We will use the term chronic pain syndrome (CPS) to describe the set of physiological, psychological, behavioral and social symptoms which tend to make us look at persistent pain, regardless of its original etiology, more as a 'sickness in itself ' rather than as the mere sign of an underlying*

physiopathological disorder". Today, chronic pain management has become one of the priorities of health care professionals, as it has become a major public health issue with high socio-economic impact as chronic persistent pain may disrupt the ability to perform physical activities, work and family life [4-7]. Indeed, even though the accurate prevalence of chronic pain has not been precisely estimated (due to variations in the definition, and difficulties to determine and collect information on the impact of daily living activities and ability to work) a World Health Organization study has reported that 22% of primary care patients present persistent pain [8]; Other studies report the existence of chronic pain with a range between 10% and 55%

[4] [9]. This results in substantial health care expenses, as Chronic pain is a challenge for healthcare systems.¹ Management of chronic pain requires a range of services, including GP visits, specialist visits, investigations, physical therapy, hospital admissions and prescription of pain medications. For example, a study by Depont et.al showed that The total mean cost per patient with low back pain over six months was 715.6 euros. Another study, by Richard [7] described the economic cost of pain in the United States showed an increase from \$560 to \$635 billion in 2010 with a productivity lost due to pain ranging from \$299 to \$335 billion. Consequently, they concluded that the annual cost of pain was greater than the annual added cost of heart disease (\$309 billion), cancer (\$243 billion), and diabetes (\$188 billion).

To date, numerous treatment modalities exist to manage chronic pain in order try to reduce public health care related expenses, including: drug use, physical therapy, surgery, and minimally invasive therapies, also known as interventional techniques, with or without imaging guidance [10-13] [14] Minimally invasive therapies have been the subject of numerous investigations and the literature is replete with studies addressing the effectiveness of interventional techniques in managing

chronic pain [14]. Indeed, Interventional pain management is a rapidly growing and evolving specialty. Advances in the field have been made thanks to the contribution of various disciplines—including anesthesiology, radiology, surgery, rehabilitation, epidemiology, nursing, and psychology— all of which are now designated specialists in pain medicine and interventional pain management. The interventional pain physician plays an important role for both a comprehensive and effective pain management program, as the help of the interventional pain physician may be sought at either diagnostic or management stages. The success of interventional pain procedures over the last two decades have made the interventional pain physician an active part in the multidisciplinary approach of pain management.

Moreover, imaging guidance has become more and more popular amongst pain interventionalist as it has been shown to improve procedure safety in some specific indications. However, the most frequent imaging guiding tools used remain fluoroscopy and ultrasound, due to their wider availability. CT scan as a guiding imaging tool on the other hand is less described.

The idea behind this thesis and the aims of this manuscript are therefore :

*** to evaluate the usefulness of CT scan guidance, a powerful and precise imaging guiding tool widely used in the field of interventional radiology, but relatively underused in the field of Interventional pain management.**

*** To benefit from this precise guiding tool to apply existing neurolytic techniques (block, infiltration and neurolysis) to never explored indications, due to difficult access without imaging guidance and to evaluate the clinical effectiveness of these novel indications**

II - Pain Historical facts

A - History of Pain [14]

The concept of pain has bothered man kind since the origin of humanity. In very ancient times, pain and magic were one and the same. Pain was considered to be due to the presence of an evil spirit within the suffering man, which could only be treated by inflicting a wound to chase the evil spirit.

Greeks (Homer among them) still considered human pain to be a sign sent by the gods. Hippocrates attempted to remove the sacred aura surrounding pain meanwhile, Aristotle and Plato kept seeing in it not a sensation, but an emotion. Galen located pain in the brain, center of all sensations and was the first to look for means of fighting pain and sickness in pharmacology and surgery. His anatomical and physiological theories were to become a dogma that nobody dared challenge for almost 15 centuries.

In the Middle Ages physicians did not seem to pay much attention to pain, even though analgesic plants were well known (opium, sage, ivy, mandrake).

A great name in both philosophy and medicine, Avicenna (980–1037) constitutes an exemplary synthesis of Hippocrates, Aristotle, and Galen. He wrote of the interaction of psyche and soma. a first step toward the biopsychosocial model.

In the Renaissance, under the influence of Lorenzo de Medici and his Academy, the modern anatomic and physiological vision of pain appeared. It was first described as sensation related to the nervous system.

The 18th and the 19th centuries were important because of progress in pharmacology in general and the fight against pain in particular. Discoveries were numerous: nitrogen dioxide was identified by Priestley in the 1770s and made use of by Davy in the 1840s; ether was described by Faraday in 1818 and used by Hickman

in the 1830s; chloroform was simultaneously found by Von Liebig in Germany, Soubeiran in France, and Guthrie in the USA.

The first general anesthesia was performed by Morton on October 16, 1846, in Boston, MA, USA, (the word anesthesia having been suggested by Oliver Wendell Holmes).

The 20th century, with the development of analgesic techniques and pharmacology, allowed man to imagine “a world without pain” for all time to come. The question remains whether that is possible and desirable.

John Bonica, in the second half of the century, defined “pain clinics,” and founded in 1973 founded the International Association for the Study of Pain (IASP).

B - History of Interventional Pain Management [15]

Interventional pain management dates back to the appearance of neural blockade and regional analgesia. Neural blockade and interventional techniques are based on the concept that pain constitutes a sensorial warning conveyed by specific nerve fibers, which can, if interrupted, lead to pain relief. The origins of blockade date back to the end of th 19th century when Koller reported the numbing effect of cocaine on the tongue [16]. Quickly, the use of neuroblocking agents (cocaine, alcohol) were described in the end the 19th and the beginning of the 20th century in various areas of pain, with an emphasis on epidural blockade [17-19]. Utility of diagnostic blockade in pain management was recognized when von Gaza [20] used procaine for determining the pathways of obscure pain (sympathetic or sensory). Following this, several authors described applications for diagnostic interventional techniques [21, 22].

The following major advances in understanding key principles of clinical anatomy were made thanks to Bodgduk in the 1980's, with emphasis on the spine [23, 24] [25]. Since then , a variety of diagnostic interventional techniques for painful conditions have emerged [26]. More recently, The International Association for the Study of Pain has developed standards for performing diagnostic blocks [27].

III- Definition and Concept of PAIN

A - Definition

1 - IASP definition

As stated above the International Association for the study of Pain (IASP) has defined pain to be : "an unpleasant sensory and emotional experience, connected with an existing or potential tissue lesion, or described in terms of such a lesion."

This definition has two advantages:

- Pain is considered as a central neuro-physio-psychological event with a double dimension, a subjective, sensory one and an emotional one, whose unpleasant character can be assessed only by the sick person.
- It justifies the painful moan of a psychological disorder, as it stresses the possibility that pain-generating mechanisms may have a physical as well as a psychological basis.

2 - Acute pain definition :

In an acute pain (that has appeared recently), the generating mechanism is often singular and somatic. It is accompanied by neurovegetative and motor signs as well as reactive anxiety.

3 - Chronic Pain definition

Chronic pain is defined as a pain that has lasted for more than 6 months. It usually continues beyond the actual cause of pain (trauma, surgery, nerve ablation) or can accompany progressive chronic disease (e.g., cancer, polyarthritis). Long lasting pain ends up affecting the psyche and it is sometimes difficult to differentiate somatic or psychological primary factors.

B - Physiopathology of Pain :

1 - Pain Due to an Excess of Nociperception

These result from a strong stimulation of the specific receptors of pain, without any lesion nor dysfunction of the peripheral or central nervous system. They stem from alterations of the viscera, the blood vessels, and/or the locomotor system. Such pain is the type found in cancer or rheumatism and can be soothed with peripheral or central analgesics, sometimes combined with co-analgesics.

2 - Neurogenic Pain

These originate in lesions of peripheral nerves (e.g., stump pain, various neuropathies), in lesions of the radices (e.g., shingles, tearing of the brachial plexus), and in vascular or traumatic lesions of the central nervous system (e.g., cerebral vascular illness, brain tumor). A typical example here is the pain caused by shingles. These pains are not soothed by standard analgesics, but by an anti-epilepsy and anti-depression treatment. Transdermal nerve stimulation is also recommended.

3 - Hysterical Pain

The diagnosis is based on the negative results of a meticulous organ checkup, a poor response to an anal- gesic treatment, and a-typical clinical picture consisting of evocative localizations, a particular description of pain, the presence of psychological signs, the particular way in which the patient relates to his/her circle of friends and family as well as to the physician, and his/her special ties to pain.

C - Neurophysiological basis to chronic pain : the biopsychosocial model

With the emergence of pathological anatomy as the fundamental science of medicine, the “biomedical model” of disease, emerged in the mid 1840's with quite a success. However, this model has shown some difficult and important limitations and raised criticism [28]. Indeed, some diseases, such as chronic pain, in various fields such as pelvic pain, facial pain, myofascial pain syndromes, and some psychiatric illness, persistent spinal pain, have been included in this category of resistant diseases to the biomedical model [29].

Thus, in the 1990s the concept of biopsychosocial model was introduced, with an emphasis on the “psychosocial” approaches, most often without the “bio.” Psychological signs of pain with four components of pain were described :

- The sensory component corresponds to the decoding of the sensory message in its quality, intensity, duration and localization characteristics
- The emotional component comes into being if pain is prolonged, and consists of anguish and/or depression.
- The cognitive component, which corresponds to the place given to pain in his/her life; it calls on his/her educational, cultural, religious experience, the contents of which determines his/her way of treating the painful information in the brain
- The behavioral component corresponds to the observable (objective) motor, verbal, and objective signs that pain determines,

However, multiple concerns related to the biopsychosocial model have been described [30]. These concerns include the reliance on self-reporting of outcomes, the disconnection between physical pathology and self-reporting, and the scientific status of the biopsychosocial model.

To date, some purists and proponents of the biopsychosocial model continue to describe this as the best and only model, whereas others argue that the biological model is also equally important. However, the scientific status of both models have and will be eternally questioned.

The most important thing to remember, whatever the model one cherishes, is the patient, which should be placed at the center of the management diagram. What is however an evidence, although not proven, is that the multidimensional mechanism of pain must call for a multidisciplinary management. This is very important, as one must not ignore the fundamental facts that pain is not explained by pure theories of either physical or psychological origins.

IV - Review of Existing Pain procedures

Various pain procedures have been used in the field of interventional pain management. The range of procedures varies from simple blocks to more complicated procedures such as thermal ablations or stimulation device implants. Because the use of certain devices is more developed in specific medical subspecialties (i.e. stimulators in neurosurgery and anesthesiology), we chose to focus on more widely accessible procedures, including blocks, infiltrations and neurolysis.

A – Neural Blocks

1. Definition

Neural Blocks, also known as blockades, block test, diagnostic infiltration or controlled diagnostic injections are performed to confirm or exclude a pain generator. A blockade is only indicated when diagnosis is uncertain despite specific therapy and clinical symptoms. Bogduk postulated that for a structure to be deemed as a cause of back pain [31]:

- ◆ The structure should have a nerve supply.
- ◆ The structure should be capable of causing pain similar to that seen clinically, ideally demonstrated in normal volunteers.
- ◆ The structure should be susceptible to diseases or injuries that are known to be painful.
- ◆ The structure should have been shown to be a source of pain in patients, using diagnostic techniques of known reliability and validity.

The use of neural blockage as a diagnostic tool in painful conditions has grown among pain specialists interventionalists in the past decades. Precision diagnostic blocks are indeed commonly performed to clarify challenging pain situations, in order

to determine the pathophysiology of clinical pain, the site of nociception, and the pathway of afferent neural signals. It is also a necessary step prior to performing more aggressive procedures such as neurolysis [32]

2. Local Anesthetic Agents

a) Physiopathology [33].

Local anesthetics are known for their ability to prevent membrane depolarization of nerve cells. Local anesthetics prevent depolarization of nerve cells by binding to cell membrane sodium channels and inhibiting the passage of sodium ions. Frequently stimulated nerves are more easily blocked [34]. The ability of a given local anesthetic to block a nerve depends on multiple factors, such as : the length and the diameter of the nerve, the presence of myelination, and the anesthetic used. The structure of local anesthetics agents presents both a lipophilic and hydrophilic end linked by a hydrocarbon chain.

- The type of linkage classifies local anesthetics as either an ester (–CO) local anesthetic, (plasma metabolization), or an amide (–NHC) local anesthetic (liver metabolization).
- The functional characteristics of local anesthetics are determined by : the dissociation constant (pKa), lipid solubility, and protein binding.
- The potency of local anesthetics is determined by lipid solubility. The higher the lipid solubility, the higher connective tissue and cell membrane penetration are, therefore increasing local anesthetic potency.
- The duration of action for local anesthetics is determined by protein binding. Local anesthetics with high affinity for protein binding remain

bound to nerve membranes longer, resulting in an increased duration of action.

b) Toxicity [35]

Physicians who use frequently use local anesthetics should be familiar with the signs and symptoms of local anesthetic toxicity. Interventional pain specialist should learn to recognize :

- *Neurotoxicity* (related mainly to amygdala dysfunction) expressed by : muscular twitching, visual disturbance, tinnitus, light-headedness, or tongue and lip numbness ; extreme patient anxiety, screaming, or concerns about imminent death are also suggestive of toxicity which may lead to generalized tonicoclonic convulsions, coma, respiratory arrest, and death.
- *Cardiotoxicity* : expressed by arrhythmias and eventual collapse. This toxicity is known to be more present with long acting anesthetics (bupivacaine and ropivacaine) compared with intermediate- and shorter-acting drugs (mepivacaine and lidocaine). [36]
- *Myotoxicity* : overdose may lead to unexplained skeletal muscle dysfunction. [37]

Because the occurrence of toxicity has been proven to be dose-dependant, maximum recommended dosages for different local anesthetics in various conditions have been published [38]. However, the maximum dosage allowed depends on various factors : Technique used (peripheral nerve block epidural analgesia), the type of nerve blocked (upper/lower limbs), the association with epinephrine, and association of local anesthetic agents. The french association of anesthesiology has published the theoretical maximum dosage allowed per local anesthetic agent [39] :

Agent	Superior LIMB	Inferior LIMB
Lidocaïne epinephrin	500 mg (7 mg·kg ⁻¹)	700 mg (10 mg·kg ⁻¹)
Mepivacaïne	400 mg (5-6 mg·kg ⁻¹)	400 mg (5-6 mg·kg ⁻¹)
Bupivacaïne epinephrin	150 mg (2 mg·kg ⁻¹)	180 mg (2,5 mg·kg ⁻¹)
Ropivacaïne	225 mg (3 mg·kg ⁻¹)	300 mg (4 mg·kg ⁻¹)

c) Frequently used local anesthetic agents

**Short acting effect*

Lidocaine. With a low pKa (7.7), 500mg,7mg.kg-1, ou 700 si epinephrine and moderate water and lipid solubility, lidocaine or lignocaine (Xylocaine [AstraZeneca, London, United Kingdom]) is the most versatile and widely used local anesthetic. Subcutaneous infiltration of lidocaine is the favored analgesic technique for many percutaneous procedures (such as venous cannulation).

Lidocaine use for PNB has also been described; however, most physicians prefer longer acting local anesthetics for PNB, so that the duration of analgesia extends well into the postoperative recovery period.

Mepivacaine. Mepivacaine (Polocaine [Abraxis BioScience Inc, Schaumburg, Ill]; Carbocaine [AstraZeneca, London, United Kingdom]) has a pKa of 7.6. 400mg, 5-6mg.kg-1In terms of function and toxicity, mepivacaine is often compared to lidocaine. In dogs, mepivacaine has been shown to be less cardiotoxic than lidocaine, however, it has been shown to be particularly toxic in neonates, and is therefore not used in neonates. Mepivacaine can be used for infiltration anesthesia with a similar onset to lidocaine (1-3 minutes) but a longer duration. It is considered

one of the least neurotoxic local anesthetics. In addition to low toxicity, mepivacaine has other properties that make it an attractive local anesthetic for intermediate-acting PNB, particularly in high-risk cardiac patients. Mepivacaine has excellent diffusion properties through tissue, allowing block success despite less than optimal needle position.

** Long acting effect*

Bupivacaine. Bupivacaine (Marcaine, Sensorcaine; both made by AstraZeneca, London, United Kingdom) has a pKa of 8.1. 2mg.kg⁻¹, 150mg without epinephrin. With an extensive history of successful use, bupivacaine is the long-acting local anesthetic to which others are compared. Although a bupivacaine block is long acting, it also has the longest latency to onset of block. It is available at low cost And is well known to have sensory and motor blocking values at low quantities anesthesia is. However, its use for large-volume techniques such as epidural or peripheral nerve anesthesia may be problematic; prolonged resuscitation following accidental intravascular injection has been reported. The recommended dosages of bupivacaine are the lowest of any of the amide local anesthetics. If patient safety were the only issue (other than cost, convenience, or availability) involved in long-acting local anesthetic selection, less toxic options would likely be used for large volume-blocks. This issue remains controversial.

Ropivacaine. Ropivacaine (Naropin, Abraxis BioScience Inc, Schaumburg, Ill) has a pKa of 8.2, an onset, recommended maximum dosage : 3mg.kg⁻¹, onset 4-6 minutes, and efficacy 8-10hours. It is chemically similar to both mepivacaine and bupivacaine. Because ropivacaine is less cardiotoxic than bupivacaine, it is the

preferred long-acting local anesthetic for peripheral nerve blocks. Ropivacaine is considered the safest long-acting local anesthetic currently available [36], but it is not completely safe (cardiovascular collapse has been reported with its use), and all standard precautions should be observed with its use. [40]

**Combination of local anesthetics*

Combinations of local anesthetics are often used in peripheral nerve blockade. This has the advantage of marrying rapid onset of some agents with longer lasting effect of others. It has been shown that there is no difference between administering the agents separately or in a mixture [41, 42]

Concerning the duration of the blockade, it has been shown that the administration of a mixture of long and short acting anesthetics increases the duration when compared to the short acting agent (by 50-70%), but reduced the duration of the block when compared to the long acting agents (25-50%) [41, 43, 44]. Concerning the onset of action of anesthetic agents, literature is controversial. Some studies [43, 44]) demonstrated a significant reduction in onset time with a combination of agents, but Gadsen reported similar onset. This difference may be due to the amount of anesthetics injected, highly different in these studies.

Local anesthetic combinations may offer a safety advantage by dose sparing of the long-acting local anesthetics, which are potentially more cardiotoxic than the short-acting local anesthetics. However, The potential occurrence of local anesthetics toxicity should be assumed to be additive and careful consideration to the total dose of local anesthetic administered should be given. [45, 46] In summary, combinations of different local anesthetic agents may provide a middle ground between fast onset of action and longer duration. This seems to be particularly true if small amounts

are administered. particularly if modest doses are administered. However, The potential for LAST should be assumed to be additive and careful consideration given to the total dose of local anesthetic administered.

In all of our procedure, we chose to associate Lidocaine for the rapid onset of action with Ropivacain for the longer duration of action and the proven inferior cardiotoxicity in contrast with bupivacaine.

B-Corticosteroid Infiltration

1-Pathophysiology

The mechanisms by which steroids exert their analgesic effects have been debated for many years. The use of corticosteroid injection in neuropathic pain has been introduced with its use in radicular pain, secondary to herniated disc or arthritis. Indeed, the rationale for injecting steroids is that they suppress inflammation of the nerve, which, although highly debated, has been described to partly explain the physiopathology of radicular pain.[47]. Corticosteroids are known to have two antiinflammatory features :

- inhibiting the enzyme phospholipase A2, which is itself an inflammatory mediator present in elevated concentrations in herniated and degenerative intervertebral disks [48]

- limiting the production of arachidonic acid. This implication is the most important, as arachidonic acid is the principal substrate for the cyclo-oxygenase and lipo-oxygenase pathways which are involved in the production eicosanoids (prostaglandins, prostacyclins, thromboxanes, and leukotrienes). These arachidonic acid byproducts, especially prostanglins, can cause or exacerbate pain via their inflammatory effects and ability to sensitize peripheral nociceptors [49].

In addition to their anti-inflammatory effects, steroids may inhibit pain via their ability to suppress ectopic discharges from injured nerve fibers [50] and depress conduction in normal unmyelinated C fibers [51].

2-Side effects

The most common and worrisome complications of corticosteroid injections are not

related to the product, but to the procedure itself, especially in case of perispinal injection: neural trauma, vascular trauma, intravascular injection, and infection [52, 53]. Infection complication are more common with intrarticular injection than periarticular. Other more benign incidents can occur following an infiltration: an immediate and generally transient painful reaction is common. A delayed inflammatory reaction, occurring after a few hours, may also occur. [53]. Corticosteroid infiltrations may generate an atrophic effect on the skin, subcutaneous and musculotendinous tissues with a risk of tendon rupture in the case of injection into the tendons. Allergic reactions can be seen and are usually due to sulphites in the excipients of certain products.

Side effects related to the administration of steroids are generally attributed either to the chemistry or to the pharmacology of steroids. The major theoretical complications of corticosteroid administration include the suppression of pituitary adrenal axis, hypocorticism, Cushing's syndrome, osteoporosis, avascular necrosis of the bone, steroid myopathy, epidural lipomatosis, weight gain, fluid retention, and hyperglycemia [54].

3-Corticosteroid agent description and Frequently used Corticosteroid agents

Concerning corticosteroid classification, there are 2 categories of products :

- Insoluble : also known as particule steroids, or ester group lead to microcrystallisation in water,
 - methylprednisolone (DEPO-MEDROL)
 - triamcinolone (HEXATRIONE,KENACORT),
 - betamethasone (CELESTENE, DIPROSTENE),

- Corivazol (ALTIM)
- Prednisolone (HYDROCORTANCYL)
- Soluble, non ester or non particle :
 - Dexamethasone (DETANCYL), is the only non particle steroid available.

Advantages of the Non-Ester Preparations are well known, as, they have the ability to be taken up quickly by the cells and therefore have a more rapid onset. But then also don't last as long, because they get washed away from the area quickly. In contrast, Ester group Cortosteroids require surrounding cells to first hydrolyze them with esterases to release the active part which implies a delayed onset but a longer duration of clinical efficacy.

Therefore, the most widely used corticosteroids have been particulate steroid such as methylprednisolone , triamcinolone and betamethasone , mainly because they present the advantage of a prolonged effect. However, severe complications, such as secondary infarctions of the spinal cord leading to paralysis have occurred in the past decade [55]. The majority of these complications have occurred with particulate steroids. Although the precise mechanism to date is still not clearly understood, one of the proposed mechanism was embolization of a medullary artery leading to infarction, due to aggregates caused by either the corticosteroid itself, or the excipient. Some studies have shown that methylprednisolone, triamcinolone, and betamethasone all contained either particles or aggregates that can act as embolic material at the arteriolar level [56]. Dexamethasone, however, seemed to present particles that were significantly smaller than red blood cells, had the least tendency to aggregation, and had the lowest density and which should significantly reduce the

risk of embolic infarcts or prevent them from occurring after intra-arterial injection [57]. However, dexamethasone seem to have shorter long term efficacy of dexametasone compared with particle steroids [58]. In France, the health authorities decided to allow none of these steroids, and only Cortivazol and Prednisolone (both particle steroids) are approved for epidural injections [59]. Cortivazol has the advantage of presenting an intermediate duration of action (up to 6 weeks) in contrast with prednisolone (up to 2 weeks). However, prednisolone is the only steroid allowed for intrathecal injection.

In summary, Cortivazol is the best option for any extra articular extra spinal infiltration, prednisolone is the another option, especially in case of perimedullar injection.

C - Neurolysis

The concept of nerve destruction is a relatively old practice. Indeed, In the early 20th century, trigeminal ganglion alcohol neurolysis was indeed described by hartel in 1912 and percutaneous destructive chemical therapy was quite successful in the following years in a variety of indications. However, the discovery of deafferentation pain sequelae diverted interventionalist towards neuromodulation rather than destruction until, in the 1960's, physical thermal neurolysis was developed : radiofrequency and cryotherapy.

1-Chemical Neurolysis :

This technique requires the administration of a chemical agent capable of destroying neural structures involved in the perception of pain to promote long lasting analgesia. They act by selectively destroying the small and large nerve fibers and have an effect on all aspects of nerve function. The size of the lesions varies according to the concentration, and therefore the quantity. However, these powerful neurolytic agents may induced a sequelae in the axonal membrane, which might explain cases of painful paresthesia observed several months following a neurolytic block : this is known to be deafferentation pain sequelae. Although the use of these agents has markedly diminished with the advent of newer analgesics and the development of safer techniques for pain management, some indications in benign and especially cancer related pain remain to date. Indeed, neurolysis is still an attractive option for pain control in many cancer patients with severe, intractable pain in whom less

aggressive maneuvers are ineffective or intolerable because of either poor physical condition or the development of side effects. Another consideration is that the painful area has responded to diagnostic blockade with a local anesthetic. The agents used for chemical neurolysis include phenol, ethyl alcohol, glycerol hypertonic saline, and other miscellaneous agents. The two neurolytic agents most widely used in the treatment of chronic pain are phenol and alcohol .

Alcohol

The neurolytic effects of ethyl alcohol at a concentration greater than 50% are well-known, but higher concentrations of alcohol (95 % to 100 %) are required for nerve destruction to be permanent. Alcohol acts on the neurons through the extraction of cholesterol and phospholipids. It causes the precipitation of lipo- and mucoproteins. Alcohol is extremely irritating to both neural structure and surrounding tissues, causing pain, burns, and local hypersensitivity. Alcohol neurolysis usually causes severe intense pain which quickly disappears in approximately 30 to 60 seconds (patients should be warned).

Because of the risk of uncontrolled diffusion, it is essential to use the smallest effective quantity and to place the needle as close as possible to the desired target.

If previous injection of anesthetics is performed (in order to diminish neurolysis pain), careful attention should be made to the dilution effect : indeed, although the minimum concentration required to obtain neurolysis is not fully known, the effect of alcohol decreases in case of extensive dilution with other products (local anesthetics, saline, iodine). Careful attention to usual safety measures to prevent vascular injection should particularly be made in case of alcohol neurolysis in order to avoid inadvertent vascular injection.

Phenol

Axons of all sizes are affected non-selectively by phenol at concentrations greater than 2 % and is available at a maximum concentration of 7%. It can easily be diluted with either glycerol or contrast media which will allow higher concentrations up to 15%. When mixed with glycerol, the solution has a low potential of diffusion, which can be an advantage to avoid inadvertent surrounding damage. Aqueous phenol is easy to use and does not cause violent pain on injection.

Neurolysis is obtained primarily due to protein denaturation, and as for alcohol, depends on the concentration used : The efficacy of 3 percent phenol in saline is comparable to that of 40 percent alcohol. Phenol is responsible for a transient local anesthetic effect for which it was initially used. : the duration of action of the analgesia following phenolization varies between 5 and 20 weeks. Phenol toxicity appears at doses greater than 8 g.

Complications of Chemical Neurolysis [60]

- *Necrosis of surrounding tissue* : due to necrosis of vascular supply
- *Neuritis*: this may appear in case of partial to the nerve with persisting nerve cell bodies. It is less likely to occur with a ganglion neurolysis. Neuritis is expressed by the occurrence of hyperesthesia and dysesthesia, sometimes worse than original pain. It is one of the limiting factors in the use of chemical neurolysis.

2-Physical Neurolysis

Radiofrequency

Principle

Radiofrequency lesioning is the application of electrical current to promote thermocoagulation and nerve destruction. Heat is generated in the tissue surrounding the electrode by applying a radiofrequency current which flows between the uninsulated tip of the inserted needle (electrode) and a grounding pad placed on the patient's limb. An electromagnetic field is created around an active electrode when the frequency is set above 250 kHz . [61]. Electric field created between these two components, induces an electric force on the ions surrounding the electrode, causing a rapid molecular oscillation. Frictional dissipation of the ionic current within the fluids causes tissue heating. The electrode is heated by the surrounding tissue and not vice versa. Previous studies have shown [62, 63] that most soft tissues coagulate when heated above 60–65°C. A temperature of 80–85°C at the surface of the electrode is sufficient to create surrounding temperature of 60–65°C and therefore induced coagulation, i.e., denaturation. The radius of action at the tip of the needle may vary, however, it is established that the active heating around the electrode will roughly correspond to two times the length of the uninsulated needle tip, i.e. active tip. The shape of the active heating around the electrode has been shown to form a prolate spheroid, with the longer axis along this of the electrode .

RF coagulation affects all nerves, myelinated, unmyelinated. and even alpha motor neurons are coagulated [64]

RF generator features :

The following features are mandatory for safe radiofrequency neurolysis :

* **Nerve stimulator** : Nerve stimulation is very important as it allows:

- to confirm proper needle placement immediately adjacent to nerve; this is performed at 50Hz to ensure the proximity of the electrode and the sensory fibers : patients will feel tingling sensation in the nerve territory
- to avoid motor nerve denaturation, as a stimulation at 2Hz will detect muscle contraction indicating proximity of motor nerves.

* **Temperature monitoring**

- Temperature monitoring is allowed thanks to the thermocouple technique : a junction of two dissimilar metal elements, producing a thermoelectric voltage, proportional to the temperature. This thermocouple is situated at the tip of the electrode, which is back heated by surrounding tissue. Bearing in mind that the temperature at the center of the electrode does not accurately reflect the effective heating temperature of surrounding tissue; especially in cases of surrounding vascular structure, which will have an effect of temperature decrease, with a rapid temperature drop a few millimeters away from the tip of the electrode [65].

This feature of RF generator can also be very useful in other areas of interventional radiology, such as tumor thermal ablation close to neural structures, allowing temperature monitoring to avoid neural damage (i.e., spinal lesions) [66].

Cryoneurolysis [67]

Principle

Cryoneurolysis, cryoneuroablation or cryoanalgesia is a specialized technique for providing long-term pain relief when pain has been shown to be caused by sensory nerves, based on the application of cold to the nerve to cause its denaturation. The freezing process is obtained through a probe (needle) in which circulates a liquid gas (usually N₂O, but can be CO₂) capable of delivering ice cold temperature of up to -70°C at the tip of the needle, creating an iceball in the surrounding tissues. The application of cold to tissues creates a conduction block, similar to the effect of local anesthetics. The extent and duration of the effect is therefore a function of the degree of cold obtained and the length of cold application[68]. Long-term pain relief from nerve freezing is obtained because of the vascular damage cause by ice crystals to the vasa vasorum, which caused endoneural oedema and cell death.

Cryo generator

As for RF generators, most Cryogenerator are equipped with built in nerve stimulator for localization of the nerve and a thermistor to identify temperature at the tip.

One of the major advantages of Cryoneurolysis is the absence of neuritis following the procedure [67]

V - Imaging Guiding Modalities

The use of imaging guidance has become very popular amongst pain physician. Interventional pain procedures are commonly performed under imaging guidance, which has slowly replaced the classical approach using anatomical landmarks. Indeed, the use of image guidance has become a standard of care in pain medicine practice guidelines as it has been shown to improve the accuracy, reproducibility (precision), safety, and diagnostic information derived from the procedure [69]. The major advantage of image guidance is the ability to control and verify accurate needle placement at correct target prior to performing the procedure (injection, neurolysis). Several imaging modality exists for interventional procedure guidance and include : Fluoroscopy, 3DCT, Ultrasound, CT and MRI.

A - Fluoroscopy : *the historical X-Ray based imaging-guiding tool*

Because fluoroscopy systems combine the ability to render high resolution real time images of bony anatomy and adjacent tissues and the versatility afforded by mobile C-arms , the fluoroscope remains the principal imaging guiding modality for pain amongst pain physicians [70]. As a resulting consequence and over the past 20 years, fluoroscopy has revolutionized medical treatment of pain and Fluoroscopic guidance is now frequently utilized in performing many interventional techniques . In the USA, approximately 50% of all pain procedures are performed under fluoroscopy [71].

Fluoroscopy offers several advantages [70]:

- *Real time visualization*, offering both a comfortable needle insertion guiding system and the ability to control real time diffusion of injectant thanks to the adjunction of iodine contrast, allowing to verify possible inadvertent vascular

catheterization [72-75]

- *Availability and relatively low cost.*

Limitations of fluoroscopy include :

- *Ionization* : the literature on either patient or operator ionization due to fluoroscopic guided interventional procedures is replete [76-78] [79], however, the risks associated with fluoroscopy ionization can significantly be reduced with appropriate clinical preventive measures [70].
- *2D imaging*, compared with cross sectional imaging (CT, MRI and more recent angiographic computed tomography). This is probably the major limitation to this guiding technique. Indeed, although real-time needle placement is possible, accurate needle placement is based on 2D projection, mainly based on visualized bony structures. Indeed, surrounding soft tissue is not depicted with fluoroscopy and therefore exact needle placement is not guaranteed with fluoroscopy, as opposed to CT, MRI or even 3D angiographic CT guidance.

B - Cone Beam CT/Angiographic computed tomography : *Fluoroscopic revolution ?*

Angiographic computed tomography (ACT) represents the evolution of 2D fluoroscopy . CBCT makes use of a single orbital C-arm rotation over a 190–220 degree arc combining a set of 2D fluoroscopic images with an image intensifier or flat panel detector. The result is a 3D volume data set with isotropic voxel size and image spatial resolution. These full volume 3D data sets allow reconstruction in all planes (axial, coronal and sagittal). CBCT has already shown its utility amongst neurointerventionalists , neurosurgeons, orthopedic surgeons [80-82].

Advantages :

- *High 3D image resolution*, with true isotropic spatial resolution, offering precise needle position visualization
- *Relative versatility*
- *Ability to combine real time visualization and cross sectional imaging*

Limitations [83]

- *Ionizing technique*
- *Cost*
- *Increased scatter* leading to higher image artifacts and decreased image to noise ratio compared with multidetector CT.

C - Ultrasound : *The clinicians' third hand ?*

With the development of hand-carried Ultrasound and the constant improvement of ultrasound systems, the question of Ultrasound being an extension of physical examination for diagnostic purposes can be shifted to the interventional field. Indeed, ultrasound guidance has become a standard practice in performing regional anesthesia [84] and is rapidly gaining popularity amongst pain physicians to help perform pain procedures [85-87]. The versatility and relatively low cost of this technique combined with the accuracy of produced images with modern US systems has helped Ultrasound become one of the mainstream imaging modalities for Pain Interventionalists, and its popularity will without doubt continue to increase in the future.

Advantages :

- *Widely available modality,*

- *minimally invasive/ not ionizing*
- *real-time and multiplanar imaging* allowing to analyze needle progression relevant to surrounding structures.
- *High spatial and contrast image resolution*, allowing to identify small soft tissue structures (i.e. : nerve, vessels)
- *No contrast media needed*

Limitations

- *Highly operator dependant technique,*
- *Mediocre needle tip visualization*
- *Limited access to deep structures*

D - CT Guidance : *the forgotten one.*

Computed tomography guidance (CT) has become over the last 30 years the modality of choice for a wide range of percutaneous non pain interventional procedures because of its superior contrast and spatial resolution and ability to image areas not well assessed by ultrasonography (US) such as the lung, retro peritoneum, and bone [88]. Interestingly, the literature remains sparse for pain procedure-specific dosimetry reports relative to CT. This may be partly explained by CT accessibility for pain practitioners. CT represents heavy, costly equipment, easily accessible to radiologists. However to date, radiologists represent a small part amongst pain physicians.

Starting in the early 1990's and especially throughout the years 2000, CT guidance began to be used by interventionally-trained radiologist pain physicians [14, 89] with

good results. During the same period, algorithms were also developed to establish CT-fluoroscopy, which introduced a real-time feature to this modality. With the constant hardware and software development and improvement, CT Fluoroscopy has become an accessible option proposed by manufacturers. The choice of using classical Sequential CT Guidance or CT Fluoroscopy remains to the physicians. Comparative studies on this subject are numerous in the literature and some authors report less ionization and faster procedure time with CT Fluoroscopy [90, 91]. However, although radiation to operator can be minimized [92], operator radiation is avoided with Sequential CT.

Advantages of CT Guidance :

- Precise pre planning needle pathway, minimizing the risk of inadvertent puncture (vessels, nerves, lung and pleura, bowel)
- precise anatomic delineation, high image resolution, 3 plane reconstruction leading to exact needle tip visualization
- Deep structure access (retroperitoneum, pre vertebral)
- no operator ionization possible

Limitations :

- Cost
- Patient ionization
- Limited possible scan plane orientation
- Contrast enhancement may be necessary (low soft tissue resolution without contrast enhancement)

E - MRI Guidance : *The Rolls, very pretty, but not accessible to everyone*

Interventional MRI has been described in the past decade as an emerging technique. Initial MRI guided procedures were performed with low field strength MRI systems [93] however with the evolution of MRI technology, clinical open bore MR Scanners have slowly been introduced as possible guiding modality, with higher field strengths, and access to MR Fluoroscopy [94].

Advantages [95]:

MRI guidance provides the addition of all the advantages from previous Imaging modalities

- Non-ionizing modality,
- Multiplanar acquisition
- Real-time guidance possible (MR Fluoroscopy)
- High image Resolution
- Deep Structure access
- Precise pre planning needle pathway

Limitations [95]:

- accurate needle visualization is more challenging, and visualization of needle may be based on indirect artifact based methods
- Osseous formation (osteophytes) are less well visualized with MR than CT
- Longer learning curve than CT
- Cost and access to the Scanner
- MRI requires specific MRI compatible material (needles)

	<i>CT</i>	<i>US</i>	<i>Fluoroscopy</i>	<i>MRI</i>
Ionization	+	-	+	-
Realtime guidance	-	+	+	+
Surrounding soft tissue visualization	+	+	-	+
Deep structure access	+	-	-	+
Image resolution	+	+	-	+

The use of CT guidance was preferred for all of the procedures performed in this thesis for several reasons :

-First, CT guidance appears as the best imaging guiding tool for precise needle positioning. Indeed, as shown above, other imaging guiding tools may offer other advantages (ie. no ionization), but none of the other imaging modalities offers such a high level of needle tip visualization and therefore precise positioning. This is the main reason why CT guidance was chosen

- Second, because of our experience in the field of CT guided procedures; In order to validate the usefulness of these new/modified techniques, we preferred avoiding possible bias related to the imaging technique used, as we are less familiar with other imaging guiding techniques.

**VI - Brief Review of existing pain interventional
techniques**

Low back pain is the most common pain complaint, followed by neck pain. Most pain complaints are for acute pain, which usually resolves in a few weeks with conservative treatments. However, sometimes the pain lingers at which point the patient may need more aggressive treatment, including a referral to pain management. For the chronic pain patients of today, there are multiple treatment options available that were uncommon or unavailable 5-10 years ago.

This brief review will only focus on the most common interventional pain procedures and their indications. Cancer related pain caused by local tumor compression and joint pain will not be reviewed.

The chosen layout of this review will follow the same pattern as the studies presented in this thesis: from the pelvis to the head.

A - Abdominal and Pelvic Pain :

Celiac Plexus Neurolysis :

The celiac plexus is an aggregate of ganglia and a dense network of nerve fibers uniting, crossing through, and surrounding the abdominal aorta . It is situated at the anterior to the aorta at L1 level. It is supplied by thoracic splanchnic, right pneumogastric and less often right phrenic afferents. Accepted indications for celiac mainly include intolerable abdominal cancer related pain caused by irritation of the celiac plexus by surrounding abdominal masses, the most frequent being pancreatic cancer. Two separate approaches have been described (anterior and poster lateral), and several imaging guiding technique have been described (fluoroscopy, US and

CT scan). Due to the deep situation and important surrounding soft tissue, CT Scan appears as the imaging guidance modality of choice [14]. Neurolysis can be performed using absolute alcohol.

Hypogastric and Impar Ganglion bloc/ Neurolysis:

Hypogastric and Impar Ganglion correspond to the end of prevertebral sympathetic chain and are involved in visceral innervation. therefore, indications of Hypogastric/Impar ganglion block are local invasion from surrounding visceral tumor, and Ganglion Impar block is also performed for coccygodynia and perineal/rectal pain.

Ilioinguinal and ilio hypogastric Nerve Block: Chronic Inguinal neuralgia involving ilioinguinal and iliohypogastric nerves is a very painful and is a well known complication of surgical procedures involving lower abdominal incision. Ilioinguinal and iliohypogastric nerves arise from the L1 root and course along the abdominal muscles layers until ASIS, distributing into the spermatic cord and scrotum. Ilioinguinal and iliohypogastric nerve block is well described in the literature and is often used in pediatric surgery, either with anatomical landmarks or ultrasound [96] [97].

Genitofemoral Nerve Block: This nerve arises from the L2 ventral root, and the genital branch may be involved in genital/groin pain., This block is very effective for genital related pain, especially testicular pain.

Lateral Femoral Cutaneous Nerve Block: This procedure is used for patients suffering from anterolateral thigh pain due to lateral femoral nerve irritation (i.e. “Paresthetica Meralgia”).

Pudendal neuralgia :

Pudendal neuralgia is a rare but debilitating condition involving severe, chronic and spontaneous pelvic/groin pain. Pain is usually exacerbated by sitting and relieved in standing position. Several risk factors have been identified : bicycle riding, vaginal delivery pelvic trauma, and intensive athletic activity. There are two potential conflicting site and therefore infiltration targets : the first is the ischial spine, and Alcock’s canal . Pudendal nerve block is very important for the establishment of pudendal neuralgia diagnosis. Ischiatic spine target is accessible to both US and Fluoroscopy, however, the alcock's canal is more easily reached with CT scan [14].

B - Lumbar Spine Pain (“Low Back Pain”)

Epidural Lumbar injection

Intervertebral disc herniation, spinal stenosis, intervertebral disc degeneration without disc herniation, and post lumbar surgery syndrome are the most common diagnoses of chronic persistent low back and lower extremity symptoms. Epidural injection is one of the most commonly performed interventions for low back pain management. Results of this procedure are variable depending on the technique performed (interlaminar, caudal, and transforaminal) and (intervertebral disc herniation, spinal stenosis, and discogenic pain).

Lumbar Epidural (Interlaminar) Steroid Injection (LESI): This is the most

common “cortisone shot” or “nerve block” for low back pain. It is most effective for patients who have a herniated disc with lumbar radiculopathy and is considered to deliver the medication closely to the assumed site of pathology. Review article conclude that evidence is good for lumbar epidural injections under fluoroscopy for radiculitis secondary to disc herniation, fair for radiculitis secondary to spinal stenosis, and fair for axial pain without disc herniation [98]

Caudal Epidural Interlaminar Steroid Injection: This injection is a variation of the LESI and injection is performed through the sacral hiatus. Results show good evidence for short- and long-term relief of chronic pain secondary to disc herniation or radiculitis. and fair evidence in managing chronic axial or discogenic pain, spinal stenosis, and post surgery syndrome.[99]

Lumbar Transforminal Epidural Injection/Selective Nerve Blocks: These injections selectively target the painful nerve root and is considered the most target-specific modality. Available data show good evidence for radiculitis secondary to disc herniation, fair for radiculitis secondary to spinal stenosis, limited for axial pain and post surgery [98]

Lumbar Facet Syndrome: [100]

As for the cervical and thoracic spine, lumbar facet syndrome is a good indication of intrarticular injection, medial nerve block or Rhizotomy. Lumbar facet pain is usually axial low back pain that sometimes radiates down the buttock to the knee. But, very rarely goes below the knee. These injections are best for patients with lumbar facet syndrome. Lumbar facet pain is usually axial low back pain that sometimes radiates down the buttock to the knee. But, very rarely goes below the knee. Both diagnostic and therapeutic blocks can be done.

Lumbar Facet Radiofrequency Ablation (RFA) or Rhizotomy: This procedure is a variation of the medial branch block, in which the facet medial branch nerves are “destroyed” with RFA. (e.g. 80 degrees Celsius). This procedure is only performed after several positive diagnostic facet blocks [100]

Lumbar Sympathetic Nerve Block/Neurolysis: This is a procedure performed for lower extremity pain, usually due to reflex sympathetic dystrophy of the leg, ankle or foot. It can also be used for other painful lower extremity conditions due to neuropathic etiologies. In case of neurolysis, chemical (alcohol) or physical (radiofrequency) have been described [14].

Sacroiliac Joint Injections: This procedure directly targets pain due to sacroiliitis or sacroiliac joint degeneration. Pain is usually localized to the low back and buttock areas but can also radiate to the groins and down the thigh. The objective of SIJ injection is double, diagnostic and therapeutic.

C - Thoracic Spine Pain

Possible etiologies of pain at the thoracic level are close to those of cervical and lumbar pain and mainly include chronic thoracic pain syndromes (discal pain , degenerative pain, spinal stenosis, facet joint syndrome) and post surgical pain. However, the prevalence of mid and upper back pain is low compared to cervical or lumbar back pain.

Thoracic interlaminar Epidural Steroid Injection [101]

As with the Cervical and Lumbar equivalents, this injection is indicated for thoracic radiculopathy, disc disease, and spinal stenosis.

Thoracic Facet Joint Injections/Blocks/Rhizotomy [102]

Indications and technique are the same as described for cervical and lumbar facet joint procedures

Intercostal Nerve Blocks/RFA [103]

These are blocks performed at the intercostal nerves of the ribs, generally for chronic chest wall pain (Intercostal Neuralgia, Postherpetic Neuralgia, persisting post-traumatic pain or post-thoracotomy syndrome. Here again, blockade or radiofrequency have been described with satisfactory outcomes

Thoracic Sympatholysis [104]

Although literature on Thoracic sympatolysis is relatively scarce, theoretical indications for thoracic sympathetic chain block/neurolysis are multiple :

Vasomotor disorders of the upper limb, Axillary or palmar hyperhidrosis
occlusive arterial disease, distal arthritis, Reynaud Syndrome, Type 1 and 2 chronic regional pain syndromes , pain of sympathetic origin of the upper limb and thoracic region. CT guidance is usually the preferred modality for this procedure [14]

E - Head and Neck

1) - Head

Occipital Neuralgia :

Occipital neuralgia is a rare neurological disorder which has been defined by the International Headache Society as a stabbing paroxysmal pain in the dermatomes of the greater, lesser or third occipital nerves. Greater Occipital Nerve block is an accepted treatment of ON. The most common site to infiltrate the GON is an anatomical landmark based site, at the superficial emergence of the nerve in the occipital region. [105]. Other described and accepted interventional pain procedures include radiofrequency [106] or neurostimulation [107], which have been extensively described under fluoroscopic guidance. Indications of performing an infiltration of the GON has been widened to other cranio facial pain syndromes, such as cervicogenic headaches, refractory migrains, and cluster headaches [108, 109].

Sphenopalatine ganglion procedures .

The sphenopalatine ganglion (SPN), also known as the pterygopalatine ganglion, is the largest extracranial group of neurons. Because of its parasympathetic components, its implication in the innervation of the face and its relation to the maxillary nerve, the Sphenopalatine ganglion been proven to be involved in various facial pain syndromes such as cluster headaches, trigeminal neuralgia, persistent idiopathic facial pain [110]. Various treatment options with mix results have been proposed, including local nerve blocks [111], radiofrequency neurolysis [112], electrical stimulation [113].

Trigeminal Ganglion and Nerve procedures:

The trigeminal nerve is the main facial sensory nerve. Facial innervation is distributed through the Trigeminal (or Gasserian) ganglion, from which arise three branches :

V1 (ophthalmic), V2 (maxillary) and V3 (mandibular), spreading from the forehead to the chin. Approaches to the trigeminal ganglion by various methods aim to relieve the pain transmitted through the trigeminal nerve. Once secondary etiologies of trigeminal neuralgia have been ruled out, diagnosis of essential trigeminal neuralgia or ('tic douloureux' is established. Interventional percutaneous fluoroscopically guided procedures to treat this conditions are well known, and include [114] : blocks, balloon compression, glycerol rhizotomy, and radiofrequency thermocoagulation.

2-Cervical

Stellate Ganglion Block:

Complex regional pain syndrome of the upper limb is a chronic impairment characterized by severe pain associated with sensory, autonomic and motor symptoms, in which the stellate ganglion (fusion of both inferior cervical and first thoracic sympathetic ganglia) has been shown to be involved [115]. Accepted treatment include fluoroscopic guided blocks [116] and radiofrequency [117].

Cervical Radiculopathy management:

Because cervical spine is commonly involved in cervicobrachialgia (disk herniation, degenerative spine, spinal stenosis) literature on cervical interventional procedures is replete. However, although effectiveness of cervical infiltration has been proven, serious adverse events have been reported [118], and therefore these procedures are currently actively debated [119]. Here is a short list of existing techniques:

Transforaminal Epidural Steroid Injection [120]: Because of documented risks including vertebral artery thrombosis and subsequent life threatening complications, this technique is less performed by pain physicians.

Interlaminar Epidural Steroid Injection [120]: Due to the nature of the procedure, it is most commonly performed under fluoroscopic guidance with contrast dye for accuracy and safety.

Periradicular modified posterior approach [121]. This technique does not imply foraminal catheterization, but rather leads to a more extraforaminal than transforaminal and equally selective nerve root block.

Indirect Approach Through the Ipsilateral Facet Joint [122]

As for the previous modified technique, this technique avoids foraminal and epidural contact. With this technique, intrarticular needle insertion is performed and injectant diffuses into the epidural and periforaminal spaces

Cervical Facet Joint Syndrome [123] :

Cervical facet syndrome usually involves pain in the neck or cervical spine. It often radiates to the shoulder, but rarely to the arm. The following procedures target cervical facet pain.

Medial Branch Blocks/Infiltrations : Usually performed under fluoroscopic or CT guidance, block is performed with either local anesthetics, steroids or both.

Cervical Facet Radiofrequency Ablation or Rhizotomy: This procedure is a variation of the medial branch block, in which the facet medial branch nerves are “destroyed” at a high temperature (e.g. 80 degrees Celsius). This procedure is only performed after diagnostic facet blocks confirm that the neck pain has a strong contributory component from the facets. The relief from RFA can last for months to years.

**VII - Clinical Applications of modified existing
techniques**

As it has already been stated, the objectives of this thesis was to assess the usefulness of CT Guidance in either new indications or modified approaches of existing techniques.

In order to do so, we applied CT Guidance in various fields of Interventional Pain procedures. Our work started with the application of existing neurolytic techniques to never performed procedures with the use of CT Guidance.

We started by applying this concept in easily accessible anatomical areas (such as ilio ingiunal nerves), and progressively applied the concept to other more difficult accessible anatomical areas (pterygopalatine fossa).

Therefore, we will present our work with a chronologic layout which, as it appears, also corresponds to an anatomical layout, from the pelvis to the head.

A - Inguinal/Groin Pain

The ilioinguinal (II), iliohypogastric (IH), and genitofemoral (GF) nerves are known as the “border nerves,” providing sensory innervation to the skin lying between the thigh and abdomen. Due to their relatively superficial location, these nerves are susceptible to be injured in surgical procedures involving lower abdomen incision. Injury to the II and IH nerves is a known risk in open appendectomy incisions, postinguinal herniorrhaphy, low-transverse incisions and during trocar insertion for laparoscopic surgery of the abdomen and pelvis. There are multiple mechanisms by which these nerves may be injured, either by direct nerve trauma with or without neuroma formation, nerve entrapment by scar tissue formation, and suturing of the nerve into fascial closure or mesh tissue. Targeting these nerves for interventional procedures has extensively been described in the literature. The most commonly performed procedure being local nerve blocks performed based on external anatomical landmarks. However, the technique of neural blockade has changed considerably in the past several decades, notably with the use of ultrasound guidance for local anesthetic blocks in the pediatric population. However, the use of radiofrequency neurolysis in this indication has not been described. The use of CT guidance in this indication (as opposed to Ultrasound) is justified by our experience in the field of Interventional CT guided procedures. In order to validate a new procedure, our goal was to avoid possible imaging guiding bias related to poor experience with a technique. Therefore, the study of ilio hypogastric and ilio inguinal nerve neurolysis was conducted under CT guidance in two phases.

- *First*, a feasibility study of radiofrequency neurolysis under CT guidance
- *Second*, a comparative study between RF neurolysis and the more commonly performed ilio inguinal infiltrations

Part I

Radiofrequency Neurolysis in the Management of Inguinal Neuralgia : Preliminary Study.

Published in Radiology, February 2012

Abstract

Purpose

To describe and evaluate the feasibility and efficacy of CT Guided Radiofrequency Neurolysis (RFN) in the management of refractory inguinal neuralgia.

Method and Materials

Local Institutional Review Board approval was obtained and written informed consent was waived. Twelve patients aged 26 to 75 years old suffering from chronic (> 6 months) inguinal pain refractory to specific medication were included between 2005 and 2011. Data on patients' demographics, clinical history and pain management history were retrospectively assessed. Pain was measured on a visual analogue scale (VAS) from 0 to 10 before and immediately after procedure and at 1, 3, 6, 9 and 12 months. Diagnosis was always confirmed by a positive nerve block test. Ambulatory CT guided radiofrequency was the rule.

Results

Sixteen RFN were performed. Pain was present for an average of 3.2 years (range: 2-8) prior to initial RFN. Mean VAS score before procedure was 7.75/10. Immediate pain relief of 100% was achieved in all patients. Pain reduction at 1,3,6,9 and 12 month follow up were statistically significant. Important pain reduction ($\geq 80\%$) was obtained in 75% of RFN procedures at 6 months follow up and in 50% of cases at 12 months. The mean duration of pain relief was 11,8 months after Radiofrequency Neurolysis with a maximum average pain reduction of 84,5%. No complications were noted per- and post-procedure.

Conclusion

Radiofrequency Neurolysis under CT Guidance is an effective technique in the management of refractory inguinal pain with lasting satisfactory pain reduction. It may be considered as an alternative treatment to surgery. These results should be confirmed by a controlled trial with a larger series of patients.

Introduction

Prevalence of chronic pelvic pain is not fully established and is most certainly underestimated [124]. Moreover, the incidence of spontaneous groin neuralgia is not known to date. Inguinal neuralgia can prove to be very painful with sometimes high socio economic impact [125-128]. It is a well known complication of surgical procedures involving lower abdominal incision such as hernia repair (up to 25%), appendicitis surgery or gynecological surgery (1,8%) [125, 126, 129, 130]. Inguinal neuropathy is also described in athlete trauma, pregnant women and secondary to tight clothing. Diagnosis of these neuralgia's is challenging and is based on physical examination, medical history and positive nerve block test. Chronic neuropathic pain is known to be difficult to treat [131] and therefore existing conservative specific inguinal neuropathy treatments are insufficient (physical therapy, oral medication, iterative nerve blocks, physiotherapy) [132, 133]. Surgical management consists of either intra-operative nerve division which presents conflicting results [134-136] or re-operative neurectomy with overall 12 month success rates of 60% to 80% [137]. However both approaches remain invasive and require highly specialized operators. We therefore hereby propose an alternative to existing treatments : ilioinguinal and iliohypogastric Radiofrequency Neurolysis (RFN) under CT-control. The purposes of this study are to describe and evaluate the feasibility and efficacy of CT Guided Radiofrequency Neurolysis in the management of refractory inguinal neuralgia..

Materials and methods

Patients suffering from established inguinal neuropathy (positive nerve block test) refractory to specific medication who benefited from ilioinguinal and iliohypogastric RFN were included in this retrospective study between August 2005 and April 2011.

Twelve patients who underwent a total of 16 RFN were therefore included. Local Institutional Review Board approval was obtained and written informed consent was waived; however all patients provided signed informed consent before they underwent RFN. Medical records of patients were reviewed by one of several authors (A.K, S.A, B.K) and the following data was collected and evaluated : demographic data (age, sex), clinical history (date of RFN, previous pain therapies) and information on Pain (detailed below).

An initial CT guided nerve block test was realized in each patient : a mixture of fast and slow acting anaesthetic (1 ml lidocaine hydrochloride 1% and 2 ml bupivacaine hydrochloride 0.25%) and 1 ml of contrast media (iodixanol 270 mg I/ml) were injected after accurate 22g needle positioning at target site under CT guidance (Figure 1a) (technical aspects of needle guidance are the same as those of RFN procedure described below). In case of immediate and total pain relief, the block test was considered positive. All patients included in the study had positive blockade tests.

Figure 1 : Images of a 44 year old patient who underwent RFN for post operative inguinal pain.

White Arrow Heads : Transverse abdominal muscle
White Arrows : Internal Oblique muscle

Figure 1a : CT scan showing satisfactory diffusion of contrast media (black arrow) during ilioinguinal and iliohypogastric (black arrow head) block test performed at level of anterior superior iliac spine (black star).

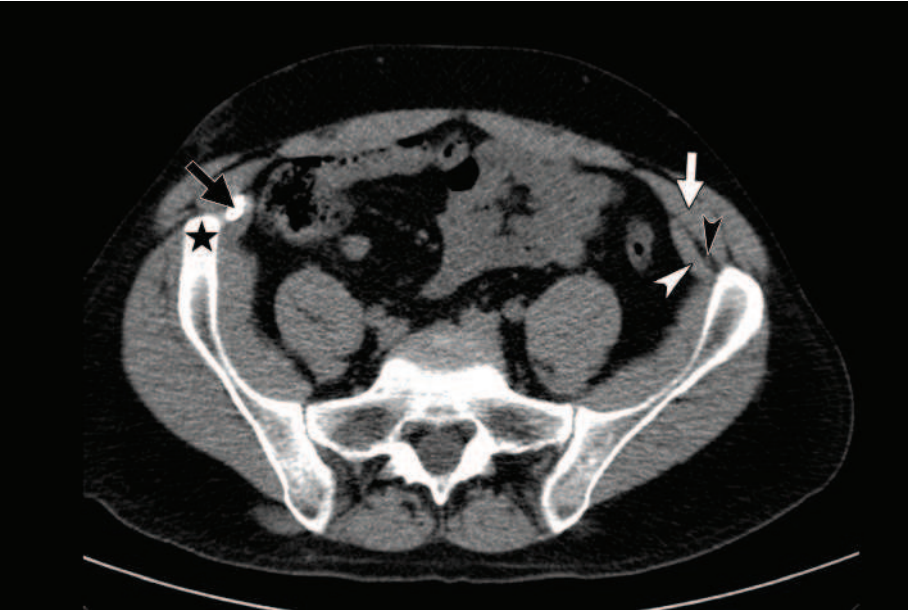
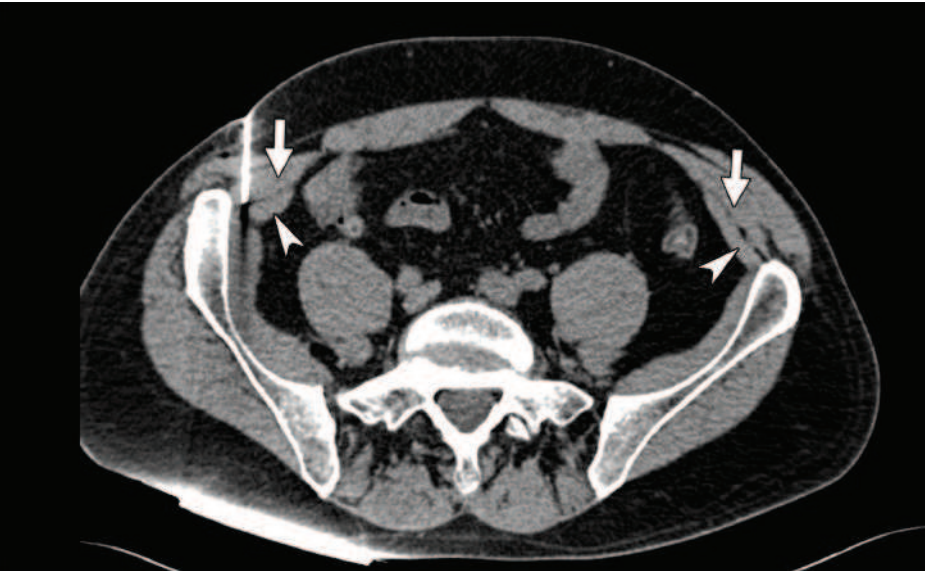

Figure 1b : CT scan showing 22 Gauge RF needle in place at defined target.



Pain :

Pain was assessed using Visual Analogue Scale (VAS) scores ranging from 0 (no pain) to 10 (most severe). A score of less than 2 was graded as mild pain, a score between 2 and 5 was graded moderate pain and a score above 5 was graded severe [138]. It was defined as chronic when lasting for at least 6 months. VAS scores were assessed face to face by authors (A.K, S.A, B.K) immediately before and after each procedure and noted in patient's medical record. The following data concerning pain were noted : etiology of pain, pain type (electric sensation, hypoesthesia, allodynia, stabbing or irritation), territory of pain (lateral cutaneous branch of iliohypogastric nerve, inguinal or scrotal region), mean duration of pain prior procedure (months) and mean efficacy of block test (days). Follow up clinical examination were then scheduled at 1, 3, 6, 9 and 12 months after procedure with interventional radiology (A.K, S.A, B.K) and pain physicians : pain was assessed using the same VAS score. Maximum pain reduction (%) and mean duration of pain relief (months) were also noted.

Procedure :

All 16 procedures were performed ambulatory under CT guidance and local anesthesia (Philips Brilliance CT 64-channel scanner, Eindhoven, The Netherlands, and Siemens Somatom Sensation CT 64-channel scanner, Erlangen, Germany). Radiofrequency generators used were RF 3FG Radionics (Burlington, New Jersey USA) and Neurotherm (Wilmington, Massachusetts USA) generators.

A planning CT scan of 2.5mm thick slices was performed at level of anterior superior iliac spine (2.5mm collimation, 1.0 pitch, 512x512 matrix) in order to locate target between the transverse abdominal muscle and the internal oblique muscle (Figure

1b).

After accurate marking of skin, local subcutaneous injection of lidocaine hydrochloride 1% was performed at defined skin entry point. RF needle (22G, 50-100mm, 5mm exposed tip) was introduced and a safe step-by-step progression of needle was realized. In the first 7 patients, regular CT control slices were used for step by step needle progression follow up as opposed to CT fluoroscopy in the last 5 patients. Once the needle tip artifact was located at defined target (Figure 1b), exact needle position immediately adjacent to the nerve was obtained in stimulation mode, generating a tingling sensation in the nerve territory. This was defined as the technical success. Needle orientation could be modified until technical success was obtained. One ml of lidocaine hydrochloride 1% was then injected before Radiofrequency Neurolysis was started. Three 90s RF cycles were performed in lesion mode respectively at 70, 80 and 90°C. After needle retrieval, control slices were realized to discard any local complications and patient was supervised 30 minutes at CT unit. Mean duration of procedure was 23.4 minutes (19- 33) and no complications were noted per- and post-procedure.

Statistical analysis

Continuous variables are expressed as mean \pm SD. A paired Student's *t* test was used to evaluate the parameters before and after RFN at scheduled follow up. Values for *p* of less than 0.05 were considered statistically significant. All statistical analysis was performed using Systat version 12 (Systat Software, Chicago,IL).

Results.

Patients :

Six women and six men with a mean age of 44.4 years (range : 26-75) were

included. The most frequent etiology was post surgical management of inguinal crural hernia repair : 7 patients (58.3%, 7/12). Three patients (25%,3/12) presented post testicular surgical pain, one patient (8.3%, 1/12) presented post acetabular fracture osteosynthesis pain, and one other patient (8.3%, 1/12) presented pain after total knee prosthesis surgery. All 12 patients had undergone previous unsuccessful pain management : neuropathic pain medication (12 cases), local steroid injection (8 cases), transcutaneous electrical nerve stimulation (4 cases), mesotherapy (3 cases), surgical reoperation (1 case). Pain was present for an average of 3.2 years (range : 2-8) prior to initial RFN was therefore considered chronic for all included patients. Mean block test efficacy duration was 24.5 days (range : 3-90). Because of recurring neuropathy after satisfactory long term pain reduction following initial procedure, three patients underwent repeated RFN : two procedures in 2 cases and 3 in an other, increasing the number of RFN procedures to 16 (table 2). Out of the 9 patients who benefited from a single RFN, 4 patients were lost to follow up after the 12 month follow up period. Two patients presented lasting pain reduction (> 36 months) and were therefore considered cured. Three patients underwent recent RFN (2010), two of which were performed only 9 months prior to study analysis. Thus twelve month follow up was possible only in 10 patients. Detailed patients' characteristics are gathered in table 1.

Table 1 : Patients' characteristics

Patient	Date RF	Age (years)	Sex	Etiology	Pain Territory	Previous TTT	Period of pain prior RFN (years)	Test block efficacy (days)
1	05/08/05	32	F	Post trauma. acetabular fracture osteosynthesis	Right Lateral cutaneous branch and inguinal	SM,LSI, TENS, mesotherapy	3	7
2	19/08/05	40	M	Inguinal hernia repair	Right Inuinal	SM, LSI	0.75	3
3	RF1 : 12/04/06 RF2 : 05/08/08	56	F	Crural hernia repair	Right Lateral cutaneous branch	SM, TENS,spinal cord stimulation	4	30
4	14/04/07	55	L	Inguinal hernia repair	Left Inguinal and scrotal region	SM	2	3
5	RF1 : 21/03/07 RF2 : 24/06/08 RF3 : 20/01/09	45	F	Crural hernia repair	Right Inguinal	SM, surgical reoperation(x2), LSI	5	10
6	02/02/07	31	M	Testicular surgery	Left Scrotal	SM,Mesotherapy	2	15
7	06/06/07	50	F	Crural hernia repair	Left Lateral cutaneous branch	SM,LSI, TENS	3	15
8	RF1 : 24/11/09 RF2 : 01/11/10	44	M	Post-traumatic testicular surgery	Right Lateral cutaneous branch	LSI, TENS, Mesotherapy	2	15
9	02/04/09	40	F	Crural hernia repair	Left Inguinal	SM,LSI,TENS	3	7
10	02/04/10	75	F	Total Knee prothesis	Right lateral cutaneous branch	SM, multiple LSI	8	90
11	09/07/10	39	M	Inguinal hernia repair, several testicular surgery (varicocelelectomy)	Left Scrotal region	SM, LSI	4	90
12	16/08/10	26	M	Multiple Testicular surgery	Right Scrotal region	SM	2	3

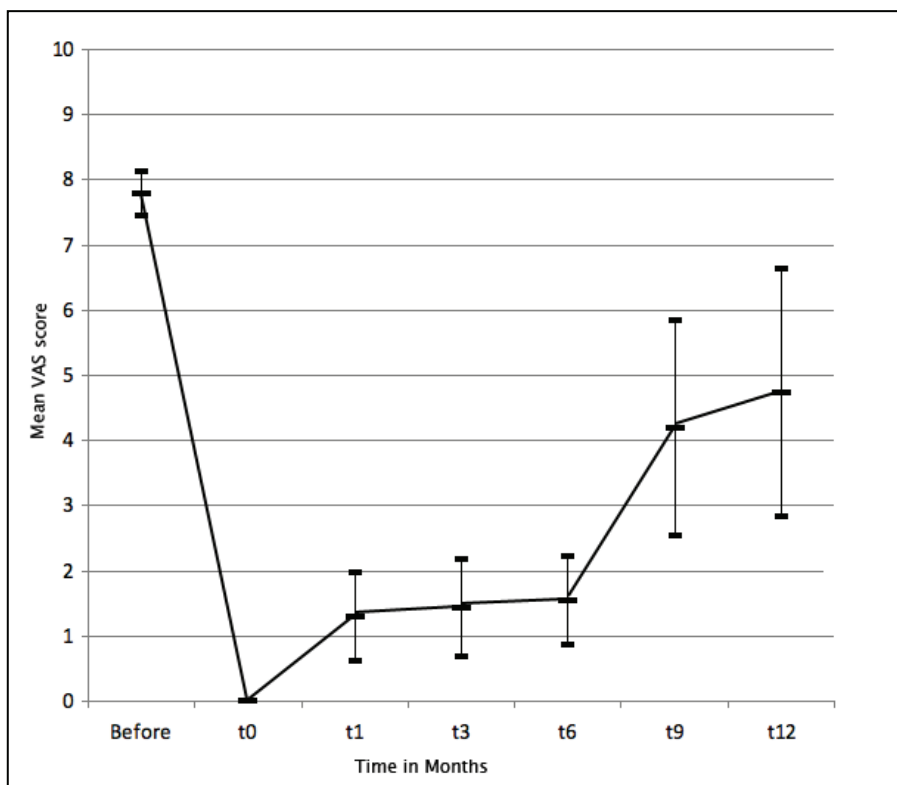
SM : Specific Medication. LSI : Local Steroid Injection. TENS : Transcutaneous Electric Nerve Stimulation

Pain :

Different types of pain were experienced by the patients : electric sensation : 10 cases, hypoesthesia : 3 cases, allodynia : 2 cases, stabbing: 3 cases, irritation : 1 case. In 50% of cases, pain consisted in paroxysmal attacks of short sharp pain superimposed on a dull background pain responsible of multiple night-waking. Painful territories involved the lateral cutaneous branch of the iliohypogastric nerve exclusively in 4 cases, inguinal region exclusively in 3 cases and scrotal region exclusively in 3 cases. Both lateral cutaneous branch and inguinal regions were involved in one case, and inguinal and scrotal regions in another.

Mean VAS before procedure was 7.75/10 and was therefore classified as severe. Detailed VAS scores and duration of pain relief are gathered in table 2. Evolution of mean VAS scores are represented in figure 2.

Figure 2 : Evolution of mean VAS scores



Statistically significant pain reduction was noted at 1, 3, 6, 9 and 12 month follow up (table 2).

Table 2 : VAS score follow up and mean pain relief duration in all 16 RFN procedures.

Patients	VAS score before RFN	1 month VAS score	3 month VAS score	6 month VAS score	9 month VAS score	12 month VAS score	Pain relief duration (months)	Maximum Pain Reduction
1	7	0	0	0	0	0	36	-100%
2	7	1	1	1	2	6	9	-85.7% (6/7)
3								
RF1	8	4	4	4	4	7	9	-50% (4/8)
RF2	9	1	1	1	1	1	18	-88.8% (8/9)
4	7	0	0	0	0	0	12	-100%
5								
RF1	9	0	0	0	0	0	14	-100%
RF2	7	0	0	0	9	9	6	-100%
RF3	9	0	0	0	7	8	6	-100%
6	8	0	0	0	0	0	36	-100%
7	7	2	2	2	9	9	8	-71.4% (5/7)
8								
RF1	8	3	4	4	7	8	6	-62.5% (5/8)
RF2	8	1	2	2	2	2	9	-87.5% (7/8)
9	7	0	0	0	7	8	6	-100%
10	7	0	0	0	0	0	6	-100%
11	8	3	3	7	7	/	3	-62.5% (5/8)
12	8	4	4	4	/	/	6	-50% (4/8)
Mean ± SD	7,8 ±0.8	1,2 ±1.5	1,3 ±1.6	1,6 ±2	3,7 ±3.6	4,2 ±3.9	11,8 ±10.1	-84.5% ±20.9
t-test		p<0,001	p<0,001	p<0,001	p<0,001	p=0,004		

The mean duration of pain relief was 11.8 months (range : 3-36) after RFN procedure with an average maximum pain reduction of 84.5% . Important pain reduction (≥80%) was obtained in 75% of RFN procedures (12/16) at 6 months follow up and in 50% of cases at 12 months (7/14 RFN). Two patients presented total pain reduction 3 years after initial RFN : they were considered cured.

Discussion :

The present study shows excellent long term pain reduction after RFN in patients with refractory inguinal pain. Indeed, a high rate (84.5%) of pain reduction was

obtained in 12 out of the 16 performed RFN with a mean duration of 11.8 months. In two cases RFN allowed definitive resolution of symptoms. All patients presented long lasting chronic pain (mean 3.2 years) refractory to existing treatments and benefited from immediate pain reduction of 100%. These encouraging results are obtained by a minimally invasive ambulatory procedure always performed under local anesthesia and realized in approximately 25min.

Existing conservative treatments are quite limited and are often inefficient. Current ilioinguinal and iliohypogastric pain management include specific medication, local steroid injection, transcutaneous electric nerve stimulation and most recently cryoablation. Oral specific medications include anti-inflammatory and neuropathic treatments, which have fare results at best. It has been shown in previous studies that the conventional 'blind' technique used for local nerve blocks has a failure rate of 10-25% of cases [139, 140]. This failure rate is partly due to the anatomical variations of both ilioinguinal and iliohypogastric nerves. Although it has been described in the literature that the use of US guidance has helped reduce this failure rate [97, 139], we think that part of the success of these nerve blocks is explained by the fact that large quantities of anesthetics (up to 15 ml) [141] are injected therefore diffusing to the nerve, regardless of the immediate proximity of the needle tip to the nerve. Cryoablation techniques seem promising but few studies exist in the literature [67, 142] and no information on long term results is available. Finally, direct nerve stimulation methods (TENS, Spinal Cord Stimulation) have shown mixed results [132, 133], with in each case desensitization to the technique resulting in poor long term efficacy.

Surgical management has been widely studied in the last decade and consists in two separate approaches : division of the nerve during hernia repair or re-operative

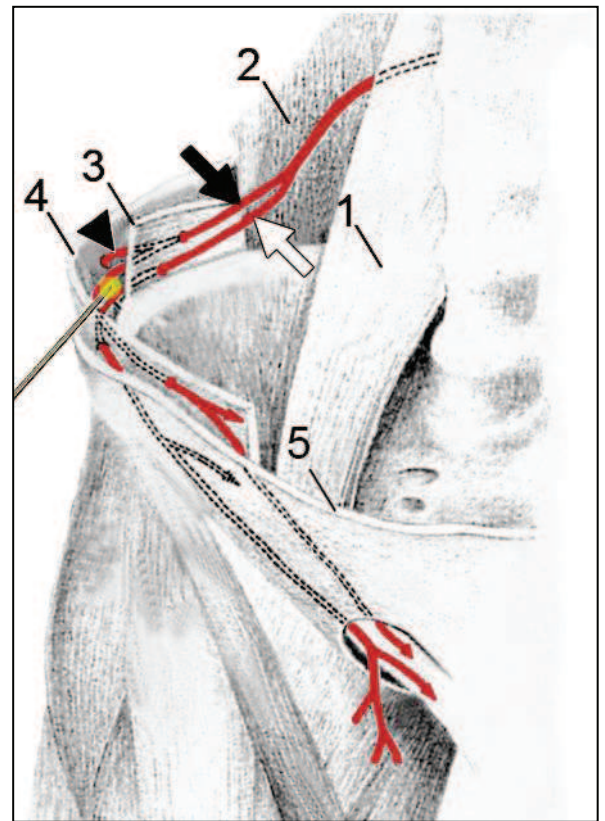
neurectomy. Some studies report less post surgical inguinal neuralgia after intraoperative nerve division [143-145] whereas others report no significant difference in patients who underwent intraoperative neurectomy [134-136]. Surgical re-operative neurectomy report 12 month follow up success rates ranging from 60% to 80 % [137, 146]. Although these results are satisfactory, revision neurectomy remains an invasive specific technique only performed by referring surgeons as it requires highly specific expertise and good anatomical knowledge [137, 146].

The anatomical variability makes it difficult for surgeons to identify ilioinguinal and iliohypogastric nerves [147]. Both nerves arise from L1 root with a possible common trunk in 35% of cases. They descend on the quadratus lumborum muscle along the parietal peritoneum, perforate the transverse abdominal muscle and course between the transverse abdominal muscle on the inside and the internal oblique on the outside at the level of anterior superior iliac spine. The iliohypogastric nerve gives a branch called lateral cutaneous branch at this level distributing in the upper lateral part of the thigh. Both nerves then pass along the inguinal canal to become subcutaneous in their territories of distribution (inguinal, groin, scrotal region and upper medial part of the thigh) (Figure 3). Their anatomical variability has been described [148, 149], with variations of up to 60% depending on the reports. These variations mainly concern the penetrating site of the muscle layers [150] but the distribution of the nerves are quite constant and overlapping.

Figure 3 : Ilioinguinal and iliohypogastric course. Depiction of RF needle placement and thermo ablation zone

Black Arrow : Iliohypogastric nerve
White Arrow : Ilioinguinal nerve
Arrow head : Lateral cutaneous branch of Iliohypogastric nerve

- 1: Psoas muscle
- 2 : Quadratus Lumbaris muscle
- 3 : Transverse Abdominal muscle
- 4 : Internal Oblique muscle
- 5 : External Oblique muscle



Because of the superficial nature of these nerves, they are often injured in surgical procedures involving lower abdominal incision. Indeed, inguinal post operative pain is reported in 10 to 25% of series of open mesh hernia repair especially when Pfannenstiel incision is performed [125, 126, 129]. In our study 7 patients (58.3%) suffered from post surgical hernia repair. Inguinal neuropathy is also described following gynecological surgery, especially after caesarian section, with a reported incidence of 1.8% [130]. Other less frequent etiologies include local non surgical compression mechanisms such as tight clothing (e.g. belts and weapon holsters), obesity [67] and pregnancy. It is also frequently described in athletes (hockey players)[151, 152]. Finally, lumbar spinal disorders by compression mechanisms at the emerging L1 root are also described in inguinal neuropathic pain.

RFN has become a specialized technique commonly used in interventional pain

management. To our knowledge, RFN under CT guidance of peripheral ilioinguinal and iliohypogastric nerves has not been described in the literature.

A case report describing RF management of inguinal neuralgia showed satisfactory results at the 3 month follow up examination [153]. Another paper studying five cases of RFN at the L1 origin of the nerve report satisfactory results lasting from 4 to 5 months [154]. In each cases, no imaging guidance techniques were used, follow up was quite limited (3 to 5 months) and only a few patients were included (5 at best).

As opposed to local injection techniques, RF neurolysis necessitates precise needle location immediately adjacent to the nerve in order to obtain satisfactory pain reduction, as the thermo ablation radius is quite small (1-2mm) [61, 63]. This can easily be obtained under CT guidance, which allows safe targeting, leading to a high technical success rate. Control slices were realized in order to discard possible local complications such as hematoma. However, the contained heating ellipsoid around the needle tip (5mm long, 1-2mm radius) allows limited injury to adjacent tissues and explains the absence of complications in our patients.

Limitations of this study are those inherent to small study samples and retrospective studies. Moreover, 12 months VAS follow up data was not available in two of the twelve patients at time of study. VAS scores at 9 and 12 months are therefore based on a reduced number of RFN procedures.

Despite these limitations, we think that RFN under CT Guidance is an effective procedure in the management of refractory inguinal pain, with lasting satisfactory pain reduction. It may be considered as an alternative treatment to surgery. These results should be confirmed by a controlled trial with a larger series of patients

Part II :

**Radiofrequency neurolysis versus local nerve infiltrations
in 41 patients with refractory chronic inguinal neuralgia,**

Published in Pain Physician, June 2012

Abstract

Background:

Chronic inguinal neuralgia involving ilioinguinal and iliohypogastric nerves is a frequent complication of surgical procedures involving a lower abdominal incision such as hernia repair, appendicitis surgery, or cesarean sections. Chronic inguinal neuralgia is a very painful condition and diagnosis can be challenging as it is an overlooked impairment. Existing specific treatments are inefficient and often fail.

Objective : The purposes of this study are to describe, evaluate, and compare ilioinguinal and iliohypogastric radiofrequency neurolysis (RFN) and local injection.

Study Design: Retrospective comparison cohort study from 2005 to 2011.

Setting: A single center, Academic Interventional Pain Management Unit

Methods: Forty-two patients suffering from chronic inguinal pain refractory to specific medication were included. A total of 18 RFN procedures (14 patients) and 28 injections (28 patients) were performed. Pain was assessed in both groups using Visual Analog Scale (VAS) scores (0-10) measured immediately before and after the procedure and at one, 3, 6, 9, and 12 months after the procedure. Mean duration of pain prior to the procedure and mean duration of pain relief were noted. Moreover, mean maximum early pain relief was assessed. All procedures were ambulatory under computed tomography (CT) guidance. Injections contained 1.5 mL of cortivazol and 3 mL of lidocaine-ropivacaine (30%-70%). Radiofrequency neurolysis was performed using a Neurotherm RF Generator. In both cases, 22-gauge needles were used. After needle retrieval, control slices were taken and the patient was supervised for 30 minutes at the CT unit.

Results: The mean age in both groups was 48.7 years. Forty-two patients (97.6%) presented postsurgical inguinal pain, 62% of which occurred after hernia repair. All included patients had undergone previously unsuccessful pain therapies. Mean VAS scores were 7.72 in the RF group and 7.46 in the infiltration group. Maximum early pain relief did not statistically differ (77% in the RFN group and 81.5% in the injection group). Mean duration of pain relief was statistically significant ($P = .005$) in the RF group (12.5 months) compared to the infiltration group (1.6 months). Mean VAS scores during the year following the procedure were all significantly in favor of radiofrequency neurolysis management.

Limitations: Those inherent to small study samples and retrospective studies.

Conclusion: Radiofrequency neurolysis appears to be significantly more effective than local nerve infiltrations. It is a safe and effective treatment for chronic inguinal pain. Local steroid injection along with local injection of anesthetics should be used as a confirmation of ilioinguinal neuropathy before performing radiofrequency neurolysis.

Introduction

Chronic Inguinal neuralgia involving ilioinguinal and iliohypogastric nerves is a very painful condition with high socioeconomic impact [125-128]. It is a well known complication of surgical procedures involving lower abdominal incision [125, 126, 129, 130]. The diagnosis of these neuralgias can be challenging and existing specific conservative treatments often fail. Ilioinguinal and iliohypogastric nerve block is well described in the literature and is often used in pediatric surgery [140]. Local injection of anesthetics and steroids is widely used in pain management and has been described in this indication with satisfactory results [155]. Moreover, Radiofrequency neurolysis (RFN) has become a common procedure in interventional pain management. We therefore studied the efficacy, safety and feasibility of both local nerve infiltration and RFN in the management of chronic ilioinguinal and iliohypogastric pain. The purposes of this study are to describe, evaluate and compare these two treatments.

Materials and methods

Forty-two patients suffering from chronic inguinal pain were included in this single center retrospective study between 2005 and 2011. Only patients who had failed specific neuropathic oral therapy were included in the study. The same treatment algorithm was always followed prior to procedure: antiepileptic drug therapy was the first line treatment ; in case of failure, tricyclic antidepressant therapy was introduced. In case of failure of either treatments, a combination of both was tried. In some cases, topical antineuralgics were used . Local Institutional Review Board approval was obtained. The data was collected in patients' medical records and included

information on demographics, clinical and pain management history.

Pain:

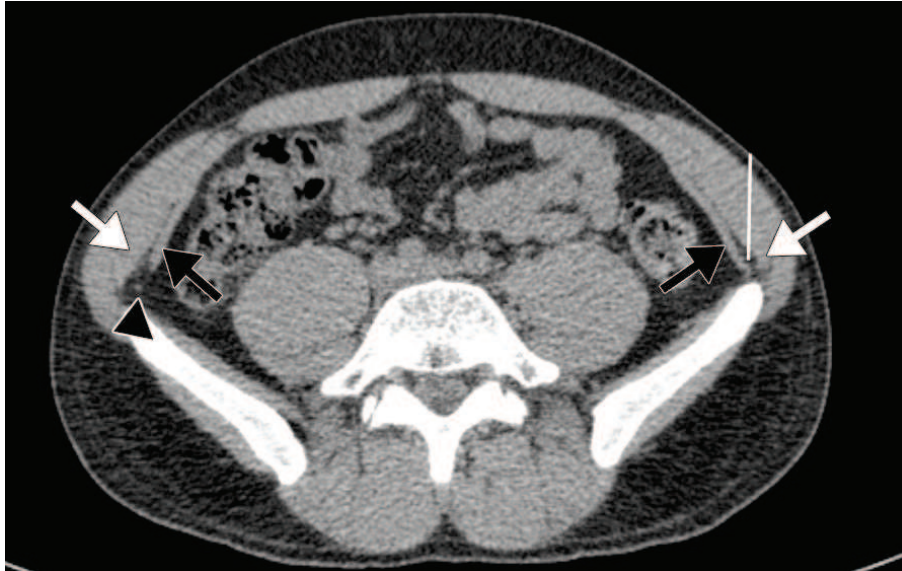Pain was assessed using Visual Analogue Scale scores (0-10) measured immediately before and after procedure and at 1, 3, 6, 9 and 12 month follow up examination. Both mean maximum early pain relief and mean duration of pain prior procedure were assessed in both groups. Pain was defined as chronic when lasting for at least 6 months. A score of less than 2 was graded as mild pain, a score between 2 and 5 was graded moderate pain and a score above 5 was graded severe [138]. Pain distribution and etiology were also noted.

Procedure:

All procedures were accomplished by one of several authors (A.K, S.A, B.K) with CT guidance on an outpatient basis (Philips Brilliance CT 64-channel scanner, Eindhoven, The Netherlands, and Siemens Somatom Sensation CT 64-channel scanner, Erlangen, Germany). An initial planning CT was performed at level of anterior superior iliac spine and target was located between the transverse abdominal muscle and the lesser oblique muscle (Figure 1).

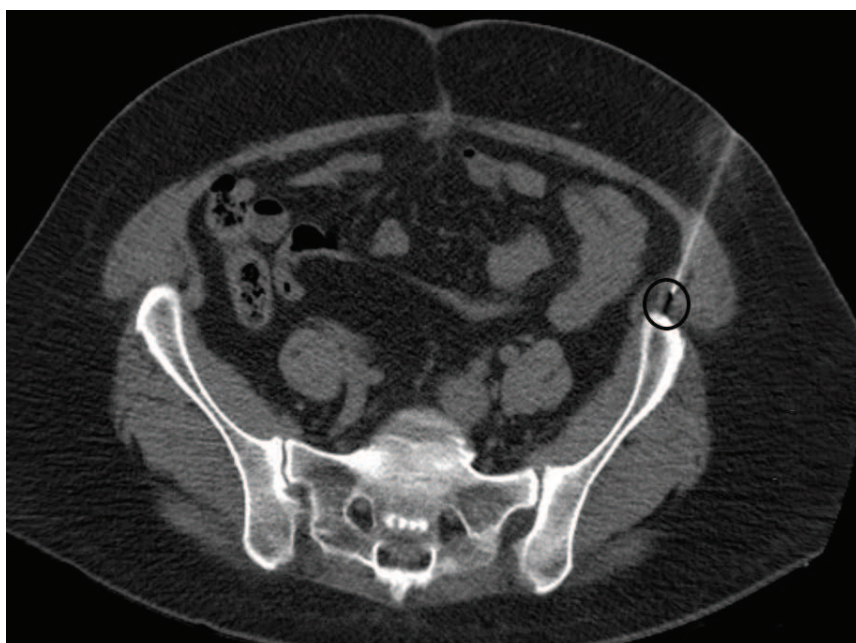
Figure 1 : Planning axial CT scan showing target location prior to needle insertion.

Black arrow : transverse abdominal muscle
White arrows : internal oblique muscle
Arrow head : ilioinguinal-iliohypogastric nerves



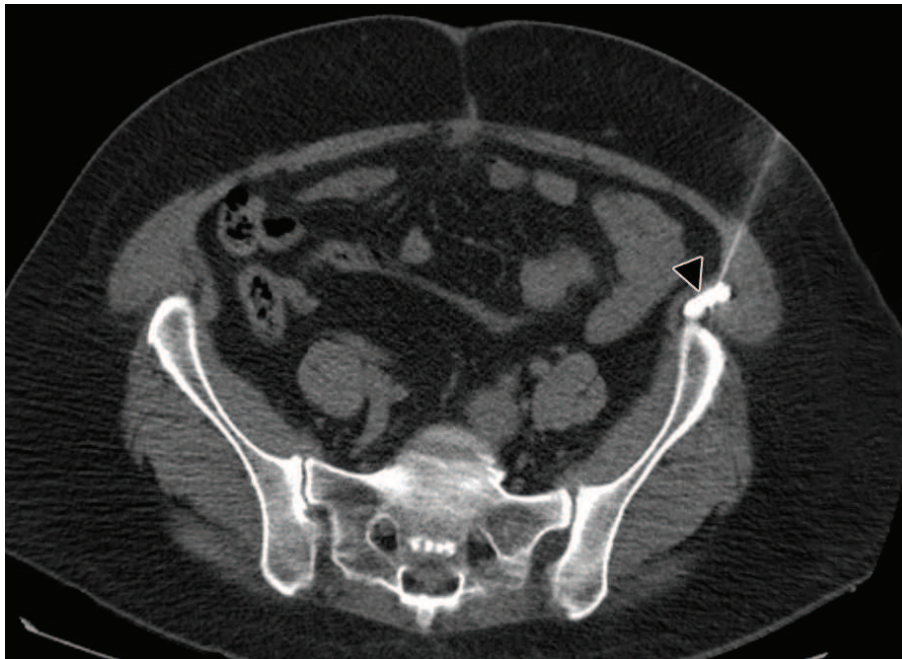
After accurate marking of skin, local subcutaneous injection of lidocaine hydrochloride 1% was performed at defined skin entry point. A safe step-by-step progression of needle (22G) was performed under CT guidance until needle tip artifact was located at defined target (Figure 2).

Figure 2 : CT slice showing needle tip artifact (black circle) at defined target.



In case of local steroid injection, diluted iodinated contrast material was injected in order to control accurate needle position. Once the contrast media diffused between the transverse abdominal muscle and the lesser oblique muscle (Figure 3), a mixture of fast and slow acting anesthetic (1 ml lidocaine hydrochloride 1% and 2 ml ropivacaine chlorhydrate were injected followed by 1.5 mL of cortivazol (3.75 mg).

Figure 3: CT Slice after injection of contrast media (arrow-head) at defined target.



One of two radiofrequency (RF) generators was used in case of RFN (RF 3FG Radionics Burlington, New Jersey USA and Neurotherm Wilmington, Massachusetts USA). Once RF needle tip artifact was located at defined target (Figure 2) (22G, 50-100mm, 5mm exposed tip), stimulation mode was used to obtain exact needle position immediately adjacent to the nerve : needle orientation could be modified until

the patient described a tingling sensation in painful territory. This was defined as the technical success of the needle positioning. One ml of lidocaine hydrochloride 1% was then injected before RFN was started. Three 90s RF cycles were performed in lesion mode respectively at 70, 80 and 90°C. After needle retrieval, control axial CT-scan was performed and patient was supervised 30 minutes at CT Unit.

Results.

Patients :

A total of 42 patients were included in our study, 14 in the RFN group and 28 in the infiltration group. Mean age in the whole population was 48.7 years : 43.9 years in the RFN group and 49.5 years in the Infiltration group. All but one patient (97.6%) presented post surgical induced chronic inguinal pain and 62% of patients presented pain after hernia repair. Etiologies of inguinal neuralgia are detailed in Table 1.

Table 1 : Etiologies of Inguinal Neuralgia in our cohort

ETIOLOGY	PATIENTS
Hernia Repair	19 (46.4%)
Multiple Hernia repair	6 (14.3%)
Testicular Surgery	5 (12.2%)
Gynecological Surgery	5 (12.2%)
Appendicitis Surgery	3 (7.3%)
Other Surgery	2 (4.9%)
Testicular and Hernia Surgery	1 (2.4%)
Trauma	1 (2.4%)

Ninety percent of patients were referred by the local pain management unit, 7% by surgeons and 2.5% by general practitioners.

Three patients in the RF group benefited from repeated RFN because of satisfactory initial results (2 RFN in 2 patients and 3 RFN in one patient). As a result, eighteen

RFN procedures were performed and 28 local nerve infiltrations. Mean duration of RFN procedure was 25.4 minutes (range 19-33 min). No side effects were noted.

Pain :

Patients' description of pain included electric sensation (85%), hypoesthesia (32%), allodynia (14%), stabbing (24%) or irritation (10%). In 62% of cases, pain consisted in paroxysmal attacks of short sharp pain superimposed on a dull background pain responsible of multiple night-waking. Painful territories were as follows (Figure 5): lateral cutaneous branch of the iliohypogastric nerve : 11 cases, inguinal region : 13 cases, scrotal region : 6 cases, lateral cutaneous branch and inguinal regions : 7 cases, inguinal and scrotal regions : 5 cases.

Pain was present for an average of 2.8 years (range : 2-5) prior to initial procedure with a mean VAS score of 7.6/10 and was therefore classified as severe. Mean VAS scores were respectively 7,72 and 7,46 in the RF group and Infiltration group. Immediate pain relief was $\geq 95\%$ in all patients thereby confirming the diagnosis. Technical success rate was 100%. Mean maximum early pain relief did not statistically differ between the two techniques (RF group : 77%, Infiltration group : 81.5%, $p = 0.54$)

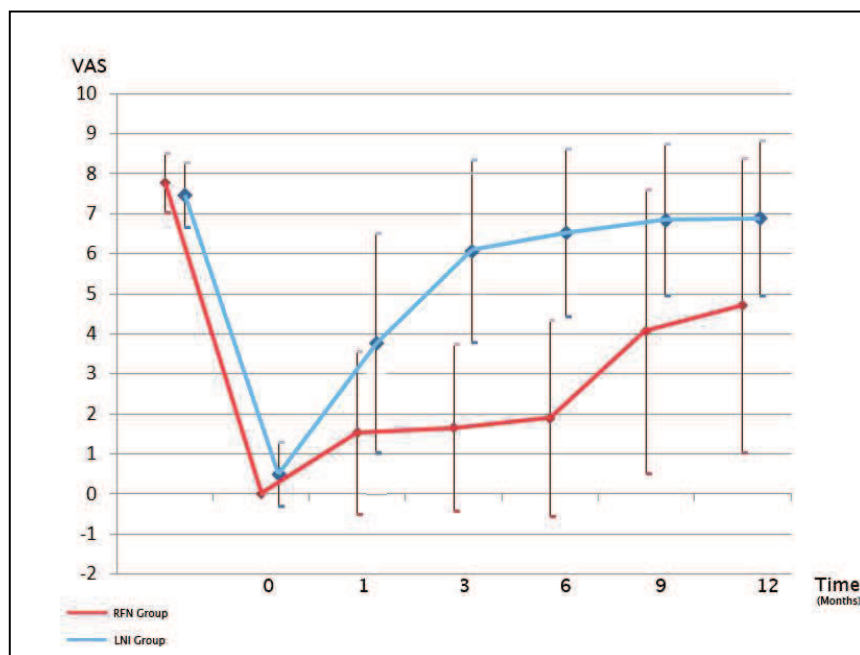
In the RF group, mean duration of pain relief (12.5 months) was significantly higher ($p = 0.005$) than in the infiltration group (1.6 months). VAS scores at 1, 3, 6, 9 and 12 month follow up examinations were statistically inferior to those of the infiltration group (see table 2).

Evolution of mean VAS scores is represented in figure 4 for both groups.

Table 2 : Mean VAS scores, pain relief duration and maximum early pain reduction in both groups :

	Before procedure	T1	T3	T6	T9	T12	Mean duration	Mean Maximum Early Pain Relief
RF Group	7.72	1.4	1.6	1.7	4.0	4.8	12.5	77%
Inf Group	7.46	4.8	6.1	6.5	6.9	6.9	1.6	81.5%
t-test	p=0.273	p<0.001	p<0.001	p<0.001	p=0.004	p=0.021	p=0.005	p=0,54

Figure 4 : Evolution of mean VAS scores in both groups during the 12 months following procedure



Two patients treated with RFN presented long term (>36months) pain relief and treatment was therefore considered definitive. We report only one failure of RFN lasting for 15 days. Important pain reduction ($\geq 80\%$) was obtained in 72% of RFN procedures (13/18) at 6 months follow up and in 44% of cases at 12 months (8/18 RFN).

In the infiltration group, mean duration of pain relief was 1.6 months and ranged from 3 hours to 12 months. We report 7 cases of pain relief lasting for 1 day or less.

Discussion :

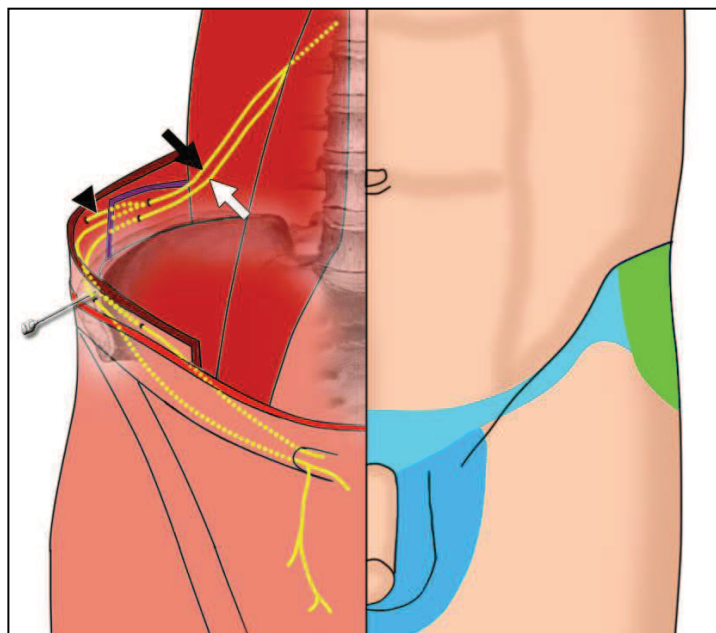
Our study showed significantly longer lasting pain relief after RFN compared to local nerve infiltration in patients with refractory inguinal neuralgia. Indeed, a mean pain reduction of 12.5 months was obtained with a mean maximum early pain relief of 77%. Only one patient was a failure in the RFN group. This patient was the first to undergo RFN in our center, and we therefore think that the failure of this RFN is partly explained by our lack of expertise in this first procedure. A previous study showed satisfactory pain reduction in 75% of patients treated with 4 to 5 repeated local infiltrations [155]. However no details are given on long-term results. Moreover, satisfactory long-term results are obtained in all but one patient with one minimally invasive procedure. Even though mean pain relief duration after local infiltration (1.6 months) appeared significantly inferior to this of RFN in our study, it remains useful as a block test for diagnosis and may furthermore induce beneficial short to mid term pain relief (up to 12 months). We therefore always perform diagnostic block with local infiltration of steroids prior to RFN in our institution to establish the diagnosis and rule out central pain. Patients are re-evaluated and RFN is performed in case of pain recurrence only after positive initial diagnostic block test .

Anatomical knowledge of ilioinguinal and iliohypogastric nerve is a necessary condition to successful image guided inguinal RFN or infiltrations (see figure 5). Both ilioinguinal and iliohypogastric nerve arise from the L1 root (common trunk in 35% of cases). Their course is quite similar, they descend on the quadratus lumborum muscle along the parietal peritoneum, perforate the transverse abdominal muscle

and course between the transverse abdominal muscle on the inside and the lesser oblique on the outside at the level of anterior superior iliac spine. The iliohypogastric nerve gives a branch called lateral cutaneous branch at this level distributing in the upper lateral part of the thigh. Both ilioinguinal and iliohypogastric nerve then pass along the inguinal canal to become subcutaneous in their territories of distribution (inguinal, groin, scrotal region and upper medial part of the thigh).

Figure 5 : Anatomical routes of both ilio-inguinal (white arrow) and ilio-hypogastric (black arrow) nerves and their territories of distribution.

- Blue : Common to both nerves
 - * Light : Inguinal region
 - * Dark : Scrotal Region
- Green : Lateral cutaneous branch (black arrow head) of ilio-hypogastric nerve distributing in upper and lateral part of thigh



Numerous anatomical variants are described in the literature (up to 60%) [148, 149] but these variations mainly concern the penetrating site of the muscle layers [150]. The distributions of the nerves are quite constant and overlapping. Because of the superficial nature of these nerves, they are often injured in surgical procedures involving lower abdominal incision. Our study showed that 97.5% of

included patients suffered from post surgical inguinal neuralgia and 62% followed hernia repair. Open mesh hernia surgery report inguinal neuralgia rates from 10 to 25%, especially when Pfannenstiel incision is performed [125, 126, 129]. Five patients (12.2%) in this study presented post gynecological surgery neuralgia. The literature reports complication rates of 1.8% especially after caesarian section [130]. Other non surgical etiologies are described in the literature : local compression mechanisms secondary to tight clothing (e.g. belts and weapon holsters), obesity [67] and pregnancy. Chronic inguinal pain is also described secondary to muscular trauma or tears of the lower abdominal muscles in athletes [151, 152]. Finally, lumbar spinal disorders by compression mechanisms at the emerging L1 root are also described in inguinal neuropathic pain. In our study only one patient presented non-surgical inguinal neuropathy (post traumatic).

Existing treatments of inguinal neuralgia are quite limited and have fair results at best. Oral specific medications including anti-inflammatory and neuropathic treatments are confronted with the difficulties of neuropathic pain management, which is a common problem in medical care [131].

Blockades of these nerves are commonly performed in pediatric surgery [140]. It is established that the use of imaging guided techniques has increased the success rate of ilioinguinal and iliohypogastric nerve blocks [97, 139, 140]. This is particularly true with RF procedures as precise needle location immediately adjacent to the nerve is mandatory to ensure the success of the procedure. Indeed, the thermo-ablation radius at the tip of the needle is quite small (1-2mm) [61, 63] and therefore the conventional blind technique used in nerve blockades is insufficient [139]. CT guidance was used in our study because of the experience and expertise acquired with this guidance technique in our unit. However we think that both local nerve

infiltrations and RFN could also be completed under US guidance (see figure 6), as is the case with inguinal blockades [97, 139, 140].

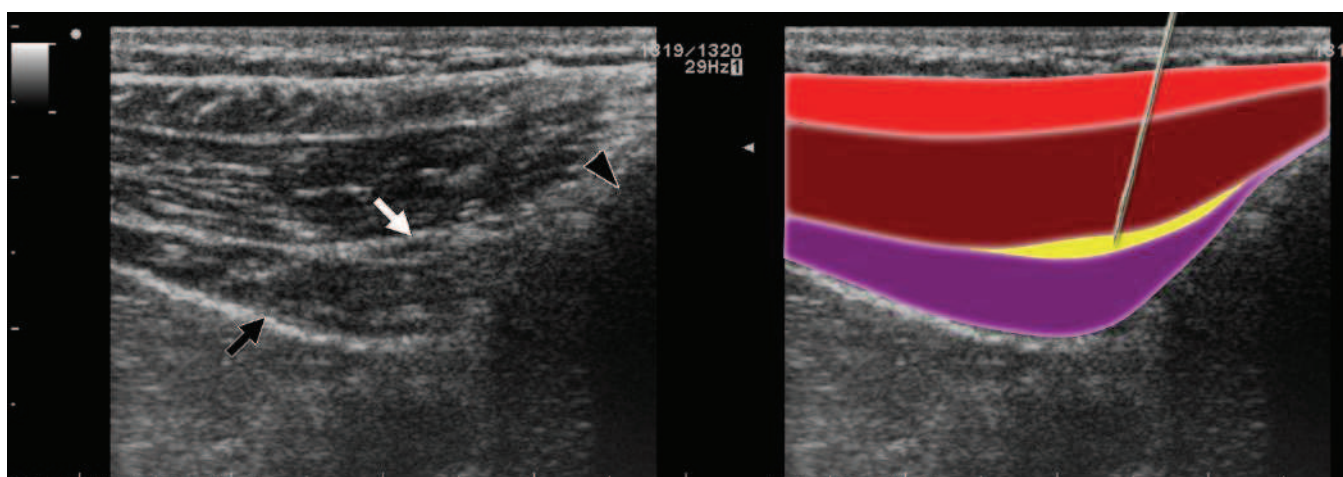
Figure 6 : Ultrasound picture taken at level of anterior superior iliac spine (black arrow head) showing the 3 layers of abdominal wall .

Blue : External Oblique muscle

Green : Internal Oblique Muscle

Pink : Transverse Abdominal Muscle

Peritoneum appears as a hyperechoic line (black arrow). Ilio-inguinal and ilio-hypogastric nerves (white arrow) are seen between internal oblique and transverse abdominal muscles. Hypothetic needle pathway is shown on figure to the right



Recent interventional pain management techniques include cryoablation and RFN. Cryoablation seems promising but only a few studies exist in the literature [67, 142] and no information on long-term results is available. RFN has become a specialized technique commonly used in interventional pain management but has never been described to our knowledge in this indication with imaging guidance. A case report describing RF management of inguinal neuralgia showed satisfactory results at the 3 month follow up examination [153]. Another study including five cases of RFN at the L1 origin of the nerve report satisfactory results lasting from 4 to 5 months [154]. In these reports, no imaging guidance techniques were used, follow up was quite limited (3 to 5 months) and only a few patients were included (5 at best).

Peripheral nerve stimulation methods (TENS, Spinal Cord Stimulation) seem to have poor long-term efficacy due to stimulation desensitization [132, 133].

Finally, surgical management of inguinal neuralgia include both division of the nerve during hernia repair and re-operative neurectomy. There seem to be no consensus whether or not the nerve should be resected during surgical procedures as some studies report significant pain reduction [143-145] whereas others report no improvement after intra operative nerve division [134-136]. These conflicting results are partly explained by the anatomical variability which makes it difficult for surgeons to identify ilioinguinal and iliohypogastric nerves [147]. On the other hand re-operative neurectomy seem to have satisfactory results (60-80% success rates) [137, 146], but it remains an invasive technique not easily accessible for patients as it requires referring specific surgeons. Limitations of our study are those inherent to small study samples and retrospective studies.

Despite these limitations, our study showed excellent technical success rates and similar important early pain intensity reduction in both groups. However, RFN showed significantly longer lasting pain relief compared to local infiltration. Local nerve infiltration may however still be performed prior RFN in order to confirm accurate inguinal neuralgia diagnosis. RFN should be considered as an alternative treatment to surgery in the management of inguinal neuralgia.

Study Commentary

Both of these studies show that CT guidance may successfully be used as an imaging guiding tool to perform ilio-inguinal and ilio-hypogastric nerve procedures.

We have shown that radiofrequency neurolysis presented longer lasting pain relief when compared with ilioinguinal infiltration.

This however calls on the following remarks/observations :

- CT Guidance does not allow direct visualization of the nerve themselves, however, a good anatomical knowledge of the nerve course allows to perform the procedure at an accurate chosen target site (facing anterior iliac spine) allowing an 'indirect visualization ' of the nerves, as the fatty space between the transverse and lesser oblique muscles (in which passes the nerves) is, on the other hand, very well seen on CT. Moreover, in some patients, the vascular pedicle may be seen
- CT guidance allows a very precise needle tip placement, whatever the patient morphology (i.e obese patients), which is not the case for Ultrasound.
- Radiofrequency needle tip positioning may be helped by the use of nerve stimulation, which enhances the chances of immediate nerve proximity of the needle

B - Head and Neck

1) Stellate Ganglion

The stellate ganglion has been proven to be involved in the pathophysiology of complex regional pain syndromes (CRPS). The natural course and physiopathology of CRPS remains elusive and existing pharmacological pain management options are controversial and inefficient. Local anesthetic blockade is an accepted technique in the management and diagnosis of upper limb CRPS. However, physiopathology of sympathetically mediated pain and precise mechanisms and effects of local anesthetics on sympathetic structures remain controversial and elusive. Anesthetists introduced local stellate ganglion blockade using injection of local anesthetic agents. However, there has been some issues described with stellate blockade : first, the efficacy of the procedure is limited in time, second, even though it is well established that stellate blockades should be performed under imaging guidance, the preferred control Imaging modality used is fluoroscopy. Moreover, some studies report the benefit of radiofrequency neurolysis of the stellate ganglion, again, performed under fluoroscopic guidance. The use of CT guidance, which we believe allows a much safer and more precise needle placement, has on the other hand not been reported in this indication.

**CT-guided Stellate Ganglion Blockade vs. Radiofrequency
Neurolysis in the Management of Refractory type I
Complex Regional Pain Syndrome of the Upper Limb**

Published in European Radiology, May 2013

Abstract

Objective

To describe and evaluate the feasibility and efficacy of CT-guided radiofrequency neurolysis (RFN) vs. local blockade of the stellate ganglion in the management of chronic refractory type I complex regional pain syndrome (CRPS) of the upper limb.

Methods

67 patients were included in this retrospective study between 2000 and 2011. All suffered from chronic upper limb type I CRPS refractory to conventional pain therapies. Thirty-three patients underwent stellate ganglion blockade and 34 benefited from radiofrequency neurolysis of the stellate ganglion. CT guidance was used in both groups. The procedure was considered effective when pain relief was equal to or greater than 50% lasting for at least 2 years.

Results

Thirty-nine women (58.2%) and 28 men (41.8%) with a mean age of 49.5 years were included in the study. Univariate analysis performed on the blockade and RFN groups showed a significantly ($P < 0.0001$) higher success rate in the RFN group (67.6%, 23/34) compared with the blockade group (21.2%, 7/33) with an odds ratio of 7.76.

Conclusion

CT-guided radiofrequency neurolysis of the stellate ganglion is a safe and successful treatment of chronic refractory type I CRPS of the upper limb. It appears to be more effective than stellate ganglion blockade.

Manuscript

Introduction

Complex regional pain syndrome (CRPS) is a chronic impairment characterized by severe pain associated with sensory, autonomic and motor symptoms [156]. The natural course and physiopathology of CRPS remains elusive and existing pharmacological pain management options are controversial and inefficient [157]. Stellate ganglion blockade is a widely performed and effective procedure in CRPS management [116], however, little information on long-term results is available and overall results show poor long-term outcome [116, 158, 159]. Radiofrequency neurolysis has become a common procedure in the management of chronic neuropathic pain [160, 161]. The purpose of this study was therefore to compare stellate ganglion blockade and radiofrequency neurolysis under CT guidance in the management of type I CRPS of the upper limb.

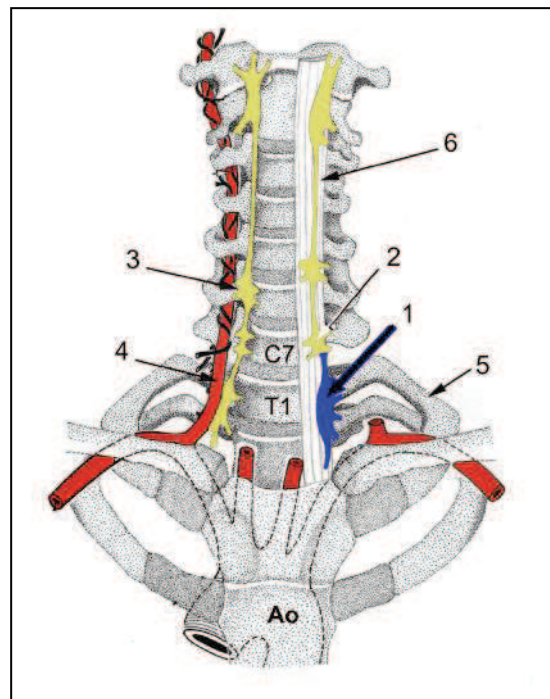
Anatomical background

Knowledge of the anatomical surroundings of the stellate ganglion is a necessary condition for a safe and successful procedure (Fig. 1 and 2). The stellate ganglion is formed by the fusion of both inferior cervical and first thoracic sympathetic ganglia in 80% of cases [162]. It appears as a rather large oval-shaped structure (2.5cm x 1cm x 0.5cm) alongside the spine axis. Even though anatomical variations are possible it lies posteriorly to the vertebral artery [163], anteriorly to the neck of the first rib (cranial component) and the transverse process of C7 vertebra (major caudal component), medially to the scalene muscle and laterally to the longus colli muscle. It is situated 0.5 cm anterior to the bony structures separated by both soft tissue and

the longus colli muscle. The caudal component lies in close proximity to the apical pleura.

Fig. 1: Anatomical figure showing the stellate ganglion.

- 1 : Left stellate ganglion
- 2: Intermediate cervical ganglion
- 3 : Superior cervical ganglion
- 4 : Right vertebral artery
- 5 : Left first rib
- 6 : Left longus colli muscle



Materials and methods

A total of 67 patients were included in this retrospective study between 2000 and 2011. All patients presented with chronic refractory upper limb CRPS type I as established by the International Association for the Study of Pain [2] and a positive stellate ganglion blockade in order to confirm diagnosis. Exclusion criteria were as follows : patients in whom CRPS type I diagnosis was not clear, patients with a negative stellate ganglion blockade, patients presenting with CRPS type II (causalgia) or upper limb neuralgia. Decision to perform either blockade or RFN was made by operator and was based on multiple factors including : - patients desire to undergo either treatment after clear information on procedure's pitfalls, possible

complications and outcome - pre procedure planning CT was also taken into account in case of technical difficulty to perform RFN. Therefore, thirty-four of the 67 patients benefited from an RFN. Therefore, the cohort was divided into two groups : the blockade group and the RFN group. In both groups, patients presented CRPS type I pain refractory to all attempted previous management.

Clinical outcome in both groups was assessed and compared. Local Institutional Review Board approval was obtained and written informed consent was waived. Medical records of patients were reviewed by one of the authors and the following data were collected and evaluated: demographic data (age, sex), clinical history (date of procedure, previous pain therapies) and information on pain (detailed below). In case of missing data, patients were contacted by phone by one of the authors.

Pain

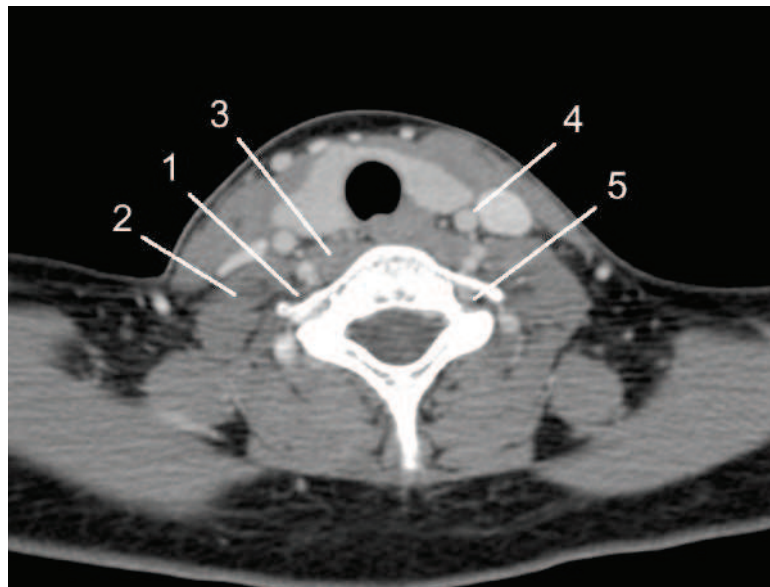
Pain was assessed using Visual Analogue Scale scores (0–10) by the authors immediately before and after the procedure and noted in patients' medical records. Regular follow-up examinations (up to 2 years after procedure) were scheduled with interventional radiology and pain physicians: pain was assessed using the same VAS scores. The procedure was considered to be effective (main efficacy criteria) when pain relief was equal to or greater than 50% lasting for at least 2 years : this was defined as clinical success. Mean duration of pain before the procedure was noted. It was defined as chronic when lasting for at least 6 months. A score of less than 2 was graded as mild pain, a score between 2 and 5 was graded moderate pain and a score above 5 was graded severe [138]. Topography and etiology of pain as well as the presence of accidents at work were also noted.

Procedures:

All procedures (RFN and blockades) were realized under local anesthesia on an outpatient basis under CT guidance and in aseptic conditions (Siemens Somatom Sensation CT 64-channel system, Erlangen, Germany). Patients were placed in supine position with their head looking opposite to the puncture site. Initial axial 2.5-mm thick planning CT from C6 to T2 vertebrae was realized with contrast media to localize the stellate ganglion and display possible intervening vascular structures [14](vertebral artery) (Fig. 2).

Fig. 2: Planning enhanced CT at C7 level.

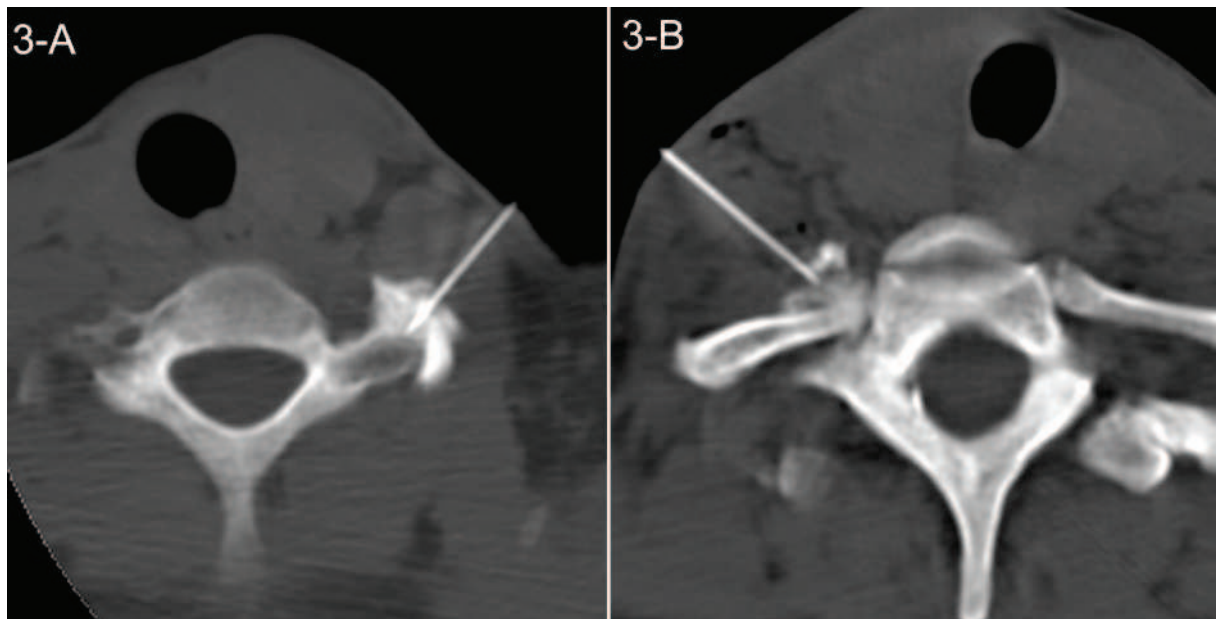
- 1 : *Right stellate ganglion*
- 2 : *Right scalene muscle*
- 3 : *Right longus colli muscle*
- 4 : *Left carotid artery*
- 5 : *Left vertebral artery*



The safest possible pathway (lateral or preferably trans-scalenic anterior lateral) was then chosen in order to avoid inadvertent vascular structure puncture and the corresponding skin entry point was marked. A safe step-by-step progression of the needle was then realized under CT guidance until the needle tip artifact was accurately placed at one of two defined targets: either between the vertebral artery and the C7 process or the neck of the first rib facing the T1 vertebral body.

In the case of blockade of the stellate ganglion, 66-mm or 88-mm long 22G needles were used and accurate needle tip placement at either C7 or T1 process level was confirmed by injection of diluted contrast media (Fig, 3).

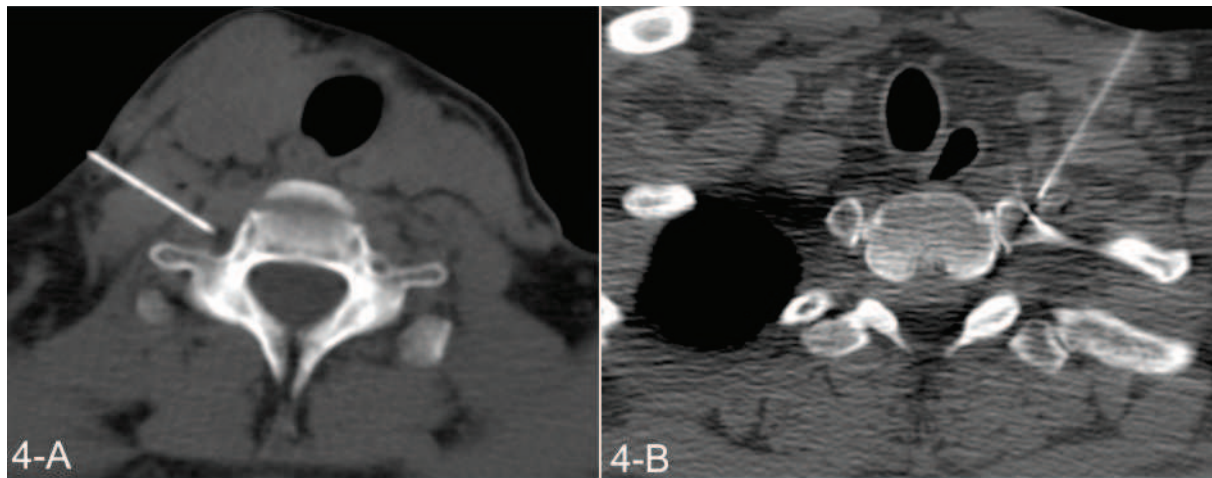
Fig. 3: Accurate contrast media diffusion at C7 (A) and T1 (B) site prior blockade



A mixture of fast and slow acting anaesthetic (2 mL of lidocaine hydrochloride [1%] and 3 mL of ropivacaine hydrochloride [0.25%]) were then injected. Average duration of blockade procedure was 15.1 min. Technical success was defined as the ability to insert the needle and inject the anaesthetic mixture at pre-planned target site

In the case of RFN, two needles were inserted at both the C7 and the T1 sites when technically possible (Fig. 4) following the same step-by-step placement until the needle tip was correctly located at the defined target sites.

Fig. 4: Accurate radiofrequency neurolysis (RFN) needle placement at C7 (A) and T1 (B) target sites



Injection of the diluted contrast material at both the C7 and the T1 sites was then realized in order to confirm both accurate needle tip placement and the absence of inadvertent arterial puncture. The radiofrequency needles used were 55-mm or 105-mm long 22G needles and two different types of generators could randomly be used: Radionics Cosman or Neurotherm Generator. Stimulation mode was then used at both 50 mHz and 2Hz in order to determine sensory perception thresholds (in volts) and to confirm the absence possible surrounding motor nerve in close proximity to the needle tip. Neurolysis was then started and three 60-s RFN cycles were performed at each level in lesion mode at 70, 80 and 90°C depending on the patients' tolerance. Needle placement could be modified between each cycle (1 mm) if necessary. Average duration of the RFN procedure was 34.5 min. Technical success was defined as the ability to satisfactorily position the RF needle and undergo 3 RF cycles at least one of two target sites.

Statistical methods

Descriptive statistics (frequencies, averages, standard deviations and extreme values) were used for population description. A global *P* value of less than 0.05 was considered to indicate a statistically significant difference. Univariate and Multivariate analyses were performed and statistical comparisons between groups used were as follows : Chi-squared test for categorical variables, Student's *t* test for Gaussian quantitative variables and the non-parametric Wilcoxon test for semi-quantitative or quantitative non-Gaussian variables. Analyses were performed using SAS v9.3 (SAS Institute Inc.; Cary, NC, USA).

Results:

Patients:

A total of 67 patients were included in this study, 39 women (58.2%) and 28 men (41.8%). Thirty-four patients benefited from a stellate ganglion radiofrequency neurolysis and 33 from a stellate ganglion blockade. . Overall mean age was 49.5 years old (range 25 to 81 years) with no significant difference between the two groups. Etiologies and topography of pain are detailed in Table 1

Pain:

Mean VAS score in both groups was 7.4 ± 0.98 and was therefore graded as severe. No statistical difference was found between the blockade group (7.3/10) and the RFN group (7.5/10).

Univariate analysis performed on the blockade and RFN groups showed a significantly ($P < 0.0001$) higher success rate in the RFN group (67.6%, 23/34) than the blockade group (21.2%, 7/33) with an OR of 7.76. A statistically significant difference in the mean duration of pain before the procedure was found (33.8 months in the blockade group vs. 16.3 in the RFN Group, $P < 0.0113$). On the other hand, no

differences were found between the two groups when comparing age, sex, side of pain and relation to accident at work. These results are detailed in Table 2.

Table 1: Distribution of etiology and topography of pain in both groups

Topography	Blockade Group	RFN Group	Total
Wrist	33.3% (11/33)	26.5% (9/34)	29.8% (20/67)
Shoulder	24.2% (8/33)	26.5% (9/34)	25.4% (17/67)
Hand & Shoulder	18.1% (6/33)	26.5% (9/34)	22.4% ¹ (5/67)
Hand	6% (2/33)	20.6% (7/34)	13.4% (9/67)
Arm	18.1% (6/33)	0%	8.9% (6/67)
Etiologies			
Post-traumatic	42.4% (14/33)	24/34 (70.6%)	56.7% (38/67)
Post-surgical	48.5% (16/33)	8/34 (23.5%)	35.8% (24/67)
Post-ganglion curettage	6% (2/33)	0	3% (2/67)
Post-hemiplegia	0%	2/34 (5.9%)	3% (2/67)
Post-zoster	3% (1/33)	0	1.5% (1/67)

Table 2 : Univariate analysis in both blockade and RFN groups.

Variables		Total (N=67)	INF (N=33)	RFN (N=34)	p-value
					Student t test
Pre procedure pain duration	Mean ± SD	24.93 ± 28.12	33.78 ± 33.78	16.33 ± 17.89	0.0113
Pre procedure VAS score	Mean ± SD	7.40 ± 0.98	7.30 ± 0.98	7.50 ± 0.99	0.4176
					Chi 2 test
Sex	F	39 (58.21%)	20 (60.61%)	19 (55.88%)	0.6951
	M	28 (41.79%)	13 (39.39%)	15 (44.12%)	
Side	D	33 (49.25%)	17 (51.52%)	16 (47.06%)	0.7153
	G	34 (50.75%)	16 (48.48%)	18 (52.94%)	
Accident at Work	Yes	31 (46.27%)	15 (45.45%)	16 (47.06%)	0.8952
	No	36 (53.73%)	18 (54.55%)	18 (52.94%)	
Efficacy	Yes	30 (44.78%)	7 (21.21%)	23 (67.65%)	0.0001 OR = 7,76
	No	37 (55.22%)	26 (78.79%)	11 (32.35%)	

No statistical difference was found when comparing efficacy and pre-procedure pain duration or VAS before the procedure. Moreover, no link was found between efficacy and sex, etiology or presence of an accident at work. These results are detailed in Table 3.

Table 3: Detailed univariate analysis results regarding the criteria efficacy

Variables		Total (n=67)	Efficacy: No (n=37)	Efficacy: Yes (n=30)	P value
					Student t test
Pre-procedure pain duration (months)	Mean ± SD	24.93± 28.12	30.65 ± 31.47	17.87 ± 21.86	0.0548
Pre-procedure VAS	Mean ± SD	7.40 ± 0.98	7.37 ± 0.98	7.43 ± 1.00	0.8225
					Chi 2 test
Sex	Female	39 (58.21%)	20 (54.05%)	19 (63.33%)	0.4438
	Male	28 (41.79%)	17 (45.95%)	11 (36.67%)	
Side	Right	33 (49.25%)	21 (56.76%)	12 (40.00%)	0.1725
	Left	34 (50.75%)	16 (43.24%)	18 (60.00%)	
Accident at Work	Yes	31 (46.27%)	19 (51.35%)	12 (40.00%)	0.3541
	No	36 (53.73%)	18 (48.65%)	18 (60.00%)	

Multivariate analysis performed on the variables procedure type, pre-procedure pain duration and etiology (traumatic vs. non traumatic) showed statistical significance between the criteria efficacy and procedure type ($P=0.0015$). Pre-procedure duration and etiology of pain were not statistically significant ($P>0.05$).

Technical success rates in the blockade and RFN group were respectively 100% and 92% (34/37) and did not statically differ. In the RFN group, three patients were not included in the study owing to technical failure of RFN due to impossible safe needle positioning; in these cases, RFN was not performed . Moreover, out of the 34 RFN procedures performed, we report 4 single-site (C7 or T1) RFN procedures. In these cases, RFN at the C7 level could not be performed owing to technical access difficulties : the proximity of motor nerve structures in 3 cases and difficult accurate C7 needle placement visualized on planning CT slices in 1 case. Three out of these four performed procedures were a clinical failure

In the blockade group the mean duration of pain relief in case of failure was 40.5 days. No complications were noted in the blockade group

In the RFN group, complication rate was very low (1.7%) and only 2 minor complications occurred: 1 case of transient Horner's syndrome (3 weeks) and 1 case of pre-vertebral hematoma.

Discussion

The present study shows significant longer lasting pain reduction with stellate ganglion RFN than stellate ganglion blockade. Indeed, >50% pain reduction lasting for at least 2 years was obtained in 67.6% of treated patients in the RFN group as opposed to 21.2% in the blockade group with an OR of 7.76. Even though the mean delay of pain before the procedure was significantly lower in the RFN group than in

the blockade group, univariate analysis did not show a significant link between efficacy and pre-procedure pain duration. Moreover, multivariate analysis confirmed the statistical link between procedure type and efficacy in favor of RFN, and no link was found between efficacy and pre-procedure pain duration or etiology. However, previous studies [164, 165] have shown better pain relief in patients who benefited from early treatment after onset of symptoms.

In the RFN group, these excellent long-term results were obtained after a single procedure with a minor complication rate of 1.7% (1 case of transient Horner's syndrome and 1 case of pre-vertebral hematoma). This very low complication rate was obtained because close attention to safety precautions was made in each patient. First, in order to avoid inadvertent vascular puncture the following precautions are mandatory : - a planning CT must be performed with contrast media and accurate CT control slices with theoretical needle pathway should be displayed during the procedure – extended (10sec) syringe aspiration should be performed prior to either the RFN or the blockade. Second, the use of stimulation mode before the RFN is crucial in order to detect a possible surrounding motor nerve needle tip contact.

We report 11 clinical failures as defined by the main efficacy criteria in the RFN group. Out of these 11 patients, 3 (27.2%) underwent a single-site stellate ganglion RFN.

In the stellate ganglion blockade group the average pain relief duration found in the case of failure of procedure was 40.5 days. These results are not negligible in these patients refractory to conventional therapies and are allowed by a simple and safe procedure as no complications were noted in this group. The same precautions as described above should be used. Although local anaesthetic blockade is a widely

accepted technique in the management and diagnosis of upper limb CRPS [158, 165, 166] both the physiopathology of sympathetically mediated pain and precise mechanisms and the effects of local anesthetics on sympathetic structures remain controversial and elusive [166]. Moreover, most studies available in the literature are concerned with the role of sympathetic blockade in the treatment of CRPS [115] and few studies are concerned with long-term effects: Wang et al [29] report pain reduction in 68% of patients at 3-year evaluation, Ackerman and Zhang [165] report partial relief in 36% of patients lasting for 12 weeks and Cepeda et al [116] published a review in 2006 of randomized control trials but were unable to assess long-term pain relief. In all of these studies, repetitive stellate ganglion blocks were performed, thereby increasing the risk of occurrence of adverse events. Such complications include injury to adjacent structures (brachial plexus, vertebral artery, esophagus, pleura and lung) or inadvertent arterial or epidural injections [26, 167, 168]. Previous studies have shown a higher complication rate with the use of the conventional blind technique, based on external anatomical landmarks [169, 170]. The use of imaging guidance such as ultrasound or fluoroscopy [164, 171] has helped to reduce the occurrence of such complications and it is now well established that stellate blockades should be performed under imaging guidance [172]. The most commonly used imaging guidance is to date without doubt fluoroscopy and several approaches have been described in the literature: C6 anterior approach [169], paratracheal C7 approach [173] and recently a new C7 oblique fluoroscopic approach [171]. Although fluoroscopic guidance has helped to reduce the complication rate of stellate ganglion blocks, some complications such as lesions to the lung or pleura may occur, especially when a C7 approach is performed in patients with emphysema. This complication can easily be overcome by the use of CT guidance, as the high image

resolution allows precise needle pathway planning, especially for the T1 target. Moreover, the accuracy of needle placement allowed by the use of CT guidance which is highly superior to that of fluoroscopic guidance explains the low complication rate (1.7%) found in our study. Finally, precise needle tip positioning is mandatory for successful RFN of the stellate ganglion. Indeed, in the case of stellate ganglion blockade, it has been shown that local anesthetics diffuse alongside the adjacent structures [174, 175] and therefore immediate needle tip positioning next to the stellate ganglion is not mandatory for a successful blockade. However in the case of RFN procedure, immediate proximity to the ganglion is mandatory for a successful neurolysis as the thermoablation radius at the tip of the needle is quite small (1–2mm) [61, 63]. Even though our results concerning the outcome of patients after stellate ganglion RFN are in agreement with those of the literature [117, 176], this study is to our knowledge the first to report two-level C7–T1 RFN under CT guidance with long-term outcome.

Limitations of our study include those inherent to retrospective studies. Moreover, pre-procedure pain duration was significantly lower in the RFN group. Even though no statistical link was shown in both univariate and multivariate analysis between efficacy and pre-procedure duration, a possible influence of pre-procedure pain duration on efficacy may not entirely be excluded.

Despite these limitations, CT-guided radiofrequency neurolysis of the stellate ganglion is a safe and successful treatment for chronic refractory CRPS type I of the upper limb. It appears to be more effective than stellate ganglion blockade.

Study Commentary

Radiofrequency Neurolysis under CT Guidance is a safe and effective treatment of refractory upper limb type I CRPS. It appears to present much higher efficacy rates compared with stellate infiltrations. Which ever the procedure (neurolysis or infiltration), CT appears to be the perfect guiding tool for a successful procedure.

Here again, the stellate ganglion is not directly seen, but the 'indirect method' is used to position the needle. CT Guidance allows to position the needle at the T1 level, which has never been described to date to perform radiofrequency neurolysis.

In order for the procedure to be effective, some very crucial points should be underlined : First, good anatomical background is mandatory in order to avoid inadvertent vascular (vertebral artery) or neural (radicular) puncture. Second, needle pathway and target planning on enhanced CT is crucial as accurate needle positioning is mandatory for a successful procedure. Third, performing a test with stimulation mode once needles are located at pre-defined target is very important in order to avoid inadvertent surrounding radicular damage.

2 - Head

a) Sphenopalatine Ganglion

Sphenopalatine ganglion (SPG) involvement in the pathogenesis of pain has been known since Sluder first described sphenopalatine neuralgia in 1908 and treated it with a Sphenopalatine ganglion block (SPGB). Over the past century, physicians have performed SPGB for pain syndromes ranging from headache and facial pain to sciatica and dysmenorrhea. Several approaches have been proposed for sphenopalatine ganglion procedures, the most commonly performed being SPG blocks and radiofrequency neurolysis, with or without imaging guidance.

The use of alcohol for SPG neurolysis has on the other hand never been described. The idea behind this study was to evaluate the effectiveness of SPG alcohol neurolysis in various cranio facial pain syndromes. Because the SPG is situated deep into the infra-temporal fossa, the use of CT guidance appeared as the best possible imaging guiding tool for precise guidance to access the pterygopalatine fossa. Moreover, as it will be described in this study, diffusion of contrast and alcohol are very well seen on CT images.

**Alcohol percutaneous neurolysis of the sphenopalatine
ganglion in the management of refractory cranio facial pain**

Published in Neuroradiology, July 2014

Abstract

Introduction

The sphenopalatine ganglion (SPN) has been proven to be involved in various types facial pain syndromes. Management of these craniofacial pain syndromes can be challenging and existing specific treatments are sometime inefficient and may fail. The purpose of this study is to describe and evaluate alcohol SPN in the management of craniofacial pain.

Methods

Forty-two patients suffering from refractory facial pain who underwent 58 consecutive SPN were included in this study between 2000 and 2013. Patients were divided into three groups : Group 'cluster headache' (CH), Group 'persistent idiopathic facial pain'(PFIP), and Group 'other'. Pain was assessed using Visual Analogue Scale scores (measured immediately before and after procedure and at regular intervals following procedure. Alcohol SPN was considered to be effective when pain relief was equal to or greater than 50% lasting for at least one month. All procedures were realized ambulatory under CT guidance and consisted of an injection of 1mL of absolute alcohol.

Results :

Overall efficacy rate of alcohol SPN was 67.2% with a mean pain relief duration of 10,3 months. Procedure was graded either not painful or tolerable by patients in 64.2%. Analysis showed a higher efficacy rate in the groups CH (76.5%) and PFIP (85.7%) compared to the group other (40%). No difference was found between groups regarding the recurrence rate.

Conclusion :

Alcohol SPN under CT Guidance appears as a safe and effective treatment of refractory facial pain, especially in cases of cluster headache and persistent idiopathic facial pain.

Introduction

The sphenopalatine ganglion (SPN), also known as the pterygopalatine ganglion, is the largest extracranial group of neurons. It is composed of both sympathetic and parasympathetic fibers, situated deeply in the pterygopalatin fossa (PPF) (Figure 1).

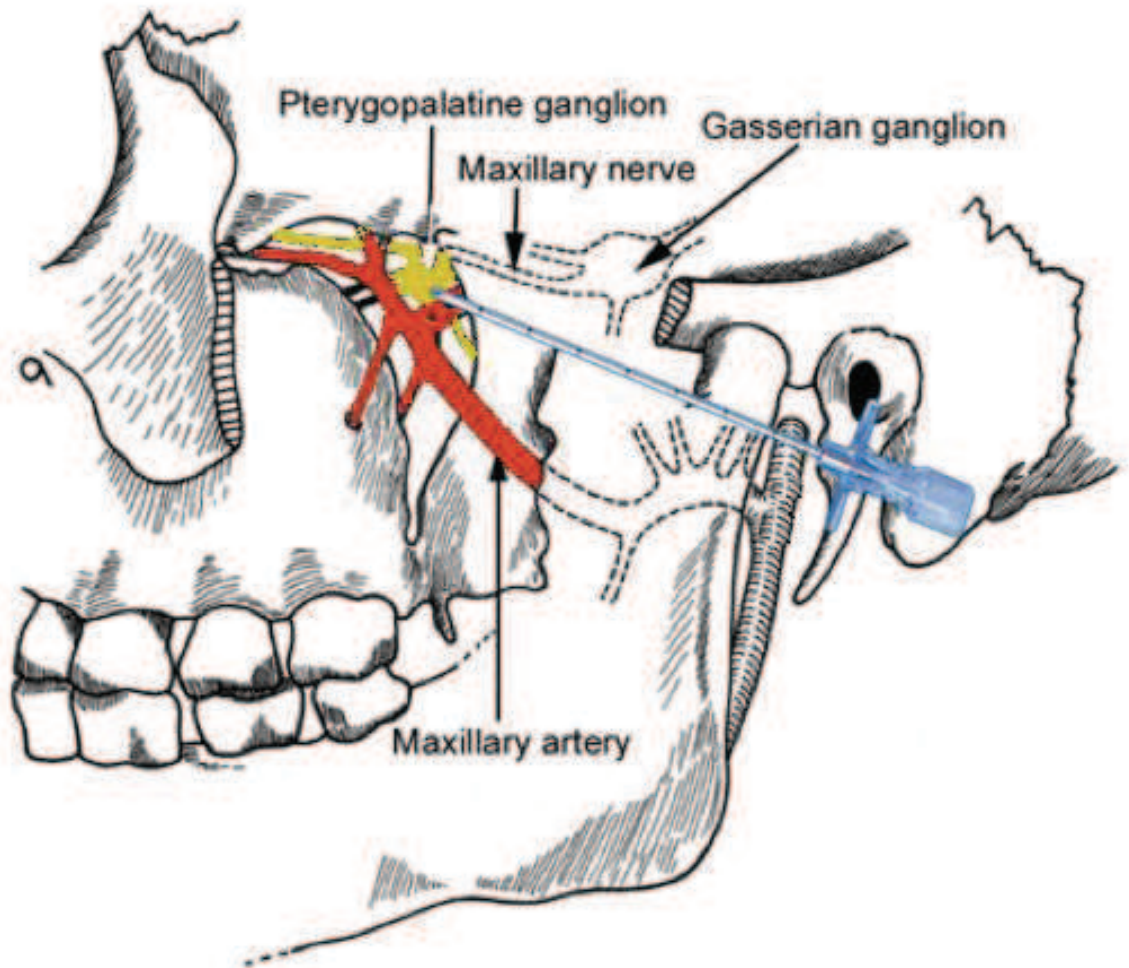


Figure 1 : Anatomical illustration of the pterygopalatin fossa and its content with needle at target site

The PPF is a triangular shaped fossa bordered anteriorly by the posterior wall of the maxillary sinus, posteriorly by the internal pterygoid process, medially by the perpendicular plate of the palatine bone and laterally by the pterygomaxillary fissure

[177, 178]. It communicates superiorly with both the inferior orbital fissure and the foramen rotundum and narrows inferiorly to become the pterygopalatine canal. [177]. The PPF contains, posteriorly the SPG and its branches located deeply in the PPF close to the sphenopalatine foramen, anteriorly the maxillary artery and its branches, which can be seen arising from the infratemporal fossa on CT scan slices (Figures 1 and 2) and superiorly, the maxillary nerve (V2) emerging from the gasserian ganglion.

Because of its parasympathetic components, its implication in the innervation of the face and its relation to the maxillary nerve, the Sphenopalatine ganglion has been proven to be involved in various facial pain syndromes such as cluster headaches [110, 179, 180], trigeminal neuralgia [181], local neoplastic compression mechanisms [182], persistent idiopathic facial pain [183] or myofascial pain of head and neck [184, 185]. The management of these facial pain syndromes can be challenging. Moreover, accurate diagnosis, especially in persistent idiopathic facial pain, can be difficult to obtain. A number of interventional-minimally-invasive techniques have been used to manage sphenopalatine-involved facial pain [186] such as local nerve blocks [111], radiofrequency neurolysis [112] or electrical stimulation [113]. CT guided alcohol neurolysis of the SPG has not yet been assessed. The combination of the safe and precise guidance allowed by CT along with the neurotoxic properties of ethanol may provide satisfactory outcome in these patients. We therefore hereby propose an alternative to existing treatment of facial pain with alcohol neurolysis of the sphenopalatine ganglion under CT Guidance. The purpose of this study is to describe this treatment and to evaluate its efficacy depending on the type of facial pain.

Materials and methods

Patients and data

Forty-two patients who underwent 58 Sphenopalatine neurolysis (SPN) were included in this retrospective study between December 2000 and December 2012. Local Institutional Review Board approval was obtained and written informed consent was waived. All patients presenting with unilateral acute or chronic facial pain who had undergone CT Guided Sphenopalatine absolute alcohol neurolysis in our Institution were considered for inclusion in the study. CT guided sphenopalatine absolute alcohol neurolysis was performed only in refractory patients to pharmacological therapy, including : oxygenotherapy, triptans, intranasal lidocain Dihydroergotamine, verapamil and lithium). Patients who had benefited from adjunct maxillary nerve infiltrations at the infraorbital foramen or neurolysis of the mandibular nerve at the foramen ovale (5 patients) and patients with insufficient data (8 patients) were excluded. Eight included patients underwent several procedures : 2 procedures in 4 patients, 3 procedures in 3 patients, 4 procedures in 1 patient and 5 procedures in 1 patient.

Patients were divided into three groups depending on type of pain : Group 'CH' included patients suffering from cluster headaches (14 patients) as defined by the International Headache Society - Group 'PIFP' included patients suffering from persistent idiopathic facial pain (PIFP) (10 patients) as defined by the IHS - Group 'other' included patients suffering from any other types of facial pain (18 patients) such as : trigeminal neuralgia, compression mechanism by neoplasm, radiotherapy sequelae, odontalgia, post zosterian pain, post traumatic pain.

Medical records of patients were reviewed by one of several authors and the following data were collected and evaluated: patients' demographics (age, sex),

information on pain (detailed below), referring physician and occurrence of side effects.

Pain :

Pain relief was the main item for evaluation of effectiveness ; Pain was evaluated using Visual Analogue Scale (VAS) scores ranging from 0 (no pain) to 10 (most severe) and was assessed face to face by authors immediately before and after each procedure and noted in patient's medical records. Regular follow up examination were then scheduled with interventional radiology and pain physicians (up to 48 months) : the same VAS score was used.

SPN was considered to be effective when pain relief was equal to or greater than 50% lasting for at least one month. Less than 50% in pain reduction was considered a failure. Ninety percent pain reduction and above was considered excellent results and a decrease of pain between 50% and 89% was considered good results. The following data concerning pain were also assessed: laterality, type of pain, duration of pain prior to procedure, pain related to the procedure (graded 0: no pain, 1:tolerable pain, 2: painful, 3:very painful), mean pain relief period following the procedure for each patient, continuation of oral medication after procedure, occurrence of recurring pain and , if applicable, duration and intensity of recurring pain.

Procedure

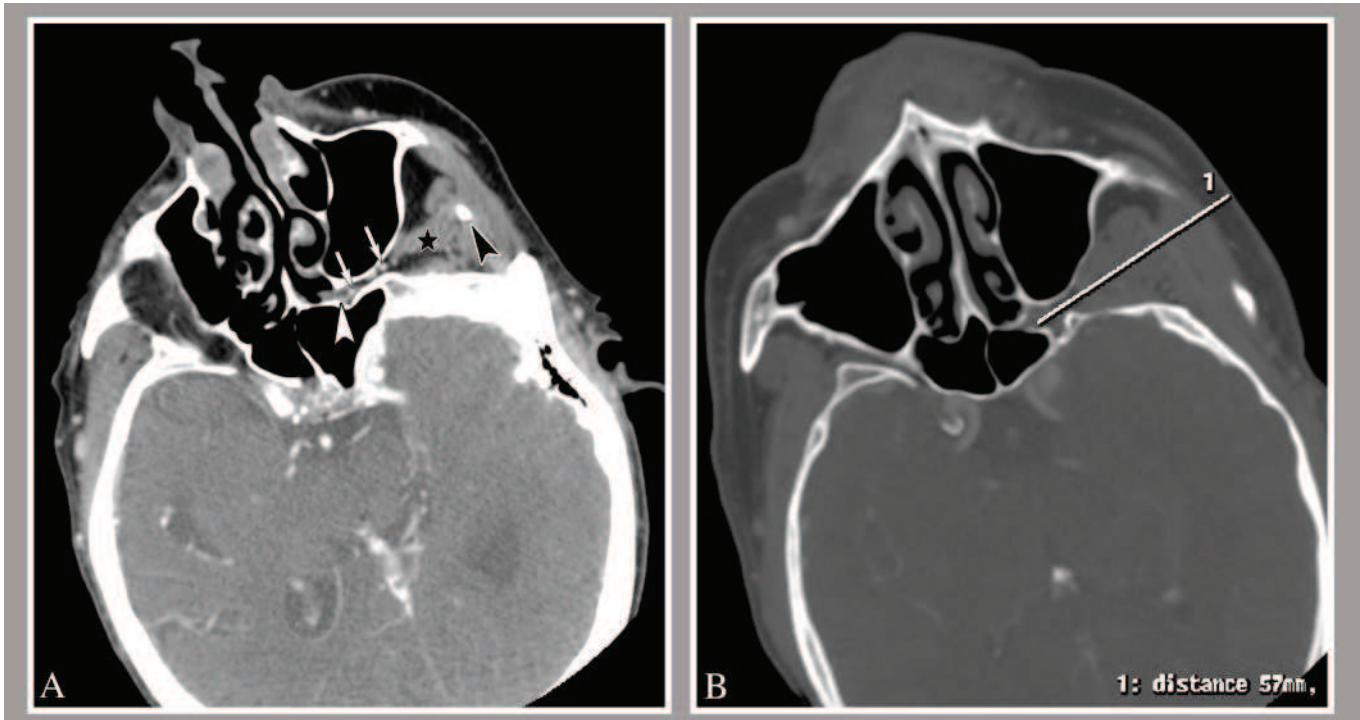
All procedures were performed ambulatory under local anesthesia and CT guidance (Philips Brilliance CT 64-channel scanner, Eindhoven, The Netherlands, and Siemens Somatom Sensation CT 64-channel scanner, Erlangen, Germany) [14]

Patient was placed in supine position, with his head facing towards the puncture site.

An Initial 2,5mm planning CT scan with enhanced contrast at level of zygomatic arch

was performed to locate target (Figure 2) : the front orifice of the pterygoidian canal in the pterygopalatin fossa.

Figure 2 : Planning enhanced CT performed prior procedure



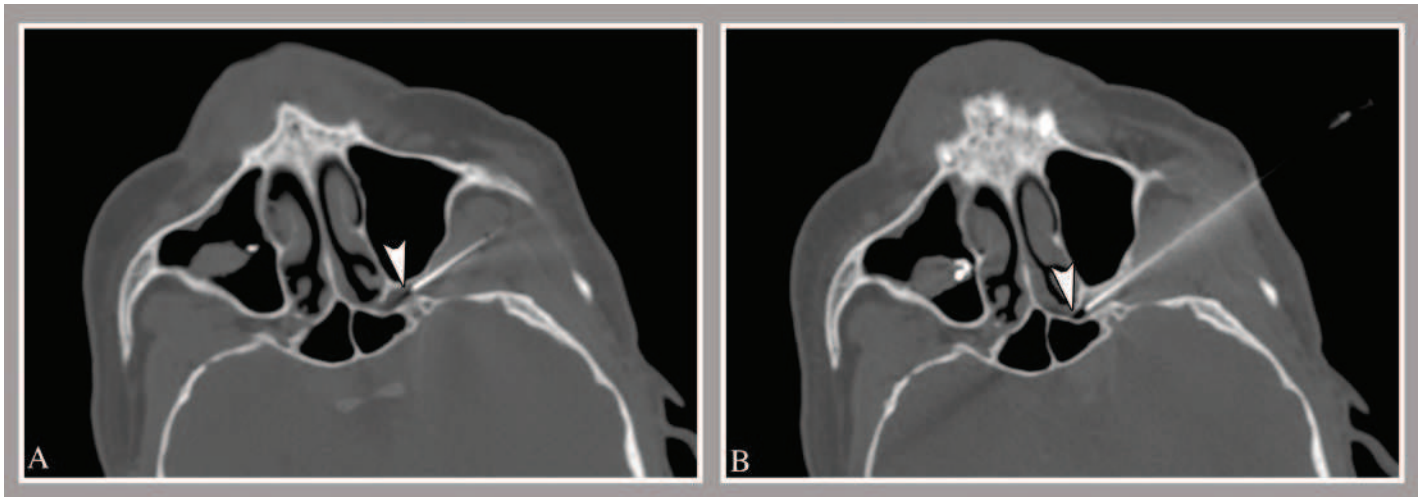
A : Infra-zygomatic Enhanced CT slice at level of Sphenopalatine fossa showing the zygomatic process (Black arrowhead), the Sphenopalatine fossa (white arrowhead) and the Maxillary artery (White arrows).

B : Infra-zygomatic Enhanced CT slice at level of Sphenopalatine fossa showing needle pathway planning

Enhanced CT was the rule in order to locate the maxillary artery and ensure accurate needle path. After accurate marking of skin entry point, area of interest was prepared with providone iodine solution and draped in sterile manner. An infrazygomatic approach was preferably used, however, a suprazygomatic approach could also be used depending on patient's anatomy and positioning (5 cases). Local injection of

lidocaine was performed at defined skin entry point and further step-by-step progression of the needle was performed until target was reached (Figure 1 and 3) at the front orifice of the pterygoidian canal in the PPF.

Figure 3 : CT slice showing needle tip placement in the sphenopalatine fossa,

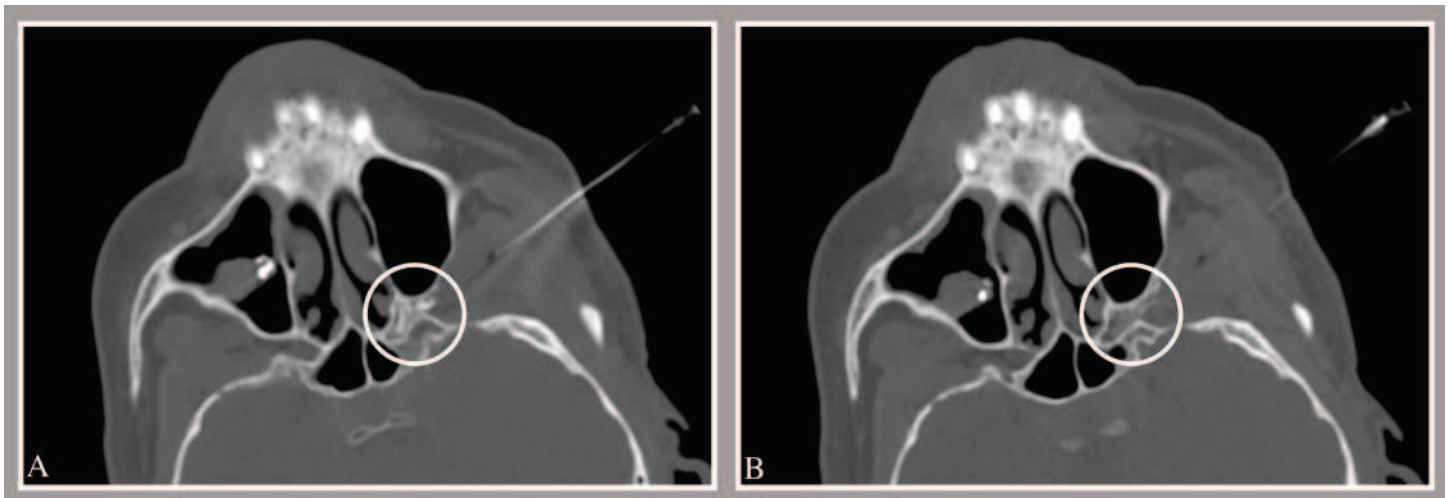


A : The needle tip artifact (white arrowhead) is not quite accurately placed in the sphenopalatine fossa.

B : Needle tip artifact accurately located in the Sphenopalatine fossa after needle replacement.

Once in place, 0.5ml of an anaesthetic (Lidocain)–contrast mixture was injected after maintaining the needle in aspiration for 10 seconds to prevent intra-vascular injection. Injection of anaesthetic at this point is important in order to prevent possible pain induced by alcohol injection. CT Slices were then realized to control contrast spreading (Figure 4A). A step by step slow instillation of 1 ml of absolute alcohol was then performed (Figure 4B). After needle retrieval, control slices were realized and patients were supervised for one hour at CT unit. Mean duration of procedure was approximately 20 minutes.

Figure 4 : CT control slices after iodine and alcohol injection



A : CT slice showing accurate iodine diffusion in the sphenopalatine fossa

B : CT Control slice after alcohol injection. Note the dilution of the contrast media which appears less hyperdense

Statistical analysis

For continuous variables data were expressed as means \pm standard deviation.

The Shapiro-Wilk test was used to determine whether variables came from a normally distributed population. As the null hypothesis was systemically rejected, non-parametric tests were then used for continuous variables (Kruskall-Wallis one-way analysis of variance test as well as Mann-Whitney U test).

For categorical variables, the comparisons were made using the Fisher's exact test.

Statistical calculations were performed with Systat software version 12.0 (Systat Software Inc., Chicago, USA). A p value of < 0.05 was considered significant for the statistical analysis.

Two separate statistical analysis were performed in this study.

First, analysis was performed in the whole cohort regarding the criteria efficacy (Yes/No) and recurrence (Yes/No) in order to detect a possible influence of variables

on the results and therefore assert comparable groups. Thus, statistical analysis on the following variables was performed: Age, Side of Pain ,Sex, Pain Duration prior procedure and VAS score prior procedure, .

Second, in order to detect possible differences in the efficacy rate depending on the etiology of the cranio-facial pain, statistical analysis was conducted in the three sub groups CH, PFIP and Other. Here again, in order to ensure comparable groups, the variables Age, Sex and Pain duration prior procedure were tested in each subgroup. Then, analysis regarding recurrence rate and efficacy rates were tested between each sub group.

Results

Patients' characteristics

Twenty-five men (59.5%) and 17 women (30.5%) were included in this study. Mean age was 51.5 years old (range 28-87). Thirty patients (68%) were referred by the Pain Management Unit, 11 patients (31.5%) by the Palliative Care Unit, and one by the Neurology Unit. Eight patients benefited from more than one SPN (5 SPN : 1 Patient; 4 SPN: 1 patient; 3 SPN: 2 patients; 2 SPN: 4 patients).

Statistical analysis showed no difference between groups CH, PFIP and Other concerning duration of pain prior procedure ($p=0.31$ - Kruskal-Wallis test). However, in the group of Cluster Head Aches the percentage of males was significantly higher than in the PFIP group and patients with Cluster Headaches were significantly younger than patients with PIFP and other headaches.

Pain (Tables 1 and 2)

Table 1 : Details on Pain , Efficacy rate and Pain Recurrence in all 58 procedures in each Group and in the whole population

	Pain duration (months)	Efficacy Rate	Recurrence Rate
Groupe CH	73.9 ± 52.7	76,50%	61%
<i>vs Gp PFIP</i>	<i>NS</i>	<i>NS</i>	<i>NS</i>
<i>vs.Gp Other</i>	<i>NS</i>	<i>p=0,004</i>	<i>NS</i>
Group PIFP	63.6 ± 70.5	85,70%	89%
<i>vs.Gp Other</i>	<i>NS</i>	<i>p=0,045</i>	<i>NS</i>
Groupe Other	56.1 ± 70.3	40%	50%
Population	63.8 ± 66.1	67%	72%

Table 2 : Detailed statistical analysis regarding the criteria Efficacy and Pain Recurrence

Variable	Total n = 58	Efficacy : No n = 19	Efficacy : Yes n = 39	P value Mann Whitney	Recurrence : No n = 11	Recurrence : Yes n = 28	P Value Mann Whitney
Age (years)	51,6	55,1	49,9	0,26	53,7	48,3	0,26
Pain Duration (months)	63,3	73	58,8	0,86	60	58,2	0,7
VAS	7,66	7,63	7,59	<i>NS</i>	7,90	7,53	<i>NS</i>
Side				Fisher exact			Fisher Exact
Right		10 (52,6%)	18 (46,1%)	0,78	3 (27,3%)	15 (53,6%)	0,1
Left		9 (47,4%)	21 (53,9%)		8 (72,7%)	13 (46,4%)	
Sex							
Female		8 (42,1%)	15 (38,4%)	1	2 (18,1%)	13 (46,4%)	0,1
Male		11 (57,9%)	24 (61,6%)		9 (81,9%)	15 (53,6%)	

Results concerning the whole cohort

Twenty patients suffered from right facial pain and 22 from left sided facial pain. Mean duration of facial pain before procedure was 5,5 years (ranging from 2 months to 20 years) with a mean VAS score of 7.66/10. Thirty-nine out of the 58 SPN performed procedures were successful, that is a global success rate of 67.2% with a

mean pain relief period of 10,3 months (range : 1-48 months). No statistical effect was observed when comparing overall efficacy with either duration of pain prior procedure or with age or VAS. Among these successful SPN, excellent results (more than 90% pain reduction) were obtained in 22 procedures (56,4%) and good results (50%-89% pain reduction) in 17 SPN (43.5%). Pain medication could be discontinued in 19 cases after successful SPN (48.7%), a decrease in pain medication was observed in 11 cases (38.2%), whereas in 9 cases (23.1%) no modification in pain medication was noted.

In 28 out of the 39 successful SPN, recurring pain occurred after a mean duration of 5.4 months after initial procedure (range 1-24 months), that is a recurrence rate of 71.7%. No statistical links between recurrence rate and either, age, initial VAS score, duration of pain prior procedure or medications after procedure were found (see table 2). The recurring pain was graded equal to the initial pain in 19 cases (67.2%), superior in 5 cases (17.8%) and inferior in 4 cases (14.2%).

Regarding the 8 patients who underwent several procedures, mean time interval between procedures was 8.5 months (ranging from 3 to 20 months)

Patients' experience of the SPN procedure were as follows: not painful (Grade 1): 7 patients 16,6 % of SPN, tolerable (Grade 2): 20 patients 47,6%, painful (Grade 3): 8 patients 19% and very painful (Grade 4): 7 patients 16,6%.

Complications encountered per or post procedure can be subcategorized into two sections: short term and long term. Short term complications (25.6%) included: 4 local hematomas (6.9%) seen on control slices (6.9%), 4 transient hemipalate anesthesia (6,9%) and 3 pain increase after procedure (5.2%). Long term complications : 2 cases of persisting hemipalate paresthesia (3.4%), 2 cases of

persisting hemipalate anesthesia (3.4%). No epistaxis or lachrimal dryness were noted.

Group Comparison :

Distribution of facial pain were as follows : Group 'CH' : 14 patients, 17 procedures (29.3%), Group 'PIFP': 10 patients, 21 procedures (36,2%), Group 'Other' 18 patients, 20 procedures (34.4%) (trigeminal neuralgia: 6, compression mechanism by neoplasm: 4, radiotherapy sequelae: 3 patients, 4 procedures, odontalgia: 3, post zosterian pain: 1 patient, 2 procedures, post traumatic : 1).

When comparing the efficacy rate between the three groups, statistical analysis showed a higher efficacy rate in the Groups CH (76.5%) and PIFP (85.7%) when compared to the Group Other (40%) ($p=0.004$ and $p=0.045$ respectively – Fisher's exact test). However, no statistical difference was found between groups CH and PIFP.

When comparing the recurring rate in each group, we found no statistical difference. However, there seem to be a tendency of pain recurrence in Group PIFP when compared to Group Other ($p=0,051$).

Finally, we found no statistical link between groups regarding the efficacy rate or recurrence rate and the duration of pain prior procedure, initial VAS scores in each group, age, sex and side of pain.

When analyzing results in subgroups of the Group Other, statistical analysis was not possible due to the small sample size in each subgroup, however, descriptive analysis showed the following efficacy rates : trigeminal neuralgia 50% (3/6), compression by neoplasm : 100% (4/4), radiotherapy sequelae : 0% (0/4), odontalgia : 0% (0/3), post-zosterian pain : 50% (1/2) and post traumatic pain : 100% (1/1).

Discussion

The present study demonstrates an overall satisfactory success rate (67.2%) of SPN in patients with various refractory long lasting (mean 5.25 years) facial pain with a mean pain relief period of 10.3 months. These results indicate that SPN using absolute alcohol may be of significant interest in the management of refractory facial pain syndromes. However, we found a high rate of recurring pain in this study (72.3%). This high level of recurrence is difficult to explain but may be partially attributed to the small amount of ethanol injected which may only cause partial neurolysis of the SPG. However, because of the immediate proximity of noble structures (i.e. optical nerve via the infraorbital fissure), we do not advocate to inject a higher amount of alcohol which may lead to uncontrolled diffusion and possible severe side effects. Alcohol SPN may however easily be repeated in case of recurring pain, as the procedure is graded not painful or mildly painful in 63% of cases.

Regarding the effectiveness of the procedure depending on the indication, it clearly appears that alcohol SPN is more effective in Persisting Idiopathic Facial Pain (85.7%) and Cluster Headache (76,3%). Concerning PIFP, these results are quite encouraging as patients suffering from these complex facial pain syndromes often have a long history of divergent diagnoses and therefore present severe refractory chronic pain with failed management. Cluster Headache, on the other hand is a well known condition, in which SPG has proven to be involved as pathophysiology of cluster headaches involves activation of the parasympathetic fibers of the SPG [110, 179, 187]. Since Sluder first described transnasal ganglion block with topical use of cocaine in 1908 with satisfactory results [188] several interventional treatment

methods have emerged. Transnasal or intranasal SPG blockade using local anesthetics [181, 184, 189, 190, 191] showed satisfactory short term results. Yang et al. [192] reported 60% pain reduction lasting for 1 week. Felisati et al. showed longer lasting results (ranging from 1 to 24 months) in 40% of cases using an endoscopic approach [193]. Surgical techniques such as ganglionectomy [194] or trigeminal nerve sectioning [195, 196] have also been described with a poor long term outcome and significant morbidity related to trigeminal denervation [112]. Radiofrequency ablation has also been described with longer lasting results : Sanders et al. found complete relief of pain in 60.7% of patients suffering from episodic CH and in 30 % of patients with chronic CH , ranging from 12 to 70 months. Narouze et al. [112], showed significant improvement in the mean attack intensity, mean attack frequency, and pain disability index before and after the procedure lasting for 18 months in 15 patients suffering from chronic cluster headaches. More recently SPG electrical stimulation has been introduced [113, 197]. Schoenen et al. showed 67.1% attack pain relief achievement with an on demand electrical stimulation device. Finally, deep brain stimulation [198-200] has shown very promising results with long lasting pain relief according to Leone et al. However, this surgical procedure remains invasive and very specific, and some authors have reported that widespread application of this technique is not yet justified [201]. When compared with other previously described techniques, our results show a similar efficacy rate and long term pain relief period.

Only one study reports the use of alcohol in cluster headaches [202]. Neurolysis was performed under endoscopic guidance via a transnasal approach and concerned patients with advanced local cancer invasion. The authors report 59% success rate at one month follow up with few complications but in 70% of cases the procedure

could not be repeated due to local tumor invasion. These results are in accordance with those of our cohort concerning tumor invasion as our study showed a satisfactory outcome at 1 month in 4 out of 4 patients treated. We therefore think that injection of alcohol through the nasal fossa can be considered as an alternate technique when confronted to difficult lateral zygomatic approach in these patients with advanced local tumor invasion which can modify the temporal fossa anatomical landmark.

Because of the small sample size in the subgroups of the group Other, we were unable to perform statistical analysis in this group. However, descriptive analysis showed a 50% success rate (3/6) in case of trigeminal neuralgia, and 100% (4/4) success rate in case of local tumor invasion. On the other hand, radiotherapy sequelae and odontalgia do not appear to be responsive to alcohol SPN as none of the performed SPN in these patients have shown effective response. However, no conclusion can be drawn due to the small number of patients.

Finally, overall persisting complication rate in our study is comparable to those of previous studies on Sphenopalatine neurolysis. However, transient complication rate (25,6%) appears lower in our study compared to other studies : Sanders [111] described temporary postoperative epistaxis in 8 cases, cheek hematoma in 11 cases and palate hypoesthesia in 9 cases, out of 66 procedures. That is an immediate complication rate of 42%. Another study, evaluating SPG radiofrequency in chronic CH reports 50% transient anesthesia of the upper gum and cheek [112]. We think that our lower complication rate can be explained by the use of CT guidance as opposed to commonly used fluoroscopic guidance. Indeed, CT guidance allows precise, accurate and safe needle guidance for SPN along with a safe visualization of contrast mixture and alcohol diffusion, thereby avoiding diffusion to

adjacent structures (inferior orbital fissure and nasal fossa). Moreover, CT guidance allows visualization of local complications such as hematomas, which cannot be seen in fluoroscopy.

In comparison with other previously described techniques, our results show a similar efficacy rate and long term pain relief period. However, the diversity of cranio facial pain studied, the heterogeneous inclusion criteria, the multiplicity of the techniques and the variations of definitions of treatment success make it difficult to compare the results of the various techniques. The results of our study show that alcohol percutaneous CT guided SPN appears to be a feasible and effective procedure, however it is difficult to assert that it is a better technique than those previously described. On the other hand, it does not require complicated devices (as is the case with stimulation or radiofrequency), it is a minimally percutaneous treatment (as opposed to surgical management), and is a cost effective treatment with low complication rates thanks to precise step by step guidance allowed by CT.

Limitations of our study are those inherent to retrospective studies and small sample size. Moreover, etiologies of facial pain included in this study are quite heterogeneous and the statistical analysis was not performed in each subgroup of the group Other due small sample sizes. Interobserver variability was not assessed. Finally, some patients benefited from several procedures which may constitute a recruitment bias.

Conclusion

Our study showed that alcohol SPN under CT Guidance appears as a safe and effective treatment of refractory facial pain (mean pain relief 10,3 months) and should be considered as a possible alternative to existing techniques in the difficult task of alleviating these patients from these intolerable painful facial conditions.

In order to avoid possible complications such as local hemorrhage (epistaxis or local hematoma) and transient palate dysesthesia, we strongly advocate the use of CT guidance . The best indications with higher success rates appears to be Cluster Headache and Persistent Idiopathic Facial Pain.

We declare that we have no conflict of interest.

Study Commentary

This study is yet another example on how the use of CT guidance has allowed to modify existing neurolytic techniques of the SPG and to adapt existing neurolytic agent to this indication, thanks to the use of CT guidance.

Indeed, the usefulness of CT guidance in this indication is clear. It allows very accurate and safe needle placement in immediate proximity to the SPG. In this indication, other imaging guiding techniques are clearly not as precise (i.e. fluoroscopy) or simply not applicable (i.e. ultrasound). Moreover, diffusion of alcohol may partly be controlled with CT guidance, as indirect visualization of contrast dilution is perfectly visualized on CT images, as shown in this study.

Overall, CT guidance appears as the most suitable imaging tool to perform SPG alcohol neurolysis,

b) Greater Occipital Nerve

Another field of interventional Pain Procedures which has gained interest amongst pain interventionalists and has extensively been studied over the past decades is occipital nerve related procedures.

Indeed, Occipital nerves have been shown to be involved in various pain syndromes, such as occipital neuralgia, cluster headaches, chronic migraines, cervicogenic headaches. Several approaches have been described, with or without imaging guidance, ranging from simple blocks to radiofrequency neurolysis and electric nerve stimulation with various results depending on the technique used. The anatomy of the greater occipital nerve is quite simple and well known, and several areas of vulnerability (detailed below) and therefore possible targets for the pain interventionalist have been described. Here again, although the Occipital Nerve is not directly visualized by CT, the exact course of the nerve may be targeted at the different possible targets. The use of CT guidance for Occipital nerve procedures has been described with satisfactory results, however, targeting the nerve along its course between the semispinalis and obliquus rectus muscles has not been studied. The following study will demonstrate how CT guidance allows to simplify and enhance safety of occipital nerve infiltration.

**A simplified CT guided approach for greater occipital nerve
infiltration in the management of Occipital Neuralgia**

Conditional Acceptance, Minor Revisions, European Radiology, October 2014

Abstract

Objectives:

To evaluate the efficacy of a simplified CT guided greater occipital nerve (GON) infiltration approach in the management of occipital neuralgia (ON)

Methods :

Local IRB approval was obtained and written informed consent was waived. Thirty three patients suffering from severe refractory ON who underwent a total of 37 CT guided GON infiltrations were included between 2012 and 2014. Infiltration of GON was performed at the first bend of the GON, between inferior obliquus capitis and semispinalis capitis muscles with local anesthetics and cortivazol.

Pain was evaluated on VAS scores. Clinical success was defined by pain relief greater than or equal to 50% lasting for at least 3 months.

Results :

Mean pain prior procedure was 8/10. Patients suffered from left GON neuralgia in 13 cases, right GON neuralgia in 16 cases and bilateral GON neuralgia in 4 cases. Clinical success rate was 86%. In case of clinical success, mean pain relief duration following procedure was 9.16 months.

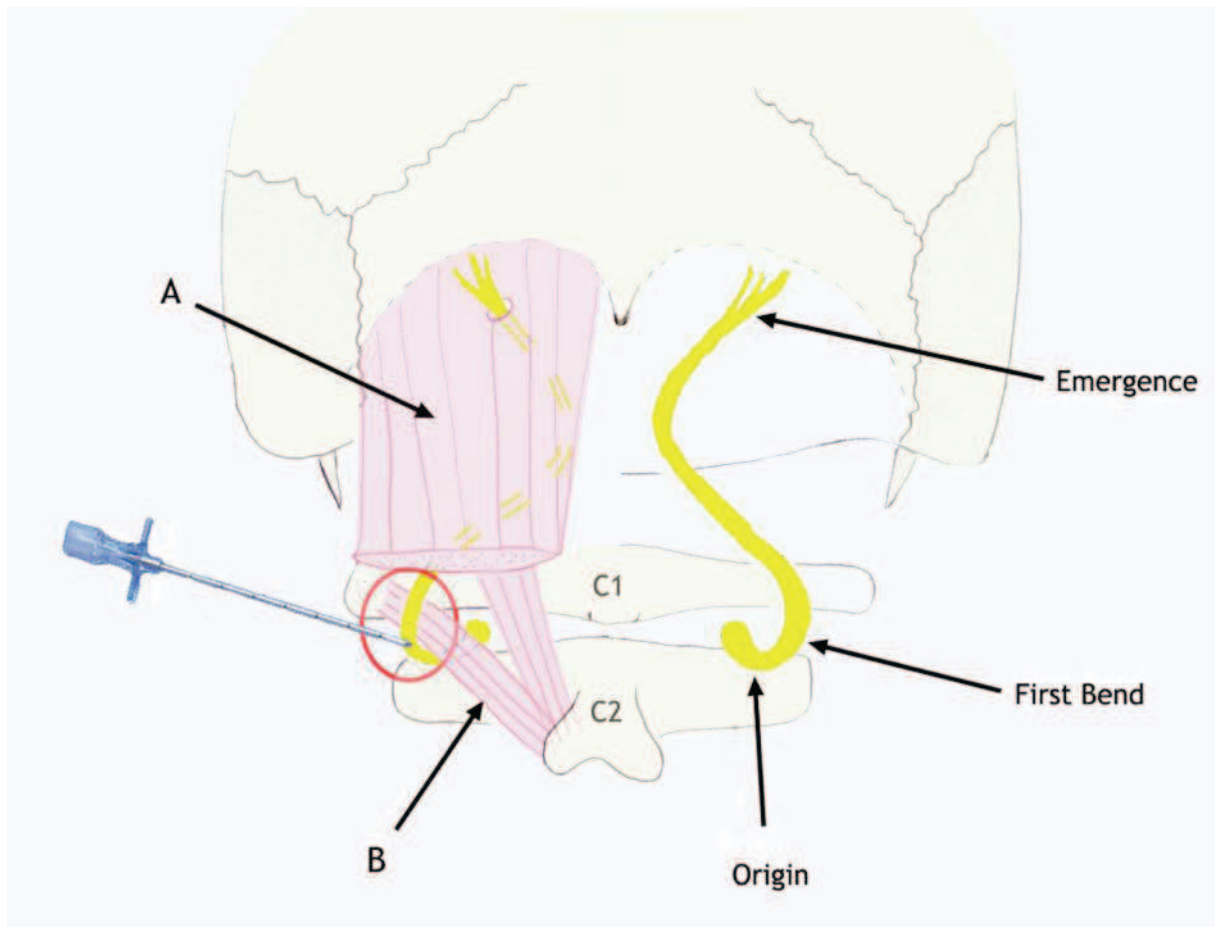
Conclusions :

This simplified CT guided infiltration approach appears to be effective in the management of refractory ON. With this technique, infiltration of the GON appears to be faster, technically easier and therefore safer compared with other previously described techniques.

Introduction

Occipital neuralgia (ON) is a rare neurological disorder which has been defined by the International Headache Society (IHS) as a stabbing paroxysmal pain in the dermatomes of the greater, lesser or third occipital nerves [203]. Greater Occipital Nerve (GON) infiltration has become a common procedure in the diagnosis and management of occipital neuralgia, as a positive nerve block is required to establish the diagnosis of ON [203]. Several possible areas of GON vulnerability have been described (Figure 1) [14, 204-207]: - first, at its origin from the C2 dorsal ramus between the atlas and the axis - second, at the first bend where the GON curves around the inferior obliquus capitis muscle - third, at its superficial emergence when perforating the aponeurosis of the trapezius muscle. GON block performed at this latter conflict site constitutes the 'classical approach' which has been described with satisfactory short term results in previous studies [208]. Infiltration, at either C1-C2 origin of the GON [209, 210] or at both C1-C2 origin and first bend sites [211] are less common but have been reported with satisfactory results. However, infiltration of the intermediate (first bend site) alone has not yet been reported. Therefore, the objective of this study was to assess the feasibility, safety and efficacy of a simplified CT guided approach at the first bend/intermediate site of the GON in the management of occipital neuralgia.

Figure 1: Anatomical drawing of the Greater Occipital Nerve showing the different areas of vulnerability.



A: Semispinalis muscle

B: Inferior oblique muscle

Red Circle: Infiltration target at the first bend of the GON, in the fatty space between inferior oblique and semispinalis muscles.

Materials and methods

Patients

Thirty-three consecutive patients suffering from ON who underwent a total of 37 infiltrations were included in this single center retrospective study between 2012 and 2014. Because the International Headache Society's [203] definition of occipital

neuralgia includes a positive ON block, and in order not to introduce a bias in our study, the diagnosis of occipital neuralgia was based on the clinical aspect (criteria A and B) of the IHS definition. Therefore, all adult patients presenting with suspected ON with refractory persisting pain for at least 3 months, were retrospectively included in the study. The exclusion criteria were as follows: recurring occipital neuralgia after positive infiltration, history of GON neurolysis (radiofrequency or neurotomy) atypical GON neuralgia, associated known history of migraine or cluster headache prior to the procedure. Local Institutional Review Board approval was obtained and informed consent was waived. The data were collected in patients' medical records and included information on patients' demographics (age, sex), clinical and pain management history (see details below). All the patients were followed up at 1 and 3 months by interventional radiologists. After 3 months, the follow up was performed by either corresponding physician (pain physician or neurologist) or phone interview according to the same scoring system. The follow up period ranged from 12 to 24 months.

Pain:

The following criteria were noted prior to the procedure: history of neck trauma or surgery, pain description, mean duration of pain, pain intensity (Visual Analog Scale score (0-10)) and laterality of pain. The pain following procedure was also assessed using Visual Analogue Scale scores (0-10). GON infiltration was considered to be effective when pain relief was equal to or greater than 50% lasting for at least three months. Less than 50% in pain reduction was considered a failure. Seventy five percent pain reduction and above was considered excellent results and a decrease of pain between 50% and 74% was considered good results. Oral medication consumption after procedure was also noted as: discontinuation, decrease, no

modification. In case of bilateral infiltration (4 patients), the effectiveness of the procedure was assessed based on both sides, and therefore a total of 37 procedures were considered for analysis. The occurrence of complications was noted as minor or major.

Table 1: Study population demographic data and pain characteristics

Variables	Study population
Demographic data	
Sex	
F	23
M	10
Age (years)	51,8
Pain characteristics	
Side	
Left	13
Right	16
Bilateral	4
Mean VAS prior procedure	8/10
Pain duration prior procedure (years)	3,16

Procedure:

All of the procedures were accomplished by one of several authors under CT guidance on an outpatient basis (Siemens Somatom Sensation CT 64-channel scanner, Erlangen, Germany). The patient was placed in prone position with the head slightly in flexion, facing towards puncture site in case of unilateral infiltration and straight in case of bilateral infiltration.

An initial non-enhanced planning CT was performed from C0 to C3 in order to determine target and safest needle pathway. Target was defined as the fatty space between inferior obliquus capitis and semi spinalis muscle at C1-C2 vertebrae level (FIGIURE 2-A).

Figure 2: Example of GON first bend infiltration in a 24 year old female patient suffering from right Occipital Neuralgia. Patient is positioned with head slightly facing towards the puncture site (right side). CT slices are at C1-C2 level.

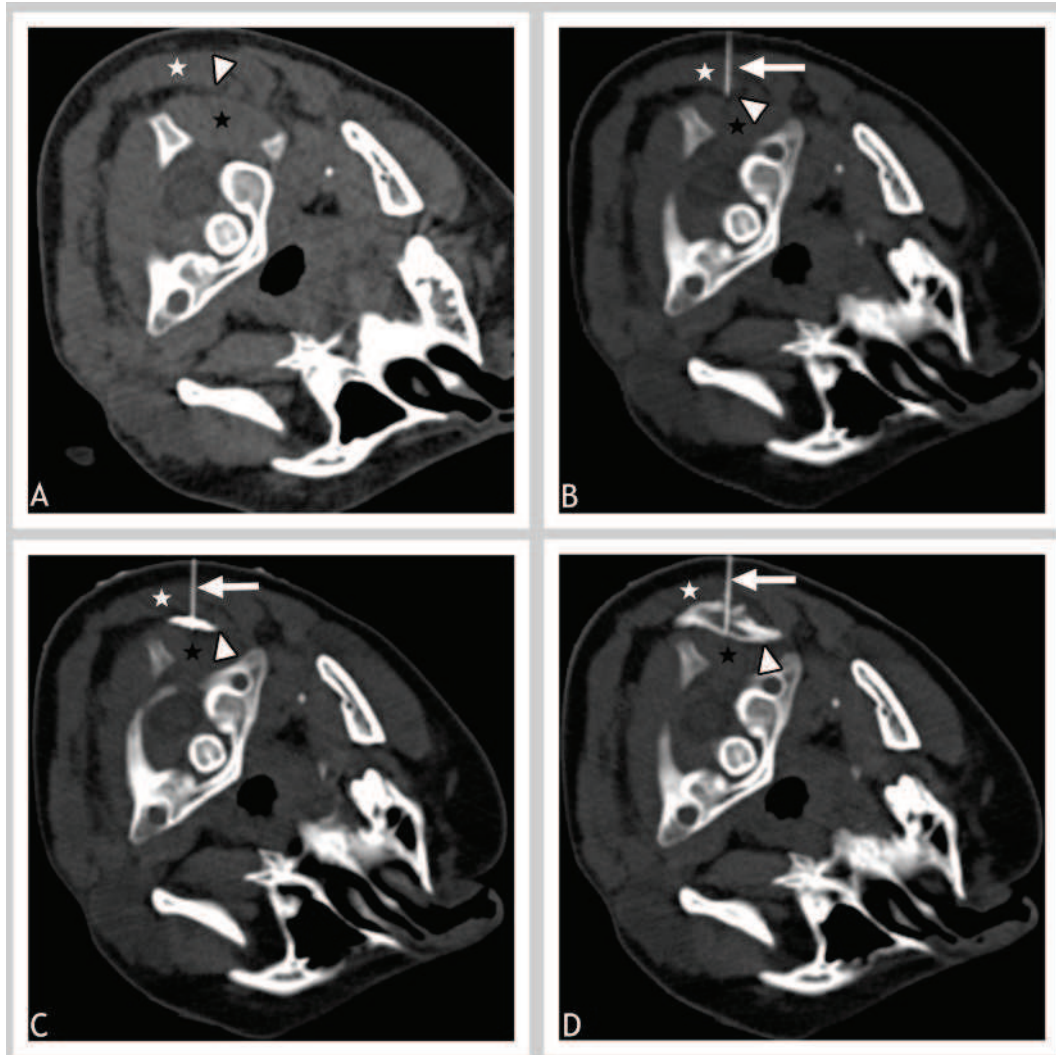


Figure A: Planning non enhanced CT showing the target of infiltration: fatty space (white arrow head) between inferior oblique (Black Star) and semispinalis (white star) muscles.

Figure B: CT after insertion of the 22G needle (White arrow) accurately positioned at the pre defined target space (white arrowhead)

Figure C: Control CT after injection of 0.5 mL of contrast media showing satisfactory diffusion in the target site (white arrowhead). Needle still in place (white arrow).

Figure D: Control CT after injection of anesthetics and corticosteroids. Note how the contrast media is diluted by the diffusion of the mixture (arrowhead) and how the diffusion is contained in the fatty space. Needle still in place (white arrow)

The corresponding skin entry point was marked on the skin, and local skin sterilization was performed. Local subcutaneous injection of lidocaine hydrochloride 1% was performed at the defined skin entry point. A safe step-by-step progression of needle (22G) was performed under CT guidance until the needle tip artifact was located at the defined target (Figure 2-B). Diluted iodinated contrast material was injected (1 ml) in order to control accurate needle position and confined diffusion of the injectant between inferior obliquus capitis and semispinalis muscles (FIGURE 2-C). A mixture of fast and slow acting anesthetic (1.5 ml lidocaine hydrochloride 1% and 3 ml ropivacaine chlorhydrate) was then injected followed by 1.5 mL of cortivazol (3.75 mg) Figure 2-D. The needle could then carefully be removed and the patient was supervised for 30 minutes at the CT Unit.

The technical success was defined as the ability to satisfactorily inject anesthetics and corticosteroids in the fatty space between inferior obliquus capitis and semispinalis muscles. The duration of the procedure was also noted.

Statistical Analysis

Studied variables were "Pain prior" (pain duration prior to the procedure), "Efficacy" (clinical efficacy, corresponding to a pain decrease of at least 50% for 3 months, noted as Yes or No), "Duration" (total pain relief duration following procedure in case of success), "Age" and "Sex".

The Shapiro Wilk test was used to determine whether continuous variables ("Pain prior", "Age", "Duration") came from a normally distributed population. As the null hypothesis was systemically rejected, non-parametric tests were then used for continuous variables (Mann Whitney U-test). To compare two different continuous variables the Pearson product-moment correlation coefficient was calculated.

For categorical variables, the comparisons were made using the Fisher's exact test. Statistical calculations were performed with Systat software version 12.0 (Systat Software Inc., Chicago, IL, USA).

A p value of <0.05 was considered significant for the statistical analysis.

Analysis was first performed in the whole cohort regarding the criteria "Efficacy" (yes/no) in order to detect a possible influence of variables on the results. Then, statistical analysis on the following variables was performed: "Age" (Mann Whitney U test), "Sex" (Fisher's exact test) and "Pain prior" (Mann Whitney U test).

Then an influence of variables "Pain prior" as well as "Age" on "Duration" was checked (Pearson correlation).

Results

Patients

A total of 33 consecutive patients including 23 females and 10 males with a mean age of 51.8 years old were included for analysis. The patients suffered from left GON neuralgia in 13 cases, right GON neuralgia in 16 cases and bilateral GON neuralgia in 4 cases. A history of cervical trauma was noted in 20/33 (60.6%) patients, and a history of cervical surgery in one patient.

Pain

Pain was present for an average of 3.16 years (range 0.5-20) prior to the procedure with a mean VAS score of 8/10 (range 6-9). The patients' description of pain varied, and included, but were not limited to, deep aching, sharp, stabbing or lancinating pain to the suboccipital region radiating to the ipsilateral forehead. Twenty seven patients described paroxysmal attacks of short sharp pain superimposed on a dull background pain.

GON infiltration was found to be effective (pain reduction >50%) in 32/37 procedures, that is an overall efficacy rate of 86.5%. In these cases, mean pain relief duration following procedure was 9.15 months (range 3-24). Excellent results (above 75% pain decrease) were obtained in 20/32 (62.5%) effective procedures (VAS score at 3 months = 1,2/10, mean decrease 87%) and good results (mean VAS = 2.8, mean decrease 62%) in 12/32 (37.5%) cases.

Pain medication could be discontinued in 15 patients (54%) after successful GON infiltration. A decrease in pain medication was observed in 6 (21%) patients. In 7 (25%) patients, no modifications in pain medication were noted.

No major complications occurred during or after procedure. Other minor side effects were seldom encountered, such as: transient cervicalgia, passing blurred vision, vagal faintness and transient (mean time 3 days) neck torticollis.

In the 5 cases of failure of GON infiltration, 3 patients benefited from a positive infiltration with a complete pain relief lasting for at least 24 hours (range 1 to 4 days), one patient benefited from 30% pain decrease lasting for 1 month and another did not benefit from pain decrease at all.

Procedure:

Intra-venous injection of contrast material for pre planning CT was avoided in all cases. Technical success was 100%. Average duration of procedure was 15.6 minutes (10-18 minutes).

Statistical Analysis

No significant statistical differences were observed for "Sex" vs "Efficacy" and "Age" vs "Efficacy", and no correlation was observed for "Pain prior" vs "Duration" and "Age" vs "Duration". However a significant difference was observed for "Pain prior" depending on "Efficacy" ($p=0.019$, $U=132.5$).

Discussion

The present study showed satisfying results with a high efficacy rate of 86% and a mean pain relief duration of 9 months following a successful procedure. These results are substantial and appear clinically significant. When analyzing the five cases of failure of GON infiltrations, failure of the procedure may be partly attributed to a long history of pain prior to procedure. Indeed, statistical analysis showed a significant link between the efficacy of the procedure and the average duration of pain prior to the procedure. In the 5 cases of failure, average pain prior to the procedure was higher than that of successful patients (6 years vs. 2.5 years). The influence of pain duration prior to the procedure on effectiveness is known to pain interventionalist, and has already been demonstrated in other procedures [32]. Therefore, we think that in the 4 patients with a positive infiltration, procedure efficacy may have been influenced by the long period of refractory intractable pain prior to the procedure. This is a significant result, which should be taken into consideration prior to performing GON infiltrations. In the remaining patient which showed no pain relief following procedure, follow up revealed the occurrence of cluster headaches (which responded to specific therapy), which may have influenced the outcome of the procedure. Despite the few cases of failures, the present study showed encouraging results, which were obtained with a simplified minimally invasive easy to perform GON infiltration approach. Advantages of this technique are numerous when compared to previously reported techniques.

First, when compared to the conventional blind technique performed at the emergence of the GON at the level of superior nuchal line, our results show similar efficacy rates (up to 85%), but with longer lasting pain relief durations (1-2 months)

[212] [213]. Moreover, our approach presents several benefits: because of high CT image resolution, CT guidance allows precise needle pathway planning and accurate and safe needle positioning along GON path between obliquus and semispinalis muscles. Indeed, it has been shown that the classical technique is not target specific [214] and that imprecise injection, especially if high volumes are injected, could lead to diffusion of the infiltration to surrounding nerve (lesser and/or third occipital nerves). Therefore, indirect methods of localizing the GON have been described, such as the use of transcranial doppler sonography [215, 216] or sensory nerve stimulation [217]. More recently, ultrasound guidance (US) has been described with satisfactory results [218, 219]. However, although the use of these guiding techniques highly improves target specific methods, it does not seem to improve duration of pain relief [215, 216, 218, 219].

Second, when compared with previously described C2 (origin) root infiltration site [209] or combination of both origin and first bend [211], the present study showed improved results. Indeed Pougard-Bellec et al. found a 71% success rate at one month after procedure decreasing to 62% at 3 months. Aubry et al. demonstrated how performing an infiltration at both the C2 root and the first bend of the nerve significantly improved the efficacy rate and pain relief period, compared with infiltration at the C2 root only (53% lasting for 4.4 months vs. 60.5% lasting for 11.5 months). The results obtained with the present simplified technique showed a higher efficacy rate and an intermediate pain relief duration of 9 months. Main advantages of this simplified approach concern safety and technical aspects. In both of these studies [209, 211], image guidance was also used and allowed accurate needle placement at the C2 root of the GON. However, higher complication risks are inherent to this infiltration site [14]: inadvertent vascular puncture (vertebral artery,

surrounding vena plexus) and inadvertent dura mater puncture. This latter complication explains why local anesthetics should not be injected at the origin of the GON as inadvertent subarachnoidal lidocaine penetration may lead to total spinal anesthesia and possibly cardiorespiratory arrest. Because the first bend infiltration site is situated at a safe distance from the vertebral artery and other vascular structures, this simplified technique appears safer as inadvertent vascular puncture is more easily avoided. Moreover, planning CT does not require injection of contrast media as the first bend site is at distance from vascular structures.

Third, this simplified GON infiltration approach allows the use of US guidance. Indeed, because of the more superficial nature of this infiltration site, US guidance may be considered. Because of our experience in the field of CT guidance, and in order to validate this new infiltration site, we chose to assess efficacy of first bend GON infiltration using CT guidance. However, it has been shown by Greher et al. [214] on a cadaver study, that this new infiltration site is ultrasound accessible and further studies are necessary to validate the use of US guidance at this site.

Finally, the high efficacy rate and long lasting results obtained with this new GON infiltration technique appears close to those described with more invasive neurotomy techniques, such as radiofrequency neurolysis, which have shown pain relief lasting between 4 and 6 months, depending on the studies [220-223].

Limitations of our study are those inherent to small study samples and retrospective studies. Moreover, we chose to use a 50% pain decrease as our main efficacy criteria, whereas other studies used 80%; however, our efficacy criteria included a 3 month pain relief, whereas other studies used shorter durations (1week or 1 month). Our study was not a comparative study, and consequently, possible adjunct placebo effect cannot be ruled out entirely. However, our long lasting pain relief highly

reduced the possibility of a placebo related bias. Finally, pain evaluation was made on VAS scores alone, which is a subjective outcome measure depending on personal interpretation and variations. The effectiveness of all the procedures performed in our Unit are evaluated with VAS scores, and we find it is a relatively simple, reliable and a sufficient way to apprehend patients response to a procedure.

Despite these limitations, the present study showed that this simplified GON infiltration approach, targeting the first bend of the GON in the fatty space between obliquus and semispinalis muscle, allows a high efficacy rate (86% at three months) with a long lasting pain relief following procedure (mean, 9 months) in the management of refractory Occipital Neuralgia. Careful attention to patient selection and particularly history of pain should be made in order to enhance the chances of procedure success. Main advantages of this technique compared with previously described image guided GON infiltration include: a faster, less invasive, technically easier and therefore safer procedure.

Study Commentary.

This study is the perfect example of how an existing already approved effective technique may be improved by the combination of good anatomical knowledge and the use of a different imaging modality.

CT scan guidance allowed to imagine a target which is known to be a vulnerability site, but which has not been tried to date, probably due to access issues. Indeed, this 'first bend' target site has never been described as a possible infiltration site . This may be explained by the relatively underused imaging guidance in this procedure. The majority of the studies available assess the blind technique, based on anatomical landmarks. Other imaging guiding modalities described are fluoroscopy for the C1-C2 target, and ultrasound in some rare studies.

Our study has shown that performing an infiltration at the first bend site was effective, under CT guidance. It allowed to simplify the technique and render it safer than previously described CT guided techniques, targeting C1-C2 site.

Another possibility to targeting the first bend site is Ultrasonography. Indeed, this first bend site is clearly accessible to Ultrasound guidance, and effectiveness of ultrasound guidance in this indication should be assessed, in order to avoid the only real downside to CT guidance : ionization.

VIII - Unidirectional Radiofrequency Probe : Future
perspectives

A - Introduction

The objective of radiofrequency ablation is to induce thermal injury to a tissue (i.e. nervous structure in case of neurotomy) through an electromagnetic energy deposition. Available Radiofrequency probes to date produce a 360°C ellipsoid thermal ablation zone, which is satisfying in most ablation/neurolysis indications especially in cases of tumor ablation where RF probe is usually placed in the center of the lesion and the objective of the procedure is to ablate, with safety margins, the surrounding tumorous tissue. However, some situations may benefit from a better control of ablation zone, as surrounding tissue may need preservation. This is particularly the case for vital structures such as vascular or neural structures surrounding ablation zones, or skin burning in case of superficial ablations. Some indications are particularly prone to possible surrounding unwanted thermal damage:

- Tumor ablation : spinal tumor ablation close to posterior wall (possible medullar damage) [224], thyroid tumor ablation (surrounding recurrent laryngeal or vagus nerve) [225], neural damage surrounding tumors (brachial plexus for upper lung or neck tumors, lumbar plexus retroperitoneal paraspinal tumors) [226], liver tumors (gall bladder diaphragm).
- Pain Management/Neurolysis : facet joint syndrome (possible motor nerve damage, muscle spasm), stellate ganglion (surrounding vertebral artery)

In order to reduce unwanted surrounding damage, several techniques have been described , either to monitor real time temperature [227] or to inject saline solution to reduce heat diffusion [228].

Another solution to avoid uncontrolled damage would be a unidirectional radiofrequency probe, capable of producing tissue destruction only on one half on the probe thereby creating a half mooned shaped thermal zone. The main advantage of such a probe would be the ability to predict the thermal zone and to subsequently orient and place the probe in such a way to avoid damage to surrounding noble structures.

The objective of this experiment was to test the feasibility of a such a probe, using a partially insulated RF probe in egg white and to observe coagulation orientation. This experiment was initially designed to assess coagulation zone depending on different parameters (active tip size, power, duration of ablation).

B - Radiofrequency Principles

The term Radiofrequency refers to an alternating electric current oscillating between high frequency ranges (200-1200kHz). In a unipolar radiofrequency procedure, the patient is placed at the center of a closed looped circuit including a dispersive electrode (grounds pads), a RF generator and a RF probe (electrode. In a bipolar radiofrequency system, the RF probe has 2 dipoles, avoiding the use of grounding pads. An alternating electrical field is induced within the surrounding probe tissue. The friction of the agitating ions in the tissue, which presents a relatively high electrical resistance, produces heat. Heat is concentrated around the probe because of the discrepancy between the size of the probe and the pads in case of unipolar systems, and between the two electrodes and the end of the probe in case of bipolar systems.

It has been shown in previous papers that well delineated thermal lesion could be produced in an homogeneous environment. Moreover, lesion size depended on multiple factors: target temperature, size of the electrode (exposed tip length and diameter) and time of ablation (to a certain extent) [229].

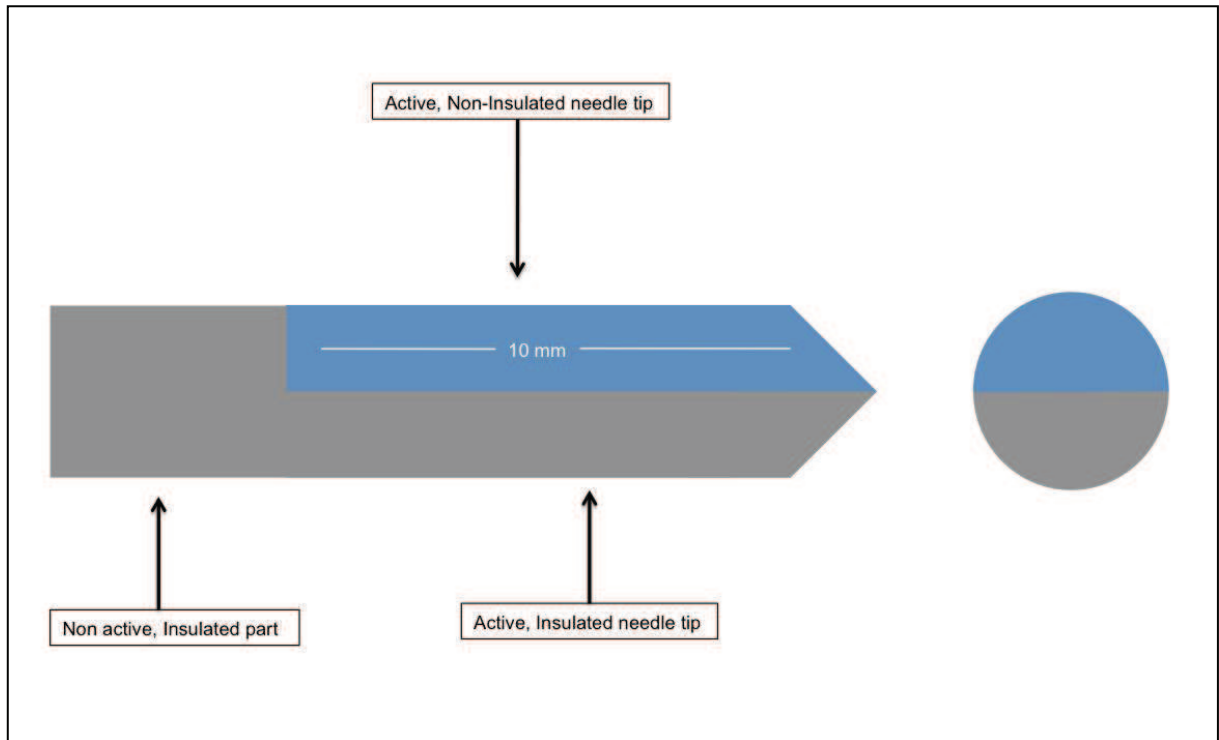
However, in a homogeneous environment and provided that the electrode configuration and temperature have been kept constant, there is a relationship between lesion size and time, with the thermal equilibrium being reached around 45 seconds. A longer exposure does not seem to influence size or shape of lesion [229, 230]. For consistent lesion making the main control parameter has been shown to be temperature, being the end result of RF.

35 -40° C	Normothermia
42 -46° C	Hyperthermia
46 -48° C	Irreversible cellular damage
50 -52° C	Coagulation necrosis
60 -100° C	Near instantaneous coagulation necrosis
> 110° C	Tissue vaporization

C - RF equipment :

For practical issues (difficulty to use grounding pads with egg white) a bipolar RF Generator was used (Celon Prosurge Micro, Teltow, Germany).

We modified an 17-gauge, 1-cm active electrode tip to develop a partially insulated electrode. Insulation of the active electrode tip was done using Polytetrafluoroethylene on one half on the surface (see Figure 1) of the active portion (1 cm) of the electrode).




D - Ablation test conditions:

Egg white was poured into a 50ml rectangular glass container.

Probe was advanced carefully until the uninsulated tip was completely submerged. Slow, downward motion of the probe prevented the formation of air bubbles in the egg white along the probe. Overall, approximately 25 RF cycles were performed. In all cases, coagulation limited to the non-insulated side of the probe was observed. There was no coagulation further than 1-2 mm posterior to the horizontal line crossing the posterior surface of the electrode.

An example of coagulation observed with and without insulation of bipolar electrode is shown in picture 1,

Picture 1 : Egg white coagulation obtained without insulation (left) and with partial insulation (right)



D - Illustrations of possible applications of such a device

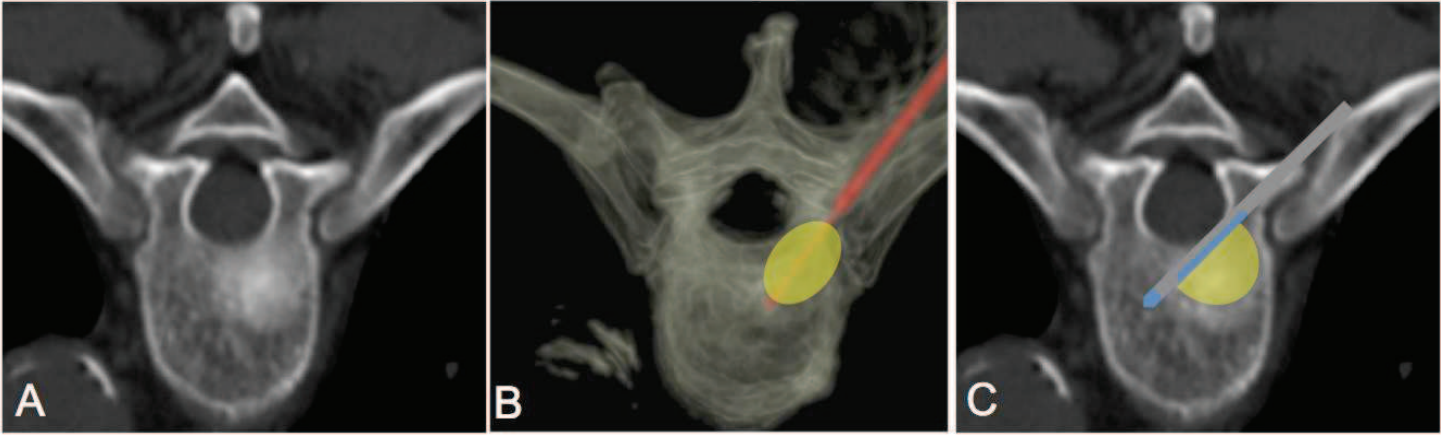
1) Tumor ablation:

Spinal tumor ablation probably represents the best application of unilateral RF probe. Indeed, between the medullar canal and the surrounding neural structures (radicular nerves), spinal lesion thermal ablation, in case of lesion situated near the posterior wall or a pedicle, present a non negligible risk of neural damage. Here are 2 example of lesions treated with thermal ablations in these locations

Example 1 :

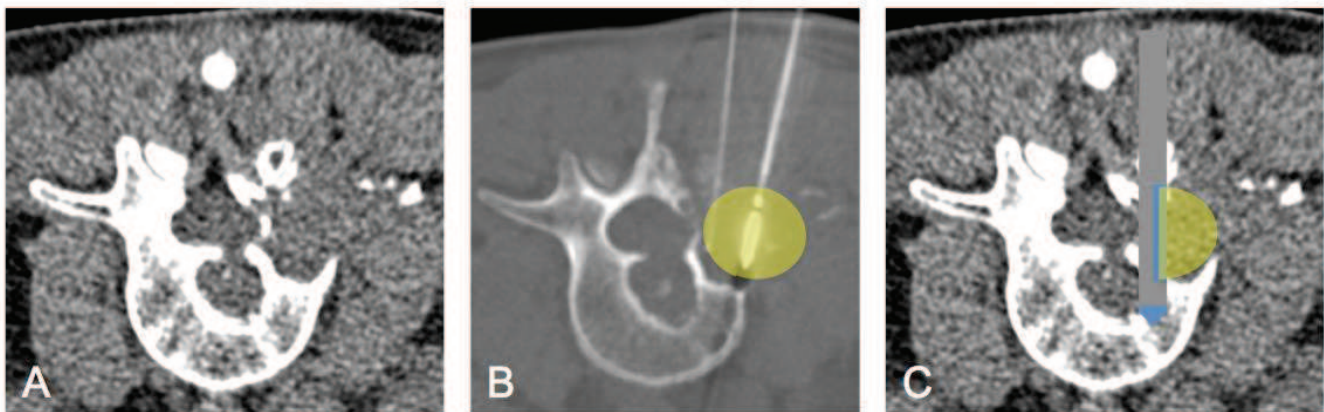
Example of a T5 secondary osteoblastic prostate metastasis treated with Radiofrequency ablation. Because of the situation and type of the lesion, thermocouple monitoring was not possible for this lesion. Only clinical examination

was performed during ablation performed under local anesthesia. Image C shows the theoretical ablation zone obtained with a unidirectional RF probe, which illustrates perfectly the added safety towards the canal, as opposed to 360° ablation in image B.



Example 2 :

Lumbar renal L3 lytic metastasis (A) in a 46-year-old man treated thermal ablation (B) with the use of a thermocouple monitoring (a thermocouple was inserted alongside the probe to monitor temperature in real time during the ablation to avoid cord injury. In yellow are represented the theoretical thermal ablation zones anticipated : image B shows a circular thermal ablation zone, approaching the spinal canal, and justifying the use of a thermocouple. Image C shows the theoretical ablation zone obtained with a unidirectional RF probe, which illustrates perfectly the added safety towards the canal, and would avoid the use of a thermocouple

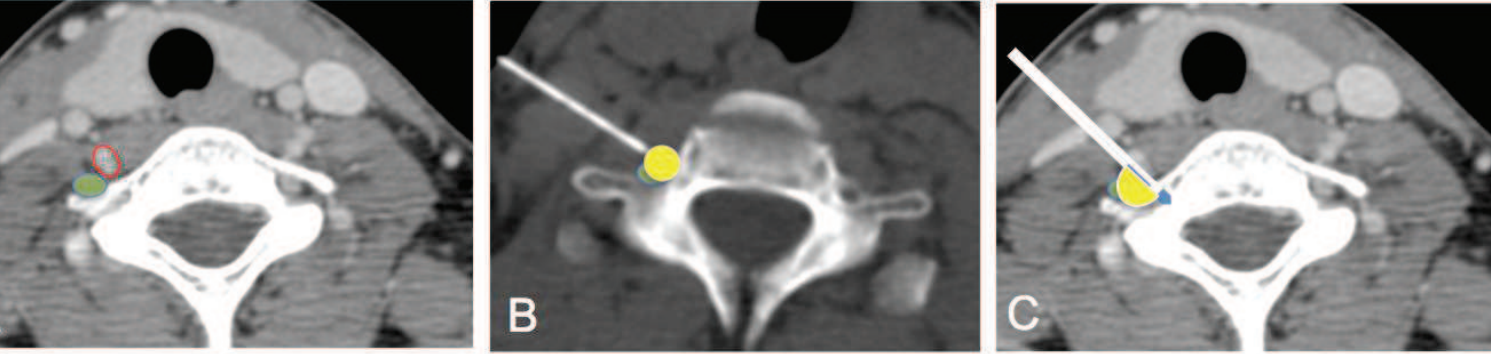


b) Neurolysis Procedures

The best probable application of a unidirectional RF probe is stellate ganglion neurolysis. Indeed, surrounding stellate ganglion are numerous vascular structures, such as venous plexus, veins and vertebral artery.

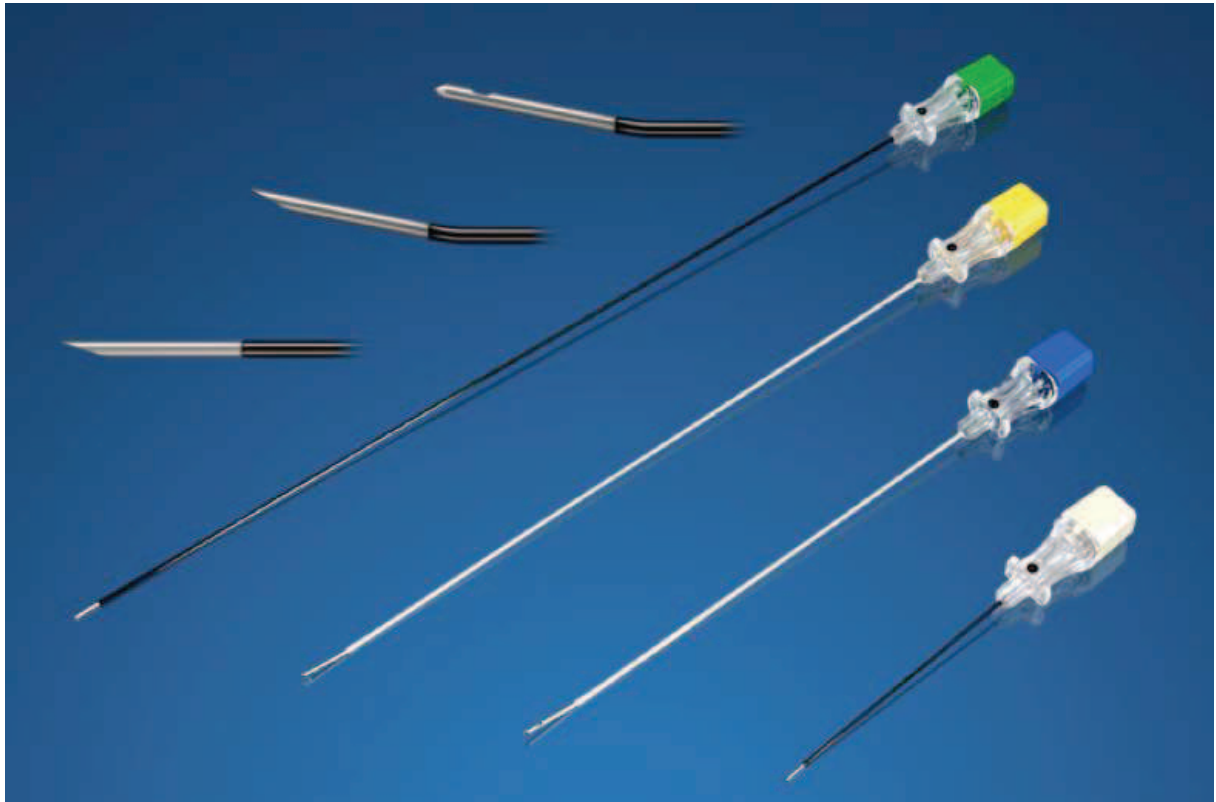The following figure (A) illustrates a case where a unidirectional RF would have been appreciated, due to the immediate contact of venous structures (red circle) to the stellate ganglion (green disk). RF Needle positioning under CT guidance often

reveals immediate proximity of needle tip to vascular structures (figure B). Theoretical thermal ablation zone in case of unidirectional probe would enhance chance of vascular damage, as illustrated in the following figure



E - Feasibility of Mass production Partially Insulated RF probe

To date, Manufacturers producing RF Generator for Neurolysis purposes offer insulated coated needle for RF probe insertion, with or without silicon (to facilitate insertion) as illustrated in figure 3 :



The insulation is present through out the whole needle and only the tip is coat free, to allow conduction and heating. Needless to say it does not seem complicated for manufacturer's to produce a partially insulated active tip, for unilateral heating.

IX - Conclusion

The efforts of the medical community in the field of pain management dates quite a while back as it is know well known that the concept of 'pain' has been 'bothering' man kind since the origin of humanity. The role and place of Interventional Pain Management in this race against pain is not so recent, as it dates back to the early 1900th century, with the discovery of neurolytic blocks. Since then, Interventional Pain Management has become a recognized distinct medical subspecialty (at least in the United States), attracting pain physicians essentially issued from the anesthesiology field. However, the difficult task of pain alleviation can not be done by one specialty alone, and the implication of multiple subspecialties, skills and efforts are needed to try to reduce the suffering of patients from persistent, chronic, refractory pain, often responsible of heavy impact on quality of life : this is the definition of multidisciplinary management.

Historically, the role of the radiologists in pain management has mainly been a diagnostic one, as diagnostic abilities of imaging keeps on improving with constant evolution of powerful diagnostic imaging tools. However, these imaging tools are becoming more and more used as an aid to either diagnostic or therapeutic interventional procedures. If fluoroscopy and Ultrasound are today widely recognized and used as imaging tools by a large part of Interventional Pain Physician, other imaging tools such as CT or MRI because of availability, cost and access issues, are less used by pain practitioners. Access to these imaging modalities is an advantage of Radiologists. Although MRI offers clearly approved advantages, the use of MRI guidance has not yet become mainstream. CT on the other end is widely democratized amongst Radiologist and is intensively used for procedure guidance in various fields of Interventional Radiology as it is well recognized to be a very precise means of guidance. The ability to use CT as an Imaging Guiding tool in the field of

Interventional Pain Management is clearly an advantage in specific indications, as accuracy is added to needle placement allowed by precise visualization of needle tip in surrounding soft tissue..

One of the objectives of this thesis was to assess the usefulness of CT guidance in modified interventional pain procedures, never described to date. Throughout the different papers published in this manuscript, we have shown that CT Guidance is an excellent Guiding tool for Interventional Pain Procedures. This is particularly the case for specific indication, requiring millimetric needle positioning, and accurate contrast diffusion. The usefulness of CT guidance was clearly demonstrated in study on Sphenopalatine Alcohol Neurolysis, where CT scan offers the best possible choice of guidance for pterygopalatine fossa targeting and the safest possible means of controlling diffusion of ethanol.

Another objective, was to assess the efficacy of modified existing interventional pain techniques. Neurolytic blocks, infiltrations, radiofrequency neurolysis or alcohol neurolysis have been used for decades with satisfying results in various indications of pain. However, the use of such and such techniques has not always been assessed by physicians, especially when CT guidance was used. Application of an existing neurolytic technique in an existing indication, or modifying an existing technique after anatomical considerations may lead to either higher efficacy rates, longer pain relief, or safer procedures.

Throughout the different studies of this thesis [32, 160, 231, 232], we have shown that :

- CT guided Radiofrequency neurolysis could successfully be used for Ilio inguinal neurolysis in patient suffering from refractory ilioinguinal pain, and for

Stellate Ganglion Neurolysis, in patients with upper CRPS type I (in both cases with a longer pain relief periods compared with infiltrations).

- Alcohol neurolysis of Sphenopalatine ganglion was a safe and effective procedure if performed under CT Guidance in selected indications: Cluster Headaches and Persistent idiopathic Facial Pain

- Greater Occipital Nerve infiltration in the fatty space between obliquus and semispinalis muscle, was an effective procedure, and technique used appeared faster, less invasive, technically easier and therefore, safer.

Although technical aspects and scientific research are essential parts of pain management in order to overcome patients' painful conditions, pain interventionalist must not forget to place the patient (and not the procedure) at the center of the management. Therefore, basic knowledge of clinical aspects of pain and emphasis on a global management of patient as a whole, as opposed to technical management alone, is mandatory for higher effectiveness and improved patient management. If this important aspect of pain management is well known of the majority of pain practitioners, others may unfortunately tend to forget it.

In spite of all the studies, data and books available to date regarding Interventional Pain Procedures, there is still a long way to go before the suffering of patients from chronic pain can be completely avoided. The reduction of persistent pain, and therefore the disturbance of quality of life, remains one of the challenges of the 21st century. In order to achieve such a goal, clinical scientists, clinicians, physicians, and even manufacturers must join forces and continue the effort of research in order to provide to these patients, the best possible available treatment options adapted to their specific conditions.

Finally, it is important to remember that interventional pain management of a patient is only a part of a more global management strategy. Thus, the management of patients in pain may not be as effective without taking into account all aspects of the pain expressed by the patient, far beyond the purely technical considerations of an interventional procedure.

XI - References

1. Schweitzer, A.O.t.e.o.t.p.f.N.Y.M., 1931:62., *A l'orée de la forêt vierge. Récits et réflexions d'un médecin en Afrique Equatoriale française de Albert Schweitzer* 1952, Paris: Albin Michel.
2. Merskey, H. and N. Bogduk, *Task Force on Taxonomy of the International Association for the Study of Pain, in Lumbar disco- genic: Classification of Chronic Pain. Descriptions of Chronic Pain Syndromes and Definition of Pain Terms, 2nd ed*, I. Press, Editor 1994: Seattle. p. 180-181.
3. Bourreau, F., *Pratique du traitement de la douleur* 1988, Rueil-Malmaison Doin.
4. Crook, J., et al., *Epidemiologic comparison of persistent pain sufferers in a specialty pain clinic and in the community*. Arch Phys Med Rehabil, 1986. **67**(7): p. 451-5.
5. Martin, B.I., et al., *Trends in health care expenditures, utilization, and health status among US adults with spine problems, 1997-2006*. Spine (Phila Pa 1976), 2009. **34**(19): p. 2077-84.
6. Reid, K.J., et al., *Epidemiology of chronic non-cancer pain in Europe: narrative review of prevalence, pain treatments and pain impact*. Curr Med Res Opin, 2011. **27**(2): p. 449-62.
7. Gaskin, D.J. and P. Richard, *The economic costs of pain in the United States*. J Pain, 2012. **13**(8): p. 715-24.
8. Gureje, O., et al., *Persistent pain and well-being: a World Health Organization Study in Primary Care*. JAMA, 1998. **280**(2): p. 147-51.
9. Harstall, C., *How prevalent is chronic pain?* . Clinical Updates, IASP, 2003. **XI; 2:1- 4**.
10. Manchikanti, L., et al., *Analysis of growth of interventional techniques in managing chronic pain in the Medicare population: a 10-year evaluation from 1997 to 2006*. Pain Physician, 2009. **12**(1): p. 9-34.
11. Ivanova, J.I., et al., *Real-world practice patterns, health-care utilization, and costs in patients with low back pain: the long road to guideline-concordant care*. Spine J, 2011. **11**(7): p. 622-32.
12. Manchikanti, L., et al., *A systematic review of randomized trials of long-term opioid management for chronic non-cancer pain*. Pain Physician, 2011. **14**(2): p. 91-121.
13. Santaguida, P.L., et al., *Complementary and alternative medicine in back pain utilization report*. Evid Rep Technol Assess (Full Rep), 2009(177): p. 1-221.
14. Kastler, B., *Interventional Radiology in Pain Treatment*, ed. Springer 2007, Berlin.
15. Manchikanti, L., et al., *Evolution of interventional pain management*. Pain Physician, 2003. **6**(4): p. 485-94.
16. Brown, D. and B. Fink, *The history of neural blockade and pain management*. In: Cousins MJ, Bridenbaugh PO (Eds.). *Neural Blockade in Clinical Anesthesia and Management of Pain*, 3 ed, ed. L.-. Raven 1998, : Lippincott- Raven, Philadelphia.

17. Tuffer, T., *Anesthésie médullaire chirurgicale par injection sous arachnoidienne lombaire de cocaïne; technique et résultats. Semaine Medicale 1900; 20:167. Semaine Medicale 1900. 20:167.*
18. Sicard, M., *Les injections médicamenteuses extradurales par voie sacrococcygienne. Comptes Rendus des Séances de la Société de Biologie et de ses Filiales 1901. 53:396-398.*
19. Pasquier, N. and D. Leri, *Injection intra-et extradurales de cocaïne à dose minimale dans le traitement de la sciatique. Bull Gen Ther, 1901. 142:196.*
20. von Gaza, W., *Die Resektion der paravertebralen Nerven und die isolierte Durchschneidung des Ramus communicans. Arch Klin Chir, 1924. 133:479.*
21. White, J., *Diagnostic novocaine block of the sensory and sympathetic nerves. A method of estimating the results which can be obtained by their permanent interruption. Am J Surg, 1930. 9:264.*
22. Steindler, A., J. Luck, and *Differential diagnosis of pain in the low back: Allocation of the source of the pain by the procaine hydrochloride method. JAMA, 1938. 110:106-113.*
23. Bogduk, N., *The clinical anatomy of the cervical dorsal rami. Spine (Phila Pa 1976), 1982. 7(4): p. 319-30.*
24. Bogduk, N., A.S. Wilson, and W. Tynan, *The human lumbar dorsal rami. J Anat, 1982. 134(Pt 2): p. 383-97.*
25. Bogduk, N., *The innervation of the lumbar spine. Spine (Phila Pa 1976), 1983. 8(3): p. 286-93.*
26. Hogan, Q.H. and S.E. Abram, *Neural blockade for diagnosis and prognosis. A review. Anesthesiology, 1997. 86(1): p. 216-41.*
27. Merskey H, B.N., *Classification of chronic pain. IASP Press, 1994.*
28. Engel, G.L., *The need for a new medical model: a challenge for biomedicine. Science, 1977. 196(4286): p. 129-36.*
29. Deyo, R.A., et al., *Overtreating chronic back pain: time to back off? J Am Board Fam Med, 2009. 22(1): p. 62-8.*
30. Gatchel, R.J. and D.C. Turk, *Criticisms of the biopsychosocial model in spine care: creating and then attacking a straw person. Spine (Phila Pa 1976), 2008. 33(25): p. 2831-6.*
31. Bogduk, N., *Clinical Anatomy of Lumbar Spine and Sacrum. 4th ed 2005, New York: Churchill Livingstone.*
32. Kastler, A., et al., *CT-guided stellate ganglion blockade vs. radiofrequency neurolysis in the management of refractory type I complex regional pain syndrome of the upper limb. European radiology, 2013. 23(5): p. 1316-22.*
33. McLure, H.A. and A.P. Rubin, *Review of local anaesthetic agents. Minerva Anesthesiol, 2005. 71(3): p. 59-74.*
34. Courtney, K.R., *Mechanism of frequency-dependent inhibition of sodium currents in frog myelinated nerve by the lidocaine derivative GEA. J Pharmacol Exp Ther, 1975. 195(2): p. 225-36.*
35. Knudsen, K., et al., *Central nervous and cardiovascular effects of i.v. infusions of ropivacaine, bupivacaine and placebo in volunteers. Br J Anaesth, 1997. 78(5): p. 507-14.*
36. Dony, P., et al., *The comparative toxicity of ropivacaine and bupivacaine at equipotent doses in rats. Anesth Analg, 2000. 91(6): p. 1489-92.*

37. McAlvin, J.B., et al., *Local toxicity from local anesthetic polymeric microparticles*. *Anesth Analg*, 2013. **116**(4): p. 794-803.
38. Rosenberg, P.H., B.T. Veering, and W.F. Urmey, *Maximum recommended doses of local anesthetics: a multifactorial concept*. *Reg Anesth Pain Med*, 2004. **29**(6): p. 564-75; discussion 524.
39. J, M. *Toxicité des anesthésiques locaux*. 2001.
40. Eledjam, J.J., et al., *Ropivacaine overdose and systemic toxicity*. *Anaesth Intensive Care*, 2000. **28**(6): p. 705-7.
41. Gadsden, J., et al., *The effect of mixing 1.5% mepivacaine and 0.5% bupivacaine on duration of analgesia and latency of block onset in ultrasound-guided interscalene block*. *Anesth Analg*, 2011. **112**(2): p. 471-6.
42. Roberman, D., et al., *Combined versus sequential injection of mepivacaine and ropivacaine for supraclavicular nerve blocks*. *Reg Anesth Pain Med*, 2011. **36**(2): p. 145-50.
43. Cuvillon, P., et al., *A comparison of the pharmacodynamics and pharmacokinetics of bupivacaine, ropivacaine (with epinephrine) and their equal volume mixtures with lidocaine used for femoral and sciatic nerve blocks: a double-blind randomized study*. *Anesth Analg*, 2009. **108**(2): p. 641-9.
44. Laur, J.J., et al., *Triple-blind randomized clinical trial of time until sensory change using 1.5% mepivacaine with epinephrine, 0.5% bupivacaine, or an equal mixture of both for infraclavicular block*. *Reg Anesth Pain Med*, 2012. **37**(1): p. 28-33.
45. Kytta, J., et al., *Cardiovascular and central nervous system effects of co-administered lidocaine and bupivacaine in piglets*. *Reg Anesth*, 1991. **16**(2): p. 89-94.
46. Mets, B., et al., *Lidocaine and bupivacaine cardiorespiratory toxicity is additive: a study in rats*. *Anesth Analg*, 1992. **75**(4): p. 611-4.
47. Furusawa, N., et al., *Herniation of cervical intervertebral disc: immunohistochemical examination and measurement of nitric oxide production*. *Spine (Phila Pa 1976)*, 2001. **26**(10): p. 1110-6.
48. Saal, J.S., *The role of inflammation in lumbar pain*. *Spine (Phila Pa 1976)*, 1995. **20**(16): p. 1821-7.
49. Petho, G. and P.W. Reeh, *Sensory and signaling mechanisms of bradykinin, eicosanoids, platelet-activating factor, and nitric oxide in peripheral nociceptors*. *Physiol Rev*, 2012. **92**(4): p. 1699-775.
50. Devor, M., R. Govrin-Lippmann, and P. Raber, *Corticosteroids suppress ectopic neural discharge originating in experimental neuromas*. *Pain*, 1985. **22**(2): p. 127-37.
51. Johansson, A., J. Hao, and B. Sjolund, *Local corticosteroid application blocks transmission in normal nociceptive C-fibres*. *Acta Anaesthesiol Scand*, 1990. **34**(5): p. 335-8.
52. Houten, J.K. and T.J. Errico, *Paraplegia after lumbosacral nerve root block: report of three cases*. *Spine J*, 2002. **2**(1): p. 70-5.

53. Huston, C.W., C.W. Slipman, and C. Garvin, *Complications and side effects of cervical and lumbosacral selective nerve root injections*. Arch Phys Med Rehabil, 2005. **86**(2): p. 277-83.
54. Hall, J.J., et al., *Iatrogenic Cushing syndrome after intra-articular triamcinolone in a patient receiving ritonavir-boosted darunavir*. Int J STD AIDS, 2013. **24**(9): p. 748-52.
55. Wybier, M., et al., *Paraplegia complicating selective steroid injections of the lumbar spine. Report of five cases and review of the literature*. European radiology, 2010. **20**(1): p. 181-9.
56. Benzon, H.T., et al., *Comparison of the particle sizes of different steroids and the effect of dilution: a review of the relative neurotoxicities of the steroids*. Anesthesiology, 2007. **106**(2): p. 331-8.
57. Derby, R., et al., *Size and aggregation of corticosteroids used for epidural injections*. Pain Med, 2008. **9**(2): p. 227-34.
58. Lee, J.W., et al., *Cervical transforaminal epidural steroid injection for the management of cervical radiculopathy: a comparative study of particulate versus non-particulate steroids*. Skeletal radiology, 2009. **38**(11): p. 1077-82.
59. Aaffsaps, *Risque de paraplégie/tétraplégie lié aux injections radioguidées de glucocorticoïdes au rachis lombaire ou cervical*, 2011 Update.
60. Jain, S. and R. Gupta, *Neural blockade with neurolytic agents in textbook of Pain management*. 1st ed, ed. Waldman2007, Philadelphia: Elsevier.
61. Cosman, E.R., et al., *Radiofrequency lesion generation and its effect on tissue impedance*. Appl Neurophysiol, 1988. **51**(2-5): p. 230-42.
62. Organ, L.W., *Electrophysiologic principles of radiofrequency lesion making*. Appl Neurophysiol, 1976. **39**(2): p. 69-76.
63. Bogduk, N., J. Macintosh, and A. Marsland, *Technical limitations to the efficacy of radiofrequency neurotomy for spinal pain*. Neurosurgery, 1987. **20**(4): p. 529-35.
64. Dreyfuss, P., et al., *Efficacy and validity of radiofrequency neurotomy for chronic lumbar zygapophysial joint pain*. Spine (Phila Pa 1976), 2000. **25**(10): p. 1270-7.
65. Cosman, E.R., B.S. Nashold, and J. Ovelman-Levitt, *Theoretical aspects of radiofrequency lesions in the dorsal root entry zone*. Neurosurgery, 1984. **15**(6): p. 945-50.
66. Kastler, A., et al., *Microwave thermal ablation of spinal metastatic bone tumors*. Journal of vascular and interventional radiology : JVIR, 2014. **25**(9): p. 1470-5.
67. Trescot, A.M., *Cryoanalgesia in interventional pain management*. Pain Physician, 2003. **6**(3): p. 345-60.
68. Evans, P.J., J.W. Lloyd, and T.M. Jack, *Cryoanalgesia for intractable perineal pain*. Journal of the Royal Society of Medicine, 1981. **74**(11): p. 804-9.
69. Manchikanti, L., et al., *Comprehensive evidence-based guidelines for interventional techniques in the management of chronic spinal pain*. Pain Physician, 2009. **12**(4): p. 699-802.

70. Schultz, D., *Fluoroscopy in the Interventional Pain Unit in, Interventional Techniques in Chronic Spinal Pain, L Manchikanti, V Singh* Vol. 1. 2007, Paducah, KY, USA.
71. Manchikanti, L., *Medicare in interventional pain management: A critical analysis*. Pain Physician, 2006. **9**(3): p. 171-97.
72. Stojanovic, M.P., et al., *The role of fluoroscopy in cervical epidural steroid injections: an analysis of contrast dispersal patterns*. Spine, 2002. **27**(5): p. 509-14.
73. Goel, A. and J.J. Pollan, *Contrast flow characteristics in the cervical epidural space: an analysis of cervical epidurograms*. Spine, 2006. **31**(14): p. 1576-9.
74. Furman, M.B., M.T. Giovanniello, and E.M. O'Brien, *Incidence of intravascular penetration in transforaminal cervical epidural steroid injections*. Spine, 2003. **28**(1): p. 21-5.
75. Furman, M.B., E.M. O'Brien, and T.M. Zgleszewski, *Incidence of intravascular penetration in transforaminal lumbosacral epidural steroid injections*. Spine, 2000. **25**(20): p. 2628-32.
76. Manchikanti, L., et al., *Risk of whole body radiation exposure and protective measures in fluoroscopically guided interventional techniques: a prospective evaluation*. BMC anesthesiology, 2003. **3**(1): p. 2.
77. Botwin, K.P., et al., *Radiation exposure to the spinal interventionalist performing lumbar discography*. Pain Physician, 2003. **6**(3): p. 295-300.
78. Botwin, K.P., et al., *Radiation exposure of the spinal interventionalist performing fluoroscopically guided lumbar transforaminal epidural steroid injections*. Archives of physical medicine and rehabilitation, 2002. **83**(5): p. 697-701.
79. Fishman, S.M., et al., *Radiation safety in pain medicine*. Regional anesthesia and pain medicine, 2002. **27**(3): p. 296-305.
80. Daly, M.J., et al., *Intraoperative cone-beam CT for guidance of head and neck surgery: Assessment of dose and image quality using a C-arm prototype*. Medical physics, 2006. **33**(10): p. 3767-80.
81. Verlaan, J.J., et al., *Three-dimensional rotational X-ray imaging for spine surgery: a quantitative validation study comparing reconstructed images with corresponding anatomical sections*. Spine, 2005. **30**(5): p. 556-61.
82. Benndorf, G., et al., *Angiographic CT in cerebrovascular stenting*. AJNR. American journal of neuroradiology, 2005. **26**(7): p. 1813-8.
83. Orth, R.C., M.J. Wallace, and M.D. Kuo, *C-arm cone-beam CT: general principles and technical considerations for use in interventional radiology*. Journal of vascular and interventional radiology : JVIR, 2008. **19**(6): p. 814-20.
84. Hopkins, P.M., *Ultrasound guidance as a gold standard in regional anaesthesia*. British journal of anaesthesia, 2007. **98**(3): p. 299-301.
85. Narouze, S., *Ultrasonography in pain medicine: a sneak peak at the future*. Pain practice : the official journal of World Institute of Pain, 2008. **8**(4): p. 223-5.
86. Narouze, S., *Atlas of ultrasound guided procedures in interventional pain management*. 2nd ed 2012, New York, NY: Springer.
87. Peng, P.W. and S. Narouze, *Ultrasound-guided interventional procedures in pain medicine: a review of anatomy, sonoanatomy, and procedures: part I:*

- nonaxial structures*. Regional anesthesia and pain medicine, 2009. **34**(5): p. 458-74.
88. Haaga, J.R., *Interventional CT: 30 years' experience*. European radiology, 2005. **15 Suppl 4**: p. D116-20.
 89. B KASTLER, C.C., D MICHALAKIS. , *Interventional procedures under CT guidance in 756 patients, incidents, side effects and how to reduce their incidence*, in RSNA2002, Radiology: Chicago.
 90. Meleka, S., et al., *Value of CT fluoroscopy for lumbar facet blocks*. AJNR. American journal of neuroradiology, 2005. **26**(5): p. 1001-3.
 91. Sheafor, D.H., et al., *Comparison of sonographic and CT guidance techniques: does CT fluoroscopy decrease procedure time?* AJR. American journal of roentgenology, 2000. **174**(4): p. 939-42.
 92. Paulson, E.K., et al., *CT fluoroscopy--guided interventional procedures: techniques and radiation dose to radiologists*. Radiology, 2001. **220**(1): p. 161-7.
 93. Fritz, J. and P.L. Pereira, *[MR-Guided pain therapy: principles and clinical applications]*. RoFo : Fortschritte auf dem Gebiete der Rontgenstrahlen und der Nuklearmedizin, 2007. **179**(9): p. 914-24.
 94. Fritz, J., et al., *Freehand real-time MRI-guided lumbar spinal injection procedures at 1.5 T: feasibility, accuracy, and safety*. AJR. American journal of roentgenology, 2009. **192**(4): p. W161-7.
 95. Fritz, J., et al., *Real-time MR fluoroscopy-navigated lumbar facet joint injections: feasibility and technical properties*. European radiology, 2008. **18**(7): p. 1513-8.
 96. Randhawa, K., et al., *Sonographic assessment of the conventional 'blind' ilioinguinal block*. Canadian journal of anaesthesia = Journal canadien d'anesthésie, 2010. **57**(1): p. 94-5.
 97. Gofeld, M. and M. Christakis, *Sonographically guided ilioinguinal nerve block*. J Ultrasound Med, 2006. **25**(12): p. 1571-5.
 98. Manchikanti, L., et al., *Effectiveness of therapeutic lumbar transforaminal epidural steroid injections in managing lumbar spinal pain*. Pain Physician, 2012. **15**(3): p. E199-245.
 99. Parr, A.T., et al., *Caudal epidural injections in the management of chronic low back pain: a systematic appraisal of the literature*. Pain Physician, 2012. **15**(3): p. E159-98.
 100. Manchikanti, L., et al., *An update of comprehensive evidence-based guidelines for interventional techniques in chronic spinal pain. Part II: guidance and recommendations*. Pain Physician, 2013. **16**(2 Suppl): p. S49-283.
 101. Benyamin, R.M., et al., *A systematic evaluation of thoracic interlaminar epidural injections*. Pain Physician, 2012. **15**(4): p. E497-514.
 102. Manchikanti, K.N., et al., *An update of evaluation of therapeutic thoracic facet joint interventions*. Pain Physician, 2012. **15**(4): p. E463-81.
 103. Engel, A.J., *Utility of intercostal nerve conventional thermal radiofrequency ablations in the injured worker after blunt trauma*. Pain Physician, 2012. **15**(5): p. E711-8.
 104. Wazieres, B.D., et al., *[Percutaneous thoracic sympathectomy under x-ray computed tomographic control in hyperhidrosis and refractory ischemia*.

- Apropos of 17 cases*]. *Annales de medecine interne*, 1996. **147**(5): p. 299-303.
105. Vanelderren, P., et al., *8. Occipital neuralgia*. *Pain practice : the official journal of World Institute of Pain*, 2010. **10**(2): p. 137-44.
 106. Vanelderren, P., et al., *Pulsed radiofrequency for the treatment of occipital neuralgia: a prospective study with 6 months of follow-up*. *Regional anesthesia and pain medicine*, 2010. **35**(2): p. 148-51.
 107. Slavin, K.V., et al., *Trigeminal and occipital peripheral nerve stimulation for craniofacial pain: a single-institution experience and review of the literature*. *Neurosurgical focus*, 2006. **21**(6): p. E5.
 108. Afridi, S.K., et al., *Greater occipital nerve injection in primary headache syndromes--prolonged effects from a single injection*. *Pain*, 2006. **122**(1-2): p. 126-9.
 109. Jurgens, T.P., et al., *Occipital nerve block is effective in craniofacial neuralgias but not in idiopathic persistent facial pain*. *The journal of headache and pain*, 2012. **13**(3): p. 199-213.
 110. Goadsby, P.J., *Pathophysiology of cluster headache: a trigeminal autonomic cephalgia*. *Lancet Neurol*, 2002. **1**(4): p. 251-7.
 111. Sanders, M. and W.W. Zuurmond, *Efficacy of sphenopalatine ganglion blockade in 66 patients suffering from cluster headache: a 12- to 70-month follow-up evaluation*. *J Neurosurg*, 1997. **87**(6): p. 876-80.
 112. Narouze, S., et al., *Sphenopalatine ganglion radiofrequency ablation for the management of chronic cluster headache*. *Headache*, 2009. **49**(4): p. 571-7.
 113. Ansarinia, M., et al., *Electrical stimulation of sphenopalatine ganglion for acute treatment of cluster headaches*. *Headache*, 2010. **50**(7): p. 1164-74.
 114. Cheng, J.S., et al., *A review of percutaneous treatments for trigeminal neuralgia*. *Neurosurgery*, 2014. **10 Suppl 1**: p. 25-33; discussion 33.
 115. Albazaz, R., Y.T. Wong, and S. Homer-Vanniasinkam, *Complex regional pain syndrome: a review*. *Ann Vasc Surg*, 2008. **22**(2): p. 297-306.
 116. Cepeda, M.S., D.B. Carr, and J. Lau, *Local anesthetic sympathetic blockade for complex regional pain syndrome*. *Cochrane Database Syst Rev*, 2005(4): p. CD004598.
 117. Forouzanfar, T., M. van Kleef, and W.E. Weber, *Radiofrequency lesions of the stellate ganglion in chronic pain syndromes: retrospective analysis of clinical efficacy in 86 patients*. *Clin J Pain*, 2000. **16**(2): p. 164-8.
 118. Van Zundert, J., M.A. Huntoon, and M. van Kleef, *Complications of transforaminal cervical epidural steroid injections*. *Spine*, 2009. **34**(22): p. 2477; author reply 2477-8.
 119. Manchikanti, L., et al., *Epidural steroid warning controversy still dogging FDA*. *Pain Physician*, 2014. **17**(4): p. E451-74.
 120. Manchikanti, L., et al., *Cervical radicular pain: the role of interlaminar and transforaminal epidural injections*. *Current pain and headache reports*, 2014. **18**(1): p. 389.
 121. Wolter, T., et al., *Cervical CT-guided, selective nerve root blocks: improved safety by dorsal approach*. *AJNR. American journal of neuroradiology*, 2009. **30**(2): p. 336-7.

122. Kelekis, A., et al., *Fluoroscopically guided infiltration of the cervical nerve root: an indirect approach through the ipsilateral facet joint*. Pain Physician, 2014. **17**(4): p. 291-6.
123. Falco, F.J., et al., *Systematic review of the therapeutic effectiveness of cervical facet joint interventions: an update*. Pain Physician, 2012. **15**(6): p. E839-68.
124. Mathias, S.D., et al., *Chronic pelvic pain: prevalence, health-related quality of life, and economic correlates*. Obstet Gynecol, 1996. **87**(3): p. 321-7.
125. O'Dwyer, P.J., A. Alani, and A. McConnachie, *Groin hernia repair: postherniorrhaphy pain*. World J Surg, 2005. **29**(8): p. 1062-5.
126. Hindmarsh, A.C., et al., *Attendance at a pain clinic with severe chronic pain after open and laparoscopic inguinal hernia repairs*. Br J Surg, 2003. **90**(9): p. 1152-4.
127. Poobalan, A.S., et al., *Chronic pain and quality of life following open inguinal hernia repair*. Br J Surg, 2001. **88**(8): p. 1122-6.
128. Kalliomaki, M.L., et al., *Long-term pain after inguinal hernia repair in a population-based cohort; risk factors and interference with daily activities*. Eur J Pain, 2008. **12**(2): p. 214-25.
129. Aasvang, E. and H. Kehlet, *Chronic postoperative pain: the case of inguinal herniorrhaphy*. Br J Anaesth, 2005. **95**(1): p. 69-76.
130. Bohrer, J.C., et al., *Pelvic nerve injury following gynecologic surgery: a prospective cohort study*. Am J Obstet Gynecol, 2009. **201**(5): p. 531 e1-7.
131. Baron, R., A. Binder, and G. Wasner, *Neuropathic pain: diagnosis, pathophysiological mechanisms, and treatment*. Lancet Neurol, 2010. **9**(8): p. 807-19.
132. Paicius, R.M., C.A. Bernstein, and C. Lempert-Cohen, *Peripheral nerve field stimulation in chronic abdominal pain*. Pain Physician, 2006. **9**(3): p. 261-6.
133. Alo, K.M. and J. Holsheimer, *New trends in neuromodulation for the management of neuropathic pain*. Neurosurgery, 2002. **50**(4): p. 690-703; discussion 703-4.
134. Ravichandran, D., B.G. Kalambe, and J.A. Pain, *Pilot randomized controlled study of preservation or division of ilioinguinal nerve in open mesh repair of inguinal hernia*. Br J Surg, 2000. **87**(9): p. 1166-7.
135. Picchio, M., et al., *Randomized controlled trial of preservation or elective division of ilioinguinal nerve on open inguinal hernia repair with polypropylene mesh*. Arch Surg, 2004. **139**(7): p. 755-8; discussion 759.
136. Bartlett, D.C., C. Porter, and A.N. Kingsnorth, *A pragmatic approach to cutaneous nerve division during open inguinal hernia repair*. Hernia, 2007. **11**(3): p. 243-6.
137. Heise, C.P. and J.R. Starling, *Mesh inguinodynia: a new clinical syndrome after inguinal herniorrhaphy?* J Am Coll Surg, 1998. **187**(5): p. 514-8.
138. Collins, S.L., R.A. Moore, and H.J. McQuay, *The visual analogue pain intensity scale: what is moderate pain in millimetres?* Pain, 1997. **72**(1-2): p. 95-7.
139. Randhawa, K., et al., *Sonographic assessment of the conventional 'blind' ilioinguinal block*. Can J Anaesth, 2010. **57**(1): p. 94-5.

140. van Schoor, A.N., et al., *Anatomical considerations of the pediatric ilioinguinal/iliohypogastric nerve block*. Paediatr Anaesth, 2005. **15**(5): p. 371-7.
141. Jankovic, D., *Regional Nerve Blocks and Infiltration Therapy*. 3rd ed 2004, Berlin: ABW Wissenschaftsverlag.
142. Campos, N.A., J.H. Chiles, and A.R. Plunkett, *Ultrasound-guided cryoablation of genitofemoral nerve for chronic inguinal pain*. Pain Physician, 2009. **12**(6): p. 997-1000.
143. Dittrick, G.W., et al., *Routine ilioinguinal nerve excision in inguinal hernia repairs*. Am J Surg, 2004. **188**(6): p. 736-40.
144. Mui, W.L., et al., *Prophylactic ilioinguinal neurectomy in open inguinal hernia repair: a double-blind randomized controlled trial*. Ann Surg, 2006. **244**(1): p. 27-33.
145. Malekpour, F., et al., *Ilioinguinal nerve excision in open mesh repair of inguinal hernia--results of a randomized clinical trial: simple solution for a difficult problem?* Am J Surg, 2008. **195**(6): p. 735-40.
146. Vuilleumier, H., M. Hubner, and N. Demartines, *Neuropathy after herniorrhaphy: indication for surgical treatment and outcome*. World J Surg, 2009. **33**(4): p. 841-5.
147. Mandelkow, H. and H. Loeweneck, *The iliohypogastric and ilioinguinal nerves. Distribution in the abdominal wall, danger areas in surgical incisions in the inguinal and pubic regions and reflected visceral pain in their dermatomes*. Surg Radiol Anat, 1988. **10**(2): p. 145-9.
148. al-dabbagh, A.K., *Anatomical variations of the inguinal nerves and risks of injury in 110 hernia repairs*. Surg Radiol Anat, 2002. **24**(2): p. 102-7.
149. Rab, M., Ebmer, and A.L. Dellon, *Anatomic variability of the ilioinguinal and genitofemoral nerve: implications for the treatment of groin pain*. Plast Reconstr Surg, 2001. **108**(6): p. 1618-23.
150. Saberski LR, T.A., Klein DS, , *Interventional Pain management*, ed. W.S. Co.1994, Philadelphia. 228.
151. Jansen, J.A., et al., *Treatment of longstanding groin pain in athletes: a systematic review*. Scand J Med Sci Sports, 2008. **18**(3): p. 263-74.
152. Brown, R.A., et al., *An 18-year review of sports groin injuries in the elite hockey player: clinical presentation, new diagnostic imaging, treatment, and results*. Clin J Sport Med, 2008. **18**(3): p. 221-6.
153. Mitra, R., A. Zeighami, and S. Mackey, *Pulsed radiofrequency for the treatment of chronic ilioinguinal neuropathy*. Hernia, 2007. **11**(4): p. 369-71.
154. Rozen, D. and J. Ahn, *Pulsed radiofrequency for the treatment of ilioinguinal neuralgia after inguinal herniorrhaphy*. Mt Sinai J Med, 2006. **73**(4): p. 716-8.
155. Palumbo, P., et al., *Treatment for persistent chronic neuralgia after inguinal hernioplasty*. Hernia, 2007. **11**(6): p. 527-31.
156. Roberts, W.J., *A hypothesis on the physiological basis for causalgia and related pains*. Pain, 1986. **24**(3): p. 297-311.
157. Quisel, A., J.M. Gill, and P. Witherell, *Complex regional pain syndrome: which treatments show promise?* J Fam Pract, 2005. **54**(7): p. 599-603.
158. Yucel, I., et al., *Complex regional pain syndrome type I: efficacy of stellate ganglion blockade*. J Orthop Traumatol, 2009. **10**(4): p. 179-83.

159. Nascimento, M.S., J.G. Klamt, and W.A. Prado, *Intravenous regional block is similar to sympathetic ganglion block for pain management in patients with complex regional pain syndrome type I*. Braz J Med Biol Res, 2010. **43**(12): p. 1239-44.
160. Kastler, A., et al., *Radiofrequency neurolysis in the management of inguinal neuralgia: preliminary study*. Radiology, 2012. **262**(2): p. 701-7.
161. Chua, N.H., K.C. Vissers, and M.E. Sluifster, *Pulsed radiofrequency treatment in interventional pain management: mechanisms and potential indications-a review*. Acta Neurochir (Wien), 2011. **153**(4): p. 763-71.
162. Ellis H, F.S., *Anatomy for the Anaesthetists*. 3 ed 1979, Oxford: Blackwell Scientific Publications.
163. Hogan, Q.H. and S.J. Erickson, *MR imaging of the stellate ganglion: normal appearance*. AJR Am J Roentgenol, 1992. **158**(3): p. 655-9.
164. Wang, J.K., K.A. Johnson, and D.M. Ilstrup, *Sympathetic blocks for reflex sympathetic dystrophy*. Pain, 1985. **23**(1): p. 13-7.
165. Ackerman, W.E. and J.M. Zhang, *Efficacy of stellate ganglion blockade for the management of type 1 complex regional pain syndrome*. South Med J, 2006. **99**(10): p. 1084-8.
166. Schurmann, M., et al., *Clinical and physiologic evaluation of stellate ganglion blockade for complex regional pain syndrome type I*. Clin J Pain, 2001. **17**(1): p. 94-100.
167. Higa, K., et al., *Retropharyngeal hematoma after stellate ganglion block: Analysis of 27 patients reported in the literature*. Anesthesiology, 2006. **105**(6): p. 1238-45; discussion 5A-6A.
168. Chaturvedi, A. and H. Dash, *Locked-in syndrome during stellate ganglion block*. Indian J Anaesth, 2010. **54**(4): p. 324-6.
169. Carron, H. and R. Litwiller, *Stellate ganglion block*. Anesth Analg, 1975. **54**(5): p. 567-70.
170. Allen, G. and B. Samson, *Contralateral Horner's syndrome following stellate ganglion block*. Can Anaesth Soc J, 1986. **33**(1): p. 112-3.
171. Abdi, S., et al., *A new and easy technique to block the stellate ganglion*. Pain Physician, 2004. **7**(3): p. 327-31.
172. Elias, M., *Cervical sympathetic and stellate ganglion blocks*. Pain Physician, 2000. **3**(3): p. 294-304.
173. Moore, D.C. and L.D. Bridenbaugh, Jr., *The anterior approach to the stellate ganglion use without a serious complication in two thousand blocks*. J Am Med Assoc, 1956. **160**(3): p. 158-62.
174. Hogan, Q.H., et al., *The spread of solutions during stellate ganglion block*. Reg Anesth, 1992. **17**(2): p. 78-83.
175. Guntamukkala, M. and P.A. Hardy, *Spread of injectate after stellate ganglion block in man: an anatomical study*. Br J Anaesth, 1991. **66**(6): p. 643-4.
176. Geurts, J. and R. Stolker, *Percutaneous radiofrequency lesion of the stellate ganglion in the treatment of pain in upper extremity reflex sympathetic dystrophy*. Pain Clinic, 1993. **6**(1): p. 17-25.

177. Robert, R., et al., [*Anatomical study of the infratemporal fossa*]. Ann Otolaryngol Chir Cervicofac, 1991. **108**(2): p. 69-76.
178. Kim, H.S., D.I. Kim, and I.H. Chung, *High-resolution CT of the pterygopalatine fossa and its communications*. Neuroradiology, 1996. **38 Suppl 1**: p. S120-6.
179. Goadsby, P.J. and L. Edvinsson, *Human in vivo evidence for trigeminovascular activation in cluster headache. Neuropeptide changes and effects of acute attacks therapies*. Brain : a journal of neurology, 1994. **117 (Pt 3)**: p. 427-34.
180. Schytz, H.W., et al., *Experimental activation of the sphenopalatine ganglion provokes cluster-like attacks in humans*. Cephalalgia, 2013. **33**(10): p. 831-41.
181. Ruskin, S., *Contributions to the study of the phenopalatine ganglion*. The Laryngoscope, 1925(35): p. 87-108.
182. Prasanna, A. and P.S. Murthy, *Sphenopalatine ganglion block and pain of cancer*. J Pain Symptom Manage, 1993. **8**(3): p. 125.
183. Cepero, R., R.H. Miller, and K.L. Bressler, *Long-term results of sphenopalatine ganglionectomy for facial pain*. Am J Otolaryngol, 1987. **8**(3): p. 171-4.
184. Ferrante, F.M., et al., *Sphenopalatine ganglion block for the treatment of myofascial pain of the head, neck, and shoulders*. Reg Anesth Pain Med, 1998. **23**(1): p. 30-6.
185. Procacci, P., et al., *Cutaneous pain threshold changes after sympathetic block in reflex dystrophies*. Pain, 1975. **1**(2): p. 167-75.
186. Tepper, S.J. and M.J. Stillman, *Cluster headache: potential options for medically refractory patients (when all else fails)*. Headache, 2013. **53**(7): p. 1183-90.
187. Burstein, R. and M. Jakubowski, *Unitary hypothesis for multiple triggers of the pain and strain of migraine*. J Comp Neurol, 2005. **493**(1): p. 9-14.
188. Sluder, G., *The role of the sphenopalatine ganglion in nasal headache*. NY State J Med, 1908. **27**:8-13.
189. Ryan, R.E., *Symptomatic relief of migraine*. Ear Nose Throat J, 1977. **56**(5): p. 225-7.
190. Windsor, R.E. and S. Jahnke, *Sphenopalatine ganglion blockade: a review and proposed modification of the transnasal technique*. Pain physician, 2004. **7**(2): p. 283-6.
191. Sluder, G., *Etiology, diagnosis, prognosis, and treatment of sphenopalatine neuralgia*. JAMA, 1913. **61**: p. 1201-1216.
192. Yang I, Y. and S. Oraee, *A novel approach to transnasal sphenopalatine ganglion injection*. Pain physician, 2006. **9**(2): p. 131-4.
193. Felisati, G., et al., *Sphenopalatine endoscopic ganglion block: a revision of a traditional technique for cluster headache*. The Laryngoscope, 2006. **116**(8): p. 1447-50.
194. Meyer, J.S., et al., *Sphenopalatine ganglionectomy for cluster headache*. Arch Otolaryngol, 1970. **92**(5): p. 475-84.

195. Jarrar, R.G., et al., *Outcome of trigeminal nerve section in the treatment of chronic cluster headache*. Neurology, 2003. **60**(8): p. 1360-2.
196. Green, M.W., *Long-term follow-up of chronic cluster headache treated surgically with trigeminal tractotomy*. Headache, 2003. **43**(5): p. 479-81.
197. Schoenen, J., et al., *Stimulation of the sphenopalatine ganglion (SPG) for cluster headache treatment. Pathway CH-1: A randomized, sham-controlled study*. Cephalalgia, 2013. **33**(10): p. 816-30.
198. Leone, M., et al., *Hypothalamic stimulation for intractable cluster headache: long-term experience*. Neurology, 2006. **67**(1): p. 150-2.
199. Leone, M., A. Franzini, and G. Bussone, *Stereotactic stimulation of posterior hypothalamic gray matter in a patient with intractable cluster headache*. N Engl J Med, 2001. **345**(19): p. 1428-9.
200. Leone, M., et al., *Success, failure, and putative mechanisms in hypothalamic stimulation for drug-resistant chronic cluster headache*. Pain, 2013. **154**(1): p. 89-94.
201. Starr, P.A., et al., *Chronic stimulation of the posterior hypothalamic region for cluster headache: technique and 1-year results in four patients*. Journal of neurosurgery, 2007. **106**(6): p. 999-1005.
202. Varghese, B. and R. Koshy, *Endoscopic transnasal neurolytic sphenopalatine ganglion block for head and neck cancer pain*. Journal of Laryngology & Otology, 2001. **115**(05): p. 385-387.
203. *The International Classification of Headache Disorders: 2nd edition*. Cephalalgia, 2004. **24 Suppl 1**: p. 9-160.
204. Bogduk, N., *The anatomy of occipital neuralgia*. Clin Exp Neurol, 1981. **17**: p. 167-84.
205. Ehni, G. and B. Benner, *Occipital neuralgia and C1-C2 arthrosis*. N Engl J Med, 1984. **310**(2): p. 127.
206. Loukas, M., et al., *Identification of greater occipital nerve landmarks for the treatment of occipital neuralgia*. Folia Morphol (Warsz), 2006. **65**(4): p. 337-42.
207. Vital, J.M., et al., *An anatomic and dynamic study of the greater occipital nerve (n. of Arnold). Applications to the treatment of Arnold's neuralgia*. Surg Radiol Anat, 1989. **11**(3): p. 205-10.
208. Evans, R.W., *Peripheral nerve blocks and trigger point injections in headache management: trigeminal neuralgia does not respond to occipital nerve block*. Headache, 2010. **50**(7): p. 1215-6; author reply 1216.
209. Pougard-Bellec, F., et al., *[Efficacy of C1-C2 block with posterior parasagittal approach in the treatment of Arnold neuralgia in 24 patients]*. J Radiol, 2002. **83**(2 Pt 1): p. 133-9.
210. Goldberg, M.E., et al., *Deep cervical plexus block for the treatment of cervicogenic headache*. Pain Physician, 2008. **11**(6): p. 849-54.
211. Aubry, S., et al., *Evaluation of the effectiveness of CT-guided infiltration in the treatment of Arnold's neuralgia*. Neuroradiology, 2009. **51**(3): p. 163-8.
212. Tobin, J. and S. Flitman, *Occipital nerve blocks: when and what to inject?* Headache, 2009. **49**(10): p. 1521-33.

213. Tobin, J.A. and S.S. Flitman, *Occipital nerve blocks: effect of symptomatic medication: overuse and headache type on failure rate*. Headache, 2009. **49**(10): p. 1479-85.
214. Greher, M., et al., *Sonographic visualization and ultrasound-guided blockade of the greater occipital nerve: a comparison of two selective techniques confirmed by anatomical dissection*. Br J Anaesth, 2010. **104**(5): p. 637-42.
215. Eom, K.S. and T.Y. Kim, *Greater occipital nerve block by using transcranial Doppler ultrasonography*. Pain Physician, 2010. **13**(4): p. 395-6.
216. Okuda, Y., et al., *Use of an ultrasound doppler flowmeter for occipital nerve block*. Reg Anesth Pain Med, 2002. **27**(4): p. 444-5.
217. Naja, Z., et al., *Nerve stimulator-guided occipital nerve blockade for postdural puncture headache*. Pain Pract, 2009. **9**(1): p. 51-8.
218. Shim, J.H., et al., *Ultrasound-guided greater occipital nerve block for patients with occipital headache and short term follow up*. Korean J Anesthesiol, 2011. **61**(1): p. 50-4.
219. Vanderhoek, M.D., H.T. Hoang, and B. Goff, *Ultrasound-guided greater occipital nerve blocks and pulsed radiofrequency ablation for diagnosis and treatment of occipital neuralgia*. Anesth Pain Med, 2013. **3**(2): p. 256-9.
220. Hamer, J.F. and T.A. Purath, *Response of Cervicogenic Headaches and Occipital Neuralgia to Radiofrequency Ablation of the C2 Dorsal Root Ganglion and/or Third Occipital Nerve*. Headache, 2014.
221. Choi, H.J., et al., *Clinical outcomes of pulsed radiofrequency neuromodulation for the treatment of occipital neuralgia*. J Korean Neurosurg Soc, 2012. **51**(5): p. 281-5.
222. Vanelderen, P., et al., *Pulsed radiofrequency for the treatment of occipital neuralgia: a prospective study with 6 months of follow-up*. Reg Anesth Pain Med, 2010. **35**(2): p. 148-51.
223. Navani, A., et al., *A case of pulsed radiofrequency lesioning for occipital neuralgia*. Pain Med, 2006. **7**(5): p. 453-6.
224. Clarencon, F., et al., *Value of percutaneous radiofrequency ablation with or without percutaneous vertebroplasty for pain relief and functional recovery in painful bone metastases*. Skeletal radiology, 2011.
225. Jeong, W.K., et al., *Radiofrequency ablation of benign thyroid nodules: safety and imaging follow-up in 236 patients*. European radiology, 2008. **18**(6): p. 1244-50.
226. Kurup, A.N., et al., *Neuroanatomic considerations in percutaneous tumor ablation*. Radiographics : a review publication of the Radiological Society of North America, Inc, 2013. **33**(4): p. 1195-215.
227. Nakatsuka, A., et al., *Percutaneous radiofrequency ablation of painful spinal tumors adjacent to the spinal cord with real-time monitoring of spinal canal temperature: a prospective study*. Cardiovascular and interventional radiology, 2009. **32**(1): p. 70-5.
228. Kang, T.W., et al., *Radiofrequency ablation for hepatocellular carcinoma abutting the diaphragm: comparison of effects of thermal protection and therapeutic efficacy*. AJR. American journal of roentgenology, 2011. **196**(4): p. 907-13.

229. Moringlane, J.R., et al., *Experimental radiofrequency (RF) coagulation with computer-based on line monitoring of temperature and power*. Acta neurochirurgica, 1989. **96**(3-4): p. 126-31.
230. Cosman, E.R., B.S. Nashold, and P. Bedenbaugh, *Stereotactic radiofrequency lesion making*. Applied neurophysiology, 1983. **46**(1-4): p. 160-6.
231. Kastler, A., et al., *Alcohol percutaneous neurolysis of the sphenopalatine ganglion in the management of refractory cranio-facial pain*. Neuroradiology, 2014. **56**(7): p. 589-96.
232. Kastler, A., et al., *Radiofrequency neurolysis versus local nerve infiltration in 42 patients with refractory chronic inguinal neuralgia*. Pain Physician, 2012. **15**(3): p. 237-44.

XII - Résumé Français

I - Introduction

« *La douleur est un maître plus terrible que la mort.* » disait Albert Schweitzer, qui reçut le prix Nobel 1952. Cette phrase démontre que le Dr Schweitzer avait, en son temps, déjà identifié l'élément le plus important du concept de la douleur : sa nature 'horrible' à l'origine d'une terrible souffrance. Le concept de la douleur date de la nuit des temps, et la lutte acharnée des soignants afin d'essayer de l'amender, remonte aux origines de l'humanité. La définition de la douleur n'a cessé d'évoluer au cours du temps et des périodes, mais c'est dans la deuxième moitié du 20e siècle, avec la création et l'organisation d'une société savante (International Association for the study of Pain, IASP) dans les années 1970, qu'est née la définition aujourd'hui la plus utilisée '*la douleur est une expérience sensorielle et émotionnelle désagréable associée à une lésion tissulaire réelle ou potentielle ou décrite dans ces termes*'.

Les études concernant la douleur, ses étiologies et les traitements possibles foisonnent dans la littérature. La notion de douleur chronique est devenue une priorité de santé publique, principalement à cause du retentissement de ces douleurs chroniques sur la qualité de vie, mais surtout et également de l'impact socio-économique qui en découle. Dans l'arsenal thérapeutique à disposition des soignants, les procédures interventionnelles sont apparues au début du 19e siècle, avec la découverte des capacités neurolytiques/neurobloqueurs de certains agents comme la cocaïne ou l'alcool. L'essor des techniques Interventionnelles dans la prise en charge de la douleur a eu lieu dans les années 1980 avec la démocratisation à la fin du 20e et début du 21e siècle des méthodes de guidages radiologiques n'ont fait qu'accentuer le développement de ces techniques, avec pour but ultime "*aussi peu de douleur que possible*" (F.Nietzche). Les progrès dans le domaine de

L'Interventionnel Antidouleur ont été réalisés grâce à la contribution de diverses disciplines, incluant l'anesthésie, la radiologie, la chirurgie, la réadaptation, la psychiatrie, l'épidémiologie, les soins infirmiers, qui sont tous désormais désignés comme des spécialistes en médecine de la douleur. L'interventionnel douleur, bien que reconnu aux Etats Unis comme une spécialité à part entière, n'est pas encore reconnue comme tel en Europe, et les médecins Interventionnels douleurs sont éclatés dans plusieurs disciplines (radiologie, anesthésie, rhumatologie). Le rôle de l'Interventionnel Douleur est devenu au fil des années très important dans la prise en charge globale car il présente un double intérêt à la fois diagnostique et thérapeutique. Le succès des procédures interventionnelles dans la douleur au cours des deux dernières décennies ont fait du médecin de la douleur interventionnelle un acteur à part entière dans l'approche multidisciplinaire de la prise en charge de la douleur.

Au cours des 20 dernières années, l'utilisation de méthode de guidage par imagerie s'est progressivement démocratisée pour devenir aujourd'hui une pratique courante. Les méthodes de guidages les plus fréquemment utilisées sont la fluoroscopie et l'échographie pour leur accessibilité. Le guidage scannographique, est quant à lui, relativement sous utilisé dans le domaine de la douleur interventionnelle, principalement à cause du cout de l'équipement et de l'accès à ces machines réservé aux radiologues. Par conséquent, les objectifs de cette thèse sont multiples:

- * D'évaluer l'intérêt du scanner comme outils de guidage, dans le domaine de la radiologie interventionnelle.

- * D'utiliser le scanner comme méthode de guidage pour :

- appliquer des techniques neurolytiques existantes (bloc, infiltration et neurolyse) dans de nouvelles indications.

- utiliser l'apport de la précision du scanner pour modifier des techniques interventionnelles existantes, les rendant plus sûres pour les patients et de mettre au point des techniques nécessitant un guidage précis (alcoolisation)

* D'évaluer l'efficacité clinique de ces nouvelles indications/procédures

* Enfin, de souligner l'importance des aspects cliniques de la gestion de la douleur interventionnelle, afin de recentrer le patient (et non pas l'aspect technique) au centre de la prise en charge.

II - Description des différentes techniques et produits disponibles en interventionnel Antidouleur

A-Block Nerveux

Un bloc nerveux (blockade, Block test, Infiltration diagnostique) est pratiqué pour affirmer ou infirmer l'origine nerveuse d'une douleur. L'indication d'un block test n'est retenue que lorsque qu'un diagnostic est incertain avec persistance d'une douleur réfractaire à un traitement spécifique adapté. Le block nerveux est en général réalisé à l'aide d'anesthésiques locaux (AL), qui agissent principalement en bloquant le canal sodique responsable de la partie initiale du potentiel d'action. Les principaux risques rapportés sont liés aux activités neurotoxiques, cardiotoxiques et myotoxiques des AL. Les principaux AL utilisés sont :

- Lidocaine : Délai d'efficacité court (2-3 minutes) , durée d'action courte (90 minutes env.). AL le plus utilisé en sous cutané.

- Mepivacaine : Délai d'efficacité court (3- 5 minutes), durée d'efficacité (110 minutes env.)

- Bupivacaine : Délai d'efficacité plus long (10-15 minutes), durée d'efficacité plus longue (jusqu'à 12 heures), cardiotoxicité même à faible dose.

- Ropivacaine : délai d'efficacité moyenne (5-10 minutes), durée d'efficacité longue (jusqu'à 9 heures), moins cardiotoxique que la bupivacaine.

Dans toutes les procédures décrites dans cette thèse, une combinaison de Lidocaine et Ropivacaine a été utilisée, afin d'allier le délai d'efficacité court de Lidocaine avec la durée d'efficacité plus longue de la Ropivacaine.

B - Infiltration de Corticoïdes

L'utilisation de corticoïdes dans les douleurs d'origines nerveuses a été initialement décrite dans les douleurs radiculaires par conflit disco-radiculaire, en diminuant la part inflammatoire de la douleur via des récepteurs nucléaires, mais également par un effet direct sur la membrane neuronale. Les effets secondaires liées à l'injection de corticoïdes sont essentiellement due au geste lui même plus qu'au produit utilisé. Cependant, les risques généraux liés à la prise de corticoïde existent, surtout en cas d'injection répétées (hypocorticisme, syndrome de cushing ou ostéoporose). Il existe deux classes de corticoïdes injectables, soluble et insoluble :

- Insoluble : ou à particules
 - méthylprednisolone (DEPO-MEDROL)
 - triamcinolone (HEXATRIONE, KENACORT),
 - betaméthasone (CELESTENE, DIPROSTENE),
 - Corivazol (ALTIM)
 - Prednisolone (HYDROCORTANCYL)
- Soluble, sans particules :
 - Dexaméthasone (DETANCYL)

Compte tenu d'effets indésirables graves rapportés ces dix dernières années avec des corticoïdes à particules (ischémie médullaire, infarctus cérébelleux), de

nombreuses études ont analysé le comportement et la taille des particules de corticoïdes comparativement aux cellules sanguines et aux diamètre des artérioles. En France, l'HAS recommande l'utilisation de Cortivazol ou Prednisolone en cas d'injection péri rachidienne, la Prednisolone étant la seule ayant l'indication d'injection intra-thécale.

Le cortivazol sera donc le corticoïde de choix utilisé pour les injections dans nos différentes études compte tenu de sa durée d'action supérieure (6 semaines contre 2 pour la Prednisolone)

C - Neurolyses

*** Chimique**

1) Ethanol

Les effets neurolytiques de l'alcool éthylique sont bien connus au delà d'une concentration de 50%, mais des concentrations plus élevées d'alcool (95% à 100%) sont nécessaires pour une destruction permanente d'un nerf. L'alcool agit sur les neurones à travers l'extraction du cholestérol et des phospholipides. Le risque principal lié à l'injection d'alcool, est la diffusion incontrôlée de l'alcool à l'injection et donc il est nécessaire d'utiliser la quantité minimale efficace. Par ailleurs, le risque de névrite post alcoolisation est connu. L'injection tissulaire d'alcool provoque une douleur brève réduite cependant par une injection préalable d'anesthésiques locaux (Lidocaine et Ropivacaine).

2) Phénol

L'effet neurolytique du phénol est obtenu grâce à la dénaturation des protéines. La concentration utilisée varie de 3 à 15%. L'avantage du phénol par rapport à l'éthanol est l'absence de douleur induite à l'injection.

*Thermique

1) Radiofréquence

Le principe de la neurolyse par radiofréquence est basé sur l'application d'un courant électrique sinusoïdale au contact du nerf, qui va induire par agitation ionique, un échauffement par friction moléculaire, et la destruction des fibres nerveuses au delà d'une température donnée (env. 60°C). La mise en place d'une aiguille creuse et son guidage jusqu'au contact du nerf permet d'insérer en coaxial dans cette aiguille, une électrode. Les générateurs de RF comprennent un témoin de température à la pointe de l'aiguille ainsi qu'une fonction de stimulation, qui permet de vérifier le bon positionnement au contact du nerf, mais aussi de vérifier l'absence d'une structure nerveuse à proximité, notamment motrice.

2) Cryoneurolyse

De la même façon que l'on applique de la chaleur par RF pour détruire un nerf, l'application de froid permet d'obtenir la dénaturation des structures nerveuses. La diffusion du froid aux structures nerveuses se fait également au travers d'une aiguille, reliée à un système circulant fermé de gaz liquide (nitrogène) qui permet l'obtention d'une température très basse d'environ -60°C autour l'aiguille. Les générateurs sont également pourvus de fonctions de stimulation et de contrôle de température.

La cryoneurolyse serait moins exposée au risque de névrite post neurolyse, bien connu avec l'alcool, mais également décrite avec la RF.

III - Descriptif des techniques de guidage radiologique

A - Fluoroscopie

La fluoroscopie, basée sur les rayons X, est aujourd'hui probablement l'outil de guidage le plus utilisé pour les gestes interventionnels antidouleur. Les avantages de cet outil de guidage sont multiples : visualisation en tant réel possible, accès et disponibilité du matériel, bonne visualisation des structures osseuses. En revanche, il s'agit d'un équipement irradiant pour le patient et l'opérateur, basé sur des images RX en projection en deux plan. Les tissus mous avoisinant ne sont pas mieux visualisés qu'en radiologie standard..

B - Fluoroscopie rotationnelle.

Il s'agit de l'évolution de la fluoroscopie. Ce système est capable de réaliser une acquisition en coupe avec reconstruction multi planaire, par rotation de 360° autour du patient. Les avantages comparés à la fluoroscopie 2D classique sont évidents : capacité d'afficher des images en coupe et 3D, meilleure résolution, visualisation des tissus mou. En revanche, il s'agit d'un matériel couteux, peu disponible et irradiant pour le patient et l'opérateur.

C - Echographie

L'échographie comme outil de guidage s'est démocratisé ces dix dernières années avec le développement de l'anesthésie loco-régionale écho-guidée. L'avantage majeur de l'échographie comparée aux techniques basées sur les rayons X est l'absence d'irradiation. De plus, l'échographie offre une très bonne visualisation des tissus avoisinants, un guidage en tant réel et est très accessible. En revanche,

l'échographie est limitée en particulier pour les cibles situées derrière un écran osseux qui arrête les ultrasons. De mêmes pour les structures situées en profondeur sont plus difficiles d'accès. L'échographie est également limitée, en fonction de la morphologie du patient (poids-épaisseur). Enfin elle est opérateur dépendant.

D - Scanner

Le scanner est très largement utilisé par les radiologues comme outils de guidage pour réaliser divers gestes interventionnels (biopsie, drainage, thermoablation). En revanche son utilisation dans les indications antidouleur est moins fréquente. Pourtant, le scanner offre une précision de guidage très intéressante, une bonne résolution d'image, une bonne visualisation du tissu avoisinant et une possibilité de planifier précisément le trajet de l'aiguille avant le geste. En revanche, il s'agit d'une technique qui demeure irradiante pour le patient,, limitée par le plan d'acquisition (inclinaison maximale 10° par rapport au plan axial), et nécessitant dans certains cas l'injection d'iode pour une meilleure visualisation des structures vasculaires à éviter sur le passage des aiguille .

E- IRM

L'IRM en tant que modalité de guidage a été introduite ces dix dernières années avec l'apparition de matériel IRM-compatible. Les avantages de l'IRM, notamment face au scanners sont multiples : non irradiant, pas de limite dans le plan d'acquisition, guidage en tant réel possible (MR Fluoroscopie). En revanche, l'accès à la machine est limité, l'IRM est moins précise pour la visualisation de structures osseuse fines, et il semblerait que la courbe d'apprentissage soit plus longue

IV - Bref Descriptif des techniques interventionnelles antidouleur existantes

A- Tête et Cou

1) - Tête

Névrалgie Occipitale :

L'implication du Nerf Grand Occipital (n. d'Arnold) est connue dans les céphalées d'origine cervicale, notamment la névrалgie occipitale. L'infiltration de ce nerfs est reconnue comme étant une technique efficace. Pour l'heure, les sites d'infiltrations décrits sont soit en sous cutané dans la région occipitale à l'émergence du nerf, soit à son origine en C1-C2. ***L'infiltration au seul site intermédiaire sous scanner n'a jamais été rapporté .***

Ganglion Sphénopalatin. .

Le ganglion sphénopalatin est connu pour son implication dans certains syndromes douloureux de la face, notamment les algies vasculaires de la face, la névrалgie trigémínée ou les algies atypiques (persistent idiopathic facial pain). Les techniques décrites à ce jour avec des résultats satisfaisant incluent : bloc nerveux, neurolyse par radiofréquence ou stimulation électrique. ***La neurolyse par alcoolisation n'a jamais été rapportée auparavant***

Nerfs Trijumeaux et Ganglion de Gasser

L'atteinte du ganglion de Gasser ou d'une de ses branches peut entraîner des névrалgies rebelles, dont la plus fréquente est l'atteinte du V2. Les traitements percutanés disponibles à ce jour sont : blocks nerveux, compression par ballonnet, neurolyse au glycerol ou radiofréquence.

2-Cervical

Ganglion Stellaire:

Le ganglion stellaire est impliqué, de part sa composante sympathique, dans le syndrome douloureux régional complexe du membre supérieur. Les techniques interventionnelles visant ce ganglion situé entre C7 et T1, sont décrites soit par guidage échographique, soit fluoroscopique, et comprennent : le block nerveux ou la radiofréquence. ***L'apport du scanner dans cette indication n'a jamais été rapporté***

Névralgie cervico-brachiale et Cervicalgie:

Les données dans la littérature concernant l'efficacité des infiltrations au rachis cervical pour brachio-cervicalgie sont nombreuses. Cependant, avec la description d'évènements indésirables graves rapportées dans les 10 dernières années (infarctus médullaire, cérébelleux) l'intérêt et la sûreté de cette procédure fait débat. Il existe de multiples voies d'abord décrites (épidurale postérieure, interlaminaire, periradiculaire) et des indications multiples également (conflit disco-radiculaire, sténose canalaire, remaniements dégénératifs).

Syndrome facettaire postérieure :

L'atteinte articulaire postérieure constitue une entité clinique bien définie, et les modalités de traitement interventionnel tels que les Blocks/Infiltrations des branches médiales des articulations zygapophysiales postérieures ou la radiofréquence (rhizotomie) des articulaires postérieures sont reconnus. Dans les deux cas, la fluoroscopie constitue la méthode de guidage la plus décrite.

B - Etage Thoracique

Dorsalgie Chronique :

La douleur dorsale chronique, bien que moins fréquente qu'aux étages lombaire ou cervicale, implique les mêmes structures anatomiques et donc les mêmes procédures: Infiltration épidurale ou peri-foraminale et Infiltration/Rhizotomie articulaire postérieure pour Syndrome Facettaire postérieure

Block/RF Intercostal : L'infiltration d'un nerf intercostal par voie sous costale est en général réalisée dans les indications suivantes : douleur post traumatique, post opératoire, névralgie post herpétique

Sympatholyse thoracique

Un geste interventionnel peut être réalisé sur la chaîne sympathique thoracique, située à la partie ventrale des corps vertébraux : la sympatholyse peut être réalisée par alcoolisation ou radiofréquence, dans les troubles vasomoteurs des membres supérieures, les hyperhidroses palmaires. L'apport du scanner dans ces indications est connu.

C - Etage Lombaire

Douleurs lombaires

Les douleurs lombaires ont les mêmes origines qu'aux étages dorsal et cervical (Discal, sténose, dégénératif, facettaire postérieur; post-opératoire). Les techniques interventionnelles sont les mêmes que décrites précédemment :

Infiltration épidurale/periforaminale

Infiltration/Rhizotomie articulaire postérieure

Block/Neurolyse Sympathique Lombaire: Comme à l'étage thoracique, la chaîne ganglionnaire sympathique pré vertébrale peut être la cible de neurolyse essentiellement dans les troubles trophiques et hyperhidroses aux membres inférieures.

D - Douleurs Abdominale et Pelvienne :

Neurolyse du plexus Cœliaque :

La neurolyse à l'alcool du plexus cœliaque est indiquée dans les douleurs viscérales, des organes alentours, notamment le cancer du pancréas. L'apport du Scanner dans cette indication est reconnu.

Block et neurolyse du plexus Hypogastrique et Ganglion impar:

Le plexus hypogastrique et le ganglion impar constitue la distalité de la chaîne prévertébrale sympathique, et joue donc un rôle dans l'innervation viscérale des organes pelviens. Ainsi, des douleurs tenaces du pelvis peuvent apparaître en cas de douleur pré coccygienne. Une autre indication de ce geste est la coccydynie.

Névralgie Ilio Inguinale:

La névralgie impliquant les nerfs Ilio Inguinal et Ilio hypogastrique est une pathologie invalidante, méconnue, et pourtant relativement fréquente puisque' elle est décrite comme compliquant les chirurgies de hernie inguinale, jusqu'à 50% en fonction des séries. L'infiltration/block est décrite comme une technique soulageant de manière transitoire les patients souffrant de cette pathologie. ***En revanche, la neurolyse par Radiofréquence, de surcroit sous guidage TDM n'a jamais été décrite auparavant dans la littérature***

Névralgie Pudendale :

La névralgie pudendale est une pathologie invalidante, entraînant des douleurs périnéales intolérables, accessible à un traitement interventionnel. L'infiltration en deux sites (épine ischiatique et canal d'Alcock) est une technique qui présente de bons résultats, mais d'efficacité transitoire. L'apport du Scanner dans cette indication est reconnu.

V - Application clinique de techniques de neurolyse et infiltration dans des indications innovantes sous guidage scanner

1- Douleurs abdomino-Inguina-Scrotale

Partie I : Etude de l'intérêt de la neurolyse par radiofréquence des nerfs ilio-inguinal et ilio hypogastrique dans les névralgies ilio inguinales : Etude Préliminaire

Publié dans *Radiology*, Février 2012

Introduction

La névralgie inguinale (incluant les neuropathies ilio-inguinales et ilio-hypogastriques) est une affection méconnue dont la fréquence est sous-estimée. En effet, elle apparaît le plus souvent dans les suites de chirurgie avec incision abdominale basse (15% après cure de hernie inguino-crurale, 1,8% post-césarienne). Le diagnostic de ces neuropathies est difficile et le traitement est souvent inefficace. Le but de cette étude est de décrire et évaluer la neurolyse par radiofréquence des nerf ilio inguinal et ilio hypogastrique dans la prise en charge de la névralgie inguinale réfractaire.

Matériel et Méthode

Dix patients âgés de 26 à 75 ans souffrant de névralgie inguinale chronique (> 6 mois) réfractaire aux médicaments spécifiques ont été rétrospectivement inclus entre 2005 et 2010. Les caractéristiques démographiques, l'histoire clinique et l'histoire de la prise en charge de la douleur ont été rétrospectivement évalués. La douleur a été mesurée sur une échelle visuelle analogique (EVA) de 0 à 10, avant et immédiatement après la procédure et à 1, 3, 6, 9 et 12 mois. Le diagnostic était

toujours confirmé par un block test positif préalable. Le geste était réalisé en ambulatoires et sous contrôle TDM.

Résultats

Quatorze neurolyses par RF ont été réalisées. La douleur était présente avant le geste pour une moyenne de 3,6 ans (extrêmes: 2-5). Le suivi moyen après RF était de 12,1 mois (extrêmes 3-36). L'EVA moyenne avant la procédure était de 7,8 / 10 (6-9). Un Soulagement immédiat de 100% a été atteint chez tous les patients. Une réduction importante ($\geq 80\%$) de la douleur a été obtenue dans 71,4% des cas de RFN à 6 mois de suivi et dans 45,5% des cas à 12 mois. La durée moyenne de soulagement de la douleur était de 9,3 mois (extrêmes: 3-36) après RF, avec une réduction moyenne de la douleur de 70% (intervalle: 50-100%). Aucune complication n'a été notée après la procédure.

Conclusion

La neurolyse par RF sous contrôle TDM est une technique efficace dans la prise en charge de la douleur inguinale réfractaire, avec une réduction satisfaisante et durable de la douleur. Cette option thérapeutique doit être considéré comme une alternative au traitement chirurgical. Ces résultats doivent être confirmés par un essai contrôlé avec un plus grand nombre de patients.

Partie II : *Comparaison de la neurolyse par radiofréquence et de l'infiltration block dans la prise en charge des névralgies ilio inguinales.*

Publié dans Pain Physician, Juin 2012

Objectif

L'objectif de cette étude est de comparer la neurolyse par radiofréquence et l'infiltration locale de corticoïdes sous guidage TDM des nerfs ilio-inguinal et ilio-hypogastrique dans la prise en charge des névralgies inguinales chroniques rebelles.

Matériel et Méthode

Quarante et un patients souffrant de douleurs inguinales chroniques réfractaires aux thérapeutiques spécifiques ont été inclus dans cette étude rétrospective menée de 2005 à 2011. Un total de 17 radiofréquences (13 patients) et 28 infiltrations (28 patients) ont été réalisées. Tous les patients étaient réfractaires aux thérapeutiques antalgiques classiques. La douleur était évaluée dans les deux groupes en utilisant l'échelle visuelle analogique (EVA) (0-10) mesurée immédiatement avant et après la procédure, et à 1, 3, 6, 9 et 12 mois après le geste. L'ancienneté moyenne de la douleur avant la procédure ainsi que la durée moyenne de soulagement post-geste ont été notés. Par ailleurs, l'efficacité maximale précoce était également relevée. Toutes les procédures ont été réalisées en ambulatoire sous contrôle TDM. Les infiltrations ont été réalisées avec l'injection de 1,5 ml de cortivazol et 4 ml de lidocaïne-Naropéine (30% - 70%). Les neurolyses par radiofréquence ont été réalisées en utilisant un générateur RF NeuroTherm. Dans les deux cas, des aiguilles de 22G ont été utilisées. Après chaque geste, des coupes TDM de contrôle étaient réalisées et le patient était surveillé 30 minutes au scanner .

Résultats:

Avant les gestes, les scores EVA étaient respectivement 7,76 et 7,46 dans le groupe RF et le groupe d'infiltration. La douleur était présente depuis une moyenne de 2,8 ans (extrêmes: 2-5) avant le geste, avec un score EVA moyen de 7.6/10. La moyenne d'âge dans les deux groupes était de 48,9 ans. Quarante patients (97,5%) présentaient une douleur inguinale après chirurgie, dont 61% après une cure chirurgicale de hernie inguinale.

L'efficacité maximale précoce sur la douleur n'était pas statistiquement différente dans les deux groupes (75,5% dans le groupe radiofréquence et 80% dans le groupe infiltration).

La durée moyenne de soulagement de la douleur était statistiquement supérieure ($p = 006$) dans le groupe RF (12,5 mois) par rapport au groupe infiltration (1,2 mois). Les scores EVA pendant l'année suivant la procédure étaient tous nettement en faveur de la neurolyse par radiofréquence.

Conclusion :

La neurolyse inguinale par radiofréquence scano-guidée présente une efficacité durable (12,5 mois en moyenne) et supérieure aux infiltrations locales (1.2 mois en moyenne) de corticoïdes pour la prise en charge des névralgies inguinales chroniques

2 - Tête-Cou

A - Cou :

Efficacité du block du vs. Radiofréquence sous guidage TDM du ganglion stellaire dans la prise en charge du Syndrome Douloureux Régional Complexe de Type 1 du membre supérieur

Publié dans European Radiology, Mai 2013

Objectif

Décrire et évaluer la faisabilité et l'efficacité de la neurolyse par radiofréquence (RFN) vs. le block neural du ganglion stellaire sous guidage TDM dans la prise en charge du Syndrome Douloureux Régional Complexe de Type 1 du membre supérieur.

Matériel et Méthodes

67 patients ont été inclus dans cette étude rétrospective entre 2000 et 2011, tous présentaient un Syndrome Douloureux Régional Complexe de Type 1 du membre supérieur réfractaire aux traitements conventionnels. Trente-trois patients ont bénéficié d'un block du ganglion stellaire et 34 ont bénéficié d'une neurolyse par radiofréquence. Un guidage par TDM était utilisé dans les deux groupes. La procédure était considérée comme efficace lorsque le soulagement de la douleur était égale ou supérieure à 50% pour une durée d'au moins 2 ans.

Résultats

Trente-neuf femmes (58,2%) et 28 hommes (41,8%) avec un âge moyen de 49,5 ans ont été inclus dans l'étude. L'analyse univariée réalisée sur les groupes block neural et le RFN a montré un taux significativement ($P < 0,0001$) plus élevé de succès dans le groupe RFN (67,6%, 23/34) par rapport au groupe de blocus (21,2%, 7/33) avec un odds ratio de 7.76.

Conclusion

La neurolyse par radiofréquence sous guidage TDM du ganglion stellaire est un traitement sûr et efficace dans la prise en charge du Syndrome Douloureux Régional Complexe de Type 1 du membre supérieur réfractaire. Ce traitement apparaît plus efficace que le block du ganglion stellaire.

B- Algie Cranio-faciales

A - Alcoolisation du ganglion Sphéno-palatin dans les syndromes algique de la face.

Publié dans *Neuroradiology*, Juillet 2014

Introduction

L'implication du ganglion sphéno-palatin (GSP) dans certains syndromes algiques de la face (telle que la névralgie trigémينية, les algies vasculaires de la face et les syndromes algiques atypiques) a été prouvée. Le traitement de certains de ces syndromes douloureux se révèle parfois être un échec par les traitements spécifiques qui sont parfois inefficaces. L'objectif principal est de décrire et évaluer la faisabilité et l'efficacité de la neurolyse à l'alcool du ganglion sphéno-palatin sous guidage TDM dans la prise en charge des douleurs cranio-faciales chroniques. L'objectif secondaire est d'évaluer l'efficacité en fonction de l'indication.

Matériel et Méthodes

Quarante-deux patients souffrant de douleurs faciales réfractaires ayant bénéficiés de 58 neurolyses consécutives du GSP ont été inclus dans cette étude entre 2000 et 2013. Les patients ont été divisés en trois groupes: le groupe "algie vasculaire de la face» (AVF), le groupe « douleur faciale idiopathique persistante» (PFIP) , et le groupe «autres». La douleur a été évaluée à l'aide de score d'échelle visuelle analogique (mesurées immédiatement avant et après la procédure et à intervalles réguliers suivants la procédure. L'alcoolisation du GSP était considérée comme efficace lorsque la douleur avait diminué d'au moins 50% pendant un période de 3 mois. Toutes les procédures ont été réalisées en ambulatoire sous contrôle tomodensitométrique avec une injection de 1 ml d'alcool absolu.

Résultats :

Le taux d'efficacité globale d'alcoolisation du GSP était de 67,2% avec une durée moyenne de soulagement de la douleur de 10,3 mois. Le vécu de la procédure par les patients était classé comme non douloureux ou tolérable dans 64,2%. L'analyse a montré un taux d'efficacité plus élevé dans les groupes AVF (76,5%) et PFIP (85,7%) comparé au groupe 'autres' (40%). Aucune différence n'a été observée entre les groupes en ce qui concerne le taux de récurrence.

Conclusion :

La neurolyse du ganglion sphéno-palatinal par alcool absolu sous guidage TDM est efficace particulièrement dans les algies vasculaires de la face et les douleurs faciales atypiques

B - Une approche simplifiée l'infiltration sous TDM du nerf grand-occipital dans le traitement de la névralgie Occipitale rebelle.

Article Accepté avec révisions mineures, European Radiology

Objectif:

Evaluer l'efficacité d'une approche simplifiée de l'infiltration du nerf grand occipital sous contrôle scanographique dans la prise en charge de la névralgie occipitale rebelle.

Méthodes:

33 patients ayant bénéficiés de 37 procédures ont été inclus dans cette étude rétrospective entre 2012 et 2014. Tous les patients inclus souffraient de névralgie occipital réfractaires aux traitements conventionnels habituels. Les procédures ont été réalisées sous TDM en ambulatoire et sous anesthésie locale. Un scanner de repérage sans injection de PDC était réalisé de C0 à C2. L'infiltration du nerf grand occipital (NGO) était réalisée exclusivement sur le site le plus superficiel au premier virage du NGO entre le muscle capitis oblique inférieure et le muscle semispinalis niveau C1-C2, en utilisant une aiguille 22G. Un mélange d'anesthésiques à action rapide et lente (1,5 mL de chlorhydrate de lidocaïne 1% et 3 ml de chlorhydrate Ropivacain 0,25%) était ensuite injecté suivie par l'injection de 1,5 ml de cortivazol au site cible. La douleur a été évaluée sur une échelle EVA immédiatement avant et après la procédure et à intervalle régulier dans les suites. Le succès technique était défini par l'aptitude à positionner avec précision la pointe de l'aiguille au niveau du site cible. Le succès clinique a été défini par une diminution de la douleur supérieure ou égale à 50% durant au moins 3 mois.

Résultats:

L'EVA moyenne avant la procédure était de 8/10. Vingt-neuf patients souffraient de douleur unilatérale (à droite, n = 16, à gauche, n = 13) et 4 de douleur bilatérale. Le succès technique de la procédure était de 100%. La durée de la procédure variait de 10 à 15 minutes. Le taux d'efficacité clinique tel que défini était de 86% (21/26 procédures). En cas d'efficacité clinique, la durée moyenne d'efficacité était de 9.16 mois.

Conclusion:

Cette nouvelle méthode d'infiltration simplifiée semble être efficace dans la prise en charge de la névralgie d'Arnold réfractaire. Avec cette nouvelle technique, l'infiltration du nerf grand occipital apparaît plus sûre, plus rapide et beaucoup plus facile techniquement par rapport aux autres décrites précédemment sur d'autres sites et moyens de guidage.

Conclusion

Au cours des 20 dernières années, l'utilisation de méthode de guidage par imagerie s'est progressivement imposé comme gold standard dans nombre d'indications Interventionel antidouleur. Les modalités de guidage les plus utilisés sont la fluoroscopie et l'échographie. Le Scanner est relativement sous-utilisé dans le domaine de la prise en charge interventionnelle de la douleur, principalement en raison des difficultés d'accès et de disponibilités pour les praticiens de la douleur.

Au travers de cette thèse, nous avons montré l'intérêt du guidage scanner dans plusieurs indications avec de bons résultats, grâce à des techniques innovantes

* L'Évaluation de l'alcoolisation percutanée du ganglion sphéno-palatin dans la prise en charge de la douleur cranio-faciale réfractaire, chez 42 patients avec taux d'efficacité globale d'alcoolisation du GSP de 67,2% et une durée moyenne de soulagement de la douleur de 10,3 mois. L'analyse a montré un taux d'efficacité élevé chez les patients avec des algies vasculaires de la face (76,5%) et des syndromes douloureux faciaux persistents (85,7%)

* L'Évaluation de l'efficacité d'une méthode simplifiée d'infiltration sous scanner du nerf grand occipital (NGO) chez 33 patients souffrant d'une névralgie occipitale avec taux de succès clinique de 86%. En cas de succès clinique, la durée moyenne de soulagement de la douleur suivant la procédure était de 9,16 mois.

*La comparaison de block vs. neurolyse par radiofréquence du ganglion stellaire sous guidage scanographique dans la prise en charge du Syndrome Douloureux Régional Complexe de Type 1 du membre supérieur chez 67 patients: on retrouve une efficacité supérieure dans le groupe RFN (67,6%, 23/34) par rapport au groupe de block (21,2%, 7/33) avec un OR de 7,76.

* L'Évaluation de la neurolyse par RF des nerfs ilio-inguinal et ilio hypogastrique chez les patients souffrant de douleurs ilio-inguinal et à l'aine réfractaire.

- L'Étude préliminaire sur 16 patients traités par RFN a montré une réduction significative de la douleur après RFN pendant 11,8 mois.
- Une deuxième étude a été menée permettant de comparer l'efficacité de la RFN et à celle de l'infiltration dans la même indication chez 42 patients: La durée moyenne de soulagement de la douleur était statistiquement supérieure ($P = 0,005$) dans le groupe RF (12,5 mois) comparé au groupe d'infiltration (1,6 mois).

Au cours de ces études publiées, nous avons montré que l'application d'une technique existante (neurolyse, infiltration) à une nouvelle indication, ou la modification d'une technique existante après des considérations anatomiques pouvait conduire à une amélioration des résultats. Dans tous les cas, le guidage par Scanner est une valeur ajoutée dans certaines indications, car elle permet en toute sécurité, le placement précis, millimétrique, de l'aiguille. Une autre solution possible afin de réduire les risques liés à certains gestes serait le développement d'une sonde de radiofréquence unidirectionnelle, capable de créer une zone d'ablation en demi sphère dont l'orientation serait contrôlable, ce qui permettrait de réduire les risques d'ablation non désirés.

Enfin, il est important de rappeler, que la prise en charge interventionnelle de la douleur d'un patient s'intègre dans une prise en charge globale, centrée autour du patient. Ainsi, la prise en charge d'un patient douloureux ne pourra se faire de manière efficace qu'en prenant en compte l'ensemble des aspects de la douleur exprimé par le patient, bien au delà des seules considérations techniques d'un geste interventionnel.

Over the past 20 years, the use of imaging guidance has progressively but very rapidly evolved to become a standard practice to date, with fluoroscopy and Ultrasound being the most popular imaging guiding tools. However, CT guidance is relatively underused in the field of Interventional pain management, mainly due to access and availability issues for pain physicians. Therefore, the objective of this thesis are multiple :

- * to evaluate the usefulness of CT scan guidance, in applying existing neurolytic techniques (block, infiltration and neurolysis) to innovative indications, allowed by the use of such an imaging guiding tool.

- * to evaluate the clinical effectiveness of these novel indications

- * Finally, to emphasize on the importance of the clinical aspects of Interventional pain management

After having reminded the definitions of the different existing techniques (neural blocks, infiltration, neurolysis) and detailed existing materials (Local anesthetics, Steroids, Chemical Neurolysis, Physical Neurolysis), a brief description of existing indication of Interventional Pain will be made. Emphasis will then be made on the assessment of innovative interventional CT Guided pain techniques in various refractory pain syndromes :

- Evaluation of Alcohol percutaneous neurolysis of the sphenopalatine ganglion in the management of refractory cranio facial pain , in 42 patients : overall efficacy rate of alcohol SPN was 67.2% with a mean pain relief duration of 10,3 months. Analysis showed a higher efficacy rate in patients with Cluster Headaches (76.5%) and Persisting Facial Idiopathic Pain (85.7%)

- Evaluation of the efficacy of a simplified CT guided greater occipital nerve (GON) infiltration approach in the management of occipital neuralgia (ON) in 33 patients : Clinical success rate was 86%. In case of clinical success, mean pain relief duration following procedure was 9.16 months.

- Evaluation of CT-guided Stellate Ganglion Blockade vs. Radiofrequency Neurolysis in the Management of Refractory type I Complex Regional Pain Syndrome of the Upper Limb in 67 patients : analysis performed on the blockade and RFN groups showed a significantly ($P < 0.0001$) higher success rate in the RFN group (67.6%, 23/34) compared with the blockade group (21.2%, 7/33) with an OR of 7.76.

- Evaluation of CT Guided ilio inguinal (II) and ilio hypogastric Radiofrequency Neurolysis (RFN) in patients with refractory ilio-inguinal and groin pain.

- * Preliminary Study on 16 patients treated with II RFN showed significant pain reduction after RFN with a mean pain relief of 11,8 months.

- * A second study was conducted to compare the effectiveness of RFN and Infiltration in the same indication in 42 patients : Mean duration of pain relief was statistically significant ($P = .005$) in the RF group (12.5 months) compared to the infiltration group (1.6 months).

Throughout these published studies, we have shown that the application of an existing neurolytic technique in a new indication, or modifying an existing technique after anatomical considerations may lead to either higher efficacy rates, longer pain reliefs, or safer procedures. In all cases, CT guidance is an added value to any procedures as it allows safe, precise accurate and effective needle placement in most procedures.

Another possible solution to reduce procedure related risks discussed in this thesis, is the development of a unidirectional radiofrequency probe, capable of producing tissue destruction only on one half of the probe thereby creating a half moon shaped thermal zone, which would reduce the risk of surrounding unwanted tissue damage. This topic merits further studies and development as possible everyday implications are numerous .