



HAL
open science

Signature moléculaire des adénocarcinomes pulmonaires de type lépidique prédominant et mucineux invasif et dérégulation

Michaël Duruisseaux

► To cite this version:

Michaël Duruisseaux. Signature moléculaire des adénocarcinomes pulmonaires de type lépidique prédominant et mucineux invasif et dérégulation. Biologie cellulaire. Université Pierre et Marie Curie - Paris VI, 2015. Français. NNT : 2015PA066277 . tel-01242978

HAL Id: tel-01242978

<https://theses.hal.science/tel-01242978>

Submitted on 14 Dec 2015

HAL is a multi-disciplinary open access archive for the deposit and dissemination of scientific research documents, whether they are published or not. The documents may come from teaching and research institutions in France or abroad, or from public or private research centers.

L'archive ouverte pluridisciplinaire **HAL**, est destinée au dépôt et à la diffusion de documents scientifiques de niveau recherche, publiés ou non, émanant des établissements d'enseignement et de recherche français ou étrangers, des laboratoires publics ou privés.

Université Pierre et Marie Curie

Ecole doctorale ED394

Laboratoire GRC-UPMC 04 Theranoscan

Signature moléculaire des adénocarcinomes pulmonaires de type lépidique prédominant et mucineux invasif et dérégulation

Par Michaël Duruisseaux

Thèse de doctorat de Sciences du Vivant

Dirigée par Marie Wislez

Présentée et soutenue publiquement le 21 septembre 2015

Devant un jury composé de :

Jacques Cadranel, Professeur des Universités, Université Paris 6 (Président du jury)

Marie Wislez, Professeur des Universités, Université Paris 6 (Directrice de thèse)

Alexis Cortot, Professeur des Universités, Université Lille Nord de France (Rapporteur)

Caroline Leroux, Directeur de Recherche, Université Claude Bernard Lyon 1 (Rapporteur)

Pierre Hainaut, Professeur des Universités, Université Joseph Fourier – Grenoble

Martine Antoine, Praticien Hospitalier, Université Paris 6

Table des matières

1. Introduction.....	6
1.1. Classification anatomo-pathologique et terminologie.....	6
1.1.1. Concept de carcinome bronchioloalvéolaire dans les classifications OMS 1999/2004	6
1.1.2. Carcinome bronchioloalvéolaire non-mucineux et mucineux	7
1.1.3. Hyperplasie adénomateuse atypique.....	7
1.2. Démembrement des carcinomes bronchioloalvéolaires.....	8
1.3. Continuum anatomo-clinique de l'hyperplasie adénomateuse atypique à l'adénocarcinome lépidoïde invasif	9
1.4. Epidémiologie	10
1.5. Pronostic.....	11
1.5.1. Séries chirurgicales	11
1.5.2. Maladies avancées.....	12
1.6. Présentation radio-clinique des adénocarcinomes lépidoïdes	14
1.6.1. Symptomatologie	14
1.6.2. Histoire naturelle.....	14
1.6.3. Formes radio-cliniques	14
1.7. Biologie	17
1.7.1. Inflammation alvéolaire et progression tumorale	17
1.7.2. Caractéristiques biologiques des adénocarcinomes lépidoïdes prédominant et mucineux invasifs 18	
1.7.2.1. Expression de TTF1, CK7 et CK20.....	18
1.7.2.2. Expression des mucines.....	18
1.7.2.3. Oncogènes	19
1.7.2.4. Récepteur à l'IGF1	21
1.8. Traitement	22
1.8.1. Chirurgie	22
1.8.2. Traitements systémiques	23

1.8.2.1. Inhibition de la voie EGFR.....	23
1.8.2.2. Chimiothérapie	24
1.8.2.3. Inhibition du protéasome	25
1.8.2.4. Approche thérapeutique actuelle	25
2. Objectif de la thèse.....	27
3. Article 1 : étude des caractéristiques cliniques et moléculaires des patients avec adénocarcinomes pulmonaires pris en charge à l'hôpital Tenon et du rôle de la mucosécrétion. 28	
3.1. Article 1.....	28
3.2. Présentation de l'article 1	28
3.3. Commentaires	29
3.4. Manuscrit article 1.....	30
4. Article 2 : étude de l'expression de MUC1, MUC2, MUC5B, MUC5AC et MUC6 dans les adénocarcinomes lépidiques prédominants et mucineux invasifs.....	38
4.1. Article 2.....	38
4.2. Présentation de l'article 2	38
4.3. Données de la littérature à propos des mucines.....	39
4.3.1. Structures et fonctions	39
4.3.2. Mucines et poumon.....	39
4.3.3. Mucines et cancer : l'exemple de MUC1.....	40
4.3.4. Mucines et cancer du poumon.....	40
4.3.4.1. Mucine transmembranaire : MUC1.....	40
4.3.4.2. Mucine sécrétoire : MUC5AC	41
4.4. Commentaires	42
4.5. Manuscrit de l'article 2.....	43
5. Article 3 : étude de la présence de réarrangement de NRG1 dans les adénocarcinomes pulmonaires mucineux invasifs.....	64
5.1. Article.....	64
5.2. Présentation de l'article	64

5.3.	Données de la littérature à propos des réarrangements NRG1	65
5.4.	Commentaires	67
5.5.	Manuscrit de l'article 3	68
6.	Article 4 : Etude du rôle pro-tumoral de la boucle autocrine CXCL10/CXCR3-A dans les adénocarcinomes mucineux invasifs	82
6.1.	Article.....	82
6.2.	Présentation de l'article	82
6.3.	Données de la littérature à propos de la voie CXCL10/CXCR3	84
6.3.1.	Structures et fonctions	84
6.3.2.	CXCL10/CXCR3 et cancer : un double rôle.....	88
6.3.2.1.	Fonctions anti-tumorales	88
6.3.2.2.	Fonctions pro-tumorales	91
6.3.2.3.	Hypothèse d'une boucle autocrine pro-tumorale.....	92
6.3.3.	CXCL10/CXCR3 et cancer du poumon.....	92
6.4.	Commentaires	93
6.5.	Manuscrit de l'article 4	95
7.	Discussion	139
7.1.	Mucosécrétion et expression des mucines	140
7.2.	Réarrangement NRG1 et AMI.....	141
7.3.	Boucle autocrine CXCL10/CXCR3-A pro-tumorale dans les AMI	142
8.	Conclusion	145
9.	Bibliographie.....	146
10.	Annexes	162
10.1.	Travaux en rapport avec le sujet de la thèse publiés par le doctorant	162
10.2.	Manuscrits correspondants.....	162
10.3.	Travaux du laboratoire auxquels le doctorant a collaboré	181
11.	Tables des figures	182
12.	Tables des tableaux	182

1. Introduction

1.1. Classification anatomo-pathologique et terminologie

Les termes d'adénocarcinome lépidique prédominant (ALP) et d'adénocarcinome mucineux invasif (AMI) sont apparus récemment dans la classification des adénocarcinomes pulmonaires et sont le fruit d'une longue évolution des concepts au sein des classifications anatomopathologiques de l'Organisation Mondiale de la Santé (OMS) de 1999 puis de 2004, et enfin de la nouvelle classification des adénocarcinomes pulmonaires publiée en 2011 (1,2). Ces deux termes font référence à l'ancienne entité anatomo-clinique appelée carcinome bronchioloalvéolaire (CBA).

1.1.1. Concept de carcinome bronchioloalvéolaire dans les classifications OMS 1999/2004

Le CBA a une définition stricte dans la classification anatomopathologique OMS 1999 puis 2004 (1). Il s'agit d'un adénocarcinome pulmonaire primitif développé au dépend des cellules épithéliales de l'unité respiratoire terminale et ne présentant aucun signe d'invasion des structures stromales, vasculaires ou pleurales. Il en résulte un respect de l'architecture pulmonaire et une prolifération le long des parois alvéolaires dénommée prolifération « lépidique ». Le diagnostic anatomopathologique ne peut être posé qu'après examen complet d'une pièce opératoire afin d'affirmer l'absence de composante invasive et on parle alors de CBA « pur ». Ceci est justifié par la démonstration d'une survie sans rechute à 5 ans de 100% des cas de CBA « pur » opérés (3–10). Il s'agit cependant d'une entité rare, représentant moins de 1% des cas en occident, environ 5 % des cas dans les séries asiatiques (11–14). La majorité des CBA comportent des foci d'invasion ou de fibrose, ou alors la prolifération lépidique est associée à d'autres sous-types histologiques (acinaire, papillaire, solide, micropapillaire) (1). Le pronostic de ces tumeurs diminue alors drastiquement (3).

A coté de la prolifération lépidique, la dissémination aérologène des cellules tumorales est la deuxième caractéristique rattachée au concept de CBA (1). Il s'agit de la capacité des cellules tumorales à s'implanter au niveau de sites pulmonaires non contigus à la tumeur primitive. Il en résulte un tropisme pulmonaire des CBA, qui ne métastasent pas en dehors du parenchyme pulmonaire ou tardivement dans l'évolution de la maladie (15–18).

1.1.2. Carcinome bronchioloalvéolaire non-mucineux et mucineux

Il existe deux sous-types de CBA se différenciant par l'aspect cytologique des cellules tumorales: le sous-type non-mucineux et le sous-type mucineux (1).

Le sous-type non-mucineux proviendrait de la transformation des pneumocytes de type II de l'épithélium alvéolaire ou des cellules de Clara de l'épithélium bronchiolaire terminal, cellules épithéliales issues de l'unité respiratoire terminale. Il est caractérisé par une prolifération de cellules de petite taille soit cubiques, soit cylindriques rappelant la morphologie des pneumocytes de type II ou des cellules de Clara avec un cytoplasme éosinophile. Par définition, elles sont dépourvues de vacuoles de mucines intracytoplasmiques et non-mucosécrétantes.

Le sous-type mucineux dérive probablement d'une métaplasie de cellules bronchiolaires et les cellules tumorales se caractérisent par leur grande taille et leur forme haute, bien différenciées avec un noyau localisé au niveau basal. Le cytoplasme est pâle et occupé par des vacuoles de mucines qui peuvent réaliser un aspect d'allure caliciforme (« goblet cell »). Ces cellules sont en général mucosécrétantes et peuvent être à l'origine d'une production abondante de mucines endo-alvéolaire.

1.1.3. Hyperplasie adénomateuse atypique

L'hyperplasie adénomateuse atypique (HAA) est une lésion hyperplasique des pneumocytes tapissant les parois alvéolaires et présentant des anomalies cytonucléaires discrètes. Il pourrait s'agir de la lésion pré-cancéreuse de certains sous-types d'adénocarcinomes pulmonaires (19,20). L'HAA consiste en des lésions de moins de 5 mm à type d'opacités en verre dépoli au scanner, de découverte fortuite radiologique ou sur une pièce opératoire. L'HAA est retrouvée dans 35% des cas sur les pièces opératoires d'adénocarcinomes pulmonaires, souvent en périphérie de la lésion invasive (21,22). L'HAA pourrait être une lésion nécessaire à l'évolution vers une prolifération lépidique non-mucineuse (2).

1.2. Démembrement des carcinomes bronchioloalvéolaires

Le terme « carcinome bronchioloalvéolaire » recouvrant des entités anatomo-cliniques de pronostic différent, la nouvelle classification anatomopathologique des adénocarcinomes pulmonaires 2011 a supprimé ce terme (2). Cette classification supprime également la mention de tous les sous-types histologiques d'adénocarcinomes invasifs présents dans une tumeur (CBA-papillaire, acineux-CBA...) comme recommandé dans la classification 2004, pour ne mentionner que la composante majoritaire dite prédominante. Les adénocarcinomes pulmonaires invasifs sont donc appelés acineux prédominant, lépidique prédominant etc...

Quatre nouvelles entités apparaissent et correspondent au CBA:

- L'adénocarcinome in situ (AIS) correspond au CBA « pur » de moins de 3 cm. Il s'agit d'une prolifération lépidique exclusive sans zone d'invasion qui peut être non-mucineuse ou mucineuse. Une chirurgie complète est considérée comme curatrice avec une survie sans rechute à 5 ans de 100% (3–10).
- L'adénocarcinome mini-invasif (AMIV). Il s'agit d'une tumeur à prolifération lépidique de moins de 3 cm avec des zones d'invasion de moins de 5 mm, et sans invasion de structures lymphatiques, vasculaires ou pleurales et sans nécrose tumorale. La tumeur peut être non-mucineuse ou mucineuse. Cette nouvelle entité est justifiée par l'hypothèse d'une survie sans rechute après chirurgie approchant 100% (3,23–27).
- L'adénocarcinome lépidique prédominant (ALP) remplace le CBA et est par définition « non-mucineux ». Il s'agit d'une prolifération lépidique prédominante non-mucineuse qui, quelque soit sa taille, s'associe à un contingent invasif de plus de 5 mm. Les tumeurs de plus de 3 cm rentrent dans cette catégorie car elles sont d'emblée considérées comme potentiellement invasives même si aucune zone d'invasion n'est constatée.
- L'adénocarcinome mucineux invasif (AMI) est un « variant » de l'ALP et remplace le CBA « mucineux ». Il s'agit d'une prolifération lépidique prédominante qui se différencie de l'ALP par son caractère mucineux.

Dans la suite du texte, le terme adénocarcinome lépidique désignera l'entité auparavant dénommée CBA, les adénocarcinomes lépidiques prédominant (ALP) seront par

définition non-mucineux et adénocarcinome mucineux invasif (AMI) par définition mucineux.

1.3.Continuum anatomo-clinique de l'hyperplasie adénomateuse atypique à l'adénocarcinome lépidique invasif

La progression lépidique et aéro-gène sont des caractéristiques retrouvées de l'HAA, à l'AIS jusqu'à l'adénocarcinome lépidique invasif qui, à la différence de l'HAA et de l'AIS, comporte nécessairement des foci d'invasion d'importance variable. On retrouve également souvent des zones de prolifération lépidique en périphérie de lésions d'autres sous-types d'adénocarcinomes pulmonaires invasifs (21,28). Basé sur ces constatations, l'hypothèse est que l'HAA est une lésion pré-cancéreuse évoluant vers l'AIS puis l'adénocarcinome lépidique invasif, à la faveur d'évènements génétiques et épigénétiques carcinogènes altérant des gènes suppresseurs de tumeur.

Ainsi, la fréquence des altérations de *p53* augmente avec le degré d'invasion. Plus la tumeur est associée à un contingent invasif, plus une perte d'hétérozygotie est retrouvée au niveau du locus 17p13 où se situe le gène *p53* (29–31). Ces pertes d'hétérozygotie sont également moins fréquentes dans les zones lépidiques périphériques comparées aux zones invasives centrales au sein d'une même lésion adénocarcinomateuse (32). De même, on observe une augmentation de la fréquence de mutation de *p53* et en corrolaire une surexpression de *p53* de l'HAA à l'adénocarcinome lépidique invasif puis finalement aux autres sous-types d'adénocarcinomes pulmonaires (33–37).

Des méthylations aberrantes au niveau des régions promotrices du gène *p16* et une perte d'expression de *p16* en résultant sont directement corrélées à l'apparition de contingent invasif (38,39). Ces altérations épigénétiques du gène *p16* semblent cruciales dans le passage de l'AIS à l'adénocarcinome lépidique prédominant.

La cycline D1 est surexprimée dans les HAA puis son expression diminue progressivement au cours de la possible séquence de carcinogénèse, suggérant son importance comme événement précoce mais non nécessaire au maintien et au développement de la tumeur (39).

Enfin, les capacités de résistance à l'apoptose augmentent de l'HAA aux formes invasives par le biais d'une augmentation de l'expression de la survivin et des télomérases (40–42).

Les mutations des gènes *EGFR* et *KRAS* sont détectées dès le stade AIS et leur fréquence est stable entre HAA, AIS puis adénocarcinomes lépidiques invasifs (19,20,43). Il s'agit probablement d'événement génétique très précoce dans la carcinogénèse ne jouant pas un rôle décisif dans la séquence HAA-AIS- adénocarcinomes lépidique invasif.

1.4.Epidémiologie

Les adénocarcinomes lépidiques présentent des caractéristiques épidémiologiques qui les distinguent parmi les cancers du poumon non à petites cellules (CBNPC).

Ils représenteraient 2 à 7% de l'ensemble des CBNPC, avec une plus grande incidence dans les populations asiatiques (16,28,44–46). Les données issues de la base de données américaines SEER (Surveillance, Epidemiology and End Results) suggéraient une augmentation modérée de l'incidence sur la période 1979-1998 (47). Ceci est probablement vrai au Japon, notamment par le biais de l'augmentation du dépistage du cancer du poumon par scanner thoracique faible dose, conduisant à un diagnostic plus précoce, notamment d'AIS(12–14,48).

Le sex ratio est proche de 1. Le tabagisme est un facteur de risque moins puissant que dans l'ensemble des CBNPC, avec une plus grande fréquence de non-fumeurs et une exposition d'intensité moindre (1).

L'incidence des AMI est plus faible que celle des ALP, bien que très variable d'une étude à une autre. Les ALP sont plus liés au tabagisme et au sexe féminin que les AMI (1,49).

La présence d'une autre maladie pulmonaire telle qu'une fibrose, particulièrement dans le cadre d'une sclérodémie systémique, ou une tuberculose pulmonaire augmenterait le risque de développer un adénocarcinome lépidique (15,50–52).

L'étiologie virale de certains adénocarcinomes lépidiques est une hypothèse débattue. Elle repose sur l'existence d'une forme ovine d'adénocarcinome pulmonaire très proche de l'adénocarcinome lépidique humain sur le plan anatomo-pathologique et clinique et dont la cause est le retrovirus ovin Jaagsiekte (JRSV) (53). L'enveloppe protéique et notamment la protéine Env du JRSV possède des fonctions oncogéniques et est l'origine de la transformation cancéreuse des cellules de l'épithélium respiratoire du mouton (54). La dissémination de la maladie peut se faire par transmission du mouton à mouton mais aucun cas de transmission mouton à humain n'a été rapporté (53). Les protéines de l'enveloppe du JRSV peuvent transformer des cellules épithéliales respiratoires humaines *in vitro* (55). Des antigènes correspondant aux protéines de l'enveloppe du JRSV et des séquences génomiques du JRSV ont pu être mises en évidence au sein de lésions tumorales pulmonaires humaines et notamment d'adénocarcinomes, mais il n'existe pas à ce jour de lien de causalité entre présence de ces éléments et un risque plus élevé de cancer pulmonaire (56–60). Une étude cas-témoins explorant les facteurs de risques d'adénocarcinomes pulmonaires de type « pneumonique » correspondant essentiellement à des adénocarcinomes lépidiques avancés, a démontré un lien indépendant entre exposition professionnelle aux chèvres et survenue d'un adénocarcinome pulmonaire de type « pneumonique » (61). Il n'existait pas de lien entre exposition professionnelle aux moutons et adénocarcinome pulmonaire de type « pneumonique ». Ce résultat n'était pas attendu et suggère un rôle carcinogène chez l'humain du virus enzootic nasal tumor virus (ENTV) caprin, qui partage de nombreuses caractéristiques génomiques et biologiques avec le JRSV (62).

1.5. Pronostic

1.5.1. Séries chirurgicales

Dans les séries chirurgicales, les adénocarcinomes lépidiques sont systématiquement reliés à un meilleur pronostic que les autres sous-types d'adénocarcinomes pulmonaires (63–67). Les études ayant adopté comme critères diagnostiques la classification OMS 2011 des adénocarcinomes pulmonaires, retrouvent pour les AIS et les MIA des survies sans rechute de l'ordre de 100% à 5 ans. Les ALP représentent clairement un sous-type histologique de

meilleur pronostic comparé aux sous-types acinaire, papillaire, solide ou micro-papillaire prédominant.

Le tableau 1 rapporte les résultats des études renseignant, et pour certaines comparant, la survie des populations de patients avec ALP et AMI. Six études montrent une valeur de mauvais pronostic de l'AMI (Manning et al., Clayton et al., Dumont et al., Caretta et al., Casali et al., Russel et al.) dont quatre statistiquement significatives, deux montrent une tendance non significative à une valeur de meilleur pronostic de l'AMI (Regnard et al., Warth et al.), et trois autres ne montrent pas de différence (Albertine et al., Yoshigawa et al.) (44,45,67–75). Cette hétérogénéité peut s'expliquer par le faible nombre d'AMI dans chaque étude lié à sa faible incidence et donc un manque de puissance statistique. Il est possible également que les études ayant démontré une valeur de mauvais pronostic aient inclus plus de maladies multifocales alors que les autres études auraient sélectionné des patients sans atteinte multifocale. La nouvelle classification OMS 2011 des adénocarcinomes pulmonaires ne permet pas de trancher puisque des études récentes appliquant rigoureusement ces critères montrent des résultats contradictoires (Warth et al., Yoshigawa et al., Russel et al.) (67,73–75). Il existe donc une tendance à une valeur de mauvais pronostic des AMI comparés aux ALP dans les séries chirurgicales sans que l'on puisse l'affirmer formellement.

1.5.2. Maladies avancées

Dans les formes avancées, les données issues des séries rétrospectives et des quelques essais thérapeutiques prospectifs suggèrent une survie globale de l'ordre de 13 mois, un peu meilleure que celle observée au cours des formes avancées des autres sous-types histologiques, qui est plutôt de l'ordre de 10 mois.

Bien qu'il n'existe que peu de données dans la littérature, les formes avancées d'AMI semblent avoir une évolution clinique plus péjorative que les formes avancées d'ALP, notamment du fait d'une propagation aérogène plus importante et d'un décès par insuffisance respiratoire (68,69).

Tableau 1. Survie des adénocarcinomes lépidiques prédominant et des adénocarcinomes mucineux invasifs

Etude	Stade	Adénocarcinome lépidique prédominant (ALP)			Adénocarcinome mucineux invasif (AMI)			Comparaison statistique ALP vs AMI	
		n	Survie globale (mois)	Survie à 5 ans (%)	Survie sans rechute (%)	n	Survie globale (mois)		Survie à 5 ans (%)
Manning et al	localisé/avancé	25	98			9	20		significatif
Clayton et al	localisé/avancé	45		61		9		11	non significatif
Dumont et al	localisé	55	OR favorisant ALP		42	OR favorisant ALP			significatif
Regnard et al	localisé/avancé	21		22	35		44		non significatif
Albertine et al	localisé	35		57	18		55		non significatif
Carretta et al	localisé/avancé	36	OR favorisant ALP		13	OR favorisant ALP			significatif
Casali et al	localise	20	81	67	13		44	35	significatif
Russel et al	localisé	10		86	10		51		non renseigné
Yoshizawa et al	localisé	29			13			76	non renseigné
Yoshizawa et al	localisé	36			10			89†	non significatif
Warth et al	localisé	34	77,4		12	88,7 mois		88,1	non renseigné

OR: Odd ratio

†: Survie sans rechute à 5 ans

1.6. Présentation radio-clinique des adénocarcinomes lépidiques

1.6.1. Symptomatologie

Dans les formes localisées, la majorité des patients sont asymptomatiques et le diagnostic est fait lors d'un examen d'imagerie thoracique fortuit ou dans le cadre d'un programme de dépistage du cancer pulmonaire (1).

Dans les formes avancées, l'état général est moins altéré que dans les autres types de cancers pulmonaires et peut être même complètement préservé au diagnostic (1). La toux est le symptôme le plus fréquent et les autres symptômes type hémoptysie, anorexie, asthénie, perte de poids sont rares et surviennent tard dans l'évolution de la maladie (1). Les crachats sont fréquents (deux tiers des patients) pouvant être très abondants et justifiant l'utilisation du terme de « bronchorrhée », typique des adénocarcinomes lépidiques avancés (1).

1.6.2. Histoire naturelle

L'évolution des adénocarcinomes lépidiques est relativement lente de même que le retentissement clinique, pouvant conduire un délai de plusieurs années entre le début des symptômes et le diagnostic (15). Ceci s'explique notamment par la progression lépidique et aérogène de la maladie, ne conduisant que rarement ou très tardivement à des métastases extra-pulmonaires. Les ganglions médiastinaux sont même rarement envahis dans les séries chirurgicales (moins de 25% des cas) (44,45,51,76,77). Ce mode de progression explique aussi le décès fréquent des patients par défaillance respiratoire lorsque la maladie arrive à son stade ultime et devient multifocale et bilatérale (15).

1.6.3. Formes radio-cliniques

Formes nodulaires isolées

C'est la forme la plus fréquente et la découverte est en général fortuite sur un examen radiologique prescrit pour une autre indication. L'examen clinique est normal. Il s'agit d'un nodule périphérique unique pouvant mesurer jusqu'à 10 cm de diamètre, en général bien limité et avec un aspect en verre dépoli ou subsolide au scanner. Les contours des nodules peuvent parfois être spiculés. Ces formes sont le plus souvent des ALP (1).

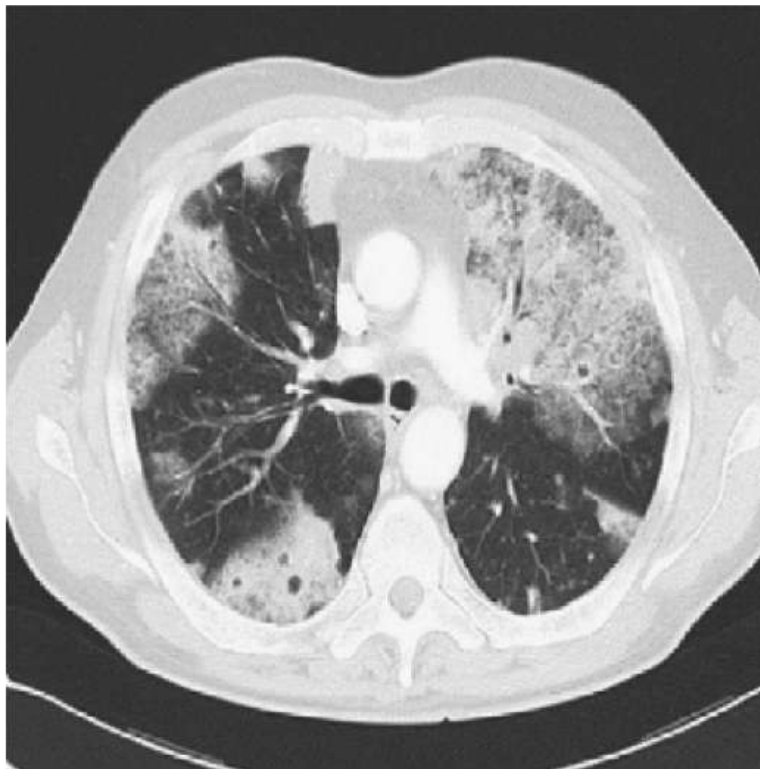
Formes diffuses

L'atteinte pulmonaire est alors multifocale et souvent bilatérale, traduisant une propagation aérogène de la maladie. Il n'existe pas de symptomatologie spécifique mais la présence d'une bronchorrhée muqueuse est typique, pouvant être extrêmement abondante (plus de 500 ml/jour) et invalidante (1). L'état général est souvent conservé au diagnostic. L'auscultation pulmonaire peut retrouver des crépitants traduisant le comblement alvéolaire. Sur le plan histologique, des zones invasives sont en général associées à la prolifération lépidique.

Formes pneumoniques

L'atteinte pulmonaire réalise un véritable aspect de pneumonie sur la radiographie et le scanner thoracique, avec des images de condensation alvéolaire dense, ayant un bronchogramme aérien, et parfois le comblement de tout un lobe, associées à des opacités en verre dépoli (figure 1) (15). Des images kystiques peuvent être visibles traduisant des zones de sécrétion intra-alvéolaire de mucine et également un « bronchogramme vasculaire » ou « angiogramme » en rapport avec le respect des structures vasculaires et la faible densité des lésions tumorales (1). L'atteinte pneumonique peut être à l'origine d'un shunt droit-gauche qui peut être sévère et à l'origine d'une hypoxémie. L'insuffisance respiratoire en découlant peut nécessiter une oxygénothérapie et être très invalidante. Sur le plan histologique, il s'agit souvent d'AMI (1).

Figure 1 : Coupe scannographique en fenêtre parenchymateuse correspondante à un aspect typique d'adénocarcinome à forme pneumonique, anciennement nommé bronchioloalvéolaire



1.7. Biologie

Les adénocarcinomes lépidiques présentent des caractéristiques biologiques spécifiques, expliquant notamment leur mode de progression lépidique et aérologène.

1.7.1. Inflammation alvéolaire et progression tumorale

Une intense réaction inflammatoire alvéolaire est décrite dans les adénocarcinomes lépidiques. Elle correspond à une alvéolite à lymphocytes ou à neutrophiles (15,78). L'alvéolite à neutrophiles est reliée à un mauvais pronostic, expliqué par le rôle important que semble jouer les polynucléaires neutrophiles alvéolaires (PNN) dans la progression tumorale (79). En effet, les PNN sont recrutés par les cellules tumorales via la sécrétion d'IL-8, puissant chemoattractant des PNN (78). Leur survie est également prolongée par l'effet anti-apoptotique de G-CSF et de GM-CSF d'origine tumorale (80). Les PNN recrutés font la promotion de la progression tumorale par deux mécanismes:

- Augmentation de la progression aérologène par augmentation de la desquamation tumorale endo-alvéolaire via une signalisation par contact cellulaire direct PNN-cellules tumorales. Ces mécanismes impliquent des couples molécule-récepteur : intercellular adhesion molecule-1/lymphocyte function-associated antigen-1, tumor necrosis factor α /récepteur au tumor necrosis factor α , l'interleukin-1 α /récepteur à l'interleukin-1 α (81).
- Augmentation de la progression lépidique par la promotion de la motilité cellulaire tumorale par l'Hepatocyte Growth Factor (HGF) synthétisé et sécrété par les PNN endo-alvéolaires (82). Les cellules tumorales expriment le récepteur Met, dont le gène est un oncogène. Une concentration élevée d'HGF endo-alvéolaire est reliée à un mauvais pronostic.

1.7.2. Caractéristiques biologiques des adénocarcinomes lépidiques prédominant et mucineux invasifs

1.7.2.1. Expression de TTF1, CK7 et CK20

Les ALP dérivent des cellules de l'unité respiratoire terminale dont les cellules expriment typiquement le thyroid transcription factor-1 (TTF-1) (49). On retrouve ainsi fréquemment une expression de TTF-1 en immunohistochimie (IHC), bien qu'elle soit faible et non homogène d'une zone tumorale à l'autre. La protéine CK-7 peut aussi être exprimée en IHC alors que l'expression de CK-20 est rare. On retrouve un profil d'expression inverse dans les AMI avec l'absence d'expression de TTF-1 et une fréquence de l'expression de CK-20 témoignant probablement d'une origine cellulaire différente (49).

1.7.2.2. Expression des mucines

La mucosécrétion est une caractéristique commune à de nombreux types d'adénocarcinomes (83). Elle s'explique par la dysrégulation des mucines (MUC), protéoglycanes physiologiquement produit par les cellules épithéliales et constituant fondamental de la couche de mucus protectrice des muqueuses. Cette famille protéique comporte 21 membres de MUC 1 à MUC 21, et promeut la croissance et la résistance à l'apoptose des cellules adénocarcinomeuses des cancers digestifs (83). Une surexpression des mucines est reliée à un mauvais pronostic dans les adénocarcinomes pulmonaires tout venant mais leur rôle précis est encore méconnu (84–86).

Deux études comparent l'expression des mucines entre ALP et AMI (27,87). Une première portait sur l'étude de l'expression des gènes *MUC1*, *MUC2*, *MUC3*, *MUC4*, *MUC5AC*, *MUC5B*, *MUC6*, et *MUC7* en hybridation in situ et de l'expression protéique de *MUC5AC* et *MUC5B* en IHC. Trente-quatre pièces opératoires d'adénocarcinomes pulmonaires dont 8 ALP et 9 IMA étaient analysées, issues d'une cohorte de patients français (87). Les AMI exprimaient l'ensemble des gènes explorés; une surexpression intense et diffuse de *MUC5AC* et *MUC5B* était caractéristique des AMI et inconstamment retrouvée dans les autres tumeurs. Le gène *MUC6* était exprimé uniquement dans les AMI. La deuxième étude portait sur 27 ALP et 7 AMI issus d'une cohorte de patients japonais et étudiait

l'expression de MUC1, MUC2, MUC5AC et MUC6 en IHC (27). De nouveau, les auteurs mettaient en évidence la surexpression de MUC5AC et de MUC6 dans les AMI.

Les cellules caliciformes de l'épithélium respiratoire exprimaient normalement MUC5AC et MUC5B tandis que les métaplasies épidermoïdes perdaient cette expression, suggérant que MUC5AC et MUC5B jouent en rôle dans le maintien d'un phénotype caliciforme et bien différencié des cellules tumorales des AMI (87). La protéine MUC6 était fortement exprimée dans les AMI. Cette information est particulièrement intéressante car il s'agit d'une expression ectopique d'un gène généralement exprimé par les cellules glandulaires pyloriques. L'expression ectopique de MUC6 est retrouvée également dans les adénocarcinomes pancréatiques et est liée à un plus mauvais pronostic. MUC6 pourrait donc jouer un rôle protumoral dans les AMI.

La régulation de l'expression de l'expression des mucines dans les adénocarcinomes lépidiques est pour l'instant inconnue.

1.7.2.3. Oncogènes

Mutation EGFR

La constatation de cas de très bonne réponse aux inhibiteurs de tyrosine kinase de l'epidermal receptor growth factor (ITK-EGFR) dans les adénocarcinomes lépidiques ont permis de mettre en évidence une grande fréquence de mutations activatrices de l'*EGFR* dans ce sous-type histologique (30,66,88–92). Les mutations *EGFR*, de même que l'augmentation du nombre de copie du gène et une polysomie d'*EGFR*, sont quasiment exclusivement observées dans les formes non-mucineuses (tableau 2).

Mutation KRAS

Les mutations de *KRAS* survenant au sein du codon 12 de l'exon 1 sont très fréquemment observées dans les AMI et significativement plus fréquentes comparées aux ALP (tableau 2). Le type de mutations *KRAS* semble également varier entre AMI et LPA (30,66,88–92). Les transitions, particulièrement de type G à A, sont plus fréquentes dans les AMI et chez les non-fumeurs tandis que les transversions sont plus fréquentes dans les ALP et chez les fumeurs.

Le rôle des mutations de *KRAS* semble majeur dans le développement des AMI et s'articule avec la perte de *Nkx2-1* (connus également comme TTF-1). Un travail a démontré qu'un modèle transgénique souris avec un fond génétique *KRAS* G12D développait systématiquement un adénocarcinome pulmonaire mucineux lorsqu'une répression de *Nkx2-1* était induite (93). Cet adénocarcinome pulmonaire est très proche morphologiquement de l'AMI. Il s'agit donc du premier modèle animal d'AMI montrant le rôle pivot de *KRAS* et de la répression de *Nkx2-1* dans sa carcinogénèse.

Tableau 2 : Comparaison de la fréquence de mutation *EGFR* et *KRAS* entre adénocarcinomes lépidiques prédominant (ALP) et adénocarcinomes mucineux invasif (AMI).

	<i>EGFR</i> muté (%)		<i>KRAS</i> muté (%)	
	ALP	AMI	ALP	AMI
Hata et al.	14/24 (58)	3/20 (15)	7/24 (29)	14/20 (70)
Finberg et al.	14/30 (47)	0/13 (0)	3/18 (17)	6/7 (86)
Sakuma et al.	15/17 (88)	2/9 (22)	1/17 (6)	6/9 (67)
Marchetti et al.	22/69 (32)	0/17 (0)	10/69 (14)	13/17 (76)
Wislez et al.	3/25 (12)	0/25 (0)	3/25 (12)	5/25 (20)
Kadota et al.	27/97 (28)	0/36 (0)	21/97 (22)	22/36 (61)
Haichuan et al.	58/71 (82)	6/44 (14)	1/71 (1)	16/44 (36)
Total	153/333 (46)	11/164 (7)	46/333 (14)	82/164 (50)

Gènes de fusion

Les gènes de fusion oncogénique impliquant des protéines à activité tyrosine kinase sont particulièrement fréquent dans les AMI et sont mutuellement exclusifs des mutations *KRAS* (94). Le réarrangement *CD74-NRG1* a été récemment découvert grâce à l'utilisation d'une nouvelle méthode d'analyse corrélant l'étude du nombre de copies de gènes et une étude du transcriptome se concentrant sur des régions du génome tumoral susceptibles d'être des zones de réarrangement ou « break point » (95). Ce réarrangement n'a été retrouvé que chez des patients non-fumeurs et souffrant d'AMI, suggérant donc que cette anomalie oncogénique est spécifique des AMI.

Des auteurs japonais ont réalisé une étude des anomalies oncogéniques à partir d'une cohorte de 90 patients ayant un AMI (94). Cinquante-six étaient mutés pour *KRAS* (62%), 2 pour *BRAF* (2%), un pour *EGFR* (1%) et un présentait un réarrangement de *ALK* (1%). Une analyse transcriptomique à haut débit des 32 AMI restant a permis de retrouver 6 cas de fusion impliquant *NRG1* (*CD74-NRG1* n=5, *SLC3A2-NRG1*, n=1) confirmant l'importance de ce type de fusion. Il est également décrit trois nouveaux réarrangements, *EZR-ERBB4* (n=1), *TRIM24-BRAF* (n=1), and *KIAA1468-RET* (n=1). Finalement, ce travail rapporte 62% de mutations *KRAS*, 11% de fusions oncogéniques et 3% de mutations oncogéniques autres et que seulement 24% des AMI ne présentent pas d'anomalie oncogénique.

Les réarrangements de *ALK*, *RET* et *ROSI* sont associés à une grande fréquence d'architecture cibriforme mucosécrétantes, suggérant un lien entre fusion oncogénique et mucosécrétion (96). Cependant, aucune explication biologique n'a été proposée à ce jour pour expliquer ce lien et il n'est pas démontré que ces oncogènes soit récurrents dans les AMI.

1.7.2.4. Récepteur à l'IGF1

Un travail français incluant exclusivement des adénocarcinomes pulmonaires lépidiques a montré une surexpression en IHC du récepteur à l'IGF1 (IGF1R) dans les AMI (n=32) comparés au ALP (n=48) (97). *In vitro*, une coopération entre les voies de signalisation amphiréguline-EGFR et IGF1/IGF1R était montrée dans une lignée cellulaire mucineuse (H358). Par ailleurs, les auteurs suggèrent que l'inhibition de la voie IGF1/IGF1R pourrait restaurer l'efficacité des ITK-EGFR.

1.8. Traitement

Le traitement de référence des adénocarcinomes lépidiques est la chirurgie, qui peut être curatrice si elle est complète. Dans les formes avancées, les traitements systémiques sont conditionnés par la présence de mutation *EGFR* ou de réarrangement *ALK* et reposent sinon sur une chimiothérapie à base de sel de platine.

1.8.1. Chirurgie

S'agissant du cancer du poumon en général, la chirurgie est le standard thérapeutique pour les maladies résécables et les adénocarcinomes lépidiques obéissent à cette règle. La lobectomie accompagnée d'un curage médiastinal exhaustif est la référence carcinologique. La chirurgie est curatrice dans les AIS et les MIA avec des survies sans rechute virtuellement de 100% à 5 ans. Dans ces cas précis, les résections atypiques peuvent être proposées mais leur place n'est pas clairement définie à l'heure actuelle, car on ne peut pas éliminer un risque de récurrence précoce dans le même lobe (7–9,98,99). La possibilité de résections minimales avec analyse anatomopathologique per-opératoire est actuellement explorée de manière très active par les équipes Asiatiques.

La chirurgie demeure une option dans le cas d'adénocarcinomes lépidiques multifocaux avec atteintes exclusivement pulmonaires et si la totalité des nodules peut être réséquée (51,100–102). Une analyse scrupuleuse des données du scanner thoracique doit exclure toute atteinte micronodulaire diffuse ou du verre dépoli multifocal suggérant une dissémination aéro-gène diffuse de la maladie.

Les tumeurs de présentation pneumonique peuvent être opérées si elles sont considérées comme résécables au prix d'une lobectomie ou d'une bi-lobectomie voir une pneumonectomie (15,45,100). La chirurgie améliore le pronostic même si les rechutes demeurent fréquentes. Dans les formes avancées, une chirurgie palliative d'un foyer pneumonique peut être discutée pour améliorer l'hypoxie secondaire liée à shunt droit-gauche provoqué par le comblement alvéolaire tumoral.

Enfin, se basant sur le fait que les adénocarcinomes lépidiques ne métastasent que rarement en dehors du parenchyme pulmonaire, la transplantation pulmonaire a été considérée comme une option thérapeutique valable. Une série de 26 patients avec une maladie diffuse et

une défaillance respiratoire chronique rapportait une survie à 5 ans de 39% et à 10 ans de 31% (103). D'autres séries présentaient des résultats moins encourageants (104,105). De manière surprenante, une rechute survenait de manière presque systématique dans le poumon natif restant et/ou le greffon (105). La transplantation est désormais considérée comme abandonnée du fait de l'amélioration des résultats des traitements systémiques dans les formes avancées.

1.8.2. Traitements systémiques

La prise en charge thérapeutique des formes diffuses repose essentiellement sur la chimiothérapie et les ITK-EGFR. La radiothérapie thoracique n'a qu'une place très restreinte du fait de la rareté de l'atteinte ganglionnaire (< 25 % des cas).

1.8.2.1. Inhibition de la voie EGFR

La constatation fréquente d'une sur-expression de l'EGFR et d'une amplification et/ou d'une mutation du gène *EGFR* ainsi que l'observation de quelques cas de réponse majeure aux ITK-EGFR ont conduit à la réalisation de plusieurs essais thérapeutiques de phase II avec ces molécules (gefitinib et erlotinib) (106–108). Les principaux résultats de ces essais sont rapportés dans le tableau 3. Il existe une hétérogénéité de réponse tumorale aux ITK-EGFR au sein des malades souffrant d'adénocarcinomes lépidiques, notamment lorsque est pris en compte le sexe, le tabagisme, l'expression de TTF1, la présence de mutation de KRAS, d'une sur-expression d'EGFR ou d'une amplification ou mutation d'EGFR ((91,106–108). Notamment, l'efficacité des ITK-EGFR semble nettement supérieure dans les ALP comparée aux AMI, ou l'usage d'ITK-EGFR semble délétère. Cependant, il est probable que l'efficacité des ITK-EGFR soit essentiellement liée à la présence d'une mutation activatrice d'EGFR, fréquente dans les ALP et rare dans les AMI, et dans une moindre mesure les résistances à la présence d'une mutation KRAS, fréquente dans les AMI. En effet, de larges essais de phase III ont démontré la supériorité des ITK-EGFR à la chimiothérapie en première ligne de traitement de CBNPC avec mutations EGFR, approche qui constitue de standard de traitement (109).

Un anticorps monoclonal humanisé inhibant EGFR, le cetuximab, a été testé en monothérapie dans un essai de phase II après échec de moins de deux lignes de traitement et chez des patients n'ayant pas reçu d'ITK-EGFR (110). Les résultats étaient décevants,

particulièrement en terme de taux de réponse objective évalué à 7% et constituant l'objectif principal.

Tableau 3 : Résultats des essais thérapeutiques de phase II au cours des adénocarcinomes lépidiques avancés

Essais	n	Taux de réponse (%)	Taux de contrôle de la maladie (%)	Survie sans progression (mois)	Survie globale (mois)
Miller, erlotinib	75	22	60	4	17
SO126, gefitinib	69	17	49	3,6	13
IFCT-0401, gefitinib	88	13	30	2,9	13,4
ECOG-1504, cetuximab	68	7	42	3,3	13,0
EORTC 08956, paclitaxel	19	11	54	2	9
SO 9714, paclitaxel	58	14	-	5	12
SO 526, pemetrexed	27	29		6	29

Les cases en gris figurent les objectifs principaux de chaque essai

1.8.2.2. Chimiothérapie

Les adénocarcinomes lépidiques ont longtemps été considérés comme des maladies chimiorésistantes. L'arrivée des chimiothérapies de troisième génération, la constatation en pratique clinique d'une efficacité de la chimiothérapie et des études exploratoires publiées depuis les années 2000 ont battu en brèche cette idée. Le paclitaxel a été testé en première ligne dans deux essais de phase II sans bras contrôle, en monothérapie et les principaux résultats sont rapportés dans le tableau 3 (111,112). Ceux-ci sont conformes à ce qui est attendu avec un médicament de troisième génération en monothérapie et en première ligne, mais les toxicités étaient rédibitoires dans l'essai SO9714 du fait d'un schéma d'administration inadapté. Une étude portant sur l'efficacité de la chimiothérapie après échec

du gefitinib dans l'essai IFCT-0401 a confirmé l'efficacité d'une bithérapie à base de sel de platine et de taxanes ; cette étude a également suggéré une efficacité du pemetrexed et le manque d'efficacité de la gemcitabine (113). Certaines données pré-cliniques concernant l'efficacité du pemetrexed et son efficacité majeure rapportée à l'occasion de quelques cas cliniques en font une molécule d'intérêt dans ce type de tumeurs, justifiant un essai de phase II Nord-Américain dont les résultats figurent dans le tableau 4 (114–117). Le pemetrexed démontre une activité remarquable en monothérapie dans cet essai mais les résultats doivent être nuancés du fait d'un arrêt prématuré de l'essai du fait d'une difficulté de recrutement. Par ailleurs, l'IFCT a évalué au cours d'un essai de phase II randomisé (IFCT-0504) l'impact d'une stratégie comportant : 1) l'utilisation d'un doublet de carboplatine-paclitaxel avec maintenance par le paclitaxel en première ligne en comparaison à l'erlotinib ; 2) l'impact d'une permutation précoce (4 semaines) de traitement en cas de non contrôle de la maladie ; 3) l'intérêt en cas de progression d'une permutation de traitement et enfin 4) l'utilisation du pemetrexed en troisième ligne de traitement. Sur les premières données disponibles, cette stratégie a considérablement amélioré le pronostic des formes étendues faisant passer leur survie globale d'environ 13 mois dans l'essai IFCT-0401 à plus de 20 mois dans l'essai IFCT-0504. La publication de l'étude IFCT-0504 est en cours.

1.8.2.3. Inhibition du protéasome

Des cas de bonne réponse au bortezomib, un inhibiteur du protéasome, dans des adéocarcinomes lépidiques au cours d'essais préliminaires de phase I a motivé un essai de phase II testant le bortezomib après échec de moins de deux lignes de traitement (118). L'efficacité était modeste (tableau 3), notamment s'agissant du taux de réponse à 5%, objectif principal de l'étude.

1.8.2.4. Approche thérapeutique actuelle

Elle repose comme dans les autres CBNPC sur la recherche d'altération oncogénique et plus spécifiquement de mutation activatrice d'*EGFR* et d'un réarrangement *ALK* et *ROS1*. En cas de mutation *EGFR*, le patient devra bénéficier d'un ITK-EGFR, et en cas de réarrangement *ALK* d'un inhibiteur spécifique appelé crizotinib, qui a démontré sa supériorité à la chimiothérapie en première ligne de traitement dans le CBNPC avec translocation *ALK*.

En l'absence de ces altérations oncogéniques, le meilleur régime de traitement est probablement un doublet de chimiothérapie sel de platine-paclitaxel. L'adjonction de bevacizumab doit être discuté comme pour tous les CBNPC (119). Il s'agit d'un anticorps monoclonal humanisé inhibant le VEGF-A, indiqué en première ligne de traitement des CBNPC avancés, et pour lequel il n'y pas de données publiées dans les adénocarcinomes lépidiques. Dans les cas des ALP, les ITK-EGFR représentent une option intéressante après échec de la chimiothérapie, le caractère non-mucineux prédisant une bonne efficacité. En revanche, il est probable que les patients souffrant d'AMI ne bénéficient pas des ITK-EGFR.

Le pemetrexed pourrait être réservé en monothérapie après échec des premières lignes de traitement.

2. Objectif de la thèse

Les adénocarcinomes lépidiques possèdent des caractéristiques cliniques et anatomo-pathologiques très spécifiques qui les individualisent au sein des adénocarcinomes pulmonaires. L'ALP en constitue la forme invasive et possède un variant mucosécrétant l'AMI. Ces deux entités se distinguent par un profil clinique différent et un pronostic semblant plus péjoratif pour les AMI probablement du fait d'une propagation aéro-gène plus rapide et d'un diagnostic au stade d'une atteinte pulmonaire multifocale. Les causes biologiques expliquant ces différences sont mal connues.

L'objectif de ce travail était d'identifier une signature moléculaire spécifique des ALP et des AMI et d'en définir les dérégulations communes et spécifiques. Les résultats ont été exploités afin de tenter d'améliorer la prise en charge thérapeutique des patients souffrant d'ALP et en particulier d'AMI qui ne bénéficient pas actuellement de traitement ciblé efficace.

Nous avons en premier lieu réalisé une description clinique et moléculaire de la cohorte des patients pris en charge dans le service de Pneumologie de l'hôpital Tenon pour un adénocarcinome lépidique en nous concentrant sur les différences entre ALP et AMI et le rôle de la mucosécrétion. Une analyse de l'expression des mucines MUC1, MUC2, MUC5B, MUC5AC et MUC6 a ensuite été réalisée et mise en relation avec les principales anomalies oncogéniques. Une recherche du réarrangement de *NRG1* a également été réalisée dans la cohorte des AMI. Finalement, le dosage d'un panel de cytokines et chimiokines dans les surnageants de LBA de patients avec adénocarcinome lépidique nous a permis d'identifier la voie CXCL10/CXCR3-A comme une boucle autocrine pro-tumorale exploitée par les AMI.

3. Article 1 : étude des caractéristiques cliniques et moléculaires des patients avec adénocarcinomes pneumoniques pris en charge à l'hôpital Tenon et du rôle de la mucosécrétion.

3.1. Article 1

Michael Duruisseaux, Martine Antoine, Nathalie Rabbe, Virginie Poulot, Jocelyne Fleury-Feith, Thibault Vieira, Armelle Lavolé, Jacques Cadranet, Marie Wislez. The impact of intracytoplasmic mucin in lung adenocarcinoma with pneumonic radiological presentation. Lung Cancer. 2014;83:334-340

3.2. Présentation de l'article 1

Ce travail proposait de décrire les caractéristiques cliniques et la présence de mutations *EGFR* et *KRAS* et de réarrangement *ALK* au sein la cohorte des patients avec adénocarcinomes pulmonaires de type « pneumonique », anciennement appelés CBA, pris en charge de 1986 à 2011 au sein du service de pneumologie de l'hôpital Tenon (120). Une étude anatomopathologique exhaustive a été réalisée en appliquant les critères de la classification OMS 2011 des adénocarcinomes pulmonaires et en utilisant une méthode cytochimique appelée PAS-diastrase pour identifier la présence de mucosécrétion intra-cytoplasmique dans les cellules tumorales. Cent-vingt patients étaient identifiés dont 48 (40%) présentaient un AMI et 38 un ALP (32%). La présence d'une mucosécrétion était détectée dans 71 tumeurs (59%) et associée à l'absence de tabagisme, à la présence d'une bronchorrhée et de crépitations à l'auscultation pulmonaire ainsi qu'à une alvéolite à neutrophiles. Dans les tumeurs mucosécrétantes, aucune mutation *EGFR* n'était détectée tandis qu'une mutation *KRAS* ou un réarrangement *ALK* étaient retrouvés dans 32% et 3% des cas, respectivement. Dans les tumeurs non-mucosécrétantes, une mutation *EGFR* ou de *KRAS* étaient détectées dans 17% et 10% des cas, respectivement, et aucun réarrangement *ALK* n'était mis en évidence. L'analyse de survie multivariée montrait que la mucosécrétion, l'alvéolite à neutrophiles et l'absence de traitement chirurgical étaient des facteurs indépendants de mauvais pronostic.

3.3.Commentaires

Ce travail montre que 72% des adénocarcinomes pulmonaires de type « pneumonique », anciennement CBA, correspondent aux AMI et ALP tels qu'ils sont définis dans la nouvelle classification OMS 2011 des adénocarcinomes pulmonaires (2). Une mucosécrétion intra-cytoplasmique était caractéristique des AMI mais pouvait également être détectée au sein de de contingent minoritaire d'autres sous-types histologiques dont les ALP. Cette mucosécrétion était reliée à une valeur indépendante de mauvais pronostic. Cet impact négatif de la mucosécrétion pourrait être due à une dérégulation spécifique de l'expression des mucines sécrétoires et au rôle pro-tumoral que cette dérégulation pourrait jouer. Cette hypothèse est explorée dans l'article 2.

Cette étude a également permis de décrire en détails une cohorte de patients avec AMI et ALP dont nous disposions des prélèvements tumoraux, que nous avons exploités dans la suite de ce travail de thèse.

3.4. Manuscrit article 1



The impact of intracytoplasmic mucin in lung adenocarcinoma with pneumonic radiological presentation



Michael Duruisseaux^a, Martine Antoine^{a,b}, Nathalie Rabbe^{a,e}, Virginie Poulot^{a,c}, Jocelyne Fleury-Feith^d, Thibault Vieira^a, Armelle Lavolé^e, Jacques Cadranel^{a,e}, Marie Wislez^{a,e,*}

^a ER2 UPMC/GRC-UPMC04 Theranoscan, Université Pierre et Marie Curie Paris 6, Paris, France

^b Service d'Anatomie pathologique, Hôpital Tenon, AP-HP, Paris, France

^c Plateforme de Génomique des Tumeurs Solides, Hôpital Tenon, AP-HP, Paris, France

^d Service d'Histologie et de Biologie Tumorale, Hôpital Tenon, AP-HP, Paris, France

^e Service de Pneumologie, Hôpital Tenon, AP-HP, Paris, France

ARTICLE INFO

Article history:

Received 12 August 2013

Received in revised form

29 December 2013

Accepted 31 December 2013

Keywords:

Lung cancer

Lepidic adenocarcinoma

Bronchoalveolar carcinoma

Mucinous variant

Mucosecretion

Prognosis

ABSTRACT

Objectives: This study investigated the clinical and prognostic impact of intracytoplasmic mucin in lung adenocarcinoma with “pneumonic” radiological presentation, formerly known as bronchioloalveolar carcinoma (BAC).

Patients and methods: Between 1986 and 2011, clinical and pathological data from 120 consecutive patients with lung adenocarcinoma with “pneumonic” radiological presentation were reviewed. Intracytoplasmic mucin was assessed using a diastase-resistant periodic acid-Schiff staining. The presence of *EGFR* or *K-Ras* mutations and *ALK* rearrangement were determined in surgical samples.

Results: The two predominant histological patterns were invasive mucinous adenocarcinoma (40%) and lepidic predominant adenocarcinoma (32%). Intracytoplasmic mucin was detected in 71 patients (59.2%) who were more likely to be non-smokers ($p = 0.04$) and have bronchorrhea ($p = 0.006$), crepitanal rales ($p = 0.02$), or neutrophil alveolitis ($p = 0.0004$). In mucin-producing tumors, *EGFR* mutation was not detected, *K-Ras* mutations and *ALK* rearrangement were present in 32% and 3% of cases, respectively. In non-mucin-producing tumors, *EGFR* and *K-Ras* mutations were detected in 17% and 10% of cases, respectively, no *ALK* rearrangement was detected. In univariate analysis, performance status > 0 , crepitanal rales, bronchorrhea, neutrophil alveolitis, bilateral extension, intracytoplasmic mucin and no surgery were associated with worse survival. In multivariate analyses, intracytoplasmic mucin, neutrophil alveolitis, and no surgery were independent factors for worse survival.

Conclusion: Intracytoplasmic mucin is associated with specific clinical characteristics and is an independent factor for worse survival in lung adenocarcinoma formerly known as BAC.

© 2014 Elsevier Ireland Ltd. All rights reserved.

1. Introduction

In the 1999/2004 World Health Organization (WHO) classification bronchioloalveolar carcinoma (BAC) was classified as a subtype of lung adenocarcinoma [1]. BAC was defined as an adenocarcinomatous proliferation along the pre-existing alveolar structure with no evidence of stromal, pleural, or vascular invasion. As a result, diagnosis could only be established after comprehensive pathological analysis of a surgical specimen. BAC was characterized by unique epidemiological, clinical, and radiological features compared to other forms of non-small-cell lung cancer [2,3].

For example, there were fewer smokers and no gender bias in this population of patients. Furthermore, it was characterized by aerogenous spread which explains the high frequency of respiratory signs at diagnosis, pulmonary relapse, and death as a result of respiratory failure [2]. This also explained the so-called “pneumonic” presentation of the disease on chest X-ray as well as the lack of solid lesions [2].

Two histological BAC subtypes could be distinguished: non-mucinous and mucinous. These two subtypes differed in their clinical features, biomarkers, and response to treatment [4–7]. While the non-mucinous subtype seemed to have a more indolent clinical course and a better prognosis than the mucinous subtype, published data were conflicting [8–15]. Surprisingly, the mucinous subtype often exhibited *K-Ras* mutations whereas the non-mucinous subtype frequently had *EGFR* mutations [16–19].

* Corresponding author at: Service de Pneumologie, Hôpital Tenon, 4 rue de la Chine, F-75970 Paris, France. Tel.: +33 156016838; fax: +33 156016991.

E-mail address: marie.wislez@tnn.aphp.fr (M. Wislez).

The two subtypes were diagnosed according to the cell-type aspects obtained from hematoxylin-and-eosin [H&S] stained slides. The non-mucinous subtype tumor cells are a mix of small cuboidal cells, columnar cells with minimal dome-shaping, columnar cells reminiscent of type II pneumocytes, or Clara cells with an eosinophilic cytoplasm. The mucinous subtype tumor cells are tall and well-differentiated cells with basally located nuclei and abundant cytoplasmic mucin.

In 2011, the IASLC/ATS/ERS classification of lung adenocarcinoma highlights the importance of differentiating between mucinous and non-mucinous subtypes [20]. Importantly, the term BAC has been removed in this new pathological classification. Lepidic tumors that are larger than 3 cm in size, contain an invasive focus of more than 5 mm, or are multifocal are to be referred to as lepidic predominant and invasive mucinous adenocarcinoma (IMA) corresponding to non-mucinous BAC and mucinous BAC, respectively [21].

No specific mucin staining is required to define IMA; indeed, demonstration of the presence of mucin is evident without any specific staining. However, we wondered if small amounts of intracytoplasmic mucin detected by diastase-resistant periodic acid-Schiff (PAS) staining could be present in the other patterns of lung adenocarcinomas.

The aim of our study was to determine the clinical and pathological characteristics associated with lung adenocarcinomas, formerly called BAC, with pneumonic presentation with special focus on intracytoplasmic mucin production evaluated by diastase-resistant PAS staining.

2. Materials and methods

2.1. Study design

The database from the Chest Department at Tenon Hospital (Assistance Publique-Hôpitaux de Paris) was retrospectively searched for all patients with adenocarcinoma formerly called BAC with pneumonic presentation, diagnosed between January 1986 and August 2011. To be included, patients had to have a histologically proven lung adenocarcinoma with a pneumonic presentation on chest X-ray as well as consolidation seen on a computed tomography [CT] scan. The chest X-ray and CT scan performed at diagnosis were reviewed by two investigators (MD, MW) before including the data. Exclusion criteria were concomitant bacterial pneumonia, obstructive pneumonia caused by an exophytic lesion that occluded the lumen of the main or lobar bronchi, and prior diagnosis of lung cancer or non-eradicated extrathoracic adenocarcinoma.

All patients had provided informed consent. The samples were collected according to French legislation and the ethical rules of our institution at the time of the study were respected.

2.2. Data collection

The following data were recorded at the time of diagnosis.

- Epidemiological data (age, gender, smoking habits); never smokers were defined as patients who had smoked less than 100 cigarettes in their lifetime.
- Clinical data (performance status [PS], weight loss, crepitan rales, bronchorrhea, cough, dyspnea); bronchorrhea was defined as sputum production >100 mL per day.
- Diagnostic procedures (fiberoptic bronchoscopy with bronchoalveolar lavage [BAL], transbronchial biopsy, CT-guide transthoracic biopsy or fine-needle aspiration, open lung biopsy, complete surgical resection).

- Clinical and pathological TNM classification (according to the seventh edition) [22]. Clinical TNM staging always included a CT scan of the chest and adrenal glands and an abdominal ultrasound or CT scan of the liver. CT or magnetic resonance imaging, scan of the brain, a bone scan, or positron-emission tomography with 18-fluorodeoxyglucose performed according to the current guidelines of the corresponding time-inclusion period. Patients with an indeterminate tumor size, because of a pneumonic-like presentation, were classified as Tx.
- Follow-up data: date of relapse, date and cause of death.

2.3. Histological review and classification

All specimens were reviewed (MA, MD). Tumors were classified using the specific terminology and criteria of the 2011 IASLC/ATS/ERS classification of lung adenocarcinoma [20]. For surgical samples, predominant and minor histological patterns as well as cell-type were specified, i.e., lepidic predominant adenocarcinoma (previously called non-mucinous BAC), or, papillary, acinar, micropapillary, solid and IMA (previously called mucinous BAC). For small samples, any identifiable pattern present was described.

2.4. Determination of intracytoplasmic mucin production

Presence of intracytoplasmic mucin production was assessed using diastase-resistant PAS staining in all samples with a 5% increment. A tumor was considered as "mucin producing" if there was more than 5% of a stained cell at 50× magnification in any histological pattern of tumor (lepidic, papillary, acinar, micropapillary, or solid) [16]. The corresponding histological pattern was specified. Diastase-resistant PAS staining in IMA was also performed and quantified as an internal positive control.

2.5. EGFR and K-Ras gene mutations and ALK rearrangement analysis

For each formalin-fixed, paraffin-embedded specimen, a 3- μ m tissue section was stained with H&S and examined by light microscopy to determine the presence of tumor cells. After isolating the DNA (QIAamp DNA mini kit, Qiagen, Courtaboeuf, France) from three 20- μ m tissue sections, *EGFR* 18–21 and *K-Ras* 2 exons were amplified and sequenced in both directions, as previously described [23]. Sequenced data were then analyzed using SeqScape software [16]. Immunostaining of the ALK fusion protein was performed on 3- μ m tissue sections and processed by a Benchmark Ventana staining module (Ventana, Roche Diagnostics, Meylan, France) using the primary monoclonal antibody against ALK (Clone 5A4, Ab 17127; Abcam, Paris, France) diluted at 1:50 for 2 h at 37 °C, as previously described [24]. A positive external control was performed, using an adenocarcinoma specimen that had been previously validated for ALK rearrangement by fluorescent in situ hybridization [FISH]. The percentage of positive cells was evaluated and staining scores were assessed as follows: 0, no staining; 1+, faint cytoplasmic staining; 2+, moderate cytoplasmic staining; and 3+, intense granular cytoplasmic staining. The presence of 10% of cells stained with an intensity of ≥ 2 was considered as positive staining [24]. Specimens with a positive score were tested for ALK rearrangement by FISH. Briefly, FISH was performed on unstained 4- μ m formalin-fixed, paraffin-embedded, tumor-tissue sections using an ALK break-apart probe set (Vysis LSI ALK Dual Color, Break Apart Rearrangement Probe; Abbott Molecular, Rungis, France) and a paraffin-pretreated reagent kit (Vysis, Abbott Molecular) according to the manufacturer's instructions. Tumor tissues were considered ALK-FISH positive if >15% of the cells showed split red and green signals and/or single red signals [24].

Table 1
Clinical characteristics of the 120 patients according to intracytoplasmic mucin status.

	Total cohort (n = 120) n (%)	Mucin producing (n = 71) n (%)	Non-mucin producing (n = 49) n (%)	p-Value
Age (years)				0.17
>65	53 (44.2)	35 (49)	18 (37)	
≤65	67 (55.8)	36 (51)	31 (63)	
Gender				0.05
Female	51 (42.5)	25 (35)	26 (53)	
Male	69 (57.5)	46 (65)	23 (47)	
Smoking status				0.04
Never smoked	37 (30.8)	27 (38)	10 (20)	
Former or current	83 (69.2)	44 (62)	39 (80)	
Performance status				0.56
0	75 (62.5)	43 (61)	32 (65)	
>0	43 (35.8)	27 (38)	16 (33)	
MD	2 (1.7)	1 (1)	1 (2)	
Loss of weight				0.18
Yes	15 (12.5)	11 (15)	4 (8)	
No	96 (80)	53 (75)	43 (88)	
MD	9 (7.5)	7 (10)	2 (4)	
Bronchorrhea				0.006
Yes	23 (19.2)	19 (27)	4 (8)	
No	87 (72.5)	44 (62)	43 (88)	
MD	10 (8.3)	8 (11)	2 (4)	
Crepitant rales				0.02
Yes	52 (43.3)	36 (51)	16 (33)	
No	57 (47.5)	27 (38)	30 (61)	
MD	11 (9.2)	8 (11)	3 (6)	
Bilateral disease				0.09
Yes	60 (50)	40 (56)	20 (41)	
No	60 (50)	31 (44)	29 (59)	
Extra thoracic metastasis				0.72
Yes	4 (3.3)	2 (3)	2 (4)	
No	109 (90.8)	64 (90)	45 (92)	
NA	7 (5.9)	5 (7)	2 (4)	
Hilar/mediastinal adenopathy				0.89
Yes	13 (10.8)	6 (9)	7 (14)	
No	107 (89.2)	65 (91)	42 (86)	
Stage IIIB/IV				0.08
Yes	54 (45)	36 (51)	18 (37)	
No	59 (49.1)	30 (42)	29 (59)	
NA	7 (5.9)	5 (7)	2 (4)	

MD, missing data; NA, data not available.

Frequency of clinical characteristics of mucosecretant and non-mucosecretant samples compared using the χ^2 test.

2.6. Statistical analysis

Comparisons between qualitative and quantitative variables were performed using the χ^2 test and the Mann–Whitney non-parametric test, respectively. Survival rates were calculated using the Kaplan–Meier method. Univariate analysis was first undertaken, followed by Cox's multivariate analysis, which included all variables with a significance level of $p < 0.1$ to identify variables associated with a risk of death. Two-sided p -values < 0.05 were considered to indicate statistical significance. Date of diagnosis was defined as the date of pathological diagnosis. The statistical tests were performed using SPSS 20.0 (IBM Corporation, New York, USA).

3. Results

3.1. Clinical characteristics

Between 1986 and 2011, 120 patients met the inclusion criteria. Their clinical characteristics are shown in Table 1. Five patients had a history of surgically treated cancer and were considered cured: bladder cancer ($n = 2$), cutaneous basocellular epithelioma ($n = 1$), breast cancer ($n = 4$, T1–T2N0M0), head and neck cancer ($n = 1$), Hodgkin's lymphoma ($n = 1$), and prostatic cancer ($n = 3$).

Specific histological markers for breast and prostatic cancers were not expressed in lung tumors.

3.2. Fiberoptic bronchoscopy and BAL results

Fiberoptic bronchoscopy was performed in all the 120 patients. BAL was performed in 105 patients (87.5%) and tumor cells were detected in 54 of them (51.4%). Cytological analysis of BAL revealed an increased total cell count (535 ± 83 cells/mm³) and an increased neutrophil cell count (196 ± 53 /mm³, $24.4 \pm 2.9\%$) (Table 2).

3.3. Histological findings

Diagnosis was obtained by surgical sample from a complete resected tumor in 57 of the 120 patients (47.5%) and by small histological sample in 63 (52.5%) (transbronchial biopsy: $n = 50$, 41.7%; transthoracic needle biopsy: $n = 9$, 7.5%; open-lung biopsy: $n = 4$, 3.3%). The two predominant histological patterns were IMA (40%) or lepidic adenocarcinoma (32%) (Table 3). In two cases with radiological presentation as small solitary alveolar opacity of less than 3 cm, the diagnosis was minimally invasive adenocarcinomas. One was a mucinous predominant tumor with a foci of less than 5 mm of mucin-producing solid adenocarcinoma and the other, a

Table 2
Cytological analysis of BAL of the total cohort and according to intracytoplasmic mucin status.

	All patients (n = 105)	Mucin producing (n = 62)	Non-mucin producing (n = 43)	p-Value
Tumor cells in BAL				
Yes	54 (51.4)	33 (53.2)	21 (48.8)	0.658
No	51 (48.6)	29 (46.8)	22 (51.2)	
Total cell count				
Cells/mm ^{3,2}	535 ± 83	491 ± 99	593 ± 161	0.851
Macrophages				
%	61.2 ± 2.7	52.8 ± 4.1	73.3 ± 3.3	0.263
Number/mm ^{3,2}	240 ± 38	181 ± 30	318 ± 83	0.096
Neutrophils				
%	24.4 ± 2.9	33.3 ± 4.5	11.9 ± 3.1	0.0004
Number/mm ^{3,2}	196 ± 53	253 ± 89	121 ± 58	0.045
Lymphocytes				
%	13 ± 1	12.9 ± 1.7	13.2 ± 1.6	0.902
Number/mm ^{3,2}	52 ± 9	46 ± 12	59 ± 17	0.86

BAL: bronchoalveolar lavage.

The frequency of tumor cells in BAL was compared between mucin producing and non-mucin producing samples using the χ^2 test. The mean numbers of cells were compared between mucin producing and non-mucin producing samples using the Mann-Whitney test.² Counts per mm³ of total BAL fluid.**Table 3**
Predominant histological patterns of the cohort and according to intracytoplasmic mucin status.

	Total cohort (n = 120) n (%)	Mucin producing (n = 71) n (%)	Non-mucin producing (n = 49) n (%)
Invasive mucinous	48 (40)	48 (68)	0
Lepidic	38 (31.6)	8 (11)	30 (61)
Acinar	16 (13.3)	2 (3)	14 (29)
Papillary	16 (13.3)	12 (17)	4 (8)
Others	0	0	0
Not identifiable	2 (1.8)	1 (1)	1 (2)

Others: Colloid, fetal and enteric variants.

predominant lepidic adenocarcinoma with a foci of less than 5 mm of mucin-producing acinar adenocarcinoma.

As the lung adenocarcinomas were heterogeneous from an histological point of view, there was a risk of bias of the predominant histological pattern by type of sample (surgical vs. small biopsy). We therefore analyzed the patterns according to the type of sample. IMA or lepidic adenocarcinoma were the most frequent patterns in both surgical and small biopsy samples (Supplementary Tables 1 and 2).

Diastase-resistant PAS staining resulted in 71 patients (59.2%) being classified as mucin-producing and 49 as non-mucin-producing (40.8%).

As expected, all IMA were positive for diastase-resistant PAS staining (with a mean of positive tumoral cells at 85% ± 15, see Supplementary Table 3) and IMA was the most frequent predominant pattern associated with mucin-producing tumors (68%) and lepidic adenocarcinoma with non-mucin-producing tumors (61%) (Fig. 1).

Comprehensive pathological analysis of the mucin-producing tumors in surgical samples (n = 28) showed that IMA was the predominant pattern in 46% of cases followed by papillary in 32%, lepidic in 18% and acinar in 4% (Supplementary Table 3). Mucin-producing cells were detected in both predominant and minor patterns (Supplementary Table 3).

Comprehensive pathological analysis of non-mucin-producing tumors in surgical samples (n = 29) showed that lepidic adenocarcinoma was the predominant pattern in 69% of cases followed by acinar in 21%, and papillary 10% (Supplementary Table 4).

3.4. Clinical features of mucin producing and non-mucin producing samples

The clinical characteristics of patients classified as mucin-producing and non-mucin-producing by diastase resistant PAS staining are shown in Table 1. Patients with mucin-producing

adenocarcinoma were more likely to be non-smokers (38% vs. 20%, $p=0.04$) and have bronchorrhea (27% vs. 8%, $p=0.006$) and crepitant rales (51% vs. 33%, $p=0.021$). Total and differential neutrophil cell counts in the BAL fluid were higher in mucin-producing than in non-mucin-producing samples (253 ± 89 vs. 121 ± 58/mm³, $p=0.045$, and 33.3 ± 4.5% vs. 11.9 ± 3.1%, $p=0.0004$, respectively) (Table 2).

3.5. EGFR, K-Ras, and ALK status

EGFR mutations were found in five (9%) and K-Ras mutations in 12 (21%) of the 57 surgical samples. One sample (2%) was positive for ALK rearrangement. The three oncogenic abnormalities were mutually exclusive. All the EGFR mutations were found in non-mucin-producing samples (5/29, 17%). Nine samples with K-Ras mutations were mucin-producing (9/28, 32%) and three non-mucin-producing (3/29, 10%). All except one were smokers. The specimen positive for ALK rearrangement was mucin-producing.

3.6. Survival analyses

No patient was lost to follow-up. Eighty-nine (74.2%) patients had died at the time of survival analysis. Fifty-five of these patients (61.8%) died of disease progression with the cause of death being respiratory failure for 44 (80%) of them. The median survival time after diagnosis was 14.2 months (range: 1–150 months). Univariate analysis revealed that PS > 0 ($p < 0.0001$), bronchorrhea ($p = 0.004$), crepitant rales ($p = 0.001$), tumor cells in BAL ($p = 0.015$), a high neutrophil count ($p = 0.001$), bilateral pulmonary extension ($p < 0.0001$), intracytoplasmic mucin ($p < 0.0001$) and non-surgical treatment ($p = 0.0001$) were linked to shorter survival times (Table 4). In the multivariate analyses, intracytoplasmic mucin ($p = 0.033$), a high neutrophil count ($p = 0.011$), and non-surgical

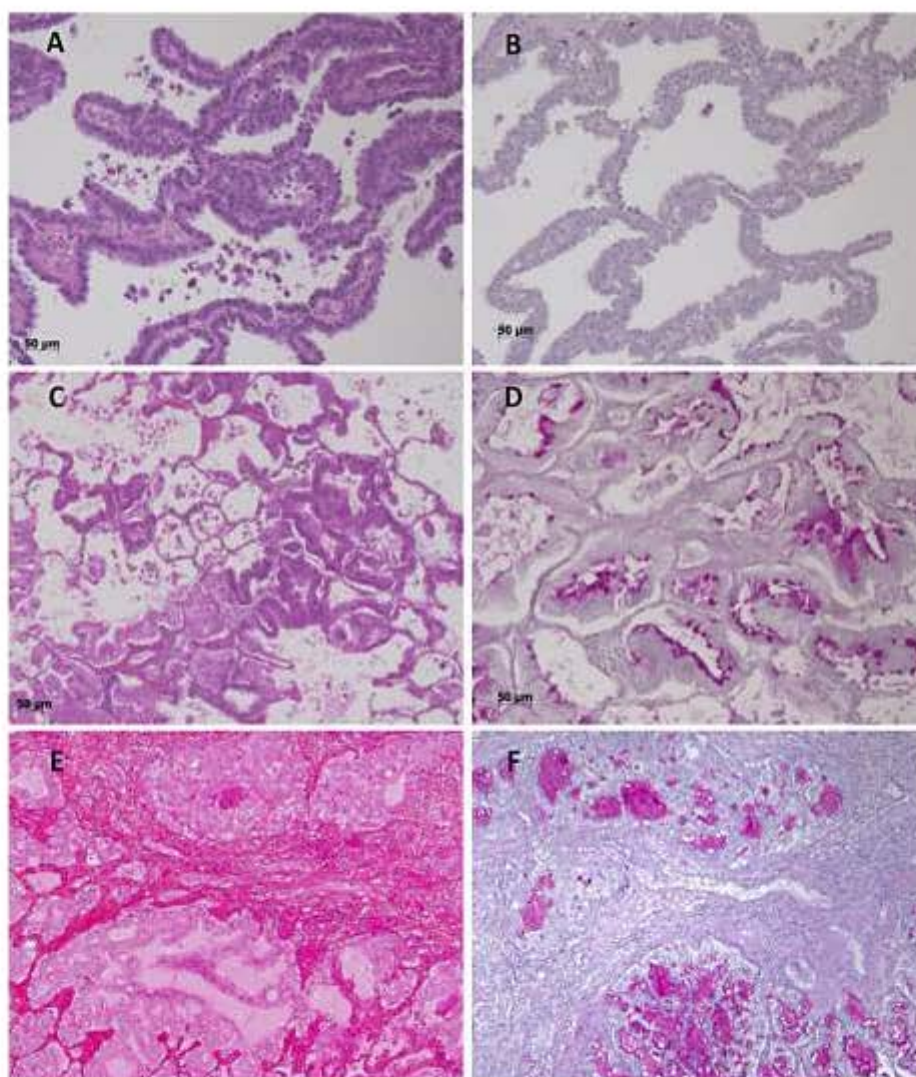


Fig. 1. (A) H&S staining of a lepidic adenocarcinoma (original 20 \times). (B) Diastase-resistant PAS staining of the same case (A) showing no PAS diastase positive intracytoplasmic vesicles (original 20 \times). (C) H&S staining of a mucinous adenocarcinoma (original 20 \times). (D) Diastase-resistant PAS staining of the same case (C) showing PAS diastase positive intracytoplasmic grains (original 20 \times). (E) H&S staining of an acinous predominant adenocarcinoma with a mucinous adenocarcinoma pattern (original 20 \times). (F) Diastase-resistant PAS staining of the same case (in E) showing PAS diastase positive intracytoplasmic vesicles in acinous and mucinous pattern (original 20 \times).

treatment ($p=0.003$) were independent prognostic factors for shorter survival times.

4. Discussion

This study shows that the two predominant histological patterns in patients with lung adenocarcinoma with a “pneumonic” presentation on chest X-ray, are IMA (40%) and lepidic adenocarcinoma (31.6%). Intracytoplasmic mucin was detected in 59% of our samples by diastase-resistant PAS staining. As expected, positive diastase-resistant PAS staining was predominant in IMA but was also observed in other histological patterns, such as papillary, acinar, or lepidic. Lastly, the presence of mucin producing cells was associated with a specific clinical phenotype and was a prognostic factor for shorter survival in multivariate analyses.

All the histological samples in our study were centrally reviewed and the predominant histological pattern was defined as recommended by the 2011 IASLC/ATS/ERS lung adenocarcinoma classification [20]. Morphological criteria, i.e., the presence of goblet or columnar-cell morphology with intracytoplasmic mucin, were used to define IMA. We found a predominant IMA pattern in 40% of cases. Compared to previously published BAC studies this

high proportion of IMA pattern is probably because we selected patients with “pneumonic” presentation [8–15]. IMA are believed to have a more aggressive clinical course by aerogenous spread with more frequent pulmonary multilobar or bilateral extension at diagnosis.

Intracytoplasmic mucin was quantified by diastase-resistant PAS staining with a 5% increment. The threshold of 5% PAS-positive cells in samples has been previously used in the *Intergrupee Franco-phonie de Cancérologie Thoracique* 0401 (IFCT-0401) and IFCT-0504 prospective trials [16,25]. All the tumors with IMA in surgical samples were positive for diastase-resistant PAS staining. Interestingly, other predominant histological patterns, such as a papillary, acinar, or lepidic pattern, demonstrated intracytoplasmic mucin. This was also found in the small samples. Lastly, solid and micro papillary adenocarcinomas were not a predominant pattern observed in this cohort and were rarely observed as a minor pattern (Supplementary Table 3). These data are consistent with our previous comprehensive analysis of 19 surgical samples of adenocarcinoma with pneumonic presentation and suggest that pneumonic presentation is rarely related to those two histological patterns [2].

The presence of intracytoplasmic mucin allowed us to distinguish a specific phenotype. Patients diagnosed with

Table 4
Univariate and multivariate analyses of factors associated with survival.

Variable	No. of patients	Univariate hazard ratio (95% CI)	p-Value	Multivariate hazard ratio (95% CI)	p-Value
Performance status					
>0	75	2.385 (1.537–3.700)	<0.0001		
=0	43	1			
Crepitant rales					
Presence	52	2.059 (1.327–3.194)	0.001		
Absence	57	1			
Bronchorrhea					
Presence	23	1.459 (1.130–1.883)	0.004		
Absence	87	1			
BAL tumor cells					
Yes	54	1.746 (1.112–2.743)	0.015		
No	51	1			
Neutrophil alveolitis, %					
>Median	57	2.252 (1.400–3.622)	0.001	1.962 (1.164–3.306)	0.011
<Median	58	1			
Bilateral extension					
Yes	60	2.369 (1.536–3.655)	<0.0001		
No	60	1			
Intracytoplasmic mucin					
Yes	71	2.264 (1.446–3.544)	<0.0001	1.860 (1.051–3.294)	0.033
No	49	1			
Surgical treatment					
No	63	3.367 (2.153–5.264)	0.0001	5.610 (1.793–17.549)	0.003
Yes	57	1			

Variables with a $p < 0.1$ in univariate analysis were entered into the multivariate analysis and were selected using a backward procedure. HR, hazard ratio; 95% CI, 95% confidence interval; BAL, bronchoalveolar lavage.

mucin-producing tumors were more likely to be non-smokers and have bronchorrhea, crepitant rales and intense neutrophil alveolitis. We also showed a link between the presence of neutrophils and intracytoplasmic mucin. This has already been reported for gastric, colo-rectal, pancreatic, biliary duct, and ovarian carcinoma, in which tumor-associated neutrophils have been associated with a mucinous subtype [26]. In inflammatory bronchial diseases, lung-infiltrating neutrophils release factors that enhance the expression of mucin [27,28]. Whether mucin expression from tumor cells can play a role in the recruitment and activation of neutrophils is unknown. In BAC, tumor cells are believed to drive neutrophil recruitment and neutrophil survival in the alveolar space [29,30]. Activated neutrophils promote arogenous spread of tumor cells via expression of factors that can stimulate desquamation and motility of tumor cells [31,32]. In our study, neutrophil alveolitis and intracytoplasmic mucin emerged as two independent factors for a shorter survival time.

Determinants of the negative prognostic significance of intracytoplasmic mucin, independently of neutrophil alveolitis, should be investigated. Mucins are constitutively secreted in the epithelium and play an important role in protecting the cell monolayers of the lung and in regulating inflammation at the epithelium surface [26]. Dysregulation of the mucin-gene expression can promote tumor growth and is associated with poor prognosis in lung, colorectal, breast, prostate, and thyroid cancers [26]. Whether intracytoplasmic mucin can be induced by oncogene activation needs to be determined.

Lastly, patients diagnosed with mucin-producing tumors were less often smokers but did not have mutated *EGFR*. *K-Ras* mutations were more frequently detected in mucin-producing (32%) than non-mucin-producing surgical samples (10%), as previously described [16–19]. The first transgenic mouse model of mucinous adenocarcinomas of the lung has recently been engineered with a combination of haploinsufficiency of *Nkx2-1* (also known as *TTF-1*) and oncogenic *K-ras* [33]. In this model, pulmonary tumors are seen to be phenotypically similar to human IMA. This strongly suggests that the *K-Ras* oncogene and haploinsufficiency of *Nkx2-1* might be involved in the acquisition of a mucin-producing phenotype in human lung carcinogenesis.

In conclusion, “pneumonic” adenocarcinomas that spread arogenously, formerly called BAC, present more frequently as IMA or lepidic adenocarcinoma. As expected, intracytoplasmic mucin production is present in IMA, but also in other patterns. Patients diagnosed with mucin-producing tumors share common clinical characteristics, including an intense neutrophil alveolitis. Almost half of the patients have extensive disease but extra pulmonary metastases are very rare. This is the reputation of IMA but interestingly, this is true for mucin-producing adenocarcinomas non IMA. Lastly, mucin-producing tumors demonstrate a shorter survival and we suggest that neutrophilic alveolitis play an important role in this poor prognosis. Molecular mechanisms involved in intracytoplasmic mucin production are largely unknown and should be investigated in future studies.

Conflict of interest statement

All the authors have no financial or personal conflicts of interest to report.

Acknowledgments

M. Duruisseaux is a post-doctoral fellow funded by “Le Fond de dotation “Recherche en Santé Respiratoire” 2010. T. Vieira is a post-doctoral fellow funded by “Le Fond de dotation “Recherche en Santé Respiratoire” 2011. This study has been supported by “Subvention 2010 et 2011 Leg Poix – La Chancellerie des Universités de Paris”.

Appendix A. Supplementary data

Supplementary data associated with this article can be found, in the online version, at <http://dx.doi.org/10.1016/j.lungcan.2013.12.016>.

References

- [1] Travis WD, Brambilla E, Muller-Hermelink HK, Harris CC. Pathology and genetics of tumors of the lung, pleura, thymus and heart. In: World Health Organisation classification of tumours. Lyon, France: IARC Press; 2004.

- [2] Wislez M, Massiani M-A, Milleron B, Souidi A, Carrette MF, Antoine M, et al. Clinical characteristics of pneumonic-type adenocarcinoma of the lung. *Chest* 2003;123(6):1868–77.
- [3] Garfield DH, Cadranet J, Wislez M, Franklin WA, Hirsch FR. The bronchioloalveolar carcinoma and peripheral adenocarcinoma spectrum of diseases. *J Thorac Oncol* 2006;1(4):344–59.
- [4] Garfield DH, Cadranet J, West HL. Bronchioloalveolar carcinoma: the case for two diseases. *Clin Lung Cancer* 2008;9(1):24–9.
- [5] Lee HY, Lee KS, Han J, Kim BT, Cho YS, Shim YM, et al. Mucinous versus nonmucinous solitary pulmonary nodular bronchioloalveolar carcinoma: CT and FDG PET findings and pathologic comparisons. *Lung Cancer* 2009;65:170–5.
- [6] Miyake H, Matsumoto A, Terada A, Yoshida S, Takaki H, Mori H. Mucin-producing tumor of the lung: CT findings. *J Thorac Imaging* 1995;10:96–8.
- [7] Sato K, Ueda Y, Shikata H, Katsuda S. Bronchioloalveolar carcinoma of mixed mucinous and nonmucinous type: immunohistochemical studies and mutation analysis of the p53 gene. *Pathol Res Pract* 2006;202:751–6.
- [8] Breathnach OS, Kwiatkowski DJ, Finkelstein DM, Godleski J, Sugarbaker DJ, Johnson BE, et al. Bronchioloalveolar carcinoma of the lung: recurrences and survival in patients with stage I disease. *J Thorac Cardiovasc Surg* 2001;123(1):42–7.
- [9] Ebbert JO, Chhatwani L, Aubry MC, Wampfler J, Stoddard S, Zhang F, et al. Clinical features of bronchioloalveolar carcinoma with new histologic and staging definitions. *J Thorac Oncol* 2010;5(8):1213–20.
- [10] Casali C, Rossi G, Marchioni A, Sartori G, Maselli F, Longo L, et al. A single institution-based retrospective study of surgically treated bronchioloalveolar adenocarcinoma of the lung: clinicopathologic analysis, molecular features, and possible pitfalls in routine practice. *J Thorac Oncol* 2010;5(6):830–6.
- [11] Carretta A, Canneto B, Calori G, Ceresoli GL, Campagnoli E, Arrigoni G, et al. Evaluation of radiological and pathological prognostic factors in surgically-treated patients with bronchoalveolar carcinoma. *Eur J Cardiothorac Surg* 2001;20(2):367–71.
- [12] Daly RC, Trastek VF, Pairolero PC, Murtaugh PA, Huang MS, Allen MS, et al. Bronchoalveolar carcinoma: factors affecting survival. *Ann Thorac Surg* 1991;51(3):368–76, discussion 376–377.
- [13] Regnard JF, Santelmo N, Romdhani N, Gharbi N, Bourcereau J, Dulmet E, et al. Bronchioloalveolar lung carcinoma: results of surgical treatment and prognostic factors. *Chest* 1998;114(1):45–50.
- [14] Dumont P, Gasser B, Rougé C, Massard G, Wihlm JM. Bronchoalveolar carcinoma: histopathologic study of evolution in a series of 105 surgically treated patients. *Chest* 1998;113(2):391–5.
- [15] Volpino P, Cavallaro A, Cangemi R, Chiarotti F, De Cesare A, Fiori E, et al. Comparative analysis of clinical features and prognostic factors in resected bronchioloalveolar carcinoma and adenocarcinoma of the lung. *Anticancer Res* 2003;23(6D):4959–65.
- [16] Wislez M, Antoine M, Baudrin L, Poulot V, Neuville A, Praderé M, et al. Non-mucinous and mucinous subtypes of adenocarcinoma with bronchioloalveolar carcinoma features differ by biomarker expression and in the response to gefitinib. *Lung Cancer* 2010;68(2):185–91.
- [17] Hata A, Katakami N, Fujita S, Kaji R, Imai Y, Takahashi Y, et al. Frequency of EGFR and KRAS mutations in Japanese patients with lung adenocarcinoma with features of the mucinous subtype of bronchioloalveolar carcinoma. *J Thorac Oncol* 2010;5(8):1197–200.
- [18] Finberg KE, Sequist LV, Joshi VA, Muzikansky A, Miller JM, Han M, et al. Mucinous differentiation correlates with absence of EGFR mutation and presence of KRAS mutation in lung adenocarcinomas with bronchioloalveolar features. *J Mol Diagn* 2007;9(3):320–6.
- [19] Sakuma Y, Matsukuma S, Yoshihara M, Nakamura Y, Noda K, Nakayama H, et al. Distinctive evaluation of nonmucinous and mucinous subtypes of bronchioloalveolar carcinomas in EGFR and K-ras gene-mutation analyses for Japanese lung adenocarcinomas: confirmation of the correlations with histologic subtypes and gene mutations. *Am J Clin Pathol* 2007;128(1):100–8.
- [20] Travis WD, Brambilla E, Noguchi M, Nicholson AG, Geisinger K, Yatabe Y, et al. International association for the study of lung cancer/American thoracic society/European respiratory society international multidisciplinary classification of lung adenocarcinoma. *J Thorac Oncol* 2011;6(2):244–85.
- [21] Travis WD, Brambilla E, Riely GJ. New pathologic classification of lung cancer: relevance for clinical practice and clinical trials. *J Clin Oncol* 2013;31(8):992–1001.
- [22] Goldstraw P, Crowley J, Chansky K, Giroux DJ, Groome PA, Rami-Porta R, et al. The IASLC Lung Cancer Staging Project: proposals for the revision of the TNM stage groupings in the forthcoming (seventh) edition of the TNM Classification of malignant tumours. *J Thorac Oncol* 2007;2:706–14.
- [23] Lynch TJ, Bell DW, Sordella R, Gurubhagavatula S, Okimoto RA, Brannigan BW, et al. Activating mutations in the epidermal growth factor receptor underlying responsiveness of non-small-cell lung cancer to gefitinib. *N Engl J Med* 2004;350(21):2129–39.
- [24] Yi ES, Chung J-H, Kullig K, Kerr KM. Detection of anaplastic lymphoma kinase (ALK) gene rearrangement in non-small cell lung cancer and related issues in ALK inhibitor therapy: a literature review. *Mol Diagn Ther* 2012;16(3):143–50.
- [25] Cadranet J. Therapeutic strategy in advanced bronchioloalveolar carcinoma; 2008. Available at: <http://clinicaltrials.gov/show/NCT00384826> [accessed 26.09.08].
- [26] Kufe DW. Mucins in cancer: function, prognosis and therapy. *Nat Rev Cancer* 2009;9(12):874–85.
- [27] Voynow JA, Young LR, Wang Y, Horger T, Rose MC, Fischer BM. Neutrophil elastase increases MUC5AC mRNA and protein expression in respiratory epithelial cells. *Am J Physiol* 1999;276(5 Pt 1):L835–43.
- [28] Shao MXG, Nadel JA. Neutrophil elastase induces MUC5AC mucin production in human airway epithelial cells via a cascade involving protein kinase C, reactive oxygen species, and TNF-alpha-converting enzyme. *J Immunol* 2005;175(6):4009–401.
- [29] Bellocq A, Antoine M, Flahault A, Philippe C, Crestani B, Bernaudin JF, et al. Neutrophil alveolitis in bronchioloalveolar carcinoma: induction by tumor-derived interleukin-8 and relation to clinical outcome. *Am J Pathol* 1998;152(1):83–92.
- [30] Wislez M, Fleury-Feith J, Rabbe N, Moreau J, Cesari D, Milleron B, et al. Tumor-derived granulocyte-macrophage colony-stimulating factor and granulocyte colony-stimulating factor prolong the survival of neutrophils infiltrating bronchoalveolar subtype pulmonary adenocarcinoma. *Am J Pathol* 2001;159(4):1423–33.
- [31] Wislez M, Antoine M, Rabbe N, Goumant V, Poulot V, Lavolé A, et al. Neutrophils promote aerogenous spread of lung adenocarcinoma with bronchioloalveolar carcinoma features. *Clin Cancer Res* 2007;13(12):3518–27.
- [32] Wislez M, Rabbe N, Marchal J, Milleron B, Crestani B, Mayaud C, et al. Hepatocyte growth factor production by neutrophils infiltrating bronchioloalveolar subtype pulmonary adenocarcinoma: role in tumor progression and death. *Cancer Res* 2003;63(6):1405–12.
- [33] Maeda Y, Hao H, Tompkins DH, Xu Y, Mucenski ML, Du L, et al. Kras(G12D) and Nkx2-1 haploinsufficiency induce mucinous adenocarcinoma of the lung. *J Clin Invest* 2012;122(12):4388–400.

4. Article 2 : étude de l'expression de MUC1, MUC2, MUC5B, MUC5AC et MUC6 dans les adénocarcinomes lépidiques prédominants et mucineux invasifs

4.1. Article 2

Duruisseaux Michaël, Antoine Martine, Mathiot Nathalie, Rodenas Anita, Lacave Roger, Poulot Virginie, Mc Leer-Florin Anne, Van Seulingen Isabelle, Duchêne Belinda, Cadranel Jacques, and Wislez Marie. Lepidic predominant adenocarcinoma and invasive mucinous adenocarcinoma display specific mucin expression. En cours d'écriture

4.2. Présentation de l'article 2

Les ALP se caractérisent par une prolifération de cellules de petite taille non mucosécrétantes. Les AMI sont constitués de cellules de grande taille avec un cytoplasme occupé par des vacuoles de mucines donnant typiquement un aspect caliciforme (« goblet cell »). Il a été suggéré une expression différentielle de MUC1, MUC2, MUC5B, MUC5AC et MUC6 au niveau ARN messenger ou protéique entre ALP et AMI (87,121). Nous proposons dans ce travail d'étudier l'expression protéique de ces mucines dans des pièces opératoires d'ALP et d'AMI et de rechercher un lien éventuel avec les caractéristiques cliniques des patients et les anomalies oncogéniques usuelles.

Une étude en IHC de l'expression de MUC1, MUC2, MUC5B, MUC5AC et MUC6 a été réalisée sur les tissus tumoraux de 52 patients (AMI, n=25 ; LPA, n=27), ainsi qu'une recherche des mutations oncogéniques *EGFR*, *KRAS*, *BRAF* et *HER2* et des réarrangements *ALK*, *ROS1* et *NRG1*. De façon attendue, les ALP étaient plus fréquents chez les fumeurs et plus souvent mutés pour EGFR tandis que les AMI survenaient préférentiellement chez des non-fumeurs et étaient significativement plus souvent mutés pour KRAS. Le sex ratio était comparable entre ALP et AMI.

MUC1 était plus fréquemment et plus fortement exprimé par les ALP que par les AMI. MUC2 n'était exprimé que dans un seul prélèvement sur les 52 et qui était un AMI. MUC5B, MUC5AC et MUC6 étaient plus fréquemment et plus fortement exprimés par les

AMI que les ALP, et leur expression était typiquement retrouvée dans le cytoplasme des cellules tumorales de type caliciforme (« goblet cells). Les tumeurs avec mutations *EGFR* (n=5) étaient toujours de type ALP et exprimaient fortement MUC1 tandis qu'elles n'exprimaient jamais MUC5B, MUC5AC et MUC6. Les tumeurs avec mutations *KRAS* (n=16) étaient majoritairement de type AMI et exprimaient plus fréquemment et plus intensément MUC5B et MUC5AC que les tumeurs sauvages pour *KRAS*.

Ce travail permet de dégager un profil d'expression spécifique des mucines par les AMI et les ALP, avec une surexpression de MUC1 dans les ALP comparée aux AMI et une expression plus fréquente et plus intense de MUC5B, MUC5AC et MUC6 dans les AMI comparée au ALP. Cette différence de profil s'explique en partie par le lien entre mutation *EGFR* et *KRAS* et expression des mucines. En effet, MUC1 est surexprimée dans les tumeurs *EGFR* mutées qui sont toutes de type ALP tandis que MUC5B et MUC5AC sont plus fréquemment et plus intensément exprimées dans les tumeurs mutés *KRAS*.

4.3. Données de la littérature à propos des mucines

4.3.1. Structures et fonctions

Les mucines sont une famille de protéines fortement glycosylées au niveau de séquences répétées d'acides aminés proline-thréonine-sérine (PTS) (83). La famille des mucines chez l'humain comporte 21 membres, de MUC1 à MUC21, et sont classées en mucines sécrétoires et transmembranaires. Les mucines sécrétoires forment un gel muqueux qui forme une barrière physique fournissant une protection aux cellules épithéliales de l'épithélium respiratoire et digestif et également des canaux sécrétoires hépatiques, pancréatiques, mammaires et rénaux. Les mucines transmembranaires jouent un rôle essentiel dans le maintien de cette couche de gel muqueux entre 10 et 100 nm de la surface cellulaire appelée glycocalyx (83).

4.3.2. Mucines et poumon

Physiologiquement, les mucines sont secrétées par les cellules caliciformes de l'épithélium respiratoire et protègent les voies respiratoires et l'épithélium alvéolaire. L'expression de MUC1 est faible et se cantonne au niveau trachéo-bronchique (83). MUC2 est faiblement exprimée dans l'ensemble de l'épithélium et parfois plus fortement au pôle

basal des cellules caliciformes, mais indétectable au sein de l'épithélium bronchiolaire et alvéolaire (122). MUC5B est fortement exprimée dans l'épithélium bronchique et dans les cellules caliciformes des glandes sous muqueuses tandis que MUC5AC est exprimé dans l'épithélium trachéobronchique et également dans les cellules caliciformes (122). MUC6 n'est pas exprimé dans l'épithélium respiratoire normal.

4.3.3. Mucines et cancer : l'exemple de MUC1

La surexpression de mucines transmembranaires est très fréquente et associée à un mauvais pronostic dans divers carcinomes et joue un rôle dans la promotion de la survie et de la croissance tumorale (83). MUC1 en représente le prototype.

Ainsi, la surexpression de MUC1 est un marqueur de mauvais pronostic dans les cancers du sein, de la thyroïde, de la prostate et du poumon (83,123). La mesure de la portion N-terminale circulante MUC1-N dans le sang, plus connu sous le nom de CA15-3, est un marqueur de réponse au traitement dans le cancer mammaire utilisé en pratique clinique (124). La surexpression de MUC1 semble être induite par un environnement pro-inflammatoire, notamment par les cytokines pro-inflammatoires comme le $TNF\alpha$, l' $IFN\gamma$ et l'IL-6 qui activent les facteurs de transcription $NF-\kappa B$ et STAT1/3 déclenchant la transcription de MUC1 (125–127). Cela conduit également à l'activation de la sous-unité C terminale de MUC1, MUC1-C, qui inhibe l'apoptose et est transloquée dans le noyau afin de déclencher la transcription d'un programme de gènes faisant la promotion de la prolifération et de la survie. La surexpression de MUC1 induit une tumorigenèse de la glande mammaire dans des modèles de souris transgéniques (128). MUC1-C peut interagir avec EGFR via leurs domaines extracellulaires et limiter la dégradation d'EGFR faisant donc la promotion de la signalisation EGFR (129–131). MUC1-C peut également s'associer et participer à la signalisation d'ERBB2 à 4, de FGFR3, de PDGFR β et de MET (83).

4.3.4. Mucines et cancer du poumon

4.3.4.1. Mucine transmembranaire : MUC1

Une hyperexpression de MUC1 est associée à tous les stades de la carcinogénèse pulmonaire et à tous les sous-types de CBNPC. MUC1 est considéré comme une protéine oncogénique dont l'hyperexpression est de mauvais pronostic (132). Cette surexpression est

associée *in vitro* à une augmentation de l'expression de VEGF par une activation de la voie AKT et ERK et il existe une corrélation positive entre densité de la néo-vascularisation dans les tumeurs pulmonaires et l'expression de MUC1 (133). MUC1 est impliquée dans l'acquisition de capacité de croissance cellulaire indépendante de l'ancrage à la matrice extracellulaire ou bien de l'adhésion cellules à cellules (134). Les lignées cellulaires de cancers du poumon KO pour MUC1 acquièrent une résistance à l'apoptose et au cisplatine (135). MUC1-C est également capable de s'oligomériser avec EGFR par l'intermédiaire de la galectine 3 et d'activer la voie EGFR et également la voie PI3K/AKT de manière autonome (83,131). Il a été montré que l'inhibition de MUC1-C inhibait le signal de survie induit par EGFR dans les modèles de cancer du poumon avec mutation *EGFR* et représentait donc une approche thérapeutique potentielle dans les cancers du poumon avec mutations *EGFR* (136).

4.3.4.2. Mucine sécrétoire : MUC5AC

L'essentiel des données disponibles sur le rôle des mucines sécrétoires dans le cancer du poumon concerne MUC5AC, qui fait partie des mucines codées par un cluster de gène en 11p15, en l'occurrence MUC2, MUC5AC, MUC5B et MUC6.

L'expression tumorale de MUC5AC est associée à une augmentation du risque de métastase et à une diminution de la survie globale et est clairement associée aux sous-types de cancers pulmonaires mucosécrétants dont les AMI (137). La régulation de son expression dans le cancer du poumon n'est qu'incomplètement comprise. L'activation d'EGFR par le TNF α aboutie à la synthèse de MUC5AC via l'activation de la voie des MAP kinases. (138) Un travail récent a montré qu'un modèle transgénique de souris associant un fond génétique avec mutation *KRAS* G12D et une haplo-insuffisance pour *Nkx2-1* (correspondant à TTF-1) aboutissait à l'apparition systématique d'un adénocarcinome pulmonaire morphologiquement identique à l'AMI humain avec notamment des cellules tumorales d'allure caliciforme (93). Les auteurs ont identifié un programme de gène directement impliqué dans ce modèle dans l'acquisition du phénotype tumorale caliciforme (goblet) dont font partie les gènes MUC5AC et MUC5B. L'expression de ces deux mucines serait donc gouvernée par l'activation de la voie *KRAS* combinée à la répression de *Nkx2-1*.

L'impact biologique de l'hyperexpression de MUC5AC est inconnu dans le cancer pulmonaire.

Aucune donnée n'existe concernant l'expression de MUC2, MUC5B, et MUC6 dans le cancer du poumon à l'exception des travaux ayant rapporté une expression préférentielle de MUC5B et MUC6 dans les IMA tandis que MUC2 était exprimé dans les IMA et les ALP et d'un travail suggérant un rôle de MUC2 et MUC6 dans la dissémination ganglionnaire (86,87,121).

4.4. Commentaires

Nous confirmons que les ALP et les AMI possèdent un profil d'expression spécifique de MUC1, MUC5B, MUC5AC et MUC6 au niveau protéique. La surexpression de MUC1 dans les ALP et de MUC5B, MUC5AC et MUC6 dans les AMI avait été suggérée au niveau ARN messager ou protéique dans de précédents travaux.

Notre travail apporte de nouvelles informations concernant le lien entre expression des mucines et anomalies oncogéniques. Ainsi, les tumeurs avec mutations *EGFR* étaient toutes des ALP et présentaient une expression intense de MUC1 et une absence d'expression de MUC5B, MUC5AC et MUC6. Cela renforce l'hypothèse soulevée in vitro d'un rôle important de MUC1-C dans le signal de survie médié par l'activation de la voie EGFR dans les cellules de cancer pulmonaire mutée *EGFR*. Le statut muté *KRAS* était étroitement lié aux AMI et à la surexpression de MUC5B et MUC5AC au sein des cellules tumorales de morphologie caliciforme. Cela correspond parfaitement aux données issues de l'étude du modèle de souris transgénique *KrasG12D/Nkx2-1^{+/-}* suggérant que la combinaison de ces deux anomalies génomiques conduit à l'expression d'un programme de gènes comprenant MUC5B et MUC5AC et aboutissant au développement de cellules tumorales adénocarcinomeuses pulmonaires de morphologie caliciforme.

4.5. Manuscrit de l'article 2

Lepidic predominant adenocarcinoma and invasive mucinous adenocarcinoma display specific mucin expression

Duruisseaux Michaël¹, Antoine Martine^{1,2} Mathiot Nathalie¹, Rodenas Anita², Lacave Roger³, Poulot Virginie^{1,3}, Mc Leer-Florin Anne⁴, Van Seulingen Isabelle⁵, Duchêne Belinda⁵, Cadranel Jacques^{1,6}, and Wislez Marie^{1,6}

1. Sorbonne Universités, UPMC Univ. Paris 06, GRC n°04, TheraScan, 4 rue de la Chine, F-75252 Paris
2. AP-HP, Hôpital Tenon, Service d'Anatomie pathologique, 4 rue de la Chine, F-75970 Paris
3. AP-HP, Hôpital Tenon, Plateforme de Génomique des Tumeurs Solides, 4 rue de la Chine, F-75970 Paris
4. Plateforme de Génétique Moléculaire des Tumeurs, Pôle de Biologie et Pathologie CHU Grenoble et INSERM U 823-Institut A Bonniot-Université J Fourier, Grenoble
5. Centre de recherche Jean-Pierre Aubert, Université de Lille, Unité INSERM UMR-S1172, Lille
6. AP-HP, Hôpital Tenon, Service de Pneumologie, 4 rue de la Chine, F-75970 Paris

INTRODUCTION

Lung cancer is the leading cause of cancer mortality worldwide, and 80% of lung cancers are non-small cell lung cancers (NSCLC). The most frequent type of NSCLC is invasive lung adenocarcinomas (LUAC) sub classified in five subtypes called lepidic, acinar, solid, papillary or micropapillary. Among them, lepidic predominant adenocarcinomas (LPA) demonstrate very specific characteristics. Indeed LPA are characterized by a unique histological pattern i.e. “lepidic growth” and a preferred lung dissemination by aerogenous spread. Lepidic growth is defined as a proliferation of pneumocytic cells growing along the native alveolar structure. Aerogenous spread correspond to the implantation of cells at sites non-contiguous with the primary tumor. Compared to other adenocarcinoma subtypes, LPA affects a population of patients, which are less frequently smokers and more frequently women.

LPA is a non-mucinous LUAC but mucinous variant exists, designated as invasive mucinous adenocarcinoma (IMA). In IMA, tumoral cells are tall and well-differentiated cells with basally located nuclei and are characterized by abundant cytoplasmic mucin. IMA demonstrate a worse prognosis than LPA probably because of its aerogenous spreading explaining its propensity for multicentric and bilateral lung involvement. The importance to separate LPA and IMA was one of the focuses of the 2011 IASLC/ATS/ERS classification of lung adenocarcinoma. LPA are associated with *EGFR* mutations whereas IMA with *KRAS* mutations and oncogenic fusion genes.

The human mucin (MUC) family has been sub-classified into secreted and transmembrane mucins. The secreted mucins MUC2, MUC5AC, MUC5B and MUC6 are encoded by the cluster of genes at locus 11p25 and form a physical barrier for

epithelial cells that line the respiratory and digestive tracts. The transmembrane mucins, for example MUC1, have a single membrane-spanning region and contribute to the protective mucous gel.

Nevertheless, deregulations in mucins expression are observed in carcinomas and could enhance survival and growth capacities of tumor cells. MUC1 has been shown to be a marker of poor prognosis in lung cancer. Overexpression of MUC1 favors proliferation and survival of lung cancer cells and MUC1 can interact with EGFR to promote proliferation. MUC2, MUC5AC, MUC5B and MUC6 role lung cancer cells biology are not well know.

In this study, we sought to describe the pattern of MUC1, MUC2, MUC5B, MUC5AC and MUC6 protein expression in IMA and LPA and relationship to clinical characteristics and common driver oncogenes.

MATERIAL AND METHOD

Patients

Between January 1992 and December 2012, 52 patients with IMA (n=25) and LPA (n=27) were diagnosed in the respiratory medicine department (Tenon Hospital, Assistance Publique-Hôpitaux de Paris, Paris, France) and were surgically treated. The diagnosis was reviewed for all patients by a lung pathologist (MA) based on the 2011 International Association for the Study of Lung Cancer/American Thoracic Society/European Respiratory Society (IASLC/ATS/ERS) lung adenocarcinoma classification. Clinical findings at diagnosis and follow-up data were recorded. All patients signed a research informed consent form, permitting analysis of their biological samples. This study was approved by our hospital's ethics human research committee.

***EGFR, KRAS, BRAF and HER2* mutation analyses**

For each formalin-fixed paraffin-embedded (FFPE) specimen, a 3- μ m tissue section was stained with H&S and examined by light microscopy to determine the percentage of tumor cells. After DNA isolation (QIAamp DNA mini kit, Qiagen, Courtaboeuf, France) from three 20 μ m tissue sections, *EGFR* mutations G719S, T790M and L858R (exons 18, 20 and 21, respectively), *KRAS* mutations G12S, G12R, G12C, G12A, G12V and G13D (exon 2) and *BRAF* mutations V600E and V600K (exon 15) were detected with TaqMan® Assays (Custom TaqMan® SNP Genotyping Assays, Life Technologies SAS, Saint Aubin, France). *EGFR* exon 19 deletions, *EGFR* exon 20 insertions and *EGFR* exon 20 insertions and *HER2* exon 20 insertion were detected by sizing analysis. Sequencing data were then analyzed using SeqScape software.

ALK and ROS1 immunohistochemistry

Immunostainings of the ALK and ROS1 fusion proteins were performed on 3- μ m tissue sections on a Benchmark Ventana staining module (Ventana, Roche Diagnostics, Meylan, France) using a primary monoclonal ALK antibody (Clone 5A4, Ab 17127; Abcam, Paris, France) or a primary monoclonal ROS1 antibody (Clone D4D6, #3287, Cell Signaling Technology, Danvers, MA, USA), as previously described. Positive external controls were performed, using a LUAC specimen that had been previously validated for *ALK* rearrangement by fluorescent in situ hybridization and the *ROS1*-rearranged cell line HCC78. The staining scores were assessed as follows: 0, no staining; 1+, faint cytoplasmic staining; 2+, moderate cytoplasmic staining; and 3+, intense granular cytoplasmic staining. The presence of 10% of cells stained with an intensity of ≥ 2 was considered as positive staining. Specimens with a positive staining score were tested for *ALK* or *ROS1* rearrangement by FISH.

***ALK*, *ROS1* and *NRG1* break-apart FISH**

FISH was performed on unstained 4- μ m FFPE tumor-tissue sections using an *ALK* break-apart probe set (Vysis LSI *ALK* Dual Color, Break Apart Rearrangement Probe; Abbott Molecular, Rungis, France) or a ZytoLight® SPEC *ROS1* Dual Color Break Apart Probe (ZytoVision, Bremerhaven, Germany) and a paraffin-pretreated reagent kit (Vysis, Abbott Molecular) according to the manufacturer's instructions. Tumor tissues were considered *ALK*- or *ROS1*-FISH positive if >15% of the cells showed split orange and green signals and/or single orange signals.

As *NRG1* fusions have been described in tumors without *EGFR/KRAS/BRAF/HER2* mutations and *ALK/ROS1* rearrangements, *NRG1* break-apart FISH was performed only in pan wild-type samples.

An *NRG1* specific fluorescent DNA probe was used, kindly provided by Zytovision (Zytolight SPEC *NRG1* Dual Color Break Apart, Zytovision, Bremerhaven, Germany). Tumor tissues were considered *NRG1*-FISH positive when >15% of the nuclei harbored either a split pattern with 3' and 5' signals separated by a distance superior to the diameter of the largest signal, or isolated 3' (orange) signals.

Mucin immunohistochemistry

Immunostaining of MUC1, MUC2, MUC5B, MUC5AC and MUC6 proteins was performed on 3- μ m tissue sections and processed by a BenchMark ULTRA Ventana® staining module (Ventana Medicals System, Roche Group, Tucson, AZ). Antigens were retrieved with CC1 pH 8,8 EDTA antigen retrieval solution (Ventana Medicals System). The primary monoclonal antibodies against MUC1 (clone Ma695, 1/400, Novocastra), MUC2 (clone cp58, 1/50, Novocastra), MUC5B (clone provided by Dr D. Swallow in Medical Research Council, London, UK, 1/800), MUC5AC (clone CLH2, 1/50, Novocastra) and MUC6 (clone CLHH5, 1/50, Novocastra) were incubated for 36 minutes respectively at 37°C. Ultra View DAB detection kit ® (Ventana Medicals System, Roche Group) were used for detection.

Three investigators (MD, MA and NM), blinded to the clinico-pathological variables, independently evaluated the immunostaining and came to a clear agreement. The scores (scale: 0–300) were ascribed by multiplying the percentage of positive stained cells (0-100% by 5% increment) by staining intensity (1+, 2+ or 3+). Tumor samples were considered positive when the immunostaining score was ≥ 10 .

Statistical analysis

Mucin immunohistochemistry staining score were expressed as median±interquartile range (IQR). For quantitative variables, comparisons were made using the Mann-Whitney non-parametric tests. For qualitative variables, the chi-squared test was used for comparisons and Spearman's rank correlation coefficient (ρ) for correlation analysis. A p -value <0.05 was considered statistically significant.

All findings were processed using SPSS 20.0 software (IBM Corporation).

RESULTS

Patient and tumour characteristics

Clinical and molecular findings of the 52 patients (IMA, n=25; LPA, n=27) are summarized in Table 1. Patients were female in 48% of the cases and non-smokers in 27%. Compared to LPA, patients with IMA were more frequently non-smokers ($p=0.04$), had more frequently *KRAS* mutations ($p=0.009$) and never had *EGFR* mutation ($p=0.024$). One patient had an *HER2* mutation and was a Caucasian heavy-smoker woman with LPA. Oncogenic rearrangements were identified in 3 patients, which were all IMA: one *ALK* rearrangement in a Caucasian smoker male, one *ROS1* rearrangement in a Caucasian non-smoker woman and one *NRG1* rearrangement in an Asian non-smoker woman. All driver oncogenes were mutually exclusive.

Mucin expression in tumor cells and normal adjacent lung tissue

MUC1, MUC2, MUC5B, MUC5AC and MUC6 expression was studied by immunohistochemistry. Representative pathological findings were shown in Figure 1.

MUC1 was expressed in the apical cytoplasmic membrane of tumor cells in 77% of cases; the median staining score was 80 (10-155). Hyperplasia of type II pneumocytes adjacent to adenocarcinoma weakly expressed MUC1.

MUC2 was not expressed, except in a single case of IMA with an intense cytoplasmic staining in almost all tumor cells. A weak staining was detected in mucous cells of submucosal glands and at the basal pole of normal goblet cells of the respiratory epithelium. MUC2 was not considered for following analysis.

MUC5B was expressed in the cytoplasm of tumor cells in 63% of patients; the median staining score was 35 (0-200). The staining was typically observed in intra-

cytoplasmic vacuoles of goblet cells in IMA. MUC5B was expressed in normal bronchiolar cells in all the patients.

MUC5AC was expressed in the cytoplasm of tumor cells in 36% of patients; median staining score was 0 (0-52.5). MUC5AC was preferentially expressed in goblet cells in IMA. No staining was detected in normal lung adjacent to the tumor.

MUC6 was expressed in the cytoplasm of tumor cells in 21% of patients; median staining score was 0 (0-0). MUC6 staining was exclusively detected in goblet cells in IMA.

Mucin expression according to clinical characteristics profile

Age, gender and smoking status were tested for a significant association with mucin expression. As shown in Table 2, only smoking status differed significantly according to mucin expression. MUC1 expression was less frequently expressed in non-smokers ($p=0.003$) whereas MUC5B, MUC5AC and MUC6 were more common in non-smokers ($p=0.043$, $p=0.012$, $p=0.02$, respectively).

Mucin expression according histological subtype

MUC1, MUC5B, MUC5AC and MUC6 expression were compared between IMA and LPA (Table 3, Figure 2).

MUC1 was more commonly expressed in LPA compared to IMA ($p=0.033$) (Table 3) and MUC1 staining score was also significantly higher in LPA compared to IMA (40 [0-110] vs. 120 [40-160], respectively; $p=0.0225$, Figure 2).

MUC5B, MUC5AC and MUC6 expression were strongly associated to IMA compared to LPA (Table 3, Figure 2). MUC5B, MUC5AC and MUC6 expression was more

frequent in IMA compared to LPA (Table 3). MUC5B staining scores was significantly higher in IMA compared to LPA (160 [60-240] vs. 0 [0-30], respectively; $p < 0.0001$), as MUC5AC staining scores (30 [0-240] vs. 0 [0-0], respectively; $p < 0.0001$) and MUC6 staining scores (0 [0-25] vs. 0 [0-0], respectively; $p < 0.0015$).

MUC1 score negatively correlated to MUC5B ($r = -0.501$, $p < 0.0001$), MUC5AC ($r = -0.395$, $p = 0.004$) and MUC6 ($r = -0.302$, $p = 0.02$) (Figure 3). MUC5B staining score strongly correlated to MUC5AC ($r = -0.665$, $p < 0.0001$) and to a lesser extent to MUC6 ($r = -0.429$, $p = 0.0015$). Finally, MUC5AC staining score strongly correlated to MUC6 ($r = -0.697$, $p < 0.0001$).

Overall, IMA commonly expressed MUC5B, MUC5AC and sometimes MUC6 and less commonly MUC1 expression. LPA widely expressed MUC1, sometimes MUC5B, and uncommonly MUC5AC and MUC6.

Mucins expression according to *EGFR* and *KRAS* status

Five patients had an *EGFR* mutation. MUC1 was always and strongly expressed in *EGFR* positive tumors (190 [160-285]) while MUC5B, MUC5AC and MUC6 were never detected (supplementary table 1).

Thirteen patients had *KRAS* mutation. MUC5B and MUC5AC were more frequently expressed in *KRAS* positive tumors than in *KRAS* negative tumors ($p = 0.002$ and $p = 0.001$, respectively). MUC5B and MUC5AC staining scores were significantly higher in *KRAS* positive tumors than in *KRAS* negative tumors (supplementary table 1).

DISCUSSION

The present study assessed the profile of expression of MUC1, MUC2, MUC5B, MUC5AC and MUC6 at the protein level in 25 IMA and 27 LPA. We provide evidence of two opposite patterns of mucin expression that differentiate IMA and LPA. IMA expressed MUC5B and MUC5AC, sometimes MUC6 and less commonly MUC1. Conversely LPA typically expressed MUC 1, less frequently MUC5B and did not express MUC5AC and MUC6. There was a clear relationship between common driver oncogenes and mucin expression. *EFGR* mutated tumors showed a strong expression of MUC1 and a lack of expression of MUC5B, MUC5AC and MUC6. *KRAS* mutated tumors frequently and strongly expressed MUC5B and MUC5AC.

This study showed that IMA expressed preferentially secreted mucins encoded by the cluster of genes at locus 11p25 gene cluster (MUC2, MUC5B, MUC5AC, MUC6). However, MUC2 was detected only in one IMA case. Two previous studies reported MUC2 protein expression by immunohistochemistry using the same primary antibody than in our study. MUC2 staining was positive in 17.5% of IMA in the 40 patients reported by Tsuta et al. In another study, MUC2 expression was estimated as high (>30% of tumor cells) in 60% of the 27 LPA and 43% of 7 IMA reported by Awaya et al. .In our study, appropriate external and internal positive controls were used and validated the quality of our assay. MUC2 is a major component of intestinal mucus and play a role for the prevention of inflammation in the intestinal epithelium. Loss of MUC2 expression increases survival and proliferation of intestinal epithelial cells, supporting its role as a tumour suppressor gene in intestine adenocarcinoma. Our results showed that MUC2 expression was down-regulated in lepidic adenocarcinoma and suggest that MUC2 could play a tumor suppressor role in this histological subtype.

MUC1 overexpression was associated with *EGFR* mutation and is mutually exclusive with MUC5B, MUC5AC and MUC6 expression. MUC1 overexpression is common in human cancers and lung cancers in particular and has not been associated to any specific activating mutations. MUC1-C subunit is an oncoprotein involved in tumorigenesis of breast and ovarian cancer *in vitro*. In NSCLC, MUC1-C interacts with EGFR and targeting MUC1-C suppresses EGFR activation and downstream AKT and MEK pathways. Combination of afatinib, an irreversible inhibitor of EGFR and GO-203, which targets MUC1-C, is synergistic in inhibiting the growth of NSCLC cells with *EGFR* mutations and T790M secondary resistance mutation. Our results have to be confirmed in a largest cohort of EGFR mutated patient.

MUC5B, MUC5AC and MUC6 were overexpressed in IMA, specifically in goblet cells. We demonstrated that MUC5B and MUC5AC protein expression was more frequent and strongly expressed in *KRAS* positive tumors. The first transgenic mouse model of mucinous adenocarcinomas of the lung has been engineered with the combination of *KRAS* mutation and the haplo insufficiency of *Nkx2-1* gene (also known as TTF-1). In this model, tumor cells were similar to human goblet tumour cells observed in IMA. A number of mRNAs including MUC5AC and MUC5B were increased in lungs of *Kras*^{G12D}/*Nkx2-1*^{+/-} mice. This supports the concept that haplo insufficiency of *Nkx2-1* and *KRAS* mutation promote goblet cells phenotype via the expression of a specific subset of genes including MUC5AC and MUC5B genes.

MUC6 is aberrantly expressed in some IMA and not in normal lung. MUC6 is normally expressed in pyloric mucus gland and is associated to pancreatic and gastric carcinoma. As previously suggested, the aberrant expression of MUC6 in some IMA supports that this subtype of lung adenocarcinoma originates from a

common endodermal precursor cell with the potential for multicellular differentiation including expression of gastric mucins.

We provide evidence of a specific profile expression of mucins in IMA and LPA. MUC5B and MUC5AC expression may play an important role in the typical goblet cell phenotype observed in IMA and is triggered by *KRAS* mutation. MUC1 could be an interesting target in LPA with *EGFR* mutation.

Table 1. Clinical and molecular characteristics of patients according to histological subtype

Table 2. Clinical characteristics according to MUC1, MUC5B, MUC5AC and MUC6 expression

Table 2. Mucin expression according to histological subtypes

Figure 1. A and B: Hematoxylin and eosin staining in IMA and LPA respectively. C and D: MUC1 staining in IMA and LPA, respectively. E and F: MUC5B staining in IMA and LPA, respectively. G and H: MUC5AC staining in IMA and LPA, respectively. I and J: MUC6 staining in IMA and LPA, respectively.

Figure 2. Comparison of mucin expression in IMA and LPA. A: MUC1 staining score. B: MUC5B staining score. C: MUC5AC staining score. D: MUC6 staining score. Central bars : median ; upper and lower bars : 25% and 75% IQR. Mann-Whitney test.

Figure 3. Correlation between mucin staining scores. A, B and C: Correlation of MUC1 with MUC5B, MUC5C and MUC6 staining score, respectively. D and E: Correlation of MUC5B with MUC5AC and MUC6 staining score, respectively. F: Correlation of MUC5AC with MUC6 staining. Spearman's rho test.

Table 1. Clinical and molecular characteristics of the patients according to histological subtype

	Total cohort (n=52) n (%)	IMA (n=25) n (%)	LPA (n=27) n (%)	p*
Age (years)				0.918
>65	17 (33)	8 (32)	9 (33)	
≤65	35 (67)	17 (68)	18 (67)	
Gender				0.262
Female	25 (48)	10 (40)	15 (55)	
Male	27 (52)	15 (60)	12 (45)	
Race				0.931
Caucasian	46 (88)	21 (84)	25 (92)	
Asian	2 (4)	1 (4)	1 (4)	
North african	4 (8)	3 (12)	1 (4)	
Smoking status				0.040
Never	14 (27)	10 (40)	4 (15)	
Former or current	38 (73)	15 (60)	23 (85)	
TNM				0.243
T1-2 N0	24 (46)	9 (36)	15 (55)	
T3N0	2 (4)	1 (4)	1 (4)	
T3N1-2	2 (4)	1 (4)	1 (4)	
TxN0	24 (46)	14 (56)	10 (37)	
Driver oncogene				
<i>EGFR</i> mutation	5 (10)	0	5 (18)	0.024
<i>KRAS</i> mutation	16 (31)	12 (48)	4 (15)	0.009
<i>HER2</i> mutation	1 (2)	0	1 (4)	0.294
<i>BRAF</i> mutation	0	0	0	—
<i>ALK</i> rearrangement	1 (2)	1 (4)	0	0.294
<i>ROS1</i> rearrangement	1 (2)	1 (4)	0	
<i>NRG1</i> rearrangement	1 (2)	1 (4)	0	0.294

*P value for comparison between clinical characteristics of IMA and LPA. Frequency compared using χ^2 test.
IMA: invasive mucinous adenocarcinoma; LPA: lepidic predominant adenocarcinoma

Table 2. Clinical characteristics of the patients according to MUC1, MUC5B, MUC5AC and MUC

	MUC1 + (n=40)	MUC1 - (n=12)	p	MUC5B + (n=33)	MUC5B - (n=19)	p	MUC5AC + (n=19)	MUC5AC- (n=33)	p	MUC6 + (n=11)	MUC6 - (n=41)	p
Age (years)			0.068			0.618			0.938			0.245
≤65	22 (55)	3 (25)		15 (45)	10 (53)		9 (47)	16 (48)		7 (64)	18 (44)	
Gender			0.417			0.282			0.938			0.245
Female	18 (45)	7 (58)		14 (42)	11 (58)		9 (47)	16 (48)		7 (64)	18 (44)	
Smoking status			0.003			0.043			0.012			0.02
Never	7 (17.5)	7 (58)		12 (37)	2 (11)		9 (47)	5 (15)		6 (54)	8 (19)	

*p value for comparison between clinical characteristics of positive or negative MUC expression. Frequency compared using χ^2 test.

Table 3. Mucin expression according to histological subtypes

	IMA (n=25) n (%)	LPA (n=27) n (%)	p
MUC1 expression			0.033
Yes	16 (64)	24 (89)	
No	9 (17)	3 (11)	
MUC5B expression			<0.0001
Yes	22 (88)	9 (33)	
No	3 (12)	16 (59)	
MUC5AC expression			<0.0001
Yes	16 (64)	3 (11)	
No	9 (17)	24 (89)	
MUC6 expression			0.001
Yes	10 (40)	1 (4)	
No	15 (60)	25 (93)	

* Frequency compared using χ^2 test.

IMA: invasive mucinous adenocarcinoma; LPA: lepidic predominant adenocarcinoma

Figure 1. A and B: Hematoxylin and eosin staining in IMA and LPA respectively. C and D: MUC1 staining in IMA and LPA, respectively. E and F: MUC5B staining in IMA and LPA, respectively. G and H: MUC5AC staining in IMA and LPA, respectively. I and J: MUC6 staining in IMA and LPA, respectively

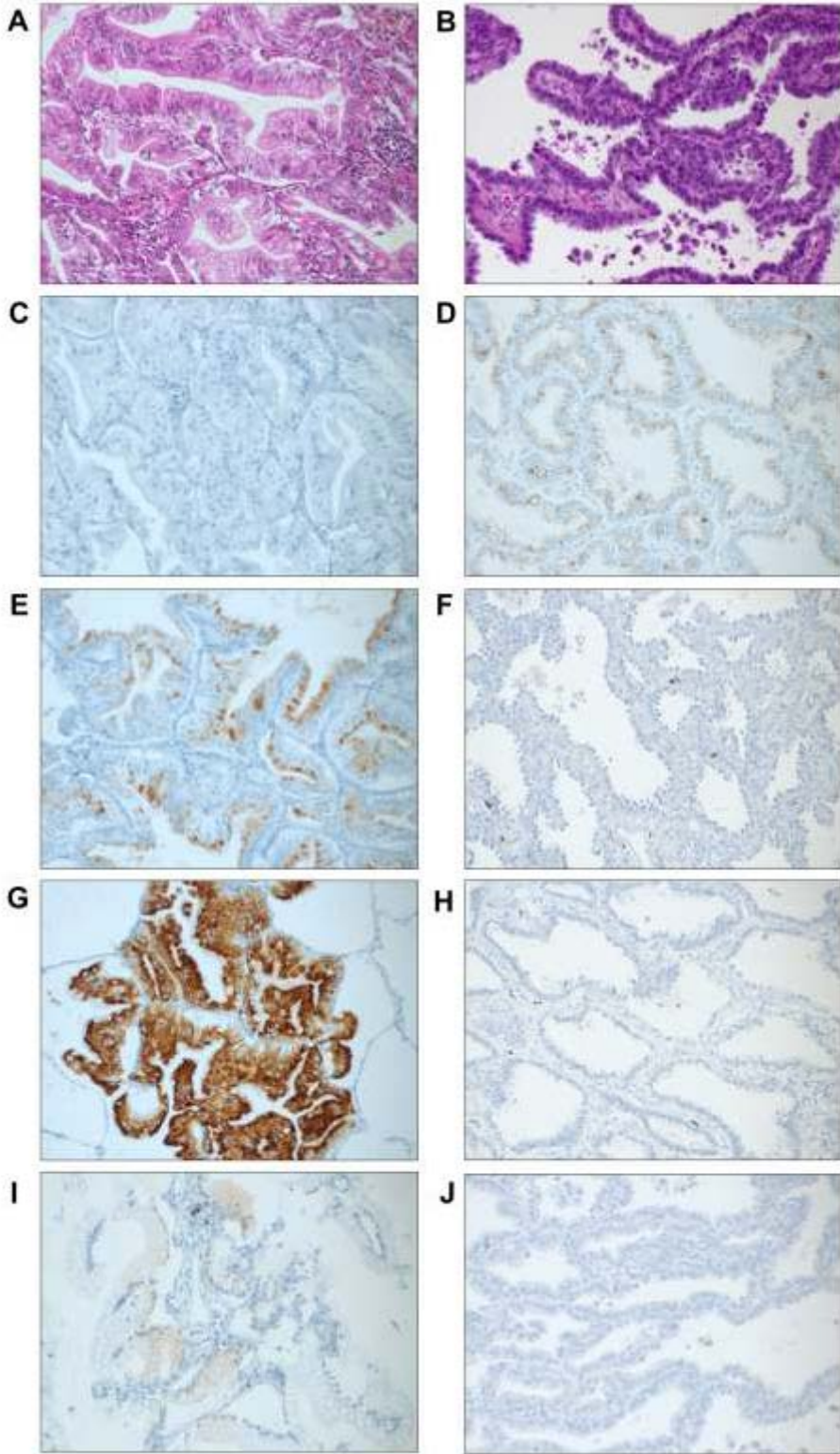


Figure 2. Comparison of mucin expression in IMA and LPA. A: MUC1 staining score. B: MUC5B staining score. C: MUC5AC staining score. D: MUC6 staining score. Central bars : median ; upper and lower bars : 25% and 75% IQR. Mann-Whitney test.

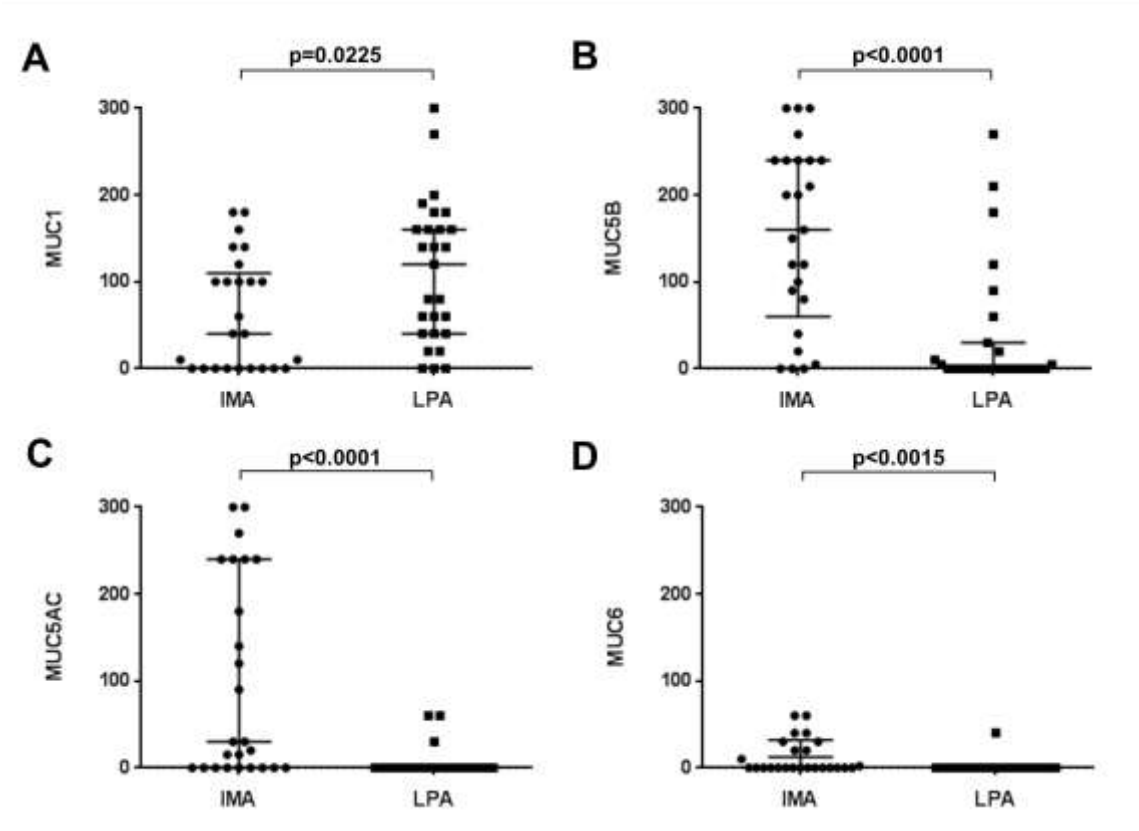
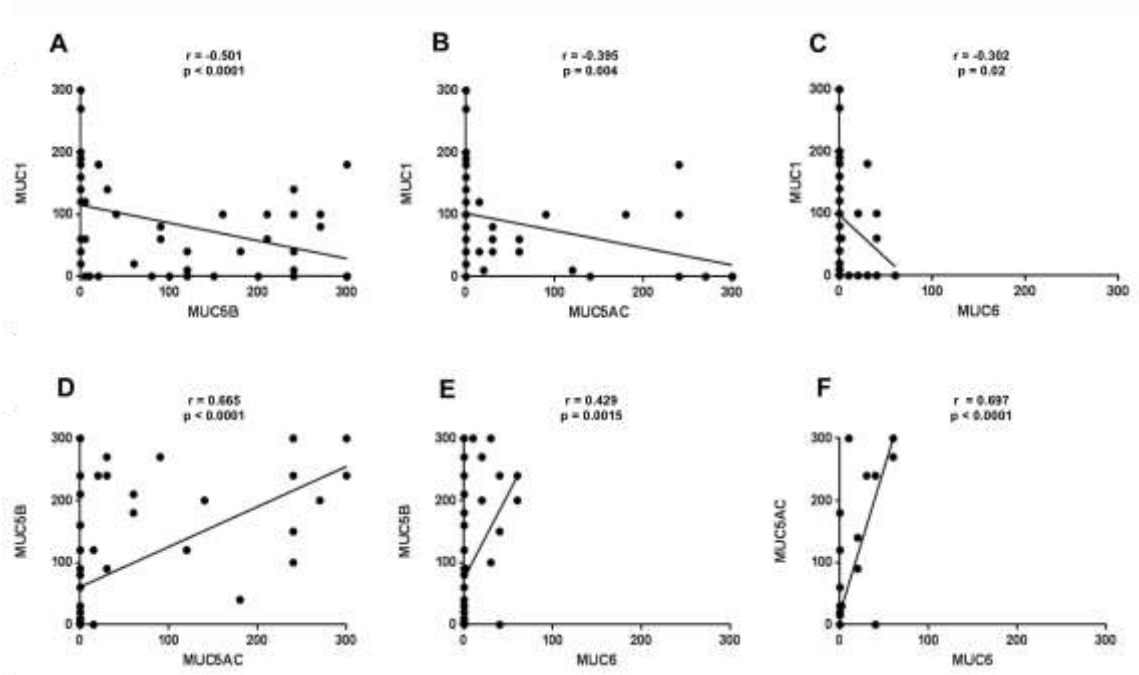


Figure 3. Correlation between mucin staining scores. A, B and C: Correlation of MUC1 with MUC5B, MUC5C and MUC6 staining score, respectively. D and E: Correlation of MUC5B with MUC5AC and MUC6 staining score, respectively. F: Correlation of MUC5AC with MUC6 staining. Spearman's rho test.



5. Article 3 : étude de la présence de réarrangement de *NRG1* dans les adénocarcinomes pulmonaires mucineux invasifs

5.1. Article

Duruiseaux Michaël, Mc Leer-Florin Anne, Antoine Martine, Poulot Virginie, Lacave Roger, Rabbe Nathalie, Cadranel Jacques, and Wislez Marie. *NRG1* fusion in a French cohort of invasive mucinous lung adenocarcinoma. En cours d'écriture

5.2. Présentation de l'article

L'existence d'un réarrangement oncogénique de *NRG1* a été récemment découvert et décrit par des techniques de haut débit transcriptomiques à partir de deux séries Asiatiques d'AMI (94,95). Nous proposons dans ce travail de rechercher la présence de réarrangement *NRG1* par une technique d'hybridation in situ par fluorescence (FISH) à partir de l'étude des pièces opératoires de notre cohorte Française d'AMI.

A l'instar des travaux déjà publiés, nous avons adopté une stratégie consistant à ne rechercher le réarrangement *NRG1* que dans les tumeurs sauvages pour les anomalies oncogéniques fréquentes et recherchées en routine en France (mutations *EGFR/KRAS/BRAF/ERBB2* et réarrangements *ALK* et *ROS1*). Parmi les 25 prélèvements d'AMI disponibles pour l'étude, 11 étaient sauvages pour les anomalies oncogéniques pré-citées et ont été soumis à une recherche de réarrangement *NRG1* par FISH. La qualité de la FISH était médiocre avec une absence de signal et donc un résultat ininterprétable sur 6 prélèvements. De manière remarquable, tous les prélèvements concernés par l'échec de la technique étaient antérieurs à 2003 mettant en exergue l'importance de l'analyse pré-analytique pour cette technique. En effet, le conditionnement des prélèvements avant 2003 ne répondait pas aux mêmes exigences de

qualité et était moins standardisé. Un réarrangement de *NRG1* était retrouvé dans un prélèvement tumoral. Le réarrangement était présent dans 100% des cellules et avec un signal FISH de bonne qualité. Il s'agissait d'une patiente d'origine vietnamienne ayant immigrée en France en 1976. Il s'agissait du seul patient d'origine asiatique de notre cohorte. La maladie a rapidement rechuté après une pneumonectomie conduisant au décès en quelques semaines.

5.3. Données de la littérature à propos des réarrangements *NRG1*

Le réarrangement *CD74-NRG1* a été récemment découvert à partir d'une cohorte de 25 adénocarcinomes pulmonaires, non-fumeurs, et sauvages pour *KRAS* et *EGFR* (95). Une nouvelle méthode d'analyse des données dédiée à la recherche de réarrangement « driver », combinant l'étude du nombre de copie de gènes et du transcriptome, a permis de découvrir un nouveau transcrit de fusion chez une patiente souffrant d'un AMI. Celui ci correspondait à la fusion des six premiers exons de *CD74* avec la région codant pour le domaine EGF-like de l'isoforme III-β3 de *NRG1*, gène codant pour la Neureguline 1 (*NRG1*). *CD74* était déjà connu pour être le « partenaire » du réarrangement de *ROS*. L'isoforme *NRG1* III-β3 est un ligand pour *ERBB2/ERBB3*, via son domaine EGF-like (139).

Ce transcrit de fusion a ensuite été recherché par RT-PCR et confirmé par FISH dans une cohorte de 102 adénocarcinomes, de patients non-fumeurs d'origine asiatique négatifs pour la recherche des principales anomalies oncogéniques connues (*EGFR*, *KRAS*, *BRAF*, *ERBB2*, *ALK*, *ROS*, *RET*) (95). Le transcrit de fusion a été retrouvé sur quatre prélèvements, tous du type AMI et issus de femmes non-fumeuses. Enfin, sur une autre cohorte de quinze AMI, également issus de patients asiatiques, 4 (27%) présentaient le gène de fusion *CD74-NRG1* et étaient issus exclusivement de femmes non-fumeuses, et 6 (40%) une mutation *KRAS*.

In vitro, des expériences de transduction du gène de fusion dans des lignées cellulaires démontrent que *CD74* code pour la portion intra et transmembranaire de la protéine de fusion

et que *NRG1 III-β3* code pour un domaine EGF-like extracellulaire qui est exposé à la surface cellulaire.

Sur le plan mécanistique, les auteurs suggèrent que la protéine de fusion *CD74-NRG1* s'hétérodimérisait avec ERBB2/ERBB3 via son domaine EGF-like extracellulaire, activant ainsi la phosphorylation de ERBB2/ERBB3 puis l'activation de la voie PIK3-AKT. *In vivo*, la présence du réarrangement *CD74-NRG1* était fortement corrélée à l'expression et la phosphorylation de ERBB2 et ERBB3, suggérant que *CD74-NRG1* pouvait s'hétérodimériser avec ces deux récepteurs. *In vitro*, l'expression ectopique de *CD74-NRG1* au sein de lignées cellulaires exprimant ERBB2 et ERBB3 conduisait à une augmentation de la quantité de p-ERBB2 et p-ERBB3 mais également de p-AKT et p-S6K. Ceci n'était pas constaté si le transcrit transduit était amputé du domaine EGF-like extracellulaire de *NRG1 III-β3*, confirmant que *CD74-NRG1* s'hétérodimérisait avec ERBB2 et ERBB3 via son domaine EGF-like extracellulaire. Enfin, l'expression ectopique de *CD74-NRG1* au sein d'une lignée cellulaire conduisait à une augmentation de la capacité de formation de colonie en milieu agar.

Une étude japonaise a confirmé l'existence de réarrangement de *NRG1* dans une série de 27 AMI « pan négatif » pour les anomalies oncogéniques usuelles (*EGFR*, *KRAS*, *BRAF*, *ERBB2*, *ALK*, *ROS*, *RET*) en utilisant une méthode d'analyse de la totalité du transcriptome (94). Un réarrangement *NRG1* était décrit dans 6 AMI, 5 du type *CD74-NRG1* et un nouveau réarrangement *SLC3A2-NRG1*, chez 5 femmes non-fumeuses et un homme fumeur. Ce travail confirme que la protéine de fusion *NRG1* activait les hétérodimères ERBB2/ERBB3 et rapporte une efficacité partielle des ITK lapatinib et afatinib dans les lignées cellulaires avec expression ectopique de la protéine de fusion *NRG1*.

Enfin, un dernier travail utilisant une technique de RNA-seq dans une cohorte de 451 adénocarcinomes et 251 carcinomes épidermoïdes a rapporté une fréquence de 3,9% des réarrangements *NRG1* dans les tumeurs sans anomalie oncogénique connue (140). Deux nouveaux partenaires de *NRG1* étaient décrits, *RBPMS-NRG1* et *WRN-NRG1*. Le sous-type histologique des cancers pulmonaires réarrangés pour *NRG1* n'était pas précisé. Cependant, HNF4 α , un marqueur récemment décrit comme caractéristique des AMI, était plus fortement exprimé en IHC dans les tumeurs avec réarrangement *NRG1* (140,141). Le caractère oncogénique du réarrangement était confirmé, l'expression de *NRG1* aboutissant à la promotion de la prolifération et des capacités de migration dans les lignées cellulaires de cancers du poumon.

5.4. Commentaires

Ce travail suggère une rareté des réarrangements *NRG1* dans les AMI issus de patients non-asiatiques et en revanche confirme l'intérêt de le rechercher chez les patients asiatiques ayant une tumeur sauvage pour les anomalies oncogéniques fréquentes.

Sa principale limite résidait dans l'échec de la technique de FISH dans 6 prélèvements du fait de l'ancienneté des prélèvements testés. Une étude en IHC de ERBB2/ERBB3 et phospho-ERBB2 et -ERBB3 est en cours afin de confirmer une activation de la voie ERBB2/ERBB3 dans le prélèvement avec réarrangement *NRG1* comparé aux autres prélèvements.

5.5. Manuscrit de l'article 3

NRG1 fusion in a French cohort of invasive mucinous lung adenocarcinoma

Duruisseaux Michaël¹, Mc Leer-Florin Anne², Antoine Martine^{1,3}, Poulot Virginie^{1,4},
Lacave Roger⁴, Rabbe Nathalie¹, Cadranel Jacques^{1,4}, and Wislez Marie^{1,4}

1. Sorbonne Universités, UPMC Univ. Paris 06, GRC n°04, Theranoscan, 4 rue de la Chine, F-75252 Paris
2. Plateforme de Génétique Moléculaire des Tumeurs, Pôle de Biologie et Pathologie CHU Grenoble et INSERM U 823-Institut A Bonniot-Université J Fourier, Grenoble
3. AP-HP, Hôpital Tenon, Service d'Anatomie pathologique, 4 rue de la Chine, F-75970 Paris
4. AP-HP, Hôpital Tenon, Plateforme de Génomique des Tumeurs Solides, 4 rue de la Chine, F-75970 Paris
5. AP-HP, Hôpital Tenon, Service de Pneumologie, 4 rue de la Chine, F-75970 Paris

INTRODUCTION

Invasive mucinous adenocarcinoma (IMA) of the lung represents 2 to 10% of all lung adenocarcinomas (LUAC). This histological subtype is considered as being one of the most malignant subtypes of LUAC, and is associated with a poor prognosis, probably due to frequent late-stage diagnosis. Standard chemotherapy is the unique treatment option at advanced stages, as to date no effective targeted therapy has shown its effectiveness.

The most commonly found genetic alterations in IMA are *KRAS* mutations, with a prevalence of 28 to 87% of cases. Recently, recurrent *CD74-NRG1* somatic gene fusions were discovered in IMA cases otherwise negative for known driver oncogenes (*EGFR*, *KRAS*, *BRAF*, *ERBB2*, *ALK*, *ROS1*, *RET*). *NRG1* is usually not expressed in normal lung and LUAC, but *NRG1* fusions lead to *NRG1* III-b3 isoform expression in IMA. By means of an extracellular EGF-like domain, *NRG1* III-b3 binds the extracellular domain of *ERBB3*, leading to heterodimerization of *ERBB3* with *ERBB2*. The resulting activation of the downstream PI3K-AKT and MAPK pathways promotes anchorage-independent growth of LUAC cell lines. As *ERBB2-ERBB3* dimers and PI3K-AKT and MAPK pathways could be targetable, *NRG1* fusions represent promising therapeutic targets. *CD74* is the most frequently found *NRG1* fusion partner, but novel *NRG1* partners have been described, such as *SLC3A2-NRG1* in a cohort of IMA and *RBPMS-NRG1*, *WRN-NRG1* and *SDC4-NRG1* in a cohort of LUAC and squamous lung carcinomas.

NRG1 fusions could drive 7 to 27% of IMA and published data suggest that these oncogenic fusions essentially occur in non-smoking women of Asian origin. In the

present study, we sought to examine the prevalence and the clinical profile associated with *NRG1* fusions in a French cohort of IMA patients.

MATERIAL AND METHOD

Twenty-five consecutive IMA patients surgically treated at Tenon Hospital (AP-HP), France, from 1991 to 2013, were retrieved from the Chest department database. The diagnosis was confirmed by a lung cancer pathologist (MA) and was based on the 2011 IASLC/ATS/ERS classification of lung adenocarcinoma. Clinical findings at diagnosis and follow-up data were recorded. All patients signed a research informed consent form, permitting analysis of their biological samples. This study was approved by our hospital's ethics human research committee.

EGFR, KRAS, BRAF and ERBB2 mutation analyses

For each formalin-fixed paraffin-embedded (FFPE) specimen, a 3- μ m tissue section was stained with H&S and examined by light microscopy to determine the percentage of tumor cells. After DNA isolation (QIAamp DNA mini kit, Qiagen, Courtaboeuf, France) from three 20 μ m tissue sections, *EGFR* mutations G719S, T790M and L858R (exons 18, 20 and 21, respectively), *KRAS* mutations G12S, G12R, G12C, G12A, G12V and G13D (exon 2) and *BRAF* mutations V600E and V600K (exon 15) were detected with TaqMan® Assays (Custom TaqMan® SNP Genotyping Assays, Life Technologies SAS, Saint Aubin, France). *EGFR* exon 19 deletions, *EGFR* exon 20 insertions and *EGFR* exon 20 insertions and ERBB2 exon 20 insertion were detected by sizing analysis. Sequencing data were then analyzed using SeqScape software.

ALK and ROS1 immunohistochemistry

Immunostainings of the ALK and ROS1 fusion proteins were performed on 3- μ m tissue sections on a Benchmark Ventana staining module (Ventana, Roche Diagnostics, Meylan, France) using a primary monoclonal ALK antibody (Clone 5A4,

Ab 17127; Abcam, Paris, France) diluted at 1:50 for 2 h at 37°C, or a primary monoclonal ROS1 antibody (Clone D4D6, #3287, Cell Signaling Technology, Danvers, MA, USA) at a dilution of 1:50 2 h at 20 °C, as previously described [24]. Positive external controls were performed, using a LUAC specimen that had been previously validated for *ALK* rearrangement by fluorescent in situ hybridization and the *ROS1*-rearranged cell line HCC78. The staining scores were assessed as follows: 0, no staining; 1+, faint cytoplasmic staining; 2+, moderate cytoplasmic staining; and 3+, intense granular cytoplasmic staining. The presence of 10% of cells stained with an intensity of ≥ 2 was considered as positive staining. Specimens with a positive staining score were tested for *ALK* or *ROS1* rearrangement by FISH.

***ALK, ROS1 and NRG1* break-apart FISH**

FISH was performed on unstained 4- μ m FFPE tumor-tissue sections using an *ALK* break-apart probe set (Vysis LSI *ALK* Dual Color, Break Apart Rearrangement Probe; Abbott Molecular, Rungis, France) or a ZytoLight® SPEC *ROS1* Dual Color Break Apart Probe (ZytoVision, Bremerhaven, Germany) and a paraffin-pretreated reagent kit (Vysis, Abbott Molecular) according to the manufacturer's instructions. Tumor tissues were considered *ALK*- or *ROS1*-FISH positive if >15% of the cells showed split orange and green signals and/or single orange signals.

As *NRG1* fusions have been described in tumors without *EGFR/KRAS/BRAF/HER2* mutations and *ALK/ROS1* rearrangements, *NRG1* break-apart FISH was performed only in pan wild-type samples.

An *NRG1* specific fluorescent DNA probe was used kindly provided by ZytoVision (Zytolight SPEC *NRG1* Dual Color Break Apart, ZytoVision, Bremerhaven, Germany). This probe contains green and orange-labeled polynucleotides, which target

sequences mapping in 8p12 proximal to the *NRG1* break point region. The 3' *NRG1* probe is labeled with an orange spectrum fluorophore and the 5' *NRG1* probe with a green spectrum fluorophore. The quality of each FISH experiment was categorized as good, moderate, mediocre or bad, according to the quality of the hybridization signals, and the presence of no to a very high fluorescent background noise, respectively. Tumor tissues were considered *NRG1*-FISH positive when >15% of the nuclei harbored either a split pattern with 3' and 5' signals separated by a distance superior to the diameter of the largest signal, or isolated 3' (orange) signals. Nuclei were counterstained with DAPI/Vectashield (Vektor Laboratories, Burlingame, CA, USA) and were analyzed with a Leica CytoVision GSL10 FISH fluorescence capture system (Leica, Nanterre, France) under a 63x oil immersion objective. Signals were enumerated with the CytoVision imaging system (Leica). At least 100 nuclei were analyzed (mean = 126) for each tumor sample.

Results

Clinical and molecular findings for the 25 IMA patients are shown in Table 2. After analysis for *EGFR*, *KRAS*, *BRAF* and *ERBB2* mutations and *ALK* and *ROS1* rearrangements, 11 samples remained wild-type for all driver oncogenes and were analyzed for *NRG1* rearrangement by break-apart FISH. The clinical findings and FISH quality and characteristics of each sample analyzed are shown in Table 3. One sample was *NRG1* FISH-positive and 100% of the tumor nuclei analyzed were positive, harboring at least one isolated orange signal, together with at least 1 fusion signal (Figure 1). This *NRG1*-positive patient was a 61 years-old non-smoking woman. She was born in Vietnam to Vietnamese parents and migrated in France in 1976. She had a history of cured left breast cancer in 1988 treated with sequential neo-adjuvant chemotherapy, radical mastectomy and chest wall irradiation, an ileal and pulmonary tuberculosis in 2003 successfully treated with antibiotics, a minimal change nephrotic syndrome requiring a daily corticosteroid treatment until 2004 and an insulin-dependent diabetes. She presented with cough and dyspnea in April 2006. Chest computed tomography (CT) showed diffuse pulmonary parenchymal involvement with alveolar consolidation and pseudo nodules with peripheral ground-glass opacities in the lower left lobe. The upper left lobe was destroyed by sequelae of tuberculosis. Diagnosis was obtained by bronchoscopic cytology. Abdominal CT, brain magnetic resonance imaging (MRI) and positron emission tomography using ¹⁸F-fluorodeoxyglucose revealed no evidence of mediastinal node involvement or extra thoracic metastasis. Because of upper left lobe destruction, a left pneumonectomy was performed. Pathological analysis revealed an IMA with some foci of enteric differentiation, which were TTF1 negative and CK7 and CK20 positive. The chest wall was invaded in an extent inferior to 1 centimeter and tumor cells were

observed in one intra-lobar node. The tumor was classified as pT3N1M0. In view of the medical history of the patient, adjuvant chemotherapy was not administered and radiotherapy of the chest wall was performed. The disease relapsed 5 months after the surgery with appearance of numerous nodules in the remaining right lung on chest CT. The patient was enrolled in the IFCT-0504 clinical trial evaluating erlotinib or carboplatin/paclitaxel in advanced lepidic adenocarcinoma and was randomized in the erlotinib arm. After 4 weeks of erlotinib, the patient presented a respiratory failure secondary to a non-documented right interstitial lung disease (ILD) which could be related to a disease progression or an erlotinib-induced ILD. She died after two weeks in intensive critical care unit.

Discussion

NRG1 fusions may be found by FISH in IMA wild-type for *EGFR*, *KRAS*, *BRAF*, *ERBB2*, *ALK* and *ROS1*. Our series of 25 IMA showed one *NRG1*-FISH positive case, corresponding to a prevalence of 4%. Previous works using high throughput transcriptome sequencing in frozen samples estimated prevalence for *NRG1* fusions in IMA of 7 to 27%. The lower prevalence in our study could be due to the lesser sensitivity of FISH assay in FFPE. The FISH signals were of poor quality in 6/11 cases and corresponded to samples fixed prior to 2003 with when pre-analytical tissue handling steps were less standardized .

The *NRG1*-FISH positive case was a Vietnamese non-smoking woman, corresponding to the expected clinical profile (Table 1). It is remarkable that the only *NRG1* positive case occurred in the sole patient of Asian ethnicity in our cohort. We assume that *NRG1* fusions occur at a lower prevalence in IMA from Caucasian patients.

The results of this study suggest the scarcity of *NRG1* fusions in IMA in Caucasian patients. However, as *NRG1* fusions could be targetable, *NRG1* FISH detection should be considered in patients with IMA “wild-type” for *EGFR*, *KRAS*, *BRAF*, *ERBB2*, *ALK* and *ROS1*.

Table 1. Clinical and molecular features of IMA patients.

	Total cohort (n=25)
	n (%)
Age (years)	
>60	14 (56)
≤60	11 (44)
Gender	
Female	10 (40)
Male	15 (60)
Race	
Caucasian	22 (88)
Asian	1 (4)
North African	2 (8)
Smoking status	
Never-smoker	10 (40)
Former or current smoker	15 (60)
Driver oncogene	
<i>EGFR</i> mutation	0 (0)
<i>KRAS</i> mutation	12 (48)
<i>HER2</i> mutation	0 (0)
<i>BRAF</i> mutation	0 (0)
<i>ALK</i> rearrangement	1 (4)
<i>ROS1</i> rearrangement	0 (0)
<i>NRG1</i> rearrangement	1 (4)

Table 2. Clinical characteristics and *NRG1* FISH results in patients with IMA pan wild-type

Sample number	Sample prior to 2003	Sex	Age	Ethnicity	Smoking status (pack-year)	NRG1 FISH	Positive tumor cells (%)	Hybridization FISH quality
1	2002	F	78	Caucasian	Never	NI	–	No FISH signal
2	2007	F	60	Caucasian	Never	Negative	1.0	Mediocre
3	1992	M	62	Caucasian	Never	NI		No FISH signal
4	2006	F	60	Caucasian	Never	Negative	1.0	Mediocre
5	2007	M	47	North African	Ever (40)	Negative	6.8	Moderate
6	2001	M	56	Caucasian	Ever (58)	NI		No FISH signal
7	1999	F	55	Caucasian	Never	NI		No FISH signal
8	2010	F	68	Caucasian	Never	Negative	7.4	Good
9	2006	F	61	Asian	Never	Positive	100	Good
10	1992	M	46	North African	Never	NI		No FISH signal
11	2001	M	57	Caucasian	Ever (65)	NI		No FISH signal

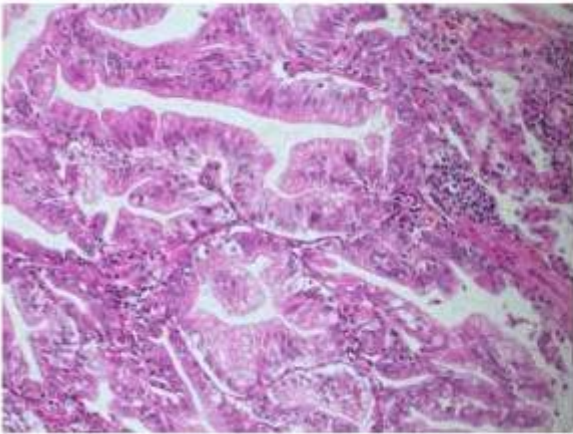
F: female; M: male; NI: Not interpretable; FISH: Fluorescent In Situ Hybridation

Table 3. Characteristics of patients with *NRG1* fusion in IMA cases reported in literature.

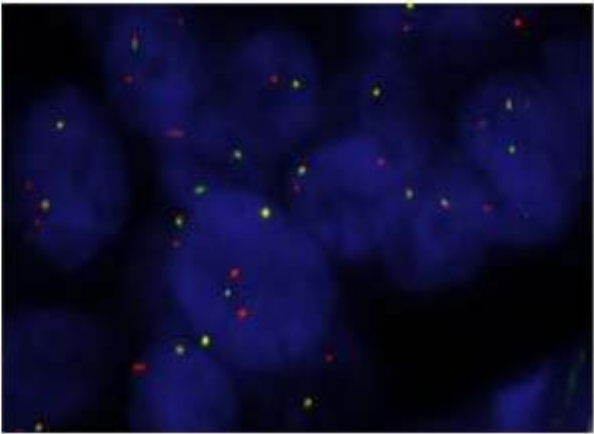
	Sex	Age	Ethnicity	Smoking status (pack-year)	Gene fusion	Reference
1	Female	64	Caucasian	Never	<i>CD74-NRG1</i>	
2	Female	73	Asian	Never	<i>CD74-NRG1</i>	
3	Female	72	Asian	Never	<i>CD74-NRG1</i>	
4	Female	66	Asian	Never	<i>CD74-NRG1</i>	
5	Female	31	Asian	Never	<i>CD74-NRG1</i>	
6	Male	55	Asian	Ever (47)	<i>CD74-NRG1</i>	
7	Female	68	Asian	Never	<i>CD74-NRG1</i>	
8	Female	78	Asian	Never	<i>CD74-NRG1</i>	
9	Female	47	Asian	Never	<i>CD74-NRG1</i>	
10	Female	53	Asian	Never	<i>CD74-NRG1</i>	
11	Female	66	Asian	Never	<i>SLC3A2-NRG1</i>	
12	Female	89	Asian	Never	<i>CD74-NRG1</i>	

Figure 1: Representative histologic features and results of *NRG1* break-apart FISH of the *NRG1*-positive case. A. Hematoxylin and eosin staining B. Interphase *NRG1* FISH analysis using the Zytolight SPEC *NRG1* Dual Color Break Apart FISH probe (ZytoVision, Bremerhaven, Germany). 100% of the tumor nuclei analyzed were positive, harboring at least one isolated orange signal, together with at least 1 fusion signal.

A.



B.



6. Article 4 : Etude du rôle pro-tumoral de la boucle autocrine CXCL10/CXCR3-A dans les adénocarcinomes mucineux invasifs

6.1. Article

Duruiseaux M, Mathiot N, Antoine M, Vieira T, Poulot V, Cadranel J, Wislez M. CXCL10/CXCR3-A autocrine loop promotes pro-tumoral capacities in invasive mucinous lung adenocarcinoma. En cours de révision dans la revue *Molecular Cancer Therapeutics*.

6.2. Présentation de l'article

L'étude de l'expression des cytokines et chimiokines dans les surnageants de liquide de lavage bronchoalvéolaires (LBA) permet d'approcher le microenvironnement tumoral des adénocarcinomes lépidiques. Cette méthode a été utilisée au sein d'une banque de surnageants congelés de LBA de 70 patients souffrant d'adénocarcinomes lépidiques dans le but de mettre en évidence une expression différentielle entre AMI et ALP. Trente cytokines ont été dosées par une méthode à haut débit (Bioplex, BIORAD®) au sein de ces échantillons et de 7 surnageants de LBA issus de personnes saines utilisés comme témoins¹. Dix étaient significativement surexprimées chez les patients comparés aux témoins: CXCL10, MCP-1, MIP-1 β , RANTES, HGF, VEGF, IL-6, IL-8, G-CSF, et l'interféron γ (IFN γ). Parmi ces dix molécules, seul CXCL10 était différentiellement exprimée entre AMI et LPA, avec une surexpression dans les LBA issus d'AMI comparés au LPA (9714pg/ml \pm 1693 vs. 3716pg/ml \pm 872, respectivement; p=0,004). La surexpression de CXCL10 dans les LBA avait par ailleurs une valeur mauvais pronostic en analyse univariée, suggérant un rôle pro-tumoral de cette chimiokine dans notre modèle.

Une étude en IHC de l'expression de CXCL10 et de son récepteur CXCR3 dans les tissus tumoraux de 54 patients (AMI, n=27 ; LPA, n=27) montrait une expression par les cellules tumorales et marginalement par les cellules mononuclées stromales. CXCL10/CXCR3 était plus fréquemment et plus intensément exprimé dans les AMI. Enfin l'expression de CXCL10 était positivement corrélée à celle de CXCR3 (r=0.527, p <0.001) et les tumeurs exprimant CXCR3 démontrait une concentration moyenne de CXCL10 dans les

LBA correspondants supérieure à celle des tumeurs n'exprimant pas CXCR3. Ces résultats suggéraient donc l'existence d'une boucle autocrine CXCL10/CXCR3 surexprimée dans les AMI. En nous appuyant sur le mauvais pronostic rattaché à la surexpression de CXCL10 dans les LBA, nous avons fait l'hypothèse que cette boucle jouait un rôle pro-tumoral.

Il existe deux variants d'épissage principaux de CXCR3, -A et -B. CXCR3-A joue un rôle pro-tumoral tandis que CXCR3-B a des caractéristiques anti-apoptotiques. Nous avons démontré par qRT-PCR sur prélèvements congelés que l'ARNm codant pour CXCR3-A était significativement surexprimé dans les AMI comparé au LPA. Un panel de lignées cellulaires d'adénocarcinomes pulmonaires dont le caractère mucineux et non-mucineux était connu (mucineuses : H2228, H358, H441 ; non-mucineuses : H322, H1650, H 1975) a été exploité. Les lignées n'exprimaient pas CXCL10 dans les surnageants à l'état basal. CXCL10 étant une chimiokine dont l'expression est induite par l'IFN γ , nous avons exposé les lignées à l'IFN γ permettant une induction de l'expression de CXCL10 dans chacune d'entre elles. CXCR3 était exprimé dans toutes les lignées en western blot ainsi que les variants -A et -B en qRT-PCR. L'exposition des lignées à des doses croissantes de CXCL10 induisait uniquement dans H2228 une variation significative de l'expression des ARNm codant pour CXCR3-A et -B, avec une augmentation de l'expression de l'ARNm de CXCR3-A d'un facteur 25 sans modification significative de l'expression de CXCR3-B. L'exposition à CXCL10 induisait également une phosphorylation d'ERK1/2 dans H2228, sans modifier les voies de signalisation explorées dans les autres lignées. H2228 a donc été choisie comme modèle cellulaire de la boucle autocrine CXCL10/CXCR3-A.

L'exposition de H2228 au CXCL10 humain recombinant (rhCXCL10) induisait une migration significative en chambre de Boyden, tandis que cela n'avait aucun effet sur H322. Nous observions également sous l'effet de CXCL10 une augmentation de l'expression du VEGF dans les surnageants de H2228, partiellement neutralisée par un anticorps anti-CXCR3. In vivo, l'expression de CXCL10 dans les LBA était fortement corrélée à celle du VEGF ($r=0.700$, $p < 0.001$) et le VEGF était surexprimé par les cellules tumorales des AMI comparés au LPA en IHC. Un modèle *in vitro* de co-culture de cellules endothéliales et fibroblastiques pulmonaires humaines a été utilisé pour évaluer les capacités « angiogéniques » des surnageants de LBA des patients et le rôle du VEGF. Le rhCXCL10 n'avait pas d'influence sur la formation de tubes vasculaires. Les LBA issus d'AMI étaient à l'origine de la formation d'un plus grand nombre de tubes vasculaires. Le bevacizumab, un

anticorps monoclonal humanisé anti-VEGFA, inhibait significativement la formation de tubes vasculaires, démontrant l'activité angiogénique du VEGF issus du LBA des patients.

6.3. Données de la littérature à propos de la voie CXCL10/CXCR3

6.3.1. Structures et fonctions

CXCL10 est une protéine de 98 acides aminés de 10 KDa. CXCL10/IP-10 (interferon gamma-induced protein) fait partie d'un petit groupe de CXC chimiokines induites par l'interféron, comprenant CXCL10, CXCL9/Mig (monokine induced by interferon) et CXCL11/I-TAC (interféron-inducible T-cell chemoattractant) (142–144). Ces trois chimiokines ont pour particularité d'activer le même récepteur, CXCR3 (144). CXCL10 est codé par un gène localisé sur le chromosome 4 sur le locus q21. Physiologiquement, CXCL10 est sécrétée en réponse à l'IFN γ par les lymphocytes, les polynucléaires neutrophiles et éosinophiles activés, les monocytes, les cellules épithéliales et endothéliales et les fibroblastes (145). C'est un médiateur central de la réponse à l'interféron, jouant un rôle chimiotactique sur les lymphocytes Th1 CXCR3⁺ activés et dans l'activation de la réponse immunitaire Th1. CXCL10 est également chimiotactique pour les monocytes, les autres types de cellules T et les cellules NK exprimant CXCR3. Il existe des variants structuraux dont l'impact biologique est inconnu (146,147). Un variant monomérique a été décrit par spectrométrie de masse et est capable de se lier au récepteur CCR3 en plus de CXCR3. Un travail a suggéré qu'une oligomérisation de CXCL10 était nécessaire au recrutement des lymphocytes T et à leur passage trans-endothélial.

CXCR3 est un récepteur transmembranaire à sept domaines appartenant à la famille des récepteurs CXCR (CXCR1 à 7) et qui est codé par un gène résidant sur le chromosome X en q13. Il s'agit d'un récepteur couplé aux protéines G (148). CXCR3 est sujet à un épissage alternatif aboutissant à au moins trois isoformes : CXCR3-A, CXCR3-B et CXCR3-alt. Ces isoformes ont un impact fonctionnel distinct (Tableau 4) en fonction du type cellulaire (148). Globalement, le variant A stimule le chimiotactisme, la migration cellulaire et la prolifération tandis que le variant B est anti-prolifératif, pro-apoptotique et angiostatique (148). Le rôle fonctionnel de CXCR3-alt est mal connu. La signalisation intracellulaire diffère en fonction du variant -A et -B (Figure 2). CXCR3-A est associé aux protéines G α i et G α q (149–152). Son activation aboutie à élévation du calcium intracellulaire et à l'activation de la voie des MAP kinases (Erk 1/2, p38, JKN) et PI3K/AKT, induisant ainsi une migration cellulaire, un

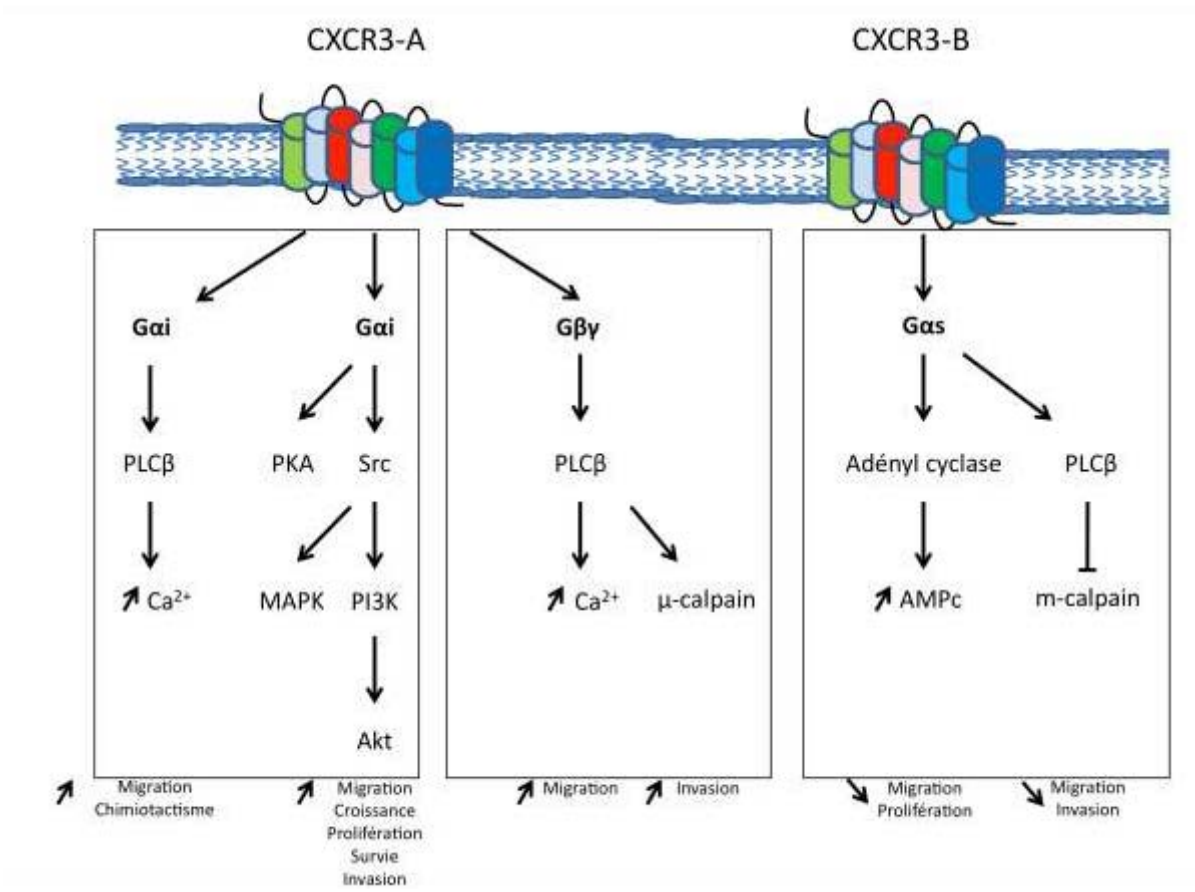
Tableau 4. Expression et activités biologiques des isoformes de CXCR3 dans les différents types cellulaires

	Isoforme de CXCR3 exprimée	Fonction(s)
Modèle souris		
Cellules endothéliales souris	CXCR3-A	Inhibition de la prolifération et de l'angiogenèse Induction de l'apoptose Dissociation de tubes vasculaires
Fibroblastes souris	CXCR3-A	Inhibition de la prolifération
Lymphocytes T souris (CD4+ Th1, CD8+ cytotoxique), cellules NK souris, cellules dendritiques souris	CXCR3-A	Activation et induction de la prolifération, chimiotactisme, induction de la migration et de l'adhésion
Modèle humain		
Cellules endothéliales humaines (HMEC)	CXCR3-B	Inhibition de la prolifération Inhibition de l'apoptose Inhibition de l'angiogenèse
Lymphocytes T humains	CXCR3-A, CXCR3-B, CXCR3-alt?	Activation et induction de la prolifération, chimiotactisme, Induction de la migration Induction de la sécrétion de cytokine
Fibroblastes humains	CXCR3-A, CXCR3-B, CXCR3-alt?	CXCR3-B : Inhibition de la prolifération CXCR3-A : Induction de la prolifération
Cellules épithéliales respiratoires humaines	CXCR3-A, CXCR3-B	CXCR3-A : Induction de la croissance et de la synthèse d'ADN
Cellules musculaires lisses de l'épithélium respiratoire	CXCR3-A, CXCR3-B, CXCR3-alt?	Induction de la migration
Pneumocytes de type II	CXCR3-A, CXCR3-B	CXCR3-A : chimiotactisme
Cellules souris de cancer du sein, de gliome, d'ostéosarcome	CXCR3-A	CXCR3-A : Induction de la croissance, potentiel métastatique
Cellules humaines de cancers de la prostate, du rein, du sein, colo-rectaux, d'ostéosarcomes, de myélomes, de gliomes	CXCR3-A, CXCR3-B	CXCR3-A : Induction de la croissance, potentiel métastatique, capacité de migration et d'invasion CXCR3-B : Inhibition de la croissance tumorale, des capacités de de migration et d'invasion

chimiotactisme, la synthèse d'ADN, la prolifération et la survie cellulaire et des capacités d'invasion (153–155). Dans le cancer de la prostate, la signalisation se fait principalement via une protéine $G\beta\gamma$ qui active la voie $PLC\beta$ induisant la migration cellulaire et des capacités d'invasion via une μ -calpain (156). CXCR3-B est associé à la protéine *Gas* qui active la voie de l'adényl cyclase, aboutissant à l'inhibition de la prolifération et de la migration dans les cellules endothéliales (157,158). Dans l'épithélium et le cancer prostatique, l'activation de CXCR3-B/*Gas* inhibe les capacités de migration et d'invasion via une augmentation de l'AMPc et une inhibition des m -calpain (156,159).

L'axe CXCL10/CXCR3 est impliqué dans un large spectre de pathologies infectieuses, inflammatoires ou cancéreuses. Le pouvoir chemoattractant de CXCL10 pour les lymphocytes CXCR3+ peut aboutir à une inflammation locale exacerbée et à des lésions tissulaires significatives, notamment dans les maladies auto-immunes comme la polyarthrite rhumatoïde, le lupus érythémateux disséminé, le syndrome de Gougerot Sjögren, la sclérodémie systémique ou encore les myopathies inflammatoires (160,161). En infectiologie, l'axe CXCL10/CXCR3 joue un rôle majeur dans la réponse immunitaire antivirale et plus particulièrement dans le cadre de l'infections à VIH, des hépatites virales, et de la Tuberculose (145,148).

Figure 2: Représentation schématique des voies de signalisation intra-cellulaires activées par CXCR3-A et -B et des conséquences sur les capacités cellulaires



6.3.2. CXCL10/CXCR3 et cancer : un double rôle

L'impact biologique de l'activation de la voie CXCL10/CXCR3 a été initialement décrit comme anti-tumorale, par le biais d'une action angiostatique et d'un rôle important dans la réponse immunitaire anti-tumorale dépendante de l'interféron. Des travaux publiés ces dix dernières années suggèrent au contraire l'existence de boucle paracrine/autocrine CXCL10/CXCR3 exploitée à leur avantage par les cellules tumorales.

6.3.2.1. Fonctions anti-tumorales

Angiostatique

La famille des CXC chimiokines est caractérisée par la présence de deux cystéines au niveau de l'extrémité N-terminal séparées par un acide aminé (C-X-C). Les CXC chimiokines peuvent être séparées en deux groupes selon la présence ou l'absence d'un motif « ELR » (acide glutamique-leucine-arginine) à proximité de l'extrémité CXC. Les CXC chimiokines ERL positive sont de puissants promoteurs de l'angiogenèse (162,163). A l'inverse, les chimiokines ELR négative sont des inhibiteurs de l'angiogenèse et sont représentées par CXCL4, CXCL9, CXCL10 et CXCL11 qui partagent toutes le même récepteur CXCR3. CXCR3 est exprimé par les cellules constituant la vascularisation et notamment les cellules endothéliales et les péricytes (163–165).

L'effet angiostatique de CXCL10/CXCR3 repose principalement sur deux preuves expérimentales:

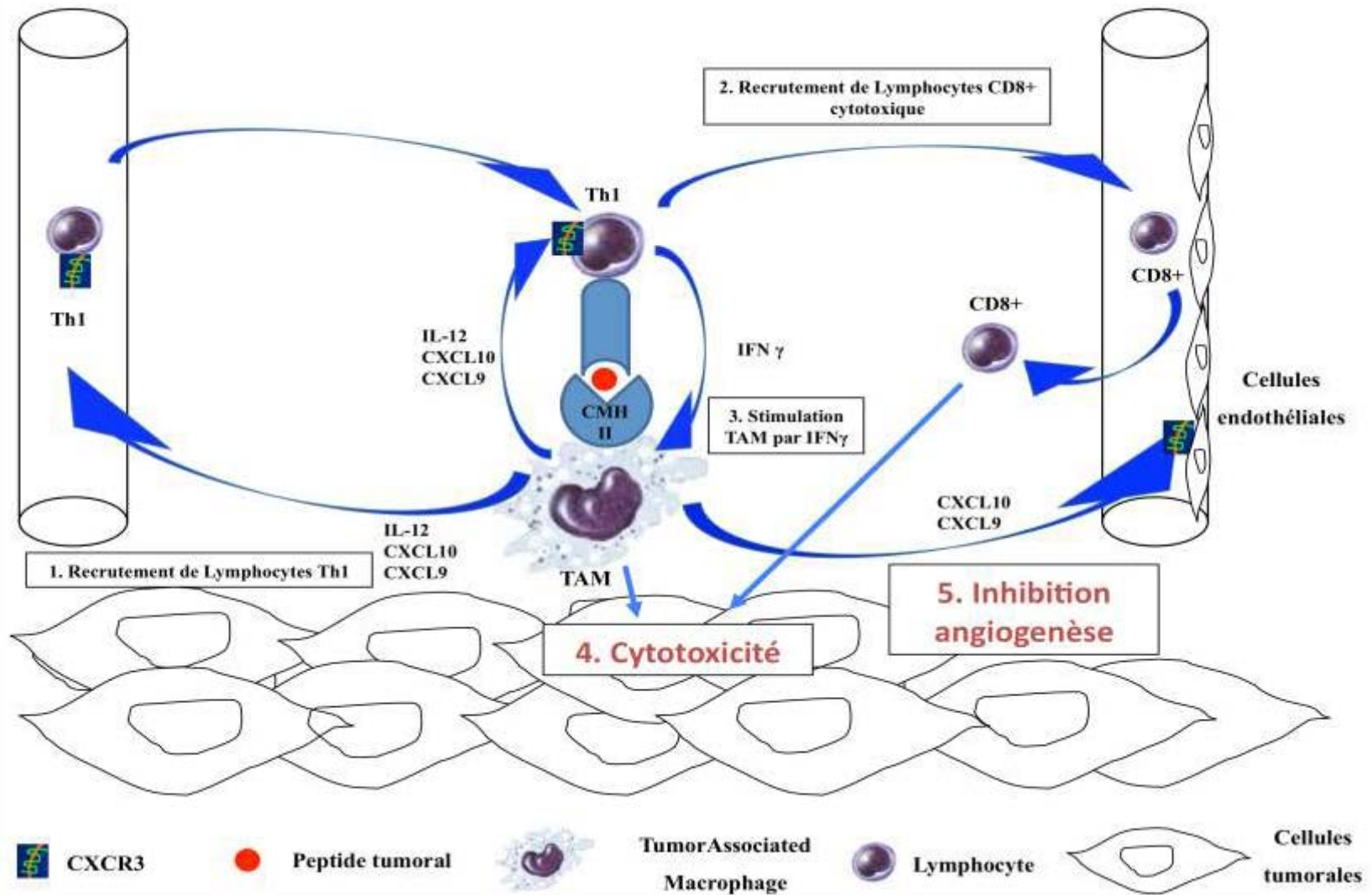
- Les modèles de cicatrisation de plaie ont permis de démontrer que les vaisseaux néoformés après la plaie exprimaient CXCR3 et qu'un traitement par CXCL10 aboutissant à la dissociation de ces néo-vaisseaux et empêchait la formation d'autres néo-vaisseaux (166).
- Les cellules endothéliales capillaires humaines HMVECs expriment CXCR3 et voit leur prolifération bloquée par l'interaction entre CXCL10 et CXCR3 (167). De plus, il semble que ce soit le variant CXCR3-B qui soit impliqué dans cette fonction.

Immunosurveillance anti-tumorale

Les chimiokines induites par l'IFN γ CXCL10 et CXCL9 jouent un rôle très important dans l'immunosurveillance anti-tumorale (Figure 3) (168). Les macrophages infiltrant la tumeur ou TAM (Tumeur-Associated Macrophages) exposent les peptides tumoraux au moyen du complexe majeur d'histocompatibilité de classe II (CMH II). Ces TAM recrutent spécifiquement des lymphocytes T helper (h) 1 via la sécrétion d'IL-12, de CXCL10 et de CXCL9. Ceux-ci deviennent « tumeur-spécifique » après avoir reconnu le CMH II à la surface des TAM et orchestrent l'immunosurveillance anti-tumorale. Les lymphocytes Th 1 activés sécrètent de l'IFN γ permettant l'acquisition par les TAM de capacité cytotoxique tumoricide, stimulent la sécrétion de CXCL10 et CXCL9 par les TAM amplifiant le recrutement de lymphocytes Th 1 CXCR3+ et donc la réponse anti-tumorale Th1, recrutent des lymphocytes CD8+ cytotoxiques tumoricides. Enfin, l'activité anti-tumorale est également médiée par les caractéristiques angiostatiques de CXCL10 et CXCL9 qui vont se lier aux récepteurs CXCR3-B à la surface des cellules endothéliales, réprimant leur capacité à proliférer et à former des capillaires.

Ces propriétés immunomodulatrices de CXCL10 ont été confirmées dans des modèles souris de mélanome et de gliomes (169).

Figure 3 : Rôle de CXCL10 et CXCL9 dans l'immunosurveillance anti-tumorale



6.3.2.2. Fonctions pro-tumorales

Cancer du sein

L'expression tumorale de CXCL10 est associée à un mauvais pronostic (170,171). Dans une série de 364 tumeurs du sein, une expression tumorale de CXCL10 était retrouvée dans 45% des cas et corrélée à l'expression tumorale de CXCR3. Le groupe de patients CXCL10/CXCR3 + avait une survie grevée (170). Les auteurs font l'hypothèse d'une action paracrine avec recrutement par la tumeur de lymphocytes CD4+ et CD8+ exprimant CXCR3 et jouant un rôle pro-tumoral et également autocrine avec promotion des capacités d'invasion des cellules tumorales. Une autre étude a montré une induction de l'expression tumorale de CXCL10 par l'activation de la voie RAS, induction aboutissant à la promotion de la prolifération via CXCR3-A (172). Enfin, une petite molécule inhibant CXCR3, l'AMG487, est capable d'inhiber la survenue de métastases pulmonaires dans un modèle souris de cancer du sein (173).

Cancer colo-rectal (CCR)

CXCL10 a été proposé comme facteur de mauvais pronostic dans les stades II et III de CCR (174). Plusieurs travaux ont montré une surexpression tumorale de CXCL10/CXCR3 au sein des localisations métastatiques des CCR avec des arguments *in vitro* supportant des capacités pro-métastatiques ganglionnaires dans les lignées cellulaires de CCR exprimant CXCR3 (175–177). L'expression de CXCR3 est associée à un moins bon pronostic et favoriserait la dissémination métastatique, les modèles murins de CCR KO pour CXCR3 étant protégés contre la dissémination métastatique hépatique et pulmonaire.

Mélanome

L'expression de CXCR3 augmente parallèlement à l'aggravation du stade de la maladie et l'effet anti-apoptotique de CXCL10 survient dans les cellules mélaniques CXCR3-A + (178). L'expression tumorale de CXCR3 accélère la dissémination ganglionnaire dans le mélanome.

Cancer du rein

CXCR3-A est surexprimé dans les cancers du rein comparé à CXCR3-B qui est peu exprimé (179). In vitro, il a été démontré que la répression de CXCR3-B supprimait l'inhibition de la croissance tumorale liée à l'activation de ce récepteur.

Ostéosarcome

Le blocage de CXCR3 inhibe la prolifération métastatique dans les modèles murins d'ostéosarcomes (180).

6.3.2.3. Hypothèse d'une boucle autocrine pro-tumorale

C'est une étude portant sur les lymphomes NK des sinus qui a clairement démontrée cette hypothèse (181). L'axe CXCL10/CXCR3 était exprimé par les cellules tumorales in vitro et in vivo et son activation faisait la promotion des capacités d'invasion des cellules lymphomateuses NK via un mécanisme autocrine.

Dans le cadre des tumeurs solides, l'hypothèse d'une promotion des capacités d'invasion via un mécanisme autocrine a été soulevée dans le cancer du sein et colo-rectal (171,175). Un travail récent a spécifiquement traité la cette question d'une boucle autocrine CXCL10/CXCR3 pro-tumorale dans les tumeurs solides (182). Les auteurs démontrent que la voie CXCL10/CXCR3 est suffisante pour la dissémination métastatique au niveau pulmonaire des cellules de mélanome via un mécanisme autocrine. Après analyse des données du Cancer Genome Atlas, l'expression tumorale de CXCL10/CXCR3 était un facteur prédictif indépendant de dissémination métastatique en analyse multivariée dans les mélanomes, les CCR et du rein.

6.3.3. CXCL10/CXCR3 et cancer du poumon

L'expression de CXCL10/CXCR3 est associée à la réponse immunitaire anti-tumorale et à l'inhibition de l'angiogenèse. Aucun travail n'a rapporté de rôle pro-tumoral. Il n'existe pas de données dans les cancers bronchiques à petites cellules.

Le rôle pivot de CXCL10/CXCR3 dans la réponse immunitaire anti-tumorale dépendante de l'IFN γ a été démontré dans des modèles souris de cancer pulmonaire (183,184). Chez

l'humain, trois études ont examiné l'expression de CXCR3 dans le cancer pulmonaire. Ohri et al. ont décrit une expression de CXCR3 dans le stroma et une association avec la présence de macrophages et un bon pronostic, confortant l'hypothèse d'un rôle important dans l'immunité anti-tumorale (185). Kowalczyk et al. ne retrouvaient pas de différence significative entre expression de CXCL10 dans la tumeur et le tissu normal adjacent, tandis que Maekawa et al. ne retrouvaient pas non plus de différence entre expression de CXCR3 dans la tumeur primitive et dans les métastases ganglionnaires correspondantes (186,187). Enfin, Iwakiri et al. décrivaient une expression d'ARN messager de CXCR3 dans chaque tumeur d'une série de 127 CBNPC de stade I mais il n'existait aucun lien entre surexpression et survie sans rechute (188). Un travail ancien avait démontré l'expression de CXCL10 par les cellules tumorales de cancers pulmonaires de type épidermoïde et le rôle de CXCL10 dans l'inhibition de la croissance tumorale et de l'angiogenèse en utilisant un modèle de xénogreffe d'une lignée d'adénocarcinome pulmonaire A549 sur des souris SCID (189).

6.4. Commentaires

Nous décrivons l'existence d'une boucle autocrine CXCL10/CXCR3 pro-tumoral, exprimée préférentiellement dans les AMI comparés aux LPA, et associée à une majoration de capacités migration et d'expression tumorale de VEGF.

Notre travail apporte plusieurs informations nouvelles s'agissant de la voie CXCL10/CXCR3 et de la biologie des cancers pulmonaires et plus particulièrement des AMI.

Il s'agit de la première étude rapportant un effet potentiellement délétère sur la survie dans les cancers pulmonaires. En effet, une surexpression de CXCL10 dans les LBA des patients est associée à une survie plus courte suggérant un rôle pro-tumoral que CXCL10/CXCR3.

Il s'agit de la première démonstration d'une boucle autocrine pro-tumorale impliquant l'isoforme-A de CXCR3 et exprimée par les cellules tumorales à la fois in vivo et in vitro. Cette boucle CXCL10/CXCR3-A majore les capacités de migration des cellules tumorales, effet attendu au regard de la littérature. L'hypothèse d'une induction de l'expression tumorale de VEGF par l'activation de la boucle autocrine CXCL10/CXCR3-A est en revanche originale. Dans les LBA des patients, il existe une corrélation positive forte entre la concentration de CXCL10 et celle de VEGF. Le VEGF est surexprimé en IHC par les cellules

tumorales d'AMI. Sur le plan mécanistique, l'exposition de H2228 à CXCL10 induit une expression de VEGF partiellement réprimée par un anticorps anti-CXCR3. Ces données soulignent l'importance de considérer les isoformes des récepteurs dont l'impact biologique peut être radicalement différent. En effet, la voie CXCL10/CXCR3-B est bien décrite comme angiostatique et dans notre travail l'induction d'une expression de VEGF est clairement reliée à l'expression de l'isoforme A.

Dans notre modèle de co-culture cellules endothéliales et fibroblastiques humaines, le VEGF issus des LBA des patients possède une activité biologique pro-angiogénique qui peut être fortement inhibée par un anticorps monoclonal humanisé, le bevacizumab. Mis en perspective avec la surexpression de CXCL10/CXCR3-A dans les AMI et son rôle dans la régulation positive de l'expression tumorale de VEGF, nous fournissons un rationnel pré-clinique à l'utilisation du bevacizumab dans le traitement des AMI dans leur forme avancée.

6.5. Manuscrit de l'article 4

CXCL10/CXCR3-A autocrine loop promotes pro-tumoral capacities in invasive mucinous lung adenocarcinoma

Duruisseaux Michaël¹, Mathiot Nathalie¹, Antoine Martine^{1,2}, Vieira Thibault^{1,3}, Poulot Virginie^{1,4}, Cadranet Jacques^{1,4}, and Wislez Marie^{1,4}

7. Sorbonne Universités, UPMC Univ. Paris 06, GRC n°04, Therascan, 4 rue de la Chine, F-75252 Paris

8. AP-HP, Hôpital Tenon, Service d'Anatomie pathologique, 4 rue de la Chine, F-75970 Paris

9. AP-HP, Hôpital Tenon, Service de Pneumologie, 4 rue de la Chine, F-75970 Paris

10. AP-HP, Hôpital Tenon, Plateforme de Génomique des Tumeurs Solides, 4 rue de la Chine, F-75970 Paris

Running title: CXCL10/CXCR3A is pro-tumoral in lung mucinous adenocarcinoma

Keywords: lung cancer, CXCL10, CXCR3, invasive mucinous adenocarcinoma, autocrine signaling

Financial support: M. Duruisseaux is a doctoral fellow funded by “*Fonds de dotation Recherche en Santé Respiratoire 2010*”, “*AgiràDom*” and “*Comité des maladies respiratoires (COMARES) de l’Isère*”. T. Vieira is a doctoral fellow funded by “*Fonds de dotation Recherche en Santé Respiratoire 2011*”. This study also received support from “*Subvention 2010 et 2011 Leg Poix - La Chancellerie des Universités de Paris*” and “*ITMO Cancer 2012 Institut National du Cancer Plan Cancer 2009-2013 « Modèles de tumeurs spontanées chez l’animal pour la recherche translationnelle en cancérologie »*”.

Correspondence to: Marie Wislez, MD, PhD, Service de Pneumologie, Hôpital Tenon, 4 rue de la Chine, F-75970, Paris; Tel: +33 1 56 01 68 38; Fax : (33) 1 56 01 69 91 ; Email: marie.wislez@tnn.aphp.fr

Conflicts of interest:

None

Table: 1

Figure: 5

Translational relevance

Patients with primary invasive mucinous lung adenocarcinoma (IMA) often present at advanced stage with bilateral pulmonary involvement. We found that IMA is characterized by an overexpression of CXCL10 and its receptor CXCR3 in tumor cells. Our study demonstrated that IMA derived pro-tumoral advantages by means of a CXCL10/CXCR3 autocrine loop, involving the CXCR3-A splice variant, known as a pro-tumoral variant in other tumor models. CXCL10/CXCR3-A enhances migratory capacities and up-regulates VEGF expression in tumor cells. Bronchoalveolar lavage from IMA cases has been shown to promote endothelial tube formation *in vitro*, which can then be inhibited by the humanized anti-VEGFA monoclonal antibody bevacizumab. IMA still has no effective treatment, and we have found that CXCL10/CXCR3 and VEGF could present valuable therapeutic targets for this unmet need.

Word count: 125/120-150

ABSTRACT

Purpose: Invasive mucinous adenocarcinoma (IMA) is a mucinous variant of lepidic predominant lung adenocarcinoma (LPA), displaying a high propensity for exclusive pulmonary involvement, and associated with worse prognosis. We postulated that cytokine expression would enable us to differentiate IMA from LPA in terms of prognosis and acquisition of specific pro-tumoral capacities.

Experimental design: A 30-cytokine panel was assessed in bronchoalveolar lavage fluids (BALF) from IMA (n=38), LPA (n=25), and control samples (n=7). We investigated expression of differentially-expressed cytokines and their receptors in surgical samples by immunochemistry (n=54) and receptor splice variants by real-time reverse transcription polymerase chain reaction (qRT-PCR) (n=14). We examined *in vitro* expression of cytokines and receptors in cell lines, exploring their functional impact on signaling pathways, proliferation, migration, and angiogenesis.

Results: Of the 30-cytokine panel, only CXCL10 was differentially expressed, namely overexpressed in IMA BALF compared to LPA. High levels of CXCL10 expression in BALF were linked to worse prognosis. *In vivo*, CXCL10 and its receptor splice variant CXCR3-A were expressed in tumor cells, suggesting a CXCL10/CXCR3-A autocrine loop. CXCL10/CXCR3-A expression was higher in IMA. *In vitro*, CXCL10 up-regulated CXCR3-A expression and Erk1/2 phosphorylation, also enhancing migration in mucinous H2228 cell lines. CXCL10 increased VEGF secretion *via* CXCR3 in H2228, yet influenced neither HGF nor IL-8 secretion. Our *in vitro* angiogenesis model demonstrated that IMA BALF promoted human lung endothelial tube formation *via* VEGF, which was inhibited by humanized anti-VEGFA monoclonal antibody bevacizumab.

Conclusions: CXCL10/CXCR3-A may therefore play a pro-tumoral role in IMA *via* an autocrine mechanism.

Word count: 245/250

INTRODUCTION

Lung adenocarcinomas are the most common histological type of non-small cell lung cancer (NSCLC) (1). Invasive adenocarcinoma consist of a mixture of different histological patterns, termed lepidic, acinar, solid, papillary, or micropapillary (2). Lepidic predominant adenocarcinomas (LPA) are characterized by “lepidic growth”, meaning proliferations of bland pneumocyte cells growing along the pre-existing alveolar structure. Compared to other NSCLC types, LPA less frequently affects smokers, and there is no gender bias found in the affected population (3). While LPA is typically a non-mucinous adenocarcinoma, a mucinous variant does exist, termed invasive mucinous adenocarcinoma (IMA) (2). In IMA, tumoral cells have the morphology of goblet or columnar cells with abundant intracytoplasmic mucin, and small basally-located nuclei, usually appearing as well differentiated cells. IMA is associated with worse prognosis than other NSCLC subtypes, probably due to its aerogenous spreading, which accounts for the common multicentric and bilateral lung involvement observed in these cases (4–14), and the lack of effective treatment at this stage. Patients with IMA usually present with respiratory signs at diagnosis. In cases of relapse following surgery, the lungs are typically exclusively involved, and patients usually die of respiratory failure in advanced stage (3,14).

The molecular mechanisms of LPA and IMA are not yet fully understood. *EGFR* mutations are associated with LPA, whereas *KRAS* mutations and oncogenic fusion genes appear to drive IMA (14–19). Both diseases are characterized by an intense inflammatory reaction involving complex interactions between tumor and inflammatory cells (20,21). This study sought to identify the cytokines or chemokines involved that are differentially expressed in LPA and IMA. We analyzed bronchoalveolar lavage fluid (BALF) supernatants and tumor tissues from patients

with LPA or IMA, identifying CXCL10 and its receptor CXCR3-A as creating a specific autocrine loop overexpressed in IMA. We thus demonstrated this loop's role in the promotion of pro-tumoral capacities in IMA.

MATERIALS AND METHODS

Clinical samples and ethical considerations

Between January 1992 and July 2010, 92 patients with LPA and IMA were diagnosed and followed up in our respiratory medicine department (Tenon Hospital, Assistance Publique-Hôpitaux de Paris, Paris, France). Our clinical findings have been summarized in the supplementary data section (Supplemental Table S1). The LPA or IMA diagnosis was reviewed for all patients by a lung pathologist (MA) based on the 2011 International Association for the Study of Lung Cancer/American Thoracic Society/European Respiratory Society (IASLC/ATS/ERS) lung adenocarcinoma classification (2). When only a small biopsy was available in case of advance disease, the terms LPA and IMA were kept for clarity though these terms should be use only after histologic examination of resection specimen. Disease stage was classified according to the seventh International TNM classification system for lung cancer (22). Follow-up data was recorded until death. Surgical exeresis was performed in 54 patients, with surgical paraffin-embedded samples available for all 54 patients, and frozen surgical samples for 14.

Bronchoalveolar lavage was used as a diagnostic tool, performed as previously described (23). Following diagnosis, the remaining BALF was spun and the supernatant aseptically separated and stored at -80°C. Frozen BALF supernatant samples were available for 70 patients.

BALF supernatants were obtained from seven control individuals subject to the diagnosis procedures. Four were men and three women, all with a mean age of 61 ± 7 years. Three were smokers, none had a history of neoplastic disease, and all exhibited normal BALF analysis results.

All patients signed a research approval informed consent form, permitting analysis of their biological samples. All informed consent forms were collected and stored in the Tenon Pathology Department (*Tumorothèque des Hôpitaux Universitaires de l'Est Parisien*, Tenon Hospital). This study was approved by our hospital's ethics human research committee.

Cell lines and culture conditions

Human H358, H322, A549, H2228, H441, and H1650 lung adenocarcinoma cell lines were purchased from the American Type Culture Collection (ATCC). The cells were cultured in either Dulbecco's Modified Eagle Medium (DMEM) (A549) or the Roswell Park Memorial Institute 1640 medium (RPMI-1640) (H358, H322, H2228, H441, H1650) with 10% fetal bovine serum (FBS), penicillin (100U/mL), and streptomycin (0.1mg/mL) (Life Technologies) at 37°C in an atmosphere containing 5% CO₂.

To detect the chemokines and cytokines, cell lines were cultured in Becton Dickinson 24-well culture plates in complete medium for 24 hours. For some experiments, cell lines were grown in a serum-free medium after 12 hours of starvation then treated for 24 hours with or without recombinant human IFN γ (rhIFN γ) (0-50ng/mL; R&D Systems), rhCXCL10 (0-250ng/mL; R&D Systems), or neutralizing monoclonal mouse anti-human CXCR3 (#49801; R&D Systems; 1:250).

The human lung primary fibroblasts (CCD16-Lu) were obtained from ATCC and the human lung microvascular endothelial cells (HMVEC-L; tissue acquisition no. 24942, lot no. 318929, #CC-2527) from Lonza. Cells were cultured in Eagle's minimum essential medium with GlutaMax™ with 10% FBS, penicillin (100U/mL), and streptomycin (0.1mg/mL) (Life Technologies), and in Endothelial Cell Growth Medium EGM™-2MV (Lonza), respectively.

Chemokine and cytokine quantification in BALF samples

Chemokine and cytokine concentrations in BALF supernatants were quantified using Bio-Plex multiplex bead-based assays by means of Bio-Plex Pro™ Human Cytokine 27-Plex Immunoassay, as well as three individual assays for human VCAM-1, growth regulated protein alpha (GRO α), and hepatocyte growth factor (HGF) (Bio-Rad Laboratories). For each cytokine calibration curve, eight standards were used. Data acquisition and analysis were completed using the Bio-Plex® 200 System with workstation Bio-Plex Manager™ software Version 5.0 (Bio-Rad Laboratories). Each condition was performed in duplicate.

Immunohistochemistry

Formalin-fixed, paraffin-embedded 3 μ m tissue sections from surgical specimens were used for CXCL10, CXCR3, and VEGF immunohistochemical (IHC) studies. After rehydration, deparaffinized sections were pretreated by microwave epitope retrieval (target retrieval solution, citrate pH 6; Dako). Endogenous peroxidase activity was quenched before a blocking step of non-specific binding sites, performed in 10% normal goat serum in tris-buffered saline (TBS)-Tween (wash buffer; Dako). Sections were incubated with the respective primary antibody, namely rabbit polyclonal antibody anti-human CXCL10 (PeproTech; 1:100), mouse monoclonal anti-human CXCR3 (#49801; R&D Systems; 1:100), or mouse monoclonal anti-human VEGF 165A (clone 6B7; Abcam; 1:80), overnight at 4°C. After the washes, sections were incubated with the polyclonal EnVision complex (Dako) and peroxidase activity was detected by diaminobenzidine. The appropriate isotype IgG was used as a negative control. Two investigators (MD and MA), blinded to the clinico-pathological variables, independently evaluated the immunostaining and came

to a clear agreement. The scores (scale: 0–300) were ascribed by multiplying the percentage of positive stained cells (0-100% by 5% increment) by staining intensity (1+, 2+ or 3+). Tumor samples were considered positive when the immunostaining score was ≥ 10 .

RNA and qRT-PCR

Total ribonucleic acid (RNA) was extracted from serum-deprived +/- rhCXCL10 (250ng/mL) -treated lung adenocarcinoma cell lines, as well as from frozen surgical samples, using QIAzol™ Lysis Reagent (Qiagen). RNA quantification and qualification were achieved by means of an Experion™ RNA StdSens Analysis kit (Bio-Rad). The details of the qRT-PCR protocol have been provided in the supplementary method section.

Western blotting analysis

Lung cancer cell lines were grown in serum-free medium, with and without rhCXCL10 (R&D Systems; 0-250ng/mL), for 24 hours. Proteins were extracted using a Bio-Plex Cell Lysis kit (Bio-Rad), in accordance with the manufacturer's instructions. Following centrifugation at 10,000 rpm for 10 min at 4°C, protein concentrations from the cell lysates were determined by inspecting the supernatants using the RC DC Protein Assay Kit II (Bio-Rad). The details of our western blotting protocol have been provided in the supplementary method section.

ELISA assays

CXCL10, VEGF, HGF, and IL-8 expression were all determined in the cell supernatants using ELISA detection kits, in accordance with the manufacturer's instructions (R&D Systems).

Cell migration assay and cell proliferation assay (MTT assay)

The migration of serum-deprived lung adenocarcinoma cells was detected with a modified Boyden Chamber assay on 24-well Transwell® plates (Corning Costar).

Cell proliferation was assayed using a WST-1 reagent proliferation kit (Roche Diagnostics) after seeding the cell lines in Becton Dickinson 96-well culture plates containing 200µL complete medium, left overnight at 37°C.

Further details of this process have been provided in the supplementary method section.

Capillary formation assay

HMVEC-L and CCD16-Lu fibroblasts were incubated together in uncoated MatTek Corp dishes, consisting of 24-well glass-bottom culture plates (20,000 cells/well) containing EGM™-2MV medium, for 72 h. The cells were washed and incubated for 6 days in endothelial basal medium (EBM-2) containing 10ng/mL of rhVEGF, as the positive control (R&D Systems), in 10% of NaCl 0.9% as the negative control, or in rhCXCL10 (50-250ng/mL) or 10% of the BALF. For some experiments, the conditioned media was supplemented with 0.1µg/mL of either humanized anti-VEGF monoclonal antibody A (Bevacizumab®, Genentech) or human IgG1k isotype control (SouthernBiotech). Conditioned media was changed every 48 to 72 hours. The cells were washed and fixed in phosphate-buffered saline (PBS) containing 4% formaldehyde for 30 min for the purposes of immunofluorescence.

Immunofluorescence

Endothelial tubes were detected using a mouse monoclonal anti-human CD31 antibody (#9G11; R&D Systems; 1:50), conjugated with Alexa Fluor 700. Cell nuclei were stained with Hoechst compound (Interchim). The number and length of endothelial tubes were analyzed by two investigators (MD and NM) on eight fields at x10 magnification using an Olympus ix83 inverted microscope for each condition of each experiment and computed by means of ImageJ software (U.S. National Institutes of Health).

Statistical analysis

Our results were expressed as mean±standard error of the mean (SEM). For quantitative variables, comparisons were made using the Mann-Whitney and Kruskal-Wallis non-parametric tests. For qualitative variables, the chi-squared test was used for comparisons and Spearman's rank correlation coefficient (ρ) for correlation analysis. A p -value <0.05 was considered statistically significant.

Survival time was defined as the time from diagnosis to death or the cut-off date, fixed at August 2011. Survival rates were calculated by means of the Kaplan-Meier method and survival curves compared using the log-rank test. Quantitative variables were coded as dichotomous (present or absent and high or low level), and the cut-off values represented the medians of distribution. Multivariate analysis was performed by means of Cox's multiple regression models. The lack of collinearity between variables was verified using the chi-squared test. Variables with a p -value <0.1 on univariate analysis were tested in the multivariate Cox model, with the final model chosen using a backward stepwise variable selection process based on the p -value

as candidate predictor. The threshold of significance was set at $p < 0.05$. All findings were processed using SPSS 20.0 software (IBM Corporation).

RESULTS

CXCL10 was differentially expressed in BALF supernatants from LPA and IMA

We assessed chemokine and cytokine concentrations in BALF supernatants from patients (n=70) and controls (n=7) by performing multiplex cytokine assays. Of the 30 proteins examined, three were undetectable (IL-2, FGF Basic, and TNF α) (Table1), whereas 10 were present in higher concentrations in patients compared to controls (CXCL10, MCP-1, MIP-1 β , RANTES, HGF, VEGF, IL-6, IL-8, G-CSF, and IFN γ) (Table1). Only CXCL10 was differentially expressed when comparing IMA with LPA (Figure 1A). CXCL10 concentration was significantly higher in IMA compared to LPA and controls (9714pg/ml \pm 1693 vs. 3716pg/ml \pm 872 vs. 504pg/ml \pm 149, respectively; p=0.004).

CXCL10 overexpression was linked to worse survival

CXCL10 was detected in all the patient BALF supernatants. On univariate analysis, a high level of CXCL10 concentration was associated with shorter survival (high vs. low: 13 vs. 40 months, p=0.016) (Figure 1B), worse performance status (p=0.004), and bilateral disease extension (p=0.009) (Supplementary Table S2). On multivariate analysis, only bilateral extension was associated with shorter survival (Supplementary Table S2).

The negative prognostic value of a high CXCL10 concentration suggests this cytokine possesses a pro-tumoral capacity. Together with CXCL10 overexpression in IMA, these results led us to focus our investigations on CXCL10 in order to discriminate at a biological level LPA from IMA.

CXCL10 and CXCR3 were overexpressed by tumor cells in IMA

We analyzed 54 surgical samples from patients with IMA (n=27) or LPA (n=27) in order to determine whether CXCL10 and its receptor CXCR3 were expressed in tumor tissues. Our pathological findings have been outlined in Figure 1C, demonstrating that CXCL10 was expressed in the cytoplasm of tumor cells in 42 (78%) patients. CXCL10 expression was uncommon in mononuclear stromal cells. CXCL10 was more commonly expressed in IMA cases compared to LPA (25/27 [93%] vs. 17/27 [63%], respectively; $p=0.009$). CXCL10 staining scores were significantly higher in IMA patients compared to those of LPA patients (110 ± 14 vs. 24 ± 2 , respectively; $p < 0.001$).

CXCR3 was expressed in the cytoplasmic membrane of tumor cells in 24 (44%) patients. CXCR3 was more frequently expressed in IMA patients compared to LPA (20/27 [74%] vs. 4/27 [15%], respectively; $p < 0.001$). CXCR3 staining scores were significantly higher in IMA patients compared to LPA (69 ± 5 vs. 17 ± 2 ; $p=0.047$).

CXCL10 staining score strongly correlated to CXCR3 staining score ($r=0.527$, $p < 0.001$) (Figure 1D). Finally, CXCR3-positive tumors exhibited higher concentrations of CXCL10 in the BALF supernatants than those detected in CXCR3-negative tumors ($p=0.005$, Supplementary Figure S1).

Taken together, these results indicate the existence of an overexpressed CXCL10/CXCR3 autocrine loop *in vivo* in IMA.

The expression of pro-tumoral CXCR3 splice variant A is higher in IMA

Several alternatively-spliced variants of the human CXCR3 receptor have previously been described (24). Among them, CXCR3-A and -B have a biological impact, with

CXCR3-A shown to possess pro-tumoral capacities, such as promoting chemotaxis and survival, while CXCR3-B leads to the inhibition of DNA synthesis and the apoptosis of tumor cells.

We examined the expression of the CXCR3-A and -B mRNA splice variants in frozen surgical samples taken from IMA (n=7) and LPA (n=7) cases, using the qRT-PCR analysis method. CXCR3-A and -B mRNA were detected in all samples. CXCR3-A mRNA was significantly overexpressed in IMA cases compared to LPA (2691±450 vs. 1227±191, respectively; p=0.022) (Supplementary Figure S2).

CXCL10/CXCR3-A acts as a functional autocrine loop in the mucinous H2228 cell line

CXCL10 and CXCR3 expression was assessed in mucinous (H2228, H358, H441) and non-mucinous (H322, H1650, A549) lung adenocarcinoma cell lines. As shown in Figure 2, lung adenocarcinoma cell lines did not secrete CXCL10 constitutively. As CXCL10 has been shown to be up-regulated by IFN γ , we exposed the cell lines to rhIFN γ . This induced a potent CXCL10 secretion in a dose-dependent manner from these cells, whether they were mucinous or non-mucinous (Figure 2A) (25–27). CXCR3 was expressed in all the cell lines at basal state, as shown by western blotting (Figure 2B). At basal state, CXCR3-A and CXCR3-B mRNA splice variants were expressed in the cell lines, as demonstrated by qRT-PCR (Figure 3). We next analyzed whether CXCL10 regulated CXCR3-A and CXCR3-B mRNA expression, as suggested by previous studies. After exposure to rhCXCL10 for 24 hours at 250ng/mL, CXCR3-A mRNA expression was up-regulated in H2228 cells with a 25-fold increased induction compared to basal state, whereas CXCR3-B mRNA expression was not significantly modified (Figure 3). The addition of rhCXCL10 did

not significantly influence CXCR3-A or CXCR3-B mRNA splice variant expression in other cell lines.

To determine whether CXCL10 affects signaling pathways, cell lines were exposed to rhCXCL10 for 24 hours at concentrations ranging from 50 to 250ng/mL of. As shown by western blotting, rhCXCL10 induced an up-regulation of Erk1/2 phosphorylation in H2228, though no effect was observed in the intracellular signaling in other cell lines (see Supplemental Figure S3).

In our study, we observed that CXCL10 secreted by tumor cells regulates CXCR3-A expression, and CXCL10/CXCR3-A up-regulates Erk1/2 phosphorylation in mucinous H2228 cell lines, suggesting that CXCL10/CXCR3-A can act as an autocrine loop. We propose using H2228 as a model of a functional CXCL10/CXCR3-A autocrine loop, and H322 as a negative control.

CXCL10/CXCR3-A promotes cell migration, not growth

We assayed the ability of CXCL10 to induce H2228 and H322 migration. Cell lines were exposed for 24 or 48 hours to different concentrations of rhCXCL10 (0,10, 50 or 250ng/ml) in a Boyden chamber. The number of migrating cells was then evaluated, revealing that rhCXCL10 induced the migration of H2228, yet not H322 cells, in a time- and dose-dependent manner (Supplemental Figure S4).

CXCL10 did not affect cell growth in either the H2228 or H322 cell lines, as assessed by MTT (3-[4, 5-dimethylthiazol-2-yl]-2, 5-diphenyltetrazolium bromide) assay (data not shown).

CXCL10/CXCR3-A promotes VEGF expression in mucinous H2228

We assessed the ability of CXCL10 to induce secretion of angiogenic factors, namely VEGF, HGF, and IL-8, in the H2228 and H322 cell lines. Exposing H2228 to rhCXCL10 for 24 hours induced a three- to four-fold increase of VEGF secretion, yet with no change in HGF or IL-8 secretion (Figure 4). Exposing H322 to rhCXCL10 did not modify VEGF, HGF, or IL-8 secretion (Figure 4).

We performed a CXCR3 neutralization experiment and found that VEGF secretion induced by rhCXCL10 was inhibited by 50% by the CXCR3 neutralizing antibody in H2228 cells (data not shown).

Our results confirmed that CXCL10/CXCR3 up-regulated VEGF secretion *in vitro* in the mucinous H2228 cell line.

CXCL10/CXCR3-A promotes “pro-angiogenic” VEGF expression in IMA

As CXCL10/CXCR3-A was involved in VEGF secretion in an autocrine manner *in vitro*, we hypothesized that CXCL10/CXCR3-A was involved in the regulation of VEGF secretion in IMA *in vivo*. CXCL10 concentrations correlated to VEGF concentrations in BALF supernatants ($r=0.700$, $p < 0.001$) *in vivo*. There was a trend towards increased expression of VEGF in the BALF of IMA compared to that of LPA ($5824.14\text{pg/ml} \pm 1778.28$ vs. $3550\text{pg/ml} \pm 1280.30$, respectively; $p=0.684$) (Table 1). Following this, we evaluated VEGF expression by means of immunohistochemical staining in surgical tumor samples of IMA ($n=27$) and LPA ($n=27$) (Figure 5). VEGF was expressed in the cytoplasm of tumor cells in 51 (94%) patients. VEGF staining scores were significantly higher in the IMA samples compared to those of LPA (96 ± 12 vs. 60 ± 10 , respectively; $p < 0.025$) (Figure 5). VEGF staining scores were positively correlated to CXCL10 staining scores ($r=0.353$, $p=0.015$).

We then proceeded to study angiogenesis *in vitro*, using a model in which human pulmonary microvascular endothelial cells (ECs) were co-cultured with human lung fibroblasts (28). In this model, exposure to rhCXCL10 at concentrations ranging from 50 to 250ng/ml for 6 days did not lead to a significant variation in tube formation in the lung ECs compared to the negative control (data not shown). Exposure to BALF supernatants from IMA (n=5) and LPA (n=5) samples induced tube formation with a trend towards a higher number of tubes seen in BALF from IMA than that of LPA (Figure 5). The stimulation of tube formation was significantly greater in two BALF supernatants from IMA compared to negative controls ($p < 0.05$) (Figure 5). This suggests that the pro-angiogenic factors contained in these BALF supernatants were functionally active. To determine the role of VEGF, humanized anti-VEGF monoclonal A antibody bevacizumab, or a human IgG1k for isotype control, were added to the BALF supernatants. Anti-VEGF A antibody led to a 65% inhibition of tube formation, suggesting that VEGF A plays a central role in BALF supernatants of LPA and IMA patients in terms of tube formation (Figure 5C).

All in all, these results strongly suggest that CXCL10/CXCR3-A plays a distinct role in the regulation of VEGF secretion in IMA. We therefore suggest that VEGF is involved in the enhancement of pro-tumoral capacities in IMA.

DISCUSSION

Our findings indicate that IMA is characterized by overexpression of CXCL10 and its receptor splice variant CXCR3-A. CXCL10/CXCR3-A acts as an autocrine loop and is involved in the acquisition of pro-migratory capacities and the up-regulation of VEGF expression.

This study sought to identify a differential profile of cytokine expression between IMA and LPA. We used a multiplex cytokine assay to assess the expression of a panel of 30 chemokines and cytokines in BALF supernatants from patients. Of the cytokines analyzed, only CXCL10 was differently expressed in the BALF supernatants of IMA compared to those of LPA. CXCL10 and its receptor CXCR3 were both expressed in tumor cells and marginally so in stromal or inflammatory cells. Furthermore, CXCL10/CXCR3 was overexpressed in IMA compared to LPA. CXCL10 and CXCR3 expression correlated strongly, suggesting the existence of an autocrine loop exploited *in vivo* by tumor cells.

CXCL10 is a member of the subfamily of IFN γ -inducible non-ELR CXC chemokines, which include CXCL9 and CXCL11, and is expressed by a large variety of human cell types (25–27). It was initially described as a major chemoattractant for monocytes, activated T cells, and natural killer cells. With this study, we have proven the existence of tumor expression of CXCL10/CXCR3 in a specific subtype of adenocarcinoma, also demonstrating that CXCL10 overexpression is linked to poorer survival. Numerous studies have reported the dual role played by CXCL10 and its receptor CXCR3 in malignancy. In several human cancer models, CXCL10/CXCR3 is involved in the anti-tumoral effects of stromal cells, such as angiostatic mechanisms or the recruitment of CXCR3-positive mononuclear cells involved in specific immune

responses (25–27,29,30). Conversely, a number of recent works have demonstrated that CXCL10/CXCR3 can promote tumor progression in natural killer nasal lymphomas, colorectal cancers (CRC), breast cancers, or myelomas, by stimulating the pro-migratory or pro-metastatic capacities of tumor cells themselves *via* autocrine or paracrine loops (31–37). CXCR3 expression in metastatic CRC cells is known to be up-regulated, associated with worse survival, and the CXCL10/CXCR3 axis promotes invasive and metastatic capacities. In breast cancer, CXCL10/CXCR3 is expressed in tumor cells and appears to play an essential role in lung metastasis “homing”.

We found that the two major splice variants of CXCR3, namely “anti-tumoral” CXCR3-B and “pro-tumoral” CXCR3-A, were differentially expressed in IMA. The expression of CXCR3-A was increased in IMA compared to that in LPA. In addition, following exposure to CXCL10, CXCR3-A expression was up-regulated in the mucinous H2228 cell line, whereas CXCR3-B expression was not modified. CXCL10/CXCR3-A stimulated cell migration in the mucinous H2228 cell line, yet not in the non-mucinous H322, which primarily expressed CXCR3-B. Considering all this data, therefore, we believe it proves that CXCR3-A up-regulation is a specific feature of IMA *in vivo* and *in vitro*, able to distinguish IMA from LPA. We also postulate that inhibiting the CXCL10/CXCR3 axis could present a therapeutic opportunity to avoid lung cancer spreading in IMA. AMG487 is a small-molecular-weight antagonist of CXCR3 and has exhibited a potential to inhibit tumor metastasis in murine models of breast cancer and osteosarcoma (36,38). Furthermore, several CXCL10 inhibitors are currently subject to clinical investigation in primary biliary cirrhosis and inflammatory diseases.

Our *in vivo* and *in vitro* results support the hypothesis of an VEGF expression up-regulation being caused by CXCL10/CXCR3-A. CXCL10 and VEGF expression were positively correlated in the BALF supernatants and tumor tissues. VEGF was found to be up-regulated by CXCL10/CXCR3 in mucinous H2228 cells, whereas no effect was observed in the CXCR3-B-positive H322 cells. These results suggest that CXCL10/CXCR3-A could enhance tumoral VEGF expression. In several tumor models, CXCL10/CXCR3 has been shown to mediate angiostatic signals through CXCR3-B expression in endothelial cells, inhibiting endothelial cell migration and proliferation (39,40). In NSCLC, CXCL10 was initially described as an angiostatic factor in a study using models of intratumor injection of CXCL10 in A549 xenografts in severe combined immunodeficient mice (41). In our investigations, we have demonstrated that A549 expressed CXCR3-B and CXCR3-A, with the latter only in very small amounts, hence supporting those previous results. Moreover, we revealed VEGF to be overexpressed in IMA. BALF supernatants from patients were found to be able to induce endothelial tube formation, and those from IMA were more “angiogenic” than those from LPA. The effective inhibition of vascular tube formation induced by BALF supernatants using the humanized anti-VEGF antibody bevacizumab demonstrated the central role of VEGF in this process. Bevacizumab is approved in combination with platin-based doublets in first-line treatment of advanced NSCLC (42). In this context, we therefore hypothesize that bevacizumab could present a particularly valuable therapeutic option in advanced IMA management.

Until recently, the CXCR3/CXCL10 axis was considered to exert potent anti-malignancy effects. Our study results were in line with those of a number of other investigations, suggesting this axis has a central role in promoting tumoral capacities

depending on CXCR3 splice variant A signaling. We demonstrated that CXCL10/CXCR3-A plays a role in enhancing VEGF expression. Overall, we have hereby provided new insights into the understanding of IMA biology, opening up the possibility of new therapeutic options for this disease known to be frequently multifocal and unresectable at diagnosis.

Words count: 3660/5000

Acknowledgment: We would like to thank the Tumorotheque HUEP (AP-HP – GH-HUEP), AP-HP, Hôpital Tenon, Service d'Anatomie Pathologique, F-75970 Paris, France, for providing the samples.

We are also indebted to Laurène Schlick (GRC n°04, Theranoscan) and Perrine Frere (Imaging and Cytometry Facility of Tenon, UMR_S 1155 Inserm, Rare and common kidney diseases, matrix remodelling and tissue repair, F-75020, Paris, Sorbonne Universités, UPMC Univ Paris 06, France) for their generous contribution to this work.

Bibliography

1. Curado MP, Edwards B, Shin HR, Storm H, Ferlay J, Heanue M, et al. Cancer incidence in five continents, Volume IX. Lyon: IARC Scientific Publications, 2007.
2. Travis WD, Brambilla E, Noguchi M, Nicholson AG, Geisinger KR, Yatabe Y, et al. International association for the study of lung cancer/american thoracic society/european respiratory society international multidisciplinary classification of lung adenocarcinoma. *J Thorac Oncol.* 2011;6:244–85.
3. Garfield DH, Cadranel JL, Wislez M, Franklin WA, Hirsch FR. The bronchioloalveolar carcinoma and peripheral adenocarcinoma spectrum of diseases. *J Thorac Oncol.* 2006;1:344–59.
4. Tsuta K, Kawago M, Inoue E, Yoshida A, Takahashi F, Sakurai H, et al. The utility of the proposed IASLC/ATS/ERS lung adenocarcinoma subtypes for disease prognosis and correlation of driver gene alterations. *Lung Cancer.* 2013;81:371–6.
5. Warth A, Muley T, Meister M, Stenzinger A, Thomas M, Schirmacher P, et al. The novel histologic International Association for the Study of Lung Cancer/American Thoracic Society/European Respiratory Society classification system of lung adenocarcinoma is a stage-independent predictor of survival. *J Clin Oncol.* 2012;30:1438–46.
6. Yoshizawa A, Motoi N, Riely GJ, Sima CS, Gerald WL, Kris MG, et al. Impact of proposed IASLC/ATS/ERS classification of lung adenocarcinoma: prognostic subgroups and implications for further revision of staging based on analysis of 514 stage I cases. *Mod Pathol.* 2011;24:653–64.
7. Garfield DH, Cadranel J, West HL. Bronchioloalveolar carcinoma: the case for two diseases. *Clin Lung Cancer.* 2008;9:24–9.
8. Breathnach OS, Kwiatkowski DJ, Finkelstein DM, Godleski J, Sugarbaker DJ, Johnson BE, et al. Bronchioloalveolar carcinoma of the lung: recurrences and survival in patients with stage I disease. *J Thorac Cardiovasc Surg.* 2001;121:42–7.
9. Ebbert JO, Chhatwani L, Aubry MC, Wampfler J, Stoddard S, Zhang F, et al. Clinical features of bronchioloalveolar carcinoma with new histologic and staging definitions. *J Thorac Oncol.* 2010;5:1213–20.
10. Casali C, Rossi G, Marchioni A, Sartori G, Maselli F, Longo L, et al. A single institution-based retrospective study of surgically treated bronchioloalveolar adenocarcinoma of the lung: clinicopathologic analysis, molecular features, and possible pitfalls in routine practice. *J Thorac Oncol.* 2010;5:830–6.
11. Carretta A, Ciriaco P, Melloni G, Bandiera A, Libretti L, Puglisi A, et al. Surgical treatment of multiple primary adenocarcinomas of the lung. *Thorac Cardiovasc Surg.* 2009;57:30–4.
12. Daly RC, Trastek VF, Pairolero PC, Murtaugh PA, Huang MS, Allen MS, et al. Bronchoalveolar carcinoma: factors affecting survival. *Ann Thorac Surg.* 1991;51:368–76; discussion 376–7.

13. Volpino P, Cavallaro A, Cangemi R, Chiarotti F, De Cesare A, Fiori E, et al. Comparative analysis of clinical features and prognostic factors in resected bronchioloalveolar carcinoma and adenocarcinoma of the lung. *Anticancer Res.* 2003;23:4959–65.
14. Duruisseaux M, Antoine M, Rabbe N, Poulot V, Fleury-Feith J, Vieira T, et al. The impact of intracytoplasmic mucin in lung adenocarcinoma with pneumonic radiological presentation. *Lung Cancer.* 2014;83:334–40.
15. Hata A, Katakami N, Fujita S, Kaji R, Imai Y, Takahashi Y, et al. Frequency of EGFR and KRAS mutations in Japanese patients with lung adenocarcinoma with features of the mucinous subtype of bronchioloalveolar carcinoma. *J Thorac Oncol.* 2010;5:1197–200.
16. Wislez M, Antoine M, Baudrin L, Poulot V, Neuville A, Pradere M, et al. Non-mucinous and mucinous subtypes of adenocarcinoma with bronchioloalveolar carcinoma features differ by biomarker expression and in the response to gefitinib. *Lung Cancer.* 2010;68:185–91.
17. Finberg KE, Sequist LV, Joshi VA, Muzikansky A, Miller JM, Han M, et al. Mucinous differentiation correlates with absence of EGFR mutation and presence of KRAS mutation in lung adenocarcinomas with bronchioloalveolar features. *J Mol Diagn.* 2007;9:320–6.
18. Sakuma Y, Matsukuma S, Yoshihara M, Nakamura Y, Noda K, Nakayama H, et al. Distinctive evaluation of nonmucinous and mucinous subtypes of bronchioloalveolar carcinomas in EGFR and K-ras gene-mutation analyses for Japanese lung adenocarcinomas: confirmation of the correlations with histologic subtypes and gene mutations. *Am J Clin Pathol.* 2007;128:100–8.
19. Fernandez-Cuesta L, Plenker D, Osada H, Sun R, Menon R, Leenders F, et al. CD74-NRG1 fusions in lung adenocarcinoma. *Cancer Discov.* 2014;4:415–22.
20. Wislez M, Beer DG, Wistuba I, Cadranell J, Saijo N, Johnson BE. Molecular biology, genomics, and proteomics in bronchioloalveolar carcinoma. *J Thorac Oncol.* 2006;1:S8–12.
21. Wislez M, Antoine M, Rabbe N, Gounant V, Poulot V, Lavolé A, et al. Neutrophils promote aerogenous spread of lung adenocarcinoma with bronchioloalveolar carcinoma features. *Clin Cancer Res.* 2007;13:3518–27.
22. Goldstraw P, Crowley J, Chansky K, Giroux DJ, Groome PA, Rami-Porta R, et al. The IASLC Lung Cancer Staging Project: proposals for the revision of the TNM stage groupings in the forthcoming (seventh) edition of the TNM Classification of malignant tumours. *J Thorac Oncol.* 2007;2:706–14.
23. Wislez M, Rabbe N, Marchal J, Milleron B, Crestani B, Mayaud C, et al. Hepatocyte growth factor production by neutrophils infiltrating bronchioloalveolar subtype pulmonary adenocarcinoma: role in tumor progression and death. *Cancer Res.* 2003;63:1405–12.
24. Billottet C, Quemener C, Bikfalvi A. CXCR3, a double-edged sword in tumor progression and angiogenesis. *Biochim Biophys Acta.* 2013;1836:287–95.
25. Singh UP, Singh S, Iqbal N, Weaver CT, McGhee JR, Lillard JW. IFN-gamma-inducible chemokines enhance adaptive immunity and colitis. *J Interferon Cytokine Res.* 2003;23:591–600.

26. Neville LF, Mathiak G, Bagasra O. The immunobiology of interferon-gamma inducible protein 10 kD (IP-10): a novel, pleiotropic member of the C-X-C chemokine superfamily. *Cytokine Growth Factor Rev.* 1997;8:207–19.
27. Lazzeri E, Romagnani P. CXCR3-binding chemokines: novel multifunctional therapeutic targets. *Curr Drug Targets Immune Endocr Metab Disord.* 2005;5:109–18.
28. Bishop ET, Bell GT, Bloor S, Broom IJ, Hendry NF, Wheatley DN. An in vitro model of angiogenesis: basic features. *Angiogenesis.* 1999;3:335–44.
29. Strieter RM, Addison CL, Ehlert JE, Keane MP, Belperio JA, Burdick MD, et al. Use of Immunodeficient Mice for the Evaluation of CXC Chemokines in the Regulation of Tumor-associated Angiogenesis. *ILAR J.* 1999;40:175–82.
30. Romagnani P, Annunziato F, Lasagni L, Lazzeri E, Beltrame C, Francalanci M, et al. Cell cycle-dependent expression of CXC chemokine receptor 3 by endothelial cells mediates angiostatic activity. *J Clin Invest.* 2001;107:53–63.
31. Moriai S, Takahara M, Ogino T, Nagato T, Kishibe K, Ishii H, et al. Production of interferon- γ -inducible protein-10 and its role as an autocrine invasion factor in nasal natural killer/T-cell lymphoma cells. *Clin Cancer Res.* 2009;15:6771–9.
32. Zipin-Roitman A, Meshel T, Sagi-Assif O, Shalmon B, Avivi C, Pfeffer RM, et al. CXCL10 promotes invasion-related properties in human colorectal carcinoma cells. *Cancer Res.* 2007;67:3396–405.
33. Murakami T, Kawada K, Iwamoto M, Akagami M, Hida K, Nakanishi Y, et al. The role of CXCR3 and CXCR4 in colorectal cancer metastasis. *Int J Cancer.* 2013;132:276–87.
34. Mulligan AM, Raitman I, Feeley L, Pinnaduwege D, Nguyen LT, O'Malley FP, et al. Tumoral lymphocytic infiltration and expression of the chemokine CXCL10 in breast cancers from the Ontario Familial Breast Cancer Registry. *Clin Cancer Res.* 2013;19:336–46.
35. Ma X, Norsworthy K, Kundu N, Rodgers WH, Gimotty PA, Goloubeva O, et al. CXCR3 expression is associated with poor survival in breast cancer and promotes metastasis in a murine model. *Mol Cancer Ther.* 2009;8:490–8.
36. Walser TC, Rifat S, Ma X, Kundu N, Ward C, Goloubeva O, et al. Antagonism of CXCR3 inhibits lung metastasis in a murine model of metastatic breast cancer. *Cancer Res.* 2006;66:7701–7.
37. Giuliani N, Bonomini S, Romagnani P, Lazzaretti M, Morandi F, Colla S, et al. CXCR3 and its binding chemokines in myeloma cells: expression of isoforms and potential relationships with myeloma cell proliferation and survival. *Haematologica.* 2006;91:1489–97.
38. Pradelli E, Karimjee-Soilihi B, Michiels J-F, Ricci J-E, Millet M-A, Vandenbos F, et al. Antagonism of chemokine receptor CXCR3 inhibits osteosarcoma metastasis to lungs. *Int J Cancer.* 2009;125:2586–94.
39. Belperio JA, Keane MP, Arenberg DA, Addison CL, Ehlert JE, Burdick MD, et al. CXC chemokines in angiogenesis. *J Leukoc Biol.* 2000;68:1–8.

40. Lasagni L, Francalanci M, Annunziato F, Lazzeri E, Giannini S, Cosmi L, et al. An alternatively spliced variant of CXCR3 mediates the inhibition of endothelial cell growth induced by IP-10, Mig, and I-TAC, and acts as functional receptor for platelet factor 4. *J Exp Med*. 2003;197:1537–49.
41. Arenberg DA, Kunkel SL, Polverini PJ, Morris SB, Burdick MD, Glass MC, et al. Interferon-gamma-inducible protein 10 (IP-10) is an angiostatic factor that inhibits human non-small cell lung cancer (NSCLC) tumorigenesis and spontaneous metastases. *J Exp Med*. 1996;184:981–92.
42. Sandler A, Gray R, Perry MC, Brahmer J, Schiller JH, Dowlati A, et al. Paclitaxel-carboplatin alone or with bevacizumab for non-small-cell lung cancer. *N Engl J Med*. 2006;355:2542–50.

Table 1. Chemokine and cytokine concentrations in bronchoalveolar lavage supernatants from patients and controls, based on multiplex antibody bead assay

Figure 1. CXCL10/CXCR3 overexpression in invasive mucinous adenocarcinoma (IMA). CXCL10 concentration was assessed in 70 bronchoalveolar lavage fluid (BALF) supernatants from patients by an antibody magnetic bead assay (Bioplex® System). Each sample was assessed in duplicate. A: CXCL10 concentrations in BALF supernatants from IMA, lepidic predominant lung adenocarcinoma (LPA), and controls (Kruskal-Wallis test, Mann-Whitney test). Each sample was assessed in duplicate. Columns: mean; bars: standard error of the mean (SEM). B: survival curve of patients with high and low CXCL10 levels in BALF supernatants (log rank test). C: CXCL10 and CXCR3 staining (brown) in IMA and LPA. D: correlation between CXCL10 and CXCR3 staining scores (Spearman's rho test)

Figure 2. CXCL10 and CXCR3 are expressed in lung adenocarcinoma cell lines. A: CXCL10 concentrations in cell line supernatants assessed by ELISA, after exposure to rhIFN γ (0, 10 or 50ng/ml) (Mann-Whitney Test). Each sample was assessed in triplicate and results are representative of three independent experiments. Columns: mean; bars: standard error of the mean (SEM); *: $p < 0.05$; **: $p < 0.005$; difference between stimulated and unstimulated cells. B: Determination of CXCR3 expression by western blotting in cell lines. Representative of three independent experiments performed for each cell line

Figure 3. CXCL10 up-regulates CXCR3-A splice variant expression in the mucinous H2228 cell line. CXCR3-A and-B messenger ribonucleic acid (mRNA) quantified by real-time reverse transcription polymerase chain reaction (qRT-PCR) in cell lines at basal state and after exposure to CXCL10 (250ng/ml) (Mann-Whitney Test). Each sample was assessed in triplicate and the results are representative of three independent experiments. Columns: mean; bars: standard error of the mean (SEM); *: $p < 0.005$; difference between basal state and unstimulated cells

Figure 4. CXCL10/CXCR3-A regulates VEGF secretion. Concentrations of VEGF, HGF, and IL-8 were assessed by ELISA in cell line supernatants at basal state and after exposure to rhCXCL10 (250ng/ml) (Mann-Whitney Test). Each sample was assessed in triplicate and the results are representative of three independent experiments. Columns: mean; bars: standard error of the mean (SEM); *: $p < 0,005$; difference between stimulated and unstimulated cells

Figure 5. VEGF is overexpressed in invasive mucinous adenocarcinoma (IMA) and promotes angiogenic capacities. A: VEGF staining (brown) in IMA and lepidic predominant lung adenocarcinoma (LPA). Mean VEGF staining score in IMA (n=27)

and LPA (n=27) (Mann-Whitney Test). Columns: mean; bars: standard error of the mean (SEM); *: $p < 0.05$; difference between staining score means of IMA and LPA. B: number of tubes formed after exposure to 10 different bronchoalveolar lavage fluid (BALF) supernatants from patients (LPA, n=5; IMA, n=5) (Kruskal-Wallis test, Mann-Whitney test). Positive control was exposure to endothelial basal medium (EBM) and negative control to rhVEGF. Each sample was assessed in duplicate and the results are of one experiment representative of three independent experiments. Columns: mean; *: $p < 0.05$; difference between negative control and BALF supernatants. C: representative image of tube formation in negative and positive controls, LPA, and IMA. D: mean number of tube formation after exposure to BALF supernatants with or without bevacizumab. Columns: mean

Table 1. Concentrations of chemokines and cytokines in bronchoalveolar lavage supernatant of the patients and control based on multiplex antibody bead assay

Mean (±SEM)		Patients (n=70)	Controls (n=8)	p*	IMA (n=38)	LPA (n=25)	p**
Chemokines (pg/ml)	GRO-α/CXCL1	793.70 (74.10)	749.79 (210.38)	>0.05			
	IP-10/CXCL10	7974.18 (1213.38)	504.28 (149.80)	0.001	9714.73 (1693.40)	3716 (872.05)	0.001
	MCP-1/CCL2	332.81 (81.04)	26.04 (11.36)	0.016	369.17 (139.31)	231.71 (66.89)	0.431
	MIP-1a/CCL3	3.25 (1.14)	2.61 (0.81)	>0.05			
	MIP-1b/CCL4	68.40 (14.98)	10.99 (3.58)	0.007	58.04 (12.83)	42.70 (12.99)	0.214
	RANTES/CCL5	93.20 (17.11)	21.22 (12.04)	0.037	97.87 (23.87)	84.48 (26.90)	0.844
Growth factors (pg/ml)	EOTAXIN/CCL11	36.69 (2.80)	31.83 (1.57)	>0.05			
	bFGF	—	—				
	HGF	705.37 (171.45)	67.62 (21.90)	0.002	666.34 (185.62)	642.70 (368.56)	0.577
Interleukins (pg/ml)	VEGF	5071.85 (1097.98)	366.74 (98.96)	0.025	5824.14 (1778.28)	3550 (1280.30)	0.684
	IL-1b	5.62 (2.19)	3.71 (1.16)	>0.05			
	IL-1ra	196.64 (98.19)	89.82 (54.40)	>0.05			
	IL-2	—	—				
	IL-4	3.86 (1.35)	3.41 (2.92)	>0.05			
	IL-5	2.41 (0.78)	1.18 (0.64)	>0.05			
	IL-6	59.44 (14.46)	2.5 (1.07)	0.007	50.99 (19.29)	47.66 (17.59)	0.800
	IL-7	42.38 (12.26)	27.65 (18.27)	>0.05			
	IL-8	224.86 (51.04)	29.17 (6.82)	0.023	167.32 (30.52)	154.41 (49.36)	0.140
	IL-9	36.00 (2.87)	27.42 (11.12)	>0.05			
	IL-10	6.12 (1.04)	5.80 (3.99)	>0.05			
	IL-12 (p70)	35.06 (5.33)	17.65 (10.56)	>0.05			
	IL-13	1.70 (0.55)	2.63 (1.18)	>0.05			
	IL-15	1.31 (0.19)	0.76 (0.24)	>0.05			
	IL-17	34.33 (4.43)	27.60 (18.23)	>0.05			
Other cytokines (pg/ml)	G-CSF	57.23 (10.47)	11.18 (6.56)	0.016	39.79 (6.44)	71.16 (22.84)	0.474
	GM-CSF	9.05 (1.47)	15.30 (5.87)	>0.05			
	IFN γ	59.82 (14.18)	18.22 (9.99)	0.041	133.64 (33.58)	58.77 (16.67)	0.100
	TNF α	—	—				
Cell adhesion molecule (pg/ml)	PDGF β	81.66 (18.40)	27.76 (14.53)	>0.05			
	VCAM-1	1173.66 (236)	292.50 (189.04)	>0.05			

NOTE: The illustrated results are from one experiment and representative of results from three experiments. All values are the means of triplicate samples

(—) designates undetectable levels

* Comparison of concentrations using the Mann-Whitney test.

** Comparison of concentrations using the Mann-Whitney test. For each occurrence, concentrations in mucinous variant adenocarcinoma, lepidic predominant adenocarcinoma, and control were all significantly different, according to Kruskal-Wallis test

IMA: invasive mucinous adenocarcinoma; LPA: lepidic predominant adenocarcinoma; SEM: standard error of the mean

Figure 1

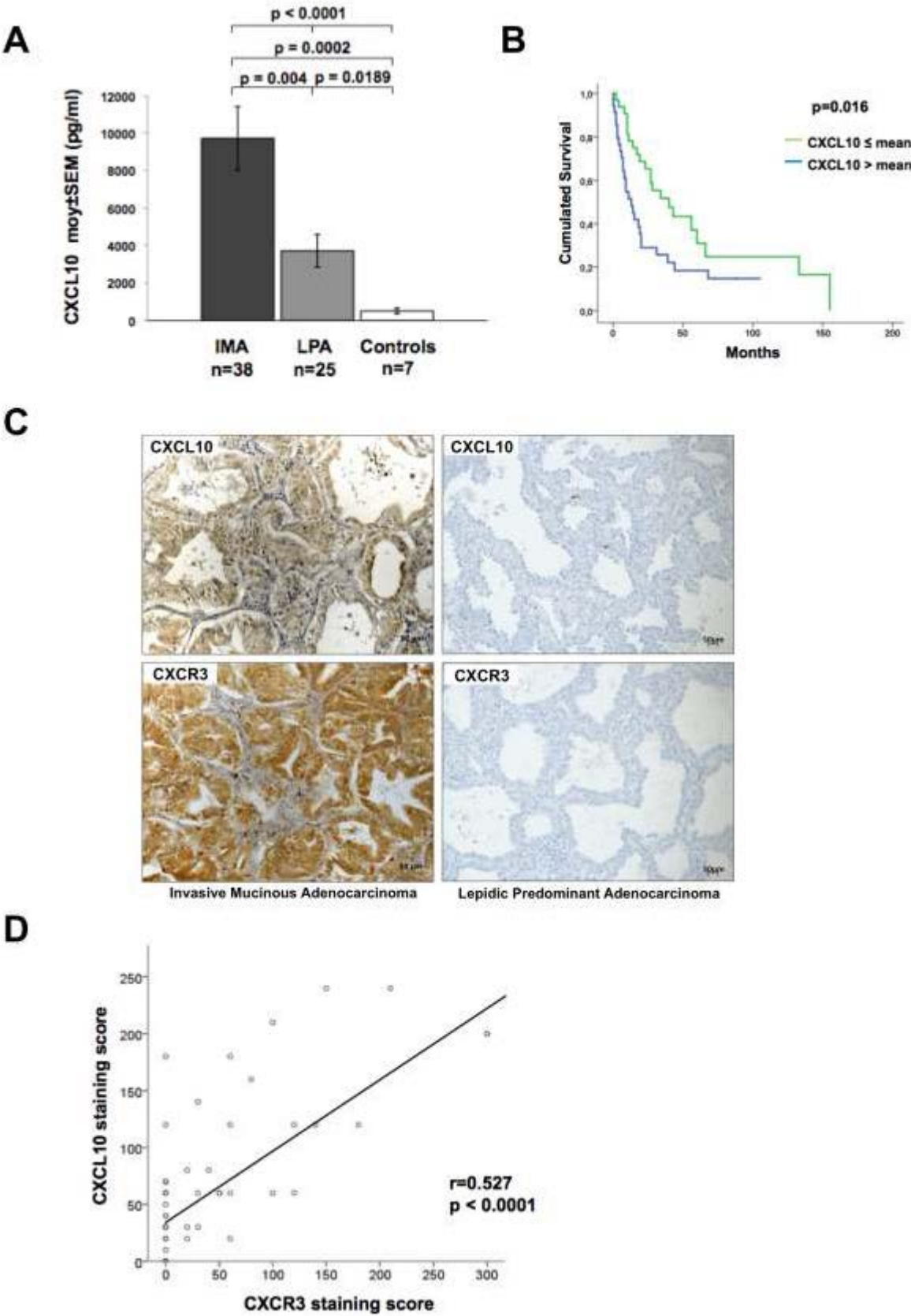


Figure 2

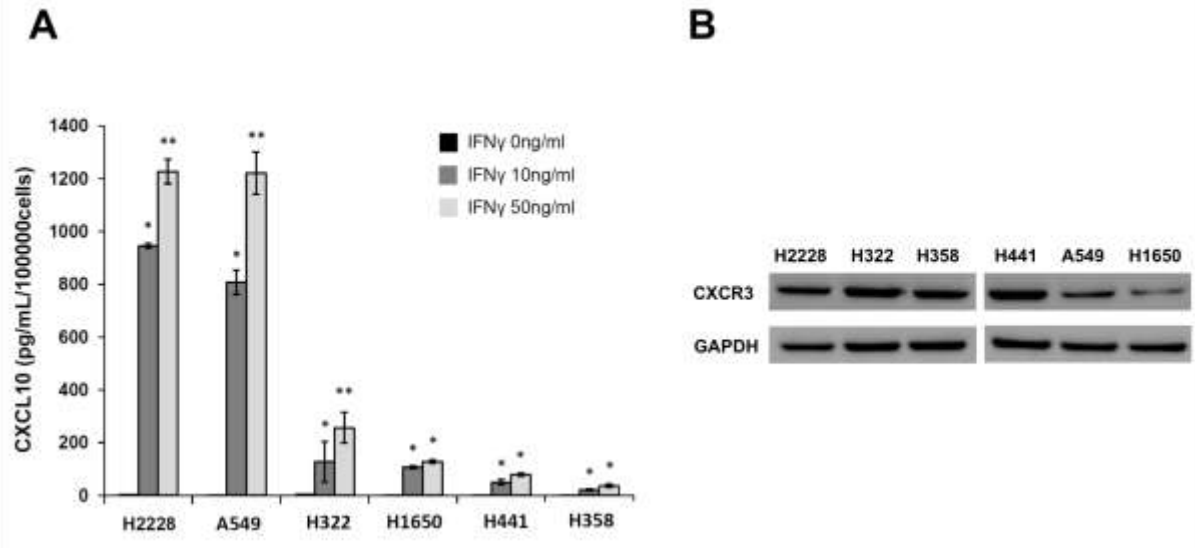


Figure 3

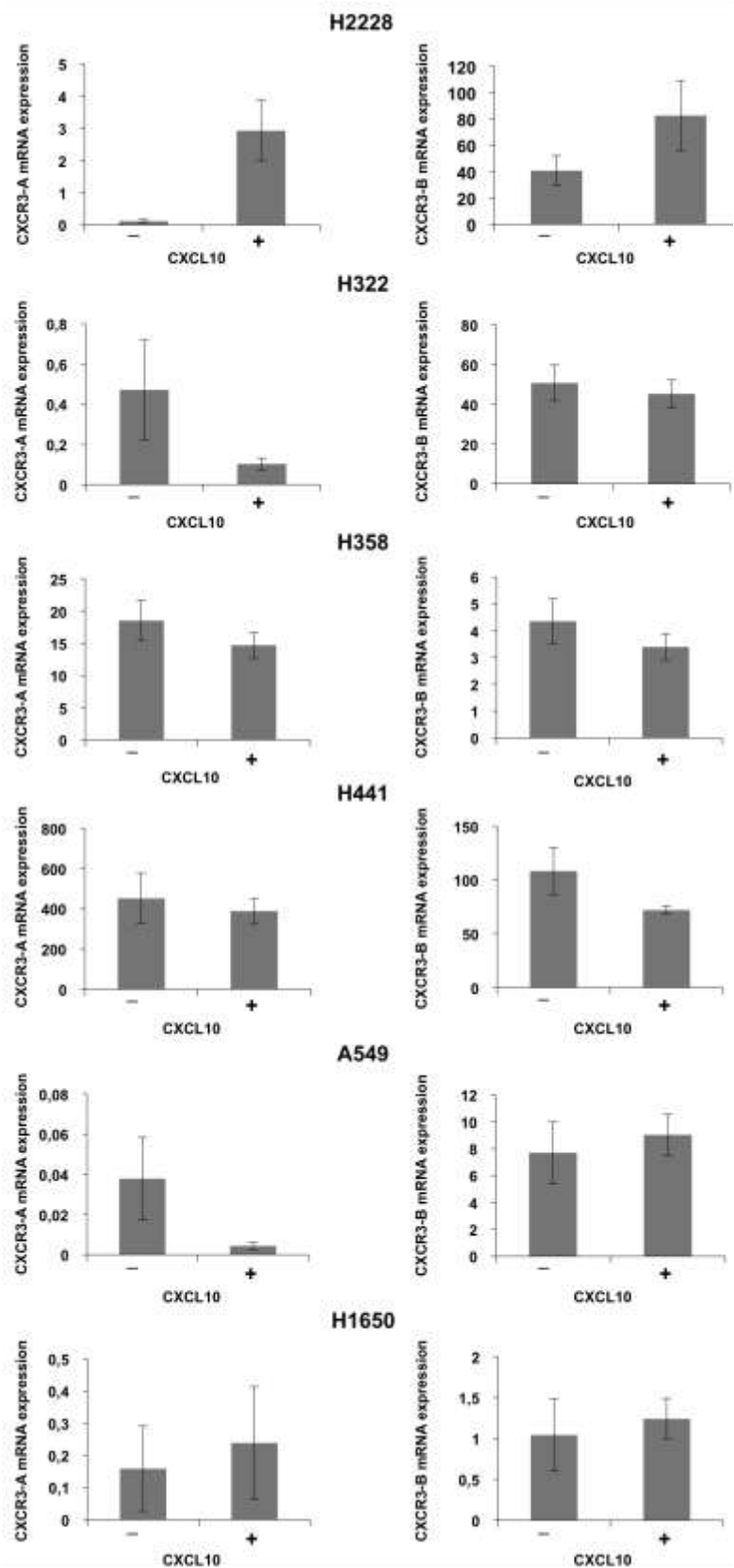


Figure 4

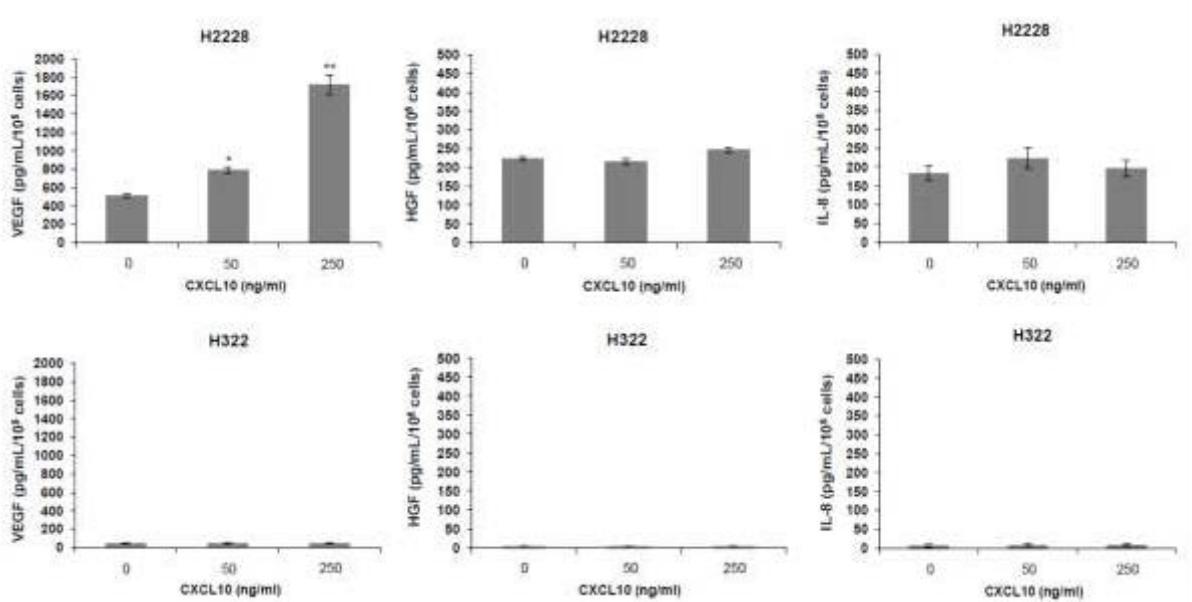
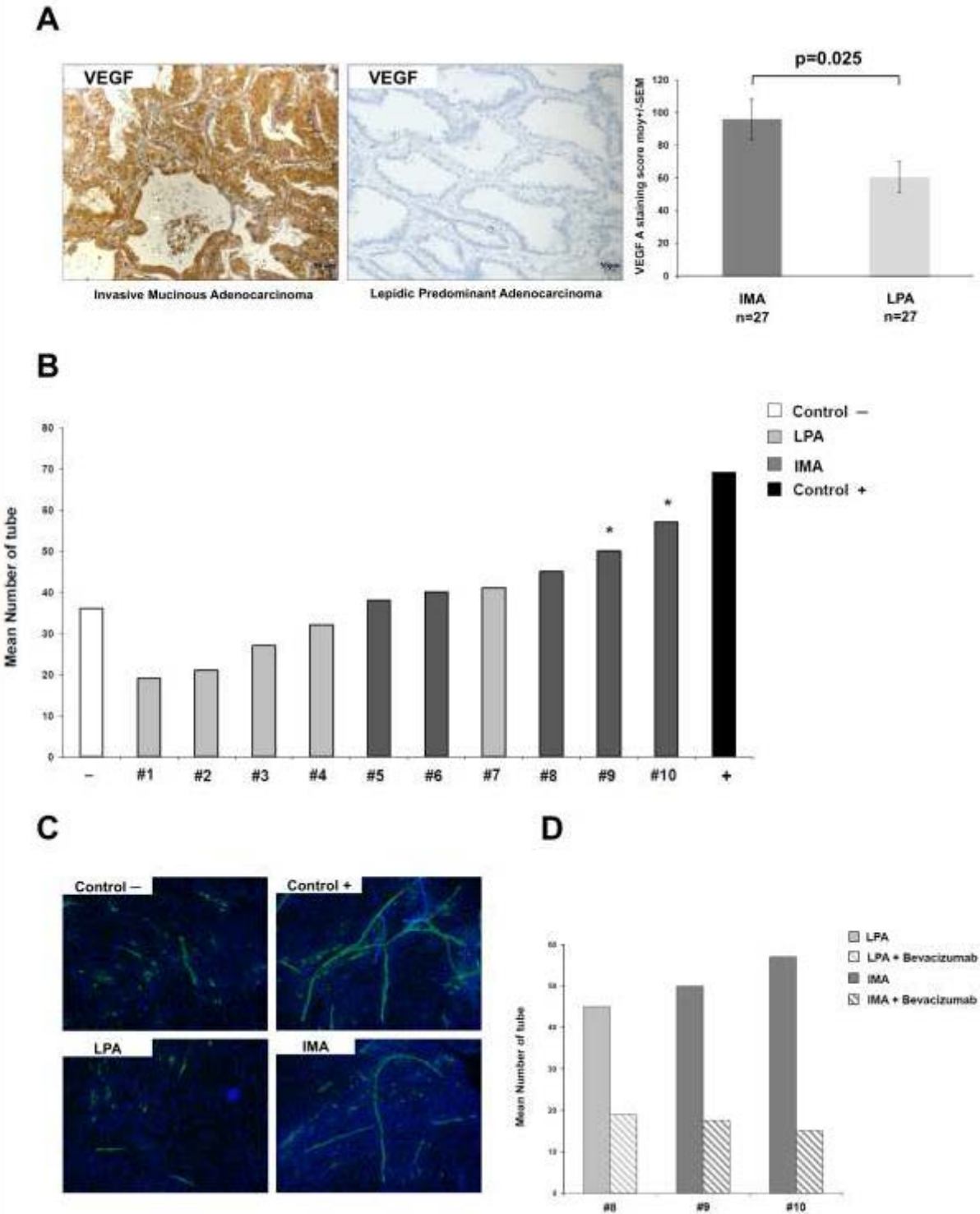


Figure 5



SUPPLEMENTAL FIGURES AND TABLES

Table 1. Clinical characteristics of the patient

	Patients (n=92)
Age (years, moy±SEM)	65±1
Gender (n,%)	
Female	42 (46)
Male	50 (54)
Smoking status (n,%)	
Never smoked	25 (27)
Former or current	67 (73)
Performance status (n,%)	
0	60 (65)
>0	30 (33)
MD	2 (3)
Bilateral disease (n,%)	
Yes	52 (58)
No	40 (42)
Histological status (n,%)	
Invasive mucinous adenocarcinoma	49 (53)
Invasive lepidic predominant adenocarcinoma	36 (39)
Cytological diagnosis	7 (8)

MD: missing data; SEM: standard error of the mean

Table 2. Univariate and multivariate analyses of factors associated with worse survival in all patients

Variable	No. of patients	Univariate hazard ratio (95% CI)	p-value	Multivariate hazard ratio (95% CI)	p-value
<i>CXCL10</i>					
High level	21	0.543 (0.279-0.986)	0.016	0.702 (0.362-1.361)	0.294
Low Level	49	1			
<i>Gender</i>					
Male	40	0.717 (0.405-1.271)	0.255		
Female	30				
<i>Age</i>					
>Mean	35	0.841 (0.482-1.467)	0.542		
<Mean	35				
<i>Smoking Status</i>					
Smoker	53	1.098 (0.559-2.157)	0.787		
Non Smoker	17				
<i>IMA vs LPA</i>					
IMA	38	0.717 (0.380-1.354)	0.306		
LPA	25	1			
<i>Performance Status</i>					
>0	27	0.409 (0.226-0.739)	0.004	0.681 (0.354-1.307)	0.248
0	41	1			
<i>Bilateral Lesion</i>					
Yes	38	0.463 (0.259-0.828)	0.009	0.632 (0.334-0.812)	0.007
No	32	1			

Variables with a $p < 0.1$ in univariate analysis were entered into the multivariate analysis and were selected using a backward procedure

HR: hazard ratio; 95% CI: 95% confidence interval; BAL: bronchoalveolar lavage; IMA: invasive mucinous adenocarcinoma; LPA: lepidic predominant lung adenocarcinoma

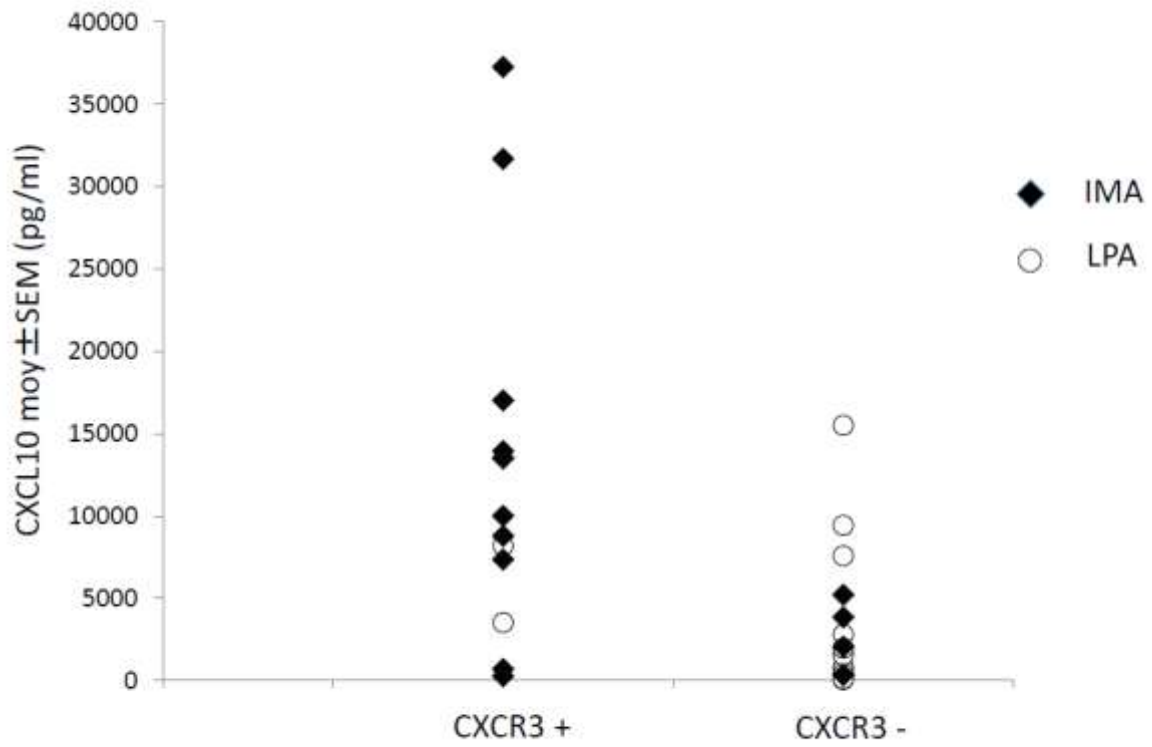


Figure 1. CXCL10 concentrations in the bronchoalveolar lavage fluid (BALF) according to CXCR3 expression

IMA: invasive mucinous adenocarcinoma; LPA: lepidic predominant lung adenocarcinoma

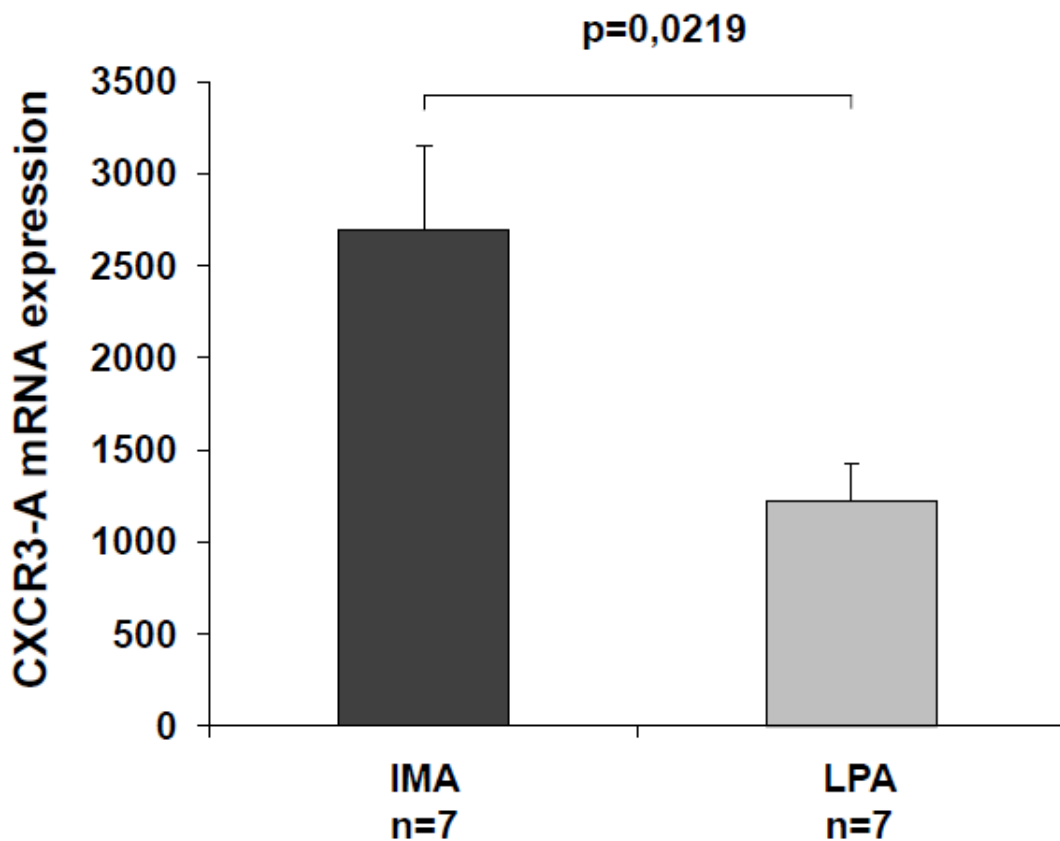


Figure 2. Comparison of CXCR3-A mRNA expression in invasive mucinous adenocarcinoma (IMA) and lepidic predominant lung adenocarcinoma (LPA). CXCR3-A messenger ribonucleic acid (mRNA) quantified by real-time reverse transcription polymerase chain reaction (qRT-PCR) in frozen samples of IMA and LPA (Mann-Whitney T

test). Each sample was assessed in duplicate and the results are of one experiment representative of three independent experiments. Columns: mean; bars: standard error of the mean (SEM); *: $p < 0.05$; difference between IMA and LPA

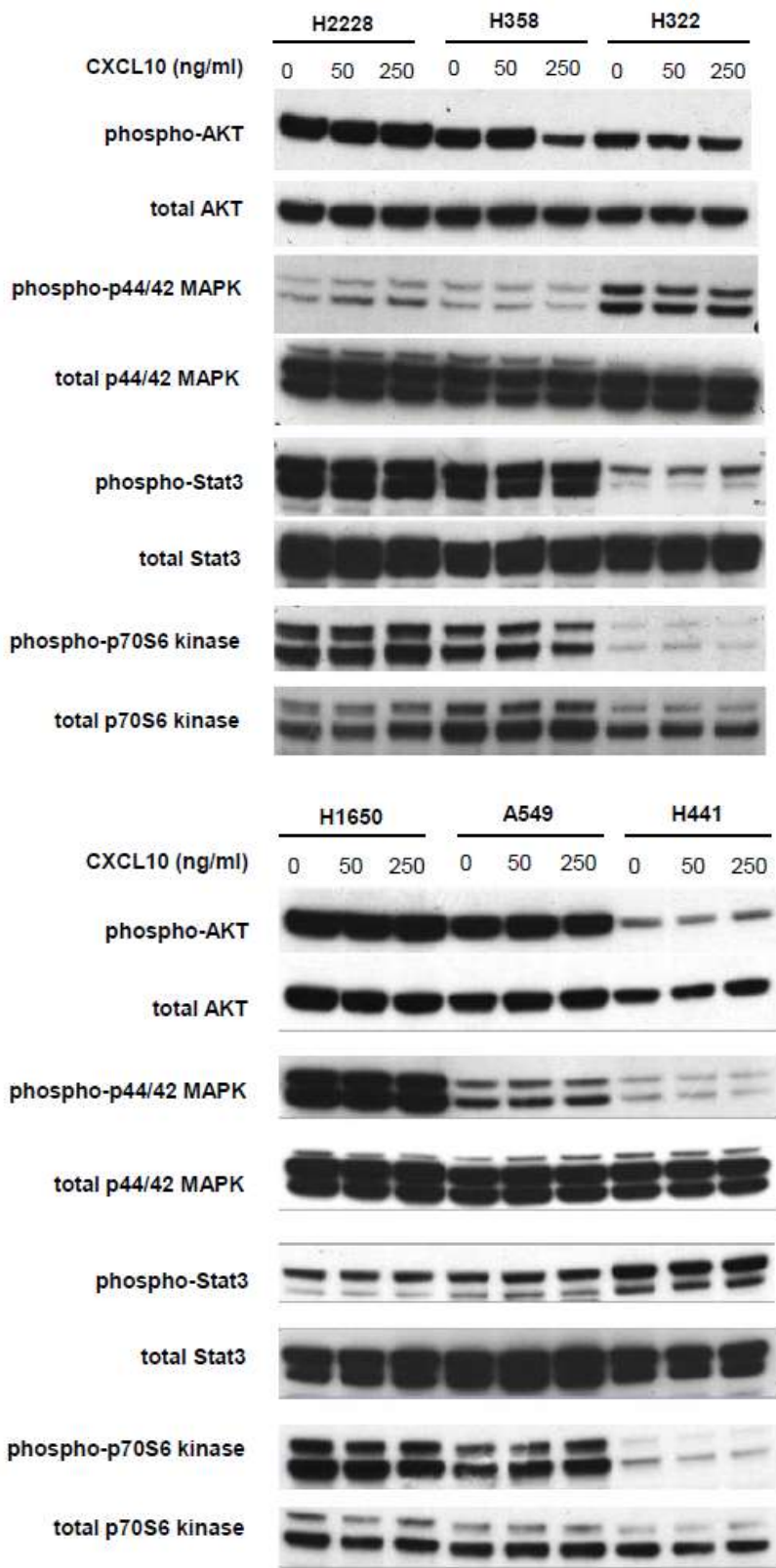


Figure 3. Determination of AKT, ERK 1/2, STAT 3, and p70/S6 expression and phosphorylation by western blotting in H2228, H358, H322, H1650, A549, and H441, stimulated by CXCL10 for the indicated points. Representative of three independent experiments performed for each cell line

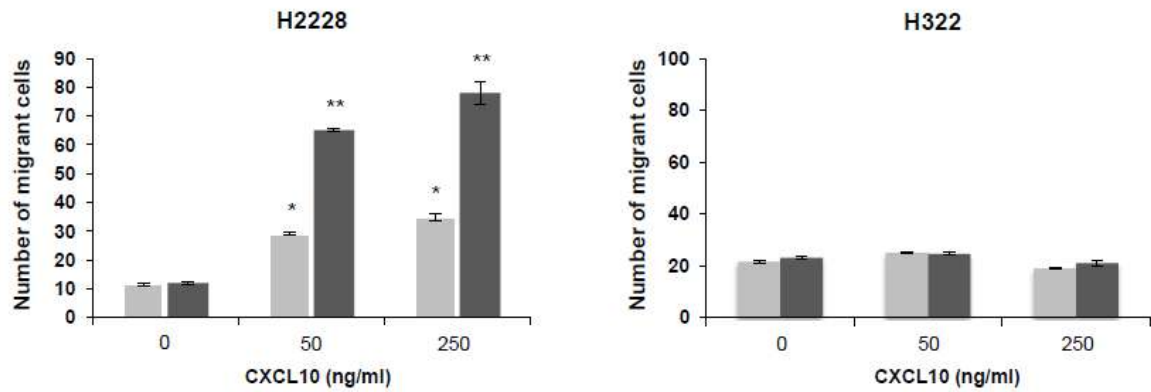


Figure 4. The migration of H2228 and H322 was assessed in 24-well modified Boyden chamber dishes after exposition to 0, 50 or 250ng/ml of rhCXCL10 for 24 or 48 hours (Kruskal-Wallis test, Mann-Whitney test). Each sample was assessed in triplicate and the results are of one experiment representative of three independent experiments. Columns: mean; bars: standard error of the mean (SEM); *: $p < 0.05$; **: $p < 0.005$; difference between stimulated and unstimulated cells

7. Discussion

Ce travail de thèse a tenté de dégager des caractéristiques cliniques et biologiques distinctes entre ALP et AMI. Ce travail s'est appuyé sur la cohorte des patients diagnostiqués et pris en charge dans le service de pneumologie de l'hôpital Tenon et les prélèvements à destination de recherche de ces patients.

Nous avons construit notre réflexion en réalisant une description clinique, anatomopathologique et moléculaire de ces patients (article 1 et 2). Nous avons montré la valeur de mauvais pronostic de la présence de la mucosecrétion présente au sein des AMI. Un profil différentiel d'expression protéique des mucines était également dégagé entre ALP et AMI. Ce travail a permis de réaliser la première description *in vivo* de l'hyperexpression de MUC1 dans les tumeurs mutées *EGFR* et d'une hyperexpression de MUC5B et MUC5AC dans les tumeurs mutées *KRAS*, confortant des hypothèses soulevées *in vitro* dans d'autres travaux.

Une recherche de réarrangement *NRG1* a été réalisée dans la cohorte des AMI sans anomalies oncogéniques usuelles à l'aide d'une technique de FISH mise au point en collaboration avec la Plateforme de Génétique Moléculaire des Tumeurs du CHU de Grenoble (Dr Anne McLeer) (article 3). Un réarrangement *NRG1* était retrouvé parmi 25 AMI chez une patiente d'origine asiatique, confirmant la plus grande fréquence de cette anomalie oncogénique dans les populations asiatiques que dans les populations caucasiennes.

Nous avons démontré l'existence d'une boucle autocrine CXCL10/CXCR3-A pro-tumorale surexprimée dans les AMI (article 4). Cette boucle autocrine faisait la promotion des capacités de migration d'une lignée cellulaire exprimant CXCL10/CXCR3-A. Nous suggérons également *in vitro* et *in vivo* que CXCL10/CXCR3-A induisait une expression tumorale de VEGF. Le VEGF issu des LBA des patients avec AMI était capable d'induire la formation de néo-vaisseaux, formation inhibée par l'anticorps monoclonal humanisé anti-VEGF bevacizumab.

7.1. Mucosécrétion et expression des mucines

Nous avons étudié les caractéristiques cliniques et anatomopathologiques de 120 patients diagnostiqués avec un adénocarcinome pulmonique, ex CBA, dans le service de pneumologie de l'hôpital Tenon (article 1) (120). Cette étude démontre que pour l'essentiel ces tumeurs correspondent aux AMI et ALP tels qu'ils sont définis dans la classification anatomopathologique des adénocarcinomes pulmonaires 2011. Nous démontrons qu'une mucosécrétion était détectée dans 100% des AMI mais pouvait également être détectée au sein de contingent minoritaire dans les ALP. Ces résultats étaient confirmés par l'étude de l'expression des mucines sécrétoires MUC5B, MUC5AC et MUC6 montrant une expression prédominante dans les AMI (article 2). La mucosécrétion était également un facteur de mauvais pronostic indépendant (article 1). MUC5B, MUC5AC et MUC6 jouent probablement un rôle important dans le phénotype mucineux et caliciforme des cellules tumorales constituant les AMI mais possiblement aussi dans l'acquisition de capacités pro-tumorales. Sur ce plan, il n'existe aucune donnée dans la littérature dans le cancer du poumon. Ceci pourrait être exploré par des expressions ectopiques de MUC5B, MUC5AC et MUC6 au sein de modèle cellulaire d'adénocarcinomes pulmonaires de fond génétique connus notamment pour les mutations de *KRAS*. En effet, il existait dans notre étude une association forte entre expression de MUC5AC et MUC5B et mutation *KRAS* (article 2). Ces données confortent les résultats issus d'un modèle souris *KRAS*^{G12D}/*Nkx2-1*^{+/-} dans lequel survient un adénocarcinome pulmonaire de morphologie identique aux AMI chez l'homme (93). Il existait dans ce modèle une régulation de l'expression de MUC5AC et MUC5B par la double altération génomique *KRAS*^{G12D}/*Nkx2-1*^{+/-} et un lien entre expression de MUC5AC et MUC5B et le phénotype caliciforme des cellules tumorales. Il serait intéressant d'explorer l'expression de MUC5AC et MUC5B chez des patients avec des cancers du poumon mucosécrétants mais sans phénotype tumoral caliciforme, comme les adénocarcinomes de type solide avec mucosécrétion notamment comme les tumeurs avec réarrangement *ALK*, pour déterminer si une expression intense de MUC5AC et MUC5B est réservée ou non au phénotype tumoral caliciforme des AMI.

L'expression de MUC1 était également associée aux tumeurs avec mutation *EGFR* dans notre étude. Il existe un rationnel *in vitro* pour un rôle de MUC1-C dans la signalisation médiée par *EGFR* dans les cellules pulmonaires mutée pour *EGFR* et dans la résistance aux ITK-*EGFR* (136). Une exploration de l'expression de MUC1 dans une large cohorte de

tumeurs mutées *EGFR* et comparée à des tumeurs avec d'autres altérations génomiques permettrait de proposer MUC1 comme une cible potentielle dans les cancers pulmonaires mutés *EGFR*.

7.2. Réarrangement *NRG1* et AMI

Nous avons décrit un réarrangement *NRG1* à l'aide d'une technique de FISH au sein d'une cohorte de 25 AMI dont 11 étaient « pan-négatifs » pour les altérations oncogéniques classiques (*EGFR/KRAS/BRAF/ERBB2/ALK/ROS1*). Des études très récentes (2014) ont décrit ce nouveau réarrangement dans les AMI motivant la mise au point du FISH *NRG1* et la recherche de réarrangement *NRG1* dans notre cohorte. En effet, deux groupes ont simultanément mis en évidence l'existence d'un réarrangement de *NRG1* au sein de cohorte d'AMI sauvages pour les altérations oncogéniques classiques (*EGFR/KRAS/BRAF/ERBB2/ALK/ROS1/RET*) (94,95). Il s'agissait quasi exclusivement de femmes asiatiques non-fumeuses. Un troisième groupe a estimé l'incidence des réarrangements de *NRG1* à 3,9% au sein d'une importante cohorte de cancers pulmonaires (n=153) dont les sous-types histologiques n'étaient pas détaillés (140). De manière intéressante, il existait dans cette étude une association entre l'expression d'HNF4A α , un marqueur diagnostique des AMI récemment décrit, et le réarrangement *NRG1*. Il existe probablement un lien entre phénotype mucineux et réarrangement *NRG1*. Ce lien pourrait être élucidé en étudiant l'impact de la protéine de fusion *NRG1* sur la régulation de l'expression des mucines, notamment MUC5B, MUC5AC et MUC6 au sein de lignées cellulaires exprimant cette protéine de fusion de manière stable.

La protéine de fusion *NRG1* agit par le biais de l'activation d'hétérodimères ERBB2/ERBB3 et les tumeurs réarrangées pour *NRG1* surexpriment ERBB2 et ERBB3 (95). Bloquer le signal induit par ces récepteurs pourrait être la meilleure stratégie pour traiter les tumeurs avec réarrangement *NRG1*. *In vitro*, une monothérapie par lapatinib ou afatinib, qui cible EGFR et ERBB2, n'est qu'incomplètement efficace dans les modèles cellulaires exprimant la protéine de fusion CD74-*NRG1*, probablement du fait de l'absence de ciblage d'ERBB3 (94). Une stratégie inhibant l'hétérodimérisation de ERBB2 et 3 serait certainement pertinente, par exemple au moyen du pertuzumab qui est capable d'empêcher cette hétérodimérisation (190). Un certain nombre d'inhibiteurs d'ERBB3 avec une activité pré-clinique intéressante sont en cours d'investigation cliniques en combinaison avec des

inhibiteurs d'ERBB2 dans les cancers du sein et gastriques surexprimant ERBB2 (Clinical trials: NTC01602406, NTC02167854, NTC01512199). Aucun cas de tumeurs avec réarrangement *NRG1* ayant été traité par une thérapie ciblée n'a été rapporté dans la littérature. Seul un essai clinique mené dans une population de patients avec cancer du poumon réarrangé pour *NRG1* pourrait permettre de valider une de ces stratégies thérapeutiques. La recherche d'un réarrangement *NRG1* par FISH ou RNA-seq pourrait être discuté au cas par cas chez les patients avec AMI avancés « pan-négatifs » et sans option thérapeutique afin de discuter une inclusion dans un essai clinique testant des inhibiteurs de ERBB2 et 3.

Notre test diagnostique par FISH était peu performant avec un résultat ininterprétable chez 6 patients sur 11, probablement du fait de l'ancienneté des prélèvements. Il est tout de même remarquable que le prélèvement positif pour un réarrangement *NRG1* soit issu d'une patiente d'origine vietnamienne, comme les cas Asiatiques décrits dans la littérature. Une étude recherchant ce réarrangement au sein d'AMI « pan-négatifs » de patients non-asiatiques et au moyen d'une technique très sensible de RNA-seq est nécessaire afin de vérifier l'hypothèse de la rareté de ce réarrangement chez ces patients.

7.3. Boucle autocrine CXCL10/CXCR3-A pro-tumorale dans les AMI

La démonstration d'un rôle pro-tumoral de la boucle autocrine CXCL10/CXCR3-A surexprimée dans les AMI s'inscrit dans un contexte de preuves grandissantes de l'implication de la voie CXCL10/CXCR3 dans la progression de nombreux cancers (article 3) (182). Son rôle important dans la croissance cellulaire, les capacités de migration et le potentiel métastatique a été montré dans les cancers colo-rectaux, les cancers du sein, les cancers du rein, les mélanomes et les lymphomes NK des sinus (171,175,178,179,181). Une étude récente a étudié les données issues du Cancer Genome Atlas et montré que l'expression tumorale de CXCL10/CXCR3 était un facteur prédictif indépendant de dissémination métastatique en analyse multivariée dans les mélanomes, les cancers colo-rectaux et du rein (182). Nos données fournissent un rationnel pour de nouvelles études explorant l'expression et le rôle pronostic de CXCL10/CXCR3 dans tous les cancers pulmonaires. Nous avons utilisé la lignée d'adénocarcinomes pulmonaires H2228 comme modèle cellulaire de boucle autocrine CXCL10/CXCR3-A du fait de son caractère mucineux. H2228 présente également une translocation *EML4-ALK*. Les tumeurs *ALK+* étant souvent associées à un contingent

mucineux, une étude de l'expression de CXCL10/CXCR3-A dans ce sous-type moléculaire de cancer pulmonaire pourrait être pertinent.

La régulation de l'expression de CXCL10/CXCR3 dans notre modèle n'est pas connue. Dans plusieurs cancers hématologiques, l'expression de CXCL10 est contrôlée par des protéines issues de la transcription d'ADN viral du virus Epstein-Barr (EBV), notamment LMP1 (Latent Membrane Protein 1) (181,191). Dans les lymphomes NK des sinus associés aux infections à EBV, CXCL10 est associé à un mauvais pronostic et la boucle autocrine CXCL10/CXCR3 joue un rôle pro-tumoral central (181). Il existe un lien entre infection virale et adénocarcinomes pulmonaires lépidiques. En effet, l'adénocarcinome pulmonaire du mouton dont la morphologie est très proche de l'adénocarcinome pulmonaire lépidique humain est provoqué par une infection par le retrovirus jaagsiekte ovin (JRSV) et notamment par l'oncoprotéine Env (53). La présence du génome ou de protéines de JRSV dans les adénocarcinomes humains a été retrouvée chez l'homme sans pouvoir faire un lien carcinogénèse de l'adénocarcinome pulmonaire chez l'homme. L'expression tumorale et éventuellement le rôle de l'axe CXCL10/CXCR3 pourrait être étudiée dans ce modèle ovin en faisant l'hypothèse que la protéine Env ou d'autres protéines issues du JRSV régulent son expression.

Notre étude fournit un rationnel pour le ciblage de la voie CXCL10/CXCR3 et du VEGF comme option thérapeutique dans les AMI. Des inhibiteurs de CXCL10 et de CXCR3 existent et sont en cours de développement clinique avancé dans le traitement de la cirrhose biliaire primitive et la polyarthrite rhumatoïde. Des essais thérapeutiques de phase I sont en cours dans les cancers du sein, les cancers du rein, les mélanomes et les cancers hématologiques mais aucune donnée préliminaire de tolérance et d'efficacité ne sont encore disponibles (145). L'usage de ces inhibiteurs est sujet à caution en cancérologie. En effet, aucun inhibiteur n'est spécifique des différents variants d'épissage de CXCR3 dont les fonctions sont très différentes. Ces médicaments pourraient donc avoir un effet délétère notamment en réprimant l'immunité antitumorale au cours de laquelle l'axe CXCL10/CXCR3 joue un rôle important. Il existe en revanche des inhibiteurs spécifique du VEGF comme le bevacizumab, anticorps monoclonal humanisé, qui possède une AMM dans le cancer du poumon avancé non épidermoïde (119). L'association du bevacizumab à la chimiothérapie pourrait être un traitement de choix dans les formes avancées d'AMI, quelque soit la ligne de traitement. Un travail est actuellement en cours au sein de l'équipe de pneumologie de l'hôpital Tenon afin

de déterminer l'efficacité du bevacizumab dans les adénocarcinomes lépidiques avancés et en particulier les AMI. L'efficacité de l'association bevacizumab-chimiothérapie sera examinée rétrospectivement et comparée à l'efficacité du bras carboplatine-paclitaxel de l'essai IFCT-0504. Le résultat de ce travail combiné à nos données pré-cliniques pourrait mener à la réalisation d'un essai thérapeutique testant l'efficacité du bevacizumab dans cette population de patients.

8. Conclusion

Ce travail a utilisé plusieurs approches afin d'améliorer la connaissance de la biologie des AMI et des ALP. Nos résultats apportent des enseignements sur la description moléculaire des AMI et dégagent notamment un mécanisme précis pro-tumoral développé par ce sous-type d'adénocarcinome pulmonaire, la boucle autocrine CXCL10/CXCR3-A. Certaines pistes thérapeutiques peuvent être envisagées à partir de ces résultats notamment l'inhibition de cette boucle ou le ciblage de l'angiogénèse. A l'ère de la médecine de précision et des techniques de recherches à haut débit d'altérations génomiques, l'étude de sous-types rares de cancers clairement définis sur le plan clinique et anatomopathologique peut permettre de mener des projets de recherche translationnelle pertinents. Ce travail de thèse participe à valider cette approche.

9. Bibliographie

1. Garfield DH, Cadranel JL, Wislez M, Franklin WA, Hirsch FR. The bronchioloalveolar carcinoma and peripheral adenocarcinoma spectrum of diseases. *J Thorac Oncol Off Publ Int Assoc Study Lung Cancer*. 2006;1:344–59.
2. Travis WD, Brambilla E, Noguchi M, Nicholson AG, Geisinger KR, Yatabe Y, et al. International association for the study of lung cancer/american thoracic society/european respiratory society international multidisciplinary classification of lung adenocarcinoma. *J Thorac Oncol Off Publ Int Assoc Study Lung Cancer*. 2011;6:244–85.
3. Noguchi M, Morikawa A, Kawasaki M, Matsuno Y, Yamada T, Hirohashi S, et al. Small adenocarcinoma of the lung. Histologic characteristics and prognosis. *Cancer*. 1995;75:2844–52.
4. Watanabe S, Watanabe T, Arai K, Kasai T, Haratake J, Urayama H. Results of wedge resection for focal bronchioloalveolar carcinoma showing pure ground-glass attenuation on computed tomography. *Ann Thorac Surg*. 2002;73:1071–5.
5. Sakurai H, Dobashi Y, Mizutani E, Matsubara H, Suzuki S, Takano K, et al. Bronchioloalveolar carcinoma of the lung 3 centimeters or less in diameter: a prognostic assessment. *Ann Thorac Surg*. 2004;78:1728–33.
6. Vazquez M, Carter D, Brambilla E, Gazdar A, Noguchi M, Travis WD, et al. Solitary and multiple resected adenocarcinomas after CT screening for lung cancer: histopathologic features and their prognostic implications. *Lung Cancer Amst Neth*. 2009;64:148–54.
7. Yamato Y, Tsuchida M, Watanabe T, Aoki T, Koizumi N, Umezu H, et al. Early results of a prospective study of limited resection for bronchioloalveolar adenocarcinoma of the lung. *Ann Thorac Surg*. 2001;71:971–4.
8. Yamada S, Kohno T. Video-assisted thoracic surgery for pure ground-glass opacities 2 cm or less in diameter. *Ann Thorac Surg*. 2004;77:1911–5.
9. Yoshida J, Nagai K, Yokose T, Nishimura M, Kakinuma R, Ohmatsu H, et al. Limited resection trial for pulmonary ground-glass opacity nodules: fifty-case experience. *J Thorac Cardiovasc Surg*. 2005;129:991–6.
10. Koike T, Togashi K, Shirato T, Sato S, Hirahara H, Sugawara M, et al. Limited resection for noninvasive bronchioloalveolar carcinoma diagnosed by intraoperative pathologic examination. *Ann Thorac Surg*. 2009;88:1106–11.
11. Rena O, Papalia E, Ruffini E, Casadio C, Filosso PL, Oliaro A, et al. Stage I pure bronchioloalveolar carcinoma: recurrences, survival and comparison with adenocarcinoma of the lung. *Eur J Cardio-Thorac Surg Off J Eur Assoc Cardio-Thorac Surg*. 2003;23:409–14.
12. Nawa T, Nakagawa T, Kusano S, Kawasaki Y, Sugawara Y, Nakata H. Lung cancer screening using low-dose spiral CT: results of baseline and 1-year follow-up studies. *Chest*. 2002;122:15–20.

13. Henschke CI, Yankelevitz DF, Mirtcheva R, McGinness G, McCauley D, Miettinen OS, et al. CT screening for lung cancer: frequency and significance of part-solid and nonsolid nodules. *AJR Am J Roentgenol.* 2002;178:1053–7.
14. Takashima S, Sone S, Li F, Maruyama Y, Hasegawa M, Kadoya M. Indeterminate solitary pulmonary nodules revealed at population-based CT screening of the lung: using first follow-up diagnostic CT to differentiate benign and malignant lesions. *AJR Am J Roentgenol.* 2003;180:1255–63.
15. Wislez M, Massiani M-A, Milleron B, Souidi A, Carette M-F, Antoine M, et al. Clinical characteristics of pneumonic-type adenocarcinoma of the lung. *Chest.* 2003;123:1868–77.
16. Zell JA, Ou S-HI, Ziogas A, Anton-Culver H. Epidemiology of bronchioloalveolar carcinoma: improvement in survival after release of the 1999 WHO classification of lung tumors. *J Clin Oncol Off J Am Soc Clin Oncol.* 2005;23:8396–405.
17. Donker R, Stewart DJ, Dahrouge S, Evans WK, Shamji FM, Maziak DE, et al. Clinical characteristics and the impact of surgery and chemotherapy on survival of patients with advanced and metastatic bronchioloalveolar carcinoma: a retrospective study. *Clin Lung Cancer.* 2000;1:211–5; discussion 216.
18. Breathnach OS, Kwiatkowski DJ, Finkelstein DM, Godleski J, Sugarbaker DJ, Johnson BE, et al. Bronchioloalveolar carcinoma of the lung: recurrences and survival in patients with stage I disease. *J Thorac Cardiovasc Surg.* 2001;121:42–7.
19. Westra WH. Early glandular neoplasia of the lung. *Respir Res.* 2000;1:163–9.
20. Ullmann R, Bongiovanni M, Halbwedl I, Fraire AE, Cagle PT, Mori M, et al. Is high-grade adenomatous hyperplasia an early bronchioloalveolar adenocarcinoma? *J Pathol.* 2003;201:371–6.
21. López JI, Colby TV, Gazdar AF. Current status of small peripheral adenocarcinomas of the lung and their importance to pathologists. *Ann Diagn Pathol.* 2005;9:115–22.
22. Yokose T, Ito Y, Ochiai A. High prevalence of atypical adenomatous hyperplasia of the lung in autopsy specimens from elderly patients with malignant neoplasms. *Lung Cancer Amst Neth.* 2000;29:125–30.
23. Suzuki K, Asamura H, Kusumoto M, Kondo H, Tsuchiya R. “Early” peripheral lung cancer: prognostic significance of ground glass opacity on thin-section computed tomographic scan. *Ann Thorac Surg.* 2002;74:1635–9.
24. Sakurai H, Maeshima A, Watanabe S, Suzuki K, Tsuchiya R, Maeshima AM, et al. Grade of stromal invasion in small adenocarcinoma of the lung: histopathological minimal invasion and prognosis. *Am J Surg Pathol.* 2004;28:198–206.
25. Borczuk AC, Qian F, Kazeros A, Eleazar J, Assaad A, Sonett JR, et al. Invasive size is an independent predictor of survival in pulmonary adenocarcinoma. *Am J Surg Pathol.* 2009;33:462–9.

26. Yim J, Zhu L-C, Chiriboga L, Watson HN, Goldberg JD, Moreira AL. Histologic features are important prognostic indicators in early stages lung adenocarcinomas. *Mod Pathol Off J U S Can Acad Pathol Inc.* 2007;20:233–41.
27. Tsuta K, Kawago M, Inoue E, Yoshida A, Takahashi F, Sakurai H, et al. The utility of the proposed IASLC/ATS/ERS lung adenocarcinoma subtypes for disease prognosis and correlation of driver gene alterations. *Lung Cancer Amst Neth.* 2013;81:371–6.
28. Fujimoto N, Segawa Y, Takigawa N, Hotta K, Kishino D, Shimono M, et al. Clinical investigation of bronchioloalveolar carcinoma: a retrospective analysis of 53 patients in a single institution. *Anticancer Res.* 1999;19:1369–73.
29. Kohno H, Hiroshima K, Toyozaki T, Fujisawa T, Ohwada H. p53 mutation and allelic loss of chromosome 3p, 9p of preneoplastic lesions in patients with nonsmall cell lung carcinoma. *Cancer.* 1999;85:341–7.
30. Marchetti A, Pellegrini S, Bertacca G, Buttitta F, Gaeta P, Carnicelli V, et al. FHIT and p53 gene abnormalities in bronchioloalveolar carcinomas. Correlations with clinicopathological data and K-ras mutations. *J Pathol.* 1998;184:240–6.
31. Ahrendt SA, Hu Y, Buta M, McDermott MP, Benoit N, Yang SC, et al. p53 mutations and survival in stage I non-small-cell lung cancer: results of a prospective study. *J Natl Cancer Inst.* 2003;95:961–70.
32. Aoyagi Y, Yokose T, Minami Y, Ochiai A, Iijima T, Morishita Y, et al. Accumulation of losses of heterozygosity and multistep carcinogenesis in pulmonary adenocarcinoma. *Cancer Res.* 2001;61:7950–4.
33. Kawasaki M, Noguchi M, Morikawa A, Matsuno Y, Yamada T, Hirohashi S, et al. Nuclear p53 accumulation by small-sized adenocarcinomas of the lung. *Pathol Int.* 1996;46:486–90.
34. Terasaki H, Niki T, Matsuno Y, Yamada T, Maeshima A, Asamura H, et al. Lung adenocarcinoma with mixed bronchioloalveolar and invasive components: clinicopathological features, subclassification by extent of invasive foci, and immunohistochemical characterization. *Am J Surg Pathol.* 2003;27:937–51.
35. McDonald JW, Pilgram TK. Nuclear expression of p53, p21 and cyclin D1 is increased in bronchioloalveolar carcinoma. *Histopathology.* 1999;34:439–46.
36. Wang X, Rao MS, Yeldandi AV. Immunohistochemical analysis of p53 mutations in bronchioloalveolar carcinoma and conventional pulmonary adenocarcinoma. *Mod Pathol Off J U S Can Acad Pathol Inc.* 1995;8:919–23.
37. Saad RS, Liu Y, Han H, Landreneau RJ, Silverman JF. Prognostic significance of HER2/neu, p53, and vascular endothelial growth factor expression in early stage conventional adenocarcinoma and bronchioloalveolar carcinoma of the lung. *Mod Pathol Off J U S Can Acad Pathol Inc.* 2004;17:1235–42.

38. Tanaka R, Wang D, Morishita Y, Inadome Y, Minami Y, Iijima T, et al. Loss of function of p16 gene and prognosis of pulmonary adenocarcinoma. *Cancer*. 2005;103:608–15.
39. Kurasono Y, Ito T, Kameda Y, Nakamura N, Kitamura H. Expression of cyclin D1, retinoblastoma gene protein, and p16 MTS1 protein in atypical adenomatous hyperplasia and adenocarcinoma of the lung. An immunohistochemical analysis. *Virchows Arch Int J Pathol*. 1998;432:207–15.
40. Nakanishi K, Kawai T, Kumaki F, Hiroi S, Mukai M, Ikeda E. Survivin expression in atypical adenomatous hyperplasia of the lung. *Am J Clin Pathol*. 2003;120:712–9.
41. Nakanishi K, Kawai T, Kumaki F, Hiroi S, Mukai M, Ikeda E, et al. Expression of mRNAs for telomeric repeat binding factor (TRF)-1 and TRF2 in atypical adenomatous hyperplasia and adenocarcinoma of the lung. *Clin Cancer Res Off J Am Assoc Cancer Res*. 2003;9:1105–11.
42. Nakanishi K, Kawai T, Kumaki F, Hiroi S, Mukai M, Ikeda E. Expression of human telomerase RNA component and telomerase reverse transcriptase mRNA in atypical adenomatous hyperplasia of the lung. *Hum Pathol*. 2002;33:697–702.
43. Cooper CA, Carby FA, Bubb VJ, Lamb D, Kerr KM, Wyllie AH. The pattern of K-ras mutation in pulmonary adenocarcinoma defines a new pathway of tumour development in the human lung. *J Pathol*. 1997;181:401–4.
44. Dumont P, Gasser B, Rougé C, Massard G, Wihlm JM. Bronchoalveolar carcinoma: histopathologic study of evolution in a series of 105 surgically treated patients. *Chest*. 1998;113:391–5.
45. Regnard JF, Santelmo N, Romdhani N, Gharbi N, Bourcereau J, Dulmet E, et al. Bronchioloalveolar lung carcinoma: results of surgical treatment and prognostic factors. *Chest*. 1998;114:45–50.
46. Hsu CP, Chen CY, Hsu NY. Bronchioloalveolar carcinoma. *J Thorac Cardiovasc Surg*. 1995;110:374–81.
47. Read WL, Page NC, Tierney RM, Piccirillo JF, Govindan R. The epidemiology of bronchioloalveolar carcinoma over the past two decades: analysis of the SEER database. *Lung Cancer Amst Neth*. 2004;45:137–42.
48. Swensen SJ, Jett JR, Hartman TE, Midthun DE, Sloan JA, Sykes A-M, et al. Lung cancer screening with CT: Mayo Clinic experience. *Radiology*. 2003;226:756–61.
49. Garfield DH, Cadranel J, West HL. Bronchioloalveolar carcinoma: the case for two diseases. *Clin Lung Cancer*. 2008;9:24–9.
50. Yang Y, Fujita J, Tokuda M, Bandoh S, Ishida T. Lung cancer associated with several connective tissue diseases: with a review of literature. *Rheumatol Int*. 2001;21:106–11.
51. Furák J, Troján I, Szoke T, Tizslavicz L, Morvay Z, Eller J, et al. Bronchioloalveolar lung cancer: occurrence, surgical treatment and survival. *Eur J Cardio-Thorac Surg Off J Eur Assoc Cardio-*

Thorac Surg. 2003;23:818–23.

52. Heikkilä L. Results of surgical treatment in bronchioloalveolar carcinoma. *Ann Chir Gynaecol.* 1986;75:183–91.
53. Leroux C, Girard N, Cottin V, Greenland T, Mornex J-F, Archer F. Jaagsiekte Sheep Retrovirus (JSRV): from virus to lung cancer in sheep. *Vet Res.* 2007;38:211–28.
54. Caporale M, Cousens C, Centorame P, Pinoni C, las Heras M De, Palmarini M. Expression of the jaagsiekte sheep retrovirus envelope glycoprotein is sufficient to induce lung tumors in sheep. *J Virol.* 2006;80:8030–7.
55. Danilkovitch-Miagkova A, Duh F-M, Kuzmin I, Angeloni D, Liu S-L, Miller AD, et al. Hyaluronidase 2 negatively regulates RON receptor tyrosine kinase and mediates transformation of epithelial cells by jaagsiekte sheep retrovirus. *Proc Natl Acad Sci U S A.* 2003;100:4580–5.
56. las Heras M De, Barsky SH, Hasleton P, Wagner M, Larson E, Egan J, et al. Evidence for a protein related immunologically to the jaagsiekte sheep retrovirus in some human lung tumours. *Eur Respir J.* 2000;16:330–2.
57. Morozov VA, Lagaye S, Löwer J, Löwer R. Detection and characterization of betaretroviral sequences, related to sheep Jaagsiekte virus, in Africans from Nigeria and Cameroon. *Virology.* 2004;327:162–8.
58. Rocca S, Sanna MP, Leoni A, Cossu A, Lissia A, Tanda F, et al. Presence of Jaagsiekte sheep retrovirus in tissue sections from human bronchioloalveolar carcinoma depends on patients' geographical origin. *Hum Pathol.* 2008;39:303–4.
59. Yousem SA, Finkelstein SD, Swalsky PA, Bakker A, Ohori NP. Absence of jaagsiekte sheep retrovirus DNA and RNA in bronchioloalveolar and conventional human pulmonary adenocarcinoma by PCR and RT-PCR analysis. *Hum Pathol.* 2001;32:1039–42.
60. Hopwood P, Wallace WAH, Cousens C, Dewar P, Muldoon M, Norval M, et al. Absence of markers of betaretrovirus infection in human pulmonary adenocarcinoma. *Hum Pathol.* 2010;41:1631–40.
61. Lutringer-Magnin D, Girard N, Cadranel J, Leroux C, Quoix E, Cottin V, et al. Professional exposure to goats increases the risk of pneumonic-type lung adenocarcinoma: results of the IFCT-0504-Epidemiology study. *PloS One.* 2012;7:e37889.
62. Leroux C, Cruz JCM, Mornex J-F. SRLVs: a genetic continuum of lentiviral species in sheep and goats with cumulative evidence of cross species transmission. *Curr HIV Res.* 2010;8:94–100.
63. Sakurai H, Asamura H, Miyaoka E, Yoshino I, Fujii Y, Nakanishi Y, et al. Differences in the prognosis of resected lung adenocarcinoma according to the histological subtype: a retrospective analysis of Japanese lung cancer registry data. *Eur J Cardio-Thorac Surg Off J Eur Assoc Cardio-Thorac Surg.* 2014;45:100–7.

64. Hung J-J, Jeng W-J, Chou T-Y, Hsu W-H, Wu K-J, Huang B-S, et al. Prognostic value of the new International Association for the Study of Lung Cancer/American Thoracic Society/European Respiratory Society lung adenocarcinoma classification on death and recurrence in completely resected stage I lung adenocarcinoma. *Ann Surg*. 2013;258:1079–86.
65. Hung J-J, Yeh Y-C, Jeng W-J, Wu K-J, Huang B-S, Wu Y-C, et al. Predictive value of the international association for the study of lung cancer/American Thoracic Society/European Respiratory Society classification of lung adenocarcinoma in tumor recurrence and patient survival. *J Clin Oncol Off J Am Soc Clin Oncol*. 2014;32:2357–64.
66. Kadota K, Villena-Vargas J, Yoshizawa A, Motoi N, Sima CS, Riely GJ, et al. Prognostic significance of adenocarcinoma in situ, minimally invasive adenocarcinoma, and nonmucinous lepidic predominant invasive adenocarcinoma of the lung in patients with stage I disease. *Am J Surg Pathol*. 2014;38:448–60.
67. Warth A, Muley T, Meister M, Stenzinger A, Thomas M, Schirmacher P, et al. The novel histologic International Association for the Study of Lung Cancer/American Thoracic Society/European Respiratory Society classification system of lung adenocarcinoma is a stage-independent predictor of survival. *J Clin Oncol Off J Am Soc Clin Oncol*. 2012;30:1438–46.
68. Manning JT, Spjut HJ, Tschen JA. Bronchioloalveolar carcinoma: The significance of two histopathologic types. *Cancer*. 1984;54:525–34.
69. Clayton F. Bronchioloalveolar carcinomas. Cell types, patterns of growth, and prognostic correlates. *Cancer*. 1986;57:1555–64.
70. Albertine KH, Steiner RM, Radack DM, Golding DM, Peterson D, Cohn HE, et al. Analysis of cell type and radiographic presentation as predictors of the clinical course of patients with bronchioalveolar cell carcinoma. *Chest*. 1998;113:997–1006.
71. Carretta A, Ciriaco P, Melloni G, Bandiera A, Libretti L, Puglisi A, et al. Surgical treatment of multiple primary adenocarcinomas of the lung. *Thorac Cardiovasc Surg*. 2009;57:30–4.
72. Casali C, Rossi G, Marchioni A, Sartori G, Maselli F, Longo L, et al. A single institution-based retrospective study of surgically treated bronchioloalveolar adenocarcinoma of the lung: clinicopathologic analysis, molecular features, and possible pitfalls in routine practice. *J Thorac Oncol Off Publ Int Assoc Study Lung Cancer*. 2010;5:830–6.
73. Russell PA, Wainer Z, Wright GM, Daniels M, Conron M, Williams RA. Does lung adenocarcinoma subtype predict patient survival?: A clinicopathologic study based on the new International Association for the Study of Lung Cancer/American Thoracic Society/European Respiratory Society international multidisciplinary lung adenocarcinoma classification. *J Thorac Oncol Off Publ Int Assoc Study Lung Cancer*. 2011;6:1496–504.
74. Yoshizawa A, Sumiyoshi S, Sonobe M, Kobayashi M, Fujimoto M, Kawakami F, et al. Validation of the IASLC/ATS/ERS lung adenocarcinoma classification for prognosis and association with EGFR and KRAS gene mutations: analysis of 440 Japanese patients. *J Thorac Oncol Off Publ Int Assoc Study Lung Cancer*. 2013;8:52–61.

75. Yoshizawa A, Motoi N, Riely GJ, Sima CS, Gerald WL, Kris MG, et al. Impact of proposed IASLC/ATS/ERS classification of lung adenocarcinoma: prognostic subgroups and implications for further revision of staging based on analysis of 514 stage I cases. *Mod Pathol Off J U S Can Acad Pathol Inc.* 2011;24:653–64.
76. Okubo K, Mark EJ, Flieder D, Wain JC, Wright CD, Moncure AC, et al. Bronchoalveolar carcinoma: clinical, radiologic, and pathologic factors and survival. *J Thorac Cardiovasc Surg.* 1999;118:702–9.
77. Grover FL, Piantadosi S. Recurrence and survival following resection of bronchioloalveolar carcinoma of the lung--The Lung Cancer Study Group experience. *Ann Surg.* 1989;209:779–90.
78. Bellocq A, Antoine M, Flahault A, Philippe C, Crestani B, Bernaudin JF, et al. Neutrophil alveolitis in bronchioloalveolar carcinoma: induction by tumor-derived interleukin-8 and relation to clinical outcome. *Am J Pathol.* 1998;152:83–92.
79. Wislez M, Antoine M, Rabbe N, Gounant V, Poulot V, Lavolé A, et al. Neutrophils promote aerogenous spread of lung adenocarcinoma with bronchioloalveolar carcinoma features. *Clin Cancer Res Off J Am Assoc Cancer Res.* 2007;13:3518–27.
80. Wislez M, Fleury-Feith J, Rabbe N, Moreau J, Cesari D, Milleron B, et al. Tumor-derived granulocyte-macrophage colony-stimulating factor and granulocyte colony-stimulating factor prolong the survival of neutrophils infiltrating bronchoalveolar subtype pulmonary adenocarcinoma. *Am J Pathol.* 2001;159:1423–33.
81. Wislez M, Philippe C, Antoine M, Rabbe N, Moreau J, Bellocq A, et al. Upregulation of bronchioloalveolar carcinoma-derived C-X-C chemokines by tumor infiltrating inflammatory cells. *Inflamm Res Off J Eur Histamine Res Soc Al.* 2004;53:4–12.
82. Wislez M, Rabbe N, Marchal J, Milleron B, Crestani B, Mayaud C, et al. Hepatocyte growth factor production by neutrophils infiltrating bronchioloalveolar subtype pulmonary adenocarcinoma: role in tumor progression and death. *Cancer Res.* 2003;63:1405–12.
83. Kufe DW. Mucins in cancer: function, prognosis and therapy. *Nat Rev Cancer.* 2009;9:874–85.
84. Kwiatkowski DJ, Harpole DH, Godleski J, Herndon JE, Shieh DB, Richards W, et al. Molecular pathologic substaging in 244 stage I non-small-cell lung cancer patients: clinical implications. *J Clin Oncol Off J Am Soc Clin Oncol.* 1998;16:2468–77.
85. Graziano SL, Gu L, Wang X, Tatum AH, Vollmer RT, Strauss GM, et al. Prognostic significance of mucin and p53 expression in stage IB non-small cell lung cancer: a laboratory companion study to CALGB 9633. *J Thorac Oncol Off Publ Int Assoc Study Lung Cancer.* 2010;5:810–7.
86. Nishiumi N, Abe Y, Inoue Y, Hatanaka H, Inada K-I, Kijima H, et al. Use of 11p15 mucins as prognostic factors in small adenocarcinoma of the lung. *Clin Cancer Res Off J Am Assoc Cancer Res.* 2003;9:5616–9.

87. Copin MC, Buisine MP, Leteurtre E, Marquette CH, Porte H, Aubert JP, et al. Mucinous bronchioloalveolar carcinomas display a specific pattern of mucin gene expression among primary lung adenocarcinomas. *Hum Pathol.* 2001;32:274–81.
88. Hata A, Katakami N, Fujita S, Kaji R, Imai Y, Takahashi Y, et al. Frequency of EGFR and KRAS mutations in Japanese patients with lung adenocarcinoma with features of the mucinous subtype of bronchioloalveolar carcinoma. *J Thorac Oncol Off Publ Int Assoc Study Lung Cancer.* 2010;5:1197–200.
89. Finberg KE, Sequist LV, Joshi VA, Muzikansky A, Miller JM, Han M, et al. Mucinous differentiation correlates with absence of EGFR mutation and presence of KRAS mutation in lung adenocarcinomas with bronchioloalveolar features. *J Mol Diagn JMD.* 2007;9:320–6.
90. Sakuma Y, Matsukuma S, Yoshihara M, Nakamura Y, Noda K, Nakayama H, et al. Distinctive evaluation of nonmucinous and mucinous subtypes of bronchioloalveolar carcinomas in EGFR and K-ras gene-mutation analyses for Japanese lung adenocarcinomas: confirmation of the correlations with histologic subtypes and gene mutations. *Am J Clin Pathol.* 2007;128:100–8.
91. Wislez M, Antoine M, Baudrin L, Poulot V, Neuville A, Pradere M, et al. Non-mucinous and mucinous subtypes of adenocarcinoma with bronchioloalveolar carcinoma features differ by biomarker expression and in the response to gefitinib. *Lung Cancer Amst Neth.* 2010;68:185–91.
92. Hu H, Pan Y, Li Y, Wang L, Wang R, Zhang Y, et al. Oncogenic mutations are associated with histological subtypes but do not have an independent prognostic value in lung adenocarcinoma. *OncoTargets Ther.* 2014;7:1423–37.
93. Maeda Y, Tsuchiya T, Hao H, Tompkins DH, Xu Y, Mucenski ML, et al. Kras(G12D) and Nkx2-1 haploinsufficiency induce mucinous adenocarcinoma of the lung. *J Clin Invest.* 2012;122:4388–400.
94. Nakaoku T, Tsuta K, Ichikawa H, Shiraishi K, Sakamoto H, Enari M, et al. Druggable oncogene fusions in invasive mucinous lung adenocarcinoma. *Clin Cancer Res Off J Am Assoc Cancer Res.* 2014;20:3087–93.
95. Fernandez-Cuesta L, Plenker D, Osada H, Sun R, Menon R, Leenders F, et al. CD74-NRG1 fusions in lung adenocarcinoma. *Cancer Discov.* 2014;4:415–22.
96. Takeuchi K, Soda M, Togashi Y, Suzuki R, Sakata S, Hatano S, et al. RET, ROS1 and ALK fusions in lung cancer. *Nat Med.* 2012;18:378–81.
97. Hurbin A, Wislez M, Busser B, Antoine M, Tenaud C, Rabbe N, et al. Insulin-like growth factor-1 receptor inhibition overcomes gefitinib resistance in mucinous lung adenocarcinoma. *J Pathol.* 2011;225:83–95.
98. Nakata M, Sawada S, Yamashita M, Saeki H, Kurita A, Takashima S, et al. Objective radiologic analysis of ground-glass opacity aimed at curative limited resection for small peripheral non-small cell lung cancer. *J Thorac Cardiovasc Surg.* 2005;129:1226–31.

99. Nakamura H, Saji H, Ogata A, Saijo T, Okada S, Kato H. Lung cancer patients showing pure ground-glass opacity on computed tomography are good candidates for wedge resection. *Lung Cancer Amst Neth.* 2004;44:61–8.
100. Ebricht MI, Zakowski MF, Martin J, Venkatraman ES, Miller VA, Bains MS, et al. Clinical pattern and pathologic stage but not histologic features predict outcome for bronchioloalveolar carcinoma. *Ann Thorac Surg.* 2002;74:1640–6; discussion 1646–7.
101. Daly RC, Trastek VF, Pairolero PC, Murtaugh PA, Huang MS, Allen MS, et al. Bronchoalveolar carcinoma: factors affecting survival. *Ann Thorac Surg.* 1991;51:368–76; discussion 376–7.
102. Roberts PF, Straznicka M, Lara PN, Lau DH, Follette DM, Gandara DR, et al. Resection of multifocal non-small cell lung cancer when the bronchioloalveolar subtype is involved. *J Thorac Cardiovasc Surg.* 2003;126:1597–602.
103. de Perrot M, Chernenko S, Waddell TK, Shargall Y, Pierre AF, Hutcheon M, et al. Role of lung transplantation in the treatment of bronchogenic carcinomas for patients with end-stage pulmonary disease. *J Clin Oncol Off J Am Soc Clin Oncol.* 2004;22:4351–6.
104. Zorn GL, McGiffin DC, Young KR, Alexander CB, Weill D, Kirklin JK. Pulmonary transplantation for advanced bronchioloalveolar carcinoma. *J Thorac Cardiovasc Surg.* 2003;125:45–8.
105. Garver RI, Zorn GL, Wu X, McGiffin DC, Young KR, Pinkard NB. Recurrence of bronchioloalveolar carcinoma in transplanted lungs. *N Engl J Med.* 1999;340:1071–4.
106. Miller VA, Riely GJ, Zakowski MF, Li AR, Patel JD, Heelan RT, et al. Molecular characteristics of bronchioloalveolar carcinoma and adenocarcinoma, bronchioloalveolar carcinoma subtype, predict response to erlotinib. *J Clin Oncol Off J Am Soc Clin Oncol.* 2008;26:1472–8.
107. West HL, Franklin WA, McCoy J, Gumerlock PH, Vance R, Lau DHM, et al. Gefitinib therapy in advanced bronchioloalveolar carcinoma: Southwest Oncology Group Study S0126. *J Clin Oncol Off J Am Soc Clin Oncol.* 2006;24:1807–13.
108. Cadranel J, Quoix E, Baudrin L, Mourlanette P, Moro-Sibilot D, Morere J-F, et al. IFCT-0401 Trial: a phase II study of gefitinib administered as first-line treatment in advanced adenocarcinoma with bronchioloalveolar carcinoma subtype. *J Thorac Oncol Off Publ Int Assoc Study Lung Cancer.* 2009;4:1126–35.
109. Cadranel J, Ruppert A-M, Beau-Faller M, Wislez M. Therapeutic strategy for advanced EGFR mutant non-small-cell lung carcinoma. *Crit Rev Oncol Hematol.* 2013;88:477–93.
110. Ramalingam SS, Lee J-W, Belani CP, Aisner SC, Kolesar J, Howe C, et al. Cetuximab for the treatment of advanced bronchioloalveolar carcinoma (BAC): an Eastern Cooperative Oncology Group phase II study (ECOG 1504). *J Clin Oncol Off J Am Soc Clin Oncol.* 2011;29:1709–14.
111. West HL, Crowley JJ, Vance RB, Franklin WA, Livingston RB, Dakhil SR, et al. Advanced bronchioloalveolar carcinoma: a phase II trial of paclitaxel by 96-hour infusion (SWOG 9714): a

Southwest Oncology Group study. *Ann Oncol Off J Eur Soc Med Oncol ESMO*. 2005;16:1076–80.

112. Scagliotti GV, Smit E, Bosquee L, O'Brien M, Ardizzoni A, Zatloukal P, et al. A phase II study of paclitaxel in advanced bronchioloalveolar carcinoma (EORTC trial 08956). *Lung Cancer Amst Neth*. 2005;50:91–6.
113. Duruisseaux M, Baudrin L, Quoix E, Wislez M, Moro-Sibilot D, Coëtmeur D, et al. Chemotherapy effectiveness after first-line gefitinib treatment for advanced lepidic predominant adenocarcinoma (formerly advanced bronchioloalveolar carcinoma): exploratory analysis of the IFCT-0401 trial. *J Thorac Oncol Off Publ Int Assoc Study Lung Cancer*. 2012;7:1423–31.
114. Duruisseaux M, Cadranet J, Pérol M, Arpin D. The role of pemetrexed in lung adenocarcinoma, mixed subtype with bronchioloalveolar carcinoma features. *Curr Drug Targets*. 2010;11:74–7.
115. Duruisseaux M, Cadranet J, Biron E, Pérol M, Guérin JC, Arpin D. Major and prolonged response to pemetrexed in two cases of lung adenocarcinoma with bronchioloalveolar carcinoma features. *Lung Cancer Amst Neth*. 2009;65:385–7.
116. Garfield DH, Franklin W. Dramatic response to pemetrexed in a patient with pneumonic-type mucinous bronchioloalveolar carcinoma. *J Thorac Oncol Off Publ Int Assoc Study Lung Cancer*. 2011;6:397–8.
117. Lau DHM, Moon J, Davies AM, Sanborn RE, Hirsch FR, Franklin WA, et al. Southwestern oncology group phase II trial (S0526) of pemetrexed in bronchioloalveolar carcinoma subtypes of advanced adenocarcinoma. *Clin Lung Cancer*. 2013;14:351–5.
118. Ramalingam SS, Davies AM, Longmate J, Edelman MJ, Lara PN, Vokes EE, et al. Bortezomib for patients with advanced-stage bronchioloalveolar carcinoma: a California Cancer Consortium Phase II study (NCI 7003). *J Thorac Oncol Off Publ Int Assoc Study Lung Cancer*. 2011;6:1741–5.
119. Sandler A, Gray R, Perry MC, Brahmer J, Schiller JH, Dowlati A, et al. Paclitaxel-carboplatin alone or with bevacizumab for non-small-cell lung cancer. *N Engl J Med*. 2006;355:2542–50.
120. Duruisseaux M, Antoine M, Rabbe N, Poulot V, Fleury-Feith J, Vieira T, et al. The impact of intracytoplasmic mucin in lung adenocarcinoma with pneumonic radiological presentation. *Lung Cancer Amst Neth*. 2014;83:334–40.
121. Tsuta K, Ishii G, Nitadori J, Murata Y, Kodama T, Nagai K, et al. Comparison of the immunophenotypes of signet-ring cell carcinoma, solid adenocarcinoma with mucin production, and mucinous bronchioloalveolar carcinoma of the lung characterized by the presence of cytoplasmic mucin. *J Pathol*. 2006;209:78–87.
122. Copin MC, Devisme L, Buisine MP, Marquette CH, Wurtz A, Aubert JP, et al. From normal respiratory mucosa to epidermoid carcinoma: expression of human mucin genes. *Int J Cancer J Int Cancer*. 2000;86:162–8.
123. Khodarev NN, Pitroda SP, Beckett MA, MacDermed DM, Huang L, Kufe DW, et al. MUC1-induced transcriptional programs associated with tumorigenesis predict outcome in breast and lung cancer.

Cancer Res. 2009;69:2833–7.

124. Rahn JJ, Dabbagh L, Pasdar M, Hugh JC. The importance of MUC1 cellular localization in patients with breast carcinoma: an immunohistologic study of 71 patients and review of the literature. *Cancer*. 2001;91:1973–82.
125. Karin M, Greten FR. NF-kappaB: linking inflammation and immunity to cancer development and progression. *Nat Rev Immunol*. 2005;5:749–59.
126. Ahmad R, Raina D, Trivedi V, Ren J, Rajabi H, Kharbanda S, et al. MUC1 oncoprotein activates the IkappaB kinase beta complex and constitutive NF-kappaB signalling. *Nat Cell Biol*. 2007;9:1419–27.
127. Ahmad R, Raina D, Joshi MD, Kawano T, Ren J, Kharbanda S, et al. MUC1-C oncoprotein functions as a direct activator of the nuclear factor-kappaB p65 transcription factor. *Cancer Res*. 2009;69:7013–21.
128. Schroeder JA, Masri AA, Adriance MC, Tessier JC, Kotlarczyk KL, Thompson MC, et al. MUC1 overexpression results in mammary gland tumorigenesis and prolonged alveolar differentiation. *Oncogene*. 2004;23:5739–47.
129. Pochampalli MR, Bitler BG, Schroeder JA. Transforming growth factor alpha dependent cancer progression is modulated by Muc1. *Cancer Res*. 2007;67:6591–8.
130. Pochampalli MR, Bejjani RM el, Schroeder JA. MUC1 is a novel regulator of ErbB1 receptor trafficking. *Oncogene*. 2007;26:1693–701.
131. Ramasamy S, Duraisamy S, Barbashov S, Kawano T, Kharbanda S, Kufe D. The MUC1 and galectin-3 oncoproteins function in a microRNA-dependent regulatory loop. *Mol Cell*. 2007;27:992–1004.
132. Nagai S, Takenaka K, Sonobe M, Ogawa E, Wada H, Tanaka F. A novel classification of MUC1 expression is correlated with tumor differentiation and postoperative prognosis in non-small cell lung cancer. *J Thorac Oncol Off Publ Int Assoc Study Lung Cancer*. 2006;1:46–51.
133. Giatromanolaki A, Koukourakis MI, Sivridis E, O’Byrne K, Cox G, Thorpe PE, et al. Coexpression of MUC1 glycoprotein with multiple angiogenic factors in non-small cell lung cancer suggests coactivation of angiogenic and migration pathways. *Clin Cancer Res Off J Am Assoc Cancer Res*. 2000;6:1917–21.
134. Makiguchi Y, Hinoda Y, Imai K. Effect of MUC1 mucin, an anti-adhesion molecule, on tumor cell growth. *Jpn J Cancer Res Gann*. 1996;87:505–11.
135. Mikami Y, Hisatsune A, Tashiro T, Isohama Y, Katsuki H. Hypoxia enhances MUC1 expression in a lung adenocarcinoma cell line. *Biochem Biophys Res Commun*. 2009;379:1060–5.

136. Kharbanda A, Rajabi H, Jin C, Tchaicha J, Kikuchi E, Wong K-K, et al. Targeting the oncogenic MUC1-C protein inhibits mutant EGFR-mediated signaling and survival in non-small cell lung cancer cells. *Clin Cancer Res Off J Am Assoc Cancer Res.* 2014;20:5423–34.
137. Yu C-J, Shih J-Y, Lee Y-C, Shun C-T, Yuan A, Yang P-C. Sialyl Lewis antigens: association with MUC5AC protein and correlation with post-operative recurrence of non-small cell lung cancer. *Lung Cancer Amst Neth.* 2005;47:59–67.
138. Lakshmanan I, Ponnusamy MP, Macha MA, Haridas D, Majhi PD, Kaur S, et al. Mucins in lung cancer: diagnostic, prognostic, and therapeutic implications. *J Thorac Oncol Off Publ Int Assoc Study Lung Cancer.* 2015;10:19–27.
139. Fernandez-Cuesta L, Thomas RK. Molecular Pathways: Targeting NRG1 Fusions in Lung Cancer. *Clin Cancer Res Off J Am Assoc Cancer Res.* 2015;21:1989–94.
140. Dhanasekaran SM, Balbin OA, Chen G, Nadal E, Kalyana-Sundaram S, Pan J, et al. Transcriptome meta-analysis of lung cancer reveals recurrent aberrations in NRG1 and Hippo pathway genes. *Nat Commun.* 2014;5:5893.
141. Sugano M, Nagasaka T, Sasaki E, Murakami Y, Hosoda W, Hida T, et al. HNF4 α as a marker for invasive mucinous adenocarcinoma of the lung. *Am J Surg Pathol.* 2013;37:211–8.
142. Singh UP, Singh S, Iqbal N, Weaver CT, McGhee JR, Lillard JW. IFN-gamma-inducible chemokines enhance adaptive immunity and colitis. *J Interferon Cytokine Res Off J Int Soc Interferon Cytokine Res.* 2003;23:591–600.
143. Neville LF, Mathiak G, Bagasra O. The immunobiology of interferon-gamma inducible protein 10 kD (IP-10): a novel, pleiotropic member of the C-X-C chemokine superfamily. *Cytokine Growth Factor Rev.* 1997;8:207–19.
144. Lazzeri E, Romagnani P. CXCR3-binding chemokines: novel multifunctional therapeutic targets. *Curr Drug Targets Immune Endocr Metab Disord.* 2005;5:109–18.
145. Liu M, Guo S, Stiles JK. The emerging role of CXCL10 in cancer (Review). *Oncol Lett.* 2011;2:583–9.
146. Booth V, Keizer DW, Kamphuis MB, Clark-Lewis I, Sykes BD. The CXCR3 binding chemokine IP-10/CXCL10: structure and receptor interactions. *Biochemistry (Mosc).* 2002;41:10418–25.
147. Campanella GSV, Grimm J, Manice LA, Colvin RA, Medoff BD, Wojtkiewicz GR, et al. Oligomerization of CXCL10 is necessary for endothelial cell presentation and in vivo activity. *J Immunol Baltim Md 1950.* 2006;177:6991–8.
148. Billottet C, Quemener C, Bikfalvi A. CXCR3, a double-edged sword in tumor progression and angiogenesis. *Biochim Biophys Acta.* 2013;1836:287–95.

149. Bonacchi A, Romagnani P, Romanelli RG, Efsen E, Annunziato F, Lasagni L, et al. Signal transduction by the chemokine receptor CXCR3: activation of Ras/ERK, Src, and phosphatidylinositol 3-kinase/Akt controls cell migration and proliferation in human vascular pericytes. *J Biol Chem.* 2001;276:9945–54.
150. Shahabuddin S, Ji R, Wang P, Brailoiu E, Dun N, Yang Y, et al. CXCR3 chemokine receptor-induced chemotaxis in human airway epithelial cells: role of p38 MAPK and PI3K signaling pathways. *Am J Physiol Cell Physiol.* 2006;291:C34–9.
151. Muehlinghaus G, Cigliano L, Huehn S, Peddinghaus A, Leyendeckers H, Hauser AE, et al. Regulation of CXCR3 and CXCR4 expression during terminal differentiation of memory B cells into plasma cells. *Blood.* 2005;105:3965–71.
152. Brightling CE, Ammit AJ, Kaur D, Black JL, Wardlaw AJ, Hughes JM, et al. The CXCL10/CXCR3 axis mediates human lung mast cell migration to asthmatic airway smooth muscle. *Am J Respir Crit Care Med.* 2005;171:1103–8.
153. Aksoy MO, Yang Y, Ji R, Reddy PJ, Shahabuddin S, Litvin J, et al. CXCR3 surface expression in human airway epithelial cells: cell cycle dependence and effect on cell proliferation. *Am J Physiol Lung Cell Mol Physiol.* 2006;290:L909–18.
154. Ji R, Lee CM, Gonzales LW, Yang Y, Aksoy MO, Wang P, et al. Human type II pneumocyte chemotactic responses to CXCR3 activation are mediated by splice variant A. *Am J Physiol Lung Cell Mol Physiol.* 2008;294:L1187–96.
155. Maru SV, Holloway KA, Flynn G, Lancashire CL, Loughlin AJ, Male DK, et al. Chemokine production and chemokine receptor expression by human glioma cells: role of CXCL10 in tumour cell proliferation. *J Neuroimmunol.* 2008;199:35–45.
156. Wu Q, Dhir R, Wells A. Altered CXCR3 isoform expression regulates prostate cancer cell migration and invasion. *Mol Cancer.* 2012;11:3.
157. Korniejewska A, McKnight AJ, Johnson Z, Watson ML, Ward SG. Expression and agonist responsiveness of CXCR3 variants in human T lymphocytes. *Immunology.* 2011;132:503–15.
158. Kim S, Bakre M, Yin H, Varner JA. Inhibition of endothelial cell survival and angiogenesis by protein kinase A. *J Clin Invest.* 2002;110:933–41.
159. Wells A, Chao YL, Grahovac J, Wu Q, Lauffenburger DA. Epithelial and mesenchymal phenotypic switchings modulate cell motility in metastasis. *Front Biosci Landmark Ed.* 2011;16:815–37.
160. Lee EY, Lee Z-H, Song YW. CXCL10 and autoimmune diseases. *Autoimmun Rev.* 2009;8:379–83.
161. Lee EY, Lee ZH, Song YW. The interaction between CXCL10 and cytokines in chronic inflammatory arthritis. *Autoimmun Rev.* 2013;12:554–7.

162. Mehrad B, Keane MP, Strieter RM. Chemokines as mediators of angiogenesis. *Thromb Haemost.* 2007;97:755–62.
163. Belperio JA, Keane MP, Arenberg DA, Addison CL, Ehlert JE, Burdick MD, et al. CXC chemokines in angiogenesis. *J Leukoc Biol.* 2000;68:1–8.
164. Romagnani P, Lasagni L, Annunziato F, Serio M, Romagnani S. CXC chemokines: the regulatory link between inflammation and angiogenesis. *Trends Immunol.* 2004;25:201–9.
165. Liang P, Cheng SH, Cheng CK, Lau KM, Lin SY, Chow EYD, et al. Platelet factor 4 induces cell apoptosis by inhibition of STAT3 via up-regulation of SOCS3 expression in multiple myeloma. *Haematologica.* 2013;98:288–95.
166. Bodnar RJ, Yates CC, Rodgers ME, Du X, Wells A. IP-10 induces dissociation of newly formed blood vessels. *J Cell Sci.* 2009;122:2064–77.
167. Romagnani P, Annunziato F, Lasagni L, Lazzeri E, Beltrame C, Francalanci M, et al. Cell cycle-dependent expression of CXC chemokine receptor 3 by endothelial cells mediates angiostatic activity. *J Clin Invest.* 2001;107:53–63.
168. Haabeth OAW, Lorvik KB, Hammarström C, Donaldson IM, Haraldsen G, Bogen B, et al. Inflammation driven by tumour-specific Th1 cells protects against B-cell cancer. *Nat Commun.* 2011;2:240.
169. Okada H. Brain tumor immunotherapy with type-1 polarizing strategies. *Ann N Y Acad Sci.* 2009;1174:18–23.
170. Mulligan AM, Raitman I, Feeley L, Pinnaduwege D, Nguyen LT, O'Malley FP, et al. Tumoral lymphocytic infiltration and expression of the chemokine CXCL10 in breast cancers from the Ontario Familial Breast Cancer Registry. *Clin Cancer Res Off J Am Assoc Cancer Res.* 2013;19:336–46.
171. Ma X, Norsworthy K, Kundu N, Rodgers WH, Gimotty PA, Goloubeva O, et al. CXCR3 expression is associated with poor survival in breast cancer and promotes metastasis in a murine model. *Mol Cancer Ther.* 2009;8:490–8.
172. Datta D, Flaxenburg JA, Laxmanan S, Geehan C, Grimm M, Waaga-Gasser AM, et al. Ras-induced modulation of CXCL10 and its receptor splice variant CXCR3-B in MDA-MB-435 and MCF-7 cells: relevance for the development of human breast cancer. *Cancer Res.* 2006;66:9509–18.
173. Walser TC, Rifat S, Ma X, Kundu N, Ward C, Goloubeva O, et al. Antagonism of CXCR3 inhibits lung metastasis in a murine model of metastatic breast cancer. *Cancer Res.* 2006;66:7701–7.
174. Jiang Z, Xu Y, Cai S. CXCL10 expression and prognostic significance in stage II and III colorectal cancer. *Mol Biol Rep.* 2010;37:3029–36.

175. Zipin-Roitman A, Meshel T, Sagi-Assif O, Shalmon B, Avivi C, Pfeffer RM, et al. CXCL10 promotes invasion-related properties in human colorectal carcinoma cells. *Cancer Res.* 2007;67:3396–405.
176. Murakami T, Kawada K, Iwamoto M, Akagami M, Hida K, Nakanishi Y, et al. The role of CXCR3 and CXCR4 in colorectal cancer metastasis. *Int J Cancer J Int Cancer.* 2013;132:276–87.
177. Kawada K, Hosogi H, Sonoshita M, Sakashita H, Manabe T, Shimahara Y, et al. Chemokine receptor CXCR3 promotes colon cancer metastasis to lymph nodes. *Oncogene.* 2007;26:4679–88.
178. Giuliani N, Bonomini S, Romagnani P, Lazzaretti M, Morandi F, Colla S, et al. CXCR3 and its binding chemokines in myeloma cells: expression of isoforms and potential relationships with myeloma cell proliferation and survival. *Haematologica.* 2006;91:1489–97.
179. Datta D, Banerjee P, Gasser M, Waaga-Gasser AM, Pal S. CXCR3-B can mediate growth-inhibitory signals in human renal cancer cells by down-regulating the expression of heme oxygenase-1. *J Biol Chem.* 2010;285:36842–8.
180. Pradelli E, Karimjee-Soilihi B, Michiels J-F, Ricci J-E, Millet M-A, Vandebos F, et al. Antagonism of chemokine receptor CXCR3 inhibits osteosarcoma metastasis to lungs. *Int J Cancer J Int Cancer.* 2009;125:2586–94.
181. Moriai S, Takahara M, Ogino T, Nagato T, Kishibe K, Ishii H, et al. Production of interferon- γ -inducible protein-10 and its role as an autocrine invasion factor in nasal natural killer/T-cell lymphoma cells. *Clin Cancer Res Off J Am Assoc Cancer Res.* 2009;15:6771–9.
182. Wightman SC, Uppal A, Pitroda SP, Ganai S, Burnette B, Stack M, et al. Oncogenic CXCL10 signalling drives metastasis development and poor clinical outcome. *Br J Cancer.* 2015;113:327–35.
183. Hillinger S, Yang S-C, Zhu L, Huang M, Duckett R, Atianzar K, et al. EBV-induced molecule 1 ligand chemokine (ELC/CCL19) promotes IFN- γ -dependent antitumor responses in a lung cancer model. *J Immunol Baltim Md 1950.* 2003;171:6457–65.
184. Andersson A, Srivastava MK, Harris-White M, Huang M, Zhu L, Elashoff D, et al. Role of CXCR3 ligands in IL-7/IL-7R α -Fc-mediated antitumor activity in lung cancer. *Clin Cancer Res Off J Am Assoc Cancer Res.* 2011;17:3660–72.
185. Ohri CM, Shikotra A, Green RH, Waller DA, Bradding P. Chemokine receptor expression in tumour islets and stroma in non-small cell lung cancer. *BMC Cancer.* 2010;10:172.
186. Kowalczyk O, Burzykowski T, Niklinska WE, Kozłowski M, Chyczewski L, Niklinski J. CXCL5 as a potential novel prognostic factor in early stage non-small cell lung cancer: results of a study of expression levels of 23 genes. *Tumour Biol J Int Soc Oncodevelopmental Biol Med.* 2014;35:4619–28.
187. Maekawa S, Iwasaki A, Shirakusa T, Kawakami T, Yanagisawa J, Tanaka T, et al. Association between the expression of chemokine receptors CCR7 and CXCR3, and lymph node metastatic potential in lung adenocarcinoma. *Oncol Rep.* 2008;19:1461–8.

188. Iwakiri S, Mino N, Takahashi T, Sonobe M, Nagai S, Okubo K, et al. Higher expression of chemokine receptor CXCR7 is linked to early and metastatic recurrence in pathological stage I nonsmall cell lung cancer. *Cancer*. 2009;115:2580–93.
189. Arenberg DA, Kunkel SL, Polverini PJ, Morris SB, Burdick MD, Glass MC, et al. Interferon-gamma-inducible protein 10 (IP-10) is an angiostatic factor that inhibits human non-small cell lung cancer (NSCLC) tumorigenesis and spontaneous metastases. *J Exp Med*. 1996;184:981–92.
190. Agus DB, Akita RW, Fox WD, Lewis GD, Higgins B, Pisacane PI, et al. Targeting ligand-activated ErbB2 signaling inhibits breast and prostate tumor growth. *Cancer Cell*. 2002;2:127–37.
191. Vockerodt M, Pinkert D, Smola-Hess S, Michels A, Ransohoff RM, Tesch H, et al. The Epstein-Barr virus oncoprotein latent membrane protein 1 induces expression of the chemokine IP-10: importance of mRNA half-life regulation. *Int J Cancer J Int Cancer*. 2005;114:598–605.

10. Annexes

10.1. Travaux en rapport avec le sujet de la thèse publiés par le doctorant

Michaël Duruisseaux, Jacques Cadranel, Elisabeth Biron, Maurice Pérol, Jean-Claude Guérin, Dominique Arpin. Major and prolonged response to pemetrexed in two cases of lung adenocarcinoma with bronchioloalveolar features. *Lung Cancer*. 2009;65(3):385-387.

Michaël Duruisseaux, Jacques Cadranel, Maurice Pérol, Dominique Arpin. The role of pemetrexed in lung adenocarcinoma, mixed subtype with bronchioloalveolar carcinoma features. *Current Drug Targets*. 2010;11(1):74-77.

Michaël Duruisseaux, Laurence Baudrin, Elisabeth Quoix, Marie Wislez, Denis, Moro-Sibilot, Jean Charles Soria, Virginie Westeel, Franck Morin, Jacques Cadranel, Denis Coëtmeur, Isabelle Monnet, Pierre Mourlanette, Jean François Morère, Chemotherapy effectiveness after first-line gefitinib treatment for advanced lepidic predominant adenocarcinoma (formerly advanced bronchioloalveolar carcinoma) : exploratory analysis of the IFCT-0401 trial. *Journal of Thoracic Oncology*. 2012;7(9):1423-1431.

Michaël Duruisseaux, Marie Wislez. CD74-*NRG1* : a new fusion gene in lung adenocarcinoma characterizing mucinous adenocarcinoma. *Bulletin du Cancer*. 2014;101(6):529-530. Français

10.2. Manuscrits correspondants



Case report

Major and prolonged response to pemetrexed in two cases of lung adenocarcinoma with bronchioloalveolar carcinoma features

Michaël Duruisseaux^a, Jacques Cadranel^b, Elisabeth Biron^c, Maurice Pérol^a,
Jean Claude Guérin^d, Dominique Arpin^{a,*}

^a Service de Pneumologie, Unité d'Oncologie Thoracique, Hôpital de la Croix Rousse, 103 Grande Rue de la Croix Rousse, 69317 Lyon Cedex, France

^b Service de Pneumologie et de Réanimation respiratoire, AP-HP, Hôpital Tenon, Paris, France

^c Hôpital privé Jean Mermoz, Lyon, France

^d Service de Pneumologie, Hôpital de la Croix Rousse, Lyon, France

ARTICLE INFO

Article history:

Received 10 November 2008

Received in revised form 19 January 2009

Accepted 22 February 2009

Keywords:

Lung cancer

Adenocarcinoma

Bronchioloalveolar carcinoma

Pemetrexed

Paclitaxel

Erlotinib

ABSTRACT

Bronchioloalveolar carcinoma (BAC) and adenocarcinoma mixed subtype with bronchioloalveolar features (ADC-WBF) represent a unique anatomic-clinical entity accounting for some 20% of non-small cell lung cancers (NSCLC). These tumors seem less sensitive to chemotherapy than other NSCLC. We report two cases of advanced ADC-WBF treated with second-line and fourth-line pemetrexed. Major and durable radiological response associated with clinical and functional improvement was achieved in both patients, without important drug toxicity. After treatment arrest, the two patients experienced progressive disease but responded to retreatment with pemetrexed. Recent data suggest that paclitaxel-based chemotherapy and epidermal growth factor receptor tyrosine kinase inhibitors could be an acceptable therapeutic strategy in unresectable CBA and ADC-WBF. The cases reported here and preclinical findings suggest a therapeutic efficacy of pemetrexed in these tumors. Prospective studies are required to evaluate this hypothesis.

© 2009 Elsevier Ireland Ltd. All rights reserved.

According to the 2004 World Health Organization (WHO) Classification of lung and pleural tumors, bronchioloalveolar carcinoma (BAC) is a subtype of pulmonary adenocarcinoma developing from acinar and terminal bronchiolar epithelial cells, without pleural, stromal or vascular invasion [1]. Diagnosis can only be established by pathological analysis of surgical specimens, excluding any evidence of histological invasion.

Because of this restrictive definition excluding unresectable disease, BAC is uncommon and accounts for only 2–5% of lung cancers [2,3]. Nevertheless, most BAC tumors display histological evidence of invasion, whereas lung adenocarcinomas often contain BAC features and are defined in the 2004 WHO Classification as an adenocarcinoma mixed subtype with BAC features (ADC-WBF) [1]. BAC and ADC-WBF belong to the same clinico-pathological spectrum of diseases with nearly identical epidemiological characteristics, clinical findings, molecular profile and treatment [4]. Recent data suggest that patients with BAC and ADC-WBF are likely to derive a benefit from paclitaxel-based chemotherapy or epidermal growth factor receptor (EGFR) tyrosine kinase inhibitors (TKI). Cases reported here suggest a therapeutic efficacy of pemetrexed in these tumors.

1. Case report 1

A 66-year-old man, current smoker, was diagnosed with mucinous ADC-WBF in November 2005. He presented with cough, profuse expectoration and dyspnea, but had maintained a WHO Performance Status (PS) of 1. Auscultation of the lungs revealed bilateral crepitant rales with no clinical evidence of extra thoracic dissemination. Chest computed tomography (CT) showed diffuse pulmonary parenchymal involvement with bilateral alveolar consolidation and pseudo nodules with peripheral ground-glass opacities. Diagnosis was obtained by bronchoscopic cytology. Abdominal CT, brain magnetic resonance imaging (MRI) and bone scintigraphy revealed no evidence of extra thoracic metastasis. Hematological, hepatic and renal biological tests were normal. Clinical staging was stage IV NSCLC and a standard first-line chemotherapy doublet was started using carboplatin at an area under the curve (AUC) of 5 mg/(ml min) on day 1 every 28 days and paclitaxel 80 mg/m² on days 1, 8 and 15. Despite improvement of disease-related symptoms after six treatment cycles, radiological images remained unchanged.

The patient received second-line treatment with pemetrexed at 500 mg/m² on day 1 every 21 days with folic acid and vitamin B12 supplementation. After six cycles, he reported no respiratory symptoms and physical examination was normal. Radiological response was considered nearly complete (Fig. 1). Pemetrexed was

* Corresponding author. Tel.: +33 472071731.

E-mail address: dominique.arpin@chu-lyon.fr (D. Arpin).

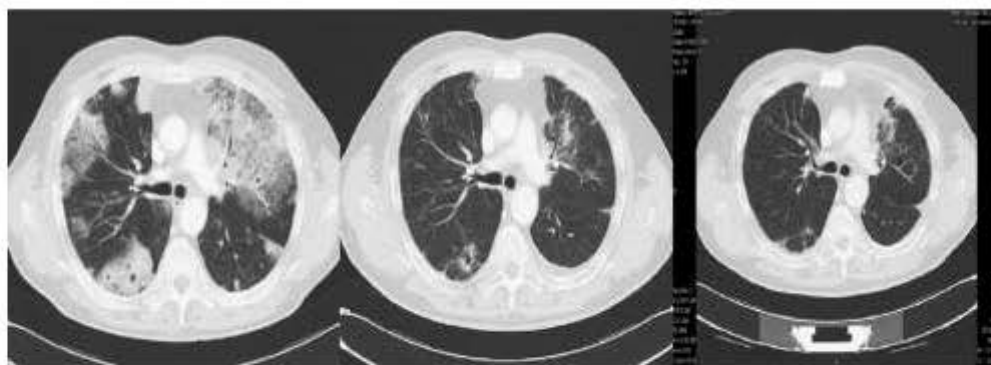

Fig. 1. Chest CT images show radiological complete response after 6 and 12 pemetrexed cycles.

well tolerated, without hematologic toxicity. Because of persistence of clinical and radiological benefit, six new chemotherapy cycles were administered. At completion of treatment, mild renal failure appeared and treatment was stopped in April 2007.

In September 2007, disease progressed with occurrence of bone metastases confirmed by scintigraphy and thoracic relapse. Pemetrexed was successfully reintroduced, and induced new clinical and radiological response.

2. Case report 2

In March 2004, a 57-year-old man, former smoker, presented with a non-mucinous ADC-WBF. Despite maintenance of PS at 1, he suffered from cough with severe bronchorrhea around 250 ml/day and disabling dyspnea. Examination of the chest showed bilateral inspiratory crepitant rales and no extra thoracic finding. Arterial partial pressure of oxygen (PaO_2) at 52 mmHg, with 82% blood oxygen saturation, required 6 l/min oxygen therapy to be normalized. CT of the chest revealed several regions of alveolar condensation, particularly in the upper left lobe and lower left and right lobes, associated with multiple pseudo nodules with peripheral ground-glass opacities. There was no evidence of extra thoracic metastasis on brain MRI, abdominal CT and positron emission tomography using 18F-fluorodeoxyglucose. Blood tests revealed mild renal failure with creatinine clearance estimated at 47 ml/min using the Cockcroft-Gault formula. In the setting of the 04-01 Intergroupe Francophone de Cancérologie Thoracique (IFCT) clinical trial, the patient received gefitinib 250 mg/day in April 2004. Two months later, objective clinical and radiological evidence of progression was observed and a second-line of treatment by carboplatin and paclitaxel was started using carboplatin at an area under the curve of 5 mg/(ml min) on day 1 every 28 days and paclitaxel 80 mg/m² on days 1, 8 and 15. After four cycles, the patient's clinical status improved, with bronchorrhea estimated at 60 ml/day and asymmetric radiological response with improvement of right lung opacities but extension in the left lung. Because of disabling hypoxemia due to left intrapulmonary shunting, a left pneumonectomy was performed in November 2004 after the fifth chemotherapy cycle. Surgery permitted discontinuation of oxygen therapy but the patient's condition was complicated by an infection of the pneumonectomy cavity requiring discontinuation of chemotherapy.

In April 2005, disease progressed in the remaining lung and weekly paclitaxel therapy was started. No efficacy was observed after three cycles. Despite mild renal failure, the patient remained fit for chemotherapy. Fourth-line full-dose pemetrexed treatment (500 mg/(m² q³) weeks) was started. After three cycles, an important regression of pulmonary opacities was observed. Treatment-related toxicity was only hematologic, easily manageable by 10% dose reduction for grade 2 neutropenia and erythropoietin administration for anemia with hemoglobin level

of 10.6 g/dl. Response was nearly complete with good tolerance after six cycles and it was decided to continue pemetrexed until disease progression or unacceptable toxicity. In November 2006, chemotherapy was stopped after 23 cycles, with persistence of response and low toxicity. The patient was hospitalized 8 months later for a thoracic relapse. Retreatment by pemetrexed induced again a long-term response that was still observed in May 2008.

3. Discussion

ADC-WBF seem to be less sensitive to chemotherapy than other NSCLC tumors. Two phase II prospective trials, enrolling a total of 77 patients, have tested 3-weeks paclitaxel as front-line treatment using two different schedules of administration: over 96 h in the 9714 Southwest Oncology Group (SWOG) trial [5] and over 3 h in the 08956 European Organisation for Research and Treatment of Cancer (EORTC) trial [6]. Response rate was low, respectively 14% and 11%, and only partial responses were obtained. The observation of dramatic and durable response to TKI and the high incidence of EGFR overexpression and/or EGFR gene amplification and/or EGFR activating mutation in ADC-WBF cells has conducted to the realization of three phase II prospective trials using gefitinib [7,8] or erlotinib [9] as first or second-line treatments. Results are comparable or superior to those obtained with paclitaxel, with response rates of 11–14% versus 17–22%, disease control rates of 54–61% versus 29–58%, and overall survival durations of 8.6–12 months versus 13–17 months for paclitaxel and TKI, respectively. Finally, the small number of trials interested in ADC-WBF, in particular the absence of phase III trial, does not permit to establish a consensus on ADC-WBF treatment.

Pemetrexed, a potent antifolate recently developed in NSCLC, targets three enzymes involved in nucleic acid synthesis, in particular thymidylate synthase [10]. Its efficacy for the second-line treatment of advanced NSCLC has been shown in a phase III trial in which ADC-WBF were not individualized [11]. In this trial, Pemetrexed with acid folic and B12 supplementation is well tolerated, notably with minimal hematologic toxicities. The rate of grade 3/4 neutropenia (5.3%) [11] is lower than observed with paclitaxel in 9714 SWOG [5] and 08956 EORTC [6] trials (43% and 21.1%, respectively). Overall, all drug-related toxicities seem to be less frequent with pemetrexed than with paclitaxel.

A recent large phase III trial [12] comparing the combination of cisplatin/pemetrexed with cisplatin/gemcitabine in the front-line treatment of advanced CBNPC has demonstrated a significant survival difference in the histological subgroup of adenocarcinomas with cisplatin/pemetrexed schedule. This could be due to a lower thymidylate synthase expression in ADC. Furthermore, pemetrexed, which induce an effective inhibition of ADC-WBF cell lines *in vitro* [15], has proved interesting for the treatment of mesothelioma [13] which shares common biological features with ADC-WBF. In fact,

the alpha folate receptor, which is highly involved in intracellular transport and in the cytotoxic activity of antifolates [14], is overexpressed in ADC-WBF cell lines at levels, respectively 2- and 2.6-fold higher than in mesothelioma and lung ADC cell lines.

Our two cases suggest that a specific ADC-WBF subgroup is probably highly sensitive to pemetrexed, and that response to retreatment is possible. Pemetrexed treatment is associated with low toxicity allowing prolonged treatment and maintenance of complete response over several months. Two phase II trials, enrolling only ADC-WBF and specifically designed for this illness, are currently conducted by the SWOG [16] and the IFCT [17] and tested pemetrexed as first-, second- or third-line treatments. Data of this research should clarify the relevance of this drug for ADC-WBF management.

Conflict of interest

The authors declare no conflict of interest.

References

- [1] Travis WD, Brambilla E, Muller-Hermelink HK, et al. Pathology and genetics of tumors of the lung, pleura, thymus and heart. In World Health Organisation Classification of Tumours. Lyon, France: IARC Press; 2004.
- [2] Zell JA, Ou S-HI, Zogas A, et al. Epidemiology of bronchioloalveolar carcinoma: improvement of survival after release of the 1999 WHO classification of lung tumors. *J Clin Oncol* 2005;23:8396–405.
- [3] Read WL, Page NC, Tierney RM, et al. The epidemiology of bronchioloalveolar carcinoma over the past two decades: analysis of the SEER database. *Lung Cancer* 2004;45:137–45.
- [4] Garfield DH, Cadranel JL, Wislez M, et al. The bronchioloalveolar carcinoma and peripheral adenocarcinoma spectrum of diseases. *J Thorac Oncol* 2006;4:344–59.
- [5] West HL, Crowley JJ, Vance RB, et al. Advanced bronchioloalveolar carcinoma: a phase II trial of paclitaxel by 96-hour infusion (SWOG 9714): a Southwest Oncology Group Study. *Ann Oncol* 2005;16:1076–80.
- [6] Scagliotti GV, Smit E, Bosquee L, et al. A phase II study of paclitaxel in advanced bronchioloalveolar carcinoma (EORTC trial 08956). *Lung Cancer* 2005;50:91–6.
- [7] West HL, Franklin WA, McCoy J, et al. Gefitinib therapy in advanced bronchioloalveolar carcinoma: Southwest Oncology Group S0126. *J Clin Oncol* 2006;24:1807–13.
- [8] Cadranel J, Quoix E, Debove P, et al. Phase II study of gefitinib (IRESSA) administered as first line treatment in patients with non-resectable adenocarcinoma with bronchioloalveolar features—final results on efficacy and survival. *J Clin Oncol* 2007;25:A7560.
- [9] Miller VA, Riely GJ, Zakowski MF, et al. Molecular characteristics of bronchioloalveolar carcinoma and adenocarcinoma, bronchioloalveolar subtype, predict response to erlotinib. *J Clin Oncol* 2008;25:1472–8.
- [10] Chattopadhyay S, Moran RG, Goldmann ID. Pemetrexed: biochemical and cellular pharmacology, mechanisms, and clinical applications. *Mol Cancer Ther* 2007;6:404–17.
- [11] Hanna N, Shepherd FA, Fossella FV, et al. Randomized phase III trial of pemetrexed versus docetaxel in patients with non-small cell lung cancer previously treated with chemotherapy. *J Clin Oncol* 2004;22:1589–97.
- [12] Scagliotti GV, Parikh P, von Pawel J, et al. Phase III study comparing cisplatin plus gemcitabine with cisplatin plus pemetrexed in chemotherapy-naïve patients with advanced-stage non-small-cell lung cancer. *J Clin Oncol* 2008;26:3543–51.
- [13] Vogelzang NJ, Rusthoven JJ, Symanowski J, et al. Phase III study of pemetrexed in combination with cisplatin versus cisplatin alone in patients with malignant pleural mesothelioma. *J Clin Oncol* 2003;21:2636–44.
- [14] Theti DS, Jackman AL. The role of alpha-folate receptor-mediated transport in the antitumor activity of antifolate drugs. *Clin Cancer Res* 2004;10:1080–9.
- [15] Tracy S, Johnson EB, Jänne AP. In-vitro effects of pemetrexed on bronchioloalveolar and adenocarcinoma of the lung. In: Proc Amer Assoc Cancer Res Meeting, 2005, abstract #5864.
- [16] Ho C, Ross H, Davies A. Phase II trial of pemetrexed in patients with selected stage IIIB/IV bronchioloalveolar carcinoma. *Clin Lung Cancer* 2006;8:220–2.
- [17] Cadranel J. Therapeutic strategy in advanced bronchioloalveolar carcinoma. October 5, 2006. Available at: <http://clinicaltrials.gov/show/NCT00384826>. Accessed September 26, 2008.

The Role of Pemetrexed in Lung Adenocarcinoma, Mixed Subtype with Bronchioloalveolar Carcinoma Features

Michaël Duruisseaux^{*1}, Jacques Cadranel², Maurice Pérol³ and Dominique Arpin⁴

¹Service de Pneumologie, Unité d'Oncologie Thoracique, Hôpital de la Croix Rousse, Lyon, France; ²Service de Pneumologie et de Réanimation, AP-HP, Hôpital Tenon, Paris, France; ³Service de Pneumologie, Unité d'Oncologie Thoracique, Hôpital de la Croix Rousse, Lyon, France; ⁴Service de Pneumologie, Unité d'Oncologie Thoracique, Hôpital de la Croix Rousse, Lyon, France and Centre Léon Bérard, Lyon, France

Abstract: Bronchioloalveolar carcinoma (BAC) and adenocarcinoma with bronchioloalveolar features (ADC-WBF) belong to the same anatomic-clinical entity and show very similar epidemiologic, clinical and biological characteristics. However there is a lack of consensus for the treatment of unresectable forms. Although epidermal growth factor receptor tyrosine kinase inhibitors and paclitaxel do have some efficacy, the aim of this review is to assess the role that pemetrexed, a new generation antifolate, could play in this context. Pemetrexed has proved to be particularly effective in advanced lung adenocarcinomas and unresectable mesotheliomas, and cases of major and sustained responses of ADC-WBF to pemetrexed have been reported. The preclinical rationale explaining this efficacy is that it inhibits the growth of BAC cell lines *in vitro*. BAC tumors overexpress FR- α , a protein involved in pemetrexed intracellular transport, at rates higher than those observed in lung adenocarcinomas and mesotheliomas and it would seem that pemetrexed efficacy is correlated to FR- α expression. The role played by thymidylate synthase expression level in sensitivity to pemetrexed also needs to be specifically explored in ADC-WBF. The results of two phase II trials, SWOG 0526 and IFCT 05-04, will hopefully provide decisive information on the relevance of pemetrexed in ADC-WBF management and the molecular predictors of response.

Keywords: Lung cancer, adenocarcinoma, bronchioloalveolar carcinoma, pemetrexed, paclitaxel, erlotinib, chemotherapy.

BRONCHIOALVEOLAR CARCINOMA: DEFINITION AND DESCRIPTION

Bronchioloalveolar carcinoma (BAC) represents one of the five subtypes of lung adenocarcinoma, according to the 2004 revised World Health Organization (WHO)/International Association for the Study of Lung Cancer (IASLC) Classification of lung and pleural tumors [1]. It has been strictly defined as a pulmonary adenocarcinoma with a pure bronchioloalveolar growth pattern, developing from acinar and terminal bronchiolar epithelial cells, without pleural, stromal or vascular invasion. According to this restrictive definition, diagnosis can only be established once pathological analysis of the tumor after complete surgical specimen resection excludes any evidence of histological invasion. This narrow definition of BAC is based on the demonstration by Noguchi, *et al.* that small peripheral adenocarcinoma with a pure BAC pattern and without evidence of invasion has a 100% 5-year survival rate [2].

On the other hand, "lepidic" progression, with colonization of abnormal cells along alveolar septae, and "aerogenous progression", with spreading of noncontiguous sites of the primary tumor, which both characterize bronchioloalveolar growth pattern, are also observed in association with other lung adenocarcinoma subtypes. Tumors from this heterogeneous group were defined in the 2004 WHO/IASLC

classification as adenocarcinoma mixed subtypes with BAC features (ADC-WBF) [1]. They display histological evidence of invasion but present BAC features, from predominant BAC to small BAC component surrounding a solid lesion. Interestingly, BAC as strictly defined above and ADC-WBF share strikingly similar epidemiologic characteristics, clinical and radiological findings, biological profiles, prognosis and treatment sensitivity [3]. The fact that these characteristics clearly distinguish ADC-WBF from other non-small cell lung cancers (NSCLC) supports the hypothesis that BAC and ADC-WBF belong to the same clinicopathological spectrum of disease. This concept was highlighted in 2004 by the first international workshop specifically focused on BAC study [4].

The 2004 WHO/IASLC classification distinguishes three cytological subtypes of BAC i.e. nonmucinous (NM), mucinous (M) or mixed. NM BAC arises from Clara cells and type II pneumocytes which are epithelial cells of the terminal respiratory unit. Atypical adenomatous hyperplasia (AAH) has recently been recognized as a preneoplastic condition of NM BAC suggesting a carcinogenesis sequence from AAH to NM BAC and lung adenocarcinoma with NM BAC features. This sequence seems to be driven by the epidermal growth factor receptor pathway [3, 5, 6]. While the NM BAC subtype is associated with a relatively favorable disease course³, M BAC, which arises from a mucinous metaplasia of bronchiolar epithelium, has a more unfavorable prognosis. The mutation of K-Ras, a potent oncogene, probably plays an important role in M BAC pathogenesis [7, 8] explaining why this subtype more frequently harbors K-Ras mutations [5]. Finally, epidermal growth factor receptors (EGFR) are

*Address correspondence to this author at the Service de Pneumologie, Unité d'Oncologie Thoracique, Hôpital de la Croix Rousse, 103 Grande Rue de la Croix Rousse Cedex 69317 Lyon, France; Tel: +33 472071731; E-mail: dominique.arpin@chu-lyon.fr

more frequently mutated and overexpressed in the NM subtype.

THERAPEUTIC ASPECTS

Chemotherapy is widely perceived to be ineffective for advanced ADC-WBF since low efficacy and high toxicity have been limiting factors in pursuing paclitaxel treatment as an attractive first-line therapy [9, 10]. Two phase II prospective trials enrolling a total of 77 patients and using different schedules of administration, tested 3-week paclitaxel as front-line treatment: a 96-hour infusion in the 9714 Southwest Oncology Group (SWOG) trial [9] and a 3-hour infusion in the 08956 European Organization for Research and Treatment of Cancer (EORTC) trial [10]. The resulting low response rates (respectively 14 and 11%) and the relatively high toxicity did not support either approach. Simultaneously, the report of patients with advanced ADC-WBF experiencing a dramatic and durable response after treatment by EGFR tyrosine kinase inhibitors (EGFR TKI) gave rise to three phase II prospective trials using gefitinib [11, 12] or erlotinib [13] as first- or second-line treatment for advanced ADC-WBF. The results of these trials were comparable or superior to those obtained with paclitaxel, with response rates of 11-14% versus 17-22%, disease control rates of 54-61% versus 29-58%, and overall survival durations of 8.6-12 months versus 13-17 months, respectively for paclitaxel and EGFR TKI.

Importantly, the different subtypes of BAC differ in therapeutic susceptibilities. Patients with NM BAC have significantly improved disease control rates under EGFR-TKI, whereas those with M BAC do not [12]. Furthermore, BAC patients who are more sensitive to EGFR-TKI therapy have increased EGFR polysomy or expression of somatic EGFR mutations [13, 14], and those who are less sensitive to this treatment are more likely to have K-Ras mutations [13]. Consistent with this, NM BAC responds favorably to EGFR therapy [12] whereas mucinous features exert a negative effect on survival in patients treated with EGFR TKI. Finally, M/mixed BAC might be more responsive to paclitaxel [9]. In summary, we do not have enough published data on the treatment of ADC-WBF, and in particular no phase III trial publications, to be able to establish consensus at this stage.

MOLECULAR DETERMINANTS OF PEMETREXED ACTIVITY

Pemetrexed belongs to the third generation of antifolates and is a remarkable inhibitor of thymidylate synthase (TS) [15]. TS generates thymidine monophosphate (dTMP) through a reductive methylation reaction using deoxyuridine monophosphate as substrate. Subsequently, dTMP is phosphorylated to thymidine triphosphate, a mandatory component of DNA synthesis and repair. Pemetrexed also targets glycinamide ribonucleotide formyl transferase (GARFT) which catalyzes the transformation of tetrahydrofolate (THF) to N10-formyl THF, and dihydrofolate reductase (DHFR) which generates THF from dihydrofolate. Therefore, this multi-target antifolate constitutes a major inhibitor of TS [15, 16] whereas its inhibitory effect on GARFT and on DHFR seems to be less important in its cytotoxic activity [16, 17].

At a cellular level multiple parameters are involved in pemetrexed activity on tumor cell growth. The most important ones are intracellular transport of pemetrexed and polyglutamation in the cell [15].

Intracellular Polyglutamation

One of the most important mechanisms explaining antifolate activity and selectivity is the polyglutamation of antifolates in the cytoplasm. The process of polyglutamation is supported by folyl-polyglutamate synthetase (FPGS) which catalyzes the production of polyglutamate derivatives. Intracellular accumulation and retention of these derivatives result in increased cytotoxic activity. The pemetrexed pentaglutamate derivative is 100 times more effective in inhibiting TS than the monoglutamate derivative [16, 17]. Furthermore, pemetrexed has a high affinity for mammalian FPGS and undergoes rapid polyglutamation [16, 18]. Intracellular pemetrexed polyglutamate derivatives thus accumulate rapidly thereby increasing the potential of TS inhibition and making pemetrexed more active than other antifolates.

Intracellular Transport of Pemetrexed

Pemetrexed harbors a high affinity for any element involved in the physiological mammalian membrane transport of folates [15]. The Reduced Folate Carrier (RFC) is the most well-known membrane transporter of both folates and antifolates and a major determinant of the activity and resistance to antifolate agents. The affinity of this carrier-mediated anion exchanger for pemetrexed is 2-fold higher than its affinity for methotrexate [19] and around 100 times higher for pemetrexed than for folic acid [19]. An impairment in RFC functions leads to a high level of resistance to most of the antifolates but not for pemetrexed [20]. This could be explained by an RFC-independent transport activity or a significant decrease in the level of cellular folates. Such a decrease enhances pemetrexed suppression of GARFT and reduces competition between folates and pemetrexed for FPGS [15].

The folate receptor FR- α is a high affinity, low capacity folate/antifolate transporter that has demonstrated its higher affinity for pemetrexed than for folic acid [15]. The endocytotic process through which folates are transported into the cells requires multiple steps [21] and the maximum rate of transport is 100 times lower than the rate mediated by the RFC [15]. Thus, FR- α participates only slightly in folate or antifolate intracellular transport. However, FR- α could play a role in pemetrexed uptake in the event of high overexpression compared to RFC expression and/or if the RFC function or other RFC independent transport processes are impaired [15, 22, 23].

PEMETREXED AND ADC-WBF: PRE-CLINICAL FINDINGS

Pemetrexed, when used in combination with cisplatin, has demonstrated superiority over the use of cisplatin alone in advanced pleural mesothelioma and is the "standard of care" in unresectable malignant pleural mesothelioma [24]. The characteristics of intracellular antifolate transport in mesothelioma cell lines favor pemetrexed in comparison

with other antifolates [25]. Mesothelioma cell lines harbor a high level of FR- α expression which is correlated with the cytotoxic activity of pemetrexed [25, 26]. Pemetrexed induces inhibition of BAC cell lines *in vitro* (NCI-H358, -H1650, -H1666, -H1781) [26]. The results are comparable with the inhibition obtained in lung adenocarcinoma cell lines (NCI-H23, -H441, -H2347, -H3122, -H3255). Interestingly, FR- α expression estimated by mRNA microarrays is respectively 2 and 2.6-fold higher in BAC than in mesothelioma and non-BAC lung adenocarcinoma [26]. Pre-clinical and clinical studies are necessary to clarify the role that FR- α might play as regards BAC sensitivity to pemetrexed and to find out if FR- α could be a predictive factor of BAC and ADC-WBF response to pemetrexed.

TS has been extensively investigated as a predictive factor of response to 5-Fluorouracil in patients with colorectal cancer [27], breast cancer [28] and head and neck cancer [29]. In NSCLC, high TS expression is correlated with higher proliferative activity and poor prognosis [30, 31]. The histological subtype seems to be a good predictor of TS expression. Squamous cell lung carcinoma demonstrated a higher TS expression level than non-squamous NSCLC [32, 33]. A large phase III trial comparing the cisplatin/pemetrexed combination with the cisplatin/gemcitabine combination in the front-line treatment of advanced NSCLC demonstrated a significant survival difference in the histological subgroup of adenocarcinoma with the cisplatin/pemetrexed schedule [34]. This suggests the clinical relevance of TS expression level in patients treated with pemetrexed, but to our knowledge, no data has been reported about TS expression level in ADC-WBF.

PEMETREXED AND ADC-WBF: CLINICAL DATA

Pemetrexed is now validated in first- and second-line treatment of NSCLC in non-squamous cell carcinoma [34, 35]. Unfortunately, ADC-WBF were not individualized in the phase III trials which led to the Food and Drug Agency approval in this setting. Thus, few data are available as regards the specific issue of pemetrexed efficacy in ADC-WBF.

The role of pemetrexed in the treatment of ADC-WBF remains to be explored. We have recently reported a major clinical and radiological response to pemetrexed in two cases of advanced ADC-WBF in second- and fourth-line treatment [36]. Interestingly, responses were maintained over 16 and 24 months, and new responses were observed after pemetrexed was withdrawn and then re-introduced. This suggests that pemetrexed targets a subset of ADC-WBF with high sensitivity to folate inhibition that does not reverse after exposure to other therapeutic agents and without induction of secondary resistance after exposure to pemetrexed.

Data provided by the Intergroupe Francophone de Cancérologie Thoracique (IFCT) 04-01 trial [12] has reinforced the hypothesis of pemetrexed activity, independently of previous EGFR-TKI or taxane exposure. In this trial, gefitinib was evaluated in front-line treatment of advanced ADC-WBF. Out of 86 patients enrolled, 46 received chemotherapy after gefitinib failure. Paclitaxel and gemcitabine based-chemotherapy were the most commonly used schedules in second-line and achieved disease control in 18/30 and 5/24

patients respectively (Duruiseaux M and Cadranel J, manuscript in preparation). Pemetrexed administered as third- and further-line therapy achieved disease control in 10/13 patients. These results led to the assessment of pemetrexed as the only third-line treatment after erlotinib and carboplatin-paclitaxel failure in the IFCT 05-04 trial which was closed in August 2009 and included more than 130 naïve patients [37]. The planned study of biological predictive factors of therapeutic response or prognostic factors of survival will assess the expression of TTF1, beta tubulin III, ERCC1 and TS protein by IHC, as well as the presence of EGFR and K-Ras mutations in tumor specimens. These data might help to define a subgroup of patients likely to benefit from a treatment with pemetrexed.

Finally, a trial specifically designed to study pemetrexed in ADC-WBF was conducted by the SWOG [38] and is now closed. This phase II trial included 99 patients with advanced BAC either treatment-naïve or having benefited from one line of treatment before the administration of pemetrexed. The results will be stratified according to whether EGFR TKI was used or not before administering pemetrexed. An analysis of folate metabolism markers, EGFR and K-Ras mutations in pretreatment tumor specimens and pre- and post-treatment blood samples has been planned. In particular, important information might be provided as regards the role of FR- α and other folate intracellular carriers as prognostic factors of clinical efficacy of pemetrexed.

CONCLUSION

Despite the common opinion that chemotherapy is ineffective for BAC and ADC-WBF, recent results suggest a significant clinical activity of chemotherapy. The good treatment index and the seemingly remarkable activity of pemetrexed based on both preclinical findings and preliminary clinical results support this hypothesis. Further investigations are needed to explore pemetrexed efficacy in ADC-WBF and molecular predictors of response, notably TS and FR- α expression. Identifying patient subgroups likely to benefit from EGFR TKI, taxane or pemetrexed therapy is an important field of investigation in trials which specifically address ADC-WBF study.

REFERENCES

- [1] Travis WD, Brambilla E, Muller-Hermelink HK, Harris CC. Pathology and genetics of tumors of the lung, pleura, thymus and heart. In World Health Organisation Classification of Tumours. Lyon, France: IARC Press 2004.
- [2] Noguchi M, Morikawa A, Kawasaki M, Matsuno Y, Yamada T, Hirohashi S, *et al.* Small adenocarcinoma of the lung. Histologic characteristics and prognosis. *Cancer* 1995; 75(12): 2844-52.
- [3] Garfield DH, Cadranel JL, Wislez M, Franklin WA, Hirsch FR. The bronchioloalveolar carcinoma and peripheral adenocarcinoma spectrum of diseases. *J Thorac Oncol* 2006; 1(4): 344-59.
- [4] Travis WD, Garg K, Franklin WA, Wistuba II, Sabloff B, Noguchi M, *et al.* Bronchioloalveolar carcinoma and lung adenocarcinoma: the clinical importance and research relevance of the 2004 World Health Organization pathologic criteria. *J Thorac Oncol* 2006; 1(9 Suppl): S13-9.
- [5] Sakuma Y, Matsukuma S, Yoshihara M, Nakamura Y, Noda K, Nakayama H, *et al.* Distinctive evaluation of nonmucinous and mucinous subtypes of bronchioloalveolar carcinomas in EGFR and K-ras gene-mutation analyses for Japanese lung adenocarcinomas:

- confirmation of the correlations with histologic subtypes and gene mutations. *Am J Clin Pathol* 2007; 128(1): 100-8.
- [6] Lantuéjoul S, Salameire D, Salon C, Brambilla E. Pulmonary preneoplasia—sequential molecular carcinogenetic events. *Histopathology* 2009; 54(1): 43-54.
- [7] Finberg KE, Sequist LV, Joshi VA, Muzikansky A, Miller JM, Han MF, *et al.* Mucinous differentiation correlates with absence of EGFR mutation and presence of KRAS mutation in lung adenocarcinomas with bronchio-loalveolar features. *J Mol Diagn* 2007; 9(3): 320-6.
- [8] Garfield DH, Cadranel J, West HL. Bronchioloalveolar carcinoma: the case for two diseases. *Clin Lung Cancer* 2008; 9(1): 24-9.
- [9] West HL, Crowley JJ, Vance RB, Franklin WA, Livingston RB, Dakhil SR, *et al.* Advanced bronchioloalveolar carcinoma: a phase II trial of paclitaxel by 96-hour infusion (SWOG 9714): a Southwest Oncology Group Study. *Ann Oncol* 2005; 16: 1076-80.
- [10] Scagliotti GV, Smit E, Bosquec L, O'Brien M, Arzozoni A, Zatlouk P, *et al.* A phase II study of paclitaxel in advanced bronchioloalveolar carcinoma (EORTC trial 08956). *Lung cancer* 2005; 50: 91-6.
- [11] West HL, Franklin WA, McCoy J, Gumerlock PH, Vance R, Lau DH, *et al.* Gefitinib therapy in advanced bronchioloalveolar carcinoma: Southwest Oncology Group Study S0126. *J Clin Oncol* 2006; 24: 1807-13.
- [12] Cadranel J, Quoix E, Baudrin L, Mourlanette P, Moro-Sibilot D, Morere JF, *et al.* IFCT-0401 trial: a phase II study of gefitinib administered as first-line treatment in advanced adenocarcinoma with bronchioloalveolar carcinoma subtype. *J Thorac Oncol* 2009; [Epub ahead of print].
- [13] Miller VA, Riehl GJ, Zakowski MF, Li AR, Patel JD, Heelan RT, *et al.* Molecular characteristics of bronchioloalveolar carcinoma and adenocarcinoma, bronchioloalveolar carcinoma subtype, predict response to erlotinib. *J Clin Oncol* 2008; 26(9): 1472-8.
- [14] Hirsch FR, Varella-Garcia M, McCoy J, West H, Xavier AC, Gumerlock P, *et al.* Increased epidermal growth factor receptor gene copy number detected by fluorescence in situ hybridization associates with increased sensitivity to gefitinib in patients with bronchioloalveolar carcinoma subtypes: a Southwest Oncology Group Study. *J Clin Oncol* 2005; 23: 6838-45.
- [15] Chattopadhyay S, Moran RG, Goldmann DL. Pemetrexed: biochemical and cellular pharmacology, mechanisms, and clinical applications. *Mol Cancer Ther* 2007; 6(2): 414-17.
- [16] Taylor EC, Kuhnt D, Shih C, Rinzel SM, Grindey GB, Barredo J, *et al.* A dideazatetrahydrofolate analogue lacking a chiral center at C-6, N-[4-[2-(2-amino-3,4-dihydro-4-oxo-7H-pyrrolo[2,3-d]pyrimidin-5-yl)ethyl]benzoyl]-L-glutamic acid, is an inhibitor of thymidylate synthase. *J Med Chem* 1992; 35: 4450-4.
- [17] Shih C, Chen VJ, Gossett LS, Gates SB, MacKellar WC, Habeck LL, *et al.* LY231514, a pyrrolo 2,3-d pyrimidine-based antifolate that inhibits multiple folate-requiring enzymes. *Cancer Res* 1997; 57(6): 1116-23.
- [18] Habeck LL, Mendelsohn LG, Shih C, Taylor EC, Colman PD, Gossett LS, *et al.* Substrate specificity of mammalian folylpolyglutamate synthetase for 5,10-dideazatetrahydrofolate analogs. *Mol Pharmacol* 1995; 48(2): 326-33.
- [19] Wang Y, Zhao R, Goldman ID. Characterization of a folate transporter in HeLa cells with a low pH optimum and high affinity for pemetrexed distinct from the reduced folate carrier. *Clin Cancer Res* 2004; 10(18 Pt 1): 6256-64.
- [20] Zhao R, Hanscom M, Chattopadhyay S, Goldman ID. Selective preservation of pemetrexed pharmacological activity in HeLa cells lacking the reduced folate carrier: association with the presence of a secondary transport pathway. *Cancer Res* 2004; 64(9): 3313-9.
- [21] Mineo C, Anderson RG. Potocytosis. Robert Feulgen Lecture. *Histochem Cell Biol* 2001; 116(2): 109-18.
- [22] Sierra EE, Brigle KE, Spinella MJ, Goldmann ID. Comparison of transport properties of the reduced folate carrier and folate receptor in murine L1210 leukemia cells. *Biochem Pharmacol* 1995; 50(8): 1287-94.
- [23] Spinella MJ, Brigle KE, Sierra EE, Goldmann ID. Distinguishing between folate receptor-alpha-mediated transport and reduced folate carrier-mediated transport in L1210 leukemia cells. *J Biol Chem* 1995; 270(14): 7842-9.
- [24] Vogelzang NJ, Rusthoven JJ, Symanowski J, Denham C, Kaukel E, Ruffie P, *et al.* Phase III study of pemetrexed in combination with cisplatin versus cisplatin alone in patients with malignant pleural mesothelioma. *J Clin Oncol* 2003; 21(14): 2636-44.
- [25] Theti DS, Jackman AL. The role of alpha-folate receptor-mediated transport in the antitumor activity of antifolate drugs. *Clin Cancer Res* 2004; 10(3): 1080-9.
- [26] Tracy S, Johnson EB, Jänne AP. *In-vitro* effects of pemetrexed on bronchioloalveolar and adenocarcinoma of the lung. *Proc Amer Assoc Cancer Res Meeting* 2005; abstract #5864.
- [27] Shirota Y, Stoehlmacher J, Brabender J, Xiong YP, Uetake H, Danenberg KD, *et al.* ERCC1 and thymidylate synthase mRNA levels predict survival for colorectal cancer patients receiving combination oxaliplatin and fluorouracil chemotherapy. *J Clin Oncol* 2001; 19(23): 4298-304.
- [28] Nishimura R, Nagao K, Miyayama H, Matsuda M, Baba K, Matsuoka Y, *et al.* Thymidylate synthase levels as a therapeutic and prognostic predictor in breast cancer. *Anticancer Res* 1999; 19(6C): 5621-6.
- [29] Shiga H, Heath EI, Rasmussen AA, Trock B, Johnston PG, Forastiere AA, *et al.* Prognostic value of p53, glutathione S-transferase pi, and thymidylate synthase for neoadjuvant cisplatin-based chemotherapy in head and neck cancer. *Clin Cancer Res* 1999; 5(12): 4097-104.
- [30] Nakagawa T, Tanaka F, Otake Y, Yanagihara K, Miyahara R, Matsuoka K, *et al.* Prognostic value of thymidylate synthase expression in patients with p-stage I adenocarcinoma of the lung. *Lung cancer* 2002; 35(2): 165-70.
- [31] Nakagawa T, Otake Y, Yanagihara K, Miyahara R, Ishikawa S, Fukushima M, *et al.* Expression of thymidylate synthase is correlated with proliferative activity in non-small cell lung cancer (NSCLC). *Lung Cancer* 2004; 43(2): 145-9.
- [32] Ceppi P, Volante M, Saviozzi S, Rapa I, Novello S, Cambieri A, *et al.* Squamous cell carcinoma of the lung compared with other histotypes shows higher messenger RNA and protein levels for thymidylate synthase. *Cancer* 2006; 107(7): 1589-96.
- [33] Scagliotti G, Monica V, Ceppi P, Righi L, Cambieri A, Volante M, *et al.* Baseline thymidylate synthase expression according to histological subtypes of non-small cell lung cancer. *ASCO Meeting Abstracts* 2009; 7521.
- [34] Scagliotti GV, Parikh P, von Pawel J, Biesma B, Vansteenkiste J, Manegold C, *et al.* Phase III study comparing cisplatin plus gemcitabine with cisplatin plus pemetrexed in chemotherapy-naive patients with advanced-stage non-small-cell lung cancer. *J Clin Oncol* 2008; 26(21): 3543-51.
- [35] Hanna N, Shepherd FA, Fossella FV, Pereira JR, De Marinis F, von Pawel J, *et al.* Randomized phase III trial of pemetrexed versus docetaxel in patients with non-small-cell lung cancer previously treated with chemotherapy. *J Clin Oncol* 2004; 22(9): 1589-97.
- [36] Duruisseaux M, Cadranel J, Biron E, Pérol M, Guérin JC, Arpin D, *et al.* Major and prolonged response to pemetrexed in two cases of lung adenocarcinoma with bronchioloalveolar carcinoma features. *Lung Cancer* 2009; 65(3): 385-7.
- [37] Cadranel J. Therapeutic strategy in advanced bronchioloalveolar carcinoma. October 5, 2006. Available at: <http://clinicaltrials.gov/show/NCT00384826>. Accessed September 26, 2008.
- [38] Ho C, Ross H, Davies A. Phase II trial of pemetrexed in patients with selected stage IIIB/IV bronchioloalveolar carcinoma. *Clin Lung Cancer* 2006; 8(3): 220-2.

Chemotherapy Effectiveness After First-Line Gefitinib Treatment for Advanced Lepidic Predominant Adenocarcinoma (Formerly Advanced Bronchioloalveolar Carcinoma)

Exploratory Analysis of the IFCT-0401 Trial

Michaël Duruisseaux, MD,* Laurence Baudrin, MBSc,† Elisabeth Quoix, MD, PhD,‡
 Marie Wislez, MD, PhD,*§ Denis Moro-Sibilot, MD, PhD,|| Daniel Coëtmeur, MD,¶
 Isabelle Monnet, MD,# Pierre Mourlanette, MD,** Jean-François Morère, MD, PhD,††
 Jean-Charles Soria, MD, PhD,‡‡ Virginie Westeel, MD, PhD,§§ Franck Morin, MBSc,†
 and Jacques Cadranel, MD, PhD*†§

Hypothesis: This study explored whether chemotherapy after first-line gefitinib was effective in patients with advanced lepidic predominant adenocarcinoma (LPA), formerly advanced bronchioloalveolar carcinoma, who were enrolled in the Intergroupe Francophone de Cancérologie Thoracique (IFCT)-0401 trial.

*ER2 and GRC-04 Theranoscan, Faculté de Médecine Pierre et Marie Curie, Université Paris VI, Paris, France; †Intergroupe Francophone de Cancérologie Thoracique (IFCT), Paris, France; ‡Hôpitaux Universitaires, Université de Strasbourg, Intergroupe Francophone de Cancérologie Thoracique (IFCT), Strasbourg, France; §Service de Pneumologie et Réanimation, AP-HP Hôpital Tenon, Intergroupe Francophone de Cancérologie Thoracique (IFCT), Paris, France; ¶Service de Pneumologie, PMAC and CHU de Grenoble, Intergroupe Francophone de Cancérologie Thoracique (IFCT), Grenoble, France; *Service de Pneumologie, Centre Hospitalier Yves Le Foll, Intergroupe Francophone de Cancérologie Thoracique (IFCT), Saint-Brieuc, France; #Service de Pneumologie, Centre Hospitalier Intercommunal de Créteil, Intergroupe Francophone de Cancérologie Thoracique (IFCT), Créteil, France; **Clinique des Cèdres, Intergroupe Francophone de Cancérologie Thoracique (IFCT), Cornebarrieu, France; ††Service d'Oncologie Médicale, AP-HP Hôpital Avicenne, Université Paris XIII, Intergroupe Francophone de Cancérologie Thoracique (IFCT), Bobigny, France; ‡‡Département de Médecine, Institut Gustave Roussy, Faculté de Médecine Paris-Sud, Université Paris XI, Intergroupe Francophone de Cancérologie Thoracique (IFCT), Villejuif, France; §§Centre Hospitalier Universitaire de Besançon, Intergroupe Francophone de Cancérologie Thoracique (IFCT), Besançon, France.

Disclosure: Dr. Quoix received consulting fees or honoraria from Roche, Lilly, and AstraZeneca, in addition to travel grants from Lilly, AstraZeneca, Merck, and Roche. Dr. Westeel received consulting fees or honoraria for Roche and Lilly, in addition to travel grants from Lilly, AstraZeneca, and Roche. Laurence Baudrin received travel grants from Lilly, AstraZeneca, and Roche. Dr. Morin received travel grants from Lilly, AstraZeneca, and Roche. Dr. Cadranel received consulting fees or honoraria from AstraZeneca, Lilly, Roche, and, in addition to travel grants from Roche. All other authors declare no conflict of interest.

Address for Correspondence: Jacques Cadranel, MD, PhD, Service de Pneumologie, Hôpital Tenon, 4 rue de la Chine, F-75970, Paris, France. E-mail: jacques.cadranel@tnn.aphp.fr

Copyright © 2012 by the International Association for the Study of Lung Cancer
 ISSN: 1556-0864/12/0709-1423

Methods: Overall, 88 patients presenting advanced LPA were enrolled in the IFCT-0401 trial, receiving gefitinib as first-line therapy. No predefined second-line treatment was mandatory in the case of progression or limiting toxicity under gefitinib. However, the carboplatin plus paclitaxel regimen was recommended for patients with a performance status (PS) 0 or 1 and gemcitabine monotherapy for those with a PS 2. For these patients, data concerning treatment efficacy was collected from the IFCT-0401 trial database.

Results: In total, 47 patients (53%) received second-line treatment after the failure of gefitinib, with 43 having PS 0 or 1. Regarding treatment, 43 were treated with chemotherapy, with 38 receiving a platinum-doublet regimen (taxane-based, n = 29; gemcitabine-based, n = 9) and five receiving monotherapy (gemcitabine, n = 3; pemetrexed, n = 2). The overall response rate (ORR) to chemotherapy was 21% (95% confidence interval [CI]: 10–36), disease control rate 56% (95% CI: 40–71), and median progression-free survival (PFS) 3.0 months (95% CI: 2.4–4.9). For patients receiving a platinum doublet (n = 38), ORR was 21% (95% CI: 10–37), with disease control rate being 55% (95% CI: 38–71), and median PFS 2.9 months (95% CI: 2.4–4.4). For patients receiving taxane-based regimen (n = 29) and gemcitabine-based regimen (n = 12), ORR was 28% and 0%, respectively, with a median PFS of 3.3 and 2.0 months, respectively, (p = 0.0243). The two patients receiving pemetrexed experienced a prolonged response. Multivariate Cox model analysis revealed that only the use of taxane-based chemotherapy or pemetrexed was related to PFS.

Conclusion: Platinum-doublet chemotherapy showed some effectiveness in treating advanced LPA patients after first-line gefitinib. Our findings also suggest that taxane-based chemotherapy and pemetrexed should be investigated further in future clinical trials.

Key Words: Non-small-cell lung cancer, Lung adenocarcinoma, Bronchioloalveolar carcinoma, Paclitaxel, Pemetrexed.

(*J Thorac Oncol.* 2012;7: 1423–1431)

Bronchioloalveolar carcinoma (BAC) is a rare histological subtype of lung adenocarcinoma (ADC), accounting for 3% to 4% of all non-small-cell lung cancers (NSCLC). The disease is defined in the 2004 revised classification of the World Health Organization (WHO) and International Association for the Study of Lung Cancer (IASLC) as an ADC proliferation arising from acinar and bronchiolar cells with no evidence of stromal, pleural, or vascular invasion.¹ Diagnosis can only be established after pathological tumor analysis excludes evidence of a histological invasion after complete surgical resection. This strict definition was substantiated by the 100% 5-year survival rate of less than 3 cm peripheral ADC, with pure BAC now termed adenocarcinoma in situ.² Former ADC with BAC features, being more frequent, has recently been termed invasive nonmucinous (NM) lepidic predominant ADC (LPA) along with its mucinous variant, as it displays several foci of invasion, but with predominant lepidic features.³ Given the “lepidic” growth pattern and aerogenous propagation of these tumors, ipsilateral, and contralateral pulmonary recurrences, but with uncommon extrapulmonary metastases,⁴ are frequently observed. This cancer type shares similar characteristics with adenocarcinoma in situ in terms of epidemiology (no gender bias; nonsmokers or mild smokers), clinical and radiological findings (better performance status [PS], less advanced diagnostic stage, ground-glass or alveolar pattern on computed tomography [CT] scan), and prognosis (more indolent course and better prognosis compared with other ADC subtypes).⁵

Historically, advanced LPA, formerly advanced BAC, was widely perceived as being chemoresistant, with older retrospective studies reporting conflicting results.^{6–11} In the prospective Eastern Cooperative Oncology Group (ECOG) 1594 trial comparing four platinum-based chemotherapy regimens as first-line therapy in advanced NSCLC patients, LPA response rates to chemotherapy were lower than other NSCLC pathological subtypes (6% versus 20%).⁶ As advanced LPA patients are frequently excluded from NSCLC trials, little is known about optimal treatment, thus justifying the initiation of specific trials.¹² There are only two nonrandomized phase II trials specifically focused on advanced LPA, studying the effectiveness of paclitaxel monotherapy.^{13,14} However, the low response rates along with unacceptable toxicity observed in the Southwest Oncology Group (SWOG) 9714 trial using a 96-hour infusion regimen did not support the use of such a chemotherapeutic approach.¹³ In addition, three phase II trials evaluated the use of epidermal growth factor receptor tyrosine kinase inhibitors (EGFR-TKI) as first-line or second-line treatment for patients with advanced LPA. Encouraging results involving control rates of 29% to 58% and overall survival of 13 to 17 months along with a favorable toxicity profile lent support to the EGFR-TKI approach (Table 1).^{15–17} Recently, similar results were reported using anti-EGFR antibody monotherapy as first-line or second-line therapy in advanced LPA patients.¹⁸

Pathological classification distinguishes three histological subtypes: NM, mucinous (M), and mixed. This histological classification appears to be clinically relevant in terms of treatment efficacy, likely due to the distinctive molecular

TABLE 1. Results of Phase II Trials in Advanced Lepidic Predominant Adenocarcinoma, Formerly Advanced Bronchioloalveolar Carcinoma, in the First-Line and Second-Line Setting

Trial	No.	ORR (%)	DCR (%)	PFS in months (median)	OS in months (median)
EORTC 08956 ¹⁴ ; paclitaxel	19	11*	54	2	9
SWOG 9714 ¹³ ; paclitaxel	58	14	—	5	12*
Miller ¹⁶ ; erlotinib	75	22*	60	4	17
SO126 ¹⁵ ; gefitinib	136	17	49	3.6	13.0*
IFCT-0401 ¹⁷ ; gefitinib	88	13	30*	2.9	13.2
ECOG-1504 ¹⁶ ; cetuximab	68	7*	42	3.3	13.0

*Trial primary endpoints

DCR, disease control rate; PFS, progression-free survival; OS, overall survival; EORTC, European Organisation for Research and Treatment of Cancer; SWOG, Southwest Oncology Group; IFCT, Intergroupe Francophone de Cancérologie Thoracique; ECOG, Eastern Cooperative Oncology Group.

tumor profile.^{19,20} NM tumors often exhibit *EGFR* mutations, with M tumors frequently presenting *K-Ras* mutations.^{21–23} Importantly, the presence of the *EGFR* mutation is predictive of EGFR-TKI response, whereas the *K-Ras* mutation appears to be associated with EGFR-TKI resistance.^{16,24} The Intergroupe Francophone de Cancérologie Thoracique (IFCT)-0401 trial showed that patients with NM tumors displayed significantly improved progression-free survival (PFS) with gefitinib, whereas patients with M tumors did not,¹⁷ which is in line with the differing molecular profiles of these two histological subtypes.²⁴ Overall survival curves, however, did not diverge until 22 months, suggesting that chemotherapy given after gefitinib was effective in patients with M tumors as “salvage” therapy. Furthermore, radiological response to the 96-hour infusion of paclitaxel in the SWOG 9714 trial was observed in the M tumors (3 of 16) and not in the NM tumors (0 of 13).¹³

The aim of this study was to describe the characteristics of patients with advanced LPA who received a second- or third-line treatment after the failure of gefitinib as part of the IFCT-0401 trial. Furthermore, we explored the effectiveness of the different therapeutic regimens administered, with a special focus on chemotherapy.

MATERIALS AND METHODS

Summary of the IFCT-0401 Trial

The prospective multicentre phase II IFCT-0401 trial was conducted between April 2004 and July 2005 to evaluate gefitinib 250 mg daily as front-line therapy in treatment-naïve patients with nonresectable advanced LPA, formerly advanced BAC.¹⁷ Disease control rate (DCR) was the primary endpoint. Eligibility criteria were the following: histologically or cytologically proven advanced LPA from the outset or after recurrence; PS of 0, 1, 2, or 3; one or more pulmonary lesions evaluable on CT scan; fiberoptic bronchoscopy with macroscopically normal findings. A chest radiograph and CT scan of the chest, brain, and upper abdomen were performed before inclusion. Response rates and disease control were assessed with the same imaging methods employed for the baseline

tumor assessment and using the WHO criteria.¹⁷ In total, 88 patients were enrolled, with none lost to follow-up. Written informed consent was obtained after providing comprehensive information about the investigational nature of the protocol. The protocol was approved by the local ethics committees and regulatory authorities.

Chemotherapy Effectiveness in Advanced LPA

Describing the effect of second-line and third-line chemotherapy was a secondary objective of the IFCT-0401 trial. No predefined second-line chemotherapy was mandatory in the case of progression or limiting toxicity under gefitinib. However, a carboplatin plus paclitaxel regimen was recommended for patients with PS 0 or 1 and gemcitabine monotherapy for those with PS 2.

Data taken from patients receiving second- and third-line treatment after the failure of gefitinib was collected from the IFCT-0401 trial database. The following data were collected for each line of treatment: PS at treatment initiation, date of first infusion, drugs used according to eight categories (cisplatin, carboplatin, paclitaxel, docetaxel, gemcitabine, vinorelbine, pemetrexed, and other), number of cycles, best response according to five categories (complete response, partial response, stable disease, progression, and nonevaluable), grade 3 and 4 treatment toxicity, and date and reason for treatment failure (progression, toxicity, death, and other).

Patients were followed up using clinical and CT evaluations every 3 months until death. Response was evaluated by CT scan and assessed by investigators according to the WHO criteria, as defined in the original IFCT-0401 protocol.¹⁷ Disease control was defined as no radiological or clinical progression at the time of best response after a minimum of 6 weeks of treatment.

EGFR and K-Ras Mutation Analysis

Overall, 62 formalin-fixed and paraffin-embedded tumor samples were collected from the 88 patients enrolled in the IFCT-0401 trial, with 34 obtained by surgical resection and 28 either by CT-directed core needle biopsy or transbronchial biopsy. Briefly, for each sample, a 3- μ m tissue section was stained with hematoxylin and eosin and examined by light microscopy to determine the presence of tumor cells. After DNA isolation (QIAamp DNA mini kit; Qiagen, Courtaboeuf, France) from three 20- μ m tissue sections, *EGFR* 18–21 and *K-Ras* 2 exons were amplified and sequenced in both directions and analyzed using the SeqScape software, as previously described.²⁴

Statistical Analysis

All eligible patients from the IFCT-0401 trial were enrolled. Characteristics of patients who did or did not receive second-line therapy were compared using the χ^2 or Fisher's exact test. Comparisons were also performed according to therapeutic regimens for patients receiving chemotherapy.

An analysis of efficacy was performed on the overall study population. Overall response rates (ORR) and DCR were given with their 95% exact confidence intervals (CI)

and compared using Fisher's exact test. PFS was defined as the time from treatment initiation to disease progression diagnosed by CT scan or to all-cause death, and was assessed using the Kaplan–Meier method. Cox univariate analysis was undertaken to identify the covariables associated with the risk of progression or death in the second-line setting. The following variables were analyzed: sex (men versus women), age (≤ 70 years versus > 70 years), PS (0–1 versus 2–3), smoking status (smoker versus nonsmoker), stage at diagnosis (I–IIIA versus IIIB–IV), respiratory symptoms score (< 9 versus ≥ 9), DCR at 3 months using gefitinib (control versus noncontrol), *EGFR* and *K-Ras* mutational status (mutated versus wild type), and second-line treatment (pemetrexed versus taxane-based versus gemcitabine-based chemotherapy). Variables with *p* value less than 0.2 were included in a multivariate Cox's regression model and selected using a backward procedure. Two-sided *p* values of less than 0.05 were considered to indicate statistical significance.

RESULTS

Characteristics of Patients Receiving Second-Line Treatment

In total, 47 of the 88 (53%) patients enrolled in the IFCT-0401 trial received second-line treatment after gefitinib failure. Table 2 compares the clinical and molecular characteristics of patients who did (*n* = 47) and did not receive second-line therapy (*n* = 41). Patients eligible for second-line treatment had a lower DCR at 3 months with the initial gefitinib therapy (*p* = 0.005). They were also younger (*p* = 0.007) and had a better PS (*p* = 0.01) at the IFCT-0401 trial inclusion. The frequency of *EGFR* and *K-Ras* mutations did not differ between the two groups.

Description of Treatment and Related Toxicity

Details of the drugs administered as second- and third-line treatment and related toxicities are provided in Table 3. Dose and schedule regimens are presented in the Supplementary Tables (Supplemental Digital Content 1 and 2, <http://links.lww.com/JTO/A315> and <http://links.lww.com/JTO/A316>). Regarding treatment, 43 patients were treated with chemotherapy as second-line treatment, with 38 receiving a platinum-doublet regimen (taxane-based, *n* = 29; gemcitabine-based, *n* = 9) and five receiving monotherapy (gemcitabine, *n* = 3; pemetrexed, *n* = 2). The clinical characteristics and *EGFR* and *K-Ras* mutational status of patients receiving taxane-based or gemcitabine-based chemotherapy were not different (Supplementary Table 1 (Supplemental Digital Content 1, <http://links.lww.com/JTO/A315>). The remaining four patients received a targeted therapy (bortezomib, *n* = 3; erlotinib, *n* = 1). Three cases of grade 3 or 4 toxicity resulted in treatment discontinuation. Two patients experienced a grade 3 sensory neuropathy under a taxane-based regimen, while one patient had a grade 4 febrile neutropenia under a gemcitabine-based regimen. In addition, 11 patients received pemetrexed monotherapy as second-line treatment (*n* = 2) or third-line treatment (*n* = 9), without any grade 3 or 4 limiting toxicity.

TABLE 2. Clinical and Biological Characteristics of Patients Who Did and Did Not Receive Second-Line Treatment After the Failure of Gefitinib

Characteristics	No. of 2nd line treatments	2nd line treatment	<i>p</i>
	n = 41	n = 47	
	n (%)	n (%)	
Sex			
Female	22 (54)	26 (55)	0.876
Male	19 (46)	21 (45)	
Age			
≤70 years	20 (49)	36 (77)	0.0068
>70 years	21 (51)	11 (23)	
Performance status			
0–1	29 (71)	43 (91)	0.0118
2–3	12 (29)	4 (8)	
Smoking			
Smoker	24 (59)	26 (55)	0.7612
Nonsmoker	17 (41)	21 (45)	
Stage at diagnosis			
Stage I–IIIA	5 (12)	10 (21)	0.2584
Stage IIIB–IV	36 (88)	37 (79)	
Histological subtype			
Nonmucinous	10 (24)	11 (23)	0.9732
Mucinous	18 (44)	20 (43)	
Unspecified	13 (32)	16 (34)	
RSS			
≤9	25 (61)	23 (49)	0.1913
>9	14 (33)	23 (49)	
MD	2 (6)	1 (2)	
<i>EGFR</i> status			
Mutated	4 (10)	3 (6)	0.6228
Wild type	22 (54)	27 (57)	
NA	3 (7)	3 (6)	
MD	12 (29)	14 (31)	
<i>K-Ras</i> status			
Mutated	5 (12)	4 (8)	0.4815
Wild type	17 (41)	24 (50)	
NA	7 (17)	5 (11)	
MD	12 (30)	14 (31)	
DCR at 3 mo with gefitinib			
No	21 (51)	39 (83)	0.0053
Yes	17 (42)	8 (17)	
MD	3 (7)	0 (0)	

p value investigated using χ^2 test or Fisher's exact test. RSS, respiratory symptoms score; MD, missing data; *EGFR*, epidermal growth factor receptor; NA, nonamplifiable; DCR, disease control rate.

Effectiveness of Second-Line and Third-Line Treatment

In the second-line setting, ORR with chemotherapy was 21% (9 of 43) (95% CI: 10–36), DCR 56% (95% CI: 40–71), and median PFS 3 months (95% CI: 2.4–4.9). For patients receiving a platinum doublet (n = 38), ORR was 21% (95% CI: 10–37), DCR 55% (95% CI: 38–71), and PFS 2.9

TABLE 3. Description of Drugs Used as Second-Line and Third-Line Therapy After the Failure of Gefitinib and Related Grade 3 or 4 Toxicities

Drugs Used	Second-Line		Third-Line	
	n (%)	Grade 3/4 Toxicity	n (%)	Grade 3/4 Toxicity
Taxane-based chemotherapy	29 (62%)	2 (7%)	6 (19%)	2 (33%)
Carboplatin-paclitaxel	24	2	2	0
Carboplatin-docetaxel	4	0	1	0
Cisplatin-docetaxel	1	0	0	0
Paclitaxel	0	0	2	2
Docetaxel	0	0	1	0
Gemcitabine-based chemotherapy	12 (26%)	1 (8%)	8 (26%)	3 (43%)
Carboplatin-gemcitabine	3	1	2	1
Cisplatin-gemcitabine	6	0	2	1
Gemcitabine	3	0	4	1
Pemetrexed	2 (4%)	0	9 (29%)	0
Others	4 (7%)	0	8 (26%)	0
Bortezomib	3	0	0	0
Erlotinib	1	0	7	0
RAD 001	0	0	1	0

months (95% CI: 2.4–4.4). Data for the ORR, DCR, and PFS after second-line therapy and third-line therapy with taxane-based chemotherapy and gemcitabine-based chemotherapy or pemetrexed monotherapy is provided in Table 4.

Univariate analysis revealed that achieving higher DCR at 3 months with gefitinib ($p = 0.04$) and using taxane-based chemotherapy ($p = 0.02$) or pemetrexed ($p = 0.02$) as second-line treatment were favorable prognostic factors for PFS (Table 5). Multivariate analysis confirmed that the type of second-line treatment was an independent prognostic factor. Kaplan–Meier curves for PFS according to the use of taxane- and gemcitabine-based chemotherapy are illustrated in Figure 1. A waterfall plot of PFS for each patient according to the third-generation drugs used for second- and third-line treatments is shown in Figure 2A, B, respectively. A waterfall plot of individual PFS values for each patient according to NM or M histological subtypes is illustrated in Figure 3. *EGFR* and *K-Ras* mutation status did not impact these results.

DISCUSSION

Little data is available concerning chemotherapy effectiveness in patients with advanced LPA. Only two noncontrolled phase II trials have examined this issue, with disappointing results obtained with the two different schedules of paclitaxel monotherapy. In the European Organisation for Research and Treatment of Cancer (EORTC) 08956 trial,¹⁴ 200 mg/m² of paclitaxel administered every 3 weeks was shown to be well tolerated, but with an ORR of 11%, leading to trial discontinuation. In the SWOG 9714 trial, the observed 14% ORR and 5-month median PFS appeared encouraging,¹³ but the 96-hour infusion schedules of paclitaxel were highly toxic, resulting in six treatment-related deaths. Consequently, this treatment

TABLE 4. Progression-Free Survival, Overall Response Rate, and Disease Response Rate of Second-Line and Third-Line Therapies After Gefitinib Treatment According to the Chemotherapy Regimen

Line	Taxane-Based Chemotherapy	Gemcitabine-Based Chemotherapy	Pemetrexed	Total	<i>p</i>
Second-Line	n = 29	n = 12	n = 2	n = 43	
PFS, mo, (95% CI)	3.3 (2.6–5.7)	2.0 (1.4–2.7)	10 and 32	3.0 (2.4–4.9)	0.0072
ORR, n, % (95% CI)	8, 28% (13–47)	0	1 (NA)	9, 21% (10–36)	0.0734
DCR, n, % (95% CI)	18, 62% (44–80)	4, 33% (10–65)	2 (NA)	24, 56% (40–71)	0.1265
Third-line	n = 6	n = 8	n = 9	n = 22	
PFS, mo, (95% CI)	3.4 (NA)	2.2 (NA)	5.7 (NA)	2.9 (2.4–4.9)	<0.0001
ORR, n, % (95% CI)	2 (NA)	1 (NA)	4 (NA)	7, 30% (13–53)	0.4490
DCR, n, % (95% CI)	4 (NA)	3 (NA)	7 (NA)	14, 61% (39–80)	0.2749

PFS, progression-free survival; DCR, disease control rate; CI, confidence interval; NA, non applicable.

TABLE 5. Univariate and Multivariate Analyses of Progression-Free Survival When Using Second-Line Chemotherapy

Variable	No. of Patients	Univariate Hazard Ratio (95% CI)	<i>p</i>	Multivariate Hazard Ratio (95% CI)	<i>p</i>
Sex					
Male	18	0.52 (0.27–1.01)	0.0549		
Female	25	1			
Age					
>70 yr	11	0.60 (0.29–1.23)	0.1662		
≤70 yr	32	1			
RSS					
<9	19	0.69 (0.37–1.29)	0.2440		
≥9	23	1			
Stage at diagnosis					
I–IIIA	7	1.00 (0.44–2.29)	0.9968		
IIIB–IV	36				
DCR at 3 mo with gefitinib					
Yes	6	0.37 (0.14–0.95)	0.0382		
No	37	1			
EGFR status					
Mutated	3	0.58 (0.17–1.98)	0.3879		
Wild type	24	1			
K-Ras status					
Mutated	22	0.47 (0.13–1.67)	0.2409		
Wild Type	3	1			
Performance status					
2	4	0.66 (0.23–1.86)	0.4267		
0–1	39	1			
Treatment used in second line					
Pemetrexed	2	0.08 (0.01–0.63)	0.0165	0.08 (0.01–0.63)	0.0165
Taxan-based chemotherapy	29	0.44 (0.21–0.90)	0.0249	0.44 (0.21–0.90)	0.0249
Gemcitabine-based chemotherapy	12	1			

option should not be considered for routine use. There is no available data regarding the efficacy of platinum-based or other chemotherapeutic regimens in patients with advanced LPA after first-line EGFR TKI.

In the IFCT-0401 trial, 53% of patients were eligible for second-line therapy. Our results suggest that platinum-based doublet regimens were well tolerated and effective after

front-line gefitinib therapy in advanced LPA. In the second-line setting, platinum-based doublets were administered to 38 out of 47 patients (81%) and had a good safety profile, with only three cases of treatment discontinuation observed due to grade 3 or 4 toxicity (Table 3). Platinum-based doublets exhibited favorable efficacy results, with an ORR of 21%, DCR of 55%, and median PFS of 2.9 months (range, 0.7–17.1 months).

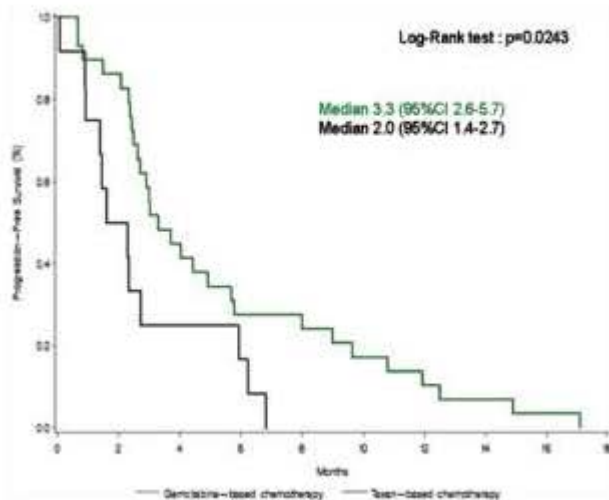


FIGURE 1. Curve for progression-free survival using gemcitabine-based chemotherapy (black line) or taxane-based chemotherapy (green line) as second-line treatment. CI, confidence interval.

Taxane-based (paclitaxel $n = 24$ and docetaxel $n = 5$) and gemcitabine-based ($n = 12$) chemotherapy were the most common regimens used in the second-line setting. However, treatment efficacy appeared to be associated with the type of platinum-based doublet or monotherapy used. The ORR, DCR, and PFS were in favor of taxane- rather than gemcitabine-based chemotherapy (ORR 28% versus 0%, $p = 0.04$; DCR 62% versus 33%, $p = 0.09$; PFS 3.3 versus 2.0 months, $p = 0.02$) (Table 4; Figs. 1 and 2). Second-line pemetrexed monotherapy was administered to two patients, demonstrating notable prolonged responses of 10 and 32 months. In multivariate analyses, the use of taxane-based chemotherapy ($n = 29$) or pemetrexed ($n = 2$) was associated with a better PFS in the second-line setting. However, caution is needed when interpreting PFS, ORR, and DCR because of our retrospective study design and the absence of a central review of radiological responses. In addition, given the small number of patients, our study lacked statistical power.

The molecular rationale behind the lack of gemcitabine efficacy in advanced LPA patients is still unclear. Gemcitabine acts by blocking DNA strand elongation through inhibition of the intracellular ribonucleoside-diphosphate reductase large subunit target encoded by the RRM1 gene. High levels of RRM1 expression were proposed to be predictors of low response rates to gemcitabine in several NSCLC clinical studies.^{25,26} However, differential RRM1 expression types in various histological NSCLC subsets, especially in LPA, were never demonstrated. In contrast, in the IFCT-0401 population, second-line taxane-based chemotherapy was associated with promising ORR (28%) contrary to the ORR observed with first-line paclitaxel monotherapy in the EORTC 08956¹⁴ and SWOG 9714¹³ trials (11% and 14%, respectively). High levels of β III-tubulin isoform expression, which is targeted by tubulin-binding agents, such as taxanes, may be predictive of poor responses to taxane- and platinum-based agents in advanced NSCLC.^{26,27} As the β III-tubulin isoform expression

is unknown with regards to LPA, LPA sensitivity to taxane-based regimens need to be further explored.

The efficacy profile of the multitargeted antifolate pemetrexed may be accounted for by the following rationale. Firstly, its efficacy profile tends to be better than that achieved with gemcitabine-based chemotherapy (Table 5; Fig. 2). Furthermore, pemetrexed efficacy appeared to be preserved when given as third-line therapy (Table 5; Fig. 2) or even fourth-line therapy (data not shown) in patients previously treated with EGFR-TKI and gemcitabine-based or taxane-based regimens. As previously reported,²⁸ two patients experienced successive responses after resuming pemetrexed therapy. This observation suggests that a subset of tumors were highly sensitive to pemetrexed without developing secondary resistance after exposure to pemetrexed. However, the molecular determinants of its efficacy are still unknown.²⁹ In a large phase III trial comparing cisplatin/pemetrexed with cisplatin/gemcitabine combinations as front-line treatment of advanced NSCLC, a significant survival difference was shown in the histological ADC subgroup when using the cisplatin/pemetrexed regimen.³⁰ A lower expression of thymidilate synthase (TS) in ADC versus squamous cell carcinoma may explain this survival difference.^{31,32} Nevertheless, no data is available regarding TS expression in advanced LPA patients. In a preclinical trial, an overexpression of FR- α , a folate receptor with high affinity for pemetrexed, was suggested to be present in LPA tumors as compared with mesothelioma and non-LPA lung ADC.³³ In a recent case report, Garfield et al. described a dramatic response to pemetrexed after the rapid failure of the carboplatin and paclitaxel regimen in a patient with a M histological subtype presenting FR- α overexpression (approximately 30% of tumor cells with 3+ intensity).³⁴

In our study, NM and M histological subtypes were not found to be strong predictors of PFS (Fig. 3), response, or DCR after chemotherapy (Supplementary Table 2, Supplemental Digital Content 2, <http://links.lww.com/JTO/A316>). When considering second- and third-line therapy, an objective response was observed in six of 14 NM tumors (43%) and eight of 29 M tumors (27%). The ORR was 31% (5 of 16) and DCR 56% (9 of 16) in patients with M tumors being treated with taxane-based regimens. As suggested in the SWOG 9714 trial, taxanes proved effective in the M subtype. Finally, *EGFR* and *K-Ras* mutation status did not impact on chemotherapy efficacy.

The observation and hypothesis that taxane-based regimens and pemetrexed allowed for disease control in cases of rapid EGFR-TKI failure were specifically addressed in the IFCT-0504 trial.³⁵ In this trial, advanced LPA patients were randomly assigned to receive either erlotinib or carboplatin and weekly paclitaxel as front-line therapy, with a crossover treatment being administered at 1 month in the case of disease progression and pemetrexed being given as third-line treatment after crossover treatment failure. Essential information is likely to arise from ongoing trials regarding the predictive role of NM or M histological subtypes, *EGFR* and *K-Ras* mutational statuses, and biological factors, such as PAS-diastase resistance staining, β III-tubulin, expression of mutator gene homologue 2, and TS by immunohistochemistry.

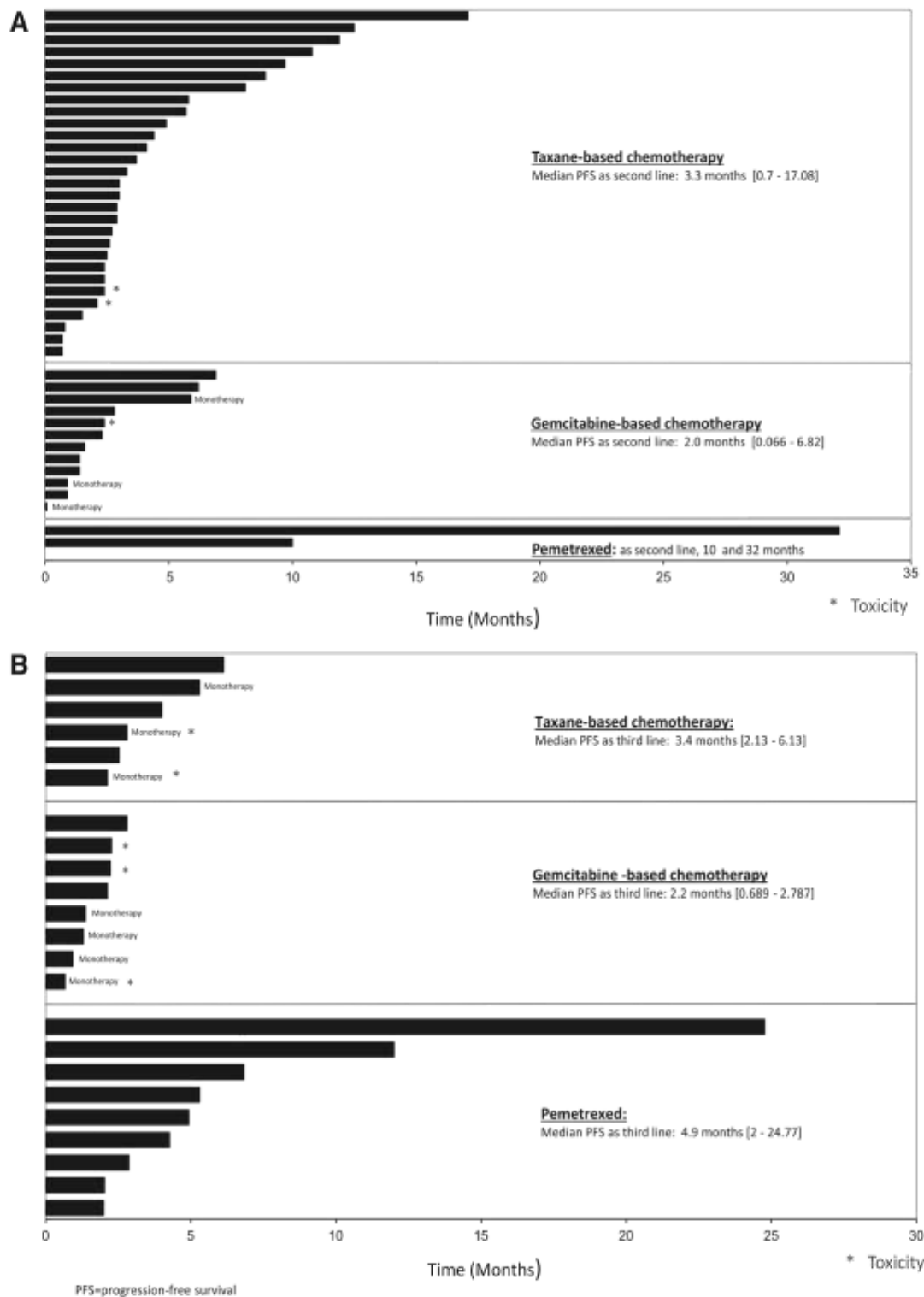


FIGURE 2. Waterfall plot of progression-free survival in second-line therapy (A) and third-line therapy (B) for each patient according to the third-generation chemotherapy regimens used. Median progression-free survival in months and its extent according to each third-generation chemotherapy regimen is shown in the insert box. Patients who discontinued treatment because of toxicity are marked with an asterisk. PFS, progression-free survival.

SWOG 0526³⁶ was the first phase II trial to investigate pemetrexed efficacy when given as first- or second-line therapy in advanced LPA patients, with an analysis of folate markers

(TS, FR- α) and *EGFR* and *K-Ras* mutational status in both tumor specimens and blood samples. The results are still pending.

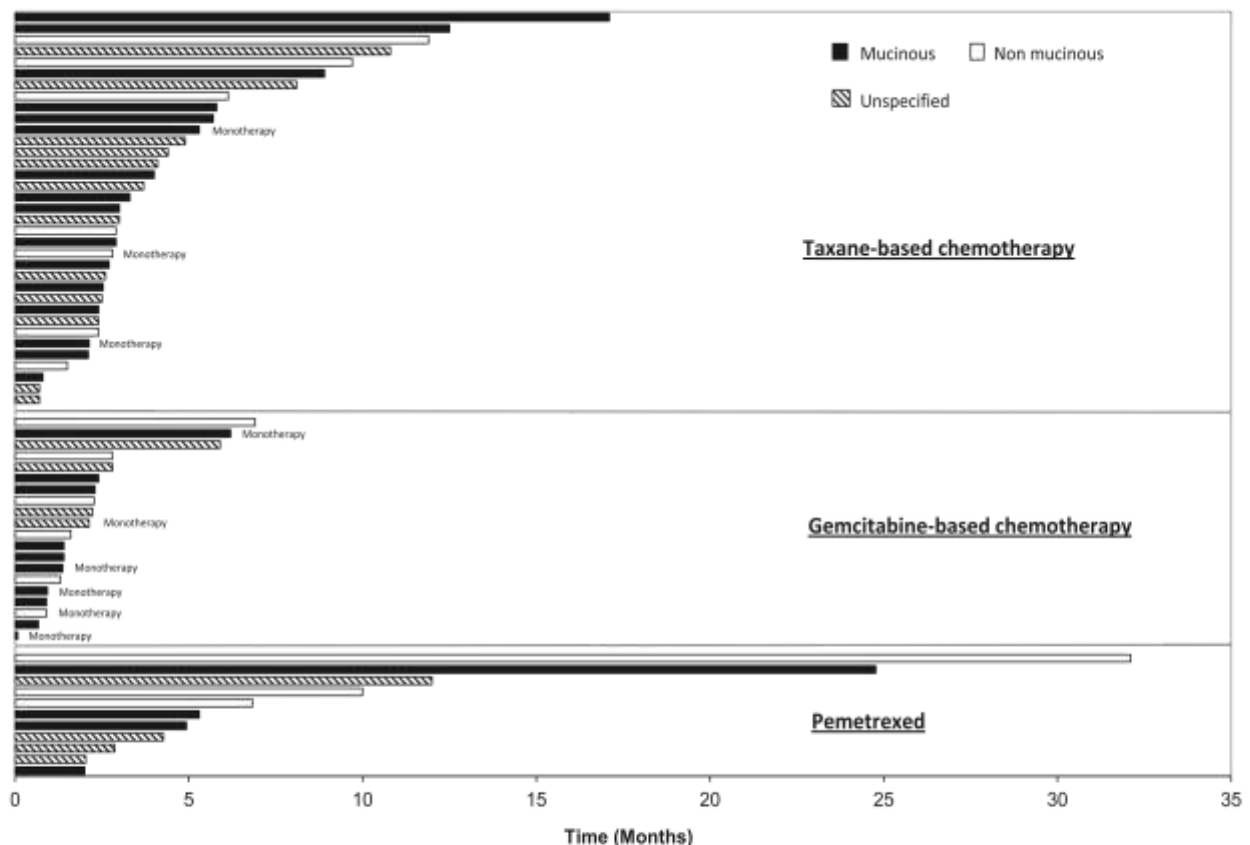


FIGURE 3. Waterfall plot of progression-free survival using second-line or third-line therapies for each patient according to histological subtypes.

In conclusion, our study results suggest that patients with advanced LPA, formerly advanced BAC, may benefit from platinum-based doublet chemotherapy after EGFR-TKI failure. In addition, platinum-taxane doublets or pemetrexed monotherapy as opposed to platinum-gemcitabine regimens appeared to be more promising candidates to be investigated in future trials. Lastly, the results of the phase II SWOG 0526 and IFCT-0504 trials are likely to be instrumental in improving our understanding of the clinical and biological predictors for paclitaxel-carboplatin doublet and pemetrexed activities in advanced LPA, thus facilitating the design of future clinical trials.

ACKNOWLEDGMENTS

Supported by Ligue Nationale Contre le Cancer (LNCC – French league against cancer). The authors thank the patients, their families, and caregivers who made this study possible.

Investigators (by contribution): Elisabeth Quoix (Hôpitaux Universitaires de Strasbourg, Strasbourg), Marie Wislez (AP-HP, Hôpital Tenon, Paris), Denis Moro-Sibilot (CHU, Grenoble), Daniel Coëtmeur (CH, Saint Brieu), Isabelle Monnet (CHI, Créteil), Pierre Mourlanette (Clinique des Cèdres, Cornebarrieu), Jean-François Morère (AP-HP, Hôpital Avicenne, Bobigny), Jean-Charles Soria (Institut Gustave Roussy, Villejuif), Virginie Westeel (CHU, Besançon), Jean-Louis Bizec (CH Bretagne Atlantique, Vannes), Suzanne Bota (CHU, Rouen), Stéphane Chouabe (CH,

Charlesville-Mézières), Eric Dansin (Centre Oscar Lambert, Lille), Gislaine Fraboulet (CH, Pontoise), Radj Gervais (Centre François Baclesse, Caen), Henri Janicot (CHU, Clermont Ferrand), Jacques Le Treut (CH, Aix-en-Provence), Gérard Oliviero (CH, Longjumeau), Eric Pichon (CHU, Tours), Gilles Robinet (CHU, Brest), Pierre-Jean Souquet (Hospices Civiles de Lyon, Lyon-Sud), and Alain Vergnenègre (Hôpital du Cluzeau, Limoges).

REFERENCES

1. Travis WD, Brambilla E, Muller-Hermelink HK, et al. Pathology and genetics of tumors of the lung, pleura, thymus and heart. In *World Health Organisation Classification of Tumours*. Lyon, France. IARC Press 2004.
2. Noguchi M, Morikawa A, Kawasaki M, et al. Small adenocarcinoma of the lung. Histologic characteristics and prognosis. *Cancer* 1995;75:2844–2852.
3. Travis WD, Brambilla E, Noguchi M, et al. International association for the study of lung cancer/american thoracic society/european respiratory society international multidisciplinary classification of lung adenocarcinoma. *J Thorac Oncol* 2011;6:244–285.
4. Wislez M, Massiani MA, Milleron B, et al. Clinical characteristics of pneumonic-type adenocarcinoma of the lung. *Chest* 2003;123:1868–1877.
5. Garfield DH, Cadranel JL, Wislez M, Franklin WA, Hirsch FR. The bronchioloalveolar carcinoma and peripheral adenocarcinoma spectrum of diseases. *J Thorac Oncol* 2006;1:344–359.
6. Kris MG, Giaccone G, Davies A, et al. Systemic therapy of bronchioloalveolar carcinoma: results of the first IASLC/ASCO consensus conference on bronchioloalveolar carcinoma. *J Thorac Oncol* 2006;1(9 Suppl): S32–S36.

7. Breathnach OS, Ishibe N, Williams J, Linnoila RI, Caporaso N, Johnson BE. Clinical features of patients with stage IIIB and IV bronchioloalveolar carcinoma of the lung. *Cancer* 1999;86:1165–1173.
8. Feldman ER, Eagan RT, Schaid DJ. Metastatic bronchioloalveolar carcinoma and metastatic adenocarcinoma of the lung: comparison of clinical manifestations, chemotherapeutic responses, and prognosis. *Mayo Clin Proc* 1992;67:27–32.
9. Heikkilä L. Results of surgical treatment in bronchioloalveolar carcinoma. *Ann Chir Gynaecol* 1986;75:183–191.
10. Sørensen JB, Hirsch FR, Olsen J. The prognostic implication of histopathologic subtyping of pulmonary adenocarcinoma according to the classification of the World Health Organization. An analysis of 259 consecutive patients with advanced disease. *Cancer* 1988;62:361–367.
11. Harpole DH Jr, Herndon JE 2nd, Young WG Jr, Wolfe WG, Sabiston DC Jr. Stage I nonsmall cell lung cancer. A multivariate analysis of treatment methods and patterns of recurrence. *Cancer* 1995;76:787–796.
12. Travis WD, Garg K, Franklin WA, et al. Bronchioloalveolar carcinoma and lung adenocarcinoma: the clinical importance and research relevance of the 2004 World Health Organization pathologic criteria. *J Thorac Oncol* 2006;1(9 Suppl):S13–S19.
13. West HL, Crowley JJ, Vance RB, et al. Southwest Oncology Group. Advanced bronchioloalveolar carcinoma: a phase II trial of paclitaxel by 96-hour infusion (SWOG 9714): a Southwest Oncology Group study. *Ann Oncol* 2005;16:1076–1080.
14. Scagliotti GV, Smit E, Bosquee L, et al. European Organisation for Research and Treatment of Cancer (EORTC) Lung Cancer Group (LCG). A phase II study of paclitaxel in advanced bronchioloalveolar carcinoma (EORTC trial 08956). *Lung Cancer* 2005;50:91–96.
15. West HL, Franklin WA, McCoy J, et al. Gefitinib therapy in advanced bronchioloalveolar carcinoma: Southwest Oncology Group Study S0126. *J Clin Oncol* 2006;24:1807–1813.
16. Miller VA, Riely GJ, Zakowski MF, et al. Molecular characteristics of bronchioloalveolar carcinoma and adenocarcinoma, bronchioloalveolar carcinoma subtype, predict response to erlotinib. *J Clin Oncol* 2008;26:1472–1478.
17. Cadranel J, Quoix E, Baudrin L, et al. IFCT-0401 Trial Group. IFCT-0401 Trial: a phase II study of gefitinib administered as first-line treatment in advanced adenocarcinoma with bronchioloalveolar carcinoma subtype. *J Thorac Oncol* 2009;4:1126–1135.
18. Ramalingam SS, Lee JW, Belani CP, et al. Cetuximab for the treatment of advanced bronchioloalveolar carcinoma (BAC): an Eastern Cooperative Oncology Group phase II study (ECOG 1504). *J Clin Oncol* 2011;29:1709–1714.
19. Garfield DH, Cadranel J, West HL. Bronchioloalveolar carcinoma: the case for two diseases. *Clin Lung Cancer* 2008;9:24–29.
20. West HL, Garfield DH. Bronchioloalveolar carcinoma: not as easy as “BAC”. *J Thorac Oncol* 2009;4:1047–1048.
21. Sakuma Y, Matsukuma S, Yoshihara M, et al. Distinctive evaluation of nonmucinous and mucinous subtypes of bronchioloalveolar carcinomas in EGFR and K-ras gene-mutation analyses for Japanese lung adenocarcinomas: confirmation of the correlations with histologic subtypes and gene mutations. *Am J Clin Pathol* 2007;128:100–108.
22. Finberg KE, Sequist LV, Joshi VA, et al. Mucinous differentiation correlates with absence of EGFR mutation and presence of KRAS mutation in lung adenocarcinomas with bronchioloalveolar features. *J Mol Diagn* 2007;9:320–326.
23. Hata A, Katakami N, Fujita S, et al. Frequency of EGFR and KRAS mutations in Japanese patients with lung adenocarcinoma with features of the mucinous subtype of bronchioloalveolar carcinoma. *J Thorac Oncol* 2010;5:1197–1200.
24. Wislez M, Antoine M, Baudrin L, et al. Non-mucinous and mucinous subtypes of adenocarcinoma with bronchioloalveolar carcinoma features differ by biomarker expression and in the response to gefitinib. *Lung Cancer* 2010;68:185–191.
25. Boukovicinas I, Papadaki C, Mendez P, et al. Tumor BRCA1, RRM1 and RRM2 mRNA expression levels and clinical response to first-line gemcitabine plus docetaxel in non-small-cell lung cancer patients. *PLoS ONE* 2008;3:e3695.
26. Chang A. Chemotherapy, chemoresistance and the changing treatment landscape for NSCLC. *Lung Cancer* 2011;71:3–10.
27. Gan PP, Pasquier E, Kavallaris M. Class III beta-tubulin mediates sensitivity to chemotherapeutic drugs in non small cell lung cancer. *Cancer Res* 2007;67:9356–9363.
28. Duruisseaux M, Cadranel J, Biron E, Pérol M, Guérin JC, Arpin D. Major and prolonged response to pemetrexed in two cases of lung adenocarcinoma with bronchioloalveolar carcinoma features. *Lung Cancer* 2009;65:385–387.
29. Duruisseaux M, Cadranel J, Pérol M, Arpin D. The role of pemetrexed in lung adenocarcinoma, mixed subtype with bronchioloalveolar carcinoma features. *Curr Drug Targets* 2010;11:74–77.
30. Scagliotti GV, Parikh P, von Pawel J, et al. Phase III study comparing cisplatin plus gemcitabine with cisplatin plus pemetrexed in chemotherapy-naïve patients with advanced-stage non-small-cell lung cancer. *J Clin Oncol* 2008;26:3543–3551.
31. Ceppi P, Volante M, Saviozzi S, et al. Squamous cell carcinoma of the lung compared with other histotypes shows higher messenger RNA and protein levels for thymidylate synthase. *Cancer* 2006;107:1589–1596.
32. Sun JM, Han J, Ahn JS, Park K, Ahn MJ. Significance of thymidylate synthase and thyroid transcription factor 1 expression in patients with nonsquamous non-small cell lung cancer treated with pemetrexed-based chemotherapy. *J Thorac Oncol* 2011;6:1392–1399.
33. Tracy S, Johnson EB, Jänne AP. In-vitro effects of pemetrexed on bronchioloalveolar and adenocarcinoma of the lung. *Proc Amer Assoc Cancer Res Meeting* 2005; abstract #5864.
34. Garfield DH, Franklin W. Dramatic response to pemetrexed in a patient with pneumonic-type mucinous bronchioloalveolar carcinoma. *J Thorac Oncol* 2011;6:397–398.
35. Cadranel J. Therapeutic strategy in advanced bronchioloalveolar carcinoma. Available at: <http://clinicaltrials.gov/show/NCT00384826>. Accessed September 26, 2008.
36. Ho C, Ross H, Davies A. Phase II trial of pemetrexed in patients with selected stage IIIB/IV bronchioloalveolar carcinoma. *Clin Lung Cancer* 2006;8:220–222.

CD74-*NRG1* : un nouveau gène de fusion dans les adénocarcinomes pulmonaires caractérisant les adénocarcinomes mucineux invasifs

Pour citer cet article : Duruisseaux M, Wislez M. *CD74-NRG1* : un nouveau gène de fusion dans les adénocarcinomes pulmonaires caractérisant les adénocarcinomes mucineux invasifs. *Bull Cancer* 2014 ; 101 : 529-30.
doi : 10.1684/bdc.2014.1982.

Les adénocarcinomes pulmonaires du non-fumeur présentent fréquemment des altérations oncogéniques de gènes codant des kinases, rendant possible des traitements efficaces par inhibiteurs de kinases. Ce modèle est illustré par le succès des inhibiteurs des kinases de l'EGFR ou ERBB1 chez les patients avec mutation activatrice du gène *EGFR* et du crizotinib lorsqu'il existe un réarrangement du gène *ALK* ou *ROS1*.

Les auteurs de l'article « *CD74-NRG1* fusions in lung adenocarcinoma », paru dans *Cancer Discovery* ont proposé de rechercher de nouvelles altérations oncogéniques en concentrant leurs efforts sur une cohorte de 25 adénocarcinomes pulmonaires de non-fumeurs, sauvage pour *KRAS* et *EGFR* [1]. Une nouvelle méthode d'analyse des données dédiée à la recherche de réarrangement « driver », combinant l'étude du nombre de copies de gènes et du transcriptome, a permis de découvrir un nouveau transcrite de fusion chez une patiente. Celui-ci correspond à la fusion des six premiers exons de *CD74* avec la région codant le domaine EGF-like de l'isoforme III-β3 de *NRG1*, gène codant la Neureguline 1 (*NRG1*). *CD74* est déjà connu pour être le « partenaire » du réarrangement de *ROS1* et l'isoforme *NRG1* III-β3 est un ligand pour *ERBB2/ERBB3*, via son domaine EGF-like.

Ce transcrite de fusion a ensuite été recherché par RT-PCR et confirmé par FISH dans une cohorte de 102 adénocarcinomes de non-fumeurs négatifs pour les anomalies oncogéniques connues (*EGFR*, *KRAS*, *BRAF*, *ERBB2*, *ALK*, *ROS*, *RET*). Il a été retrouvé dans quatre prélèvements, tous du type mucineux invasif et chez des femmes non fumeuses. Enfin, sur une autre cohorte de quinze adénocarcinomes mucineux invasifs, quatre (27 %) présentaient le gène de fusion *CD74-NRG1* et six (40 %) une mutation *KRAS*.

In vitro, des expériences de transduction du gène de fusion dans des lignées cellulaires démontrent que *CD74* code la portion intra- et transmembranaire de la protéine de fusion et que *NRG1* III-β3 code un domaine EGF-like extracellulaire qui est uniquement exposé à la surface cellulaire sans être sécrété.

Sur le plan mécanistique, les auteurs suggèrent que la protéine de fusion *CD74-NRG1* s'hétérodimérise avec *ERBB2/ERBB3* via son domaine EGF-like extracellulaire, activant ainsi la phosphorylation de *ERBB2/ERBB3* puis l'activation de la voie *PIK3-AKT*. *In vivo*, la présence du réarrangement *CD74-NRG1* est fortement corrélée à l'expression et la phosphorylation de *ERBB2* et *ERBB3*, suggérant que *CD74-NRG1* puisse s'hétérodimériser avec ces deux récepteurs. *In vitro*, l'expression ectopique de *CD74-NRG1* au sein de lignée cellulaire exprimant *ERBB2* et *ERBB3* conduit à une augmentation de la quantité de p-*ERBB2* et p-*ERBB3* mais également de p-*AKT* et p-*S6K*. Cela n'est pas constaté si le transcrite transduit est amputé du domaine EGF-like extracellulaire de *NRG1* III-β3, confirmant que *CD74-NRG1* s'hétérodimérise avec *ERBB2* et *ERBB3* via son domaine EGF-like extracellulaire. Enfin, l'expression ectopique de *CD74-NRG1* au sein d'une lignée cellulaire conduit à une augmentation de la capacité de formation de colonie en milieu agar.

L'équipe de Roman Thomas met ici en évidence un nouveau réarrangement en utilisant deux approches originales. Les auteurs ont d'abord « enrichi » la population étudiée en tumeurs présentant potentiellement une nouvelle anomalie moléculaire oncogénique. La cohorte initiale ($n = 25$) ne comprenait que des tumeurs de non-fumeurs et sauvages pour *KRAS* et *EGFR*. Une fois le réarrangement *CD74-NRG1* découvert dans cet échantillon, il a été

Michaël Duruisseaux^{1,3},
Marie Wislez^{2,3}
¹ CHU de Grenoble,
Pôle thorax et vaisseaux,
Service de pneumologie,
Unité d'oncologie
thoracique, Boulevard
de la Chantourne,
38700 La Tronche, France
² AP-HP, Hôpital Tenon,
Service de pneumologie,
4, rue de la Chine,
75020 Paris, France
³ GRC-UPMC 04 Therascan,
France
<marie.wislez@trn.aphp.fr>

recherché dans une cohorte plus importante ($n=102$) de tumeurs de non-fumeurs et sauvages pour toutes les altérations oncogéniques connues, augmentant ainsi la probabilité de détecter des tumeurs *CD74-NRG1* positives. Avec cette méthode relativement économe en prélèvement, une nouvelle altération oncogénique rare est décrite, pouvant concerner 1,7 % des adénocarcinomes pulmonaires selon les auteurs. Sur le plan technologique, une nouvelle méthode d'analyse des données corrèle l'étude du nombre de copies de gène et le transcriptome en se concentrant sur des régions du génome tumoral susceptibles d'être des zones de réarrangement ou « break point ». Les détails de cette méthode seront publiés dans un autre article.

Finalement, cet article apporte une avancée majeure dans la connaissance de la biologie des adénocarcinomes mucineux invasifs, correspondant dans la nouvelle classification aux anciens carcinomes bronchiolo-alvéolaires de type mucineux. Cette entité rare se distingue des autres

adénocarcinomes pulmonaires par une atteinte pulmonaire souvent multifocale au diagnostic, et une histoire naturelle très particulière avec une progression souvent exclusivement pulmonaire aboutissant au décès par insuffisance respiratoire. *CD74-NRG1* n'a été observé que dans ce type histologique, ouvrant de nouvelles perspectives de recherche et de traitement dans cette maladie pour l'instant orpheline de traitement innovant, notamment par l'inhibition des voies ERBB2/ERBB3.

Liens d'intérêts : les auteurs déclarent ne pas avoir de lien d'intérêt en rapport avec cet article.

Référence

1. Fernandez-Cuesta L, Plenker D, Osada H, et al. *CD74-NRG1* fusions in lung adenocarcinoma. *Cancer Discov* 2014 ; 4 : 415-22.

10.3. Travaux du laboratoire auxquels le doctorant a collaboré

Thibault Vieira, Michaël Duruisseaux, Anne Marie Ruppert, Jacques Cadranel, Martine Antoine, Marie Wislez. Pulmonary sarcomatoid carcinoma. *Bulletin du cancer*. 2012;99(10):995-1001.

Etienne Giroux Leprieur, Martine Antoine, Thibault Vieira, Michaël Duruisseaux, Virginie Poulot, Nathalie Rabbe, Laure Belmont, Valérie Gounant, Armelle Lavolé, Anne Marie Ruppert, Jacques Cadranel, Marie Wislez. Clinical and molecular features in patients with advanced non-small-cell lung carcinoma refractory to first-line platinum-based chemotherapy. *Lung Cancer*. 2013;79(2):167-172.

Thibault Vieira, Nicolas Girard, Myriam Ung, Isabelle Monnet, Aurélie Cazes, Pierre Bonnette, Michaël Duruisseaux, Julien Mazières, Martine Antoine, Jacques Cadranel, Marie Wislez. Efficacy of first-line chemotherapy in patients with advanced lung sarcomatoid carcinoma. *Journal of Thoracic Oncology*. 2013;8(12):1574-1577.

Nathalie Rozensztajn, Anne Marie Ruppert, Armelle Lavolé, Etienne Giroux Leprieur, Michaël Duruisseaux, Thibault Vieira, Nathalie Rabbe, Roger Lacave, Martine Antoine, Jacques Cadranel, Marie Wislez. Factors associated with early progression of non-small-cell lung cancer treated by epidermal growth factor receptor tyrosine-kinase inhibitors. *Cancer Medecine*. 2014;3(1):61-69.

Thibault Vieira, Martine Antoine, Anne Marie Ruppert, Vincent Fallet, Michaël Duruisseaux, Etienne Giroux Leprieur, Virginie Poulot, Nathalie Rabbe, Laurène Schlick, Michèle Beau-Faller, Roger Lacave, Armelle Lavolé, Jacques Cadranel, Marie Wislez. Blood vessel invasion is a major feature and factor of poor prognosis in sarcomatoid carcinoma of the lung. *Lung Cancer*. 2014;85(2):276-281.

Virginie Hervé, Nathalie Rabbe, Guillemineault Laurent, Flora Paul, Laurène Schlick, Nathalie Azzopardi, Michaël Duruisseaux, Dominique Fouquet, Julien Montharu, Françoise Redini, Guillaume Paintaud, Etienne Lemarié, Jacques Cadranel, Marie Wislez, Nathalie Heuzé-Vourc'h. VEGF neutralizing aerosol therapy in primary pulmonary adenocarcinoma with K-ras activating-mutations. *Mabs*. 2014;6(6):1638-1648.

11. Tables des figures

- Figure 1 :** Coupe scannographique en fenêtre parenchymateuse correspondant à un aspect typique d'adénocarcinome à forme pulmonique anciennement nommé bronchioloalvéolaire.....16
- Figure 2 :** Représentation schématique des voies de signalisation intra-cellulaires activées par CXCR3-A et -B et des conséquences sur les capacités cellulaires.....87
- Figure 3 :** Rôle de CXCL10 et CXCL9 dans l'immunosurveillance anti-tumorale.....90

12. Tables des tableaux

- Tableau 1 :** Survie des adénocarcinomes lépidiques prédominant et des adénocarcinomes mucineux invasifs.....13
- Tableau 2 :** Comparaison de la fréquence de mutation *EGFR* et *KRAS* entre adénocarcinomes lépidiques prédominant (ALP) et adénocarcinomes mucineux invasifs (AMI).....20
- Tableau 3 :** Résultats des essais thérapeutiques de phase II au cours des adénocarcinomes lépidiques avancés.....24
- Tableau 4 :** Expression et activités biologiques des isoformes de CXCR3 dans les différents types cellulaires85

RESUME

Les adénocarcinomes lépidiques prédominant (ALP) sont une entité originale sur le plan histologique, clinique et biologique parmi les adénocarcinomes pulmonaires. Il s'agit de tumeurs non-mucineuses mais il existe un variant mucineux, l'adénocarcinome mucineux invasif (AMI), caractérisé par un plus mauvais pronostic et l'absence de traitement efficace dans les formes avancées. L'objectif de ce travail était d'étudier les différences moléculaires distinguant ALP et AMI et d'en dégager les implications biologiques. Après avoir détaillé les caractéristiques cliniques et les altérations oncogéniques d'une cohorte d'ALP et d'AMI, nous avons exploité les banques de prélèvements issus de cette cohorte. Une étude de l'expression en immunohistochimie des mucines MUC1, 2, 5B, 5AC et 6 au sein des pièces opératoires de 27 ALP et 27 AMI montrait un profil d'expression spécifique entre ALP et AMI. L'expression de MUC1 était associée aux ALP, celle de MUC5AC, 5B et 6 aux AMI. L'expression de MUC1 était associée aux mutations *EGFR* et MUC5B et 5AC aux mutations *KRAS*. Un réarrangement *NRG1* a été détecté par FISH dans 1 AMI sur 25. La chimiokine CXCL10 était surexprimée dans les surnageants de lavages broncho-alvéolaires (LBA) de patients avec AMI (n=38) comparés aux ALP (n=25), et cette surexpression était de mauvais pronostic. La voie cytokine/récepteur CXCL10/CXCR3-A était surexprimée dans les AMI, faisait la promotion de la migration des cellules tumorales mucineuses et gouvernait l'expression tumorale de VEGF. Le VEGF issu du LBA des patients était à l'origine *in vitro* d'une augmentation significative de la formation de tubes vasculaires inhibée par l'anti-VEGF bevacizumab. Le ciblage de CXCL10/CXCR3-A et du VEGF pourraient être des options thérapeutiques dans les AMI. Ces résultats permettent d'affiner les connaissances biologiques des ALP et des AMI et dégagent des voies de recherche originales qui pourraient amener au développement de nouveaux traitements.

Mots-clés : Cancer ; Poumon ; Lepidique ; Mucine ; Cytokine ; CXCL10 ; CXCR3 ; NRG1

SUMMARY

Lepidic predominant adenocarcinoma (LPA) represents an original entity in terms of histological, clinical and biological characteristics among adenocarcinomas of the lung. While LPA is typically a non-mucinous adenocarcinoma, a mucinous variant does exist, termed invasive mucinous adenocarcinoma (IMA), associated with a worse prognosis and a lack of effective treatment in advanced diseases. This work sought to study molecular differences between LPA and IMA, and explore their biological meanings. A cohort of LPA and AMI has been studied in regard of clinical characteristics and oncogenic drivers and samples from this cohort were exploited. An immunohistochemical study of expression of mucins MUC1, 2, 5B, 5AC and 6 in surgical samples of 27 LPA and 27 IMA showed different profile of expression between LPA and IMA. MUC1 expression was associated to MUC1 and MUC5AC, 5B and 6 to IMA. MUC1 was associated to *EGFR* mutations and MUC5B and 5AC to *KRAS* mutations. One *NRG1* rearrangement was detected by FISH in one in 25 IMA. The CXCL10 chemokine was overexpressed in bronchoalveolar lavage fluid (BALF) supernatants of IMA (n=38) compared to LPA (n=25). This overexpression was linked to worse prognosis. The cytokine/receptor axis CXCL10/CXCR3-A was overexpressed in IMA and promoted migration of mucinous tumoral cells and driven tumoral expression of VEGF. VEGF from BALF of patients significantly enhanced human lung endothelial tubes formation *in vitro* which was inhibited by anti-VEGF bevacizumab. CXCL10/CXCR3 and VEGF could present valuable therapeutic targets in IMA. These results improve knowledges in biology of LPA and AMI and identify new lines of research which could lead to development of new therapies.

Key words: Cancer ; Lung ; Lepidic ; Mucin ; Cytokine ; CXCL10 ; CXCR3 ; NRG1