



HAL
open science

Mechanisms of delayed wound healing in various models of human diseases

van Tuan Nguyen

► **To cite this version:**

van Tuan Nguyen. Mechanisms of delayed wound healing in various models of human diseases. Human health and pathology. Université Pierre et Marie Curie - Paris VI, 2015. English. NNT : 2015PA066280 . tel-01285303

HAL Id: tel-01285303

<https://theses.hal.science/tel-01285303>

Submitted on 9 Mar 2016

HAL is a multi-disciplinary open access archive for the deposit and dissemination of scientific research documents, whether they are published or not. The documents may come from teaching and research institutions in France or abroad, or from public or private research centers.

L'archive ouverte pluridisciplinaire **HAL**, est destinée au dépôt et à la diffusion de documents scientifiques de niveau recherche, publiés ou non, émanant des établissements d'enseignement et de recherche français ou étrangers, des laboratoires publics ou privés.

PIERRE AND MARIE CURIE UNIVERSITY

Graduate school of Physiology, Physiopathology and Therapeutics

**Mechanisms of delayed wound healing in various models
of human diseases**

Presented by

Van Tuan NGUYEN

PhD Thesis

Specialty: Physiology, Physiopathology and Therapeutics

Directed by Prof. Sélim ARACTINGI

Presented on 7th September 2015

In front of the jury consist of:

Pr Stephane Hatem	President
Dr Kiarash Khosrotehrani	Reviewer
Dr Michel Simon	Reviewer
Dr Charles Durand	Examinator
Dr Nicolette Farman	Examinator
Pr Sélim Aractingi	Thesis Supervisor

Acknowledgment:

I am happy to say a thank to the jury members for taking the time to evaluate my thesis. I especially thank to the reviewers have reviewed my manuscript and helping me to improve it through their remarks and proposals.

I acknowledge Vietnamese government for supporting me the scholarship during 3 years.

I also acknowledge FRM for giving me the funding for the important fourth year of thesis.

I would like say a huge thank to my supervisor, Sélim for supporting and taking care my life during four years in Paris. I always see you as my father.

I would like to say a big thank to my advisor, Nicolette who always beside me during four years. I particularly thank you for your huge help and putting up me during the months of writing the manuscript and thesis. Thank you for the world formed research, for giving an excellent job and for sending me your knowledge.

Karine Raymond, many thanks for teaching me techniques and giving me useful suggestions and comment. But also for the long hours of discussions during manipulations as well as motivation and support you have given me during these years. Especially, I would acknowledge you for your important help in applying the funding for the fourth year of my thesis.

Happy to thank Frederic have mounted the MR and wound healing project and help us in our reflections. Thanks to members from your lab: Basile, Soumaya, Christian.

I would also like to send a thank to my friend, Dany who has always offered extremely useful suggestions and comment for my work.

Thanks to Michele, Marie-Jo and Aude forever taking the time to help me.

Thanks to my colleagues from the laboratory both past and present: Sarah, Thomas, Geoffroy, Zhe, Mathieu, Romain, for taking the time to give me a help for discussion and manipulations in the laboratory.

I thank the friends, colleagues in Saint Antoine Research Center for the help you have given me at all levels.

Thanks to my friends in UEVF for the funny time.

Thanks to all my friends and family for your support during these four years.

Finally, I especially thank my wife, Lĩnh for take caring all of house work and never complain each time I leave home from early and come back very late at night.

Thanks to my daughter, Thảo Anh who always happy with us in our most difficult time.

**Mechanisms of delayed wound healing
in various models of human diseases**

Abstract :

Impaired wound healing is a major unsolved clinical problem in aging, diabetes, sickle cell disease (SCD), glucocorticoid (GC) therapy or Cushing syndrome.

First, we investigated the mechanisms underlying SCD ulcers, using SAD transgenic mouse model with mutated human beta globin. Old SAD mice displayed delayed healing correlated with the severity of anemia and hemolysis, as in human SCD, related to impaired cutaneous angiogenesis and poor endothelial progenitor cell (EPC) mobilization from the bone marrow. CXCL12 secretion by keratinocytes and inflammatory cells in SAD wounds was low. Noticeably, local wound therapy with EPCs or with recombinant CXCL12 restored wound angiogenesis and healing in old SAD mice.

Second, we questioned the role of mineralocorticoid receptor (MR) in wound healing and proposed that MR blockade could improve reepithelialization in pathological situations (GC-treated skin, diabetic mouse models); I also participated to the demonstration that MR blockade limits GC-induced epidermal atrophy in human skin. We used skin explants from mouse and humans, full thickness skin wounds on the back of mice, and analyzed wound closure after skin biopsy in healthy volunteers pre-treated with GC, as a post-hoc study of the SPIREPI clinical trial. We found that MR blockers can rescue the pathological delayed wound healing while they did not modify wound closure in normal condition. We show that the improvement of GC-induced wound healing delay by MR blockade involves restoration of keratinocyte proliferation and down-regulation of the epithelial sodium channel. These results suggest an important and entirely novel role for MR in to improve delayed wound closure.

Résumé:

Le retard de cicatrisation (RETCIC) est un problème clinique majeur, touchant les gens âgés, les diabétiques, drépanocytaires (DR), ou traités par les glucocorticoïdes (GC). Nous avons abordé les mécanismes des ulcères DR dans un modèle transgénique ayant un gène beta globine humain muté (SAD). Les souris SAD âgées ont un RETCIC corrélé au degré d'anémie et d'hémolyse, comme dans la DR humaine ; le RETCIC est lié à l'altération de l'angiogenèse cutanée et un faible recrutement de cellules endothéliales progénitrices (EPC) depuis la moelle. La sécrétion de CXCL12 dans la plaie par les kératinocytes et les cellules inflammatoires est diminuée. Fait notable, le traitement local de la plaie par des EPC ou du CXCL12 recombinant restaurent l'angiogenèse et une cicatrisation des souris SAD âgées.

Nous avons ensuite abordé le rôle du récepteur minéralocorticoïde dans la cicatrisation cutanée, et proposé ses antagonistes (MRA) pour améliorer le RETCIC en pathologie (traitement local GC, diabète murin); j'ai aussi participé à la démonstration de l'effet bénéfique des MRA sur l'atrophie épidermique GC-induite chez l'homme. A l'aide d'explants de peau murine et humaine, de plaies cutanées créées sur le dos de souris, et par l'analyse de la cicatrisation de biopsies chez le volontaire sain après traitement GC (étude post-hoc de l'essai SPIREPI), nous montrons que les MRA améliorent le RETCIC pathologique, et n'affectent pas la peau saine normale. Nous avons montré que l'effet bénéfique des MRA topiques implique une augmentation de la prolifération kératinocytaire et le canal sodium épithélial. Ces résultats montrent un rôle inédit et important du MR cutané dans la cicatrisation.

Key words:

Skin

Wound healing

Sickle cell disease

Leg ulcers

SAD

Angiogenesis

Endothelial progenitor cells

Inflammation

Proliferation

Re-epithelialization

Mineralocorticoid receptor

Glucocorticoid

Aldosterone

Antagonist

CXCL12

Laboratory attachment:

All works of my thesis have been done at the "Team of progenitors and endothelial cells during and after pregnancy", led by Professor Sélim Aractingi.

Address:

Laboratory of progenitors and endothelial cells during and after pregnancy

Saint Antoine research center, UPMC/INSERM UMR S 938

27 rue de Chaligny

75012 Paris

FRANCE

CONTENTS

CHAPTER 1 - INTRODUCTION.....	10
<i>I - A - Mechanisms implicated in normal skin wound healing</i>	<i>11</i>
<i>I - B - Endothelial progenitor cell- a key actor of angiogenesis and wound repair</i>	<i>28</i>
<i>I - C - Re-epithelialization: role of nuclear receptors and ligands</i>	<i>33</i>
<i>I - D - Abnormal wound healing in human and/or mice context.....</i>	<i>35</i>
II - AIMS OF WORK	39
CHAPTER 2 - DELAYED WOUND HEALING IN MURINE MODEL OF SICKLE CELL DISEASE	40
I - INTRODUCTION	40
<i>I - A - Sickle cell disease.....</i>	<i>40</i>
<i>I - B - Sickle cell Leg ulcers</i>	<i>45</i>
<i>I - C - Murine model of sickle cell disease</i>	<i>46</i>
II - ARTICLE 1: SUBMITTED	48
CHAPTER 3 - ROLE OF MINERALOCORTICOID RECEPTOR IN SKIN WOUND HEALING	83
I - INTRODUCTION: BIOLOGY OF MINERALOCORTICOID RECEPTOR	83
<i>I - A - Structure of mineralocorticoid receptor.....</i>	<i>84</i>
<i>I - B - The ligands of mineralocorticoid receptor.....</i>	<i>85</i>
<i>I - C - Mineralocorticoid receptor specificity.....</i>	<i>86</i>
<i>I - D - Mineralocorticoid receptor and pathology of skin</i>	<i>88</i>
II - ARTICLE 2:	91
III - ARTICLE 3:	121
GENERAL DISCUSSION, CONCLUSIONS AND PERSPECTIVES	132
CHAPTER 4 - REFERENCES.....	146

CHAPTER 1 - INTRODUCTION

The primary function of the skin is to serve as a protective barrier against the environment. Loss of the integrity of large portions of this barrier -as a result of injury or disease- may lead to major complications or even death. The ability of the skin to repair any wound is therefore a main skin “duty” in order to keep a proper homeostasis. Wound healing represents therefore a major organ functional ability of the skin in humans as well as in mammals.

Skin repair is a multistep complex biological process that requires a close interaction of multiple cell types in a highly coordinated program. It involves hemostasis, inflammation, angiogenesis, migration and proliferation of progenitor cells, as well as production and remodeling of the extracellular matrix (ECM). As a peculiar example recent studies have allowed a better understanding of the intervention of distant stem cells derived from distant tissues such as bone marrow in order to allow cutaneous healing.

Abnormalities of wound healing are very common. These lead mainly to impaired repair that itself provokes chronic ulcers. The causes of such healing delays are multiple. During the work of this PhD, we chose to focus on the mechanisms implicated in a severe circumstance of wound healing delay, namely sickle cell disease. We also extended my work toward the implication of a new pathway implicated in cutaneous repair, namely mineralocorticoid receptor (MR) activation. Such pathway may play a beneficial role in important disease with healing delay such as diabetes and skin adverse reactions to glucocorticoid treatments.

I - A - Mechanisms implicated in normal skin wound healing

The normal mammalian response to cutaneous injury occurs in overlapping stages: detersion, inflammation, new tissue formation, and remodeling (Singer and Clark 1999; Gurtner et al. 2008). Full healing is achieved only after a long lag time that may reach one year in humans. Many cellular and molecular players are involved in well-orchestrated dynamic and very complex processes. These phenomena include phagocytosis, production of enzymes and reactive oxygen species, cell proliferation, cell apoptosis, and migration that occur at different time points. Recent discoveries have led to many attempts to cell and stem cell therapies for pathological wound healing (Lau et al. 2009). The main achievements concerning the four phases of cutaneous wound healing will be summarized here.

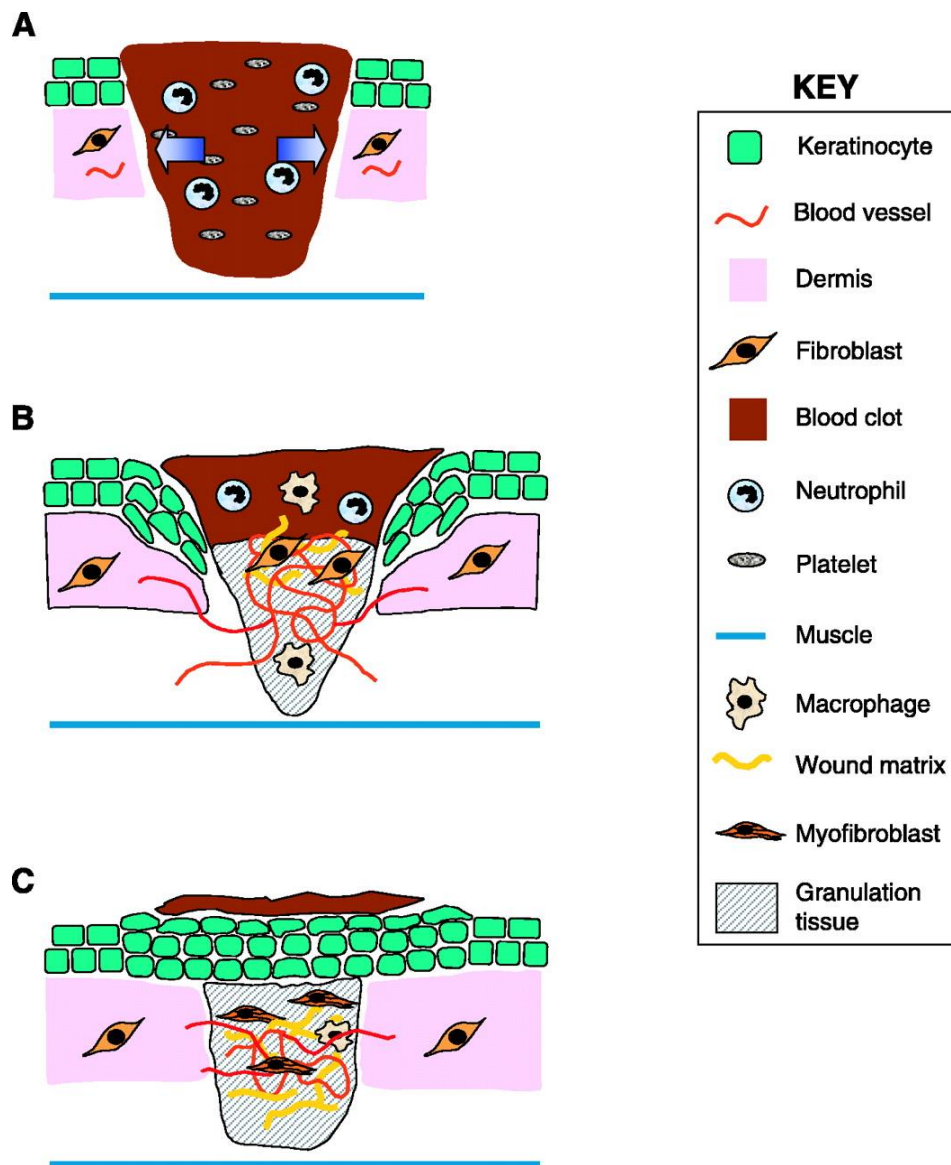


Figure 1. Stages of wound healing process.

Schematic representation of the three different phases of wound repair (Werner and Grose 2003).

A- Inflammatory phase: 12–24 h after injury the wounded area is filled with a blood clot. Neutrophils have invaded into the clot.

B- New tissue formation: at days 3–7 after injury, the majority of neutrophils have undergone apoptosis. Instead, macrophages are abundant in the wound tissue at this stage of repair. Endothelial cells migrate into the clot; they proliferate and form new blood vessels. Fibroblasts migrate into the wound tissue, where they proliferate and deposit extracellular matrix. The new tissue is called granulation tissue.

Keratinocytes proliferate at the wound edge and migrate down the injured dermis and above the provisional matrix.

C- Tissue remodeling: 1–2 weeks after injury the wound is completely filled with granulation tissue. Fibroblasts have transformed into myofibroblasts, leading to wound contraction and collagen deposition. The wound is completely covered with a neo-epidermis.

I - A - 1 - Inflammatory phase

This stage corresponds to the classical early stage of wound repair although all phases are redundant (Figure 2). Components of the coagulation cascade, inflammatory pathways and immune system are needed to prevent ongoing blood and fluid losses, to remove dead and dying tissues and to prevent infection. This stage involves hemostasis first, and mechanisms of inflammatory response as the second step.

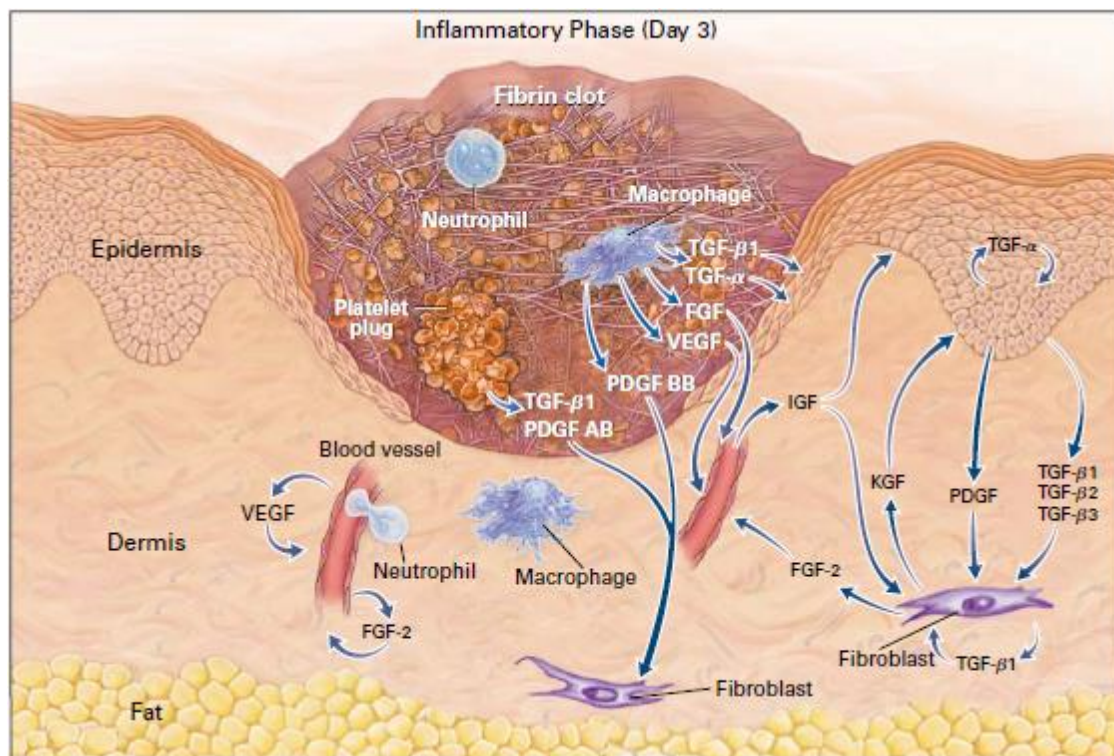


Figure 2. The first stage of wound healing – inflammation.

Schematic representation of main cellular actors involved in wound inflammation (Singer and Clark 1999).

1- Hemostasis

Skin injury causes vascular disruption and extravasation of blood constituents. The first step of wound healing is thus hemostasis to stop the bleeding. During this initial phase, three steps occur in a rapid sequence. Vascular spasm is the first response as the blood vessels constrict in the earlier minutes to prevent ongoing blood and fluid losses. In the second step, the activated platelets and endothelial cells from existing but altered dermal capillaries will play a major role. The formation of the platelet plug results from the platelet aggregation at the sites of vessel breaks. Platelets stick together to form a temporary seal that covers the break in the vessel wall. This plug is fragile. Its strengthening requires the formation of a blood clot which, leading to the formation of a fibrin clot. Such aggregated platelets on altered endothelia provides an important matrix scaffold for neutrophils and monocytes (Tonnesen et al. 2000). Indeed such scaffold reinforced by the fibrin clot also serves as a gradient of cytokines, chemokines and growth factors that are able to direct inflammatory cell recruitment. To do so, platelets secrete several chemokines and growth factors implicated in early wound repair stage such as IL-1, TNF, TGF- α , TGF- β , PDGF and VEGF, platelet factor IV (PF4) and complement proteins (Broughton et al. 2006; Barrientos et al. 2008). In addition, activated endothelial cells activate COX-2 and -synthesize products of arachidonic acid degradation, namely various prostaglandins that cause vasodilation and an augmentation of vascular permeability, and leukotrienes, particularly LTB₄, which activate and recruit neutrophils and macrophages (Broughton et al. 2006).

2- Inflammatory response

Shortly after plug formation, polymorphonuclear leukocytes (neutrophils, PMN) begin to transmigrate into the wound site, followed later by monocytes/macrophages. They are recruited to the wound in response to IL-1, TNF, TGF- β , PF4 mainly coming from platelets, and later from activated endothelial cells.

As said, neutrophils invade the wound in large numbers, within a few minutes of injury, as a result of IL-1, TNF, TGF- β , PF4 secretion locally (Singer and Clark 1999). Neutrophils transmigrate through the vascular wall by diapedesis, this being

facilitated by the modifications of permeability induced by secreted prostaglandins. The primary function of recruited neutrophils is the debridement of devitalized tissue and phagocytosis of foreign particles, as well as bacteria. These neutrophils also secrete proteolytic enzymes such as serine proteases (cathepsin G, proteinase-3, elastase, urokinase-type plasminogen activator) and metalloproteases (Weiss 1989). As a consequence of the functionality of myeloperoxidase (MPO), PMN generate cationic peptides and oxygen free radicals, which display anti-microbial activity (Broughton et al. 2006; Eming et al. 2007). Furthermore, some studies showed that neutrophils are an important source for pro-angiogenic factors, including VEGF-A and IL-8 (Li et al. 2003; Ancelin et al. 2004; Ohki et al. 2005; Schrufer et al. 2006). During normal wound healing in mice, the number of PMN is maximal at day 2 of the wound and then gradually decreases and disappears, even before complete re-epithelialization (Kim et al. 2008). Their presence in large numbers is observed in chronic wounds (Simpson and Ross 1972; Diegelmann 2003). Neutrophils are eliminated primarily by apoptosis and then by phagocytosis by macrophages (Witko-Sarsat et al. 2011).

The influx of neutrophils is quickly followed by the migration of monocytes. These are recruited from the circulating blood and marrow to the wound site in response to chemo-attractants and differentiate locally into macrophages (Werner and Grose 2003). In addition to these major newly recruited monocytes/macrophages, another population of resident skin macrophage is also presented at the wound side, although with a low density and minor role (MacDonald et al. 2010). The infiltration of macrophages increase during the inflammatory stage, peak at day 2 of the wound and their number gradually decreases during maturation stage, but these cells are massively remained at later time (Martin and Leibovich 2005). There are several evidences for characteristic of macrophages. Some reports have demonstrated macrophages in wound as the IL4 activated cells since these macrophages express various markers of tissue remodeling after activated by IL4 (Raes et al. 2002; Wynes and Riches 2003; Mosser and Edwards 2008; Martinez et al. 2009). In contrast, a work on aseptic wounds described wound macrophages as cells bearing the activation markers such as TNF α , mannose receptor (Daley et al. 2010).

The importance of inflammatory cells in wound healing is a hot topic. Macrophages are the cells that are responsible for ending the local inflammation steps as well as

the initiation of the following steps of proliferation, angiogenesis, granulation tissue formation, fibroblasts recruitment, and remodeling of the wound (DiPietro 1995). However all these tasks relate on two types of macrophages, called the M1 and M2 macrophages. Of note, the M1 macrophages are activated in response to microbial agents like lipopolysaccharide (LPS) and inflammatory cytokines like $IFN\gamma$. In turn, these cells exhibit antimicrobial properties by release of many important pro-inflammatory cytokines such as $TNF\alpha$, $IL-1\beta$, $IL-6$, or $IL-12$, and overexpress MHC class II molecules. On the other hand, M2 macrophages, which seen as a result of activation macrophages by $IL4$ and $IL13$, are activated macrophages. They are a much more heterogeneous population, composed of all macrophages that do not correspond to M1 characteristics (Gordon 2003; Mantovani et al. 2004). It has been reported that M2 macrophages play an important role in angiogenesis, wound healing and the protection against parasitic infection (Gordon 2003). However, these cells are also involved in several diseases, such as fibrosis, allergy (Duffield 2003).

Thus, both M1 and M2 macrophages are pivotal for healing process. Therefore, the balance between the two phenotypes is important in the different stage of wound healing. More M1 macrophages are needed to remove debris and to kill invading pathogens, while M2 macrophages may have more important role in later phases. In this context, study of Sindrilaru et al indicate that an unrestrained proinflammatory M1 macrophage population lead to alteration of wound healing in humans and mice (Sindrilaru et al. 2011).

The infiltration of macrophages into wound bed is changed during the healing process suggesting different roles of these inflammatory cells in the diverse phases of wound repair. Indeed, it has recently been demonstrated that early depletion of macrophages during the inflammation phase of a surgical wound leads to a reduction of angiogenesis and the formation of granulation tissue together with an alteration of the re-epithelialization (Mirza et al. 2009; Lucas et al. 2010). In contrast, an invalidation of macrophages during the intermediate stage of proliferation causes a hemorrhage in wound and prevents the transition to the maturation and remodeling phase. Finally, depletion of macrophages during the late phase of remodeling does not affect the final result (Goren et al. 2009; Lucas et al. 2010). However, it has been suggested that inflammatory cells are not needed for wound closure since the study showed that wound healing on PU.1 null mice (which lacked macrophages, mast

cells and functional neutrophils) treated with antibiotic is similar to wild types. The actions of macrophages are mediated by the secretion of a large number of cytokines and growth factors including EGF, TGF- α , TGF- β , PDGF and VEGF, IL-1, IL-6 and TNF- α (Barrientos et al. 2008). Macrophages also participate to the debridement of wounds by releasing NO in the extracellular medium by the action of iNOS induced by IL-1 and TNF- α (Goldman et al. 2004).

Of note, in addition to neutrophils and macrophages, other innate immune cells, such as mast cells, dendritic cells, eosinophils and basophils can be recruited in the wound bed (Noble and Jiang 2006). Moreover, a role for T cells and B cells in the wound healing process has also been demonstrated. Indeed, in the absence of dendritic cell-derived T cells, healing is delayed (Jameson et al. 2002), and epidermally-derived T cells locally secrete growth factors in the skin during the healing process (Toulon et al. 2009). Mice that are deficient in B-1 cells exhibit increased inflammatory cell infiltration, particularly neutrophils, and have a delayed healing response (Oliveira et al. 2010).

I - A - 2 - New tissue formation

This proliferative phase includes, angiogenesis, and proliferation and migration of fibroblasts, synthesis of components of the extracellular matrix of the dermis and finally keratinocyte proliferation. It is characterized by the formation of granulation tissue and results in healing of the wound.

1- Angiogenesis and vasculogenesis

Angiogenesis is a vital component of the normal healing process. In addition to angiogenesis which consists a sprouting of capillaries from preexisting blood vessels, several studies suggest that the vasculogenesis process also participates in the vascular regeneration during wound healing. It consists of generation of new vessels, from endothelial progenitor cells (EPCs) mostly derived from the marrow or even resident skin (Amoh et al. 2004; Eming et al. 2007) (**figure 4**).

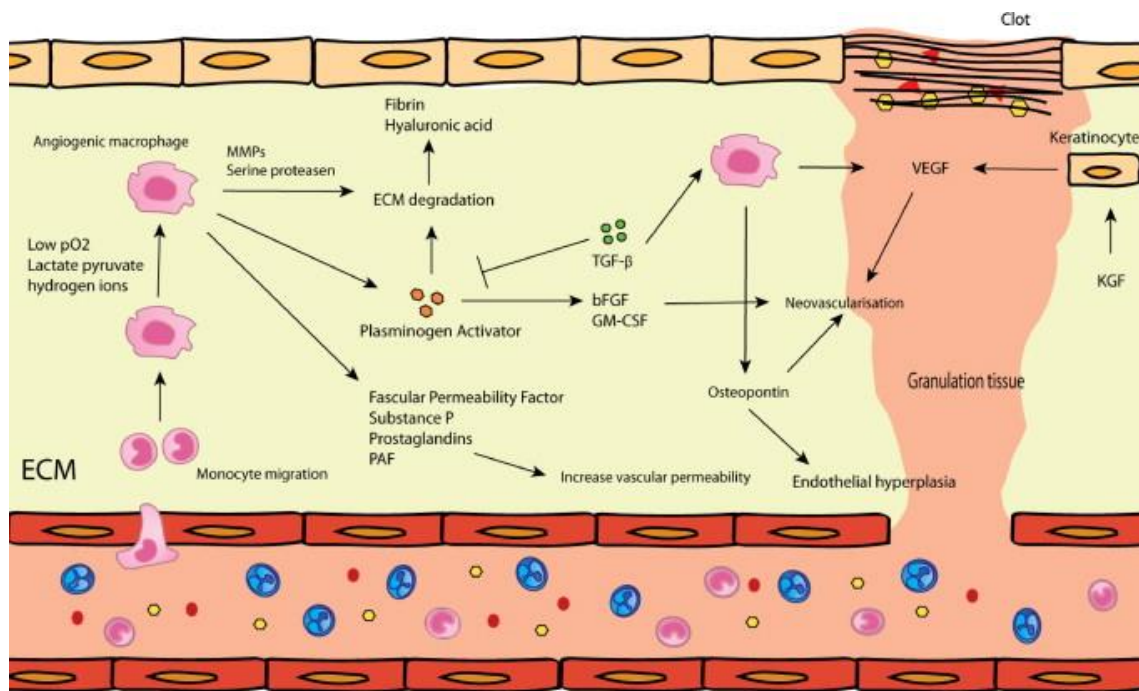


Figure 4. Angiogenesis and vasculogenesis: This is part of the proliferative phase. Angiogenesis is predominantly regulated by macrophages, endothelial cells and keratinocytes. The most important mediator during this phase is VEGF (Mahdavian Delavary et al. 2011).

In setting of injury, resident skin endothelial cells (ECs) migrate into the wound at the leading tip of capillaries, forming tube-like structures (ref) that continue to extend, branch, and creating networks. These events are first promoted by the resident skin progenitors, and of course require a dynamic temporally and spatially regulated interaction between ECs various angiogenic factors, and surrounding ECM proteins (Tonnesen et al. 2000). The angiogenic factors that can stimulate wound angiogenesis are gradually being elucidated. Indeed, FGF-1 and FGF-2 are the first members of FGF family to be discovered that have potent angiogenic activity (ref). Fibrin and fibrinogen bound FGF-2 could enhance the proliferation of ECs through induction of intergrin $\alpha v \beta 3$ and FGF-R1 (Sahni et al. 1999; Sahni and Francis 2004). In addition, induction of $\alpha v \beta 3$ by FGF-2 can also facilitate localization of MMP-2 to ECs that can subsequent promote EC migration (Brooks et al. 1996). Furthermore, FGF-2 together with VEGF, TNF-a and hypoxia could promote increase of plasmin levels, which activates invasion of ECs into fibrin matrix, modulating EC migration and angiogenesis (Koolwijk et al. 1996).

In addition to FGF, VEGF is vital angiogenic factor in wound angiogenesis. This protein is secreted by numerous cell types including keratinocytes, macrophages, ECs, fibroblasts. Regarding to functional activity, it has been demonstrated that VEGF can bind to fibrin or fibrinogen, that in turn facilitates localization and mitogenic activity of VEGF at wound sites in modulating EC proliferation (Sahni and Francis 2000). Of note, functional activity of VEGF is also enhanced through the interaction with its receptor VEGFR. Indeed, VEGFR2 that express on surface of ECs, interacts with VEGF and induce the activity of ECs, stimulate the formation of new capillary. Moreover, the activity of VEGF is modulated by up-regulation of several integrin receptors ($\alpha v\beta 3$, $\alpha 1\beta 1$, and $\alpha 2\beta 1$) and enhanced expression of the anti-apoptotic protein Bcl-2 (Senger et al. 1996; Senger et al. 1997). The expression of VEGF during wound healing is variety and is regulated by many factors including hypoxia, eNOS derived NO, and inflammatory cytokines (Murohara et al. 1998; Murohara et al. 1998). Of note, VEGF is highly expressed during granulation tissue formation from day 4 through 7 after wounding, promoting the EC proliferation, migration and modulate angiogenesis, while FGF-2 expression peak after initial wound and declines towards day 7, suggesting the different role of these factors in wound angiogenesis (Nissen et al. 1998).

Furthermore, there are many other molecules that are known to be involved in angiogenesis during wound healing, such as Angiopoietins (Angs), Tie-1, Tie-2, TGF- β . Angs comprise a family of four ligands that are EC-specific growth factors, exhibiting separate but synergistic effects with VEGF on angiogenesis. They act by means of the Tie2 receptor, which is mainly expressed on surface of ECs (Papapetropoulos et al. 2000; Tonnesen et al. 2000). Ang-1 induces the association of new vessels with pericytes and vascular smooth muscle cells, resulting in their stabilization. In contrast, Ang-2 acts as an antagonistic ligand of Tie-2 receptor and induces destabilization and remodeling vessels (Saharinen et al. 2011). Both Ang-1 and Ang-2 as well as Tie-2 are expressed in wound tissue, especially the upregulation of Ang-2 and Tie-2 was observed upon injury. Interestingly, overexpression of Ang-1 in wound of diabetic mice stimulated various events of wound healing including angiogenesis (Bitto et al. 2008). TGF- β could promotes angiogenesis through stimulate the recruitment of macrophages that then would produce other active angiogenesis factors (Tonnesen et al. 2000).

In addition to angiogenesis and vasculogenesis derived from local progenitors, several studies have shown the recruitment of bone marrow-originated cells into cutaneous wounds (Asahara et al. 1999; Fathke et al. 2004; Galiano et al. 2004; Bluff et al. 2007; Okuno et al. 2011). Fathke *et al.* using marrow chimeric mice demonstrated the presence, of endothelial cells deriving from the marrow in healing skin specimens. These authors reported that less than 0.1% of total cells from the marrow are present in wounds and co-express CD31 by day 28 after wounding (Fathke et al. 2004). Asahara *et al.* studied the bone marrow-derived cells (BMDCs) in the skin wounds of wild-type (WT) mice transplanted with bone marrow of transgenic lacZ protein, which was under the control of an endothelial-specific promoter flk-1 or tie-2. The number of endothelial progenitor cells (EPCs) CD34+ CD31+ from the marrow was maximal at day 4 after surgical wound and decreased to a very low level after 4 weeks once the healing has ended (Asahara et al. 1999). In the same way, using the Tie2/lacZ bone marrow transplant (BMT) model, Bluff *et al.* also found BM-derived EPCs in skin wounds. The kinetics was not the same, the number of marrow derived EPC increased gradually from day 5 and peaked at 14 days post wounding (Bluff et al. 2007). This may relate to wounding differences. In contrast, using a GFP-bone marrow chimeric mice, Okuno *et al.* showed that BMDCs found in acute and chronic wounds did not express CD31, but rather the leukocyte antigens CD45 (70%) and CD11b (45%) by flow cytometry, and F4/80 by immunohistochemistry. These wound recruited marrow- cells appear to be M2 macrophages, recruited under the chemotactic action of CSF. They express metalloproteinases. Indeed, pharmacological inhibition of CSF or invalidation of CSF-1 gene led to a delayed angiogenesis and wound healing (Okuno et al. 2011). In the same study, when the recipient mice were grafted with full VEGFR2-GFP bone marrow cells, GFP cells co-expressing CD31 were detected in the skin wounds. In contrast, when mice were grafted with the LysM-GFP bone marrow, GFP cells detected in the wounds expressed F4/80 (Okuno et al. 2011). Therefore there seem to be in the marrow a population of progenitors able to form vessels in the wounded skin as well as another population of myeloid cells that secrete VEGFa and stimulate paracrine angiogenesis. In addition, bone marrow-derived mesenchymal stem cells (MSCs) are capable of differentiating into endothelial cells (Wu et al. 2007). These reports are therefore at least partly contradictory and open the question of the degree

of involvement of bone marrow-derived EPCs in angiogenesis and vasculogenesis during skin wound healing.

Several recent studies have demonstrated the impact of EPCs during wound healing process (Montesinos et al. 2004; Bauer et al. 2006; Bluff et al. 2007). By using Tie2/GFP BMT model, Montesinos *et al.* have found very few (approximately 1%) BM-derived EPCs in the newly formed vasculature of excisional wounds at day 3, although this proportion increased to 3% by 6 days post wounding, with 3.34 ± 0.63 BM-derived EPCs per mm² at day 6 (Montesinos et al. 2004). In agreement with this, studies of Bluff *et al.* showed the low frequency and temporal expression of EPCs in newly formed vessels in granulation tissue, suggesting that they do not make a significant contribution to the neovascularization of cutaneous incisional wounds. Indeed, EPCs contributed only $4.4\% \pm 1.5\%$ of total ECs in the granulation tissue (Bluff et al. 2007). In contrast, other investigators have shown a larger EPC recruitment to this wound type (Bauer et al. 2006)

2- Migration and proliferation of fibroblasts

Fibroblasts proliferate, migrate to the center of wound and invade the granulation tissue. They are activated essentially by growth factors PDGF, EGF and FGF and inflammatory cytokines IL-1 and TNF- α secreted by platelets, macrophages and keratinocytes (Broughton et al. 2006) (**Figure 5**).

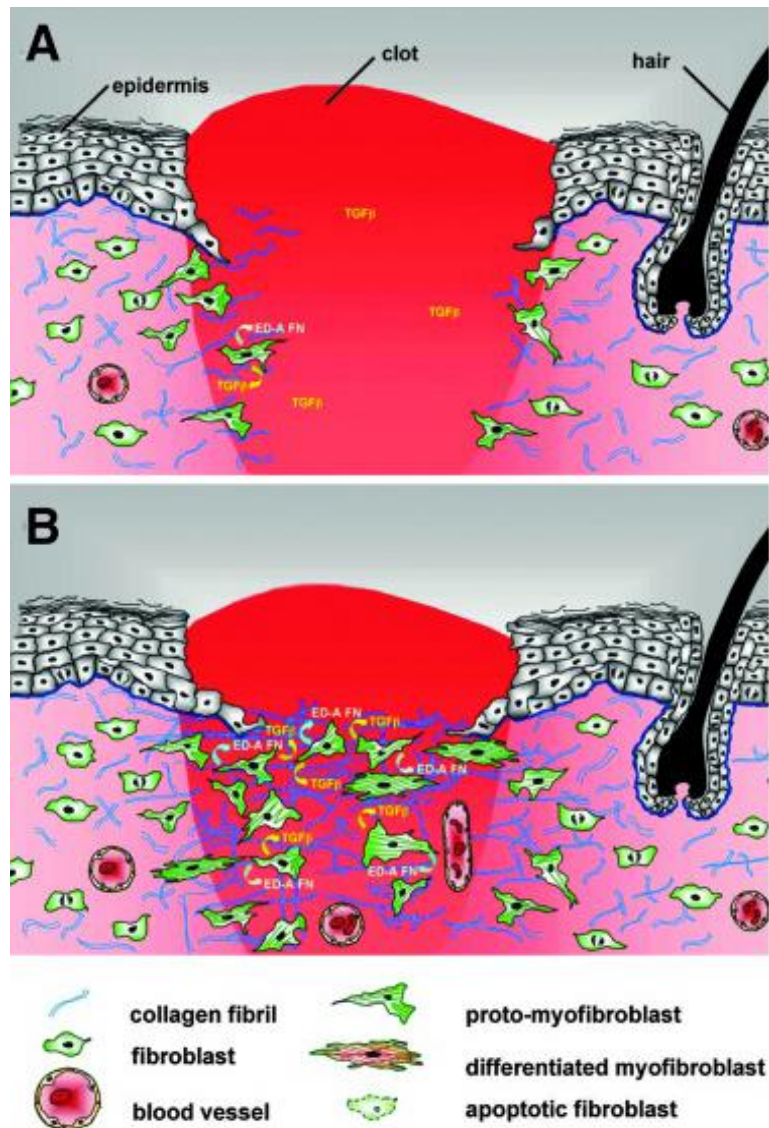


Figure 5. Migration and proliferation of fibroblast in wound

Source: (Van De Water et al. 2013)

(A) In normal tissues, fibroblasts are shielded from “routine” external mechanical perturbations in the skin by ECM. Following a skin injury, the wound is filled with a provisional matrix of fibrin, fibronectin and a complement of growth factors and cytokines. Fibroblasts, along with blood vessels, are stimulated to migrate into center of wound, forming granulation tissue. **(B)** Tractional forces accompanying fibroblast migration are responsible for local areas of increased stiffness in newly made collagen. Focal adhesion assembly is increased with increasing stiffness and this is accompanied by clustering of integrins within focal adhesions and increased stress fiber assembly resulting in fibroblast acquisition of the proto-myofibroblast phenotype.

In response to platelet, endothelial and macrophages cytokines, fibroblasts synthesize initially a provisional extracellular matrix composed of collagen type III glycosaminoglycans, elastin, and fibronectin (Broughton et al. 2006). During this process, cellularity at the wound site increases and this proliferative phase lasts for several days until the wound area is filled to restore tissue integrity. The dermal-epidermal interaction is crucial during this phase and during all the remaining healing process. In incisional wounds, TGF- β expression is maximal at day 7 and modulates remodeling of the extracellular matrix. TGF- β stimulates the synthesis of type I collagen by fibroblasts, inhibits the production of matrix metalloproteases (MMPs) and increases the production of tissue inhibitors of metalloproteinases (TIMPs) (Barrientos et al. 2008). In excisional wounds, TGF- β stimulates the differentiation of fibroblasts into myofibroblasts. Such cells express smooth muscle actin (α -SMA), have contractile activity and cause contraction of the wound (Darby et al. 1990; Sethi et al. 2002).

There are conflicting data on the origin of fibroblasts repopulating skin wounds. In their model of chimeric transplanted GFP marrow mouse, Fathke *et al.* showed the presence of BMDCs in the skin wounds at a late time (day 42), having a fusiform fibroblast-like appearance, capable of contracting collagen matrix *in vitro* and expressing collagen I and III. They also showed that collagen I was also expressed by dermal non-bone marrow-derived cells (GFP- cells) (Fathke et al. 2004). These results suggest that at least part of the dermal cells secreting collagen I derived from bone marrow. In contrast to these results, it was recently shown using another model, that wound fibroblasts expressing collagen type I were never of marrow origin (Higashiyama et al. 2011). All these data leaves the subject of the origin of fibroblasts involved in wound healing pending for further works.

3- Re-epithelialization

Re-epithelialization of injured skin is a major and later step in the formation of new tissue. It generally involves the migration of adjacent epidermal keratinocytes into center of wound, the proliferation of keratinocytes from wound edges and or hair follicles remnants. The wound re-epithelialization is ensured by local epidermal

progenitor cells from the wound edges as well as by epithelial stem cells from hair follicles or sweat glands (Martin 1997; Miller et al. 1998; Roh and Lyle 2006; Lau et al. 2009). This process is activated by signaling pathways of epithelial and non-epithelial cells at the wound edges, which release a myriad of different cytokines and growth factors, e.g. hepatocyte growth factor (HGF), fibroblast growth factor (FGF), epidermal growth factors (EGF), insulin-like growth factor-1 (IGF-1) (Werner and Grose 2003). Wound re-epithelialization is also promoted by various receptors such as G-protein coupled receptors, tyrosine kinase receptors (Sano et al. 1999; Amendt et al. 2002; Ashcroft et al. 2003; Chmielowiec et al. 2007; Raja et al. 2007), or nuclear receptors as peroxisome-proliferator-activated receptors, androgen, estrogen and glucocorticoid receptors (Icre et al. 2006; Michalik and Wahli 2006; Pullar et al. 2006)

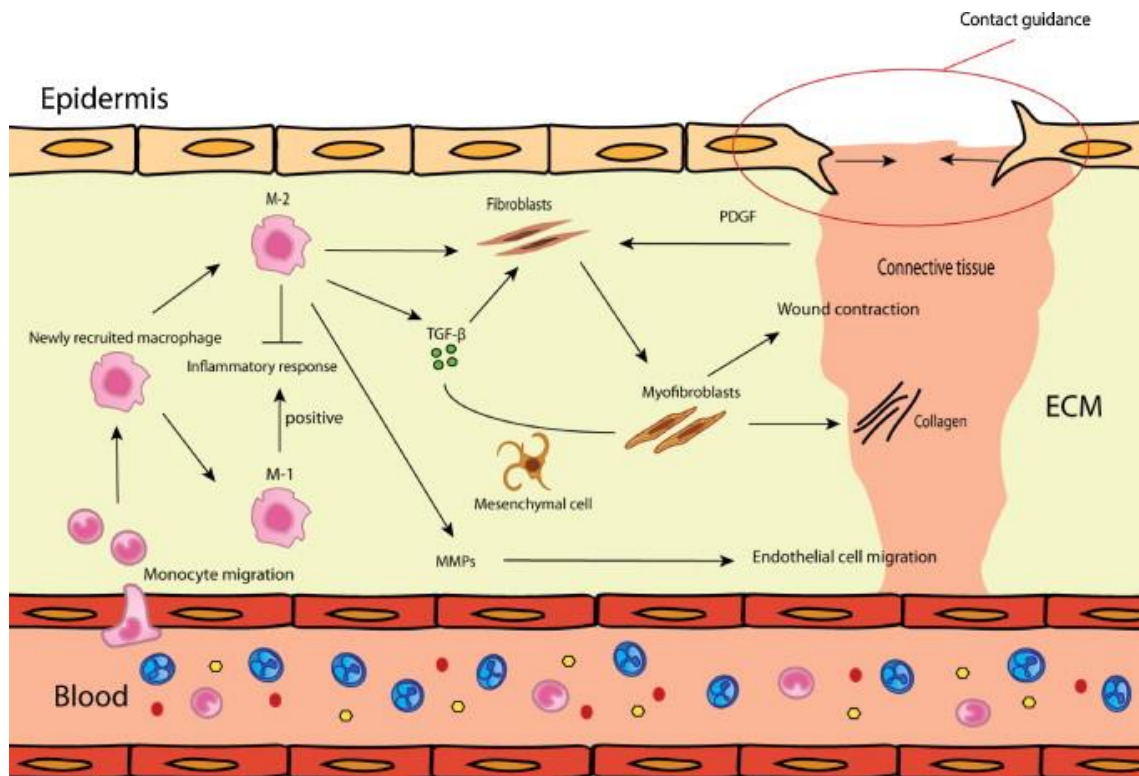


Figure 3. The new tissue formation phase (including reepithelialization): during this phase active fibroplasia, neovascularization and reepithelization occurs. Dependent on the macrophage phenotype more or less ECM is produced via fibroblasts and myofibroblasts (Mahdavian Delavary et al. 2011)

Keratinocyte migration is an early event in wound re-epithelialization (Hell E et al 1979). The keratinocytes initially respond to an injury by migrating from the edges of the wound. Desmosomes are cell-cell junctions that provide the tensile strength of the tissue. Basal epidermal keratinocytes at the wound edge change morphologically: they become flattened and desmosomes, are altered (Matsuzaki et al. 2004). As a result of the morphological changes, epidermal cells at the edge of a wound display lateral mobility and an ability to migrate. Hemidesmosomes, are junctions that link the epidermal cells to the basement membrane. They becomes also altered in order to allow keratinocytes to migrate (Matsuzaki et al. 2004). In addition to wound edges, the keratinocyte migration occurs also from remaining skin appendages.

Multiple elements are involved in keratinocyte migration and re-epithelialization, including the ECM, MMPs, integrin receptors, and growth factors. The effect of the keratinocyte growth factor (KGF) on re-epithelialization and wound healing is still discussed. KGF mRNA is highly expressed during wound healing (Werner et al. 1992) and KGF stimulates keratinocyte proliferation and migration (Tsuboi et al. 1993). Sanz Garcia et al. identified that EGF, KGF and basic FGF (bFGF) all promote wound re-epithelialisation (Sanz Garcia et al. 2000). However, Guo et al. reported that mice null for the KGF gene showed no delay in healing of dorsal incisional wounds and tail wounds (Guo et al. 1996). In mice where FGF function had been blocked in the epidermis using a truncated FGFR2-IIIb, Werner et al. reported healing of incisional dorsal wounds was delayed (Werner et al. 1994).

TGF- β 1 is also one of the most important players for epithelial cell migration during re-epithelialization (O'Kane and Ferguson 1997), as it stimulates the expression of integrin subunits that promote keratinocyte migration on the provisional ECM.

Keratinocytes use their surface integrin receptors to interact with a fibronectin-rich provisional matrix. The direction of migration is also regulated by the binding of keratinocytes integrin receptors on the newly formed collagen molecules in the wound bed. Dissociation of this binding allows the keratinocytes to migrate from the edges toward the wound center. MMPs also play an important role in keratinocyte migration by their involvement in this dissociation. Migrating keratinocytes produce MMPs, such as MMP-9, which specifically degrades type IV collagen and laminins in the basement membrane. This allows cells to leave the basement membrane and migrate into the wound (Parks 1999).

It has been shown that the decrease in caspase-8 expression in keratinocytes of wound edges raises keratinocyte proliferation (Lee et al. 2009). Migrating keratinocytes express keratins 6 and 16, lose the expression of gap junction proteins as connexin 43 (Brandner et al. 2004), and overexpress β 1 integrin, allowing them to interact with components of the extracellular matrix (ECM) of granulation tissue and to migrate to cover the wound (Margadant et al. 2010). Once keratinocytes cover all the granulation tissue, they lose the expression of keratin 6 and 16 and start to express keratins 14 and 5 of the basal layer. These keratinocytes synthesize proteases such as MMP-1 and basement membrane proteins such as laminin-5, which allow them to re-epithelialize the wound (Eming et al. 2007). Basal keratinocytes differentiate thereafter following the physiological epidermal program, giving suprabasal layers expressing keratins 1 and 10, and subsequently the terminal differentiation markers including filaggrin, loricrin and involucrin (Singer and Clark 1999). It has been nicely shown that in addition to interfollicular epidermal progenitors, hair follicle stem cells were also involved in wound re-epidermization (Ito et al. 2005).

A restoration of an intact basement membrane that connects the epidermis and dermis occurs through proteins secretion by keratinocytes and fibroblasts (Li et al. 2007; Gurtner et al. 2008) (Figure 3).

I - A - 3 - Tissue remodelling phase

After the recruitment of inflammatory cells, the angiogenesis, cell proliferation, and re-epithelialization steps, have finished; we are facing healed skin but that still is far from a normal skin. At that time point, begins the remodeling phase. This stage aims to restore a better tissue structural integrity and functional competence. This last phase consists in the synthesis of the dermal extra cellular matrix and its subsequent changes over time. During this period, there is a balance between the synthesis of new components of the extracellular matrix and their degradation by proteases. The processes of regression of granulation tissue are not well known. Key elements of this stage are the regression of vascular structures, decrease of leukocyte infiltrate which returns progressively to a normal level and substitution of transient components of the extracellular matrix as vitronectin, fibronectin and type III collagen

by the permanent collagenous fibrous components such as type I collagen (Li et al. 2007). The apoptosis of leukocytes and endothelial cells is a major mechanism, responsible for the decrease of their number in the granulation tissue (Desmouliere et al. 1995). Other mechanisms involve the reduction of local expression of growth factors and chemokines, decreasing the recruitment and proliferation, and the augmentation of expression of anti-inflammatory and anti-angiogenic cytokines (DiPietro 1995).

The formation of the extracellular matrix follows a specific process during wound healing. Initially, the matrix is composed of fibrin and fibronectin as a result from hemostasis. Glycosaminoglycans and proteoglycans are then synthesized by fibroblasts (Broughton et al. 2006). This primary matrix will then be replaced by a more resistant and organized matrix composed of collagen. In healthy skin, collagen in the dermis consists of 80-90% of type I and 10-20% type III. However, during early steps of wound healing, type III collagen becomes the predominant collagen synthesized by fibroblast in granulation tissue. Col III first appears after 48 to 72 hours (30%) and is maximally secreted between 5 and 7 days. The peak of type III collagen is precocious and matches with a peak of fibronectin (Ehrlich and Krummel 1996; Li et al. 2007). MMPs and their inhibitors (TIMPs) are responsible for the remodeling of extracellular matrix components. Their activity and synthesis is influenced by changes in local concentrations of TGF, PDGF, IL-1 and EGF (Henry and Garner 2003). Collagen synthesis is continued for 4 to 5 weeks after wound. The initially deposited collagen is thinner than that in a non-injured normal skin and oriented parallel to the skin surface. It will be subsequently digested, and new, thicker and organized collagen is deposited in bunches along the skin tension lines. Nevertheless, the dermis will never recover its original structure and the wound will not recover its strength at 100%: at one week, the healing skin displays 3% of its original strength. It increases progressively to 30% in 3 weeks, and 80% after 3 months (Diegelmann 2003; Broughton et al. 2006).

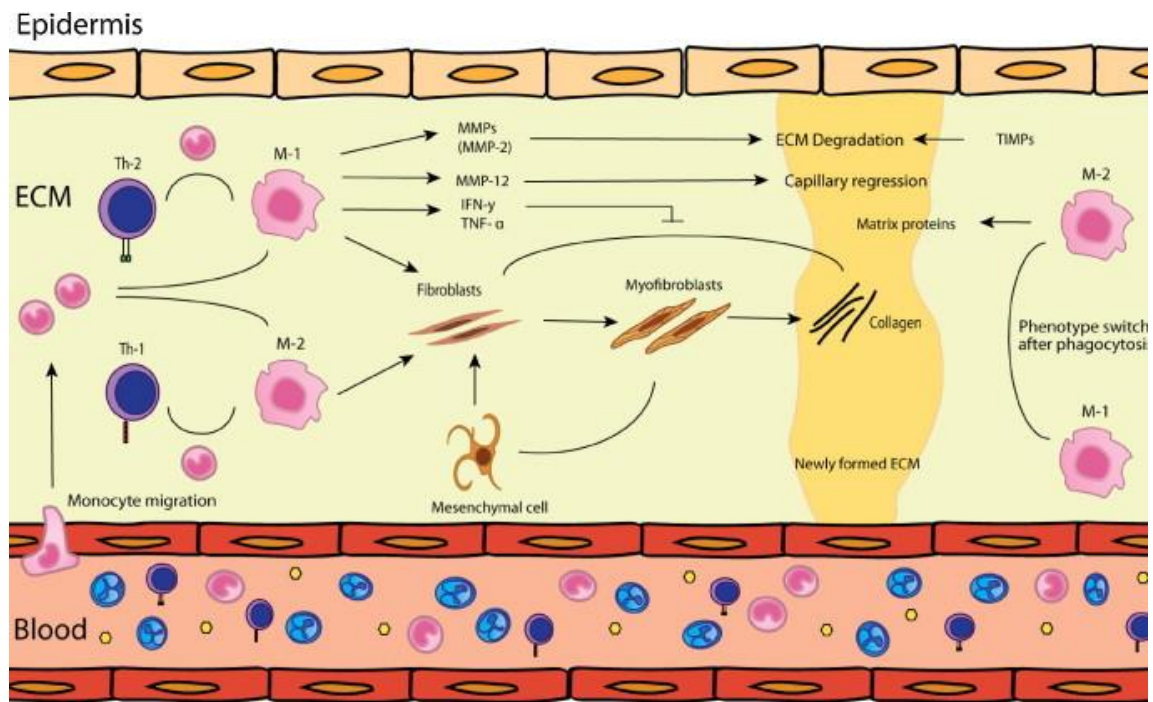


Figure 6. Tissue remodeling phase: During this phase the balance between ECM-breakdown and -formation is important and determines the eventual scar result. The balance is determined by among others the micro-environment, macrophage phenotype and T-cell response (Mahdavian Delavary et al. 2011).

I - B - Endothelial progenitor cell- a key actor of angiogenesis and wound repair

EPCs are bone marrow-derived progenitor cells that were first discovered as significant contributors to neovascularization by Asahara *et al.* (Asahara et al. 1997). In response to injury, these cells are recruited into circulation and homed to ischemia sites; these cells undergo *in situ* differentiation, and ultimately participate to the formation of new vessels (Asahara et al. 1999; Carmeliet 2004) (**Figure 7**).

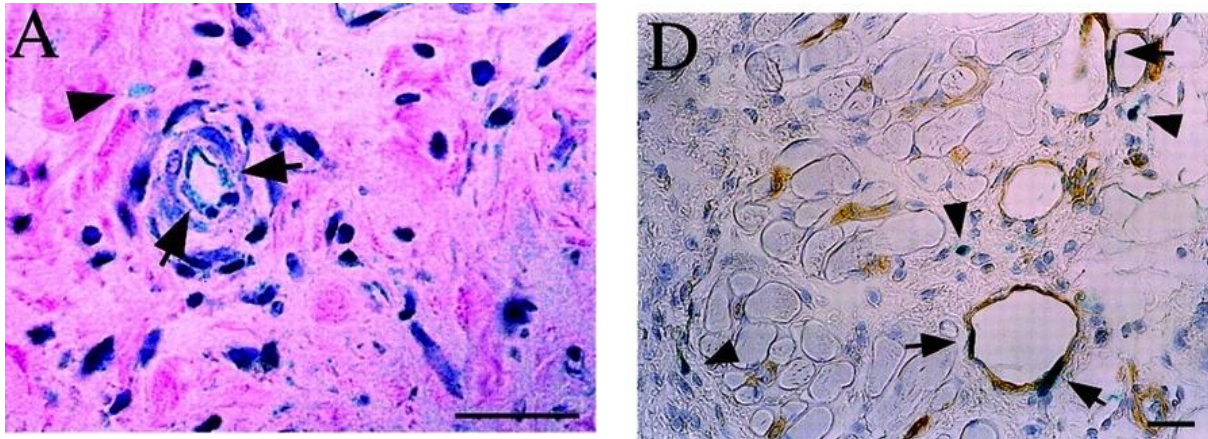


Figure 7 : Implication of EPCs in wound angiogenesis and vasculogenesis

Light microscopic detection of EPCs in wound-healing site created in skin of Flk-1/LZ/BMT and Tie-2/LZ/BMT mice. Flk-1–expressing EPCs in granulation tissue (A) of Flk-1/LZ/BMT and Tie-2–expressing EPCs in blood vessels (D) of Tie-2/LZ/BMT were observed 4 days after wounding (Asahara et al. 1999).

Although the molecular identification of EPCs remains a topic of debate, studies suggest that two functionally distinct subpopulations exist based on *in vitro* isolation techniques: early outgrowth EPCs and late outgrowth EPCs (Sieveking et al. 2008; Asahara et al. 2011). Specifically, early outgrowth EPCs appear to function in a paracrine role in promoting neovascularization whereas late growth EPCs directly differentiate into endothelial tubes (Sieveking et al. 2008). EPCs have been characterized and classified based on multiple markers. However, none of the markers used are specific for EPCs (Timmermans et al. 2009). However, a common feature of EPCs is their functional ability to mobilize and home to injured areas and promote vessel formation (Lamping 2007). Although the mobilization of EPCs is a complex event and that the mechanisms that specifically recruit these cells to wound sites remain under investigation, numerous molecules and signaling pathways have already been addressed and showed to be implicated in this process. EPCs are thought to mobilize from BM and home to areas of endothelial damage via adhesion molecules. Alternatively, resident EPC may be present at low levels in tissues (ref). The secreted proteases cathepsin L and MMP2 regulate the transmigration of EPCs. These cells may subsequently mature and differentiate towards the endothelial lineage (Urbich et al. 2005; Cheng et al. 2007).

Of note, nitric oxide (NO) signaling and reactive oxygen species (ROS) have also been implicated in EPC mobilization and activity (Gallagher et al. 2007; Hamed et al. 2009). Moreover, previous studies indicate that EPCs are mobilized in response to tissue ischemia. This probably results through cytokine and/or chemokine secretion from ischemic tissue, thereby augmenting neovascularization of ischemic tissues (Takahashi, T 1999; Ishida, Y 2012).

Among cytokines implicated in EPC mobilization and angiogenesis, the family of vascular endothelial growth factors (VEGF) and their receptors have been identified as the most potent and predominant ones (Roskoski 2008; Carmeliet and Jain 2011). VEGFs are endothelial cell specific mitogens and potent inducers of vascular permeability. They play a crucial role in endothelial cell motility; stimulate vascular endothelial cell growth, survival, and proliferation and eventually increase the number of capillaries. This wide range of effects is mediated in part by the multiple VEGF members, VEGF-A through VEGF-D and in associated with three VEGF receptor-tyrosine kinases, known as VEGFR-1, -2 and -3, as well as with co-receptors including neuropilins (Nrp) (Figure 8) (Ferrara 2004; Olsson et al. 2006; Eming et al. 2007).

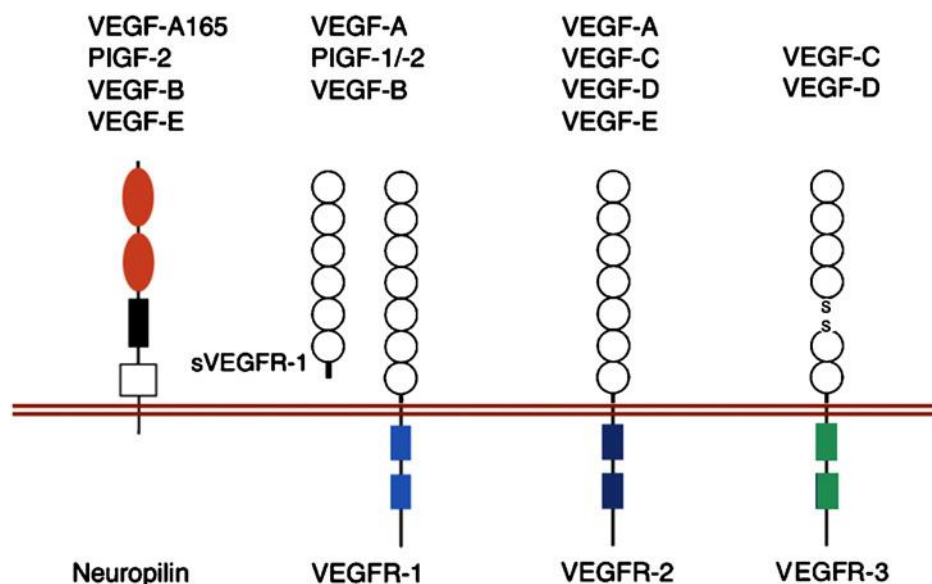


Figure 8. Schematic representation of interactions between VEGF family members and their receptors. This is a complex network of interactions of VEGF family members with transmembrane and soluble VEGFR-1 (sVEGFR-1), VEGFR-2, VEGFR-3, and Nrp (Eming et al. 2007) .

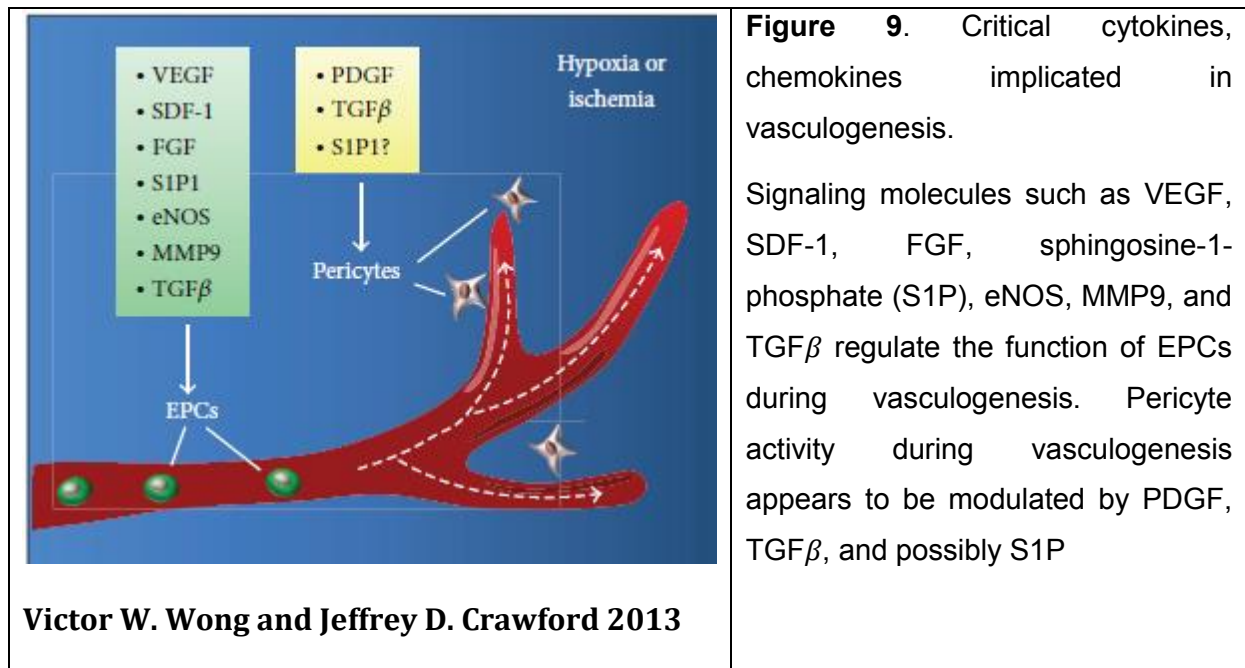
Each subtype of VEGF is secreted by one or several cell types and appears to be involved in angiogenesis and vasculogenesis via different signaling pathways. VEGF-A, the first and the most important member of VEGF family, has been shown to promote vasculogenesis, by signaling through VEGF receptor-2 (Asahara et al. 1999). Studying a diabetic murine model, Frank *et al.* have provided for the first time a causative link between decreased VEGF-A activity, impaired wound angiogenesis and delayed wound healing (Frank et al. 1995). Since then, several studies have shown that VEGF levels are indeed increased following tissue injury, and that this level correlated with the migration of EPCs to ischemic area (Asahara et al. 1999; Tepper et al. 2005). In addition, it has been shown that topical VEGF-A application improves the delayed wound healing in diabetic mice through local upregulation of other angiogenic cytokines and recruitment of BMDCs (Galiano et al. 2004). VEGF-A has also been reported to regulate the expression of endothelial cell surface proteins, known as integrins, that link cells with various members of the ECM. Integrins, which comprise a family of transmembrane heterodimeric proteins, play a major role in controlling EPC mobilization and homing to injury and ischemic areas (Caiado and Dias 2012). According to its powerful angiogenic ability, VEGF-A even has been applied in clinical therapy for some human ischemic diseases (you need reference here).

There are various sources for VEGF-A secretion during wound healing. These include keratinocytes, macrophages, platelets, neutrophils and mast cells. The expression of these proteins can be regulated by numerous factors including growth factors, pro-inflammatory cytokines, hormones and cellular stress (Fukumura et al. 1998; Kishimoto et al. 2000; Pages and Pouyssegur 2005). One of the best characterized mechanisms of VEGF-A synthesis in wound healing as well as other settings is hypoxia-inducible factor-1 (HIF-1). HIF-1 is a transcription factor that exists as a dimeric complex, consisting of a cytoplasmic α subunit and a nuclear β subunit (Ceradini and Gurtner 2005). During hypoxia, HIF-1 α translocates into the nucleus to form a complex with HIF-1 β , initiating the transcription of genes inducing angiogenesis including VEGF and chemokine stromal cell-derived factor-1 α (SDF-1 α). Thus, strategies to stabilize HIF-1 α may enhance EPC mobilization and function

(Ceradini et al. 2004; Hoenig et al. 2008) and therefore improve delayed wound healing (Botusan et al. 2008; Thangarajah et al. 2009).

Besides VEGF, other peptides have been shown to modulate EPC recruitment during wound healing. Chemokines also crucial players in EPC and hematopoietic stem cell (HSC) trafficking and angiogenesis during wound healing process. CCL5 is one of these. An elegant study by Ishida et al. was able to demonstrate that CCL5/CCR5 interaction is an important molecular pathway for modulation of EPCs and eventual neovascularization during wound healing process. Indeed, CCL5 is secreted at day 1 post wounding by F480 infiltrating macrophages and allows mobilization of CCR5+ EPC from marrow to granulation tissue. (Ishida et al. 2012). This study also demonstrated that EPCs are important not only as the progenitors of endothelial cells, but also as the source of growth factors during tissue repair important for other healing steps (Ishida et al. 2012).

The chemokine CXCL12 (also known as SDF-1) and its specific receptor CXCR4 is another important factor mediating recruitment of various stem/progenitor cells like EPCs or Hematopoietic stem cells. Indeed, CXCL12 that express in different tissues can stimulate the adhesion, migration and homing of progenitor cells from circulation to ischemic tissues. In contrast, blockade of this chemokine in ischemic tissue or CXCR4 on circulating cells reduce the mobilization of progenitors to sites of injury (Ceradini et al. 2004). Importantly, the level of SDF-1 expression in injured tissue correlates with stem cell recruitment and healing. The EPC recruitment into tissue depends on the upregulation of SDF-1 (Askari et al. 2003; Yamaguchi et al. 2003; Ceradini et al. 2004). Consistent with this view, it has been reported that the impaired EPC homing and poor angiogenesis in diabetic wounds are due to decreased level of SDF-1. And this defect could be reversed by therapy of this chemokine into wounds (Gallagher et al. 2007). In contrast, inhibition of SDF-1 leads to further impairment of wound healing, decrease angiogenesis in the diabetic mice (Bermudez et al. 2011). Of note, the expression of SDF-1 is regulated by many factors, such as hypoxia or the activity of eNOS (Ceradini et al. 2004; Gallagher et al. 2007).



I - C - Re-epithelialization: role of nuclear receptors and ligands

Re-epithelialization is an important step in the formation of new tissue after wounding, involving both proliferation and migration of keratinocytes from the edges of wound to reconstitute a complete barrier. This process is promoted by many signaling pathways with the critical involvement of various families of receptors including nuclear receptors (NR), such as peroxysome-proliferator-activated receptors (PPAR), androgen (AR), estrogen (ER) and glucocorticoid (GR) receptors and their ligands (Icre et al. 2006; Michalik and Wahli 2006; Pullar et al. 2006). It is generally considered that estrogens enhance wound repair, while androgens impair wound healing. Role of estrogens and its receptor are different between male and female. Activation of estrogen receptor by its ligand estrogen markedly delays wound re-epithelialization in male mice (Gilliver et al. 2010), while systemic or topical estrogen treatment can reverse age-related impaired healing in animal models and humans females, in association with accelerated re-epithelialization, reduced local inflammation and enhanced matrix deposition (Ashcroft et al. 1997; Ashcroft et al. 1999; Hardman et al. 2008). The sex difference in the effects of systemic estrogen treatment on wound re-epithelialization may partly be explained by a fundamental difference in the response of keratinocytes to estrogens: cells cultured from female

mice migrate more rapidly following treatment with an estrogen 17- β -estradiol (Emmerson et al. 2009); those from male donors were unresponsive to estrogen in the same assay. Another critical actor in wound re-epithelialization is AR. Lai and colleagues have demonstrated that monocytes/macrophages-specific deletion of AR lead to improvement of wound healing, whereas keratinocyte- and fibroblast-specific ARKO mice do not. Even though AR in keratinocytes and fibroblasts is dispensable for overall wound healing, AR in these 2 cell types plays key but opposing roles to regulate re-epithelialization. Keratinocyte AR promoted re-epithelialization, while fibroblast AR suppressed it (Lai et al. 2009). Among three subtypes of PPAR, PPAR α and β are important modulators for the re-epithelialization during wound healing and each of them plays a specific role in this process. PPAR α is mainly involved in the early inflammation phase of the healing, whereas PPAR β is implicated in the control of keratinocyte proliferation (Michalik et al. 2001). In contrast, PPAR δ has been reported to contribute to the wound healing, not only by accelerating the migration of keratinocytes but also by promoting extracellular matrix-mediated cellular interactions at the wound edge through TGF-1/Smad3 signaling-dependent or - independent pathway (Ham et al. 2010). Moreover, according to Nakamura *et al.* this receptor is also involved in the corneal epithelial wound healing (Nakamura et al. 2012). Vitamin D hormone metabolites and analogues inhibit the proliferation of cultured keratinocytes that may bring benefits in human hyperproliferative skin diseases such as psoriasis (Lehmann 2009). In contrast, the thyroid hormones stimulate keratinocyte proliferation, and therefore accelerate wound healing (Safer et al. 2005). Finally, GR and its ligands are classical modulators of skin proliferation and differentiation. Glucocorticoids derivatives are frequently used in acute and chronic inflammatory diseases; however, unwanted side-effects, such as epidermal atrophy or delayed wound healing are common, limiting their long-term use (Schacke et al. 2002; Barnes and Adcock 2009; De Bosscher and Haegeman 2009). Study of Sanchis *et al.* showed that overexpression of GR in keratinocytes lead to a reduced re-epithelialization and delayed wound healing, in correlation with repressed KGF expression and decreased ERK activity (Sanchis et al. 2012). The role of GR and glucocorticoids in skin and cutaneous wound healing will be detailed later (MR chapter).

I - D - Abnormal wound healing in human and/or mice context

As detailed above, normal wound healing is crucial in restoring the cutaneous barrier in order to allow the skin to perform its dedicated functions, such as preventing infection by foreign agents and fluid loss. The healing process is not only complex but also fragile. The kinetics and quality of skin healing are major parameters in the clinical practice. They are under the influence of several factors. Various abnormalities in any of these may alter normal healing leading to chronic wounds. Again, such situation can be responsible for a significant morbidity and mortality that place chronic wounds as a major public health problems that we will discuss below.

I - D - 1 - Age-related delayed wound healing

The ageing process in humans is well known to be detrimental to wound healing. Although the exact mechanisms of this age related process are remained unclear, it has been demonstrated that an increase in fragility of aged skin together with impaired immune response and cellular ageing contribute to impaired wound healing in the elderly, associated to disruption of the normal phases of repair, leading to an increase in healing time following injury (Thomas 2001).

Archival studies highlight several events which contribute to age-related delayed healing. First, platelet function was found to be impaired in the elderly patients, indicated by a significantly longer “closure time”, and assessed by measuring the time taken for platelets to occlude a Platelet Function Analyser-PFA 100™ (Boldt et al. 2001). In addition, Fukaya et al. determined that platelet aggregation is increased with age, indicating a delayed wound hemostasis in aged individuals (Fukaya et al. 2000). Second, the impaired healing of the elderly has been strongly linked to excessive inflammation; especially neutrophil recruitment and protease production in response to the increased pro-inflammatory cytokine production (Ashcroft et al. 1998; Ashcroft and Ashworth 2003). Moreover, study of Reed *et al.* showed that together with aging, dermal fibroblast proliferation and migration are impaired (Reed et al. 2001). The proliferation and migration of epithelial cells during wound healing is also delayed with intrinsic ageing in both healthy human subjects and animal models (Holt et al. 1992; Ashcroft et al. 1997). More interestingly, the majority of studies have

associated ageing with a decreased angiogenesis in relation with a defect in the production of VEGF (Swift et al. 1999) and TGF- β (Rivard et al. 1999) or with an alteration in matrix synthesis and reduced proliferation of progenitor endothelial cells (Reed and Edelberg 2004).

I - D - 2 - Chronic wounds

Chronic wounds are wounds that have failed to progress through the normal stages of healing leading to a prolonged loss of substance. In the human setting, chronic wounds are usually defined by a persistence of an unhealed wound for at least 3 months. However, such classification does not fit with all situation since normal healing depends also of the age, surface of initial wound as well as the medical care that has been given.. .

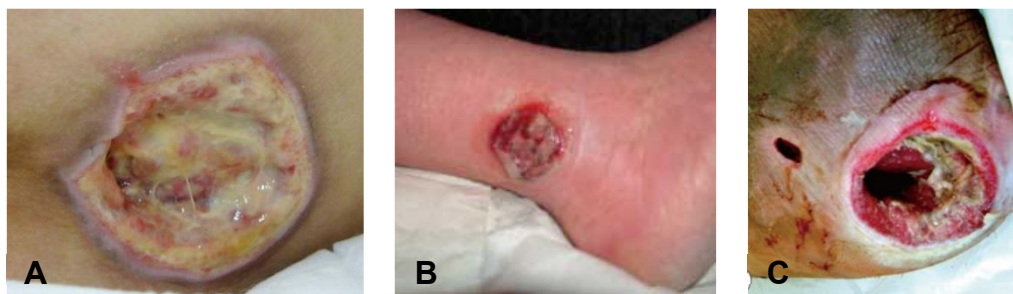


Figure 10. Types of chronic wounds: A) pressure ulcer (Inui et al. 2010), B) venous leg ulcer (Grey et al. 2006), C) diabetic foot ulcer (Olea et al. 2014)

In Western countries, the most common causes of chronic ulcers are vascular diseases that are responsible for up to 70% affected patients (Nwomeh et al. 1998) (Figure 10). The vascular disorders causing chronic wounds can either derive from large diameter vessels diseases or in contrast small diameter vessels diseases. Disorders of lower limbs large diameter arteries or veins can indeed lead to ischemia. Once ischemia having led to tissue necrosis, a complete wound repair cannot occur because of the same ischemic mechanisms. Causes of lower limbs atheroma are mainly (a) tobacco intake, (b) overweight, (c) elevated cholesterol levels, (d) diabetes, (e) hypertension. Causes of venous insufficiency are (a) genetic background, (b) repeated pregnancies in females (c) overweight, (d) prolonged

standing at work. More rarely, ischemia can result from microangiopathies which are small vessels diseases. These are found mainly in diabetes and more rarely in neuropathies, nutritional deficiencies, some genetic diseases, systemic auto-immune diseases (Fonder et al. 2008). In developing countries, the most common causes of chronic wounds are specific infections, arterial disease and traumatism (Sibanda et al. 2009).

As mentioned above, diabetes is responsible for frequent delayed healing. Diabetes can induce tissue hypoxemia through the induction of large vessels atheroma, neuropathy induced pressure ulcers, increased susceptibility to infections or microangiopathy. The mechanisms of microangiopathy have been addressed by animal model studies or in humans. Microangiopathy has been shown in db/db mice to result from an alteration of EPC mobilization from marrow to wounds (Gallagher et al. 2007; Marrotte et al. 2010). Therefore the importance of these EPC mobilization is illustrated by its implication in diabetic wounds.

In addition to the cases of the chronic wounds mentioned above, many issues of delayed wound healing have been reported are steroids related. Indeed, glucocorticoids, that are wide used to treat chronic inflammatory or auto-immune diseases, usually accompanied by side-effects including skin atrophy and delayed wound healing (Hengge et al. 2006). In the same context of wound healing, while estrogen is considered to enhance wound repair and therefore the deprivation of this steroid as the major factor controlling delayed healing in elderly subjects; androgen, in contrast, is important factor of the delayed wound healing. Indeed, many genes, that are known to be associated with delayed healing, such as growth factor alpha (*TGF α*), arginase 1 (*ARG1*) have been found to be altered in elderly male subjects, are also known to be estrogen regulated (Hardman and Ashcroft 2008), while the deletion of androgen receptor in monocytes/macrophages lead to improvement of wound healing (Lai et al. 2009).

Chronic ulcers are sources of various and sometimes serious complications in patients. These may include skin infections, contact dermatitis, subcutaneous fibrosis with secondary functional limitation of the adjacent joints (ankylosis), and moreover chronic pain with risk of depression or mood disorders. These complications, in addition to functional impairment, have psychological impact and lead to a worsening in the quality of life of affected patients.

When chronic wounds are severe and worsen despite adapted treatment, amputation may be necessary. In the United States, the incidence of secondary amputation to a diabetic leg ulcer is estimated to reach 11.3/1000 patient-years (Adler et al. 1999). Importantly, prolonged ulcers may be complicated by the development of squamous cell carcinoma arising on one part of the wound (Menke et al. 2007). The incidence of burn scars undergoing malignant transformation has been reported to be 0.77 to 2% of affected cases. All parts of the body can be concerned, but the extremities and the scalp are most frequently affected (Copcu 2009).

In USA currently 1 to 2% of individuals will be affected by leg ulceration during their lifetime, and this figure will likely increase with the aging population (Fonder et al. 2008; Piel et al. 2013). Every year in the United States, about 6.5 million people present one or several chronic skin ulcers secondary to venous insufficiency, diabetes or pressure ulcers (Singer and Clark 1999). In Europe, 5-15% of individuals between 30 and 70 years suffer from venous insufficiency, including at least 1% with varicose ulcer (Welt et al. 2009). Similarly, the prevalence of type II diabetes in the United States is 2% and the incidence of leg ulcers in these diabetic patients is 15% (Reiber 1996). In addition, an increase of these numbers is expected due to the aging of the population and the high prevalence of the causes of poor healing in the elderly (Nelzen et al. 1996). Indeed, healing mechanisms are modified in aging skin. Even, in the absence of any specific disorder, skin in old patients will heal in a longer kinetics (Taylor et al. 2005). This relates with various mechanisms including a reduction in stem cell compartment.

Medical care for chronic ulcers has a very high cost from society. In the US, the total cost of care and morbidity of skin wounds is estimated 13 to 15 billion USD per year and the treatment of venous ulcers alone amounted to 3 billion (Bergan et al. 2006; Fonder et al. 2008). It has become mandatory to develop new treatments that are effective and easily accessible for wound healing problems. This makes it crucial to understand the cellular and molecular mechanisms involved in this phenomenon.

II - Aims of work

As detailed above, impaired wound healing is a major clinical problem in various situations including in subjects treated by corticosteroids/corticoids, in the elderly and in pathological conditions, such as diabetes, sickle cell disease or Cushing syndrome. Efforts towards improving wound healing represent a major challenge, to improve quality of life. It is therefore important to further improve the understanding about the mechanisms underlying the normal and abnormal wound healing in those situations. In this work, we aimed to address two questions :

1. Develop a murine model for SCD ulcers to improve the understanding of the cellular and molecular pathways responsible for a long-lasting and severe sickle cell leg ulcers.
2. Investigate specific targets in delayed cutaneous wound healing in various pathological situations such as glucocorticoid treated patients, diabetes) and more specifically the implication of the mineralocorticoid receptor inhibition.

CHAPTER 2 - DELAYED WOUND HEALING IN MURINE

MODEL OF SICKLE CELL DISEASE

I - Introduction

I - A - Sickle cell disease

I - A - 1 - Genetics

Sickle cell disease (SCD) is a recessive autosomic disorder of the β globin chain of hemoglobin. It is one of the most common severe genetic diseases reported in many countries worldwide (Weatherall et al. 2005; Piel et al. 2010). It results from a single mutation at the β -globin gene in which the 17th nucleotide thymine is replaced by adenine and as a consequence, the sixth amino acid in the β -globin chain changed to valine instead of glutamic acid (Pauling et al. 1949; Bunn 1997). Hemoglobin S (HbS) produced as a result of this defect, is poorly soluble and polymerizes under deoxygenated condition, giving sickle-shaped red blood cells (RBCs) (Bunn 1997). These cells are heterogeneous in genotypes and phenotypes as Herrick first described in 1910 (Figure 11) (Herrick 2001; Rees et al. 2010).

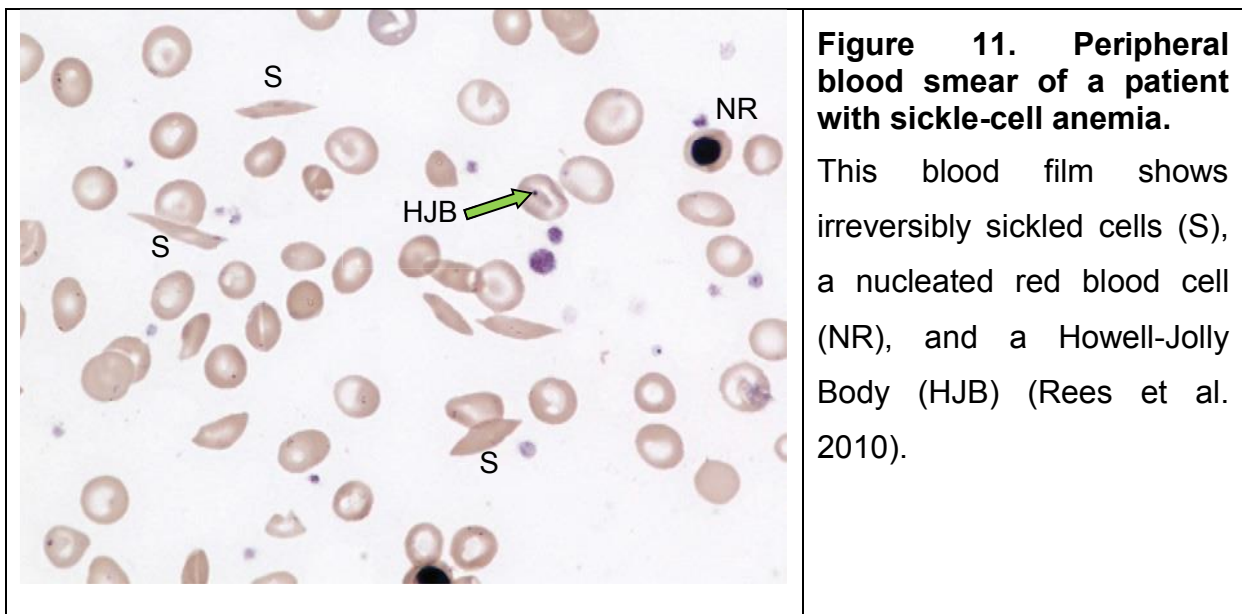


Figure 11. Peripheral blood smear of a patient with sickle-cell anemia.

This blood film shows irreversibly sickled cells (S), a nucleated red blood cell (NR), and a Howell-Jolly Body (HJB) (Rees et al. 2010).

I - A - 2 - Epidemiology

Sickle cell anemia (SCA) occurs with the highest prevalence in low- and middle income countries. Especially, the greatest burden of the disease lies in sub-Saharan Africa, with the prevalence of sickle cell trait ranges between 10 and 45% (Okwi et al. 2010; Piel et al. 2013). According to a recent report, more than 230 000 children with SCA were born in this region every year, that represents about 79.2% of the global total SCA world wideband this proportion is expected to increase to 88% by 2050 (Modell and Darlison 2008; Piel et al. 2013). Moreover, this disorder is of growing importance. Indeed, beyond its old geographical distribution, and due to population migrations, it became recently the most frequent genetic disease diagnosed in Western countries such as the United Kingdom and France (Piel et al. 2010; Piel et al. 2013). In these two countries, the incidence of SCD is around 1/1500 to 1/3800 newborns per year (Piel et al. 2010; Thuret et al. 2010).

I - A - 3 - Clinical presentation

SCD begins usually in infancy. It is characterized by different signs and symptoms. These include many life-threatening complications including acute chest syndrome, but also various tissue damage such as stroke, pulmonary hypertension, renal damage, and bone infarct. These complications of SCD have long been as driven by any of two major pathophysiological processes: micro-vascular occlusion and hemolysis (**figure 12**) (Lane 1996; Rees et al. 2010)

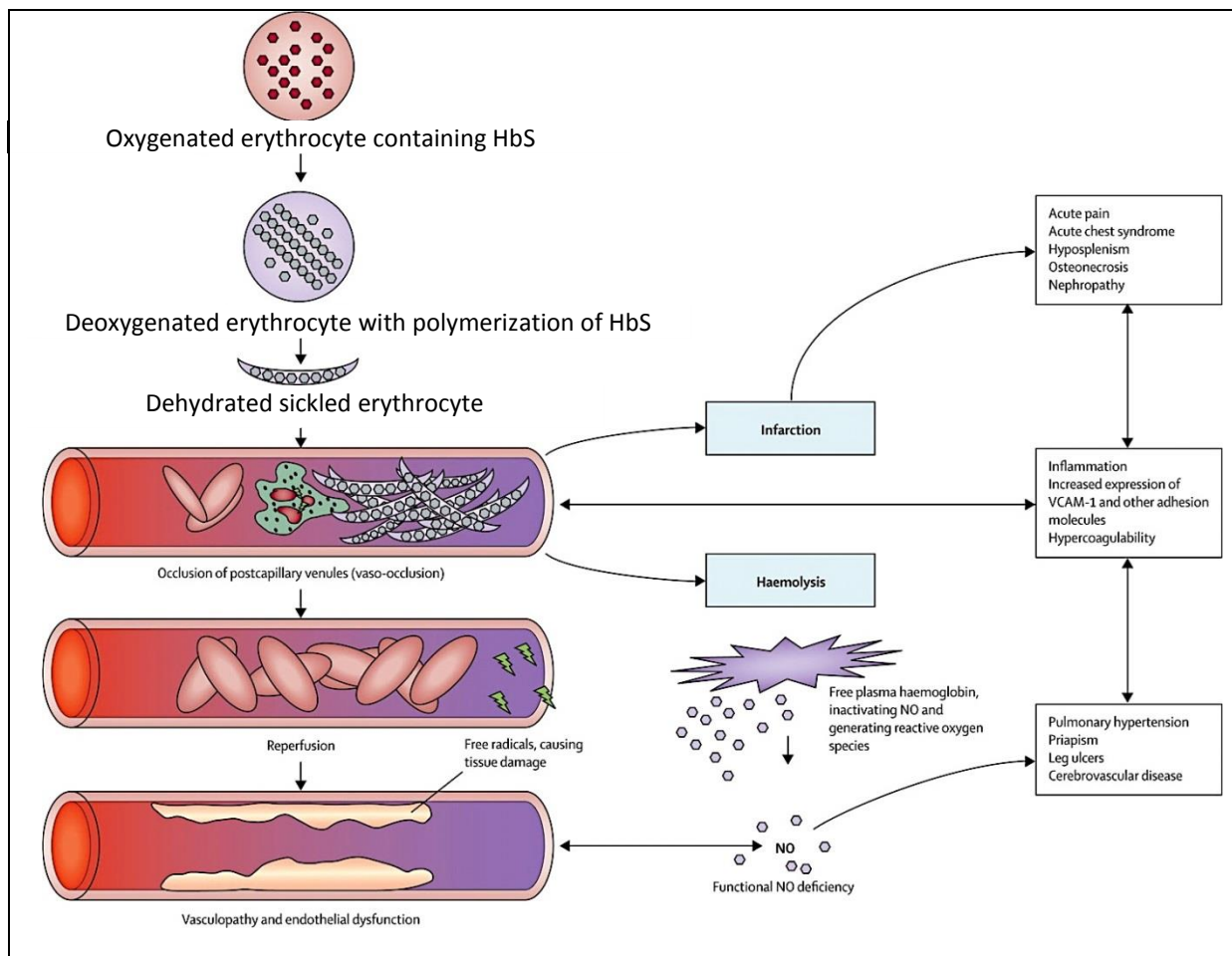


Figure 12. Pathophysiology of sickle cell disease

The roles of HbS polymerisation, hyperviscosity, vaso-occlusion, haemolysis, and endothelial dysfunction are shown. Deoxygenation causes HbS to polymerise, leading to sickled erythrocytes. Vaso-occlusion results from the interaction of sickled erythrocytes with leucocytes and the vascular endothelium. Vaso-occlusion then leads to infarction, haemolysis, and inflammation; inflammation enhances the expression of adhesion molecules, further increasing the tendency of sickled erythrocytes to adhere to the vascular endothelium and to worsen vaso-occlusion. Reperfusion of the ischaemic tissue generates free radicals and oxidative damage. The damaged erythrocytes release free haemoglobin in to the plasma, which strongly bind to nitric oxide, causing functional nitric oxide deficiency and contributing to the development of vasculopathy. HbS=sickle haemoglobin. NO=nitric oxide. VCAM=vascular cell-adhesion molecule. (Rees et al. 2010)

Sickle cell vascular occlusion: under deoxygenated condition, HbS Hb loose their solubility and become polymerized. Such polymerized b chains lead to the sickle rigid, RBCs. These are stiff cells that cannot easily circulate in narrow capillary beds and therefore they occlude microvessels in various tissues. Progressively, the entrapment of erythrocytes and leucocytes in the microcirculation increases. This, occlusion induces an interaction between these sickle erythrocytes and endothelial cells of vessel wall that lead to vascular adhesion of erythrocytes and leukocytes as well as tissue ischemia. HERE you should speak about the adhesion molecules that play a role There is no enough molecular data although there are lot of papers. It is important to note that beside the polymerization of HbS, the inflammatory trapped cells play a role to enhance the vascular obstruction. Indeed, in transgenic mice expressing HbS, cycles of experimental hypoxia but also treatment with pro-inflammatory drugs lead both to enhance endothelial leucocyte-erythrocyte adhesive interactions in the postcapillary venules leading to vascular occlusion (Osarogiagbon et al. 2000; Frenette 2002; Turhan et al. 2002; Belcher et al. 2003). Such ischemia events are followed by reperfusion. These ischemia reperfusion cycles induce oxidant stress, with activation of vascular oxidases (Wood et al. 2005) and inflammatory stress (Frenette 2002; Belcher et al. 2003; Belcher et al. 2005).

Hemolysis: Apart from vaso-occlusion, ischemia and reperfusion, hemolytic anemia with hemolysis is another consequence of polymerization of HbS. Several data indicate that hemolysis is another pathophysiological mechanism in SCD tissue damage. However, controversial data are still found. Hemolysis has been known to be a causative reason of anemia, fatigue, and cholelithiasis, but there is now evidence that it also contributes to the development of vasculopathy and tissue damage. Patients with SCD have a risk of vasculopathy, characterized by systemic and pulmonary hypertension, endothelial dysfunction, and proliferative changes in the intima and smooth muscle of blood vessels (Pegelow et al. 1997; Ohene-Frempong et al. 1998; Gladwin et al. 2004; Kato et al. 2006). Studies have suggested that some complications of SCD namely priapism, pulmonary hypertension and leg ulceration were associated with low concentration of steady state hemoglobin and high level of intravascular hemolysis (Ataga et al. 2006; Kato et al. 2007). An association between the development of pulmonary hypertension and the level of

hemolytic anemia was noted in several studies of SCD patients (Gladwin et al. 2004; Ataga et al. 2006; De Castro et al. 2008; Minniti et al. 2009).

How hemolysis leads to tissue damage? Briefly, high level of free hemoglobin is released after intravascular hemolysis in capillaries. Such free Hb quenches Nitric Oxide (NO) and leads to the generation of reactive oxygen species. This may happen either directly or indirectly via NADP oxidase or via xanthine oxidase. Decreased NO bioavailability is responsible for platelet and tissue factor activation leading to the activation of the coagulation cascade (Figure 13) (Gladwin and Kato 2008).

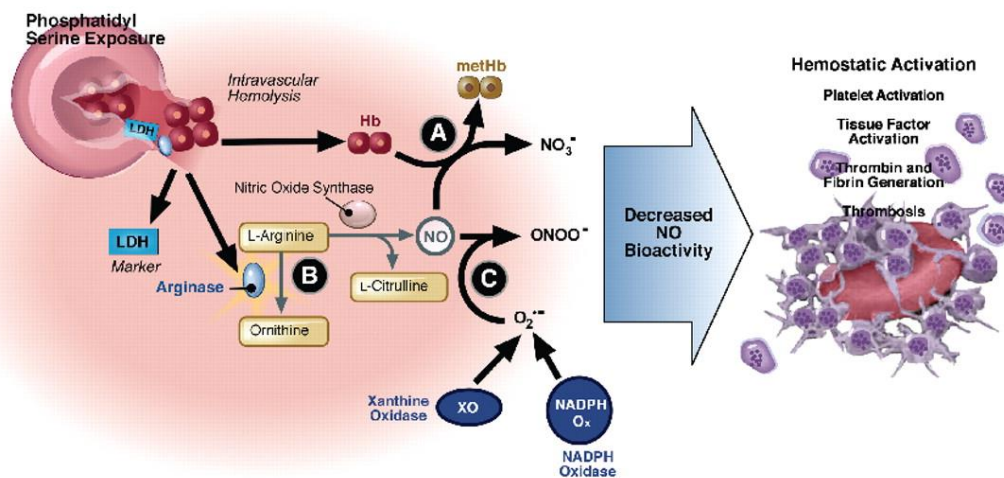


Figure 13. Hemolysis-associated hemostatic activation in SCD.

Intravascular hemolysis releases hemoglobin into plasma which quenches NO and generates ROS (directly via fenton chemistry or via induction of xanthine oxidase and NADP oxidase). In addition, arginase I is released from the red blood cell during hemolysis and metabolizes arginine, the substrate for NO synthesis, further impairing NO synthesis. The depletion of NO is associated with pathological platelet activation and tissue factor expression. Hemolysis and splenectomy are also associated with phosphatidylserine exposure on red cells which can activate tissue factor and form a platform for coagulation (Gladwin and Kato 2008).

Besides, low NO availability induces the release of Endothelin-1 (ET-1), -a potent vasoconstrictive peptide- by activated endothelial cells: ET-1 plasma levels have been reported abnormally high in SCD patients and murine models while the levels of ET-1 were found to be elevated in the kidney and lung after vaso-occlusive crisis

(Rybicki and Benjamin 1998; Tharaux et al. 2005; Sabaa et al. 2008). Finally, endothelin receptor antagonist (bosentan) treatment was shown to prevent kidney and lung damage in hypoxia/reoxygenation induced SCD events in a transgenic mouse model of sickle cell disease (Sabaa et al. 2008).

I - B - Sickle cell Leg ulcers

Leg ulcers are a severe and poorly known complication of SCD. It affect between 2.5 and 40% of patients depending on the countries evaluated (Halabi-Tawil et al. 2008). The peak is observed in Jamaica while the lowest level is in Saudi Arabia. SCD leg ulcers is a very chronic manifestation of SCD (**Figure 14**) that develops on lower limbs after the age of 15 years. Such ulcers are the longest-lasting type of ulcer encountered in adults, with one study reporting ulcers lasting up to 300 months (Halabi-Tawil et al. 2008; Minniti et al. 2014). These ulcers are unique or multiple. They occur usually after a triggering event such as a traumatism, an insect bite or an itch but fail to heal afterwards. SCD ulcers are resistant to all current treatments including skin grafts (Marti-Carvajal et al. 2014). Probably due, to this long-lasting nature of the ulcers, SCD ulcers display a high level of complications. There are soft tissue infections in %, tibio tarsal ankylosis in 50% of affected patients, soft tissue infections and chronic pain (Halabi-Tawil et al. 2008).

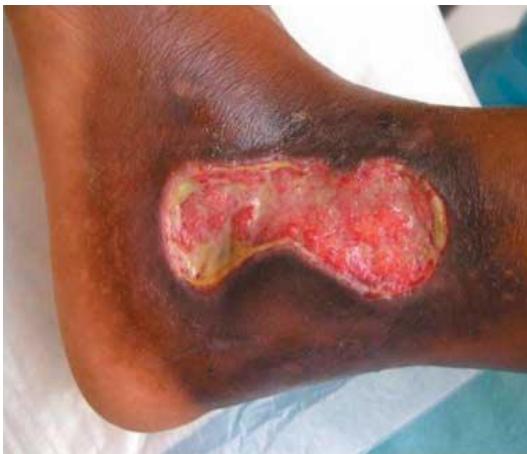

Figure 14. Sickle cell leg ulcers

Source: (Amini-Adle et al. 2007)

In contrast, the pathogenesis of sickle cell associated leg ulcers remains poorly known. Indeed, it has been considered that SCD manifestations including leg ulcers are associated with the elevated blood viscosity- related vaso-occlusion or with the

hemolysis and endothelial dysfunction alternative subphenotype (Aslan et al. 2001; Bowers et al. 2003; Gladwin et al. 2004; Wang et al. 2004; Ataga et al. 2006; Bowers et al. 2013; Connes et al. 2013). However, these features are not consistent with other series. In addition, leg ulcers are not seen in other chronic haemolytic diseases such as paroxysmal nocturnal hemoglobinuria (Bunn et al. 2010; Yoshino et al. 2012). Finally, a recent well conducted study did not find hypoxia in skin ulcers in SCD patients as compared to various controls (Bowers et al. 2013). At this point, hemolysis-induced vasoconstriction does not appear to constitute the unique mechanism of prolonged ulcers in SCD patients. Therefore, other skin wound healing pathways are probably altered in these recipients.

Only a few studies have investigated sickle cell ulcers in human. In addition to the association studies cited above, two papers have reported biopsies of ulcers (Francillon et al. 1996; Minniti et al. 2014). In these studies with a small number of cases, authors found the mural fibrin thrombi, luminal narrowing and progressive vascular occlusion in the ulcer beds. There was also unusual proliferation of abnormal blood vessels with microangiopathic changes including fibrinoid necrosis in the vessel walls, and fragmented RBCs within vessel walls (Minniti et al. 2014). These interesting data thus reveal changes to cutaneous vessels in SCD ulcers. However, biopsies were obtained from ulcers that were several months old. Therefore it is impossible to determine whether these changes are primary events or

I - C - Murine model of sickle cell disease

To date, two murine models of SCD have indeed been developed. SAD mice harbor a recombinant h β -globin transgene expressing human hemoglobin SAD ($\alpha 2\beta 2$ SAD), which contains 2 mutations (Antilles [β^{231}] and D Punjab [β^{121Q}]) in addition to the β^{S6V} mutation, the most frequently found mutation in human SCD. SAD mice express 19% of human sickle cell hemoglobin (HbS) along with mouse hemoglobin. Under hypoxic conditions, SAD red blood cells show sickling properties and dehydration in vitro, typical of SCD. Homozygous SAD mice die in utero, but hemizygous SAD have reduced survival, priapism and kidney defects. They are used as a SCD murine model (Sabaa et al. 2008).

The Berkeley SCD mice have targeted deletions of murine hemoglobin ($\alpha^{-/-}$, $\beta^{-/-}$) with a knockintransgene containing human sickle cell hemoglobin (α , β^S ; $A\gamma$, $G\gamma$, β).

Berkeley mice express human mutated hemoglobin almost exclusively and harbor several hematological and pathological similarities with human SCD including erythrocyte sickling, intravascular hemolysis, severe anemia, leukocytosis, multiorgan infarct, and glomerulosclerosis (Manci et al. 2006).

II - Article 1: Submitted

Sickle cell ulcers are caused by impaired endothelial progenitor cell mobilization and inadequate CXCL12 secretion in skin wounds

Van Tuan Nguyen, Dany Nassar, Frédéric Batteux, Karine Raymond,
Pierre-Louis Tharaux, and Sélim Aractingi

Manuscript submitted to Journal of Investigative Dermatology (JID-2015-0318)

In process of Revise & Resubmit



Sickle cell ulcers are caused by impaired endothelial progenitor cell mobilization and inadequate CXCL12 secretion in skin wounds

Journal:	<i>Journal of Investigative Dermatology</i>
Manuscript ID:	JID-2015-0318
Manuscript Type:	Original Article
Date Submitted by the Author:	22-Apr-2015
Complete List of Authors:	Nguyen, Van Tuan; INSERM, UMR S938, Saint Antoine Research Center Nassar, Danny; Department of Anatomy, Cell Biology and Physiology, Faculty of Medicine, American University of Beirut Batteux, Frédéric; Hôpital Cochin, Laboratoire d'Immunologie biologique; Institut Cochin, U1016 Raymond, Karine; INSERM, UMR S938, Saint Antoine Research Center Tharaux, Pierre-Louis; Paris Cardiovascular Centre, Inserm UMRS-970 Aractingi, Selim; INSERM, UMR S938, Saint Antoine Research Center; Hopital Cochin, Dermatology
Key Words:	SAD mice, Angiogenesis, EPC mobilization, CXCL12, Sickle cell ulcers

SCHOLARONE™
Manuscripts

1
2
3
4
5
6
7
8
9
10
11
12
13
14
15
16
17
18
19
20
21
22
23
24
25
26
27
28
29
30
31
32
33
34
35
36
37
38
39
40
41
42
43
44
45
46
47
48
49
50
51
52
53
54
55
56
57
58
59
60

Sickle cell ulcers are caused by impaired endothelial progenitor cell mobilization and inadequate CXCL12 secretion in skin wounds

Short title: CXCL12 deficiency in sickle cell ulcers

Van Tuan Nguyen^{1,2}, Dany Nassar¹⁻⁴, Frédéric Batteux⁵, Karine Raymond¹,
Pierre-Louis Tharaux⁶, and Sélim Aractingi^{1,5,7}

Affiliations:

¹Progenitors and endothelial cells during and after pregnancy laboratory, INSERM UMR_S 938, Centre de Recherche St Antoine, Paris, France

²UPMC - Université Paris 6 France

³Department of Dermatology, American University of Beirut Medical Centre, Beirut, Lebanon

⁴Department of Anatomy, Cell Biology and Physiology, Faculty of Medicine, American University of Beirut, Beirut, Lebanon

⁵Faculty of Medicine, Université Paris Descartes - Paris 5, France

⁶Paris Center for Cardiovascular Research, Inserm UMRS-970

⁷Department of Dermatology, Hôpital Cochin-Tarnier, Paris, France

Corresponding author:

Sélim Aractingi, M.D., Ph.D

Faculty of Medicine, Université Paris Descartes -Paris 5, France.

89 rue d'Assas, 75006 Paris, France

E-mail: selim.aractingi@gmail.com

Phone number: +33 62 03 86 240

Fax number: +33 14 00 11 423

1
2
3
4
5
6
7
8
9
10
11
12
13
14
15
16
17
18
19
20
21
22
23
24
25
26
27
28
29
30
31
32
33
34
35
36
37
38
39
40
41
42
43
44
45
46
47
48
49
50
51
52
53
54
55
56
57
58
59
60

ABSTRACT

Leg ulcers are a major complication of sickle cell disease occurring in 2.5 to 40% of patients. Leg ulcers are responsible for frequent complications because they are often long-lasting and are very resistant to therapy. Although their occurrence is associated with hyper-hemolysis, the mechanisms underlying sickle cell ulcers remain poorly understood. Here, we show that skin wound healing is severely altered in old SAD sickle cell mice but is normal in young animals, consistent with reports in humans. Alterations of wound healing were associated with impaired blood and lymphatic angiogenesis in the wound beds and poor endothelial progenitor cell mobilization from the bone marrow. CXCL12 secretion by keratinocytes and inflammatory cells was low in the wounds of SAD mice. Local therapy with endothelial progenitor cells or with recombinant CXCL12 injections restored wound angiogenesis and rescued the healing defect together with mobilization of circulating EPCs. This is the first study of the cellular and molecular mechanisms of sickle cell ulcers in a murine model that provides promising therapeutic perspectives for clinical trials.

Key words: Wound healing, Angiogenesis, EPC mobilization, CXCL12, Sickle cell ulcers, SAD mice.

1
2
3
4
5
6
7
8
9
10
11
12
13
14
15
16
17
18
19
20
21
22
23
24
25
26
27
28
29
30
31
32
33
34
35
36
37
38
39
40
41
42
43
44
45
46
47
48
49
50
51
52
53
54
55
56
57
58
59
60

INTRODUCTION

Sickle cell disease (SCD) was once largely confined to populations of Sub-Saharan Africa but has recently become the most frequent genetic disease diagnosed in developed countries such as the United Kingdom and France (Piel et al, 2010). In these two countries, the incidence of SCD is around 1/1500 to 1/3800 newborns/year (Piel et al, 2010; Thuret et al, 2010). The modern management of SCD has substantially extended the life expectancy of affected patients to around 61 years (Elmariah et al, 2014). Leg ulcers are a severe complication of SCD that affect between 2.5 and 40% of patients (Halabi-Tawil et al, 2008). SCD leg ulcers are a very chronic manifestation of SCD, and are the longest-lasting type of ulcer encountered in adults, with one study reporting ulcers lasting up to 300 months (Halabi-Tawil et al, 2008; Minniti et al, 2014). These ulcers are resistant to all treatments (Marti-Carvajal et al, 2014). The long-lasting nature of the ulcer can lead to many complications, including tibio-tarsal ankylosis, soft tissue infections and chronic pain (Halabi-Tawil et al, 2008).

Little is known about the pathogenesis of SCD leg ulcers. It has been proposed that the manifestations of SCD are related to high blood viscosity and vaso-occlusion or to hemolysis and endothelial dysfunction (Gladwin et al, 2004; Ataga et al, 2006; Bowers et al, 2013; Connes et al, 2013). A study published in 2006 showed that leg ulcers were associated with high levels of LDH and bilirubin (Ataga et al, 2006). In light of this report, several authors have proposed that ulcers in SCD are primarily related to hemolysis. Intravascular hemolysis releases hemoglobin into the blood stream that results in nitric oxide (NO) scavenging leading to vasoconstriction (Aslan et al, 2001; Reiter et al, 2002; JisonGladwin, 2003; Gladwin et al, 2004). However, two other studies did not confirm this association (De Castro et al, 2008; Pashankar et al, 2008). In addition, leg ulcers do not occur in other chronic hemolytic diseases such as paroxysmal nocturnal hemoglobinuria (Bunn et al, 2010), and a recent study did not find hypoxia in skin ulcers in SCD patients (Bowers et al, 2013). Thus, hemolysis-induced vasoconstriction does not appear to be the only mechanism behind long-lasting ulcers in SCD patients. Indeed, other skin wound healing pathways are probably altered in these patients.

Only a few studies have investigated SCD ulcers in humans. In addition to the association studies cited above, two papers have reported biopsies of SCD ulcers (Francillon et al, 1996; Minniti et al, 2014). These studies demonstrate mural fibrin

1
2
3
4
5
6
7
8
9
10
11
12
13
14
15
16
17
18
19
20
21
22
23
24
25
26
27
28
29
30
31
32
33
34
35
36
37
38
39
40
41
42
43
44
45
46
47
48
49
50
51
52
53
54
55
56
57
58
59
60

thrombi, luminal narrowing and progressive vascular occlusion in ulcer beds and the unusual proliferation of abnormal blood vessels with microangiopathic changes including fibrinoid necrosis and fragmented RBCs within vessel walls (Minniti et al, 2014). These interesting data thus reveal changes to cutaneous vessels in SCD ulcers. However, biopsies were obtained from ulcers that were several months old. Therefore, we cannot determine whether these changes are primary events or secondary changes occurring in ulcerated granulation tissue (Minniti et al, 2014). SCD ulcers can be triggered or worsened by various types of trauma (Halabi-Tawil et al, 2008; Delaney et al, 2013), therefore, it is unethical to perform sequential biopsies on patients.

Here, we developed a murine model of SCD ulcers. We show that delayed wound healing in SCD is caused by the impaired recruitment of endothelial progenitor cells as a consequence of inadequate CXCL12 secretion in the wound bed.

1
2
3
4
5
6
7
8
9
10
11
12
13
14
15
16
17
18
19
20
21
22
23
24
25
26
27
28
29
30
31
32
33
34
35
36
37
38
39
40
41
42
43
44
45
46
47
48
49
50
51
52
53
54
55
56
57
58
59
60

RESULTS

Wound healing is altered in old SAD mice

SAD mice did not exhibit any hair or skin abnormalities on macroscopic examination, both at 8 weeks and 12 months of age. Histological examination revealed no differences in epidermal, dermal and hypodermal thickness between SAD mice and their WT littermates at 8 weeks and 12 months of age (Figure 1a and b; Supplementary Figure S2a-f online and data not shown). However, the diameter of CD31+ blood vessels assessed on whole skin mounts was slightly lower in SAD mice than in WT mice (14.37 vs 17.58 μm , respectively, $n=12$; $P < 0.01$, Mann-Whitney) (Figure 1c and d).

Surgical wounds were performed on the back skin of 8 week-old SAD mice and their WT littermates. The speed of wound closure was similar between the two groups (Supplementary Figure S1a and b online). However, we repeated these experiments on older (12-month-old) mice because leg ulcers in SCD patients occur in severely anemic individuals over the age of 15. Interestingly, at this age, wound closure was substantially slower in SAD mice than in their WT littermates. Indeed, the wound surface at day 7, expressed as a percentage of the wound surface at day 0, was 32.21% in SAD mice and 24.27% in WT mice ($n=9$; $P < 0.01$, Mann-Whitney) (Figure 1e and f). This healing delay was confirmed by studying wound sections at day 7: the neo-epidermal tongues on both edges of the wounds studied on keratin-14-labelled sections were significantly shorter in SAD mice than in WT mice (Figure 1g and h). Interestingly, the surface area of SAD wounds at day 5 was significantly correlated with both the severity of hemolysis and anemia (Figure 1i and j).

Angiogenesis is impaired in the wounds of SAD mice

To investigate better the cellular mechanisms implicated in the delayed healing of SAD mice, we analyzed wound specimens at day 7 after wounding.

We found that fewer Ki67+ proliferating keratinocytes and dermal cells were present in the wounds of SAD mice than in those of WT mice, revealing that cellular proliferation of both neo-epidermis and granulation tissue was impaired in SAD mice (Figure 2a and b). We found no difference in the cell counts of infiltrating Gr-1+ neutrophils (Figure 2c and d) and F4.80+ macrophages (Figure 2f and g) in the wound beds of SAD and WT mice at day 7 post-wounding. Accordingly, FACS

1
2
3 analysis of wound specimens obtained earlier, at days 2 and 5 after wounding also
4 did not reveal any differences in counts of CD11b⁺F4.80⁻Ly6G⁺ neutrophils (Figure
5 2e) or CD11b⁺F480⁺Ly6G⁻Ly6C⁺ macrophages between the two strains (Figure 2h).
6 Finally, the number of circulating CD11b⁺Ly6G⁺Ly6C⁺ neutrophils (Figure 3a and b)
7 and CD11b⁺Ly6G⁻Ly6C⁺ monocytes (Figure 3c and d) in the peripheral blood,
8 counted by FACS analysis at days 2 and 5, was similar in SAD and WT mice.
9

10 We assessed angiogenesis by double immunostaining wound sections at day 7 with
11 anti-CD31 and anti-Lyve-1. Blood and lymphatic vessel density was substantially
12 lower in SAD wounds than in WT wounds (Figure 2i and j), suggesting an
13 impairment in angiogenesis in SAD mice. This finding was confirmed by FACS
14 analysis of CD45⁺CD31⁺ endothelial cell (EC) content in wounds at day 5 (the
15 number of ECs was 47.9% lower in SAD than in WT mice, n=13, P< 0.01, Mann-
16 Whitney) (Figure 2l and m).
17
18

19 **Endothelial progenitor cell proliferation and mobilization is impaired in SAD** 20 **mice**

21 During skin wound healing, endothelial progenitor cells (EPCs) proliferate in the
22 bone marrow and migrate to peripheral blood in order to participate in wound
23 angiogenesis (Roncalli et al, 2008; Barcelos et al, 2009). Therefore, we
24 hypothesized that impaired angiogenesis in SAD wounds can be a consequence of
25 the poor proliferation/mobilization of bone marrow EPCs. Bone marrow and blood
26 mononuclear cells were isolated at day 0 and 5 post-wounding, then analyzed by
27 FACS. At baseline, the number of CD34⁺CD11b⁻CD31⁺ EPCs was similar in marrow
28 and blood of SAD as compared to WT (Figure 3c and d). In contrast, at day 5 post-
29 wounding, a significantly lower count of EPC was found in the bone marrow of SAD
30 mice than in that of WT mice (29.1% lower) (n=10, P< .05, Mann-Whitney) (Figure
31 3d and e) and the same was true of CD34⁺CD11b⁻CD31⁺ EPCs in the blood (53.3%
32 lower in SAD mice) (n=7, P< 0.01, Mann-Whitney) (Figure 3d and f).
33
34

35 We sought to rule out an intrinsic functional defect of EPCs; therefore, we isolated
36 EPCs from the bone marrow of old SAD and WT mice (n=3) and assessed *in vitro*
37 their proliferation by the MTT assay and their differentiation by acetylated-low density
38 lipoprotein (Ac-LDL)/Lectin double staining. After 7 days of culture, both the
39 differentiation (Figure 3g and h) and proliferation (Figure 3i) of EPCs *in vitro* was
40 similar between SAD and WT mice. Similarly, the proportion of cells expressing the
41
42
43
44
45
46
47
48
49
50
51
52
53
54
55
56
57
58
59
60

1
2
3 endothelial cell markers CD34 and VEGFR2 was not different between SAD and WT
4 mice (Figure 3j and k).
5
6

7 8 **EPC therapy *in situ* rescues the delayed healing of SAD wounds**

9 We sought to assess whether poor EPC recruitment to skin wounds is responsible
10 for impaired angiogenesis and the delayed healing of wounds in SAD mice;
11 therefore, we assessed whether *in situ* cell therapy with EPCs rescues this
12 phenotype. Fresh EPCs (2.5×10^5 cells) isolated from young WT mice were injected
13 into SAD wounds at day 2 after wounding. PBS was injected into the wounds of SAD
14 control mice. At day 9, the wound surface - expressed as a percentage of the wound
15 surface at day 0 - was 17.7% in the EPC-injected group and 32.6% in the PBS group
16 ($n=7$, $P < 0.01$, ANOVA) (Figure 4a and b). Neo-epidermal tongues were longer in the
17 EPC-injected group than in the PBS control group (1251 vs 836 μm , respectively;
18 $n=7$, $P < 0.05$, Mann-Whitney) (Figure 4c and d). There was also more epidermal cell
19 proliferation (Figure 4e and f) and blood vessel angiogenesis (Figure 4g and i) in
20 SAD wounds injected with EPCs than in those injected with PBS.
21

22 We also injected EPCs derived from SAD mice into SAD wounds to investigate
23 further the defect in EPC mobilization. Again, wound closure was strongly improved
24 by the injection of SAD EPCs, in contrast with the PBS control group ($n=5$, $P < 0.01$,
25 ANOVA) (Figure 4a and b). Therefore, *in situ* injections of EPCs, whether obtained
26 from SAD or from WT mice, were able to rescue the wound healing delay.
27
28

29 30 **CXCL12 secretion is low in SAD wounds**

31 We wished to understand the molecular pathways implicated in defective EPC
32 mobilization. We focused on well-known growth factors and chemokines involved in
33 cell migration and angiogenesis. RT-PCR revealed that mRNA levels of CXCL12,
34 IL6, VEGFa, VEGFR-2, Tie-1, Tie-2 and CXCR4 were significantly lower in SAD
35 wounds than in WT wounds ($n=8$) (Figure 5a). We chose to focus on CXCL12
36 because it stimulates angiogenesis in the altered skin wounds of diabetic mice
37 (Gallagher et al, 2007). Moreover, we found a correlation between the level of
38 CXCL12 mRNA expression in wounds and the level of circulating EPCs in the
39 peripheral blood (Figure 5b) highlighting the importance to focus on this pathway.
40 Finally, we studied the source of CXCL12 in wounds. We sorted the main cell types
41 from wound of SAD and WT mice at day 3 post-wounding. CXCL12 mRNA levels
42
43
44
45
46
47
48
49
50
51
52
53
54
55
56
57
58
59
60

1
2
3 were significantly lower in CD45⁺CD31⁺PDGFR α ⁻ keratinocytes and CD45⁺
4 leukocytes from SAD wounds than in those from WT wounds. CXCL12 expression
5 was similar in CD45⁺CD31⁺ endothelial cells and CD45⁺CD31⁺PDGFR α ⁺ fibroblasts
6 (n=5) (Figure 5c).
7
8
9

10 11 **CXCL12 injections rescue the wound healing delay of old SAD mice**

12 We then asked whether the local delivery of CXCL12 to SAD wounds rescues the
13 delay in wound healing observed in these mice. Recombinant CXCL12 (SDF-1 α)
14 protein or PBS were injected into SAD wound tissue at days 0 and 2 (n=6 for SDF-
15 1 α and 5 for PBS). Planimetry showed that the surface area of wounds injected with
16 SDF-1 α was significantly lower than those injected with PBS (wound surface at day
17 9 - as a percentage of wound surface at day 0 - was 18.9 in the SDF-1 α group vs
18 31.8 in the PBS group, $P < 0.05$, ANOVA) (Figure 6a and b). This finding was
19 confirmed by neo-epidermal tongue measurements on wound sections at day 9,
20 showing that re-epithelialization was stronger after SDF-1 α injections than after PBS
21 injections: 1250 μm in the SDF-1 α group vs 739 μm in the PBS group ($P < 0.05$,
22 Mann-Whitney) (Figure 6c and d). Furthermore, angiogenesis was significantly
23 enhanced in SDF-1 α -treated wounds (Figure 6g and h). Importantly, when SDF-1 α
24 has been injected in wounds, we found a three-fold increase in circulating EPCs at
25 day 9 (Figure 6j and k). Moreover, there was a positive correlation between the SDF-
26 1 α stimulated increase in wound vessels and the SDF-1 α stimulated increase in
27 circulating EPC (Figure 6l).
28
29
30
31
32
33
34
35
36
37
38
39
40
41
42
43
44
45
46
47
48
49
50
51
52
53
54
55
56
57
58
59
60

DISCUSSION

Here, we describe an altered wound healing in a mouse model of SCD and used it to study the cellular and molecular mechanisms of sickle cell ulcers. We found that surgical wounds in transgenic SAD mice showed delayed healing that correlated with the severity of anemia and hemolysis. These features resemble those of ulcers in human SCD. Indeed, many studies have shown an association between leg ulcers and a hyper-hemolytic phenotype with high levels of reticulocytosis, which is also present in our mice (Kato et al, 2006; Taylor et al, 2008; Minniti et al, 2014). In addition, leg ulcers develop only after 15 years in SCD patients, at a median age of 21 years (Halabi-Tawil et al, 2008). Accordingly, the defect in wound healing reported here was restricted to old SAD mice. Therefore, the altered healing of surgical wounds in old SAD mice is relevant to the human disease and these animals are therefore a new and original model for the study of sickle cell ulcers. Importantly, our study did not focus on the initial events leading to skin ulcers but rather on the healing abnormalities that prevent recovery. This is a major unresolved health problem in affected individuals because ulcers can last a long time in SCD patients, up to 25 years, and are associated with many complications (Halabi-Tawil et al, 2008; Minniti et al, 2014).

Wound healing is a multistep process that requires well-orchestrated inflammatory, vascular and cellular proliferation steps. We first analyzed inflammatory infiltration in SAD wounds and found no abnormalities in Gr-1⁺ neutrophil and F4.80⁺ macrophage counts. This contrasts with previously published data reporting that hypoxia/reperfusion induces hepatopathy in SAD mice and is associated with high counts of neutrophils and macrophages in the bloodstream and liver (Siciliano et al, 2011). Therefore, the pathophysiology of sickle cell ulcers appears to differ from that of other organ damage in SCD.

Angiogenesis is one of the key steps in skin wound healing. We found that CD31⁺ blood vessel content was 44% lower and Lyve-1 lymphatic vessel content was 66% lower in the wounds of SAD mice than in those of their WT littermates. FACS analysis confirmed the poor recruitment of CD31⁺CD45⁻ endothelial cells: 47% fewer cells were detected in SAD wounds than in WT wounds, indicating that quantitative blind immuno-labeling was a robust tool. Interestingly, treatment with granulocyte/macrophage colony-stimulating factor (GM-CSF) -that stimulates

1
2
3 pericyte-like perivascular mural cells to secrete VEGFa- improves SCD ulcer healing
4 (Pieters et al, 1995; Alikhan et al, 2004; Mery et al, 2004; Zhao et al, 2014).
5
6 Angiogenesis disorders in tissues may result from various abnormalities including
7
8 from EPC defects (Loomans et al, 2004; Fadini et al, 2005; Fadini et al, 2005;
9
10 Tepper et al, 2010). We therefore studied EPC recruitment in wounded SAD mice.
11
12 We found that the number of EPCs in bone marrow and blood post-wounding was
13
14 significantly lower in SAD mice than in WT mice, while this number was similar at
15
16 baseline. These results indicate inadequate EPC proliferation and mobilization in
17
18 bone marrow of wounded SAD mice. Proliferation and differentiation *in vitro* were
19
20 similar between SAD and WT EPCs, indicating the absence of an intrinsic disorder of
21
22 these cells. In addition, WT and SAD EPCs injected directly into SAD wounds
23
24 rescued delayed healing by restoring the defect of angiogenesis. Therefore, these
25
26 results strongly suggest that in old SAD mice, defective EPC
27
28 proliferation/mobilization is a consequence of micro-environmental changes in SAD
29
30 marrow. This situation differs from that of diabetes where db/db EPCs display an
31
32 intrinsically abnormal phenotype *in vitro* and *in vivo* (Marrotte et al, 2010).
33
34 Transcript levels of several cytokines, chemokines and growth factors implicated in
35
36 EPC mobilization and angiogenesis were low in SAD wounds, including CXCL12 and
37
38 its receptor CXCR4. We focused on CXCL12/CXCR4 axis since it plays an important
39
40 role in the mobilization of progenitor cells to the periphery under various conditions
41
42 including wound healing (Avniel et al, 2006; Mazo et al, 2011; Hu et al, 2013). In
43
44 addition, there was a correlation between the level of CXCL12 in wounds and the
45
46 level of circulating EPCs. Accordingly, the injection of CXCL12 into the wounds of
47
48 SAD mice enabled the wounds to heal as quickly as controls. This healing rescue
49
50 was associated with a 3-fold increase in circulating EPCs in CXCL12 treated mice.
51
52 Moreover, the improvement in cutaneous angiogenesis in the SAD mice was strictly
53
54 proportional with the observed increase in circulating EPC. These findings strongly
55
56 suggest that CXCL12-induced increase in EPC mobilization was responsible for the
57
58 observed SAD wound healing. Therefore, the defect in the CXCL12/CXCR4 axis is a
59
60 major event leading to impaired EPC recruitment to skin wounds in SAD mice. In
SCD patients, plasma CXCL12 levels are higher than in healthy controls (Landburg
et al, 2009). However, levels of CXCL12 do not increase during vaso-occlusive
crisis, in contrast with healthy individuals. Our SAD mice are characterized by
inadequate CXCL12 production in response to skin wounding, which has also been

10

1
2
3
4
5
6
7
8
9
10
11
12
13
14
15
16
17
18
19
20
21
22
23
24
25
26
27
28
29
30
31
32
33
34
35
36
37
38
39
40
41
42
43
44
45
46
47
48
49
50
51
52
53
54
55
56
57
58
59
60

suggested to occur in humans during vaso-occlusive crisis. The low expression of CXCL12 involved both keratinocytes and CD45⁺ leukocytes in healing skin. Our findings are partly consistent with reports in diabetic mice, showing that CXCL12 levels are low in skin because of the impaired production of CXCL12 by keratinocytes and myofibroblasts (Gallagher et al, 2007; Bermudez et al, 2011). Healing delay can be partly improved by chemokine injection (Gallagher et al, 2007). Finally, inhibition of CXCR4 through the topical application of AMD 3100 to diabetic wounds induces EPC mobilization (Nishimura et al, 2012).

In summary, old SAD mice show a delay in wound healing that correlates with the severity of anemia and hemolysis, thus resembling closely the situation in humans. This healing delay is caused by inadequate EPC proliferation and mobilization secondary to defective CXCL12 secretion by keratinocytes and leukocytes in wounded skin. Future studies should analyze CXCL12 in SCD patients with ulcers and assess the benefit of CXCL12 therapy in clinical trials.

1
2
3
4
5
6
7
8
9
10
11
12
13
14
15
16
17
18
19
20
21
22
23
24
25
26
27
28
29
30
31
32
33
34
35
36
37
38
39
40
41
42
43
44
45
46
47
48
49
50
51
52
53
54
55
56
57
58
59
60

MATERIALS AND METHODS

Mice

The SAD-1 (SAD) mouse has been described previously (Trudel et al, 1991). Briefly, this is a transgenic mouse that harbors a mutated form of human β globin. SAD Hbb^{S/S} hemizygous and wild-type (C57BL/6 background) mice used for this study were housed in a dedicated pathogen-free environment and were used in accordance with European Community guidelines and approved by our Institutional Animal Care and Use Committee.

Surgical wounds and morphometric analysis

Mice were anesthetized by inhalation of isofluorane (AeraneH, Baxter, Deerfield, IL). After depilation, full-thickness surgical wounds were generated on the back of mice with 6 or 8-mm disposable biopsy devices (Kai Europe GmbH). All tissues above the panniculus carnosus were excised. Wounds were then left uncovered. Pictures of wounds were taken at indicated days after wounding using a Sony CybershotH 10.1 megapixels DSC-W180 digital camera. Wound surface at each time-point was expressed as a percentage of the initial surface of each wound at day 0.

For tissue collection, mice were killed in a CO₂ chamber. Tissues were harvested and either snap-frozen in liquid nitrogen and stored at -80°C for RNA extraction or immunolabeling; or fixed in 4% formaldehyde for 12 h at 4°C and then embedded in paraffin for histological analysis.

Whole mount staining

The cartilage-free ventral sides of ears were collected and fixed in 4% PFA (in PBS) for 12 h at 4°C. The tissues were processed as already published (Lebrin et al, 2010; Lee et al, 2014). Goat polyclonal anti-mouse VEGFR-3 (R&D Systems) and rat anti-mouse CD31 antibodies (clone MEC 13.3, eBioscience), were used. All fluorescently-labeled samples were analyzed with a confocal microscope (Leica).

EPC injections in skin wounds

Bone marrow-derived CD34⁺CD11b⁻CD31⁺ EPCs were sorted from of 8 week-old SAD and WT female mice. A total of 2.5×10^5 sorted cells suspended in 100 μ l PBS

12

1
2
3
4
5
6
7
8
9
10
11
12
13
14
15
16
17
18
19
20
21
22
23
24
25
26
27
28
29
30
31
32
33
34
35
36
37
38
39
40
41
42
43
44
45
46
47
48
49
50
51
52
53
54
55
56
57
58
59
60

pH 7.4 were then injected into four diametrically opposed points at the wound site (5 mm from the wound edges) at day 2 after wounding. Control mice were treated with PBS in the same way.

CXCL12 (SDF-1 α) injections in skin wounds

SDF-1 α protein (CliniSciences) was reconstituted in PBS pH 7.4 and injected at a dose of 25 μ g/kg into four diametrically opposed points of the wound site at day 0 and day 2 after wounding. Control mice were treated with PBS in the same way.

For Review Only

1
2
3
4
5
6
7
8
9
10
11
12
13
14
15
16
17
18
19
20
21
22
23
24
25
26
27
28
29
30
31
32
33
34
35
36
37
38
39
40
41
42
43
44
45
46
47
48
49
50
51
52
53
54
55
56
57
58
59
60

CONFLICT OF INTEREST

The authors state no conflict of interest

ACKNOWLEDGEMENTS

V.T.N. collection and assembly of data, data analysis and interpretation, manuscript writing;

D.N. collection and assembly of initial data; data analysis and interpretation, manuscript writing;

F.B. performed the ROS experiments;

K.R. helped in imaging and FACS analysis;

P.L.T. provided the SAD strain and helped to resolve experimental issues;

S.A. conception and design, data analysis and interpretation, manuscript writing.

The authors are grateful to several people for providing regular scientific advice and help. We thank Michèle Oster for technical support in histology, Tatiana Ledent and Delphine Muller (Animal Facility, Saint-Antoine Research Center), Sylvie Dumont and Fatiha Merabtene (Histo-morphology Platform, IFR65, Saint-Antoine Research Center), Anne-Marie Faussat (Cytometry Platform, IFR65, Saint-Antoine Research Center), Romain Morichon (Cellular and Tissue Imaging Platform, IFR65, Saint-Antoine Research Center), Hélène Fohrer-Ting and Estelle Devèvre (Cellular Imaging and Cytometry Center (CICC), Cordeliers Research Center, Paris, France).

FUNDING SOURCES

Van Tuan Nguyen was supported by the Vietnamese Government, the Fondation pour la Recherche Médicale (FRM) and AREMPH. Dany Nassar was partly funded by the Region Ile de France DIM Stempole and AREMPH. This work was partly funded by the Société Française de Dermatologie.

1
2
3
4
5
6
7
8
9
10
11
12
13
14
15
16
17
18
19
20
21
22
23
24
25
26
27
28
29
30
31
32
33
34
35
36
37
38
39
40
41
42
43
44
45
46
47
48
49
50
51
52
53
54
55
56
57
58
59
60

References

- Alikhan MA, Carter G, Mehta P (2004). Topical GM-CSF hastens healing of leg ulcers in sickle cell disease. *Am J Hematol* 76: 192.
- Aslan M, Ryan TM, Adler B, et al (2001). Oxygen radical inhibition of nitric oxide-dependent vascular function in sickle cell disease. *Proc Natl Acad Sci U S A* 98: 15215-20.
- Ataga KI, Moore CG, Jones S, et al (2006). Pulmonary hypertension in patients with sickle cell disease: a longitudinal study. *Br J Haematol* 134: 109-15.
- Avniel S, Arik Z, Maly A, et al (2006). Involvement of the CXCL12/CXCR4 pathway in the recovery of skin following burns. *J Invest Dermatol* 126: 468-76.
- Barcelos LS, Duplaa C, Krankel N, et al (2009). Human CD133+ progenitor cells promote the healing of diabetic ischemic ulcers by paracrine stimulation of angiogenesis and activation of Wnt signaling. *Circ Res* 104: 1095-102.
- Bermudez DM, Xu J, Herdrich BJ, et al (2011). Inhibition of stromal cell-derived factor-1alpha further impairs diabetic wound healing. *J Vasc Surg* 53: 774-84.
- Bowers AS, Reid HL, Greenidge A, et al (2013). Blood viscosity and the expression of inflammatory and adhesion markers in homozygous sickle cell disease subjects with chronic leg ulcers. *PLoS One* 8: e68929.
- Bunn HF, Nathan DG, Dover GJ, et al (2010). Pulmonary hypertension and nitric oxide depletion in sickle cell disease. *Blood* 116: 687-92.
- Connes P, Lamarre Y, Hardy-Dessources MD, et al (2013). Decreased hematocrit-to-viscosity ratio and increased lactate dehydrogenase level in patients with sickle cell anemia and recurrent leg ulcers. *PLoS One* 8: e79680.
- De Castro LM, Jonassaint JC, Graham FL, et al (2008). Pulmonary hypertension associated with sickle cell disease: clinical and laboratory endpoints and disease outcomes. *Am J Hematol* 83: 19-25.
- Delaney KM, Axelrod KC, Buscetta A, et al (2013). Leg ulcers in sickle cell disease: current patterns and practices. *Hemoglobin* 37: 325-32.
- Elmariah H, Garrett ME, De Castro LM, et al (2014). Factors associated with survival in a contemporary adult sickle cell disease cohort. *Am J Hematol* 89: 530-5.
- Fadini GP, Agostini C, Avogaro A (2005). Endothelial progenitor cells in cerebrovascular disease. *Stroke* 36: 1112-3; author reply 13.
- Fadini GP, Miorin M, Facco M, et al (2005). Circulating endothelial progenitor cells are reduced in peripheral vascular complications of type 2 diabetes mellitus. *J Am Coll Cardiol* 45: 1449-57.
- Francillon YJ, Jilly PN, Varricchio F, et al (1996). Histochemical analysis of growth factor, fibronectin, and iron content of sickle cell leg ulcers. *Wound Repair Regen* 4: 240-3.
- Gallagher KA, Liu ZJ, Xiao M, et al (2007). Diabetic impairments in NO-mediated endothelial progenitor cell mobilization and homing are reversed by hyperoxia and SDF-1 alpha. *J Clin Invest* 117: 1249-59.
- Gladwin MT, Sachdev V, Jison ML, et al (2004). Pulmonary hypertension as a risk factor for death in patients with sickle cell disease. *N Engl J Med* 350: 886-95.
- Halabi-Tawil M, Lionnet F, Girot R, et al (2008). Sickle cell leg ulcers: a frequently disabling complication and a marker of severity. *Br J Dermatol* 158: 339-44.

- 1
2
3 Hu C,Yong X,Li C, *et al* (2013). CXCL12/CXCR4 axis promotes mesenchymal stem cell
4 mobilization to burn wounds and contributes to wound repair. *J Surg Res* 183:
5 427-34.
6
7 Jison ML, Gladwin MT (2003). Hemolytic anemia-associated pulmonary hypertension of
8 sickle cell disease and the nitric oxide/arginine pathway. *Am J Respir Crit Care*
9 *Med* 168: 3-4.
10
11 Kato GJ,McGowan V,Machado RF, *et al* (2006). Lactate dehydrogenase as a biomarker of
12 hemolysis-associated nitric oxide resistance, priapism, leg ulceration, pulmonary
13 hypertension, and death in patients with sickle cell disease. *Blood* 107: 2279-85.
14
15 Landburg PP,Nur E,Maria N, *et al* (2009). Elevated circulating stromal-derived factor-1
16 levels in sickle cell disease. *Acta Haematol* 122: 64-9.
17
18 Lebrin F,Srun S,Raymond K, *et al* (2010). Thalidomide stimulates vessel maturation and
19 reduces epistaxis in individuals with hereditary hemorrhagic telangiectasia. *Nat*
20 *Med* 16: 420-8.
21
22 Lee KM,Danuser R,Stein JV, *et al* (2014). The chemokine receptors ACKR2 and CCR2
23 reciprocally regulate lymphatic vessel density. *EMBO J* 33: 2564-80.
24
25 Loomans CJ,de Koning EJ,Staal FJ, *et al* (2004). Endothelial progenitor cell dysfunction: a
26 novel concept in the pathogenesis of vascular complications of type 1 diabetes.
27 *Diabetes* 53: 195-9.
28
29 Marrotte EJ,Chen DD,Hakim JS, *et al* (2010). Manganese superoxide dismutase
30 expression in endothelial progenitor cells accelerates wound healing in diabetic
31 mice. *J Clin Invest* 120: 4207-19.
32
33 Marti-Carvajal AJ, Knight-Madden JM, Martinez-Zapata MJ (2014). Interventions for
34 treating leg ulcers in people with sickle cell disease. *Cochrane Database Syst Rev*
35 12: CD008394.
36
37 Mazo IB, Massberg S, von Andrian UH (2011). Hematopoietic stem and progenitor cell
38 trafficking. *Trends Immunol* 32: 493-503.
39
40 Mery L, Girot R, Aractingi S (2004). Topical effectiveness of molgramostim (GM-CSF) in
41 sickle cell leg ulcers. *Dermatology* 208: 135-7.
42
43 Minniti CP,Delaney KM,Gorbach AM, *et al* (2014). Vasculopathy, inflammation, and
44 blood flow in leg ulcers of patients with sickle cell anemia. *Am J Hematol* 89: 1-6.
45
46 Nishimura Y,Ii M,Qin G, *et al* (2012). CXCR4 antagonist AMD3100 accelerates impaired
47 wound healing in diabetic mice. *J Invest Dermatol* 132: 711-20.
48
49 Pashankar FD,Carbonella J,Bazzy-Asaad A, *et al* (2008). Prevalence and risk factors of
50 elevated pulmonary artery pressures in children with sickle cell disease.
51 *Pediatrics* 121: 777-82.
52
53 Piel FB,Patil AP,Howes RE, *et al* (2010). Global distribution of the sickle cell gene and
54 geographical confirmation of the malaria hypothesis. *Nat Commun* 1: 104.
55
56 Pieters RC,Rojer RA,Saleh AW, *et al* (1995). Molgramostim to treat SS-sickle cell leg
57 ulcers. *Lancet* 345: 528.
58
59 Reiter CD,Wang X,Tanus-Santos JE, *et al* (2002). Cell-free hemoglobin limits nitric oxide
60 bioavailability in sickle-cell disease. *Nat Med* 8: 1383-9.
61
62 Roncalli JG,Tongers J,Renault MA, *et al* (2008). Endothelial progenitor cells in
63 regenerative medicine and cancer: a decade of research. *Trends Biotechnol* 26:
64 276-83.
65
66 Siciliano A,Malpeli G,Platt OS, *et al* (2011). Abnormal modulation of cell protective
67 systems in response to ischemic/reperfusion injury is important in the
68 development of mouse sickle cell hepatopathy. *Haematologica* 96: 24-32.

1
2
3
4
5
6
7
8
9
10
11
12
13
14
15
16
17
18
19
20
21
22
23
24
25
26
27
28
29
30
31
32
33
34
35
36
37
38
39
40
41
42
43
44
45
46
47
48
49
50
51
52
53
54
55
56
57
58
59
60

Taylor JG, Nolan VG, Mendelsohn L, et al (2008). Chronic hyper-hemolysis in sickle cell anemia: association of vascular complications and mortality with less frequent vasoocclusive pain. *PLoS One* 3: e2095.

Tepper OM, Carr J, Allen RJ, Jr, et al (2010). Decreased circulating progenitor cell number and failed mechanisms of stromal cell-derived factor-1alpha mediated bone marrow mobilization impair diabetic tissue repair. *Diabetes* 59: 1974-83.

Thuret I, Sarles J, Merono F, et al (2010). Neonatal screening for sickle cell disease in France: evaluation of the selective process. *J Clin Pathol* 63: 548-51.

Trudel M, Saadane N, Garel MC, et al (1991). Towards a transgenic mouse model of sickle cell disease: hemoglobin SAD. *EMBO J* 10: 3157-65.

Zhao J, Chen L, Shu B, et al (2014). Granulocyte/macrophage colony-stimulating factor influences angiogenesis by regulating the coordinated expression of VEGF and the Ang/Tie system. *PLoS One* 9: e92691.

For Review Only

1
2
3 **FIGURE LEGENDS**
4
5
6

7 **Figure 1. Delayed skin wound healing occurs in old SAD mice**

8 (a) Skin sections from old SAD and WT mice stained with HPS (hematoxylin
9 phloxine saffran), (b) thickness of epidermis (Epider), dermis (Der) and hypodermis
10 (Hypoder) (n=5). (c) Whole mount staining for CD31 and VEGFR3 in normal ear skin
11 from old mice, (d) measurement of blood and lymphatics diameter. (e) Wound
12 healing kinetics, and (f) measurement of wound area (n=9). (g) Anti-K14 staining at
13 day 7, with measurement of the (h) neo-epidermal tongues and (i) gaps (n=9). (j-k)
14 Correlation of SAD wound area at day 5 with levels of hemoglobin (anemia) (j) and
15 with reticulocyte counts (hemolysis) (k). Mean \pm SEM. b, d, f, h and i- Mann-Whitney
16 test: * P <0.05; ** P <0.01 SAD vs WT. j and k- Pearson test: * P <0.05; ** P <0.01. Scale
17 bars: 100 μ m.
18
19
20
21
22
23
24
25
26

27 **Figure 2. Angiogenesis is impaired in the wound beds of SAD mice**

28 (a) Anti-Ki67 staining of wound sections at day 7, dotted lines indicating the dermal
29 epidermal junction (DEJ). (b) Quantification of Ki67⁺ cells. (c) Anti-Gr-1 and (f) anti-
30 F4.80 staining on wound sections at day 7, with quantification of Gr-1⁺ neutrophils
31 (d) and F4.80⁺ macrophages (g) (n=9). (e,h) FACS analysis of wound cell
32 suspensions for quantification of neutrophils and macrophages (n=6). (i) Double
33 staining of CD31 and Lyve-1 on wound sections at day 7, with measurement of the
34 (j) vessel numbers and (k) relative area occupied by vessels (n=9). (l-m) FACS
35 analysis of wound cells for the quantification of endothelial cells (n=13). Mean \pm
36 SEM. * P <0.05, ** P <0.01, *** P <0.001 SAD vs WT, Mann-Whitney test. Scale bars:
37 100 μ m.
38
39
40
41
42
43
44
45
46

47 **Figure 3. Impairment of endothelial progenitor cell proliferation and**
48 **mobilization in SAD mice**

49 (a-c) FACS analysis of peripheral blood mononuclear cells for quantification of (a,b)
50 neutrophils and (a,c) monocytes in SAD and WT mice (n=3 to 6); (d-f) FACS
51 analysis of endothelial progenitor cells (EPCs) in (d,e) marrow and (d,f) peripheral
52 blood at day 0 and day 5 post-wounding (n=6 to 10). At day 5 post-wounding,
53 marrow mononuclear cells were cultured and analyzed after 7 days. (g) Double
54
55
56
57
58
59
60

1
2
3 staining with Dil-Ac-LDL and Lectin, and (h) quantification of differentiating double-
4 labeled cells. (i) Proliferation of cultured EPCs (MTT assay). (j) Cultured EPCs
5 labeled with anti-VEGFR2 and anti-CD34, with (k) quantification of the
6 CD34⁺VEGFR2⁺ cells (n=3). Mean ± SEM. **P*<0.05, ***P*<0.01 SAD vs WT, Mann-
7 Whitney test. g and j- arrowheads indicate double positive cells.
8
9
10

11
12 **Figure 4. Delayed wound healing in SAD mice is rescued by EPC therapy**

13 (a) Photographs of wounds, (b) measurement of wound area. (c-i) SAD wounds
14 injected with WT EPCs or PBS harvested at day 9 (n=7). (c) K14 staining, and (d)
15 length of neo-epidermal tongues. (e) Ki67 staining, (f) quantification of Ki67⁺ cells in
16 the neo-epidermis (Epider) and in granulation tissue (Der). (g) Double staining for
17 CD31 and Lyve-1, with quantification of the (h) vessel number and (i) relative area
18 occupied by vessels. Mean ± SEM. b- ANOVA: **P*<0.05, ***P*<0.01, ****P*<0.001 WT
19 + PBS vs SAD + PBS; §*P*<0.05, §§*P*<0.01 SAD + PBS vs SAD + WT EPC; #*P*<0.05,
20 ##*P*<0.01 SAD + PBS vs SAD + SAD EPC. d,f,h and i- Mann-Whitney test: **P*<0.05,
21 ***P*<0.01, ****P*<0.001 SAD + PBS vs SAD + WT EPC. Scale bars: 100 μm.
22
23
24
25
26
27
28
29
30

31 **Figure 5. CXCL12 expression is low in SAD wounds**

32 (a) Quantitative RT-PCR analysis of total wounded skin at day 5, analyzing genes
33 implicated in angiogenesis and EPC mobilization in SAD and WT mice (n=8). (b)
34 Correlation between CXCL12 mRNA expression in wounds and level of circulating
35 EPCs in the blood at day 5 after wounding (n=8). (c) Quantitative RT-PCR analysis
36 of CXCL12 mRNA expression in the four main cell types isolated from wounded skin
37 at day 3 (n=5). Mean ± SEM. **P*<0.05, ***P*<0.01; SAD vs WT, Mann-Whitney test.
38
39
40
41
42
43
44

45 **Figure 6. *In situ* injection of SDF-1α (CXCL12) rescues the healing delay of**
46 **SAD mice**

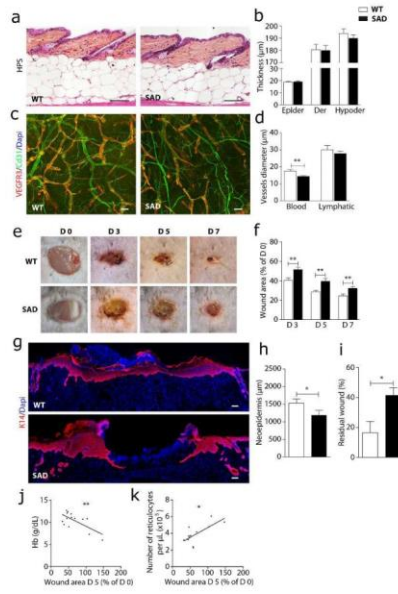
47 (a) Photographs of wounds, (b) measurement of wound area. (c-i) SAD wounds
48 injected with SDF-1α or PBS harvested at day 9 (n=5 to 6). (c) K14 staining, with (d)
49 length of neo-epidermal tongues. (e) Ki67 staining, (f) quantification of Ki67⁺ cells in
50 the neo-epidermis (Epider) and granulation tissue (Der). (g) Double staining for
51 CD31 and Lyve-1, with quantification of the (h) vessel number and (i) relative area
52 occupied by vessels. (j-k) FACS analysis of CD34⁺CD11b⁻CD31⁺ EPCs in peripheral
53
54
55
56
57
58
59
60

1
2
3 blood at day 9 post-wounding (n=6). (l) Correlation between level of circulating EPCs
4 in the blood and number of blood vessels in wounds at day 9 (n=6). Mean±SEM. b-
5 ANOVA: ** $P < 0.01$ WT + PBS vs SAD + PBS; § $P < 0.05$, §§ $P < 0.01$ SAD + PBS vs SAD
6 + SDF-1 α . d,f,h,i,k- Mann-Whitney test. * $P < 0.05$, ** $P < 0.01$; SAD + PBS vs SAD +
7 SDF-1 α . I-Pearson test: *** $P < 0.001$.
8
9
10
11
12
13
14
15
16
17
18
19
20
21
22
23
24
25
26
27
28
29
30
31
32
33
34
35
36
37
38
39
40
41
42
43
44
45
46
47
48
49
50
51
52
53
54
55
56
57
58
59
60

For Review Only

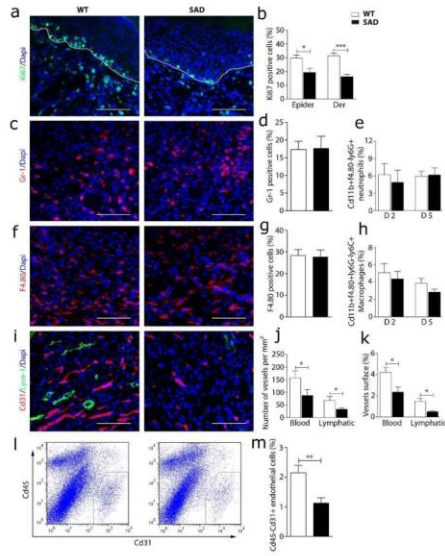
1
2
3
4
5
6
7
8
9
10
11
12
13
14
15
16
17
18
19
20
21
22
23
24
25
26
27
28
29
30
31
32
33
34
35
36
37
38
39
40
41
42
43
44
45
46
47
48
49
50
51
52
53
54
55
56
57
58
59
60

Figure 1



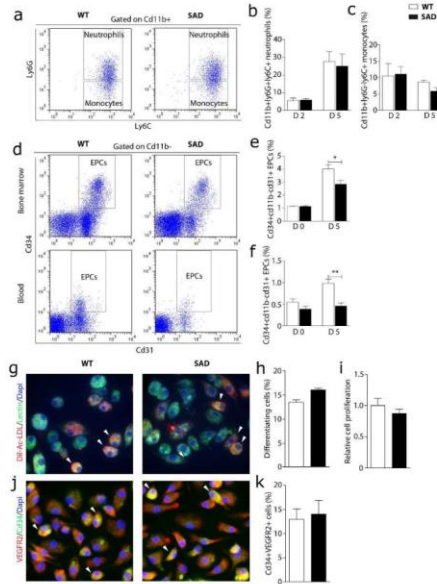
1
2
3
4
5
6
7
8
9
10
11
12
13
14
15
16
17
18
19
20
21
22
23
24
25
26
27
28
29
30
31
32
33
34
35
36
37
38
39
40
41
42
43
44
45
46
47
48
49
50
51
52
53
54
55
56
57
58
59
60

Figure 2



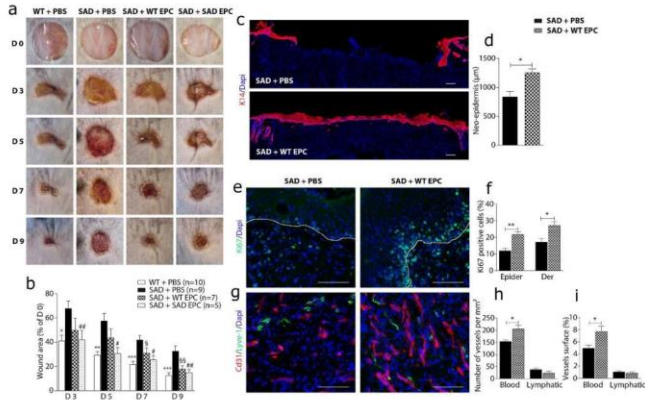
1
2
3
4
5
6
7
8
9
10
11
12
13
14
15
16
17
18
19
20
21
22
23
24
25
26
27
28
29
30
31
32
33
34
35
36
37
38
39
40
41
42
43
44
45
46
47
48
49
50
51
52
53
54
55
56
57
58
59
60

Figure 3



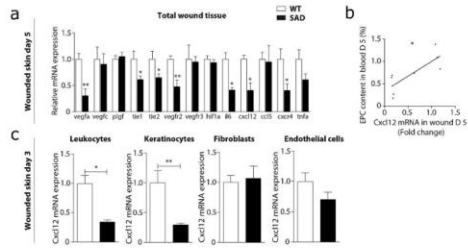
1
2
3
4
5
6
7
8
9
10
11
12
13
14
15
16
17
18
19
20
21
22
23
24
25
26
27
28
29
30
31
32
33
34
35
36
37
38
39
40
41
42
43
44
45
46
47
48
49
50
51
52
53
54
55
56
57
58
59
60

Figure 4



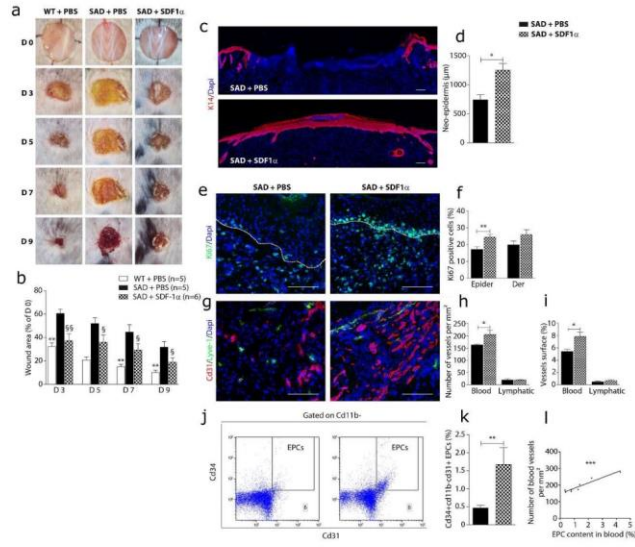
1
2
3
4
5
6
7
8
9
10
11
12
13
14
15
16
17
18
19
20
21
22
23
24
25
26
27
28
29
30
31
32
33
34
35
36
37
38
39
40
41
42
43
44
45
46
47
48
49
50
51
52
53
54
55
56
57
58
59
60

Figure 5



1
2
3
4
5
6
7
8
9
10
11
12
13
14
15
16
17
18
19
20
21
22
23
24
25
26
27
28
29
30
31
32
33
34
35
36
37
38
39
40
41
42
43
44
45
46
47
48
49
50
51
52
53
54
55
56
57
58
59
60

Figure 6



SUPPLEMENTARY FIGURES

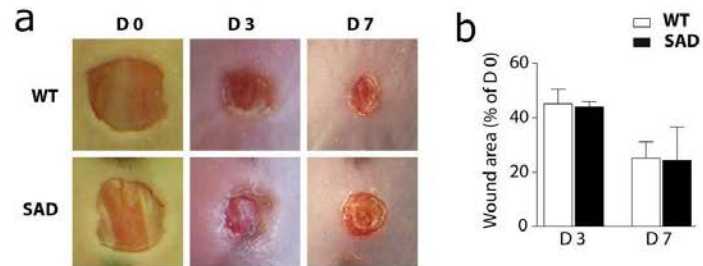

Figure S1. Normal healing of young SAD wounds.

(a) Photographs of wounds at days 0, 3 and 7 in young (8 weeks-old) SAD and WT mice. (b) Measurement of residual wound area related to initial wounded area (day 0) in these animals (n=3).

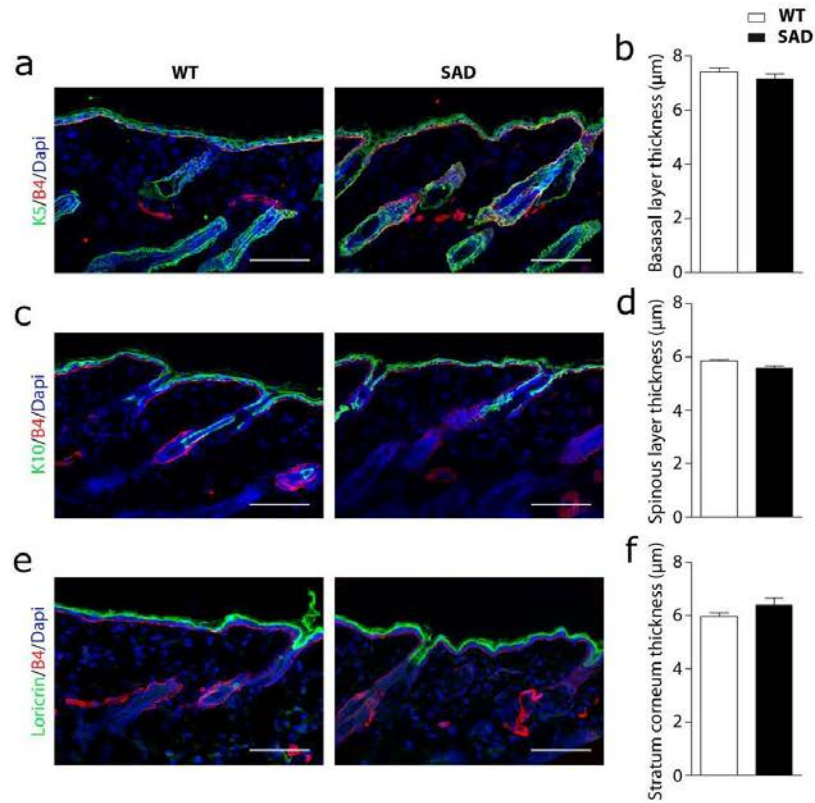


Figure S2. Normal epidermal differentiation in skin from old SAD mice.

Analysis of various markers of epidermal differentiation in back skin of 12 months-old SAD and WT mice. (a,c,e) Immunofluorescence staining of SAD and WT skin for keratin 5 (K5), keratin 10 (K10) and loricrin (green) in combination with basal membrane marker (beta 4 integrin- B4) (red). (b,d,f) Measurement of the respective thickness of K5-labeled basal layer (b), K10-labeled spinous layer (d) and Loricrin-labeled stratum corneum layer (f) in SAD and WT skin. Scale bars: 100 μm

1
2
3
4
5
6
7
8
9
10
11
12
13
14
15
16
17
18
19
20
21
22
23
24
25
26
27
28
29
30
31
32
33
34
35
36
37
38
39
40
41
42
43
44
45
46
47
48
49
50
51
52
53
54
55
56
57
58
59
60

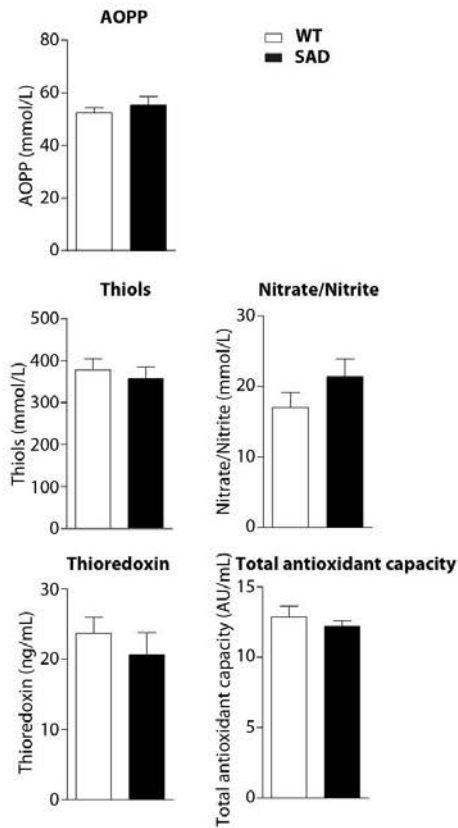


Figure S3. No increase of oxidative stress in SAD wounded mice

After 7 days of wounding, serum was harvested from venous blood of SAD and WT mice and analyzed for different components revealing oxidative stress as described in methods. Measurement of AOPP, Thiols, Nitrate/nitrite, thioredoxin concentration and total antioxidant capacity in SAD and WT sera (n=5).

SUPPLEMENTARY MATERIALS AND METHODS**Reagents and Antibodies**

Recombinant murine SDF-1 α (CXCL12) was purchased from CliniSciences. The following antibodies were used for immunofluorescence staining: rabbit polyclonal anti-keratin 5, rabbit polyclonal anti-keratin 10, rabbit polyclonal anti-keratin 14 (Covance); rabbit polyclonal anti-Ki67, rat anti-beta-4 integrin (clone 346-11A), rat anti-F4/80 (clone Cl:A3-1), rabbit polyclonal anti-CD31, rat anti-CD34 (clone MEC 14.7), and rabbit polyclonal anti-Lyve-1 (Abcam); rat anti-mouse CD31 (clone MEC 13.3), rat anti-Gr-1 (clone RB6-8C5) (eBioscience); and goat polyclonal anti-mouse VEGFR3 (R&D System). For flow cytometric analysis, the following antibodies were used: FITC-conjugated rat anti-F4/80 (clone BM8), FITC-conjugated rat anti-CD31 (clone 390), APC-conjugated rat anti-CD45 (clone 30F11) (Biolegend); PerCP-conjugated rat anti-CD11b (clone M1/70), PE-conjugated rat anti-Ly6C (clone HK1.4), APC-conjugated rat anti-CD34 (clone RAM 34), PE-conjugated anti-CD140 (clone APA5) (eBioscience); APC-conjugated rat anti-Ly6G (clone 1A8) (BD Bioscience).

Immunofluorescence analysis

Immunolabeling was performed on 6 μ m cryosections. Sections were prepared, fixed in ice-cold acetone and blocked with 2% BSA/PBS. Cells grown on glass coverslips were fixed with 1% paraformaldehyde/PBS. Subsequently, PBS containing 0.1% Triton X-100 or 2% BSA was used for permeabilization and blocking, respectively. Samples were then incubated with primary antibodies for 2 h at room temperature. Isotype Ig served as a negative control. The secondary antibodies used were Alexa Fluor 488 and Alexa Fluor 555 (Molecular Probes) conjugated antibodies. Samples were examined and photographed using a Nikon Eclipse 90i fluorescent microscope equipped with a Nikon DS-Fi1C digital camera (Nikon). Labeled cells were counted without knowledge of the corresponding experimental condition in three different fields and reported as a percentage of total DAPI stained nuclei. Wound angiogenesis and wound re-

1
2
3 epithelialization were also assessed in a blind manner as described previously
4
5 (Khosrotehrani *et al*, 2011; Nassar *et al*, 2012).
6

7 8 **FACS analysis and cell sorting** 9

10 Wound tissue harvested at day 2, 3 or 5 after wounding was used for FACS analysis,
11 according to established methods with minor modifications (Nassar *et al*, 2012).
12

13 Mononuclear cells were isolated from blood and marrow as described previously
14 (Marrotte *et al*, 2010). These cells were used for FACS analysis or cell sorting. Briefly,
15 10⁶ cells were re-suspended in 1% FBS/PBS, incubated with a combination of
16 fluorescence-conjugated antibodies in the dark for 1 h on ice. FACS data were acquired
17 using a BD LSR II cytometer (BD Pharmingen), and analyzed with FlowJo software
18 (TreeStar Inc., Ashland, OR, USA). Different cell populations were calculated as a
19 percentage of total living cells. EPCs were sorted using a BD Vantage Flow cytometer
20 (BD Pharmingen).
21
22
23
24
25
26
27
28
29

30 **EPC culture assay**

31 Bone marrow was flushed out of mouse femurs with 5 mM EDTA/PBS pH 8.0 using a
32 25-gauge needle, separated by vigorous pipetting, and then centrifuged for 5 minutes
33 (400 g, 4°C). Mononuclear cells were isolated and plated onto a vitronectin-coated
34 (Sigma-Aldrich) 6-well plate at 8.5 × 10⁵ cell/cm² in EGM-2 (Lonza) at 37°C, 5% CO₂.
35 After 4 days of culture, non-adherent cells were removed. EGM-2 medium was changed
36 daily.
37

38 After 7 days of culture, attached cells were phenotyped by labeling with Dil-acLDL (10
39 µg/ml; Invitrogen) and FITC-lectin (10 µg/ml; Sigma-Aldrich). Cells demonstrating
40 double-positive Dil-acLDL and lectin staining were identified as differentiating
41 EPCs. (Marrotte *et al*, 2010) In addition, the expression of CD34, VEGFR2 was analyzed
42 by immunostaining. The proliferation of cultured EPCs was examined by the MTT assay.
43
44
45
46
47
48
49
50
51

52 **Real time RT-PCR**

53 Total RNA was isolated from wounded skin using TRIzol reagent (Invitrogen) in tissue
54 grinders, or from sorted cells. The Maxima First Strand cDNA synthesis kit (Thermo
55
56
57
58
59
60

1
2
3
4
5
6
7
8
9
10
11
12
13
14
15
16
17
18
19
20
21
22
23
24
25
26
27
28
29
30
31
32
33
34
35
36
37
38
39
40
41
42
43
44
45
46
47
48
49
50
51
52
53
54
55
56
57
58
59
60

Scientific) was used to synthesize cDNA from 0.5 µg of total RNA. Real-time PCR was performed with 2 ng of cDNA as a template in a final volume of 10 µl, using the LightCycler 480 SYBR Green I Master kit (Roche) and a LightCycler® 480 Real-Time PCR System (Roche). All samples were assayed in triplicate. The expression of each target gene was normalized to the relative levels of GAPDH (which was set to "1"), and results were expressed as a fold change. Primers were purchased from Qiagen.

Evaluation of serum oxidative stress

The level of oxidative stress was determined through measuring Advanced Oxidation Protein Products (AOPP), thiols, nitrate/nitrite concentration, the antioxidant capacity and the thioredoxin activity in serum samples harvested from venous blood of SAD and WT mice at day 7 after wounding as already described by Hebert-Schuster and Coriat (Hebert-Schuster *et al*, 2012; Coriat *et al*, 2014).

Statistical analysis

All values were expressed as means ± SEM. Differences between the means of two groups were assessed with the Mann Whitney test. Differences between multiple groups were analyzed by 1-way ANOVA. P < 0.05 was considered statistically significant.

1
2
3
4
5
6
7
8
9
10
11
12
13
14
15
16
17
18
19
20
21
22
23
24
25
26
27
28
29
30
31
32
33
34
35
36
37
38
39
40
41
42
43
44
45
46
47
48
49
50
51
52
53
54
55
56
57
58
59
60

References

- Coriat R, Alexandre J, Nicco C, Quinquis L, Benoit E, Chereau C, Lemarechal H, Mir O, Borderie D, Treluyer JM, Weill B, Coste J, Goldwasser F, Batteux F (2014) Treatment of oxaliplatin-induced peripheral neuropathy by intravenous mangafodipir. *J Clin Invest* 124: 262-272.
- Hebert-Schuster M, Borderie D, Grange PA, Lemarechal H, Kavian-Tessler N, Batteux F, Dupin N (2012) Oxidative stress markers are increased since early stages of infection in syphilitic patients. *Arch Dermatol Res* 304: 689-697.
- Khosrotehrani K, Nguyen Huu S, Prignon A, Avril MF, Boitier F, Oster M, Mortier L, Richard MA, Maubec E, Kerob D, Mansard S, Merheb C, Moguelet P, Nassar D, Guegan S, Aractingi S (2011) Pregnancy promotes melanoma metastasis through enhanced lymphangiogenesis. *Am J Pathol* 178: 1870-1880.
- Marrotte EJ, Chen DD, Hakim JS, Chen AF (2010) Manganese superoxide dismutase expression in endothelial progenitor cells accelerates wound healing in diabetic mice. *J Clin Invest* 120: 4207-4219.
- Nassar D, Droitcourt C, Mathieu-d'Argent E, Kim MJ, Khosrotehrani K, Aractingi S (2012) Fetal progenitor cells naturally transferred through pregnancy participate in inflammation and angiogenesis during wound healing. *Faseb J* 26: 149-157.

CHAPTER 3 - Role of mineralocorticoid receptor in skin wound healing

I - Introduction: Biology of mineralocorticoid receptor

The steroid aldosterone is the main mineralocorticoid hormone; it is synthesized in the glomerular zone of the adrenal cortex in response to hyperkalemia or sodium depletion, as the end-point of activation of the renin-angiotensin system (Rossier et al. 2015). Aldosterone stimulates renal sodium reabsorption and potassium excretion, therefore playing a major role in the control of blood pressure and extracellular volume homeostasis.

The molecular and cellular events involved in aldosterone effects in the distal tubule, the connecting tubule and the collecting duct (referred as aldosterone-sensitive distal nephron) have been elucidated (Pearce et al. 2015; Penton et al. 2015; Rossier et al. 2015). Aldosterone binds to the mineralocorticoid receptor (MR), a ligand-dependent transcription factor belonging to the nuclear receptor superfamily (Viengchareun et al. 2007; Zennaro et al. 2009). After nuclear translocation of the hormone-receptor complex, it binds to glucocorticoid response elements (GRE) within the promoter region of aldosterone-induced genes to modulate their transcription (there is no mineralocorticoid-specific response element; MR, GR and AR as well as progesterone receptors bind to the same GREs). This will trigger an increase in the activity and number of sodium transporters or channels. In a typical mineralocorticoid target cell, as the renal collecting duct principal cell, the sodium enters the cell through the amiloride-sensitive apical sodium channel (ENaC, for Epithelial Sodium Channel), and is extruded from the cell to the peritubular space by the sodium pump Na-K-ATPase located in the basolateral membrane (Pearce et al. 2015; Rossier et al. 2015). ENaC and Na-K-ATPase are coordinately activated and up-regulated in the presence of aldosterone, leading to an increase in transepithelial sodium reabsorption via the transcellular route. Aldosterone also stimulates sodium reabsorption in the distal nephron through enhanced expression of the thiazide-sensitive NaCl cotransporter and potassium secretion through K channels as ROMK (Pearce et al. 2015; Penton et al. 2015; Rossier et al. 2015).

I - A - Structure of mineralocorticoid receptor

The mineralocorticoid receptor (MR) is a member of the nuclear receptor (NR) superfamily of ligand-dependent transcription factors, together with the glucocorticoid receptor (GR), the androgen receptor (AR), the progesterone receptor, the estrogen receptor, the thyroid hormone receptor, the retinoic acid receptor (RAR), the peroxisome proliferator-activated receptor (PPAR), the vitamin D receptor (VDR) and numerous orphan receptors (Gronemeyer et al. 2004; Bookout et al. 2006; Lu et al. 2006). In human, the MR has 984 amino acids (aa), encoded by the NR3C2 gene located on chromosome 4, with 10 exons (the first two exons, 1 α and 1 β , are un-translated) (Morrison et al. 1990; Zennaro et al. 1995), while the rat and mouse MR gene is located on chromosome 19, and differs slightly in having three un-translated exons, encoding a 981 aa protein (Kwak et al. 1993). MR protein has a classical structure of nuclear receptor, with three main domains: a N-terminal domain, followed by a central DNA-binding domain (DBD), and a C-terminal ligand-binding domain (LBD) (**Figure 15**) (Viengchareun et al. 2007; Pippal and Fuller 2008)

- The N-terminal domain, consists of 602 aa, is the longest among all the steroid receptors. It possesses several functional domains responsible for ligand-independent transactivation or transrepression including two distinct activation functions-1 regions (AF-1a and AF-1b) and a central inhibitory region. These different regions of the N-terminal domain recruit co-regulators responsible for modulating the transcriptional activity of MR in a highly selective manner and have been considered to be important determinants of mineralocorticoid selectivity (Pascual-Le Tallec and Lombes 2005).

-The DBD contains two motifs of zinc finger's structure that permit binding to DNA and dimerization of receptors. The MR can form homodimers (MR-MR) or can heterodimerize with the GR (MR-GR). The two zinc finger's structures are necessary for binding to hormone responsive elements (HRE). Thus, this domain has the ability to recognize specific target DNA sequences. The MR binds to GRE; there is no MR-specific HRE.

- The LBD is a complex and multifunctional domain that is conserved between species. This domain possesses a ligand-dependent AF-2 and participates in multiple functions, including ligand binding, nuclear localization, dimerization,

interaction with heat shock proteins (HSPs), and transcriptional co-activators and ligand-dependent transactivation via AF-2 domain (Viengchareun et al. 2007).

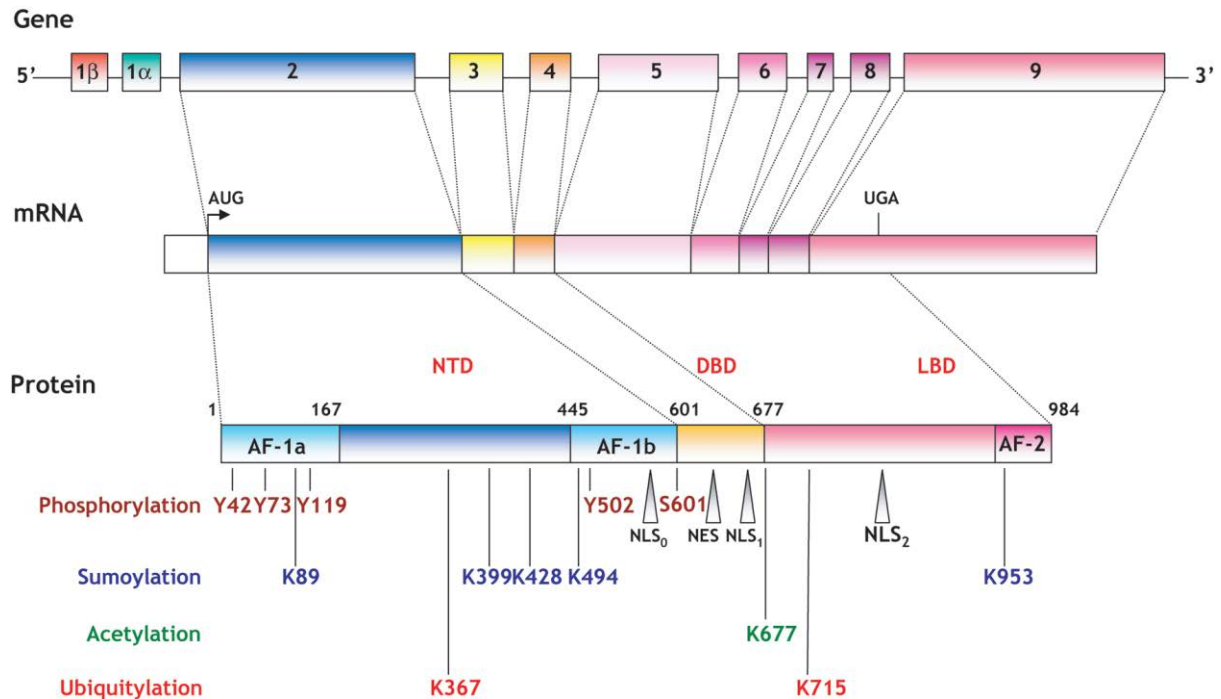


Figure 15. Schematic representation of human MR structure (Viengchareun et al. 2007).

MR gene, mRNA, protein, functional domains and associated posttranslational modifications are depicted. The human MR (hMR) gene is composed of ten exons, including two untranslated first exons (1α and 1β). The receptor has distinct functional domains (activation function AF-1a, AF-1b and AF-2) and nuclear localization signals (NLS₀, NLS₁ and NLS₂), as well as one nuclear export signal (NES). The positioning of amino acids targeted for phosphorylation, sumoylation, acetylation and ubiquitylation is indicated.

I - B - The ligands of mineralocorticoid receptor

Aldosterone and glucocorticoids (cortisol in humans, corticosterone in rodents) are the physiological ligands of MR. These two hormones bind with the same high affinity to MR, even though the dynamic binding parameters and the functional properties of glucocorticoid - MR complexes are somehow different from that of aldosterone - MR (Lombes et al. 1994; Hellal-Levy et al. 1999). According to Hellal-Levy, the aldosterone - MR complex is more effective in terms of transcriptional activity than

glucocorticoid - MR complex (Hellal-Levy et al. 1999). In addition, progesterone and androgens can also bind to the MR and exert partial agonist or antagonist effects depending on the cellular context (Quinkler et al. 2003; Marissal-Arvy et al. 2004; Takeda et al. 2007).

MR antagonists (MRA) have been developed and are currently used in human clinical care (Maron and Leopold 2010). Spironolactone, the most widely used MRA, was approved as a diuretic and natriuretic drug for the management of hypertension and primary aldosteronism, and later on to treat heart failure (Menard 2004). This is a potent competitive MRA but poorly selective, as it also inhibits the androgen and progesterone receptors, leading to side effects such as gynecomastia, impotence and menstrual disorders. At high concentrations it may also interfere with the GR (Kolkhof and Borden 2012). Eplerenone, a second general MRA, is a very specific antagonist but less effective than spironolactone (MR has about 100 to 500 times less affinity for eplerenone than for spironolactone) (Colussi et al. 2013). Of note, the use of MRAs that do not need to be metabolized into active moieties for full efficacy, such as eplerenone may be preferred when effects are expected relatively rapidly after treatment; short half-life is important to consider for safety concerns to yield rapid decrease of active moieties when stopping therapy in case of toxic effect.

In addition to spironolactone and eplerenone, other MRA molecules are used for research on animal or *in vitro* models including canrenone, RU28318 or RU26752. Canrenone, an active metabolite of spironolactone, is also used in some countries for human use. An injectable preparation (potassium canrenoate) is available (Armani et al. 2014). Moreover, novel non-steroidal compounds were also identified or generated recently as potent and selective MRAs, such as BR-4628, BAY 94-8862 (Finerenone) (belonging to the dihydropyridines: L-type calcium channel antagonists), PF-03882845 and SM-368229 (Pitt et al. 2013; Collin et al. 2014; Pitt et al. 2015).

I - C - Mineralocorticoid receptor specificity

It has been shown that the MR can bind cortisol and aldosterone with equal high affinity ($K_d = 0.5\text{nM}$) (Hellal-Levy et al. 1999; Farman and Rafestin-Oblin 2001). The mechanisms of differential activation of the MR by the two corticosteroid hormones

allowing tissue-specific effects can be considered at the pre-receptor, receptor, and post-receptor levels (Pascual-Le Tallec and Lombes 2005).

The metabolism of cortisol is a key mechanism for maintaining MR selectivity in some target tissues. Indeed, the concentration of cortisol in plasma is 100 to 1000 times higher than that of aldosterone; the mineralocorticoid selectivity mainly depends, at a cellular level, on the enzymatic activity of 11-beta-hydroxysteroid dehydrogenase type 2 (11HSD2), which converts cortisol into inactive cortisone, resulting in the preferential aldosterone-dependent MR activity (Farman and Rafestin-Oblin 2001) (Figure 16). However, the mineralocorticoid specificity is not only ensured by 11HSD2 because its expression is mainly restricted to sodium-transporting epithelial cells. HSD2 is very low or absent in some MR-expressing tissues such as the myocardium and hippocampus. This is a strong indication that other molecular mechanisms are important determinants of receptor specificity and action.

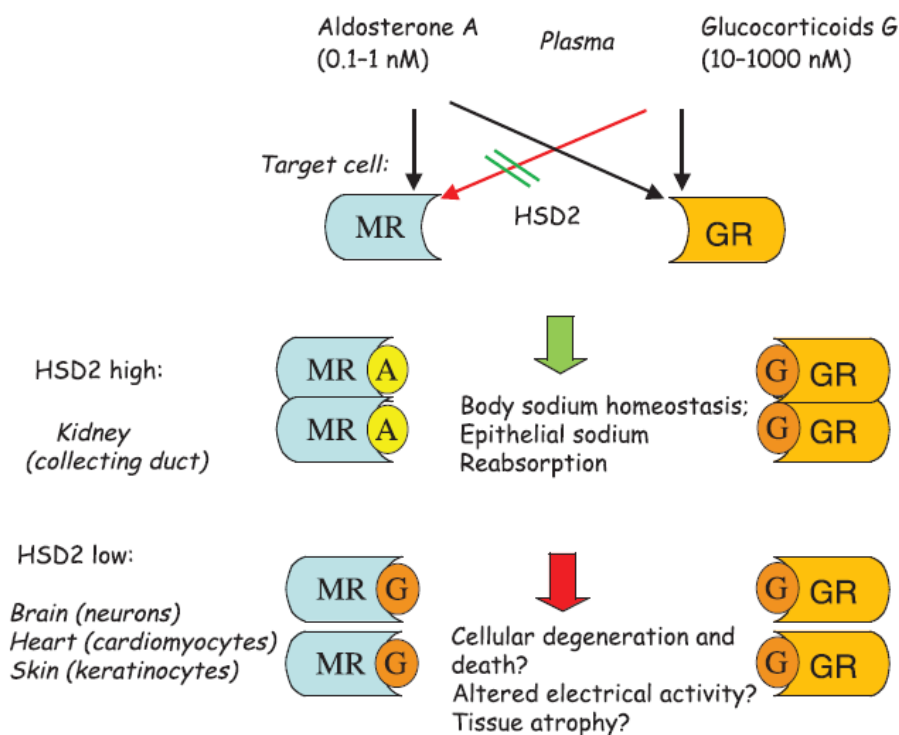


Figure 16. Schematic representation of the MR selectivity. Aldosterone target cells express both the MR and the GR. The MR may be occupied by aldosterone (kidney cells) and also by glucocorticoids (that are much more abundant than aldosterone in the plasma) in cells with low activity of the glucocorticoid-metabolizing

enzyme 11HSD2, leading to distinct transcriptional regulations (aldo-MR versus gluco-MR).

At the receptor level, mineralocorticoid selectivity is conferred by ligand-induced conformational changes of MR, which differ in presence of gluco- and mineralocorticoid ligands leading to differential transactivation activity. It has been shown that aldosterone dissociates more slowly from the receptor and induces more efficient transactivation than cortisol (Lombes et al. 1994; Farman and Rafestin-Oblin 2001). The N-/C-terminal interaction of the MR, which may serve to stabilize ligand binding to the receptor (Li et al. 2006; Centenera et al. 2008), is stronger in the presence of aldosterone than cortisol (Rogerson and Fuller 2003), suggesting another important step towards ligand specificity of the MR.

At the post-receptor level, several post-translational modifications, such as phosphorylation, ubiquitination, may occur and modify MR activity (Viengchareun et al. 2007).

I - D - Mineralocorticoid receptor and pathology of skin

The notion of excessive/inappropriate MR activity in diseases originates from several pathological situations, in animal models and human subjects, revealing the benefit of treatments with MR blockers. Indeed, efficiency of MR antagonists to reduce excessive/inappropriate MR activation in cardio-vascular pathology was provided in experimental and clinical situations. Pioneer clinical trials showed that spironolactone or eplerenone added on top of standard care limits morbidity and mortality in patients with cardiac insufficiency or following myocardial infarction (Pitt et al. 1999; Pitt et al. 2003). MR blockade improves vascular dysfunction (Leopold et al. 2007; Koenig and Jaffe 2014), limits progression towards renal failure (Shavit et al. 2012), or restores vision in patients with chronic serous chorioretinopathy, a vision-threatening eye disease (Zhao et al. 2012). MR antagonism was also shown to be beneficial in diabetes and metabolic syndrome; it improves glucose tolerance, decreases insulin resistance, plasma levels of triglycerides and pro-inflammatory cytokines (Guo et al. 2008; Hirata et al. 2009; Wada et al. 2010).

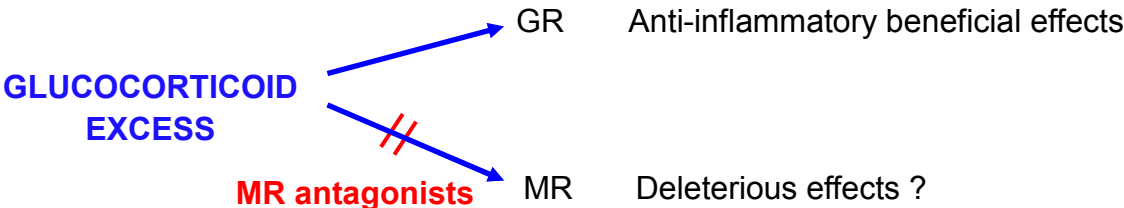
MR is expressed in different part of skin such as epidermis, hair follicle, sweat and sebaceous glands, vessels, suggesting its multiple functions in cutaneous tissue (Kenouch et al. 1994; Zennaro et al. 1997; Farman et al. 2010). Glucocorticoids are widely used in clinical treatments of chronic inflammatory or auto- immune skin diseases. However, aside the great efficacy, treatments with glucocorticoids are often accompanied by unwanted side-effects including skin atrophy and delayed wound healing, of great concern for patients (Hengge et al. 2006). Glucocorticoids classically act through binding to the glucocorticoid receptor (GR); they can also bind, even with higher affinity, to the MR; MR-glucocorticoid complexes may contribute to glucocorticoid-induced side-effects in the skin (Sainte Marie et al. 2007; Farman et al. 2010).

Firstly, unexpected roles of MR in epidermal keratinocytes have been highlighted by Sainte Marie *et al*, by using a mouse model expressing the human MR under the control of a keratinocyte-specific promoter (K5-MR mice) (Sainte Marie et al. 2007). Post-natal induction of MR was associated with alopecia and dysmorphism of hair follicles, whereas gestational expression of the MR led to premature skin barrier formation and epidermal atrophy (Sainte Marie et al. 2007). The pathways regulated by epidermal MR are still poorly identified. Of note, we have recently reported that the 3 subunits of the epithelial sodium channel (ENaC) are overexpressed in the skin of K5-MR mice at birth (Maubec et al. 2015). The enhanced ENaC expression may depend on glucocorticoid-activated MR, because of the perinatal rise in plasma glucocorticoid concentration. The blockade of MR could limit the glucocorticoid-induced epidermal atrophy and and it is accompanied by reduced ENaC expression (Sainte Marie et al. 2007; Maubec et al. 2015). The blockade of the activity of ENaC also rescued the reduced keratinocyte proliferation and epidermal atrophy, suggesting an involvement of ENaC activation in the glucocorticoid-stimulated epidermal MR cascade (Maubec et al., 2015), and pointing on mineralocorticoid signaling as a novel epidermal modulator.

In addition to their effects on epidermis, aldosterone and MR antagonists have been reported as modulators of elastin and collagen production in dermis of human skin (Mitts et al. 2010). Restoration of dermal homeostasis by MR antagonism may rely on anti-fibrotic and anti-inflammatory actions, leading to improve collagen structural organization and remodeling and cellularity, a mechanism also occurring in heart

diseases. In a mouse model of aging skin, associating UV irradiation and metabolic syndrome, Nagase *et al.* revealed beneficial action of MR blockade in some aging-like features (Nagase et al. 2013). Recently, Tiganescu *et al.* showed that the aging-dependent dermal atrophy and delayed wound healing in mice were restored by inactivation of the glucocorticoid-activating enzyme 11HSD1 (a reductase that converts inactive glucocorticoids as cortisone into active ones, as cortisol)); 11HSD1 is expressed in epidermis, and its inactivation leads to reduced local glucocorticoid production, thus limiting the possibility of MR occupancy (Tiganescu et al. 2013).

Since the activity of the MR-protecting enzyme 11HSD2 is minimal in human epidermis (Kenouch et al. 1994), it permits MR occupancy by glucocorticoids. Glucocorticoid activation of the MR is most likely to occur in face of local application of dermocorticoids. Whether and how this mechanism could participate to some of the deleterious side-effects of dermocorticoids, as skin atrophy and delayed wound healing, is an important therapeutical issue, as it could be limited by local co-administration of MR antagonists.



II - Article 2:

MINERALOCORTICOID RECEPTOR ANTAGONISM IMPROVES RE-EPITHELIALIZATION OF PATHOLOGICAL CUTANEOUS WOUNDS

Van Tuan Nguyen, Nicolette Farman, Eve Maubec, Dany Nassar, Dorinne Desposito,
Ludovic Waeckel, Sélim Aractingi, Frederic Jaisser

Manuscript in preparation

**MINERALOCORTICOID RECEPTOR ANTAGONISM IMPROVES
RE-EPITHELIALIZATION OF PATHOLOGICAL CUTANEOUS WOUNDS**

Van Tuan Nguyen, Nicolette Farman, Eve Maubec, Dany Nassar, Dorinne Desposito, Ludovic Waeckel, Sélim Aractingi*, Frederic Jaisser*

* contributed equally

ABSTRACT

Impaired cutaneous wound healing is a social burden, occurring as a consequence of glucocorticoid excess or treatments, and in several pathologies including diabetes. Glucocorticoids (GC) can bind to the mineralocorticoid receptor (MR), resulting in its excessive activation, as demonstrated in cardiovascular diseases, from the beneficial effects of MR antagonists (MRA) on morbidity and mortality. We hypothesized that dermatological use of MRA could be beneficial to improve the reepithelialization of pathological wounds and favor their closure.

Cutaneous ointment of mouse skin and incubation of human skin explants in organotypic culture with the potent GC Clobetasol (Clo) induced delayed wound closure and growth of epidermal tongues, associated with reduced proliferation of keratinocytes. Reepithelialisation of the wounds was rescued by MRA local application. The benefit of MR blockade is explained by the observed enhanced MR and epithelial sodium channel (ENaC) expression in Clo-treated mouse skin ; ENaC blockade by Phenamil in cultured human skin explants also improved GC-induced impaired growth of epidermal tongues.

Since MR excessive activation has been reported in diabetes, we performed wounds in mouse models of diabetes (streptozotocin and db mice, that heal poorly) and found that local MRA ointment accelerated their impaired closure.

In a post-hoc analysis of the SPIREPI clinical trial performed in healthy volunteers, we showed that local MRA ointment over post-biopsy wounds of Clo-treated skin zones was also accelerated.

In conclusion, we show here a repositionning of old pharmacological agents, to improve wound closure, when applied locally over diseased skin (while normal skin was unaffected). We propose that development of new formulations of MRA for cutaneous application should bring benefit to patients with impaired wound closure.

INTRODUCTION

Cutaneous wound healing is a complex biological phenomenon. The process includes successive stages, with initial inflammation and activation of the coagulation cascade, followed by new tissue formation and tissue remodeling (Gurtner et al. 2008). Full healing is yielded only after a long lagtime (about one year in humans). Re-epithelialization of injured skin is an early step in the formation of new tissue, involving keratinocyte migration and proliferation from the edges of the wound. This process is activated by signaling pathways originating from epithelial and nonepithelial cells at the wound edges, which release cytokines and growth factors (Werner and Grose 2003). Nuclear receptors as peroxysome-proliferator-activated receptors, androgen, estrogen and glucocorticoid receptors were also demonstrated to mediate wound re-epithelialization (Icre et al. 2006; Michalik and Wahli 2006; Pullar et al. 2006).

Impaired wound healing is a major clinical problem in various situations including subjects treated by corticosteroids/dermocorticoids, in the elderly and in pathological conditions, such as diabetes, sickle cell disease or Cushing syndrome (Bulkley and Roberts 1974; Trent and Kirsner 2004; Menke et al. 2007; Biswas et al. 2011). Efforts towards improving wound healing represent a major challenge, to improve quality of life.

Glucocorticoid treatments are often accompanied by delayed wound healing and skin atrophy, causing great concern to patients (Hengge et al. 2006). Glucocorticoids classically act through binding to the glucocorticoid receptor (GR); they can also bind with high affinity to another closely related member of the nuclear receptor superfamily, the mineralocorticoid receptor (MR) (Farman and Rafestin-Oblin 2001; Viengchareun et al. 2007). The MR and its mineralocorticoid ligand aldosterone are regulators of renal sodium reabsorption, fluid homeostasia and blood pressure, due to the aldosterone-MR action in the kidney (Farman and Rafestin-Oblin 2001; Viengchareun et al. 2007). In mineralocorticoid-sensitive tissues, glucocorticoids are inactivated by the enzyme 11 beta hydroxysteroid dehydrogenase type II (HSD2), preventing their binding to the MR, which is therefore selectively activated by aldosterone (Farman and Rafestin-Oblin 2001; Odermatt and Kratschmar 2012). In some tissues/cells where the enzyme is absent, glucocorticoids (that largely prevail in the plasma) may activate the MR, as for example in the heart or brain.

Both the MR and the GR are expressed in epidermal keratinocytes (Farman et al. 2010). While it is established that glucocorticoids delay wound healing through binding to the GR (Youm et al. 2013; Tiganeşcu et al. 2014), the role of epidermal MR is mostly unknown (Farman et al.

2010). Because of the absence of epidermal HSD2 (Kenouch et al. 1994), we hypothesized that some cutaneous deleterious side effects of glucocorticoids could depend partly on inappropriate MR activation by glucocorticoids. As a consequence, we propose that local (cutaneous) MR antagonism may bring some benefit to patients treated with glucocorticoids. Indeed we showed recently that the epidermal atrophy induced by clobetasol, a potent dermocorticoid, could be limited by co-administration of the MR blockers (Maubec et al. 2015).

Interestingly, several reports also point on the involvement of the renin-angiotensin-aldosterone system (RAAS) in diabetes and insulin resistance, leading to the proposal that administration of MR antagonists could reduce pathological events in diabetes (Guo et al. 2006; Guo et al. 2008; Hirata et al. 2009; Adel et al. 2014; Sato 2015). We reasoned that delayed skin wound healing in diabetic mice might also be improved by MR blockade.

In this study, we questioned whether locally applied MR blockers could improve the early phase of cutaneous wound closure of mouse models of delayed wound healing (glucocorticoid treatment, type I and type II diabetes) and in glucocorticoid-treated cultured human skin explants. We searched for mechanism of the observed beneficial effects. We also monitored wound closure after skin biopsy in healthy volunteers treated for one month with the dermocorticoid clobetasol, to evaluate spironolactone effect, as a post-hoc study of the SPIREPI clinical trial (ClinicalTrials.gov: NCT01407471).

MATERIAL AND METHODS

Reagents and Antibodies

Reagents and drugs were purchased from Sigma-Aldrich unless specified. Spironolactone, potassium canrenoate or eplerenone (Tocris Bioscience, Bio-Techne) were used as MR antagonists. Culture medium was from Gibco® (Life Technologies).

The following antibodies were used for immunofluorescence staining: rabbit polyclonal anti-keratin 14 (Covance); rat anti-F4/80 (clone CI:A3-1), rat anti-Gr-1 (clone RB6-8C5) (eBioscience); rabbit anti polyclonal ki67 (Novocastra), rabbit polyclonal anti CD3 (Novocastra); antibody against cytokeratine 17 (K17, kindly provided by P. Coulombe)

Mouse experiments

The use of mice was in accordance with the guidelines of the European Community and approved by our Institutional Animal Care and Use Committee.

Skin explants from newborn mice overexpressing the MR

Skin explants from neonatal mice were used to point on the role of the MR on the epithelial phase of healing. Mice with overexpression of the MR in basal keratinocytes (K5-MR) have been previously characterized (Sainte Marie et al. 2007). Skin explants from newborn K5-MR mice (they die shortly after birth) and their control littermates were cultured as described (Mazzalupo et al. 2002). After decapitation, patches from 0.5-1 day-old pups were obtained from the ventral skin, using a 4 mm biopsy punch (NM Medical); each patch was placed directly on a well of 24-wells tissue culture plates with the dermis facing the plastic for 30 min to favor adhesion. Then 0.5 ml of the keratinocyte culture medium warmed at 37°C (cFAD: DMEM/HamF12 (3/1, v/v), insulin 5 µg/ml, T3 2nM, transferrin 5 µg/ml, epidermal growth factor 10 ng/ml, fungizone 0.5 µg/ml, 5% decomplexed charcoal-stripped fetal bovine serum (Life Technologies) and cholera toxin 0.1 nM (Tebu-Bio) were gently added. Medium was changed daily. After 7 days of culture, explants were harvested and fixed for 10 min with 4% paraformaldehyde, rinsed in PBS; antibody against cytokeratine 17 (K17, kindly provided by P. Coulombe, 1:5000) was used for immunolabelling to visualize the outgrowth of keratinocytes (Mazzalupo et al. 2002). The outgrowth of keratinocytes was measured using the ImageJ software (NIH); the surface is expressed in mm² (after subtraction of the surface of the initial punch).

In vivo wound healing assay in mice

Wound healing assay were performed either in normal C57BL6 mice or in mice pre-treated once a day with topical clobetasol over backskin (Dermoval gel, 0.05% clobetasol propionate, GlaxoSmithKline) for 10 days before wounding, or in diabetic mice. Type I diabetes was induced by streptozotocin (4 weeks after 5 daily i.p. injections of 50 mg/kg streptozotocin to mice). Db/db mice (BKS(D)-Leprdb/J, Janvier) were used as a model of type II diabetes. All mice were 10-12 weeks old females.

Mice were anesthetized by inhalation of isofluorane (AeraneH, Baxter). After depilation, four full-thickness wounds were generated on the back of mice with 6 mm diameter disposable biopsy devices (Kai Europe GmbH). All tissues above the panniculus carnosus were excised. Wounds were then left uncovered and 0.5 mM potassium canrenoate (Canre) or PBS (50µL

for each wound), were locally applied twice daily until sacrifice. Pictures of the wounds were taken using a Sony CybershotH 10.1 megapixels DSC-W180 digital camera. Wound surface was expressed as percentage of the initial surface of each wound at day 0. For tissue collection, mice were killed in a CO₂ chamber. Tissues were harvested, snap-frozen in liquid nitrogen and stored at -80°C for RNA extraction or immunolabeling.

Human skin explants culture

To study the *ex vivo* effect of MR blockade on the human epithelialization, human skin explants were placed in organotypic culture. Human skin was collected from breast reduction surgery (obtained after informed consent of the subjects and ethical approval of the Comité de Protection des Personnes Ile de France V) and explant culture was performed for 6 days as described (Maubec et al. 2015). Explants were cultured in the presence of clobetasol (Sigma-Aldrich, 10 µM in 0.2% ethanol; the concentration of clobetasol was much lower than that of commercial gel preparations used in dermatology, usually 0.05% i. e. 1 mM). Three MR antagonists: spironolactone (10 µM in 0.2% ethanol) or potassium canrenoate (10 µM in PBS) or eplerenone (10 µM in 0.2% DMSO) were used. Control explants were incubated with the drugs alone, or the solvents alone. The effect of Phenamil (100 nM), a blocker of the epithelial sodium channel ENaC, was also evaluated. After 6 days in culture, explants were frozen and processed for measurement of the length and surface of the epidermal tongues (Meier et al. 2013). Keratinocyte proliferation (ki67 index) was measured as described (Maubec et al. 2015).

Wound healing in healthy subjects

The SPIREPI clinical trial (ClinicalTrials.gov Identifier: NTC01407471) was designed to evaluate the interest of topical spironolactone administration to prevent corticoid-induced epidermal atrophy in healthy volunteers as primary outcome. Detailed protocol has been previously provided (Maubec et al. 2015). Four zones on the forearm of each participant (2 zones on each arm) were treated with hydro-alcoholic gels containing placebo, or 5% spironolactone, or 0.05% clobetasol propionate, or 0.05% clobetasol+5% spironolactone, administered 6 days a week during 29 days. Skin biopsy (3 mm biopsy punch) was performed on day 29. Subsequent treatments (up to day 48) were either placebo (over zones previously treated with placebo or clobetasol) or spironolactone (over zones previously treated with spironolactone alone or associated with clobetasol); clobetasol applications were not continued for ethical reasons, as it is known to delay wound healing. After biopsy, clinical

examination and photography of the treated zones by dermatologists was performed to monitor eventual local reactions. The surface of the wounds at day 3 after biopsy (i.e. before formation of crust) was measured (using the Image J software) on photographs of wounds by 2 investigators blind to the treatments.

Immunofluorescence experiments

Immunolabeling was performed on 6 μm cryosections. Sections were fixed in ice-cold acetone and blocked with 2% BSA/PBS. Samples were then incubated with primary antibodies for 2 h at room temperature. Isotype IgG served as a negative control. The secondary antibodies used were Alexa Fluor 488 and Alexa Fluor 555 conjugated antibodies (Molecular Probes). Samples were examined and photographed using a Nikon Eclipse 90i fluorescent microscope equipped with a Nikon DS-Fi1C digital camera (Nikon). Labeled cells were counted without knowledge of the corresponding experimental condition in three different fields and reported as a percentage of total DAPI stained nuclei. Wound re-epithelialization was also assessed in a blind manner as described previously (Khosrotehrani et al. 2011; Nassar et al. 2012).

Real time RT-PCR

Total RNA was isolated from normal or wounded skin using TRIzol reagent (Invitrogen). The Maxima First Strand cDNA synthesis kit (Thermo Scientific) was used to synthesize cDNA from 0.5 μg of total RNA. Real-time PCR was performed using the LightCycler 480 SYBR Green I Master kit (Roche) and a LightCycler[®] 480 Real-Time PCR System (Roche). Samples were assayed in triplicate. The expression of genes was normalized to the relative levels of beta-actin. Primers were designed and purchased from Eurogentec; sequences are reported in Table S1.

Statistical analysis

Results are expressed as means \pm SEM. Differences between the means of two groups were assessed with the Mann Whitney test. Differences between multiple groups were analyzed by 1-way ANOVA followed by Newman-Keuls Multiple Comparison test. $P < 0.05$ was considered statistically significant.

RESULTS

MR blockade improves keratinocyte outgrowth of skin explants issued from K5-MR newborn mice

The overexpression of the MR in keratinocytes (K5-MR mouse model) during gestation leads to early post-natal death (Sainte Marie et al. 2007). Collection of skin was possible few hours after birth. The excentric outgrowth of keratinocytes around cultured explants of neonatal skin features the re-epithelialization of wound (Mazzalupo et al. 2002; Wong and Coulombe 2003). After 7 days of culture the keratinocyte outgrowth of skin explants from K5-MR pups was limited, compared to that of their control littermates (**Figure 1**). The impairment of outgrowth of K5-MR skin appeared to be related to the MR overexpression, since addition of the MR antagonist canrenoate (Canre) all along explant culture partly restored the defect of keratinocyte outgrowth of K5-MR explants (**Figure 1**). These results point on the MR as an actor in the wound re-epithelialization.

MR blockade rescues glucocorticoid-induced impaired wound re-epithelialization in mice

As GC can bind the MR, in addition to GR, we questioned whether MR blockade could improve the GC-related delayed wound healing in mouse skin.

The cutaneous expression level of MR mRNA was increased by four-fold by clobetasol treatment in wounded skin and in the surrounding normal skin (**Figure 2, A and B**), providing clues to the possibility of MR occupancy by locally-applied glucocorticoids. Cutaneous GR mRNA levels were not or marginally affected (**Figure 2, A and B**).

In control mice, MR antagonism by Canre applied over the wounds did not modify their closure at day 3 and 5; glucocorticoid pre-treatment delayed wound closure, as expected (**Figure 2, C and D**). Noticeably the application of Canre to the wounds of clobetasol-treated skin improved clearly their closure. Indeed, the wound surface at day 3 and 5, expressed as a percent of the wound surface at day 0, was normalized (**Figure 2, C and D**).

Reduction in wound size could rely on re-epithelialization or/and wound contraction. Analysis of cryosections of wound specimens at day 5 allowed determining that MR blockade induces re-epithelialization of wounds in clobetasol-pre-treated mice, as illustrated by the longer neo-epidermal tongues on wound sections (**Figure 2, E and F**). Canre-treated mice showed shorter residual wound length (the distance between two edges) (**Figure 2, E and G**). The improvement of re-epithelialization by Canre was accompanied by a higher number of Ki67-

positive proliferating keratinocytes in neo-epidermis of wounds, 5 day after wounding of clobetasol-treated skin (**Figure 2, H and I**). In contrast, we did not observe any change in dermal cell proliferation in granulation tissue after canrenoate treatment (**Figure 2, H and I**). Canre did not modify the dermal inflammation markers (Gr-1, F4.80 and CD3 immunofluorescence) at day 5 after wounding of clobetasol-treated skin (**Figure S1**). Thus MR blockade improves re-epithelialization of glucocorticoid-treated mouse skin and restores proliferation of epidermal keratinocytes, without affecting the underlying dermis.

MR antagonism rescues the GC-induced impaired wound healing in cultured human skin explants

We tested our hypothesis in human skin explants maintained in organotypic culture, and assessed the MR specificity of the effect by testing 3 MR antagonists. The formation of neo-epithelial tongues at the edges of cultured human skin explants features some aspects of wound healing including re-epithelialization (Meier et al. 2013). In the absence of clobetasol in the incubation medium, the length and surface area of epithelial tongues were not influenced by addition of the MR blockers canrenoate or spironolactone or eplerenone (**Figure 3 A-C**). In the presence of 10 μ M clobetasol, the neo-epithelialization was reduced; addition of the each MR blocker (spironolactone, canrenoate or eplerenone) clearly restored the outgrowth of epithelial tongues (**Figure 3 A-C**). The beneficial effect observed with canrenoate or spironolactone (that can block the MR but also other steroid hormone receptors) was similar to that obtained with the highly MR-specific antagonist eplerenone. Fewer ki67-positive proliferating cells were present in the epidermis of explants treated by clobetasol (8.0%) than in those of control (12.1%), indicating that glucocorticoid inhibits keratinocyte proliferation of skin explants in culture (**Figure 3, D and E**). Noticeably the decreased proliferation index was rescued by co-incubation of clobetasol with each of the 3 MR blockers (while these drugs did not affect the epidermal proliferation in explants that were not incubated with the glucocorticoid) as shown on **Figure 3, D and E**.

Topical glucocorticoid treatment enhances ENaC expression in the wound of mouse skin

To get insights in the mechanism by which MR blockade improves the glucocorticoid-induced delayed healing, we questioned whether cutaneous MR challenged with clobetasol affect the expression of the epithelial sodium channel ENaC, a classical MR target in the kidney (Kusche-Vihrog et al. 2010). Epidermal keratinocytes express ENaC (Brouard et al.

1999; Mauro et al. 2002) and we found here that clobetasol treatment of mouse back skin is associated with enhanced alpha ENaC transcripts, that was fully blunted when Canrenoate was added on top of the glucocorticoid (**Figure 4 A**). Thus the epithelial sodium channel ENaC belongs to the cutaneous MR cascade.

Blockade of ENaC improves the GC-induced defect in tongue formation in human skin explants

To evaluate whether ENaC activity is involved in wound re-epithelialization, we monitored the effect of the ENaC blocker Phenamil on the formation of epithelial tongues in human skin explants. Clobetasol-induced reduced neo-epithelialization is corrected by Phenamil, suggesting that activity of the sodium channel participates in the glucocorticoid-induced defect of growth of the epithelial tongue (**Figure 4 B-D**).

MR blockade improves the delayed wound healing in diabetic mice

Beneficial effects of treatments with MR antagonists have been reported on cardiovascular and renal functions (Guder et al. 2007; Mihailidou et al. 2009; Shavit et al. 2012). The wound healing is impaired in diabetic patients; Type I diabetes induced by streptozotocin injections has been demonstrated to be a model of delayed skin wound healing (Stallmeyer et al. 2002; Luo et al. 2004). We confirm that the skin heals more slowly in STZ mice than in control mice (**Figure 5, C and D**). We also found that STZ mice has a 6-fold higher level of MR mRNA in the skin, while GR mRNA was also moderately (1.5-fold) enhanced (**Figure 5, A and B**). Canrenoate applied over the STZ wounds twice a day during 5 days resulted in reduced surface area of STZ wounds (compared to PBS application) (**Figure 5, C and D**). Thus, in this model of type I diabetes, local MR blockade accelerates wound closure.

The db/db mouse model reproduces several features of type II diabetes, including delayed healing of cutaneous wounds (Hamed et al. 2009; Marrotte et al. 2010). The MR and GR mRNA levels of skin from db/db mice are slightly but significantly increased, compared to their non-diabetic controls (**Figure 6, A and B**). The skin wounds of db/db mice exhibited very slow healing, compared to those of control mice and canrenoate application improved at least partially the delayed healing of db/db mouse skin (**Figure 6, C and D**). Therefore, topical administration of the MR antagonist also appears beneficial to favor wound closure in Type II diabetic mice.

MR blockade and wound closure in healthy volunteers

The SPIREPI clinical trial was designed to evaluate the efficiency of MR blockade to limit GC-induced epidermal atrophy in 23 healthy subjects (Maubec et al. 2015). After 4 weeks clobetasol exposure (with/without spironolactone), a wound was created by the biopsy. As a post-hoc analysis of the SPIREPI study, we compared the surface of wounds at day 3 following skin biopsy, i.e. at the early stage of wound closure. As shown on **Figure 7**, application of the clobetasol gel resulted in larger wound area, and spironolactone gel significantly increased wound size (in the zone where spironolactone was applied in the absence of clobetasol, the size of the wound was similar to placebo gel administration). Therefore the improvement of the early phase of wound closure by spironolactone also occurs *in vivo* in glucocorticoid-treated skin of healthy subjects (**Figure 7**).

DISCUSSION

Several recent reports pointed on the involvement of steroids and their nuclear receptors in cutaneous wound healing. Estrogens accelerate epidermal healing of acute wounds in elderly women, an effect mediated by the beta (not alpha) epidermal estrogen receptor (Campbell et al. 2010). Androgens have an opposite effect, i.e. delayed wound healing (Ashcroft and Mills 2002). Overexpression of the GR in keratinocytes or glucocorticoid administration delay wound healing (Sanchis et al. 2012). Here we add another nuclear receptor to the list of transcription factors modulating wound healing, and show that MR activity can be targeted by local application of antagonists. We reveal that MR blockade favors re-epithelialization of wound in pathological mouse models (gluco treatment, diabetes). Of note, MR blockade is ineffective in normal (healthy) skin. We have provided clues for MR-dependency of the delayed wound re-epithelialization using a transgenic mouse model with MR overexpression in keratinocytes (K5-MR newborn mice). Efficiency of spironolactone or canrenoate on mouse back skin or human explants organotypic culture also favor this view, although these drugs are not fully specific for MR. Indeed they can antagonize other nuclear receptors, particularly the androgen receptor (Kolkhof and Borden 2012). However in human explants, pharmacological blockade of cutaneous MR by eplerenone, a highly specific MR antagonist, was also efficient to restore keratinocyte growth. Therefore MR blockade improves re-epithelialization of pathological wounds.

The question of the ligand of cutaneous MR merits to be discussed. In the absence of 11 β -HSD2 in epidermis, it is likely that glucocorticoids rather than aldosterone preferentially bind to the MR. In addition to exogenous (therapeutic) glucocorticoids or endogenous hypersecretion (Cushing disease), local corticosteroidogenesis has been evidenced in the skin (Vukelic et al. 2010). Whether local steroidogenesis is subjected to regulation in pathological situations (and in wound healing) is remained unknown. In addition, glucocorticoids may be locally produced by the enzyme 11 β -HSD1 (acting as reductase, at opposite to 11 β -HSD2) present in epidermis (Kenouch et al. 1994), thus further modulating activation of MR. The role of 11 β -HSD1 has been highlighted in aging skin, where wound healing is also impaired despite no major change in plasma cortisol concentration; one mechanism is the age-dependent increase in the enzyme 11 β -HSD1, that enhances regeneration of glucocorticoids; topical treatment with an 11 β -HSD1 inhibitor accelerates healing of dorsal wounds in mice and improves cutaneous healing in aged 11 β -HSD1 KO mice (Tiganescu et al. 2013).

In this study, we have found that MR mRNA expression is enhanced in the skin of type I and type II diabetes mouse models, and following local application of the potent dermocorticoid clobetasol. To our knowledge, there is very limited information on cutaneous MR levels in skin pathology. Of note, an increase in cutaneous MR has been reported in the skin of mice with metabolic syndrome (Nagase et al. 2013). The efficiency of cutaneous MR blockade to improve wound closure as reported here in pathological situations may be explained by enhanced MR expression. More generally, the notion of excessive/inappropriate MR activity in pathology originates from the benefits of treatments with MR blockers in several diseases. Efficiency of MR antagonists to reduce excessive/inappropriate MR activation in cardiovascular pathology was provided in experimental and clinical situations. Pioneer clinical trials showed that spironolactone or eplerenone added on top of standard care limits morbidity and mortality in patients with cardiac insufficiency or following myocardial infarction (Pitt et al. 1999; Pitt et al. 2003). MR blockade improves vascular dysfunction (Leopold et al. 2007; Adel et al. 2014; Koenig and Jaffe 2014), limits progression towards renal failure (Shavit et al. 2012) and restores vision in patients with chronic serous chorioretinopathy, a vision-threatening eye disease (Zhao et al. 2012). MR antagonism was also shown to be beneficial in diabetes and metabolic syndrome; it improves glucose tolerance, decreases insulin resistance, plasma levels of triglycerides and pro-inflammatory cytokines (Guo et al. 2008; Hirata et al. 2009; Wada et al. 2010)

We have shown that MR blockade promotes epidermal re-epithelialization of pathological wounds. In addition MR blockers may also limit inflammation and remodeling of dermis in chronic wounds. It has been reported that aldosterone and MR antagonists modulate elastin and collagen content of human skin (Mitts et al. 2010). As inferred from their effects in other tissues (myocardial infarction, vascular and renal remodelling), MR antagonists may reduce dermal inflammation, oxydative stress and fibrosis, thus providing additional benefits to improve wound healing (Palatinus et al. 2010).

Following wounding, re-epithelialization is required. It involves migration and proliferation of keratinocytes. Proliferation rate is altered by glucocorticoids, and we found that MR antagonism restores epidermal proliferation rate, in mouse skin as well as in human explants, thus providing a mechanism for this beneficial effect. Reports of MR affecting proliferation are controversial and experimental evidences concern essentially endothelial cells in the context of cardiac or vascular ischemic diseases (Gravez et al. 2015). Our previous study in human skin, demonstrated that spironolactone applied on human skin restores the glucocorticoid-induced impaired proliferation of keratinocytes (Maubec et al. 2015).

The mechanisms involved in the beneficial effect of MR antagonists on wound healing may include reduction of keratinocyte ENaC activity. Dysruption of epidermal integrity by wounding generates lateral electric fields that drive keratinocyte migration (Zhao et al. 2006). It has been inferred that the activity of ion transporters or channels in keratinocytes is related to changes in chemical gradients and electric fields at the wound site, although the nature of the transporters or channels are not fully defined (Zhao et al. 2006). Whether excessive ENaC activity at the edges of the wounds could participate to glucocorticoid-dependent pathological healing through alterations in the wound electric fields is ignored. If this were the case, MR blockade may limit such phenomenon through reduction in ENaC expression and activity, thus improving cutaneous wound closure.

From this study, we suggest that local application of MR antagonists may bring significant benefit to patients. Novel formulations designed to improve epidermal delivery of MR antagonists should be designed, as the skin is highly impermeable. The advantage of local treatment is to limit occurrence of systemic effects of these drugs. Indeed MR antagonists (spironolactone and eplerenone) favour renal sodium excretion and potassium reabsorption, possibly increasing plasma potassium levels, at least in subjects with impaired renal function. Spironolactone may induce gynecomastia and sexual dysfunctions, due to blockade of androgen receptor.

ACKNOWLEDGEMENTS

We thank Gaëlle Gendronneau for her help in setting up the culture of mouse skin explants.

We are indebted to Maud Steff and Stéphanie Leclerc-Mercier for their follow-up of the volunteers of the SPIREPI clinical trial up to complete wound healing ; We acknowledge the SPIREPI group that was involved in the SPIREPI study (Maubec et al. 2015).

REFERENCES

- Adel H., Taye A. and Khalifa M. M. (2014). "Spironolactone improves endothelial dysfunction in streptozotocin-induced diabetic rats." Naunyn-Schmiedeberg's Arch Pharmacol **387**(12): 1187-1197.
- Ashcroft G. S. and Mills S. J. (2002). "Androgen receptor-mediated inhibition of cutaneous wound healing." J Clin Invest **110**(5): 615-624.
- Biswas M., Gibby O., Ivanova-Stoilova T. and Harding K. (2011). "Cushing's syndrome and chronic venous ulceration--a clinical challenge." Int Wound J **8**(1): 99-102.
- Brouard M., Casado M., Djelidi S., Barrandon Y. and Farman N. (1999). "Epithelial sodium channel in human epidermal keratinocytes: expression of its subunits and relation to sodium transport and differentiation." J Cell Sci **112** (Pt 19): 3343-3352.
- Bulkley B. H. and Roberts W. C. (1974). "Steroid therapy during acute myocardial infarction. A cause of delayed healing and of ventricular aneurysm." Am J Med **56**(2): 244-250.
- Campbell L., Emmerson E., Davies F., Gilliver S. C., Krust A., Chambon P., Ashcroft G. S. and Hardman M. J. (2010). "Estrogen promotes cutaneous wound healing via estrogen receptor beta independent of its antiinflammatory activities." J Exp Med **207**(9): 1825-1833.
- Farman N., Maubec E., Poeggeler B., Klatter J. E., Jaisser F. and Paus R. (2010). "The mineralocorticoid receptor as a novel player in skin biology: beyond the renal horizon?" Exp Dermatol **19**(2): 100-107.
- Farman N. and Rafestin-Oblin M. E. (2001). "Multiple aspects of mineralocorticoid selectivity." Am J Physiol Renal Physiol **280**(2): F181-192.
- Gravez B., Tarjus A., Pelloux V., Ouvrard-Pascaud A., Delcayre C., Samuel J., Clement K., Farman N., Jaisser F. and Messaoudi S. (2015). "Aldosterone promotes cardiac endothelial cell proliferation in vivo." J Am Heart Assoc **4**(1): e001266.
- Guder G., Bauersachs J., Frantz S., Weismann D., Allolio B., Ertl G., Angermann C. E. and Stork S. (2007). "Complementary and incremental mortality risk prediction by cortisol and aldosterone in chronic heart failure." Circulation **115**(13): 1754-1761.
- Guo C., Martinez-Vasquez D., Mendez G. P., Toniolo M. F., Yao T. M., Oestreicher E. M., Kikuchi T., Lapointe N., Pojoga L., Williams G. H., Ricchiuti V. and Adler G. K. (2006). "Mineralocorticoid receptor antagonist reduces renal injury in rodent models of types 1 and 2 diabetes mellitus." Endocrinology **147**(11): 5363-5373.
- Guo C., Ricchiuti V., Lian B. Q., Yao T. M., Coutinho P., Romero J. R., Li J., Williams G. H. and Adler G. K. (2008). "Mineralocorticoid receptor blockade reverses obesity-related changes in expression of adiponectin, peroxisome proliferator-activated receptor-gamma, and proinflammatory adipokines." Circulation **117**(17): 2253-2261.
- Gurtner G. C., Werner S., Barrandon Y. and Longaker M. T. (2008). "Wound repair and regeneration." Nature **453**(7193): 314-321.
- Hamed S., Brenner B., Aharon A., Daoud D. and Roguin A. (2009). "Nitric oxide and superoxide dismutase modulate endothelial progenitor cell function in type 2 diabetes mellitus." Cardiovasc Diabetol **8**: 56.
- Hengge U. R., Ruzicka T., Schwartz R. A. and Cork M. J. (2006). "Adverse effects of topical glucocorticosteroids." J Am Acad Dermatol **54**(1): 1-15; quiz 16-18.

- Hirata A, Maeda N, Hiuge A, Hibuse T, Fujita K, Okada T, Kihara S, Funahashi T and Shimomura I. (2009). "Blockade of mineralocorticoid receptor reverses adipocyte dysfunction and insulin resistance in obese mice." *Cardiovasc Res* **84**(1): 164-172.
- Icre G, Wahli W. and Michalik L. (2006). "Functions of the peroxisome proliferator-activated receptor (PPAR) alpha and beta in skin homeostasis, epithelial repair, and morphogenesis." *J Invest Dermatol Symp Proc* **11**(1): 30-35.
- Kenouch S, Lombes M, Delahaye F, Eugene E, Bonvalet J. P. and Farman N. (1994). "Human skin as target for aldosterone: coexpression of mineralocorticoid receptors and 11 beta-hydroxysteroid dehydrogenase." *J Clin Endocrinol Metab* **79**(5): 1334-1341.
- Khosrotehrani K, Nguyen Huu S, Prignon A, Avril M. F., Boitier F., Oster M., Mortier L., Richard M. A., Maubec E., Kerob D., Mansard S., Merheb C., Moguelet P., Nassar D., Guegan S. and Aractingi S. (2011). "Pregnancy promotes melanoma metastasis through enhanced lymphangiogenesis." *Am J Pathol* **178**(4): 1870-1880.
- Koenig J. B. and Jaffe I. Z. (2014). "Direct role for smooth muscle cell mineralocorticoid receptors in vascular remodeling: novel mechanisms and clinical implications." *Curr Hypertens Rep* **16**(5): 427.
- Kolkhof P. and Borden S. A. (2012). "Molecular pharmacology of the mineralocorticoid receptor: prospects for novel therapeutics." *Mol Cell Endocrinol* **350**(2): 310-317.
- Kusche-Vihrog K., Callies C., Fels J. and Oberleithner H. (2010). "The epithelial sodium channel (ENaC): Mediator of the aldosterone response in the vascular endothelium?" *Steroids* **75**(8-9): 544-549.
- Leopold J. A., Dam A., Maron B. A., Scribner A. W., Liao R., Handy D. E., Stanton R. C., Pitt B. and Loscalzo J. (2007). "Aldosterone impairs vascular reactivity by decreasing glucose-6-phosphate dehydrogenase activity." *Nat Med* **13**(2): 189-197.
- Luo J. D., Wang Y. Y., Fu W. L., Wu J. and Chen A. F. (2004). "Gene therapy of endothelial nitric oxide synthase and manganese superoxide dismutase restores delayed wound healing in type 1 diabetic mice." *Circulation* **110**(16): 2484-2493.
- Marrotte E. J., Chen D. D., Hakim J. S. and Chen A. F. (2010). "Manganese superoxide dismutase expression in endothelial progenitor cells accelerates wound healing in diabetic mice." *J Clin Invest* **120**(12): 4207-4219.
- Maubec E., Laouenan C., Deschamps L., Nguyen V. T., Scheer-Senarich I., Wackenheim-Jacobs A. C., Steff M., Duhamel S., Tubiana S., Brahim N., Leclerc-Mercier S., Crickx B., Perret C., Aractingi S., Escoubet B., Duval X., Arnaud P., Jaisser F., Mentre F. and Farman N. (2015). "Topical Mineralocorticoid Receptor Blockade Limits Glucocorticoid-Induced Epidermal Atrophy in Human Skin." *J Invest Dermatol*.
- Mauro T., Guitard M., Behne M., Oda Y., Crumrine D., Komuves L., Rassner U., Elias P. M. and Hummler E. (2002). "The ENaC channel is required for normal epidermal differentiation." *J Invest Dermatol* **118**(4): 589-594.
- Mazzalupo S., Wawersik M. J. and Coulombe P. A. (2002). "An ex vivo assay to assess the potential of skin keratinocytes for wound epithelialization." *J Invest Dermatol* **118**(5): 866-870.
- Meier N. T., Haslam I. S., Pattwell D. M., Zhang G. Y., Emelianov V., Paredes R., Debus S., Augustin M., Funk W., Amaya E., Kloepper J. E., Hardman M. J. and Paus R. (2013). "Thyrotropin-releasing hormone (TRH) promotes wound re-epithelialisation in frog and human skin." *PLoS One* **8**(9): e73596.
- Menke N. B., Ward K. R., Witten T. M., Bonchev D. G. and Diegelmann R. F. (2007). "Impaired wound healing." *Clin Dermatol* **25**(1): 19-25.

- Michalik L. and Wahli W. (2006). "Involvement of PPAR nuclear receptors in tissue injury and wound repair." *J Clin Invest* **116**(3): 598-606.
- Mihailidou A. S., Loan Le T. Y., Mardini M. and Funder J. W. (2009). "Glucocorticoids activate cardiac mineralocorticoid receptors during experimental myocardial infarction." *Hypertension* **54**(6): 1306-1312.
- Mitts T. F., Bunda S., Wang Y. and Hinek A. (2010). "Aldosterone and mineralocorticoid receptor antagonists modulate elastin and collagen deposition in human skin." *J Invest Dermatol* **130**(10): 2396-2406.
- Nagase T., Akase T., Sanada H., Minematsu T., Ibuki A., Huang L., Asada M., Yoshimura K., Nagase M., Shimada T., Aburada M., Nakagami G. and Sugama J. (2013). "Aging-like skin changes in metabolic syndrome model mice are mediated by mineralocorticoid receptor signaling." *Aging Cell* **12**(1): 50-57.
- Nassar D., Droitcourt C., Mathieu-d'Argent E., Kim M. J., Khosrotehrani K. and Aractingi S. (2012). "Fetal progenitor cells naturally transferred through pregnancy participate in inflammation and angiogenesis during wound healing." *Faseb J* **26**(1): 149-157.
- Odermatt A. and Kratschmar D. V. (2012). "Tissue-specific modulation of mineralocorticoid receptor function by 11beta-hydroxysteroid dehydrogenases: an overview." *Mol Cell Endocrinol* **350**(2): 168-186.
- Palatinus J. A., Rhett J. M. and Gourdie R. G. (2010). "Translational lessons from scarless healing of cutaneous wounds and regenerative repair of the myocardium." *J Mol Cell Cardiol* **48**(3): 550-557.
- Pitt B., Remme W., Zannad F., Neaton J., Martinez F., Roniker B., Bittman R., Hurley S., Kleiman J. and Gatlin M. (2003). "Eplerenone, a selective aldosterone blocker, in patients with left ventricular dysfunction after myocardial infarction." *N Engl J Med* **348**(14): 1309-1321.
- Pitt B., Zannad F., Remme W. J., Cody R., Castaigne A., Perez A., Palensky J. and Wittes J. (1999). "The effect of spironolactone on morbidity and mortality in patients with severe heart failure. Randomized Aldactone Evaluation Study Investigators." *N Engl J Med* **341**(10): 709-717.
- Pullar C. E., Rizzo A. and Isseroff R. R. (2006). "beta-Adrenergic receptor antagonists accelerate skin wound healing: evidence for a catecholamine synthesis network in the epidermis." *J Biol Chem* **281**(30): 21225-21235.
- Sainte Marie Y., Toulon A., Paus R., Maubec E., Cherfa A., Grossin M., Descamps V., Clemessy M., Gasc J. M., Peuchmaur M., Glick A., Farman N. and Jaisser F. (2007). "Targeted skin overexpression of the mineralocorticoid receptor in mice causes epidermal atrophy, premature skin barrier formation, eye abnormalities, and alopecia." *Am J Pathol* **171**(3): 846-860.
- Sanchis A., Alba L., Latorre V., Sevilla L. M. and Perez P. (2012). "Keratinocyte-targeted overexpression of the glucocorticoid receptor delays cutaneous wound healing." *PLoS One* **7**(1): e29701.
- Sato A. (2015). "The necessity and effectiveness of mineralocorticoid receptor antagonist in the treatment of diabetic nephropathy." *Hypertens Res* **38**(6): 367-374.
- Shavit L., Lifschitz M. D. and Epstein M. (2012). "Aldosterone blockade and the mineralocorticoid receptor in the management of chronic kidney disease: current concepts and emerging treatment paradigms." *Kidney Int* **81**(10): 955-968.

- Stallmeyer B., Anhold M., Wetzler C., Kahlina K., Pfeilschifter J. and Frank S. (2002). "Regulation of eNOS in normal and diabetes-impaired skin repair: implications for tissue regeneration." *Nitric Oxide* **6**(2): 168-177.
- Tiganescu A., Hupe M., Uchida Y., Mauro T., Elias P. M. and Holleran W. M. (2014). "Increased glucocorticoid activation during mouse skin wound healing." *J Endocrinol* **221**(1): 51-61.
- Tiganescu A., Tahrani A. A., Morgan S. A., Otranto M., Desmouliere A., Abrahams L., Hassan-Smith Z., Walker E. A., Rabbitt E. H., Cooper M. S., Amrein K., Lavery G. G. and Stewart P. M. (2013). "11beta-Hydroxysteroid dehydrogenase blockade prevents age-induced skin structure and function defects." *J Clin Invest* **123**(7): 3051-3060.
- Trent J. T. and Kirsner R. S. (2004). "Leg ulcers in sickle cell disease." *Adv Skin Wound Care* **17**(8): 410-416.
- Viengchareun S., Le Menuet D., Martinerie L., Munier M., Pascual-Le Tallec L. and Lombes M. (2007). "The mineralocorticoid receptor: insights into its molecular and (patho)physiological biology." *Nucl Recept Signal* **5**: e012.
- Vukelic S., Stojadinovic O., Pastar I., Vouthounis C., Krzyzanowska A., Das S., Samuels H. H. and Tomic-Canic M. (2010). "Farnesyl pyrophosphate inhibits epithelialization and wound healing through the glucocorticoid receptor." *J Biol Chem* **285**(3): 1980-1988.
- Wada T., Kenmochi H., Miyashita Y., Sasaki M., Ojima M., Sasahara M., Koya D., Tsuneki H. and Sasaoka T. (2010). "Spironolactone improves glucose and lipid metabolism by ameliorating hepatic steatosis and inflammation and suppressing enhanced gluconeogenesis induced by high-fat and high-fructose diet." *Endocrinology* **151**(5): 2040-2049.
- Werner S. and Grose R. (2003). "Regulation of wound healing by growth factors and cytokines." *Physiol Rev* **83**(3): 835-870.
- Wong P. and Coulombe P. A. (2003). "Loss of keratin 6 (K6) proteins reveals a function for intermediate filaments during wound repair." *J Cell Biol* **163**(2): 327-337.
- Youm J. K., Park K., Uchida Y., Chan A., Mauro T. M., Holleran W. M. and Elias P. M. (2013). "Local blockade of glucocorticoid activation reverses stress- and glucocorticoid-induced delays in cutaneous wound healing." *Wound Repair Regen* **21**(5): 715-722.
- Zhao M., Celerier I., Bousquet E., Jeanny J. C., Jonet L., Savoldelli M., Offret O., Curan A., Farman N., Jaisser F. and Behar-Cohen F. (2012). "Mineralocorticoid receptor is involved in rat and human ocular chorioretinopathy." *J Clin Invest* **122**(7): 2672-2679.
- Zhao M., Song B., Pu J., Wada T., Reid B., Tai G., Wang F., Guo A., Walczysko P., Gu Y., Sasaki T., Suzuki A., Forrester J. V., Bourne H. R., Devreotes P. N., McCaig C. D. and Penninger J. M. (2006). "Electrical signals control wound healing through phosphatidylinositol-3-OH kinase-gamma and PTEN." *Nature* **442**(7101): 457-460.

FIGURE LEGENDS

Figure 1. Outgrowth of keratinocytes from neonatal mouse skin explants is dependent on MR

A: Explants of dorsal skin from newborn control (CT) and transgenic mice overexpressing the MR in keratinocytes (K5-MR) were cultured for 7 days with/without the MR antagonist Canrenoate (Canre).

B: Outgrowth of epidermis, featuring re-epithelialization step of wound healing, was quantified; it was reduced in K5-MR explants and Canrenoate partially improves the outgrowth.

Comparison between groups was made by 1-way ANOVA followed by Newman-Keuls Multiple Comparison test- * $P < 0.05$. N = 18 CTL and 18 K5-MR pups from 7 litters.

Figure 2. Glucocorticoid-induced impaired mouse skin wound healing is restored by MR blockade

A-B: Quantitative RT-PCR analysis of MR and GR mRNA expression in the wounded zone and in the surrounding intact skin in Clobetasol (Clo)-treated mice, relative to values in control PBS-treated mice (n=4).

C: Photographs of wounds at day 0, 3 and 5 post wounding from dorsal skin of mice pre-treated 10 days with Clo or PBS, and treated after the skin punch (Day 0) with Canrenoate (Canre) for 5 days.

D: Quantification of the wound area at days 3, 5, expressed as percent of the wound area at day 0 (6 mm diameter wounds) (n=5 to 12 mice per group).

E: Anti-K14 (red) labeled wound cryostat sections at day 5.

F-G: Quantification of the length of neo-epidermal tongues (**F**) and size of residual wound (expressed as % of initial wound size) (**G**) (n=10 mice).

H: Anti-Ki67 (green) staining showing proliferating cells in the neo-epidermis (Epider) and the dermal tissue (Der) of wound sections at day 5 after wounding; dotted lines indicate the dermo-epidermis junction.

I: Quantification of Ki67⁺ proliferating cells in the neo-epidermis (Epider) and the dermal tissue (Der) (n=10).

Panels A, B, F, G, I: Mann-Whitney test; panel D: 1-way ANOVA followed by Newman-Keuls Multiple Comparison test: * $P < 0.05$; ** $P < 0.01$; *** $P < 0.001$. Scale bars: 100 μm .

Figure 3. MR blockade restores impaired keratinocyte outgrowth of glucocorticoid-treated human skin explants in culture

Skin explants were collected after 6 days of organotypic culture with/without drugs (clo : clobetasol, and 3 different MR antagonists, Spiro: spironolactone; Canre: canrenoate; Eple: eplerenone).

A: Photographs of explant sections after H&E staining, showing the neo-epidermal tongues growing at the edges of the explants

B-C: Measurement of the neo-epidermal tongues, expressed as length (B) or surface (C).

D: Photographs of Ki67 (green)-labelled explant sections..

E: Quantification of proliferating keratinocytes, expressed as percentage of total epidermal cells.

* $P < 0.05$; ** $P < 0.01$; *** $P < 0.001$, 1-way ANOVA followed by Newman-Keuls Multiple Comparison test, human skin samples from 8 subjects. A and D: dotted lines indicate the neo-epidermal tongues. Scale bars: 100 μm .

Figure 4. The sodium channel ENaC is involved in wound healing

A: Quantitative RT-PCR analysis of αENaC mRNA expression in the wounded skin from mice (treatments as in figure 2); 4 mice per group.

B-D: Human skin explants in culture: the ENaC blocker phenamil (Phena) improves the glucocorticoid-induced impaired growth of epidermal tongues, as illustrated on photographs of explant sections stained with H&E (B), and quantified as length (C) or surface (D) of neo-epidermis.

* $P < 0.05$, ** $P < 0.01$; *** $P < 0.001$, 1-way ANOVA followed by Newman-Keuls Multiple Comparison test, Human skin samples from 8 subjects. In **B**: dotted lines indicate the neo-epidermal tongues. Scale bars: 100 μm .

Figure 5: MR blockade improves the delayed wound healing in streptozotocin-induced type I diabetes in mice

A-B: Quantitative RT-PCR analysis of MR and GR mRNA expression in the skin and cutaneous wound of control (open bar) and STZ mice (black bar) (n=4 mice for CT; 8 for STZ).

C-D: Delayed wound closure in STZ induced mice is accelerated by application of canrenoate over the wound, as shown on photographs of wounds (**C**) and quantification of wound area at day 3 and day 5 post-wounding (**D**), expressed as percent of the wound area at day 0 (6 mm diameter wounds) (n=4 to 7 mice per group)

* $P < 0.05$, ** $P < 0.01$; *** $P < 0.001$. 1-way ANOVA followed by Newman-Keuls Multiple Comparison test.

Figure 6: MR blockade rescues the impaired wound closure in type II diabetic mice

A-B: Quantitative RT-PCR analysis of MR and GR mRNA expression in the skin and cutaneous wound of control (open bar) and db/db mice (black bar) (n=8 mice per group).

C-D: Delayed wound closure in db/db mice is improved by application of canrenoate over the wound, as shown on photographs of wounds (**C**) and quantification of wound area at day 3 and day 5 post-wounding (**D**), expressed as percent of the wound area at day 0 (6 mm diameter wounds) (n=4 to 5 mice per group).

* $P < 0.05$; *** $P < 0.001$, 1-way ANOVA followed by Newman-Keuls Multiple Comparison test.

Figure 7: Wound closure in healthy volunteers from the SPIREPI study

After one month daily application of clobetasol alone or associated with spironolactone, skin biopsies were made, and wounds were photographed using dermatoscope (clobetasol application was not continued after biopsy).

A: Photographs of wounds at day 3 after biopsy

B: Surface of the wounds at day 3 post-biopsy was measured by using Image J software: broken lines shows the wound surface in each of the 4 zones (control, spironolactone alone, clobetasol, or both), for each of the 23 subjects included in the SPIREPI trial.

*** $P < 0.001$, ANOVA for repeated measures, followed by Newman-Keuls Multiple Comparison test.

Figure S1: MR blockade do not modify inflammation in glucocorticoid-pretreated mouse skin wounds

Inflammatory cells (neutrophils, macrophages, T cells) infiltration was analyzed on cryo-section of wound specimens harvested at day 5 post wounding and treatment of canrenoate or PBS.

A-B: Immunostaining for Gr-1 (red) (A) and quantification of Gr-1+ neutrophils in granulation tissue

C-D: Immunostaining for F4.80 (red) (A) and quantification of F4.80+ macrophages in granulation tissue

E-F: Immunostaining for CD3 (green) (A) and quantification of CD3+ T cells in granulation tissue

Statistics were done by using Mann-Whitney test. Scale bars: 100 μm .

Figure 1

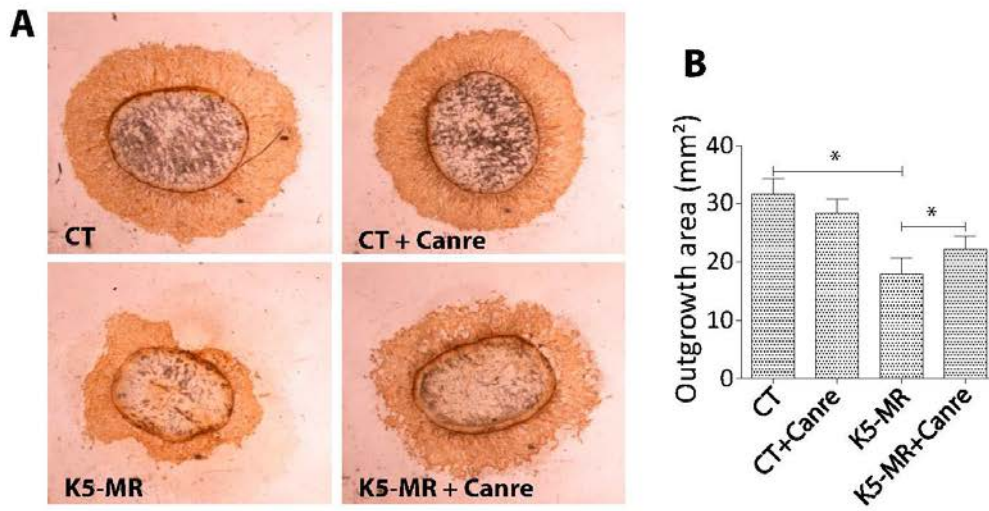


Figure 2

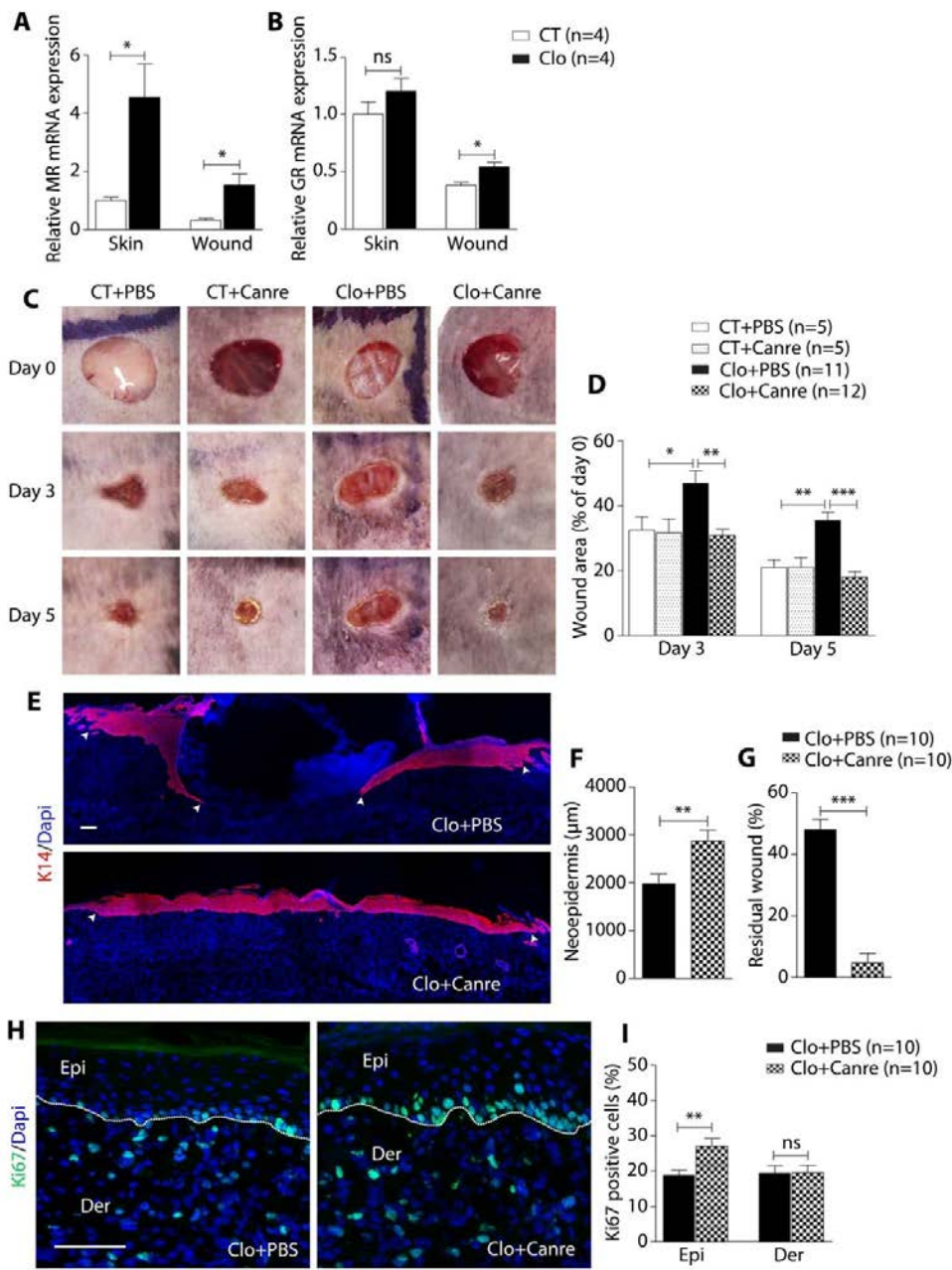


Figure 3

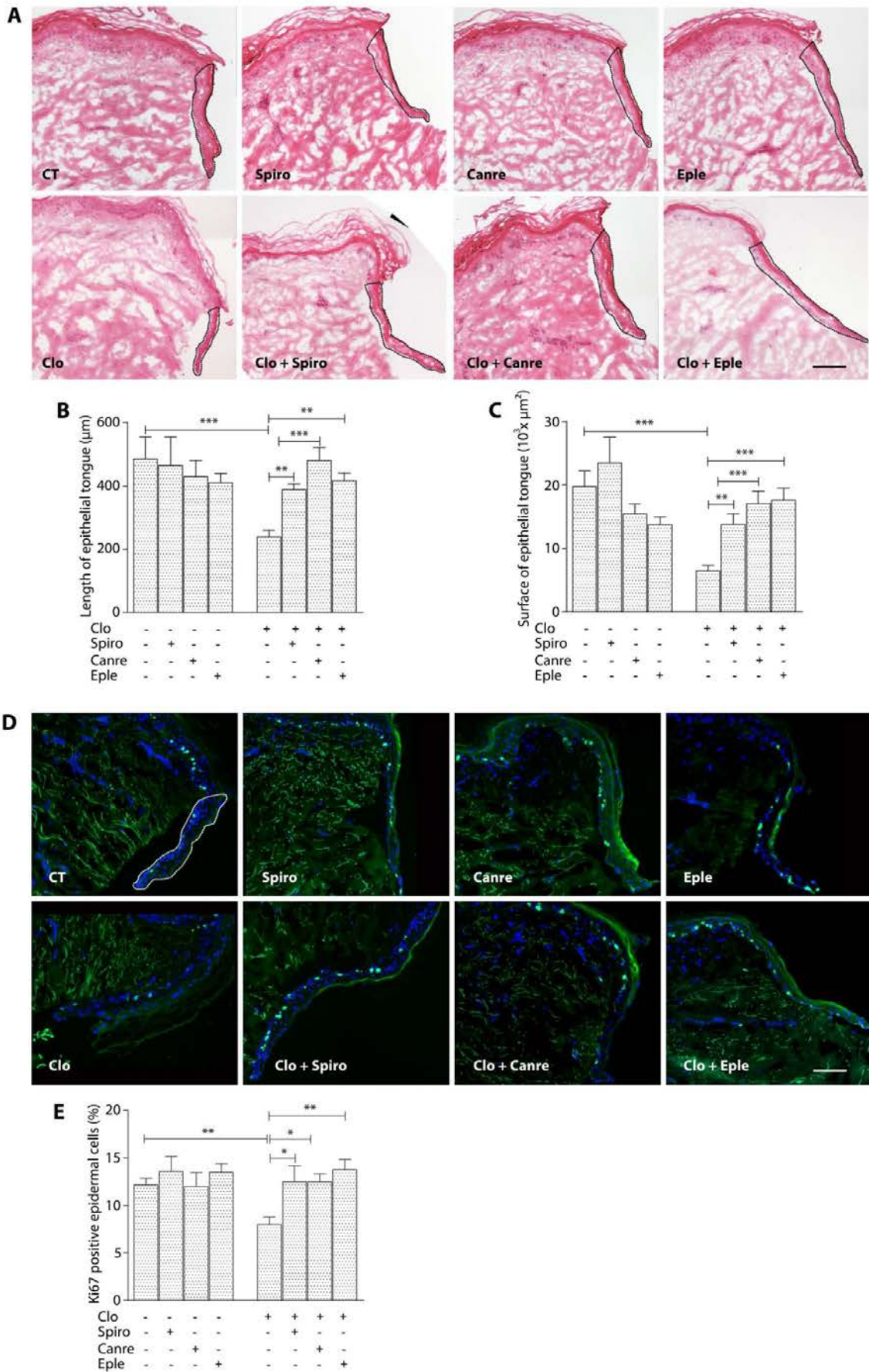


Figure 4

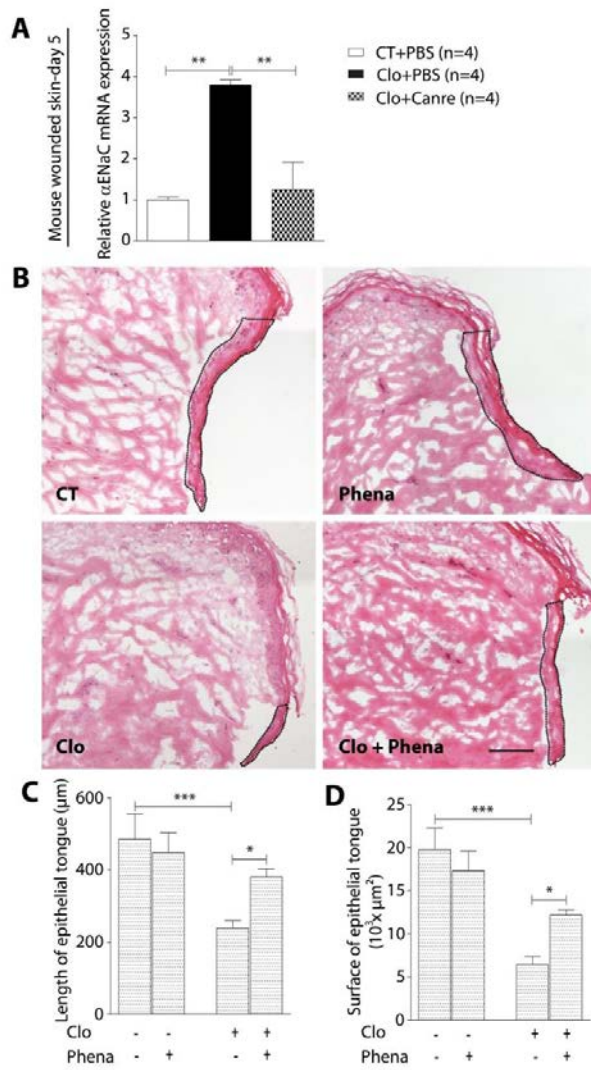


Figure 5

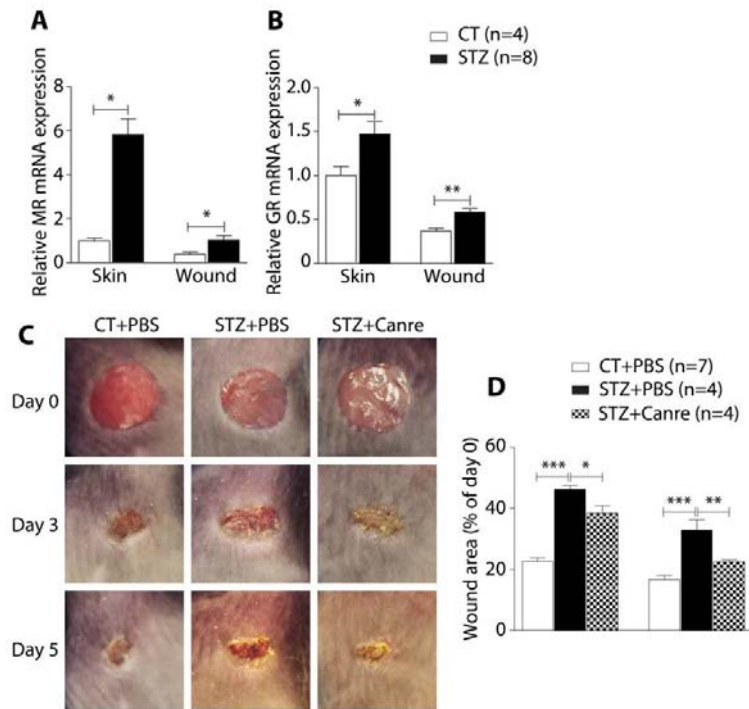


Figure 6

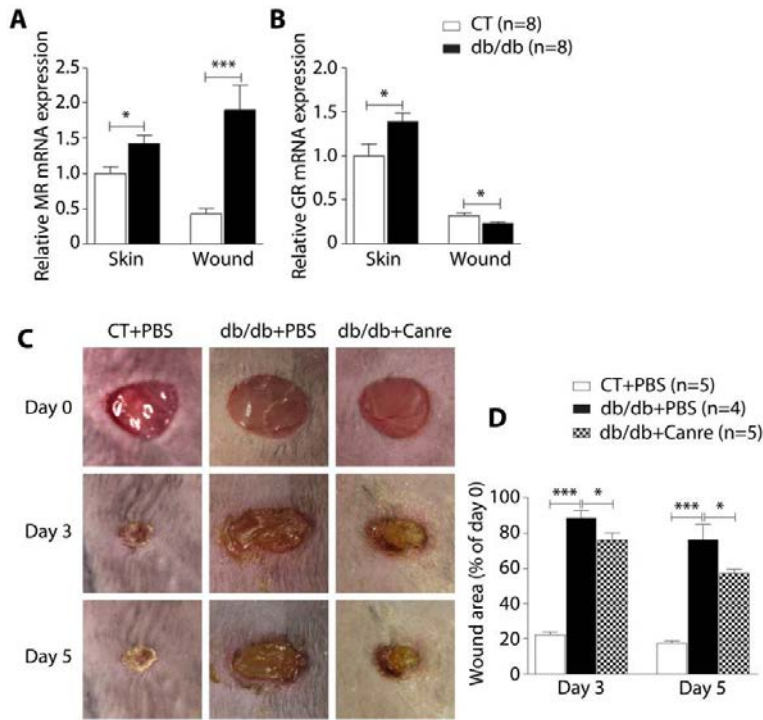


Figure 7

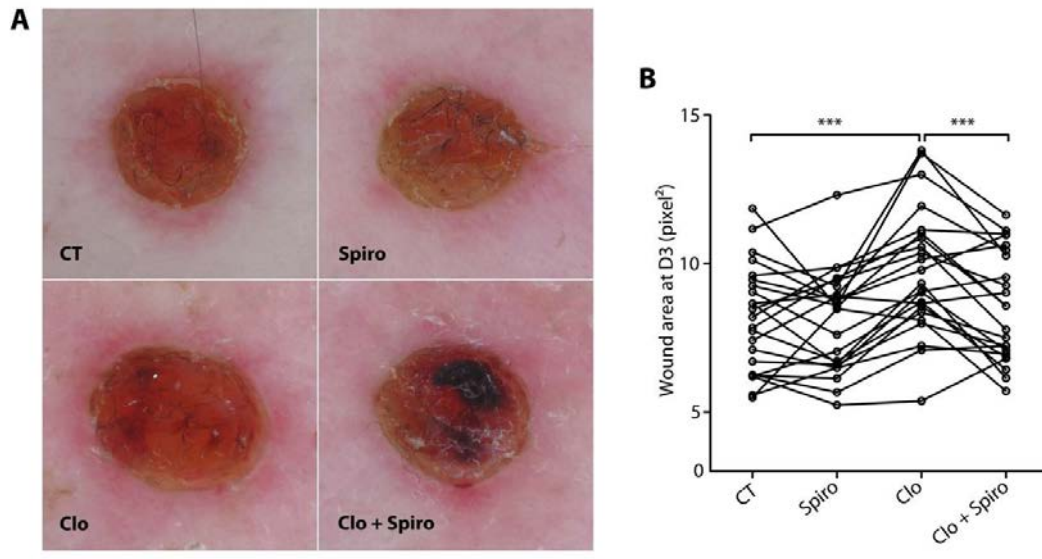
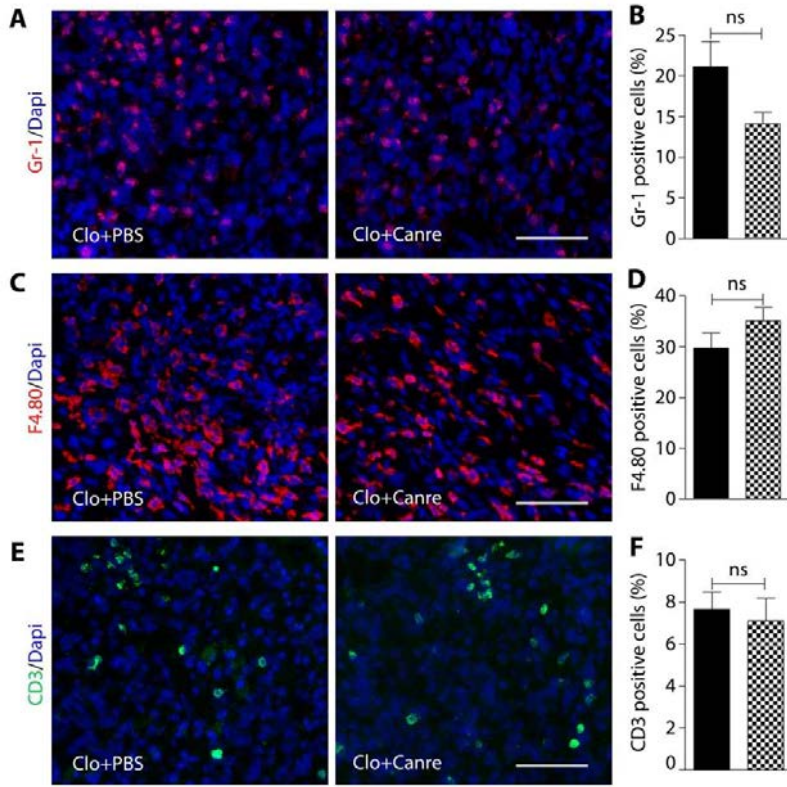


Figure S1



III - Article 3:

I also participated to the work documenting the benefit of MR blockade to limit the glucocorticoid-induced epidermal atrophy (Maubec et al. 2015). In this study, we first reproduced a classical and major deleterious side effect of glucocorticoids, by showing that the potent glucocorticoid clobetasol induces epidermal atrophy in cultured human skin explants and in subjects with local treatment of the glucocorticoid as a gel (in 23 healthy volunteers from the SPIREPI clinical trial). We asked whether glucocorticoid-induced epidermal atrophy could be related to inappropriate activation of cutaneous MR by glucocorticoids. Interestingly, we found that the epidermal atrophy could be limited when glucocorticoid was co-administrated with a MRA (canrenoate or eplerenone), ex vivo in cultured human skin explants and in vivo in the SPIREPI study. Although the mechanisms of this beneficial effect are far from being elucidated, we showed that addition of MRA was associated with the restoration of impaired keratinocyte proliferation. Furthermore, the blockade of the activity of ENaC by phenamil also improved the epidermal atrophy in skin explants and fully restored the impaired keratinocyte proliferation. These results suggest that ENaC activity may participate to the glucocorticoid-stimulated epidermal MR cascade. Altogether, these findings identify MR as a factor regulating epidermal homeostasis and suggest that topical MR blockade could limit glucocorticoid-induced epidermal atrophy.

Article 3:

Topical Mineralocorticoid Receptor Blockade Limits Glucocorticoid-Induced Epidermal Atrophy in Human Skin

Eve Maubec, Cédric Laouénan*, Lydia Deschamps*, Van Tuan Nguyen*,
Isabelle Scheer-Senarich*, Anne-Catherine Wackenheim-Jacobs, Maud Steff,
Stéphanie Duhamel, Sarah Tubiana, Nesrine Brahim, Stéphanie Leclerc-Mercier,
Béatrice Crickx, Claudine Perret, Selim Aractingi, Brigitte Escoubet, Xavier Duval,
Philippe Arnaud, Frederic Jaisser, France Mentré, and Nicolette Farman.

*The second two authors have equally contributed to the present work.

Published- Journal of Investigative Dermatology (2015) 135, 1781–1789

Topical Mineralocorticoid Receptor Blockade Limits Glucocorticoid-Induced Epidermal Atrophy in Human Skin

Eve Maubec^{1,2}, Cédric Laouénan^{2,3,4,19}, Lydia Deschamps^{5,19}, Van Tuan Nguyen^{6,7,19}, Isabelle Scheer-Senyarich^{1,19}, Anne-Catherine Wackenheim-Jacobs⁸, Maud Steff^{1,2}, Stéphanie Duhamel^{7,9}, Sarah Tubiana^{2,3,10}, Nesrine Brahimi¹, Stéphanie Leclerc-Mercier¹¹, Béatrice Crickx^{1,2}, Claudine Perret^{7,9}, Selim Aractingi^{12,13}, Brigitte Escoubet^{2,9,14}, Xavier Duval^{2,3,10}, Philippe Arnaud^{15,16,17,18}, Frederic Jaisser^{7,9}, France Mentre^{2,3,4} and Nicolette Farman^{7,9}

A major deleterious side effect of glucocorticoids is skin atrophy. Glucocorticoids activate the glucocorticoid and the mineralocorticoid (MR) receptor, both present in the epidermis. We hypothesized that glucocorticoid-induced epidermal atrophy may be related to inappropriate occupancy of MR by glucocorticoids. We evaluated whether epidermal atrophy induced by the topical glucocorticoid clobetasol could be limited by coadministration of MR antagonist. In cultured human skin explants, the epidermal atrophy induced by clobetasol was significantly limited by MR antagonism (canrenoate and eplerenone). Blockade of the epithelial sodium channel ENaC by phenamil was also efficient, identifying a role of MR-ENaC cascade in keratinocytes, acting through restoration of clobetasol-induced impairment of keratinocyte proliferation. In the SPIREPI randomized double-blind controlled trial, gels containing clobetasol, the MR antagonist spironolactone, both agents, or placebo were applied on four zones of the forearms of 23 healthy volunteers for 28 days. Primary outcome was histological thickness of the epidermis with clobetasol alone or clobetasol+spironolactone. Spironolactone alone did not affect the epidermal thickness but coapplication of clobetasol and spironolactone significantly limited clobetasol-induced atrophy and was well tolerated. Altogether, these findings identify MR as a factor regulating epidermal homeostasis and suggest that topical MR blockade could limit glucocorticoid-induced epidermal atrophy.

Journal of Investigative Dermatology (2015) 135, 1781–1789; doi:10.1038/jid.2015.44; published online 9 April 2015

¹Assistance Publique Hôpitaux de Paris (APHP), Hôpital Bichat Claude Bernard, Département de Dermatologie, Paris, France; ²Université Paris Diderot, Sorbonne Paris Cité, Paris, France; ³UMR 1137, INSERM, IAME, Paris, France; ⁴APHP, Hôpital Bichat Claude Bernard, Département de Biostatistiques, Paris, France; ⁵APHP, Hôpital Bichat Claude Bernard, Département d'Anatomopathologie, Paris, France; ⁶UMR 938, INSERM, Centre de Recherches St Antoine, Paris, France; ⁷Université Pierre et Marie Curie, Paris, France; ⁸APHP, Hôpital Bichat Claude Bernard, Département de Radiologie, Paris, France; ⁹UMR 1138, INSERM, Centre de Recherche des Cordeliers, Paris, France; ¹⁰APHP, Hôpital Bichat Claude Bernard, Centre d'Investigation Clinique 007, Paris, France; ¹¹APHP, Hôpital Necker-Enfants Malades, Département d'Anatomie et Cytologie Pathologiques, Paris, France; ¹²Hôpital Cochin Tamier, Département de Dermatologie, Paris, France; ¹³Université Paris Descartes, Paris, France; ¹⁴APHP, Hôpital Bichat Claude Bernard, Département de Physiologie, Paris, France; ¹⁵APHP, Hôpital Bichat Claude Bernard, Département de Pharmacie, Paris, France; ¹⁶Université Paris Descartes, Chimie ParisTech, Paris, France; ¹⁷UMR 8151, CNRS, Paris, France and ¹⁸UMR 1022, INSERM, Paris, France

Correspondence: Eve Maubec, Hôpital Bichat Claude Bernard, Département de Dermatologie, 46 rue Henri Huchard, Paris 75018, France.
E-mail: eve.maubec@inserm.fr

¹⁹These authors contributed equally to this work.

Abbreviations: ENaC, epithelial sodium channel; GC, glucocorticoid; GR, GC receptor; HSD2, 11- β -hydroxysteroid dehydrogenase type 2; MR, mineralocorticoid receptor

Received 9 September 2014; revised 13 January 2015; accepted 26 January 2015; accepted article preview online 10 February 2015; published online 9 April 2015

INTRODUCTION

Topical glucocorticoids (GCs) are widely used to treat chronic inflammatory or autoimmune skin diseases. Their main cutaneous side effect is skin atrophy that depends on the duration and dose of treatment (Rhen and Cidlowski, 2005; Schoepe *et al.*, 2006). There is no effective management other than steroid withdrawal, and hence the need for agents that limit the GC-induced skin atrophy.

GCs as endogenous hormones and exogenous therapeutic agents act mainly through binding to the GC receptor (GR) and cause changes in gene expression, mediating transcriptional transrepression or transactivation (Rhen and Cidlowski, 2005; Gross and Cidlowski, 2008; De Bosscher *et al.*, 2010). GCs may also bind to and activate the mineralocorticoid receptor (MR), a closely related nuclear receptor (Farman and Rafestin-Oblin, 2001). The activation of the MR is classically attributed to binding of aldosterone, the mineralocorticoid hormone that regulates renal sodium reabsorption and blood pressure through tight control of the activity of the epithelial sodium channel (ENaC) (Farman and Rafestin-Oblin, 2001). However, the MR can bind aldosterone and GC with equal high affinity; in renal target cells and other tissues, illicit

occupancy of the MR by GCs is prevented by coexpression of the MR and the GC-inactivating enzyme 11- β -hydroxysteroid dehydrogenase type 2 (HSD2) (Farman and Rafestin-Oblin, 2001; Zennaro *et al.*, 2009). In cells where HSD2 activity is low, such as cardiomyocytes or neurons, the MR may be predominantly occupied by GCs in the normal state or in pathology (Farman and Rafestin-Oblin, 2001; Mihailidou *et al.*, 2009; Zennaro *et al.*, 2009; Nguyen Dinh Cat and Jaïsser, 2012). Therefore, some effects of GCs may relate to occupancy of the MR rather than the GR.

The human skin expresses the MR in sweat gland ducts (where it regulates sodium concentration in sweat) and also in sebaceous glands, in hair follicles, in vascular endothelial cells, and in the epidermis (Kenouch *et al.*, 1994). The role of MR and its downstream pathways in epidermal keratinocytes is largely unknown (Sainte Marie *et al.*, 2007; Farman *et al.*, 2010; Perez, 2011). In addition, evidence has been provided for endogenous production of corticosterone and cortisol and metabolism of corticosteroids in the skin (Slominski *et al.*, 1996, 1999; Ito *et al.*, 2005; Slominski *et al.*, 2005a, b, 2006; Zoller *et al.*, 2008; Slominski *et al.*, 2013a, 2014). Steroidogenic activity can start *de novo* from cholesterol and can be locally regulated (Slominski *et al.*, 2004 and 2013b). Targeted expression of the MR in basal keratinocytes in mice (K5-MR mice) results in prenatal premature skin barrier formation and epidermal atrophy, leading to early postnatal death (Sainte Marie *et al.*, 2007). This phenotype is reminiscent of the well-known GC-induced epidermal atrophy. The epidermal atrophy could depend on excessive/inappropriate occupancy of the MR by the high perinatal level of GCs in pups, as the enzymatic activity of HSD2 is very low in epidermal keratinocytes (Kenouch *et al.*, 1994). Thus, we hypothesized that MR-bound GC complexes may participate in GC-induced epidermal atrophy. This notion has important clinical relevance as this deleterious effect might be limited by pharmacological MR antagonism. The classical MR blockers (spironolactone or its metabolite canrenoate) have been used safely for decades in the treatment of hypertension, and more recently to improve outcomes of patients with cardiac failure and following myocardial infarction; these drugs are not fully specific for the MR, as they also interact with the androgen receptor (and GR, at high doses) (Kolkhof and Borden, 2012). Eplerenone is MR specific but less potent and poorly soluble; its clinical use is more recent, and novel nonsteroidal MR blockers are now under development (Kolkhof and Borden, 2012).

In this study, we used cultured human skin explants to test the hypothesis and provide insights into the underlying mechanisms. Translation of the hypothesis to human skin physiopathology was evaluated through a placebo-controlled clinical trial in healthy volunteers. We show here that MR blockade limits the epidermal atrophy and the impaired keratinocyte proliferation induced by the widely used topical GC clobetasol in human skin explants. To provide mechanistic insights, we identified ENaC as an epidermal actor, as its blockade restored the GC-induced impaired keratinocyte proliferation in skin explants. In the randomized double-blind SPIREPI phase 2 clinical trial, we provide evidence that our findings have clinical relevance, as topical spironolactone

administration in healthy volunteers leads to improvement of the clobetasol-induced epidermal atrophy.

RESULTS

MR blockade in human skin explants improves GC-induced epidermal atrophy

We evaluated *ex vivo* the effect of MR blockade in human skin explants maintained in organotypic culture. Compared with control-treated explants (median of epidermal thickness: 62.8 μ m), 6 days of incubation of explants with clobetasol added to the culture medium reduced epidermal thickness by one-third (median: 41.3 μ m; $P=0.0001$, Wilcoxon paired test), as illustrated in Figure 1 and Supplementary Table S1 online. Noticeably, clobetasol-induced epidermal atrophy was improved by coinubation with canrenoate ($P=0.0002$, Wilcoxon paired test), as shown in Figure 1a–c and Supplementary Table S1 online. GCs impair the proliferation of keratinocytes (Zoller *et al.*, 2008). Clobetasol reduced the epidermal Ki 67 proliferation index (a marker of dividing cells) by 33–45% (Figure 1d and Supplementary Table S2 online). MR antagonism by canrenoate, associated with clobetasol, fully corrected the impaired proliferation of keratinocytes (Figure 1d and Supplementary Table S2 online). In the absence of GC challenge, incubation with canrenoate alone did not significantly modify the Ki67 index.

We conducted another series of experiments in human explants treated *ex vivo* with the highly specific MR antagonist eplerenone. As shown in Figure 1e–g and Supplementary Tables S1 and S2 online, it also limited GC-induced epidermal atrophy and impaired keratinocyte proliferation (as the less specific spironolactone metabolite canrenoate does). These results strongly suggest that inappropriate MR occupancy is involved in the epidermal atrophy observed in the presence of clobetasol.

ENaC activity is involved in the GC-induced epidermal atrophy

Overexpression of MR in mouse skin (K5-MR mice) leads to an increase in the expression of the epithelial sodium channel ENaC (Supplementary Data and Figure S1 online). We questioned the link between ENaC activity and GC-induced epidermal atrophy in human skin explants. As shown in Figure 2a–c and Supplementary Table S1 online, blockade of epidermal ENaC activity with the specific ENaC inhibitor phenamil partially but significantly improved the GC-induced epidermal atrophy within 6 days of treatment ($P=0.02$, Wilcoxon paired test). Phenamil fully corrected the impaired proliferation generated by clobetasol (Figure 2d and e and Supplementary Table S2 online).

Altogether, these results argue for the involvement of an MR–ENaC cascade in the control of GC alteration of epidermal thickness, acting through a mechanism including regulation of epidermal proliferation.

The SPIREPI clinical trial shows benefit of topical spironolactone in limiting GC-induced epidermal atrophy

We conducted the SPIREPI clinical trial to evaluate whether topical administration of the MR antagonist spironolactone could limit GC-induced skin atrophy in healthy volunteers.

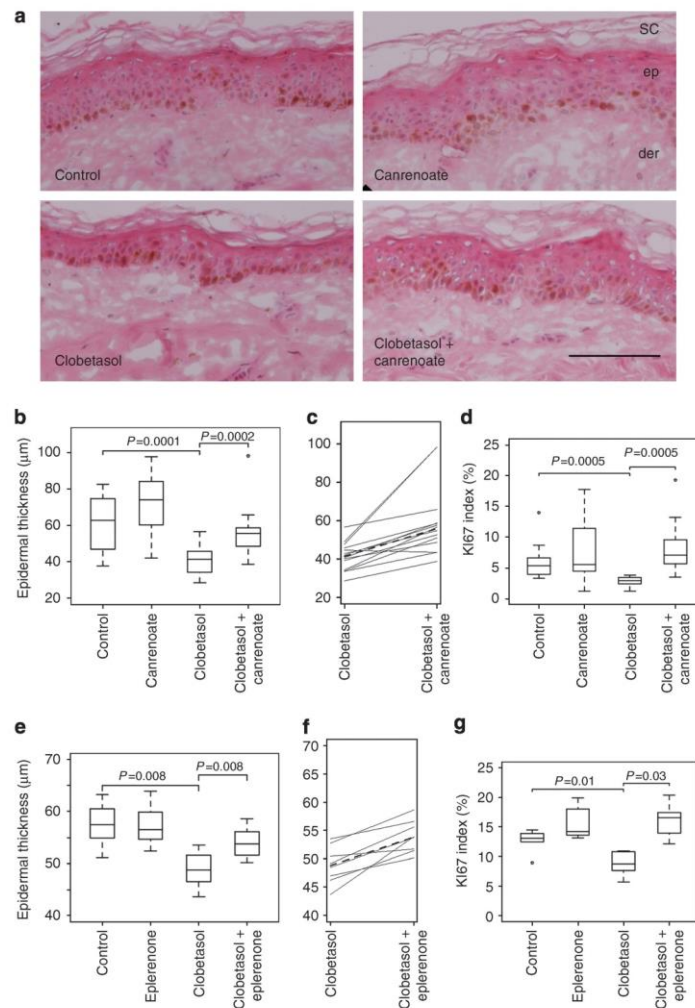


Figure 1. Variations in epidermal thickness and keratinocyte proliferation in cultured human skin explants. Explants were incubated with solvent (control), mineralocorticoid receptor (MR) antagonist, clobetasol, or clobetasol+MR antagonist. (a) Photographs of tissue (bar = 0.1 mm). **Effects of canrenoate (10 µm):** (b) epidermal thickness (µm); (c) clobetasol (100 nm) compared with clobetasol+canrenoate; values from the same subject are linked, with dashed line for median; (d) KI67 index in the canrenoate series. **Effects of eplerenone (10 µm):** (e) epidermal thickness; (f) eplerenone compared with clobetasol+eplerenone; (g) KI67 index in the eplerenone series. Graphs are box-and-whisker plot with median (rule inside the box), 75th and 25th percentile (top and bottom of box), 10th and 90th percentiles (bars projecting up and down) of epidermal thickness (in µm), and outlier values falling outside. Comparisons of treatments: Wilcoxon paired test. der, dermis; ep, epidermis; SC, stratum corneum.

Study participants. The SPIREPI randomized, double-blind, crossover phase 2 efficacy trial was conducted between September 2011 and March 2012. Of the 26 subjects initially enrolled, 3 were not evaluable for primary outcome (one withdrawal of consent and two protocol nonadherence) and were excluded from the analyses. Baseline characteristics of the subjects are provided in Supplementary Table S3 online. The 23

participants adhered to the protocol, missing no more than three applications over the 29-day initial period.

Primary outcome: epidermal thickness measured on histological sections on day 29. Topical GC application (clobetasol) resulted in histological epidermal atrophy on day 29, compared with placebo ($P=0.0002$, Wilcoxon paired test) as expected

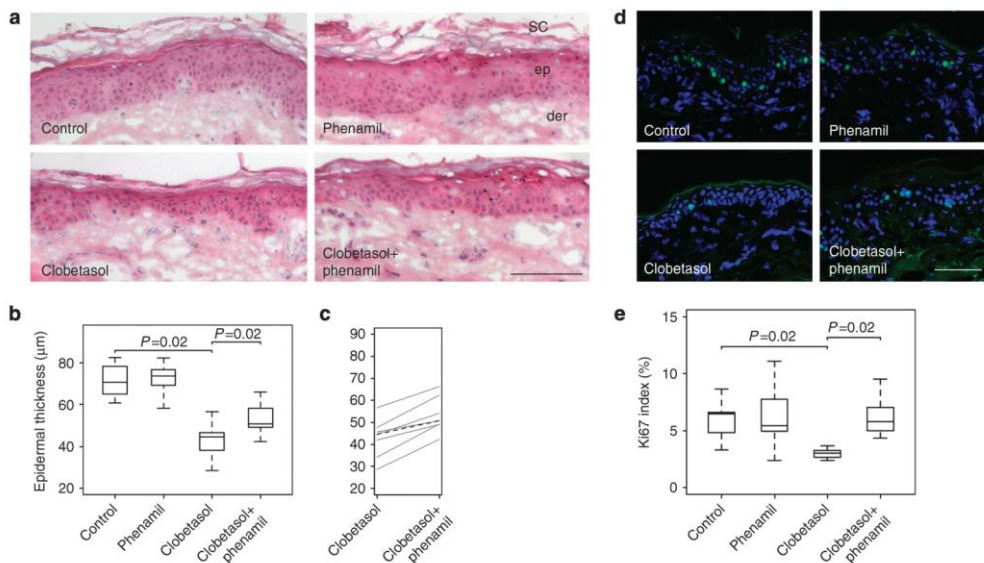


Figure 2. Effect of epithelial sodium channel (ENaC) blockade in human skin explants. Skin explants from seven subjects were incubated with solvent, phenamil (an ENaC blocker), clobetasol, or clobetasol+phenamil. (a) Photographs of tissue sections (bar=0.1 mm). (b) Epidermal thickness: box-and-whisker plots as described in Figure 1. (c) Effect of clobetasol+ phenamil on epidermal thickness compared with clobetasol alone; values from samples issued from the same subject are linked and the dashed line shows the median value for each treatment. (d) Immunofluorescence photographs of tissue sections labeled with Ki67 antibody (bar=0.1 mm). (e) Ki67 index; box-and-whisker plots as described in Figure 1. Differences were evaluated by Wilcoxon paired test. der, dermis; ep, epidermis; SC, stratum corneum.

(Figure 3 and Supplementary Table S4 online). Spironolactone added to clobetasol significantly ($P=0.04$, Wilcoxon paired test) increased epidermal thickness, compared with clobetasol alone (Figure 3 and Supplementary Table S4 online). Equivalence of epidermal thickness between spironolactone and placebo treatments was significant (two one-sided test equivalence test, $P=0.02$), indicating that spironolactone alone (i.e., in the absence of concomitant GC application) does not affect epidermal thickness. Of note, three participants had almost no change in epidermal thickness and three presented with thicker epidermis following clobetasol application (Figure 3c); they were referred to as GC resistant. In the *post hoc* analysis on the 17 clobetasol responders (those with clobetasol-induced epidermal atrophy), the beneficial effect of spironolactone added to clobetasol was more marked ($P=0.001$, Wilcoxon paired test, Figure 3e and Supplementary Table S4 online).

Secondary outcomes: whole-skin thickness measured by ultrasound and level of expression of MR and GR in the epidermis. Ultrasound (Figure 4a) is a valuable tool for monitoring whole-skin thickness (measuring epidermis+dermis). As shown in Figure 4b, this method detected a reduction in whole-skin thickness following clobetasol treatment (compared with placebo) on day 29, and that was already significant on day 15 (data not shown). No significant difference in whole-skin thickness could be evidenced between

clobetasol and clobetasol+spironolactone treatments ($P=0.07$, Wilcoxon paired test) when the 23 healthy volunteers were considered. Of note, when considering only the 17 clobetasol responders on the histological epidermal thickness criteria (Figure 4c), the addition of spironolactone to clobetasol significantly increased whole-skin thickness ($P=0.004$, Wilcoxon paired test). Both MR and GR (Supplementary Figure S2 online) were evidenced in keratinocytes; nuclear labeling was more prevalent in basal layers than in superficial keratinocytes. For each subject the estimated intensity of MR or GR staining varied somewhat with treatments, although with great dispersion. Although spironolactone application did not noticeably affect the intensity of nuclear MR or GR immunostaining, there was a tendency for reduced MR staining with clobetasol (which was improved in the presence of coadministered spironolactone) and GR expression was lower after clobetasol treatment alone or in association with spironolactone.

Adverse events. Kalemia was not affected after 29 days of spironolactone application (not shown). No infection was seen after biopsy. Skin atrophy clinically featured with linear telangiectasia was seen only by dermoscopic examination. A single case of grade 2 contact dermatitis that occurred after 24 days of treatment with clobetasol required discontinuation of application for 3 days. No contact dermatitis to spironolactone occurred.

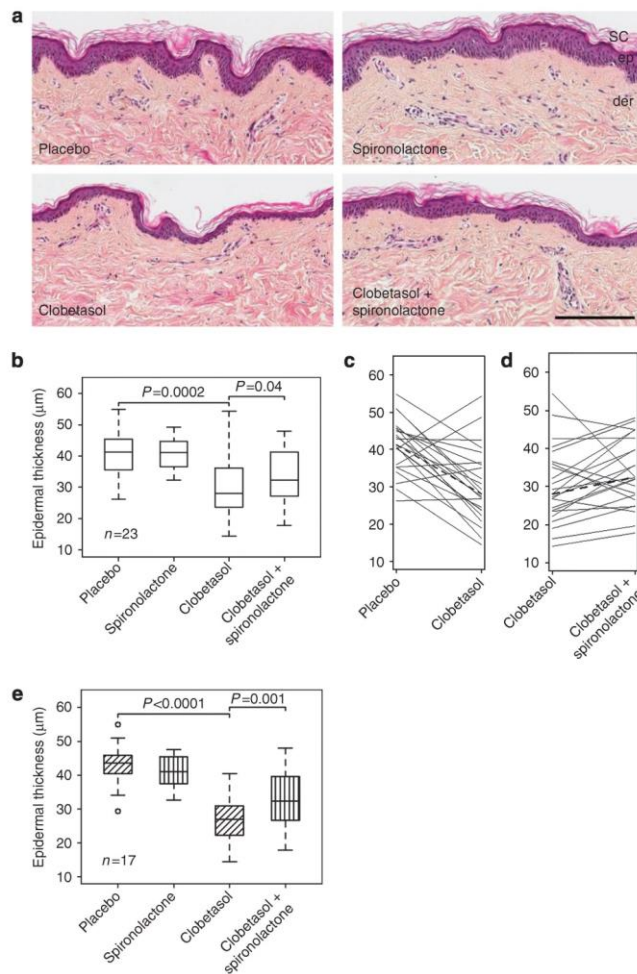


Figure 3. SPIREPI trial: epidermal thickness determined on histological sections of skin biopsy (day 29) in healthy volunteers. (a) Histology (hematoxylin-eosin staining) of skin treated with each treatment (bar=0.5 mm). (b) Plots of epidermal thickness (in µm) measured by histology in all healthy volunteers (n=23) according to treatment. Box-and-whisker plots as described in Figure 1. (c and d) Clobetasol compared with placebo in c and with clobetasol+spirinolactone in d. Values from the same subject are linked and the dashed line shows the median value for each treatment. (e) Hatched box-and-whisker plots of epidermal thickness in the 17 healthy volunteers who were clobetasol responders (post hoc analysis). Differences were evaluated using Wilcoxon paired test. der, dermis; ep, epidermis; SC, stratum corneum.

DISCUSSION

The skin atrophy that appears during GC therapy is a major concern for patients. The reduction of epidermal thickness is known to be more pronounced and to occur earlier than the reduction of dermal thickness (Cossmann and Welzel, 2006). Mechanisms are not fully understood and may differ between the epidermis and the dermis. They include reduced keratinocyte proliferation, direct or indirect reduction in collagen synthesis, or enhanced degradation, and likely affect other

proteins of the extracellular matrix (proteoglycans and elastin) and matrix metalloproteases (Schoepe *et al.*, 2006). Because the MR is expressed in keratinocytes, we focused our investigations on the epidermis, although the dermis may also be somewhat affected by MR blockade (Mitts *et al.*, 2010).

The role of the GR in controlling epidermal homeostasis has been highlighted by transgenic mouse models: mice over-expressing GR in keratinocytes exhibit epidermal atrophy,

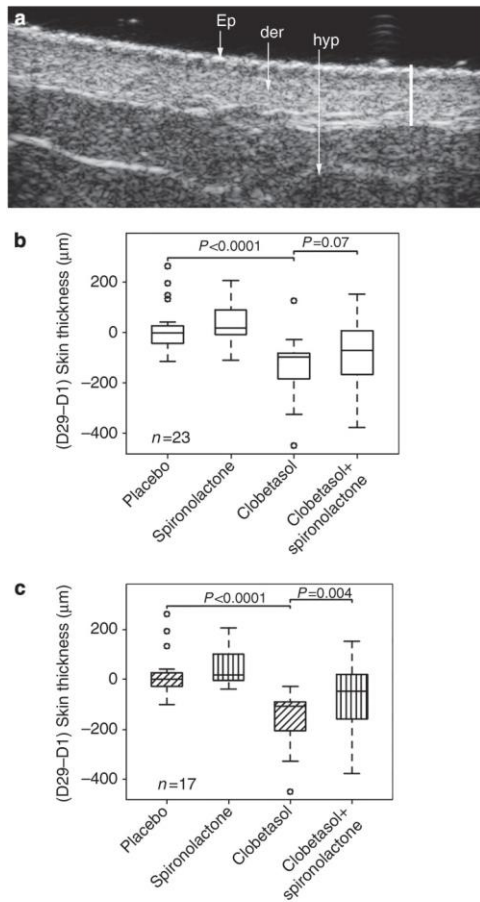


Figure 4. SPIREPI trial: ultrasound measurement of whole-skin thickness in healthy volunteers according to treatment. (a) Representative high-resolution ultrasound imaging of epidermis+dermis thickness. White bar (1 mm) extends over the epidermis+dermis. (b) Change in ultrasound measurement (in μm) of whole-skin thickness for all volunteers ($n=23$). (c) The *post hoc* analysis for the 17 clobetasol responders. Values are provided as difference in whole-skin thickness between measurements performed on day 1 (D1) and day 29 (D29). Box-and-whisker plots are as described in Figure 1. Differences were evaluated using Wilcoxon paired test. der, dermis; Ep, epidermis; hyp, hypodermis.

whereas mice lacking GR in keratinocytes have thicker skin (Perez, 2011). GR regulates gene transcription through multiple mechanisms (Rhen and Cidlowski, 2005; De Bosscher *et al.*, 2010).

The search for drugs that would limit GC-induced skin atrophy represents a major therapeutic challenge. One option relies on defining SEGRA (Selective GR Agonists) with full

anti-inflammatory potency dissociated from deleterious effects (Schacke *et al.*, 2004; Rhen and Cidlowski, 2005; Schacke *et al.*, 2007). Although very appealing, this strategy has yielded molecules that have still not reached the preclinical stage. We now propose another approach to limit some deleterious cutaneous events in GC-treated subjects.

We show that MR blockade improves epidermal atrophy on human skin submitted to GC challenge, whereas the normal (untreated) epidermis is unaffected. The mechanism of this beneficial effect involves activity of the epithelial sodium channel ENaC and keratinocyte proliferation. Early reports on the incremental efficacy of MR antagonism in cardiovascular diseases led to the notion of inappropriate activation of the MR in pathology (Pitt *et al.*, 1999 and 2003). MR antagonism improves cardiovascular mortality and morbidity and this is attributed (at least in part) to illicit MR occupancy by GCs (Guder *et al.*, 2007; Mihailidou *et al.*, 2009). Several studies showed benefits of MR antagonism to attenuate progression toward end-stage renal failure (Shavit *et al.*, 2012) and to improve insulin resistance, vascular damage (Bender *et al.*, 2013), metabolic syndrome (Zennaro *et al.*, 2009), cardiovascular diseases (Maron and Leopold, 2010; Leopold, 2011; Nguyen Dinh Cat and Jaisser, 2012), and central serous chorioretinitis (Zhao *et al.*, 2012). Here we provide evidence that the epidermal atrophy due to topical GCs relies in part on excessive occupancy of MR by GCs. The low levels of the MR-protecting enzyme HSD2 in human epidermis (Kenouch *et al.*, 1994) favor such a mechanism by limiting the local inactivation (metabolism) of GCs. Whether application of clobetasol or spironolactone over the skin could modify the local corticosteroid synthesis/metabolism is not known, and represents an interesting and unknown issue. For instance, one can speculate that application of these drugs could interfere with local steroidogenesis, thus modulating MR occupancy. MR expression may be enhanced in pathological conditions, providing a basis to explain the efficacy of MR blockade; for example, MR mRNA is enhanced in the kidney of diabetic db/db mice (Guo *et al.*, 2006) or in the heart of rats with myocardial infarction (Milik *et al.*, 2007; Takeda *et al.*, 2007). MR expression was found to be increased in full-thickness skin in an aging-like mouse model induced by metabolic syndrome and UV irradiation; the authors reported that topical application of MR antagonist spironolactone suppressed the aging-like changes in the skin (Nagase *et al.*, 2013). In this study, MR immunohistochemistry signal appears to be somewhat lower after application of clobetasol ointment. Changes in the expression levels of MR/GR may depend on the duration of the treatment (to limit deleterious effects?) and the potency of the dermocorticoid. Eventual variations (up or down) in MR expression in pathology or on treatments, in the skin as well as in other cells (kidney, lung, heart, neurons and so on), have been scarcely addressed in the literature.

We found that ENaC belongs to a pathway modulated by mineralocorticoid receptor activity in keratinocytes. In the kidney, ENaC is regulated by aldosterone and GCs at the transcriptional level and even more through posttranscriptional mechanisms, modulating the number of active

channels and their opening probability (Soundararajan *et al.*, 2010). ENaC is involved in epidermal homeostasis (Brouard *et al.*, 1999; Mauro *et al.*, 2002; Guitard *et al.*, 2004). Differentiation of human epidermal keratinocytes in culture is associated with major enhancement of expression of the ENaC β -subunit (Brouard *et al.*, 1999). Keratinocyte-specific knockout of the ENaC α -subunit in mice results in epidermal hyperplasia (Mauro *et al.*, 2002). Cutaneous ENaC mRNA levels were not evaluated in full-thickness human skin samples because of the confounding presence of several ENaC-expressing cells in the whole skin in addition to the epidermis (sweat and sebaceous glands, hair follicle, vascular endothelial cells), precluding proper interpretation of epidermis-specific events. Because of these limitations, we have chosen to address the end point of the ENaC pathway—i.e., its activity. Our finding that ENaC blockade by phenamil enhances epidermal thickness in human skin explants exposed to GCs provides functional evidence for the involvement of ENaC; it is consistent with the hyperplasia observed with genetic ablation of α -ENaC (Mauro *et al.*, 2002). Moreover, the GC-induced reduction in proliferation of epidermal keratinocytes in human skin explants is corrected by MR antagonism as well as by ENaC blockade with phenamil. These results favor the view that restoration of keratinocyte proliferation is dependent on a cascade involving both the GC-activated MR and ENaC.

The beneficial effect of topical MR antagonism was found to be of limited amplitude; the atrophy induced by clobetasol and the beneficial effect of MR blockade were more marked in explants incubated *ex vivo* with canrenoate than in the clinical trial. This is possibly due to several factors. First, it may be related to drugs. Preliminary experiments designed to assess *ex vivo* skin permeability of human skin to spironolactone gel showed a very low transcutaneous passage. Efforts toward improved formulation of the poorly soluble spironolactone for dermatological use will be required. Second, not all subjects of the clinical trial developed epidermal atrophy after GC treatment: 6 out of 23 subjects were apparently GC resistant. When considering only the 17 GC-responsive individuals, the beneficial antiatrophic effect of spironolactone was more pronounced (Figure 3e, $P=0.001$). Third, it may be related to variability in treatment duration (6 days *ex vivo*, vs. 1 month *in vivo*). It is conceivable that long-term *in vivo* treatments possibly lead to compensatory/adaptive events. It should be underlined that several other mechanisms (mostly unknown) besides MR activation may be involved in the GC-induced epidermal atrophy.

A limitation of our trial is its focus on healthy volunteers; however, it is an essential step before similar investigations in chronic skin diseases. We used spironolactone rather than a more specific drug to antagonize the MR in the SPIREPI clinical trial because spironolactone has been largely used in clinical trials as an MR antagonist. However, spironolactone or canrenoate lacks specificity as it may also block the androgen receptor as well as other steroid receptors (Fagart *et al.*, 2010; Kolkhof and Borden, 2012). Eplerenone or novel nonsteroidal compounds (Kolkhof and Borden, 2012)

reformulated for skin application should be considered in future trials.

Based on the hypothesis of inappropriate MR occupancy by topical GCs and on the results reported here, we propose that the topical MR blockade may be a therapeutic option, to our knowledge previously unreported, to limit to some extent the epidermal atrophy induced by glucocorticoids.

MATERIALS AND METHODS

Human skin explants in culture

Human skin obtained from breast reduction surgery was kept at 4°C and skin punches were excised (3 mm diameter, Disposable Biopsy Punch, Kai Europe, Solingen, Germany). The patients were fully informed and had no objection to the skin discarded from surgery being used for research purposes. Written patient consent was not required because French law considers that it is not mandatory for noninterventional biological collection for immunological and molecular research. This procedure was approved by the mentioned institutional review board (ethical approval of the Comité de Protection des Personnes Ile de France V). Full-thickness skin explants were placed in organotypic culture (see Supplementary Data online). Explants from 14 subjects were incubated in the presence of clobetasol propionate (Sigma-Aldrich, Saint-Quentin Fallavier, France, 100 nM in 0.2% ethanol); of note, the concentration of clobetasol used was much lower than that of commercial gel preparations used in dermatology, usually 0.05%, i.e., 1 mM alone or with the MR antagonist potassium canrenoate (Sigma-Aldrich, 10 μ M in phosphate-buffered saline). A second series of explants from 8 subjects was challenged with the MR-specific blocker eplerenone (Tocris Bioscience, R&D System Europe, Lille, France, 10 μ M in 0.1% DMSO). A third series of explants from 7 subjects was incubated in the presence of clobetasol alone or with the epithelial sodium channel ENaC blocker phenamil (Sigma-Aldrich, 100 nM in 0.2% DMSO). Control explants were incubated with the drugs alone, or with the solvents alone. On day 6, explants were frozen and processed for measurement of epidermal thickness and keratinocyte proliferation (KI 67 index) as detailed in Supplementary Data online.

The SPIREPI clinical trial

The SPIREPI randomized double-blind controlled trial (ClinicalTrials.gov: NCT01407471) is a single-center interventional phase 2 study. Healthy volunteers were enrolled at the Centre for Clinical Investigation at Bichat Hospital, Paris, France. Determination of sample size, randomization, blinding procedures, and the participant flow diagram are detailed in Supplementary Data online.

Participants. Study participants were included if they were 21–50 years of age, without gender selection. Exclusion criteria were chronic skin disease or atrophy, treatment with oral corticosteroids or MR antagonists, and pregnancy. Participants provided written informed consent according to French regulations, and the study received approval from the Comité de Protection des Personnes Ile de France IV (Hopital Saint Louis, Paris, France: institutional review board 2008-006951-39 A) and from the French National Agency for Medicines and Health Products Safety (agreement A100208-15).

Treatments. Four zones (A, B, C, and D) of 1.75 \times 1.75 cm were defined on the inner face of the forearms of each participant with

a permanent ink marker (two zones on each forearm, separated by 6 cm of untreated skin, to avoid drug–drug interaction in case of lateral diffusion of drugs). The four treatments were applied daily for 4 weeks: placebo (T1), clobetasol 0.05% (T2), spironolactone 5% (100-fold excess) (T3), and clobetasol 0.05% +spironolactone 5% (T4) (see Supplementary Methods section online). Spironolactone was chosen because of its long-term use in humans (oral administration), and even in some reports of topical use to treat acne (Walton *et al.*, 1986).

Follow-up. Treatments were administered daily (except Saturday and Sunday) for 29 days by personnel at the Centre for Clinical Investigation on the defined zones; on Saturday, the applications were performed by the volunteers at home. At each visit (days 1, 15, and 29) the occurrence of telangiectasia was assessed semiquantitatively as an early sign of steroid-induced atrophy in each zone (examination by eye and dermoscopy). Biopsy punches (3 mm diameter, 7 mm deep) were performed on day 29 at the center of each treated zone after local xylocaine anesthesia. After biopsy, clobetasol applications were discontinued and clinical monitoring was performed up to complete wound closure. Kalemia was measured on days 1 and 29.

Outcomes and procedures. The primary outcome was epidermal thickness measured on histological sections of biopsy (day 29). Secondary outcomes were whole-skin thickness measured by ultrasound and the level of expression of MR and GR in the epidermis. Details are provided in Supplementary Information online. For histological measurement of epidermal thickness, 4- μ m-thick sections of skin biopsy were stained with hematoxylin–eosin. Epidermal thickness is expressed in μ m. Noninvasive measurement of whole-skin thickness (that includes epidermis +dermis) was evaluated by high-resolution ultrasound imaging. Whole-skin thickness (in μ m) was calculated as the mean of the measurements from three independent scans for each treated zone. Receptor expression in the epidermis was assessed by immunohistochemistry using the 6G1 antibody against MR generated by Gomez-Sanchez *et al.* (2006) and the Santa Cruz GR E20 antibody against GR (Zhao *et al.*, 2012).

Statistical analyses

For within-group analyses in cultured human skin explants (issued from the same subject) and in the SPIREPI clinical trial (as treatments were applied on the four skin zones from each volunteer), the Wilcoxon paired test was used.

In the SPIREPI clinical trial, analyses were performed for all subjects who had undergone a biopsy on day 29 and did not miss more than 3 days of treatment. Epidermal thickness measured on histological sections on day 29 was compared (Wilcoxon paired test) between placebo- and clobetasol-treated zones and between clobetasol- and clobetasol+spironolactone-treated zones. Equivalence of epidermal thickness was assessed between spironolactone- and placebo-treated zones with a nonparametric Wilcoxon two one-sided test with a predefined equivalence limit of 10% of the median epidermal thickness in the placebo-treated zone. The same comparisons were carried out on ultrasound assessment of whole-skin thickness between days 1 and 29.

In *post hoc* analysis, primary and secondary outcomes were also analyzed for the subgroup of clobetasol responders—i.e., in the

17 subjects whose epidermis thickness was lower in the clobetasol than in the placebo-treated zones.

Results are provided as median values, as indicated in the legend of figures; analyses were performed using SAS v9.3 statistical software (SAS Institute, Cary, NC).

CONFLICT OF INTEREST

The authors state no conflict of interest.

ACKNOWLEDGMENTS

The sponsor of the SPIREPI trial was Assistance Publique-Hopitaux de Paris (Département de la Recherche Clinique et du Développement). We thank Celso Gomez-Sanchez for providing the antibody against the MR. We are indebted to Amel Ouslimani and Elodie Soler for the management of the regulatory aspect of the SPIREPI trial. We thank the on-site staff of Bichat hospital, I Poirier, M Marcot, P Rolland, V Vignali, E Marcault, C Estellat, F Tubach, G Arcangeli, and V Descatoire, for their involvement in the SPIREPI trial. This study was funded by Assistance Publique-Hopitaux de Paris (Département de la Recherche Clinique et du Développement, contrat d'initiation à la recherche clinique CRC 07-009), Société Française de Dermatologie, and Institut National de la Santé Et de la Recherche Médicale.

SUPPLEMENTARY MATERIAL

Supplementary material is linked to the online version of the paper at <http://www.nature.com/jid>

REFERENCES

- Bender SB, McGraw AP, Jaffe IZ *et al.* (2013) Mineralocorticoid receptor-mediated vascular insulin resistance: an early contributor to diabetes-related vascular disease? *Diabetes* 62:313–9
- Brouard M, Casado M, Djelidi S *et al.* (1999) Epithelial sodium channel in human epidermal keratinocytes: expression of its subunits and relation to sodium transport and differentiation. *J Cell Sci* 112: 3343–52
- Cossmann M, Welzel J. (2006) Evaluation of the atrophogenic potential of different glucocorticoids using optical coherence tomography, 20-MHz ultrasound and profilometry; a double-blind, placebo-controlled trial. *Br J Dermatol* 155:700–6
- De Bosscher K, Haegeman G, Elewaut D. (2010) Targeting inflammation using selective glucocorticoid receptor modulators. *Curr Opin Pharmacol* 10: 497–504
- Fagart J, Hillisch A, Huyet J *et al.* (2010) A new mode of mineralocorticoid receptor antagonism by a potent and selective nonsteroidal molecule. *J Biol Chem* 285:29932–40
- Farman N, Maubec E, Poeggeler B *et al.* (2010) The mineralocorticoid receptor as a novel player in skin biology: beyond the renal horizon? *Exp Dermatol* 19:100–7
- Farman N, Rafestin-Oblin ME. (2001) Multiple aspects of mineralocorticoid selectivity. *Am J Physiol Renal Physiol* 280:F181–92
- Gomez-Sanchez CE, de Rodriguez AF, Romero DG *et al.* (2006) Development of a panel of monoclonal antibodies against the mineralocorticoid receptor. *Endocrinology* 147:1343–8
- Gross KL, Cicilowski JA. (2008) Tissue-specific glucocorticoid action: a family affair. *Trends Endocrinol Metab* 19:331–9
- Guder G, Bauersachs J, Frantz S *et al.* (2007) Complementary and incremental mortality risk prediction by cortisol and aldosterone in chronic heart failure. *Circulation* 115:1754–61
- Guillard M, Leyvraz C, Hummler E. (2004) A nonconventional look at ionic fluxes in the skin: lessons from genetically modified mice. *News Physiol Sci* 19:75–9
- Guo C, Martínez-Vasquez D, Mendez GP *et al.* (2006) Mineralocorticoid receptor antagonist reduces renal injury in rodent models of types 1 and 2 diabetes mellitus. *Endocrinology* 147:5363–73

- Ito N, Ito T, Kromminga A *et al.* (2005) Human hair follicles display a functional equivalent of the hypothalamic-pituitary-adrenal axis and synthesize cortisol. *FASEB J* 19:1332–4
- Kenouch S, Lombes M, Delahaye F *et al.* (1994) Human skin as target for aldosterone: coexpression of mineralocorticoid receptors and 11 beta-hydroxysteroid dehydrogenase. *J Clin Endocrinol Metab* 79:1334–41
- Kolkhof P, Borden SA. (2012) Molecular pharmacology of the mineralocorticoid receptor: prospects for novel therapeutics. *Mol Cell Endocrinol* 350:310–7
- Leopold JA. (2011) Aldosterone, mineralocorticoid receptor activation, and cardiovascular remodeling. *Circulation* 124:e466–8
- Maron BA, Leopold JA. (2010) Aldosterone receptor antagonists: effective but often forgotten. *Circulation* 121:934–9
- Mauro T, Guitard M, Behne M *et al.* (2002) The ENaC channel is required for normal epidermal differentiation. *J Invest Dermatol* 118:589–94
- Mihailidou AS, Loan Le TY, Mardini M *et al.* (2009) Glucocorticoids activate cardiac mineralocorticoid receptors during experimental myocardial infarction. *Hypertension* 54:1306–12
- Milik E, Szczepanska-Sadowska E, Maslinski W *et al.* (2007) Enhanced expression of mineralocorticoid receptors in the heart after the myocardial infarct in rats. *J Physiol Pharmacol* 58:745–55
- Mitts TF, Bunda S, Wang Y *et al.* (2010) Aldosterone and mineralocorticoid receptor antagonists modulate elastin and collagen deposition in human skin. *J Invest Dermatol* 130:2396–406
- Nagase T, Akase T, Sanada H *et al.* (2013) Aging-like skin changes in metabolic syndrome model mice are mediated by mineralocorticoid receptor signaling. *Aging Cell* 12:50–7
- Nguyen Dinh Cat A, Jaissner F (2012) Extrarenal effects of aldosterone. *Curr Opin Nephrol Hypertens* 21:147–56
- Perez P. (2011) Glucocorticoid receptors, epidermal homeostasis and hair follicle differentiation. *Dermatoendocrinol* 3:166–74
- Pitt B, Remme W, Zannad F *et al.* (2003) Eplerenone, a selective aldosterone blocker, in patients with left ventricular dysfunction after myocardial infarction. *N Engl J Med* 348:1309–21
- Pitt B, Zannad F, Remme WJ *et al.* (1999) The effect of spironolactone on morbidity and mortality in patients with severe heart failure. Randomized Aldactone Evaluation Study Investigators. *N Engl J Med* 341:709–17
- Rhen T, Cidlowski JA. (2005) Antiinflammatory action of glucocorticoids—new mechanisms for old drugs. *N Engl J Med* 353:1711–23
- Sainte Marie Y, Toulon A, Paus R *et al.* (2007) Targeted skin overexpression of the mineralocorticoid receptor in mice causes epidermal atrophy, premature skin barrier formation, eye abnormalities, and alopecia. *Am J Pathol* 171:846–60
- Schacke H, Berger M, Rehwinkel H *et al.* (2007) Selective glucocorticoid receptor agonists (SEGRAs): novel ligands with an improved therapeutic index. *Mol Cell Endocrinol* 275:109–17
- Schacke H, Schottelius A, Docke WD *et al.* (2004) Dissociation of transactivation from transrepression by a selective glucocorticoid receptor agonist leads to separation of therapeutic effects from side effects. *Proc Natl Acad Sci USA* 101:227–32
- Schoepe S, Schacke H, May E *et al.* (2006) Glucocorticoid therapy-induced skin atrophy. *Exp Dermatol* 15:406–20
- Shavit L, Lifschitz MD, Epstein M. (2012) Aldosterone blockade and the mineralocorticoid receptor in the management of chronic kidney disease: current concepts and emerging treatment paradigms. *Kidney Int* 81:955–68
- Slominski A, Ermak G, Mihm M. (1996) ACTH receptor, CYP11A1, CYP17 and CYP21A2 genes are expressed in skin. *J Clin Endocrinol Metab* 81:2746–9
- Slominski A, Gomez-Sanchez CE, Foecking MF *et al.* (1999) Metabolism of progesterone to DGC, corticosterone and 18OHDGC in cultured human melanoma cells. *FEBS Lett* 455:364–6
- Slominski A, Zbytek B, Nikolakis G *et al.* (2013a) Steroidogenesis in the skin: implications for local immune functions. *J Steroid Biochem Mol Biol* 137: 107–23
- Slominski A, Zbytek B, Semak I *et al.* (2005a) CRH stimulates POMC activity and corticosterone production in dermal fibroblasts. *J Neuroimmunol* 162: 97–102
- Slominski A, Zbytek B, Szczesniewski A *et al.* (2005b) CRH stimulation of corticosteroids production in melanocytes is mediated by ACTH. *Am J Physiol Endocrinol Metab* 288:E701–6
- Slominski A, Zbytek B, Szczesniewski A *et al.* (2006) Cultured human dermal fibroblasts do produce cortisol. *J Invest Dermatol* 126:1177–8
- Slominski A, Zjawiony J, Wortsman J *et al.* (2004) A novel pathway for sequential transformation of 7-dehydrocholesterol and expression of the P450_{scc} system in mammalian skin. *Eur J Biochem* 271:4178–88
- Slominski AT, Manna PR, Tuckey RC. (2014) Cutaneous glucocorticosteroidogenesis: securing local homeostasis and the skin integrity. *Exp Dermatol* 23:369–74
- Slominski AT, Zmijewski MA, Zbytek B *et al.* (2013b) Key role of CRF in the skin stress response system. *Endocr Rev* 34:827–84
- Soundararajan R, Pearce D, Hughey RP *et al.* (2010) Role of epithelial sodium channels and their regulators in hypertension. *J Biol Chem* 285:30363–9
- Takeda M, Tatsumi T, Matsunaga S *et al.* (2007) Spironolactone modulates expressions of cardiac mineralocorticoid receptor and 11beta-hydroxysteroid dehydrogenase 2 and prevents ventricular remodeling in post-infarct rat hearts. *Hypertens Res* 30:427–37
- Walton S, Cunliffe WJ, Lookingbill P *et al.* (1986) Lack of effect of topical spironolactone on sebum excretion. *Br J Dermatol* 114:261–4
- Zennaro MC, Caprio M, Feve B (2009) Mineralocorticoid receptors in the metabolic syndrome. *Trends Endocrinol Metab* 20:444–51
- Zhao M, Celerier J, Bousquet E *et al.* (2012) Mineralocorticoid receptor is involved in rat and human ocular chorioretinopathy. *J Clin Invest* 122: 2672–9
- Zoller NN, Kippenberger S, Thaci D *et al.* (2008) Evaluation of beneficial and adverse effects of glucocorticoids on a newly developed full-thickness skin model. *Toxicol In Vitro* 22:747–59

General discussion, conclusions and perspectives

With increasing life expectancy, the elderly populations are expanding at a high rate, with an escalating incidence of relative pathologies, such as dementia, osteoporosis, stroke, and a risk of delayed healing which in turn leads to a higher incidence of chronic wounds. Management of chronic wounds is prolonged, time consuming and therefore is responsible for a very high cost for many countries, especially in western ones. Importantly, prolonged wounds are responsible for a high rate of complications. Some of these such as severe infection or carcinoma are life threatening. In the same way, as detailed before, chronic resistant and progressive wounds may need amputation. In view of all that consequences, chronic wounds have a public health impact.

The current “gold standard” of wound management comprises regular assessment for infection and risk factors, and daily or multi weekly care of the wound with dressings and/or debridement of necrotic or fibrinous tissue. Other measures focus on secondary complications, such as reducing infection, using silver-impregnated dressings (White and McIntosh 2008) or maggot debridement therapy (Sherman 2003; Bowling et al. 2007). Besides the symptomatic measures, it is mandatory to consider etiological and or mechanistic treatments measures. The most frequent causes of ulcers are arterial or venous disease. Thereof, restorations of arterial flux through exercise, avoidance of atheroma risk factors, are necessary in such patients. In the same way, compression dressings for venous ulcers are needed each day (Enoch et al. 2006). Offloading therapy is recommended for diabetic ulcers (Edmonds 2006). However, there are no treatment that stimulates wound healing. In the past decade, topical PDGF has been approved for diabetic ulcers but was afterwards withdrawn from the market, possibly because of low efficiency.

Therefore, a better understanding of the molecular and cellular mechanisms underlying chronic non-healing wounds is still needed. While there are differences between the mechanisms of each type of delayed wound healing, there are also several common factors that may be found in various diseases. These include for

example prolonged and excessive inflammation, ineffective reepithelialisation, impaired angiogenesis (Menke et al. 2007).

In the first part of the thesis work, we focused on the mechanisms involved in sickle cell ulcers. The reason why we chose this disease comes from the clinical situation of affected patients. Indeed, although Sickle cell disease (SCD) is an orphan disease, the course of ulcers is very intriguing. The first peculiar fact is the variation in SS patients of the ulcer incidence. This varies between 0 and 40% depending on the countries, although there are no any linkage between ulcers and the SCD haplotype (Halabi-Tawil et al. 2008). However, the unique genetic study that was done has demonstrated polymorphisms in genes intervening in angiogenesis (Nolan et al. 2006). SCD ulcers most usually develops after a triggering event: traumatism mainly, but also insect bite or itching (ref). Once the wound has developed, the course is going to be prolonged in a subset of affected patients. Very impressively, the duration of SCD ulcers is really the most prolonged that may concern human beings, especially that these are still young adults. Indeed, in the series of our department the duration with ulcerated skin was 240 months (Halabi-Tawil et al. 2008). In accordance, another most recent study has even found higher duration that are 300 months (Minniti et al. 2014). Thinking about that duration of ulcer at the same site is a main point in discussing the pathogenesis of SCD ulcers. Indeed, in other thrombotic diseases such as cryoglobulinemia or antiphospholipid syndromes, the ulcers develop due to hypoxia. But afterwards, and even without any specific treatments, each ulcerated lesion will usually heal. This is not the case in SCD patients: their skin wounds persist. Even red blood cell transfusions and/or autologous skin grafting can induce at the best transient improvements with frequent recurrences at the same site (ref). At that point, we postulated that besides and whatever are the ulcer inducing mechanisms, these patients may have a severe abnormality in healing mechanisms.

Another close reason for performing the first work is the absence of availability of tissues to study the healing pathways in humans. Indeed, these patients are affected with very painful ulcers. All procedures, even wound care are very painful. Performing biopsies will be therefore difficult. In addition, since interpretation of the changes found depends on the stage of ulcers, several repeated biopsies will be needed. As an example the study of Marti Cavajal, the most powerful in vivo human

study in SCD, has collected samples with a real variability in time course of the ulcers (Marti-Carvajal et al. 2014). Finally, biopsies may worsen the course of SCD ulcers as any traumatism.

Therefore, at the beginning of this work, we were facing the challenge of finding the best way to address the question of poor wound healing in SCD. There were no animal model for SCD ulcers and still no recognized one. There were however mice with genetic engineering that were used for other tissue disorders of the disease. This is why we decided to put our efforts in developing a model for SCD skin delayed healing that could allow us to study the mechanisms of this pathogenic phenomenon.

Here, we were able to show that cutaneous wound healing is severely altered in old SAD mice, whereas young animals do not show any abnormality. Importantly, the healing delay in old SAD mice correlated with the degree of anemia and hemolysis. These features of SAD mice parallel the characteristics of ulcers in SCD patients. Indeed, leg ulcers develop only after 15 years in sickle cell anemia patients, at a median age of 21 years, when the features of SCD have been fully developed (Halabi-Tawil et al. 2008). In addition, most of these ulcers present in correlation with a hyper-hemolytic phenotype with increased reticulocytosis (Kato et al. 2006; Taylor et al. 2008; Minniti et al. 2011; Minniti et al. 2014). Therefore, the poor healing of wounds in old SAD mice appears pertinent to mimic the human SCD leg ulcers and these animals are therefore a new and original model for the study of sickle cell ulcers.

Crucially wound angiogenesis was altered in SAD mice. This reduction appeared to be secondary, at least partly, to a decreased EPC proliferation and mobilization from the bone marrow. Furthermore, a decreased CXCL12 expression by keratinocytes and leukocytes was found in SAD wounds. This was corroborated by the fact that local injection of extra EPCs or better the recombinant CXCL12 into SAD wounds restored the angiogenesis impairment and rescued the healing defect, with a parallel enhanced EPC mobilization. This is the first study of the cellular and molecular mechanisms implicated in sickle cell ulcers in a murine model that provides promising therapeutic perspectives for clinical trials.

Interestingly, normal skin of old SAD mice shows a decrease in blood vessel diameter while vessel numbers are unmodified. This phenotype may relate to

hemolysis with consequent reduced NO concentration and vasoconstriction that are common features of SCD patients (Frenette 2002; Kato et al. 2006; Mack and Kato 2006). on later specimens to depict the mechanisms implicated in delayed healing of SAD wounds. At day 7 post wounding, we found a significant decrease in CD31⁺ blood vessels as well as in Lyve-1⁺ lymphatic vessels in SAD wounds as compared to WT littermates. These decreases are associated with the fewer recruitment of CD31⁺CD45⁻ endothelial cells in SAD wounds than in WT wounds. These results are consistent with the observations in SCD patients, where the treatment with granulocyte/macrophage colony-stimulating factor (GM-CSF) -that stimulates pericyte-like perivascular mural cells to secrete VEGFa- improves angiogenesis and ulcer healing (Pieters et al. 1995; Alikhan et al. 2004; Mery et al. 2004; Zhao et al. 2014).

In tissue injury, EPCs -as precursors of endothelial cells- proliferate and are released from bone marrow into circulating peripheral blood and incorporated into the foci of neovascularization at wound sides. They have been demonstrated to be implicated in multiple aspects of angiogenesis occurring during wound healing process as well as tumours. Importantly, impaired EPC recruitment has been shown to be involved in delayed wound healing in several disorders such as diabetes (Loomans et al. 2004; Fadini et al. 2005; Fadini et al. 2005; Tepper et al. 2010). In this context, the impaired wound healing was improved by direct topical application of extra EPCs into the wounds but also through hyperbaric oxygen that stimulates EPC mobilization or injection of factors mediating EPC mobilization and angiogenesis (Gallagher et al. 2007; Marrotte et al. 2010). Of note, some teams have described improvement of ulcer healing by hyperbaric oxygen in SCD patients. However, the mechanism of such improvement has not been studied. The the impaired wound angiogenesis we found in SAD mice was related to low EPCs content in bone marrow and blood post-wounding while this number was similar at baseline. These results suggest an inability to increase the EPC proliferation and mobilization from the bone marrow of SAD mice in response to injury. Moreover, to answer to the question of the functional activity of EPCs in old SAD mice, we have studied the phenotype of these cells *in vitro* condition without the SCD environment. Our results showed that *in vitro*, SAD EPCs expressed normal abilities of proliferation and differentiation, indicating the absence of an intrinsic disorder of these cells. This result is equal to *in vivo* results,

showing that SAD EPCs exhibited the same efficiency on wound repair as WT EPCs. Indeed, both WT and SAD EPCs injected directly into SAD wounds were able to rescue the impaired healing of SAD mice by restoring the defect of angiogenesis. These results strongly suggest that defective EPC mobilization in old SAD mice is a consequence of micro-environmental changes in marrow. This situation differs from that of diabetes where db/db EPCs display an intrinsically abnormal phenotype *in vitro* and *in vivo* (Marrotte et al. 2010). Altogether our results strongly suggest that the defect of EPCs in old SAD mice is the defect of mobilization only.

EPC mobilization can be modulated by various intrinsic and extrinsic factors. Here, we found a significant decrease in the expression of several cytokine or chemokine encoding genes including VEGFa, VEGFR2, Tie1, Tie2, IL6, CXCL12 and its receptor CXCR4 in SAD wounds. The CXCL12/CXCR4 axis plays an important role in the homing of progenitor cells in the bone marrow, and in their mobilization to the periphery under various conditions including wound healing (Avniel et al. 2006; Mazo et al. 2011; Hu et al. 2013). Importantly, we found here a correlation between the mRNA level of CXCL12 in wounds and the content of circulating EPCs in the blood. The injection of CXCL12 into the wounds of SAD mice enabled the wounds to heal as quickly as controls. This improvement of healing is accompanied by the increase in circulating EPCs in CXCL12-treated mice. Importantly, the improvement in EPC mobilization in the SAD mice is positively correlated with the observed increase in wound angiogenesis after CXCL12 injection. These findings strongly suggest that CXCL12-induced increase in EPC mobilization is responsible for the improvement of SAD wound healing. Therefore, the defect in the CXCL12/CXCR4 axis is a major event leading to impaired EPC recruitment and angiogenesis defect to skin wounds in old SAD mice. This is at variance with a previous observation showing an higher CXCL12 levels in plasma of SCD patients than in healthy controls (Landburg et al. 2009). However, levels of this chemokine did not increase during vaso-occlusive crisis, in contrast with healthy subjects as one should expect. This can indicate a human defect in CXCL12 increase in wound reponse. We believe that this should be addressed in the human setting soonly in view of our results.

The low expression of CXCL12 originates from both keratinocytes and CD45⁺ leukocytes in healing skin. Our findings are partly in accordance with the observation

that the impaired angiogenesis and delayed wound healing in diabetic mice, are associated with the reduction of CXCL12 secretion in wound by keratinocytes and myofibroblasts, and that these defects can be improved, at least in part, by chemokine injection (Gallagher et al. 2007). In accordance with this notion, inhibition of SDF-1 α in the wounds through lentivirus further decreased angiogenesis and healing delay in diabetic mice (Bermudez et al. 2011). Furthermore, inhibition of CXCR4 through topical application of AMD 3100 to diabetic wounds also induces EPC mobilization (Nishimura et al. 2012). Several studies have shown that beside the effect in inducing EPC mobilization, local injection of some chemokines, such as granulocyte-colony stimulating factor, led to unwanted side-effects with an associated increase in leukocytes resulting in inflammation (Morimoto et al. 1990). From this context, the questions about the safety and clinical utility of these chemokines were raised. However, our SAD mice did not show any abnormality in skin after CXCL12 injection. Future studies should nevertheless address the question of consequences of CXCL12 injections in wound on other organs as well as on blood cell counts.

During the inflammatory stage of wound healing, neutrophils and macrophages are two main important cell types that infiltrate to wound area to prevent ongoing blood and fluid losses, to phagocytize bacteria and debris to prevent infection. Several reports have demonstrated an up-regulation of inflammatory pathways in SCD patients with ulcers, suggesting an involvement of inflammation in pathogenesis of this disorder (Lard et al. 1999; Bowers et al. 2013; Minniti et al. 2014). However, using different techniques in repeated experiments, we did not observe any changes in recruitment of neutrophil and macrophage/monocyte at the skin and peripheral blood levels after wounding. These results indicate that there is no implication of neutrophils and macrophages migration in the SCD delayed healing. In clinical series above referenced, the comparisons were made between patients with and without ulcers. While, the power of our study was to compare SAD and WT littermates at the same stage of wound healing where quantitative analysis of cell infiltrate was done. We believe this is an unbiased tool for addressing inflammatory abnormal changes. Our observations appear to be different with the previously published data reporting a high content of neutrophils and macrophages in the bloodstream and liver of SAD mice, in association with hepatopathy induced by hypoxia/reperfusion (Siciliano et al. 2011). However, our SAD mice -housed in specific pathogen free conditions- did not

have higher neutrophil counts after surgical wounding. Altogether, our results indicate that the abnormal healing in SAD mouse appears to differ from other SCD organ damage through the absence of neutrophil and macrophages increase.

In conclusion, old SAD mice present a delayed healing that correlates with anemia and haemolysis and therefore parallel the human situation. This prolonged healing delay relates to the poor EPC proliferation and mobilization from the bone marrow, due to impaired CXCL12 secretion by keratinocytes and leukocytes in wounded skin. However, the question of why these cells have this defect still remains unanswered. Future studies should target on exploring the link between sickle cell anemia and the defect of CXCL12 secretion by keratinocytes and leukocytes in the wounding process. Physiologically, CXCL12 expression is known to be induced in a wide variety of cell types in response to stimuli including ischemia and hypoxia (Ceradini et al. 2004; Miller et al. 2005; Lee et al. 2006). Interestingly, hypoxia and diminished bioavailability of NO, caused by the hemolysis and vaso-occlusion, are common features that induce mortality and morbidity in SCD patients and animal models, (Reiter et al. 2002; Kato et al. 2006; Sabaa et al. 2008). From this context, one possible hypothesis for the decreased CXCL12 expression in SAD wounds is that there is an inability to overexpress this chemokine in SAD mice in response to ischemia-induced hypoxia (as occurring in normal situation). This impairment can be explained by the defect of signal connection between bone marrow microenvironment and cutaneous tissue in SAD mice. Future studies are needed to examine more specifically whether there is any abnormality in marrow microenvironment of SAD mice that can affect CXCL12 secretion in skin, and EPC mobilization from bone marrow niches to circulation. One important event should be explored is the production of NO and the reactive oxygen species inside marrow environment of SAD mice in the setting of wounding. Moreover, it is also important to analyse the impact of CXCL12 pathway in patients with SCD ulcers. Since mice did not show significant side effects after CXCL12 injection (Gallagher et al. 2007), and in view of the severity of SCD ulcers, this peptide could be a promising therapy in clinical trials for improving this condition.

In addition to CXCL12/CXCR4 axis, other molecules or pathways that can be responsible for the delayed healing of SAD wounds and sickle cell ulcers should be

explored, to get further understanding about the pathogenesis, and to open on new therapies for management of this disorder. In this regard, we have performed the RNA sequencing analysis of EPCs isolated from bone marrow of old SAD and WT mice after 5 days of wounding. Interestingly, our preliminary results point on some molecules and pathways that can be involved in the delayed wound healing of SAD mice, since some upstream pathways are significantly up-regulated in SAD mice vs WT, together with several down-regulated pathways.

Among activated pathways, histone deacetylase (HDAC) appears to be the most interesting, since the activation score is high, and since HDAC inhibitors have been shown to exhibit multiple modalities of benefit for some disorders including SCD (Balasubramanian et al. 2008; Hebbel et al. 2010). Indeed, HDACs are enzymes that affect gene expression through their influence on chromatin-modifications, by controlling the acetylation of the core histones. The acetylation and deacetylation of histones play a significant role as transcriptional regulators in various cell types. HDAC inhibitors such as trichostatin A (TSA) have been shown to inhibit vascular cell adhesion molecule-1 and tissue factor expression that are present at high level in SCD (Belcher et al. 2005; Inoue et al. 2006; Wang et al. 2007; Bowers et al. 2013). Consistently, studies of Hebbel and colleagues indicate that TSA and its analog SAHA (suberoylanilide hydroxamic acid) could provide true, multimodality, salubrious therapy for prevention and treatment of chronic vasculopathy of SCD (Hebbel et al. 2010). SAHA is also already approved for clinical human use in other disorder as cutaneous T-cell lymphoma. Moreover, Du and colleagues have recently demonstrated that HDAC inhibition prevents cell death, increase cell survival, and reduces the production of ROS and apoptosis in cardiomyocytes exposed to hypoxia/reoxygenation (Du et al. 2015). More interestingly, class I and III HDAC inhibitors have been shown to accelerate cutaneous wound healing in a mouse model through stimulating keratinocyte proliferation and NO production (Spallotta et al. 2013). Hence, testing the effects of HDAC inhibitors for improving the delayed healing of SAD wounds should be done in order to provide a promising therapy for treatment of sickle cell leg ulcers. In addition to HDAC, several molecules, pathways such as NR1H2, NR1H3, or ABCA1, that are activated in SAD mice, should be interesting to explore.

In contrast to the up-regulated pathways, several genes or pathways appeared to be inhibited in SAD vs WT mice, including upstream of PDGF-BB, CCL2/CCR2, CCL5/CCR5 signalling. These molecules are known to play important roles in multiple aspects of wound healing process. PDGF-BB (Platelet-derived growth factor) is a protein known to generally enhance cell growth, progenitor cell migration and angiogenesis. Therefore, this is a beneficial molecule used for treatment of chronic and non-healing foot ulcer in some diseases, such as diabetes (Nagai and Embil 2002; Chan et al. 2006; Allen et al. 2014). Together with CXCL12/CXCR4 signalling, CCR5-, and CCR2- mediated signalling are major regulators of EPC homing into injured sites. Indeed, the expression of CCR5 and its ligand CCL5 is up-regulated in response to injury. This chemokine is expressed by various cell types including macrophages and endothelial cells. Importantly, the CCL5/CCR5 interaction can directly control EPC recruitment, thereby contributing to neovascularization and subsequent wound healing (Ishida et al. 2012). Hence, the impact of these molecules and signalling in the delayed healing of SAD wounds need to be studied in order to modulate impaired angiogenesis and poor healing of SAD wounds.

A key aim of the second part of this thesis was the identification of a novel pathway that influences the cutaneous wound closure. The objectives were to identify the cellular and molecular effects of MR and its antagonists in the early phase of healing, focusing on re-epithelialization. Our results open on the possibility to develop alternative treatments to accelerate wound repair in pathological situations.

Although it is known that glucocorticoids (endogenous or exogenous) delay wound healing, via binding to the GR (Youm et al. 2013; Tiganescu et al. 2014), additional mechanisms may exist. Indeed glucocorticoid-induced skin atrophy, another severe deleterious effect of glucocorticoids, is limited by topical administration of MR blockers, as shown in a recent report (where I was involved; see the article 3 in chapter 3) by an experimental *ex vivo* approach and *in vivo* test through the SPIREPI clinical trial in healthy volunteers (Maubec et al. 2015). In this part of my thesis, we hypothesized that MR-bound glucocorticoid complexes may be one mechanism for glucocorticoid-induced impaired wound re-epithelialization.

In order to expand our understanding of the role of mineralocorticoid signaling during cutaneous wound healing, the role of the MR was assessed through different approaches: we used skin explants from a transgenic mouse model with keratinocyte-specific MR overexpression (K5-MR mice), local application of different MR antagonists over wounds of adult wild-type mouse back skin and human skin explants in organotypic culture. We focused mostly on the model of impaired wound healing featured by dermocorticoid pretreatment, and also tested the efficiency of MR blockers on impaired wound healing in mouse models of diabetes.

First, we found that MR antagonism does not influence the wound closure in healthy skin. Benefit was observed only on pathological skin. This is important to notice, to avoid excessive extrapolation of our results.

The reduced outgrowth of skin explants from K5-MR mice can be partly reversed by treatment with the MRA canrenoate, suggesting a role of MR in the delayed wound re-epithelialization. MRA also induced wound re-epithelialization in pathological murine models (local glucocorticoid treatment, diabetes), where the wound closure is known to be impaired. The efficiency of the MRAs canrenoate or spironolactone on human skin explants in organotypic culture was also observed, although these compounds are not fully specific for MR, as they can be antagonists for other nuclear receptors such as androgen receptor (Kolkhof and Borden 2012). This is why we also treated human explants with the highly specific MR antagonist eplerenone, that also showed the same efficiency in improving re-epithelialization as spironolactone and canrenoate (because of its very poor solubility, it was not tested over mouse backskin). Thus, we provided evidence that MR blockade improves re-epithelialization of pathological wounds. As a preliminary step in human study of effects of MRA in patients, we showed that the healthy volunteers of the SPIREPI study that were treated locally with clobetasol, exhibited delayed closure of the wound following skin biopsy that was slightly improved in the zones where spironolactone was associated with clobetasol.

We identified some of the mechanisms at the origin of the beneficial effect of MRA on the wound re-epithelialization. Firstly, we have shown that the MR is overexpressed in the skin of mice pre-treated with the dermocorticoid clobetasol, and mice with type I and type II diabetes. Such up-regulation provides clues to understand why MRA can be efficient in these pathological situations. Of note, an upregulation of MR in skin of

mice with UV irradiation and metabolic syndrome has been previously reported (Nagase et al. 2013). In this model, considered by the authors as featuring aging skin, MRA treatment (topical spironolactone) reversed the enhanced oxidative stress and inflammation markers, and the histological lesions of the skin (Nagase et al. 2013). Thus the efficiency of cutaneous MR blockade to improve wound closure in pathological situations may be explained by enhanced MR expression. More generally, benefits of treatment with MR blockers to limit pathology have been reported in experimental and clinical situations including cardiac insufficiency or following myocardial infarction (Pitt et al. 1999; Pitt et al. 2003), vascular dysfunction (Leopold et al. 2007; Adel et al. 2014; Koenig and Jaffe 2014), renal failure (Shavit et al. 2012), chronic serous chorioretinopathy (Zhao et al. 2012), and metabolic syndrome and diabetes-induced complications (Guo et al. 2008; Hirata et al. 2009; Wada et al. 2010). In addition to pathological situations mentioned above, MRA also improved wound closure in a murine model of sickle cell disease with delayed wound healing (SAD mice). Indeed in preliminary experiments, we observed that local canrenoate application over dorsal wounds of 6 SAD mice (2 years old) resulted in enhanced wound closure at day 5, that was twice that of wounds treated with PBS ($p= 0.0022$). Such observation requires confirmation; it will be also mandatory to investigate MR mRNA levels in this setting. Thus, although the underlying mechanisms are far from being known, blockade of MR may represent a useful therapeutic approach in dermatology. Future studies need to be done on other models of skin pathology to investigate the cellular and molecular pathways implicated in the wound healing modulation of MR.

The question of which cell type express enhanced MR level will be interesting to study. To identify that, the expression of MR should be analyzed in cells sorted from skin and wound, or through immunostaining of skin sections with cell-specific markers. As an illustration of this question, the search for cells involved in delayed wound healing following androgen receptor stimulation revealed that effect of androgens depend on the androgen receptor expressed by macrophages, not by keratinocytes (Ashcroft and Mills 2002; Lai et al. 2009). Whether this is also the case for MR-sensitive impaired wound closure should be determined.

The MR-dependent cascade in abnormal wound re-epithelialization involves control of keratinocyte proliferation rate: we report here that clobetasol-induced impaired

wound closure was associated with reduction in epidermal Ki67 index, that was fully restored when MRA were applied onto the wound. Future experiments should characterize this effect more precisely. Another MR-related event is the modulation of expression of the epithelial sodium channel ENaC. The three subunits of ENaC (alpha, beta and gamma) are expressed in epidermis, and participate to epidermal homeostasis (Brouard et al. 1999). The keratinocyte-specific knock out of ENaC alpha subunit in mice results in epidermal hyperplasia (Mauro et al. 2002). We found that the glucocorticoid-induced overexpression of α ENaC in wounds of mouse back skin was reversed by local administration of canrenoate on the wounds. We also observed, in our *ex vivo* wound healing assay, that the glucocorticoid-induced delayed epidermal outgrowth of human skin explants in culture was improved by co-incubation with phenamil, a blocker of this channel. Our finding that ENaC blockade by phenamil enhances re-epithelialization in human skin explants exposed to glucocorticoids provides functional evidence for the involvement of ENaC in wound closure. It would be interesting to evaluate the wounding capacity of the skin of mice with invalidation of ENaC subunits in keratinocytes.

Another main cutaneous side effect of glucocorticoids is skin atrophy characterised by thin, shiny, and fragile skin with telangiectasia or bruising. I participated to a recent study investigating whether glucocorticoid-induced epidermal atrophy may be caused in part by inappropriate occupancy of MR by glucocorticoids (Maubec et al. 2015). We showed that local MRA treatment limits the epidermal atrophy and the impaired keratinocyte proliferation induced by clobetasol in cultured human skin explants. We also identified ENaC as a novel epidermal MR target, possibly participating to the beneficial effect of MR antagonism, through restoration of keratinocyte proliferation. In the randomized double-blind SPIREPI phase 2 clinical trial, we provided evidence that these findings have clinical relevance, as topical spironolactone administration in healthy volunteers led to improvement of the clobetasol-induced epidermal atrophy (Maubec et al. 2015).

In addition to benefit of MR blockade on epidermis (to improve keratinocyte proliferation and re-epithelialization) reported here, MRA may also affect other events in the dermis after wounding, such as inflammation, angiogenesis, and dermal remodeling. In the SPIREPI study, we observed that skin atrophy induced by dermocorticoid was improved at the level of whole skin (measured by echography),

i.e. not only in epidermis (MAUBEC 2015). Endothelial (and smooth muscle) vascular cells, sweat and sebaceous glands, infiltrating monocyte-macrophages, and perhaps EPC recruited at the wound site, all express the MR and may be targets of local application of MRA. It has been reported that aldosterone and MR antagonists modulate elastin and collagen content of human skin or mouse skin (Mitts et al. 2010). MR blockade could reduce oxidative stress and improve endothelial function (Rajagopalan et al. 2002; Schafer et al. 2003). Adel et al showed that spironolactone improves endothelial dysfunction in streptozotocin-induced diabetic rats, at least partially via its anti-inflammatory and anti-oxidative effects (Adel et al. 2014). Of major interest is the recent report that EPC express the MR and that EPC treatment with aldosterone induces translocation of the MR and impairs functions of EPC, such as differentiation, migration, through increase in reactive oxygen species; in this study, impairment of EPC function was rescued by pharmacological blockade or genetic ablation of the MR (Thum et al. 2011). Although we did not observe changes in the number of the inflammatory cell infiltration in clobetasol-treated skin in the presence or absence of MRA, the effect of MRAs in inflammation or angiogenesis in the wound, as well as the recruitment of bone marrow-originating cells, would be an important issue to investigate. The same questions may arise for impaired wound healing of diabetic mouse models. Since our preliminary results showed that the MRA canrenoate improves delayed wound healing of SAD mice (that show an impaired angiogenesis and poor mobilization of EPCs), the efficiency of MRA in these events should be studied in the next step.

From our findings that MR antagonism improves glucocorticoid-induced epidermal atrophy and impaired wound closure, it is tempting to propose local application of MRA to bring benefit to patients. Local MRA treatment of the abnormal skin should limit systemic effects of these drugs. It will be also important to determine whether the benefits of glucocorticoids are maintained in the presence of MRA. MR blockers should be reformulated to enhance their penetration inside the skin. Additional studies should allow extending our findings to glucocorticoid-treated patients with chronic skin diseases, to evaluate safety of topical spironolactone treatment and its ability for improving tolerance to topical glucocorticoids and quality of life.

In conclusion, my thesis work has been focussed on impaired wound healing, to clarify some of the mechanisms involved and possibly to open new therapeutical possibilities. My contribution to the field will be a strong motivation for my projects.

CHAPTER 4 - REFERENCES

- Adel H., Taye A. and Khalifa M. M. (2014). "Spironolactone improves endothelial dysfunction in streptozotocin-induced diabetic rats." Naunyn Schmiedeberg's Arch Pharmacol **387**(12): 1187-1197.
- Adler A. I., Boyko E. J., Ahroni J. H. and Smith D. G. (1999). "Lower-extremity amputation in diabetes. The independent effects of peripheral vascular disease, sensory neuropathy, and foot ulcers." Diabetes Care **22**(7): 1029-1035.
- Alikhan M. A., Carter G. and Mehta P. (2004). "Topical GM-CSF hastens healing of leg ulcers in sickle cell disease." Am J Hematol **76**(2): 192.
- Allen R. J., Jr., Soares M. A., Haberman I. D., Szpalski C., Schachar J., Lin C. D., Nguyen P. D., Saadeh P. B. and Warren S. M. (2014). "Combination therapy accelerates diabetic wound closure." PLoS One **9**(3): e92667.
- Amendt C., Mann A., Schirmacher P. and Blessing M. (2002). "Resistance of keratinocytes to TGFbeta-mediated growth restriction and apoptosis induction accelerates re-epithelialization in skin wounds." J Cell Sci **115**(Pt 10): 2189-2198.
- Amini-Adle M., Auxenfans C., Allombert-Blaise C., Deroo-Berger M. C., Ly A., Jullien D., Faure M., Damour O. and Claudy A. (2007). "Rapid healing of long-lasting sickle cell leg ulcer treated with allogeneic keratinocytes." J Eur Acad Dermatol Venereol **21**(5): 707-708.
- Amoh Y., Li L., Yang M., Moossa A. R., Katsuoka K., Penman S. and Hoffman R. M. (2004). "Nascent blood vessels in the skin arise from nestin-expressing hair-follicle cells." Proc Natl Acad Sci U S A **101**(36): 13291-13295.
- Ancelin M., Chollet-Martin S., Herve M. A., Legrand C., El Benna J. and Perrot-Applanat M. (2004). "Vascular endothelial growth factor VEGF189 induces human neutrophil chemotaxis in extravascular tissue via an autocrine amplification mechanism." Lab Invest **84**(4): 502-512.
- Armani A., Cinti F., Marzolla V., Morgan J., Cranston G. A., Antelmi A., Carpinelli G., Canese R., Pagotto U., Quarta C., Malorni W., Matarrese P., Marconi M., Fabbri A., Rosano G., Cinti S., Young M. J. and Caprio M. (2014). "Mineralocorticoid receptor antagonism induces browning of white adipose

- tissue through impairment of autophagy and prevents adipocyte dysfunction in high-fat-diet-fed mice." Faseb J **28**(8): 3745-3757.
- Asahara T., Kawamoto A. and Masuda H. (2011). "Concise review: Circulating endothelial progenitor cells for vascular medicine." Stem Cells **29**(11): 1650-1655.
- Asahara T., Masuda H., Takahashi T., Kalka C., Pastore C., Silver M., Kearne M., Magner M. and Isner J. M. (1999). "Bone marrow origin of endothelial progenitor cells responsible for postnatal vasculogenesis in physiological and pathological neovascularization." Circ Res **85**(3): 221-228.
- Asahara T., Murohara T., Sullivan A., Silver M., van der Zee R., Li T., Witzenbichler B., Schatteman G. and Isner J. M. (1997). "Isolation of putative progenitor endothelial cells for angiogenesis." Science **275**(5302): 964-967.
- Asahara T., Takahashi T., Masuda H., Kalka C., Chen D., Iwaguro H., Inai Y., Silver M. and Isner J. M. (1999). "VEGF contributes to postnatal neovascularization by mobilizing bone marrow-derived endothelial progenitor cells." EMBO J **18**(14): 3964-3972.
- Ashcroft G. S. and Ashworth J. J. (2003). "Potential role of estrogens in wound healing." Am J Clin Dermatol **4**(11): 737-743.
- Ashcroft G. S., Dodsworth J., van Boxtel E., Tarnuzzer R. W., Horan M. A., Schultz G. S. and Ferguson M. W. (1997). "Estrogen accelerates cutaneous wound healing associated with an increase in TGF-beta1 levels." Nat Med **3**(11): 1209-1215.
- Ashcroft G. S., Greenwell-Wild T., Horan M. A., Wahl S. M. and Ferguson M. W. (1999). "Topical estrogen accelerates cutaneous wound healing in aged humans associated with an altered inflammatory response." Am J Pathol **155**(4): 1137-1146.
- Ashcroft G. S., Horan M. A. and Ferguson M. W. (1998). "Aging alters the inflammatory and endothelial cell adhesion molecule profiles during human cutaneous wound healing." Lab Invest **78**(1): 47-58.
- Ashcroft G. S. and Mills S. J. (2002). "Androgen receptor-mediated inhibition of cutaneous wound healing." J Clin Invest **110**(5): 615-624.

- Ashcroft G. S., Mills S. J., Flanders K. C., Lyakh L. A., Anzano M. A., Gilliver S. C. and Roberts A. B. (2003). "Role of Smad3 in the hormonal modulation of in vivo wound healing responses." Wound Repair Regen **11**(6): 468-473.
- Askari A. T., Unzek S., Popovic Z. B., Goldman C. K., Forudi F., Kiedrowski M., Rovner A., Ellis S. G., Thomas J. D., DiCorleto P. E., Topol E. J. and Penn M. S. (2003). "Effect of stromal-cell-derived factor 1 on stem-cell homing and tissue regeneration in ischaemic cardiomyopathy." Lancet **362**(9385): 697-703.
- Aslan M., Ryan T. M., Adler B., Townes T. M., Parks D. A., Thompson J. A., Tousson A., Gladwin M. T., Patel R. P., Tarpey M. M., Batinic-Haberle I., White C. R. and Freeman B. A. (2001). "Oxygen radical inhibition of nitric oxide-dependent vascular function in sickle cell disease." Proc Natl Acad Sci U S A **98**(26): 15215-15220.
- Ataga K. I., Moore C. G., Jones S., Olajide O., Strayhorn D., Hinderliter A. and Orringer E. P. (2006). "Pulmonary hypertension in patients with sickle cell disease: a longitudinal study." Br J Haematol **134**(1): 109-115.
- Avniel S., Arik Z., Maly A., Sagie A., Basst H. B., Yahana M. D., Weiss I. D., Pal B., Wald O., Ad-El D., Fujii N., Arenzana-Seisdedos F., Jung S., Galun E., Gur E. and Peled A. (2006). "Involvement of the CXCL12/CXCR4 pathway in the recovery of skin following burns." J Invest Dermatol **126**(2): 468-476.
- Balasubramanian S., Ramos J., Luo W., Sirisawad M., Verner E. and Buggy J. J. (2008). "A novel histone deacetylase 8 (HDAC8)-specific inhibitor PCI-34051 induces apoptosis in T-cell lymphomas." Leukemia **22**(5): 1026-1034.
- Barnes P. J. and Adcock I. M. (2009). "Glucocorticoid resistance in inflammatory diseases." Lancet **373**(9678): 1905-1917.
- Barrientos S., Stojadinovic O., Golinko M. S., Brem H. and Tomic-Canic M. (2008). "Growth factors and cytokines in wound healing." Wound Repair Regen **16**(5): 585-601.
- Bauer S. M., Goldstein L. J., Bauer R. J., Chen H., Putt M. and Velazquez O. C. (2006). "The bone marrow-derived endothelial progenitor cell response is impaired in delayed wound healing from ischemia." J Vasc Surg **43**(1): 134-141.

- Belcher J. D., Bryant C. J., Nguyen J., Bowlin P. R., Kielbik M. C., Bischof J. C., Hebbel R. P. and Vercellotti G. M. (2003). "Transgenic sickle mice have vascular inflammation." Blood **101**(10): 3953-3959.
- Belcher J. D., Mahaseth H., Welch T. E., Vilback A. E., Sonbol K. M., Kalambur V. S., Bowlin P. R., Bischof J. C., Hebbel R. P. and Vercellotti G. M. (2005). "Critical role of endothelial cell activation in hypoxia-induced vasoocclusion in transgenic sickle mice." Am J Physiol Heart Circ Physiol **288**(6): H2715-2725.
- Bergan J. J., Schmid-Schonbein G. W., Smith P. D., Nicolaides A. N., Boisseau M. R. and Eklof B. (2006). "Chronic venous disease." N Engl J Med **355**(5): 488-498.
- Bermudez D. M., Xu J., Herdrich B. J., Radu A., Mitchell M. E. and Liechty K. W. (2011). "Inhibition of stromal cell-derived factor-1alpha further impairs diabetic wound healing." J Vasc Surg **53**(3): 774-784.
- Bitto A., Minutoli L., Galeano M. R., Altavilla D., Polito F., Fiumara T., Calo M., Lo Cascio P., Zentilin L., Giacca M. and Squadrito F. (2008). "Angiopoietin-1 gene transfer improves impaired wound healing in genetically diabetic mice without increasing VEGF expression." Clin Sci (Lond) **114**(12): 707-718.
- Bluff J. E., Ferguson M. W., O'Kane S. and Ireland G. (2007). "Bone marrow-derived endothelial progenitor cells do not contribute significantly to new vessels during incisional wound healing." Exp Hematol **35**(3): 500-506.
- Boldt J., Huttner I., Suttner S., Kumle B., Piper S. N. and Berchthold G. (2001). "Changes of haemostasis in patients undergoing major abdominal surgery--is there a difference between elderly and younger patients?" Br J Anaesth **87**(3): 435-440.
- Bookout A. L., Jeong Y., Downes M., Yu R. T., Evans R. M. and Mangelsdorf D. J. (2006). "Anatomical profiling of nuclear receptor expression reveals a hierarchical transcriptional network." Cell **126**(4): 789-799.
- Botusan I. R., Sunkari V. G., Savu O., Catrina A. I., Grunler J., Lindberg S., Pereira T., Yla-Herttuala S., Poellinger L., Brismar K. and Catrina S. B. (2008). "Stabilization of HIF-1alpha is critical to improve wound healing in diabetic mice." Proc Natl Acad Sci U S A **105**(49): 19426-19431.
- Bowers A. J., Scully S. and Boylan J. F. (2003). "SKIP3, a novel Drosophila tribbles ortholog, is overexpressed in human tumors and is regulated by hypoxia." Oncogene **22**(18): 2823-2835.

- Bowers A. S., Reid H. L., Greenidge A., Landis C. and Reid M. (2013). "Blood viscosity and the expression of inflammatory and adhesion markers in homozygous sickle cell disease subjects with chronic leg ulcers." PLoS One **8(7)**: e68929.
- Bowling F. L., Salgami E. V. and Boulton A. J. (2007). "Larval therapy: a novel treatment in eliminating methicillin-resistant *Staphylococcus aureus* from diabetic foot ulcers." Diabetes Care **30(2)**: 370-371.
- Brandner J. M., Houdek P., Husing B., Kaiser C. and Moll I. (2004). "Connexins 26, 30, and 43: differences among spontaneous, chronic, and accelerated human wound healing." J Invest Dermatol **122(5)**: 1310-1320.
- Brooks P. C., Stromblad S., Sanders L. C., von Schalscha T. L., Aimes R. T., Stetler-Stevenson W. G., Quigley J. P. and Cheresch D. A. (1996). "Localization of matrix metalloproteinase MMP-2 to the surface of invasive cells by interaction with integrin alpha v beta 3." Cell **85(5)**: 683-693.
- Brouard M., Casado M., Djelidi S., Barrandon Y. and Farman N. (1999). "Epithelial sodium channel in human epidermal keratinocytes: expression of its subunits and relation to sodium transport and differentiation." J Cell Sci **112 (Pt 19)**: 3343-3352.
- Broughton G., 2nd, Janis J. E. and Attinger C. E. (2006). "Wound healing: an overview." Plast Reconstr Surg **117(7 Suppl)**: 1e-S-32e-S.
- Bunn H. F. (1997). "Pathogenesis and treatment of sickle cell disease." N Engl J Med **337(11)**: 762-769.
- Bunn H. F., Nathan D. G., Dover G. J., Hebbel R. P., Platt O. S., Rosse W. F. and Ware R. E. (2010). "Pulmonary hypertension and nitric oxide depletion in sickle cell disease." Blood **116(5)**: 687-692.
- Caiado F. and Dias S. (2012). "Endothelial progenitor cells and integrins: adhesive needs." Fibrogenesis Tissue Repair **5**: 4.
- Carmeliet P. (2004). "Manipulating angiogenesis in medicine." J Intern Med **255(5)**: 538-561.
- Carmeliet P. and Jain R. K. (2011). "Molecular mechanisms and clinical applications of angiogenesis." Nature **473(7347)**: 298-307.

- Centenera M. M., Harris J. M., Tilley W. D. and Butler L. M. (2008). "The contribution of different androgen receptor domains to receptor dimerization and signaling." Mol Endocrinol **22**(11): 2373-2382.
- Ceradini D. J. and Gurtner G. C. (2005). "Homing to hypoxia: HIF-1 as a mediator of progenitor cell recruitment to injured tissue." Trends Cardiovasc Med **15**(2): 57-63.
- Ceradini D. J., Kulkarni A. R., Callaghan M. J., Tepper O. M., Bastidas N., Kleinman M. E., Capla J. M., Galiano R. D., Levine J. P. and Gurtner G. C. (2004). "Progenitor cell trafficking is regulated by hypoxic gradients through HIF-1 induction of SDF-1." Nat Med **10**(8): 858-864.
- Chan R. K., Liu P. H., Pietramaggiori G., Ibrahim S. I., Hechtman H. B. and Orgill D. P. (2006). "Effect of recombinant platelet-derived growth factor (Regranex) on wound closure in genetically diabetic mice." J Burn Care Res **27**(2): 202-205.
- Cheng X. W., Kuzuya M., Nakamura K., Maeda K., Tsuzuki M., Kim W., Sasaki T., Liu Z., Inoue N., Kondo T., Jin H., Numaguchi Y., Okumura K., Yokota M., Iguchi A. and Murohara T. (2007). "Mechanisms underlying the impairment of ischemia-induced neovascularization in matrix metalloproteinase 2-deficient mice." Circ Res **100**(6): 904-913.
- Chmielowiec J., Borowiak M., Morkel M., Stradal T., Munz B., Werner S., Wehland J., Birchmeier C. and Birchmeier W. (2007). "c-Met is essential for wound healing in the skin." J Cell Biol **177**(1): 151-162.
- Collin M., Niemann F. and Jaisser F. (2014). "Mineralocorticoid receptor modulators: a patent review (2007 - 2012)." Expert Opin Ther Pat **24**(2): 177-183.
- Colussi G., Catena C. and Sechi L. A. (2013). "Spironolactone, eplerenone and the new aldosterone blockers in endocrine and primary hypertension." J Hypertens **31**(1): 3-15.
- Connes P., Lamarre Y., Hardy-Dessources M. D., Lemonne N., Waltz X., Mouguel D., Mukisi-Mukaza M., Lalanne-Mistrih M. L., Tarer V., Tressieres B., Etienne-Julan M. and Romana M. (2013). "Decreased hematocrit-to-viscosity ratio and increased lactate dehydrogenase level in patients with sickle cell anemia and recurrent leg ulcers." PLoS One **8**(11): e79680.
- Copcu E. (2009). "Marjolin's ulcer: a preventable complication of burns?" Plast Reconstr Surg **124**(1): 156e-164e.

- Daley J. M., Brancato S. K., Thomay A. A., Reichner J. S. and Albina J. E. (2010). "The phenotype of murine wound macrophages." J Leukoc Biol **87**(1): 59-67.
- Darby I., Skalli O. and Gabbiani G. (1990). "Alpha-smooth muscle actin is transiently expressed by myofibroblasts during experimental wound healing." Lab Invest **63**(1): 21-29.
- De Bosscher K. and Haegeman G. (2009). "Minireview: latest perspectives on antiinflammatory actions of glucocorticoids." Mol Endocrinol **23**(3): 281-291.
- De Castro L. M., Jonassaint J. C., Graham F. L., Ashley-Koch A. and Telen M. J. (2008). "Pulmonary hypertension associated with sickle cell disease: clinical and laboratory endpoints and disease outcomes." Am J Hematol **83**(1): 19-25.
- Desmouliere A., Redard M., Darby I. and Gabbiani G. (1995). "Apoptosis mediates the decrease in cellularity during the transition between granulation tissue and scar." Am J Pathol **146**(1): 56-66.
- Diegelmann R. F. (2003). "Analysis of collagen synthesis." Methods Mol Med **78**: 349-358.
- Diegelmann R. F. (2003). "Excessive neutrophils characterize chronic pressure ulcers." Wound Repair Regen **11**(6): 490-495.
- DiPietro L. A. (1995). "Wound healing: the role of the macrophage and other immune cells." Shock **4**(4): 233-240.
- Du J., Zhang L., Zhuang S., Qin G. J. and Zhao T. C. (2015). "HDAC4 degradation mediates HDAC inhibition-induced protective effects against hypoxia/reoxygenation injury." J Cell Physiol **230**(6): 1321-1331.
- Duffield J. S. (2003). "The inflammatory macrophage: a story of Jekyll and Hyde." Clin Sci (Lond) **104**(1): 27-38.
- Edmonds M. (2006). "Diabetic foot ulcers: practical treatment recommendations." Drugs **66**(7): 913-929.
- Ehrlich H. P. and Krummel T. M. (1996). "Regulation of wound healing from a connective tissue perspective." Wound Repair Regen **4**(2): 203-210.
- Eming S. A., Brachvogel B., Odorisio T. and Koch M. (2007). "Regulation of angiogenesis: wound healing as a model." Prog Histochem Cytochem **42**(3): 115-170.
- Eming S. A., Krieg T. and Davidson J. M. (2007). "Inflammation in wound repair: molecular and cellular mechanisms." J Invest Dermatol **127**(3): 514-525.

- Emmerson E., Campbell L., Ashcroft G. S. and Hardman M. J. (2009). "Unique and synergistic roles for 17beta-estradiol and macrophage migration inhibitory factor during cutaneous wound closure are cell type specific." Endocrinology **150**(6): 2749-2757.
- Enoch S., Grey J. E. and Harding K. G. (2006). "ABC of wound healing. Non-surgical and drug treatments." Bmj **332**(7546): 900-903.
- Fadini G. P., Agostini C. and Avogaro A. (2005). "Endothelial progenitor cells in cerebrovascular disease." Stroke **36**(6): 1112-1113; author reply 1113.
- Fadini G. P., Miorin M., Facco M., Bonamico S., Baesso I., Grego F., Menegolo M., de Kreutzenberg S. V., Tiengo A., Agostini C. and Avogaro A. (2005). "Circulating endothelial progenitor cells are reduced in peripheral vascular complications of type 2 diabetes mellitus." J Am Coll Cardiol **45**(9): 1449-1457.
- Farman N., Maubec E., Poeggeler B., Klatte J. E., Jaisser F. and Paus R. (2010). "The mineralocorticoid receptor as a novel player in skin biology: beyond the renal horizon?" Exp Dermatol **19**(2): 100-107.
- Farman N. and Rafestin-Oblin M. E. (2001). "Multiple aspects of mineralocorticoid selectivity." Am J Physiol Renal Physiol **280**(2): F181-192.
- Fathke C., Wilson L., Hutter J., Kapoor V., Smith A., Hocking A. and Isik F. (2004). "Contribution of bone marrow-derived cells to skin: collagen deposition and wound repair." Stem Cells **22**(5): 812-822.
- Ferrara N. (2004). "Vascular endothelial growth factor: basic science and clinical progress." Endocr Rev **25**(4): 581-611.
- Fonder M. A., Lazarus G. S., Cowan D. A., Aronson-Cook B., Kohli A. R. and Mamelak A. J. (2008). "Treating the chronic wound: A practical approach to the care of nonhealing wounds and wound care dressings." J Am Acad Dermatol **58**(2): 185-206.
- Francillon Y. J., Jilly P. N., Varricchio F. and Castro O. (1996). "Histochemical analysis of growth factor, fibronectin, and iron content of sickle cell leg ulcers." Wound Repair Regen **4**(2): 240-243.
- Frank S., Hubner G., Breier G., Longaker M. T., Greenhalgh D. G. and Werner S. (1995). "Regulation of vascular endothelial growth factor expression in cultured keratinocytes. Implications for normal and impaired wound healing." J Biol Chem **270**(21): 12607-12613.

- Frenette P. S. (2002). "Sickle cell vaso-occlusion: multistep and multicellular paradigm." Curr Opin Hematol **9**(2): 101-106.
- Fukaya S., Iwamoto T., Kin K. and Takasaki M. (2000). "[Factors influencing platelet function in elderly patients with chronic phase thrombotic diseases]." Nihon Ronen Igakkai Zasshi **37**(8): 619-626.
- Fukumura D., Xavier R., Sugiura T., Chen Y., Park E. C., Lu N., Selig M., Nielsen G., Taksir T., Jain R. K. and Seed B. (1998). "Tumor induction of VEGF promoter activity in stromal cells." Cell **94**(6): 715-725.
- Galiano R. D., Tepper O. M., Pelo C. R., Bhatt K. A., Callaghan M., Bastidas N., Bunting S., Steinmetz H. G. and Gurtner G. C. (2004). "Topical vascular endothelial growth factor accelerates diabetic wound healing through increased angiogenesis and by mobilizing and recruiting bone marrow-derived cells." Am J Pathol **164**(6): 1935-1947.
- Gallagher K. A., Liu Z. J., Xiao M., Chen H., Goldstein L. J., Buerk D. G., Nedeau A., Thom S. R. and Velazquez O. C. (2007). "Diabetic impairments in NO-mediated endothelial progenitor cell mobilization and homing are reversed by hyperoxia and SDF-1 alpha." J Clin Invest **117**(5): 1249-1259.
- Gilliver S. C., Emmerson E., Campbell L., Chambon P., Hardman M. J. and Ashcroft G. S. (2010). "17beta-estradiol inhibits wound healing in male mice via estrogen receptor-alpha." Am J Pathol **176**(6): 2707-2721.
- Gladwin M. T. and Kato G. J. (2008). "Hemolysis-associated hypercoagulability in sickle cell disease: the plot (and blood) thickens!" Haematologica **93**(1): 1-3.
- Gladwin M. T., Sachdev V., Jison M. L., Shizukuda Y., Plehn J. F., Minter K., Brown B., Coles W. A., Nichols J. S., Ernst I., Hunter L. A., Blackwelder W. C., Schechter A. N., Rodgers G. P., Castro O. and Ognibene F. P. (2004). "Pulmonary hypertension as a risk factor for death in patients with sickle cell disease." N Engl J Med **350**(9): 886-895.
- Goldman A., Rubin C., Gomez S., Palermo M. S. and Tasat D. R. (2004). "Functional age-dependent changes in bronchoalveolar lavage rat cells." Cell Mol Biol (Noisy-le-grand) **50 Online Pub**: OL649-655.
- Gordon S. (2003). "Alternative activation of macrophages." Nat Rev Immunol **3**(1): 23-35.

- Goren I., Allmann N., Yogev N., Schurmann C., Linke A., Holdener M., Waisman A., Pfeilschifter J. and Frank S. (2009). "A transgenic mouse model of inducible macrophage depletion: effects of diphtheria toxin-driven lysozyme M-specific cell lineage ablation on wound inflammatory, angiogenic, and contractive processes." Am J Pathol **175**(1): 132-147.
- Grey J. E., Harding K. G. and Enoch S. (2006). "Venous and arterial leg ulcers." Bmj **332**(7537): 347-350.
- Gronemeyer H., Gustafsson J. A. and Laudet V. (2004). "Principles for modulation of the nuclear receptor superfamily." Nat Rev Drug Discov **3**(11): 950-964.
- Guo C., Ricchiuti V., Lian B. Q., Yao T. M., Coutinho P., Romero J. R., Li J., Williams G. H. and Adler G. K. (2008). "Mineralocorticoid receptor blockade reverses obesity-related changes in expression of adiponectin, peroxisome proliferator-activated receptor-gamma, and proinflammatory adipokines." Circulation **117**(17): 2253-2261.
- Guo L., Degenstein L. and Fuchs E. (1996). "Keratinocyte growth factor is required for hair development but not for wound healing." Genes Dev **10**(2): 165-175.
- Gurtner G. C., Werner S., Barrandon Y. and Longaker M. T. (2008). "Wound repair and regeneration." Nature **453**(7193): 314-321.
- Halabi-Tawil M., Lionnet F., Girot R., Bachmeyer C., Levy P. P. and Aractingi S. (2008). "Sickle cell leg ulcers: a frequently disabling complication and a marker of severity." Br J Dermatol **158**(2): 339-344.
- Ham S. A., Kim H. J., Kang E. S., Eun S. Y., Kim G. H., Park M. H., Woo I. S., Chang K. C., Lee J. H. and Seo H. G. (2010). "PPARdelta promotes wound healing by up-regulating TGF-beta1-dependent or -independent expression of extracellular matrix proteins." J Cell Mol Med **14**(6B): 1747-1759.
- Hamed S., Brenner B., Aharon A., Daoud D. and Roguin A. (2009). "Nitric oxide and superoxide dismutase modulate endothelial progenitor cell function in type 2 diabetes mellitus." Cardiovasc Diabetol **8**: 56.
- Hardman M. J. and Ashcroft G. S. (2008). "Estrogen, not intrinsic aging, is the major regulator of delayed human wound healing in the elderly." Genome Biol **9**(5): R80.

- Hardman M. J., Emmerson E., Campbell L. and Ashcroft G. S. (2008). "Selective estrogen receptor modulators accelerate cutaneous wound healing in ovariectomized female mice." Endocrinology **149**(2): 551-557.
- Hebbel R. P., Vercellotti G. M., Pace B. S., Solovey A. N., Kollander R., Abanonu C. F., Nguyen J., Vineyard J. V., Belcher J. D., Abdulla F., Osifuye S., Eaton J. W., Kelm R. J., Jr. and Slungaard A. (2010). "The HDAC inhibitors trichostatin A and suberoylanilide hydroxamic acid exhibit multiple modalities of benefit for the vascular pathobiology of sickle transgenic mice." Blood **115**(12): 2483-2490.
- Hellal-Levy C., Couette B., Fagart J., Souque A., Gomez-Sanchez C. and Rafestin-Oblin M. (1999). "Specific hydroxylations determine selective corticosteroid recognition by human glucocorticoid and mineralocorticoid receptors." FEBS Lett **464**(1-2): 9-13.
- Hengge U. R., Ruzicka T., Schwartz R. A. and Cork M. J. (2006). "Adverse effects of topical glucocorticosteroids." J Am Acad Dermatol **54**(1): 1-15; quiz 16-18.
- Henry G. and Garner W. L. (2003). "Inflammatory mediators in wound healing." Surg Clin North Am **83**(3): 483-507.
- Herrick J. B. (2001). "Peculiar elongated and sickle-shaped red blood corpuscles in a case of severe anemia. 1910." Yale J Biol Med **74**(3): 179-184.
- Higashiyama R., Nakao S., Shibusawa Y., Ishikawa O., Moro T., Mikami K., Fukumitsu H., Ueda Y., Minakawa K., Tabata Y., Bou-Gharios G. and Inagaki Y. (2011). "Differential contribution of dermal resident and bone marrow-derived cells to collagen production during wound healing and fibrogenesis in mice." J Invest Dermatol **131**(2): 529-536.
- Hirata A., Maeda N., Hiuge A., Hibuse T., Fujita K., Okada T., Kihara S., Funahashi T. and Shimomura I. (2009). "Blockade of mineralocorticoid receptor reverses adipocyte dysfunction and insulin resistance in obese mice." Cardiovasc Res **84**(1): 164-172.
- Hoening M. R., Bianchi C. and Sellke F. W. (2008). "Hypoxia inducible factor-1 alpha, endothelial progenitor cells, monocytes, cardiovascular risk, wound healing, cobalt and hydralazine: a unifying hypothesis." Curr Drug Targets **9**(5): 422-435.

- Holt D. R., Kirk S. J., Regan M. C., Hurson M., Lindblad W. J. and Barbul A. (1992). "Effect of age on wound healing in healthy human beings." Surgery **112**(2): 293-297; discussion 297-298.
- Hu C., Yong X., Li C., Lu M., Liu D., Chen L., Hu J., Teng M., Zhang D., Fan Y. and Liang G. (2013). "CXCL12/CXCR4 axis promotes mesenchymal stem cell mobilization to burn wounds and contributes to wound repair." J Surg Res **183**(1): 427-434.
- Icre G., Wahli W. and Michalik L. (2006). "Functions of the peroxisome proliferator-activated receptor (PPAR) alpha and beta in skin homeostasis, epithelial repair, and morphogenesis." J Investig Dermatol Symp Proc **11**(1): 30-35.
- Inoue K., Kobayashi M., Yano K., Miura M., Izumi A., Mataka C., Doi T., Hamakubo T., Reid P. C., Hume D. A., Yoshida M., Aird W. C., Kodama T. and Minami T. (2006). "Histone deacetylase inhibitor reduces monocyte adhesion to endothelium through the suppression of vascular cell adhesion molecule-1 expression." Arterioscler Thromb Vasc Biol **26**(12): 2652-2659.
- Inui S., Konishi Y., Yasui Y., Harada T. and Itami S. (2010). "Successful Intervention for Pressure Ulcer by Nutrition Support Team: A Case Report." Case Rep Dermatol **2**(2): 120-124.
- Ishida Y., Kimura A., Kuninaka Y., Inui M., Matsushima K., Mukaida N. and Kondo T. (2012). "Pivotal role of the CCL5/CCR5 interaction for recruitment of endothelial progenitor cells in mouse wound healing." J Clin Invest **122**(2): 711-721.
- Ito M., Liu Y., Yang Z., Nguyen J., Liang F., Morris R. J. and Cotsarelis G. (2005). "Stem cells in the hair follicle bulge contribute to wound repair but not to homeostasis of the epidermis." Nat Med **11**(12): 1351-1354.
- Jameson J., Ugarte K., Chen N., Yachi P., Fuchs E., Boismenu R. and Havran W. L. (2002). "A role for skin gammadelta T cells in wound repair." Science **296**(5568): 747-749.
- Kato G. J., Gladwin M. T. and Steinberg M. H. (2007). "Deconstructing sickle cell disease: reappraisal of the role of hemolysis in the development of clinical subphenotypes." Blood Rev **21**(1): 37-47.

- Kato G. J., Hsieh M., Machado R., Taylor J. t., Little J., Butman J. A., Lehky T., Tisdale J. and Gladwin M. T. (2006). "Cerebrovascular disease associated with sickle cell pulmonary hypertension." Am J Hematol **81**(7): 503-510.
- Kato G. J., McGowan V., Machado R. F., Little J. A., Taylor J. t., Morris C. R., Nichols J. S., Wang X., Poljakovic M., Morris S. M., Jr. and Gladwin M. T. (2006). "Lactate dehydrogenase as a biomarker of hemolysis-associated nitric oxide resistance, priapism, leg ulceration, pulmonary hypertension, and death in patients with sickle cell disease." Blood **107**(6): 2279-2285.
- Kenouch S., Lombes M., Delahaye F., Eugene E., Bonvalet J. P. and Farman N. (1994). "Human skin as target for aldosterone: coexpression of mineralocorticoid receptors and 11 beta-hydroxysteroid dehydrogenase." J Clin Endocrinol Metab **79**(5): 1334-1341.
- Kim M. H., Liu W., Borjesson D. L., Curry F. R., Miller L. S., Cheung A. L., Liu F. T., Isseroff R. R. and Simon S. I. (2008). "Dynamics of neutrophil infiltration during cutaneous wound healing and infection using fluorescence imaging." J Invest Dermatol **128**(7): 1812-1820.
- Kishimoto J., Ehama R., Ge Y., Kobayashi T., Nishiyama T., Detmar M. and Burgeson R. E. (2000). "In vivo detection of human vascular endothelial growth factor promoter activity in transgenic mouse skin." Am J Pathol **157**(1): 103-110.
- Koenig J. B. and Jaffe I. Z. (2014). "Direct role for smooth muscle cell mineralocorticoid receptors in vascular remodeling: novel mechanisms and clinical implications." Curr Hypertens Rep **16**(5): 427.
- Kolkhof P. and Borden S. A. (2012). "Molecular pharmacology of the mineralocorticoid receptor: prospects for novel therapeutics." Mol Cell Endocrinol **350**(2): 310-317.
- Koolwijk P., van Erck M. G., de Vree W. J., Vermeer M. A., Weich H. A., Hanemaaijer R. and van Hinsbergh V. W. (1996). "Cooperative effect of TNFalpha, bFGF, and VEGF on the formation of tubular structures of human microvascular endothelial cells in a fibrin matrix. Role of urokinase activity." J Cell Biol **132**(6): 1177-1188.
- Kwak S. P., Patel P. D., Thompson R. C., Akil H. and Watson S. J. (1993). "5'-Heterogeneity of the mineralocorticoid receptor messenger ribonucleic acid:

- differential expression and regulation of splice variants within the rat hippocampus." Endocrinology **133**(5): 2344-2350.
- Lai J. J., Lai K. P., Chuang K. H., Chang P., Yu I. C., Lin W. J. and Chang C. (2009). "Monocyte/macrophage androgen receptor suppresses cutaneous wound healing in mice by enhancing local TNF-alpha expression." J Clin Invest **119**(12): 3739-3751.
- Lamping K. (2007). "Endothelial progenitor cells: sowing the seeds for vascular repair." Circ Res **100**(9): 1243-1245.
- Landburg P. P., Nur E., Maria N., Brandjes D. P., Biemond B. J., Schnog J. B. and Duits A. J. (2009). "Elevated circulating stromal-derived factor-1 levels in sickle cell disease." Acta Haematol **122**(1): 64-69.
- Lane P. A. (1996). "Sickle cell disease." Pediatr Clin North Am **43**(3): 639-664.
- Lard L. R., Mul F. P., de Haas M., Roos D. and Duits A. J. (1999). "Neutrophil activation in sickle cell disease." J Leukoc Biol **66**(3): 411-415.
- Lau K., Paus R., Tiede S., Day P. and Bayat A. (2009). "Exploring the role of stem cells in cutaneous wound healing." Exp Dermatol **18**(11): 921-933.
- Lee P., Lee D. J., Chan C., Chen S. W., Ch'en I. and Jamora C. (2009). "Dynamic expression of epidermal caspase 8 simulates a wound healing response." Nature **458**(7237): 519-523.
- Lee R. H., Hsu S. C., Munoz J., Jung J. S., Lee N. R., Pochampally R. and Prockop D. J. (2006). "A subset of human rapidly self-renewing marrow stromal cells preferentially engraft in mice." Blood **107**(5): 2153-2161.
- Lehmann B. (2009). "Role of the vitamin D3 pathway in healthy and diseased skin-- facts, contradictions and hypotheses." Exp Dermatol **18**(2): 97-108.
- Leopold J. A., Dam A., Maron B. A., Scribner A. W., Liao R., Handy D. E., Stanton R. C., Pitt B. and Loscalzo J. (2007). "Aldosterone impairs vascular reactivity by decreasing glucose-6-phosphate dehydrogenase activity." Nat Med **13**(2): 189-197.
- Li A., Dubey S., Varney M. L., Dave B. J. and Singh R. K. (2003). "IL-8 directly enhanced endothelial cell survival, proliferation, and matrix metalloproteinases production and regulated angiogenesis." J Immunol **170**(6): 3369-3376.
- Li J., Chen J. and Kirsner R. (2007). "Pathophysiology of acute wound healing." Clin Dermatol **25**(1): 9-18.

- Li J., Fu J., Toumazou C., Yoon H. G. and Wong J. (2006). "A role of the amino-terminal (N) and carboxyl-terminal (C) interaction in binding of androgen receptor to chromatin." Mol Endocrinol **20**(4): 776-785.
- Lombes M., Kenouch S., Souque A., Farman N. and Rafestin-Oblin M. E. (1994). "The mineralocorticoid receptor discriminates aldosterone from glucocorticoids independently of the 11 beta-hydroxysteroid dehydrogenase." Endocrinology **135**(3): 834-840.
- Loomans C. J., de Koning E. J., Staal F. J., Rookmaaker M. B., Verseyden C., de Boer H. C., Verhaar M. C., Braam B., Rabelink T. J. and van Zonneveld A. J. (2004). "Endothelial progenitor cell dysfunction: a novel concept in the pathogenesis of vascular complications of type 1 diabetes." Diabetes **53**(1): 195-199.
- Lu N. Z., Wardell S. E., Burnstein K. L., Defranco D., Fuller P. J., Giguere V., Hochberg R. B., McKay L., Renoir J. M., Weigel N. L., Wilson E. M., McDonnell D. P. and Cidlowski J. A. (2006). "International Union of Pharmacology. LXV. The pharmacology and classification of the nuclear receptor superfamily: glucocorticoid, mineralocorticoid, progesterone, and androgen receptors." Pharmacol Rev **58**(4): 782-797.
- Lucas T., Waisman A., Ranjan R., Roes J., Krieg T., Muller W., Roers A. and Eming S. A. (2010). "Differential roles of macrophages in diverse phases of skin repair." J Immunol **184**(7): 3964-3977.
- MacDonald K. P., Palmer J. S., Cronau S., Seppanen E., Olver S., Raffelt N. C., Kuns R., Pettit A. R., Clouston A., Wainwright B., Branstetter D., Smith J., Paxton R. J., Cerretti D. P., Bonham L., Hill G. R. and Hume D. A. (2010). "An antibody against the colony-stimulating factor 1 receptor depletes the resident subset of monocytes and tissue- and tumor-associated macrophages but does not inhibit inflammation." Blood **116**(19): 3955-3963.
- Mack A. K. and Kato G. J. (2006). "Sickle cell disease and nitric oxide: a paradigm shift?" Int J Biochem Cell Biol **38**(8): 1237-1243.
- Mahdavian Delavary B., van der Veer W. M., van Egmond M., Niessen F. B. and Beelen R. H. (2011). "Macrophages in skin injury and repair." Immunobiology **216**(7): 753-762.

- Manci E. A., Hillery C. A., Bodian C. A., Zhang Z. G., Luty G. A. and Collier B. S. (2006). "Pathology of Berkeley sickle cell mice: similarities and differences with human sickle cell disease." Blood **107**(4): 1651-1658.
- Mantovani A., Sica A., Sozzani S., Allavena P., Vecchi A. and Locati M. (2004). "The chemokine system in diverse forms of macrophage activation and polarization." Trends Immunol **25**(12): 677-686.
- Margadant C., Charafeddine R. A. and Sonnenberg A. (2010). "Unique and redundant functions of integrins in the epidermis." Faseb J **24**(11): 4133-4152.
- Marissal-Arvy N., Lombes M., Petterson J., Moisan M. P. and Mormede P. (2004). "Gain of function mutation in the mineralocorticoid receptor of the Brown Norway rat." J Biol Chem **279**(38): 39232-39239.
- Maron B. A. and Leopold J. A. (2010). "Aldosterone receptor antagonists: effective but often forgotten." Circulation **121**(7): 934-939.
- Marrotte E. J., Chen D. D., Hakim J. S. and Chen A. F. (2010). "Manganese superoxide dismutase expression in endothelial progenitor cells accelerates wound healing in diabetic mice." J Clin Invest **120**(12): 4207-4219.
- Marti-Carvajal A. J., Knight-Madden J. M. and Martinez-Zapata M. J. (2014). "Interventions for treating leg ulcers in people with sickle cell disease." Cochrane Database Syst Rev **12**: CD008394.
- Martin P. (1997). "Wound healing--aiming for perfect skin regeneration." Science **276**(5309): 75-81.
- Martin P. and Leibovich S. J. (2005). "Inflammatory cells during wound repair: the good, the bad and the ugly." Trends Cell Biol **15**(11): 599-607.
- Martinez F. O., Helming L. and Gordon S. (2009). "Alternative activation of macrophages: an immunologic functional perspective." Annu Rev Immunol **27**: 451-483.
- Matsuzaki K., Inoue H. and Kumagai N. (2004). "Re-epithelialisation and the possible involvement of the transcription factor, basonuclin." Int Wound J **1**(2): 135-140.
- Maubec E., Laouenan C., Deschamps L., Nguyen V. T., Scheer-Senyearich I., Wackenheim-Jacobs A. C., Steff M., Duhamel S., Tubiana S., Brahimi N., Leclerc-Mercier S., Crickx B., Perret C., Aractingi S., Escoubet B., Duval X., Arnaud P., Jaisser F., Mentre F. and Farman N. (2015). "Topical

- Mineralocorticoid Receptor Blockade Limits Glucocorticoid-Induced Epidermal Atrophy in Human Skin." J Invest Dermatol.
- Mauro T., Guitard M., Behne M., Oda Y., Crumrine D., Komuves L., Rassner U., Elias P. M. and Hummler E. (2002). "The ENaC channel is required for normal epidermal differentiation." J Invest Dermatol **118**(4): 589-594.
- Mazo I. B., Massberg S. and von Andrian U. H. (2011). "Hematopoietic stem and progenitor cell trafficking." Trends Immunol **32**(10): 493-503.
- Menard J. (2004). "The 45-year story of the development of an anti-aldosterone more specific than spironolactone." Mol Cell Endocrinol **217**(1-2): 45-52.
- Menke N. B., Ward K. R., Witten T. M., Bonchev D. G. and Diegelmann R. F. (2007). "Impaired wound healing." Clin Dermatol **25**(1): 19-25.
- Mery L., Girot R. and Aractingi S. (2004). "Topical effectiveness of molgramostim (GM-CSF) in sickle cell leg ulcers." Dermatology **208**(2): 135-137.
- Michalik L., Desvergne B., Tan N. S., Basu-Modak S., Escher P., Rieusset J., Peters J. M., Kaya G., Gonzalez F. J., Zakany J., Metzger D., Chambon P., Duboule D. and Wahli W. (2001). "Impaired skin wound healing in peroxisome proliferator-activated receptor (PPAR)alpha and PPARbeta mutant mice." J Cell Biol **154**(4): 799-814.
- Michalik L. and Wahli W. (2006). "Involvement of PPAR nuclear receptors in tissue injury and wound repair." J Clin Invest **116**(3): 598-606.
- Miller J. T., Bartley J. H., Wimborne H. J., Walker A. L., Hess D. C., Hill W. D. and Carroll J. E. (2005). "The neuroblast and angioblast chemotaxic factor SDF-1 (CXCL12) expression is briefly up regulated by reactive astrocytes in brain following neonatal hypoxic-ischemic injury." BMC Neurosci **6**: 63.
- Miller S. J., Burke E. M., Rader M. D., Coulombe P. A. and Lavker R. M. (1998). "Re-epithelialization of porcine skin by the sweat apparatus." J Invest Dermatol **110**(1): 13-19.
- Minniti C. P., Delaney K. M., Gorbach A. M., Xu D., Lee C. C., Malik N., Koroulakis A., Antalek M., Maivelett J., Peters-Lawrence M., Novelli E. M., Lanzkron S. M., Axelrod K. C. and Kato G. J. (2014). "Vasculopathy, inflammation, and blood flow in leg ulcers of patients with sickle cell anemia." Am J Hematol **89**(1): 1-6.

- Minniti C. P., Sable C., Campbell A., Rana S., Ensing G., Dham N., Onyekwere O., Nouraie M., Kato G. J., Gladwin M. T., Castro O. L. and Gordeuk V. R. (2009). "Elevated tricuspid regurgitant jet velocity in children and adolescents with sickle cell disease: association with hemolysis and hemoglobin oxygen desaturation." Haematologica **94**(3): 340-347.
- Minniti C. P., Taylor J. G. t., Hildesheim M., O'Neal P., Wilson J., Castro O., Gordeuk V. R. and Kato G. J. (2011). "Laboratory and echocardiography markers in sickle cell patients with leg ulcers." Am J Hematol **86**(8): 705-708.
- Mirza R., DiPietro L. A. and Koh T. J. (2009). "Selective and specific macrophage ablation is detrimental to wound healing in mice." Am J Pathol **175**(6): 2454-2462.
- Mitts T. F., Bunda S., Wang Y. and Hinek A. (2010). "Aldosterone and mineralocorticoid receptor antagonists modulate elastin and collagen deposition in human skin." J Invest Dermatol **130**(10): 2396-2406.
- Modell B. and Darlison M. (2008). "Global epidemiology of haemoglobin disorders and derived service indicators." Bull World Health Organ **86**(6): 480-487.
- Montesinos M. C., Shaw J. P., Yee H., Shamamian P. and Cronstein B. N. (2004). "Adenosine A(2A) receptor activation promotes wound neovascularization by stimulating angiogenesis and vasculogenesis." Am J Pathol **164**(6): 1887-1892.
- Morimoto A., Sakata Y., Watanabe T. and Murakami N. (1990). "Leucocytosis induced in rabbits by intravenous or central injection of granulocyte colony stimulating factor." J Physiol **426**: 117-126.
- Morrison N., Harrap S. B., Arriza J. L., Boyd E. and Connor J. M. (1990). "Regional chromosomal assignment of the human mineralocorticoid receptor gene to 4q31.1." Hum Genet **85**(1): 130-132.
- Mosser D. M. and Edwards J. P. (2008). "Exploring the full spectrum of macrophage activation." Nat Rev Immunol **8**(12): 958-969.
- Murohara T., Asahara T., Silver M., Bauters C., Masuda H., Kalka C., Kearney M., Chen D., Symes J. F., Fishman M. C., Huang P. L. and Isner J. M. (1998). "Nitric oxide synthase modulates angiogenesis in response to tissue ischemia." J Clin Invest **101**(11): 2567-2578.

- Murohara T., Horowitz J. R., Silver M., Tsurumi Y., Chen D., Sullivan A. and Isner J. M. (1998). "Vascular endothelial growth factor/vascular permeability factor enhances vascular permeability via nitric oxide and prostacyclin." Circulation **97**(1): 99-107.
- Nagai M. K. and Embil J. M. (2002). "Becaplermin: recombinant platelet derived growth factor, a new treatment for healing diabetic foot ulcers." Expert Opin Biol Ther **2**(2): 211-218.
- Nagase T., Akase T., Sanada H., Minematsu T., Ibuki A., Huang L., Asada M., Yoshimura K., Nagase M., Shimada T., Aburada M., Nakagami G. and Sugama J. (2013). "Aging-like skin changes in metabolic syndrome model mice are mediated by mineralocorticoid receptor signaling." Aging Cell **12**(1): 50-57.
- Nakamura Y., Nakamura T., Tarui T., Inoue J. and Kinoshita S. (2012). "Functional role of PPARdelta in corneal epithelial wound healing." Am J Pathol **180**(2): 583-598.
- Nelzen O., Bergqvist D. and Lindhagen A. (1996). "The prevalence of chronic lower-limb ulceration has been underestimated: results of a validated population questionnaire." Br J Surg **83**(2): 255-258.
- Nishimura Y., Li M., Qin G., Hamada H., Asai J., Takenaka H., Sekiguchi H., Renault M. A., Jujo K., Katoh N., Kishimoto S., Ito A., Kamide C., Kenny J., Millay M., Misener S., Thorne T. and Losordo D. W. (2012). "CXCR4 antagonist AMD3100 accelerates impaired wound healing in diabetic mice." J Invest Dermatol **132**(3 Pt 1): 711-720.
- Nissen N. N., Polverini P. J., Koch A. E., Volin M. V., Gamelli R. L. and DiPietro L. A. (1998). "Vascular endothelial growth factor mediates angiogenic activity during the proliferative phase of wound healing." Am J Pathol **152**(6): 1445-1452.
- Noble P. W. and Jiang D. (2006). "Matrix regulation of lung injury, inflammation, and repair: the role of innate immunity." Proc Am Thorac Soc **3**(5): 401-404.
- Nolan V. G., Adewoye A., Baldwin C., Wang L., Ma Q., Wyszynski D. F., Farrell J. J., Sebastiani P., Farrer L. A. and Steinberg M. H. (2006). "Sickle cell leg ulcers: associations with haemolysis and SNPs in Klotho, TEK and genes of the TGF-beta/BMP pathway." Br J Haematol **133**(5): 570-578.

- Nwomeh B. C., Yager D. R. and Cohen I. K. (1998). "Physiology of the chronic wound." Clin Plast Surg **25**(3): 341-356.
- O'Kane S. and Ferguson M. W. (1997). "Transforming growth factor beta s and wound healing." Int J Biochem Cell Biol **29**(1): 63-78.
- Ohene-Frempong K., Weiner S. J., Sleeper L. A., Miller S. T., Embury S., Moohr J. W., Wethers D. L., Pegelow C. H. and Gill F. M. (1998). "Cerebrovascular accidents in sickle cell disease: rates and risk factors." Blood **91**(1): 288-294.
- Ohki Y., Heissig B., Sato Y., Akiyama H., Zhu Z., Hicklin D. J., Shimada K., Ogawa H., Daida H., Hattori K. and Ohsaka A. (2005). "Granulocyte colony-stimulating factor promotes neovascularization by releasing vascular endothelial growth factor from neutrophils." Faseb J **19**(14): 2005-2007.
- Okuno Y., Nakamura-Ishizu A., Kishi K., Suda T. and Kubota Y. (2011). "Bone marrow-derived cells serve as proangiogenic macrophages but not endothelial cells in wound healing." Blood **117**(19): 5264-5272.
- Okwi A. L., Byarugaba W., Ndugwa C. M., Parkes A., Ocaido M. and Tumwine J. K. (2010). "An up-date on the prevalence of sickle cell trait in Eastern and Western Uganda." BMC Blood Disord **10**: 5.
- Olea M. S., Centeno N., Aybar C. A., Ortega E. S., Galante G. B., Olea L. and Juri M. J. (2014). "First report of myiasis caused by *Cochliomyia hominivorax* (Diptera: Calliphoridae) in a diabetic foot ulcer patient in Argentina." Korean J Parasitol **52**(1): 89-92.
- Oliveira H. C., Popi A. F., Bachi A. L., Nonogaki S., Lopes J. D. and Mariano M. (2010). "B-1 cells modulate the kinetics of wound-healing process in mice." Immunobiology **215**(3): 215-222.
- Olsson A. K., Dimberg A., Kreuger J. and Claesson-Welsh L. (2006). "VEGF receptor signalling - in control of vascular function." Nat Rev Mol Cell Biol **7**(5): 359-371.
- Osarogiagbon U. R., Choong S., Belcher J. D., Vercellotti G. M., Paller M. S. and Hebbel R. P. (2000). "Reperfusion injury pathophysiology in sickle transgenic mice." Blood **96**(1): 314-320.
- Pages G. and Pouyssegur J. (2005). "Transcriptional regulation of the Vascular Endothelial Growth Factor gene--a concert of activating factors." Cardiovasc Res **65**(3): 564-573.

- Papapetropoulos A., Fulton D., Mahboubi K., Kalb R. G., O'Connor D. S., Li F., Altieri D. C. and Sessa W. C. (2000). "Angiopoietin-1 inhibits endothelial cell apoptosis via the Akt/survivin pathway." J Biol Chem **275**(13): 9102-9105.
- Parks W. C. (1999). "Matrix metalloproteinases in repair." Wound Repair Regen **7**(6): 423-432.
- Pascual-Le Tallec L. and Lombes M. (2005). "The mineralocorticoid receptor: a journey exploring its diversity and specificity of action." Mol Endocrinol **19**(9): 2211-2221.
- Pauling L., Itano H. A. and et al. (1949). "Sickle cell anemia a molecular disease." Science **110**(2865): 543-548.
- Pearce D., Soundararajan R., Trimpert C., Kashlan O. B., Deen P. M. and Kohan D. E. (2015). "Collecting duct principal cell transport processes and their regulation." Clin J Am Soc Nephrol **10**(1): 135-146.
- Pegelow C. H., Colangelo L., Steinberg M., Wright E. C., Smith J., Phillips G. and Vichinsky E. (1997). "Natural history of blood pressure in sickle cell disease: risks for stroke and death associated with relative hypertension in sickle cell anemia." Am J Med **102**(2): 171-177.
- Penton D., Czogalla J. and Loffing J. (2015). "Dietary potassium and the renal control of salt balance and blood pressure." Pflugers Arch **467**(3): 513-530.
- Piel F. B., Hay S. I., Gupta S., Weatherall D. J. and Williams T. N. (2013). "Global burden of sickle cell anaemia in children under five, 2010-2050: modelling based on demographics, excess mortality, and interventions." PLoS Med **10**(7): e1001484.
- Piel F. B., Patil A. P., Howes R. E., Nyangiri O. A., Gething P. W., Dewi M., Temperley W. H., Williams T. N., Weatherall D. J. and Hay S. I. (2013). "Global epidemiology of sickle haemoglobin in neonates: a contemporary geostatistical model-based map and population estimates." Lancet **381**(9861): 142-151.
- Piel F. B., Patil A. P., Howes R. E., Nyangiri O. A., Gething P. W., Williams T. N., Weatherall D. J. and Hay S. I. (2010). "Global distribution of the sickle cell gene and geographical confirmation of the malaria hypothesis." Nat Commun **1**: 104.

- Pieters R. C., Rojer R. A., Saleh A. W., Saleh A. E. and Duits A. J. (1995). "Molgramostim to treat SS-sickle cell leg ulcers." Lancet **345**(8948): 528.
- Pippal J. B. and Fuller P. J. (2008). "Structure-function relationships in the mineralocorticoid receptor." J Mol Endocrinol **41**(6): 405-413.
- Pitt B., Anker S. D., Bohm M., Gheorghide M., Kober L., Krum H., Maggioni A. P., Ponikowski P., Voors A. A., Zannad F., Nowack C., Kim S. Y., Pieper A., Kimmeskamp-Kirschbaum N. and Filippatos G. (2015). "Rationale and design of MinerAlocorticoid Receptor antagonist Tolerability Study-Heart Failure (ARTS-HF): a randomized study of finerenone vs. eplerenone in patients who have worsening chronic heart failure with diabetes and/or chronic kidney disease." Eur J Heart Fail **17**(2): 224-232.
- Pitt B., Kober L., Ponikowski P., Gheorghide M., Filippatos G., Krum H., Nowack C., Kolkhof P., Kim S. Y. and Zannad F. (2013). "Safety and tolerability of the novel non-steroidal mineralocorticoid receptor antagonist BAY 94-8862 in patients with chronic heart failure and mild or moderate chronic kidney disease: a randomized, double-blind trial." Eur Heart J **34**(31): 2453-2463.
- Pitt B., Remme W., Zannad F., Neaton J., Martinez F., Roniker B., Bittman R., Hurley S., Kleiman J. and Gatlin M. (2003). "Eplerenone, a selective aldosterone blocker, in patients with left ventricular dysfunction after myocardial infarction." N Engl J Med **348**(14): 1309-1321.
- Pitt B., Zannad F., Remme W. J., Cody R., Castaigne A., Perez A., Palensky J. and Wittes J. (1999). "The effect of spironolactone on morbidity and mortality in patients with severe heart failure. Randomized Aldactone Evaluation Study Investigators." N Engl J Med **341**(10): 709-717.
- Pullar C. E., Rizzo A. and Isseroff R. R. (2006). "beta-Adrenergic receptor antagonists accelerate skin wound healing: evidence for a catecholamine synthesis network in the epidermis." J Biol Chem **281**(30): 21225-21235.
- Quinkler M., Meyer B., Oelkers W. and Diederich S. (2003). "Renal inactivation, mineralocorticoid generation, and 11beta-hydroxysteroid dehydrogenase inhibition ameliorate the antimineralocorticoid effect of progesterone in vivo." J Clin Endocrinol Metab **88**(8): 3767-3772.

- Raes G., Noel W., Beschin A., Brys L., de Baetselier P. and Hassanzadeh G. H. (2002). "FIZZ1 and Ym as tools to discriminate between differentially activated macrophages." Dev Immunol **9**(3): 151-159.
- Raja, Sivamani K., Garcia M. S. and Isseroff R. R. (2007). "Wound re-epithelialization: modulating keratinocyte migration in wound healing." Front Biosci **12**: 2849-2868.
- Rajagopalan S., Duquaine D., King S., Pitt B. and Patel P. (2002). "Mineralocorticoid receptor antagonism in experimental atherosclerosis." Circulation **105**(18): 2212-2216.
- Reed M. J. and Edelberg J. M. (2004). "Impaired angiogenesis in the aged." Sci Aging Knowledge Environ **2004**(7): pe7.
- Reed M. J., Ferrara N. S. and Vernon R. B. (2001). "Impaired migration, integrin function, and actin cytoskeletal organization in dermal fibroblasts from a subset of aged human donors." Mech Ageing Dev **122**(11): 1203-1220.
- Rees D. C., Williams T. N. and Gladwin M. T. (2010). "Sickle-cell disease." Lancet **376**(9757): 2018-2031.
- Reiber G. E. (1996). "The epidemiology of diabetic foot problems." Diabet Med **13 Suppl 1**: S6-11.
- Reiter C. D., Wang X., Tanus-Santos J. E., Hogg N., Cannon R. O., 3rd, Schechter A. N. and Gladwin M. T. (2002). "Cell-free hemoglobin limits nitric oxide bioavailability in sickle-cell disease." Nat Med **8**(12): 1383-1389.
- Rivard A., Fabre J. E., Silver M., Chen D., Murohara T., Kearney M., Magner M., Asahara T. and Isner J. M. (1999). "Age-dependent impairment of angiogenesis." Circulation **99**(1): 111-120.
- Rogerson F. M. and Fuller P. J. (2003). "Interdomain interactions in the mineralocorticoid receptor." Mol Cell Endocrinol **200**(1-2): 45-55.
- Roh C. and Lyle S. (2006). "Cutaneous stem cells and wound healing." Pediatr Res **59**(4 Pt 2): 100R-103R.
- Roskoski R., Jr. (2008). "VEGF receptor protein-tyrosine kinases: structure and regulation." Biochem Biophys Res Commun **375**(3): 287-291.
- Rossier B. C., Baker M. E. and Studer R. A. (2015). "Epithelial sodium transport and its control by aldosterone: the story of our internal environment revisited." Physiol Rev **95**(1): 297-340.

- Rybicki A. C. and Benjamin L. J. (1998). "Increased levels of endothelin-1 in plasma of sickle cell anemia patients." Blood **92**(7): 2594-2596.
- Sabaa N., de Franceschi L., Bonnin P., Castier Y., Malpeli G., Debbabi H., Galaup A., Maier-Redelsperger M., Vandermeersch S., Scarpa A., Janin A., Levy B., Girot R., Beuzard Y., Leboeuf C., Henri A., Germain S., Dussaule J. C. and Tharaux P. L. (2008). "Endothelin receptor antagonism prevents hypoxia-induced mortality and morbidity in a mouse model of sickle-cell disease." J Clin Invest **118**(5): 1924-1933.
- Safer J. D., Crawford T. M. and Holick M. F. (2005). "Topical thyroid hormone accelerates wound healing in mice." Endocrinology **146**(10): 4425-4430.
- Saharinen P., Eklund L., Pulkki K., Bono P. and Alitalo K. (2011). "VEGF and angiopoietin signaling in tumor angiogenesis and metastasis." Trends Mol Med **17**(7): 347-362.
- Sahni A. and Francis C. W. (2000). "Vascular endothelial growth factor binds to fibrinogen and fibrin and stimulates endothelial cell proliferation." Blood **96**(12): 3772-3778.
- Sahni A. and Francis C. W. (2004). "Stimulation of endothelial cell proliferation by FGF-2 in the presence of fibrinogen requires alphavbeta3." Blood **104**(12): 3635-3641.
- Sahni A., Sporn L. A. and Francis C. W. (1999). "Potentiation of endothelial cell proliferation by fibrin(ogen)-bound fibroblast growth factor-2." J Biol Chem **274**(21): 14936-14941.
- Sainte Marie Y., Toulon A., Paus R., Maubec E., Cherfa A., Grossin M., Descamps V., Clemessy M., Gasc J. M., Peuchmaur M., Glick A., Farman N. and Jaisser F. (2007). "Targeted skin overexpression of the mineralocorticoid receptor in mice causes epidermal atrophy, premature skin barrier formation, eye abnormalities, and alopecia." Am J Pathol **171**(3): 846-860.
- Sanchis A., Alba L., Latorre V., Sevilla L. M. and Perez P. (2012). "Keratinocyte-targeted overexpression of the glucocorticoid receptor delays cutaneous wound healing." PLoS One **7**(1): e29701.
- Sano S., Itami S., Takeda K., Tarutani M., Yamaguchi Y., Miura H., Yoshikawa K., Akira S. and Takeda J. (1999). "Keratinocyte-specific ablation of Stat3 exhibits

- impaired skin remodeling, but does not affect skin morphogenesis." EMBO J **18**(17): 4657-4668.
- Sanz Garcia S., Santos Heredero X., Izquierdo Hernandez A., Pascual Pena E., Bilbao de Aledo G. and Hamann C. (2000). "Experimental model for local application of growth factors in skin re-epithelialisation." Scand J Plast Reconstr Surg Hand Surg **34**(3): 199-206.
- Schacke H., Docke W. D. and Asadullah K. (2002). "Mechanisms involved in the side effects of glucocorticoids." Pharmacol Ther **96**(1): 23-43.
- Schafer A., Fraccarollo D., Hildemann S. K., Tas P., Ertl G. and Bauersachs J. (2003). "Addition of the selective aldosterone receptor antagonist eplerenone to ACE inhibition in heart failure: effect on endothelial dysfunction." Cardiovasc Res **58**(3): 655-662.
- Schrufer R., Sulyok S., Schymeinsky J., Peters T., Scharffetter-Kochanek K. and Walzog B. (2006). "The proangiogenic capacity of polymorphonuclear neutrophils delineated by microarray technique and by measurement of neovascularization in wounded skin of CD18-deficient mice." J Vasc Res **43**(1): 1-11.
- Senger D. R., Claffey K. P., Benes J. E., Perruzzi C. A., Sergiou A. P. and Detmar M. (1997). "Angiogenesis promoted by vascular endothelial growth factor: regulation through alpha1beta1 and alpha2beta1 integrins." Proc Natl Acad Sci U S A **94**(25): 13612-13617.
- Senger D. R., Ledbetter S. R., Claffey K. P., Papadopoulos-Sergiou A., Peruzzi C. A. and Detmar M. (1996). "Stimulation of endothelial cell migration by vascular permeability factor/vascular endothelial growth factor through cooperative mechanisms involving the alphavbeta3 integrin, osteopontin, and thrombin." Am J Pathol **149**(1): 293-305.
- Sethi K. K., Yannas I. V., Mudera V., Eastwood M., McFarland C. and Brown R. A. (2002). "Evidence for sequential utilization of fibronectin, vitronectin, and collagen during fibroblast-mediated collagen contraction." Wound Repair Regen **10**(6): 397-408.
- Shavit L., Lifschitz M. D. and Epstein M. (2012). "Aldosterone blockade and the mineralocorticoid receptor in the management of chronic kidney disease:

- current concepts and emerging treatment paradigms." Kidney Int **81**(10): 955-968.
- Sherman R. A. (2003). "Maggot therapy for treating diabetic foot ulcers unresponsive to conventional therapy." Diabetes Care **26**(2): 446-451.
- Sibanda M., Sibanda E. and Jonsson K. (2009). "A prospective evaluation of lower extremity ulcers in a Zimbabwean population." Int Wound J **6**(5): 361-366.
- Siciliano A., Malpeli G., Platt O. S., Lebouef C., Janin A., Scarpa A., Olivieri O., Amato E., Corrocher R., Beuzard Y. and De Franceschi L. (2011). "Abnormal modulation of cell protective systems in response to ischemic/reperfusion injury is important in the development of mouse sickle cell hepatopathy." Haematologica **96**(1): 24-32.
- Sieveking D. P., Buckle A., Celermajer D. S. and Ng M. K. (2008). "Strikingly different angiogenic properties of endothelial progenitor cell subpopulations: insights from a novel human angiogenesis assay." J Am Coll Cardiol **51**(6): 660-668.
- Simpson D. M. and Ross R. (1972). "The neutrophilic leukocyte in wound repair a study with antineutrophil serum." J Clin Invest **51**(8): 2009-2023.
- Sindrilaru A., Peters T., Wieschalka S., Baican C., Baican A., Peter H., Hainzl A., Schatz S., Qi Y., Schlecht A., Weiss J. M., Wlaschek M., Sunderkotter C. and Scharffetter-Kochanek K. (2011). "An unrestrained proinflammatory M1 macrophage population induced by iron impairs wound healing in humans and mice." J Clin Invest **121**(3): 985-997.
- Singer A. J. and Clark R. A. (1999). "Cutaneous wound healing." N Engl J Med **341**(10): 738-746.
- Spallotta F., Cencioni C., Straino S., Nanni S., Rosati J., Artuso S., Manni I., Colussi C., Piaggio G., Martelli F., Valente S., Mai A., Capogrossi M. C., Farsetti A. and Gaetano C. (2013). "A nitric oxide-dependent cross-talk between class I and III histone deacetylases accelerates skin repair." J Biol Chem **288**(16): 11004-11012.
- Swift M. E., Kleinman H. K. and DiPietro L. A. (1999). "Impaired wound repair and delayed angiogenesis in aged mice." Lab Invest **79**(12): 1479-1487.
- Takeda Y., Zhu A., Yoneda T., Usukura M., Takata H. and Yamagishi M. (2007). "Effects of aldosterone and angiotensin II receptor blockade on cardiac

- angiotensinogen and angiotensin-converting enzyme 2 expression in Dahl salt-sensitive hypertensive rats." Am J Hypertens **20**(10): 1119-1124.
- Taylor J. E., Laity P. R., Hicks J., Wong S. S., Norris K., Khunkamchoo P., Johnson A. F. and Cameron R. E. (2005). "Extent of iron pick-up in deferoxamine-coupled polyurethane materials for therapy of chronic wounds." Biomaterials **26**(30): 6024-6033.
- Taylor J. G. t., Nolan V. G., Mendelsohn L., Kato G. J., Gladwin M. T. and Steinberg M. H. (2008). "Chronic hyper-hemolysis in sickle cell anemia: association of vascular complications and mortality with less frequent vasoocclusive pain." PLoS One **3**(5): e2095.
- Tepper O. M., Capla J. M., Galiano R. D., Ceradini D. J., Callaghan M. J., Kleinman M. E. and Gurtner G. C. (2005). "Adult vasculogenesis occurs through in situ recruitment, proliferation, and tubulization of circulating bone marrow-derived cells." Blood **105**(3): 1068-1077.
- Tepper O. M., Carr J., Allen R. J., Jr., Chang C. C., Lin C. D., Tanaka R., Gupta S. M., Levine J. P., Saadeh P. B. and Warren S. M. (2010). "Decreased circulating progenitor cell number and failed mechanisms of stromal cell-derived factor-1alpha mediated bone marrow mobilization impair diabetic tissue repair." Diabetes **59**(8): 1974-1983.
- Thangarajah H., Yao D., Chang E. I., Shi Y., Jazayeri L., Vial I. N., Galiano R. D., Du X. L., Grogan R., Galvez M. G., Januszyk M., Brownlee M. and Gurtner G. C. (2009). "The molecular basis for impaired hypoxia-induced VEGF expression in diabetic tissues." Proc Natl Acad Sci U S A **106**(32): 13505-13510.
- Tharaux P. L., Hagege I., Placier S., Vayssairat M., Kanfer A., Girot R. and Dussaule J. C. (2005). "Urinary endothelin-1 as a marker of renal damage in sickle cell disease." Nephrol Dial Transplant **20**(11): 2408-2413.
- Thomas D. R. (2001). "Age-related changes in wound healing." Drugs Aging **18**(8): 607-620.
- Thum T., Schmitter K., Fleissner F., Wiebking V., Dietrich B., Widder J. D., Jazbutyte V., Hahner S., Ertl G. and Bauersachs J. (2011). "Impairment of endothelial progenitor cell function and vascularization capacity by aldosterone in mice and humans." Eur Heart J **32**(10): 1275-1286.

- Thuret I., Sarles J., Merono F., Suzineau E., Collomb J., Lena-Russo D., Levy N., Bardakdjian J. and Badens C. (2010). "Neonatal screening for sickle cell disease in France: evaluation of the selective process." J Clin Pathol **63**(6): 548-551.
- Tiganescu A., Hupe M., Uchida Y., Mauro T., Elias P. M. and Holleran W. M. (2014). "Increased glucocorticoid activation during mouse skin wound healing." J Endocrinol **221**(1): 51-61.
- Tiganescu A., Tahrani A. A., Morgan S. A., Otranto M., Desmouliere A., Abrahams L., Hassan-Smith Z., Walker E. A., Rabbitt E. H., Cooper M. S., Amrein K., Lavery G. G. and Stewart P. M. (2013). "11beta-Hydroxysteroid dehydrogenase blockade prevents age-induced skin structure and function defects." J Clin Invest **123**(7): 3051-3060.
- Timmermans F., Plum J., Yoder M. C., Ingram D. A., Vandekerckhove B. and Case J. (2009). "Endothelial progenitor cells: identity defined?" J Cell Mol Med **13**(1): 87-102.
- Tonnesen M. G., Feng X. and Clark R. A. (2000). "Angiogenesis in wound healing." J Investig Dermatol Symp Proc **5**(1): 40-46.
- Toulon A., Breton L., Taylor K. R., Tenenhaus M., Bhavsar D., Lanigan C., Rudolph R., Jameson J. and Havran W. L. (2009). "A role for human skin-resident T cells in wound healing." J Exp Med **206**(4): 743-750.
- Tsuboi R., Sato C., Kurita Y., Ron D., Rubin J. S. and Ogawa H. (1993). "Keratinocyte growth factor (FGF-7) stimulates migration and plasminogen activator activity of normal human keratinocytes." J Invest Dermatol **101**(1): 49-53.
- Turhan A., Weiss L. A., Mohandas N., Coller B. S. and Frenette P. S. (2002). "Primary role for adherent leukocytes in sickle cell vascular occlusion: a new paradigm." Proc Natl Acad Sci U S A **99**(5): 3047-3051.
- Urbich C., Heeschen C., Aicher A., Sasaki K., Bruhl T., Farhadi M. R., Vajkoczy P., Hofmann W. K., Peters C., Pennacchio L. A., Abolmaali N. D., Chavakis E., Reinheckel T., Zeiher A. M. and Dimmeler S. (2005). "Cathepsin L is required for endothelial progenitor cell-induced neovascularization." Nat Med **11**(2): 206-213.

- Van De Water L., Varney S. and Tomasek J. J. (2013). "Mechanoregulation of the Myofibroblast in Wound Contraction, Scarring, and Fibrosis: Opportunities for New Therapeutic Intervention." Adv Wound Care (New Rochelle) **2**(4): 122-141.
- Viengchareun S., Le Menuet D., Martinerie L., Munier M., Pascual-Le Tallec L. and Lombes M. (2007). "The mineralocorticoid receptor: insights into its molecular and (patho)physiological biology." Nucl Recept Signal **5**: e012.
- Wada T., Kenmochi H., Miyashita Y., Sasaki M., Ojima M., Sasahara M., Koya D., Tsuneki H. and Sasaoka T. (2010). "Spironolactone improves glucose and lipid metabolism by ameliorating hepatic steatosis and inflammation and suppressing enhanced gluconeogenesis induced by high-fat and high-fructose diet." Endocrinology **151**(5): 2040-2049.
- Wang J., Mahmud S. A., Bitterman P. B., Huo Y. and Slungaard A. (2007). "Histone deacetylase inhibitors suppress TF-kappaB-dependent agonist-driven tissue factor expression in endothelial cells and monocytes." J Biol Chem **282**(39): 28408-28418.
- Wang X., Tanus-Santos J. E., Reiter C. D., Dejam A., Shiva S., Smith R. D., Hogg N. and Gladwin M. T. (2004). "Biological activity of nitric oxide in the plasmatic compartment." Proc Natl Acad Sci U S A **101**(31): 11477-11482.
- Weatherall D., Hofman K., Rodgers G., Ruffin J. and Hrynkow S. (2005). "A case for developing North-South partnerships for research in sickle cell disease." Blood **105**(3): 921-923.
- Weiss S. J. (1989). "Tissue destruction by neutrophils." N Engl J Med **320**(6): 365-376.
- Welt K., Hinrichs R., Weiss J. M., Burgdorf W., Krieg T. and Scharffetter-Kochanek K. (2009). "Skin diseases in Europe. Wound healing." Eur J Dermatol **19**(4): 413-416.
- Werner S. and Grose R. (2003). "Regulation of wound healing by growth factors and cytokines." Physiol Rev **83**(3): 835-870.
- Werner S., Peters K. G., Longaker M. T., Fuller-Pace F., Banda M. J. and Williams L. T. (1992). "Large induction of keratinocyte growth factor expression in the dermis during wound healing." Proc Natl Acad Sci U S A **89**(15): 6896-6900.

- White R. and McIntosh C. (2008). "Topical therapies for diabetic foot ulcers: standard treatments." J Wound Care **17**(10): 426, 428-432.
- Witko-Sarsat V., Pederzoli-Ribeil M., Hirsch E., Sozzani S. and Cassatella M. A. (2011). "Regulating neutrophil apoptosis: new players enter the game." Trends Immunol **32**(3): 117-124.
- Wood K. C., Hebbel R. P. and Granger D. N. (2005). "Endothelial cell NADPH oxidase mediates the cerebral microvascular dysfunction in sickle cell transgenic mice." Faseb J **19**(8): 989-991.
- Wu Y., Chen L., Scott P. G. and Tredget E. E. (2007). "Mesenchymal stem cells enhance wound healing through differentiation and angiogenesis." Stem Cells **25**(10): 2648-2659.
- Wynes M. W. and Riches D. W. (2003). "Induction of macrophage insulin-like growth factor-I expression by the Th2 cytokines IL-4 and IL-13." J Immunol **171**(7): 3550-3559.
- Yamaguchi J., Kusano K. F., Masuo O., Kawamoto A., Silver M., Murasawa S., Bosch-Marce M., Masuda H., Losordo D. W., Isner J. M. and Asahara T. (2003). "Stromal cell-derived factor-1 effects on ex vivo expanded endothelial progenitor cell recruitment for ischemic neovascularization." Circulation **107**(9): 1322-1328.
- Yoshino N., Okada D., Ujiie H., Akiyama H., Nishimura Y., Koizumi K. and Shimizu K. (2012). "Venous hemangioma of the posterior mediastinum." Ann Thorac Cardiovasc Surg **18**(3): 247-250.
- Youm J. K., Park K., Uchida Y., Chan A., Mauro T. M., Holleran W. M. and Elias P. M. (2013). "Local blockade of glucocorticoid activation reverses stress- and glucocorticoid-induced delays in cutaneous wound healing." Wound Repair Regen **21**(5): 715-722.
- Zennaro M. C., Caprio M. and Fève B. (2009). "Mineralocorticoid receptors in the metabolic syndrome." Trends Endocrinol Metab **20**(9): 444-451.
- Zennaro M. C., Farman N., Bonvalet J. P. and Lombes M. (1997). "Tissue-specific expression of alpha and beta messenger ribonucleic acid isoforms of the human mineralocorticoid receptor in normal and pathological states." J Clin Endocrinol Metab **82**(5): 1345-1352.

- Zennaro M. C., Keightley M. C., Kotelevtsev Y., Conway G. S., Soubrier F. and Fuller P. J. (1995). "Human mineralocorticoid receptor genomic structure and identification of expressed isoforms." J Biol Chem **270**(36): 21016-21020.
- Zhao J., Chen L., Shu B., Tang J., Zhang L., Xie J., Qi S. and Xu Y. (2014). "Granulocyte/macrophage colony-stimulating factor influences angiogenesis by regulating the coordinated expression of VEGF and the Ang/Tie system." PLoS One **9**(3): e92691.
- Zhao M., Celerier I., Bousquet E., Jeanny J. C., Jonet L., Savoldelli M., Offret O., Curan A., Farman N., Jaisser F. and Behar-Cohen F. (2012). "Mineralocorticoid receptor is involved in rat and human ocular chorioretinopathy." J Clin Invest **122**(7): 2672-2679.