



HAL
open science

Schmallenberg virus : Pathogenesis of the infection in domestic ruminants and circulation in wild ruminants

Eve Laloy

► **To cite this version:**

Eve Laloy. Schmallenberg virus : Pathogenesis of the infection in domestic ruminants and circulation in wild ruminants. Agricultural sciences. Université Paris Sud - Paris XI, 2015. English. NNT : 2015PA114836 . tel-01310151

HAL Id: tel-01310151

<https://theses.hal.science/tel-01310151>

Submitted on 2 May 2016

HAL is a multi-disciplinary open access archive for the deposit and dissemination of scientific research documents, whether they are published or not. The documents may come from teaching and research institutions in France or abroad, or from public or private research centers.

L'archive ouverte pluridisciplinaire **HAL**, est destinée au dépôt et à la diffusion de documents scientifiques de niveau recherche, publiés ou non, émanant des établissements d'enseignement et de recherche français ou étrangers, des laboratoires publics ou privés.

UNIVERSITÉ PARIS-SUD 11

ECOLE DOCTORALE :

INNOVATION THÉRAPEUTIQUE : DU FONDAMENTAL A L'APPLIQUÉ

PÔLE : MICROBIOLOGIE / THERAPEUTIQUES ANTIINFECTIEUSES

DISCIPLINE : Virologie

ANNÉE 2015 - 2016

SÉRIE DOCTORAT N°

THÈSE DE DOCTORAT

soutenue le 29/09/2015 par

Eve LALOY

**Virus Schmallenberg : Pathogénèse de l'infection chez les ruminants domestiques et
circulation chez les ruminants sauvages**

**Schmallenberg virus: Pathogenesis of the infection in domestic ruminants and
circulation in wild ruminants**

Directeur de thèse : Stéphan ZIENTARA Assimilé Professeur, Directeur de l'UMR 1161
ANSES/INRA/ENVA Virologie

Composition du jury :

Président du jury :

Prénom NOM

Rapporteurs :

Martin BEER

Professeur, Directeur de l'Institute of Diagnostic Virology
au Friedrich-Loeffler-Institut

Sandra SCHOLES

Consultante en Anatomie Pathologique Vétérinaire,
Edinburgh Disease Surveillance Centre

Examineurs :

Stéphane BERTAGNOLI

Professeur, Ecole Nationale Vétérinaire de Toulouse

Audrey ESCLATINE

Professeur, Faculté de Pharmacie de Châtenay-Malabry

Laurence FIETTE

Chercheur, Institut Pasteur

Nadia HADDAD

Professeur, Ecole Nationale Vétérinaire d'Alfort

Yves MILLEMANN

Professeur, Ecole Nationale Vétérinaire d'Alfort

Membres invités :

Emmanuel BREARD

Chercheur, UMR 1161 ANSES/INRA/ENVA Virologie

Nathalie CORDONNIER

Maître de Conférences, Ecole Nationale Vétérinaire
d'Alfort

Ce qu'un mot ne sait pas, un autre le révèle ;
Les mots heurtent le front comme l'eau le récif ;
Ils fourmillent, ouvrant dans notre esprit pensif
Des griffes ou des mains, et quelques-uns des ailes

Victor Hugo

Acknowledgments

First, I would like to thank the members of the **defense committee** for this PhD thesis: Sandra Scholes and Martin Beer, who kindly accepted to review my manuscript. I feel very sorry I am not Shakespeare.

Nadia Haddad and Yves Millemann for their enthusiasm and their long-lasting interest.

Audrey Esclatine and Stéphane Bertagnoli, I am in debt to you for coming to my defense.

Laurence Fiette, you have always been an inspiration to me.

Nathalie Cordonnier and Emmanuel Bréard, my co-supervisors, who strongly supported me all along the last three years.

Stéphan Zientara, my main supervisor, without your endless energy and dedication this thesis would not exist.

I also wish to thank the members of the **doctoral supervisory committee**. Claire Ponsart, Nathalie Cordonnier, Nadia Haddad, Yves Millemann, Emmanuel Bréard, Stéphan Zientara, you have spent time to check my PhD was going the right way.

I am grateful to the members of the five-country **consortium** of veterinary research institutes that conducted studies on Schmallenberg virus, especially the coordinator Wim Van der Poel, and Norbert Stockhofe (Central Veterinary Institute, the Netherlands), for productive discussions.

Merci à mes **collègues** Nathalie Cordonnier, Edouard Reyes-Gomez et Jean-Jacques Fontaine pour votre soutien ces dernières années. Sans vos encouragements et vos heures supplémentaires, il m'aurait été impossible de mener à bien ce travail.

Merci à Gaston, mon « père de thèse » à défaut d'être mon père de clinique. Ta disponibilité et ta bienveillance sont précieuses.

Je souhaite remercier toutes les autres personnes qui ont collaboré à ce travail :

Les membres de l'**UMR 1161 Virologie ANSES-INRA-ENVA**, qui m'ont accueillie à bras ouverts et m'ont enveloppée de cette bonne ambiance, unique. En particulier l'équipe EVIR : Stéphan, Damien, Julie, Corinne, Manu, Cyril, Cindy, Annabelle, Greg, Aurore, Gaston, Virginie, Alexandra : travailler avec vous est un plaisir et cela devait être écrit. Merci à mes co-doctorantes, Anne-Laure, Chloé et Julie, pour votre patience face à mes innombrables interrogations. Merci à Typhaine, ancienne étudiante à l'ENVA, que j'ai eu plaisir à encadrer en thèse de doctorat vétérinaire.

Benoît Durand (**Unité Epidémiologie de l'ANSES**) et Claire Ponsart (**Unité Zoonoses bactériennes de l'ANSES**), qui ont piloté R avec un entrain hors du commun.

Isabelle Lagrange (**Laboratoire d'hématologie ENVA**) qui m'a accueillie dans son laboratoire avec mes tubes et mes questions.

Vincent Mauffré et Fabienne Constant (**UMR Biologie de la reproduction INRA-ENVA**) pour leurs précieuses suggestions.

Sophie Rossi de l'**ONCFS** pour sa patience et ses enseignements.

L'équipe du **laboratoire d'Anatomie pathologique de l'ENVA** : Agnès, Sophie, Patricia, Hélène et Hélène, Fara, Narcisse, Jean-Luc, Sandrine et les résidents. Merci pour votre soutien toutes ces années. J'adresse toute ma gratitude à Sophie pour les discussions scientifiques régulières que nous avons entretenues. Mille mercis à Hélène H. qui m'a accueillie sous son toit pendant mes passages à l'INRA de Nouzilly. Merci à Haintso, qui a accepté de travailler sur les tissus de chèvres lors de son stage au laboratoire.

Parmi les membres de l'**INRA de Nouzilly** :

Sascha Trapp, thank you for your dedication to the SBV project and your words of advice. A toute l'équipe de la **PFIE**, merci pour votre accueil chaleureux et votre investissement. Céline, Mickaël, Rémi, Sylvain, Didier, j'ai apprécié vos encouragements et salue votre disponibilité. Merci à Marie, en stage à la PFIE, pour sa participation.

Les membres du **Laboratoire National de Contrôle des Reproducteurs**, en particulier Maxime Raimbourg et Nathalie Pozzi : merci pour votre implication dont la constance mérite d'être soulignée.

L'équipe de la **Ménagerie du Jardin des Plantes**, en particulier Norin Chai qui s'est démené pour financer notre projet sur les animaux de zoo et le valoriser. Merci à Claire Réjaud pour sa réactivité au long du projet. Merci à Cindy, étudiante de l'ENVT, pour son engagement sur ce projet malgré la distance géographique qui nous a souvent séparées.

I wish to thank Jacques Kaandorp from **SafariPark Beekse Bergen** for its contribution to this work.

Je remercie enfin mes amis, mes proches et mon très proche, qui m'ont aidé à préserver cette petite flamme intérieure, malgré les coups de vent.

Virus Schmallerberg : Pathogénèse de l'infection chez les ruminants domestiques et circulation chez les ruminants sauvages

Le virus Schmallerberg (SBV) appartient au genre *Orthobunyavirus*, au sein de la famille des *Bunyaviridae*. Ce nouveau virus, découvert en 2011 au nord-ouest de l'Europe, affecte les ruminants domestiques. Il est responsable de signes cliniques discrets chez les adultes et de malformations congénitales chez les nouveau-nés. Ces travaux de thèse s'inscrivent dans les projets d'étude de la pathogénèse de l'infection à SBV et de l'épidémiologie de la maladie, dans le cadre d'un programme de recherche européen sur le virus. Ce manuscrit inclut de nouvelles données, telles les cinétiques de la virémie et de la séroconversion chez les ovins et caprins, après infection expérimentale par SBV. La possibilité d'infection par SBV par voie vaginale est démontrée expérimentalement chez la chèvre. Après infection expérimentale de chèvres gestantes entre 28 et 42 jours de gestation, une mortalité fœtale ou des lésions du système nerveux central des fœtus peuvent survenir. Enfin, la sensibilité de plusieurs espèces de ruminants sauvages et exotiques de parcs zoologiques vis-à-vis de SBV est démontrée pour la première fois.

Mots clés : Virologie ; Arbovirus ; Orthobunyavirus ; Virus Schmallerberg ; Infection expérimentale ; Reproduction ; Caprins ; Ovins ; Faune sauvage ; Ruminants exotiques ; Parc zoologique.

Schmallenberg virus: Pathogenesis of the infection in domestic ruminants and circulation in wild ruminants

Schmallenberg virus (SBV) belongs to the genus *Orthobunyavirus* in the family *Bunyaviridae*. This new virus was discovered in 2011 in Northwestern Europe in domestic ruminants. Infection by SBV is associated with mild clinical signs in adult and congenital malformations in the progeny. In the scope of the European research program on SBV in the pathogenesis and epidemiology areas, the works included in this thesis provide new data about SBV infection in livestock and wild and exotic ruminants. The kinetics of viremia and seroconversion after experimental SBV infection are described in sheep and goats. This manuscript includes evidence of SBV infection via vaginal route in goats. Experimental SBV infection in pregnant goats between 28 and 42 days of gestation can lead to death or central nervous system lesions in fetuses. Evidence of susceptibility to SBV in several species of wild and exotic ruminants kept in zoos is described for the first time.

Keywords : Virology; Arbovirus; Orthobunyavirus; Schmallenberg virus; Experimental infection; Reproduction; Caprine; Ovine; Wildlife; Exotic ruminants; Zoological park.

Laboratoire de rattachement :

UMR Virologie 1161 ANSES-INRA-ENVA

ANSES

23 avenue du Général de Gaulle

94704 Maisons-Alfort

France

Table of contents

1	Introduction	1
2	State of the Art.....	4
2.1	Discovery of a new virus	4
2.1.1	History	4
2.1.2	Structure.....	4
2.1.3	Phylogeny.....	6
2.2	Epidemiology	9
2.2.1	Susceptible species.....	9
2.2.2	Transmission	12
2.2.3	Geographical repartition	15
2.2.4	Risk factors	16
2.3	Clinical signs and lesions in affected animals	18
2.3.1	Non-pregnant adults	18
2.3.2	Pregnant females and their offspring.....	19
2.3.3	Hypotheses on the pathogenesis of the lesions in fetuses and newborns	24
2.4	Impact on livestock farming, on wild ruminants	30
2.5	Diagnostics and preventive measures	32
2.5.1	Diagnostics	32
2.5.2	Preventive measures.....	37
3	Aims of the Thesis.....	41
4	Experiments	43
4.1	Pathogenesis in domestic ruminants.....	43
4.1.1	Infection of adult sheep (published paper).....	43
4.1.2	Infection of adult, non-pregnant goats	47
4.1.3	Infection of adult goats around the time of insemination and during pregnancy	51
4.2	Circulation in wild and exotic ruminants	66
4.2.1	Free-ranging wild ruminants in France	66
4.2.2	Wild and exotic ruminants kept in zoos in France and the Netherlands	70

5	<i>Discussion</i>	74
5.1	Pathogenesis of the infection with SBV: hypotheses drawn from experimental infection in domestic ruminants	74
5.1.1	Pathogenesis of the infection in males and non-pregnant females.....	74
5.1.2	Pathogenesis of the infection in pregnant females	79
5.2	Rapid and broad dissemination of the virus among wild and exotic ruminants	89
5.2.1	A quick spread in many species and in various ecosystems.....	89
5.2.2	Wild ruminants: do they play a role in SBV dissemination in domestic ruminants?.....	91
5.3	Consequences in the field: impact and preventive measures	92
5.3.1	Domestic ruminants	92
5.3.2	Wild and exotic ruminants	93
6	<i>Future directions</i>	95
6.1	Pathogenesis of the infection in goats	95
6.2	SBV circulation in wild and exotic ruminants	96
7	<i>Conclusion</i>	98
8	<i>References</i>	100
9	<i>Appendix</i>	

List of figures

Figure 1. Morphology of SBV: schematic drawing on the left, electronic microscopy on the right (bar = 100 nm).	5
Figure 2. Phylogenetic relationships of Simbu serogroup viruses for the M (A), L (B), and S (C) coding regions.7	
Figure 3. Regions (NUTS2) with at least one SBV herd confirmed by direct detection by period of first report (Afonso et al., 2014).	15
Figure 4. Gross and histological lesions from SBV-infected fetuses (Herder et al., 2012).	22
Figure 5. Hypothetic consequences of SBV infection in pregnant goats and ewes depending on the stage of gestation.	26
Figure 6. Experimental design.	51
Figure 7. Evolution of the LH concentration in goats from groups A and D after sponge removal.	57
Figure 8. Evolution of the progesterone concentration (P4, ng/mL) in serum in groups A, B and D.	58
Figure 9. Evolution of the progesterone concentration (P4, ng/mL) in serum in groups C and D'.	59
Figure 10. Hypothetical pathogenesis after SBV infection in adult non-pregnant ruminants.	78
Figure 11. Outcomes and pathogenesis after SBV infection in adult pregnant goat.	88

List of tables

Table 1. Detection of SBV infection in wild and exotic ruminants from the wild or kept in captivity.	10
Table 2. Lesions in fetuses and newborns associated with spontaneous SBV infection in domestic ruminants.	21
Table 3. Lesions in fetuses and newborns associated with AKAV infection in domestic ruminants.	23
Table 4. Impact of SBV infection in domestic ruminants in Europe and France, by species.	31
Table 5. Pregnancy outcomes per group.	55
Table 6. In a subset of organs containing SBV RNA without associated lesions in experimentally infected goat fetuses: lesions found in SBV-infected neonates in the field, arguments for and against a causal link between SBV RNA presence and lesion formation.	86

Abbreviations

ANSES: Agence Nationale de Sécurité sanitaire de l'alimentation, de l'environnement et du travail

AKAV: Akabane virus

BDV: Border disease virus

BHK cells: baby hamster kidney cells (cell culture)

BTV: Bluetongue virus

BVDV: Bovine viral diarrhea virus

CNS: central nervous system

CPT-Tert cells: sheep choroid plexus cells (cell culture)

CVV: Cache Valley virus

dg: day(s) of gestation

dpi: day(s) post-infection

ENVA: Ecole Nationale Vétérinaire d'Alfort

HE: Hematoxylin-eosin

HES: Hematoxylin-eosin-saffron

INRA: Institut Nationale de la Recherche Agronomique

IHC: immunohistochemistry

ISH: *in situ* hybridization

KC cells: *Culicoides variipennis* larvae cells (cell culture)

OIE: World Organization for Animal Health (historical acronym from the French "Office International des Epizooties"³⁰)

SBV: Schmallenberg virus

TCID₅₀: 50% tissue culture infectious doses

1 INTRODUCTION

Schmallenberg virus (SBV), belonging to the genus *Orthobunyavirus* in the family *Bunyaviridae*, was discovered in 2011 in Northwestern Europe (Hoffmann et al., 2012b), five years after the emergence of Bluetongue Virus serotype 8 (BTV-8) in the same area (Wilson and Mellor, 2009). Similarly to BTV, SBV is an arbovirus transmitted by midges of the genus *Culicoides* (De Regge et al., 2012) and cause clinical disease in domestic ruminants (van den Brom et al., 2012; Hoffmann et al., 2012b).

The disease associated with SBV is an example of an emerging disease, as defined by the World Organization for Animal Health (OIE): ‘a new occurrence in an animal of a disease, infection or infestation, causing a significant impact on animal or public health resulting from: (i) a change of a known pathogenic agent or its spread to a new geographic area or species; or (ii) a previously unrecognized pathogenic agent or disease diagnosed for the first time’ (OIE, 2015). As a reaction to this emerging disease, the European Commission identified in February 2012 the major areas for which research was needed prior to decision making about regulation and control. These areas were the pathogenesis, the epidemiology and the diagnostic of SBV-associated disease. A consortium gathering laboratories from Belgium, Germany, France, the Netherlands and the United Kingdom has performed a large part of the corresponding studies.

The studies presented in this PhD thesis have been carried out in the scope of the consortium research program in the pathogenesis and epidemiology areas. I was involved in pathogenesis studies focusing on small domestic ruminants, especially the goat - as determined by the task allocation planned by the Consortium. The epidemiologic studies included in this thesis deal with exposure of wild and exotic ruminants to SBV.

In chapter 2, a review about SBV will provide general knowledge about the virus, a state of the art about epidemiology of the disease as well as work hypotheses about pathogenesis of the lesions associated with SBV. The objectives of the thesis will be detailed in chapter 3, followed by the corresponding works in chapter 4. A general discussion and future directions will be provided in chapter 5 and chapter 6, respectively.

2 STATE OF THE ART

2.1 Discovery of a new virus

2.1.1 History

In summer and fall 2011, an unidentified disease was reported in dairy cattle in Germany and in the Netherlands. The clinical signs were not specific, including fever, decreased milk production and diarrhea. No known agent could be identified in the affected cattle. Sequences of a new virus were then detected after metagenomic analysis on blood samples. This virus was named “Schmallenberg virus” after the city of Schmallenberg from where the first positive samples came. Phylogenetic analyses showed that the virus belonged to the Simbu serogroup in the genus *Orthobunyavirus*. Viruses of this serogroup had not been identified previously in Europe (Hoffmann et al., 2012b).

A retrospective study on ruminant brain tissues archived from 1961 to 2010 in Germany showed no SBV RNA or antigen in these tissues by *in situ* hybridization (ISH) and immunohistochemistry (IHC), respectively (Gerhauser et al., 2014). Thus, SBV was probably not present in northwestern Europe before 2011. The way it was introduced remains unknown. One hypothesis is transport by aircraft of infected midges, e.g. on flowers or on exotic animals from as yet unrecognized areas where SBV would be enzootic (Gale et al., 2015).

2.1.2 Structure

Viruses from the family *Bunyaviridae* are enveloped viruses with a segmented RNA genome. SBV-virions are about 100 nm in diameter (Figure 1).

The genome of viruses in the *Orthobunyavirus* genus is made of three segments of negative-sense single-stranded RNA: L (large), M (medium) and S (small). These segments encode four structural proteins and two non-structural proteins:

- The S segment encodes the nucleoprotein N and the non-structural protein NSs;
- The M segment encodes a polyprotein, which is cleaved into two surface glycoproteins (Gn and Gc) and the non-structural protein NSm;
- The L segment encodes the RNA-dependent RNA polymerase (RdRp or L protein).
- In the virion, the genome is included in a ribonucleoprotein: each segment is associated to many copies of the nucleoprotein N and a few copies of the polymerase (Briese et al., 2013; Doceul et al., 2013; Wernike et al., 2014a).

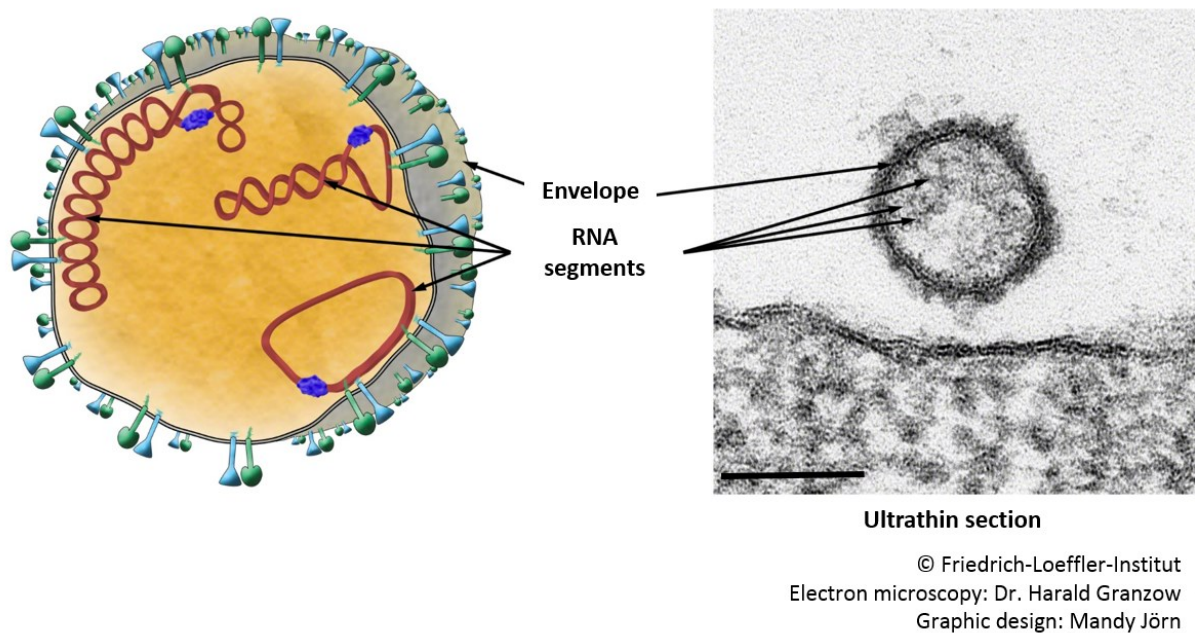


Figure 1. Morphology of SBV: schematic drawing on the left, electronic microscopy on the right (bar = 100 nm).

RNA segments are associated with N nucleoproteins (not shown) and L proteins (in purple on the schematic drawing). Courtesy of Dr H. Granzow and M. Jörn, FLI.

The surface glycoproteins Gn and Gc are type I integral membrane proteins that are embedded in the envelope. Their C-terminal parts, also known as cytoplasmic tails, are towards the intraviral space while the N-terminal parts are in contact with the outer environment. Their functions have not been fully elucidated but they are necessary for budding of viruses of the genus *Orthobunyavirus*. They may be involved in virus fusion and entry into the cells as well (Strandin et al., 2013).

The nucleoprotein N is the most abundant protein in the virion and in infected cells. Its major role is encapsidation of the genome but it may be involved in transcription and replication of the viral RNA (Wernike et al., 2014a).

In viruses from the genus *Orthobunyavirus*, the NSs protein is not essential for virus growth *in vitro* but is involved in viral pathogenesis. Functions of the NSm protein are still unknown, yet it may participate in viral assembly (Eifan et al., 2013), probably in the Golgi apparatus (Doceul et al., 2013).

The L protein of bunyaviruses has a double activity: it acts both as an RNA polymerase and as an endonuclease. As an endonuclease, the L protein cleaves cellular messenger RNAs, leading to capped primers that initiate transcription of viral messenger RNAs; this process is known as ‘cap-snatching’ (Briese et al., 2013).

2.1.3 Phylogeny

The *Orthobunyavirus* genus belongs to the *Bunyaviridae* family. This family encompasses 350 viruses that are divided into 5 genera: *Orthobunyavirus*, *Hantavirus*, *Nairovirus*, *Phlebovirus* and *Tospovirus*. Viruses from the latter genus infect plants whereas viruses from the other genera infect vertebrates (Doceul et al., 2013).

The *Orthobunyavirus* genus is made of more than 170 viruses allocated to 18 serogroups (Doceul et al., 2013). The *Orthobunyavirus* genus includes viruses responsible for disease in humans, as Oropouche virus (Simbu serogroup), or Jamestown Canyon virus and La Crosse virus (California serogroup), and viruses responsible for disease in ruminants, as Aino virus and Akabane virus (Simbu serogroup) or Cache Valley virus (Bunyamwera serogroup) (Briese et al., 2013; Hoffmann et al., 2012a).

SBV was found to be closely related to viruses of the Simbu serogroup when it was discovered. The most similar sequences were from Shamonda virus, Aino virus and Akabane virus (AKAV), three viruses that can be found in cattle (Hoffmann et al., 2012b). None of these viruses has been detected in continental Europe: Shamonda virus has been detected in Nigeria, Japan and Korea; AKAV has been found in Australia, Japan, Korea, Israel, Saudi Arabia, Kenya, Sudan, Cyprus and Turkey; Aino virus has been found in Japan, Korea and Australia (Lievaart-Peterson et al., 2012).

In addition to reassortment (genetic shift), bunyaviruses can evolve via point mutation (genetic drift) (Briese et al., 2013). Genetic variability has been shown in SBV, with a hypervariable region in the M segment corresponding to the glycoprotein Gc (Coupeau et al., 2013; Fischer et al., 2013a; Hofmann et al., 2015; Rosseel et al., 2012). However, as yet, this variability does not correlate with the time of collection, the geographical location, or the host of the SBV strains (Fischer et al., 2013a; Hofmann et al., 2015).

2.2 Epidemiology

2.2.1 Susceptible species

EFSA has defined the species susceptible to SBV as the species in which SBV can replicate, with or without clinical signs (EFSA, 2014). ‘Receptive species’ means the same. According to EFSA, there are three categories of susceptible species to SBV:

- Species in which SBV has been detected in association with clinical signs;
- Species in which SBV has been detected (direct detection);
- Species in which antibodies against SBV have been detected (indirect detection) (EFSA, 2014).

2.2.1.1 Ruminants

In this manuscript, ‘ruminant’ is used in a broad sense, meaning any artiodactyl from the Ruminantia taxon or from the Tylopoda taxon (Camelidae).

2.2.1.1.1 Domestic ruminants

Herein are considered the usual domestic ruminants in Europe: cattle, sheep, and goats.

In all these species, direct and indirect detection of SBV and clinical signs in adults or in their offspring have been identified (van den Brom et al., 2012; Garigliany et al., 2012; Herder et al., 2012; Wernike et al., 2014a). The clinical signs will be detailed later in the manuscript (part 2.3).

2.2.1.1.2 Wild and exotic ruminants

SBV-infection has been detected in several species among wild and exotic ruminants.

Species in which SBV-RNA or antibodies have been detected are summarized in Table 1.

Table 1. Detection of SBV infection in wild and exotic ruminants from the wild or kept in captivity.

Species	Antibodies against SBV	SBV RNA	Country	Context	Reference
Alpaca (<i>Vicugna pacos</i>)	x		UK, Austria	Captive animals	(Jack et al., 2012) (Steinrigl et al., 2014)
Alpaca (<i>Vicugna pacos</i>)	x	x	Germany	Experimental infection on captive adult animals	(Schulz et al., 2013)
European bison (<i>Bison bonasus</i>)	x		Poland	Free-ranging animals	(Larska et al., 2013a) (Larska et al., 2014)
Water buffalo (<i>Bubalus bubalis</i>)	x		Turkey	Captive animals (farm)	(Azkur et al., 2013)
Red deer (<i>Cervus elaphus</i>)	x		Belgium, Italy, Poland, Austria, UK	Free-ranging wild animals	(Linden et al., 2012) (Chiari et al., 2014) (Larska et al., 2013a) (Steinrigl et al., 2014) (Barlow et al., 2013) (Larska et al., 2014)
Sika deer (<i>Cervus Nippon</i>)	x		Austria	Not specified	(Steinrigl et al., 2014)
Chamois (<i>Rupicapra rupicapra</i>)	x		Italy, Austria, Spain	Free-ranging wild animals	(Chiari et al., 2014) (Steinrigl et al., 2014) (Fernández-Aguilar et al., 2014)
Roe deer (<i>Capreolus capreolus</i>)	x		Austria, Belgium, Spain, Poland	Free-ranging wild animals	(Steinrigl et al., 2014) (Linden et al., 2012) (Fernández-Aguilar et al., 2014) (Larska et al., 2014)
Fallow deer (<i>Dama dama</i>)	x		Austria, UK, Poland	Free-ranging wild animals	(Steinrigl et al., 2014) (Barlow et al., 2013) (Larska et al., 2014)
Elk (<i>Alces alces</i>)		x	Poland	A free-ranging 6 month-old calf	(Larska et al., 2013a)
Mouflon (<i>Ovis aries musimon</i>)	x		Poland	Not specified	(Larska et al., 2014)
Llama (<i>Lama glama</i>)	x	x	Germany	Experimental infection on captive adult animals	(Schulz et al., 2013)
Llama (<i>Lama glama</i>)	x		Austria	Not specified	(Steinrigl et al., 2014)

Reindeer (<i>Rangifer</i> <i>tarandus</i>)	x	Austria	Not specified	(Steinrigl et al., 2014)
---	---	---------	---------------	--------------------------

In addition, in two zoological parks in the United Kingdom, antibodies against SBV have been detected in the following ruminant species: Bongo (*Tragelaphus eurycerus*), Banteng (*Bos javanicus*), Congo buffalo (*Syncerus caffer*), European bison (*Bison bonasus*), Gaur (*Bos gaurus*), Gemsbok (*Oryx gazelle*), Greater kudu (*Tragelaphus strepsiceros*), Moose (*Alces americanus*), Nile lechwe (*Kobus megaceros*), Pere David's deer (*Elaphurus davidianus*), Reindeer (*Rangifer tarandus*), Roan antelope (*Hippotragus equinus*), Scimitar-horned oryx (*Oryx dammah*), Sitatunga (*Tragelaphus spekii*), and Yak (*Bos mutus*) (EFSA, 2014).

In spite of detection of SBV antibodies and RNA, clinical signs related to SBV infection have not been described in these wild and exotic species.

After experimental inoculation, alpacas and llamas showed a SBV RNAemia in the 9 days post infection (dpi) without clinical signs. SBV antibodies were first detected between 9 and 21 dpi (Schulz et al., 2013). In a field study in Germany, llamas and alpacas owners did not reported clinical signs or congenital malformations (Schulz et al., 2013).

A 6 month-old elk, found alone in a national park in Poland, showed weakness, hyperthermia hyperventilation, muscle tremors, and hind limb paresis: acute pneumonia was diagnosed. It died 5 days later despite treatment. Suppurative bronchopneumonia was found at necropsy and SBV RNA was detected in the serum. Bronchopneumonia and SBV infection were probably unrelated, yet the authors speculate SBV infection could have impaired the immune response in the elk, facilitating the pneumonia (Larska et al., 2013a). However, they did not report hematological or histological abnormalities to support the latter hypothesis.

2.2.1.2 Non-ruminants

As several viruses from the genus *Orthobunyavirus* can cause disease in humans, the possibility of SBV transmission from animals to humans was one of the most important question to answer at the beginning of the epizootics. Molecular and serological testing have been performed on exposed populations in Germany and in the Netherlands. SBV RNA and antibodies against SBV were not detected (Ducombe et al., 2012; Reusken et al., 2012). The

public health risk for SBV was concluded to be ‘absent or extremely low’ (Reusken et al., 2012).

In two zoological parks in the United Kingdom, antibodies against SBV have been detected in Onager (*Equus hemionus*) and Grevy’s zebra (*Equus grevyi*). However, SBV RNA has not been detected in samples from horse (*Equus caballus*) offspring tested in the Netherlands (EFSA, 2013).

Antibodies against SBV have been found in free-ranging wild boar (*Sus scrofa*) in Belgium (Desmecht et al., 2013). After SBV experimental infection, domestic pigs seroconverted but did not show clinical signs or SBV RNAemia (Poskin et al., 2014a), suggesting they are receptive to SBV though they do not develop disease.

SBV infection can occur in dogs, albeit few cases have been reported. In Sweden, antibodies against SBV have been found in one dog (Wensman et al., 2013). In France, SBV RNA was found in the brain of a puppy showing torticollis and degenerative encephalopathy while antibodies against SBV were detected in the mother (Sailleau et al., 2013a) (cf. appendix). Nevertheless, in Belgium, a serologic survey did not detect any positive sample in 132 dogs (Garigliany et al., 2013). SBV infection is probably a rare event in dogs.

Finally, a mouse model of infection has been developed with the type I Interferon receptor knock-out (IFNAR^{-/-}) mice. After experimental subcutaneous inoculation, SBV RNA was found in blood and organs; the mice lose weight and some died. Thus, this mouse strain is susceptible to SBV infection (Wernike et al., 2012a).

2.2.2 Transmission

2.2.2.1 Vectors

SBV is an arbovirus, which is “a virus which in nature can infect hematophagous arthropods by their ingestion of infected vertebrate blood. It multiplies in the arthropod’s tissues and is transmitted by bite to other susceptible vertebrates” (Mellor, 2000).

Biting midges, small blood-sucking insects of the genus *Culicoides*, are the putative vectors for SBV. Their life cycle include eggs, larvae (four larval instars), pupa and adults (Carpenter et al., 2013). The midges are usually active from April to October in the United Kingdom

(Tarlinton et al., 2012). The species in which SBV RNA has been found in Europe are *C. obsoletus* complex (i.e. *C. obsoletus* sensu stricto and *C. scoticus*), *C. dewulfi* and *C. chiopterus* (Elbers et al., 2013a, 2013b; Goffredo et al., 2013; Rasmussen et al., 2012, 2014; De Regge et al., 2012). *C. punctatus* and *C. nubeculosus* may be involved as well (Balenghien et al., 2014; Larska et al., 2013b).

Vector competence has not been established under laboratory conditions for any of the aforementioned species, except for *C. scoticus*, because these species are hard to feed and to breed in the laboratory (Balenghien et al., 2014; Veronesi et al., 2013). Nevertheless, competence may be inferred from field data by two methods:

- By dissecting midges and performing SBV RT-qPCR on heads only: detection of SBV RNA in the head means the salivary glands are infected (De Regge et al., 2012);
- By analysis of the distribution of Cq-values after SBV RT-qPCR: a recent study showed a bimodal distribution of Cq-values indicated the ability for a species to be a vector (Veronesi et al., 2013).

Both methods have confirmed the vector competence of midges of the *C. obsoletus* complex, *C. dewulfi* and *C. chiopterus* (De Regge et al., 2012, 2014). These species belong to the subgenus *Avaritia*, known to breed on dung (Lühken et al., 2014) and bog land (Koenraad et al., 2014).

A few studies have been carried out to elucidate the role of mosquitoes in SBV transmission. No SBV RNA was found in 50,000 mosquitoes trapped in Germany in 2011 (Wernike et al., 2014b). Experimental oral infection of *Aedes albopictus* and *Culex pipiens* mosquitoes did not result in SBV replication to transmissible levels, suggesting these two species are unlikely to be true vectors of SBV (Balenghien et al., 2014).

The role of other arthropods as SBV vectors has not been explored.

2.2.2.2 Vertical transmission in ruminants

SBV can be transmitted vertically from the pregnant female to its offspring. Congenital malformations associated to SBV RNA have been found in newborns, stillborn or aborted animals in sheep, cattle, and goats (van den Brom et al., 2012; Garigliany et al., 2012; Herder et al., 2012). Vertical transmission in other species has not been reported.

2.2.2.3 Horizontal transmission in ruminants

SBV RNA has been detected in fecal, oral and nasal swabs in subcutaneously-inoculated cows (Wernike et al., 2013a). Nevertheless, direct transmission of SBV from an infected ruminant to a naïve one by contact or by oral or nasal route is unlikely. Indeed, oral inoculation to cattle and nasal inoculation to sheep failed to produce RNAemia (Martinelle et al., 2015; Wernike et al., 2013a). Moreover, naïve cows in contact with viremic cows for 24 days did not show RNAemia and remained seronegative, as determined by SBV-specific ELISA (Wernike et al., 2012b).

Whether SBV can be sexually transmitted is still unknown. Bulls can excrete SBV in their semen, as shown by detection of infectious SBV in a few bovine semen samples from the field (Hoffmann et al., 2013; Ponsart et al., 2014; Schulz et al., 2014). However, the ability of the female to be infected by the vaginal route during artificial insemination or natural service has not been assessed. This topic deserves interest, as cows have been successfully infected with AKAV by uterine route at the time of artificial insemination (Parsonson et al., 1981a).

2.2.2.4 Overwintering

In May 2012 in France, eight months after the likely introduction date of SBV in the country (Zanella et al., 2013), evidence of acute infection was found in cows in France, suggesting SBV could overwinter or was reintroduced (Sailleau et al., 2013b). SBV overwintering was confirmed in Germany after acute infections that occurred in summer and fall 2012 (Conraths et al., 2013). SBV has then overwintered in 2013 and 2014, with new cases or SBV RNA detection being reported each vector season (Wernike et al., 2015).

Several mechanisms could account for SBV overwintering. First, SBV may persist in its host: it seems unlikely at least in domestic ruminants, because viremia appeared to be short-lasting in adults (Hoffmann et al., 2012b) and SBV RNA is not often detected in malformed newborns (Bouwstra et al., 2013; De Regge et al., 2013). Characteristics of viremia in most of the susceptible wild or exotic ruminants remain unknown. Second, transovarial transmission of the virus in the vector might be involved in overwintering: one study reported SBV RNA in nulliparous females of *C. obsoletus* complex and *C. punctatus* (Larska et al., 2013b). Third, SBV may persist in adult midges during winter, as postulated for African Horse Sickness

Virus (Mellor, 2000). Adult midges of the *C. obsoletus* complex are able to survive, without blood meal, for 10 days at 4°C and up to 92 days at temperatures between 17°C and 25°C (Goffredo et al., 2004). As *C. obsoletus* midges have the ability to live indoors (endophagy) (Koenraad et al., 2014), infected midges could thus survive in the coldest months in barns and infect vertebrates once the temperature rises. This hypothesis is supported by evidence of transmission of SBV to cattle in winter 2013 in Germany, after a rise in temperature above 5°C for a few days (Wernike et al., 2013b). Finally, as yet unidentified vectors could play a role in SBV transmission and overwintering.

2.2.3 Geographical repartition

From Germany, the Netherlands, and Belgium, where it was initially detected in 2011, SBV has then spread quickly to other European countries along the four cardinal directions (Figure 3) (Afonso et al., 2014), up to 320 km from the northern polar circle in Sweden (Chenais et al., 2013).

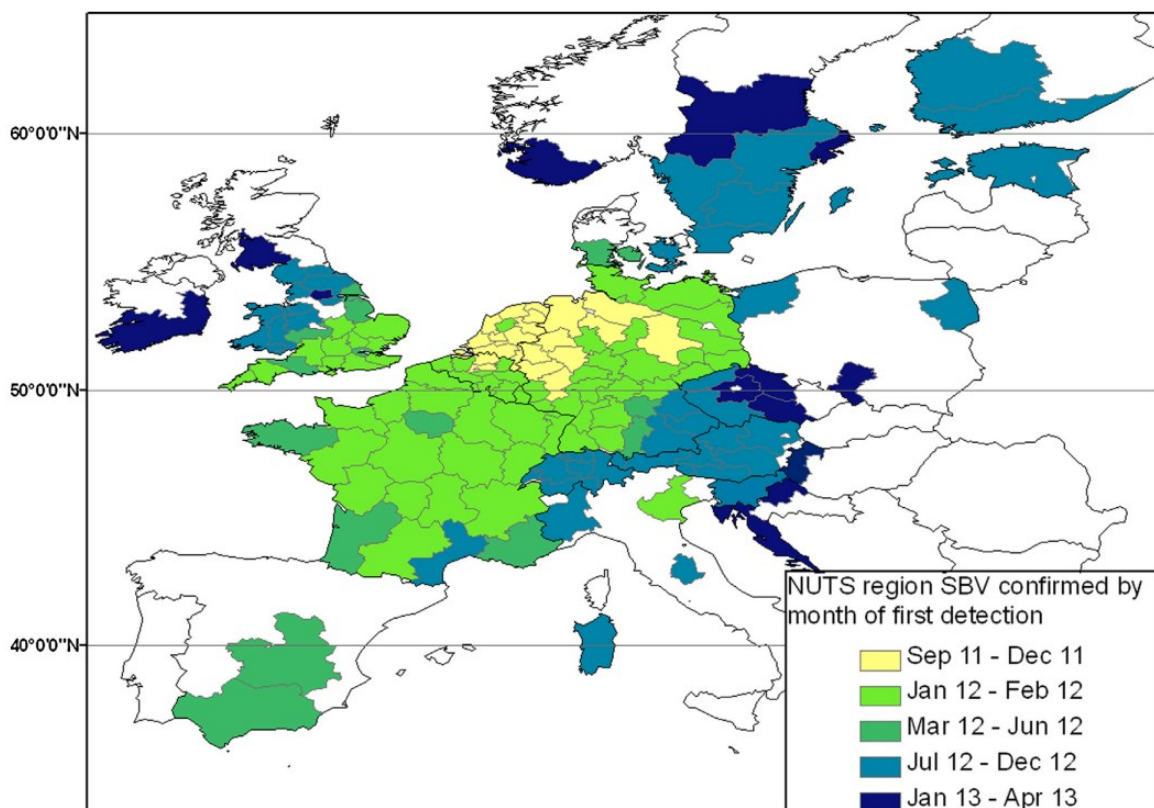


Figure 3. Regions (NUTS2) with at least one SBV herd confirmed by direct detection by period of first report (Afonso et al., 2014).

NUTS: Nomenclature of territorial units for statistics

In addition, antibodies against SBV have been found in 2013 in cows in Lithuania (Lazutka et al., 2014), and in cows and sheep in Greece (Chaintoutis et al., 2014), demonstrating presence of SBV in these countries.

Outside of Europe, in Turkey, SBV RNA was detected in aborted cattle and sheep fetuses in June 2012 (Yilmaz et al., 2014), suggesting a spread from northern Europe to Turkey. In this country antibodies to SBV have been found by ELISA in samples collected before 2011 (Azkur et al., 2013); however viral neutralization was not performed, thus cross-reactivity with other viruses from the Simbu serogroup cannot be excluded.

Finally, SBV might be circulating in Africa. Antibodies to SBV have been detected by ELISA in cattle, sheep and goats in Mozambique, in 2013; yet, the possibility of cross-reactivity with other viruses from the Simbu serogroup precludes a definitive conclusion (Blomström et al., 2014). Lesions retrospectively consistent with SBV infection have been found in sheep offspring in South Africa in 2006 and 2008, but tests specific for SBV detection were not available at this time (Leask et al., 2013).

2.2.4 Risk factors

The risk of SBV infection seems to differ among ruminant species. In wildlife, SBV seroprevalence was higher in heavy wild ruminants than in light wild ruminants in Poland in 2013 (Larska et al., 2014). Regarding domestic ruminants, within-herd prevalence was found to be lower in sheep than in cattle, in Germany (Helmer et al., 2015). In addition, goats have been shown to have a lower risk of SBV infection than sheep in Germany (Helmer et al., 2015).

These differences can be a consequence of intrinsic differences in susceptibility of these species to SBV. Experimentally, cattle needs a lower SBV infectious dose than sheep to be successfully infected (Poskin et al., 2014b; Wernike et al., 2012b).

Alternatively, the differences between species may depend on their difference of exposure to midges. *Culicoides* spp. find their hosts after their odor (Koenraadt et al., 2014) and have developed host preferences. Cattle was found to be more attractive than sheep for midges of the *C. obsoletus* complex in Germany (Ayllón et al., 2014). Housing conditions may also facilitate exposure of some species to midges. Indeed, the moist cesspool under slatted floors

in cow barns may offer breeding sites for *Culicoides* spp. while sheep barns display most often deep litter, which may not favor midges larval development (Helmer et al., 2015).

For a given species, breeding conditions are also a risk factor for SBV infection. Indoor dairy cow herds showed lower SBV seroprevalence of SBV than outdoor herds, probably due lower midge exposure of cattle kept indoors (Tarlinton and Daly, 2013; Veldhuis et al., 2014a). The housing conditions were also found to influence seroprevalence in goats, with the outdoor herds tending to have a higher within-herd seroprevalence in France and in Germany (Helmer et al., 2013; Valas et al., 2014).

Other factors have been found to influence the probability of domestic ruminants from a farm to be infected by SBV. According to a study in the Netherlands, presence of one or more dogs in the farm, on the one hand, and purchase of silage, on the other hand, were found to be associated with an increased odd of malformations in newborn lambs (Luttikholt et al., 2014). As shown previously, dogs may be infected by SBV but viremia in this species has not been characterized, thus their role in SBV dissemination is still unknown. The biological link between the purchase of silage and SBV-associated malformations remains unclear.

2.3 Clinical signs and lesions in affected animals

In this section, the clinical signs and lesions associated with SBV infection in domestic ruminants will be described and compared with those involving two other members of the genus *Orthobunyavirus* that infect domestic ruminants: AKAV and Cache Valley virus (CVV).

2.3.1 Non-pregnant adults

2.3.1.1 Clinical signs

At first, SBV infection was discovered in non-pregnant dairy cows in Germany. It was responsible for short-lasting non-specific clinical signs, namely fever, decreased milk production, and diarrhea (Hoffmann et al., 2012b). One report suggests that goats infected by SBV may also experience diarrhea and reduction in milk yield (Helmer et al., 2013). Fever, diarrhea and decreased milk production have been sometimes reported in sheep from the field, without an obvious causal link with SBV infection (Lievaart-Peterson et al., 2012; Luttkholt et al., 2014).

Likewise, AKAV infection can result in subclinical disease in adult ruminants (Spickler, 2009) and in a drop of milk production in dairy cows (Horikita et al., 2005). However, more severe clinical signs have been reported in adult cattle. In 2000 and 2010 in Korea, outbreaks of neurological signs associated with AKAV infection occurred in 2 to 7 years-old and in 4 to 72 months-old cows, respectively. The clinical signs included hypersensitivity, tremors, locomotor ataxia, and lameness (Lee et al., 2002; Oem et al., 2012). No clinical signs have been reported in association with CVV infection in adult ruminants.

2.3.1.2 Lesions

No lesions have been described in association with SBV infection in non-pregnant adult ruminants in the field.

During the outbreak of neurological signs associated with AKAV infection in Korea in 2000 in adult cows, 5 affected cows were slaughtered and submitted to post-mortem examination. They were devoid of gross lesions, but histological examination revealed similar lesions in their brains and spinal cords. The brain, especially the pons and medulla oblongata, was characterized by moderate to severe perivascular infiltrations of lymphocytes, macrophages, and plasma cells with multifocal gliosis and neuronal necrosis. In the spinal cord, similar lesions were found in the ventral horns with lymphohistiocytic perivascular cuffing, gliosis, and neuronal necrosis and loss. Overall, these lesions corresponded to a non-suppurative encephalomyelitis (Lee et al., 2002).

Phylogenetic analyses showed the AKAV strain responsible for this Korean outbreak was closely related to Iriki strain, an AKAV strain that has been associated earlier with encephalitis in adult cattle in Japan (Oem et al., 2012). Despite the absence of lesions in adults associated with SBV infection, up to now, we cannot exclude that new strains with the ability to trigger encephalitis in adults may emerge in the future.

2.3.2 Pregnant females and their offspring

After discovery of SBV in non-pregnant adult cows in Germany, epizootics of congenital malformations were reported in sheep in the Netherlands. They were associated in about half of the cases with detection of SBV RNA in the brains from the affected newborns (van den Brom et al., 2012), showing the ability of SBV to cross the placenta in pregnant ewes and to cause lesions in the growing embryo or fetus.

2.3.2.1 *Clinical signs in pregnant females and in newborns*

At parturition, pregnant females infected by SBV can show clinical signs of dystocia when their offspring is malformed (van den Brom et al., 2012). During pregnancy, there are several lines of evidence SBV could be associated with embryonic or fetal death and abortion. In flocks affected by SBV, increased numbers of repeat breeders and increased rate of abortions suggest early embryonic or fetal loss and abortions in ewes (Dominguez et al., 2014; Lievaart-

Peterson et al., 2012; Luttkiholt et al., 2014; Saegerman et al., 2014) and goats (Dominguez et al., 2014; Helmer et al., 2013). In cattle flocks affected by SBV, increased numbers of repeat breeders and of early embryonic deaths have been reported as well (Dominguez et al., 2014). All the aforementioned data come from retrospective studies. In addition, one report describes an association between early fetal death (around 60 days of gestation (dg)) in two cows and SBV genome in the corresponding allantoic fluids (Steinrigl et al., 2014).

The birth of both one malformed and one healthy offspring has been described in SBV-infected cattle (Wernike et al., 2014c) and sheep (van den Brom et al., 2012). In the affected sheep flocks, the lambs were either malformed, dummy with inability to suckle or normal (van den Brom et al., 2012). Neurological signs have also been described in a newborn calf infected in utero by SBV: hypertonicity, hyperreflexia, depression, blindness, ventrolateral strabismus, and inability to stand (Garigliany et al., 2012). These neurological signs are suggestive of SBV-induced lesions in the central nervous system (CNS).

During an outbreak of AKAV infection of pregnant cows in Japan in 1973-1974, a succession of different clinical signs were noticed. Abortions, stillbirths, premature births and neonatal deaths were seen at the beginning of the outbreak. Then, the newborn calves were alive but displayed musculoskeletal malformations as torticollis and arthrogryposis. At the end of the outbreak, the newborn calves showed blindness or tongue paralysis (Konno et al., 1982).

Similarly, infection of sheep with CVV in the field was associated with stillbirths, mummified fetuses, malformed fetuses or newborns, and weak lambs as well (Edwards et al., 1989).

2.3.2.2 Lesions in fetuses and newborns

A wide range of lesions have been described in fetuses and newborns with proven or presumptive infection by SBV during gestation (Table 2). The most common lesions affect the skeletal muscle, the CNS and the axial skeleton; they can occur together in combination (Herder et al., 2012; Peperkamp et al., 2014; Seehusen et al., 2014). The animals may show arthrogryposis (Figure 4) associated with histological evidence of muscular hypoplasia (Figure 4), characterized by a reduction in number and diameter of the myofibrils, with or without loss of cross-striation in myofibrils and fatty replacement (Herder et al., 2012; Seehusen et al., 2014). In the CNS, the most common lesions are hydranencephaly, porencephaly, hydrocephalus, cerebellar hypoplasia and micromyelia (Figure 4); they are

sometimes associated with nonsuppurative inflammation and neuronal degeneration and necrosis (Figure 4). The animals often display vertebral malformations, including lordosis, kyphosis, scoliosis, and torticollis, and may show brachygnathism inferior (Figure 4) (Herder et al., 2012).

Table 2. Lesions in fetuses and newborns associated with spontaneous SBV infection in domestic ruminants.

	Gross lesions	Histological lesions	Ref.
Bovine	Porencephaly, hydrocephalus, hydranencephaly, brain stem hypoplasia, cerebellar hypoplasia, cerebellar dysplasia, micromyelia, arthrogryposis, torticollis, lordosis, scoliosis, kyphosis, cranial malformations, brachygnathism inferior, prognathism, ectopia cordis, lung hypoplasia, ventricular septal defect	Non-suppurative meningoencephalitis, non-suppurative poliomyelitis, skeletal muscle hypoplasia, lymphoid depletion in thymus and lymph node, chronic hepatitis	(Garigliany et al., 2012) (Peperkamp et al., 2012) (Herder et al., 2012) (Seehusen et al., 2014) (Peperkamp et al., 2014) (Bayrou et al., 2014)
Ovine	Arthrogryposis, torticollis, lordosis, scoliosis, kyphosis, brachygnathism inferior, domed skull, flattened skull, hydranencephaly, hydrocephalus, micrencephaly, macrocephaly, brainstem hypoplasia, cerebral hypoplasia, cerebellar hypoplasia, cerebellar dysplasia, micromyelia, cardiac ventricular septal defect, unilateral hydronephrosis, colonic atresia	Non-suppurative meningoencephalitis, skeletal muscle hypoplasia, lymphoid depletion in spleen or lymph node, cataract, decreased hematopoietic cellularity in bone marrow	(van den Brom et al., 2012) (Herder et al., 2012) (Peperkamp et al., 2014)
Caprine	Arthrogryposis, vertebral deformities, brachygnathism inferior, hydrocephalus, porencephaly, cerebellar hypoplasia, lung hypoplasia	Non-suppurative meningoencephalitis, non-suppurative poliomyelitis	(Herder et al., 2012) (Wagner et al., 2014)

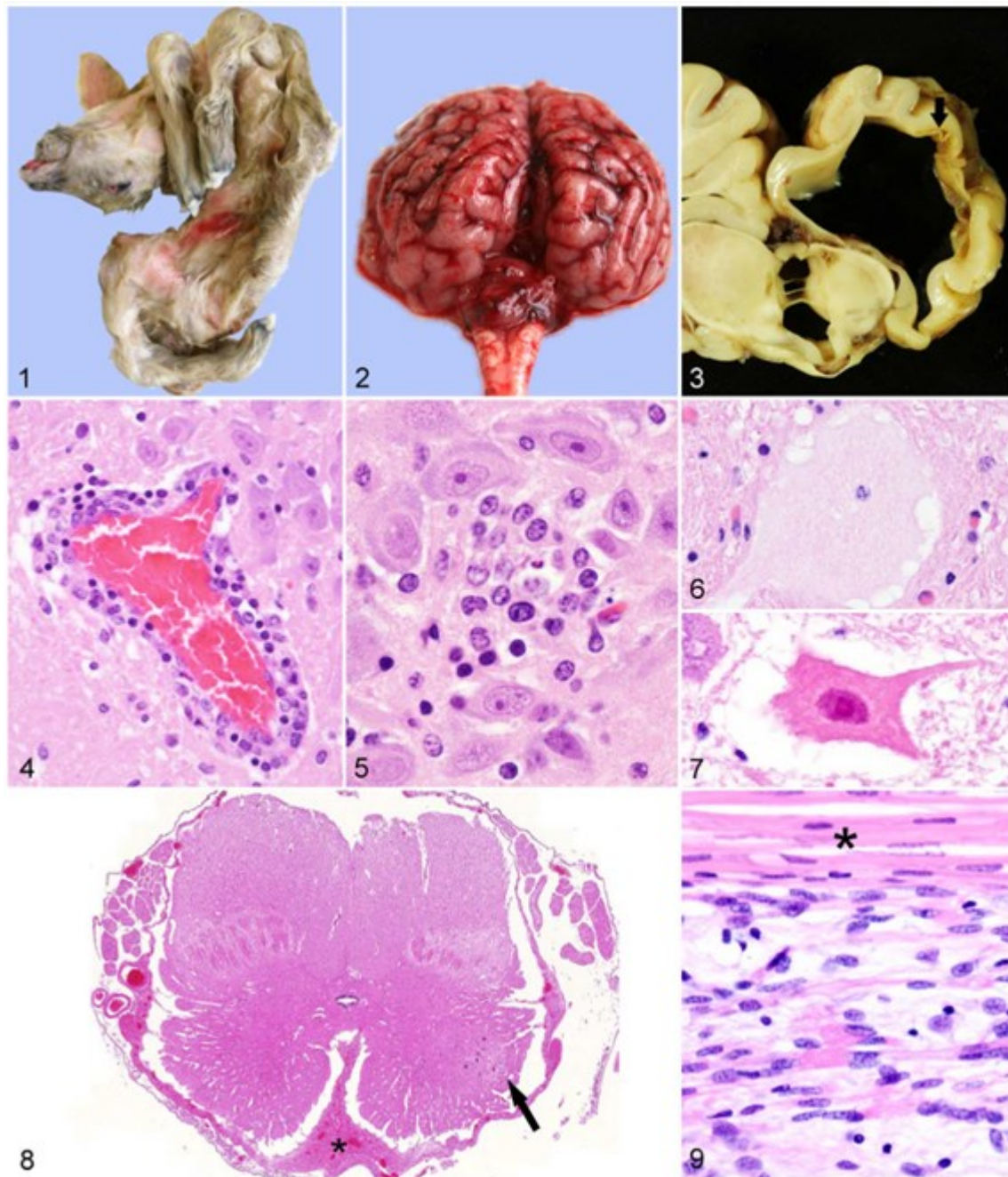


Figure 4. Gross and histological lesions from SBV-infected fetuses (Herder et al., 2012).

(1) Aborted ovine fetus with arthrogryposis, torticollis, and brachygnathism inferior. (2) Cerebellar hypoplasia in a bovine fetus. (3) Brain from a bovine fetus. Hydrocephalus and porencephaly (arrow) in the adjacent cerebral parenchyma. (4) Brain; goat. Perivascular lymphocytes and macrophages. Hematoxylin-Eosin (HE). (5) Brain; goat. Glial nodule of microglia/macrophages. HE. (6) Brain; sheep. Chromatolysis, with dispersion of Nissl substance, swelling, and homogeneous cytoplasmic eosinophilia of a neuron. HE. (7) Brain; calf. Hyper eosinophilic, necrotic neuron. HE. (8) Cervical spinal cord; calf. Micromyelia with severe reduction of gray matter and few neurons in one ventral horn (arrow). Ventral meningeal fibrosis (asterisk). HE. (9) Skeletal muscle; sheep. Myofibrillar hypoplasia with few residual normal muscle fibers (asterisk). HE.

The nature of the musculoskeletal and nervous lesions associated with SBV are similar in cattle and sheep. Still, the severity of the CNS lesions may be higher in lambs than in calves

(Peperkamp et al., 2014). The lesions have not been as extensively described in goats as in cattle and sheep.

Gross and histological lesions associated with AKAV infection in domestic ruminants are very similar to those described above for SBV. They are detailed in Table 3. The CNS, the skeletal muscle and the axial skeleton are again the most affected systems.

Table 3. Lesions in fetuses and newborns associated with AKAV infection in domestic ruminants.

	Context	Gross lesions	Histological lesions	Ref.
Bovine	<i>Spontaneous infection</i>	Arthrogryposis, scoliosis, kyphosis, lordosis, torticollis, porencephaly, hydranencephaly	Muscle hypoplasia or atrophy, decrease in the number of neurons in the ventral horns in the spinal cord, nonsuppurative encephalomyelitis, retinal atrophy	(Konno et al., 1982) (Ushigusa et al., 2000)
	<i>Experimental infection</i>	Same as above (normal fetuses were also found)	Muscle degeneration and atrophy, decrease in the number of neurons in the ventral horns in the spinal cord, suppurative meningoencephalitis, cerebellar dysplasia	(Kirkland et al., 1988)
Ovine	<i>Experimental infection</i>	Arthrogryposis, scoliosis, kyphosis, lordosis, torticollis, porencephaly, hydranencephaly, dwarfism, brachygnathism inferior, micrencephaly, lung hypoplasia (normal fetuses were also found)	Muscle atrophy and degeneration, myelitis and/or neuronal loss in the ventral horns in the spinal cord, meningoencephalitis and/or cysts and malacia in the brain, subependymal rosettes in the brain, thymic depletion	(Hashiguchi et al., 1979) (Parsonson et al., 1977) (Parsonson et al., 1981b) (Narita et al., 1979)
Caprine	<i>Experimental infection</i>	Arthrogryposis, scoliosis, torticollis, hydranencephaly	Degeneration and necrosis in skeletal muscle and/or myositis, non-suppurative encephalitis	(Kurogi et al., 1977) (Konno and Nakagawa, 1982)

Likewise, the lesions described in the offspring of SBV-infected sheep in the field include lesions of the skeletal muscle (arthrogryposis with skeletal muscle hypoplasia), of the CNS (hydrocephalus, hydranencephaly, micrencephaly, cerebellar hypoplasia, micromyelia with loss of motor neurons, porencephaly), and spinal column deformities (Edwards et al., 1989).

In addition, oligohydramnios, i.e. the close apposition of the amniotic membrane to the fetal body, was described after experimental in utero inoculation of CVV to pregnant ewes at 35 dg (Hoffmann et al., 2012a). The latter lesion may however rely upon the route of inoculation.

2.3.3 Hypotheses on the pathogenesis of the lesions in fetuses and newborns

Previous works on CVV and AKAV have brought pieces of information about the pathogenesis of the viral-induced lesions. Given that SBV is phylogenetically close to these viruses and causes very similar clinical signs and lesions, it is likely they are involved in common mechanisms of disease. By analogy with these virus, it is thus possible to formulate hypotheses regarding the pathogenesis of the lesions induced by SBV.

2.3.3.1 *Factors influencing the development of lesions in fetuses and newborns*

From the literature, both the age of the conceptus (i.e., the embryo or fetus with its placenta) and the inoculum have an impact on the development of lesions in fetuses and newborns.

2.3.3.1.1 *Influence of the age of the conceptus at the time of infection*

In cattle, an experimental infection with AKAV showed a sequential development of lesions depending on the stage of pregnancy at which the cow was infected. Hydranencephaly and porencephaly developed in fetuses after infection between 76 and 104 dg. Arthrogyriposis developed in fetuses infected later, when infection took place between 103 and 174 dg. No lesions were found in fetuses born from cows infected before 76 dg (Kirkland et al., 1988). As the authors suggested, the absence of fetal lesions before 76 dg may be explained by immaturity of the placentomes until this day, with subsequent isolation and protection of the conceptus from the virus (Kirkland et al., 1988). However, they could not monitor the early embryonic development, thus they could not exclude embryonic mortality when infection took place before 76 dg (Kirkland et al., 1988).

Similarly, in sheep, the lesions that developed seem to depend on the age of the conceptus at the time of infection with AKAV. A study from Japan showed that, when experimental

infection occurred between 29 and 45 dg, newborns displayed arthrogryposis and hydranencephaly. After inoculation between 30 and 70 dg, abnormal newborns were either weak, with or without porencephaly, or dwarf; there were also stillborn lambs. However, if the inoculation took place between 90 and 100 dg, all the newborns were normal (Hashiguchi et al., 1979). Another experimental infection of pregnant ewes with AKAV showed that brain lesions (necrosis and gliosis) could still occur after inoculation at 90 dg (Narita et al., 1979).

One study showed that the ovine fetuses infected transplacentally could produce neutralizing antibodies against AKAV as soon as 64 dg (Hashiguchi et al., 1979). The development of the immune system in the fetus may inhibit viral progression and subsequent lesions; therefore it may be one reason for the lack of lesions at late stages of gestation. However, the immune system activity may not be the only factor responsible for this lack of lesions. An experimental inoculation of AKAV intraperitoneally in ovine fetuses at 120 dg resulted in a strong immune response, yet the fetuses showed damage in brain and skeletal muscle (McClure et al., 1988). The authors suggested that the stage of maturity of the target-organs may be of greater importance in determining its susceptibility to virus-induced damage than the fetal immune response (McClure et al., 1988).

The susceptibility window of goat fetuses to AKAV infection has been partially described. An experimental infection of a pregnant goat by AKAV at 40 dg resulted in one malformed fetus but a normal twin fetus. The malformed fetus displayed hydranencephaly, arthrogryposis, scoliosis, and torticollis (Kurogi et al., 1977). Another experimental infection at 30 and 60 dg led to degeneration and necrosis in the skeletal muscle and/or myositis in all fetuses at 10 dpi. Only the fetuses infected at 60 dg showed also non-suppurative encephalitis (Konno and Nakagawa, 1982).

In summary, the susceptibility of the growing embryo or fetus to AKAV infection may depend on:

- The maturity of the placentomes: if the infection of the pregnant female takes place before maturity; the conceptus may be protected from viral invasion;
- The stage of maturity of the target-organs: with increasing maturity, the target organs may be no more susceptible to the virus;

- The stage of development of the fetal immune system: with increasing development, the immune system could inhibit the progression of the virus and the virus-induced damage.

By analogy with AKAV, hypotheses can be drawn on the effects of SBV infection in pregnant females depending on the stage of gestation. Figure 5 shows the putative consequences of SBV infection in pregnant ewes and goats.




Figure 5. Hypothetic consequences of SBV infection in pregnant goats and ewes depending on the stage of gestation.

By analogy with data from experimental infection with AKAV (Hashiguchi et al., 1979; Konno and Nakagawa, 1982; Narita et al., 1979). AI: artificial insemination; CNS: central nervous system; dg: day of gestation; SKM: skeletal muscle.

2.3.3.1.2 Influence of the inoculum

Several teams have performed AKAV inoculations in pregnant ewes and their results sometimes differed. As an example, one study showed that lesions in fetuses occurred only if the inoculation had taken place between 30 and 36 dg but not between 38 and 82 dg (Parsonson et al., 1977), while another study showed fetal lesions after inoculation between 29 and 70 dg (Hashiguchi et al., 1979). In these cases, the protocols were similar regarding the route of inoculation (intravenous), but they differed in the strains used as well as in the number of passages and the host species used for passage. The authors of the second study hypothesize that the difference in results could rely upon the difference in virulence between the two inocula, depending on the viral strain and the history of passages (Hashiguchi et al.,

1979). Moreover, the viral load of the inoculum could also exert an influence on the severity of the damage in fetal tissues.

2.3.3.2 Mechanisms involved in the development of lesions at the tissue level

2.3.3.2.1 Microscopic lesions and correlation with tissular and cellular tropism

In one study, pregnant ewes were inoculated at 35 dg with CVV and were sequentially slaughtered between 42 and 63 dg. The results suggest two hypotheses about the mechanism of lesion formation.

First, this study shows a progression of the microscopic lesions in the fetuses along with the course of infection between 7 and 28 dpi. Between 7 and 10 dpi, the brain displayed necrosis in matrix and intermediate zones of the cerebral cortex and brainstem; necrosis was also noticed in the dorsal horns of the spinal cord and in the skeletal muscle, without vascular lesions. At 14 dpi, hydrocephalus *ex vacuo* was noticed, and myositis with mononuclear cells and granulocytes was seen in skeletal muscle. Then, between 21 dpi and 28 dpi, the histological lesions were hydrocephalus *ex vacuo*, myositis with muscle hypoplasia, and micromyelia (Hoffmann et al., 2012a). This sequential progression suggests that hydrocephalus *ex vacuo*, and probably hydranencephaly, proceed from necrosis of progenitor cells in the brain.

Second, the microscopic lesions were associated with the presence of CVV in the affected tissues, i.e. the skeletal muscle and the CNS. Viral RNA and antigen, as determined by ISH and IHC, were associated with necrotic foci in muscle, brain and spinal cord. The target cells were progenitor cells in the periventricular area in the brain, and myofibers in the muscle; positive cells were also found in the spinal cord but their nature was not identified (Hoffmann et al., 2012a). This association between lesions, viral RNA and viral antigen are suggestive of a direct effect of the virus in the aforementioned tissues.

The pathogenesis of skeletal muscle hypoplasia (and the associated arthrogryposis) is a matter of debate. In calves with arthrogryposis, a relationship has been described between the lesions observed in spinal cord and the side(s) affected by arthrogryposis: bilateral depletion of the ventral horn neurons was associated to bilateral arthrogryposis while unilateral depletion of

these neurons was associated to unilateral arthrogryposis (Kirkland et al., 1988). Depletion of ventral horn neurons has also been described in SBV-infected animals (Herder et al., 2012); as a consequence denervation may occur in skeletal muscle, followed by failure of muscle development (Seehusen et al., 2014).

However, muscular lesions have been found in fetuses devoid of spinal cord lesions. Ten days after intravenous inoculation of AKAV to pregnant goats at 60 dg, fetuses displayed degeneration and necrosis in skeletal muscle, but no lesions were observed in spinal cord (Konno and Nakagawa, 1982). These results suggests that AKAV may directly damage skeletal muscle.

Finally, the muscular hypoplasia could result both from damage to the myofibers as well as from motor neuron loss, as hypothesized for CVV (Hoffmann et al., 2012a).

2.3.3.2.2 Insights in cellular and molecular consequences of SBV infection

To study the pathogenesis of SBV in the brain, a mouse model of SBV infection was developed with NIH-Swiss mice. Intracerebral inoculation resulted in death and severe brain lesions with malacia and hemorrhage in the cerebral cortex, multifocal vacuolation in the white matter of the cerebrum, as well as lymphocytic perivascular cuffing in the grey matter. These lesions were associated with SBV antigen in neurons (Varela et al., 2013), which is in favor of a direct role for SBV in inducing this range of lesions. In addition, activated caspase-3 staining in the brain has been later associated with SBV intracerebral infection of NIH-Swiss mice (Barry et al., 2014), suggesting apoptosis may be one mechanism leading to the SBV-induced degenerative lesions in the brain.

To explore whether the viral protein NSs of SBV was a virulence factor, a NSs deletion mutant (SBV Δ NSs) was produced by reverse genetics. Its virulence was then tested in NIH-Swiss mice by intracerebral inoculation. The SBV Δ NSs showed an attenuated phenotype, characterized by a delay in the time of mice death in comparison to the wild type SBV. This defined SBV NSs as virulence factor (Varela et al., 2013).

In vitro, SBV Δ NSs was able to induce the production of IFN in several cell lines while wild type SBV was not, showing that SBV NSs inhibits the IFN response of the host (Varela et al., 2013). SBV NSs has also the ability to induce the degradation of the RPB1 subunit of RNA polymerase II in vitro, thus inhibiting transcription and protein synthesis. The inhibition of the

IFN response may be a consequence of this global inhibition of transcription (Barry et al., 2014). Besides, a transcriptomic study showed that, *in vitro*, SBV NSs elicits a shutdown in the expression of genes involved in innate immunity. Nevertheless, this shutdown is incomplete as a few antiviral genes were still induced during SBV infection (Blomström et al., 2015).

SBV NSs is also able to enhance the rate of apoptotic cell death *in vitro* (Barry et al., 2014).

In domestic ruminants, SBV is responsible for a range of clinical signs and lesions that are similar to those found in association with CVV and AKAV. By analogy with these extensively-studied viruses, we could develop working hypotheses on the pathogenesis of the lesions that will be discussed along with the corresponding experiments later in the manuscript. Results from recent *in vitro* and *in vivo* studies of SBV brought additional pieces of information on the consequences of SBV infection at the cellular and molecular level.

2.4 Impact on livestock farming, on wild ruminants

The impact of SBV epizootics on livestock have been evaluated through several studies. A SBV-affected herd was defined as a herd with malformed offspring with laboratory confirmation of SBV infection (Dominguez et al., 2014; Harris et al., 2014; Saegerman et al., 2014); or as a herd with clinical signs in adult cattle or malformed newborns consistent with SBV infection (Veldhuis et al., 2014a); or as a herd with clinical signs in adult cattle or malformed newborns and laboratory confirmation of SBV infection (Afonso et al., 2014). One study compared farms which had sent samples to laboratories for SBV testing versus farms which had not send samples for SBV testing (Poskin et al., 2015).

SBV impact in infected herds originated mainly from stillbirth or malformations in fetuses and neonates (Dominguez et al., 2014; Poskin et al., 2015; Raboisson et al., 2014). This affected offspring could not be bred and sold, leading to money loss. As an example, in beef suckler farms, SBV impact has been estimated to reach 26€ to 43€ per cow per year in France and 29€ to 36€ per cow per year in the United Kingdom (Raboisson et al., 2014). Besides, emotional impact has been reported in sheep farmers, due to the sight of malformations and to the stress raised by this new disease (Harris et al., 2014).

The impact on adults was evaluated as limited, resulting mainly from dystocia in sheep and cattle (Poskin et al., 2015) and from milk loss in dairy cattle (Veldhuis et al., 2014a). In the Netherlands, in dairy cattle from SBV-affected herds, the average milk loss was 1.71kg per day per cow in the four weeks defined as SBV-infection period in August and September 2011 (Veldhuis et al., 2014a). Impact on fertility was not evaluated in every study. In dairy cattle, fertility parameters showed a slight reduction in SBV-affected herds in Germany and the Netherlands in 2011 (Veldhuis et al., 2014b). In 2012, in SBV-affected farms, a 2-fold reduction in prolificacy was observed in ewes in Belgium (Saegerman et al., 2014) while goat and sheep farmers reported more frequent repeated estrus or early embryonic deaths in France (Dominguez et al., 2014).

Between species, morbidity and malformation rates associated to SBV infection differed, as shown in Table 4. In SBV-affected herds in France in 2012-2013, the median frequency of

offspring morbidity (stillbirth or malformation) was significantly higher in lambs than in calves or kids (Dominguez et al., 2014). Considering SBV impact as resulting mainly of affected offspring, SBV impact has therefore been higher in sheep farms than in goat or cattle farms.

Table 4. Impact of SBV infection in domestic ruminants in Europe and France, by species.

Context of the study	Reference		Cattle	Goats	Sheep
Europe, August 2011- April 2013	(Afonso et al., 2014)	Confirmed herds	5,281	136	2,917
		Herds with AHS observed	89%	91%	93%
		Herds with AHS observed > 1	0.34%	0.00%	5.15%
		Herds with acute infection in adults	6%	1%	3%
France, 2012-2013	(Dominguez et al., 2014)	Dead or deformed offspring in affected herds (mean ± std dev)	7.1% ±18.4%	4.8% ±27.5%	15.7% ±30.4%
		AHS in affected herds (mean ± std dev)	2.9% ±13.0%	1.7% ±2.6%	7.8% ±11.8%

AHS: arthrogryposis-hydranencephaly syndrome

In addition to its impact on livestock and farming, SBV had an economic impact on European trade due to trade restrictions. The United States of America have banned importation of ruminant semen and embryos collected before June 1, 2011 in Europe since February 2012 (USDA APHIS, 2015). Other countries outside Europe restricted cattle semen trade, leading overall to a drop of 11 to 26% in the number of semen doses exported outside Europe in 2012 (EFSA, 2014).

Although the impact on livestock has been evaluated, the impact on wild and exotic ruminants remains unknown.

2.5 Diagnostics and preventive measures

2.5.1 Diagnostics

Clinical disease in adults is mild or absent, hence SBV diagnostics cannot rely upon clinical signs. In addition, malformations in the offspring are not specific of SBV infection: in Europe, similar malformations can be found after infection of the pregnant female by other viruses (Border disease virus (BDV), BTV, and Bovine viral diarrhea virus (BVDV)) or after ingestion of lupine by the pregnant female. Outside Europe, possible causes would include AKAV (Spickler, 2009) and Aino virus (Tsuda et al., 2004).

Diagnostics of SBV infection can be achieved by isolation of SBV or detection of SBV genome in samples from the animal (direct diagnosis) or by detection of the serological reaction of the animal following SBV infection (indirect diagnosis).

2.5.1.1 Direct diagnosis

2.5.1.1.1 Detection of infectious virus

Virus isolation is one technique that allows detection of infectious virus. Virus isolation of SBV can be performed on several types of cells: KC cells (*Culicoides variipennis* larvae cells), BHK-21 cells (baby hamster kidney cells), and Vero cells with a cytopathic effect on the latter two (Hoffmann et al., 2012b; Van Der Poel et al., 2013). In addition, SBV has been reported to grow efficiently in other cell lines, especially in CPT-Tert cells, which are sheep choroid plexus cells immortalized with the simian virus 40 (SV40) T antigen and human telomerase reverse transcriptase (hTERT) (Arnaud et al., 2010; Elliott et al., 2013; Varela et al., 2013).

Alternatively, infectious virus can be detected after inoculation on IFN^{-/-} mice. After inoculation with infectious SBV, these mice can lose weight and even die (Wernike et al., 2012a) or only show viremia and seroconversion (Sailleau et al., 2013b; Ponsart et al., 2014).

2.5.1.1.1.2 Detection of viral genome by RT-qPCR

Protocols for RT-qPCR have been developed at the same time the virus was discovered (Hoffmann et al., 2012b). The most widely used protocol is the SBV-S3 assay targeting the S segment (Bilk et al., 2012). A comparison between several RT-qPCR assays showed that this SBV-S3 assay is the most sensitive while another assay targeting the M segment (SBV-M1) is the most specific for detection of SBV RNA (Fischer et al., 2013b). New methods are being developed to allow for PCR testing outside the laboratory, via transportable devices (Aebischer et al., 2014)

Viral genome can be detected in blood or serum samples, but RNAemia seems to be short-lasting in cattle: about a week (Hoffmann et al., 2012b; Wernike et al., 2013a). Nevertheless, SBV RNA has been found at two-week intervals in blood samples from lambs in the field in 2012, suggesting a longer viremia in sheep than in cattle (Claine et al., 2013).

In malformed fetuses or newborns, SBV RNA is mostly found in placental fluids, the umbilical cord and the CNS (Bilk et al., 2012). According to one study on sheep and cattle, in the CNS, the brain stem is the sample in which SBV RNA is most likely to be detected (De Regge et al., 2013).

However, SBV RNA is not so often found in malformed offspring. After testing of 348 lambs showing arthrogryposis and hydranencephaly in 2011-2012 in the Netherlands, SBV RNA was found in only 40% of lambs while antibodies against SBV were detected in 90%, and in 58% of 111 calves (van Maanen et al., 2012). Similar results were obtained in Belgium; the absence of SBV RNA associated with presence of antibodies against SBV was interpreted by the authors as a viral clearance, maybe via the humoral response (De Regge et al., 2013).

Therefore, in malformed fetuses or newborns, diagnostic of SBV infection would be best achieved through serological testing together with genome detection.

2.5.1.1.1.3 Detection of viral antigen in tissue slices by immunohistochemistry

SBV immunohistochemistry (IHC) aims at revealing SBV antigens in tissue slices. Protocols have been performed on paraffin-embedded, formalin-fixed tissue samples. In one protocol,

the primary antibody was a monoclonal antibody raised against Tinaroo virus (Peperkamp et al., 2012). Later, a polyclonal antibody raised against SBV nucleoprotein was employed in another protocol (Varela et al., 2013). The resulting staining was cytoplasmic, as expected for a virus with cytoplasmic replication. In SBV-infected calves and lambs, target cells were neurons in the cerebral cortex, brainstem and spinal cord (Peperkamp et al., 2012; Varela et al., 2013).

2.5.1.1.1.4 Detection of viral genome in tissue slices by *in situ* hybridization

In situ hybridization (ISH) allows visualization of SBV genome in tissue slices. One protocol has been developed on paraffin-embedded, formalin-fixed tissue samples, with a probe detecting a part of the S segment (Hahn et al., 2013). Positive cells in the CNS of SBV-infected young ruminants appeared as randomly distributed clusters of neurons in cerebrum, cerebellum, brain stem, medulla oblongata, and spinal cord (Hahn et al., 2013). However, this technique has a low sensitivity: only 10 out of 82 SBV RT-qPCR positive animals were ISH-positive (Hahn et al., 2013).

2.5.1.2 Indirect diagnosis: Serology

2.5.1.2.1 Humoral immune response to SBV

2.5.1.2.1.1 In the adult

The immune response to SBV has been described mostly in cattle. After SBV inoculation to naïve cows, antibodies against SBV were detected between 14 and 21 dpi (Wernike et al., 2013a). The effect on lymphoid populations in blood has been characterized in the same study. The absolute number of IgM +B lymphocytes, but not of CD8+T lymphocytes, increased in peripheral blood for 10 days after infection, suggesting humoral response, but not T-cell-mediated cytotoxicity, is involved in virus clearance after first infection in adult cows (Wernike et al., 2013a).

As yet, antibody persistence has not been fully characterized. In cattle in the field, specific antibodies have been shown to persist at least 2 years (Elbers et al., 2014).

Via colostrum intake, the offspring of ruminants absorb the maternal antibodies and acquire passive immunity for a limited amount of time. In calves, maternal antibodies against SBV are lost 5 to 6 months after birth (Elbers et al., 2014). Therefore, in cattle, vaccination should not be done before the calves are 6 months-old.

2.5.1.2.1.2 In the fetus

Ruminants have a synepitheliochorial placenta that blocks any exchange of antibody from the mother to the fetus. The newborn gains access to maternal antibodies via colostrum intake only. Therefore, if the fetus mounts a humoral response during pregnancy, this response can be detected in newborns before colostrum intake.

SBV infection in a ruminant fetus during pregnancy can elicit a humoral response from the fetus. Antibodies against SBV have been detected in 90% of 348 lambs and in 58% of 111 calves showing arthrogryposis and hydranencephaly in 2011-2012 in the Netherlands (van Maanen et al., 2012).

The window in which SBV infection would trigger antibody production in the fetus is not known. Nevertheless, data from experimental infection with the closely related AKAV indicate this window may be large: neutralizing antibodies were detected from the serum in newborn lambs after inoculation between 28 and 101 dg (Hashiguchi et al., 1979), and in newborn goats after inoculation between 40 and 115 dg (Kurogi et al., 1977).

2.5.1.2.2 Detection of antibodies against SBV

Several techniques are available to look for antibodies against SBV in a serum sample. Reference sera from seropositive sheep and cattle have been validated through an interlaboratory trial and are now available (van der Poel et al., 2014).

2.5.1.2.2.1 Indirect immunofluorescence assay

Indirect immunofluorescence assays can be performed on plates containing SBV-infected BHK-21 cells (clone BRS5) as antigen matrix (Bréard et al., 2013). However, this technique may be the least sensitive for detection of antibodies to SBV (Bréard et al., 2013).

2.5.1.2.2.2 Viral neutralization

Several protocols of viral neutralization have been described (Bréard et al., 2013; Loeffen et al., 2012; Mansfield et al., 2013). They are based on the ability of neutralizing antibodies to prevent the cytopathic effect SBV can elicit in Vero or BHK cells. Viral neutralization is often considered as a gold standard for detection of SBV antibodies (Bréard et al., 2013; van der Heijden et al., 2013). Viral neutralization combines two advantages as a serological tool. First, it can be performed on samples from all kind of animal species, because it is not species-specific. Second, it provides a quantitative result, allowing to follow the evolution of antibody titers in time for a given animal (Mansfield et al., 2013). However, viral neutralization has disadvantages: each test is time-consuming (it lasts about 6 days) and cannot be automated (Bréard et al., 2013).

2.5.1.2.2.3 ELISA

ELISA testing is a faster method than viral neutralization, allowing for testing a larger number of samples in the same amount of time. First, indirect ELISA assays were available: one based on a recombinant SBV nucleoprotein antigen (Bréard et al., 2013), the other based on whole SBV virus (van der Heijden et al., 2013). A competitive ELISA was later commercialized (ID Screen® Schmallenberg virus Competition Multi-species, IDvet Laboratories, Montpellier, France).

Albeit more practical, ELISA may be slightly less sensitive than VNT to detect SBV antibodies, especially SBV nucleoprotein antigen-based indirect ELISA (van der Poel et al., 2014; Poskin et al., 2014b).

In addition to serum, milk samples can be submitted to ELISA testing (but not to viral neutralization because of the milk toxicity on cells). ELISA can be performed on milk samples either from bulk tank to evaluate the exposure of dairy cattle at the farm level (Balmer et al., 2014; Humphries and Burr, 2012; Johnson et al., 2014; Tarlinton and Daly, 2013), or from individuals to identify which cows have been exposed to SBV (Daly et al., 2015).

2.5.2 Preventive measures

Contrary to what happened with BTV-8, animal movements have not been restricted in Europe during the SBV outbreak. Retrospectively, modelling of SBV spread in the United Kingdom indicates that a movement ban would have had a very limited influence on virus spread (Gubbins et al., 2014a). Indeed, midge dispersal is considered as the main transmission route of SBV (Gubbins et al., 2014a, 2014b; Sedda and Rogers, 2013).

Suitable measures include defense against midges and early acquisition of anti-SBV immunity. Preventive measures have been developed for livestock animals, but could also apply to wild and exotic ruminants kept in captivity.

2.5.2.1 Protection against midges

A topic treatment against external parasites may be used during the period of maximal activity of *Culicoides* spp., i.e. summer months (Helmer et al., 2013) and during the window of susceptibility of pregnant females. Deltamethrin, a pyrethroid, has been shown to decrease *Culicoides* feeding rates for 35 days in sheep (Weiher et al., 2014).

Permanent housing may limit the exposure to midges (Helmer et al., 2013). If grazing is required, then the animals should be back indoors before sunset, because midges' activity is greatest around sunset (Koenraadt et al., 2014).

Insect traps may help to reduce the number of midges in barns (Helmer et al., 2013). As the *Culicoides* species implicated in SBV transmission breed on dung (Lühken et al., 2014), frequent dung removal may also limit the number of midges that develop in barns.

In sheep, mating after August decreased the odds of malformations in lambs in 2011 (Luttikholt et al., 2014), probably due to decreased exposure to midges during the window of susceptibility of pregnant ewes. Therefore, in order to protect pregnant females, the mating period can be scheduled to coincide with the months of decreased abundance of *Culicoides* spp. Thus, the insemination would be planned in October or November for goats (Helmer et al., 2013) and sheep.

Protection against midges can decrease the risk of exposure to SBV, however contact between ruminants and midges cannot be totally avoided. It is safer to make the animals gain immunity against SBV.

2.5.2.2 Protection by development of acquired immunity against SBV

Given the impact of SBV is mostly due to offspring morbidity, the individuals to be protected are the naïve females that are going to breed. In sheep, natural immunity seems to protect pregnant ewes against SBV reinfection (Rodríguez-Prieto et al., 2014). If vaccines are not available, the farmer should move naïve females to an area where SBV is known to circulate before mating time, as advised for AKAV (Anonymous, 2013). Vaccination is however more convenient and reliable.

Inactivated SBV vaccines candidates have been produced after growth on baby hamster kidney (BHK-21) and monkey kidney (MA-104) cell lines, with saponine and aluminium hydroxide as adjuvants. After two consecutive administrations in sheep and cattle, followed by challenge infection, several candidates elicited a neutralizing antibody response and were able to prevent RNAemia (Wernike et al., 2013c). One of the MA-104 based candidates has been showed to work as well with a single injection in sheep (Hechinger et al., 2014). Two inactivated vaccines have been available with a Market Authorization for cattle and sheep since 2013 (British Veterinary Association, 2013; Merial, 2013). The length of immunity after vaccination remains unknown in cattle and sheep. As yet, no vaccine is available for goats.

Furthermore, pilot studies on deletion mutants of SBV showed promising for production of live attenuated vaccines in the future. A double deletion mutant lacking NSs and NSm was able to induce seroconversion in cattle and to protect them after SBV challenge. Live attenuated vaccines are of interest because they are often more efficacious than inactivated vaccines (Kraatz et al., 2015).

Vaccination combines two advantages: it protects the individuals and it can also be used to break the SBV transmission chain. Modelling studies revealed this tactical approach could be beneficial to reduce SBV spread even if only cattle are vaccinated (Bessell et al., 2014).

3 AIMS OF THE THESIS

The studies presented in this document were carried out to describe and understand the consequences of SBV infection in domestic ruminants, on the one hand, and to explore the exposure of free-ranging or captive wild and exotic ruminants to SBV, on the other hand.

As to SBV infection in domestic ruminants, the specific objectives were:

- In non-pregnant adult ruminants:
 - To describe the clinical signs, the kinetics of viremia and seroconversion, the distribution of the virus and the lesions after SBV infection in non-pregnant adult sheep and goats; to formulate hypotheses on the pathogenesis of these lesions;
 - To establish a reliable goat model of SBV infection.
- In pregnant goats:
 - To identify the window of susceptibility of the growing embryo or fetus;
 - After SBV inoculation in this window: to describe the outcome of pregnancy, the distribution of the virus in fetuses, and the lesions in fetuses; to formulate hypotheses on the pathogenesis of these lesions.
- In goats around the time of insemination:
 - To evaluate the effects of SBV infection on the hypothalamic-pituitary-ovarian axis and on the outcome of the fecundation;
 - To determinate the consequences of intravaginal inoculation of SBV.

Regarding exposure of wild and exotic ruminants to SBV, the specific objectives were:

- In free-ranging wild ruminants: to evaluate the spread of SBV in France in 2011-2012 ;
- In captive wild and exotic ruminants, in France and in the Netherlands:
 - To identify the species susceptible to SBV infection;
 - In these species, to describe the clinical signs and lesions associated to SBV infection.

4 EXPERIMENTS

4.1 Pathogenesis in domestic ruminants

4.1.1 Infection of adult sheep

Experimental inoculation of adult sheep with SBV was performed in several laboratories in order to describe the clinical signs, the kinetics of viremia and seroconversion, and the distribution of the virus and the lesions. The results have been gathered in the following paper, published in *Veterinary Microbiology* (Wernike et al., 2013d).

I participated in necropsies, sample collection, histological analyses, and RT-qPCR assays.



ELSEVIER

Contents lists available at ScienceDirect

Veterinary Microbiology

journal homepage: www.elsevier.com/locate/vetmic

Schmallenberg virus experimental infection of sheep



Kerstin Wernike^a, Bernd Hoffmann^a, Emmanuel Bréard^b, Anette Bøtner^c,
 Claire Ponsart^d, Stéphan Zientara^b, Louise Lohse^c, Nathalie Pozzi^d,
 Cyril Viarouge^b, Pierre Sarradin^e, Céline Leroux-Barc^e, Mickael Riou^e,
 Eve Laloy^b, Angele Breithaupt^{f,1}, Martin Beer^{a,*}

^a Institute of Diagnostic Virology, Friedrich-Loeffler-Institut (FLI), Suedufer 10, 17493 Greifswald – Insel Riems, Germany

^b ANSES, UMR 1161 ANSES/INRA/ENVA, Avenue du Général de Gaulle 23, 94706 Maisons-Alfort, France

^c National Veterinary Institute, Technical University of Denmark, Lindholm 4771, Kalvehave, Denmark

^d LNCR, National Laboratory for Sanitary Controls in Breeding Animals, 13 rue Jouët, 94704 Maisons-Alfort, France

^e INRA, UE1277 PFIE Plateforme d'Infectiologie Expérimentale, F-37380 Nouzilly, France

^f Department of Experimental Animal Facilities and Biorisk Management, Friedrich-Loeffler-Institut (FLI), Suedufer 10, 17493 Greifswald – Insel Riems, Germany

ARTICLE INFO

Article history:

Received 28 March 2013

Received in revised form 30 May 2013

Accepted 10 June 2013

Keywords:

Schmallenberg virus

Orthobunyavirus

Sheep

Experimental infection

ABSTRACT

Since late 2011, a novel orthobunyavirus, named Schmallenberg virus (SBV), has been implicated in many cases of severely malformed bovine and ovine offspring in Europe. In adult cattle, SBV is known to cause a mild transient disease; clinical signs include short febrile episodes, decreased milk production and diarrhoea for a few days. However, the knowledge about clinical signs and pathogenesis in adult sheep is limited.

In the present study, adult sheep of European domestic breeds were inoculated with SBV either as cell culture grown virus or as virus with no history of passage in cell cultures. Various experimental set-ups were used. Sampling included blood collection at different time points during the experimental period and selected organ material at autopsy.

Data from this study showed, that the RNAemic period in sheep was as short as reported for cattle; viral genome was detectable for about 3–5 days by real-time RT-PCR. In total, 13 out of 30 inoculated sheep became RNAemic, with the highest viral load in animals inoculated with virus from low cell culture passaged or the animal passaged material. Contact animals remained negative throughout the study. One RNAemic sheep showed diarrhoea for several days, but fever was not recorded in any of the animals. Antibodies were first detectable 10–14 days post inoculation. Viral RNA was detectable in spleen and lymph nodes up to day 44 post inoculation.

In conclusion, as described for cattle, SBV-infection in adult sheep predominantly results in subclinical infection, transient RNAemia and a specific antibody response. Maintenance of viral RNA in the lymphoreticular system is observed for an extended period.

© 2013 Elsevier B.V. All rights reserved.

1. Introduction

In late 2011 a novel orthobunyavirus of the Simbu serogroup, referred to as “Schmallenberg virus” (SBV), was discovered near the German-Dutch border and thereafter spread rapidly to other European countries (European Food Safety Authority, 2012; Hoffmann et al., 2012). Recently, it has been shown that SBV is most related to Douglas and Sathuperi virus (Goller et al., 2012). Affected adult cattle

* Corresponding author. Tel.: +49 38351 71200; fax: +4938351 7 275.
 E-mail address: martin.beer@fli.bund.de (M. Beer).

¹ Present address: Institute of Veterinary Pathology, Department of Veterinary Medicine, Freie Universität Berlin, Oertzenweg 19b, 14163 Berlin, Germany.

show none or only mild clinical signs, however, an infection of SBV-naïve cows and ewes during a critical period of pregnancy may lead to severe foetal malformations (Garigliany et al., 2012; Herder et al., 2012); reviewed in (Beer et al., 2013; Wernike et al., 2013b). Insect vectors play an essential role in the spread of SBV; viral genome has been detected in different field collected *Culicoides* spp. (De Regge et al., 2012; Rasmussen et al., 2012).

Based on an experimental infection study with calves, the viraemic period in cattle seems to be short (Hoffmann et al., 2012). However, very little is known about the duration of viraemia as well as the progress of the disease and development of antibodies to SBV in adult sheep. In the present study, two different types of inoculum were compared regarding the ability to induce RNAemia and humoral immunity in sheep: culture-grown virus and an SBV field strain that was passaged in cattle only (delivered as infectious serum). In addition, to investigate the tissue tropism and potential persistence in any of the organ systems, the animals were euthanized at different time points after infection and analyzed for the presence of SBV.

2. Materials and methods

All experimental protocols were reviewed by a state ethics commission and have been approved by the competent authority (Denmark: Danish Animal Experimentation Inspectorate, licence no. 2008/561-1541; France: "Secrétariat Permanent du Comité d'Ethique en Expérimentation Animale Val de Loire" C 37-175-3, 21 of June 2012; Germany: State Office for Agriculture, Food Safety and Fisheries of Mecklenburg-Vorpommern, Rostock, Germany, ref. LALLF M-V TSD/7221.3-1.1-004/12).

2.1. Inocula

Two different types of inoculum were used in the different experiments: (1) cell culture-grown SBV, and (2) cattle serum containing SBV.

Cell culture grown SBV was produced as follows: For group A and B, virus was isolated from cow blood on KC cells (cell line L1062, Collection of Cell Lines in Veterinary Medicine, Friedrich-Loeffler-Institut, Insel Riems, Germany; derived from *Culicoides variipennis* midges (Wechsler et al., 1991)). After initial isolation on KC cells as previously described (Hoffmann et al., 2012) the virus was passaged five times in baby hamster kidney (BHK) cells (cell line L0164) (inoculum I: KC/BHK₅), alternatively once in BHK cells, again in KC cells and again in BHK cells (inoculum II: KC/BHK/KC/BHK). For group C, virus was isolated from lamb brain and passaged 3 times on Vero cells (inoculum III: Vero). Inoculum I contained 10^{6.2} tissue culture infectious doses per ml (TCID₅₀/ml), inoculum II 10⁷ TCID₅₀/ml and inoculum III contained 10⁸ TCID₅₀/ml, as determined by end-point titration on the respective cells.

Cattle serum containing SBV was collected for group E and F. Briefly, a whole blood sample of a SBV-positive cow was injected into another heifer, two and three days after inoculation serum was taken, tested in further cattle regarding infectivity and stored at -70 °C until use (Wernike et al., 2012).

2.2. Sheep and experimental design

The animal experiments were conducted at different time points in the BSL-3 facilities of the National Veterinary Institute, Lindholm, Denmark, of the Plate-Forme d'Infectiologie Expérimentale, Institut National de la Recherche Agronomique, Tours, France and of the Friedrich-Loeffler-Institut, Insel Riems, Germany.

An overview of the experimental setup is shown in Fig. 1. In total 37 SBV-naïve adult sheep of European domestic breeds were assigned to 7 groups. Male and female animals were distributed equally. Twenty-three sheep in 3 groups were inoculated with culture-grown virus: 4 sheep received 1 ml of inoculum I subcutaneously (s.c.) (group A), 3 animals received 1 ml of inoculum II s.c.

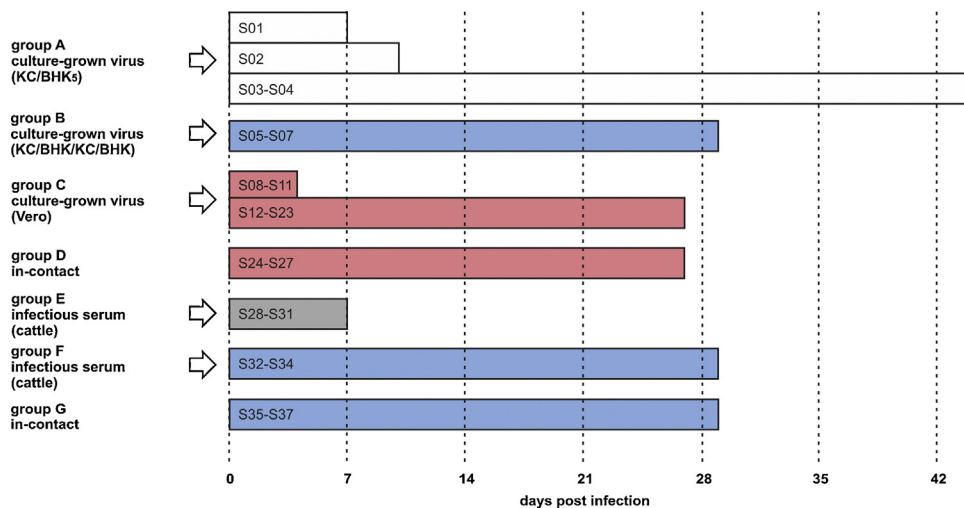


Fig. 1. Experimental design. Animal groups highlighted in the same colour were housed together. (For interpretation of the references to color in this figure legend, the reader is referred to the web version of the article.)

(group B) and 16 were intramuscularly inoculated with 2.5 ml of inoculum III (group C). Two groups (E, F) of 4 and 3 animals respectively received 1 ml of the infectious cattle serum s.c. Seven sheep in two groups (D, G) were injected with 1 ml phosphate-buffered saline s.c. and kept as controls. Groups B, F and G were housed together and group C was kept together with group D.

All animals were monitored for clinical signs every day, rectal body temperatures were measured daily and serum samples were taken at regular intervals. Sequential killing was performed (see Fig. 1) and a large panel of organ materials was collected at autopsy, including fine dissection of genital tracts (Table 1).

2.3. Real-time PCR and serology

RNA from serum samples was extracted using the MagAttract Virus Mini M48 Kit for automated extraction (Qiagen, Germany) or MagNA Pure LC Total Nucleic Acid Isolation Kit (Roche, Denmark) or QiaAmp Viral RNA Kit (Qiagen, France) according to the manufacturer's recommendations.

SBV genome load was determined in all laboratories by the S segment-specific real-time reverse transcription PCR (RT-qPCR) as described previously (Bilk et al., 2012). The tissue samples collected at autopsy were homogenized; RNA was extracted and tested by RT-qPCR as well.

Serum samples were analyzed with a commercially available SBV antibody ELISA (ID Screen® Schmallenberg virus Indirect, IDvet, France) (Breard et al., 2013).

3. Results

3.1. Clinical observation and pathology

One sheep (S03; see Fig. 1) had diarrhoea for 4 days (days 8 to 11 after inoculation [dpi]), and 2 sheep (S03 and S04) had a snotty nose for about 1 week (starting at dpi 15 and dpi 8, respectively); well being and appetite were never depressed in any animal. Body temperatures were within a normal range for all animals, and no fever peak was seen.

Apart from slightly enlarged mesenteric lymph nodes of S06 and S32-S34 autopsy did not reveal any significant gross lesions.

3.2. Real-time PCR and serology

In all sheep of group A, viral RNA was detected in serum for 4 or 5 days, starting at dpi 1, 2 and 4, respectively (Fig. 2). Antibodies were found in S02 from dpi 10, S03 from day 14 and S04 from dpi 22 onwards by ELISA. In S01, which was euthanized one week after infection, no antibodies could be detected (Fig. 3A).

In 2 out of 3 animals of group B, SBV genome was detectable in serum for 3 days (dpi 3–5 and dpi 4–6), while in sheep S05 for 5 days (dpi 4–8) (Fig. 2). In S05 antibodies were detected 14 days after infection for the first time, in S06 after 21 days and S07 remained below cut-off until euthanized on dpi 29 (Fig. 3A).

Viral RNA could not be detected in serum in the animals of group C (Vero) at any time (Fig. 2). Nevertheless, in 6 out

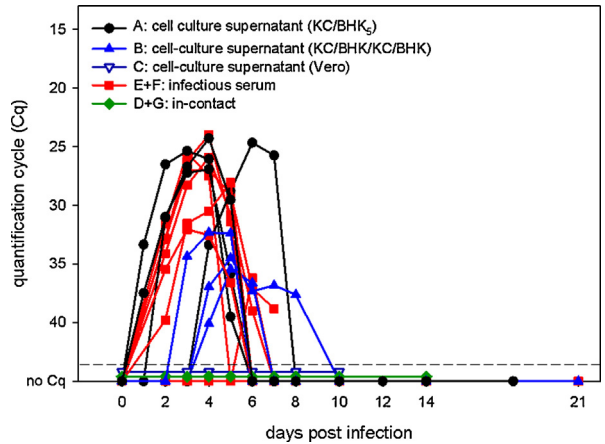


Fig. 2. RT-qPCR results for serum.

of 12 of these animals, which were euthanized at dpi 27, SBV-specific antibodies were found (see Fig. 3B).

Six out of 7 sheep inoculated with infectious serum (group E and F) showed detectable amounts of viral RNA from dpi 2 until dpi 5, 6 or 7 (Fig. 2). Antibodies were found

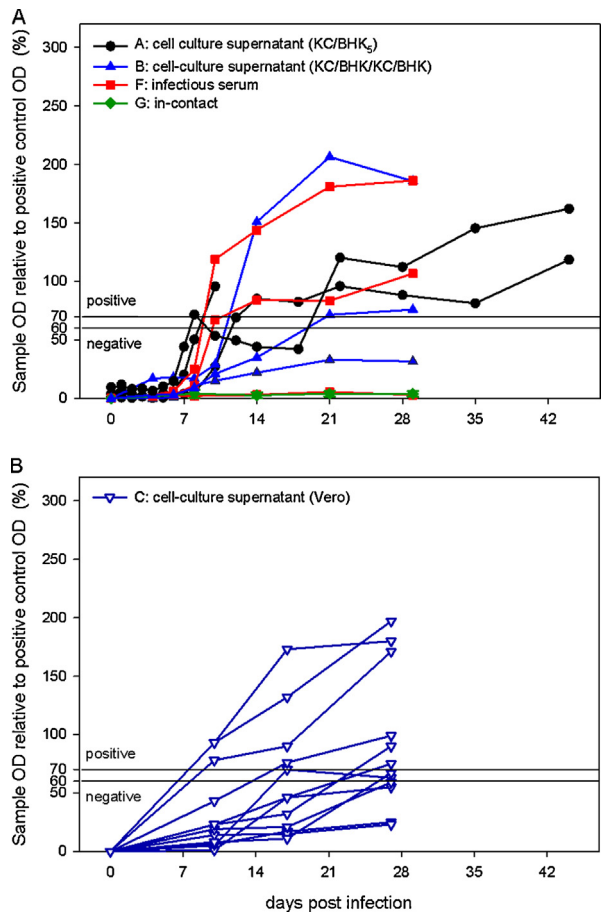


Fig. 3. Results of the SBV antibody ELISA of the groups A, B, F, G (3A) and C (3B). Animals of group E were slaughtered 7 days after inoculation, no serological tests were performed.

Table 1
RT-qPCR results for organ samples taken at autopsy.

Sample material	A: KC/BHK ₅				B: KC/BHK/KC/BHK			C: Vero				E: infectious serum				F: infectious serum			G: control		
	S01	S02	S03	S04	S05	S06	S07	S08	S09	S10	S11	S28	S29	S30	S31	S32	S33	S34	S35	S36	S37
	7 dpi	10 dpi	44 dpi	44 dpi	29 dpi	29 dpi	29 dpi	4 dpi	4 dpi	4 dpi	4 dpi	7 dpi	7 dpi	7 dpi	7 dpi	29 dpi	29 dpi	29 dpi	29 dpi	29 dpi	29 dpi
Serum	-	-	-	-	-	-	-	-	-	-	-	-	-	-	-	-	-	-	-	-	-
Cerebellum	35.4	29.8	-	-	-	-	-	-	-	-	-	-	-	-	-	-	-	-	-	-	-
Cerebrum	-	-	-	-	-	-	39.0	-	-	-	-	-	-	-	-	-	-	-	-	-	-
Medulla	-	-	-	-	-	-	-	-	-	-	-	-	-	-	-	-	-	-	-	-	-
Ovary	-	-	-	-	-	-	-	-	-	-	-	-	43.3	-	-	-	-	-	-	-	-
Cumulus cells	-	-	-	-	-	-	-	-	-	-	-	-	-	-	-	-	-	-	-	-	-
Oocytes	-	-	-	-	-	-	-	-	-	-	-	-	-	-	-	-	-	-	-	-	-
Follicular fluid	-	-	-	-	-	-	-	-	-	-	-	-	-	-	-	-	-	-	-	-	-
Uterus	-	-	-	-	-	-	-	-	-	-	-	-	-	-	-	-	-	-	-	-	-
Epididymis	-	-	-	-	-	-	-	-	-	-	-	-	-	-	-	-	-	-	-	-	-
Testicle	-	-	-	-	-	-	-	-	-	-	-	-	-	-	-	-	-	-	-	-	-
Seminal vesicle	-	-	-	-	-	-	-	-	-	-	-	-	-	-	-	-	-	-	-	-	-
Aorta artery	-	-	-	-	-	-	-	-	-	-	-	-	-	-	-	-	-	-	-	-	-
Heart	-	-	-	-	-	-	-	-	-	-	-	-	-	-	-	-	-	-	-	-	-
Lung	37.9	41.1	40.7	-	-	-	-	-	-	-	-	-	-	-	-	-	-	-	-	-	-
Kidney	-	38.9	39.1	39.0	-	-	36.5	-	-	-	-	-	-	-	-	-	-	-	-	-	-
Liver	-	-	-	-	-	-	-	-	-	-	-	-	-	-	-	-	-	-	-	-	-
Jejunum incl. Peyer's Patches	-	-	-	-	-	-	-	-	-	-	-	-	-	-	-	-	-	-	-	-	-
Skin	-	-	-	-	-	-	-	-	-	-	-	-	-	-	-	-	-	-	-	-	-
Muscles inoculation site	-	-	-	-	-	-	-	-	-	-	31.4	-	-	-	-	44.6	-	-	-	-	-
Lymph node inoculation site	-	-	-	-	-	38.7	-	37.1	-	34.7	-	-	34.2	34.4	36.1	-	-	-	-	-	-
Mandibular lymph node	-	-	-	-	-	-	-	-	-	-	-	-	-	-	-	40.6	-	-	-	-	-
Mesenteric lymph node	22.1	22.7	27.5	29.8	41.1	35.8	33.9	-	-	-	-	-	-	-	-	-	-	41.5	-	-	-
Spleen	28.5	27.8	27.2	28.9	-	-	28.6	-	-	-	-	38.8	31.2	38.4	30.8	33.5	-	-	-	-	-
Tonsil	-	-	-	-	-	-	-	-	-	-	-	-	-	-	-	38.8	-	-	-	-	-

–, no Cq value after 45 cycles.

in two sheep between dpi 10 and 14 by ELISA for the first time (Fig. 3A), 4 further animals were euthanized one week after inoculation, no antibodies were detected (data not shown). In the remaining sheep (S33) as well as in all in-contact animals viral RNA was not detectable at any time (see Fig. 2) and none of them showed any antibody response.

Viral RNA was detected in the spleens of 10 animals, the mesenteric lymph nodes of 8 sheep, the lymph nodes close to the inoculation site of 6 animals, the mandibular lymph node of one sheep, one tonsil sample, in the kidney of 4 sheep, in the ovarian tissue of 1 ewe, the muscle samples taken at the area of inoculation of 2 sheep, in lung samples of 3 animals, the cerebellum of two sheep, and in one cerebrum sample (Table 1).

4. Discussion

In late 2011, SBV was identified for the first time in blood samples of diseased adult cows by a metagenomic approach. Thereafter, the virus has been implicated in many cases of severely malformed bovine, but also ovine offspring (Beer et al., 2013; Dominguez et al., 2012; Garigliany et al., 2012; Herder et al., 2012; Lievaart-Peterson et al., 2012). Though more than 90% of sheep from Dutch herds known to be infected or suspected to be so are seropositive (Loeffen et al., 2012), no clinical signs in adult sheep have been reported in the period of presumed infection. After natural or experimental SBV infection of cattle, affected animals showed fever, decreased milk production and diarrhoea for a few days (Hoffmann et al., 2012). In the present study, a short RNAemia, as previously reported for cattle (Hoffmann et al., 2012; Wernike et al., 2012), was observed in the sheep experimentally inoculated in this study, while only one single sheep out of 13 RNAemic animals showed clinical signs (diarrhoea) for several days as well. Therefore, our results in recently published analyses and the study presented here suggest a rather similar course of SBV-infection both in sheep and cattle.

RNAemia was not induced by all types of inoculation materials. Following inoculation with SBV isolated from a brain of a lamb on Vero cells, RNA was for example not detectable in serum samples despite a very high cell culture titre of about 10^8 TCID₅₀/ml. In contrast, RNAemia was induced by the virus isolated from the blood of a cow on KC cells and passaged on BHK-cells. A possible explanation for the change in virus phenotype, including a reduced virulence in the natural host, could be a selection of attenuated variants after passages in cell culture. This phenomenon has also been described for several other bunyaviruses (Griot et al., 1993; Lundkvist et al., 1997; Ogawa et al., 2007). Further explanations are (1) the different origins of the sample materials from which viruses were isolated (blood of a diseased adult cow vs. brain material from a malformed new-born lamb), (2) the initial switch between cell lines of mammalian and insect origin or (3) the different route of inoculation (i.m. vs. s.c.). Nevertheless, differences in virulence of SBV have not been observed between subcutaneously and intravenously inoculation of cattle with PCR-positive blood (Hoffmann et al., 2012); intramuscular inoculation of caprine foetuses with the closely related Akabane virus (AKAV) led to typical

lesions such as encephalomyelitis and polymyositis (Konno and Nakagawa, 1982). Consequently, it is very likely that the cell culture adaptation may be responsible for the absence of RNAemia. However, further sequence analyses and studies based on reverse genetics are necessary for clarification.

Despite the lack of RNAemia in serum samples from all animals of group C, half of the animals became positive in the SBV-ELISA. Furthermore, inoculation with virus, isolated from the blood of a cow on KC cells, did not result in seroconversion in two sheep. One of them had already been euthanized after one week, and referring to similar observations for AKAV, it was killed before a detectable amount of antibodies could be induced (Inaba and Matumoto, 1990; Radostits et al., 2007).

One sheep inoculated with infectious serum showed neither RNAemia nor seroconversion, which could be caused by failed injection or interpreted as a status of resistance to SBV infection. A missing RNAemia has also been seen for Bluetongue virus. Albeit consistently PCR-negative sheep seroconverted, antibodies were detected later after inoculation and in lower titres than in RNAemic animals (Eschbaumer et al., 2009; Wäckerlin et al., 2010). Whether the same is true for SBV and sheep without RNAemia develop neutralizing antibodies later after inoculation requires further investigation.

In conclusion, both infectious serum and low passage cell culture material is a viable option for an SBV-infection model. Nevertheless, all materials have to be first evaluated in an in vivo study, and passaging of SBV imposes the risk of a complete loss of virulence and infectivity in the natural host. As soon as serum passaged in sheep only becomes available, this material should be also tested to allow a comparison to the cattle-derived materials.

Detection of viral RNA in lymph nodes, particularly in the mesenteric lymph node, and spleen samples taken at autopsy (up to day 44) indicates an affinity to and possible persistence in the lymphoreticular system; identical observations have been reported recently in cattle also (Wernike et al., 2012, 2013a). In one ewe, viral RNA was detected in the ovarian tissue taken 7 days after inoculation. To our knowledge, this is the first evidence showing that the virus may be present in the genital tract after experimental infection. This finding is in agreement with a previous report dedicated to Akabane virus in cattle (Parsonson et al., 1981). However, no RNA was detected from the male genital tract in contrary to recent findings regarding semen in bulls (ProMED-mail, 2012a,b).

Further studies will be necessary to determine the relevance of these findings and the role for pathogenesis of SBV.

In summary, the short RNAemia, the mild or absent clinical symptoms and the persistence of viral RNA in the lymphoreticular system shows that SBV infection of adult sheep is very similar to that of adult cattle.

Conflict of interest statement

The authors have not any financial, personal, or professional interests that could be construed to have influenced this paper.

Acknowledgements

Patrick Zitzow and Helle Rasmussen provided excellent technical assistance. Donata Kalthoff's help with the animal experiment and the dedicated animal care by the staff of the isolation units (The National Veterinary Institute at Lindholm, Denmark; INRA, PFIE Plateforme d'Infectiologie Expérimentale, France; Friedrich-Loeffler-Institut, Germany,) is gratefully acknowledged. Many thanks to the technical staff of the PFIE (in particular Guillaume Martin, Aléxis Pléau and Rémi Delaunay, the pilots of the sheep's experiments) in France, to Maxime Raimbourg, from the LNCr technical staff involved in autopsies and genital tract dissections and to Corinne Sailleau and Alexandra Desprat (UMR 1161 ANSES/INRA/ENVA in Maisons-Alfort, France). This study was supported by the Germany Federal Ministry of Food, Agriculture and consumer protection and the European Union as outlined in Council Decision 2012/349/EU concerning a financial contribution by the Union for studies on Schmallenberg virus and by the Danish Ministry of Food, Agriculture and Fisheries, within the GUDP and the ERA-NET EMIDA – OrbiNet project.

References

- Beer, M., Conraths, F.J., van der Poel, W.H.M., 2013. Schmallenberg virus – a novel orthobunyavirus in Europe. *Epidemiology and Infection* 141, 1–8.
- Bilk, S., Schulze, C., Fischer, M., Beer, M., Hlinak, A., Hoffmann, B., 2012. Organ distribution of Schmallenberg virus RNA in malformed newborns. *Vet. Microbiol.* 159 (1–2), 236–238.
- Breard, E., Lara, E., Comtet, L., Viarouge, V., Doceul, V., Desprat, A., Vitour, D., Pozzi, N., Cay, A.B., De Regge, N., Pourquier, P., Schirrmeyer, H., Hoffmann, B., Beer, M., Sailleau, C., Zientara, S., 2013. Validation of a commercially available indirect ELISA using a nucleocapsid recombinant protein for detection of Schmallenberg virus antibodies. *PLoS One*.
- De Regge, N., Deblauwe, I., De Deken, R., Vantieghem, P., Maddier, M., Geysen, D., Smeets, F., Losson, B., van den Berg, T., Cay, A.B., 2012. Detection of Schmallenberg virus in different *Culicoides* spp. by real-time RT-PCR. *Transbound. Emerging Dis.* 59 (6) 471–475.
- Dominguez, M., Hendrikx, P., Zientara, S., Calavas, D., Jay, M., Touratier, A., Languille, J., Fediaevsky, A., 2012. Preliminary estimate of Schmallenberg virus infection impact in sheep flocks – France. *Vet. Rec.* 171 (17) 426.
- Eschbaumer, M., Hoffmann, B., König, P., Teifke, J.P., Gethmann, J.M., Conraths, F.J., Probst, C., Mettenleiter, T.C., Beer, M., 2009. Efficacy of three inactivated vaccines against bluetongue virus serotype 8 in sheep. *Vaccine* 27, 4169–4175.
- EuropeanFoodSafetyAuthority, 2012. Schmallenberg virus: analysis of the epidemiological data and assessment of impact. *EFSA J.* 10 (6) 2768 (89 pp.).
- Garigliani, M.M., Hoffmann, B., Dive, M., Sartelet, A., Bayrou, C., Cassart, D., Beer, M., Desmecht, D., 2012. Schmallenberg virus in calf born at term with porencephaly, Belgium. *Emerg. Infect. Dis.* 18, 1005–1006.
- Goller, K.V., Höper, D., Schirrmeyer, H., Mettenleiter, T., Beer, M., 2012. Schmallenberg virus as possible ancestor of Shamonda virus. *Emerg. Infect. Dis.* 18 (10) 1644–1646.
- Griot, C., Gonzalez-Scarano, F., Nathanson, N., 1993. Molecular determinants of the virulence and infectivity of California serogroup bunyaviruses. *Annu. Rev. Microbiol.* 47, 117–138.
- Herder, V., Wohlsein, P., Peters, M., Hansmann, F., Baumgartner, W., 2012. Salient lesions in domestic ruminants infected with the emerging so-called schmallenberg virus in Germany. *Vet. Pathol.* 49 (4) 588–591.
- Hoffmann, B., Scheuch, M., Hoper, D., Jungblut, R., Holsteg, M., Schirrmeyer, H., Eschbaumer, M., Goller, K.V., Wernike, K., Fischer, M., Breithaupt, A., Mettenleiter, T.C., Beer, M., 2012. Novel orthobunyavirus in cattle, Europe, 2011. *Emerg. Infect. Dis.* 18, 469–472.
- Inaba, Y., Matumoto, M., 1990. Chapter 43: Akabane virus. In: Dinter, S., Morien, B. (Eds.), *Virus Infections of Vertebrates, Vol. III. Virus Infections of Ruminants*. Elsevier Science Publishers B.V., Amsterdam, pp. 467–480.
- Konno, S., Nakagawa, M., 1982. Akabane disease in cattle: congenital abnormalities caused by viral infection. *Experimental disease. Vet. Pathol.* 19, 267–279.
- Lievaert-Peterson, K., Luttkholt, S.J.M., Van den Brom, R., Vellema, P., 2012. Schmallenberg virus infection in small ruminants – first review of the situation and prospects in Northern Europe. *Small Rumin. Res.* 106, 71–76.
- Loeffen, W., Quak, S., De Boer-Luijtz, E., Hulst, M., Van Der Poel, W., Bouwstra, R., Maas, R., 2012. Development of a virus neutralisation test to detect antibodies against Schmallenberg virus and serological results in suspect and infected herds. *Acta Vet. Scand.* 54, 44.
- Lundkvist, A., Cheng, Y., Sjolander, K.B., Niklasson, B., Vaheri, A., Plyusnin, A., 1997. Cell culture adaptation of *Puumala hantavirus* changes the infectivity for its natural reservoir, *Clethrionomys glareolus*, and leads to accumulation of mutants with altered genomic RNA S segment. *J. Virol.* 71, 9515–9523.
- Ogawa, Y., Kato, K., Tohya, Y., Akashi, H., 2007. Characterization of temperature-sensitive Akabane virus mutants and their roles in attenuation. *Arch. Virol.* 152, 1679–1686.
- Parsonson, I.M., Della-Porta, A.J., Snowdon, W.A., O'Halloran, M.L., 1981. The consequences of infection of cattle with Akabane virus at the time of insemination. *J. Comp. Pathol.* 91, 611–619.
- ProMED-mail, 2012a. Schmallenberg virus – Europe (33): Serology, Archive Number: 20120405.1091807. <http://www.promedmail.org> [posted 05.04.12]
- ProMED-mail, 2012b. Schmallenberg virus – Europe (76): virus RNA in bovine semen, Archive Number: 20121220.1460864. <http://www.promedmail.org> [posted 20.12.12]
- Radostits, O.M., Gay, C.C., Hinchcliff, K.W., Constable, P.D., 2007. Congenital arthrogryposis and hydranencephaly; Akabane disease; Cache Valley virus disease. In: *Veterinary Medicine: A textbook of the diseases of cattle, horses, sheep, pigs and goats*. 10th ed. Saunders Ltd., pp. 1207–1209.
- Rasmussen, L.D., Kristensen, B., Kirkeby, C., Rasmussen, T.B., Belsham, G.J., Bodker, R., Botner, A., 2012. *Culicoides* as vectors of schmallenberg virus. *Emerg. Infect. Dis.* 18, 1204–1206.
- Wäckerlin, R., Eschbaumer, M., König, P., Hoffmann, B., Beer, M., 2010. Evaluation of humoral response and protective efficacy of three inactivated vaccines against bluetongue virus serotype 8 one year after vaccination of sheep and cattle. *Vaccine* 28, 4348–4355.
- Wechsler, S.J., McHolland, L.E., Wilson, W.C., 1991. A RNA virus in cells from *Culicoides variipennis*. *J. Invertebr. Pathol.* 57, 200–205.
- Wernike, K., Eschbaumer, M., Breithaupt, A., Hoffmann, B., Beer, M., 2012. Schmallenberg virus challenge models in cattle: infectious serum or culture-grown virus? *Vet. Res.* 43, 84.
- Wernike, K., Eschbaumer, M., Schirrmeyer, H., Blohm, U., Breithaupt, A., Hoffman, B., Beer, M., 2013a. Oral exposure, reinfection and cellular immunity to Schmallenberg virus in cattle. *Vet. Microbiol.* 165 (1–2), 155–159.
- Wernike, K., Hoffmann, B., Beer, M., 2013b. Schmallenberg virus. In: Roth, J., Richt, J., Morozov, I. (Eds.), *Vaccines and Diagnostics for Transboundary Animal Diseases Dev Biol. Karger, Basel*, pp. 161–168.

4.1.2 Infection of adult, non-pregnant goats

Experimental inoculation of SBV to adult non-pregnant goat was performed in order to describe the clinical signs, the kinetics of viremia and seroconversion, and the distribution of the virus and the lesions in this species. This study included a follow-up of SBV excretion in buck semen. The results are detailed in the following paper, published in *BMC Veterinary Research*.


I was involved in necropsies, sample collection, histological analyses, and RT-qPCR assays. I wrote the draft.

RESEARCH ARTICLE

Open Access

Schmallenberg virus: experimental infection in goats and bucks



E. Laloy^{1*} , M. Riou², C. Barc², G. Belbis³, E. Bréard⁴, S. Breton², N. Cordonnier¹, D. Crochet², R. Delaunay², J. Moreau², N. Pozzi⁷, M. Raimbourg⁷, P. Sarradin², S. Trapp^{5,6}, C. Viarouge⁴, S. Zientara⁴ and C. Ponsart⁷

Abstract

Background: Schmallenberg virus (SBV) is an emerging *Orthobunyavirus* of ruminant livestock species currently circulating in Europe. SBV causes a subclinical or mild disease in adult animals but vertical transmission to pregnant dams may lead to severe malformations in the offspring. Data on the onset of clinical signs, viremia and seroconversion in experimentally infected adult animals are available for cattle and sheep but are still lacking for goats.

For a better understanding of the pathogenesis of SBV infection in adult ruminants, we carried out experimental infections in adult goats. Our specific objectives were: (i) to record clinical signs, viremia and seroconversion; (ii) to monitor viral excretion in the semen of infected bucks; (iii) to determine in which tissues SBV replication took place and virus-induced lesions developed.

Results: Four goats and two bucks were inoculated with SBV. Virus inoculation was followed by a short viremic phase lasting 3 to 4 days and a seroconversion occurring between days 7 and 14 pi in all animals. The inoculated goats did not display any clinical signs, gross lesions or histological lesions. Viral genomic RNA was found in one ovary but could not be detected in other organs. SBV RNA was not found in the semen samples collected from two inoculated bucks.

Conclusions: In the four goats and two bucks, the kinetics of viremia and seroconversion appeared similar to those previously described for sheep and cattle. Our limited set of data provides no evidence of viral excretion in buck semen.

Background

In the late summer/autumn 2011, a disease outbreak with diarrhea, drop of milk production, and fever was reported in adult cattle in Western Europe. These symptoms could not be attributed to any known infectious agent. Metagenomic analyses on blood samples from affected animals in Germany led to the identification of a new *Orthobunyavirus* that was named the Schmallenberg virus (SBV) [1]. This emerging virus was later found to induce teratogenesis in pregnant cattle, sheep, and goats leading to typical malformations in the offspring [2].

Experimental infections of adult sheep and cattle with SBV resulted in subclinical infections with a short viremic

phase. Seroconversion in the infected animals occurred about two weeks post inoculation (pi) [1, 3–5]. To our knowledge, no report on the pathogenesis of experimental SBV infections in adult goats has been published.

SBV is transmitted by biting midges (*Culicoides* spp.). The possibility of sexual transmission between ruminants has not yet been elucidated [2]. Infectious SBV has been detected in bovine semen samples from the field [6–8] and SBV RNA could be detected in semen from experimentally infected bulls [9]. Whether SBV can be excreted in buck semen is still unknown.

In this study, we carried out experimental infections of SBV in adult goats. Our specific objectives were: (i) to record the development of clinical signs, viremia and seroconversion in goats; (ii) to monitor the excretion of SBV in buck semen after inoculation; (iii) to determine in which tissues SBV replication took place and virus-

* Correspondence: elaloy@vet-alfort.fr

¹Université Paris-Est, Ecole Nationale Vétérinaire d'Alfort, Unité d'anatomie pathologique, 7 avenue du Général de Gaulle, 94704 Maisons-Alfort, France
Full list of author information is available at the end of the article

induced lesions developed in adult bucks and non-gravid goats, with special emphasis on the genital tract.

Methods

All experiments were conducted in accordance with the guidelines of the Council European Directive (2010/63/UE). All experimental procedures were approved by the ethical review board of the Val de Loire (CEEA VdL, committee number n°19, number 2012-02-11).

Experimental design

Five adult Alpine goats, one adult Saanen buck and one adult Alpine buck were purchased from local breeders (INRA Center, Bourges, France) and were housed in the Biosafety Level 3 and insect-proof animal facilities of the National Institute of Agricultural Research (INRA), Research Loire Valley Center (PFIE, Nouzilly, France). All purchased animals were SBV-negative as determined by ELISA and RT-qPCR.

Two goats (designated A and B) were inoculated subcutaneously on day 0 with 1 mL of SBV-containing bovine serum kindly provided by the Friedrich-Loeffler-Institut (FLI), Germany [3]. Two goats (designated C and D) were inoculated on day 0 with 1 mL of SBV-containing ovine whole blood collected at the PFIE during a previous experimental infection trial [5]. One goat from each group was killed at day 7 pi and the remaining goats were killed at day 14 pi. The two bucks (designated E and F) were inoculated subcutaneously at day 0 with 1 mL of the FLI serum and killed at day 28 pi. One goat (designated G) was inoculated subcutaneously on day 0 with 1 mL of sterile saline solution and served as an in-contact negative control until it was killed at day 28 pi.

During the course of the trial, all animals were monitored twice daily, and body temperatures were recorded by telemetric measurement with rumen temperature sensors (Small Bolus®, Médria, Châteaubourg–France). After inoculation, whole blood and serum samples were collected daily during the first week and then at days 14 and 28 pi. Buck semen was collected at day 0 and then twice a week. At necropsy, all the organs were macroscopically evaluated and a panel of tissue samples was collected for histopathology and RT-qPCR (spleen, pre-scaphular lymph node, skeletal muscle, aorta, liver, kidney, lung, small intestine, brain, skin, ovary, oviduct, uterus, testis, and epididymis).

Real-time PCR

Ovaries were dissected and follicular fluid, cumulus cells, oocytes and interstitial tissue were separated from each other prior to total RNA extraction. RNA from blood and tissue samples was extracted using the LSI MagVet™ Universal Isolation kit (Life Technologies SAS, Saint-Aubin, France) and King Fisher magnetic particle

processor (Thermo Scientific™, Illkirch, France) according to the manufacturers' instructions. RNA from semen samples was extracted with Trizol® LS Reagent [6].

The samples were then tested for the presence of SBV RNA by RT-qPCR as previously described [10]. Quantification cycle (Cq) threshold value was 40, with higher values regarded as negative.

Serology

Serum samples were submitted to SBV specific ELISA testing (ID Screen Schmallenberg virus Indirect®, monocupule, IDvet) and virus neutralization test (VNT) [11].

Histopathological examination

After fixation in 10 % buffered formalin, tissues were routinely processed, sliced at 4 μm, stained with Hematoxylin-Eosin-Saffron (HES) and examined by light microscopy.

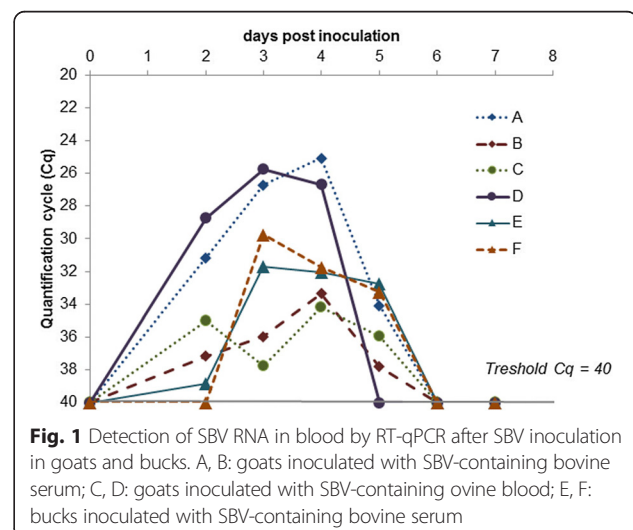
Results

Clinical and post-mortem observations

The goats and bucks did not exhibit any clinical signs. No fever peak was detected in any of the animals. No significant gross lesion was found at necropsy.

Real-time PCR

SBV RNA was detected in the blood of all inoculated animals for 3 to 4 days, starting between day 1 and 3 pi (Fig. 1). From day 6 pi, SBV RNA became undetectable. Cq values during RNAemia in all animals ranged from 25 to 39. The intensity of RNAemia differed in 2 of the 4 inoculated goats, with goats A and D showing a maximal Cq value of about 25 while goats B and C showed a maximal Cq value of about 35, independently of the inoculum (ovine EDTA blood or bovine serum). All sampled tissues scored negative for SBV by RT-qPCR in



bucks and goats, except for one ovary in goat C (interstitial ovarian tissue with a non-normalized Cq value of 34). The semen from the bucks remained negative for SBV from day 0 until the end of the trial, as determined by RT-qPCR.

Serology

The ELISA results for inoculated animals are shown in Fig. 2. Goats B and C, killed at day 7 pi, remained seronegative. Antibodies to SBV were detected in goats A and D at 14 pi by ELISA and at day 9 pi by VNT (titers: 128 and 96 respectively). Antibodies to SBV were detected in buck E at day 28 pi by ELISA and at day 14 pi by VNT (titer: 64). Buck F was found seropositive at day 14 pi by ELISA and VNT (titer: 96). The mock-inoculated goat remained seronegative until day 28 pi (as determined by ELISA).

Histopathological examination

No significant lesions were found in any of the animals. Rare coccidian parasites were seen in the intestine from goats B, C and G.

Discussion

Our results show that, in goats and bucks, inoculation of SBV is followed by a short viremic phase lasting 3 to 4 days followed by seroconversion between day 7 and day 14 pi. Importantly, these clear signs of successful experimental infection were not accompanied by any clinical sign, including fever.

These observations are in accordance with data from experimental infection studies with sheep and cattle inoculated subcutaneously with infectious serum. In sheep, RNAemia was detected a few days after infection and lasted

for 3 to 7 days, while SBV-specific antibodies appeared between 7 and 9 days pi (detection by VNT) [12] or between 10 and 14 days pi (detection by ELISA) [5]. Data from this experiment in goats show a trend towards a higher sensitivity of VNT compared to ELISA at the beginning of the seroconversion. Poskin et al. [12] had similar observations in sheep and suggested that this difference could be due to the ability of VNT to detect both IgM and IgG, while the ELISA can only detect IgG. Following experimental infection, sheep did not show any clinical sign [12] or almost no sign, with diarrhea being reported in one case [5]. In cattle, RNAemia could be detected for less than a week after inoculation [1, 3, 4] with detection by ELISA of SBV-specific antibodies two weeks pi [3, 4]. Clinical signs were absent [3, 4] or limited to fever or diarrhea [1].

In cattle and sheep, after experimental inoculation, SBV genomic RNA was most consistently found in lymphoid organs, i.e. spleen and lymph nodes, especially the mesenteric lymph nodes [3–5, 9, 12]. This was not the case in any of the four goats and two bucks inoculated in the present study; however we did not collect the mesenteric lymph nodes. The only organ where SBV genome was found was one ovary of a single goat. Interestingly, the SBV genome had already been found in the ovary of one experimentally infected sheep [5], but the significance of this finding remains unknown. No significant gross lesions or histological lesions were found in our study. Similarly, experimental infections of cattle or sheep did not result in gross lesions at necropsy [3–5, 12]. So far, in experimentally infected adult ruminants, the presence of SBV genome in a given organ has not been reported to be associated with any lesion in this organ.

No SBV genome was found between day 0 and day 28 pi (end of the trial) in the semen samples obtained from the two inoculated bucks. This result differs from the observations made after experimental infection of two bulls with SBV-containing cell culture supernatants [9]. Viral genome could be detected in the semen of both bulls for the first week following inoculation and, in the case of one bull, as late as at day 19 pi (the trial ended at day 25 pi). SBV excretion in bovine semen has also been reported from the field [6–8] but, to our knowledge, this has never been reported for bucks. However, the small size of our inoculated group precludes a conclusion regarding the excretion of SBV in caprine semen and the risk of sexual transmission.

The data from this study match those from reports of natural infection by SBV in domestic ruminants: clinical signs of infection are either mild or absent in adults. The most important effects of SBV infection are malformations in the offspring due to vertical transmission in pregnant dams [2]. A study of the impact of SBV in French domestic ruminants showed that only 2 % of the kids born in goat herds with congenital SBV cases showed

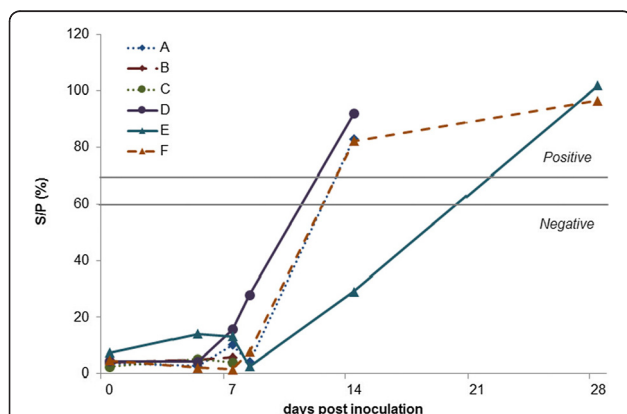


Fig. 2 Detection of SBV specific antibodies by ELISA after SBV inoculation in goats and bucks. A, B: goats inoculated with SBV-containing bovine serum; C, D: goats inoculated with SBV-containing ovine blood; E, F: bucks inoculated with SBV-containing bovine serum. S/P < 60 %: negative; S/P > 70 %: positive and S/P between 60 % and 70 %: doubtful

malformations [13]. The same study reported a potential effect of SBV infection in the early stages of pregnancy, based on reports of repeated estrus or early embryonic loss, especially in small ruminants [13]. The effects of SBV infection in pregnant goats, however, remain to be elucidated.

Conclusions

Following experimental infection in goats with SBV, the kinetics of viremia and seroconversion were found to be similar to earlier reported kinetics in sheep and cattle. No clinical signs were associated to infection, in agreement with reports from the field. SBV RNA was found in one ovary but not in other organs. The SBV genome was not found in semen from the two inoculated bucks but this limited set of data does not exclude the risk of viral transmission by artificial insemination or natural service.

Abbreviations

Cq: Quantification cycle; FLI: Friedrich-Loeffler-Institut; HES: Hematoxylin-eosin-saffron; PFIE: Plate-Forme d'Infectiologie Expérimentale; pi: Post inoculation; SBV: Schmallenberg virus; VNT: Virus neutralization test.

Competing interests

The authors declare that they have no competing interests.

Authors' contributions

Study conception and design: ST, SZ, CP, PS, MRi, EB. Acquisition of data: EL, CB, GB, EB, SB, NC, DC, JM, NP, MRa, MRi, CV, RD. Analysis and interpretation of data: EL, EB, NP, CP, SZ, MRi. Drafting of manuscript: EL. Critical revision: EB, SZ, NC, ST, CB, CP, MRi. All authors read and approved the final manuscript.

Acknowledgements

This study was supported and financed by the European Union (Council decision 2012/349/EU) and the General Direction of Food (DGAL, Ministry of Agriculture) for studies on Schmallenberg virus. We are grateful to Thierry Pineau, the leader of department of Animal Health in INRA, coordinator of European project for the experiments with goats in France. We wish to thank Kerstin Wernike (FLI) for providing infectious bovine serum. Many thanks to the direction of the PFIE, especially Bertrand Schwartz, and to the zootechnical staff of the PFIE, especially the team working in confinement unit with the goats. We thank Marc Chodkiewicz for careful editing of the manuscript.

Author details

¹Université Paris-Est, Ecole Nationale Vétérinaire d'Alfort, Unité d'anatomie pathologique, 7 avenue du Général de Gaulle, 94704 Maisons-Alfort, France. ²INRA Centre Val de Loire, UE-1277 Plateforme d'Infectiologie Expérimentale, secteur 3, route de Crotelles, 37380 Nouzilly, France. ³Université Paris-Est, Ecole Nationale Vétérinaire d'Alfort, Unité de pathologie des animaux de production, 7 avenue du Général de Gaulle, 94704 Maisons-Alfort, France. ⁴ANSES, UMR 1161 Virologie ANSES-INRA-ENVA, 23 avenue du Général de Gaulle, 94704 Maisons-Alfort, France. ⁵INRA Centre Val de Loire, UMR 1282 Infectiologie et Santé Publique, 37380 Nouzilly, France. ⁶Université François Rabelais de Tours, UMR 1282 Infectiologie et Santé Publique, 37000 Tours, France. ⁷LNCR, Laboratoire national de contrôle des reproducteurs, 13 rue Jouët, 94703 Maisons-Alfort, France.

Received: 2 May 2015 Accepted: 30 July 2015

Published online: 22 August 2015

References

- Hoffmann B, Scheuch M, Höper D, Jungblut R, Holsteg M, Schirrmeyer H, et al. Novel Orthobunyavirus in Cattle, Europe, 2011. *Emerg Infect Dis*. 2012;8:469–72.
- Wernike K, Conraths F, Zanella G, Granzow H, Gache K, Schirrmeyer H, et al. Schmallenberg virus—two years of experiences. *Prev Vet Med*. 2014;116:423–34.
- Wernike K, Eschbaumer M, Breithaupt A, Hoffmann B, Beer M. Schmallenberg virus challenge models in cattle: infectious serum or culture-grown virus? *Vet Res*. 2012;43:84.
- Wernike K, Eschbaumer M, Schirrmeyer H, Blohm U, Breithaupt A, Hoffmann B, et al. Oral exposure, reinfection and cellular immunity to Schmallenberg virus in cattle. *Vet Microbiol*. 2013;165:155–9.
- Wernike K, Hoffmann B, Bréard E, Bötner A, Ponsart C, Zientara S, et al. Schmallenberg virus experimental infection of sheep. *Vet Microbiol*. 2013;166:461–6.
- Hoffmann B, Schulz C, Beer M. First detection of Schmallenberg virus RNA in bovine semen, Germany, 2012. *Vet Microbiol*. 2013;167(3–4):289–95.
- Ponsart C, Pozzi N, Bréard E, Catinot V, Viard G, Sailleau C, et al. Evidence of excretion of Schmallenberg virus in bull semen. *Vet Res*. 2014;45:37.
- Schulz C, Wernike K, Beer M, Hoffmann B. Infectious Schmallenberg virus from bovine semen, Germany. *Emerg Infect Dis*. 2014;20:338–40.
- Van Der Poel WH, Parlevliet JM, Verstraten ER, Kooi EA, Hakze-Van Der Honing R, Stockhofe N. Schmallenberg virus detection in bovine semen after experimental infection of bulls. *Epidemiol Infect*. 2014;142:1495–500.
- Bilk S, Schulze C, Fischer M, Beer M, Hlinak A, Hoffmann B. Organ distribution of Schmallenberg virus RNA in malformed newborns. *Vet Microbiol*. 2012;159:236–8.
- Bréard E, Lara E, Comtet L, Viarouge C, Doceul V, Desprat A, et al. Validation of a commercially available indirect ELISA using a nucleocapsid recombinant protein for detection of Schmallenberg virus antibodies. *PLoS One*. 2013;doi: 10.1371/journal.pone.0053446.
- Poskin A, Martinelle L, Mostin L, Van Campe W, Dal Pozzo F, Saegerman C, et al. Dose-dependent effect of experimental Schmallenberg virus infection in sheep. *Vet J*. 2014;201:419–22.
- Dominguez M, Gache K, Touratier A, Perrin JB, Fediaevsky A, Collin E, et al. Spread and impact of the Schmallenberg virus epidemic in France in 2012–2013. *BMC Vet Res*. 2014;10:248.

Submit your next manuscript to BioMed Central and take full advantage of:

- Convenient online submission
- Thorough peer review
- No space constraints or color figure charges
- Immediate publication on acceptance
- Inclusion in PubMed, CAS, Scopus and Google Scholar
- Research which is freely available for redistribution

Submit your manuscript at
www.biomedcentral.com/submit



4.1.3 Infection of adult goats around the time of insemination and during pregnancy

4.1.3.1 Overview of the experimental design

This study includes two protocols, which took place at different time points. One protocol (protocol 1) was designed to investigate the effects of SBV inoculation in goats around the time of insemination and involved groups A to D' (protocol 1). The other protocol was designed to investigate the effects of SBV inoculation on pregnant goats and involved groups E to G (protocol 2). An overview of the experimental design is shown in figure 6.

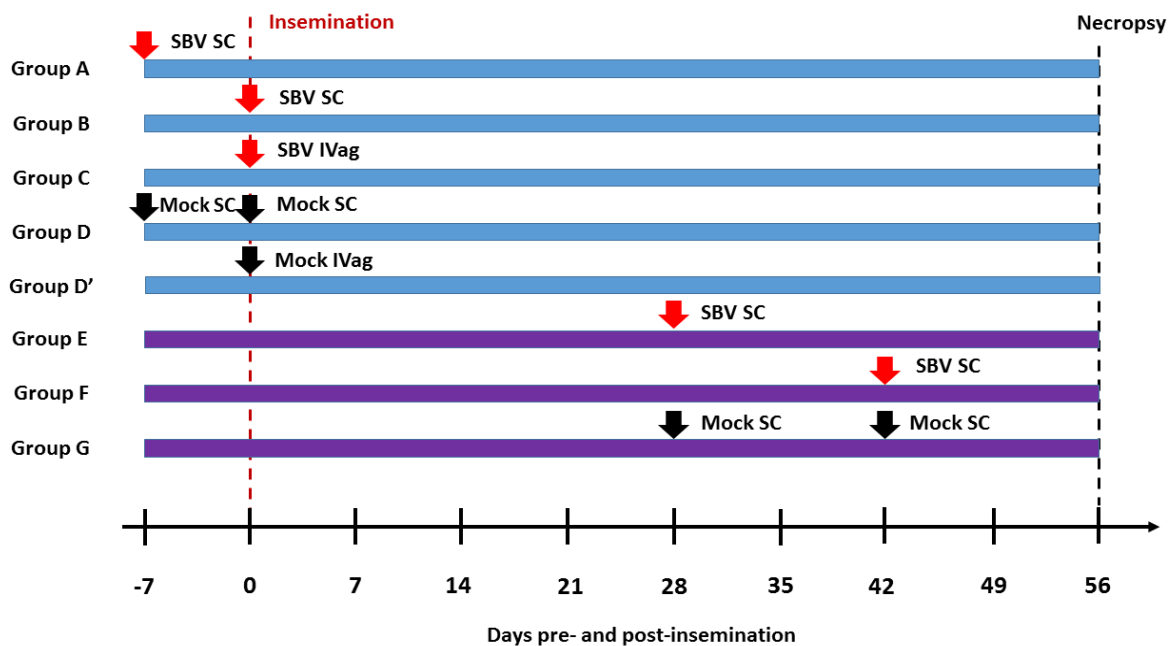


Figure 6. Experimental design.

Goats were inoculated either subcutaneously (SC) or intravaginally (IVag), with either viral inoculum (SBV) or virus-free material (mock). In group D, one half of the group was mock-inoculated at day -7 before insemination while the other half was mock-inoculated on day 0. In group G, one half of the group was mock-inoculated at day 28 after insemination while the other half was mock-inoculated at day 42.

4.1.3.2 *Infection around the time of insemination*

This part corresponds to the protocol 1. This protocol was designed to investigate the effects of SBV inoculation around the time of insemination and involved 5 groups of goats (A to D’).

I was involved in the protocol design. I performed necropsies, sample collection, histological analyses, and RT-qPCR assays. I performed data analysis.

4.1.3.2.1 *Materials and methods*

- **Experimental design**

Thirty-four adult Alpine goats were purchased from local breeders (INRA Center, Bourges, France) and were housed in the Biosafety Level 3 and insect-proof animal facilities of the National Institute of Agricultural Research (INRA), Research Loire Valley Center (PFIE, Nouzilly, France). All purchased animals were seronegative for SBV (ELISA), Q fever (complement fixation test) and brucellosis (complement fixation test and seroagglutination test). They were also Border disease virus and SBV-negative as determined by RT-qPCR. Vaginal sponges (Syncro-part 45mg, CEVA) were inserted in the goats’ vagina to synchronize estrus. On the day of insemination, each goat was artificially inseminated with two semen straws. Pregnant status was assessed at days 35 and 42 after insemination by ultrasonography. Three goats were excluded from the study because ultrasonography showed they were pseudogestant. Accordingly, the groups detailed below includes only 31 goats.

In groups A (8 goats) and B (7 goats), animals were inoculated subcutaneously with 1mL of SBV-containing bovine serum kindly provided by the Friedrich-Loeffler-Institut (FLI), Germany (Wernike et al., 2012b), at day 7 before insemination and at the day of insemination, respectively. The group D (the control group for A and B) included 5 goats that received 1mL of sterile saline solution subcutaneously. In the group C (7 goats) the animals were inoculated intravaginally with SBV-spiked semen (made from the FLI serum) at the time of insemination. The group D’ (the control group for C) included 4 goats that received SBV-negative serum (as determined by PCR) intravaginally at the time of insemination.

During the course of the trial, all animals were monitored twice daily, and body temperatures were recorded by telemetric measurement with rumen temperature sensors (Small Bolus®, Médria, Châteaubourg – France). After inoculation, whole blood and serum samples were collected daily during the first week and then once a week until the end of the experiment. Whole blood samples were then submitted to hematology analysis (full blood count) and to RT-qPCR. All the animals were euthanized at day 56 after insemination.

- **Luteinizing hormone (LH) and progesterone follow-up**

To follow the LH surge in the goats from the groups A and D, blood samples were collected every 4 hours from 22h to 42h after sponge removal, then submitted to ELISA testing for quantification of LH levels. To follow the serum progesterone in the goats from the groups A, B, C, D and D', blood samples were collected daily from the day of insemination to day 7 after insemination then submitted to ELISA testing for quantification of progesterone levels.

- **Necropsy, tissue collection and preparation**

At necropsy, all the organs from the goats were macroscopically evaluated and a panel of tissue samples was collected for histopathology, virus isolation and RT-qPCR (spleen, prescapular lymph node, ovary, oviduct, uterus, and vagina). In the pregnant goats, the fetus were examined and measured (crown-rump length) and a panel of tissue samples was collected for histopathology and RT-qPCR (brain, vertebrae with spinal cord, skeletal muscle, heart, kidney, eye, lung, intestine, liver, thymus, umbilical cord, and mandible from the fetus; placentomes, amniotic and allantoic membranes). Amniotic and allantoic fluid were collected for RT-qPCR only. One aliquot of each tissue sample was homogenized with 500µl of MEM. After a centrifugation (2000g 5min at 4°C), the supernatant was collected and used for RNA extraction.

- **Serology**

Serum samples were submitted to SBV specific ELISA testing (ID Screen Schmallenberg virus Competition Multispecies®, IDvet) according to the manufacturers' instructions.

- **RT-qPCR**

RNA from blood and tissue samples was extracted using the LSI MagVet™ Universal Isolation kit (Life Technologies SAS, Saint-Aubin, France) and King Fisher magnetic particle

processor (Thermo Scientific™, Illkirch, France) according to the manufacturers' instructions. The samples were then tested for the presence of SBV RNA by RT-qPCR targeting the S segment as previously described (Bilk et al., 2012). Quantification cycle (Cq) threshold value was 40, with higher values regarded as negative.

- **Histology**

After fixation in 10% buffered formalin, tissues were routinely processed, sliced at 4 µm, stained with Hematoxylin-Eosin-Saffron (HES) and examined by light microscopy

4.1.3.2.2 Results

- **Clinical signs, viremia and seroconversion in goats**

No clinical signs were observed. The full blood counts showed slight eosinophilia in groups A and D'. One goat from the group A and one goat from the group B had ruminal temperature of 40°C 1 day post-inoculation (dpi) and from 2 to 3 dpi, respectively; two goats from group C had ruminal temperature of 40°C, one at 7 dpi, the other several times at -3, 0, 1 and 6 dpi. No fever peak were detected in any of the other goats after inoculation. SBV RNA was detected in the blood of all the goats from groups A and B for 4 to 6 dpi, starting between 2 and 4 dpi. SBV RNA was detected in the blood of only one goat in group C, starting at 4 dpi and lasting 4 days; this goat did not show hyperthermia. No SBV RNA was detected in the blood of the other goats from group C and in mock-inoculated goats. All the goats with RNAemia were found seropositive between days 7 and 14 pi. Antibodies against SBV were not found in the other goats.

- **Pregnancy outcomes**

The pregnancy outcomes are summarized in table 5.

Table 5. Pregnancy outcomes per group.

Group	Number of pregnant goats	Total number of goats	Number of fetuses*
A	2	8	2
B	5	7	10
C	3	7	5
D and D'	3	9	5

*All fetuses were viable, except one fetus in group B and two fetuses in group C that were found dead (autolyzed).

- **Gross and histological lesions**

No gross or histological lesions were found in fetuses.

In the adults, abscesses consistent with *Corynebacterium pseudotuberculosis* infection were found in two goats from group A (in mesenteric lymph nodes or mammary gland), two goats

from group B (in mesenteric lymph nodes or mammary gland), two goats from group C (lung or spleen), one goat from group D (spleen and ovarian ligament) and one goat from group D' (liver).

Granulomatous lymphadenitis consistent with *Mycobacterium avium* subsp. *paratuberculosis* infection was found in two goats from group A and one goat from group C, associated with cachexia in the latter. Cachexia was also found in one goat from group D without associated lesion.

Amyloidosis was detected in the spleen or lymph nodes of one goat from group A, one goat from group B and one goat from group D, often in combination to abscesses or granulomatous lymphadenitis.

Two goats displayed severe chronic mastitis (groups B and C). Slight acute suppurative endometritis was detected histologically, but not at gross examination, in one goat from group D and one goat from group D'.

In the ovaries, histological examination revealed lymphoplasmacytic infiltrates in the corpus luteum in 3 goats from group B, 2 goats from group C, and one goat from each other group D, D' and A. The severity was minimal, limited to one focus to a few foci with less than 10 lymphocytes and plasma cells each.

- **Virus distribution**

SBV RNA was not detected in any tissue from the goats and the fetuses, including placental samples.

- **Hormonal modifications after inoculation around the time of insemination**

The rise in LH concentration in serum occurred at different time points after sponge removal in each group, with inter-individual variability (Figure 7).

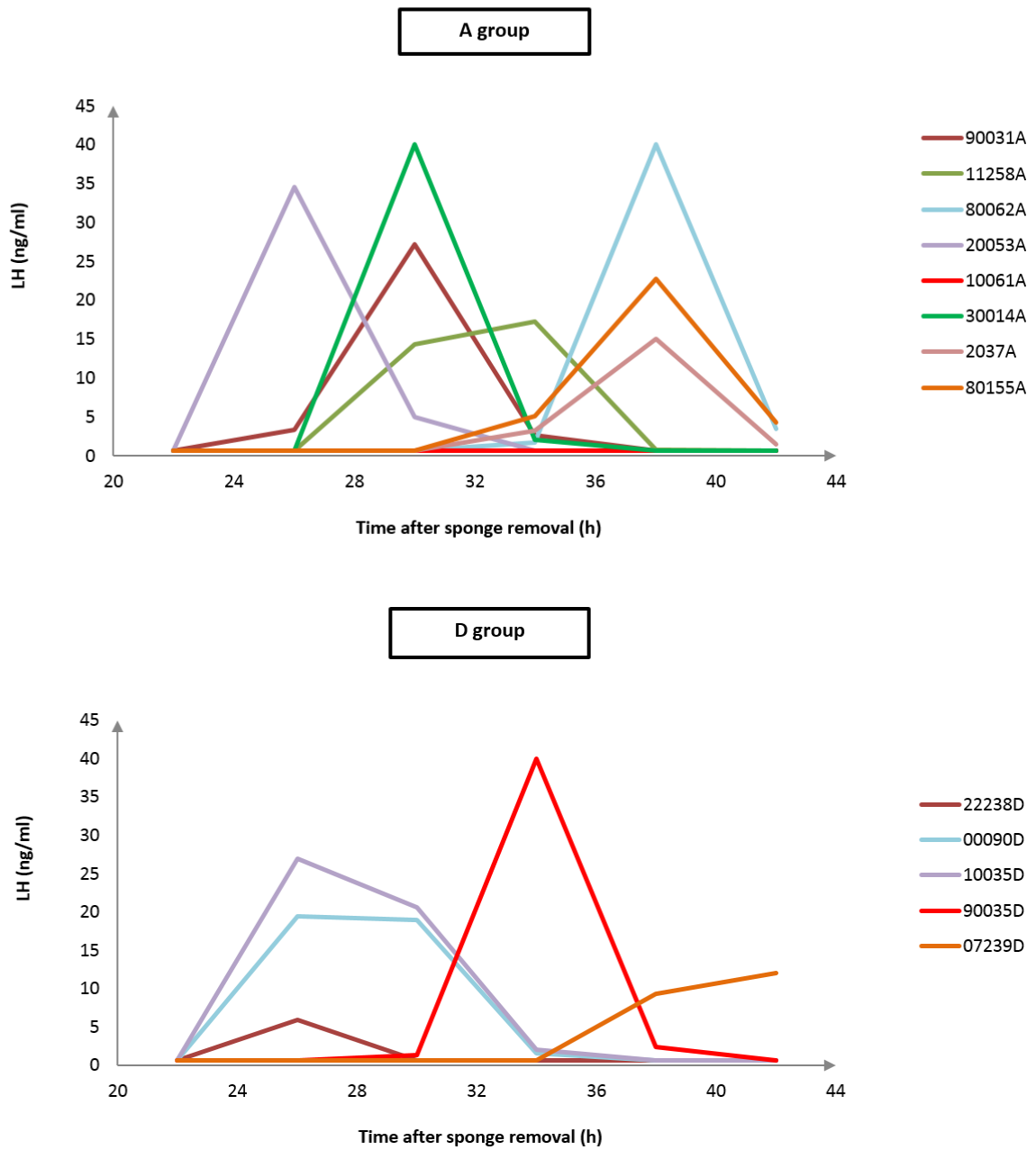


Figure 7. Evolution of the LH concentration in goats from groups A and D after sponge removal.

The rise in progesterone in each group is shown in Figures 8 and 9. In several group included in controls, the progesterone dropped after an initial rise. The corresponding goats were not pregnant.

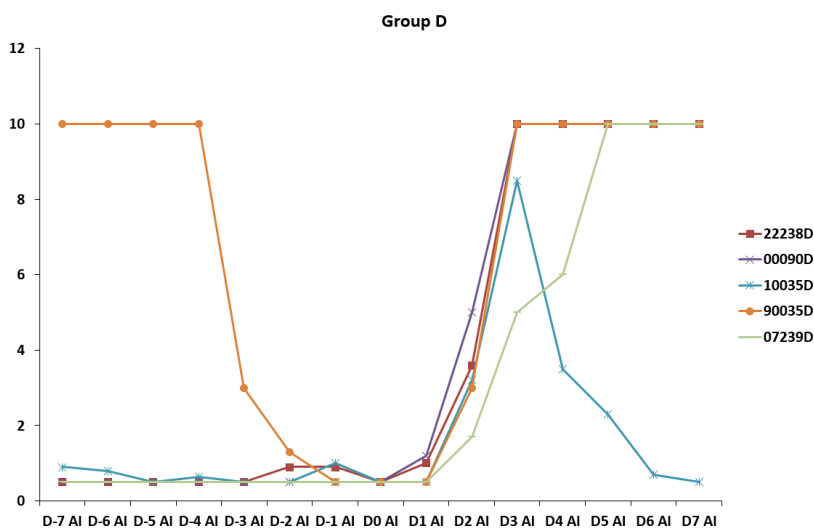
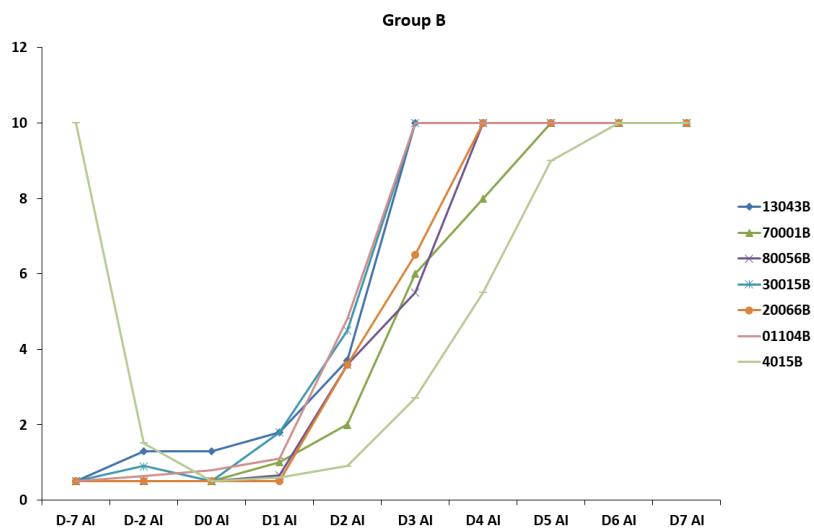
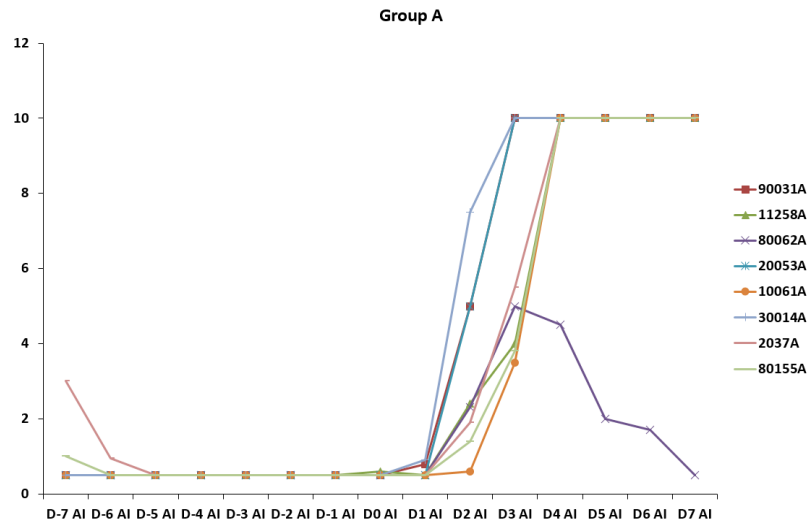


Figure 8. Evolution of the progesterone concentration (P4, ng/mL) in serum in groups A, B and D. AI: artificial insemination.

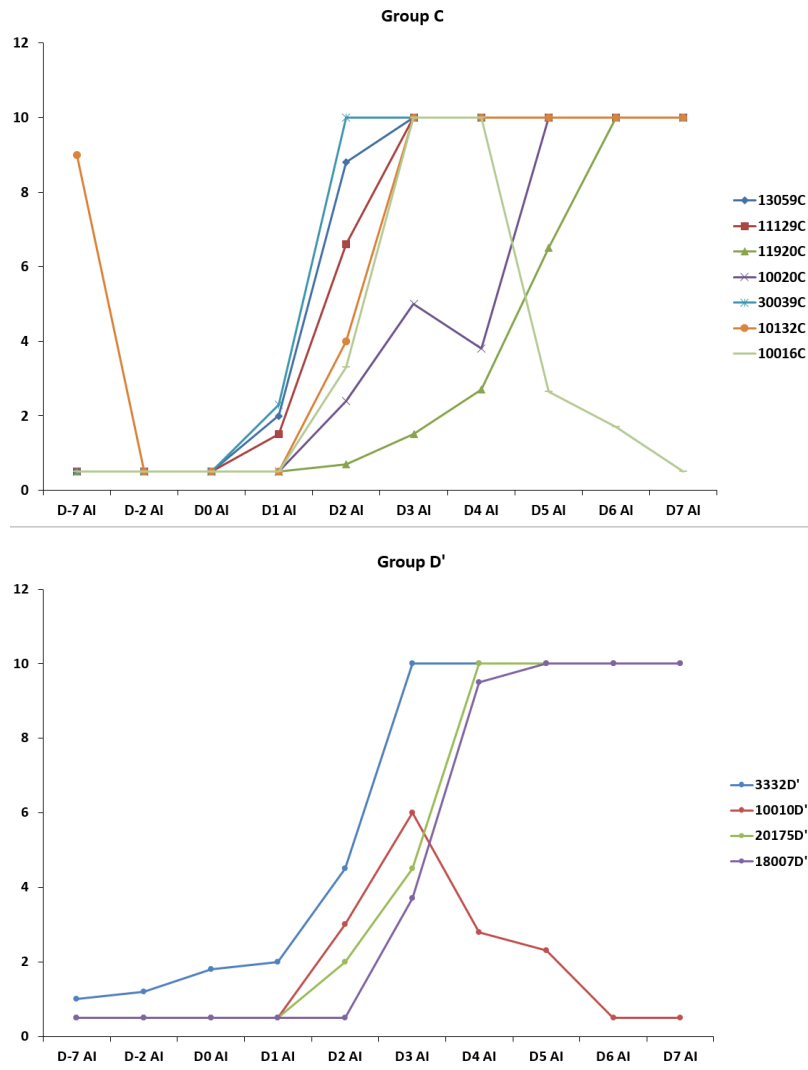


Figure 9. Evolution of the progesterone concentration (P4, ng/mL) in serum in groups C and D'. AI: artificial insemination.

In group C, the only goat with SBV viremia (goat 30039C) displayed a progesterone rise within normal limits.

4.1.3.2.3 Discussion

Most of the goats included in the control group (D) were not in good condition. Some of them displayed lesions associated with chronic general disease, as paratuberculosis or amyloidosis. The others had inflammatory lesions in the genital tract. All these conditions could have impaired their ability to have a normal pregnancy. Indeed, most of them were not pregnant at the end of the study. Because of this inadequate control group, comparisons between the infected goats and the control goats for hormonal levels and pregnancy outcome seem not appropriate. In addition, lesions evocative of chronic general disease or genital tract inflammation were also detected in goats from other groups, leading to intra-group heterogeneity. It would have been necessary to exclude several goats in order to further interpret the results, however the groups are already small.

This study shows that intravaginal inoculation with SBV may lead to a viremia in goats. Similarly, experimental intrauterine inoculation with AKAV at the time of insemination resulted in viremia in cows. In spite of this viremia, 6/10 cows had a successful pregnancy and the newborns did not display lesions. The only lesion in these cows was an infiltration of the corpus luteum by lymphocytes and plasma cells (Parsonson et al., 1981a). Lymphoplasmacytic infiltrates were also detected in the corpus luteum in the goats in our study, yet they were of minimal severity. In addition, they were detected in goats from each group: A, B, C, D and D'. They were thus not considered significant.

The only goat that developed viremia following intravaginal insemination was pregnant with one fetus. At necropsy, the fetus was found dead (autolyzed). SBV RNA was not detected in this fetus, hence a causal link with SBV is unlikely. The cause of this fetal death is not known.

In this study, the intravaginal insemination was performed with the same material as for artificial insemination. This material could have damaged the vaginal mucosa, causing erosions allowing the virus to access more easily to the blood circulation. Natural service may not have the same effects. Therefore, we can conclude that in goats, viremia can occur after intravaginal exposure to SBV in a context of artificial insemination.

4.1.3.3 *Infection during pregnancy*

This part corresponds to the protocol 2 and is developed in the following draft (in preparation). For clarity purpose, the names of the groups have been changed in the paper: groups E, F, and G are named G28, G42, and Control, respectively.

I was involved in the protocol design. I performed necropsies, sample collection, histological and immunohistological analyses, and RT-qPCR assays. I performed data analysis. I wrote the draft.

1 **Consequences of Schmallenberg virus experimental infection in pregnant goats**

2 Eve Laloy*, Emmanuel Bréard, Sascha Trapp, Nathalie Pozzi, Mickaël Riou, Céline Barc,
3 Sylvain Breton, Rémi Delaunay, Nathalie Cordonnier, Sophie Chateau-Joubert, Didier
4 Crochet, Joël Moreau, Julie Gouzil, Typhaine Hébert, Thierry Chaumeil, Maxime Raimbourg,
5 Cyril Viarouge, Benoît Durand, Claire Ponsart, Stéphan Zientara

6

7 *Corresponding author. Tel.: +33 143 967 270; fax: +33 143 967 293. Email address:

8 elaloy@vet-alfort.fr (E. Laloy)

9 -Université Paris-Est, Ecole Nationale Vétérinaire d'Alfort, Unité d'anatomie pathologique, 7
10 avenue du Général de Gaulle, 94704 Maisons-Alfort, France

11 -INRA Centre Val de Loire, UE-1277 Plateforme d'Infectiologie Expérimentale, secteur 3,
12 route de Crotelles, 37380 Nouzilly, France

13 - Université Paris-Est , ANSES, UMR 1161 Virologie ANSES-INRA-ENVA, 23 avenue du
14 Général de Gaulle, 94704 Maisons-Alfort, France

15 -INRA Centre Val de Loire, UMR 1282 Infectiologie et Santé Publique, 37380 Nouzilly,
16 France

17 -Université François Rabelais de Tours, UMR 1282 Infectiologie et Santé Publique, 37000
18 Tours, France

19 -LNCR, Laboratoire national de contrôle des reproducteurs, 13, rue Jouët, 94703 Maisons-
20 Alfort, France

21

22

23 **Abstract**

24 Schmallenberg virus is an emerging virus responsible for congenital malformations in the
25 offspring of domestic ruminants. Infection of pregnant animals may also cause early
26 embryonal losses. To determine the susceptibility of the goat in early gestation to
27 Schmallenberg virus, we inoculated the virus to pregnant goats at days 28 and 42 of gestation
28 and followed the goats until day 55 of gestation. Viremia occurred in all the goats without
29 clinical signs. Embryonic and early fetal deaths were observed in several goats infected at 28
30 or 42 days of gestation and were associated with viral genome detection in the
31 embryos/fetuses. Among the surviving fetuses, two displayed lesions in the central nervous
32 system (porencephaly) associated with the detection of viral genome and antigens. All the
33 fetuses from goats infected at day 42 of gestation, and the majority of fetuses from goats
34 infected at day 28 of gestation, contained viral genome. Viral genome was widely distributed
35 in these fetuses and their placenta and infectious virus could be isolated from several organs
36 and placentomes from living fetuses. These results show that the pregnant goat is susceptible
37 to Schmallenberg virus infection between 28 and 42 days of gestation. The outcomes of the
38 infection at this stage of gestation, as determined at day 55 of gestation, include embryonic or
39 fetal deaths, living fetuses with central nervous system lesions, and living fetuses without
40 detectable lesions.

41

42 **Keywords** (indexing terms): Goat, Reproduction, Schmallenberg virus, Orthobunyavirus,
43 Experimental infection

44

45

46

47 **Introduction**

48 Schmallenberg virus (SBV) emerged in summer and autumn 2011 in Western Europe
49 associated to an outbreak of diarrhea, drop of milk production, and fever in adult cattle.
50 Metagenomic analyses on blood samples from affected animals living near the city of
51 Schmallenberg, in Germany, led to the identification of this new Orthobunyavirus, within the
52 family *Bunyaviridae* (1). SBV was later found to induce congenital malformations in
53 newborns in the offspring of cattle, sheep, and goats: arthrogryposis with muscular
54 hypoplasia, malformations of the central nervous system (CNS), and vertebral malformations
55 were the most common (2,3). In non-pregnant adult ruminants, however, clinical signs are in
56 general mild to absent (4).

57 As determined by phylogenetic analyses, SBV belongs to the Simbu serogroup within the
58 genus Orthobunyavirus. Several viruses among this serogroup, namely Akabane virus
59 (AKAV), Aino virus, and Shamonda virus, can cause diseases in domestic ruminants (1).
60 AKAV has been extensively studied for more than 25 years. It is responsible for abortions,
61 stillbirths, premature births and congenital malformations in newborns while it elicits only
62 subclinical or asymptomatic disease in non-pregnant adult animals. Pregnant ewes and goats
63 are most susceptible between 28 and 56 days of gestation; infection at this stage leads to
64 arthrogryposis and/or CNS malformations in the offspring (5).

65 After a study in the highest goat-specialized region of France, goats have been suggested to be
66 less susceptible to SBV infection than sheep and cattle (6). Another study on the impact of
67 SBV in France in 2012-2013 revealed that 8% of lambs, 3% of the calves, and 2% of kids
68 born in SBV-infected herds showed congenital malformations, with farmers reporting early
69 embryonal losses in females from the 3 species (7). The window of susceptibility of the
70 pregnant goats to SBV remains unknown.

71 In this study, we carried out experimental infections of SBV in pregnant goats at early stages
72 of gestation, 28 and 42 days after insemination. Our specific objectives were: (i) to assess
73 whether the embryo or fetus is susceptible to SBV when pregnant goats are inoculated at 28
74 and 42 days of gestation; (ii) to describe the pregnancy outcomes and the lesions in growing
75 fetuses; (iii) to determine the tissues and cells targeted by SBV in the fetus, in cases of
76 successful transplacental SBV transmission.

77

78

79

80

81

82

83

84

85

86

87

88

89

90

91

92 **Materials and methods**

93 All experimental procedures were approved by the ethics committee of the Val de Loire
94 (CEEA VdL, committee number n°19, number 00770.02)

95

96 Animals

97 13 adult Alpine goats and 16 adult Saanen goats were purchased from local breeders (INRA
98 Center, Bourges, France) and were housed in the Biosafety Level 3 and insect-proof animal
99 facilities of the National Institute of Agricultural Research (INRA), Research Loire Valley
100 Center (PFIE, Nouzilly, France). All purchased animals were seronegative for SBV (ELISA),
101 Q fever (complement fixation test) and brucellosis (complement fixation test and
102 seroagglutination test). They were also Border disease virus and SBV-negative as determined
103 by RT-qPCR.

104

105 Experimental design

106 Vaginal sponges (Syncro-part 45mg, CEVA) were inserted in the goats' vagina to
107 synchronize estrus. On the day of insemination, each goat was artificially inseminated with
108 two semen straws. Pregnant status was assessed at days 35 and 42 after insemination by
109 ultrasonography. The goats that were not pregnant at day 42 post insemination (15/29) were
110 excluded from the study. The numbers of animals per group indicated below do not include
111 these animals.

112 The protocol involved 3 groups: one group inoculated at day 28 post insemination (G28; 5
113 goats), one group inoculated at day 42 post insemination (G42; 5 goats) and a control group (4
114 goats). The goats from the group G28 and from the group G42 were inoculated

115 subcutaneously with 1mL of SBV-containing bovine serum kindly provided by the Friedrich-
116 Loeffler-Institut (FLI), Germany (8). The control group received 1mL of sterile saline
117 solution subcutaneously at day 28 (2 animals) and day 42 (2 animals) post insemination.

118 During the course of the trial, all animals were monitored twice daily, and body temperatures
119 were recorded by telemetric measurement with rumen temperature sensors (Small Bolus®,
120 Médria, Châteaubourg – France). After inoculation, whole blood and serum samples were
121 collected daily during the first week and then once a week until the end of the experiment.
122 The whole blood samples were then submitted to hematology analysis (full blood count) and
123 to RT-qPCR. The animals were euthanized at day 53, 54 or 55 after insemination.

124

125 Necropsy, tissue collection and preparation

126 At necropsy, all the organs from the goats were macroscopically evaluated and a panel of
127 tissue samples was collected for histopathology and RT-qPCR (spleen, prescapular lymph
128 node, ovary, oviduct, uterus, and vagina). In the pregnant goats, the fetus were examined and
129 measured (crown-rump length) and a panel of tissue samples was collected for histopathology
130 and RT-qPCR (brain, spinal cord within vertebrae, skeletal muscle from the hindlimb (thigh),
131 heart, kidney, eye, lung, intestine, liver, thymus, umbilical cord, and mandible from the fetus;
132 placentomes, amniotic and allantoic membranes). Fetal umbilical blood and amniotic and
133 allantoic fluid were collected for RT-qPCR only. One aliquot of each tissue sample was
134 homogenized with 500µl of MEM. After centrifugation (2000g 5min at 4°C), the supernatant
135 was collected and used as inoculum or for RNA extraction.

136

137

138 Serology

139 Serum samples were submitted to SBV specific ELISA testing (ID Screen Schmallenberg
140 virus Competition Multispecies®, IDvet) according to the manufacturers' instructions.

141

142 RT-qPCR

143 RNA from blood, fetal fluids and tissue samples was extracted using the LSI MagVet TM
144 Universal Isolation kit (Life Technologies SAS, Saint-Aubin, France) and King Fisher
145 magnetic particle processor (Thermo Scientific™, Illkirch, France) according to the
146 manufacturers' instructions. The samples were then tested for the presence of SBV RNA by
147 RT-qPCR targeting the S segment, as previously described (9). Quantification cycle (Cq)
148 threshold value was 40, with higher values regarded as negative.

149

150 Viral isolation

151 A subset of samples was submitted to viral isolation by two passages on Vero cells (African
152 green monkey kidney epithelial cells). The same subset was later passaged twice on CPT-Tert
153 cells (10). Briefly, fresh cell monolayers of Vero or CPT-Tert were prepared as follows: 20
154 000 Vero (or CPT-Tert) cells per well were added in 96 wells microtiter plates with 200µL of
155 MEM (GIBCO) containing 10% fetal calf serum and 1% sodium pyruvate per well (for CPT-
156 Tert cells: 200µL of Iscove's Modified Dulbecco's Medium (IMDM, GIBCO) containing
157 10% fetal calf serum, 1% sodium pyruvate and 1% non-essential amino acids). The cells were
158 incubated 1 day at 37°C and then supernatants were discarded and monolayers washed with
159 200µL of MEM. Fifty µl of inoculum (tissue or fluid) was added per well and incubated 1h at
160 room temperature. The inoculum was discarded and 200µL of MEM containing 5% fetal calf

161 serum and 1% sodium pyruvate were added per well (for CPT-Tert cells: 200 μ L of IMDM
162 containing 10% fetal calf serum, 1% sodium pyruvate and 1% non-essential amino acids). The
163 plates were incubated 1 week at 37°C and frozen at -80°C until a second passage on fresh
164 monolayer cells was carried out. Fifty μ L of each first passage supernatant was then used as
165 inoculum, and after 1h of contact with the cells, it was removed and 200 μ L of medium was
166 added. The plates were incubated 1 week at 37°C and frozen at -80°C until needed for RT-
167 qPCR analyses. A result was considered as positive in a well only if cell lysis was associated
168 with evidence of viral genome replication by RT-qPCR.

169

170 Histology, immunohistochemistry and image analysis

171 After fixation in 10% buffered formalin, tissues were routinely processed, sliced at 4 μ m,
172 stained with hematoxylin-eosin-saffron (HES) or Kluver-Barrera (brain and spinal cord only)
173 and examined by light microscopy. Immunohistochemistry was performed using a DXT
174 automat (Ventana Medical Systems; Roche Diagnostics) with streptavidin-biotin-peroxidase
175 complex method with DAB as a substrate and hematoxylin counterstaining. The primary
176 antibodies used are listed in Table 1.

177

178

179

180

181

182

183

184 Table 1. Primary antibodies used for immunohistochemistry.

Antibody	Provider/manufacture	Species	Dilution
SBV	Massimo Palmarini and Mariana Varela, University of Glasgow, UK*	Rabbit polyclonal	1/3000
Activated caspase 3	Cell Signaling Technology, Danvers, Massachusetts, USA	Rabbit polyclonal	1/200
Ki67 (MIB-1)	DAKO, Glostrup, Denmark	Mouse monoclonal	1/50
CD3 (A0452)	DAKO, Glostrup, Denmark	Rabbit polyclonal	1/200
CD79 (HM57)	AbD Serotec, Kidlington, UK	Mouse monoclonal	1/1000

185 *Reference: (11)

186 Positivity for activated caspase 3 (Casp3) and positivity for Ki 67 in samples of fetal muscle
 187 were evaluated by computer-assisted image analysis. Pictures were taken by an ImagerZ1
 188 Zeiss microscope and an AxioCam HRc Zeiss camera. Casp3-positive cells were manually
 189 counted on each slide and expressed per area (Zen pro digital imaging for light microscopy,
 190 Carl Zeiss S.A.S., Le Pecq, France). Quantitative analysis of Ki67 was performed on five
 191 representative images 40x per slide; for each image the ratio between the area occupied by
 192 positive nuclei and the total area occupied by nuclei was calculated (AxioVision 4.6.3 Zeiss
 193 software measurement tool Carl Zeiss S.A.S., Le Pecq, France).

194

195 Statistical analyses

196 A logistic model was used to compare the fetal mortality between groups. Because several
 197 fetuses could be carried by the same goat, this model was fitted using generalized estimating
 198 equations, the goat ID being used as a grouping factor.

199 Two linear models were fitted using generalized estimating equations (i) to compare the fetal
 200 length between groups (because several fetuses could be carried by the same goat, the goat ID
 201 was used as a grouping factor), and taking into account the ‘dead or alive’ status of the fetus;

202 (ii) to compare the Ki67 ratio in fetal muscle between groups (repeated measures were
203 performed for the same fetus, the fetus ID was thus uses as a grouping factor).

204 A general linear model was used to analyze data about the diameter of placentomes. The
205 independent variable was the maximal diameter of the placentomes (one diameter in cm per
206 goat), and explanatory variables were the group (infected –G28 or G42, or control), the breed
207 (Alpine or Saanen), the age of the goat (in years, treated as a categorical variable), and the
208 number of fetuses carried by the goat (treated as a categorical variable). An univariate
209 analysis was performed to select the explanatory variables associated to the maximal diameter
210 of the placentomes, with a p-value <0.20. A multivariate model was then fitted including the
211 explanatory variables thus selected. The absence of collinearity between explicative variables
212 was verified based on the variance inflation factor.

213 P-values <0.05 were considered significant throughout the analysis. Statistical analyses were
214 conducted using R software (R Foundation for Statistical Computing, Vienna, Austria,
215 <http://www.R-project.org/>) with Car (12) and Geepack packages (13).

216

217

218

219

220

221

222

223

224

225 **Results**

226 Clinical signs, viremia and seroconversion in goats

227 No clinical signs were observed. No fever peak were detected in any of the goats. Full blood
228 counts were similar for the SBV- and the mock-inoculated goats all along the study. The SBV
229 RNA was detected in the blood of all the goats from groups G28 and G42 for 4 to 6 days,
230 starting between 2 and 4 days post-inoculation (dpi). One goat from group G28 showed
231 intermittent viremia with SBV RNA found again at 15 dpi. No SBV RNA was detected in the
232 blood of mock-inoculated goats. All the goats with RNA-emia were found seropositive
233 between 7 and 14 dpi. Antibodies against SBV were not found in the serum of mock-
234 inoculated goats.

235

236 Pregnancy outcomes

237 Pregnancy outcomes are showed in Table 2. Prolificacy was 2.2 fetuses per goat in groups
238 G28 and G42 and 2.5 fetuses per goat in the control group. However, 5/11 fetuses in group
239 G28 as well as in group G42 were autolyzed; this indicates they were already dead before
240 euthanasia. Fetal death was more likely to occur in group G28 or in group G42 than in control
241 ($P < 0.0001$). In case of twin pregnancy, fetal death was observed either in both fetuses or only
242 in one of them, or in none of them. In case of triplet pregnancy, one or two fetuses were found
243 dead.

244

245

246

247

248 Table 2. Pregnancy outcomes.

Group	No. of fetal death	Total no. of fetuses	No. of pregnant goats	Prolificacy (no. of fetuses per goat)	No. of goats carrying at least 1 dead fetus
G28	5 ^a	11	5	2.2	3
G42	5 ^b	11	5	2.2	3
Control	0 ^{a,b}	10	4	2.5	0

249 ^a and ^b: P<0.05

250

251 Gross and histological lesions

252 At necropsy, we found an abscess in one mesenteric lymph node in 2 goats from G28 and an
253 abscess in the spleen in 2 goats from G42; histologically, they were consistent with abscesses
254 due to *Corynebacterium pseudotuberculosis*. Diffuse, chronic lymphoplasmacytic mastitis
255 and focal, chronic suppurative bronchopneumonia were also found in a goat from G28 and a
256 goat from G42, respectively. These lesions were most likely of bacterial origin. No gross or
257 histological lesions were seen in any of the control goats.

258 In the placenta, we observed a unique allantoic sac including all the fetuses in most of the
259 cases of twin or triplet pregnancy (total fusion). In 6 goats (2 goats in each group) the placenta
260 contained 2 allantoic sacs, one per uterine horn, including one (no fusion) or two fetuses
261 (partial fusion). In every placenta, the placentomes displayed multiple small foci of
262 hemorrhages: placental hematomas (normal in this species). For a given goat, the placentomes
263 were of varying size: the smallest placentomes ranged from 0.5 to 1 cm in diameter while the
264 largest placentomes ranged from 1 to 4 cm in diameter. The maximal diameter was measured
265 for 4 goats in each group (all selected goats had at least one living fetus except one goat from

266 group G42 with 2 dead fetuses Univariate analysis allowed selecting age and breed as
267 explanatory variables. Multivariate analysis showed a significant difference in the maximal
268 diameter of placentomes between infected (G28 and G42) and control goats (lower diameter
269 in infected goats, Figure 1) on the one hand, and between Alpine and Saanen goats on the
270 other hand (higher diameter in Saanen goats). The goats included in the analysis were all
271 carrying at least one living fetus except one goat from G42, thus fetal mortality alone cannot
272 explain the smaller maximal diameter of placentomes in the infected goats. Histologically,
273 foci of degeneration and necrosis of the placentomes, involving both fetal and maternal parts
274 on approximately 5 to 10% of the surface, were seen only in 2 goats from G42, one carrying 2
275 living fetuses and the other one carrying 2 dead fetuses.

276 The fetuses from G28 and G42 did not display gross abnormalities except autolytic changes in
277 some of them (fetal death) and wide variation in crown-rump length, ranging from 3 to 8.8 cm
278 in G28 and from 7.5 to 9 cm in G42 (Figure 2 A and B). No gross lesions were observed in
279 fetuses from control goats; their length ranged from 8 to 9.2 cm. The crown-rump length was
280 significantly lower in fetuses from G28 than in those from control goats, but there was no
281 significant difference between the length of fetuses from G42 and the length of fetuses from
282 control goats (Figure 2 A). However, when we added the 'dead or alive' status of the fetuses
283 as an explanatory variable, the difference between the length of fetuses from G28 and from
284 controls was not significant anymore. Thus, the difference relied more on the 'dead or alive'
285 status than on the group.

286 Histological lesions were found in the cerebrum of 2 fetuses, one from G28 and one from
287 G42, both with an 'alive' status before euthanasia. In the neopallium, bilaterally around the
288 lateral ventricles, there was a circumferential loss of cells within the periventricular layer with
289 cavitation: porencephaly (Figure 3 A, B and C). The cavitation was twice wider in the fetus
290 from G28 than in the one from G42, in transverse brain sections from the same level. In both

291 cases, porencephaly was associated with multiple foci of hemorrhage with
292 erythrophagocytosis by macrophage-like cells, and with hyperplasia of small caliber, venule-
293 like vessels. In addition, the wall of these vessels was thickened and irregular, made of
294 hypertrophic endothelial cells with prominent nuclei (Figure 3 D). The other fetuses did not
295 show any brain lesions. No lesions were found in the spinal cord of any fetus; the ventral
296 horns already displayed a few well-differentiated neurons. Skeletal muscle was similar in
297 control fetuses and in fetuses from G28 and G42 (Figure 4 A). We did not find any lesions in
298 the other fetal organs, except in the umbilical cord of the fetus from G28 with porencephaly.
299 In this fetus, both umbilical arteries showed a focal, superficial infiltration of their wall by
300 round cells (figure 5 A). This infiltrate was located below a focus of endothelial loss, partially
301 covered by an aggregate of fetal blood cells enmeshed in small amounts of fibrin
302 (thrombosis). Among the round cells infiltrating the wall were a few CD3-positive cells: T
303 lymphocytes (figure 5 D). No cells were CD79-positive. Overall, the lesions were consistent
304 with chronic, bilateral, focal umbilical arteritis with thrombosis.

305

306 SBV distribution in goats and fetuses

307 Distribution of SBV RNA and SBV antigens in the organs from inoculated goats and their
308 fetuses is shown in figure 3. SBV RNA and SBV antigens were not found in the goats and
309 fetuses from the control group.

310 SBV RNA was detected in 3/5 goats from G28 and 5/5 goats from G42. It was detected more
311 constantly in the placentome than in the proper goat tissues in both groups. The placentome
312 was also the tissue where the highest RNA quantity was detected, in G42 only, with Cq values
313 ranging from 20 to 25, while in the other tissues, and in placentomes from the G28 goats, the
314 Cq ranged from 25 to 38 (non-normalized data from samples of the same volume). For the

315 two goats from G28 with one allantoic sac per uterine horn, the placentomes from the right
316 side were RT-qPCR negative whereas those from the left side were positive. By
317 immunohistochemistry, SBV antigen was found in the placentomes of 1 goat from G28 and 4
318 goats from G42, being located in the cytoplasm of giant syncytial cells on the maternal side as
319 well as in the cytoplasm of binucleate trophoblastic cells on the fetal side (Figure 6). SBV was
320 successfully isolated in Vero cells (but not in CPT-Tert cells) from a placentome from a G42
321 goat, but not from another one from a G28 goat.

322 SBV RNA was found in 6/11 fetuses from G28, including all the fetuses found dead in this
323 group and one fetus found alive - the one with porencephaly. For two goats from G28 with
324 triplet pregnancy but separate right and left allantoic sacs, SBV RNA was found in the two
325 fetus from the left horn but not in the one from the right one. The results obtained in
326 placentomes from these goats paralleled those found in fetuses, with SBV RNA being found
327 in the left horn but not in the right horn. The fetuses from the two G28 goats that were devoid
328 of SBV RNA in their organs did not contain SBV RNA either. All the fetuses from G42
329 contained SBV RNA, whatever their 'alive or dead' status. For any fetus with a positive
330 result, all the sampled organs, the umbilical blood and the amniotic and allantoic fluids and
331 membranes contained SBV RNA, with few exceptions (one G28 fetus with a negative
332 amniotic fluid, one G42 fetus with a negative umbilical blood and one G42 fetus with
333 negative results in the eye, mandible, and amniotic membrane). The Cq values were similar in
334 G28 fetuses and in G42 fetuses for a given organ, with the lowest values found in muscle,
335 kidney, heart, eye, liver, spinal cord, brain, intestine, lung and mandible (Cq values ranging
336 from 15 to 25), especially for muscle, kidney and heart (Cq values: 14-20).

337 In fetuses, SBV antigens were found in several organs. In the cerebrum, it was found in
338 association with histological lesions of porencephaly (one G28 fetus and one G42 fetus); the
339 antigen was in the cytoplasm of progenitor cells located in the periventricular layer (Figure 3

340 F). In three G42 fetuses (including the one with cerebral porencephaly), SBV antigens were
341 also found in the cerebellum, without histological lesions; there were foci of 10 to 50 positive
342 cells in the external granular layer with rare positive cells in the underlying layers. In the
343 thoracic and lumbar parts of the spinal cord from one G28 fetus (the one with porencephaly)
344 and two G42 fetuses, rare positive cells were observed in the ventral horn; they were located
345 around neurons and morphologically consistent with astrocytes. SBV antigens were detected
346 in the cytoplasm of cells in the kidney, heart and skeletal muscle of one G28 fetus and almost
347 all G42 fetuses. In the kidney, the positive cells were at the periphery of the cortex, appearing
348 as groups of adjacent cells in rudimentary glomeruli and tubules as well as scattered
349 undifferentiated cells under the renal capsule (Figure 6 H). In the heart and skeletal muscle,
350 multifocal adjacent cells were positive: mostly secondary myotubes with rare primary
351 myotubes in the skeletal muscle (Figure 4 B), and cardiomyocytes in the heart (Figure 6 F).
352 The mandible of one G28 fetus and three G42 fetuses showed SBV antigens in the cytoplasm
353 of scattered chondrocytes (Figure 6 D). SBV antigens were also detected in the wall of one
354 umbilical artery from the G28 fetus that displayed bilateral umbilical arteritis; the positive
355 cells were parallel spindle cells consistent with smooth muscle cells (figure 5 C). SBV
356 antigens were not found in any fetal eye stricto sensu, however a few myotubes in the
357 surrounding eyelids were positive.

358 SBV viral isolation was successful in Vero cells (but not in CPT-Tert cells) using
359 homogenates from the following fetal organs: the intestine and the eye in one G28 fetus and
360 the eye, the lung and the umbilical cord in one G42 fetus. Viral isolation was unsuccessful in
361 all the other sampled tissues.

362

363 Table 3. Distribution of SBV RNA and SBV antigens in the organs of SBV-inoculated goats
 364 and their fetuses. For a given organ, the number of animals with positive results is detailed for
 365 each technique, followed by the total number of tested animals in brackets.

	Organ	Technique	Group	
			G28	G42
Fetuses and their amniotic and allantoic sacs	Brain	RT-qPCR	6 (11)	11 (11)
		IHC	1 (2)	3 (8)
	Spinal cord within vertebrae	RT-qPCR	1 (5)	11 (11)
		IHC	1 (7)	3 (7)
	Skeletal muscle	RT-qPCR	1 (5)	11 (11)
		IHC	1 (2)	6 (7)
	Kidney	RT-qPCR	1 (6)	11 (11)
		IHC	1 (3)	7 (7)
	Heart	RT-qPCR	1 (5)	11 (11)
		IHC	1 (3)	7 (7)
	Mandible	RT-qPCR	1 (6)	10 (11)
		IHC	1 (2)	3 (6)
	Eye	RT-qPCR	1 (5)	10 (11)
		IHC	0 (2)	0 (7)
	Thymus	RT-qPCR	1 (5)	11 (11)
	Liver	RT-qPCR	3 (8)	11 (11)
	Intestine with meconium	RT-qPCR	1 (6)	11 (11)
	Lung	RT-qPCR	1 (6)	11 (11)
	Umbilical cord	RT-qPCR	4 (8)	11 (11)
	Umbilical blood	RT-qPCR	2 (6)	9 (10)
Amniotic membrane	RT-qPCR	7 (10)	10 (11)	
Amniotic fluid	RT-qPCR	6 (11)	11 (11)	
Allantoic membrane*	RT-qPCR	4 (7)	7 (7)	
Allantoic fluid*	RT-qPCR	4 (7)	6 (6)	
Goats and placentomes	Mesenteric lymph node	RT-qPCR	2 (4)	5 (5)
	Spleen	RT-qPCR	0 (4)	4 (5)
	Ovary	RT-qPCR	2 (5)	1 (5)
	Oviduct	RT-qPCR	3 (5)	4 (5)
	Uterus	RT-qPCR	3 (5)	4 (5)
	Placentome	RT-qPCR	3 (4)	5 (5)
		IHC	1 (4)	4 (5)

366 IHC: immunohistochemistry. * The allantoic sacs were totally fused in most cases of twin or triplet pregnancy
 367 except in 4 goats whose placenta displayed 1 allantoic sac per horn.

368

369 Apoptosis and cell proliferation in fetal muscle

370 To screen for apoptosis in the fetal muscle, the density of activated caspase 3-positive cells
371 per surface area was measured in muscle from three SBV-positive fetuses (as determined by
372 RT-qPCR), including the two fetuses with porencephaly, and from two control fetuses.
373 Muscle from the SBV-positive fetuses and from control fetuses displayed, on average, 4.5 and
374 1.7 positive cells per mm² (standard deviation 3.2 and 0.6), respectively. The difference in
375 density was not significant between the SBV-positive fetuses and the control fetuses.
376 Nevertheless, a trend towards higher densities of positive cells (6.1 to 6.5 cells per mm²) was
377 observed in the muscle from the two SBV-positive fetuses with porencephaly in comparison
378 to the muscle from control fetuses.

379 To assess cell proliferation in the fetal muscle, the Ki67 ratio, defined as the ratio between the
380 area occupied by positive nuclei and the total area occupied by nuclei, was assessed in the
381 muscle of 3 SBV-positive fetuses and 4 control fetuses. The Ki67 ratio was significantly
382 higher in SBV-positive fetuses than in control fetuses (figure 7).

383

384

385

386

387

388

389

390

391

392 **Discussion**

393 Our results indicate that the vertical transmission of SBV from a pregnant goat to its fetus(es)
394 can occur between 28 and 42 days of gestation. In ruminants, fetal-maternal exchange occurs
395 in specialized structures in the placenta: the placentomes. In sheep, SBV has been shown to
396 cross the placenta after inoculation at day 38 or at day 45 of gestation, with SBV RNA
397 detection in the placentomes and some fetuses at 7 dpi (14). In this study, placentomes from
398 all the G42 goats contained viral genome and, for at least one of them, infectious virus, at 12
399 dpi (end of the trial) while placentomes from the majority of the G28 goats contained viral
400 genome at 26 dpi (end of the trial). However, in the G28 goats with fetuses in separate left
401 and right allantoic sacs, SBV genome was only found on the placentomes and the associated
402 fetuses from one side and not from the other. Thus, either the virus may not diffuse
403 homogeneously within the maternal uterus or, in some cases, its diffusion may be stopped
404 locally at the level of the placentomes.

405 Following placental crossing, SBV disseminated widely in the goat fetus. SBV genome was
406 found in blood, CNS, muscle, cartilage, lung, meconium, umbilical cord, and in fetal
407 membranes and fluids: this is in line with the organs that have been found positive in newborn
408 or stillborn ruminants in the field (9,15,16). In addition, SBV genome was found in the
409 thymus and the liver of many infected fetuses in this study; thus, SBV can disseminate in
410 these organs at least transiently. We also found infectious virus in the eye; however,
411 considering the immunohistochemistry results, the muscular part of the eyelids seems to be
412 the site of viral replication while the globe itself may not.

413 As determined by immunohistochemistry, the target cells of SBV in the goat fetuses were (i)
414 progenitor cells: on the one hand, in the brain: periventricular layer cells in the cerebrum and

415 external granular layer cells in the cerebellum (17); on the other hand, in the kidney:
416 subcapsular undifferentiated cells (ii) cells engaged in their differentiation process in muscle:
417 secondary myotubes (18), in the kidney: cells from rudimentary glomeruli and tubules, and in
418 the heart: growing cardiomyocytes (iii) well-differentiated cells in the mandible:
419 chondrocytes. It has been previously shown that the neurons from the CNS are target cells for
420 SBV in young ruminants (11,19) and in mice (11). After their experimental inoculation of
421 AKAV during early pregnancy in the ewe, Parsonson et al. (20) also found viral antigens in
422 the brain, especially in the cerebrum but they did not mention a target zone or cell.

423 In the goat fetuses, the infection by SBV was associated with 3 different outcomes, which
424 could occur within the same litter. The infected fetuses were either dead (10/17, 5 from G28
425 and 5 from G42), or alive with lesions (2/17, 1 from G28 and 1 from G42: 2 fetuses with
426 porencephaly), or alive without lesions (5/17, G42 only). In the latter case, we can
427 hypothesize either that the lesions were not yet developed at 12 dpi, or that the infection
428 would have been cleared later in gestation.

429 Fetal death was often associated with reduced fetal length. If we consider there was no growth
430 retardation associated with fetal death, the smallest fetuses died around 38 to 40 days of
431 gestation (end of the embryonic period) in G28 and around 49-52 days of gestation in G42
432 (21). Thus, embryonic or fetal death could occur as soon as 10 dpi, i.e. around a week after
433 viremia in the pregnant goat. Embryonic or early fetal death can easily be overlooked by the
434 farmers and could have been underestimated in the field. Indeed, evidence of embryonal or
435 early fetal loss in the field in association with SBV infection in goats has only been reported
436 in the literature in 2013 for German herds (22) and in 2014 for French herds (7), one and two
437 years, respectively, after the emergence of the virus in Europe. As hyperthermia was absent in
438 the SBV-inoculated goats, its causal role in embryonic or fetal death is unlikely. Embryonic

439 or early fetal death can also occur because of placental failure or because of disruption of the
440 expression of developmental genes.

441 Our findings of reduced maximal diameters of placentomes in infected goats and of
442 degenerative changes observed in placentomes from 2 goats from G42 in association with
443 abundant SBV antigens, suggest that SBV could reduce the efficiency of the feto-maternal
444 exchange. This hypothesis deserves to be further explored for example through an evaluation
445 of the proportion of apoptotic cells and evaluation of blood vessels density and caliber in
446 placentomes. The umbilical arteritis with partial thrombosis observed in one (viable) fetus in
447 association with SBV antigen may be incidental or may represent another way for the virus to
448 lead to fetal ischemia by disruption of the fetal blood circulation. The expression of fetal
449 genes was not evaluated in this study but a recent report showed that SBV down-regulate in
450 vitro the expression of a transcription factor involved in embryonic development (23). The
451 ability of SBV to influence the expression of key-genes for embryonic and fetal development
452 remains to be determined.

453 Lesions were found in the CNS of only two out of 17 infected fetuses. This low frequency
454 was expected as reports from the field in France state that only 2% of the goat kids born in
455 SBV-infected herds display congenital malformations (7). The 2 fetuses displayed
456 porencephaly in the neopallium. Porencephaly is one of the frequent lesions associated with
457 SBV transplacental infection in newborn or stillborn domestic ruminants (24,3,25–27).
458 However, the porencephaly lesions we observed at 2 months of gestation may have later
459 evolved into hydrocephaly or even hydranencephaly, which are also typical lesions found in
460 SBV-infected young ruminants (2,3,26,27). Indeed, the cavitation and loss of cells in the goat
461 fetuses were within the periventricular zone that contains bipotential progenitor cells (17).
462 These cells give rise to neuronal progenitor cells and glial progenitor cells. The latter are
463 precursors to astrocytes and oligodendrocytes but also to the radial glial cells, temporary cells

464 that guide the young neurons during their migration in the cortex in midpregnancy (17). Cell
465 death in any of these precursors could thus result in hypoplasia of the neopallium, with
466 resulting hydranencephaly (26) or hydrocephalus ex vacuo (3), depending on the severity of
467 cell loss. SBV could elicit cell death in the CNS directly or indirectly through ischemia. On
468 the one hand, SBV is able to trigger apoptosis in vitro in CPT-Tert cells and in vivo in the
469 brain of mice (28), suggesting cell loss may rely upon direct viral effects in the brain.
470 Supporting this hypothesis is the detection of SBV antigens-positive cells around the areas of
471 cavitation in the fetuses from the present study. On the other hand, evidence of blood vessel
472 damage was noticed in the fetuses' brains in this study, appearing as acute hemorrhages in the
473 areas of cavitation, as well as in the CNS of neonates in another study, appearing as chronic
474 hemorrhages often associated with tissue destruction (25). Although we did not noticed
475 vasculitis or viral antigen in small-caliber blood vessels in the brain of the goat fetuses, the
476 ability of SBV to elicit brain ischemia by blood vessel damage cannot be excluded; it may
477 have occurred at an earlier time point during the course of infection. The blood vessels
478 associated to porencephaly in fetal brains were hyperplastic with marked hypertrophy of the
479 endothelial cells. It may be a non-specific reactive change secondary to cell loss. This
480 vascular proliferation has also been described in the brain of goat fetuses about 10 days after
481 inoculation of AKAV (29). In these fetuses infected by AKAV, muscular degeneration and
482 necrosis have also been reported and may determine in part the muscular hypoplasia seen in
483 the newborns (29). In the present study, no histological lesions were seen in skeletal muscle
484 despite evidence of SBV infection; we cannot exclude they would have occurred later in
485 gestation. We found a trend in increased apoptosis in muscle from infected fetuses bearing
486 porencephaly than in muscle from infected fetuses without lesions or control fetuses.
487 Unexpectedly, the rate of cell proliferation was higher in muscle from the infected fetus than
488 in muscle from control fetuses. This proliferation could be either a reactive event secondary to

489 previous cell loss or, less likely, a direct effect of the virus. Overall, these results support only
490 weakly the hypothesis of a direct destructive action of SBV on fetal muscle. Muscle
491 hypoplasia in newborns may also result from SBV-determined neuronal loss in the spinal cord
492 (26,30). An alternative mechanism would be the disruption of muscle cell differentiation by
493 the virus.

494

495 **Conclusion**

496 Vertical transmission of SBV through the placenta can occur between 28 and 42 days of
497 gestation in pregnant goats. The virus is widely distributed in infected fetuses. Following
498 SBV infection between 28 and 42 days of gestation, embryonic or fetal death can occur and,
499 in the surviving fetuses, CNS lesions may develop. Embryonic or early fetal death due to SBV
500 infection in goats may have been overlooked during the first year of SBV spread in Europe
501 and could have led to an underestimation of the impact of the virus on goat farming.

502

503 **Conflicts of interest:** none

504 **Acknowledgements**

505 This study was supported and financed by the European Union (Council decision
506 2012/349/EU) and the General Direction of Food (DGAL, Ministry of Agriculture) for studies
507 on Schmallenberg virus. We wish to thank Kerstin Wernike (FLI), Massimo Palmarini and
508 Mariana Varela (University of Glasgow) and Sandra Scholes (SAC Consulting Veterinary
509 Services, Edinburgh Disease Surveillance Centre) for providing infectious bovine serum, anti-
510 SBV polyclonal serum and control slides for immunohistochemistry, respectively. We also
511 thank Yves Millemann and Daniel Marc for helpful discussion. Many thanks to Jean-Luc

512 Servely for assistance in image analysis and to Agnès Champeix and Patricia Wattier for
513 technical support. We are grateful to Thierry Pineau, the leader of department of Animal
514 Heath in INRA, coordinator of European project for the experiments with goats in France.
515 Many thanks to Bertrand Schwartz and Pierre Sarradin, and to the zootechnical staff of the
516 PFIE, especially the team working in confinement unit with the goats.

517

518 **References**

- 519 1. Hoffmann B, Scheuch M, Höper D, Jungblut R, Holsteg M, Schirrmeier H, et al. Novel
520 Orthobunyavirus in Cattle, Europe, 2011. *Emerg Infect Dis.* mars 2012;18(3):469-72.
- 521 2. Van den Brom R, Luttikholt SJM, Lievaart-Peterson K, Peperkamp NHMT, Mars MH, van
522 der Poel WHM, et al. Epizootic of ovine congenital malformations associated with
523 Schmallerberg virus infection. *Tijdschr Diergeneeskd.* févr 2012;137(2):106-11.
- 524 3. Herder V, Wohlsein P, Peters M, Hansmann F, Baumgärtner W. Salient lesions in
525 domestic ruminants infected with the emerging so-called Schmallerberg virus in
526 Germany. *Vet Pathol.* juill 2012;49(4):588-91.
- 527 4. Wernike K, Conraths F, Zanella G, Granzow H, Gache K, Schirrmeier H, et al.
528 Schmallerberg virus-two years of experiences. *Prev Vet Med.* 15 oct
529 2014;116(4):423-34.
- 530 5. Spickler AR. Akabane disease [Internet]. The Center for Food Security and Public Health,
531 Iowa State University; 2009 [cité 5 juill 2015]. Disponible sur:
532 <http://www.cfsph.iastate.edu/Factsheets/pdfs/akabane.pdf>
- 533 6. Valas S, Baudry C, Ehrhardt N, Leven A, Thirion M, Aubert C, et al. Serosurvey of
534 Schmallerberg Virus Infection in the Highest Goat-Specialized Region of France.
535 *Transbound Emerg Dis.* 27 janv 2014;
- 536 7. Dominguez M, Gache K, Touratier A, Perrin J-B, Fediaevsky A, Collin E, et al. Spread and
537 impact of the Schmallerberg virus epidemic in France in 2012-2013. *BMC Vet Res.*
538 2014;10:248.
- 539 8. Wernike K, Eschbaumer M, Breithaupt A, Hoffmann B, Beer M. Schmallerberg virus
540 challenge models in cattle: infectious serum or culture-grown virus? *Vet Res.* févr
541 2012;43(1):84.
- 542 9. Bilk S, Schulze C, Fischer M, Beer M, Hlinak A, Hoffmann B. Organ distribution of
543 Schmallerberg virus RNA in malformed newborns. *Vet Microbiol.* 14 sept 2012;159(1-
544 2):236-8.

- 545 10. Arnaud F, Black SG, Murphy L, Griffiths DJ, Neil SJ, Spencer TE, et al. Interplay between
546 Ovine Bone Marrow Stromal Cell Antigen 2/Tetherin and Endogenous Retroviruses. *J*
547 *Virol.* mai 2010;84(9):4415-25.
- 548 11. Varela M, Schnettler E, Caporale M, Murgia C, Barry G, McFarlane M, et al.
549 Schmallenberg Virus Pathogenesis, Tropism and Interaction with the Innate Immune
550 System of the Host. *PLoS Pathog.* 10 janv 2013;9(1):e1003133.
- 551 12. Fox J, Weisberg S. An {R} Companion to Applied Regression, Second Edition. [Internet].
552 Second Edition. Sage; 2011. Disponible sur: URL:
553 <http://socserv.socsci.mcmaster.ca/jfox/Books/Companion>
- 554 13. Højsgaard S, Halekoh U, Yan J. The R Package geepack for Generalized Estimating
555 Equations. *J Stat Softw.* 2006;15(2):1-11.
- 556 14. Norbert Stockhofe, Marcel Hulst, Renate Hakze, Piet Vellema, Wim van der Poel.
557 Transplacental infection of Schmallenberg virus in the fist trimester of gestation is
558 highly efficient in sheep. Bruxelles; 2013.
- 559 15. Balseiro A, Royo LJ, Gómez Antona A, García Marín JF. First Confirmation of
560 Schmallenberg Virus in Cattle in Spain: Tissue Distribution and Pathology. *Transbound*
561 *Emerg Dis.* 6 nov 2013;
- 562 16. Wisløff H, Nordvik BS, Sviland S, Tønnessen R. The first documented clinical case of
563 Schmallenberg virus in Norway: fetal malformations in a calf. *Vet Rec.* 1 févr
564 2014;174(5):120.
- 565 17. Fred Sinowatz. Chapter 10: Development of the central and peripheral nervous system.
566 *Essentials of Domestic Animal Embryology.* Saunders Elsevier; 2010. p. 120-62.
- 567 18. Fred Sinowatz. Chapter 16: Musculo-skeletal system. *Essentials of Domestic Animal*
568 *Embryology.* Saunders Elsevier; 2010. p. 286-316.
- 569 19. Hahn K, Habierski A, Herder V, Wohlsein P, Peters M, Hansmann F, et al. Schmallenberg
570 virus in central nervous system of ruminants. *Emerg Infect Dis.* janv 2013;19(1):154-5.
- 571 20. Parsonson IM, McPhee DA, Della-Porta AJ, McClure S, McCullagh P. Transmission of
572 Akabane virus from the ewe to the early fetus (32 to 53 days). *J Comp Pathol.* août
573 1988;99(2):215-27.
- 574 21. Gall CF, Stier C-H, Frahm K. Age estimation of goat fetus. *Small Rumin Res.* juin
575 1994;14(1):91-4.
- 576 22. Helmer C, Eibach R, Tegtmeyer PC, Humann-Ziehank E, Ganter M. Survey of
577 Schmallenberg virus (SBV) infection in German goat flocks. *Epidemiol Infect.* nov
578 2013;141(11):2335-45.
- 579 23. Blomström A-L, Gu Q, Barry G, Wilkie G, Skelton JK, Baird M, et al. Transcriptome
580 analysis reveals the host response to Schmallenberg virus in bovine cells and
581 antagonistic effects of the NSs protein. *BMC Genomics.* 2015;16:324.

- 582 24. Garigliany M-M, Hoffmann B, Dive M, Sartelet A, Bayrou C, Cassart D, et al.
583 Schmallenberg virus in calf born at term with porencephaly, Belgium. *Emerg Infect Dis.*
584 *juin 2012;18(6):1005-6.*
- 585 25. Herder V, Hansmann F, Wohlsein P, Peters M, Varela M, Palmarini M, et al.
586 Immunophenotyping of Inflammatory Cells Associated with Schmallenberg Virus
587 Infection of the Central Nervous System of Ruminants. *PLoS ONE.* 7 mai
588 2013;8(5):e62939.
- 589 26. Bayrou C, Garigliany M-M, Sarlet M, Sartelet A, Cassart D, Desmecht D. Natural
590 Intrauterine Infection with Schmallenberg Virus in Malformed Newborn Calves. *Emerg*
591 *Infect Dis.* août 2014;20(8):1327-30.
- 592 27. Peperkamp NH, Luttikholt SJ, Dijkman R, Vos JH, Junker K, Greijdanus S, et al. Ovine and
593 Bovine Congenital Abnormalities Associated With Intrauterine Infection With
594 Schmallenberg Virus. *Vet Pathol.* 26 nov 2014;
- 595 28. Barry G, Varela M, Ratinier M, Blomström A-L, Caporale M, Seehusen F, et al. NSs
596 protein of Schmallenberg virus counteracts the antiviral response of the cell by
597 inhibiting its transcriptional machinery. *J Gen Virol.* août 2014;95(Pt 8):1640-6.
- 598 29. Konno S, Nakagawa M. Akabane Disease in Cattle: Congenital Abnormalities caused by
599 Viral Infection. *Experimental Disease. Vet Pathol Online.* 1 mai 1982;19(3):267-79.
- 600 30. Seehusen F, Hahn K, Herder V, Weigand M, Habierski A, Gerhauser I, et al. Skeletal
601 Muscle Hypoplasia Represents the Only Significant Lesion in Peripheral Organs
602 of Ruminants Infected with Schmallenberg Virus during Gestation. *J Comp Pathol.* août
603 2014;151(2-3):148-52.

604

605

606

607

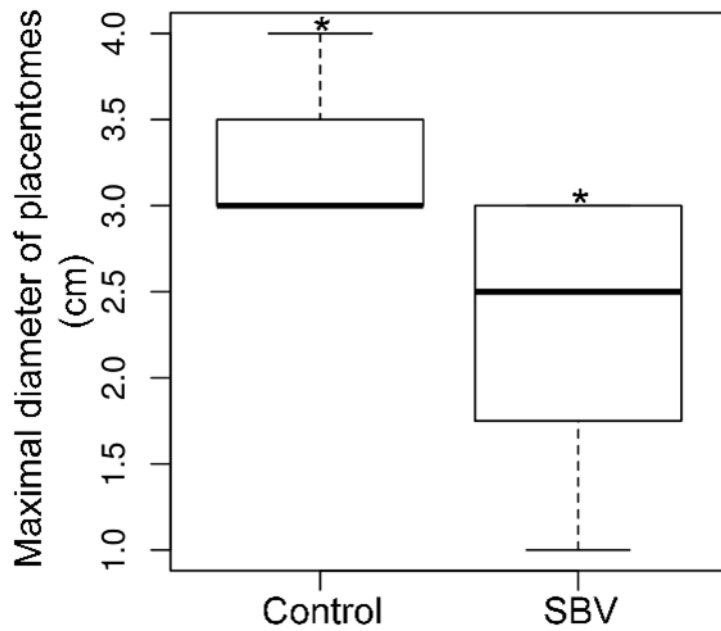
608

609

610

611

612



613

614 **Figure 1.** Box-plot showing the maximal diameter of the placentomes from pregnant goats in
615 the control group (control) and in the SBV-inoculated group (SBV) including both G28 and
616 G42. *P < 0.05.

617

618

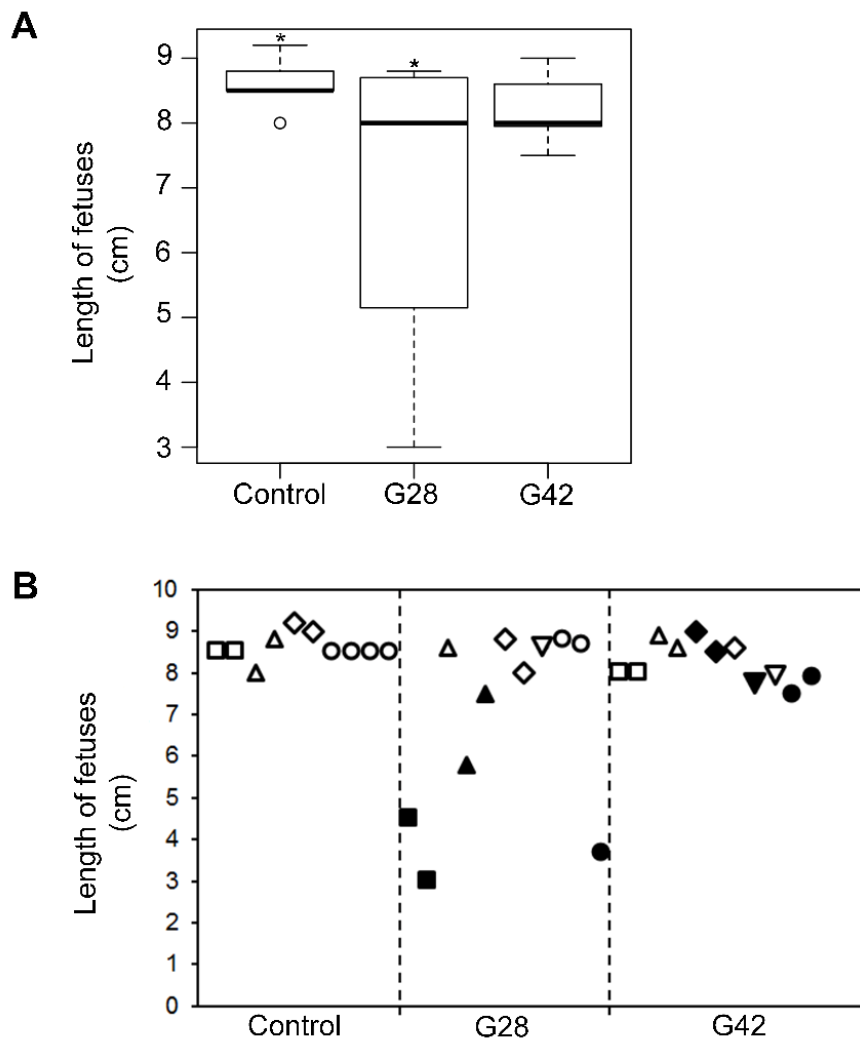
619

620

621

622

623

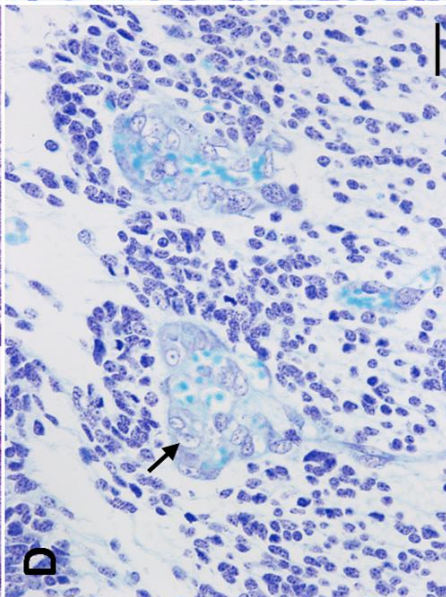
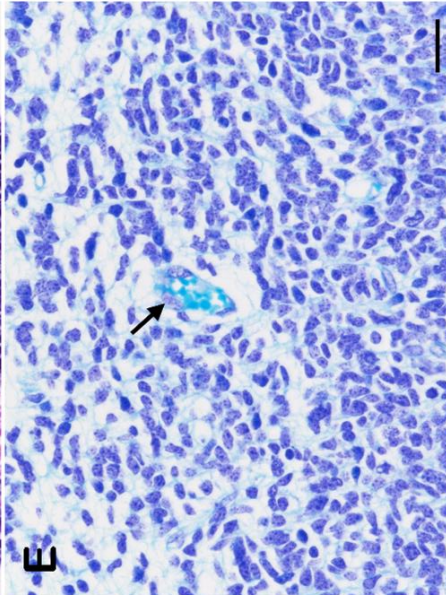
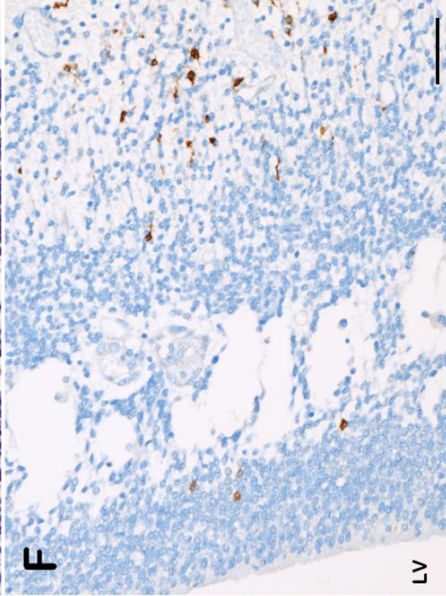
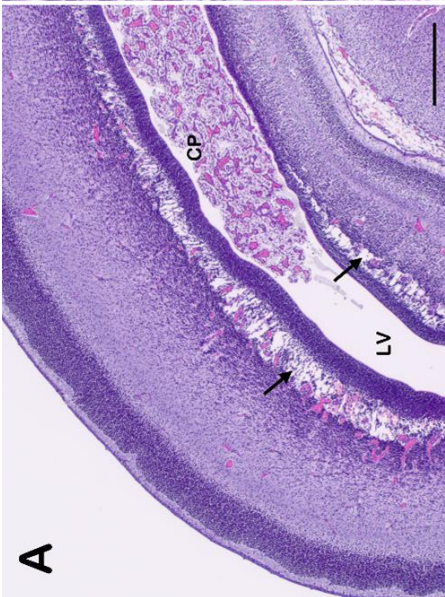
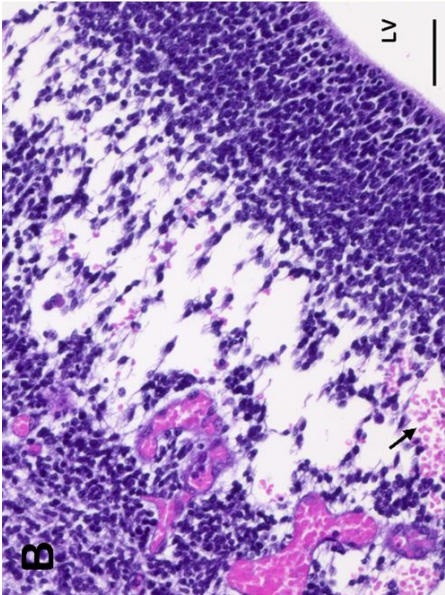
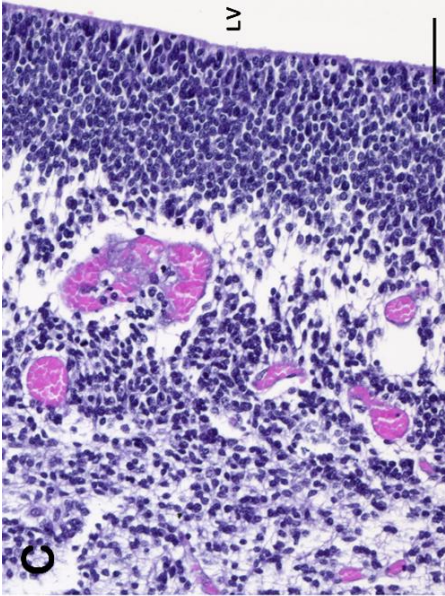


625

626 **Figure 2.** Crown-rump length of the goat fetuses. (A) Box-plot: length of fetuses from the
 627 control goats (control), from the G28 and the G42 goats. (B) Detailed length per fetus in each
 628 group. Symbols filled in black correspond to dead fetuses, whereas unfilled symbols
 629 correspond to living fetuses. Within each group, fetuses from the same mother have the same
 630 symbol (filled or unfilled depending on their status).

631

632



634

635

636

637

638 **Figure 3.** Lesions and SBV antigen localization in the brain of goat fetuses. (A) Brain,
639 cerebrum, goat fetus from G28. Cavitation in the periventricular layer: porencephaly (arrows).
640 CP: choroid plexus. LV: lateral ventricle. HES, bar=500 μm . (B) Brain, cerebrum, goat fetus
641 from G28. Porencephaly in the periventricular layer with hemorrhage (arrow). LV: lateral
642 ventricle. HES, bar=50 μm . (C) Brain, cerebrum, goat fetus from G42. Porencephaly in the
643 periventricular layer. LV: lateral ventricle. HES, bar=50 μm . (D) Brain, cerebrum, goat fetus
644 from G28. Porencephaly in the periventricular layer. The endothelial cells lining the venules
645 are hypertrophic (arrow). Kluver-Barrera stain, bar=20 μm . (E) Brain, cerebrum, control
646 fetus. A normal venule (arrow) in the periventricular layer. Kluver-Barrera stain, bar=20 μm .
647 (F) Brain, cerebrum, goat fetus from G28. SBV-positive cells around the cavitation in the
648 periventricular layer. LV: lateral ventricle. IHC SBV, bar=20 μm .

649

650

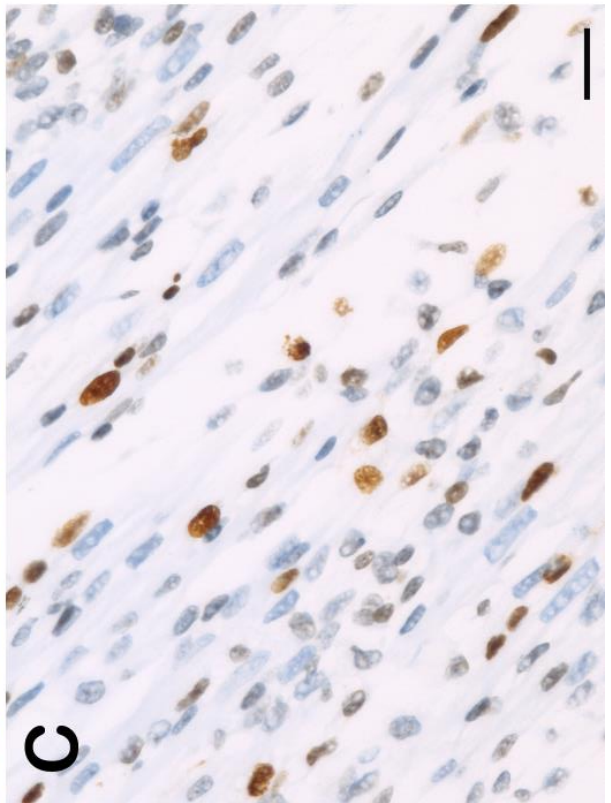
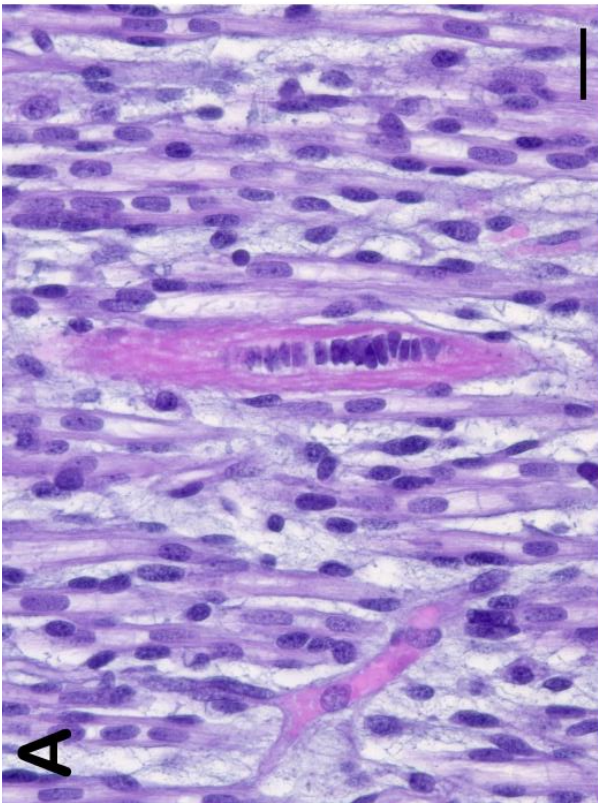
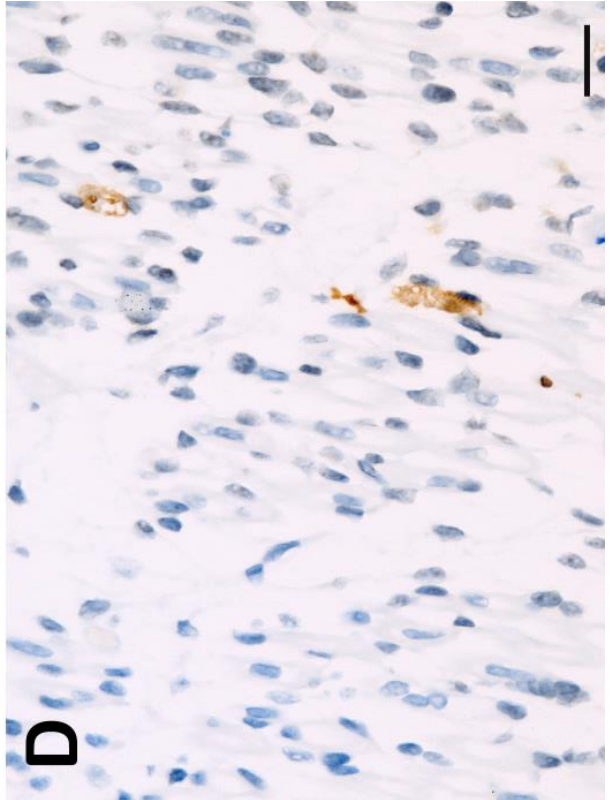
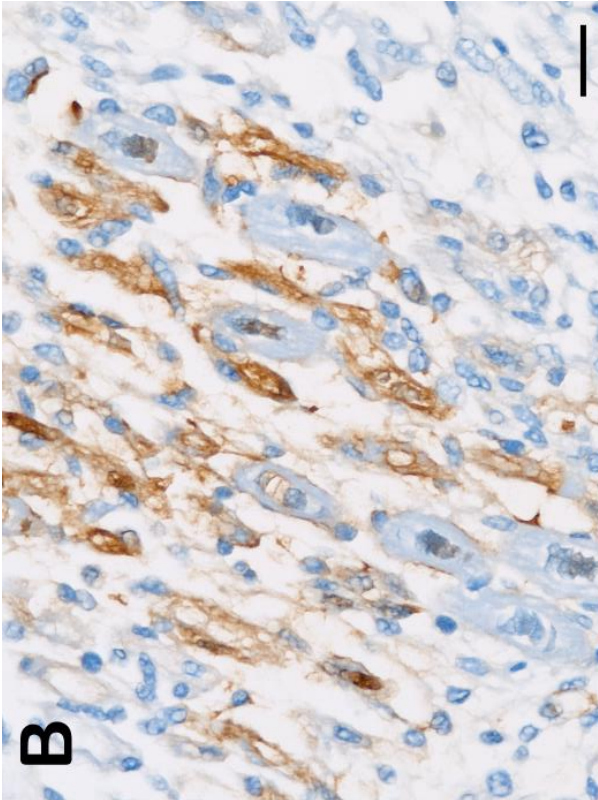
651

652

653

654

655



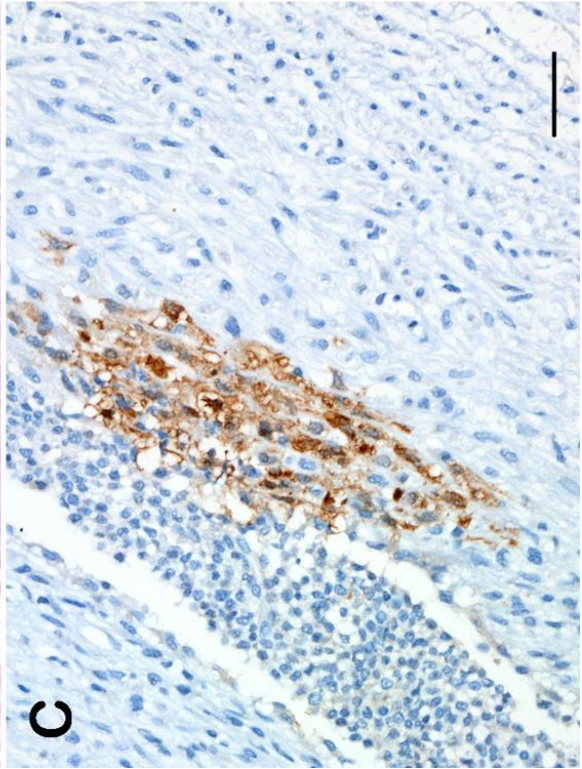
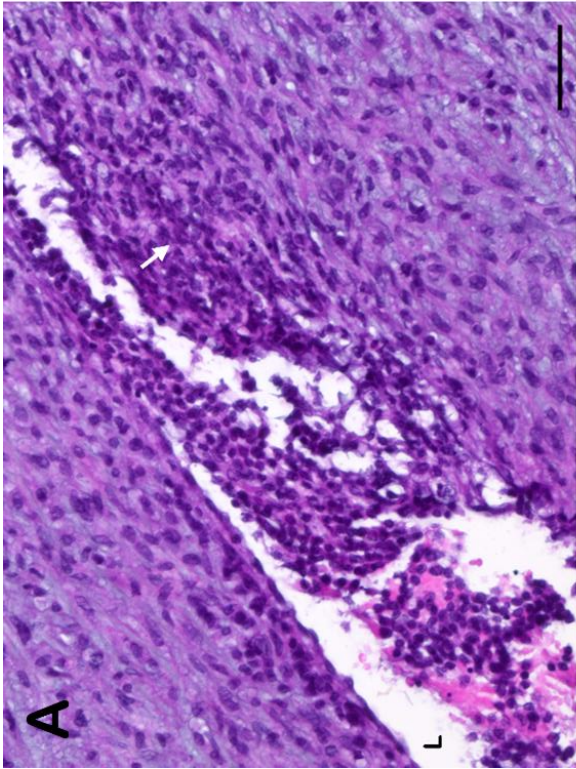
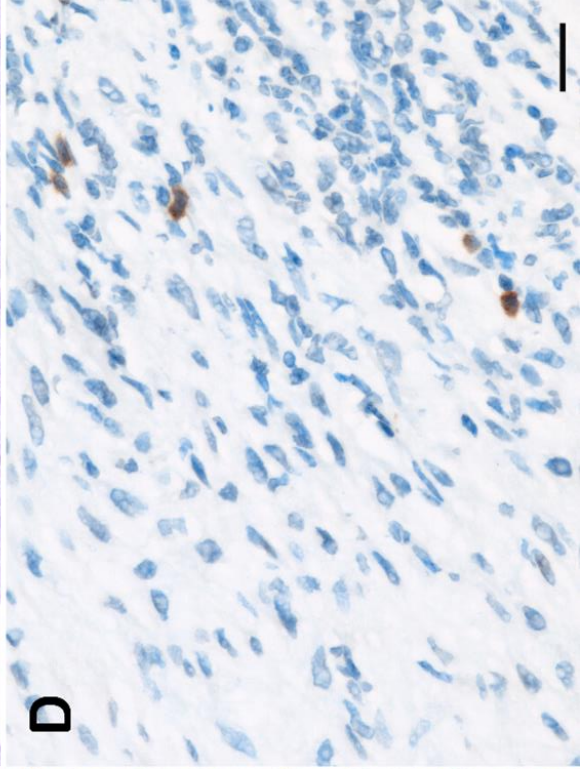
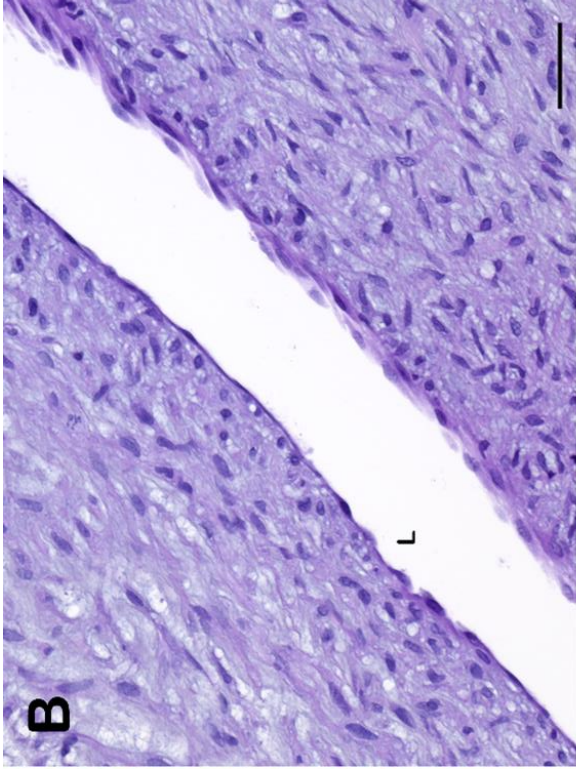
656

657

658

659
660
661
662
663
664
665
666
667
668
669
670
671
672
673
674
675
676
677
678
679

Figure 4. Skeletal muscle of a SBV-infected fetus. (A) Skeletal muscle, goat fetus from G28. A large primary myotube is in the center, surrounded by smaller secondary myotubes. HES, bar=20 μ m. (B) Skeletal muscle, goat fetus from G28. Several secondary myotubes are SBV-positive (cytoplasmic staining). IHC SBV, bar=20 μ m. (C) Skeletal muscle, goat fetus from G28. Many nuclei of myotubes are Ki67-positive. IHC Ki67, bar=20 μ m. (D) Skeletal muscle, goat fetus from G28. A few myotubes show activated caspase 3 positivity in their cytoplasm. IHC activated caspase 3, bar=20 μ m.



680

681

682

683

684

685

686

687

688 **Figure 5.** Lesions and SBV antigen localization in the umbilical cord from one SBV-infected
689 fetus. (A) Umbilical cord, umbilical artery, goat fetus from G28. The wall is focally infiltrated
690 by round cells (white arrow); a thrombus partially fills the lumen. L: lumen of the umbilical
691 artery. HES stain, bar=50 μ m. (B) Umbilical cord, umbilical artery, control goat fetus. The
692 wall is made of smooth muscle cells and is devoid of round cells. L: lumen of the umbilical
693 artery. HES stain, bar=50 μ m. (C) Umbilical cord, same umbilical artery as in A. SBV-
694 positive spindle cells in the wall of the artery, morphologically consistent with smooth muscle
695 cells. IHC SBV, bar=50 μ m. (D) Umbilical cord, detail of the wall of the umbilical artery
696 shown in A. On the right, the wall is infiltrated by round cells, some of which are CD3-
697 positive. IHC CD3, bar=20 μ m.

698

699

700

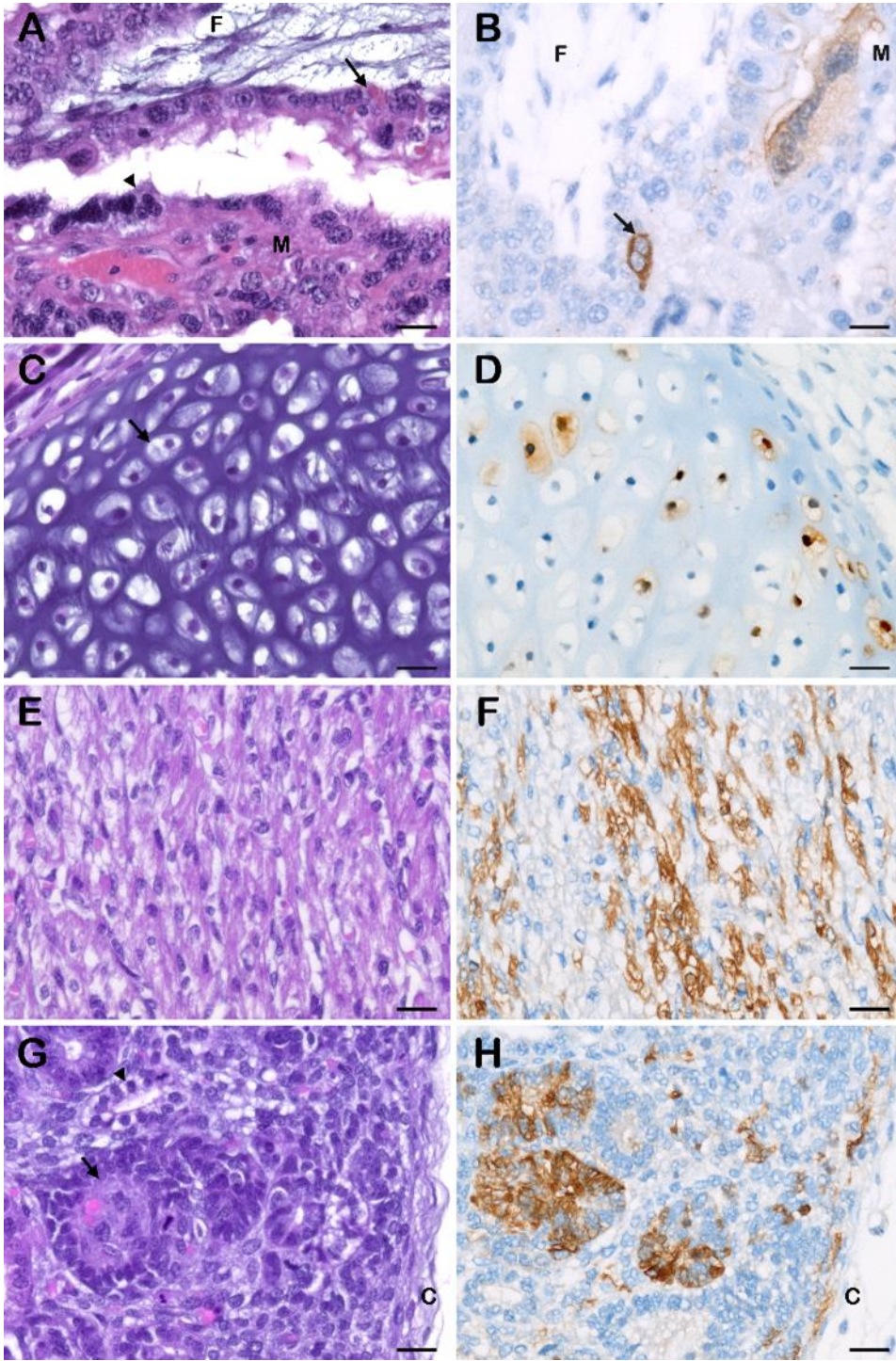
701

702

703

704

705



706

707

708

709

710

711

712

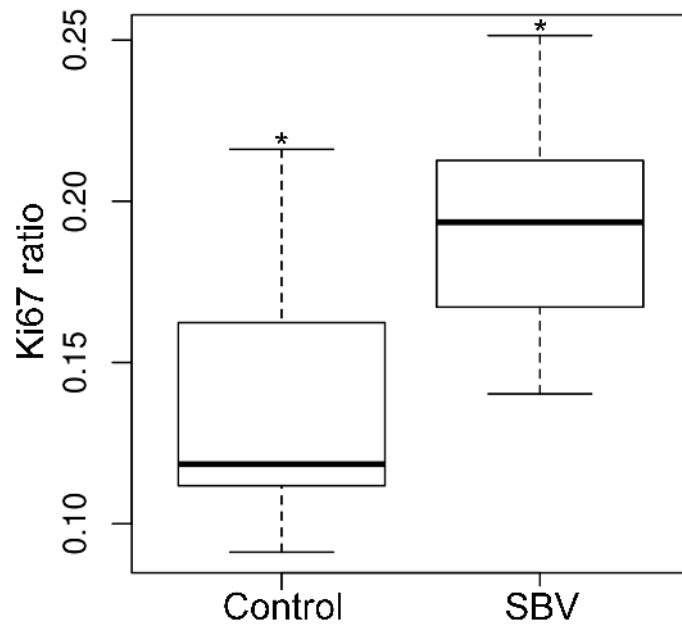
713

714

715 **Figure 6.** Placentome, kidney, heart and mandible from SBV-infected goat fetuses:
716 histological aspect and SBV antigen localization. (A) Placentome, goat and fetus from G42.
717 Focal disjunction of maternal septum and fetal villus close to a placental hemorrhage, with
718 erythrophagocytic trophoblast (arrow) on the fetal villus. F: fetal villus. M: maternal septum.
719 Arrowhead: giant syncytial cell. HES stain, bar=20 μ m. (B) Placentome, goat and fetus from
720 G42. A syncytial giant cell on the maternal side and a trophoblastic binucleate cell on the
721 fetal side (arrow) are SBV-positive. F: fetal villus. M: maternal septum. IHC SBV, bar=20
722 μ m. (C) Mandible, cartilage, goat fetus from G28. The cartilage is made of chondrocytes
723 (arrow) and extracellular matrix. HES stain, bar=20 μ m. (D) Mandible, cartilage, goat fetus
724 from G28. Several chondrocytes are SBV-positive. IHC SBV bar=20 μ m. (E) Heart,
725 myocardium, goat fetus from G28. The myocardium is made of cardiomyocytes interspersed
726 with blood capillaries. HES stain, bar=20 μ m. (F) Heart, myocardium, goat fetus from G28.
727 Several cardiomyocytes are SBV-positive. IHC SBV, bar=20 μ m. (G) Kidney, periphery of
728 the cortex, goat fetus from G28. A rudimentary glomerulus (arrow and a rudimentary tubule
729 (arrowhead) are developing in the cortex. C: capsule. HES stain, bar=20 μ m. (H) Kidney,
730 periphery of the cortex, goat fetus from G28. SBV-positive cells appear as groups of adjacent
731 cells in rudimentary glomeruli and tubules as well as scattered undifferentiated cells under the
732 renal capsule. IHC SBV, bar=20 μ m. C: capsule.

733

734



735

736

737

738 **Figure 7.** Ki67 ratio in the thigh muscles from fetuses from the control group (control) and

739 from fetuses from the SBV-infected group (SBV) including G28 and G42. *P < 0.05.

740

741

742

743

744

745

746

747

748 **Highlights**

- 749 • Goats were inoculated with Schmallerberg virus at 28 and 42 days of gestation.
- 750 • Most of the fetuses were transplacentally infected.
- 751 • Embryonic and fetal deaths were observed.
- 752 • In some of the surviving fetuses, lesions developed in the central nervous system.

753

4.2 Circulation in wild and exotic ruminants

4.2.1 Free-ranging wild ruminants in France

A serologic study was performed to evaluate the spread of SBV in red deer populations in France in 2011-2012. The results are described in the following paper, published in *Emerging Infectious Diseases* (Laloy et al., 2014).

I participated in data selection and analysis. I wrote the draft.

Schmallenberg Virus Infection among Red Deer, France, 2010–2012

Eve Laloy,¹ Emmanuel Bréard, Corinne Sailleau, Cyril Viarouge, Alexandra Desprat, Stéphane Zientara, François Klein, Jean Hars, and Sophie Rossi¹

Schmallenberg virus infection is emerging in European domestic and wild ruminants. We investigated the serologic status of 9 red deer populations to describe virus spread from September 2010 through March 2012 among wildlife in France. Deer in 7 populations exhibited seropositivity, with an average seroprevalence of 20%.

In summer and fall 2011, an unidentified disease was reported in dairy cattle in Germany and the Netherlands, causing decreased milk production, fever, and diarrhea (1,2). The virus associated with these clinical signs was identified as a new member of the genus *Orthobunyavirus* of the Simbu serogroup and named Schmallenberg virus (SBV) (2). This virus was later associated with abortions and congenital malformations in calves, lambs, and kids in several European countries (3). Serologic testing among wild cervids in Belgium revealed antibodies against Schmallenberg virus in roe deer (*Capreolus capreolus*) and red deer (*Cervus elaphus*) (4). Seroprevalence was already high (27% on average) in wild cervids in October 2011 in Belgium, suggesting that the virus began circulating months earlier (before August 2011). It has recently been shown that SBV had already circulated in *Culicoides* vectors in Belgium during August and September 2011 (5). Although SBV has been closely monitored among domestic ruminants in France, suggesting that clinical cases and antibodies appeared almost at the same time during 2011–2012 (6), little is known about the geographic spread of SBV in wildlife. To correct this lack of data, we conducted a serologic study using serum specimens collected from red deer in different regions in France.

Author affiliations: Ecole Nationale Vétérinaire d'Alfort, Maisons-Alfort, France (E. Laloy); French Agency for Food Environmental and Occupational Health and Safety, Maisons-Alfort (E. Bréard, C. Sailleau, C. Viarouge, A. Desprat, S. Zientara); French Wildlife and Hunting Agency, Bar-le-Duc, France (F. Klein); and French Wildlife and Hunting Agency, St Benoist, France (J. Hars, S. Rossi)

DOI: <http://dx.doi.org/10.3201/eid2001.130411>

The Study

Blood samples from 502 red deer, which had been either killed by gunshot or captured, were collected within 9 French departments (administrative units) during 1 or 2 sampling seasons (i.e., during September 2010–January 2011 and September 2011–March 2012). The serum specimens were first screened by using an SBV indirect ELISA (i-ELISA) that was previously validated for the serum specimens from cattle, sheep, and goats (ELISA ID Screen Schmallenberg Virus Indirect, Bicipule; ID Vet, Montpellier, France) (7). The results were expressed as S/P values using the cutoff recommended for domestic species ($S/P = [\text{optical density sample (S)}/\text{optical density positive control (P)}] \times 100$); $S/P < 60\%$, negative; $S/P > 70\%$, positive; and $S/P 60\text{--}70\%$, doubtful result). Serum specimens were also tested with a new competitive ELISA (c-ELISA; ELISA ID Screen Schmallenberg Virus Competitive; ID Vet). Positive results by c-ELISA corresponded to a percentage of inhibition (PI) < 50 , doubtful result if $40 < PI \leq 50$, and negative when $PI > 50$. The antigen used in both c-ELISA and i-ELISA is the same N recombinant protein. A subset of samples were also subjected to a seroneutralization test (SNT) as described (7).

Of 502 serum specimens, 492 could be tested by using i-ELISA and 486 by using c-ELISA. The 2 ELISA methods exhibited a 92% match (449/486). Because our samples (taken from dead animals in nonsterile conditions) generated bacterial contamination or cytotoxicity, conclusive SNT results were available from 114 animals only: 64 samples with positive or doubtful i-ELISA results and 50 samples ($S/P > 20$) with negative i-ELISA results. A large part of the serum specimens that were positive or doubtful by ELISA methods were also positive for SBV by SNT, suggesting a good specificity of both methods, though slightly better for c-ELISA than for i-ELISA (Table 1). Many serum specimens that tested negative by i-ELISA or c-ELISA (all collected during 2011–2012) were positive by SNT (Table 1). Even though the c-ELISA kit appeared slightly more sensitive than the i-ELISA kit, these results suggest that SNT is the most sensitive technique for detecting antibodies against SBV in a recently infected population of red deer. These results are consistent with the fact that SNT and c-ELISA are able to detect IgG and IgM, whereas i-ELISA detects only IgG that appears after the IgM adaptive response (E. Bréard, pers. comm.). Considering the performance of serologic methods in that study, seroprevalence was finally estimated as the proportion of positive or doubtful serum specimens by using the c-ELISA kit.

The number of samples collected in each department, the proportion of positive specimens, and the date of first

¹These authors contributed equally to this article.

Table 1. Serologic results for red deer serum samples tested for Schmallenberg virus with SNT, i-ELISA, and c-ELISA*

ELISA method	SNT method			
	SNT positive, n = 97		SNT negative, n = 17	
	Positive or doubtful	Negative	Positive or doubtful	Negative
i-ELISA	57	40	7	10
c-ELISA	67	30	6	11
i-ELISA and c-ELISA	49	22	6	9

*SNT, seroneutralization test; i-ELISA, indirect ELISA; c-ELISA, competitive ELISA.

observation of seropositive result are indicated in Table 2. The 56 serum specimens collected during September 2010–February 2011 in northeastern and southwestern France (Bas-Rhin and Pyrenees-Atlantiques departments) were negative by both ELISAs. From September 2011 through March 2012, a total of 7 of 9 departments exhibited at least 1 seropositive specimen by c-ELISA. Among these 7 departments, the average seroprevalence was 20% (95% CI 16%–24%), with significant variations between the 7 departments exhibiting seropositive results (8%–49%) ($\chi^2 = 67.4$, $df = 6$, $p < 0.001$). Seroprevalence was not influenced by the animal's age, suggesting an equal exposure of fawns born in 2011 and older animals ($\chi^2 = 0.16$, $df = 2$, $p = 0.92$). It is thus likely that SBV had not spread to France before red deer in France gave birth to young in spring 2011 (mid-May to early June) (8). Seroprevalence varied significantly with the period ($\chi^2 = 25.0$, $df = 2$, $p < 0.001$). On average, seroprevalence was higher in December 2011–January 2012 (31%; 95% CI 25%–37%) compared with September–November 2011 (7%; 95% CI 3%–12%) or February–March 2011 (14%; 95% CI 7%–22%).

These results suggest that SBV was actively circulating during fall 2011 until mid-November or early December. In agreement with the findings of Linden et al. for Belgium (4), we consider that the mild temperature observed in France in fall 2011 may have favored a late activity of vectors (9). The date of first occurrence of seropositive red deer and the seroprevalence observed in each department (Table 2) were not strictly dependent on the distance from the Meurthe-et-Moselle department

where the first domestic case (congenital form) had been confirmed on January 25, 2012 (10) (Figure). This result possibly arose because of uncontrolled variations in the sampling dates of red deer between the 9 departments and still unknown factors associated with SBV spread. Nevertheless, most of the departments that exhibited seropositive red deer from September 2011 to March 2012 had also reported clinical cases in domestic flocks during January–March 2012 (Figure).

In southwestern France (near the Pyrénées Mountains), a red deer seropositive for SBV was observed in the Hautes-Pyrénées department, whereas congenital clinical cases of SBV infection in domestic livestock (congenital malformations on kids) had been reported by March 30, 2012, in the neighboring Pyrénées-Atlantiques department (E. Bréard, pers. comm.) (Figure). These results suggest similar spread of SBV among red deer and domestic livestock during fall 2011 at the department level. In 2012, no evidence of abortions or malformations was reported in red deer or other native wildlife ruminant species within the populations monitored by wildlife biologists or zoo veterinarians in France (S. Rossi, A. Decors, A. Lécu, pers. comm.). However, specific studies exploring the effect of SBV on the reproductive success of wild species are still lacking.

Conclusions

This study provides a preliminary view of SBV spread among wild cervids in France during 2010–2012. Our data suggest that SBV spread quickly from northeastern to southwestern France (≈ 800 km) between October and

Table 2. Results of c-ELISA and indication of first seropositive result for Schmallenberg virus in red deer, by department, France, 2010–2012*

Department	Average distance to Meurthe-et-Moselle department, km†	No. positive samples/ no. tested in 2010–2011 (95% CI, %)	2011–2012		First positive result, 2011
			No. positive samples/no. tested	Mean prevalence, % (95% CI)	
Moselle	46		4/26	15 (2–29)‡	Nov 5
Haute-Marne	102		26/53	49 (36–63)‡	Nov 12
Bas-Rhin	103	0/41 (<7)§	8/53	15 (6–25)‡	Oct 25
Côte d'Or	184		11/37	30 (15–45)‡	Dec 3
Oise	282		26/69	38 (26–49)‡	Dec 19
Loir-et-Cher	375		11/132	8 (4–13)‡	Nov 25
Hautes-Pyrénées	789	0/14 (<19)§	1/12	8 (0–30)‡	Dec 10
Corsica	749		0/23	0 (<12)§	
Pyrénées Atlantiques	815		0/26	0 (<11)§	

*c-ELISA, competitive ELISA.

†Department where first domestic clinical cases were reported, January 25, 2012.

‡95% CIs were estimated by assessing a binomial distribution of seroprevalence.

§Upper value of the 95% CI was estimated according a hypergeometric distribution of the risk to detect at least 1 positive result ($p = 1 - \exp(\ln(0.05)/N)$, with N being the sample size).

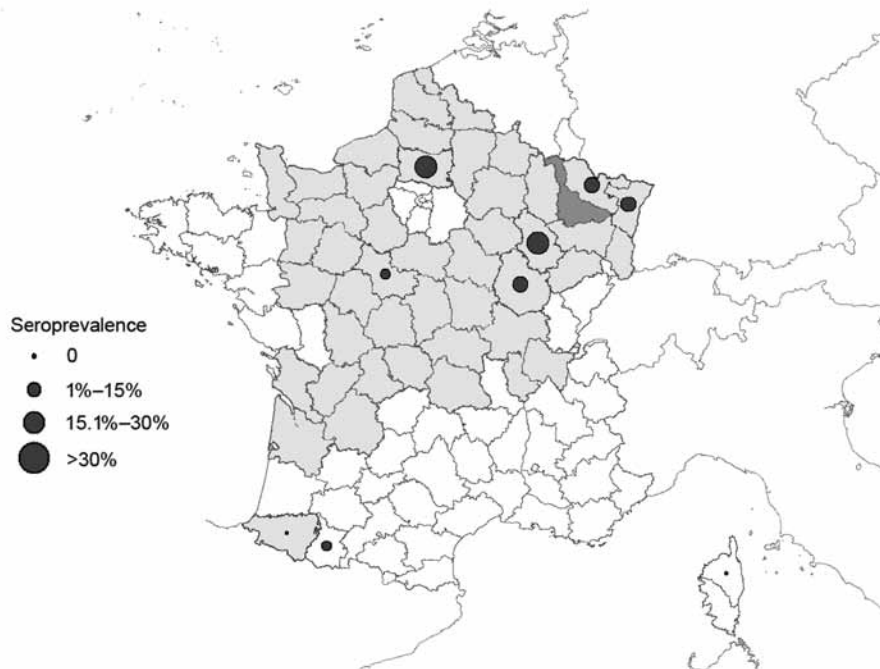


Figure. Sites where serum samples were obtained from red deer (9 departments), showing average seroprevalence for Schmallenberg virus, France, 2010–2012. Dark gray shading indicates Meurthe-et-Moselle department, where the first domestic case was found; light gray shading indicates departments where clinical cases were found during January–March 2012; and white indicates departments where no clinical cases occurred during January–March 2012.

December 2011. Our data also show the match of SBV spread among red deer and domestic flocks at the level of the department and highlight the perspective that red deer can be a sentinel of SBV spread for livestock. We also pinpointed the relevance of new competition ELISA for improving SBV surveillance in wildlife species, even though SNT remained the most reliable assay for SBV antibody detection in red deer. Further studies that encompass several years and include a larger number of species and localities would help provide a more complete picture of virus spread and risk factors in wildlife (11).

Acknowledgments

We are grateful to the hunters, technicians from departmental hunters' Federations, agents of the French Game and Wildlife Agency, of the Natural Park of Corsica and of the French Forest Agency, and veterinarians and technicians from the local and national reference laboratories. Special thanks go to Stéphane Barber, Richard Beitia, Nicolas Thion, Dominique Odier, Stevan Mondoloni, Jérôme Mery, Guy Puthiot, Dominique Gauthier, Corinne Novella, Eric Gueneau, Norchen Chenoufi, and Martine Wanner.

We thank the French Wildlife and Hunting Agency and the French Agency for Food, Environmental and Occupational Health and Safety for their financial support. We also thank the ID-VET company for the gift of c- and I-ELISA kits needed for this study.

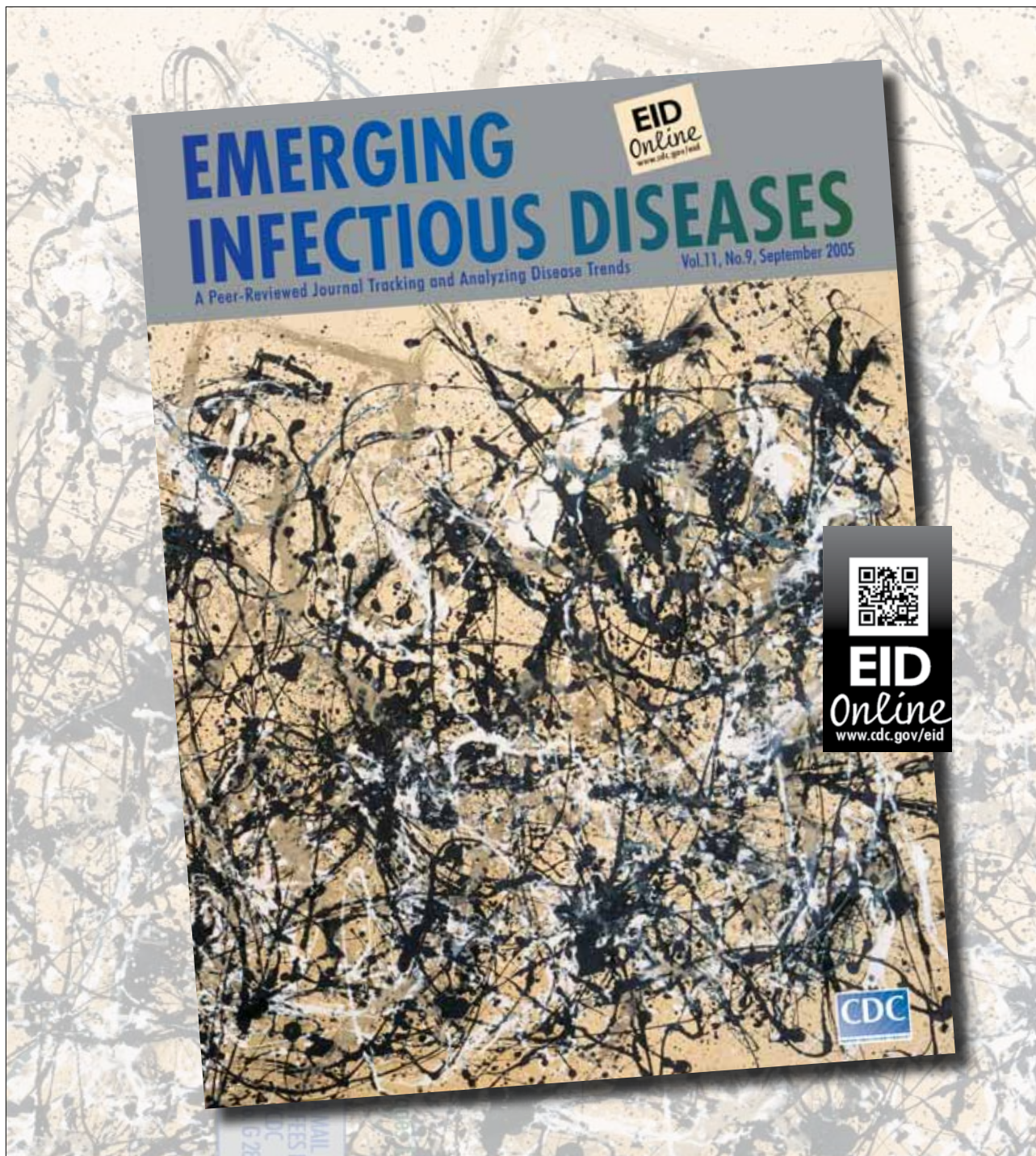
Dr Laloy is an assistant professor in the Pathology Department at the National Veterinary School of Alfort. Her research interests focus on virology and microbiology, especially on emerging pathogens such as Schmallenberg virus.

References

1. Muskens J, Smolenaars AJ, van der Poel WH, Mars MH, van Wuijckhuise L, Holzhauser M, et al. Diarrhea and loss of production on Dutch dairy farms caused by the Schmallenberg virus [in Dutch]. *Tijdschr Diergeneeskd*. 2012;137:112–5.
2. Hoffmann B, Scheuch M, Hoper D, Jungblut R, Holsteg M, Eschbaumer M, et al. Novel orthobunyavirus in cattle, Europe, 2011. *Emerg Infect Dis*. 2012;18:469–72. <http://dx.doi.org/10.3201/eid1803.111905>
3. Garigliany MM, Bayrou C, Kleijnen D, Cassart D, Jolly S, Linden A, et al. Schmallenberg virus: a new Shamonda/Sathuperi-like virus on the rise in Europe. *Antiviral Res*. 2012;95:82–7. <http://dx.doi.org/10.1016/j.antiviral.2012.05.014>
4. Linden A, Desmecht D, Volpe R, Wirtgen M, Gregoire F, Pirson J, et al. Epizootic spread of Schmallenberg virus among wild cervids, Belgium, fall 2011. *Emerg Infect Dis*. 2012;18:2006–8. <http://dx.doi.org/10.3201/eid1812.121067>
5. De Regge N, Deblauwe I, De Deken R, Vantieghem P, Madder M, Geysen D, et al. Detection of Schmallenberg virus in different *Culicoides* spp. by real-time RT-PCR. *Transbound Emerg Dis*. 2012;59:471–5. <http://dx.doi.org/10.1111/tbed.12000>
6. Dominguez M, Hendriks P, Zientara S, Calavas D, Jaÿ M, Touratier A, et al. Preliminary estimate of Schmallenberg virus infection impact in sheep flocks—France. *Vet Rec*. 2012;171:426. <http://dx.doi.org/10.1136/vr.100883>
7. Bréard E, Lara E, Comtet L, Viarouge C, Doceul V, Desprat A, et al. Validation of a commercially available indirect ELISA using a nucleocapsid recombinant protein for detection of Schmallenberg virus antibodies. *PLoS ONE*. 2013;8:e53446. <http://dx.doi.org/10.1371/journal.pone.0053446>
8. Loe LE, Bonenfant C, Mysterud A, Gaillard JM, Langvatn R, Klein F, et al. Climate predictability and breeding phenology in red deer: timing and synchrony of rutting and calving in Norway and France. *J Anim Ecol*. 2005;74:579–88. <http://dx.doi.org/10.1111/j.1365-2656.2005.00987.x>

9. MeteoFrance. Bilan de l'automne 2011 [cited 2013 Jan 18]. http://climat.meteofrance.com/chgt_climat2/bilans_climatiques/archives/2011/automne2011?page_id=15485
10. Brugere-Picoux J, Angot JL. The spread of Schmallenberg virus in Europe: a new disease in ruminant livestock. *Bull Acad Vet Fr.* 2012;165:5-8 [in French]. http://www.academie-veterinaire-defrance.org/fileadmin/user_upload/Bulletin/pdf/2012/numero_1/O5.pdf
11. Rossi S, Pioz M, Beard E, Durand B, Gibert P, Gauthier D, et al. Bluetongue dynamics in French wildlife: exploring the driving forces. *Transbound Emerg. Dis.* In press. Abstract available at <http://onlinelibrary.wiley.com/doi/10.1111/tbed.12061/abstract>

Address for correspondence: Sophie Rossi, ONCFS Game and Wildlife Agency–Wildlife Diseases, Micropolis la Berardie Gap 05000, France; email: sophie.rossi@oncfs.gouv.fr



4.2.2 Wild and exotic ruminants kept in zoos in France and the Netherlands

This study was carried out to look for evidence of SBV infection in captive wild and exotic ruminants, in France and in the Netherlands. Retrospective analysis of medical records were performed to search clinical signs evocative of SBV infection.

The results are presented in the following draft, submitted for publication in *Emerging Infectious Diseases*.

I performed RT-qPCR, ELISA and viral neutralization assays. I was involved in data selection and analysis. I wrote the draft.

1 **SEROLOGIC AND MOLECULAR EVIDENCE OF SCHMALLEMBERG VIRUS CIRCULATION IN ZOO**
2 **RUMINANTS, FRANCE AND THE NETHERLANDS**

3 **Authors:** Eve Laloy, Cindy Braud, Emmanuel Bréard, Jacques Kaandorp, Aude Bourgeois,
4 Muriel Kohl, Gilles Meyer, Corinne Sailleau, Cyril Viarouge, Stéphan Zientara, Norin Chai

5 **Corresponding author:** Eve Laloy, elaloy@vet-alfort.fr

6 **Author affiliations:**

7 Ménagerie du Jardin des Plantes, Muséum National d'Histoire Naturelle, 57 rue Cuvier, 75005
8 Paris, France (A. Bourgeois, N. Chai, M. Kohl, C. Réjaud) ; UMR Virologie 1161,
9 ANSES/INRA/ENVA-UPEC, Laboratoire de Santé animale, ANSES, 14 rue Pierre et Marie
10 Curie, 94700 Maisons-Alfort, France (C. Braud, E. Bréard, E. Laloy, C. Sailleau, C.
11 Viarouge, S. Zientara); Safaripark Beekse Bergen, Beekse Bergen 1, 5081 NJ Hilvarenbeek,
12 the Netherlands (J. Kaandorp); UMR 1225 IHAP Interaction Hôtes Agents Pathogènes, Ecole
13 Nationale Vétérinaire de Toulouse, 23 Chemin des Capelles, 31076 Toulouse cedex, France
14 (G. Meyer)

15 **Word count: text: 801 words**

16 **Running title:** Schmallenberg virus circulation in zoo ruminants

17 **Keywords:** Orthobunyavirus, exotic ruminants, zoological park, arbovirus, Schmallenberg
18 virus, serology, viremia

19 **Title:** Serologic and molecular evidence of Schmallenberg virus circulation in zoo ruminants,
20 France and the Netherlands

21

22

23 **Text**

24 Schmallenberg virus (SBV), a new *Orthobunyavirus* of the *Bunyaviridae* family, emerged in
25 August 2011 in north-western Europe (1) and spread to most parts of Europe via *Culicoides*
26 vectors (2). Most infections are asymptomatic in adult ruminants, yet fever, milk drop and
27 diarrhea have been reported (1). SBV is responsible for congenital malformations in newborn
28 calves, lambs and goat kids. It has also been associated with abortions (3). The virus affects
29 domestic livestock, but antibodies against SBV have also been found in free-ranging wild
30 ruminants in several European countries (3–5,7) and in wild and exotic ruminants kept in
31 captivity in the United Kingdom and in Austria (3,4). This study was carried on to investigate
32 the exposure to SBV of wild and exotic ruminants kept in one zoological park in France and
33 one in the Netherlands.

34 The investigation was carried out on 42 serum samples (39 animals) collected between 2011
35 and 2014 in the SafariPark Beekse Bergen (SPBB, Hilvarenbeek, the Netherlands) and on 16
36 serum samples (14 animals) collected between 2013 and 2015 in the Ménagerie du Jardin des
37 Plantes, Muséum National d'Histoire Naturelle (MJP, Paris, France).

38 First, the presence of SBV-specific antibodies in the samples was determined by ELISA
39 (ELISA ID Screen® SBV Competition, ID Vet, France) and by virus neutralization test
40 (VNT) according to a protocol previously described (6). The two methods gave identical
41 results except for five samples found negative by ELISA and positive by VNT. VNT has
42 proved more sensitive than ELISA for detecting antibodies against SBV in red deer (7).

43 Antibodies against SBV were found in 30/53 animals by VNT: 11/14 animals from MJP and
44 19/39 animals from SPBB (Table). Positive results were found in samples collected every
45 year from 2011 to 2015; the earliest positive result was found in a sample collected in
46 September 2011 (SPBB). Several seropositive ruminants from MJP were either born in Paris

47 or transferred to Paris from some other European park before 2010, which suggests that they
48 were exposed to SBV in Paris. SBV antibodies were found in 3 consecutive samples collected
49 in October 2011, September 2012 and March 2013 from a sable antelope in SPBB
50 (*Hippotragus niger niger*) but also in 3 consecutive samples collected in October 2013,
51 February 2014 and September 2014 in a bharal (*Pseudois nayaur*) from MJP. These data
52 indicate that SBV antibodies can persist for one year or more in these two species.

53 SBV-specific RT-qPCR targeting the S segment (8) of the virus was then performed on every
54 sample. One sample from a SBV seronegative wildebeest (*Connochaetes taurinus taurinus*)
55 collected in September 2011 in SPBB was found positive (Cq = 30). Several in-house
56 conventional RT-PCR targeting the S, L, and M segments were then performed on this sample
57 and allowed us to retrieve a 2,866 bp partial sequence from the M segment and a 1,374 bp
58 partial sequence from the L segment (deposited in GenBank under the accession numbers
59 KR828816 and KR828815, respectively). Genetic analyses based on BLAST revealed that the
60 L and M partial sequences had 100 and 99.79% identity, respectively, with SBV sequences
61 from cows.

62 IFNAR^{-/-} mice have been reported to be susceptible to SBV infection (9). To test the presence
63 of infectious SBV in the wildebeest sample, we inoculated subcutaneously three adult IFNAR^{-/-}
64 mice with 100µL of serum per mouse. The mice showed no clinical signs and no SBV
65 genome could be amplified from their blood at days 4 and 11 after inoculation (by RT-qPCR).
66 No SBV antibodies were found by ELISA and VNT in their sera at day 21 after inoculation.
67 The meaning of these negative isolation results remains unclear. It may be that initially viable
68 virus disappeared due to poor storage conditions (-20°C for 3 years).

69 According to the medical records of SPBB no clinical signs possibly related to an SBV
70 infection were observed in the ruminants during the period studied. Abortions were reported

71 in MJP in two bharals in 2011 and 2012 and in one West Caucasian tur (*Capra caucasica*
72 *caucasica*) in 2013. No correlation can be drawn between these abortions and the SBV
73 serological results since the sampling did not take place immediately afterwards.

74 Unfortunately, no material from aborted fetuses was tested by SBV RT-qPCR.

75 This study demonstrates the circulation of SBV in 18 wild and exotic ruminant species kept in
76 captivity in the Netherlands and in France between 2011 and 2015. Exposure to the virus may
77 occur even in an urban area (such as Paris center). For the first time, we report evidence of
78 SBV viremia in a blue wildebeest which was seronegative by ELISA and VNT when the
79 serum was collected. SBV RNA has previously been found in an elk (5) but the duration of
80 viremia was not determined. Further investigations are required to determine whether SBV is
81 responsible for congenital malformations or abortions in zoo ruminants.

82

83 **Acknowledgments**

84 This study was supported and financed by the Muséum National d'Histoire Naturelle (grant
85 identification: ATM - Collections vivantes 2014 & 2015). We are grateful to Dylan Duby and
86 Claire Réjaud. We thank Manjula Deville and Marc Chodkiewicz for editing of the
87 manuscript.

88

89 **References**

- 90 1. Hoffmann B, Scheuch M, Höper D, Jungblut R, Holsteg M, Schirrmeier H, et al. Novel
91 Orthobunyavirus in Cattle, Europe, 2011. *Emerg Infect Dis.* 2012;18(3):469-72.
- 92 2. Wernike K, Conraths F, Zanella G, Granzow H, Gache K, Schirrmeier H, et al.
93 Schmallenberg virus-two years of experiences. *Prev Vet Med.* 2014;116(4):423-34.

- 94 3. Steinrigl A, Schiefer P, Schleicher C, Peinhopf W, Wodak E, Bagó Z, et al. Rapid spread
95 and association of Schmallenberg virus with ruminant abortions and foetal death in
96 Austria in 2012/2013. *Prev Vet Med.* 2014;116(4):350-9.
- 97 4. EFSA (European Food Safety Authority), 2014. Schmallenberg virus: State of the Art.
98 EFSA journal 2014; 12(5):3681, 54 pp. [cited 2015 May 17].
99 <http://www.efsa.europa.eu/en/efsajournal/pub/3681.htm>
- 100 5. Larska M, Krzysiak M, Smreczak M, Polak MP, Zmudziński JF. First detection of
101 Schmallenberg virus in elk (*Alces alces*) indicating infection of wildlife in Białowieża
102 National Park in Poland. *Vet J.* 2013;198(1):279-81.
- 103 6. Bréard E, Lara E, Comtet L, Viarouge C, Doceul V, Desprat A, et al. Validation of a
104 commercially available indirect ELISA using a nucleocapside recombinant protein for
105 detection of Schmallenberg virus antibodies. *PloS One.* 2013;8(1):e53446.
- 106 7. Laloy E, Bréard E, Sailleau C, Viarouge C, Desprat A, Zientara S, et al. Schmallenberg
107 virus infection among red deer, France, 2010-2012. *Emerg Infect Dis.* 2014;20(1):131-4.
- 108 8. Bilk S, Schulze C, Fischer M, Beer M, Hlinak A, Hoffmann B. Organ distribution of
109 Schmallenberg virus RNA in malformed newborns. *Vet Microbiol.* 2012;159(1-2):236-8.
- 110 9. Wernike K, Breithaupt A, Keller M, Hoffmann B, Beer M, Eschbaumer M.
111 Schmallenberg Virus Infection of Adult Type I Interferon Receptor Knock-Out Mice.
112 *PloS One.* 2012;7(7):e40380.

113

114

115

116

117 **Table: Number of animals seropositive to Schmallenberg virus as determined by virus**
 118 **neutralization test, among exotic and wild ruminants from two zoological parks,**
 119 **between 2011 and 2015**

Species	Number of seropositive animals (total)
Blue wildebeest (<i>Connochaetes taurinus taurinus</i>) *	3 (5) §
Springbok (<i>Antidorcas Marsupialis</i>) *	3 (5) §
Sable antelope (<i>Hippotragus niger niger</i>) *	3 (3) §
Waterbuck (<i>Kobus ellipsiprymnus ellipsiprymnus</i>) *	1 (4) §
Nyala (<i>Tragelaphus angasii</i>) *	1 (2) §
Père David's deer (<i>Elaphurus davidianus</i>) *	1 (1)
Gemsbok (<i>Oryx gazella gazella</i>) *	1 (1)
African buffalo (<i>Syncerus caffer caffer</i>) *	1 (1) §
Persian fallow deer (<i>Dama mesopotamica</i>) *	1 (1) §
Vietnamese sika deer (<i>Cervus nippon pseudaxis</i>) *	1 (1)
Blackbuck (<i>Antilope cervicapra</i>) *	0 (6)
Axis deer (<i>Cervus axis</i>) *	0 (2)
Red forest duiker (<i>Cephalophus natalensis</i>) *	0 (1)
Common eland (<i>Taurotragus oryx</i>) *	0 (1)
Watussi (<i>Bos taurus taurus watussi</i>) *	0 (1)
Yak (<i>Bos grunniens grunniens</i>) ‡	4 (5)
West caucasian tur (<i>Capra caucasica caucasica</i>) †	2 (2) §
Bharal (<i>Pseudois nayaur</i>) †	2 (3) §
Markhor (<i>Capra falconeri</i>) †	2 (3) §
Arkal ural sheep (<i>Ovis aries arkal</i>) †	1 (1) §
Rocky mountain goat (<i>Oreamnus americanus</i>) †	1 (1) §
Vigogna (<i>Vicugna vicugna</i>) †	1 (1) §
Gaur (<i>Bos gaurus</i>) †	1 (1)
Pygmy goat (<i>Capra aegagrus hircus</i>) †	0 (1)

120

121 * Animals from the SafariPark Beekse Bergen (Hilvarenbeek - the Netherlands); samples
 122 collected between 2011 and 2014

123 † Animals from the Ménagerie du Jardin des Plantes (Muséum National d'Histoire Naturelle,
 124 Paris - France); samples collected between 2013 and 2015

125 ‡ Animals from both zoological parks

126 § Antibodies against Schmallenberg virus described for the first time in this species

5 DISCUSSION

5.1 Pathogenesis of the infection with SBV: hypotheses drawn from experimental infection in domestic ruminants

5.1.1 Pathogenesis of the infection in males and non-pregnant females

5.1.1.1 *Characteristics of the inoculation: route and inoculum*

In vivo studies with SBV have been performed by several teams on different species, namely cattle, sheep and goat. A major challenge was to standardize the model for each species. Standardization is necessary to compare results coming from different studies, otherwise the interpretation is limited.

The SBV inoculum must contain a critical dose to produce a homogeneous response in adult sheep (Poskin et al., 2014b) and cattle (Wernike et al., 2012b). A SBV-containing serum passaged in cattle, containing 2.0×10^3 TCID₅₀/mL (TCID₅₀: 50% tissue culture infectious dose), was inoculated (1mL per animal) undiluted, at 1/10, 1/100, and 1/1000 dilutions in cattle (Wernike et al., 2012b) and sheep (Poskin et al., 2014b). RNAemia was detected in all the animals inoculated with undiluted and 1/10 diluted serum, and in all the cows inoculated with 1/100 diluted serum. However, only 1/3 sheep showed RNAemia at this dilution. After inoculation with 1/1000 diluted serum, RNAemia was detected in only one cow and not in any sheep (Poskin et al., 2014b; Wernike et al., 2012b). Therefore, to have a homogeneous response in a group of animals, the critical dose per animal for this inoculum would be 20 TCID₅₀ for cattle and 200 TCID₅₀ for sheep.

In addition, the origin of the SBV inoculum has to be properly chosen to produce a reliable induction of viremia in adult cattle: virus-containing serum passaged in cattle is suitable but cell culture-grown virus does not seem appropriate (Wernike et al., 2012b). In sheep, the experiments included in this manuscript (part 4.1.1.) did not reveal differences in the kinetics

of viremia after inoculation with infected serum passaged in cattle or inoculation with virus grown on KC and BHK cells. However, sheep inoculated with virus grown on Vero cells did not show RNAemia (Wernike et al., 2013d). This discrepancy can be explained by selection of attenuated variants after passages in Vero cells, while the alternation between KC and BHK cells may help to maintain genome stability (Wernike et al., 2012b). Alternative explanations include the different origin of the initial samples from which SBV was isolated, on the one hand, and the different route of inoculation (subcutaneous for infectious serum and KC/BHK cell culture-grown virus, intramuscular for Vero cell culture-grown virus), on the other hand (Wernike et al., 2013d).

In the experiments presented in part 4.1.2., adult non-pregnant goats were inoculated with the virus-containing serum passaged in cattle that had been used successfully in cattle (Wernike et al., 2012b) and sheep (Wernike et al., 2013d). The inoculation was followed by RNAemia in all the infected goats. This inoculum was later used successfully for the inoculation of pregnant goats. A few adult non-pregnant goats were inoculated with whole blood sampled from a sheep inoculated with this serum (i.e. after a passage in sheep). Although the number of inoculated animals was small and did not allow for statistical testing, the RNAemia was similar to the one detected in the goats inoculated with the initial serum.

Several routes of inoculation with SBV have been experimentally tested. Cattle have been submitted to oral, subcutaneous, and intravenous inoculations. Only the subcutaneous and intravenous inoculations led to SBV infection in the animals (Hoffmann et al., 2012b; Wernike et al., 2013a). In sheep, intradermal and subcutaneous inoculations were followed by RNAemia while intranasal inoculation failed to generate RNAemia (Martinelle et al., 2015). Intradermal inoculation is similar to the natural route of infection by *Culicoides* species, however subcutaneous inoculation is easier to perform (Martinelle et al., 2015). Accordingly, subcutaneous inoculation was performed in adult non-pregnant goats as well as in adult pregnant goats (cf. experiments 4.1.2 and 4.1.3.3), resulting in successful RNAemia in all the inoculated animals.

Once the inoculum (infected serum passaged in cattle) and the route (subcutaneous) had been validated in goats, the intravaginal route was tested in comparison to the standard route (subcutaneous). Intravaginal inoculation and subcutaneous inoculation resulted in viremia in 1/7 goats and 8/8 goats respectively (cf. experiments 4.1.3.2). Thus, intravaginal inoculation can lead to viremia in goats, yet this route may be less effective than the subcutaneous one.

The circumstances of the intravaginal inoculation, i.e. at the same time that artificial insemination, may have helped the virus to reach the blood circulation via small erosions of the mucosa. Therefore, our results suggest intravaginal transmission may occur in goats in a context of artificial insemination.

5.1.1.2 Hematolymphopoietic organs and organs of the genital tract: are they target-organs for SBV?

After experimental infection of adult ruminants, SBV RNA has been found mainly in the hematolymphopoietic organs: in the mesenteric, superficial cervical and mandibular lymph nodes, the spleen and tonsils in sheep (Martinelle et al., 2015; Poskin et al., 2014b; Wernike et al., 2013d); in the mesenteric, mandibular and inguinal lymph nodes, the Peyer's patches (an intestinal component of the gut-associated lymphoid tissue) and tonsils in cattle (Van Der Poel et al., 2013; Wernike et al., 2012b, 2013a). Surprisingly, in non-pregnant goats, SBV RNA was not detected in the spleen and in the prescapular lymph nodes (close to the site of inoculation). Unfortunately, the mesenteric lymph nodes were not sampled (cf. experiments 4.1.2). In pregnant goats, SBV RNA was frequently found in the mesenteric lymph nodes (cf. experiments 4.1.3.3).

In sheep, SBV RNA was detected in the mesenteric lymph node and the spleen up to 44 dpi, indicating SBV may have an affinity for these organs (Wernike et al., 2013d). Whether hematolymphopoietic organs could be a persistence site for SBV remains to be elucidated. Viral isolation was unsuccessful in the RT-qPCR positive mesenteric and inguinal lymph nodes from two experimentally infected bulls (Van Der Poel et al., 2013). In other studies, viral isolation has not been performed on the hematolymphopoietic organs, hence whether they contain infectious virus is still unknown. The SBV-containing cells in these organs have not been determined either.

In cattle, infectious SBV has been detected in semen samples from two experimentally infected bulls, yet SBV RNA was not detected in the genital tract (prostate, testis, bulbourethral gland, and epididymis) of these bulls at 24 dpi (Van Der Poel et al., 2013). After experimental infection of bucks and rams, SBV RNA was not detected in the genital

tract (epididymis, testis, and seminal vesicle) either (Wernike et al., 2013d) (cf experiments 4.1.2). Buck semen was collected from 0 to 28 dpi but remained negative by SBV RT-qPCR. One major limitation of these studies is that they have been performed on small numbers of animals.

Infectious SBV has been detected in a few bovine semen samples from the field (Hoffmann et al., 2013; Ponsart et al., 2014; Schulz et al., 2014). Viral RNA was detected in every semen sample for 3 months after natural infection in one bull (Ponsart et al., 2014), while viral RNA excretion in semen was intermittent in two bulls (Hoffmann et al., 2013). Viral RNA could be detected in both the seminal cell fraction and in the seminal plasma from several bulls, with lower Cq (thus higher copy numbers) in the former (Hoffmann et al., 2013). Altogether, these data from the field are suggestive of a persistence of SBV in these bulls, either in cells from the genital tract, or in cells from another organ with frequent diffusion or cell-associated migration to the genital tract.

As to the female genital tract, SBV RNA has been found in the ovary from both a single goat (cf. experiment 4.1.2) and a single ewe 7 days after experimental inoculation (Wernike et al., 2013d). In both animals, viral RNA was detected in the ovarian interstitial tissue but not in the follicular fluid, cumulus cells, and oocytes (Wernike et al., 2013d). Unfortunately, viral isolation from these organs was not performed. The significance of these findings remains to be determined.

Other organs have been shown to contain SBV RNA after experimental inoculation in sheep,: muscle (inoculation site, up to 29 dpi), cerebellum (up to 10 dpi), cerebrum (up to 29 dpi), lung (up to 44 dpi), and kidney (up to 44 dpi) in one or two animals each (Martinelle et al., 2015; Poskin et al., 2014b; Wernike et al., 2013d). No lesions and clinical signs were associated to these findings. Viral isolation was not performed in these organs. Whether SBV could persist in these organs is still unknown.

5.1.1.3 Summary

Taking into account the data gathered from the field and from experimental infections, a hypothetical pathogenesis of SBV in adult non-pregnant ruminants is proposed in Figure 10.

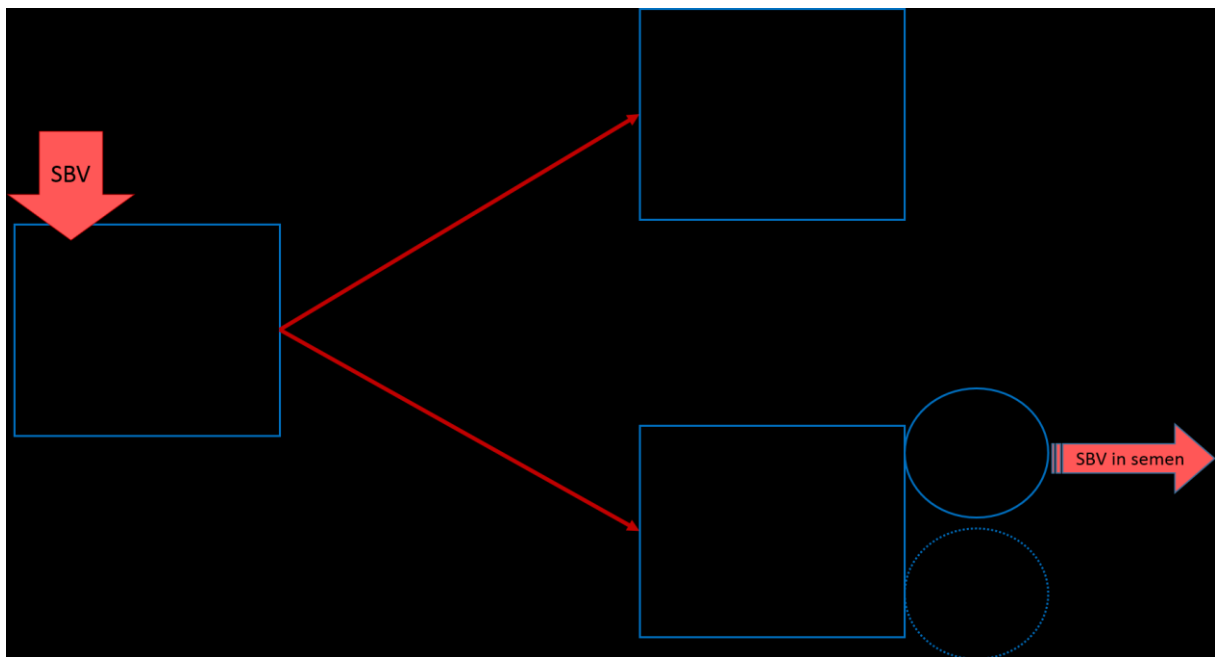


Figure 10. Hypothetical pathogenesis after SBV infection in adult non-pregnant ruminants.
The excretion of SBV in semen has been shown in cattle only.

5.1.2 Pathogenesis of the infection in pregnant females

As shown for goats, SBV infection in pregnant females can lead to several outcomes for the offspring. The pathogenesis of these outcomes will be discussed at the animal level and the tissue level.

5.1.2.1 *Window of susceptibility*

The window of susceptibility of the growing embryo or fetus in pregnant goats is at least between 28 and 42 dg (cf. experiments in part 4.1.3.3). In cattle, a field study has shown this window to be at least between 60 and 144 dg, in association with the birth of malformed or dead calves (Wernike et al., 2014c).

It is likely the vertical transmission of SBV to the embryo could not occur before the placentomes are mature, i.e. before 20 dg in sheep and goats and before 32 dg in cattle (Dantzer and Leiser, 2006).

As earlier mentioned in this manuscript (part 2.3.3.1.1), the end of the window of susceptibility may rely upon the stage of maturation of the target organs, on the one hand, and the competency of the immune system, on the other hand.

In the brain, one of the major target organs, we have shown that SBV replicates mainly in the undifferentiated cells of the periventricular zone and in the cerebellar granular cell layer in 56 dg-old goat fetuses (cf. experiments in part 4.1.3.3). Later in pregnancy, this pool of undifferentiated cells, which may be the most SBV-susceptible cells, will slowly decrease. In addition, the more advanced the pregnancy is, the more mature the blood-brain barrier is. In sheep, the blood-brain barrier begins to mature between 50 and 60 dg (Evans et al., 1974). From 60 dg on, this barrier may limit the distribution of SBV to the brain (Varela et al., 2013).

The development of the immune system has been more studied in the ovine fetus than in the goat fetus. In the ovine fetus, cell-mediated immunity as well as humoral immunity develop as soon as 70 dg, exemplified by the ability of the fetus to reject allografts and to produce specific antibodies at this time (Sammin et al., 2009). Development of specific immunity with immune memory in ovine neonates following oral DNA vaccination at 120 dg shows that the ovine fetus is immunocompetent at 120 dg (Gerdtts et al., 2002). Therefore, from 70 dg on, SBV distribution is probably restricted by the action of the immune system. Nevertheless, the

immune system may also worsen SBV-induced lesions, as described earlier in the SBV-infected goat fetus with umbilical arteritis.

5.1.2.2 The placentome: site of crossing, site of persistence?

Our results have shown a tropism of SBV for the goat placentome, with infection of trophoblastic binucleate cells and giant syncytial cells (cf. experiments in part 4.1.3.3). The SBV tropism for trophoblastic cells has also been shown in vitro, with infection of ovine trophoblastic cell (oTr-1) culture (Varela et al., 2013).

The placentome is the gateway for the virus to invade the fetus. However, after inoculation of SBV at 28 dg to goats with twin or triplet pregnancy, 28 days later some fetuses and their fetal membranes were spared while the other(s) were infected (cf. experiments in part 4.1.3.3). Diffusion of the virus at 28 dg was thus not homogeneous in the uterus and then in placentomes; alternatively, the virus was blocked in the maternal side of some placentomes.

The way the virus crosses the placental barrier, from the maternal blood to the fetal blood, is not known. Like many bacteria responsible for placentitis in sheep, the virus may cross in the hemophagous areas, i.e. the areas of hemorrhage in the ruminants' placentomes (Sammin et al., 2009). As the fetal trophoblast exerts a phagocytic activity on the red blood cells in these areas, it could be speculated that the trophoblast would phagocytose viral particles at the same time. Nevertheless, SBV do not seem associated with blood cells as the SBV-associated viremia is very short (Hoffmann et al., 2012b, 2013).

Placentomes from experimentally infected pregnant goats can contain infectious SBV or at least, SBV antigen and RNA, until 28 dpi (cf. experiments in part 4.1.3.3). After experimental infection of pregnant ewes with AKAV, infectious virus was detected until 60 dpi in the placentomes, suggesting the placentomes may be a site of viral persistence (Parsonson et al., 1981c). Indeed, the placenta is a site where the maternal immune response is limited. In sheep, ovine trophoblasts and feto-maternal syncytia do not express MHC class I molecules (Sammin et al., 2009). This means that intracellular infection of the trophoblasts and syncytia with a pathogen would not trigger recognition and killing by cytotoxic T lymphocytes. Besides, in sheep the trophoblast secretes interferon tau and the endometrial glands secretes serpins; these proteins inhibit in vitro activation of lymphocytes (Sammin et al., 2009). Ovine uterine serpins also inhibits natural killer cell function (Padua and Hansen, 2010). Thus, the placenta may represent a protected niche for SBV replication and persistence.

5.1.2.3 *Pathogenesis of embryonic/fetal death*

SBV infection has been associated with embryonic loss, abortion and stillbirth. Embryonic or fetal death can result either from anomalies in the environment (the mother, the placenta) or from anomalies in the embryo or fetus itself.

First, the embryo is susceptible to variation in temperature and can die because of hyperthermia. In experimentally SBV-infected goats, some dead kids were suspected to be dead at the end of the embryonic period, yet no hyperthermia was detected (cf. experiments in part 4.1.3.3). This mechanism was unlikely the cause of the embryonic death in this experiment.

Second, an infection of the placenta may lead to embryonic or fetal death through several mechanisms. In case of a true placentitis, the feto-maternal exchange has a reduced efficiency, the placental endocrine function may be disrupted, and the local immunomodulation may be lost with resultant immune expulsion (Sammin et al., 2009). In SBV infection in pregnant goats, no placentitis could be detected but SBV was replicating in the trophoblastic cells and the giant syncytial cells (cf. experiments in part 4.1.3.3). The placental endocrine function was not evaluated, thus the hypothesis of a disruption by SBV was not explored. However, our results suggest SBV may impair the feto-maternal exchange. Indeed, the maximal diameter of placentomes was reduced in infected goats. The goats included in the analysis were all carrying at least one live fetus except one goat from G42, thus fetal mortality alone cannot explain the smaller maximal diameter of placentomes in the infected goats. Therefore, SBV infection may have an effect on placentomes development, either by inhibiting their growth or by triggering partial degeneration and loss. Moreover, degenerative changes were found in placentomes from 2 goats from G42 in association with abundant SBV antigens (cf. experiments in part 4.1.3.3). Similarly, after experimental infection of pregnant ewes with AKAV, degeneration and necrosis was noticed in the fetal villi in placentomes, with AKAV antigen positivity in the areas of necrosis (Parsonson et al., 1988). Altogether, these results suggest an ability of both viruses to damage placentomes. With severe damage, embryonic or fetal mortality could result by ischemia.

Finally, embryonic or fetal death can occur secondary to down-regulation of the expression of genes related to embryonic or fetal development, alone or in combination with associated up-regulation of genes related to pro-inflammatory response (Sanad et al., 2015).

5.1.2.4 Pathogenesis of lesions in fetuses and newborns

SBV infection can result in a wide range of lesions in fetuses and newborns. The most affected organs or systems are the CNS, the skeletal muscle, and the axial skeleton.

5.1.2.4.1 In the CNS

In two goat fetuses whose mothers were experimentally infected at 28 dg and 42 dg, porencephaly was found at 55 dg in the cerebrum, associated with SBV antigen in surrounding cells (cf. experiments in part 4.1.3.3). The cell loss was located in the periventricular zone, which contains bipotential progenitor cells (Fred Sinowatz, 2010a). Importantly, these cells give rise to neuronal progenitor cells and glial progenitor cells. The latter are precursors not only to astrocytes and oligodendrocytes but also to the radial glial cells, which are temporary cells that guide the young neurons during their migration in the cortex in midpregnancy (Fred Sinowatz, 2010a). Therefore, cell loss in this area could have evolved later into hydrocephalus *ex vacuo* or hydranencephaly.

Cell loss could have resulted either from a direct SBV-driven cytopathic effect, or from ischemia. The association of SBV antigen with the lesions in goat fetuses is in favor of the former mechanism (cf. experiments in part 4.1.3.3). After infection of pregnant sheep by AKAV, no vascular lesions were found in lambs, suggesting that the direct destruction of undifferentiated neural cells was a major event in the pathogenesis (Narita et al., 1979). In the goat fetuses with porencephaly, the brain blood vessels did not show damage or inflammation, yet acute hemorrhages were detected in the areas of cell loss (cf. experiments in part 4.1.3.3). Hemosiderosis has been found in the brain of SBV RNA positive neonatal ruminants, indicating chronic hemorrhages (Herder et al., 2013). In addition, after intracerebral inoculation in mice, acute hemorrhage was detected at 48h post-infection, earlier than malacia, which occurred at 72h post-infection (Varela et al., 2013). These data support vascular disruption as a cause of porencephaly (Herder et al., 2013). However, no vascular

necrosis and thrombosis has been reported up to now in the brain of SBV-infected fetuses. In addition, cell tropism of SBV in ruminants includes both neurons (Hahn et al., 2013; Peperkamp et al., 2012; Varela et al., 2013) and, at least in vitro, endothelial cells (Barry et al., 2014; Varela et al., 2013). Therefore, both cytopathic effect and ischemia have to be considered as possible mechanism of SBV-induced cell loss in the fetal brain.

The range of CNS lesions associated with SBV in the field includes inflammation, appearing as lymphohistiocytic meningoencephalitis (Herder et al., 2013). If malformations of the CNS were detected in all cases of lymphohistiocytic meningoencephalitis in neonatal ruminants from one study, inflammation was present only in a minority of neonates displaying malformations in the CNS (Herder et al., 2013). Viral antigen was often associated with the inflammation; this can be interpreted as a close interaction between SBV expression and the local immune response (Herder et al., 2013). Another interpretation could be that detection of both viral antigen and inflammation indicates an infection in late stages of pregnancy, before viral clearance and after maturation of the immune system. Accordingly, Peperkamp et al. hypothesize that an infection early in gestation would result in severe dysplastic lesions and viral clearance at the time of parturition, whereas a late gestational SBV infection would result in encephalomyelitis with detectable viral RNA and antigen (Peperkamp et al., 2014).

5.1.2.4.2 In the skeletal muscle

In SBV-infected goat fetuses at 55 dg, no histological lesions were seen in skeletal muscle despite SBV RNA and antigen were abundant in this tissue (cf. experiments in part 4.1.3.3). We hypothesize the lesions could be not yet developed at this stage but SBV could already have an effect on apoptosis and cell cycle in myotubes. There was a trend in greater apoptosis in muscle from infected fetuses bearing porencephaly than in muscle from infected fetuses without lesions or control fetuses. Unexpectedly, the rate of cell proliferation was higher in muscle from the infected fetus than in muscle from control fetuses (cf. experiments in part 4.1.3.3). This proliferation could be either a reactive event secondary to previous cell loss or, less likely, a direct effect of the virus. Overall, these results support only weakly the hypothesis of a direct destructive action of SBV on fetal muscle.

In SBV-infected newborn calves, a correlation has been shown between the degree of overall body deformity and a progressively greater reduction in the diameter of the spinal cord, on the

one hand, and with fewer spinal neurons, on the other hand. This suggests arthrogryposis could result directly from denervation atrophy of skeletal muscle (Bayrou et al., 2014). In SBV-infected goat fetuses, neuron loss in the ventral horn of the spinal cord was not detected (cf. experiments in part 4.1.3.3). Nevertheless, morphometry would be more accurate than conventional histological examination in the evaluation of neuron density.

An alternative mechanism would be the disruption of muscle cell differentiation by the virus. Indeed, in SBV RNA-positive neonates, the hypoplastic skeletal muscle is made of small myofibers that sometimes lack cross striations (Seehusen et al., 2014). To explore this possibility, the expression of myogenic regulator factors (Fred Sinowatz, 2010b) in the fetal muscle could be compared between SBV-infected and control fetuses. In vitro work with primary bovine fibroblasts has shown SBV is able to downregulate a transcription factor involved in embryonic development (Blomström et al., 2015), paving the way for further research in this area.

5.1.2.4.3 In other organs

One SBV-infected goat fetus displayed a bilateral umbilical arteritis with thrombosis and SBV antigen in spindle cells in the wall (cf. experiments in part 4.1.3.3). This finding was unexpected as SBV-associated lesions in the umbilical cord have not been reported to our knowledge. This arteritis may be an incidental finding; alternatively, it may represent a way for the virus to lead to fetal ischemia by disruption of the fetal blood circulation. A tropism for the arterial wall has been described for CVV, which antigen has been detected in the media of the aorta in ovine fetuses inoculated experimentally at 35 dg. However, presence of CVV antigen was not associated with histological lesions from 7 to 28 dpi (Hoffmann et al., 2012a). A tropism of SBV for ovine endothelial cells has been shown in vitro (Barry et al., 2014; Varela et al., 2013), but SBV antigen was not detected in endothelial cells in infected goat fetuses (cf. experiments in part 4.1.3.3). Whether SBV infection of endothelial cells in the fetus would result in vascular lesions remains to be demonstrated.

SBV antigen and RNA were detected in the mandible and vertebrae of SBV-infected goat fetus at 55 dg (cf. experiments in part 4.1.3.3). At this stage, these bones are made of a hyaline cartilaginous model that will become bone later by endochondral ossification (Fred Sinowatz, 2010b). SBV antigen was found in the cytoplasm of well-differentiated

chondrocytes, yet no lesions were detected in the cartilage. SBV could elicit malformations in the axial skeleton by damaging the cartilaginous model of future bones, or by disrupting the expression of key genes for bone development. The former hypothesis requires sequential analyses on bone at different stages of fetal development in goats. The latter hypothesis can be explored through transcriptomic analyses in the fetal bone, with a focus on Notch and Wnt pathways, major pathways for development of the axial skeleton (Dittmer and Thompson, 2015), and on the transcription factors *Cbfa1* and Indian hedgehog that are involved in the late steps of endochondral ossification (Fred Sinowatz, 2010b).

In SBV-infected goat fetuses, SBV RNA was detected in several other organs that seldom display lesions in newborns after in utero SBV infection in the field (Table 6). No gross or histological lesions were found in these organs in goat fetuses (cf. experiments in part 4.1.3.3). Therefore, a causal link between presence of SBV RNA and lesions in the corresponding organ in neonates is far from being established. Table 6 gives, by organ, earlier reported lesions associated with SBV infection in the literature, and, when possible, arguments for and against a causal link between SBV RNA presence and lesion formation.

Table 6. In a subset of organs containing SBV RNA without associated lesions in experimentally infected goat fetuses: lesions found in SBV-infected neonates in the field, arguments for and against a causal link between SBV RNA presence and lesion formation.

Organ	Lesions in SBV-infected neonates in the field	FOR a causal link	AGAINST a causal link
Kidney	Unilateral hydronephrosis in a sheep (Herder et al., 2012)	CVV infection in ovine fetuses: focal necrosis in tubular epithelial cells of the renal cortex (Hoffmann et al., 2012a)	Renal necrosis was minimal and found in 1 fetus only (Hoffmann et al., 2012a)
Eye	Bilateral cataract in a sheep (Herder et al., 2012)		In SBV-infected goat fetuses, antigen in the eyelid but not in the globe itself
Lung	Lung hypoplasia in a goat (Herder et al., 2012); lymphocytic interstitial pneumonia in calves (Bayrou et al., 2014)	Lung hypoplasia in lambs after AKAV infection (Parsonson et al., 1981b)	Lymphocytic interstitial pneumonia detected in control calves (Bayrou et al., 2014)
Heart	Cardiac ventricular septal defect in a sheep (Herder et al., 2012)		CVV infection in ovine fetuses: CVV antigen in cardiomyocytes without lesions (Hoffmann et al., 2012a)
Digestive tube	Colonic atresia in a sheep (Herder et al., 2012)		SBV RNA detected in meconium swabs of 6/9 clinically healthy calves (Wernike et al., 2014c)
Liver	Chronic lymphohistiocytic hepatitis in calves (Seehusen et al., 2014)		Chronic lymphohistiocytic hepatitis also found in age-matched control calves (Seehusen et al., 2014)
Lymphoid organs	Lymphoid depletion in lymph node, thymus, and spleen in lambs and calves (Herder et al., 2012; Seehusen et al., 2014).	Lymphoid depletion in the thymus in lambs after AKAV infection (Parsonson et al., 1977).	Lymphoid depletion also found in age-matched control lambs (Seehusen et al., 2014).

The arguments for a causal link, presented in Table 6, are weak as they are few and they do not refer to SBV but to other viruses from the genus *Orthobunyavirus*. There are more arguments against a causal link between SBV RNA and lesion development in these organs.

5.1.2.5 Summary

After SBV crosses the placenta, embryonic or fetal death may occur. If the fetus survives, lesions may develop in utero in the CNS, the skeletal muscle and the axial skeleton. The third outcome after fetal infection by SBV is in utero development without lesions, followed by birth of a normal neonate. Indeed, SBV RNA has been detected in meconium swabs of 6/9 clinically healthy calves with high SBV-antibody titers before colostrum intake (Wernike et al., 2014c). The authors speculate that both the antibody response and the detection of SBV RNA may be the consequence of extensive SBV-replication, which only seldom lead to abortion, malformation or stillbirth (Wernike et al., 2014c).

Considering SBV infection can result in the birth of healthy neonates, then arises the question of immunotolerance. Immunotolerance with persistence of the virus has been described for Bovine viral diarrhea virus (BVDV) in calves. The persistently infected animals are a hidden source of infection and are a major concern for disease control. Persistence of the virus in newborn calves occurs if the infection takes place between 40 and 125 dg with a noncytopathogenic strain of BVDV (Brodersen, 2014). Despite SBV infection of pregnant cows before 90 dg, in the field, high titers of precolostral SBV-specific antibodies have been detected in their calves, indicating immunotolerance was not induced (Wernike et al., 2014c).

After experimental infection of pregnant goats at 42 dg, we reported SBV RNA-positive fetuses that were alive and devoid of lesions at 12 dpi (cf. experiments in part 4.1.3.3). The slaughter time point may have been too early to detect all the SBV-induced lesions; alternatively, the virus could have been cleared later without damaging the fetuses. The latter hypothesis is suggested by the virus clearance occurring between 7 and 28 dpi after CVV infection at 35 dg in ovine fetuses (Hoffmann et al., 2012a). CVV clearance may result from the ability of the ovine fetus to develop both an innate immune response and an adaptive immune response early in gestation, i.e. before 70 dg (Rodrigues Hoffmann et al., 2013).

To conclude this part about the pathogenesis of lesions after SBV infection in pregnant females, a diagram recapitulating the three outcomes after SBV infection of pregnant goats is proposed in Figure 11.

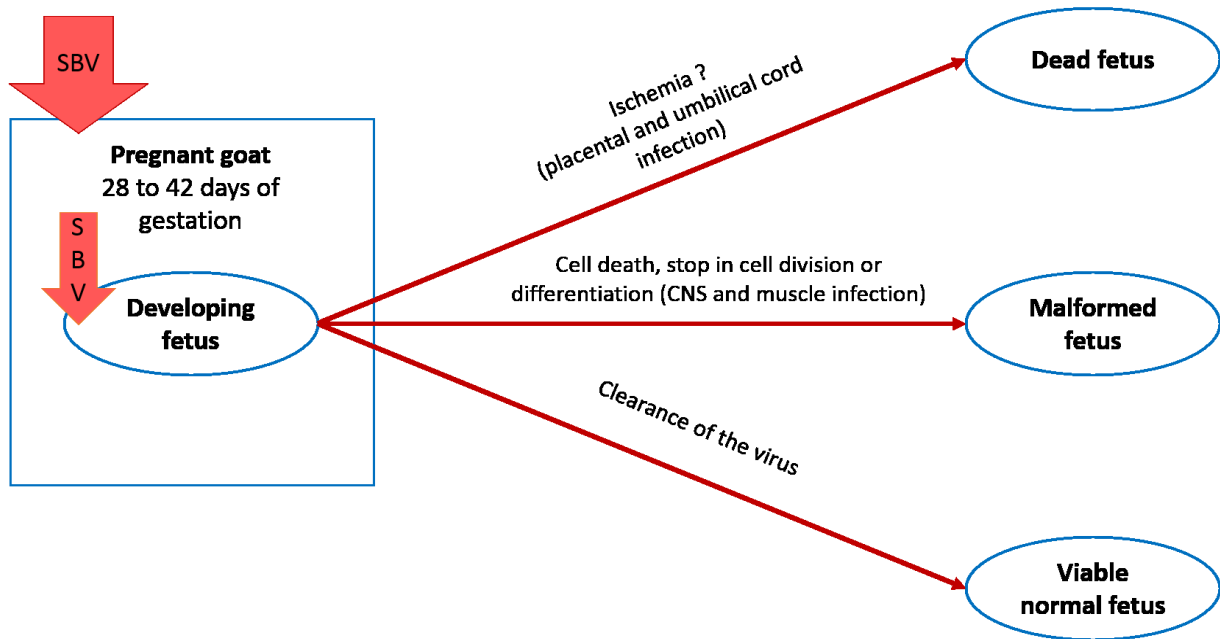


Figure 11. Outcomes and pathogenesis after SBV infection in adult pregnant goat.
 From data shown in part 4.1.3.3.

5.2 Rapid and broad dissemination of the virus among wild and exotic ruminants

5.2.1 A quick spread in many species and in various ecosystems

In Europe, SBV disseminated quickly in domestic ruminants (Afonso et al., 2014; Steinrigl et al., 2014), with a higher rate of spread in comparison to BTV-8 (Sedda and Rogers, 2013). The spread was rapid in wild ruminants as well. Indeed, the results presented in part 4.2.1 revealed a high speed of spread in red deer populations in France and similar results were earlier described for red deer and roe deer in Belgium (Linden et al., 2012).

Models of SBV spread in Europe and in the United Kingdom have been developed and indicate midge dispersal was the main transmission route of SBV (Gubbins et al., 2014a, 2014b; Sedda and Rogers, 2013), through downwind movements or a combination of downwind and random movements (Sedda and Rogers, 2013). However, average wind speed in Europe during SBV spread and during BTV-8 spread was similar, between 3 and 5 m/s (Sedda and Rogers, 2013). Additional factors may explain the faster spread of SBV in comparison to BTV.

First, in Northwestern Europe, the area of virus circulation from summer 2011 to April 2012 corresponds to an area affected by drought between March and May 2011. This match suggests drought could have enhanced the spread and circulation of SBV, although the biological mechanism is unknown (Calzolari and Albieri, 2013). Second, in comparison to BTV, in spite of a shorter viremia in the host, SBV has been predicted to have a higher probability of transmission from host to vector, a shorter latent period in the vector, a lower threshold temperature for replication and a faster replication when temperature is above the threshold (Gubbins et al., 2014a). All these characteristics may explain why SBV has spread faster than BTV-8. Nevertheless, these predictions were made via computer-assisted modelling and have to be verified biologically.

Finally, data from the field suggest competence of midges for SBV may be higher than for BTV (Rossi et al., 2015). SBV virus has been detected in relatively high number of midges (Elbers et al., 2013a; De Regge et al., 2012), even in small pools of midges while BTV detection in similar pools was rarer (Veronesi et al., 2013). This high proportion of SBV-infected midges may have enhanced virus spread in Europe.

In addition to a high speed of spread, SBV has circulated in numerous species of wild and exotic ruminants. The results presented in part 4.2.2 revealed for the first time evidence of SBV infection in 13 species. Combined to the 28 species of wild and exotic ruminants earlier reported to be receptive (cf. chapter 2), then SBV has circulated in at least 41 species of non-domestic ruminant in Europe, demonstrating a wide range of receptive hosts.

In France, SBV spread to a larger range of hosts in free-ranging wild ruminants than BTV did. Antibodies against SBV were found in roe deer, mouflon, chamois, and ibex while antibodies against BTV were absent or found in a low proportion of animals in these species (Rossi et al., 2014, 2015). This difference in host range may rely upon a higher number of hosts receptive to SBV but also upon a difference in the species of vectors able to transmit each virus to wild ruminants (Rossi et al., 2015).

SBV circulated in a wide range of species but also in a wide range of ecosystems.

The results from part 4.2.1 revealed that ruminants have been exposed to SBV in the Ménagerie du Jardin des Plantes, a zoological park in the city center of Paris, suggesting the vectors of SBV can live, or at least survive, in urban areas. The zoological park environment may have allowed *Culicoides* spp. to live in this area, given that high quantities of *Culicoides* midges have already been described in Chester zoo in England (Vilar et al., 2011). Moreover, *C. obsoletus*, *C. scoticus*, *C. chiopterus* and *C. punctatus* can choose opportunistically their bloodmeal host, feeding on common wood pigeon if need be (Lassen et al., 2011).

Wild ruminants have also been exposed to SBV in mountainous areas. In Austria, Italy and Spain, antibodies to SBV have been detected in chamois, which lives in high alpine areas (Chiari et al., 2014; Fernández-Aguilar et al., 2014; Schiefer et al., 2013). As suggested by Schiefer et al., exposure to SBV has occurred through vectors that either were natural inhabitants of alpine sites or disseminated there (Schiefer et al., 2013). In several wild species in France, although SBV seroprevalence was found to be on average higher at low altitude than at high altitude, seroprevalence up to 70% was detected in Alpine ibex in one area above 1500m (Rossi et al., 2015). In comparison to SBV, BTV seroprevalence at this altitude was lower (Rossi et al., 2014, 2015).

5.2.2 Wild ruminants: do they play a role in SBV dissemination in domestic ruminants?

The role of wild species in the dissemination of SBV is still unknown. We can speculate they could participate to SBV overwintering, as maintenance hosts of SBV. SBV viremia is short-lasting in domestic ruminants and in the llama and the alpaca, however it has not been characterized in the other wild and exotic ruminants. As red deer populations are abundant in Europe, they might be a reservoir of SBV if long-lasting or recurrent viremia occurs in this species. Experimental infection may be useful to describe viremia in red deer.

Conversely, wild ruminants may be only spillover hosts of SBV. SBV has spread in wild ruminants and domestic livestock at the same time during fall 2011 in France (part 4.2.1). However, a delay of one year has been recorded between the domestic cases and a high seroprevalence in wild ruminants living in mountainous areas in France and Italy (Chiari et al., 2014; Rossi et al., 2015). This delay may be due to different vector species for SBV between mountain wild ruminants and domestic ruminants, or to exposure of mountain ruminants after a spillover from domestic ruminants (Rossi et al., 2015). Furthermore, the domestic ruminant density has been shown to influence positively the SBV infection in wild ruminants in Poland. In addition, SBV seroprevalence was lower in wild ruminants than in domestic ruminants in Poland in 2013. These data from Poland are consistent with SBV infection in wild ruminants occurring secondary to spillover from domestic ruminants (Larska et al., 2014).

In summary, evidence from the field are not consistent with a major role of wild ruminants in SBV dissemination. However, there is a need to characterize SBV viremia in wild ruminants to evaluate the risk they can pose to domestic ruminants (Tarlinton et al., 2013).

5.3 Consequences in the field: impact and preventive measures

5.3.1 Domestic ruminants

Sexual transmission of SBV has not been proven as yet. Evidence of SBV excretion in semen come from studies in cattle (Hoffmann et al., 2013; Van Der Poel et al., 2013; Ponsart et al., 2014; Schulz et al., 2014) whereas SBV viremia after intravaginal inoculation during artificial insemination was demonstrated in goats (part 4.1.3.2). Whether cows can be infected by vaginal route remains to be determined; if so, the consequences on pregnancy should be evaluated. SBV excretion was not detected after experimental SBV infection in bucks (part 4.1.2), however only very few bucks were included in the study. Additional testing of semen batches is needed to assess whether bucks can excrete SBV in the semen. To protect SBV-naïve females, vaccination before mating or artificial insemination is advised.

Evidence of embryonal or early fetal loss in the field in association with SBV infection in goats has only been reported in the literature in 2013 for German herds (Helmer et al., 2013) and in 2014 for French herds (Dominguez et al., 2014), one and two years, respectively, after the emergence of the virus in Europe.

Embryonic or early fetal death in domestic ruminants could have been underestimated in the field. First, they can easily be overlooked by the farmers, limiting the number of reports. Second, at the European scale, data about reproduction in livestock, for example the number of abortions and of return to service per herd is not easily available (Afonso et al., 2014). Therefore, the estimation of the impact of SBV on early pregnancy was limited in Europe.

In France, the spread of SBV has influenced the clinical surveillance system of bovine brucellosis, a system based on abortion notification. Indeed, the spread of SBV was associated with an increase in the numbers of farmers that had notified abortion in 2012 and 2013. This increase may result from an increase in abortion occurrence due to SBV and/or from the farmers' increased propensity in notifying abortions in this period (Bronner et al., 2015). The increase in notifying farmers was thus not easy to interpret. In France, a syndromic surveillance could be useful to improve the monitoring of abortions in cattle (Bronner et al., 2015).

Syndromic surveillance can be defined as “the routine monitoring of one or several indicators for the early detection of adverse health events” (Madouasse et al., 2013). Milk yield in cattle has been tested as an indicator for the emergence of vector borne disease, yet the system described by the authors had to be improved due to low specificity (Madouasse et al., 2013). Indicators of fertility and prolificacy in livestock deserve to be monitored.

The window of susceptibility of pregnant goats to SBV infection is at least between 28 and 42 dg (part 4.1.3.3). Preventive measures should be applied to prevent SBV infection in naïve female goats before mating or artificial insemination. They include protection against midges, and acquisition of an adaptive immunity against SBV, as detailed in part 2.5.2. However, commercialized vaccines have not yet been tested in goats.

5.3.2 Wild and exotic ruminants

As yet, SBV impact for free-ranging wild ruminants is unknown. One suspected case in roe deer kids in France has been evoked (Rossi et al., 2015), yet no malformations have been reported in red deer from the populations studied in part 4.2.1, in 2012. No gross lesions evocative of SBV infection and no SBV RNA were found in 27 fetuses and newborns from red deer in Belgium at the beginning of the SBV epizootic (Linden et al., 2012) and in 7 chamois fetuses in Spain in 2013 (Fernández-Aguilar et al., 2014). Obviously, it is more difficult to detect malformed newborns in the wild than in farms.

Considering SBV infects wild ruminants and might elicit clinical disease, its impact would depend on the breeding period of each species. In roe deer, mating occurs in July or August, with embryonic diapause a few days after. Pregnancy starts again with implantation in December and birth in May or June (Aitken, 1974). Thus, the period at risk is early embryonal life, before embryonic diapause, when the midges are active. In red deer, mating occurs in October or December and births take place in May or July (Guinness et al., 1971). During the first months of pregnancy, red deer females are unlikely to be exposed to midges, except when the weather favors midges’ activity beyond October.

In contrast to red deer and roe deer, which are not endangered species, several ruminant species kept in zoos are threatened by extinction. Among them are three species that has been found seropositive for SBV (cf. part 4.2.2).

The Pere David's deer (*Elaphurus davidianus*) is extinct in the wild but has been rescued through breeding in captivity. This species is native from China (Zhigang and Harris, 2008). The breeding season takes place in summer (Asher et al., 1988), then births occur 270-300 days later (Zhigang and Harris, 2008). Females can be exposed to SBV via midges during the first half of pregnancy.

The Mesopotamian Fallow deer (*Dama mesopotamica*) is found in Iran and has been reintroduced in Israel. With less than 250 mature individuals in Iran, this species is considered as endangered (Rabiei and Saltz, 2013). Mating takes place in August and early September, then calving occurs at the end of March to early April (Rabiei and Saltz, 2013). The period over which females can be exposed to midges overlaps with pregnancy.

The West Caucasian Tur (*Capra caucasica*) is found in the western part of the Great Caucasus Mountains in Georgia and Russia. The total population was estimated at 5,000-6,000 animals in 2004 and has been decreasing, thus this species is considered as endangered (Weinberg, 2008). In this species, the rut lasts from mid-November until the beginning of January; births occurs from May to July (Weinberg, 2008). Exposure to SBV could occur during the second half of pregnancy.

Vaccination, unless mandatory, is not widely used in zoological parks. It could interfere with control of the serological status when the animal comes to a new park. As animal exchange is frequent, facultative vaccination is seldom performed (Norin Chai, personal communication). Until SBV is proven to put zoo animals at risk, prevention of SBV infection will not be developed in zoological parks. Nevertheless, serological testing in the dams and submission of samples from aborted, stillborn or malformed newborn animals for SBV RT-qPCR testing is advised.

6 FUTURE DIRECTIONS

6.1 Pathogenesis of the infection in goats

The work presented in this thesis has led to hypotheses on the pathogenesis of the infection in pregnant goats. To elucidate further the way SBV induces malformations and death in the offspring, the following studies could be performed:

- ***Immunohistochemistry and morphometry on tissue slices***

To identify more precisely target cells in CNS, IHC should be performed on fetal tissues to see if the affected cells are bipotential progenitor cells only or if there are already differentiating into neurons or glial cells. To assess ventral horn neuron density in spinal cord with accuracy, morphometry should be performed on fetal tissues.

To look for an effect of SBV on the vascularization in placentomes, the capillary area density and capillarity cross sectional area could be measured in caruncles and cotyledons from infected animals and controls. It could be interesting to combine this morphometry study with a comparison of copy numbers of VEGF mRNA in placentomes between infected animals and controls.

- ***Transcript analysis or proteomics on fetal tissues to look for difference in the expression of developmental and immune genes***

As to developmental genes, the expression of myogenic regulator factors (Fred Sinowatz, 2010b) in the fetal muscle could be compared between SBV-infected and control fetuses. The influence of SBV on bone development could be explored through transcriptomic analyses in the fetal bone, with a focus on Notch and Wnt pathways, major pathways for development of the axial skeleton (Dittmer and Thompson, 2015), and on the transcription factors Cbfa1 and Indian hedgehog that are involved in the late steps of endochondral ossification (Fred Sinowatz, 2010b).

Whether the goat fetuses infected by SBV are able to mount an innate immunity early in gestation is not known. The ability to develop innate immunity earlier than 70 dg has been showed for ovine fetuses inoculated experimentally with Cache valley virus at 35 dg (Rodrigues Hoffmann et al., 2013). The samples obtained from SBV-infected and control goat

fetuses could be submitted to RT-qPCR targeting transcripts of genes involved in the innate immunity, for example: IFN- α , IFN- β , TNF- α , IL-1; and, considering the response against a single stranded RNA virus: TLR7 and TLR8. Besides, mucosal chemokine CCL25, expressed early in gestation in the thymus of ovine fetuses, is supposed to have an important role in colonization of the thymus by lymphocytes (Meurens et al., 2007). As SBV infection has been associated with lymphocyte depletion in the thymus in some affected newborns (Herder et al., 2012; Seehusen et al., 2014), we may hypothesize that SBV disrupt colonization of the thymus via CCL25 shutdown. It could be interesting to compare the copy number of CCL25 mRNA in the thymus from our infected goat fetuses and the control goat fetuses.

The purpose of pathogenesis studies is to elucidate the mechanisms leading to diseases. In the end, they can bring a basis for prevention and treatment. Vaccines are now available to protect ruminants against SBV infection. However, they have not been tested on goats. A first step would be testing on adult non-pregnant goats. Furthermore, the safety of SBV vaccines has not been tested on pregnant females; this would be useful to evaluate for live virus vaccines that will be produced in the future, as they might have a teratogenic effect if inoculated accidentally in pregnant animals (Tarlinton et al., 2012). A second step would include vaccine administration to pregnant cows, ewes, and goats, followed by SBV challenge and survey of the pregnancy outcome.

6.2 SBV circulation in wild and exotic ruminants

The role of wild ruminants in dissemination of SBV remains unclear. Among wild ruminants, red deer populations are very abundant in Europe. In order to elucidate if red deer could play a role in dissemination of SBV, experimental infection on red deer could be performed to describe the duration of SBV viremia in this species. In addition, to explore the possibility of maintenance of SBV in wildlife, SBV RNA could be sought by RT-qPCR on serum samples from free-ranging wild ruminants that are stored in several laboratories in France.

The effects of SBV on reproduction of wild and exotic ruminants kept in zoos have not been characterized. Staff in zoological parks may be asked to send samples from stillborn or aborted fetuses for SBV-specific PCR testing.

Finally, the origin of SBV has not been elucidated. Serological testing could be performed outside of Europe, on local species of ruminants, to look for antibodies against SBV.

7 CONCLUSION

SBV was identified and isolated only a few months after description of the corresponding clinical signs in cattle, whereas AKAV-associated lesions in calves were described 18 years before the virus was isolated and the causal link between AKAV and the lesions was made (Wilks, 2014). The emergence of SBV has been associated from the beginning with transparency in reporting, generous exchanges of reagents and collaborative research between the European countries (Wilks, 2014).

In the scope of the European research program on SBV in the pathogenesis and epidemiology areas, the works included in this thesis provided new data about SBV infection in livestock and wild and exotic ruminants. We participated in the description of the kinetics of viremia and seroconversion after experimental SBV infection in sheep and goats. We demonstrated goats can be infected by SBV via vaginal route. We showed fetal deaths or central nervous system lesions can occur in goat fetuses after SBV infection between 28 and 42 days of gestation. We described for the first time evidence of susceptibility to SBV in several species of wild and exotic ruminants kept in zoos.

In 2013, the within-herd SBV seroprevalence in cows in Sweden and Belgium, as well as in goats in France, was heterogeneous with low values in some herds, indicating that SBV-naïve animals remained two years after the epizootics (Chenais et al., 2013; Méroc et al., 2013). Thus, recurrence of SBV could be expected in 2014; it did happen in Germany, with acute disease in adult cattle and increased frequency of malformations in the offspring (Wernike et al., 2015). This scenario may repeat over time, given the animals left naïve after one vector season will allow recurrence of the infection the next vector season. Depending on the duration of the immunity, clinical expression of the disease will appear as sporadic outbreaks, or further epizootics if immunity at population level declines (Dominguez et al., 2014).

8 REFERENCES

- Aebischer, A., Wernike, K., Hoffmann, B., and Beer, M. (2014). Rapid genome detection of Schmallenberg virus and bovine viral diarrhoea virus by use of isothermal amplification methods and high-speed real-time reverse transcriptase PCR. *J. Clin. Microbiol.* *52*, 1883–1892.
- Afonso, A., Abrahantes, J.C., Conraths, F., Veldhuis, A., Elbers, A., Roberts, H., Van der Stede, Y., Méroc, E., Gache, K., and Richardson, J. (2014). The Schmallenberg virus epidemic in Europe-2011-2013. *Prev. Vet. Med.* *116*, 391–403.
- Aitken, R.J. (1974). Delayed implantation in roe deer (*Capreolus capreolus*). *J. Reprod. Fertil.* *39*, 225–233.
- Anonymous (2013). Akabane Disease in Animals. *In*: Department of Agriculture and Fisheries, Queensland Government, Australia. Available at: <https://www.daf.qld.gov.au/animal-industries/animal-health-and-diseases/a-z-list/akabane> (accessed July 27, 2015).
- Arnaud, F., Black, S.G., Murphy, L., Griffiths, D.J., Neil, S.J., Spencer, T.E., and Palmarini, M. (2010). Interplay between Ovine Bone Marrow Stromal Cell Antigen 2/Tetherin and Endogenous Retroviruses. *J. Virol.* *84*, 4415–4425.
- Asher, G.W., Adam, J.L., Otway, W., Bowmar, P., van Reenan, G., Mackintosh, C.G., and Dratch, P. (1988). Hybridization of Pere David's deer (*Elaphurus davidianus*) and red deer (*Cervus elaphus*) by artificial insemination. *J. Zool.* *215*, 197–203.
- Ayllón, T., Nijhof, A.M., Weiher, W., Bauer, B., Allène, X., and Clausen, P.-H. (2014). Feeding behaviour of *Culicoides* spp. (Diptera: Ceratopogonidae) on cattle and sheep in northeast Germany. *Parasit. Vectors* *7*, 34.
- Azkur, A.K., Albayrak, H., Risvanli, A., Pestil, Z., Ozan, E., Yilmaz, O., Tonbak, S., Cavunt, A., Kadı, H., Macun, H.C., et al. (2013). Antibodies to Schmallenberg virus in domestic livestock in Turkey. *Trop. Anim. Health Prod.* *45*, 1825–1828.
- Balenghien, T., Pagès, N., Goffredo, M., Carpenter, S., Augot, D., Jacquier, E., Talavera, S., Monaco, F., Depaquit, J., Grillet, C., et al. (2014). The emergence of Schmallenberg virus across *Culicoides* communities and ecosystems in Europe. *Prev. Vet. Med.* *116*, 360–369.
- Balmer, S., Vöggtlin, A., Thür, B., Büchi, M., Abril, C., Houmard, M., Danuser, J., and Schwermer, H. (2014). Serosurveillance of Schmallenberg virus in Switzerland using bulk tank milk samples. *Prev. Vet. Med.* *116*, 370–379.
- Barlow, A., Green, P., Banham, T., and Healy, N. (2013). Serological confirmation of SBV infection in wild British deer. *Vet. Rec.* *172*, 429.
- Barry, G., Varela, M., Ratinier, M., Blomström, A.-L., Caporale, M., Seehusen, F., Hahn, K., Schnettler, E., Baumgärtner, W., Kohl, A., et al. (2014). NSs protein of Schmallenberg virus

counteracts the antiviral response of the cell by inhibiting its transcriptional machinery. *J. Gen. Virol.* *95*, 1640–1646.

Bayrou, C., Garigliany, M.-M., Sarlet, M., Sartelet, A., Cassart, D., and Desmecht, D. (2014). Natural intrauterine infection with Schmallenberg virus in malformed newborn calves. *Emerg. Infect. Dis.* *20*, 1327–1330.

Bessell, P.R., Auty, H.K., Searle, K.R., Handel, I.G., Purse, B.V., and de C Bronsvooort, B.M. (2014). Impact of temperature, feeding preference and vaccination on Schmallenberg virus transmission in Scotland. *Sci. Rep.* *4*, 5746.

Bilk, S., Schulze, C., Fischer, M., Beer, M., Hlinak, A., and Hoffmann, B. (2012). Organ distribution of Schmallenberg virus RNA in malformed newborns. *Vet. Microbiol.* *159*, 236–238.

Blomström, A.-L., Stenberg, H., Scharin, I., Figueiredo, J., Nhambirre, O., Abilio, A.P., Fafetine, J., and Berg, M. (2014). Serological screening suggests presence of Schmallenberg virus in cattle, sheep and goat in the Zambezia Province, Mozambique. *Transbound. Emerg. Dis.* *61*, 289–292.

Blomström, A.-L., Gu, Q., Barry, G., Wilkie, G., Skelton, J.K., Baird, M., McFarlane, M., Schnettler, E., Elliott, R.M., Palmarini, M., et al. (2015). Transcriptome analysis reveals the host response to Schmallenberg virus in bovine cells and antagonistic effects of the NSs protein. *BMC Genomics* *16*, 324.

Bouwstra, R.J., Kooi, E.A., de Kluijver, E.P., Verstraten, E.R. a. M., Bongers, J.H., van Maanen, C., Wellenberg, G.J., van der Spek, A.N., and van der Poel, W.H.M. (2013). Schmallenberg virus outbreak in the Netherlands: routine diagnostics and test results. *Vet. Microbiol.* *165*, 102–108.

Bréard, E., Lara, E., Comtet, L., Viarouge, C., Doceul, V., Desprat, A., Vitour, D., Pozzi, N., Cay, A.B., De Regge, N., et al. (2013). Validation of a commercially available indirect ELISA using a nucleocapside recombinant protein for detection of Schmallenberg virus antibodies. *PloS One* *8*, e53446.

Briese, T., Calisher, C.H., and Higgs, S. (2013). Viruses of the family Bunyaviridae: are all available isolates reassortants? *Virology* *446*, 207–216.

British Veterinary Association (2013). VMD authorises SBV vaccine for use in the UK. *Vet. Rec.* *172*, 543–543.

Brodersen, B.W. (2014). Bovine viral diarrhoea virus infections: manifestations of infection and recent advances in understanding pathogenesis and control. *Vet. Pathol.* *51*, 453–464.

van den Brom, R., Luttikholt, S.J.M., Lievaart-Peterson, K., Peperkamp, N.H.M.T., Mars, M.H., van der Poel, W.H.M., and Vellema, P. (2012). Epizootic of ovine congenital malformations associated with Schmallenberg virus infection. *Tijdschr. Diergeneesk.* *137*, 106–111.

Bronner, A., Morignat, E., Touratier, A., Gache, K., Sala, C., and Calavas, D. (2015). Was the French clinical surveillance system of bovine brucellosis influenced by the occurrence and surveillance of other abortive diseases? *Prev. Vet. Med.* *118*, 498–503.

- Calzolari, M., and Albieri, A. (2013). Could drought conditions trigger Schmallenberg virus and other arboviruses circulation? *Int. J. Health Geogr.* *12*, 7.
- Carpenter, S., Groschup, M.H., Garros, C., Felipe-Bauer, M.L., and Purse, B.V. (2013). Culicoides biting midges, arboviruses and public health in Europe. *Antiviral Res.* *100*, 102–113.
- Chaintoutis, S.C., Kiossis, E., Giadinis, N.D., Brozos, C.N., Sailleau, C., Viarouge, C., Bréard, E., Papanastassopoulou, M., Zientara, S., Papadopoulos, O., et al. (2014). Evidence of Schmallenberg virus circulation in ruminants in Greece. *Trop. Anim. Health Prod.* *46*, 251–255.
- Chenais, E., Ståhl, K., Frössling, J., Blomqvist, G., Näslund, K., Svensson, L., Renström, L., Mieziowska, K., Elvander, M., and Valarcher, J.F. (2013). Schmallenberg Virus beyond Latitude 65°N. *Transbound. Emerg. Dis.*
- Chiari, M., Sozzi, E., Zanoni, M., Alborali, L.G., Lavazza, A., and Cordioli, P. (2014). Serosurvey for Schmallenberg virus in alpine wild ungulates. *Transbound. Emerg. Dis.* *61*, 1–3.
- Claine, F., Coupeau, D., Wiggers, L., Muylkens, B., and Kirschvink, N. (2013). Schmallenberg virus among female lambs, Belgium, 2012. *Emerg. Infect. Dis.* *19*, 1115–1117.
- Conraths, F.J., Kämer, D., Teske, K., Hoffmann, B., Mettenleiter, T.C., and Beer, M. (2013). Reemerging Schmallenberg virus infections, Germany, 2012. *Emerg. Infect. Dis.* *19*, 513–514.
- Coupeau, D., Claine, F., Wiggers, L., Kirschvink, N., and Muylkens, B. (2013). In vivo and in vitro identification of a hypervariable region in Schmallenberg virus. *J. Gen. Virol.* *94*, 1168–1174.
- Daly, J.M., King, B., Tarlinton, R.A., Gough, K.C., Maddison, B.C., and Blowey, R. (2015). Comparison of Schmallenberg virus antibody levels detected in milk and serum from individual cows. *BMC Vet. Res.* *11*, 56.
- Dantzer, V., and Leiser, R. (2006). Placentation. *In: Dellmann's Textbook of Veterinary Histology*, (Wiley-Blackwell), pp. 279–296.
- Desmecht, D., Garigliany, M.-M., Beer, M., Schirrmeyer, H., Paternostre, J., Volpe, R., and Linden, A. (2013). Detection of antibodies against Schmallenberg virus in wild boars, Belgium, 2010-2012. *In: Proceedings of the 31th Congress of the International Union of Game Biologists* (Brussels, Belgium).
- Dittmer, K.E., and Thompson, K.G. (2015). Approach to Investigating Congenital Skeletal Abnormalities in Livestock. *Vet. Pathol.* *52*, 851-861.
- Doceul, V., Lara, E., Sailleau, C., Belbis, G., Richardson, J., Bréard, E., Viarouge, C., Dominguez, M., Hendrikx, P., Calavas, D., et al. (2013). Epidemiology, molecular virology and diagnostics of Schmallenberg virus, an emerging orthobunyavirus in Europe. *Vet. Res.* *44*, 31.

- Dominguez, M., Gache, K., Touratier, A., Perrin, J.-B., Fediaevsky, A., Collin, E., Bréard, E., Sailleau, C., Viarouge, C., Zanella, G., et al. (2014). Spread and impact of the Schmallenberg virus epidemic in France in 2012-2013. *BMC Vet. Res.* *10*, 248.
- Ducomble, T., Wilking, H., Stark, K., Takla, A., Askar, M., Schaade, L., Nitsche, A., and Kurth, A. (2012). Lack of evidence for Schmallenberg virus infection in highly exposed persons, Germany, 2012. *Emerg. Infect. Dis.* *18*, 1333–1335.
- Edwards, J.F., Livingston, C.W., Chung, S.I., and Collisson, E.C. (1989). Ovine arthrogryposis and central nervous system malformations associated with in utero Cache Valley virus infection: spontaneous disease. *Vet. Pathol.* *26*, 33–39.
- EFSA (2013). Schmallenberg virus: Analysis of the epidemiological data. Supporting publications 2013:EN-429, 22pp.
- EFSA (2014). Schmallenberg virus: State of the Art. *EFSA journal* 2014; 12(5):3681, 54 pp.
- Eifan, S., Schnettler, E., Dietrich, I., Kohl, A., and Blomström, A.-L. (2013). Non-structural proteins of arthropod-borne bunyaviruses: roles and functions. *Viruses* *5*, 2447–2468.
- Elbers, A.R.W., Meiswinkel, R., van Weezep, E., Sloet van Oldruitenborgh-Oosterbaan, M.M., and Kooi, E.A. (2013a). Schmallenberg virus in *Culicoides* spp. biting midges, the Netherlands, 2011. *Emerg. Infect. Dis.* *19*, 106–109.
- Elbers, A.R.W., Meiswinkel, R., van Weezep, E., Kooi, E.A., and van der Poel, W.H.M. (2013b). Schmallenberg Virus in *Culicoides* Biting Midges in the Netherlands in 2012. *Transbound. Emerg. Dis.* DOI 10.1111/tbed.12128.
- Elbers, A.R.W., Stockhofe-Zurwieden, N., and van der Poel, W.H.M. (2014). Schmallenberg virus antibody persistence in adult cattle after natural infection and decay of maternal antibodies in calves. *BMC Vet. Res.* *10*, 103.
- Elliott, R.M., Blakqori, G., van Knippenberg, I.C., Koudriakova, E., Li, P., McLees, A., Shi, X., and Szemiel, A.M. (2013). Establishment of a reverse genetics system for Schmallenberg virus, a newly emerged orthobunyavirus in Europe. *J. Gen. Virol.* *94*, 851–859.
- Evans, C.A., Reynolds, J.M., Reynolds, M.L., Saunders, N.R., and Segal, M.B. (1974). The development of a blood-brain barrier mechanism in foetal sheep. *J. Physiol.* *238*, 371–386.
- Fernández-Aguilar, X., Pujols, J., Velarde, R., Rosell, R., López-Olvera, J.R., Marco, I., Pumarola, M., Segalés, J., Lavín, S., and Cabezón, O. (2014). Schmallenberg virus circulation in high mountain ecosystem, Spain. *Emerg. Infect. Dis.* *20*, 1062–1064.
- Fischer, M., Hoffmann, B., Goller, K.V., Höper, D., Wernike, K., and Beer, M. (2013a). A mutation “hot spot” in the Schmallenberg virus M segment. *J. Gen. Virol.* *94*, 1161–1167.
- Fischer, M., Schirrmeier, H., Wernike, K., Wegelt, A., Beer, M., and Hoffmann, B. (2013b). Development of a pan-Simbu real-time reverse transcriptase PCR for the detection of Simbu serogroup viruses and comparison with SBV diagnostic PCR systems. *Virol. J.* *10*, 327.
- Fred Sinowatz (2010a). Chapter 10: Development of the central and peripheral nervous system. *In: Essentials of Domestic Animal Embryology*, (Saunders Elsevier), pp. 120–162.

- Fred Sinowatz (2010b). Chapter 16: Musculo-skeletal system. *In: Essentials of Domestic Animal Embryology*, (Saunders Elsevier), pp. 286–316.
- Gale, P., Kelly, L., and Snary, E.L. (2015). Pathways for entry of livestock arboviruses into Great Britain: assessing the strength of evidence. *Transbound. Emerg. Dis.* *62*, 115–123.
- Garigliany, M.-M., Hoffmann, B., Dive, M., Sartelet, A., Bayrou, C., Cassart, D., Beer, M., and Desmecht, D. (2012). Schmallenberg virus in calf born at term with porencephaly, Belgium. *Emerg. Infect. Dis.* *18*, 1005–1006.
- Garigliany, M.-M., Desmecht, D., Bayrou, C., and Peeters, D. (2013). No serologic evidence for emerging Schmallenberg virus infection in dogs (*Canis domesticus*). *Vector Borne Zoonotic Dis. Larchmt. N* *13*, 830–833.
- Gerdtts, V., Snider, M., Brownlie, R., Babiuk, L.A., and Griebel, P.J. (2002). Oral DNA vaccination in utero induces mucosal immunity and immune memory in the neonate. *J. Immunol. Baltim. Md* *1950* *168*, 1877–1885.
- Gerhauser, I., Weigand, M., Hahn, K., Herder, V., Wohlsein, P., Habierski, A., Varela, M., Palmarini, M., and Baumgärtner, W. (2014). Lack of schmallenberg virus in ruminant brain tissues archived from 1961 to 2010 in Germany. *J. Comp. Pathol.* *150*, 151–154.
- Goffredo, M., Romeo, G., Monaco, F., Di Gennaro, A., and Savini, G. (2004). Laboratory survival and blood feeding response of wild-caught *Culicoides obsoletus* Complex (Diptera: Ceratopogonidae) through natural and artificial membranes. *Vet. Ital.* *40*, 282–285.
- Goffredo, M., Monaco, F., Capelli, G., Quaglia, M., Federici, V., Catalani, M., Montarsi, F., Polci, A., Pinoni, C., Calistri, P., et al. (2013). Schmallenberg virus in Italy: a retrospective survey in *Culicoides* stored during the bluetongue Italian surveillance program. *Prev. Vet. Med.* *111*, 230–236.
- Goller, K.V., Höper, D., Schirrmeier, H., Mettenleiter, T.C., and Beer, M. (2012). Schmallenberg virus as possible ancestor of Shamonda virus. *Emerg. Infect. Dis.* *18*, 1644–1646.
- Gubbins, S., Turner, J., Baylis, M., van der Stede, Y., van Schaik, G., Abrahantes, J.C., and Wilson, A.J. (2014a). Inferences about the transmission of Schmallenberg virus within and between farms. *Prev. Vet. Med.* *116*, 380–390.
- Gubbins, S., Richardson, J., Baylis, M., Wilson, A.J., and Abrahantes, J.C. (2014b). Modelling the continental-scale spread of Schmallenberg virus in Europe: approaches and challenges. *Prev. Vet. Med.* *116*, 404–411.
- Guinness, F., Lincoln, G.A., and Short, R.V. (1971). The reproductive cycle of the female red deer, *Cervus elaphus* L. *J. Reprod. Fertil.* *27*, 427–438.
- Hahn, K., Habierski, A., Herder, V., Wohlsein, P., Peters, M., Hansmann, F., and Baumgärtner, W. (2013). Schmallenberg virus in central nervous system of ruminants. *Emerg. Infect. Dis.* *19*, 154–155.

Harris, K.A., Eglin, R.D., Hayward, S., Milnes, A., Davies, I., Cook, A.J.C., and Downs, S.H. (2014). Impact of Schmallenberg virus on British sheep farms during the 2011/2012 lambing season. *Vet. Rec.* *175*, 172.

Hashiguchi, Y., Nanba, K., and Kumagai, T. (1979). Congenital abnormalities in newborn lambs following Akabane virus infection in pregnant ewes. *Natl. Inst. Anim. Health Q. (Tokyo)* *19*, 1–11.

Hechinger, S., Wernike, K., and Beer, M. (2014). Single immunization with an inactivated vaccine protects sheep from Schmallenberg virus infection. *Vet. Res.* *45*, 79.

van der Heijden, H.M.J.F., Bouwstra, R.J., Mars, M.H., van der Poel, W.H.M., Wellenberg, G.J., and van Maanen, C. (2013). Development and validation of an indirect Enzyme-linked immunosorbent assay for the detection of antibodies against Schmallenberg virus in blood samples from ruminants. *Res. Vet. Sci.* *95*, 731–735.

Helmer, C., Eibach, R., Tegtmeyer, P.C., Humann-Ziehank, E., and Ganter, M. (2013). Survey of Schmallenberg virus (SBV) infection in German goat flocks. *Epidemiol. Infect.* *141*, 2335–2345.

Helmer, C., Eibach, R., Tegtmeyer, P.C., Humann-Ziehank, E., Runge, M., and Ganter, M. (2015). Serosurvey of Schmallenberg Virus Infections in Sheep and Goat Flocks in Lower Saxony, Germany. *Transbound. Emerg. Dis.* *62*, 425–436.

Herder, V., Wohlsein, P., Peters, M., Hansmann, F., and Baumgärtner, W. (2012). Salient lesions in domestic ruminants infected with the emerging so-called Schmallenberg virus in Germany. *Vet. Pathol.* *49*, 588–591.

Herder, V., Hansmann, F., Wohlsein, P., Peters, M., Varela, M., Palmarini, M., and Baumgärtner, W. (2013). Immunophenotyping of Inflammatory Cells Associated with Schmallenberg Virus Infection of the Central Nervous System of Ruminants. *PLoS ONE* *8*, e62939.

Hoffmann, A.R., Welsh, C.J., Varner, P.W., de la Concha-Bermejillo, A., Ball, J.M., Ambrus, A., and Edwards, J.F. (2012a). Identification of the target cells and sequence of infection during experimental infection of ovine fetuses with Cache Valley virus. *J. Virol.* *86*, 4793–4800.

Hoffmann, B., Scheuch, M., Höper, D., Jungblut, R., Holsteg, M., Schirrmeier, H., Eschbaumer, M., Goller, K.V., Wernike, K., Fischer, M., et al. (2012b). Novel Orthobunyavirus in Cattle, Europe, 2011. *Emerg. Infect. Dis.* *18*, 469–472.

Hoffmann, B., Schulz, C., and Beer, M. (2013). First detection of Schmallenberg virus RNA in bovine semen, Germany, 2012. *Vet. Microbiol.* *167*, 289–295.

Hofmann, M.A., Mader, M., Flückiger, F., and Renzullo, S. (2015). Genetic stability of Schmallenberg virus in vivo during an epidemic, and in vitro, when passaged in the highly susceptible porcine SK-6 cell line. *Vet. Microbiol.* *176*, 97–108.

Horikita, T., Yoshinaga, S., Okatani, A.T., Yamane, I., Honda, E., and Hayashidani, H. (2005). Loss of milk yield due to Akabane disease in dairy cows. *J. Vet. Med. Sci. Jpn. Soc. Vet. Sci.* *67*, 287–290.

- Humphries, D., and Burr, P. (2012). Schmallerberg virus milk antibody ELISA. *Vet. Rec.* *171*, 511–512.
- Jack, C., Anstaett, O., Adams, J., Noad, R., Brownlie, J., and Mertens, P. (2012). Evidence of seroconversion to SBV in camelids. *Vet. Rec.* *170*, 603.
- Johnson, A., Bradshaw, B., Boland, C., and Ross, P. (2014). A bulk milk tank study to detect evidence of spread of Schmallerberg virus infection in the south-west of Ireland in 2013. *Ir. Vet. J.* *67*, 11.
- Kirkland, P.D., Barry, R.D., Harper, P.A., and Zelski, R.Z. (1988). The development of Akabane virus-induced congenital abnormalities in cattle. *Vet. Rec.* *122*, 582–586.
- Koenraadt, C.J., Balenghien, T., Carpenter, S., Ducheyne, E., Elbers, A.R., Fife, M., Garros, C., Ibáñez-Justicia, A., Kampen, H., Kormelink, R.J., et al. (2014). Bluetongue, Schmallerberg - what is next? Culicoides-borne viral diseases in the 21st Century. *BMC Vet. Res.* *10*, 77.
- Konno, S., and Nakagawa, M. (1982). Akabane disease in cattle: congenital abnormalities caused by viral infection. *Experimental disease. Vet. Pathol.* *19*, 267–279.
- Konno, S., Moriwaki, M., and Nakagawa, M. (1982). Akabane disease in cattle: congenital abnormalities caused by viral infection. *Spontaneous disease. Vet. Pathol.* *19*, 246–266.
- Kraatz, F., Wernike, K., Hechinger, S., König, P., Granzow, H., Reimann, I., and Beer, M. (2015). Deletion mutants of Schmallerberg virus are avirulent and protect from virus challenge. *J. Virol.* *89*, 1825–1837.
- Kurogi, H., Inaba, Y., Takahashi, E., Sato, K., and Goto, Y. (1977). Experimental infection of pregnant goats with Akabane virus. *Natl. Inst. Anim. Health Q. (Tokyo)* *17*, 1–9.
- Laloy, E., Bréard, E., Sailleau, C., Viarouge, C., Desprat, A., Zientara, S., Klein, F., Hars, J., and Rossi, S. (2014). Schmallerberg virus infection among red deer, France, 2010-2012. *Emerg. Infect. Dis.* *20*, 131–134.
- Larska, M., Krzysiak, M., Smreczak, M., Polak, M.P., and Zmudziński, J.F. (2013a). First detection of Schmallerberg virus in elk (*Alces alces*) indicating infection of wildlife in Białowieża National Park in Poland. *Vet. J. Lond. Engl. 1997* *198*, 279–281.
- Larska, M., Lechowski, L., Grochowska, M., and Żmudziński, J.F. (2013b). Detection of the Schmallerberg virus in nulliparous *Culicoides obsoletus/scoticus* complex and *C. punctatus*--the possibility of transovarial virus transmission in the midge population and of a new vector. *Vet. Microbiol.* *166*, 467–473.
- Larska, M., Krzysiak, M.K., Kęsik-Maliszewska, J., and Rola, J. (2014). Cross-sectional study of Schmallerberg virus seroprevalence in wild ruminants in Poland at the end of the vector season of 2013. *BMC Vet. Res.* *10*, 967.
- Lassen, S.B., Nielsen, S.A., Skovgård, H., and Kristensen, M. (2011). Molecular identification of bloodmeals from biting midges (Diptera: Ceratopogonidae: *Culicoides* Latreille) in Denmark. *Parasitol. Res.* *108*, 823–829.

- Lazutka, J., Zvirbliene, A., Dalgediene, I., Petraityte-Burneikiene, R., Spakova, A., Sereika, V., Lelesius, R., Wernike, K., Beer, M., and Sasnauskas, K. (2014). Generation of Recombinant Schmallenberg Virus Nucleocapsid Protein in Yeast and Development of Virus-Specific Monoclonal Antibodies. *J. Immunol. Res.* 2014.
- Leask, R., Botha, A.M., and Bath, G.F. (2013). Schmallenberg virus--is it present in South Africa? *J. S. Afr. Vet. Assoc.* 84, E1–E4.
- Lee, J.K., Park, J.S., Choi, J.H., Park, B.K., Lee, B.C., Hwang, W.S., Kim, J.H., Jean, Y.H., Haritani, M., Yoo, H.S., et al. (2002). Encephalomyelitis associated with akabane virus infection in adult cows. *Vet. Pathol.* 39, 269–273.
- Lievaart-Peterson, K., Lutikholt, S.J.M., Van den Brom, R., and Vellema, P. (2012). Schmallenberg virus infection in small ruminants – First review of the situation and prospects in Northern Europe. *Small Rumin. Res.* 106, 71–76.
- Linden, A., Desmecht, D., Volpe, R., Wirtgen, M., Gregoire, F., Pirson, J., Paternostre, J., Kleijnen, D., Schirrmeyer, H., Beer, M., et al. (2012). Epizootic spread of Schmallenberg virus among wild cervids, Belgium, Fall 2011. *Emerg. Infect. Dis.* 18, 2006–2008.
- Loeffen, W., Quak, S., de Boer-Luijtz, E., Hulst, M., van der Poel, W., Bouwstra, R., and Maas, R. (2012). Development of a virus neutralisation test to detect antibodies against Schmallenberg virus and serological results in suspect and infected herds. *Acta Vet. Scand.* 54, 44.
- Lühken, R., Steinke, S., Wittmann, A., and Kiel, E. (2014). Impact of flooding on the immature stages of dung-breeding *Culicoides* in Northern Europe. *Vet. Parasitol.* 205, 289–294.
- Lutikholt, S., Veldhuis, A., van den Brom, R., Moll, L., Lievaart-Peterson, K., Peperkamp, K., van Schaik, G., and Vellema, P. (2014). Risk factors for malformations and impact on reproductive performance and mortality rates of Schmallenberg virus in sheep flocks in the Netherlands. *PloS One* 9, e100135.
- van Maanen, C., van der Heijden, H., Wellenberg, G.J., Witteveen, G., Lutikholt, S., Bouwstra, R., Kooi, B., Vellema, P., Peperkamp, K., and Mars, J. (2012). Schmallenberg virus antibodies in bovine and ovine fetuses. *Vet. Rec.* 171, 299.
- Madouasse, A., Marceau, A., Lehébel, A., Brouwer-Middelesch, H., van Schaik, G., Van der Stede, Y., and Fourichon, C. (2013). Evaluation of a continuous indicator for syndromic surveillance through simulation. application to vector borne disease emergence detection in cattle using milk yield. *PloS One* 8, e73726.
- Mansfield, K.L., La Rocca, S.A., Khatri, M., Johnson, N., Steinbach, F., and Fooks, A.R. (2013). Detection of Schmallenberg virus serum neutralising antibodies. *J. Virol. Methods* 188, 139–144.
- Martinelle, L., Poskin, A., Dal Pozzo, F., Mostin, L., Van Campe, W., Cay, A.B., De Regge, N., and Saegerman, C. (2015). Three Different Routes of Inoculation for Experimental Infection with Schmallenberg Virus in Sheep. *Transbound. Emerg. Dis.*

McClure, S., McCullagh, P., Parsonson, I.M., McPhee, D.A., Della-Porta, A.J., and Orsini, A. (1988). Maturation of immunological reactivity in the fetal lamb infected with Akabane virus. *J. Comp. Pathol.* *99*, 133–143.

Mellor, P.S. (2000). Replication of arboviruses in insect vectors. *J. Comp. Pathol.* *123*, 231–247.

Merial (2013). Merial Receives Approval For New Vaccine To Prevent Schmallenberg Disease In Livestock. Available at: <http://merial.com/en/press-releases/merial-receives-approval-for-new-vaccine-to-prevent-schmallenberg-disease-in-livestock/> (accessed July 28, 2015).

Méroc, E., Poskin, A., Van Loo, H., Van Driessche, E., Czaplicki, G., Quinet, C., Riocreux, F., De Regge, N., Caij, B., van den Berg, T., et al. (2013). Follow-up of the Schmallenberg Virus Seroprevalence in Belgian Cattle. *Transbound. Emerg. Dis.* DOI 10.1111/tbed.12050.

Meurens, F., Whale, J., Brownlie, R., Dybvig, T., Thompson, D.R., and Gerds, V. (2007). Expression of mucosal chemokines TECK/CCL25 and MEC/CCL28 during fetal development of the ovine mucosal immune system. *Immunology* *120*, 544–555.

Narita, M., Inui, S., and Hashiguchi, Y. (1979). The pathogenesis of congenital encephalopathies in sheep experimentally induced by Akabane virus. *J. Comp. Pathol.* *89*, 229–240.

Oem, J.-K., Yoon, H.-J., Kim, H.-R., Roh, I.-S., Lee, K.-H., Lee, O.-S., and Bae, Y.-C. (2012). Genetic and pathogenic characterization of Akabane viruses isolated from cattle with encephalomyelitis in Korea. *Vet. Microbiol.* *158*, 259–266.

OIE (2015). *Terrestrial Animal Health Code: Glossary*.

Padua, M.B., and Hansen, P.J. (2010). Evolution and function of the uterine serpins (SERPINA14). *Am. J. Reprod. Immunol. N. Y. N* 1989 *64*, 265–274.

Parsonson, I.M., Della-Porta, A.J., and Snowdon, W.A. (1977). Congenital abnormalities in newborn lambs after infection of pregnant sheep with Akabane virus. *Infect. Immun.* *15*, 254–262.

Parsonson, I.M., Della-Porta, A.J., Snowdon, W.A., and O'Halloran, M.L. (1981a). The consequences of infection of cattle with Akabane virus at the time of insemination. *J. Comp. Pathol.* *91*, 611–619.

Parsonson, I.M., Della-Porta, A.J., and Snowdon, W.A. (1981b). Akabane virus infection in the pregnant ewe. 2. Pathology of the foetus. *Vet. Microbiol.* *6*, 209–224.

Parsonson, I.M., Della-Porta, A.J., O'Halloran, M.L., Snowdon, W.A., Fahey, K.J., and Standfast, H.A. (1981c). Akabane virus infection in the pregnant ewe. 1. Growth of virus in the foetus and the development of the foetal immune response. *Vet. Microbiol.* *6*, 197–207.

Parsonson, I.M., McPhee, D.A., Della-Porta, A.J., McClure, S., and McCullagh, P. (1988). Transmission of Akabane virus from the ewe to the early fetus (32 to 53 days). *J. Comp. Pathol.* *99*, 215–227.

Peperkamp, K., Dijkman, R., van Maanen, C., Vos, J., Wouda, W., Holzhauser, M., van Wuijckhuise, L., Junker, K., Greijdanus, S., and Roumen, M. (2012). Polioencephalo-myelitis in a calf due to infection with Schmallerberg virus. *Vet. Rec.* *170*, 570.

Peperkamp, N.H., Luttikholt, S.J., Dijkman, R., Vos, J.H., Junker, K., Greijdanus, S., Roumen, M.P., van Garderen, E., Meertens, N., van Maanen, C., et al. (2014). Ovine and Bovine Congenital Abnormalities Associated With Intrauterine Infection With Schmallerberg Virus. *Vet. Pathol.* DOI 10.1177/0300985814560231.

Van Der Poel, W.H.M., Parlevliet, J.M., Verstraten, E.R.A.M., Kooi, E.A., Honing, R.H.-V. Der, and Stockhofe, N. (2013). Schmallerberg virus detection in bovine semen after experimental infection of bulls. *Epidemiol. Infect.* 1–6.

van der Poel, W.H.M., Cay, B., Zientara, S., Steinbach, F., Valarcher, J.F., Bøtner, A., Mars, M.H., Hakze-van der Honing, R., Schirrmeyer, H., and Beer, M. (2014). Limited interlaboratory comparison of Schmallerberg virus antibody detection in serum samples. *Vet. Rec.* *174*, 380.

Ponsart, C., Pozzi, N., Bréard, E., Catinot, V., Viard, G., Sailleau, C., Viarouge, C., Gouzil, J., Beer, M., Zientara, S., et al. (2014). Evidence of excretion of Schmallerberg virus in bull semen. *Vet. Res.* *45*, 37.

Poskin, A., Van Campe, W., Mostin, L., Cay, B., and De Regge, N. (2014a). Experimental Schmallerberg virus infection of pigs. *Vet. Microbiol.* *170*, 398–402.

Poskin, A., Martinelle, L., Mostin, L., Van Campe, W., Dal Pozzo, F., Saegerman, C., Cay, A.B., and De Regge, N. (2014b). Dose-dependent effect of experimental Schmallerberg virus infection in sheep. *Vet. J. Lond. Engl.* *1997 201*, 419–422.

Poskin, A., Méroc, E., Behaeghel, I., Riocreux, F., Couche, M., Van Loo, H., Bertels, G., Delooz, L., Quinet, C., Dispas, M., et al. (2015). Schmallerberg Virus in Belgium: Estimation of Impact in Cattle and Sheep Herds. *Transbound. Emerg. Dis.* DOI 10.1111/tbed.12367.

Rabiei, A., and Saltz, D. (2013). *Dama mesopotamica*. The IUCN Red List of Threatened Species. Version 2015.1. Available at: <http://www.iucnredlist.org/details/6232/0> (accessed June 6, 2015).

Raboisson, D., Waret-Szkuta, A., Rushton, J., Häsler, B., and Alarcon, P. (2014). Application of integrated production and economic models to estimate the impact of Schmallerberg virus for various beef suckler production systems in France and the United Kingdom. *BMC Vet. Res.* *10*, 254.

Rasmussen, L.D., Kristensen, B., Kirkeby, C., Rasmussen, T.B., Belsham, G.J., Bødker, R., and Bøtner, A. (2012). Culicoids as vectors of Schmallerberg virus. *Emerg. Infect. Dis.* *18*, 1204–1206.

Rasmussen, L.D., Kirkeby, C., Bødker, R., Kristensen, B., Rasmussen, T.B., Belsham, G.J., and Bøtner, A. (2014). Rapid spread of Schmallerberg virus-infected biting midges (*Culicoides* spp.) across Denmark in 2012. *Transbound. Emerg. Dis.* *61*, 12–16.

- De Regge, N., Deblauwe, I., De Deken, R., Vantieghem, P., Madder, M., Geysen, D., Smeets, F., Losson, B., van den Berg, T., and Cay, A.B. (2012). Detection of Schmallenberg virus in different *Culicoides* spp. by real-time RT-PCR. *Transbound. Emerg. Dis.* *59*, 471–475.
- De Regge, N., van den Berg, T., Georges, L., and Cay, B. (2013). Diagnosis of Schmallenberg virus infection in malformed lambs and calves and first indications for virus clearance in the fetus. *Vet. Microbiol.* *162*, 595–600.
- De Regge, N., Madder, M., Deblauwe, I., Losson, B., Fassotte, C., Demeulemeester, J., Smeets, F., Tomme, M., and Cay, A.B. (2014). Schmallenberg virus circulation in *Culicoides* in Belgium in 2012: field validation of a real time RT-PCR approach to assess virus replication and dissemination in midges. *PLoS One* *9*, e87005.
- Reusken, C., van den Wijngaard, C., van Beek, P., Beer, M., Bouwstra, R., Godeke, G.-J., Isken, L., van den Kerkhof, H., van Pelt, W., van der Poel, W., et al. (2012). Lack of evidence for zoonotic transmission of Schmallenberg virus. *Emerg. Infect. Dis.* *18*, 1746–1754.
- Rodrigues Hoffmann, A., Dorniak, P., Filant, J., Dunlap, K.A., Bazer, F.W., de la Concha-Bermejillo, A., Welsh, C.J., Varner, P., and Edwards, J.F. (2013). Ovine Fetal Immune Response to Cache Valley Virus Infection. *J. Virol.* *87*, 5586–5592.
- Rodríguez-Prieto, V., Kukielka, D., Mouriño, M., Paradell, H., Plaja, L., Urniza, A., and Sánchez-Vizcaíno, J.M. (2014). Natural Immunity of Sheep and Lambs Against the Schmallenberg Virus Infection. *Transbound. Emerg. Dis.* DOI 10.1111/tbed.12256.
- Rosseel, T., Scheuch, M., Höper, D., De Regge, N., Caij, A.B., Vandenbussche, F., and Van Borm, S. (2012). DNase SISPA-next generation sequencing confirms Schmallenberg virus in Belgian field samples and identifies genetic variation in Europe. *PLoS One* *7*, e41967.
- Rossi, S., Pioz, M., Beard, E., Durand, B., Gibert, P., Gauthier, D., Klein, F., Maillard, D., Saint-Andrieux, C., Saubusse, T., et al. (2014). Bluetongue dynamics in French wildlife: exploring the driving forces. *Transbound. Emerg. Dis.* *61*, e12–e24.
- Rossi, S., Viarouge, C., Faure, E., Gilot-Fromont, E., Gache, K., Gibert, P., Verheyden, H., Hars, J., Klein, F., Maillard, D., et al. (2015). Exposure of Wildlife to the Schmallenberg Virus in France (2011-2014): Higher, Faster, Stronger (than Bluetongue)! *Transbound. Emerg. Dis.* DOI 10.1111/tbed.12371.
- Saegerman, C., Martinelle, L., Dal Pozzo, F., and Kirschvink, N. (2014). Preliminary survey on the impact of Schmallenberg virus on sheep flocks in South of Belgium. *Transbound. Emerg. Dis.* *61*, 469–472.
- Sailleau, C., Boogaerts, C., Meyrueix, A., Laloy, E., Bréard, E., Viarouge, C., Desprat, A., Vitour, D., Doceul, V., Boucher, C., et al. (2013a). Schmallenberg virus infection in dogs, France, 2012. *Emerg. Infect. Dis.* *19*, 1896–1898.
- Sailleau, C., Bréard, E., Viarouge, C., Desprat, A., Doceul, V., Lara, E., Languille, J., Vitour, D., Attoui, H., and Zientara, S. (2013b). Acute Schmallenberg virus infections, France, 2012. *Emerg. Infect. Dis.* *19*, 321–322.
- Sammin, D., Markey, B., Bassett, H., and Buxton, D. (2009). The ovine placenta and placentitis-A review. *Vet. Microbiol.* *135*, 90–97.

- Sanad, Y.M., Jung, K., Kashoma, I., Zhang, X., Kassem, I.I., Saif, Y.M., and Rajashekara, G. (2015). Insights into potential pathogenesis mechanisms associated with *Campylobacter jejuni*-induced abortion in ewes. *BMC Vet. Res.* *10*, 274.
- Schiefer, P., Steinrigl, A., Wodak, E., Deutz, A., and Schmoll, F. (2013). Detection of SBV Antibodies in wild ruminants in Austria, 2012. *In: Proceedings of the International Meeting on Emerging Diseases and Surveillance*, (Vienna, Austria), p. 189.
- Schulz, C., Beer, M., and Hoffmann, B. (2013). Schmallerberg virus infection in South American camelids. In *Proceedings of the Epizone 7th Annual Meeting* (Bruxelles, Belgium).
- Schulz, C., Wernike, K., Beer, M., and Hoffmann, B. (2014). Infectious Schmallerberg Virus from Bovine Semen, Germany. *Emerg. Infect. Dis.* *20*, 337–339.
- Sedda, L., and Rogers, D.J. (2013). The influence of the wind in the Schmallerberg virus outbreak in Europe. *Sci. Rep.* *3*, 3361.
- Seehusen, F., Hahn, K., Herder, V., Weigand, M., Habierski, A., Gerhauser, I., Wohlsein, P., Peters, M., Varela, M., Palmarini, M., et al. (2014). Skeletal Muscle Hypoplasia Represents the Only Significant Lesion in Peripheral Organs of Ruminants Infected with Schmallerberg Virus during Gestation. *J. Comp. Pathol.* *151*, 148–152.
- Spickler, A.R. (2009). Akabane disease. *In: The Center for Food Security and Public Health*, Iowa State University. Available at: <http://www.cfsph.iastate.edu/Factsheets/pdfs/akabane.pdf> (accessed July 5, 2015).
- Steinrigl, A., Schiefer, P., Schleicher, C., Peinhopf, W., Wodak, E., Bagó, Z., and Schmoll, F. (2014). Rapid spread and association of Schmallerberg virus with ruminant abortions and foetal death in Austria in 2012/2013. *Prev. Vet. Med.* *116*, 350–359.
- Strandin, T., Hepojoki, J., and Vaheri, A. (2013). Cytoplasmic tails of bunyavirus Gn glycoproteins-Could they act as matrix protein surrogates? *Virology* *437*, 73–80.
- Tarlinton, R., and Daly, J. (2013). Testing for Schmallerberg virus. *Vet. Rec.* *172*, 190.
- Tarlinton, R., Daly, J., Dunham, S., and Kydd, J. (2012). The challenge of Schmallerberg virus emergence in Europe. *Vet. J. Lond. Engl.* *197*, 10–18.
- Tarlinton, R., Daly, J., Dunham, S., and Kydd, J.H. (2013). Schmallerberg virus: could wildlife reservoirs threaten domestic livestock? *Vet. J. Lond. Engl.* *198*, 309–310.
- Tsuda, T., Yoshida, K., Ohashi, S., Yanase, T., Sueyoshi, M., Kamimura, S., Misumi, K., Hamana, K., Sakamoto, H., and Yamakawa, M. (2004). Arthrogryposis, hydranencephaly and cerebellar hypoplasia syndrome in neonatal calves resulting from intrauterine infection with Aino virus. *Vet. Res.* *35*, 531–538.
- USDA APHIS (2015). Schmallerberg virus information. Available at: http://www.aphis.usda.gov/wps/portal?ldmy&urle=wcm%3Apath%3A%2Faphis_content_library%2Fsa_our_focus%2Fsa_animal_health%2Fsa_animal_disease_information%2Fsa_cattle_health%2Fsa_schmallerburg%2Fct_schmallerberg_virus_information (accessed July 28, 2015).

- Ushigusa, T., Uchida, K., Murakami, T., Yamaguchi, R., and Tateyama, S. (2000). A pathologic study on ocular disorders in calves in southern Kyushu, Japan. *J. Vet. Med. Sci. Jpn. Soc. Vet. Sci.* *62*, 147–152.
- Valas, S., Baudry, C., Ehrhardt, N., Leven, A., Thirion, M., Aubert, C., and Vialard, J. (2014). Serosurvey of Schmallenberg Virus Infection in the Highest Goat-Specialized Region of France. *Transbound. Emerg. Dis.* DOI 10.1111/tbed.12205.
- Varela, M., Schnettler, E., Caporale, M., Murgia, C., Barry, G., McFarlane, M., McGregor, E., Piras, I.M., Shaw, A., Lamm, C., et al. (2013). Schmallenberg virus pathogenesis, tropism and interaction with the innate immune system of the host. *PLoS Pathog.* *9*, e1003133.
- Veldhuis, A.M.B., Carp-van Dijken, S., van Wuijckhuise, L., Witteveen, G., and van Schaik, G. (2014a). Schmallenberg virus in Dutch dairy herds: potential risk factors for high within-herd seroprevalence and malformations in calves, and its impact on productivity. *Vet. Microbiol.* *168*, 281–293.
- Veldhuis, A.M.B., Santman-Berends, I.M.G.A., Gethmann, J.M., Mars, M.H., van Wuyckhuise, L., Vellema, P., Holsteg, M., Höreth-Böntgen, D., Conraths, F.J., and van Schaik, G. (2014b). Schmallenberg virus epidemic: impact on milk production, reproductive performance and mortality in dairy cattle in the Netherlands and Kleve district, Germany. *Prev. Vet. Med.* *116*, 412–422.
- Veronesi, E., Henstock, M., Gubbins, S., Batten, C., Manley, R., Barber, J., Hoffmann, B., Beer, M., Attoui, H., Mertens, P.P.C., et al. (2013). Implicating *Culicoides* biting midges as vectors of Schmallenberg virus using semi-quantitative RT-PCR. *PloS One* *8*, e57747.
- Vilar, M.J., Guis, H., Krzywinski, J., Sanderson, S., and Baylis, M. (2011). *Culicoides* vectors of bluetongue virus in Chester Zoo. *Vet. Rec.* *168*, 242.
- Wagner, H., Eskens, U., Nesseler, A., Riese, K., Kaim, U., Volmer, R., Hamann, H.-P., Sauerwald, C., and Wehrend, A. (2014). [Pathologic-anatomical changes in newborn goats caused by an intrauterine Schmallenberg virus infection]. *Berl. Münch. Tierärztl. Wochenschr.* *127*, 115–119.
- Weiber, W., Bauer, B., Mehlitz, D., Nijhof, A.M., and Clausen, P.-H. (2014). Field trials assessing deltamethrin (Butox®) treatments of sheep against *Culicoides* species. *Parasitol. Res.* *113*, 2641–2645.
- Weinberg, P. (2008). *Capra caucasica*. The IUCN Red List of Threatened Species. Version 2015.1. Available at: <http://www.iucnredlist.org/details/3794/0> (accessed June 17, 2015).
- Wensman, J.J., Blomqvist, G., Hjort, M., and Holst, B.S. (2013). Presence of antibodies to Schmallenberg virus in a dog in Sweden. *J. Clin. Microbiol.* *51*, 2802–2803.
- Wernike, K., Breithaupt, A., Keller, M., Hoffmann, B., Beer, M., and Eschbaumer, M. (2012a). Schmallenberg virus infection of adult type I interferon receptor knock-out mice. *PloS One* *7*, e40380.
- Wernike, K., Eschbaumer, M., Breithaupt, A., Hoffmann, B., and Beer, M. (2012b). Schmallenberg virus challenge models in cattle: infectious serum or culture-grown virus? *Vet. Res.* *43*, 84.

- Wernike, K., Eschbaumer, M., Schirrmeier, H., Blohm, U., Breithaupt, A., Hoffmann, B., and Beer, M. (2013a). Oral exposure, reinfection and cellular immunity to Schmallenberg virus in cattle. *Vet. Microbiol.* *165*, 155–159.
- Wernike, K., Kohn, M., Conraths, F.J., Werner, D., Kameke, D., Hechinger, S., Kampen, H., and Beer, M. (2013b). Transmission of Schmallenberg virus during Winter, Germany. *Emerg. Infect. Dis.* *19*, 1701–1703.
- Wernike, K., Nikolin, V.M., Hechinger, S., Hoffmann, B., and Beer, M. (2013c). Inactivated Schmallenberg virus prototype vaccines. *Vaccine* *31*, 3558–3563.
- Wernike, K., Hoffmann, B., Bréard, E., Bötner, A., Ponsart, C., Zientara, S., Lohse, L., Pozzi, N., Viarouge, C., Sarradin, P., et al. (2013d). Schmallenberg virus experimental infection of sheep. *Vet. Microbiol.* *166*, 461–466.
- Wernike, K., Conraths, F., Zanella, G., Granzow, H., Gache, K., Schirrmeier, H., Valas, S., Staubach, C., Marianneau, P., Kraatz, F., et al. (2014a). Schmallenberg virus—two years of experiences. *Prev. Vet. Med.* *116*, 423–434.
- Wernike, K., Jöst, H., Becker, N., Schmidt-Chanasit, J., and Beer, M. (2014b). Lack of evidence for the presence of Schmallenberg virus in mosquitoes in Germany, 2011. *Parasit. Vectors* *7*, 402.
- Wernike, K., Holsteg, M., Schirrmeier, H., Hoffmann, B., and Beer, M. (2014c). Natural Infection of Pregnant Cows with Schmallenberg Virus – A Follow-Up Study. *PLoS ONE* *9*, e98223.
- Wernike, K., Hoffmann, B., Conraths, F.J., and Beer, M. (2015). Schmallenberg Virus Recurrence, Germany, 2014. *Emerg. Infect. Dis.* *21*, 1202–1204.
- Wilks, C.R. (2014). Schmallenberg virus: responding to disease emergence in real time. *Vet. Rec.* *174*, 378–379.
- Wilson, A.J., and Mellor, P.S. (2009). Bluetongue in Europe: past, present and future. *Philos. Trans. R. Soc. Lond. B. Biol. Sci.* *364*, 2669–2681.
- Yanase, T., Kato, T., Aizawa, M., Shuto, Y., Shirafuji, H., Yamakawa, M., and Tsuda, T. (2012). Genetic reassortment between Sathuperi and Shamonda viruses of the genus Orthobunyavirus in nature: implications for their genetic relationship to Schmallenberg virus. *Arch. Virol.* *157*, 1611–1616.
- Yilmaz, H., Hoffmann, B., Turan, N., Cizmecigil, U.Y., Richt, J.A., and Van der Poel, W.H.M. (2014). Detection and partial sequencing of Schmallenberg virus in cattle and sheep in Turkey. *Vector Borne Zoonotic Dis. Larchmt.* *N 14*, 223–225.
- Zanella, G., Raballand, C., Durand, B., Sailleau, C., Pelzer, S., Benoit, F., Doceul, V., Zientara, S., and Bréard, E. (2013). Likely Introduction Date of Schmallenberg Virus into France According to Monthly Serological Surveys in Cattle. *Transbound. Emerg. Dis.* [10.1111/tbed.12198](https://doi.org/10.1111/tbed.12198).

Zhigang, J., and Harris, R. (2008). *Elaphurus davidianus*. The IUCN Red List of Threatened Species. Version 2015.2. Available at: <http://www.iucnredlist.org/details/7121/0> (accessed July 24, 2015).

9 APPENDIX

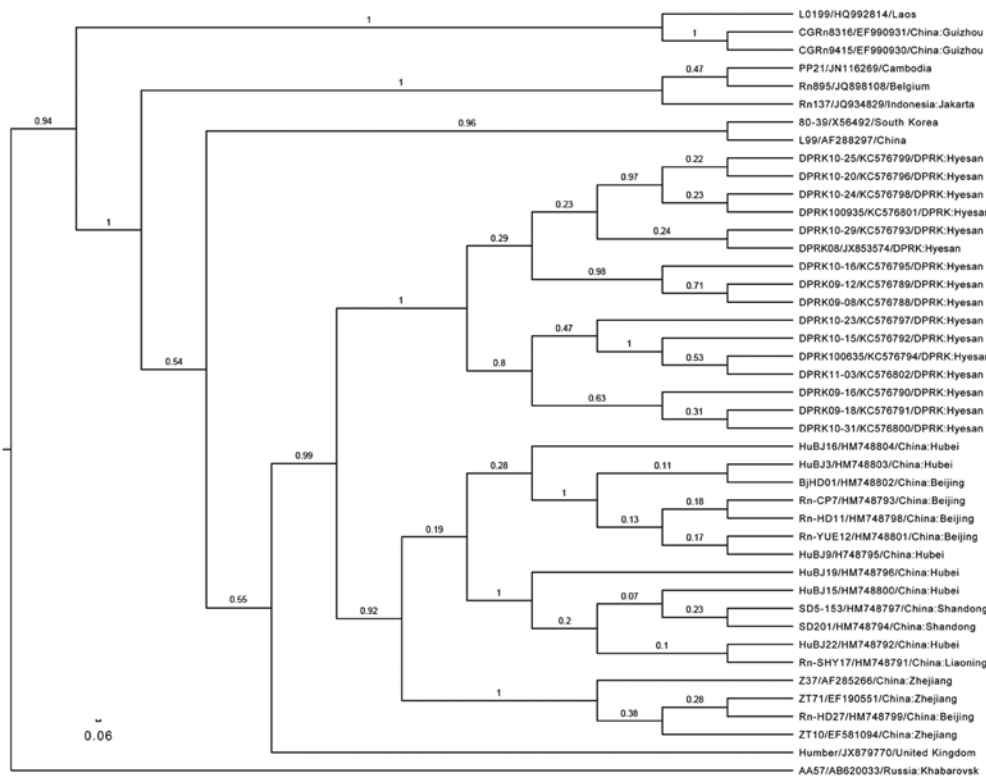


Figure. Phylogenetic tree, based on a 330-bp amplicon of the Seoul virus (SEOV) RNA-dependent RNA polymerase gene, depicted in FigTree 1.4.0 (www.molrevolution.org/software/phylogenetics/figtree). The tree was generated by using the uncorrelated lognormal distribution relaxed molecular clock model and SRD06 substitution model in BEAST1.74 (7). SEOV strain name/GenBank accession no/country: The location is shown in taxa. The posterior number is shown for each branch. Clades A and D were established as described (2). Scale bar represents number of nucleotide changes per site.

References

- Kariwa H, Yoshimatsu K, Arikawa J. Hantavirus infection in East Asia. *Comp Immunol Microbiol Infect Dis*. 2007;30:341–56. <http://dx.doi.org/10.1016/j.cimid.2007.05.011>
- Lin XD, Guo WP, Wang W, Zou Y, Hao ZY, Zhou DJ, et al. Migration of Norway rats resulted in the worldwide distribution of Seoul hantavirus today. *J Virol*. 2012;86:972–81. <http://dx.doi.org/10.1128/JVI.00725-11>
- Kim HC, Klein TA, Chong ST, Collier BW, Usa M, Yi SC, et al. Seroprevalence survey of rodents collected at a U.S. military installation, Yongsan Garrison, Seoul, Republic of Korea. *Mil Med*. 2007;172:759–64
- Yao LS, Qin CF, Pu Y, Zhang XL, Liu YX, Liu Y, et al. Complete genome sequence of Seoul virus isolated from *Rattus norvegicus* in the Democratic People's Republic of Korea. *J Virol*. 2012;86:13853. <http://dx.doi.org/10.1128/JVI.02668-12>
- Wang H, Yoshimatsu K, Ebihara H, Ogino M, Araki K, Kariwa H, et al. Genetic diversity of hantaviruses isolated in China and characterization of novel hantaviruses isolated from *Niviventer confucianus* and *Rattus rattus*. *Virology*. 2000;278:332–45. <http://dx.doi.org/10.1006/viro.2000.0630>
- Klempa B, Fichet-Calvet E, Lecompte E, Auste B, Aniskin V, Meisel H, et al. Hantavirus in African wood mouse, Guinea. *Emerg Infect Dis*. 2006;12:838–40. <http://dx.doi.org/10.3201/eid1205.051487>
- Drummond AJ, Suchard MA, Xie D, Rambaut A. Bayesian phylogenetics with BEAUti and the BEAST 1.7. *Mol Biol Evol*. 2012;29:1969–73. <http://dx.doi.org/10.1093/molbev/mss075>
- Shapiro B, Rambaut A, Drummond AJ. Choosing appropriate substitution models for the phylogenetic analysis of protein-coding sequences. *Mol Biol Evol*. 2006;23:7–9. <http://dx.doi.org/10.1093/molbev/msj021>
- Tamura K, Peterson D, Peterson N, Stecher G, Nei M, Kumar S. MEGA5: molecular evolutionary genetics analysis using maximum likelihood, evolutionary distance, and maximum parsimony methods. *Mol Biol Evol*. 2011;28:2731–9. <http://dx.doi.org/10.1093/molbev/msr121>
- Yan Y, Yao L, Hu G, Du Z, Li M, Zhang Y. Genetic subtypes and distribution of Seoul virus in Jilin. *Chinese Journal of Vector Biology and Control*. 2006;17:324–6.

Address for correspondence: Baoliang Xu, Chinese Academy of Inspection and Quarantine, Beijing 100123, China; email: xubl@caiq.gov.cn

Schmallenberg Virus Infection in Dogs, France, 2012

To the Editor: In 2011, Schmallenberg virus (SBV) emerged in Europe (1); the virus spread into France in January 2012 (2). During January–March 2012, a total of >1,000 cases were reported in France, mainly in stillborn and newborn lambs with congenital malformations.

In March 2012, neurologic disorders were detected in five 15-day-old puppies (Belgian shepherd) from a dog breeding kennel in northwestern France (Orne). We report data suggesting that these puppies were infected with SBV.

In June 2012, the kennel veterinarian contacted a veterinary school (Unité de Médecine de l'Élevage et du Sport Breeding and Sport Medicine Unit, Maisons-Alfort, France) after neurologic signs of ataxia, exotropia, a

head tilt, and stunted growth were observed in a litter of 5 puppies. Four of the puppies had died at 5–6 weeks of age. The veterinarian collected blood samples from the surviving puppy at 3 months of age, and the puppy was euthanized for necropsy. Severe torticollis was observed during the necropsy, but no other macroscopic signs were detected. The brain, including the cerebellum; a part of the spine; and cerebrospinal fluid (CSF) were collected for further investigation. Specific PCR analyses for canine coronavirus, *Neospora caninum*, *Toxoplasma gondii*, and canine minute virus were performed on CSF; all test results were negative. The brain tissue was fixed in formalin and processed for histologic examination. Features of degenerative encephalopathy, including neuronal vacuolation, neuropil vacuolation, and minimal gliosis, were observed.

Because some clinical signs were evocative of SBV infection and the puppy was born in an area where the virus was circulating actively in cattle and sheep, veterinarians decided to investigate SBV as a possible etiology. Serum samples from the 3-month-old puppy and the dam were tested by virus neutralization test (VNT), according to the protocol used for ruminant serum. The results were negative for the puppy but positive (titer 128) for the mother. Specific competitive SBV ELISA (IDVet, Montpellier, France) against the SBV N protein showed similar results.

Real-time reverse transcription PCR (RT-PCR) was performed (3) to detect the presence of the SBV genome in the cerebellum. Because the sample was paraffin-embedded, RNA was extracted from 5- μ m sections, as described (4). All of the extracted cerebellum sections had positive test results (cycle threshold range 33–36); the extraction and PCR controls all showed negative results. To confirm these positive results, conventional RT-PCR was used to amplify a 573-nt sequence of the SBV S segment. The amplification

product was sequenced, and a BLAST analysis was performed (www.ncbi.nlm.nih.gov/BLAST). An identity of 100% was obtained with the SBV small gene segment from a ruminant (GenBank accession no. KC108860). An immunohistochemical assay was also performed; the result was negative.

The remaining 7 female dogs in the breeding kennel were tested for SBV in October 2012; 1 showed positive test results by VNT (titer 256), which confirmed that SBV was circulating in the kennel. This positive dam had a litter of puppies in December 2012, but no signs developed, and the puppies were not tested. In March 2013, repeat testing was done on serum samples from the 2 dogs that had shown positive results. Results for both animals were positive by VNT (titers 32 for the dam and 128 for the other dog) and ELISA.

Taken together, specific SBV antibodies in the mother and the SBV genome in her puppy suggest that these dogs experienced SBV infection. The absence of detectable SBV antibodies in the puppy in this investigation suggests that transplacental infection occurred before the onset of fetal immune competence. Maternal infection probably occurred in January or February 2012; entomologic monitoring conducted in France showed the presence of *Culicoides* spp. midges, a vector of SBV, during this period in northwestern France. In addition, because the puppies were born in March 2012 and SBV antibodies were still detectable in the mother in March 2013, the duration of SBV antibodies in dogs appears to be ≥ 1 year. In cattle and sheep, the SBV genome persists in an infected fetus and is detectable after birth by real-time RT-PCR, despite gestation length (5,6).

Few reports on orthobunyavirus infections in dogs are available. Two serologic studies from the United States (7) and Mexico (8) found antibodies against La Crosse virus, South River virus, and Jamestown Canyon

virus in dogs. Two other reports described cases in which La Crosse virus was detected in canine littermates who had clinical encephalitis (9) or neurological disorders (10).

It is unclear if the apparent SBV infection we detected in these dogs was an isolated event or if other cases occurred elsewhere but were not detected because they were not investigated. Further serologic and clinical surveys are needed to estimate SBV prevalence in dogs and the virus' involvement in the occurrence of neurological signs in puppies.

Acknowledgments

We thank Francine Larangot for collecting biological samples and Muriel Couplier and Julie Valloire-Lucot for contributing to this study.

This project was funded by ANSES, Royal Canin, and Unité de Médecine de l'Élevage.

**Corinne Sailleau,
Cassandre Boogaerts,
Anne Meyrueix,
Eve Laloy, Emmanuel Bréard,
Cyril Viarouge,
Alexandra Desprat,
Damien Vitour, Virginie Doceul,
Catherine Boucher,
Stéphan Zientara,
Alexandra Nicolier,
and Dominique Grandjean**

Author affiliations: ANSES, Maisons-Alfort, France (C. Sailleau, E. Bréard, C. Viarouge, A. Desprat, D. Vitour, V. Doceul, S. Zientara); Ecole Nationale Vétérinaire d'Alfort, Maisons-Alfort (C. Boogaerts, A. Meyrueix, E. Laloy, D. Grandjean); Royal Canin, Aimargues, France (C. Boucher); and Vet Diagnostics, Lyon, France (A. Nicolier)

DOI: <http://dx.doi.org/10.3201/eid1911.130464>

References

- Hoffmann B, Scheuch M, Höper D, Jungblut R, Holsteg M, Schirrmeyer H, et al. Novel orthobunyavirus in cattle, Europe, 2011. *Emerg Infect Dis*. 2012;18:469–72. <http://dx.doi.org/10.3201/eid1803.111905>

2. Dominguez M, Calavas D, Jaÿ M, Languille J, Fediaevsky A, Zientara S, et al. Preliminary estimate of Schmallenberg virus infection impact in sheep flocks—France. *Vet Rec.* 2012;171:426. <http://dx.doi.org/10.1136/vr.100883>
3. Bilk S, Schulze C, Fischer M, Beer M, Hlinak A, Hoffmann B. Organ distribution of Schmallenberg virus RNA in malformed newborns. *Vet Microbiol.* 2012;159:236–8. <http://dx.doi.org/10.1016/j.vetmic.2012.03.035>
4. Bhudevi B, Weinstock D. Detection of bovine viral diarrhoea virus in formalin fixed paraffin embedded tissue sections by real time RT-PCR (Taqman). *J Virol Methods.* 2003;109:25–30. [http://dx.doi.org/10.1016/S0166-0934\(03\)00040-5](http://dx.doi.org/10.1016/S0166-0934(03)00040-5)
5. Garigliany MM, Hoffmann B, Dive M, Sartelet A, Bayrou C, Cassart D, et al. Schmallenberg virus in calf born at term with porencephaly, Belgium. *Emerg Infect Dis.* 2012;18:1005–6.
6. van den Brom R, Luttkholt SJ, Lievaart-Peterson K, Peperkamp NH, Mars MH, van der Poel WH, et al. Epizootic of ovine congenital malformations associated with Schmallenberg virus infection. *Tijdschr Diergeneeskd.* 2012;137:106–11.
7. Godsey MS Jr, Amoo F, Yuill TM, Defoliart GR. California serogroup virus infections in Wisconsin domestic animals. *Am J Trop Med Hyg.* 1988;39:409–16.
8. Blitvich BJ, Saiyasombat R, Da Rosa AT, Tesh RB, Calisher CH, Garcia-Rejon JE, et al. Orthobunyaviruses, a common cause of infection of livestock in the Yucatan Peninsula of Mexico. *Am J Trop Med Hyg.* 2012;87:1132–9. <http://dx.doi.org/10.4269/ajtmh.2012.12-0188>
9. Black SS, Harrison LR, Pursell AR, Cole JR Jr, Appel MJ, Shope RE, et al. Necrotizing panencephalitis in puppies infected with La Crosse virus. *J Vet Diagn Invest.* 1994;6:250–4. <http://dx.doi.org/10.1177/104063879400600218>
10. Tatum LM, Pacy JM, Frazier KS, Weege JF, Baldwin CA, Hullinger GA, et al. Canine LaCrosse viral meningoencephalomyelitis with possible public health implications. *J Vet Diagn Invest.* 1999;11:184–8. <http://dx.doi.org/10.1177/104063879901100216>

Address for correspondence: Corinne Sailleau, Agence nationale de sécurité sanitaire de l'alimentation, de l'environnement et du travail, Laboratoire de santé animale, 23 av Gal de Gaulle, 94706 Maisons-Alfort, France; email: corinne.sailleau@anses.fr

All material published in *Emerging Infectious Diseases* is in the public domain and may be used and reprinted without special permission; proper citation, however, is required.

Geographic Co-distribution of Influenza Virus Subtypes H7N9 and H5N1 in Humans, China

To the Editor: Human infection with a novel low pathogenicity influenza A(H7N9) virus in eastern China has recently raised global public health concerns (1). The geographic sources of infection have yet to be fully clarified, and confirmed human cases from 1 province have not been linked to those from other provinces. While some studies have identified epidemiologic characteristics of subtype H7N9 cases and clinical differences between these cases and cases of highly pathogenic influenza A(H5N1), another avian influenza affecting parts of China (2–4), the spatial epidemiology of human infection with influenza subtypes H7N9 and H5N1 in China has yet to be elucidated. To test the hypothesis of co-distribution of high-risk clusters of both types of infection, we used all available data on human cases in mainland China and investigated the geospatial epidemiologic features.

Data on individual confirmed human cases of influenza (H7N9) from February 19, 2013, through May 17, 2013, and of influenza (H5N1) from October 14, 2005, through May 17, 2013, were collected from the Chinese Center for Disease Control and Prevention. The definitions of these cases have been described (3,5). A total of 129 confirmed cases of influenza (H7N9) (male:female ratio 2.39:1) and 40 confirmed cases of influenza (H5N1) (male:female ratio 0.90:1) were included in the analysis. The median age of persons with influenza (H7N9) was higher than for persons with influenza (H5N1) (58 years vs. 27 years; $z = -7.73$; $p < 0.01$). Most (75.0%) persons with influenza

(H5N1) had direct contact (e.g., occupational contact) with poultry (including dead and live birds) or their excrement and urine, whereas most (64.3%) persons with influenza (H7N9) had only indirect exposure to live poultry, mainly during visits to live poultry markets.

Reported cases of influenza (H5N1) were distributed over 40 townships in 16 provinces, whereas cases of influenza (H7N9) were relatively more concentrated, in 108 townships but only 10 provinces (Figure). To identify a spatial overlap between the primary cluster of influenza (H7N9) cases, detected in April 2013 (relative risk [RR] 78.40; $p < 0.01$), and the earliest space-time cluster of influenza (H5N1) cases, detected during November 2005–February 2006 (RR 65.27; $p < 0.01$), we used spatio-temporal scan statistics with a maximum spatial cluster size of 5% of the population at risk in the spatial window and a maximum temporal cluster size of 25% of the study period in the temporal window (6) (Figure). The results suggest that the overlap is not perfect and is concentrated around an area southeast of Taihu Lake (south of Jiangsu Province), bordering the provinces of Anhui and Zhejiang. Smaller clusters of influenza (H7N9) cases were identified in the boundary of Jiangsu and Anhui Province (8 cases; RR 64.86; $p < 0.01$) and Jiangxi Province (Nanchang County and Qingshanhu District) (4 cases; RR 105.67; $p < 0.01$). A small cluster of influenza (H5N1) cases was detected during 2012–2013 along the boundaries of Guanshanhu, Yunyan, and Nanming Counties in Guizhou Province (3 cases; RR 496.60; $p < 0.01$).

In addition, family clustering, defined as ≥ 2 family members with laboratory-confirmed cases, was found for influenza (H7N9) cases during March–April 2013 in Shanghai and Jiangsu Provinces and for influenza (H5N1) cases during December 2007 in Jiangsu Province.

- **Court résumé de la thèse**

Le virus Schmallenberg (SBV) affecte les ruminants domestiques. Il est responsable de signes cliniques discrets chez les adultes et de malformations congénitales chez les nouveau-nés. Ces travaux apportent de nouvelles données sur la pathogenèse de l'infection à SBV chez les ruminants domestiques, en particulier chez la chèvre. La sensibilité de plusieurs espèces de ruminants sauvages vis-à-vis du virus est démontrée.

- **Mots clés :**

Virologie ; Arbovirus ; Orthobunyavirus ; Virus Schmallenberg ; Infection expérimentale ;
Reproduction ; Caprins ; Ovins ; Faune sauvage ; Ruminants exotiques ; Parc zoologique.

- **Laboratoire de rattachement :**

UMR Virologie 1161 ANSES-INRA-ENVA, Maisons-Alfort, France.

PÔLE : MICROBIOLOGIE / THERAPEUTIQUES ANTIINFECTIEUSES

UNIVERSITÉ PARIS-SUD 11

UFR «FACULTÉ DE PHARMACIE DE CHATENAY-MALABRY »

5, rue Jean Baptiste Clément

92296 CHÂTENAY-MALABRY Cedex