



**HAL**  
open science

# Identification de substrats arythmogènes et des mécanismes de décompensation dans une population de tétralogie de Fallot à l'âge adulte et perspectives de prise en charge ultérieure

François Roubertie

► **To cite this version:**

François Roubertie. Identification de substrats arythmogènes et des mécanismes de décompensation dans une population de tétralogie de Fallot à l'âge adulte et perspectives de prise en charge ultérieure. Cardiologie et système cardiovasculaire. Université de Bordeaux, 2015. Français. NNT : 2015BORD0421 . tel-01312214

**HAL Id: tel-01312214**

**<https://theses.hal.science/tel-01312214>**

Submitted on 4 May 2016

**HAL** is a multi-disciplinary open access archive for the deposit and dissemination of scientific research documents, whether they are published or not. The documents may come from teaching and research institutions in France or abroad, or from public or private research centers.

L'archive ouverte pluridisciplinaire **HAL**, est destinée au dépôt et à la diffusion de documents scientifiques de niveau recherche, publiés ou non, émanant des établissements d'enseignement et de recherche français ou étrangers, des laboratoires publics ou privés.

THÈSE PRÉSENTÉE  
POUR OBTENIR LE GRADE DE  
**DOCTEUR DE**  
**L'UNIVERSITÉ DE BORDEAUX**

ÉCOLE DOCTORALE : **Sciences de la Vie et de la Santé**

SPÉCIALITÉ : Biologie Cellulaire et Physiopathologie

Par François ROUBERTIE

**Identification de substrats arythmogènes et des mécanismes de  
décompensation dans une population de tétralogie de Fallot à l'âge adulte et  
perspectives de prise en charge ultérieure.**

Sous la direction de : Professeur Jean-Benoît THAMBO

Soutenue le 21 Décembre 2015

Membres du jury :

|                     |            |                           |            |
|---------------------|------------|---------------------------|------------|
| M. ROQUES Xavier    | Professeur | Université de Bordeaux    | Président  |
| M. FRAISSE Alain    | Professeur | Université de Marseille   | rapporteur |
| M. HENAINE Roland   | Professeur | Université de Lyon        | rapporteur |
| M. LEGUERRIER Alain | Professeur | Université de Rennes      | Examineur  |
| M. SZTARK François  | Professeur | Université de Bordeaux    | Examineur  |
| M. AMEDRO Pascal    | Docteur    | Université de Montpellier | Examineur  |



## **Titre en français**

Identification de substrats arythmogènes et des mécanismes de décompensation dans une population de tétralogie de Fallot à l'âge adulte et perspectives de prise en charge ultérieure.

## **Résumé :**

Le nombre d'adultes porteurs d'une tétralogie de Fallot opérée dans l'enfance est en constante augmentation. Initialement, ces patients étaient considérés comme guéris. A l'âge adulte, ils présentent en fait des complications d'ordre rythmique, responsables de morts subites, et des complications d'ordre mécanique : dilatation du ventricule droit (VD) liée à l'insuffisance pulmonaire chronique, séquellaire de la première chirurgie de réparation de la cardiopathie. Les mécanismes de l'arythmie ainsi qu'une éventuelle interaction entre la dysfonction VD et la survenue de ces arythmies ne restent que partiellement élucidés.

Dans ce travail, en couplant les données d'études cliniques et les données expérimentales issues d'un modèle animal (MA) mimant une tétralogie de Fallot réparée, nous avons montré que 1) l'échocardiographie ne pouvait pas se substituer à l'IRM pour la surveillance des patients avec tétralogie de Fallot réparée 2) la valvulation pulmonaire restait une intervention à risque de mortalité 3) une bioprothèse non stentée était une bonne solution pour effectuer cette valvulation 4) en cas de fuite tricuspidiennne sévère lors de cette valvulation, une plastie était indispensable 5) plusieurs gènes participaient au remodelage ventriculaire droit (analyse génétique effectuée sur le MA) 6) le remodelage électrophysiologique du VD (MA) s'accompagnait de propriétés pro-arythmogènes.

Les mécanismes de décompensation sont intriqués : un lien entre dysfonction VD et arythmie paraît bien établi. D'autres analyses électrophysiologiques sont en cours au niveau du ventricule gauche (MA), pour rechercher d'autres mécanismes pro-arythmogènes.

## **Mots clés en français**

Arythmie ; traitement de l'arythmie (ablation et chirurgie) ; fibrillation atriale et flutter ; cardiopathie congénitale ; cardiopathie congénitale adulte ; tétralogie de Fallot ; échocardiographie ; électrophysiologie (cartographie) ; prothèse valvulaire (bioprothèse) ; imagerie par résonnance

magnétique nucléaire ; resynchronisation bi-ventriculaire ; valve pulmonaire (bioprothèse) ; ARN ;  
puce d'expression transgénomique ; valve tricuspide ; ventricule droit

## **Title**

Adult with a repaired tetralogy of Fallot: to assess mechanism of arrhythmia onset and  
ventricular failure in this population: future potential treatment

## **Abstract:**

The number of adults with a repaired tetralogy of Fallot is increasing. In the past, those patients were considered healed. Nonetheless, they present arrhythmogenic issues, with frequent sudden death, and mechanical complications: right ventricular dilation due to long lasting pulmonary valve regurgitation, secondary to surgical repair. The origin of arrhythmia and its interaction with right ventricular dysfunction is only partially understood.

In this study, combining clinical with experimental data, we pointed out: 1) concerning the follow-up of this population, echocardiography is not a substitute to MRI 2) operative mortality of pulmonary valve replacement (PVR) still exists 3) a stentless bioprosthesis represents a valid solution for PVR 4) a valve repair is mandatory for severe tricuspid valve regurgitation at PVR 5) the genetic analysis carried out in an animal model of repaired tetralogy of Fallot, demonstrated the involvement of numerous genes in right ventricular remodeling 6) remodeling of the right ventricle in this animal model generates pro-arrhythmic substrate.

Heart failure mechanisms in repaired tetralogy of Fallot are complex: a link between right ventricular dysfunction and arrhythmias is demonstrated. Further studies are needed to investigate other pro-arrhythmic mechanisms involving the left ventricle.

## **Keywords**

Arrhythmia ; Arrhythmia therapy (ablation, surgery) ; Atrial fibrillation (AF), flutter ;  
Congenital heart disease, CHD ; CHD, in adults ; CHD, tetralogy of Fallot ; Echocardiography ;

Electrophysiology (including mapping) ; Heart valve prosthesis (bioprosthesis) ; Magnetic resonance imaging, MRI ; Pacing, resynchronization/biventricular ; Pulmonary valve (bioprosthesis valves) ; RNA ; microarray based gene expression analysis ; Tricuspid valve ; Ventricle, right

**Laboratoire**

Inserm U.1045 : Centre de recherche Cardio-Thoracique de Bordeaux

Adresse : Université de Bordeaux Bât TP - Zone sud - 3ème étage 146, rue Léo-Saignat 33076

Bordeaux cedex

**Remerciements : membres du jury :**

**Monsieur le professeur Xavier Roques : *président de thèse* :**

Vous m'avez fait découvrir la chirurgie cardiaque et vous m'avez fait aimer cette spécialité. Vous m'avez permis ensuite de faire de la chirurgie cardiaque, je vous dois donc beaucoup, et plus encore. J'ai énormément appris à vos côtés. Vous êtes un de mes maîtres. Merci d'avoir accepté de juger ce travail et d'être le président de cette thèse.

**Monsieur le professeur Jean-Benoît Thambo : *directeur de thèse* :**

Je te remercie de m'avoir confié ce sujet passionnant et d'avoir accompagné la construction de ce travail avec ton énergie habituelle. Nous connaissons tous tes qualités ; je ne parlerai que d'une seule : ta loyauté. Je rajouterai qu'on a commencé cette aventure il y a quelques années et qu'on a encore beaucoup à faire. Merci de ton soutien indéfectible et de ta confiance.

**Monsieur le professeur Alain Fraisse : *rapporteur* :**

Merci d'avoir accepté d'être rapporteur de cette thèse, c'est vraiment un honneur pour moi. Vous avez fait votre rapport avec rapidité, intérêt et considération, merci encore.

**Monsieur le professeur Roland Henaine : *rapporteur* :**

Merci, Roland, d'avoir accepté d'être rapporteur de cette thèse et du grand intérêt que tu as porté à ce travail. Ton engagement dans la chirurgie cardiaque congénitale, ton investissement à Lyon, tout le travail que tu as fourni pour être professeur, m'ont servi d'exemple à suivre. C'est un honneur pour moi de te recevoir à Bordeaux.

**Monsieur le professeur François Sztark : *juge* :**

Je vous remercie d'avoir accepté de juger cette thèse. Vous étiez mon rapporteur de mi-thèse et j'ai pu apprécier alors votre intérêt pour les cardiopathies congénitales.

**Monsieur le professeur Alain Leguerrier : *juge* :**

Je vous remercie sincèrement de participer à ce jury de thèse et de juger ce travail.

**Monsieur le docteur Pascal Amedro : *juge* :**

Merci d'avoir accepté de juger ce travail, j'espère qu'il suscitera votre intérêt.

## **Remerciements à l'équipe de cardiopédiatrie :**

A l'ensemble des médecins de cette équipe

- Xavier Iriart, Pierre-Emmanuel Séguéla, Jean-Bernard Selly et Zakaria Jalal : vous m'avez tous les 4 beaucoup aidé au cours de ce travail. Merci.

- Aux autres médecins : Jean-Baptiste Mouton, Julie Thomas, Elodie Perdreau, Mathieu Le Bloa et Emmanuelle Fournier

- Aux médecins qui sont partis vers d'autres hôpitaux : Alexandre Bretonneau, Alice Horovitz, Maxime de Guillebon, Marie Nelson

Votre bon état d'esprit et votre envie à tous de progresser m'ont toujours impressionné ! C'est un bonheur et une chance que de pouvoir travailler avec vous.

A l'équipe d'anesthésie réanimation, sans vous, rien n'est possible :

Philippe Mauriat, Nadir Tafer, Charlotte Sgro, Simone Goanni.

A celles qui sont parties ailleurs : Emmanuelle Guérin, Béatrice Roux.

A l'équipe des premières heures : Alain Coiffic, Monique Collot, Bruno Bourdarias, Youssef Abdelmoumen, Christine Poussot, Amid Afiane.

Aux médecins qui travaillent souvent avec notre équipe :

Les rythmologues : Pierre Bordachar, Philippe Ritter, Sylvain Ploux : travailler à vos côtés est très enrichissant... merci à Pierre (qui ne le sait pas) de m'avoir redonné l'envie de publier...

Les rythmologues : Frédéric Sacher et Nicolas Derval : votre expertise est si précieuse pour nous et nos patients

Les généticiens : Caroline Rooryck-Thambo (merci vraiment de ton aide pour cette thèse)

Les médecins qui s'occupent de la transplantation : Karine et Vincent.

A l'ensemble du personnel, dévoué pour les enfants et les familles : du 6<sup>ème</sup> Ouest, de la réanimation et des soins intensifs pédiatriques. Merci également au personnel de chirurgie cardiaque adulte qui prend en charge les patients adultes congénitaux.

Enfin, une pensée particulière pour l'ensemble du personnel du bloc opératoire, investi dans les cardiopathies congénitales et qui font un travail formidable au quotidien.

Une pensée pour Françoise Yssartier : tu nous as donné à tous l'envie de bien travailler ; continue longtemps à t'occuper de Mécénat chirurgie cardiaque...

## **Remerciements à mes maitres et collègues :**

Remercier, c'est prendre le risque d'oublier certaines personnes .... , tout oublié de ma part est involontaire : chaque stage (d'interne) et tous les chirurgiens, que j'ai pu rencontrer au cours de ma formation, m'ont beaucoup appris.

- Je remercie donc l'ensemble des chirurgiens qui m'ont formé au cours de l'internat.

- Je remercie mes maitres et collègues chirurgiens cardiaques bordelais, j'ai appris de vous tous et je continue à apprendre à vos côtés :

Professeur Deville et Professeur Baudet : vos conseils ont toujours été judicieux.

Docteur Nadine Laborde : je te dois beaucoup, tu m'as mis le pied à l'étrier, je ne l'oublie pas

Docteur Nicolas Elia : tu as été plus que patient avec moi et tu m'as beaucoup appris

Docteur Jean-Philippe Guibaud, Emmanuel Choukroun, Francesco Madonna, Pierre Oses et Julien Peltan.

Professeur Laurent Barandon : ta bienveillance à l'égard des cardiopathies congénitales a été un moteur pour moi et pour l'équipe de cardiopédiatrie

Professeur Louis Labrousse : ton soutien m'as permis de franchir bien des obstacles....tu es en fait le père de ce modèle animal mimant une tétralogie de Fallot réparée, on te doit donc tous beaucoup.

- Je remercie mes maitres et collègues chirurgiens cardiaques parisiens :

Professeur Pascal Vouhé : j'ai eu la chance de travailler et d'apprendre énormément à vos côtés

Professeur Olivier Raisky

Professeur Alain Serraf : je reste admiratif de votre inventivité

Docteur Emre Belli : j'ai appris à tes côtés, merci

Je n'oublie pas les docteurs Tamisier, Lebret, Roussin et Ly.

- Enfin je remercie avec le plus grand respect le professeur Bernard Kreitmann : ta bienveillance et ta gentillesse forcent le respect ; j'ai la chance de pouvoir continuer à apprendre à tes côtés ; merci de

nous avoir rejoint dans cette aventure Bordelaise (j'ai une pensée amicale et pleine de respect pour ta femme Jeanine, car je sais que d'avoir quitter Marseille pour Bordeaux n'est pas facile pour elle).

- Je remercie aussi les assistants, chefs de clinique qui m'ont aidé ces dernières années, vous avez été ou vous êtes encore, pour certain, un maillon indispensable au service de chirurgie des cardiopathies congénitales :

Dr Nesseris : vraiment merci de ton aide, tu as beaucoup donné et je te rassure, c'est pas fini !

Dr Al-Yamani : tu vas continuer une partie des chirurgies de ce modèle

- Enfin, merci au docteur Abdelmoumen, anesthésiste réanimateur, tu as endormi nos porcelets et tu as beaucoup donné indirectement pour ce travail, merci à toi.



## **Remerciements à ma famille :**

A mes parents, ma sœur, ma grand-mère, qui m'ont toujours soutenu et encouragé dans mes études et mon travail (à mon grand-père que je n'oublie pas et qui me manque)

Aux membres de ma famille (cousins, oncles, tantes...) : vous êtes mes racines

A mes amis et à la Corrèze (je n'oublie pas d'où je viens)

A Maxime

A Eva

A Marie, ma femme, pour sa patience et son amour... : je t'ai.. !

## Présentations orales et affichées

### ESSR 2009 Nimes: 44th Congress of the European Society for Surgical Research

- Experimental animal model of systolic and diastolic right ventricular failure (SDRVF)
- **F. Roubertie**, L. Labrousse, J. B. Thambo, P. Bordachard, M. N. Laborde and X. Roques

### British Journal of Surgery 2009; 96(S5): 1 – 72 (abstract)

- Experimental animal model of systolic and diastolic right ventricular failure (SDRVF)
- **F. Roubertie**, L. Labrousse, J. B. Thambo, P. Bordachard, M. N. Laborde and X. Roques

### 62th congrès SFCTCV (Société Française de Chirurgie Thoracique et Cardio-Vasculaire) 2009 (Lille) : prix de la présentation orale

- Amélioration de la fonction cardiaque par stimulation biventriculaire chez un modèle animal (cochon) de tétralogie de Fallot.
- **F Roubertie**, P Bordachar, M Guillebon, L Labrousse, MN Laborde, X Roques, A Bretonneau, JB Thambo

### HRS (Heart Rythm Society) 2011 San Francisco

- Correction of echocardiographic dyssynchrony by biventricular pacing in patients with repaired tetralogy of Fallot. Heart Rhythm 2011, PO3-169.
- De Guillebon M, Bordachar P, Iriart X, **Roubertie F**, Haissaguerre M, Thambo JB

### 64th congrès SFCTCV 2011 (Lyon)

- Effets aigus de la stimulation en période réfractaire sur un modèle animal d'insuffisance cardiaque droite chronique.
- **F Roubertie**, Zemmoura A, Thambo J-B, Labrousse L, Ritter P, Dos Santos P, X. Roques, Bordachar P.

### 66th congrès SFCTCV 2013 (Marseille)

- Remplacement de la valve pulmonaire par prothèse porcine sans armature chez l'adulte après correction de tétralogie de Fallot : résultats à moyen terme.
- Georgios Nesseris, **François Roubertie**, Jean-Benoît Thambo, Xavier Iriart, Nadir Tafer, Philippe Mauriat, Xavier Roques

### Congrès médico-chirurgical de la F.C.P.C. (filiale de cardiologie pédiatrique et congénitale) : Nantes 2013

- Modèle animal de dysfonction ventriculaire droite avec bloc de branche droit reproduisant la physiologie post-opératoire d'une tétralogie de Fallot.
- **F. Roubertie**

### 7ème Assises de Génétique Humaine et Médicale. (Bordeaux, 29-31 janvier 2014)

- Etudes transcriptomiques sur tissu myocardique de modèles animaux porcins chroniques de Tétralogie de Fallot opérée.
- Charron S, **Roubertie F**, Benoist D, Dubes V, Bernus O, Haissaguerre M, Bordachar P, Thambo JB, Rooryck-Thambo C.

### HRS (Heart Rythm Society) 2014

- Pro-arrhythmic ventricular remodeling in a porcine model of repaired tetralogy of Fallot
- Virginie Dubes, David Benoist, **François Roubertie**, Stephen Gilbert, Marion Constantin, Delphine Elbes, Delphine Vieillot, Sabine Charron, Hubert Cochet, Bruno Quesson, Caroline Rooryck-Thambo, Pierre Bordachar, Michel Haissaguerre, Jean-Benoit Thambo, and Olivier Bernus

**SFC XXV journées Européennes de la Société Française de Cardiologie 2015. Paris**

- Pro-arrhythmic ventricular remodeling in a porcine model of repaired tetralogy of Fallot
- **F. Roubertie**, V. Dubes, D. Benoist, S. Gilbert, M. Constantin, D. Elbes, D. Vieillot, S. Charron, H. Cochet, B. Quesson, C. Rooryck-Thambo, M. Haissaguerre, P. Bordachar, O. Bernus, J.-B. Thambo

**25es Journées Européennes de la SFC (Paris 2015)**

- Transcriptomic and proteomic studies in a porcine model of repaired Tetralogy of Fallot
- Charron S, **Roubertie F**, Benoist D, Dubes V, Bernus O, Haissaguerre M, Bordachar P, Thambo JB, Rooryck C.

**Congrès médico-chirurgical de la F.C.P.C. : Martinique 2015**

- Remplacement valvulaire pulmonaire par thoracotomie postérieure.
- **F. Roubertie** (Bordeaux)

## Articles acceptés inclus dans cette thèse :

1. Roubertie F et al. **Left posterolateral thoracotomy: an alternative approach for pulmonary valve replacement.** Ann Thorac Surg. 2014;97:691-3
2. Ramanan S, Doll N, Boethig D, Tafer N, Horke A, Roques X, Hemmer WB, Roubertie F. **Pulmonary-Valve Replacement in Adults: Results With the Medtronic Freestyle Valve.** Ann Thorac Surg. 2015;100:1047-53
3. Selly JB, Iriart X, Roubertie F et al. **Multivariable assessment of the right ventricle by echocardiography in patients with repaired tetralogy of Fallot undergoing pulmonary valve replacement: a comparative study with magnetic resonance imaging.** Arch Cardiovasc Dis. 2015;108:5-15.
4. Séguéla PE, Roubertie F. **Distortion of the left anterior descending coronary artery after pulmonary valve replacement.** Catheter Cardiovasc Interv. 2015;Nov3
5. Thambo JB, Roubertie F et al. **Validation of an animal model of right ventricular dysfunction and right bundle branch block to create close physiology to postoperative tetralogy of Fallot.** Int J Cardiol. 2012;154:38-42
6. Charron S, Roubertie F. et al. **Identification of Region-Specific Myocardial Gene Expression Patterns in a Chronic Swine Model of Repaired Tetralogy of Fallot.** PLoS One. 2015 Aug 7;10

## Articles soumis inclus dans cette thèse :

1. Roubertie F., Séguéla PE et al. : **Tricuspid Valve Repair Associated To Pulmonary Valve Replacement In Adults With Repaired Tetralogy Of Fallot**  
European Heart Journal
2. David Benoist and Virginie Dubes, François Roubertie et al. : **Pro-Arrhythmic Remodeling of the Right Ventricle in a Porcine Model of Repaired Tetralogy of Fallot.**  
Cardiovascular Research
3. François Roubertie, Zakaria Jalal, Emmanuelle Fournier et al. : **Unexpected internalisation of a pulmonary artery band in a porcine model of tetralogy of Fallot.**  
Journal of Thoracic and Cardiovascular Surgery

## Articles acceptés non inclus dans cette thèse, en rapport avec ce travail :

1. Thambo JB, Dos Santos P, De Guillebon M, Roubertie F et al. **Biventricular stimulation improves right and left ventricular function after tetralogy of Fallot repair: acute animal and clinical studies.**  
Heart Rhythm. 2010;7:344-50.
2. François Roubertie, Maxime de Guillebon, Louis Labrousse, Pierre Bordachar, Xavier Roques, Pierre Dos Santos, Jean-Benoît Thambo. **Amélioration de la fonction cardiaque par stimulation interventriculaire chez un modèle animal mimant les principales caractéristiques d'une tétralogie de Fallot opérée.**  
Le journal de chirurgie thoracique et cardio-vasculaire Mars 2011

## **Abréviations :**

CC = cardiopathie congénitale

CIV = communication interventriculaire

IP = insuffisance pulmonaire

PA = potentiel d'action

RVP = remplacement valvulaire pulmonaire

TF = tétralogie de Fallot

TV = tachycardie ventriculaire

VD = ventricule droit

## SOMMAIRE

|   |    |
|---|----|
| 1. Préambule.....   | 4  |
| 1.1. Etats des lieux de la population des adultes congénitaux en France.....                        | 4  |
| 1.2. Etats des lieux de la population des adultes congénitaux avec Tétralogie de Fallot.....        | 5  |
| réparée en France   |    |
| 1.3. Rappel anatomique, physiopathologique et rappel sur la réparation chirurgicale .....           | 6  |
| de la TF  |    |
| 1.4. Les patients opérés de tétralogie de Fallot ne sont pas guéris !.....                          | 7  |
| 1.5. Références.....  | 11 |
| 2. Problématique Générale.....  | 14 |
| 2.1. Références.....  | 17 |
| 3. Objectifs et mise en œuvre du travail.....   | 19 |
| 3.1. Références.....  | 22 |
| 4. Première partie : travaux de recherche clinique chez les patients avec tétralogie de Fallot..... | 23 |
| opérée  |    |
| 4.1. Premier travail : problématique des reinterventions chirurgicales.....                         | 23 |
| 4.1.1 Introduction.....   | 23 |
| 4.1.2 Résultats.....  | 24 |
| 4.1.3 Conclusion.....   | 24 |
| 4.1.4 Références.....   | 26 |
| 4.1.5 Perspectives.....   | 27 |
| 4.1.6 Références.....   | 29 |
| 4.2. Deuxième travail : évaluation d'une bio-prothèse non stentée pour la valvulation.....          | 31 |
| pulmonaire  |    |
| 4.2.1 Introduction.....   | 31 |
| 4.2.2 Résultats.....  | 34 |
| 4.2.3 Conclusion.....   | 35 |
| 4.2.4 Références.....   | 37 |
| 4.2.5 Perspectives.....   | 42 |
| 4.2.6 Références.....   | 44 |
| 4.3. Troisième travail : nouveaux paramètres échographiques d'évaluation.....                       | 45 |
| 4.3.1 Introduction.....   | 45 |
| 4.3.2 Résultats.....  | 46 |
| 4.3.3 Conclusion.....   | 46 |
| 4.3.4 Références.....   | 48 |

## Sommaire

|   |    |
|---|----|
| 4.4. Quatrième travail : complication aigüe après valvulopathie pulmonaire.....             | 50 |
| 4.4.1 Introduction.....   | 50 |
| 4.4.2 Résultats.....  | 51 |
| 4.4.3 Conclusion.....   | 51 |
| 4.4.4 Références.....   | 53 |
| 4.5. Cinquième travail : prise en charge d'une fuite tricuspéidienne significative.....     | 54 |
| lors de la valvulopathie pulmonaire   |    |
| 4.5.1 Introduction.....   | 54 |
| 4.5.2 Résultats.....  | 55 |
| 4.5.3 Conclusion.....   | 56 |
| 4.5.4 Références.....   | 57 |
| 4.5.5 Perspectives.....   | 58 |
| 4.5.6 Références.....   | 60 |
| 5. Deuxième partie : travaux de recherche fondamentale réalisés chez un modèle de gros..... | 64 |
| animal mimant une TF réparée :  |    |
| 5.1. Premier travail : validation du modèle animal  |    |
| 5.1.1 Introduction.....   | 64 |
| 5.1.2 Méthodes.....   | 65 |
| 5.1.3 Résultats.....  | 65 |
| 5.1.4 Conclusion.....   | 66 |
| 5.1.5 Perspectives.....   | 67 |
| 5.1.6 Références.....   | 68 |
| 5.2. Deuxième travail : Génétique : Identification de profils d'expressions géniques.....   | 69 |
| chez un modèle animal de TF réparée   |    |
| 5.2.1 Introduction et Objectifs.....  | 69 |
| 5.2.2 Méthodes.....   | 69 |
| 5.2.3 Résultats.....  | 70 |
| 5.2.4 Conclusion.....   | 71 |
| 5.2.5 Perspectives.....   | 72 |
| 5.2.6 Références.....   | 73 |
| 5.3. Troisième travail : Mécanismes pro-arythmogènes découverts au niveau du VD.....        | 74 |
| chez notre modèle animal  |    |
| 5.3.1 Introduction.....   | 74 |
| 5.3.2 Objectifs.....  | 77 |
| 5.3.3 Méthodes.....   | 77 |
| 5.3.4 Résultats.....  | 77 |
| 5.3.5 Conclusion.....   | 78 |

## Sommaire

|  |     |
|--|-----|
| 5.3.6 Références.....  | 80  |
| 5.3.7 Perspectives.....  | 82  |
| 5.3.8 Références.....  | 86  |
| 5.4. Quatrième travail : Modification « accidentelle » de notre modèle animal..... | 95  |
| 5.4.1 Introduction.....  | 95  |
| 5.4.2 Résultats.....   | 96  |
| 5.4.3 Conclusion.....  | 96  |
| 5.4.4 Références.....  | 98  |
| 5.4.5 Perspectives.....  | 99  |
| 6. Conclusion.....   | 100 |
| 6.1 Problématique 1.....   | 100 |
| 6.2 Problématique 2.....   | 102 |
| 6.3 Références.....  | 105 |



# 1. PREAMBULE, INTERET DU SUJET

## 1.1 Etats des lieux de la population des adultes congénitaux en France

Actuellement, presque 1 enfant sur 100 naît avec une cardiopathie congénitale (CC). Un tiers de ces enfants aura besoin d'une intervention dans leur premier mois de vie par cathétérisme interventionnel ou par chirurgie cardiaque. On sait qu'une nouvelle intervention à l'âge adulte sera nécessaire pour au moins un tiers des opérés.

De nombreux progrès ont été effectués depuis la première chirurgie cardiaque avec réparation intra-cardiaque d'une CC en 1952. Les résultats de cette chirurgie n'ont cessé de progresser sur les 30 dernières années, et ceci, depuis l'essor dans les années 1970, de la correction des CC en période néonatale. Ces bons résultats sont liés à l'amélioration conjointe des techniques chirurgicales et des techniques de réanimation en pré et postopératoire (qualité des ventilateurs, utilisation des bêta-bloquants (1), apparition de la prostine (2), apparition du NO ou utilisation des assistances circulatoires post-cardiotomie). Mais c'est plus largement, une meilleure compréhension des CC qui a permis cette amélioration des résultats, avec le développement notamment d'une imagerie de qualité en pré-opératoire (TDM, IRM, ou l'échographie trans-thoracique, trans-oesophagienne et 3D) ; l'imagerie permet également une meilleure surveillance des patients opérés.

La mortalité opératoire des procédures les plus complexes, réalisées en période néo-natale, a diminué de 70% (3) dans les années 1960 à moins de 10% (4) actuellement. Ainsi aujourd'hui (en fait depuis une vingtaine d'années) plus de 85% des patients survivent à leur cardiopathie et atteignent l'âge adulte. En France, on estime que l'ensemble des patients ayant une CC est de plus de 300 000 individus, avec une population d'enfants porteurs d'une CC équivalente à la population d'adultes porteurs d'une CC. On estime même qu'aujourd'hui, il y a en France comme aux Etats-Unis, plus d'adultes avec une CC (opérée ou non) que d'enfants avec une CC (5). En ce qui concerne les adultes congénitaux, leur nombre est en augmentation constante ; ils représentent une nouvelle entité sur le plan médical, avec laquelle différentes spécialités médico-chirurgicales vont devoir composer. Cette population d'adultes congénitaux est finalement mal connue, voire inconnue puisque « nouvelle », et

## Préambule

les challenges qu'elle présente vont être multiples. Pour ne citer que certains de ces challenges : la dysfonction ventriculaire droite, les arythmies, l'insuffisance cardiaque, sans compter d'autres, encore inconnus pour l'instant...

### 1.2 Etats des lieux de la population des adultes congénitaux avec Tétralogie de Fallot réparée en France

La tétralogie de Fallot (et les formes associées) est une des CC les plus fréquentes. Elle représente 10% des CC. La tétralogie de Fallot (TF) est la plus fréquente des cardiopathies cyanogènes avec une incidence estimée à 421 cas par million de naissances vivantes (6). La chirurgie de cure complète de TF (en excluant les formes associées) représentait 5,2% de l'ensemble des actes de chirurgie cardiaque congénitale effectués, dans la database américaine de la STS (Society of Thoracic Surgeon) (7).

Il est important de rappeler que le taux de survie de cette cardiopathie chez les patients non opérés est de 15% à l'âge de 1 an et donc proche de zéro à l'âge de 30 ans (8). Les causes de décès sont en rapport avec les complications directes ou indirectes de la cyanose (malaises, accidents vasculaires cérébraux secondaires à la polyglobulie, abcès cérébraux liés au shunt droit-gauche).

Cette cardiopathie cyanogène a connue deux avancées majeures dans sa prise en charge médico-chirurgicale qui ont totalement transformé son pronostic. La première avancée a eu lieu le 29 novembre 1944 quand Alfred Blalock (9) et Helen Taussig, au Johns Hopkins Hospital, à Baltimore, ont eu l'idée de réaliser la première palliation de cette cardiopathie en anastomosant l'artère sous-clavière gauche sur l'artère pulmonaire gauche par thoracotomie gauche chez un enfant cyanosé de 1 an. Six ans plus tard, en 1950, déjà mille interventions similaires avaient été réalisées (10). La deuxième avancée majeure correspond au premier cas de cure complète de TF réalisé chez un enfant de 10 ans, aux Etats-Unis (11) ; il a été effectué le 31 août 1954, sous circulation croisée : c'est à dire que la circulation chez l'enfant avait été assurée par un de ses parents, en « connectant » l'enfant aux vaisseaux fémoraux de ces parents !... Le premier cas rapporté de réparation complète, sous circulation extracorporelle « traditionnelle », a été effectué en 1955 à la Mayo Clinic, Rochester, aux USA

## Préambule

par l'équipe de Kirklin (12). Quelques années plus tard la première série de cure complète de TF était publiée par la même équipe (13) ...La chirurgie de réparation complète de TF allait être réalisée en pratique courante dans les années 1970 dans l'ensemble des pays occidentaux.

La mortalité opératoire allait rapidement diminuer, suivant les progrès médico-chirurgicaux, passant de 20% (14) pour les premières séries publiées, avec un âge moyen à l'opération de 12 ans, à des taux de mortalité variant de 0% à 3% (15, 16), pour les séries les plus récentes, avec un âge moyen à l'opération de 6 mois.

### 1.3 Rappel anatomique, physiopathologique et rappel sur la réparation chirurgicale de la TF

Rappel anatomique : La première description d'une TF remonte à 1888, par Étienne-Louis Arthur Fallot (17), qui avait décrit l'association anatomique de 4 anomalies : une communication interventriculaire (CIV) / une sténose pulmonaire / une dextroposition de l'aorte, située à cheval entre le ventricule droit (VD) et le ventricule gauche / et une hypertrophie ventriculaire droite.

Rappel physiopathologique : La TF est une cardiopathie cono-troncale due à une anomalie de migration des cellules de la crête neurale. Ceci est responsable d'une bascule antéro-droite du septum conal, qui entraîne ainsi une CIV par défaut d'alignement septal, et une sténose de la voie pulmonaire (comprenant, le plus souvent, l'association d'une sténose infundibulaire du VD et d'une sténose valvulaire avec hypoplasie de l'anneau pulmonaire). La dextroposition de l'aorte et l'hypertrophie ventriculaire droite ne sont que les conséquences de deux anomalies précédentes (CIV et sténose pulmonaire).

Sur le plan hémodynamique, la CIV large maintient une égalisation de pressions entre le ventricule gauche et le VD. La surcharge barométrique imposée au VD par la sténose pulmonaire, est responsable d'un shunt droite-gauche par la CIV lorsque les pressions droites deviendront supra systémiques, entraînant alors une cyanose sans insuffisance cardiaque (18).

## Préambule

Rappels chirurgicaux : La réparation chirurgicale consiste à fermer la CIV et à lever la sténose pulmonaire vers l'âge de 6 mois de vie (19). Deux voies d'abord chirurgicales existent : la réparation par voie trans-ventriculaire, qui a été la première décrite, et qui reste encore utilisée aujourd'hui; et la réparation par voie trans-atriale ou atrio-pulmonaire, décrite plus récemment.

*Description de la voie trans-ventriculaire* : La voie d'abord est une longue ventriculotomie droite, qui permet, dans un premier temps, de fermer la CIV au moyen d'un patch synthétique, puis, dans un second temps, de traiter le rétrécissement pulmonaire (section ou résection de bandes musculaires hypertrophiées). L'anneau pulmonaire est ensuite calibré : si sa taille est inférieure à une valeur limite (définie en fonction de la surface corporelle du patient), l'anneau pulmonaire est ouvert et un patch dit trans-annulaire mis en place pour élargir l'anneau mais aussi la ventriculotomie droite. Si l'anneau pulmonaire est de taille satisfaisante, celui-ci est conservé, et la ventriculotomie fermée, le plus souvent par un patch, pour élargir la zone incisée (**Figure 1**, en annexe de ce chapitre, (20)).

*Description de la voie trans-atriale ou atrio-pulmonaire* : cette technique associe une incision atriale droite et une incision longitudinale du tronc de l'artère pulmonaire. La CIV et une majeure partie de la sténose pulmonaire sont réparées au travers de la valve tricuspide ; la levée de la sténose pulmonaire est complétée au travers d'une ouverture dans le tronc de l'artère pulmonaire (**Figure 2**, en annexe de ce chapitre, (20)). Le but de cette technique est de traiter l'obstruction pulmonaire en évitant au maximum une cicatrice de ventriculotomie (21, 22).

### 1.4 Les patients opérés de tétralogie de Fallot ne sont pas guéris !

Une des premières fausses idées véhiculée dans les 1980, était la notion de cure complète et donc de guérison « totale » après une chirurgie de TF (5). A cause de ce concept erroné, certains enfants opérés ont pu atteindre l'âge adulte sans être suivis par un cardio-pédiatre ou même par un cardiologue adulte, puisqu'ils n'en avaient en théorie pas besoin !

Le développement récent et rapide de cette population d'adultes congénitaux avec TF réparée s'est accompagné de la mise en évidence de complications spécifiques qui se sont révélées

## Préambule

progressivement avec le vieillissement de ces patients. Les patients après la « cure complète » n'étaient donc pas guéris...certaines complications avaient un retentissement à type de symptomatologie à l'effort, mais d'autres complications tardives étaient susceptibles d'entraîner des morts subites.

Schématiquement, on peut différencier ces complications en :

- complications d'ordre mécanique (avec la dilatation ventriculaire droite liée à l'insuffisance pulmonaire)
- complications d'ordre rythmiques
- décompensation cardiaque : l'insuffisance cardiaque

Ces complications sont de mieux en mieux connues mais beaucoup restent encore à comprendre pour mieux les traiter et surtout pour mieux les prévenir, c'est ce que nous essaierons d'exposer au cours de ce travail de thèse.

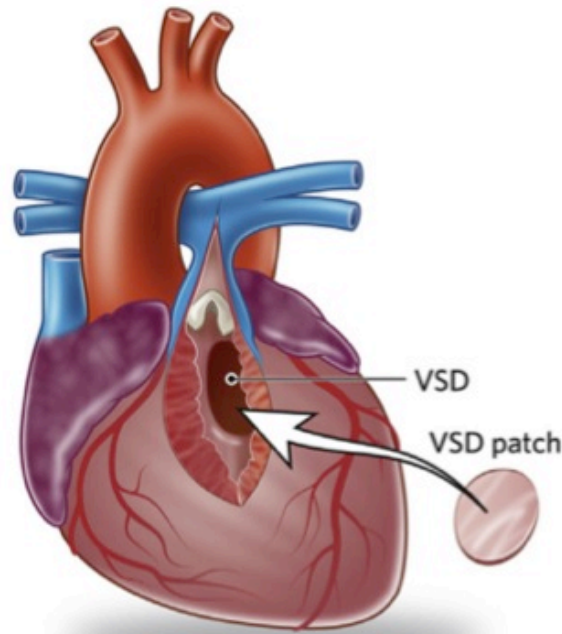
Aux côtés de ces complications « très cardiologiques », propres à la TF réparée, se surajoutent d'autres complications souvent communes à l'ensemble des CC, que nous n'aborderons pas au cours de cette thèse :

- Les pathologies cardiaques non-congénitales, acquises : coronaropathie du fumeur, endocardite
- Les pathologies extracardiaques, non-congénitales : grossesse, cancer...
- Les complications sociétales (assurance) ou professionnelles (maintient dans la « normalité de l'emploi »)
- les complications d'ordre psychologique (anomalie chromosomique ou syndrome génétique), voire psychiatrique. Ainsi une étude retrouvait chez 306 patients avec TF (**23**), 28% d'anomalie chromosomique ou de syndrome génétique, parmi lesquels 32% de délétion 22q11, 15% de trisomie et 14% de l'association VACTERL/VATER .

Quelque soit la complication d'ordre cardiologique présentée par un patient, une prise en charge globale et multidisciplinaire de ces patients sera indispensable pour traiter également les

## **Préambule**

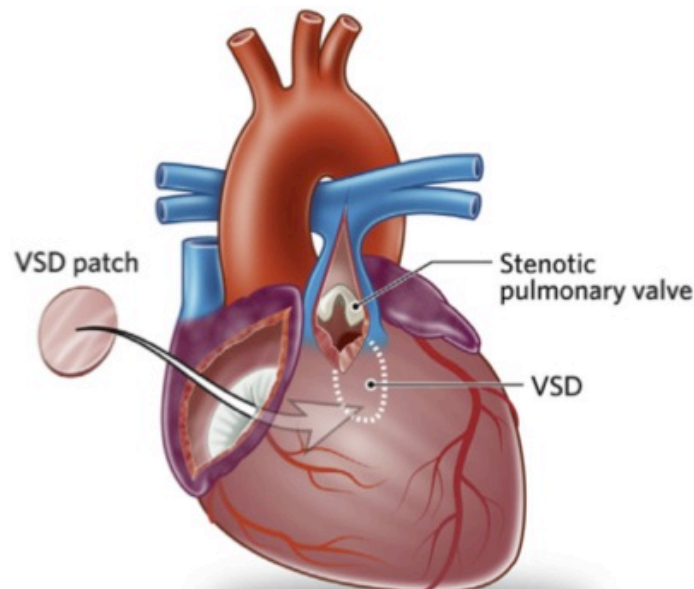
complications extra-cardiaques. Des équipes médicales (en dehors du domaine cardiologique) et paramédicales (psychologues, assistantes sociales, etc.) se sont progressivement constituées pour prendre en charge ces adultes congénitaux (GUCH des anglo-saxon) dans notre CHU.



*D'après D'Udekem et al J Am Coll Cardiol, 2014*

**Figure 1. Réparation de TF par voie trans-ventriculaire.**

La communication interventriculaire est fermée au travers d'une ventriculotomie. La ventriculotomie est ici étendue vers le tronc de l'artère pulmonaire en franchissant l'anneau pulmonaire.



*D'après D'Udekem et al J Am Coll Cardiol, 2014*

**Figure 2. Réparation de TF par voie trans-atriale ou voie atriopulmonaire.**

La communication interventriculaire est fermée au travers d'une atriotomie droite et de la valve tricuspide. Quand l'anneau pulmonaire est ouvert, la taille de la ventriculotomie est ici extrêmement réduite, comparée à la voie d'abord trans-ventriculaire.

### 1.5. Références

1. Garson A Jr, Gillette PC, McNamara DG. Propranolol: the preferred palliation for tetralogy of Fallot. *Am J Cardiol* 1981;47:1098–1104.
2. Elliott RB, Starling MB, Neutze JM. Medical manipulation of the ductus arteriosus. *Lancet* 1975;1:140–142.
3. Macmahon B, McKeown T, Record RG: The incidence and life expectancy of children with congenital heart disease. *Br Heart J* 1953;15:121-129.
4. Daebritz SH: Update in adult congenital cardiac surgery. *Pediatr Control* 2007;28:96-104.
5. Guleserian KJ. Adult congenital heart disease: surgical advances and options. *Prog Cardiovasc Dis.* 2011;53:254-64.
6. Hoffman JI, Kaplan S. The incidence of congenital heart disease. *J Am Coll Cardiol* 2002;39:1890–1900.
7. Jacobs JP, Jacobs ML, Mavroudis C, et al. (2008) Executive Summary: The Society of Thoracic Surgeons Congenital Heart Surgery Database Ninth Harvest (July 1, 2004 to June 30, 2008). Durham, NC: The Society of Thoracic Surgeons and Duke Clinical Research Institute.
8. Brickner ME, Hillis LD, Lange RA: Congenital heart disease in adults: First of two parts. *Nw Engl J Med* 2000;342:256-263.
9. Blalock A, Taussig HB. The surgical treatment of malformations of the heart in which there is pulmonary stenosis or pulmonary atresia. *JAMA* 1945;128:189–202.



## Préambule

10. Taussig HB. Neuhauser Lecture: Tetralogy of Fallot: early history and late results. *Am J Roentgenol* 1979;133:422–431.
11. Gott VL, C. Walton Lillehei and total correction of tetralogy of Fallot. *Ann Thorac Surg* 1990;49:328–332.
12. Kirklin JW, Dushane JW, Patrick RT, et al. Intracardiac surgery with the aid of a mechanical pump-oxygenator system (gibbon type): report of eight cases. *Proc Staff Meet Mayo Clin* 1955;30:201–206.
13. Kirklin JW, Ellis FH, McGoon DC, et al: Surgical treatment for the tetralogy of Fallot by open intracardiac repair. *J Thorac Surg* 1959;37:22-51.
14. Murphy JG, Gersh BJ, Mair DD, et al. Long-term outcome in patients undergoing surgical repair of tetralogy of Fallot. *N Engl J Med* 1993;329:593–599.
15. Stewart RD, Backer CL, Young L, et al. Tetralogy of Fallot: results of a pulmonary valve-sparing strategy. *Ann Thorac Surg* 2005;80:1431–1438; discussion 1438–1439.
16. Kanter KR, Kogon BE, Kirshbom PM, et al. Symptomatic neonatal tetralogy of Fallot: repair or shunt? *Ann Thorac Surg* 2010;89:858–863.
17. Fallot A. Contribution à l'anatomie pathologique de la maladie bleue (cyanose cardiaque). *Marseille Méd* 1888;25:77-40
18. Bricker ME, Hillis LD, Lange RA. Congenital heart disease in adults. *N Engl J Med*. 2000;342:256-263.

## Préambule

19. Al Habib, Jacobs JP, Mavroudis C et al. Contemporary patterns of management of tetralogy of Fallot: data from the Society of Thoracic Surgeons Database. *Ann Thorac Surg.* 2010;90:813-9
20. d'Udekem Y, Galati JC, Rolley GJ, et al. Low risk of pulmonary valve implantation after a policy of transatrial repair of tetralogy of Fallot delayed beyond the neonatal period: the Melbourne experience over 25 years. *J Am Coll Cardiol.* 2014;63:563-8.
21. Karl TR, Sano S, Pornviliwan S, Mee RB. Tetralogy of Fallot: favorable outcome of nonneonatal transatrial, transpulmonary repair. *Ann Thorac Surg.* 1992;54:903-7.
22. Stellin G, Milanesi O, Rubino M et al. Repair of tetralogy of Fallot in the first six months of life: transatrial versus transventricular approach. *Ann Thorac Surg.* 1995;60:S588-91.
23. Michielon G, Marino B, Formigari R, et al. Genetic syndromes and outcome after surgical correction of tetralogy of Fallot. *Ann Thorac Surg* 2006;81:968–975.

### 2. Problématique Générale :

On a vu au chapitre précédent que les patients avec TF réparée étaient en augmentation constante (1). En raison des progrès d'hier et notamment des efforts importants consacrés à optimiser les procédures chirurgicales et les techniques de réanimation, la population des patients adultes congénitaux opérés est en pleine croissance et pose de plus en plus de complications spécifiques (2). Ces complications et leurs morbi-mortalités inhérentes (dysfonction du VD, arythmie, insuffisance cardiaque) surviennent essentiellement après la deuxième décennie : les trois quarts des patients avec TF réparée présentent ainsi au moins un événement significatif avant l'âge de 40 ans, incluant 50% de re-intervention pour valvulation pulmonaire, 17% d'arythmie (supra-ventriculaire et ventriculaire) et 3% d'insuffisance cardiaque (3).

Les différentes interventions chirurgicales proposées pour les CC ont certes apporté un gain très significatif en termes de mortalité et de qualité de vie, mais il est admis, que dans la majorité des cas, la correction d'une malformation cardiaque congénitale ne garantit pas la pleine restauration de la fonction cardiaque et s'accompagne de cicatrices (ou séquelles) anatomiques et fonctionnelles. Ainsi les études anatomiques, de cœurs d'adultes opérés d'une CC dans l'enfance, ont mis en évidence des modifications de l'ultrastructure myocardique et notamment des zones de fibrose interstitielle dont l'extension progresse sensiblement avec le temps (4-6). Cette fibrose endomyocardique, isolée ou associée à d'autres facteurs aggravatifs, semble jouer un rôle déterminant dans l'altération de la fonction myocardique systolique et diastolique et dans la survenue des complications rythmiques (troubles de la conduction, arythmie auriculaire ou ventriculaire, et donc mort subite).

On a vu que les principales complications cardiologiques, rencontrées chez les adultes avec TF réparée sont :

- **les complications d'ordre mécanique**: inéluctables, car inhérentes à la réparation chirurgicale; en effet, 50% des chirurgies de « cure complète » de TF dans la petite enfance s'accompagnent de la mise en place d'un patch trans-annulaire, ce qui a pour conséquence une fuite pulmonaire libre mais qui sera bien tolérée, cliniquement, pendant de nombreuses années. Avec le temps cette régurgitation

## Problématique Générale

pulmonaire va s'accompagner d'une dilatation du ventricule droit (VD), voire d'une fuite tricuspide, et progressivement les patients vont devenir symptomatique à l'effort.

- **les complications d'ordre rythmique** : avec les troubles du rythme supra-ventriculaires et surtout les troubles du rythme ventriculaires, qui sont à risque de mort subite. Les morts subites d'origine rythmique représentent chez les adultes avec TF réparée, la cause principale de décès prématurés dans cette population.

- **l'insuffisance cardiaque**, liée à une dysfonction bi-ventriculaire, vraisemblable stade ultime de la maladie.

Certaines réponses thérapeutiques ont été apportées pour essayer de traiter les **complications mécaniques**. Le but est de freiner l'évolution de la dysfonction ventriculaire droite (et donc du remodelage fibreux...), pour l'instant, uniquement, chez des patients symptomatiques. La valvuloplastie pulmonaire chirurgicale en reste le meilleur exemple : elle permet d'améliorer les symptômes quand le VD n'est pas trop dilatée mais elle n'a pas montré d'amélioration de la survie (7), ni d'amélioration en ce qui concerne la diminution des arythmies (8, 9) dans cette population. Les questions concernant la valvuloplastie pulmonaire restent donc ouvertes et nombreuses : Quand faut-il opérer (10) ? Faut-il opérer plus tôt et faut-il opérer les patients asymptomatiques ?

A côté de ces questions concernant les indications opératoires, qui sont d'ordre stratégiques, d'autres questions importantes, pratiques et quotidiennes, restent sans réponse : choix et durabilité d'une prothèse valvulaire, que faire devant une fuite tricuspide associée lors de la valvuloplastie pulmonaire ?

**En ce qui concerne l'arythmie**, des progrès ont été réalisés dans la compréhension de certains mécanismes (zone de conduction lente autour des cicatrices chirurgicales pourvoyeuses de tachycardies ventriculaires, *cf. plus loin dans cette thèse*), mais l'intrication d'autres mécanismes physiopathologiques dans la survenue de ces arythmies (dilatation du VD et fibrose interstitielle inhérente) complexifie la situation, ce qui explique l'absence de consensus et rend les traitements aléatoires. La recherche active de foyers d'arythmies, l'ablation dans des situations à risque prédéfinies, voire le recours au défibrillateur dans ces populations ne sont pas clairement codifiés et ne sont réalisés que dans quelques centres dans le monde.

## Problématique Générale

**Quant à l'insuffisance cardiaque**, stade ultime de l'évolution de la maladie, elle est le révélateur d'un manque de connaissance du monde médical face à cette nouvelle population de malade (méconnaissance de l'évolution naturelle de la maladie, absence de traitement proposé avant l'irréversibilité de la maladie, parfois absence d'un suivi adapté...). Elle est le révélateur parfois aussi, du manque de moyens investis dans ce domaine particulier qui est la population des adultes avec CC. Au stade de l'insuffisance cardiaque, les assistances circulatoires de longue durée permettent en théorie de combler une partie des limites à l'accès à la transplantation pour ces patients, mais ne sont utilisées en pratique que de manière exceptionnelle. Certaines voies de recherche comme la resynchronisation cardiaque (11, 12) (développées à Bordeaux) ont pu montrer des résultats préliminaires intéressants mais restent à confirmer.

**Les travaux présentés ici ne cherchent à répondre qu'à une partie des problématiques posée par les adultes avec TF réparée.**

Ils font suite à des travaux de recherche clinique, menés dans notre département, chez des patients adultes avec TF réparée, qui ont bénéficié d'un remplacement valvulaire pulmonaire (RVP) ; les problématiques accompagnant ces RVP restent encore nombreuses, avec peu de réponses apportées dans la littérature (quel bio-prothèse choisir ? que faire d'une fuite tricuspide significative lors du RVP ? évaluation de nouveaux paramètres échographiques pour le suivi de cette population...).

A côté de ces travaux cliniques, d'autres travaux de recherche, plus fondamentaux, se sont appuyés sur un modèle de gros animal, développé pour essayer de mieux appréhender les mécanismes des arythmies ventriculaires en se focalisant sur le rôle de la fibrose myocardique (liée à la dilatation du VD, lié elle-même à la régurgitation pulmonaire).

### 2.1. Références

1. Guleserian KJ. Adult congenital heart disease: surgical advances and options. *Prog Cardiovasc Dis.* 2011;53:254-64.
2. Marelli AJ, Mackie AS, Ionescu-Ittu R, Rahme E, Pilote L. Congenital heart disease in the general population: changing prevalence and age distribution. *Circulation* 2007;115:163-172
3. Cuypers JA, Menting ME, Konings EE, et al. Unnatural history of tetralogy of Fallot: prospective follow-up of 40 years after surgical correction. *Circulation.* 2014;130:1944-53.
4. Jones M, Ferrans VJ, Morrow AG, Roberts WC. Ultrastructure of crista supraventricularis muscle in patients with congenital heart diseases associated with right ventricular outflow tract obstruction. *Circulation* 1975;51:39-67.
5. Jones M, Ferrans VJ. Myocardial degeneration in congenital heart disease. Comparison of morphologic findings in young and old patients with congenital heart disease associated with muscular obstruction to right ventricular outflow. *Am J Cardiol* 1977;39:1051-1063.
6. Jones M, Ferrans VJ. Myocardial ultrastructure in children and adults with congenital heart disease. *Cardiovasc Clin* 1979;10:501-530.
7. Harrild D.M, Berul C.I, Cecchin F et al. Pulmonary Valve Replacement in Tetralogy of Fallot: Impact on Survival and Ventricular Tachycardia. *Circulation* 2009;119;445-451.

## Problématique Générale

8. Ferraz Cavalcanti PE, Sá MP, Santos CA. Pulmonary valve replacement after operative repair of tetralogy of Fallot: meta-analysis and meta-regression of 3,118 patients from 48 studies. *J Am Coll Cardiol.* 2013;62:2227-43.
9. Karamlou T, Silber I, Lao R et al. Outcomes after late reoperation in patients with repaired tetralogy of Fallot: the impact of arrhythmia and arrhythmia surgery. *Ann Thorac Surg* 2006;81:1786-93.
10. Hallbergson A, Gauvreau K, Powell AJ, Geva T. Right ventricular remodeling after pulmonary valve replacement: early gains, late losses. *Ann Thorac Surg.* 2015;99:660-6.
11. Dubin AM, Janousek J, Rhee E et al. Resynchronization therapy in pediatric and congenital heart disease patients: an international multicenter study. *J Am Coll Cardiol.* 2005;46:2277-83.
12. Thambo JB, Dos Santos P, de Guillebon M et al. Biventricular stimulation improves right and left ventricular function after tetralogy of Fallot repair: acute animal and clinical studies. *Heart Rhythm* 2010;7:344-50.

## Objectifs

### 3. Objectifs et mise en œuvre du travail de recherche :

On a vu que les mécanismes de décompensation des patients avec TF réparée sont multiples (dysfonction du VD, arythmies, interaction entre la dysfonction VD et les arythmies). Les données issues de la clinique et de la recherche plus fondamentale doivent pouvoir se compléter pour essayer de mieux appréhender cette population de malade. L'objectif était donc de mener un travail translationnel. Un double travail s'est ainsi organisé pour coupler les résultats de la recherche clinique avec les résultats de la recherche plus fondamentale.

Un travail de recherche clinique s'est donc organisé au sein du CHU de Bordeaux. Il existe à Bordeaux et dans la région Aquitaine une cohorte importante de patients, avec TF réparée, qui ont été suivis et pour certains réopérés pour effectuer un RVP. La file active de ces patients adultes réopérés est de plus de 100 patients (en 2012). L'existence de cette cohorte doit beaucoup aux « pionniers » de la chirurgie cardiaque congénitale bordelaise, que sont les professeurs Fontan et Baudet, dont la renommée est internationale suite à leurs travaux sur la « circulation de Fontan » (1).

En parallèle, un travail de recherche s'est inscrit dans le cadre de l'unité de recherche Inserm cardio-thoracique U1045 (en lien également avec L'Institut de Rythmologie et Modélisation Cardiaque LIRYC, Université de Bordeaux). Ce travail avait pour but d'étudier les mécanismes du développement des arythmies ventriculaires chez un modèle de gros animal mimant une TF réparée. Ce modèle animal, mimant les caractéristiques des patients avec TF opérée, a permis de nombreuses analyses en terme d'imagerie (données échocardiographiques et d'IRM), en terme également d'hémodynamiques, d'histologie, de biologie moléculaire et génétique, et enfin en terme d'analyse électrophysiologique par cartographie optique.

**La première partie de ce travail** porte sur les résultats observés sur notre cohorte de patients suivis pour la plupart au CHU de Bordeaux.

De nombreuses questions restent sans réponse chez ces patients: choix de la valve à implanter, avec la meilleure durabilité possible ? Quelle attitude chirurgicale devant une fuite tricuspide significative



## Objectifs

associée lors de la valvulation pulmonaire ? Quelle tactique chirurgicale employée devant une aorte ascendante dilatée, souvent adhérente au sternum, chez ces patients multi-opérés ?

Nous avons cherché à répondre à ces questions ; ainsi nous avons pu évaluer les résultats d'une bioprothèse non stentée (en l'occurrence, la valve Freestyle, Medtronic). Nous avons également essayé d'évaluer l'intérêt de la plastie tricuspide chez ces patients où une fuite tricuspide est fréquemment associée au moment du RVP. Enfin, nous rapportons, une nouvelle voie d'abord chirurgicale qui peut avoir un intérêt quand l'aorte ascendante est adhérente à la face postérieure du sternum.

En marge de ces questions posées, nous avons pu également évaluer l'apport de nouveaux paramètres échocardiographiques pour la surveillance des patients avec TF réparée. Enfin, nous rapportons une complication, jamais décrite, de distorsion coronaire, dans les suites immédiates d'une valvulation pulmonaire, traitée par angioplastie stent de l'interventriculaire antérieure.

**La deuxième partie de ce travail**, de recherche fondamentale, a permis tout d'abord de créer un modèle animal, fiable et reproductible, mimant les séquelles observées chez l'humain après TF réparée. Ce modèle animal a tout d'abord été validé. Puis des recherches portant sur l'impact hémodynamique de la resynchronisation (en phase aigue) ont pu être effectuées sur ce modèle (2). Des travaux étudiant les mécanismes pro-arythmogènes ont été effectués au niveau du VD ; des travaux similaires sur le ventricule gauche sont également en cours. Une analyse de biologie moléculaire et de génétique a pu être réalisée sur ce modèle. Enfin, de manière « accidentelle », nous avons pu mettre en évidence le caractère aléatoire des cerclages du tronc de l'artère pulmonaire (en fonction du matériel employé pour les réaliser), ce qui peut modifier les caractéristiques et les séquelles observées sur notre modèle animal.

Ce travail s'est construit à partir d'une collaboration étroite entre différentes expertises. Le caractère multidisciplinaire a vraiment eu ici tout son sens.

Pour le travail clinique, l'implication des chirurgiens et cardio-pédiatres a permis la réalisation d'une base de données efficace, indispensable pour tous les travaux effectués. L'expertise en échographie et IRM des Dr Iriart, Séguéla et Selly a été prédominante pour les travaux cliniques. La volonté du Dr

## Objectifs

Ramanan (chirurgienne indienne cardio-pédiatrique) nous a permis de collaborer avec le centre de Stuttgart en Allemagne (étude bi-centrique), pour publier la plus importante série de valve Freestyle implantées sur la voie de sortie du ventricule droit.

Pour le travail de recherche, les travaux ont donc été menés au sein de l'unité Inserm U1045 (en collaboration avec le LIRYC). Les travaux encadrés par le professeur Thambo, ont été développés en collaboration avec l'équipe d'Olivier Bernus (responsable du LIRYC), avec notamment David Benoist et Virginie Dubes : leur apport dans la compréhension des arythmies sur ce modèle a été prédominant. Les travaux de biologie moléculaire ont bénéficié de l'implication du Docteur Caroline Rooryck-Thambo du service de génétique et de biologie moléculaire des Professeurs Didier Lacombe et Benoît Arveiler.

La collaboration avec l'institut INRA de Poitiers (Centre de recherche Poitou-Charentes situé exactement sur les sites de Rouillé et Lusignan) a été très efficace; nous remercions, d'ailleurs, l'ingénieur responsable du site M. Stéphane Ferchaud, pour sa patience, sa disponibilité et son soutien sans faille au cours de ces années. Une grande partie des animaux a été opérée sur ce site puisque la ferme, où nous hébergions les animaux au début du travail, a perdu ces accréditations (ceci lié à un durcissement de la réglementation de la recherche animale en 2013). Nous avons donc dû rechercher dans l'urgence un nouveau centre d'accueil pour les animaux opérés : ce fut l'INRA de Poitiers ; au total, nous avons hélas, perdu presque 18 mois dans l'élaboration de nos travaux de recherche ! (Ceci lié au financement de l'INRA, à l'obtention de l'accord des différents comités éthiques locaux, etc.)

## Objectifs

### 3.1 Références

1. Fontan F, Baudet E. Surgical repair of tricuspid atresia. *Thorax*. 1971;26:240-8.
2. Thambo JB, Dos Santos P, De Guillebon M, Roubertie F et al. Biventricular stimulation improves right and left ventricular function after tetralogy of Fallot repair: acute animal and clinical studies. *Heart Rhythm*. 2010;7:344-50.

## Première partie : clinique.

### 4.1 Premier travail : considérations chirurgicales : problématique des reinterventions chez les adultes avec TF réparée :

#### **4.1.1 Introduction**

Une des problématiques majeures posées chez les adultes opérés d'une CC, et donc chez les adultes avec TF réparée, est liée aux reinterventions, car ces patients ont souvent été multi-opérés dans l'enfance (1, 2). Ceci est particulièrement vrai dans le cas des TF puisqu'ils peuvent avoir eu une première thoracotomie gauche pour réaliser un Blalock (en période néo-natale) puis une seconde thoracotomie droite (ou une sternotomie) pour réaliser un autre Blalock, car l'enfant a grandi et a commencé à désaturer. Enfin l'enfant peut avoir eu sa cure complète par sternotomie suivie d'autres sternotomies pour corriger d'éventuelles lésions résiduelles (CIV résiduelle, sténose résiduelle sur la voie de sortie du VD, etc.).

Ces multiples opérations « subies » par les patients peuvent rendre une nouvelle intervention de chirurgie cardiaque chez l'adulte, particulièrement difficile, voire à risque vital pour le patient. Chez les patients avec CC opérée, le risque de mortalité opératoire augmente en effet avec le nombre de thoracotomie/sternotomie (2) qu'a eu le patient dans ses antécédents: la mortalité hospitalière passe ainsi de 1,8% pour un antécédent de thoracotomie/sternotomie, à 8% quand le patient a eu 4 thoracotomies/sternotomies (3). Les adhérences développées entre l'aorte ascendante ou un VD dilaté et le sternum expliquent en partie ces résultats.

Une autre caractéristique des patients avec TF réparée, est qu'ils présentent souvent une aorte ascendante dilatée (média-nécrose kystique similaire au maladie aortique annulo-ectasiant) (4). Ces aortes sont donc plus « fragiles » qu'une aorte ascendante « normale » ; et elles peuvent être collées à la face postérieure du sternum (1, 5). Dans ce cas de figure, la recherche d'une voie d'abord

chirurgicale alternative peut se justifier, pour essayer de diminuer le risque de « blessure aortique » en cas de re-sternotomie. (Cf. en annexe : le case report publié dans les *Annals of Thoracic Surgery* : *Roubertie F et al. Left posterolateral thoracotomy: an alternative approach for pulmonary valve replacement. Ann Thorac Surg. 2014;97:691-3.*)

#### **4.1.2 Résultats :**

Une thoracotomie postéro-latérale gauche a donc été effectuée pour réaliser la chirurgie de RVP, avec mise en place d'une canule artérielle et d'une canule veineuse par abord fémoral (avec drainage veineux actif), pour la mise en place de la circulation extracorporelle. Une chirurgie de valvulation pulmonaire, de plastie de l'artère pulmonaire gauche et de résection d'anévrisme infundibulaire a pu être effectuée, sous circulation extracorporelle, à cœur battant. Ceci a permis d'éviter la re-sternotomie, tout en réalisant un geste chirurgicale similaire à celui qui aurait été réalisé avec une voie d'abord plus conventionnelle de re-sternotomie.

#### **4.1.3 Conclusion :**

Les reinterventions, chez les adultes avec TF réparée ou chez les adultes avec CC multi-opérées, peuvent être un véritable challenge chirurgical, et se révéler être à risque vital. Des règles simples, à respecter par l'équipe chirurgicale, permettent d'éviter bien des écueils.

Règle numéro 1 : Avant de programmer ce type de re-intervention, les précédents comptes-rendus opératoires doivent être analysés en profondeur, de même que l'ensemble du ou des dossier(s) du patient. Souvent consommateur de temps, cette étape fondamentale ne doit pas être négligée. De nombreuses informations importantes « oubliées au fil du temps » ou passées au second plan peuvent être rattrapées par l'analyse des dossiers.

Règle numéro 2 : Un bilan pré-opératoire s'impose avec la réalisation d'une imagerie de qualité (TDM ou IRM) de l'étage thoracique (adhérence du massif cardiaque, de l'aorte voire du tronc de l'artère pulmonaire au sternum), du cou (vaisseaux du cou avec la perméabilité des carotides et jugulaires) mais également des carrefours fémoraux. Ces données sont à confronter à celles des échographies

doppler périphériques. En effet, le capital veineux et artériel de ces patients a pu être mis à mal au cours de la réalisation antérieure de cathétérismes, de la mise en place de pacemaker ou de défibrillateurs par voie endo-vasculaire, voire de cannulations périphériques (pour effectuer des circulations extracorporelles), responsables de thromboses veineuses et/ou artérielles. La connaissance du réseau vasculaire est donc fondamentale en cas de nécessité de mise en place d'une circulation extracorporelle périphérique fémorale ou jugulaire. (6).

Règle numéro 3 : S'acharner à respecter les deux premières règles et souvent penser qu'une lésion qui justifie l'indication peut en fait masquer d'autres lésions secondaires : recherche de CIV résiduelle ou de communication inter-atriale résiduelle, d'anévrisme infundibulaire, de fuite tricuspide ou de sténose d'une branche pulmonaire comme dans notre case report. La présence d'un shunt résiduel peut être particulièrement à risque d'embolie gazeuse en cas de blessure de l'oreillette droite ou du VD lors de la réentrée sternale ; ceci est également vrai pour la chirurgie de RVP menée à cœur battant sous circulation extracorporelle d'assistance.

Règle numéro 4 : Enfin, il faut « prendre le temps de réfléchir » à ces dossiers souvent complexes mais heureusement rarement urgents. La notion de bénéfice/risque (7) est particulièrement importante dans ce contexte et doit nous faire choisir la meilleure option chirurgicale possible. La mortalité opératoire après valvulation pulmonaire chez les adultes avec TF réparée est faible (<2%) ; le choix d'une voie d'abord chirurgicale alternative dans certains cas sélectionnés (aorte ascendante dilatée et adhérente au sternum) peut contribuer à diminuer cette mortalité. Après RVP, une amélioration de la symptomatologie a été rapportée (8), ce qui n'est pas le cas en ce qui concerne le nombre des arythmies ou le nombre de décès dans le suivi ; il s'agit donc d'une intervention essentiellement fonctionnelle, non « vitale », d'où la nécessité accrue dans ce contexte de tendre vers une mortalité proche de zéro.

Règle numéro 5 : Importance de l'échographie trans-oesophagienne en per-opératoire pour contrôler la réparation chirurgicale. Cet examen est aussi « le dernier rempart », qui permet parfois de mettre évidence d'autres lésions associées, passées jusque là inaperçues, mais qui seront à réparer en même temps que le RVP.

#### 4.1.4 Références

1. Barnard J, Hoschtitzky A, Hasan R. Pulmonary valve replacement through a left thoracotomy approach. *Ann Thorac Surg* 2012;93:306–8.
2. Giamberti A, Chessa M, Abella R, et al. Morbidity and mortality risk factors in adults with congenital heart disease undergoing cardiac reoperations. *Ann Thorac Surg* 2009;88:1284–9.
3. Brown ML, Dearani JA, Burkhart HM: The adult with congenital heart disease: medical and surgical considerations for management. *Curr Opin Ped* 2009;21:561-564.
4. Dearani JA, Burkhart HM, Stulak JM, Sundt TM, Schaff HV. Management of the aortic root in adult patients with conotruncal anomalies. *Semin Thorac Cardiovasc Surg Pediatr Card Surg Annu* 2009;122–9.
5. Henaine R, Yoshimura N, Di Filippo S, Ninet J. Pulmonary valve replacement in repaired tetralogy of Fallot by left thoracotomy avoid ascending aorta injury. *J Thorac Cardiovasc Surg* 2011;141:590–2.
6. Guleserian KJ. Adult congenital heart disease: surgical advances and options. *Prog Cardiovasc Dis*. 2011;53:254-64.
7. Vouhé PR. Adult congenital surgery: current management. *Semin Thorac Cardiovasc Surg*. 2011;23:209-15.
8. Harrild DM, Berul CI, Cecchin F, Geva T, Gauvreau K, Pigula F, et al. Pulmonary valve replacement in tetralogy of Fallot: impact on survival and ventricular tachycardia. *Circulation* 2009;119:445–51.

### 4.1.5 Perspectives cliniques suite à ce premier travail : les dilatations de l'aorte ascendante chez les adultes avec TF réparée :

Une étude rétrospective transversale multicentrique récente (1) a rapporté la prévalence des dilatations de l'aorte chez les patients avec TF réparée. Seules des mesures écho-cardiographiques ont été utilisées pour évaluer les diamètres aortiques. Une dilatation de l'aorte ascendante était définie : soit comme ayant un diamètre >40mm ou soit comme étant >1,5 fois la mesure du diamètre mesuré attendu (en se basant sur des abaques pour la surface corporelle et l'âge du patient). Les résultats retrouvaient presque 30% de dilatation dans cette population, pour une valeur seuil de 40 mm, mais seulement 7% de dilatation lorsqu'on se basait par rapport aux abaques. Des fuites valvulaires aortiques modérées ou sévères étaient retrouvées chez 3,5% des patients, mais chez 14% des patients avec une aorte ascendante dilatée par rapport aux abaques. Cette étude concluait que les fuites valvulaires aortiques significatives étaient rares et que les dilatations de l'aorte ascendante étaient peu fréquentes également (quand indexées sur des abaques) ; au total, l'étude était globalement rassurante en ce qui concerne les aortes ascendantes chez les patients avec TF réparée. Cependant, les indications chirurgicales de remplacement de l'aorte, sont basées sur des mesures de diamètres non indexées (2), ce qui diminue la portée des conclusions de l'étude précédente.

La question sous-jacente, qui reste sans réponse, est la suivante : le risque de rupture ou de dissection des aortes dilatées des adultes avec TF réparée, est-il comparable aux patients avec bicuspidie valvulaire aortique ou avec maladie de Marfan ? Une maladie intrinsèque de l'aorte ascendante a été rapportée dans cette population, à type de média-nécrose kystique (3). Les cas rapportés de dissections aortiques (4-6), chez les patients avec TF réparée, sont extrêmement rares (3 case report dans la littérature) ; ces dissections aortiques ne s'étaient produites, à chaque fois, que dans un contexte de dilatation majeure de l'aorte ascendante (>70 mm). Par ailleurs, la notion de bénéfice/risque reste fondamentale, puisqu'on sait que les gestes complémentaires réalisés en plus du geste chirurgicale principale (la valvulation pulmonaire) augmentent le risque de morbi-mortalité (7). L'attitude chirurgicale admise (8), mais qui ne fait pas l'objet de recommandation dans cette



population, est de remplacer l'aorte ascendante lors du RVP, quand le diamètre est  $>55$  mm, de surveiller quand  $<50$ mm ; entre 50 et 55 mm, la décision chirurgicale dépend d'autres facteurs comme l'espérance de vie ou l'existence d'une fuite valvulaire aortique.

Au total, alors que la dilatation de l'aorte ascendante est une problématique connue dans cette population, une réponse claire concernant leur prise en charge n'existe pas. Seules d'autres études (multicentriques, menées en France par exemple) pourraient aider à clarifier les données concernant l'aorte ascendante chez les patients avec TF réparée : une étude prospective sur le devenir des aortes ascendantes paraît réalisable assez facilement aujourd'hui, d'autant plus que ces patients sont surveillés régulièrement par IRM et/ou TDM. Il serait également intéressant de connaître le nombre de geste chirurgical réalisé sur l'aorte ascendante en France, au moment de la chirurgie de RVP, et avec quels critères retenus pour poser l'indication.

#### 4.1.6 Références

1. Mongeon FP, Gurvitz MZ, Broberg CD, et al: Aortic root dilatation in adults with surgically repaired tetralogy of Fallot: A multicenter cross-sectional study. *Circulation* 2013;127:172-179
2. Hiratzka LF, Bakris GL, Beckman JA, et al: 2010 ACCF/AHA/AATS/ACR/ASA/SCA/SCAI/SIR/STS/SVM guidelines for the diagnosis and management of patients with thoracic aortic disease: A report of the American College of Cardiology Foundation/American Heart Association Task Force on Practice Guidelines, American Association for Thoracic Surgery, American College of Radiology, American Stroke Association, Society of Cardiovascular Anesthesiologists, Society for Cardiovascular Angiography and Interventions, Society of Interventional Radiology, Society of Thoracic Surgeons, and Society for Vascular Medicine. *Circulation* 2010;121:266-369
3. Niwa K. Aortic root dilatation in tetralogy of Fallot long-term after repair—histology of the aorta in tetralogy of Fallot: evidence of intrinsic aortopathy. *Int J Cardiol* 2005;103:117–19.
4. Kim WH, Seo JW, Kim SJ, et al: Aortic dissection late after repair of tetralogy of Fallot. *Int J Cardiol* 2005;101:515-516
5. Konstantinov IE, Fricke TA, d'Udekem Y, et al: Aortic dissection and rupture in adolescents after tetralogy of Fallot repair. *J Thorac Cardiovasc Surg* 2010;140:71-73
6. Rathi VK, Doyle M, Williams RB, et al: Massive aortic aneurysm and dissection in repaired tetralogy of Fallot; diagnosis by cardiovascular magnetic resonance imaging. *Int J Cardiol* 2005;101:169-170

7. Kogon B, Grudziak J, Sahu A, et al: Surgery in adults with congenital heart disease: Risk factors for morbidity and mortality. *Ann Thorac Surg* 2013;95:1377-1382

8. Dearani JA, Burkhart HM, Stulak JM, et al: Management of the aortic root in adult patients with conotruncal anomalies. *Semin Thorac Cardiovasc Surg Pediatr Card Surg Annu* 2009;12:122-129

mediated by digestive enzymes produced by teratoma-derived pancreatic secretions, which damaged the tumor wall. This postulation correlates with finding of high levels of amylase in the patient's pleural and cystic fluids. Superior vena cava syndrome was caused by external compression of a loculated cystic fluid secondary to teratoma rupture into the mediastinum.

To our knowledge, teratoma with rupture into the mediastinum complicated by superior vena cava syndrome has not been reported previously. Surgical excision is the favorable treatment for ruptured mediastinal teratomas. Moreover, the decision to perform surgery promptly may avert potentially life-threatening complications, including superior vena cava syndrome and acute mediastinitis, as described in this case. In conclusion, early diagnosis and prompt surgical intervention of ruptured teratomas are crucial for preventing its devastating outcomes.

---

We would like to thank Hsu Yu-Ting for providing image type-setting assistance.

---

## References

1. Fulcher AS, Proto AV, Jolles H. Cystic teratoma of the mediastinum: demonstration of fat/fluid level. *AJR Am J Roentgenol* 1990;154:259-60.
2. Strollo DC, Rosado de Christenson ML, Jett JR. Primary mediastinal tumors. Part 1: tumors of the anterior mediastinum. *Chest* 1997;112:511-22.
3. Choi SJ, Lee JS, Song KS, Lim TH. Mediastinal teratoma: CT differentiation of ruptured and unruptured tumors. *AJR Am J Roentgenol* 1998;171:591-4.
4. Suwatanapongched T, Kiatboonsri S, Visessiri Y, Boonkasem SA. 30-year-old woman with intermittent cough and a mass-like opacity in the right upper lobe. *Chest* 2011;140:808-13.
5. Rosado-de-Christenson ML, Templeton PA, Moran CA. From the archives of the AFIP. Mediastinal germ cell tumors: radiologic and pathologic correlation. *Radiographics* 1992;12:1013-30.

---

## Left Posterolateral Thoracotomy: An Alternative Approach for Pulmonary Valve Replacement

François Roubertie, MD, Roland Henaine, MD, Xavier Roques, MD, PhD, and Jean-Benoît Thambo, MD, PhD

Department of Cardiovascular Surgery, Bordeaux Heart University Hospital, University of Bordeaux II, Bordeaux; Department of Cardiac Surgery, Cardiologic Hospital Louis Pradel, Lyon; and Department of Pediatric and Adult Congenital Heart Disease, Bordeaux Heart University Hospital, University of Bordeaux II, Bordeaux, France

---

Accepted for publication May 15, 2013.

Address correspondence to Dr Roubertie, Department of Cardiovascular Surgery, Haut Lévêque Hospital, 1 avenue Magellan, 33600 Pessac, France; e-mail: [francois.roubertie@chu-bordeaux.fr](mailto:francois.roubertie@chu-bordeaux.fr).

Pulmonary valve replacement in adults who have a repaired tetralogy of Fallot is realized through a redo median sternotomy. A dilated ascending aorta is often present and adherent to the sternum and can be injured during sternum reentry, with dramatic consequences. We report on an adult patient with a corrected tetralogy of Fallot who underwent pulmonary valve replacement, thick transannular patch excision, and left pulmonary artery enlargement. Surgery was performed through a left posterolateral thoracotomy. This surgical approach was safe and efficient and, compared with the left anterior thoracotomy approach, offered many more possibilities.

(Ann Thorac Surg 2014;97:691-3)

© 2014 by The Society of Thoracic Surgeons

Redo sternotomy can cause excessive risks to adult patients with a repaired tetralogy of Fallot (TOF) and a dilated ascending aorta. In contrast, the left chest is often protected from previous surgery and is easy to access. Our opinion is that a posterolateral thoracotomy approach in these patients has been underused, although it offers excellent results and is a safer procedure.

We report on a case of an adult with a repaired TOF to support our opinion. The patient underwent pulmonary valve replacement (PVR) and enlargement of the left pulmonary artery (LPA) ostium through a posterolateral thoracotomy. This surgical approach avoided injuring the aorta, which firmly adhered to the sternum.

Our patient was a 20-year-old woman who had undergone three previous interventions: two modified Blalock shunts through a right and then left anterior thoracotomy, at 3 months and 1 year of age, and a complete repair with a transannular patch through a median sternotomy at 3 years of age.

The patient was referred for severe pulmonary valve regurgitation and classified as New York Heart Association (NYHA) status II. A transesophageal echocardiograph showed no residual shunt. Preoperative magnetic resonance imaging confirmed severe regurgitation, with a right ventricular end-diastolic volume index of 155 mL/m<sup>2</sup>. A computed tomographic (CT) scan showed the ascending aorta closely adherent to the sternum and ostial stenosis of the LPA (Fig 1). The pulmonary-artery trunk diameter was 23 mm.

The patient was positioned in a right lateral decubitus position, with the hips rotated posteriorly to a 50-degree angle. The chest was opened via a left posterolateral thoracotomy through the fifth intercostal space. A normothermic cardiopulmonary bypass was attached to the left femoral artery and vein; a long venous cannula was positioned into the mid-right atrium under transesophageal echocardiographic guidance. Decreased ventilation eased left-lung dissection, and pericardial adhesions were freed. Surgery was performed on the beating heart. A bloodless operative field was obtained

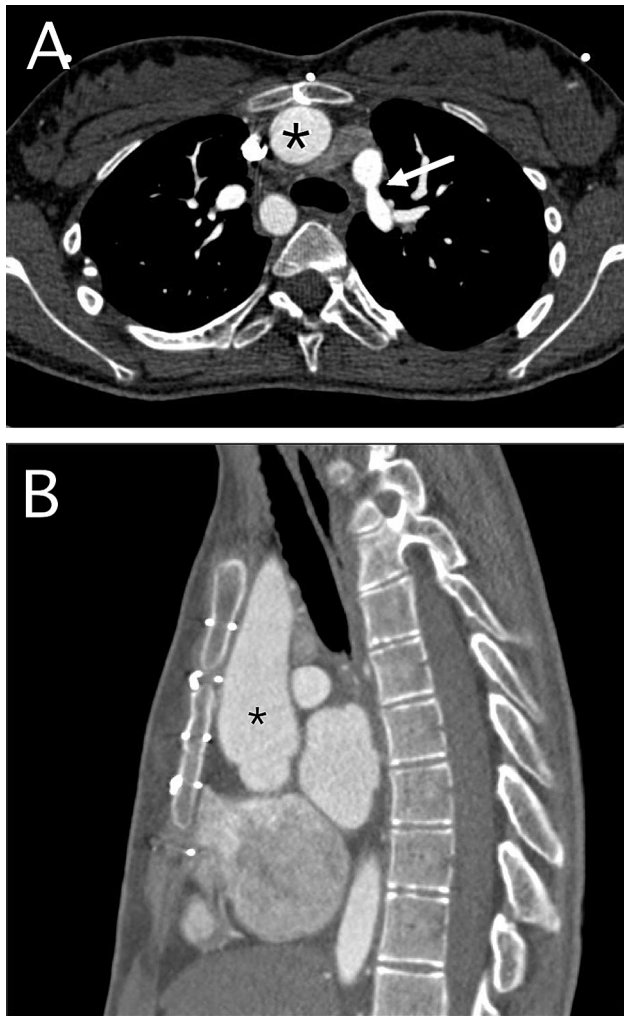


Fig 1. Preoperative angiographic CT scan showing (A) a transverse cross section and (B) a longitudinal cross section of an ascending aorta adhering to the sternum (black asterisk). The white arrow shows the left pulmonary artery ostial stenosis.

using a vacuum-assisted venous return. The right ventricular outflow tract, main pulmonary trunk and LPA were exposed. The thick transannular patch was entirely excised. Incision into the pulmonary trunk was extended beyond the LPA ostial stenosis. An equine pericardial patch (Edwards Lifesciences, Irvine, CA) was positioned over the right ventricular outflow tract. A 21-mm Carpentier-Edwards pericardial bioprosthesis (Edwards Lifesciences) was inserted partly onto the pulmonary annulus and partly onto the infundibular equine patch (Fig 2). Enlargement of the LPA and trunk was then constructed with a similar equine patch.

The postoperative course was uneventful with a quick recovery. After 24 months of follow-up, the patient was in NYHA state I and had a peak systolic prosthesis gradient of 17 mm Hg, and no regurgitation was noted on echocardiography. A CT scan 6 months postoperatively showed no LPA stenosis.

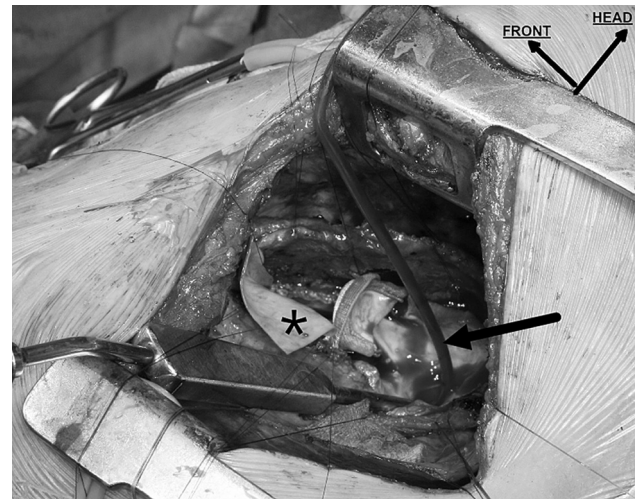


Fig 2. Operative view through the left posterolateral thoracotomy. The black asterisk shows the equine pericardial patch partially sewn onto the right ventricular infundibulum. The bioprosthesis is implanted into the posterior half of the pulmonary annulus. The black arrow shows a vent placed in the left pulmonary branch when the ostial stenosis has been opened. The front and head of the patient are indicated in this view.

### Comment

Left posterolateral thoracotomy, for multiple-time redo mitral valve surgery, has already been proved as safe and effective to prevent injury to cardiac structures [1], but it has never been used for PVR.

The presence of an enlarged ascending aorta [2], more or less adherent to the sternum [3, 4], is frequent in adults with a repaired TOF. In this case, a repeated sternotomy and sternum reentry could be challenging. Furthermore, adults with congenital heart disease, as well as adults with a repaired TOF undergoing cardiac operation, have often undergone several previous sternotomies [4, 5]. In addition, severe postoperative morbidity and operative mortality [5] are related to the number of prior operative procedures. Despite this finding, PVR is usually performed through a repeated median sternotomy [2], and it could represent a technical challenge when the aorta is dilated and adherent to the sternum. In contrast, posterolateral thoracotomy provides excellent access. PVR was easy to perform, and associated surgical procedures were performed without difficulty.

In this report, an alternative to the classical redo sternotomy was necessary because the ascending aorta was adhered firmly to the sternum. Although a left anterior thoracotomy [3, 4] can be performed on isolated PVRs with a large native pulmonary-artery trunk, this surgical approach was not possible in our case; indeed, our patient had already undergone a prior left anterior thoracotomy, and LPA stenosis was not appropriate with this surgical approach. Furthermore, PVR through an anterior thoracotomy is nearly impossible when the pulmonary artery trunk is not dilated, as occurred in our case. PVR, thick



transannular patch excision, and LPA stenosis were realized using one procedure through a posterolateral thoracotomy, whereas only isolated PVR is feasible through an anterior thoracotomy. Percutaneous PVR is used only for conduit or homograft stenosis [6]; therefore it was not indicated in this case.

Although operative mortality (<2%) and morbidity rates for PVR in adult patients are considered low, they can be reduced further with proper access. Indeed, better access may be critical because more adults with a repaired TOF [7] will require PVR to prevent chronic right ventricular overload. Symptomatic patients with a right ventricular end-diastolic volume greater than 150 mL/m<sup>2</sup>, as assessed by magnetic resonance imaging, is a current indication for conducting a PVR to prevent right ventricular dysfunction. A safer approach is also essential because late PVR has not been proved efficient at reducing the incidence of arrhythmia or death in adults with a repaired TOF [8].

In conclusion, the posterolateral thoracotomy procedure does not have to be selected because of specific circumstances, as occurred in our case, but can be considered a safe option when the ascending aorta is dilated and adherent to the sternum [3] or can be considered when the enlarged right heart is adherent to the back of the sternum [4]. Chronic right ventricular volume overload resulting from long-lasting pulmonary valve regurgitation leads to frequent right ventricular or atrium dilation with right ventricular dysfunction [7]. Furthermore, right ventricular outflow tract scar, akinesia, or aneurism are frequently found in adults with a repaired TOF who underwent an infundibular or transannular patch insertion. Lesions, such as LPA stenosis or a right ventricular outflow tract aneurism, can also use this approach.

Although our experience is based on a single case, we prefer this approach because morbidity and mortality are essentially associated with redo sternotomy. The use of left posterolateral thoracotomy, when feasible, should reduce the operative risks for adult patients with a repaired TOF and a dilated ascending aorta.

## References

1. Suzuki Y, Pagani FD, Bolling SF. Left thoracotomy for multiple-time redo mitral valve surgery using on-pump beating heart technique. *Ann Thorac Surg* 2008;86:466–71.
2. Dearani JA, Burkhart HM, Stulak JM, Sundt TM, Schaff HV. Management of the aortic root in adult patients with conotruncal anomalies. *Semin Thorac Cardiovasc Surg Pediatr Card Surg Annu* 2009;122–9.
3. Henaine R, Yoshimura N, Di Filippo S, Ninet J. Pulmonary valve replacement in repaired tetralogy of Fallot by left thoracotomy avoid ascending aorta injury. *J Thorac Cardiovasc Surg* 2011;141:590–2.
4. Barnard J, Hoschtitzky A, Hasan R. Pulmonary valve replacement through a left thoracotomy approach. *Ann Thorac Surg* 2012;93:306–8.
5. Giamberti A, Chessa M, Abella R, et al. Morbidity and mortality risk factors in adults with congenital heart disease undergoing cardiac reoperations. *Ann Thorac Surg* 2009;88:1284–9.
6. Khambadkone S, Coats L, Taylor A, et al. Percutaneous pulmonary valve implantation in humans: results in 59 consecutive patients. *Circulation* 2005;112:1189–97.
7. Nollert G, Fischlein T, Bouterwek S, Böhmer C, Klinner W, Reichart B. Long-term survival in patients with repair of tetralogy of Fallot: 36-year follow-up of 490 survivors of the first year after surgical repair. *J Am Coll Cardiol* 1997;30:1374–83.
8. Harrild DM, Berul CI, Cecchin F, Geva T, Gauvreau K, Pigula F, et al. Pulmonary valve replacement in tetralogy of Fallot: impact on survival and ventricular tachycardia. *Circulation* 2009;119:445–51.

## The “TEVAR-First” Approach to DeBakey I Aortic Dissection With Mesenteric Malperfusion

Bradley G. Leshnower, MD, Ravi K. Veeraswamy, MD, Yazan M. Duwayri, MD, and Edward P. Chen, MD

Divisions of Cardiothoracic Surgery, and Vascular Surgery and Endovascular Therapy, Emory University School of Medicine, Atlanta, Georgia

Acute DeBakey type 1 aortic dissection presenting with mesenteric malperfusion is a lethal variant of all dissection-related malperfusion syndromes with reported mortality rates of 38% to 75%. Conventional surgical treatment involves proximal aortic replacement to restore true lumen perfusion, followed by mesenteric revascularization if malperfusion persists. In an attempt to improve the dismal outcomes associated with this malperfusion syndrome, we have instituted a [thoracic endovascular aortic repair] “TEVAR-First” approach in hemodynamically stable patients, which allows for earlier true lumen expansion and resolution of the malperfusion syndrome.

(Ann Thorac Surg 2014;97:693–6)

© 2014 by The Society of Thoracic Surgeons

Acute DeBakey I aortic dissection (D1AD) with mesenteric malperfusion is a rare (3%) and lethal variant of aortic dissection [1]. Emergent proximal aortic reconstruction to resect the primary intimal tear and restore true lumen flow, followed by open or endovascular mesenteric revascularization represents the current standard of care. However this treatment algorithm has resulted in a 63% mortality rate based upon the latest International Registry of Acute Aortic Dissection report [1]. These dismal results are likely due to advanced end-organ injury due to prolonged ischemia prior to restoration of true lumen blood flow. In an attempt to improve survival in patients presenting with D1AD and mesenteric malperfusion, we have implemented a “TEVAR-First” approach to rapidly

Accepted for publication June 3, 2013.

Address correspondence to Dr Leshnower, Emory University School of Medicine, 1365-A Clifton Rd NE, Ste 2236, Atlanta, GA 30322; e-mail: bleshno@emory.edu.

## 4.2 Deuxième travail : évaluation d'une bio-prothèse non stentée pour effectuer la valvulation pulmonaire chez des adultes avec TF réparée :

### 4.2.1 Introduction

La complication la plus fréquente, rencontrée après TF réparée, est la fuite pulmonaire résiduelle. Elle est liée à l'ouverture chirurgicale, lors de la réparation complète, de la voie de sortie du ventricule droit. Une fuite pulmonaire est presque systématiquement retrouvée, quand un patch trans-annulaire a du être mis en place pour ouvrir l'anneau pulmonaire (1, 2). Même lorsque l'anneau pulmonaire a pu être conservé, une fuite pulmonaire sera également fréquemment retrouvée (20% (3) à 40% (4) des indications de valvulation pulmonaire selon les séries).

Les patients, qui ont été opérés sans conservation de l'anneau pulmonaire, ont des stades cliniques NYHA similaires à ceux avec anneau pulmonaire conservé (5, 6). Par contre, les épreuves d'effort sont clairement plus altérées chez les patients qui ont eu un patch trans-annulaire (7, 8). De même, les données IRM montrent que la fuite pulmonaire conduit à une dysfonction ventriculaire droite, même chez les patients asymptomatiques (1, 2).

Cette régurgitation pulmonaire a pour conséquence une surcharge volumétrique du VD, qui conduit avec le temps à une dysfonction ventriculaire droite, parfois accompagnée d'une fuite tricuspide (par dilatation de l'anneau) (9). Pour les cas les plus graves, une dysfonction ventriculaire gauche peut s'associer à la dysfonction du VD (10). Vraisemblablement, cette fuite pulmonaire est également un des principaux trigger des troubles du rythme (ventriculaires et supra-ventriculaires) et de la mort subite (11, 12), chez les adultes avec TF réparée. La valvulation pulmonaire est donc une option thérapeutique logique pour stopper ces mécanismes de décompensation chez les patients avec TF réparée.

[Ce que l'on sait de la valvulation pulmonaire :](#)

La valvulation pulmonaire permet de stopper la fuite pulmonaire. Elle améliore ainsi la dysfonction du VD (13) et elle améliore la symptomatologie des patients, en améliorant leur capacité fonctionnelle à l'effort (14). L'amélioration des volumes ventriculaires droits (télé-diastolique et télé-systolique), ainsi que la fonction du VD, est limitée quand les volumes du VD ont atteint une taille critique en pré-opératoire ; 90% des patients avec un volume VD télé-diastolique <170ml/m<sup>2</sup> en pré-opératoire auront des volumes VD normaux en postopératoire, ce qui ne sera le cas pour aucun patient avec un volume VD télé-diastolique préopératoire >170ml/m<sup>2</sup> (15).

Bien que le RVP soit l'acte chirurgical le plus souvent réalisé chez les patients avec TF réparée (16), le timing de cette opération (quand la réaliser ?) et les effets positifs de cette opération restent controversés notamment en ce qui concerne l'amélioration de la survie. Aucune série ne retrouve une amélioration nette de celle-ci chez les patients après valvulation pulmonaire. Une étude, basée sur le suivie de 2 groupes d'adultes avec TF réparée (un groupe avec et un groupe sans valvulation pulmonaire), ne retrouvait pas de différence entre les deux groupes en ce qui concerne la survenue des morts subites ou des épisodes de tachycardies ventriculaires (17). Dans cette même étude, il n'y avait pas non plus de différence dans le changement de la durée du QRS.

Les résultats sont également controversés en ce qui concerne l'effet de la valvulation pulmonaire sur la survenue des arythmies ventriculaires. Une série montrait une diminution des tachycardies ventriculaires (TV) de 23% à 9% après valvulation (18), alors qu'une autre série montrait une absence de diminution de l'incidence des TV et des morts subites dans 2 groupes appariés avec et sans valvulation (19). De même les résultats sont contradictoires en ce qui concerne la durée du QRS avec soit une diminution après valvulation (20), soit une diminution transitoire avant nouvel allongement (21) ou au mieux une stabilisation (18).

Les données de la littérature sont donc contradictoires. Si une amélioration fonctionnelle correspondant à une amélioration des volumes du VD paraît démontrée, l'amélioration de la fonction du VD (fraction d'éjection) est déjà moins claire (22, 23) ; ce qui précède reste conditionné au fait de ne pas opérer trop tard (24). Une amélioration en ce qui concerne la survie et la survenue des arythmies n'est pas encore aujourd'hui démontrée. La valvulation pulmonaire n'est donc à l'heure actuelle qu'une intervention fonctionnelle.



Rappel : recommandations concernant les indications de valvulation pulmonaire (15, 25) :

- Insuffisance pulmonaire (IP) sévère avec des symptômes cliniques
- ou dysfonction du VD ou dilatation du VD à l'IRM (>170 ml/m<sup>2</sup> de volume télé-diastolique du VD) + IP sévère
- ou arythmies supra-ventriculaires ou ventriculaires + IP sévère
- ou diminution de la capacité à l'effort objectivée par à l'épreuve d'effort + IP sévère
- ou aggravation d'une fuite tricuspide + IP sévère
- ou durée du QRS > 180 msec + IP sévère

Choix d'une prothèse valvulaire :

La valvulation pulmonaire étant une chirurgie fonctionnelle, « non vitale », le choix d'une prothèse et de sa durabilité devient crucial, surtout si cette prothèse doit être implantée précocement pour obtenir les meilleurs résultats possibles sur la fonction et les volumes du VD.

Différents substituts valvulaires ont été utilisés pour réaliser un RVP: des homogreffes pulmonaires (14, 26), des conduits valvés biologiques (27) ou différents type de bioprothèses (péricardiques ou porcines) mises en position orthotopique (avec élargissement de la partie antérieure de la voie de sortie du VD par un patch de Gore-Tex ou par un patch hétérologue) (22, 28). Certaines équipes ont pu utiliser des valves mécaniques pour réaliser la valvulation pulmonaire (29) ; le but était d'obtenir une valvulation « définitive » chez ces patients multi-opérés, pour éviter d'autres interventions, mais avec des risques de thrombose de valve ou d'hémorragie liés au traitement anticoagulant au long cours.

Peu de différences sont retrouvées en ce qui concerne les résultats : tous les substituts « biologiques » sont efficaces pour diminuer la fuite pulmonaire et améliorer la fonction et les volumes ventriculaires droits ; la question de la durabilité du résultat, qui est crucial, n'est toujours pas résolue : aucun substitut n'ayant montré une supériorité par rapport à l'autre. En effet, une série récente (22), insiste sur le caractère palliatif et temporaire de la valvulation pulmonaire, car après une phase d'amélioration de la fonction et des volumes du VD en postopératoire immédiat, une altération

des résultats a lieu quelques années après la chirurgie (7 à 10 ans), avec un remodellement négatif du VD lié à une dégénérescence, même modeste, de la bioprothèse (sur le mode de la sténose, de la fuite ou des 2 processus réunis).

**Comme beaucoup d'équipes travaillant sur les adultes avec TF réparée, nous avons cherché à évaluer les résultats d'une bioprothèse non stentée : la valve biologique Freestyle (Medtronic, Minneapolis, MN) utilisée en position pulmonaire.** (Cf ; en annexe : *Ramanan S, Doll N, Boethig D, Tafer N, Horke A, Roques X, Hemmer WB, Roubertie F. Pulmonary-Valve Replacement in Adults: Results With the Medtronic Freestyle Valve. Ann Thorac Surg. 2015;100:1047-53*).

#### 4.2.2 Résultats

Le choix d'implanter cette bioprothèse était lié au fait de son utilisation fréquente dans le service de chirurgie cardiaque adulte du CHU de Bordeaux, pour réaliser des remplacements valvulaires aortiques associés à un remplacement de l'aorte ascendante (intervention de Bentall). Les résultats à Bordeaux, comme dans d'autres équipes, étaient très bons, équivalents à ceux des homogreffes aortiques, avec des profils hémodynamiques supérieurs aux bioprothèses stentées (30), et avec d'excellents résultats à 10 ans (31). Ces bons résultats sur la voie d'éjection gauche nous ont conduit à utiliser cette prothèse pour valver la voie d'éjection du VD. Le régime de pression du VD étant inférieur à celui du ventricule gauche, une durabilité augmentée de la bioprothèse pouvait être attendue. Les publications concernant l'utilisation de cette bioprothèse pour valver le VD étaient par ailleurs rares, et avec des résultats contradictoires (32-35).

Pour donner plus de poids à notre étude, nous avons mené une étude bi-centrique (Bordeaux et Stuttgart), avec 115 patients enrôlés (52 Fallot et 63 Ross), ayant tous eu une valve Freestyle implantée comme conduit valvé en position orthotopique sur la voie de sortie du VD. Pour ce travail, j'ai donc été amené à encadrer le docteur Ramanan (chirurgien cardiaque pédiatrique d'origine indienne), lauréate du prix Francis Fontan (bourse d'1 an à l'étranger pour parfaire une formation en chirurgie cardiaque pédiatrique), décerné par l'EACTS (European Association for Cardio-Thoracic

Surgery). Le Dr Ramanan a passé 6 mois dans le service, après avoir passé 6 mois en Allemagne à Hannovre.

En ce qui concerne les adultes avec TF réparée, les résultats de la bioprothèse Freestyle ont été bons: pas de thrombose et un seul cas d'endocardite traité médicalement, avec une évolution favorable. Le taux de survie était de 96.1% à 1 et 5 ans. Le gradient de pic systolique échographique à la sortie de l'hôpital et à moyen terme (3 ans) était de 14.4 +/- 5.1 et 18.9 +/- 5.8 mm Hg, respectivement. L'absence de sténose significative (gradient de pic >50mmhg) était de 96.2% à 3 ans et 5 ans. L'absence de régurgitation significative (modérée ou sévère) était de 96.2% et 94.2% à 3 ans et 5 ans.

Deux patients avec un gradient > 50 mmhg ont été réopérés, à 13 et 26 mois postopératoire, avec mise en place d'une nouvelle bioprothèse Freestyle dans un cas et mise en place d'une valve par voie endo-vasculaire Melody (Medtronic) pour l'autre cas. Aucune des valves Freestyle explantées ne présentait des signes de calcifications ou de dégénérescence des feuillets valvulaires. Au total 9 reinterventions ont été effectuées (2 chez les patients avec TF réparée et 7 chez les Ross) pour sténose de la bioprothèse Freestyle. Le mécanisme de dysfonction de la bioprothèse était lié à une obstruction fibreuse (équivalent d'un pannus) située à la ligne de suture proximale d'implantation de la valve. Nous avons pu mettre en évidence que l'implantation directe de la bioprothèse sur l'ostium du VD était un facteur de risque de reintervention ( $p=0.01$  en analyse multi-variée); la mise en place d'un patch, en péricarde hétérologue, servant d'élargissement de l'hémi-circonférence antérieure de la suture proximale était au contraire protecteur de sténose valvulaire. Le mécanisme supposé est une discongruence entre la collerette de suture de la Freestyle, à la fois fine et assez rigide, et l'ostium du VD, qui est très souvent large ; la suture directe crée des turbulences hémodynamiques conduisant à la formation d'un pannus.

### 4.2.3 Conclusion

La bioprothèse Freestyle a montré des résultats qui semblent équivalents à ceux des bioprothèses stentées en ce qui concerne la durabilité. Le diamètre de l'orifice efficace d'une Freestyle

est supérieure de 2 à 4 mm par rapport à celui d'une bioprothèse stentée lié à l'élimination du stent (36). Les bioprothèses Freestyle sont donc une alternative intéressante pour la valvulation pulmonaire. La possibilité récemment décrite et relativement aisée en cas de dégénérescence, de mise place d'une valve Melody par voie percutanée à l'intérieur des ces prothèses, les rendent encore plus attractives (37, 38).

Nous continuerons à suivre cette cohorte de patients pour valider les résultats de cette bioprothèse sur le long terme.

#### 4.2.4 Références

1. Roest AA, Helbing WA, Kunz P, et al. Exercise MR imaging in the assessment of pulmonary regurgitation and biventricular function in patients after tetralogy of Fallot repair. *Radiology* 2002;223:204–211.
2. Singh GK, Greenberg SB, Yap YS, et al. Right ventricular function and exercise performance late after primary repair of tetralogy of Fallot with the transannular patch in infancy. *Am J Cardiol* 1998;81:1378–1382.
3. Cramer JW, Ginde S, Hill GD, et al. Tricuspid repair at pulmonary valve replacement does not alter outcomes in tetralogy of Fallot. *Ann Thorac Surg* 2015;99:899-904.
4. Ramanan S, Doll N, Boethig D, et al. Pulmonary-Valve Replacement in Adults: Results With the Medtronic Freestyle Valve. *Ann Thorac Surg.* 2015;100:1047-53.
5. Bacha EA, Scheule AM, Zurakowski D, et al. Long-term results after early primary repair of tetralogy of Fallot. *J Thorac Cardiovasc Surg* 2001;122:154–161
6. Kirklin JK, Kirklin JW, Blackstone EH, *et al.* Effect of transannular patching on outcome after repair of tetralogy of Fallot. *Ann Thorac Surg* 1989;48:783–791
7. Horneffer PJ, Zahka KG, Rowe SA, *et al.* Long-term results of total repair of tetralogy of Fallot in childhood. *Ann Thorac Surg* 1990;50:179–183; discussion 183–185.
8. Carvalho JS, Shinebourne EA, Busst C, et al. Exercise capacity after complete repair of tetralogy of Fallot: deleterious effects of residual pulmonary regurgitation. *Br Heart J* 1992;67:470–473.

9. Therrien J, Marx GR, Gatzoulis MA. Late problems in tetralogy of Fallot - recognition, management and prevention. *Cardiol Clin.* 2002;3:395–340.
10. Frigiola A, Redington AN, Cullen S, et al. Pulmonary regurgitation is an important determinant of right ventricular contractile dysfunction in patients with surgically repaired tetralogy of Fallot. *Circulation* 2004;110(Suppl 1):II153–157.
11. Gatzoulis MA, Till JA, Redington A et al. Depolarization and repolarization inhomogeneity after repair of tetralogy of Fallot. The substrate for malignant ventricular tachycardia. *Circulation.* 1995;92:231–237.
12. Gatzoulis MA, Balaji S, Webber SA, et al. Risk factors for arrhythmias and sudden death in repaired tetralogy of Fallot; a multi-centre study. *Lancet.* 2000;356:975–981.
13. Discigil B, Dearani JA, Puga FJ, et al. Late pulmonary valve replacement after repair of tetralogy of Fallot. *J Thorac Cardiovasc Surg* 2001;121:344–351.
14. Eyskens B, Reybrouck T, Bogaert J, et al. Homograft insertion for pulmonary regurgitation after repair of tetralogy of Fallot improves cardiorespiratory exercise performance. *Am J Cardiol* 2000;85:221–225.
15. Therrien J, Provost Y, Merchant N, et al. Optimal timing for pulmonary valve replacement in adults after tetralogy of Fallot repair. *Am J Cardiol* 2005;95:779–782.
16. Hawkins JA, Sower CT, Lambert LM, et al. Stentless porcine valves in the right ventricular outflow tract: improved durability? *Eur J Cardiothorac Surg* 2009;35:600–5.

17. Gengsakul A, Harris L, Bradley TJ, *et al.* The impact of pulmonary valve replacement after tetralogy of Fallot repair: a matched comparison. *Eur J Cardiothorac Surg* 2007;32:462–468.
18. Therrien J, Siu SC, Harris L, *et al.* Impact of pulmonary valve replacement on arrhythmia propensity late after repair of tetralogy of Fallot. *Circulation* 2001;103:2489–2494.
19. Harrild DM, Berul CI, Cecchin F, *et al.* Pulmonary valve replacement in tetralogy of Fallot: impact on survival and ventricular tachycardia. *Circulation* 2009;119:445–451.
20. van Huysduynen BH, van Straten A, Swenne CA, *et al.* Reduction of QRS duration after pulmonary valve replacement in adult Fallot patients is related to reduction of right ventricular volume. *Eur Heart J* 2005;26:928–932.
21. Oosterhof T, Vliegen HW, Meijboom FJ, *et al.* Long- term effect of pulmonary valve replacement on QRS duration in patients with corrected tetralogy of Fallot. *Heart* 2007;93:506–509.
22. Hallbergson A, Gauvreau K, Powell AJ, Geva T. Right ventricular remodeling after pulmonary valve replacement: early gains, late losses. *Ann Thorac Surg* 2015;99:660-666.
23. Ferraz Cavalcanti PE, Sa MPBO, Santos CA, *et al.* Pulmonary valve replacement after operative repair of tetralogy of fallot: meta-analysis and meta-regression of 3,118 patients from 48 studies. *J Am Coll Cardiol* 2013;62:2227–43.
24. Therrien J, Siu SC, McLaughlin PR, *et al.* Pulmonary valve replacement in adults late after repair of tetralogy of Fallot: are we operating too late? *J Am Coll Cardiol.* 2000;36:1670 –1675.
25. Geva T: Indications and timing of pulmonary valve replacement after tetralogy of Fallot repair. *Semin Thorac Cardiovasc Surg Pediatr Card Surg Annu* 2006:11-22.

26. Ghez O, Tsang VT, Frigiola A, et al. Right ventricular outflow tract reconstruction for pulmonary regurgitation after repair of tetralogy of Fallot. Preliminary results. *Eur J Cardiothorac Surg* 2007;31:654–8.
27. Champsaur G, Robin J, Curtil A, et al. Long-term clinical and hemodynamic evaluation of porcine valved conduits implanted from the right ventricle to the pulmonary artery. *J Thorac Cardiovasc Surg* 1998;116:793–804.
28. Homann M, Haehnel JC, Mendler N, et al. Reconstruction of the RVOT with valved biological conduits: 25 years experience with allografts and xenografts. *Eur J Cardiothorac Surg* 2000;17:624–630.
29. Deorsola L, Abbruzzese PA, Aidala E, et al. Pulmonary valve replacement with mechanical prosthesis: long-term results in 4 patients. *Ann Thorac Surg* 2010;89:2036–2038.
30. Melina G, Mitchell A, Amrani M, Khaghani A, Yacoub MH. Transvalvular velocities after full aortic root replacement: results from a prospective randomized trial between the homograft and the Medtronic Freestyle bioprosthesis. *J Heart Valve Dis* 2002;11:54–8.
31. Mohammadi S, Baillet R, Voisine P, Mathieu P, Dagenais F. Structural deterioration of the Freestyle aortic valve: mode of presentation and mechanisms. *J Thorac Cardiovasc Surg* 2006;132:401–6.
32. Novick WM, Anic D, Lora Solf A, et al. Medtronic Freestyle valve for right ventricular reconstruction in pediatric Ross operations. *Ann Thorac Surg* 2004;77:1711–26.



33. Hartz RS, Deleon SY, Lane J, et al. Medtronic freestyle valves in right ventricular outflow tract reconstruction. *Ann Thorac Surg* 2003;76:1896–900.
34. Kanter KR, Fyfe DA, Mahle WT, Forbess JM, Kirshbom PM. Results with the freestyle porcine aortic root for right ventricular outflow tract reconstruction in children. *Ann Thorac Surg* 2003;76:1889–95.
35. Erek E, Yalcinbas YK, Salioglu E, et al. Fate of stentless bio-prostheses on right side of the heart. *Asian Cardiovasc Thorac Ann* 2003;11:58–62.
36. Park SZ, Reardon MJ. Current status of stentless aortic xenografts. *Curr Opin Cardiol* 2000;15:74–81.
37. Miskovic A, Monsefi N, Doss M, Ozaslan F, Karimian A, Moritz A. Comparison between homografts and Freestyle bioprosthesis for right ventricular outflow tract replacement in Ross procedures. *Eur J Cardiothorac Surg* 2012;42:927–33.
38. Bonhoeffer P, Boudjemline Y, Saliba Z et al. Transcatheter implantation of a bovine valve in pulmonary position: a lamb study. *Circulation*. 2000;102:813– 816.

#### 4.2.5 Perspectives cliniques suite à ce deuxième travail : concernant le substitut valvulaire à utiliser pour le RVP

La problématique du choix d'une valve en position pulmonaire est la même que pour n'importe quelle autre valve : l'idéal est d'avoir à disposition une valve qui ne nécessite pas d'anticoagulant au long cours, facilement disponible, et dont les propriétés restent stables dans le temps et si possible peu onéreuse. Malheureusement, cet idéal n'existe pas.

Les différentes valves biologiques (stentées ou non stentées), utilisées en position pulmonaire, ont toutes montré des résultats acceptables à moyen terme. Globalement, 10 ans après la valvulation pulmonaire, l'absence de re-intervention sur la voie pulmonaire était de 85% (1, 2), et de 75% à 15 ans (2). Une hypothétique durabilité augmentée, par leur positionnement sur la voie pulmonaire due à un régime de pression plus bas par rapport à leur positionnement au niveau valvulaire aortique, reste à démontrer (3). La possibilité de pouvoir implanter une valve percutanée, à l'intérieur des bioprothèses ou des homogreffes, a diminué les craintes sur leur durabilité. Malgré tout, toutes ces valves biologiques restent par nature palliatives. On a vu que la fuite pulmonaire était l'élément de décompensation principal chez les patients avec TF réparée. La valvulation pulmonaire a pour but de stopper cette fuite pulmonaire ; mais une dégénérescence de la bioprothèse, à priori même modérée, peut entraîner un remodellement négatif du VD et donc être en elle-même un facteur de décompensation.

Les homogreffes pulmonaires, utilisées pour le RVP lors de l'intervention de ROSS, ont de très bons résultats : avec une absence de dysfonction de l'homogreffe nécessitant une re-intervention de 94% à 8 ans de suivi (4), avec une majorité d'enfants dans la série. Toujours pour le Ross, les homogreffes pulmonaires sont supérieures aux bioprothèses (5). La disponibilité des homogreffes reste une problématique majeure, non encore résolue en France. Cette problématique reste vraie, y compris aux Etats-Unis, où elles sont utilisées dans moins 10% des cas de valvulation pulmonaire chez les adultes avec TF réparée (2). Pourtant, comme pour l'intervention de Ross, elles semblent montrer de meilleurs résultats par rapport aux autres substituts valvulaires (bioprothèses péricardiques surtout) (2).

Une très forte volonté locale Bordelaise, impulsée par l'arrivée du Professeur Kreitmann, cherche à améliorer cette disponibilité : un travail de fond a été mené auprès de la banque de tissus de Bordeaux pour **relancer un processus de prélèvement actif des homogreffes pulmonaires** en partenariat avec d'autres CHU (Limoges et Poitiers) et d'autres CHG de la région.

Dans l'avenir nous espérons pouvoir réaliser la majorité des valvulations pulmonaires en utilisant des homogreffes pulmonaires. Nous prévoyons dans 5 ans d'évaluer les résultats des homogreffes pulmonaires utilisées pour le RVP chez les adultes avec TF réparée, afin de confirmer ou pas, les bons résultats publiés sur de petites séries de malade (6).

Nous chercherons par ailleurs à mettre en place **une étude de type PHRC**, en ce qui concerne les valvulations pulmonaires effectuées chez des patients avec dysfonction bi-ventriculaire. La resynchronisation a montré un intérêt en phase aigüe chez les patients avec TF réparée (7). Les patients avec dysfonction bi-ventriculaire ont souvent un asynchronisme intraventriculaire droit et gauche et un asynchronisme interventriculaire ; un bloc de branche droit est très souvent associé dans ce contexte. Le resynchronisation (par voie chirurgicale), associée à une chirurgie de RVP, semble être une alternative intéressante pour les patients avec dysfonction bi-ventriculaire au moment du RVP : une étude multicentrique est le seul moyen d'inclure « rapidement » un nombre conséquent de patients pour juger de l'efficacité de cette stratégie.

## 4.2.6 Références

1. Yemets IM, Williams WG, Webb GD, et al. Pulmonary valve replacement late after repair of tetralogy of Fallot. *Ann Thorac Surg.* 1997;64:526-30.
2. Sabate Rotes A, Eidem BW, Connolly HM, et al. Long-term follow-up after pulmonary valve replacement in repaired tetralogy of Fallot. *Am J Cardiol.* 2014;114:901-8.
3. Fukada J, Morishita K, Komatsu K, et al. (1997) Influence of pulmonic position on durability of bioprosthetic heart valves. *Ann Thorac Surg.* 64, 1678–1680; discussion 1680–1681.
4. Elkins RC, Knott-Craig CJ, Ward KE, et al. (1998) The Ross operation in children: 10-year experience. *Ann Thorac Surg* 65, 496–502.
5. Miskovic A, Monsefi N, Doss M, Ozaslan F, Karimian A, Moritz A. Comparison between homografts and Freestyle bioprosthesis for right ventricular outflow tract replacement in Ross procedures. *Eur J Cardiothorac Surg* 2012;42:927–33.
6. d’Udekem Y, Rubay J, Shango-Lody P, et al. (1998) Late homograft valve insertion after transannular patch repair of tetralogy of Fallot. *J Heart Valve Dis* 7, 450–454.
7. Thambo JB, Dos Santos P, De Guillebon M, Roubertie F et al ; Biventricular stimulation improves right and left ventricular function after tetralogy of Fallot repair: acute animal and clinical studies. *Heart Rhythm.* 2010;7:344-50.

# Pulmonary-Valve Replacement in Adults: Results With the Medtronic Freestyle Valve

Sowmya Ramanan, MRCSEd, MCh, Nicolas Doll, MD, Dietmar Boethig, MD, PhD, Nadir Tafer, MD, Alexander Horke, MD, Xavier Roques, MD, PhD, Wolfgang Bruno Hemmer, MD, and François Roubertie, MD

Departments of Cardiovascular Surgery, and Cardiac Anesthesiology, Bordeaux Heart University Hospital, University of Bordeaux II, Bordeaux, France; Department of Cardiac Surgery, Sana Cardiac Surgery Stuttgart GmbH, Stuttgart, Germany; and Department of Cardiothoracic, Transplantation, and Vascular Surgery, Hannover Medical School, Hannover, Germany

**Background.** We used the Medtronic Freestyle valve (Medtronic, Minneapolis, MN) as an orthotopic conduit in pulmonary valve replacement in repaired tetralogy of Fallot and as part of the Ross procedure. Midterm outcomes and hemodynamic status of this conduit were analyzed and performances in both subgroups were compared.

**Methods.** From February 2002 to July 2012, 115 Freestyle valves were implanted in 52 patients with tetralogy of Fallot and 63 patients within the Ross procedure. Preoperative and perioperative data were reviewed retrospectively in this bicentric study.

**Results.** Mean age at valve surgery was  $37 \pm 13$  years. Median implanted valve size was 27 mm (21 to 29). Early postoperative mortality was 3.48%. There was 100% follow-up for the survivors at a mean of  $4.38 \pm 2.52$  years. There was 1 case of thromboembolism (0.89%), 6 endocarditis (5.4%), and 9 (7.8%) conduit re-interventions.

Echocardiography at discharge and last follow-up showed average peak systolic transvalvular gradients of  $12.4 \pm 5.1$  and  $18.7 \pm 8.8$  mm Hg, respectively. Ten patients had significant proximal anastomotic gradients of greater than 50 mm Hg and 4 moderate conduit regurgitations. Survival was 96.52%. No valve degeneration was seen in 87.82% at 5 years. The only risk factor identified for valve re-intervention was conduit implantation without infundibular hood ( $p = 0.01$  in multivariate analysis).

**Conclusions.** Mid-term data show that Freestyle valves are well suited for pulmonary valve replacement in adults in both categories. The surgical technique used in valve implantation is important to ensure conduit durability. These results and accessibility to the Freestyle valve make this an acceptable alternative to homografts.

(Ann Thorac Surg 2015;100:1047–53)

© 2015 by The Society of Thoracic Surgeons

Pulmonary valve replacement (PVR) in cases of repaired tetralogy of Fallot (TOF) or as part of the Ross procedure are the most common surgical procedures in the right ventricular outflow tract (RVOT) in adults [1].

Stentless bioprosthesis resemble aortic homografts and offer a better hemodynamic profile when used for aortic valve replacement in adults [2]. Various stentless bioprosthesis, such as the TorontoSPV (St. Jude Medical, St. Paul, MN) [3] or Edwards Prima Plus valves (Edwards LifeSciences Corporation, Irvine, CA) [1], when used for RVOT reconstruction in young adults and children, have shown excellent intermediate term durability. The Medtronic Freestyle valve (Medtronic, Minneapolis, MN) has been rarely used as RVOT conduits and has produced mixed results [4–9]. However, its promising results in the aortic position prompted us to analyze its usage in RVOT reconstruction, in adults. We evaluated the midterm outcomes and hemodynamic status of this stentless valve

conduit, when used for RVOT reconstruction in the Ross procedure or for PVR in adult repaired TOF.

## Patients and Methods

### Study Population

Retrospective data were collected on all adult patients who had a Medtronic Freestyle valve implanted during PVR after repaired TOF (and equivalents) or a Ross procedure. A total of 115 patients underwent this procedure in Bordeaux Heart University Hospital and Sana Cardiac Surgery Stuttgart GmbH, between February 2002 and July 2012. The surgeries included 63 Ross procedures and 52 cases of TOF. Patients who received a valved conduit during initial correction of TOF and pulmonary atresia were excluded from this study.

### Indications for Pulmonary Valve Replacement in the Adult Tetralogy of Fallot Group

The PVR was considered according to the guidelines recommended by Geva and colleagues [10]. Diagnoses included repaired TOF with severe pulmonary regurgitation (PR) or mixed lesions with moderate stenosis. All

Accepted for publication May 1, 2015.

Address correspondence to Dr Roubertie, Department of Cardiovascular Surgery, Haut Lévêque Hospital, 1 Av Magellan, 33600 Pessac, France; e-mail: francois.roubertie@chu-bordeaux.fr.

cases were reoperations, except for 1 case of TOF with an absent pulmonary valve.

#### *Indications for Surgery in the Adult Ross Group*

Indications were aortic stenosis, regurgitation, or mixed lesions. All patients were operated on electively.

#### *Data Collection and Follow-Up*

Perioperative data were collected from the hospital records and details were pooled in the RVOT registry (Hannover Medical School) for combined analyses. Data were collected between May and July 2014. The duration of the follow-up was defined as the period between surgery and the last clinical visit. Institutional review boards at both hospitals approved the study. Informed written consent was obtained from all included patients. All patients were closely followed up in 2 referring centers (Bordeaux and Stuttgart) with at least 1 annual visit obtaining clinical details and serial echocardiography. No patients were lost to follow-up.

#### *Preoperative Variables*

All data were retrieved from medical records. Past medical history, and demographic and anatomic data were systematically reviewed.

**THE TOF GROUP.** Preoperative assessment consisted of echocardiographic measurement of PR, ventricular function, and the peak echocardiography gradient by pulse-wave Doppler. Patients without a previously implanted pacemaker ( $n = 3$ ) underwent cardiac magnetic resonance imaging.

**THE ROSS GROUP.** Transthoracic echocardiography was used to evaluate aortic and pulmonary valves before the Ross procedure. Patients with a previous cardiac surgery underwent CT scan.

#### *Operative Variables and Details*

**THE TOF GROUP.** Closure of residual atrial or ventricular septal defects was realized with aortic cross-clamping (ACC) and warm-blood cardioplegia. Isolated PVR and pulmonary branch stenosis arterioplasty or resections of right infundibular aneurysm were performed on the beating heart.

**THE ROSS GROUP.** The surgical technique used has been described in detail previously [11–13]. Patients received a freestanding aortic root replacement without or with autograft reinforcement.

#### *Technique Used for Freestyle Valve Implantation*

First, the pulmonary bifurcation and left and right pulmonary branches were dissected free. The distal main pulmonary artery was transected just proximal to the bifurcation. The xenograft was first anastomosed in an end-to-end fashion to the pulmonary confluence using a continuous polypropylene suture. Length adjustment was rarely necessary and, when needed, the conduit was trimmed distally to reduce the height of the prosthesis.

Two different techniques were employed for the proximal anastomosis, based on surgeon preference,

without a time difference in the use of these techniques. In 57 cases the posterior margin of the proximal Freestyle valve was anastomosed to the leading edge of the RVOT using continuous polypropylene sutures. The proximal RVOT was reconstructed anteriorly with a hood made from a glutaraldehyde-treated autologous pericardial patch. This patch was implanted along the anterior rim of the proximal Freestyle valve and was used as a “gusset” to close over the anterior part of the RVOT. In 58 cases, proximal anastomosis of the conduit to the leading edge of the RVOT was performed directly without an anterior infundibular hood.

#### *Postoperative Variables*

A transthoracic echocardiography was performed before discharge and at various intervals after discharge. Routine postoperative antiplatelet therapy was given for the initial 3 months. In the TOF group, postoperative cardiac magnetic resonance imaging was carried out at 1 year postoperatively in 44 patients, excluding 6 patients with pacemaker implants.

#### *Definitions*

Functional status was determined according to New York Heart Association functional class. Early postoperative death was defined as any death that occurred within 30 days of surgery or during the same hospital admission. Overall mortality was defined as death occurring from the time of surgery to the most recent follow-up [14].

Significant stenosis of the conduit was defined as a trans-valvular or trans-anastomotic gradient of greater than 50 mm Hg measured along the conduit by pulsed-wave Doppler. The PR was graded as none (grade 0), mild (grade 1), moderate (grade 2), or severe (grade 3) by Doppler echocardiography. Significant regurgitation was defined as moderate or severe valve insufficiency.

Valve degeneration was defined as significant conduit valve stenosis (peak gradient 50 mm Hg or more), significant regurgitation, or a combination of both. Valve re-intervention was defined as any reoperation or catheter-based re-intervention that replaced a dysfunctional valve or transcatheter pulmonary valve implantation. The indication for re-intervention was a gradient of greater than 50 mm Hg or severe regurgitation with RV dysfunction.

Valve re-intervention was defined as any reoperation or catheter-based re-intervention that replaced a dysfunctional valve or transcatheter pulmonary valve implantation. The indication for re-intervention was a gradient of greater than 50 mm Hg or severe regurgitation with RV dysfunction.

#### *Statistical Analysis*

Statistical analyses were carried out using SPSS 21 (SPSS Inc, Chicago, IL). The follow-up data on survival, reoperation, re-intervention, and conduit function were analyzed using standard Kaplan-Meier analyses, with a log-rank test. Nonparametric, binomial, and descriptive statistics were computed, as appropriate. Descriptive data for continuous variables are reported as medians, ranges,

**Table 1. Operative Demographic Data, Hemodynamic Performance, and Outcome of the Freestyle Valve Conduit at Midterm in Adult Tetralogy of Fallot (TOF) and Ross Groups, Considering Surgical Technique Used at Valve Implantation**

| Variable                                  | Ross<br>(n = 63)    | TOF<br>(n = 52)    |
|---|---------------------|--------------------|
| Mean age (years)                          | 42.3 ± 14.2 (17-68) | 31 ± 11.92 (16-64) |
| Median conduit diameter (mm)              | 27 (25-29)          | 25 (21-29)         |
| Mean peak gradient <sup>a</sup> (mm Hg)   | 17.7 ± 10.9 (4-122) | 18.9 ± 5.8 (5-90)  |
| Freedom from re-intervention <sup>b</sup> | 88.89%              | 96.15%             |
| With infundibular patch (n)               | 10                  | 47                 |
| Explants (n)                              | 0                   | 0                  |
| Without infundibular patch (n)            | 53                  | 5                  |
| Explants (n)                              | 7                   | 2                  |

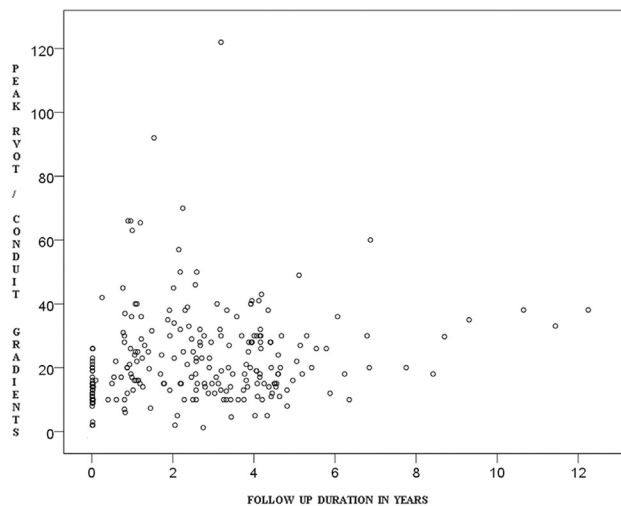
<sup>a</sup> At 3 years follow-up time. <sup>b</sup> At 5 years follow-up time.

and means ± standard deviations. In univariate analysis, the Fisher exact test was used to analyze binary variables. For multivariate analysis, a backward stepwise logistic regression was performed. A *p* value of less than 0.05 was considered statistically significant.

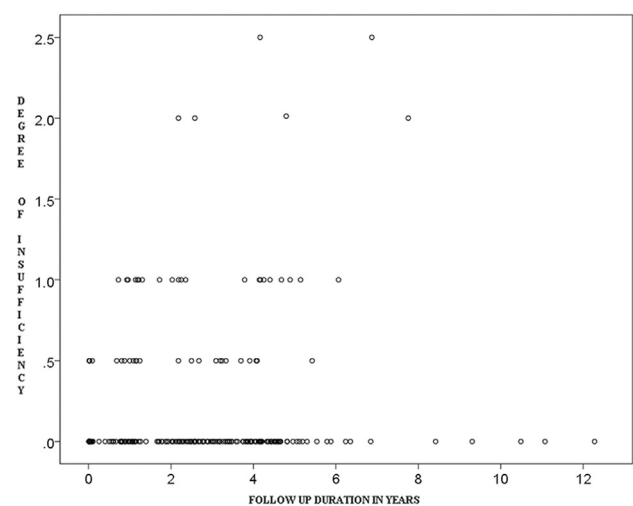
**Results**

The results are summarized in Table 1. Mean age at surgery was 37 ± 13 years (range, 16 to 68). There were 72 males and 43 females. Indications in the TOF group were severe PR (n = 46) or mixed lesions with moderate RVOT stenosis (n = 6). Indications in the Ross group were aortic stenosis (n = 36), regurgitation (n = 6), or mixed lesions (n = 21). Median implanted valve size was 27 (range, 21 to 29). Early postoperative mortality was 3.48%. The follow-up was completed by 100% of the survivors within a mean time of 4.38 ± 2.52 years (range, 0.60 to 12.27). There were no late deaths. There was 1 case of thromboembolism

(0.89%), 6 cases of endocarditis (5.4%), and 9 (7.8%) valve re-interventions during follow-up. Echocardiography at discharge showed mean and peak systolic RVOT gradients of 6.4 ± 3.1 mm Hg and 12.4 ± 5.1 mm Hg, respectively. At echocardiography at 3 years postoperatively, we saw mean and peak systolic RVOT gradients of 12.4 ± 5.1 and 18.7 ± 8.8 mm Hg, respectively (Fig 1). At last follow-up, 10 patients had significant proximal anastomotic gradients of greater than 50 mm Hg. Freedom from significant stenosis was 93% and 91.3%, at 3 and 5 years, respectively. Four survivors had moderate conduit regurgitation (Fig 2). The regurgitation was central, without valve or conduit calcification at echocardiography. Freedom from significant regurgitation was 97.4% and 96.5% at 3 and 5 years. Freedom from valve degeneration was 90.5% and 87.8% at 3 and 5 years. Survival was 96.5% at 1 and 5 years.



**Fig 1. Distribution of peak systolic pressure gradient across the Freestyle valve calculated by transthoracic Doppler echocardiography plotted against the time interval from operation to echocardiographic examination. (RVOT = right ventricle outflow tract.)**



**Fig 2. Distribution of degree of regurgitation across the Freestyle valve calculated by transthoracic Doppler echocardiography plotted against the time interval from operation to echocardiographic examination.**



### The TOF group

Mean age at initial complete correction was 2.8 years (range, 0.1 to 15 years); a transannular patch had been used in 60% of patients. Mean cardiopulmonary bypass time was  $103.5 \pm 54.4$  minutes and mean ACC time in 11 patients was  $71.3 \pm 26$  minutes.

In-hospital mortality in the TOF group was 3.8%. There were 2 early deaths on postoperative days 17 and 45. Both patients had severe RV dysfunction preoperatively that necessitated postoperative extracorporeal life support but died of multiorgan failure in 1 case and septic shock in the other. Mean follow-up for the survivors was  $4.7 \pm 2.2$  years (range, 1.0 to 12.3).

There were no incidences of prosthetic thromboembolism. There was 1 case of Freestyle valve endocarditis, which was treated medically. One patient required orthotopic heart transplantation at 16 months for biventricular heart failure, with a normally functioning Freestyle valve conduit, without any signs of calcification or degeneration at the cardiac explant.

Echocardiography at hospital discharge and at the last follow-up showed average peak systolic RVOT gradients of  $14.4 \pm 5.1$  and  $18.9 \pm 5.8$  mm Hg, respectively. There were 2 patients with peak gradients of greater than 50 mm Hg at the proximal anastomosis. Both required a conduit re-intervention for proximal obstruction at the anastomotic site at 13 and 26 months after initial surgery, with peak gradients of 90 and 70 mm Hg, respectively (a detailed description is given in the Analysis of Explantation section of this article). Freedom from significant stenosis was 96.2% at 3 years and 5 years. There were 3 cases of moderate conduit regurgitation on follow-up. Freedom from significant regurgitation was 96.2% and 94.2% at 3 and 5 years, respectively. Preoperatively, 70% of patients were in New York Heart Association functional class II or greater compared with 18% of patients postoperatively ( $p < 0.001$ ). Freedom from valve degeneration was 100%, 94.2%, and 90.4% at 1, 3, and 5 years, respectively. The overall survival rate was 96.1% at 1 and 5 years.

### The Ross Group

Mean CPB time was  $165 \pm 35$  minutes (range, 130 to 200 minutes) and mean ACC time was  $120 \pm 24$  minutes (range, 96 to 144 minutes). Early postoperative mortality was 3.2%. There were 2 early deaths on postoperative days 5 and 15. Both patients had severe LV dysfunction postoperatively, related to coronary events that necessitated postoperative extracorporeal life support; both failed to recover and ultimately died of multiorgan failure.

Mean follow-up duration was  $4.0 \pm 0.9$  years (range, 0.6 to 6.3). The overall survival rate was 96.8% at 1 and 5 years, respectively. Echocardiography at hospital discharge and at the last follow-up had mean peak systolic RVOT gradients of  $9.4 \pm 6.7$  mm Hg (range, 0 to 71) and  $17.7 \pm 10.9$  mm Hg (range, 0 to 122), respectively.

Eight patients had peak gradients of greater than 50 mm Hg at the proximal anastomosis. Seven conduit

explantations were required between 11 and 40 months after the initial surgery, with peak gradients ranging from 50 to 120 mm Hg. (A detailed description is provided in "Analysis of Explantations".) The proximal anastomotic gradient did not increase further during the follow-up of patients who did not undergo any intervention. Freedom from significant stenosis was 90.4% and 87.3% at 3 years and 5 years.

One patient had moderate conduit regurgitation. Freedom from significant regurgitation was 100% at 3 years and 98.4% at 5 years. There was one case of thromboembolism, in a patient, with pulmonary artery pressure assessed with a Swan-Ganz catheter in the ICU, and 5 cases of endocarditis: all were treated medically.

There was one case of thromboembolism, in a patient, with pulmonary artery pressure assessed with a Swan-Ganz catheter in the ICU, and five cases of endocarditis: all were treated medically.

Freedom from valve degeneration was 95.2%, 90.5%, and 85.7% at 1, 3, and 5 years, respectively. The overall survival rate was 96.8% at 5 years.

### Analysis of Explantation

There were 9 valve-related re-interventions (TOF group, 2; ROSS group, 7) within the group of 58 patients (15.5%) where the conduit had been directly anastomosed to the right infundibulum without an anterior infundibular hood. Discharge echocardiography after the initial surgery showed normal gradients. Eight conduits were replaced; with a homograft ( $n = 7$ ), with a new Freestyle prosthesis with an anterior infundibular hood ( $n = 1$ ), and 1 transcatheter valve implantation (Medtronic Melody).

These procedures were required at a mean of 24 months (range, 11 to 40) after the initial surgery. The postoperative course was uneventful in all patients after the re-intervention. At replacement, the valve conduit itself was unobstructed, with no structural valve deterioration or calcification. Nonstructural dysfunction in the form of a fibrous ridge and excessive tissue in-growth was found under the proximal anastomosis that caused obstruction (Fig 3). Histologic findings were otherwise nonspecific.

There were no explants in the patients where the anterior infundibulum was augmented ( $n = 57$ ); neither was any serial increase in transvalvar gradients noted in this subset. The only factor found associated with risk of reintervention was the absence of an infundibular patch in univariate analysis and logistic multivariate analysis (Table 2). Furthermore, in a backward stepwise logistic regression, the only factor retrieved after 8 iterations was the absence of an infundibular patch.

The only factor found associated with risk of re-intervention was the absence of an infundibular patch in univariate analysis and logistic multivariate analysis (Table 2). Furthermore, in a backward stepwise logistic regression, the only factor retrieved after 8 iterations was the absence of an infundibular patch.

Freedom from explantation in the group with an anterior infundibular hood was 100% at 5 years. In



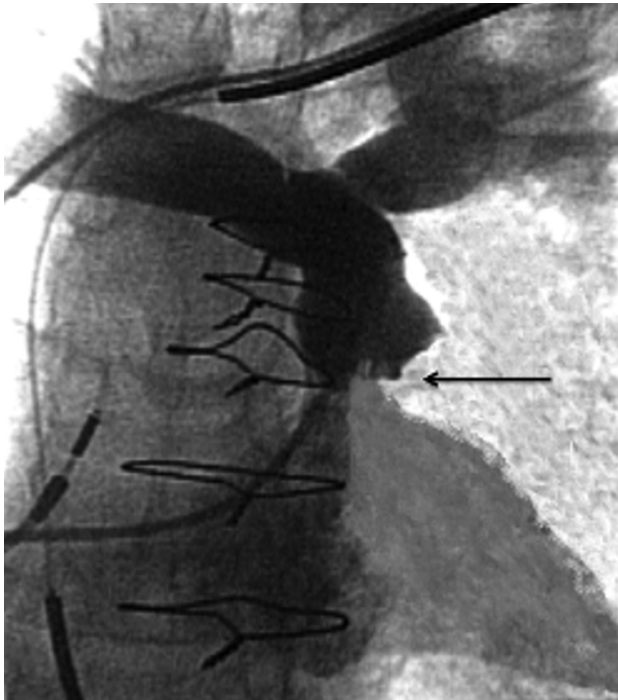

Fig 3. Angiographic image (frontal view) showing infundibular obstruction (arrow) in a case without anterior patch.

comparison, freedom from explantation in the group without an anterior hood was 94.82% at 1 year, 86.2% at 3 years, and 84.48% at 5 years (Fig 4).

### Comment

Historically, a variety of various valve substitutes have been used for PVR in adults, including mechanical [15], xenograft [16, 17], and homograft valves [18], all with varying degrees of success. Homograft valves, considered the gold standard, present with initially good hemodynamic performance but calcify over time and become insufficient when used in RVOT reconstruction [18], and their availability is often limited.

The Medtronic Freestyle valve is a stentless porcine aortic root bioprosthesis, with anti-mineralization treatment to reduce cusp calcification [19]. In a randomized prospective study performed at the Royal Brompton Hospital [2] in adults for aortic-root replacement, the rate of calcification in Freestyle valves was found to be significantly lower than in homografts. Excellent 10-year follow-up results with very low incidences of structural-valve deterioration, in the form of leaflet tears and minimal calcification, were reported when used in the aortic position [20].

The effective orifice area of the selected prosthesis has been reported to be critical in PVR. The recommended acceptable valve area is 1 to 1.3 cm<sup>2</sup>/m<sup>2</sup> or greater [17]. This stentless bioprosthesis provides a physiologically shaped root with normal leaflet coaptation and normal geometry of the sinuses of Valsalva. The effective valve

Table 2. Analysis of Potential Risk Factors for Pulmonary Valve Re-intervention

| Variable                   | p Value Univariate | p Value Multivariate |
|----------------------------|--------------------|----------------------|
| Age at operation           | 0.91               | 0.6                  |
| <25 years                  |                    |                      |
| Between 25 and 32 years    |                    |                      |
| >32 years                  |                    |                      |
| Valve size                 | 0.74               | 0.3                  |
| 21 and 23 mm               |                    |                      |
| 25 mm                      |                    |                      |
| 27 mm                      |                    |                      |
| 29 mm                      |                    |                      |
| Weight at operation        | 0.72               | 0.81                 |
| >80 kg                     |                    |                      |
| <80 kg                     |                    |                      |
| Procedure                  | 0.18               | 0.96                 |
| TOF                        |                    |                      |
| Ross                       |                    |                      |
| Male sex                   | 1                  | 0.72                 |
| Concomitant procedure      | 1                  | 0.52                 |
| Yes                        |                    |                      |
| No                         |                    |                      |
| Previous sternotomies      | 0.65               | 0.88                 |
| None or 1                  |                    |                      |
| 2 or 3                     |                    |                      |
| Without infundibular patch | 0.0027             | 0.01                 |

TOF = tetralogy of Fallot.

orifice size is 2 to 4 mm larger than a stented valve of the same size through elimination of the stent and the accompanying sewing ring [21]. These features contribute to reduced transvalvular gradients and improve hemodynamic performance.

These data (larger orifice area and excellent results when used in the aortic position) make implantation of Freestyle valves, in adults undergoing RVOT, a logical alternative. In the pulmonary circuit, where hemodynamic stress is not as marked as in the left ventricular outflow tract, long-term durability with the Freestyle valve should be expected.

In the literature, available data concerning Freestyle results in RVOT are limited, and mainly presented for children, with discordant results. When used for PVR, for various indications, in the pediatric age group excellent short-term hemodynamic performance was reported for the Freestyle valve in 13 cases [22]. Another series reported that only 1 reoperation was needed after 30 months of follow-up in 56 children [8]. In contrast, other studies have observed a significant increase in peak transvalvular gradients after 21 months of follow-up, with a relatively high incidence of reoperation [23].

Mid-term success was reported when used for RVOT reconstruction in the Ross procedure [4, 6], including pediatric cases [5]. However, these promising results were not confirmed in another study, which showed a

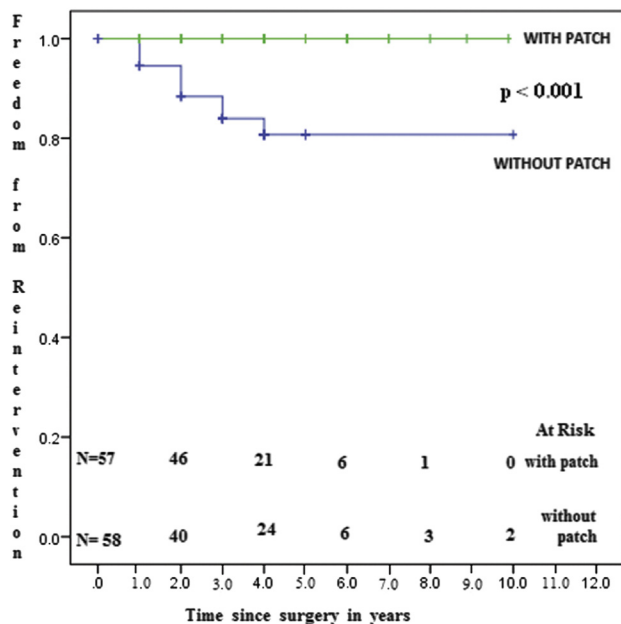


Fig 4. Freedom from Freestyle valve re-intervention in the with, and without, infundibular patch groups.

significantly higher risk of re-intervention compared with pulmonary homograft [9].

In this series, our early mortality rate of 3.48% is comparable with those of other investigators [24]. With respect to the hemodynamic performance of the conduit, results were satisfactory in terms of PR; 96.52% of the patients had no PR at 5 years. We do not have any clear explanation for moderate regurgitation in 4 patients at midterm follow-up time. These patients need to be closely followed to search for increasing or stabilization of valve insufficiency.

Overall freedom from stenosis at 5 years follow-up was 91.3%. The average peak systolic RVOT gradient was  $18.7 \pm 8.8$  mm Hg at 3 years (not statistically different with discharge). This has been already described in 2 studies that mainly involved children, which found no increase in postoperative transvalvular gradients at a mean of 16 months [7] and 2.5 years [8].

Conduit replacements were required in 7.82% in our series, with all interventions performed for proximal anastomotic obstruction, which was caused by a circumferential rim of obstructive neointima or pannus just beneath the valve in patients who did not receive an anterior infundibular hood. This difference between the performance of the conduit in the absence versus presence of an anterior hood was statistically significant ( $p = 0.01$ ). Analysis of the explanted valves did not demonstrate any degeneration or calcification of the valve leaflets or conduit wall. Others authors found that the valves and wall of the bioprosthesis were calcified and that caused RVOT obstruction [9, 23].

Nonstructural dysfunction, caused by fibrous stricture or subvalvular pannus, has been also reported in other series. Miskovic and colleagues [9] explained that the stricture

could be induced by an early post inflammatory reaction and pronounced immunologic response and rejection of the xenograft. The bioprosthetic conduit is also more inflexible and thick when compared with a pulmonary homograft; this may promote proximal anastomosis stenosis. They [9] reported this in 6 patients (8.2%) in a series of 73 adult patients who underwent the Ross procedure. While describing the surgical technique employed, they reported that in 19 of the 73 patients an autologous pericardial sleeve was inter-positioned between the proximal end of the stentless xenograft and the RVOT to reduce the risk of torsion-triggered conduit-valve stenosis at the proximal end of the graft. This resulted in encouraging early echocardiographic results between 6 and 12 months. The longer term outcomes for this subset of patients were not reported. They also describe that the specific type of proximal stenosis, when it does not have severe calcification, can be treated with transcatheter balloon angioplasty or stent implantation, which avoids the burden of reoperation for these patients [9]. Other authors [1] obtained a favorable outcome with another stentless bioprosthesis (Edwards Prima Plus valve) when used for PVR with a pericardial patch anterior augmentation. The lack of length of the bioprosthetic valve conduit without an infundibular hood augmentation has already been reported as another explanation for postoperative RVOT stenosis [1, 8].

Drawing inferences from our personal experience and other reported studies, we propose that hemodynamic turbulence at the anastomosis site causes endothelial injury and secondary endothelial proliferation, thus causing delayed localized infundibular obstruction. While performing a direct end-to-end anastomosis there is disproportion between the circumferences of the RV infundibulum and the proximal conduit, even when the conduit is sized accurately for body-surface area. The relatively thick proximal sewing ring, with very little conduit material proximal to the valve leaflets in this design of xenograft conduit, seems to cause turbulence and shrinkage at the proximal anastomosis, especially when used without an infundibular hood. Furthermore, with the hood the Freestyle does not kink and this also keeps the valve component as distal as possible, which avoids compression and distortion once the sternum is closed. This also avoids delayed infundibular obstruction.

The Freestyle bioprosthesis offers several potential advantages. First, it is readily available. The results compare favorably with homografts inserted for PVR [4-6]. Implantation is relatively simple. However, a proximal extension in the form of an anterior hood is necessary on one hand to get the valve into a position that maintains its normal straight orientation without distortion of the valve, and on the other hand to enlarge and reduce shrinkage at the proximal anastomosis.

This study has several limitations inherent to any retrospective study and which limit data collection to variables available in medical records. This study lacked a comparison group (pulmonary homograft or stented biologic valve) to strengthen the midterm results of the stentless valve used in our series with or without an infundibular patch augmentation.

These mid-term data show that the Freestyle valve is well suited for RVOT replacement in adults with a repaired TOF and in Ross procedures, especially when implanted with an anterior infundibular hood. These results and valve availability make this an acceptable alternative to homografts.

## References

1. Hawkins JA, Sower CT, Lambert LM, et al. Stentless porcine valves in the right ventricular outflow tract: improved durability? *Eur J Cardiothorac Surg* 2009;35:600–5.
2. Melina G, Mitchell A, Amrani M, Khaghani A, Yacoub MH. Transvalvular velocities after full aortic root replacement: results from a prospective randomized trial between the homograft and the Medtronic Freestyle bioprosthesis. *J Heart Valve Dis* 2002;11:54–8.
3. Black MD, Ley SJ, Regal A-M, Shaw RE. Novel approach to right ventricular outflow tract reconstruction using a stentless porcine valve. *Ann Thorac Surg* 2008;85:195–8.
4. Bilal MS, Aydemir NA, Cine N, et al. Intermediate-term results of Medtronic freestyle valve for right ventricular outflow tract reconstruction in the Ross procedure. *J Heart Valve Dis* 2006;15:696–701.
5. Novick WM, Anic D, Lora Solf A, et al. Medtronic Freestyle valve for right ventricular reconstruction in pediatric Ross operations. *Ann Thorac Surg* 2004;77:1711–26.
6. Schmid FX, Keyser A, Wiesenack C, Holmer S, Birnbaum DE. Stentless xenografts and homografts for right ventricular outflow tract reconstruction during the Ross operation. *Ann Thorac Surg* 2002;74:684–8.
7. Hartz RS, Deleon SY, Lane J, et al. Medtronic freestyle valves in right ventricular outflow tract reconstruction. *Ann Thorac Surg* 2003;76:1896–900.
8. Kanter KR, Fyfe DA, Mahle WT, Forbess JM, Kirshbom PM. Results with the freestyle porcine aortic root for right ventricular outflow tract reconstruction in children. *Ann Thorac Surg* 2003;76:1889–95.
9. Miskovic A, Monsefi N, Doss M, Özaskan F, Karimian A, Moritz A. Comparison between homografts and Freestyle bioprosthesis for right ventricular outflow tract replacement in Ross procedures. *Eur J Cardiothorac Surg* 2012;42:927–33.
10. Geva T. Indications for pulmonary valve replacement in repaired tetralogy of Fallot: the quest continues. *Circulation* 2013;128:1855–7.
11. Weimar T, Charitos EI, Liebrich M, et al. Quo vadis pulmonary autograft—the Ross procedure in its second decade: a single-center experience in 645 patients. *Ann Thorac Surg* 2014;97:167–74.
12. Böhm JO, Botha CA, Rein JG, Roser D. Technical evolution of the Ross operation: midterm results in 186 patients. *Ann Thorac Surg* 2001;71(5 Suppl):S340–3.
13. Böhm JO, Hemmer W, Rein JG, et al. A single-institution experience with the Ross operation over 11 years. *Ann Thorac Surg* 2009;87:514–20.
14. Akins CW, Miller DC, Turina MI, et al. Guidelines for reporting mortality and morbidity after cardiac valve interventions. *Ann Thorac Surg* 2008;85:1490–5.
15. Shin HJ, Kim YH, Ko JK, Park IS, Seo DM. Outcomes of mechanical valves in the pulmonic position in patients with congenital heart disease over a 20-year period. *Ann Thorac Surg* 2013;95:1367–71.
16. Lee C, Park CS, Lee CH, et al. Durability of bioprosthetic valves in the pulmonary position: long-term follow-up of 181 implants in patients with congenital heart disease. *J Thorac Cardiovasc Surg* 2011;142:351–8.
17. Fiore AC, Rodefeld M, Turrentine M, et al. Pulmonary valve replacement: a comparison of three biological valves. *Ann Thorac Surg* 2008;85:1712–8.
18. Ghez O, Tsang VT, Frigiola A, et al. Right ventricular outflow tract reconstruction for pulmonary regurgitation after repair of tetralogy of Fallot. Preliminary results. *Eur J Cardiothorac Surg* 2007;31:654–8.
19. Gott JP, Pan-Chih, Dorsey LM, et al. Calcification of porcine valves: a successful new method of antimicrobialization. *Ann Thorac Surg* 1992;53:207–16.
20. Mohammadi S, Baillot R, Voisine P, Mathieu P, Dagenais F. Structural deterioration of the Freestyle aortic valve: mode of presentation and mechanisms. *J Thorac Cardiovasc Surg* 2006;132:401–6.
21. Park SZ, Reardon MJ. Current status of stentless aortic xenografts. *Curr Opin Cardiol* 2000;15:74–81.
22. Chard RB, Kang N, Andrews DR, Nunn GR. Use of the Medtronic Freestyle valve as a right ventricular to pulmonary artery conduit. *Ann Thorac Surg* 2001;71(5 Suppl):S361–4.
23. Ereik E, Yalcinbas YK, Salioglu E, et al. Fate of stentless bioprostheses on right side of the heart. *Asian Cardiovasc Thorac Ann* 2003;11:58–62.
24. Discigil B, Dearani JA, Puga FJ, et al. Late pulmonary valve replacement after repair of tetralogy of Fallot. *J Thorac Cardiovasc Surg* 2001;121:344–51.

## 4.3 Troisième travail : nouveaux paramètres échographiques

### d'évaluation des adultes avec TF réparée :

#### 4.3.1 Introduction

Le diagnostic initial de TF est généralement réalisé au moyen de l'échographie cardiaque trans-thoracique ; celle-ci est souvent complétée aujourd'hui, en per-opératoire de la réparation complète, d'une échocardiographie trans-oesophagienne voire d'une échocardiographie épicaudique.

L'association du M-mode, du mode bidimensionnelle et du mode doppler permet une évaluation complète de l'anatomie (1, 2), que ce soit pour la recherche d'une ou plusieurs CIV(s) ou pour l'identification du site prédominant de la sténose ventriculaire droite (sous-valvulaire, valvulaire ou supra-valvulaire pulmonaire). De même, l'échographie permet de détecter, dans la grande majorité des cas, les anomalies de trajets coronaires (3).

Pour le suivi et la surveillance au long cours des patients opérés, l'échographie est globalement moins intéressante; ceci malgré l'apparition de nouvelles modalités, comme l'échographie cardiaque 3D (en trois dimensions), qui semblait prometteuse pour l'évaluation fonctionnelle et morphologique du VD (4).

L'IRM est en effet aujourd'hui le gold standard, en ce qui concerne la surveillance au long cours des patients adultes avec TF réparée, et plus largement des adultes avec CC opérées (5). Plusieurs études ont montré que l'IRM était supérieure à l'échographie, aussi bien en ce qui concerne la mesure des volumes et la mesure de la fonction du VD, que pour l'évaluation de la fuite valvulaire pulmonaire (6-8). Ces mesures IRM servent de références, sur lesquelles sont posées les indications de valvulation pulmonaire, particulièrement chez les patients pauci ou asymptomatiques (9, 10). Par exemple, pour des mesures <45% de la fraction d'éjection du VD à l'IRM, on commence à parler de ventricule droit avec une dysfonction modérée (11). D'autres valeurs seuils IRM existent, comme le diamètre télé-diastolique du VD > à 150 ml/m<sup>2</sup>, qui fait aujourd'hui souvent poser l'indication de RVP.

Nous avons cherché à savoir dans ce travail si l'échographie cardiaque de par sa grande disponibilité, sa facilité d'accès, et son faible coût, pouvait être utilisée comme moyen de surveillance à la place ou en complément de l'IRM pour les patients adultes avec TF réparée. (Cf en annexe : *Selly JB, Iriart X, Roubertie F et al. Multivariable assessment of the right ventricle by echocardiography in patients with repaired tetralogy of Fallot undergoing pulmonary valve replacement: a comparative study with magnetic resonance imaging. Arch Cardiovasc Dis. 2015;108:5-15*).

### 4.3.2 Résultats

Les données échocardiographiques (TAPSE, S'VD mesuré avec le TDI et MPI) n'étaient pas fiables pour évaluer la fonction du VD en pré ou postopératoire. La seule mesure, bien corrélée à l'IRM pour évaluer la fonction VD, était la fraction de raccourcissement de surface.

L'utilisation de l'échographie 3D pour la mesure de la fonction VD montrait une excellente corrélation avec l'IRM en pré et post-opératoire ( $r=0.96$  et  $r=0.98$ , respectivement). L'échographie 3D, utilisée pour la mesure des volumes ventriculaires gauche et droit en pré et post-opératoire, montrait également une excellente corrélation avec l'IRM. Une des limites d'ordre pratique était liée à l'utilisation de l'échographie 3D, puisque celle-ci (liée aux limites de la sonde 3D) n'était utilisable que chez 46% des patients en pré-opératoire et 57% en post-opératoire. Une autre limite était que l'échographie 3D avait tendance à sous-estimer les volumes ventriculaires, liée à la difficulté de mesure de l'infundibulum du VD avec cette technique.

Au total, la fraction de raccourcissement de surface et l'échographie 3D étaient de bons indices diagnostiques de l'altération de la fonction ventriculaire droite.

### 4.3.3 Conclusion :

La surveillance des patients avec TF réparée est multimodale mais l'IRM reste le gold standard. Les paramètres usuels échocardiographiques de mesure de la fonction du VD, essentiellement mesurée à l'entrée du ventricule droit, comme le TAPSE, ne sont pas fiables dans ce contexte. Nous avons validé de nouveaux paramètres échocardiographiques de surveillance qui

peuvent permettre de diminuer la fréquence de réalisation des IRM et donc le coût de la prise en charge globale de ces patients.

La principale limite reste la tendance de l'échocardiographie à sous-estimer les volumes ventriculaires ; avec pour conséquence possible de « rater le moment de l'indication » et donc éventuellement de retarder une chirurgie de valvulation pulmonaire au détriment du patient. D'autres études permettront d'affiner ces résultats.

#### 4.3.4 Références

1. Dadlani GH, John JB, Cohen MS. Echocardiography in tetralogy of Fallot. *Cardiol Young* 2008;18:22–28.
2. Gatzoulis MA, Soukias N, Ho SY, et al. Echocardiographic and morphological correlations in tetralogy of Fallot. *Eur Heart J* 1999;20:221–231.
3. Need LR, Powell AJ, del Nido P, et al. Coronary echocardiography in tetralogy of Fallot: diagnostic accuracy, resource utilization and surgical implications over 13 years. *J Am Coll Cardiol* 2000;36:1371–1377.
4. Kjaergaard J, Petersen CL, Kjaer A, et al. Evaluation of right ventricular volume and function by 2D and 3D echocardiography compared to MRI. *Eur J Echocardiogr* 2006;7:430–438.
5. Bonello B, Kilner PJ. Review of the role of cardiovascular magnetic resonance in congenital heart disease, with a focus on right ventricle assessment. *Arch Cardiovasc Dis* 2012;105:605-13.
6. Geva T, Powell AJ, Crawford EC, et al. Evaluation of regional differences in right ventricular systolic function by acoustic quantification echocardiography and cine magnetic resonance imaging. *Circulation* 1998;98:339–345.
7. Roest AA, Helbing WA, Kunz P, et al. Exercise MR imaging in the assessment of pulmonary regurgitation and biventricular function in patients after tetralogy of Fallot repair. *Radiology* 2002;223:204–211.

8. van den Berg J, Wielopolski PA, Meijboom FJ, et al. Diastolic function in repaired tetralogy of Fallot at rest and during stress: assessment with MR imaging. *Radiology* 2007;243:212–219.
9. Therrien J, Provost Y, Merchant N, et al. Optimal timing for pulmonary valve replacement in adults after tetralogy of Fallot repair. *Am J Cardiol* 2005;95:779–782.
10. Knauth A, Gauvreau K, Landzberg M. Right ventricular size and function and age at repair predict major adverse outcomes late after tetralogy of Fallot repair (abstr). *Circulation* 2005;112:II681.
11. Haddad F, Hunt SA, Rosenthal DN, Murphy DJ. Right ventricular function in cardiovascular disease, part I: anatomy, physiology, aging, and functional assessment of the right ventricle. *Circulation* 2008;117:1436-48





Available online at  
**ScienceDirect**  
www.sciencedirect.com

Elsevier Masson France  
**EM|consulte**  
www.em-consulte.com/en



## CLINICAL RESEARCH

# Multivariable assessment of the right ventricle by echocardiography in patients with repaired tetralogy of Fallot undergoing pulmonary valve replacement: A comparative study with magnetic resonance imaging



Évaluation multiparamétrique du ventricule droit par échocardiographie chez les patients avec une tétralogie de Fallot ayant bénéficié d'une chirurgie de remplacement valvulaire pulmonaire : étude comparative à l'IRM

Jean-Bernard Selly<sup>a,\*</sup>, Xavier Iriart<sup>a</sup>,  
François Roubertie<sup>a</sup>, Philippe Mauriat<sup>a</sup>, Jan Marek<sup>b</sup>,  
Emmanuelle Guilhon<sup>a</sup>, Karim Jamal-Bey<sup>c</sup>,  
Jean-Benoît Thambo<sup>a</sup>

<sup>a</sup> Division of Congenital Heart Disease, Bordeaux Hospital University Center, avenue de Magellan, 33604 Bordeaux, France

<sup>b</sup> Great Ormond Street Hospital for Children, London, United Kingdom

<sup>c</sup> Division of Pediatrics, Reunion Hospital University Center, Saint-Pierre, Reunion

Received 22 December 2013; received in revised form 17 July 2014; accepted 23 July 2014  
Available online 12 November 2014

**Abbreviations:** 3D, three-dimensional; AUC, area under the receiver operating characteristic curve; FAC, fractional area change; LV, left ventricle; MPI, myocardial performance index; MRI, magnetic resonance imaging; PVR, pulmonary valve replacement; ROC, receiver operating characteristic; RT3DE, real-time three-dimensional echocardiography; RVEDV, right ventricular end-diastolic volume; RVEF, right ventricular ejection fraction; RVESV, right ventricular end-systolic volume; rTOF, repaired tetralogy of Fallot; RV, right ventricle/ventricular; RVOT, right ventricular outflow tract; TAPSE, tricuspid annular plane systolic excursion; TAPSV, tricuspid annular peak systolic velocity; TOF, tetralogy of Fallot.

\* Corresponding author.

E-mail address: [bernardselly@hotmail.com](mailto:bernardselly@hotmail.com) (J.-B. Selly).

<http://dx.doi.org/10.1016/j.acvd.2014.07.054>

1875-2136/© 2014 Elsevier Masson SAS. All rights reserved.

**KEYWORDS**

Tetralogy of Fallot;  
Echocardiography;  
Magnetic resonance  
imaging;  
Pulmonary valve  
replacement;  
Right ventricle

**MOTS CLÉS**

Tétralogie de Fallot ;  
Échocardiographie ;  
IRM ;  
Remplacement  
valvulaire  
pulmonaire ;  
Ventricule droit

**Summary**

**Background.** – Evaluation of the right ventricle (RV) using transthoracic echocardiography is challenging in patients with repaired tetralogy of Fallot (rTOF).

**Aims.** – To evaluate the accuracy of conventional echocardiographic variables and real-time three-dimensional echocardiography (RT3DE) in assessing right ventricular (RV) volumes and function compared with magnetic resonance imaging (MRI), in adult patients with rTOF and referred for pulmonary valve replacement (PVR).

**Methods.** – Complete echocardiography was performed on 26 consecutive patients referred for PVR, before and 1 year after surgery. All variables were compared with MRI.

**Results.** – Correlations between conventional variables and MRI were absent or poor when assessing RV ejection fraction (RVEF), except for fractional area of change (FAC;  $r=0.70$ ,  $P<0.01$  before PVR;  $r=0.68$ ,  $P<0.01$  after PVR) and RT3DE ( $r=0.96$ ,  $P<0.01$  before PVR;  $r=0.98$ ,  $P<0.01$  after PVR). The RV volume correlation between RT3DE and MRI was excellent before and after surgery for RV end-diastolic volume ( $r=0.88$ ,  $P<0.01$  and  $r=0.91$ ,  $P<0.01$ , respectively) and RV end-systolic volume ( $r=0.92$ ,  $P<0.01$  and  $r=0.95$ ,  $P<0.01$ , respectively). The accuracy of these indices, as a diagnostic test for impaired RV (<45%), was good: Youden's indexes varied from 0.47 to 0.89; areas under the receiver operating characteristic curve before and after PVR were 0.86 and 0.81 for FAC and 0.98 and 0.97 for RT3DE, respectively.

**Conclusion.** – Commonly used echocardiography variables, such as tricuspid annular plane systolic excursion and tricuspid annular peak systolic velocity, did not sensitively evaluate global RVEF. A global approach, that includes the whole RV and integration of its different components, was more reliable in patients with rTOF.

© 2014 Elsevier Masson SAS. All rights reserved.

**Résumé**

**Contexte.** – L'évaluation du ventricule droit (VD) par l'échocardiographie trans-thoracique est un véritable défi chez les patients avec une tétralogie de Fallot corrigée.

**Objectifs.** – Nous avons ainsi évalué la précision des paramètres échocardiographiques conventionnels et ceux de l'échocardiographie en 3D pour analyser les volumes et la fonction du VD en comparaison à l'évaluation par IRM, chez les patients adultes avec tétralogie de Fallot corrigée adressés pour une chirurgie de remplacement valvulaire pulmonaire (RVP).

**Méthodes.** – Une échocardiographie complète a été réalisée chez 26 patients adressés pour RVP, avant chirurgie et un an après chirurgie. Les paramètres obtenus ont été comparés à ceux issus de l'IRM.

**Résultats.** – La corrélation entre les paramètres conventionnels et l'IRM était absente ou faible en termes d'analyse de la fonction du VD excepté pour la fraction de raccourcissement de surface FRS ( $r=0,70$ ,  $p<0,01$  et  $r=0,68$ ,  $p<0,01$ , avant et après RVP, respectivement) et l'échocardiographie 3D ( $r=0,96$ ,  $p<0,01$  et  $r=0,98$ ,  $p<0,01$  avant et après RVP, respectivement). La corrélation des volumes ventriculaires entre l'échocardiographie 3D et l'IRM était excellente avant et après RVP pour le volume télé-diastolique du VD ( $r=0,88$ ,  $p<0,01$  et  $r=0,91$ ,  $p<0,01$ , respectivement), et pour le volume télé-systolique ( $r=0,92$ ,  $p<0,01$  et  $r=0,95$ ,  $p<0,01$ , respectivement). La précision de ces mêmes indices en tant que test diagnostique de l'altération de la fonction VD (< 45%) était bonne : les indices de Youden variaient de 0,47 à 0,89 et les aires sous la courbe de 0,86 et 0,81 pour la FRS, 0,98 et 0,97 pour l'échocardiographie 3D, respectivement avant et après RVP.

**Conclusion.** – Les paramètres échocardiographiques habituellement utilisés, comme le TAPSE et le S'VD, ne sont pas sensibles à évaluer la fonction du VD. Une approche globale, qui prend en compte l'ensemble du VD et l'intégration de ses différents composants, est plus adaptée chez les patients avec tétralogie de Fallot corrigée.

© 2014 Elsevier Masson SAS. Tous droits réservés.

**Introduction**

Tetralogy of Fallot (TOF) is the most common cause of cyanotic congenital heart disease, and is associated with a high prevalence of pulmonary regurgitation following repair,

which often requires later pulmonary valve replacement (PVR) [1]. Monitoring right ventricular (RV) volume and function is mandatory when managing these patients.

Echocardiography is the most widely available and cost-effective imaging modality, but its use in assessing the right

ventricle (RV) after repaired TOF (rTOF) remains challenging. American and European guidelines [2] for chamber quantification recommend the use of different variables to assess RV function, such as tricuspid annular plane systolic excursion (TAPSE) and tricuspid annular peak systolic velocity (TAPSV) using tissue Doppler imaging, myocardial performance index (MPI) and fractional area of change (FAC). These variables have been validated in patients with coronary artery disease and cardiomyopathy. Other advanced variables, such as real-time three-dimensional echocardiography (RT3DE), are promising in assessing RV function [2]. The normal RV contraction pattern is different from that of the left ventricle (LV) because of different muscle fibre organization and low vascular bed impedance [3]. Longitudinal shortening is the main component of RV systolic function, and measurement of simple variables, such as TAPSE or TAPSV, has enabled assessment of RV function in a simple, repeatable and reproducible way in normal subjects and in patients with ischaemic heart disease [4,5]. However, there are few data on the reliability of these conventional or advanced variables in patients with rTOF associated with a severely dilated RV related to chronic pulmonary regurgitation.

The objective of this study was to evaluate the accuracy of echocardiographic variables, including conventional variables (TAPSE, MPI, FAC, TAPSV) and RT3DE, to assess RV volume and function compared with magnetic resonance imaging (MRI), in patients with rTOF referred for PVR, as MRI is widely accepted as the gold standard for RV assessment in patients with congenital heart disease [6]. Patients were re-evaluated 1 year after surgery to determine the effects of surgery and any change to these variables.

## Methods

### Subjects

We enrolled 26 consecutive patients referred for PVR between 2010 and 2011 in the Adult Congenital Heart Disease Clinic at the University Hospital of Bordeaux. All patients were evaluated before and 1 year after surgery. Our institutional review board approved the study and all subjects gave their informed consent. Transthoracic echocardiography and MRI at rest were performed on the same day or on a subsequent day, according to the following protocols.

### Echocardiography

#### Standard echocardiography

Transthoracic echocardiography was performed using Vivid 7<sup>®</sup> (GE Vingmed Ultrasound A.S., Horten, Norway) by two experienced cardiologists (J.-B.S. and X.I.). All echocardiographic recordings were stored digitally for offline analysis. Measurements were made in three cardiac cycles, and average values were used for statistical analyses.

TAPSE was assessed in M-mode in the apical four-chamber view, and RV end-diastolic and end-systolic areas were assessed in the same view. From these measurements, we calculated the FAC. TAPSV at the junction of the RV free wall and the tricuspid annulus was assessed using pulsed tissue

Doppler echocardiography. The RV MPI – defined as (isovolumic contraction + isovolumic relaxation time)/ejection time – was also assessed by Doppler echocardiography.

### Three-dimensional echocardiography

#### Data acquisition

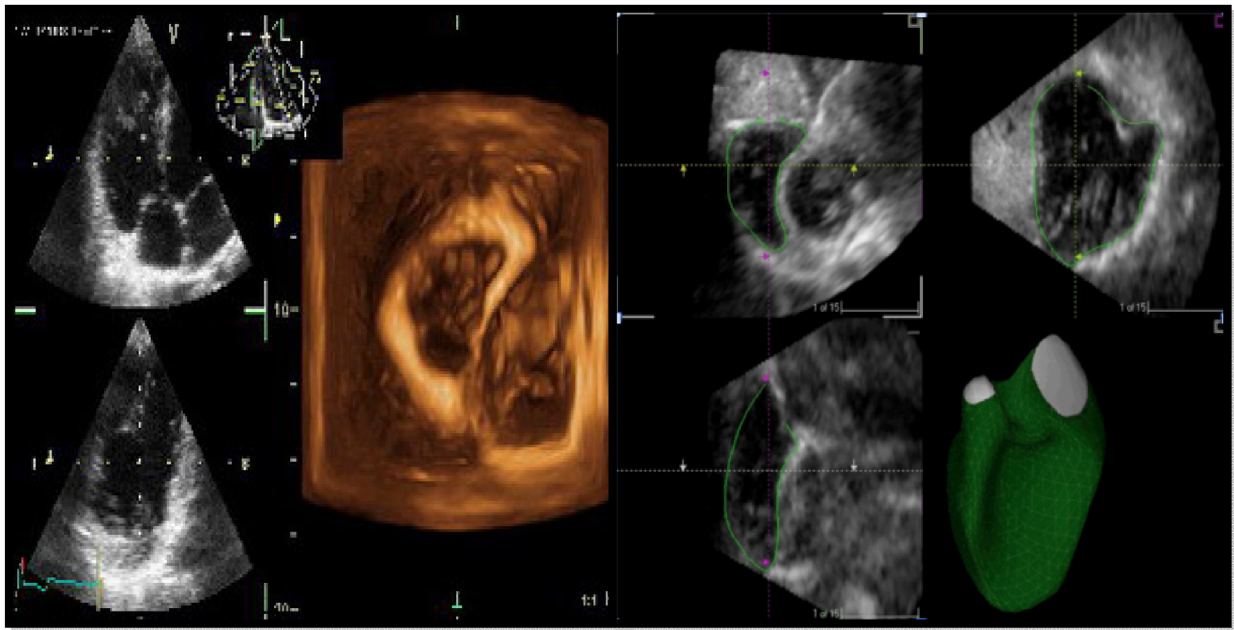
Three-dimensional echocardiography was performed using a 3V matrix-array transducer (1–4 MHz). The entire echocardiography dataset was acquired from a single apical transducer location that was slightly modified from the traditional apical four-chamber view: the right-sided structures were maximized and clearly visualized, and appeared in the centre of the field of view. Data acquisition required electrocardiogram gating, so output was not truly in real-time, but was actually reconstructed from four subvolumes. The entire reconstructed three-dimensional (3D) dataset was first inspected for whole-body motion artefacts that might have occurred during data acquisition. The reconstructed data were then reviewed as a loop with a temporal resolution of 55–65 ms (15–18 vol/s).

#### Automated border detection and volume-computation algorithm

Analyses of original raw data were performed using dedicated RV analysis software (TomTec Imaging Systems GmbH, Munich, Germany) using the usual protocol for this software, as described in our previous study [7]. The 3D dataset could be manipulated offline by a series of translational, rotational and pivoting manoeuvres to best visualize RV inflow and outflow tracts, and to display the reference planes. End-diastolic and end-systolic phases were first defined, then contours were manually drawn in end-diastolic and end-systolic images for three selected images (four-chamber, coronal and sagittal views) and adjusted as closely as possible to the endocardial border (Fig. 1). Heavy parietal trabeculations were included in the RV chamber, as performed using MRI. These contours served to initiate the semiautomatic algorithm. Using this method and blinded to the MRI results, the software analysed RV volumes and function.

### Magnetic resonance imaging

MRI was performed on a 1.5T system (Sonata; Siemens, Erlangen, Germany) with a phased-array radiofrequency receiver coil placed on the chest. All images were gated to the electrocardiogram. Double oblique long-axis and four-chamber scouts were acquired to obtain a true short-axis reference. Steady-state free-precession prospectively electrocardiogram-gated breath-hold images, encompassing the whole RV, were then acquired in the short-axis orientation, with no gaps between the slices (TrueFISP sequence: slice thickness, 7 mm; TE, 1.53 ms; TR, 33.6 ms [depending on the R–R interval]; matrix, 256 × 256 mm; field of view, 38 cm). RV end-systolic volume (RVESV), RV end-diastolic volume (RVEDV) and RV ejection fraction (RVEF) were measured on a postprocessing workstation (Leonardo; Siemens), using commercially available software (Syngo Argus; Siemens), by a radiologist blinded to the results of the echocardiography (Fig. 2).



**Figure 1.** Right ventricle assessment by three-dimensional echocardiography.

## Statistical analyses

Relationships between the echocardiographic variables of RV function and MRI of RVEF were evaluated using Pearson's correlation coefficient and linear regression. The same method was used to compare the RV volumes obtained by RT3DE with MRI RV volumes. To estimate echocardiographic semi-quantitative impaired RV systolic function, the data were presented as means  $\pm$  standard deviations. Stratified correlation, according to whether MRI RVEF was normal or not, was done, and a Fisher's z-transformation was used to compare the correlations. A threshold value of 45% for MRI RVEF was chosen according to the reference radionuclide and the MRI results described in the review of RV function by Haddad et al. [8]. A *P*-value  $<0.05$  was considered statistically significant. Statistical analyses were performed using SAS software (version 9.1; SAS Institute, Cary, NC, USA) and receiver operating characteristic (ROC) curve analyses were obtained using R (version 2.15.2; R Foundation for Statistical Computing, Vienna, Austria).

## Results

### Study population

Twenty-six patients with rTOF were included in this study. All patients underwent surgical PVR for severe pulmonary regurgitation, defined as MRI pulmonary regurgitation fraction  $>40\%$  and peak velocity across the RV outflow tract (RVOT)  $<2.5$  m/s. The patients' characteristics are presented in Table 1: their mean age was  $27 \pm 12$  years.

### Magnetic resonance imaging results

The MRI results are shown in Table 2. In our study, 17 (65%) patients had an RVEDV of  $>150$  mL/m<sup>2</sup>. One year after PVR, RVEDV had decreased significantly from  $152.1 \pm 38.5$

to  $111.7 \pm 31.7$  mL/m<sup>2</sup> ( $P < 0.01$ ) and RVESV had decreased from  $91.6 \pm 32.5$  to  $66.2 \pm 27.6$  mL/m<sup>2</sup> ( $P < 0.01$ ). There was no significant change in RVEF when measured by MRI.

### Echocardiographic results

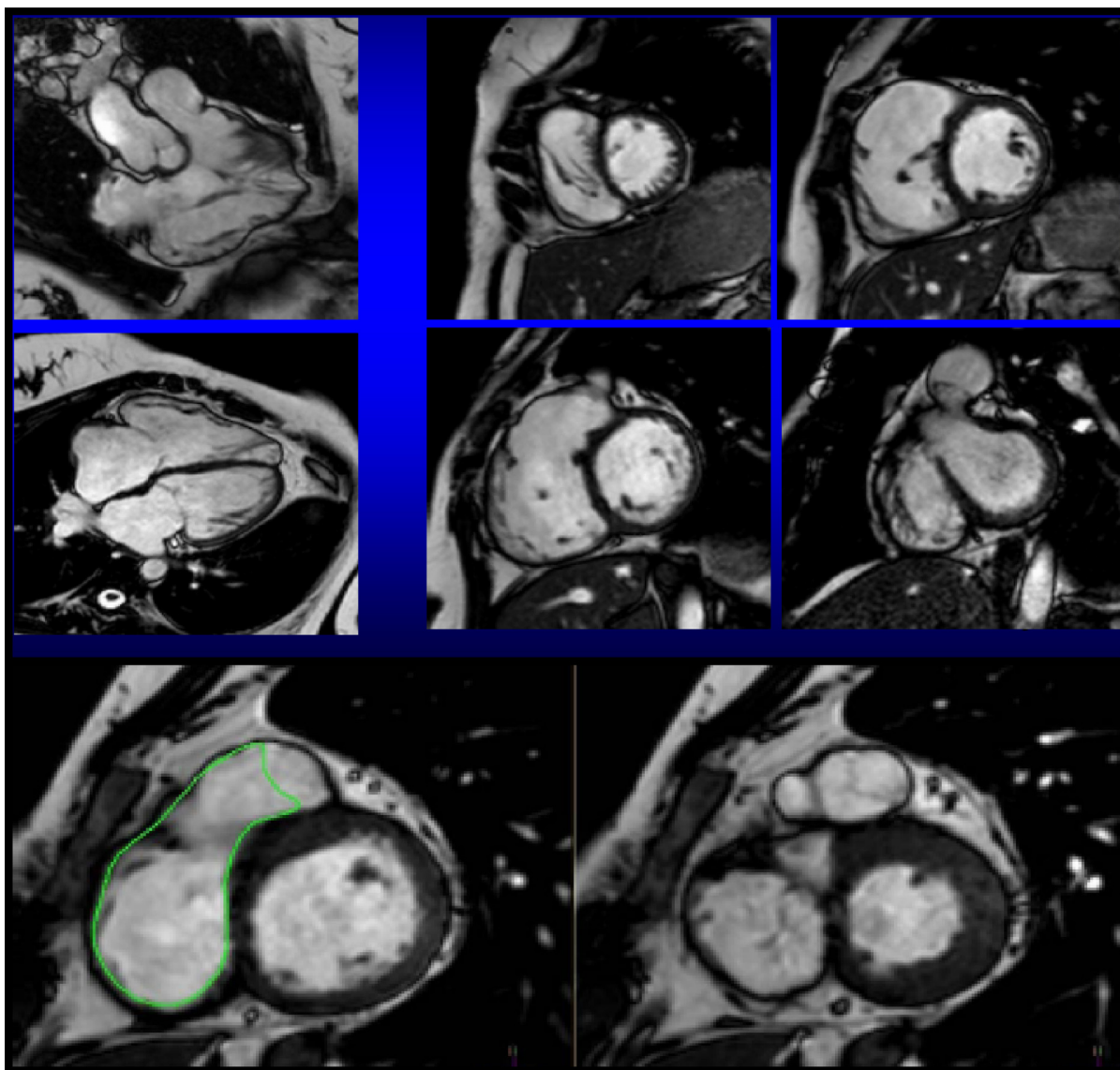
All patients had echocardiography before PVR and 1 year after surgery. The overall results and the numbers of

**Table 1** Patients' characteristics.

|  |             |
|--|-------------|
| Age (years), mean $\pm$ S.D.                             | 27 $\pm$ 12 |
| Ratio men: women, n/n                                    | 16/10       |
| Palliative surgery, n                                    | 14          |
| Complete repair (years), mean                            | 4           |
| Transannular patch, n                                    | 16          |
| Delay between complete repair and PVR (years), mean      | 24          |
| NYHA classification, n                                   |             |
| I  | 9           |
| II   | 10          |
| III  | 6           |
| IV   | 1           |
| PVR indication, n  |             |
| Severe PR, RVEDV $>150$ mL/m <sup>2</sup> , symptomatic  | 14          |
| Severe PR, RVEDV $<150$ mL/m <sup>2</sup> , symptomatic  | 6           |
| Severe PR, RVEDV $>150$ mL/m <sup>2</sup> , asymptomatic | 6           |

NYHA: New York Heart Association; PVR: pulmonary valve replacement; PR: pulmonary regurgitation; RVEDV: right ventricular end-diastolic volume.





**Figure 2.** Right ventricle assessment by magnetic resonance imaging.

patients in whom respective variables were assessed are shown in [Table 3](#). Assessment of standard variables was feasible for most patients. Assessment was more difficult for RT3DE variables before PVR because of the larger RV volumes. The feasibility of RT3DE was 46% before surgery and 57% 1 year after surgery.

One year after PVR, RVEDV had decreased significantly from  $94.9 \pm 23.9$  to  $67.4 \pm 20.1$  mL/m<sup>2</sup> ( $P < 0.01$ ) and RVESV had decreased from  $57.4 \pm 18.9$  to  $39.4 \pm 20.3$  mL/m<sup>2</sup> ( $P < 0.01$ ) based on RT3DE analysis. There was no significant change in RVEF when assessed by RT3DE.

**Table 2** Magnetic resonance imaging results (n = 26).

| MRI variable               | Before surgery | After surgery | P <sup>a</sup> |
|----------------------------|----------------|---------------|----------------|
| RVEDV (mL/m <sup>2</sup> ) | 152.1 ± 38.5   | 111.7 ± 31.7  | <0.01          |
| RVESV (mL/m <sup>2</sup> ) | 91.6 ± 32.5    | 66.2 ± 27.6   | <0.01          |
| RVEF (%)                   | 41.1 ± 12.5    | 44.4 ± 10.3   | 0.30           |

Data are mean ± standard deviation. MRI: magnetic resonance imaging; RVEDV: right ventricular end-diastolic volume; RVEF: right ventricular ejection fraction; RVESV: right ventricular end-systolic volume.  
<sup>a</sup> Student's t.

**Agreement between echocardiographic variables and right ventricular ejection fraction by magnetic resonance imaging**

[Table 4](#) shows the correlations between echocardiographic variables of RV function and RVEF assessed by MRI before and 1 year after surgery. The commonly used variables, such as TAPSE, TAPSV and MPI, did not correlate significantly with MRI RVEF assessment. In contrast, FAC and RT3DE were highly correlated with MRI, both before and after surgery (FAC:  $r = 0.70$ ,  $P < 0.01$  preoperatively and  $r = 0.68$ ,  $P < 0.01$  postoperatively; RT3DE:  $r = 0.96$ ,  $P < 0.01$  preoperatively and  $r = 0.98$ ,  $P < 0.01$  postoperatively). Bland-Altman

**Table 3** Echocardiographic results ( $n=26$ ).

| Echocardiography variable  | Before surgery  |          | After surgery   |          | $P^a$ |
|----------------------------|-----------------|----------|-----------------|----------|-------|
|                            | Mean $\pm$ S.D. | $n^b$    | Mean $\pm$ S.D. | $n^b$    |       |
| TAPSE (mm)                 | 17.2 $\pm$ 2.9  | 26       | 16.2 $\pm$ 2.9  | 26       | NS    |
| TAPSV (cm/s)               | 9.7 $\pm$ 2.3   | 26       | 8.9 $\pm$ 1.7   | 26       | NS    |
| MPI                        | 0.35 $\pm$ 0.21 | 24       | 0.38 $\pm$ 0.14 | 24       | NS    |
| FAC (%)                    | 45.9 $\pm$ 10.9 | 24       | 38.8 $\pm$ 11.1 | 26       | 0.06  |
| RVEDV (mL/m <sup>2</sup> ) | 94.9 $\pm$ 23.9 | 12 (46%) | 67.4 $\pm$ 20.1 | 15 (57%) | 0.01  |
| RVESV (mL/m <sup>2</sup> ) | 57.4 $\pm$ 18.9 | 12       | 39.4 $\pm$ 20.3 | 15       | 0.03  |
| RVEF by RT3DE (%)          | 40.2 $\pm$ 10.3 | 12       | 44.1 $\pm$ 11.4 | 15       | 0.39  |

FAC: fractional area of change; MPI: myocardial performance index; NS: not significant; RT3DE: real-time three-dimensional echocardiography; RVEDV: right ventricular end-diastolic volume; RVEF: right ventricular ejection fraction; RVESV: right ventricular end-systolic volume; S.D.: standard deviation; TAPSE: tricuspid annular plane systolic excursion; TAPSV: tricuspid annular peak systolic velocity.

<sup>a</sup> Student's *t*-test.

<sup>b</sup> Number of patients in whom the variable was assessed.

curves confirmed the accuracy of FAC and RT3DE in assessing RVEF compared with MRI before and after PVR: the mean bias was  $0.2 \pm 4.4$  before PVR and  $-0.4 \pm 4.3$  after PVR for RT3DE, and  $-2.9 \pm 22.1$  before PVR and  $3 \pm 20.9$  after PVR for FAC (Fig. 3).

### Agreement between echocardiographic variables for estimation of impaired right ventricular function

We also aimed to determine which variables provided a reliable estimation of impaired RV systolic function. In accordance with the lower range of RV normal function of 45% [8], the echocardiographic variables were analysed before and after surgery using this threshold, based on the MRI RVEF measurement.

Results in Table 5 show that FAC could significantly determine impaired RV systolic function, before and after surgery. TAPSE, tissue Doppler imaging and MPI were not relevant in estimating impaired RV function.

By tracing the ROC curves, the best FAC thresholds for determining impaired RV function were 44.5% before PVR (area under the ROC curve [AUC] = 0.86; Se = 0.86; Sp = 0.67; Youden's index = 0.53) and 36.8% after PVR (AUC = 0.81; Se = 0.74; Sp = 0.73; Youden's index = 0.47). For RT3DE,

the best thresholds were 41% before PVR (AUC = 0.98; Se = 1; Sp = 0.89; Youden's index = 0.89) and 48.5% after PVR (AUC = 0.97; Se = 0.89; Sp = 0.1; Youden's index = 0.89; Fig. 4).

### Agreement between echocardiographic variables and right ventricular volumes assessed by magnetic resonance imaging

Table 6 and Fig. 5 show that the correlation for RV volume between RT3DE and MRI was excellent, both before and after surgery ( $r=0.88$ ,  $P<0.01$  and  $r=0.91$ ,  $P<0.01$ , respectively, for RVEDV;  $r=0.92$ ,  $P<0.01$  and  $r=0.95$ ,  $P<0.01$ , respectively, for RVESV). Correlation was even better post-operatively, as the volumes had decreased dramatically.

We found that RT3DE analysis was reproducible: the correlations between MRI and RT3DE (the volume variations for each individual before and after surgery) were excellent ( $r=0.94$ ,  $P<0.01$  for RVEDV;  $r=0.93$ ,  $P<0.01$  for RVESV).

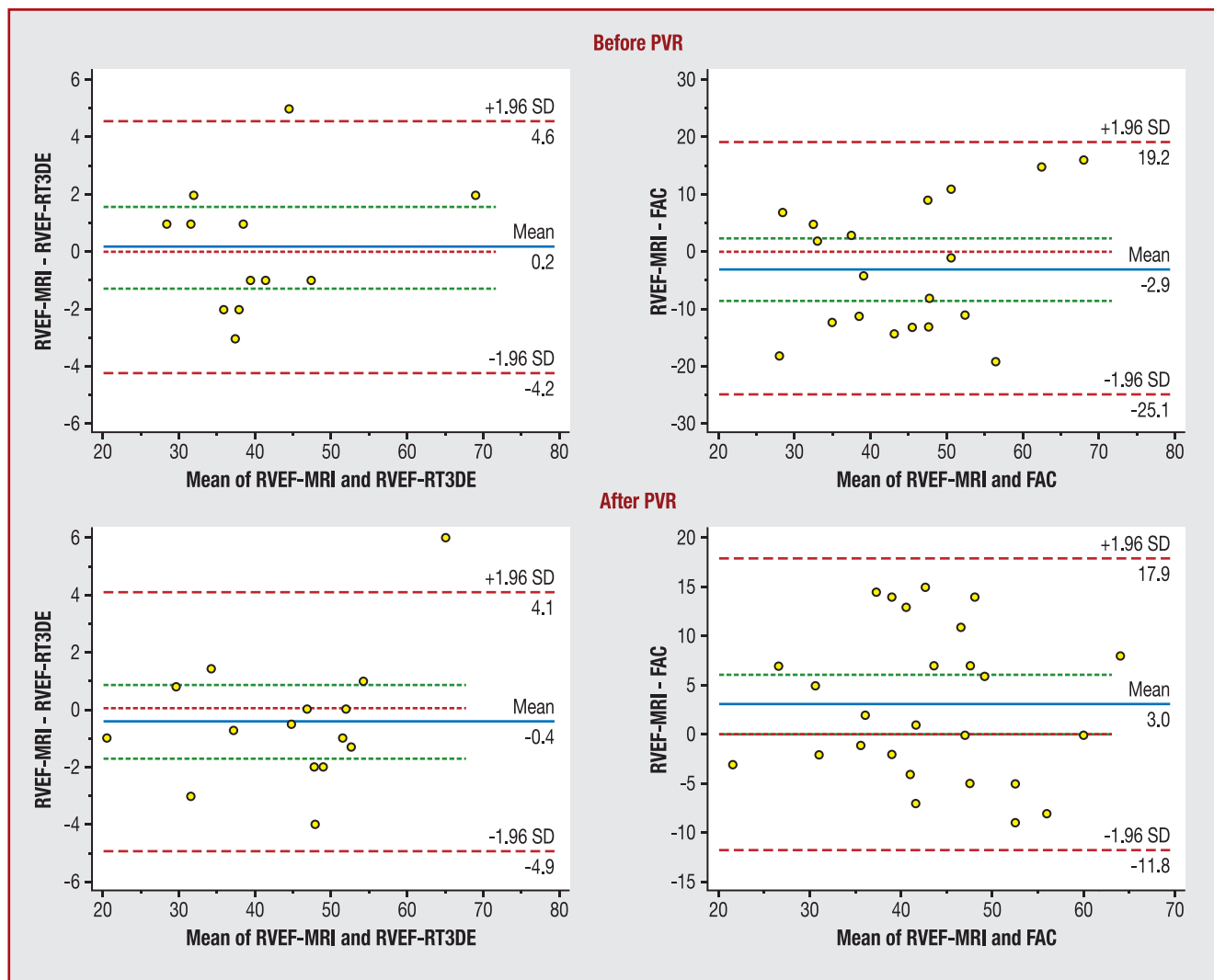
### Limitations

Despite an excellent correlation with MRI, the feasibility of RT3DE remains limited in severely dilated RVs, which is why

**Table 4** Agreement between echocardiographic variables and measurement of right ventricular ejection fraction by magnetic resonance imaging.

| Echocardiography variable | Before surgery: RVEF by MRI |       | After surgery: RVEF by MRI |       |
|---------------------------|-----------------------------|-------|----------------------------|-------|
|                           | $r$                         | $P$   | $r$                        | $P$   |
| TAPSE                     | 0.11                        | 0.64  | 0.17                       | 0.38  |
| TAPSV                     | 0.08                        | 0.72  | 0.39                       | 0.06  |
| MPI                       | 0.07                        | 0.82  | 0.27                       | 0.24  |
| FAC                       | 0.70                        | <0.01 | 0.68                       | <0.01 |
| RVEF by RT3DE             | 0.96                        | <0.01 | 0.98                       | <0.01 |

FAC: fractional area of change; RT3DE: real-time three-dimensional echocardiography; RVEDV: right ventricular end-diastolic volume; RVEF: right ventricular ejection fraction; RVESV: right ventricular end-systolic volume; TAPSE: tricuspid annulus-plane systolic excursion; TAPSV: tricuspid annulus-peak systolic velocity.



**Figure 3.** Bland-Altman plots depicting accuracy of fractional area of change (FAC) and real-time three-dimensional echocardiography (RT3DE) in assessing right ventricular ejection fraction (RVEF) compared with magnetic resonance imaging (MRI), before and after pulmonary valve replacement (PVR). SD: standard deviation.

RT3DE analysis was performed on 46% of the patients before surgery and on 57% after PVR.

We also need to underline the major underestimation of RV volumes by RT3DE compared with MRI. RVESV and RVEDV assessed by RT3DE were underestimated by around 41% before and after PVR compared with the assessment of RV volumes by MRI.

### Discussion

In our study, longitudinal shortening variables focused on RV inflow (TAPSE, TAPSV) showed no significant correlation with global systolic RV function using MRI. Similar findings have been reported in recent studies in both adults and children with rTOF and chronic volume overload [9–11]. The most

**Table 5** Echocardiographic variables and measurement of right ventricular ejection fraction with significant agreement with estimation of impaired right ventricular ejection fraction by magnetic resonance imaging.

| Echocardiography variable | Before surgery         |                       | After surgery          |                        |
|---------------------------|------------------------|-----------------------|------------------------|------------------------|
|                           | RVEF MRI <45% (n = 19) | RVEF MRI >45% (n = 7) | RVEF MRI <45% (n = 11) | RVEF MRI >45% (n = 15) |
| FAC (%)                   | 41.2 ± 9.5             | 54 ± 8.2              | 32 ± 7.3               | 43.3 ± 10.3            |
| RVEF by RT3DE (%)         | 36.1 ± 4.9             | 52.7 ± 13.1           | 33.25 ± 8              | 51.1 ± 4.3             |

Data are mean ± standard deviation. FAC: fractional area of change; MRI: magnetic resonance imaging; RT3DE: real-time three-dimensional echocardiography; RVEF: right ventricular ejection fraction.

**Table 6** Agreement between echocardiographic and magnetic resonance imaging right ventricular volume variables.

|                       | RVEDV by MRI |          | RVESV by MRI |          |
|-----------------------|--------------|----------|--------------|----------|
|                       | <i>r</i>     | <i>P</i> | <i>r</i>     | <i>P</i> |
| <i>Before surgery</i> |              |          |              |          |
| RVEDV by RT3DE        | 0.88         | <0.01    | 0.67         | 0.02     |
| RVESV by RT3DE        | 0.80         | <0.01    | 0.92         | <0.01    |
| <i>After surgery</i>  |              |          |              |          |
| RVEDV by RT3DE        | 0.91         | <0.01    | 0.90         | <0.01    |
| RVESV by RT3DE        | 0.92         | <0.01    | 0.95         | <0.01    |

MRI: magnetic resonance imaging; RT3DE: real-time three-dimensional echocardiography; RVEDV: right ventricular end-diastolic volume; RVESV: right ventricular end-systolic volume.

likely reason for this is the altered regional contraction pattern in this population, which may be caused by altered muscle fibre orientation. Sanchez-Quintana et al. reported that TOF patients have a middle layer of circumferential fibres in their RVs that is not present in normal RVs [3]. Such a middle layer is normally present in the LV and contains circumferential fibres that are involved in radial shortening.

Furthermore, RV shape in patients with TOF differs from normal subjects in several ways [11]: patients with TOF have a larger normalized cross-sectional area and the RV has a rounder shape in its apical planes. Morcos et al. and Sheehan et al. have described the importance of apex remodelling and demonstrated that the apex is more important than the base in TOF patients with impaired RV function [10,11].

In addition, the interventricular septum undergoes relatively less enlargement. Also, patients with TOF have a bulging basal tricuspid valve. This basal bulging is amplified by tilting the tricuspid annulus, and could be an additional explanation for the lack of sensitivity of the commonly used TAPSE and TAPSV as markers for global RV function. In contrast, the use of variables that integrate both longitudinal and circumferential shortening, such as FAC or RT3DE, may improve evaluation of global RV systolic function.

FAC is known to have a good correlation with MRI RVEF in adult patients with acquired disease (Arnould et al. [12] reported  $r=0.68$  and  $P<0.01$ ; Leong et al. [13] reported  $r=0.71$  and  $P<0.01$ ). In our study, FAC was the only commonly used echocardiographic variable that was significantly correlated with RVEF estimated by MRI. Greutmann et al. [14] have shown that FAC was significantly lower in rTOF patients, with RVEF by MRI <35% compared with rTOF patients who had RVEF by MRI >50%. This is probably because of the integration of the different contraction patterns of the RV body analysed by FAC, which integrates longitudinal and radial components of contraction. Kutty et al. [15] recently demonstrated that regional dysfunction of the RVOT reduces the accuracy of TAPSV to evaluate global RV systolic function. Although several studies have examined the utility of TAPSV in TOF, these investigations did not address the potentially confounding effect of RVOT dysfunction on myocardial velocities at the base of the RV [9,11,15].

In patients with large akinetic or dyskinetic RVOT patches and/or scar tissue, measurements of tissue velocities at the base of the RV may not accurately reflect global RV systolic function. This may be because, in the normal heart, the

function of the inflow and outflow components of the RV are closely related, whereas this relationship is weak and unpredictable in patients who have undergone rTOF. Consequently, in the presence of a dyskinetic RVOT, longitudinal tissue velocity at the base of the RV free wall does not reliably reflect global RV systolic function [10].

Most patients in our study had a transannular patch and severe RV dilatation; as a consequence, potential RVOT dysfunction supports the lack of correlation between TAPSE, TAPSV and RVEF when measured by MRI.

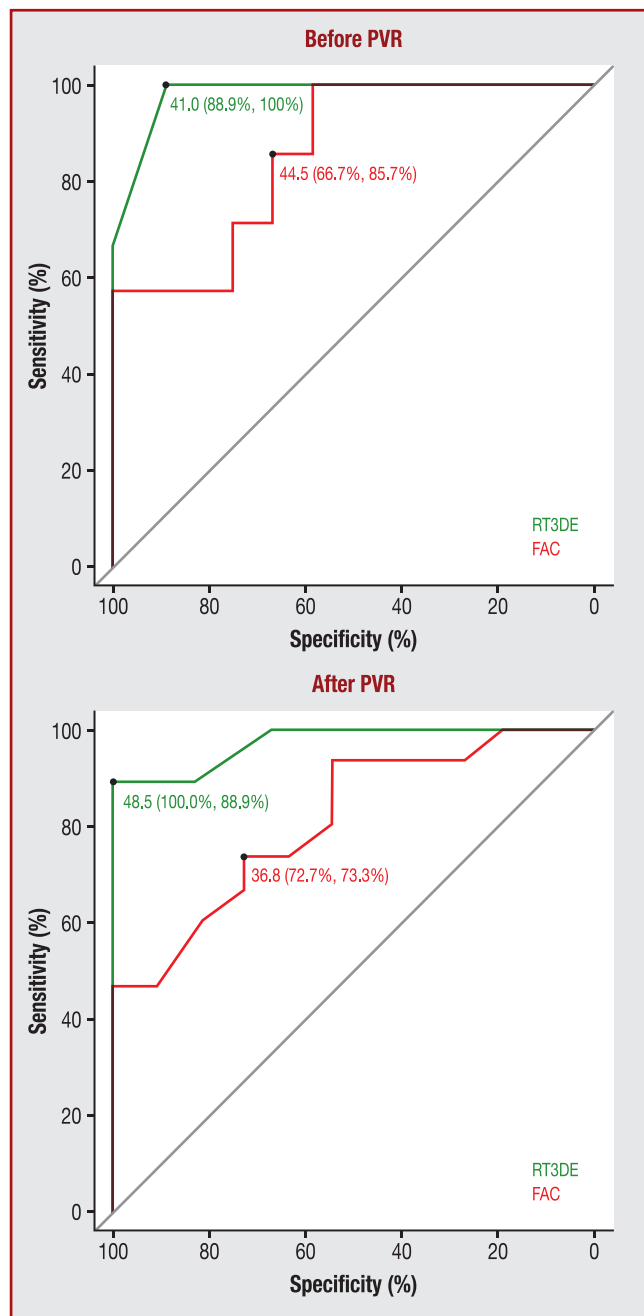
MPI is useful in high afterload with prolonged isovolumic contraction and relaxation. In high preload with low pulmonary pressure, such as with rTOF, isovolumic times are very short. We believe that in patients with RV volume overload, MPI should not be used for assessing RV systolic or diastolic function because a change in MPI could reflect a change in RV loading rather than a change in intrinsic myocardial function.

Speckle-tracking variables not described in our study could be useful for assessing RV function. Indeed Scherptong et al. [16] specifically studied RV peak systolic longitudinal strain in adult patients with rTOF and found a significant correlation between MRI RVEF and global longitudinal strain rate in a follow-up of 18 adult patients (mean age, 33 years) with TOF ( $r=-0.80$  and  $P<0.01$ ). Dragulescu et al. [17] found very striking differences in regional myocardial function, especially in the RV longitudinal apical deformation between atrial septal defect and rTOF; while apical RV deformation was significantly increased in the atrial septal defect group, they found a very significant decrease in RV apical function in the TOF group. Further studies are needed to understand these mechanisms, but cardiopulmonary bypass-related ischaemia associated with acute change in loading conditions might be involved, as suggested in the review by Klitsie et al. [18].

### Three-dimensional echocardiographic variables

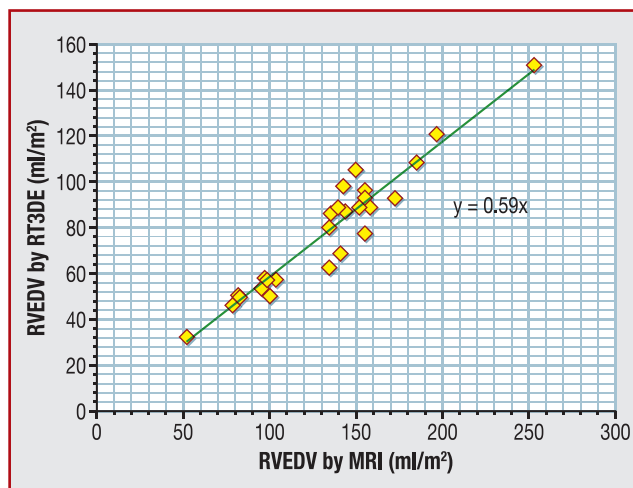
We compared our volumes analyses with those from the meta-analysis by Shimada et al. [19]. Underestimation was found to be almost systematic and had a large range (–5 to –50%). However, only three studies analysed rTOF patients [20–22]: our group in 2009, Grewal et al. in 2009 and van





**Figure 4.** Receiver operating characteristic curves illustrating the capacity to detect impaired right ventricular function with fractional area of change (FAC) and real-time three-dimensional echocardiography (RT3DE), before and after pulmonary valve replacement (PVR).

der Zwaan et al. in 2010; the mean underestimations were  $-18.70$ ,  $-25$ , and  $-34\%$ , respectively. In our current study, underestimation was  $-41.6\%$  before PVR and  $-41.3\%$  after PVR. In the previous study published by our group, we found an underestimation of  $-18.70\%$ , but we included both TOF patients and normal subjects, which meant that RV volumes were much smaller than in our current study. In our opinion, the accuracy of 3D echocardiography diminishes with larger RV volumes, partly because of the difficulty in including dilated RVOTs. This is supported by a recent study by



**Figure 5.** Right ventricular end-diastolic volume (RVEDV) correlation between magnetic resonance imaging (MRI) and real-time three-dimensional echocardiography (RT3DE), and determination of the correlation factor.

Dragulescu et al. [23], in which they found an underestimation by RT3DE of only around 7% concerning RVEDV in patients aged between 7 and 18 years with rTOF. By comparison, in an adult cohort in 2011, Crean et al. found underestimations with RT3DE of  $-34\%$  for RVEDV and  $-42\%$  for RVESV [24]. These underestimations may be related to a boundary tracing error, which remains the largest source of error when using 3D echocardiography methods, especially at the level of the RVOT. The use of a matrix-array transducer can also be responsible for this underestimation [19].

Despite this underestimation, agreement of 3D RV volume analyses, done by using echocardiography in our study, is excellent compared with MRI data, which was also shown by Grewal et al. and van der Zwaan et al. [21,22].

The main limitation of echocardiography (in our specific population) was the limited feasibility, which was only 46% before PVR but 57% after PVR, because of a volume decrease in RV, which permitted a better-quality acoustic window. Indeed, video clips of the two-dimensional apical four-chamber view do not predict the final RV volumes, as there is often a lack of echocardiographic resolution in the RVOT.

### Right ventricle modification after PVR

In our study, after PVR, there was a significant reduction in RVEDV and RVESV and no change in RVEF assessed using MRI, as previously reported [25–28]. Few data are available concerning the evolution of echocardiographic variables for RV assessment after PVR. Knirsch et al. [29] showed that no significant change occurred in FAC or MPI, 6 months after PVR, as was shown in our study.

Another issue is the impact of pericardial constrain after pericardectomy on longitudinal function; and cardiopulmonary bypass-related ischaemia might also be concerned. Further studies are needed to understand these mechanisms.

This study compares extensive multivariable echocardiography with MRI for assessing of the RV in two different

physiological conditions. A non-invasive tool to monitor RV is of crucial importance in TOF patients. PVR has shown potential to improve RV and LV haemodynamics, but the best timing for this intervention remains controversial. A global approach seems more reliable than the commonly used variables: the RV inflow contraction pattern needs to be related to the complex remodelling that encompasses the apex and the RVOT.

## Conclusion

The most commonly used segmental variables used to analyse the basal free wall (TAPSE and TAPSV) appear to be insensitive regarding RV systolic function, whereas FAC, which integrates longitudinal and radial components of contraction, seems to correlate well with MRI. The correlations between RT3DE and MRI were excellent in evaluations before and after surgery, but RT3DE underestimated the RV volumes compared with MRI, and feasibility remained limited.

A global approach, using either FAC or RT3DE, gave a good estimation of RV function in patients with rTOF. This multi-variable approach may reduce the need for MRI to determine RV volumes and function. However, the limitations need to be ascertained to avoid underestimating RV dilation and postponing PVR. Multimodality imaging is a good strategy for the serial follow-up of patients with rTOF, before and after PVR; it can potentially reduce the burden and costs for patients and healthcare systems, by reducing the use of MRI – which remains the gold standard for assessing the RV – when RV dilatation and impaired RV systolic function are suspected.

## Disclosure of interest

The authors declare that they have no conflicts of interest concerning this article.

## References

- [1] Bacha EA, Scheule AM, Zurakowski D, et al. Long-term results after early primary repair of tetralogy of Fallot. *J Thorac Cardiovasc Surg* 2001;122:154–61.
- [2] Rudski LG, Lai WW, Afilalo J, et al. Guidelines for the echocardiographic assessment of the right heart in adults: a report from the American Society of Echocardiography endorsed by the European Association of Echocardiography, a registered branch of the European Society of Cardiology, and the Canadian Society of Echocardiography. *J Am Soc Echocardiogr* 2010;23:685–713 [quiz 86–8].
- [3] Sanchez-Quintana D, Anderson RH, Ho SY. Ventricular myoarchitecture in tetralogy of Fallot. *Heart* 1996;76:280–6.
- [4] Ghio S, Recusani F, Klersy C, et al. Prognostic usefulness of the tricuspid annular plane systolic excursion in patients with congestive heart failure secondary to idiopathic or ischemic dilated cardiomyopathy. *Am J Cardiol* 2000;85:837–42.
- [5] Kaul S, Tei C, Hopkins JM, Shah PM. Assessment of right ventricular function using two-dimensional echocardiography. *Am Heart J* 1984;107:526–31.
- [6] Bonello B, Kilner PJ. Review of the role of cardiovascular magnetic resonance in congenital heart disease, with a focus on right ventricle assessment. *Arch Cardiovasc Dis* 2012;105:605–13.
- [7] Iriart X, Montaudon M, Lafitte S, et al. Right ventricle three-dimensional echography in corrected tetralogy of Fallot: accuracy and variability. *Eur J Echocardiogr* 2009;10:784–92.
- [8] Haddad F, Hunt SA, Rosenthal DN, Murphy DJ. Right ventricular function in cardiovascular disease, part I: anatomy, physiology, aging, and functional assessment of the right ventricle. *Circulation* 2008;117:1436–48.
- [9] Bonnemains L, Stos B, Vaugrenard T, Marie PY, Odille F, Boudjemline Y. Echocardiographic right ventricle longitudinal contraction indices cannot predict ejection fraction in post-operative Fallot children. *Eur Heart J Cardiovasc Imaging* 2012;13:235–42.
- [10] Morcos P, Vick 3rd GW, Sahn DJ, Jerosch-Herold M, Shurman A, Sheehan FH. Correlation of right ventricular ejection fraction and tricuspid annular plane systolic excursion in tetralogy of Fallot by magnetic resonance imaging. *Int J Cardiovasc Imaging* 2009;25:263–70.
- [11] Sheehan FH, Ge S, Vick 3rd GW, et al. Three-dimensional shape analysis of right ventricular remodeling in repaired tetralogy of Fallot. *Am J Cardiol* 2008;101:107–13.
- [12] Arnould MA, Gougnot S, Lemoine S, et al. Quantification of right ventricular function by 2D speckle imaging and three-dimensional echography. Comparison with MRI. *Ann Cardiol Angeiol (Paris)* 2009;58:74–85.
- [13] Leong DP, Grover S, Molaei P, et al. Nonvolumetric echocardiographic indices of right ventricular systolic function: validation with cardiovascular magnetic resonance and relationship with functional capacity. *Echocardiography* 2012;29:455–63.
- [14] Greutmann M, Tobler D, Biaggi P, et al. Echocardiography for assessment of regional and global right ventricular systolic function in adults with repaired tetralogy of Fallot. *Int J Cardiol* 2012;157:53–8.
- [15] Kutty S, Zhou J, Gauvreau K, Trincado C, Powell AJ, Geva T. Regional dysfunction of the right ventricular outflow tract reduces the accuracy of Doppler tissue imaging assessment of global right ventricular systolic function in patients with repaired tetralogy of Fallot. *J Am Soc Echocardiogr* 2011;24:637–43.
- [16] Scherptong RW, Mollema SA, Blom NA, et al. Right ventricular peak systolic longitudinal strain is a sensitive marker for right ventricular deterioration in adult patients with tetralogy of Fallot. *Int J Cardiovasc Imaging* 2009;25:669–76.
- [17] Dragulescu A, Grosse-Wortmann L, Redington A, Friedberg MK, Mertens L. Differential effect of right ventricular dilatation on myocardial deformation in patients with atrial septal defects and patients after tetralogy of Fallot repair. *Int J Cardiol* 2013;168:803–10.
- [18] Klitsie LM, Roest AA, Blom NA, ten Harkel AD. Ventricular performance after surgery for a congenital heart defect as assessed using advanced echocardiography: from doppler flow to 3D echocardiography and speckle-tracking strain imaging. *Pediatr Cardiol* 2014;35:3–15.
- [19] Shimada YJ, Shiota M, Siegel RJ, Shiota T. Accuracy of right ventricular volumes and function determined by three-dimensional echocardiography in comparison with magnetic resonance imaging: a meta-analysis study. *J Am Soc Echocardiogr* 2010;23:943–53.
- [20] Cheung EW, Wong WH, Cheung YF. Meta-analysis of pulmonary valve replacement after operative repair of tetralogy of Fallot. *Am J Cardiol* 2010;106:552–7.
- [21] Grewal J, Majdalany D, Syed I, Pellikka P, Warnes CA. Three-dimensional echocardiographic assessment of right ventricular volume and function in adult patients with congenital heart disease: comparison with magnetic resonance imaging. *J Am Soc Echocardiogr* 2010;23:127–33.

- [22] van der Zwaan HB, Helbing WA, McGhie JS, et al. Clinical value of real-time three-dimensional echocardiography for right ventricular quantification in congenital heart disease: validation with cardiac magnetic resonance imaging. *J Am Soc Echocardiogr* 2010;23:134–40.
- [23] Dragulescu A, Grosse-Wortmann L, Fackoury C, Mertens L. Echocardiographic assessment of right ventricular volumes: a comparison of different techniques in children after surgical repair of tetralogy of Fallot. *Eur Heart J Cardiovasc Imaging* 2012;13:596–604.
- [24] Crean AM, Maredia N, Ballard G, et al. 3D echo systematically underestimates right ventricular volumes compared to cardiovascular magnetic resonance in adult congenital heart disease patients with moderate or severe RV dilatation. *J Cardiovasc Magn Reson* 2011;13:78.
- [25] Dragulescu A, Grosse-Wortmann L, Fackoury C, et al. Echocardiographic assessment of right ventricular volumes after surgical repair of tetralogy of Fallot: clinical validation of a new echocardiographic method. *J Am Soc Echocardiogr* 2011;24:1191–8.
- [26] Ghez O, Tsang VT, Frigiola A, et al. Right ventricular outflow tract reconstruction for pulmonary regurgitation after repair of tetralogy of Fallot. Preliminary results. *Eur J Cardiothorac Surg* 2007;31:654–8.
- [27] Oosterhof T, Meijboom FJ, Vliegen HW, et al. Long-term follow-up of homograft function after pulmonary valve replacement in patients with tetralogy of Fallot. *Eur Heart J* 2006;27:1478–84.
- [28] Therrien J, Provost Y, Merchant N, Williams W, Colman J, Webb G. Optimal timing for pulmonary valve replacement in adults after tetralogy of Fallot repair. *Am J Cardiol* 2005;95:779–82.
- [29] Knirsch W, Dodge-Khatami A, Kadner A, et al. Assessment of myocardial function in pediatric patients with operated tetralogy of Fallot: preliminary results with 2D strain echocardiography. *Pediatr Cardiol* 2008;29:718–25.

## 4.4 Quatrième travail : complication aiguë (infarctus du myocarde) après RVP chez un adulte avec TF réparée

### 4.4.1 Introduction

La valvulation pulmonaire chez les patients avec TF réparée est l'acte chirurgical le plus fréquemment réalisé au niveau de la voie de sortie du VD chez l'adulte (avec ou sans CC) (1). Depuis la première publication de valvulation pulmonaire chez des patients avec TF réparée (2), de très nombreuses publications ont suivi, et ont rapporté des taux de mortalité, pour la plupart, inférieur à 3% (3, 4). La mortalité et la morbidité opératoire, après RVP, sont donc faibles. Les décès surviennent le plus souvent chez des patients opérés avec des dysfonctions ventriculaires droites préopératoires sévères, associées ou non, à des dysfonctions ventriculaires gauches (5).

Les autres causes de décès sont d'origine ischémiques, par lésions coronaires lors de la chirurgie (6). Le plus souvent, il s'agit de compression coronaire dont la prise en charge est : soit chirurgicale (dépose de la valve pulmonaire avec mise en place d'une prothèse plus petite ou avec mise en place d'une prothèse avec un design différent), soit par cathétérisme interventionnel avec mise en place de stent coronaire (7). En effet, le tronc coronaire passe immédiatement en arrière du tronc de l'artère pulmonaire, donc une valve biologique ou mécanique « rigide » peut venir le comprimer. C'est d'ailleurs ce phénomène qui est particulièrement redouté et donc recherché, lors de la mise en place d'une valve pulmonaire par voie percutanée (8), en réalisant des phases de test avec contrôle angiographique avant de mettre en place ce type de dispositif (9). A noter que le risque de compression coronaire est à associer aux variations de l'anatomie coronaire décrites chez les TF, avec notamment l'interventriculaire antérieure qui naît de la coronaire droite et croise l'infundibulum en avant du tronc de l'artère pulmonaire (10, 11).

La compression coronaire est une complication connue et redoutée de la chirurgie cardiaque valvulaire, et ceci, quelque soit la valve cardiaque remplacée. La compression coronaire est particulièrement redoutée après chirurgie de remplacement valvulaire mitrale (par compression de la

circonflexe) ou après remplacement valvulaire aortique (12) (par compression du tronc coronaire gauche).

**Nous avons décrit un nouveau mécanisme de lésion coronaire après chirurgie de remplacement valvulaire pulmonaire.** (Cf. le case report publié dans *Catheterization and Cardiovascular Interventions* : Séguéla PE, Roubertie F. *Distortion of the left anterior descending coronary artery after pulmonary valve replacement. Catheter Cardiovasc Interv. 2015;Nov3*).

#### 4.4.2 Résultats :

Nous avons mis en évidence un nouveau mécanisme d'atteinte coronaire après RVP, qui est la distorsion coronaire ou plicature coronaire. Cette complication peut s'expliquer par les nombreuses adhérences épicaudiques qui existaient chez ce patient multi-opéré. Par ailleurs, l'atteinte exceptionnelle de l'interventriculaire antérieure (plutôt que du tronc coronaire gauche) a pu également être rapportée dans notre description clinique. Un stenting de cette coronaire a permis de rétablir une perméabilité coronaire « normale ». Le choix du stenting (versus une reprise chirurgicale) s'est fait devant l'accessibilité quasi immédiate au cathétérisme interventionnel pour revasculariser au plus vite la zone ischémique et ainsi préserver le maximum possible de myocarde fonctionnel.

#### 4.4.3 Conclusion :

Une prise en charge multidisciplinaire rapide (chirurgien, réanimateur et cathétériseur interventionnel), chez ce patient, a permis de rattraper une situation clinique particulièrement grave et exceptionnelle.

La valvulation pulmonaire considérée comme un geste chirurgicale simple, n'exclue pas la plus grande vigilance face aux événements coronariens pouvant compliquer cette chirurgie. Toute arythmie ventriculaire qu'on pourrait considérer comme « normale » (chez ces patients qui font souvent des arythmies ventriculaires) dans la phase postopératoire immédiate de RVP (épisode de

tachycardie ventriculaire non soutenue par exemple) nécessite une exploration immédiate coronaire par coronarographie pour démasquer une compression ou une distorsion coronaire.

#### 4.4.4 Références

1. Hawkins JA, Sower CT, Lambert LM, et al. Stentless porcine valves in the right ventricular outflow tract: improved durability? *Eur J Cardiothorac Surg* 2009;35:600–5.
2. Idriss FS, Markowitz A, Nikaidoh H. Insertion of Hancock valve for pulmonary valve insufficiency in previously repaired tetralogy of Fallot. *Circulation* 1976;53,II–100(abstr).
3. Yemets IM, Williams WG, Webb GD, et al. Pulmonary valve replacement late after repair of tetralogy of Fallot. *Ann Thorac Surg* 1997;64:526–530.
4. Discigil B, Dearani JA, Puga FJ, et al. Late pulmonary valve replacement after repair of tetralogy of Fallot. *J Thorac Cardiovasc Surg* 2001;121:344–51.
5. Ramanan S, Doll N, Boethig D, Tafer N, Horke A, Roques X, Hemmer WB, Roubertie F. Pulmonary-Valve Replacement in Adults: Results With the Medtronic Freestyle Valve. *Ann Thorac Surg*. 2015;100:1047-53.
6. Sabate Rotes A, Eidem BW, Connolly HM, et al. Long-term follow-up after pulmonary valve replacement in repaired tetralogy of Fallot. *Am J Cardiol*. 2014;114:901-8.
7. Divekar AA, Lee JJ, Tymchak WJ, Rutledge JM. Percutaneous coronary intervention for extrinsic coronary compression after pulmonary valve replacement. *Catheter Cardiovasc Interv* 2006;67:482-4.
8. Morray BH, McElhinney DB, Cheatham JP, et al. Risk of coronary artery compression among patients referred for transcatheter pulmonary valve implantation: a multicenter experience. *Circ Cardiovasc Interv* 2013;6:535-42.

## Case Report

# Distortion of the Left Anterior Descending Coronary Artery After Pulmonary Valve Replacement

Pierre-Emmanuel Séguéla,<sup>1\*</sup> MD, François Roubertie,<sup>2</sup> MD, and Jean-Benoit Thambo,<sup>3</sup> MD, PhD

Injury of the left main coronary artery may sometimes complicate a pulmonary valve replacement (PVR). We present the case of a 39-year-old man, with post-operative distortion of the left anterior descending coronary artery, which caused onset of ventricular arrhythmia associated with electrocardiographic signs of myocardial ischemia. A coronary angiogram revealed the cause of the lesion. Stenting the coronary artery restored normal coronary blood flow and improved the patient's condition. Through this case, we describe a new life-threatening complication after PVR. © 2015 Wiley Periodicals, Inc.

**Key words:** congenital heart disease; coronary stent; post-operative myocardial ischemia

## INTRODUCTION

Surgical pulmonary valve replacement (PVR) is commonly performed to treat severe pulmonary valve regurgitation in adults with a repaired tetralogy of Fallot. Similar to transcatheter pulmonary valve implantation (TPVI), this procedure may be complicated by coronary injury, mainly compression [1,2]. We report the case of a patient with post-operative left anterior descending coronary artery (LAD) injury caused by distortion of the vessel, which caused a life-threatening condition. Percutaneous stent implantation (PCI) restored normal functioning of the coronary artery.

## CASE REPORT

A male patient had undergone two palliative interventions during infancy for a tetralogy of Fallot. At 3 years of age, he had a complete repair with a transannular patch. All operations were performed through a median sternotomy. At the age of 39, the patient was referred for severe pulmonary valve regurgitation. He was NYHA status II. A preoperative MRI confirmed severe regurgitation, with a right ventricular end-diastolic volume index of 170 mL/m<sup>2</sup> and a preserved right ventricular ejection fraction (45%). The coronary arteries were preoperatively assessed by a CT scan and were considered to have no stenosis or distortion.

Surgery was performed on the beating heart under normothermic cardiopulmonary bypass conditions. After proper calibration, and without undue tension between the pulmonary valve annulus and the bioprosthesis sewing ring, a Carpentier-Edwards® bioprosthetic valve (27 mm) was implanted into the orthotopic position. The patient was weaned off the bypass without difficulty and was taken to the intensive care unit, but then suddenly suffered a short episode of ventricular fibrillation. A twelve-lead electrocardiogram showed elevation of

<sup>1</sup>Congenital and Pediatric Cardiology Unit, Hôpital Haut Lévéque, Avenue de Magellan, 33604 PESSAC, Cedex, France

<sup>2</sup>Cardiovascular Surgery Unit, Hôpital Haut Lévéque, Avenue de Magellan, 33604 PESSAC, Cedex, France

<sup>3</sup>Congenital and Pediatric Cardiology Unit, Hôpital Haut Lévéque, Avenue de Magellan, 33604 PESSAC, Cedex, France

Conflict of interest: None.

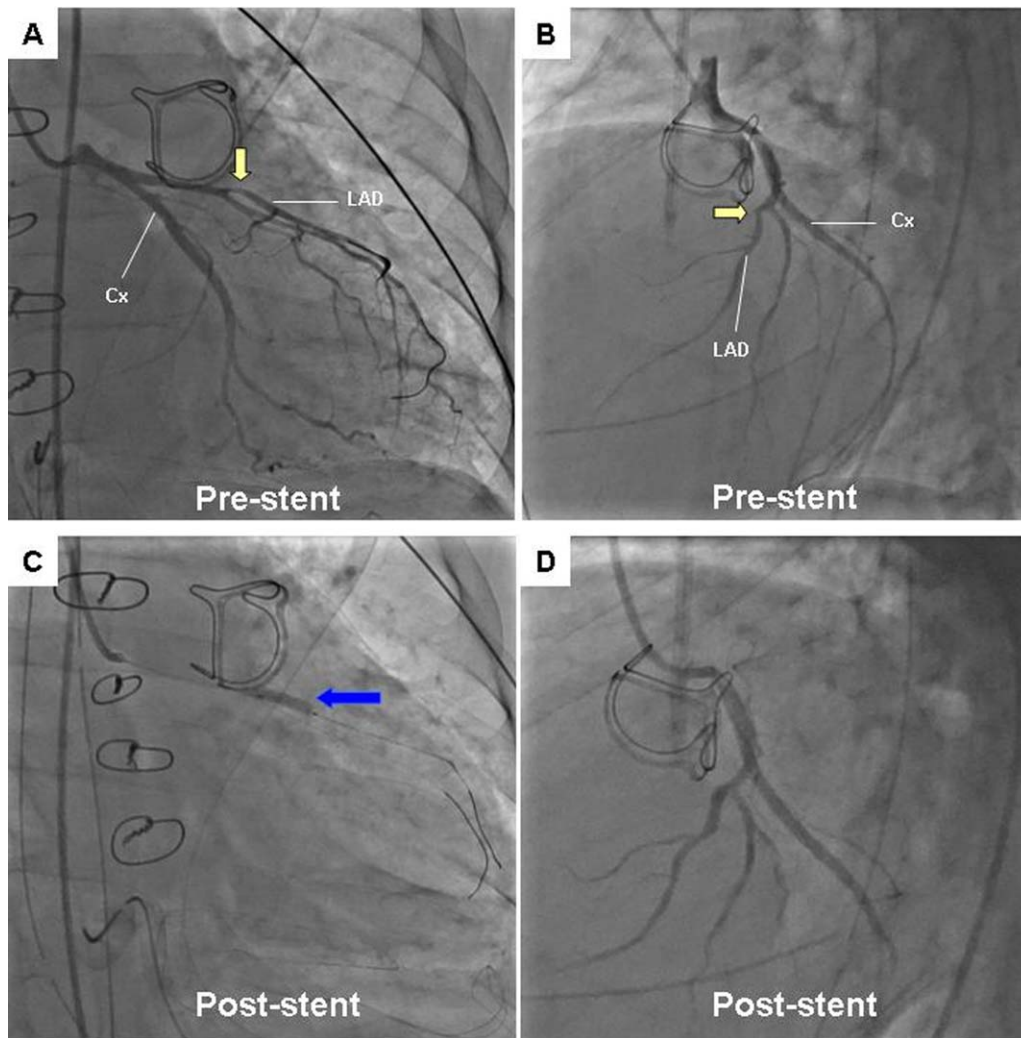
\*Correspondence to: Pierre-Emmanuel Séguéla, Congenital and Pediatric Cardiology Unit, Hôpital Haut Lévéque, Avenue de Magellan, 33604 PESSAC Cedex, France. E-mail: peseguella@yahoo.fr

Received 6 May 2015; Revision accepted 1 October 2015

DOI: 10.1002/ccd.26270

Published online 00 Month 2015 in Wiley Online Library (wileyonlinelibrary.com)





**Fig. 1.** Coronary angiogram. **A:** Selective left coronary angiogram of the right anterior oblique plane and **(B)** the left anterior oblique plane, showing distortion of the proximal left anterior descending coronary artery (LAD) (yellow arrow), which was associated with the sewing ring of the prosthesis. The distance between the ring of the prosthetic valve and the LAD confirmed that the LAD was not externally compressed.

The LAD seemed to be attracted by the epicardial scar tissue, as shown by the abnormal angulation. **C:** A stent (blue arrow) was placed to remove the abnormal angulation of the LAD, **(D)** thus restoring normal coronary flow. Cx: circumflex coronary artery. [Color figure can be viewed in the online issue, which is available at [wileyonlinelibrary.com](http://wileyonlinelibrary.com).]

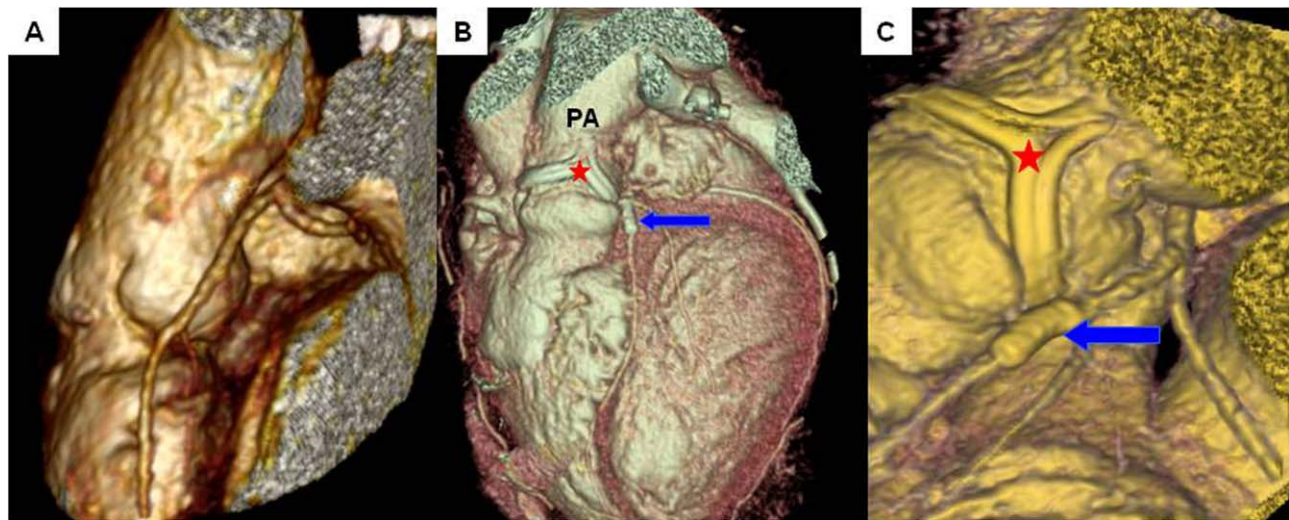
the ST-segment, suggestive of anterior myocardial ischemia. Cardiac troponin I was 10.25 ng/mL. A trans-thoracic echocardiograph revealed global left ventricular dysfunction.

We performed an urgent coronary angiogram, which revealed abnormal angulation of the proximal LAD (Fig. 1). The distance between the sewing ring of the bioprosthetic valve and the LAD, and the shape of the angulation suggested that the underlying mechanism was a distortion rather than external compression. A bare metal stent (Kaname® 2.75 mm × 15 mm; Terumo) was successfully emplaced to restore normal coronary blood flow (Fig. 1). An intra-aortic balloon

pump was inserted and used for 7 days. The patient was weaned off inotropic support on postoperative day 8. The patient recovered normal left ventricular function and was discharged on postoperative day 15, under an oral therapy that combined two antiplatelet agents. A post-procedural CT scan depicted the exact anatomical relationship between the LAD and the bioprosthesis, and the patency of the coronary artery (Fig. 2).

## DISCUSSION

Post-operative injury of the left coronary artery is a rare event that occurs mostly after aortic-valve



**Fig. 2.** Volume-rendered CT scan. **A:** Preoperative CT scan showing the normal course and the normal caliber of the LAD before redo surgery. **B:** CT scan showing the anatomical relationship between the ring of the prosthetic valve (red star) and the expanded stent (blue arrow), and **(B)** the near normal axis and angulation of the LAD after stent deployment. PA: Pulmonary artery. [Color figure can be viewed in the online issue, which is available at [wileyonlinelibrary.com](http://wileyonlinelibrary.com).]

replacement [3]. This complication is mostly represented by extrinsic compression of the left main stem. Owing to the fact that the left main stem is in close proximity to the pulmonary root, coronary compression may also complicate PVR or TPVI, especially in patients with a tetralogy of Fallot and/or a coronary anomaly [1,2]. To avoid this issue, which is observed in 5% of cases of TPVI, accurate pre-procedural delineation of the course of the proximal coronary artery is required [2]. Even if the coronary arteries are far from the right ventricular outflow tract, it is impossible to predict, using a pre-procedural CT scan and/or an MRI, in what direction the conduit will open during balloon dilation, which makes angiography always necessary before TPVI. During open-heart surgery, dense adhesions within the pericardium can make difficult to identify the course of the coronary artery, which means that the risk of coronary compression remains.

While a compression mostly affects the left main stem, (which is posterior to the pulmonary artery trunk), the LAD remains classically free of injury (due to its lateral course). However, we assumed that, in our case, the underlying mechanism was caused by distortion of the LAD rather than extrinsic compression by the bioprosthesis sewing ring. Indeed, an angiogram showed that the angulation of the LAD had caused this condition. Furthermore, at the time of surgery, the bioprosthesis had fitted the pulmonary valve annulus without undue tension. Fibrous adhesions within the pericardium, secondary to previous surgeries, could have been responsible for the lack of pliability of the epicardial tissue, and may explain why this distortion

occurred. Intravascular ultrasound, a technique that could have helped us to determine the mechanism of coronary injury, was not performed because of the extreme hemodynamic instability of the patient.

Because of the variable relationship between the circumflex coronary artery and the mitral valve, direct injury or distortion of the circumflex coronary artery is a well-known complication of mitral-valve repair/replacement. Similarly, the distance between the LAD and the pulmonary valve may vary from patient to patient. Therefore, a continuous suture line is more likely to distort the LAD when it is close to the pulmonary annulus.

As a surgical revision is efficient to release the adhesions surrounding the coronary vessel, PCI is debatable in this context. In addition, surgery avoids stent-related issues, especially in young patients. Decision for percutaneous or surgical treatment largely depends on the local interventional and surgical expertise. For our patient, PCI was immediately available and was considered to be the best option to increase the potential for a viable myocardium. Indeed, PCI is increasingly used as a remedy for acute myocardial ischemia caused by iatrogenic injury of the coronary artery [1,3,4]. Moreover, some authors consider PCI to be the treatment of choice in the context of hemodynamic instability and on-going myocardial ischemia. In cases of focal coronary artery disease (short stent, no overlap, and no coronary artery disease), the risk of stent thrombosis is theoretically less than that for atherosclerotic coronary artery disease, particularly when patients receive a dual antiplatelet therapy [5].

## CONCLUSION

As with coronary compression, PVR can be complicated by distortion of the LAD. This rare event should be considered in cases of post-operative myocardial ischemia. In this case, PCI was safe and efficient for a patient with hemodynamic instability.

## ACKNOWLEDGMENT

The authors warmly thank Lionel Leroux for his help in performing coronary angiogram.

## REFERENCES

1. Divekar AA, Lee JJ, Tymchak WJ, Rutledge JM. Percutaneous coronary intervention for extrinsic coronary compression after pulmonary valve replacement. *Catheter Cardiovasc Interv* 2006; 67:482–484.
2. Morray BH, McElhinney DB, Cheatham JP, Zahn EM, Berman DP, Sullivan PM, Lock JE, Jones TK. Risk of coronary artery compression among patients referred for transcatheter pulmonary valve implantation: A multicenter experience. *Circ Cardiovasc Interv* 2013; 6:535–542.
3. Mirkovic T, Knezevic I, Breclj A, Kranjec I, Noc M. Extrinsic left main compression: Review of the literature. *J Interv Cardiol* 2009;22:550–555.
4. Schneider M, Wiebe W, Hraška V, Zartner P. Coronary interventions in congenital heart diseases: From preterm to young adult patients. *J Interv Cardiol* 2013;26:287–294.
5. Chaikriangkrai K, Polsani V, Wei L, Kleiman N, Chang SM. Stenting of a left main coronary artery compressed by a dilated main pulmonary artery. *Catheter Cardiovasc Interv* 2013;82: E684–E687.

## 4.5 Cinquième travail : prise en charge d'une fuite tricuspidiennne significative, lors du RVP, chez l'adulte avec TF réparée :

### 4.5.1 Introduction

La valvulation pulmonaire, chez les adultes avec TF réparée, est associée à plusieurs questions dont les réponses restent soumises à controverse. Le remplacement d'une aorte ascendante dilatée ou l'abstention, lors de la valvulation pulmonaire, est une de ces questions (1). Une autre question concerne la prise en charge des insuffisances tricuspides significatives au moment de la valvulation pulmonaire, avec de rares données sur lesquelles s'appuyées dans la littérature (2-5), pour pouvoir prendre un décision.

Aujourd'hui, il est clairement établi qu'une plastie tricuspide est bénéfique pour les patients qui ont une fuite tricuspide significative, au moment de la réalisation de pontages coronaires ou d'un remplacement valvulaire mitral, voire aortique ; c'est à dire en cas de dysfonction ventriculaire gauche prédominante, d'origine ischémique ou valvulaire (6). Une stratégie similaire reste à démontrer en ce qui concerne les atteintes prédominantes du VD, avec fuite tricuspide associée, comme dans la tétralogie de Fallot réparée.

La présence d'une fuite tricuspide significative (modérée ou sévère) est retrouvée chez 19% (7) à 52% (2) des patients avec une indication de valvulation pulmonaire. Le mécanisme principal de la fuite tricuspide est la dilatation de l'anneau, secondaire à la dilatation du VD, elle-même secondaire à l'IP. Certaines équipes réalisent une plastie tricuspide systématiquement pour les fuites tricuspides significatives au moment du RVP (3). Aux critères « classiques » faisant porter l'indication de valvulation pulmonaire (8) chez les patients avec TF réparée, ces mêmes équipes (3) rajoutent comme autre critère, l'apparition ou l'aggravation d'une fuite tricuspide associée à une dilatation du VD.

D'autres équipes (2) ont montré que la réalisation ou non d'une plastie tricuspide, en cas de fuite tricuspide significative lors de la valvulation pulmonaire, n'avait pas d'incidence sur le degré de la fuite en postopératoire ; la fuite tricuspide était toujours significativement réduite à 6 mois postopératoire, avec ou sans plastie tricuspide associée. Les auteurs concluaient à une absence d'intérêt de

la plastie tricuspide pour cette population de patient; à noter dans cette série (2), que le groupe qui avait bénéficié d'une plastie tricuspide avait une fuite tricuspide plus importante par rapport au groupe sans plastie (2.7 vs 2.2,  $p=0.008$ ), ainsi qu'un anneau tricuspide plus dilaté en pré-opératoire. Kogon et al. (4) ont rapporté des résultats similaires chez 35 patients avec fuite tricuspide significative : 16 ont eu une plastie tricuspide et 19 ont eu une valvulotomie pulmonaire isolée. A 1 mois post-opératoire, tous les patients avaient une diminution de leur fuite tricuspide, associée à une diminution des volumes du VD. Le même groupe (5) a montré que la plastie tricuspide pouvait même être délétère dans ce contexte, avec une incidence plus importante à long-terme de fuite tricuspide dans le groupe de malade où une plastie avait été réalisée.

Ces résultats, très contradictoires, nous ont conduit à étudier dans notre cohorte de patients, les résultats de la prise en charge d'une fuite tricuspide significative lors du RVP. (Cf ; en annexe, l'article soumis à *European Heart Journal* : *Roubertie F., Séguéla PE et al. Tricuspid Valve Repair Associated To Pulmonary Valve Replacement In Adults With Repaired Tetralogy Of Fallot*).

#### 4.5.2 Résultats

**Pour les fuites tricuspides modérées**, nos résultats étaient similaires à ceux déjà publiés (2, 4); les patients avaient tous une réduction significative de leur fuite tricuspide avec la valvulotomie pulmonaire, qu'elle soit associée ou non à une plastie de la valve tricuspide.

Contrairement à ce qui a été publié dans la littérature (2-5), nous avons montré dans ce travail que la plastie tricuspide avait un intérêt majeur pour **les fuites tricuspides pré-opératoires sévères** ; en effet, nous ne rapportons aucun cas de fuite tricuspide postopératoire significative dans le groupe valvulotomie pulmonaire et plastie tricuspide, contre 80% de fuite postopératoire significative dans le groupe sans plastie tricuspide ( $p=0.002$ ).

L'insuffisance tricuspide est souvent d'origine fonctionnelle, liée dans la majorité des cas à une dilatation de l'anneau, secondaire à la dilatation du VD. Nous avons mis en évidence dans ce travail, un facteur de risque, jamais décrit, de fuite tricuspide significative au moment de la valvulotomie

pulmonaire : il s'agit de la détection à l'échocardiographie, d'une fuite tricuspide significative, dans la première année postopératoire suivant la cure complète de tétralogie de Fallot ( $p < 0.001$ ).

### 4.5.3 Conclusion

La valvulation pulmonaire, chez les patients avec TF réparée, se fait souvent chez des patients multi-opérés. Tout geste chirurgical associé lors du RVP nécessite de peser le rapport bénéfice/risque attendu de ce geste; en effet, des études ont montré que tout geste chirurgical secondaire associé à l'acte chirurgical principal était un facteur de risque de morbi-mortalité supplémentaire (5). Nous avons montré pour la première fois que la plastie tricuspide au moment de la valvulation pulmonaire, pour les fuites tricuspides sévères, étaient bénéfiques pour les patients et qu'elle s'accompagnait non seulement d'une diminution de la fuite tricuspide mais également d'une amélioration du stade clinique NYHA chez ces patients ( $p = 0.002$ ).

Ces résultats, qui sont nouveaux dans la littérature, seront à confirmer par d'autres équipes.



#### 4.5.4 Références

1. Kogon BE, Rosenblum JM, Mori M. Current Readings: Issues Surrounding Pulmonary Valve Replacement in Repaired Tetralogy of Fallot. *Semin Thorac Cardiovasc Surg*. 2015;27:57-64.
2. Cramer JW, Ginde S, Hill GD, et al: Tricuspid repair at pulmonary valve replacement does not alter outcomes in tetralogy of Fallot. *Ann Thorac Surg* 2015;99:899-904.
3. Said SM, Dearani JA, Burkhart HM, et al. Management of tricuspid regurgitation in congenital heart disease: is survival better with valve repair? *J Thorac Cardiovasc Surg* 2014;147:412-417.
4. Kogon B, Patel M, Leong T, McConnell M, Book W. Management of moderate functional tricuspid valve regurgitation at the time of pulmonary valve replacement: is concomitant tricuspid valve repair necessary? *Pediatr Cardiol* 2010;31:843-848.
5. Kogon B, Grudziak J, Sahu A, et al. Surgery in adults with congenital heart disease: Risk factors for morbidity and mortality. *Ann Thorac Surg* 2013;95:1377-1382
6. Rogers JH, Bolling SF. The tricuspid valve: current perspective and evolving management of tricuspid regurgitation. *Circulation* 2009;119:2718-2725.
7. Kobayashi J, Kawashima Y, Matsuda H, et al. Prevalence and risk factors of tricuspid regurgitation after correction of tetralogy of Fallot. *J Thorac Cardiovasc Surg* 1991;102:611-616.
8. Geva T. Indications for pulmonary valve replacement in repaired tetralogy of Fallot: the quest continues. *Circulation* 2013;128:1855-1857.

### 4.5.5 Perspective clinique concernant la régurgitation tricuspide chez les adultes avec TF réparée

Notre étude apporte de nouvelles données en ce qui concerne la prise en charge de la fuite tricuspide, puisqu'il apparaît que la plastie est bénéfique pour les fuites sévères. Quelques équipes prônent une attitude de plastie tricuspide pour les fuites sévères (1), lors de la valvulation pulmonaire chez les adultes avec TF réparée, sans apporter de données concernant les résultats d'une telle stratégie ; ces mêmes équipes soulignent l'absence de consensus sur cette question.

On pourrait imaginer mener une étude française multicentrique prospective, mais également dans un premier rétrospective, pour essayer de confirmer les résultats de notre travail.

### Autre perspective clinique : est-il envisageable au moment de la réparation complète des TF d'éviter la fuite valvulaire pulmonaire ?

Autrement dit, peut-on préparer l'avenir lors de la première chirurgie ? Dans l'idéal, la chirurgie des TF doit répondre à 3 impératifs qui sont : 1 fermer la CIV / 2 levée la sténose infundibulaire, en préservant la fonction et la géométrie du VD et en limitant les cicatrices au maximum sur celui-ci / et 3 garder une valve pulmonaire compétente.

La chirurgie d'une TF (levée de l'obstacle infundibulaire +/- valvulaire pulmonaire) est souvent incompatible avec les 2 derniers impératifs. Depuis 50 ans et les premières cures complètes de TF, les progrès chirurgicaux ont été constants et ont essayé de tendre vers cet idéal. Les premières chirurgies se faisaient par voie trans-ventriculaire, avec une résection extensive, voire exagérer de l'obstacle infundibulaire, ce qui laissait des fuites pulmonaires libres et des cicatrices ventriculaires importantes (2) (Figure 1, chapitre préambule).

Les connaissances sur les conséquences de la fuite pulmonaire vont progressivement évoluer. Elle fut considérée au départ comme bénigne, car sans différence retrouvée à long terme en ce qui concerne le stade NYHA, entre les patients avec anneaux préservés ou avec patch trans-annulaire (3, 4). Plus tard, la fuite pulmonaire est apparue être à l'origine de la dysfonction ventriculaire droite (5) et à l'origine d'une majeure partie des troubles du rythme (6). L'idée de laisser une voie de sortie du



VD sans la moindre sténose résiduelle va évoluer vers le fait de laisser une sténose résiduelle modérée (7), qui apparaît moins délétère avec le temps.

Les techniques chirurgicales vont s'adapter à cette stratégie : c'est la cas de la technique dite « atrio-pulmonaire » (8, 9) (**Figure 2**, chapitre préambule). Cette technique visait à réaliser la chirurgie sans faire d'incision ventriculaire : la fermeture de la CIV et la résection de l'obstacle infundibulaire étaient effectuées par voie trans-atriale et trans-tricuspide. Une incision du tronc de l'artère pulmonaire permettait de réaliser, en complément, une commissurotomie de la valve pulmonaire, en cas de fusion commissural. Si l'anneau pulmonaire devait être ouvert, c'était au prix d'une incision très courte de l'infundibulum. (**Figure 3, 4 et 5** en annexe de ce chapitre)

Plus récemment encore, des techniques de préservation de la valve pulmonaire native sont apparues, avec des plasties d'élargissement des valvules pulmonaires, qui sont réalisables même lors de la mise en place de patch trans-annulaire (10-13) ; ces nouvelles techniques sont censées réduire l'IP postopératoire (**Figure 6** en annexe de ce chapitre). Des évaluations, ne serait-ce qu'à moyen terme, n'existent pas aujourd'hui.

La technique atrio-pulmonaire ou les techniques encore plus récentes de réparation valvulaire ne montreront une éventuelle amélioration des résultats et de la fonction ventriculaire droite que dans une, voire deux décennies... les premiers résultats paraissent prometteurs (14).

Nous avons, à Bordeaux, mis en place un protocole de préservation valvulaire après cure complète de TF : soit en réalisant une plastie de valve avec du péricarde autologue, soit en implantant une monocusp en goretex. Les premiers résultats de court terme sont prometteurs avec une absence de fuite pulmonaire chez ces patients alors que l'anneau pulmonaire avait été ouvert. Des analyses à moyen terme dans un premier temps, et à long terme dans un deuxième temps, permettront de valider cette stratégie comme pouvant préserver la fonction ventriculaire droite.

### 4.5.6 Références

1. Sabate Rotes A, Eidem BW, Connolly HM, et al. Long-term follow-up after pulmonary valve replacement in repaired tetralogy of Fallot. *Am J Cardiol.* 2014;114:901-8.
2. Kirklin JW, Blackstone EH, Pacifico AD, Kirklin JK, Bargeron LM Jr. Risk factors for early and late failure after repair of tetralogy of Fallot, and their neutralization. *Thorac Cardiovasc Surg* 1984; 32: 208–14.
3. Bacha EA, Scheule AM, Zurakowski D, et al. (2001) Long-term results after early primary repair of tetralogy of Fallot. *J Thorac Cardiovasc Surg* 122, 154–161.
4. Kirklin JK, Kirklin JW, Blackstone EH, et al. (1989) Effect of transannular patching on outcome after repair of tetralogy of Fallot. *Ann Thorac Surg* 48, 783–791.
5. Roest AA, Helbing WA, Kunz P, et al. (2002) Exercise MR imaging in the assessment of pulmonary regurgitation and biventricular function in patients after tetralogy of Fallot repair. *Radiology* 223, 204–211
6. Gatzoulis MA, Balaji S, Webber SA, et al. (2000) Risk factors for arrhythmia and sudden cardiac death late after repair of tetralogy of Fallot: a multicentre study. *Lancet* 356, 975–981.
7. Van Arsdell G, Yun TJ. An apology for primary repair of tetralogy of Fallot. *Semin Thorac Cardiovasc Surg Pediatr Card Surg Annu* 2005: 128–31.
8. Karl TR, Sano S, Pornviliwan S, Mee RB. Tetralogy of Fallot: favorable outcome of nonneonatal transatrial, transpulmonary repair. *Ann Thorac Surg* 1992; 54: 903–07.

9. Stewart RD, Backer CL, Young L, et al. (2005) Tetralogy of Fallot: results of a pulmonary valve-sparing strategy. *Ann Thorac Surg* 80, 1431–1438; discussion 1438–1439.

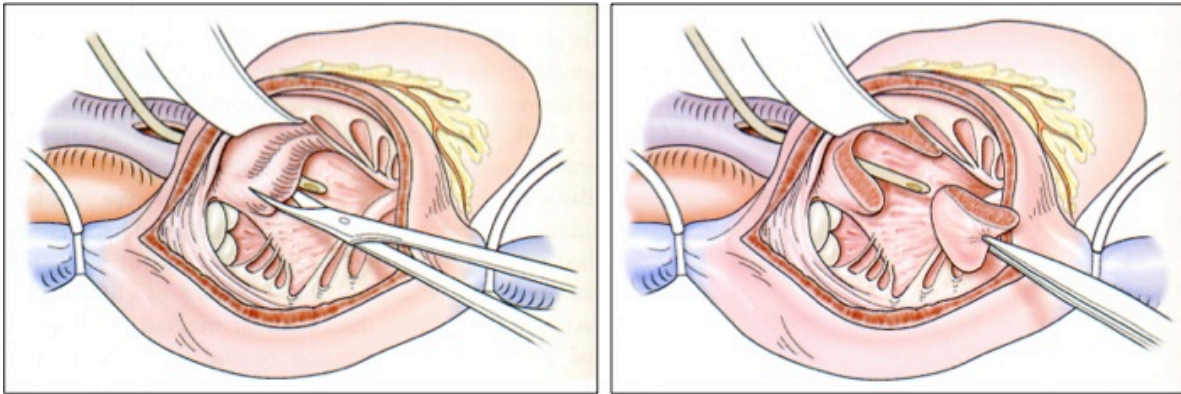
10. Vida VL, Angelini A, Guariento A, Frescura C, Fedrigo M, Padalino M, Sanders SP, Thiene G, Stellin G. Preserving the pulmonary valve during early repair of tetralogy of Fallot: Anatomic substrates and surgical strategies. *J Thorac Cardiovasc Surg*. 2015 May;149(5):1358-63.

11. Sung SC, Kim S, Woo JS, et al. Pulmonic valve annular enlargement with valve repair in tetralogy of Fallot. *Ann Thorac Surg* 2003;75:303- 305

12. Anagnostopoulos P, Azakie A, Natarajan S, et al. Pulmonary valve cusp augmentation with autologous pericardium may improve early outcome for tetralogy of Fallot. *J Thorac Cardiovasc Surg* 2007;133:640- 647

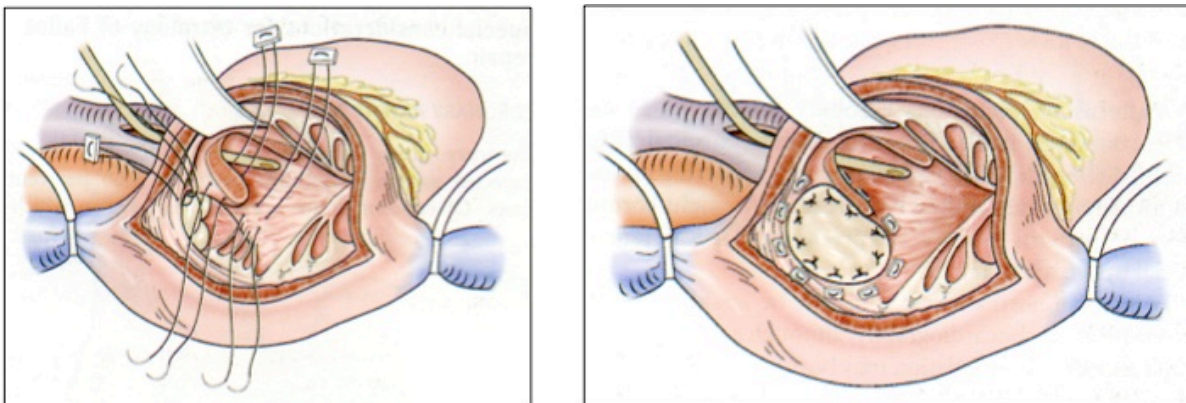
13. Bacha E. Valve-sparing options in tetralogy of Fallot surgery. *Semin Thorac Cardiovasc Surg Pediatr Card Surg Annu*. 2012;15:24-6.

14. Stellin G, Milanesi O, Rubino M, et al. (1995) Repair of tetralogy of Fallot in the first six months of life: transatrial versus transventricular approach. *Ann Thorac Surg* 60(6 Suppl), S588–S591.



**Figure 3. Réparation de TF par voie trans-atriale ou voie atriopulmonaire.**

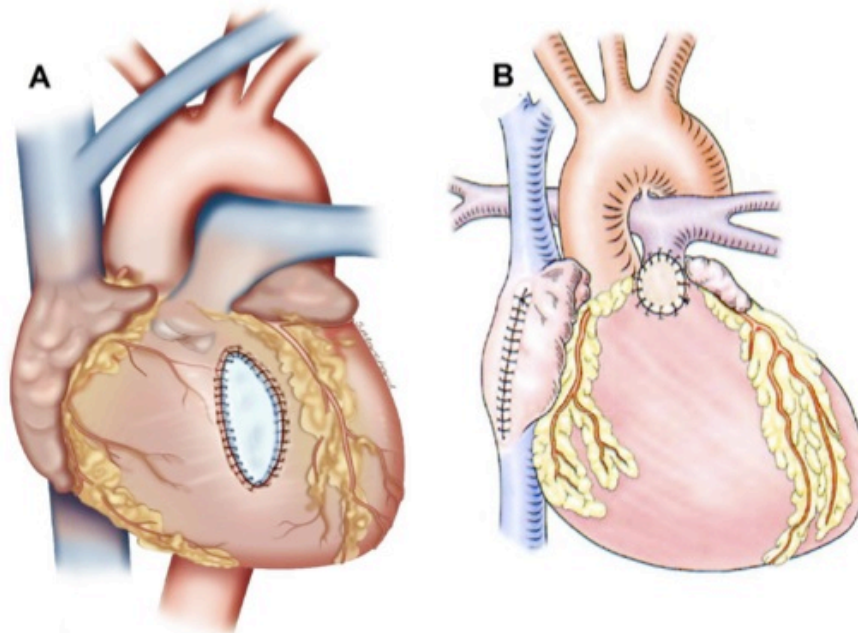
La sténose musculaire infundibulaire est levée au travers de l'orifice tricuspide. Le tronc de l'artère pulmonaire est ouvert pour vérifier la valve pulmonaire (éventuellement une commissurotomie est réalisée).



**Figure 4. Réparation de TF par voie trans-atriale ou voie atriopulmonaire.**

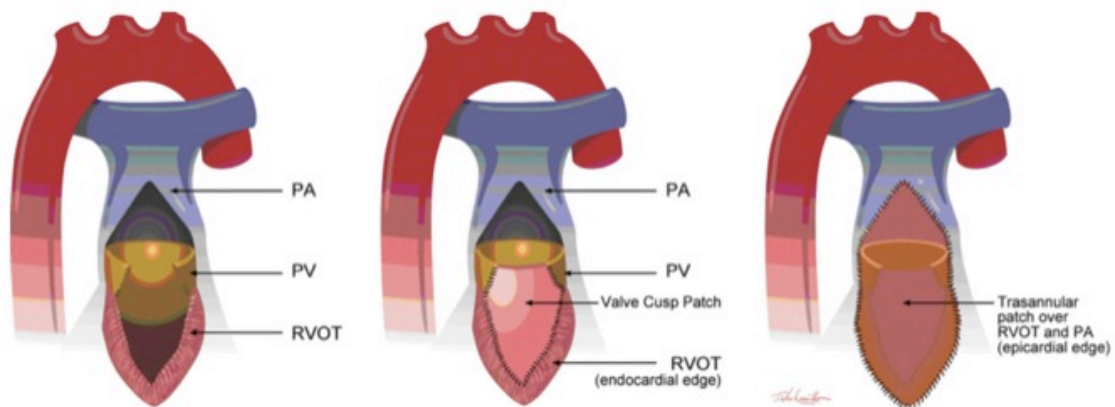
La communication interventriculaire est fermée au travers de l'orifice tricuspide. A droite de l'image, le patch de fermeture de la CIV est mis en place.

**Figure 3, 4 et 5** : issues de Gardner et Spray. Operative Cardiac Surgery. Fifth Edition. Editeur : Hodder Arnold 2004;589-703.



**Figure 5. Comparaison des cicatrices laissées sur le VD après réparation complète de TF.**

- A. Voie trans-ventriculaire: long patch alors que l'anneau n'est pas ouvert.
- B. Voie atrio-pulmonaire: patch (et donc cicatrice) très court, alors que l'anneau pulmonaire est ouvert: il s'agit donc d'un patch trans-annulaire.



*Bacha. Semin Thorac Cardiovasc Surg Pediatr Card Surg Annu. 2012*

**Figure 6. Plastie de reconstruction d'une valvule pulmonaire à l'aide d'un patch péricardique autologue.**

Dans cet exemple, il y a mise en place d'un patch trans-annulaire.

(PA = tronc de l'artère pulmonaire; RVOT = voie de sortie du VD; PV = valve pulmonaire).



# European Heart Journal

## TRICUSPID VALVE REPAIR ASSOCIATED TO PULMONARY VALVE REPLACEMENT IN ADULTS WITH REPAIRED TETRALOGY OF FALLOT --Manuscript Draft--

|  |   |
|--|---|
| <b>Manuscript Number:</b>                            |   |
| <b>Full Title:</b>                                   | TRICUSPID VALVE REPAIR ASSOCIATED TO PULMONARY VALVE REPLACEMENT IN ADULTS WITH REPAIRED TETRALOGY OF FALLOT  |
| <b>Article Type:</b>                                 | Clinical paper  |
| <b>Keywords:</b>                                     | Tetralogy of Fallot; Congenital heart disease; Pulmonary valve replacement; Tricuspid regurgitation; Tricuspid valve repair.  |
| <b>Corresponding Author:</b>                         | Pierre-Emmanuel Séguéla, M.D.<br>Centre Chirurgical Marie-Lannelongue<br>Le Plessis-Robinson, FRANCE  |
| <b>Corresponding Author Secondary Information:</b>   |   |
| <b>Corresponding Author's Institution:</b>           | Centre Chirurgical Marie-Lannelongue  |
| <b>Corresponding Author's Secondary Institution:</b> |   |
| <b>First Author:</b>                                 | François Roubertie  |
| <b>First Author Secondary Information:</b>           |   |
| <b>Order of Authors:</b>                             | François Roubertie<br>Pierre-Emmanuel Séguéla, M.D.<br>Zakaria Jalal<br>Xavier Iriart<br>Xavier Roques<br>Bernard Kreitmann<br>Mohammed Al-Yamani<br>Jean-Benoit Thambo   |
| <b>Order of Authors Secondary Information:</b>       |   |
| <b>Abstract:</b>                                     | <p>Pulmonary valve replacement (PVR) is often performed in adults with repaired tetralogy of Fallot (TOF). For patients who have tricuspid regurgitation (TR), tricuspid valve repair (TVR) associated to PVR is still debating.</p> <p><b>Aims:</b> We sought to evaluate the interest of TVR at the time of PVR.</p> <p><b>Methods and results:</b> We retrospectively reviewed 104 patients with repaired TOF (or its equivalent) who underwent PVR (2002-2014). Mean age at initial complete correction and at PVR was <math>1.5 \pm 0.5</math> years and <math>26.3 \pm 9.5</math> years, respectively. Forty-one patients had significant preoperative TR: 24 were moderate (group-M) and 17 were severe (group-S). A total of 16 TVR were performed (8 for each group). Moderate and severe tricuspid regurgitation observed in the first year following the initial complete repair were significantly associated with severe TR at PVR (<math>p &lt; 0.001</math>). Annulus tricuspid valve dilation was significantly associated with moderate/severe tricuspid regurgitation at PVR (<math>p &lt; 0.001</math>). Early postoperative mortality after PVR was 1.9%. There was 100% follow-up of survivors at a mean of <math>4.6 \pm 2.9</math> years. Survival was 98% at 1 and 5 years. In group-M patients, TR was improved regardless of TVR. Whereas, in the group-S, a residual significant TR was reported in 7 patients who did not have TVR, no case was observed for patients who underwent concomitant TVR (<math>p = 0.002</math>). Among these patients with residual significant TR, 2 needed a tricuspid valve replacement. The functional status (NYHA classification) of group-S patients was significantly improved by concomitant TVR.</p> <p><b>Conclusions:</b> In adults with repaired TOF, TVR is a safe procedure when performed at</p> |

|   |   |
|---|---|
|   | the time of PVR. In case of severe preoperative TR, TVR improves both tricuspid valve function and functional status of the patients at mid-term follow-up. |
| <b>Suggested Reviewers:</b>   | Tal Geva<br>tal.geva@cardio.chboston.org<br>Well-known specialist in the field of congenital heart disease  |
| <b>Additional Information:</b>  |   |
| <b>Question</b>   | <b>Response</b>   |
| Did you cite ESC guidelines where appropriate?  | yes   |
| Some manuscripts may not be able to be published in the European Heart Journal. In such cases, a paper might be considered suitable for another journal from the ESC family. If the editors think your paper may be appropriate for another ESC journal, would you like it to be transferred to that journal's editors for consideration? | No, I do not want my submission to be considered for transfer   |
| As Corresponding Author, I take full responsibility for all information declared in this notification.  | Yes   |
| As Corresponding Author, I agree to be the principal correspondent with the Editorial Office, review the edited manuscript and proof, and make decisions about releasing manuscript information to the media, federal agencies, etc.  | Yes   |
| All persons who have made substantial contributions to the manuscript (e.g. data acquisition, analysis, or writing / editing assistance), but who do not fulfill authorship criteria, are named with their specific contributions in the Acknowledgements Section of the manuscript.  | Yes   |
| All persons named in the Acknowledgements Section have provided the Corresponding Author with written permission to be named in the manuscript.   | Yes   |
| If an Acknowledgements Section is not included in the paper then no other persons have made substantial contributions to this manuscript.   | Yes   |
| Please enter the names of the authors who <b>&lt;b&gt;&lt;i&gt;Conceived and designed the research&lt;/i&gt;&lt;/b&gt;</b>  | François Roubertie<br>Pierre-Emmanuel Séguéla<br>Xavier Roques<br>Bernard Kreitmann   |
| Please enter the names of the authors who <b>&lt;b&gt;&lt;i&gt;Performed statistical analysis&lt;/i&gt;&lt;/b&gt;</b>   | François Roubertie<br>Mohammed El-Yamani  |
| Please enter the names of the authors who <b>&lt;b&gt;&lt;i&gt;Acquired the data&lt;/i&gt;&lt;/b&gt;</b>  | François Roubertie<br>Zakaria Jalal<br>Xavier Iriart  |

|  |   |
|--|---|
| Please enter the names of the authors who <b>&lt;b&gt;&lt;i&gt;Drafted the manuscript&lt;/b&gt;&lt;/i&gt;</b>  | Pierre-Emmanuel Séguéla                                       |
| Please enter the names of the authors who <b>&lt;b&gt;&lt;i&gt;Made critical revision of the manuscript for key intellectual content&lt;/b&gt;&lt;/i&gt;</b>                 | François Roubertie<br>Bernard Kreitmann<br>Jean-Benoit Thambo |
| Please enter the names of the authors who did anything else on the manuscript other than what we have listed:  | Anyone  |
| This manuscript represents valid and substantiated work.   | Yes   |
| If asked, I will provide or fully cooperate in obtaining and providing the original data on which the manuscript is based so the editors or their designates can examine it. | Yes   |
| The paper under question is being submitted by an ESC Working Group.   | No  |
| Each person listed as co-author has been entered as contributing to at least one part of the manuscript  | Yes   |





**Pr Jean-Benoit THAMBO**  
*Professeur des universités  
Praticien hospitalier  
Chef de service*

**Dr Xavier IRIART**  
*Cardiologue*  
**Dr Jean-Baptiste MOUTON**  
**Dr Pierre-Emmanuel SEQUELA**  
*Pédiatres - Soins Intensifs et réanimation*  
**Dr Julie THOMAS-CHABANEIX**  
*Cardiologie congénitale du fœtus à l'adulte  
Praticiens hospitaliers*

**Dr Jean-Bernard SELLY**  
**Dr Marie VENIARD-NELSON**  
*Chefs de clinique - Assistants*

**Dr Romain GIRARDOT**  
**Dr Maria JIMENEZ**  
*Praticiens attachés*

**Dr Pierre BORDACHAR**  
*Rythmologie congénitale  
enfants et adultes*  
**Dr Frédéric SACHER**  
*Electrophysiologie congénitale  
enfants et adultes*

**Dr Caroline ROORYCK-THAMBO**  
*Cardiogénétique*  
**Dr Romain GIRARDOT**  
*Echographie fœtale*  
**Dr Karine NUBRET-LE CONIAT**  
*Transplantation cardio-thoracique*  
**Rendez-vous Tél. 05 57 65 61 10**  
**Rendez-vous urgent Tél. 05 57 65 65 38**

**Cécile ESCOBEDO**  
*Psychologue*  
Tél. 05 57 65 68 40 - Poste 56 840

---

**Secrétariats**  
Fax 05 57 65 68 28  
**Consultations sur rendez-vous**  
Tél. 05 57 65 61 10  
**Hospitalisation de jour enfants**  
Tél. 05 57 65 61 09  
**Hospitalisation adultes et enfants**  
Tél. 05 57 65 64 65

---

**Hospitalisation enfants 6e Ouest**  
**Sandrine LESUEUR**  
*Cadre de santé*  
Tél. 05 57 65 68 95 / 05 57 65 62 78  
05 57 65 65 35 (secteur nourrissons)  
05 57 65 67 95 (urgences 24h/24)  
Fax 05 57 65 61 58

**Hospitalisation adultes 6e Est**  
**Nathalie BISBAU**  
*Cadre de santé*  
Tél. 05 57 65 60 92  
Tél. 05 57 65 64 28 - Fax 05 57 65 68 28

prenom-compose.nom-compose@chu-bordeaux.fr

Bordeaux, the 6<sup>th</sup> of November 2015.

Dear Editor,

Please find enclosed our manuscript entitled "Tricuspid valve repair associated to pulmonary valve replacement in adults with repaired tetralogy of Fallot".

We are honored to present you a single center retrospective study on the interest of tricuspid valve repair when performed at the time of pulmonary valve replacement in repaired tetralogy of Fallot. Indeed, this cohort is the largest ever reported in this particular population of adults with congenital heart disease (which is an increasing challenge for both cardiologists and surgeons). We believe that this issue could be of interest for your readers.

Hoping that this work will interest you and looking forward to hearing from you,

Yours sincerely,

Dr Pierre-Emmanuel Séguéla, Corresponding author.

**TRICUSPID VALVE REPAIR ASSOCIATED TO PULMONARY VALVE REPLACEMENT  
IN ADULTS WITH REPAIRED TETRALOGY OF FALLOT**

**Tricuspid regurgitation and pulmonary valve replacement**

François Roubertie, MD<sup>1</sup>; Pierre-Emmanuel Séguéla, MD<sup>2</sup>; Zakaria Jalal, MD<sup>2</sup>; Xavier Iriart, MD<sup>2</sup>;  
Xavier Roques, MD, PhD<sup>1</sup>; Bernard Kreitmann, MD, PhD<sup>1</sup>; Mohammed Al-Yamani, MD<sup>1</sup>; Jean-  
Benoît Thambo, MD, PhD<sup>2</sup>.

<sup>1</sup> Department of Cardiovascular Surgery, Bordeaux University Hospital, France

<sup>2</sup> Department of Pediatric Cardiology, Bordeaux University Hospital, France

**Corresponding author:**

Dr Pierre-Emmanuel Séguéla

Department of Pediatric cardiology

Hôpital Haut Lévêque – Bordeaux University Hospital

Avenue de Magellan

33600 Pessac, France

Phone: +33 557656456

Fax: +33 557656452

Email: [peseguella@yahoo.fr](mailto:peseguella@yahoo.fr)

**Word count:** 4900.

**Disclosure of interest:** None.

## Abstract

Pulmonary valve replacement (PVR) is often performed in adults with repaired tetralogy of Fallot (TOF). For patients who have tricuspid regurgitation (TR), tricuspid valve repair (TVR) associated to PVR is still debating.

**Aims:** We sought to evaluate the interest of TVR at the time of PVR.

**Methods and results:** We retrospectively reviewed 104 patients with repaired TOF (or its equivalent) who underwent PVR (2002-2014). Mean age at initial complete correction and at PVR was  $1.5 \pm 0.5$  years and  $26.3 \pm 9.5$  years, respectively. Forty-one patients had significant preoperative TR: 24 were moderate (group-M) and 17 were severe (group-S). A total of 16 TVR were performed (8 for each group). Moderate and severe tricuspid regurgitation observed in the first year following the initial complete repair were significantly associated with severe TR at PVR ( $p < 0.001$ ). Annulus tricuspid valve dilation was significantly associated with moderate/severe tricuspid regurgitation at PVR ( $p < 0.001$ ). Early postoperative mortality after PVR was 1.9%. There was 100% follow-up of survivors at a mean of  $4.6 \pm 2.9$  years. Survival was 98% at 1 and 5 years. In group-M patients, TR was improved regardless of TVR. Whereas, in the group-S, a residual significant TR was reported in 7 patients who did not have TVR, no case was observed for patients who underwent concomitant TVR ( $p = 0.002$ ). Among these patients with residual significant TR, 2 needed a tricuspid valve replacement. The functional status (NYHA classification) of group-S patients was significantly improved by concomitant TVR.

**Conclusions:** In adults with repaired TOF, TVR is a safe procedure when performed at the time of PVR. In case of severe preoperative TR, TVR improves both tricuspid valve function and functional status of the patients at mid-term follow-up.

**Keywords:** Tetralogy of Fallot; Congenital heart disease; Pulmonary valve replacement; Tricuspid regurgitation; Tricuspid valve repair.

**Abbreviations**

CMR = cardiac magnetic resonance imaging

PR = pulmonary regurgitation

PVR = pulmonary valve replacement

RV = right ventricle

RVOT = right ventricular outflow tract

TOF = tetralogy of Fallot

TR = tricuspid regurgitation

TVR = tricuspid valve repair

1  
2  
3  
4  
5  
6  
7  
8  
9  
10  
11  
12  
13  
14  
15  
16  
17  
18  
19  
20  
21  
22  
23  
24  
25  
26  
27  
28  
29  
30  
31  
32  
33  
34  
35  
36  
37  
38  
39  
40  
41  
42  
43  
44  
45  
46  
47  
48  
49  
50  
51  
52  
53  
54  
55  
56  
57  
58  
59  
60  
61  
62  
63  
64  
65

## Introduction

1  
2 Usually, a tetralogy of Fallot (TOF) is completely repaired during infancy using a trans-annular patch  
3 that relieves right ventricle (RV) obstruction. Then, the right ventricular outflow tract (RVOT) usually  
4 grows proportionally with the child. However, unvalved RVOT induces long-term pulmonary  
5 regurgitation (PR) and causes chronic volume overload of the RV. Resultant delayed RV dysfunction,  
6 propensities towards arrhythmia and potential heart failure may necessitate, in adulthood, a pulmonary  
7 valve replacement (PVR) (1). Although PVR in repaired TOF represents, in adults, a frequent surgical  
8 procedure of the RVOT, surgical management of an associated tricuspid regurgitation (TR), which is  
9 observed in up to 30% of patients, remains debated (2-4). Indeed, only scarce data on the surgical  
10 management of TR at the time of PVR have been published so far with controversial results (5-8).

11  
12 In these adult patients with repaired TOF, who underwent PVR, we sought, 1) to determine factors  
13 that predispose to the development of significant preoperative TR, and 2) to evaluate the efficacy of a  
14 concomitant TVR at the time of PVR.

## Methods

### *Patient selection*

15  
16  
17  
18  
19  
20  
21  
22  
23  
24  
25  
26  
27  
28  
29  
30  
31  
32  
33  
34  
35  
36  
37 All adult patients (aged >16 years) who underwent PVR after a repaired TOF or equivalent in  
38 Bordeaux University Hospital between January 2002 and January 2014, were included in this  
39 retrospective study. Patients who received a valved conduit during initial correction were excluded  
40 from the study. A review of the medical records was undertaken after the institutional ethic committee  
41 of Bordeaux University Hospital had approved the study. Patients were informed but a written consent  
42 form was not required, according to French law, because the studies were part of the regular  
43 management of the patients. No examinations were performed only for the purpose of the study.

### *Data collection*

44  
45  
46  
47  
48  
49  
50  
51  
52  
53  
54  
55  
56  
57  
58  
59  
60  
61  
62  
63  
64  
65  
66  
67  
68  
69  
70  
71  
72  
73  
74  
75  
76  
77  
78  
79  
80  
81  
82  
83  
84  
85  
86  
87  
88  
89  
90  
91  
92  
93  
94  
95  
96  
97  
98  
99  
100  
101  
102  
103  
104  
105  
106  
107  
108  
109  
110  
111  
112  
113  
114  
115  
116  
117  
118  
119  
120  
121  
122  
123  
124  
125  
126  
127  
128  
129  
130  
131  
132  
133  
134  
135  
136  
137  
138  
139  
140  
141  
142  
143  
144  
145  
146  
147  
148  
149  
150  
151  
152  
153  
154  
155  
156  
157  
158  
159  
160  
161  
162  
163  
164  
165  
166  
167  
168  
169  
170  
171  
172  
173  
174  
175  
176  
177  
178  
179  
180  
181  
182  
183  
184  
185  
186  
187  
188  
189  
190  
191  
192  
193  
194  
195  
196  
197  
198  
199  
200  
201  
202  
203  
204  
205  
206  
207  
208  
209  
210  
211  
212  
213  
214  
215  
216  
217  
218  
219  
220  
221  
222  
223  
224  
225  
226  
227  
228  
229  
230  
231  
232  
233  
234  
235  
236  
237  
238  
239  
240  
241  
242  
243  
244  
245  
246  
247  
248  
249  
250  
251  
252  
253  
254  
255  
256  
257  
258  
259  
260  
261  
262  
263  
264  
265  
266  
267  
268  
269  
270  
271  
272  
273  
274  
275  
276  
277  
278  
279  
280  
281  
282  
283  
284  
285  
286  
287  
288  
289  
290  
291  
292  
293  
294  
295  
296  
297  
298  
299  
300  
301  
302  
303  
304  
305  
306  
307  
308  
309  
310  
311  
312  
313  
314  
315  
316  
317  
318  
319  
320  
321  
322  
323  
324  
325  
326  
327  
328  
329  
330  
331  
332  
333  
334  
335  
336  
337  
338  
339  
340  
341  
342  
343  
344  
345  
346  
347  
348  
349  
350  
351  
352  
353  
354  
355  
356  
357  
358  
359  
360  
361  
362  
363  
364  
365  
366  
367  
368  
369  
370  
371  
372  
373  
374  
375  
376  
377  
378  
379  
380  
381  
382  
383  
384  
385  
386  
387  
388  
389  
390  
391  
392  
393  
394  
395  
396  
397  
398  
399  
400  
401  
402  
403  
404  
405  
406  
407  
408  
409  
410  
411  
412  
413  
414  
415  
416  
417  
418  
419  
420  
421  
422  
423  
424  
425  
426  
427  
428  
429  
430  
431  
432  
433  
434  
435  
436  
437  
438  
439  
440  
441  
442  
443  
444  
445  
446  
447  
448  
449  
450  
451  
452  
453  
454  
455  
456  
457  
458  
459  
460  
461  
462  
463  
464  
465  
466  
467  
468  
469  
470  
471  
472  
473  
474  
475  
476  
477  
478  
479  
480  
481  
482  
483  
484  
485  
486  
487  
488  
489  
490  
491  
492  
493  
494  
495  
496  
497  
498  
499  
500  
501  
502  
503  
504  
505  
506  
507  
508  
509  
510  
511  
512  
513  
514  
515  
516  
517  
518  
519  
520  
521  
522  
523  
524  
525  
526  
527  
528  
529  
530  
531  
532  
533  
534  
535  
536  
537  
538  
539  
540  
541  
542  
543  
544  
545  
546  
547  
548  
549  
550  
551  
552  
553  
554  
555  
556  
557  
558  
559  
560  
561  
562  
563  
564  
565  
566  
567  
568  
569  
570  
571  
572  
573  
574  
575  
576  
577  
578  
579  
580  
581  
582  
583  
584  
585  
586  
587  
588  
589  
590  
591  
592  
593  
594  
595  
596  
597  
598  
599  
600  
601  
602  
603  
604  
605  
606  
607  
608  
609  
610  
611  
612  
613  
614  
615  
616  
617  
618  
619  
620  
621  
622  
623  
624  
625  
626  
627  
628  
629  
630  
631  
632  
633  
634  
635  
636  
637  
638  
639  
640  
641  
642  
643  
644  
645  
646  
647  
648  
649  
650  
651  
652  
653  
654  
655  
656  
657  
658  
659  
660  
661  
662  
663  
664  
665  
666  
667  
668  
669  
670  
671  
672  
673  
674  
675  
676  
677  
678  
679  
680  
681  
682  
683  
684  
685  
686  
687  
688  
689  
690  
691  
692  
693  
694  
695  
696  
697  
698  
699  
700  
701  
702  
703  
704  
705  
706  
707  
708  
709  
710  
711  
712  
713  
714  
715  
716  
717  
718  
719  
720  
721  
722  
723  
724  
725  
726  
727  
728  
729  
730  
731  
732  
733  
734  
735  
736  
737  
738  
739  
740  
741  
742  
743  
744  
745  
746  
747  
748  
749  
750  
751  
752  
753  
754  
755  
756  
757  
758  
759  
760  
761  
762  
763  
764  
765  
766  
767  
768  
769  
770  
771  
772  
773  
774  
775  
776  
777  
778  
779  
780  
781  
782  
783  
784  
785  
786  
787  
788  
789  
790  
791  
792  
793  
794  
795  
796  
797  
798  
799  
800  
801  
802  
803  
804  
805  
806  
807  
808  
809  
810  
811  
812  
813  
814  
815  
816  
817  
818  
819  
820  
821  
822  
823  
824  
825  
826  
827  
828  
829  
830  
831  
832  
833  
834  
835  
836  
837  
838  
839  
840  
841  
842  
843  
844  
845  
846  
847  
848  
849  
850  
851  
852  
853  
854  
855  
856  
857  
858  
859  
860  
861  
862  
863  
864  
865  
866  
867  
868  
869  
870  
871  
872  
873  
874  
875  
876  
877  
878  
879  
880  
881  
882  
883  
884  
885  
886  
887  
888  
889  
890  
891  
892  
893  
894  
895  
896  
897  
898  
899  
900  
901  
902  
903  
904  
905  
906  
907  
908  
909  
910  
911  
912  
913  
914  
915  
916  
917  
918  
919  
920  
921  
922  
923  
924  
925  
926  
927  
928  
929  
930  
931  
932  
933  
934  
935  
936  
937  
938  
939  
940  
941  
942  
943  
944  
945  
946  
947  
948  
949  
950  
951  
952  
953  
954  
955  
956  
957  
958  
959  
960  
961  
962  
963  
964  
965  
966  
967  
968  
969  
970  
971  
972  
973  
974  
975  
976  
977  
978  
979  
980  
981  
982  
983  
984  
985  
986  
987  
988  
989  
990  
991  
992  
993  
994  
995  
996  
997  
998  
999  
1000

1 reviewed. Patient's informations were collected between July 2014 and December 2014. Duration of  
2 the follow-up was defined as the period between surgery and the last clinical visit. All patients had a  
3 periodic follow-up with their own cardiologist and were additionally closely followed up in Bordeaux  
4 University Hospital with at least one annual visit to obtain clinical details and to undergo a serial  
5 echocardiography. No patient was lost to follow-up.  
6  
7  
8  
9

### 10 11 12 ***Surgical indication***

13 Two experimented surgeons performed indifferently the procedures. PVR was considered according to  
14 the guidelines proposed by Geva et al: when an indexed RV end-diastolic volume at cardiac magnetic  
15 imaging (CMR) exceeded 150 mL/m<sup>2</sup>, when impaired RV function was present, or when NYHA  
16 functional class-III symptoms or worse was present (9). The decision to perform an associated TVR  
17 for moderate or severe TR was based on the surgeon's preference.  
18  
19  
20  
21  
22  
23  
24  
25  
26  
27

### 28 ***Technique used for PVR***

29 Three types of pulmonary valve were inserted into the orthotopic position depending of the surgeon's  
30 preference, without a time difference in the use of these pulmonary valves. The implanted valves were:  
31 the Carpentier-Edwards Perimount bovine pericardial valve (Edwards LifeSciences Corporation,  
32 Irvine, CA, USA), the Hancock porcine-valved (DuPont, Wilmington, DE, USA) Dacron conduit  
33 (Medtronic, Minneapolis, MN, USA), and the Medtronic Freestyle valve (Medtronic, Minneapolis,  
34 MN, USA).  
35  
36  
37  
38  
39  
40  
41  
42  
43  
44  
45

### 46 ***Technique used for TVR***

47 A tricuspid valve rigid ring annuloplasty was systematically used (MC3, Edwards Life-sciences  
48 Corporation, Irvine, CA, USA); the ring was positioned from the antero-septal commissure to the  
49 coronary sinus. When a disrupted commissural chordae at the antero-septal commissure or septal  
50 leaflet distortion secondary to patch closure of ventricular septal defect was found, a concomitant  
51 tricuspid valve suture plasty (commissuroplasty) was added, by approximating together the adjacent  
52 edges of the leaflets at this commissure, thus partially obliterating the commissure.  
53  
54  
55  
56  
57  
58  
59  
60  
61  
62  
63  
64  
65

1  
2  
3  
4  
5  
6  
7  
8  
9  
10  
11  
12  
13  
14  
15  
16  
17  
18  
19  
20  
21  
22  
23  
24  
25  
26  
27  
28  
29  
30  
31  
32  
33  
34  
35  
36  
37  
38  
39  
40  
41  
42  
43  
44  
45  
46  
47  
48  
49  
50  
51  
52  
53  
54  
55  
56  
57  
58  
59  
60  
61  
62  
63  
64  
65

### ***Preoperative features***

To determine if significant TR occurred early or late after a complete repair, we reviewed echocardiographic studies obtained within 1 year of a complete repair but after initial hospital discharge. The preoperative (before PVR) echocardiographic assessment consisted of measurement of ventricular function, measurement of the maximal instantaneous Doppler gradient across the RVOT, and graduation of PR as none (grade 0), mild (grade 1), moderate (grade 2), or severe (grade 3). According to the American Society of Echocardiography guidelines, TR was graded, using the width of the vena contracta in an apical four-chamber view, as none/trivial, mild, moderate, or severe (10). Moderate TR and severe TR were considered as significant TR. Significant stenosis of the pulmonary valve was defined as a trans-valvular maximal instantaneous Doppler gradient of >50 mmHg measured along the RVOT. The lateral tricuspid annulus diameter was determined from an apical four-chamber view. All patients except four with a previously implanted pacemaker had a preoperative CMR to measure the pulmonary regurgitant fraction, right and left ventricular end-diastolic and end-systolic volumes, and RV function. All patients with at least one episode of supra ventricular (atrial flutter/fibrillation) or ventricular arrhythmia were preoperatively mapped and treated in the catheterization laboratory (radiofrequency ablation). The most common diagnosis was TOF with or without pulmonary valve atresia. All the patients had severe PR or mixed lesions with moderate stenosis (RVOT with a peak gradient <40 mmHg). All cases were reoperations, except for one case of TOF with an absent pulmonary valve.

### ***Operative features***

Initial TOF repair was performed using a trans-ventricular approach. At PVR, all patients underwent a preoperative trans-esophageal echocardiography. Cardiopulmonary bypass in normothermia was used in all cases, with bicaval cannulation through a redo sternotomy (except in one patient). The operation was conducted with the heart beating for isolated PVR, or PVR associated with pulmonary branch arterioplasty, or resection of a right infundibular aneurysm. Closure of a residual atrial or ventricular septal defect or an aortic-valve replacement was performed with aortic cross-clamping and warm-

1 blood cardioplegia. TVR were performed with or without aortic cross-clamping, depending of the  
2 surgeon's preference according to the presence of an atrial or a ventricular septal defect.  
3  
4  
5

### 6 *Postoperative features*

7  
8 A transthoracic echocardiography was performed before discharge and at various intervals after  
9 discharge. Significant postoperative TR was defined as moderate or severe valve insufficiency.  
10 Routine postoperative antiplatelet therapy was given for the first 3 postoperative months. CMR was  
11 carried out at 1 year postoperatively in 93 patients: 8 patients with a pre- or postoperative implanted  
12 pacemaker, 2 deceased patients and 1 transplanted patient did not have postoperative CMR.  
13 Transthoracic echocardiography and CMR results were systematically reviewed from the medical  
14 records to formulate a database. Routine postoperative cardiac catheterization was not performed.  
15  
16 Early postoperative death was defined as any death that occurred within 30 days of surgery or during  
17 the same hospital admission. Overall mortality was defined as death occurring from the time of  
18 surgery to the most recent follow-up.  
19  
20  
21  
22  
23  
24  
25  
26  
27  
28  
29  
30  
31  
32  
33

### 34 *Definitions*

35  
36 Heart failure was classified according to the NYHA functional class. To evaluate the impact of TVR,  
37 we divided the 41 patients with significant (moderate/severe) TR into two groups: a moderate group  
38 (group-M) and a severe group (group-S) (Figure 1). For each group, we compared patients who had  
39 undergone PVR alone with those who had undergone concomitant TVR. Pulmonary valve  
40 degeneration was defined as a significant pulmonary valve stenosis, a significant regurgitation, or a  
41 combination of both. The indication for pulmonary valve reintervention was a gradient of >50 mmHg  
42 or severe regurgitation with RV dysfunction. The indication for tricuspid valve reintervention was  
43 severe TR associated with NYHA class-III functional status.  
44  
45  
46  
47  
48  
49  
50  
51  
52  
53  
54  
55  
56  
57  
58  
59  
60  
61  
62  
63  
64  
65



### *Statistical analysis*

1  
2 Statistical analysis was performed using the software SPSS 21 (SPSS Inc., Chicago, IL, USA). The  
3  
4 follow-up data on survival, reoperation, reintervention, and pulmonary or tricuspid valve function  
5  
6 were analyzed using standard Kaplan–Meier analyses. Descriptive data for continuous variables are  
7  
8 reported as medians, ranges, and means  $\pm$  standard deviations (SD). The  $\chi^2$  test or Fisher's exact test  
9  
10 were used to analyze the categorical variables. Student's t-test or the non-parametric Wilcoxon U-test  
11  
12 was performed to analyze the continuous variables. A *p*-value of  $<0.05$  was considered statistically  
13  
14 significant.  
15  
16  
17  
18

## **Results**

### *Population characteristics*

19  
20  
21  
22  
23  
24  
25  
26 A total of 104 adult patients (64 males, 40 females) with a repaired TOF, or equivalent, underwent  
27  
28 PVR with insertion of a bioprosthetic valve. Demographic data, principal diagnoses, and concomitant  
29  
30 procedures at PVR time are listed in Table 1. Thirty-seven patients underwent one palliative procedure  
31  
32 before complete correction (7 Waterston shunts, 28 Blalock shunts, and 2 percutaneous PV  
33  
34 dilatations). Mean age at initial complete correction (corrective surgery) was  $20.1 \pm 17.2$  months and  
35  
36 mean age at RVP was  $26.3 \pm 9.5$  years. No patient had TR before the first corrective surgery. Mean  
37  
38 interval time between initial TOF complete repair and PVR was  $24.8 \pm 9.3$  years. At the time of PVR,  
39  
40 94 patients had a repaired TOF with severe PR; 10 patients had mixed lesions with moderate stenosis.  
41  
42 Mean cardiopulmonary bypass time was  $94.3 \pm 48.1$  min. Mean aortic cross-clamping time (18  
43  
44 patients) was  $68.1 \pm 23.0$  min. 16 patients had a TVR (of which 10 on the beating heart) with a mean  
45  
46 cardiopulmonary bypass time of  $111.2 \pm 51.2$  min. Mean cardiopulmonary bypass time was  $89.3 \pm$   
47  
48  $47.3$  min for patients who did not have concomitant TVR. Mean prosthetic implanted pulmonary valve  
49  
50 diameter was 25 mm (range: 21–29 mm). At the time of RVOT reconstruction, 32 patients (31%) had  
51  
52 one or two additional procedures, for a total of 44 associated procedures (42%) at the time of PVR.  
53  
54  
55  
56  
57  
58 The most common additional procedure was TVR in 16 patients (16 annuloplasty with a flexible ring  
59  
60  
61  
62  
63  
64  
65

with 7 additional partial closures of the antero-septal commissure) (Figure 1). Three patients underwent peroperative epicardial lead and pacemaker implantation for preoperative sinus-node dysfunction.

In-hospital mortality was 1.9%. There were two early deaths on postoperative days 17 and 45. Both patients had severe RV dysfunction preoperatively that necessitated postoperative extra-corporeal life support, but died of multi-organ failure in one case and septic shock in the other. There was no death among the patients who underwent TVR. There was a 100% follow-up for the survivors at a mean of 54.6 months (range: 6–150). There were no late deaths and survival was 98% at 1 and 5 years, respectively (Figure 2). One patient required orthotopic heart transplantation at 16 months for biventricular heart failure. Two patients with a maximal instantaneous peak gradient of >50 mmHg at the proximal anastomosis of the Freestyle valve, underwent a conduit reintervention (at 13 and 26 months postoperatively), and one patient with a high-grade pulmonary valve regurgitation underwent a trans-catheter pulmonary valve implantation (at 25 months postoperatively) (Figure 3). Among the patients with severe TR who underwent PVR alone, 2 suffered symptomatic severe TR during the postoperative course. They both required subsequent tricuspid valve replacement using a bioprosthetic valve.

### ***Predictors of significant TR***

Analyses for potential risk factors for moderate or severe TR after a repaired TOF are summarized in Table 2. The detection of moderate or severe TR in the first year after the initial corrective surgery was significantly associated with the existence of severe TR at PVR ( $p<0.001$ ). Annulus tricuspid valve dilation was also associated with moderate/severe TR ( $p<0.001$ ). RV volume, RV function, age at the first corrective surgery or age at PVR, was not significantly associated with moderate/severe TR.

### ***Effect of PVR on RV volume and function***

PVR was efficient in both cohorts (none/mild TR vs. moderate/severe TR) at improving RV volume and function and at decreasing PR (Table 3).

### ***Evaluation of group-M patients***

1  
2 Among the 24 patients, 8 underwent TVR and PVR and 16 underwent PVR alone. The preoperative  
3  
4 variables were comparable between these two subgroups (Table 4). There was no statistical difference  
5  
6 in postoperative variables, and no patient suffered from significant postoperative TR in either  
7  
8 subgroup.  
9

### ***Evaluation of group-S patients***

10  
11  
12  
13 Among the 17 patients, 8 underwent TVR and PVR and 9 underwent PVR alone. The preoperative  
14  
15 variables were comparable between these two subgroups (Table 5). Whereas there was no significant  
16  
17 postoperative TRs in the sub-group who underwent TVR and PVR, 7 significant postoperative TRs  
18  
19 were noted in the group without TVR ( $p=0.002$ ). Of them, 2 had, in a second time, a tricuspid valve  
20  
21 replacement. For these two patients, a TVR was not initially considered because of multiple previous  
22  
23 operations (fourth sternotomy in both). While all the patients who had TVR and PVR were classified  
24  
25 as NYHA functional class-I, only 22% of patients who had PVR alone were classified as class-I  
26  
27 ( $p=0.002$ ).  
28  
29  
30  
31  
32  
33  
34

## **Discussion**

### ***Insights from left-side heart diseases***

35  
36  
37  
38  
39  
40 Increasing evidence from acquired heart failure studies (secondary to left-sided heart disease, either  
41  
42 ischemic or mitral-valve disease) has shown that severe functional TR results in reduced late survival  
43  
44 and is associated with the onset of symptoms, atrial fibrillation and heart failure (11). Consequently,  
45  
46 TVR at the time of coronary-artery bypass surgery or mitral-valve surgery is believed to be beneficial  
47  
48 and should be considered as a standard of care (12). Furthermore, it was advocated that any patient  
49  
50 with substantial annular dilation should undergo TVR even if there is no TR at the time of surgery  
51  
52 (13). To date, it is still unclear if the concept of TVR performed in left-sided heart pathology can be  
53  
54 extrapolated to congenital right-sided heart disease.  
55  
56  
57  
58  
59  
60  
61  
62  
63  
64  
65

### *TR in repaired TOF*

1  
2 In adults with repaired TOF, functional TR is common and is mainly due to annulus dilation which is  
3  
4 caused by RV dilation, itself secondary to long-lasting PR. In our series, the incidence of significant  
5  
6 TR was 39.5%, which is comparable to previously reported incidences, varying from 19% to 58% (3-  
7  
8 5). A recent study highlighted the fact that early reduction (in the first 2–3 postoperative years  
9  
10 following PVR) in RV size, progressively deteriorates at 7 to 10 years post-PVR, leading to reverse  
11  
12 remodeling and worsened RV function (14). This secondary deterioration has been mostly inherent to  
13  
14 a subsequent progressive bio-prosthetic pulmonary valve dysfunction, but some has been attributed to  
15  
16 a TR (14). This finding corroborates the fact that TR itself may play a role in the development of RV  
17  
18 failure. Thus, Said et al argued for early PVR before the development or the progression of TR in  
19  
20 relation to an annular dilation (6). As a consequence, these authors systematically perform a TVR for  
21  
22 moderate/severe TR when associated with severe dilation of the tricuspid annulus (6). Importantly, the  
23  
24 decision for TVR should be made preoperatively because the conditions of anesthesia generally reduce  
25  
26 TR by at least one grade. In contrast, Cramer et al reported that TVR at the time of PVR may not have  
27  
28 a clinical benefit, with a similar TR grade at 6 months postoperatively with or without TVR (in the  
29  
30 absence of a clear tricuspid valve abnormality) (5). However, in this study, patients who underwent  
31  
32 PVR alone had a slightly lower grade of TR (2.2 vs 2.7,  $p=0.008$ ) and a slightly smaller tricuspid valve  
33  
34 annulus diameter, compared to patients who underwent concomitant TVR. Similarly, Kogon et al  
35  
36 reported the outcomes of 35 patients who had at least moderate TR at PVR: of which 16 underwent  
37  
38 PVR with concomitant TVR and 19 underwent PVR alone (7). The degree of TR and RV dilation  
39  
40 decreased significantly at 1 month postoperatively, with or without TVR, concomitantly with a  
41  
42 reduction in RV size and volume. However, the fact that, for severe TR, 8 of the 9 patients underwent  
43  
44 an annuloplasty has to be underscored. Nonetheless, leaving a moderate TR at PVR is probably a  
45  
46 valuable strategy for secondary (i.e. with annulus dilation) moderate TR. Indeed, in our study, all  
47  
48 group-M patients had no significant TR at mid-term, with or without concomitant TVR. Thus, PVR  
49  
50 was efficient at improving RV volume and function, and this mechanism probably explains the  
51  
52 decrease in moderate TR simultaneously to the decrease in tricuspid annulus diameter. In contrast, for  
53  
54 our patients with severe preoperative TR, a TVR was beneficial. Indeed, at mid-term postoperatively,  
55  
56  
57  
58  
59  
60  
61  
62  
63  
64  
65

1 no group-S patients who underwent TVR had significant TR. In a retrospective multicenter study, it  
2 was found that, longtime after PVR, TR grade remained lower in patients with TVR ( $p<0.001$ ) (15).  
3  
4 Moreover, it was stated that patients with severe preoperative TR had a higher risk for adverse events  
5  
6 during a 5-year follow-up.  
7

### 8 9 10 *Mechanisms of TR*

11  
12 When reviewing the echocardiographic data obtained within the first year after initial complete repair,  
13  
14 significant TR was a risk factor for severe TR at the time of PVR. Mahle et al found that, in some  
15  
16 patients, significant TR occurred early after a repaired TOF and may have preceded RV dilation (4).  
17  
18 TRs were caused by structural valve abnormalities (tethered septal leaflet and prolapsing or flailing  
19  
20 leaflet), and were potentially related to the previous surgical intervention. Those data suggest that two  
21  
22 mechanisms exist to explain TR: 1) a functional etiology (due to annulus dilation) associated with  
23  
24 moderate TR and 2) an iatrogenic etiology caused by chordal disruption or tricuspid septal-leaflet  
25  
26 distortion secondary to ventricular septal defect closure at the time of complete TOF repair. The  
27  
28 iatrogenic etiology can be worsened by the functional etiology. Consequently, it seems important to  
29  
30 avoid TR following a complete TOF repair. In our series, most patients underwent a TOF repair and  
31  
32 its subsequent ventricular septal defect closure through the RV. Nowadays, ventricular septal defect is  
33  
34 usually closed through the right atrium, making it easier to assess the tricuspid valve and to close the  
35  
36 antero-septal commissure if necessary. Contrary to previous study, we did not find that RV volume  
37  
38 was correlated to the development of TR (3).  
39  
40  
41  
42  
43  
44  
45

### 46 *Benefit-risk balance of TVR*

47  
48 The risks and benefits of operating on the tricuspid valve during PVR must be carefully ascertained.  
49  
50 Performing a concomitant operation in adults with congenital heart disease is a risk factor for adverse  
51  
52 events (16). Furthermore, the additional operative time and aortic cross-clamp time required to  
53  
54 perform TV annuloplasty should also be considered. Antunes stated that concomitant annuloplasty  
55  
56 would not add excessive time to a cardiopulmonary bypass and aortic cross clamping (17).  
57  
58 Furthermore, TV surgery with the heart unclamped (either beating or fibrillating) during minimally  
59  
60  
61  
62  
63  
64  
65

1  
2  
3  
4  
5  
6  
7  
8  
9  
10  
11  
12  
13  
14  
15  
16  
17  
18  
19  
20  
21  
22  
23  
24  
25  
26  
27  
28  
29  
30  
31  
32  
33  
34  
35  
36  
37  
38  
39  
40  
41  
42  
43  
44  
45  
46  
47  
48  
49  
50  
51  
52  
53  
54  
55  
56  
57  
58  
59  
60  
61  
62  
63  
64  
65

invasive tricuspid valve surgery, has already been described (17, 18). The surgical technique used to repair the tricuspid valve is relatively easy and straightforward. Moreover, congenital abnormalities of the tricuspid valve have been rarely reported in TOF (4). Thus, for isolated functional TR, an annuloplasty is employed. In case of iatrogenic lesion, a partial closure of the antero-septal commissure is performed associated with an annuloplasty ring to stabilize the repair and to reduce the annular diameter, which is often dilated due to long-lasting PR. The application of a rigid (or semi-rigid) ring has been shown to offer the most durability over time in series that have compared flexible bands to plication annuloplasty techniques (like De-Vega's semi-circular annuloplasty technique). This technique should therefore be considered as a standard of care (19). In our study, the group-S patients with significant residual TR (none of which have concomitant TVR) had significantly a worse NYHA status and two of these seven patients underwent in a second time a tricuspid valve replacement. Considering the fact that tricuspid valve reoperations are strongly associated with high mortality rates and poor long-term outcomes, evaluate potential benefits of TVR is of great importance (17).

### *Limits*

This study has several limitations inherent to its retrospective and observational aspect. Indeed, data collection was limited to variables that were available in the medical records. Furthermore, patients were not randomized but chosen based on an individual surgeon's preference, so creating an inherent selection bias with regards to performing TVR or not. Although we have reported the benefits of TVR during PVR for severe TR over an early- and mid-term follow-up, longer-term studies are needed to determine the longevity of TVR in this context. Kogon et al suggested that concomitant TVR may impair long-term tricuspid valve function with a higher degree of TR in patients that undergo PVR with concomitant TVR (8). Of note, a semi-rigid or rigid annuloplasty ring in this study was rarely used (19%).

### **Conclusions**

TR is frequently encountered in adult patients with repaired TOF (or equivalent). Its pathophysiology

1 seems to be multifactorial. TVR performed at the time of PVR is safe and feasible. While TVR does  
2 not seem to be extremely beneficial for patients with moderate preoperative TR, this procedure  
3 appears to be of interest for patients with severe preoperative TR. Thus, TVR, for severe TR, should  
4 be systematically considered when PVR is planned. Further studies are needed to confirm the good  
5 mid-term outcomes of these patients.  
6  
7  
8  
9

10  
11  
12  
13  
14  
15  
16 **Acknowledgements:** None.  
17  
18  
19  
20  
21  
22  
23  
24  
25  
26  
27  
28  
29  
30  
31  
32  
33  
34  
35  
36  
37  
38  
39  
40  
41  
42  
43  
44  
45  
46  
47  
48  
49  
50  
51  
52  
53  
54  
55  
56  
57  
58  
59  
60  
61  
62  
63  
64  
65

## References

1. Cheung MM, Konstantinov IE, Redington AN. Late complications of repair of tetralogy of Fallot and indications for pulmonary valve replacement. *Semin Thorac Cardiovasc Surg* 2005; 17:155-159.
2. Hawkins JA, Sower CT, Lambert LM, Kouretas PC, Burch PT, Kaza AK, Puchalski MD, Yetman AT. Stentless porcine valves in the right ventricular outflow tract: improved durability? *Eur J Cardiothor Surg* 2009;35:600-605.
3. Kobayashi J, Kawashima Y, Matsuda H, Nakano S, Miura T, Tokuan Y, Arisawa J. Prevalence and risk factors of tricuspid regurgitation after correction of tetralogy of Fallot. *J Thorac Cardiovasc Surg*-. 1991; 102:611-616.
4. Mahle WT, Parks WJ, Fyfe DA, Sallee D. Tricuspid regurgitation in patients with repaired Tetralogy of Fallot and its relation to right ventricular dilatation. *Am J Cardiol* 2003; 92:643-645.
5. Cramer JW, Ginde S, Hill GD, Cohen SB, Bartz PJ, Tweddell JS, Earing M. Tricuspid repair at pulmonary valve replacement does not alter outcomes in tetralogy of Fallot. *Ann Thorac Surg* 2015; 99:899-904.
6. Said SM, Dearani JA, Burkhart HM, Connolly HM, Eidem B, Stensrud PE, Schaff HV. Management of tricuspid regurgitation in congenital heart disease: is survival better with valve repair? *J Thorac Cardiovasc Surg* 2014; 147:412-417.
7. Kogon B, Patel M, Leong T, McConnell M, Book W. Management of moderate functional tricuspid valve regurgitation at the time of pulmonary valve replacement: is concomitant tricuspid valve repair necessary? *Pediatr Cardiol* 2010; 31:843-848.
8. Kogon B, Grudziak J, Sahu A, Jokhadar M, McConnell M, Book W, Oster M. Surgery in adults with congenital heart disease: Risk factors for morbidity and mortality. *Ann Thorac Surg* 2013; 95:1377-1382
9. Geva T. Indications for pulmonary valve replacement in repaired tetralogy of Fallot: the quest continues. *Circulation* 2013; 128:1855-1857.
10. Zoghbi WA, Chambers JB, Dumesnil JG, Foster E, Gottdiener JS, Grayburn PA, Khandheria BK, Levine RA, Marx GR, Miller FA Jr, Nakatani S, Quiñones MA, Rakowski H, Rodriguez LL, Swaminathan M, Waggoner AD, Weissman NJ, Zabalgoitia M. Recommendations for evaluation of



1  
2  
3  
4  
5  
6  
7  
8  
9  
10  
11  
12  
13  
14  
15  
16  
17  
18  
19  
20  
21  
22  
23  
24  
25  
26  
27  
28  
29  
30  
31  
32  
33  
34  
35  
36  
37  
38  
39  
40  
41  
42  
43  
44  
45  
46  
47  
48  
49  
50  
51  
52  
53  
54  
55  
56  
57  
58  
59  
60  
61  
62  
63  
64  
65

prosthetic valves with echocardiography and Doppler ultrasound: a report from the American Society of Echocardiography's Guidelines and Standards Committee and the Task Force on Prosthetic Valves, developed in conjunction. *J Am Soc Echocardiogr* 2009; 22:975–1014.

11. Nath J, Foster E, Heidenreich PA. Impact of tricuspid regurgitation on long-term survival. *J Am Coll Cardiol* 2004; 43:405-409.

12. Rogers JH, Bolling SF. The tricuspid valve: current perspective and evolving management of tricuspid regurgitation. *Circulation* 2009; 119:2718-2725.

13. Dreyfus GD, Corbi PJ, Chan KM, Bahrami T. Secondary tricuspid regurgitation or dilatation: which should be the criteria for surgical repair? *Ann Thorac Surg.* 2005; 79:127-132.

14. Hallbergson A, Gauvreau K, Powell AJ, Geva T. Right ventricular remodeling after pulmonary valve replacement: early gains, late losses. *Ann Thorac Surg* 2015; 99:660-666.

15. Bokma JP, Winter MM, Oosterhof T, Vliegen HW, van Dijk AP, Hazekamp MG, Koolbergen DR, Groenink M, Mulder BJ, Bouma BJ. Severe tricuspid regurgitation is predictive for adverse events in tetralogy of Fallot. *Heart* 2015; 101:794-799.

16. Kogon B, Mori M, Alsoufi B, Kanter K, Oster M. Leaving moderate tricuspid valve regurgitation alone at the time of pulmonary valve replacement: a worthwhile approach. *Ann Thorac Surg* 2015; 99:2117-2122.

17. Antunes MJ, Barlow JB. Management of tricuspid valve regurgitation. *Heart* 2007; 93: 271-276.

18. Lee TC, Desai B, Glower DD. Results of 141 consecutive minimally invasive tricuspid valve operations: An 11-year experience. *Ann Thorac Surg* 2009; 88:1845-1850.

19. Tang GH, David TE, Singh SK, Maganti MD, Armstrong S, Borger MA. Tricuspid valve repair with an annuloplasty ring results in improved long-term outcomes. *Circulation* 2006(suppl); 114:577-581.

1  
2  
3  
4  
5  
6  
7  
8  
9  
10  
11  
12  
13  
14  
15  
16  
17  
18  
19  
20  
21  
22  
23  
24  
25  
26  
27  
28  
29  
30  
31  
32  
33  
34  
35  
36  
37  
38  
39  
40  
41  
42  
43  
44  
45  
46  
47  
48  
49  
50  
51  
52  
53  
54  
55  
56  
57  
58  
59  
60  
61  
62  
63  
64  
65

## Figure legends

**Figure 1.** Flow chart showing the distribution of the patients according to the functional status of the tricuspid valve.

PVR: Pulmonary valve replacement; TR: Tricuspid regurgitation; TVR: Tricuspid valve repair.

**Figure 2.** Overall survival to death from the time of PVR in adults with repaired tetralogy of Fallot, with 95% Confidence Interval.

**Figure 3.** Overall survival to death or reoperation (redo PVR, redo TVR, or heart transplantation) from the time of PVR in adults with repaired TOF, with 95% Confidence Interval.

**Table 1.** Population characteristics.

|   | <b>Patients (n=104)</b> |
|---|-------------------------|
| Gender, <i>n</i> (%)                        |                         |
| Male  | 64 (61)                 |
| Female                                      | 40 (39)                 |
| Principal diagnosis, <i>n</i>               |                         |
| TOF   | 96                      |
| DORV with VSD and PS                        | 5                       |
| TOF with APVS                               | 1                       |
| Critical PS                                 | 2                       |
| Age at initial operation (years)            | 1.67 (0.7-15.1)         |
| Trans-annular patch, <i>n</i> (%)           | 64 (62)                 |
| Age at PVR (years)                          | 26.3 (16-56)            |
| Time from initial repair to PVR (years)     | 24.8 (13-54)            |
| Aortic cross-clamp time (min) [n=18]        | 68.1 ± 23.0             |
| Cardiopulmonary bypass time (min)           | 94.3 ± 48.1             |
| Moderate or severe TR at PVR, <i>n</i> (%)  | 41 (39.5)               |
| Associated procedure at PVR, <i>n</i> (%)   | 44 (42)                 |
| TVR   | 16                      |
| Pulmonary-branch arterioplasty <sup>□</sup> | 6                       |
| Infundibular aneurism resection             | 6                       |
| Residual ASD closure                        | 8                       |
| Residual VSD closure                        | 2                       |
| Bentall procedure                           | 1                       |
| AVR   | 1                       |
| Pacemaker or cardioverter/defibrillator     | 4                       |

APVS = absent pulmonary valve syndrome; ASD = atrial septal defect; AVR = aortic valve repair;  
DORV= double-outlet right ventricle; PS = pulmonary stenosis; PVR = pulmonary valve replacement;  
TOF = tetralogy of Fallot; TR = tricuspid regurgitation; TVR = tricuspid valve repair; VSD =  
ventricular septal defect

<sup>1</sup>: One patient underwent a bilateral pulmonary branch arterioplasty

**Table 2.** Determinants of tricuspid regurgitation at the time of pulmonary valve replacement in adults with repaired tetralogy of Fallot.

|  | none/mild TR<br>(n=63) | moderate TR<br>(group-M)<br>(n=24) | severe TR<br>(group-S)<br>(n=17) | p-value |
|--|------------------------|------------------------------------|----------------------------------|---------|
| Prior systemic-to-pulmonary shunt                      | 22 (35)                | 8 (33)                             | 7 (41)                           | 0.862   |
| Age at TOF repair (months)                             | 18.4±6                 | 25.5±7                             | 18.9±8                           | 0.221   |
| Age at PVR (years)                                     | 26.4±10                | 25.3±9                             | 27.0±9                           | 0.830   |
| Surgical interval (years)                              | 24.8±9                 | 23.2±10                            | 25.6±9                           | 0.895   |
| Moderate/severe TR at early echo <sup>‡</sup>          | 0                      | 0                                  | 8                                | <0.001  |
| RV end-diastolic volume at CMR<br>(mL/m <sup>2</sup> ) | 157.1±36               | 163.6±41                           | 173.8±26                         | 0.160   |
| RV ejection fraction at CMR (%)                        | 43.1±10                | 39.7±11                            | 40.2±6                           | 0.573   |
| Tricuspid annulus diameter (mm)                        | 29.4±2.6               | 33.2±2.6                           | 36.9±2.3                         | <0.001  |

Continuous variables are expressed as mean ± SD and nominal variables as effective and percentages in brackets (%)

<sup>‡</sup>: moderate or severe TR found at echocardiography in the early postoperative period (first year), following a complete TOF repair

CMR = cardiac magnetic-resonance imaging; PVR = pulmonary valve replacement; RV = right ventricle; TOF = tetralogy of Fallot; TR = tricuspid regurgitation

**Table 3.** Echocardiographic and cardiac magnetic-resonance imaging measurements according to the severity of tricuspid regurgitation at the time of pulmonary valve replacement in adult patients with repaired tetralogy of Fallot.

| Variable   | No/mild TR at PVR ( <i>n</i> =63) |                 |                 | Moderate/severe TR at PVR ( <i>n</i> =41) |                 |                 |
|------------|-----------------------------------|-----------------|-----------------|---|-----------------|-----------------|
|            | Pre-op.                           | 1 year post-op. | <i>p</i> -value | Pre-op.                                   | 1 year post-op. | <i>p</i> -value |
| PR grade   | 3.1±0.4                           | 0.4±0.3         | <0.001          | 3.2±0.3                                   | 0.4±0.3         | <0.001          |
| RVEF       | 44.5±6                            | 48.9±6          | <0.001          | 40±6.5                                    | 43.9±6.3        | <0.001          |
| RVESV (mL) | 69.8±17                           | 45.2±14         | <0.001          | 77±22                                     | 50.7±20         | <0.001          |
| RVEDV (mL) | 162±22                            | 81±18           | <0.001          | 167.3±27                                  | 86±28           | <0.001          |

PR = pulmonary regurgitation; PVR = pulmonary valve replacement; RVEDV = right ventricle end-diastolic volume; RVEF = right ventricle ejection fraction; RVESV = right ventricle end-systolic volume; TR = tricuspid regurgitation

**Table 4.** Features of patients with moderate tricuspid regurgitation at the time of pulmonary valve replacement (group-M) according to the surgical procedure (PVR alone or TVR associated to PVR).

| Variable                          | PVR alone (n=16) | PVR and TVR (n=8) | p-value |
|-----------------------------------|------------------|-------------------|---------|
| Variable: preoperative            |                  |                   |         |
| Prior palliative surgery (%)      | 5 (31)           | 3 (19)            | 1.00    |
| Age at TOF repair (months)        | 28.0±41          | 20.4±8            | 0.601   |
| Age at PVR (years)                | 25.6±8           | 24.6±12           | 0.539   |
| Surgical interval (years)         | 24.8±8           | 23.0±12           | 0.283   |
| TR at early echo <sup>‡</sup> (n) | 0                | 0                 | 1.00    |
| TV annulus diameter (mm)          | 33.3±3           | 33±2.3            | 0.951   |
| NYHA                              | 2.3±0.4          | 2.8±0.7           | 0.061   |
| RVEF (%)                          | 41.5±7           | 38.1±8            | 0.417   |
| RVESV (mL)                        | 71.3±17          | 80.5±28           | 0.645   |
| RVEDV (mL)                        | 160.2±19         | 166.4±33          | 1.00    |
| Variable: postoperative           |                  |                   |         |
| NYHA                              | 1±0              | 1.3±0.7           | 0.157   |
| RVEF (%)                          | 44.3±7           | 43.4±11           | 0.653   |
| RVESV (mL)                        | 49.0±22          | 58±29             | 0.706   |
| RVEDV (mL)                        | 86±32            | 98±45             | 0.807   |
| Moderate or severe TR (n)         | 0                | 0                 | 1.00    |
| Re-operation for TR               | 0                | 0                 | 1.00    |

Continuous variables are expressed as mean ± SD; nominal variable as number and percentages in brackets (%)

<sup>‡</sup>: Moderate or greater TR found at echocardiography in the early postoperative period (first year), following a complete TOF repair.

PVR = pulmonary valve replacement; RVEDV = right ventricle end-diastolic volume; RVEF = right-ventricle ejection fraction; RVESV = right-ventricle end-systolic volume; TOF = tetralogy of Fallot; TR = tricuspid regurgitation; TVR = tricuspid valve repair.



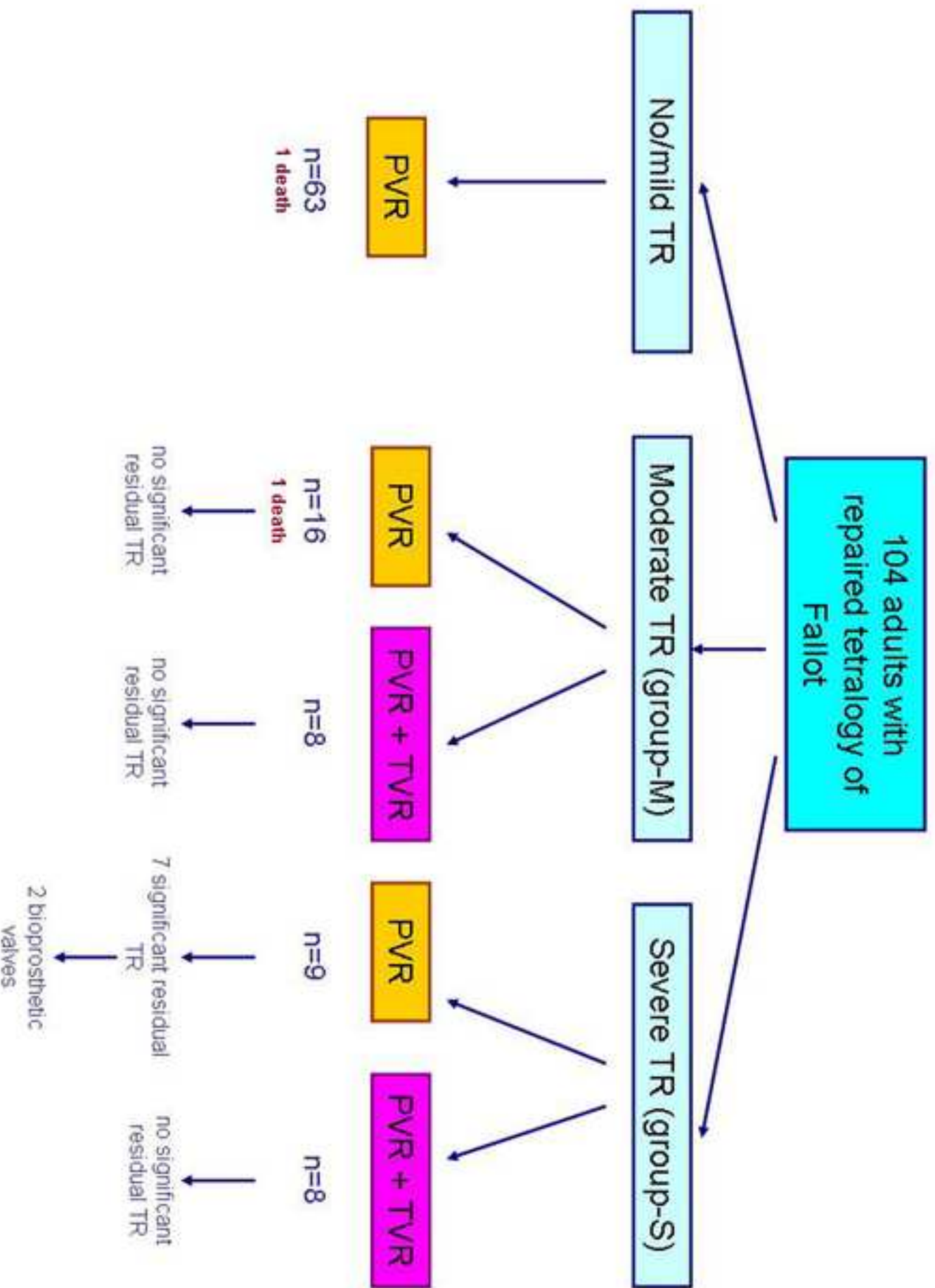
**Table 5.** Features of patients with severe tricuspid regurgitation at the time of pulmonary valve replacement (group-S) according to the surgical procedure (PVR alone or TVR associated to PVR)..

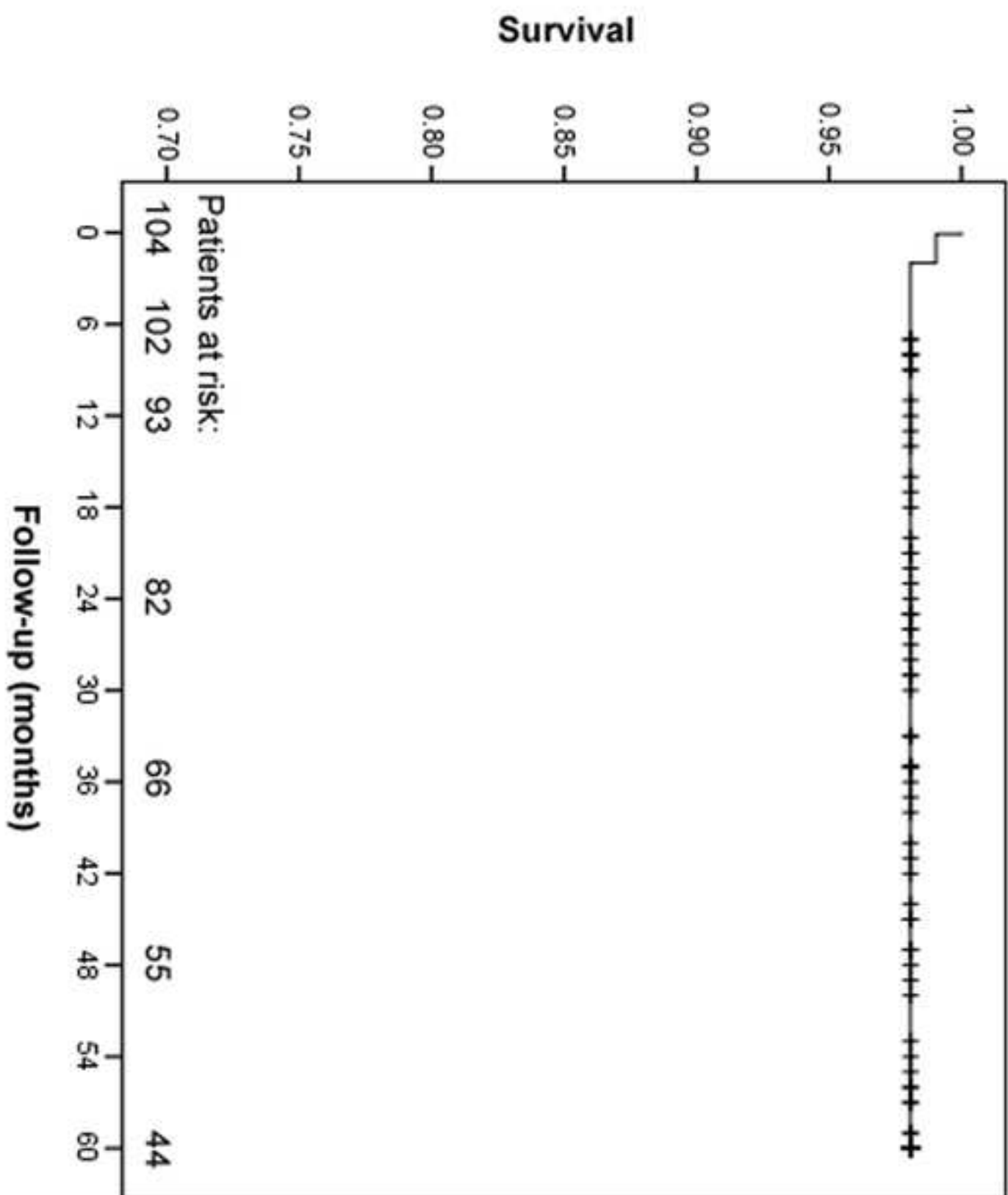
| Variable                          | PVR alone (n=9) | PVR and TVR (n=8) | p-value      |
|-----------------------------------|-----------------|-------------------|--------------|
| Variable: preoperative            |                 |                   |              |
| Prior palliative surgery (%)      | 5 (56)          | 2 (22)            | 0.335        |
| Age at TOF repair (months)        | 20.1±9          | 17.3±2            | 0.335        |
| Age at PVR (years)                | 27.8±10         | 26.1±9            | 0.885        |
| Surgical interval (years)         | 26.2±9          | 24.9±9            | 0.809        |
| TR at early echo <sup>‡</sup> (n) | 3 (33)          | 5 (55)            | 0.347        |
| TV annulus diameter (mm)          | 36.8±2          | 37.0±2            | 0.922        |
| NYHA                              | 3±0.5           | 2.6±0.5           | 0.148        |
| RVEF (%)                          | 38.3±5          | 42.5±5            | 0,347        |
| RVESV (mL)                        | 86.4±26         | 75.4±20           | 0.466        |
| RVEDV (mL)                        | 179±35          | 168±15            | 0.379        |
| Variable: postoperative           |                 |                   |              |
| NYHA                              | 2.2±1           | 1±0               | <b>0.002</b> |
| RVEF (%)                          | 43.3±4          | 46.1±2            | 0.059        |
| RVESV (mL)                        | 53.8±17         | 47.7±14           | 0.602        |
| RVEDV (mL)                        | 86.8±18         | 80±9              | 0.511        |
| Moderate or severe TR (n)         | 7 (78)          | 0                 | <b>0.002</b> |
| Re-operation for TR               | 2 (22)          | 0                 | 0.47         |

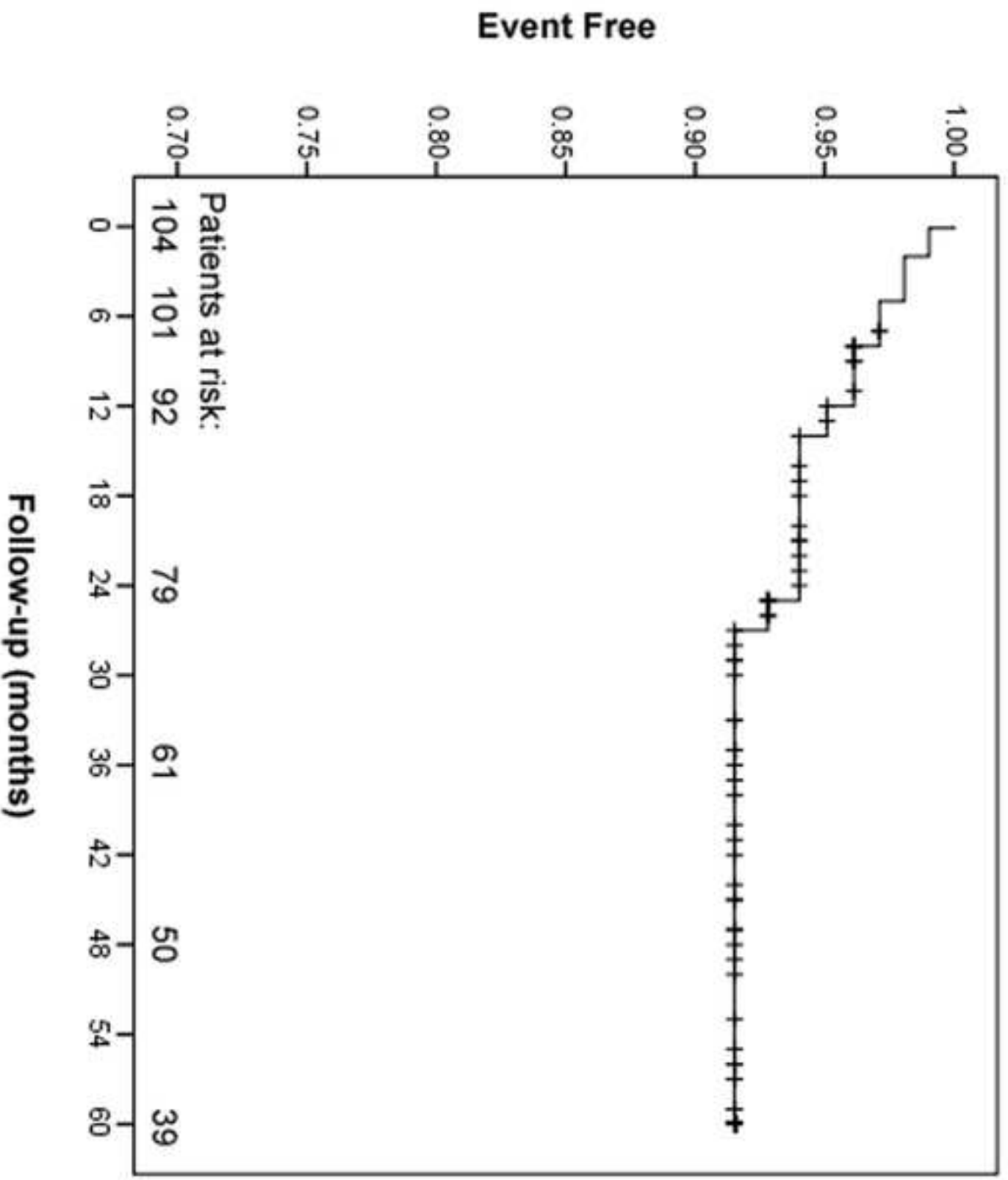
Continuous variables are expressed as mean ± SD; nominal variable as number and percentages in brackets (%)

<sup>‡</sup>: Moderate or greater TR found at echocardiography in the early postoperative period (first year), following a complete TOF repair.

PVR = pulmonary valve replacement; RVEDV = right-ventricle end-diastolic volume; RVEF = right-ventricle ejection fraction; RVESV = right-ventricle end-systolic volume; TOF = tetralogy of Fallot; TR = tricuspid regurgitation; TVR = tricuspid valve repair.







Word count : 4900

The authors do hereby declare that all illustrations and figures in the manuscript are entirely original and do not require reprint permission.

## Deuxième partie : recherche.

### 5.1 Premier travail : Développement d'un modèle animal de TF réparée

#### 5.1.1 Introduction

Les patients adultes avec TF réparée dans l'enfance représentent un nombre de malade de plus en plus important. Les séries de patients, rapportant les résultats de la valvulation pulmonaire, sont nombreuses. Une simple recherche internet, en utilisant le site Pubmed, réalisée début septembre 2015 avec les termes « Fallot pulmonary valve replacement » donne accès à 392 publications. On a déjà vu, que malgré une littérature médicale abondante, ils existent de nombreuses inconnues:

- A quel moment de l'évolution de ces patients faut-il valver la voie pulmonaire, pour espérer une récupération optimale de la fonction ventriculaire droite ?
- Pourquoi certains patients évoluent vers une dysfonction ventriculaire gauche associée à celle du VD ?
- Place de la resynchronisation bi-ventriculaire chez ces patients qui présentent souvent un asynchronisme intra-ventriculaire droit et intra-ventriculaire gauche, avec un QRS allongé typique de bloc de branche droit
- Type de valve à implanter chirurgicalement et place éventuelle de la valvulation pulmonaire percutanée ?
- Comment mieux appréhender les arythmies (supra-ventriculaires mais surtout ventriculaires qui sont responsables des morts subites) que développent fréquemment ces patients et éventuellement comment les prévenir ?



Les études cliniques restent indispensables pour répondre à certaines questions posées (voir la première partie de cette thèse). Cependant, il nous paraissait intéressant de créer un modèle d'étude de gros animal, qui aurait pu présenter des caractéristiques anatomiques, hémodynamiques et électrophysiologiques, proches de celles observées chez les patients adultes, qui ont eu une TF opérée dans l'enfance. Ce modèle animal pourrait ainsi permettre, dans un premier temps, de mieux comprendre les mécanismes de l'arythmie que vont développer ces patients (analyse biomoléculaire, étude de la propagation de la dépolarisation, étude histologique, etc.).

Ce modèle pourrait également permettre, dans un deuxième temps, de tester l'impact de différentes solutions thérapeutiques. (Cf. en annexe, l'article : *Thambo JB, Roubertie F et al. Validation of an animal model of right ventricular dysfunction and right bundle branch block to create close physiology to postoperative tetralogy of Fallot. Int J Cardiol. 2012;154:38-42*).

### **5.1.2 Méthodes**

Nous avons induit une fuite pulmonaire, ainsi qu'une sténose pulmonaire modérée, et nous avons mis en place un patch infundibulaire chez 15 porcelets (avec un groupe également de 7 porcelets contrôle). Ces animaux ont été opérés par thoracotomie gauche. Quatre mois après cette première intervention, ces animaux ont bénéficié d'une étude hémodynamique et de mesures échocardiographiques, qui ont été comparées avec les résultats obtenus chez 42 adultes avec TF opérée et 30 adultes contrôle, sans anomalie congénitale cardiaque.

### **5.1.3 Résultats**

Trois animaux (20%) sont décédés durant la phase post-opératoire immédiate (n=1) ou entre les 2 interventions (n=2). Une analyse hémodynamique, avec mesure des Dp/Dt max du VD et du ventricule gauche, a pu être évaluée chez les 12 animaux vivants restants. Une échocardiographie épicaudique a pu être réalisée chez l'ensemble des animaux pour compléter l'étude. Par rapport au groupe contrôle d'animaux sains, le modèle présente une dilatation ventriculaire droite, une dysfonction ventriculaire droite, une dysfonction ventriculaire gauche modérée et un asynchronisme

bi-ventriculaire significatif. L'activation électrique épicaudique correspond à un bloc de branche droit avec retard d'activation du VD par rapport au ventricule gauche et retard d'activation de l'infundibulum et de la paroi latérale du VD par rapport au septum.

La comparaison, entre ce modèle animal et les patients avec TF réparée, retrouve des similitudes importantes en termes de durée de QRS, de fuite pulmonaire, de dysfonction bi-ventriculaire et d'asynchronisme ventriculaire. Ce modèle était donc validée comme mimant les séquelles observées après TF réparée chez l'adulte.

### **5.1.4 Conclusion**

Le modèle ainsi créé est viable, avec une mortalité très limitée. Il reproduit étroitement certaines caractéristiques observées chez les patients après TF opérée.

Il existe certaines limites à ces similitudes. Le bloc de branche droit n'est pas le résultat d'une lésion per-opératoire, comme classiquement observé après fermeture de CIV, mais survient dans un second temps en rapport avec la dilatation du VD et la fibrose intra-myocardique. Par ailleurs, d'autres facteurs (substrats génétiques, hypoxémie en pré-opératoire de la cure complète), indépendants de la chirurgie, et donc non pris en compte par notre modèle, peuvent jouer un rôle important dans le remodelage ventriculaire.

### 5.1.5 Perspectives concernant le modèle animal mimant une TF réparée

Ce modèle semble prometteur pour chercher à mieux à **comprendre les mécanismes physiopathologiques** (moléculaire, cellulaire ou tissulaire) **des arythmies** chez les TF réparée (voir chapitre arythmie, plus loin dans cette thèse).

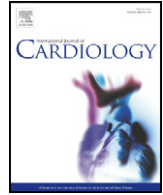
Il paraît aussi prometteur pour valider, dans le futur, **l'impact de différentes thérapeutiques, comme la valvulation percutanée** avec différentes prothèses, qu'on pourrait effectuer **à différents stades de l'évolution de la maladie** (2, 4, 6 et 8 mois après la première chirurgie). On pourrait ainsi connaître le moment auquel la valvulation pulmonaire aurait le plus d'impact en ce qui concerne la récupération du VD.

En effet, l'âge moyen auquel est réalisée la valvulation pulmonaire varie d'un centre à l'autre aux Etats-Unis, avec des différences allant de 13 ans à 28 ans ! **(1, 2)**. Même si les derniers résultats des séries cliniques semblent montrer qu'il faille opérer tôt ces patients : les patients opérés au stade NYHA I ou II ont une meilleure survie à 15 ans, que les patients opérés au stade NYHA III ou IV (90% vs. 67%) **(3)**. Quoiqu'il en soit, la survie à 15 ans pour l'ensemble des patients opérés de RVP, reste bien inférieure à celle de la population générale (80% vs. 98%) **(3)**, ce qui démontre que de nombreux progrès sont à faire dans les indications médico-chirurgicales, et plus largement, dans la compréhension de cette pathologie.

Ce modèle pourrait également servir à **valider d'autres thérapeutiques comme la resynchronisation en phase chronique**. Nous réaliserions 2 groupes d'animaux : un groupe stimulé et un groupe non stimulé afin d'évaluer l'impact anatomique, tissulaire, cellulaire, moléculaire et génétique de la resynchronisation sur ce modèle d'insuffisance cardiaque droite. En ce qui concerne la resynchronisation bi-ventriculaire en phase aigüe, ce modèle a déjà fait l'objet d'une publication **(4)**, à Bordeaux, avec des résultats qui semblaient prometteurs (confirmés par une resynchronisation en phase aigüe effectuées chez quelques patients avec TF réparée).

### 5.1.6 Références

1. O'Byrne ML, Glatz AC, Mercer-Rosa L, et al. Trends in pulmonary valve replacement in children and adults with tetralogy of fallot. *Am J Cardiol.* 2015;115:118-24.
2. Ferraz Cavalcanti PE, Sá MP, Santos CA, et al. Pulmonary valve replacement after operative repair of tetralogy of Fallot: meta-analysis and meta-regression of 3118 patients from 48 studies. *J Am Coll Cardiol* 2013;62:2227-2243.
3. Sabate Rotes A, Eidem BW, Connolly HM, et al. Long-term follow-up after pulmonary valve replacement in repaired tetralogy of Fallot. *Am J Cardiol.* 2014;114:901-8.
4. Thambo JB, Dos Santos P, De Guillebon M, Roubertie F et al. Biventricular stimulation improves right and left ventricular function after tetralogy of Fallot repair: acute animal and clinical studies. *Heart Rhythm.* 2010;7:344-50.



## Validation of an animal model of right ventricular dysfunction and right bundle branch block to create close physiology to postoperative tetralogy of Fallot

Jean-Benoit Thambo<sup>b,c,\*</sup>, Francois Roubertie<sup>b</sup>, Maxime De Guillebon<sup>a,b</sup>, Louis Labrousse<sup>b,c</sup>, Xavier Iriart<sup>b</sup>, Hopewell Ntsinjana<sup>d</sup>, Stephane Lafitte<sup>b,c</sup>, Sylvain Ploux<sup>a,b</sup>, Michel Haissaguerre<sup>b</sup>, Xavier Roques<sup>b</sup>, Pierre Dos Santos<sup>a,b,c</sup>, Pierre Bordachar<sup>b,c</sup>

<sup>a</sup> University Bordeaux 2, 33000 Bordeaux, France

<sup>b</sup> University Hospital of Bordeaux, 33000 Bordeaux, France

<sup>c</sup> INSERM U 828, 33600 Pessac, France

<sup>d</sup> Health Sciences Faculty, University of the Witwatersrand, Johannesburg, South Africa

### ARTICLE INFO

#### Article history:

Received 2 June 2010

Accepted 19 August 2010

Available online 18 September 2010

#### Keywords:

Tetralogy of Fallot

Congenital heart disease

Cardiac resynchronization

Right ventricular dysfunction

Ventricular dyssynchrony, swine model, outcome of repair tetralogy of Fallot

### ABSTRACT

**Background:** In the past 5 years a few number of studies and case reports have come out focusing on biventricular (BiV) stimulation for treatment of congenital heart disease related ventricular dysfunction. The few available studies include a diverse group of pathophysiological entities ranging from a previously repaired tetralogy of Fallot (TOF) to a functional single ventricle anatomy. Patient's status is too heterogeneous to build important prospective study. To well understand the implication of prolonged electromechanical dyssynchrony we performed a chronic animal model that mimics essential parameters of postoperative TOF.

**Methods:** Significant pulmonary regurgitation, mild stenosis, as well as right ventricular outflow tract (RVOT) scars were induced in 15 piglets to mimic repaired TOF. 4 months after hemodynamics and dyssynchrony parameters were compared with a control group and with a population of symptomatic adult with repaired TOF.

**Results:** Comparing the animal model with the animal control group on echocardiography, RV dilatation, RV and LV dysfunction, broad QRS complex and dyssynchrony were observed on the animal model piglets. Moreover, epicardial electrical mapping showed activation consistent with a right bundle branch block. The animal models displayed the same pathophysiological parameters as the post TOF repair patients in terms of QRS duration, pulmonary regurgitation biventricular dysfunction and dyssynchrony.

**Conclusion:** This chronic swine model mimics electromechanical ventricular activation delay, RV and LV dysfunction, as in adult population of repair TOF. It does appear to be a very useful and interesting model to study the implication of dyssynchrony and the interest of resynchronization therapy in TOF failing ventricle.

© 2010 Elsevier Ireland Ltd. All rights reserved.

### 1. Introduction

Isolated right heart failure is a relatively common disorder with multiple causes such as congenital heart disease, pulmonary arterial hypertension, right ventricular infarction, and acquired right heart valvular disease. The pathophysiology and clinical course of these diseases are often poorly understood. As a result of major improvements in surgical technique, postoperative care and medical management in recent years the population of adults with repaired tetralogy of Fallot (TOF) and other congenital heart diseases is

increasing. The growth of this population is linear [1] and the mortality rate, at least in the early adult years, is relatively low [2]. This nascent demographic phenomenon is creating major issues concerning the optimal management of adults with congenital heart disease [3]. The surgical repair of TOF is highly successful, though may be later complicated by right ventricular dysfunction due to volume and pressure overload and by late sudden death. The incompletely understood mechanisms of these delayed adverse developments may be partially due to the surgically-induced permanent right bundle branch block (BBB) and ventricular dyssynchrony [4–9]. Therapeutic options remain limited. Implantation of a cardiac resynchronization therapy defibrillator has recently been proposed in TOF patients to decrease sudden death and to improve hemodynamic status. However, studies of the safety and efficacy of cardiac resynchronization in patients with congenital heart disease and RV dysfunction are limited to case reports, retrospective analyses of heterogeneous

\* Corresponding author. Hospital Haut Lévêque, Service des Pathologies Cardiaques Congénitales de l'Enfant et de l'Adulte, Pessac 33604, France. Tel.: +33 5 57 65 64 65; fax: +33 5 57 65 68 28.

E-mail address: [jean-benoit.thambo@chu-bordeaux.fr](mailto:jean-benoit.thambo@chu-bordeaux.fr) (J.-B. Thambo).

populations and small crossover trials conducted in the immediate postoperative period [10–15]. To identify risk factors leading to sudden death in TOF patients [16–18] and to define mechanisms involved in hemodynamic improvement induced by cardiac resynchronization [8,19], we aimed to develop a viable and reproducible swine model recapitulating the findings of right heart failure and right bundle branch block observed after prior surgical repair of TOF.

The aims of the present study were to 1) develop a reliable and reproducible long-term swine model of RV dysfunction and RV dyssynchrony and 2) to compare echocardiographic measurements of right ventricular dysfunction, dilatation and dyssynchrony in this animal model and adult patients with previously repaired TOF.

## 2. Methods

### 2.1. Studies in an animal model of repaired TOF

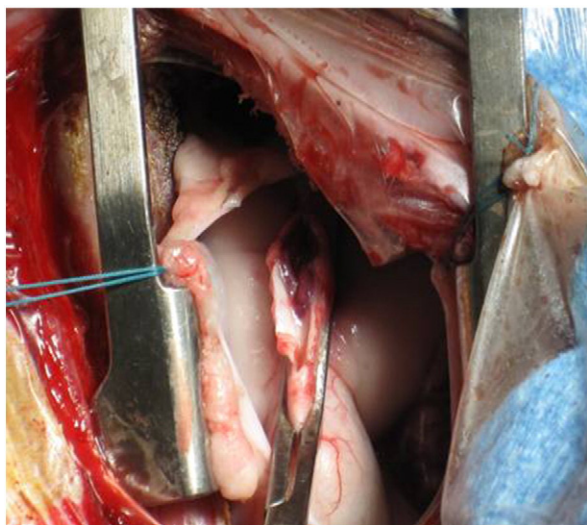
Our experimental protocols were in compliance with the *Guiding Principles in the Use and Care of Animals* published by the National Institutes of Health (NIH Publication No. 85-23, Revised 1996).

#### 2.1.1. Construction of the swine model

The experimental study included 15 newborn piglets weighing <8 kg. Animals were sedated with a 20-mg/kg, intramuscular injection of ketamine hydrochloride, and anesthetized with 10 mg/kg of sodium pentobarbital before endotracheal intubation. Anesthesia was continued with ketamine 500-mg/h, and prophylactic intravenous antimicrobials were administered. Peripheral oxygen saturation, heart rate, and blood pressure were monitored continuously. All surgical study animals received a muscle-sparing left thoracotomy between the fourth or fifth interspace.

Surgical intervention was then designed to cause (Fig. 1)

- 1) RV volume overload from valvular regurgitation effected by means of placement of a vascular clamp longitudinally across the pulmonary valve annulus without obstruction of the RV outflow tract. A 2-cm incision was made longitudinally across the pulmonary annulus, and 2 pulmonary valve leaflets were excised. A 2-cm-long elliptically shaped polytetrafluorethylene patch was sewn in place with 6-0 nonabsorbable monofilament sutures across the annulus to ensure complete disruption of valve integrity.
- 2) RV pressure overload, via a pulmonary artery band placed 1 cm distal to the valve annulus. After dissection, a loosely tied tape was passed around the artery and secured for a final diameter of approximately 2 cm.
- 3) RV outflow tract scar, a 1-cm full-thickness incision was made longitudinally over the infundibulum up to but not including the valve annulus and then repaired with the placement of a 1-cm-long elliptically shaped polytetrafluorethylene patch to ensure scar formation.



**Fig. 1.** Surgery procedure: Sparing left thoracotomy between the fourth or fifth interspace. Vascular clamp is longitudinally placed across the pulmonary valve annulus without obstruction of the RV outflow tract, longitudinal incision on 2 cm and excision of 2 pulmonary valve leaflets. Closure using an elliptically shaped polytetrafluorethylene patch sewn with nonabsorbable monofilament sutures.

After completion of the procedure, animals were extubated and received supplemental oxygen and analgesia as needed before their transfer to a long-term postoperative care facility.

#### 2.1.2. Study of the animal model

The index operation was performed in 15 animals, of whom 1 died in the immediate, and 2 in the late postoperative period. After 4 months of postoperative recovery, the animals were sedated, intubated and anesthetized in the catheterization laboratory, as described earlier. A 7F catheter was introduced into the internal jugular vein for infusion of pharmaceuticals and fluids. The heart was exposed via median sternotomy and lateral thoracotomy and suspended in a pericardial cradle. After stabilization for 20 min, baseline LV pressure, aortic flow and the surface electrocardiogram were recorded. The signals were digitized at 200 Hz and stored on disk for off-line analysis. Echocardiographic measurements were then performed in the first 7 animals alive. The same experimental protocol was carried out, and the same measurements were made for comparison in a control group of 7 age-matched, previously non-operated animals.

#### 2.1.3. Electroanatomic mapping in the animal model

Five animals were similarly operated 4 months after the index procedure and underwent epicardial electroanatomic mapping with Carto™ (Biosense Webster, Diamond Bar, CA), as previously described [20]. The torso of the animal was covered by 3 magnetic fields of different frequencies. A location reference was fixed on the back of the pig while a mapping catheter navigated on the epicardium of the animal. The magnetic sensor equipped in the tip of the catheter and the location reference compared the intensities of the 3 magnetic fields ensuring that the location of the catheter could be accurately determined. Color-coded, 3-dimensional maps of epicardial activation were constructed.

### 2.2. Studies in adult patients with TOF

A total of 42 consecutive patients aged >18 years with a history of surgically repaired TOF, in sinus rhythm with electrocardiographic signs of the right bundle branch block (QRS duration >120 ms) were prospectively included for an echocardiographic evaluation. Exclusion criteria were inadequate transthoracic window for echocardiographic examination and the presence of a pacing device. Electrocardiographic and ultrasound data from these patients were compared with those obtained from 30 control subjects, matched for age and free of any history of acquired or congenital heart disease. The median age was  $29 \pm 6$  years in patients vs.  $26 \pm 7$  years in controls ( $P = \text{ns}$ ). The median age at TOF repair was  $5.4 \pm 4.7$  years. Twenty-four patients were in NYHA functional class I, 15 in class II, and 3 in class III, despite optimal medical therapy. The mean QRS duration in the TOF group was  $154 \pm 21$  ms with an RBBB aspect vs.  $88 \pm 8$  ms in the control group ( $p < 0.0001$ ).

### 2.3. Echocardiographic study in the animal model and in patients

The animals with the model of repaired TOF, the control animals, the patients with TOF and the control patients underwent the same echocardiographic protocol. Transthoracic echocardiography was performed with a Vivid 7 digital ultrasound system (GE/VingMed, Horten, Norway) (Fig. 2). Echocardiographic cine-loops of 3 cardiac cycles were analyzed off-line to confirm the presence of pulmonic valve stenosis. By using continuous Doppler waveforms, the pulmonary regurgitation pressure half-time (PHT) was measured. The PHT was measured from the initial linear downslope of the pulmonary regurgitation waveform. A PHT value of <100 ms determined a severe pulmonary regurgitation. Tissue Doppler imaging of segmental wall motion was used to quantify intra-LV and intra-RV dyssynchrony as previously described. Briefly, intra-LV dyssynchrony was defined as the difference between the shortest and longest of 4 basal LV electromechanical delays (lateral, septal, anterior and inferior). Intra-RV dyssynchrony was defined as the difference between electromechanical delay of septum and RV free wall. The systolic RV function was assessed by measuring of peak systolic TDI velocity ~1 cm towards the apex from the lateral tricuspid valve annulus in the apical four-chamber view.

### 2.4. Statistical analysis

Data were expressed as mean value  $\pm$  SD. Comparisons between the groups were made using Student's *t*-test. Control subjects and animals were included in the study to estimate the range of ventricular dyssynchrony, contractility and dimensions in the population with normal cardiac function and no history of cardiomyopathy. For all analyses, a *P*-value less than 0.05 was considered statistically significant.

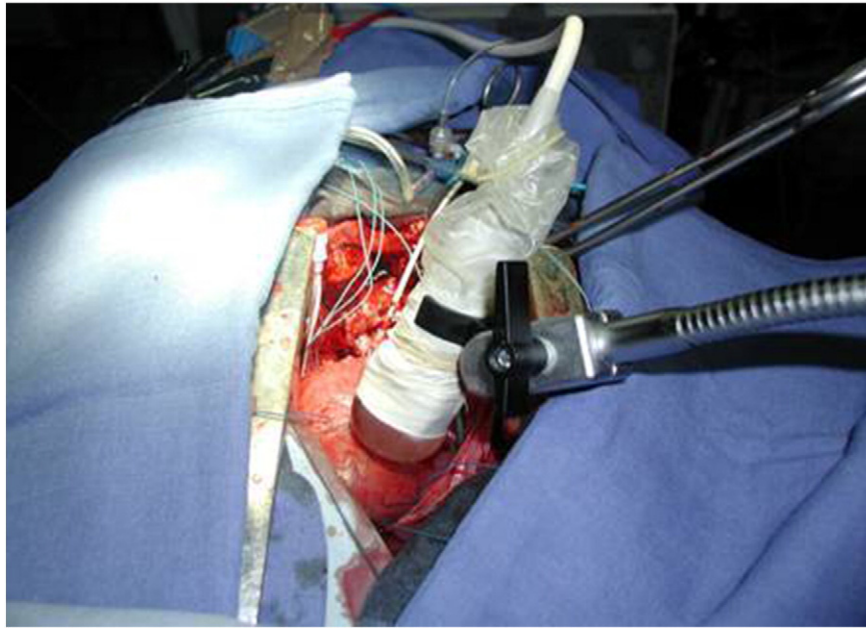
## 3. Results

### 3.1. Animal experiments

#### 3.1.1. Characteristics of the animal model

Compared to the control group, the operated animals developed prominent pulmonic stenosis and regurgitation, RV pressure and





**Fig. 2.** Echocardiographic study of the animal model using a Vivid 7 digital ultrasound system (GE/VingMed, Horten, Norway).

volume overload, marked RV enlargement, depressed LV and RV function, bilateral intraventricular dyssynchrony and increased QRS duration (Table 1, Fig. 3).

### 3.1.2. Electroanatomic activation

Epicardial electroanatomic maps created during sinus rhythm (SR) showed an activation sequence consistent with right BBB. The first activated area was the baso-lateral LV, and the last was the RV free wall (Fig. 4).

### 3.2. Echocardiographic study in TOF patients

Compared to the control group, the patients with TOF demonstrated moderated left ventricular dysfunction, altered right ventricular systolic function. Ten patients had severe pulmonary regurgitation and 32 patients had mild to moderate pulmonary regurgitation. The mean gradient across the pulmonary outflow tract

was  $19 \pm 13$  mm Hg ( $p < 0.0001$  vs. controls). A significant right and left ventricular dyssynchrony was found, data is shown in Table 1.

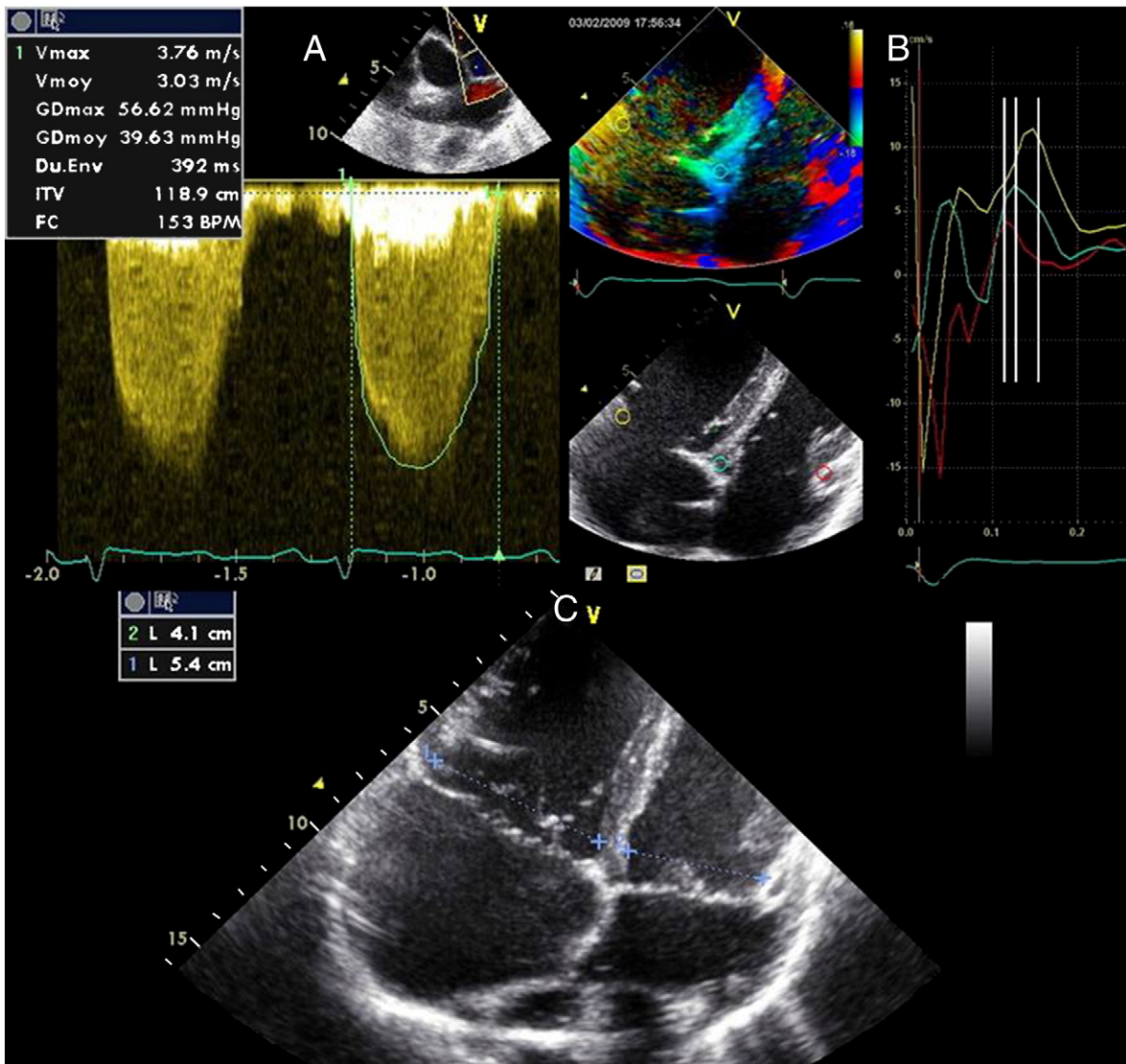
### 3.3. Comparison between the operated animals and TOF patients

Many parameters of the animal model performed are quite similar to TOF patients, particularly in terms of conduction delay and asynchrony. After 4 months, we observed a 54% increase of QRS duration in animal model vs. 75% in TOF patients. Pulmonary regurgitation goes from insignificant to moderate and pulmonic gradient from  $4 \pm 4$  mm Hg to  $21 \pm 15$  mm Hg in the two conditions. LV ejection fraction decrease of 27% for animal model and 14% in TOF patients. Mild to moderate right ventricular dysfunction was displayed in both (RV Sa = 10.7 cm/s in animal model vs. 10.1 cm/s in TOF patients). Significant right and left ventricular dyssynchrony is found in the two conditions. The animal model manages to mimic the same dyssynchrony as TOF patients (Table 1).

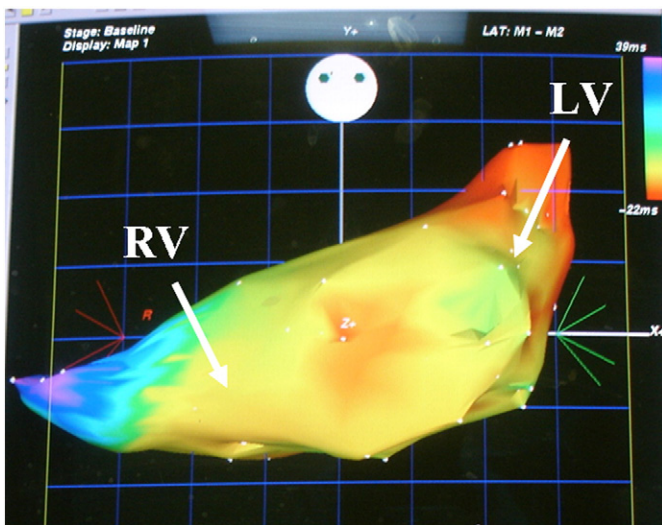
**Table 1**  
Characteristics of operated vs. control animals and tetralogy of Fallot (TOF) patients vs. control.

|  | Human           |                                      |       | Animal               |                     |       |
|--|-----------------|--------------------------------------|-------|----------------------|---------------------|-------|
|  | TOF<br>(n = 42) | Healthy control subjects<br>(n = 30) | p     | Operated<br>(n = 12) | Controls<br>(n = 7) | p     |
| QRS duration, ms                                 | 154 ± 21        | 88 ± 8                               | <0.01 | 82 ± 13              | 53 ± 2              | <0.01 |
| Pulmonary regurgitant fraction, %                | 35 ± 12         | –                                    | <0.01 | 33 ± 4               | 0                   | <0.01 |
| RVOT Doppler gradient, mm Hg                     | 19 ± 13         | 2 ± 2                                | <0.01 | 21.8 ± 7             | 4 ± 2               | <0.01 |
| LV ejection fraction, %                          | 58 ± 9          | 68 ± 4                               | <0.05 | 48 ± 6               | 66 ± 3              | <0.01 |
| RV Sa, cm/s                                      | 10.1 ± 2.2      | 15.1 ± 2                             | <0.01 | 10.7 ± 1.7           | 14 ± 2              | <0.01 |
| Intra-right dyssynchrony, ms                     | 37 ± 12         | 18 ± 8                               | <0.05 | 25 ± 4               | 13 ± 2              | <0.01 |
| Intra-left dyssynchrony, ms                      | 34 ± 12         | 20 ± 10                              | <0.05 | 26 ± 3               | 12 ± 3              | <0.01 |
|  | Human           |                                      |       | Animal               |                     |       |
|  | TOF<br>(n = 8)  | Healthy control<br>(n = 7)           | p     | Operated<br>(n = 8)  | Controls<br>(n = 8) | p     |
| Left ventricular dP/dt <sub>max</sub> , mm Hg/s  | 1279 ± 160      | 1461 ± 383                           | <0.05 | 2066 ± 554           | 2836 ± 488          | <0.01 |
| Right ventricular dP/dt <sub>max</sub> , mm Hg/s | 435 ± 113       | 473 ± 62                             | ns    | 513 ± 72             | 712 ± 81            | <0.01 |
| Right ventricular pressure, mm Hg                | 54 ± 11         | 34.5 ± 8                             | <0.01 | 42 ± 14              | 18 ± 6              | <0.01 |
| Peak systolic                                    |                 |                                      |       |                      |                     |       |

Values are means ± SEM. RVOT = right ventricular outflow tract, LV = left ventricle, RV = right ventricle.



**Fig. 3.** Characteristics of the animal model. A) Prominent gradient between right ventricle and pulmonary artery; B) right bundle branch block with activation proceeding from the LV lateral wall to the septum and finally the RV free wall; and C) marked right ventricular dilatation.



**Fig. 4.** Electroanatomic mapping in the animal model. Epicardial electroanatomic maps show an activation sequence consistent with right BBB. The first activated area is the baso-lateral LV, and the last is the RV free wall.

**4. Discussion**

Tetralogy of Fallot is the most common cyanotic congenital cardiac defect characterized by the association of 4 anatomic features (1) sub-pulmonary infundibular stenosis, (2) ventricular septal defect, (3) rightward deviation of the aortic valve with overriding of the ventricular septum, and (4) right ventricular hypertrophy [21]. Before the advent of surgical intervention, it was unusual for a patient to reach adult age. The history of the surgical treatment of TOF is over 60 years old with a progressive shift away from palliation to early primary repair. Surgical repair involves closing the ventricular septal defect and relieving the right ventricular outflow tract obstruction. To avoid residual obstruction, transannular patching has been applied during a few decades despite the risk of pulmonary regurgitation. A majority of adults with repaired tetralogy of Fallot currently demonstrate persistent postoperative anatomic abnormalities. Long-term mechanical problems after surgical repair include right ventricular volume overload from pulmonary regurgitation, residual outflow tract obstruction, ventricular enlargement and hypertrophy, biventricular dysfunction, atrial and ventricular scars, right bundle branch block and electromechanical ventricular delay [22,23]. Sudden death and progressive heart failure are the most common causes of death in this population [16,18]. To assess



the different therapeutic options and to test the future therapeutic innovations, an animal model mimicking the sequelae after surgical repair seems required.

The present animal model, which combines right ventricular volume and pressure overload, appears reliable, reproducible, and associated with a low mortality. This animal model seems to emulate some of the main mechanical and electrophysiologic abnormalities observed in patients with repaired tetralogy of Fallot. Echocardiographic measurements confirmed prominent right ventricular dilatation and dysfunction. Interestingly, the difference between animal model and their controls and between control patients and adults with tetralogy of Fallot seemed very similar in terms of the parameter of ventricular function or volume. Notably, animals also showed moderate left ventricular dysfunction, as observed in humans after surgical repair of TOF and in some patients with long-standing lung disease and right ventricular dysfunction. Finally, this model was associated with the development of right and left ventricular electromechanical dyssynchrony. Our swine model of right ventricular dysfunction and right bundle branch block is not a perfect replica of repaired TOF since, it does not include the anatomic or genetic substrate, such as malalignment of the ventricular septum, ventricular septal defect, or subvalvar pulmonary stenosis and it has no surgically-induced right bundle branch block. Indeed, the index operation did not markedly prolong QRS duration. Any additional contribution of the initial hypoxemia and genetic alterations to the development of late left and right ventricular dysfunction or arrhythmias are not accounted for in this condition [24,25]. The model, nevertheless, closely reproduced the electrophysiologic and mechanical abnormalities found in patients with this disorder, including the delayed development of the right bundle branch block [8,9,19]. The animals developed QRS widening as they aged as seen in humans. Echocardiography and epicardial mapping confirmed the typical right bundle branch block, with early electrical and mechanical activations of the lateral LV wall and delayed activation of the RV free wall. Section of the right bundle branch during surgery would probably have created more important electromechanical delays and QRS complexes but the index procedure would have become more risky with a much higher mortality.

As a result of the progress made in the surgical repair and the survival into adulthood of patients suffering from congenital heart disease, right ventricular dysfunction is the object of growing interest, although the therapeutic options remain limited. The present study demonstrates marked biventricular dyssynchrony in adults suffering from tetralogy of Fallot. Adults with congenital heart disease may represent a new population who could benefit from electrical therapies. A few case reports and non-randomized retrospective studies, which included inhomogeneous patient populations suffering from congenital heart disease, suggest that cardiac resynchronization has favorable effects on cardiac function. We believe that the present model may help for the demonstration of the hemodynamic benefit induced by biventricular pacing, for the assessment of different pacing configurations. Moreover, this model may be used for preliminary studies about the interest of new materials such as percutaneous pulmonary valve implantation to study RV pressure and volume overload effect and combination effect of resynchronization and pulmonary valve implantation in patient with important alteration of RV function.

Thus, the model recapitulated the findings of right heart failure and right BBB observed after prior surgical repair of TOF, and in patients with RV failure and right BBB due to primary lung disease.

## Acknowledgement

The authors of this manuscript have certified that they comply with the Principles of Ethical Publishing in the International Journal of Cardiology [26].

## References

- [1] Wren C, O'Sullivan JJ. Survival with congenital heart disease and need for follow up in adult life. *Heart* 2001;85:438–43.
- [2] Bolger AP, Coats AJ, Gatzoulis MA. Congenital heart disease: the original heart failure syndrome. *Eur Heart J* 2003 May;24(10):970–6.
- [3] Webb CL, Jenkins KJ, Karpawich PP, et al. Congenital Cardiac Defects Committee of the American Heart Association Section on Cardiovascular Disease in the Young. Collaborative care for adults with congenital heart disease. *Circulation* 2002;105:2318–23.
- [4] Peng EW, Lilley S, Knight B, et al. Synergistic interaction between right ventricular mechanical dyssynchrony and pulmonary regurgitation determines early outcome following tetralogy of Fallot repair. *Eur J Cardiothorac Surg* 2009;36(4):694–702.
- [5] Vogel M, Sponring J, Cullen S, Deanfield JE, Redington AN. Regional wall motion and abnormalities of electrical depolarization and repolarization in patients after surgical repair of tetralogy of Fallot. *Circulation* 2001;103:1669–73.
- [6] Uebing A, Gibson DG, Babu-Narayan SV, et al. Right ventricular mechanics and QRS duration in patients with repaired tetralogy of Fallot: implications of infundibular disease. *Circulation* 2007;116:1532–9.
- [7] Davlouros PA, Kilner PJ, Hornung TS, et al. Right ventricular function in adults with repaired tetralogy of Fallot assessed with cardiovascular magnetic resonance imaging: detrimental role of right ventricular outflow aneurysms or akinesia and adverse right-to-left ventricular interaction. *J Am Coll Cardiol* 2002;40:2044–52.
- [8] Bordachar P, Iriart X, Chabaneix J, et al. Presence of ventricular dyssynchrony and haemodynamic impact of right ventricular pacing in adults with repaired tetralogy of Fallot and right bundle branch block. *Europace* 2008;10:967–71.
- [9] Abd El Rahman MY, Hui W, Yigitbasi M, et al. Detection of left ventricular asynchrony in patients with right bundle branch block after repair of tetralogy of Fallot using tissue-Doppler imaging-derived strain. *J Am Coll Cardiol* 2005;45:915–21.
- [10] Janousek J, Tomek V, Chaloupecky V, Gebauer RA. Dilated cardiomyopathy associated with dual-chamber pacing in infants: improvement through either left ventricular cardiac resynchronization or programming the pacemaker off allowing intrinsic normal conduction. *J Cardiovasc Electrophysiol* 2004;15:470–4.
- [11] Janousek J, Vojtovic P, Hucin B, et al. Resynchronization pacing is a useful adjunct to the management of acute heart failure after surgery for congenital heart defects. *Am J Cardiol* 2001;88:145–52.
- [12] Dubin AM, Feinstein JA, Reddy VM, Hanley FL, Van Hare GF, Rosenthal DN. Electrical resynchronization: a novel therapy for the failing right ventricle. *Circulation* 2003;107:2287–9.
- [13] Strieper M, Karpawich P, Frias P, et al. Initial experience with cardiac resynchronization therapy for ventricular dysfunction in young patients with surgically operated congenital heart disease. *Am J Cardiol* 2004;94:1352–4.
- [14] Dubin AM, Janousek J, Rhee E, et al. Resynchronization therapy in pediatric and congenital heart disease patients: an international multicenter study. *J Am Coll Cardiol* 2005;46:2277–83.
- [15] Janousek J, Tomek V, Chaloupecky VA, et al. Cardiac resynchronization therapy: a novel adjunct to the treatment and prevention of systemic right ventricular failure. *J Am Coll Cardiol* 2004;44:1927–31.
- [16] Khairy P, Harris L, Landzberg MJ, et al. Implantable cardioverter-defibrillators in tetralogy of Fallot. *Circulation* 2008;117(3):363–70.
- [17] Khairy P, Dore A, Poirier N, et al. Risk stratification in surgically repaired tetralogy of Fallot. *Expert Rev Cardiovasc Ther* 2009;7(7):755–62.
- [18] Gatzoulis MA, Balaji S, Webber SA, et al. Risk factors for arrhythmia and sudden cardiac death late after repair of tetralogy of Fallot: a multicentre study. *Lancet* 2000;356:975–81.
- [19] Gatzoulis MA, Till JA, Somerville J, Redington AN. Mechano-electrical interaction in tetralogy of Fallot: QRS prolongation relates to right ventricular size and predicts malignant ventricular arrhythmias and sudden death. *Circulation* 1995;92:231–7.
- [20] Callans DJ, Ren JF, Michele J, Marchlinski FE, Dillon SM. Electroanatomic left ventricular mapping in the porcine model of healed anterior myocardial infarction. Correlation with intracardiac echocardiography and pathological analysis. *Circulation* 1999;100:1744–50.
- [21] Brickner ME, Hillis LD, Lange RA. Congenital heart disease in adults. First of two parts. *N Engl J Med* 2000;342:256–63.
- [22] Nollert G, Fischlein T, Bouterwek S, Böhmer C, Klinner W, Reichart B. Long-term survival in patients with repair of tetralogy of Fallot: 36-year follow-up of 490 survivors of the first year after surgical repair. *J Am Coll Cardiol* 1997;30:1374–83.
- [23] Murphy JG, Gersh BJ, Mair DD, et al. Long-term outcome in patients undergoing surgical repair of tetralogy of Fallot. *N Engl J Med* 1993;329:593–9.
- [24] Milerova M, Charvatova Z, Skarka L, et al. Neonatal cardiac mitochondria and ischemia/reperfusion injury. *Mol Cell Biochem* 2010;335:147–53.
- [25] Zeppenfeld K, Schalij MJ, Bartelings MM, et al. Catheter ablation of ventricular tachycardia after repair of congenital heart disease: electroanatomic identification of the critical right ventricular isthmus. *Circulation* 2007;116:2241–52.
- [26] Coats AJ. Ethical authorship and publishing. *Int J Cardiol* 2009;131:149–50.

## 5.2 Identification de profils d'expressions géniques, dépendants de différentes régions myocardiques, chez notre modèle animal chronique de TF réparée.

### 5.2.1 Introduction et Objectifs

Contrairement à l'insuffisance cardiaque ventriculaire gauche, l'insuffisance ventriculaire droite est aujourd'hui mal comprise et son traitement reste en grande partie empirique. En particulier, les mécanismes moléculaires, qui sous-tendent les différentes étapes du remodelage du VD et sa progression vers l'insuffisance cardiaque, demeurent obscurs. A ce propos, l'ESC (European Society of Cardiology) proposait récemment (2014) de multiplier les travaux moléculaires pour mieux comprendre la dysfonction du VD, notamment chez les modèles animaux.

Notre modèle de gros animal, chronique et validé, imitant les paramètres (et séquelles) essentiels d'une TF réparée, a été étudié au niveau moléculaire. L'objectif de ce travail était de réaliser une analyse du profil d'expression transcriptomique, au niveau des deux ventricules des cochons opérés, au stade d'insuffisance cardiaque droite par surcharge volumétrique préférentielle. Ce travail a été réalisé en collaboration avec le Dr Caroline Rooryck-Thambo du laboratoire Maladies Rares : Génétique et Métabolisme (MRGM), EA 4576.

(Cf. en annexe, l'article : *Charron S, Roubertie F. et al. Identification of Region-Specific Myocardial Gene Expression Patterns in a Chronic Swine Model of Repaired Tetralogy of Fallot. PLoS One. 2015 Aug 7;10).*

### 5.2.2 Méthodes

Nos cochons ont été opérés à quelques semaines de vie (exérèse de valvules pulmonaires, patch trans-annulaire et cerclage peu serré, par thoracotomie gauche) et ont été investigués à l'âge de 5 mois et demi.

Des prélèvements biopsiques (de 0.5 x 0.5 cm au niveau du muscle myocardique de la paroi libre du VD et de la paroi latérale du VG) ont été effectués chez 7 cochons « opérés type TF » et chez 5 cochons « sains » ; puis ces prélèvements ont été congelés immédiatement dans de l'azote liquide. A partir de ces biopsies, l'ARN était extrait (200 ng.) puis du cADN synthétisé, puis enfin du cARN synthétisé. Ce cARN a été étudié à l'aide de puces d'expression pangénomiques pour réaliser une étude transcriptomique dans les différentes régions myocardiques prélevées. Deux régions distinctes (endocarde et épicarde) des deux ventricules ont été analysées.

Les niveaux d'expression de chaque localisation ont été comparés, afin de décrypter, les mécanismes et voies de signalisation conduisant à la dysfonction ventriculaire droite et aux arythmies chez les animaux mimant une TF réparée chirurgicalement. Les données de la puce d'expression ont ensuite été confirmées par technique ciblée de RT-PCR quantitative, pour les gènes les plus dérégulés et possédant des fonctions intéressantes, et une étude protéique par Western blot a également été réalisée pour certains gènes candidats.

### 5.2.3 Résultats

Plusieurs gènes ont été confirmés pour leur participation à un remodelage ventriculaire droit et à l'insuffisance ventriculaire droite et certains nouveaux gènes candidats ont été décrits.

En particulier, ces données ont confirmé *FRZB* comme nouveau marqueur de l'insuffisance cardiaque droite sur surcharge volumétrique. Par ailleurs, des gènes de la fonction contractile et du maintien de l'homéostasie calcique (*SLN*, *ACTC1*, *PLCD4*, *PLCZ*), des gènes potentiellement liés à l'arythmie (*MYO5B*, *KCNA5*), et des gènes liés à l'organisation cellulaire et au cytosquelette (*XIRP2*, *COL8A1*, *KCNA6*) ont été parmi les gènes les plus dérégulés dans les VD (endocardes) des cochons mimant une TF réparée. Ces données étaient confirmées par RT-PCR.

Les profils d'expression au niveau du ventricule gauche suivent la même tendance que le VD mais de manière moins prononcée, pouvant faire poser l'hypothèse d'un gradient d'expression moléculaire progressant du VD vers le ventricule gauche. En particulier, la contrainte mécanique

pourrait se transmettre du VD vers le ventricule gauche, médiée par des altérations moléculaires et cellulaires liées à certains gènes.

### **5.2.4 Conclusion**

La nature et l'étendue de l'expression des gènes variant avec le temps, il serait intéressant, dans l'avenir, de réaliser d'autres études transcriptomiques à différentes périodes postopératoires (2 mois, 4 mois et 8 mois) et d'étudier ainsi la progression du remodelage moléculaire chez notre modèle animal.

### 5.2.5 Perspectives de recherche clinique suite au travail précédent

Une étude récente portant sur certaines protéines a été effectuée sur des fragments chirurgicaux de myocarde du VD d'enfant opérés de réparation complète de TF (1).

Une étude similaire à celle effectuée sur notre modèle animal serait intéressante à réaliser chez les adultes avec TF réparée, lors de la valvulation pulmonaire. On pourrait prélever un fragment de myocarde du VD (site encore à déterminer mais vraisemblablement de la paroi libre du VD, comme chez notre modèle animal), pour pouvoir réaliser une analyse de biologie moléculaire. Une analyse transcriptomique serait possible : avec l'avantage chez l'humain, que tous les gènes sont annotés, contrairement à notre modèle de gros animal.

Une étude gène candidat serait également possible, avec l'avantage, là encore, qu'il existe pour l'humain des puces d'intérêts comme par exemple : la puce d'intérêt qui comporte l'ensemble des gènes codants pour les canaux ioniques de la cellule musculaire cardiaque. Des demandes d'accord préalable auprès de la CCPPRB sont déjà obtenues.

On pourrait alors comparer les résultats à ceux de notre étude et surement compléter ces premiers résultats.

### Perspectives de recherche fondamentale suite au travail précédent

On pourrait imaginer réaliser une analyse transcriptomique à différentes périodes postopératoires (2 mois, 4 mois et 8 mois) chez notre modèle animal, mais qui aurait pu bénéficier d'une valvulation pulmonaire percutanée (à l'âge de 3 mois par exemple). On pourrait démontrer alors que cette thérapeutique a un impact positif ou non sur le remodelage moléculaire. L'âge auquel est effectué la valvulation pulmonaire percutanée peut être variable, ce qui multiplie les possibilités d'analyse.

La même étude pourrait être envisagée en utilisant la resynchronisation.

### 5.2.6 Références

1. Kolcz J, Drukala J, Bzowska M et al. The expression of connexin 43 in children with Tetralogy of Fallot. Cellular & molecular biology letters 2005;10:287-303.

RESEARCH ARTICLE

# Identification of Region-Specific Myocardial Gene Expression Patterns in a Chronic Swine Model of Repaired Tetralogy of Fallot

Sabine Charron<sup>1,2</sup>, François Roubertie<sup>1,2,3</sup>, David Benoist<sup>1,2</sup>, Virginie Dubes<sup>1,2</sup>, Stephen H. Gilbert<sup>1,2,4</sup>, Marion Constantin<sup>1,2</sup>, Delphine Vieillot<sup>5</sup>, Delphine Elbes<sup>1,2,6</sup>, Bruno Quesson<sup>1,2</sup>, Pierre Bordachar<sup>1,2,3</sup>, Michel Haissaguerre<sup>1,2,3</sup>, Olivier Bernus<sup>1,2</sup>, Jean-Benoit Thambo<sup>1,2,3</sup>, Caroline Rooryck<sup>1,3,7\*</sup>

**1** L'Institut de Rythmologie et Modélisation Cardiaque LIRYC, Université de Bordeaux, Pessac, France, **2** Inserm U1045 CRCTB, Université de Bordeaux, Bordeaux, France, **3** Hôpital cardiologique Haut-Lévêque, CHU de Bordeaux, Pessac, France, **4** Max Delbrück Center for Molecular Medicine, Berlin, Germany, **5** Plateforme Technologique d'Innovation Biomédicale, Université de Bordeaux, Pessac, France, **6** University of Oxford, Institute of Biomedical Engineering, Oxford, United-Kingdom, **7** Laboratoire Maladies Rares: Génétique et Métabolisme (MRGM), EA 4576, Université de Bordeaux, Bordeaux, France

\* [caroline.rooryck-thambo@chu-bordeaux.fr](mailto:caroline.rooryck-thambo@chu-bordeaux.fr)



**OPEN ACCESS**

**Citation:** Charron S, Roubertie F, Benoist D, Dubes V, Gilbert SH, Constantin M, et al. (2015) Identification of Region-Specific Myocardial Gene Expression Patterns in a Chronic Swine Model of Repaired Tetralogy of Fallot. PLoS ONE 10(8): e0134146. doi:10.1371/journal.pone.0134146

**Editor:** Robert W Dettman, Northwestern University, UNITED STATES

**Received:** February 25, 2015

**Accepted:** July 6, 2015

**Published:** August 7, 2015

**Copyright:** © 2015 Charron et al. This is an open access article distributed under the terms of the [Creative Commons Attribution License](https://creativecommons.org/licenses/by/4.0/), which permits unrestricted use, distribution, and reproduction in any medium, provided the original author and source are credited.

**Data Availability Statement:** All relevant data are within the paper and its Supporting Information files.

**Funding:** The authors received no specific funding for this work.

**Competing Interests:** The authors have declared that no competing interests exist.

## Abstract

Surgical repair of Tetralogy of Fallot (TOF) is highly successful but may be complicated in adulthood by arrhythmias, sudden death, and right ventricular or biventricular dysfunction. To better understand the molecular and cellular mechanisms of these delayed cardiac events, a chronic animal model of postoperative TOF was studied using microarrays to perform cardiac transcriptomic studies. The experimental study included 12 piglets (7 rTOF and 5 controls) that underwent surgery at age 2 months and were further studied after 23 (+/- 1) weeks of postoperative recovery. Two distinct regions (endocardium and epicardium) from both ventricles were analyzed. Expression levels from each localization were compared in order to decipher mechanisms and signaling pathways leading to ventricular dysfunction and arrhythmias in surgically repaired TOF. Several genes were confirmed to participate in ventricular remodeling and cardiac failure and some new candidate genes were described. In particular, these data pointed out *FRZB* as a heart failure marker. Moreover, calcium handling and contractile function genes (*SLN*, *ACTC1*, *PLCD4*, *PLCZ*), potential arrhythmia-related genes (*MYO5B*, *KCNA5*), and cytoskeleton and cellular organization-related genes (*XIRP2*, *COL8A1*, *KCNA6*) were among the most deregulated genes in rTOF ventricles. To our knowledge, this is the first comprehensive report on global gene expression profiling in the heart of a long-term swine model of repaired TOF.

## Introduction

Tetralogy of Fallot (TOF) is the most frequent cyanotic congenital heart disease in humans with an incidence of 1/3600 live births [1]. Surgical early primary repair is highly successful

and the population of adults with repaired Tetralogy of Fallot is increasing rapidly. However, the long-term outcome of these patients may be complicated by right ventricular [RV] or biventricular dysfunction and by sudden cardiac death (around 5%). The incompletely understood mechanisms of these delayed events may partially be due to surgically-induced permanent right bundle branch block (BBB) and ventricular dyssynchrony [2,3,4]. Unlike left ventricular failure, RV failure is poorly understood and its management remains largely empirical. In particular, the molecular mechanisms underlying different stages of ventricular remodeling and its progression towards heart failure (HF) remain obscure. Indeed, a recent position paper from the ESC working Group on Myocardial Function have emphasized the interest of working on the functional and molecular changes occurring in the right ventricle [5].

In order to better understand the implication of prolonged dyssynchrony, we established and characterized a chronic large animal model that mimicked essential parameters of postoperative TOF [6]. This model represents a reliable long-term swine model of RV dysfunction and dyssynchrony, with echocardiographic measurements comparable to adult patients with early surgical repaired TOF. Indeed, large animal models have a closer physiology to humans than small mammal models and are more appropriate to study the pathophysiological changes associated with ventricular remodeling.

Moreover, in the past decade, the completion of *Sus Scrofa* genome sequencing (Sscrofa10.2, INSDC Assembly, Aug 2011) led to the development of commercially available pig cDNA microarrays that could be used to detect changes in swine genes expression.

In the present study, we aimed at deciphering the sequence of molecular events and pathways leading to the progression of ventricular dysfunction and arrhythmias, by studying gene expression profiles of repaired Fallot (rTOF) pigs' hearts compared to control animals (sham-operated), in four different localizations of the heart (epicardium and endocardium of right and left ventricles), by a whole genome approach. Some transcripts were selected to verify the accuracy and reproducibility of the microarray data by real-time qRT-PCR.

## Materials and Methods

The experimental protocol followed the European rules for animal experimentation (European legislation 2010/63/UE—2010) which was implemented under French legislation from February 2013 and following which all animal experimental protocols, including the present study, at our Institution were reviewed and approved by the local Ethics Committee "Comité d'Ethique en Expérimentation Animale de Bordeaux—CEEA50. The experimental protocols were in compliance with the Guiding Principles in the Use and Care of Animals published by the National Institutes of Health (NIH Publication No. 85–23, Revised 1996).

### rTOF swine model

The experimental study included 12 piglets (7 rTOF and 5 controls), aged three months and weighing less than 12 kg, at the time of surgery. The animal model was established as previously described [6]. Briefly, after left thoracotomy of seven piglets, the RV outflow tract was partially occluded with a clamp and incised longitudinally across the pulmonic valve annulus. The operation was designed to cause RV volume overload from valvular regurgitation by excision of two pulmonic valve leaflets, RV pressure overload by a loose tape partially occluding the pulmonary artery, and RV outflow tract scar around the patch placed to close the RV incision. Five piglets were sham operated to serve as controls. After the procedure was completed, the animals were extubated and received supplemental oxygen and analgesia as needed, before their transfer to a long-term postoperative care facility. After intervention, qualitative cardiac



evaluation of the pigs was performed by echocardiogram and color Doppler in order to confirm the pulmonary regurgitation in the rTOF pigs.

After 23 (+/- 1) weeks of postoperative recovery, cardiac function was assessed in anesthetized pigs (isoflurane 2%, Vibrac) by cardiac magnetic resonance in a Siemens Magnetom Avanto 1.5T MRI scanner (Erlangen, Germany). Animals were euthanized, their hearts excised and washed in ice-cold cardioplegic solution to remove any residual blood.

### Tissue collection and RNA extraction

Myocardial samples were dissected out and immediately frozen into liquid nitrogen. Biopsies were then stored at -80°C until RNA extraction. Total RNA was extracted from tissues using QIAzol reagent (Qiagen, USA). RNA was purified and DNase treated using the QIAGEN RNeasy Kit. RNA purity and integrity, were assessed both by spectrophotometry (NanoDrop ND-1000, NanoDrop Technologies) and nanoelectrophoresis (2100 Bioanalyzer, Agilent Technologies).

### Microarray Hybridization and scanning

cDNA was synthesized from 200 ng of total-RNA using the direct cDNA Labeling System. Aminoallyl-cRNA was synthesized from cDNA using the Superscript Indirect cDNA Labeling System. The cRNA was purified using RNeasy QIAGEN RNeasy Kit.

Labeling and hybridization of the cRNA was performed with Agilent Whole Porcine Genome Oligo (4 × 44 K) Microarrays (one-color platform), according to the manufacturer's protocols. The slides were scanned and analyzed using the histogram method with default settings in an Agilent G2565C Microarray Scanner System with SureScan Technology.

### Annotation of the porcine microarray

Among the 43,603 probes present on the Porcine 44K Agilent microarray (V2), only 15,458 of these were annotated with HUGO Gene Nomenclature Committee (HGNC) gene symbols [7], corresponding to about 7600 genes. This incomplete annotation was probably due to the presence of former ESTs (Expressed Sequence Tags) that no longer belong to *Sus Scrofa* after the completion of the pig genome sequencing project. More probes were annotated using GeneBank and Basic local Alignment Search tool program (BLAST, NCBI).

### Microarray Data Analysis

Hierarchical clustering of the significantly differentially expressed (DE) genes from microarray data was carried out by the Genespring software (Agilent Technologies), with a p-value corrected by Benjamini Hochberg False Discovery Rate (FDR). Different softwares were used to interpret the biological functions and canonical pathways of the gene lists: Visualization and Integrated Discovery Online platform (<http://david.abcc.ncifcrf.gov/>) [8], using Gene ontology (GO) terms and the Database for Annotation, with a threshold of a minimum three genes annotated at each node, Panther Pathway (<http://www.pantherdb.org/pathway/>) and Ingenuity Pathway Analysis (IPA, <http://www.ingenuity.com>)

### Reverse Transcription quantitative PCR (RT-qPCR)

In order to confirm the reliability of the expression profile from the microarray analyses, the expression level of some genes was assessed by real-time RT-qPCR.

Sequences for primers were obtained from Ensembl Genome Browser. Primers were designed using Primer designing tool (NCBI) and synthesized at Sigma Aldrich. 1µg of RNA

was reversed transcribed using a cDNA Reverse Transcription kit (Life Technologies) according to the manufacturer's protocol. Quantitative PCR was performed in a 25  $\mu$ L reaction volume (2  $\mu$ L cDNA, 12.5  $\mu$ L of SYBR Premix (BIO-RAD), a volume of 10  $\mu$ M upstream and downstream primers respectively, and added ddH<sub>2</sub>O to 25  $\mu$ L) on the BIO-RAD C 100 Touch Thermal Cycler / CFX96 Real time System. Real-time PCR conditions were as follows: 3 min at 95.0°C, 40 cycles of denaturation at 95°C for 30 s followed by 30 s annealing and elongation at 60°C. Efficiency of primer pairs was previously evaluated. Melting curves were obtained at the end of each run to confirm a single PCR product. All samples were run in triplicate. Non-template controls were included in each run to exclude contamination and nonspecific amplification. Expression levels of samples were normalized by using a normalization factor calculated by the software CFX Manager (BIO-RAD). This normalization factor was calculated based on RT-qPCR results for two selected reference genes, *HPRT1* and *GUSB*. This allowed quantification of the target gene in one sample relative to that in another (the calibrator) using the “ $2^{-\Delta\Delta C_t}$  method” of calculating fold changes in gene expression.

## Results

Upon cardiac magnetic resonance examination at  $23 \pm 1$  weeks, Fallot pigs presented with significantly decreased RV ejection fraction and increased RV end-diastolic volume compared to controls indicating RV dysfunction and RV dilation respectively (S1 Fig).

We first performed microarray experiments on myocardial biopsies from the right ventricle (endocardium and epicardium separately), because we expected more changes in this particular region with an animal model of right ventricular dysfunction. We observed the biggest list of statistically significant DE genes in the endocardium of the right ventricle and focused on the exploration of these genes. We then explored the left ventricle (endocardium and epicardium).

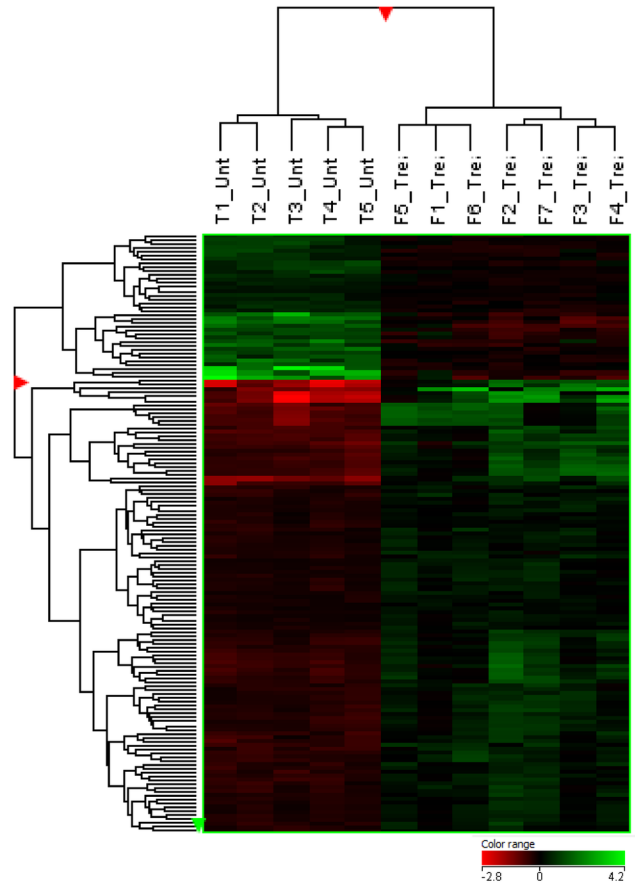
### Microarray Profiling of the endocardium of the right ventricle

Out of the 43,603 probes represented on the Sus Scrofa microarray (Agilent), 153 probes were significantly different in rTOF pigs versus controls, after preprocessing and statistical analysis (fold change  $>1.2$ ;  $p < 0.05$ ) (Fig 1). These 153 probes correspond to 69 annotated genes with 54 HUGO genes (other than LOC) (S1 Table) implicated in different processes, notably heart failure markers genes, calcium handling and contractile function-related genes, electrophysiology and arrhythmia-related genes, cytoskeleton/cellular organization-related genes, that may be of particular interest for our model.

The biological processes depicting genes that were deregulated in rTOF hearts are shown in Fig 2. “Metabolic process” (GO:0008152) and “Cellular process” (GO:0009987) are the most represented processes.

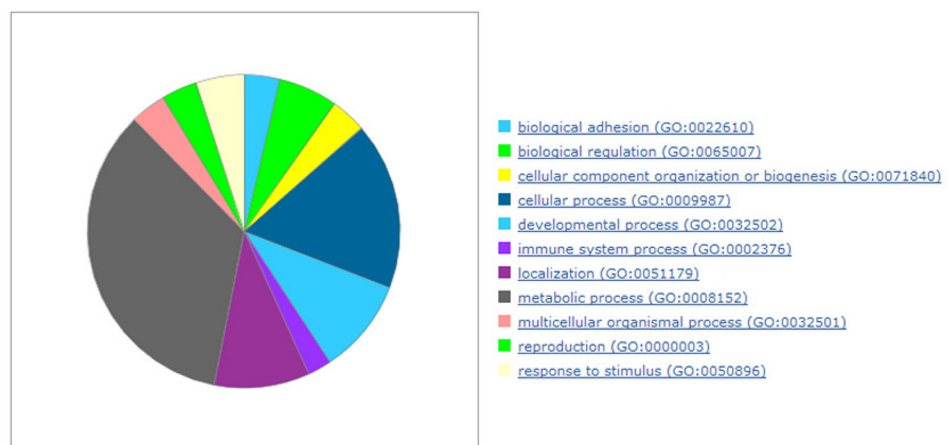
### Functional Pathway and Network Analysis

To investigate the interconnectivity of the differentially regulated genes with other gene products, pathways, and biological processes, molecular networks were formed with IPA software. These networks include genes from our transcriptomic data and their interactions with genes that are biologically relevant to the pathway, coding for hub molecules not altered in our experiments. Fig 3 shows the 22 most significant canonical pathways related to the 54 DE HUGO genes. Among these signaling cascades, the first is the NRF2-mediated Oxidative Stress Response that triggers apoptosis and necrosis. Then, the gap junction signaling related to electrical impulse propagation, the actin cytoskeleton signaling mediating cell motility and cell reshaping in response to extracellular stimuli, are the canonical pathways mostly involved.



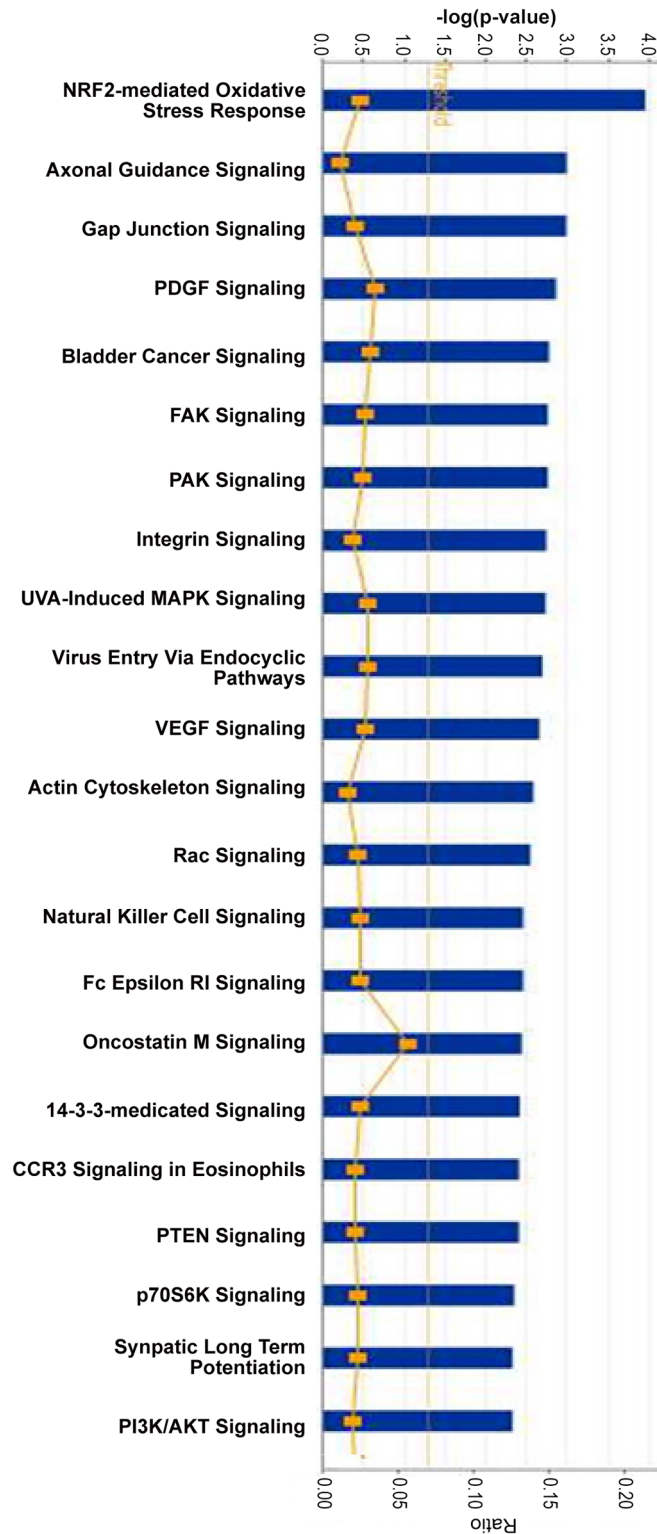
**Fig 1. Heatmap displaying the 153 most differentially expressed probes ( $p < 0.05$   $FC > 1.2$ ) in the RV Endocardium of 5 controls pigs (T1 to T5) and of 7 rTOF pigs (F1 to F7).** The red and green colors indicate relative transcript abundance (red = overexpressed, green = downregulated). The columns represent the 12 samples while the rows correspond to the 153 probes. Samples were classified using hierarchical clustering, according to similarity in change in relative transcript abundance.

doi:10.1371/journal.pone.0134146.g001



**Fig 2. The significant gene ontology biological processes in the RV Endocardium.**

doi:10.1371/journal.pone.0134146.g002



**Fig 3. Functional categorization analysis of the most significant pathways represented in the microarray-generated list of the 54 most differentially expressed genes (Ingenuity software) in the RV Endocardium of rTOF pigs.** The p-values (blue bars) were calculated using the right-tailed Fisher's exact test. The threshold (yellow line) is set to a p-value = 0.05. The ratios (yellow dots and curve) represent the number of molecules of the experiment related to the number of total molecules involved in the pathways.

doi:10.1371/journal.pone.0134146.g003

Other signaling pathways are linked to angiogenesis (PDGF and VEGF signaling), and to cellular adhesion (FAK signaling). The genes involved in these canonical pathways are listed in [S2 Table](#).

The top 4 networks among the genes most differentially expressed are represented in [Fig 4A](#). Each network was identified based on a numerical rank score according to the degree of relevance of the network to the molecules of our genes set and based on the hypergeometric distribution calculated as  $-\log$  (Fisher's exact test result). Genes involved in "Molecular transport, Cellular Growth and Proliferation" and "Endocrine system development and Function, Lipid Metabolism" were significantly overrepresented among differentially expressed genes. [Fig 4B](#) displays the network #2 with the highest number of genes of interest. In this network, ERK-PKC-MAPK are central hub molecules.

### Altered expression of genes implicated in different processes

Specifically, relative to controls, rTOF pigs changed expression of heart failure markers genes—Secreted frizzled-related protein 1 (*FRZB*), calcium handling and contractile function-related genes—Sarcolipin (*SLN*), Alpha cardiac actin (*ACTC1*), Calsequestrin (*CASQ1*), Troponin (*TNNT1*), Myotilin (*MYOT*), Phospholipase C Z (*PLCZ*), Phospholipase C D4 (*PLCD4*), electrophysiology and arrhythmia-related genes—Myosin 5B (*MYO5B*), Four and a half LIM domains protein 1 (*FHL1C*), Collagen type VIII (*COL8A1*), Potassium voltage-gated channel subfamily A member 6 (*KCNA6*) and Cytoskeleton/Cellular organization-related genes—Xin actin-binding repeat-containing protein 2 (*XIRP2*), Nexin (*SERPINE2*) ([Fig 5A](#)).

### Validation of Gene Expression Pattern from Microarray Data Using qRT-PCR

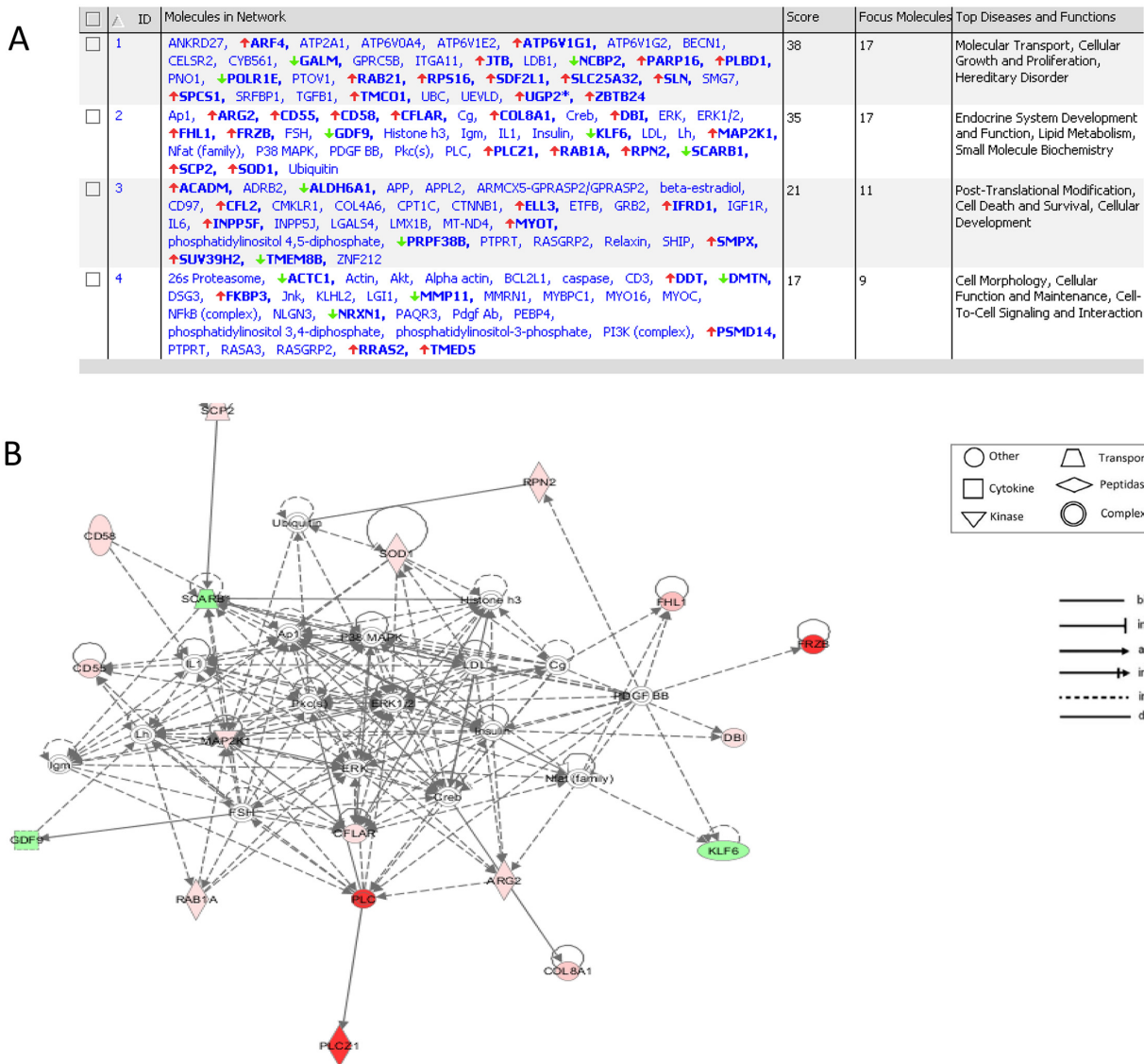
Representative genes were selected for validation via qRT-PCR, using the same tissue samples used in the microarray. For these fourteen genes, the fold changes obtained via microarray analysis demonstrated substantial agreement with the fold change values determined via qRT-PCR (Pearson correlation coefficient  $R > 0.7$ ,  $p < 0.05$ ) thereby confirming the microarray data ([Fig 5B](#)). Two genes were no longer significantly deregulated using qPCR: *FHL1C* and *MYOT*. This could be due to different isoforms not tested by qPCR (9 targets deregulated in microarray for each of these two genes).

### Altered expression of other candidate genes

We aimed to explore expression changes in candidate genes: *BNP* (Brain Natriuretic Peptide) as a heart failure marker, *SERCA2A2* (Sarcoplasmic/endoplasmic reticulum calcium ATPase 2, *ATP2A2*), known to be down regulated in failing hearts, and *KCNA5* coding for Kv1.5 which seems to interact with *MYO5B* and *FHL1C* (found deregulated in our microarray data) ([Fig 6](#)). We observed a statistically significant upregulation of *KCNA5* in the rTOF pigs compared to controls, and a trend to downregulation of *ATP2A2* in the rTOF pigs compared to controls. We observed a trend to upregulation of *BNP* ( $p = 0,10$ ), however one of the 7 rTOF animals had a much stronger expression of *BNP* compared to others ([S2 Fig](#)). This rTOF pig also had one of the largest RV end-diastolic volume (data not shown).

### Expression Profiling in four different regions of the myocardium

Performing the same experiments and statistical analyses on the three other localizations (right ventricle epicardium, left ventricle endocardium and left ventricle epicardium), we found a marked heterogeneity of regional gene expression. Target genes were globally differentially



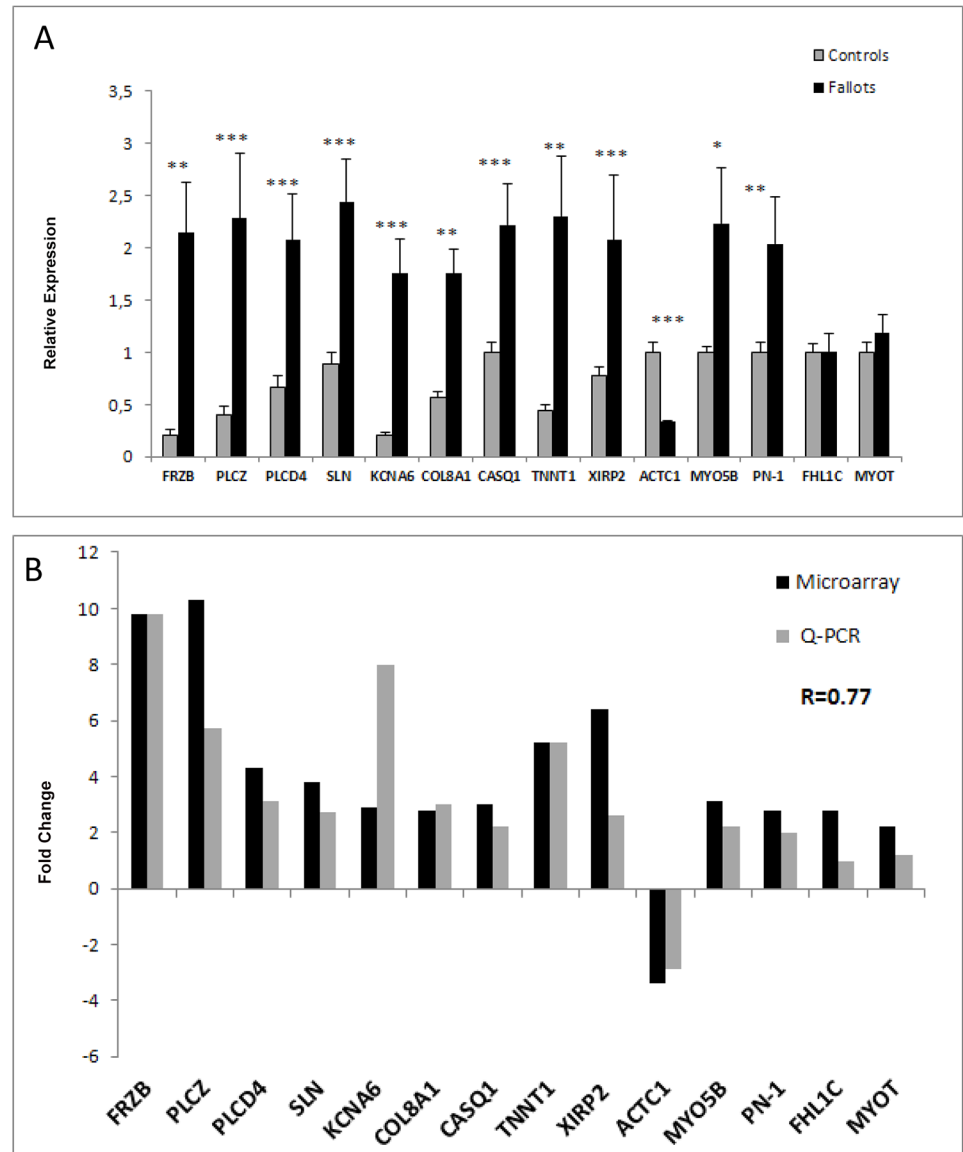
**Fig 4.** A. Ingenuity Pathway Analysis (IPA) generated 4 molecular networks assembled from DE genes the RV endocardium of rTOF pigs versus Controls (genes in bold) in the RV Endocardium. B. IPA Network #2. based upon differentially expressed genes that were upregulated and down regulated in the RV Endocardium.

doi:10.1371/journal.pone.0134146.g004

expressed in the same way as in the RV endocardium, between the rTOF and the controls, but with no statistical significant p-value ( $p > 0.05$ ). Table 1 shows the fold change and p-values for 14 genes of interest chosen from the RV endocardium transcriptomic data, for the three other locations.

We then used a candidate gene approach and studied, by quantitative RT-PCR, samples from the four localizations by testing 5 genes: *FRZB*, *PLCZ*, *TNNT1*, *XIRP2* and *ACTC1* (Fig 7). Surprisingly, we observed significant deregulation of these genes in the four localizations but with a lower FC. This could be due to the much higher sensitivity of qPCR compared to microarray.





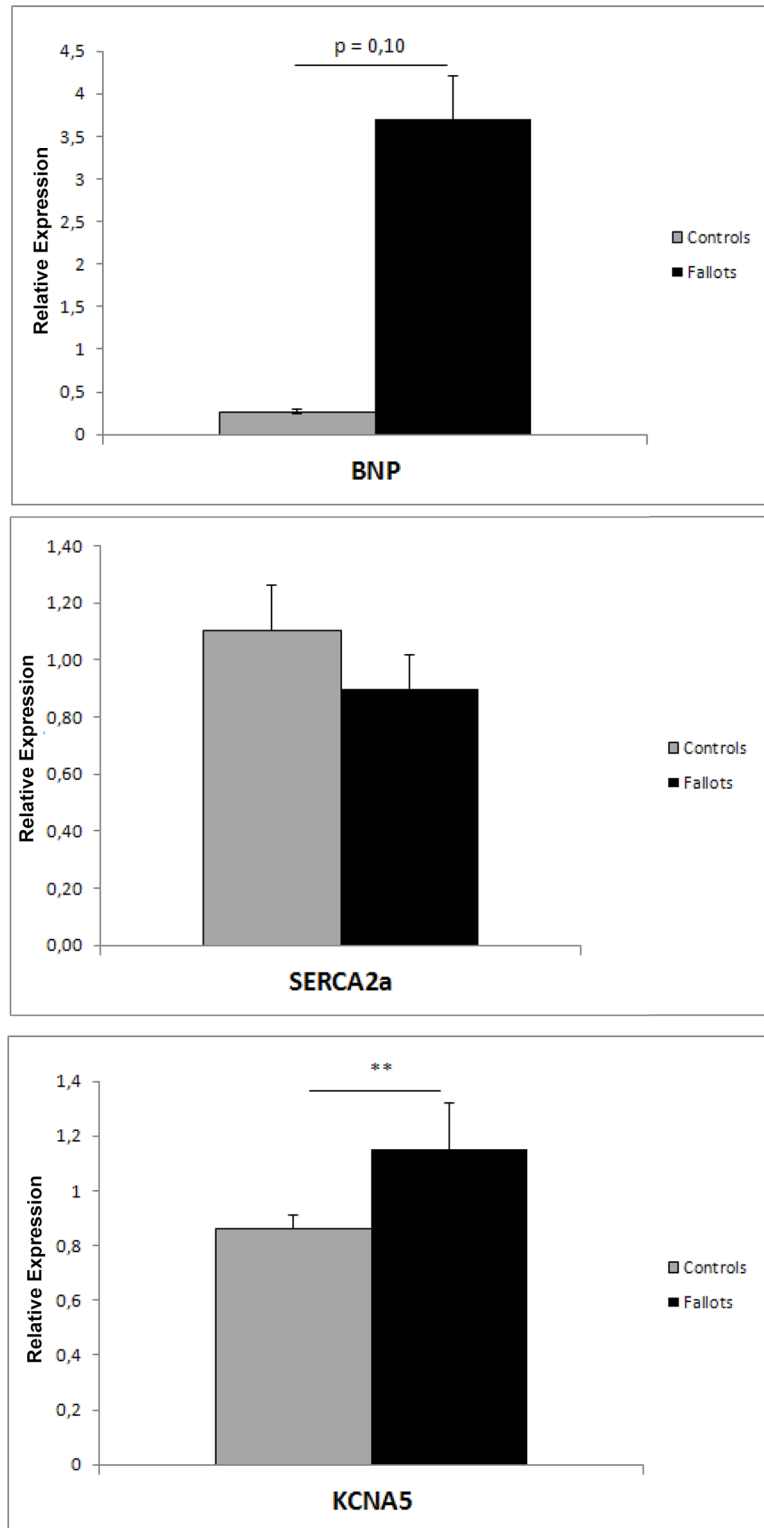
**Fig 5.** A. Relative expression (RT-qPCR) of genes in samples from the RV Endocardium of controls (grey bars) and rTOF (black bars) hearts. Transcript expression is normalized to the reference genes HPRT1 and GUSB. Two sided T-Test Statistical significance of  $n = 5$  Controls and  $n = 7$  rTOF hearts (\* $P < 0.05$ , \*\* $P < 0.01$ , \*\*\* $P < 0.001$ ) B. Fold change comparison in samples from the RV Endocardium ( $n = 5$  Controls and  $n = 7$  rTOF hearts) based on RT-qPCR results and microarray expression data. Pearson correlation coefficient  $R = 0.77$  ( $p = 0.001$ ).

doi:10.1371/journal.pone.0134146.g005

## Discussion

To our knowledge, this study represents the first characterization of myocardial transcriptomic profiles in a long-term swine model of surgically repaired Tetralogy of Fallot. Not surprisingly, the most statistically differentially expressed genes were identified in the endocardium of the right ventricle, as expected in a model of RV primitive pathogenesis.

According to Panther Pathway software, the analysis of the 54 most DE genes in the RV endocardium revealed two main biological processes: cellular process and metabolic process. Ingenuity Pathway software pointed out the most significant canonical pathways including



**Fig 6. Relative expression (RT-qPCR) of *BNP*, *Serca2a* (*ATP2A2*) and *KCNA5* genes in samples from the RV Endocardium of controls (grey bars) and rTOF (black bars) hearts.** Transcript expression is normalized to the reference genes *HPRT1* and *GUSB*. Two sided T-Test Statistical significance of n = 5 Controls and n = 7 rTOF hearts (\*P <0.05, \*\*P <0.01, \*\*\*P <0.001).

doi:10.1371/journal.pone.0134146.g006



**Table 1. Fold change comparison between samples from the RV endocardium (rTOF (n = 7) versus controls (n = 5)), RV epicardium (rTOF (n = 4) versus controls (n = 4)), LV epicardium (rTOF (n = 4) versus controls (n = 4)), and LV endocardium (rTOF (n = 7) versus controls (n = 5)) based on microarray expression data of 14 genes.**

| Gene Symbol   | Description  | RV Endo        | RV Epi       | LV Epi        | LV Endo      |
|---------------|--|----------------|--------------|---------------|--------------|
| <i>PLCZ</i>   | Phospholipase C (Zeta)                                       | 10.3 (0.025)   | 5.3 (0.378)  | 1.5 (1.000)   | 2.0 (0.675)  |
| <i>FRZB</i>   | Secreted frizzled-related protein                            | 9.8 (0.042) *  | 17.4 (0.378) | 4.4 (1.000)   | 2.3 (0.528)  |
| <i>XIRP2</i>  | Xin actin-binding repeat-containing protein 2                | 6.4 (0.003) ** | 2.1 (0.542)  | -1.3 (1.000)  | 0.9 (0.915)  |
| <i>TNNT1</i>  | Troponin   | 5.2 (0.023) *  | 3.4 (0.429)  | 2.7 (1.000)   | 2.0 (0.511)  |
| <i>PLCD4</i>  | Phospholipase C D4   | 4.3 (0.031) *  | 2.2 (0.378)  | 1.3 (1.000)   | 1.5 (0.858)  |
| <i>SLN</i>    | Sarcolipin   | 3.8 (0.034) *  | 1.9 (0.588)  | 2.2 (1.000)   | -1.2 (0.858) |
| <i>MYO5B</i>  | Myosin   | 3.1 (0.004) ** | 2.0 (0.438)  | 2.9 (1.000)   | 2.9 (0.315)  |
| <i>CASQ1</i>  | Calsequestrin  | 3.0 (0.004) ** | 2.4 (0.378)  | 1.4 (1.000)   | 1.3 (0.793)  |
| <i>KCNA6</i>  | Potassium voltage-gated channel subfamily A member 6 (Kv1.6) | 2.9 (0.028) *  | 8.5 (0.378)  | 2.0 (1.000)   | 4.0 (0.361)  |
| <i>COL8A1</i> | Collagen type VIII   | 2.8 (0.040) *  | 1.09 (0.79)  | -1.32 (1.000) | -1.27 (0.75) |
| <i>FHL1C</i>  | Four and a half LIM domains protein 1                        | 2.8 (0.037) *  | 1.9 (0.400)  | 1.2 (1.000)   | 1.3 (0.511)  |
| <i>PN-1</i>   | Nexin  | 2.8 (0.006) ** | 1.7 (0.452)  | 1.3 (1.000)   | 1.1 (0.922)  |
| <i>MYOT</i>   | Myotilin   | 2.2 (0.042) *  | 1.6 (0.468)  | 1.0 (1.000)   | 1.3 (0.616)  |
| <i>ACTC1</i>  | Actin  | -3.4 (0.040) * | -1.6 (0.536) | -1.6 (1.000)  | -1.4 (0.717) |

Statistical significance (\*P <0.05, \*\*P <0.01, \*\*\*P <0.001).

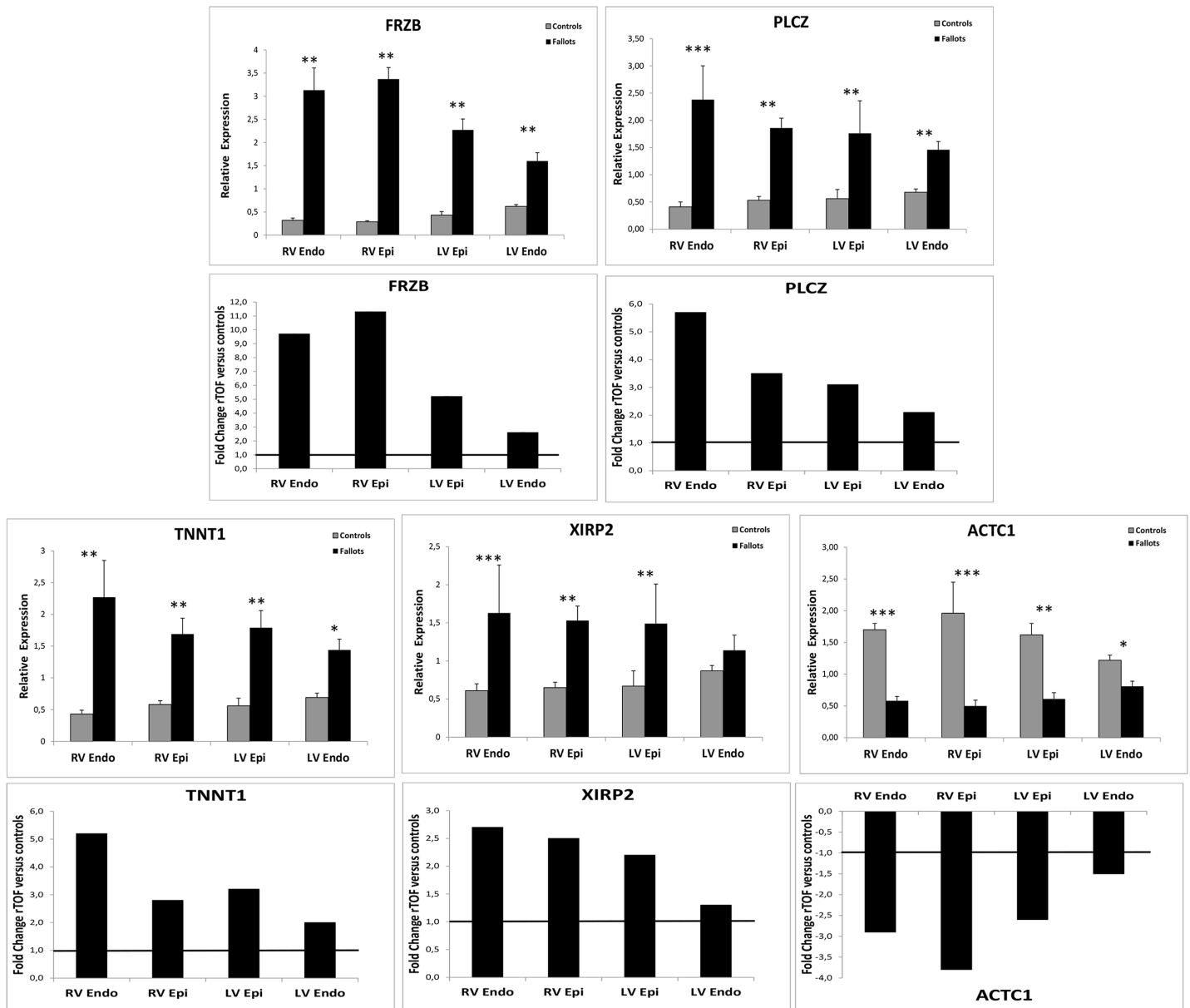
doi:10.1371/journal.pone.0134146.t001

oxidative stress, energy metabolism, cell communication (gap junction signaling), cell adhesion and reshaping in response to external stimuli, angiogenesis. Molecular networks were also formed with IPA software involving the lipid metabolism that may reflect the changes in energy metabolism associated with ventricular hypertrophy. In this network, ERK-PKC--MAPK are central hub molecules. The role of the pathway MAPK/ERK/PKC in cardiac hypertrophy has been well established [9,10].

Differentially expressed genes identified by microarrays were further validated using RTqPCR. We confirmed the level of transcript abundance of fourteen genes of interest using RT-qPCR, and the Fold Changes were concordant in most cases. Among the most de-regulated genes in the endocardium of right ventricle, we identified some genes of special interest.

### Heart failure markers

The BNP (Brain Natriuretic Peptide) is a cardiokine that also belongs to the fetal cardiac gene program and is used as a biomarker of cardiac hypertrophy and heart failure in humans because it is secreted in response to myocardial stretching. As expected, its expression tended to be upregulated among our rTOF pigs. The *FRZB* gene codes for a secreted frizzled-related protein B expressed in ventricular myocardium and involved in the Wnt/ $\beta$ -catenin signaling cascade affecting cell proliferation signals and endocardial cushion morphogenesis [11]. This gene was found overexpressed in human failing ventricular myocardium linked to overload-associated myocyte apoptosis [12]. Its overexpression observed in our rTOF pigs is in accordance with these previous findings and confirm *FRZB* as a marker of cardiac failure due to overload. Of note, myocardial mRNA levels (and serum levels) of a cardiokine called Frizzled-related protein 3, were found elevated in patients with end-stage HF (levels correlated with HF severity and BNP dosage)[13]. These observations may also make these secreted proteins new potential therapeutic targets.



**Fig 7. Relative expression (RT-qPCR) of genes in control (open bars) and Fallots (closed bars) pigs' hearts and Fold change comparison between samples of the four localizations.** Transcript expression is normalized to the reference genes HPRT1 and GUSB. Two sided T-Test Statistical significance of  $n = 5$  Controls and  $n = 7$  rTOF hearts (\* $P < 0.05$ , \*\* $P < 0.01$ , \*\*\* $P < 0.001$ ).

doi:10.1371/journal.pone.0134146.g007

### Calcium handling and contractile function genes

The SERCA2a protein (encoded by *ATP2A2*), is a key regulator of intracellular  $Ca^{2+}$  trafficking, pumping it back to Sarcoplasmic Reticulum during myocardial relaxation. It is also a member of the fetal cardiac gene program which is reactivated with cardiac hypertrophy. This protein tended to be down-regulated in the RV of the rTOF pigs compared to controls (even if the difference was not significant), as it was observed in human RV endomyocardial biopsies at early stage of the Fallot disease (in immature cardiomyocytes with hypertrophy and hypoxia from children aged 15 to 29 months) [14]. This downregulation of *ATP2A2* is typical of heart

failure, and was also recently described in a rat model of right heart failure [15]. Studies from Sharma or Ronkainen also pointed out a downregulation of *ATP2A2* in the cardiomyocytes of hypoxia-induced hypertrophic RV [16,17].

*SLN* coding for sarcolipin also belongs to the Ca<sup>2+</sup> regulatory protein family. It is predominantly expressed in the cardiac atria in humans, however there are chamber specific and species specific differences in its expression [18]. *SLN* and *PLN* (phospholamban) are two small structurally similar proteins that inhibit *SERCA2a* and regulate cardiac contractility [19]. The increased expression of *SLN* in our model represents a new finding compared to the study by Wu et al. that did not find any deregulation of this gene at the RNA and protein level in human cardiomyocytes, and compared to other studies studying *SLN* under several pathological conditions [14,19]. Interestingly, Sarcolipin was found up-regulated 50 fold in the hypertrophied ventricles of *Nkx2.5* null mice [20]. Mouse models overexpressing *SLN* had reduced *SERCA2a* activity and *in vivo* measurements of cardiac function showed a significant decrease of +dP/dt and -dP/dt with ventricular hypertrophy. The inhibitory effect of *SLN* on these models was reversed by a  $\beta$ adrenergic agonist, isoproterenol, which restored cardiac contractility [21].

The absence of concomitant deregulation of *PLN* (data not shown) could argue for a possible independent role of *SLN* in inhibiting *SERCA2a*, as previously hypothesized [19].

*ACTC1*, coding for a cytoskeletal protein or alpha cardiac actin, was the most significantly downregulated gene in our set and was already described as associated with the pathogenesis of dilated cardiomyopathy and heart failure in several expression studies [22]. Autosomal dominant mutations in *ACTC1* were found in familial Atrial septal Defect and reduced expression of *ACTC1* was observed in different congenital heart diseases in humans including Tetralogy of Fallot [23]. Our data could suggest that this gene was more linked to the adaptative ventricular remodeling than to the genetically determined congenital cardiac malformation.

*CASQ1* was found significantly up regulated in the rTOFs, however this isoform is predominantly expressed in the skeletal muscle in humans and pigs (*CASQ2* being the main cardiac isoform).

Phospholipases C D4 and Z were found upregulated in the rTOF pigs confirming the link of phospholipase C with PKC / Frizzled / Wnt signaling pathway [24].

## Electrophysiology and arrhythmia-related genes

Myosin 5B coding for the unconventional myosin motor VB (among 3 members A, B, C of the class V of the myosin superfamily) is overexpressed in our model. It is a molecular motor that was recently found to regulate the cell surface trafficking of ion channels, such as *Kv1.5* (*KCNA5* gene) and control channel recycling in rat cardiomyocytes [25]. The *KCNA5* gene was also significantly upregulated in the right ventricles of our rTOF pigs. This gene, mainly expressed in the atrium, mediates *IK<sub>ur</sub>* and contributes to atrial repolarization. It has also been shown to be expressed in the human left ventricle [26] and would be functional in canine ventricular myocytes [27]. It was observed in mice ventricular myocytes, contributing to repolarization [28]. However, its contribution to repolarization in human or pig ventricles remains to be demonstrated.

*FHL1C* was a good candidate gene as this protein, predominantly expressed in skeletal and cardiac muscle, is implicated in several hereditary myopathies and was also shown to interact *in vitro* with the voltage-gated Potassium channel *Kv1.5* [29]. However its overexpression found in microarrays was not confirmed with qPCR. Maybe this could be due to the existence of different isoforms of the gene. Further experiments are needed in order to explore this hypothesis.

## Cytoskeleton/Cellular organization-related genes

*KCNA6* (encoding Kv1.6 channel) is significantly expressed in human cardiac fibroblasts [30] while its expression has never been described in human or pig ventricular myocytes. Moreover, in the mouse, undifferentiated cardiac *c-kit* (+) cells, Kv1.6 was shown to participate in regulating cell proliferation [31]. Thus, the increase in *KCNA6* expression we observed in our animal model may reflect fibroblast proliferation.

*XIRP2* (overexpressed in rTOF pigs) belongs to the evolutionarily conserved, muscle specific, actin-binding Xin gene family. This protein (mXin $\beta$ ) has a role in the intercalated disc maturation and post-natal heart growth in mice [32]. This gene was up regulated in several *in vitro* and *in vivo* models of hypertrophy and heart failure at early stage [33]. *XIRP2* appeared to be an essential mediator of angiotensin II-induced pathological cardiac remodeling, a direct transcriptional target of Angiotensin II signaling pathway in cardiac muscle, through MEF2A (myocyte enhancer factor), involved in cell survival pathway in cardiac stress signaling [34,35].

Interestingly, *COL8A1* was found significantly activated in our rTOF group as it was already observed in the cardiac RV of a mouse model of pulmonary artery clipping [36]. This collagen, upregulated in rTOF pigs, seems to be associated with arterial stiffness [37] but could also be a marker of RV remodeling.

## Regional variations in gene expression

Transcriptional responses in the left ventricle in our set of experiments followed the same tendency than for the right ventricle, but were much less strong. Comparison of the expression levels of different genes (*TNNT1*, *FRZB*, *ACTC1*, *PLCZ* and *XIRP2*), in all four locations, led to hypothesize the existence of a molecular “gradient” of expression progressing from the RV to the LV of rTOF pigs. Mechanical stress could be transmitted from RV to LV through molecular and cellular alterations mediated by transcriptomic changes of certain genes. The nature and extent of gene expression vary with time. Indeed, distinct transcriptional changes were observed at different time-points after pulmonary artery clipping surgery in a mouse model [36]. Therefore it will be of interest to perform transcriptomic studies at different stages post-surgery and study the progression of the molecular remodeling in our animal model.

## Limitations

mRNA deregulations may not always reflect abnormal protein levels, since translational processes and post-translational modifications may occur. We performed some protein studies by western blot in order to confirm the mRNA changes at the protein level: for example *TNNT1* protein tend to be upregulated in the rTOF pigs, as observed in mRNA studies (S3 Fig). Studies on phosphorylation of different proteins will also be of interest in order to decipher post-translational changes already observed in cardiac failure.

Moreover, the incomplete annotation of the *sus scrofa* microarray constitutes a limitation of this study as important genes, not present or not annotated in the chip, could be missed and signaling pathways of interest could be incompletely deciphered. This led us to have a complementary target gene approach by performing RT-qPCR directly on other genes of interest.

## Conclusion

Cardiac studies performed on pigs proved to be of interest as large animal models have a closer physiology to humans than small mammal models. Moreover, use of cDNA microarrays is a good and cost-effective tool to identify new candidate genes by systematic exploration of gene expression on a genome-wide scale. By providing wide information it should permit potential

comparisons among different models and contribute to a greater understanding of the molecular mechanisms linked to cardiac disease.

## Supporting Information

**S1 Fig. Final day cardiac function evaluation in Control and Fallot pigs.** Anesthetised pigs underwent cardiac magnetic resonance examination at  $23 \pm 1$  weeks. A: Cardiac equatorial short axis view of a Fallot pig showing RV hypertrophy, dilation and septal bulging. B: RV end-diastolic volume (RVEDV) was significantly increased in Fallot pigs compared to Control indicating RV dilatation. C: RV ejection fraction (RVEF) was significantly lower in Fallot pigs than Controls highlighting RV dysfunction. Control N = 4, Fallot N = 6, \* P < 0.05; \*\*\* P < 0.001. (TIF)

**S2 Fig. BNP gene expression in Rv endocardium.** Relative expression (RT-qPCR) of BNP gene in samples from the RV endocardium of controls and rTOF hearts. Transcript expression is normalized to the reference genes HPRT1 and GUSB. (TIF)

**S3 Fig. TNNT1 Western blot.** 50 $\mu$ g of total protein were loaded for TNNT1 Western blot analysis. Quantification of band intensity was calculated after normalization for total protein loaded (p = 0.08). (TIF)

**S1 Table. List of 54 HUGO genes differentially expressed in rTOF pigs (microarrays data).** (TIF)

**S2 Table. List of genes involved in each of the 22 most significant canonical pathways (IPA).** (TIF)

## Acknowledgments

We thank the staff of molecular genetics laboratory of CHU Bordeaux for their technical help and for microarrays scanning facilities.

## Author Contributions

Conceived and designed the experiments: CR SC FR DB OB JBT PB. Performed the experiments: SC FR DB VD MC DV SG DE BQ. Analyzed the data: CR SC DB. Wrote the paper: CR SC. Head of the research department: MH.

## References

1. Apitz C, Webb GD, Redington AN. Tetralogy of Fallot. *Lancet*. 2009; 374: 1462–1471. doi: [10.1016/S0140-6736\(09\)60657-7](https://doi.org/10.1016/S0140-6736(09)60657-7) PMID: [19683809](https://pubmed.ncbi.nlm.nih.gov/19683809/)
2. Uebing A, Gibson DG, Babu-Narayan SV, Diller GP, Dimopoulos K, Goktekin O, et al. Right ventricular mechanics and QRS duration in patients with repaired tetralogy of Fallot: implications of infundibular disease. *Circulation*. 2007; 116: 1532–1539. PMID: [17875972](https://pubmed.ncbi.nlm.nih.gov/17875972/)
3. Bordachar P, Iriart X, Chabaneix J, Sacher F, Lafitte S, Jais P, et al. Presence of ventricular dyssynchrony and haemodynamic impact of right ventricular pacing in adults with repaired Tetralogy of Fallot and right bundle branch block. *Europace*. 2008; 10: 967–971. doi: [10.1093/europace/eun178](https://doi.org/10.1093/europace/eun178) PMID: [18603611](https://pubmed.ncbi.nlm.nih.gov/18603611/)
4. Abd El Rahman MY, Hui W, Yigitbasi M, Dsebissowa F, Schubert S, Hetzer R, et al. Detection of left ventricular asynchrony in patients with right bundle branch block after repair of tetralogy of Fallot using tissue-Doppler imaging-derived strain. *J Am Coll Cardiol*. 2005; 45: 915–921. PMID: [15766829](https://pubmed.ncbi.nlm.nih.gov/15766829/)

5. Leite-Moreira AF, Lourenco AP, Balligand JL, Bauersachs J, Clerk A, De Windt LJ, et al. ESC Working Group on Myocardial Function Position Paper: how to study the right ventricle in experimental models. *Eur J Heart Fail.* 2014; 16: 509–518. doi: [10.1002/ejhf.66](https://doi.org/10.1002/ejhf.66) PMID: [24574252](https://pubmed.ncbi.nlm.nih.gov/24574252/)
6. Thambo JB, Roubertie F, De Guillebon M, Labrousse L, Iriart X, Ntsinjana H, et al. Validation of an animal model of right ventricular dysfunction and right bundle branch block to create close physiology to postoperative tetralogy of Fallot. *Int J Cardiol.* 2012; 154: 38–42. doi: [10.1016/j.ijcard.2010.08.063](https://doi.org/10.1016/j.ijcard.2010.08.063) PMID: [20851478](https://pubmed.ncbi.nlm.nih.gov/20851478/)
7. Gray KA, Yates B, Seal RL, Wright MW, Bruford EA. Genenames.org: the HGNC resources in 2015. *Nucleic Acids Res.* 2015; 43: D1079–1085. doi: [10.1093/nar/gku1071](https://doi.org/10.1093/nar/gku1071) PMID: [25361968](https://pubmed.ncbi.nlm.nih.gov/25361968/)
8. Huang da W, Sherman BT, Lempicki RA. Systematic and integrative analysis of large gene lists using DAVID bioinformatics resources. *Nat Protoc.* 2009; 4: 44–57. doi: [10.1038/nprot.2008.211](https://doi.org/10.1038/nprot.2008.211) PMID: [19131956](https://pubmed.ncbi.nlm.nih.gov/19131956/)
9. Zhang W, Elimban V, Nijjar MS, Gupta SK, Dhalla NS. Role of mitogen-activated protein kinase in cardiac hypertrophy and heart failure. *Exp Clin Cardiol.* 2003; 8: 173–183. PMID: [19649217](https://pubmed.ncbi.nlm.nih.gov/19649217/)
10. Bueno OF, Molkentin JD. Involvement of extracellular signal-regulated kinases 1/2 in cardiac hypertrophy and cell death. *Circ Res.* 2002; 91: 776–781. PMID: [12411391](https://pubmed.ncbi.nlm.nih.gov/12411391/)
11. Gitler AD, Lu MM, Jiang YQ, Epstein JA, Gruber PJ. Molecular markers of cardiac endocardial cushion development. *Dev Dyn.* 2003; 228: 643–650. PMID: [14648841](https://pubmed.ncbi.nlm.nih.gov/14648841/)
12. Schumann H, Holtz J, Zerkowski HR, Hatzfeld M. Expression of secreted frizzled related proteins 3 and 4 in human ventricular myocardium correlates with apoptosis related gene expression. *Cardiovasc Res.* 2000; 45: 720–728. PMID: [10728394](https://pubmed.ncbi.nlm.nih.gov/10728394/)
13. Askevold ET, Aukrust P, Nymo SH, Lunde IG, Kaasboll OJ, Aakhus S, et al. The cardiokine secreted Frizzled-related protein 3, a modulator of Wnt signalling, in clinical and experimental heart failure. *J Intern Med.* 2014; 275: 621–630. doi: [10.1111/joim.12175](https://doi.org/10.1111/joim.12175) PMID: [24330105](https://pubmed.ncbi.nlm.nih.gov/24330105/)
14. Wu Y, Feng W, Zhang H, Li S, Wang D, Pan X, et al. Ca<sup>2+</sup>-regulatory proteins in cardiomyocytes from the right ventricle in children with congenital heart disease. *J Transl Med.* 2012; 10: 67. doi: [10.1186/1479-5876-10-67](https://doi.org/10.1186/1479-5876-10-67) PMID: [22472319](https://pubmed.ncbi.nlm.nih.gov/22472319/)
15. Benoist D, Stones R, Benson AP, Fowler ED, Drinkhill MJ, Hardy ME, et al. Systems approach to the study of stretch and arrhythmias in right ventricular failure induced in rats by monocrotaline. *Prog Biophys Mol Biol.* 2014; 115: 162–172. doi: [10.1016/j.pbiomolbio.2014.06.008](https://doi.org/10.1016/j.pbiomolbio.2014.06.008) PMID: [25016242](https://pubmed.ncbi.nlm.nih.gov/25016242/)
16. Sharma S, Taegtmeyer H, Adroque J, Razeghi P, Sen S, Ngumbela K, et al. Dynamic changes of gene expression in hypoxia-induced right ventricular hypertrophy. *Am J Physiol Heart Circ Physiol.* 2004; 286: H1185–1192. PMID: [14630626](https://pubmed.ncbi.nlm.nih.gov/14630626/)
17. Ronkainen VP, Skoumal R, Tavi P. Hypoxia and HIF-1 suppress SERCA2a expression in embryonic cardiac myocytes through two interdependent hypoxia response elements. *J Mol Cell Cardiol.* 2011; 50: 1008–1016. doi: [10.1016/j.yjmcc.2011.02.017](https://doi.org/10.1016/j.yjmcc.2011.02.017) PMID: [21382378](https://pubmed.ncbi.nlm.nih.gov/21382378/)
18. Vangheluwe P, Schuermans M, Zador E, Waelkens E, Raeymaekers L, Wuytack F. Sarcolipin and phospholamban mRNA and protein expression in cardiac and skeletal muscle of different species. *Biochem J.* 2005; 389: 151–159. PMID: [15801907](https://pubmed.ncbi.nlm.nih.gov/15801907/)
19. Bhupathy P, Babu GJ, Periasamy M. Sarcolipin and phospholamban as regulators of cardiac sarcoplasmic reticulum Ca<sup>2+</sup> ATPase. *J Mol Cell Cardiol.* 2007; 42: 903–911. PMID: [17442337](https://pubmed.ncbi.nlm.nih.gov/17442337/)
20. Pashmforoush M, Lu JT, Chen H, Amand TS, Kondo R, Pradervand S, et al. Nkx2-5 pathways and congenital heart disease; loss of ventricular myocyte lineage specification leads to progressive cardiomyopathy and complete heart block. *Cell.* 2004; 117: 373–386. PMID: [15109497](https://pubmed.ncbi.nlm.nih.gov/15109497/)
21. Asahi M, Otsu K, Nakayama H, Hikoso S, Takeda T, Gramolini AO, et al. Cardiac-specific overexpression of sarcolipin inhibits sarco(endo)plasmic reticulum Ca<sup>2+</sup> ATPase (SERCA2a) activity and impairs cardiac function in mice. *Proc Natl Acad Sci U S A.* 2004; 101: 9199–9204. PMID: [15201433](https://pubmed.ncbi.nlm.nih.gov/15201433/)
22. Asakura M, Kitakaze M. Global gene expression profiling in the failing myocardium. *Circ J.* 2009; 73: 1568–1576. PMID: [19638707](https://pubmed.ncbi.nlm.nih.gov/19638707/)
23. Jiang HK, Qiu GR, Li-Ling J, Xin N, Sun KL. Reduced ACTC1 expression might play a role in the onset of congenital heart disease by inducing cardiomyocyte apoptosis. *Circ J.* 2010; 74: 2410–2418. PMID: [20962418](https://pubmed.ncbi.nlm.nih.gov/20962418/)
24. Dawson K, Aflaki M, Nattel S. Role of the Wnt-Frizzled system in cardiac pathophysiology: a rapidly developing, poorly understood area with enormous potential. *J Physiol.* 2013; 591: 1409–1432. doi: [10.1113/jphysiol.2012.235382](https://doi.org/10.1113/jphysiol.2012.235382) PMID: [23207593](https://pubmed.ncbi.nlm.nih.gov/23207593/)
25. Schumacher-Bass SM, Vesely ED, Zhang L, Ryland KE, McEwen DP, Chan PJ, et al. Role for myosin-V motor proteins in the selective delivery of Kv channel isoforms to the membrane surface of cardiac myocytes. *Circ Res.* 2014; 114: 982–992. doi: [10.1161/CIRCRESAHA.114.302711](https://doi.org/10.1161/CIRCRESAHA.114.302711) PMID: [24508725](https://pubmed.ncbi.nlm.nih.gov/24508725/)



26. Ordog B, Brutyo E, Puskas LG, Papp JG, Varro A, Szabad J, et al. Gene expression profiling of human cardiac potassium and sodium channels. *Int J Cardiol.* 2006; 111: 386–393. PMID: [16257073](#)
27. Sridhar A, da Cunha DN, Lacombe VA, Zhou Q, Fox JJ, Hamlin RL, et al. The plateau outward current in canine ventricle, sensitive to 4-aminopyridine, is a constitutive contributor to ventricular repolarization. *Br J Pharmacol.* 2007; 152: 870–879. PMID: [17700726](#)
28. Odagiri F, Inoue H, Sugihara M, Suzuki T, Murayama T, Shioya T, et al. Effects of candesartan on electrical remodeling in the hearts of inherited dilated cardiomyopathy model mice. *PLoS One.* 2014; 9: e101838. doi: [10.1371/journal.pone.0101838](#) PMID: [25000405](#)
29. Poparic I, Schreibmayer W, Schoser B, Desoye G, Gorischek A, Miedl H, et al. Four and a half LIM protein 1C (FHL1C): a binding partner for voltage-gated potassium channel K(v1.5). *PLoS One.* 2011; 6: e26524. doi: [10.1371/journal.pone.0026524](#) PMID: [22053194](#)
30. Li GR, Sun HY, Chen JB, Zhou Y, Tse HF, Lau CP. Characterization of multiple ion channels in cultured human cardiac fibroblasts. *PLoS One.* 2009; 4: e7307. doi: [10.1371/journal.pone.0007307](#) PMID: [19806193](#)
31. Han Y, Chen JD, Liu ZM, Zhou Y, Xia JH, Du XL, et al. Functional ion channels in mouse cardiac c-kit (+) cells. *Am J Physiol Cell Physiol.* 2010; 298: C1109–1117. doi: [10.1152/ajpcell.00207.2009](#) PMID: [20130208](#)
32. Wang Q, Lin JL, Reinking BE, Feng HZ, Chan FC, Lin CI, et al. Essential roles of an intercalated disc protein, mXinbeta, in postnatal heart growth and survival. *Circ Res.* 2010; 106: 1468–1478. doi: [10.1161/CIRCRESAHA.109.212787](#) PMID: [20360251](#)
33. Wang Q, Lin JL, Erives AJ, Lin CI, Lin JJ. New insights into the roles of Xin repeat-containing proteins in cardiac development, function, and disease. *Int Rev Cell Mol Biol.* 2014; 310: 89–128. doi: [10.1016/B978-0-12-800180-6.00003-7](#) PMID: [24725425](#)
34. Lu B, Yu H, Zwartbol M, Ruirok WP, van Gilst WH, de Boer RA, et al. Identification of hypertrophy- and heart failure-associated genes by combining in vitro and in vivo models. *Physiol Genomics.* 2012; 44: 443–454. doi: [10.1152/physiolgenomics.00148.2011](#) PMID: [22353257](#)
35. McCalmon SA, Desjardins DM, Ahmad S, Davidoff KS, Snyder CM, Sato K, et al. Modulation of angiotensin II-mediated cardiac remodeling by the MEF2A target gene Xirp2. *Circ Res.* 2010; 106: 952–960. doi: [10.1161/CIRCRESAHA.109.209007](#) PMID: [20093629](#)
36. Kreyborg K, Uchida S, Gellert P, Schneider A, Boettger T, Voswinkel R, et al. Identification of right heart-enriched genes in a murine model of chronic outflow tract obstruction. *J Mol Cell Cardiol.* 2010; 49: 598–605. doi: [10.1016/j.yjmcc.2010.07.014](#) PMID: [20673770](#)
37. Levy D, Larson MG, Benjamin EJ, Newton-Cheh C, Wang TJ, Hwang SJ, et al. Framingham Heart Study 100K Project: genome-wide associations for blood pressure and arterial stiffness. *BMC Med Genet.* 2007; 8 Suppl 1: S3. PMID: [17903302](#)

## 5.3 Mécanismes pro-arythmogènes découverts au niveau du VD chez notre modèle animal

### **5.3.1 Introduction : rappel concernant les arythmies dans cette population de patient :**

La survenue d'une arythmie soutenue est fréquente chez les patients avec TF réparée. Une étude multicentrique incluant 556 patients avec TF réparée, retrouvait chez 40% de ces patients un épisode d'arythmie (supra-ventriculaire ou ventriculaire), avec une prévalence qui augmentait avec l'âge (1). (**Figure 7**, en annexe de ce chapitre).

#### Rappel : les arythmies atriales

Les arythmies atriales surviennent environ chez 20% des patients avec TF réparée (1). Il s'agit le plus souvent de mécanismes de macro-réentrée atriale droite, dépendant de l'isthme cavo-tricuspidé (2), ou de la paroi latérale de l'oreillette (isthme entre une cicatrice d'atriotomie droite et la veine cave inférieure). Ces arythmies sont accessibles à l'ablation endo-cavitaire avec de bons résultats (3). Ces patients peuvent également présenter des tachycardies atriales focales, ainsi que de la fibrillation auriculaire, qui devient alors le type d'arythmie prédominant à un stade d'évolution le plus tardif de la maladie.

Les arythmies atriales sont liées aux interventions chirurgicales préalables, responsables de cicatrices, mais aussi au retentissement hémodynamique de la cardiopathie. Les tachycardies atriales par réentrée sont ainsi associées à la dilatation atriale droite ; alors que la fibrillation auriculaire est plutôt associée aux marqueurs d'atteinte du cœur gauche, à savoir dilatation de l'oreillette gauche, dysfonction du ventricule gauche et âge plus avancé (1).

Les facteurs de risque d'arythmie atriale sont l'âge lors de cure complète, une fuite tricuspide significative, une dilatation de l'oreillette droite, une dysfonction du VD, une fuite pulmonaire sévère, un obstacle sur la voie de sortie du VD (1, 2, 4, 5). La survenue d'arythmies supra-ventriculaires



augmentent de manière significative la morbidité (journée d'hospitalisation, insuffisance cardiaque congestive, accident vasculaire cérébral) et la mortalité, dans la population des cardiopathies congénitales en général, et en particulier chez les adultes opérés de TF (4, 6).

### Rappel : les arythmies ventriculaires :

Les arythmies ventriculaires surviennent environ chez 15% des patients (1). Elles sont à l'origine des morts subites (7, 8) qui sont fréquentes dans cette population. La mort subite est estimée à 2% par décennie tous âges confondus, mais s'élève jusqu'à 0,6 à 1,0 % par an pour les patients de plus de 25 ans, soit un risque largement supérieur à celui de la population générale du même âge (9).

Le mécanisme principal de ces TVs est lié à des macro-réentrées, situées au niveau de zones de conduction lente, « séquelles » de la réparation chirurgicale complète dans les premières années de vie du patient (cicatrice fibreuse autour du patch de fermeture de la CIV ou de la ventriculotomie). Dès 1994, des études électro-physiologiques peropératoires associées à des prélèvements histologiques, permettaient de relier ces zones de conduction lente aux cicatrices (fibreuse) chirurgicales de la ventriculotomie (10). D'autres travaux plus récents (11) ont montré que les circuits de réentrée chez les patients avec TF réparée dépendaient des caractéristiques anatomiques, soit naturelles (anneaux valvulaires), soit induites par la chirurgie de réparation (cicatrices et patches chirurgicaux). Au total quatre isthmes anatomiques sont ainsi impliqués: (**Figure 8**, en annexe de ce chapitre) :

- isthme 1 : entre anneau tricuspide et cicatrice/patch infundibulaire
- isthme 2 : entre anneau pulmonaire et cicatrice/patch ventriculaire antérieur
- isthme 3 : entre anneau pulmonaire et cicatrice/patch de fermeture de CIV ;
- isthme 4 : entre anneau tricuspide et cicatrice/patch de fermeture de CIV.

Pour résumé, l'initiation d'une TV par réentrée nécessite un substrat, constitué d'une zone de conduction lente (encore appelée isthme), bordée par du tissu électriquement inexcitable (fibrose cicatricielle, anneau valvulaire, matériel prothétique, etc.) et la survenue d'un bloc unidirectionnel, souvent consécutif à une extrasystole ventriculaire.

Tous les patients avec TF réparée ont, obligatoirement, des zones de conduction lente, séquelles de la chirurgie ; or, tous les patients ne présenteront pas au cours de leur évolution une TV. Donc, d'autres facteurs interviennent dans la genèse de ces arythmies ventriculaires. La dysfonction et la dilatation du VD +/- du ventricule gauche semble jouer un rôle important (12), vraisemblablement en diminuant la tolérance hémodynamique des TVs et en exposant davantage à des arythmies ventriculaires plus polymorphes allant jusqu'à la fibrillation ventriculaire.

### Facteurs de risque de mort subite :

Les patients avec TF réparée sont donc une population à haut risque de mort subite (7, 8). De nombreux facteurs de risque de TV ont été publiés pour essayer de repérer les patients les plus à risque : la dysfonction du VD, la dysfonction ventriculaire gauche, une durée du QRS > 180 msec, l'âge à la cure complète, les antécédents d'arythmie atriale, les antécédents d'arythmie ventriculaire, la taille de la ventriculotomie, l'existence d'un patch trans-annulaire, etc. (4, 8, 13-15).

La multiplicité de ces facteurs de risque, leur présence retrouvée ou non d'une étude à l'autre, montrent en fait que le mécanisme physiopathologique de l'arythmie ventriculaire dans cette population reste encore aujourd'hui mal compris.

### Hypothèse physiopathologique sur le mécanisme des arythmies ventriculaires

Le raisonnement général, probable mais non prouvé est le suivant : l'IP est considérée comme le principal substrat hémodynamique de TV et de mort subite (8). Il existe une interaction mécano-électrique puisque la dilatation du VD (induite par la régurgitation pulmonaire) a été corrélée à un élargissement du QRS et à la survenue d'arythmies ventriculaires graves (12). Un bloc de branche droit est retrouvé par ailleurs chez 95% des patients (16) en postopératoire de la première cure complète, lié à une lésion des tissus de conduction qui peut être proximale (dans la région de la CIV), moyenne ou distale (au niveau des fibres de Purkinje lors de l'infundibulotomie). Ce bloc de branche droit va s'aggraver progressivement en raison de la fibrose myocardique et de la dilatation du VD. Une durée de QRS >180ms et son augmentation progressive avec le temps reste le facteur de risque principal de TV et de mort subite dans cette population. (8).

### 5.3.2 Objectifs du travail sur notre modèle animal

Afin de mieux comprendre les mécanismes arythmogènes dans la TF réparée, nous avons caractérisé le remodelage électrophysiologique du VD dans notre modèle animal porcin de TF réparée. Pour cette étude qui se voulait translationnelle, une approche intégrative de l'animal in vivo à la molécule a été adoptée afin d'identifier et de suivre les mécanismes pro-arythmiques à ces différents niveaux, et permettre la mise en évidence de marqueurs spécifiques ainsi que l'identification de cibles thérapeutiques.

### 5.3.3 Matériels et méthodes

#### Données IRM

La fonction cardiaque des animaux a été étudiée in vivo par IRM. Ainsi nous avons pu mettre en évidence les caractéristiques fonctionnelles et anatomiques rencontrées : une régurgitation pulmonaire ainsi qu'une hypertrophie et une dilatation du VD, accompagnées d'une dysfonction de ce ventricule (fraction d'éjection du VD : Sham =  $51 \pm 11\%$  ; animaux mimant une TF réparée =  $31 \pm 6\%$ ). Au stade étudié, les animaux présentaient un mouvement paradoxal du septum interventriculaire sans dysfonction notable du ventricule gauche.

### 5.3.4 Résultats

#### Protocole d'étude : cartographie optique

La cartographie optique haute résolution de l'activité électrique des VD, isolés et perfusés, a permis de mettre en évidence un remodelage électrophysiologique profond chez ces animaux, qui était à l'origine de la susceptibilité arythmique et de la complexité des arythmies observées dans les VD des animaux mimant une TF réparée.

Ce remodelage affectait la repolarisation du VD, dont l'hétérogénéité, analysée à travers la durée du potentiel d'action (PA), était fortement augmentée dans le VD de ces animaux. Cette dispersion de la

durée du PA se retrouvait au niveau épicaudique, et se traduisait par un prolongement de la durée des PA du VD antérieur, et une tendance à un raccourcissement des PA au niveau du VD postérieur, aboutissant à une inversion du gradient antéro-postérieur.

D'autre part, le gradient trans-mural de durée du PA (de l'épicarde à l'endocarde) était lui aussi inversé, rappelant ainsi un phénotype d'insuffisance cardiaque gauche.

#### Protocole d'étude : analyse moléculaire

Les analyses moléculaires (qPCR, western-blot) ont permis de mettre en évidence au niveau du VD antérieur un remodelage trans-mural différentiel de l'expression de Kv4.3, un canal ionique médiant le courant potassique transitoire sortant (Ito). Ainsi la baisse d'expression de cette protéine côté épicaudique, participait à l'augmentation de la durée du PA dans cette région, alors que son augmentation côté endocardique participait au raccourcissement du PA de cette région. D'autre part, l'augmentation épicaudique de la durée du PA au niveau du VD antérieur semblait également liée à une augmentation de l'expression de MiRP1 une protéine régulatrice des courants potassiques IKr et IKs.

#### Protocole d'étude : activation du VD

L'activation du VD des animaux mimant une TF réparée était caractérisée par une conduction lente et discontinue, présentant de multiples régions de ralentissement au-delà de la zone cicatricielle infundibulaire. La diminution des vitesses de conduction dans le sens longitudinal aux fibres myocardiques semblait liée à la baisse d'expression de la connexine-43 alors que la diminution observée dans le sens transversal était liée à une prolifération de la matrice extracellulaire mise en évidence par histologie et par une étude transcriptomique.

### **5.3.5 Conclusion de notre travail**

La dysfonction VD aggrave la fibrose et donc le potentiel arythmogène chez ces patients. Il y a donc un terrain propice à ce que certains patients développent une arythmie grave sur les zones de conduction lente, séquelles de la chirurgie.

Ce remodelage ouvre de nouvelles perspectives cliniques puisque les modifications électrophysiologiques observées dans notre modèle animal pourraient permettre à terme l'identification de patients à risque arythmique élevé et un ciblage thérapeutique adapté.

### 5.3.6 Références

1. Khairy P, Aboulhosn J, Gurm MZ et al. Arrhythmia burden in adults with surgically repaired tetralogy of Fallot: a multi-institutional study. *Circulation*. 2010;122:868-75.
2. Le Gloan L, Guerin P, Mercier LA, et al. Clinical assessment of arrhythmias in tetralogy of Fallot. *Expert Rev Cardiovasc Ther* 2010;8:189–197.
3. Mah DY, Alexander ME, Cecchin F, Walsh EP, Triedman JK. The electroanatomic mechanisms of atrial tachycardia in patients with tetralogy of Fallot and double outlet right ventricle. *J Cardiovasc Electrophysiol*. 2011;22:1013-7.
4. Harrison DA, Siu SC, Hussain F et al. Sustained atrial arrhythmias in adults late after repair of tetralogy of fallot. *Am J Cardiol*. 2001;87:584-8.
5. Roos-Hesselink J, Perlroth MG, McGhie J, et al. Atrial arrhythmias in adults after repair of tetralogy of Fallot. Correlations with clinical, exercise, and echocardiographic findings. *Circulation* 1995;91:2214–2219.
6. Bouchardy J, Therrien J, Pilote L, et al. Atrial arrhythmias in adults with congenital heart disease. *Circulation*. 2009;120:1679-86.
7. Gillette PC, Yeoman MA, Mullins CE, McNamara DG. Sudden death after repair of tetralogy of Fallot. Electrocardiographic and electrophysiologic abnormalities. *Circulation*. 1977;56:566-71.
8. Gatzoulis MA, Balaji S, Webber SA, et al. Risk factors for arrhythmia and sudden cardiac death late after repair of tetralogy of Fallot: a multicentre study. *Lancet*. 2000;356:975-81.

9. Walsh EP. Sudden death in adult congenital heart disease: risk stratification in 2014. *Heart Rhythm*. 2014;11:1735-42.
10. Misaki T, Tsubota M, Watanabe G, et al. Surgical treatment of ventricular tachycardia after surgical repair of tetralogy of Fallot. Relation between intraoperative mapping and histological findings. *Circulation* 1994;90:264–271.
11. Zeppenfeld K, Schalij MJ, Bartelings MM et al. Catheter ablation of ventricular tachycardia after repair of congenital heart disease: electroanatomic identification of the critical right ventricular isthmus. *Circulation*. 2007;116:2241-2252.
12. Gatzoulis MA, Till JA, Somerville J, Redington AN. Mechanoelectrical interaction in tetralogy of Fallot. QRS prolongation relates to right ventricular size and predicts malignant ventricular arrhythmias and sudden death. *Circulation*. 1995;92:231-7.
13. Dietl CA, Cazzaniga ME, Dubner SJ, et al. Life-threatening arrhythmias and RV dysfunction after surgical repair of tetralogy of Fallot. Comparison between transventricular and transatrial approaches. *Circulation* 1994;90:II7–II12.
14. Khairy P, Landzberg MJ, Gatzoulis MA, et al. Value of programmed ventricular stimulation after tetralogy of Fallot repair: a multicenter study. *Circulation* 2004;109:1994–2000.
15. Ghai A, Silversides C, Harris L, et al. Left ventricular dysfunction is a risk factor for sudden cardiac death in adults late after repair of tetralogy of Fallot. *J Am Coll Cardiol* 2002;40:1675–1680.
16. Friedli B. Arrhythmia after surgery for congenital cardiopathies. What studies? What treatment? *Arch Mal Coeur Vaiss* 1996;89:351–357.

### 5.3.7 Perspectives

#### Perspective de recherche sur notre modèle animal

Les anomalies retrouvées au niveau du VD des animaux mimant une TF réparée semblent expliquer la sensibilité aux arythmies graves de ces animaux. Il serait donc intéressant de **tester l'effet thérapeutique de certains médicaments** comme les inhibiteurs de l'enzyme de conversion, qui pourraient avoir un effet intéressant sur le remodelage ventriculaire droit (**1**) ; en recommençant alors les mêmes analyses après quelques mois de traitement.

**Une étude similaire, concernant le ventricule gauche** des animaux mimants une TF réparée et des animaux Sham, est actuellement en cours dans notre unité : avec une étude électrophysiologique du potentiel d'action, couplée à une étude génétique et histologique. Les résultats préliminaires sont très intéressants et surprenants puisqu'on retrouve également un caractère pro-arythmogène au niveau de ce ventricule gauche.

Les ventricules gauches des animaux opérés sont plus sensibles à l'arythmie lors des manipulations par rapport aux ventricules gauches des animaux Sham. Le gradient trans-mural de durée du potentiel d'action (de l'épicarde à l'endocarde) est inversé entre animaux sham et animaux mimant une TF réparée. La pente de restitution de la durée du potentiel d'action était beaucoup plus aigue chez les animaux mimant une TF opérée par rapport aux Sham : ceci est en lien avec un effet pro-arythmogène reconnue. La vitesse de conduction du potentiel d'action est diminuée dans le sens longitudinal ; elle est inchangée dans le sens transversal. Il existe des remaniements au niveau du VD mais également au niveau du ventricule gauche en ce qui concerne la fibrose. Au total, il semble exister au niveau du ventricule gauche des animaux opérés un effet pro-arythmogène, similaire à celui observé chez les patients avec insuffisance cardiaque gauche. (**Figure 9-12**, en annexe de ce chapitre).



## Perspective de recherche clinique : étude clinique multicentrique (Bordeaux, Leiden, Montréal)

### Rappel sur l'ablation de l'arythmie ventriculaire dans cette population

L'ablation des circuits de tachycardie (**Figure 13**, en annexe de ce chapitre) (cryoablation pour la chirurgie (**2, 3**) ou radiofréquence pour l'endo-vasculaire (**4, 5**)) fait partie, depuis plus de 20 ans, de l'arsenal thérapeutique disponible pour prendre en charge les arythmies ventriculaires chez les patients avec TF réparée. Le principe de l'ablation reste le même en chirurgie, comme en endo-vasculaire : bloquer les potentiels circuits de macro-rentree en créant une lésion connectant les cicatrices/patches chirurgicaux aux anneaux valvulaires.

Suite aux travaux de Zeppenfeld (**6**) et à l'identification des quatre isthmes anatomiques précédemment décrits (**Figure 8**, en annexe de ce chapitre), qui sont responsables de zones de conduction lente, il est proposé une ablation ciblée de ceux impliqués dans les TV. Les résultats de l'ablation dans cette population avec TF réparée sont bons autant en chirurgie qu'en endo-vasculaire : absence de récurrence à 5 ans dans une cohorte chirurgicale de 9 patients aux antécédents de TV, qui ont eu une cryoablation (**7**). Quant à l'ablation endo-vasculaire dans une population similaire, il était retrouvé, à 30 mois, 90% d'absence de récurrence de TV (**6**).

Toute ablation nécessite au préalable une exploration électro-physiologique avec stimulation ventriculaire programmée. Cet examen ne déclenche que les TV par réentrée. Elle est réalisée par voie veineuse fémorale, consistant classiquement en une stimulation du VD à l'apex, d'une part, et au niveau de l'infundibulum, d'autre part. Pour les deux sites, un, deux, puis trois extrastimuli à couplage décroissant sont appliqués sur un train de cycles ventriculaires imposés à 600 ms dans un premier temps, puis à 400 ms dans un deuxième temps. Le déclenchement d'une TV soutenue monomorphe inférieure à 270/min est pathologique. L'exploration électro-physiologique intègre également une cartographie de voltage en rythme sinusal, qui, même en l'absence de TV inducible, permet d'apprécier un éventuel substrat arythmogène (topographie et étendue des zones cicatricielles, mise

en évidence d'isthmes anatomiques, etc.) : elle est réalisée par « contact mapping » au moyen d'électrodes enregistrant des électrogrammes locaux, à la surface endocardique, avec un repérage anatomique par fluoroscopie. Un système récent, de cartographie électro-anatomique, sans fluoroscopie, permet de modéliser une reconstruction tridimensionnelle de la cavité cardiaque en intégrant les différentes données électrophysiologiques (8) (délai d'activation et amplitude du signal). (Figure 14 et 15, en annexe de ce chapitre).

### Rappel sur les indications actuelles de l'exploration électro-physiologique

De multiples critères (incluant la symptomatologie, le statut hémodynamique et les antécédents chirurgicaux) doivent être pris en compte pour envisager une exploration électro-physiologique (9, 10). La limite principale de l'exploration électro-physiologique en pratique clinique reste le taux, non négligeable, de faux négatifs, estimé à 22,6 % (11).

### Rappel sur les indications d'ablation chez les adultes avec TF réparée

Concernant l'ablation, les dernières recommandations précisent que l'ablation par cathéter dans les cardiopathies congénitales de l'adulte (9) n'est pas considérée de manière isolée comme un traitement prophylactique approprié en cas de cardiopathie à risque de mort subite (classe III, niveau de preuve C).

### Le protocole d'étude multicentrique (Bordeaux, Leiden, Montréal)

Il consistait à inclure tous les patients avec TF réparée (qui avait une indication de valvulation pulmonaire) dans un **protocole d'exploration électrophysiologique pré-opératoire** ; tous les patients **inductibles bénéficiaient d'une procédure d'ablation par voie endo-vasculaire. En cas d'échec, une cryoablation chirurgicale** était réalisée lors de la valvulation pulmonaire, guidée par les informations obtenues lors de l'exploration électrophysiologique. Les objectifs du travail étaient de :

- corréler les caractéristiques des isthmes (taille, localisation, nombre, vitesse de conduction) à l'inductibilité des patients ainsi qu'à la survenue d'évènements rythmiques
- connaître les résultats sur les arythmies, d'une stratégie active d'exploration électrophysiologique et d'ablation

**En parallèle de ce protocole, à partir de la même cohorte de patients, une étude de l'apport de l'IRM en haute résolution** est menée : il vise à confronter les données anatomiques apportées par l'IRM aux données électrophysiologiques apportées par la cartographie invasive (protocole en collaboration avec le Dr Hubert Cochet du service de radiologie du Pr. LAURENT à l'hôpital Haut-Lévêque et avec le Dr Frédéric Sacher du service de rythmologie du Pr Haïssaguerre) (**Figure 16**, en annexe de ce chapitre). La présence de rehaussement tardif au gadolinium autour des patchs chirurgicaux correspond aux zones de fibrose et de bas voltage identifiées par la cartographie électro-anatomique (**12**). La quantification semi-automatique du rehaussement tardif tridimensionnel en haute résolution est aujourd'hui possible dans la TF réparée et pourrait devenir un outil complémentaire incontournable dans l'évaluation individuelle du risque rythmique (**13**).

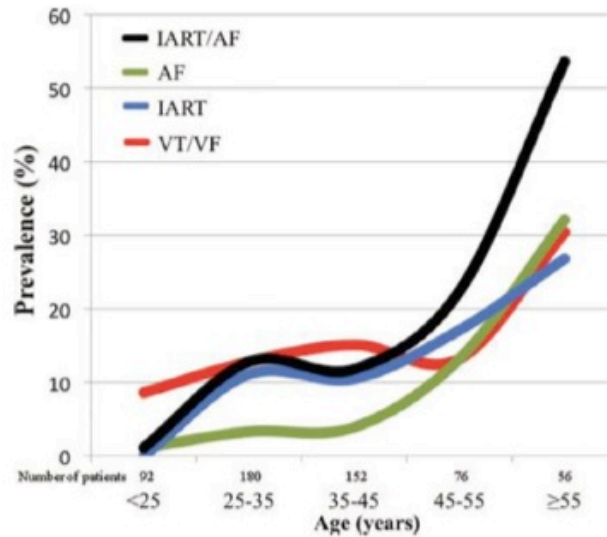
#### Autre protocole d'étude clinique qui sera mis en place prochainement

Les données apportées par l'IRM haute résolution paraissent prometteuses en ce qui concerne les arythmies. Nous chercherons à savoir s'il existe une corrélation entre les données de l'IRM (et la quantification de la fibrose) et les épreuves d'effort VO<sub>2</sub> max que nous ferons passer à tous les patients avec TF réparée.

### 5.3.8 Références

1. Babu-Narayan SV, Uebing A, Davlouros PA, et al. Randomised trial of ramipril in repaired tetralogy of Fallot and pulmonary regurgitation: the APPROPRIATE study (Ace inhibitors for Potential PRevention Of the deleterious effects of Pulmonary Regurgitation In Adults with repaired TEtralogy of Fallot). *International journal of cardiology* 2012;154:299- 305.
2. Downar E, Harris L, Kimber S et al. Ventricular tachycardia after surgical repair of tetralogy of Fallot: results of intraoperative mapping studies. *J Am Coll Cardiol.* 1992;20:648-55.
3. Misaki T, Tsubota M, Watanabe G et al. Surgical treatment of ventricular tachycardia after surgical repair of tetralogy of Fallot. Relation between intraoperative mapping and histological findings. *Circulation.* 1994;90:264-271.
4. Chinushi M, Aizawa Y, Kitazawa H,et al. Successful radiofrequency catheter ablation for macroreentrant ventriculartachycardias in a patient with tetralogy of Fallot after corrective surgery. *Pacing Clin Electrophysiol.* 1995;18:1713-1716.
5. Horton RP, Canby RC, Kessler DJ et al. Ablation of ventricular tachycardia associated with tetralogy of Fallot: demonstration of bidirectional block. *J Cardiovasc Electrophysiol.* 1997;8:432-435.
6. Zeppenfeld K, Schalij MJ, Bartelings MM et al. Catheter ablation of ventricular tachycardia after repair of congenital heart disease: electroanatomic identification of the critical right ventricular isthmus. *Circulation.* 2007;116:2241-2252.
7. Therrien J, Siu SC, Harris L et al. Impact of pulmonary valve replacement on arrhythmia propensity late after repair of tetralogy of Fallot. *Circulation.* 2001;103:2489-94.

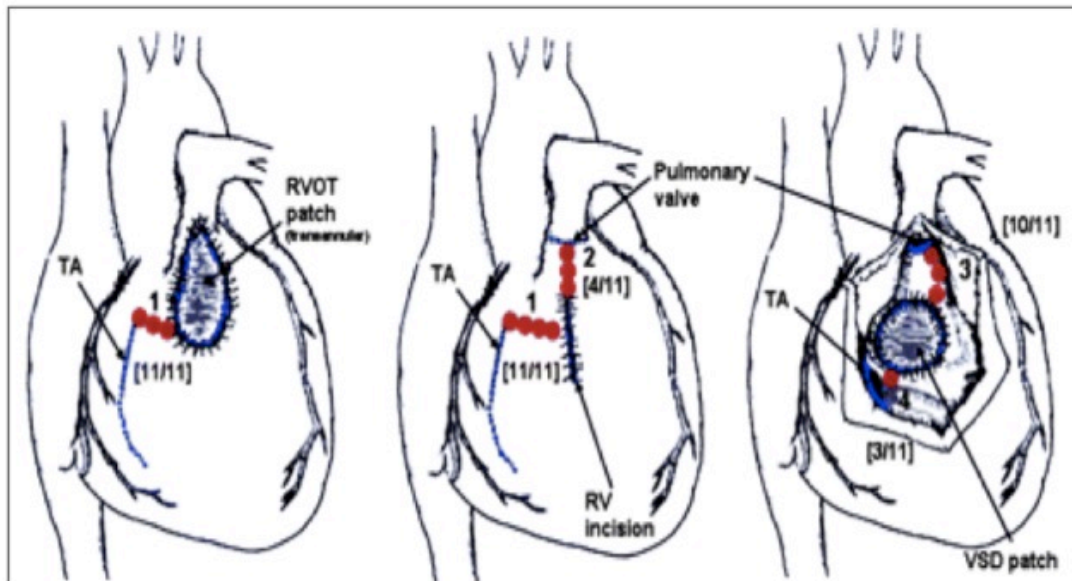
8. Akca F, Bauernfeind T, Witsenburg M et al. Acute and long-term outcomes of catheter ablation using remote magnetic navigation in patients with congenital heart disease. *Am J Cardiol.* 2012;110:409-14.
9. Khairy P, Van Hare GF, Balaji S et al. PACES/HRS Expert Consensus Statement on the Recognition and Management of Arrhythmias in Adult Congenital Heart Disease. *Can J Cardiol.* 2014;30:e1-e63.
10. Pedersen CT, Kay GN, Kalman J, Borggrefe M et al. EHRA/HRS/APHRS expert consensus on ventricular arrhythmias. *Europace.* 2014;16:1257-83
11. Khairy P. Programmed ventricular stimulation for risk stratification in patients with tetralogy of Fallot: a Bayesian perspective. *Nat Clin Pract Cardiovasc Med.* 2007;4:292-3.
12. Mavrogeni S, Petrou E, Kolovou G, Theodorakis G, Iliodromitis E. Prediction of ventricular arrhythmias using cardiovascular magnetic resonance. *Eur Heart J Cardiovasc Imaging.* 2013;14:518-25.
13. Stirrat J, Rajchl M, Bergin L, et al. High-resolution 3-dimensional late gadolinium enhancement scar imaging in surgically corrected Tetralogy of Fallot: clinical feasibility of volumetric quantification and visualization. *J Cardiovasc Magn Reson.* 2014;1;16:76.



Khairy P et al., *Circulation*, 2010.

**Figure 7. Prévalence des tachyrythmies après réparation de TF selon l'âge.**

(AF=fibrillation atriale, IART=tachycardie atriale par réentrée, VT=tachycardie ventriculaire, VF=fibrillation ventriculaire).

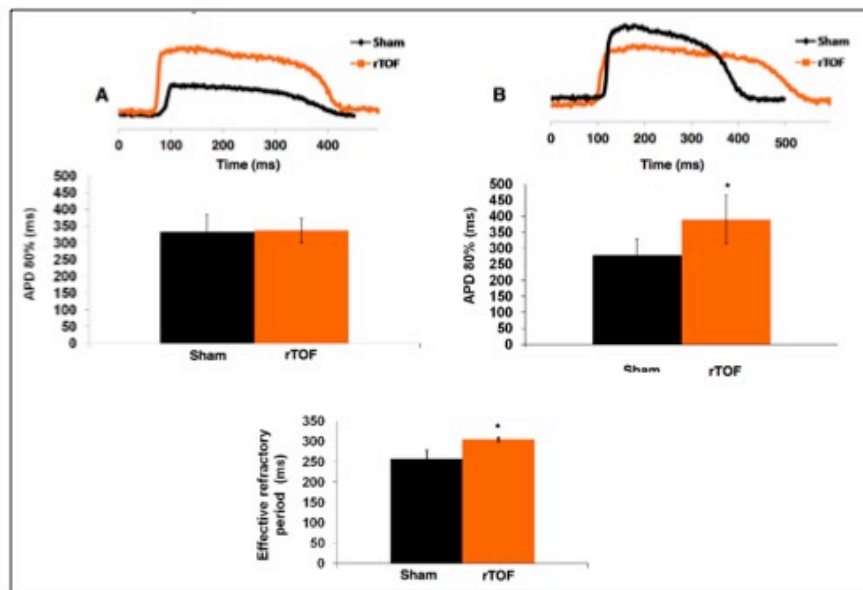


Zeppenfeld K et al., *Circulation*, 2007.

**Figure 8. Les différents isthmes retrouvés après cure complète de TF.**

Les différents isthmes sont représentés en rouge avec leur fréquence sur 11 patients explorés. (RV = ventricule droit, RVOT = infundibulum pulmonaire, TA = anneau tricuspide, VSD = CIV)

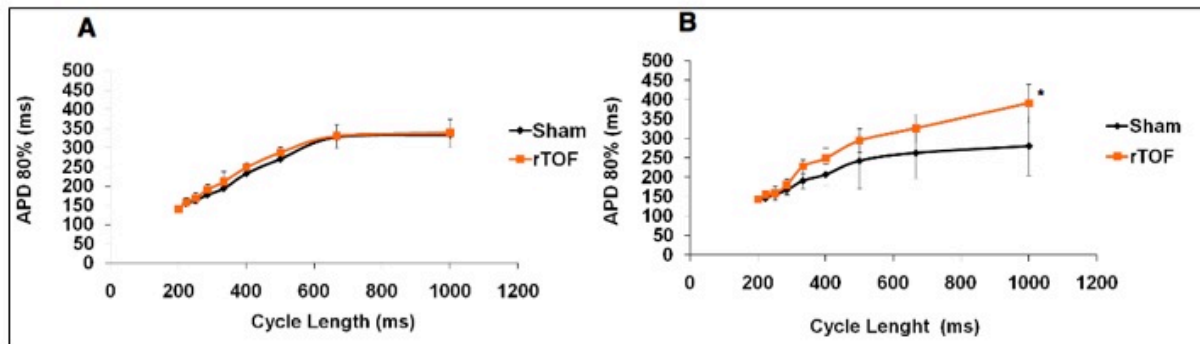
## Travail fondamental (VG): durée du potentiel d'action



**Figure 9:** A= endocarde B=épicarde

- $P < 0.05$
- *rTOF* = animaux mimant une TF réparée / VG = ventricule gauche

## Travail fondamental (VG): pente de restitution du potentiel d'action

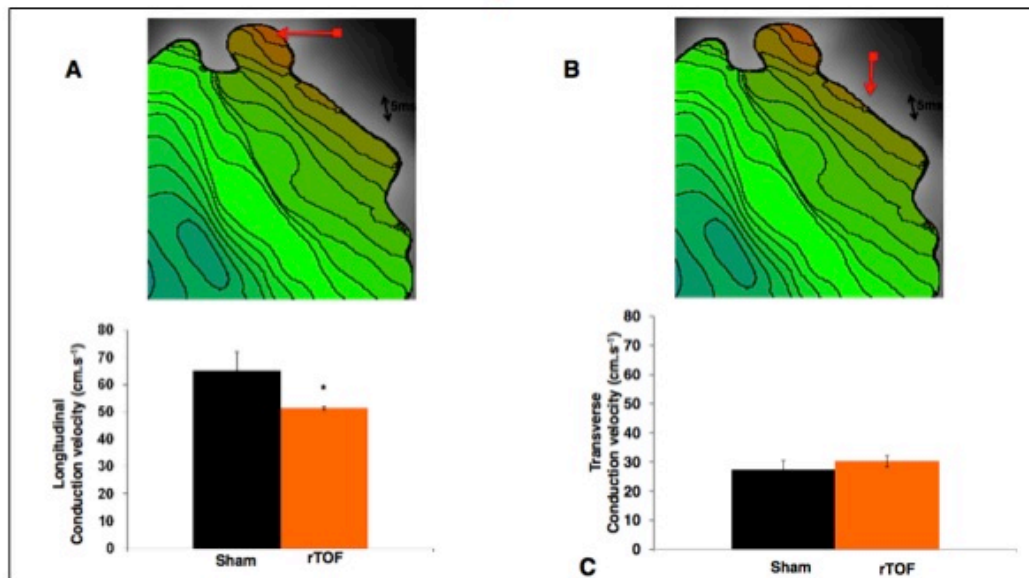


**Figure 10:**

- A= endocarde B= épicarde
- $P < 0.05$
- *rTOF* = animaux mimant une TF réparée / *VG* = ventricule gauche



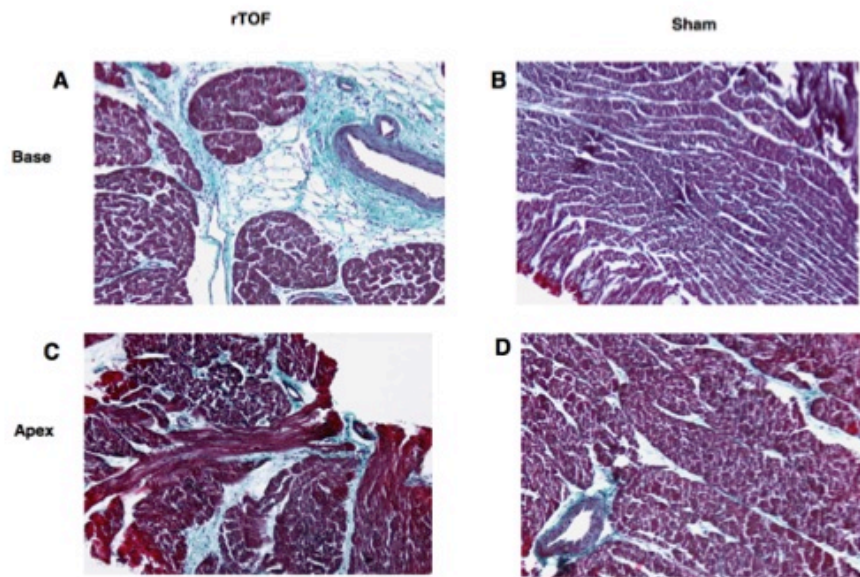
## Travail fondamental (VG): vitesse de conduction du potentiel d'action



**Figure 11:**

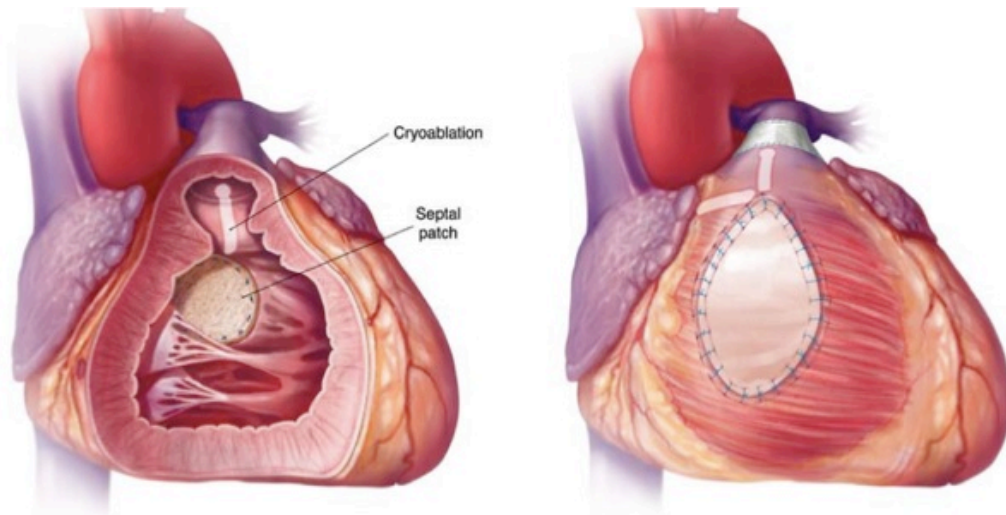
- A= sens longitudinal    B= sens transversal
- $P < 0.05$
- *rTOF* = animaux mimant une TF réparée / *VG* = ventricule gauche

## Travail fondamental: histologie du VG



**Figure 12:**

- Augmentation du contenu en collagène (en bleu) sur les prélèvements effectués à la base et apex du ventricule gauche chez les animaux rTOF.
- *rTOF = animaux mimant une TF réparée / VG = ventricule gauche*

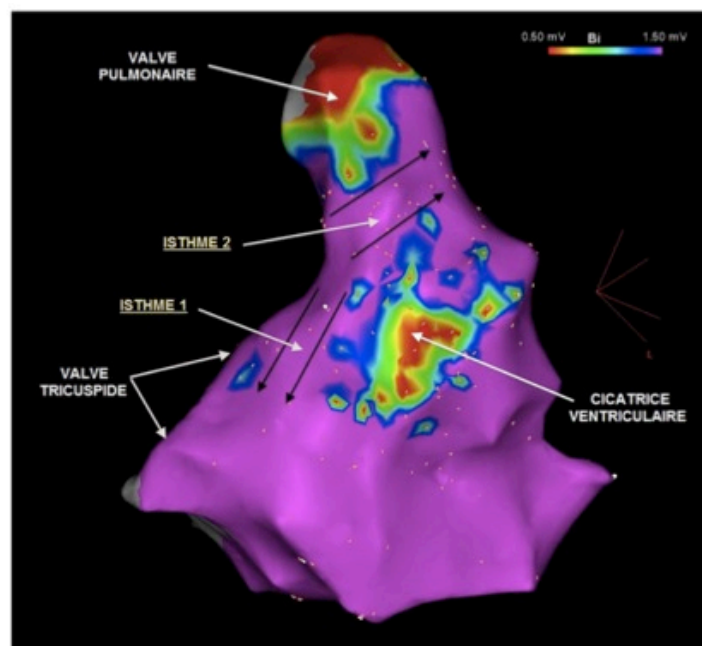


*Sabete Roses A et al., Circ Arrhythm Electrophysiol, 2015.*

**Figure 13. Lignes de cryoablation chirurgicales lors de la valvulopathie pulmonaire .**

Image de gauche: cryoablation de l'anneau pulmonaire étendue jusqu'au patch de fermeture de communication interventriculaire.

Image de droite: du patch infundibulaire vers l'anneau pulmonaire ou, latéralement, du patch vers l'anneau tricuspide.

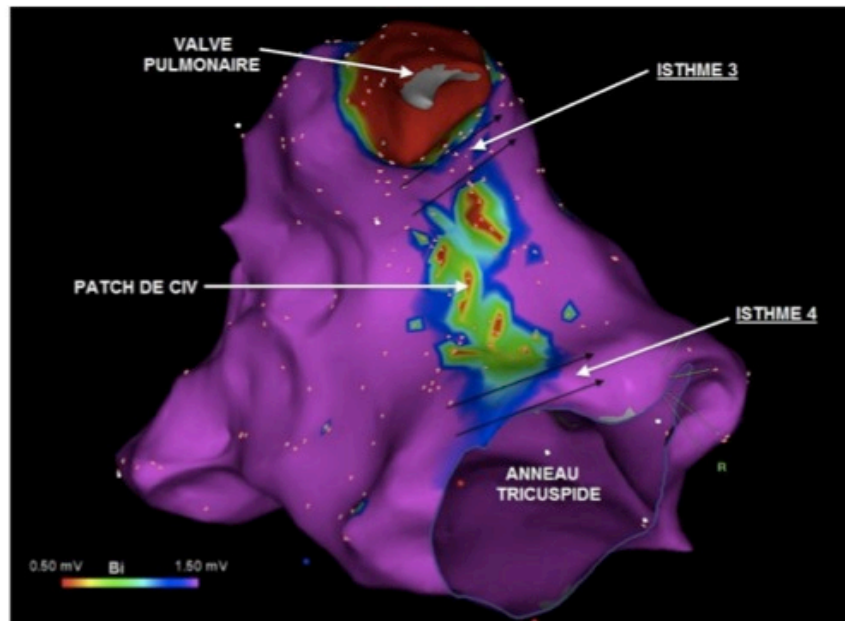


*Remerciement au Dr Sacher, CHU Bordeaux.*

**Figure 14. Cartographie électro-anatomique de voltage du ventricule droit en bipolaire, vue antérieure.**

Deux isthmes anatomiques sont identifiables :

- l'isthme 1, entre l'anneau tricuspide et la cicatrice du patch ventriculaire antérieur
- l'isthme 2, entre l'anneau pulmonaire et la cicatrice du patch ventriculaire antérieur

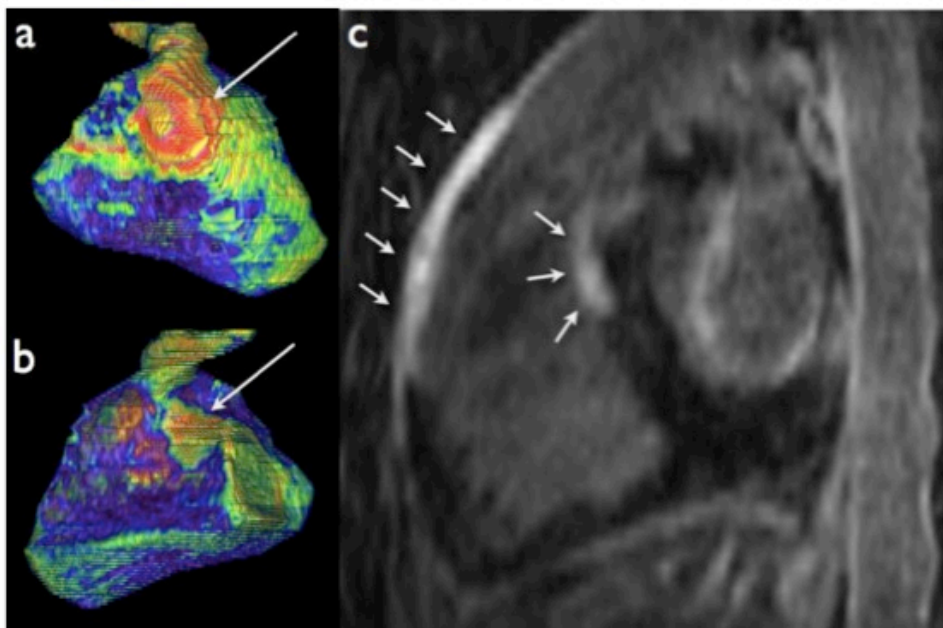


*Remerciement au Dr Sacher, CHU Bordeaux.*

**Figure 15. Cartographie électro-anatomique de voltage du ventricule droit en bipolaire, vue postérieure modifiée.**

*Deux isthmes anatomiques sont identifiables :*

- l'isthme 3, entre l'anneau pulmonaire et la cicatrice du patch de CIV
- l'isthme 4, entre l'anneau tricuspide et la cicatrice du patch de CIV  
(CIV = communication interventriculaire)



**Figure 16. Apport de l'IRM de rehaussement tardif à haute résolution spatiale dans l'étude des cicatrices post-opératoires chez les patients avec TF réparée. .**

- Reconstitutions en rendu de volume du VD. La méthode permet une analyse des contours et des isthmes associés aux cicatrices (flèches) d'infundibulotomie (a) et de fermeture de CIV (b).
- En (c), visualisation des 2 patches (flèches) (infundibulaire et CIV) sur image IRM de rehaussement tardif.



# Cardiovascular Research

## Pro-Arrhythmic Remodeling of the Right Ventricle in a Porcine Model of Repaired Tetralogy of Fallot --Manuscript Draft--

|  |   |
|--|---|
| <b>Manuscript Number:</b>                            |   |
| <b>Full Title:</b>                                   | Pro-Arrhythmic Remodeling of the Right Ventricle in a Porcine Model of Repaired Tetralogy of Fallot   |
| <b>Short Title:</b>                                  | Pro-arrhythmic Substrate in Repaired Tetralogy of Fallot  |
| <b>Article Type:</b>                                 | Original Article  |
| <b>Keywords:</b>                                     | Tetralogy of Fallot; Arrhythmia; Remodeling; Right ventricle; Conduction  |
| <b>Corresponding Author:</b>                         | David Benoist<br>Universite de Bordeaux<br>Pessac, FRANCE   |
| <b>Corresponding Author Secondary Information:</b>   |   |
| <b>Corresponding Author's Institution:</b>           | Universite de Bordeaux  |
| <b>Corresponding Author's Secondary Institution:</b> |   |
| <b>First Author:</b>                                 | David Benoist   |
| <b>First Author Secondary Information:</b>           |   |
| <b>Order of Authors:</b>                             | David Benoist <span style="color: red;">D. Benoist et V. Dubes sont co-premiers auteurs</span><br>Virginie Dubes<br>François Roubertie<br>Stephen H Gilbert<br>Sabine Charron<br>Marion Constantin<br>Delphine Elbes<br>Delphine Vieillot<br>Bruno Quesson<br>Hubert Cochet<br>Michel Haïssaguerre<br>Caroline Rooryck<br>Bordachar Pierre<br>Jean-Benoit Thambo<br>Olivier Bernus  |
| <b>Order of Authors Secondary Information:</b>       |   |
| <b>Abstract:</b>                                     | <p><b>Aims:</b> The growing adult population with surgically-corrected tetralogy of Fallot (TOF) is at risk of developing arrhythmias and sudden cardiac death in the long term. The structural and electrophysiological remodeling of the right ventricle (RV) may contribute to arrhythmia generation in these patients. Here, we investigate this remodeling in a large animal model reproducing TOF post-operative features.</p> <p><b>Methods and Results:</b> Pigs mimicking repaired TOF (rTOF) underwent cardiac MRI functional characterization and presented with pulmonary regurgitation, RV hypertrophy, dilatation and dysfunction compared to Sham-operated animals (Sham).</p> |

|                             |   |
|-----------------------------|---|
|                             | <p>Optical mapping of rTOF RV-perfused wedges revealed a significant prolongation of RV activation time with slower conduction velocities and regions of conduction slowing well beyond the surgical scar. A reduced Connexin-43 protein expression and a remodeling of extracellular matrix-related gene expression were found in rTOF RVs, with an increase in collagen content that correlated with prolonged RV activation time. RV action potential duration (APD) was prolonged in the epicardial anterior region at early and late repolarization level, thus contributing to a greater APD heterogeneity and to altered transmural and antero-posterior APD gradients in rTOF RV. APD remodeling involved changes in the expression of Kv4.3 and MiRP1. Spontaneous arrhythmias were more frequent in rTOF wedges and more complex in the anterior than in the posterior RV.</p> <p>Conclusions: Significant remodeling of RV conduction and repolarization properties was found in an animal model of repaired TOF with RV overload and dysfunction. This remodeling generates a pro-arrhythmic substrate likely to contribute to sudden cardiac death in rTOF patients.</p> |
| <b>Suggested Reviewers:</b> |   |
| <b>Opposed Reviewers:</b>   |   |

## **Pro-Arrhythmic Remodeling of the Right Ventricle in a Porcine Model of Repaired Tetralogy of Fallot**


David Benoist; Virginie Dubes; François Roubertie; Stephen H. Gilbert; Sabine Charron; Marion Constantin; Delphine Elbes; Delphine Vieillot; Bruno Quesson; Hubert Cochet; Michel Haïssaguerre; Caroline Rooryck; Pierre Bordachar; Jean-Benoit Thambo; Olivier Bernus

**Aims** – The growing adult population with surgically-corrected tetralogy of Fallot (TOF) is at risk of developing arrhythmias and sudden cardiac death in the long term. The structural and electrophysiological remodeling of the right ventricle (RV) may contribute to arrhythmia generation in these patients. Here, we investigate this remodeling in a large animal model reproducing TOF post-operative features.

**Methods and Results** – Pigs mimicking repaired TOF (rTOF) underwent cardiac MRI functional characterization and presented with pulmonary regurgitation, RV hypertrophy, dilatation and dysfunction compared to Sham-operated animals (Sham). Optical mapping of rTOF RV-perfused wedges revealed a significant prolongation of RV activation time with slower conduction velocities and regions of conduction slowing well beyond the surgical scar. A reduced Connexin-43 protein expression and a remodeling of extracellular matrix-related gene expression were found in rTOF RVs, with an increase in collagen content that correlated with prolonged RV activation time. RV action potential duration (APD) was prolonged in the epicardial anterior region at early and late repolarization level, thus contributing to a greater APD heterogeneity and to altered transmural and antero-posterior APD gradients in rTOF RV. APD remodeling involved changes in the expression of Kv4.3 and MiRP1. Spontaneous arrhythmias were more frequent in rTOF wedges and more complex in the anterior than in the posterior RV.

**Conclusions** – Significant remodeling of RV conduction and repolarization properties was found in an animal model of repaired TOF with RV overload and dysfunction. This remodeling generates a pro-arrhythmic substrate likely to contribute to sudden cardiac death in rTOF patients.

Dr. David Benoist, PhD  
Electrophysiology and Heart Modeling Institute  
Hôpital Xavier Arnoz  
Avenue du Haut-Lévêque  
33604 Pessac  
Tel : +33 (0)5 57 10 27 61  
Email : david.benoist@u-bordeaux.fr



September 28<sup>th</sup> 2015,

Dear Prof. Sipido,

We have submitted our manuscript entitled “Pro-Arrhythmic Remodeling of the Right Ventricle in a Porcine Model of Repaired Tetralogy of Fallot” by D. Benoist *et al.* for consideration by *Cardiovascular Research* as an original research article. This manuscript, or part of it, has neither been published nor is currently under consideration for publication by any other journal. I declare that co-authors have read the manuscript and approved its submission to *Cardiovascular Research* and that we agree to pay for the printing of colour figures. Author contributions were as follow: DB, FR, BQ, HC, MH, CR, PB, JBT, OB conceived and designed the experiments; DB, VD, FR, SHG, SC, MC, DE, DV, BQ performed the experiments; DB, VD, SHG, SC, OB analyzed the data; DB, OB wrote the paper.

Tetralogy of Fallot is the most common cyanotic congenital heart disease in the world. Survival to adulthood has considerably improved in patients with TOF over the last 60 years thanks to significant improvements in the surgical approach. However, this success is hampered by late complications among which life-threatening arrhythmias that affect a significant proportion of the adult TOF population. Our study aimed at characterizing the electrophysiological remodeling of the right ventricle (RV) in a large animal model of repaired TOF that closely reproduce human pathophysiological condition (Thambo *et al.* 2012).

Novel aspects: We identified the presence of an electrophysiological remodeling leading to a pro-arrhythmic substrate in our pig model of post-operative TOF using a systems approach (from in vivo to molecular level). This remodeling was characterized by a significant disruption in RV conduction properties well beyond the scar area as well as regional changes in action potential duration (APD) which altered APD gradients and increased APD dispersion. Mechanisms were identified and involved a remodeling of the extracellular matrix as well as changes in ion channel expression.

Interest to readers: We believe this translational work will be of interest to *Cardiovascular Research* readers as it brings to light potential markers and novel mechanisms contributing to arrhythmia and SCD incidence in surgically-corrected TOF and more generally in RV dysfunction. The arrhythmic burden in the rapidly-growing adult congenital population is likely to increase significantly in the next decades while arrhythmia management remains challenging in these patients. RV electrophysiological remodeling characterization in surgically-corrected TOF could help identifying patients at risk of life-threatening arrhythmias and may suggest therapeutic interventions such as pulmonary valve replacement or specific antiarrhythmic therapy.

We are looking forward to the outcome of the review process.

Thambo JB, Roubertie F, De Guillebon M, Labrousse L, Iriart X, Ntsinjana H, Lafitte S, Ploux S, Haissaguerre M, Roques X, Dos Santos P, Bordachar P. Validation of an animal model of right ventricular dysfunction and right bundle branch block to create close physiology to postoperative tetralogy of fallot. *International journal of cardiology.* 2012;154:38-42.

Yours Sincerely,

David Benoist



## **Pro-Arrhythmic Remodeling of the Right Ventricle in a Porcine Model of Repaired Tetralogy of Fallot**

David Benoist, PhD<sup>1,2\*</sup>; Virginie Dubes, MSc<sup>1,2\*</sup>; François Roubertie, MD<sup>1,2,3</sup>; Stephen H. Gilbert, PhD<sup>1,2,4</sup>; Sabine Charron, MSc<sup>1,2</sup>; Marion Constantin, MSc<sup>1,2</sup>; Delphine Elbes, PhD<sup>1,2,5</sup>; Delphine Vieillot, TA<sup>6</sup>; Bruno Quesson, PhD<sup>1,2</sup>; Hubert Cochet, MD, PhD<sup>1,2,3</sup>; Michel Haïssaguerre, MD<sup>1,2,3</sup>; Caroline Rooryck, MD, PhD<sup>7</sup>; Pierre Bordachar, MD, PhD<sup>1,2,3</sup>; Jean-Benoit Thambo, MD, PhD<sup>1,2,3</sup>; Olivier Bernus, PhD<sup>1,2</sup>

<sup>1</sup> IHU LIRYC, L'Institut de Rythmologie et Modélisation Cardiaque, Fondation Bordeaux Université, Bordeaux, France

<sup>2</sup> Inserm U1045, Centre de Recherche Cardio-Thoracique de Bordeaux, Université de Bordeaux, Bordeaux, France

<sup>3</sup> CHU de Bordeaux, Hôpital Cardiologique du Haut-Lévêque, Pessac, France

<sup>4</sup> Max Delbrück Center for Molecular Medicine, Berlin, Germany

<sup>5</sup> University of Oxford, Institute of Biomedical Engineering, Oxford, United-Kingdom

<sup>6</sup> Plateforme Technologique d'Innovation Biomédicale, Université de Bordeaux, Pessac, France

<sup>7</sup> E.A. 4576, Maladies Rares : Génétique et Métabolisme, Université de Bordeaux, Bordeaux, France

\* These authors contributed equally to this work.

**Short Title:** Pro-arrhythmic substrate in repaired TOF

**Corresponding author:** Dr. David Benoist

IHU LIRYC  
PTIB - Hôpital Xavier Arnoz  
Avenue Haut Leveque  
33604 Pessac  
France  
Email : david.benoist@u-bordeaux.fr  
Phone : +33(0)5 35 38 19 68  
Fax: +33 (0)5 57 10 28 69

**Word count : 6977**

## Abstract

**Aims** – The growing adult population with surgically-corrected tetralogy of Fallot (TOF) is at risk of developing arrhythmias and sudden cardiac death in the long term. The structural and electrophysiological remodeling of the right ventricle (RV) may contribute to arrhythmia generation in these patients. Here, we investigate this remodeling in a large animal model reproducing TOF post-operative features.

**Methods and Results** – Pigs mimicking repaired TOF (rTOF) underwent cardiac MRI functional characterization and presented with pulmonary regurgitation, RV hypertrophy, dilatation and dysfunction compared to Sham-operated animals (Sham). Optical mapping of rTOF RV-perfused wedges revealed a significant prolongation of RV activation time with slower conduction velocities and regions of conduction slowing well beyond the surgical scar. A reduced Connexin-43 protein expression and a remodeling of extracellular matrix-related gene expression were found in rTOF RVs, with an increase in collagen content that correlated with prolonged RV activation time. RV action potential duration (APD) was prolonged in the epicardial anterior region at early and late repolarization level, thus contributing to a greater APD heterogeneity and to altered transmural and antero-posterior APD gradients in rTOF RV. APD remodeling involved changes in the expression of Kv4.3 and MiRP1. Spontaneous arrhythmias were more frequent in rTOF wedges and more complex in the anterior than in the posterior RV.

**Conclusions** – Significant remodeling of RV conduction and repolarization properties was found in an animal model of repaired TOF with RV overload and dysfunction. This remodeling generates a pro-arrhythmic substrate likely to contribute to sudden cardiac death in rTOF patients.

**Keywords:** Tetralogy of Fallot; right ventricle; arrhythmia; remodeling; conduction

## Introduction

Tetralogy of Fallot (TOF) is the most frequent cyanotic congenital heart defect with a prevalence of 3.5 per 10,000 births<sup>1</sup>. Over the last decades, improvements in the timing and approach of surgical correction have considerably improved survival to adulthood. However, the adult survivor population is at risk of developing sustained ventricular arrhythmias and sudden cardiac death (SCD) late after surgery, with a respective incidence of 11.9 % and 8.3% 35 years after repair<sup>2</sup>.

The role of scar regions due to right ventriculotomy and ventricular septal defect repair in supporting macroreentry circuits and monomorphic ventricular tachycardia (VT) is well established<sup>3-5</sup>. Procedural success of radiofrequency ablation remains challenging<sup>6</sup> but recent studies targeting well-defined isthmuses appeared promising<sup>4,7</sup>.

In the context of SCD, there is evidence for the implication of RV volume and pressure overload in sustained ventricular arrhythmias in repaired Fallot patients<sup>8,9</sup>. QRS interval prolongation and dispersion are well-documented predictors of ventricular arrhythmias among corrected adult patients and have been linked to RV dilatation<sup>10</sup>. Moreover, it has been suggested that RV unloading secondary to pulmonary valve replacement may prevent a worsening of these markers and when associated with intraoperative cryoablation, reduce ventricular arrhythmia incidence<sup>11</sup>. Global heterogeneity of repolarization, measured as QTc or JTc dispersion, was also found increased in patients with repaired TOF and was considered as a useful marker to refine arrhythmic risk stratification<sup>8,12</sup>.

Previous studies have suggested that RV overload may lead to a ventricular remodeling likely to enhance the risk of sustained ventricular arrhythmias, as commonly reported in heart failure<sup>13</sup>. We aimed at characterizing this remodeling in the RV of a porcine model mimicking TOF post-operative lesions which was previously established in our laboratory<sup>14</sup>. A better understanding of the electrophysiological and structural substrates late after TOF repair appear an essential first step in investigating and developing novel specific anti-arrhythmic therapeutic approaches.

## Methods

An expanded Methods section is available in the Online Data Supplement.

All experiments were performed according to the European Union Council Directive 86/609/EEC for the protection of animals used for scientific purposes and with local ethical committee approval.

### Animal Model

The animal model of repaired TOF (rTOF N=7) was produced as previously described<sup>14</sup>. Briefly, Large White piglets (< 12kg) were pre-medicated with ketamine (10 mg/kg, IM, Vibrac) and acepromazine (0.1 mg/kg, Vetoquinol). Anesthesia was induced with sodium pentobarbital (5 mg/kg, IV, Ceva) and maintained with isoflurane (2% in 100% O<sub>2</sub>, Vibrac) after endotracheal intubation. Following left lateral thoracotomy, 2 pulmonary valve leaflets were excised, a PTFE patch was sewn across the pulmonary annulus and pulmonary artery banding was performed using a loose-tied tape. For sham-operated animals, only the lateral thoracotomy was performed (Sham N=5). Cardiac function and remodeling was assessed 23 ± 1 weeks post-surgery as detailed below.

### Cardiac Magnetic Resonance Imaging

Pigs were pre-medicated and anaesthetized as described above. A conventional cardiac magnetic resonance (CMR) examination was carried out as described in Bogaert et al<sup>15</sup>, using a Siemens Magnetom Avanto 1.5T MRI scanner (Erlangen, Germany). All images were taken during end-expiratory ventilation stop. Right-ventricular short-axis TrueFISP cine-image stacks and phase-contrast MRI were obtained under manual-breathhold. CMR analysis was performed by a single investigator. Quantification of ventricular function was carried out using the Siemens syngo ARGUS Ventricular Function software package.

### **Euthanasia, cardiac harvesting and tissue collection**

Following a median sternotomy to expose the heart, anesthetized animals received an intravenous dose of heparin (200 UI/kg, PanPharma) and were euthanized by injection of sodium pentobarbital (10 ml from 200 mg/ml stock). The heart was quickly excised, the aorta cannulated and the myocardium flushed with an ice-cold cardioplegic solution. The heart and, after careful dissection, the RV wall were weighed. Samples were dissected out from the anterior RV epi- and endocardium and snap-frozen into liquid nitrogen for molecular biology studies and kept at -80°C until use.

### **Optical mapping of cardiac electrical activity**

The right coronary artery was cannulated at the ostium level and perfused with cardioplegic solution while suturing major arterial leaks. The RV was installed in a chamber, immersed and perfused (20 mL/min) with a modified Krebs-Henseleit solution (37°C). The preparation was electrically stimulated in the mid-free wall region. Contraction was abolished using the electro-mechanical uncoupler blebbistatin (10 µM, Enzo Life Sciences) before loading with a 10 µM bolus of di-4-ANEPPS (Biotium). Fluorescent signals were recorded subsequently from the epi- and endocardial surfaces at 1 kHz using a MiCam Ultima CMOS camera (SciMedia USA Ltd) with a spatial resolution of 1 x 1 mm. Optical data were filtered and activation and repolarization properties were analyzed using BraviAna software (Brainvision). Arrhythmias were quantified and analyzed for dominant frequency and regularity.

### **Histological studies**

Immediately after RV dissection, transmural blocks (1.5 x 1.5 cm) of myocardium were taken from the apex of the RV and fixed in 4% paraformaldehyde at 4°C (Sham, rTOF N=4). After dehydration in ethanol, samples were embedded in paraffin, sectioned and stained with Masson's Trichrome. Images were obtained at a 10X magnification on a Nikon Eclipse 80i microscope equipped with a CCD camera. Collagen quantification was performed blindly by color thresholding using ImageJ software (NIH) and expressed as a percentage of total section area.

### **Western blot**

Proteins (50 µg) were separated on 12% acrylamide gels (TGX Stain-Free precast gels, Bio-Rad), under reducing conditions followed by semi-dry transfer (Trans-blot Turbo, Bio-Rad). PVDF membranes were probed with primary antibodies overnight followed by secondary antibodies for 2h. Following total hybridized protein imaging under UV light, signals were revealed by enhanced chemiluminescence (Thermo Scientific). Signal quantification was performed using ImageJ (NIH) and specific band intensity was normalized to the total protein intensity of each lane.

### **Data analysis**

Data are expressed as means ± SD. Statistical analysis was performed using SigmaStat software. Statistical differences between groups were tested using unpaired or paired Student tests or their non-parametric equivalent and linear regression as appropriate. Statistically significant difference was assumed for  $P < 0.05$ .

## **Results**

### **Animal model**

A significant increase in heart weight and RV weight normalized to BSA were found in rTOF pigs, highlighting the presence of a RV hypertrophy in these animals (Table 1). Pulmonary artery flow analysis at the level of the valve revealed the presence of a diastolic retrograde flow in all rTOF pigs which was absent in Sham pigs. The degree of regurgitation, quantified as a percentage of stroke volume was significantly higher in rTOF animals. RV hypertrophy, dilatation and leftward septal bulging could be identified on in vivo CMR images of rTOF pigs (see Supplemental Figure 1). In these

animals, RV dilatation was reflected by an increase in both end-systolic and end-diastolic RV volumes normalized to BSA (Table 1). RV stroke volume normalized to BSA remained unchanged but RV ejection fraction was significantly reduced in rTOF pigs versus Shams indicating RV dysfunction.

### Action potential duration heterogeneity in rTOF right ventricles

Mean APD80 across the whole epi- and endocardial surface was the same between both groups (Figure 1A). However, an elevated APD80 heterogeneity was identified in rTOF preparations. Quantitative analysis of APD80 distribution across the entire RV revealed an increased dispersion of APD80 in the rTOF epicardium, but not the endocardium, compared to Sham (Figure 1B).

This increased heterogeneity in the RV epicardium was associated with a differential remodeling in the anterior and posterior RV (Figure 2A). At 1 Hz, rTOF APD20 and APD80 were prolonged in the anterior RV epicardium resulting in a significant difference with Sham anterior but also with rTOF posterior epicardial APD80 (Figure 2B, C). In contrast to the epicardium, the anterior APD20 was shorter in rTOF than Sham RV endocardium with no significant difference at the APD80 level (Figure 2D, E). For both Sham and rTOF RVs, APD20 and APD80 were shorter in the anterior than in the posterior endocardium. . At increased pacing frequencies (i.e. up to 5 Hz), Sham and rTOF APD20 and APD80 restitution properties were similar in all RV regions (Supplemental Figure 2), although increasing stimulation frequency revealed significantly shorter APD20s in the posterior epicardium of rTOF RVs compared to Sham. Interestingly, KCND3 (Kv4.3) expression was inversely regulated in the epi- and endocardium of rTOF RVs such that it was reduced in the epicardium but increased in the endocardium compared to Sham (Supplemental Figure 3). This observation was further confirmed at the protein level (Supplemental Figure 4). In addition, KCNE2 (MiRP1) mRNA expression was significantly greater in rTOF epi- and endocardium than Sham (Supplemental Figure 3).

### Action potential duration gradients in rTOF right ventricles

In the epicardium and endocardium of Sham animals, longer APD80s in the posterior than in the anterior RV resulted in a positive RV posterior to anterior APD80 difference (APD80<sub>POST-ANT</sub> gradient). This gradient was reversed and significantly different from Sham on the epicardial surface of rTOF RVs (Figure 3A). In the RV endocardium of rTOF pigs, APD80<sub>POST-ANT</sub> gradient remained positive and similar to Sham but significantly different from the rTOF epicardium. The APD80<sub>POST-ANT</sub> epicardial gradient was significantly different from Sham at low pacing frequencies (1 – 2 Hz). When stimulation frequency was increased above 2 Hz, APD80<sub>POST-ANT</sub> gradients decreased in all Sham and rTOF RV regions leading to similar gradient values between the different groups (Figure 3B). Similarly, the epicardial antero-posterior gradient was reversed at the APD20 level in rTOF RVs compared to Sham and significantly different to the endocardial gradient (Supplemental Figure 5).

The transmural APD80 gradient (APD80<sub>ENDO-EPI</sub>) was also reversed in the anterior rTOF RV as a consequence of epicardial APD80 prolongation in this region. Thus, rTOF anterior RV APD80<sub>ENDO-EPI</sub> gradient was significantly different from Sham anterior and from rTOF posterior gradients (Figure 3C). APD80<sub>ENDO-EPI</sub> gradient decreased rapidly as stimulation frequency was increased in Sham anterior RV leading to similar gradient values between the Sham and rTOF animals (Figure 3D). Similarly, the opposite transmural regulation of APD20 in the anterior rTOF RV resulted in a reversed APD20<sub>ENDO-EPI</sub> gradient which was significantly different to the posterior transmural gradient (Supplemental Figure 5).

### Right ventricular activation and conduction velocity

Epicardial and endocardial RV activation maps revealed a disorganized activation in rTOF preparations with multiple regions of conduction slowing located in both anterior and posterior regions (Figure 4A). Total activation time of the RV was prolonged in rTOF epicardium and endocardium compared to Sham (Figure 4B). Masson's Trichrome staining showed increased collagen deposition and some degree of muscle fiber disarray in RV apical sections from rTOF hearts (Figure 5A). Collagen content quantification confirmed the presence of a significant increase in interstitial collagen in rTOF RV sections compared to Sham (Figure 5B). A positive linear correlation

was found between the endocardial activation time and both the collagen content (Figure 5C) and the RV end-diastolic volume (Figure 5D). Additionally, our transcriptomic approach revealed the presence of a significant remodeling of the extracellular matrix (ECM) in the anterior rTOF endocardium. The expression of several genes coding for proteins forming or involved in the regulation of the ECM was modified in the rTOF endocardium compared to Sham (Supplemental Table 1). Interestingly, the regulation of 18 of these 22 genes is commonly associated with ECM proliferation.

Moreover, a significant decrease in longitudinal and transverse conduction velocities was found in rTOF RV epicardium (Figure 6A) and endocardium (Figure 6B). RV conduction velocities decreased with rate in both experimental groups such that the difference was preserved over a range of stimulation frequencies in the epicardium and the endocardium (Supplemental Figure 6). Although Connexin-43 mRNA expression was not significantly altered in the anterior rTOF RV, its protein level was lower in the rTOF RV epicardium than in Sham (Figure 6 A) but remained unchanged in the endocardium (Figure 6B).

### Arrhythmias

Spontaneous arrhythmias (often developing secondary to an increase in pacing frequency during our restitution protocol) were more frequently observed in rTOF perfused isolated RVs than in Sham (Figure 7A). Interestingly, there was a negative linear correlation between the number of arrhythmic events and the transverse conduction velocity measured at 1 Hz on the endocardium of rTOF preparations (Figure 7B). Most rTOF arrhythmias (14/16) were sustained VT episodes with the exception of 2 ventricular fibrillation episodes. VT dominant frequency was similar in the anterior and posterior RV regions (Anterior  $3.31 \pm 1.54$  Hz; Posterior  $3.89 \pm 1.34$  Hz) but was lower than in the 2 arrhythmic episodes observed in Sham preparations (Anterior  $9.77 \pm 1.38$  Hz; Posterior  $11.12 \pm 0.54$  Hz). However, VT regularity was heterogeneous across rTOF RVs (Figure 7C), with a lower regularity in the anterior than in the posterior region (Figure 7D).

### Discussion

We found a significant remodeling of RV properties which generates a pro-arrhythmic substrate in an animal model of repaired TOF. Previous work investigating arrhythmia mechanisms in this pathological condition were based on electrocardiographic and endocardial mapping and could not fully address this question. To the best of our knowledge, this is the first report of a significant remodeling of the ECM and the electrophysiological properties across the whole RV in the context of post-operative TOF. This RV remodeling involved (i) a concomitant increase in epicardial and decrease in endocardial APD<sub>20</sub> which was mirrored by Kv4.3 expression pattern (ii) an increase in epicardial APD<sub>80</sub> and heterogeneity together with an alteration of the physiological APD gradients (iii) a prolonged activation time due to slower conduction velocities and localized regions of slow conduction well beyond the scar regions which may be related to lower Connexin-43 expression and a proliferation of the ECM with an increase in myocardial collagen deposition. In conjunction with RV scars, this substrate appears to be correlated to the occurrence of spontaneous arrhythmias *ex vivo* and may thus contribute to the higher risk for SCD in patients with surgically-corrected TOF.

### Slow and discontinuous RV activation in repaired tetralogy of Fallot

QRS prolongation has become a hallmark in patients with repaired TOF with a duration exceeding 180 ms considered a predictor of severe ventricular arrhythmias which was linked to RV dilatation<sup>10, 16</sup>. The QRS interval is a global index of cardiac activation and RV mechanisms associated with QRS prolongation in corrected patients remain unclear.

We have previously identified this QRS feature in our animal model<sup>14, 17</sup>. In the present study, we find significant conduction disturbances in the RV associated with the RV end-diastolic volume. Our results suggest that longer RV activation time was related to the presence of multiple regions of

conduction slowing throughout the RV. Interestingly, this observation is reminiscent of the fractionated electrograms observed all over the RV in an endocardial mapping study in TOF-corrected patients<sup>18</sup> and may be due to diffuse fibrosis throughout the RV as seen in advanced-stage dilated cardiomyopathy<sup>19</sup>. In patients with repaired TOF, CMR-based imaging techniques have allowed the localization of fibrosis within and beyond the scar region<sup>20, 21</sup> and higher degrees of fibrosis were associated with the occurrence of arrhythmias<sup>22</sup>. In this study, we also showed a remodeling in the expression of genes coding for proteins which are constitutive (e.g. Keratin 18, Cartilage intermediate layer protein) or regulate the ECM (e.g. Fibroblast growth factor 9). The net effect of this regulation is expected to favor ECM proliferation (for 18 out of 22 genes), and is likely to contribute to conduction slowing. Surprisingly, our transcriptomic approach did not unveil any significant alteration in the expression of the major cardiac collagen or metalloproteinase (MMP) subtypes. Instead, we found an upregulation of collagen type VIII and a downregulation of MMP type 11 which may represent a remodeling specific to combined pressure and volume RV overload. This analysis also brought to light potential new markers of ECM remodeling in the overloaded RV such as serpin-family proteins (Nexin-1, Serpine1) known to be critical players in ECM regulation in several organs<sup>23</sup>, or Galectin-1 (LGALS1), a  $\beta$ -galactoside binding lectin from the same family as Galectin-3, a well-described pro-fibrotic protein shown to be upregulated in hypertrophy and heart failure<sup>24</sup>. Interestingly, the expression of several proteins known to be regulated by mechanical stress such as Brain Natriuretic peptide (BNP)<sup>25</sup>, Tenascin-C (TNC)<sup>26</sup>, Mitogen-activated protein kinase kinase 1 (MAP2K1)<sup>27</sup> was altered in rTOF pigs, further highlighting the role of RV dilatation in ECM regulation. ECM regulation in the RV of rTOF pigs contributes to a global gene expression remodeling described in a recent study<sup>28</sup>. Moreover, the slower conduction velocities we observed in the rTOF RV epicardium are likely related to the decrease in epicardial Connexin-43 expression. A similar decrease in Connexin-43 expression was found in RV biopsies from patients with tetralogy of Fallot<sup>29</sup> and in human failing hearts in which it was associated with reduced conduction velocity<sup>30</sup>. In the context of repaired TOF, RV dilatation and renin-angiotensin system activation may contribute to Connexin-43 downregulation as demonstrated in the acutely stretched RV of anesthetized dogs<sup>31</sup>.

### **Heterogeneous RV repolarization in repaired tetralogy of Fallot**

Available information regarding RV repolarization in repaired TOF are limited and controversial. Electrocardiographic studies have shown a prolongation<sup>32</sup>, a shortening<sup>8</sup> or no change<sup>16</sup> in QTc or JTc duration in these patients. These variations are likely to originate from differences in surgical approach but also in patient's age at surgery and follow-up which have been suggested as arrhythmic risk factors<sup>33</sup>. Variable degrees of RV overload due to differences in age and surgical procedure could explain the different QT/JT duration between patient cohorts. In the present study, we found a heterogeneous APD remodeling with a significant APD prolongation in the anterior RV epicardium of rTOF pigs. There was a trend for a reduction in KCNH2 (Kv11.1) mRNA expression in the anterior RV epicardium of rTOF compared to Sham pigs and a significant upregulation of KCNE2 (MiRP1), a  $\beta$ -subunit which has been shown to repress the ion currents mediated by Kv11.1 (IKr) and Kv7.1 (IKs)<sup>34, 35</sup> which could contribute to the APD prolongation in the anterior RV epicardium. The distinct embryological origin and electrophysiology<sup>36</sup> and the proximity of the infundibular scar may predispose the anterior RV to this remodeling. A similar RV remodeling with longer APDs in the anterior epicardium was found in an animal model of RV hypertension<sup>37</sup> which showed high arrhythmia susceptibility<sup>38</sup>. However, in this animal model APD was globally increased in the RV, whereas in our study mean RV APD was unchanged. It is possible to speculate that the trend for shorter APD observed in the posterior RV of our animal model may be due to chronic RV volume overload as seen in an acute study<sup>39</sup> while a pressure-overload specific remodeling of the anterior RV may lead to APD prolongation in this region.

An opposite transmural remodeling of the APD20 was found in rTOF anterior RVs which was mirrored by Kv4.3 mRNA and protein expression suggesting a transcriptional regulation of this protein. This remodeling resembles that described in the failing human left ventricle where the transient outward Ca<sup>2+</sup>-insensitive current ( $I_{to1}$ ), which is mainly carried by Kv4.3, was shown to be reduced in

epicardial myocytes while unchanged in the endocardium<sup>40</sup>. In addition to modulating APD20, regulation of this current may also alter late APD repolarization as seen in human and rabbit atrial myocytes<sup>41</sup>. In the pig left ventricle, the presence of  $I_{to1}$  and the expression of Kv4.3 was questioned by some<sup>42</sup> but not all<sup>43</sup>. Here we show for the first time the presence of Kv4.3 in the pig RV at the mRNA and protein level and our results suggest that  $I_{to1}$  plays a role in the regulation of early APD repolarization in this species.

Dispersion of APD leads to dispersion of refractoriness and is known to predispose to reentry<sup>13, 44</sup>. Dispersion of repolarization has commonly been described on ECGs of patients with repaired TOF<sup>8, 12</sup>. In rTOF pigs, we show a significant increase in epicardial APD dispersion which was in part related to the epicardial APD prolongation in the anterior RV. Moreover, this remodeling led to a significant decrease in the transmural APD gradient at early and late repolarization levels in the anterior region but not the posterior region in rTOF preparations. A reduced transmural APD gradient has been described in human left-sided heart failure and was related to a larger increase in APD in the epicardium than in the endocardium<sup>45</sup> as observed in the anterior RV of rTOF animals. Another consequence of the regional variations in APD in rTOF RVs is a decrease and reversal of the antero-posterior APD gradient at early and late repolarization levels in the epicardium but not in the endocardium. Regionalization of the transmural and antero-posterior APD gradient alterations enhances APD dispersion in rTOF RVs and is therefore likely to further increase the risk of reentry. However, in patients with corrected TOF, no correlation was found between RV volume and QTc or JTc dispersion<sup>8</sup> and in rTOF pigs, RV APD did not correlate significantly with RV volume or the number of arrhythmic events. This suggests that RV dispersion of repolarization may not be directly related to dilatation in repaired TOF patients and is not a major contributor to arrhythmia initiation in this context although its contribution to arrhythmia maintenance and precipitation to fibrillation cannot be ruled out.

### Arrhythmias

Spontaneous arrhythmias occurring during the restitution pacing protocol were more frequent in rTOF than Sham RVs and the number of arrhythmia per preparation correlated with transverse endocardial conduction velocity. This finding further highlights the link between prolonged RV activation and arrhythmia reported in patients<sup>2, 10</sup>. Moreover, the correlation between RV activation time and end-diastolic volume indirectly links RV dilatation to an increased arrhythmic risk. Interestingly, Zeltser and colleagues isolated the different lesions of a similar swine model and showed that sustained arrhythmias could only be induced in 23% of pigs with a RVOT scar versus 83% in pigs with pulmonary insufficiency and RVOT scar<sup>46</sup>. This illustrates the pro-arrhythmic synergy of RV overload and surgical scarring in this context.

Most of the arrhythmic episodes observed in isolated rTOF ventricles were sustained tachycardia (14/16) that required cardioversion. The lower VT dominant frequency observed in rTOF hearts compared to Sham episodes may be related to the slower, discontinuous activation and heterogeneous repolarization of the rTOF RV. Despite their lower dominant frequency, rTOF VT episodes displayed a heterogeneous regularity index distribution with less regularity in the anterior RV which appeared to be the most remodeled RV region.

### Clinical implications

The characterization of the RV electrophysiological remodeling in surgically-corrected TOF has direct clinical implications as it could help identify patients at risk of complex arrhythmias and SCD and may suggest therapeutic interventions such as pulmonary valve replacement, radiofrequency ablation, or cardiac resynchronization. Moreover, antiarrhythmic therapy aimed at this remodeling may prevent SCD or improve radiofrequency ablation success.

According to the results from the present study and others<sup>21, 22</sup>, therapeutically targeting fibrosis to reduce the arrhythmic risk and improve RV function in patients with repaired TOF appears interesting. The renin-angiotensin system is activated in these patients<sup>47</sup> and is likely to promote myocardial fibrosis. Angiotensin converting enzyme (ACE) inhibition has proven disappointing in a



clinical trial<sup>48</sup>. The study was limited by the small number of patients and the short duration of the protocol and other anti-fibrotic drugs such as T galectin-3 inhibitors<sup>49</sup> should not be disregarded. Furthermore, since fibrosis is likely triggered by chronic volume overload and stretch<sup>50</sup>, early surgical interventions aiming at correcting pulmonary regurgitation prior to significant RV remodeling could be another potential therapeutic approach.

### **Limitations**

Our animal model aimed at reproducing post-operative Fallot hemodynamics and electrophysiology in healthy pigs in the absence of TOF. However, factors independent of surgery (e.g. genetic substrate<sup>51</sup>, hypoxemia<sup>52</sup>) may play a role in the ventricular remodeling and arrhythmia generation. We did not apply specific pacing protocols to investigate the vulnerability to ventricular arrhythmias due to experimental time constraints on the *ex vivo* tissue preparations. However, the occurrence of spontaneous arrhythmias arising during the restitution protocol by gradually increasing the pacing frequency from a single stimulation location indicates a strong arrhythmogenic substrate in the rTOF animals.

### **Conclusion**

We found a significant remodeling of RV conduction and repolarization properties in a porcine model reproducing TOF repair lesions. In the volume- and pressure-overloaded RV, ECM proliferation and Connexin-43 downregulation conspire to slow electrical propagation while APD heterogeneity appeared to involve a specific remodeling in Kv4.3 and MiRP1 expression in the anterior RV. This remodeling is likely to contribute to the arrhythmogenic substrate, arrhythmia complexity and SCD in corrected TOF patients.

### **Funding**

This work was funded by the Agence Nationale de la Recherche through the grant ANR-10-IAHU04-LIRYC and through the EU FP7 IRSES program CORDIS3D (IRSES-GA-2013-317767). D.B. was funded by a Fondation Recherche Médicale fellowship and S.H.G. was funded by a European Union Marie Curie fellowship.

### **Conflict of Interest**

None declared

## References

1. Egbe A, Uppu S, Lee S, Ho D, Srivastava S. Changing prevalence of severe congenital heart disease: a population-based study. *Pediatric cardiology* 2014;**35**:1232-1238.
2. Gatzoulis MA, Balaji S, Webber SA, Siu SC, Hokanson JS, Poile C, Rosenthal M, Nakazawa M, Moller JH, Gillette PC, Webb GD, Redington AN. Risk factors for arrhythmia and sudden cardiac death late after repair of tetralogy of Fallot: a multicentre study. *The Lancet* 2000;**356**:975-981.
3. Downar E, Harris L, Kimber S, Mickleborough L, Williams W, Sevapsidis E, Masse S, Chen TC, Chan A, Genga A, et al. Ventricular tachycardia after surgical repair of tetralogy of Fallot: results of intraoperative mapping studies. *Journal of the American College of Cardiology* 1992;**20**:648-655.
4. Zeppenfeld K, Schalij MJ, Bartelings MM, Tedrow UB, Koplán BA, Soejima K, Stevenson WG. Catheter ablation of ventricular tachycardia after repair of congenital heart disease: electroanatomic identification of the critical right ventricular isthmus. *Circulation* 2007;**116**:2241-2252.
5. Khairy P, Stevenson WG. Catheter ablation in tetralogy of Fallot. *Heart Rhythm* 2009;**6**:1069-1074.
6. Morwood JG, Triedman JK, Berul CI, Khairy P, Alexander ME, Cecchin F, Walsh EP. Radiofrequency catheter ablation of ventricular tachycardia in children and young adults with congenital heart disease. *Heart Rhythm* 2004;**1**:301-308.
7. Kapel GF, Reichlin T, Wijnmaalen AP, Piers SR, Holman ER, Tedrow UB, Schalij MJ, Stevenson WG, Zeppenfeld K. Re-entry using anatomically determined isthmuses: a curable ventricular tachycardia in repaired congenital heart disease. *Circulation Arrhythmia and electrophysiology* 2015;**8**:102-109.
8. Helbing WA, Roest AA, Niezen RA, Vliegen HW, Hazekamp MG, Ottenkamp J, de Roos A, van der Wall EE. ECG predictors of ventricular arrhythmias and biventricular size and wall mass in tetralogy of Fallot with pulmonary regurgitation. *Heart (British Cardiac Society)* 2002;**88**:515-519.
9. Marie PY, Marcon F, Brunotte F, Briancon S, Danchin N, Worms AM, Robert J, Pernot C. Right ventricular overload and induced sustained ventricular tachycardia in operatively "repaired" tetralogy of Fallot. *The American journal of cardiology* 1992;**69**:785-789.
10. Gatzoulis MA, Till JA, Somerville J, Redington AN. Mechanoelectrical interaction in tetralogy of Fallot. QRS prolongation relates to right ventricular size and predicts malignant ventricular arrhythmias and sudden death. *Circulation* 1995;**92**:231-237.
11. Therrien J, Siu SC, Harris L, Dore A, Niwa K, Janousek J, Williams WG, Webb G, Gatzoulis MA. Impact of pulmonary valve replacement on arrhythmia propensity late after repair of tetralogy of Fallot. *Circulation* 2001;**103**:2489-2494.
12. Gatzoulis MA, Till JA, Redington AN. Depolarization-repolarization inhomogeneity after repair of tetralogy of Fallot. The substrate for malignant ventricular tachycardia? *Circulation* 1997;**95**:401-404.
13. Coronel R, Wilders R, Verkerk AO, Wiegerinck RF, Benoist D, Bernus O. Electrophysiological changes in heart failure and their implications for arrhythmogenesis. *Biochimica et biophysica acta* 2013;**1832**:2432-2441.
14. Thambo JB, Roubertie F, De Guillebon M, Labrousse L, Iriart X, Ntsinjana H, Lafitte S, Ploux S, Haissaguerre M, Roques X, Dos Santos P, Bordachar P. Validation of an animal model of right ventricular dysfunction and right bundle branch block to create close physiology to postoperative tetralogy of Fallot. *International journal of cardiology* 2012;**154**:38-42.
15. Bogaert J. Cardiac Function. In: Bogaert J, Dymarkowski S, Taylor AM, Muthurangu V, eds. *Clinical Cardiac MRI*, Springer ed: Springer, 2012:109-165.

16. Berul CI, Hill SL, Geggel RL, Hijazi ZM, Marx GR, Rhodes J, Walsh KA, Fulton DR. Electrocardiographic markers of late sudden death risk in postoperative tetralogy of Fallot children. *Journal of cardiovascular electrophysiology* 1997;**8**:1349-1356.
17. Thambo J-B, Dos Santos P, De Guillebon M, Roubertie F, Labrousse L, Sacher F, Iriart X, Lafitte S, Ploux S, Jais P, Roques X, Haissaguerre M, Ritter P, Clementy J, Narayan SM, Bordachar P. Biventricular stimulation improves right and left ventricular function after tetralogy of Fallot repair: Acute animal and clinical studies. *Heart Rhythm* 2010;**7**:344-350.
18. Deanfield JE, McKenna WJ, Presbitero P, England D, Graham GR, Hallidie-Smith K. Ventricular arrhythmia in unrepaired and repaired tetralogy of Fallot. Relation to age, timing of repair, and haemodynamic status. *British heart journal* 1984;**52**:77-81.
19. Assomull RG, Prasad SK, Lyne J, Smith G, Burman ED, Khan M, Sheppard MN, Poole-Wilson PA, Pennell DJ. Cardiovascular magnetic resonance, fibrosis, and prognosis in dilated cardiomyopathy. *Journal of the American College of Cardiology* 2006;**48**:1977-1985.
20. Broberg CS, Chugh SS, Conklin C, Sahn DJ, Jerosch-Herold M. Quantification of diffuse myocardial fibrosis and its association with myocardial dysfunction in congenital heart disease. *Circulation Cardiovascular imaging* 2010;**3**:727-734.
21. Wald RM, Haber I, Wald R, Valente AM, Powell AJ, Geva T. Effects of regional dysfunction and late gadolinium enhancement on global right ventricular function and exercise capacity in patients with repaired tetralogy of Fallot. *Circulation* 2009;**119**:1370-1377.
22. Babu-Narayan SV, Kilner PJ, Li W, Moon JC, Goktekin O, Davlouros PA, Khan M, Ho SY, Pennell DJ, Gatzoulis MA. Ventricular fibrosis suggested by cardiovascular magnetic resonance in adults with repaired tetralogy of fallot and its relationship to adverse markers of clinical outcome. *Circulation* 2006;**113**:405-413.
23. Ghosh AK, Vaughan DE. PAI-1 in tissue fibrosis. *Journal of cellular physiology* 2012;**227**:493-507.
24. de Boer RA, Voors AA, Muntendam P, van Gilst WH, van Veldhuisen DJ. Galectin-3: a novel mediator of heart failure development and progression. *European journal of heart failure* 2009;**11**:811-817.
25. Yoshimura M, Yasue H, Okumura K, Ogawa H, Jougasaki M, Mukoyama M, Nakao K, Imura H. Different secretion patterns of atrial natriuretic peptide and brain natriuretic peptide in patients with congestive heart failure. *Circulation* 1993;**87**:464-469.
26. Yamamoto K, Dang QN, Kennedy SP, Osathanondh R, Kelly RA, Lee RT. Induction of tenascin-C in cardiac myocytes by mechanical deformation. Role of reactive oxygen species. *The Journal of biological chemistry* 1999;**274**:21840-21846.
27. Lal H, Verma SK, Smith M, Guleria RS, Lu G, Foster DM, Dostal DE. Stretch-induced MAP kinase activation in cardiac myocytes: differential regulation through beta1-integrin and focal adhesion kinase. *Journal of molecular and cellular cardiology* 2007;**43**:137-147.
28. Charron S, Roubertie F, Benoist D, Dubes V, Gilbert SH, Constantin M, Vieillot D, Elbes D, Quesson B, Bordachar P, Haissaguerre M, Bernus O, Thambo J-B, Rooryck C. Identification of Region-Specific Myocardial Gene Expression Patterns in a Chronic Swine Model of Repaired Tetralogy of Fallot. *PLoS ONE* 2015;**10**:e0134146.
29. Kolcz J, Drukala J, Bzowska M, Rajwa B, Korohoda W, Malec E. The expression of connexin 43 in children with Tetralogy of Fallot. *Cellular & molecular biology letters* 2005;**10**:287-303.
30. Glukhov AV, Fedorov VV, Kalish PW, Ravikumar VK, Lou Q, Janks D, Schuessler RB, Moazami N, Efimov IR. Conduction remodeling in human end-stage nonischemic left ventricular cardiomyopathy. *Circulation* 2012;**125**:1835-1847.
31. Hussain W, Patel PM, Chowdhury RA, Cabo C, Ciaccio EJ, Lab MJ, Duffy HS, Wit AL, Peters NS. The Renin-Angiotensin system mediates the effects of stretch on conduction velocity, connexin43 expression, and redistribution in intact ventricle. *Journal of cardiovascular electrophysiology* 2010;**21**:1276-1283.

32. Sarubbi B, Pacileo G, Ducceschi V, Russo MG, Iacono C, Pisacane C, Iacono A, Calabro R. Arrhythmogenic substrate in young patients with repaired tetralogy of Fallot: role of an abnormal ventricular repolarization. *International journal of cardiology* 1999;**72**:73-82.
33. Walsh EP. Sudden death in adult congenital heart disease: risk stratification in 2014. *Heart Rhythm* 2014;**11**:1735-1742.
34. Abbott GW, Sesti F, Splawski I, Buck ME, Lehmann MH, Timothy KW, Keating MT, Goldstein SA. MiRP1 forms IKr potassium channels with HERG and is associated with cardiac arrhythmia. *Cell* 1999;**97**:175-187.
35. Wu DM, Jiang M, Zhang M, Liu XS, Korolkova YV, Tseng GN. KCNE2 is colocalized with KCNQ1 and KCNE1 in cardiac myocytes and may function as a negative modulator of I(Ks) current amplitude in the heart. *Heart Rhythm* 2006;**3**:1469-1480.
36. Boukens BJ, Sylva M, de Gier-de Vries C, Remme CA, Bezzina CR, Christoffels VM, Coronel R. Reduced sodium channel function unmasks residual embryonic slow conduction in the adult right ventricular outflow tract. *Circulation research* 2013;**113**:137-141.
37. Benoist D, Stones R, Benson AP, Fowler ED, Drinkhill MJ, Hardy ME, Saint DA, Cazorla O, Bernus O, White E. Systems approach to the study of stretch and arrhythmias in right ventricular failure induced in rats by monocrotaline. *Progress in biophysics and molecular biology* 2014;**115**:162-172.
38. Benoist D, Stones R, Drinkhill M, Bernus O, White E. Arrhythmogenic substrate in hearts of rats with monocrotaline-induced pulmonary hypertension and right ventricular hypertrophy. *American journal of physiology Heart and circulatory physiology* 2011;**300**:H2230-2237.
39. Greve G, Lab MJ, Chen R, Barron D, White PA, Redington AN, Penny DJ. Right ventricular distension alters monophasic action potential duration during pulmonary arterial occlusion in anaesthetised lambs: evidence for arrhythmogenic right ventricular mechano-electrical feedback. *Experimental physiology* 2001;**86**:651-657.
40. Nabauer M, Beuckelmann DJ, Uberfuhr P, Steinbeck G. Regional differences in current density and rate-dependent properties of the transient outward current in subepicardial and subendocardial myocytes of human left ventricle. *Circulation* 1996;**93**:168-177.
41. Workman AJ, Marshall GE, Rankin AC, Smith GL, Dempster J. Transient outward K<sup>+</sup> current reduction prolongs action potentials and promotes afterdepolarisations: a dynamic-clamp study in human and rabbit cardiac atrial myocytes. *The Journal of physiology* 2012;**590**:4289-4305.
42. Li GR, Du XL, Siow YL, O K, Tse HF, Lau CP. Calcium-activated transient outward chloride current and phase 1 repolarization of swine ventricular action potential. *Cardiovascular research* 2003;**58**:89-98.
43. Lacroix D, Gluais P, Marquie C, D'Hoinne C, Adamantidis M, Bastide M. Repolarization abnormalities and their arrhythmogenic consequences in porcine tachycardia-induced cardiomyopathy. *Cardiovascular research* 2002;**54**:42-50.
44. Kuo CS, Munakata K, Reddy CP, Surawicz B. Characteristics and possible mechanism of ventricular arrhythmia dependent on the dispersion of action potential durations. *Circulation* 1983;**67**:1356-1367.
45. Glukhov AV, Fedorov VV, Lou Q, Ravikumar VK, Kalish PW, Schuessler RB, Moazami N, Efimov IR. Transmural dispersion of repolarization in failing and nonfailing human ventricle. *Circulation research* 2010;**106**:981-991.
46. Zeltser I, Gaynor JW, Petko M, Myung RJ, Birbach M, Waibel R, Ittenbach RF, Tanel RE, Vetter VL, Rhodes LA. The roles of chronic pressure and volume overload states in induction of arrhythmias: an animal model of physiologic sequelae after repair of tetralogy of Fallot. *The Journal of thoracic and cardiovascular surgery* 2005;**130**:1542-1548.
47. Mainwaring RD, Lamberti JJ, Moore JW, Billman GF, Carter TL, Nelson JC. Tetralogy of Fallot repair results in activation of the renin-angiotensin-aldosterone system. *European heart journal* 1996;**17**:1421-1425.

48. Babu-Narayan SV, Uebing A, Davlouros PA, Kemp M, Davidson S, Dimopoulos K, Bayne S, Pennell DJ, Gibson DG, Flather M, Kilner PJ, Li W, Gatzoulis MA. Randomised trial of ramipril in repaired tetralogy of Fallot and pulmonary regurgitation: the APPROPRIATE study (Ace inhibitors for Potential PRevention Of the deleterious effects of Pulmonary Regurgitation In Adults with repaired TEtralogy of Fallot). *International journal of cardiology* 2012;**154**:299-305.
49. Yu L, Ruifrok WP, Meissner M, Bos EM, van Goor H, Sanjabi B, van der Harst P, Pitt B, Goldstein IJ, Koerts JA, van Veldhuisen DJ, Bank RA, van Gilst WH, Sillje HH, de Boer RA. Genetic and pharmacological inhibition of galectin-3 prevents cardiac remodeling by interfering with myocardial fibrogenesis. *Circulation Heart failure* 2013;**6**:107-117.
50. Hutchinson KR, Stewart JA, Jr., Lucchesi PA. Extracellular matrix remodeling during the progression of volume overload-induced heart failure. *Journal of molecular and cellular cardiology* 2010;**48**:564-569.
51. Michielon G, Marino B, Formigari R, Gargiulo G, Picchio F, Digilio MC, Anaclerio S, Oricchio G, Sanders SP, Di Donato RM. Genetic syndromes and outcome after surgical correction of tetralogy of Fallot. *The Annals of thoracic surgery* 2006;**81**:968-975.
52. Chowdhury UK, Sathia S, Ray R, Singh R, Pradeep KK, Venugopal P. Histopathology of the right ventricular outflow tract and its relationship to clinical outcomes and arrhythmias in patients with tetralogy of Fallot. *The Journal of thoracic and cardiovascular surgery* 2006;**132**:270-277.

## Table Legends

**Table 1 – Animal weights and cardiac magnetic resonance characterization.** Data were obtained 23 ± 1 weeks post-surgery. Values are means ± SD. Animal numbers for Sham-operated (Sham) and repaired tetralogy of Fallot (rTOF) groups are indicated in each column. Statistical difference between Sham and rTOF is indicated for each parameter. BSA: body surface area; PRF: pulmonary regurgitation fraction; RV-ESVi: right ventricular end-systolic volume indexed to BSA; RV-EDVi: right ventricular end-diastolic volume indexed to BSA; RV-SVi: right ventricular stroke volume indexed to BSA; RVEF: right ventricular ejection fraction.

## Figure Legends

**Figure 1 – Mean right ventricular action potential duration and dispersion from epicardial and endocardial surfaces.** (A) Mean action potential duration at 80% repolarization (APD80) measured over the whole epicardial and endocardial surface while paced at 1 Hz were similar in Sham (black) and rTOF (grey) RVs. (B) APD80 dispersion in the epicardium and endocardium of Sham and rTOF RVs paced at 1 Hz. APD80 dispersion was increased in rTOF epicardium. Data are means  $\pm$  SD. \*\*  $P < 0.01$ , Sham N=4, rTOF N=5-6.

**Figure 2 – Regional action potential duration in Sham and rTOF right ventricles.** (A) Representative optical action potential traces from the RV anterior and posterior epicardium (EPI) and endocardium (ENDO) from Sham (black) and rTOF (grey) pigs. Epicardial APD20 (B) and APD80 (C) were prolonged in the anterior RV of rTOF pigs compared to Sham. (D), Endocardial APD20 was shorter in the anterior rTOF RV than in Sham and posterior rTOF RV. (E) APD80 from Sham and rTOF RVs were not different at 1 Hz pacing frequency. Shorter APD80 was observed in the anterior region than in the posterior for both groups. Data are means  $\pm$  SD. \*  $P < 0.05$ , Sham N=4, rTOF N=5-6.

**Figure 3 – Action potential duration gradients in the right ventricle of Sham and rTOF pigs.** (A) RV antero-posterior APD80 gradient (APD80<sub>POST-ANT</sub>, see methods for calculation) was reversed in rTOF (grey) epicardium and significantly different from Sham (black) epicardial and rTOF endocardial gradients at 1 Hz pacing frequency. (B) RV Antero-posterior APD80 gradient at different basic cycle lengths (BCL) from Sham (black) epicardium (solid line), endocardium (dashed line); and rTOF (grey) epicardium (solid line) and endocardium (dashed line). (C) RV transmural APD80 gradient (APD80<sub>ENDO-EPI</sub>, see methods for calculation) was reversed and significantly different from Sham in the anterior region while remaining unchanged in rTOF posterior region upon pacing at 1 Hz. (D) RV transmural APD80 gradient at different BCL from Sham anterior, posterior RV; and rTOF anterior and posterior RV. Data are means  $\pm$  SD. \*\*  $P < 0.01$ , \*  $P < 0.05$ , Sham N=4, rTOF N=5-6.

**Figure 4 – Right ventricular activation in Sham and rTOF preparations.** (A) Representative epicardial and endocardial activation maps from Sham and rTOF RVs with 5ms-spaced isochrones. Multiple areas of slowed conduction were typically observed (yellow arrows) throughout rTOF RVs. (B) Epicardial and endocardial activation times measured at 1 Hz pacing frequency were prolonged in rTOF (grey) RVs compared to Sham (black). Data are means  $\pm$  SD. \*\*  $P < 0.01$ , \*  $P < 0.05$ , Sham N=4, rTOF N=5-6.

**Figure 5 – Collagen content in Sham and rTOF right ventricles.** (A) Example images from histological sections of Sham and rTOF RVs stained with Masson's Trichrome. Note the greater collagen staining (blue) and the disorganized myocardial structure in rTOF section. (B) Collagen content, quantified as a percentage of total section area was increased in rTOF RVs compared to Sham. RV endocardial activation time correlated linearly with RV end-diastolic volume indexed to body surface area (RV-EDVi) (C) and collagen content (D). Data are means  $\pm$  SD. \*  $P < 0.05$ , Sham N=4, rTOF N=4-6.

**Figure 6 – Conduction velocities and Connexin-43 expression in Sham and rTOF right ventricles.** Epicardial (A) and endocardial (B) conduction velocities (CV<sub>EPI</sub>; CV<sub>ENDO</sub>) measured in the RV mid-free wall while pacing at 1Hz were reduced in the longitudinal (fast) and transverse (slow) directions of propagation in rTOF (grey) compared to Sham (black) preparations. Connexin-43 expression was decrease in the anterior RV epicardium of rTOF pigs (C) but not in the endocardium (D) compared to Sham. Data are means  $\pm$  SD. \*\*  $P < 0.01$ , \*  $P < 0.05$ , Sham N=3-4, rTOF N=3-6.

**Figure 7 – Quantification and regularity of right ventricular arrhythmias.** (A) The mean number of spontaneous ex vivo arrhythmias observed following an increase in stimulation frequency in a perfused RV was significantly increased in rTOF preparations. (B) The total number of arrhythmic events per preparation correlated with endocardial transverse conduction velocity (CV-Transverse<sub>ENDO</sub>). (C) Example of a regularity index map from a rTOF RV during an episode of ventricular tachycardia (VT). Note the heterogeneity in arrhythmia regularity across the RV. (D) Mean arrhythmia regularity index was lower in RV anterior than in RV posterior region in rTOF preparations (n=14 VT events). Data are means  $\pm$  SD. \*\* P < 0.01, \* P < 0.05, Sham N=4, rTOF N=6.

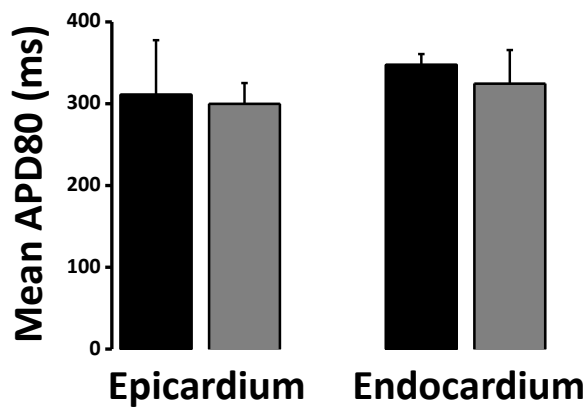


Table 1

|                                     | Sham        | rTOF        | p-value |
|-------------------------------------|-------------|-------------|---------|
|                                     | <i>N</i> =4 | <i>N</i> =6 |         |
| <b><i>Animal weights</i></b>        |             |             |         |
| Body weight(kg)                     | 48 ± 6      | 61 ± 11     | 0.05    |
| BSA (m <sup>2</sup> )               | 0.93 ± 0.07 | 1.05 ± 0.05 | 0.02    |
| Heart weight/BSA(g/m <sup>2</sup> ) | 202 ± 14    | 283 ± 21    | 0.01    |
| RV weight/BSA (g/m <sup>2</sup> )   | 78 ± 4      | 133 ± 16    | 0.02    |
| <b><i>CMR characterization</i></b>  |             |             |         |
| Heart rate (beats/min)              | 117 ± 15    | 98 ± 12     | 0.09    |
| PRF (%)                             | 0           | 9 ± 7       | 0.03    |
| RV-ESVi (ml/m <sup>2</sup> )        | 37 ± 6      | 122 ± 19    | < 0.001 |
| RV-EDVi (ml/m <sup>2</sup> )        | 75 ± 5      | 179 ± 42    | 0.002   |
| RV-SVi (ml/m <sup>2</sup> )         | 39 ± 10     | 57 ± 24     | 0.14    |
| RVEF (%)                            | 51 ± 11     | 31 ± 6      | 0.03    |

Table 1

**A**



**B**

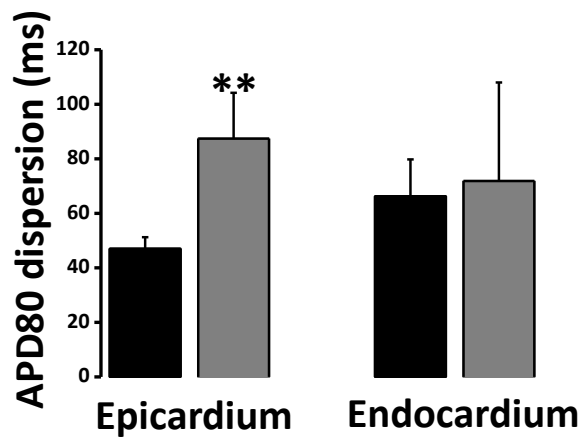


Figure 2

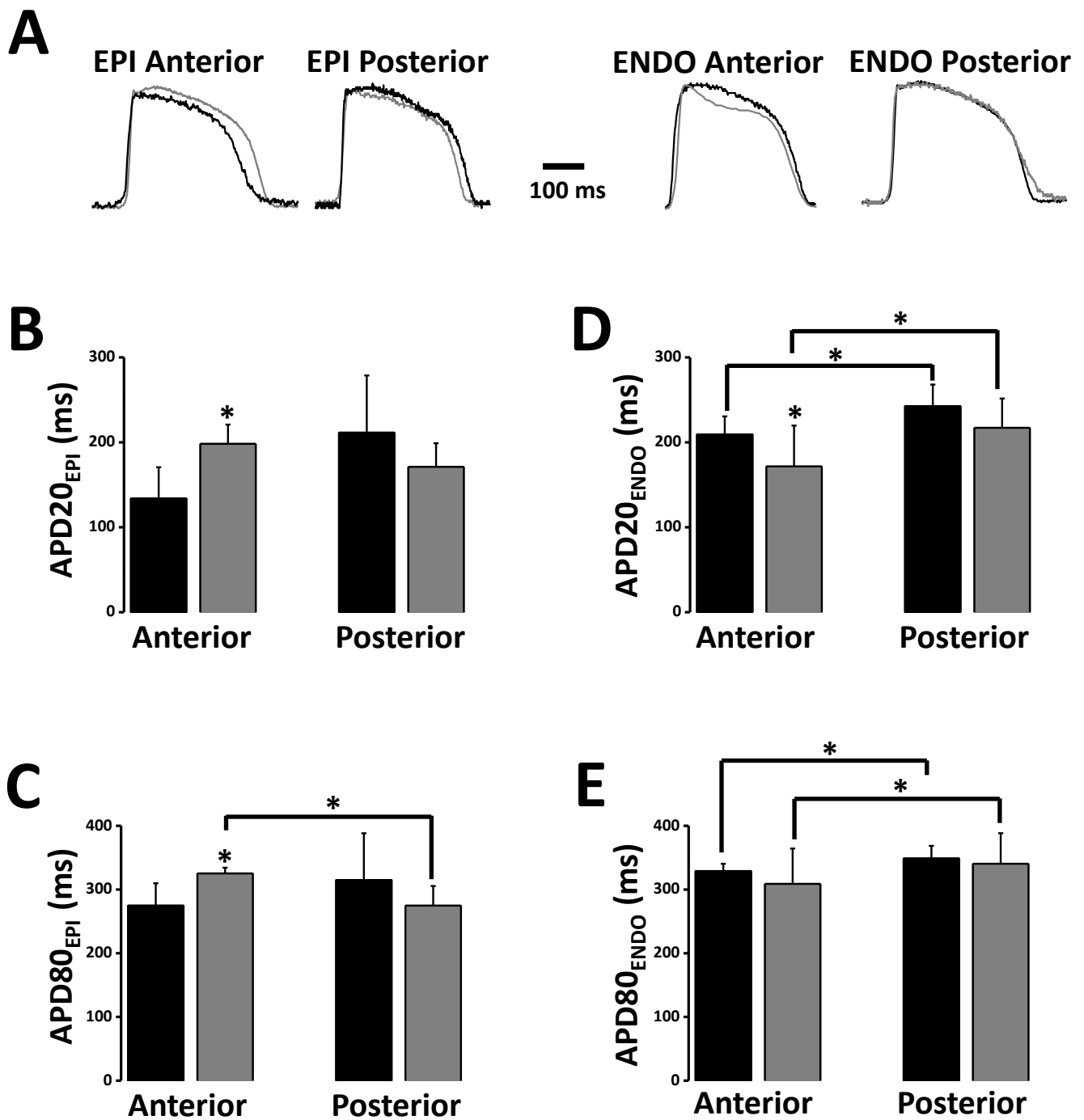


Figure 2

Figure 3

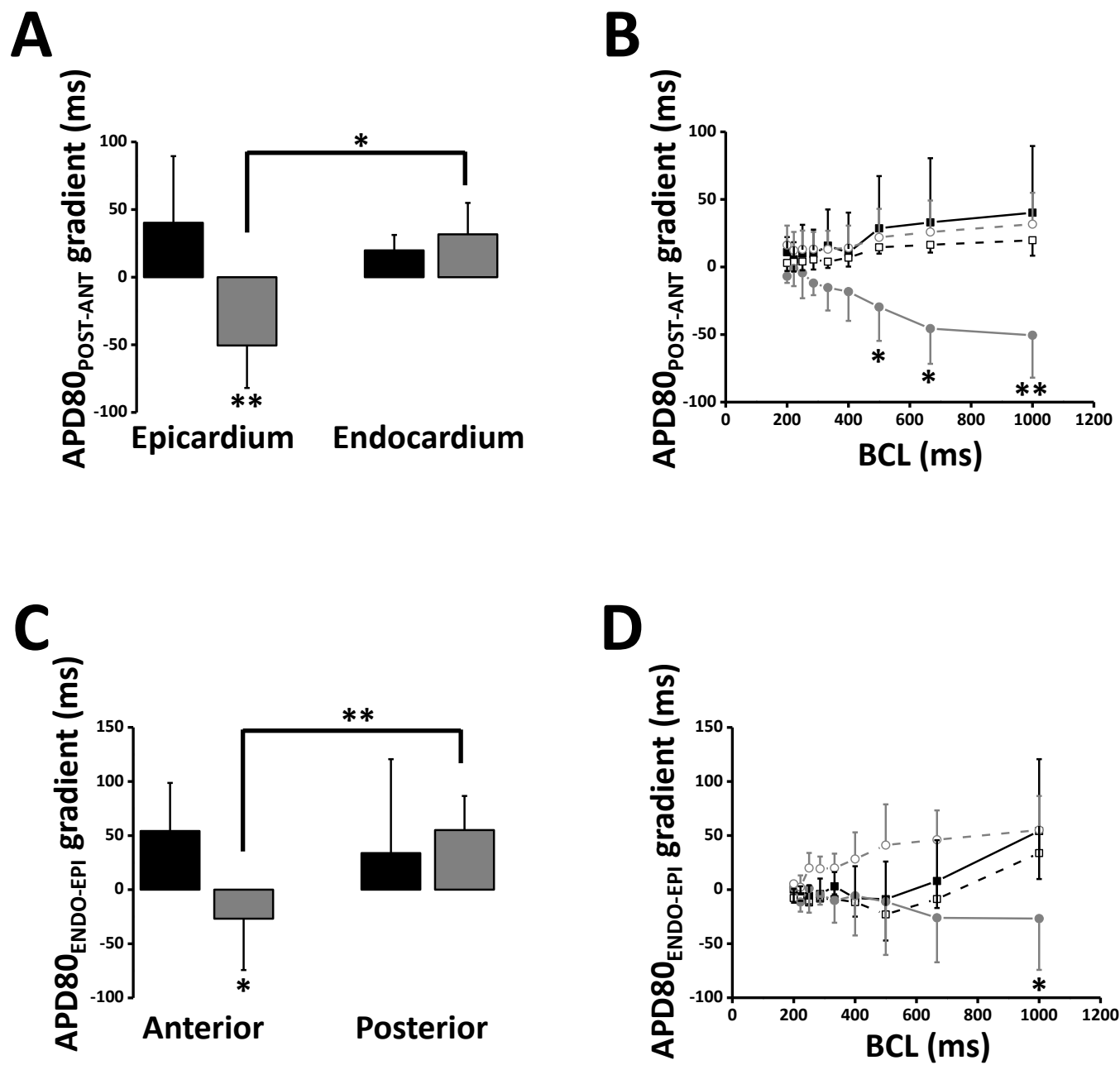


Figure 3

Figure 4

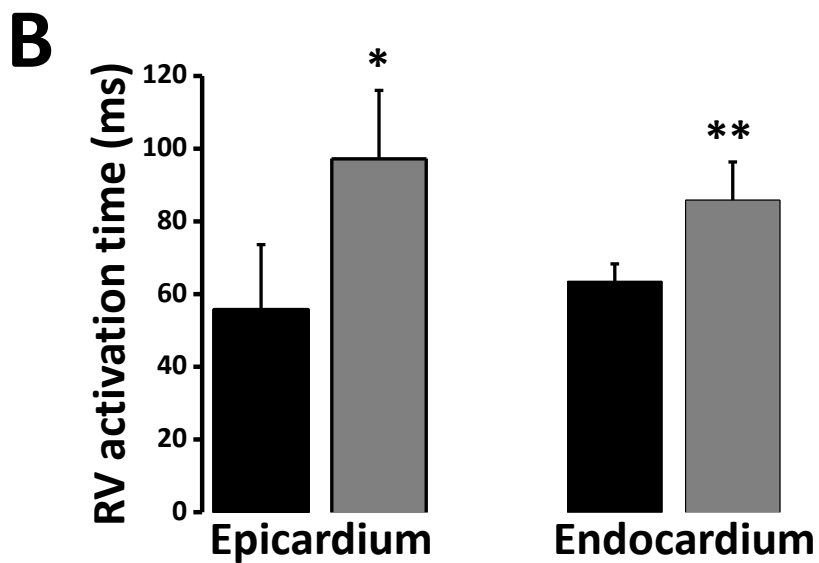
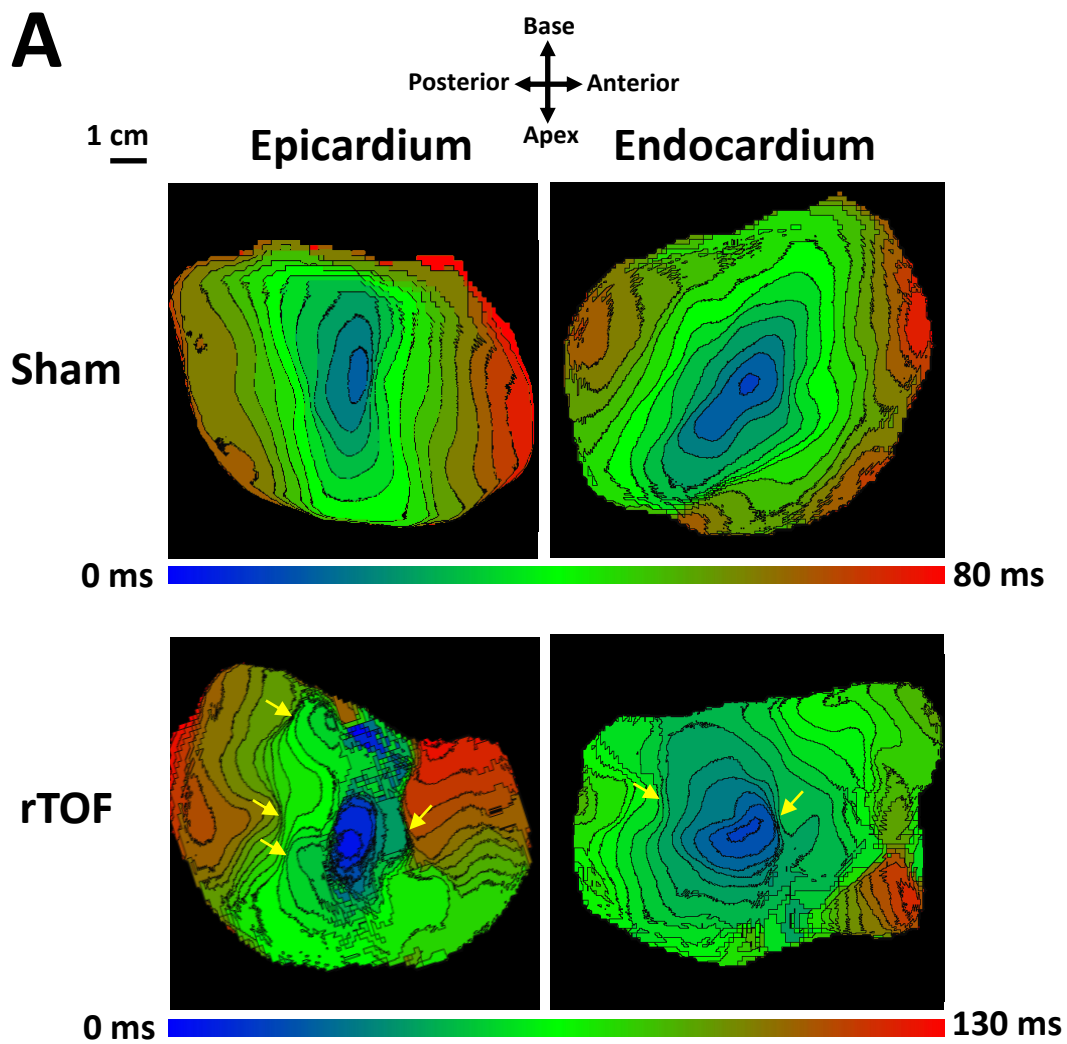
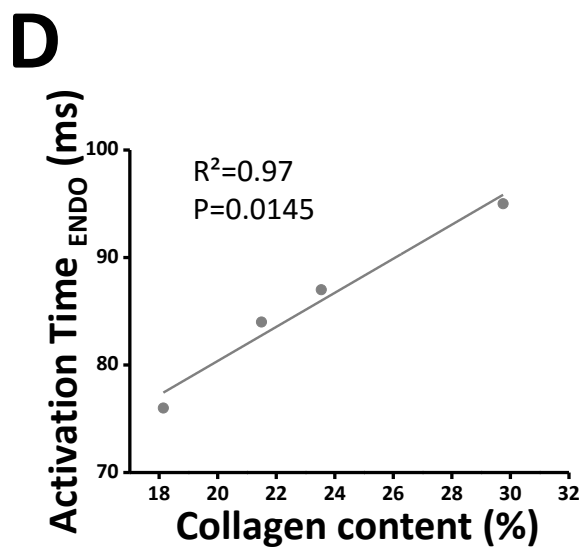
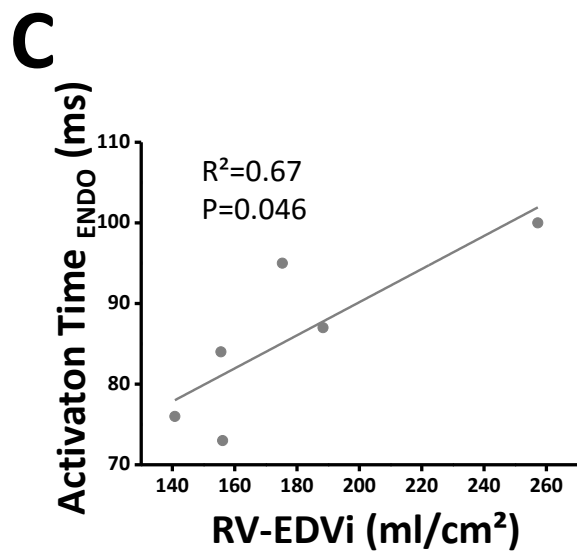
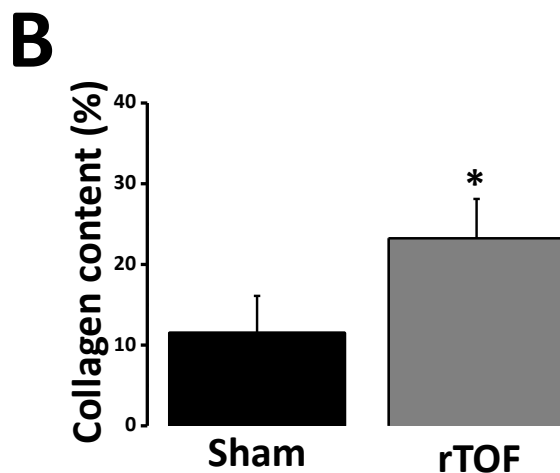
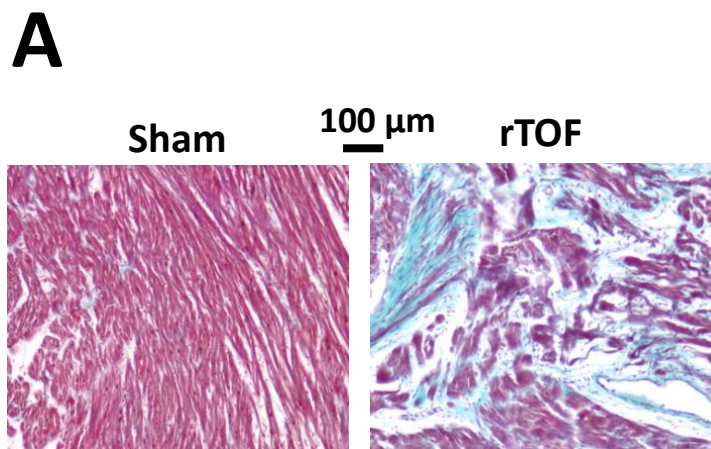


Figure 4



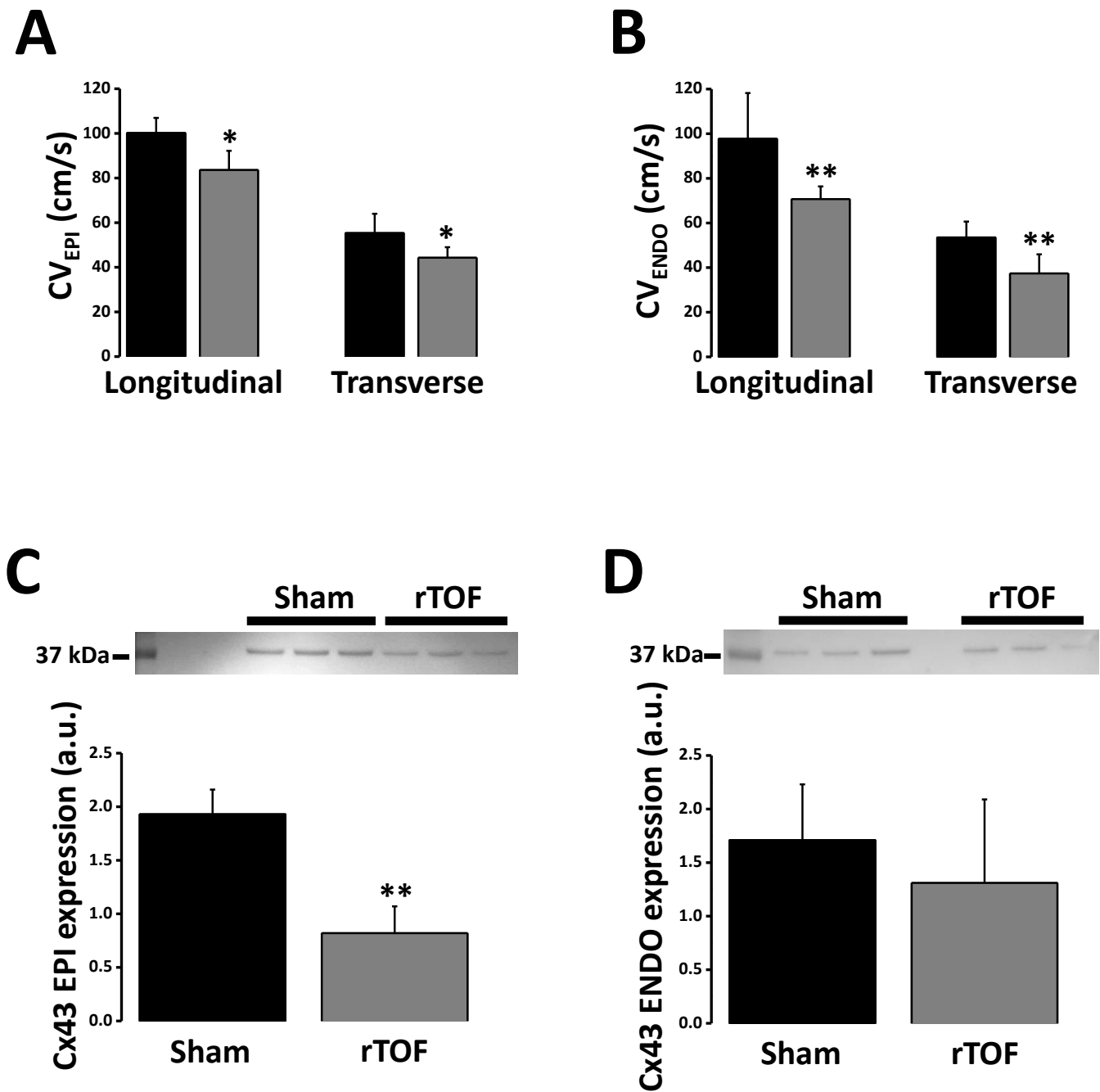


Figure 7

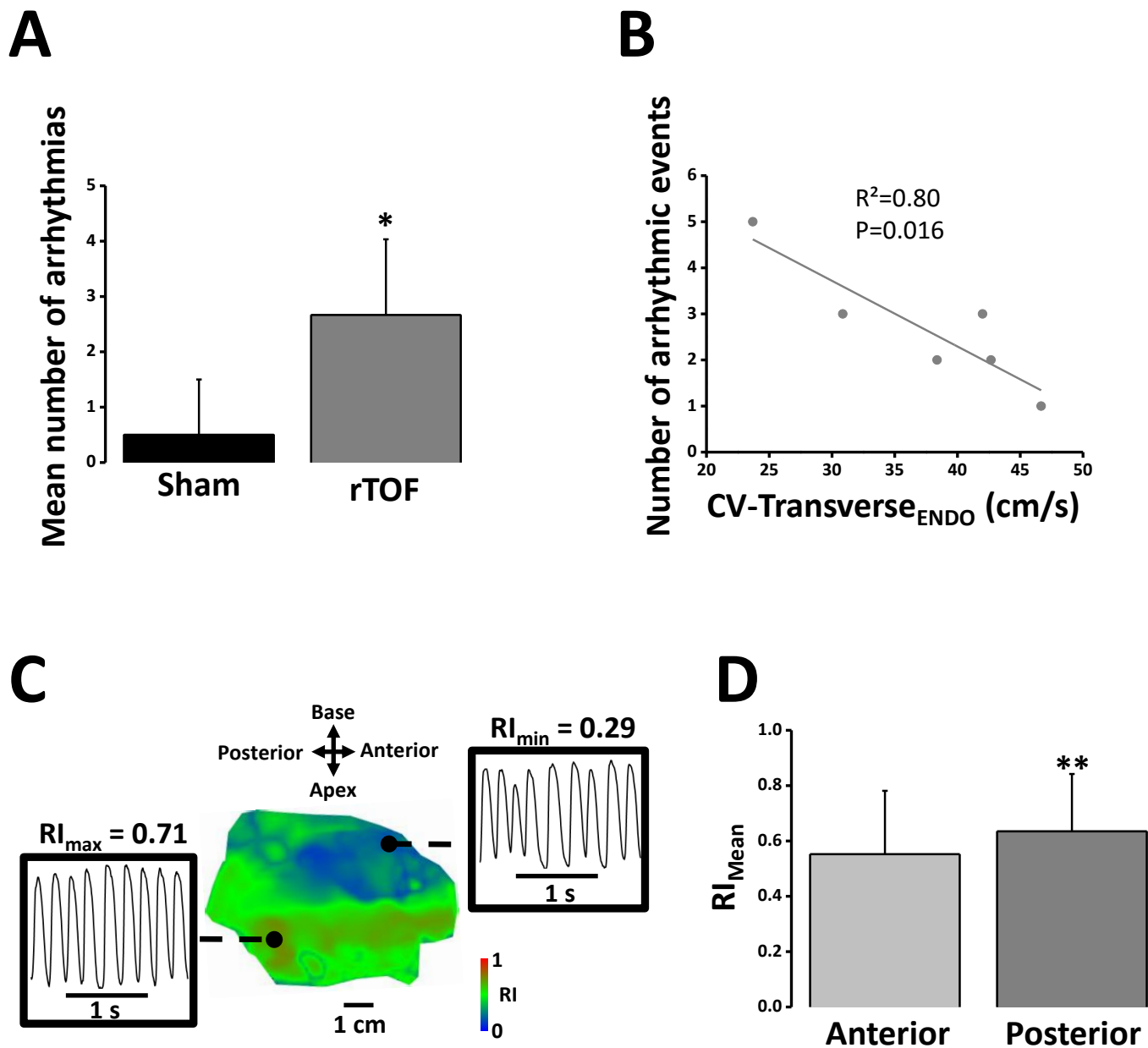


Figure 7



## **SUPPLEMENTAL MATERIAL**

**TITLE: Arrhythmogenic Remodeling of the Right Ventricle in a Porcine Model of Repaired Tetralogy of Fallot**

**Authors:** David Benoist, PhD; Virginie Dubes, MSc; François Roubertie, MD; Stephen H. Gilbert, PhD; Sabine Charron, MSc; Marion Constantin, MSc; Delphine Elbes, PhD; Delphine Vieillot, TA; Bruno Quesson, PhD; Hubert Cochet, MD, PhD; Michel Haïssaguerre, MD; Caroline Rooryck, MD, PhD; Pierre Bordachar, MD, PhD; Jean-Benoit Thambo, MD, PhD; Olivier Bernus, PhD

## **SUPPLEMENTAL METHODS**

### **Animal Model**

The animal model of repaired TOF (rTOF N=6) was produced as previously described<sup>1</sup>. Briefly, Large White piglets (< 12kg) were pre-medicated with ketamine (10 mg/kg, IM, Vibrac) and acepromazine (0.1 mg/kg, Vetoquinol). Anesthesia was induced with sodium pentobarbital (5 mg/kg, IV, Ceva) and maintained with isoflurane (2% in 100% O<sub>2</sub>, Vibrac) after endotracheal intubation. The anterior side of the heart was accessed by lateral thoracotomy. The pulmonary artery was longitudinally clamped, a 2 cm incision was made across the pulmonary annulus and 2 pulmonary valve leaflets were excised. A PTFE patch was sewn across the annulus and pulmonary artery banding was performed using a loose-tied tape (2 cm diameter). For sham-operated animals, only the lateral thoracotomy was performed (Sham N=4). At the end of the procedure, piglets received supplemental oxygen and analgesia as appropriate before their transfer to the animal house. Cardiac function and remodeling was assessed 23 ± 1 weeks post-surgery as detailed below.

### **Cardiac Magnetic Resonance Imaging**

Pigs were pre-medicated and anaesthetized as described above. A conventional cardiac magnetic resonance (CMR) examination was carried out as described in Bogaert et al<sup>2</sup>, using a Siemens Magnetom Avanto 1.5T MRI scanner (Erlangen, Germany) with maximum gradient strength of 200 mT/m and a slew rate of 45 mT/m/ms. Briefly, pigs were placed in dorsal recumbancy (supine) and ECG leads placed after shaving and hair removal with thioglycolic acid/KOH cream (Veet, Reckitt Benckiser, UK) and the telemetric vector electrocardiogram was used for gating of the Siemens CMR sequences. All images were taken during end-expiratory ventilation stop. Localizer views were followed by right-ventricular short-axis TrueFISP cine-image stacks (from the cardiac apex to the level of the pulmonary valve) under manual-breathhold. For pulmonary artery flow measurement phase-contrast MRI was carried out under manual-breathhold with the velocity encoding (VENC) set to 130

cm/s and the acquisition plane set parallel to and 1 cm above the pulmonary valve plane. CMR analysis was performed by a single investigator. Quantification of ventricular function was carried out using the Siemens syngo ARGUS Ventricular Function software package with manual drawing of a right ventricular endocardial contour, from which RV end-systolic, end-diastolic, stroke volume and ejection fraction were determined. These values were indexed to body surface area (BSA) using the equation from Kelley et al<sup>3</sup>. The pulmonary regurgitation fraction was calculated using the Siemens syngo ARGUS Flow software package with the rephased images used to draw the analysis ROI and quantification calculated from the phase images. Pulmonary regurgitation fraction was calculated as the ratio of pulmonary retrograde to antegrade flow volume (expressed as a percentage)<sup>4</sup>.

#### **Euthanasia and cardiac harvesting**

Following a median sternotomy to expose the heart, animals received an intravenous dose of heparin (200 UI/kg, PanPharma) and were euthanised by injection of sodium pentobarbital (10 mL from 200 mg/ml stock). The heart was quickly excised, the aorta cannulated and the myocardium flushed with an ice-cold cardioplegic solution containing (in mM): 110 NaCl, 1.2 CaCl<sub>2</sub>, 16 KCl, 16 MgCl<sub>2</sub>, 10 NaHCO<sub>3</sub>, 9 Glucose supplemented with Heparin (2500 UI/L). The heart and, after careful dissection, the RV wall were weighed.

#### **Optical mapping of cardiac electrical activity**

The right coronary artery was cannulated at the ostium level and perfused with cardioplegic solution while suturing major arterial leaks. The RV was installed in a chamber, immersed and perfused (20 mL/min) with a modified Krebs-Henseleit solution (37°C) containing (in mM): 130 NaCl, 24 NaHCO<sub>3</sub>, 1.2 NaH<sub>2</sub>PO<sub>4</sub>, 1 MgCl<sub>2</sub>, 5.6 Glucose, 4 KCl, 1.8 CaCl<sub>2</sub> constantly gassed with 95% O<sub>2</sub> - 5% CO<sub>2</sub>. The preparation was electrically stimulated in the mid-free wall region using bipolar electrodes at 1.5 time threshold. Contraction was abolished using the electro-mechanical uncoupler blebbistatin (10 µM, Enzo Life Sciences) before loading with a 10 µM bolus of di-4-ANEPPS (Biotium). The dye was

excited using 530 nm LEDs and the voltage-sensitive fluorescent light separated using a  $650 \pm 50$  nm filter. Fluorescent signals were recorded subsequently from the epi- and endocardial surfaces at 1 kHz using a MiCam Ultima CMOS camera (SciMedia USA Ltd) with a spatial resolution of 1 x 1 mm. Pacing frequency was increased from 1 Hz to 5 Hz by 0.5 Hz increments to construct restitution curves and arrhythmias occurring during these protocols were quantified. Prior to data analysis, background fluorescence was subtracted and signals were filtered (3 x 3 spatial and 3 x 3 cubic filter). A mask was applied to the camera image in order to remove noisy areas due to remaining epicardial adhesions. Action potential duration was measured at 20% (APD20) and 80% repolarization (APD80) in 5 x 5 mm regions set on the anterior and posterior side of the RV at mid-height between base and apex. APD80 dispersion was calculated as the difference between the 95<sup>th</sup> and the 5<sup>th</sup> percentile of the APD80 distribution across the RV. Transmural APD20 and APD80 gradient (APD<sub>ENDO-EPI</sub> gradient) was obtained by subtracting the epicardial APD from the endocardial value of the same region. RV posterior to anterior APD20 and APD80 gradient (APD<sub>POST-ANT</sub> gradient) was calculated for the epicardium and the endocardium by subtracting anterior APD to the posterior value. Local activation times were calculated at 50% of the action potential upstroke and total epicardial and endocardial activation time was calculated as the time difference between the earliest and the latest activation time across each RV surface. Conduction velocity was measured at proximity of the pacing site by measuring the distance covered by the wavefront over a 20 ms interval in the direction of fast (longitudinal) and slow (transverse) propagation. Arrhythmia dominant frequency was assessed by Fourier transform analysis and regularity index calculated as the transform power at the dominant frequency normalized to total power.

### **Histological studies**

Immediately after RV dissection, transmural blocks (1.5 x 1.5 cm) of myocardium were taken from the apex of the RV and fixed in 4% paraformaldehyde (Sham, rTOF N=4). The samples were then dehydrated by successive immersions into increasing (70%, 90%, 100%) ethanol concentrations,

rinned with Toluene, embedded in paraffin and stored at -20°C until use. After serial transmural sectioning of the sample (8 µm thickness), sections were mounted on slides and stained with Masson's Trichrome using a HMS 70 slide stainer. Images were obtained at a 10X magnification on a Nikon Eclipse 80i microscope equipped with a CCD camera and saved using NIS Elements 3.2 software. Analysis was performed blindly by color thresholding using ImageJ software. Blue-stained areas corresponding to collagen were expressed as a percentage of the section total area. Perivascular and epicardial collagen staining were excluded from the quantification.

### **Western blot**

Tissue samples were homogenized in RIPA buffer (Sigma Aldrich) supplemented with proteases and phosphatases inhibitor cocktails (Sigma Aldrich) and sonicated. Proteins were then extracted by centrifugation at 12 000 g for 15 min at 4°C, their concentration determined by bicinchoninic acid assay (Thermo Scientific) and kept at -80°C until use. Proteins (50 µg) were separated on 12% acrylamide gels (TGX Stain-Free precast gels, Bio-Rad), under reducing conditions followed by semi-dry transfer (Trans-blot Turbo, Bio-Rad). PVDF membranes were then probed with primary antibodies (Connexin-43, 1:500, Sigma-Aldrich; Kv4.3, 1:200, Merck Millipore) overnight followed by secondary antibodies (Goat anti-rabbit, 1:2000, Bio-Rad). Following total hybridized protein imaging under UV light, Connexin-43 and Kv4.3 specific signals were revealed by enhanced chemiluminescence (Thermo Scientific). Signal quantification was performed using ImageJ (NIH) and specific band intensity was normalized to the total protein intensity of each lane.

### **RNA extraction**

Total RNA was extracted from tissues using QIAzol reagent (Qiagen, USA). RNA was purified and DNase-treated using a Qiagen RNeasy® Kit. RNA purity and integrity, were assessed both by spectrophotometry (NanoDrop ND-1000, NanoDrop Technologies) and nanoelectrophoresis (2100 Bioanalyzer, Agilent Technologies).

### **Quantitative RT-PCR of ion channels**

Sequences for primers were obtained from Ensembl Genome Browser. Primers were designed using Primer designing tool (NCBI) and synthesized at Sigma Aldrich. 1µg of RNA was reversed transcribed using a cDNA Reverse Transcription kit (Life Technologies) according to the manufacturer's protocol. Quantitative PCR was performed in a 25 µL reaction volume (2 µL cDNA, 12,5 µL of SYBR® Premix (BIO-RAD), a volume of 10 µM upstream and downstream primers respectively, and added ddH<sub>2</sub>O to 25 µL) on the Bio-Rad C 100 Touch Thermal Cycler / CFX96 Real time System. Real-time PCR conditions were as follows: 3 min at 95.0 °C, 40 cycles of denaturation at 95 °C for 30 s followed by 30 s annealing and elongation at 60 °C. Efficiency of primer pairs was previously evaluated. Melting curves were obtained at the end of each run to confirm a single PCR product. All samples were run in triplicate. Non-template controls were included in each run to exclude contamination and nonspecific amplification. Expression levels of samples were normalized by using a normalization factor calculated by the software CFX Manager (Bio-Rad). This normalization factor was calculated based on RT-qPCR results for two selected reference genes, *HPRT1* and *GUSB*.

### **Microarray profiling of RV endocardium gene expression**

cDNA was synthesized from 200 ng of total-RNA using the direct cDNA Labeling System. Aminoallyl-cRNA was synthesized from cDNA using the Superscript Indirect cDNA Labeling System. The cRNA was purified using RNeasy QIAGEN RNeasy® Kit.

Labeling and hybridization of the cRNA was performed with Agilent Whole Porcine Genome Oligo Microarrays (one-color platform), according to the manufacturer's protocols. The slides were scanned and analyzed using the histogram method with default settings in an Agilent G2565C Microarray Scanner System with SureScan Technology. Analysis of microarray data was performed using Genespring® software (Agilent Technologies), with a p-value corrected by Benjamini Hochberg False Discovery Rate (FDR).

**Data analysis**

Data are expressed as means  $\pm$  SD. Statistical analysis was performed using SigmaStat software. Statistical differences between groups were tested using unpaired or paired Student tests or their non-parametric equivalent and linear regression as appropriate. Statistically significant difference was assumed for  $P < 0.05$ .

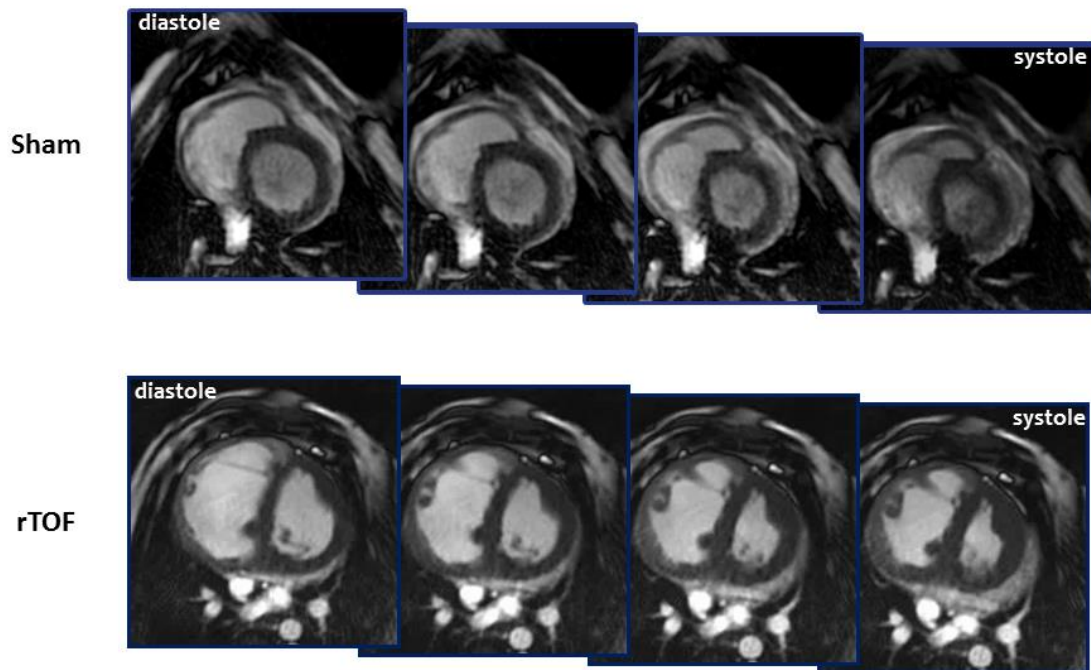
## SUPPLEMENTAL TABLES

| Gene Symbol  | Gene description                                 | Fold Change | Regulation |
|--------------|--|-------------|------------|
| BNP          | Brain natriuretic peptide                        | 13.5        | Up         |
| FRZB         | Frizzled-related protein                         | 9.2         | Up         |
| KRT18        | Keratin 18                                       | 6.5         | Up         |
| CILP         | Cartilage intermediate layer protein             | 4.9         | Up         |
| FGF9         | Fibroblast growth factor 9                       | 3.9         | Up         |
| CTHRC1       | Collagen triple helix repeat containing 1        | 3.6         | Up         |
| COL8A1       | Collagen type VIII, alpha 1                      | 3.1         | Up         |
| TNC          | Tenascin-C                                       | 2.9         | Up         |
| GHRH         | Growth hormone releasing hormone                 | 2.8         | Up         |
| PN-1         | Nexin-1  | 2.8         | Up         |
| MT1A         | Metallothionein 1A                               | 2.7         | Up         |
| COMP         | Cartilage oligomeric matrix protein              | 2.5         | Up         |
| MMP11        | Matrix metalloproteinase 11                      | 2.4         | Down       |
| INHA         | Inhibin, alpha                                   | 2.2         | Up         |
| LGALS1       | Lectin galactoside-binding, soluble              | 2.2         | Up         |
| HYAL1        | Hyaluronoglucosaminidase                         | 2.1         | Up         |
| IGFBP2       | Insulin-like growth factor binding protein 2     | 2.1         | Up         |
| IL18         | Interleukin 18                                   | 2           | Up         |
| SERPINE1     | Serpin peptidase inhibitor, clade E, member 1    | 2           | Up         |
| MAP2K1       | Mitogen-activated protein kinase kinase 1        | 1.6         | Up         |
| LOC100627866 | Transforming growth factor beta regulator 1-like | 1.5         | Up         |
| KLF6         | Kruppel-like factor 6                            | 1.4         | Down       |

**Supplemental Table 1 – Microarray analysis of extracellular matrix-related gene expression in the anterior RV endocardium.** Changes in gene expression were determined in rTOF and Sham endocardial samples from the anterior RV using cRNA microarrays. Twenty-two genes constitutive or regulating the extracellular-matrix were differentially expressed (up- or down-regulated) in the rTOF compared to Sham with a fold change between 1.4 and 13.5. Corrected p-values < 0.05 for all 22 genes. Sham N=5, rTOF N=7.

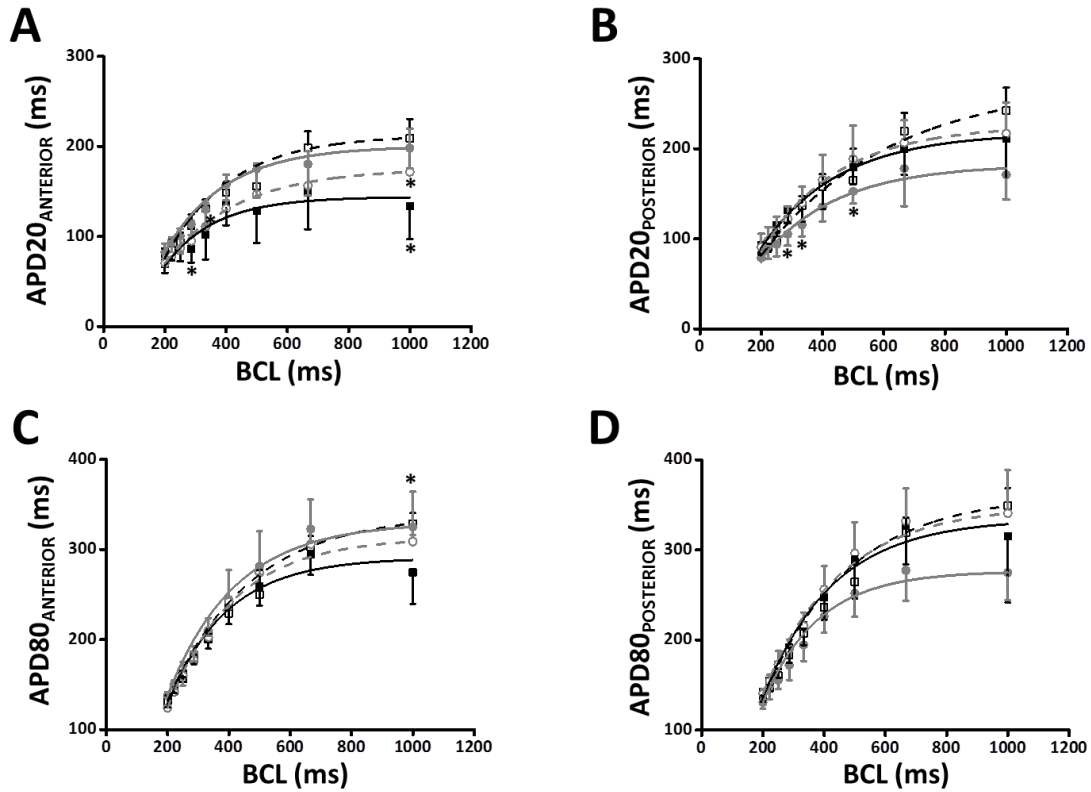


## SUPPLEMENTAL FIGURES



### Supplemental Figure 1 – Sequential images of a Sham and rTOF heart during a cardiac cycle.

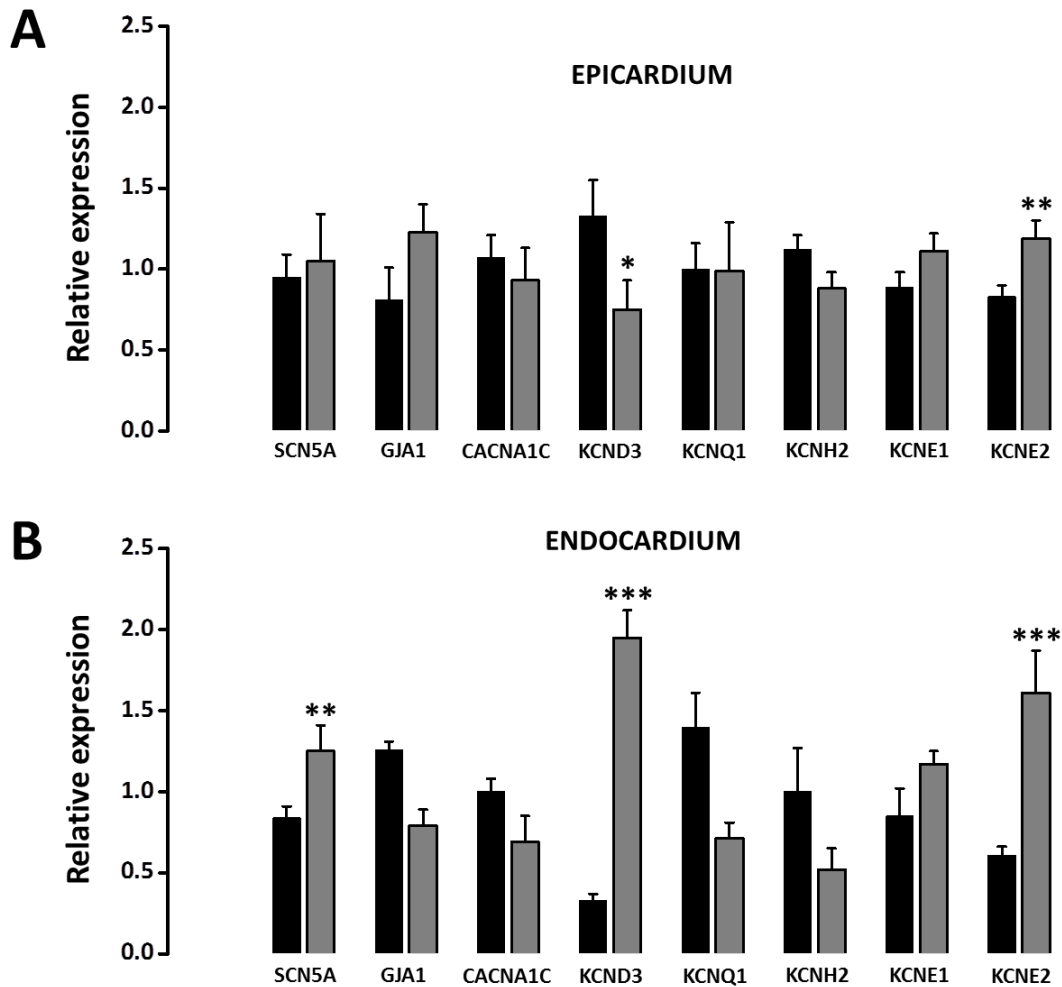
Cardiac MRI (cMRI) equatorial short axis slices from a cine loop of the heart of a Sham and a rTOF pig showing evenly temporally separated images from diastole (left panel) to systole (right panel). RV hypertrophy and dilatation can be observed in rTOF images. Note the presence of a leftward interventricular septum bulging in rTOF images.



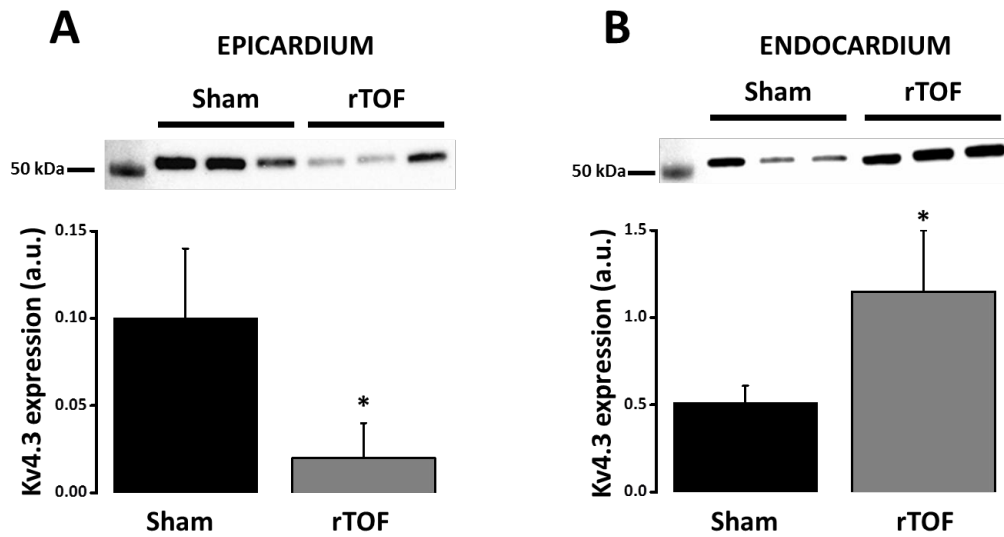
**Supplemental Figure 2 – Regional action potential duration restitutions in Sham and rTOF RVs.**

APD20 restitution in the RV anterior (A) and posterior (B) regions of Sham (black) and rTOF (grey) epicardium (solid lines) and endocardium (dashed lines). APD80 restitution in the RV anterior (C) and posterior (D) regions of Sham and rTOF (grey) epicardium (solid lines) and endocardium (dashed lines). APD20 and APD80 restitution properties were similar for both groups in all regions with the exception of rTOF posterior epicardial APD20 values that became significantly shorter than in Sham.

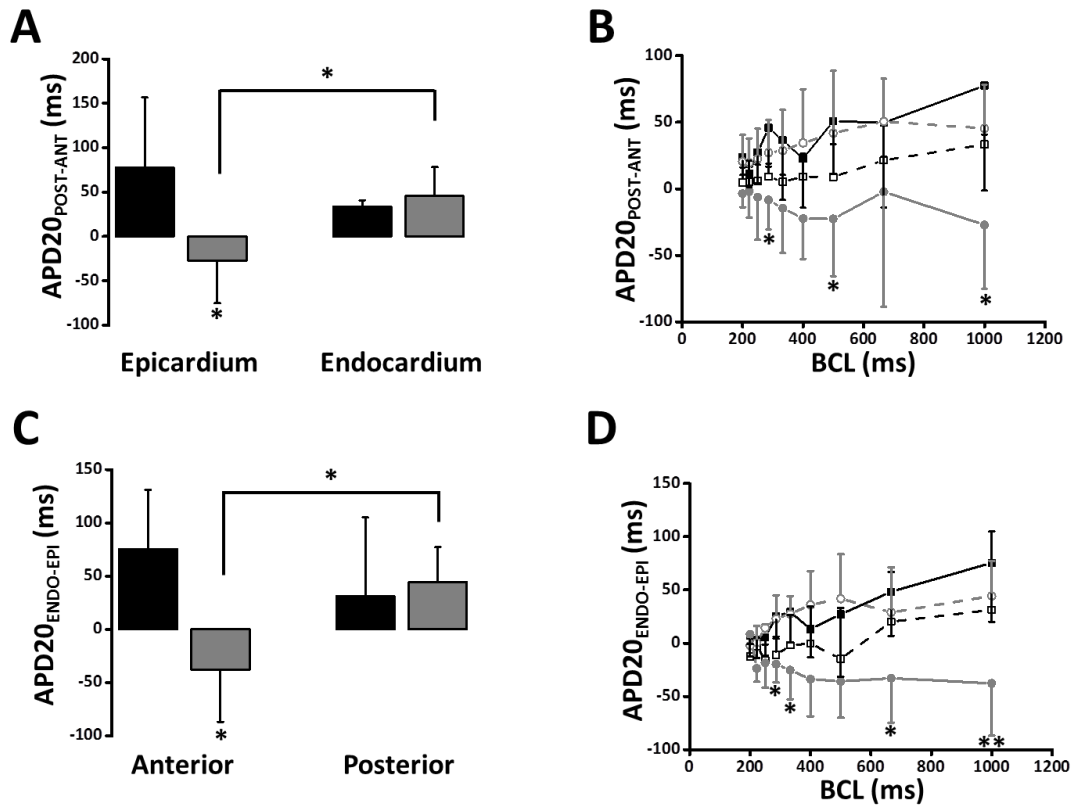
Data are means  $\pm$  SD. \*  $P < 0.05$  Sham vs. rTOF in the epicardium. Sham N=4, rTOF N=5-6.



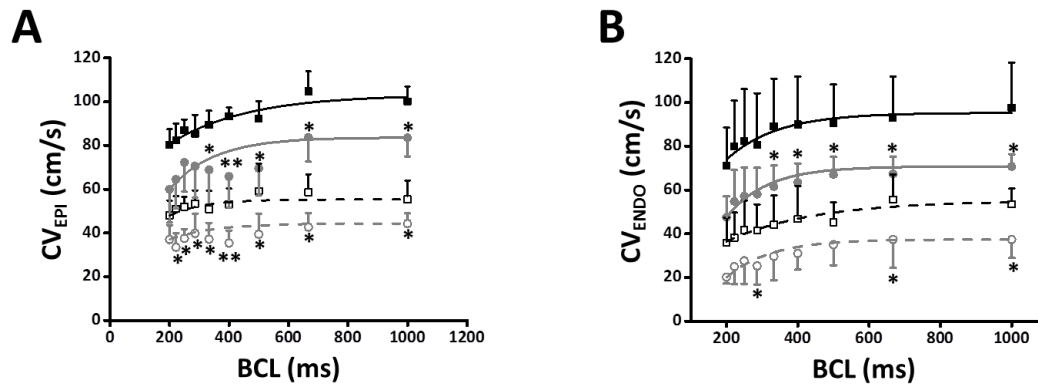
**Supplemental Figure 3 – mRNA expression of the main ventricular ion channels in the anterior RV of Sham and rTOF pigs.** (A) In the epicardium, the expression of KCND3 (Kv4.3) was significantly downregulated and KCNE2 (MiRP1) was significantly upregulated in rTOF (grey) compared to Sham (black) RVs. (B) In the endocardium, mRNA levels for SCN5A (Nav1.5), KCND3 and KCNE2 were significantly increased in rTOF compared to Sham RVs. Note the difference in transmural regulation of KCND3. Transcript expression was normalized to the expression of GUSB and HPRT1. Data are means  $\pm$  SD. \*  $P < 0.05$ , \*\*  $P < 0.01$ , \*\*\*  $P < 0.001$ , Sham N=5, rTOF N=7.



**Supplemental Figure 4 – Kv4.3 protein expression in the anterior endocardium of Sham and rTOF RVs.** Kv4.3 expression was decreased in the anterior epicardium (**A**) but increased in the endocardium (**B**) of rTOF RVs (grey) compared to Sham (black). Kv4.3 band intensity was normalized to total hybridized proteins (see Methods). Data are means  $\pm$  SD. \*  $P < 0.05$ , Sham  $N=3$ , rTOF  $N=3$ .



**Supplemental Figure 5 – APD20 gradients in the right ventricle of Sham and rTOF pigs.** (A) RV antero-posterior APD80 gradient ( $APD20_{POST-ANT}$ ) was reversed in rTOF (grey) epicardium and significantly different from Sham (black) epicardial and rTOF endocardial gradients at 1 Hz pacing frequency. (B) RV Antero-posterior APD20 gradient at different basic cycle lengths (BCL) from Sham (black) epicardium (solid line), endocardium (dashed line); and rTOF (grey) epicardium (solid line) and endocardium (dashed line). (C) RV transmural APD20 gradient ( $APD20_{ENDO-EPI}$ ) was reversed and significantly different from Sham in the anterior region while remaining unchanged in rTOF posterior region upon pacing at 1 Hz. (D) RV transmural APD20 gradient at different BCL from Sham anterior, posterior RV; and rTOF anterior and posterior RV. Data are means  $\pm$  SD. \*\*  $P < 0.01$ , \*  $P < 0.05$ , Sham  $N=4$ , rTOF  $N=5-6$ .



**Supplemental Figure 6 – Conduction velocity restitutions in Sham and rTOF RVs.** Epicardial (A) and endocardial (B) restitution of conduction velocity measured at various cycle lengths (BCL) in the longitudinal (solid lines) and transverse (dashed lines) directions in rTOF (grey) and Sham (black). Conduction velocities in the longitudinal and transverse directions were lower in rTOF than in Sham RVs over a range of pacing frequencies. Data are means  $\pm$  SD. \*\*  $P < 0.01$ , \*  $P < 0.05$ , Sham  $N=4$ , rTOF  $N=5-6$ .

## SUPPLEMENTAL REFERENCES

1. Thambo JB, Roubertie F, De Guillebon M, Labrousse L, Iriart X, Ntsinjana H, Lafitte S, Ploux S, Haissaguerre M, Roques X, Dos Santos P, Bordachar P. Validation of an animal model of right ventricular dysfunction and right bundle branch block to create close physiology to postoperative tetralogy of Fallot. *International journal of cardiology* 2012;**154**:38-42.
2. Bogaert J. Cardiac Function. In: Bogaert J, Dymarkowski S, Taylor AM, Muthurangu V, eds. *Clinical Cardiac MRI*, Springer ed: Springer, 2012:109-165.
3. Kelley KW, Curtis SE, Marzan GT, Karara HM, Anderson CR. Body surface area of female swine. *Journal of animal science* 1973;**36**:927-930.
4. Bove T, Bouchez S, De Hert S, Wouters P, De Somer F, Devos D, Somers P, Van Nooten G. Acute and chronic effects of dysfunction of right ventricular outflow tract components on right ventricular performance in a porcine model: implications for primary repair of tetralogy of fallot. *Journal of the American College of Cardiology* 2012;**60**:64-71.

## 5.4 Modification « accidentelle » de notre modèle animal : internalisation du cerclage du tronc de l'artère pulmonaire.

### 5.4.1 Introduction

Après avoir mis au point et validé notre modèle de gros animal mimant une TF réparée, d'autres séries d'animaux ont été opérées pour réaliser diverses recherches, comme la resynchronisation en aigue (1). Au départ, les animaux étaient opérés à la Plateforme Technologique d'Innovation Biomédicale (PTIB) de Bordeaux rattachée à l'unité INSERM 1034. Une fois opérés, les animaux étaient rapatriés dans une ferme située dans les Landes, où ils séjournaient entre 3 et 4 mois. Les conditions et les règles d'expérimentation sur les animaux se sont durcies en 2013, et la ferme qui hébergeait les animaux opérés a perdu ses accréditations. Nous nous sommes alors rapprochés de l'INRA de Poitiers, et après 18 mois d'interruption, nous avons pu reprendre nos recherches.

L'environnement chirurgical était totalement différent à Poitiers : l'INRA était spécialisée dans la génétique de la reproduction chez les porcins; aucune intervention de chirurgie « lourde » n'avait été réalisée là bas. Nous avons donc transporté un mini bloc opératoire sur ce site : respirateur autonome, seringues électriques, différents scopes de surveillance, bistouri électrique, matériels chirurgicales, système d'aspiration autonome, l'ensemble du consommable, etc. Nous avons eu la chance cependant que l'INRA possède une salle à double flux (salle d'insémination).

Je remercie d'ailleurs l'ensemble des acteurs qui ont participé à de très nombreuses reprises à cette « aventure » : le Dr. Abdelmoumen (anesthésiste dans le service de chirurgie adulte) et l'ensemble des assistants de chirurgie qui nous ont accompagné à tour de rôle pour nous aider. L'ensemble du personnel de l'INRA de Poitiers a été aussi très professionnel et très aidant.

Nous avons pu réaliser la chirurgie dans de bonnes conditions ; la mortalité péri-opératoire est restée très basse. Nous avons cependant changé le mode de réalisation du cerclage sur notre modèle, ceci lié aux conditions locales : nous avons mis en place autour du tronc de l'artère pulmonaire un cerclage du type fil non résorbable (fil tressé en polyester) (Ti-Cron 5 (Covidien, Mansfield, MA)) ; à



Bordeaux, nous avons utilisé des bandelettes de Goretex pour réaliser le cerclage. Nous ne pensons pas que cela modifierait les résultats.

### **5.4.2 Résultats**

Nous avons opéré trois groupes d'animaux à un poids moyen de 12 kg.:

- un groupe TF avec patch trans-annulaire + cerclage peu serré (n=4)
- un groupe IP avec patch trans-annulaire isolé (n=4)
- et un groupe contrôle Sham (n=4)

Les animaux ont été revus et évalués en moyenne 4 mois après la première chirurgie. Les données échocardiographiques et IRM retrouvaient une IP importante chez les animaux TF et IP par rapport au Sham, de même qu'une dilatation importante du VD et une altération de la fonction ventriculaire droite. L'échocardiographie ne retrouvait pas de sténose significative au niveau du tronc de l'artère pulmonaire (pas de différence entre les groupes TF et IP).

L'examen macroscopique des cœurs prélevés retrouvait une dilatation et un poids plus important des cœurs des groupes TF et IP ; les cœurs du groupe TF étaient significativement plus lourds que les cœurs du groupe IP.

Le reste de l'examen macroscopique a mis en évidence une internalisation du cerclage à l'intérieur du tronc de l'artère pulmonaire : avec un fil de cerclage parfaitement intact. Ceci expliquait l'inefficacité de ce cerclage. Une analyse histologique a donc été réalisée sur les troncs d'artère pulmonaire des animaux TF, qui a montré une désorganisation de la média en regard de l'ancien cerclage avec une fibrose cicatricielle. La paroi vasculaire était le siège d'une présence de cellules inflammatoires, et d'une désorganisation des cellules musculaires et des fibres élastiques. En amont du cerclage, on mettait en évidence une hypertrophie musculaire démontrant que le cerclage avait été efficace un certain temps.

### **5.4.3 Conclusion**

Nous avons rapporté ici une complication non attendue chez notre modèle animal. Ce phénomène a exceptionnellement été décrit dans la littérature en pratique clinique (2, 3), jamais sur un modèle animal (4). L'internalisation d'un cerclage réalisé autour de la crosse de l'aorte, a été décrite une fois en recherche, sur un modèle de souris d'hypertrophie ventriculaire gauche (5). Nous suspectons un mécanisme inflammatoire lié au fil pour expliquer ce phénomène.

Nous avons, sans le vouloir, créer un modèle qui se rapproche plus de ce qu'on observe actuellement en pratique clinique après cure complète de TF : la stratégie aujourd'hui étant de tolérer une sténose modérée postopératoire pour limiter la fuite pulmonaire (6). Rapidement cette sténose va s'estomper avec la croissance de l'enfant, pour ne laisser qu'une fuite pulmonaire modérée à sévère comme celle retrouvée dans notre groupe animal TF.

#### 5.4.4 Références

1. Thambo JB, Dos Santos P, De Guillebon M, Roubertie F et al. Biventricular stimulation improves right and left ventricular function after tetralogy of Fallot repair: acute animal and clinical studies. *Heart Rhythm*. 2010 ;7:344-50.
2. Danilowicz D, Presti S, Colvin S. The Disappearing Pulmonary Artery Band. *Pediatr Cardiol* .1990;11:47-49.
3. Schmidt-Habelmann P, Sivening F Erfahrungen mit der bandelung der pulmonal-arterie. *Thoraxchirurgie*.1966;14:541-5.
4. Lambert V, Gouadon E, Capderou A, Le Bret E, Ly M, Dinanian S et al. Right ventricular failure secondary to chronic overload in congenital heart diseases: benefits of cell therapy using human embryonic stem cell-derived cardiac progenitors. *J Thorac Cardiovasc Surg*. 2015;149:708-15.
5. Lygate CA, Schneider JE, Hulbert K, ten Hove M, Sebag-Montefiore LM, Cassidy PJ et al. Serial high resolution 3D-MRI after aortic banding in mice: band internalization is a source of variability in the hypertrophic response. *Basic Res Cardiol*. 2006;101:8-16.
6. Bacha E. Valve-sparing options in tetralogy of Fallot surgery. *Semin Thorac Cardiovasc Surg Pediatr Card Surg Annu*. 2012;15:24-6.

### **5.4.5 Perspectives de recherche**

Nous allons poursuivre nos recherches en utilisant la même technique de cerclage (internalisation) sur quelques animaux. Nous essaierons de mieux comprendre le phénomène d'internalisation en multipliant les échocardiographies. Au printemps 2016, nous devrions pouvoir réaliser nos recherches directement sur le site du LIRYC à Bordeaux et garder les animaux opérés sur ce même site, ce qui facilitera la surveillance.

**Title: Unexpected internalisation of a pulmonary artery band in a porcine model of tetralogy of Fallot**

**Authors:** François Roubertie, MD <sup>1,2,\*</sup>; Zakaria Jalal, MD <sup>1,2,\*</sup>; Emmanuelle Fournier, MD <sup>1,2</sup>; Virginie Dubes <sup>2</sup>; David Benoist, PhD<sup>2</sup>; Jerome Naulin <sup>2</sup>; Samantha Delmond <sup>3</sup>; Michel Haissaguerre, MD, PhD<sup>1,2</sup>; Olivier Bernus, PhD<sup>2</sup>; Jean-Benoit Thambo, MD, PhD<sup>1,2</sup>

<sup>1</sup> University Hospital of Bordeaux – Department of Paediatric and Adult Congenital Heart Defects, Pessac, France.

<sup>2</sup> L'Institut de Rythmologie et Modélisation Cardiaque LIRYC, Université de Bordeaux, Pessac, France; Inserm U1045 CRCTB, Université de Bordeaux, Bordeaux, France.

<sup>3</sup> University Hospital of Bordeaux, CIC 1401, Bordeaux, France.

\* François Roubertie and Zakaria Jalal contributed equally to this work

**Corresponding author:** Zakaria Jalal, MD

University Hospital of Bordeaux, Avenue Magellan - 33600 Pessac, France

Telephone: 00 33 5 57 65 64 65

Fax: 00 33 5 57 65 68 28

E-mail: jalalzakaria1@gmail.com

**Word count:** 3500 (excluant abstract et réf)

**Conflict of interest:** The authors have no conflict of interest.

**Funding:** None

**ARTICLE soumis au Journal of Thoracic and Cardio-Vascular Surgery**

**ABSTRACT**

**Objective:** To report our experience of an unexpected internalization of a pulmonary artery band in the vascular lumen, which occurred in a chronic porcine model of repaired tetralogy of Fallot (TOF).

**Methods:** Fourteen piglets were divided into 3 groups: (1) TOF animals (pulmonary artery band plus pulmonary valvotomy); (2) PI animals (pulmonary valvotomy) and (3) control animals. A non-absorbable coated braided polyester was used to perform the pulmonary banding instead of a Gore-Tex band. Echocardiography and magnetic resonance imaging were performed 4 months post operatively. After animal sacrifice, pulmonary artery histological analysis was performed in animals with band internalization.

**Results:** Significant postsurgical pulmonary regurgitation and right ventricular enlargement were present in the TOF and PI, compared with control animals while no significant pulmonary stenosis was observed in TOF animals when compared with PI group. Post-mortem examination of all TOF animals revealed the constricting band to be intact, but partially internalized into the pulmonary artery lumen, allowing blood flow around the stenosis. Histological sections of band pulmonary artery in the internalized area showed a significant disorganisation of the medial layer with a large scarring and fibrosing reaction surrounding the outside of the band and presence of inflammatory cells suggesting a significant inflammatory response during band internalization.

**Conclusions:** Band internalization may occur after pulmonary artery banding using a non-absorbable coated braided polyester in a chronic porcine model of repaired TOF. This unusual complication was likely due to the type of material used for banding.

**Words: 244**

**Glossary of abbreviations**

TOF: tetralogy of Fallot

RV: right ventricular

PA: pulmonary artery

RVOT: right ventricular outflow tract

PI: pulmonary valve insufficiency

MRI: magnetic resonance imaging

SHAM: sham-operated

PR: pulmonary regurgitation

## **INTRODUCTION**

Tetralogy of Fallot (TOF) is known to be the most common form of cyanotic congenital heart disease, accounting for approximately 10% of heart defects (1). Although surgical repair has improved the overall survival, operated patients are prone to develop late complications such as right ventricular (RV) dysfunction, life-threatening ventricular arrhythmias, major electrical conduction disorders and sudden death (2,3). The desire to identify and to stratify patients' risk has prompted investigation into potential mechanisms leading to the development of delayed adverse events.

In order to better understand the pathophysiology of these long-term complications, our team characterized a chronic porcine model that mimicked essential parameters of postoperative TOF (4,5). The index operation was designed to cause (1) RV pressure overload by a loose Gore-Tex tape partially occluding the main pulmonary artery (PA), (2) RV volume overload from pulmonary regurgitation by excision of two pulmonary valvular leaflets and (3) RV outflow tract (RVOT) scar around the patch placed to close the RV incision. Therefore, it has been validated as a reliable long-term model of RV dysfunction and dyssynchrony, with echocardiographic and ECG measurements comparable to adult patients with repaired TOF.

On this model, we first demonstrated favourable hemodynamic effects conferred by acute bi-ventricular stimulation in chronic RV dysfunction and we recently characterized the global gene expression profiling in the heart after TOF repair (4,6).

However, a subset of patients undergoes TOF surgical repair using large trans-annular RVOT patch, resulting in isolated pulmonary insufficiency (PI) and chronic volume overload without significant stenosis (7). In order to investigate the differences in terms of electrophysiological ventricular remodelling between these 2 hemodynamic settings (i.e. RV pressure and volume overload versus isolated RV volume overload), we designed a study comparing 2 groups of operated pigs: TOF pigs and animals with isolated PI. Surprisingly, we observed in TOF pigs



Article soumis : JTCS : pulmonary band internalisation

a complete internalization of the pulmonary band, resulting in disappearance of RVOT gradient and RV pressure overload. In this paper, we sought described the clinical and histological characteristics of this unusual complication of PA banding.

## **METHODS**

The experimental protocol followed the European rules for animal experimentation (European legislation 2010/63/UE—2010), which was implemented under French legislation from February 2013 and following which, all animal experimental protocols, including the present study, at our Institution were reviewed and approved by the local Ethics Committee “*Comité d’Ethique en Expérimentation Animale de Bordeaux—CEE50*”. The experimental protocols were in compliance with the *Guiding Principles in the Use and Care of Animals* published by the National Institutes of Health (NIH Publication No. 85–23, Revised 1996).

### **Animal Model**

The animal model of repaired TOF (rTOF N=4) was produced as previously described (4). Briefly, Large White piglets (< 12kg) were pre-medicated with ketamine (10 mg/kg, IM, Vibrac) and acepromazine (0.1 mg/kg, Vetoquinol). Anesthesia was induced with sodium pentobarbital (5 mg/kg, IV, Ceva) and maintained with isoflurane (2% in 100% O<sub>2</sub>, Vibrac) after endotracheal intubation. The anterior side of the heart was accessed by muscle-sparing left lateral thoracotomy. The pulmonary artery was longitudinally and partially clamped, a 2 cm incision was made across the pulmonary annulus and one or two pulmonary valve leaflets were excised. A polytetrafluorethylene patch was sewn across the annulus, and a pulmonary artery banding was performed using a loosely nonabsorbable coated braided polyester (Ti-Cron (Covidien, Mansfield, MA)) for TOF animals (n = 4). PI animals (n = 4) underwent only a trans-annular patch with one or two leaflets excised.

For sham-operated animals, only the left lateral thoracotomy was performed (n = 4). At the end of the procedure, piglets received supplemental oxygen and analgesia as appropriate before their transfer to the animal house. Cardiac function and remodeling were assessed 114 ± 3 days post-surgery as detailed below.

### **Echocardiography**

Transthoracic echocardiography was performed with a Vivid 7 digital ultrasound system (GE/VingMed, Horten, Norway). The pulmonary annulus was measured at the maximal pulmonary valve opening during systole. The presence of pulmonary stenosis or regurgitation was visualized using color Doppler flow. Transpulmonary gradient through the pulmonary band was evaluated by continued Doppler flow. The tricuspid/mitral diameters ratio was calculated from tricuspid and mitral annulus diameters measured at the maximal valve opening during diastole.

### **Cardiac Magnetic Resonance Imaging**

Pigs were pre-medicated and anaesthetized as described above. A conventional cardiac magnetic resonance (CMR) examination was carried out using a Siemens Magnetom Avanto 1.5T MRI scanner (Erlangen, Germany) with maximum gradient strength of 200 mT/m and a slew rate of 45 mT/m/ms. Briefly, pigs were placed in dorsal recumbancy (supine) and ECG leads placed after shaving and hair removal with thioglycolic acid/KOH cream (Veet, Reckitt Benckiser, UK) and the telemetric vector electrocardiogram was used for gating of the Siemens CMR sequences. All images were taken during end-expiratory ventilation stop. Localizer views were followed by right-ventricular short-axis TrueFISP cine-image stacks (from the cardiac apex to the level of the pulmonary valve) under manual-breathhold. For pulmonary artery flow measurement phase-contrast MRI was carried out under manual-breathhold with the velocity encoding (VENC) set to 130 cm/s and the acquisition plane set parallel to and 1 cm above the pulmonary valve plane. CMR analysis was performed by a single investigator. Quantification of ventricular function was carried out using the Siemens syngo ARGUS Ventricular Function software package with manual drawing of a right ventricular endocardial contour, from which RV end-systolic, end-diastolic, stroke volume and ejection fraction were determined. These values were indexed to body surface area (BSA). The pulmonary regurgitation fraction was calculated using the Siemens syngo

ARGUS Flow software package with the rephased images used to draw the analysis ROI and quantification calculated from the phase images. Pulmonary regurgitation fraction was calculated as the ratio of pulmonary retrograde to antegrade flow volume (expressed as a percentage).

### **Euthanasia and cardiac harvesting**

Following a median sternotomy to expose the heart, animals received an intravenous dose of heparin (200 UI/kg, PanPharma) and were euthanised by injection of sodium pentobarbital (10 mL from 200 mg/ml stock). The heart was quickly excised, the aorta cannulated and the myocardium flushed with an ice-cold cardioplegic solution containing (in mM): 110 NaCl, 1.2 CaCl<sub>2</sub>, 16 KCl, 16 MgCl<sub>2</sub>, 10 NaHCO<sub>3</sub>, 9 Glucose supplemented with Heparin (2500 UI/L). The heart and, after careful dissection, the RV wall and the left ventricle were weighed. The pulmonary artery trunk and two centimeters of infundibulum proximal to the pulmonary artery valve were harvested for macroscopic investigation and histopathologic examination.

### **Histological studies**

Tissue samples were fixed in 4% formalin and embedded in paraffin. Sections (6 mm thick) were stained with Hematoxylin-Eosin-Saffron (inflammatory reaction and tissue organization evaluation), Orcein (elastic fibers organization) and alpha smooth muscle actin (IHC staining protocol to evaluate smooth muscle cell behavior). Slides were examined at x 100 and x 200 magnifications, with NIKON Eclipse microscope, and analyzed with NIS Elements D (3.12 version) software.

### **Data analysis**

Data are expressed as means  $\pm$  SD. Statistical differences between groups were tested using non-parametric Mann–Whitney or Kruskal–Wallis tests as appropriate. Statistically

significant difference was assumed for  $p < 0.05$ . Statistical analysis was performed using SigmaStat software.

## **RESULTS**

### **Animal characteristics**

At baseline, all animals had a comparable weight, according to their age of 5 weeks. No death occurred during or after the procedure. After a mean delay of  $114 \pm 3$  days, no growth variability was found between the 3 groups. Animals were similar in each group in terms of age, weight, body surface area and heart rates (Table 1). No clinical sign of heart failure was observed.

### **Transthoracic echocardiography**

In TOF pigs, a minimal indentation was seen on the main PA on the site of the banding, however, no significant stenosis was observed through the RVOT in these animals when compared with PI (RVOT peak velocity of  $1.8 \pm 0.4$  m/s vs  $1.4 \pm 0.3$  m/s ; ns). In TOF and PI animals, an important PR was detected by color Doppler with obvious signs of RV dilation, demonstrated by an increased tricuspid/mitral annulus ratio. Conversely, SHAM group animals showed normal echocardiographic parameters during the analysis (Table 1).

### **Magnetic resonance imaging**

Significant postsurgical PR was present in the TOF and PI groups (pulmonary regurgitation fraction of  $23,3 \pm 10,4$  % and  $23,7 \pm 6$ %, respectively,  $p = 0.14$ ). This PR induced a significant RV enlargement in TOF and PI groups, compared with the SHAM group. In TOF and PI groups, mean RV indexed end-diastolic volume was  $163 \pm 12$  and  $137 \pm 16$  and, mean RV indexed end-systolic volume was  $97 \pm 11$  and  $86 \pm 11$ , respectively. RV ejection fraction was significantly decreased in TOF and PI groups compared with SHAM pigs. No statistical difference was observed between PI and TOF animals regarding RV volume and function even though TOF pigs tended to have a more dilated RV (Table 1, Figures 1).

### **Post mortem macroscopic evaluation**

TOF and PI groups hearts were heavier than the SHAM group hearts. The indexed weight difference between operated (TOF and PI) and SHAM animals was significant for right ventricles, but not for left ventricles (Table 1). Among operated animals, TOF pigs hearts were significantly heavier than PI hearts.

Regarding the RVOT and PA anatomy, no abnormality was detected in SHAM and PI pigs.

In TOF animals gross examination, the band was not seen on the external PA wall. Indeed, in all TOF animals, the constricting band had been partially internalized into the PA lumen. Suture material floated within the vessel lumen leading to a double route for blood flow i.e. through the band and around it. The constricting band and the suture knot were intact, which ruled out the possibility of simple breakage or knot slippage to explain these observations (Figure 2).

When the pulmonary artery was incised longitudinally, the band internalization was clearly seen on one vessel side while there was an obvious scar due to the band erosion on the opposite vessel side, corresponding to the initial banding suture (Figure 2).

### **Histopathological results**

Among histological sections performed within the site of band internalization, we observed a significant disorganisation of the medial layer with a large scarring and fibrosing reaction surrounding the outside of the band on HE staining. Inflammatory cells (such as lymphocytes, eosinophils or macrophages) were found within this area suggesting a significant inflammatory response during band internalization. Orcein staining showed a disruption of elastic fibres on band internalization site. Alpha actine immunostaining similarly demonstrated muscular fibres disruption within the same area, which may weaken the vessel wall and lead to aneurismal formation (Figure 3).

Histological sections performed on the opposite vessel side showed a reduced wall thickness on the initial banding suture site. Clear vascular wall remodelling with medial and adventitial layers fibrosis and elastic fibres disorganization was also observed. These abnormalities may also induce aneurismal formation (Figure 4).

Sections performed proximal to the band site – toward the RVOT – revealed a significant muscular layer hypertrophy with a regular organization of muscular and elastic fibres.

Conversely, sections performed distal to the band toward pulmonary bifurcation showed disorganized elastic fibres, which may weaken the vessel. This was likely due to the hemodynamic turbulences induced by the pulmonary banding.

## **DISCUSSION**

In this paper we report our experience of an unexpected pulmonary artery band internalization, which occurred in a previously described and validated model of repaired tetralogy of Fallot. To the best of our knowledge this is the first report of PA band erosion in an animal model. We assume that this complication is due to a change in banding suture material (coated braided polyester instead of Gore-Tex band) between our firsts experiments (4-6) and the latter. Indeed, for logistical reasons, in this last study TOF pigs operations were moved in another laboratory in which no Gore-Tex bands were available. Thinking that it would have no consequence, the surgeon decided to slightly modify the protocol and to perform the band with coated braided polyester leading to this unexpected complication.

### **An extremely rare complication**

Although PA banding is a relatively safe operation, it has been associated with several complications including impingement and/or stenosis of one or both of the branch PAs, distortion of the pulmonary valve, PA pseudo-aneurysm and exceptionally band erosion/internalization (8).

To our knowledge, only thirteen clinical cases of band erosion have been reported in the literature so far (9-17). Erosion or cut-through diagnosis was made from 10 days up to 6 years after the first surgery. In 8 cases, the band internalization was concomitant with recurrent congestive heart failure due to recanalization of the pulmonary artery around the band leading to a disappearance of the hemodynamic gradient. Other clinical presentations included local infection (n=2) or sudden death due to pulmonary artery false aneurysm thrombosis or rupture (n=2) and haemolysis (n=1). Eight patients died. Diagnosis of band erosion was made either during reintervention or necropsy. Materials used for the banding suture were Teflon, umbilical tape and silastic tape.



This phenomenon has been reported in a murine left ventricular hypertrophy model created with a transverse aortic band performed with a 7-0 polypropylene monofilament suture (18). Authors observed an unexpected decrease in left ventricular hypertrophy that was shown to be due to an internalization of the band into the aortic lumen in 16% of the animals in post mortem analysis. Of note, in that experiment, visual inspection at post-mortem found the band to be intact with the knot still firmly tied excluding inefficient surgical technique or failure of the banding material, which is consistent with our findings. Authors confirmed their observation prospectively by a subsequent *in vivo* 3D-MRI analysis that clearly showed the band internalization within the transverse aorta in 25% of mice. Authors also postulated that band internalization might be undertaken by genetic modifications, as it was only observed in a subset of genetically modified mice.

This was not likely the case of our experiment as our pigs were not genetically modified but 100% of them had band internalization. Moreover, the observation of band internalization correlates with a change in the materials used to create the band i.e. a non-absorbable coated braided polyester suture instead of Gore-Tex band.

### **Pathophysiology of band erosion**

It seems obvious that the band material plays a key role in the genesis of band internalization. Indeed, this complication occurred with the use of a non-absorbable coated braided polyester but not with Gore-Tex band, which was used in our previous publications (4,5). Moreover, in this experiment, band internalization occurred in 100% of animals, which were same Landrace pigs used previously to validate our model. No acute complication was observed however, as TOF pigs presented with no significant RV to PA gradient on echography, a banding-related issue was suspected. On gross examination, we found that the constricting band was partially internalized into the PA lumen with suture material floating within the vessel. The constricting band and the suture knot were intact, which ruled out the possibility

of simple breakage or knot slippage to explain this complication.

Histological sections of band internalization site showed a significant disorganisation of the medial layer with a large scarring and fibrosing reaction surrounding the outside of the band and presence of inflammatory cells suggesting a significant inflammatory response during band internalization. Moreover, elastic and muscular fibres disruption was observed. On the opposite vessel side, there was an obvious scar due to the band erosion, with a reduced wall thickness, medial and adventitial layers fibrosis and elastic fibres disorganization. All these abnormalities may weaken the vessel wall and lead to aneurismal formation.

This is consistent with the findings of Lygate et al. on aortic band internalization in mice (18). Based on these findings, we suggest the following mechanisms to explain band erosion: the high pressures due to the band led to a damage of the adventitial and medial layers underlying the suture and to local inflammatory response. This inflammation then stimulates adventitial proliferation and fibrosis around the band, leading to a migration of the latter through the medial layer until a critical point where the muscular and elastic fibres rupture, making a small portion of the band breaking free from the wall within the vessel lumen. This may occur on a portion of the vessel wall where the thickness is reduced.

The reason for which the band erosion did occur with a non-absorbable coated braided polyester wire and did not with Gore-Tex band is still partially unexplained. The thickness of the suture material may play a role in band internalization occurrence although Lygate et al. observed a persistence of erosion when using a thicker 5-0 polypropylene suture (18). The composition of the suture material and its propensity to induce inflammatory and immunologic responses must also be taken into account. Band erosion was not observed in other published porcine models of repaired TOF in which the banding was performed using umbilical tapes (19-22).

Finally, vascular wall thickness and zones of local weakness role also need to be investigated.

### **Clinical implication**

The unexpected observation of band internalization in TOF pigs must not call into question the validity of our model. As stated above, this complication was most likely due to a change in suture band material that was dictated by logistical constraints. In our previous publications, the RV pressure overload due to the PA banding was significant and clearly assessed by echocardiographic measurements (4,5).

In this experiment, we observed that TOF pigs had heavier and thicker RV compared with PI pigs, suggesting that the banding induced a temporary but efficient RV pressure overload, before internalization. A sequential clinical, echocardiographic and pathologic analysis is warranted to exactly assess the timing of these modifications and the exact process of band internalization.

However, one could argue that we accidentally created a model that reproduces the course of a repaired TOF using contemporary techniques. Indeed, nowadays, the most diffused surgical strategy is based on the assumption that the pulmonary valve must be preserved and that a mixed lesion of moderate pulmonary stenosis and associated insufficiency is superior to the complete relief of obstruction and free pulmonary regurgitation (23). Using this technique, operated patients often present with a moderate stenosis that progressively disappears with child growth, leaving a mild or no stenosis associated with moderate to severe PI, as observed in this model after band internalization. This has obviously to be precised in further experiments.

Regarding the use of PA banding in clinical practice, the risk of band erosion occurrence underscores the need of a close clinical and echocardiographic follow-up of these patients. Even though this complication is extremely rare, it must be kept in mind in case of decrease of Doppler gradient during follow-up.

### **Limitations**

As this paper aimed to report an unexpected and accidental observation, it carries some inherent limitations. As it was not planned in our initial protocol, no early echocardiographic assessment was performed to evaluate the efficacy of the PA banding. Moreover, a monthly sequential follow-up would have allowed us to better understand the timing of these modifications and the accurate pathophysiology of band internalization.

## **CONCLUSION**

Band internalization may occur after pulmonary artery banding using a non-absorbable coated braided polyester, in a chronic porcine model of repaired tetralogy of Fallot. This unexpected and accidental complication was most likely due to a change in suture band material. The latter led to a damage of adventitial and medial underlying layers and to local inflammatory response that weakened the vascular wall and resulted in pulmonary artery erosion. Further experiments are warranted to better assess the exact pathophysiology of this extremely rare complication.

**Acknowledgment: none**

## REFERENCES

1. Bolger AP, Coats AJ, Gatzoulis MA. Congenital heart disease: the original heart failure syndrome. *Eur Heart J*. 2003;24:970–6.
2. Nollert G, Fischlein T, Bouterwek S, Böhmer C, Klinner W, Reichart B. Long-term survival in patients with repair of tetralogy of Fallot: 36-year follow-up of 490 survivors of the first year after surgical repair. *J Am Coll Cardiol*. 1997;30:1374–83.
3. Cuypers JA, Menting ME, Konings EE, Opić P, Utens EM, Helbing WA et al. Unnatural history of tetralogy of Fallot: prospective follow-up of 40 years after surgical correction. *Circulation*. 2014;130:1944-53.
4. Thambo JB, Roubertie F, De Guillebon M, Labrousse L, Iriart X, Ntsinjana H et al. Validation of an animal model of right ventricular dysfunction and right bundle branch block to create close physiology to postoperative tetralogy of Fallot. *Int J Cardiol*. 2012;154:38-42.
5. Thambo JB, Dos Santos P, De Guillebon M, Roubertie F, Labrousse L, Sacher F et al. Biventricular stimulation improves right and left ventricular function after tetralogy of Fallot repair: acute animal and clinical studies. *Heart Rhythm*. 2010 ;7:344-50.
6. Charron S, Roubertie F, Benoist D, Dubes V, Gilbert SH, Constantin M, et al. Identification of Region-Specific Myocardial Gene Expression Patterns in a Chronic Swine Model of Repaired Tetralogy of Fallot. *PLoS One*. 2015;10(e0134146).
7. Chaturvedi RR, Redington AN. Pulmonary regurgitation in congenital heart disease. *Heart*. 2007;93:880–9.
8. Takayama H, Sekiguchi A, Chikada M, Noma M, Ishizawa A, Takamoto S. Mortality of pulmonary artery banding in the current era: recent mortality of PA banding. *Ann Thorac Surg*. 2002;74:1219-23.
9. Schmidt-Habelmann P, Sivening F Erfahrungen mit der bandelung der pulmonal-arterie. *Thoraxchirurgie*. 1966;14:541-5.

10. Rohmer J, Brom AG, Nauta J. Bands inside the pulmonary artery. A complication of the Dammann-Muller procedure. *Ann Thorac Surg.*1967;3:449-54.
11. Idriss FA, Riker WL, Paul HH. Banding of the pulmonary artery: a palliative surgical procedure. *J Pediatr Surg.*1968;3:465-74.
12. Verel D, Taylor DG, Emery JL. Failure of pulmonary artery banding due to migration of the band. *Thorax.* 1970;25:126-8.
13. Hunt CE, Formanek G, Levine MA, Castaneda A, Moiler JH. Banding of the pulmonary artery. Results in 111 children. *Circulation.*1971;43:395-406.
14. Menahem S, Venables AW. Pulmonary artery banding in isolated or complicated ventricular septal defects. *Br Heart J.* 1972;34:87-94.
15. Mahle S, Nicoloff DM, Knight L, Moller JH. Pulmonary artery banding: long-term results in 63 patients. *Ann Thorac Surg.*1979;27:216-24.
16. Kutsche LM, Alexander JA, Van Mierop LH. Hemolytic anemia secondary to erosion of a Silastic band into the lumen of the pulmonary trunk. *Am J Cardiol.* 1985;55:1438-9.
17. Danilowicz D, Presti S, Colvin S. The Disappearing Pulmonary Artery Band. *Pediatr Cardiol.* 1990;11:47-49.
18. Lygate CA, Schneider JE, Hulbert K, ten Hove M, Sebag-Montefiore LM, Cassidy PJ et al. Serial high resolution 3D-MRI after aortic banding in mice: band internalization is a source of variability in the hypertrophic response. *Basic Res Cardiol.* 2006;101:8-16.
19. Zeltser I, Gaynor JW, Petko M, Myung RJ, Birbach M, Waibel R et al. The roles of chronic pressure and volume overload states in induction of arrhythmias: an animal model of physiologic sequelae after repair of tetralogy of Fallot. *J Thorac Cardiovasc Surg.* 2005;130:1542-8.
20. Lambert V, Capderou A, Le Bret E, Rücker-Martin C, Deroubaix E, Gouadon E et al. Right ventricular failure secondary to chronic overload in congenital heart disease: an

experimental model for therapeutic innovation. *J Thorac Cardiovasc Surg.* 2010;139:1197-204.

21. Bove T, Vandekerckhove K, Bouchez S, Wouters P, Somers P, Van Nooten G. Role of myocardial hypertrophy on acute and chronic right ventricular performance in relation to chronic volume overload in a porcine model: relevance for the surgical management of tetralogy of Fallot. *J Thorac Cardiovasc Surg.* 2014;147:1956-65.

22. Lambert V, Gouadon E, Capderou A, Le Bret E, Ly M, Dinanian S et al. Right ventricular failure secondary to chronic overload in congenital heart diseases: benefits of cell therapy using human embryonic stem cell-derived cardiac progenitors. *J Thorac Cardiovasc Surg.* 2015;149:708-15.

23. Bacha E. Valve-sparing options in tetralogy of Fallot surgery. *Semin Thorac Cardiovasc Surg Pediatr Card Surg Annu.* 2012;15:24-6.



**TABLES**

|   | <b>SHAM (n=4)</b> | <b>PI (n=4)</b> | <b>TOF (n=4)</b> | <b>p-value</b> |
|---|-------------------|-----------------|------------------|----------------|
| <b>Weight (kg)</b>                        | 74,5 ± 7,7        | 72,8 ± 9,2      | 72,3 ± 9,9       | ns             |
| <b>Body surface area (m<sup>2</sup>)</b>  | 1,24 ± 0,09       | 1,22 ± 0,10     | 1,22 ± 0,09      | ns             |
| <b>Heart Weight/BSA (g/m<sup>2</sup>)</b> | 202 ± 14          | 211 ± 15        | 283 ± 21         | p<0,005 **, #  |
| <b>RV Weight/BSA (g/m<sup>2</sup>)</b>    | 78 ± 4            | 81 ± 7          | 133 ± 16         | p<0,005 **, #  |
| <b>Delay from surgery (days)</b>          | 112,5 ± 3,7       | 115,5 ± 3,5     | 116,5 ± 3,1      | ns             |
| <b>Heart rate (beats/min)</b>             | 117 ± 15          | 105 ± 14        | 98 ± 12          | ns             |
| <b><u>TRANSTHORACIC ECHOGRAPHY</u></b>    |                   |                 |                  |                |
| <b>RV-PA peak velocity</b>                | 0.9 ± 0.3         | 1.4 ± 0.3       | 1.8 ± 0.4        | p<0,05*, **    |
| <b>Tricuspid/Mitral annulus ratio`</b>    | 0.8 ± 0.05        | 1.16 ± 0.06     | 1.22 ± 0.05      | p<0,005 **, #  |
| <b><u>MRI STUDY</u></b>                   |                   |                 |                  |                |
| <b>RV regurgitation fraction (%)</b>      | 0                 | 23,7 ± 6        | 23,3 ± 10,4      | p<0,005 **, ** |
| <b>RVi EDV (mL/m<sup>2</sup>)</b>         | 94,6 ± 7,4        | 137,5 ± 16,2    | 163,5 ± 12,6     | p<0,005 **, ** |
| <b>RVi ESV (mL/m<sup>2</sup>)</b>         | 51,5 ± 5          | 86,5 ± 11,3     | 97,4 ± 11,1      | p<0,005 **, ** |
| <b>Stroke Volume (mL)</b>                 | 53,4 ± 4,1        | 62,6 ± 11,2     | 80,1 ± 6,3       | p<0,001 **     |
| <b>RV ejection fraction (%)</b>           | 45,6 ± 1,2        | 37,2 ± 1,4      | 40,5 ± 3,1       | p<0,05*, **    |

**Table 1 : Population characteristics, echographic and cardiac MRI data at the end of follow-up.**

\* Sham group versus PIs group; \*\* Sham group versus Fallot group; # PIs group versus Fallot group.

RV, right ventricle. LV, left ventricle. RVi EDV, right ventricular indexed End-diastolic volume. RVi ESV, right ventricular indexed End-systolic volume.

## **FIGURE LEGENDS**

**Figure 1. Right ventricular end-systolic (A) and end-diastolic (B) volumes indexed of SHAM, PI and TOF animals.** RVi EDV, right ventricular indexed End-diastolic volume. RVi ESV, right ventricular indexed End-systolic volume. Groups are plotted as mean  $\pm$  standard deviation ; \*  $p < 0.05$ .

**Figure 2. Macroscopic view of the pulmonary artery of TOF pigs n°3 and 4, which were opened from the bifurcation proximally toward the banding.** **A & B:** The constricting band was partially internalized into the PA lumen (black arrow) with an adherent thrombus seen in animal n°3 (asterisk). See that the constricting band and the suture knot were intact. **C:** After longitudinal incision of the pulmonary, the band internalization was clearly seen on one vessel side (black arrow), while there was an obvious scar due to the band erosion on the opposite vessel side, corresponding to the initial banding suture (white arrow).

**Figure 3. Histological sections from TOF animals in the area of PA internalization after H & E (A, B), Alpha-actin (C), and Orcein staining (D) - Magnification (A, D : x 10, B : x 100 ; C: x40).** **A & B:** Significant disorganisation of the medial layer of the vessel with a large scarring and fibrosing reaction surrounding the outside of the band (black arrow). B is a higher magnification of A focusing on the scarring reaction. C: Alpha actine immunostaining showing muscular fibres disruption within the same area (asterisk). D: Orcein staining showing a disruption of elastic fibres on band internalization site (asterisk). PA: pulmonary artery.

**Figure 4. Histological sections from TOF animals in the scar left by band internalization on the opposite vessel side after H & E (A), Orcein (B, C), and Alpha-actin staining (D) -**

**Magnification (A, B: x 10, C: x 200 ; D: x40). A & B :** Significant reduction of wall thickness on the initial banding suture site (black arrows). C is a higher magnification of B showing the vascular wall remodelling with elastic fibres disorganization. D: vascular wall remodelling after band cut-through with medial and adventitial layers fibrosis (asterisk). PA: pulmonary artery.

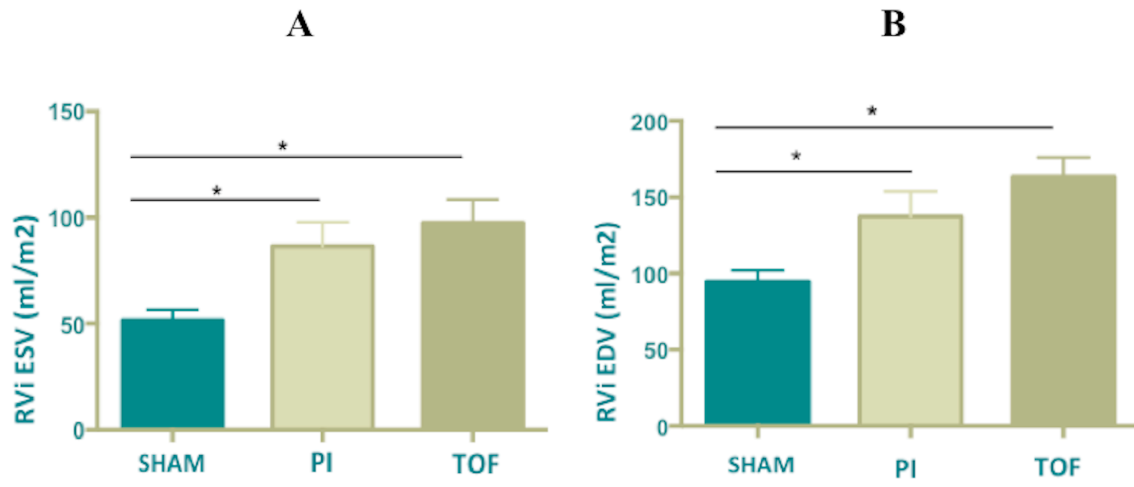


Figure 1

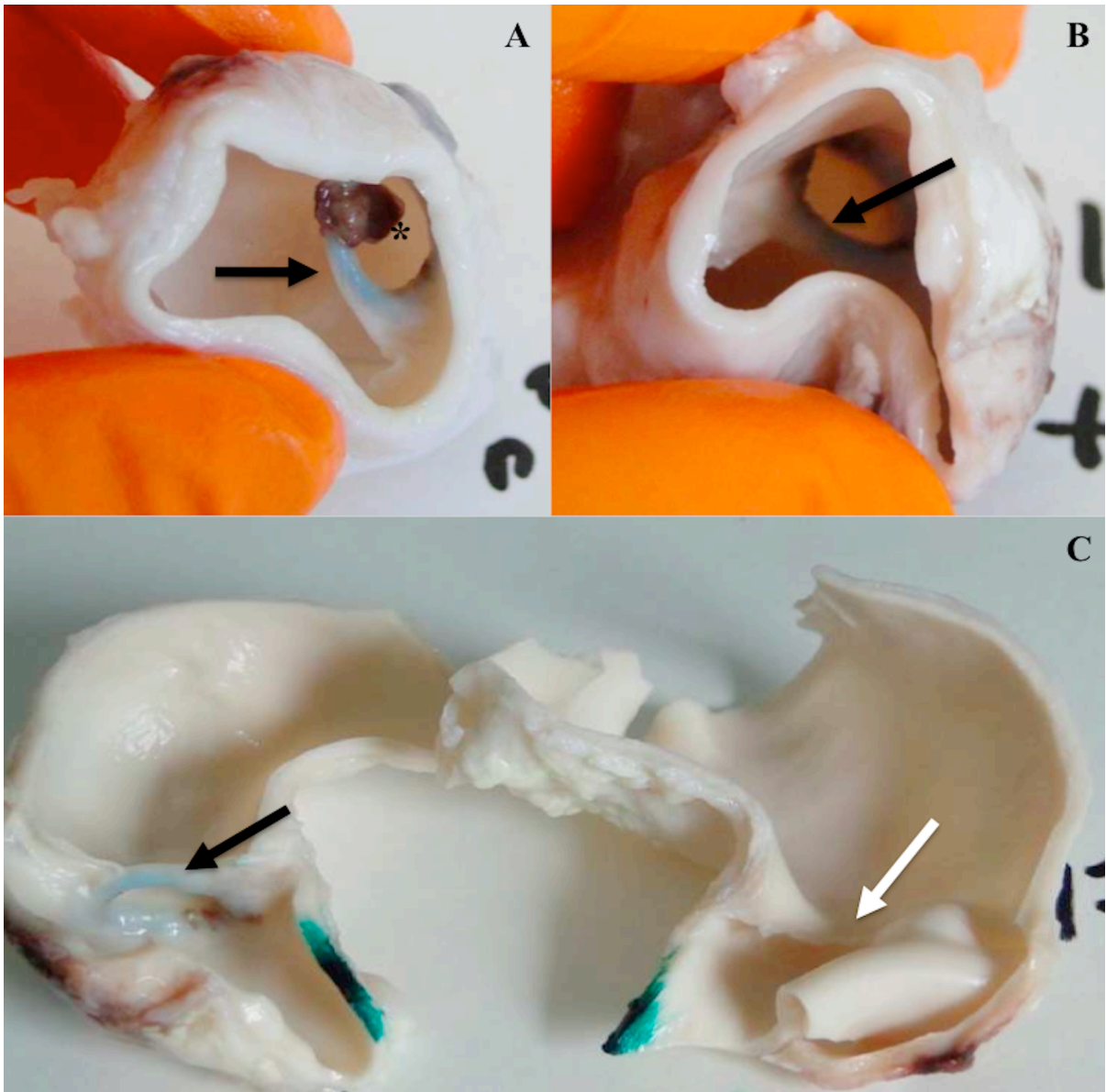


Figure 2

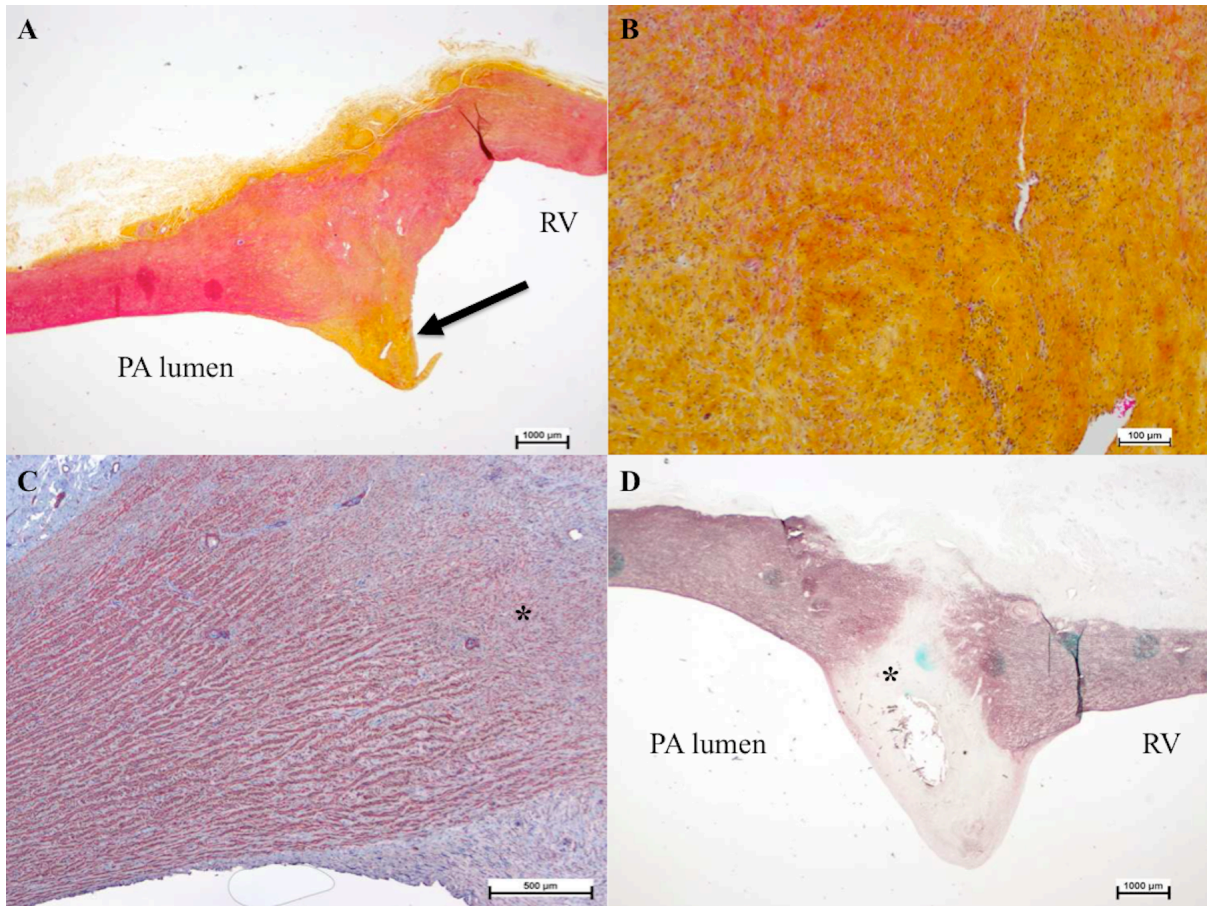


Figure 3



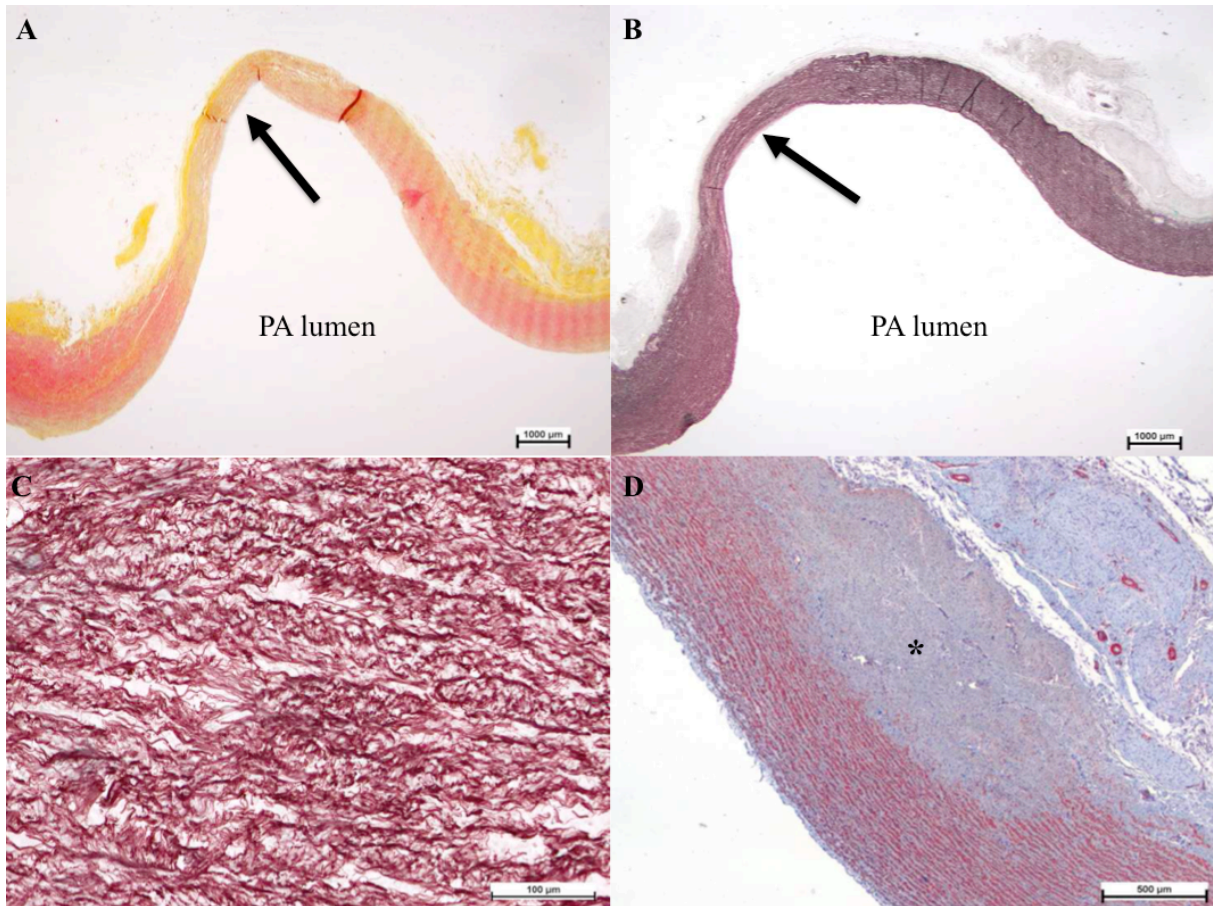


Figure 4

## Conclusion

# 6. Conclusion

Les adultes porteurs d'une CC sont une population nouvelle, dont la spécificité n'a été que récemment reconnue (1). Cette population pose un double problème, que l'on doit essayer de résoudre pour améliorer l'espérance de vie de nos patients ainsi que leur qualité de vie.

## **6.1 Problématique n°1 : prise en charge des patients d'un point de vue organisationnel : Où prendre en charge ces patients ? Dans quel type de structure?**

### **Des recommandations existent**

Curieusement des recommandations, à ce propos existent et ont été publiées (2) ; elles sont de Class I, et insistent sur 6 points :

- 1. **avoir un centre régional (tertiaire) de référence**, adapté à la taille de la population (entre 8 et 10 millions d'habitants) : avec une organisation claire et lisible avec les autres centres hospitaliers secondaires pour les patients urgents et non urgents.
- 2. **une organisation en réseau** coordonnée par le centre régional : avec un programme d'éducation des patients et de leur famille, ainsi qu'un programme d'enseignement pour les cardiologues adultes et les cardio-pédiatres. La transition doit être organisée (passage de l'adolescence à l'âge adulte légal) : donc la question de savoir qui doit suivre ces patients, entre le cardiologue adulte ou le cardiopédiatre, doit être résolue.
- 3. Créer un **passport médical complet** pour chaque patient ayant une CC.
- 4. Identifier clairement pour chaque patient **une personne de référence** (car plus grande fréquence dans cette population des patients sous tutelle/curatelle) ; fréquence aussi des limitations « psycho-sociales ».
- 5. Avoir **un médecin** généraliste ou un cardiologue de ville **de référence**



## Conclusion

- 6. Le centre de référence régional s'engage à **transmettre les informations** concernant le patient au structure de soins de proximité (médecin généraliste ; personnel paramédical de proximité ; cardiologue du centre hospitalier de proximité)

## Problématique de la France

Autant la prise en charge des patients adultes porteur d'une CC est bien organisée dans les pays anglo-saxons (Canada, Etats-Unis ou Grande-Bretagne) depuis le milieu des années 1990, autant la France accuse beaucoup de retard avec peu ou pas de structures dédiées à cette population.

On sait par exemple depuis quelques années que les patients porteurs d'une CC doivent être opérés par des chirurgiens cardiaques pédiatriques (et l'environnement dans lequel ils travaillent habituellement, avec des anesthésistes réanimateurs habitués à ces pathologies, cardio-pédiatres...) : dans une étude multicentrique américaine, la mortalité postopératoire hospitalière diminue significativement dans cette population, de 4,8% (chirurgien cardiaque adulte) à 1,9% (chirurgien cardio-pédiatrique) (3). Dans cette série (3), il était rappelé l'importance d'un nombre minimale d'interventions à réaliser par an pour avoir de bons résultats, et une diminution du cout financier de l'intervention chirurgicale quand elle était réalisée par un chirurgien cardio-pédiatrique (4). L'environnement en tant que tel, à savoir hôpital d'adulte ou hôpital d'enfant, peut également influencer sur les résultats (5).

Pour revenir à la France, les patients adultes avec CC sont suivis soit par des cardiologues adultes ou soit par des cardiologues pédiatres, voire parfois par aucun médecin. Les interventions chirurgicales sont réalisées vraisemblablement, pour 50% des cas par des chirurgiens cardiaques adultes et pour le reste, par des chirurgiens cardio-pédiatriques. Le manque de visibilité de structures de soins adaptées pour ces patients rend leur suivi compliqué et les résultats des soins aléatoires.

On a vu l'importance d'avoir des équipes multidisciplinaires pour prendre en charge ces patients car les problèmes posés sont multiples (en imagerie médicale, en rythmologique, en chirurgie, en cathétérisme interventionnel, etc.). L'important au delà du débat sur hôpital d'enfants ou d'adultes, c'est d'avoir des unités et des médecins spécialisés dans le domaine des CC, en nombre suffisant (au moins 2 chirurgiens par exemple) et qui ont reçu une formation spécifique (DESC) ; bien entendu le personnel paramédicale doit être formé à la spécificité de ces patients.

## Conclusion

Des centres de référence en France, à haut volume, sont indispensables pour la qualité des soins et pour accumuler des données qui serviront à écrire les recommandations de demain.

## 6.2 Problématique n°2 : prise en charge sur un plan strictement médical: les indications, les résultats, les stratégies en cours d'évolution.

Des recommandations existent (2, 6), mais sont souvent incomplètes et évoluent constamment (7, 8) du fait du caractère nouveau de cette population, qui reste en valeur absolue peu importante par rapport à la population des patients coronariens ou à la population des patients avec insuffisance cardiaque.

### Importance de la recherche clinique

Les recommandations manquent. Chaque centre avec une activité conséquente essaie d'apporter sa pierre à l'édifice en construction : c'est ce que nous essayons de faire dans notre centre en ce qui concerne notamment les adultes avec TF réparée. Les études cliniques, même uni-centriques et rétrospectives restent intéressantes dans ce domaine, car nous manquons de données sur lesquelles poser les indications.

Nous restons optimistes dans l'avenir pour finaliser un ou deux PHRC qui ferait gagner beaucoup de temps à la communauté médicale ; la resynchronisation lors de valvulation pulmonaire chez des patients avec TF réparée et dysfonction bi-ventriculaire est une étude que nous espérons mener rapidement.

La dysfonction bi-ventriculaire, stade ultime de la maladie, reste sans réponse thérapeutique adaptée aujourd'hui. Elle est liée à des mécanismes de décompensation qui n'ont pas été pris en charge ou pris en charge trop tard au cours de l'évolution de la maladie. Il y a quelques années la fuite pulmonaire après cure complète de TF était considérée comme bénigne. Puis on a compris qu'elle était délétère, d'où l'idée logique de réaliser un RVP. On a vu au cours de ce travail que la simple

## Conclusion

valvulation pulmonaire était insuffisante pour répondre à tous les problèmes posés (quand valver ? etc.). Dans ce contexte, où on atteint les limites de la clinique, l'apport d'un modèle animal qui mime les séquelles observées après cure complète de TF peut être d'un apport précieux.

## Importance de la recherche fondamentale

Pour les arythmies, on a vu que les résultats sur notre modèle étaient prometteurs. D'autres publications vont suivre concernant les mécanismes des arythmies liées au ventricule gauche. Ces travaux semblent venir compléter les connaissances cliniques concernant les TV par macro-réentrée au niveau des isthmes de conduction lente : manifestement le remodelage du VD lié à l'IP est pro-arythmogène en lui-même. Donc l'idée d'une valvulation pulmonaire précoce, pour stopper ces mécanismes, semblent avoir du sens : c'est ce que nous chercherons à démontrer dans nos prochaines recherches.

La valvulation pulmonaire percutanée (9) occupe une place de plus en plus importante en pratique clinique : il y a quelques années encore, elle n'était utilisée que pour valver d'anciens conduits implantés chirurgicalement (10). Aujourd'hui les indications semblent s'élargir (11, 12), avec des séries publiées chez des adultes avec TF réparée : souvent, l'implantation de ces valves percutanées sur voie pulmonaire native demandent des techniques complexes de cathétérisme interventionnel ; les résultats, prometteurs, demandent à être confirmés. Ces techniques ne semblent pouvoir s'appliquer pour l'instant qu'à 15% (13) des patients. Notre modèle animal présente toutes les caractéristiques pour servir à l'étude de ces nouvelles prothèses (14, 15), voire pour tester des procédures hybrides (16, 17) et augmenter le champ de l'application clinique.

## Conclusion en quelques mots

Ce travail de thèse ouvre sur de nombreuses possibilités de recherche clinique et de recherche fondamentale. L'association des deux permettra dans l'avenir de mieux appréhender les mécanismes des arythmies dans cette population de patient. Leur association permettra également de mieux comprendre cette pathologie aux multiples facettes intriquées les unes avec les autres. Des réponses complémentaires sont probablement à rechercher au niveau cellulaire chez notre modèle animal :

## **Conclusion**

l'étude de la physiologie des cellules myocardiques (contraction notamment), de leur métabolisme calcique et du fonctionnement des canaux ioniques (patch-clamp) sont actuellement en cours.

## Conclusion

### 6.3 Références

1. Somerville J: Management of adults with congenital heart disease: An increasing problem. *Annu Rev Med* 1997;48:283-293.
2. Warnes CA, Williams RG, Bashore TM, et al: ACC/AHA guidelines for the management of adults with congenital heart disease. *J Am Coll Cardiol* 2008;118:e714-e833
3. Karamlou T, Diggs BS, Person T, et al: National practice patterns for management of adult congenital heart disease: Operation by pediatric heart surgeons decreases in-hospital death. *Circulation* 2008;118:1-8.
4. Dearani JA: Surgery for adults with congenital heart disease should be performed by congenital heart surgeons. *J Thorac Cardiovasc Surg* 138:5-7, 2009
5. Karamlou T, Diggs BS, Ungerleider RM, et al: Adults or big kids: What is the ideal clinical environment for management of grown-up patients with congenital heart disease? *Ann Thor Surg* 2010;90:573-579.
6. Baumgartner H, Task Force on the Management of Grown-up Congenital Heart Disease of the European Society of Cardiology: ESC guidelines for the management of grown-up congenital heart disease. *Eur Heart J* 2010;31:2915-2957
7. Daebritz SH: Update in adult congenital cardiac surgery. *Pediatr Cardiol* 2007;28:96-104
8. Guleserian KJ: Adult congenital heart disease: Surgical advances and options. *Prog Cardiovasc Dis* 2011;53:254-264

## Conclusion

9. Bonhoeffer P, Boudjemline Y, Saliba Z, et al. Transcatheter implantation of a bovine valve in pulmonary position: a lamb study. *Circulation* 2000; 102: 813–16.
10. Khambadkone S, Coats L, Taylor A, et al. (2005) Percutaneous pulmonary valve implantation in humans: results in 59 consecutive patients. *Circulation* 112, 1189–1197.
11. Momenah T, Oakley R, Najashi K, et al: Extended application percutaneous pulmonary valve implantation. *J Am Coll Cardiol* 53: 1859-1863, 2009
12. Malekzadeh-Milani S, Ladouceur M, Cohen S, et al: Results of transcatheter pulmonary valvulation in native or patched right ventricular outflow tracts. *Arch Cardiovasc Dis* 107: 592-598, 2014
13. Jalal Z, Thambo J, Boudjemline Y: The future of transcatheter pulmonary valvulation. *Arch Cardiovasc Dis* 107:635-642, 2014
14. Schievano S, Taylor AM, Capelli C, et al: First- in-man implantation of a novel percutaneous valve: A new approach to medical device development. *EuroIntervention* 5:745-750, 2010
15. Basquin A, Pineau E, Galmiche L, et al: Transcatheter valve insertion in a model of enlarged right ventricular outflow tracts. *J Thorac Cardiovasc Surg* 139:198-208, 2010
16. Boudjemline Y, Schievano S, Bonnet C, et al: Off-pump replacement of the pulmonary valve in large right ventricular outflow tracts: A hybrid approach. *J Thorac Cardiovasc Surg* 129:831-837, 2005

## Conclusion

17. Schreiber C, Horer J, Vogt M, et al: A new treatment option for pulmonary valvar insufficiency: First experiences with implantation of a self-expanding stented valve without use of cardiopulmonary bypass. *Eur J Cardiothorac Surg* 31:26-30, 2007