



HAL
open science

Pathophysiology of vertical nystagmus in infancy

Matthieu Robert

► **To cite this version:**

Matthieu Robert. Pathophysiology of vertical nystagmus in infancy. Neuroscience. Université Sorbonne Paris Cité, 2016. English. NNT : 2016USPCB008 . tel-01584471

HAL Id: tel-01584471

<https://theses.hal.science/tel-01584471>

Submitted on 8 Sep 2017

HAL is a multi-disciplinary open access archive for the deposit and dissemination of scientific research documents, whether they are published or not. The documents may come from teaching and research institutions in France or abroad, or from public or private research centers.

L'archive ouverte pluridisciplinaire **HAL**, est destinée au dépôt et à la diffusion de documents scientifiques de niveau recherche, publiés ou non, émanant des établissements d'enseignement et de recherche français ou étrangers, des laboratoires publics ou privés.

Université Paris Descartes

Ecole doctorale Cerveau Cognition Comportement

COGNition and ACTion Group, UMR 8257 CNRS-IRBA-Université Paris Descartes

Étiopathogénie des nystagmus verticaux du nourrisson

Par Matthieu Robert

Thèse de doctorat de Neurosciences

Dirigée par Pierre-Paul Vidal

Présentée et soutenue publiquement le 17 mars 2016

Devant un jury composé de :

VIDAL Pierre-Paul, DR1, Directeur,





DENIS Danièle, Professeur des Universités, Rapporteur,

BORRUAT François-Xavier, Professeur d'ophtalmologie, Rapporteur,

BRÉMOND-GIGNAC Dominique, Professeur des Universités,

GAYMARD Bertrand, Maître de Conférences des Universités,

ZEE David Samuel, Professeur de neurologie.

    Except where otherwise noted, this work is licensed under
<http://creativecommons.org/licenses/by-nc-nd/3.0/>
[Insérer le logo correspondant à la licence choisie]

Résumé (français) :

L'étude des nystagmus du nourrisson est difficile pour des raisons méthodologiques. La plupart des études sont donc réalisées chez des adultes et *a posteriori*. Ces études chez l'adulte ont permis la révision des classifications des nystagmus infantiles, avec la consolidation des concepts de syndrome du nystagmus précoce et de nystagmus de type latent. La séméiologie et l'étiopathogénie des nystagmus du nourrisson – notamment des formes comportant un élément vertical et des formes transitoires – reste donc à étudier.

Dans ce but :

1. Nous avons développé de nouvelles techniques d'enregistrement des mouvements oculaires chez les nourrissons, utilisables dans le cadre d'une consultation. Elles incluent de nouveaux stimuli, un appareil d'enregistrement des mouvements oculaires spécialement conçu pour le nourrisson et de nouvelles méthodes d'analyse statistique du signal. Nous avons vérifié la faisabilité de ces enregistrements chez 28 nourrissons atteints de nystagmus.
2. Nous avons étudié systématiquement 32 cas de nystagmus de type *spasmus nutans*, classiquement considéré comme une entité bénigne idiopathique, avec un examen clinique complet, une imagerie cérébrale, une électrophysiologie visuelle et des enregistrements oculo-moteurs. Dans 53,1% des cas, le *spasmus nutans* était le symptôme d'une autre maladie : neurologique (34,3%), notamment des gliomes du chiasma (21,9%), ou rétinienne (12,5%). Une atteinte des voies visuelles antérieures est probablement en cause dans la physiopathologie des *spasmus nutans*.
3. Huit cas de nystagmus ayant conduit au diagnostic de gliome des voies optiques (GVO) ont été également enregistrés et étudiés. L'âge d'apparition du nystagmus allait de 2,5 à 10 mois. Le GVO était toujours chiasmatique et constituait une sous-population spécifique. Le nystagmus était toujours de type *spasmus nutans*. Les enregistrements oculo-moteurs montraient : une fréquence entre 2,7 et 5 Hz, une morphologie sinusoïdale du nystagmus, une dissociation et une dysconjugaison particulière, avec une opposition de phase (180°) entre les oscillations des deux yeux dans le plan horizontal mais une correspondance de phase dans le plan vertical, à l'origine d'un mouvement semblable à un mouvement de convection. Rarement et brièvement, le rapport de phase changeait. Ces caractéristiques orientent vers des oscillations dans le système des vergences, possiblement la conséquence d'une atteinte des afférences sensorielles des centres du contrôle vergentiel dans le tronc cérébral, secondaire au GVO et survenant pendant la période sensible du développement visuel.
4. Cinq cas de nystagmus *upbeat* chez des nourrissons avec des rétines et une imagerie cérébrale normale ont été étudiés. Le nystagmus était observé en décubitus et électivement déclenché par des rotations de la tête en position allongée. Dans tous les cas, une résolution spontanée était observée après quelques mois d'évolution. Les caractéristiques de ce type de nystagmus suggèrent une participation du système otolithique, suivie d'une recalibration secondaire des circuits vestibulo-oculaires.

En conclusion, le développement de techniques d'enregistrement des mouvements oculaires adaptées aux nourrissons aide à la compréhension de l'étiopathogénie de variétés mal décrites de nystagmus, notamment dans les cas comportant un élément vertical et dans les cas transitoires. Les processus de maturation des voies visuelles antérieures et des centres de contrôle de l'oculomotricité semblent jouer un rôle central dans les mécanismes de ces nystagmus.

Title: Pathophysiology of vertical nystagmus in infancy

Abstract:

Studying infantile nystagmus during infancy is difficult for methodological reasons. Most such studies have been performed in adults and *a posteriori*. These studies in adults allowed for an improvement

in the existing classifications, with now robust knowledge about the two most frequent varieties of infantile nystagmus: infantile nystagmus syndrome and fusion maldevelopment nystagmus syndrome. The characteristics and pathophysiology of nystagmus in infants—notably varieties of nystagmus with a vertical component and transitory nystagmus— need further study.

For this reason:

1. We developed new techniques for the recording of eye movements in infants in the setting of a clinic. They include new stimuli, the use of specially-designed infrared photo-oculography eyetrackers and new statistical analysis paradigms. We assessed these techniques in a population of 28 infants with a nystagmus.
2. We systematically studied 32 cases of *spasmus nutans*, classically considered an idiopathic entity, with comprehensive clinical examination, brain imaging, electrophysiology, nystagmus recording. In 53.1% of cases, it led to the diagnosis of another condition: a neurological disease (34.3%), including cases of chiasmal gliomas (21.9%), or a retinal dysfunction (12.5%). Anterior visual pathway dysfunction is likely involved in the pathophysiology of *spasmus nutans*.
3. Eight cases of nystagmus having led to a diagnosis of optic pathway glioma (OPG) were also recorded and studied. Age at nystagmus onset was 2.5-10 months. The associated OPG always involved the chiasm, and represent a specific subpopulation of OPG. Clinically, the nystagmus was always classified as *spasmus nutans* type. Oculographic recordings showed frequencies of 2.7-5 Hz, sinusoidal waveforms, dissociation and a special type of disconjugacy, with a 180° horizontal phase shift and no vertical phase shift, exhibiting a “convection-like” movement pattern. Rarely and for short periods of time, the phase shift could change. These characteristics point towards oscillations in the vergence system, which could possibly result from the specific disruption of the vergence centres afferences in the brainstem, induced by the OPG during the sensitive period of visual development.
4. Five cases of upbeat nystagmus in infants with normal retinas and normal brain imaging were studied. The nystagmus mostly occurred in supine position and could be triggered by head rotations in the supine position. All resolved spontaneously. The characteristics of this nystagmus suggest an involvement of the otolithic system, with a secondary recalibration of the vestibulo-ocular pathways.

In conclusion, the development of infant-friendly devices for eye-movements recording helps providing new insights on the pathophysiology of poorly described varieties of nystagmus, including nystagmus with a vertical component and transitory nystagmus. The maturation process of both the anterior visual pathways and the oculomotor pathways appears to be central in the mechanisms of these nystagmus.

Mots clés (français) : nystagmus, enregistrements oculomoteurs, réflectométrie infra-rouge, syndrome du nystagmus précoce, *spasmus nutans*, gliome des voies visuelles, nystagmus upbeat

Keywords: nystagmus, oculomotor recordings, infrared reflectometry, infantile nystagmus syndrome, *spasmus nutans*, optic pathway glioma, upbeat nystagmus

Contents

<i>Remerciements</i>	p. 9
List of illustrations	p. 14
List of tables	p. 16
List of abbreviations	p. 17
Advisory note	p. 18
Illustrated glossary	p. 19
Introduction: nystagmus in infancy	p. 22
Chapter I: Classifications of nystagmus	p. 23
Chapter II: Phenomenology of nystagmus	p. 26
i.II.1. Introduction	
i.II.2. Phenomenology of infantile nystagmus syndrome	
i.II.3. Phenomenology of fusion maldevelopment nystagmus syndrome	
i.II.4. Phenomenology of <i>spasmus nutans</i> syndrome	
Chapter III: Aetiology of nystagmus	p. 38
i.III.1. Introduction	
i.III.2. Disorders classically associated to infantile nystagmus syndrome	
<i>i.III.2.1. Introduction</i>	
<i>i.III.2.2. Albinism</i>	
<i>i.III.2.3. Ocular media opacities</i>	
<i>i.III.2.4. Leber congenital amaurosis</i>	
<i>i.III.2.5. Optic nerve hypoplasia; infantile optic nerve atrophy</i>	
<i>i.III.2.6. Aniridia</i>	
<i>i.III.2.7. Achromatopsia and S-cone monochromatism</i>	
<i>i.III.2.8. Congenital stationary night blindness</i>	
<i>i.III.2.9. Idiopathic infantile nystagmus syndrome</i>	
i.III.3. Pathological associations to fusion maldevelopment nystagmus syndrome	
i.III.4. Pathological associations to <i>spasmus nutans</i> syndrome	
<i>i.III.4.1. Introduction</i>	
<i>i.III.4.2. Chiasmal gliomas</i>	
<i>i.III.4.3. White matter diseases</i>	
<i>i.III.4.4. Retinal dystrophies</i>	
<i>i.III.4.5. Retinal stationary dysfunction syndromes</i>	
<i>i.III.4.6. Idiopathic spasmus nutans</i>	
Chapter IV: Pathophysiological hypotheses on nystagmus in infancy	p. 52
i.IV.1. Pathophysiological hypotheses on infantile nystagmus syndrome	
<i>i.IV.1.1. Introduction</i>	
<i>i.IV.1.2. The classical “sensory” hypotheses</i>	
<i>i.IV.1.3. The classical “motor” hypotheses</i>	
<i>i.IV.1.4. New sensory and motor hypotheses</i>	

i.IV.2. Pathophysiological hypotheses on fusion maldevelopment nystagmus syndrome	
i.IV.3. Pathophysiological hypotheses on <i>spasmus nutans</i> syndrome	
Chapter V: Synthesis and questions	p. 58
i.V.1. Practical decision trees	
i.V.2. Practical and theoretical questions	
Part I: Novel oculomotor recording techniques in infants and children	p. 62
Chapter I: Stimuli	p. 63
I.I.1. Screens and stimuli	
I.I.2. Stimuli for calibration and fixation	
I.I.3. Stimuli for opto-kinetic nystagmus recording	
<i>I.I.3.1. Monocular testing of optokinetic nystagmus</i>	
<i>I.I.3.2. Binocular testing of optokinetic nystagmus</i>	
I.I.4. Other stimuli	
Chapter II: Eye trackers	p. 70
I.II.1. Existing eyetrackers	
<i>I.II.1.1. Electro-oculography</i>	
<i>I.II.1.2. Photo-oculography</i>	
<i>I.II.1.3. Video-oculography</i>	
<i>I.II.1.4. Magneto-oculography</i>	
I.II.2. Requirements for studying nystagmus in children	
I.II.3. Development of the Eyefant	
Chapter III: Mathematical methods of analysis	p. 74
I.III.1. Calibration	
I.III.2. Nystagmus waveform analysis	
I.III.3. Calculation and representation of indexes allowing for characterization of a nystagmus	
Chapter IV: Clinical applications	p. 80
I.IV.1. Methods	
I.IV.2. Results	
I.IV.3. Conclusion	
Chapter V: Quantifying chiasmal decussation	p. 83
I.V.1. Introduction	
I.V.2. Quantifying chiasmal decussation by using Diffusion Tensor Imaging	
I.V.2.1. Introduction	
I.V.2.2. Methods	
I.V.2.3. Results	
I.V.2.4. Discussion	
I.V.2. Quantifying chiasmal decussation by using Visual Evoked Potentials	
I.V.3.1. Introduction	
I.V.3.2. Methods	
I.V.3.3. Results	
I.V.3.4. Discussion	

Part II: <i>Spasmus nutans</i>, chiasmal gliomas-associated nystagmus and benign intermittent upbeat nystagmus	p. 93
Chapter I: <i>Spasmus nutans</i>	p. 93
II.I.1. Introduction	
II.I.1.1. <i>Historical reports and associated conditions</i>	
II.I.1.2. <i>Characteristics of spasmus nutans-type nystagmus</i>	
II.I.1.3. <i>Spasmus nutans-associated head nodding</i>	
II.I.1.4. <i>Spasmus nutans-associated head turn</i>	
II.I.1.5. <i>Aim of the study</i>	
II.I.2. Material and methods	
II.I.3. Results	
II.I.4. Discussion	
Chapter II: Nystagmus associated with optic pathway gliomas	p. 101
II.II.1. Introduction	
II.II.2. Material and methods	
II.II.3. Results	
II.II.4. Discussion	
Chapter III: Benign intermittent upbeat nystagmus in infancy	p. 124
II.III.1. Introduction	
II.III.2. Case series	
II.III.3. Discussion	
Conclusion and perspectives	p. 130
Articles and communications related to the thesis	p. 132
Résumé	p. 133
References	p. 135

À Madame le Docteur Isabelle Ingster-Moati,

Je te dédie cette thèse qui est là grâce à toi,

J'aurais tant à te remercier Isabelle,

Pour ton exemple, ton sourire, ton courage, ton enthousiasme,

ta profonde humanité, ton intelligence, ta modestie et pour tes encouragements,

*Tu as été beaucoup plus que la constante lumière d'optimisme et d'espoir dans les moments
difficiles à l'hôpital, beaucoup plus qu'un modèle de bonté et de rigueur au travail,*

Tu es partie trop tôt mais tu es là tous les jours avec moi dès qu'un patient sourit,

J'espère que je saurai me montrer digne de la confiance dont tu m'as honoré.

Remerciements

À mes parents,

À mes grands-parents,

À mes arrière-grands-parents,

À Anish,

À Antoine,

À Astrid,

En témoignage d'affection.

Ce travail m'a quelque peu privé de vous ces dernières années ; pardon et merci de votre soutien sans faille et de votre affection.

A notre Directeur de thèse,

Monsieur le Docteur Vidal,

Qui nous a fait l'honneur de diriger ce travail et de nous accepter au sein de son équipe,

En témoignage de notre vive gratitude pour la confiance qu'il a constamment témoignée à notre égard, pour ses conseils avisés, pour son enthousiasme communicatif et ses encouragements dans les moments difficiles.

Aux membres de notre Jury :

Monsieur le Professeur David S. Zee,

My relationship with The neurology of eye movements, with never left my room since the day I acquired the fourth version in Gower street, has been a source of many extatic moments. It largely contributed to my attraction to oculomotor disorders. In addition to the numerous and impressive discoveries made under your direction, the clarity of your book strikes me every time I open it after a clinic. It is an immense honour for me to have you in my jury.

Monsieur le Professeur Borruat,

Pour nos échanges fructueux, sa rigueur scientifique, sa confiance renouvelée, son dynamisme académique et la richesse de son enseignement. Nous le remercions pour l'honneur qu'il nous a fait acceptant de juger ce travail,

Madame le Professeur Denis,

Pour son constant soutien, ses encouragements et ses conseils avisés. Sa force de travail, ses connaissances et sa générosité forcent notre admiration. Nous lui sommes extrêmement reconnaissant de l'honneur qu'elle nous fait en acceptant de juger ce travail,

Monsieur le Docteur Gaymard,

En témoignage de notre profond respect pour son enthousiasme communicatif, son aide précieuse dans l'exploration des troubles oculomoteurs complexes de l'adulte et sa constante disponibilité au service des patients,

Madame le Professeur Brémond-Gignac,

Qu'elle trouve ici l'expression de notre admiration pour son énergie constructrice et reconstructrice, son dynamisme, sa rigueur, son soutien sans faille, ses conseils, sa constante disponibilité et son exemple quotidien au travail.

À nos Maîtres et Collègues du service d'ophtalmologie de l'Hôpital des Enfants-malades

Monsieur le Professeur Dufier,

Pour son accueil enthousiaste, son école de rigueur, qu'il trouve ici la marque de notre vive reconnaissance pour son enseignement,

Mesdames les Docteurs Bandini, Berniolles, Constantin, Khechine, van Kote, Dénier, Michel, de Monteynard, Espinasse-Berrod, Girard, Kaluszyner, Landier, Libeskind, Padovani, Pon, Rabearivela, Seghir, Schmitt,

Messieurs les Docteurs Abitbol, Adjadj, Allali, Aymard, Boumendil, Bourdin, Chayestemehr, Fayet, Ghazi, Orssaud, Roche, Tazartes et Vergne,

À mes Maîtres et Collègues de l'Hôpital des Enfants malades, pour le dynamisme intellectuel qu'ils insufflent chaque jour à mon travail et qui constitue ma principale addiction :

Mesdames les Professeurs Abadie, Boddaert, Bodemer, Desguerre, de Lonlay, Vaivre-Douret, et Sermet.

Messieurs les Professeurs Munnich, Fischer, Aigrain, Brunelle, Chalumeau, Garabédian, Golse, Hadj-Rabia, Hermine, Lortholary, Sainte-Rose, Salomon Valayannopoulos et Zehra.

À nos Maîtres de neuro-ophtalmologie des hôpitaux de Londres :

Messieurs les Professeur Kennard et Plant,

Messieurs les Docteurs Nachev et Acheson,

Madame le Docteur Graham,

À nos Maîtres d'internat d'ophtalmologie des hôpitaux de Caen :

Monsieur le Professeur Mouriaux,

Monsieur le Docteur Billotte,

Monsieur le Docteur Letessier

Madame le Docteur Abadie,

Madame le Docteur Miocque,

À nos Maîtres d'internat de psychiatrie des hôpitaux de Nantes :
Messieurs les Professeur Besançon, Vanelle et Vénisse,
Messieurs les Docteur Vignal et Thomas,

À nos Maîtres d'externat des hôpitaux de Nantes :
Messieurs les Professeurs Péchereau, Damier et Planchon.

À nos Maîtres d'anatomie de la faculté de médecine de Nantes :
Messieurs les Professeurs Robert, Leborgne, Rogez, Armstrong,
En témoignage de reconnaissance pour la qualité de l'enseignement que nous avons reçu,
qu'ils trouvent ici l'expression de nos hommages respectueux.

À nos collègues d'internat,
Loeiz, Magali, Lionel, Céline, Julie, Haythem, Boris, Caroline, Nicolas, Emmanuel, Sophie et
Thomas,

À tout le personnel du service d'ophtalmologie de l'Hôpital des Enfants malades, pour leur
compétence et leur bonne humeur, pour avoir été l'indispensable et constant soutien au cours
de toutes ces années et sans qui cette thèse n'aurait pas vu le jour.

À tous nos amis.

List of illustrations

Fig 1. The four basic nystagmus waveforms	p. 20
Fig 2. Conjugacy and association	p. 21
Fig 3. Frequency and amplitude	p. 21
Fig 4. List of the forty-nine types of nystagmus, from Hertle & Dell’Osso, 2013	p. 23
Fig 5. Diagram for the representation of the clinical characteristics of a nystagmus	p. 26
Fig 6. Clinical characteristics of infantile nystagmus syndrome (INS) in an infant	p. 28
Fig 7. Clinical characteristics of infantile nystagmus syndrome in an older child	p. 29
Fig 8. Infantile nystagmus syndrome (INS) waveforms by Hertle & Dell’Osso, 2013	p. 30
Fig 9. Clinical characteristics of the pure latent form of fusion maldevelopment nystagmus syndrome (FMNS)	p. 32
Fig 10. Clinical characteristics of the manifest latent form of fusion maldevelopment nystagmus syndrome (FMNS)	p. 33
Fig 11. Fusion maldevelopment nystagmus syndrome (FMNS) typical waveform	p. 34
Fig 12. Clinical characteristics of an example of <i>spasmus nutans</i>-type, right monocular, nystagmus	p. 35
Fig 13. Version 1.5 of the behavioural ocular motor system model from Dell’Osso, from Hertle R. and Dell’Osso L., 2013	p. 56
Fig 14. Pathways of vestibular nystagmus, opto-kinetic nystagmus and fusion maldevelopment nystagmus syndrome, by Brodsky, 2004	p. 57
Fig 15. Decision tree (1). A nystagmus in a child	p. 59
Fig 16. Decision tree (2). An infantile nystagmus syndrome in a child	p. 60
Fig 17. Decision tree (3). A <i>spasmus nutans</i> syndrome in a child	p. 60
Fig 18. One of the stimuli used to attract the child’s attention, for calibration purposes	p. 65

Fig 19. Stimulus used to elicit the look opto-kinetic nystagmus	p. 68
Fig 20. Stimulus used to elicit the stare opto-kinetic nystagmus	p. 68
Fig 21. The Eyefant eyetracker	p. 73
Fig 22. Using the projective transformation which best maps the signal to the stimuli inputs	p. 74
Fig 23. Using singular spectrum analysis in order to isolate the nystagmus waveform from other movements (“detrend”)	p. 76
Fig 24. Representation of maximal speed as a function of the amplitude for a mixed population of saccades and pathological eye oscillations	p. 76
Fig 25. Heat map representation of a case of typical infantile nystagmus syndrome with a null zone in the right gaze	p. 79
Fig 26. Heat map representation of a case of <i>spasmus nutans</i> syndrome	p. 79
Fig 27. Schematic representation of the patients’ inclusion process	p. 105
Fig 28. Oculographic characteristics of typical optic pathway glioma-associated nystagmus (1)	p. 107
Fig 29. Oculographic characteristics of typical optic pathway glioma-associated nystagmus (2)	p. 110
Fig 30. Gadolinium-enhanced T1 axial imaging of the optic pathway gliomas	
Fig 31. Schematic representation of the disruption in the vergence system circuitry possibly leading to the specific OPG-associated nystagmus	p. 111
Fig 32. Oculographic recording by infrared reflectometry of a benign intermittent upbeat nystagmus in childhood	p. 126

List of tables

Table 1. Loci and genes implicated in idiopathic infantile nystagmus syndrome	p. 48
Table 2. Clinical characteristics of the infants recorded	p. 82
Table 3. Characteristics of the patients studied with 5-channel VEP	p. 90
Table 4. Characteristics of <i>spasmus nutans</i> cases included in the study	p. 99
Table 5. Clinical characteristics at diagnosis	p. 112
Table 6. Imaging and histologic characteristics	p. 113
Table 7. Treatments characteristics and visual outcome	p. 114
Table 8. Nystagmus characteristics	p. 115
Table 9. Clinical features in five patients affected by transient intermittent upbeat nystagmus	p. 126

List of abbreviations

CNS: Central nervous system

CSNB: Congenital stationary night blindness

EOG: electro-oculography

ERG: electroretinogram

FMNS: Fusion maldevelopment nystagmus syndrome

INS: Infantile nystagmus syndrome

OKN: optokinetic nystagmus

VEPs: Visual evoked potentials

Advisory Note

While the functional anatomy of physiological nystagmus has been unfolded over the last decades, much remains to be understood about pathological nystagmus. Despite extensive readings, we were not able, before beginning this work, to distinguish robust knowledge from hypotheses in the field of pathological nystagmus. Our daily clinical practice in a paediatric ophthalmology department was both challenging and frustrating by the lack of systematic reliable recording of nystagmus. We decided, despite warnings from several mentors, to undertake a thesis work about nystagmus, with two initial directions: a practical one, the development of new, reliable and reproducible methods of recording in infants; a theoretical one, the unfolding of the pathophysiology of pathological nystagmus. Dr Vidal accepted to direct this work and we thoroughly thank him for his constant support and irreducible enthusiasm.

This work has been a fantastic test for our nerves –lack of budget, numerous technical issues, maternity leaves, disease and death of our regretted closer mentor. Although we now can use on a daily basis satisfactory oculomotor recordings of nystagmus in infants, regarding the pathophysiology of nystagmus, the more our knowledge has grown, the more the number of questions have increased.

The opinions expressed here are under the sole responsibility of the author.

Illustrated Glossary

Nystagmus: “repetitive, to-and-fro movements of the eyes that are initiated by slowphases” (Leigh and Zee, 2006)

Pendular nystagmus: nystagmus consisting of sinusoidal slow-phases oscillations (fig. 1A). This is sometimes referred as “pure” pendular nystagmus, as opposed to “asymmetric” pendular nystagmus, where the waveform is an asymmetric sinusoid.

Jerk nystagmus: nystagmus consisting of an alternation of slow drift and corrective quick phase. Despite the quick-phase genesis of nystagmus, by convention the direction of the quick phase defines the nystagmus direction. According to the speed over the duration of the slow phase, one may distinguish: constant velocity slow phases (fig. 1B), increasing velocity slow phases (fig. 1C) and decreasing velocity slow phases (fig. 1D).

Conjugate/dysconjugate nystagmus: When both eyes are oscillating in the same direction, a nystagmus is said conjugate (fig. 2A). The large majority of nystagmus are conjugate. When both eyes are not oscillating in the same direction, the nystagmus is said disconjugate (or disjunctive, fig. 2B).

Associated/dissociated nystagmus: When the size of the oscillations differs in both eyes, the nystagmus is said dissociated. The large majority of nystagmus are “associated”.

Monocular nystagmus: the extreme form of dissociated nystagmus, when eye oscillations are seen only in one eye, is called monocular nystagmus (fig. 2C). Many clinically monocular nystagmus are actually dissociated binocular nystagmus, with infraclinical oscillations in the apparently still eye.

Nystagmus amplitude: peak-to-peak magnitude, measured in degrees (or, clinically, in mm., fig. 3). Small amplitudes : amplitudes $\leq 5^\circ$; medium amplitudes : amplitudes from 5 to 15° ; large amplitudes : amplitudes $> 15^\circ$ (Duke-Elder, 1949).

Nystagmus frequency: number of oscillations per second, expressed in Hz (fig.3). Usually, low frequencies: frequencies $\leq 2\text{Hz}$; medium frequencies: frequencies from 2 to 5 Hz; high frequencies $> 5\text{ Hz}$.

Oculographic representations: By convention, time is along the x-axis, amplitude in degree along the y-axis; for horizontal recordings, right is up and left is down; for vertical recordings, up is up and down is down.

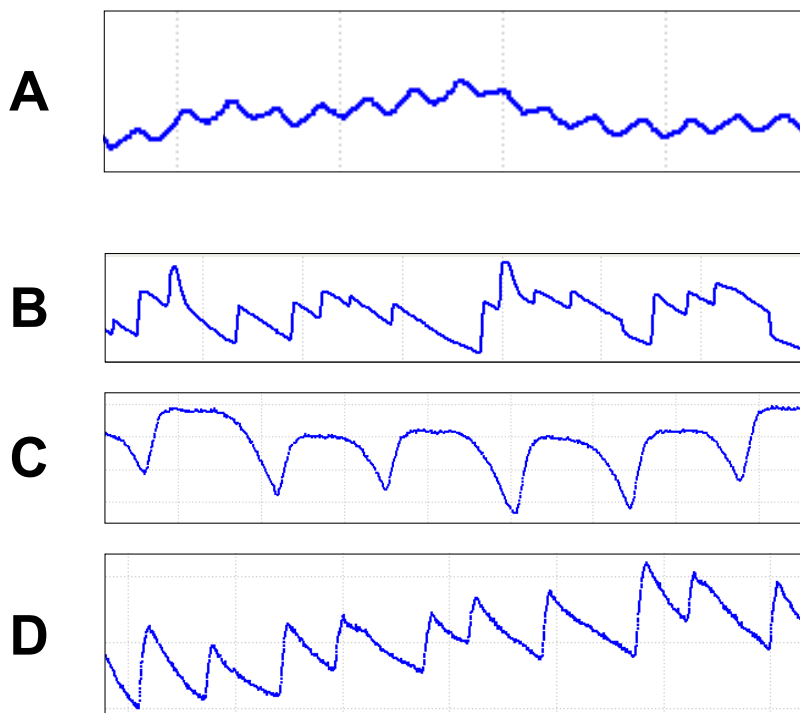


Fig 1. The four basic nystagmus waveforms

A: pendular; B, C, D: jerk (beating to the right); B: with constant-velocity slow phase; C: with increasing velocity slow phase; D: with decreasing velocity slow phase. When not specified, recordings were obtained with the Eyefant*.

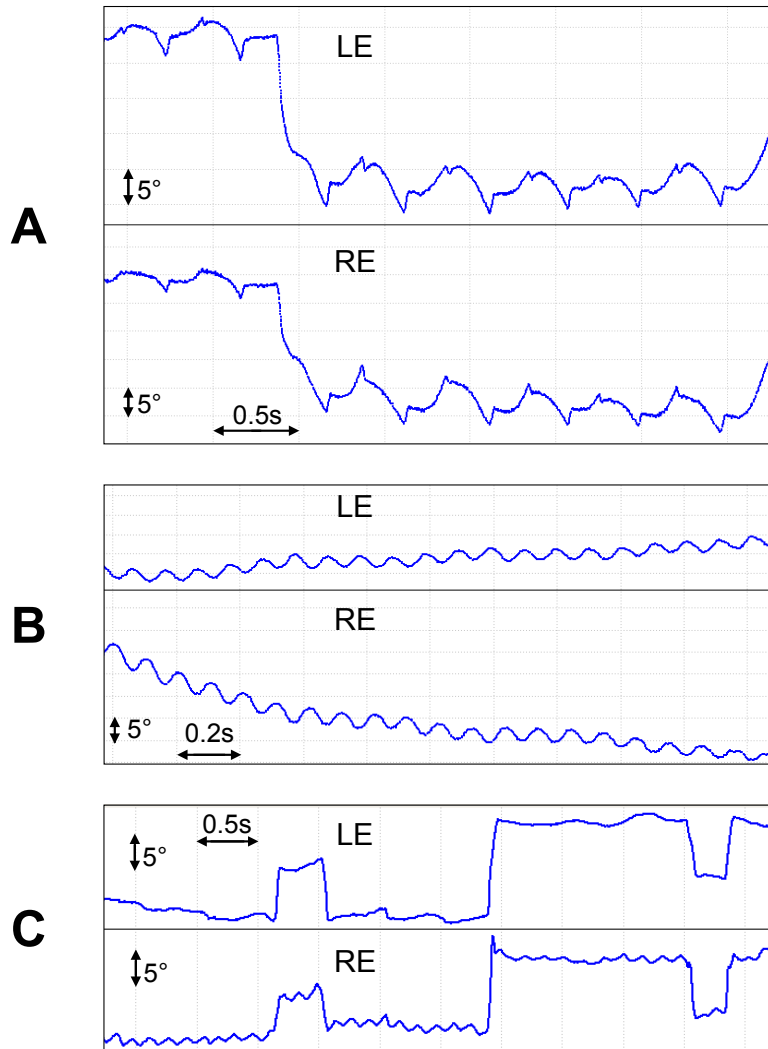


Fig 2. Conjugacy and association

A: conjugate nystagmus; B: disconjugated nystagmus (180° phase opposition); C: dissociated nystagmus (amplitude in the right eye is superior to the left, here to the extreme: right monocular nystagmus).

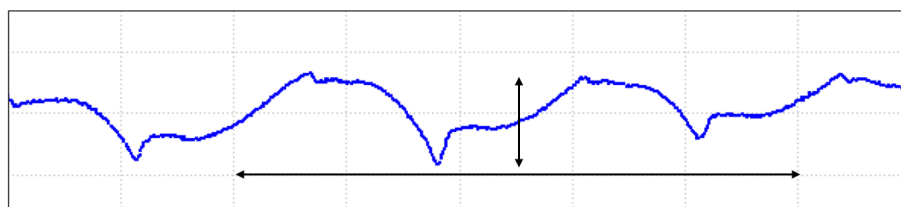


Fig 3. Frequency and amplitude

The frequency of a nystagmus is the number of oscillations per second (here, one second is represented by the horizontal arrow; nystagmus frequency = 2Hz).

The amplitude of a nystagmus is the peak to peak magnitude (represented here by the vertical arrow. Each vertical graduation=5°; nystagmus amplitude = 7.5°)

Introduction: nystagmus in infancy

Nystagmus –from the greek *νυσταγμός* (nustagmos), which designates the nodding of the head when one is falling into sleep– is defined as an involuntary, periodic eye movement caused by a slow drift of fixation. Nystagmus is often classified into two to three major families: physiological nystagmus; pathological nystagmus, often divided between early-onset and acquired nystagmus. Pathological nystagmus causes numerous questions, both practical and theoretical.

This introduction will focus on the three main entities encountered in infants: INS, FMNS and *spasmus nutans* syndrome. The two first were formerly often considered as “congenital” (like infantile strabismus), as they appear within the first weeks of life, while the third appears in the first months of life.

In 2001, the Classification of eye movement abnormalities and strabismus (CEMAS) study group, published recommendations and a new classification, with new denominations of nystagmus (Group, 2001). These new denominations have been criticised, particularly in Europe, as they are sometimes difficult to translate to other languages (for instance, *fusion maldevelopment nystagmus syndrome* is uneasy to translate to French) and as they are based on presumed pathophysiology instead of being descriptive. However, this new classification is more and more used in the literature and we shall therefore use its denominations in this text.

The CEMAS classification distinguishes nine families of “pathologic nystagmus”:

- 1- Infantile nystagmus syndrome (INS), comprising the former “motor congenital”, “sensory congenital” nystagmus,
- 2- Fusion maldevelopment nystagmus syndrome (FMNS), comprising the former “latent” and latent manifest” nystagmus,
- 3- *Spasmus nutans* syndrome,
- 4- Vestibular nystagmus, comprising peripheral vestibular imbalance nystagmus (1), central vestibular imbalance nystagmus (2) and central vestibular instability nystagmus (3), better known as periodic alternating nystagmus,
- 5- Gaze holding deficiency nystagmus, comprising eccentric gaze nystagmus and associated rebound nystagmus (1) and gaze holding instability nystagmus (2),
- 6- Vision loss nystagmus, comprising monocular, binocular (“searching”), chiasmatic (“seesaw”) and post-chiasmatic vision loss nystagmus,
- 7- Other pendular nystagmus associated with diseases of central myelin, including oculo-palatal tremor and other varieties of nystagmus,
- 8- Ocular bobbing,
- 9- Lid nystagmus.

The first half of the classification is more largely used than the second.

Another classical way (Spaeth, 1950) though still largely in use, to order nystagmus in clinics was to distinguish them according to the “target organ” and the target specialist: there would then be three families of nystagmus: “ophtalmological nystagmus” (INS, FMNS and maybe idiopathic forms of *spasmus nutans* and anterior pathway vision loss nystagmus), “otology nystagmus” (peripheral vestibular imbalance nystagmus) and “neurological nystagmus” (all the other ones). The first ones are mainly horizontal and called “fixation nystagmus” as their amplitude increases on fixation attempts; the second ones are also horizontal but their

amplitude increases when fixation is suppressed; the third ones are mainly vertical or torsional and their amplitude is little affected by fixation.

Chapter II: Phenomenology of nystagmus

i.II.1. Introduction

A pathological nystagmus should always be examined under binocular, right and left eye viewing conditions, and for each condition in the nine positions of gaze (straight gaze, also called primary position of gaze; right gaze; left gaze; upgaze; left upgaze; right upgaze; downgaze; left downgaze, right downgaze) and during convergence. In the case of one or several head turn(s) or tilt(s), the nystagmus should also be examined in the preferred position(s) of gaze. A classical example of missed diagnosis in case of an examination only in the horizontal plane is eccentric gaze nystagmus. A nystagmus should also be examined long enough –and/or a sufficient number of times– so as to allow for observation of changes over time, which may be missed otherwise. A classical example of missed diagnosis in case of a too short examination is periodic alternating nystagmus.

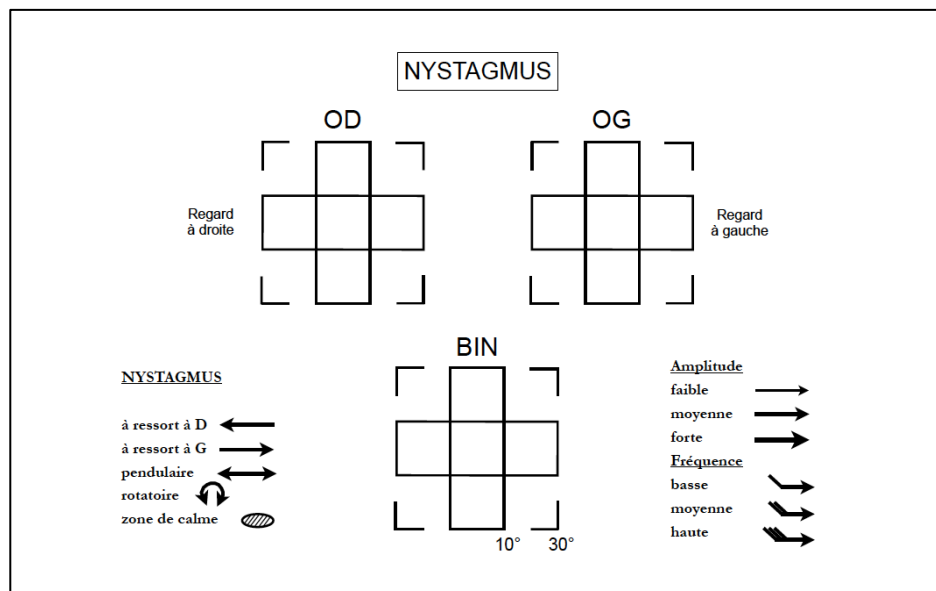


Fig 5. Diagram for the representation of the clinical characteristics of a nystagmus (based on Kestenbaum proposal, formalised by Klainguti)

Clinical observation remains the main –and often the only– way clinicians use to classify a nystagmus. It is advised to represent –rather than to only describe– the characteristics of a

nystagmus. Many diagrams to represent it do exist. They are based on Kestenbaum initial proposal (fig. 5) (Kestenbaum, 1961), which applies as such in the case of conjugated nystagmus –in the case of dissociated or disconjugated nystagmus, the same diagrams should be theoretically represented twice, i.e. six diagrams should theoretically be represented.

Oculomotor recordings also provide a different, independent, set of information, which can be used to classify a nystagmus. It should be systematically performed in the case of any nystagmus, so as to be useful in difficult and atypical cases. Only “otology” nystagmus are actually most often recorded in Europe, probably for historical reasons. In case of a nystagmus, oculomotor recordings should be done in the dark with no fixation; during fixation; with optokinetic stimuli; and if possible one should also study saccades and pursuit. All these stages should be performed under binocular, right monocular and left monocular viewing conditions. However, from a clinical perspective, even the most basic monocular recording in the horizontal plane, with only a few seconds of fixation under binocular viewing conditions, by providing most useful indications on the waveform of the nystagmus, sometimes allows for classification of an atypical nystagmus, in addition to the clinical observations made previously.

The most studied nystagmus are also the most frequently encountered: INS, FMNS and peripheral vestibular nystagmus.

i.II.2. Phenomenology of infantile nystagmus syndrome

The last classifications, including the CEMAS, have united two formerly distinct entities: motor congenital nystagmus and sensory congenital nystagmus. This union precisely results from undistinguishable phenomenology between these two entities.

Infantile nystagmus syndrome is usually first noticed between 4 and 12 weeks of age, hence the inappropriateness of the former adjective “congenital”. Observations of neonates or infants just before typical nystagmic movements appear are rare. One such observation

showed the presence of square wave jerks at the age of five weeks, before nystagmus movements appeared at the age of eight weeks (Gottlob, 1997).

The typical nystagmus of INS is horizontal in all positions of gaze; typically pendular in the primary position of gaze, in straight upgaze and in straight downgaze and jerk in any lateral position of gaze, beating to the left in the left gaze and to the right in the right gaze.

Within the first months, INS is usually of low frequency and large amplitude, with an obvious pendular component often compared by the parents to slow car wipers (fig. 6). Its amplitude increases during the initial days or weeks, before dramatically decreasing, while its frequency increases, before the age of 1.5 years (Theodorou et al. , 2015).

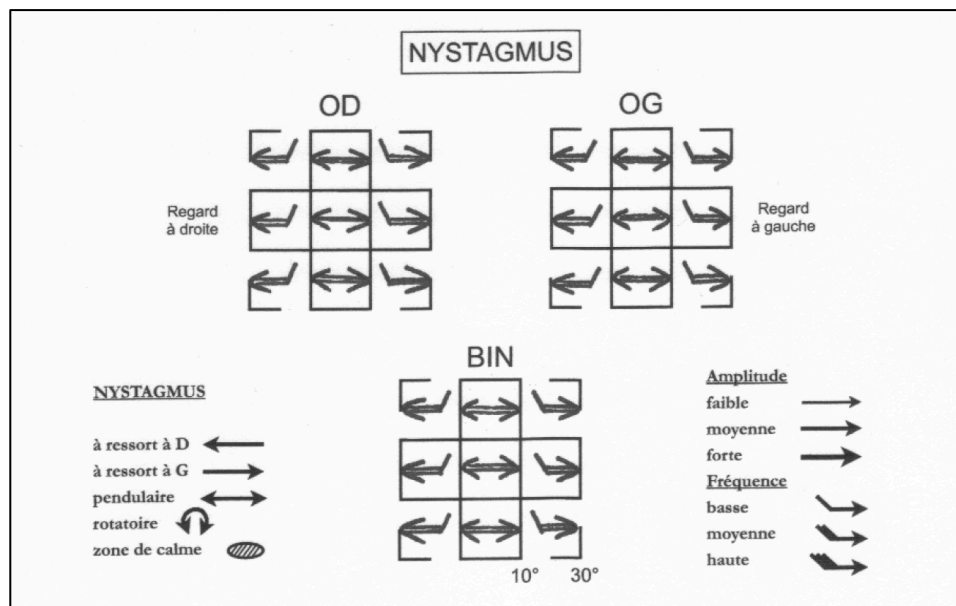


Fig 6. Clinical characteristics of infantile nystagmus syndrome in an infant

Low frequency and large amplitude pendular nystagmus in the primary position of gaze; jerk in the lateral positions of gaze; horizontal in all positions of gaze.

The pendular component may either decrease or disappear in one or several position(s) of gaze, called null zone(s) (fig. 7). It may also completely disappear clinically, while the jerk component in the lateral positions of gaze remains. The null zone is most often in the horizontal plane (xy plane, along the z axis) to the right or to the left, causing a head turn to the left or to the right, respectively (Graf et al. , 2001). More rarely, the null zone can be in

the vertical plane, with a compensatory chin-up or chin-down posture (Schild et al. , 2009). Sometimes, the null zone can be along the y axis, with a resulting head tilt (Lueder and Galli, 2012). All these head positions are often referred to as “anomalous head postures”. When present, the null zone in the horizontal plane is, in 2/3rd to 3/4th of cases, located to the right, with a compensatory head turn to the left side (Graf et al. , 2001), the reason for this being so far unknown. The null zone is either a zone where the nystagmus is absent, or usually pendular. On each side of the null zone, the nystagmus amplitude increases and the nystagmus beats to a different direction. This is specific to INS and often allows, in atypical cases, to clinically assess the diagnosis of INS. The null zone(s) may vary over time; it (they) may also vary according to the distance of the fixation point. Although usually the characteristics of INS do not or little vary according to the viewing condition –binocular vs right vs left eye fixating–, in rare cases, the null zone(s) may vary according to the viewing condition, possibly giving to an INS apparent phenotype of an FMNS. In some patients, the nystagmus also dampens for near vision; this is called the convergence null.

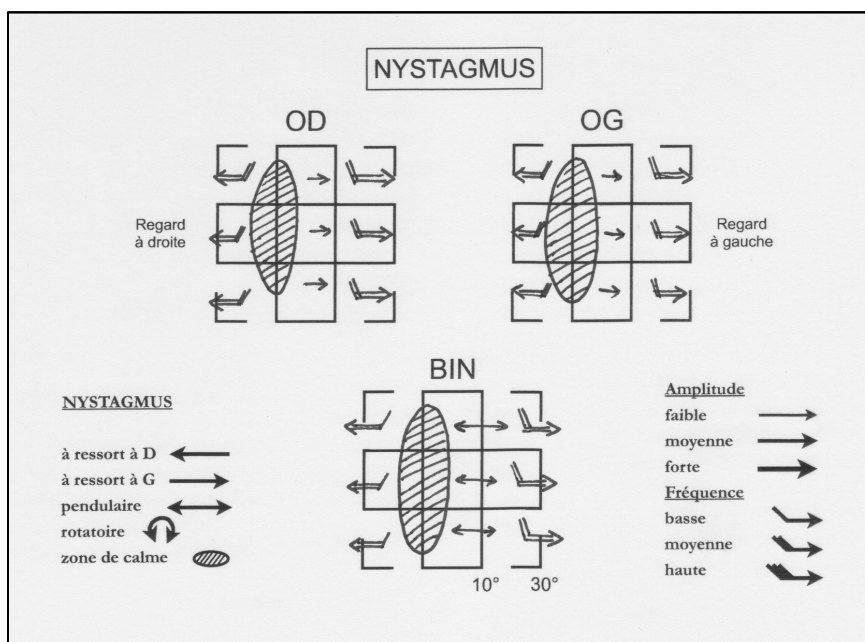


Fig 7. Clinical characteristics of infantile nystagmus syndrome in an older child

Higher frequency and smaller amplitude pendular nystagmus, with a position of lesser amplitude called null zone in the right gaze; jerk with opposite direction on both sides of the null zone; horizontal in all positions of gaze.

In most cases, these clinical characteristics allow for INS diagnosis after a careful clinical observation. In some cases, however, the diagnosis may remind hypothetical. A second set of signs have accumulated over the years, resulting from oculomotor recordings, although in the vast majority of studies and for obvious reasons, these signs resulted from recordings in adults. The main specific characteristics of INS from a quantitative oculomotor perspective are: pendular, or increasing velocity slow phases and distinctive waveforms with foveation periods and breaking saccades. These waveforms have been identified and classified into 16 different types, of which 12 are said “pathognomonic” of INS (fig. 8) (Hertle and Dell'Osso, 2013).

-
-
-
-
-
-
-
-
-
-
-
-
-
-
-

Fig 8. Infantile nystagmus syndrome (INS) waveforms from Hertle & Dell’Osso, 2013 (Hertle and Dell’Osso, 2013)

Out of the 16 different waveforms types encountered in INS, 12 (*) are pathognomonic of INS.

PSN: pursuit-system nystagmus; P: pendular, AP: asymmetric pendular, P_{FS}*: pendular with foveating saccades, PP*: pseudopendular, PP_{FS}*: pseudopendular with foveating saccades; J:

jerk, PJ*: pseudojerk, J_{EF}*: jerk with extended foveation, PC*: pseudocycloid, PJ*: pseudojerk; L: left, R: right.

VVSN: visual vestibular system nystagmus; J: jerk, T*: triangular, BDJ*: bidirectional jerk. DJR_A*: dual-jerk right with accelerating slow phases (PSN), DP_{FS}*: dual pendular with foveating saccades (PSN); NOT: nucleus of the optic tract; DJR_{EF}*: dual-jerk right with extended foveation (PSN); DJR_L: dual-jerk with right linear slow phases (VVSN).

i.II.3. Phenomenology of fusion maldevelopment nystagmus syndrome

While INS on its own is a clinical entity, FMNS, although it may be the prominent feature of the clinical presentation, is part of another entity: infantile strabismus. It is always and by definition, associated with infantile strabismus (Dell'Osso et al. , 1983). At one end of the clinical spectrum, the strabismus may be a microtropia, or microstrabismus (patent strabismus with a small deviation angle: equal or inferior to 8 diopters if horizontal, 4 diopters if vertical), difficult to assess, while the nystagmus is obvious. On the other hand, at the other end of the spectrum, an obvious early esotropia can be associated to a minimal, purely latent, FMNS. It is also always associated with a peculiar visual sensory cortical organisation, called “abnormal retinal correspondence”, which should better be designated as the absence of a normal retinal correspondence– to the point that FMNS is considered one of the motor signs of this sensory organisation. This peculiar sensory organisation also accounts for the fact that stereoscopy is never possible in these patients: they therefore cannot fixate with both eyes together, whatever the strabismus angle, and whatever the prisms added during the examination. They can only fixate either with the right or with the left eye. They can spontaneously alternate or have a preferred eye for fixation, the other one possibly being variously amblyopic.

Fusion maldevelopment nystagmus syndrome is clinically characterised by a jerk nystagmus, the characteristics of which change according to the viewing conditions: under monocular viewing conditions, the eye is beating “away from the covered eye”: to the right when the right eye is viewing; to the left when the left eye is viewing (Group, 2001). The nystagmus

respects Alexander's law: its amplitude increases in abduction. Under binocular viewing conditions, the nystagmus may be either absent: it is then a pure latent nystagmus (fig. 9); or present, but its amplitude is usually lesser than under monocular viewing conditions.

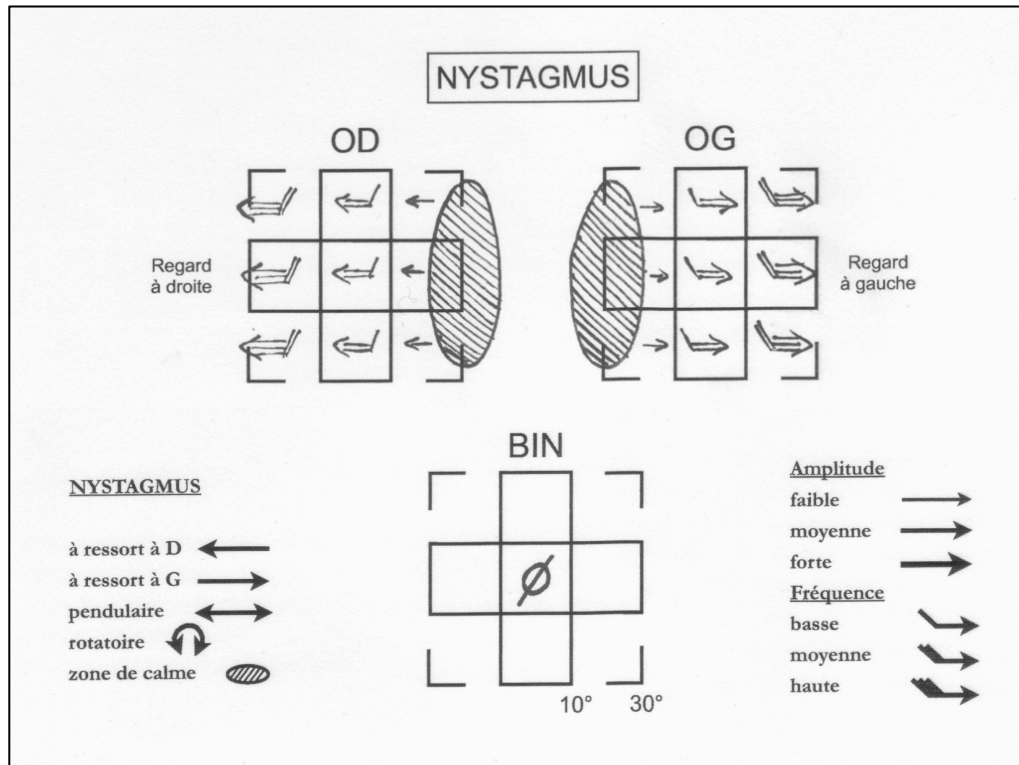


Fig 9. Clinical characteristics of the pure latent form of fusion maldevelopment nystagmus syndrome (FMNS)

No nystagmus is observed under binocular viewing conditions. A jerk nystagmus beating to the right is seen under right monocular viewing conditions; to the left under left monocular viewing conditions.

When also present under binocular viewing conditions, the nystagmus characteristics are similar to the ones of either of both monocular viewing conditions (fig. 10). It is then usually associated to amblyopia, and the characteristics under binocular viewing conditions are the ones of the non-amblyopic eye viewing condition, which is the eye fixating spontaneously. There is no null zone here: the zone of lesser amplitude of the nystagmus is in adduction, hence in such patients a head-turn with a fixation in adduction. The preferred position of fixation may sometimes be in extreme adduction. In any case, there is never any inversion of

the direction of the nystagmus beyond the area of lesser amplitude, unlike what is seen in an INS null zone.

Quantified oculomotor recordings have defined the oculomotor characteristics of FMNS: its slow phases are typically of decreasing velocity (fig. 11), however they can also be linear (Abadi and Scallan, 2000). They are never of exponential velocity, as in INS. They do not exhibit foveation periods, as INS do. Foveation occurs during the slow phase, whose speed usually allows for good visual acuity (Dell'Osso et al. , 1995).

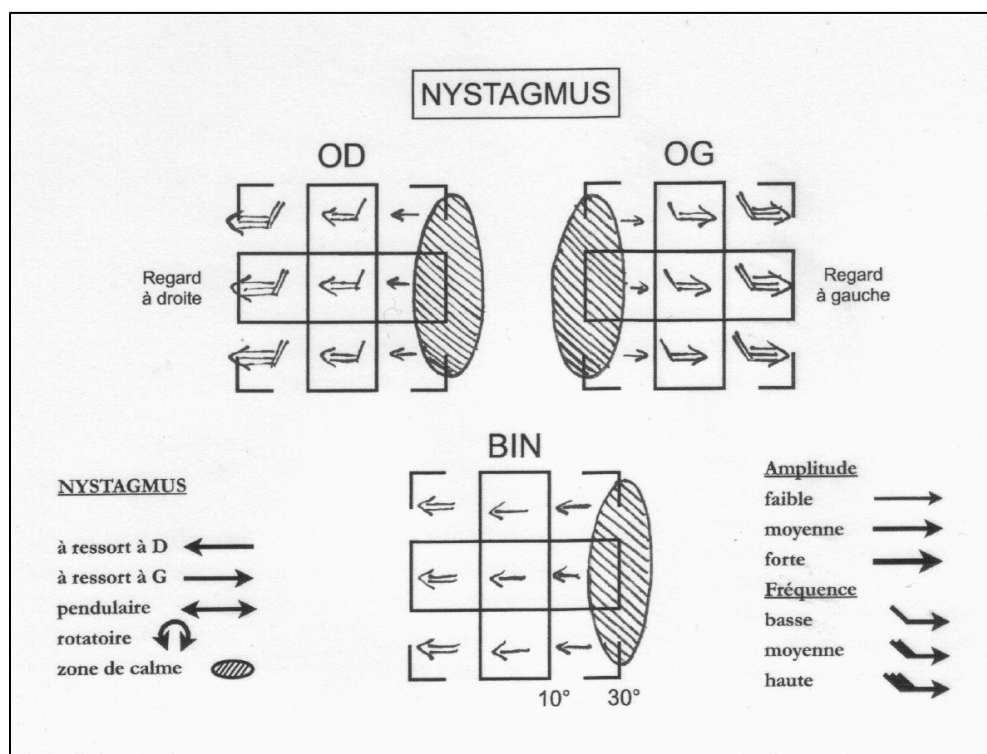


Fig 10. Clinical characteristics of the latent manifest form of fusion maldevelopment nystagmus syndrome (FMNS)

A jerk nystagmus beating to the right is seen under right monocular viewing conditions; to the left under left monocular viewing conditions. Under binocular viewing conditions, the nystagmus characteristics are the same as under monocular viewing conditions when of the non fixating eye is covered (here, the right eye is the fixating eye).

These characteristics provide explanations on how INS and FMNS can possibly be confused despite careful clinical observation (Dell'Osso et al. , 1979): strabismus is always present in FMNS, but a microtropia may easily be missed; in the other hand, INS may be associated to strabismus (for instance accommodative strabismus).

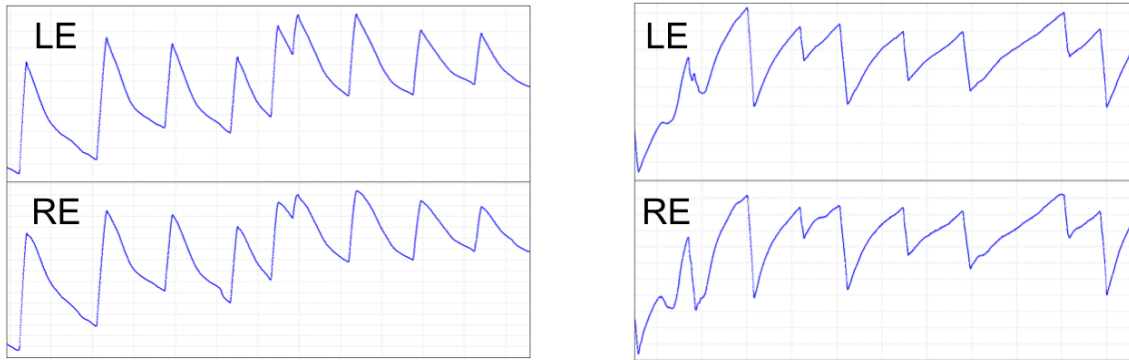


Fig 11. Fusion maldevelopment nystagmus syndrome (FMNS) typical waveform

Slow phase velocity is decreasing. On the left: the left eye is covered; under right eye monocular viewing (nystagmus beating to the right). On the right: the right eye is covered; under left eye monocular viewing (nystagmus beating to the left)

Not exceptionally, patients with FMNS alternate their fixating eye so that the fixating eye is always the adducting eye: they can begin to read a sentence while fixing with their right eye and finish it while fixing with their right eye. If the strabismus angle is small, the clinician can mistake these two zones of lesser amplitude in adduction with two true null zones and mistake an FMNS for an INS. At least theoretically, an INS associated with a strabismus might exhibit two different null zones according to the fixating eye and might therefore be mistaken as an FMNS. In addition to these situations, INS and FMNS can be associated together (Abadi and Scallan, 1999). The only way to distinguish between these is to carefully analyse the oculomotor recordings.

i.ii.4. Phenomenology of *spasmus nutans* syndrome

The literature regarding *spasmus nutans* is much poorer than that for INS or FMNS, probably due to two factors: its relative rarity and the fact that it often vanishes over time and therefore does not allow for recordings in adults, unlike INS and FMNS. An extended description and discussion about *spasmus nutans* is given in Part II.

Classical clinical descriptions (Dickson, 1895, Norton and Cogan, 1954, Østerberg, 1937, Raudnitz, 1897) define its characteristics: always pendular, of small amplitude, high frequency, often intermittent, often multidirectional, and often –or for some authors systematically– dissociated –that is to say of different amplitude between both eyes, even to the point of being apparently unilateral– and/or disconjugated–both eyes not oscillating in phase (fig. 12). Its onset is said to be later than INS or FMNS, although no inferior limit has been given; for idiopathic forms, it resolves spontaneously between age 3 and 6 years. Sometimes, the amplitude of the nystagmus increases in abduction. It may be associated with a head nodding or/and a head turn, although these are neither constant nor specific.




Fig 12. Clinical characteristics of an example of *spasmus nutans*-type, right monocular, nystagmus

There is extreme dissociation between the two eyes, as the left eye does not clinically exhibit a nystagmus. The nystagmus observed in the right eye is multidirectional, of small amplitude and high frequency.

Only one article from 1987, to the best of our knowledge, systematically studied the oculomotor characteristics of *spasmus nutans* (Weissman et al. , 1987). They showed disconjugacy in all cases, under the form of phase differences between both eyes, most often of 180°, which, however, varied over time. These phase switches are, according to the authors, the hallmark of *spasmus-nutans*.

Although other articles report *spasmus nutans* oculomotor recordings (Gottlob et al. , 1995, Gottlob et al. , 1990, Gresty et al. , 1976), they did not address the nature of the dysconjugacy –that is the variations of each eye’s oscillations related to the other.

The CEMAS criteria state: “Infantile onset, variable conjugacy, small frequency, low amplitude oscillation, abnormal head posture and head oscillation, improves (“disappears”) during childhood, normal MRI/CT scan of visual pathways. Ocular motility recordings –high frequency (>10 Hz), asymmetric, variable conjugacy, pendular oscillations”, with common associated findings: “Disconjugate, asymmetric, multiplanar, family history of strabismus, may be greater in one (abducting) eye, constant, head posture/oscillation (horizontal or vertical), usually no associated sensory system deficits, may have associated strabismus and amblyopia, may increase with convergence, head bobbing, head posture may be compensatory” (Group, 2001). A few comments can be made about this definition. First, *spasmus nutans* “syndrome” is restricted to the “idiopathic” form –that is to say restricted to cases where this syndrome is not associated to any known condition– of a particular syndrome, called itself a syndrome and not a disease. Notwithstanding the fact that the diagnosis of *spasmus nutans* can here only be made retrospectively (“improves (“disappears”) during childhood”), this definition means that no name is given to the other expressions of the same syndrome; the adopted perspective is the opposite as the one adopted for INS, where sensory and motor types are united (a same perspective would restrict the designation of INS to the sole ex-motor congenital nystagmus). Second, it does not consider as necessary the main criterion according to Weismann *et al.*, as conjugacy is called “variable”, without further precision. Third, the chosen inferior frequency limit is surprising, as such a limit would exclude almost all the reported cases of *spasmus nutans* from this designation: it indeed almost never fits with published cases of *spasmus nutans* –in Weissman study, no case had a

frequency >10Hz (Weissman et al. , 1987); in Gottlob study, only two cases out of ten had a frequency >10Hz (Gottlob et al. , 1995).

Chapter III: Aetiology of nystagmus

i.III.1. Introduction

The use of the word “aetiology” –the “study of the causes”– here, is probably inappropriate, since a pathological association only becomes a “cause” when a satisfactory pathophysiological link between the pathological association and its consequence has been proven and recognised as such by the scientific community. No such link has been established between any of the pathological associations of the various forms of nystagmus, even for the case of fusion maldevelopment and FMNS, where the motor and sensory expressions of this better understood syndrome –by comparison to the others– may result from each other, according to the chicken and egg causality dilemma, or even for another, unsuspected, cause. In this chapter, we shall study the diverse conditions associated to the various nystagmus syndromes presented previously.

i.III.2. Pathological associations to infantile nystagmus syndrome

i.III.2.1. Introduction

The following list of pathological conditions possibly associated to INS is reported in most textbooks and review papers on INS: ocular media opacities (including corneal opacities, congenital cataract, vitreous opacities), albinism, Leber congenital amaurosis, aniridia, achromatopsia, S cone monochromatism, CSNB, optic nerve hypoplasia, optic nerve atrophy (Brodsky, 2010, Hertle, 2008, Leigh and Zee, 2006).

Practical conclusions are as follows. While in the absence of either optic nerve hypoplasia or pale optic disc with normal ERG there is no need for MRI scans in INS in the clinical setting, the interest of ERG has been demonstrated on many instances (Brecelj and Stirn-Kranjc, 2004, Kurent et al. , 2015).

Several questions, however, remain. They were suggested by our clinical experience: while INS was almost systematically seen in some of these conditions—such as albinism—, it was never encountered in some other conditions –aniridia, achromatopsia, S cone monochromatism—, where the observed nystagmus had none of the characteristics of INS. We therefore conducted a systematic search in the literature for each condition classically associated with INS.

i.III.2.2. Albinism

Albinism was the model of sensory congenital nystagmus; it is still a model of INS. The term actually designates a deficit in melanin biosynthesis, affecting either the eyes and the skin (oculo-cutaneous albinism, OCA), or only the eyes—the albinism is then called “ocular albinism”, although it was recently suggested that OA1, also called GPR143, the G-protein coupled receptor expressed by the muted gene *Oa1*, may actually be expressed largely in the central and peripheral nervous systems and that the disease might not be confined to the eyes (Fukuda et al. , 2015). The pigmentation of the eyes is therefore variably reduced and so is the one of the skin and hair in OCA. Oculocutaneous albinism is a very large spectrum, from complete forms (OCA type 1A), to *formes frustes*, the diagnosis of which is difficult, as any of the clinical sign may be missing and where pigmentation may appear within normal limits. Among the ophthalmological signs are: photophobia, INS, iris transillumination, diffuse chorio-retinal hypopigmentation, typical foveal hypoplasia most often grade 3 (Lee et al. , 2013) but also optic nerve hypoplasia and positive kappa angle (pseudo-exotropia with the Krimsky method) due to a longer distance between the optic disc and the line of separation between the nasal and the temporal ganglion cells (Brodsky, 2008, Brodsky and Fray, 2004). Nystagmus characteristics in albinism are typical of INS (Hertle et al. , 2004, Weiss et al. , 2011), with aperiodic alternating features in a third of the cases, supposedly corresponding to

temporal shifts in the null zone, and constituting a distinct entity from acquired, regular periodic alternating nystagmus (Abadi and Pascal, 1994, Hertle et al. , 2009). Crossing abnormalities of variable importance at the level of the chiasm are systematically found: too many ganglion cells are crossing; they are considered the hallmark of the diagnosis in dubious cases and require specific VEP methods (Apkarian and Shallo-Hoffmann, 1991, Breceelj, 2014, Breceelj and Stirn-Kranjc, 2004, Breceelj et al. , 2012, Dorey et al. , 2003, Hoffmann et al. , 2005, Neveu et al. , 2005, Neveu et al. , 2003, Pott et al. , 2003, Soong et al. , 2000, Tremblay et al. , 1996). At least four genes have been shown to be implicated in oculocutaneous albinism, with an autosomal recessive transmission: *TYR* (causing OCA1A, formerly called tyrosinase negative albinism), *OCA2*, *TYRP1* and *MATP*. Ocular albinism is X-linked and secondary to mutations in *OAI*. Oculocutaneous albinism can sometimes be syndromic. In Hermansky-Pudlak syndrome, true albinism of variable severity is observed, in association with bleeding diathesis, secondary to deficient storage of platelets. Nystagmus has all characteristics of INS, with APAN features in half of the cases (Gradstein et al. , 2005). True albinism with nystagmus is almost never seen in Chediak-Higashi syndrome, nor is it in Griscelli syndrome. It is also very rare in Prader-Willi syndrome (1% of cases) and almost never seen in Angelman syndrome.

The very nature of the link by which melanin controls the crossing of the projections involved in binocular vision is still not entirely clear (Balkema and Drager, 1990, Nadal-Nicolas et al. , 2014).

Two hypotheses have been proposed regarding the association between foveal hypoplasia and crossing abnormalities: classically, foveal hypoplasia has been seen as the cause of the excessive crossing and of the low vision, itself causing the motor instability of the eyes. This hypothesis probably results from erroneous interpretation of Cogan's 1967's paper on Congenital nystagmus (Cogan, 1967, Dell'Osso et al. , 2007); it was applied to all "sensory"

congenital nystagmus. Another hypothesis states that foveal hypoplasia could as well result from the crossing abnormality (Sloper, 2006, van Genderen et al. , 2006).

i.III.2.3. Ocular media opacities

Classically, visual deprivation, which may result from congenital cataract, if left untreated or treated too late, causes a “searching nystagmus”, now called binocular vision loss nystagmus, in the case of a binocular deprivation (Gottlob et al. , 1996), while monocular visual deprivation causes the “*syndrome du monoptalme fonctionnel congénital*”, (Spielmann, 1989), later translated as “syndrome of monocular infantile blindness with bilateral nystagmus” (Kushner, 1995), which is a hemi-FMNS. Although we were not able to find any relevant study, we observed that at least some cases of untreatable infantile blindness, a true INS preceded the transformation into a binocular vision loss nystagmus. Binocular vision loss nystagmus in children has been characterised: it consists in horizontal or vertical small-amplitude nystagmus (either pendular or jerk with any possible kind of slow phase characteristics; when jerk, with a periodical change of orientation) superimposed on larger oscillations (Gottlob et al. , 1996). Recent studies have also shown, that monocular relative visual deprivation could not only cause FMNS, but also INS either alone or in association with FMNS– and that binocular relative visual deprivation could not only be associated with INS, but also with FMNS, here also either alone or in association with INS (Birch et al. , 2012).

i.III.2.4. Leber congenital amaurosis

Leber congenital amaurosis is by definition a mixed, congenital, severe, retinal dystrophy, with typical clinical signs and no detectable response on the ISCEV global ERG, neither for the cones nor for the rods responses. The typical clinical signs are: a nystagmus, whose

characteristics are said to be initially the ones of INS (Jacobs et al. , 2009, Kurent et al. , 2015), various photophobia and/or hemeralopia, Franceschetti sign (the child presses his fingers against his eyes) and signs of low vision. We were not able to find any study assessing the nature of nystagmus in Leber congenital amaurosis: studies in humans mention the presence of a nystagmus, or in some rare instances its clinical aspect; two studies, however, have systematically assessed the characteristics of this nystagmus, though both in RPE-65-deficient Briard dogs (Jacobs et al. , 2006, Kurent et al. , 2015). Typical INS can certainly reveal a Leber congenital amaurosis; binocular low vision nystagmus can also –at least in older infants– be associated with Leber congenital amaurosis (Gottlob et al. , 1996); however, reports have also mentioned the possibility for Leber congenital amaurosis to be associated with vertical nystagmus, in particular upbeat nystagmus within the first year of age, before being replaced by horizontal nystagmus (Hoyt and Gelbart, 1984). It is not clear, whether these vertical components are always associated with typical INS and what their relative incidence is.

i.III.2.5. Optic nerve hypoplasia; infantile optic nerve atrophy

Optic nerve hypoplasia is a cause of early-onset nystagmus and low vision. It can be either isolated, or associated to various cerebral malformations, in the context of “septo-optic dysplasia”. Optic nerve atrophy in infants is extremely rare while pale optic discs are frequent, and in this context almost always associated to a retinal dystrophy, even though the retina appears clinically normal. True optic nerve atrophy in infants is almost only seen in the context of malignant osteopetrosis, a recessive autosomal disorder causing compression of both optic nerves in the optic canal, in addition to the most severe haematologic disorders resulting from bone marrow compression. These instances are much rarer than the previous. Thirteen cases of bilateral optic nerve hypoplasia have been systematically studied at various

ages, as early as three months of age (Gottlob et al. , 1996). All exhibited a characteristic binocular low vision nystagmus and not an INS. The incidence –and possibly the duration in case of a temporary phenomenon– of INS in these conditions does not seem to have been studied.

i.III.2.6. Aniridia

Aniridia is a severe dysgenesis of the human eye, far from being restricted to an absence of iris. It includes limbal insufficiency, which results in progressive corneal opacification, goniodysgenesis, possibly resulting in glaucoma, complete or partial absence of iris and typical foveal hypoplasia grade 1 (consisting in an isolated absence of extrusion of the plexiform layers at the level of the fovea) (Thomas et al. , 2011) to grade 4 (consisting in absence of extrusion of the plexiform layers –as in grade 1–, plus absence of foveal pit –as in grade 2–, plus absence of outer segment line lengthening –as in grade 3–, plus absence of outer nuclear layer widening) (Park and Oh, 2013). It may result from genetic mutation in *PAX6*–it is then clinically isolated– or in chromosomal deletion 11p –it is then associated with Wilms tumour, genito-urinary malformations and growth retardation within the WAGR syndrome. There is some doubt regarding the possibility of crossing abnormalities in aniridia (Merrill and Summers, 2012), but this was ruled out by a previous study using trusted methodology (Neveu et al. , 2005). We were not able to find, in any of the many existing clinical studies on aniridia, any mention more precise than “nystagmus”, “present” or “absent”. The possibility for upbeat nystagmus to be associated with aniridia has been mentioned in one case (Good et al. , 1990). Thomas *et al.* recently reported a family with autosomal-dominant nystagmus and foveal hypoplasia but clinically normal iris, exhibiting different characteristics in different family members and not fitting INS criteria, where a mutation in *PAX6* was found (Thomas et al. , 2014).

i.III.2.7. Achromatopsia and S-cone monochromatism

Achromatopsia and S-cone monochromatism are cone dysfunction syndromes, as opposed to retinal dystrophies. This classical distinction is probably not relevant from a fundamental perspective, as evidence is accumulating in favour of subclinical evolution of these stationary syndromes (Michaelides et al. , 2005, Thomas et al. , 2011, Thomas et al. , 2012); however, it is relevant from a clinical point of view, as during a human life, the visual function is not decreasing.

Achromatopsia is an autosomal recessive stationary disorder characterised by an absence of functioning cones. Clinically, children with achromatopsia exhibit a delay in visual function development, low vision, intense photophobia and absence of colour discrimination. The ERG shows no detectable cone responses, while the rod response is normal. Mutations in *CNGA3*, *CNGB3*, *GNAT2* and *PDE6H* have been described (Remmer et al. , 2015). Atypical foveal hypoplasia consisting of continuous inner retinal layers (i.e. absence of extrusion of plexiform layers) in the foveal area with evidence of disruption of the ellipsoid zone (with variable hyporeflectivity, also called “cavitation”, which increases over time) is found with SD-OCT (Lee et al. , 2013, Thomas et al. , 2011, Thomas et al. , 2011). Although achromatopsia is almost always cited amongst the list of conditions associated with INS, including in the CEMAS classification, where it appears with albinism as one of the two cited examples of INS “associated sensory system deficits” (Group, 2001), we were not able to find any report of assessed INS having led to an achromatopsia diagnosis. Instead, oblique pendular nystagmus was reported (Gottlob and Reinecke, 1994, Shawkat et al. , 2000, Yee et al. , 1985). Children with achromatopsia were shown to exhibit oblique pendular nystagmus, with a frequency between 3 and 12 Hz and an amplitude between 1° and 10° (Gottlob and Reinecke, 1994). The oscillations were either always in phase, or more frequently either out of phase, or alternating in-phase and out-of-phase periods of time. In no case was the

nystagmus dissociated (i.e. nystagmus amplitudes were similar for both eyes). In half cases, the nystagmus was intermittent, while it was constant in the other half. Pursuit of the optokinetic drum was normal both horizontally and vertically in 100% of cases. Head oscillations were assessed in all cases, although clinically obvious in only a minority of cases. From the age of thirty, although bursts of pendular nystagmus similar to the one recorded in children could persist, jerk, oblique, conjugated nystagmus appeared in the primary position of gaze, with frequencies between 0.5 Hz and 9 Hz and amplitudes between 0.5° and 5° (Gottlob and Reinecke, 1994). The velocity of the slow phase was decreasing or decreasing and increasing. The direction of the fast phase changed from 10° to 20° of eccentricity, to beat up in upgaze, down in downgaze, to the right in right gaze and to the left in left gaze.

S-cone monochromatism (formerly known as blue-cone monochromatism or “incomplete achromatopsia”) is an X-linked disorder characterised by the absence of cone opsin M and L: only the S-cones and the rods are functional among the photoreceptors of the outer retina. Clinically, the male infants affected exhibit similar though less severe clinical signs than in achromatopsia. Electroretinogram showed reduced cone responses and a normal rod response. Mutations are found in *OPNILW* and *OPNIMW*. On SD-OCT, variable macular thinning has been reported, with focal disruption of the inner segment ellipsoid band at the level of the normal S-cone-free zone (Carroll et al. , 2012). Nystagmus characteristics in children were similar to the ones of children with achromatopsia (Gottlob and Reinecke, 1994). Fine vertical jerk nystagmus was also found in S-cone monochromatism carriers with 20/20 or better visual acuity in one study, suggesting that the nystagmus is intrinsic to the disease and not directly caused by the visual defect (Gottlob, 1994).

The term “incomplete achromatopsia” should now be only used for patients with a mild phenotype of cone dysfunction syndrome, but with mutations in either of the genes affected in achromatopsia.

i.III.2.8. Congenital stationary night blindness

Congenital stationary night blindness (CSNB) designates a heterogeneous group of retinal disorders classically considered as “rod dysfunction” (i.e. non progressive) syndromes. They actually affect signal processing within photoreceptors, retinoid recycling in the retinal pigment epithelium or signal transmission via retinal bipolar cells (Zeitz et al. , 2015). They are not systematically associated with “night blindness” (also called hemeralopia), but the historical term yet remained in use. They can be classified in different groups: with abnormal fundus (*fundus albipunctatus* and Oguchi disease); with normal fundus. Within the CSNB with normal fundus, two phenotypes are described from the ERG results: the Riggs phenotype and the Schubert-Bornschein phenotype. Within the Schubert-Bornschein phenotype, two subtypes of CSNB can be described: type 1 (also called “complete”, corresponding to a transmission defect involving the ON-bipolar pathway) and type 2 (also called “incomplete”, corresponding to a transmission defect involving the ON- and the OFF-bipolar pathways). These forms can both be either X-linked or autosomal recessive. Only patients with CSNB with Schubert-Bornschein ERG phenotype (both types) may also exhibit a nystagmus.

Fewer contradictory studies have assessed the characteristics of nystagmus in CSNB: a group reported in 2008 in a study on ten patients (6-46 years, mean 17.1 years, median 12.5 years) with CSNB (two type 1 and eight type 2) the nystagmus to be always of *spasmus nutans* type (always disconjugate) (Pieh et al. , 2008), while in another study from 2012 on eight patients with CSNB, it was reported –by the same group– to be never of *spasmus nutans* type (never disconjugate) and to have characteristics compatible with INS (Abbas et al. , 2012).

In addition to these uncertain nystagmus characteristics, additional features have been reported in one single article, only in boys before the age of two or three, consisting in transient tonic downgaze associated with large upbeat saccades followed by a slow

downwards movement in the attempts to look up (intermittent large upbeat nystagmus) (Simonsz et al. , 2009).

i.III.2.9 Idiopathic infantile nystagmus syndrome

Most cases of INS, which are not associated either to albinism or a cause of early low vision (ocular media opacities, Leber congenital amaurosis, optic nerve hypoplasia or atrophy), have an apparent X-linked genetic transmission, with variable expression in the female carriers. Visual acuity, as opposed to other cases, is better than 3/10 (Thomas et al. , 2008). Mutations in *FRMD7* (Xq26.2) have been found in the majority of such cases, and even in a few sporadic cases (He et al. , 2008, Shiels et al. , 2007, Tarpey et al. , 2006, Zhang et al. , 2007). *FRMD7*-associated X-linked “idiopathic” INS therefore constitutes, together with albinism, the other main model for INS.

Although by definition the phenomenology of *FRMD7* INS is typical INS, some particularities have been found: significant anomalous head posture seems to be less prevalent in *FRMD7* INS (15% (Thomas et al. , 2008)) than in other INS (19% in mixed cases of INS before 6 months of age (Hertle et al. , 2002), 53% in mixed cases of INS (Abadi and Whittle, 1991)) and even than in other idiopathic INS (51% (Thomas et al. , 2008)), which suggests that the null zone is central in most *FRMD7* INS cases. This is in accordance with the fact that *FRMD7* INS had lower amplitudes in the primary position of gaze (Thomas et al. , 2008). The penetrance of *FRMD7*-associated nystagmus varies across families, between 0% and 100%. It seems more complete for missense mutations than for nonsense mutations (Self and Lotery, 2007). Two hypotheses have been proposed: the asymmetrical X inactivation would only occur in the case of nonsense *FRMD7* mutations; or the non truncated proteins would have a negative dominant effect (Self and Lotery, 2007). Female carriers without nystagmus sometimes exhibit, however, a pathological optokinetic nystagmus (Watkins et al. , 2012).

Two other loci had been identified within the chromosome X. The gene (initially called NYS1, then renamed HGNC NYS5), located in Xp11.4-p11.3 (Cabot et al. , 1999), has yet not been identified. Mutations in the *CASK* gene, also located in Xp11.4 and associated with X-linked mental retardation, have been described in two families with X-linked mental retardation and “nystagmus”, presented as “congenital nystagmus”; however, no recording was made and there is confusion in the text between gaze-evoked nystagmus and INS (Hackett et al. , 2010). Within the locus Xp22.2, GPR143 (HGNC NYS6) is known to cause pure ocular albinism. Mutations in GPR143, however, have been reported in patients with idiopathic nystagmus and no sign of oculo-cutaneous albinism (Peng et al. , 2009).

Few dominant forms have also been described. The genes HGCN NYS2 and NYS3, involved within the locus 6p12 (Kerrison et al. , 1996) and 7p11.2 (Klein et al. , 1998), respectively, have not been identified.

Locus	Gene	Transmission	OMIM phenotype number	HGNC gene symbol	Frequency
Xq26-q27	FRMD7	X	310 700	NYS1	Many families
Xp11.4-p11.3	?	X	300 589	NYS5	One family (French)
Xp11.4	<i>CASK</i>	X	300 749	<i>CASK</i>	Two families
Xp22.2	GPR143	X	300 808	NYS6	3 families (Chinese)
6p12	?	AD	164 100	NYS2	1 family (African-american)
7p11.2	?	AD	608 345	NYS3	1 family (German)

Table 1. Loci and genes implicated in idiopathic infantile nystagmus syndrome

AD: autosomal dominant, X: X-linked

i.III.3. Pathological associations to fusion maldevelopment nystagmus syndrome

Infantile strabismus, which is often associated with FMNS, is often associated with prematurity (11% of early exotropia cases and 12% of early esotropia cases, according to one

series), or with neurological disorder (17% of early exotropia cases and 18% of esotropia cases, according to ones series) (Hunter and Ellis, 1999). The variety of neurological disorders involved, however, precludes any aetiological speculation beyond the admitted fact that they all disturb either sensory afferences or motor alignment, or both, during the sensitive period of visual development (Bui Quoc and Milleret, 2014).

Fusion maldevelopment nystagmus syndrome has also been reported with a variable incidence in Down syndrome (Averbuch-Heller et al. , 1999, Feliuss et al. , 2014).

i.III.4. Pathological associations to *spasmus nutans* syndrome

i.III.4.1. Introduction

The second part of this work is devoted to *spasmus nutans*. As discussed above, there is no consensus as to what should be called *spasmus nutans*. Here is therefore a short overview of what has been considered in the literature as disorders possibly associated to *spasmus nutans*, without discussion on whether what has been described qualifies as *spasmus nutans*.

i.III.4.2. Chiasmal gliomas

Suprasellar tumours, mainly chiasmal gliomas, have been demonstrated to be possibly associated with *spasmus nutans* in young children (Albright et al. , 1984, Antony et al. , 1980, Baram and Tang, 1986, Donin, 1967, Farmer and Hoyt, 1984, Garty et al. , 1985, Kelly, 1970, Koenig et al. , 1982, Lavery et al. , 1984, Schulman et al. , 1979, Toledano et al. , 2015).

i.III.4.3. White matter diseases

Cases of *spasmus nutans* associated with dysmyelination in infants –such as Pelizaeus-Merzbacher syndrome (Penner et al. , 1987, Pham-Dinh et al. , 1991, Scheffer et al. , 1991) or Leigh syndrome (Smith et al. , 2000) have been reported.

i.III.4.4. Retinal dystrophies

A few cases have been reported, where the nystagmus associated with some retinal dystrophies has been described as having *spasmus nutans* characteristics: two twin brothers with Bardet-Beidl syndrome (Gottlob and Helbling, 1999), two cases of cone-rod dystrophies (Shawkat et al. , 2000).

i.III.4.5. Retinal stationary dysfunction syndromes

Although often cited as a cause of INS, cone stationary dysfunction syndromes (achromatopsia and S-cone monochromatism) are associated with a nystagmus which sometimes fits the most restrictive definitions of *spasmus nutans*, and which always fits the least restrictive ones (Gottlob and Reinecke, 1994, Shawkat et al. , 2000, Yee et al. , 1985).

Similarly CSNB of Schubert-Bornschein ERG phenotype, as stated above, is –at least often– associated with a nystagmus, which characteristics are also the ones of *spasmus nutans* (Lambert and Newman, 1993, Pieh et al. , 2008, Shawkat et al. , 2000).

i.III.4.5. Idiopathic spasmus nutans

The only entity deserving its denomination according to many authors, one of the “causes” for a syndrome for others, idiopathic *spasmus nutans* remains a mystery. By definition it resolves over time –although remaining infra-clinical oscillations have been recorded after its clinical resolution(Gottlob et al. , 1995)– and its diagnosis is at least an elimination diagnosis, or even a diagnosis *a posteriori*. It has been reported to be associated with a lack of light during the first months of life (Raudnitz, 1897); with poor socio-economical conditions (Herman, 1918, Østerberg, 1937, Raudnitz, 1897, Still, 1906); with African-american ethnicity or African

descent (Gottlob et al. , 1990, King et al. , 1986, Weissman et al. , 1987); but its cause and mechanisms remain a matter of debate.

Chapter IV: Pathophysiological hypotheses on nystagmus in infancy

i.IV.1. Pathophysiological hypotheses on infantile nystagmus syndrome

i.IV.1.1. Introduction

Since 1967, “congenital nystagmus” (now INS) has been divided into two groups, resulting from pathophysiological considerations (Cogan, 1967, Dell'Osso et al. , 2007, Proudlock and Gottlob, 2011): “sensory”, when an anatomic abnormality or a functional disturbance of the eye or the afferent, anterior visual pathways could be identified; “motor”, when it was not the case, supposing then a primary defect in the “oculomotor” system. Although this dichotomy tends to fade from a clinical point of view while INS is more and more considered as a single entity, it persists in the pathophysiological hypotheses proposed to explain its mechanisms.

i.IV.1.2. The classical “sensory” hypotheses

The discovery that foveal hypoplasia, even if not seen ophthalmoscopically, is actually present in most cases of patients with INS, not only in albinism, but also in X-linked, “idiopathic” forms of INS, previously considered as the hallmark of “motor” INS (Proudlock and Gottlob, 2011, van Genderen et al. , 2006), may strengthen the hypothesis of foveal hypoplasia being the cause of INS. Crossing abnormalities, which have been considered as resulting from foveal hypoplasia, are also found in more many cases of INS than only the ones associated with albinism: CSNB (Tremblay et al. , 1996, Ung et al. , 2005), achiasma (Apkarian and Bour, 2001), or even “idiopathic” cases (Huang et al. , 2006, van Genderen et al. , 2006). The traditional view on these afferent anatomical defects was that in affecting visual development, they would lead to low vision and cause the eyes oscillations. Vision, however, is sometimes much better in some cases of INS, than in other congenital conditions

not associated with INS. This hypothesis is therefore not sufficient to explain why foveal hypoplasia is often associated with INS.

It has been suggested that, instead that the crossing abnormalities result from the foveal hypoplasia, these crossing abnormalities might interfere with foveal development and result in foveal hypoplasia (van Genderen et al. , 2006). As stated by Sloper, chiasmal misrouting is sometimes not associated with foveal hypoplasia, both in albinism and in CSNB (Sloper, 2006). Both foveal hypoplasia and chiasmal misrouting might result from a third primary mechanism (Sloper, 2006).

i.IV.1.3. The classical “motor” hypotheses

Instability in the oculo-motor pathways involved in gaze stability has long been postulated as being the cause of idiopathic INS (Dell'Osso et al. , 2007).

In addition to the cases where INS is not found to be associated to any sensory abnormality, which were previously referred to as “motor” nystagmus, structural abnormalities have been described on oculo-motor pathways (Denis et al. , 2010).

i.IV.1.4. New sensory and motor hypotheses

- The discovery of FRMD7

The discovery of FRMD7, however, was followed by strong hope in unfolding the intricate pathophysiological hypothesis regarding INS (Gottlob and Proudlock, 2014). Indeed, FRMD7 mutations are present in half of X-linked “idiopathic” INS cases. It now appears that FRMD7 encodes a plasma-membrane cytoskeleton coupling protein. It co-localizes with the actin of primary neurones and promotes neurone outgrowth. The FRMD7 protein also interacts with CASK (the calcium/calmodulin-dependent serine protein kinase), which links the plasma membrane to the actin cytoskeleton in neurons. It also interacts with Rho-GDIalpha, a

regulator of the actin cytoskeleton. The FRMD7 protein has been shown to be expressed in the human embryo both in the developing neural retina and in oculomotor structures such as the cerebellum, the vestibule-ocular and the optokinetic systems. In the end, the old chicken-and-egg debate around the respective contributions of the “sensory/afferent” vs. the “motor” systems to the pathophysiology of INS reappears, while the discovery of FRMD7 and its functions does not allow to progress in this debate.

Developmental models, more than new insights from the genetic, have however renewed the field of the pathophysiology of INS.

- Hypothesis based on disturbance of the optokinetic reflex

Optican and Zee first proposed a model for INS, based on a gaze-holding network (neural integrator) with both position and velocity loops. In normal subjects, the position feedback would be positive and the velocity feedback would be negative, while in patients with INS, the velocity feedback would be reversed, leading to instability of the neural integrator (Optican and Zee, 1984).

Huang et al. reformulated the hypothesis that INS might be, in many instances, due to an inverted retinal slip, transforming the normally negative feedback loop of the optokinetic system into a positive feedback loop, leading to instability of the optokinetic system and hence to INS (Huang et al. , 2011, Huang et al. , 2006). The retinal slip would be inverted in the case of chiasmal misrouting, such as seen both in many situations associated with INS in humans: albinism (Apkarian and Shallo-Hoffmann, 1991, Dorey et al. , 2003, Hoffmann et al. , 2005, Pott et al. , 2003, Soong et al. , 2000), but also CSNB (Tremblay et al. , 1996), idiopathic cases (van Genderen et al. , 2006), where excessive crossing was found, or achiasma (van Genderen et al. , 2006), which is defined by insufficient crossing. Two animal models of INS are also associated with crossing abnormalities: mutant, achiasmatic, Belgian

sheepdogs (Dell'Osso and Williams, 1995) and mutant *belladonna* zebrafish larvae (Huang et al. , 2006).

- Hypothesis based on disturbance of contrast sensitivity to high-spatial frequencies

Harris and Berry hypothesised that INS could be an adaptive response of the visual system to abnormally poor high spatial frequency sensitivity. In such a visual system –for instance in the case of foveal hypoplasia or opacities of the ocular media–, image contrast could be optimally perceived with the help of oscillatory eye movements with increasing velocity waveforms (Harris and Berry, 2006).

- Hypothesis based on smooth pursuit damping instability and tonic imbalance in the visual-vestibular system

Dell'Osso developed a behavioural ocular motor system model capable of simulating normal and abnormal responses to various target inputs. According to a previous version of this model, INS was explained by an excessive positive feedback around the common neural integrator. According to the last version of this model (OMS model Dell'Osso, fig. 13), INS would always be caused by instability in smooth pursuit damping (responsible for the waveforms called “pursuit system nystagmus waveforms”, cf. fig. 8), plus a variable amount of tonic imbalance in the visual-vestibular system (responsible for the waveforms called “visual vestibular system nystagmus waveforms”, cf. fig 8, and for the combination of these waveforms with the former, cf. fig. 8): INS would be a motor oscillation with known motor causes (Hertle and Dell'Osso, 2013, Jacobs and Dell'Osso, 2002).

-
-
-
-
-
-

Fig 13. Version 1.5 of the behavioural ocular motor system model from Dell’Osso, from Hertle R. and Dell’Osso L., 2013 (Hertle and Dell’Osso, 2013)

Sensory defects would then only be the precipitating factor of INS. Any disruption to the afferent visual system in the early stages of visual development then might result in INS in predisposed individuals. Hertle and Dell’Osso hypothesise that either “a small percentage of individuals are born with a motor system that is precariously close to oscillation”, or that “nature has evolved the oculomotor system in such a way that the horizontal system is close to instability in many individuals”. They propose that in individuals without any sensory defect, the oculomotor system is so instable, due to genetic factors, that even normal visual inputs after birth are not sufficient to stabilise it; while in others, the associated sensory defect precipitates a predisposed instable oculomotor system to oscillate (Hertle and Dell’Osso, 2013).

i.IV.2. Pathophysiological hypotheses on fusion maldevelopment nystagmus syndrome

According to Hertle and Dell'Osso, the direct cause of FMNS is a tonic imbalance that drives the eyes with constant velocity, producing linear slow phases. Two main hypotheses have been developed in order to explain why this imbalance occurs.

The first hypothesis is the persisting naso-temporal asymmetry in the optokinetic reflex; the second is egocentric direction confusion.

Persistence of the normal, primitive, immature, asymmetric OKN, beyond the age of six months and over their whole life in patients with early strabismus has been known for years (Roelofs, 1954). The asymmetry of OKN is a useful sign of early strabismus. According to many authors, FMNS would be the optokinetic component of ocular rotation, expressed under conditions of monocular fixation. Infantile strabismus, by altering visual pathways development, would preserve this primitive subcortical motion detection system (Brodsky and Tusa, 2004); FMNS could then be considered the ocular counterpart of peripheral vestibular nystagmus (fig. 14). An animal model has been developed to further understand these mechanisms (Hoffmann et al. , 1996).

-
-
-
-
-
-

Fig 14. Pathways of vestibular nystagmus, opto-kinetic nystagmus and fusion maldevelopment nystagmus syndrome, by Brodsky, 2004 (Brodsky and Tusa, 2004)

AC: anterior canal, PC: posterior canal, HC: horizontal canal, LGN: lateral geniculate nucleus, CC: *corpus callosum*, NOT: nucleus of the optic tract, MLF: medial longitudinal fasciculus, MR: medial rectus, LR: lateral rectus.

The fact that patients with FMNS are able to use retinal slip information to adapt to motion-detection sensitivities (Schor, 1983) has been interpreted as an evidence against the first hypothesis (Hertle and Dell'Osso, 2013). Another hypothesis has been developed and supported by Dell'Osso *et al.* and Tychsen *et al.*, among others.

i.IV.3. Pathophysiological hypotheses on *spasmus nutans* syndrome

Unlike INS and FMNS, *spasmus nutans* nystagmus has not been the topic of many pathophysiological discussions. Although aetiological factors have been discussed (see above), no hypothesis has been developed, apart from the suggestion of a dysfunction in the normal yoking mechanisms of the version system (Weissman *et al.* , 1987).

Chapter V: Synthesis and questions

i.V.1. Practical decision trees

It is possible, from a systematic analysis of the literature, to build a practical decision tree for the clinician confronted to a nystagmus in a child. This tree, however, differs largely from available trees, because of the lack of evidence for many diagnoses being ever associated with INS, and from strong evidence for many diagnoses to be actually associated to different types of nystagmus.

One may clinically distinguish four distinct groups of nystagmus phenotype, each corresponding to a limited list of causes:

1°) INS (onset within the three first months of life)

- Albinism
- Ocular media opacity
- Leber congenital amaurosis
- Optic nerve hypoplasia or atrophy
- Idiopathic INS, generally X-linked, generally associated with an *FRMD7* mutation

2°) FMNS (onset within the three first months of life)

- Prematurity
- Neurological disorder
- Idiopathic FMNS

3°) *Spasmus nutans*-type nystagmus, with an inclusive definition: high frequency, small amplitude, pendular nystagmus, possibly multidirectional, possibly dissociated, possibly disconjugated (variable onset)

- Optic chiasm glioma
- Dysmyelination syndrome
- Early-onset retinal dystrophy
- Cone dysfunction syndrome (achromatopsia, S-cone monochromatism)
- CSNB of Schubert-Bornschein phenotype (type 1 or 2)
- Idiopathic *spasmus nutans*

4°) Other presentations (variable onset)

- Rare “neurological”, vestibular or visual varieties of nystagmus.

Similar localisation value than in adults, with the exception of upbeat nystagmus, possibly associated with anterior visual pathways abnormalities.

A decision tree may be proposed (fig. 15,16 and 17).

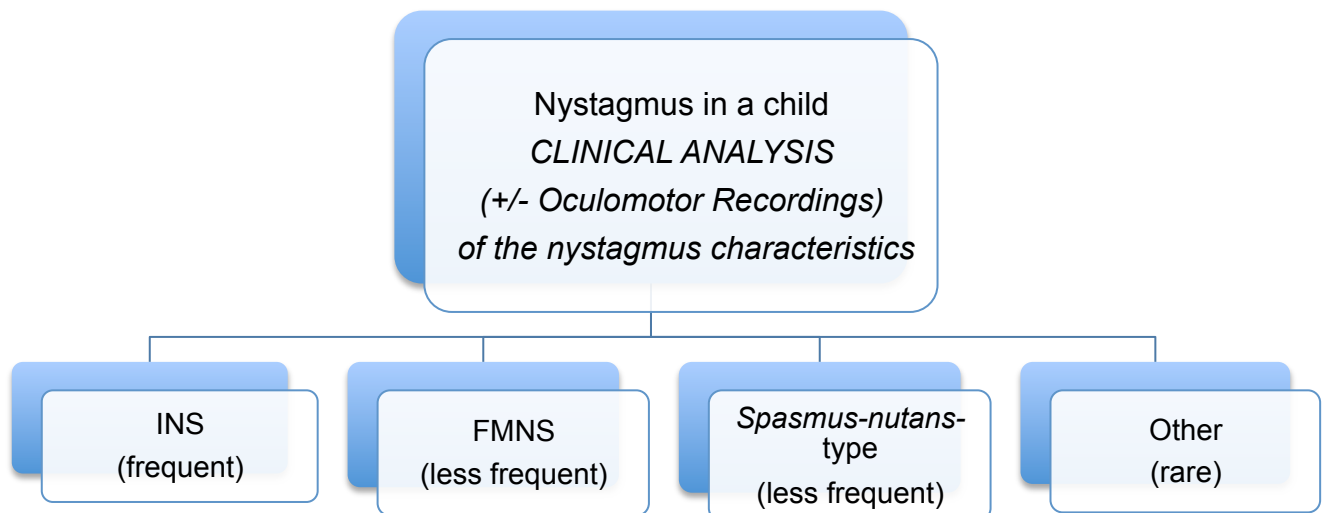


Fig 15. Decision tree (1). A nystagmus in a child

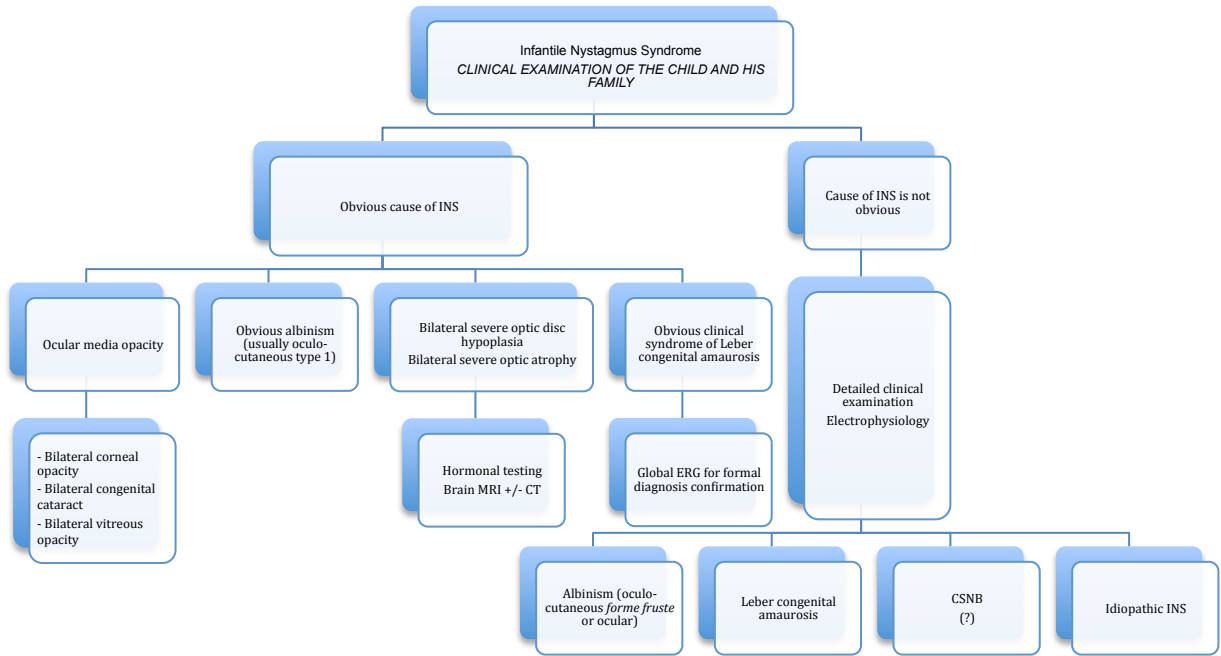


Fig 16. Decision tree (2). An infantile nystagmus syndrome in a child

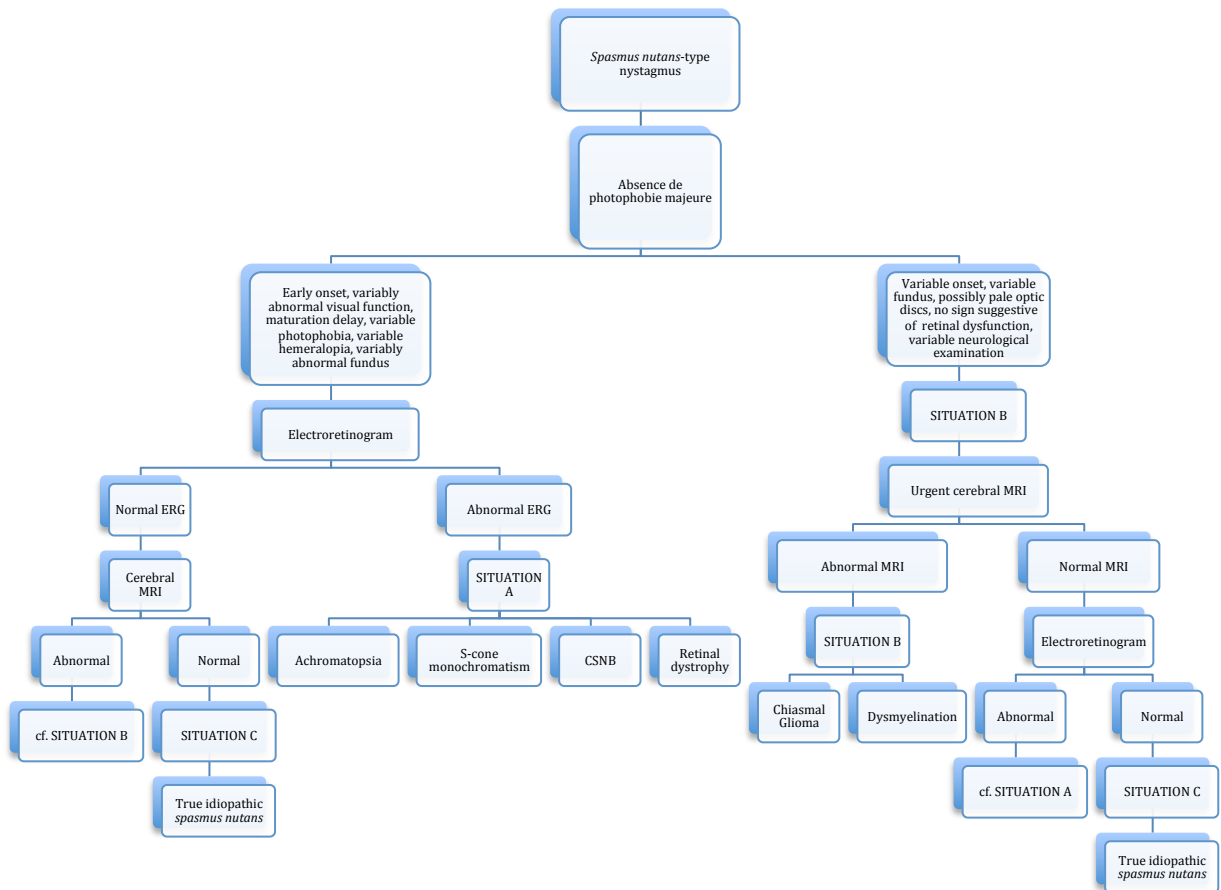


Fig 17. Decision tree (3). A spasmus nutans syndrome in a child

i.V.2. Practical and theoretical questions

The reading of the literature about nystagmus reveals a striking contrast between the recent progress –and state of technicity– of the research about genetic aspects of nystagmus in the one hand, and the relative paucity and imprecision of the description of the clinical features of nystagmus, especially in the infantile field, which partly results from a lack of reliable recording methods in infants. Most published studies are about the two most frequent varieties of nystagmus in infants: INS and FMNS. *Spasmus nutans* remains a variously defined entity, poorly described and studied. Some rare varieties of nystagmus have not been phenotypically described.

We therefore wanted to develop and assess recording methods, which could be used routinely in infants. We then aimed to use these methods for poorly studied clinical varieties of nystagmus in infancy.

Part I: Novel oculomotor recording techniques in infants and children

Before this work, we used motor electro-oculography (EOG) for oculomotor studies performed in the department (Robert et al. , 2014). Motor EOG is a robust method and remains largely used in paediatrics: it is largely available in specialised department, as it uses the same devices than the ones used for visual electrophysiology. It cannot therefore be used outside such laboratories. Spatial resolution (1-2°) is sometimes problematic, especially for low amplitude nystagmus. The main disadvantage of motor EOG is the long duration of the set up, which invariably causes infants to cry, so that additional time has to be added before the infant goes back to a quiet state, and before the recording may begin. Despite being largely available, this method is therefore rarely used for clinical purposes and remains a research tool. The large majority of studies on “congenital nystagmus” have actually been performed on adult patients with “congenital nystagmus”.

One of our aims was to develop and use new tools to record infantile nystagmus in the clinical setting, which could also be largely used for clinical purposes. During the development process of such methods, we encountered many technical issues, notwithstanding the intrinsic difficulties related to the specificities of young children examination. We developed, in collaboration with engineers and mathematicians, new stimulation and oculomotor recording techniques especially devoted to young children and infants.

Chapter I: Stimuli

As for any neuro-physiological recording, oculomotor recordings need stimuli.

I.1.1. Screens and stimuli

Screens were chosen among easily accessible varieties of screens, in order to be used as such in clinical settings. For all stimuli requiring screens, 19'' screens (37,5 x 30 cm) were used these are the largest screens easily available in most public hospitals.

The child was placed 50 cm from the screen, so that the stimulation field was 41° horizontally and 33° vertically. As the visual field of a 9-month-old infant covers 20 to 50° from the fixation point according to the gaze direction (Dobson et al. , 1998), such a screen covers a large proportion of the infant's visual field. Two screens connected to the same PC are therefore required: one for the stimuli display, another one to follow the recordings and start the stimuli.

In order to attract the child's attention and direct it to the screen, we adapted a method used in the electrophysiology laboratory at Great Ormond Street Hospital for sick children in London: a cartoon with image and sound track appropriate to the child's age is displayed on the screen for a few seconds. The visual stimulus then replaces the cartoon images, while the sound track of the cartoon remains on. The image of the cartoon then appears again. The child's attention is maintained on the screen; the duration of each stimulus is necessarily limited by the time limitations of the child's attention and can be ideally adapted to each child.

I.1.2. Stimuli for calibration and fixation

Calibration is necessary for any oculomotor recording analysis and is a major issue when recording eye movements in children. Only frequency evaluation and to some extent

waveform analysis may be made without proper calibration. The nature of the calibration used will be treated in chapter III of this part. Calibration is usually made before any recording session and uses a stimulus displayed at various locations of the screen at a given distance from a quiet and still subject, who fixates the stimulus at each location and makes saccades between each location. This, in an infant, may be a challenge.

Other methods have therefore been developed in order to skip such a calibration in an infant population. Theodorou *et al.* used the characteristics of the main sequence of ocular saccades in order to calibrate *a posteriori* their recordings (Theodorou et al. , 2015). Considering: on the one hand the systematic presence of saccades on any oculomotor recording with no specific stimulus, and on the other hand the reproducible relationship between the distance, the duration and the speed of a saccade, known as the main sequence, the authors have proposed and used a method of calibration *a posteriori*, using visual recognition of the saccades and deducing the parameters needed for the calibration. The main problem of this method is that the characteristics of the main sequence actually vary between centrifugal and centripetal saccades. Most of studies have actually focused on centrifugal saccades, from a fixation target to a peripheral target. Most spontaneous saccades considered here do not come from, nor go to the primary position of gaze, hence their main sequence is different from the one considered as a reference. Another problem of this method is that detected saccades go to 50°, while the eye tracker loses its linearity from 25°. Therefore, the calibration of the eye movements between 25 and 50° is not strictly appropriate.

Another method would consist in using the vestibulo-ocular reflex: by rotating the chair on which the child is seated –usually on his parents lap– of a known angle, one may then deduct the presumed characteristics of the eye movements. However, it is here difficult to reproduce with precision the position of the chair at start and end and also therefore the rotation angle.

From 4 or 5 months of age, it is usually possible to attract the attention of a child with normal development by a coloured target on a homogeneous screen. We developed a series of stimuli based on this principle, to be used from the age of 4 months. An orange cat head, or a small pink pig on a black screen, was usually displayed (fig. 18). It changed position every 5s., and moved to the nine positions of gaze with a 20° eccentricity. This same stimulus therefore also allowed for saccades fixation appreciation.




Fig 18. One of the stimuli used to attract the child's attention, for calibration purposes

I.1.3. Stimuli for optokinetic nystagmus recording

Studying the optokinetic nystagmus (OKN) in infantile nystagmus may be interesting. The OKN can be tested either binocularly or monocularly.

I.1.3.1. Monocular testing of optokinetic nystagmus

Before five months of age, infants present an asymmetry of the OKN under monocular viewing conditions: responses to temporo-nasal stimulation are better than responses to naso-temporal stimulations. Between five and 11 months of age, this asymmetry decreases progressively, so that at age 11 months, in a normal infant, OKN responses under monocular

viewing are symmetrical (Valmaggia et al. , 2003). This, however, depends on the speed of the stimulus: with 15°/s stimuli, OKN are symmetrical at age 10 months; with 30°/s stimuli, OKN are symmetrical at age 11 months (Valmaggia et al. , 2003).

This asymmetry persists in a well-know pathological condition: infantile strabismus. It is clinically assessable; it is *a posteriori* quantifiable through oculomotor recordings (Valmaggia et al. , 2004). True asymmetry between temporo-nasal and naso-temporal OKN is therefore a motor marker of abnormal retinal correspondence, a peculiar cortical organisation of the visual sensory system.

1.1.3.2. Binocular testing of optokinetic nystagmus

Yee *et al.* (Yee et al. , 1980), in a study using a 2-metre diameter OKN drum, showed that several pattern of OKN could be seen by patients with INS:

- Normal pattern;
- Superimposition—a normal OKN pattern is superimposed with pendular oscillations, visible during the slow phases of normal OKN, corresponding to INS pendular patterns in the primary position of gaze;
- Pseudo-inversion, in either or both directions—the nystagmus beats in the direction of the stimulation instead of beating away, but the slow phase has increasing velocity: it therefore corresponds to a jerk pattern of INS;
- True inversion—jerk nystagmus, constant velocity slow phase, beating in the direction of the stimulus instead of beating in the opposite direction.

Recording the OKN in patients with INS therefore would lead to distinguish five types of INS, based on OKN responses. “True inversion” of OKN, although it is recognised as such by many authors (Chen et al. , 2014, Collewijn et al. , 1985, Kennard and Lueck, 1989), is considered as others as an artefact, corresponding to gaze-modulated spontaneous nystagmus shifted by optokinetic nystagmus (Halmagyi et al. , 1980, Jacobs and Dell'Osso, 2004, Lueck

et al. , 1989) –i.e. they actually deny the existence of “true inversion” of OKN in INS patients and consider that all so-called “inversions” are actually cases of pseudo-inversion of OKN.

Unlike many studies on OKN, Yee study used a true OKN drum, with 2.5cm large bands, in order to stimulate the whole visual field at various speeds. Such a device is difficult to export in a clinic.

As the optimal duration of a stimulation in an infant does not exceed a few minutes, the choice of only one speed of stimulation was required. The 15°/s speed allows for the earliest responses and was therefore chosen.

Two kinds of OKN are described: stare OKN and look OKN. They may be generated while the stimulus is the same—typically, alternating black and white stripes: achromatic stimuli with opposed luminance (Kashou et al. , 2010)—, by giving different instructions to the subjects. When the subject is asked to look ahead without trying to follow, or even to pay attention to the stripes, the response is designated as *stare*; when he is asked to follow the stripes, the response is called *look*. Clinically, *look* OKN varies according to subjects: it is irregular, made out of large amplitudes saccades and pursuit segments, alternating with *stare* type responses. *Stare* OKN, by contrast, is very reproducible from one subject to another, with alternating saccades and pursuit segments of similar amplitude, giving on a recording the appearance of a factory roof.

What each of the OKN represents is not clear. Functional MRI studies suggest that the *look* OKN neuro-anatomical pathways are similar to the ones of saccades and pursuit, while stare OKN neuro-anatomical pathways would predominantly use infra-tentorial pathways (Kashou et al. , 2010). So do the archaic OKN, as opposed to the mature one. No hypothesis, however, can be formulated from these similarities, as the adult stare OKN is actually symmetrical. In the clinical setting, the look OKN is often used in order to study saccades and pursuit.

In the paediatric field, verbal instructions cannot be used and the stimuli have to carry by themselves non-verbal instructions, in order to study *look* vs. *stare* OKN. In the clinical setting, a Barany cylinder with additional little cartoons between the stripes is often used for *look* OKN. We chose to display on our screen coloured cars including small details (fig. 19). In order to stimulate *stare* OKN, instead of using black and white stripes (achromatic stimuli with opposed luminance, maximal contrast and a square luminance profile), which allows for true pursuit from one side of the screen to the other, we chose to use variable sizes of spots: achromatic stimuli with opposed luminance but intermediate contrast and a smooth, sinusoidal luminance profile (fig. 20) . Both stimuli sets were conceived by Jan Ober, Poznan, Poland.



Fig 19. Stimulus used to elicit the look opto-kinetic nystagmus (by J. Ober, Poznan)



Fig 20. Stimulus used to elicit the stare opto-kinetic nystagmus (from J. Ober, Poznan)

I.I.4. Other stimuli

Few other stimuli are needed for the examination of nystagmus in infants. Classical sinusoidal pursuit stimuli (amplitude 40°, speed 15°/s, horizontal and vertical), small and large saccades (10 et 20°, respectively), were developed and used according to the same method, alternating stimuli and cartoons, when required.

Chapter II: Eye trackers

I.II.1. Existing eyetrackers

Several varieties of eye trackers are used currently (Bedell and Stevenson, 2013, Eggert, 2007, Leigh and Zee, 2015). A standardisation project on the topic of eye data quality is ongoing. Its aim is to compare the performance of available eyetrackers, their suitability for valid measurement of eye movements classes and types and to design methods and measures for valid comparison. This project (EDQ) is led and administered by the Eye Movement Researchers' Association (EMRA) in collaboration with the Communication by Gaze Interaction Association (COGAIN).

I.II.1.1. Electro-oculography

Electro-oculography uses the corneo-retinal standing potential variations, which result from the eye movements. Assuming that the resting potential is constant, the recorded potential measures the eye position.

This technique offers several advantages: its availability (it is present in any visual electrophysiology laboratory as the technique is similar to the one used for sensory EOG, the fact that is independent from lid aperture (it is the only method that can be used during sleep) and relatively cheap.

However, EOG is long to set up (10 to 15 min); the recording devices are heavy, the spatial resolution is from 1 to 2°, the level of noise is variable, lid artefacts may be challenging.

I.II.1.2. Photo-oculography

Several techniques are based on photo-oculography. The most used are based on infrared reflectometry and track the scleral-iris edge of the eye by measuring the amount of scattered light from infrared sources.

These techniques offer several advantages: their low to intermediate cost, the often small volume of the device, the often excellent resolution (0.5° or better), the low level of noise. However, the range of linearity is often limited.

I.II.1.3. Video-oculography

Many systems are now based in video technology, tracking the pupil of reflected corneal images. The camera resolution, the digitisation rate and frame rate are highly variable according to the model. A few systems allow binocular recording; a few distant systems, by incorporating a head monitor, correct for limited movements of the head.

Their advantages are the often excellent resolution (0.5° or better), the often low level of noise.

Their main inconveniencies are: the high cost of the robust distant models, while other models imply a headgear; the often large volume of the device, which is often difficult to set in a clinic.

I.II.1.4. Magneto-oculography

Magneto-oculography uses a corneo-scleral lens, which contains thin coils of wire and is placed in a magnetic field. It is by far the most precise and reliable eye movement recording technique. However, it is not realistically possible to use it in the clinical practice, due to: the high price of the device and coils, the size of the installation and the necessity of wearing a lens during examination.

I.II.2. Requirements for studying nystagmus in children

Pre-requisites for an “ideal” oculomotor recording technique in the clinical setting have been listed by Quéré in 1989 (Péchereau et al.). They included four preconditions and ten technical

conditions. The method should be: painless, atraumatic (1); head free (2); useable at any age (3); available for a reasonable price (4). Technically, it should allow for: simultaneous recording of both eyes (1); recording of any type of eye movement (2); recording in the three planes (3); recording both eyes open or closed, or either eye being patched (4); recording despite a strabismus, through the possibility of compensating the strabismic angle (5); recording in real time (6); quantified recording (7); possibilities of archiving the results (8). Back in 1989, as for now, no existing technique fits these ideal requirements.

I.II.3. Development of the Eyefant

Oculometry in paediatric ophthalmology or neurology is poorly developed. It has, however, been developed in another research field: development neuropsychology. Both the devices used in this field, and in adult oculomotor laboratories, have led our work of finding and developing new recording techniques in infants and children.

Techniques involving the use of a head-gear, even when disclaimed of being specially devoted for children, are not appropriate for infants or even children with neurodevelopmental abnormalities.

Most techniques used in development neuropsychology use distant video-based devices, used to track the gaze of the child, the scan paths of his watching a scene. The resolution of most of these techniques is insufficient for abnormal eye movements' recordings; besides, most of these do not allow for binocular recording. We tested the few available video-based techniques in infants and conceived the installation for recording of the infant eye movements with such techniques. Although they would have been a solution, they exhibited two main disadvantages: their price and the lack of flexibility of not transportable, heavy devices devoted for research purposes.

Jan Ober proposed to develop a device that would be specially devoted to the recording of abnormal eye movements in infants and young children, based on the principles of direct infrared reflectometry developed in his laboratory. After having discussed and compared many possible options, the device chosen would be a highly portable, child-friendly device, which would not require to place the infrared emitters/sensors around the eye, as they would be located between the eyes, in the “shadow” of the nose, the design of the nose bridge and the distance between both sensors being calculated according to the anatomy of the face of young infants and inter-ocular distance according to the age—two distinct devices were produced: one for infants below the age of 12 months, another one for older infants or children (fig. 21). The device would record binocularly in the two planes: horizontal and vertical. The sampling frequency is 1000Hz, the spatial resolution 0.1° . The linearity range is $\pm 35^\circ$ horizontally and $\pm 20^\circ$ vertically. The transmission of the data to the PC is Bluetooth-based, allowing for a very quick set up, on the lap of the parent, without any connection from the chair.

Recording and analysis used the last versions of JazzRecorder* and JazzManager* softwares, under Windows 7.



Fig 21. The Eyefant eyetracker (from Ober* consulting, Poland)

Chapter III: Mathematical methods of analysis

The content of this chapter results from the collaboration with Émile Contal and Thomas Moreau, from the *Centre de Mathématiques et Leurs Applications* (CMLA), ENS Cachan (Pr Nicolas Vayatis), within COGNAC-G.

I.III.1. Calibration

Calibration was made *a posteriori*, allowing for all recordings to be performed in the shortest time possible. This was crucial in order to ensure the best possible attention from the infant throughout all the duration of the recording session. The targets' positions on the screen inducing eye movements in the linearity range of the Eyefant*, linear transformations were used. The projective transformation, also called homography—a line remains a line—that best correlates the signal recorded in the XY plane with the expected signal, was used to displace fixation sites and was used for any recording from the same series (fig. 22).

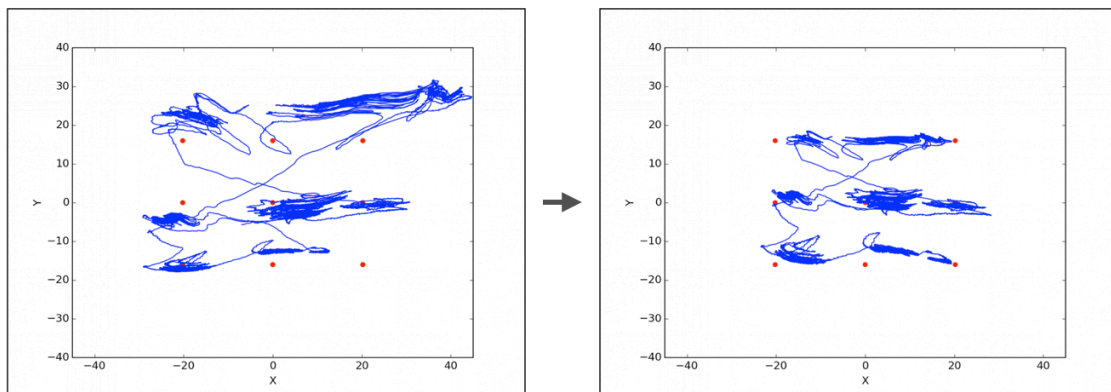


Fig 22. Using the projective transformation (homography) which best maps the signal to the stimuli inputs

Technical steps of this calibration were: the temporal realignment of the signal, in order to suppress the possible delay compared to the theoretical signal (1); the search for the projective transformation which best minimises the quadratic difference between the transformed signal

and the theoretical signal (2); the use of this transformation to the whole signal of the recordings from one series. A “series” of recordings here, by definition, contains all the recordings following the display of calibration stimuli. Constant visual check of the infants allowed to make sure the Eyefant remained stable on the infant’s head. In case it moved, a new calibration was realised, defining a new series. Due to the use of videos, this occurrence was not frequent.

I.III.2. Nystagmus waveform analysis

A simple analysis of the slow phase of a nystagmus usually allows for classification as INS or FMNS. In the atypical situations where a mathematical analysis of the recorded signal was required, singular spectrum analysis (SSA) (Golyandina et al. , 2001) was used, in order to isolate the nystagmus waveforms from other eye movements. This method allows for an adaptive extraction of the trend of a signal. In analysing all the sub-series of the original signal for a given scale, common behaviours can be found. The trend component was then considered to be the component explaining the most the global variation of the signal (fig. 23). One drawback of this method is that the trend can be scattered on several different computed components. In order to automatize the trend extraction step, a grouping step is needed. For the robustness of the trend extraction, the grouping step used a k-means algorithm to regroup similar components (Moreau et al. , 2015). The signals for the nystagmus movement were then analysed using traditional signal processing tools. Nystagmus frequency was estimated by using the maximum of the correlogram. In order to know the conjugacy of a nystagmus, the same principle was used in order to compute the phase delay of the movements of the eyes, based on the maximum of the cross correlation function between the two movement signals (right eye vs. left eye).

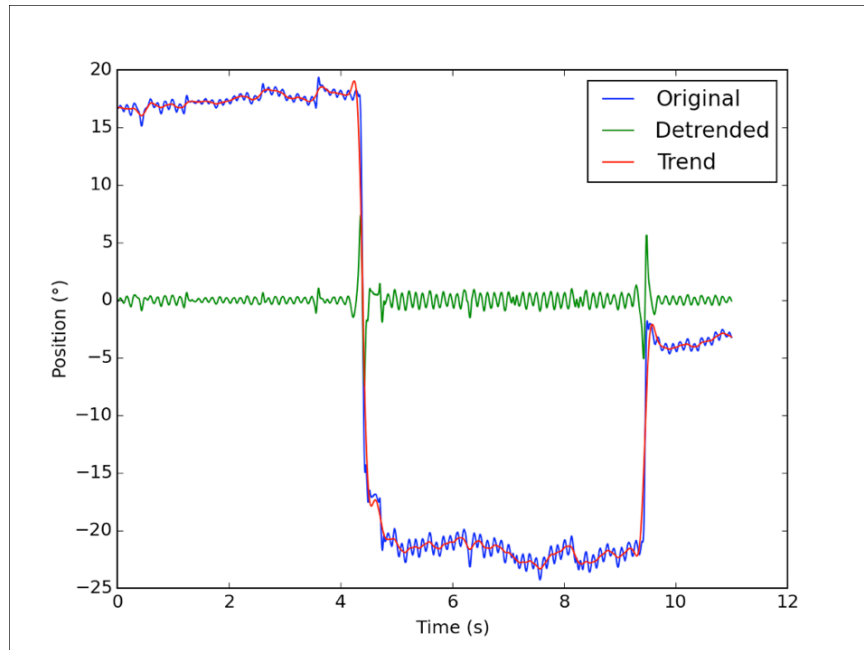


Fig 23. Using singular spectrum analysis in order to isolate the nystagmus waveform from other movements (“detrend”)

In some pathological situations, the oscillations frequency was so high and their amplitudes so small, that their very nature—saccades vs. pursuit movements—was not obvious. The fit of the main sequence defines a saccade. All ocular movements were then reported in a graph representing maximal speed as a function of the amplitude. It was then possible to assess the position both ocular oscillations and true saccades, in order to see whether the former were in the continuity of—and therefore of the same nature than—the latter (fig. 24).

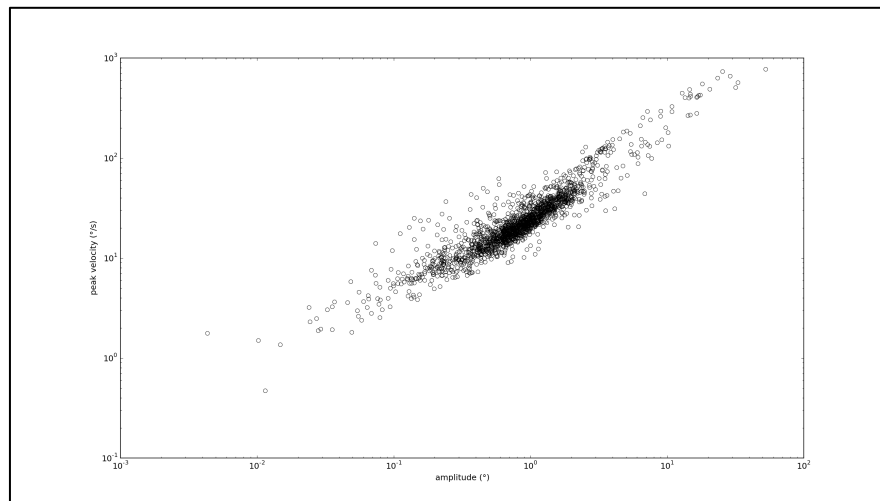


Fig 24. Representation of maximal speed as a function of the amplitude in an example of a mixed population of saccades and pathological eye oscillations

I.III.3. Calculation and representation of indexes allowing for characterization of a nystagmus

In addition to the waveform quality, a nystagmus can be characterized by quantitative parameters: its frequency, amplitude, and in the case of INS, the relative duration of its foveation periods. In idiopathic INS, Dell'Osso showed a correlation between visual acuity and the characteristics of foveation periods. The Nystagmus Foveation Function (NFF) was the first indicator of the best possible visual acuity of a patient with INS (Dell'Osso et al. , 1992). The NFF was later implemented and two other functions followed: the Nystagmus Acuity Function (NAF) and more recently the eXpanded Nystagmus Acuity Function (NAFX) (Dell'Osso and Jacobs, 2002, Jacobs and Dell'osso, 2010). The NAFX only depends on the characteristics of the waveforms of a nystagmus and it is therefore independent from the sensory visual system of the patient; it is therefore supposed to be linearly correlated to the visual acuity, yet in the absence of any associated sensory dysfunction. It is linearly correlated to the “potential”, the “theoretical” visual acuity, often different from the best patient’s visual acuity, since the latter depends on the patient’s associated sensory visual dysfunctions, often associated with INS. The NAFX was introduced in 2002 and has not been replaced since then. The nystagmus optimal fixation function (NOFF) has been proposed in case of high level of noise on the recording and may therefore be interesting in children (Feliuss et al. , 2011).

The NAF is obtained by assessing which proportion of the eye trajectory is both close enough from the target and slow enough (low enough speed so as to allow for a good visual acuity defining the foveation period). It then uses well defined exponentials in order to get a score. Three parameters are therefore considered: the target, the position threshold to be “close” and the speed threshold to be “slow”. While calculating the NAF, the two parameters of speed and position are fixed, respectively at $\pm 0.5^\circ$ and $\pm 4^\circ/s$. One refers to such periods of time as

“foveation windows”. The NAFX proposes to also allow such calculation to larger windows, so as to make the calculation more coherent. In the current formulas, the choice of both window parameters is made by the one who is doing the calculation. In order to automatize the calculation, here the NAFX was calculated with all the possible window values, before keeping the best value –there are 12 possible thresholds for the position and 7 for the speed, therefore 84 possible windows. The choice of the target position is not always clearly defined; in some articles, the median or the mean are used. We here adopted a similarly computerised approach, in calculating the NAFX for a thousand possible positions, and keeping the best score.

These quantified characteristics of a nystagmus vary according to gaze position and, in case of associated strabismus, according to the position of the fixating eye (binocular vision, *vs.* right monocular, *vs.* left monocular vision), hence the difficulty for the clinician to interpret the results of such quantified exploration from a list of numbers.

In order to present the results in an immediate, comprehensible way for the clinician, we decided to use heatmaps to represent the result of the recordings of a nystagmus in the different positions of gaze. These representations are displayed in a conventional way, as if the patient were looking at the examiner. These representations are therefore close to the ones used in the clinic based on Kestenbaum diagrams, except they are quantitative (fig. 25 and 26).

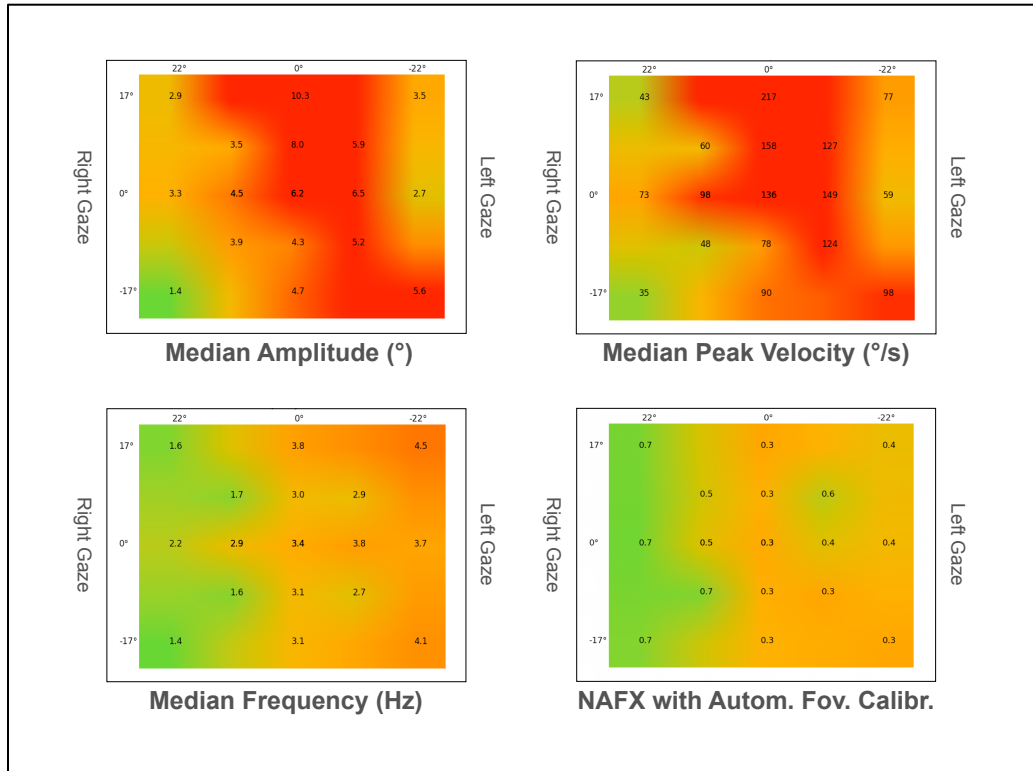


Fig 25. Heat map representation of a case of infantile nystagmus syndrome with a null zone in the right gaze

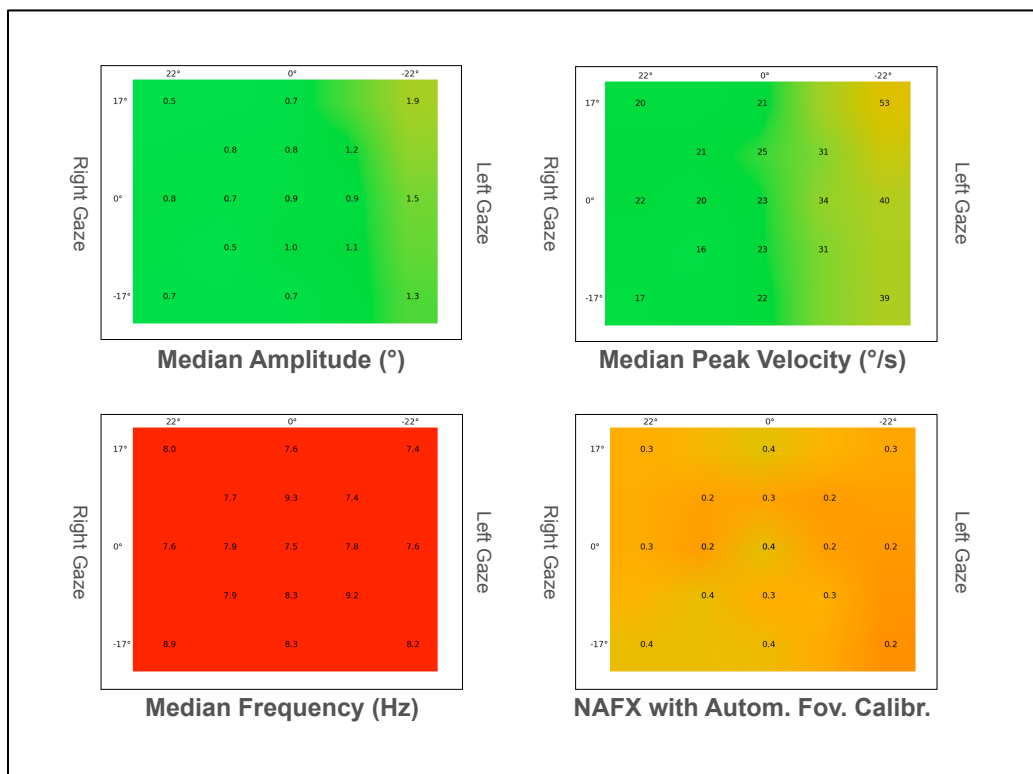


Fig 26. Heat map representation of a case of *spasmus nutans* syndrome

Chapter IV: Clinical applications

We present here the twenty-eight first cases of infants with an early-onset nystagmus (first noticed before the age 6 months), clinically studied and recorded with the Eyefant, in order to study the feasibility of such recordings in an infant population.

I.IV.1. Methods

The first thirty infants, aged 3 to 15 months, presenting spontaneous abnormal eye movements, who underwent, in 2013 and 2014, in addition to a complete clinical examination and video recording, oculomotor recordings using the Eyefant*, were reviewed.

I.IV.2. Results

In 28 cases, the recordings gave interpretable responses allowing for classification of the spontaneous abnormal ocular movements (table 2). In 12 cases, two recording sessions have been realised. In 28 cases, fixation could be recorded; in 12 cases, optokinetic nystagmus recording was also realised, in 7 out of 12 cases, responses according to all modalities could be obtained and interpreted (*stare* opto-kinetic nystagmus with both eyes viewing to the right, to the left, up and down; under monocular right eye viewing and under monocular left eye viewing, temporo-nasal and naso-temporal).

I.IV.3. Conclusion

The Eyefant provides an alternative to distant recording techniques in infants. It allows for detailed analysis of the horizontal and vertical eye movements including the one with high temporal frequency and low amplitude.

The main limitation –which is not specific in an infant– is the need for eyelid opening and child cooperation. The use of videos is very helpful. Ideally, two people are required for the recordings, in addition to the parents, in order for one to check the device and attract the child’s attention and for the other to display the stimuli and decide when to record.

Case n°	Sex	Age (months)	Clinical Context	Nystagmus Type
1	M	6	West syndrome	<i>Spasmus nutans</i>
2	F	11	Vermian dysplasia	Pendular non classified
3	F	15	None	<i>Spasmus nutans</i> (idiopathic)
4	F	11	Oculo-cutaneous Albinism	INS
5	M	11	Oculo-cutaneous Albinism	INS
6	M	12	None	INS (X-linked)
7	F	11	Oculo-cutaneous Albinism	INS
8	F	9	None	True familial flutter
9	F	9	None	<i>Spasmus nutans</i> (idiopathic)
10	F	11	NF2	INS
11	M	12	None	INS
12	F	15	None	INS (albinism)
13	F	4	Optic disc hypoplasia, achiasma	See saw
14	M	12	None	Idiopathic vertical nystagmus
15	M	11	None	FMNS
16	M	15	Familial nystagmus	Familial vertical nystagmus
17	M	15	Chiasmal glioma	<i>Spasmus nutans</i>
18	M	13	Chiasmal glioma	<i>Spasmus nutans</i>
19	F	8	Early esotropia	Upbeat and FMNS (CSNB)
20	F	15	Conradi-Hünemann-Happle syndrome	INS
21	F	10	Familial nystagmus	<i>Spasmus nutans</i> (CSNB)
22	M	7 and 9	None	<i>Spasmus nutans</i> (dysmyelination)
23	M	10	None	INS
24	F	15	Down syndrome	INS
25	C	9	Chiasmal glioma	<i>Spasmus nutans</i>

26	E	12	None	INS (albinism)
27	H	15	None	<i>Spasmus nutans</i> (idiopathic)
28	T	15	None	<i>Spasmus nutans</i> (achromatopsia)

Table 2. Clinical characteristics of the infants recorded. Clinical context means information provided with the referral letter. Diagnoses in brackets in nystagmus type are the diagnoses made after appropriate investigations

Chapter V: Quantifying chiasmal decussation

I.V.1. Introduction

The hypothesis of anomalous chiasmal crossing as a central mechanism in INS has been recently revisited by several groups in recent articles.

Historically, albinism has been the first condition where abnormal –excessive– crossing of the ganglion cells at the level of the chiasm has been demonstrated. Diverse methods using visual evoked potentials (VEPs), realised according to a specific method using two to five active electrodes on the scalp in front of each occipital lobe, were developed to first demonstrate the excess of crossing ganglion cells –this is now considered to be the most sensitive sign of albinism–, then to quantify it, using several coefficients.

More recently, other conditions associated with nystagmus and exhibiting anomalous crossing were also studied: congenital stationary night blindness (CSNB), achiasma, dissociated vertical deviation and Kartagener syndrome.

In nine out of ten patients with CSNB type 2, Tremblay *et al.* demonstrated a crossed VEP asymmetry pattern similar to the one observed in albinism (Tremblay *et al.* , 1996). The nystagmus was defined as “mild”, without characterisation. In another study on 20 patients with CSNB (11 with CSNB type 1 and 9 with CSNB type 2), Ung *et al.*, also using VEPs, found misrouting in 3 of the 11 cases with CSNB type 1 but in none of the cases with CSNB type 2, in contradiction with the first study (Ung *et al.* , 2005). Two of these three patients had “nystagmus”, but here also it was not characterised. Both studies used trusted methodology and both albino controls and normal controls. Contradictory observations have been made about nystagmus in CSNB: a group reported in 2008 in a study on ten patients (6-46 years, mean 17.1 years, median 12.5 years) with CSNB (two type 1 and eight type 2) the nystagmus to be always of *spasmus nutans* type (always disconjugate) (Pieh *et al.* , 2008), while in another study from 2012 on eight patients with CSNB, it was reported by the same group to

be never of *spasmus nutans* type (never disconjugate) and to have characteristics compatible with INS (Abbas et al. , 2012). The reasons for these striking differences were not hypothesised. Since different recording devices were used between both studies, these differences could result from recording artefacts in the first study. It may also be that the characteristics of nystagmus in CSNB change over time. The characteristics of the nystagmus associated with crossing excess in CSNB are therefore not known.

The other condition associating nystagmus and crossing abnormalities is achiasma, also called non-decussating retinal-fugal fibre syndrome. Here, a lesser proportion of ganglion cells –or even no ganglion cell at all, in the case of complete chiasmal aplasia– is crossing at the level of the chiasm. Although the diagnosis may be suspected on a cerebral MRI-scan, it is confirmed –and it can also be quantified –by VEPs (Apkarian and Bour, 2001, Apkarian et al. , 1995, Brecej, 2014, Brecej et al. , 2012, Sami et al. , 2005). This condition is classically associated with see-saw nystagmus. Studies showed, however, that the nystagmus could exhibit both characteristics of seesaw and INS (Apkarian and Bour, 2001), and even could be purely horizontal in some cases (Sami et al. , 2005).

A study on dissociated vertical deviation (DVD), a motor sign of abnormal retinal correspondence, part of early esotropia syndrome, showed that 77.4% of patients with DVD exhibited similar crossing abnormalities than albino patients, suggesting an association between FMNS and chiasmal misrouting (Fitzgerald and Billson, 1984).

In another study, three patients with nystagmus and foveal hypoplasia, one of them also having Kartagener syndrome; none of them having any other sign of albinism, also exhibited similar chiasmal misrouting than seen in albinism (van Genderen et al. , 2006).

It is therefore conceivable that misrouting of the ganglion cells is associated with various types of nystagmus. Visual evoked potentials are often difficult to interpret in the case of a nystagmus in an infant, suggesting that chiasmal misrouting might be more frequent than

previously suspected. Several studies, however, demonstrated that many patients with INS did not exhibit any chiasmal misrouting (Shallo-Hoffmann and Apkarian, 1993). The hypothesis developed by the Staumann group relies on the fact that chiasmal misrouting, in inverting the retinal slip, would transform the optokinetic system to an unstable positive feedback loop (Huang et al. , 2011) and produce the characteristic jerk waveforms of INS with accelerating slow phases.

As both MRI-scans and VEPs can be systematically used in the follow up of children with gliomas and as VEPs are also realised together with ERGs in patients with nystagmus as part of the systematic work-up, we decided to systematically quantify the chiasmal decussation in these populations.

I.V.2. Quantifying chiasmal decussation by using Diffusion Tensor Imaging

I.V.2.1. Introduction

Diffusion tensor imaging (DTI) is a new method using diffusion-weighted MRI sequences. It is based on the Brownian motion of water molecules, driven by internal thermal energy: while individual motion is random, global motion follows deterministic laws. The mobility of molecules can be characterized by a physical constant: the diffusion coefficient (D ($\text{mm}^2 \cdot \text{s}^{-1}$)). In a large structure, the diffusion of water is considered free and is said isotropic. In smaller structures such as axons, molecules diffuse more freely along fibers than perpendicular to them: the diffusion is said anisotropic. In case of anisotropy, diffusion cannot be characterized by the constant D : it then requires a tensor D_{xyz} , with three components (D_x , D_y and D_z) in the three directions of space. If one assumes that the direction of the fastest diffusion indicates the overall orientation of the axon fibres, one then can use the anisotropy effect to map out the orientation in space of the white matter tracks in the brain. Various algorithms allow for tract reconstruction: average fibre orientation is estimated from diffusion anisotropy at each pixel,

and a line is propagated from a pixel of interest (“starting seed”), following the fibre orientation: this is called tractography. Coloured maps can then be obtained. Tractograms can give informations about the morphometry of fibres and bundles, as well as anatomical connectivity between sets of regions (Ahn and Lee, 2011).

Successful results have been published in health and disease in using DTI to follow the corticospinal tract (Ahn and Lee, 2011, Jang, 2011), however, although it is possible to follow the ganglion cells within the optic nerve and within the optic bundles, the chiasma level has been so far disappointing.

I.V.2.2. Methods

We conducted in 2012 a pilot study in ten MRI-scans from infants without anomaly of the optic pathways but having benefitted from a brain MRI for a posterior fossa tumour and five MRI-scans from infants with optic pathway gliomas involving the chiasm, all aged 6 months to two years. Magnetic resonance imaging was obtained from a 1.5 Tesla Signa GE* MRI-scan. Using several algorithms, we tried to follow the tracts first in normals then in patients, within the chiasm.

I.V.2.3. Results

Whatever the method used, we failed to obtain sufficient anisotropy at the level of the chiasm, even in normals, in order to continue the streamlines both from the optic nerves and from the optic bundles.

I.V.2.4. Discussion

Other groups also failed to follow the ganglion cells through the chiasm (Zhang et al. , 2012), while in one study the authors could successfully differentiate the crossed vs the uncrossed

fibres in the chiasm, allowing for theoretical quantification (Hofer et al. , 2010). Two main reasons may account for these divergent results: first, we used a 1.5T MRI, as the first group. Second, the subjects from second group were aged 26-29, while myelination is not completed at the age of the infants we studied and this may increase the reasons for having being unable to follow tracts through the optic chiasm.

I.V.3. Quantifying chiasmal decussation by using Visual Evoked Potentials

I.V.3.1. Introduction

Several studies have addressed the question of quantifying chiasmal decussation by using VEPs, which are currently the gold standard –and the only method available for it. Many technical problems are encountered in the case of infantile nystagmus, resulting from the presence of a nystagmus and from the age of the patients. Visual evoked potentials –unlike electroretinogram– are not a direct response of the visual system to a stimulus: they result from the mathematical treatment of the variations of a series of electrophysiological potentials extracted from the electroencephalographic activity in the visual cortex regarded from the overlying scalp. The number of stimulations should be predetermined and identical for every patient (usually between 50 and 100 per recording).

Stimuli generally used for VEPs are either flash, or pattern reversal, commonly using a 48-cm-diagonal screen at a 100 cm distance from the subject. In the case of children, a few teams, specialised in paediatrics, are using larger screens, in order to increase the reproducibility of the results: due to the ocular saccades made by the child during the examination, when using a small screen, parts of his visual field falls out of the screen, resulting in additional variability of the resulting signal between two stimuli (Thompson and Liasis, 2012). In the case of nystagmus, pattern reversal is not appropriate, as it does not give reproducible results. Either flash, or onset-offset (ON-OFF) stimuli must be used. While

interpreting the results, one must be aware of the possibility of paradoxical lateralisation, according to the nature of the used stimulus (Halliday et al. , 1976, Holder, 1978, Holder, 2004, Thompson and Liasis, 2012). Anatomical lateralisation designates the situation where the signal recorded in front of the right visual cortex reflects the activity of the right visual cortex. Paradoxical lateralisation designates the situation where the signal recorded in front of the right visual cortex reflects the activity of the left visual cortex and vice versa. This is due to the anatomical orientation of the primary visual cortex, pointing towards the opposite cortex. The lateralisation of the signal is therefore paradoxical in the case of ON-OFF stimuli on large screens. It switches to anatomical lateralisation while the size of the screen diminishes. For other types of stimuli, the lateralization is anatomical (Halliday et al. , 1976, Holder, 1978, Holder, 2004, Thompson and Liasis, 2012). By using various types of stimuli, the localisation of a lesion can therefore be hypothesised from VEP results.

There is, in the basic recommended situation of routine VEPs, one active electrode in the midline, on the posterior scalp (Odom et al. , 2010). In order to compare the signal from each lobe, the use of three active electrodes is recommended (Odom et al. , 2010). In the case of albinism, which is the main application of such VEPs, some groups have used two (Jansonius et al. , 2001, Pott et al. , 2003, Tremblay et al. , 1996) or three (Brecelj et al. , 2012, Fitzgerald and Billson, 1984, Hoffmann et al. , 2011, Ung et al. , 2005) active electrodes. Some other groups have advertised the use of five active electrodes, in order to further sensitize the results (Apkarian and Shallo-Hoffmann, 1991, Dorey et al. , 2003, Neveu et al. , 2005, Neveu et al. , 2003, Soong et al. , 2000, van Genderen et al. , 2006).

Analysis of results can rely on comparing the signal from the right and from the left hemisphere by subtracting them, or by using various indexes quantifying the proportion of crossed *vs* uncrossed ganglion cells, proposed by Apkarian and Shallo-Hoffmann (Apkarian and Shallo-Hoffmann, 1991, Dorey et al. , 2003), by Tremblay *et al.* (Tremblay et al. , 1996),

by Jansonius *et al.* (Brecelj *et al.* , 2012, Jansonius *et al.* , 2001, Pott *et al.* , 2003, van Genderen *et al.* , 2006), or by Soong *et al.* (Soong *et al.* , 2000).

I.V.3.2. Methods

Reversal of pattern, ON-OFF and flash VEP were performed with the 48-cm-diagonal screen at a 30 cm distance from the child, using the LED stimulator Vision Monitor MonPack 2003 by Metrovision system (Pérenchies, France) adapted from the International Society for Clinical Electrophysiology of Vision (ISCEV) protocol (Odom *et al.* , 2010). A 30cm-distance modified protocol was chosen in order to minimize the gaze movements effect linked to the small size of the screen (cf. discussion). Flash stimuli used a frequency of 2 Hz; pattern stimuli used usual ISCEV parameters with 60', 30' and 15' check size stimuli. Pattern reversal stimuli used a 2 Hz stimulation frequency and usual ISCEV parameters. For ON-OFF stimuli, stimulation was: ON (42 ms) – OFF (400 ms), using 60', 30' and 15' ckeck size stimuli, with 100% contrast and a mean luminance of 120 cd/m². After skin preparation, five tinned, copper-cup occipital active electrodes were placed respectively at Oz, O1, O2, O7 and O8, equally placed 3 cm apart. The reference electrodes were placed at the midline frontal cortex, 1 cm above the hairline. Common ground was placed on the ear lobe. Treatment used 64 averages. A minimum of two sets of trials was realised for each modality; both eyes open, the left eye patched and then the right eye patched. We used translucent patching for pattern stimuli in order to minimise as much as possible the latent part of the nystagmus, which can be seen not only in FMNS, but also in INS. For flash stimuli, we used conventional patching. A complete recording would therefore comprise 54 sets of trial and responses. These were realised in the same order for each patient, so as to record useful information in a similar fashion in case the complete recording session could not be performed due to the child participation. Forty patients were studied according to this technique (table 3).

Case n°	Sex	Age	Diagnosis
1	F	41 y-o	Maculopathy
2	M	9 m-o	Nyst SN (idiop)
3	M	9 m-o	Nyst INS (optic disc hypoplasia)
4	M	3 y-o	Nyst INS (Leber congenital amaurosis)
5	F	32 y-o	Maculopathy
6	M	14 m-o	Nyst INS (alb)
7	M	11 m-o	Nyst INS (alb)
8	M	12 m-o	Nyst INS (alb)
9	F	9 y-o	Maculopathy
10	M	3 y-o	Nyst SN (OPG)
11	F	2 y-o	Nyst SN (OPG)
12	F	11 m-o	Nyst INS (idiop) + K-H-H
13	F	8 m-o	Nyst SN (idiop)
14	M	9 m-o	Nyst INS (alb)
15	M	9 y-o	Small scotoma
16	F	11 m-o	Nyst SN (retinal dystrophy)
17	F	4 y-o	Nyst SN (achromatopsia)
18	M	5 m-o	Nyst INS (idiop)
19	M	6 y-o	Nyst INS (idiop)
20	M	13 m-o	Nyst SN (OPG)
21	M	12 m-o	Nyst INS (idiop)
22	F	8 m-o	Nyst INS (alb)
23	F	20 m-o	Nyst SN (idiop)
24	F	18 m-o	Nyst INS (alb)
25	M	6 y-o	Nyst INS (alb)
26	M	4 y-o	Nyst INS (alb)
27	M	3 y-o	Nyst INS (alb)
28	M	4 y-o	Nyst SN (idiop)
29	M	4 y-o	Nyst SN (CSNB)
30	F	3 y-o	Nyst SN (idiop)
31	M	11 m-o	Nyst INS (Idiop)
32	M	2 y-o	Nyst INS (alb)
33	M	12 m-o	Nyst INS (idiop)
34	M	3 y-o	Nyst INS (alb type 3)
35	F	11 m-o	Nyst SN (idiop)
36	F	2 y-o	Nyst SN (Down syndrome)
37	M	13 m-o	Nyst SN + Cornelia de Lange syndrome
38	F	13 m-o	Nyst INS (alb)
39	F	2 y-o	Nyst INS (alb)
40	M	41 y-o	Nyst INS (alb)

Table 3. Characteristics of the patients studied with 5-channel VEP.

Idiop: idiopathic; SN: *spasmus nutans*; Alb: albinism; OPG: optic pathway glioma; K-H-H: Konradi-Hünemann-Happle syndrome.

I.V.3.3. Results

Thirty-six of them exhibited a nystagmus of variable nature (22 INS, 14 SN), including 14 cases of genetically proven albinism. All such diagnoses were not known at the time of the recordings. The four control patients with a maculopathy were expected to exhibit a crossed asymmetry of pre-chiasmatic type; the 14 cases of albinism were *a posteriori* expected to exhibit a crossed asymmetry of chiasmatic type showing excess of decussation. In the 22 other cases, no prediction was made.

For all patients, a pre-analysis was made before using the raw data for decussation coefficients calculation, in order to assess the repeatability (test-retest reliability) of the measurements. This first analysis compared, for each patient, the culmination peak and amplitude of each wave (N2 for the flash VEP; N75, P100, N135 for the pattern reversal VEP; CI, CI, CIII for the ON-OFF VEP) between the two (or more) sets of trials of each modality. This first evaluation was made clinically while interpreting the results.

In only five cases (cases 1, 5, 9, 15, 40), the recordings were clinically considered repeatable for all modalities (flash, pattern reversal and ON-OFF), allowing for robust conclusions and calculations of decussation coefficients using the raw data. In all other cases, despite numerous alterations attempts to the stimuli and signal treatment, we failed in obtaining repeatable results among recording series.

I.V.3.4. Discussion

The five cases where the responses were clinically considered as repeatable were also the five older cases (above 6 years of age).

This gross lack of repeatability across sets of trials in children recordings was considered a lack of robustness of the test and we therefore decided to stop any further analysis of decussation coefficients.

Hypotheses can be formulated regarding the reasons for our inability to obtain repeatable results in young children cases. Repeatable VEP in children is difficult to obtain and few teams in the world are actually routinely using VEP for quantified appreciation of visual pathway function. Our numerous attempts to improve the recording conditions with the furnisher did not result in any substantial improvement of the repeatability across trials. One of the main problems came from regular bugs due to the use of 5 channels instead of 2. The whole system would switch off, while switching it in took around 5 minutes. Meanwhile, the child would have lost his temper, which resulted in undistinguishable waves. However, this explanation does not suffice, as pre-bugs results were not sufficiently reproducible either.

One hypothesis may explain the failure for reversal of patterns and ON-OFF stimulations: it is as provided by the team from Great Ormond Street Hospital for Sick Children, London. They consider the use of small checkerboards inappropriate for children, as their gaze constantly moves, unlike adults who can fixate the centre of the checkerboard for the whole duration of the trial. In order to avoid this problem, they have developed and proposed specific stimuli for children: a video chosen by the child is displaced on the screen and then from time to time replaced by the stimulus. The child's attention is still directed to the screen, while the soundtracks remains on. They also use large screens, so that even in case the child does not fixate the centre of the screen anymore, the stimulus is still of the same nature (as it is a checkerboard). We could not display videos on our screens. Music behind the screen was used, however. We could not obtain a system with specific large screens devoted to children, which necessitates a whole installation for which we did not obtain the necessary credits.

The lack of repeatability for flash VEP in children is hard to explain without addressing a technical issue inherent to the 2003 device used for the recordings.

Part II: *Spasmus nutans*, chiasmal gliomas-associated nystagmus and upbeat nystagmus

Chapter I: *Spasmus nutans*

II.I.1. Introduction

II.I.1.1. Historical reports and associated conditions

Since Raudnitz's description in 1897, *spasmus nutans* designates a triad associating nystagmus, head nodding and head turn (Raudnitz, 1897). This, actually, had already been reported in the previous year by Dickson (Dickson, 1895).

The nystagmus of the *spasmus nutans* itself is specific and allows for characterisation as a *spasmus nutans* type nystagmus *per se*: it is of small amplitude, high frequency, often intermittent, often multidirectional, and often –or for some authors systematically, and this is a point of controversy– dissociated –that is to say of different amplitude between both eyes, even to the point of being apparently unilateral– and/or disconjugated –both eyes not oscillating in phase. This nystagmus, or the complete syndrome, appear usually within the first year of life (or more rarely within the second year of life) (Arnoldi and Tychsén, 1995, King et al. , 1986, Weissman et al. , 1987) and have been initially described as an environmental-related entity of spontaneously good prognosis. Initial reports mention the systematic resolution of the *spasmus nutans* between age 3 and 6 years (Jayalakshmi et al. , 1970). Raudnitz, in a later article published a few years after the initial one, noticed the striking decrease of the incidence of *spasmus nutans* in the suburbs of Prague, attributed to an improvement in the housing. He hypothesised that *spasmus nutans* might result from abnormal maturation of the visual system when an infant is not sufficiently exposed to

daylight. The theory according which *spasmus nutans* was linked to poor socio-economical conditions prevailed over the following years (Herman, 1918, Østerberg, 1937, Raudnitz, 1897, Still, 1906).

Since 1967, however, several articles have reported cases of spasmus nutans related to chiasmal tumours, mainly gliomas (Albright et al. , 1984, Antony et al. , 1980, Baram and Tang, 1986, Donin, 1967, Farmer and Hoyt, 1984, Garty et al. , 1985, Kelly, 1970, Koenig et al. , 1982, Lavery et al. , 1984, Schulman et al. , 1979). More recently, cases of spasmus nutans associated with dysmyelination in infants –such as Pelizaeus-Merzbacher (Penner et al. , 1987, Pham-Dinh et al. , 1991, Scheffer et al. , 1991) or Leigh (Smith et al. , 2000) syndromes– or retinal dystrophies (Gottlob and Helbling, 1999, Lambert and Newman, 1993) or retinal stationary dysfunctions (Gottlob and Reinecke, 1994, Gottlob et al. , 1995, Lambert and Newman, 1993) have also been reported.

This chronology of medical descriptions accounts for the current semantic confusion regarding *spasmus nutans*: most authors restrict the term to the benign, idiopathic form of the syndrome (whose diagnosis is only certain *a posteriori*), while secondary forms are considered differential diagnoses; while others use the term to designate a clinical entity, whatever the potential pathological associations.

One of the practical resulting consequences is the persisting wrong idea that *spasmus nutans* (the clinical presentation) always means a benign affection, that it needs no work-up unlike other kinds of nystagmus, allowing for parents' reassurance. Hence often long delays between the nystagmus onset and the underlying, often serious, diagnosis. Another confusion is that many clinicians believe that head nodding is pathognomonic of *spasmus nutans* –and is therefore reassuring– while it is often seen in association with an INS, and while concerning *spasmus nutans*, the nystagmus has a similar value even if not associated with head nodding.

For practical purposes, here, we chose to use here the term *spasmus nutans* in its primary meaning: a clinical picture, whatever its pathological associations. In order to limit confusion, we shall use the term *spasmus nutans*-type nystagmus to designate the type of nystagmus described above.

The prevalence of *spasmus nutans* is unknown. It is believed to be rare, but it is probably underestimated, because the nystagmus is often so subtle (small amplitude), that many parents and even many physicians do not notice it; and also because in its idiopathic form, it spontaneously resolves within the first months or years of life. No sex predominance has been noticed. It is said to be more prevalent in African-american ethnicity or in infants of African descent: 52-80% according to studies (Gottlob et al. , 1990, King et al. , 1986, Weissman et al. , 1987). The reasons for these prevalence differences –genetic or environmental– are unknown.

II.I.1.2. Characteristics of spasmus nutans-type nystagmus

Spasmus nutans-type nystagmus is often multidirectional, more often horizontal or horizonto-rotatory than vertical (Doummar et al. , 1998, Gottlob et al. , 1990, Norton and Cogan, 1954); it is pendular, of small amplitude (0.5 to 3°) and low frequency (5 to 15 Hz) (Gottlob et al. , 1995); it is often of greater amplitude in the abducting eye. It is most often bilateral, but asymmetrical, i.e. dissociated (of different amplitude between both eyes). It may be unilateral, at least clinically –Doummar *et al.* described three unilateral cases out of sixteen *spasmus nutans* (Doummar et al. , 1998).

One study assessed specifically the precise oculographic characteristics of *spasmus nutans*, using eye movement recording. It added quantified criteria to previous definitions: the presence of interocular phase difference (that is, the dissociation between the right and the left eye oscillations), most of the time a 180° phase difference (making the nystagmus qualify as

“convergent-divergent nystagmus”) and the variability of this difference over time, with phase shifts, the movements of both eyes being even some time conjugate (Weissman et al. , 1987).

The CEMAS criteria (Group, 2001) are extensively discussed in section i.II.3, in particular in regard to the limitations regarding the frequency of *spasmus nutans*.

Do all *spasmus nutans* show disconjugacy? Or is disconjugacy an obligatory criterion for the diagnosis of *spasmus nutans*? Or how would one designate a nystagmus with all other criteria but which would be conjugate –in case such a nystagmus does exist? This question is crucial. Disconjugacy is rarely seen in nystagmus in general. As *spasmus nutans* has small amplitude and low frequency, it is usually impossible to answer these questions clinically. In case differential diagnoses were to exist (i.e. nystagmus with the other characteristics of *spasmus nutans*, except dysconjugacy), the diagnosis of *spasmus nutans* would compulsorily require formal oculomotor recordings.

II.I.1.3. Spasmus nutans-associated head nodding

Head nodding is characterised by rhythmic oscillation of the head, most often along the z axis (the child “makes no with his head”) or the x axis (the child “makes yes with his head”), or more rarely along the y axis (Indian yes) (Doummar et al. , 1998), with a slow frequency (2 to 3 Hz) and a variable amplitude (2 Hz to 25 Hz) (Gottlob et al. , 1992). These movements disappear while lying down and during sleep; they may be accentuated by ocular fixation (Arnoldi and Tychsen, 1995).

The pathophysiology of these head movements is a matter of debate. For some authors, these head oscillations are compensatory of the eye oscillations. Gottlob *et al.*, found that in 21 out of 35 studied cases, nystagmus characteristics changed when head movements were present: it tended to become more symmetrical, slower, of larger amplitude and to beat in the opposite direction as the head, which, according to them, suggests that head nodding would be

compensatory of the nystagmus (Gottlob et al. , 1992). In a case studied by Gresty *et al.*, the nystagmus was showed to be absent when head oscillations were present. In this case, the head oscillations were believed to be a learned behavioural pattern abolishing the eye oscillations (Gresty et al. , 1976).

II.1.1.4. Spasmus nutans-associated head turn

Out of the three components of the historical triad, the head turn is the least frequently encountered –30 to 100%, according to series and according to the definition (Chrousos et al. , 1985, Doummar et al. , 1998); it is a turn along the z-axis and/or the y-axis or more rarely the x-axis. Once again, it has been hypothesised to compensate the nystagmus through a vestibular mechanism (Chrousos et al. , 1985).

II.1.1.5. Aim of the study

In 1995, Arnoldi and Tychsen reviewed 67 consecutive children diagnosed with *spasmus-nutans*. They found no case of glioma among them. They also stated that in cases where *spasmus nutans* was associated with a tumour, other clinical signs would also be present. They established a list of situations where urgent neuro-imaging should be advised: onset after 12 months of age, relative afferent pupillary defect, optic disc pallor, vertical nystagmus, hydrocephalus or growth delay (Arnoldi and Tychsen, 1995).

To the best of our knowledge, no systematic study has evaluated the respective incidence of tumours, neurodegenerative diseases, retinal dystrophies and retinal stationary dysfunctions by the systematic use of MRI and electroretinography in a population of infants with *spasmus nutans*.

We wanted to see what the incidence of associated conditions in a population of infants with *spasmus nutans* referred to a tertiary centre was, and if practical conclusions regarding the recommended work-up could be drawn from these data.

II.1.2. Material and methods

Children referred to the neuro-ophthalmology clinic between November 1, 2009 and November 1, 2014, for a *spasmus nutans* and having benefitted from a systematic work-up, were retrospectively reviewed. *Spasmus nutans* was clinically defined as a pendular nystagmus with a medium to high frequency, a small amplitude and a dissociation (amplitude difference) and/or a disconjugacy (phase difference) between the two eyes. It could be intermittent, horizontal, vertical, torsional or multidirectional and dissociated to the extent of being purely monocular. It could be associated with head tilt or head nodding. The work-up included neuro-ophthalmological examination with dilated fundus, recording of the nystagmus (video recording and eye tracking with a child-friendly dedicated infrared photo-reflectometry eye tracker, Ober Consulting®, Poland, when possible), cerebral imaging (MRI-scan) and a full-field electroretinogram (Metrovision®, France), according to the ISCEV recommendations (Marmor et al. , 2009). Cases with incomplete investigations, cases with already known diagnosis and also incidentally presenting a *spasmus nutans* and cases with obvious associated photophobia at first visit were excluded. The combination of these data allowed us to classify each case in one of three groups of categories of *spasmus nutans* (revealing a neurological disease, revealing a retinal disease, or idiopathic,) and to compare their relative proportions.

II.1.3. Results

Thirty-two children (19 males, 13 females) were included (table 4).

Case n°	Sex	Ethnic origin	Age	HN	HT	Side	Diagnosis	Code
1	F	North African	6	0	1	LE	L (PLA2G6)	N
2	F	Black african	4,5	1	1	LE	I	I
3	F	Caucasian	18	0	0	Variable	OPG Glioma	N
4	M	Black african	42	0	1	LE	I	I
5	F	Caucasian	1	0	0	Variable	I	I
6	M	Caucasian	24	0	0	Not clear	Retinal dystrophy + L	R + N
7	M	Caucasian	1,5	0	0	Not clear	Retinal dystrophy +L	R + N
8	F	North African	6	0	1	Not clear	Retinal dystrophy	R
9	F	North African	11	1	1	LE>RE	I	I
10	F	Caucasian	6	0	0	LE>RE	OPG Glioma	N
11	M	Caucasian	2,5	0	1	Variable	OPG Glioma	N
12	M	Caucasian	10	0	0	Not clear	OPG Glioma	N
13	M	Caucasian	36	0	0	Variable	ONH + dysmorphia	N
14	M	Caucasian	3	1	1	Variable	I	I
15	F	Caucasian	2	0	1	Variable	I	I
16	M	North African	3,5	0	1	RE, variable	I	I
17	M	North African	0	0	0	Variable	Retinal dystrophy	R
18	M	North African	1	1	1	Not clear	I	I
19	F	Caucasian	2,5	1	0	Variable	Achromatopsia	R
20	F	North African	16	0	0	RE>LE	L (saposine B deficiency)	N
21	M	Caucasian	24	0	0	LE	I	I
22	M	Caucasian	4	1	0	Not clear	OPG Glioma	N
23	M	Black african	9	0	1	Variable	I	I
24	M	Caucasian	4	0	1	Variable	OPG Glioma	N
25	M	Black african	6	0	0	Variable	I	I
26	F	Black african	4	1	1	Variable	I	I
27	F	Black african	23	1	1	Variable	I	I
28	M	Black african	7	0	0	Not clear	L	N
29	M	North African	9	0	0	RE	I	I
30	M	Black african	3	0		Variable	CNSB	R
31	M	Pacific Ocean	7	0	1	Variable	OPG Glioma	N
32	F	Black african	3	0	1	Variable	I	I

Table 4. Characteristics of *spasmus nutans* cases included in the study

Age: age when spasmus nutans was first noticed; HN: head nodding, 0: absent, 1: present; HT: head turn or tilt: 0: absent, 1: present; Side: indicated when monocular, variable means dissociation variable over time, not clear means dissociation difficult to assess clinically; Diagnosis: I: idiopathic, L: leucodystrophy; Code: N for neurological cause, I for idiopathic, R for retinal cause.

The nystagmus had been noticed at a median age of 6 months. In 53.1% of cases (n=17), it led to the diagnosis of another condition. Most often a neurological disease was diagnosed (34.3%, n=11): a voluminous chiasmal glioma involving the chiasm in seven cases (21.9%), a neurodegenerative process in three cases –one case of metachromatic leukodystrophy with saposine B deficiency, one case of PLA2G6 neuro-axonal dystrophy, one case of leukodystrophy with no found aetiology– and one case of cerebral dysmorphism including dysmorphism of the *corpus callosum* and the lateral *sulci* and associated with a bilateral optic nerve hypoplasia. In 12.5% of cases (n=4), the children exhibited a retinal dysfunction –two cases of early mixed retinal dystrophies corresponding to a rod-cone phenotype, one case of achromatopsia with no obvious photophobia, one case of congenital stationary night blindness. In two cases (two brothers), both a neurodegenerative process and a retinal dystrophy were diagnosed, related to a unique metabolic disorder. In 46.9% (n=15) of cases, *spasmus nutans* was considered benign idiopathic.

II.1.4. Discussion

This study shows that diagnosing a *spasmus nutans* leads to the diagnosis of an associated central nervous system (CNS) affection (as the retina can be considered part of the CNS) in a majority of cases. In all such cases, the pathological process is located on the optic pathways, between the retina and the lateral geniculate. The detailed pathophysiology remains unclear. It is discussed in the next chapter in the case of chiasmal gliomas.

The mechanisms of idiopathic forms are even less clear, as no abnormality of either the ERG or the MRI, despite specific protocols dedicated to the study of the visual pathways, were ever found. Subtle dysfunction of the anterior visual pathways during the sensitive period of visual development, however, is likely and cannot be ruled out.

Chapter II: Nystagmus associated with optic pathway gliomas

II.II.1. Introduction

While acquired nystagmus can be the sign of a brain tumour, this is almost never the case for early-onset nystagmus. “Early-onset” nystagmus were previously designated as “congenital”, but this term has been abandoned, as they appear usually between 4 and 12 weeks of life, and by convention before 6 months of age. Optic pathways glioma (OPG)-associated nystagmus can be misleading in many ways: it is considered an “acquired” form of nystagmus, but it can appear so early that the age of onset might not be discriminant (Toledano et al. , 2015). It is often described as a *spasmus-nutans*-type nystagmus, and can also disappear secondarily –like idiopathic *spasmus-nutans*–, while the tumour actually remains stable (Brodsky and Keating, 2014). These rare nystagmus are the source of multiple challenges. Clinically, if misdiagnosed as infantile nystagmus syndrome (INS), the underlying OPG diagnostic may be delayed; although far less frequent than INS or other varieties of nystagmus, they have led some clinicians to systematically prescribe brain imaging to any infant presenting with a nystagmus, while this may not be necessary in the great majority of cases. More generally, the pathophysiology of disconjugate and dissociated nystagmus resulting from an optic pathway anomaly is so far unexplained. There is to date no series describing systematically the clinical and oculographic characteristics of OPG-associated nystagmus and the literature remains poor and contradictory on that topic. The Classification of Eye Movement Abnormalities and Strabismus (CEMAS) does not even mention them (Group, 2001).

Spasmus nutans-type nystagmus definitions are numerous and are a source of confusion. Historically, Raudnitz reported in 1897 a triad of nystagmus, head turn and head oscillations occurring in infants living in a dark quarter of Prague (Raudnitz, 1897). This nystagmus was

reported to appear between 6 and 12 months of age, to always disappear after a few months or years of evolution and to represent a benign entity. Since 1967, however, many cases, most often isolated case reports, have stressed on the possible association with suprasellar tumours, mainly OPG (Albright et al. , 1984, Antony et al. , 1980, Baram and Tang, 1986, Donin, 1967, Farmer and Hoyt, 1984, Garty et al. , 1985, Kelly, 1970, Koenig et al. , 1982, Lavery et al. , 1984, Schulman et al. , 1979). Since then, the term *spasmus-nutans* has been either designating the clinical syndrome whatever its cause, or the specific, benign entity. The CEMAS chose the latter and proposed criteria for *spasmus nutans* syndrome: “Infantile onset, variable conjugacy, small frequency, low amplitude oscillation, abnormal head posture and head oscillation, improves (“disappears”) during childhood, normal MRI/CT scan of visual pathways. Ocular motility recordings –high frequency (>10 Hz), asymmetric, variable conjugacy, pendular oscillations”, with common associated findings: “Disconjugate, asymmetric, multiplanar, family history of strabismus, may be greater in one (abducting) eye, constant, head posture/oscillation (horizontal or vertical), usually no associated sensory system deficits, may have associated strabismus and amblyopia, may increase with convergence, head bobbing, head posture may be compensatory” (Group, 2001). Very few studies including oculomotor recordings have addressed the matter. Weissman *et al.* studied seven patients with *spasmus-nutans* and showed that in all cases, both eyes exhibited phase differences, most often of 180°, which varied over time (Weissman et al. , 1987). This was ascertained by the authors as being the hallmark of *spasmus-nutans*. Formal eye movements recordings are here most helpful, as the high frequency and the low amplitude often preclude any such observation through the naked eye. Arnoldi and Tychsen reviewed 67 consecutive children diagnosed with *spasmus-nutans* among whom none had evidence of a glioma (Arnoldi and Tychsen, 1995). On the other hand, Hamelin *et al.* found a “nystagmus” in 22% of 18 children with OPG (Hamelin et al. , 2000), while Toledano *et al.* found monocular

nystagmus at diagnosis in 41% of 22 children with measurable OPG (Toledano et al. , 2015). The authors are not aware of any study about OPG-associated nystagmus including formal oculomotor recordings.

Infantile nystagmus syndrome may be observed in infants with low vision resulting from anterior visual pathway dysfunction. It usually then secondarily evolves to a vision loss nystagmus, which is a jerk, conjugate nystagmus with horizontal, vertical and torsional components, often of large amplitude (Group, 2001). Visual loss nystagmus is present in old children with OPG with the worst functional evolution, but both INS and vision loss nystagmus seem distinct from most descriptions of OPG-associated nystagmus. Monocular visual loss due to optic nerve involvement can be associated either with a slow, pendular, purely vertical nystagmus, often referred to as Heimann-Bielschowsky phenomenon, or sometimes with a low amplitude horizontal nystagmus (Good et al. , 1993). This would be consistent with some cases of reported OPG-associated nystagmus, although it has been suggested that in the case of monocular OPG-associated nystagmus, the eye with the nystagmus could be the one with the best vision (Farmer and Hoyt, 1984). Lesions at the optic chiasm and parasellar lesions can also rarely be associated with pendular seesaw nystagmus. Seesaw nystagmus has been attributed either to the effects of an associated midbrain compression –which can be seen in some cases of OPG– or to the effects of the resulting temporal visual loss, inactivating the calibration mechanism for eye movements normally compensating for head rotations in roll (Leigh and Zee, 2015). Again, OPG-associated nystagmus descriptions are not compatible with seesaw nystagmus.

In that context, many questions related to important clinical issues remain unsolved. Are OPG-associated nystagmus always of *spasmus nutans*-type? Can they sometimes fit the criteria of INS? Do they ever exhibit the complete triad of *spasmus-nutans*, including head oscillations, or, as suggested by some authors (Hertle and Dell'Osso, 2013), does the presence

of associated head-oscillations associated with a *spasmus nutans*-type nystagmus preclude it being associated with a tumour? Do OPG associated with a nystagmus at diagnosis have specific characteristics? What is the mechanism of OPG-associated nystagmus?

II.II.2. Material and methods

The way patients were selected is summarised in figure 27. Children (0-18 year-old) having presented with optic pathway gliomas at the paediatric neuro-ophthalmology clinic in the *Hôpital Universitaire Necker-Enfants malades* between October 2009 and October 2014 (so as to allow for a follow-up of at least one year, until October 2015) were prospectively recorded in the database for rare diseases CEMARA. Those having been revealed by a nystagmus were identified. Children having been referred to the clinic over the same period of time for a nystagmus, which onset had been before two years of age, were similarly registered. Nystagmus that had appeared secondarily, as a consequence of an already known diagnosis, were not included. Nystagmus clinically classified as *spasmus nutans*-type were identified, as well as nystagmus having led to the diagnosis of a brain tumour. *Spasmus nutans*-type nystagmus was defined as pendular, medium or high frequency, low-amplitude, often multidirectional, with dissociation between the movements of the right *vs.* the left eye. Cases of children presenting with a nystagmus with a later onset were not included, since these cases are not all seen in the paediatric neuro-ophthalmology clinic, therefore not systematically registered in databases. Only the children who also benefitted from reproducible nystagmus recordings at diagnosis (video recording and/or infrared photorelectometry with the Eyefant*, Ober consulting, Poland, an eyetracker specifically designed for young children and allowing for binocular recording at 1000 Hz) were included.

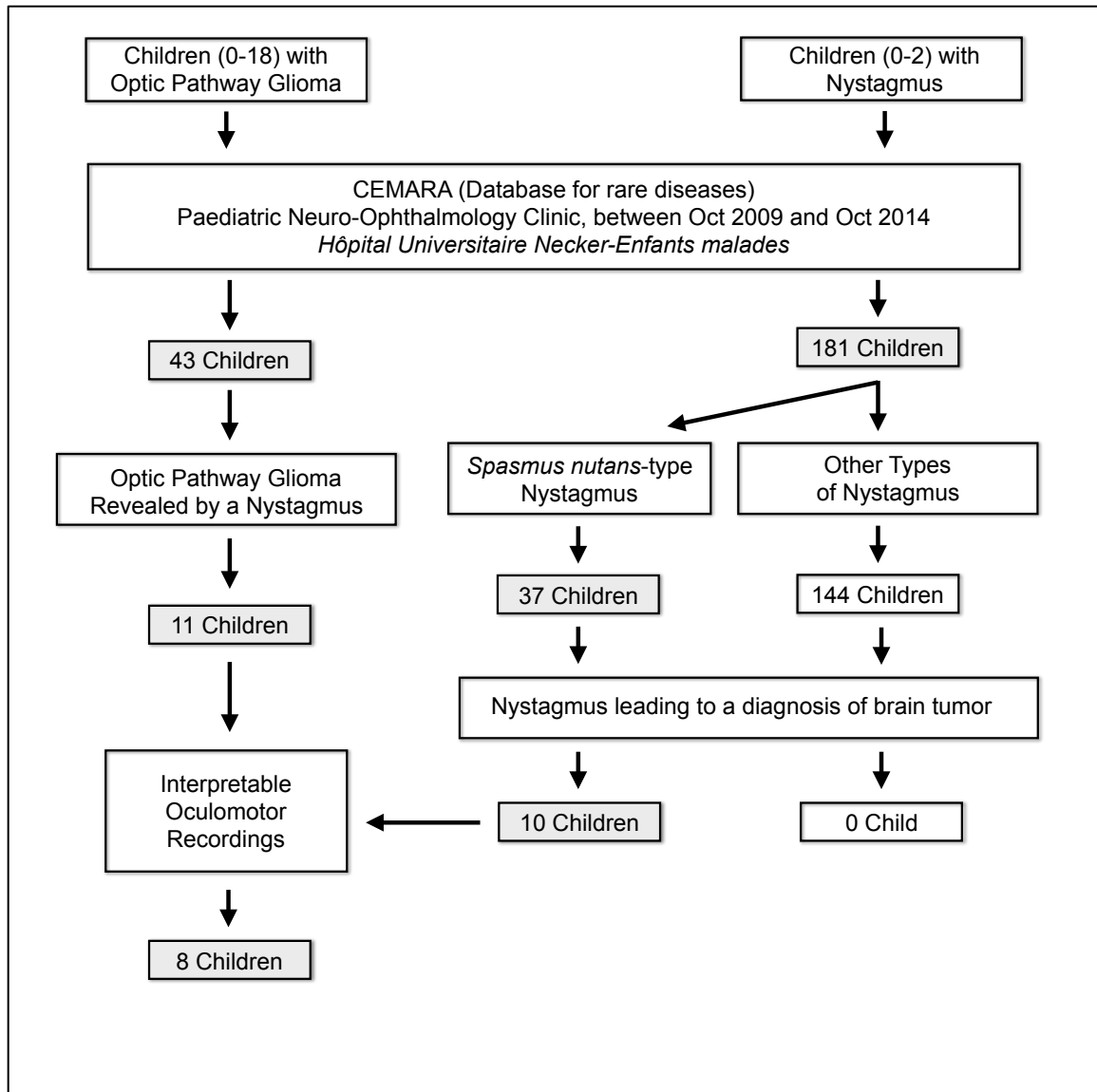


Fig 27. Schematic representation of the patients' inclusion process

All had benefited from systematic ophthalmological examination, initially and during follow-up. All children diagnosed with OPG were followed-up by an interdisciplinary team comprising paediatric oncologists, neurosurgeons, paediatric endocrinologists, pathologists and ophthalmologists. Decisions were taken during neuro-oncology staff meetings. In the absence of clinical diagnostic criteria for neurofibromatosis type 1, the children benefitted from initial biopsy and histology, except for cases of intrinsic limited forms in young infants after consensual discussion. All children benefitted from hormonal check-up, both at initial evaluation and during follow-up. Visual evoked potentials (VEP) were performed in five

cases, in order to better quantify the infants' visual function. Reversal of pattern, ON-OFF and flash VEP were performed with the 48-cm-diagonal screen at a 100 cm distance from the child, using the LED stimulator Vision Monitor MonPack by Metrovision system (Pérenchies, France) according to the International Society for Clinical Electrophysiology of Vision (ISCEV) protocol with five tinned, copper-cup occipital active electrodes (Odom et al. , 2010).

The clinical and oculographic characteristics of the nystagmus; the clinical, imaging and histological characteristics of the OPG were studied. The treatments' modalities and the visual outcomes were studied. When the Eyefant* was used, the nystagmus was recorded in the primary position of gaze, under binocular, right and left monocular viewing conditions; for movements requiring stimuli, a 19'' screen was used with stimuli especially designed for infants. The infant was placed on his/her parent's lap, 50cm from the screen. Calibration was made *a posteriori*, using the movements of the eyes doing saccades from a central cue to four to eight eccentric locations. Before analysing the characteristics of the signals, singular spectrum analysis (SSA) was used, in order to isolate the nystagmus waveforms from other eye movements (Golyandina et al. , 2001). This method allows for an adaptive extraction of the trend of a signal. In analysing all the sub-series of the original signal for a given scale, common behaviours can be found. The trend component was then considered to be the component explaining the most the global variation of the signal (fig. 28). One drawback of this method is that the trend can be scattered on several different computed components. In order to automatize the trend extraction step, a grouping step is needed. For the robustness of the trend extraction, the grouping step used a k-means algorithm to regroup similar components (Moreau et al. , 2015). The signals for the nystagmus movement were then analysed using traditional signal processing tools. For each eye, the main frequency of the movement was estimated, using the maximum of the correlogram. The same principle was

used to compute the phase delay of the movements of the eyes, based on the maximum of the cross correlation function between the two movement signals.

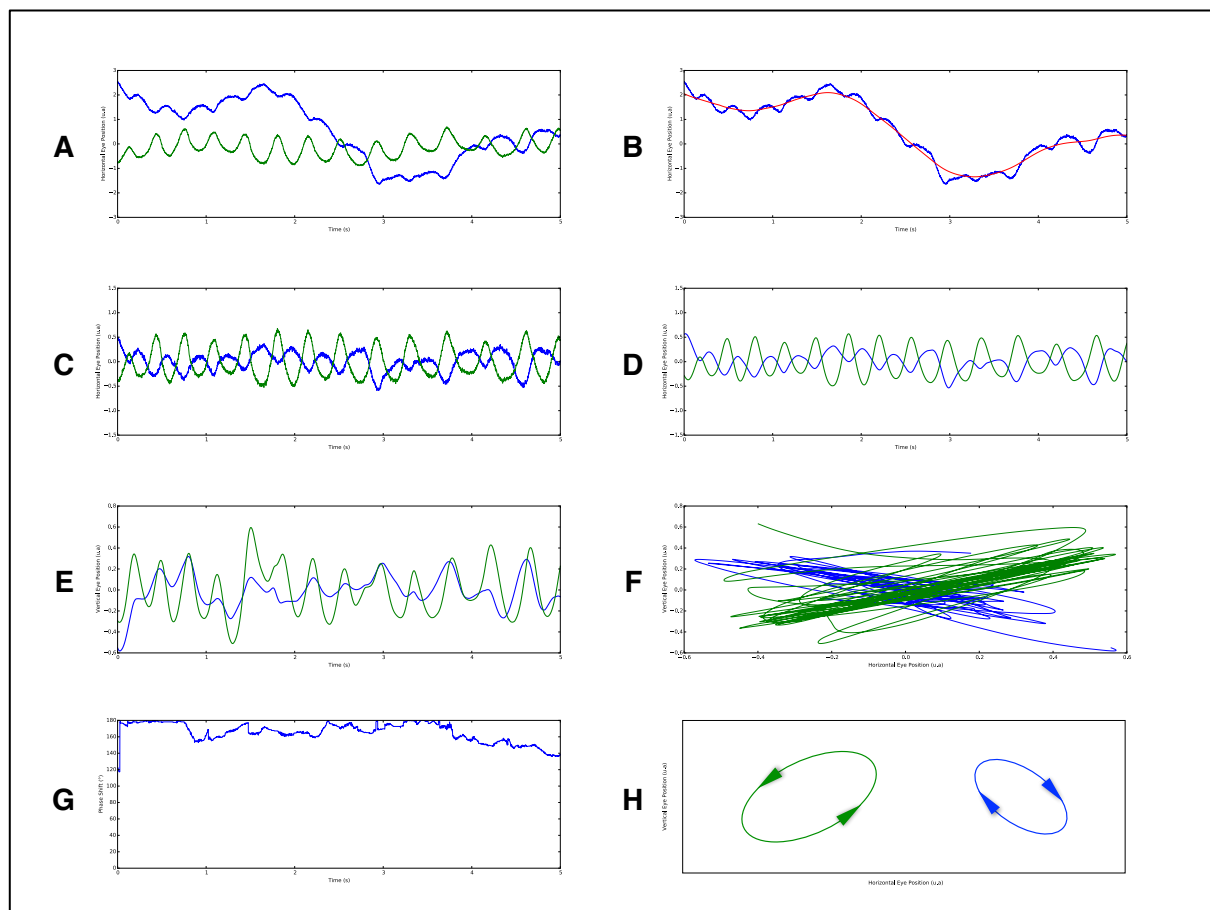


Fig 28. Oculographic characteristics of typical optic pathway glioma-associated nystagmus (1)

(A) Raw signal of the horizontal component of the nystagmus recorded with the Eyefant[®]: right eye in green, left eye in blue. **(B)** Extraction of the signal trend (in red), using singular spectrum analysis. **(C)** Horizontal nystagmus signal. **(D)** Smoothed horizontal nystagmus signal using a second order butterworth lowpass filter with cutting frequency 35Hz; both eyes are oscillating in the horizontal plane with a 180° phase difference. **(E)** Smoothed vertical nystagmus signal; both eyes are oscillating in phase in the vertical plane. **(F)** Raw signal of both horizontal and vertical components of the nystagmus superimposed during the five considered seconds; the nystagmus direction appears to be mainly oblique. **(G)** Phase shift of the horizontal component of the nystagmus. **(H)** Schematic representation of the nystagmus represented as the position of both eyes in the coronal plane: the movement of both eyes can be compared with the convection movement of water molecules, going up and towards the centre, then down and away from the centre; right eye amplitude is larger than left eye amplitudes.

II.II.3. Results

The patients were selected in three ways (fig. 27). First, over the studied period of time, 43 children presented at the neuro-ophthalmology clinic with an OPG and were consequently followed up. Out of these, 11 children were diagnosed through a nystagmus. Second, over the same period of time, 181 infants were referred to the neuro-ophthalmology clinic for a nystagmus that had appeared before the age of two years. Thirty-seven of them were clinically classified as *spasmus nutans*-type and did not exhibit obvious signs of retinal dysfunction or dystrophy on the first evaluation –these including a family history of retinal dystrophy or stationary retinal dysfunction, obvious photophobia, oculo-digital sign, or abnormal fundus in favour of a retinal dystrophy. They all benefited from a brain imaging. In ten cases an OPG was diagnosed. Third, the same ten cases were also found when selecting the association “nystagmus with onset before two years” and “brain tumour”. The difference between the three ways to identify these patients (11 with the first way vs. 10 with the second and third way) can be explained by the fact that one of the children from the OPG group exhibited nystagmus at the age of three. This correspondence between these ways of identifying the patients also means that in all cases, nystagmus having led to the diagnosis of a cerebral tumour had been clinically classified as *spasmus nutans*-type (never as infantile nystagmus syndrome (INS) or fusion maldevelopment nystagmus syndrome (FMNS) (Group, 2001)), and that in all cases the cerebral tumour was an OPG. In three cases, no interpretable recording was available –one of these three cases was also the one who exhibited a nystagmus at the age of three.

Eight children were therefore included. The characteristics of their nystagmus and tumours are summarised in tables 5 to 8. Age at nystagmus onset was 2.5-10 months (mean=5.8, median=5.5, SD=2.4). Delay between nystagmus onset and glioma diagnosis was 0-13 months (mean=1.9, median=0.5, SD=4.5). In three cases, initial clinical examination showed

early signs of Russel diencephalic syndrome –associating variable degrees of weight loss, emaciation, hydrocephalus and euphoria– in association with the nystagmus. In two cases, frank optic atrophy was clinically obvious; in one case a papilledema was noticed; in five cases, however, the fundus was considered either strictly normal or possibly within normal limits. Although no clear crossed asymmetry pattern was ever detected, it was not possible to get reproducible enough VEP to allow for robust description and analysis of VEP topography. In one case, the classic triad of *spasmus nutans* syndrome was complete, with head tilt and head oscillations associated to the specific nystagmus; in two cases, the nystagmus was associated with head oscillations alone; in two other cases, with head tilt alone. In all cases, the nystagmus consisted in medium to high frequency (2.7-5 Hz, mean=3.7 Hz, median=3.6, SD=0.8), low amplitude, multidirectional, disconjugated (i.e. not in phase) and dissociated (i.e. not of the same amplitude) movements of the eyes. There was no difference in the waveforms between binocular and monocular viewing conditions or according to the gaze direction. The dissociation was clinically obvious to the human eye in the cases with the lowest frequency and/or in cases where the nystagmus was very asymmetrical, at least at some stage of the evolution (four cases), to the point of being apparently unilateral, also only at some stage (two cases). In two cases, the dissociation was unsuspectable clinically, even on videos watched at real speed by oculomotor experts (MR, OZ and PPV). In all cases, however, disconjugacy was obvious on recordings, with most of the time a 180° interocular phase difference between the horizontal components of the two eyes, which horizontally beat out of phase, while the vertical components beat in phase, resulting in a characteristic “convection-like” oscillatory movement of the eyes, with a frank dissociation between the two eyes, highly variable over time (Fig. 28 and 29). In four cases, phase variations were observed over the length of the recordings, occurring at irregular intervals and usually lasting for less than a second to a few seconds, without any apparent trigger. Whenever identifiable,

the waveforms were always truly sinusoidal. In six cases, the nystagmus resolved between age 6.5 and age 24 months. In two cases, the nystagmus was still present, though rarely, at age 3 and 5 years. Concerning case six, after an initial period of three months, the nystagmus disappeared for a month, while visual function and general health decreased, before reappearing with visual function improvement.

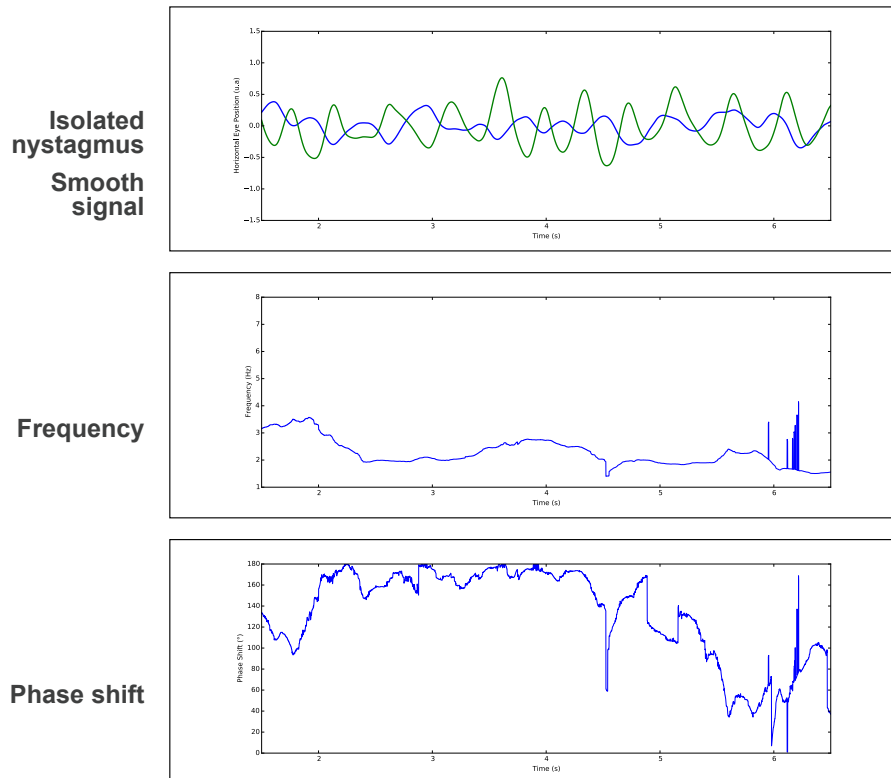


Fig 29 Oculographic characteristics of typical optic pathway glioma-associated nystagmus (2)

From child 4 recordings. Phase shift: from sec. 1.5 to 5, both eyes are oscillating in the horizontal plane with a 180° phase shift; from sec 5 to 6.5, both eyes are oscillating almost in phase.

In all cases but one, the tumour volume was big (>28x28x20mm, up to 51x30x47mm), always involving the chiasm (Table 6 and fig. 30). In six cases, post-gadolinium enhancement was seen in the tumour periphery, while in the centre, the anatomical shape of a thickened chiasm could be seen, without enhancement; in three cases among these six, the global tumour shape respected the form of the chiasm, leading to a four-leaf clover appearance. In two cases, there

was global enhancement of the tumour and the chiasm was undistinguishable within the tumour. In two cases, histology was not available. In five out of six cases, the tumours were pilocytic astrocytomas, while in the sixth case it consisted in a pilo-mixoid astrocytoma grade II.

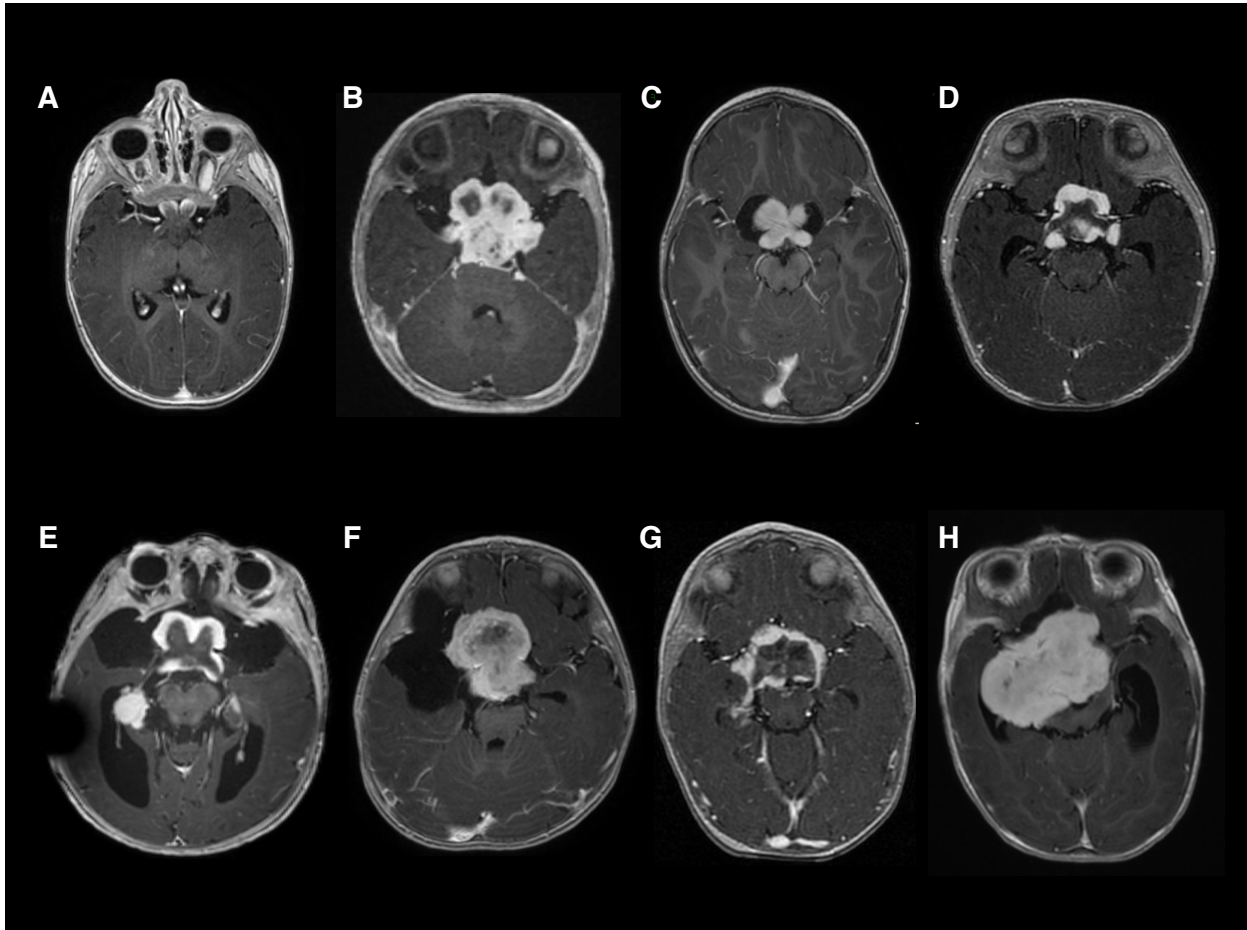


Fig 30. Gadolinium-enhanced T1 axial imaging of the optic pathway gliomas.
(A) Patient 1. **(B)** Patient 2. **(C)** Patient 3. **(D)** Patient 4. **(E)** Patient 5. **(F)** Patient 6. **(G)** Patient 7. **(H)** Patient 8.

In all cases, a chemotherapy was initiated, according to the SIOP-LGG 2004 protocol (EU trial-20555) comparing classical induction with vincristine-carboplatine for 10 weeks with reinforced induction with vincristine-carboplatine-etoposide for 10 weeks, followed in all cases by vincristine and carboplatine for a total treatment duration of 18 months. In selected cases a debulking surgery was also performed, initially in three cases and secondarily in one case. Visual outcome was highly variable and could not be correlated with either the delay

between nystagmus onset and OPG diagnostic, the characteristics of the tumour or the treatments administered: in two cases bilateral profound visual impairment was noticed over the two months following diagnosis, in three cases, profound visual impairment developed in one eye, while the fellow eye exhibited moderate to no visual impairment; in three cases, only little to moderate symmetrical visual impairment was noticed at last examination.

Children	Age at nystagmus onset (months)	Age at glioma diagnosis (months)	Associated general signs at diagnosis	Visual function	Optic discs at fundoscopy	VEP (+ made, - not made)
1	5.5	5.5	Head oscillations long before nystagmus onset	Normal (Teller cards)	Normal	+
2	2.5	3	Head tilt Collier sign	Normal behaviour	Doubtful minimal optic atrophy	-
3	10	23	-	Normal behaviour	Bilateral severe optic atrophy	+
4	4	4.5	Head oscillations, Head tilt, Minimal hydrocephalus, Collier sign, Corticotrope deficiency	Intermittent fixation	Papilledema	+
5	4	4	Hydrocephalus Bilateral VI nerve paresis	Normal (Teller cards)	Bilateral severe optic atrophy	+
6	7.5	8	Weight loss, Bulging fontanel, Corticotrope deficiency	Normal (Teller cards)	Doubtful minimal optic atrophy	+
7	7	8	Head tilt	Normal behaviour Teller cards: inferior to age norms	Normal	-
8	5.5	5.5	Weight loss, Head oscillations before nystagmus onset, Hydrocephalus, Collier sign, Panhypopituitarism	Normal behaviour	Doubtful minimal optic atrophy	-

Table 5. Clinical characteristics at diagnosis

Children	Location	Gadolinium enhancement	Tumour size at diagnosis transverse x antero-post x sagittal (volume)	Metastasis	Cyst	Histologic type	<i>BRAF V600e</i>	<i>KIAA1549-BRAF</i>
1	Optic nerves, chiasm, optic tract	+ Peripheral	Largest diameter of the optic nerve = 10mm	-	-	-	-	-
2	Optic nerves, chiasm, optic tract with infratentorial infiltration	+ Peripheral	51x40x37 mm supra and infratent	+	+	Pilocytic astrocytoma	0	WT
3	Optic nerves, chiasm, optic tract	+ Peripheral	33x30x21 mm (10.4 ml)	-	-	Pilocytic astrocytoma	NF	NF
4	Optic nerves, chiasm, optic tract	+ Peripheral	28x28x24 mm	-	-	Pilocytic astrocytoma	NF	NF
5	Optic nerves, chiasm	+ Peripheral	36x29x26 mm	-	+ frontal (big)	-	-	-
6	Optic nerves, chiasm, optic tract	+ Global, uniform	42x38x36 mm and cyst 60x35 mm	-	+	Pilocytic astrocytoma	-	-
7	Chiasm, optic tract	+ Peripheral	45x30mm	+ bulb, T1 and T6	+	Pilocytic astrocytoma	-	<i>Biopsy made on metastasis</i>
8	Optic nerves, chiasm, optic tract	+ Global, uniform	51x34x44 mm	-	+ (small)	Pilo-myxoid astrocytoma Grade II	-	-

Table 6. Imaging and histologic characteristics

Children	Treatments: first line	Treatments: second line	Treatments: third line and following	Visual outcome (age at last examination)
1	SIOP LGG 2004 Stable then MRI progression	Velbe 1/week	-	OD: >0,2 R2; OS: severe amblyopia (4 y-o)
2	SIOP LGG 2004	VCR CPM/VCR Cisplatine	Debulking, Cystic derivation, Vinblastine, Avastin- Irinotecan	Profound visual impairment within the two months following diagnosis; NLP; severe bilateral optic atrophy (2 y-o)
3	SIOP LGG 2004	-	-	1.1/10 R12 // 1.5/10 R3 (5 y-o)
4	SIOP LGG 2004	TPCV	-	Profound visual impairment within the two months following diagnosis; NLP; major photophobia; severe bilateral optic atrophy (2.5 y-o)
5	Debulking SIOP LGG 2004	-	-	> 1.6/10 R1/3 // 1.6/10 R1/3 (4 y-o)
6	Debulking SIOP LGG 2004	-	-	Profound visual impairment OD within the two months following diagnosis; OD: NLP; OG: normal behaviour (> R10) (2.5 y-o)
7	SIOP LGG 2004 (1 year only, parents decision)	Re-evolution age 2.5; no treatment; spontaneous regression	-	Moderate visual impairment in both eyes, no amblyopia (4 y-o)
8	Debulking SIOP LGG 2004 (10 weeks) TPCV	TPCV	-	Light perception OD / Follows small targets OS; photophobia; severe bilateral optic atrophy, OD>OS (2 y-o)

Table 7. Treatments characteristics and visual outcome

TPCV: Thioguanine, Procarbazine, CCNU or Lomustine, Vincristine

NLP: no light perception

Children	Nystagmus mean frequency (Hz)	Multi directional	Laterality	Age at nystagmus resolution	Oculomotor anomalies after initial nystagmus resolution
1	3.0	+	Bilateral, initially RE>LE, then LE>RE	Still present age 3 years	-
2	5.0	+	ODS then OD>OS	7 months	Stability, then searching nystagmus and III nerve paresis with Xt
3	3.6	+	Right eye alone first, then bilateral, RE>LE	Still rarely present age 5 years	-
4	3.6	+ pseud o-R	OD>OG sur EOM 180° OP	6.5 months	Stability, then searching nystagmus and Xt
5	4.5	+	-	24 months	-
6	3.0	+	RE>LE	18 months	Et
7	4.0	+	-	15 months	-
8	2.7	+ pseud o-R	RE initially, then RE>LE	12 months	Variable Xt Crossed fixation with LE

Table 8. Nystagmus characteristics

Xt: exotropia; Et: esotropia

II.II.4. Discussion

We describe here a series of patients diagnosed with OPG through nystagmus. All of them were between 2.5 and 10-month-old when the nystagmus was first noted. In all cases, the nystagmus characteristics were similar: multidirectional, medium to high frequency, low amplitude, highly variable over time, disconjugate and dissociated. Such nystagmus could not clinically be confused with an INS or a FMNS. Both eyes were rarely oscillating with independent frequency; most of the time they exhibited a “convection-like” oscillatory movement, with a 180° horizontal phase shift and no vertical phase shift. In all cases, the OPG were Dodge grade 2 or 3, centred by the chiasm, with always peripheral or global

gadolinium enhancement, which constitutes a specific subpopulation of OPG. Two cases out of eight were metastatic, which is also unusual. Eleven cases of tumours were diagnosed among the 37 cases of nystagmus clinically classified as *spasmus nutans*-type. All were OPG. By contrast, no case of brain tumour was diagnosed within the 143 children with other types of early-onset nystagmus. The high incidence of *spasmus nutans* (and hence of tumours) in this series likely reflects the selection bias of a tertiary referral paediatric hospital.

This study also allows for three practical considerations regarding nystagmus and OPG. First, age cannot be discriminant in differentiating secondary nystagmus, since in at least one case the nystagmus was present before 12 weeks of age, and in at least five cases, the nystagmus was present before six months of age –and could therefore be considered “early onset”. Not only can a nystagmus present before 12 months be associated with an OPG, but such early onset is the rule for these nystagmus. Second, the presence of associated head oscillations is not specific of idiopathic *spasmus nutans*-type nystagmus –unlike what was recently suggested (Hertle and Dell'Osso, 2013)–, since it was noticed in three cases in this series. Third, in all cases but one, visual behaviour was normal at onset, and in the majority of cases (five out eight patients), despite the large volume of the glioma, the fundus was initially considered within normal limits. Therefore, considering that in all cases treatment was indicated from diagnosis, and considering the relative rarity of such nystagmus as opposed to INS and FMNS, the controversy as to whether imaging should be performed in cases of *spasmus nutans*-type nystagmus even if the visual function and the fundus are considered normal (Arnoldi and Tychsen, 1995, Lee, 1996, Newman et al. , 1990) can be solved: we recommend urgent imaging to be also performed in all cases of *spasmus nutans*-type nystagmus, unless signs of retinal dystrophy or dysfunction are present.

Farmer and Hoyt reported that in asymmetrical OPG-associated nystagmus, the most oscillating eye was not necessarily the one with the lowest vision (Farmer and Hoyt, 1984). A

quick analysis of the present series would reach similar conclusions, as case one, who eventually developed severe amblyopia in the left eye, first exhibited an asymmetrical nystagmus with larger amplitude in the right eye. However, at that stage the vision was evaluated as being normal, while when a frank left amblyopia developed, the nystagmus asymmetry switched, with a larger nystagmus amplitude in the left eye. In the two other cases where unilateral amblyopia developed, the nystagmus also predominated in the amblyopic eye.

How can the peculiar nystagmus associated with these eight cases of OPG be described and classified? In all cases, the nystagmus characteristics fitted the usual definition of *spasmus nutans*-type nystagmus: pendular, medium (3-4 Hz) or high frequency (5Hz), low amplitude, multidirectional, with a dissociation between both eyes' movements. Here we do not consider the frequency limit criterion proposed by the CEMAS (Group, 2001), which almost never fits with cases of published *spasmus nutans* cases –in Weissman study, no case had a frequency >10Hz (Weissman et al. , 1987); in Gottlob study, only two cases out of ten had a frequency >10Hz (Gottlob et al. , 1995). Although the frequencies observed here are in the high range of nystagmus frequencies observed in INS at similar ages –and in the low range of *spasmus nutans*-type nystagmus– they are clearly not discriminant. However, the absence of any jerk component in lateral gaze –the nystagmus always consisting of pendular oscillations whatever the position of gaze–, allows to easily rule out clinically the hypothesis of both an INS or an FMNS. So do the often predominant vertical component and also the dissociation of both eye movements, which was clinically obvious in three cases with medium frequency: one unilateral, one very asymmetrical –both observed during initial examination–, plus one case where the nystagmus was reported to have been initially unilateral. In other cases, the high frequency and low amplitude characteristics of the nystagmus precluded any clinical analysis of the interocular phase relationship. Hence, based on clinical characteristics alone, the

nystagmus was always classified within the category of *spasmus nutans*-type nystagmus. Notwithstanding the debate around what “*spasmus nutans*” should designate –the idiopathic form of a given syndrome, or the syndrome itself whatever its cause–, the definition of *spasmus nutans*-type nystagmus itself is challenging: for most authors, it is a clinical diagnostic as defined above, while for others, what defines *spasmus nutans* is the interocular phase difference (that is, the dissociation between the right and the left eye oscillations) and the variability of this difference over time (Weissman et al. , 1987), which most often requires one or several formal oculomotor recordings. An interocular phase difference was assessed in all cases reported here, most of the time a 180° phase shift; in four cases a variability of this phase difference over time could also be assessed. It is likely that with repeated oculomotor recordings, similar phase shifts would have been found in the four cases where they were not identified. Based on these results, no difference therefore allowed to distinguish between OPG gliomas and *spasmus nutans*-type nystagmus, even when applying recording-based definitions. The “convection” pattern of the OPG-associated nystagmus does not only fit with the characteristics of *spasmus nutans*-type nystagmus; it has also been reported in “convergent-divergent acquired pendular nystagmus”, which has been described in a few adult patients (Averbuch-Heller et al. , 1995, Galvez-Ruiz et al. , 2011, Gresty et al. , 1982, Mossman et al. , 1990, Schwartz et al. , 1986, Sharpe et al. , 1975, Yang et al. , 2006).

What mechanism can give rise to such a nystagmus? Although in the present series, when an amblyopia was present, the amblyopic eye exhibited larger nystagmus amplitudes, the hypothesis of low vision as the cause for the nystagmus is unlikely: in all cases but one, there was still no sign of low vision at nystagmus onset and in many cases even for months after onset. Instead, here the nystagmus preceded the variable visual loss, while vision-loss nystagmus follows severe vision loss after a variable delay. Additionally, such pattern has not been described in other instances of vision loss nystagmus: early monocular vision loss can

give rise to binocular, jerk nystagmus beating away from the amblyopic eye, which characteristics are similar to a hemi-FMNS (Kushner, 1995) –the syndrome of monocular infantile blindness with bilateral nystagmus–, but also, more rarely, to monocular, pendular, high-frequency and low-amplitude, horizontal, monocular nystagmus (Good et al. , 1993); late monocular vision loss can give rise to monocular, low-frequency and low-amplitude, vertical, monocular nystagmus –the so-called Heimann-Bielschowsky phenomenon– (Smith et al. , 1982); binocular vision loss can lead to continuous jerk nystagmus, with horizontal, vertical and torsional components –also called “searching nystagmus”–, but also, more rarely, to medium-frequency and medium-amplitude, horizontal, binocular, symmetrical nystagmus (Good et al. , 1997), or even more rarely, to seesaw nystagmus, mainly but not always, in the case of lesions at the optic chiasm (May and Truxal, 1997). None of these four categories of nystagmus could be mistaken for the nystagmus described here.

Another hypothesis would rely on the early crossing alterations induced by a chiasmal lesion. According to a recent hypothesis, disruption in the negative feedback function of the physiological optokinetic nystagmus system with inversion of the retinal slip might be the cause of several varieties of early onset nystagmus (Huang et al. , 2011). In almost all cases, such disruption results from constitutional misrouting of the ganglion cells, such as in oculocutaneous albinism or achiasma. The OPG from the present series represent the most early set of OPG, with an acquired, early disturbance of the normal repartition between crossing and uncrossing ganglion cells at the level of the chiasm. Like chiasmatic compression, chiasmatic infiltration –be it tumoural or inflammatory– can cause bitemporal hemianopia, by affecting more selectively the crossed axonal fibres. The most consistent hypothesis for this susceptibility of the nasal fibres to compression is based on structural collapse theories as applied to crossing vs noncrossing fibers (McIlwaine et al. , 2005). The nystagmus associated with OPG could be a model of acquired, early disruption of the optokinetic system, interfering

with the calibration of the visual system during the sensitive period of visual development. Such imperfectly calibrated oculomotor system could precisely produce a pendular nystagmus –one achiasmatic zebrafish *belladonna* mutant was shown to exhibit a pendular-waveform nystagmus (Huang et al. , 2011). However, this hypothesis is unlikely for two reasons. First, we failed to show any consistent crossed asymmetry in the five children we recorded with VEPs. This, however, may be due to a lack of robustness in the technique used, since the stimuli were displayed on a small screen, while bigger ones allows for better reproducibility in VEPs in the infant age set (Thompson and Liasis, 2012). Second, this hypothesis does not account for the 180° phase difference between both eyes horizontal components: both practically and theoretically, such a failure in the calibration of the oculomotor system would give rise to conjugated nystagmus.

As synthesised by Averbuch-Heller *et al.* (Averbuch-Heller et al. , 1995), the two theoretical possibilities to give rise to the pattern of a “convergent-divergent acquired pendular nystagmus” are either a dysfunction in the normal yoking mechanisms of the version system with a 180° phase shift –as also proposed by some authors as an explanation for *spasmus nutans* (Weissman et al. , 1987)–, or oscillations in the vergence system (Schwartz et al. , 1986, Sharpe et al. , 1975). Here, the OPG-associated nystagmus is also dissociated, which also points towards vergence movements. Although variations in the phase interactions between the two eyes were recorded, those were always brief (often lasting for less than a second), compared to the large majority of the recordings where the horizontal phase shift was 180°. The strict conjugacy of the vertical component also makes the first possibility unlikely. The response of the vergence system is traditionally believed to be slow. Most reported cases of convergent-divergent acquired pendular nystagmus had low velocities and frequencies (around 1Hz) and therefore fitted with this possibility (Schwartz et al. , 1986, Sharpe et al. , 1975). Experiments have shown, however, that the slow vergence system could

oscillate at frequencies up to 2.5 Hz (Hung et al. , 1986), while in two cases from Averbuch-Heller *et al.*, the nystagmus frequency was as high as 6 Hz. The slow vergence system is a negative feedback system and may oscillate either through an increase in gain or delay within the system internal feedback loops, or through external oscillation imposing upon the system (Averbuch-Heller et al. , 1995). The high frequencies recorded in most of our patients suggest either pathological changes increasing the gain or decreasing the delay within this system, or external oscillations. While most pathological lesions –such as decrease in the myeline conduction speed– would increase the delay, a loss of inhibitory connections could increase it. However, such oscillations would then be electively provoked when the vergence system is operating, that is during near vision, which is not what was observed in our patients, unless one postulates that the lack of maturity of the vergence system at a young age could account for such frequent instability and result in a highly-variable-in-time pattern of oscillations. The other possibility would imply an external, linear, neuronal oscillator –for instance within the cerebellum– projecting to the slow vergence system (Averbuch-Heller et al. , 1995). Another hypothesis would implicate the recently studied fast vergence system, which is responsible for the fast vergence movements occurring during rapid eye movement sleep (Cullen and Van Horn, 2011, Escudero and Vidal, 1996); however, its neural bases are still a matter of debate; these movements are disconjugate, which could possibly account for the observed variations in the phase shift over time.

How can oscillations in the vergence system result from the presence of an OPG? Within the slow vergence system, chiasmal gliomas strongly affect all the visual afferences of the *nucleus reticularis tegmenti pontis* (NRTP), through the superior colliculi and through the frontal eye fields (Fig. 30). The NRTP projects to the fastigial nucleus, the dentate nucleus and the posterior interposed nucleus (IP). These are reciprocate, mainly inhibitory connections. The IP is a central element within the vergence system, with efferences to the

medial recti via the supra-oculomotor area. Instability in the feedback loops between the NRTP and its cerebellar efferences, mainly the IP, could lead to sinusoidal oscillations in the vergence system. This was experimentally shown in monkeys with selective lesions of the NRTP, who exhibited convergent-divergent oscillations (Gamlin and Mitchell, 1993). Furthermore, it was showed that the IP could produce theta oscillations under experimental conditions in rabbits (Hoffmann and Berry, 2009). The frequency of theta oscillations in infants is known to range from 3.6 to 5.6 Hz, which is also close to the frequencies of OPG-associated nystagmus (Orekhova et al. , 2006). The next question is: if this specific oscillation pattern results from such a common process, why would it only be noticed in infants with early chiasmal gliomas? A theoretically possible mechanism to consider –either in isolation or in conjunction with the one following– could be the contribution of some metabolic changes occurring in these children through pituitary compression and possibly acting on membrane proteins at the level of the previously discussed brainstem or cerebellar nuclei involved in the control of vergence, although no such common change can be identified. Anatomic considerations, however, suffice in providing a plausible pathophysiological mechanism: early chiasmal gliomas actually represent a unique pathological situation, where an early tumour grows and alters the visual pathways at the very age of a critical period of visual development, between three and nine months of age; hence probably the homogenous time of onset of this nystagmus. Earlier or later, similar processes do not give rise to the same nystagmus. Early chiasmal gliomas are one of the very few conditions –if not the only one– and hence the model of a process, which progressively and partly affects vision at the beginning of the critical period of visual development. The understanding of its clinical expressions is therefore of considerable interest for visual neuroscience and should benefit from ongoing larger studies in the field.

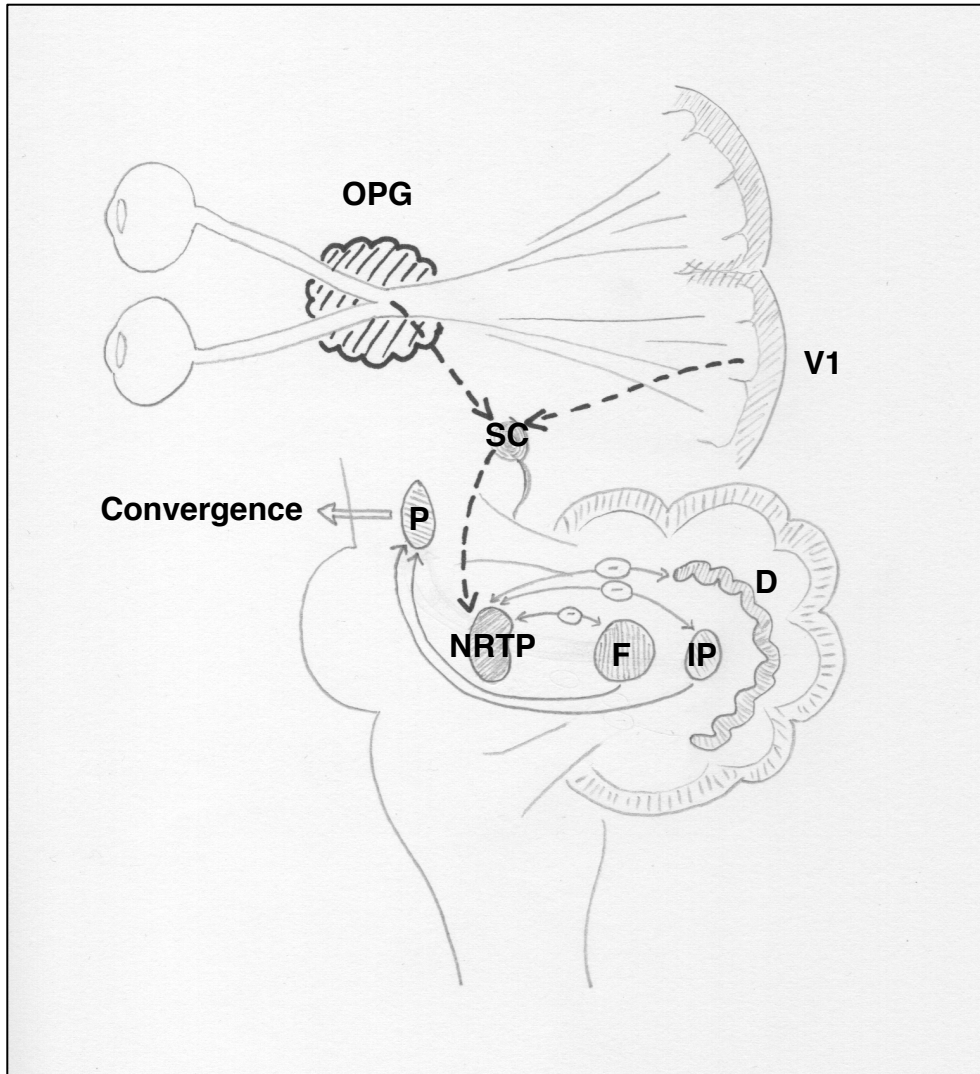


Fig 31. Schematic representation of the disruption in the vergence system circuitry possibly leading to the specific OPG-associated nystagmus

Afferences (directly from the optic bundles or from V1: the primary visual cortex, via SC: the superior *colliculi*) to the *nucleus reticularis tegmenti pontis* (NRTP) are affected by big chiasmal gliomas at the age of the sensitive period of visual development; this can result in instability in the feedback loop between the NRTP and its cerebellar efferences (F: fastigial nucleus, IP: posterior interposed nucleus, D: dentate nucleus) and lead to sinusoidal oscillations in the vergence system.

Chapter III: Benign intermittent upbeat nystagmus in infancy

III.I.1. Introduction

Upbeating nystagmus is usually considered a form of central vestibular nystagmus. Observed in primary position of gaze, it often increases in upgaze but not in lateral gaze. Though a rare and usually transient phenomenon, upbeat nystagmus in adults is known to be associated with an acute dysfunction of the brainstem or cerebellum. In children, upbeat nystagmus is even rarer and is therefore a poorly known phenomenon. Retinal and anterior visual pathway diseases are a well recognised cause of permanent upbeat nystagmus (Leigh and Zee, 2015). Various ocular motor disorders –tonic downgaze or upgaze, opsoclonus, skew deviation– have been documented to possibly occur as transient phenomena in healthy neonates (Hoyt, 1987). Cases of spontaneously resolvable nystagmus of various types have also been reported in children (Good et al. , 2003). Here we present five cases of intermittent upbeat nystagmus in healthy infants, without any association with a neurologic or an ocular condition. All of them resolved spontaneously.

III.I.2. Case series

All cases of infants referred to the paediatric neuro-ophthalmology clinic at Necker-Enfants Malades Hospital in Paris, France, between 2010 and 2013, in which the diagnosis of benign intermittent upbeat nystagmus was made, were retrospectively reviewed. Examination consisted in a review of the patient's medical and familial history. Visual function, fundus examination, strabismus and refraction under cycloplegia were evaluated. Eye movements were examined in all body positions. Video recording were performed for all patients. One of them also benefited from eye movement recording by infrared reflectometry oculography (fig.

32). Table 9 summarises the clinical findings for each patient. All presented an intermittent upbeat nystagmus with spontaneous resolution without any other ocular or neurological abnormality. In all cases the nystagmus characteristics consisted in unique, strikingly similar and highly recognisable features: eyes beating up (that is with the slow phase oriented downwards), with very large quick phase amplitudes due to a baseline position in downgaze (from mild to obvious downgaze), with a beating frequency comprised between 1.5 and 2.5 Hz; the nystagmus occurred mostly in supine position; it could always be triggered or frankly enhanced by head rotations in the supine position about the longitudinal axis of the body, whatever the direction of the rotation. When so triggered, the nystagmus only faded with a time constant of several minutes. The occurrence of the nystagmus never interfered the slightest with the infant's behaviour or visual attention. Parents reported the nystagmus to mainly occur during nursing or just after waking up, i.e. when infants were in a reclined position or drowsy. None of them had an abnormal head posture suggesting a null point position (i.e. a position of gaze in which nystagmus is diminished and, therefore, visual acuity improved). Alternating occlusion did not alter eye movements. Age at onset was from the first weeks of life to two months. Age at resolution was from five to 14 months. For participant 5, strong emotions were also reported as being a triggering factor by the parents. For participants 2 and 5, obvious tonic downgaze was associated with the upbeat nystagmus. No superior lid retraction was noticed. For participant 5, slow phases measured by oculography had constant speed waveforms (fig. 32).

Patient	Sex	Age at Onset	Age at Resolution	Medical History	Nystagmus Frequency	Exacerbating Factor	Associated Features	Follow-up duration after resolution of the symptoms
1	F	2 months	6 months	Haemorrhagic vomiting at 2 months	2Hz	Head rotation	None	3 years
2	F	First weeks of life	14 months	None	1.5 Hz	Head rotation	Tonic downgaze	1 year
3	F	1 month	5 months	Optic atrophy in a maternal cousin	2 Hz	Head rotation	None	1 year
4	M	2 months	6 months	None	2 Hz	Head rotation	None	6 months
5	F	First weeks of life	6 months	Consanguineous parents	2.5 Hz	Head rotation Strong emotions	Tonic downgaze Esotropia	5 months

Table 9. Clinical features in five patients affected by transient intermittent upbeat nystagmus

The episodes were mostly observed in supine position. F: female ; M: male

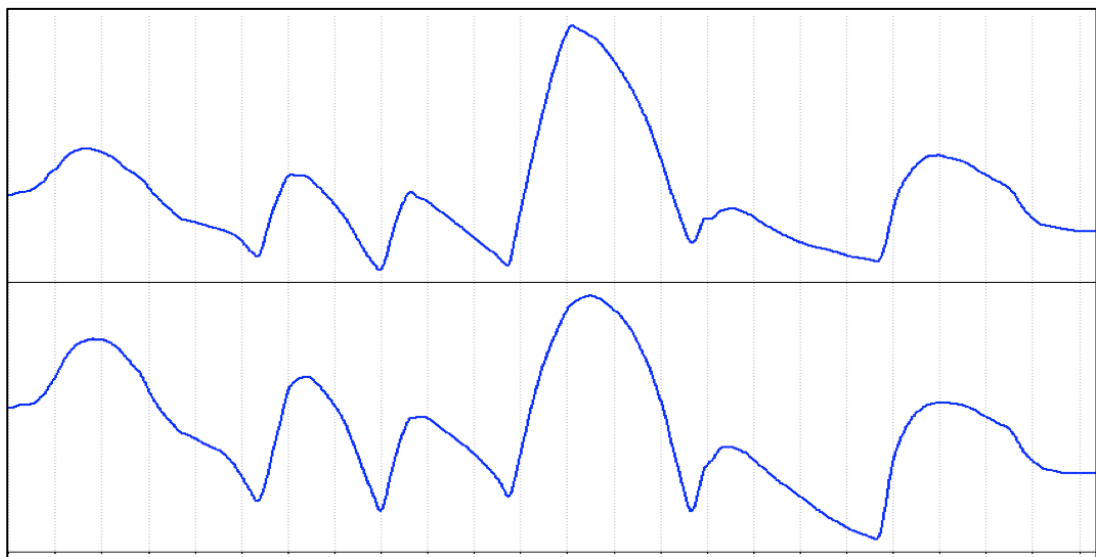


Figure 32. Oculographic recording by infrared reflectometry of a benign intermittent upbeat nystagmus in childhood

Vertical axis, top: left eye and bottom: right eye. Each graduation on the x axis =0,5s; the y scale is not indicated on purpose, due to the nystagmus amplitude, beyond the limits of linearity of the Eyefant.

Children were evaluated for other neurological signs by a neuro-paediatrician. All had a normal general and neurological development. They all systematically underwent neuroimaging by MRI, which was normal in each case. Oto-neurological systematic examinations, including caloric tests and off-vertical axis rotation, were also all normal. No treatment was introduced. The strictly normal fundus examination, the normal visual function, the spontaneous favourable evolution and the intermittent positional nature of the nystagmus allowed us to clinically eliminate an anterior visual pathway disease as a cause of the eye movement. No visual electrophysiological investigation was therefore performed. The nystagmus spontaneously disappeared within a few months after having first become less frequent.

III.1.3. Discussion

We describe here a homogeneous group of five healthy infants with a specific isolated transient positional large upbeat nystagmus that spontaneously disappeared within a few months. All further investigations were normal and no aetiology was found. We propose to refer to this newly described entity as: benign intermittent upbeat nystagmus in infancy.

Transient abnormal ocular motor phenomena are known to sometimes occur in healthy newborns and infants –transient strabismus, tonic downgaze, tonic upgaze, opsoclonus, skew deviation (Hoyt, 1987)– and are all retrospectively considered idiopathic if they both spontaneously disappear and do not precede any visual abnormality. Transient nystagmus has also been reported: Good *et al.* (Good et al. , 2003) described six infants with diverse sorts of transient idiopathic nystagmus which all shared the characteristic of having disappeared within the first year of life. One of their cases (case n°7) might actually correspond to the entity we describe here, though the description provided does not allow to conclude. The

authors interpreted the transient nystagmus as indicative of a fragile period of postnatal maturation of the ocular motor system.

Upbeat nystagmus occurs in various conditions in adults; it is much more uncommonly seen in children. It is considered, until proven otherwise, as the sign of an underlying neurological disease (Leigh and Zee, 2015). Lesion of cerebellum or brainstem must be first eliminated by neuroimaging –preferentially MRI. Nevertheless, permanent upbeat in neonates can also be associated with retinal or anterior visual pathway diseases (Leigh and Zee, 2015) such as Leber congenital amaurosis, aniridia or severe optic nerve hypoplasia and does not necessarily imply neurological disease. In such cases, visual function is severely impaired and delayed. Upbeat nystagmus can sometimes be influenced by posture. Cases of upbeat nystagmus on forward gaze in upright and supine positions that changed to downbeat nystagmus in prone position have been described (Leigh and Zee, 2015). Goldblum (Goldblum and Efron, 1994) reported two cases of healthy infants with constant tonic downgaze and upbeat nystagmus on attempted upgaze, which was accentuated when neonates were in the supine position. What the authors called “upbeat nystagmus associated with tonic downward deviation in healthy neonates” certainly refers to the same entity as the one we describe here. They proposed immaturity of the vestibular system as a cause for this transient developmental phenomenon.

Pathophysiology of upbeat nystagmus is not clearly established. Three potential mechanisms resulting in disruption of the mechanisms responsible for keeping vertical gaze steady have been proposed (Leigh and Zee, 2015): 1. disruption of the pathways involved in the upward vestibulo-ocular reflex that are going from the anterior semi-circular canals to the ocular motor nuclei ; 2. failure of vertical upward smooth pursuit system ; 3. dysfunction of vertical neural integrator that is involved in vertical gaze holding. Upbeat nystagmus may be associated with upgaze holding dysfunction as downbeat nystagmus may be associated with

downgaze holding dysfunction. Benign intermittent downgaze and upbeat nystagmus appear to be closely related conditions. Both disorders were clearly associated in two of our patients, while it is not easy to conclude in the three other cases, the gaze of a normal infant being often directed slightly below the straight position of gaze. Otherwise downbeat nystagmus is known to be minimal in supine position through an overacting otolith-ocular reflex in case of lesions of the vestibulocerebellum (Marti et al. , 2002). Upbeat nystagmus could be in analogy maximal in supine position.

The fact that in all cases the nystagmus was elicited in supine position points towards its dependency on gravity, therefore towards a mechanism involving the utriculo and/or the sacculo-ocular networks. In supine position, the utricle/sacculle balance is reversed compared to the upright position, with a greater stimulation of the utricle. When turning the head in the supine position, both lateral semi-circular canals are excited and should elicit a horizontal vestibulo-ocular nystagmus; instead, a large upbeat nystagmus occurs. Positional modulation is a well-recognised feature of many downbeat nystagmus, but it has also been reported in cases of upbeat nystagmus (Leigh and Zee, 2015). We hypothesize therefore that in the case of benign intermittent upbeat nystagmus in infancy, the primary mechanism could be an inadequate wiring of the semi-circular and otolithical first order vestibular neurons, which are known to converge on the second order vestibular neurons (Angelaki and Cullen, 2008). It may be corrected at an older age when a more intense motor activity imposes a recalibration of the vestibulo-ocular pathways.

Conclusion and perspectives

Despite numerous warnings about the difficulties of studying infantile nystagmus in infancy, our motivation has remained intact throughout this work. The technical issues are unlimited and complex and some nystagmus are intermittent. However, oculomotor recording techniques have benefitted from recent progress and are now conceivable in the setting of a paediatric clinic.

Even with acute clinical expertise, the limits of the human eye are often challenged in the case of many forms of nystagmus exhibited by infants; actually by most nystagmus that are neither an INS, nor a FMNS. They are often of small amplitude, of high frequency, often intermittent and not purely horizontal. The CEMAS subclassification of nystagmus is most convincing in having well defined its two first entities: INS, a single and large entity and FMNS. Among the seven following entities, however, many have not been the topic of as many works as the first two ones, especially infantile varieties. A new era for the description of these forms is probably beginning, with the systematic quantified recording of abnormal eye movements from their onset over the time. Not only will such procedures potentially and directly benefit the patient in helping for his/her diagnosis, but they will also permit the constitution of anonymised databases, allowing for pathological correlations and for progress in the comprehension of the mechanisms of nystagmus.

Beyond technical difficulties in getting quantified and calibrated data, another issue when making pathophysiological hypotheses about infantile nystagmus is to think with an adult references, and forgetting or minimizing the crucial role of the maturation of both the sensory and the motor visual systems. Better understanding of the normal maturation of the visual system will probably help unfold many remaining nystagmus mysteries.

Annexe

Articles and communications related to the thesis

1. **VIDAL PP., ROBERT MP.** Ocular vestibular evoked myogenic potentials: the missing link. *J Physiol*, 2012 Jul 1; 590 (13) : 2953.

2. **ROBERT MP., INGSTER-MOATI I., ALBUISSON E., CABROL D., GOLSE B, VAIVRE-DOURET L.** Vertical and horizontal smooth pursuit eye movements in children with developmental coordination disorder. *Dev Med Child Neurol*. 2014 Jun; 56(6): 595-600.

3. **ROBERT MP., MICHEL S., ADJADJ E., BODDAERT N., DESGUERRE I., VIDAL PP.** Benign intermittent upbeat nystagmus in infancy: a new clinical entity. *Eur J Paediatr Neurol*. 2015 Mar; 19(2): 262-5.

4. **MARTIN G., GAVARD-PERRET A., ZAMBROWSKI O., INGSTER-MOATI I., BODDAERT N., VIDAL P-P., ROBERT M.** Spasmus nutans often reveals an underlying, potentially severe, disease. *Invest Ophthalmol Vis Sci*. 2015 Jun; 56(7): 5214.

5. **ROBERT MP., MOREAU T., GRILL J., GREVENT D., ZAMBROWSKY O., VARLET P., CONTAL E., MARTIN G., BREMOND-GIGNAC D., INGSTER-MOATI I., DUFOUR C., BRUGIERES L., VAYATIS N., BODAERT N., SAINTE-ROSE C., BLAUWBLOMME T., PUGET S., VIDAL P-P.** Optic pathway gliomas-associated nystagmus. *Submitted*.

Résumé (français) :

L'étude des nystagmus du nourrisson est difficile pour des raisons méthodologiques. La plupart des études sont donc réalisées chez des adultes et *a posteriori*. Ces études chez l'adulte ont permis la révision des classifications des nystagmus infantiles, avec la consolidation des concepts de syndrome du nystagmus précoce et de nystagmus de type latent. La séméiologie et l'étiopathogénie des nystagmus du nourrisson – notamment des formes comportant un élément vertical et des formes transitoires – reste donc à étudier.

Dans ce but :

1. Nous avons développé de nouvelles techniques d'enregistrement des mouvements oculaires chez les nourrissons, utilisables dans le cadre d'une consultation. Elles incluent de nouveaux stimuli, un appareil d'enregistrement des mouvements oculaires spécialement conçu pour le nourrisson et de nouvelles méthodes d'analyse statistique du signal. Nous avons vérifié la faisabilité de ces enregistrements chez 28 nourrissons atteints de nystagmus.
2. Nous avons étudié systématiquement 32 cas de nystagmus de type *spasmus nutans*, classiquement considéré comme une entité bénigne idiopathique, avec un examen clinique complet, une imagerie cérébrale, une électrophysiologie visuelle et des enregistrements oculo-moteurs. Dans 53,1% des cas, le *spasmus nutans* était le symptôme d'une autre maladie : neurologique (34,3%), notamment des gliomes du chiasma (21,9%), ou rétinienne (12,5%). Une atteinte des voies visuelles antérieures est probablement en cause dans la physiopathologie des *spasmus nutans*.
3. Huit cas de nystagmus ayant conduit au diagnostic de gliome des voies optiques (GVO) ont été également enregistrés et étudiés. L'âge d'apparition du nystagmus allait de 2,5 à 10 mois. Le GVO était toujours chiasmatique et constituait une sous-population spécifique. Le nystagmus était toujours de type *spasmus nutans*. Les enregistrements oculo-moteurs montraient : une fréquence entre 2,7 et 5 Hz, une morphologie sinusoïdale du nystagmus, une dissociation et une dysconjugaison particulière, avec une opposition de phase (180°) entre les oscillations des deux yeux dans le plan horizontal mais une correspondance de phase dans le plan vertical, à l'origine d'un mouvement semblable à un mouvement de convection. Rarement et brièvement, le rapport de phase changeait. Ces caractéristiques orientent vers des oscillations dans le système des vergences, possiblement la conséquence d'une atteinte des afférences sensorielles des centres du contrôle vergentiel dans le tronc cérébral, secondaire au GVO et survenant pendant la période sensible du développement visuel.
4. Cinq cas de nystagmus *upbeat* chez des nourrissons avec des rétines et une imagerie cérébrale normale ont été étudiés. Le nystagmus était observé en décubitus et électivement déclenché par des rotations de la tête en position allongée. Dans tous les cas, une résolution spontanée était observée après quelques mois d'évolution. Les caractéristiques de ce type de nystagmus suggèrent une participation du système otolithique, suivie d'une recalibration secondaire des circuits vestibulo-oculaires.

En conclusion, le développement de techniques d'enregistrement des mouvements oculaires adaptées aux nourrissons aide à la compréhension de l'étiopathogénie de variétés mal décrites de nystagmus, notamment dans les cas comportant un élément vertical et dans les cas transitoires. Les processus de maturation des voies visuelles antérieures et des centres de contrôle de l'oculomotricité semblent jouer un rôle central dans les mécanismes de ces nystagmus.

Title: Pathophysiology of vertical nystagmus in infancy

Abstract:

Studying infantile nystagmus during infancy is difficult for methodological reasons. Most such studies have been performed in adults and *a posteriori*. These studies in adults allowed for an improvement

in the existing classifications, with now robust knowledge about the two most frequent varieties of infantile nystagmus: infantile nystagmus syndrome and fusion maldevelopment nystagmus syndrome. The characteristics and pathophysiology of nystagmus in infants—notably varieties of nystagmus with a vertical component and transitory nystagmus— need further study.

For this reason:

1. We developed new techniques for the recording of eye movements in infants in the setting of a clinic. They include new stimuli, the use of specially-designed infrared photo-oculography eyetrackers and new statistical analysis paradigms. We assessed these techniques in a population of 28 infants with a nystagmus.
2. We systematically studied 32 cases of *spasmus nutans*, classically considered an idiopathic entity, with comprehensive clinical examination, brain imaging, electrophysiology, nystagmus recording. In 53.1% of cases, it led to the diagnosis of another condition: a neurological disease (34.3%), including cases of chiasmal gliomas (21.9%), or a retinal dysfunction (12.5%). Anterior visual pathway dysfunction is likely involved in the pathophysiology of *spasmus nutans*.
3. Eight cases of nystagmus having led to a diagnosis of optic pathway glioma (OPG) were also recorded and studied. Age at nystagmus onset was 2.5-10 months. The associated OPG always involved the chiasm, and represent a specific subpopulation of OPG. Clinically, the nystagmus was always classified as *spasmus nutans* type. Oculographic recordings showed frequencies of 2.7-5 Hz, sinusoidal waveforms, dissociation and a special type of disconjugacy, with a 180° horizontal phase shift and no vertical phase shift, exhibiting a “convection-like” movement pattern. Rarely and for short periods of time, the phase shift could change. These characteristics point towards oscillations in the vergence system, which could possibly result from the specific disruption of the vergence centres afferences in the brainstem, induced by the OPG during the sensitive period of visual development.
4. Five cases of upbeat nystagmus in infants with normal retinas and normal brain imaging were studied. The nystagmus mostly occurred in supine position and could be triggered by head rotations in the supine position. All resolved spontaneously. The characteristics of this nystagmus suggest an involvement of the otolithic system, with a secondary recalibration of the vestibulo-ocular pathways.

In conclusion, the development of infant-friendly devices for eye-movements recording helps providing new insights on the pathophysiology of poorly described varieties of nystagmus, including nystagmus with a vertical component and transitory nystagmus. The maturation process of both the anterior visual pathways and the oculomotor pathways appears to be central in the mechanisms of these nystagmus.

Mots clés (français) : nystagmus, enregistrements oculomoteurs, réflectométrie infra-rouge, syndrome du nystagmus précoce, *spasmus nutans*, gliome des voies visuelles, nystagmus upbeat

Keywords: nystagmus, oculomotor recordings, infrared reflectometry, infantile nystagmus syndrome, *spasmus nutans*, optic pathway glioma, upbeat nystagmus

References

- Abadi RV, Pascal E. Periodic alternating nystagmus in humans with albinism. *Investigative Ophthalmology and Visual Science*. 1994 Nov; 35: 4080-6.
- Abadi RV, Scallan C. Manifest latent and congenital nystagmus waveforms in the same subject A need to reconsider the underlying mechanisms of nystagmus. *Neuro-Ophthalmology*. 1999; 21: 211-21.
- Abadi RV, Scallan CJ. Waveform characteristics of manifest latent nystagmus. *Investigative Ophthalmology and Visual Science*. 2000 Nov; 41: 3805-17.
- Abadi RV, Whittle J. The nature of head postures in congenital nystagmus. *Arch Ophthalmol*. 1991 Feb; 109: 216-20.
- Abbas A, McLean RJ, Gottlob I. Clinical Characteristics And Assessment Of Nystagmus Waveforms In Congenital Stationary Night Blindness And Aland Island Disease. *Investigative Ophthalmology and Visual Science*. 2012; 53: 516-.
- Ahn S, Lee SK. Diffusion tensor imaging: exploring the motor networks and clinical applications. *Korean J Radiol*. 2011 Nov-Dec; 12: 651-61.
- Albright AL, Scwabassi RJ, Slamovits TL, Bergman I. Spasmus nutans associated with optic gliomas in infants. *Journal of Pediatrics*. 1984 Nov; 105: 778-80.
- Angelaki DE, Cullen KE. Vestibular system: the many facets of a multimodal sense. *Annu Rev Neurosci*. 2008; 31: 125-50.
- Antony JH, Ouvrier RA, Wise G. Spasmus nutans: a mistaken identity. *Arch Neurol*. 1980 Jun; 37: 373-5.
- Apkarian P, Bour LJ. See-saw nystagmus and congenital nystagmus identified in the non-decussating retinal-fugal fiber syndrome. *Strabismus*. 2001 Sep; 9: 143-63.
- Apkarian P, Bour LJ, Barth PG, Wenniger-Prick L, Verbeeten B, Jr. Non-decussating retinal-fugal fibre syndrome. An inborn chiasmatic malformation associated with visuotopic misrouting, visual evoked potential ipsilateral asymmetry and nystagmus. *Brain*. 1995 Oct; 118 (Pt 5): 1195-216.
- Apkarian P, Shallo-Hoffmann J. VEP projections in congenital nystagmus; VEP asymmetry in albinism: a comparison study. *Investigative Ophthalmology and Visual Science*. 1991 Aug; 32: 2653-61.
- Arnoldi KA, Tychsen L. Prevalence of intracranial lesions in children initially diagnosed with disconjugate nystagmus (spasmus nutans). *Journal of Pediatric Ophthalmology and Strabismus*. 1995 Sep-Oct; 32: 296-301.
- Averbuch-Heller L, Dell'Osso LF, Jacobs JB, Remler BF. Latent and congenital nystagmus in Down syndrome. *J Neuroophthalmol*. 1999 Sep; 19: 166-72.
- Averbuch-Heller L, Zivotofsky AZ, Remler BF, Das VE, Dell'Osso LF, Leigh RJ. Convergent-divergent pendular nystagmus: possible role of the vergence system. *Neurology*. 1995 Mar; 45: 509-15.
- Balkema GW, Drager UC. Origins of uncrossed retinofugal projections in normal and hypopigmented mice. *Visual Neuroscience*. 1990 Jun; 4: 595-604.
- Baram TZ, Tang R. Atypical spasmus nutans as an initial sign of thalamic neoplasm. *Pediatric Neurology*. 1986 Nov-Dec; 2: 375-6.
- Bedell HE, Stevenson SB. Eye movement testing in clinical examination. *Vision Res*. 2013 Sep 20; 90: 32-7.
- Birch EE, Wang J, Feliuss J, Stager DR, Jr., Hertle RW. Fixation control and eye alignment in children treated for dense congenital or developmental cataracts. *Journal of AAPOS*. 2012 Apr; 16: 156-60.
- Brecelj J. Visual electrophysiology in the clinical evaluation of optic neuritis, chiasmal tumours, achiasmia, and ocular albinism: an overview. *Documenta Ophthalmologica*. 2014 Oct; 129: 71-84.
- Brecelj J, Stirn-Kranjc B. Visual electrophysiological screening in diagnosing infants with congenital nystagmus. *Clinical Neurophysiology*. 2004 Feb; 115: 461-70.

- Brecelj J, Sustar M, Pecaric-Meglic N, Skrbec M, Stirn-Kranjc B. VEP characteristics in children with achiasmia, in comparison to albino and healthy children. *Documenta Ophthalmologica*. 2012 Apr; 124: 109-23.
- Brodsky MC. Positive angle kappa: a confounding variable in the diagnostic testing of patients with albinism. *Br J Ophthalmol*. 2008 Apr; 92: 577-8.
- Brodsky MC. *Pediatric neuro-ophthalmology*: Springer; 2010.
- Brodsky MC, Fray KJ. Positive angle kappa: a sign of albinism in patients with congenital nystagmus. *Am J Ophthalmol*. 2004 Apr; 137: 625-9.
- Brodsky MC, Keating GF. Chiasmal glioma in spasmus nutans: a cautionary note. *J Neuroophthalmol*. 2014 Sep; 34: 274-5.
- Brodsky MC, Tusa RJ. Latent nystagmus: vestibular nystagmus with a twist. *Arch Ophthalmol*. 2004 Feb; 122: 202-9.
- Bui Quoc E, Milleret C. Origins of strabismus and loss of binocular vision. *Front Integr Neurosci*. 2014; 8: 71.
- Cabot A, Rozet JM, Gerber S, Perrault I, Ducroq D, Smahi A, et al. A gene for X-linked idiopathic congenital nystagmus (NYS1) maps to chromosome Xp11.4-p11.3. *Am J Hum Genet*. 1999 Apr; 64: 1141-6.
- Carroll J, Dubra A, Gardner JC, Mizrahi-Meissonnier L, Cooper RF, Dubis AM, et al. The effect of cone opsin mutations on retinal structure and the integrity of the photoreceptor mosaic. *Investigative Ophthalmology and Visual Science*. 2012 Dec; 53: 8006-15.
- Chen CC, Bockisch CJ, Olasagasti I, Weber KP, Straumann D, Huang MY. Positive or negative feedback of optokinetic signals: degree of the misrouted optic flow determines system dynamics of human ocular motor behavior. *Investigative Ophthalmology and Visual Science*. 2014 Apr; 55: 2297-306.
- Chrousos GA, Reingold DR, Chu FC, Cogan DG. Habitual head turning in spasmus nutans: an oculographic study. *J Pediatr Ophthalmol Strabismus*. 1985 May-Jun; 22: 113-6.
- Cogan DG. Congenital nystagmus. *Canadian Journal of Ophthalmology*. 1967 Jan; 2: 4-10.
- Collewijn H, Apkarian P, Spekreijse H. The oculomotor behaviour of human albinos. *Brain*. 1985 Mar; 108 (Pt 1): 1-28.
- Cullen KE, Van Horn MR. The neural control of fast vs. slow vergence eye movements. *Eur J Neurosci*. 2011 Jun; 33: 2147-54.
- Dell'Osso L, Traccis S, Abel L. Strabismus—a necessary condition for latent and manifest latent nystagmus. *Neuro-Ophthalmology*. 1983; 3: 247-57.
- Dell'Osso LF, Hertle RW, Daroff RB. "Sensory" and "motor" nystagmus: erroneous and misleading terminology based on misinterpretation of David Cogan's observations. *Arch Ophthalmol*. 2007 Nov; 125: 1559-61.
- Dell'Osso LF, Jacobs JB. An expanded nystagmus acuity function: intra- and intersubject prediction of best-corrected visual acuity. *Documenta Ophthalmologica*. 2002 May; 104: 249-76.
- Dell'Osso LF, Leigh RJ, Sheth NV, Daroff RB. Two types of foveation strategy in 'latent' nystagmus: fixation, visual acuity and stability. *Neuroophthalmology*. 1995 Aug; 15: 167-86.
- Dell'Osso LF, Schmidt D, Daroff RB. Latent, manifest latent, and congenital nystagmus. *Arch Ophthalmol*. 1979 Oct; 97: 1877-85.
- Dell'Osso LF, van der Steen J, Steinman RM, Collewijn H. Foveation dynamics in congenital nystagmus. I: Fixation. *Documenta Ophthalmologica*. 1992; 79: 1-23.
- Dell'Osso LF, Williams RW. Ocular motor abnormalities in achiasmatic mutant Belgian sheepdogs: unyoked eye movements in a mammal. *Vision Res*. 1995 Jan; 35: 109-16.
- Denis D, Girard N, Toesca E, Zanin E, Gambarelli N, Lebranchu P, et al. [MRI in congenital nystagmus]. *J Fr Ophtalmol*. 2010 Mar; 33: 189-205.
- Dickson G. Spasmus nutans, or the nodding spasm. *The Lancet*. 1895; 146: 845-6.
- Dobson V, Brown AM, Harvey EM, Narter DB. Visual field extent in children 3.5-30 months of age tested with a double-arc LED perimeter. *Vision Res*. 1998 Sep; 38: 2743-60.
- Donin JF. Acquired monocular nystagmus in children. *Canadian Journal of Ophthalmology*. 1967 Jul; 2: 212-5.

- Dorey SE, Neveu MM, Burton LC, Sloper JJ, Holder GE. The clinical features of albinism and their correlation with visual evoked potentials. *Br J Ophthalmol*. 2003 Jun; 87: 767-72.
- Doummar D, Roussat B, Beauvais P, Billette de Villemeur T, Richardet JM. [Spasmus nutans: apropos of 16 cases]. *Arch Pediatr*. 1998 Mar; 5: 264-8.
- Duke-Elder W. Text-book of ophthalmology. London: Henry Kimpton; 1949.
- Eggert T. Eye movement recordings: methods. *Developments in Ophthalmology*. 2007; 40: 15-34.
- Escudero M, Vidal PP. A quantitative study of electroencephalography, eye movements and neck electromyography characterizing the sleep-wake cycle of the guinea-pig. *Eur J Neurosci*. 1996 Mar; 8: 572-80.
- Farmer J, Hoyt CS. Monocular nystagmus in infancy and early childhood. *Am J Ophthalmol*. 1984 Oct 15; 98: 504-9.
- Felius J, Beauchamp CL, Stager DR, Sr. Visual acuity deficits in children with nystagmus and Down syndrome. *Am J Ophthalmol*. 2014 Feb; 157: 458-63.
- Felius J, Fu VL, Birch EE, Hertle RW, Jost RM, Subramanian V. Quantifying nystagmus in infants and young children: relation between foveation and visual acuity deficit. *Investigative Ophthalmology and Visual Science*. 2011 Nov; 52: 8724-31.
- Fitzgerald BA, Billson FA. Dissociated vertical deviation: evidence of abnormal visual pathway projection. *Br J Ophthalmol*. 1984 Nov; 68: 801-6.
- Fukuda N, Naito S, Masukawa D, Kaneda M, Miyamoto H, Abe T, et al. Expression of ocular albinism 1 (OA1), 3, 4- dihydroxy- L-phenylalanine (DOPA) receptor, in both neuronal and non-neuronal organs. *Brain Research*. 2015 Mar 30; 1602: 62-74.
- Galvez-Ruiz A, Roig C, Muñoz S, Arruga J. Convergent-divergent nystagmus as a manifestation of oculopalatal tremor. *Neuro-Ophthalmology*. 2011; 35: 276-9.
- Gamlin P, Mitchell K. Reversible lesions of nucleus reticularis tegmenti pontis affect convergence and ocular accommodation. *Soc Neurosci Abstr*; 1993; 1993. p. 346.
- Garty BZ, Weitz R, Mimouni M, Bauman B. Spasmus nutans as a presenting sign of diencephalic syndrome. *Journal of Pediatrics*. 1985 Sep; 107: 484.
- Goldblum TA, Effron LA. Upbeat nystagmus associated with tonic downward deviation in healthy neonates. *Journal of Pediatric Ophthalmology and Strabismus*. 1994 Sep-Oct; 31: 334-5.
- Golyandina N, Nekrutkin V, Zhigljavsky AA. Analysis of time series structure: SSA and related techniques: CRC press; 2001.
- Good W, Brodsky M, Hoyt C, Ahn J. Upbeating nystagmus in infants: A sign of anterior visual pathway disease. *Binoc Vis Q*. 1990; 5: 13-8.
- Good WV, Hou C, Carden SM. Transient, idiopathic nystagmus in infants. *Developmental Medicine and Child Neurology*. 2003 May; 45: 304-7.
- Good WV, Jan JE, Hoyt CS, Billson FA, Schoettker PJ, Klaeger K. Monocular vision loss can cause bilateral nystagmus in young children. *Developmental Medicine and Child Neurology*. 1997 Jun; 39: 421-4.
- Good WV, Koch TS, Jan JE. Monocular nystagmus caused by unilateral anterior visual-pathway disease. *Developmental Medicine and Child Neurology*. 1993 Dec; 35: 1106-10.
- Gottlob I. Eye movement abnormalities in carriers of blue-cone monochromatism. *Investigative Ophthalmology and Visual Science*. 1994 Aug; 35: 3556-60.
- Gottlob I. Infantile nystagmus. Development documented by eye movement recordings. *Investigative Ophthalmology and Visual Science*. 1997 Mar; 38: 767-73.
- Gottlob I, Helbling A. Nystagmus mimicking spasmus nutans as the presenting sign of Bardet-Biedl syndrome. *Am J Ophthalmol*. 1999 Dec; 128: 770-2.
- Gottlob I, Proudlock FA. Aetiology of infantile nystagmus. *Curr Opin Neurol*. 2014 Feb; 27: 83-91.
- Gottlob I, Reinecke RD. Eye and head movements in patients with achromatopsia. *Graefes Arch Clin Exp Ophthalmol*. 1994 Jul; 32: 392-401.
- Gottlob I, Wizov SS, Reinecke RD. Spasmus nutans. A long-term follow-up. *Investigative Ophthalmology and Visual Science*. 1995 Dec; 36: 2768-71.

- Gottlob I, Wizov SS, Reinecke RD. Head and eye movements in children with low vision. *Graefes Arch Clin Exp Ophthalmol*. 1996 Jun; 234: 369-77.
- Gottlob I, Zubcov A, Catalano RA, Reinecke RD, Koller HP, Calhoun JH, et al. Signs distinguishing spasmus nutans (with and without central nervous system lesions) from infantile nystagmus. *Ophthalmology*. 1990 Sep; 97: 1166-75.
- Gottlob I, Zubcov AA, Wizov SS, Reinecke RD. Head nodding is compensatory in spasmus nutans. *Ophthalmology*. 1992 Jul; 99: 1024-31.
- Gradstein L, FitzGibbon EJ, Tsilou ET, Rubin BI, Huizing M, Gahl WA. Eye movement abnormalities in hermansky-pudlak syndrome. *Journal of AAPOS*. 2005 Aug; 9: 369-78.
- Graf M, Droutsas K, Kaufmann H. Surgery for nystagmus related head turn: Kestenbaum procedure and artificial divergence. *Graefes Arch Clin Exp Ophthalmol*. 2001 Jun; 239: 334-41.
- Gresty M, Leech J, Sanders M, Eggars H. A study of head and eye movement in spasmus nutans. *Br J Ophthalmol*. 1976 Sep; 60: 652-4.
- Gresty MA, Ell JJ, Findley LJ. Acquired pendular nystagmus: its characteristics, localising value and pathophysiology. *Journal of Neurology, Neurosurgery and Psychiatry*. 1982 May; 45: 431-9.
- Group CW. A national eye institute sponsored workshop and publication on the classification of eye movement abnormalities and strabismus (CEMAS). The National Eye Institute Publications. 2001.
- Hackett A, Tarpey PS, Licata A, Cox J, Whibley A, Boyle J, et al. CASK mutations are frequent in males and cause X-linked nystagmus and variable XLMR phenotypes. *European Journal of Human Genetics*. 2010 May; 18: 544-52.
- Halliday AM, Halliday E, Kriss A, McDonald WI, Mushin J. The pattern-evoked potential in compression of the anterior visual pathways. *Brain*. 1976 Jun; 99: 357-74.
- Halmagyi GM, Gresty MA, Leech J. Reversed optokinetic nystagmus (OKN): mechanism and clinical significance. *Annals of Neurology*. 1980 May; 7: 429-35.
- Hamelin N, Becquet F, Dureau P, Pierre-Kahn A, Dufier JL. Particularités cliniques des gliomes du chiasma. Etude rétrospective sur une série de 18 patients. *J Fr Ophtalmol*. 2000 Sep; 23: 694-8.
- Harris C, Berry D. A developmental model of infantile nystagmus. *Semin Ophthalmol*. 2006 Apr-Jun; 21: 63-9.
- He X, Gu F, Wang Z, Wang C, Tong Y, Wang Y, et al. A novel frameshift mutation in FRMD7 causing X-linked idiopathic congenital nystagmus. *Genet Test*. 2008 Dec; 12: 607-13.
- Herman C. Head shaking with nystagmus in infants, a study of sixty four cases. *Trans Am Pediatr Soc*. 1918; 30: 38-54.
- Hertle RW. Nystagmus in infancy and childhood. *Seminars in Ophthalmology*; 2008: Informa UK Ltd UK; 2008. p. 307-17.
- Hertle RW, Anninger W, Yang D, Shatnawi R, Hill VM. Effects of extraocular muscle surgery on 15 patients with oculo-cutaneous albinism (OCA) and infantile nystagmus syndrome (INS). *Am J Ophthalmol*. 2004 Dec; 138: 978-87.
- Hertle RW, Dell'Osso LF. Nystagmus in Infancy and Childhood: Current Concepts in Mechanisms, Diagnoses, and Management: Oxford University Press; 2013.
- Hertle RW, Maldonado VK, Maybodi M, Yang D. Clinical and ocular motor analysis of the infantile nystagmus syndrome in the first 6 months of life. *Br J Ophthalmol*. 2002 Jun; 86: 670-5.
- Hertle RW, Reznick L, Yang D. Infantile aperiodic alternating nystagmus. *Journal of Pediatric Ophthalmology and Strabismus*. 2009 Mar-Apr; 46: 93-103.
- Hofer S, Karaus A, Frahm J. Reconstruction and dissection of the entire human visual pathway using diffusion tensor MRI. *Front Neuroanat*. 2010; 4: 15.
- Hoffmann KP, Distler C, Markner C. Optokinetic nystagmus in cats with congenital strabismus. *J Neurophysiol*. 1996 Apr; 75: 1495-502.
- Hoffmann LC, Berry SD. Cerebellar theta oscillations are synchronized during hippocampal theta-contingent trace conditioning. *Proceedings of the National Academy of Sciences of the United States of America*. 2009 Dec 15; 106: 21371-6.

- Hoffmann MB, Lorenz B, Morland AB, Schmidtborn LC. Misrouting of the optic nerves in albinism: estimation of the extent with visual evoked potentials. *Investigative Ophthalmology and Visual Science*. 2005 Oct; 46: 3892-8.
- Hoffmann MB, Wolynski B, Bach M, Meltendorf S, Behrens-Baumann W, Golla F. Optic nerve projections in patients with primary ciliary dyskinesia. *Investigative Ophthalmology and Visual Science*. 2011 Jun; 52: 4617-25.
- Holder GE. The effects of chiasmal compression on the pattern visual evoked potential. *Electroencephalography and Clinical Neurophysiology*. 1978 Aug; 45: 278-80.
- Holder GE. Electrophysiological assessment of optic nerve disease. *Eye (Lond)*. 2004 Nov; 18: 1133-43.
- Hoyt CS. Nystagmus and other abnormal ocular movements in children. *Pediatric Clinics of North America*. 1987 Dec; 34: 1415-23.
- Hoyt CS, Gelbart SS. Vertical nystagmus in infants with congenital ocular abnormalities. *Ophthalmic Paediatrics and Genetics*. 1984 Dec; 4: 155-61.
- Huang MY, Chen CC, Huber-Reggi SP, Neuhauss SC, Straumann D. Comparison of infantile nystagmus syndrome in achiasmatic zebrafish and humans. *Ann N Y Acad Sci*. 2011 Sep; 1233: 285-91.
- Huang YY, Rinner O, Hedinger P, Liu SC, Neuhauss SC. Oculomotor instabilities in zebrafish mutant *belladonna*: a behavioral model for congenital nystagmus caused by axonal misrouting. *J Neurosci*. 2006 Sep 27; 26: 9873-80.
- Hung GK, Semmlow JL, Ciuffreda KJ. A dual-mode dynamic model of the vergence eye movement system. *IEEE Transactions on Biomedical Engineering*. 1986 Nov; 33: 1021-8.
- Hunter DG, Ellis FJ. Prevalence of systemic and ocular disease in infantile exotropia: comparison with infantile esotropia. *Ophthalmology*. 1999 Oct; 106: 1951-6.
- Jacobs JB, Dell'Osso LF. A hypothetical fixation system capable of extending foveation in congenital nystagmus. *Ann N Y Acad Sci*. 2002 Apr; 956: 608-10.
- Jacobs JB, Dell'Osso LF. Congenital nystagmus: hypotheses for its genesis and complex waveforms within a behavioral ocular motor system model. *J Vis*. 2004 Jul 27; 4: 604-25.
- Jacobs JB, Dell'Osso LF. Extending the eXpanded Nystagmus Acuity Function for vertical and multiplanar data. *Vision Res*. 2010 Feb 8; 50: 271-8.
- Jacobs JB, Dell'Osso LF, Hertle RW, Acland GM, Bennett J. Eye movement recordings as an effectiveness indicator of gene therapy in RPE65-deficient canines: implications for the ocular motor system. *Investigative Ophthalmology and Visual Science*. 2006 Jul; 47: 2865-75.
- Jacobs JB, Dell'Osso LF, Wang ZI, Acland GM, Bennett J. Using the NAFX to measure the effectiveness over time of gene therapy in canine LCA. *Investigative Ophthalmology and Visual Science*. 2009 Oct; 50: 4685-92.
- Jang SH. Diffusion tensor imaging studies on corticospinal tract injury following traumatic brain injury: a review. *NeuroRehabilitation*. 2011; 29: 339-45.
- Jansonius NM, van der Vliet TM, Cornelissen FW, Pott JW, Kooijman AC. A girl without a chiasm: electrophysiologic and MRI evidence for the absence of crossing optic nerve fibers in a girl with a congenital nystagmus. *J Neuroophthalmol*. 2001 Mar; 21: 26-9.
- Jayalakshmi P, Scott TF, Tucker SH, Schaffer DB. Infantile nystagmus: a prospective study of spasmus nutans, and congenital nystagmus, and unclassified nystagmus of infancy. *J Pediatr*. 1970 Aug; 77: 177-87.
- Kashou NH, Leguire LE, Roberts CJ, Fogt N, Smith MA, Rogers GL. Instruction dependent activation during optokinetic nystagmus (OKN) stimulation: An fMRI study at 3T. *Brain Research*. 2010 Jun 8; 1336: 10-21.
- Kelly TW. Optic glioma presenting as spasmus nutans. *Pediatrics*. 1970 Feb; 45: 295-6.
- Kennard C, Lueck CJ. Oculomotor abnormalities in diseases of the basal ganglia. *Rev Neurol (Paris)*. 1989; 145: 587-95.
- Kerrison JB, Arnould VJ, Barmada MM, Koenekoop RK, Schmeckpeper BJ, Maumenee IH. A gene for autosomal dominant congenital nystagmus localizes to 6p12. *Genomics*. 1996 May 1; 33: 523-6.

- Kestenbaum A. Clinical methods of neuro-ophthalmologic examination. 2nd ed. New York Grune & Stratton; 1961.
- King RA, Nelson LB, Wagner RS. Spasmus nutans. A benign clinical entity? Arch Ophthalmol. 1986 Oct; 104: 1501-4.
- Klein C, Vieregge P, Heide W, Kemper B, Hagedorn-Greiwe M, Hagenah J, et al. Exclusion of chromosome regions 6p12 and 15q11, but not chromosome region 7p11, in a German family with autosomal dominant congenital nystagmus. Genomics. 1998 Nov 15; 54: 176-7.
- Koenig SB, Naidich TP, Zaparackas Z. Optic glioma masquerading as spasmus nutans. Journal of Pediatric Ophthalmology and Strabismus. 1982 Jan-Feb; 19: 20-4.
- Kurent A, Stirn-Kranjc B, Breclj J. Electroretinographic characteristics in children with infantile nystagmus syndrome and early-onset retinal dystrophies. Eur J Ophthalmol. 2015 Jan-Feb; 25: 33-42.
- Kushner BJ. Infantile unioocular blindness with bilateral nystagmus. A syndrome. Arch Ophthalmol. 1995 Oct; 113: 1298-300.
- Lambert SR, Newman NJ. Retinal disease masquerading as spasmus nutans. Neurology. 1993 Aug; 43: 1607-9.
- Lavery MA, O'Neill JF, Chu FC, Martyn LJ. Acquired nystagmus in early childhood: a presenting sign of intracranial tumor. Ophthalmology. 1984 May; 91: 425-53.
- Lee A. Neuroimaging in all cases of spasmus nutans. Journal of Pediatric Ophthalmology and Strabismus. 1996 Jan-Feb; 33: 68-9.
- Lee H, Sheth V, Bibi M, Maconachie G, Patel A, McLean RJ, et al. Potential of handheld optical coherence tomography to determine cause of infantile nystagmus in children by using foveal morphology. Ophthalmology. 2013 Dec; 120: 2714-24.
- Leigh RJ, Zee DS. The Neurology of Eye Movements. New York: Oxford University Press; 2006.
- Leigh RJ, Zee DS. The neurology of eye movements. Fifth Edition ed. New York: Oxford University Press; 2015.
- Lueck CJ, Tanyeri S, Mossman S, Crawford TJ, Kennard C. Unilateral reversal of smooth pursuit and optokinetic nystagmus. Rev Neurol (Paris). 1989; 145: 656-60.
- Lueder GT, Galli M. Oblique muscle surgery for treatment of nystagmus with head tilt. Journal of AAPOS. 2012 Aug; 16: 322-6.
- Marmor MF, Fulton AB, Holder GE, Miyake Y, Brigell M, Bach M, et al. ISCEV Standard for full-field clinical electroretinography (2008 update). Documenta Ophthalmologica. 2009 Feb; 118: 69-77.
- Marti S, Palla A, Straumann D. Gravity dependence of ocular drift in patients with cerebellar downbeat nystagmus. Annals of Neurology. 2002 Dec; 52: 712-21.
- May EF, Truxal AR. Loss of vision alone may result in seesaw nystagmus. J Neuroophthalmol. 1997 Jun; 17: 84-5.
- McIlwaine GG, Carrim ZI, Lueck CJ, Chrisp TM. A mechanical theory to account for bitemporal hemianopia from chiasmal compression. J Neuroophthalmol. 2005 Mar; 25: 40-3.
- Merrill KS, Summers CG. Positive angle kappa: a possible sign of aniridia. American Orthoptic Journal. 2012; 62: 70-6.
- Michaelides M, Johnson S, Simunovic MP, Bradshaw K, Holder G, Mollon JD, et al. Blue cone monochromatism: a phenotype and genotype assessment with evidence of progressive loss of cone function in older individuals. Eye (Lond). 2005 Jan; 19: 2-10.
- Moreau T, L. O, N. V. Groupement automatique pour l'analyse du spectre singulier. Groupe de Recherche et d'Etudes en Traitement du Signal et des Images (GRETSI); 2015; Lyon; 2015.
- Mossman SS, Bronstein AM, Gresty MA, Kendall B, Rudge P. Convergence nystagmus associated with Arnold-Chiari malformation. Arch Neurol. 1990 Mar; 47: 357-9.
- Nadal-Nicolas FM, Salinas-Navarro M, Jimenez-Lopez M, Sobrado-Calvo P, Villegas-Perez MP, Vidal-Sanz M, et al. Displaced retinal ganglion cells in albino and pigmented rats. Front Neuroanat. 2014; 8: 99.
- Neveu MM, Holder GE, Sloper JJ, Jeffery G. Optic chiasm formation in humans is independent of foveal development. Eur J Neurosci. 2005 Oct; 22: 1825-9.

- Neveu MM, Jeffery G, Burton LC, Sloper JJ, Holder GE. Age-related changes in the dynamics of human albino visual pathways. *Eur J Neurosci*. 2003 Oct; 18: 1939-49.
- Newman SA, Hedges TR, Wall M, Sedwick LA. Spasmus nutans--or is it? *Surv Ophthalmol*. 1990 May-Jun; 34: 453-6.
- Norton EW, Cogan DG. Spasmus nutans; a clinical study of twenty cases followed two years or more since onset. *AMA Arch Ophthalmol*. 1954 Sep; 52: 442-6.
- Norton EWD, Cogan DG. Spasmus nutans: a clinical study of 20 cases followed two years or more since onset. *Arch Ophthalmol*. 1954; 52: 442-6.
- Odom JV, Bach M, Brigell M, Holder GE, McCulloch DL, Tormene AP, et al. ISCEV standard for clinical visual evoked potentials (2009 update). *Documenta Ophthalmologica*. 2010 Feb; 120: 111-9.
- Optican LM, Zee DS. A hypothetical explanation of congenital nystagmus. *Biological Cybernetics*. 1984; 50: 119-34.
- Orekhova EV, Stroganova TA, Posikera IN, Elam M. EEG theta rhythm in infants and preschool children. *Clinical Neurophysiology*. 2006 May; 117: 1047-62.
- Østerberg G. On spasmus nutans. *Acta Ophthalmol*. 1937; 15: 457-67.
- Park KA, Oh SY. Clinical characteristics of high grade foveal hypoplasia. *Int Ophthalmol*. 2013 Feb; 33: 9-14.
- Péchereau A, Bailly G, Bourron-Madignier M, Delplace M, Gaymard B, Malauzat O, et al. *Les Mouvements Oculaires en Pratique Courante (1989): MA Quéré pour Lissac Opticiens*.
- Peng Y, Meng Y, Wang Z, Qin M, Li X, Dian Y, et al. A novel GPR143 duplication mutation in a Chinese family with X-linked congenital nystagmus. *Mol Vis*. 2009; 15: 810-4.
- Penner MW, Li KC, Gebarski SS, Allen RJ. MR imaging of Pelizaeus-Merzbacher disease. *Journal of Computer Assisted Tomography*. 1987 Jul-Aug; 11: 591-3.
- Pham-Dinh D, Popot JL, Boespflug-Tanguy O, Landrieu P, Deleuze JF, Boue J, et al. Pelizaeus-Merzbacher disease: a valine to phenylalanine point mutation in a putative extracellular loop of myelin proteolipid. *Proceedings of the National Academy of Sciences of the United States of America*. 1991 Sep 1; 88: 7562-6.
- Pieh C, Simonsz-Toth B, Gottlob I. Nystagmus characteristics in congenital stationary night blindness (CSNB). *Br J Ophthalmol*. 2008 Feb; 92: 236-40.
- Pott JW, Jansonius NM, Kooijman AC. Chiasmal coefficient of flash and pattern visual evoked potentials for detection of chiasmal misrouting in albinism. *Documenta Ophthalmologica*. 2003 Mar; 106: 137-43.
- Proudlock F, Gottlob I. Foveal development and nystagmus. *Ann N Y Acad Sci*. 2011 Sep; 1233: 292-7.
- Raudnitz R. Zur Lehre von Spasmus Nutans. *Jb Kinderheilkd*. 1897; 45: 145.
- Remmer MH, Rastogi N, Ranka MP, Ceisler EJ. Achromatopsia: a review. *Curr Opin Ophthalmol*. 2015 Jul; 26: 333-40.
- Robert MP, Ingster-Moati I, Albuissou E, Cabrol D, Golse B, Vaivre-Douret L. Vertical and horizontal smooth pursuit eye movements in children with developmental coordination disorder. *Developmental Medicine and Child Neurology*. 2014 Jun; 56: 595-600.
- Roelofs CO. Optokinetic nystagmus. *Doc Ophthalmol Proc Ser*. 1954; 7-8: 579-650.
- Sami DA, Saunders D, Thompson DA, Russell-Eggitt IM, Nischal KK, Jeffrey G, et al. The achiasmia spectrum: congenitally reduced chiasmal decussation. *Br J Ophthalmol*. 2005 Oct; 89: 1311-7.
- Sanders M, Glaser J, Smith J. Alternating windmill nystagmus. *Neuro-Ophthalmology*. 1973; 7: 133-6.
- Scheffer IE, Baraitser M, Wilson J, Harding B, Kendall B, Brett EM. Pelizaeus-Merzbacher disease: classical or connatal? *Neuropediatrics*. 1991 May; 22: 71-8.
- Schild AM, Fricke J, Russmann W, Neugebauer A. Kestenbaum procedure on the vertical rectus muscles with simultaneous compensation of the induced cyclodeviation for nystagmus patients with chin-up or chin-down head posture. *Graefes Arch Clin Exp Ophthalmol*. 2009 Oct; 247: 1395-400.
- Schor CM. Subcortical binocular suppression affects the development of latent and optokinetic nystagmus. *American Journal of Optometry and Physiological Optics*. 1983 Jun; 60: 481-502.
- Schulman JA, Shults WT, Jones JM, Jr. Monocular vertical nystagmus as an initial sign of chiasmal glioma. *Am J Ophthalmol*. 1979 Jan; 87: 87-90.

- Schwartz MA, Selhorst JB, Ochs AL, Beck RW, Campbell WW, Harris JK, et al. Oculomasticatory myorhythmia: a unique movement disorder occurring in Whipple's disease. *Annals of Neurology*. 1986 Dec; 20: 677-83.
- Self J, Lotery A. A review of the molecular genetics of congenital Idiopathic Nystagmus (CIN). *Ophthalmic Genet*. 2007 Dec; 28: 187-91.
- Shallo-Hoffmann J, Apkarian P. Visual evoked response asymmetry only in the albino member of a family with congenital nystagmus. *Investigative Ophthalmology and Visual Science*. 1993 Mar; 34: 682-9.
- Sharpe JA, Hoyt WF, Rosenberg MA. Convergence-evoked nystagmus. Congenital and acquired forms. *Arch Neurol*. 1975 Mar; 32: 191-4.
- Shawkat FS, Kriss A, Thompson D, Russell-Eggitt I, Taylor D, Harris C. Vertical or asymmetric nystagmus need not imply neurological disease. *Br J Ophthalmol*. 2000 Feb; 84: 175-80.
- Shiels A, Bennett TM, Prince JB, Tychsen L. X-linked idiopathic infantile nystagmus associated with a missense mutation in FRMD7. *Molecular Vision*. 2007; 13: 2233-41.
- Simonsz H, Florijn R, Van Minderhout H, Bergen A, Kamermans M. Nightblindness-associated transient tonic downgaze (NATTD) in infant boys with chin-up head posture. *Strabismus*. 2009; 17: 158-64.
- Sloper J. Chicken and egg. *Br J Ophthalmol*. 2006 Sep; 90: 1074-5.
- Smith DE, Fitzgerald K, Stass-Isern M, Cibis GW. Electroretinography is necessary for spasmus nutans diagnosis. *Pediatric Neurology*. 2000 Jul; 23: 33-6.
- Smith JL, Flynn JT, Spiro HJ. Monocular vertical oscillations of amblyopia. The Heimann-Bielschowsky phenomenon. *J Clin Neuroophthalmol*. 1982 Jun; 2: 85-91.
- Soong F, Levin AV, Westall CA. Comparison of techniques for detecting visually evoked potential asymmetry in albinism. *Journal of AAPOS*. 2000 Oct; 4: 302-10.
- Spaeth EB. Nystagmus: Its diagnostic significance. *AMA archives of ophthalmology*. 1950; 44: 549-60.
- Spielmann A. Le strabisme sensoriel du nourrisson ou syndrome du «monophtalme» congénital. *J Fr*. 1989.
- Still G. Head nodding with nystagmus in infants. *Lancet*. 1906; 2: 207-9.
- Tarpey P, Thomas S, Sarvananthan N, Mallya U, Lisgo S, Talbot CJ, et al. Mutations in FRMD7, a newly identified member of the FERM family, cause X-linked idiopathic congenital nystagmus. *Nature Genetics*. 2006 Nov; 38: 1242-4.
- Theodorou M, Clement R, Taylor D, Moore A. The development of infantile nystagmus. *Br J Ophthalmol*. 2015 May; 99: 691-5.
- Thomas MG, Kumar A, Kohl S, Proudlock FA, Gottlob I. High-resolution in vivo imaging in achromatopsia. *Ophthalmology*. 2011 May; 118: 882-7.
- Thomas MG, Kumar A, Mohammad S, Proudlock FA, Engle EC, Andrews C, et al. Structural grading of foveal hypoplasia using spectral-domain optical coherence tomography a predictor of visual acuity? *Ophthalmology*. 2011 Aug; 118: 1653-60.
- Thomas MG, McLean RJ, Kohl S, Sheth V, Gottlob I. Early signs of longitudinal progressive cone photoreceptor degeneration in achromatopsia. *Br J Ophthalmol*. 2012 Sep; 96: 1232-6.
- Thomas S, Proudlock FA, Sarvananthan N, Roberts EO, Awan M, McLean R, et al. Phenotypical characteristics of idiopathic infantile nystagmus with and without mutations in FRMD7. *Brain*. 2008 May; 131: 1259-67.
- Thomas S, Thomas MG, Andrews C, Chan WM, Proudlock FA, McLean RJ, et al. Autosomal-dominant nystagmus, foveal hypoplasia and presenile cataract associated with a novel PAX6 mutation. *European Journal of Human Genetics*. 2014 Mar; 22: 344-9.
- Thompson DA, Liasis A. Visual electrophysiology: how it can help you and your patient. In: Hoyt CS, Taylor D, editors. *Pediatric ophthalmology and strabismus 4th ed*. London: Elsevier; 2012. p. 55-62.
- Toledano H, Muhsinoglu O, Luckman J, Goldenberg-Cohen N, Michowitz S. Acquired nystagmus as the initial presenting sign of chiasmal glioma in young children. *Eur J Paediatr Neurol*. 2015 Nov; 19: 694-700.

- Tremblay F, De Becker I, Cheung C, LaRoche GR. Visual evoked potentials with crossed asymmetry in incomplete congenital stationary night blindness. *Investigative Ophthalmology and Visual Science*. 1996 Aug; 37: 1783-92.
- Ung T, Allen LE, Moore AT, Trump D, Zito I, Hardcastle AJ, et al. Is optic nerve fibre mis-routing a feature of congenital stationary night blindness? *Documenta Ophthalmologica*. 2005 Nov; 111: 169-78.
- Valmaggia C, Proudlock F, Gottlob I. Optokinetic nystagmus in strabismus: are asymmetries related to binocularity? *Investigative Ophthalmology and Visual Science*. 2003 Dec; 44: 5142-50.
- Valmaggia C, Rutsche A, Baumann A, Pieh C, Bellaiche Shavit Y, Proudlock F, et al. Age related change of optokinetic nystagmus in healthy subjects: a study from infancy to senescence. *Br J Ophthalmol*. 2004 Dec; 88: 1577-81.
- van Genderen MM, Riemsdag FC, Schuil J, Hoeben FP, Stilma JS, Meire FM. Chiasmal misrouting and foveal hypoplasia without albinism. *Br J Ophthalmol*. 2006 Sep; 90: 1098-102.
- Watkins RJ, Thomas MG, Talbot CJ, Gottlob I, Shackleton S. The Role of FRMD7 in Idiopathic Infantile Nystagmus. *J Ophthalmol*. 2012; 2012: 460956.
- Weiss AH, Kelly JP, Phillips JO. Relationship of slow-phase velocity to visual acuity in infantile nystagmus associated with albinism. *Journal of AAPOS*. 2011 Feb; 15: 33-9.
- Weissman BM, Dell'Osso LF, Abel LA, Leigh RJ. Spasmus nutans. A quantitative prospective study. *Arch Ophthalmol*. 1987 Apr; 105: 525-8.
- Yang S, Jeong J, Kim JG, Yoon YH. Progressive venous stasis retinopathy and open-angle glaucoma associated with primary pulmonary hypertension. *Ophthalmic Surg Lasers Imaging*. 2006 May-Jun; 37: 230-3.
- Yee RD, Baloh RW, Honrubia V. Study of congenital nystagmus: optokinetic nystagmus. *Br J Ophthalmol*. 1980 Dec; 64: 926-32.
- Yee RD, Farley MK, Bateman JB, Martin DA. Eye movement abnormalities in rod monochromatism and blue-cone monochromatism. *Graefes Arch Clin Exp Ophthalmol*. 1985; 23: 55-9.
- Zeitz C, Robson AG, Audo I. Congenital stationary night blindness: an analysis and update of genotype-phenotype correlations and pathogenic mechanisms. *Prog Retin Eye Res*. 2015 Mar; 45: 58-110.
- Zhang Q, Xiao X, Li S, Guo X. FRMD7 mutations in Chinese families with X-linked congenital motor nystagmus. *Molecular Vision*. 2007; 13: 1375-8.
- Zhang Y, Wan SH, Wu GJ, Zhang XL. Magnetic resonance diffusion tensor imaging and diffusion tensor tractography of human visual pathway. *Int J Ophthalmol*. 2012; 5: 452-8.