



HAL
open science

New contribution of paleoparasitology in the middle east and first data on the iranian plateau adjacent area

Masoud Nezamabadi

► To cite this version:

Masoud Nezamabadi. New contribution of paleoparasitology in the middle east and first data on the iranian plateau adjacent area. Parasitology. Université de Franche-Comté, 2014. English. NNT : 2014BESA2050 . tel-01680175

HAL Id: tel-01680175

<https://theses.hal.science/tel-01680175>

Submitted on 10 Jan 2018

HAL is a multi-disciplinary open access archive for the deposit and dissemination of scientific research documents, whether they are published or not. The documents may come from teaching and research institutions in France or abroad, or from public or private research centers.

L'archive ouverte pluridisciplinaire **HAL**, est destinée au dépôt et à la diffusion de documents scientifiques de niveau recherche, publiés ou non, émanant des établissements d'enseignement et de recherche français ou étrangers, des laboratoires publics ou privés.



UFR DES SCIENCES ET TECHNIQUES DE L'UNIVERSITE DE FRANCHE-COMTE

Laboratoire Chrono-Environnement (UMR UFC/CNRS 6249 USC INRA)

ECOLE DOCTORALE « ENVIRONNEMENTS-SANTE »

Thèse

Présentée en vue de l'obtention du grade de
DOCTEUR DE L'UNIVERSITE DE FRANCHE-COMTE
Spécialité : Paléoparasitologie

NEW CONTRIBUTION OF PALEOPARASITOLOGY IN THE MIDDLE EAST AND FIRST DATA
ON THE IRANIAN PLATEAU AND ADJACENT AREAS.

Par

Masoud NEZAMABADI

Le 18 décembre 2014

Membres du Jury :

Adauto J. G. de ARAUJO , Professeur, Fundação Oswaldo Cruz	Rapporteur
Piers D. MITCHELL , Docteur, University of Cambridge	Rapporteur
Wim VAN NEER , Professeur, Université de Leuven	Examineur
Françoise LE MORT , Chargée de Recherches au CNRS, UMR 5133	Examineur
Marjan MASHKOUR , Chargée de Recherches au CNRS, UMR 7209	Encadrant
Matthieu LE BAILLY , Maître de conférences, Université de Franche-Comté, UMR 6249	Co-directeur
Hervé RICHARD , Directeur de Recherches au CNRS, UMR 6249	Directeur

ACKNOWLEDGEMENTS

This dissertation would not have come into existence if not for the assistance of faculty, friends, and family. I would like to express my deep gratitude and appreciation to my advisor, Dr. Matthieu Le Bailly, for his guidance, advice and critique throughout all stages of this project. He has continually provided considerate comments on my work and made time to discuss my research. I owe an enormous debt of gratitude to Dr. Marjan Mashkour for her invaluable support, understanding and encouragement. I would like to extend special thanks to Prof. Hervé Richard, Prof. Adauto Jose Goncalves de Araujo, Dr. Piers D. Mitchell, Prof. Wim Van Neer and Dr. Françoise Le Mort for their valuable and constructive suggestions and for serving as members on my committee. The Cultural Services of the French Embassy in Iran, the doctoral school of University of Franche-Comté, Campus France, CROUS, CNRS and the Natural History Museum in Paris deserve my gratitude for setting me on this path and financial support. I also gratefully acknowledge the institutional support that I have received while working on this project. In particular, I thank Dr. Fereidoun Biglari from the National Museum of Iran, Abolfazl Aali from the Museum of Zanjan (Iran), and Prof. Thomas Stöllner from Anthropology Department of Ruhr University at Bochum. I owe sincere thankfulness to the members of the paleoparasitology research group: Benjamin Dufour, Céline Maicher, Cecilia Villemin, Alizé Hoffmann, Nathalie Côté and Kévin Roche and also to all members and employees of the laboratory of Chrono-Environment in the University of Franche-Comté for their friendship and assistance.

Finally, I would like to thank my family members, my mom, my sisters and my friends in Iran and France who provided me with moral support, encouragement, motivation and inspiration throughout the course of my study.

And my beloved wife, Elham, thank you for everything.

Contents

General introduction.....	5
Chapter 1 : Introduction to paleoparasitology.....	8
1.1 Introduction	9
1.2 Parasite markers	10
1.2.1 Macro-remains.....	11
1.2.2 Paleo-antigens.....	11
1.2.3 Ancient DNA	12
1.2.4 Eggs	12
Chapter 2 : A review of the ancient parasitism in the Middle East.....	14
2.1 Introduction	15
2.2 Egypt	17
2.2.1 Helminth finding(s).....	19
2.2.2 Protozoa finding(s)	23
2.2.3 Ectoparasite finding(s).....	24
2.3 Sudan	27
2.3.1 Helminth finding(s).....	29
2.3.2 Protozoa finding(s)	30
2.3.3 Ectoparasite finding(s).....	30
2.4 Israel	32
2.4.1 Helminth finding(s).....	34
2.4.2 Protozoa finding(s)	35
2.4.3 Ectoparasite finding(s).....	35

2.5	Cyprus	38
2.6	Iran.....	40
2.7	Syria.....	42
Chapter 3 : Study sites and materials		44
3.1	Introduction	45
3.2	Sampling strategies.....	46
3.3	Study sites.....	49
3.3.1	Iran	49
3.3.2	Syria.....	65
3.3.3	Azerbaijan.....	66
3.3.4	Saudi Arabia	68
3.3.5	Oman.....	68
3.3.6	Sudan	69
3.3.7	Egypt.....	69
Chapter 4 : Methods		77
4.1	Introduction	78
4.2	Laboratory techniques (used at the University of Franche-Comte)	79
4.2.1	Microscopy analyses.....	79
4.2.2	ELISA Technique	87
4.3	Preventing contaminations and false positive results.....	89
Chapter 5 : Results and discussion.....		91
5.1	Introduction	92
5.2	Trematode findings.....	95
5.2.1	Fasciolidae	100

5.2.2	Paramphistomatidae.....	106
5.2.3	Diplostomatidae.....	108
5.2.4	Dicrocoeliidae.....	110
5.3	Cestode findings.....	113
5.3.1	Taeniidae.....	114
5.3.2	<i>Hymenolepis</i> sp.....	124
5.3.3	Anoplocephalidae.....	127
5.4	Nematode findings.....	130
5.4.1	<i>Ascaris</i> sp.....	131
5.4.2	<i>Enterobius vermicularis</i>	139
5.4.3	<i>Trichuris</i> sp.....	144
5.4.4	<i>Oxyuris Equi</i>	153
5.4.5	Order: Strongylida.....	156
5.5	Acanthocephalan findings.....	160
5.6	Coccidian findings.....	164
Chapter 6 : Conclusion.....		168
References.....		174
Annexes.....		204
Table of figures.....		208
Tables.....		214
Publications and presentations.....		215

General introduction

The main subject of this PhD work is the study of ancient human/animal parasite remains (particularly helminth eggs) in the archaeological sites within the Middle East region.

Previous studies on paleoparasitology in the archeological sites and materials in the Middle East region had showed the presence of a wide diversity of parasites. Therefore, as being a historically geographic and cultural crossroads, the analyses and interpretations of parasitic infections in this region could give further data on past inhabitant life, but also on ancient migrations and exchange ways between populations. However, such studies are scant so far in the eastern part of the Middle East and mainly concern Egypt, Sudan, Israel, and Cyprus in the western part of this region.

Despite paleoparasitology is still rarely used by local archaeologists and anthropologists in the Middle East, receiving the archaeological samples for this PhD research was done by corresponding with the archaeologist in different geographical and chronological parts of the region. Control of sampling from the archaeological samples has been carried out also by sending the protocol of sampling and publishing two articles about generalities of paleoparasitology (Nezamabadi et al., 2011; 2013c). The samples from the archaeological sites in Syria, Saudi Arabia, Oman, Azerbaijan, Sudan and Egypt, have been sent by the archaeologist to the laboratory of Besancon, University of Franche-Comte. However, samplings from some of the Iranian sites have been done by participating directly in the archaeological excavations or post excavations.

In addition, the present study was performed to describe paleoparasitological analysis of received archaeological samples from seven aforementioned countries located in the Middle East region. This work indicates that paleoparasitology researches in the Iranian plateau, Mesopotamia, Anatolia, Caucasus, Arabian Peninsula, Northeastern Africa and adjacent areas are required to complete the ancient parasitic data in these areas, adding to the already (and new) information from the other parts of the Middle East. Expanding the picture of ancient parasitic environment in the Middle East region improves also our knowledge on the global paleoparasitological data.

I have framed this dissertation within six chapters. Chapter one provides basic information on the parasite markers analysed by paleoparasitology. Chapter two reviews previous paleoparasitological researches on the ancient parasitic infections in the Middle East countries. Chapter three outlines the protocol of sampling in paleoparasitology and also reviews the studied

materials and archaeological sites in this research. Chapter four explores the laboratory techniques and analysis methods used to recover parasitic markers. Chapter five provides the analysis results and discusses possible paleoparasitological explanations for observed parasitic markers. Chapter six integrates the information provided in other chapters to conclude the effectiveness of paleoparasitological data of the Middle East region in the sub-disciplines of archaeological and parasitological studies at this area.

Chapter 1 : Introduction to paleoparasitology

1.1 Introduction

Parasites have accompanied humans and/or animals for several million years and evolved with their hosts. Also human parasites lived around us and evolved in relation to the changes in our way of life over time and space (Araujo and Ferreira, 2014).

Understanding human and animal health in the past by placing the data into respective context could help archaeologists, paleontologists and paleopathologists to perform and interpret some information about origins and evolution of parasitic infections. Moreover, some species of human parasites are significant causes of endemic or epidemic diseases in the world such as malaria, leishmaniasis, ascariasis, bilharziosis, hydatidosis, lymphatic filariosis, sleeping sickness, amoebic dysentery, hookworm infection, etc., and have some important effects on cultural development (Reinhard and Araujo, 2008; Nozais, 2003). Therefore, parasites can be use as markers for improving our knowledge particularly about lifeways, health and diseases of past population as well as evolution of infections (Ferreira, 2014).

Paleoparasitology is the study of parasites in human and animal remains from archaeological and paleontological contexts. It focused on the analysis of all of the parasitic markers which could be retraced by using adjusted methods and tools in this research field to illustrate the history of relationships between parasite infection, environment and the behavior of hosts (Araujo and Ferreira, 2000; Araujo et al., 2003; Reinhard and Araujo., 2008).

Paleopathology, as well as the study of the health status and sanitary conditions of ancient people, is one of the first aims in paleoparasitology. The recovery of ancient parasites allows to discuss the presence of possible symptoms by ancient population. Moreover study of parasitic disease could help us for better understanding of their origin and evolution over past time and estimate their possible evolution in the future (Anastasiou and Mitchell, 2013). Therefore, paleoparasitology needs to review archaeological, paleontological, zooarchaeological, archaeobotanical and paleoenvironmental data, historical documents or manuscripts, and other related studies in order to interpret and analyze ancient parasitology.

The presence of parasites in archaeological contexts could show various characteristics as the social (Bouchet et al., 2003a), cultural (Matsui et al., 2003; Le Bailly et al., 2005; Reinhard and Araujo, 2008; Reinhard, 1988), ethnological (Horne, 1985; Harter et al., 2004) and even

ideological (Starna, 1992) status of ancient populations. The knowledge and the interpretation of the parasite life cycle and the host-parasite association can also bring information on the life style, as diet and food preparation (Callen and Cameron, 1960; Fry, 1980; Reinhard et al., 1985; Reinhard, 1992), management of organic (fecal) matters, and medicinal development (Reinhard et al., 1985; Chaves and Reinhard, 2006).

The compilation of the past occurrences of parasites in different times and regions have also been used as evidences of prehistoric human migrations (Andrews, 1976; Hume et al., 2003; Araujo et al., 1988; Araujo et al., 2008; Araujo and Ferreira, 1995), geographical distribution and paleoepidemiology of disease by human but also by animals (Hermann, 1988; Miller et al., 1992; Nozais, 2003; Dittmar, 2009; Leles et al., 2010; Le Bailly and Bouchet, 2010).

Because of the relationship between certain parasites and their specific ecological conditions (Reinhard, 1992), parasite remains can be a valuable source to complete the paleoenvironmental reconstruction like climate change and ecological characteristics of an ancient site (Martinson et al., 2003; Arriaza et al., 2010; Montenegro et al., 2006). Such analyses can also provide additional data concerning the function of uncharacterized dug structures in archeology. Moreover, parasitologists, like zooarchaeologists, deal with domestication and cross-infection between humans and animals (Kliks, 1983; Martinson et al., 2003; Sianto et al., 2009; Dittmar, 2009).

1.2 Parasite markers

In paleoparasitological studies, ancient human and animal parasite evidences are identified based on the recovery of their preserved markers of different natures.

Various manifestations of parasitic activity are recovered in archaeological materials, such as eggs or body parts, ancient DNA, preserved antigens, and ectoparasite (arthropods) macro-remains, which are markers of the parasitic pathogens in the human/animal environment. Nevertheless, review of the researches in the field of paleoparasitology show that a majority of recovered markers are of the eggs of gastrointestinal helminths when studying ancient organic materials such as coprolites, internal organ remnants, or soil sediments polluted by fecal matter (Ferreira, 2014).

1.2.1 Macro-remains

The remains of arthropods such as ectoparasites (Samuels, 1965; Dittmar et al., 2003; Guerra et al., 2003) or vectors (Martins-Neto, 2003; Azar and Nel, 2003; Hume et al., 2003) may be preserved in different archaeological and paleontological contexts. Also in very few cases, some body parts of parasites such as helminths have been found (Curry et al., 1979; Reinhard, 1985; Reinhard et al., 1988; Tapp and Wildsmith, 1992, Bouchet and Paicheler, 1995; David, 1997).

Remains of lice, ticks and fleas can be observed under a light microscopy or stereomicroscope, on the skin, hair or clothes and grooming accessories of ancient people (Reinhard and Buikstra, 2003). Ancient DNA of these ectoparasites could be also extracted from preserved specimens of them from animal or human mummies (Dittmar et al., 2003; Raoult et al., 2008; Dittmar, 2014).

The remnants of insects and animals (vectors and reservoirs) and other hosts of parasites are also studied in the fields of zooarchaeology and paleoentomology (Tougaard and Renvoisé, 2008; Insoll and Hutchins, 2005; Azar and Nel, 2003; Martins-Neto, 2003).

1.2.2 Paleo-antigens

Malaria, Leishmaniasis, Chagas disease and amoebic dysentery are some prominent diseases caused by single-celled organisms known as protozoa. The parasitic protozoa have been the cause of some diseases and even death with a global distribution. The sensitivity of parasitic structures of protozoa, led them to be less resistant to taphonomic processes. Therefore, they are not recovered easily from archaeological and paleontological contexts and their traces can be identified via their parasitic antigens or macroscopic examinations of lesions or very rarely by traditional microscopy (Pizzi and Schenone, 1954; Witenberg, 1961; Reinhard et al., 2003; Le Bailly, 2005; Frias et al., 2013). Furthermore, some parasitic diseases such as cysticercosis can be retraced by their antigen or direct observation of their preserved cysts in rare cases (Bruschi et al., 2006).

Recovering parasite paleo-antigens requires the use of different immunological techniques such as ELISA or immune-fluorescence.

Advances in immunology over the last ten years improved knowledge about some ancient human protozoa of medical importance such as the pathogenic amoeba, *Entamoeba histolytica*, (Gonçalves et al., 2004; Le Bailly and Bouchet, 2006) or giardiasis (Faulkner et al., 1989; Gonçalves et al., 2002; Le Bailly et al., 2008).

1.2.3 Ancient DNA

Ancient DNA is a valuable marker which could remain in some ancient organic materials such as parasite remains particularly in coprolites and latrine sediments (Dittmar, 2014). The determination of ancient DNA can prove the family, genus and species of the parasitic elements and be used in the comparative study of parasites.

The use of molecular biology in the study of ancient parasite DNA is currently a challenge for paleoparasitologists (Ferreira et al., 2000; Iñiguez et al., 2006, Leles et al., 2008; Loreille et al., 2001; Martinez et al., 2003). However, recent developments of molecular biology tools over last decade allow us to extract and identify of some parasite DNA from human and animal parasite remains that improve our understanding of parasitic infections in the past. Therefore, molecular biology tools provide new possibilities for comparing of ancient and modern parasite genes. For instances, analysis of ancient DNA of roundworm eggs such as *Ascaris* sp. (Loreille et al. 2001; Leles et al. 2008; Oh et al. 2010), human pinworm (*Enterobius vermicularis*) (Iniguez et al., 2006) and human whipworm (*Trichuris trichiura*) are extremely helpful to identify the species level or show different polymorphisms at different archaeological sites. Endo- and ectoparasitic diseases which are investigated up to now by analysis of ancient DNA include malaria, leishmaniasis, Chagas disease, roundworm, whipworm, pinworm, Chinese liver fluke, fleas and lice. The presence of some of these disease caused by single celled parasites such as malaria, leishmaniasis and Chagas disease in ancient remains can only be identified through immunology or molecular biology (Anastasiou and Mitchell, 2013).

1.2.4 Eggs

The eggs are produced by adult worms or helminths parasitizing human or animal gastrointestinal tracts. Their size varies from 30 to 150 µm and they can be recovered from

archaeological and paleontological samples or museum specimens related to human or animal activities (Pike, 1968; Reinhard et al., 1988; Le Bailly et al., 2006a; Bouchet, 2003). The different form, size, color and other specific characteristics of each parasite egg can be distinguished by using a microscope to identify parasite genera, or even species. Parasite eggs are identified by their size, shape, color and other specific characteristics.

In another point of view, helminth eggs are historically the first markers that were used to study ancient parasites (Ruffer, 1910). They are still the major residues that can be extracted from archaeological and paleontological samples.

Chapter 2 : A review of the ancient parasitism in the Middle East

2.1 Introduction

In comparison to the other parts of the world, for example in Europe or in the Americas, almost few paleoparasitological data exist for the Middle-East region (Fig. 2.1). Moreover, these data are concentrated in the western part of the Middle-East, creating an important unsteadiness. The totality of the data in paleoparasitology with significant results comes from Egypt, Sudan, Cyprus, Israel and Syria (Fig. 2.2) (Nezamabadi et al., 2011). Consequently the past distribution and history of parasites and their relationship to ancient populations for the entire region remain unclear. Therefore, developing paleoparasitological research is needed in the other archaeological areas in the Middle East to complete ancient parasite data. It could give us a geographical/chronological insight on the Middle East parasitism over time and its connection with adjacent areas as Mesopotamia, Anatolian and Iranian plateau, or Arabian Peninsula.

In this chapter, a comprehensive review is provided on the available data obtained from the studies performed at present on ancient parasites in the Middle-East. These data are divided into helminth, protozoa and ectoparasite finding categories for each country, as follows:

- Egypt
- Sudan
- Israel
- Cyprus
- Iran
- Syria

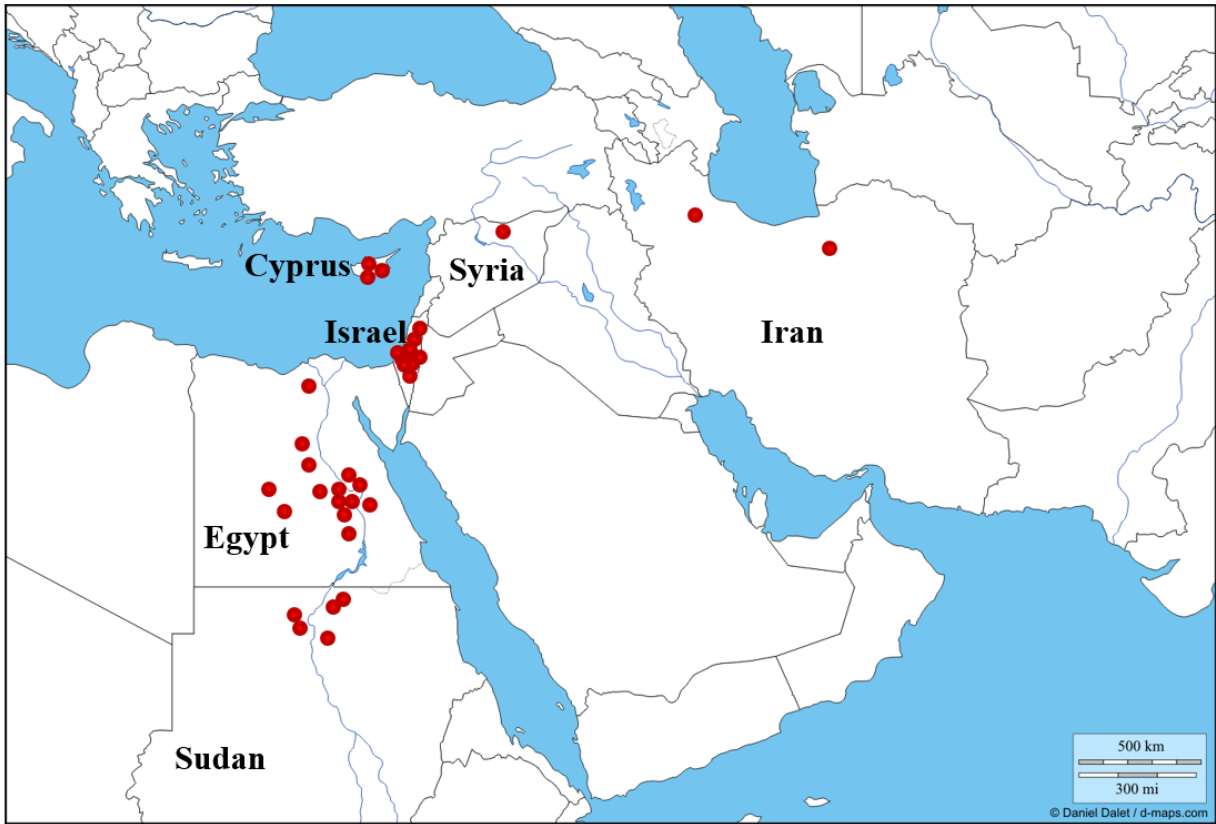


Figure 2.1: The Middle East countries which have already data in the field of paleoparasitology.

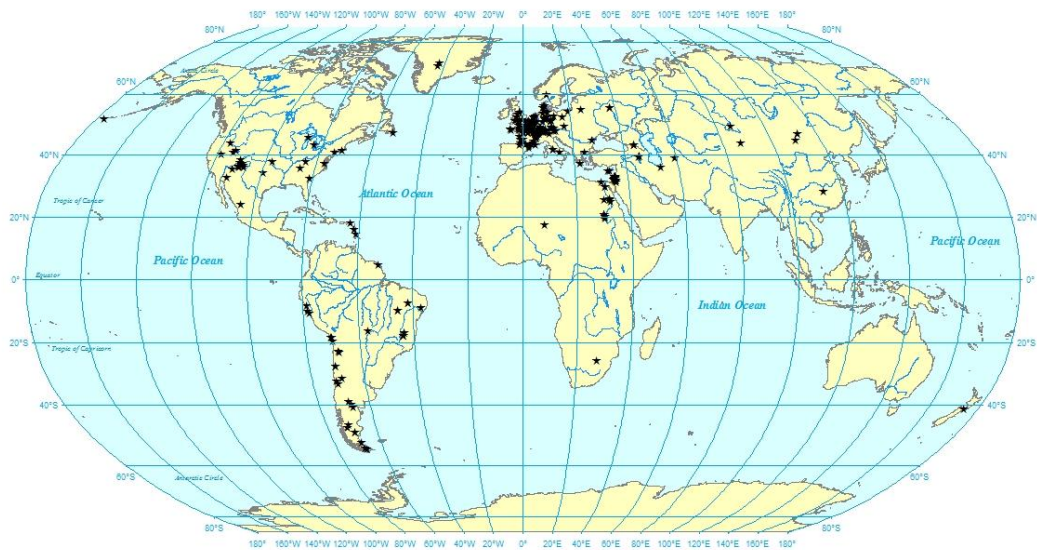


Figure 2.2: A perspective of available paleoparasitological studies in the world.

2.2 Egypt

The impetus for the study of ancient parasitism in the Middle East and the other parts of the world has come from prominent studies of mummified bodies in Egypt. The hyper-arid environmental conditions of the Egyptian desert play an important role for the well conservation of organic remains such as artificial/natural mummies. The association of mummies' preservation and dryness of the desserts has been studied by Cockburn and his colleagues (Cockburn et al., 1998). Consequently, the well-preserved Egyptian mummified bodies provided, and continue to provide, some of the best opportunities for bioarchaeological and paleopathological studies (Ruffer, 1910; Hart et al., 1977; David, 1997; Aufderheide, 2003). Mummified bodies, in particular natural mummies, are good sources for paleoparasitological data (Araujo et al., 2000). Therefore, the remains of hairs, skin, internal organs and their contents from human or animal mummies have been studied occasionally by paleoparasitology, and revealed a variety of endo- and ectoparasitic evidences for the last century up to present (Gonçalves et al., 2003; Bouchet et al., 2003; Sianto et al., 2009). Another source of information about ancient parasitism in Egypt has come from the ancient writings. The Egyptian climate has provided proper conditions (compare to other Middle Eastern countries) for the preservation of papyri, which some of them gave important information about ancient medicine and health status in Egypt (Joachim, 1890; Nunn and Tapp, 2000; Halioua, 2004). However, in the paleoparasitological researches performed during current millennia, some results have been derived from analysis of fecal samples associated with human burials in Egyptian archaeological sites. All of the positive samples in the field of paleoparasitology in Egypt have been referred to 14 known sites, except two samples; one from mummy #1770 from Manchester collection housed in England, and the other from a mummy housed in Italy (in the city hall of Narni) which its location of discovery was not mentioned in the available literatures (Tapp, 1979; Bruschi et al., 2006). Among known Egyptian sites, Thebes has the maximum number of referred reports on paleoparasitology. This site is located on the east bank of the Nile River where has been an ancient Egyptian city within the modern city of Luxor. Karnak is the name of the largest temple complexes at Thebes. Two sites of Akhmim and Antinoe are also the other sites at the East bank of the Nile, North of Thebes. All of the other sites in which ancient parasitic evidences were mentioned are situated at the West bank of the Nile: Gebelein, Tomb of Parannefer, Abydos, Deir el-Bahri, Deir el-Medineh, Hierakonpolis, Asyut, and Saqqara. Moreover, two sites of Kellis and El-Deir are located respectively in Dakhleh and Kharga, two oases in central Egypt.

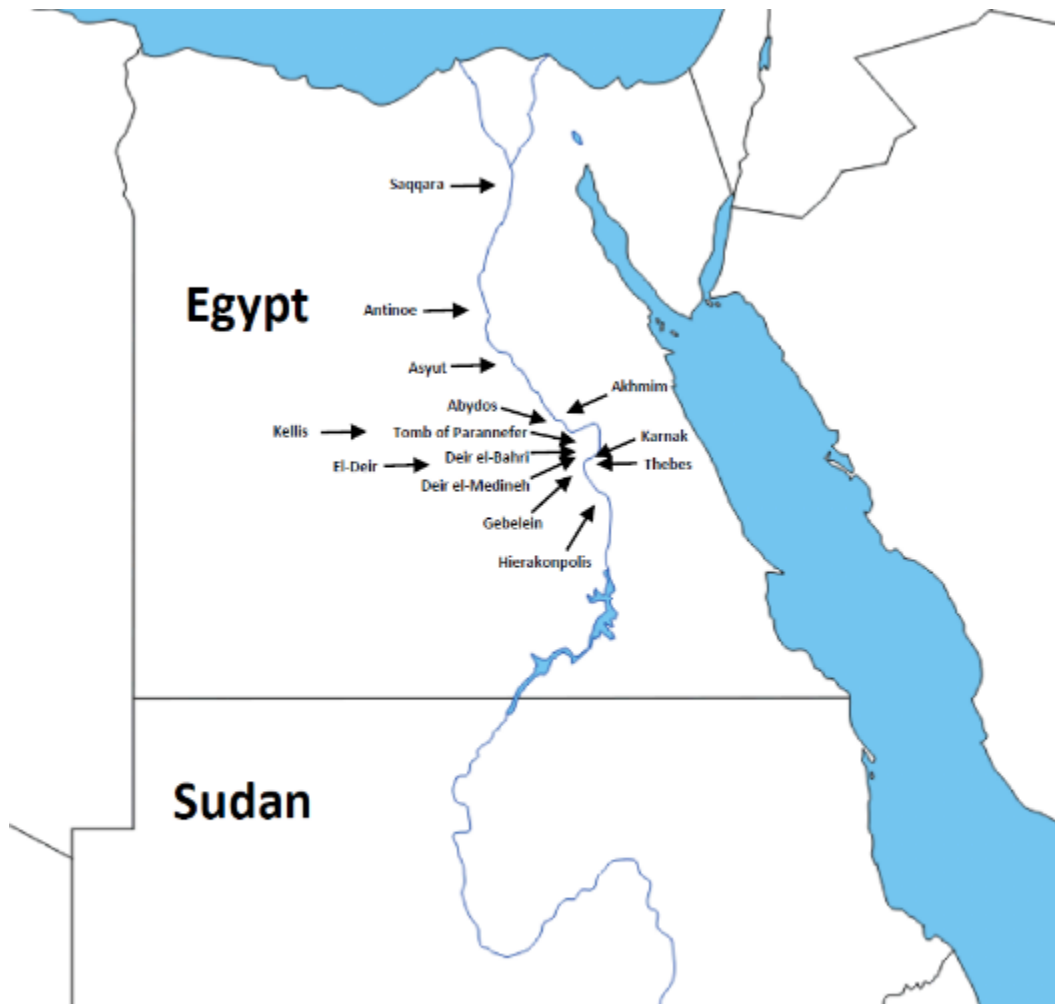

Figure 2.3: Location of archaeological sites related to paleoparasitological data in Egypt.

Paleoparasitological results of Egypt up to now have presented a diversity of helminthic, protozoan and ectoparasitic infections for a chronological continuum from around 5000 to 500 years before present. The interpretation of these findings mostly has linked with the proximity or distance to the Nile River which has been historically the major water source of Egypt and northern Sudan, and therefore the main lifeline of civilization in these regions since prehistoric times. However, it seems that the amount of studies on paleoparasitology of the Egyptian sites has not developed consistent with the broadly number of archaeological excavations and findings in Egypt. Furthermore, majority of Egyptian paleoparasitological data so far, has been concentrated on

human-originated samples and information on animal parasitism in ancient Egypt (particularly on endo-parasitism) is scarce.

2.2.1 Helminth finding(s)

When the microscopy is today the major tool allowing the recovery of ancient parasite markers, the really first findings of Ruffer (1910) were the results of a histological investigation. Ruffer could identify calcified eggs of *Schistosoma haematobium* by microscopic observation of histological sections which were prepared from the kidneys of two Egyptian mummies dated to the twentieth dynasty in Egypt (1250-1000 BC). Despite the fact that no images were provided for these findings, Ruffer's description is recognized as the first report of ancient parasitism in the world (Ruffer, 1910). Such information on schistosomiasis in ancient population was consistent with the written evidences of hematuria has been noted in medical papyri such as the Ebers papyrus found in Egypt and dated to 1500 BC (David, 1997, Nunn and Tapp, 2000). Moreover, schistosomiasis has been one of the major parasitic diseases in Egypt, up to recent decades (El-Khoby et al., 2000; Barakat, 2013).

After Ruffer's work, a gap of six decades was observed before the publication of the next report of ancient parasitic findings from Egypt. This second observation was the work of Cockburn and colleagues (1975). They have reported the presence of ascariasis in histological preparations of intestinal tissues from an artificial mummy, PUM II, dated to the late Ptolemaic period (170 BC) (Cockburn et al., 1975).

At about the same time, during the 1970s, a multidisciplinary investigation including various types of analyses was conducted on the mummies of the Manchester collection by the Manchester Mummy Team directed by Rosalie David. A first autopsy on one of the Manchester mummies, Mummy #1770, provided the evidence of Guinea worm infection (*Dracunculus medinensis*). A calcified adult worm was found in the anterior abdominal wall of the mummy. Mummy #1770 was that of a female child dated to the Ptolemaic Period (300-30 BC) contemporary with Greco-Roman era. This observation was carried out by applying paleohistology and radiological investigations (Isherwood et al., 1979; Tapp, 1979; David, 1997). The medical papyri of Ebers, page 875, was the sole known written reference for ancient dracunculiasis in Egypt (Nunn and Tapp, 2000).

In 1974, the use of histology and electronic microscopy on another body of the Manchester collection, the mummy Nakht-ROM I, dated to around 1200 BC, allowed the recovery of calcified eggs of *Schistosoma* sp. and *Taenia* sp., as well as possible parasitic cyst of *Trichinella spiralis* and macro-remains of adult liver fluke (*Fasciola hepatica*) (De Boni et al. 1977; Horne and Lewin 1977; Reyman et al. 1977).

At the end of the 1970s, in another work on Manchester collection, histological sections were sampled from a woman mummy who called Asru (#1777) and dated to around 700 BC. Intestinal tissues of this mummy removed at the time of mummification and placed between her legs, showed evidence of *Strongyloides* sp. infestation. *Strongyloides* sp. larvae have been found in the wall of her small intestine (Tapp, 1979; Nunn and Tapp, 2000).

In the early 1990s, Deelder et al used ELISA tool for the first time to study samples from different Egyptian mummies: Nakht-ROM I (1200 BC, see above) and a predynastic adolescent mummy (BM 32753) dated to 3200 BC. Authors found preserved paleo-antigen of *Schistosoma* (CAA) in both mummies. The results from BM 32753 are currently the most ancient parasitic evidence retraced in Egypt up to now (Deelder et al., 1990).

Moreover, several filarial worms were found by Tapp and colleagues (1992) during the examination of histological sections of connective tissue (part of the scrotum) from Natsef Amun (the Leeds mummy), who lived around 1100 BC and was a priest at the Temple of Amun in Karnak (Tapp and Wildsmith, 1992; Tapp, 1997; Nunn and Tapp, 2000).

Still during the second part of the 1990s, other evidences of parasitic infection were founded in two Egyptian mummies dated to 1450 BC. Horne and Redford (1995) have reported the presence of schistosomiasis in the sections of the urinary bladder taken from mummy 4 and dracunculiasis in the sections of a small sample taken from left anterior tibia of mummy 9. Both of these mummies have been discovered in the tomb of Parannefer in the Valley of the Nobles located on the west bank of the Nile River (Horne and Redford, 1995; Nunn and Tapp 2000).

At the beginning of the current century, some paleoparasitological works reported the recovery of helminth by using microscopy. In 2002, Horne reported the first recovery of embryonated eggs of *Enterobius vermicularis* in fecal samples associated with skeletal remains of two mummies from Kellis sites in the Dakhleh Oasis, dated to the roman occupation period (30 BC-395 AD). Also one of these samples contained several unidentified helminth eggs but similar to *Acanthocephala* (Horne, 2002).

During her thesis work between 2000 and 2003, Harter revealed a diversity of helminth eggs from Egyptian archaeological samples. In a first paleoparasitological analysis of a canopic jar discovered in the excavations of Asyut, Harter could find *Trichuris* eggs by rehydration of its contents, and proved the antiquity of human trichuriasis in Egypt between 1540 and 1070 BC. These type of jars were used by the ancient Egyptians during mummification and evisceration process of corpse to collect organs such as the liver and intestines of their owner for the afterlife in their beliefs (Harter, 2003). Another results of Harter works were the recovery of *Ascaris* sp. and of *Taenia* sp. eggs in samples from an embalming reject jar from Saqqara, dated from the 25th dynasty (715-656 BC). This analysis currently presented the most ancient evidence of ascariasis in Egypt (Harter et al., 2003).

Also in a sample from the site of Deir el-Medineh, Harter could identify eggs of three other helminths. *Diphyllobothrium* sp., *Trichuris* sp. as well as Ancylostomid ova were found in an organic remain sample taken from internal area of a naturally mummified body dated to 400-300 BC (Harter, 2003).

The other findings belonged to other samples from Saqqara, are dated to a same period as previously (400-330 BC). Eggs of *Diphyllobothrium* sp., *Fasciola* sp. and *Trichuris* sp. were identified in organic remain samples taken from two natural mummified bodies found in a necropolis at the site of Saqqara (Harter, 2003; Harter-Lailheugue and Bouchet, 2004).

In 2006, Bruschi et al. reported a case of cysticercosis caused by *Taenia solium* in a young woman Egyptian mummy dated to the late Ptolemaic period, and currently kept in a museum at Narni in Italy. Histopathological analyses of the cystic structure and lesions clearly showed characteristic features of the larval stage (cysticercus) of the pig tapeworm in the stomach wall of this mummy. In addition to the histological observations, an immunohistochemical test using indirect immunofluorescence was employed to identify the parasite at the species level and confirmed the diagnostic. This result is the first diagnosis of ancient human cysticercosis in paleoparasitology.



Figure 2.4: Embalming rejects jar, Department of Egyptian antiquity, Louvre Museum, France (Harter et al., 2003).

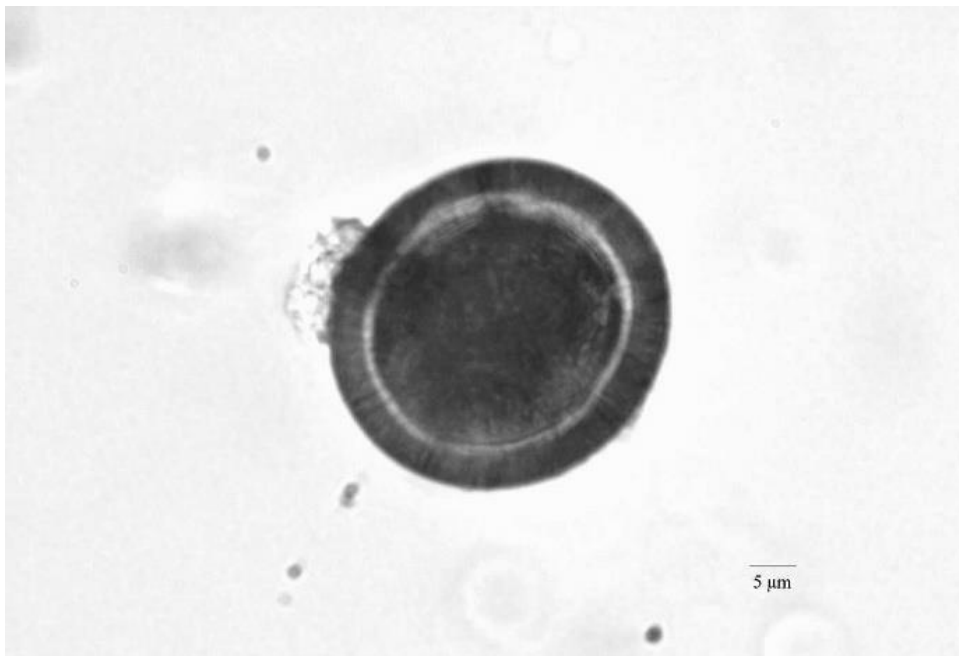

Figure 2.5: *Taenia* sp. egg recovered in a mummy from Oasis of Kharga, Egypt (Le Bailly et al., 2010).

As the last ancient human parasitism report up to now from Egypt, Le Bailly et al. (2010) have reported tapeworm infection while analysing fecal samples of various mummies from the site of El-Deir, located in the Oasis of Kharga. Eggs of *Taenia* sp were identified in a mummy coming from an ancient Christian cemetery excavated in this site and dated between the end of the fourth century and the beginning of the fifth century AD.

2.2.2 Protozoa finding(s)

At the end of the 1970s, on the mummy Nakht-ROM I, Cockburn analyzed a piece of spleen and reported a high positivity for malaria by indirect fluorescent antibody test (Cockburn, 1981).

In 2006, Zink and colleagues provided the first proof for visceral leishmaniasis (*Leishmania donovani* DNA) in 4 of the 91 Egyptian mummies dating back around 4,000 years. The positive samples were originated from a Middle Kingdom tomb of Thebes (2050–1650 BC). This analysis has also provided the first molecular evidences of ancient parasitism in the Middle East (Zink et al., 2006).

Another study on blood protozoa in Egypt has been carried out by Bianucci et al. (2008). They could report immunological evidence of *Plasmodium falciparum* and *Plasmodium* spp. malaria by analysis on skin and muscle samples of an Egyptian child mummy (527B), discovered in Gebelein and dated to the Early Dynastic Period (2820 and 2630 B.C). This Mummy is presently housed in a museum at Turin in Italy.

Still an investigation on retracing of ancient malaria has been carried out by Nerlich et al. (2008). By using of molecular techniques, they could identify ancient DNA for *Plasmodium falciparum* in Egyptian mummy tissues dated between 1500 and 500 BC. In their analysis, 2 of 91 bone tissue samples from ancient mummies and skeletons discovered in the sites of Abydos and Thebes were positive for malaria. These results were obtained from two different adult individuals with osteopathologic evidence of chronic anemia.

The oldest genetic proof for malaria on a precisely dated mummies was reported by Hawass et al. (2010). They applied genetic testing for analysis of eleven royal mummies dating to 1410-1324 BC who were suspected of being associated to Tutankhamun and 5 royal mummies dating to 1550-1479 BC. The results were *Plasmodium falciparum* specific genes which revealed evidences

of malignant tertian malaria in 4 mummies including Tutankhamun, Thuya, Yuya, and TT320-CCG61065.

Moreover, during past two decades, some immunological researches have been carried out to recover *Plasmodium falciparum* histidine-rich protein 2, such as using the ParaSight™-F test (Miller et al., 1994; Cerutti et al., 1999; Rabino Massa et al., 2000). But further investigations on living patients showed that the monoclonal IgG antibody used in these tests could have cross-reaction with the rheumatoid factor in blood. Therefore, the results could be false positive for malaria in such studies (Iqbal et al., 2000; Moody, 2002).

2.2.3 Ectoparasite finding(s)

In 1991, Palma reported the first findings of an ectoparasite from Egypt when founding human head lice during the analysis of a wooden comb at the site of Antinoe dated between the fifth and sixth centuries AD (Palma, 1991). His observation contained whole bodies or parts of seven specimens of head lice (*Pediculus humanus capitis*) including one egg/nit.

Also preliminary report of excavation at Hierakonpolis published by Friedman et al. (1999) has pointed out to recovery of hatched and unhatched eggs of head lice *Pediculus humanus capitis*. These eggs have been founded in hair samples which were taken from some human burials at this site and analyzed by Fletcher in 1998.

By using scanning electron microscopy, Fletcher (2002) has reported another recovery of adult head louse *Pediculus humanus capitis* dated to 3000 BC from the site of Abydos.

More recently, another study in the site of El-Deir was carried out on animal mummies dated to the Roman period in Egypt, between 1st and 4th century AD. Huchet et al. could identified for the first time in paleoparasitology, two blood sucking ectoparasites, including the brown dog tick (*Rhipicephalus sanguineus*) and the louse fly (*Hippobosca longipennis Fabricius*), as well as puparia of sarcosaprophagous flies which is a potential source of myiasis, in a dog mummy (Huchet et al., 2013). This study has also provided the sole report of animal parasites so far in paleoparasitology of Egypt.



Figure 2.6: *Rhipicephalus sanguineus* Latr. recovered from the dog's mummy (left) and the louse fly *Hippobosca longipennis* F. recovered from the dog's coat (right), El-Deir, Egypt (Huchet et al., 2013).

	Site	Sample(s)	Date	Parasite(s)	Reference(s)
Egypt	Gebelein	Mummy 32753 (British Museum)	5,150 BP	<i>Schistosoma</i> sp.	Deelder et al., 1990.
	Abydos	Hair sample	4,950 BP	<i>Pediculus humanus capitis</i>	Fletcher, 2002.
	Gebelein	Mummy 527B (Turin)	4,770-4,580 BP	<i>Plasmodium falciparum</i>	Bianucci et al., 2008.
	Thebes	Mummies	4,000-3,600 BP	<i>Leishmania donovani</i>	Zink et al. (2006)
	Thebes	Mummies: Tutankhamun, Thuya, Yuya, and TT320-CCG61065	3,360-3,274 BP	<i>Plasmodium falciparum</i>	Hawass et al., 2010.
	Asyut	Canopic jar (Biella and Turin)	3,490-3,020 BP	<i>Trichuris</i> sp.	Harter, 2003.
	Tomb of Parannefer	Mummy 9	3,400 BP	<i>Dracunculus medinensis</i>	Horne and Redford, 1995.
		Mummy 4		<i>Schistosoma haematobium</i>	
	Thebes	Mummies	3,450-2,450 BP	<i>Plasmodium falciparum</i>	Nerlich et al., 2008.
	Thebes	20th Dynasty mummies	3,200-2,950 BP	<i>Schistosoma haematobium</i>	Ruffer, 1910.
	Deir el-Bahri	Mummy Nakht-ROM I (Manchester)	3,200 BP	<i>Schistosoma haematobium</i> <i>Schistosoma mansoni</i> ¹ <i>Fasciola</i> sp. (worm remains) <i>Trichinella spiralis</i> (cyst) <i>Taenia</i> sp. <i>Plasmodium</i> sp.	Horne and Lewin, 1977; De Boni et al., 1977; Reyman et al., 1977; Cockburn, 1981; Deelder et al, 1990 ; David, 1997; Nunn and Tapp, 2000.
	Karnak	Mummy Natsef Amun (Leeds)	3,050 BP	Filarial worms	Tapp, 1996.
	Thebes	Mummy Asru: #1777 (Manchester)	2,650 BP	<i>Strongyloides</i> sp. (worm remains) <i>Echinococcus granulosus</i> (hydatid cyst)?	Tapp, 1986; Nunn and Tapp, 2000; David, 1997.
	Saqqara	Embalming rejects jar	2,665-2,606 BP	<i>Ascaris</i> sp. <i>Taenia</i> sp.	Harter, 2003; Harter et al., 2003.
	Deir el-Medineh	Mummy	2,350-2,250 BP	<i>Diphyllobothrium</i> sp. <i>Trichuris</i> sp. Ancylostomid	Harter, 2003.
	Saqqara	Natural mummies	2,350-2,250 BP	<i>Fasciola</i> sp. <i>Diphyllobothrium</i> sp. <i>Trichuris</i> sp.	Harter, 2003.
	?	Mummy #1770 (Manchester)	2,250-1,980 BP	<i>Dracunculus medinensis</i>	Tapp, 1979.
	?	Mummy (Narni)	2,150-1,950 BP	<i>Taenia solium</i>	Bruschi et al., 2006.
	Akhmim	Mummy (PUM II)	2,120±70 BP	<i>Ascaris</i> sp.	Cockburn et al., 1975.
	Kellis	Fecal samples	1,980-1,555 BP	<i>Enterobius vermicularis</i> Acanthocephala	Horne, 2002.
Antinoe	Comb	1,550-1,450 BP	<i>Pediculus humanus capitis</i>	Palma, 1991.	
Hierakonpolis	Hair sample (human burials)	?	<i>Pediculus humanus capitis</i>	Friedman et al., 1999.	
El-Deir	Human mummy (fecal samples)	1,550-1,450 BP	<i>Taenia</i> sp.	Le Bailly et al., 2010.	
El-Deir	Dog mummy	1,850-1,450 BP	<i>Rhipicephalus sanguineus</i> <i>Hippobosca longipennis</i> Fabricius <i>Sarcosaprophagous flies</i>	Huchet et al., 2013.	

Table 2.1: Paleoparasitological findings in Egypt, classified by dating.

¹ The *Schistosoma* eggs without obvious spines that may have been ova of *S. mansoni*.

2.3 Sudan

All paleoparasitological data from Sudan result at present from the Upper Nubia. Geographically and historically, land of Nubia has been referred to the northern parts of modern Sudan in southern Nile valley. Based on archaeological information, past era of ancient Egypt and Nubian territory are closely related to each other. Moreover, being along the Nile River has provided agricultural/pastoral lands and communities over the times in Nubia, unlike the other geographical regions of Sudan where are mostly covered by deserts (Emberling, 2011). Because of the arid climate of Upper Nubia, natural mummies as well as preserved fragments of skin, muscle, brain and hair have been discovered in the archaeological sites of this region like elsewhere in Egypt.

The first paleoparasitological report concerning Sudan archeology, comes from the work of Miller et al (1992) on mummies from Wadi Halfa situated on the shores of “Lake Nubia”. There is also a report on retracing of ancient protozoan parasitism by Zink et al. (2006) from Kulubnarti, located between the second and third cataracts of the Nile River in Upper Nubia.

All of the later data on paleoparasitology of Sudan resulted from the work of S. Harter (2003) on mummies and burials of three sites of Sudan: Sai Island, Sedeinga and Kerma.

The site of Sai is an island located between the second and third cataract of the Nile in Sudan. 31 samples of soft tissue remains, organic sediments and coprolites taken from different cemeteries of Sai were analyzed by Harter. These samples were dated to five different periods from 2700 BC up to 1500 AD.

The site of Kerma is located on the East bank of the Nile, 20 km from the Third Cataract. Harter has studied 11 samples collected from natural human and animal (Sheep/Goat) mummies revealed in the graves of the necropolis of Kerma (East cemetery). The nature of samples consists of coprolites, soft tissue taken from internal body contents and organic sediments. The recovered helminth eggs from the samples of Kerma are dated to five time periods between 2400 and 1425 BC.

Further paleoparasitological analysis by Harter has been carried out on 7 samples (hair and organic remains) from the site of Sedeinga and dated to from 275 BC to 1500 AD. This

archaeological site is located between the Second and the Third Cataract, on the west bank of the Nile and represented by a vast necropolis and a temple dedicated to the wife of Amenhotep III.

However, the ancient parasite findings in five above mentioned sites could be also interpreted considering the proximity of their location to the Nile River.

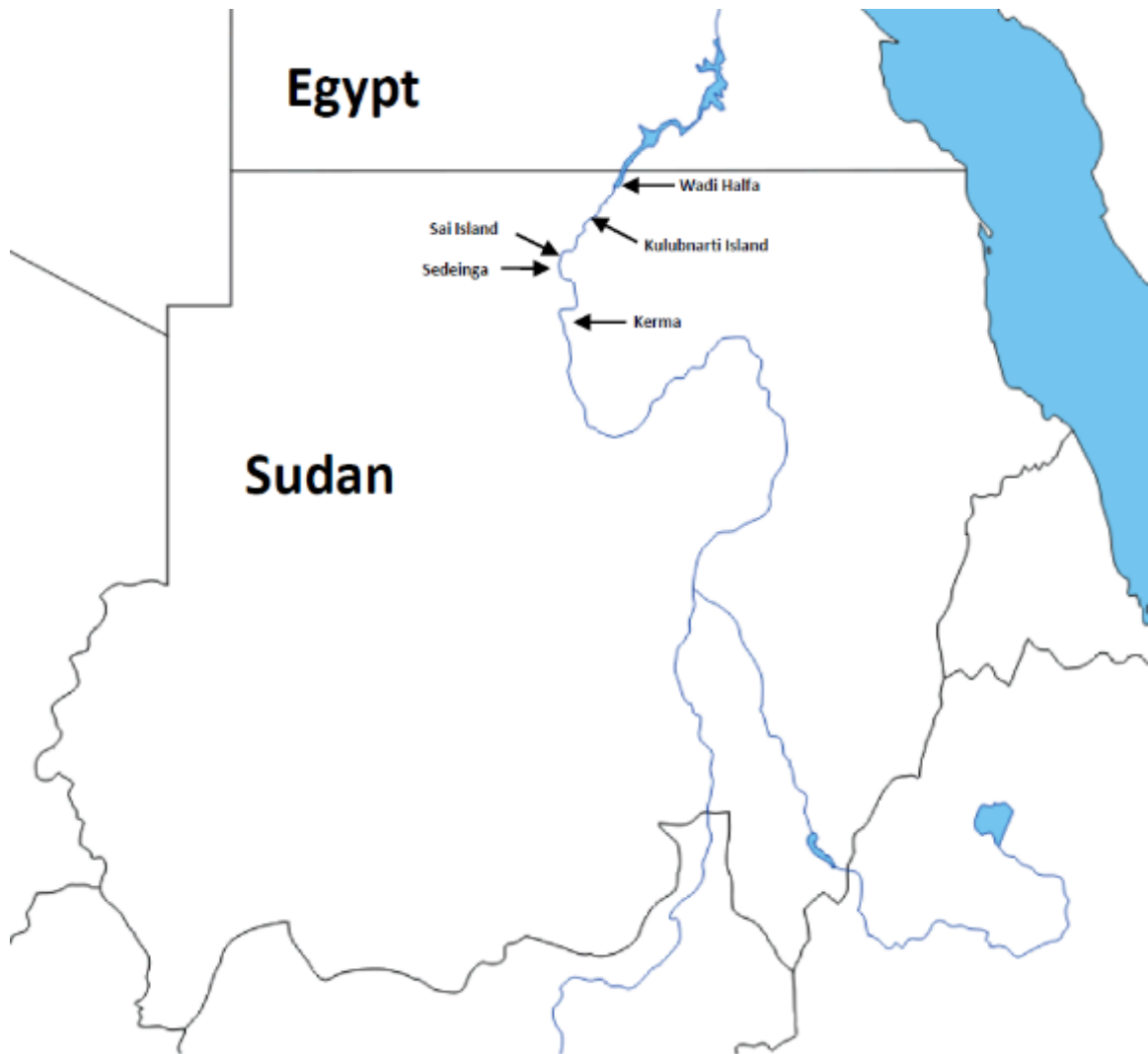

Figure 2.7: Location of archaeological sites related to paleoparasitological data in Sudan.

2.3.1 Helminth finding(s)

In 1992, Miller's team used ELISA tool and could detect *Schistosoma* antigen in desiccated brain and skin samples of 15 naturally mummified bodies from the site of Wadi Halfa dated to 350-550 AD (Miller et al., 1992). They could detect preserved paleo-antigen of *Schistosoma* (CAA) in mentioned mummies.

One decade later, Harter (2003) has identified a variety of helminth taxa in different time periods and individuals from the sites of Sai, Kerma and Sedeinga.

Harter has reported nematode findings recovered from samples of Sai (dated from 2700 BC up to 1500 AD), consist of the eggs of *Ascaris lumbricoides*, *Trichuris* sp. and *Enterobius vermicularis* as well as ova and body parts of adult worms of *Syphacia obvelata*. She has also mentioned to observation of Ancylostomid eggs in this site.

From the class of Cestoda, eggs of *Taenia* sp., *Diphyllobothrium* sp. and *Hymenolepis* sp. were the helminth markers discovered in Sai.

Several eggs of trematodes such as *Fasciola* sp. as well as *Schistosoma* sp. including *mansoni* and *haematobium* species, were the other findings of Sai Island (Harter-Lailheugue and Bouchet 2004).

In the site of Kerma (2400 - 1425 BC), the nematode eggs of *Ascaris lumbricoides* as well as *Trichuris* sp. were recovered by Harter (2003). Also Harter could find tapeworm eggs *Taenia* sp. in this site.

The other paleoparasitological findings by Harter in Kerma were several eggs of *Dicrocoelium* sp. By recovery of this species of trematodes, she could provide the first and also one of the two sole reports on ancient dicrocoeliasis in the Middle East. The other trematodes reported by her from Kerma were the eggs of *Fasciola* sp. and *Schistosoma* sp. (*mansoni* and *haematobium*).

In the site of Sedeinga (dated to from 275 BC to 1500 AD), Harter has found *Ascaris lumbricoides*, *Trichuris* sp. and *Enterobius vermicularis* ova as well as the eggs of *Taenia* and *Hymenolepis* species. The other findings of Sedeinga were also *Schistosoma* sp. (*mansoni* and *haematobium*) and few eggs of *Fasciola* sp (Harter-Lailheugue and Bouchet 2004).

In Harter's study, archaeological information such as the funerary contexts, the sampling locations and nature of the studied samples has made it possible to be relatively sure about the

specific determination of *Ascaris* eggs. Therefore, she could confirm the belonging of these eggs to *lumbricoides* species (Harter, 2003; Harter-Lailheugue and Bouchet 2004).

2.3.2 Protozoa finding(s)

Miller and colleagues had another immunological analysis in 1994 to the identification of *Plasmodium falciparum* antigen for retracing malaria in the mummies of Wadi Halfa as well as some samples from Egyptian natural mummies. They reported one positive result for a Nubian and six for Egyptian mummy samples (Miller et al., 1994). Nevertheless, the commercial kit (ParaSight™-F) used in this study was controversial and could show false positivity in presence of rheumatoid factors in the samples (Iqbal et al. 2000, Moody 2002).

In 2006, Zink et al. provided aDNA evidences of infection by *Leishmania donovani* in 9 of the 70 ancient Nubian mummy's samples dated to the early Christian period, from 550 to 1500 AD. These markers of leishmaniasis were present in bone marrow samples taken from naturally mummified human remains from two early Christian burial sites at Kulubnarti.

2.3.3 Ectoparasite finding(s)

Upper Nubia samples were enriched through scalps mainly from the sites of Kerma and Sedeinga. Microscopic observation of the hair and scalp samples from these two sites was used by Harter to determine infestation by lice (*Pediculus* sp.) as ectoparasitic marker. She could find *Pediculus* sp. in one individual from Kerma and another in Sedeinga (Harter, 2003).

	Site	Sample(s)	Date	Parasite(s)	Reference(s)	
Sudan	Sai	Human burial	4,650 BP	<i>Schistosoma</i> sp. <i>Ascaris</i> sp. <i>Enterobius vermicularis</i>	Harter, 2003.	
	Sai	Human burial	2,650-2,250 BP	<i>Fasciola</i> sp. <i>Schistosoma</i> sp. <i>Diphyllobothrium</i> sp. <i>Taenia</i> sp. Ancylostomid	<i>Ascaris</i> sp. <i>Enterobius vermicularis</i> <i>Syphacia obvelata</i> <i>Trichuris</i> sp.	Harter, 2003.
	Sai	Human burial	2,225-1,600 BP	<i>Fasciola</i> sp. <i>Schistosoma</i> sp. <i>Hymenolepis</i> sp. <i>Taenia</i> sp. Ancylostomid	<i>Ascaris</i> sp. <i>Enterobius vermicularis</i> <i>Syphacia obvelata</i> <i>Trichuris</i> sp.	Harter, 2003.
	Sai	Human burial	1,650-450 BP	<i>Schistosoma</i> sp. <i>Taenia</i> sp. <i>Ascaris</i> sp. <i>Trichuris</i> sp.	Harter, 2003.	
	Sai	Human burial	450 BP	<i>Schistosoma</i> sp. <i>Hymenolepis</i> sp. <i>Ascaris</i> sp. <i>Trichuris</i> sp.,	Harter, 2003.	
	Kerma	Animal remains	3,835-3,515 BP	<i>Dicrocoelium</i> sp.	Harter, 2003.	
	Kerma	Animal remains	3,700-3,375 BP	<i>Dicrocoelium</i> sp.	Harter, 2003.	
	Kerma	Animal remains	4,350-4,000 BP	<i>Dicrocoelium</i> sp.	Harter, 2003.	
	Kerma	Human burial	4,350-3,700 BP	<i>Schistosoma</i> sp. <i>Fasciola</i> sp. <i>Taenia</i> sp.	<i>Ascaris</i> sp. <i>Trichuris</i> sp. <i>Pediculus humanus</i>	Harter, 2003.
	Kerma	Animal remains	4,000-3,700 BP	<i>Dicrocoelium</i> sp.	Harter, 2003.	
	Sedeinga	Human burial	2,225-1,600 BP	<i>Ascaris</i> sp. <i>Enterobius vermicularis</i> <i>Trichuris</i> sp.	Harter, 2003.	
	Sedeinga	Human burial	1,650-450 BP	<i>Schistosoma</i> sp. <i>Fasciola</i> sp. <i>Hymenolepis</i> sp. <i>Taenia</i> sp. <i>Ascaris</i> sp.	<i>Enterobius vermicularis</i> <i>Trichuris</i> sp. <i>Pediculus humanus</i>	Harter, 2003.
	Wadi Halfa	Mummies (Brain and skin remains)	1,600-1,400 BP	<i>Schistosoma haematobium</i>	Miller et al., 1992.	
	Kulubnarti	Mummies (bone marrow samples)	1,450-400 BP	<i>Leishmania donovani</i>	Zink et al., 2006.	

Table 2.2: Paleoparasitological findings in Sudan.



Figure 2.8: *Pediculus capitis* egg, attached to the hair, magnification 100 ×, Kerma, Sudan (Harter, 2003).

2.4 Israel

The historically religious and cultural importance of ancient Palestine situated between ancient Egypt, Syria, Mesopotamia and Arabian Peninsula, has granted a particular significance for the archaeological findings in this part of the Middle East region. Some information on life style of past inhabitants in this area is available in the religious literatures. For instance, the Bible or other important ancient manuscripts discovered in 1947 such as “Dead Sea Scrolls”, sheds the light on ancient hygiene situation such as toilet practices, louse infestation and etc. (Vermes, 2004; Mumcuoglu, 2008). Therefore, some of the findings on ancient parasitic infections so far in Israel could be compared with these ancient writings in few cases, for studying the relation between ancient beliefs, practices and sanitary or health conditions.

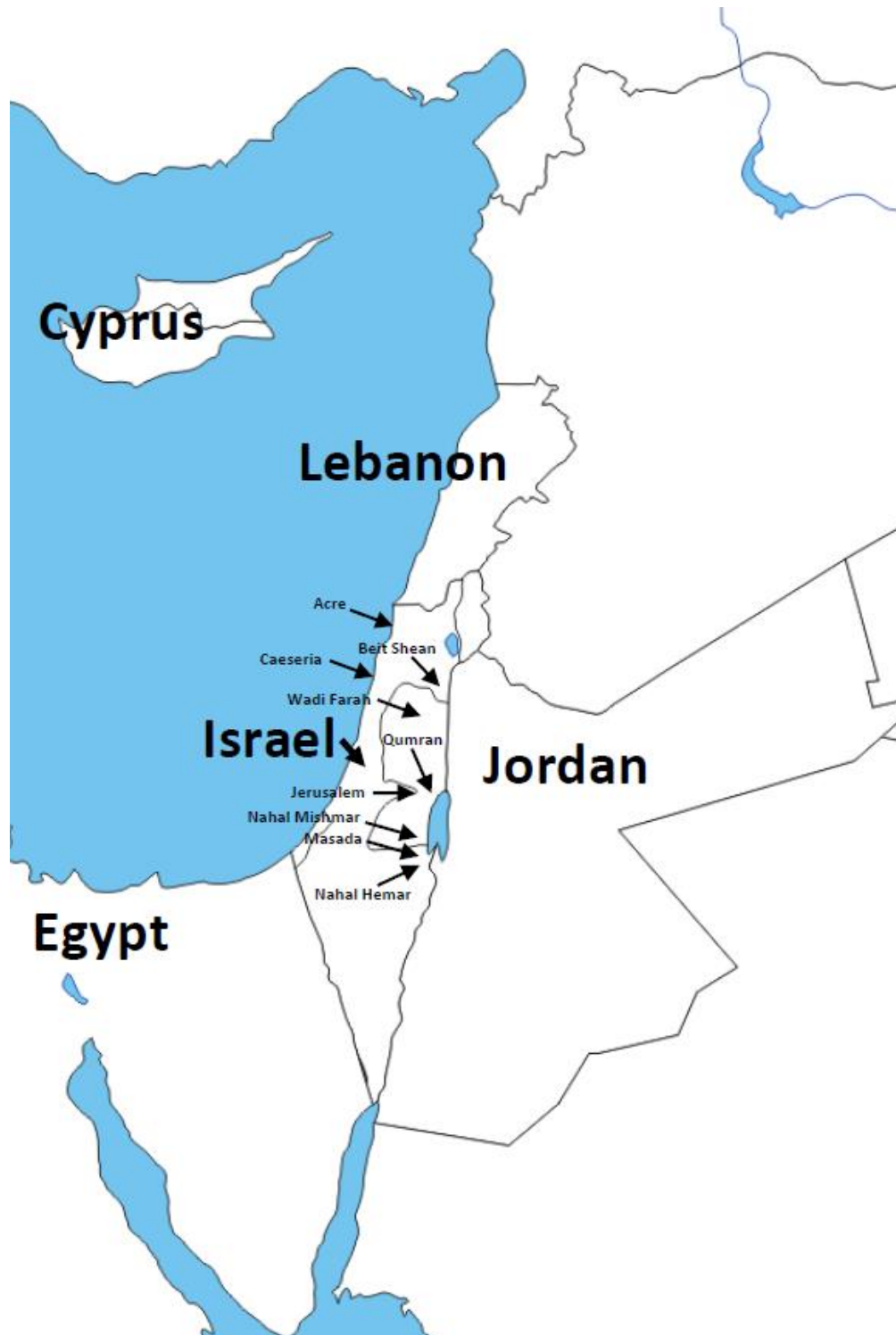

Figure 2.9: Location of archaeological sites related to paleoparasitological data in Israel.

2.4.1 Helminth finding(s)

Witenberg in 1961 has published the first report on the study of ancient parasites from Israel. In this short report, the author pointed to the presence of *Trichuris trichiura* eggs (with no images and description of findings) during microscope observation. For this analysis, he has used a detergent (Triton) to treat two coprolite samples dated to the Bar-Kochba period (132-135 AD) from Judean Desert cave in Nahal-Mishmar Valley (Witenberg, 1961).

In 1991, Cahill and colleagues reported their studies on two toilet seats were uncovered in strata dating between 7th and 6th centuries BC in the “City of David”, one of the major archaeological sites in Jerusalem. They examined the soil of the cesspits beneath the toilet seats and could identify the remains of fecal matter mixed with calcareous ash containing large numbers of *Taenia* sp. and *Trichuris trichiura* eggs (Cahill et al., 1991).

Furthermore, another report in 1991 by Zias presented two calcified cysts founded in the abdominal cavity of an individual buried in a tomb, outside of the “City of David”. The analyses revealed that these calcified cysts, dated to the Herodian period, were probably hydatid cysts caused by *Echinococcus granulosus* (Zias, 1991).

In 2001, Mitchell and Stern found helminth eggs in soil samples taken from a latrine dated to 13th century AD in an ancient hospital excavated in the archaeological site of Acre. The biological origin of the samples being attributed to human, authors identified *Ascaris lumbricoides*, *Trichuris trichiura*, and *Diphyllobothrium latum* by using microscopy (Mitchell and Stern, 2001).

A remarkable diversity of parasite species is provided by Harter’s PhD thesis (2003) on Israeli samples yielded from four archaeological sites. She observed eggs of *Ascaris* sp., *Trichuris* sp., and *Taenia* sp. in an organic sediment sample yielded from a small pit dated to the early first century BC in Qumran. From the site of Beit Shean located in the Jordan Valley, eggs of *Ascaris* sp., *Trichuris* sp., *Fasciola* sp., *Taenia* sp., and *Diphyllobothrium* sp. were recovered from two samples taken from a latrine belonging to Roman-Byzantine period. *Ascaris* sp. and *Diphyllobothrium* sp. eggs were also found in two samples from a latrine excavated in Caeseria, dated to 3rd century AD and located between Tel Aviv and Haifa. Furthermore, Harter could recover the animal parasite *Toxocara canis* from a fecal sample of hyena (*Hyena crocuta*) dated to ninth century AD in Kasy Yehud (probably Kaser el-Yahud near Jericho) (Harter, 2003; Harter et al., 2004).

In a further analysis of some selected samples from northwest of the site of Qumran, Zias and colleagues (2006) reported the findings of *Ascaris* sp., *Trichuris* sp., *Enterobius vermicularis*, and *Taenia* sp. eggs in four soil sediment samples as well as *Dicrocoelium* sp. eggs in a soil sample from an ancient animal stable (Zias et al., 2006).

The parasitic findings such as *Ascaris* sp., *Trichuris* sp. and *Taenia* sp. in soil samples taken from the site of Qumran have proved the presence of latrines inside this ancient religious area. These data are controversial with some religious laws which are mentioned in “Dead Sea Scrolls” about prohibition of defecating at the area (Harter et al., 2004; Zias et al 2006).

Finally in 2007, Mitchell and Tepper published a second paleoparasitological report for Acre. Two type of helminth eggs *Trichuris trichiura* and *Taenia* sp. resulted from the analysis of another medieval cesspool in Acre (Mitchell and Tepper, 2007).

2.4.2 Protozoa finding(s)

Witenberg in 1961 has published the first ancient protozoan report in the Middle East, on microscopy observation of cyst of three unicellular parasite taxa including *Entamoeba histolytica*, *Giardia duodenalis*, *Chilomastix mesnili* and a non-parasitic cyst of *Entamoeba coli* in two above mentioned coprolite samples from Judean Desert cave in Nahal-Mishmar Valley (Witenberg, 1961). However, no images and description of these controversial findings were available in his report.

Furthermore, retracing of protozoan parasites in the site of Acre has been carried out by Mitchell and colleagues in 2008. They used ELISA tools and had positive results for *Entamoeba histolytica* and *Giardia duodenalis* in samples taken from two above mentioned medieval latrines in Acre (Mitchell et al., 2008).

2.4.3 Ectoparasite finding(s)

Mumcuoglu and Zias in 1988, could recover human head lice *Pediculus humanus capitis* evidences in combs from excavated sites of Masada, Qumran and Wadi Farah in the Judean and Negev deserts dated between 100 BC and 800 AD (Mumcuoglu and Zias, 1988). They could also recover louse eggs with around 9000 year old antiquity founded in hair samples from an ancient

inhabitant of a cave located near the Dead Sea (Mumcuoglu and Zias, 1991). This finding is the most ancient reported ectoparasitic markers in the Middle East. Moreover, the remains of a body louse *Pediculus humanus humanus* have been found in textile samples at the Masada fortress dated from the Roman period (Mumcuoglu et al., 2003).

The infestation by lice is mentioned in the Bible as the third plague. This reference and the other Sumerian, Akkadian, and Egyptian sources show that this ectoparasite has been well known for the ancient inhabitants of these regions (Mumcuoglu, 2008).




Figure 2.10: A delousing comb, Christmas Cave (dated to the 1st c. B.C. and A.D), Israel (Mumcuoglu and Gunneweg 2012).

	Site	Sample(s)	Date	Parasite(s)	Reference(s)
Israel	Nahal Hemar	Hair samples	8,850-8,250 BP	<i>Pediculus humanus capitis</i>	Mumcuoglu and Zias, 1991.
	Jerusalem	Cesspit (soil sediments)	2,550-2,450 BP	<i>Trichuris trichiura</i> <i>Taenia</i> sp.	Cahill et al., 1991.
	Qumran	Organic sediments	2,050-2,018 BP	<i>Ascaris</i> sp. <i>Trichuris</i> sp. <i>Enterobius vermicularis</i> <i>Dicrocoelium</i> sp. <i>Taenia</i> sp.	Harter, 2003; Harter et al. 2004; Zias et al., 2006.
	Qumran	Combs	2,050-1,150 BP	<i>Pediculus humanus capitis</i>	Mumcuoglu and Zias, 1988; Mumcuoglu, 2008
	Wadi Farah				
	Jerusalem	Human burial	1,950-1,850 BP	<i>Echinococcus granulosus</i> (hydatid cyst)	Zias, 1991; Zias and Mumcuoglu, 1991
	Masada	Combs, Textiles	1,884-1,876 BP	<i>Pediculus humanus capitis</i> <i>Pediculus humanus humanus</i>	Mumcuoglu et al., 2003; Mumcuoglu, 2008
	Nahal-Mishmar Valley	Human coprolite	1,790 BP	<i>Entamoeba histolytica</i> <i>Giardia duodenalis</i> <i>Chilomastix mesnili</i> <i>Trichuris trichiura</i>	Witenberg, 1961.
	Beit Shean	Latrine soil sediments	1,750-1,650 BP	<i>Ascaris</i> sp. <i>Trichuris</i> sp. <i>Fasciola</i> sp. <i>Taenia</i> sp. <i>Diphyllobothrium</i> sp.	Harter, 2003.
	Caeseria	Latrine soil sediments	Roman period	<i>Ascaris</i> sp. <i>Diphyllobothrium</i> sp.	Harter, 2003.
	Kasy Yehud ²	Fecal sample of hyena	1,150-1,050 BP	<i>Toxocara canis</i>	Harter, 2003.
	Acre	Latrine soil sediments	750-650 BP	<i>Ascaris lumbricoides</i> <i>Trichuris trichiura</i> <i>Taenia</i> sp. <i>Diphyllobothrium latum</i> <i>Entamoeba histolytica</i> <i>Giardia duodenalis</i>	Mitchell and Stern, 2001, Mitchell and Tepper, 2007, Mitchell et al., 2008.

Table 2.3: Paleoparasitological findings in Israel.

² Probably the site of Kaser el-Yahud near Jericho in the East of Israel.

2.5 Cyprus

Cyprus is an ancient crossroad of many civilizations and has an important role for comparing the paleoparasitological data between Europe, Asia and Africa. During the past two decades bioarchaeological analyses in the island have increased (Harper and Fox, 2008; Le mort, 2008; Vigne et al., 2012).

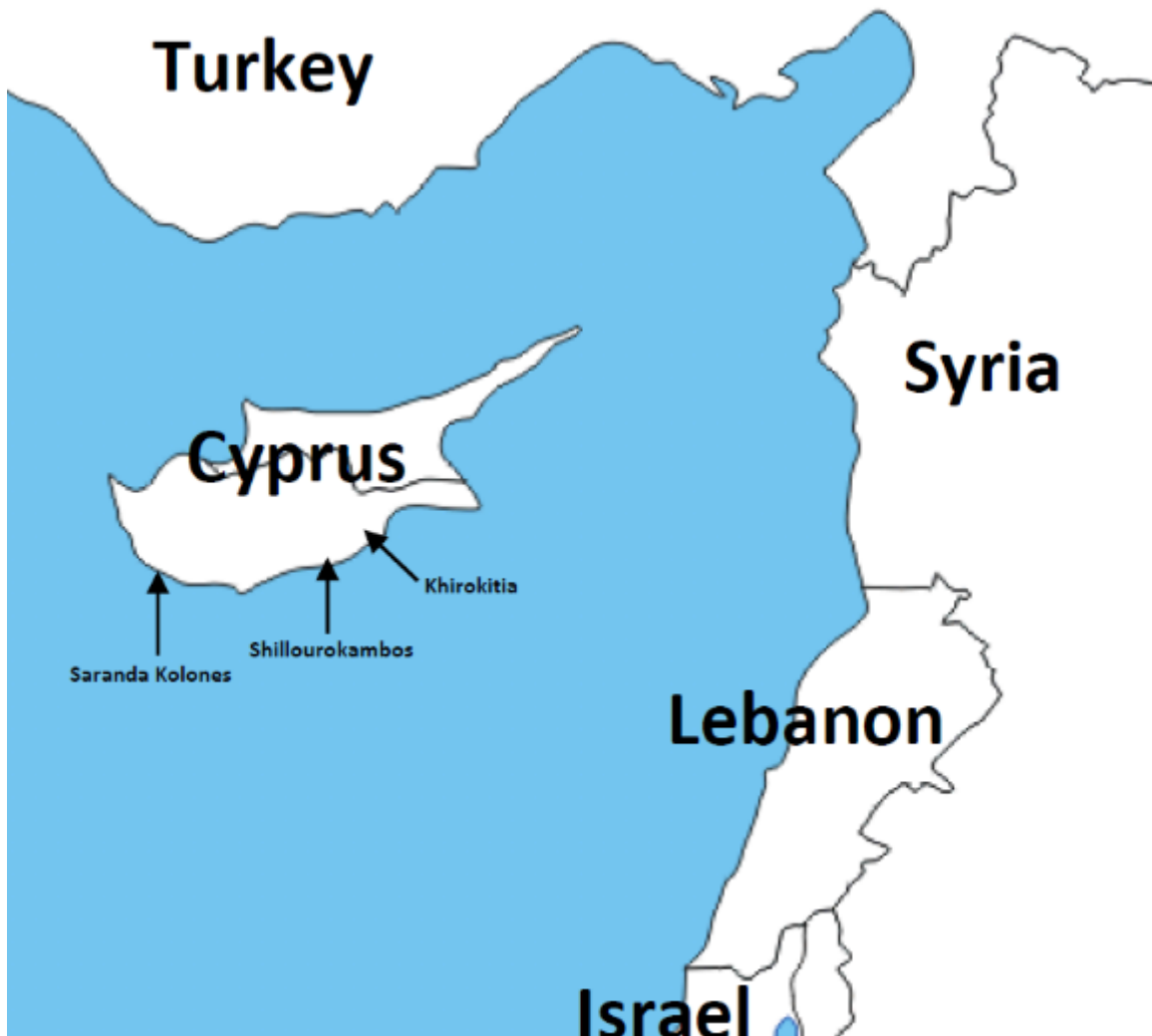

Figure 2.11: Location of archaeological sites related to paleoparasitological data in Cyprus.

The paleoparasitological researches among Cypriot archaeology were since years limited to the analysis of soil sediments and human/animal remains recovered from two sites of Shillourokambos and Khirokitia (Harter, 2003). Recently, new data from soil sediments of a latrine inside a medieval castle in Saranda Kolones were provided by Anastasiou and Mitchel (2013).

The helminth eggs discovered by Harter in Shillourokambos from the Neolithic periods are the most ancient findings in the Middle East region. She analyzed five sediment samples collected from the area of the hip bone of human burials dated to the pre-pottery Neolithic period, between 8500 and 7500 BC, and the findings were the eggs of *Ascaris lumbricoides*, *Trichuris* sp., *Taenia* sp., *Diphyllobothrium* sp., and *Fasciola* sp. Further significant discovery in Shillourokambos was the recovery of one egg of *Toxocara cati* in a sample from domestic cat burial dated to 7600-7500 BC (Le Mort, 2008). Moreover, Harter could recover the eggs of *Ascaris lumbricoides*, *Trichuris* sp., and one egg of *Taenia* sp. by analysis of seven organic materials from burials of Khirokitia site dated to 6590 ± 260 B.C (Harter, 2003; Harter-Lailheugue et al., 2005).

	Site	Sample(s)	Date	Parasite(s)	Reference(s)
Cyprus	Shillourokambos	Human burial	10,450 BP	<i>Ascaris lumbricoides</i> <i>Trichuris</i> sp. <i>Fasciola</i> sp. <i>Taenia</i> sp.	Harter, 2003; Harter-Lailheugue et al., 2005.
	Shillourokambos	Human burial	10,000-9,000 BP	<i>Ascaris lumbricoides</i> <i>Trichuris</i> sp.	Harter, 2003; Harter-Lailheugue et al., 2005.
	Shillourokambos	Human burial	9,550-9,450 BP	<i>Ascaris lumbricoides</i> <i>Trichuris</i> sp. <i>Fasciola</i> sp. <i>Taenia</i> sp. <i>Diphyllobothrium</i> sp.	Harter, 2003; Harter-Lailheugue et al., 2005.
		Cat burial		<i>Toxocara cati</i>	
	Khirokitia	Human burial	8,540±260 BP	<i>Ascaris lumbricoides</i> <i>Trichuris</i> sp. <i>Taenia</i> sp.	Harter, 2003; Harter-Lailheugue et al., 2005.
	Frankish castle of Saranda Kolones	Latrine soil sediments	759-728 BP	<i>Ascaris lumbricoides</i> <i>Trichuris trichiura</i>	Anastasiou and Mitchell, 2013.

Table 2.4: Paleoparasitological findings in Cyprus.

The recent paleoparasitological study in Cyprus has been carried out by Anastasiou and Mitchell (2013). They have provided data on ancient human ascariasis and trichuriasis evidenced by eggs founded in the site of Frankish castle of Saranda Kolones. They analyzed the soil sediments recovered from a latrine inside this castle which was occupied between 1191 and 1222 AD.

2.6 Iran

Iranian plateau is located in the eastern part of the Middle East. As mentioned above this region had no significant paleoparasitological finding before the present study. The first effort to study of ancient parasitism in archaeological sites of Iran has been carried out by Le Bailly and Bouchet in 2005 for the site of Kharand. After them, there is a published report for the site of Chehrabad saltmine by Pollard et al (2008) which had not positive result and was only the description of a study to find parasite elements in two coprolite samples from this ancient saltmine.

The unique evidence of ancient parasite reported from Iran (before the present work) is one *Trichuris* sp. egg which has been found by Le Bailly in 2005 among the analysis of the 8 soil sediments from the site of Kharand (Le Bailly, unpublished report). Kharand is a necropolis located in the North East of the central Iranian plateau and the samples were taken from burial contexts are dated to Iron Ages of Iran (Nezamabadi et al., 2013c).

	Site	Sample(s)	Date	Parasite(s)	Reference(s)
Iran	Kharand	Soil sediments from burial	3350-2500 BP	<i>Trichuris</i> sp.	Nezamabadi et al., 2013c.

Table 2.5: Paleoparasitological finding(s) in Iran.

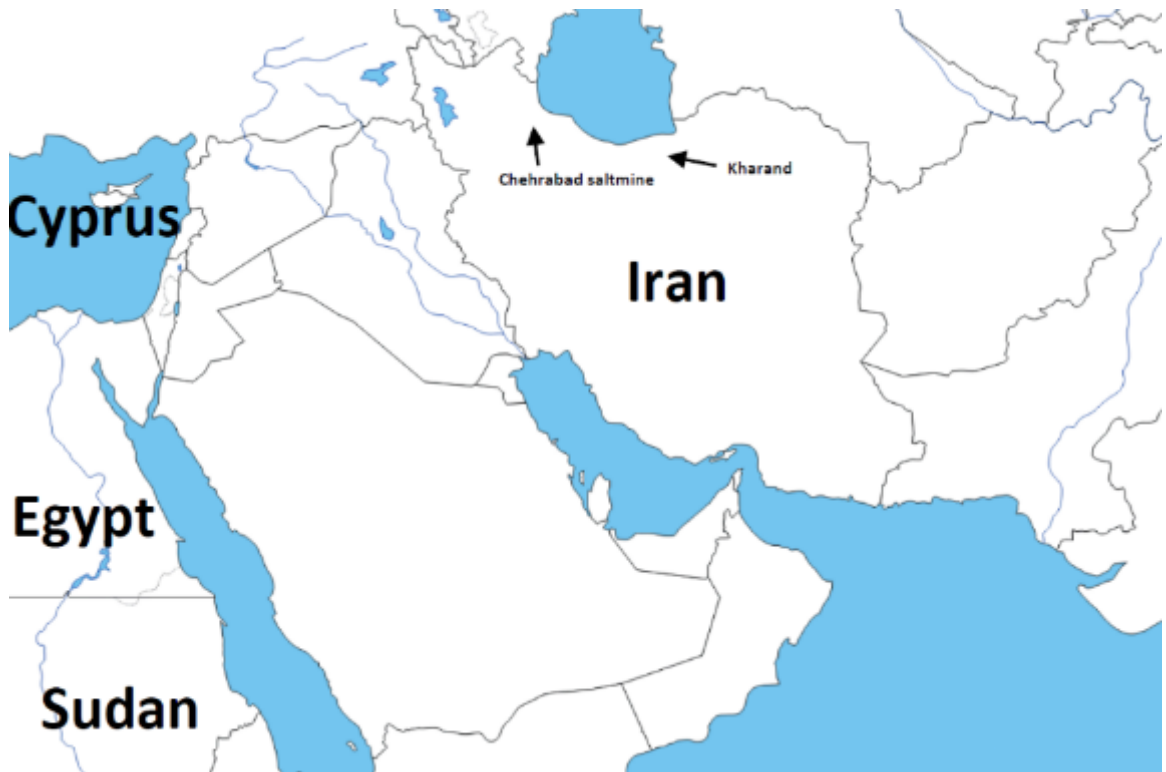

Figure 2.12: Location of archaeological sites related to paleoparasitological studies in Iran.

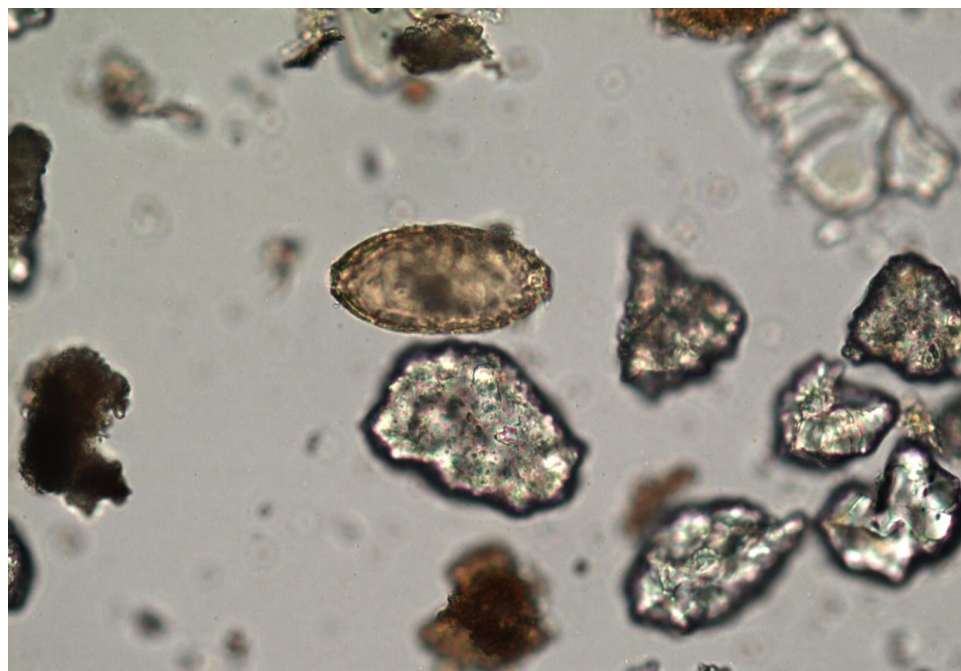


Figure 2.13: *Trichuris* sp. egg from Kharand, Iran. Egg size: $57 \times 24 \mu\text{m}$ (Photo: M. Le Bailly).

2.7 Syria

Paleoparasitology data from Syria is limited to one single report published recently by Anastasiou and her colleagues (2014). Except her work, there is no data so far on the study of ancient parasitism from Mesopotamian region. This report on ancient parasitism in Syria comes from analysis of collected sediment from the pelvic area of human skeletal remains dated 6500–6000 BP, discovered at Tell Zeidan. This site is located in northern Syria in the Euphrates river valley. The evidence of schistosome egg recovered from Tell Zeidan suggests the presence of schistosomiasis in 6000 years ago in this part of the Middle East.

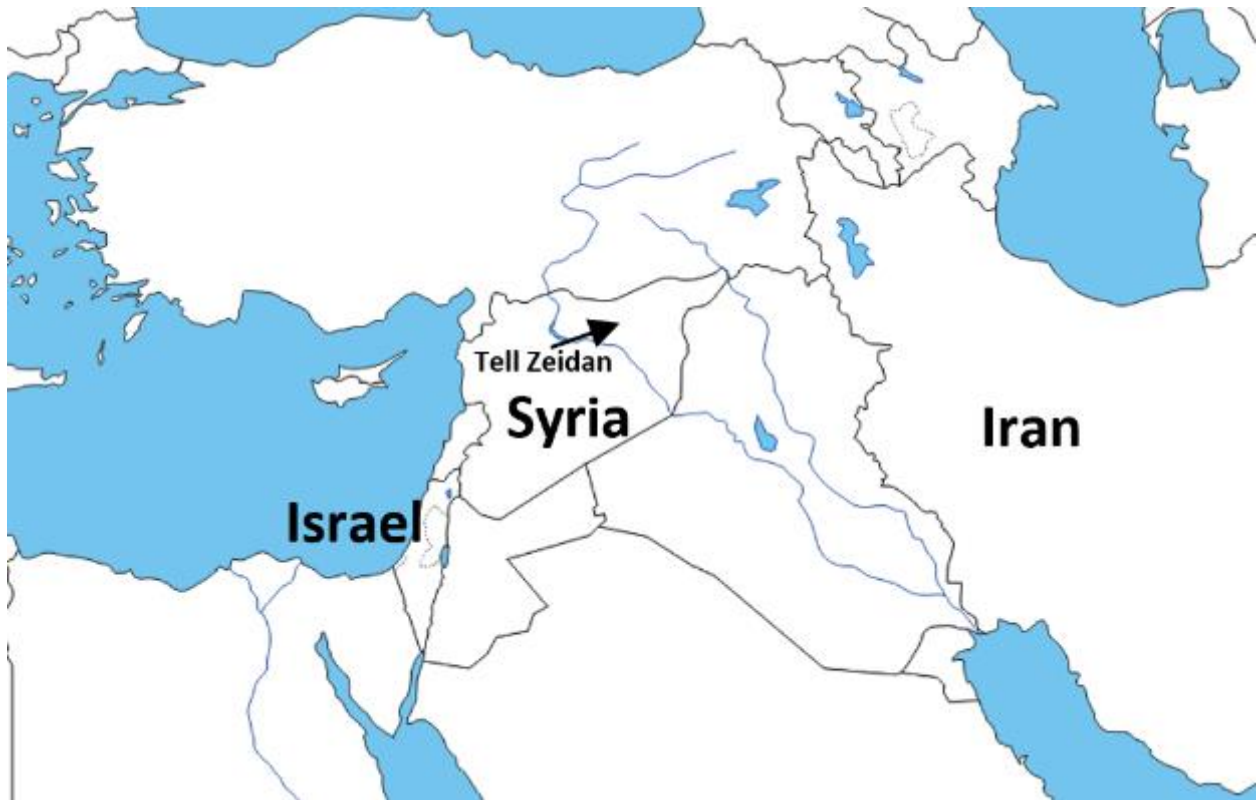


Figure 2.14: Location of an archaeological site related to paleoparasitological studies in Syria.

	Site	Sample(s)	Date	Parasite(s)	Reference(s)
Syria	Tell Zeidan	Soil sediments from human skeleton	6500–6000 BP	<i>Schistosoma</i> sp.	Anastasiou et al., 2014

Table 2.6 : Paleoparasitological finding(s) in Syria.

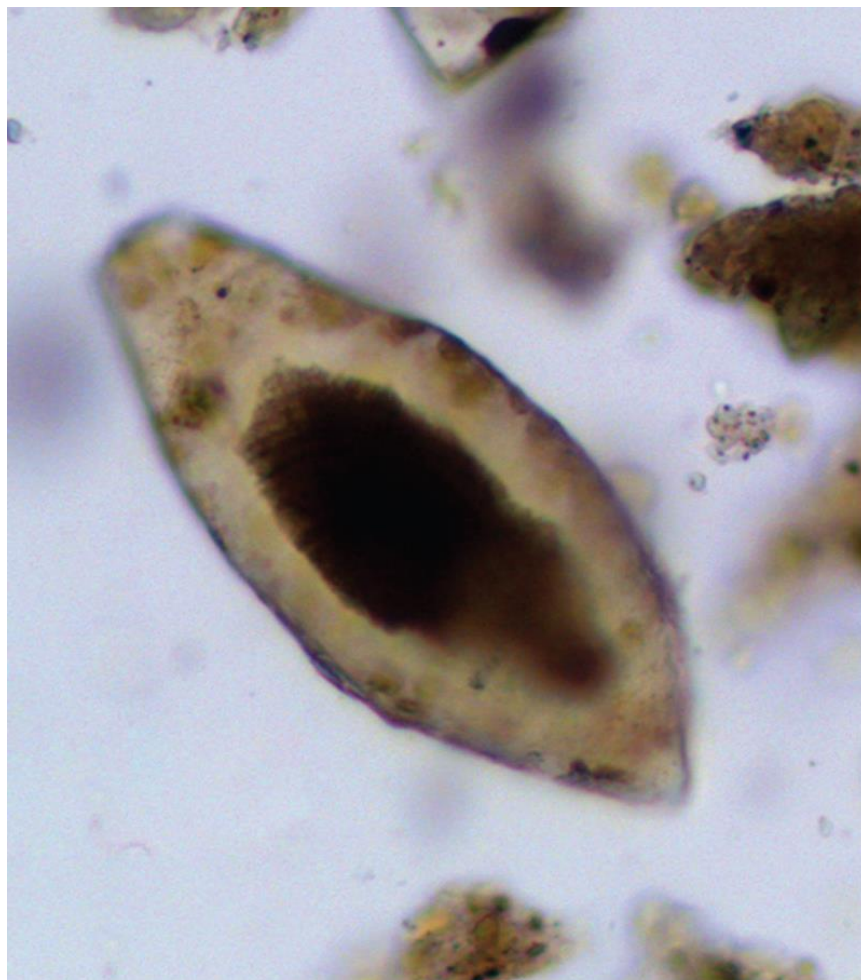


Figure 2.15: A schistosome egg recovered from a human burial, Tell Zeidan, Syria, dated to 6500–6000 BP. Egg size: $132 \times 56 \mu\text{m}$ (Anastasiou et al., 2014).

Chapter 3 : Study sites and materials

3.1 Introduction

The set of samples studied in my PhD work are all collected from archeological sites situated in the Middle East countries including Iran, Azerbaijan, Syria, Saudi Arabia, and Oman in the western and southwestern Asia as well as Egypt and Sudan in the northeastern Africa. Except some Paleolithic dated samples from Iran, the remaining part of the samples came from sites from the Neolithic up to the Sassanid period throughout the region. The majority of the archaeological researches in Iran have been concentrated on the western regions of Iran. Therefore majority of our received samples for the present PhD work covered northwestern through southwestern Iran. Scanty samples from northern, north eastern and central of Iran are also among the present analysed samples.

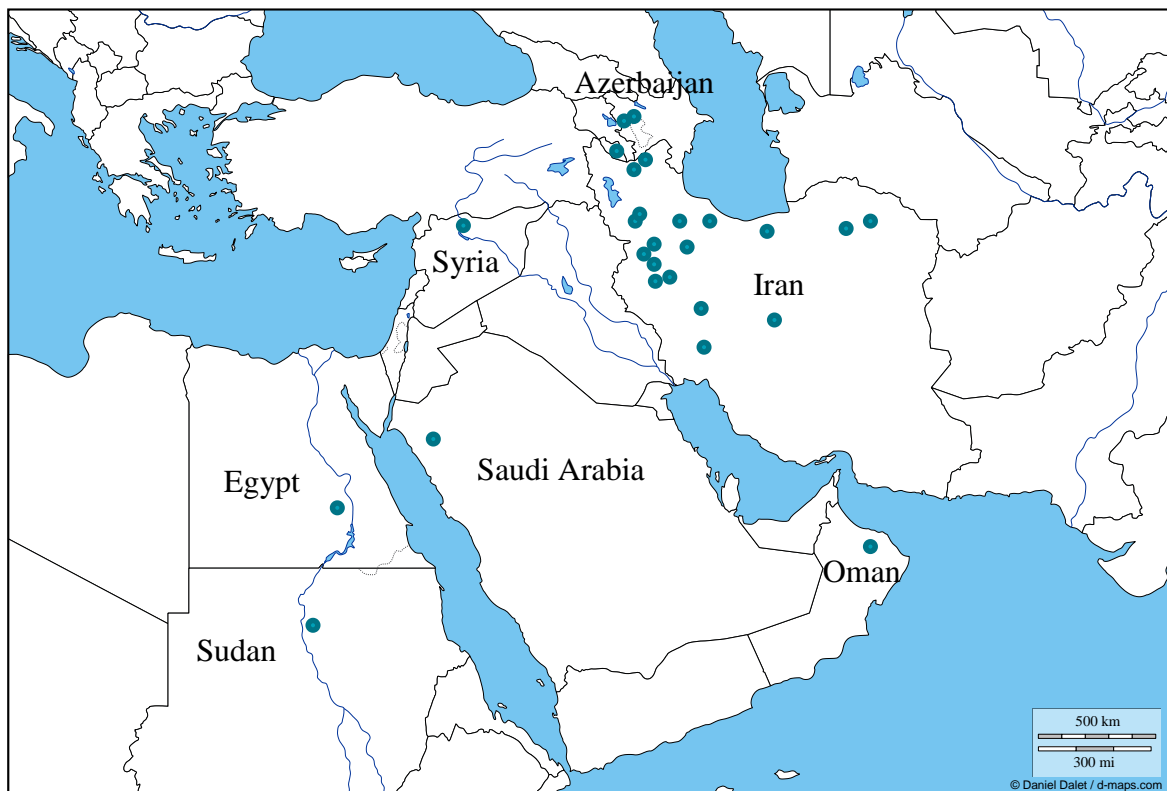

Figure 3.1: A map of studied sites.

3.2 Sampling strategies

In practice, parasites can be found in all contexts impacted by human/animal activities. Since paleoparasitology essentially focuses on intestinal parasites, all elements or structures containing or polluted by human or animal fecal matter which may accumulate parasites could be analyzed.

The major contexts or structures on which paleoparasitological analyses may be conducted are coprolites, sediment samples from skeletons, occupation layers, latrines, cesspits, and etc.

The sampling strategies in the present PhD research include a protocol which has been sent to the archaeologist in the region and used to taking samples from archeological layers during excavations or from archeological materials. These strategies are summarized in Table 3.1 (Le Bailly et al., 2003; Nezamabadi et al, 2011).

Ancient sample	Context	Sampling
Coprolites	In places on the corpses of mummies (human or animal).	Taking whole of the coprolite sample.
	In places on the skeletons (human or animal).	
	Individual findings in archaeological layers.	
	Except contexts.	
	Subjacent with the coprolites on depth.	Taking sediments around 3 cm under coprolites. The vertical migration of eggs by scrubbing and leaching was highlighted.
Sediments	Related to the skeletons (human or animal).	The pelvic and abdominal cavities, between the hipbones and the last coasts, and around the scalp. Also just near the top and below the bones.
	Sediment enriched out of organic matter, grounds of habitats (human and animal circulations).	Taking samples regularly in the layer to improve the representativeness of the sampling.
	Latrines.	Taking away in several stratigraphic units, or in several points (at least top, middle and bottom of each layer).
	Cesspits.	
	Pits and wells.	
Organic remains	Tissues or organs such as liver, intestines, lungs, skin, muscles,...	When not well preserved, the theoretical location can be considered.
	Hairs of head, body and pelvis.	Taking 1 cm sediment under hairs. Do not wash.
Other samples	Fabrics, linens associated with the mummies and the skeletons.	Especially textiles in contact with natural cavities or putrefaction juices.
	Contents of mud, earthenware jars, pots and etc...	Depending of the artifact, a strategy may be discussed with the parasitologists.

Table 3.1: Paleoparasitology sampling strategy.

Majority of the soil sediments and coprolites from archaeological layers, burials, skeletons and natural mummified bodies in the present study, have been collected by archaeologists and have been sent to our laboratory in Besancon, France. Also some of the samples have been collected during participation in excavation projects or post excavation studies during 2008 to 2014.

The Table 3.1 shows a summary of analyzed samples in this PhD work. 275 samples from 30 archaeological sites have been analyzed under microscopy (Figure 3.2; Table 3.2).

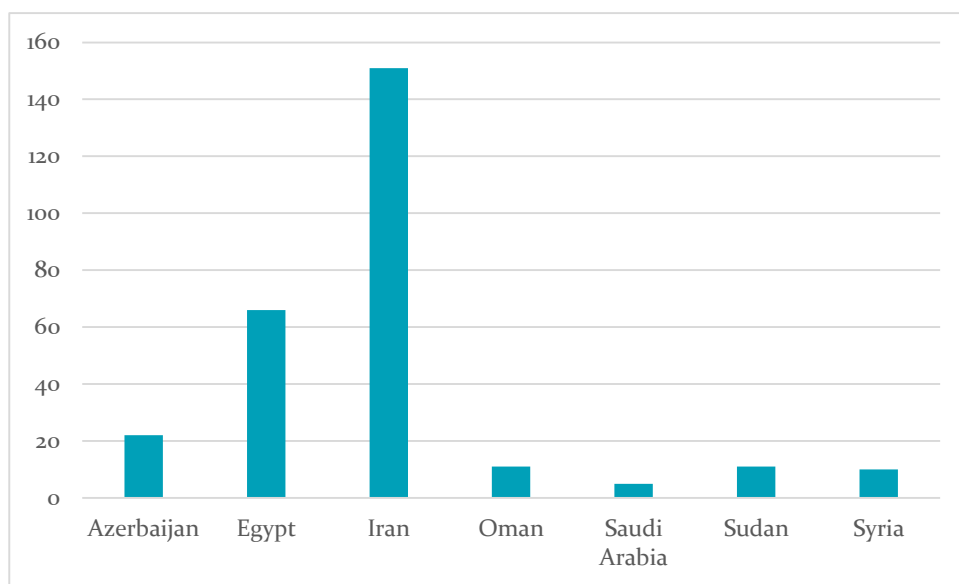


Figure 3.2: Count of analyzed samples by country in present PhD work.

Country	Site	Type of Sample	Taken from	Origin	Number of analyzed samples	Dating / Period
Azerbaijan	Boyuk qishlak	Soil sediment	Burial / Skeleton	Human	2	Bronze Age
	Mentesh Tepe	Soil sediment	Burial / Skeleton	Human	18	Neolithic 6 th Millennium BC Bronze Age
	Ovçular-Tepesi	Soil sediment	Burial / Skeleton	Human	2	Neolithic
Egypt	Hierakonpolis L11 C	Coprolite	Layers	Human Animal	51	3900 - 3300 BC
	Hierakonpolis HK6	Coprolite / intestinal contents	Burial / Skeleton	Human Animal	14	3700 - 3500 BC
Iran	AQ Tepe	Soil sediment	Burial / Skeleton	Human	5	Sassanid - Islamic period
	Chehrabad saltmine	Soil sediment/ Coprolite	Mummified bodies / Layers	Human Animal Unknown	47	7 th Century BC – 7 th Century AD
	Darband B	Soil sediment	Layers	Unknown	2	Lower Paleolithic
	Dareh Shahr	Soil sediment	Burial / Skeleton	Human	3	5000 BC
	Deh Paeen necropolis	Soil sediment	Burial / Skeleton	Human	6	2000-1000 BC
	Gandomzar	Soil sediment	Burial / Skeleton	Human	9	Bronze Age - Iron Age
	Haft tape	Soil sediment	Burial / Skeleton	Human	23	2000-1000 BC
	Hasanlu	Soil sediment	Skeleton	Human	3	6 th Millennium BC - 3 rd Century AD
	Kohneh Pasgah Tape	Soil sediment	Burial / Skeleton / Layers	Human Animal Unknown	6	Late Chalcolithic - Iron Age
	Khar Cave	Soil sediment	Layers	Unknown	13	Paleolithic - Neolithic
	Kohneh Tape Si	Soil sediment	Skeleton	Human	1	3000- 2000 BC
	Komishan Cave	Soil sediment	Layers	Unknown	1	Epipaleolithic
	Koul Tarikeh	Soil sediment	Skeleton	Human	3	700 BC
	Qabrestan	Soil sediment	Skeleton	Human	3	Chalcolithic
	Qale Bozi Cave	Soil sediment	Layers	Unknown	4	Middle Paleolithic
	Sang Chaxmaq	Soil sediment	Burial / Skeleton	Human	2	7 th - 5 th Millennium BC
	Tepe Chalow	Soil sediment	Burial / Skeleton	Human	9	4 th – 1 st Millennium BC
	Tepe Mussaei Ravasar	Soil sediment	Burial / Skeleton	Human	1	Neolithic Islamic periods
	Wezmeh Cave	Soil sediment	Skeleton	Animal	3	Paleolithic
	Yafteh Cave	Soil sediment	Layers	Unknown	4	Upper Paleolithic
Zagheh	Soil sediment	Skeleton	Human	3	6 th - 5 th Millennium BC	
Oman	RA'S AL-HAMRA RH-10	Soil sediment	Burial / Skeleton	Human	11	4 th Millennium BC
Saudi Arabia	Medineh Saleh	Soil sediment	Burial / Skeleton	Human	5	1 st Century AD
Sudan	Kerma	Coprolite	Burial / Skeleton	Animal	11	2400 BC – 1500 AD
Syria	Tell Halula	Soil sediment	Burial / Skeleton	Human	10	8200 - 5400 BC

Table 3.2: Description of the analyzed samples.

3.3 Study sites

3.3.1 Iran

Archeological investigations in Iran and adjacent countries have revealed ancient cultural interactions and important ties between Iran and Mesopotamia, Eastern Anatolia, Caucasus, Central Asia and also ancient population in Arabian Peninsula and Indian subcontinent. Therefore collecting the samples from Iran has an important role for paleoparasitological study of the eastern part of the Middle East region (see chapter II).

The geography of Iran is characterized by high mountain ranges that enclose plains of varying sizes, climate and cultural history. Most of these plateaus are covered by colluvial and alluvial deposits from the surrounding mountains, which can be either arid or fertile, depending on the regional climate (Schmidt and Fazeli, 2007).

Due to the lack of paleoparasitological studies in the Iranian plateau, this type of analysis remained unknown for the Iranian archaeologist. Therefore collecting the archaeological samples was performed through correspondence with local archaeologists in different geographical and chronological parts of Iran. The quality control of the sampling from archaeological contexts was communicated through a protocol sheet of sampling which was also published in two general papers on paleoparasitology. Also, the author contributed personally to the sampling by participating in excavations or post excavation periods.

Most of the archaeological research in Iran, since the beginning in 19th century has been concentrated on the western regions of Iran. Therefore the majority of our samples for this work covered North West to South West of Iran. However, some archaeological excavations and surveys have shown the richness of prehistoric and historic occupations in the other parts of Iran. Scanty samples from northern, north eastern, western and central Iran are among present analyzed samples.

3.3.1.1 Chehrabad saltmine

The archaeological site of Chehrabad (called also Douzlakh) is located in the Zanjan province, close to one of the main ancient trade routes between the central plateau and northwest

of Iran (Majidzadeh, 1982). The area is situated at the confluence of seasonal streams of Talkheh-Rud and Chehrabad River, with a series of mounds within a semi-arid steppe. The site is an ancient salt mine lying 1350 m asl. This region has a continental climate, up to 140 mm precipitation form of snowing in winter, the lowest temperatures around -8 °C and the average peak of temperatures around 32 °C in the summer (Aali et al., 2012a; 2012b).

The archaeological field studies have been carried out at the site since 1994 and revealed some exceptional characteristics such as the many well preserved organic materials. Six naturally mummified human bodies (called “Salt Men”), all killed in falls during mining accidents were recovered so far from this site along with extremely well preserved bioarchaeological remains, such as leather, textiles, wood, animal and plant remains. At least two separate mining collapses have occurred in Chehrabad between 1,500 BP and 2,500 BP. Salt Men #3, #4 and #5 were died during the first accident in the mine which occurred around 2300 years ago. The other disaster has occurred in the salt mine several centuries after and Salt Men #1, #2 and #6 were killed (Aali, 2005; Pollard et al., 2008; Aali et al, 2012a, 2012b).

Discovery of mummies was unprecedented in the Iranian archaeology. Salty environment of this site could lead the body remains to mummification by dehydration, inhibition of bacterial growth and protecting of the tissues from decomposing. The mummy #1 including a booted leg and a head with long hair and beard, is dated to the late Parthian up to the early Sassanian period (around 3rd century AD) according to the radiocarbon absolute dating. The mummy #2, a man whose hair, beard and soft tissues were well-preserved, belong to the late Sassanian period dated between 430 and 570 AD. Salt Man #3, mostly skeletonized with only a few remains of soft tissue, has an Achaemenid date around 400 BC. The Salt Man #4 is sole intact mummified body, radiocarbon dated to 405-380 BC which corresponds to the end of the Achaemenid time period. His estimated age is 15-17 years. Salt Man #5 with decayed of most of the soft tissues has only remained in small areas on the arms, legs, face, chest, and pelvis. This corpse is also Achaemenid dated same as Mummies #3 and #4. A naturally mummified bat has been found on right beside of Mummy #5. Belonging to the Late Sassanian period and dated between 432 and 611 AD, Salt Man #6 consists of a cranium without a mandible and a larger fragment of a pelvic bone (Pollard et al., 2008; Aali et al, 2012a, 2012b).

The bodies of Salt Men #2, #3, #4 and #5 were unearthed within Trenches A at the site. Salt Man #1 was also discovered accidentally (before starting of the archaeological excavations) at the west of Trenches A. Furthermore, during the excavation, a number of other human remains such as bones, soft tissue, hair, and human coprolites have been found in Trenches A, B and C (Figure 3.4). Pieces of human bone and soft tissue discovered in Trench A, belong probably to Salt Men #2 and #3. Also, hair remains and human bone fragments found in Trench C, may not belong to one of the mummies found so far (Aali et al, 2012a, 2012b).

Based on the comparative isotope analysis, Salt Men #1 and #2 most probably belong to the regional surrounding, around modern Qazvin or Tehran or northern Iran. Salt Men #3, #4 and #5 are isotopically different and suggest a possible migration from a faraway region in northeastern Iran or Central Asia (Pollard et al., 2010).

A small assemblage of extremely well preserved animal bones was also found in Chehrabad. Bat, bird, murid, rat, lizard, amphibian and micro-vertebrate remains as well as sheep/goat, cattle and pig bones are the majority of animal bone remains in the site (Mashkour, unpublished report). Besides faunal remains, a mummified dog (trapped or killed by other animals) has been discovered recently at the site (Figure 3.7). These mummy remains, as well as the other mentioned organic remains, are exceptional and extremely promising elements, which highlight the importance of the site for bioarchaeological studies including paleoparasitological analyses.

The samples analyzed for this study come from the mummified specimens #2 and #5 which are currently on exhibit in the Archaeological Museum of Zanjan, Iran. Three samples were taken from mummy #2 after soft brushing the surface of the pelvic bones and femoral heads. Six sediment samples attached to the skeleton around the pelvis, chest and abdominal cavity were collected from the second body (mummy #5). For both mummies, skull or limb materials were used as control samples (Figure 3.5 and 3.6). Moreover, due to the very special preservation conditions at the site, lots of human, animal and unknown originated coprolites had been found in the archaeological layers of different exploitation periods. Some of the coprolites and the soil sediments linked with them, have been sent to our laboratory in Besancon for paleoparasitological analyses.



Figure 3.3: The landscape of Chehrabad saltmine, Iran.



Figure 3.4: Salt rocks at Chehrabad saltmine, Iran (Photo: A. Aali).

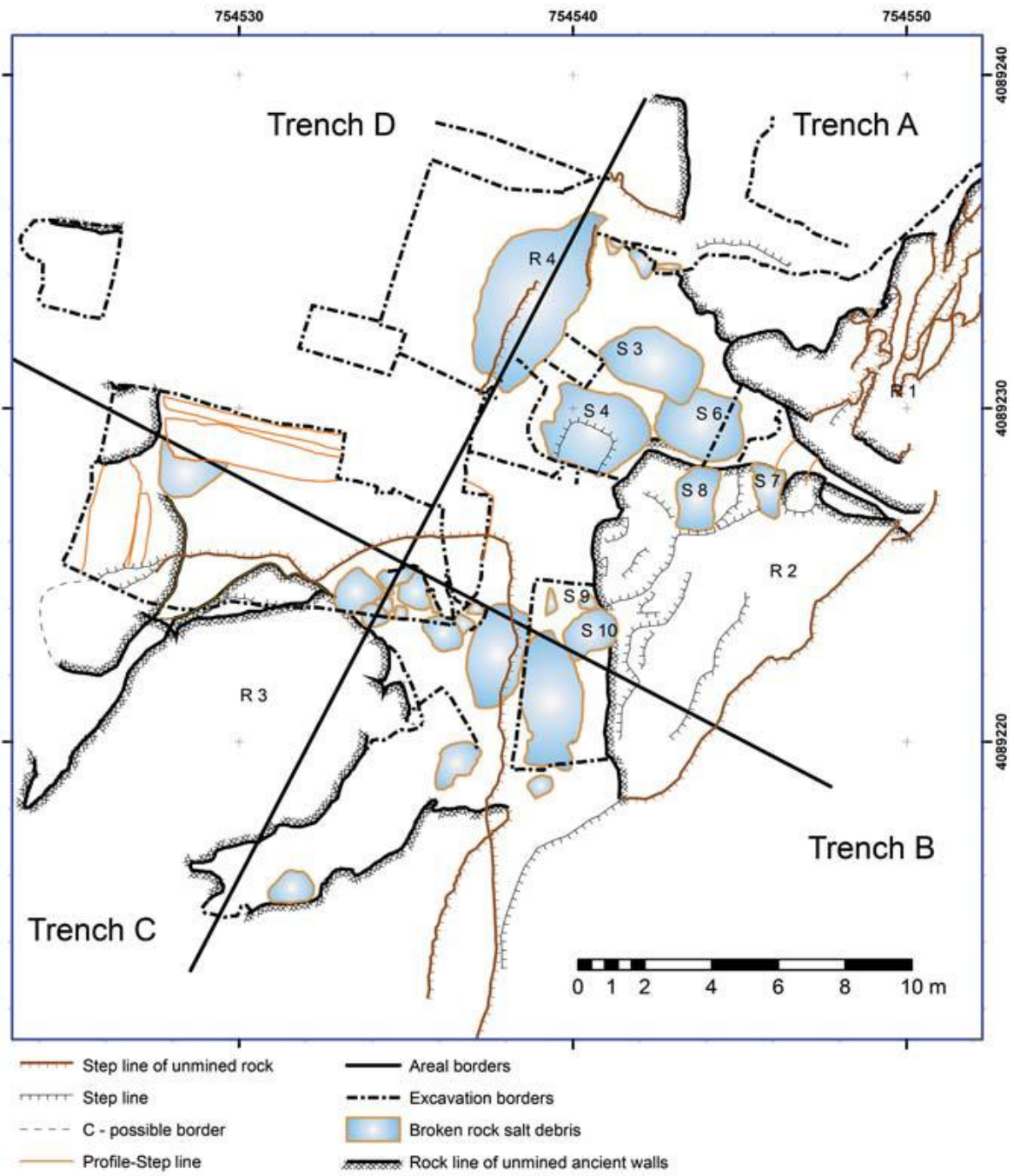


Figure 3.5: Location of the Trenches A to D in Chehrabad saltmine excavations, Iran (Ali et al., 2012).



Figure 3.6: Mummy #5. Chehrabad saltmine, Iran (Photo: K. Stange, DBM / Miras Farhangi, Aali et al., 2012).

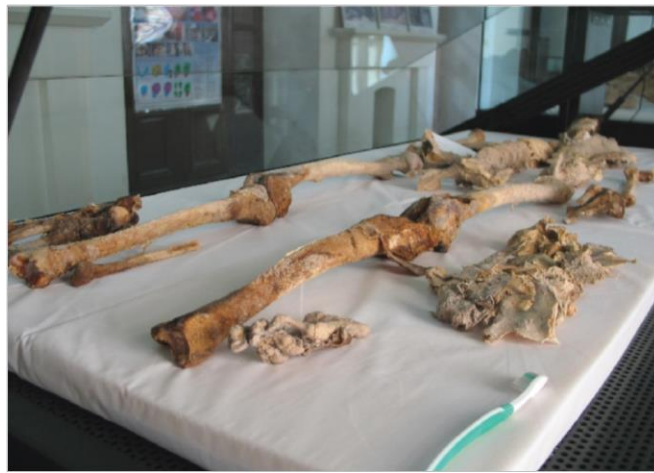

Figure 3.7: Mummy #2. Archaeological Museum of Zanjan, Iran.



Figure 3.8: Natural mummified body of a dog, Chehrabad saltmine, Iran (Photo: Miras Farhangi Zanjan).

3.3.1.2 Kul-Tarike

The necropolis of Kul-Tarike is situated between 2 archaeological sites of Ziwyé and Karaftu in the region of northern Iranian Kurdistan in the Zagros Mountains. The site has an elevation around 2000m above sea level. It is an area with a harsh winter and heavy snow fall climate, characterized by high average annual precipitation. These characteristics provide possibility of dry farming and animal husbandry in the area (Rezvani and Roustaei, 2007).

The site is known as a Mannaean site dated to the first millennium BC in the Northwestern of Iran. Two campaigns of excavation were carried out by the Iranian archaeologists in 2001 and 2003. These excavations revealed ten graves with walls built of stone. Some bronze, iron and ceramic materials were found within each of them, near the human skeletons. Each grave contained one or two human skeleton (Rezvani and Roustaei, 2007). The skeletal remains are kept in the National Museum of Iran.

Three soil sediments attached to the pelvic area of the skeletons placed in the museum have been collected for paleoparasitology.

3.3.1.3 Haft tape

Haft Tape is an ancient site at the nearby sites of Choqa Zanbil and Susa and situated in the most fertile part of Khuzestan plain in southwestern Iran (Negahban, 1991). All of these sites are the main archaeological sites of the Elamite periods (around 3000 BC - 500 BC). The site of Haft Tape consists of 14 ancient mounds with different sizes. Excavation at the site (1965-1979) has revealed a large temple and also a funerary complex for the king Tepti Ahar and his family who were ruling as an Elamite King family in the 15th century BC. All of them have been buried in this site (Negahban, 1984).

The climate of Khuzestan plain is generally hot and occasionally humid. This relatively flat region is one of the largest plain in Iran which has some of the plains and marsh lands, irrigated by some rivers such as Karun and Karkheh. The region is in the east of Mesopotamian borders. Therefore, we can find there, one of the most ancient historical/cultural interaction between early human civilizations in the Middle East.

Twenty three soil sediment samples for paleoparasitology came from burials near this complex which were excavated since 2003 by a team of German-Iranian archaeologists (Mofidi-Nasrabadi, 2003; 2010). Each of the skeletons have been found in own big ceramic vessels. For sampling, soft brushing the skeleton have been done. But because of the lack of the pelvic girdle bones in them, most of the soil sediments have been collected from the residues accumulated in the holder boxes which were provided for osteoarchaeological studies after the excavations at the site.

3.3.1.4 Kohne Tepesi and Kohne Pasgāh Tepesi

Both of these sites are located near the city of Khomarlu at the periphery of the Arax River Basin in the province of Eastern Azerbaijan, northern part of northwestern Iran. The region located in Kura-Araxes lowlands. Arax is the most important permanent river in northwestern borders of Iran. The favorable climate conditions in this area has provided a rich agricultural environment which is fed by streams, rivers and springs since past times up to now. Archaeological evidences at these sites, show the presences of different cultural phases from the Late Chalcolithic through to the Iron Age (3rd to 1st millennium BC). Both sites were excavated as part of a rescue archeological program related to the construction of the Khoda Afarin Dam (Maziar, 2010; Zalaghi, personal communication).

Seven soil sediment samples from these sites taken by Iranian archaeologist (Maziar and Zalaghi) from the occupation layers, pits and human burials (abdominal cavity) have been sent to our laboratory at Besancon.

3.3.1.5 Khar Cave

Khar Cave excavated by Smith (1967), is a large cave in the Bisetun Mountain in Kermanshah, western Iran. Based on archaeological excavations and surveys, this region has lots of prehistoric sites and most ancient human settlements in Iran. This region has a climate influenced by the proximity to the Zagros Mountains with a little bit high annual precipitation compared to the other regions of Iran. The survey at this cave revealed archaeological deposits and

provided data on prehistoric cultural continuity or discontinuity in the Upper Pleistocene up to early Holocene in southwestern Asia. The fauna and flora consumed by some human groups at this site also could give further information into the climatic conditions during Paleolithic up to Neolithic times. Faunal remains at the site show the majority consumption of sheep and goat by inhabitants (Hesse, 1989).

Thirteen soil sediment samples from different layers of this cave which are kept in the National museum of Iran, have been selected for paleoparasitological analyses.

3.3.1.6 Wezmeh Cave

This Cave is another paleontological/archaeological site located in in the western-central Zagros in Kermanshah, western Iran. The cave is at an elevation of 1430 m above the sea level. A layer of calcium carbonate deposited as flowstone could be seen, particularly towards the rear of the cave. This part of Iranian plateau has a moderate and mountainous climate influenced by the proximity to the Zagros Mountains with a little bit high annual precipitation compare to the other regions of Iran.

The cave site of Wezmeh was discovered and excavated by Iranian archaeologists and revealed a Holocene Chalcolithic archeological assemblage (Trinkaus et al., 2008; Mashkour et al., 2009).

A Pleistocene large faunal assemblage with different preservational characteristics and patina, as well as a human premolar tooth of Upper Paleolithic age (dated to 20–25 ka BP) and also Chalcolithic archaeological remains (ceramics and a small number of lithics) have been discovered so far in the cave. The faunal remains studied by M. Mashkour showed presence of the extremely diverse faunal spectra with high percentage of carnivore remains such as red fox (*Vulpes vulpes*), spotted hyena (*Crocuta crocuta*), brown bear (*Ursus arctos*), wolf (*Canis lupus*), felids and also herbivores remains such as equids and rhinoceros (*Dicerorhinus* sp.) at the site (Mashkour et al., 2009).

Three of the soil sediments taken by F. Biglari (Mashkour et al., 2009) from different layers of this cave which are kept in the National museum of Iran, have been selected for paleoparasitological analysis.

3.3.1.7 Tepe Mussaei

Tepe Mussaei is a complex of three ancient mounds in Kermanshah province, located near the city of Ravansar, western Iran. The western region of Iran has lots of prehistoric sites, based on archaeological excavations and surveys. Some of the most important archaeological excavation projects have been done in this region to answer the questions about the western ancient human settlements in prehistoric times of Iran.

The final excavation report of this site has not been published yet. But in some short report, the excavators noted that the site of Tepe Mussaei is dated between Neolithic up to post Islamic periods. Also some archaeological remains such as ceramics, stone tools and faunal remains belong to these times have been revealed in the site. Different settlement layers in this site could provide information about possible modifications in the lifeways of inhabitants in this area.

The faunal remains of the sites consist of two buried equid and cattle (Mashkour et al., unpublished report). M. Mashkour and her colleagues sampled the sediment attached to the bones and especially limb bones.

3.3.1.8 Qaleh Bozi Cave

Qaleh Bozi is a Middle Paleolithic complex of caves sites at altitudes between 1750 to 1810 m above sea level, located about 25 km southwest of Isfahan, in central Iran. Most of this region experiences a moderate and dry weather, with a milder climate in the mountain areas and a cold weather in the winter season. Zaiandeh Rud River as the largest river in the central plateau of Iran flows at the proximity of this cave site.

These caves represent the first Middle Paleolithic site discovered in this region of Iran. This archaeological complex includes two rockshelters and a cave on the southern face of a

limestone mountain. The excavations of this site over the past decade, revealed a rich lithic artifact mostly in a fresh condition and well-preserved faunal assemblage contains macro and micro-vertebrate remains. The prehistoric human activity is also evidenced by study of burnt and cut marked animal bones. The majority of the identified bone remains belong to herbivores, particularly Equids (Biglary et al., 2006).

During the excavation in 2008, I had opportunity to collect some soil sediments from different occupation layers of the site. Four samples from this site were studied in my PhD work.

3.3.1.9 Tepe Sang-i Chaxmāq

Two ancient mounds of Sang-i Chaxmāq are located in Bastām area, near Shāhrud in northeastern Iran. Masuda's excavations in 1971-1975 revealed Neolithic occupation layers having an unbroken archeological sequence from the 7th to the early 5th millennium BC in this site consists of two low mounds. The levels at the site can be divided into four phases: Aceramic Neolithic, Early Ceramic Neolithic, Late Ceramic Neolithic, and Transitional Chalcolithic. This site provides archaeological data for better understanding of the spread and adoption of Neolithic lifeways into eastern ancient Iran and southern Central Asia (Masuda, 1973; Thornton, 2013).

Ceramics, lithic and bone tools, plant and animal remains as well as the burials laid on their side in a fetal position were recovered from the site. Furthermore, a considerable shift in lifestyle and subsistence could be observed from the early levels up to top levels in this site (Thornton, 2013).

One soil sediment attached to an unknown part of animal skeleton from a recent excavation, has been sent to our laboratory for paleoparasitology study.

3.3.1.10 Dareh Shahr (Chom Qileh)

This site of Chom Qileh is located near Dareh Shahr County (ancient Saimareh) in Ilam Province, western Iran. The climate in this region is warm, although the mountainous areas of Ilam are relatively cold.

Based on historical evidence, this region has been a part of the ancient Elamite Empire. Also the limited archaeological studies in this region indicate the antiquity of tribal residence at the area.

The site of Chom Qileh excavated as part of a rescue archeological program related to the construction of the Saimareh Dam and revealed the occupation layers dated to Neolithic up to Chalcolithic Ages (Moghaddam, personal communication).

In general, the effects of moisture and the soil characteristics in the most of Zagros mountain region in western Iran are largely in work to decompose the human and animal remains. In the last two seasons of excavation by A. Moghaddam at this site in 2008 and 2009, some burials dated around 7000 BP were recovered, mostly as infant skeletons which are now stored in Dareh Shahr Museum in Iran. These kinds of samples are very interesting and important in paleoparasitology, because their analyses could show autochthonous rather than imported parasitic infections.

In 2010, I could collect three samples of soil sediments attached to the pelvic area of infant skeletons which are kept in the Dareh Shahr museum.

3.3.1.11 Gandomzār

The necropolis of Gandomzār is another archaeological site located in the ancient area of Saimareh, Ilam (west of Iran). The site has excavated in 2011 by the Iranian archaeologists (R. Borujeni) as part of a rescue archeological program related to the construction of the Saimareh Dam and revealed burials belong to Bronze and Iron ages in Iran. This necropolis is situated on a mound with limestone structures.

Nine samples were used for paleoparasitological analyses which were soil sediments attached to the pelvic area and other parts of human bone remains. These samples have been collected and sent to our laboratory by M. Mashkour.

3.3.1.12 Komishan Cave

This cave, as an Epipaleolithic site in north of Iran discovered in 2001, is located in Southeast of the Caspian Sea near the prehistoric sites of Huto and Kamarband and 10km west of the city of Behshahr. Most of this region experiences a moderate and humid weather with little temperature change. Nevertheless, the mountain areas have a cold weather with snowing in the winter season and a milder climate in summer (Mahforuzi, 2003).

One of the aims on excavation in this Epipaleolithic complex was to provide some information on the earliest Holocene settlements in the southeastern part of the Caspian Sea. The majority of the animal bone remains in this cave was recovered from a pit, dominated by the Gazelles and also contains carnivores (fox, canids, felids, and seals), birds and etc. (Mashkour et al., 2010). One soil sample from an excavated pit (kept in National museum of Iran) was selected for paleoparasitological analyses.

3.3.1.13 Tepe Hasanlu

The site of Hasanlu is one of the prominent archeological mound located in south of Lake Urmia, in the province of West Azerbaijan, northwestern Iran. Excavations at the site between 1956 and 1974 directed by R. Dyson, provided some extremely well preserved buildings, artifacts, and skeletal remains dated to the end of the 9th century BC.

The site situated in a small plain in the region known as Solduz. The climate of the region is largely influenced by the rainy winds of the Atlantic Ocean and Mediterranean. Heavy snowing during the winter season caused by cold northerly winds affects the region.

The site has occupation layers continuously from the 6th millennium BC to the 3rd century AD. Some of the human skeleton remains which have been discovered by Dyson during the excavations of Hasanlu, are kept in the Archaeological Institute of Tehran University. Three soil sediment samples have been taken by soft brushing of the femur heads of these human skeleton remains for present PhD work.

3.3.1.14 Tepe Zāgheh

Qazvin plain on the western part of central Iranian plateau is an important archeological area which has a cold but dry climate, due to its position in proximity of south of the Alborz mountain ranges. Archaeological excavations on the Qazvin Plain provide information about the changes in sedentary communities and ancient populations from early occupation to the later prehistoric era in the region (Negahban 1977, 1979; Mollasalehi et al., 2006).

Tepe Zāgheh is an early urban settlement dated to 6th and 5th millennium BC and located in Qazvin plain. E. Negahban has excavated this site for the first time in 1970s. Due to some specific features and significance of this site to provide information about prehistoric populations in ancient Iran, the excavations continued up to recent decades (Mashkour, 2000).

Some interdisciplinary studies have been done at this site. A large amount of faunal remains and some burial have revealed during the excavations at the site (Shirazi et al., 2006).

Three soil samples linked with the lower parts of human skeletons which are kept in the Archaeological Institute of Tehran University, were analyzed with paleoparasitological aims.

3.3.1.15 Tepe Qabrestan

Tepe Qabrestan is another site in Qazvin plain, excavated first time by E. Negahban in 1970s with the aim of understanding the transition from hunter-gatherer societies to more sedentary communities. This site is a Chalcolithic site buried in alluvium dated to 4th millennium BC. Negahban initially has reported that Tepe Qabrestan was occupied when Zāgheh was deserted and recent radiocarbon dating could be an evidence for a shift of occupation from Zāgheh to Qabrestan (Negahban, 1977; Majidzadeh, 1982; Mashkour, 2000; Schmidt and Fazeli, 2007; Pollard et al., 2012).

Three soil sediments have been taken from the human occupation layers and burials in Tepe Qabrestan which are kept in the Archaeological Institute of Tehran University has been selected for paleoparasitological study.

3.3.1.16 Darband cave

The recent excavations by F. Biglari and V. Jahani (2011) at this cave site, revealed Lower Paleolithic evidences of human settlements in northern Iran in the Gilan Province. This region has a humid subtropical climate characterized by the heaviest range of rainfall in Iran and a very high humidity because of the marshy character of the coastal plains which can reach up to 90 percent in summer.

The faunal remains and lithic artifacts assemblage discovered in this site could have 200 to 300 kilo year antiquity (dating back at least to Middle Pleistocene), collected and studied by M. Mashkour and F. Biglari (Biglari and Jahani, 2011). This collection is kept in the national museum of Iran, in Tehran.

Large numbers of cave bear bone remains at the site probably were accumulated through their natural mortality. It was the first evidence of the bone remains represented at Darband Cave for this taxon of cave bear (*Spelearctos deningeri*) in Iran. Therefore the presence of this carnivore could provide valuable information about the farthest extension of the Caucasian population of Pleistocene cave bears to the north region of Iran (Biglari et al., 2007).

Two soil sediments attached to the vertebral bones of this cave bear were paleoparasitologically analyzed.

3.3.1.17 Yāfteh Cave

Yāfteh Cave in Khorramābād Valley (Lorestan province) is an Upper Paleolithic site located in the western part of the Central Zagros in southwestern Iran (Hole and Flannery, 1968). The climate in this region is characterized as much colder than Mediterranean climates, but there is extremely hot in the summer with very low humidity and sufficiently wet for rain fed agriculture in the winter season.

The recent re-excavations at Yāfteh Cave carried out by a joint Iranian-Belgian team has revealed a rich assemblages of lithic artifacts and faunal remains in a small 2 x 2 m test pit (Otte et al. 2007; Shidrang, 2007). The taxonomic identifications of the faunal remains in recent excavations showed the presences of small herbivores contain ovi-caprids and gazelles, as well as

medium and large herbivores such as family Cervidae and genus *Bos* which were hunted by the inhabitants of Yāfteh. Also the micro-vertebrate remains could be used for better understanding of paleoenvironmental conditions during Paleolithic settlement at the site (Mashkour et al., 2012).

The dating of the site ranged mainly between 36 and 28 kilo years BP, based on recent radiocarbon dating (Otte et al., 2011). During recent excavation at the site has been, the soil sediments from different levels of the pit layers were collected and four of them were selected for paleoparasitology study.

3.3.1.18 Āq Tepe

The ancient mound of Āq Tepe is situated near to the city of Pish Qaleh and Atrak River, in North Khorasan province, northeastern Iran (Malek Shahmirzadi and Nokandeh, 2001). The region has influenced by a mountain climate and hence the weather is relatively mild in summers and cold in winter seasons.

The rescue excavation at Āq Tepe was carried out in 2012. The archaeological excavation report of this site has not been published yet and in some short description of the site, the excavator (A. Vahdati) has stated that this site revealed some human burials dated to Sassanid up to post Islamic periods.

Five soil sediments were collected by archaeologists from pelvic area and abdominal cavity of human skeletons for paleoparasitological analyses.

3.3.1.19 Chalow

The ancient site of Chalow is another ancient site situated in North Khorasan province, near the city Sankhast in northeastern Iran. The region has influenced by a mountain climate and hence the weather is relatively mild in summers and cold in winter seasons (Biscione and Vahdati, 2011).

The excavation at this site carried out in 2013 by a joint Iranian - Italian team. This site has revealed a large settlement layers contain the Chalcolithic period to the Iron Age in ancient Iran

(fourth to the first millennium BC). Also evidences of cultural relations between Iran and Central Asia in the Bronze Age were discovered in this site.

Some burials revealed during the excavation at Chalow which contain human skeletons buried squatting in right side with some funerary gifts as well as cooking utensils contain food remain. Nine soil sediments collected by A. Vahdati from inside the pelvic and stomach area as well as rib cages of these skeletons, were studied in present work.

3.3.2 Syria

Syria is located in northern edge of Fertile Crescent containing the comparatively moist and fertile lands in western Asia and situated in the Middle Euphrates valley. This country has an antiquity of earliest Neolithic culture which includes some centers of beginnings for agriculture and cattle breeding.

In this work, we have received one series of samples from the ancient site of Tell Halula (ca. 10th millennium BP). The paleoparasitological aim was to compare the results with the other regions within the Middle East countries.

Tell Halula is one of the largest Neolithic sites in north of Syria, located around 105 kilometers east of Aleppo and 25 kilometers northwest of Membij in the Ar-Raqqah governorate of Syria. The site was excavated in 1991 by the Spanish archaeological mission, directed by Miquel Molist.

The excavations have revealed the remains of rectangular houses, some of them associated burials under the floors of the houses. The burials included more than hundred incomplete skeletons. Occupation layers of the site were dated from 7750 BC to 6780 BC. Halula stated as a representative site for the beginnings of agriculture. Three main excavated periods reported at the site: Middle and Late Pre-Pottery Neolithic B (M-PPNB, 8200-7500 BC and L-PPNB, 7500-7000 BC, respectively), Early Pottery Neolithic (E-PN, Pre-Halaf, 7000-6100 BC), and Late Pottery Neolithic (L-PN, Proto-Halaf and Halaf, 6100-5400 BC). Population changes occurred in different layers of this site hypothesized a possible consequence of exceeding in the capacity of the agroecosystem (Ortiz et al., 2013; Ferrio et al., 2012). Therefore the studies such as

paleoparasitology on retracing of infectious infections at the site could provide further data to help archaeologist for considering new insights about their questions.

10 samples of soil sediments taken from pelvic and abdominal cavity of human burials at the site, were studied.

3.3.3 Azerbaijan

Azerbaijan is a country located in the southern Caucasus region as a crossroad of Western Asia and Eastern Europe and also adjacent with North West of Iranian plateau. Southern Caucasus bordered by the Black Sea to the west, the Caspian Sea to the east, and the southern slopes of the Greater Caucasus Mountains to the north.

Azerbaijan has an Alpine climate in some areas and dry steppe climate in other regions. The Kura and Araxes are the most prominent rivers which run through the Kura-Araxes Lowland in Azerbaijan. These lowlands are very important in aspect of archaeology of South Caucasus. The ancient Kura-Araxes culture has been historically in related to the adjacent archaeological areas from North Caucasus to upper Mesopotamia and the northern Levant. The Upper Paleolithic evidences are the most ancient human settlement attested in Azerbaijan territory (Marro et al., 2011; Lyonnet and Helwing, 2012).

In this study, soil sediments analyzed from three archaeological sites of Azerbaijan consist of samples from Mentesh Tepe (sent by M. Poulmarch), Ovçular Tepesi (sent by C. Marro) and Boyuk Kesik (sent by M. Casanova).

3.3.3.1 Mentesh Tepe

The site of Mentesh Tepe is a small mound located in the Tovuz region of western Azerbaijan. Tovuz region situated between Shemkir and Agstafa, 360 km from Baku.

The excavations uncovered occupation layers dated from the Neolithic and Chalcolithic up to the Early Bronze Age at this site and provided important evidences on sedentary life in the

5th millennium BC and more mobile lifeways in the Early Bronze Age (Lyonnet and Helwing, 2012).

Some pits and burials consist of human infant and collective burials, were revealed during excavations in different layers of Mentesh Tepe. Eighteen soil sediment samples taken from pelvic and abdominal cavities of mentioned burials were analyzed in laboratory of paleoparasitology in Besancon.

3.3.3.2 Ovçular Tepesi

Ovçular Tepesi is located in the valley of the Arpaçay River in Nakhchivan. The site lies on top of a natural mound rising above the river. The area of the site has a dry continental climate and bordered to the north by the Zangezur Mountains. The recent excavations at Ovçular Tepesi in Nakhchivan were part of the Middle-Araxes Archaeological Project which has been started from 2006 by the Franco-Azerbaijani archaeological team. These excavations at the site could provide more evidences on relationships between Late Chalcolithic and Kuro-Araxes communities and yielded new data on ancient cultural contexts in the Middle Araxes valley (Marro et al., 2011; Berthon et al., 2013).

For paleoparasitology of this site, two soil sediments taken from abdominal cavity of skeletons discovered in human burials were analyzed.

3.3.3.3 Boyuk Kesik

Boyuk Kesik is an ancient site in the Tovuz region, west of Azerbaijan. Excavations at this site provided some archaeological evidences on ancient relations between Transcaucasian and Syro-Mesopotamian cultures. Also several infant jar burials have been found in this site contained the remnants of newborn children but were not associated with burial gifts. The most ancient occupation layers of the site are dated to the 4th millennium BC (Marro et al., 2011).

Two soil sediment samples were collected from the burials at the site for paleoparasitology study.

3.3.4 Saudi Arabia

The site of Madā'in Sāleh (Hegra) is an ancient pre-Islamic site located in the Al-Ula sector, within the Al Madinah Region of West of Saudi Arabia. The climate is characterized by very little rainfall, extremely hot summers and milder winters in this region (Nehmé, 2011).

Excavations at the site have revealed tombs contained remains of burials from the Nabataean period (1st century AD) such as bones, leather, textile, wood and etc. This site is famous for its well-preserved remains, especially the 131 rock-cut monumental tombs, belong to the Nabatean period.

Following the recent excavations under the archaeological project at this ancient site, five soil sediments and ten hair and leather samples all taken from the tomb IGN 117 have been sent by N. Delhopital to the laboratory of paleoparasitology in Besancon.

The aims were to retrace endoparasitic elements such as helminth eggs in the soil sediments and ectoparasitic remains in hair or leather samples, to gain additional possible information on ancient health, sanitary, diet and lifeway of the past habitants and to complete paleopathological data at the site.

3.3.5 Oman

The prehistoric site of Ras al-Hamra was discovered first time by archaeological survey conducted in the 1970, but the actual excavations started in 1980. The site is dated to the fourth millennium BC (Usai, 2005).

Excavations in this site, has revealed the presence of settlements built of sand, shells, fish bones, ash, and coal and ornaments made of shells. This site is called also “The early Omani Fishermen Civilization”.

The skeletons discovered in the burials at the site were in a sitting position facing the sea. Some of the soil sediments attached to these skeletons were selected for paleoparasitology analyses.

3.3.6 Sudan

The ancient site of Kerma is the capital of Kerma Kingdom and is one of the largest Nubian archaeological sites. It is located on the right bank of the Nile, in a large basin between the Third and Fourth Cataract. The Kerma has also one of the richest prehistoric period layers extending all the Nubian empire, including thousands of graves, tombs and occupation strata. The Kerma site has at least 9,500 years antiquity. This site has three distinct sub-periods: the Old Kerma (2400-2050 BC), the Middle Kerma (2050-1750 BC) and Classic Kerma (1750 BC -1500 AD) (Bonnet, 2004; Emberling, 2011).

Funerary structures were revealed during excavations on the site of Kerma, mainly within its necropolis KCE. Some of them contained buried human individuals, but also animals that could be sacrificed.

The samples analyzed in this study consist of coprolites and abdominal contents collected from herbivore burials which frequently encountered in excavations at the necropolis of Kerma.

3.3.7 Egypt

Hierakonpolis (city of hawks) or Nekhen is located in Upper Egypt (Figure 3.1), on the west bank of the Nile, between the modern towns of Esna and Edfu. Climate of this area is very arid due to its situation in the zone of subtropical arid deserts, being far from the sea, sitting at low altitudes (ca. 80-100 m asl) and the absence of orographic rain. Furthermore, the area is characterized by high temperature, low relative humidity, high evaporation and very low rainfall: 1.4-5.3 mm per year (Marinova et al., 2013).

Antiquity of Hierakonpolis begins from limited occupation during the Badarian period (ca. 4500 - 4000 BC). It is the largest site from the Pre- and Protodynastic settlements in Upper Egypt (3800 - 3100 BC). Its maximum size was in the early Naqada II period (ca. 3700 BC) with at least 5,000 and possibly more than 10,000 inhabitants as the religious and political capital of Upper Egypt up to the end of the Predynastic period (ca. 3200 - 3100 BC). This site is the most important site for understanding the foundations of Egyptian civilization and could have a central role in the transition from prehistory to history of Egypt (Friedman, 2011).

Other discoveries at Nekhen include the Tomb 100, the oldest tomb with painted decoration on its plaster walls (Figure 3.8). The tomb is dated to the Naqada II c period from 3500 BC until 3200 BC. The decoration shows presumed religious scenes and images that include figures of asses or zebras, ibex, ostriches, lionesses, impala, gazelles, and cattle that were appeared in Egyptian culture for thousand years.

The oldest known zoological collection was revealed during excavations at Hierakonpolis in 2009 of a menagerie that dates to ca. 3500 BC. The diversity of animals included hippos, hartebeest, elephants, baboons, wildcats and etc. (Figure 3.9 and 3.10).

The ruins of the city originally were excavated at the end of the nineteenth century. More recently, the site was excavated further by a multinational team of archaeologists, Egyptologists, geologists, and members of other sciences. The Egyptian samples analyzed in this PhD work come from two locality from Hierakonpolis: Locality 6 and Locality 11C.

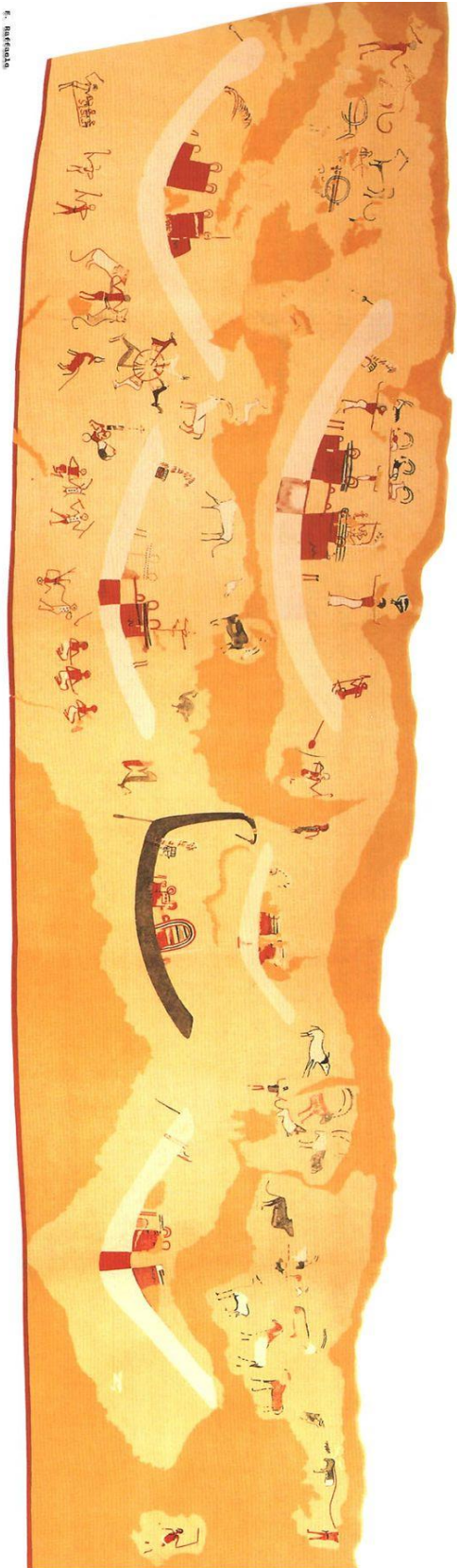


Figure 3.9: Diversity of animals in a painting discovered in Hierakonpolis, Tomb 100, dated to 3500BC, (<http://xoomer.virgilio.it/francescoraf/hesyra/Hierakonpolis-tomb100.htm>).

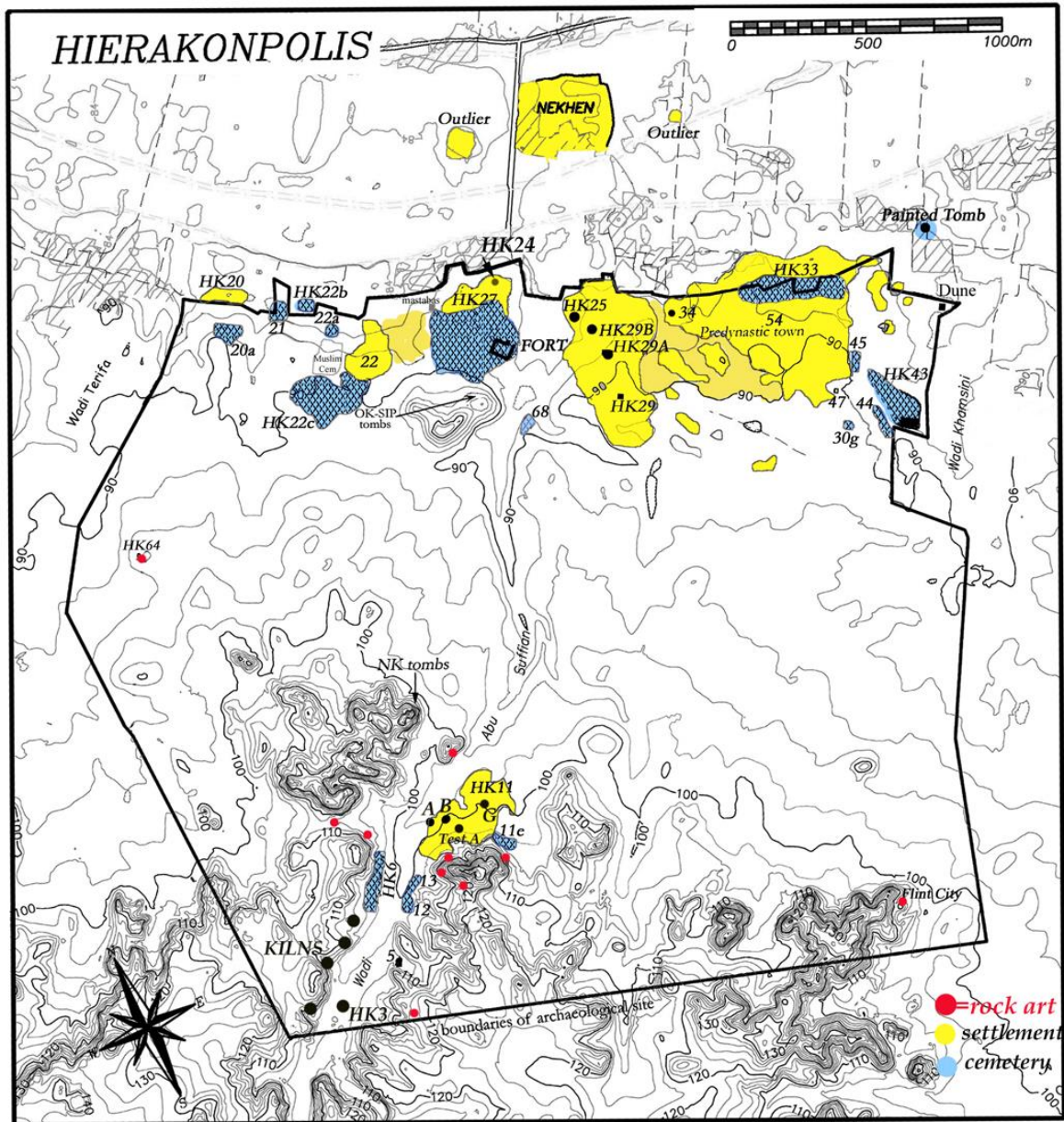


Figure 3.10: Location of Localities HK6 and 11C, Hierakonpolis, Egypt (<http://hierakonpolis-online.org>).

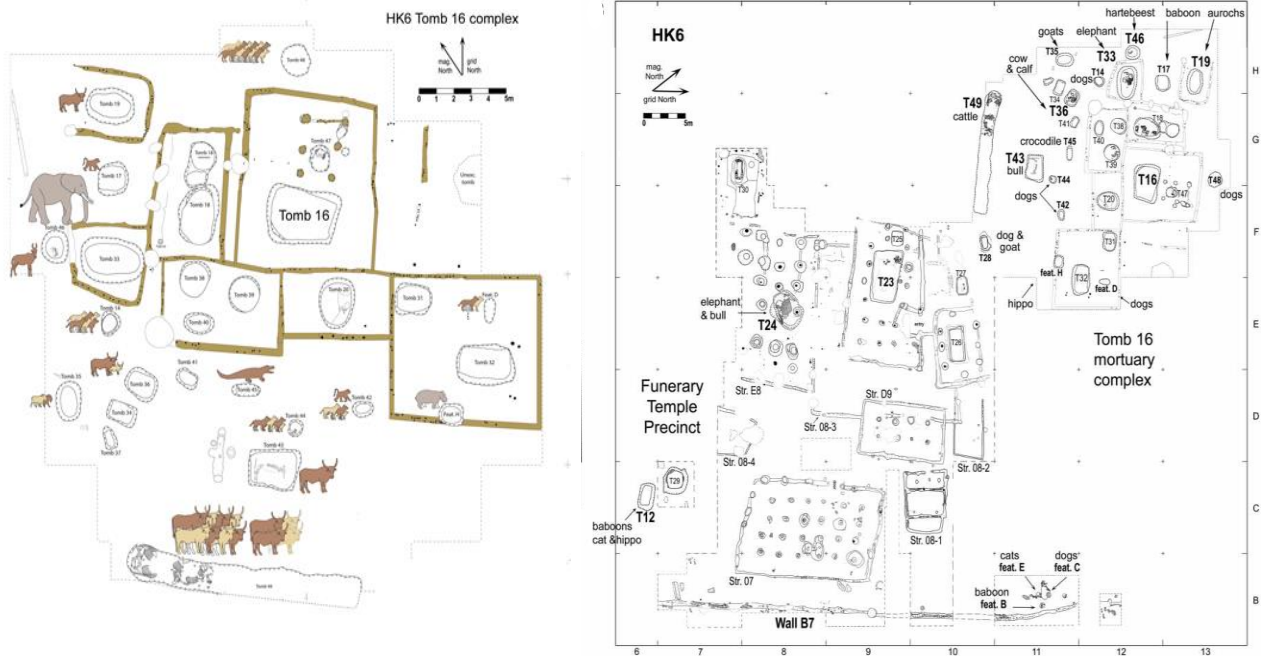


Figure 3.11: HK6 in 2011 season excavation (Marinova et al., 2013).

3.3.7.1 Hierakonpolis: Locality 6

Excavations at the Elite Predynastic and Early Dynastic cemetery HK6 (since 1979 to present) have revealed a large amount and variety of animals buried, which were interred alone or in association with human bodies. The species contain local animals such as hippopotamus, aurochs and wild donkey as well as more exotic species such as the elephants and baboons probably brought from much farther south (upper Nubia) (Van Neer, 2011; <http://hierakonpolis-online.org>).

The elite cemetery at HK6 is located in the central wadi, covering an area of about 7000 m². At its center was a series of wood-built funerary. The elite constructed their tombs and as a further display of their power and wealth, the elite also surrounded their tombs with subsidiary graves containing an array of human and animal associates. The cemetery is unique for the quantity of animal burials (Van Neer et al., 2004; Friedman, 2008).

The HK6 samples analyzed for the present study come from animal burials in tomb 19, 33, 36, 43, 44, 46, and 49 (Fig. 3.10), which were dated to the Naqada IC-IIA period (c. 3700 - 3500

BC) (Adams, 2002; Friedman et al., 2011; Van Neer, 2011). They are originate from the intestinal tract of buried animals, both domestic and wild: three elephant samples (Tomb 33), two samples from dog (Tomb 44) two samples from hartebeest (Tomb 46), an aurochs sample (Tomb 19) and six samples from domestic cattle (Tombs 36 and 49). Furthermore one sample was from a child burial (Tomb 43).

Archaeobotanical study of the gut contents of the elephant from Tomb 33 suggests that the animal had been feeding on or near settlement refuse. Also, the gut content of cows no. 3 and no. 4 from Tomb 49 and the aurochs from Tomb 19 showed that their diets were based almost completely on wild plants. They were grazed in the rural areas near the site or along the Nile's banks and wet areas along large irrigation canals where sedges and other wetland species grow (Marinova et al., 2013).

3.3.7.2 Hierakonpolis: Locality 11

Locality 11 is an activity-specific site and one of the largest concentrations of Predynastic (Amratian) settlements in Hierakonpolis. Its resources have been ideal for kilns and grazing herds. This locality is a large and multi-component area which covers approximately 68,000 m² of the site of Hierakonpolis Located on a terrace of the Great Wadi (Wadi Abu Suffian). One of these components called "Locality 11 C" with 85 m² area (Harlan, 1982; Baba, 2009; <http://hierakonpolis-online.org>).

Trash mounds, pottery kilns and habitation areas have been revealed during excavations at the site. One of the trash mounds which named "mound A" were excavated in 1978 and 1979 (Test A and B). Also, a cemetery is located on the south west of the locality 11.

The locality 11 with its significance archaeological characteristics is an ideal site to provide data on prehistory, paleoenvironment and subsistence strategies of this area in ancient Egypt (Harlan, 1982).

According to radiocarbon dating (table 3.1) this locality is dated to the early Predynastic period (Amartian or Naqada I up to the middle of the Naqada II) (Harlan, 1982; Baba, 2009).

Level	Dating
Level 6 (Mound A)	4900±65 BP / 3792±65 BC
Level 14 (Mound A)	4750±75 BP / 3638±75 BC
Level 7 (unit 6.5 N- 21 W)	4570±80 BP / 3403±80 BC

Table 3.3: The radiocarbon dating of locality 11C (Harlan, 1982).

The analysis of archaeological features, internal settlement patterns, stratigraphy and the material culture indicate a seasonally settlement at Locality 11 C. Pottery production and a seasonal livestock maintenance are two principal characteristic of the locality 11 C. Domestic activities at the site has showed also that the dung cakes carefully stacked and stored for use in hearths (Harlan, 1982).

The well-preserved faunal assemblage of Locality 11 is predominated by domestic species (cattle, sheep/goat and pig) and also contains hunted species including gazelle (*Gazella dorcas*), hippopotamus (*Hippopotamus amphibius*), fox (*Vulpes rueppelli*) and crocodile (*Crocodylus niloticus*). Moreover, Nile perch (*Lates niloticus*) and Synodontis catfish are the most common fish remains at the site (<http://hierakonpolis-online.org>).

Fecal materials consist of human and animal coprolites recovered from two season of excavation (1978 and 1979) at the Locality 11 C have been analyzed in the present paleoparasitological study. They have been taken from different archaeological levels from Test A (Figure 3.12).

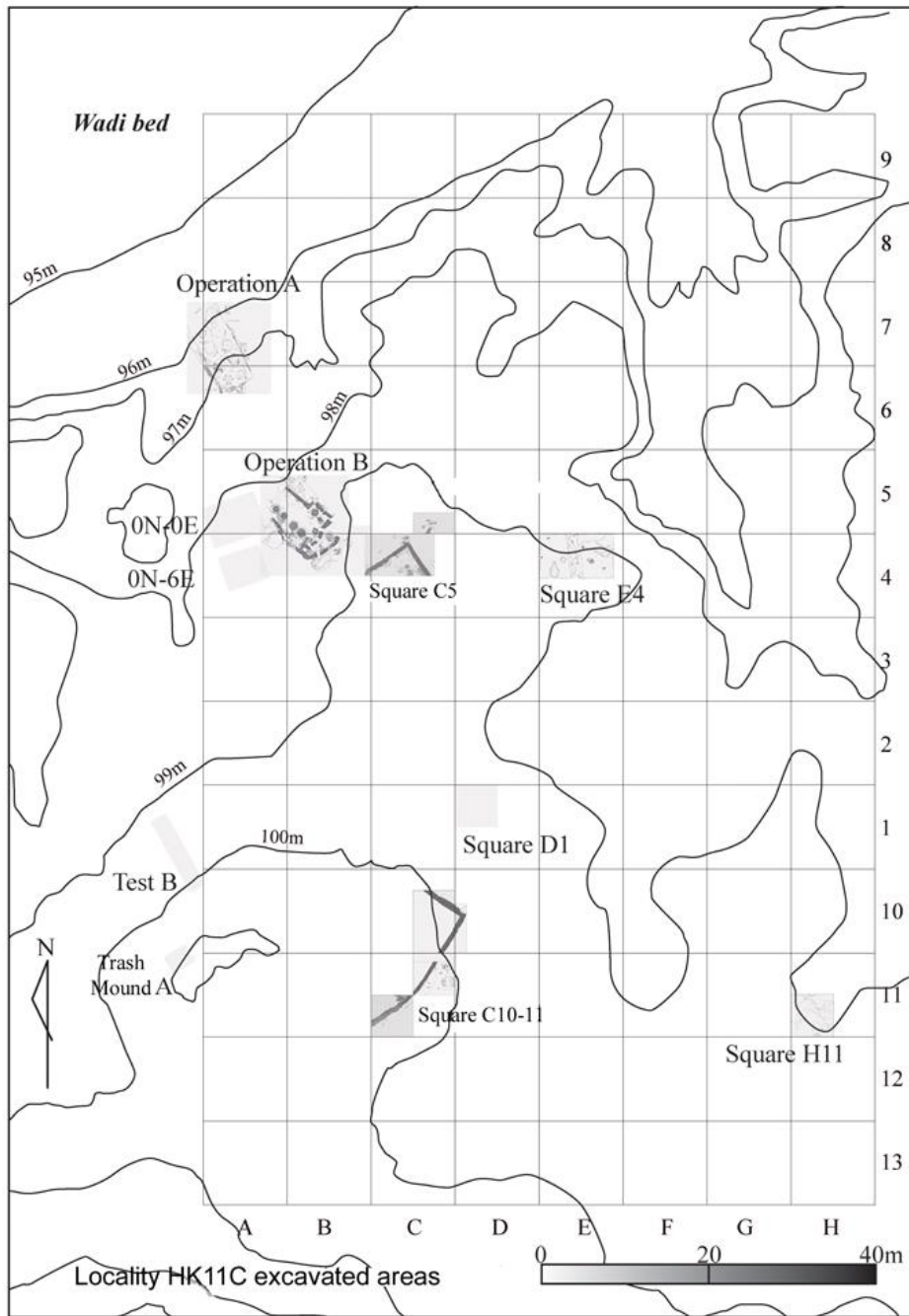


Figure 3.12: Location of Test A (Trash Mound A) at the Locality 11C, Hierakonpolis, Egypt (<http://hierakonpolis-online.org>).

Chapter 4 : Methods

4.1 Introduction

Since the works of Ruffer (1910), when he could find *Schistosoma haematobium* eggs by using histological techniques in the kidney tissue of an Egyptian mummy, paleoparasitology emerged. From that time until now, this field of paleopathology has applied different methods, techniques and tools to obtain large amount of data on ancient parasites.

Using light microscopy has been the most applicable way to demonstrate parasitic markers particularly the helminth eggs since the pioneering works up to now (Fugassa, 2014).

Szidat (1944) could identify *Trichuris trichiura*, *Ascaris lumbricoides* and *Diphyllobothrium latum* eggs in the intestinal contents of two bog bodies (Faulkner and Reinhard, 2014). After his findings, the studies on ancient parasites were accelerated over the past decades. In 1947, Van Cleave and Rose, described a method of rehydration for study of dried zoological specimens such as helminths which were kept in museum collections. Pizzi and Schenone (1954) have reported the first finding of ancient parasitic protozoan cysts under microscope. Taylor (1955) used the techniques of veterinary parasitology to recover ancient helminth eggs in archaeological sediments with animal origin. Callen and Cameron (1960), demonstrated their work on rehydration of desiccated ancient feces by soaking of coprolites in 0.5% aqueous solution of trisodium phosphate for 72 hours. Samuels (1965) rehydrated ancient human fecal remains by using a solution of sodium hydroxide and EDTA. Using zinc phosphate solution for flotation (Pike and Biddle, 1966), Formol-ether for concentration (Fry and Moore, 1969) and hydrochloric acid for rehydration (Jones, 1983) of ancient parasite eggs, were some of the further examples of paleoparasitological techniques in preparation of archaeological materials. The mentioned parasitological techniques were developed during the next decades by researchers in the field of paleoparasitology. Recently, Dufour and Le Bailly tested a new method for the extraction of parasite eggs in archaeological sediments by using different combinations of acid (hydrochloric and hydrofluoricacids) and base (sodium hydroxide) (Dufour and Le Bailly, 2013).

On the other hand, in the late 20th century, biochemistry and immunology developed the techniques to retrace paleo-antigens and applied by researchers in the field of paleoparasitology of the protozoan (Faulkner et al., 1989). Recovering parasite paleo-antigens by the use of the immunological techniques such as ELISA and immune-fluorescence over the recent decades

improved our knowledge about ancient protozoan such as *Entamoeba histolytica* and *Giardia* sp. (Faulkner et al., 1989; Gonçalves et al., 2002; 2004; Le Bailly, 2005; Le Bailly and Bouchet, 2006b; Le Bailly et al., 2008; Mitchell et al., 2008; Bartosova et al., 2011; Yeh et al., 2014).

Molecular biology was also increasingly applied in paleoparasitology since the works of Loreille and her colleagues on the ancient DNA of *Ascaris* sp (Loreille et al., 2001). Recent developments of such studies are helpful particularly to identify the species level or show different polymorphisms at different archaeological sites (Iniguez et al., 2006; Leles et al. 2008; Oh et al. 2010; Anastasiou and Mitchell, 2013; Leles et al., 2014).

Today, based on developments of laboratory techniques, variety of methods and tools are applied to different archaeological materials, to retrace ancient parasite markers: microscopic observation for identifying helminth eggs and macro-remains, immunology mostly for protozoa and molecular biology for more precise identification and comparison of parasite species.

4.2 Laboratory techniques (used at the University of Franche-Comte)

In this study, numerous of light microscopy analyses have been carried out on coprolites and sediment samples taken from mummies, skeletons, burials, occupation layers related to human or animal activities. Furthermore, ELISA technique has been used to retrace protozoan paleo-antigens of *Entamoeba histolytica* in some of them.

4.2.1 Microscopy analyses

The first aim in this part of work was to search helminth eggs as the main parasitic markers in the collected archaeological material (Bouchet et al., 2001; Le Bailly, 2011). The eggs of helminth could be preserved in coprolites, organic remains and soil sediments which are polluted by fecal matters. They are resistant forms of the parasite cycle in the environment, and therefore are clearly identifiable evidence of the presence of adult parasitic worms which could indicate ancient human or animal parasitism in archaeology. The persistence of these parasitic forms not only is related to the nature of their eggshell resistance but also is affected by intensity of

taphonomic processes (especially in archaeological contexts) which transform helminth eggs in both chemical and physical levels. These changes can alter biological and morphological factors of the eggs such as porosity, mass and shape. Therefore medical laboratory techniques which are applied for parasitological analysis of modern feces cannot be effective for ancient fecal matters (Le Bailly, 2005; Reinhard et al., 1986).

The technique of standard RHM protocol (Rehydration/Homogenization/Micro-sieving) used for sample preparation in this work has been developed in the laboratory of Reims for several years (Bouchet et al., 2001; Le Bailly, 2005) and has been continued to use at the university of Franch-Comte since 2010. The results by this method have been repeatedly compared with those of more conventional methods of medical coprology (Dommelier et al., 1998; Harter, 2003), and also with modified rehydration solutions (Dufour and Le Bailly, 2013). The results have shown that standard RHM method provides a more complete range of the biodiversity of highlighted parasitic elements.

Therefore this method was the main technique used for paleoparasitological study of received samples during this work.

All of the arrived samples at the laboratory of paleoparasitology in the university of Franch-Comte, were recorded in a notebook and also in an excel file. The name of country, city, archaeological site, number of sample, origin, year of excavation, and the name of the head of archaeological excavation were indicated. For simplicity, the samples were labelled according to an internal laboratory code.

4.2.1.1 Rehydration

Using of rehydration technique for studying of dried zoological specimens was begun by Van Cleave and Ross in 1947 and continued by Callen and Cameron and others in bioarchaeology (Van Cleave and Ross, 1947; Callen and Cameron, 1960; Fry, 1960; 1977). It was adapted by different laboratories to study ancient parasites (Bryant et al., 1975; Reinhard et al., 1991; Ferreira et al., 1992).

The rehydration phase can be done in several ways and by using different solution such as Na₃PO₄ (TSP), NaOH, NaOH + EDTA, Alcohol, H₂O deionizer, HCL, and trisodium phosphate 0.5% + glycerinated water 5% (Van Cleave and Ross, 1947; Callen and Cameron, 1960; Harter, 2003; Le Bailly, 2005).

The method employed in this work is included using of trisodium phosphate 0.5% and glycerinated water 5%. Each archaeological sample was placed in an Erlenmeyer flask and then the solutions of trisodium phosphate and glycerol were added in portions of about 50/50 up to 100 ml overall (Figure 4.1). Each sample was rehydrated for one week in this rehydration solution but may be extended depending on the state of hardness or desiccation of the materials. To allow maximum and more effective rehydration, shaking the sample is needed occasionally. It aims to loosen the samples to make the second step easier. Also few drops of formalin solution 10% were added into the flask to prevent the growth of bacteria, fungi and algae which may be hinder for further proceedings as well as microscopy readings (Le Bailly, 2005).

4.2.1.2 Homogenization

In this step the rehydrated samples were transferred into a mortar and crushed with a pestle. Then they are placed in the flasks and passed through an ultrasonic bath (model Fisherbrand FB15063, 50-60 Hz) for 1 minute (Figure 4.2). This phase is one of the most important steps of preparation since it will allow separating the parasitic elements from their fossil sedimentary matrix to leave them in the solution.

It is important not to exceed 1 minute in the ultrasonic bath to avoid of losing some parasitological information (Warnock and Reinhard, 1992).



Figure 4.1: Rehydration of the samples.



Figure 4.2: Homogenizing process by using a mortar and a pestle as well as an ultrasonic bath.

4.2.1.3 Micro-sieving

Once the sample is crushed and homogenized, it is filtered into a column of four sieves with a mesh sized decreasing: 315 microns, 160 microns, 50 microns and 25 microns (Figure 4.3). The materials with size larger than 315 and also 160 microns were discarded. As parasitic helminth eggs measure commonly between 30 and 160 μm in length and 15 to 90 μm in width depending on the species (Ash and Orihel, 2007), the elements collected on the 25 and 50 micron sieves used for microscopy analysis. This range of the mesh size (25 to 160 μm) could cover majority of parasite eggs. Using sieves 50 μm allows separating possible findings of parasite eggs into two size categories and makes easier their identification via light microscopy. To ensure better filtration, the column is placed under a constant flow of distal water by using an ultrafiltration system which prevents contamination by microorganisms that could grow in the normal water pipes. Then the column is separated and each sieve passed again under a constant flow of distilled water. The laboratory was equipped by water filtration Direct-QTM 5 traded by Millipore [®] (Figure 4.4).

4.2.1.4 Storage of samples

Residual sediments in the two last sieves (50 μm and 25 μm) were collected and placed in separate PVC hemolysis tubes (4 ml) capped with a few drops of 10% formalin (Figure 4.5). The tubes were labeled 25 and 50 as well as each sample number. It means that the fractions larger than 25 microns and smaller than 160 microns were kept and used for the detection of eggs. This range size could cover majority of helminth eggs.



Figure 4.3: Micro-sieves column.



Figure 4.4: Direct-QTM 5 traded by Millipore ®.

4.2.1.5 Observations by optical microscopy

Twenty slides from each prepared sample were analyzed using light microscopy (x100, x400 and x600), and findings were photographed and measured.

By using a Pasteur pipette collected samples were mounted between slides and coverslips (22 x 22 mm). The slides and coverslips were discarded after each comprehensive microscopic observation. Fractions of 25 microns and 50 microns were read under an optical microscope (LEICA DMIL LED). The parasites observed by the optical microscopy were noted on a note book. Other elements presented in the samples which were part of the "microscopic landscape" were also reported. And the possible presence of microfungi spores, diatoms, insect fragments, pollen and other plant debris is also indicated. Optical microscope used in the laboratory was equipped with a recording camera device (LEICA EC3) mounted on head and connected to a computer, which allowed taking digital images directly (Figure 4.6). The computer was equipped with image analysis software (LAS-EZ-V2-0-0) which stored digital images on the hard disk. This software allows measuring the eggs very quickly.

By using this method, it is possible to identify helminth eggs on the basis of morphological criteria and morphometry to the genus, and sometimes to the species level.

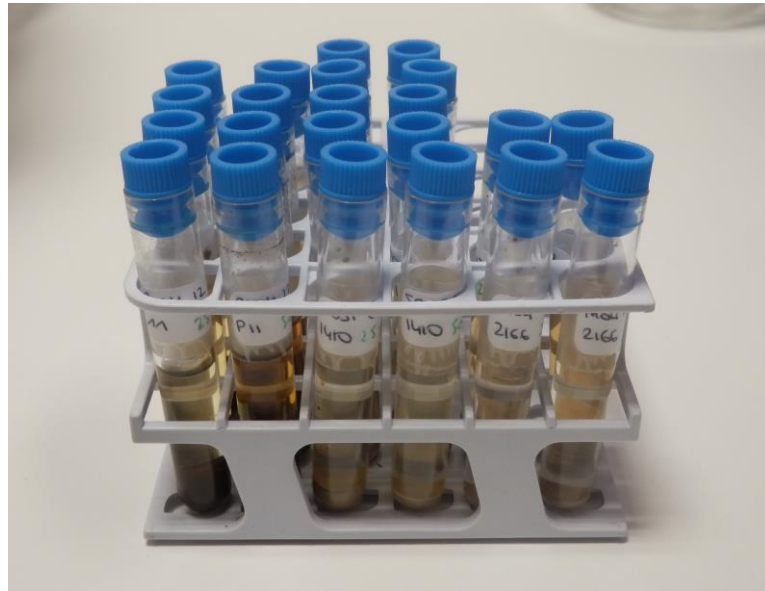


Figure 4.5: Prepared samples in PVC hemolysis tubes.




Figure 4.6: Light microscopy analysis.

4.2.2 ELISA Technique

Paleoparasitology has used immunology over the recent decades for detecting protozoa in archaeological samples. Indeed, antigens of parasitic protozoans can remain identifiable for a long time, even with the use of commercially available kits (Faulkner et al., 1989; Gonçalves et al., 2002; 2004; Le Bailly, 2005; Le Bailly and Bouchet, 2006b; Le Bailly et al., 2008; Mitchell et al., 2008; Bartosova et al., 2011; Yeh et al., 2014).

ELISA (Enzyme Linked Immuno Sorbent Assay) technique is one of the most sensitive and specific methods to search antigens such as parasitic paleo-antigens. Detecting of *E. histolytica* antigens have had the majority of positive results up to now in paleoparasitology of the protozoans among using of the available commercial ELISA kits. Therefore, in attempts to detect the *E. histolytica* copro-antigen in the present studied samples, the commercial kit “*E. histolytica IP*” has been used, which detects this antigen on the basis of ELISA. This kit has produced by TECHLAB ® in the United States.

The “*E. histolytica IP*” kit (Figure 4.7) allows the rapid detection of pathogenic amoeba *Entamoeba histolytica* in the fresh stools of patients with diarrhea or dysentery. However, it had also positive results in coprolites or archaeological sediments polluted by fecal matter (Le Bailly, 2005).

The kit involves very specific monoclonal antibodies for detecting antigens of the parasite (a galactose-specific adhesin) in fecal specimens. Immobilized polyclonal anti-adhesin of *Entamoeba histolytica* is attached to the bottom of the wells of the ELISA plate (96 wells). These polyclonal antibodies bind to the specific antigen on the surface of amoeba. Finally, the antigen is revealed by a monoclonal antibody called “conjugate antibody” which is linked with a peroxidase enzyme. If the parasite is present, its antigen binds to the “conjugate antibody”. The peroxidase enzyme uses substrate and a color develops due to the complex of antibody-antigen-enzyme. By adding a stop solution provided in the kit, yellow color will be resulted. The measurements of final colored solution in each well will be carried out on an ELISA reader at 450 nm.

In present study, samples which had human origin were selected for ELISA and rehydrated by adding only ultrapure distal water on them. They were mixed and put in the refrigerator at 2-5 °C (for avoiding bacterial/fungal growth) (Le Bailly, 2005).

The samples were examined in triplets. The result of each test was only valid when positive and negative controls of the kit reached an absorbency value given by manufacture of the kit. A sample is considered positive when the value of absorbency reaches more than fixed cut-off value.

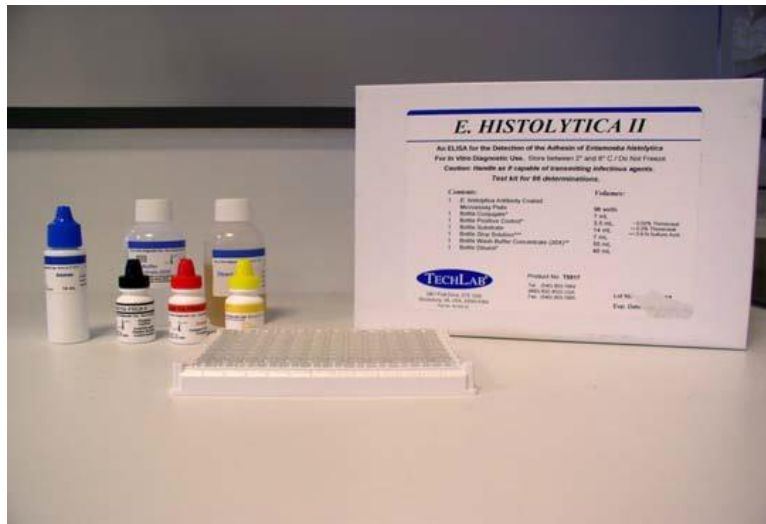

Figure 4.7: “*E. histolytica* II” kit components.



Figure 4.8: ELISA plate reader device.

4.3 Preventing contaminations and false positive results

Contamination of archaeological materials during sampling or processes of laboratory techniques could due to false positive results in paleoparasitology. Therefore, clean and aseptic conditions should be considered in paleoparasitological sampling and also during extraction and preparation of the samples from sediments or coprolites in the laboratory.

Using new sterile or disposable instruments could prevent contamination of the samples, during sampling, moving the materials and extraction process of the samples in the laboratory (Fugassa, 2014).

Recording carefully the received samples and related information is important in the laboratory.

Also a preparation sheet (Table 4.1) filled in the following manner could control and compare final positive results to decrease false positivity by contaminations over the preparation process and repeat this step if necessary.

SITES	Date of rehydration	Date of treatment	COLUMN1	COLUMN2	COLUMN3	COLUMN4
name	x	y	Sample1	Sample2	Sample3	Sample4
name	w	z	Sample...	Sample...	Sample...	Sample...

Table 4.1: Preparation sheet at the laboratory of paleoparasitology, UFC, Besancon, France.

During process of extracting, adequate washing of the instruments, meshes, sinks and cleaning of the used devices could prevent contaminations with remains of previous analysed materials. Using ultrasonic bath device also is strongly recommended to destroy possible parasitic remains in meshes.

Moreover, false positive results could be also occurred in microscopical studies, by misdiagnosis of non-parasite elements. For example, some of the fungi, spores or pollens could be similar to parasite eggs, especially when the taphonomic processes alter them.

Furthermore, the various conditions could effect on procedures of ELISA techniques and provide false positive or negative results. Chemical interactions, preservation conditions as well as the specificity and sensitivity level of the ELISA kit are some factors which should be considered.

Chapter 5 : Results and discussion

5.1 Introduction

The process of parasitism and the interaction between host and parasite need the presence of a parasite “in” or “on” a host organism. To evidence this presence in archaeological samples in the field of paleoparasitology, we need to search the parasitic markers in the human/animal specimens particularly linked with fecal matters (see chapter IV). Paleoparasitological findings during microscopic observation are mostly helminth eggs. Nevertheless, preserved larvae emitted by viviparous intestinal parasites (Reinhard, 1985; Reinhard et al., 1988) or the chitinous exoskeletons of ectoparasites (Reinhard and Buikstra, 2003) could be observed sometimes by light microscopy analysis. According to the applied methods and tools, as well as the nature of the analyzed samples, all revealed significant markers in this study were of helminth eggs and protozoan oocyst.

Endoparasitic helminths are divided to the classes of trematodes and cestodes within the phylum of the Platyhelminths (flatworms) and the classes of nematodes and acanthocephalan within the phylum of Nematelminths. The findings in this thesis include the parasite eggs in all the aforementioned major classes of helminthes. Furthermore, some found elements (oocysts) are attributable to the family of Eimeriidae as protozoan parasite.

The diagnosis of each identified taxa was based on the morphologic and morphometric characteristics of the parasitic elements. Morphometry has been made for the length and width of each taxa in order of several microns by measuring the dimensions of the parasitic elements accompanied by standard deviations. Statistical calculations of morphometric variations show that the measured sizes were always in accordance with the morphometric data of the current parasitic diagnosis (Thienpont et al., 1986; Ash and Orihel, 2007; Mehlhorn, 2008).

Of 275 total samples (from 30 archaeological sites) which were analysed in this PhD thesis, only 25 samples/subsamples from Hierakonpolis in Egypt and 17 samples from Chehrabad Saltmine in Iran revealed parasitic markers. Therefore, 85% of the analysed samples were negative in the light microscopy analyses. On the other hand, applying ELISA technique to detect *Entamoeba histolytica* had no positive results for 30 selected samples from human specimens associated with fecal remains.

The interpretation of the negative results from this paleoparasitological research needs considering different issues. Several physical and chemical factors in the environment such as temperature, humidity and oxygen tension could influence the life cycle of these parasites. The same factors play an important role in preservation of the parasite eggs in archaeological areas. The nature of samples and materials in archaeological contexts, the possibility of true and/or false negative results (which could not be mostly distinguished in paleoparasitological analyses), badly targeted sampling, poor preservation conditions and the low quantity of the parasitic marker remains in the analysed samples could be of the reasons. Also some of the biologic aspects of different parasite species lead them to be undistinguishable in archaeological materials.

The samples in this thesis were received from one of the first attempts for paleoparasitological sampling in archaeology of this region, particularly in Iran, Syria, Azerbaijan, Oman and Saudi Arabia. Because of the lack of information about paleoparasitology in the Middle East archaeology, I tried to analyze the majority of the samples which I've received from the archaeologists at the area. I was not able to participate in all related excavations in different countries and archaeological sites in the studied region and therefore, a protocol of sampling has been sent to the local archaeologists to inform them about the target samples which could provide results in paleoparasitology. Moreover, some soil sediments were collected from the materials which were excavated in the past decades. Some samples came also from the pits or unknown parts of the human or animal skeletons and burials. Therefore, except the abdominal/pelvic cavity samples collected by myself and the received coprolite specimens, the question remains whether some other received soil sediments representing the contents of the abdominal/pelvic areas or not.

Furthermore, all of the important factors which have influences on taphonomic processes and preservation of parasitic markers over times could lead the analyses to the negative results. Specific climatic conditions, physical, chemical and microbial agents, geological structures and other known or unknown environmental factors could lead parasitic markers to decay in the archaeological sites. For instance, most of the countries within the Middle East region are situated in the high (basic) pH soil areas according to the available global soil pH maps (figure 5.1). To find a link between the positive or negative paleoparasitological results and the environmental characteristics of the archaeological sites such as soil pH, I tried to put most of the available global paleoparasitological data up to now on a world soil pH map by using a geospatial analysis software

(ArcGIS). Because of the some limitations such as unavailability of certain soil pH maps as well as lack of accessing to the paleoparasitological studies with the negative results, I couldn't find a correlation between soil pH and parasitic marker remains at present. But such study could continue and repeat with soil pH or the other soil characteristics and environmental factors in future by using more complete data.

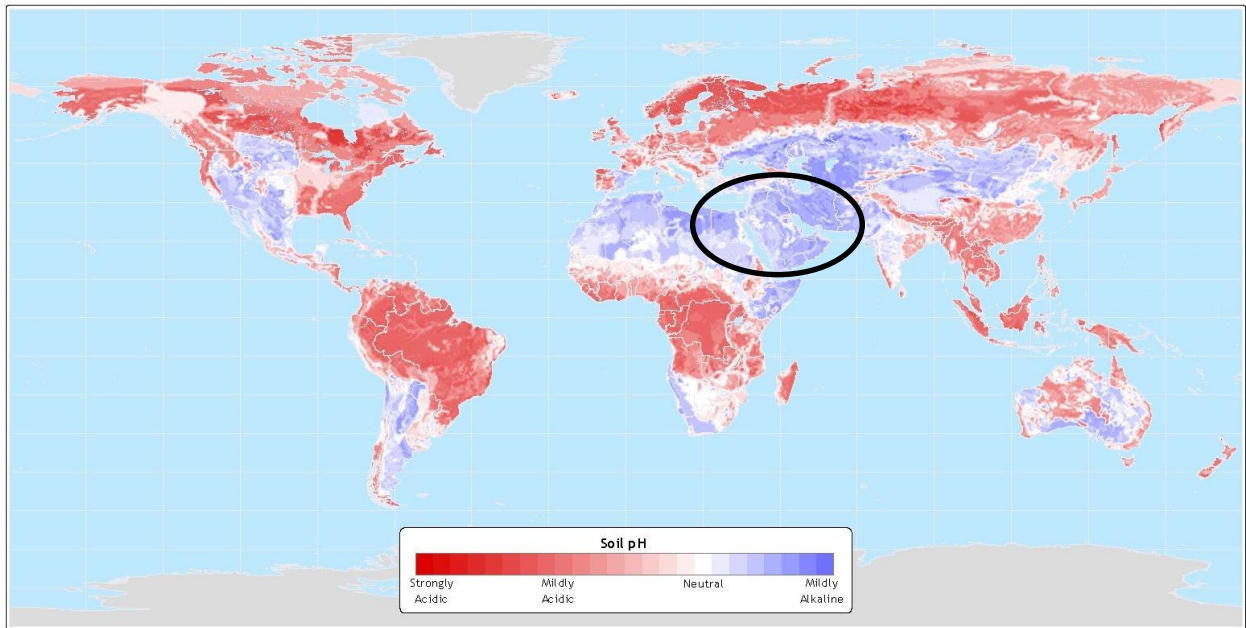


Figure 5.1: A map of world soil pH (http://www.sage.wisc.edu/atlas/maps/soilph/atl_soilph.jpg). The circle shows the Middle East region.

The negative results could also be interpreted as true cases. The paleoepidemiology of the ancient parasitic diseases in the archaeological areas is unclear before (and mostly even after) paleoparasitological studies, therefore, the proportion of infected human/animal individuals in an archaeological site that could remain often uncertain. On the other hand, the excavation reports of the studied sites in this thesis have no mention to the latrine and/or cesspit findings during the excavations. Latrine/cesspit structures commonly accumulate the fecal remains of several infected or health individuals over time. Nevertheless, the identification of these structures is sometimes difficult in archaeological excavations. Since the analysed samples in this study came only from

coprolites, burials, skeleton/bone remains, the soil sediments polluted by fecal materials and not from the latrines or cesspits, therefore, the result for analyses of each sample/subsample is associated to one individual or very few individuals.

Moreover, all the aforementioned factors could be the reasons for negative ELISA results to retrace *Entamoeba histolytica* paleo-antigens in the analysed samples. Despite the possibility of true negative results, we can consider also the false negativity results in ELISA associated with the limitations of the ELISA commercial kits and procedures.

In this chapter, the recovered parasitic ova during the analysis of archaeological samples from Middle Eastern sites are presented and discussed by the order of each taxa as follows:

- Trematodes
- Cestodes
- Nematodes
- Acanthocephala
- Coccidia

5.2 Trematode findings

The trematodes which have been identified in this study are within one group of flukes which infects digestive system (liver or intestine) of human and/or animals. According to the origin of the samples as well as morphology comparison between the identified fluke eggs in two coprolite samples received from the site of Hierakonpolis (Egypt), they belong to most possible families: Fasciolidae, Paramphistomatidae categorized in the order of Echinostomatida and less probably Diplostomatidae in the order of Strigeidida. One of these coprolites has originated from human or carnivores, and the other one has an aurochs (*Bos primigenius*) origin. Furthermore, a sole identified fluke egg found in one herbivore coprolite sample from Chehrabad saltmine (Iran) belongs to family Dicrocoeliidae from order Plagiorchiida (Soulsby, 1968; Maclean et al., 1999; Mehlhorn, 2008).

The sample **ID: H21** is originated from intestine content of aurochs buried in Hierakonpolis. The egg measurement for 9 identified fluke eggs in this sample was 132 to 191 μm (average: 149 μm) in length, and 74 to 106 (average: 90 μm) in widths (Figure 5.3).

The subsample **ID: H9d** from Hierakonpolis was a part of main coprolite sample (HK11/Test A/level 13) consist of the different pieces of desiccated coprolites originated from carnivores and possibly human. In this sample, the measurements have been made on 35 identified fluke eggs which were morphologically intact (not broken or wizened). The egg measurement for 24 eggs was 138 to 172 μm (average: 154 μm) in length, and 81 to 102 (average: 93 μm) in widths. The measurement for the other eggs (n=11) showed that they were wider than the available width size ranges for Fasciolidae/Paramphistomatidae. Therefore, these 11 fluke ova categorized as the unidentified fluke (Figure 5.2). Regarding the important size difference, and considering that the preservation conditions were the same for all the eggs from sample H9d, we can hypothesize that these eleven eggs belong to another taxa of fluke.

The sole *Dicrocoelium* sp. egg recovered in fecal polluted soil sediment from Chehrabad saltmine (sample **ID: C73**) measured 40 \times 27 μm . Unfortunately, no datation is given for this sample.

Moreover, the sample **ID: H21** and **H9d** from Hierakonpolis contained several broken, folded or wizened fluke eggs that could not be identified with certainty (Figure 5.10). In these cases, the eggs were not possibly well-preserved.

Identified	Measured egg(s)			Site	Dating	Sample	Origin	ID
	Count	Length (μm)	Width (μm)					
Fasciolidae	24	154 \pm 10	93 \pm 5.6	Hierakonpolis (HK6)	3700 - 3500 BC	Intestinal content	Aurochs	H21
Paramphistomatidae								
Unidentified fluke								
Fasciolidae	9	149 \pm 19	90 \pm 12	Hierakonpolis (Locality 11C)	3900 - 3300 BC	Coprolite	Carnivore / Human	H9d
Paramphistomatidae								
Diplostomatidae (<i>Alaria</i> sp.?)								
<i>Dicrocoelium</i> sp.	1	40	27	Chehrabad Salt mine	without dating	Coprolite	Herbivore	C73

Table 5.1: Identified eggs in the class of Trematoda.

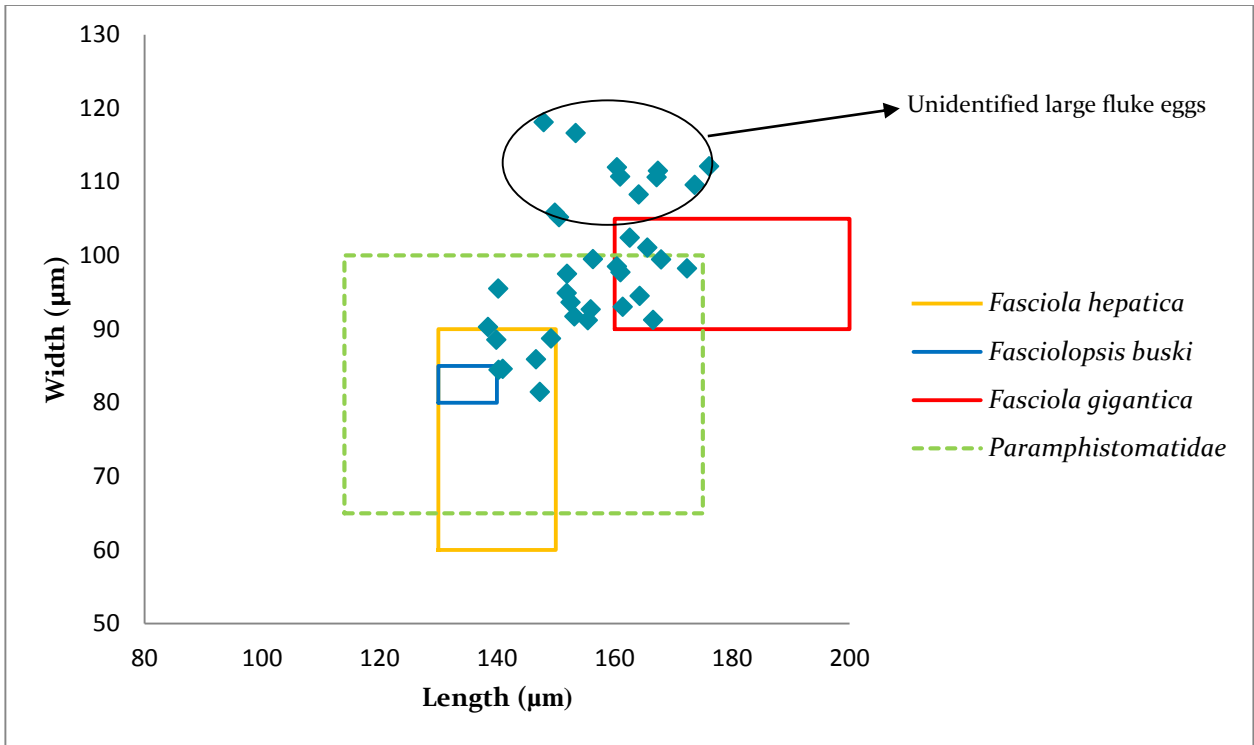


Figure 5.2: Morphometric analysis of identified fluke eggs in sample ID: H21.

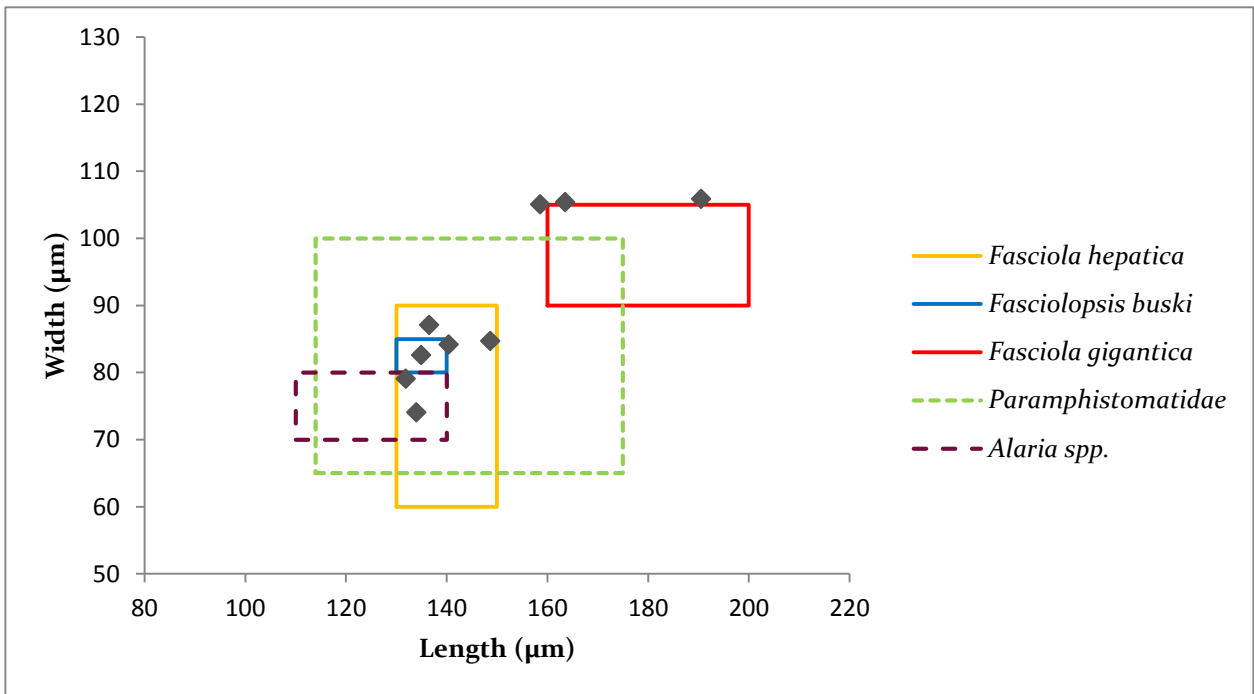


Figure 5.3: Morphometric analysis of identified fluke eggs in subsample ID: H9d.

All the aforementioned trematodes are food-borne zoonotic parasites, the reservoirs and definitive hosts of which could be a wide range of domestic and wild animals. Their distribution in humans has associated with local eating habits. Therefore, identifying them in archaeological samples allows us to achieve some information about ancient diet and also parasitic threats of human/animal health in specific contexts. Moreover such trematodes have serious economic impact by infecting productive animals such as cattle, sheep, goats, pigs, and buffaloes in different parts of the world (Kaufmann, 1996).

The infection by identified flukes in this study needs the presence of the obligatory intermediate hosts such as aquatic or terrestrial snails and mostly the presence of edible plants when encysted metacercaria attaching to them. The aquatic plant sources of infection for Fasciolidae and Paramphistomatidae include dandelion (*Taraxacum dens leonis*), watercress (*Nasturtium officinale*), mash (*Valerianella oleria*), chicory (*Cichorium intybus*), or wild mint (*Mentha aquatica*), water caltrop (*Trapa bicornis*, *Trapa natans*), water chestnut (*Eliocharis tuberosa*), water bamboo (*Zizania aquatic*), water hyacinth (*Eukhornia crassipes*), water morning glory (*Ipomoea aquatic*), lotus (*Nymphaea lotus*), parsley (*Petroselinum crispum*), water lettuce (*Pistia stratiotes*), and others (Maclean et al., 1999). Furthermore, remained paralyzed ants attached to the herbage and grass could be sources of Dicrocoeliidae infection especially in herbivores.

Measuring from around 3 mm to 75 cm in length, different species in adult stage are visible by naked eye (commonly in slaughtered ruminant hosts) and their shapes have been described as spatulate, piriform, lanceolate, or leaflike (Maclean et al., 1999; Mehlhorn, 2008; Roberts and Janovy Jr., 2009). Therefore, it could be possible that the ancient people would be aware of the presence of these flatworms in their infected livestock (particularly when slaughtering cattle, sheep, goat, pig and etc.). For instance, the size of adult worm of *Dicrocoelium dendriticum* is 6 to 10 mm, *Fasciola hepatica* is 20 to 30 mm, *Fasciolopsis buski* is 20 to 75 mm, *Paramphistomum* spp. are 3 to 12 mm, and *Alaria allata* measures approximately 3 to 6 mm (Soulsby, 1968; Mehlhorn, 2008).

The life cycles are indirect and relatively similar in these flukes. The adult worm in definitive host produces eggs which are excreted in feces, fall to the ground and be scattered by animals or rainwater. Then, they hatch as ciliated miracidia and enter appropriate first-intermediate

host snails. Also it is possible that the eggs be ingested directly by the snails and then miracidia hatch within snails' body. Sporocyst, redia, and cercaria are the further stages for asexual reproduction of miracidia within the snails' body. Subsequently and commonly in Fasciolidae and Paramphistomatidae, free-swimming tailed cercaria leave the snail and encyst as metacercaria when attaching to aquatic plants. *Alaria* spp. has amphibian second-intermediate hosts such as tadpole or adult frog. In Dicrocoeliidae, tailed cercaria leave the snails within slime-balls and then, ants become second intermediate hosts when eating slime-balls. The definitive (or accidental) hosts are contaminated by ingestion of these plants, or second intermediate hosts carrying infective forms of the parasite which are the excysted metacercaria. Metacercaria mostly are found on aquatic vegetation or within an intermediate host, but they could be also encysted on some sticks, and rocks or be freely in the water (Roberts and Janovy Jr., 2009). Finally in these different fluke families, the metacercaria migrate to liver, the bile ducts, or stay in the small intestine and develop into adults. These hermaphrodite adults could produce new eggs to continue the life cycle.

The eggs of these types of fluke parasites are commonly ellipsoid or oval in shape and have an operculum at one end through which the larva eventually will escape. But in archaeological samples identified fluke eggs are often deprived of their operculum and therefore, their measurements are less than those of recorded in the literatures.

Molecular biological techniques have been applied so far in some researches for amplification of parasitic aDNA in the field of paleoparasitology (Guhl et al. 1997, Araújo et al. 1998; Loreille et al., 2001, Martinez et al., 2003, Iñiguez et al., 2006). Using these methods in recent researches could help to identify the species level of the parasite remains such as trematode eggs (Leles et al., 2014). Moreover, the analyses carried out by archaeobotanists, malacologists, palynologists, and entomologists about an archaeological site and its related areas allow us to better interpret trematode remain findings according to the variety of the life cycles and intermediate hosts for different flukes. For instance, study of molluscs and aquatic plant remains (if found close to the site) could be illustrative for more explaining of possible sources of trematode infection at the area.

Schistosoma sp., *Fasciola* sp. and *Dicrocoelium* sp. are the trematode species reported so far from west of the Middle East, in Egypt, Sudan, Israel and Cyprus (see chapter II). Available study reports on paleoparasitological findings around the Middle East show that the fluke eggs in

the archaeological material from European continent, is largely dominated by *Fasciola sp.* and *Dicrocoelium sp.* from the class Trematoda (Bouchet et al., 2003; Dittmar and Teegen 2003). Also from other parts of Africa there is only one report of ancient fluke egg (*Dicrocoelium sp.*) discovered in South Africa (Dittmar and Steyn, 2004). In northern neighbored regions of the Middle East, in Russia, North Caucasus and middle Asia (South Turkmenistan), there is a recent review by Savinetsky and Khrustalev (2013) which presents findings of animal parasites through analysis of ancient animal dung layers and coprolites. This investigation contains fluke eggs including *Fasciola sp.* and *Dicrocoelium sp.* with herbivore origin as well as *Alaria alata* eggs in dog coprolites (Savinetsky and Khrustalev, 2013). Furthermore, paleoparasitological studies in eastern Asia have revealed a different pattern of small sized trematode eggs such as *Clonorchis sp.*, *Gymnophalloides sp.*, and *Metagonimus sp.* in Korea and Japan (Han et al., 2003; Matsui et al., 2003; Seo et al., 2007; Shin et al., 2009; 2011).

5.2.1 Fasciolidae

According to morphometry of the findings (Figures 5.2 and 5.3) some of the recovered fluke eggs from two samples of Hierakonpolis (subsample **ID: H9d** and sample **ID: H21**) could be identified as family Fasciolidae (Figures 5.4, 5.5, and 5.6). Concerning to the nature of samples as well as mentioned characteristics and size dividing, these eggs could correspond to *Fasciola hepatica* or *gigantica*, *Fascioloides magna* and possibly *Fasciolopsis buski*.

The aurochs origin of sample **ID: H21** make us assured that this was a true animal infection with flukes. False parasitism (or pseudoparasitism) with the fluke could have resulted commonly in humans and carnivores from eating wide variety of infected mammals' organs which contain fluke eggs. Thus, we can consider a possibility of false parasitism with family Fasciolidae for bovine meat consumers at the site of Hierakonpolis. In this possible case, the eggs would have passed through the human digestive tract without any particular transformation or pathogenicity.

Moreover, these trematode findings prove that the environment in Hierakonpolis region was enough proper for developing of the intermediate gastropod hosts and also edible plants which involved in the life cycle of these flukes. Therefore, the possible presence of true human infections

could be considered for the ancient occupants of Hierakonpolis, in cases of consumption of aquatic plants linked with encysted metacercaria.

Subsample **ID: H9d** is a small piece of desiccated coprolite (weight: 0.9 gr) and it's not clear that it is originated from carnivores or human. As mentioned before, the archaeological report of Hierakonpolis has stated that the origin of the sample HK11/Test A/level 13 is principally carnivore coprolite mixed with small fragments of possible human specimens and subsample **ID: H9d** was a separated part of this mixed coprolite sample. In both cases of considering carnivores or human origin for this subsample, false parasitism is highly probable. Other evidences of Fasciolidae infection in bovine are available at the site (as can be seen in sample **ID: H21**). However, possibility of true infection also must be considered.

The Fasciolidae family includes some genera of trematodes which are important in medical and veterinary parasitology. The life cycle of species in this family consist of one intermediate gastropod host: freshwater snails from family Lymnaeidae (for *Fasciola* and *Fascioloides* sp.) or Planorbidae (for *Fasciolopsis buski*). The fossilized shells of planorbid fresh water snails such as *Bulinus truncatus* and *Biomphalaria alexandrina* have been preserved in a paleolithic site in the Egyptian desert (Wendorf et al. 1976; Abou-El-Naga, 2013). Aquatic freshwater plants are also essential to continue the development of the egg. The definitive host commonly could be ruminant, equine, camelids, elephants, swine, or accidentally humans and carnivores which are contaminated by ingestion of these plants containing metacercaria. Fasciolidae adult worms are localized commonly in the intrahepatic bile ducts and small intestine of the definitive host (Kaufmann, 1996; Foreyt, 2001; Chiodini et al., 2003; Mehlhorn, 2008).

In the genus of *Fasciola*, the presence of adult worms in the bile ducts of the host could cause Fascioliasis. This infection has relatively high pathological significance. Traumatic hepatitis (may result in death), mechanical and toxic irritation, irregular fever, stomach pain, allergies, hepatomegaly, hemorrhage, anemia, cholangitis and eventually necrosis and fibrosis of the bile ducts in the host could occur by immature or adult worms of *Fasciola* (Maclean et al., 1999; Ballweber, 2001; Mehlhorn, 2008). Furthermore, decreased production and weaning weights are significant problems for the livestock. In cattle and small ruminants the pathogenesis is partly attributable to the invasive stages in the liver and the blood feeding in the bile ducts by the adults. Infected livers are unsuitable for human consumption, resulting in the loss of an important source

of protein (Foreyt, 2001). Humans become infected to *Fasciola* sp. by eating vegetation contaminated with infective cercaria.

Fascioloides magna is species of Fasciolidae family commonly found in present North America, European countries and South Africa, which may cause severe disease in deer, equine, cattle, sheep, and goats by continuous tissue migration. The signs were similar to fascioliasis and a single migrating fluke could be cause of death for the host (Mehlhorn, 2008).

Fasciolopsis buski is another species belonging to a different genus in this family, distributed nowadays mainly in southwestern Asia. It causes fasciolopsiasis commonly in pigs, dogs and occasionally in humans. This trematode is called the giant intestinal fluke and its adults occupy duodenum and jejunum of the small intestine. Lightly infection by this worm could be asymptomatic. Presence of a large number of worms in heavy infections could cause intestinal obstruction, abscess formation, diarrhea, nausea, vomiting, edema, anemia, and ascites (Foreyt, 2001; Chiodini et al., 2003; Mehlhorn, 2008).

The eggs in Fasciolidae family are oval in shape and are operculate. Smooth edges of operculum are characteristics for differential diagnoses between Fasciolidae and Paramphistomatidae eggs. The egg size variation in Fasciolidae is from 130 to 200 microns in long and 60 to 105 microns in wide. The eggshell is smooth, thin, with slight thickening at the poles. Eggs of *Fasciola* and *Fascioloides* species are similar to those of the intestinal flukes *Fasciolopsis buski* and echinostomes and their identification can be confused with each other. In the Fasciolidae family, two major infectious species for human are *Fasciola hepatica* which is the most widespread and *Fasciola gigantica* which is more common in present tropical areas and particularly in South Asia, Southeast Asia, and Africa (Maclean et al., 1999; Mehlhorn, 2008). In the Middle East, The Nile delta has one of the high infection rates to Fascioliasis at present time (Mas-Coma et al., 1999; Muller, 2001). Fascioliasis has been also widespread in high altitude regions and northern parts of Iran, particularly close to the Caspian Sea (Moghaddam et al., 2004; Rokni, 2008).

Measurement of different sizes in Fasciolidae family is applicable for distinguishing the eggs of two species of *Fasciola hepatica* and *gigantica*. *F. hepatica* eggs are 130-150 microns in long and 60-90 microns in wide. whereas *F. gigantica* eggs are much larger, measuring between

160 and 200 microns in long and 90 to 105 microns in wide (Maclean et al., 1999). The *Fasciolopsis buski* eggs are also measured to 130-140 in 80-85 microns (Chiodini et al, 2003). Furthermore, the width of the operculum of both *F. hepatica* and *F. magna* eggs is less than one-third of the egg width (Searcey et al., 2013). As another diagnostic methods, ELISA techniques could be use recently to detect *Fasciola* coproantigens (Muller, 2001).

Beside significant zoonotic infection of humans, trematode parasites in Fasciolidae family have been considerable importance in livestock health since ancient times especially in temperate regions such as Egypt. These parasites could be significant threat for ancient economic subsistence by decreasing livestock production sources. Moreover climatic changes may alter some factors for development of different life stages of these parasite species or presences of the intermediate hosts such as snails. Therefore, identifying Fasciolidae eggs in archaeological sites such as Hierakonpolis, could interpret some environmental condition according to the related dating of the samples.

Faunal analysis to find shells of *Lymnea* sp. and botanical analyses to find a liver fluke vegetation type in an archaeological site and its related areas could help us to discuss about potential of the region for endemicity of this family. The presence of the snails suggests the ecological potential for the presence of this internal parasite. Humans mainly get infected by eating watercress (*Nasturtium officinale*) and so ingesting the encysted metacercariae sitting on the leaves.

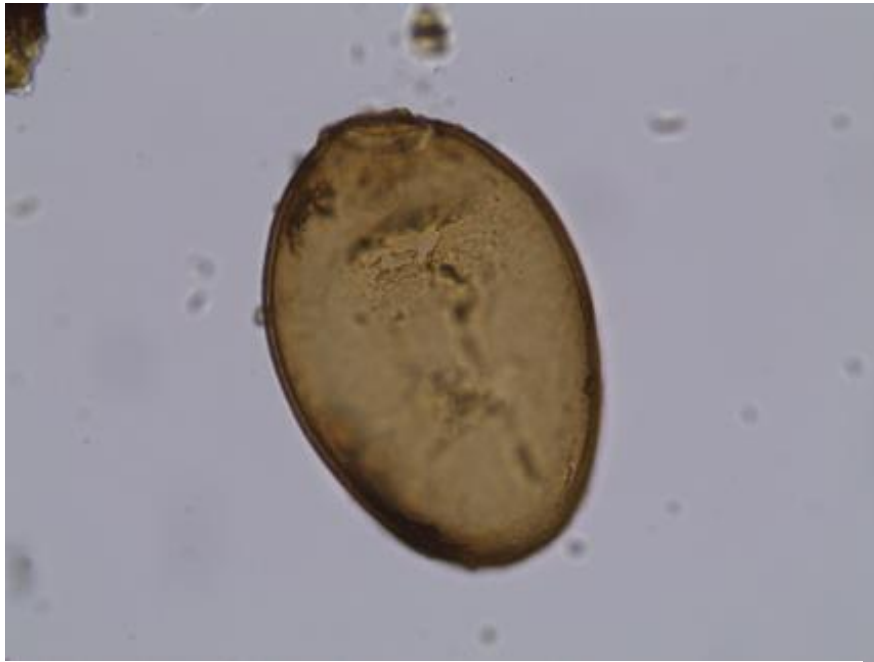

Figure 5.4: Fasciolidae egg, operculum on the one pole (top), size: $160 \times 110 \mu\text{m}$, magnification $400\times$, sample ID: H21, Hierakonpolis.

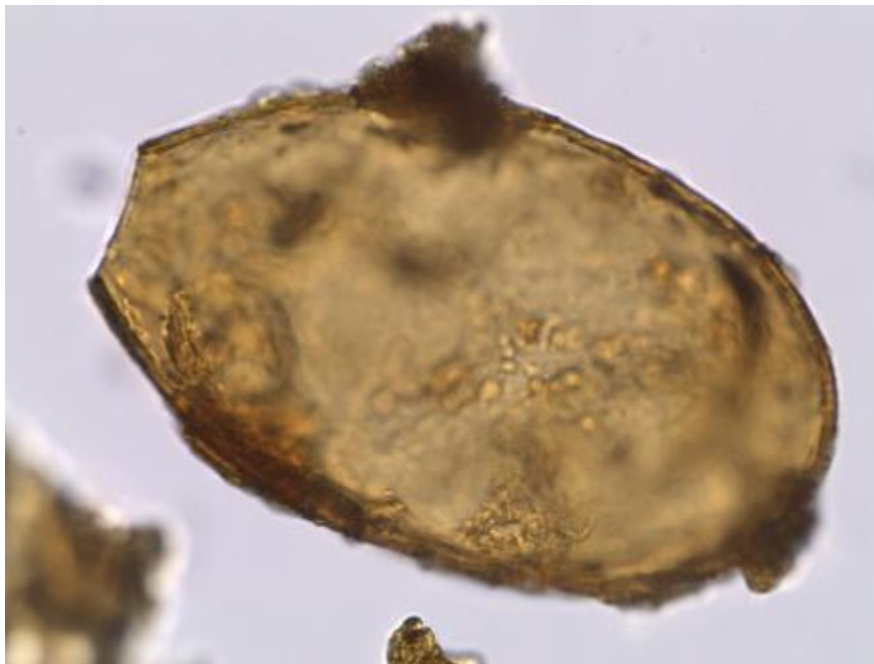


Figure 5.5: Fasciolidae egg, deprived operculum on the left pole, size: $168 \times 99 \mu\text{m}$, magnification $630\times$, sample ID: H21, Hierakonpolis.

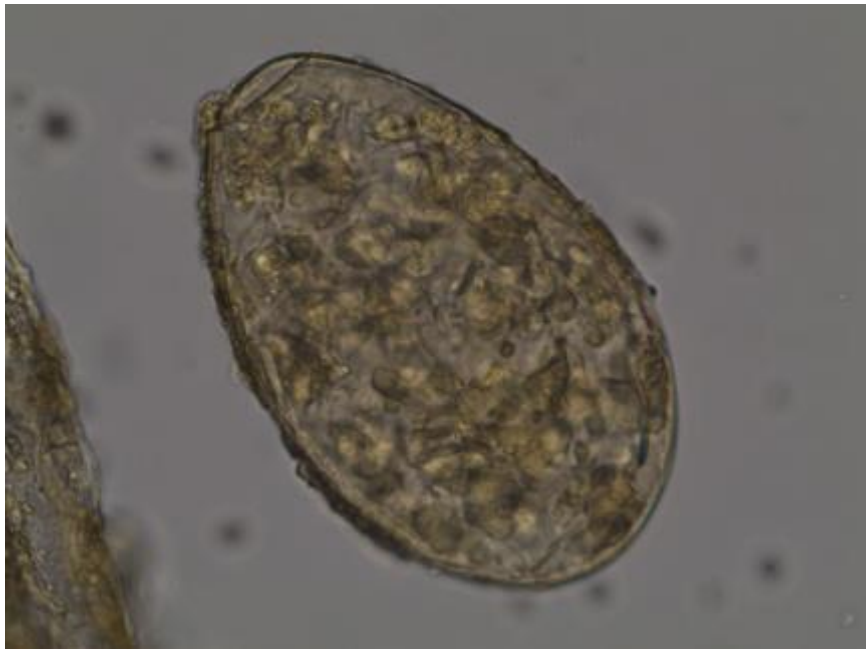

Figure 5.6: Fasciolidae egg, operculum on top, size: $131 \times 79 \mu\text{m}$, magnification $630\times$, with internal content, subsample ID: H9d, Hierakonpolis.




Figure 5.7: Paramphistomatidae egg, deprived operculum on the right pole, size: $150 \times 106 \mu\text{m}$, magnification $630 \times$, sample ID: H21, Hierakonpolis.

5.2.2 Paramphistomatidae

Thin-shelled and operculated eggs of Paramphistomatidae are ellipsoid or rhomboidal in shape and have variation in size (114 to 175 μm \times 65 to 100 μm) depending on species. They are similar to *Fasciola* eggs but typically in modern specimens have a clearer (and less brown) appearance unlike to *Fasciola* eggs. Vitelline cells and unembryonated ovum also could be seen in these eggs (Muller, 2001; Zajac and Conboy, 2012; Elsheikha and Patterson, 2013). Serrated edges of operculum could be another diagnostic characteristic for Paramphistomatidae eggs and could help in the differential diagnoses between Fasciolidae and Paramphistomatidae eggs.

Several specimens of identified fluke eggs in two samples from Hirakonpolis (sample **ID: H21** and **H9d**) have such morphology and morphometry characters.

Paramphistomum species are trematode parasites with a worldwide distribution. They have one water snail intermediate host in their life cycle such as *Planorbis*, *Bulinus*, *Stagnicola*, or *Anisus* species. Ruminants are as main final hosts for paramphistome infections. But the other mammals such as camelids, elephants, pigs, monkeys, apes, rats and also humans could be the other hosts (Muller, 2001; Roberts and Janovy Jr., 2009; Zajac and Conboy, 2012). They may cause significant intestinal problems in ruminants called paramphistomosis. The adult worms live in the rumen and reticulum without significant clinical disease, but the pathological effects of infection are appeared in heavy infection by immature flukes within the small intestine. Enteritis, diarrhea, inappetence, dehydration, and death in severe cases in young domestic or wild ruminants could be as pathological signs. The most reported pathogenic species are *Gastrodiscoides hominis*, *Paramphistomum microbothrium*, *P. ichikawai*, *P. cervi*, *Cotylophoron cotylophoron*, and various species of *Gastrothylax*, *Fishoederius*, and *Calicophoron* (Kaufmann, 1996; Foreyt, 2001; Mehlhorn, 2008; Elsheikha and Patterson, 2013). *Gastrodiscoides hominis* and *Watsonius watsoni* could be also as human-parasitic member of the paramphistomes (Muller, 2001; Mehlhorn, 2008).

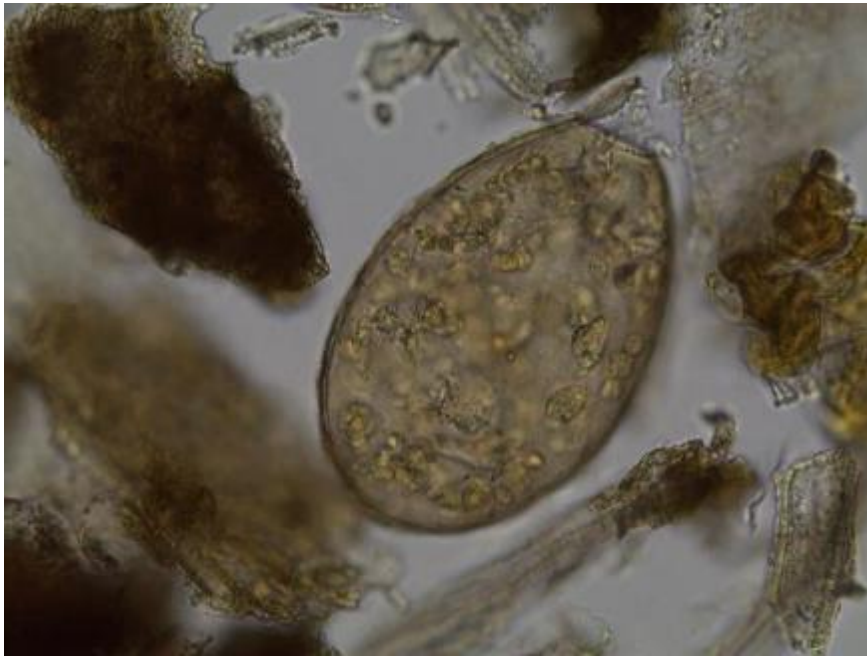


Figure 5.8: Paramphistomatidae egg, operculum on top, size: $159 \times 105 \mu\text{m}$, magnification $400 \times$, with internal content, subsample ID: H9d, Hierakonpolis.

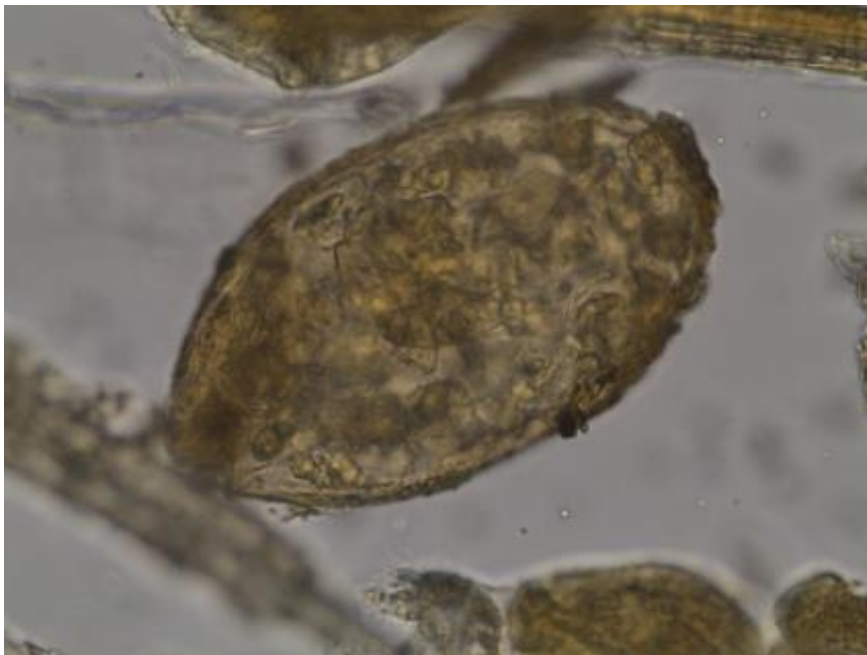


Figure 5.9: Unidentified fluke egg resembling that of *Alaria* spp., size: $134 \times 74 \mu\text{m}$, magnification $630 \times$, with internal content, subsample ID: H9d, Hierakonpolis.

5.2.3 Diplostomatidae

Considering a carnivore origin for Subsample **ID: H9d** in Hierakonpolis, we can add another fluke parasite belonging to family Diplostomatidae (*Alaria* sp.?) to our possible range of identification circle (Figures 5.3 and 5.9). *Alaria* spp. infects commonly carnivores such as dogs and foxes mostly in European nowadays countries. This fluke lives in the small intestine and has two intermediate hosts as well as a variety of paratenic hosts. Snails (*Planorbis*, *Heliosoma*, *Lymnaea*, and *Anisus* species) are first intermediate host for production of cercaria, and vertebrates such as pigs, amphibian and reptiles are secondary or paratenic hosts which preserve mesocercariae form. Within the paratenic host, the parasite retains its infectivity toward the definitive host. Final carnivore hosts by eating mesocercariae inside the paratenic host could be infected and metacercaria migrate to lung and then adults appear in intestine. Catarrhal duodenitis is reported as pathogenicity for infection to this fluke. In cases of human infection with mesocercariae of *Alaria* spp. (for example by ingestion of undercooked contaminated frog legs), the signs could be flu-like symptoms at the first days and continuously could due to anaphylactic shock, extensive local or diffuse hemorrhage and death. The eggs of *Alaria* spp. are large and similar to Fasciolidae and the egg size is 110 to 140 μm in length and 70 to 80 μm in width (Soulsby, 1968; Mehlhorn, 2008; Möhl et al., 2009).

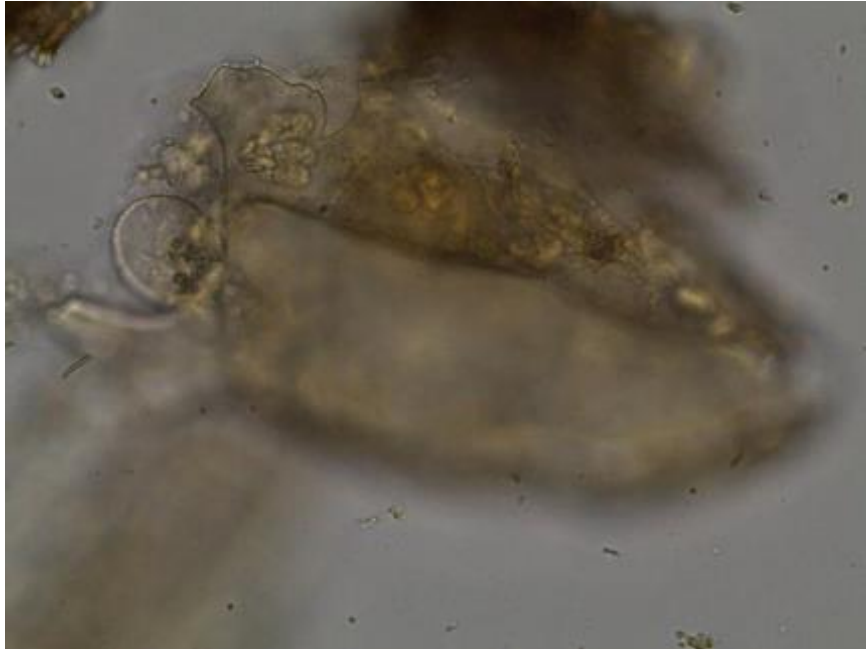


Figure 5.10: Unidentified broken fluke egg, magnification 630 ×, subsample ID: H9d, Hierakonpolis.

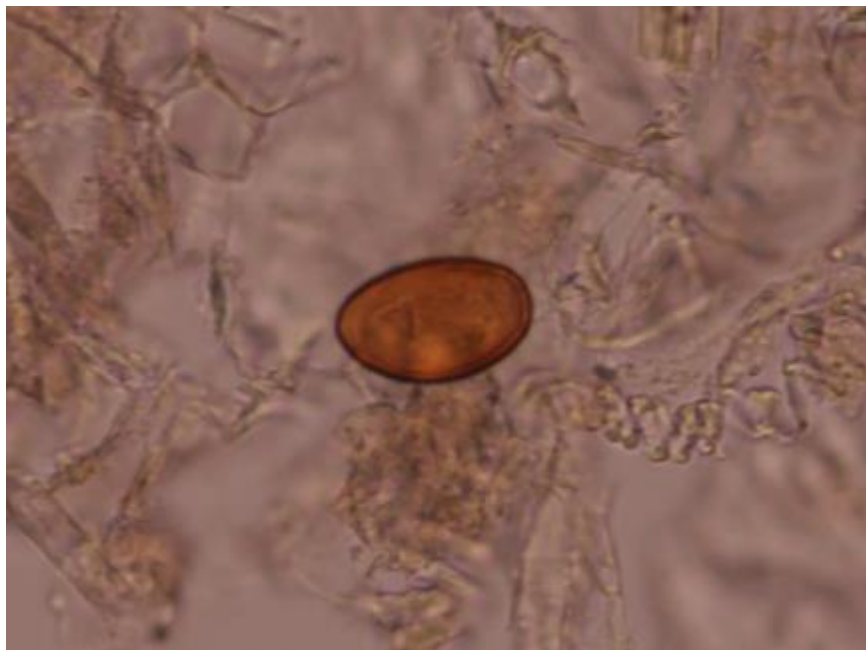


Figure 5.11: *Dicrocoelium* sp. egg, size: 40 × 27 μm, magnification 400 ×, sample ID: C73, Chehrabad Saltmine.

5.2.4 Dicrocoeliidae

A single *Dicrocoelium* egg was observed in a sediment sample (**ID: C73**) polluted by herbivore coprolite taken from Chehrabad saltmine archaeological layers (Nezamabadi et al., 2013a). This recovery is especially interesting because it is the first known fluke infection in animal - and human - remains found in the archaeological sites of the Iranian Plateau and eastern part of the Middle East. Finding of this egg suggests that a proportion of the livestock in Chehrabad suffered from lancet fluke infestation. Considering the origin of the sediment sample, it is almost certain that this finding reflects true infestation of herbivore host due to an uptake of infested ants with raw plants. It must, however, also be taken into consideration that ancient saltminers could have a pseudoparasitism consequence of ingesting raw or undercooked liver of parasitized herbivores (e.g. cattle and sheep) as their food (meat food) which zooarchaeological study at Chehrabad has proved their presence at the site. In this possible case, the detected eggs could pass unchanged through the digestive tract. True human infection is exceptional and resulting accidentally by ingestion of infected ants by metacercaria (Magi et al., 2009).

This fluke family has a worldwide distribution and wide host range including wild and domestic mammals such as ruminants (cattle, buffaloes, sheep, goats, deer, camelids), horses, pigs, dogs, rodents, lagomorphs, and accidentally humans (Elsheikha and Patterson, 2013). Searcey et al. (2013) have reported the oldest true human infection to *D. dendriticum* by findings of its eggs in the liver of Zweeloo Woman, dated to Roman period in the Netherlands.

The main genus of this family is *Dicrocoelium* (lancet liver fluke) which predominantly infects cattle, sheep and goat. Its life cycle involves two intermediaries. The first intermediate host for complex life cycle of *Dicrocoelium* species is a terrestrial snail (main genera in the old world: *Zebrina*, *Cochlicella* or *Helicella*) which swallow the eggs of *Dicrocoelium* sp. As mentioned before, the second intermediate host will be ants, commonly belonging to two genus: *Formica* sp. and *Lasius* sp. These ants clamp themselves by their mandibles to leaves of plants such as grasses or herbs and remain paralyzed as long as the temperature remains below 20°C. Infected ants may also be found in raw fruit, vegetables and even drinking water. Infection (dicrocoeliasis) occurs usually by ingesting ants infected by the parasite at the larva stage, during raw vegetation of herbivore definitive host. Inside the small intestine of definitive host, immature flukes release from the ant body and enter the liver by migrating up the bile ducts. The adult fluke could live in the

gallbladder and bile ducts of its herbivorous host for many years and the eggs are passed in the feces of the infected herbivore. However, the pathological changes caused by *Dicrocoelium* sp. in the liver, gallbladder and bile duct are less severe than those seen in Fascioliasis and even heavy infections could be asymptomatic. In the cases of immense infection (presences of thousands of adult *dicrocoelium* sp. in the infected individual), the signs could be abdominal pain, liver enlargement, hepatic cirrhosis and proliferation of bile duct epithelium, anaemia, icterus, body weight loss, and disturbance of diary production (such as meat and milk) and reproduction indicators of the livestock (Kaufmann, 1996; Ballweber, 2001; Otranto and Traversa, 2002; Mehlhorn, 2008).

Currently, dicrocoeliasis has a worldwide distribution which needs suitable environmental conditions for the life of intermediate hosts and presences of the final hosts. The most common species in Europe, Asia and North Africa is *Dicrocoelium lanceolatum*. In tropical Africa, there is a closely related species, *Dicrocoelium hospes* (Otranto and Traversa, 2002; Mehlhorn, 2008).

Dicrocoelium eggs are ellipse shape and operculate with a thick shell and dark brown color. Their size is between 36 and 45 microns long and 20-30 microns wide. They are typically asymmetrical and tend to be flattened on one side. The operculum is relatively broad, flattened, and about two thirds of the egg width. It may be also indistinct in some cases. These eggs can survive in different environmental conditions even very dry or cold without losing their infectivity (Foreyt, 2001, Ash and Orihel 2007; Mehlhorn, 2008; Zajac and Conboy, 2012).

In 2010, the occurrence, distribution and migration evidences of ancient dicrocoeliasis have been summarized and classified chrono-geographically by Le Bailly and Bouchet through study of paleoparasitological records. They discussed about relationships between ancient human/animal migrations and presences of dicrocoeliasis in the archaeological areas of the old and new world. Also, they emphasized that the *Dicrocoelium* findings could represent herding and breeding habits and probably alimentary behavior of ancient human over the world (Le Bailly and Bouchet, 2010).

The most ancient recovery of *Dicrocoelium* sp. eggs is dated to earlier than 550,000 years BP (during Pleistocene period in France) by analysis of a coprolite sample from a cave near Tautavel, called “Caune de l’Arago” (Jouy-Avantin et al., 1999). Therefore, dicrocoeliasis has a long time presence in the Old World.

In a similar context and time period as Chehrabad saltmine, finding of high number of *Dicrocoelium* eggs have been reported from preserved human fecal remains at the salt mines of Hallein in Europe (Austria), dated to Iron Age, 500 - 200 years BC (Aspöck et al., 1973; 1974; 1999).

Although the records are not very numerous, the presence of *Dicrocoelium* sp. has been proved in few archaeological sites of African continent. Discovered dicrocoelid eggs in ancient Africa consists one report from outside of the Middle East region, reported by Dittmar and Steyn in 2004 among coprolite analysis found at the archaeological site of K2 in South Africa, and another report by Harter (2003) during her study on coprolite samples from the necropolis of Kerma in Nubia (Ancient Sudan). K2 site is dated from 10th to 11th AD as the late African Iron Ages (Dittmar and Steyn, 2004) and Kerma's finding consist of four periods of time between 4350 and 3375 BP (Harter, 2003).

Furthermore, there is a sole report from ancient Israel in the ancient Middle East region which shows dicrocoeliasis in a soil sample from an ancient animal stable excavated in the site of Qumran dated to 2050-2018 BP (Zias et al., 2006).

Moreover, recent paleoparasitological studies in northwestern adjacent regions of Iran, prove the ancient distribution of *Dicrocoelium* sp. in North Caucasus, eastern Caspian Sea, dated from 4100 BP up to 18th century (Savinetsky and Khrustalev, 2013).

The presence of *Dicrocoelium* sp. in Chehrabad saltmine provides new clues about the antiquity of this parasite in the Iranian Plateau, as well as some aspects of ancient environment, climate, and also interactions between ancient human and animal inhabitants at the area of this site and their parasites.

5.3 Cestode findings

According to the origin of the analysed samples as well as morphology of some of them, the tapeworm eggs identified during this research consist of taeniid, hymenolepid and anoplocephalid cestodes. All the known originated samples with cestode findings, consist at least one human and/or carnivore origin.

Identified	Measured egg(s)			Site	Dating	Sample	Origin	ID	
	Count	Length (µm)	Width (µm)						
<i>Taenia</i> sp.	62	37±2.0	32±1.2	Chehrabad Salt mine	Achaemenid period (7th Century - 4th Century BC)	Soil sediment	Human mummy	C61	
								C62	
								C64	
								C65	
						Coprolite	Human	C33	
Taeniid	80	36±2.6	32±2.2	Chehrabad Salt mine	Achaemenid period (7th Century - 4th Century BC)	Soil sediment	Unknown Human?	C80	
								C82	
								C86	
						Soil sediment	Unknown	C83	
								C85	
	Soil sediment	Unknown	C94						
			without dating	Unknown Human?	C81				
	123	37±2.2	33±1.6	Hierakonpolis (Locality 11C)	3900 - 3300 BC	Coprolite	Carnivore Human	Unidentified	H1a
									H4c
									H4f
							Carnivore Human	Unidentified	H5d
									H7b
									H7c
									H7d
							Human Carnivore	Unidentified	H7e
H8a									
H8b									
Carnivore Herbivore Human	Unidentified	H14b							
		Hierakonpolis (HK6)	3700 - 3500 BC	Sediment from pelvic area	Dog	H28			
								H29	
<i>Hymenolepis</i> sp.	1	50	39	Hierakonpolis (Locality 11C)	3900 - 3300 BC	Coprolite	Carnivore Human	H7d	
	1	54	47	Hierakonpolis (HK6)	3700 - 3500 BC	Sediment from pelvic area	Dog	H28	
Anoplocephalid	12	93±7.1	63±4.3	Hierakonpolis (Locality 11C)	3900 - 3300 BC	Coprolite	Carnivore Human	H1c	

Table 5.2: Identified eggs in the class of Cestoda.

5.3.1 Taeniidae

In this PhD work, 12 taeniid eggs were recovered from Chehrabad human mummy #5 dated to Achaemenid period. As the samples (**ID: C61, 62, 64, 65, 67**) were of human origin, the identified eggs indicated the presence of human taeniasis at the site (Nezamabadi et al., 2013b). Human taeniasis was the only significant parasitic disease linked to human food and ancient diet in Chehrabad. Therefore, the presence of *Taenia* sp. eggs in samples of human origin indicates the consumption of raw or undercooked beef, sheep, goat or pork meat, all of which are represented in archaeozoological assemblages from the Iranian plateau and Chehrabad (Mashkour, 2002; 2006).

Other remarkable taeniid eggs came from a human coprolite analysis in Chehrabad. This coprolite sample (**ID: C33**) is dated to Achaemenid period and presents a large amount of taeniid eggs (average count per microscopy slide: 775 eggs). This coprolite supports the ancient presence of human taeniasis during Achaemenid period at the site.

Moreover, the identified tapeworm eggs from Chehrabad were recovered from occupation layers. These soil sediments samples (**ID: C80, 81, 82, 83, 85, 86**) were potentially polluted by both human and animal fecal matter. Therefore, it was not possible to identify the origin (human or animal) of these taeniid eggs. All of these samples also came from Achaemenid period at the site.

The sole taeniid egg was recovered from a sediment sample (**ID: C94**) dated to Sassanid period. But the location of sampling is close to Achaemenid layers and we can consider probably a possibility of communication for this case.

Taeniid eggs from Hierakonpolis were found in 11 subsamples which consist of mixed human and carnivore coprolites. The significant findings were subsample **ID: H7b** with an average of 759 eggs count per microscopy slide.

Only two coprolite samples (**ID: H28** and **H29**) from Hierakonpolis have a certain origin of dog and revealed taeniid eggs.

The majority of tapeworms of medical and veterinary importance belong to the order of Cyclophyllidea which contains Family Taeniidae. This group of taeniid tapeworms includes the

two most important genera: *Taenia* sp. and *Echinococcus* sp. According to the nature of the studied samples in this PhD work, identified eggs could most probably belong to one or both of these genera.

Taenia solium (pork tapeworm), *Taenia saginata* (beef tapeworm), *Echinococcus granulosus* (dog tapeworm) and *Echinococcus multilocularis* are the causes of most prominent and worldwide spread infection to taeniid tapeworms (Roberts and Janovy Jr., 2009; Torgerson, 2014).

The taeniid cestodes have different larval stages stage (metacestode) inside cysts in their life cycles. They are all foodborne. When eggs are consumed by intermediate hosts, the eggs hatch into an oncosphere, which pass through the intestinal walls and form the metacestode. Cysticercoid, cysticercus, or hydatid cysts are examples of this cyst form of the parasite. The consumption of each of these metacestodes could infect definitive hosts (Cox, 2004; Mehlhorn, 2008; Torgerson, 2014).

Although species of taeniid cannot be differentiated by egg observation, the species can be clearly differentiated by microscopy observation of their body in adult stages (for example by comparing of their scolex) or by molecular biology (González et al., 2002; Knapp et al., 2011).

However, the detection of some of the taeniid copro-antigens in feces by using ELISA techniques has been experienced (Deplazes et al., 1991; Machnicka et al., 1996; Guezala et al 2009) and probably this immunology technique could have application in paleoparasitology.

Taeniid eggs have been reported from several archaeological sites and mummies mostly from the old world and rarely from American continent. However, some cases of taeniid cyst remains have been analyzed in paleoparasitological studies particularly in mummies. There is a case of cysticercosis caused by *Taenia solium* from an Egyptian mummy (Bruschi et al., 2006).

Also, the ancient echinococcosis has been evidenced by study of hydatid cyst remains in European and American continent (Weiss and Moller-Christensen, 1971; Wells and Dallas, 1975; Williams, 1985). Such evidences also recorded from Egypt and Israel in the Middle East (see chapter II).

A review of the taeniid finding in the middle east (see chapter II) show that the most ancient evidences of human taeniasis in this region have been recorded from Cyprus by analysis of samples from human burials in Shillourokambos and Khirokitia dated to around 10,500-6,500 BP. All of the *Taenia* sp. eggs identified in Egyptian paleoparasitology have been recovered from artificial and natural human mummified bodies as well as one embalming rejects jar associated with ancient human mummification, which are dated between 3200 and 1450 BP. Furthermore, all the *Taenia* eggs found at Sai, Kerma and Sedeinga in Sudan come from analysis of human burials dated from 4,350 to 450 BP. However, in different archaeological contexts in Israel, the taeniid eggs have been identified in latrine, cesspit and organic sediments dated from 2550 to 650 BP.

5.3.1.1 *Taenia* sp.

It is known from the Ebers papyrus (1550 BC) that people in ancient Egypt were infected with at least one species of *Taenia* (Hoepli, 1956).

The adult worms of *Taenia saginata* and *T. solium* are found in humans with a cosmopolitan geographical distribution. Infection to *T. saginata* (taeniasis saginata or beef tapeworm infection) occurs in almost all countries where beef is eaten raw or undercooked. Pork is not so often eaten undercooked as beef. Therefore, beef tapeworm infection is more common than the pork tapeworm (*T. solium*). However, *T. solium* infection is more problematic and has a distribution particularly in countries where pork is eaten raw or undercooked. People are infected by either the beef or the pork tapeworm with about 50-60 million cases in the world (Cox, 2004; Todd, 2014).

The adult tapeworms within the final host, embed their scolex in the mucosa of the wall of the ileum or jejunum, and the rest of their bodies (proglottides) extend throughout the lumen. In adult *T. solium*, the scolex is pear-shaped, 1- 2 mm in diameter, with four large suckers and a hooked rostellum. Adult *T. saginata* has no rostellum or hooks.

The adult *T. solium* is a long tapeworm (2 - 3 m in length) and *T. saginata* is longer (sometimes up to 15 m). They could have up to 4000 proglottides. Each mature proglottid measures about 12 mm wide and 10 mm long and each gravid proglottid contains about 80,000 -100,000

eggs. The presence of active proglottides in the feces could be often the first and only sign of infection. It is possible to feel their movement when crawling out through the anus (Muller, 2001). Ancient physicians were aware of the presence of gravid proglottides of the tapeworms in the feces of infected humans (Hoepli, 1956).

Taeniid eggs are very resistant and can survive 60 -180 days on pastures, 16 days in sewage at 18°C and for many weeks in the river water. They are also resistant to the ambient temperature and can survive for up to 1 h at 50°C. The important factor for their survival is moisture and they cannot be alive in desiccation (Muller, 2001).

The eggs are deposited in human feces, often inside the gravid proglottid. Also, they may actively migrate through the anus. They are spherical and measure between 50 and 60 microns in diameter, when they have an outer vitelline layer. However, this thin layer is very fragile and often lost, and does not generally resist particularly to diagenetic processes in soils. Therefore, only embryophores of taeniids are detected particularly in paleoparasitological analyzes. The embryophore is also spherical and its diameter ranges from 25 to 43 microns. Thick shell of embryophore is brown and made up of keratin blocks which give it a striated appearance. It protects an embryo so-called oncosphere or hexacanth. Hooks (six hooklets) of oncosphere are sometimes visible under the microscope. The eggs are morphologically identical to those of *Echinococcus sp.* and many other taeniids (Ash and Orihel, 2007; Taylor et al., 2007; Mehlhorn, 2008).

Eggs may be released from the proglottid, whether in the gut or on the ground. For further development, the eggs need to be ingested by cattle or pigs which act as the intermediate host. The gastric secretions dissolve the shell of embryophore and the oncosphere hatches in the duodenum. Oncosphere penetrates the mucosa by the hooklets, enters the venous capillaries or the mesenteric lymph vessels and is carried throughout the body by the circulation until reaching the muscles. They lose the embryonic hooks there and develop into infective cysticercus larva in 10 -12 weeks or sometimes longer (Muller, 2001).

Cysticercus larva may develop also in many other tissues such as the liver, kidneys, brain and eyes. Cysts in pigs are commonly found in the heart muscle, masseters, diaphragm and tongue. Cysts in calves survive for longer than those in mature cattle. Cysticerci in cattle and pigs are

economically very important. It could occur also in sheep, goats, buffalo, reindeer, giraffes, llamas, wild boars, dogs and cats (Kaufmann, 1996; Roberts and Janovy Jr., 2009).

The cysticerci are ovoid and white in color and measure between 5 and 20 mm (Muller, 2001; Mehlhorn, 2008). They are thus easily visible to the naked eye as white dots and therefore the ancient people could be aware of their presence in slaughtered pigs, cattle and ruminants.

Two forms of food-borne zoonotic infections with *Taenia* sp. are described: “Cysticercosis” and “taeniasis” (Dorny et al., 2009). Humans become infected with the adult tapeworms from eating raw or undercooked beef or pork which contain the cysticerci. The protoscolex of the cysticercus evaginates in the duodenum, attaches to the wall of the ileum and the worm matures in 5 - 12 weeks and begins to form proglottides.

Moreover, humans can become infected with the cysticerci as the larval stages of *Taenia* sp. (mostly *T. solium*) by the accidental ingestion of eggs (presumably on vegetables or in water) or possibly by reinfection of gravid proglottides. Dissemination of the eggs occurs commonly by unhygienic disposal of human feces. Moreover, the role of birds, particularly seagulls, as well as flies in the dissemination of *Taenia* eggs from sewages to fields has been noted (Muller, 2001; Roberts and Janovy Jr., 2009).

Usually the presence of an adult tapeworm in human causes no clinical symptoms. Sometimes vague abdominal pain, headache, nausea, diarrhea, constipation, dehydration weakness and even terminal anemia are found. Loss of appetite and weight could also occur. Moreover, slight traumatic damage to the mucosa could be seen at the site of attachment of the scolex. Perforation of the wall of the intestine which causes very rarely death has also been reported (Muller, 2001; Mehlhorn, 2008).

Human infection with the cysticercus stage normally has far more serious problems than the presence of an adult tapeworm. A pathological signs depend on the localization of the cysts which are spread throughout the body. The most important serious effects are caused by the presence of cysts in the central nervous system especially in the brain (Mehlhorn, 2008).

Taenia asiatica (*Taenia saginata asiatica*) is a recently named species (or as subspecies of *T. saginata*). Cysticerci of this taeniid worm are found in the liver and mesenteries of pigs and

wild boars, as well as in cattle, goats and monkeys in southeastern Asia and a similar form has been reported from areas of Africa. Infection to cysticercus of *T. asiatica* can also occur in humans, as with *T. solium* (Ito et al., 2003; Ash and Orihel, 2007).

Moreover *T. crassiceps*, *T. multiceps* and *T. serialis* are among of the important species within the genus of *Taenia* which are the tapeworms of dogs and wild carnivores. Their cysticerci occur in various rodents, sheep, goats and other herbivore mammals. Cases of human infection to their cyst have been also reported (Soulsby, 1968; Taylor et al., 2007; Mehlhorn, 2008; Roberts and Janovy Jr., 2009).

5.3.1.2 *Echinococcus* sp.

Within the genus *Echinococcus*, *E. granulosus* and *E. multilocularis* are two of the most important species frequently reported in parasitology (Mehlhorn, 2008).

Echinococcus granulosus is found mostly in domestic sheep and cattle throughout the world. There are also wild carnivore/wild herbivore cycles. Cystic echinococcosis (hydatid disease) is resulted by infection to this species of *Echinococcus*.

The adult tapeworm becomes attached to the small intestine of dogs and other carnivores. It has a scolex, neck and 3 - 5 proglottides, measuring always less than 1 cm in length. The gravid proglottid measures 0.5 - 2 mm and contains about 5000 eggs. The gravid proglottides disintegrate in the intestine of carnivores and the eggs are passed out in their feces. The eggs are indistinguishable from that of *Taenia* species. They can survive for 6 - 12 months on soil and are the infective stage for humans. The herbivore intermediate hosts such as cattle, buffalo, goat, pig, horse or camel ingest the eggs when grazing. The life cycle continues relatively similar to *Taenia* species with some differences in the structure of the larval cyst and its contents (Muller, 2001; Mehlhorn, 2008; Roberts and Janovy Jr., 2009)

Clinical signs in intermediate host (as well as human as a possible accidental host) depend on the number and location of hydatid cysts within the infected individual. Cysts are usually single. The larval stage which called “hydatid cyst” could be found in various sites in humans, principally the liver and lungs. However, in children cyst is diagnosed more often in the lungs. Completely

calcified cysts are not commonly pathogenic and have no symptoms. In some cases the presence of the calcified hydatid cyst are only diagnosed after death, in an autopsy. Pruritus and urticarial rash are some allergic reactions resulted when rupturing a cyst and releasing of cyst contents. In this case, an acute anaphylactic shock as well as gastrointestinal disturbances, dyspnoea, cyanosis and even death could be resulted (Mehlhorn, 2008; Roberts and Janovy Jr., 2009).

In animals, echinococcosis is often asymptomatic. However, the main symptom is anal pruritus in heavy infections, which favor parasite transmission (Kaufmann, 1996; Taylor et al., 2007).

Echinococcus multilocularis is the cause of “alveolar” echinococcosis. Infection occurs in animals and occasionally in humans. Human cases principally report from Holarctic areas and the Middle East (Muller, 2001; Roberts and Janovy Jr., 2009).

The adult tapeworms are smaller than *E. granulosus* and the life cycle is similar to that of *E. granulosus* except that adult tapeworms are found in about some species of wild carnivore, principally the fox, and occasionally the dog and cat, while the usual intermediate hosts are the rodent species (Taylor et al., 2007).

Clinical signs are the cysts particularly in the liver. The alveolar echinococcosis is one of the most dangerous helminth infections of humans. The liver parenchyma, bile ducts and blood vessels are destroyed and the symptoms such as biliary obstruction and portal hypertension appear. The first sign of infection is often hepatomegaly. The cyst is not thick-walled and has an outer laminated layer which protects the parasite from host immune responses. Therefore, the infection has no symptoms due to pressure effects. Necrosis of the cyst with abscess formation may also occur. Metastasis of the cysts via the bloodstream could form new cysts, particularly in the lungs and brain. This condition is often mistaken for a carcinoma (Mehlhorn, 2008; Roberts and Janovy Jr., 2009).

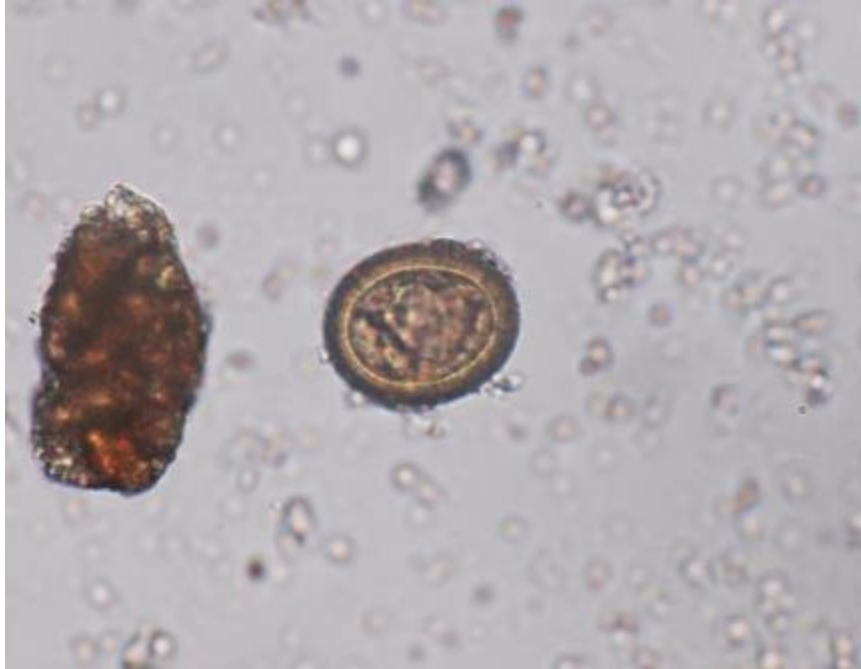

Figure 5.12: *Taenia sp.* egg, displaying characteristic striated eggshell, size: $37 \times 30 \mu\text{m}$, magnification $630\times$, sample ID: C64, Mummy #5, Chehrabad saltmine, Iran.

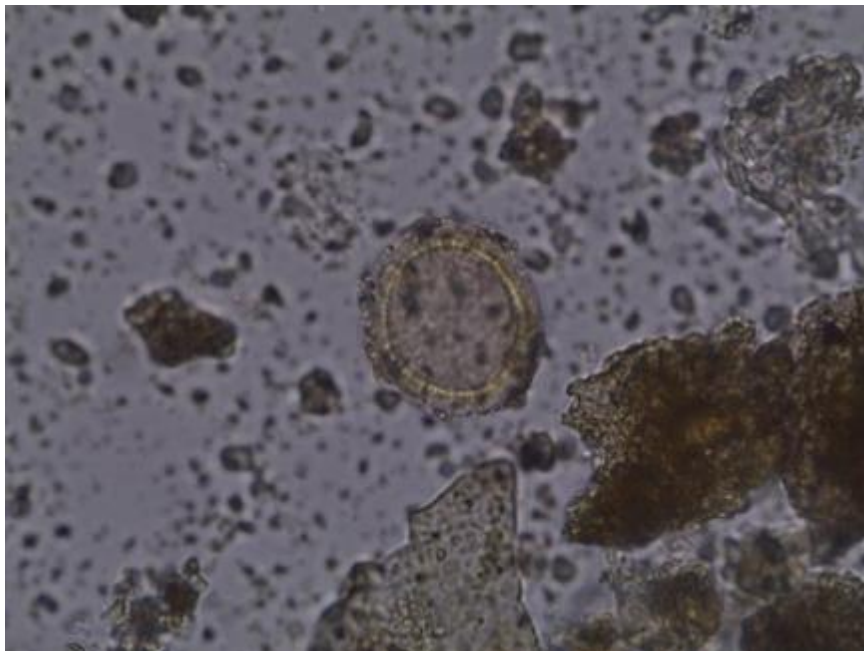


Figure 5.13: Taeniid egg, displaying characteristic striated eggshell, size: $42 \times 38 \mu\text{m}$, magnification $630\times$, sample ID: H29, Hierakonpolis, Egypt.

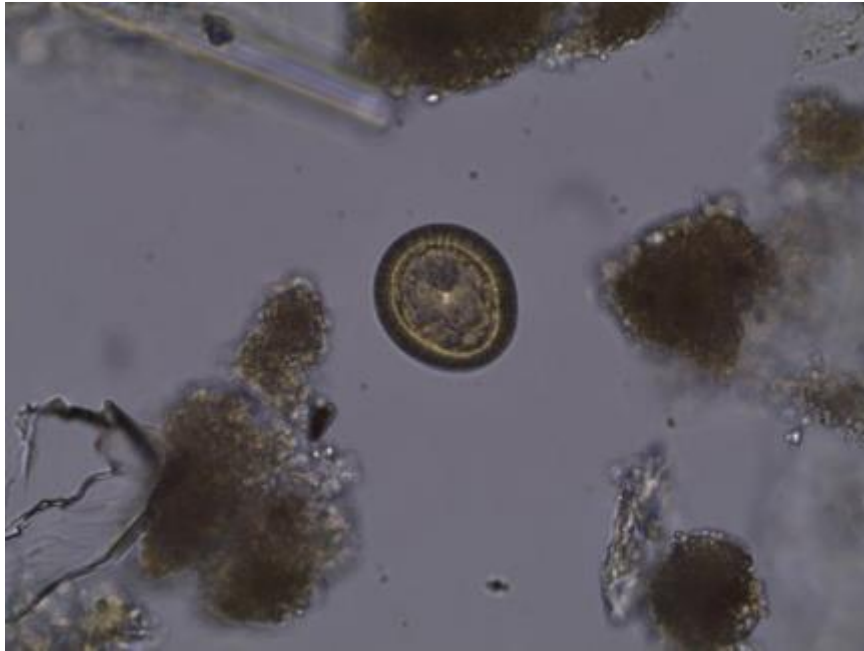


Figure 5.14: Taeniid egg, displaying characteristic striated eggshell, size: $33 \times 30 \mu\text{m}$, magnification $630\times$, subsample ID: H1a, Hierakonpolis, Egypt.

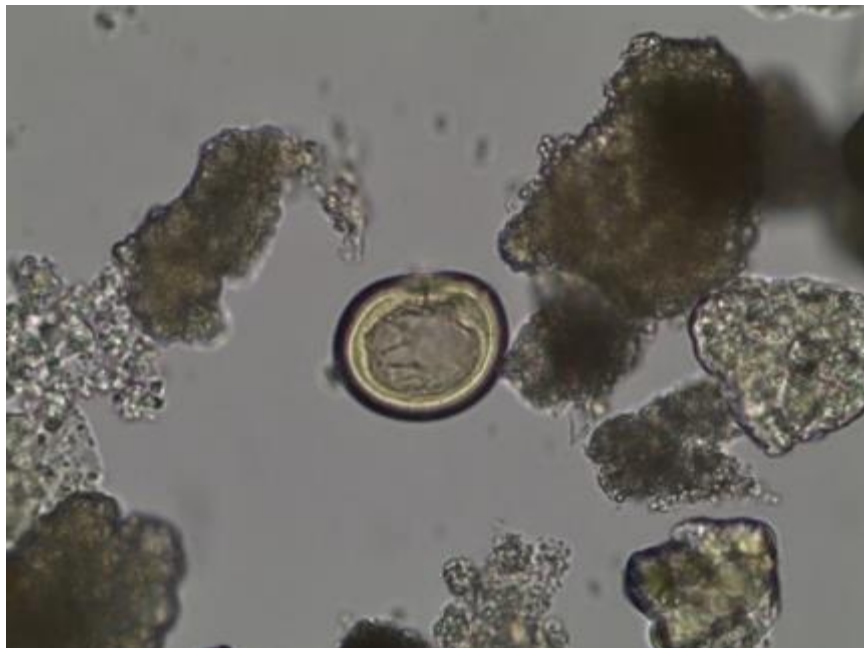


Figure 5.15: Taeniid egg, displaying characteristic striated eggshell and the hooks inside, size: $39 \times 34 \mu\text{m}$, magnification $630\times$, subsample ID: H4c, Hierakonpolis, Egypt.

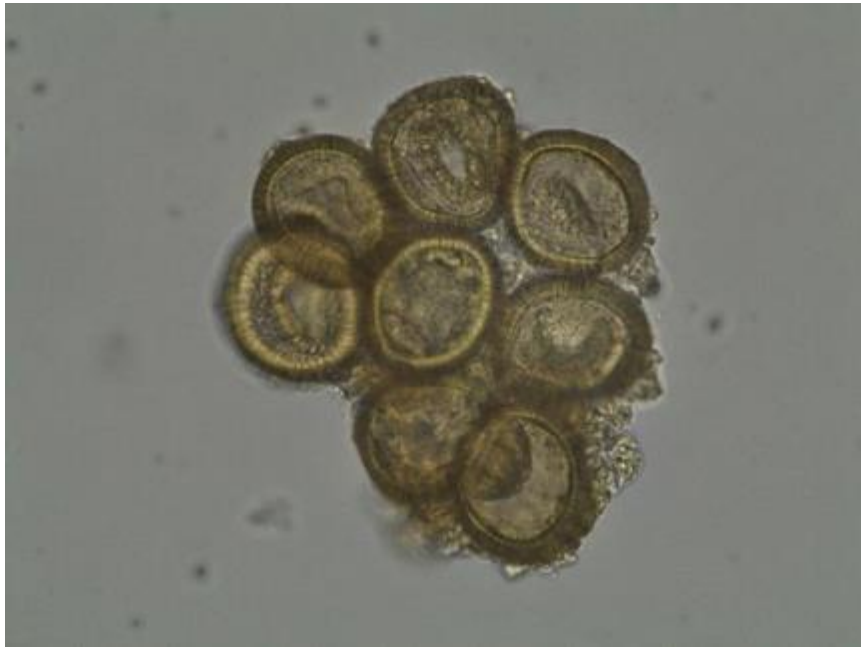

Figure 5.16: Taeniid eggs, displaying characteristic striated eggshell, average size: $36 \times 32 \mu\text{m}$, magnification $630\times$, subsample ID: H7b, Hierakonpolis, Egypt.

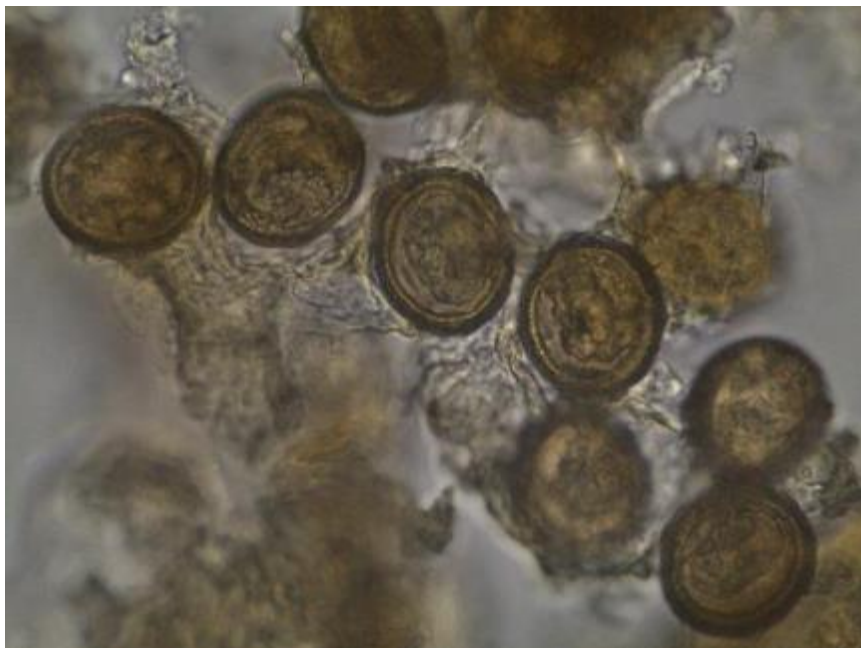


Figure 5.17: *Taenia* sp. eggs, displaying characteristic striated eggshell, average size: $37 \times 32 \mu\text{m}$, magnification $630\times$, sample ID: C33, Chehrabad saltmine, Iran.

5.3.2 *Hymenolepis* sp.

Hymenolepid findings in present study were only two eggs in two different samples from Hierakonpolis. One *Hymenolepis* egg was recovered in sample **ID: H28** which originated from dog pelvis. The latter egg was identified in subsample **ID: H7d** which has carnivore origin mixed with human coprolite.

Hymenolepid cestodes required to complete their life cycle by involving of an arthropod (insect) as intermediate host, and a rodent as definitive host (Mehlhorn, 2008).

Hymenolepis nana is a species of hymenolepid cestodes which primarily parasitize rodents, found also in humans and has a unique life cycle. This cestode can complete its entire life cycle in the gut of a single host (Ito, 1997). *H. nana* also called *Vampirolepis nana*, *Rodentolepis nana* or “dwarf tapeworm” is one of the smallest tapeworms with a size of 2-4 cm. Its scolex has 4 suckers and a crown of hooks. The strobila can consist of up to 200 proglottides which are wider than long. The eggs are round, with a diameter of 30 - 50 × 40 - 60 microns, white and translucent and have dual filaments emerging from the poles of the inner membrane layer. Inside the egg, is an oncosphere provided with three pairs of hooks. The eggs have a thin hyaline shell which is susceptible to heat and desiccation. Therefore, transmission occurs mostly by direct contact between the definitive hosts. Thus, the principal mode of transmission between humans is “hand to mouth”, and less frequently due to contaminated water and food (Ash and Orihel, 2007; Mehlhorn, 2008; Roberts and Janovy Jr., 2009).

The adult worms inhabit the small intestine of the definitive host, particularly the upper two thirds of the ileum. Their eggs leave the host’s body through the feces. They are immediately infective after leaving the host. Human infection occurs by ingestion of embryonated eggs. Infection can occur also by consuming infected insects which act as intermediate hosts (an alternative cycle). In the small intestine the eggs hatch and let release a hexacanth embryo, which penetrates the intestinal mucosa to form (in about 4 days) a larva called cysticercoid. By completing this development, larva is released, returns to the intestinal lumen and will be fixed to the gut wall. It develops to adult form of the parasite, which is fixed by its scolex to the mucosa. The entire cycle is about 3 weeks, since ingestion of embryonated eggs until reaching adult stage worm and be capable of producing new eggs by hermaphrodite sexual reproduction. Adult

parasites have a life span of several weeks. Sometimes internal autoinfection may also occur (Chiodini et al, 2003, Cox, 2004; Mehlhorn, 2008; Roberts and Janovy Jr., 2009).

H. nana infection produces nonspecific symptoms such as headache, abdominal pain, vomiting, nausea and diarrhea. A slight infection causes no symptoms or only vague abdominal discomfort occurs. However, a severe infection can also cause secondary aplastic anemia and eosinophilia (Mehlhorn, 2008). Today, the infection is mainly common in school children (WHO, 2004).

Harter (2003) has reported *Hymenolepis* sp. eggs from Sai and Sedeinga in Sudan dated from 2225 BP up to 150 BP (see chapter II).

Moreover, the oldest hymenolepid finding eggs before this study is dated to 4000-2000 BP reported from Brazil (Gonçalves et al., 2003). Therefore, both *Hymenolepis* sp. eggs identified in the samples from localities 6 and 11C of Hierakonpolis, are of the most ancient cases of hymenolepid findings so far which are dated between 3900 and 3300 BC.

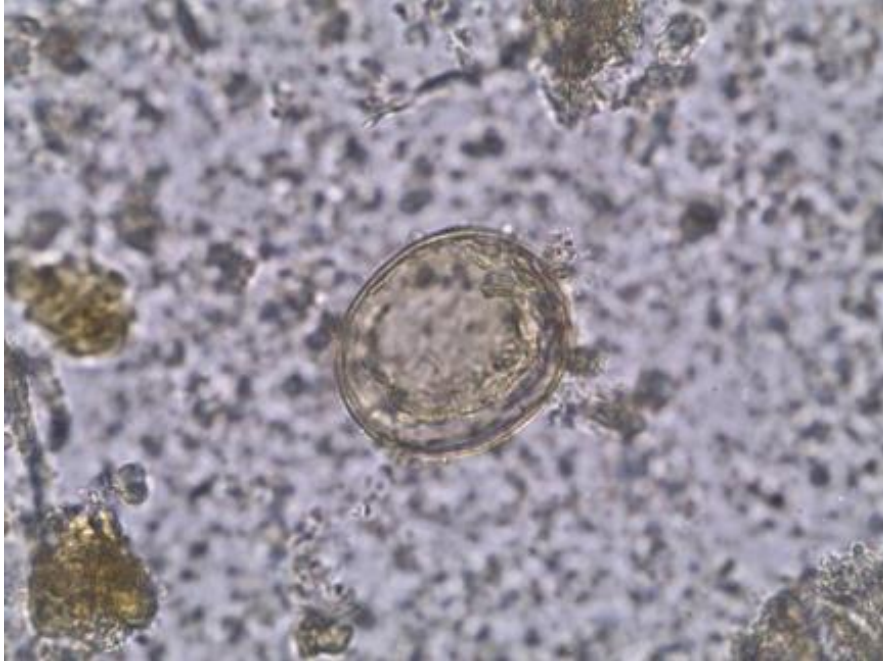


Figure 5.18: *Hymenolepis* sp. egg, displaying eggshell with a hexacanth embryo, size: $54 \times 47 \mu\text{m}$, magnification $630\times$, sample ID: H28, Hierakonpolis, Egypt.

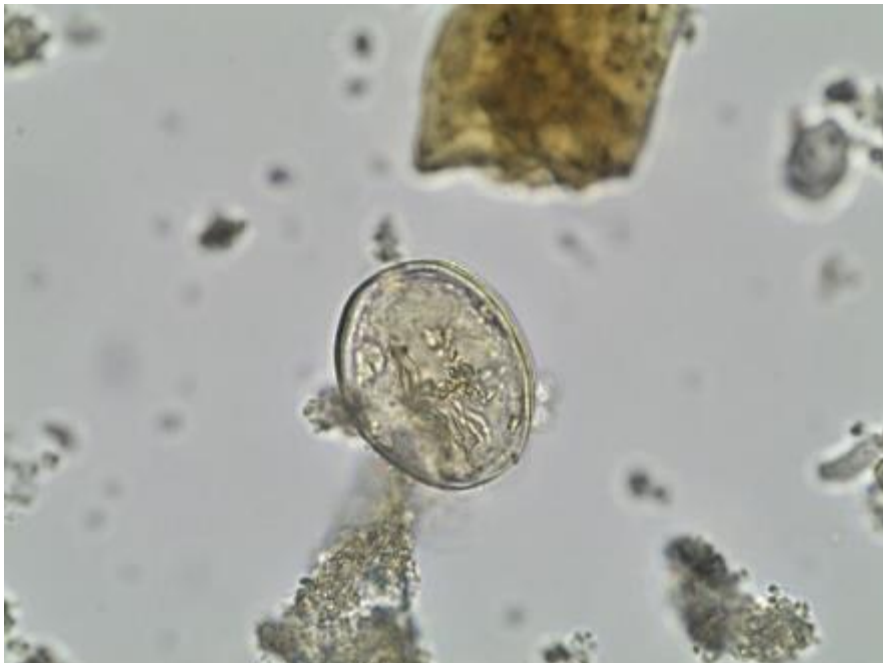

Figure 5.19: *Hymenolepis* sp. egg, displaying eggshell with a hexacanth embryo, size: $50 \times 39 \mu\text{m}$, magnification $630\times$, subsample ID: H7d, Hierakonpolis, Egypt.

5.3.3 Anoplocephalidae

12 identified eggs of anoplocephalid eggs could be measured morphometrically in subsample **ID: H1c** from Hierakonpolis. This sample has carnivore origin mixed with possibly human coprolites. Anoplocephalid cestodes infect mainly herbivores. Therefore, if the coprolite originated from carnivores, the presence of these eggs in this subsample could be described by possible coprophagy or the consumption of an infected herbivorous animal (Fugassa et al., 2006).

Anoplocephalid species are very difficult to identify by their eggs. Also, because of the particular morphological features as well as bad preservation of the recovered eggs, measuring of them has been accomplish only on intact eggs, which resulted an average size of $93 \times 63 \mu\text{m}$. In this sense, the eggs found in the present study, based on their aspect and size, could be attributed to *Anoplocephala* sp. (Thienpont et al., 1986).

Two categories of animal specific tapeworms are within this family: tapeworms of horses (*Anoplocephala* sp. and *Paranoplocephala* sp.) and tapeworms of ruminants (*Moniezia* sp.). Their intermediate stage (cysticeroid) occurs in forage mites of the family Oribatidae (Taylor et al., 2007).

The adult worms in this family have not rostellum and hooks in the scolex. The width size of their gravid segments is more than the length size. The adults are varied in size and in different species measure from 1 cm up to 10 meter (Soulsby, 1968; Mehlhorn, 2008).

The eggs are ingested by intermediate hosts which are arthropods (mostly oribatid mites). The oncosphere hatches and migrates to the hemocoel of mite, where it develops to the second larval type (cysticeroid). The growth rate is dependent to the ambient temperature. The final host will be infected when swallowing of infected intermediate hosts. The cysticeroids evaginate in the intestine of the final host and develop directly into adult tapeworms in 4 - 8 weeks (Soulsby, 1968; Mehlhorn, 2008).

Adult anoplocephalids live in the middle third of the small intestine and rarely produce harmful effects on the host. Heavy infestations associated with diarrhea and ill thriving, particularly concomitant with infection by gastrointestinal nematodes may often cause greater pathologic effects (Mehlhorn, 2008).

Moniezia expansa is an important species of anoplocephalids which has worldwide distribution and lives in the small intestine of ruminants. Intermediate oribatid mites are ingested together with herbage. Anemia, diarrhea and weight/productivity loss are the most common signs of disease. Diagnosis is done by finding the characteristic proglottids around the anus or by the determination of eggs in the feces (Kaufmann, 1996; Taylor et al., 2007).

Anoplocephala magna and *Paranoplocephala mamillana* are the other species found in the small intestine of horses. They have commonly no clinical symptoms. However, *Anoplocephala perfoliata* could cause spasmodic colic and ileal impaction colic in the equids. Moreover, *Mathevotaenia* sp. could infect humans. The infection occurs by ingestion of infected beetles when eating as food or as medical remedies. Also, some of the anoplocephalids are found in rodents and lagomorphs such as *Cittotaenia* sp. (Mehlhorn, 2008; Beltrame et al., 2013).

Anoplocephalid cestodes have been rarely reported in paleoparasitology. The sole evidence so far of anoplocephalids in archaeological material from the Old World is that of an egg of *Anoplocephala perfoliata* in a piece of cloth from a medieval tomb in Spain (Hidalgo-Arguello et al., 2003).

The eggs were also recovered frequently in canid and rodent coprolites from archaeological and paleontological sites in Argentina (Fugassa et al., 2006; Sardella and Fugassa, 2009; Fugassa et al., 2010; Beltrame et al., 2012; 2013).

Species	Egg size (µm)	Final host
<i>Moniezia expansa</i>	50-60	Ruminants
<i>Anoplocephala magna</i>	50-60	Horses
<i>Anoplocephala perfoliata</i>	60-80	Horses
<i>Thysaniezia</i> sp.	25	Ruminants
<i>Stilesia</i> sp.	25	Ruminants
<i>Avitellina</i> sp.	20 × 40	Ruminants
<i>Cittotaenia</i> sp.	40	Lagomorpha

Table 5.3: Anoplocephalid egg size (important species).

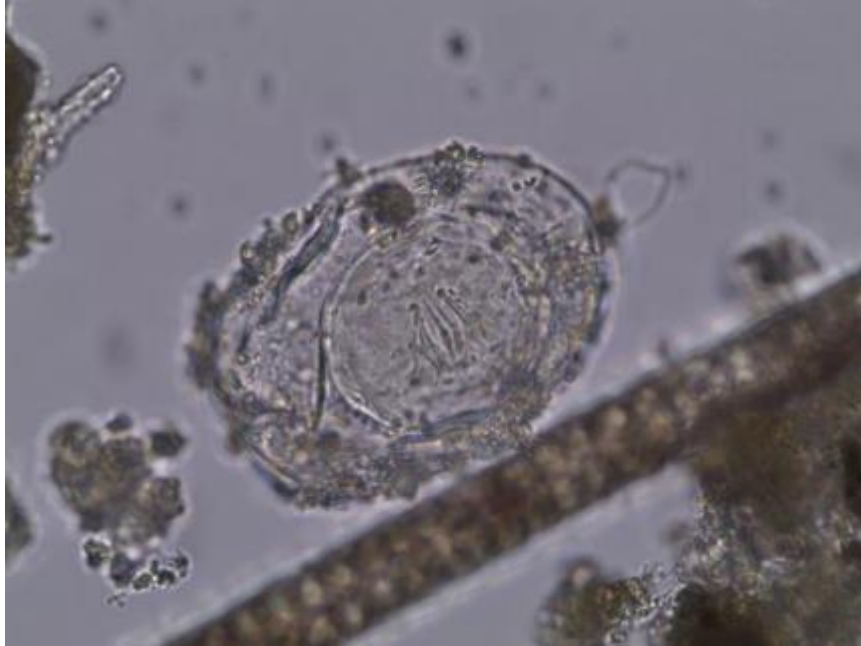

Figure 5.20: Anoplocephalid egg, displaying bad preservation of outer covering membrane of eggshell, a hexacanth embryo inside, size: $92 \times 64 \mu\text{m}$, magnification $630\times$, subsample ID: H1c, Hierakonpolis, Egypt.

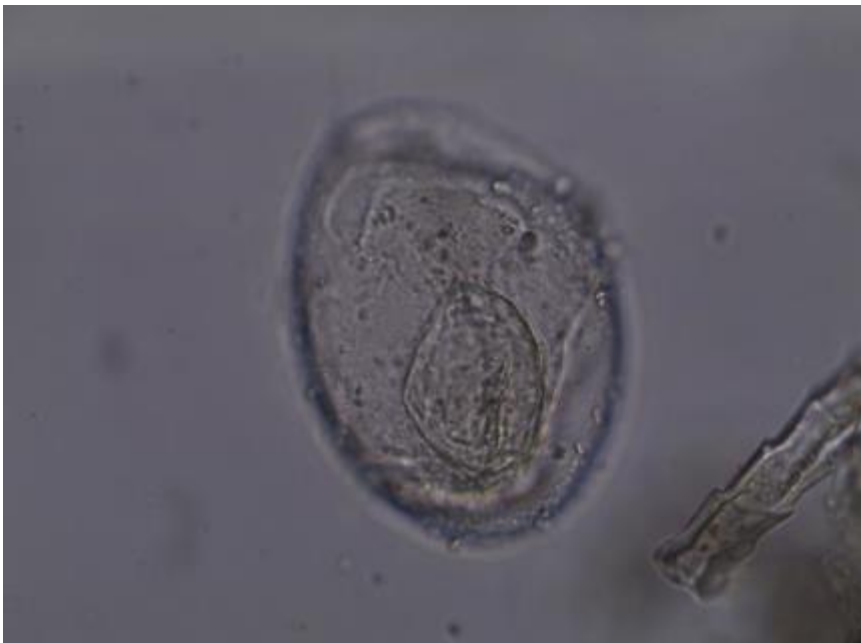

Figure 5.21: Anoplocephalid egg, displaying bad preservation of outer covering membrane of eggshell, a hexacanth embryo inside, size: $100 \times 72 \mu\text{m}$, magnification $630\times$, subsample ID: H1c, Hierakonpolis, Egypt.

5.4 Nematode findings

Majority of the nematode finding eggs in the present analysed samples come from Chehrabad saltmine. The findings in this site consist of roundworm (*Ascaris* sp.), whipworm (*Trichuris* sp.), human pinworm (*Enterobius vermicularis*), horse pinworm (*Oxyuris equi*) and

Identified	Measured egg(s)			Site	Dating	Sample	Origin	ID
	Count	Length (µm)	Width (µm)					
<i>Ascaris</i> sp.	1	50	42	Chehrabad Salt mine	Achaemenid period (7th Century - 4th Century BC)	Soil sediment	Unknown Human?	C82
	3	65±1.2	49±1.2		Sassanid period (3rd Century - 7th Century AD)		Unknown	C75
<i>Ascaris lumbricoides</i>	14	66±5.7	49±2.9	Chehrabad Salt mine	Sassanid period (3rd Century - 7th Century AD)	Coprolite	Human	C31
<i>Enterobius vermicularis</i>	15	60±3.0	30±1.4	Chehrabad Salt mine	Achaemenid period (7th Century - 4th Century BC)	Soil sediment	Unknown Human?	C82
					Sassanid period (3rd Century - 7th Century AD)	Coprolite	Human	C31
					without dating	Soil sediment	Unknown Human?	C81
<i>Oxyuris equi</i>	3	79±2.9	41±3.6	Chehrabad Salt mine	Achaemenid period (7th Century - 4th Century BC)	Soil sediment	Unknown Human?	C82
					Unknown		C83	
					Sassanid period (3rd Century - 7th Century AD)	Coprolite	Unknown	C32
<i>Trichuris</i> sp.	5	51±1.9	27±2.4	Chehrabad Salt mine	Achaemenid period (7th Century - 4th Century BC)	Soil sediment	Unknown	C85
					without dating			
	19	56±3.1	30±1.4	Hierakonpolis (Locality 11C)	3900 - 3300 BC	Coprolite	Carnivore Human	H1a
							Carnivore Human	H1e
1	58	29				Carnivore Herbivore Rodents?	H3c	
<i>Trichuris trichiura</i>	42	53±3.3	27±1.5	Chehrabad Salt mine	Sassanid period (3rd Century - 7th Century AD)	Coprolite	Human	C31
Strongylid / Trichostrongylid	5	77±2.9	43±3.6	Chehrabad Salt mine	Sassanid period (3rd Century - 7th Century AD)	Coprolite	Unknown	C32

Table 5.4: Identified eggs in the class of Nematoda

strongyles (strongylid / trichostrongylid) taxa. Nevertheless, the nematode findings in Hierakonpolis, only consist of whipworm eggs.

5.4.1 *Ascaris* sp.

In the present study, the eggs of *Ascaris* sp. have been identified in two soil sediments (Nezamabadi et al., 2013a) as well as one coprolite sample from Chehrabad saltmine. These findings are the first evidences of ascariasis in the Iranian Plateau and could add to our knowledge on ancient ascariasis in the east region of the Middle-East.

The soil sediments have been sampled from the occupation layers and their origins are not known. One of these samples is dated to Sassanid period (**ID: C75**). Three eggs of *Ascaris* with the average size of $65 \times 49 \mu\text{m}$ have been recovered from this soil sediment (Figure 5.23).

The other positive sample (**ID: C82**) is dated to Achaemenid period. The sole identified *Ascaris* egg in this soil sediment is measured $50 \times 42 \mu\text{m}$. This egg size is considerably smaller than the other identified roundworm eggs at the site (Figures 5.22 and 5.24).

The most number of *Ascaris* egg findings in Chehrabad come from one coprolite sample (**ID: C31**) belong to a Sassanid layer with some recent contamination. The archaeologists were not assured about human origin of this coprolite. The *Ascaris* eggs in this coprolite were accompanied with *Trichuris* sp. eggs and *Enterobius vermicularis*. The presence of *Enterobius vermicularis* as a human-specific parasite could be an evidence for the human origin of this coprolite (Figure 5.25). Therefore, we can propose that the *Ascaris* egg recovered from this sample consist of the species of *Ascaris lumbricoides*, the human roundworm. The average size for these eggs is $66 \times 49 \mu\text{m}$ ($n=14$). Also one identified egg in this coprolite was measured $84 \times 41 \mu\text{m}$ which is morphologically comparable to unfertilized *Ascaris* eggs (Figures 5.22 and 5.26).

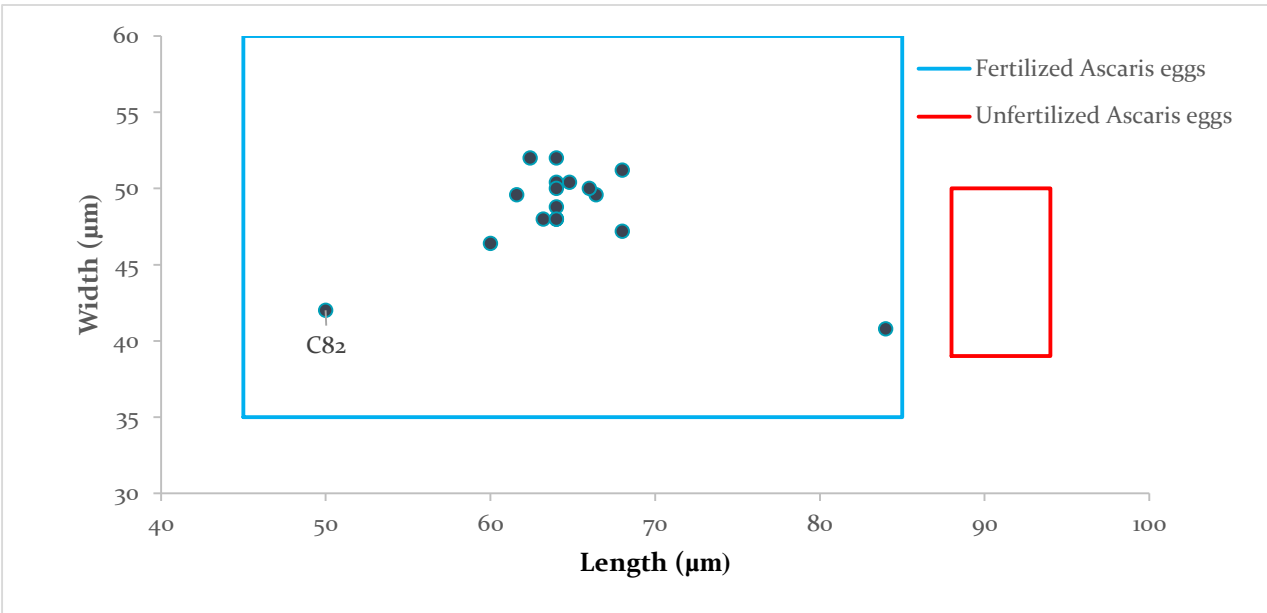


Figure 5.22: Morphometric analysis of identified *Ascaris* eggs in samples (ID: C75, C82 and C31) from Chehrabad saltmine, Iran.

The roundworm of the genus of *Ascaris* (Family: Ascarididae) is a lumen-dwelling nematode which has been one of the most known nematode parasitic worms since ancient time (Crompton 2001; Bouchet et al., 2003). This helminth has been described at least from fifth century BC by the ancient physicians such as Hippocrates (460–399 BC) (Grove, 1990). The Adult *Ascaris* sp. is the largest intestinal roundworm with a size up to 40 cm long and 5 mm wide. Therefore, we can expect that the ancient people were probably familiar with this nematode since prehistoric times due to its adult size, infection symptoms, abundance, and cosmopolitan distribution (Ransom and Foster, 1919; Mehlhorn, 2008; Roberts and Janovy Jr., 2009).

Ascaris infection which called ascariasis is common in both temperate and tropical regions with adequate moisture. Human and pigs are two of major hosts for roundworm. *A. lumbricoides* is the species which causes one of the most common human helminth infection (human ascariasis) with a worldwide distribution and approximately 60,000 human deaths per year in nowadays (<http://www.who.int>; Roberts and Janovy Jr., 2009). Also, *A. suum* has been known so far as a different species which is the cause of animal ascariasis recorded mostly from pigs. Eggs of both species are undistinguishable morphologically. However, some researchers have supposed that these two mentioned roundworms are one species, based on morphological (Ransom and Foster,

1919; Schwartz, 1920; 1926) and recently by paleoparasitological and genetic evidences (Leles et al., 2012). Moreover, there is some hypotheses about the transmission of *Ascaris* between and among humans and pigs (cross-infectivity) and its possible associations with animal domestication (Crompton 2001; Loreille and Bouchet, 2003; Roberts and Janovy Jr., 2009; Leles et al., 2012; Peng and Criscione, 2012).

In a direct life cycle (without intermediate host), the resistant eggs of *Ascaris* sp. are excreted in the feces from adult worms which live in the small intestine of their hosts. These eggs pollute the soils or plants and could be spread by water in the environment. The eggs are not immediately infective after leaving the infected host and require a holding period in a suitable environment (10–40 days, depending on the environment temperature as well as sufficient humidity and atmospheric oxygen) to develop the second-stage larvae inside themselves as infective form of parasite. The optimum temperature for development of *Ascaris* egg is 22 to 26°C (Taylor et al., 2007). Ingesting the embryonated eggs containing second-stage larva may result in infection of a new host or re-infection of the previous host. Therefore, infected individuals could show unsafe disposal of feces, and inadequate agricultural and food hygiene. Infection of human host particularly may occur from “hand to mouth”, or consuming undercooked food or ingesting contaminated food with ripe eggs (e.g., not adequately washed edible plants). After oral uptake of infectious eggs, they hatch and the larvae escape from the eggshell within the stomach or intestine of the animal or human host (Yoshida, 1919a; 1920; Soulsby, 1968; Mehlhorn, 2008).

Ascariasis is known as one of the most important soil-transmitted helminthic infection, and also as an important socioeconomically disease (WHO, 2004; 2006). In the case of human ascariasis, the larvae penetrate the mucosa and submucosa of the small intestine wall and migrate by the way of lymphatic streams or blood vessels passing through the heart into the other organs and tissues, particularly the liver and then to the lungs where they enter the bronchi, trachea and alveoli. They stay in the lung for at least 2–3 weeks and continue their development. The presence and migrating of the larvae in the lung gives rise to allergic symptoms associated to the pulmonary system in previously infected and sensitized individuals. Pulmonary reactions include bronchopneumonia, bronchitis with bronchospasm. Coughing up of immature worms is reported especially in children. The larvae in the lungs continue their development, break into the air spaces of the lung and migrate to the mouth cavity through the trachea. Most larvae are swallowed and

again passing down the alimentary canal to the small intestine of the host and grow to be mature. The adult male worms are 15-20 cm in long but the female worms are longer and sized between 20 and 40 cm. One female *Ascaris* can lay 200 to 200,000 eggs per day. A massive infection by ascariasis can be fatal especially in children, in a severe nutritional drain or by resulting in intestinal obstruction, because of the worm number and mass. The adult worms may migrate out of the gut into the oesophagus and mouth. Vomiting up of adult worms could occur in this stage. Also they can migrate to the bile duct, pancreatic duct or appendix and occasionally the liver and cause abdominal pains, diarrhea, fever, appendicitis, and jaundice. Peritonitis caused by perforating of the gut and necrotic tracts in the liver are the other pathological signs. Moreover, serious pathological damage on extra-intestinal sites occurs in heavy infections (e.g. in eyes, brain, and etc.). Furthermore, infection (or reinfection) by *Ascaris* contributes to malnutrition and growth retardation in children (Yoshida, 1919a; 1919b; Soulsby, 1968; Crompton 2001; Chiodini et al, 2003; Mehlhorn, 2008; Roberts and Janovy Jr., 2009). The present global infection by human ascariasis has been reported up to 1.2 billion (WHO, 2006).

In the other hand, ascariasis is generally more prevalent in young pigs and reported as the most damaging digestive worm disease for them. In the ordinary moderate infections, adult pigs have no defined pathogenesis. In heavy infection, stunting, poor growth, and coughing occurs particularly in young individuals and loss in performance, weight loss, anorexia, diarrhea, constipation as well as intestinal or bile duct blockage appears in them. The larval stages can cause severe damage to the liver or the lung, even death. Also in slaughtered pigs, fibrosis in the liver associated with larval migration could be observed as white spots which called “milk spots” (Soulsby, 1968; Kaufmann, 1996; Crompton 2001; Foreyt, 2001; Taylor et al., 2007; Elsheikha and Patterson, 2013). Furthermore, the larval stages of pig roundworm can cause lung symptoms in humans and the other animals. It shows the potential zoonotic disease of pig ascariasis (Zajac and Conboy, 2011).

Chickens as paratenic hosts (Olsen et al., 2000), dogs as biological transmitter by coprophagy of feces (Traub et al., 2002; Shalaby et al, 2010), and carrying of *Ascaris* eggs by cockroaches as transport host and even egg carrying by windborne dust could probably play an important role in disseminating and environmental contamination of the disease in some areas.

Uncooked vegetables when using “nightsoil” (human feces) as fertilizer could be also another important mechanical vector of *Ascaris* eggs (Roberts and Janovy Jr., 2009).

The eggs of *Ascaris* sp. are one of the most reported findings in paleoparasitology. Eggs are commonly found in coprolites, intestinal contents of mummies, and in other kind of archaeological material. When the origin of the studied samples is known as human (for example in study of human coprolites and latrines), the paleoparasitologists have been able to mention their *Ascaris* egg findings in specie level as *Ascaris lumbricoides*. Based on biology and life cycle of this parasite, findings of *Ascaris* eggs in the archaeological samples could show low levels of hygiene and sanitation in related ancient habitants or individuals at the site and also provide some evidence associated with their lifeways.

The fertilized eggs of *Ascaris* sp. measure 45-75 μm in length and 35-50 μm in width (medium-sized ova). They are round or ellipse-shaped with a thick and rough albuminous outer mammillated layer. The eggshell also contains a very thick colorless middle layer as well as an inner layer with a thin yolk membrane. This multilayered eggshell which contains the lipid inside its structure provides an extraordinary chemical/temperature resistance layer for *Ascaris* sp. ova against desiccation in the environment for several years (Taylor et al., 2007). Fresh eggs are golden brown, but the contents of the egg are colorless or pale yellow. The content could be an unsegmented cell with rough granules (Rai et al., 1996). The unfertilized ova are generally larger (88-94 μm in length by 39-50 μm), narrower and more elongate and the egg content is full of large round granules. The unfertilized egg of *Ascaris* is atypical and non-infectious form of parasite and usually seen when there is an uninseminated female, or one in early stages of oviposition inside the infected host (Foster 1914; Roberts and Janovy Jr., 2009).

The appearance of the ova of *Ascaris* sp. as seen in archaeological samples is similar to observed eggs in fresh feces. However, the ancient eggs could differ so widely from the normal egg of *Ascaris* and cause considerable confusion on the part of observers, and may even be misleading in appearance as to be nonparasitic elements. In a study on SEM examination of ancient parasite eggs, Shin and his colleagues have compared morphologically the ancient and fresh helminth eggs to identify the preservation status of them in archaeological recoveries (Shin et al., 2009). In their observation, most of the ancient *A. lumbricoides* eggs were severely broken or pressed flat.

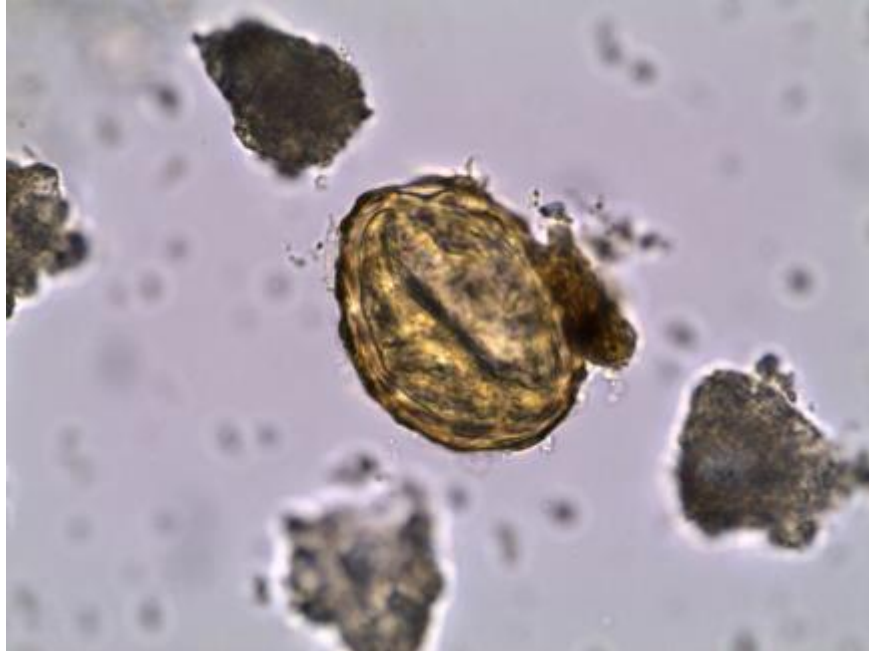


Figure 5.23: *Ascaris* sp. egg, displaying characteristic thick, mammillated outer shell, size: $65 \times 49 \mu\text{m}$, magnification $630\times$, sample ID: C75, Chehrabad saltmine, Iran.

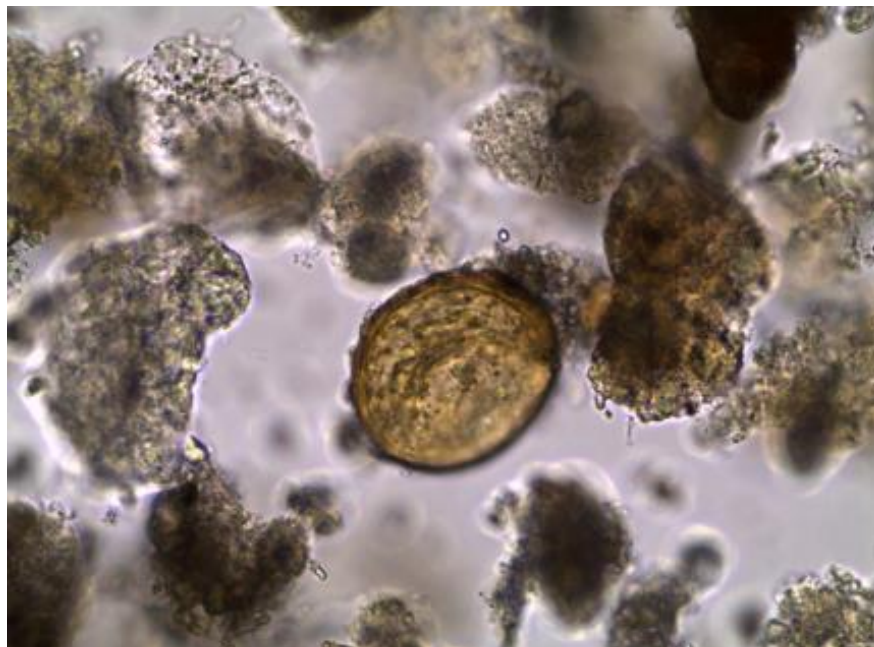


Figure 5.24: *Ascaris* sp. egg, displaying characteristic thick, mammillated outer shell, size: $52 \times 42 \mu\text{m}$, magnification $630\times$, sample ID: C82, Chehrabad saltmine, Iran.

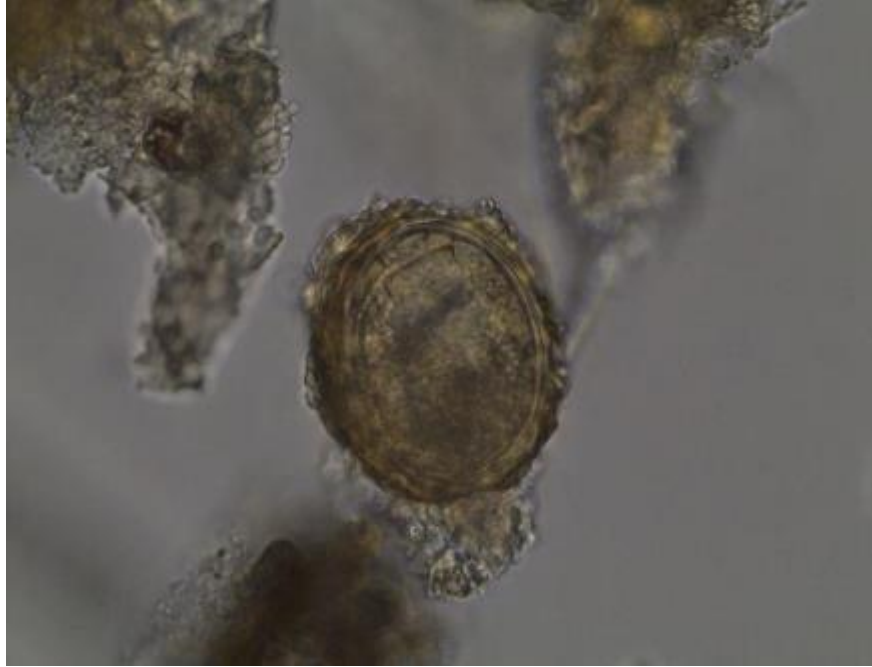

Figure 5.25: *Ascaris lumbricoides* egg, displaying characteristic thick, mammillated outer shell, size: $66 \times 49 \mu\text{m}$, magnification $630\times$, sample ID: C31, Chehrabad saltmine, Iran.

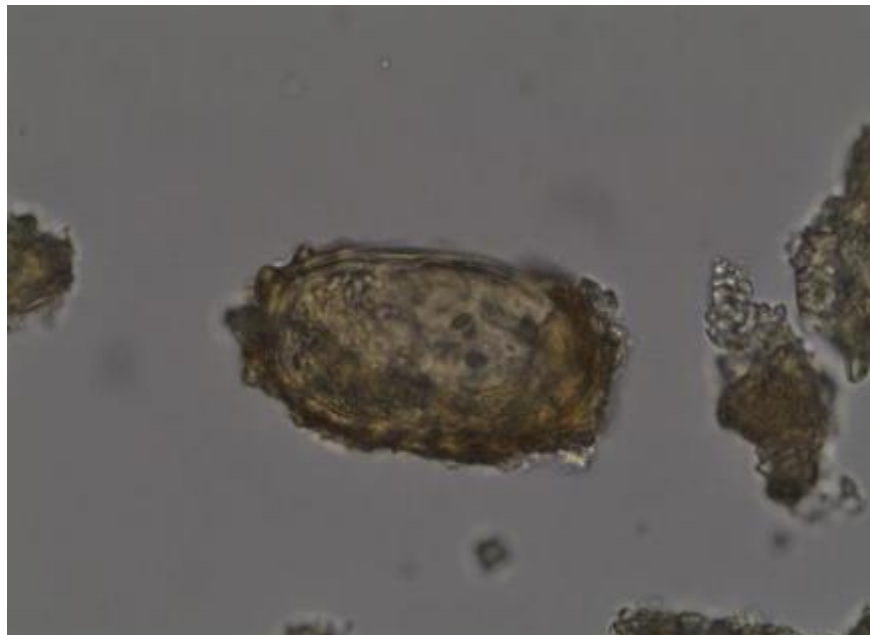


Figure 5.26: *Ascaris lumbricoides* egg (probable unfertilized), displaying characteristic thick, mammillated outer shell, size: $88 \times 41 \mu\text{m}$, magnification $630\times$, sample ID: C31, Chehrabad saltmine, Iran.

From a paleopathological point of view, the association of these *A. lumbricoides* eggs with the presence of a human parasite (*E. vermicularis*) make us assured that the presence of at least one infected human by ascariasis at the site. The other *Ascaris* eggs could be associated with both human or pig ascariasis.

As a soil transmitted parasite, presences of *Ascaris* sp. (include *A. lumbricoides*) eggs in salt-preserved sediment and fecal samples of Chehrabad can indicate circumstances of human and/or animal health through a possible sedentary lifestyle and possible cross-infection between saltminers and their livestock such as pigs. Zooarchaeological evidences of pig bones reported from this site could support these possibilities. Furthermore some human and animal fecal remain at the site, prove the inadequate disposal of them during mining activity and it reflects the hygiene habits of ancient miners in Chehrabad. Poor sanitary conditions as well as a limited and contained space of the mine could provide a proper environment for continuation of parasitic life cycles and transmission of anthrozooses parasites such as *Ascaris* sp. Also these findings demonstrate the poor hygienic conditions, beside the prevalence of *Ascaris* infections since Achaemenid to Sassanid period in the northwestern region of Iran.

In the same salty context of Chehrabad, *Ascaris lumbricoides* eggs have been reported from coprolite specimens of Hallstatt and Durnberg sites in Europe dated to European Iron Age (Aspöck et al. 1973; 1999; 2000; 2007). Also the most ancient *Ascaris* eggs recovered until now has been reported from European continent. They are the 30,000 year old upper Paleolithic ova from the site of Arcy-sur-Cure, Yonne, France (Bouchet et al. 1996).

In African continent, *Ascaris lumbricoides* have been reported from Late Stone Age coprolites in South Africa (Evans et al., 1996).

In paleoparasitology of Asian countries (in China, Japan and Korea), eggs of *Ascaris lumbricoides* and *Ascaris* sp. have been found in samples dating from 100 BC up to the 19th century (Han et al., 2003; Matsui et al., 2003; Seo et al., 2007; Oh et al., 2010; Shin et al., 2009a; 2009b; 2011; Kim et al., 2013).

The oldest *Ascaris* eggs recovered so far in the Middle East were collected by Harter from human burials dated to the pre-pottery Neolithic period, between 8500 and 7500 BC in Shillourokambos, Cyprus (Harter, 2003). Ancient ascariasis has been reported also from

archaeological samples in Egypt, Sudan and Israel dated between third millennium BC and 15th century AD (see chapter II).

Surprisingly, there is no record of *Ascaris* finding in the recent work of Savinetsky and Khrustalev (2013), who could recover a large amount and variety of parasite eggs in samples from Mongolia, Middle Asia and Russia.

5.4.2 *Enterobius vermicularis*

Findings of *Enterobius vermicularis* in this study consist of 12 eggs with average size of 60×30 µm recovered in a coprolite sample (**ID: C31**) as well as three other eggs with average size of 59×30 µm in two soil sediments (**ID: C81** and **C82**) from Chehrabad Saltmine (Nezamabadi et al., 2013a).

Enterobius vermicularis finding is the lone real specific human parasite recovered in the studied soil samples and coprolites in this PhD work. It could help us to be assure about the human origin of one coprolite sample (**ID: C31**). Therefore, we can conclude about the species of the other parasite eggs found in this coprolite sample through a high reliability. However, this conclusion is not possible for the soil sediment samples (**ID: C81** and **C82**). Although, both of this sediments have no certain origin, they have been attached to probable human coprolites in the archaeological layers of Chehrabad. One of them (sample **ID: C82**) contains horse pinworm among its recovered parasite eggs. Horse pinworm (*Oxyuris equi*) is an animal specific parasite. Therefore, contamination of human and animal feces is not far from mind for soil sediment samples in Chehrabad, particularly sample **ID: C82**.

Moreover, pinworm could particularly develop in close environments and communities as Chehrabad. Recovery of these pinworm eggs in the layers helps us in better understanding the sanitary conditions of the miners, and their low personal hygiene status. The estimated life time of the mummified individuals at this site ranges between 35 and 45 years. As noted above, current human pinworm infection mainly occurs in childhood. Nonetheless, analyses performed on ancient Nubian populations showed that all age classes were infected by *E. vermicularis* (Harter, 2003).

Sample **ID: C81** and **ID: C82** are dated to Achaemenid period and sample **ID: C31** is Sassanian. It shows the presence and continuity of the health and hygiene problem associated with enterobiasis for the habitants in Chehrabad saltmine and its area between 6th century BC and 6th century AD.

Enterobius vermicularis belongs to a category of intestinal helminth known as pinworm and parasitize exclusively humans. *Enterobius gregorri* has been also suggested as another species of human pinworm in the same genus as *Enterobius vermicularis* with differences in morphological characteristics (Hugot, 1983). However, there is some doubt in parasitology about this new species. Indeed, it is not still clear that this morphological difference is genetically coded or not (Totkova et al., 2003; Lotfy, 2004; Roberts and Janovy Jr., 2009).

Enterobius vermicularis (human pinworm) is an example of an inherited parasite, which has been present in human ancestors and has a long history of coevolution with its human host. Men and pinworms have been coexisting together in Africa long time before human dispersion throughout the continents (Hugot et al. 1999). This pinworm has currently the widest helminthic geographical distribution in the world, which is due to its ready transmissibility and close association with humans (Mehlhorn, 2008). Being an exclusively human parasite can be argued that any organic material containing eggs of *E. vermicularis* should be probably of human origin (Gonçalves et al., 2003).

As *Ascaris* and *Trichuris* sp., *E. vermicularis* is cosmopolitan and has a direct life cycle without intermediary hosts, but it is not in the category of the soil transmitted helminth and doesn't need stages in the soil (Cox, 2004). The complete life cycle of *Enterobius vermicularis* lasts 2 to 4 weeks. After ingesting the embryonated egg, the larva is released in the small intestine, particularly the duodenum, where it passes into the large intestine for developing to adult. In some cases, hatched larvae may enter the intestine directly via the anus, or occasionally via the vagina of women. The adult worms are small size, thin and white. The female is about 8-13 mm and the male is approximately 2-3 mm in long. The location of adult worms could be in the intestinal tract of the host, mostly in the caecum, appendix, colon and rectum. Unlike other intestinal helminths, they are unable to injure or penetrate the mucosa. They live in the intestinal epithelial cells and feeding on bacteria. The eggs are passed by migrating gravid females (at night) in the anus and perianal area (up to 14,000 eggs/female). The adult female could be sometimes found on the surface

of fecal matters. Adults' life time is short and estimated to be up to 2 months. The eggs are embryonated to the first stage larva within 3-4 hours (at optimum temperature 35°C). They need oxygen for complete development and do not develop below about 22°C. These embryonated eggs are usually found in the folds of skin around the anus and also can be discharged onto the surface of the fecal matters or found in sewages. Most of the eggs found inside the feces are unembryonated. Moreover, immature larval stages of *E. vermicularis* could be found rarely in feces samples. Some of the laid eggs will attach to the skin or clothing, or fall and join the dust and can remain infective for several weeks if humidity conditions are proper. However, the desiccation is a fast-killing factor for them. The eggs can survive for 2-6 days under cold and wet conditions, but their survival in a dry environment with temperatures above 25 ° C is greatly diminished (Mehlhorn, 2008; Roberts and Janovy Jr., 2009).

Human pinworm ova can directly infect other host or re-infect (retroinfect) the same host (principally children) by ingestion of the eggs via “hand to mouth”, ano-oral and fecal-oral route or through inhaled airborne. By scratching, eggs attached to the skin accumulate under fingernails, where they remain and become able to reinfect the same host or pass to others. It has also been noted that the dust has an important role as a potential source of infection through inhalation of eggs and subsequent swallowing (Cox, 2004; Ash and Orihel, 2007; Mehlhorn, 2008; Roberts and Janovy Jr., 2009). Infection to these parasites is known as enterobiasis or threadworm infection and occurs mostly through direct transmission from person to person in the immediate domestic environment, especially in crowding (familial or group infection). Low standards of personal hygiene are a prominent factor for increasing of the prevalence. Threadworm infection occurs today in all climates, all lifeways and people of all socioeconomic groups. There is about 300–500 million people (especially children) infected with human pinworm (WHO, 2004; Mehlhorn, 2008).

The majority of enterobiasis cases are symptomless. Nevertheless, very large numbers of worms in heavy infection lead to more serious consequences. Two aspects of pathogenesis have been noted for enterobiasis: damage caused by worms within the intestine and damage resulting from egg deposition around the anus. A characteristic clinical symptom is commonly due to anal pruritus, which can lead to very severe irritation, itching and then sleep disturbance preferably at night. Vaginal migration of adult worms in female infected humans can also involve the vulva which is the commonest cause of pruritus vulvae in girls. This case can be accompanied with acute

urinary tract infection. Secondary infection of the anal region may occur by scratching. Mild catarrhal inflammation, nausea, diarrhea, loss of appetite and irritability are the other reported symptoms. Surrounding dead female worms by small granulomas within the reproductive tract of female host occur when the worms reach the peritoneal cavity from intestinal perforations or following their migration. Hence, there is no particular pathological lesion caused by *Enterobius vermicularis*. Cases of appendicitis have been also reported but the role of pinworms in causing appendicitis is in doubt. Moreover, the possible transmission of *Dientamoeba fragilis* (in the absence of its cyst) via eggshell of *Enterobius vermicularis* can be the cause of diarrheas, sometimes with blood and mucus in infected host (Muller, 2001; Roberts and Janovy Jr., 2009).

The white and translucent eggs are medium-sized, asymmetrical ovoid and flattening on one side which morphologically forms the egg as "D" letter shape. The egg has a double membrane consists of four layers: one inner lipid membrane, two chitinous layers and one albuminous smooth outer layer. Its size is 50-60 µm in length and 20-30 µm in width. The egg content could be a small, granular mass in the shape of an irregular oval, or contains a morula in advanced stage of development or a first-stage larva (Ash and Orihel, 2007).

The presence of *E. vermicularis* in historic times has been documented in ancient literatures from China, Greece, India and Persia in the old world (Hoepfely, 1959). However, finding of *E. vermicularis* eggs in a 10,000 year old human coprolite in Hogup and Danger Caves (North America), represents the earliest paleoparasitological evidence of association between human and pinworm in the new world (Fry and Moor, 1969). Most of the ancient findings of human pinworm have been reported so far from American continent (Gonçalves et al., 2003).

There are few reports of recovered pinworms up to the present from the old world. Two findings have been reported from European continent dated to Medieval Age and 15th century AD (Gonçalves et al., 2003). Also, only 2 reports come from southeastern Asia: in a Han Dynasty mummy in China with 2100 years antiquity (Wei, 1973) and in a Medieval Korean mummy dated to 1630 AD (Shin et al., 2011).

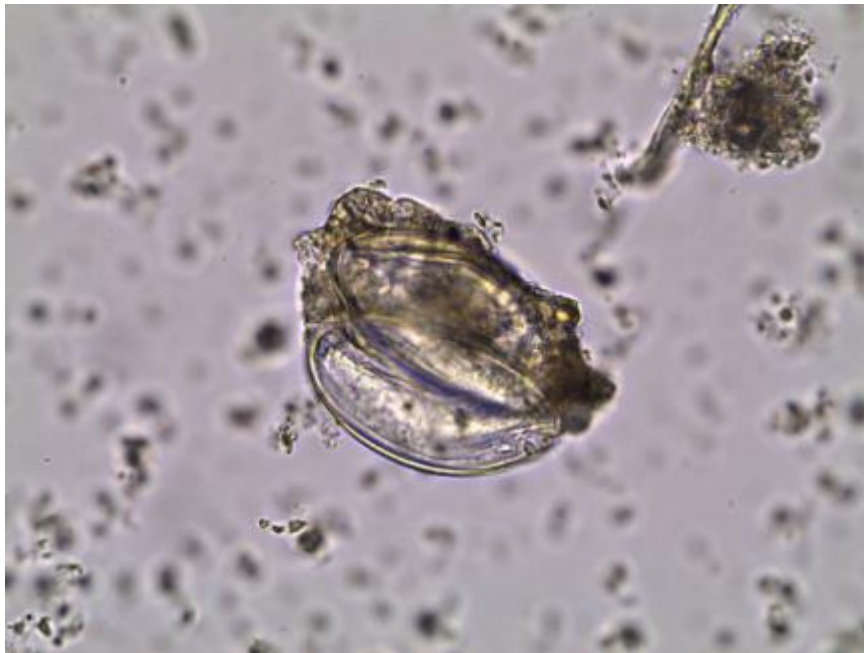

Figure 5.27: Two *Enterobius vermicularis* eggs, displaying characteristic “D” shape eggshell, average size: $58 \times 31 \mu\text{m}$, magnification $630\times$, sample ID: C82, Chehrabad saltmine, Iran.

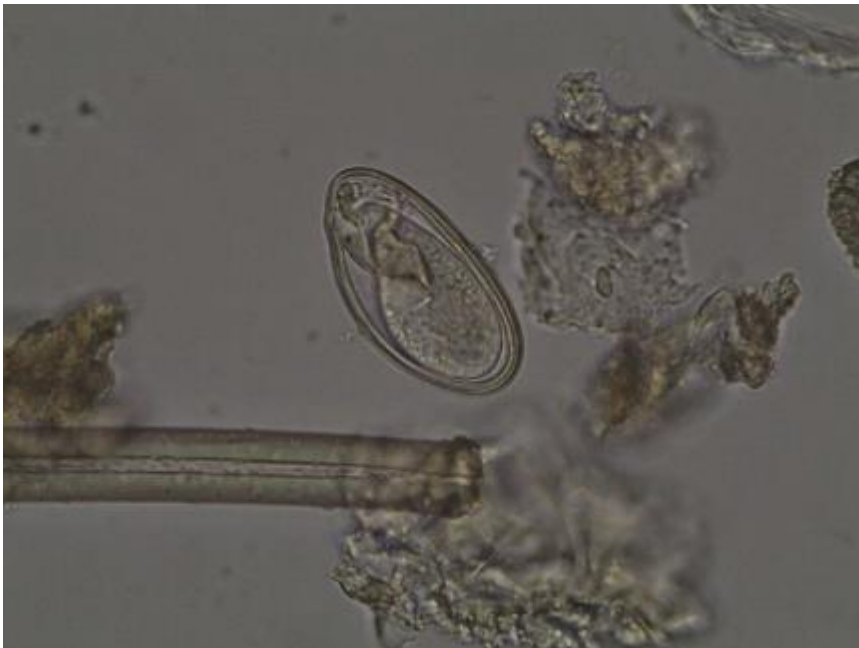

Figure 5.28: *Enterobius vermicularis* egg, displaying characteristic “D” shape eggshell, embryonated, size: $59 \times 30 \mu\text{m}$, magnification $630\times$, sample ID: C31, Chehrabad saltmine, Iran.

The presence of pinworm eggs in Egyptian archeological samples has been reported by Horne in 2002, who has recovered embryonated eggs of *Enterobius vermicularis* in fecal samples associated with skeletal remains of two mummies from Kellis sites in the Dakhleh Oasis, dated to the roman occupation period (30 BC-395 AD) (Horne, 2002).

The other report from the Middle East region is Harter's works who has recovered the eggs of *Enterobius vermicularis* in 3 samples from Sai, dated between 4,650 and 1600 BP and in two samples dated from 2,225 to 450 BP at Sedeinga, both sites located in Sudan (Harter, 2003). Furthermore, Zias and colleagues (2006) have reported the findings of *Enterobius vermicularis* by analysis of four soil sediment samples with 2,000 years antiquity from the site of Qumran, Israel (Zias et al., 2006).

5.4.3 *Trichuris* sp.

In this study, the eggs of *Trichuris* sp. were identified in two soil sediments (**ID: C81** and **C85**) (Nezamabadi et al., 2013a) as well as one coprolite sample (**ID: C31**) from Chehrabad saltmine. Egg size measurements of trichurid findings in these samples all were within the size category of *T. trichiura* / *T.suis*. However, human origin of the coprolite sample **ID: C31** and soil sediment **ID: C81** (which had been attached to a human coprolite) allow us to suppose that the species of trichurid findings in these samples are *Trichuris trichiura*. Nevertheless, as discussed above, possibility of a zoonotic infestation (or infection) with pig trichuriasis must be considered.

These whipworm eggs are the second evidences of trichuriasis in the Iranian Plateau. Previously, one *Trichuris* egg has been identified in soil sediment from the site of Kharand by Le Bailly and Bouchet in 2005 dated to Iron Ages of North central Iran (Nezamabadi et al., 2013c). The dating of present findings from Chehrabad saltmine covers both Achaemenid and Sassanid periods. In addition, all of *Trichuris* findings up to now in Iran prove that the antiquity of trichuriasis in the Iranian Plateau dates back at least to the Iron Age (First millennium BC) and continue in Achaemenid Empire (550 - 330 BC) up to Sassanid dynasty (224 – 651 AD). It shows also poor sanitary conditions in the northern habitant areas of ancient Iran, like the other parts of the ancient world.

The other *Trichuris* findings were identified in three subsamples (**ID: H1a, H1e** and **H3c**) from Hierakonpolis coprolites. Both subsamples **ID: H1a** and **H1e**, come from a collected coprolite sample which consists of mixed human and carnivore feces remains. Therefore, identified trichurid eggs in these subsamples could be *Trichuris trichiura* or *T.suis* based on their morphometric analysis. Subsample **ID: H3c** was a part of mixed collected carnivore, herbivore and possibly rodent feces. Size measurement of the sole *Trichuris* egg identified in this specimen, propose *T.suis* for identifying the species. All of these subsamples have been taken from Locality 11 at the site of Hierakonpolis. It shows that the ancient trichuriasis in Egypt have been prevalent at least from about fourth millennium BC (3800-3500 BC).

According to the morphometric analysis of identified *Trichuris* sp. eggs in the samples from Chehrabad Saltmine and Hierakonpolis (figure: 5.27 and table 5.4), the average of egg size in Chehrabad is smaller than Hierakonpolis. However, all of them are within the range of *Trichuris trichiura* or *T.suis* egg size.

Some of the *Trichuris* eggs identified in Chehrabad Saltmine are also smaller in length than the *Trichuris trichiura* or *T.suis*. Moreover, few *Trichuris* eggs recovered from Hierakonpolis are wider than *T.suis*. These variations in egg size in *Trichuris* sp. frequently were found in modern eggs (Yoshikava et al., 1989). On the other hand, according to the size ranges available for the known species of *Trichuris*, it is not possible to resemble them as the other species such as *T. vulpis*, *T. ovis*, *T.muris* and etc. Therefore, aforementioned eggs could be *Trichuris trichiura* or *T.suis* ova which influenced by different taphonomy process and preservation conditions in to dissimilar contexts of Chehrabad saltmine (salty environment) and Hierakonpolis (hyper arid environment).

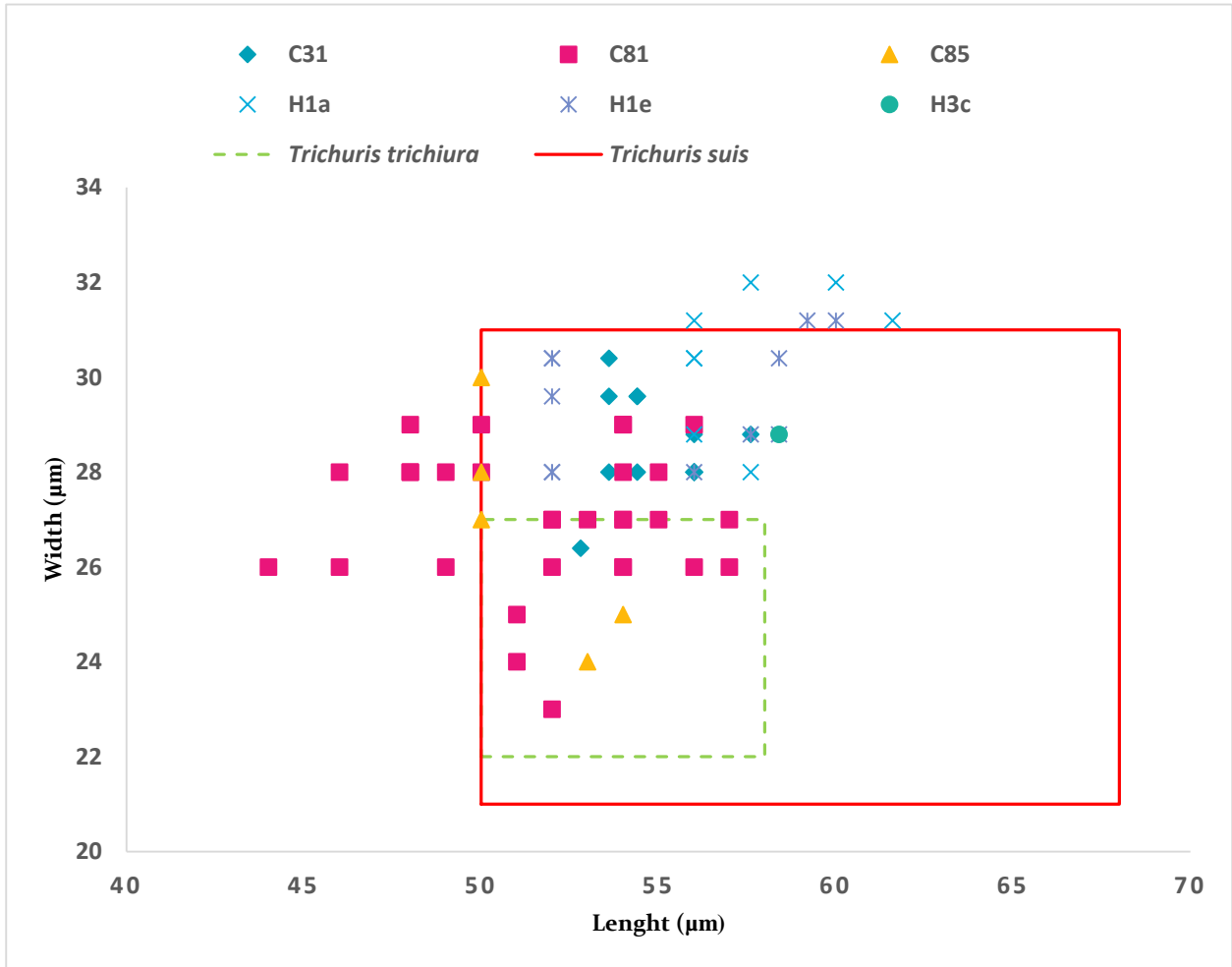


Figure 5.29: Morphometric analysis of identified *Trichuris* sp. eggs in samples (ID: C75, C82 and C31) from Chehrabad saltmine, Iran, in compare with subsamples (ID: H1a, H1e and H3c) from Hierakonpolis, Egypt.

Trichuris sp. or whipworm (in Family: Trichuridae), is a soil-transmitted nematodes that causes a parasitic infection known as human/animal trichuriasis. The generic name “*Trichocephalus*” is also used for this genus. *Trichuris* is highly prevalent in all parts of the world but more common in warm humid countries and has a variety of domestic and wild mammalian hosts such as pigs, cats, dogs, sheep, cows, rabbits, rats and mice, lemurs and monkeys (Taylor et al., 2007). More than 70 species of the genus *Trichuris* has been recorded so far in the literatures (Roberts and Janovy Jr., 2009; Horton, 2014). *Trichuris trichiura* is the species which infect

primates and humans predominantly of children and its distribution is closely related with poverty and poor fecal hygiene (Cooper and Bundy, 1988; Stephenson et al., 2000; Caumes et al., 2005). The other important species are *T. suis* in pigs, *T. ovis* in goats, sheep, cattle and other ruminants, *T. vulpis* in dogs and foxes, *T. felis*, *T. campanula* and *T. serrata* in cats, and *T. muris* in small rodents (Soulsby, 1968; Kaufmann, 1996; Taylor et al., 2007; Mehlhorn, 2008).

The adult worms are dioecious and measured between 3 and 8 cm long in different species (Soulsby, 1968; Bundy and Cooper, 1989). They could be seen by naked eye in slaughtered animals or in rectal prolapsus (in human or animals) caused by severe trichuriasis (Ash and Orihel, 2007; Roberts and Janovy Jr., 2009). Therefore, it is expected that the ancient physicians, hunters and animal farmers were familiar with this nematode.

The dynamics of *Trichuris* infection are similar to those of *Ascaris* sp with same environmental conditions. *Trichuris* sp. doesn't require intermediate hosts in its direct life cycle. One female worm in the intestinal tract can produce between 3,000 and 20,000 eggs per day (Bundy and Cooper, 1989). The eggs after leaving the host body with feces to the environment will develop in two weeks to several months depending on the ambient temperature, and adequate moisture and oxygen. Direct sunlight and temperature below 9 °C and above 52 °C is fetal conditions for the eggs and shaded, warm (25-34 °C) and moist soils are ideal for their developing (Bundy and Cooper, 1989; Stephenson et al., 2000). They can remain viable in optimal conditions up to several years while the soil does not dry out (Soulsby, 1968) but this viability of the eggs are less resistant to drying, compared to *Ascaris lumbricoides* (Maya et al., 2012). Humans or animals become infected directly by ingestion of embryonated eggs containing first-stage larva (L₁) through contaminated food, soil or water. Infection or re-infection via "hand to mouth" and raw consumption of vegetables (as *Ascaris* sp.) are also common for human host (Satin, 2014). The ingested eggs will release the L₁ larva which penetrates the glands within the mucosa of the distal ileum, caecum and colon. After occurring four moults, the adult *Trichuris* worms emerge and attach on the mucosal surface of caecum or colon by embedding their anterior end (head) in the mucosa (Bundy and Cooper, 1989; Taylor et al., 2007).

This intestinal helminth rarely causes clinical signs and in most cases is asymptomatic. However, the severity of the disease in the host is related to the number of helminths (Mehlhorn, 2008). The clinical signs in a massive trichuriasis are loss in performance, abdominal pain,

diarrhea, dysentery, dehydration, failure to thrive, weight loss, terminal anemia, rectal prolapsus, and rarely colonic obstruction or perforation. Heavy infections associated with severe and often hemorrhagic inflammation of the cecum or colon has been reported in dogs. Occasionally, adult *Trichuris* worms could be expelled in the feces. In some cases the feces may be speckled with fresh blood (bloody stools) (Kaufmann, 1996, Taylor et al., 2007; Mehlhorn, 2008).

The main pathology of human trichuriasis occurs by traumatic injury to the mucosal surface of the large intestine. The hemorrhagic lesions are caused by the adult worms burrowing tunnels into the mucosa of the large intestine to feed from intercellular fluids (not blood) (Satin, 2014; Horton, 2014). Local inflammation, edema and hemorrhage, with few histological changes as well as prolapse of the rectal mucosa could be resulted by *T. trichiura* in human (Bundy and Cooper, 1989; Stephenson et al., 2000). The present global infection by human trichuriasis has been reported up to 795 million with a majority in Southeast Asia and endemic in all tropical and subtropical regions (<http://www.who.int>; WHO, 2006). Closely related species such as *Trichuris suis* (from pigs) or *Trichuris muris* (from mice) could also infect humans, but the infection is self-curing and the life cycle of parasites will not be completed (Satin, 2014). *T. trichiura* is sometimes found in multiple infections (polyparasitism) with *Ascaris lumbricoides* and hookworms as well as invasion of intestinal protozoa such as *Entamoeba histolytica* (Stephenson et al., 2000). Therefore, we can consider this issue for selecting the archaeological samples when using ELISA technique for detecting intestinal protozoa.

The characteristic eggs of *Trichuris* allow accurate diagnosis in both fresh samples and archaeological remains. They are brown, lemon or barrel-shaped with a double membrane thick egg shell and two transparent plugs in both poles. Unlike *Capillaria* sp. eggs, no characteristic ornamentation appears on *Trichuris* eggs. In species of *Trichuris* sp. the eggs have identical morphologies. Therefore, the size of eggs is often used in paleoparasitology for identifying the species of *Trichuris* in soil sediments and coprolites of unknown origin (Confalonieri et al., 1985). Some of the *Trichuris* eggs measurement has been summarized in the Table 5.5.

The ancient trichuriasis has been proved previously in Egyptian archeological findings (see chapter II). The whipworm eggs finding in organic remain sample taken from internal area of naturally mummified bodies from the sites of Deir el-Medineh and Saqqara, both are dated to 2300 BP. Furthermore, *Trichuris trichiura* eggs were recovered from a canopic jar discovered in the

excavations of Asyut dated around 3500 - 3000 BP. The human origin in this case allows the paleoparasitologist to certainly identify the species level of the findings (Harter, 2003). In the other hand, recovery of whipworm eggs could use to show the nature of content in this canopic jar (Harter-Lailheugue and Bouchet, 2005). *Trichuris* eggs were also found in the sites of Sai, Kerma and Sedeinga in Sudan (upper Nubia) dated from 4300 to 450 BP (Harter, 2003). Therefore, these findings are the most ancient evidences of trichuriasis in Egypt and Sudan.

The hardness of *Trichuris* eggs sorts them as a relatively common findings in paleoparasitological analysis even more than *Ascaris* sp. which is another frequent recovered eggs in archaeological contexts (Gonçalves et al., 2003). Reflecting the poor sanitary conditions, these two nematode eggs are often found together in archaeological contexts same as in modern cases (Bouchet et al., 2003; Chaves da Rocha et al, 2006; Ash and Orihel, 2007; Leles et al., 2010).

The most ancient evidences of trichuriasis in paleoparasitology dates back to prehistoric times with the demonstration of *Trichuris* eggs in archaeological findings: in a rodent coprolite from the site of Pedra Furada (Brazil) dated from 30,000 to 8,450 BP (Ferreira et al., 1991), in human burials at Shillourokambos (Cyprus) dated between 10,500 and 9,500 BP (Harter, 2003) and in an unknown origin coprolite from Kruger Cave site (South Africa) dated between 10,000 and 7,000 BP (Evans et al. 1996).

The whipworm eggs also recovered from the rectum of mummified human remains of Neolithic Alpine “Ice man” (Ötzi) dated to 5200 - 5300 BP (Aspöck et al. 1996) and also in the prehistoric saltmines of Hallstatt and Hallein in Europe with 2300 years antiquity in Europe (Aspöck et al., 1973, 1974).

In the Middle East region, antiquity of human trichuriasis in Israel has been evidenced from 2500 BP in Jerusalem (Cahill et al., 1991) to 650 BP in Acre (Mitchell and Stern, 2001, Mitchell and Tepper, 2007).

From the northern areas of the Middle East egg findings of *Trichuris* sp. have been reported by analysis of samples from deposits of sheep dung (*Ovis aries*) at the sites of Tseydon rock-shelter and Uilsa in North Caucasus dated to recent centuries (since 350 years ago) (Savinetsky and Khrustalev 2013).

In southeastern Asian countries, eggs of *Trichuris sp.* are commonly reported in analysis of mummies or archaeological samples (Wei, 1973; Han et al., 2003; Matsui et al., 2003; Seo et al., 2007; Oh et al., 2010; Shin et al., 2009a; 2009b; 2011; Kim et al., 2013).

Species	Main host(s)	Length (μm)	Width (μm)
<i>Trichuris trichiura</i>	Humans	50-58	22-27
<i>Trichuris suis</i>	Pigs	50-68	21-31
<i>Trichuris vulpis</i>	Foxes, dogs, cats	70-90	30-41
<i>Trichuris ovis</i>	Cattle, sheep, goat	70-80	30-42
<i>Trichuris muris</i>	Rodents	67- 70	31-35

Table 5.5: Measurements of some important species of *Trichuris* eggs.

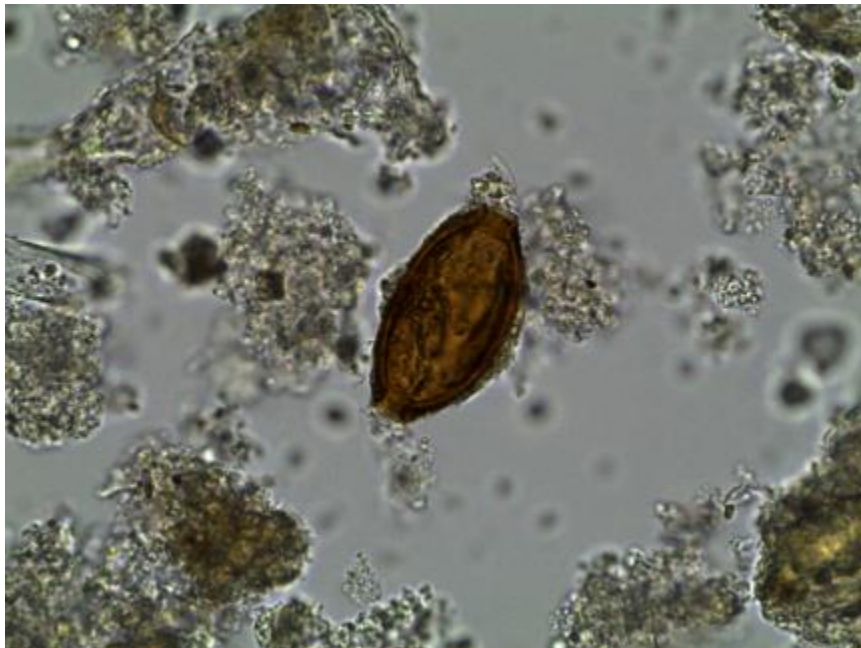


Figure 5.30: *Trichuris sp.* egg, displaying characteristic thick eggshell with deprived of polar plugs, size: $53 \times 27 \mu\text{m}$, magnification $630\times$, sample ID: C81, Chehrabad saltmine, Iran.

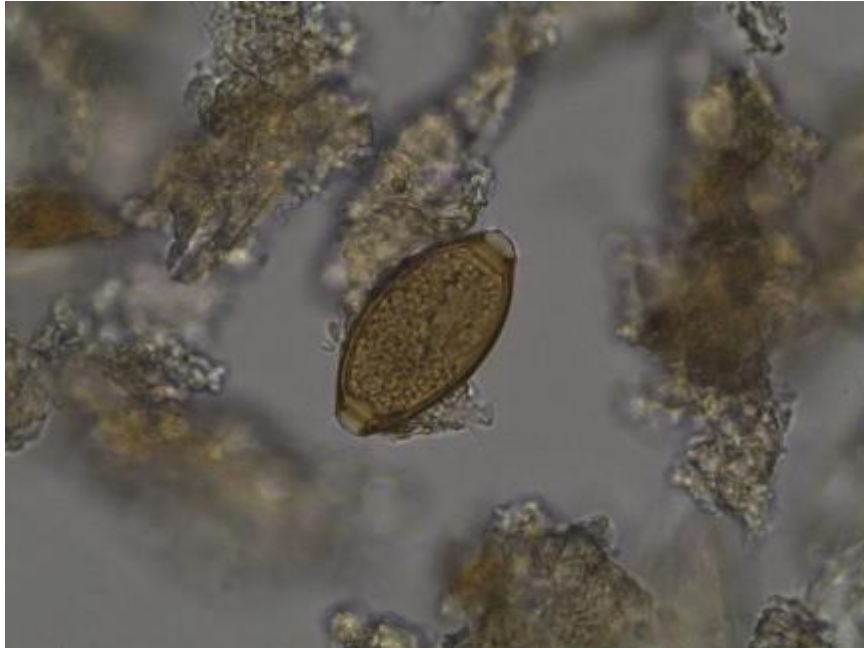

Figure 5.31: *Trichuris trichiura* egg, displaying characteristic thick eggshell with typical polar plugs, size: $56 \times 28 \mu\text{m}$, magnification $630\times$, sample ID: C31, Chehrabad saltmine, Iran.

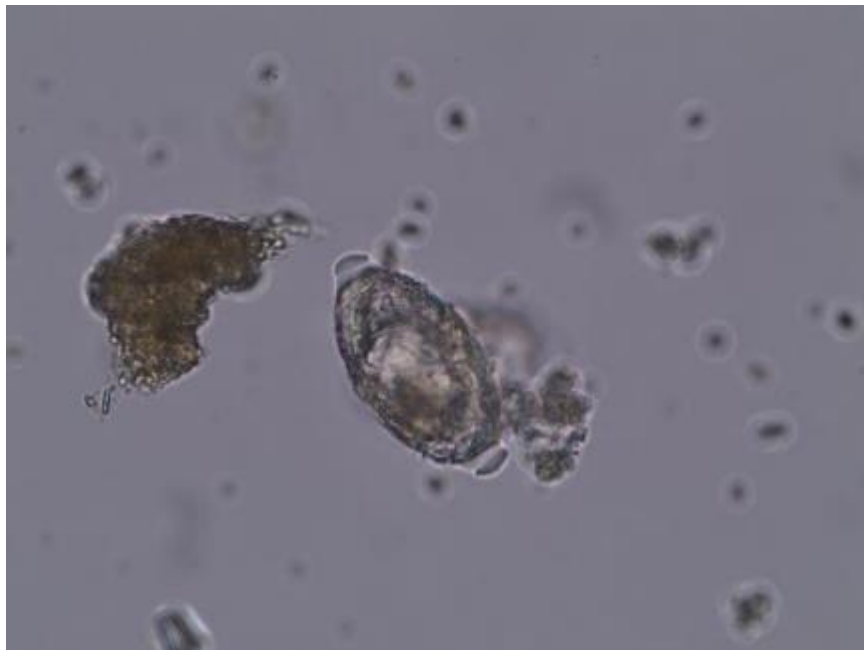


Figure 5.32: *Trichuris* sp. egg, displaying mineralized eggshell with typical polar plugs, size: $56 \times 30 \mu\text{m}$, magnification $630\times$, subsample ID: H1a, Hierakonpolis, Egypt.

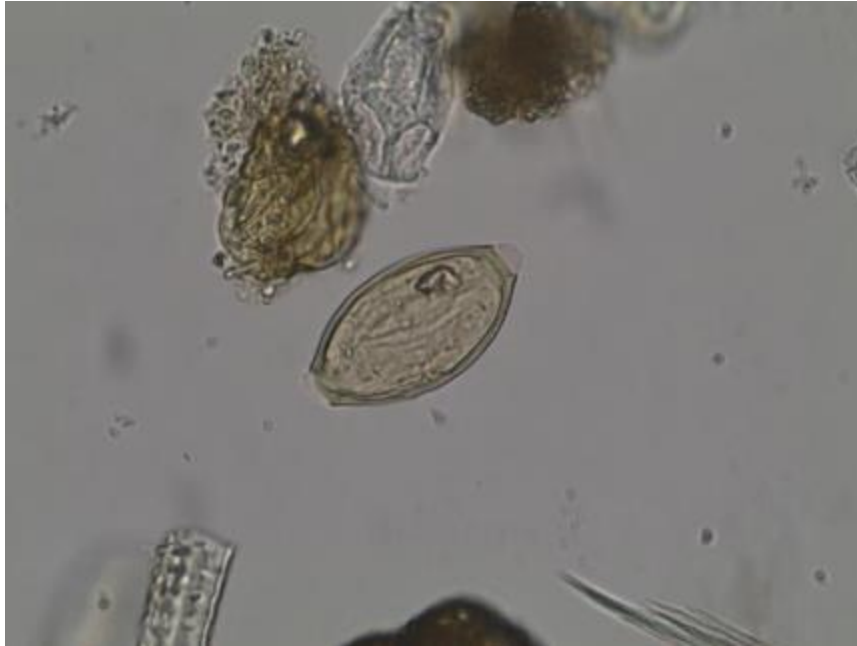


Figure 5.33: *Trichuris* sp. egg, displaying characteristic thick eggshell with the one remained typical polar plugs and possibly an already formed larva, size: $58 \times 29 \mu\text{m}$, magnification $630\times$, subsample ID: H3c, Hierakonpolis, Egypt.

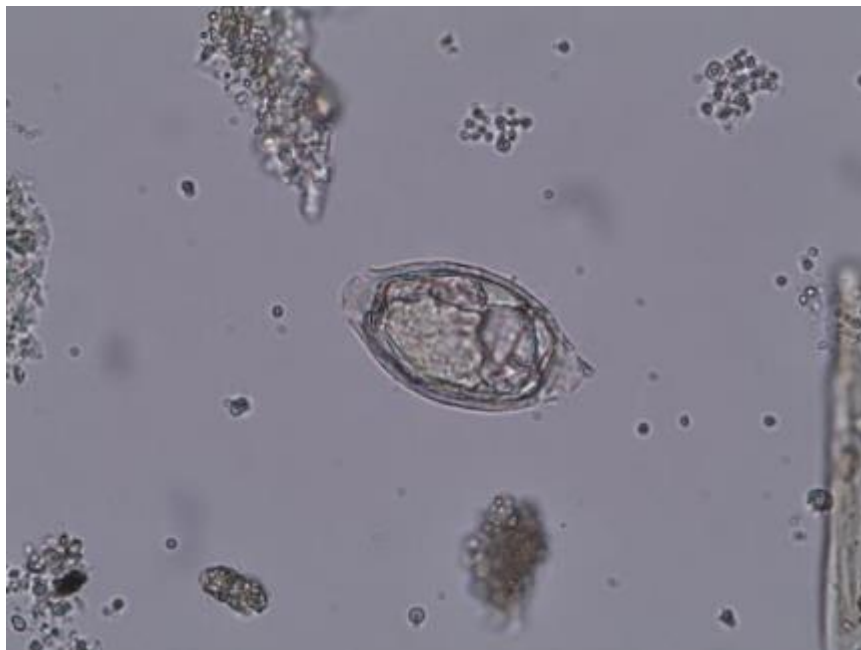


Figure 5.34: *Trichuris* sp. egg, displaying bad preservation of eggshell with broken polar plugs, size: $60 \times 31 \mu\text{m}$, magnification $630\times$, subsample ID: H1e, Hierakonpolis, Egypt.

5.4.4 *Oxyuris Equi*

This specific animal parasite was identified in two soil sediments (**ID: C82** and **C83**) belonging to Achaemenid period (Nezamabadi et al., 2013a) and one coprolite sample (**ID: C32**) belonging to Sassanid period from Chehrabad saltmine. These recoveries indicate equine presence (horses, donkeys, or the Asian wild ass) at the site. Presence of this parasite proposes animal (equid) origin for coprolite sample **ID: C32**. Evidences of other parasite species in this coprolite (trichostrongyloid/strongylid eggs) could support also consideration of its animal (equid) origin. However, for the soil sediment sample **ID: C82** and **C83**, only a soil contamination with human and equid feces could be considered according to the taeniid and *Enterobius vermicularis* findings in them.

Equine have been presented during Achaemenid and Sassanid period at the site, and used as livestock for traction or for salt transport. Ancient oxyuriasis at Chehrabad also provides information on equine health status in northwest Iran during first millennium BC up to 6th century AD.

Oxyuris equi or horse pinworm has a worldwide distribution in horses, donkeys and other equids (Soulsby, 1968; Kaufmann, 1996).

Adult pinworms are found in the colon. However, adult gravid female worms migrate to the rectum and anus to lay clusters of sticky eggs on anal and perineal area. Gray-white adult females are relatively robust with a size up to 15 cm in length and maybe find in feces of equids. Furthermore in slaughtered equine, mature females with long, pointed tail could be found in cecum, colon, and rectum. Morphological characteristics of this worm probably allowed the ancient physician such as Hippocrates (460-377 BC) and Galen (130-200 AD) to be familiar with the horse pinworm (Brothwell and Sandison, 1967).

Environmental contamination occurs when cementing fluid dries and cracks allowing eggs to fall off or egg masses are rubbed off by horse's attempt to relieve associated pruritus. Fecal contamination of food and water is the main way of distribution of equine oxyuriasis (Ballweber, 2011). Infective third larval-stage develops within the egg in 4 - 5 days (Taylor et al., 2007; Zajac and Conboy, 2011). Horses acquire infection by ingesting eggs containing the larva. Eggs hatch in the small intestine and larvae move directly to cecum or colon where they mature.

This animal specific parasite has a direct life cycle with autoinfection as *Enterobius vermicularis* (human pinworm), which can quickly lead to large increases in worm numbers, in the immediate environment especially in small enclosures and stables. The infection is often asymptomatic and in moderate numbers may aid digestion (Elsheikha and Patterson, 2013). However, heavy burdens of worms may cause diminished performance, anal pruritus, irritation and weight loss. Also, intestinal obstruction occurs occasionally in cases of advanced infections. Feeding activities of fourth larval-stage may cause inflammation of cecal and colonic mucosa. And egg-laying activity of female worms causes pruritus, may lead to persistent rubbing. Clinical signs may include vague signs of abdominal discomfort and/or persistent rubbing of tailhead which can lead to broken hairs and “rat tail” appearance or scarification. Behavioral problems also occur in infected equine (Kaufmann, 1996; Taylor et al, 2007; Mehlhorn, 2008).

Identification of grayish-yellow, scale-like egg masses on the perineal skin is possible by equine owners in infected animals.

Eggs are rarely found on routine fecal flotation. Detected eggs are operculated, ovoid, slightly asymmetrical, yellowish, thick-shelled, and flattened on one side, may or may not be larvated and measure $74-99 \times 38-45 \mu\text{m}$ (Zajac and Conboy, 2011).

A nearby paleoparasitological example of horse pinworm infection, contemporary with the Achaemenid period, came from a Scythian kurgan (293-294 BC) excavated in Berel, Kazakhstan (Le Bailly et al., 2008). The presence of horse pinworm infection in central Asia and northwestern Iran during the same period is interesting, considering that isotopic studies prove a northern origin for some of the human bodies recovered in the mine (Aali et al., 2012b; Ramorali et al., 2010). This could provide additional evidence for human movements and relationships in this region which was attested by other archaeological evidences (Crubézy et al., 2006).

Ancient presences of *Oxyuris equi* have been also attested in paleoparasitology of European continent, by finding of its very characteristic eggs in archaeological samples dated between 1st century BC and 16th century AD (Jansen and Over, 1966; Jones, 1988; Da Rocha et al., 2006; Yeh et al., 2014).

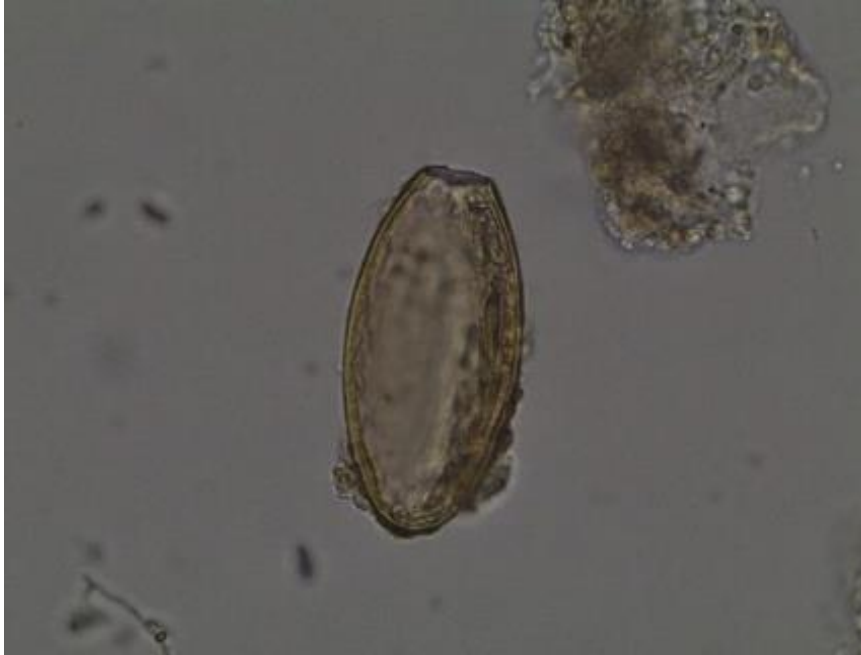

Figure 5.35: *Oxyuris equi* egg, displaying characteristic asymmetrical thick eggshell and polar plug, size: $81 \times 40 \mu\text{m}$, magnification $630\times$, sample ID: C32, Chehrabad saltmine, Iran.

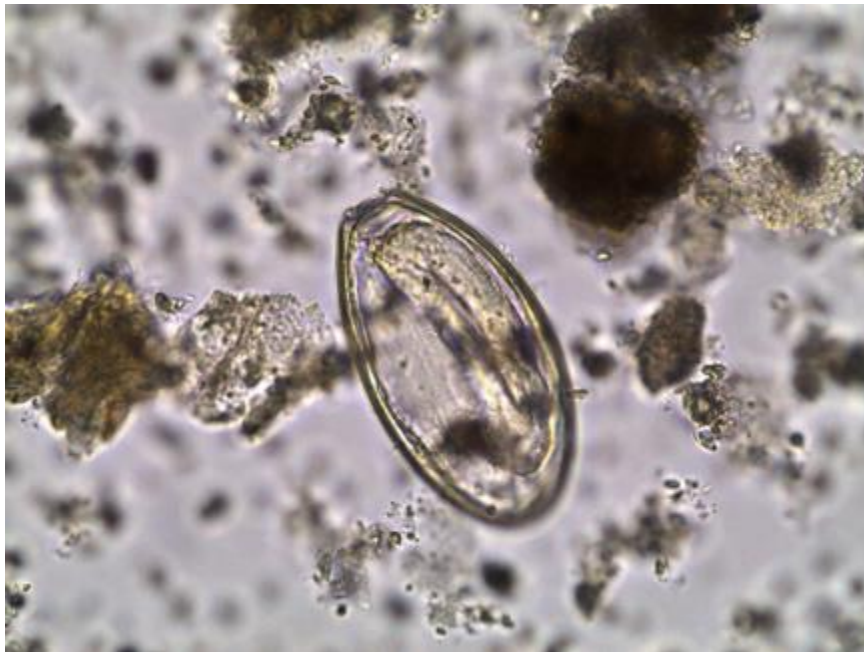

Figure 5.36: *Oxyuris equi* egg, displaying characteristic asymmetrical thick eggshell with polar plug and a larva inside, size: $81 \times 45 \mu\text{m}$, magnification $630\times$, sample ID: C82, Chehrabad saltmine, Iran.

5.4.5 Order: Strongylida

In this study, the finding eggs which are morphologically resemble to *Strongylus* and/or *Trichostrongylus* sp. have an average size $77 \times 43 \mu\text{m}$, all found in a coprolite sample (**ID: C32**) from Chehrabad saltmine and dated to Sassanid period. In this coprolite, the other identified eggs were *Oxyuris equi* which prove the animal (equid) origin of this sample.

These findings provide the first evidences on presence of these species in historic times of the Iranian Plateau and also the Middle East region.

Same as the modern cases, *Strongylus* and *Trichostrongylus* eggs in archaeological findings are very similar to those of ancylostomids and recognize from each other by the size measurement. Ancylostomid eggs were reported from ancient Egypt and Sudan (see chapter 2) and also from a frozen burial site in Berel (dated to 294 BC) in Kazakhstan (Crubézy et al., 2006). Furthermore, Strongylidea eggs were recovered in Berel associated with *Oxyuris equi* eggs, by analyses of the samples taken from gastrointestinal tract of horses inhumed at this site (Le Bailly et al., 2008).

5.4.5.1 Family: Strongylidae

Nematode species in the family Strongylidae are abundant. Some of them are common in the caecum and colon of equids. The known species of strongyles are about 55 species. Less than 20 species commonly infect horses. Important species of the genus *Strongylus* (*S. vulgaris*, *S. equinus*, *S. edentatus*, *S. asini*) are 1 - 5 cm long in adult male and female, and dark gray to yellowish-brown in color. They usually may be found in the same horse at the same time (mixed infections) (Soulsby, 1968; Kaufmann, 1996; Mehlhorn, 2008).

Third-stage infective larvae of *Strongylus* sp. ingested by the grazing animal penetrate large intestinal mucosa and molt to fourth larval stage. Then invade the submucosal arterioles, migrate along the intima to cranial mesenteric artery where they molt to fifth-stage and remain for several months after infection. The penetration and migration of larvae cause small hemorrhages in the intestinal wall. Also, by rising in body temperature in heavy infections, the fourth-stage larvae migrate in the intima of the mesenteric arteries which cause inflammatory reactions. After

returning to the lumen of the large intestine, they will be mature and produce eggs. The *Strongylus* eggs are similar to those of the trichostrongyles (Taylor et al., 2007; Mehlhorn, 2008).

The larval stages of the *Strongylus* spp. have more specific clinical signs especially on the cardiovascular system. Adult strongylids feed by attaching to the glandular epithelium of the large intestine. Bleeding may occur by incidental damage to blood vessels. Deep ulcers and lesions in the gut wall could be the cause of anemia. The other clinical signs are failure to thrive, dullness, poor performance, loss of appetite and weight in infected animals. Death may occurs in severe infections (Soulsby, 1968; Kaufmann, 1996; Taylor et al., 2007; Mehlhorn, 2008).

Species	Length (µm)	Width (µm)
<i>Strongylus vulgaris</i> <i>Strongylus equinus</i> <i>Strongylus edendatus</i>	70 - 93	40–54
<i>Cyathostomum coronatum</i>	74- 90	49-69

Table 5.6: Strongylidae egg size (corresponding to the identified eggs in the present study)

5.4.5.2 Family: Trichostrongylidae

Trichostrongylus is a genus belonging to the superfamily Trichostrongyloidea, similar to hookworms, comprising more than 35 species that parasitize many animals, mostly herbivorous mammals, particularly ruminants, rodents, pigs, horses as well as birds and occasionally infect humans. Several of these species as *T. axei*, *T. vitrinus*, *T. capricola*, *T. colubriformis* and *T. Oriental*, are common in Asia and Africa. Infection by species of *Trichostrongylus* reaching a prevalence of about 70% were recorded in endemic areas of southwestern Iran and also in a village in Egypt (Roberts and Janovy Jr., 2009). They cause severe gastrointestinal diseases called trichostrongylosis and inhabit usually the digestive tract of herbivores (Mehlhorn, 2008).

The adults of *Trichostrongylus* measure less than 1 cm long and are thin worm. Their eggs are very similar to those of hookworm, but are longer, reaching about 100 microns, and pointed at one end. Infections are usually so light and produce no symptoms. Pathological signs in infected humans and animals are similar. Most of *Trichostrongylus* species are hematophagous, but human cases described usually not severe anemia. Other symptoms that may cause infection are nonspecific. A heavy infection can cause anemia enteritis, diarrhea and sometimes cholecystitis. Furthermore, anorexia, progressive emaciation, listlessness, and weakness as well as productivity loss are the clinical signs in ruminants. It has been reported that animals with very high loads of *Trichostrongylus* infectious may die after several weeks. These worms have a more or less cosmopolitan distribution in man (Soulsby, 1968; Kaufmann, 1996; Taylor et al., 2007; Mehlhorn, 2008; Roberts and Janovy Jr., 2009).

The adult worms live attached to the upper part of the small intestine mucosa. In humans they could inhabit the distal jejunum and ileum, and sometimes they can invade the bile ducts. Their eggs leave the host's body with intestinal movements. At that time it has not yet formed the embryo and the status of the egg is morula. They require warm temperatures and high humidity for development in the environment. Eggs embryonate on the ground and release the larvae, which remain in the environment, preferably in the grass, until they are ingested by animals that are its definitive hosts. When swallowed, they reach the small intestine, where they attach to the walls and develop into the adult form over a period of about 21 days, without pulmonary cycle (which occurs in *Ancylostoma* sp.) (Taylor et al., 2007; Mehlhorn, 2008; Roberts and Janovy Jr., 2009).

Human infections are rare but may occur worldwide. Close contact with ruminants has one of the most important roles in transmission of infective larvae. Human infection (same as herbivores) occurs by ingestion of infective 3rd-stage larvae during consumption of vegetable contaminated with night soil. Infection by the cutaneous is another route of infection, especially when preparing animal dung as fuel (Mehlhorn, 2008).

Trichostrongylus axei is one of the most important species in the family of Trichostrongylidae which cause mostly chronic and mild trichostrongylosis in horses. It is cause of typical lesions in horses mainly in the glandular part of the stomach. *T. axei* lives also in the abomasum of ruminants such as cattle, sheep, and goats and rarely in pigs, usually part of a mixed infection with other helminthes (Taylor et al., 2007; Mehlhorn, 2008).

Hyostrogylus rubidus is a trichostrongylid which parasitize the stomach of swine. The lesions produced by this nematode are similar to those caused by *Ostertagia* in ruminants (Mehlhorn, 2008).

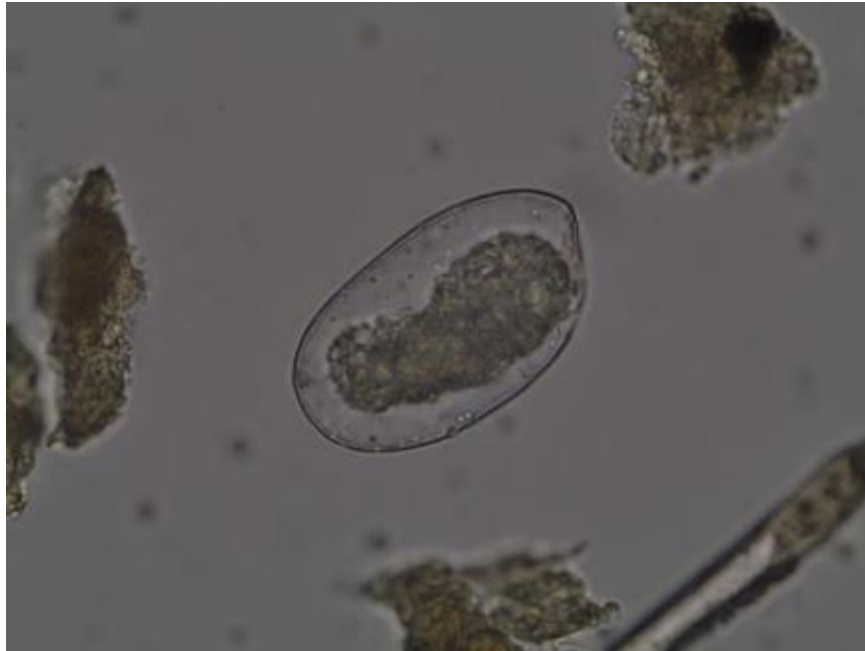


Figure 5.37: Strongylid/Trichostrongylid egg, displaying content remains, size: $80 \times 46 \mu\text{m}$, magnification $630\times$, sample ID: C32, Chehrabad saltmine, Iran.

Species	Length (μm)	Width (μm)
<i>Trichostrongylus</i> sp.	75–118	31–56
<i>Ostertagia</i> sp.	65-100	30-50
<i>Haemonchus</i> sp.	70-85	41-48
<i>Hyostrogylus</i> sp.	71-80	35-42

Table 5.7: Some important Trichostrongylidae egg size (corresponding to the identified eggs in the present study).

Ancient human infection with *Trichostrongylus* has been reported by Reinhard et al. (1985) in the archaeological record in U.S. sites. Oldest context in which it has made the diagnosis of *Trichostrongylus* come from paleoparasitological study of Dust Devil Cave, Utah, United States from strata dated to 6800-4800 BC (Gonçalves et al., 2003).

5.5 Acanthocephalan findings

Recovered acanthocephalan eggs in present study all come from Egyptian coprolite samples from Hierakonpolis (subsamples **ID: H2c, H2e, H5d and H9d**). The average size of acanthocephalan eggs in these samples was $87 \times 43 \mu\text{m}$.

Archaeological report of Hierakonpolis has stated that the origin of the coprolites involved in the main sample **ID: H5** are mix of herbivore, carnivore and possibly human. However, the sample **ID: H2** is mix of carnivore and possibly human coprolites.

Therefore, human infection by acanthocephalans is one of the possibilities in Hierakonpolis in addition to probable animal infection.

Identified	Measured egg(s)			Site	Dating	Sample	Origin	ID
	Count	Length (μm)	Width (μm)					
Acanthocephala	10	87 ± 5.9	43 ± 4.7	Hierakonpolis (Locality 11C)	3900 - 3300 BC	Coprolite	Carnivore/ Human	H2c
							Carnivore/ Human	H2e
							Carnivore/ Herbivore/ Human/ Unidentified	H5d
							Carnivore/ Human	H9d

Table 5.8: Identified acanthocephalan eggs.

All of the species in the phylum Acanthocephala are parasitic and their structure is similar to both the nematodes and the Platyhelminthes, closely related to nematodes (Soulsby, 1968; Mehlhorn, 2008). Adult worms have a size mostly under 1 cm in length but some species may be up to 70 cm. They also called thorny-headed worms due to a principal diagnostic character which is the presence of a proboscis armed with rows of hooks for attachment to the host internal tissues.

They have no intestine and take up nutrition by parenteral absorption (Taraschewski, 2000; Taylor et al., 2007; Mehlhorn, 2008).

They are heterosexual and males are smaller than females. The indirect life cycle of acanthocephalans usually involves an insect or crustacean as intermediate host which ingest the eggs of acanthocephalans. The eggs are elongated spindle-shaped with a thick shell and contains a larvae (acanthor) which has an anterior circle of hooks and spines on the surface. The acanthor of *Moniliformis* species is mostly more elliptical than *Macracanthorhynchus* spp (Taylor et al., 2007; Fugassa et al., 2011).

Acanthocephalans use a variety of vertebrates as the definitive hosts (Mehlhorn, 2008) but are not found in humans because the intermediate hosts (such as cockroaches) are not likely to be ingested.

Two genus of *Moniliformis* sp. which parasitize rats and *Macracanthorhynchus* sp. which is common in pigs, are also occasional parasites of humans belonging to class of Archiacanthocephala (Taraschewski, 2000, Ash and Orihel, 2007).

The clinical signs in human could be gastrointestinal disturbances with diarrhea, exhaustion accompanied by coughing and fever, ringing in the ears, vomiting and also serious complications such as perforation of the intestine and ulcerative lesions. Also adult worm could be seen in the feces (Taraschewski, 2000).

The eggs found in the present study, based on their morphological aspect and size, could be attributed to *Moniliformis* and not to *Macracanthorhynchus* species.

Moniliformis parasitize occasionally humans. Some infected human cases have been reported from throughout of the world including Iran and Egypt (Ward and Nelson, 1967; Berenji et al., 2007). Infection in rodents is common and cosmopolitan. Dogs and cats could also be infected. They inhabit in the small intestine and their proboscis is deeply embedded in the mucosa. The anterior proboscis in the adult worms is cylindrical and has rows of curved hooks (Taraschewski, 2000).

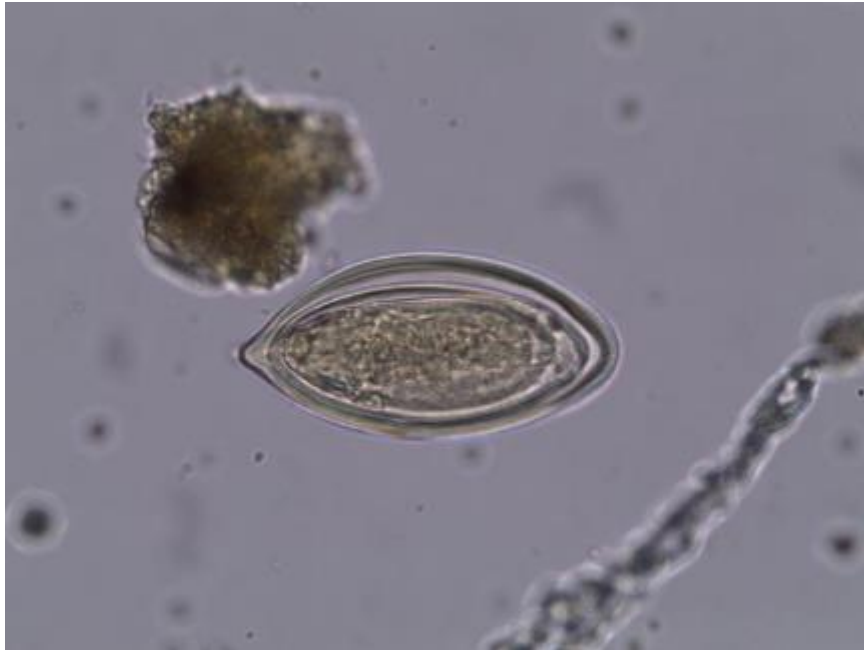

Figure 5.38: Acanthocephalan egg, displaying characteristic eggshell with an acanthor larvae inside, size: $78 \times 40 \mu\text{m}$, magnification $630\times$, subsample ID: H2c, Hierakonpolis, Egypt.

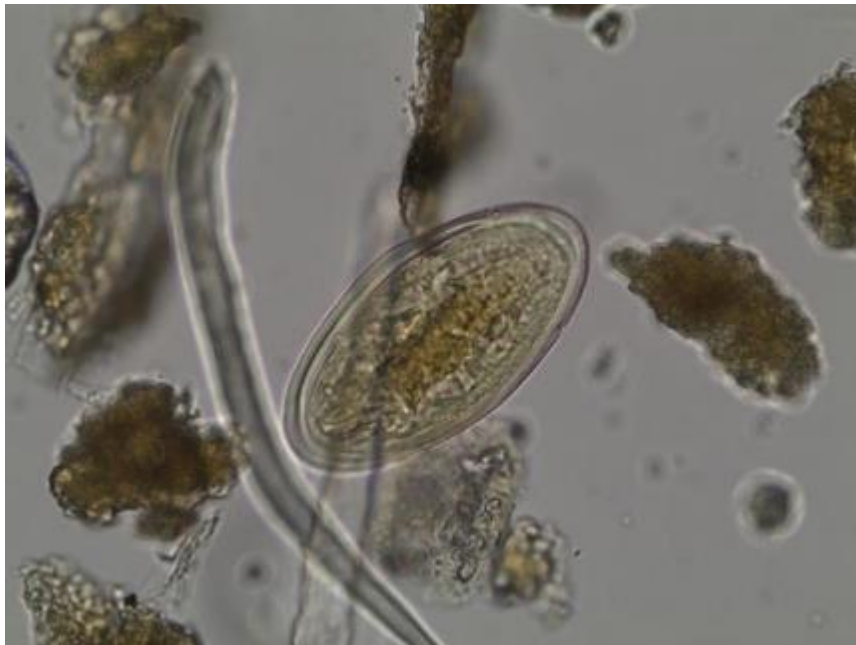

Figure 5.39: Acanthocephalan egg, displaying characteristic eggshell with an acanthor larvae inside, size: $90 \times 46 \mu\text{m}$, magnification $630\times$, subsample ID: H5d, Hierakonpolis, Egypt.

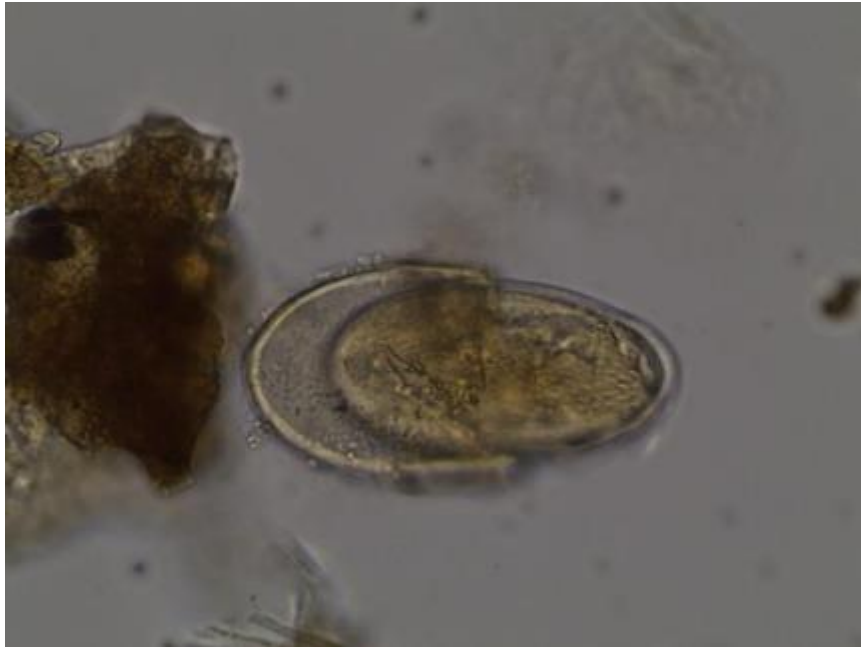


Figure 5.40: Acanthocephalan egg, displaying broken eggshell with a voiding (or hatching?) acanthor larvae, estimated size: $84 \times 50 \mu\text{m}$, magnification $630\times$, subsample ID: H9d, Hierakonpolis, Egypt.

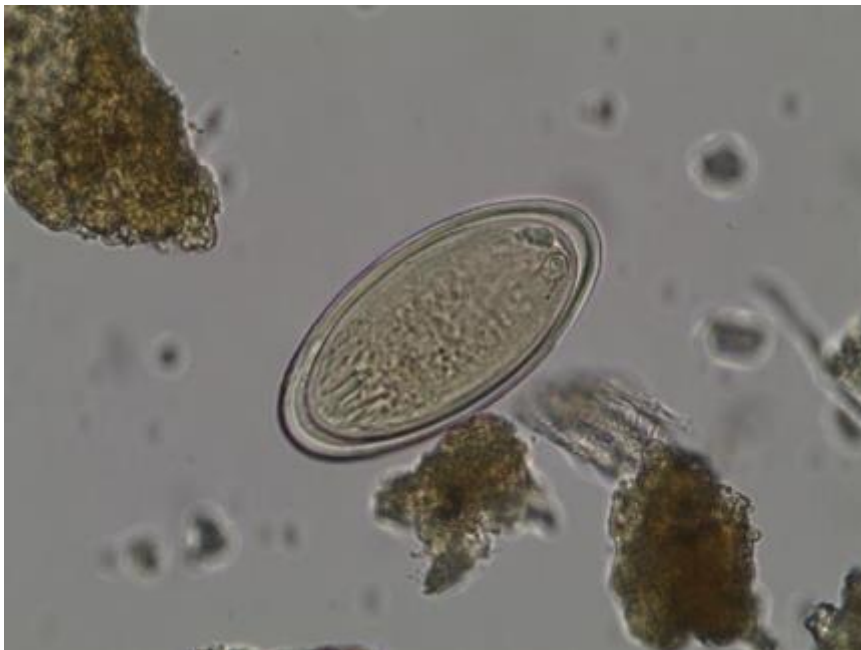

Figure 5.41: Acanthocephalan egg, displaying characteristic eggshell with an acanthor larvae inside, size: $84 \times 42 \mu\text{m}$, magnification $630\times$, subsample ID: H2e, Hierakonpolis, Egypt.

The elongated eggs have a thick, smooth and clear shell and measure 70 - 125 μm \times 30 - 65 μm . The eggshell has three characteristic envelopes and contains a spiny acanthor larva when passed in the feces. The larva inside the egg can survive for months in the soil. When the egg is ingested by beetles or cockroaches, the larva develop to the infective stage after several weeks.

The encysted larval stages called cystacanths. Ingestion of cystacanths could cause infection of mammalian hosts (usually the rat). Human infection occurs by the accidental ingestion of grain beetles (Taraschewski, 2000; Ash and Orihel, 2007; Mehlhorn, 2008).

Some of the coprolites from grain-eating prehistoric humans in a cave in Utah (USA) contained acanthocephalan eggs, which were probably of *Moniliformis* (Moore et al., 1969). Furthermore, Fugassa and his colleagues (2011) recognized an acanthocephalan (consistent with species of *Macracanthorhynchus*) in association with *Enterobius vermicularis* eggs by analyses of a coprolite sample from Antelope Cave in Arizona.

There is only one case previously reported from paleoparasitology of the Middle East region which has evidenced first findings of acanthocephalan eggs in Egypt. These findings include acanthocephalan eggs accompanied with the eggs of *Enterobius vermicularis* in fecal samples associated with skeletal remains of two mummies from Kellis sites in the Dakhleh Oasis, dated to the roman occupation period (30 BC-395 AD) (Horne, 2002).

5.6 Coccidian findings

In this study, the oocysts of *Eimeria spp.* were identified in subsample **ID: H9a** from Hierakonpolis. The sample **ID: H9** has a carnivore origin mixed with possibly human coprolite. The average size of the oocysts was 81 \times 66 μm . Based on this morphometry and also morphology of the findings, it seems that they are resemble to *E. leuckarti* and *E. macusaniensis* which parasitize respectively equids and camelids. Therefore it could be an evidence for coprophagy of equid/camelid feces by carnivores or due to the ingestion of contaminated meat or offal by human or carnivores.

Identified	Measured egg(s)			Site	Dating	Sample	Origin	ID
	Count	Length (µm)	Width (µm)					
<i>Eimeria</i> sp.	5	81±4.9	66±7.0	Hierakonpolis (Locality 11C)	3900 - 3300 BC	Coprolite	Carnivore/Human	H9a

Table 5.9: Identified coccidian eggs.

A number of coccidian species in class of Coccidea are in the genus of *Eimeria* which cause an infection to this parasitic protozoan. The infection is eimeriosis, but generally called coccidiosis. The diseases occur commonly in young ruminants and also have been reported in horses, camelids, pigs, rodents, rabbits, and avian (poultry) as well as fishes. Some species of coccidian also could be found in human and canine which cause diarrhea and abdominal pain. Only few of many identified species of *Eimeria spp.* are clinical importance. *Eimeria bovis* and *E. zuernii* are two of the most important coccidian which may induce subclinical disease, the lesions in the large intestine and also moderate to severe hemorrhagic diarrhea in the calves. Watery diarrhea is also related to infection of the small intestine of the grazing calves with *E. alabamensis*. The other species such as *E. ovinoidalis*, *E. bakuensis*, *E. ninakohlyakimovae*, *E. arloingi* and *E. ahsata* are of the most pathogenic species particularly in sheep and goats. *Eimeria leuckarti* is the only *Eimeria sp.* occurring in horses and cause diarrhea in young horses (Kaufmann, 1996; Taylor et al, 2007; Mehlhorn, 2008; Roberts and Janovy Jr., 2009).

Two typical signs of coccidiosis are dehydration and hypoproteinaemia. Also fever, anorexia, retarded growth, productivity loss, and anemia may be observed in severe cases. Coccidiosis rarely is related to mortality and as a self-limiting disease generally disappears after 2–14 days (Mehlhorn, 2008).

In its life cycle, the oocysts of *Eimeria spp.* shed in the feces are ingested by the next host. The oocysts release sporocysts in the small intestine. Subsequently, sporozoites hatch from the

sporocysts and penetrate into the intestinal cells. Schizonts, merozoites, gamonts of different sex, microgamonts, and macrogamonts, male and female gametes are respectively the other forms of the parasite when developing within the intestine cell. Finally oocysts are formed and set free via host feces (Mehlhorn, 2008; Roberts and Janovy Jr., 2009).

The most ancient coccidian oocysts have been found in coprolite samples dated to around 10,500 BP reported from Rampart Cave, Arizona, U.S. (Schmidt et al., 1992). The *Eimeria* sp. findings also were reported mostly from American continent (Ferreira et al., 1992; Fugassa and Barberena, 2006; Fugassa et al., 2008; Fugassa et al., 2010). Among them *Eimeria lobatoi* was a new species discovered for the first time in the archaeological materials, in deer coprolites dated to 9000 BP at the site of Perna I, northeast Brazil (Ferreira et al., 1992). Moreover, one report of *Eimeria* sp., probably *E. mira*, which is a protozoa of red squirrel, has been found in Denmark. It recovered from the intestine of the Bog Man from Grauballe, dated between 1540 and 1740 BP. The infection occurs probably due to the ingestion of contaminated meat or offal (Hill, 1990).

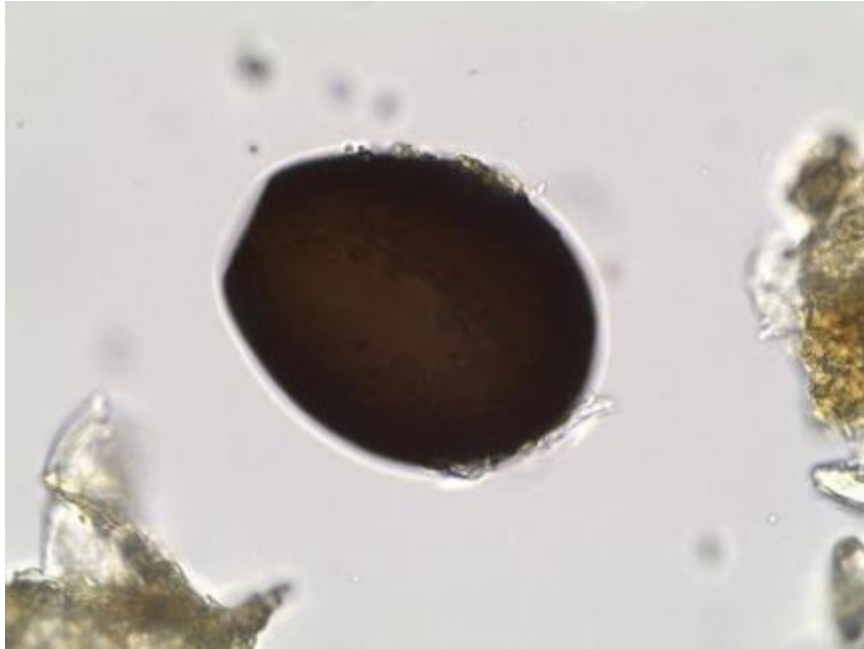


Figure 5.42: *Eimeria* sp. oocyst, displaying characteristic morphology of coccidian oocyst, size: $82 \times 68 \mu\text{m}$, magnification $630\times$, subsample ID: H9a, Hierakonpolis, Egypt.

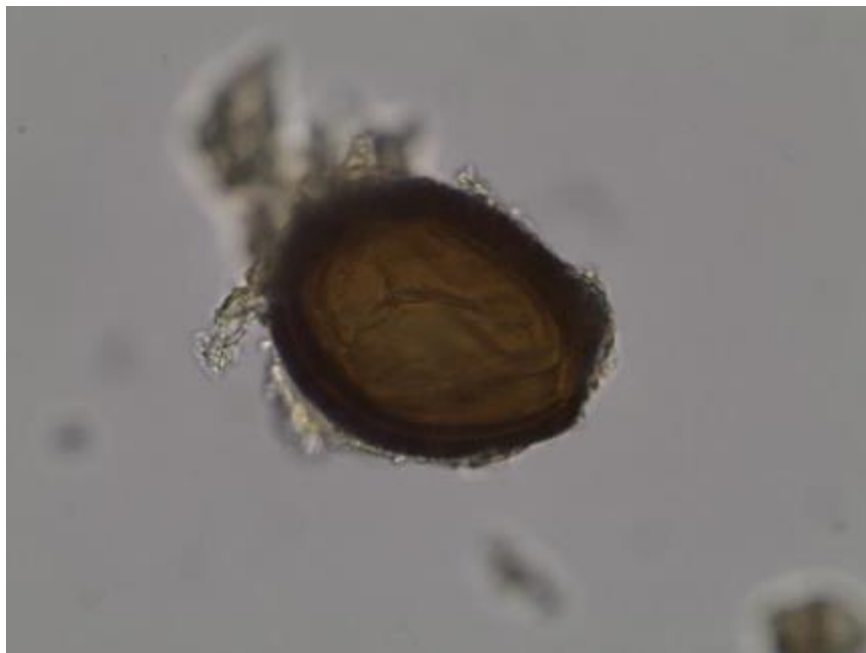


Figure 5.43: *Eimeria* sp. oocyst, displaying characteristic morphology of coccidian oocyst, size: $75 \times 58 \mu\text{m}$, magnification $630\times$, subsample ID: H9a, Hierakonpolis, Egypt.

Chapter 6 : Conclusion

The understanding of the history of parasitism has some application in archaeology, parasitology, and biology and sometimes in other sub-disciplines of these sciences.

Since one century, the study of ancient parasites, named paleoparasitology, exists and develops. This research field aims in understanding the history and the evolution of host-parasite relationship, and gives additional knowledge especially on ancient human population way of life. Also paleopathology, diet, funerary practices, and cultures are some topics in the field of anthropology that can be enquired by working on preserved parasite markers. Besides these information, findings of animal specific parasites can help us to compare modern veterinary parasitology with ancient animal parasitic environment due to the geographical distribution of their hosts. From another point of view, we can find additional data on the origin of domestication for domestic animals and the mutual effects and interactions between parasites, human, animal and environments during the process of domestication in the past.

Being a historically geographic and cultural crossroads, the Middle East is an important area which can provide information on ancient parasitism. However, there was no equilibrium on previous paleoparasitological studies in the archaeological sites of the Middle Eastern countries. Former studies on paleoparasitology in this area had shown the presence of a wide diversity of parasites (mostly human parasites) in the western parts of the region.

This study of ancient parasites in this region tries to provide a large scale of paleoparasitological analyses of the samples from the Iranian Plateau and adjacent countries in western Asia consist of Iran, Azerbaijan, Syria, Oman and Saudi Arabia and at the same time analyze the samples from two countries in northeastern Africa: Egypt and Sudan. The parasitic evidences presented in this research are added into our knowledge of the past parasitic environment of the Middle East and give impetus to the expansion of paleoparasitology in the archaeological areas within the region, particularly in the countries with no paleoparasitological data up to now.

275 samples were analysed using RHM protocol for the extraction of helminth eggs/protozoan oocysts and 30 samples were analysed by applying ELISA technique for the presence of the unicellular protozoa *Entamoeba histolytica*.

Despite the negative results, study of the materials from Azerbaijan, Saudi Arabia and Oman provide the first paleoparasitological analyses for the identification of ancient helminth

remains in archaeology of these countries. The interpretation of the negative results in paleoparasitology of the Iranian plateau and adjacent areas needs considering different environmental issues. Several physical and chemical factors influencing on the preservation of the parasite eggs and associated with the geology, climate, and weather could be related to the negativity of 85% of the samples in this research. The preservation status of parasite eggs remains a major question in the future and needs more geomorphological, pedological and taphonomic investigations. Also, badly targeted sampling, low quantity of the parasitic markers and/or sometimes the low number of studied samples for some sites could be the other possible explanations for this amount of negativity. In the eastern part of the Middle-East, finding particular contexts in which parasite markers can be preserved could be a challenge in the future investigations in this region.

The positive results in this research are limited to the archaeological sites of Chehrabad saltmine in Iran and Hierakonpolis in Egypt.

The first evidences of ancient human and animal helminthiasis in Iran by a variety of parasite taxa including roundworm, tapeworm, human and horse pinworm as well as strongyles and lancet liver fluke are presented in this research. It also provides the second evidence of whipworm infection in past Iran.

The results obtained from Chehrabad saltmine in Iran revealed the presence of five different parasite species in analysed samples dated to Achaemenid period (7th Century - 4th Century BC). *Ascaris* sp., *Trichuris* sp., and *Enterobius vermicularis*, as well as taeniid tapeworms (including *Taenia* sp.) identified in Achaemenid dated samples can be used as a proxy to reconstruct aspects of the daily life of the ancient saltminers in Chehrabad, like their poor hygiene conditions, dietary habits (consist of the meat of sheep, goat, cattle or pig) and food preparation ways. Also these finding could be compared with the similar paleoparasitological findings in the contemporary sites within the Persian Empire territory during the Achaemenid period such as Jerusalem in Israel, Saqqara and Deir el-Medineh in Egypt as well as Sai in Sudan. At the same time, the extracted animal-specific parasite remains of *Oxyuris equi* in the Achaemenid period of Chehrabad could be compared with the previous horse pinworm egg findings in the site of Berel (Kazakhstan) dated to the same period. These findings provide a new source of evidence to hypothesize that the Chehrabad saltmine occupants may have had ancient contacts with the central

Asia regions at least from the first millennium BC. The possible links between these two sites could be for instance salt traction by equines from Chehrabad to the central Asia and also human migration as saltminers from the central Asia to Chehrabad. The ancient contacts between northwestern Iran and central Asia were attested before by isotopic analysis and archaeological studies and could impact on the transmission of infectious human/animal diseases associated with poor levels of hygiene.

Further identified parasite findings from Chehrabad belonging to Sassanid period (3rd Century - 7th Century AD), consist of *Ascaris lumbricoides*, *Trichuris trichiura*, *Enterobius vermicularis*, *Oxyuris equi*, strongylid/trichostrongylid and taeniids have provided a glimpse into the health status of ancient saltminers and their associated animals. These data provided also important information towards understanding the continuation of parasitism and poor levels of hygiene at the site up to Sassanid period. Paleoparasitological data available from the contemporary sites in the Middle East with Sassanid layers of Chehrabad saltmine such as the sites of Caeseria and Beit Shean in Israel, Kellis and El-Deir in Egypt, Sedeinga and Sai in Sudan shows some similarities of parasitic environment in different areas of the Middle East region during the Sassanid period, and suppose a most ancient arrival of some parasites in this region.

In addition, reconstructing the parasitic past Iranian Plateau and its adjacent areas, paleoparasitology of this region could demonstrate the associations between already ancient parasitic findings in Russia, Caucasus and Turkmenistan from the northern regions, Mongolia and Kazakhstan from the northeastern areas and Syria, Israel, Cyprus, Egypt and Sudan from the western adjacent of the Iranian Plateau. These data could be used to studies on past inhabitant life, but also on ancient migrations and possible exchange ways between populations in the study area.

Despite the paleoparasitological record of a diversity of parasite taxa in already data from ancient Egypt, this PhD work revealed the first evidences of animal infection by intestinal flukes, anoplocephalid, acanthocephalan and coccidian in this country. Moreover, the presence of liver flukes, taeniids and trichurids are evidenced in this research, added to the already data on these taxa from ancient Upper Egypt. The identification of the fasciolid, paramphistomatid, hymenolepid and taeniid helminth eggs in both localities of HK11C (3900 - 3300 BC) and HK6 (3700 - 3500 BC) at the site of Hierakonpolis suggests that the parasitic disease in this area had been prevalent over the 4th millennium BC during the Naqada period.

Furthermore, the identification of *Trichuris* sp., taeniid, hymenolepid and acanthocephalan eggs in Locality 11C at Hierakonpolis represent the most ancient evidences of infection by whipworm, tapeworm and acanthocephalan parasites in Africa. Moreover, the presences of anoplocephalid and coccidian species in Locality 11C introduced the first records of these parasitic taxa into paleoparasitology of Asian and African continent.

On the other hand, only two cases of paleoparasitological analysis of coprolites in Egyptian archaeological sites have been carried out before the present PhD research. The identification of at least 8 parasite taxa in human/animal coprolites from Hierakonpolis, indicated again the significance of such analysis in hyper-arid environments such as Egypt and northeastern Africa.

Moreover, the use of molecular biology and new tools for the identification of parasitic diseases, could improve future studies for the reconstruction of the past parasitic environment within the Middle East region.

In addition, the identified ancient parasitic diseases in this research are still problematic in today local public health at the studied area. Therefore, these data could also help parasitologists to better understand the role of ancient geographical distribution of such parasitic diseases on today parasitic environment of the Middle East.

References

- Aali, A., 2005. Salt men. Iranian Center for Archaeological Research.
- Aali, A., Abar, A., Boenke, N., Pollard, M., Rühli, F., Stöllner, T., 2012. Ancient salt mining and salt men: the interdisciplinary Chehrabad Douzlakh project in north-western Iran. *Antiquity* 86.
- Aali, A., Rühli, F., Abar, A., Stöllner, T., 2012. The salt men of Iran: The salt mine of Douzlakh, Chehrabad. *Archäologisches Korrespondenzblatt* 42, 61–81.
- Abou-El-Naga, I.F., 2013. *Biomphalaria alexandrina* in Egypt: Past, present and future. *Journal of biosciences* 38, 665–672.
- Adams, B., 2002. Locality 6, Hierakonpolis. *Cahiers Caribéens d’Égyptologie* n 3, 4.
- Anastasiou, E., Lorentz, K.O., Stein, G.J., Mitchell, P.D., 2014. Prehistoric schistosomiasis parasite found in the Middle East. *The Lancet Infectious Diseases* 14, 553–554.
- Anastasiou, E., Mitchell, P.D., 2013a. Human intestinal parasites from a latrine in the 12th century Frankish castle of Saranda Kolones in Cyprus. *International Journal of Paleopathology* 3, 218–223.
- Anastasiou, E., Mitchell, P.D., 2013b. Paleopathology and genes: investigating the genetics of infectious diseases in excavated human skeletal remains and mummies from past populations. *Gene* 528, 33–40.
- Andrews, J.R., 1976. The parasitology of the Maori in pre-European times. *The New Zealand medical journal* 84, 62–65.
- Araújo, A., Ferreira, L.F., 1995. Oxyuriasis and prehistoric migrations. *História, Ciências, Saúde-Manguinhos* 2, 99–109.
- Araújo, A., Ferreira, L.F., 2000. Paleoparasitology and the antiquity of human host-parasite relationships. *Memórias do Instituto Oswaldo Cruz* 95, 89–93.

- Araújo, A., Ferreira, L.F., 2014. Parasitism, in: Ferreira, L.F., Araújo, A., Reinhard, K. (Eds.), *Foundations of Paleoparasitology*. International Federation for Tropical Medicine, pp. 111–119.
- Araújo, A., Ferreira, L.F., Confalonieri, U., Chame, M., 1988. Hookworms and the peopling of America. *Cadernos de Saúde Pública* 4, 226–233.
- Araújo, A., Jansen, A.M., Bouchet, F., Reinhard, K., Ferreira, L.F., 2003. Parasitism, the diversity of life, and paleoparasitology. *Memórias do Instituto Oswaldo Cruz* 98, 5–11.
- Araújo, A., Reinhard, K., Bastos, O.M., Costa, L.C., Pirmez, C., Iñiguez, A., Vicente, A.C., Morel, C.M., Ferreira, L.F., 1998. Paleoparasitology: perspectives with new techniques. *Revista do Instituto de Medicina Tropical de São Paulo* 40, 371-376.
- Araújo, A., Reinhard, K.J., Ferreira, L.F., 2000. The role of mummy studies in paleoparasitology. *Chungará (Arica)* 32, 111–115.
- Araújo, A., Reinhard, K.J., Ferreira, L.F., Gardner, S.L., 2008. Parasites as probes for prehistoric human migrations? *Trends in parasitology* 24, 112–115.
- Arriaza, B., Amarasiriwardena, D., Cornejo, L., Standen, V., Byrne, S., Bartkus, L., Bandak, B., 2010. Exploring chronic arsenic poisoning in pre-Columbian Chilean mummies. *Journal of Archaeological Science* 37, 1274–1278.
- Ash, L.R., Orihel, T.C., 2007. *Ash and Orihel's atlas of human parasitology*. American Society of Clinical Pathologists Press.
- Aspöck, H., 2000. Paläoparasitologie: Zeugen der Vergangenheit. *Nova Acta Leopoldina* 83, 159–181.
- Aspöck, H., Auer, H., Picher, O., 1995. The mummy from the Hauslabjoch: a medical parasitology perspective. *Alpe Adria Microbiology Journal* 2, 105–114.
- Aspöck, H., Auer, H., Picher, O., 1996. *Trichuris trichiura* eggs in the neolithic glacier mummy from the Alps. *Parasitology Today* 12, 255–256.

- Aspöck, H., Auer, H., Picher, O., 1999. Parasites and parasitic diseases in prehistoric human populations in Central Europe. *Helminthologia* 36, 139–145.
- Aspöck, H., Barth, F.E., Flamm, H., Picher, O., 1974. Parasitäre Erkrankungen des Verdauungstraktes bei prähistorischen Bergleuten von Hallstatt und Hallein (Österreich). *Mitt. Anthropol. Ges. Wien* 103, 41–47.
- Aspöck, H., Boenke, N., Kofler, W., Oeggl, K., Picher, O., Stöllner, T., 2007. The Dürrnberg miners during the Iron Age-new results by interdisciplinary research. *Beiträge zur Ur-und Frühgeschichte Mitteleuropas* 47, 109–126.
- Aufderheide, A.C., 2003. *The scientific study of mummies*. Cambridge University Press.
- Azar, D., Nel, A., 2003. Fossil psychodoid flies and their relation to parasitic diseases. *Memórias do Instituto Oswaldo Cruz* 98, 35–37.
- Baba, M., 2009. Pottery production at Hierakonpolis during the Naqada II period: Toward a reconstruction of the firing technique. *British Museum Studies in Ancient Egypt and Sudan (BMSAES)* 13, 1–24.
- Ballweber, L.R., 2001. *Veterinary Parasitology: The Practical Veterinarian*. Butterworth-Heinemann, USA.
- Barakat, R.M., 2013. Epidemiology of schistosomiasis in Egypt: travel through time: review. *Journal of Advanced Research* 4, 425–432.
- Bartošová, L., Ditrich, O., Beneš, J., Frolík, J., Musil, J., 2011. Paleoparasitological findings in medieval and early modern archaeological deposits from Hradební Street, Chrudim, Czech Republic. *Interdisciplinaria Archaeologica–Natural Sciences in Archaeology* 2, 27–38.
- Beltrame, M.O., Fugassa, M.H., Barberena, R., Udrizar Sauthier, D.E., Sardella, N.H., 2013. New record of anoplocephalid eggs (Cestoda: Anoplocephalidae) collected from rodent coprolites from archaeological and paleontological sites of Patagonia, Argentina. *Parasitology international* 62, 431–434.

- Beltrame, M.O., Fugassa, M.H., Sardella, N.H., Civalero, M.T., Aschero, C., 2011. Raptor pellets as zooarchaeological material for paleoparasitological studies in Patagonia. *Journal of Archaeological Science* 38, 1511–1515.
- Beltrame, M.O., Sardella, N.H., Fugassa, M.H., Barberena, R., 2012. A palaeoparasitological analysis of rodent coprolites from the Cueva Huenul 1 archaeological site in Patagonia (Argentina). *Memórias do Instituto Oswaldo Cruz* 107, 604–608.
- Berenji, F., Fata, A., Hosseininejad, Z., 2007. A case of *Moniliformis moniliformis* (Acanthocephala) infection in Iran. *The Korean journal of parasitology* 45, 145–148.
- Berthon, R., Decaix, A., Kovács, Z.E., Van Neer, W., Tengberg, M., Willcox, G., Cucchi, T., 2013. A bioarchaeological investigation of three late Chalcolithic pits at Ovçular Tepesi (Nakhchivan, Azerbaijan). *Environmental Archaeology* 18, 191–200.
- Bianucci, R., Mattutino, G., Lallo, R., Charlier, P., Jouin-Spriet, H., Peluso, A., Higham, T., Torre, C., Rabino Massa, E., 2008. Immunological evidence of *Plasmodium falciparum* infection in an Egyptian child mummy from the Early Dynastic Period. *Journal of Archaeological Science* 35, 1880–1885.
- Biglari, F., Jahani, V., 2011. The Pleistocene Human Settlement in Gilan, Southwest Caspian Sea: Recent Research. *Eurasian Prehistory* 8, 3–28.
- Biglari, F., Javeri, M., Mashkour, M., Yazdi, M., Shidrang, S., Tengberg, M., Taheri, K., Darvish, J., Otte, M., Biglari, F., 2006. Test Excavations at the Middle Paleolithic sites of Qaleh Bozi, southwest of central Iran: a preliminary report, in: *Iran Palaeolithic. Proceedings of the XV World Congress UISPP, Lisbon*. pp. 4–9.
- Biglari, F., Shidrang, S., 2007. The lower paleolithic occupation of Iran. *Near Eastern Archaeology* 69, 160.
- Biscione, R., Vahdati, A., 2011. Excavations at Tepe Challow, Northern Khorasan, Iran. *Studi Micenei ed Egeo-Anatolici* 53, 236–241.

- Bonnet, C., 2004. The Kerma Culture, in Welsby, D., and Anderson, J. R. (eds.), Sudan – Ancient Treasures. An exhibition of recent discoveries from the Sudan National Museum London, pp. 70–82
- Bouchet, F., 1995. Recovery of helminth eggs from archeological excavations of the Grand Louvre (Paris, France). *The Journal of parasitology* 81, 785–787.
- Bouchet, F., 2003. La paleoparasitologie, une discipline scientifique et médicale aux services de l'archéologie. *Bulletin de la Société archéologique champenoise* 96, 50–54.
- Bouchet, F., Baffier, D., Girard, M., Morel, P., Paicheler, J.-C., David, F., 1996. Paléoparasitologie en contexte pléistocène: premières observations à la Grande Grotte d'Arcy-sur-Cure (Yonne), France. *Comptes rendus de l'Académie des sciences. Série 3, Sciences de la vie* 319, 147–151.
- Bouchet, F., Guidon, N., Dittmar, K., Harter, S., Ferreira, L.F., Chaves, S.M., Reinhard, K., Araújo, A., 2003a. Parasite remains in archaeological sites. *Memórias do Instituto Oswaldo Cruz* 98, 47–52.
- Bouchet, F., Harter, S., Le Bailly, M., 2003b. The state of the art of paleoparasitological research in the Old World. *Memórias do Instituto Oswaldo Cruz* 98, 95–101.
- Bouchet, F., Harter, S., Paicheler, J.C., Araújo, A., Ferreira, L.F., 2002. First recovery of *Schistosoma mansoni* eggs from a latrine in Europe (15-16th centuries). *Journal of Parasitology* 88, 404–405.
- Bouchet, F., Paicheler, J.C., 1995. Paleoparasitology: presumption of a case with bilharzia of the 15th century at Montbéliard (Doubs, France). *Comptes Rendus De L'académie Des Sciences. Série III, Sciences De La Vie* 318, 811–814.
- Bruschi, F., Masetti, M., Locci, M.T., Ciranni, R., Fornaciari, G., 2006. Cysticercosis in an Egyptian mummy of the late Ptolemaic period. *The American journal of tropical medicine and hygiene* 74, 598–599.
- Bundy, D.A.P., Cooper, E.S., 1989. *Trichuris* and *Trichuriasis* in Humans. *Advances in Parasitology* 28, 107–173.

- Cahill, J., Reinhard, K., Tarler, D., Warnock, P., 1991. It had to happen. Scientists examine remains of ancient bathroom. *The Biblical archaeology review* 17, 64–69.
- Caldwell, F.C., Caldwell, E.L., 1926. Are *Ascaris lumbricoides* and *Ascaris suilla* identical? *The Journal of Parasitology* 13, 141–145.
- Callen, E.O., Cameron, T.W.M., 1960. A prehistoric diet revealed in coprolites. *New Scientist* 8.
- Caumes, J.-L., Bronstein, J.-A., Klotz, F., 2005. Trichocéphales et trichocéphalose. *EMC-Maladies infectieuses* 2, 140–145.
- Cerutti, N., Marin, A., Massa, E.R., Savoia, D., 1999. Immunological investigation of malaria and new perspectives in paleopathological studies. *Bollettino della Societa italiana di biologia sperimentale* 75, 17–20.
- Chaves, S.A. de M., Reinhard, K.J., 2006. Critical analysis of coprolite evidence of medicinal plant use, Piauí, Brazil. *Palaeogeography, Palaeoclimatology, Palaeoecology* 237, 110–118.
- Chiodini, P.L., Moody, A.H., Manser, D.W., 2003. Atlas of medical helminthology and protozoology, 4th ed. Churchill Livingstone, Edinburgh.
- Cockburn, A., 1981. Ancient parasites on the west bank of the Nile. *The Lancet* 318, 938.
- Cockburn, A., Barraco, R.A., Reyman, T.A., Peck, W., 1975. Autopsy of an Egyptian mummy. *Science* 187, 1155–1160.
- Cockburn, A., Cockburn, E., Reyman, T.A., 1998. Mummies, disease and ancient cultures. Cambridge University Press.
- Confalonieri, U.E., Ribeiro Filho, B., Ferreira, L.F., Araújo, A., 1985. *Trichuris trichiura* infection in Colonial Brazil. *Paleopathol News* 35, 13–14.
- Contis, G., David, A.R., 1996. The epidemiology of bilharzia in ancient Egypt: 5000 years of schistosomiasis. *Parasitology Today* 12, 253–255.
- Cooper, E.S., Bundy, D.A.P., 1988. *Trichuris* is not trivial. *Parasitology Today* 4, 301–306.

- Cox, F.E., 2004. History of human parasitic diseases. *Infectious disease clinics of North America* 18, 171–188.
- Crompton, D.W.T., 2001. Ascaris and ascariasis. *Advances in parasitology* 48, 285–375.
- Crubézy, E., Magnaval, J.-F., Francfort, H.-P., Ludes, B., Larrouy, G., 2006. Herodotus, the Scythes and hookworm infection. *The Lancet* 367, 1520.
- Curry, A., Anfield, C., Tapp, E., 1979. Electron microscopy of the Manchester mummies, in: *The Manchester Museum Mummy Project: Multidisciplinary Research on Ancient Egyptian Mummified Remains*. Manchester University Press, Manchester, pp. 103–111.
- David, A.R., 1997. Disease in Egyptian mummies: the contribution of new technologies. *The Lancet* 349, 1760–1763.
- David, A.R., 2000. 5000 years of schistosomiasis in Egypt. *Chungará (Arica)* 32, 133–135.
- David, A.R., 2008. *Egyptian mummies and modern science*. Cambridge.
- David, A.R., Contis, G., 1996. Paleopathology on schistosomiasis in Egyptian mummies. *Parasitology Today* 12, 167.
- De Boni, U., Lenczner, M.M., Scott, J.W., 1977. Autopsy of an Egyptian mummy. 6. *Trichinella spiralic* cyst. *Canadian Medical Association Journal* 117, 472.
- Deelder, A.M., Miller, R.L., De Jonge, N., Krijger, F.W., 1990. Detection of schistosome antigen in mummies. *The Lancet* 335, 724–725.
- Deplazes, P., Gottstein, B., 1991. A monoclonal antibody against *Echinococcus multilocularis* Em2 antigen. *Parasitology* 103, 41–49.
- Dittmar, K., 2009. Old parasites for a new world: the future of paleoparasitological research. a review. *The Journal of Parasitology* 95, 365–371.
- Dittmar, K., 2014. Paleoparasitology and ancient DNA, in: Ferreira, L.F., Araújo, A., Reinhard, K. (Eds.), *Foundations of Paleoparasitology*. International Federation for Tropical Medicine, pp. 277–288.

- Dittmar, K., Mamat, U., Whiting, M., Goldmann, T., Reinhard, K., Guillen, S., 2003. Techniques of DNA-studies on prehispanic ectoparasites (*Pulex* sp., Pulicidae, Siphonaptera) from animal mummies of the Chiribaya culture, Southern Peru. *Memórias do Instituto Oswaldo Cruz* 98, 53–58.
- Dittmar, K., Steyn, M., 2004. Paleoparasitological analysis of coprolites from K2, an Iron Age archaeological site in South Africa: the first finding of *Dicrocoelium* sp. eggs. *Journal of Parasitology* 90, 171–173.
- Dittmar, K., Teegen, W.R., 2003. The presence of *Fasciola hepatica* (Liver-fluke) in humans and cattle from a 4,500 Year old archaeological site in the Saale-Unstrut Valley, Germany. *Memórias do Instituto Oswaldo Cruz* 98, 141–143.
- Dorny, P., Praet, N., Deckers, N., Gabriel, S., 2009. Emerging food-borne parasites. *Veterinary parasitology* 163, 196–206.
- Dufour, B., Le Bailly, M., 2013. Testing new parasite egg extraction methods in paleoparasitology and an attempt at quantification. *International Journal of Paleopathology* 3, 199–203.
- El-Khoby, T., Galal, N., Fenwick, A., Barakat, R., El-Hawey, A., Nooman, Z., Habib, M., Abdel-Wahab, F., Gabr, N.S., Hammam, H.M., 2000. The epidemiology of schistosomiasis in Egypt: summary findings in nine governorates. *The American journal of tropical medicine and hygiene* 62, 88–99.
- Elsheikha, H.M., Patterson, J.S., 2013. *Veterinary Parasitology: Self-Assessment Colour Review (Veterinary Self-Assessment Color Review Series)*. Manson, USA.
- Emberling, G., 2011. *Nubia: ancient kingdoms of Africa*. Inst. for the Study of the Ancient World, New York Univ.
- Fahmy, A.G., Friedman, R.F., Fadl, M., 2008. Archaeobotanical studies at Hierakonpolis locality HK6: The Pre and Early Dynastic elite cemetery. *Archeo-Nil* 18, 169–83.
- Faulkner, C.T., Patton, S., Johnson, S.S., 1989. Prehistoric parasitism in Tennessee: evidence from the analysis of desiccated fecal material collected from Big Bone Cave, Van Buren County, Tennessee. *The Journal of parasitology* 75(3), 461–3.

- Faulkner, C.T., Reinhard, K.J., 2014. A Retrospective Examination of Paleoparasitology and its Establishment in the Journal of Parasitology. *Journal of Parasitology* 100(3), 253-9.
- Ferreira, L.F., 2014. An introduction to paleoparasitology, in: Ferreira, L.F., Araújo, A., Reinhard, K. (Eds.), *Foundations of Paleoparasitology*. International Federation for Tropical Medicine, pp. 27–41.
- Ferreira, L.F., Araújo, A., Confalonieri, U., Chame, M., Gomes, D.C., 1991. Trichuris eggs in animal coprolites dated from 30,000 years ago. *The Journal of parasitology* 77, 491–493.
- Ferreira, L.F., Britto, C., Cardoso, M.A., Fernandes, O., Reinhard, K., Araújo, A., 2000. Paleoparasitology of Chagas disease revealed by infected tissues from Chilean mummies. *Acta Tropica* 75, 79–84.
- Ferrio, J.P., Arab, G., Buxó, R., Guerrero, E., Molist, M., Voltas, J., Araus, J.L., 2012. Agricultural expansion and settlement economy in Tell Halula (Mid-Euphrates valley): A diachronic study from early Neolithic to present. *Journal of Arid Environments* 86, 104–112.
- Fletcher, J., 2002. Ancient Egyptian hair and wigs. *The Ostrakon the journal of the Egyptian study society* 13.
- Foreyt, W.J., 2001. *Veterinary parasitology reference manual*, 5th ed. Blackwell.
- Fornaciari, G., Gaeta, R., 2014. Paleoparasitology of Helminths, in: Bruschi, F. (Ed.), *Helminth Infections and Their Impact on Global Public Health*. Springer, pp. 29–47.
- Foster, W.D., 1914. Observations on the Eggs of *Ascaris lumbricoides*. *The Journal of Parasitology* 1, 31–36.
- Frías, L., Leles, D., Araújo, A., 2013. Studies on protozoa in ancient remains-A Review. *Memórias do Instituto Oswaldo Cruz* 108, 1–12.
- Friedman, R.F., 2008. The cemeteries of Hierakonpolis. *Archeo-Nil* 18, 8–29.
- Friedman, R.F., 2011. Hierakonpolis. Wiley Online Library.

- Friedman, R.F., Friedman, R.F., Maish, A., Fahmy, A.G., Darnell, J.C., Johnson, E.D., 1999. Preliminary report on field work at Hierakonpolis: 1996-1998. *Journal of the American Research Center in Egypt* 36, 1–35.
- Friedman, R.F., Van Neer, W., Linseele, V., 2011. The elite Predynastic cemetery at Hierakonpolis: 2009-2010 update. *Egypt at its Origins* 3, 157–191.
- Fry, G.F., 1980. The prehistoric diet and parasite in the dessert West of North America. In: *Early Native Americans: Prehistoric Demography, Economy, and Technology*. pp. 325–339.
- Fry, G.F., Moore, J.G., 1969. *Enterobius vermicularis*: 10,000-year-old human infection. *Science* 166, 1620–1620.
- Fugassa, M.H., 2014. Paleoparasitological diagnosis, in: Ferreira, L.F., Reinhard, K.J., Araújo, A. (Eds.), *Foundations of Paleoparasitology*. International Federation for Tropical Medicine, pp. 223–254.
- Fugassa, M.H., Barberena, R., 2006. Caves and ancient zoonoses: paleoparasitology of the Orejas De Burro 1 site (Santa Cruz, Argentina). *Magallania (Punta Arenas)* 34, 57–62.
- Fugassa, M.H., Beltrame, M.O., Sardella, N.H., Civalero, M.T., Aschero, C., 2010. Paleoparasitological results from coprolites dated at the Pleistocene–Holocene transition as source of paleoecological evidence in Patagonia. *Journal of Archaeological Science* 37, 880–884.
- Fugassa, M.H., Denegri, G.M., Sardella, N.H., Araújo, A., Guichón, R.A., Martinez, P.A., Civalero, M.T., Aschero, C., 2006. Paleoparasitological records in a canid coprolite from Patagônia, Argentina. *Journal of Parasitology* 92, 1110–1113.
- Fugassa, M.H., Reinhard, K.J., Johnson, K.L., Gardner, S.L., Vieira, M., Araújo, A., 2011. Parasitism of prehistoric humans and companion animals from Antelope Cave, Mojave County, Northwest Arizona. *Journal of Parasitology* 97, 862–867.
- Fugassa, M.H., Sardella, N.H., Taglioretti, V., Reinhard, K.J., Araújo, A., 2008. Eimeriid oocysts from archaeological samples in Patagonia, Argentina. *Journal of Parasitology* 94, 1418–1420.

- Gonçalves, M.L.C., Araújo, A., Duarte, R., Da Silva, J.P., Reinhard, K., Bouchet, F., Ferreira, L.F., 2002. Detection of *Giardia duodenalis* antigen in coprolites using a commercially available enzyme-linked immunosorbent assay (English). *Transactions of the Royal Society of Tropical Medicine and Hygiene* 96, 640–643.
- Gonçalves, M.L.C., Araújo, A., Ferreira, L.F., 2003. Human intestinal parasites in the past: new findings and a review. *Memórias do Instituto Oswaldo Cruz* 98, 103–118.
- Gonçalves, M.L., Da Silva, V. L., De Andrade, C.M., Reinhard, K., Da Rocha, G.C., Le Bailly, M., Bouchet, F., Ferreira, L.F., Araújo, A., 2004. Amoebiasis distribution in the past: first steps using an immunoassay technique (English). *Transactions of the Royal Society of Tropical Medicine and Hygiene* 98, 88–91.
- Grove, D.I., 1990. *A history of human helminthology*. CAB International Wallingford, UK.
- Guerra, R. de M.S.N., Gazêta, G.S., Amorim, M., Duarte, A.N., Serra-Freire, N.M., 2003. Ecological analysis of acari recovered from coprolites from archaeological site of northeast Brazil. *Memórias do Instituto Oswaldo Cruz* 98, 181–190.
- Guezala, M.-C., Rodriguez, S., Zamora, H., Garcia, H.H., Gonzalez, A.E., Tembo, A., Allan, J.C., Craig, P.S., 2009. Development of a species-specific coproantigen ELISA for human *Taenia solium* taeniasis. *The American journal of tropical medicine and hygiene* 81, 433–437.
- Guhl, F., Jaramillo, C., Yockteng, R., Vallejo, G.A., Caárdenas-Arroyo, F., 1997. *Trypanosoma cruzi* DNA in human mummies. *The lancet* 349, 1370.
- Halioua, B., 2004. *Histoire de la médecine*. 2 e éd. Masson, Paris.
- Han, E.-T., Guk, S.-M., Kim, J.-L., Jeong, H.-J., Kim, S.-N., Chai, J.-Y., 2003. Detection of parasite eggs from archaeological excavations in the Republic of Korea. *Memórias do Instituto Oswaldo Cruz* 98, 123–126.
- Harlan, J.F., 1982. Excavations at Locality 11C. in: Hoffman, M.A. (ed.), *The Predynastic of Hierakonpolis-An Interim Report*, Egyptian Studies Association, pp. 14–25.

- Harper, N.K., Fox, S.C., 2008. Recent research in Cypriot bioarchaeology. *Bioarchaeology of the Near East* 2, 1–38.
- Harter-Lailheugue, S., Bouchet, F., 2006a. Palaeoparasitological study of atypical elements of the low and High Nile Valley. *Bulletin de la Societe de pathologie exotique* (1990) 99, 53–57.
- Harter-Lailheugue, S., Bouchet, F., 2006b. Paléoparasitologie. *Bull Soc Pathol Exot* 99, 53–57.
- Harter-Lailheugue, S., Le Mort, F., Vigne, J.-D., Guilaine, J., Le Brun, A., Bouchet, F., 2005. Premières Données Parasitologiques sur les populations humaines précéramiques chypriotes (VIII e et VII e millénaires av. J.-C.). *Paléorient* 31(2), 43–54.
- Harter, S., 2003. Implication de la Paléoparasitologie dans l'étude des populations anciennes de la vallée du Nil et de proche-orient: étude de cas. PhD thesis, Université de Reims-Champagne Ardenne, Reims, France, 265 pp.
- Harter, S., Bouchet, F., Mumcuoglu, K.Y., Zias, J.E., 2004. Toilet practices among members of the Dead Sea scrolls sect at Qumran (100 BCE-68 CE). *Revue de Qumran* 21, 579–584.
- Harter, S., Le Bailly, M., Janot, F., Bouchet, F., 2003. First paleoparasitological study of an embalming rejects jar found in Saqqara, Egypt. *Memórias do Instituto Oswaldo Cruz* 98, 119–121.
- Hart, G.D., Cockburn, A., Millet, N.B., Scott, J.W., 1977. Lessons learned from the autopsy of an Egyptian mummy. *Canadian Medical Association Journal* 117, 415.
- Hawass, Z., Gad, Y.Z., Ismail, S., Khairat, R., Fathalla, D., Hasan, N., Ahmed, A., Elleithy, H., Ball, M., Gaballah, F., 2010. Ancestry and pathology in King Tutankhamun's family. *JAMA* 303, 638–647.
- Herrmann, B., 1988. Parasite remains from mediaeval latrine deposits: an epidemiologic and ecologic approach. *Parasite Remains from Mediaeval Latrine Deposits: an Epidemiologic and Ecologic Approach*. Note et monographie technique n°24, 135-142, CNRS, Paris.

- Hesse, B., 1989. Paleolithic faunal remains from Ghar-i-Khar, western Iran. in: P. J. Crabtree, D. Campana, O. K. Ryan (eds.), Early animal domestication and its cultural context. Philadelphia, MASCA, The University Museum, pp. 37-45.
- Hidalgo-Argüello, M.R., Diez Banos, N., Fregeneda Grandes, J., Prada Marcos, E., 2003. Parasitological analysis of Leonese royalty from collegiate-basilica of St. Isidoro, León (Spain): Helminths, protozoa, and mites. *Journal of Parasitology* 89, 738–743.
- Hill, G., 1990. Recent finds of parasitic evidence in coprolites". *Paleopathol News* 69, 9–10.
- Hoeppli, R., 1956. The knowledge of parasites and parasitic infections from ancient times to the 17th century. *Experimental Parasitology* 5, 398–419.
- Hole, F., Flannery, K.V., 1968. The prehistory of southwestern Iran: a preliminary report. *Proceedings of the Prehistoric Society (New Series)* 33, 147–206.
- Horne, P.D., 1985. A review of the evidence of human endoparasitism in the pre-Columbian New World through the study of coprolites. *Journal of Archaeological Science* 12, 299–310.
- Horne, P.D., 2002. First evidence of enterobiasis in ancient Egypt. *Journal of Parasitology* 88, 1019–1021.
- Horne, P.D., Lewin, P.K., 1977. Autopsy of an Egyptian mummy. 7. Electron microscopy of mummified tissue. *Canadian Medical Association Journal* 117, 472.
- Horne, P., Redford, S., 1995. Aspergillosis and dracunculiasis in mummies from the tomb of Parannefer. *Paleopathol News* 92, 10–12.
- Horton, J., 2014. Helminth-Nematode: *Trichuris trichiura*, in: Motarjemi, Y. (Ed.), *Encyclopedia of Food Safety*. Academic Press, Waltham, pp. 111–115.
- <http://hierakonpolis-online.org> [WWW Document], n.d.
- Huchet, J.B., Callou, C., Lichtenberg, R., Dunand, F., 2013. The dog mummy, the ticks and the louse fly: Archaeological report of severe ectoparasitosis in Ancient Egypt. *International Journal of Paleopathology* 3, 165–175.

- Hugot, J.P., 1982. *Enterobius gregorii* (Oxyuridae, Nematoda), a new human parasite. *Annales de parasitologie humaine et comparee* 58, 403–404.
- Hugot, J.-P., Reinhard, K.J., Gardner, S.L., Morand, S., 1999. Human enterobiasis in evolution: Origin, specificity and transmission. *Parasite (Paris, France)* 6, 201–208.
- Hume, J.C., Lyons, E.J., Day, K.P., 2003. Human migration, mosquitoes and the evolution of *Plasmodium falciparum*. *Trends in parasitology* 19, 144–149.
- Iñiguez, A.M., Reinhard, K., Carvalho Gonçalves, M.L., Ferreira, L.F., Araújo, A., Paulo Vicente, A.C., 2006. SL1 RNA gene recovery from *Enterobius vermicularis* ancient DNA in pre-Columbian human coprolites. *International journal for parasitology* 36, 1419–1425.
- Insoll, T., Hutchins, E., 2005. The archaeology of disease: molluscs as potential disease indicators in Bahrain. *World archaeology* 37, 579–588.
- Iqbal, J., Sher, A., Rab, A., 2000. *Plasmodium falciparum* histidine-rich protein 2-based immunocapture diagnostic assay for malaria: cross-reactivity with rheumatoid factors. *Journal of clinical microbiology* 38, 1184–1186.
- Isherwood, I., Jarvis, H., Fawcett, R.A., 1979. Radiology of the Manchester mummies, in: David, A.R. (ed.) *The Manchester Museum Mummy Project*. Manchester University Press, Manchester, pp. 25–64.
- Ito, A., 1997. Basic and applied immunology in cestode infections: from *Hymenolepis* to *Taenia* and *Echinococcus*. *International journal for parasitology* 27, 1203–1211.
- Ito, A., Nakao, M., Wandra, T., 2003. Human taeniasis and cysticercosis in Asia. *The Lancet* 362, 1918–1920.
- Jansen Jr, J., Over, H.J., 1964. Observations on helminth infections in a roman army-camp. *Proc 1st Int Congr Parasitol, Roma, Italy* 791.
- Joachim, H., 1890. *Papyrus Ebers: The first complete translation from the Egyptian*. Reimer: Berlin.

- Jones, A., Hutchinson, A., Nicholson, C., 1988. The worms of Roman horses and other finds of intestinal parasite eggs from unpromising deposits. *Antiquity* 62, 275–276.
- Jones, A.K.G., 1983. A coprolite from 6-8 pavement. Council for British Archaeology, *The Archaeology of York: The Past Environment of York, Environment and Living Conditions at Two Anglo-Scandinavian Sites*, Council for British Archaeology, pp. 225–229.
- Kaufmann, J., 1996. Parasitic infections of domestic animals: a diagnostic manual. ILRI (aka ILCA and ILRAD).
- Kim, M.-J., Shin, D.H., Song, M.-J., Song, H.-Y., Seo, M., 2013. Paleoparasitological Surveys for Detection of Helminth Eggs in Archaeological Sites of Jeolla-do and Jeju-do. *The Korean journal of parasitology* 51, 489–492.
- Kliks, M.M., 1983. Paleoparasitology: on the origins and impact of human-helminth relationships, in: Croll, N.A. and J. H. Cross (eds.), *Human ecology and infectious disease*, Academic Press, pp. 291–313.
- Kloos, H., David, R., 2002. The paleoepidemiology of schistosomiasis in ancient Egypt. *Human Ecology Review* 9, 14–25.
- Knapp, J., Nakao, M., Yanagida, T., Okamoto, M., Saarma, U., Lavikainen, A., Ito, A., 2011. Phylogenetic relationships within *Echinococcus* and *Taenia* tapeworms (Cestoda: Taeniidae): An inference from nuclear protein-coding genes. *Molecular phylogenetics and evolution* 61, 628–638.
- Le Bailly, M., 2005. Évolution de la relation hôte/parasite dans les systèmes lacustres nord alpins au Néolithique (3900-2900 BC), et nouvelles données dans la détection des paléoantigènes de Protozoa. Université de Reims Champagne- Ardenne, PhD thesis, Reims, France, 291 pp.
- Le Bailly, M., Barbin, V., Balasescu, A., Popovici, D., Bouchet, F., Paicheler, J.-C., 2006. Nouvelle approche taphonomique des coprolithes du Tell d'hârşova (Roumanie): contribution de la cathodoluminescence (French). *Comptes rendus. Palévol* 5, 919–925.

- Le Bailly, M., Bouchet, F., 2006a. Paléoparasitologie et immunologie. L'exemple d'*Entamoeba histolytica*. *ArcheoSciences. Revue d'archéométrie* 30, 129–135.
- Le Bailly, M., Bouchet, F., 2010. Ancient dicrocoeliosis: Occurrence, distribution and migration. *Acta tropica* 115, 175–180.
- Le Bailly, M., Gonçalves, M.L., Harter-Lailheugue, S., Prodéo, F., Araujo, A., Bouchet, F., 2008a. New finding of *Giardia intestinalis* (Eukaryote, Metamonad) in Old World archaeological site using immunofluorescence and enzyme-linked immunosorbent assays. *Memórias do Instituto Oswaldo Cruz* 103, 298–300.
- Le Bailly, M., Lepetz, S., Samashev, Z., Francfort, H.-P., Bouchet, F., 2008b. Palaeoparasitological study of gastro-intestinal content in horses at a Scythian kurgan (3rd century BC) found in Kazakhstan. *Anthropozoologica* 43, 69–75.
- Le Bailly, M., Leuzinger, U., Schlichtherle, H., Bouchet, F., 2005. *Diphyllobothrium*: Neolithic parasite? *The Journal of parasitology* 91, 957-9.
- Le Bailly, M., Mouze, S., Da Rocha, G.C., Heim, J.-L., Lichtenberg, R., Dunand, F., Bouchet, F., 2010. Identification of *Taenia* sp. in a mummy from a Christian necropolis in El-Deir, Oasis of Kharga, ancient Egypt. *Journal of Parasitology* 96, 213–215.
- Le Mort, F., 2008. Infant burials in pre-pottery Neolithic Cyprus: Evidence from Khiroitia, in: Bacvarov, K. (Ed.), *Babies Reborn: Infant/Child Burials in Pre-and Protohistory, Papers in Honor of Patricia Smith*, Oxford: Archaeopress, pp. 23–32.
- Leles, D., Araújo, A., Ferreira, L.F., Vicente, A.C.P., Iñiguez, A.M., 2008. Molecular paleoparasitological diagnosis of *Ascaris* sp. from coprolites: new scenery of ascariasis in pre-Colombian South America times. *Memórias do Instituto Oswaldo Cruz* 103, 106–108.
- Leles, D., Cascardo, P., Freire, A. dos S., Maldonado Jr, A., Sianto, L., Araújo, A., 2014. Insights about echinostomiasis by paleomolecular diagnosis. *Parasitology international* 63, 646–649.

- Leles, D., Reinhard, K.J., Fugassa, M., Ferreira, L.F., Iñiguez, A.M., Araújo, A., 2010. A parasitological paradox: Why is ascarid infection so rare in the prehistoric Americas? *Journal of Archaeological Science* 37, 1510–1520.
- Lesko, L.H., 1994. *Pharaoh's Workers: the villagers of Deir el Medina*. Cornell University Press.
- Loreille, O., Bouchet, F., 2003. Evolution of ascariasis in humans and pigs: a multi-disciplinary approach. *Memórias do Instituto Oswaldo Cruz* 98, 39–46.
- Loreille, O., Roumat, E., Verneau, O., Bouchet, F., Hänni, C., 2001. Ancient DNA from *Ascaris*: extraction amplification and sequences from eggs collected in coprolites. *International journal for parasitology* 31, 1101–1106.
- Lotfy, W., 2004. On the reality of *Enterobius gregorii* (Hugot, 1983).
- Lyonnet, B., Helwing, B., 2012. Holocene landscape and human modes of occupation in the Kura Valley (Azerbaijan). in: *Ancient Kura 2010-2011: The first two seasons of joint field work in the Southern Caucasus*. *Archäologische Mitteilungen aus Iran und Turan* 44, 1–3.
- Machnicka, B., Dziemian, E., Zwierz, C., 1996. Detection of *Taenia saginata* antigens in faeces by ELISA. *Applied parasitology* 37, 106–110.
- Maclean, J.D., Cross, J., Mahanty, S., 1999. Liver, lung, and intestinal fluke infections. *Tropical Infectious Diseases: Principles, Pathogens and Practice* 2, 1349–1369.
- Magi, B., Frati, E., Bernini, L., Sansoni, A., Zanelli, G., 2009. *Dicrocoelium dendriticum*: a true infection? *Le infezioni in medicina: rivista periodica di eziologia, epidemiologia, diagnostica, clinica e terapia delle patologie infettive* 17, 115–116.
- Mahforouzi, A., 2003. A Preliminary report on archaeological surveys and excavations in east of Mazandaran Province. *Archaeological Reports, Iranian Center for Archaeological Research* 2, 263–278.
- Majidzadeh, Y., 1982. Lapis Lazuli and the Great Khorasan Road. *Paléorient* 8(1), 59–69.
- Malek Shahmirzadi, S., Nokandeh, J., 2001. *Aq Tepe*. Iran Cultural Heritage Organization, Tehran (in Persian).

- Marinova, E., Linseele, V., Kühn, M., 2013a. Bioarchaeological research on animal dung—possibilities and limitations. *Environmental Archaeology* 18, 1–3.
- Marinova, E., Ryan, P., Van Neer, W., Friedman, R., 2013b. Animal dung from arid environments and archaeobotanical methodologies for its analysis: An example from animal burials of the Predynastic elite cemetery HK6 at Hierakonpolis, Egypt. *Environmental Archaeology* 18, 58–71.
- Marro, C., Bakhshaliyev, V., Ashurov, S., 2011. Excavations at Ovçular Tepesi (Nakhchivan, Azerbaijan). Second Preliminary Report: The 2009-2010 Seasons. *Anatolia Antiqua* 19, 53–100.
- Martinez, E.M., Correia, J.A.S., Villela, E.V., Duarte, A.N., Ferreira, L.F., Bello, A.R., 2003. Random amplified polymorphic DNA analysis of DNA extracted from *Trichuris trichiura* (Linnaeus, 1771) eggs and its prospective application to paleoparasitological studies. *Memórias do Instituto Oswaldo Cruz* 98, 59–62.
- Martins-Neto, R.G., 2003. The fossil tabanids (*Diptera Tabanidae*): when they began to appreciate warm blood and when they began transmit diseases? *Memórias do Instituto Oswaldo Cruz* 98, 29–34.
- Martinson, E., Reinhard, K.J., Buikstra, J.E., Cruz, K.D. de la, 2003. Pathoecology of Chiribaya parasitism. *Memórias do Instituto Oswaldo Cruz* 98, 195–205.
- Mas-Coma, M.S., Esteban, J.G., Bargues, M.D., 1999. Epidemiology of human fascioliasis: a review and proposed new classification. *Bull World Health Organ* 77, 340–46.
- Mashkour, M., 2000. Paleoenvironmental Investigations in the Qazvin Plain (Iran), in: Matthiae, P. (Ed.), *Proceedings of the First International Congress on the Archaeology of the Ancient Near East, Rome, May 18th-23rd 1998*. Università degli studi di Roma “La Sapienza”, Dipartimento di scienze storiche, archeologiche e antropologiche dell’antichità.
- Mashkour, M., 2002. Chasse et élevage au nord du Plateau central iranien entre le Néolithique et l’Âge du Fer. *Paléorient* 28, 27–42.

- Mashkour, M., 2006. Boars and Pigs: A view from the Iranian Plateau., in: Lion, B., Michel, C. (Eds.), *De La Domestication Au Tabou: Le Cas Des Suidés Dans Le Proche-Orient Ancien*. de Boccard.
- Mashkour, M., Chahoud, J., Mahforouzi, A., 2010. Faunal remains from the Epipaleolithic site of Komishan Cave and its dating, preliminary results. *Journal of Iranian Archaeology* 1, 32–37.
- Mashkour, M., Monchot, H., Trinkaus, E., Reyss, J.-L., Biglari, F., Bailon, S., Heydari, S., Abdi, K., 2009. Carnivores and their prey in the Wezmeh cave (Kermanshah, Iran): a late Pleistocene refuge in the Zagros. *International Journal of Osteoarchaeology* 19, 678–694.
- Mashkour, M., Radu, V., Mohaseb, A., Darvish, J., 2012. The Upper Paleolithic faunal remains from Yafteh cave (central Zagros), 2005 campaign. A preliminary study, in: Otte, M., Shidrang, S., Flas, D. (Eds.), *The Aurignacian of Yafteh Cave and Its Context (2005-2008 Excavations)*. ERAUL 132, Liège, pp. 117–126.
- Masuda, S., 1973. Excavation at Tappe Sang-E Cagmaq, in: *Proceedings of the 1st Annual Symposium of Archaeological Research in Iran*. pp. 1–2.
- Matsui, A., Kanehara, M., Kanehara, M., 2003. Palaeoparasitology in Japan: discovery of toilet features. *Memórias do Instituto Oswaldo Cruz* 98, 127–136.
- Maya, C., Torner-Morales, F.J., Lucario, E.S., Hernandez, E., Jimenez, B., 2012. Viability of six species of larval and non-larval helminth eggs for different conditions of temperature, pH and dryness. *Water research* 46, 4770–4782.
- Maziar, S., 2010. Excavations at Köhné Pāsgāh Tepesi, the Araxes Valley, Northwest Iran: First Preliminary Report. *Ancient Near Eastern Studies* 47, 165–193.
- Mehlhorn, H., 2008. *Encyclopedia of Parasitology*: AM. Springer.
- Miguel González, L., Montero, E., Puente, S., López-Velez, R., Hernández, M., Sciutto, E., Harrison, L.J., Parkhouse, R.M.E., Gárate, T., 2002. PCR tools for the differential diagnosis of *Taenia saginata* and *Taenia solium* taeniasis/cysticercosis from different geographical locations. *Diagnostic microbiology and infectious disease* 42, 243–249.

- Miller, R.L., Armelagos, G.J., Ikram, S., De Jonge, N., Krijger, F.W., Deelder, A.M., 1992. Palaeoepidemiology of *Schistosoma* infection in mummies. *BMJ: British Medical Journal* 304, 555.
- Miller, R.L., Ikram, S., Armelagos, G.J., Walker, R., Harer, W.B., Shiff, C.J., Baggett, D., Carrigan, M., Maret, S.M., 1994. Diagnosis of *Plasmodium falciparum* infections in mummies using the rapid manual Para Sight™-F test. *Transactions of the Royal Society of Tropical Medicine and Hygiene* 88, 31–32.
- Mitchell, P.D., Anastasiou, E., Syon, D., 2011. Human intestinal parasites in crusader Acre: evidence for migration with disease in the medieval period. *International Journal of Paleopathology* 1, 132–137.
- Mitchell, P.D., Stern, E., 2000. Parasitic intestinal helminth ova from the latrines of the 13th century crusader hospital of St John in Acre, Israel, in: *Paleopathology Association 13th Biennial European Members Meeting*, Chieti. pp. 21–22.
- Mitchell, P.D., Stern, E., 2001. Parasitic intestinal helminth ova from the latrines of the 13th century crusader hospital of St. John in Acre, Israel. in: La Verghetta, M., Capasso, L. (Eds.), *Proceedings of the XIIIth European Meeting of the Paleopathology Association*, Chieti Italy. Teramo: Edigrafital S.p.A., pp. 207–213.
- Mitchell, P.D., Stern, E., Tepper, Y., 2008. Dysentery in the crusader kingdom of Jerusalem: an ELISA analysis of two medieval latrines in the city of Acre (Israel). *Journal of Archaeological Science* 35, 1849–1853.
- Mitchell, P.D., Tepper, Y., 2007. Intestinal parasitic worm eggs from a crusader period cesspool in the city of Acre (Israel). *Levant* 39, 91–95.
- Mofidi Nasrabadi, B., 2003. Archäologische Untersuchungen in Haft Tappeh, Iran. *Archäologische Mitteilungen aus Iran und Turan* 35, 225–239.
- Mofidi Nasrabadi, B., 2010. Archäologische Untersuchungen in Horriyeh und Dehno, Khuzestan (Iran). *Iranica antiqua* 45, 259–376.

- Moghaddam, A.S., Massoud, J., Mahmoodi, M., Mahvi, A.H., Periago, M.V., Artigas, P., Fuentes, M.V., BARGUES, M.D., Mas-Coma, S., 2004. Human and animal fascioliasis in Mazandaran province, northern Iran. *Parasitology research* 94, 61–69.
- Möhl, K., Große, K., Hamedy, A., Wüste, T., Kabelitz, P., Lücker, E., 2009. Biology of *Alaria* spp. and human exposition risk to *Alaria mesocercariae*—a review. *Parasitology research* 105, 1–15.
- Mollasalehi, H., Mashkour, M., Chaichi Amirkhiz, A., Naderi, R., 2006. An Introductory Report of the Archaeological Investigations: The Results of the Stratigraphy and Chronography of the Pre-historic Zageh Area in Ghazvin Plain in 2004 (1383 A.H.). *Bastanshenasi (Archaeology)* 2, 26–46.
- Montenegro, A., Araujo, A., Eby, M., Ferreira, L.F., Hetherington, R., Weaver, A.J., 2006. Parasites, Paleoclimate, and the peopling of the Americas. *Current Anthropology* 47, 193–200.
- Moody, A., 2002. Rapid diagnostic tests for malaria parasites. *Clinical microbiology reviews* 15, 66–78.
- Moore, J.G., Fry, G., Englert Jr, E., 1969. Thorny headed worm infection in pre-historic Utahans. *Clinical Research* 17, 149.
- Muller, R., 2001. *Worms and human disease*. CABI publishing.
- Mumcuoglu, K.Y., 2008. Human lice: pediculus and pthirus, in: *Paleomicrobiology*. Springer, pp. 215–222.
- Mumcuoglu, K.Y., Gunneweg, J., 2010. A head louse egg, *Pediculus humanus capitis* found in a louse comb excavated in The Christmas Cave, which dates to the 1st c. B.C. and A.D., in: Gunneweg, J., Greenblatt, C.L. (Eds.), *Outdoor Qumran and the Dead Sea. Its impact on the indoor bio- and material cultures at Qumran and the Judean Desert manuscript*. Proceedings of the joint Hebrew University and COST Action D-42 Cultural Heritage Workshop held at the Hebrew University of Jerusalem in May 25-26, 2010.

- Mumcuoglu, K.Y., Zias, J., 1988. Head lice, *Pediculus humanus capitis* (Anoplura: Pediculidae) from hair combs excavated in Israel and dated from the first century BC to the eighth century AD. *Journal of medical entomology* 25, 545–547.
- Mumcuoglu, K.Y., Zias, J., 1991. Pre-pottery Neolithic B head lice found in Nahal Hemar Cave and dated 6,900-6,300 BCE (uncalibrated). *Atikot* 20, 167–168.
- Mumcuoglu, K.Y., Zias, J., Tarshis, M., Lavi, M., Stiebel, G.D., 2003. Body louse remains found in textiles excavated at Masada, Israel. *Journal of medical entomology* 40, 585–587.
- Negahban, E.O., 1977. Preliminary report of Qazvin expedition. *Marlik* 2, 26–44.
- Negahban, E.O., 1979. A brief report on the painted building of Zaghe (late 7th-early 6th millennium BC). *Maison René-Ginouvès*.
- Negahban, E.O., 1984. Haft Tepe Roundels: An Example of Middle Elamite Art. *American Journal of Archaeology* 88, 3–10.
- Nehmé, L., Wazizeh, W.A., Benech, C., Charloux, G., Delhopital, N., Durand, C., Fiema, Z.T., Al-Hâitî, K., De Procé, S.M., Müller, N.-A., 2011. Report on the fourth excavation season (2011) of the Madâ'in Sâlih archaeological project.
- Nerlich, A.G., Schraut, B., Dittrich, S., Jelinek, T., Zink, A.R., 2008. *Plasmodium falciparum* in ancient Egypt. *Emerging infectious diseases* 14, 1317.
- Nezamabadi, M., Aali, A., Stöllner, T., Mashkour, M., Le Bailly, M., 2013a. Paleoparasitological analysis of samples from the Chehrabad salt mine (Northwestern Iran). *International Journal of Paleopathology* 3, 229–233.
- Nezamabadi, M., Harter-Lailheugue, S., Le Bailly, M., 2011. Paleoparasitology in the Middle-East: State of the research and potential. *Tüba-Ar* 14, 205–213.
- Nezamabadi, M., Mashkour, M., Aali, A., Stöllner, T., Le Bailly, M., 2013b. Identification of *Taenia* sp. in a Natural Human Mummy (Third Century BC) from the Chehrabad Salt Mine in Iran. *The Journal of parasitology* 99, 570–572.

- Nezamabadi, M., Mashkour, M., Le Bailly, M., 2013c. Archaeoparasitology in the Iranian Plateau (in Persian). *Bastan Pajouhi* 12 and 13, 108–113.
- Nozais, J.-P., 2003. The origin and dispersion of human parasitic diseases in the Old World (Africa, Europe and Madagascar). *Memórias do Instituto Oswaldo Cruz* 98, 13–19.
- Nunn, J.F., Tapp, E., 2000. Tropical diseases in ancient Egypt. *Transactions of the Royal Society of Tropical Medicine and Hygiene* 94, 147–153.
- Oh, C.S., Seo, M., Chai, J.Y., Lee, S.J., Kim, M.J., Park, J.B., Shin, D.H., 2010. Amplification and sequencing of *Trichuris trichiura* ancient DNA extracted from archaeological sediments. *Journal of Archaeological Science* 37, 1269–1273.
- Olsen, A., Permin, A., Roepstorff, A., 2001. Chickens and pigs as transport hosts for *Ascaris*, *Trichuris* and *Oesophagostomum* eggs. *Parasitology* 123, 325–330.
- Ortiz, A., Chambon, P., Molist, M., 2013. “Funerary bundles” in the PPNB at the archaeological site of Tell Halula (middle Euphrates valley, Syria): analysis of the taphonomic dynamics of seated bodies. *Journal of Archaeological Science* 40, 4150–4161.
- Otranto, D., Traversa, D., 2002. A review of dicrocoeliosis of ruminants including recent advances in the diagnosis and treatment. *Veterinary parasitology* 107, 317–335.
- Otte, M., Biglari, F., Flas, D., Shidrang, S., Zwyns, N., Mashkour, M., Naderi, R., Mohaseb, A., Hashemi, N., Darvish, J., 2007. The Aurignacian in the Zagros region: new research at Yafteh cave, Lorestan, Iran. *Antiquity* 81, 82-96.
- Otte, M., Shidrang, S., Zwyns, N., Flas, D., 2011. New radiocarbon dates for the Zagros Aurignacian from Yafteh cave, Iran. *Journal of human evolution* 61, 340–346.
- Palma, R.L., 1991. Ancient head lice on a wooden comb from Antinoe, Egypt. *Journal of Egyptian archaeology* 77, 194.
- Peng, W., Criscione, C.D., 2012. Ascariasis in people and pigs: New inferences from DNA analysis of worm populations. *Infection, Genetics and Evolution* 12, 227–235.
- Pike, A., Biddle, M., 1966. Parasite eggs in medieval Winchester. *Parasite* 40, 293–296.

- Pike, A.W., 1968. Recovery of helminth eggs from archaeological excavations, and their possible usefulness in providing evidence for the purpose of an occupation. *Nature* 219, 303 – 304.
- Pizzi, T., Schenone, H., 1954. Hallazgo de huevos de *Trichuris trichiura* en contenido intestinal de un cuerpo arqueológico incaico. *Boletín Chileno de Parasitología* 9, 73-75.
- Pollard, A.M., Brothwell, D.R., Aali, A., Buckley, S., Fazeli, H., Dehkordi, M.H., Holden, T., Jones, A.K.G., Shokouhi, J.J., Vatandoust, R., 2008. Below the salt: A preliminary study of the dating and biology of five salt-preserved bodies from Zanzan Province, Iran. *Iran* 46, 135–150.
- Pollard, A.M., Davoudi, H., Mostafapour, I., Valipour, H.R., Fazeli Nashli, H., 2012. A New Radiocarbon Chronology for the Late Neolithic to Iron Age in the Qazvin Plain. *The International Journal of Humanities* 19, 1–41.
- Rabino Massa, E., Cerutti, N., Savoia, M.D., 2000. Malaria in Ancient Egypt: paleoimmunological investigation on Predynastic mummified remains. *Chungará (Arica)* 32, 7–9.
- Ramaroli, V., Hamilton, J., Ditchfield, P., Fazeli, H., Aali, A., Coningham, R.A.E., Pollard, A.M., 2010. The Chehr Abad “Salt men” and the isotopic ecology of humans in ancient Iran. *American journal of physical anthropology* 143, 343–354.
- Ransom, B.H., Foster, W.D., 1919. Recent discoveries concerning the life history of *Ascaris lumbricoides*. *The Journal of Parasitology* 5, 93–99.
- Raoult, D., Reed, D.L., Dittmar, K., Kirchman, J.J., Rolain, J.-M., Guillen, S., Light, J.E., 2008. Molecular identification of lice from pre-Columbian mummies. *Journal of Infectious Diseases* 197, 535–543.
- Reinhard, K.J., 1985. *Strongyloides stercoralis* in the Prehistoric Southwest, in: Merbes, C., Miller, R.J. (Eds.), *Health and Disease in the Prehistoric Southwest*. pp. 234–242.
- Reinhard, K.J., 1988. Cultural ecology of prehistoric parasitism on the Colorado Plateau as evidenced by coprology. *American Journal of Physical Anthropology* 77, 355–366.

- Reinhard, K.J., 1992a. Parasitology as an interpretive tool in archaeology. *American Antiquity* 57, 231–245.
- Reinhard, K.J., 1992b. Patterns of diet, parasitism, and anemia in prehistoric west North America, in: Stuart-McAdam, P. and Kent S. (eds), *Diet, Demography, and Disease: Changing Perspectives on Anemia*, New York: Aldine de Gruyter. pp. 219–258.
- Reinhard, K.J., Ambler, J.R., McGuffie, M., 1985. Diet and parasitism at dust devil cave. *American Antiquity* 50(4), 819–824.
- Reinhard, K.J., Araújo, A., 2008. Archaeoparasitology. *Encyclopedia of Archaeology*.
- Reinhard, K.J., Buikstra, J., 2003. Louse infestation of the Chiribaya culture, southern Peru: variation in prevalence by age and sex. *Memórias do Instituto Oswaldo Cruz* 98, 173–179.
- Reinhard, K.J., Confalonieri, U.E., Hermann, B., Ferreira, L.F., Araújo, A.J.G., 1988. Recovery of parasite remains from coprolites and latrines: aspects of paleoparasitological techniques. *Homo* 37, 217–239.
- Reyman, T.A., Zimmerman, M.R., Lewin, P.K., 1977. Autopsy of an Egyptian mummy. 5. Histopathologic investigation. *Canadian Medical Association Journal* 117, 470.
- Rezvani, H., Roustaei, K., 2007. A preliminary report on two seasons of excavations at Kul Tarike cemetery, Kurdistan, Iran. *Iranica antiqua* 42, 139–184.
- Roberts, L., Janovy Jr., J., 2009. *Gerald D. Schmidt and Larry S. Roberts' Foundations of Parasitology*. McGraw-Hill.
- Rocha, G.C. da, Harter-Lailheugue, S., Le Bailly, M., Araújo, A., Ferreira, L.F., Serra-Freire, N.M. da, Bouchet, F., 2006. Paleoparasitological remains revealed by seven historic contexts from “Place d’Armes”, Namur, Belgium. *Memórias do Instituto Oswaldo Cruz* 101, 43–52.
- Rokni, M.B., 2008. The present status of human helminthic diseases in Iran. *Annals of tropical medicine and parasitology* 102, 283–295.

- Ruffer, M.A., 1910. Note on the presence of "*Bilharzia Haematobia*" in Egyptian mummies of the twentieth dynasty [1250-1000 BC]. *British Medical Journal* 1, 16.
- Samuels, R., 1965. Parasitological study of long-dried fecal samples. *Memoirs of the Society for American Archaeology* 19, 175–179.
- Sardella, N.H., Fugassa, M.H., 2009. Paleoparasitological analysis of rodent coprolites in Holocene samples from Patagonia, Argentina. *Journal of Parasitology* 95, 646–651.
- Satin, M., 2014. History of Food Safety and Related Sciences: History of Foodborne Disease – Part I – Ancient History, in: Motarjemi, Y. (Ed.), *Encyclopedia of Food Safety*. Academic Press, Waltham, pp. 1–6.
- Savinetsky, A.B., Khrustalev, A.V., 2013. Paleoparasitological investigations in Mongolia, Middle Asia and Russia. *International Journal of Paleopathology* 3, 176–181.
- Schmidt, A., Fazeli, H., 2007. Tepe Ghabristan: a Chalcolithic tell buried in alluvium. *Archaeological Prospection* 14, 38–46.
- Schmidt, G.D., Duszynski, D.W., Martin, P.S., 1992. Parasites of the extinct Shasta ground sloth, *Nothrotheriops shastensis*, in Rampart Cave, Arizona. *The Journal of parasitology* 78, 811–816.
- Schwartz, B., 1920. The biological relationships of ascarids. *The Journal of Parasitology* 6, 115–123.
- Searcey, N., Reinhard, K.J., Egarter-Vigl, E., Maixner, F., Piombino-Mascalì, D., Zink, A.R., van der Sanden, W., Gardner, S.L., Bianucci, R., 2013. Parasitism of the Zweeloo Woman: Dicrocoeliasis evidenced in a Roman period bog mummy. *International Journal of Paleopathology* 3, 224–228.
- Seo, M., Guk, S.-M., Kim, J., Chai, J.-Y., Bok, G.D., Park, S.S., Oh, C.S., Kim, M.J., Yi, Y.S., Shin, M.H., 2007. Paleoparasitological report on the stool from a Medieval child mummy in Yangju, Korea. *Journal of Parasitology* 93, 589–592.

- Shalaby, H.A., Abdel-Shafy, S., Derbala, A.A., 2010. The role of dogs in transmission of *Ascaris lumbricoides* for humans. *Parasitology research* 106, 1021–1026.
- Shidrang, S., 2007. The Early Upper Paleolithic lithic assemblages from F15 test pit (2005), Yafteh Cave, Iran: a typo-technological study. MA thesis, Università degli Studi di Ferrara.
- Shin, D.H., Chai, J.Y., Park, E.A., Lee, W., Lee, H., Lee, J.S., Choi, Y.M., Koh, B.J., Park, J.B., Oh, C.S., 2009. Finding ancient parasite larvae in a sample from a male living in late 17th century Korea. *Journal of Parasitology* 95, 768–771.
- Shin, D.H., Lim, D.-S., Choi, K.-J., Oh, C.S., Kim, M.J., Lee, I.S., Kim, S.B., Shin, J.E., Bok, G.D., Chai, J.Y., 2009. Scanning electron microscope study of ancient parasite eggs recovered from Korean mummies of the Joseon Dynasty. *Journal of Parasitology* 95, 137–145.
- Shin, D.H., Oh, C.S., Lee, S.J., Chai, J.Y., Kim, J., Lee, S.D., Park, J.B., Choi, I., Lee, H.J., Seo, M., 2011. Paleo-parasitological study on the soils collected from archaeological sites in old district of Seoul City. *Journal of Archaeological Science* 38, 3555–3559.
- Sianto, L., Chame, M., Silva, C.S.P., Gonçalves, M.L.C., Reinhard, K., Fugassa, M., Araújo, A., 2009. Animal helminths in human archaeological remains: a review of zoonoses in the past (English). *Revista do Instituto de Medicina Tropical de São Paulo* 51, 119–130.
- Soulsby, E.J.L., 1968. Helminths, arthropods and protozoa of domestic animals. (of Mönnig's Veterinary helminthology and entomology). Bailliere, Tindall and Cassell, London.
- Starna, W.A., 1992. The biological encounter: Disease and the ideological domain. *American Indian Quarterly* 26, 511–519.
- Stephenson, L.S., Holland, C.V., Cooper, E.S., 2000. The public health significance of *Trichuris trichiura*. *Parasitology* 121, S73–S95.
- Szidat, L., 1944. Über die Erhaltungsfähigkeit von Helmintheneiern in vor-und frühgeschichtlichen Moorleichen. *Zeitschrift für Parasitenkunde* 13, 265–274.

- Tapp, E., 1979. Disease in the Manchester mummies, in: *The Manchester Museum Mummy Project: Multidisciplinary Research on Ancient Egyptian Mummified Remains*. Manchester University Press, Manchester, pp. 95–102.
- Tapp, E., 1997. The Leeds Mummy. *Medical Historian: Bulletin of Liverpool Medical History Society* 9, 3–13.
- Tapp, E., Wildsmith, K., 1992. The autopsy and endoscopy of the Leeds mummy, in: *The Mummy's Tale*. pp. 132–153.
- Taraschewski, H., 2000. Host-parasite interactions in Acanthocephala: A morphological approach. *Advances in parasitology* 46, 1–179.
- Taylor, E.L., 1955. Parasitic helminths in mediaeval remains. *Vet Rec* 67, 216–218.
- Thienpont, D., Rochette, F., Vanparijs, O.F.J., 1986. Diagnosing helminthiasis through coprological examination.
- Thornton, C.P., 2013. Tappeh Sange Chakhmaq: a new look, in: *The Neolithisation of Iran*. pp. 241–257.
- Todd, E.C.D., 2014. Foodborne Diseases: Overview of Biological Hazards and Foodborne Diseases, in: Motarjemi, Y. (Ed.), *Encyclopedia of Food Safety*. Academic Press, Waltham, pp. 221–242.
- Torgerson, P.R., 2014. Helminth-Cestode, in: Motarjemi, Y. (Ed.), *Encyclopedia of Food Safety*. Academic Press, pp. 63–69.
- Totkova, A., Klobusicky, M., Holkova, R., Valent, M., 2003. *Enterobius gregorii*-reality or fiction? *Bratislavské lekárske listy* 104, 130–133.
- Tougaard, C., Renvoisé, E., 2008. Rodents and palaeogenetics: New perspectives. *Comptes Rendus Palevol* 7, 125–134.
- Traub, R.J., Robertson, I.D., Irwin, P., Mencke, N., Thompson, R.A., 2002. The role of dogs in transmission of gastrointestinal parasites in a remote tea-growing community in northeastern India. *The American journal of tropical medicine and hygiene* 67, 539–545.

- Trinkaus, E., Biglari, F., Mashkour, M., Monchot, H., Reyss, J.-L., Rougier, H., Heydari, S., Abdi, K., 2008. Late Pleistocene human remains from Wezmeh cave, western Iran. *American journal of physical anthropology* 135, 371–378.
- Usai, D., 2005. Chisels or perforators? The lithic industry of Ras al-Hamra 5 (Muscat, Oman), in: *Proceedings of the Seminar for Arabian Studies* (35). pp. 293–301.
- Van Cleave, H.J., Ross, J.A., 1947. A method for reclaiming dried zoological specimens. *Science* (New York, NY) 105, 318–318.
- Van Neer, W., 2011. Two more wild animals from the Elite Cemetery. *Nekhen news* 23, 10–11.
- Van Neer, W., Linseele, V., Friedman, R., 2004. Animal burials and food offerings at the elite cemetery HK6 of Hierakonpolis, in: *Egypt at Its Origins. Studies in Memory of Barbara Adams* (Proceedings of the International Conference Origin of the State. Predynastic and Early Dynastic Egypt-Krakow, 28/08-01/09/02). pp. 67–130.
- Vermes, G., 2004. *The complete Dead Sea Scrolls in English*. Penguin.
- Vigne, J.-D., Briois, F., Zazzo, A., Willcox, G., Cucchi, T., Thiébaud, S., Carrère, I., Franel, Y., Touquet, R., Martin, C., 2012. First wave of cultivators spread to Cyprus at least 10,600 y ago. *Proceedings of the National Academy of Sciences* 109, 8445–8449.
- Ward, H.L., Nelson, D.R., 1967. Acanthocephala of the genus *Moniliformis* from rodents of Egypt with the description of a new species from the Egyptian spiny mouse (*Acomys cahirinus*). *The Journal of parasitology* 53, 150–156.
- Wei, O., 1973. Internal organs of a 2100-year-old female corpse. *The Lancet* 302, 1198.
- Weiss, D.L., Møller-Christensen, V., 1971. Leprosy, echinococcosis and amulets: a study of a medieval Danish inhumation. *Medical history* 15, 260–267.
- Wells, C., Dallas, C., 1975. Romano-British pathology. *Antiquity* 50, 53–55.
- Wendorf, F., Schild, R., Said, R., Haynes, C.V., Gautier, A., Kobusiewicz, M., 1976. The prehistory of the Egyptian Sahara. *Science* 193, 103–114.

- W.H.O, 2004. The World Health Report [Online document]. URL <http://www.who.int/whr/2004/en/> (accessed 6.15.14).
- W.H.O, 2006. Preventive chemotherapy in human helminthiasis : coordinated use of anthelmintic drugs in control interventions : a manual for health professionals and programme managers. WHO Library Cataloguing-in-Publication Data.
- Williams, J.A., 1985. Evidence of hydatid disease in a Plains Woodland burial. *The Plains Anthropologist* 30, 25–28.
- Witenberg, G., 1961. Human parasites in archaeological findings. *Bull Israel Expl Soc* 25, 86.
- Yeh, H.-Y., Pluskowski, A., Kalējs, U., Mitchell, P.D., 2014. Intestinal parasites in a mid-14th century latrine from Riga, Latvia: fish tapeworm and the consumption of uncooked fish in the medieval eastern Baltic region. *Journal of Archaeological Science* 49, 83–89.
- Yoshikawa, H., Yamada, M., Matsumoto, Y., Yoshida, Y., 1989. Variations in egg size of *Trichuris trichiura*. *Parasitology research* 75, 649–654.
- Zajac, A.M., Conboy, G.A., 2012. *Veterinary clinical parasitology*. John Wiley and Sons.
- Zias, J., 1991. Current archaeological research in Israel: death and disease in ancient Israel. *The Biblical Archaeologist* 54(3), 147–159.
- Zias, J.E., Tabor, J.D., Harter-Lailheugue, S., 2006. Toilets at Qumran, the Essenes, and the scrolls: new anthropological data and old theories. *Revue de Qumran* 22, 631–640.
- Zias, J., Mumcuoglu, K.Y., 1991. Case reports on paleopathology: calcified hydatid cysts. *Paleopathol News* 73, 7–8.
- Zink, A.R., Spigelman, M., Schraut, B., Greenblatt, C.L., Nerlich, A.G., Donoghue, H.D., 2006. Leishmaniasis in ancient Egypt and upper Nubia. *Emerging infectious diseases* 12, 1616.

Annexes

Site	Archaeological ID	Lab ID	Sample	Origin	Identified
Chehrabad Salt mine	983-215	C61	Soil sediment	Human mummy	<i>Taenia</i> sp.
	983-216	C62	Soil sediment	Human mummy	<i>Taenia</i> sp.
	983-217	C64	Soil sediment	Human mummy	<i>Taenia</i> sp.
	983-218	C65	Soil sediment	Human mummy	<i>Taenia</i> sp.
	983-218	C67	Soil sediment	Human mummy	<i>Taenia</i> sp.
	3558-0	C33	Coprolite	Human	<i>Taenia</i> sp.
	3558-1	C80	Soil sediment	Unknown Human?	Taeniid
	3352-0	C82	Soil sediment	Unknown Human?	<i>Ascaris</i> sp. <i>Enterobius vermicularis</i> <i>Oxyuris equi</i> Taeniid
	3182-1	C83	Soil sediment	Unknown	<i>Oxyuris equi</i> Taeniid
	3501	C85	Soil sediment	Unknown	<i>Trichuris</i> sp. Taeniid
	3526-1	C86	Soil sediment	Unknown Human?	Taeniid

Annexe 1: Identified eggs in analyzed samples dated to Achaemenid period (7th Century - 4th Century BC) from Chehrabad Saltmine, Iran.

Site	Archaeological ID	Lab ID	Sample	Origin	Identified
Chehrabad Salt mine	3061	C94	Soil sediment	Unknown	Taeniid
	2506-0	C31	Coprolite	Human	<i>Ascaris lumbricoides</i> <i>Trichuris trichiura</i> <i>Enterobius vermicularis</i>
	2646-0	C32	Coprolite	Unknown	<i>Oxyuris equi</i> Strongylid / Trichostrongylid
	3046	C75	Soil sediment	Unknown	<i>Ascaris</i> sp.

Annexe 2: Identified eggs in analyzed samples dated to Sassanid period (3rd Century - 7th Century AD) from Chehrabad Saltmine, Iran.

Site	Archaeological ID	Lab ID	Sample	Origin	Identified
Chehrabad Salt mine	2927-0	C81	Soil sediment	Human?	<i>Trichuris</i> sp. <i>Enterobius vermicularis</i> Taeniid
	2462-0	C73	Coprolite	Herbivore	<i>Dicrocoelium</i> sp.

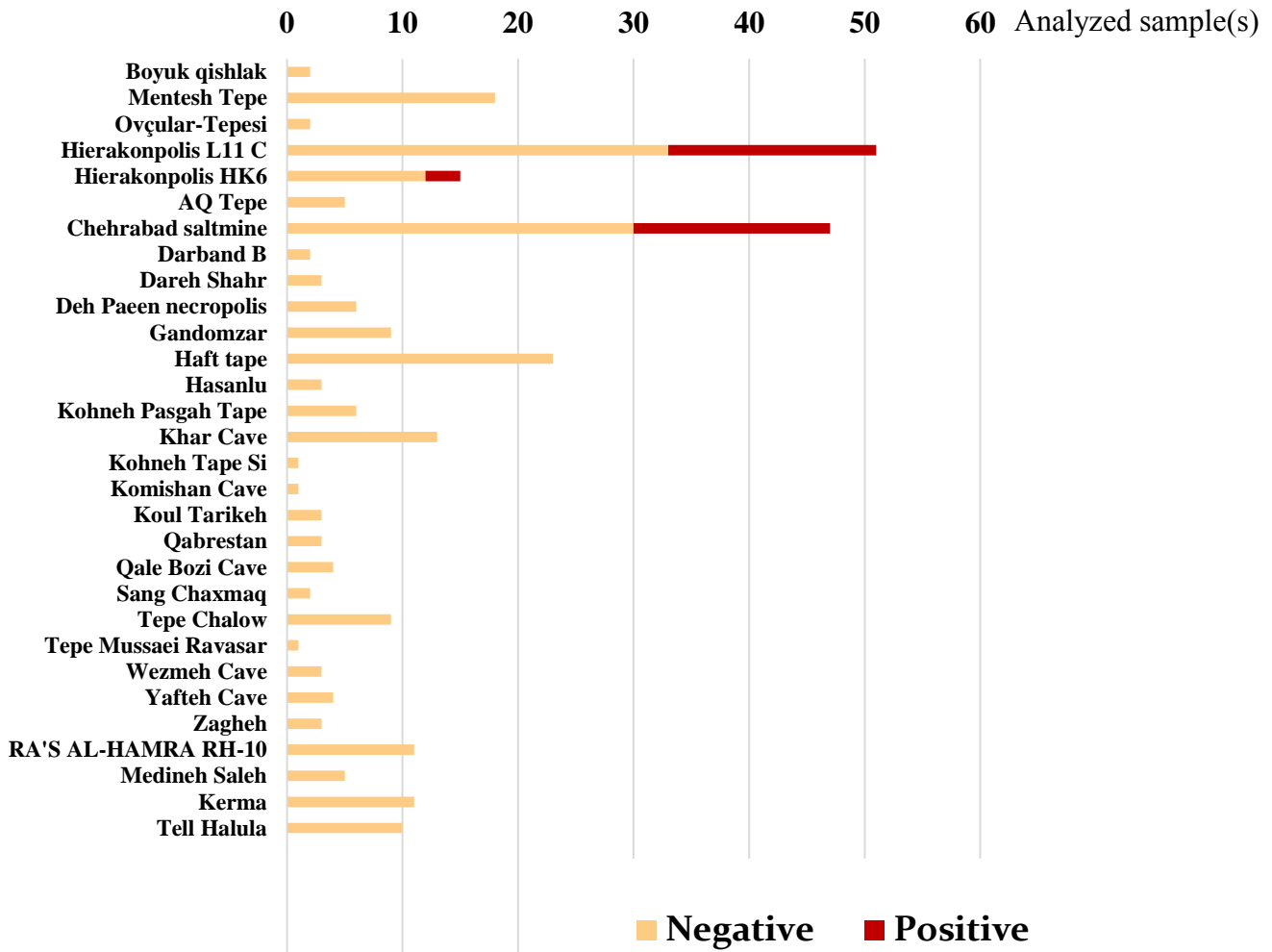
Annexe 3: Identified eggs in analyzed samples without dating from Chehrabad Saltmine, Iran.

Site	Archaeological ID	Lab ID	Sample	Origin	Identified
Hierakonpolis (Locality 11C)	HK11 / Test A / level 9	H1a	Coprolite	Carnivore Human	<i>Trichuris</i> sp. Taeniid Unidentified Nematode
		H1c	Coprolite	Carnivore Human	Anoplocephalid
		H1e	Coprolite	Carnivore Human	<i>Trichuris</i> sp.
	HK11 / Test A / level 11	H2c	Coprolite	Carnivore Human	Acanthocephala Unidentified Nematode
		H2e	Coprolite	Carnivore Human	Acanthocephala Unidentified Nematode
	HK11 / Test A / level 4	H3c	Coprolite	Carnivore Herbivore Rodents?	<i>Trichuris</i> sp.
	HK11 / Test A / level 10	H4c	Coprolite	Carnivore Human	Taeniid
		H4f	Coprolite	Carnivore Human	Taeniid
	HK11 / Test A / level 7	H5b	Coprolite	Carnivore Herbivore Human Unidentified	Unidentified Nematode
		H5c	Coprolite	Carnivore Herbivore Human Unidentified	Unidentified Nematode
		H5d	Coprolite	Carnivore Herbivore Human Unidentified	Taeniid Acanthocephala
	HK11 / Test A / level 8	H7b	Coprolite	Carnivore Human	Taeniid
		H7c	Coprolite	Carnivore Human	Taeniid
		H7d	Coprolite	Carnivore Human	Taeniid <i>Hymenolepis</i> sp.
		H7e	Coprolite	Carnivore Human	Taeniid
	HK11 / Test A / level 6	H8a	Coprolite	Human (?) Carnivore	Taeniid Unidentified Nematode
		H8b	Coprolite	Human (?) Carnivore	Taeniid
	HK 11 / Test A / level 13	H9a	Coprolite	Carnivore Human	<i>Eimeria</i> sp.
		H9d	Coprolite	Carnivore Human	Fasciolidae Paramphistomatidae <i>Alaria</i> sp.? Acanthocephala
	HK 11 / Test A / level 5	H14b	Coprolite	Carnivore Herbivore Human	Taeniid
H14c		Coprolite	Carnivore Herbivore Human	Unidentified Nematode	

Annexe 4: Identified eggs in analyzed samples dated to 3900 - 3300 BC from Hierakonpolis (Locality 11C), Egypt.

Site	Archaeological ID?	Lab ID	Sample	Origin	Identified
Hierakonpolis (HK6)	Tomb 19	H21	Intestinal content	Aurochs	Fasciolidae Paramphistomatidae Unidentified fluke
	Tomb 44 sample (a)	H28	Sediment from pelvic area	Dog	Taeniid <i>Hymenolepis</i> sp.
	Tomb 44 sample (b)	H29	Sediment from pelvic area	Dog	Taeniid

Annexe 5: Identified eggs in analyzed samples dated to 3700 - 3500 BC from Hierakonpolis (Locality HK6), Egypt.



Annexe 6: Description of the analyzed samples from studied sites.

Table of figures

Figure 2.1: The Middle East countries which have already data in the field of paleoparasitology.	16
Figure 2.2: A perspective of available paleoparasitological studies in the world.....	16
Figure 2.3: Location of archaeological sites related to paleoparasitological data in Egypt.	18
Figure 2.4: Embalming rejects jar, Department of Egyptian antiquity, Louvre Museum, France (Harter et al., 2003).	22
Figure 2.5: <i>Taenia</i> sp. egg recovered in a mummy from Oasis of Kharga, Egypt (Le Bailly et al., 2010).	22
Figure 2.6: <i>Rhipicephalus sanguineus</i> Latr. recovered from the dog's mummy (left) and the louse fly <i>Hippobosca longipennis</i> F. recovered from the dog's coat (right), El-Deir, Egypt (Huchet et al., 2013).	25
Figure 2.7: Location of archaeological sites related to paleoparasitological data in Sudan.	28
Figure 2.8: <i>Pediculus capitis</i> egg, attached to the hair, magnification 100 ×, Kerma, Sudan (Harter, 2003).	32
Figure 2.9: Location of archaeological sites related to paleoparasitological data in Israel.	33
Figure 2.10: A delousing comb, Christmas Cave (dated to the 1st c. B.C. and A.D), Israel (Mumcuoglu and Gunneweg 2012).	36
Figure 2.11: Location of archaeological sites related to paleoparasitological data in Cyprus.	38
Figure 2.12: Location of archaeological sites related to paleoparasitological studies in Iran.	41

Figure 2.13: <i>Trichuris</i> sp. egg from Kharand, Iran. Egg size: 57 × 24 μm (Photo: M. Le Bailly).....	41
Figure 2.14: Location of an archaeological site related to paleoparasitological studies in Syria.	42
Figure 2.15: A schistosome egg recovered from a human burial, Tell Zeidan, Syria, dated to 6500–6000 BP. Egg size: 132 × 56 μm (Anastasiou et al., 2014).	43
Figure 3.1: A map of studied sites.	45
Figure 3.2: Count of analyzed samples by country in present PhD work.....	47
Figure 3.3: The landscape of Chehrabad saltmine, Iran.....	52
Figure 3.4: Salt rocks at Chehrabad saltmine, Iran (Photo: A. Aali).	52
Figure 3.5: Location of the Trenches A to D in Chehrabad saltmine excavations, Iran (Aali et al., 2012).	53
Figure 3.6: Mummy #5. Chehrabad saltmine, Iran (Photo: K. Stange, DBM / Miras Farhangi, Aali et al., 2012).....	54
Figure 3.7: Mummy #2. Archaeological Museum of Zanjan, Iran.	54
Figure 3.8: Natural mummified body of a dog, Chehrabad saltmine, Iran (Photo: Miras Farhangi Zanjan).	54
Figure 3.9: Diversity of animals in a painting discovered in Hierakonpolis, Tomb 100, dated to 3500BC, (http://xoomer.virgilio.it/francescoraf/hesyra/Hierakonpolis-tomb100.htm). .	71
Figure 3.10: Location of Localities HK6 and 11C, Hierakonpolis, Egypt (http://hierakonpolis-online.org).	72
Figure 3.11: HK6 in 2011 season excavation (Marinova et al., 2013).	73
Figure 3.12: Location of Test A at the Locality 11C, Hierakonpolis, Egypt (http://hierakonpolis-online.org).	76
Figure 4.1: Rehydration of the samples.	82
Figure 4.2: Homogenizing process by using a mortar and a pestle as well as an ultrasonic bath.....	82

Figure 4.3: Micro-sieves column.	84
Figure 4.4: Direct-QTM 5 traded by Millipore ®.....	84
Figure 4.5: Prepared samples in PVC hemolysis tubes.....	86
Figure 4.6: Light microscopy analysis.	86
Figure 4.7: “E. histolytica II” kit components.	88
Figure 4.8: ELISA plate reader device.....	88
Figure 5.1: A map of world soil pH (http://www.sage.wisc.edu/atlas/maps/soilph/atl_soilph.jpg). The circle shows the Middle East region.....	94
Figure 5.2: Morphometric analysis of identified fluke eggs in sample ID: H21.	97
Figure 5.3: Morphometric analysis of identified fluke eggs in subsample ID: H9d.....	97
Figure 5.4: Fasciolidae egg, operculum on the one pole (top), size: 160 × 110 µm, magnification 400×, sample ID: H21, Hierakonpolis.	104
Figure 5.5: Fasciolidae egg, deprived operculum on the left pole, size: 168 × 99 µm, magnification 630×, sample ID: H21, Hierakonpolis.	104
Figure 5.6: Fasciolidae egg, operculum on top, size: 131 × 79 µm, magnification 630×, with internal content, subsample ID: H9d, Hierakonpolis.	105
Figure 5.7: Paramphistomatidae egg, deprived operculum on the right pole, size: 150 × 106 µm, magnification 630 ×, sample ID: H21, Hierakonpolis.....	105
Figure 5.8: Paramphistomatidae egg, operculum on top, size: 159 × 105 µm, magnification 400 ×, with internal content, subsample ID: H9d, Hierakonpolis.	107
Figure 5.9: Unidentified fluke egg resembling that of <i>Alaria</i> spp., size: 134 × 74 µm, magnification 630 ×, with internal content, subsample ID: H9d, Hierakonpolis.	107
Figure 5.10: Unidentified broken fluke egg, magnification 630 ×, subsample ID: H9d, Hierakonpolis.	109
Figure 5.11: <i>Dicrocoelium</i> sp. egg, size: 40 × 27 µm, magnification 400 ×, sample ID: C73, Chehrabad Saltmine.....	109

Figure 5.12: <i>Taenia</i> sp. egg, displaying characteristic striated eggshell, size: 37 × 30 μm, magnification 630×, sample ID: C64, Mummy #5, Chehrabad saltmine, Iran.....	121
Figure 5.13: Taeniid egg, displaying characteristic striated eggshell, size: 42 × 38 μm, magnification 630×, sample ID: H29, Hierakonpolis, Egypt.	121
Figure 5.14: Taeniid egg, displaying characteristic striated eggshell, size: 33 × 30 μm, magnification 630×, subsample ID: H1a, Hierakonpolis, Egypt.	122
Figure 5.15: Taeniid egg, displaying characteristic striated eggshell and the hooks inside, size: 39 × 34 μm, magnification 630×, subsample ID: H4c, Hierakonpolis, Egypt.	122
Figure 5.16: Taeniid eggs, displaying characteristic striated eggshell, average size: 36 × 32 μm, magnification 630×, subsample ID: H7b, Hierakonpolis, Egypt.....	123
Figure 5.17: <i>Taenia</i> sp. eggs, displaying characteristic striated eggshell, average size: 37 × 32 μm, magnification 630×, sample ID: C33, Chehrabad saltmine, Iran.	123
Figure 5.18: <i>Hymenolepis</i> sp. egg, displaying eggshell with a hexacanth embryo, size: 54 × 47 μm, magnification 630×, sample ID: H28, Hierakonpolis, Egypt.....	126
Figure 5.19: <i>Hymenolepis</i> sp. egg, displaying eggshell with a hexacanth embryo, size: 50 × 39 μm, magnification 630×, subsample ID: H7d, Hierakonpolis, Egypt.	126
Figure 5.20: Anoplocephalid egg, displaying bad preservation of outer covering membrane of eggshell, a hexacanth embryo inside, size: 92 × 64 μm, magnification 630×, subsample ID: H1c, Hierakonpolis, Egypt.....	129
Figure 5.21: Anoplocephalid egg, displaying bad preservation of outer covering membrane of eggshell, a hexacanth embryo inside, size: 100 × 72 μm, magnification 630×, subsample ID: H1c, Hierakonpolis, Egypt.....	129
Figure 5.22: Morphometric analysis of identified <i>Ascaris</i> eggs in samples (ID: C75, C82 and C31) from Chehrabad saltmine, Iran.	132
Figure 5.23: <i>Ascaris</i> sp. egg, displaying characteristic thick, mammillated outer shell, size: 65 × 49 μm, magnification 630×, sample ID: C75, Chehrabad saltmine, Iran.....	136
Figure 5.24: <i>Ascaris</i> sp. egg, displaying characteristic thick, mammillated outer shell, size: 52 × 42 μm, magnification 630×, sample ID: C82, Chehrabad saltmine, Iran.....	136

Figure 5.25: <i>Ascaris lumbricoides</i> egg, displaying characteristic thick, mammillated outer shell, size: 66 × 49 μm, magnification 630×, sample ID: C31, Chehrabad saltmine, Iran.	137
Figure 5.26: <i>Ascaris lumbricoides</i> egg (probable unfertilized), displaying characteristic thick, mammillated outer shell, size: 88 × 41 μm, magnification 630×, sample ID: C31, Chehrabad saltmine, Iran.	137
Figure 5.27: Two <i>Enterobius vermicularis</i> eggs, displaying characteristic “D” shape eggshell, average size: 58 × 31 μm, magnification 630×, sample ID: C82, Chehrabad saltmine, Iran.	143
Figure 5.28: <i>Enterobius vermicularis</i> egg, displaying characteristic “D” shape eggshell, embryonated, size: 59 × 30 μm, magnification 630×, sample ID: C31, Chehrabad saltmine, Iran.	143
Figure 5.29: Morphometric analysis of identified <i>Trichuris</i> sp. eggs in samples (ID: C75, C82 and C31) from Chehrabad saltmine, Iran, in compare with subsamples (ID: H1a, H1e and H3c) from Hierakonpolis, Egypt.....	146
Figure 5.30: <i>Trichuris</i> sp. egg, displaying characteristic thick eggshell with deprived of polar plugs, size: 53 × 27 μm, magnification 630×, sample ID: C81, Chehrabad saltmine, Iran.	150
Figure 5.31: <i>Trichuris trichiura</i> egg, displaying characteristic thick eggshell with typical polar plugs, size: 56 × 28 μm, magnification 630×, sample ID: C31, Chehrabad saltmine, Iran.	151
Figure 5.32: <i>Trichuris</i> sp. egg, displaying mineralized eggshell with typical polar plugs, size: 56 × 30 μm, magnification 630×, subsample ID: H1a, Hierakonpolis, Egypt.	151
Figure 5.33: <i>Trichuris</i> sp. egg, displaying characteristic thick eggshell with the one remained typical polar plugs and possibly an already formed larva, size: 58 × 29 μm, magnification 630×, subsample ID: H3c, Hierakonpolis, Egypt.	152
Figure 5.34: <i>Trichuris</i> sp. egg, displaying bad preservation of eggshell with broken polar plugs, size: 60 × 31 μm, magnification 630×, subsample ID: H1e, Hierakonpolis, Egypt.	152

Figure 5.35: <i>Oxyuris equi</i> egg, displaying characteristic asymmetrical thick eggshell and polar plug, size: 81 × 40 μm, magnification 630×, sample ID: C32, Chehrabad saltmine, Iran.	155
Figure 5.36: <i>Oxyuris equi</i> egg, displaying characteristic asymmetrical thick eggshell with polar plug and a larva inside, size: 81 × 45 μm, magnification 630×, sample ID: C82, Chehrabad saltmine, Iran.....	155
Figure 5.37: Strongylid/Trichostrongylid egg, displaying content remains, size: 80 × 46 μm, magnification 630×, sample ID: C32, Chehrabad saltmine, Iran.	159
Figure 5.38: Acanthocephalan egg, displaying characteristic eggshell with an acanthor larvae inside, size: 78 × 40 μm, magnification 630×, subsample ID: H2c, Hierakonpolis, Egypt.	162
Figure 5.39: Acanthocephalan egg, displaying characteristic eggshell with an acanthor larvae inside, size: 90 × 46 μm, magnification 630×, subsample ID: H5d, Hierakonpolis, Egypt.	162
Figure 5.40: Acanthocephalan egg, displaying broken eggshell with a voiding (or hatching?) acanthor larvae, estimated size: 84 × 50 μm, magnification 630×, subsample ID: H9d, Hierakonpolis, Egypt.....	163
Figure 5.41: Acanthocephalan egg, displaying characteristic eggshell with an acanthor larvae inside, size: 84 × 42 μm, magnification 630×, subsample ID: H2e, Hierakonpolis, Egypt.	163
Figure 5.42: <i>Eimeria</i> sp. oocyst, displaying characteristic morphology of coccidian oocyst, size: 82 × 68 μm, magnification 630×, subsample ID: H9a, Hierakonpolis, Egypt.....	167
Figure 5.43: <i>Eimeria</i> sp. oocyst, displaying characteristic morphology of coccidian oocyst, size: 75 × 58 μm, magnification 630×, subsample ID: H9a, Hierakonpolis, Egypt.....	167

Tables

Table 2.1: Paleoparasitological findings in Egypt, classified by dating.	26
Table 2.2: Paleoparasitological findings in Sudan.	31
Table 2.3: Paleoparasitological findings in Israel.	37
Table 2.4: Paleoparasitological findings in Cyprus.	39
Table 2.5: Paleoparasitological finding(s) in Iran.	40
Table 2.6 : Paleoparasitological finding(s) in Syria.	43
Table 3.1: Paleoparasitology sampling strategy.	46
Table 3.2: Description of the analyzed samples.	48
Table 3.3: The radiocarbon dating of locality 11C (Harlan, 1982).	75
Table 4.1: Preparation sheet at the laboratory of paleoparasitology, UFC, Besancon, France.	89
Table 5.1: Identified eggs in the class of Trematoda.	96
Table 5.2: Identified eggs in the class of Cestoda.	113
Table 5.3: Anoplocephalid egg size (important species).	128
Table 5.4: Identified eggs in the class of Nematoda.	130
Table 5.5: Measurements of some important species of Trichuris eggs.	150
Table 5.6: Strongylidae egg size (corresponding to the identified eggs in the present study).	157
Table 5.7: Some important Trichostrongylidae egg size (corresponding to the identified eggs in the present study).	159
Table 5.8: Identified acanthocephalan eggs.	160
Table 5.9: Identified coccidian eggs.	165

Publications and presentations

Papers:

- 2014 ***Paleoparasitology: detection of parasites in archaeological remains.*** Nezamabadi M, Mashkour M & Le Bailly M, Proceedings of the international conference of young archaeologists, Iran (2014): 627-630 (in Persian).
- 2013 ***Paleoparasitological analysis of samples from the Chehrabad salt mine (Northwestern Iran).*** Nezamabadi M, Aali A, Stöllner T, Mashkour M, Le Bailly M, International Journal of Paleopathology.
- 2013 ***Paleoparasitology in the Iranian plateau and the Middle East.*** Nezamabadi M, Mashkour M & Le Bailly M, Bastanpazhuhi: Persian Journal of Iranian Studies (Archaeology). **12-13**:102-107 (in Persian).
- 2012 ***Identification of Taenia sp. in a natural human mummy (3RD century BC) from the Chehrabad saltmine in Iran.*** Nezamabadi M, Mashkour M, Aali A, Stöllner T, Le Bailly M, The Journal of Parasitology.
- 2012 ***Ancient salt mining in North Western Iran: the interdisciplinary Chehrabad Douzlakh project in north-western Iran.*** Aali, A., A. Abar, N. Boenke, M. Pollard, F. Rühli, T. Stöllner, i. c. with, D. Brothwell, I. Good, M. Le Bailly, K. Link, M. Mashkour, G. Mowlavi, M. Nezamabadi, H. Vahdati Nasab & C. Warinner. Antiquity Project Gallery **86**:333-335.
- 2011 ***Paleoparasitology in the Middle-East: State of the research and potential.*** Nezamabadi M, Harter-Lailheugue S, Le Bailly M, *Tüba-Ar.* **14**: 205-213.
- 2011 ***Mannaean Faunal Remains from Tepe Qalaichi; Northwestern Iran (9th- 7th B.C.).*** Nezamabadi M, Mashkour M, Kargar B, Iranian Archaeology, 2.

Seminars:

- 2013 ***Ancient tapeworm eggs in a natural mummy from Iran.*** Nezamabadi M, Mashkour M, Boenke N, Aali A, Stöllner T, Le Bailly M, 8th World Congress on Mummy Studies, Rio de Janeiro, Brazil.
- 2013 ***The helminth eggs identified in Chehrabad saltmine.*** Nezamabadi M, Le Bailly M, 2nd international workshop: "The Saltmen of Iran", Ruhr-Universität Bochum, Germany.
- 2012 ***Paleoparasitology studies in the Middle East.*** Nezamabadi M, le Bailly M, Richard H, Journée des doctorants, UFC, Besançon, France.
- 2012 ***A paleoparasitological study of the ancient salt miners in Chehrabad (Northwestern Iran).*** Nezamabadi M, Aali A, Stöllner T, Le Bailly M, The 19th european meeting of the paleopathology association, Lille, France.
- 2010 ***New investigations in paleoparasitology in Iran. Status of Parasitic Infections in Present and Past Iran.*** Mowlavi Gh, Nezamabadi M, Mashkour M, Workshop: Palaeoparasitology among Bioarchaeological method, Lyon, France.

Posters:

- 2013 ***The first ancient parasite eggs identified in Iran,*** Nezamabadi M, Le Bailly M, XIXe Colloque du GMPCA (Archéométrie), 22-26 Avril 2013, Université de Caen Basse - Normandie - France.
- 2008 ***Bovids of Boukan; Faunal Remains of a Mannaean Site (9th- 7th c. BC), Northwestern Iran,*** Nezamabadi M, Hassanzadeh Y and Mashkour M, 9th Meeting of ASWA, Al Ain, Abu Dhabi emirate, United Arab Emirates.