



**HAL**  
open science

# Mapping the anatomo-functional organization of human sensorimotor system : a multi-modal approach

Pierre-Aurélien Beuriat

► **To cite this version:**

Pierre-Aurélien Beuriat. Mapping the anatomo-functional organization of human sensorimotor system : a multi-modal approach. Neuroscience. Université de Lyon, 2019. English. NNT : 2019LYSE1246 . tel-02397038

**HAL Id: tel-02397038**

**<https://theses.hal.science/tel-02397038>**

Submitted on 6 Dec 2019

**HAL** is a multi-disciplinary open access archive for the deposit and dissemination of scientific research documents, whether they are published or not. The documents may come from teaching and research institutions in France or abroad, or from public or private research centers.

L'archive ouverte pluridisciplinaire **HAL**, est destinée au dépôt et à la diffusion de documents scientifiques de niveau recherche, publiés ou non, émanant des établissements d'enseignement et de recherche français ou étrangers, des laboratoires publics ou privés.



Université Claude Bernard



N° d'ordre NNT : 2018LYSEL246

THESE de DOCTORAT de L'UNIVERSITE DE LYON

Opérée au sein de

L'UNIVERSITE CLAUDE BERNARD LYON 1

ECOLE DOCTORALE ED 476 NSCo  
Neurosciences et Cognition

SPECIALITE DE DOCTORAT  
Neuroscience

Soutenue publiquement le 4 Novembre 2019 à Lyon  
par

Monsieur Pierre-Aurélien BEURIAT

# **MAPPING THE ANATOMO- FUNCTIONAL ORGANIZATION OF HUMAN SENSORIMOTOR SYSTEM: A MULTIMODAL APPROACH**

## **JURY**

**Mme Elena Daprati** (DR, Université de Rome, Rapporteur)

**Mme Gwenaëlle Catheline** (MCU, École Pratique des Hautes Études, Université de Bordeaux)

**Mr Bertrand Devaux** (PU-PH, Université Paris Descartes, Rapporteur)

**Mr Federico Di Rocco** (PU-PH, Université de Lyon, Président du Jury)

**Mr Carmine Mottolèse** (PH, Université de Lyon, Co-Directeur de Thèse)

**Mr Michel Desmurget** (DR, ISCMJ-CNRS, Co-Directeur de Thèse)

**MOTS-CLES :**

Anglais : Electrical Stimulation, Brain Mapping, Cerebellum, Cerebrum, Somatotopy, Volitional Movements, Neurosurgery, Motor Evoked Potentials, Somatosensory Evoked potentials, Diffusion Tensor Images, Anatomico-Functional Organization, Human

Français : Stimulation Electrique, Cartographie cérébrale, Cervelet, Cerveau, Somatotopie, Mouvement Volontaire, Neurochirurgie, Potentiels Evoqués Moteurs, Potentiels Evoqués Sensoriels, Imagerie par Résonance Magnétique de Diffusion, Organisation Anatomico-Fonctionnelle, Humain

**INTITULE ET ADRESSE DE L'U.F.R. OU DU LABORATOIRE :**

Institut des Sciences Cognitives Marc Jeannerod, CNRS/UMR 5229  
67 boulevard Pinel  
69675 Bron Cedex

## REMERCIEMENTS

### **A mon Président de thèse**

#### **Au Professeur Federico Di Rocco**

Tu me fais l'honneur de présider le jury de ma thèse. Merci de m'accompagner et de me soutenir tous les jours dans mon parcours hospitalo-universitaire. Je ferai tout pour honorer ta confiance. Sois assuré de ma gratitude et de mon profond respect.

### **A mes rapporteurs**

#### **Au Docteur Elena Daprati et au Professeur Bertrand Devaux**

Vous me faites l'honneur de juger ce travail. Solliciter vos compétences et votre expérience pour juger ce travail m'a semblé une évidence. Veuillez trouver ici l'expression de mon profond respect.

### **A mes directeurs de thèse**

#### **Au Docteur Carmine Mottolese**

Monsieur, je suis honoré et tellement reconnaissant de pouvoir poursuivre vos recherches. Vous m'avez appris et transmis l'envie de la recherche fondamentale autant que l'art de la chirurgie. Grâce à vous, aujourd'hui, je peux soutenir cette deuxième thèse. Soyez assuré de mon dévouement présent et futur pour tout ce que vous m'avez transmis. J'espère porter dignement et le plus longtemps possible votre héritage de l'école Lyonnaise. Merci !

#### **A Monsieur Michel Desmurget**

Depuis mes débuts en M2 à tes côtés, je ne cesse d'apprendre ce qu'est la recherche fondamentale. Merci de ton aide précieuse dans la réalisation de cette thèse. Je suis impatient de continuer à travailler avec ton équipe car tant de projets sont encore à aboutir.

### **A mes juges**

#### **A Madame Gwenaëlle Catheline**

Merci d'avoir accepté de juger ce projet avec autant de curiosité et de bienveillance. Veuillez trouver ici l'expression de mes très sincères remerciements

**Au Docteur Alexandru Szathmari**

Merci de continuer à me soutenir. Je suis heureux de pouvoir travailler avec toi tous les jours. Soit assuré de mon respect et de mon amitié.

**A Madame Angela Sirigu**

Merci de m'avoir accueilli dans votre laboratoire. Soyez assurée de ma reconnaissance et de mon profond respect.

**A Madame Irène Cristofori**

Très heureux de pouvoir continuer à travailler ensemble. Je suis persuadé que notre collaboration sera fructueuse. Merci de ton aide dans la rédaction de ce manuscrit.

**Au Docteur Isabelle Sabatier**

Je suis heureux de pouvoir te compter parmi mes amis en plus de notre excellente collaboration professionnelle.

**Au Docteur Christophe Rousselle**

Tu nous as quitté récemment pour de nouveaux horizons. Malgré le fait que tu nous manques, je te souhaite beaucoup de bonheur et une très bonne retraite.

**Au personnel paramédical du bloc opératoire de l'Hôpital Femme Mère Enfant**

J'ai passé des moments formidables avec vous. J'espère pouvoir continuer à travailler encore longtemps avec vous.

**Au personnel paramédical du service de Neurochirurgie Pédiatrique de l'Hôpital Femme Mère Enfant**

Merci de votre soutien dans les moments difficiles, de votre gentillesse et de votre affection.

Je dédie ce travail

### **A Marine**

Tu es la femme de ma vie. Sans toi, je n'aurais jamais réussi à être là où je suis aujourd'hui professionnellement mais aussi et surtout personnellement. Tu me soutiens coûte que coûte sans (presque !) jamais te plaindre. Avec toi, la vie est plus facile et tellement heureuse. Grâce à toi, j'ai la chance d'avoir une famille magnifique. J'ai hâte que la vie continue à tes côtés ainsi qu'avec nos enfants, Camille et Marceau.

### **A mes parents**

Votre soutien est toujours le même depuis plus de 33 ans. Quoi dire d'autre que MERCI, de m'avoir aidé à devenir l'homme que je suis aujourd'hui. Vous êtes des parents et maintenant grands-parents exceptionnels.

### **A ma sœur, Christophe et ma/mon futur/e nièce/neveu**

Le bonheur que vous vivez me remplit de joie. Tellement hâte de rencontrer la/le futur/e numéro de la famille et des réunions de famille avec tous les cousins !! Il va peut-être devoir se séparer de *Sacha*...

### **A mon frère**

Je continuerai à te soutenir sois en persuader. Garde ta ligne créative et le Grammy va arriver.

### **A mes beaux-parents, mes belles sœurs et beaux-frères et mes nièces**

Je suis tellement heureux de vous avoir comme famille

### **A mes grands-parents**

### **A mes amis de toujours : Timothée et Caroline, Nader, Emile et Claire, Pierre, Mathilde, Pauline, Franklin et Sophie**

Le temps passe et ne fait que renforcer notre amitié. Je tiens tellement à vous.

### **A celles et ceux qui m'ont soutenu**

Merci de tout cœur

## RESUME

Le but de cette thèse était d'étudier l'organisation anatomo-fonctionnelle du système sensori-moteur humain et la façon dont les mouvements volontaires sont produits et contrôlés. En effet, ces questions ne sont pas encore élucidées et mobilisent médecins, philosophes, psychologues et plus récemment neuroscientifiques. De nombreuses théories ont été avancées au cours du temps et ce, depuis des siècles. Avec le développement de l'imagerie cérébrale, des méthodes de corrélation anatomo-clinique et de stimulation électrique directe cérébrale, de nombreuses avancées scientifiques ont pu être réalisées. Ces trois approches complémentaires ont été utilisées dans cette thèse afin d'améliorer la compréhension de l'organisation sensori-motrice cérébrale.

Dans la première étude (soumise à publication), nous avons montré que la chirurgie cérébrale éveillée utilisant la stimulation électrique directe est une procédure sûre et efficace chez les enfants, afin de réduire le déficit neurologique post-opératoire. L'approche améliore la précision de la détection des zones éloquentes, comme cela a été démontré chez les adultes, avec une bonne tolérance neuro-psychologique et psychologique. Des facteurs spécifiques et des adaptations liées à l'âge doivent être pris en compte, tel qu'un bilan minutieux préopératoire de chaque patient. Une évaluation psychologique et neuropsychologique est essentielle pour le succès de la procédure. Il ressort de ce travail qu'une préparation intensive adaptée à l'âge peut permettre d'offrir une chirurgie en condition vigile, même chez de jeunes enfants de 9 à 10 ans. L'utilisation de la stimulation sous-corticale, en particulier, améliore la précision de la détection des zones fonctionnelles.

Dans une deuxième série de deux études, nous avons montré que la partie dorso-postérieure dorsale du cortex pariétal (DPPr) est une structure clé dans l'organisation complexe du mouvement manuel fin chez l'homme, à travers la mise en oeuvre d'une boucle sensori-pariéto-motrice.

La première étude (publiée, *Current Biology* 2018) montre que la stimulation électrique directe d'une région corticale focale dans la partie dorso-postérieure du cortex pariétal, entraîne l'inhibition de la production du mouvement manuel, c'est-à-dire bloque l'initiation et la réalisation de ce dernier, sans produire de contraction musculaire ni de sensation consciente de mouvement. De manière intéressante, l'enregistrement des potentiels évoqués sensoriels montre que ces sites inhibiteurs reçoivent des signaux afférents en provenance du membre supérieur. Plusieurs hypothèses explicatives possibles sont discutées. Au final, seules deux semblent suffisamment robustes pour expliquer les résultats recueillis. La première renvoie à l'existence d'une boucle inhibitrice spécifique. Les sites d'inhibition pariétaux agiraient alors en stimulant les neurones moteurs inhibiteurs du cortex moteur primaire (M1). Cette boucle pourrait être déclenchée de manière endogène (par exemple pour empêcher toute réponse anticipée durant la préparation motrice) ou exogène à travers ses afférences sensorielles. La deuxième hypothèse est plus générale. Elle suggère que la stimulation électrique empêcherait la transmission d'un signal d'erreur continu émis depuis DPPr vers M1, qui normalement pilote l'activité des neurones moteurs. Cette interruption entraînerait l'arrêt du mouvement. Malheureusement, sur la base des données cliniques disponibles, il n'est pas possible de déterminer la validité respective de ces hypothèses et la possibilité que l'inhibition du mouvement repose sur l'activation d'un circuit inhibiteur dédié ou de perturbation d'une boucle générale de contrôle moteur.

Dans la seconde étude (en cours de soumission), nous avons pour objectif d'identifier précisément les bases anatomiques du circuit pariétal inhibiteur précédemment décrit. Grâce à la tractographie de diffusion (DTI), nous avons réussi à isoler des projections ipsilatérales spécifiques reliant les sites d'inhibition du DPPr, retrouvés dans la première étude, avec la zone dévolue au contrôle distal fin dans les cortex primaires moteurs (M1) et sensoriels (S1). Ces données montrent que la boucle pariétale inhibitrice est directe depuis S1 vers DPPr vers M1



(même s'il n'est pas possible d'exclure l'existence d'échanges bi-directionnels entre ces aires). Par leur focalisation sur les aires de contrôle de la motricité manuelle distale, elles indiquent aussi que ce circuit n'est pas lié au contrôle de la motricité du membre supérieur en général (pointage, saisie) comme cela a souvent été proposé, mais au contrôle de la motricité distale fine.

Dans les deux dernières études, nous nous sommes intéressés à une structure fondamentale de notre système nerveux central qui supporte 50 % des invasions tumorales chez l'enfant : le cervelet.

Le but de la première (en cours de soumission) était de déterminer si les lésions précoces étaient oui ou non prédictives d'une récupération déficitaire à long terme après prise en compte des covariables les plus critiques (ce que n'avaient pas fait les études antérieures contradictoires). Nous avons mesuré la récupération fonctionnelle à long terme chez 3 groupes de quinze survivants de lésions de la fosse postérieure. Les 3 groupes étaient comparables en ce qui concerne leurs caractéristiques tumorales (taille, nature et localisation) mais opérés à différents âges : jeune ( $\leq 7$  ans), moyen ( $> 7$  ans et  $\leq 13$  ans) et tardif ( $> 13$  ans). La qualité de vie (échelles cliniques : Health-related Quality of Life -hrQol- et Performance Status -PS-), les performances motrices (ataxie -ICARS- et motricité fine -Pegboard-) et cognitives (quotient intellectuel -FSIQ-) furent mesurées. L'âge précoce lors de la chirurgie, une lésion des noyaux profonds cérébelleux et la nécessité d'une radiothérapie post-opératoire, révélèrent une influence significativement négative et indépendante sur la récupération à long terme des participants. Le volume de la tumeur et le délai entre la chirurgie et l'évaluation n'avaient aucun impact statistique détectable. L'influence négative du jeune âge lors de la chirurgie était significative dans tous les domaines : qualité de vie (hrQol, PS), fonctionnement moteur (ICARS ; Pegboard) et fonctionnement cognitif (FSIQ). Ces résultats confirment l'existence d'une période critique de développement au cours de laquelle la "machine à apprendre"

cérébelleuse revêt une importance cruciale. Ces données plaident en faveur de la mise en œuvre de programmes de rééducation précoces et intenses chez les enfants de moins de 7 ans après traitement d'une lésion de la fosse cérébrale postérieure.

Dans la deuxième étude, nous nous sommes intéressés à l'organisation somato-sensorielle du cervelet et à l'existence d'une organisation somatotopique au sein de celui-ci. Dans ce but, nous avons enregistré les potentiels évoqués somesthésiques cérébelleux avec des électrodes corticales chez 10 patients opérés de tumeurs focales situées à l'extérieur du cervelet (par exemple, la glande pinéale, la lame quadrijumelle). La stimulation électrique a été utilisée pour provoquer des contractions actives dans 9 muscles : visage (orbiculaire oris), membre supérieur (biceps, triceps, extenseur, fléchisseur du carpe radialis, éminence thénar, éminence hypothénar) et membre inférieur (tibial antérieur, gastrocnémien). Nous avons montré que la stimulation électrique des muscles périphériques pouvait déclencher des PES sur le cortex cérébelleux, mais de manière non homogène. La quasi-totalité des réponses étaient situées (i) dans la région cérébelleuse antérieure / supéro-postérieure (lobules HV-HVI), et (ii) dans la région cérébelleuse postéro-inférieure (lobules HVIIb-HVIII). Pour la plupart, les signaux enregistrés étaient ipsilatéraux, bien qu'une fraction importante (environ 30%) des entrées contralatérales ait été observée pour la main. Aucune somatotopie n'a été identifiée, du moins dans la région antérieure / supéro-postérieure où les représentations de la bouche et du membre supérieur se chevauchaient sans ségrégation spatiale. D'un point de vue fonctionnel, cette étude ne nous permet pas de déterminer les voies anatomiques qui acheminent les PES cérébelleux qui pourraient être les voies spinocérébelleuses ou indirectement à travers les principales zones sensori-motrices corticales (en particulier S1).

## **LISTES DES ABBREVIATIONS**

ABS : Awake Brain Surgery

CNS : Central Nervous System

DES : Direct Electrical Stimulation

DPPr : DorsoPosterior Parietal region

DTI : Diffusion Tensor Images

EDC : Extensor Digitorum Communis

EEG : ElectroEncephaloGram

EMG : ElectroMyoGram

fMRI/MRI : functional Magnetic Resonance Imaging/ Magnetic Resonance Imaging

GBM : GlioBlastoMA

ICU : IntensiveCare Unit

ICP : IntraCranial Pressure

LGG : Low Grade Glioma

M1 : Primary Motor Cortex

MEP : Motor Evoked Potential

MIP : Medial IntraParietal

OO : Orbicularis Oris

PET : Positron Emission Imaging

PPC : Posterio Parietal cortex

S1: Primary Sensory Cortex

SEP : Sensory Evoked Potential

# Table des matières

INTRODUCTION .....	13
A) PERI OPERATIVE MAPPING OF THE CEREBRAL CORTEX.....	16
<b>A-1) Scientific Background.....</b>	<b>17</b>
<b>A-2) Paper 1: Awake brain surgery in children – a single center experience .....</b>	<b>22</b>
1) ABSTRACT .....	23
2) INTRODUCTION.....	24
3) METHODS.....	25
a) Preoperative Evaluation.....	26
b) Surgical Technique and Mapping .....	26
c) Postoperative Evaluation.....	28
4) RESULTS .....	29
a) Patient demographics and initial presentation.....	29
b) Surgical outcome and histopathological diagnosis .....	29
c) Neurological outcome and perioperative complications .....	30
5) DISCUSSION .....	31
6) CONCLUSION.....	34
7) TABLE .....	40
B) SOMATOTOPIC ORGANIZATION OF THE CEREBRAL CORTEX.....	41
<b>B-1) Scientific Background.....</b>	<b>42</b>
<b>B-2) Paper 2: Selective inhibition of volitional hand movements after stimulation of the Dorsoposterior parietal cortex in humans.....</b>	<b>47</b>
1) HIGHLIGHTS .....	48
2) eTOC Blurb.....	48
3) SUMMARY.....	48
4) RESULTS .....	49
a) Evoking motor inhibition by stimulating the dorsoposterior parietal cortex .....	49
b) Functional properties of parietal inhibition sites.....	51
c) Evoking motor inhibition by stimulating precentral areas.....	52
5) DISCUSSION .....	53
7) FIGURES AND VIDEOS .....	64
8) STAR METHODS.....	69
9) SUPPLEMENTAL DATA.....	74
<b>B-3) Paper 3: A sensory-parieto-motor pathway dedicated to hand movement control in humans .....</b>	<b>81</b>
1) SUMMARY.....	82
2) INTRODUCTION.....	82
3) METHODS.....	84
4) RESULTS .....	85
5) DISCUSSION .....	86
6) FIGURES .....	98
7) SUPPLEMENTAL DATA.....	102
C) ROLE OF THE CEREBELLUM IN SENSORI-MOTOR AND HIGHER-LEVEL FUNCTIONS.....	104
<b>C-1) Scientific Background.....</b>	<b>105</b>

<b>C-2) Paper 4: Cerebellar lesions at a young age predict poorer long-term recovery .....</b>	<b>109</b>
1) ABSTRACT .....	110
2) INTRODUCTION.....	111
3) PATIENTS AND METHODS .....	113
a) Patients .....	113
b) Clinical assessments.....	115
c) Cognitive and sensorimotor assessments .....	116
d) Tumor volume and preservation of cerebellar nuclei.....	117
4) RESULTS .....	118
5) DISCUSSION .....	119
6) FIGURES .....	131
7) SUPPLEMENTAL INFORMATION.....	134
<b>C-3) Paper 5: Mapping somatosensory representation in the human cerebellum.....</b>	<b>137</b>
1) ABSTRACT .....	138
2) INTRODUCTION.....	139
3) MATERIAL AND METHODS .....	141
a) Subjects .....	141
b) Peri-operative mapping.....	141
c) Localizing stimulation sites.....	143
4) RESULTS .....	144
5) DISCUSSION .....	145
6) CAPTIONS:.....	155
<b>GENERAL DISCUSSION .....</b>	<b>158</b>
<b>REFERENCES .....</b>	<b>163</b>

# **INTRODUCTION**

How are volitional movements produced and controlled? This "simple" question has long been a major subject of investigations for scholars, philosophers, psychologists, clinicians and (more recently) neuroscientists. The idea that the brain controls body movements is not new. It was first proposed during the 30<sup>th</sup> century BC in *Edwin Smith Surgical Papyrus* (Taylor and Gross 2003). Since then, many observations of patients experiencing contralateral deficit following head trauma have been reported but doctors were more focused on treating the deficit than investigating causality; at least until Galen of Pergamon (129-199). This Greek physician, writer, and philosopher exercised a tremendous influence on medical sciences. His theory of movement production lasted for more than 1500 years. It included a clear differentiation between motor and sensory nerves, which were all seen as carrying "psychic pneuma". The brain was then represented as a pump that "moved the psychic pneuma from the sense organs into the ventricles, then into the motor nerves, and finally into the muscles, causing their contraction by inflation" (Taylor and Gross 2003). As time passed, researchers finally proved that pneuma was not the transmitter of brain signals. Electricity was, as initially proposed by Alexandre Monroe (1697-1762). This will be discussed below in more details.

Following Galen's contribution, progresses were quite slow. The role of the cerebral cortex, for instance, took centuries to be identified. This "rind" (as it was called by Latin scholars) was first considered a feeder for other tissues rather than a central structure for sensorimotor control. Its functional importance was not identified before the 18<sup>th</sup> century (Taylor and Gross 2003). Same for the cerebellum, which key role in motor control was not identified before the beginning of the nineteenth century (Manni and Petrosini 2004).

The twentieth century allowed for a much quicker evolution owing to major technical and conceptual advances (Kandel et al. 2013). In humans, three contribution were especially relevant: (i) neuroimaging (including the development of functional Magnetic Resonance Imaging (fMRI), Positron Emission Tomography (PET) or Diffusion Tensor Images (DTI)

(Leeds and Kieffer 2000); (ii) anatomo-functional observations in patients (Broca 1865; Scoville and Milner 1957); (iii) Direct Electrical Stimulation (DES) during awake brain surgeries (Desmurget et al. 2013). The latter approach was mainly popularized by the well-known work of Wilder Penfield, who used DES for identifying functional areas and epileptic loci in his patients (Penfield and Boldrey 1937). As discussed below in more details, DES is now a standard clinical tool, used to minimize the risk of post-operative deficits in patients (Lohkamp et al. 2019). Although this tool serves only and strictly clinical purposes, it has generated an enormous amount of valuable fundamental data. As mentioned in a recent review, *"had DES not been employed, our comprehension of the organization of the sensorimotor systems involved in movement execution, language production, the emergence of action intentionality or the subjective feeling of movement awareness would have been greatly undermined"* (Desmurget and Sirigu 2015).

Neuroimaging (mainly DTI), anatomo-functional correlations and DES are the three main (complementary) methods used in the present thesis which goal is to improve our understanding of sensorimotor organization in humans. Within this framework, three main topics were addressed. The first one evaluates the use and potential benefits of DES for tumor resections and preservation of functions in a pediatric cohort. The second one deals with the cortical control of movement and, in particular, the involvement of the posterior parietal cortex in the control (and inhibition) of hand movements. The third one analyzes the factors that predict sensorimotor recovery in patients submitted to a surgical resection of a cerebellar tumor. For each of these topics, a brief introduction to the state of the art and available knowledge will first be provided. Then, the relevant papers will be presented, followed by a short discussion of the main findings. A more general discussion will be provided in the final section.



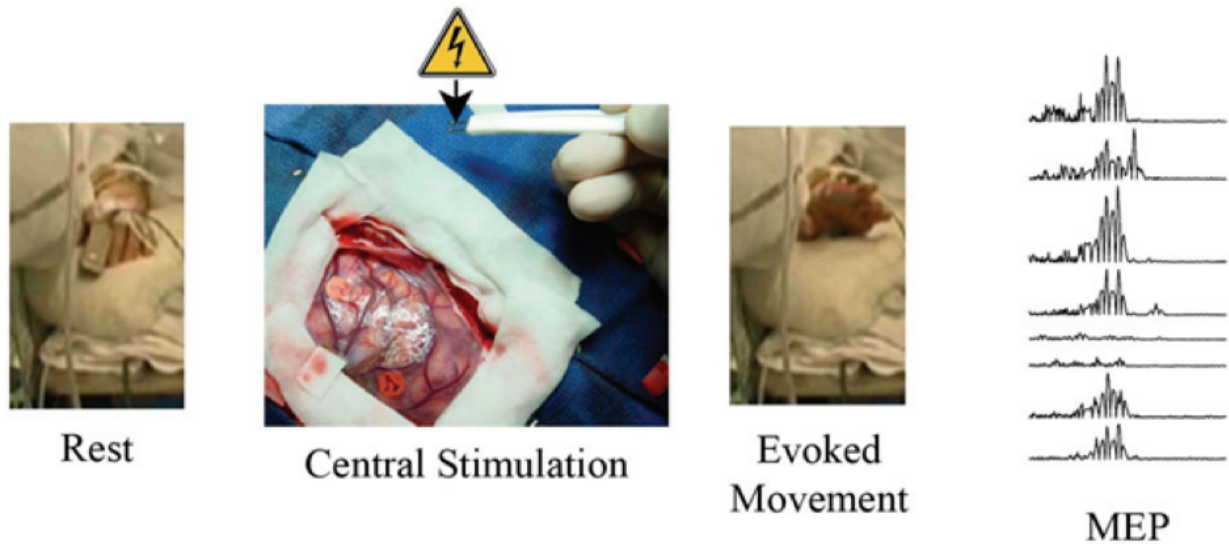
# **A) PERI OPERATIVE MAPPING OF THE CEREBRAL CORTEX**

## A-1) Scientific Background

Many discoveries came with the advent of electricity in the 17<sup>th</sup> and 18<sup>th</sup> century. Luigi Galvani (1737-1798) was the first to prove that applying an electrical current to the sciatic nerve evoked a muscle contraction in a frog's leg (Galvani 1791). This observation was rapidly reproduced and extended by Fritsch and Hitzig who showed that (i) DES of the cerebral cortex of dogs evoked localized, topographically organized muscle contractions in the contralateral hemibody (e.g., spasms); (ii) lesions of the cortical areas that evoked movements when electrically stimulated caused paralyzes within the body parts that responded to the stimulation (Fritsch and Hitzig n.d.). Three main conclusions emerged from these observations: first, the cortex controls motor functions, at least partially; second, the cortex can be excited by an electrical current and this excitation propagates to body muscles; third, the regions of the brain that control body movements are organized topographically.

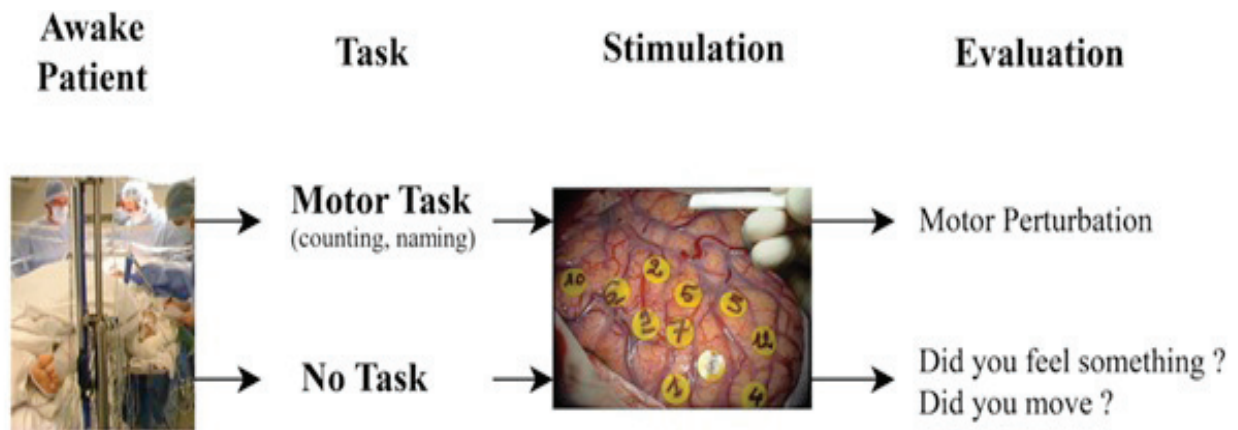
These findings were a tremendous breakthrough in neuroscience. They opened the door to the use of DES to identify the anatomo-functional organization of the human brain (Desmurget and Sirigu 2015). As emphasized above, it is Wilder Penfield who made this technique a standard mapping tool in patients during awake brain surgeries (Penfield and Boldrey 1937). Since then, beside the introduction of some major technical improvements, the main approach remained unchanged. Typically, DES is delivered through a standard bipolar electrode placed on the brain area to be tested (Figure 1). The probe is made out of 2 spherical steel tips spaced 5 mm apart. A constant voltage stimulator is then used to produce a train of low-frequency biphasic pulses (pulse frequency 60 Hz, single-pulse phase duration 1 msec, and amplitude 2-8 mA). The duration of the stimulation ranges between 1 to 5 second. Initial stimulus intensity is generally set at a low level (1 mA; to minimize the risk of seizure) and is progressively

increased (up to 10-12 mA) if no response is observed. This protocol allows identifying efferent pathways, as shown in figure 1 below.



**Figure 1** : Illustration of the motor mapping procedure. On the right, increased muscle activity induced by stimulation (Motor evoked potentials-MEPs) as measured by electromyography (EMG) at the periphery (e.g., hand muscle).

However, DES can also be used to map conscious sensory responses and eloquent (functional) regions (figure 2). In this case, DES is delivered on the cortical surface while the patient is either at rest or performing a motor task (talk or open-close the hand). In the first situation the patient is asked whether the stimulation evoked a movement or a specific feeling (tingling, intention to move, etc; Desmurget and Sirigu 2009). In the second situation, it can be estimated whether task performance is impaired by the stimulation (Sanai, Mirzadeh, and Berger 2008).



**Figure 2** : *Illustration of the functional mapping procedure.*

However, DES is not devoid of limitations and major criticisms have often been raised about its use, namely that the response induced by the stimulation could be triggered not by the cortical region directly stimulated but rather by other, interconnected regions (Taylor and Gross 2003). The reason for such a claim is that the current delivered to the brain may spread in an uncontrolled manner (Strick 2002; Borchers et al. 2011). According to this view, the effect of DES could be partially explained by uncontrolled activation or inhibition of local and distant neural populations. For instance, when one stimulates the parietal cortex and a specific behavior is elicited (e.g. intention to move), this behavior could reflect the activation or the inhibition of remote regions, for instance precentral, through stimulation of axonal pathways (Karnath, Borchers, and Himmelbach 2010). However, many direct and indirect evidence now exists that this knee-jerk criticism is invalid and that DES does not spread in a meaningless jumble, at least for the high-intensity/high-frequency protocols that are used during brain surgery (Desmurget et al. 2013; Histed, Ni, and Maunsell 2013; Logothetis et al. 2010). In particular, remote effects due to current spread would not be able to explain the major positive impact of DES on the existence and magnitude of post-operative deficits in patients (Sanai, Mirzadeh, and Berger 2008; Chang et al. 2011). Of course, DES does not activate cellular populations as "natural", autogenous recruitments do. This technic generates unnatural patterns of neural

activation. However, despite this limitation it remains a useful and powerful methods for: (i) driving/identifying descending motor pathways (Penfield and Boldrey 1937; Desmurget et al. 2014); (ii) evoking conscious feelings by stimulating neural populations with sensory properties (Desmurget and Sirigu 2009); (iii), disrupting "natural" neural activity during the realization of an ongoing task (Desmurget et al. 2018b; Sanai, Mirzadeh, and Berger 2008).

When it was developed, a century ago, awake brain surgery aimed to correlate functional and pathological brain areas throughout epilepsy surgery, while stimulating different critical regions of the cortex (Elsberg 1925). Later on, this principle was translated to tumor surgery and generated the basis for today's awake surgery procedures. Applied as a standardized approach, the use of DES aims at optimizing tumor removal while preserving neurological functions (Berger and Ojemann 1992; Surbeck, Hildebrandt, and Duffau 2015). Allowing seizure control besides minimizing operative morbidity made awake brain surgery a common intervention tool in adults for intrinsic brain tumors (notably low-grade glioma) in eloquent areas. The outcome of awake brain surgery in adult patients, including morbidity, mortality, treatment conditions and neuropsychological aspects has been widely studied and reported in several cohorts (Serletis and Bernstein 2007; Beez et al. 2013; Boetto et al. 2015; Gupta et al. 2007). Some of these studies were performed as randomized or multi-center trials in order to include large patient populations (Serletis and Bernstein 2007; Boetto et al. 2015; Taylor and Bernstein 1999). More importantly, the results of these and other studies have been predominantly positive, especially in terms of preserving neurological functions, extent of tumor resection and perioperative complication rate, all of these factors increasing overall survival (Boetto et al. 2015; Hervey-Jumper et al. 2015; Meng, Berger, and Gelb 2015; Paldor et al. 2016).

Unfortunately, comparable observations within pediatric populations remain pending (Trevisi, Roujeau, and Duffau 2016; Riquin et al. 2017; Akay et al. 2016). While awake brain

surgery is now a standard of care in adults, equivalent benefits of awake brain surgery to pediatric patients is withheld, due to an assumed increased psychological fragility in children and age-related cooperation capacity interfering with feasibility and psychological outcome (Trevisi, Roujeau, and Duffau 2016; Riquin et al. 2017).

This key issue was addressed in the present thesis. The accompanying paper reports the methods and results of a single-center case series of awake brain surgeries in children with intra-operative electrocortical mapping for the resection of eloquent central nervous system lesions. The study includes neurologic and psychological outcome results, our procedure algorithm and derived recommendations for managing Awake Brain Surgery (ABS) in the pediatric patients.

# A-2) Paper 1: Awake brain surgery in children – a single center experience

*Submitted*

Pierre-Aurélien Beuriat, MD<sup>1,2</sup>\*, Laura-Nanna Lohkamp, MD, MSc<sup>1</sup>\*, , Michel Desmurget, PhD<sup>2</sup>, Irène Cristofori, PhD<sup>2</sup>, Alexandru Szathmari, MD, PhD<sup>1</sup>, Ludivine Huguet<sup>1</sup>, Federico Di Rocco, MD, PhD<sup>1</sup>, Carmine Mottolese, MD, PhD<sup>1</sup>

\* Both authors contributed equally to this work

<sup>1</sup>Department of Pediatric Neurosurgery, Hôpital Femme Mère Enfant, Université Claude Bernard Lyon 1, France

<sup>2</sup>Center for Cognitive Neuroscience, Lyon, France

Corresponding Author:

Carmine Mottolese, MD, PhD

Department of Pediatric Neurosurgery, Hôpital Femme Mère Enfant, Université Claude Bernard Lyon 1, Lyon, France

Email: [Carmine.Mottolese@chu-lyon.fr](mailto:Carmine.Mottolese@chu-lyon.fr)

## 1) ABSTRACT

**Introduction:** Awake brain surgery (ABS) represents a rare surgical procedure in children as age and psychological aspects, which are considered to interfere with its feasibility and psychological outcome, limit its application. Only few pediatric case series have been reported so far, indicating a more complex translation of this surgical approach to children. However, the advances in neuropsychological testing and monitoring may have a substantial impact on ameliorating the eligibility of children undergoing awake procedures. This study addresses the condition of ABS in a pediatric cohort, focusing on its practicability and diversified outcome aspects.

**Methods:** We performed a retrospective review and prospective outcome analysis of pediatric patients with CNS lesions undergoing ABS between 2005 and 2018, completed at the University of Lyon, France.

**Results:** Eighteen children were considered for ABS with respect to the eloquent location of their CNS lesions documented in their pre-operative MRI. Seventeen of them underwent asleep-awake-asleep brain surgery. The cohort included 5 males and 12 females. The median age at surgery was 14.8 years, (range: 9.4 to 17.6 years). Intra-operative testing included electrocortical stimulation while pursuing speech or motor activity. Most of the lesions were intrinsic tumors of glial origin. A complete tumor removal was achieved in 11 patients (65%). Postoperative neurological deficits were transiently observed in 2 patients, whereas severe psychological reactions occurred in 1 child. Persistent attention deficits were found in 2 patients. One patient experienced an infectious complication requiring antibiotic treatment. Two patients died during follow-up due to tumor progression. The mean duration of follow up was 22,2 months (range: 3,4 to 46,8 months).

**Conclusions:** ABS was shown to be beneficial in terms of efficient tumor resection beside simultaneous preservation of neurological functions. Psychological preparation of the families



and the children is essential to increase the number and age range of patients, who can benefit from this technique. Neuropsychological testing before and after surgery is essential to determine cognitive outcome, which can be altered in a minority of patients.

## **2) INTRODUCTION**

Awake brain surgery (ABS) represents a standardized surgical procedure in adults for lesions in functional areas. This technique has significantly evolved over the last decades and became, in combination with advanced neuronavigation and neuromonitoring in addition to novel anesthetic protocols the standard of care in the resection of supratentorial eloquent lesions and epileptogenic foci[1-3]. The primary goal of ABS is to maximize the extent of resection while preserving neurological function using intra-operative electrocortical mapping with testing of language and sensorimotor functions in an awake patient[4-6]. A meta-analysis revealed a 58% reduced neurological morbidity and improved resection extent compared to procedures without intraoperative stimulation mapping[7]. Another systematic review, considering the outcome results of in total 951 patients, showed that ABS was related to a shorter hospital stay (4 vs. 9 days), fewer neurological deficits (7% vs. 23%) compared with equivalent surgeries under general anesthesia[8]. In addition, ABS was well tolerated and not related to increased pain, anxiety or posttraumatic stress after careful evaluation and preparation of the patients[9-11]. Therefore, ABS was credited an overall beneficial value in eloquent epilepsy and tumor surgery and established as a standard procedure in adults[4, 12]. Given the suspected increased psychological fragility and age-related, multifactorial complexity of children, there remains a substantial gap in transitioning this technique to pediatrics[13-16]. In practice the main limitation represents the preemptive psychological assessment and individualized preparation of the patient, which might interfere with a time

sensitive lesion removal, especially in highly malignant lesions. Only few studies have addressed the specific context of ABS in children and adolescents[17-24]. The biggest neurosurgical case series were reported by Balogun et al (10 patients), Requin et al (7 patients) and Air et al (6 patients)[16, 17, 20]. Another big cohort, including 12 patients, has been reported from an anesthesiological management perspective by Soriano et al[25]. All of them state favorable outcomes and beneficial aspects, and therefore underline its feasibility and safety in children. However, further studies are required to reach significant patient numbers that allow conclusive evaluation of its utility, neurological and psychological outcome and standardized practicability.

Herein we report a single-center case series of ABS in children with intra-operative electrocortical mapping for resection of eloquent CNS lesions. The study includes neurologic and psychological outcome results, our procedure algorithm and derived recommendations for managing ABS in the pediatric patients.

### **3) METHODS**

We performed a retrospective review of all pediatric patients, who were considered for ABS based on their MRI results with evidence of a supratentorial lesion located within or adjacent to eloquent regions. Among 18 patients 17 were accounted suitable for this type of surgery with respect to clinical presentation, psychological eligibility and obtained agreement. All patients could be submitted to further pre-operative psychological testing. Finally, 17 patients successfully completed ABS including language and sensorimotor mapping. All surgeries were performed by one single surgeon (C.M.) between 2005 and 2018 at the department of pediatric neurosurgery, Hôpital Femme Mère Enfant, University of Lyon, France. Complete patient records were available from all of the patients, permitting exact assessment of demographic

and perioperative imaging data, complications and long-term outcomes. In addition, neuropsychological and psychological evaluations were reviewed. REB approval and consent for this review was obtained.

#### **a) Preoperative Evaluation**

Preoperative imaging included MRI with and without gadolinium enhancement and in 16 out of 17 patients functional MRI was obtained. Preoperative clinical evaluation comprised an overall neurological exam and an electroencephalogram in patients with seizures. In addition, pre-operative psychological (L.H.) and neuropsychological testing (M.D.) was conducted in 15 children. The intensity of pre-emptive preparation was adjusted to the individual need of the patient. Furthermore, the intra-operative tasks and images for intra-operative recognition were explained pre-emptively by one of the accompanying neurosurgeons (PA.B., LN.L). Separate consent was obtained for any type of data recording and processing.

#### **b) Surgical Technique and Mapping**

Intravenous prophylactic antibiotics and anti-convulsants were administered on a standardized basis at the beginning of the surgery. The patients were brought in a supine or lateral position and placed on a specific mattress inflated with air, aiming for highest patient comfort prior to anesthesia induction and head fixation in the Mayfield clamp. The marked incision site was infiltrated with 0.25% bupivacaine including epinephrine in order to avoid bleeding. The anesthesiologist performed an additional scalp block of the supraorbital, temporal, retroauricular and occipital nerves. All procedures were performed as asleep–awake–asleep technique, using a combination of propofol and fentanyl/remifentanyl and laryngeal mask airway placement[26]. Additional arterial line, bladder catheter placement and

installation of neuromonitoring were accomplished after start of anesthesia. The surgical field was draped in a conventional sterile fashion using transparent materials to allow an easy communication and interaction between the surgeon, the anesthesiologist, the neuropsychologist and the patient. A dedicated neuropsychologist (M.D.) and another neurosurgeon (PA.B., LN.L.) were present throughout the entire procedure in order to interact with the patient and to observe eventual seizures or deficits. Intra-operative neuronavigation (Medtronic, StealthStation, Minneapolis, USA) was used. An important technical aspect of the surgery was to provide a large bone flap, which exposes the entire functional cortex in order to optimize mapping and to avoid constriction of the brain in case of cerebral swelling and herniation. Once the craniotomy was made and the dura mater exposed, anesthesia was progressively reduced and the laryngeal mask removed. The patient was accompanied during waking up by the neuropsychologist. Meanwhile the dura was opened. When full alertness of the patient was confirmed and the neuropsychologist approved the patient to be ready, cortical stimulation was initiated using bipolar electrodes (OCS2 Ojemann Cortical Stimulator, Integra LifeSciences, Plainsboro, NJ, USA) assessing the language and motor function[15, 27, 28]. Cortical stimulation was performed for duration of 5 seconds with a 100 microseconds pulse width at 60 Hz frequency. The starting intensity was 1 milliampere being progressively increased if required to a maximum of 7 milliamperes for each stimulated location. The single locations were numbered and attributed to functional or non-functional sites, all of them being tested repetitively for definite confirmation[28]. The exact coordinate of the stimulation site was recorded with the neuronavigation software. Cold irrigation was performed regularly in order to improve the conductivity of the stimuli. Additional subcortical stimulation was performed during lesionectomy. Throughout the stimulation episodes, electrical activity was measured in 10 contralateral muscle groups via electromyography covering the face/mouth (zygomaticus/orbicularis oris; electrodes were placed to record combined activity in these two

muscles), neck (sternocleidomastoid), elbow (biceps, triceps), wrist (extensor digitorum communis, flexor carpi radialis), hand (thenar, hypothenar) and foot (tibialis anterior, gastrocnemius) using the ISIS IOM Inomed neuromonitoring system (Inomed Medizintechnik; Tenningen, Germany). During the stimulation periods the patients completed specific tasks, related to the local functionality of the stimulated region, such as recognizing and naming objects, counting and responding to questions for speech mapping. Few of the patients were tested in two languages, if applicable. Motor mapping was conducted by requesting specific movements of either isolated parts or of the entire limb. Any alterations in speech, motor function or seizures were video recorded. Constant close interactions were maintained throughout the procedure between the surgeon (C.M., A.S.), the neuropsychologist and the anesthesiologist as well as the patient. Anesthesia was restarted and the laryngeal mask re-inserted after completed lesionectomy. Termination of the surgery was conducted as per procedure standards and patients were observed for the first 24 hours in ICU.

### **c) Postoperative Evaluation**

Postoperative evaluation included MR Imaging and post-interventional psychological and neuropsychological assessment beside standard follow up of neurological functions. MR Imaging was obtained within 24 hours after surgery in all patients focusing on the extent of resection and post-operative changes versus complications. Further assessments were scheduled 3, 6 and 12 months after the operation on an outpatient basis. Neurologic alterations were monitored closely and submitted to further investigations, such as EEG, speech therapy etc. if required.

## **4) RESULTS**

### **a) Patient demographics and initial presentation**

Between 2005 and 2018 a total of 17 patients underwent asleep-awake-asleep brain surgery (Table 1). The gender ratio was 5:12 (m:f). The age distribution was more prominent in the adolescent age group with a median age at the time point of surgery of 14.8 years, (range: 9.4 to 17.6 years). Two patients, both of them females, were younger than 10 years. The main presenting symptom were partial or generalized seizures, occurring in 9 of the 17 patients. Other initial symptoms were: headaches (3 patients), nausea with vomiting as a sign of increased ICP (2 patients), visual disturbances (2 patients), increased fatigue (2 patients) and gait disturbances/paresthesia (2 patients). One patient underwent a MRI scan for depression and was incidentally found to have a left parietal lesion. Two or more of the above-named symptoms occurred in 4 patients. Fifteen patients underwent surgery for tumor resection and two patients for vascular lesions (cavernoma). Ten out of 17 patients showed lesions on the left hemisphere. Hemispheric dominance was assessed in all patients. Twelve patients (70%) were left-handed and 5 patients (30%) right handed. Among those 5 right-handed patients, language was lateralized to the left side in two cases.

### **b) Surgical outcome and histopathological diagnosis**

All of the procedures including testing were completed but one and overall tolerance was well among 16 out of 17 patients. One patient claimed exhaustion at the end of the awake phase, became uncooperative and required stronger neuropsychological support for successful completion. Intra-operative seizures or transient deficits were observed in 5 of the patients (30%). Partial seizures occurred in 3 patients (17,6%), one of them lasting more than 2 minutes requiring anesthesiological intervention. The other seizures were self-limiting and eventually settled by administrating cold water on the stimulated area. Speech arrests were noted in 3 patients (17.6%) and abnormal motor responses/paresthesia in 4 out of 17 patients (23.5%).

Anesthesiological complications did not occur in any of the patients. All specimens were sent for histopathological analysis and most of them found to be of glial origin, 11 of them were low-grade gliomas (LGG). Two patients underwent ABS for resection of vascular lesions. A detailed overview of all diagnosed entities is given in table 1. Complete resection was achieved in 9 out of 15 tumor patients (65%) and in 2 out of 2 patients (100%) with a vascular lesion. Incomplete resection was based on intra-operative decision-making with respect to prior confirmed functionality of the region in order to preserve language or motor function. Incomplete resections were documented in 4 of the LGG patients and two GBM patients.

### **c) Neurological outcome and perioperative complications**

The neurological outcome was assessed in the immediate post-operative phase, daily throughout the hospital course and within follow-up appointments in the outpatient clinic after 3, 6 and 12 months and after every year according to our oncological follow-up protocol. The individual follow-up periods ranged between 4.4 and 48.6 months with a mean duration of 22.2 months. Transient neurologic deficits were noted in the early post-operative phase in 2 patients: one suffered from expressive aphasia and one experienced weakness of his left upper extremity. Both showed significant improvement within the first days and recovered completely over time. None of the patients was diagnosed with a permanent neurological deficit. One patient, who was noted to be aphasic, developed a delayed wound infection with intracerebral abscess formation < 2 cm diameter confirmed by MRI. She underwent a two-month-course of antibiotic treatment until her final MRI demonstrated complete resolution. Another patient suffered from a post-traumatic stress disorder during the late post-operative course, which required repetitive psychological interventions. Three other patients showed transient critical psychological changes in the immediate post-operative phase. Further neuropsychological changes were reported in 2 out of 17 patients, who suffered from persisting attention deficits.

## 5) DISCUSSION

In this study we successfully performed ABS with intra-operative cortical stimulation and mapping in 16 out of 17 children with intrinsic brain tumors or vascular lesions in eloquent areas. Eighteen children were considered for this specific type of procedure and 17 of them were accounted suitable with respect to age, clinical presentation and psychological eligibility. Overall tolerance was high, while neurologic functions were successfully preserved with unchanged long-term neurologic outcomes. A sustained psychological disorder was recorded in one patient. Another 2 patients suffered from persisting attention deficits at 6 months of follow-up confirmed by neuropsychological testing. These results indicate that ABS in children is equally feasible, safe and effective as in adults. However, specific factors and age-related adaptations need to be considered.

An extensive pre-operative work-up of each individual patient, including psychological and neuropsychological assessment is essential for the success of the procedure, as it was recently likewise recommended in adults[29]. The attested eligibility was in most of the cases confirmed by an uneventful procedure without any psychological side effects. One patient experienced the procedure of ABS as terrifying and overall negative. She presented with persisting depressive thoughts in the post-operative period and expressed herself in anger and discomfort indicating a post-traumatic stress disorder. Disregarding the psychological deterioration, ABS was successfully applied in this patient in terms of neuroprotection and resection extent as optimal precondition for progression free survival.

Two patients were younger than 10 years, the youngest 9.4 years at the time point of the procedure, which might re-raise the question of age limitations for this type of surgery[30, 31]. Both patients tolerated the procedure equally well and did not show any psychological or neurological deterioration during their post-operative course. The failure rate in our cohort, meaning interruption of the awake phase, was 6% (1 patient). This confirms that age-adapted



intensive preparation, optionally including additional methods, such as hypnosis[21], may enable offering ABS even to younger children on an individual basis as demonstrated in single case reports[22, 23]. Although the patient's age is generally discussed as the limiting factor for ABS, the psychological structure and the "maturity" of the patient have the highest impact on tolerance and outcome of the procedure. In patients that are naturally quiet and show a non-anxious behavior, it is possible to realize the ABS with a good pre-operative preparation even below the age of 10.

Further considerations have to be made for the technical aspects of the procedure in our cohort. Of note is, that a complete lesion removal could be accomplished only in 11 out of 17 patients. This was related to the intraoperative findings of cortical stimulation and mapping, which was prioritized in all cases for intraoperative decision-making. In these patients cortical and subcortical stimulation indicated a clear risk of functional deficits when passing beyond the determined boundaries. This fact emphasizes the relevance and validity of this technique in eloquent lesions. A technical nuance of our protocol is the additional use of subcortical stimulation, which ameliorates to our opinion the accuracy and extent of functional discrimination with respect to depth and vascular supply. Furthermore, it helps to overcome discrepancies between the derived functional area via cortical mapping and the pre-operative functional MRI. In this study two patients were discovered with transient post-operative deficits: one patient, who underwent subtotal resection of a low-grade glioma developed an expressive aphasia and another patient, who underwent surgery for cavernoma resection was discovered with a partial motor deficit of the upper left extremity. Knowing that ABS with intra-operative electrical mapping correlates directly with increased resection extent, especially in LGG, one could argue that our threshold for aggressive resection was very high[29]. Another way to interpret these valuable neurological outcome results is to state a high accuracy of the performed cortical stimulation and mapping as the resection extent in 15 cases was successfully

tailored by the obtained stimulation and mapping responses. Standardized protocols and recommendations for intraoperative cortical stimulation and mapping, which offer beside overall neurophysiological comprehension decided technical instructions, such as duration of stimulation, step-wise increase of stimulation intensity and distinction of local responses, would therefore precipitate optimization of the procedure. Moreover, they would allow comparability as well as reproducibility of different settings and awake procedures[32, 33]. Extension of cortical mapping to sensorimotor, visuospatial, higher cognitive, and emotional functions, which are situated within presumed "non-language" areas such as the right "non-dominant" hemisphere would tap the full potential of this beneficial technique[29]. Following this specific evolution in adult patients, especially in those with LGG, a significant effort should be made for establishing these methods equally in children.

The favorable results of this study and those of few other case series do not suggest that ABS in children is related to worsened clinical or psychological outcome compared to adults[16-18, 20, 21]. Contrarily, ABS with intraoperative cortical stimulation is currently the only reliable method that allows significant improvement of the benefit/risk ratio of tumor resection, especially in LGG[34]. Therefore, the technique is considered as the gold standard in adult neuro-oncological surgery, leading to a significant decrease of postoperative morbidity while maximizing the extent of resection with respect to functional limits[12, 29]. Yet, despite its utility, it is reported only in few pediatric patients, demonstrating a large translational gap from applied adult methodology to children. This might be explainable by the complexity of pediatric patients, however may only require few additional pre-emptive considerations, such as intensified neuropsychological assessment, psychological support, and dedicated anesthesiologists. Moreover, the necessity to realize this protocol within a structured setting, adapted to pediatric patients needs to be taken into account. With respect to evolving treatment standards and quality of care this gap can and must be closed as emphasized by these results.

## **6) CONCLUSION**

ABS can be performed as a safe and efficient procedure in children, highlighting equivalent benefits as in adults, while relative tolerance in younger children was shown to be high. Pre-emptive precise neuropsychological and psychological evaluation is mandatory for choosing wisely an eligible set of patients, but does not guarantee unchanged neuropsychological outcome. The application of ABS in patients under the age of 9 should be considered in selected cases after careful evaluation.

## **REFERENCES**

1. Taylor MD, Bernstein M (1999) Awake craniotomy with brain mapping as the routine surgical approach to treating patients with supratentorial intraaxial tumors: a prospective trial of 200 cases. *Journal of neurosurgery* 90: 35-41 doi:10.3171/jns.1999.90.1.0035
2. Serletis D, Bernstein M (2007) Prospective study of awake craniotomy used routinely and nonselectively for supratentorial tumors. *Journal of neurosurgery* 107: 1-6 doi:10.3171/jns-07/07/0001
3. Sanai N, Mirzadeh Z, Berger MS (2008) Functional outcome after language mapping for glioma resection. *The New England journal of medicine* 358: 18-27 doi:10.1056/NEJMoa067819
4. Hervey-Jumper SL, Li J, Lau D, Molinaro AM, Perry DW, Meng L, Berger MS (2015) Awake craniotomy to maximize glioma resection: methods and technical nuances over a 27-year period. *Journal of neurosurgery* 123: 325-339 doi:10.3171/2014.10.jns141520
5. Sacko O, Lauwers-Cances V, Brauge D, Sesay M, Brenner A, Roux FE (2011) Awake craniotomy vs surgery under general anesthesia for resection of supratentorial lesions. *Neurosurgery* 68: 1192-1198; discussion 1198-1199 doi:10.1227/NEU.0b013e31820c02a3
6. Sanai N, Berger MS (2008) Glioma extent of resection and its impact on patient outcome. *Neurosurgery* 62: 753-764; discussion 264-756 doi:10.1227/01.neu.0000318159.21731.cf
7. De Witt Hamer PC, Robles SG, Zwinderman AH, Duffau H, Berger MS (2012) Impact of intraoperative stimulation brain mapping on glioma surgery outcome: a meta-analysis. *Journal of clinical oncology : official journal of the American Society of Clinical Oncology* 30: 2559-2565 doi:10.1200/jco.2011.38.4818
8. Brown T, Shah AH, Bregy A, Shah NH, Thambuswamy M, Barbarite E, Fuhrman T, Komotar RJ (2013) Awake craniotomy for brain tumor resection: the rule rather than the

exception? *Journal of neurosurgical anesthesiology* 25: 240-247  
doi:10.1097/ANA.0b013e318290c230

9. Beez T, Boge K, Wager M, Whittle I, Fontaine D, Spena G, Braun S, Szelenyi A, Bello L, Duffau H, Sabel M (2013) Tolerance of awake surgery for glioma: a prospective European Low Grade Glioma Network multicenter study. *Acta neurochirurgica* 155: 1301-1308  
doi:10.1007/s00701-013-1759-0

10. Manninen PH, Tan TK (2002) Postoperative nausea and vomiting after craniotomy for tumor surgery: a comparison between awake craniotomy and general anesthesia. *Journal of clinical anesthesia* 14: 279-283

11. Hol JW, Klimek M, van der Heide-Mulder M, Stronks D, Vincent AJ, Klein J, Zijlstra FJ, Fekkes D (2009) Awake craniotomy induces fewer changes in the plasma amino acid profile than craniotomy under general anesthesia. *Journal of neurosurgical anesthesiology* 21: 98-107  
doi:10.1097/ANA.0b013e318192d4aa

12. Freyschlag CF, Duffau H (2014) Awake brain mapping of cortex and subcortical pathways in brain tumor surgery. *Journal of neurosurgical sciences* 58: 199-213

13. Everett LL, van Rooyen IF, Warner MH, Shurtleff HA, Saneto RP, Ojemann JG (2006) Use of dexmedetomidine in awake craniotomy in adolescents: report of two cases. *Paediatric anaesthesia* 16: 338-342 doi:10.1111/j.1460-9592.2005.01697.x

14. McClain CD, Landrigan-Ossar M (2014) Challenges in pediatric neuroanesthesia: awake craniotomy, intraoperative magnetic resonance imaging, and interventional neuroradiology. *Anesthesiology clinics* 32: 83-100 doi:10.1016/j.anclin.2013.10.009

15. Ojemann SG, Berger MS, Lettich E, Ojemann GA (2003) Localization of language function in children: results of electrical stimulation mapping. *Journal of neurosurgery* 98: 465-470 doi:10.3171/jns.2003.98.3.0465

16. Riquin E, Dinomais M, Malka J, Lehouste T, Duverger P, Menei P, Delion M (2017) Psychiatric and psychological impact of surgery while awake in children for resection of brain tumors. *World neurosurgery* doi:10.1016/j.wneu.2017.03.017
17. Air EL, Ostrem JL, Sanger TD, Starr PA (2011) Deep brain stimulation in children: experience and technical pearls. *Journal of neurosurgery Pediatrics* 8: 566-574 doi:10.3171/2011.8.peds11153
18. Akay A, Ruksen M, Cetin HY, Seval HO, Islekel S (2016) Pediatric Awake Craniotomy for Brain Lesions. *Pediatric neurosurgery* 51: 103-108 doi:10.1159/000442988
19. Ard J, Doyle W, Bekker A (2003) Awake craniotomy with dexmedetomidine in pediatric patients. *Journal of neurosurgical anesthesiology* 15: 263-266
20. Balogun JA, Khan OH, Taylor M, Dirks P, Der T, Carter Snead Iii O, Weiss S, Ochi A, Drake J, Rutka JT (2014) Pediatric awake craniotomy and intra-operative stimulation mapping. *Journal of clinical neuroscience : official journal of the Neurosurgical Society of Australasia* 21: 1891-1894 doi:10.1016/j.jocn.2014.07.013
21. Delion M, Terminassian A, Lehouste T, Aubin G, Malka J, N'Guyen S, Mercier P, Menei P (2015) Specificities of Awake Craniotomy and Brain Mapping in Children for Resection of Supratentorial Tumors in the Language Area. *World neurosurgery* 84: 1645-1652 doi:10.1016/j.wneu.2015.06.073
22. Klimek M, Verbrugge SJ, Roubos S, van der Most E, Vincent AJ, Klein J (2004) Awake craniotomy for glioblastoma in a 9-year-old child. *Anaesthesia* 59: 607-609 doi:10.1111/j.1365-2044.2004.03675.x
23. Riquin E, Martin P, Duverger P, Menei P, Delion M (2017) A case of awake craniotomy surgery in an 8-year-old girl. *Child's nervous system : ChNS : official journal of the International Society for Pediatric Neurosurgery* 33: 1039-1042 doi:10.1007/s00381-017-3463-

24. Sheshadri V, Chandramouli BA (2016) Pediatric awake craniotomy for seizure focus resection with dexmedetomidine sedation-a case report. *Journal of clinical anesthesia* 32: 199-202 doi:10.1016/j.jclinane.2016.03.009
25. Soriano SG, Eldredge EA, Wang FK, Kull L, Madsen JR, Black PM, Riviello JJ, Rockoff MA (2000) The effect of propofol on intraoperative electrocorticography and cortical stimulation during awake craniotomies in children. *Paediatric anaesthesia* 10: 29-34
26. Hagberg CA, Gollas A, Berry JM (2004) The laryngeal mask airway for awake craniotomy in the pediatric patient: report of three cases. *Journal of clinical anesthesia* 16: 43-47 doi:10.1016/j.jclinane.2003.02.011
27. Ojemann G, Ojemann J, Lettich E, Berger M (1989) Cortical language localization in left, dominant hemisphere. An electrical stimulation mapping investigation in 117 patients. *Journal of neurosurgery* 71: 316-326 doi:10.3171/jns.1989.71.3.0316
28. Kombos T, Suess O, Kern BC, Funk T, Hoell T, Kopetsch O, Brock M (1999) Comparison between monopolar and bipolar electrical stimulation of the motor cortex. *Acta neurochirurgica* 141: 1295-1301
29. Duffau H (2018) Is non-awake surgery for supratentorial adult low-grade glioma treatment still feasible? *Neurosurgical review* 41: 133-139 doi:10.1007/s10143-017-0918-9
30. Pasquet A (1954) Combined regional and general anesthesia for craniotomy and cortical exploration. II. Anesthetic considerations. *Current researches in anesthesia & analgesia* 33: 156-164
31. Berger MS (1996) The impact of technical adjuncts in the surgical management of cerebral hemispheric low-grade gliomas of childhood. *Journal of neuro-oncology* 28: 129-155
32. So EL, Alwaki A (2018) A Guide for Cortical Electrical Stimulation Mapping. *Journal of clinical neurophysiology : official publication of the American Electroencephalographic Society* 35: 98-105 doi:10.1097/wnp.0000000000000435

33. Szelenyi A, Bello L, Duffau H, Fava E, Feigl GC, Galanda M, Neuloh G, Signorelli F, Sala F (2010) Intraoperative electrical stimulation in awake craniotomy: methodological aspects of current practice. *Neurosurgical focus* 28: E7 doi:10.3171/2009.12.focus09237
34. Duffau H (2005) Intraoperative cortico-subcortical stimulations in surgery of low-grade gliomas. *Expert review of neurotherapeutics* 5: 473-485 doi:10.1586/14737175.5.4.473



## 7) TABLE

**Table 1**

Summary of patient demographics, lesion/tumor location, surgical resection, histopathology and complications

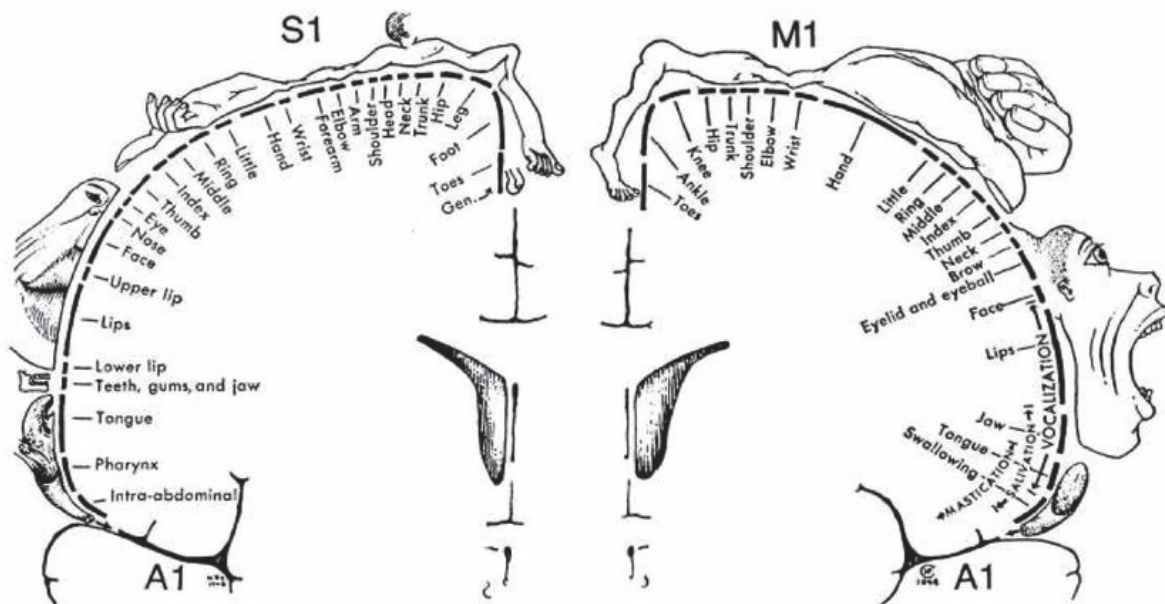
Patient	Age (years)	Sex (F/M)	Presenting Symptoms	Tumor location	Diagnostic tests pre-OP	Extent of resection	Histopathology	Complications
1	15,2	M	Seizures	Left temporo-parietal junction	EEG	GTR	ANET	None
2	16,1	F	Seizures	Left parietal	EEG, fMRI	GTR	Ganglioglioma	None
3	16,7	M	Seizures	Right precentral	EEG, fMRI	STR	Astrocytoma	None
4	14,5	F	H/A, nausea/vomiting	Left parietal	fMRI	GTR	Medulloepithelioma	None
5	15,8	F	Diplopia, nausea/vomiting	Left parietal	fMRI	STR	GBM	None
6	13	F	Seizures	Right temporo-parietal junction	EEG, fMRI	GTR	DNET	None
7	14,1	F	H/A, visual disturbances, paresthesia	Right temporo-parietal junction	fMRI	GTR	Meningeoma	None
8	11	F	Gait disturbances	Right central	fMRI	STR	GBM	None
9	15	M	Malaise	Left central	fMRI	GTR	Astrocytoma	None
10	14,8	F	H/A	Left temporo-occipital	fMRI	GTR	Astrocytoma	None
11	11,5	F	Seizures	Left parietal	EEG, fMRI	GTR	Ganglioglioma	None
12	16	M	Seizures	Right parieto-occipital	EEG, fMRI	STR	Ganglioglioma	None
13	9,9	F	Incidental finding (IRM pour depression)	Left parietal	fMRI	GTR	Ganglioglioma	Major anxiety disorder
14	17,6	F	Seizures	Left frontal	EEG, fMRI	GTR	Cavernoma	None
15	9,4	M	Partial seizures	Right frontal	EEG, fMRI	GTR	Cavernoma	Motor deficit of left upper extremity
16	17,4	F	Partial seizures	Left parietal	EEG, fMRI	STR	Asrocytoma	Expressive aphasia, abscess
17	12,1	F	Partial seizures	Left temporal	EEG, fMRI	STR	Low grade glioma	None

ANET = angiocentric neuroepithelial tumor, DNET = dysembryoblastic epithelial tumor, EEG = electroencephalogram, F = female, fMRI = functional magnetic resonance imaging, GBM = glioblastoma multiforme, GTR = gross total resection, H/A = headaches, M = male, STR = subtotal resection.

# **B) SOMATOTOPIC ORGANIZATION OF THE CEREBRAL CORTEX**

## B-1) Scientific Background

The somatotopic organization of the primary motor and sensory cortex was first described by Penfield (Penfield and Boldrey 1937). It is one of the rare "neuroscientific dogma" that withstood the test of time. This organization, designated "Penfield's homunculus" is an ordered representation of the cortical areas of the primary motor and sensory cortices that control different part of the human body. As shown in the figure 3 below, this ordered representation follows a medial-lateral organization that goes from the leg, to the arm, to the hand, to the face. During the last few decades, additional arguments supporting this view have been provided by neuroimaging and electrophysiological studies (Grafton, Woods, and Mazziotta 1993; Lotze et al. 2000; Plow et al. 2010; Hlustik et al. 2001; Alkadhi et al. 2002; Yang et al. 1993; Zeharia et al. 2012; Takanashi et al. 2003).



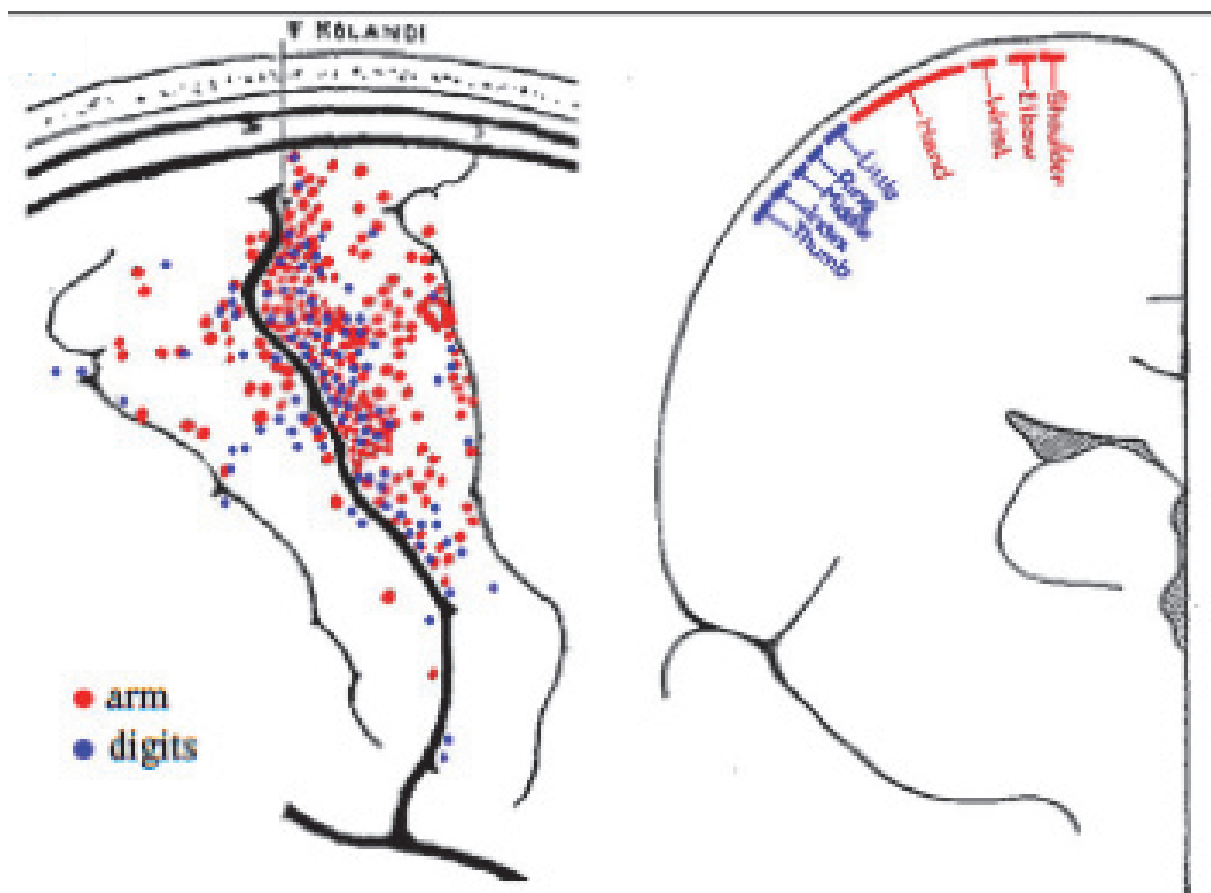
**Figure 3 :** Cortical homunculus by Wilder Graves Penfield. Adapted from Penfield and Boldrey 1937.

However, during the last decade, evidence was provided that Penfield's homunculus is not an accurate description of sensorimotor organization, or at least it cannot account for large inter-individual differences (Sanes and Schieber 2001; Branco et al. 2003; Farrell et al. 2007). Electrophysiological studies in human (Branco et al. 2003; Farrell et al. 2007; Meier et al. 2008; Sanes et al. 1995) and non-human (Gould et al. 1986; Donoghue, Leibovic, and Sanes 1992; Schieber and Hibbard 1993) primates have reported that the organization of the neural population related to different body area were strongly overlapping and intermingled. For example, Branco and colleagues showed that mouth and face representations were above finger and leg representations in many individual subjects (Branco et al. 2003).

Another debated topic related to Penfield's work, concerns the strict segregation of M1 and S1 (Matyas et al. 2010). For example, the cortical hand area (defined as the area that evoke hand movements when stimulated at the lowest DES) is detected in the post central gyrus in most subjects (Nii et al. 1996; Haseeb et al. 2007). These findings are nevertheless in contradiction with other results showing that motor responses evoked by the stimulation of S1 are rare, weak and often inhibitory (Tate et al. 2014; Widener and Cheney 1997). In monkeys, the stimulation parameters applied to M1 and S1 to evoke a motor response are different from those used in humans, with lower currents needed for M1 (Preuss, Stepniewska, and Kaas 1996; Fogassi et al. 1994). Several explanations may support this discrepancy and the fact that there is no clear segregation between M1 and S1 in some human studies. One is technical. In effect, the tools that are available now to localize the stimulation sites (i.e., the neuronavigation system) was not available at Penfield's time and he, himself, acknowledged that "the Rolandic fissure [and thus M1 and S1] can hardly be recognized" (Penfield and Boldrey 1937). Another one is surgical. In effect, the cortical areas available for stimulation in humans rarely include the intrasulcal region, which harbors a large fraction of M1 and S1. These hidden parts seem to be the most sensitive to electrical stimulation. Limiting the stimulation to the visible (gyral)

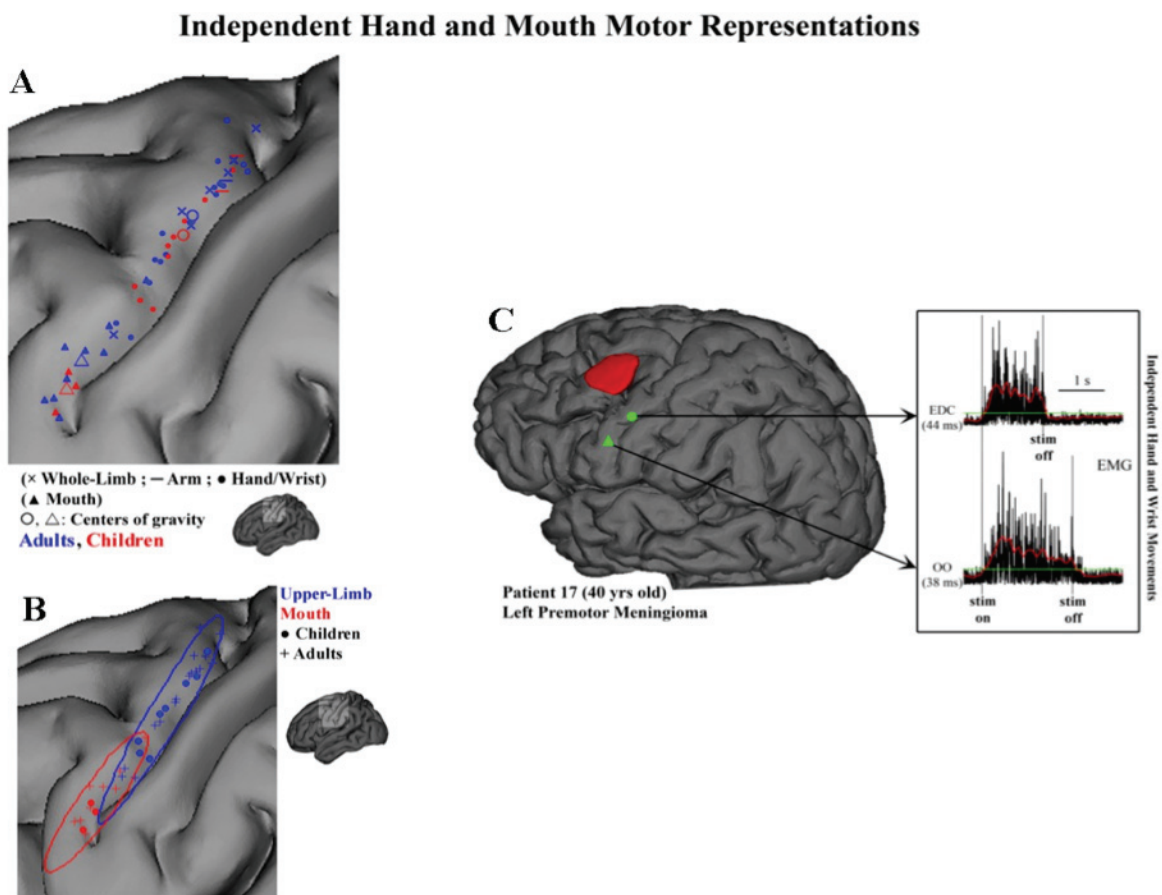
portions of M1 and S1, may explain why the hand hotspot is sometimes reported in S1 in humans.

Strikingly, the artificial nature of Penfield's homuncular model is quite easy to appreciate when we look back at the author's original data. In figure 4, the red dots correspond to upper limb responses (shoulder, elbow, wrist and hand -non differentiated by Penfield-) and the blue dots to correspond to finger responses. We can clearly see the overlap and the redundancy between all the responsive sites. This intermingling between stimulation sites is sharply in contrast with the nicely ordered map later reconstructed by Penfield.



**Figure 4 :** *Discrepancies between Penfield's nicely ordered map (right panel) and the individual responsive site (left panel). Adapted from Desmurget and Sirigu 2015*

Still, beyond these observations, both Penfield's data and more recent recordings fail to support the existence of a totally random organization of sensorimotor maps (Penfield and Boldrey 1937; Desmurget et al. 2014). Although an important degree of overlap tends to exist between segments, a clear gradient seems to emerge, which goes from the lower-limb (medial), to the upper-limb (medial-lateral) to the face (lateral). As shown in figure 5, this is true in both adults and young children.



**Figure 5 :** (A) Cortical sites evoking independent movements of the upper limb and the mouth when electrically stimulated. Upper limb responses are segmented into whole limb (shown as an ex), proximal arm (shown as a dash), and distal hand/wrist (shown as a filled circle) responses. Mouth responses are shown as triangles. Children and adult responses are shown, respectively, in red and blue. Large empty symbols indicate the centers of gravity of the sites evoking upper limb and mouth responses. Data are shown after registration of the individual

*MRI to the Montreal Neurological Institute (MNI) template. Right stimulations are reported on the left hemisphere. (B) Projection on the cortical surface of the 99% confidence ellipses computed from the sites evoking independent movements of the upper limb (blue) and mouth (red). Adult (crosses) and children (circles) responses are displayed (C) Individual example of independent movements of the wrist (extensor digitorum communis, EDC) and mouth (orbicularis oris, OO). The envelope of the rectified EMG response (red curve), the threshold for EMG onset (horizontal green line; mean EMG + 2\*SD for the 1,000 ms before stimulation onset), the stimulation onset and offset (vertical dashed lines), and the EMG latencies are shown. Stimulation sites (green symbols) and tumor (red mass) are shown on the reconstructed 3D brain of the subject. Adapted from Desmurget 2014*

To summarize, recent studies (Sanes and Schieber 2001; Branco et al. 2003; Farrell et al. 2007; Meier et al. 2008) and a re-evaluation of Penfield's results show that sensorimotor representations are not organized in a sequential rigidly ordered way, but rather in a global medial-lateral gradient going from the leg to the face. Within this gradient, intersegmental body parts overlap in multiple non-contiguous areas.

# **B-2) Paper 2: Selective inhibition of volitional hand movements after stimulation of the Dorsoposterior parietal cortex in humans**

*Published : Curr Biol. 2018 Oct 22;28(20):3303-3309.e3*

Michel Desmurget<sup>1</sup>, Nathalie Richard<sup>1</sup>, Pierre-Aurélien Beuriat<sup>1,2</sup>, Alexandru Szathmari<sup>1,2</sup>,  
Carmine Mottolese<sup>1,2</sup>, Jean-René Duhamel<sup>1</sup>, Angela Sirigu<sup>1,\*</sup>.

<sup>1</sup> Institute of Cognitive Neuroscience Marc Jeannerod & University of Lyon, CNRS / UMR  
5229,

67 Bd Pinel, 69500 Bron, France

<sup>2</sup> Department of Pediatric Neurosurgery, Hôpital Femme Mère Enfant, 59 Bd Pinel, 69500,  
Bron, France

**\*Correspondance (and lead contact for the paper): [sirigu@isc.cnrs.fr](mailto:sirigu@isc.cnrs.fr)**



## 1) HIGHLIGHTS

- The dorso-posterior parietal cortex was focally stimulated during brain surgeries
- Stimulation inhibited execution and initiation of contralateral hand movements
- Speech, ipsilateral hand movements or lower-limb movements remained unaffected
- This selectivity differs from the general inhibition evoked by frontal stimulations

## 2) eTOC Blurp

Desmurget et al. show that electrical stimulation at focal cortical sites in the dorso-posterior parietal region (DPPr) blocks the execution of volitional hand movements. This blockage is highly selective. It does not disrupt speech or movements performed with other body parts (ex: the foot). DPPr is a key element of the motor inhibition network.

## 3) SUMMARY

Inhibition is a central component of motor control. Although current models emphasize the involvement of frontal networks [1, 2] indirect evidence suggests a potential contribution of the posterior parietal cortex (PPC). This region is active during inhibition of upper-limb movements to undesired targets [3] and its stimulation with single magnetic pulses can depress motor evoked potentials [4, 5]. Also, it has been speculated that alien hand movements caused by focal parietal lesions reflect a release of inhibition from PPC to M1 [6]. Considering these observations, we instructed 16 patients undergoing awake brain surgery to perform continuous hand movements while electrical stimulation was applied over PPC. Within a restricted dorso-posterior area, we identified focal sites where stimulation prevented movement initiation and instantly inhibited ongoing responses (which restarted promptly at stimulation offset).

Inhibition was selective of the instructed response. It did not affect speech, hand movements passively generated through muscle electrical stimulation or the ability to initiate spontaneous actions with other body segments (e.g. the feet). When a patient inadvertently performed a bilateral movement, a bilateral inhibition was found. When asked to produce unilateral movements this patient presented a contralesional but not ipsilateral inhibition. This selectivity contrast sharply with the unspecific inhibitions reported by previous studies within frontal regions where speech and all limbs are typically affected (as we here confirm in a subset of patients) [7-10]. These results provide direct evidence that a specific area in the dorso-posterior parietal cortex can inhibit volitional upper-limb responses with high selectivity.

#### **4) RESULTS**

##### **a) Evoking motor inhibition by stimulating the dorsoposterior parietal cortex**

In 16 patients (Table S1), we stimulated 114 sites homogeneously distributed over PPC (Figure S1). At rest, none of these sites evoked motor responses. Conscious sensorimotor perceptions (ex: tingling, illusions of movements, etc.) were identified at 14 sites (Figure S1). These observations are consistent with previous reports [11-13].

In 10 patients, in the dorso-posterior parietal region (DPPr), around the convexity of the intraparietal sulcus (Figure 1), functional mapping identified 12 sites where stimulation produced insuperable motor inhibitions (Table S2). At these sites, stimulation prevented the patients from initiating hand movement when at rest. When stimulation was applied during movement execution, the ongoing response was interrupted (Figure 2A; Videos S1 & S2). Motor inhibition was prompt and time-locked with the stimulation (Figures 2A-D). Time of EMG cessation was estimated, for each arrest trial ( $n = 12$ ), as the latency with which EMG signal fell within  $3*SD$  of mean rest activity (see Methods). It occurred, on average,  $126 (\pm 30)$

ms after stimulation onset. Likewise, motor release was estimated from the latency with which EMG signal rose above  $3 \times \text{SD}$  of mean rest activity ( $n = 12$ ). It occurred  $142 (\pm 33)$  ms after stimulation ending.

Stimulation affected selectively the contralateral hand (Figure 2B). While this hand was blocked, the patients remained able to talk (Video S1) or initiate spontaneous movements of the ipsilateral hand or the feet (figure 2C). Strikingly, though, one patient inadvertently performed the task with the two hands (figure 2D). In this case stimulation had a bilateral effect and both hands were blocked. This blockage was still observed when the patient was instructed to perform the task with the contralesional (left non-dominant) hand only. However, it disappeared and stimulation had no effect, when the patient was asked to use the ipsilesional (right dominant) hand only. This observation clearly shows that stimulation inhibited selectively task-related muscles.

Although motor inhibition was easily identified visually during per-operative evaluation (Videos S1 & S2), we conducted off-line analyses to quantitatively estimate the magnitude of EMG reduction at inhibition sites. For each trial, we computed the root mean square amplitude of the electromyogram (RMSE) of the *flexor carpi radialis* muscle across 10 time bins covering the pre and post-stimulation phases (Figure 3). Friedman's Anova (FA) was then used to evaluate mean changes in RMSE signals across bins. For the contralesional hand ( $n = 12$ ), cortical stimulation caused RMSE to significantly drop (FA;  $X^2_9 > 71$ ,  $p < 7 \times 10^{-12}$ ). For the ipsilesional hand ( $n = 8$ ), no effect was found (FA,  $X^2_9 < 4.5$ ,  $p > .90$ ).

To avoid ambiguity, it may be worth noting that our inability to identify inhibition responses in 6 patients (37.5 %) can be explained by the clinical context of our study. Indeed, in each region of interest (here DPPr), per-operative mapping only evaluates a subset of clinically relevant points and eloquent sites can easily be "missed". For instance, in well-identified frontal language regions, mapping fails to identify language related response in

almost 40 % of the patients [14]. To further address this issue, we performed a Monte Carlo simulation. As detailed in the Method section, we took into account, the proportion of eloquent inhibition sites in DPPr (from 25 % -inferred from our data- to 50 % -artificially high-) and the number of stimulations performed for each subject within this region (from 0 to 7). When the rate for eloquent sites was 25 %, the 95 % confidence interval of the simulated distribution ranged from 3.9 to 10.7 "silent" subjects. When the rate for eloquent sites was 50 % it ranged from 1.0 to 6.2 subjects. In other words, clinical subsampling fully accounts for our inability to find inhibition sites in 6 subjects.

#### **b) Functional properties of parietal inhibition sites**

When cortical stimulation was delivered either at rest or while hand muscles were passively contracted through peripheral electrical stimulation, parietal inhibition sites were totally silent (Table S2). They failed to evoke muscle contractions or any sort conscious feelings (sensory perceptions, intentions to move, etc.; supplemental Video S1).

During motor inhibition, all patients were fully aware of their inability to move. Typical verbatim were as follows: "I cannot do it, it's hard" or "I cannot move anymore" (Video S1). When prompted to describe how they felt after the stimulation, the patients reported that they felt the blockage, and they could not move, no matter how hard they tried.

Following motor testing, as part of the clinical procedure, sensory inputs were mapped with cortical surface electrodes, in response to electrically-triggered movements of the face and contralateral limb muscles (Table S2). Most inhibition sites (10/12; 83 %) received statistically significant sensory inputs from hand muscles (figure 2A-D). None of these sites received significant afferent inputs from the face or the lower limb. Mean latency of the hand-evoked sensory signals for the 10 inhibition sites receiving significant inputs was 51 ( $\pm$  13) ms (for each site, latency was defined as the onset of the first 10 ms epoch that rose above 3\*SD of the

rest baseline signal; see Methods). The origin of these inputs cannot be determined from the present study. However, an indirect pathway, involving the primary somatosensory cortex (S1) seems likely in light of existing evidence that latencies of neural responses are typically shorter in S1 (< 30 ms [15, 16]) and that posterior parietal sensory potentials are abolished following S1 excision [17, 18].

### **c) Evoking motor inhibition by stimulating precentral areas**

Motor blockages have already been reported in past studies following frontal stimulations (for a review [1]). Consistently, these blockages have been shown to have a broad unspecific inhibitory influence on sensorimotor systems (see discussion). To illustrate this point, we report 5 observations of precentral blockages obtained in 4 patients (Tables S1 and S3), in the dorsal part of the precentral gyrus and the posterior part of the superior frontal gyrus (Figure 1), using the same procedures as the ones described above for parietal mapping. For all these sites a general, unspecific inhibition of motor activity was observed. In contrast to parietal sites, frontal sites did not selectively inhibit contralateral hand movements. They also disrupted speech and ipsilateral hand movements (Figure 4, Table S3, Video S3). For contralateral hand movements ( $n = 5$ ), latencies between stimulation onset and EMG cessation (estimated from the latency with which EMG signal fell within  $3 \times SD$  of mean rest activity; see Methods) were strikingly longer than latencies identified for parietal sites ( $546 (\pm 347)$  ms-; Mann Whitney U-test,  $z = 3.2$ ,  $p < .0005$ ) (Video S3). Finally, no somatosensory inputs were recorded at the frontal inhibition sites.

Group analyses, similar to the ones performed for parietal patients, confirmed these observations (Figure 3). Cortical stimulation caused the mean RMSE of the *flexor carpi radialis* to significantly drop, for both the ipsi ( $n = 5$ ) and contralesional ( $n = 5$ ) hands (FA;  $X^2_9 > 22$ ,  $ps < .0.01$ ).

## 5) DISCUSSION

To summarize, our results indicate that electrical stimulation at focal sites in the dorso-posterior part of the parietal cortex (a region here designated DPPr) prevents movement initiation and instantly blocks ongoing responses. Anatomically, DPPr might be the homologue of the medial intraparietal area (MIP) in macaque or more generally of the so-called the parietal reach region (PRR) [19-21]. Inhibition sites within this region do not trigger movement or conscious sensations when stimulated at rest. However, they receive direct somatosensory inputs from hand muscles. Several hypotheses can be put forward to account for these findings.

First, it could be that electrical stimulation blocks the descending motor output. This could occur, for instance, through the recruitment of the spinal inhibitory circuitry via direct corticospinal projections. Recently, such projections have been identified for hand muscles, in the monkey, within the lateral part of area 5 [22]. However, it is highly unlikely that this pathway mediates the motor inhibitions observed in the present study. Indeed, this hypothesis cannot explain our observation, in one patient, that the hand ipsilateral to the stimulation site can be blocked in the context of a bilateral coordinated response while remaining unaffected in the context of a unilateral response (see below). Also, it is not consistent with functional data showing that this parietal descending pathway does not block muscle contractions but evoke motor responses when stimulated, even at low intensities [22]. Our parietal inhibition sites did not evoke such motor responses. In fact, no parietal stimulation site did, in agreement with previous large-scale clinical studies which also failed to identify muscle contractions following stimulation of PPC in humans, even at high intensities [11-13]. This result contradicts the accumulating evidence that long-trains of microstimulation in anterior PPC can evoke complex arm, hand, and face movements in non-human primates [23, 24]. Although the origin of this discrepancy remains unclear, it may reflect differences in stimulation parameters between

humans and monkeys and/or the inability of surface stimulation to reach the depth of the intraparietal sulcus where motor parietal zones could be buried [22, 23, 25, 26].

Another hypothesis could be that the blockage of the motor output occurs through remote recruitments, in particular, those directed at the well-known frontal inhibitory regions [1]. This possibility, is unlikely. Indeed, the motor blockages identified to date, in frontal regions, are strikingly different from the motor blockages we observed in DPPr. Typically, as confirmed by the illustrative examples provided in the present study, frontal inhibition sites have a broad unspecific influence on sensorimotor systems. In their seminal paper Luders et al. indicated that electrically-evoked motor blockages in precentral areas always involve a combined disruption of body movements (often bilaterally) and speech [7]. Likewise, Chassagon et al. showed, for the frontal medial wall, that hand motor inhibitions occur together with speech disruption in 80 % of the cases [9]. Similar observations were reported for the supplementary motor area (SMA) [8] and the primary motor cortex (M1) [10]. This lack of specificity contrasts sharply with our observation, in DPPr, that only the instructed hand movement was disrupted. In response to electrical stimulation, speech was never perturbed and, for unilateral movements, only the contralateral hand was affected. Interestingly, in one instance where the patient inadvertently performed a coordinated movement of both hands, stimulation evoked a bilateral blockage. When this patient was then asked to use his contra and ipsilateral hands alone, for confirmation, only the former was blocked. A global inhibition involving remote precentral structures, through blind current spread, cannot account for these results.

From a functional point of view, selective inhibition is a necessary element of efficient motor control. For instance, its existence is critical for: (i) freezing the motor plant during action planning (i.e. for avoiding early movement release); (ii) preventing residual uncontrolled muscle activity when the motor-goal has been reached; or (iii) impeding the release of

irrelevant movements toward environmental distractors. The parietal inhibition sites identified in the present study can subserve these functions. In agreement with this claim, anatomical studies, in monkeys, have identified direct and indirect (via the premotor regions in particular) projections from DPPr to M1 areas controlling hand/arm movements [25, 27, 28]. Also, neuroimaging experiments have identified increased neural activity in the dorso-posterior parietal cortex (at MNI coordinates close to the ones found here; Figure 1) during sustained inhibition of finger movements toward undesired target [3]. In the same vein, dual-TMS protocols have revealed that a conditioning magnetic pulse delivered over the anterior part of DPPr can depress motor evoked potentials triggered, in the first dorsal interosseous, by a test pulse delivered over the ipsilateral M1 [4, 5]. Finally, and most importantly, clinical observations have shown that focal parietal injuries encompassing DPPr can cause a rare clinical condition where the hand of the patient moves "alone" outside his/her conscious will [6, 29-31]. In one subject with a selective lesion of the superior parietal lobe, these alien movements have been reported to reflect uncontrolled neural activity within M1. It was suggested that this activity was inhibited by parietal control signals in healthy subjects [6]. The fact that most parietal inhibition sites described in the present study (10/12) receive detectable short-latency sensory inputs (around 50 ms) might be relevant to this point. Indeed, this finding suggests that the efficiency of parietal inhibition could rely on an internal sensory-to-motor feedback-loop. According to this view, sensory inputs would be the entry signal of a closed-circuit allowing, with minimal delay, to reinforce the inhibitory output from DPPr to M1 when an unwanted muscle response is detected. Recently, indirect evidence has been provided in monkeys showing that long cortical connections between different functional zones in PPC can activate inhibitory neurons to block competing movements [25]. It is tempting to speculate that a similar organization can account for the ability of DPPr to inhibit motor activity in precentral



motor regions. However, there is an alternative view to this appealing hypothesis. It originates in the known contribution of DPPr to basic motor control.

During the last two decades, converging evidence have been provided that the dorso-posterior part of PPC, around the intraparietal sulcus, continuously monitor movement execution [26, 32-34]. Computationally, this process is assumed to take the form of a real-time controller that steadily modulates neural activity in primary motor regions with the aim of progressively nullifying the "motor error" [35-38]; a parameter that is defined as the difference between the goal of the movement and the ongoing state of the motor plant. Because of transmission delays, the latter is thought to be estimated through a forward model integrating motor outflows and sensory inputs [36-39]. When the motor error reaches zero, the movement stops. Within this framework, motor inhibition could be a consequence of disrupting neural computations in DPPr. According to this view, electrical stimulation would prevent the transmission of the real-time error-signal that drives motor activity in primary motor regions (or would cause these regions to interpret the disorganized upcoming signal as a null-error signal). As a consequence, the ongoing movement would promptly stop. Under natural conditions, this mechanism might represent a very parsimonious and efficient strategy to achieve selective motor inhibition. Unfortunately, based on our clinical data, it is not possible to determine the respective validity of this hypothesis and the previously evoked possibility that movement inhibition relies on a dedicated circuit.

To sum up, our results indicate that electrical stimulation at focal sites within a restricted area of the dorso-posterior parietal cortex, inhibits volitional upper-limb motor responses with high selectivity. Identification of this inhibitory process is of primary importance to understand how intended actions are suppressed either at the preparation stage or following movement completion. Also, our data shed light on the etiology of alien hand movements evoked, in some patients, after focal parietal lesions.

### **Acknowledgments**

We are grateful to CNRS for their support to this research. This work was also supported by the Agence Nationale de la Recherche (ANR-12-BSV4-0018-01; ANR-16-CE37-0017-01) and by the LABEX CORTEX (ANR-11-LABX-0042) of Université de Lyon, within the ANR program "Investissements d'Avenir" (ANR-11-IDEX-0007). We thank the patients for accepting to participate in this study and the clinical staff for help during cortical mapping.

### **Declaration of Interests**

The authors declare no competing interests.

## REFERENCES

1. Filevich, E., Kuhn, S., and Haggard, P. (2012). Negative motor phenomena in cortical stimulation: implications for inhibitory control of human action. *Cortex* 48, 1251-1261.
2. Aron, A.R., Robbins, T.W., and Poldrack, R.A. (2014). Inhibition and the right inferior frontal cortex: one decade on. *Trends Cogn. Sci.* 18, 177-185.
3. Lindner, A., Iyer, A., Kagan, I., and Andersen, R.A. (2010). Human posterior parietal cortex plans where to reach and what to avoid. *J. Neurosci.* 30, 11715-11725.
4. Koch, G., Fernandez Del Olmo, M., Cheeran, B., Ruge, D., Schippling, S., Caltagirone, C., and Rothwell, J.C. (2007). Focal stimulation of the posterior parietal cortex increases the excitability of the ipsilateral motor cortex. *J. Neurosci.* 27, 6815-6822.
5. Mackenzie, T.N., Bailey, A.Z., Mi, P.Y., Tsang, P., Jones, C.B., and Nelson, A.J. (2016). Human area 5 modulates corticospinal output during movement preparation. *Neuroreport* 27, 1056-1060.
6. Assal, F., Schwartz, S., and Vuilleumier, P. (2007). Moving with or without will: functional neural correlates of alien hand syndrome. *Ann. Neurol.* 62, 301-306.
7. Luders, H.O., Lesser, R.P., Dinner, D.S., Morris, H.H., Wyllie, E., Godoy, J., and Hahn, J.H. (1992). A negative motor response elicited by electrical stimulation of the human frontal cortex. *Adv. Neurol.* 57, 149-157.
8. Chauvel, P.Y., Rey, M., Buser, P., and Bancaud, J. (1996). What stimulation of the supplementary motor area in humans tells about its functional organization. *Adv. Neurol.* 70, 199-209.
9. Chassagnon, S., Minotti, L., Kremer, S., Hoffmann, D., and Kahane, P. (2008). Somatosensory, motor, and reaching/grasping responses to direct electrical stimulation of the human cingulate motor areas. *J. Neurosurg.* 109, 593-604.

10. Nii, Y., Uematsu, S., Lesser, R.P., and Gordon, B. (1996). Does the central sulcus divide motor and sensory functions? Cortical mapping of human hand areas as revealed by electrical stimulation through subdural grid electrodes. *Neurology* 46, 360-367.
11. Penfield, W., and Boldrey, E. (1937). Somatic motor and sensory representation in the cerebral cortex of man as studied by electrical stimulation. *Brain* 60, 389-443.
12. Tate, M.C., Herbet, G., Moritz-Gasser, S., Tate, J.E., and Duffau, H. (2014). Probabilistic map of critical functional regions of the human cerebral cortex: Broca's area revisited. *Brain* 137, 2773-2782.
13. Desmurget, M., Reilly, K.T., Richard, N., Szathmari, A., Mottolese, C., and Sirigu, A. (2009). Movement intention after parietal cortex stimulation in humans. *Science* 324, 811-813.
14. Sanai, N., Mirzadeh, Z., and Berger, M.S. (2008). Functional outcome after language mapping for glioma resection. *N. Engl. J. Med.* 358, 18-27.
15. Forss, N., Hari, R., Salmelin, R., Ahonen, A., Hamalainen, M., Kajola, M., Knuutila, J., and Simola, J. (1994). Activation of the human posterior parietal cortex by median nerve stimulation. *Exp. Brain Res.* 99, 309-315.
16. Mauguiere, F., Merlet, I., Forss, N., Vanni, S., Jousmaki, V., Adeleine, P., and Hari, R. (1997). Activation of a distributed somatosensory cortical network in the human brain. A dipole modelling study of magnetic fields evoked by median nerve stimulation. Part I: Location and activation timing of SEF sources. *Electroencephalogr Clin. Neurophysiol.* 104, 281-289.
17. Allison, T., McCarthy, G., Wood, C.C., and Jones, S.J. (1991). Potentials evoked in human and monkey cerebral cortex by stimulation of the median nerve. A review of scalp and intracranial recordings. *Brain* 114 (Pt 6), 2465-2503.

18. Allison, T., Wood, C.C., McCarthy, G., and Spencer, D.D. (1991). Cortical somatosensory evoked potentials. II. Effects of excision of somatosensory or motor cortex in humans and monkeys. *J. Neurophysiol.* *66*, 64-82.
19. Grefkes, C., and Fink, G.R. (2005). The functional organization of the intraparietal sulcus in humans and monkeys. *J. Anat.* *207*, 3-17.
20. Vesia, M., and Crawford, J.D. (2012). Specialization of reach function in human posterior parietal cortex. *Exp. Brain Res.* *221*, 1-18.
21. Konen, C.S., Mruczek, R.E., Montoya, J.L., and Kastner, S. (2013). Functional organization of human posterior parietal cortex: grasping- and reaching-related activations relative to topographically organized cortex. *J. Neurophysiol.* *109*, 2897-2908.
22. Rathelot, J.A., Dum, R.P., and Strick, P.L. (2017). Posterior parietal cortex contains a command apparatus for hand movements. *Proc. Natl. Acad. Sci. U S A* *114*, 4255-4260.
23. Cooke, D.F., Taylor, C.S., Moore, T., and Graziano, M.S. (2003). Complex movements evoked by microstimulation of the ventral intraparietal area. *Proc. Natl. Acad. Sci. U S A* *100*, 6163-6168.
24. Gharbawie, O.A., Stepniewska, I., and Kaas, J.H. (2011). Cortical connections of functional zones in posterior parietal cortex and frontal cortex motor regions in new world monkeys. *Cereb. Cortex* *21*, 1981-2002.
25. Kaas, J.H., and Stepniewska, I. (2016). Evolution of posterior parietal cortex and parietal-frontal networks for specific actions in primates. *J. Comp. Neurol.* *524*, 595-608.
26. Andersen, R.A., Andersen, K.N., Hwang, E.J., and Hauschild, M. (2014). Optic ataxia: from Balint's syndrome to the parietal reach region. *Neuron* *81*, 967-983.
27. Borra, E., and Luppino, G. (2017). Functional anatomy of the macaque temporo-parieto-frontal connectivity. *Cortex* *97*, 306-326.

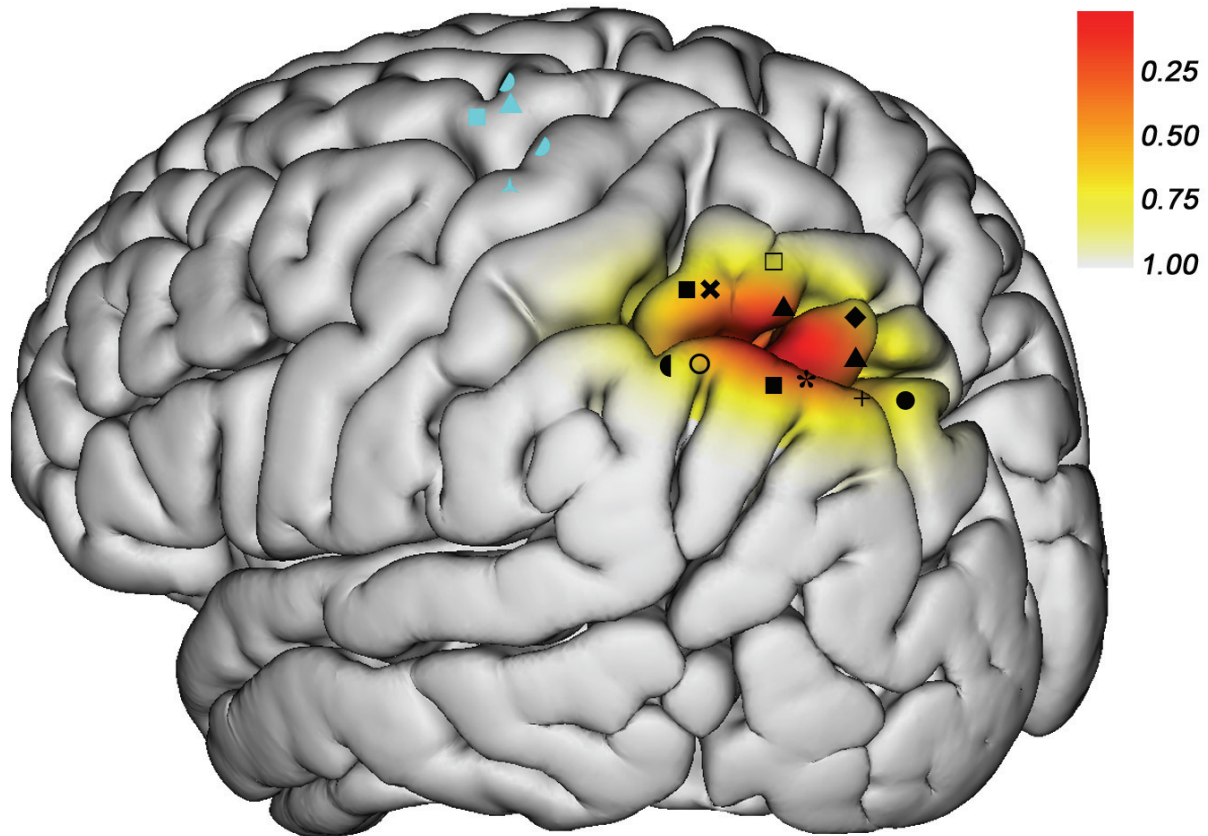
28. Rizzolatti, G., Luppino, G., and Matelli, M. (1998). The organization of the cortical motor system: new concepts. *Electroencephalogr. Clin. Neurophysiol.* *106*, 283-296.
29. Kessler, J., and Hathout, G. (2009). Dominant posterior-variant alien hand syndrome after acute left parietal infarction. *Clin. Neurol. Neurosurg.* *111*, 633-635.
30. Kim, Y.D., Lee, E.S., Lee, K.S., and Kim, J.S. (2010). Callosal alien hand sign following a right parietal lobe infarction. *J. Clin. Neurosci.* *17*, 796-797.
31. Kloesel, B., Czarnecki, K., Muir, J.J., and Keller, A.S. (2010). Sequelae of a left-sided parietal stroke: posterior alien hand syndrome. *Neurocase* *16*, 488-493.
32. Desmurget, M., Epstein, C.M., Turner, R.S., Prablanc, C., Alexander, G.E., and Grafton, S.T. (1999). Role of the posterior parietal cortex in updating reaching movements to a visual target. *Nat. Neurosci.* *2*, 563-567.
33. Tunik, E., Frey, S.H., and Grafton, S.T. (2005). Virtual lesions of the anterior intraparietal area disrupt goal-dependent on-line adjustments of grasp. *Nat. Neurosci.* *8*, 505-511.
34. Mulliken, G.H., Musallam, S., and Andersen, R.A. (2008). Forward estimation of movement state in posterior parietal cortex. *Proc. Natl. Acad. Sci. U S A* *105*, 8170-8177.
35. Desmurget, M., and Grafton, S.T. (2000). Forward modeling allows feedback control for fast reaching movements. *Trends Cogn. Sci.* *4*, 423-431.
36. Todorov, E. (2004). Optimality principles in sensorimotor control. *Nat Neurosci* *7*, 907-915.
37. Guigon, E., Baraduc, P., and Desmurget, M. (2007). Computational motor control: redundancy and invariance. *J. Neurophysiol.* *97*, 331-347.
38. Diedrichsen, J., Shadmehr, R., and Ivry, R.B. (2010). The coordination of movement: optimal feedback control and beyond. *Trends Cogn. Sci.* *14*, 31-39.

39. Wolpert, D.M., Ghahramani, Z., and Jordan, M.I. (1995). An internal model for sensorimotor integration. *Science* 269, 1880-1882.
40. Berger, M.S., and Ojemann, G.A. (1992). Intraoperative brain mapping techniques in neuro-oncology. *Stereotact. Funct. Neurosurg.* 58, 153-161.
41. Desmurget, M., Richard, N., Harquel, S., Baraduc, P., Szathmari, A., Mottolese, C., and Sirigu, A. (2014). Neural representations of ethologically relevant hand/mouth synergies in the human precentral gyrus. *Proc. Natl. Acad. Sci. U S A* 111, 5718-5722.
42. Sanai, N., and Berger, M.S. (2010). Intraoperative stimulation techniques for functional pathway preservation and glioma resection. *Neurosurg. Focus* 28, E1.
43. Chang, E.F., Clark, A., Smith, J.S., Polley, M.Y., Chang, S.M., Barbaro, N.M., Parsa, A.T., McDermott, M.W., and Berger, M.S. (2011). Functional mapping-guided resection of low-grade gliomas in eloquent areas of the brain: improvement of long-term survival. *J. Neurosurg.* 114, 566-573.
44. Berger, M.S., and Rostomily, R.C. (1997). Low grade gliomas: functional mapping resection strategies, extent of resection, and outcome. *J. Neurooncol.* 34, 85-101.
45. Sala, F., Manganotti, P., Grossauer, S., Tramontanto, V., Mazza, C., and Gerosa, M. (2010). Intraoperative neurophysiology of the motor system in children: a tailored approach. *Childs Nerv. Syst.* 26, 473-490.
46. Mottolese, C., Szathmari, A., Beuriat, P.A., Sirigu, A., and Desmurget, M. (2015). Sensorimotor mapping of the human cerebellum during pineal region surgery. *Neurochirurgie* 61, 101-105.
47. Bickel, C.S., Gregory, C.M., and Dean, J.C. (2011). Motor unit recruitment during neuromuscular electrical stimulation: a critical appraisal. *Eur. J. Appl. Physiol.* 111, 2399-2407.

48. Niddam, D.M., Chen, L.F., Wu, Y.T., and Hsieh, J.C. (2005). Spatiotemporal brain dynamics in response to muscle stimulation. *Neuroimage* 25, 942-951.
49. Niddam, D.M., Yeh, T.C., Wu, Y.T., Lee, P.L., Ho, L.T., Arendt-Nielsen, L., Chen, A.C., and Hsieh, J.C. (2002). Event-related functional MRI study on central representation of acute muscle pain induced by electrical stimulation. *Neuroimage* 17, 1437-1450.
50. Ripolles, P., Marco-Pallares, J., de Diego-Balaguer, R., Miro, J., Falip, M., Juncadella, M., Rubio, F., and Rodriguez-Fornells, A. (2012). Analysis of automated methods for spatial normalization of lesioned brains. *Neuroimage* 60, 1296-1306.
51. Eickhoff, S.B., Stephan, K.E., Mohlberg, H., Grefkes, C., Fink, G.R., Amunts, K., and Zilles, K. (2005). A new SPM toolbox for combining probabilistic cytoarchitectonic maps and functional imaging data. *Neuroimage* 25, 1325-1335.
52. Klein, A., and Tourville, J. (2012). 101 labeled brain images and a consistent human cortical labeling protocol. *Front. Neurosci.* 6, 171.
53. Mottolese, C., Richard, N., Harquel, S., Szathmari, A., Sirigu, A., and Desmurget, M. (2013). Mapping motor representations in the human cerebellum. *Brain* 136, 330-342.
54. Clancy, E.A., Bouchard, S., and Rancourt, D. (2001). Estimation and application of EMG amplitude during dynamic contractions. *IEEE Eng. Med. Biol. Mag.* 20, 47-54.
55. Blair, R.C., and Karniski, W. (1993). An alternative method for significance testing of waveform difference potentials. *Psychophysiology* 30, 518-524.
56. Carota, F., Posada, A., Harquel, S., Delpuech, C., Bertrand, O., and Sirigu, A. (2010). Neural dynamics of the intention to speak. *Cereb. Cortex* 20, 1891-1897.
57. Good, P.I. (2000). *Permutation tests: a practical guide to resampling methods for testing hypotheses*, Second Edition (Berlin: Springer-Verlag).
58. Johnson, R.A., and Wichern, D.W. (1982). *Applied multivariate statistical analysis*, Second Edition (Englewood Cliffs, New Jersey: Prentice Hall).

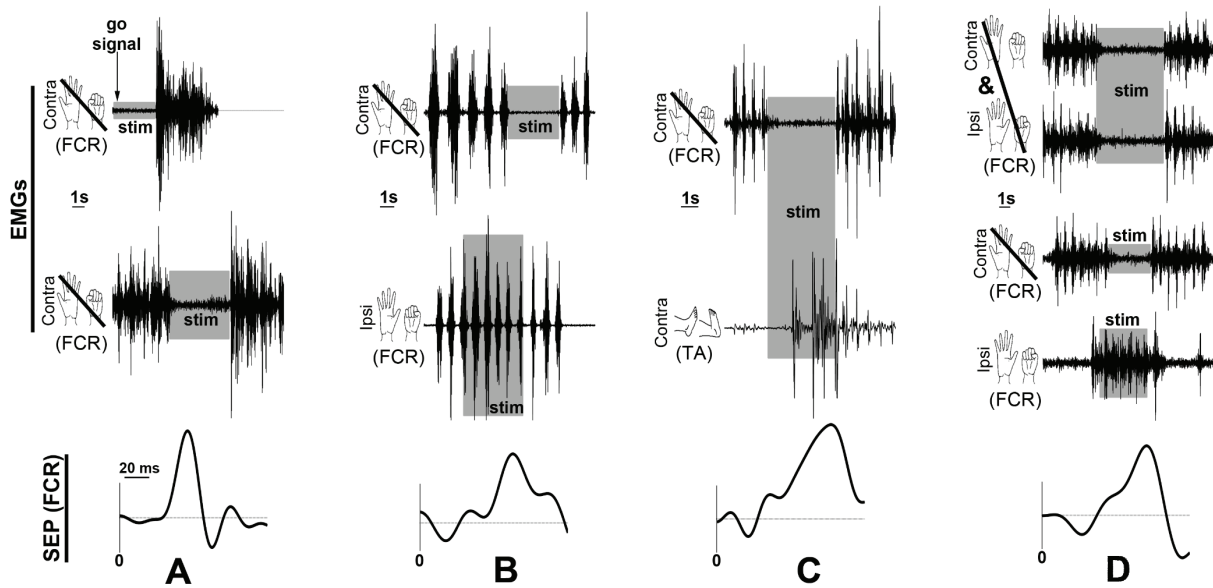


## 7) FIGURES AND VIDEOS



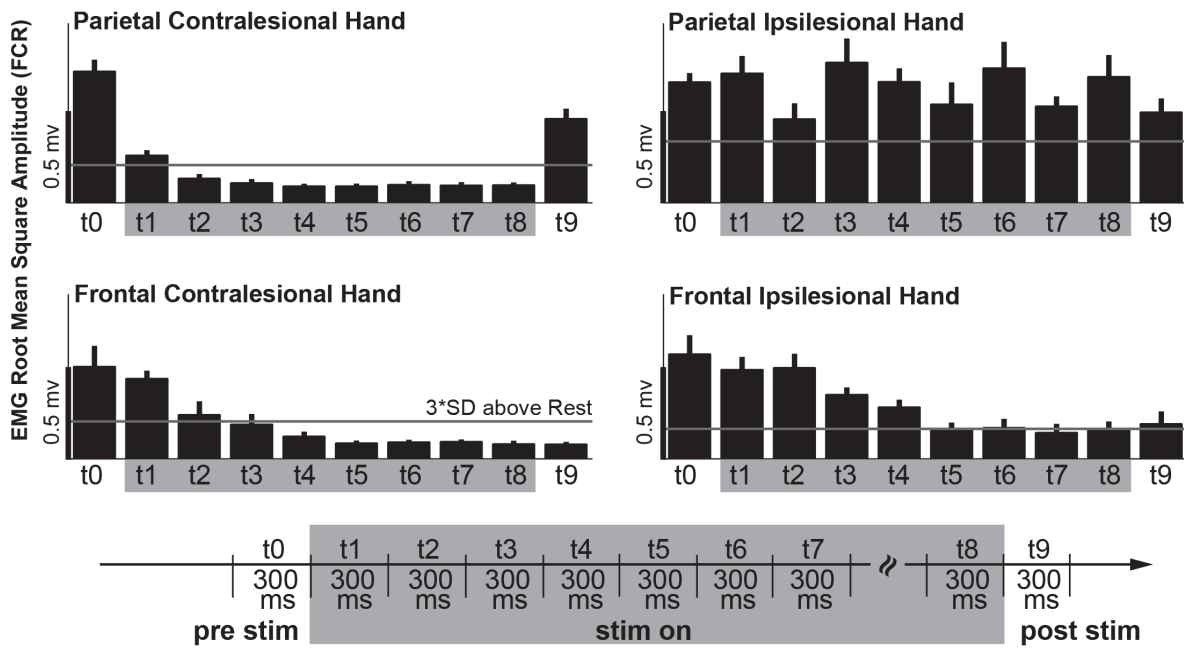
**Figure 1. Anatomical distribution of inhibition sites.**

Parietal (black symbols; mean MNI coordinates: -37.9 -64.4 59.3) and frontal (blue symbols; mean MNI coordinates: -28.4 -6.5 -73.3) inhibition sites (one symbol per patient; duplicates - e.g. ▶- show different observations for the same patient). The color map shows confidence ellipsoids plotted over the cortical surface from the parietal inhibition sites. The yellow border displays 95% confidence ellipsoid. See also Figure S1 and Videos S1 to S3



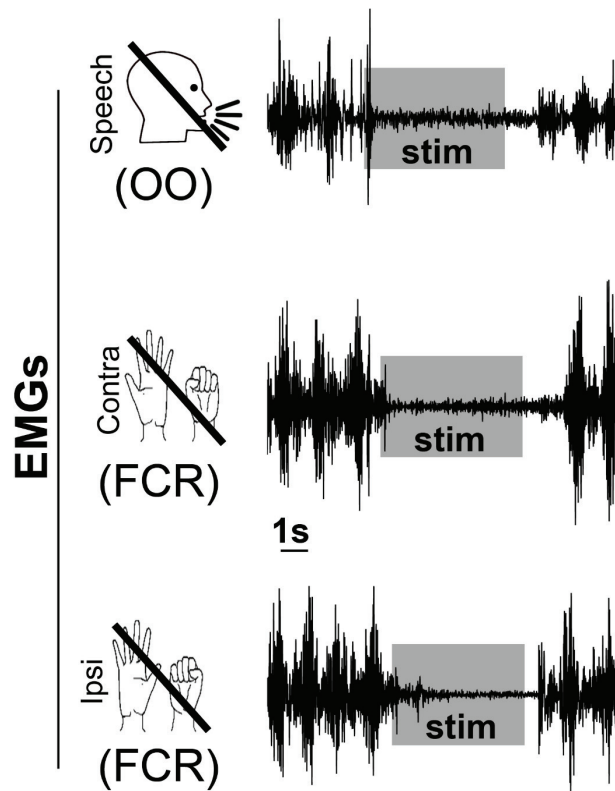
**Figure 2. Illustration of the motor and sensory properties of parietal inhibition sites**

Electromyographic signals (EMGs) recorded in four subjects while stimulating (stim, grey rectangles) parietal inhibition sites and mean somatosensory evoked potentials recorded from these sites (SEP; 200 trials per curve). Each column shows data for a different subject and cortical site (in figure 1A: A, black circle; B, upper black square; C, empty circle; D, empty square). *Flexor Carpi Radialis* (FCR); *Tibialis Anterior* (TA). See also Figure S2, Tables S2 and Videos S1-S2.



**Figure 3. Mean EMG variations across time for both hands (ipsi and contralateral) and both stimulation areas (parietal and frontal).**

Bar graphs show the average EMG root mean square amplitude of the *Flexor Carpi Radialis* muscle (FCR), across different time bins. Data are shown for both hands (contra and ipsilesional) and both patient populations (parietal and frontal). Vertical lines represent standard errors. The horizontal grey line, on each graph, represents 3 standard deviations (SD) above the rest root mean square amplitude (see Methods). The bottom part of the figure provides a schematic representation of the different time bins. Grey rectangles display the stimulation period. See also Tables S2-S3 and Videos S1 to S3.



**Figure 4. Illustration of the motor properties of frontal inhibition sites**

Electromyographic signals (EMGs) recorded in one subject while stimulating (stim, grey rectangles) a frontal inhibition site (blue triangle in figure 1). *Flexor Carpi Radialis* (FCR); *Orbicularis Oris* (OO). See also Figure S2, Table S3 and Video S3

Videos can be found with this article online at <https://doi.org/10.1016/j.cub.2018.08.027>

**Video S1, Parietal stimulation. Related to Figures 1, 2 and 3.**

This video shows that: (1) when the patient is continuously moving her hand, electrical stimulation instantly blocks the movement which restarts promptly at stimulation offset; (2) the patient remains able to talk during motor blockage; (3) when the patient is at rest electrical stimulation of the blockage site triggers no movement or sensation.

**Video S2, Parietal stimulation. Related to Figures 1, 2 and 3.**

This video shows that: (1) when the patient is at rest, electrical stimulation prevents hand movement initiation; (2) electrical stimulation of the hand inhibition site does not affect passive hand movements triggered through muscle stimulation; (3) electrical stimulation of the hand inhibition site does not affect speech.

**Video S3, Frontal stimulation. Related to Figures 1, 3 and 4.**

This video shows that electrical stimulation blocks both speech and hand movements, with a long latency.

## 8) STAR METHODS

### CONTACT FOR REAGENT AND RESOURCE SHARING

Further information and requests for resources should be directed to and will be fulfilled by the Lead Contact, Angela Sirigu (sirigu@isc.cnrs.fr)

### EXPERIMENTAL MODEL AND SUBJECT DETAILS

Clinical data were collected per-operatively during surgeries for tumor removal, in 20 patients operated under local anesthesia (see Table S1). 16 of these patients required parietal mapping and 4 required frontal mapping. The clinical protocol was approved by the local ethics committee (CPP, Lyon Sud-Est IV, Centre Léon Berard, Lyon; N°DGS2007-0161) and sponsored by CNRS. Prior surgery, patients (or the parents for the minor children) were informed by the senior neurosurgeon about the surgical and stimulation procedures and gave a formal consent.

### METHOD DETAILS

Per-operative tests used standard procedures [40, 41] and were performed with the goal of minimizing the risk of post-operative sequelae [42, 43]. Sensorimotor and language functions were evaluated using direct electrical stimulation (DES) and somatosensory evoked potential (SEP). Only the outcomes of sensorimotor evaluations are considered in this report.

***Motor evoked potentials (MEP).*** MEP were investigated using standard, well-defined, procedures [41, 44, 45]. Electrical stimulation was delivered through a bipolar electrode placed on the cortical surface. The probe was made out of 2 spherical steel tips located 5 mm apart. A constant voltage stimulator (Nimbus Cortical Stimulator, Newmedic) was used to produce a train of low-frequency biphasic pulses (pulse frequency 60 Hz, single-pulse phase duration 1 ms, amplitude 2 to 8 mA). The duration of the stimulation varied from 2 to 5 seconds. Initial

stimulus intensity was set to 2 mA and was then increased to 4 mA and 8 mA. If no motor response was observed at the highest intensity, the site was classified as "silent" (or non-responsive).

**Motor control sites (MCS).** MCS were characterized as sites which stimulation (i) did not evoke MEP at rest; but (ii) disrupted an ongoing movement. To identify these sites the patients were requested to perform continuous open-close hand movements ( $\approx 1$  Hz). Electrical stimulation was delivered using standard parameters (see above) just before the patients were instructed to start their movements or during movement execution. Patients were briefly trained to perform this open-close task the day before surgery.

**Electromyography (EMG).** During the pre-operative phase of the surgery, the patients were prepared for EMG recordings. Disposable surface Ag/AgCl electrodes (Viasys) were placed bilaterally on the face (*orbicularis oris*) upper limb (*biceps*, *triceps*, *extensor digitorum communis*, *flexor carpi radialis*, *thenar eminence*, *hypothenar eminence*) and lower-limb (*tibialis anterior*, *gastrocnemius*). During surgery EMG signals were differentially amplified, sampled at 10kHz, filtered in a 30–300 Hz frequency band, displayed on a computer screen, and visually assessed. These signals were then stored for further processing (see quantification and statistical analyses below).

**Somatosensory evoked potentials (SEP).** Like MEP, SEP were investigated using standard procedures [41, 46]. The surface electrodes positioned during the pre-operative phase for EMG recording (see above) were electrically stimulated to provoke muscle contractions. In this protocol, commonly employed in rehabilitation and research settings to mimic voluntary movements [47], the afferent signals collected in the sensorimotor regions reflect the recruitment of cutaneous and proprioceptive afferent fibers (group I and II) [48, 49]. Stimulation consisted in standard electrical trains (9 pulses, 500  $\mu$ s wide, 10 ms interpulse interval) delivered at a 2.7 Hz frequency. Stimulation intensity varied from 5 to 20 mA,

depending on patients, target muscle and measured impedances. SEP were recorded on the cerebral cortex in a bipolar way using cortex strip electrodes (1 or 2 grids of 4 to 6 contacts). During surgery SEP were collected at a 10 kHz sampling rate and filtered within a 0.5 to 300 Hz frequency band. A period of 120 ms was considered after each stimulus onset. For each cortical site and peripheral muscle, mean curves were obtained in real time by averaging 200 individual trials. The resulting curves were displayed on a computer screen, and visually assessed. Then, they were saved for off-line processing.

***Localization of brain sites.*** The procedure for localizing stimulation sites has been described in a previous publication (see supplemental information in [13]). A neuronavigation system was used to guide surgeries. This system was used to record coordinates of the stimulation sites on individual high resolution MR images. Spatial normalization of preoperative MR images into the MNI space (ICBM152) was performed using the robust [50] segmentation procedure of SPM12. Lesion areas were manually defined from preoperative MR images and excluded from the normalization transformation. Anatomical localization within the parietal cortex were determined from MNI coordinates using the probabilistic cytoarchitectonic maps provided by the Jülich Research Center [51], as available in the Anatomy toolbox of SPM. 3D surface rendering images, combining data from all subjects, were generated using a surface-based template labelled with FreeSurfer 5.3 (<https://surfer.nmr.mgh.harvard.edu/>) according to the Mindboggle atlas [52].

#### QUANTIFICATION AND STATISTICAL ANALYSES

***Motor responses and latencies.*** Standard off-line treatments were applied to the stored EMG signals to identify significant motor responses and their latencies [41, 53]. The envelope of the surface EMG was estimated by a scheme of demodulation, smoothing, and relinearization [54]. Rest EMG (mean -M- and standard deviation -SD-) was determined from the 1000 ms rest



period preceding stimulation (MEP) or movement (hand motor task) onset. For MEPs, the site was considered responsive if stimulation caused the EMG envelope to rise above the  $M + 3*SD$  threshold. EMG onset was defined as the first point of the first 100 ms epoch of the EMG envelope located above this threshold. The same approach was used for the hand motor task. EMG onset was defined as the first point of the first 100 ms epoch of the EMG envelope located above the  $M + 3*SD$  threshold. EMG cessation (or inhibition) was defined as the first point located below the  $M + 3*SD$  threshold. See Figure S2.

***Somatosensory responses and latencies.*** Significance of stored SEP signals was assessed for each subject using a standard procedure [41, 55, 56]. A baseline curve was first defined by averaging all individual signals. For each time sample, a t-test was then computed between the SEP and the baseline curves, using a 95% significance level. Periods showing more than 100 consecutive significant t-tests (corresponding to a 10 ms period) were considered significant. Latencies were computed from significant curves as the onset of the first 10 ms period above or below 3 standard deviations of the mean signal averaged from all non-significant curves. In a last step, SEP activities were filtered with a 100 Hz low-pass filter for display purpose.

***EMG group analyses.*** Individual EMG signals were segmented into 10 time bins (Figure 3). The root mean square amplitude of the EMG signal of the *Flexor Carpi Radialis* muscle was computed for each time bin. Friedman's Anova was then used for determining significant differences across time bins.

***Distribution of stimulated sites.*** Permutation tests were used to determine statistical significance of the differences observed between the densities of stimulation and recording sites in the IPL and SPL regions ( $10^4$  permutations [57]). Statistical threshold was set at  $\alpha = 0.05$ .

***Confidence ellipsoids for inhibition sites.*** The 3D Gaussian probability distribution of inhibition sites (Figure 1A) was estimated and then approximated with a 2D Gaussian

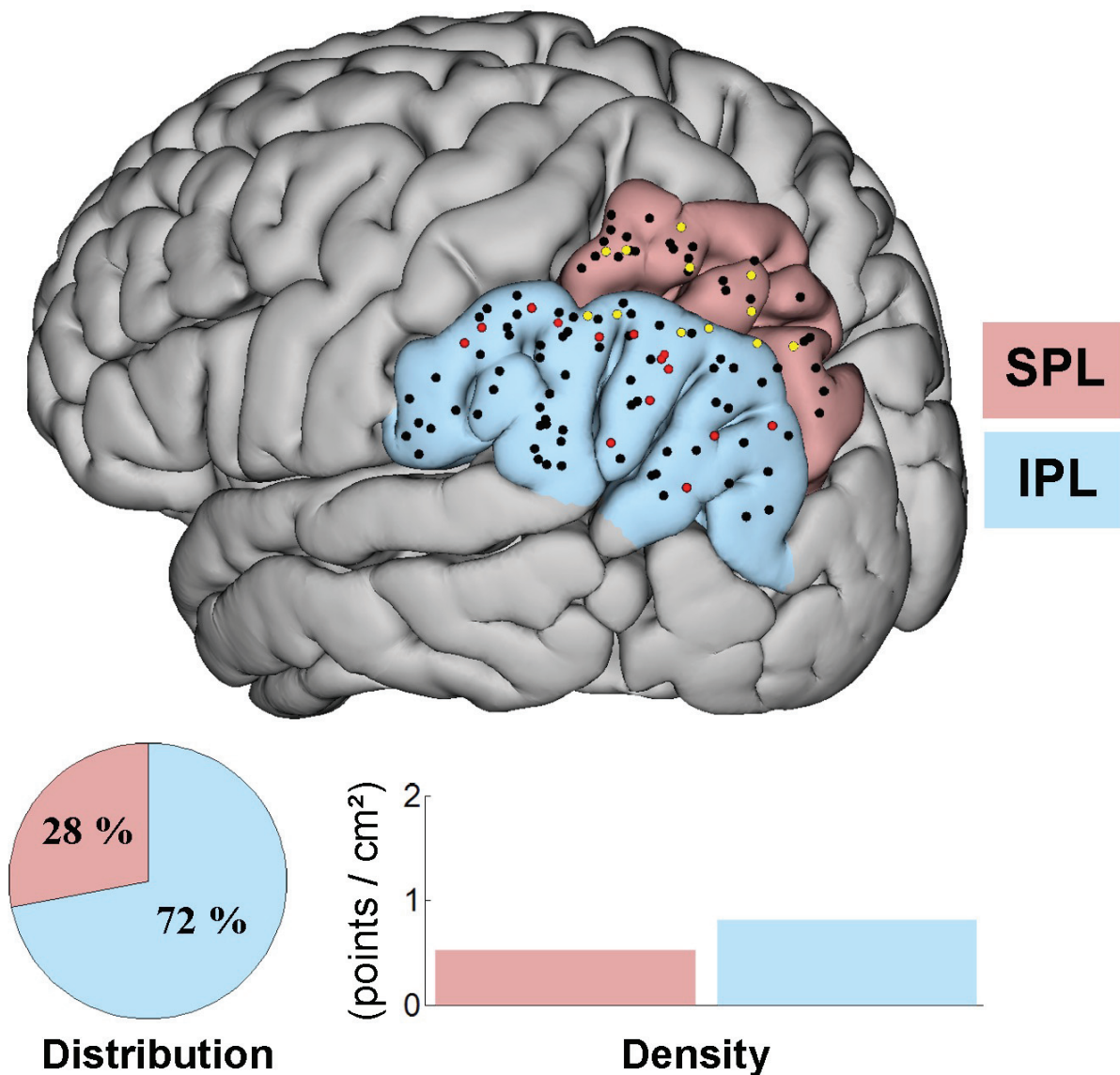
distribution in the plane defined by the two largest eigenvectors of the dataset. Confidence isovalues (Chi-Square probabilities [58]) associated with this Gaussian distribution were then drawn on the template cortical surface using a color scale from 99.5% (for cortical points of the regions containing at least 99.5% of the sites -yellow-) to 0.005% (for cortical points of the regions containing at most 0.005% of the sites -red-).

**Monte Carlo Simulation.** We investigated how many subjects of our sample ( $n = 16$ ) are expected to show a lack of inhibitory response. A Monte Carlo simulation was performed (100,000 repetitions) knowing: the proportion "p" of eloquent sites within DPPr (i.e. the proportion of sites that evoke motor inhibition when stimulated; p was varied from 25 % -inferred from our data- to 50 % -artificially high-); the number "n" of sites stimulated in each subject within DPPr (n ranged from 7 to 0 -one subject was only stimulated in the inferior parietal lobe-). Each repetition involved 2 steps: (1) for each subject, given p, we randomly drew n sites and determined whether one of them was eloquent; (2) we determined the total number of "silent subjects". Finally, the 95% confidence interval of the simulated distribution was computed (i.e. the 95% interval within which, for any study, the number of silent subjects should fall).

#### **DATA AND SOFTWARE AVAILABILITY**

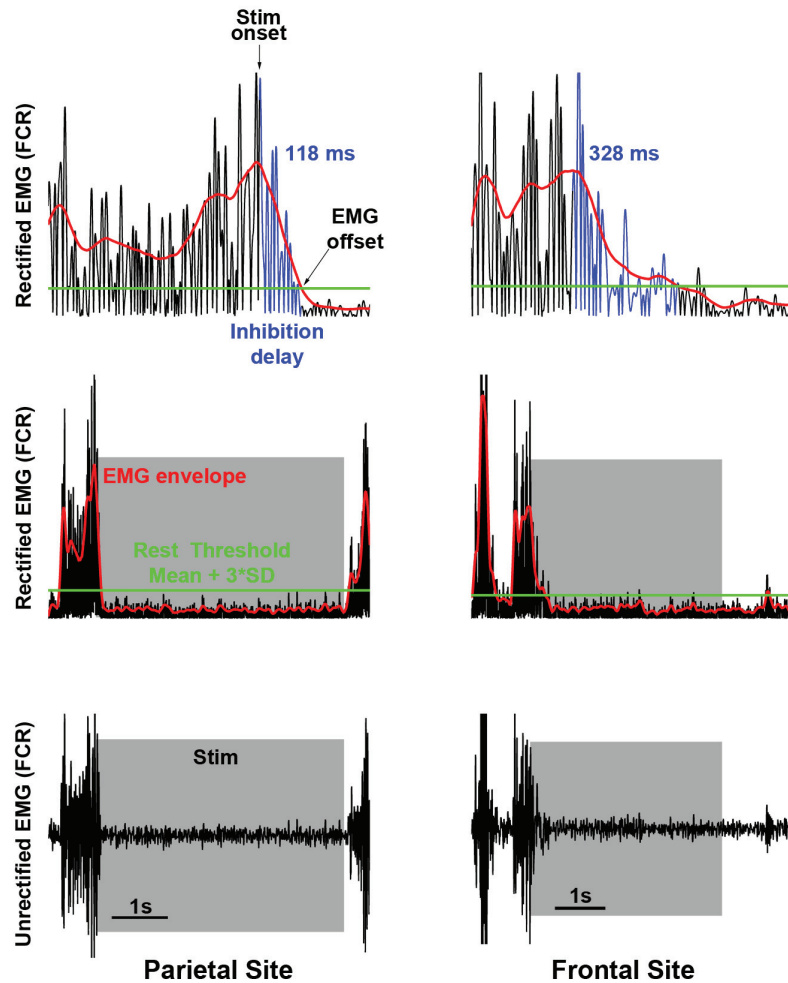
Analysis-specific code and data are available by request to the Lead Contact: Angela Sirigu (sirigu@isc.cnrs.fr)

## 9) SUPPLEMENTAL DATA



**Figure S1. Distribution of all the parietal sites stimulated in 16 awake patients (n = 114). Related to Figure 1.** Black points represent cortical locations that failed to evoke any sensory or motor response when stimulated. Red points represent locations where conscious sensory feelings were reported by the patient in response to electrical stimulation (ex: tingling or illusions of movement). Yellow points represent locations where motor inhibitions were found

(same points as in Figure 1). Data are shown after registration of the individual MRI on the ICBM152 template [1] segmented with the Mindboggle cortical labeling [2] using FreeSurfer 5.3 (<https://surfer.nmr.mgh.harvard.edu/>). Right stimulations are reported on the left hemisphere. Superior parietal lobule (SPL) is shown in red, inferior parietal lobule (IPL) in shown in blue (IPL includes the 2 regions designated supramarginal lobule and inferior parietal lobule in the Mindboggle labeling atlas). Pies show the percentage of stimulations performed in each of these regions. Bar-graphs display corresponding densities (stim / cm<sup>2</sup>). Permutation tests (see Methods) indicate that these densities are statistically comparable within the two regions ( $p > .70$ ).



**Figure S2. Illustration of the computational procedure used for extracting the delay of EMG cessation after cortical stimulation. Related to Figures 2 and 4 and Star Methods (section "motor responses and latencies").** Examples are shown for a parietal (left panels) and frontal (right panels) site. Bottom panels display the initial filtered non rectified EMG signals for the *flexor carpi radialis* muscle (FCR; as shown in figures 3 and 4). Middle panels show the rectified signals with their envelopes (red curves, see Methods for computational details) and the rest thresholds (green lines,  $3 \times \text{SD}$  above the mean the rest signal, see Methods for computational details). Top panels show a time expanded version of the peri-stimulation period. Values reported on each graph (118 ms and 328 ms) correspond to the EMG cessation (or inhibition) delay.

<b>Patients</b>	<b>Sex</b>	<b>Age</b>	<b>Tumor</b>	<b>Pre-operative symptoms</b>
S1	Female	48	Left superior parietal glioma	Speech difficulties
S2	Female	19	Left post-central cavernoma	Headaches
S3	Female	62	Right parieto-temporal glioma	Headaches
S4	Female	61	Left superior parietal meningioma	Vertigo Right hand paresthesia
S5	Male	35	Right postcentral cavernoma	Headaches / Vomiting
S6	Female	16	Left inferior parietal glioma	Headaches
S7	Male	46	Right central aspecific glial tissue	Seizures
S8	Male	53	Left parieto-temporal glioma	Seizures
S9	Female	63	Left parieto-temporal glioma	Seizures
S10	Male	17	Right parieto-temporal glioma	Headaches / Vomiting
S11	Female	35	Left intra-parietal sulcus glioma	Seizures
S12	Female	14	Left inferior parietal glioma	Quadrantopsia
S13	Female	16	Left parieto-temporal glioma	Diplopia
S14	Female	14	Right central glioma	Seizures
S15	Female	15	Left central meningioma	Right upper-limb motor difficulties
S16	Female	15	Left inferior parietal glioma	Headaches School difficulties
S17	Male	36	Right precentral glioma	Seizures
S18	Female	14	Right precentral glioma	Seizures
S19	Female	62	Right precentral ependymoma	Headaches
S20	Female	22	Right precentral cavernoma	Headaches

**Table S1. Demographic and clinical characteristics of the patients (n = 20). Related to table S2 and Star Methods (section "experimental model and subject details").** The shaded part of the table relates to parietal patients; the non-shaded part to frontal patients.

	Rest	Hand Contralateral		Hand Ipsilateral		Both Hands	Speech	Passive Muscles	Spontaneous Movement	Somatosensory evoked-potentials		
		Ongoing	Initiation	Ongoing	Initiation					Hand	Face	Foot
<b>Tested</b>	12	12	5	8	0	1	12	2	-	12	12	12
<b>Positive</b>	0	12 100 % (inhibition)	5 100 % (inhibition)	0 0 %	-	1  (inhibition)	12 0 %	0	5  speech: 2 face: 1 hand ipsi: 1 foot: 1	10 83 %	0 0 %	0 0 %

**Table S2. Summary of the mapping protocol and results for the 12 inhibition sites identified in parietal patients. Related to Figures 2 and 3 and Result section "evoking motor inhibition by stimulating the dorsoposterior parietal cortex".** "Rest": stimulation was delivered while the patient was at rest, doing no task. "Ongoing": stimulation was delivered while the patient was performing the task (open/close the hand or speaking). "Initiation": stimulation was delivered before the instruction to move. "Spontaneous movements" refer to movements performed spontaneously by the patient during ongoing inhibition of the contralateral hand. "Passive Muscles" refer to a condition in which movements of the hand were evoked passively through peripheral electrical stimulation of hand muscles (using a stimulation protocol described in the Methods -section "somatosensory evoked potentials"-). This condition was investigated for two reasons. First, to determine whether inhibition sites could be identified in patients who cannot be submitted to awake surgeries (such as young children). Second, to investigate the hypothesis that cortical stimulation causes hand movement inhibition by recruiting the spinal inhibitory interneurons that control hand muscle motoneurons. We found no effect of stimulating the parietal inhibition sites on these passively-evoked movements (see also video S2).

	<b>Hand Contra (ongoing)</b>	<b>Hand Ipsi (ongoing)</b>	<b>Speech (ongoing)</b>	<b>SEP (Hand contra)</b>	<b>Inhibition delay</b>
<b>Frontal inhibition Sites</b>	5/5 (100 %)	3/5 (arrest) 2/5 (drop in magnitude) (100 % disrupted)	4/5 (arrest) 1/5 (dysarthria) (100 % disrupted)	0/5 (0 %)	546 ms (±347)
<b>Parietal inhibition Sites</b>	12/12 (100 %)	0/8 (0 %)	0/12 (0 %)	10/12 (83 %)	126 ms (± 30)
<b>Statistics (frontal vs parietal)</b>	-	Proportion Test p < 0.01	Proportion Test p < 0.0005	Proportion Test p < 0.01	Mann Withney U-Test p < 0.0005
<b>Probabilities</b>	-	All disruption sites (n = 5) are in the frontal region "by chance" p = .00078 $\frac{5! \times 8!}{13!}$	All disruption sites (n = 5) are in the frontal region "by chance" p = .00016 $\frac{5! \times 12!}{17!}$	All SEP (n= 10) are at parietal sites "by chance" p = .0034 $\frac{(12! \times 7!)}{(2! \times 17!)}$	-

**Table S3. Summary of the functional differences between frontal and parietal arrest sites.**

**Related to Figures 3 and 4 and Result section ("*evoking motor inhibition by stimulating precentral areas*").** Statistics (Chi-square test of proportions [3]) and probability calculations are reported to show that functional differences between frontal and parietal sites are significant.



## REFERENCES

1. Fonov, V., Evans, A.C., McKinstry, R.C., Alml, C.R., and Collins, D.L. (2009). Unbiased nonlinear average age-appropriate brain templates from birth to adulthood. *Neuroimage* 47, S102.
2. Klein, A., and Tourville, J. (2012). 101 labeled brain images and a consistent human cortical labeling protocol. *Front Neurosci* 6, 171.
3. Millot, G. (2011). *Understanding and performing statistical tests with R*, 2nd edition [in french]. (Bruxelles: DeBoeck).

# B-3) Paper 3: A sensory-parieto-motor pathway dedicated to hand movement control in humans

*To be submitted*

Pierre-Aurélien Beuriat<sup>1,2,3\*</sup>, Achille Teillac<sup>1,2,4\*</sup>, Nathalie Richard<sup>1,2</sup>, Lara Bardi<sup>1,2</sup>, Alexandru Szathmari<sup>1,2,3</sup>, Carmine Mottolose<sup>1,2,3</sup>, Angela Sirigu<sup>1,2</sup> and Bassem Hiba<sup>1,2</sup>,  
Michel Desmurget<sup>1,2</sup>

\* These authors contributed equally to this work

## **Author' Affiliations:**

<sup>1</sup> Institute of Cognitive Neuroscience Marc Jeannerod, CNRS / UMR 5229, 69500 Bron, France

<sup>2</sup> Université Claude Bernard, Lyon 1, 69100 Villeurbanne, France

<sup>3</sup> Department of Pediatric Neurosurgery, Hôpital Femme Mère Enfant, 69500, Bron, France

<sup>4</sup> Institut de neurosciences cognitives et intégratives d'Aquitaine, CNRS / UMR 5287, 33076 Bordeaux, France

## 1) SUMMARY

A recent per-operative study indicates that stimulation of a specific posterior parietal subregion, receiving sensory afferences from intrinsic hand muscles, instantly inhibits ongoing hand movements when stimulated. We tried to identify the anatomical bases of this observation using diffusion MRI tractography. To this end, we analyzed multiple-shell data from 26 right-handed subjects of the Human Connectome Project (HCP). In both hemispheres, we found significant ipsilateral connections between the parietal subregion of interest and the cortical territories devoted to hand control in the primary motor (M1) and primary somatosensory (S1) cortex. These results suggest the existence of a sensorimotor control loop specifically dedicated to the execution of hand movements.

## 2) INTRODUCTION

Inhibition is an essential component of sensorimotor control. It is commonly attributed to frontal processing (Filevich *et al.*, 2012; Aron *et al.*, 2014). However, recent evidence has also demonstrated a specific contribution of the posterior parietal cortex (PPC). This anatomical duality is assumed to reflect a functional dissociation: while frontal areas would support a global suppressive mechanism recruited, for instance, in response to sudden unexpected events (Wessel and Aron, 2017), parietal networks would rather be involved in the selective inhibition of unwanted action during the preparation and execution of voluntary movements (Lindner, 2018). In agreement with this later view a recent per-operative study (Desmurget *et al.*, 2018) showed that direct cortical stimulation of frontal areas (in the dorsal part of the premotor cortex) result in a general freezing of the motor system; as already observed in previous studies (Luders *et al.*, 1992; Chauvel *et al.*, 1996; Nii *et al.*, 1996; Chassagnon *et al.*, 2008). By contrast, parietal stimulations caused a selective inhibition of

contralateral hand responses during movement planning or execution. In other words, as a result of parietal stimulation the subjects were unable to initiate or carry on an open/close movement of the hand, but they remained able to talk, move the ipsilateral hand or raise the foot. Parietal inhibitory sites were reported to be located in the dorsoposterior parietal region (DPPr; figure 1), within the human homologue of the medial intraparietal area (MIP) in macaque or more generally of the so-called parietal reach region (PRR) (Grefkes and Fink, 2005; Vesia and Crawford, 2012; Konen *et al.*, 2013). DPPr stimulation was claimed to act by inhibiting primary motor cortex (M1) activity. In agreement with this hypothesis, anatomical studies, in non-human primates, have identified direct and indirect (via the premotor regions in particular) projections from DPPr to M1 areas controlling hand/arm movements (Rizzolatti *et al.*, 1998; Kaas and Stepniewska, 2016; Borra and Luppino, 2017). Also, it was shown that a conditioning-TMS pulse delivered over DPPr could significantly depress motor evoked potentials triggered, in hand muscles, by a test pulse delivered over the ipsilateral M1 (Koch *et al.*, 2007; Mackenzie *et al.*, 2016). Moreover, when DPPr is focally lesioned, alien hand movements have been reported due to the emergence of unwanted (spontaneous) activity with M1 (Assal *et al.*, 2007). Finally, in monkeys, anatomical studies have identified direct and indirect projections from DPPr to M1 areas controlling hand/arm movements (Rizzolatti *et al.*, 1998; Kaas and Stepniewska, 2016; Borra and Luppino, 2017).

Beyond these observations, recording of somatosensory evoked potentials (SEP) also revealed that parietal inhibitory sites received short-latency afferent inputs from intrinsic hand muscles; which was not the case of frontal freezing sites. These sensory inputs were claimed to be routed through the primary somatosensory cortex (S1) (Desmurget *et al.*, 2018) in light of existing evidence showing, in humans and monkeys, that S1 excision abolishes posterior parietal SEP (Allison *et al.*, 1991a; Allison *et al.*, 1991b). Functionally, this type of afferent

inputs was believed to be important for maintaining motor inhibition in response to spontaneous, unwanted motor activity in arm muscles.

So, taken together, these observations suggest that DPPr is part of a functional network receiving afferent inputs from S1 hand area and sending efferent outputs to M1 hand area (figure 2). However, direct evidence supporting this claim is still lacking, especially in humans. In particular, the issue whether this functional network is specifically related to hand control remains unclear. To date, no evidence has been reported regarding the potential impact of DPPr stimulation on whole upper-limb movements. Also, even if the model above is true, it remains unclear how neural signals are transmitted across cortical regions. The heavy temporal constraints acting on motor control / inhibitory systems, suggest that these connections should be direct. However, evidence supporting these predictions is still missing.

The present study aims to address the issues above using diffusion MRI (dMRI). This unique non-invasive technique scans the movement of water molecules along nervous fibers. By following this movement, neural pathways, hereafter named *streamlines*, can be reconstructed (Poupon *et al.*, 2000; Ito *et al.*, 2002; Jeurissen *et al.*, 2019). Overall, connectivity data here obtained from this method validate the existence of the sensory-parieto-motor functional loop postulated in figure 2. They also confirm that this loop is specifically related to fine distal hand control.

### **3) METHODS**

The Human Connectome Project (HCP) is a unique dataset of more than 500 healthy volunteers aiming to be used by the scientific community to shed light on the anatomical and functional connectivity of the human brain (Van Essen *et al.*, 2013). The dMRI preprocessed scans we used from this dataset are made of multiple-shell samples (b=1000, 2000 and 3000

s/mm<sup>2</sup> with 90 gradient directions each) and 18 b=0 s/mm<sup>2</sup>. All these scans have been corrected for artefact distortions (Sotiropoulos *et al.*, 2013) and their spatial resolution is 1.25 mm isotropic.

Within the database, we randomly identified 26 right-handed subjects. Then, for each subject, we identified the DPPr region of interest (ROI) using the boundaries of the 95 % confidence area determined from our previous per-operative study (figure 1) (Desmurget *et al.*, 2018). As illustrated in supplemental figure S1, we did this for both hemispheres using the individual white and pial surfaces computed with FreeSurfer (Fischl, 2012).

Next, we used standard computational procedure to identify the streamlines connecting our region of interest with M1 and S1. First, we performed a spherical deconvolution based post-processing steps. These steps led to the probabilistic reconstruction of the tractogram with the MRtrix3 software (Tournier *et al.*, 2019). Second, we filtered the final whole brain tractogram to identify ipsilateral streamlines connecting our areas of interest (parietal / S1 and parietal / M1). M1 and S1 were defined from Destrieux's parcellation (Destrieux *et al.*, 2010). Third, for each subject and the identified streamlines we computed the streamlines density volume using the classical track-density imaging method (Calamante *et al.*, 2011). This volume was projected onto the individual pial surface to get a surface distribution of the streamlines density on the sensory and motor areas of interest. In a last step, we averaged these streamlines density textures and created the average pial mesh for all subjects. These density textures were finally mapped on the average pial mesh.

#### **4) RESULTS**

As illustrated in figure 3, we found the mean streamlines density to converge within circumscribed areas of the pre- and postcentral gyri. These areas were in the part of the

sensorimotor strip where upper-limb functions are represented (Penfield and Boldrey, 1937; Desmurget *et al.*, 2014). More precisely, they were within the middle knee of the central lobe (Ribas, 2010), an anatomical marker that is typically assumed to define the functional hot-spot for distal hand control, both in the primary motor (Yousry *et al.*, 1997; Vigano *et al.*, 2019) and the primary sensorimotor (White *et al.*, 1997; Sastre-Janer *et al.*, 1998) cortex. The results and streamline distributions were identical for both hemispheres.

As observed in our previous per-operative study (Desmurget *et al.*, 2018) and as postulated by in figure 2, streamlines identified in M1 and S1 originated in the same area of DPPr (figure 4). In other words, the same parietal region was connected to M1 and S1. This, also, was true for both hemispheres.

## 5) DISCUSSION

To summarize, these results identify two white matter pathways linking the same subregion of DPPr with the hand areas of (i) the primary somatosensory cortex and (ii) the primary motor cortex. This finding is consistent with the conclusion of the per-operative study that drove the present research. As shown by this study a localized area within DPPr receives short-latency somatosensory signals from the hand muscles and instantly inhibits ongoing hand responses (or prevents their initiation) when electrically stimulated (Desmurget *et al.*, 2018).

Before going further in the discussion, it seems worth mentioning that the hypothesis-driven approach used in the present research minimizes the risk that the anatomical connections we identified reflect the tendency of current diffusion tractography algorithms to produce a large amount of false-positive bundles (Maier-Hein *et al.*, 2017). In other words, while diffusion tractography might produce disputable conclusions when used in isolation (David *et al.*, 2019), it represents a powerful cross-validation tool when used in conjunction with other

techniques such as functional MRI (Guye *et al.*, 2003), histology (Dell'Acqua *et al.*, 2013), polarized light imaging (Mollink *et al.*, 2017), tract-tracing (Jbabdi *et al.*, 2013), deep brain stimulation (Calabrese, 2016), direct electrical stimulation (Kamada *et al.*, 2009). But this does not mean that tractography is "just" a validation technique. It is also important for addressing some limits of other methods, including per-operative ones. In particular, based on stimulation protocols, the existence of remote activations can never be formally rejected (Karnath *et al.*, 2010). It is thus possible that the motor blockages caused by parietal stimulations does not reflect the inhibitory properties of this regions per-se but the indirect recruitment of some well-known frontal inhibitory regions (Filevich *et al.*, 2012). The present tractography study weakens this claim by identifying a strong direct connection between DPPr and M1 hand area. This finding is consistent with the observation that inhibition patterns observed in response to frontal and parietal stimulations are strongly different (Desmurget *et al.*, 2018).

Beyond these observations, another important issue concerns the possibility that motor inhibition induced by stimulating DPPr reflects a general disruption of the process of movement monitoring; a disruption that should not only affect hand movements but upper-limb volitional responses as a whole. In agreement with this view, it has been shown that DPPr acts as a real-time controller that continuously monitors ongoing reaching and grasping movements. Typically, this controller is modeled in the form of a real-time optimal feedback loop that steadily drives neural activity in M1, so as to progressively nullify the distance between the ongoing state of the motor plant (indirectly estimated by integrating sensory inflows and motor outflows (Wolpert *et al.*, 1995)) and the goal of the movement (Todorov, 2004; Diedrichsen *et al.*, 2010; Franklin and Wolpert, 2011). When the error reaches zero, the movement ceases. It is now well admitted that DPPr is involved in state estimation and the on-line control of action (Desmurget and Grafton, 2000; Andersen *et al.*, 2014; Archambault *et al.*, 2015). In monkeys, parietal neurons in area 5 have been reported to encode instantaneous movement trajectories



(Mulliken *et al.*, 2008) through processing proprioceptive sensory signals related to joint excursions (Hyvarinen, 1982). In this area, neural activity correlates with hand path adjustments observed when the location of a visual target changes unexpectedly at movement onset (Battaglia-Mayer *et al.*, 2013). In humans, lesions of the superior parietal lobe (SPL) impair state estimation (Wolpert *et al.*, 1998). Also, transient neural inactivation produced through transcranial magnetic stimulation (TMS) over the intraparietal sulcus disrupts automatic motor corrections in visually-directed reach and grasp tasks (Desmurget *et al.*, 1999; Tunik *et al.*, 2005; Chib *et al.*, 2009; Reichenbach *et al.*, 2014). Compatible results have been provided by neuroimaging studies showing robust feedback-related responses in SPL for point-to-point hand movements (Desmurget *et al.*, 2001; Diedrichsen *et al.*, 2005; Reichenbach *et al.*, 2011).

Our tractography results are not compatible with this general model. Indeed, we found DPPr connections to be concentrated within the pre and postcentral territories dedicated to hand movements. The "motor control" hypothesis would predict more widespread projections to the regions where arm and wrist muscles are represented. Indeed, the evidence provided above is not limited to hand movements. It mostly concerns whole-arm reaching movements. Thus, our data support the existence of a specific sensori-parieto-motor network devoted to hand distal control, including inhibition. Within this network, stimulation of DPPr could cause movement inhibition through a direct recruitment of M1 inhibitory neurons (hypothesis of a dedicated inhibitory network). However, it could also act by preventing affecting hand motor control (hypothesis of a motor control network). In this case, the transmission of the motor command to M1 or by forcing the transmission of a null error signal. Under natural conditions, these two mechanisms would be very parsimonious and efficient ways of achieving selective motor inhibition. Planning and monitoring of reaching movements could rely on more dorsal premotor areas (Wise *et al.*, 1997; Christensen *et al.*, 2007; Kaas and Stepniewska, 2016). Based on the

evidence available, it cannot be decided which hypothesis is valid: the inhibition network hypothesis or the motor control hypothesis. Still, it seems likely that neural signals flows, at least for a part, from S1 to DPPr to M1. But, here again, the extent to which M1 also retro-projects to DPPr and DPPr to S1 cannot be evaluated. In other words, whether the white matter pathways identified in these study are uni- or bidirectional (and in what proportion) cannot be addressed from our data.

One last point remains to be discussed regarding the novelty of our results. In a recent paper aiming at studying the superior longitudinal fasciculus (SLF) Hecht and colleagues used dMRI tractography to perform a virtual dissection of this WM bundle (Hecht *et al.*, 2015). More specifically, they extracted the superior-most branch corresponding to the SLF-I linking the SPL with the supplementary motor area (SMA), the posterior dorsolateral prefrontal cortex, the dorsal premotor cortex, and the rostral part of primary motor cortex. It could be that the parieto-motor pathway identified in the present study is a new, not yet identified, ramification of this large bundle. To address this possibility, we performed a virtual dissection of the three components of the SLF-I. In most case, results were inconclusive. Indeed, the DPPr-M1 bundle described in the present experiment started and ended in two parietal and motor regions previously identified as unconnected. At the same time however, this bundle followed (and sometimes was included) within the SLF-1 tract. The same conclusion was reached for the S1-DPPr bundle. These inconclusive results are illustrated for one representative subject in supplemental figure S2.

To summarize, our results show the existence of a functional sensorimotor loop, linking the cortical territories devoted to hand control in the primary motor and primary somatosensory cortex, with a subregion of DPPr. This finding confirms, clarifies and generalizes recent per-operative observations showing that specific sites in DPPr receives somatosensory signals from

hand muscles and cause instantaneous inhibition of hand movements when stimulated. Whether the bundles we identified should be considered a new branch of the SLF-1 remains unclear.

## **REFERENCES**

- Allison T, McCarthy G, Wood CC, Jones SJ. Potentials evoked in human and monkey cerebral cortex by stimulation of the median nerve. A review of scalp and intracranial recordings. *Brain* 1991a; 114 ( Pt 6): 2465-503.
- Allison T, Wood CC, McCarthy G, Spencer DD. Cortical somatosensory evoked potentials. II. Effects of excision of somatosensory or motor cortex in humans and monkeys. *J Neurophysiol* 1991b; 66: 64-82.
- Andersen RA, Andersen KN, Hwang EJ, Hauschild M. Optic ataxia: from Balint's syndrome to the parietal reach region. *Neuron* 2014; 81: 967-83.
- Archambault PS, Ferrari-Toniolo S, Caminiti R, Battaglia-Mayer A. Visually-guided correction of hand reaching movements: The neurophysiological bases in the cerebral cortex. *Vision Res* 2015; 110: 244-56.
- Aron AR, Robbins TW, Poldrack RA. Inhibition and the right inferior frontal cortex: one decade on. *Trends Cogn Sci* 2014; 18: 177-85.
- Assal F, Schwartz S, Vuilleumier P. Moving with or without will: functional neural correlates of alien hand syndrome. *Ann Neurol* 2007; 62: 301-6.
- Battaglia-Mayer A, Ferrari-Toniolo S, Visco-Comandini F, Archambault PS, Saberi-Moghadam S, Caminiti R. Impairment of online control of hand and eye movements in a monkey model of optic ataxia. *Cereb Cortex* 2013; 23: 2644-56.
- Borra E, Luppino G. Functional anatomy of the macaque temporo-parieto-frontal connectivity. *Cortex* 2017; 97: 306-26.
- Calabrese E. Diffusion Tractography in Deep Brain Stimulation Surgery: A Review. *Front Neuroanat* 2016; 10.

- Calamante F, Tournier J-D, Heidemann RM, Anwander A, Jackson GD, Connelly A. Track density imaging (TDI): Validation of super resolution property. *Neuroimage* 2011; 56: 1259-66.
- Chassagnon S, Minotti L, Kremer S, Hoffmann D, Kahane P. Somatosensory, motor, and reaching/grasping responses to direct electrical stimulation of the human cingulate motor areas. *J Neurosurg* 2008; 109: 593-604.
- Chauvel PY, Rey M, Buser P, Bancaud J. What stimulation of the supplementary motor area in humans tells about its functional organization. *Adv Neurol* 1996; 70: 199-209.
- Chib VS, Krutky MA, Lynch KM, Mussa-Ivaldi FA. The separate neural control of hand movements and contact forces. *J Neurosci* 2009; 29: 3939-47.
- Christensen MS, Lundbye-Jensen J, Geertsen SS, Petersen TH, Paulson OB, Nielsen JB. Premotor cortex modulates somatosensory cortex during voluntary movements without proprioceptive feedback. *Nat Neurosci* 2007; 10: 417-9.
- David S, Heemskerk AM, Corrivetti F, Thiebaut de Schotten M, Sarubbo S, Corsini F, *et al.* The Superoanterior Fasciculus (SAF): A Novel White Matter Pathway in the Human Brain? *Front Neuroanat* 2019; 13: 24.
- Dell'Acqua F, Bodi I, Slater D, Catani M, Modo M. MR Diffusion Histology and Micro-Tractography Reveal Mesoscale Features of the Human Cerebellum. *Cerebellum* 2013; 12: 923-31.
- Desmurget M, Epstein CM, Turner RS, Prablanc C, Alexander GE, Grafton ST. Role of the posterior parietal cortex in updating reaching movements to a visual target. *Nat Neurosci* 1999; 2: 563-7.
- Desmurget M, Grafton ST. Forward modeling allows feedback control for fast reaching movements. *Trends Cogn Sci* 2000; 4: 423-31.

- Desmurget M, Grea H, Grethe JS, Prablanc C, Alexander GE, Grafton ST. Functional Anatomy of Nonvisual Feedback Loops during Reaching: A Positron Emission Tomography Study. *J Neurosci* 2001; 21: 2919-28.
- Desmurget M, Richard N, Beuriat PA, Szathmari A, Mottolese C, Duhamel JR, *et al.* Selective Inhibition of Volitional Hand Movements after Stimulation of the Dorsoposterior Parietal Cortex in Humans. *Curr Biol* 2018; 28: 3303-9 e3.
- Desmurget M, Richard N, Harquel S, Baraduc P, Szathmari A, Mottolese C, *et al.* Neural representations of ethologically relevant hand/mouth synergies in the human precentral gyrus. *Proc Natl Acad Sci U S A* 2014; 111: 5718-22.
- Destrieux C, Fischl B, Dale A, Halgren E. Automatic parcellation of human cortical gyri and sulci using standard anatomical nomenclature. *Neuroimage* 2010; 53: 1-15.
- Diedrichsen J, Hashambhoy Y, Rane T, Shadmehr R. Neural correlates of reach errors. *J Neurosci* 2005; 25: 9919-31.
- Diedrichsen J, Shadmehr R, Ivry RB. The coordination of movement: optimal feedback control and beyond. *Trends Cogn Sci* 2010; 14: 31-9.
- Filevich E, Kuhn S, Haggard P. Negative motor phenomena in cortical stimulation: implications for inhibitory control of human action. *Cortex* 2012; 48: 1251-61.
- Fischl B. FreeSurfer. *Neuroimage* 2012; 62: 774-81.
- Franklin DW, Wolpert DM. Computational mechanisms of sensorimotor control. *Neuron* 2011; 72: 425-42.
- Grefkes C, Fink GR. The functional organization of the intraparietal sulcus in humans and monkeys. *J Anat* 2005; 207: 3-17.
- Guye M, Parker GJ, Symms M, Boulby P, Wheeler-Kingshott CA, Salek-Haddadi A, *et al.* Combined functional MRI and tractography to demonstrate the connectivity of the human primary motor cortex in vivo. *Neuroimage* 2003; 19: 1349-60.

- Hecht EE, Gutman DA, Bradley BA, Preuss TM, Stout D. Virtual dissection and comparative connectivity of the superior longitudinal fasciculus in chimpanzees and humans. *Neuroimage* 2015; 108: 124-37.
- Hyvarinen J. The parietal cortex of monkey and man. Berlin: Springer-Verlag; 1982.
- Ito R, Mori S, Melhem E. Diffusion tensor brain imaging and tractography. *Neuroimaging Clin N Am* 2002; 12: 1-19.
- Jbabdi S, Lehman JF, Haber SN, Behrens TE. Human and Monkey Ventral Prefrontal Fibers Use the Same Organizational Principles to Reach Their Targets: Tracing versus Tractography. *J Neurosci* 2013; 33: 3190-201.
- Jeurissen B, Descoteaux M, Mori S, Leemans A. Diffusion MRI fiber tractography of the brain. *NMR in Biomedicine* 2019; 32: e3785.
- Kaas JH, Stepniewska I. Evolution of posterior parietal cortex and parietal-frontal networks for specific actions in primates. *J Comp Neurol* 2016; 524: 595-608.
- Kamada K, Todo T, Ota T, Ino K, Masutani Y, Aoki S, *et al.* The motor-evoked potential threshold evaluated by tractography and electrical stimulation. *J Neurosurg* 2009; 111: 785-95.
- Karnath HO, Borchers S, Himmelbach M. Comment on "Movement intention after parietal cortex stimulation in humans". *Science* 2010; 327: 1200.
- Koch G, Fernandez Del Olmo M, Cheeran B, Ruge D, Schippling S, Caltagirone C, *et al.* Focal stimulation of the posterior parietal cortex increases the excitability of the ipsilateral motor cortex. *J Neurosci* 2007; 27: 6815-22.
- Konen CS, Mruczek RE, Montoya JL, Kastner S. Functional organization of human posterior parietal cortex: grasping- and reaching-related activations relative to topographically organized cortex. *J Neurophysiol* 2013; 109: 2897-908.

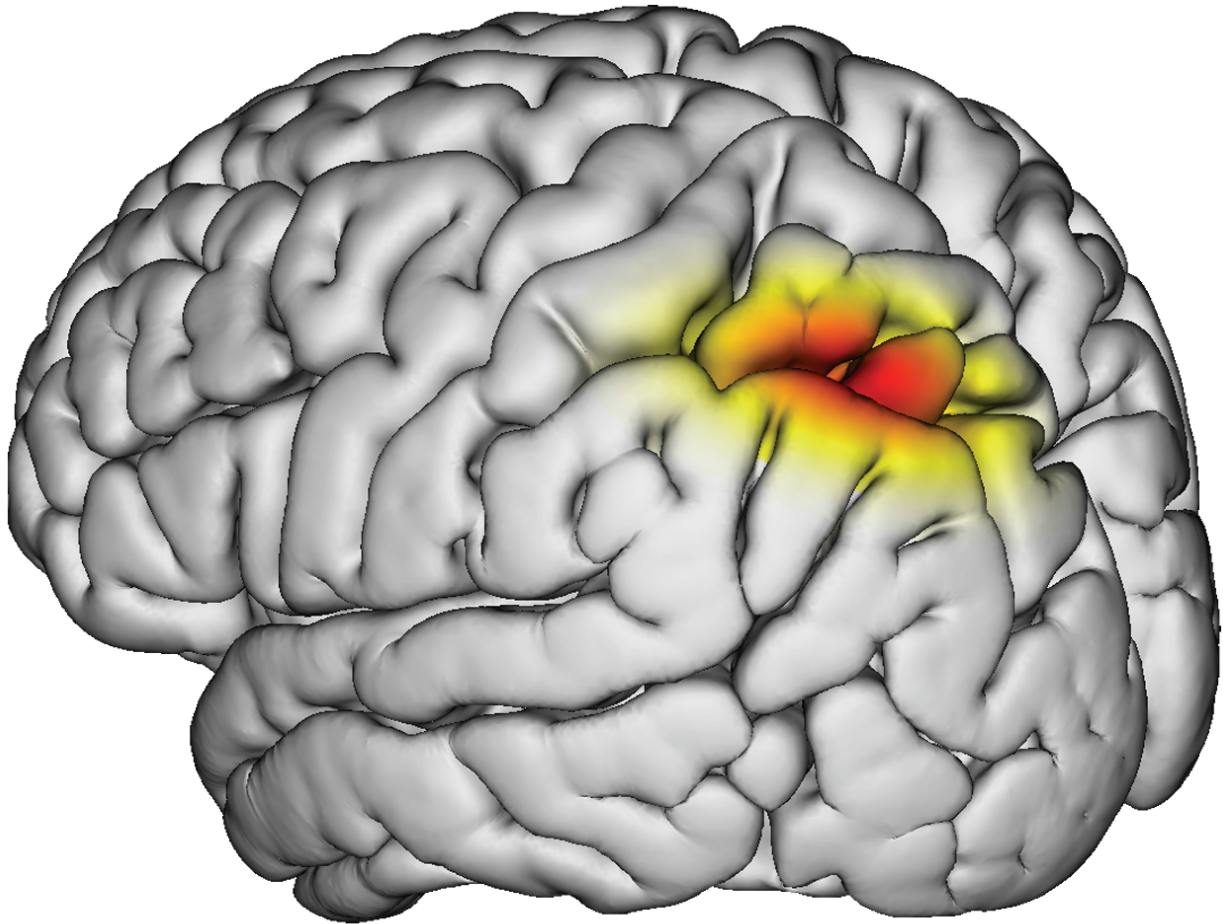
- Lindner A. Motor Control: Parietal Stimulation Prevents Voluntary Hand Movement. *Curr Biol* 2018; 28: R1200-R2.
- Luders HO, Lesser RP, Dinner DS, Morris HH, Wyllie E, Godoy J, *et al.* A negative motor response elicited by electrical stimulation of the human frontal cortex. *Adv Neurol* 1992; 57: 149-57.
- Mackenzie TN, Bailey AZ, Mi PY, Tsang P, Jones CB, Nelson AJ. Human area 5 modulates corticospinal output during movement preparation. *Neuroreport* 2016; 27: 1056-60.
- Maier-Hein KH, Neher PF, Houde JC, Cote MA, Garyfallidis E, Zhong J, *et al.* The challenge of mapping the human connectome based on diffusion tractography. *Nat Commun* 2017; 8: 1349.
- Mollink J, Kleinnijenhuis M, Cappellen van Walsum A-Mv, Sotiropoulos SN, Cottaar M, Mirfin C, *et al.* Evaluating fibre orientation dispersion in white matter: Comparison of diffusion MRI, histology and polarized light imaging. *Neuroimage* 2017; 157: 561-74.
- Mulliken GH, Musallam S, Andersen RA. Forward estimation of movement state in posterior parietal cortex. *Proc Natl Acad Sci U S A* 2008; 105: 8170-7.
- Nii Y, Uematsu S, Lesser RP, Gordon B. Does the central sulcus divide motor and sensory functions? Cortical mapping of human hand areas as revealed by electrical stimulation through subdural grid electrodes. *Neurology* 1996; 46: 360-7.
- Penfield W, Boldrey E. Somatic motor and sensory representation in the cerebral cortex of man as studied by electrical stimulation. *Brain* 1937; 60: 389-443.
- Poupon C, Clark CA, Frouin V, Régis J, Bloch I, Le Bihan D, *et al.* Regularization of diffusion-based direction maps for the tracking of brain white matter fascicles. *Neuroimage* 2000; 12: 184-95.



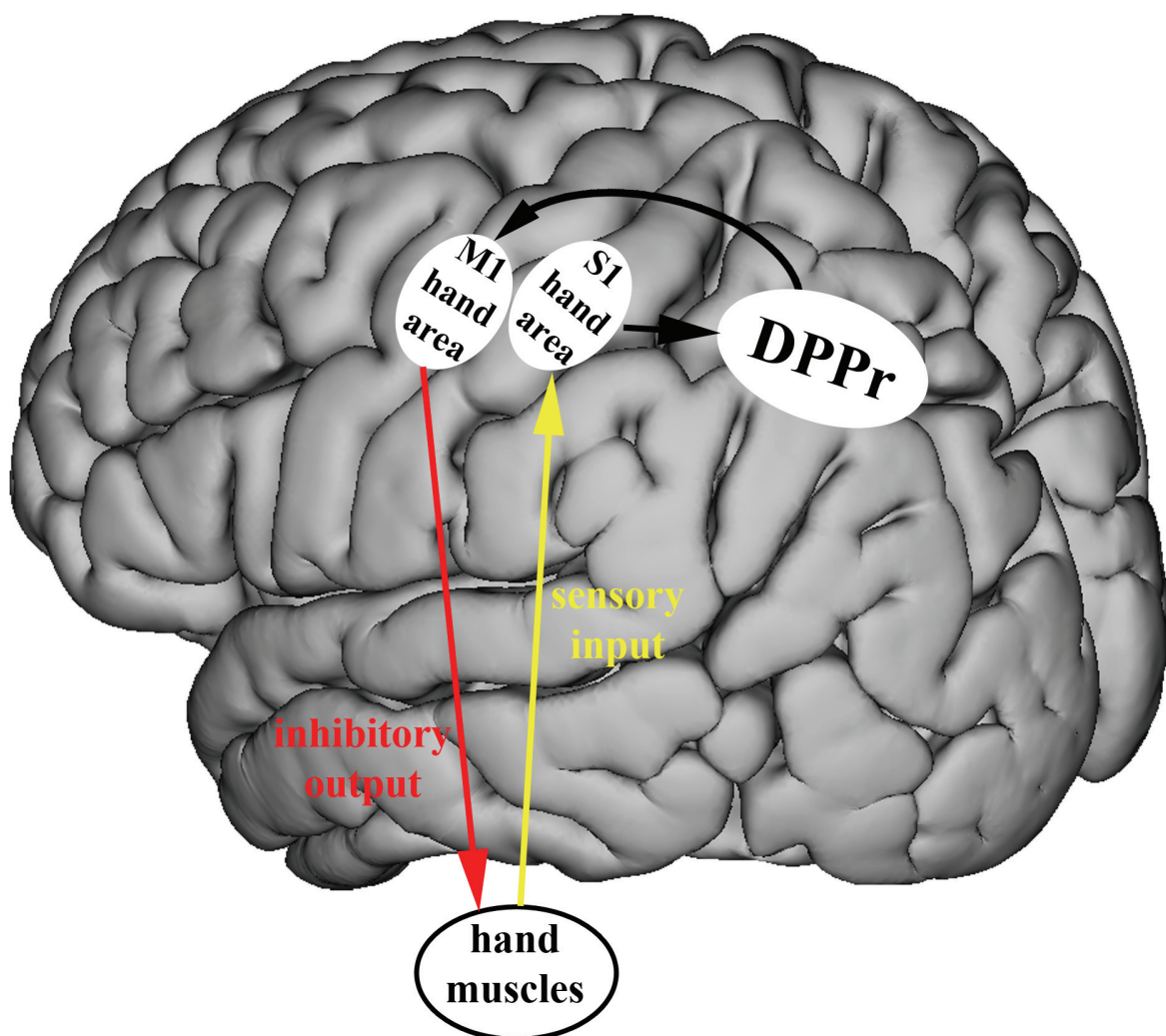
- Reichenbach A, Bresciani JP, Peer A, Bulthoff HH, Thielscher A. Contributions of the PPC to online control of visually guided reaching movements assessed with fMRI-guided TMS. *Cereb Cortex* 2011; 21: 1602-12.
- Reichenbach A, Thielscher A, Peer A, Bulthoff HH, Bresciani JP. A key region in the human parietal cortex for processing proprioceptive hand feedback during reaching movements. *Neuroimage* 2014; 84: 615-25.
- Ribas GC. The cerebral sulci and gyri. *Neurosurg Focus* 2010; 28: E2.
- Rizzolatti G, Luppino G, Matelli M. The organization of the cortical motor system: new concepts. *Electroencephalogr Clin Neurophysiol* 1998; 106: 283-96.
- Sastre-Janer FA, Regis J, Belin P, Mangin JF, Dormont D, Masure MC, *et al.* Three-dimensional reconstruction of the human central sulcus reveals a morphological correlate of the hand area. *Cereb Cortex* 1998; 8: 641-7.
- Sotiropoulos SN, Jbabdi S, Xu J, Andersson JL, Moeller S, Auerbach EJ, *et al.* Advances in diffusion MRI acquisition and processing in the Human Connectome Project. *Neuroimage* 2013; 80: 125-43.
- Todorov E. Optimality principles in sensorimotor control. *Nat Neurosci* 2004; 7: 907-15.
- Tournier JD, Smith RE, Raffelt DA, Tabbara R, Dhollander T, Pietsch M, *et al.* MRtrix3: A fast, flexible and open software framework for medical image processing and visualisation. *Neuroimage* 2019; (in press).
- Tunik E, Frey SH, Grafton ST. Virtual lesions of the anterior intraparietal area disrupt goal-dependent on-line adjustments of grasp. *Nat Neurosci* 2005; 8: 505-11.
- Van Essen D, Smith S, Barch D, Behrens T, Yacoub E, Ugurbil K. The WU-Minn Human Connectome Project: An overview. *Neuroimage* 2013; 80: 62-79.
- Vesia M, Crawford JD. Specialization of reach function in human posterior parietal cortex. *Exp Brain Res* 2012; 221: 1-18.

- Vigano L, Fornia L, Rossi M, Howells H, Leonetti A, Puglisi G, *et al.* Anatomic-functional characterisation of the human "hand-knob": A direct electrophysiological study. *Cortex* 2019; 113: 239-54.
- Wessel JR, Aron AR. On the Globality of Motor Suppression: Unexpected Events and Their Influence on Behavior and Cognition. *Neuron* 2017; 93: 259-80.
- White LE, Andrews TJ, Hulette C, Richards A, Groelle M, Paydarfar J, *et al.* Structure of the human sensorimotor system. I: Morphology and cytoarchitecture of the central sulcus. *Cereb Cortex* 1997; 7: 18-30.
- Wise SP, Boussaoud D, Johnson PB, Caminiti R. Premotor and parietal cortex: corticocortical connectivity and combinatorial computations. *Annu Rev Neurosci* 1997; 20: 25-42.
- Wolpert DM, Ghahramani Z, Jordan MI. An internal model for sensorimotor integration. *Science* 1995; 269: 1880-2.
- Wolpert DM, Goodbody SJ, Husain M. Maintaining internal representations: the role of the human superior parietal lobe. *Nat Neurosci* 1998; 1: 529-33.
- Yousry TA, Schmid UD, Alkadhi H, Schmidt D, Peraud A, Buettner A, *et al.* Localization of the motor hand area to a knob on the precentral gyrus. A new landmark. *Brain* 1997; 120 ( Pt 1): 141-57.

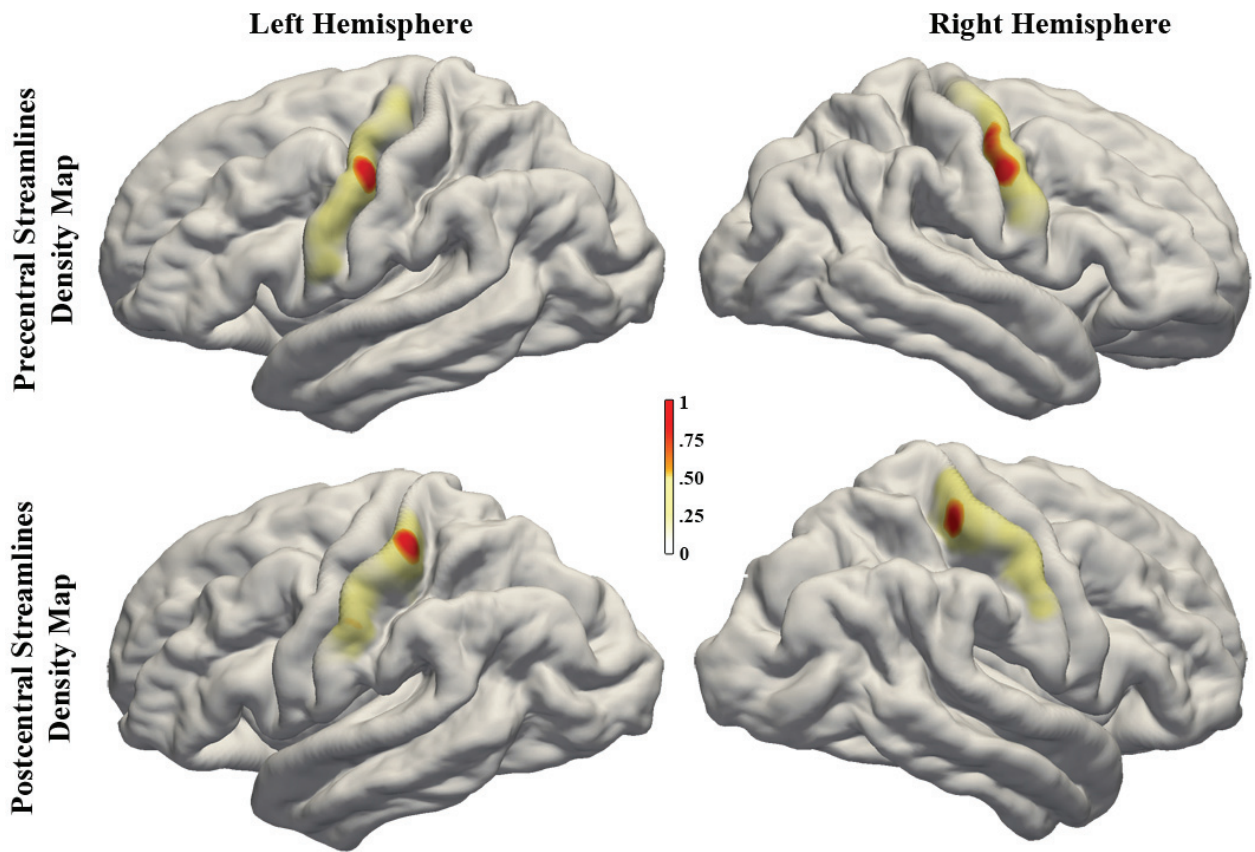
## 6) FIGURES



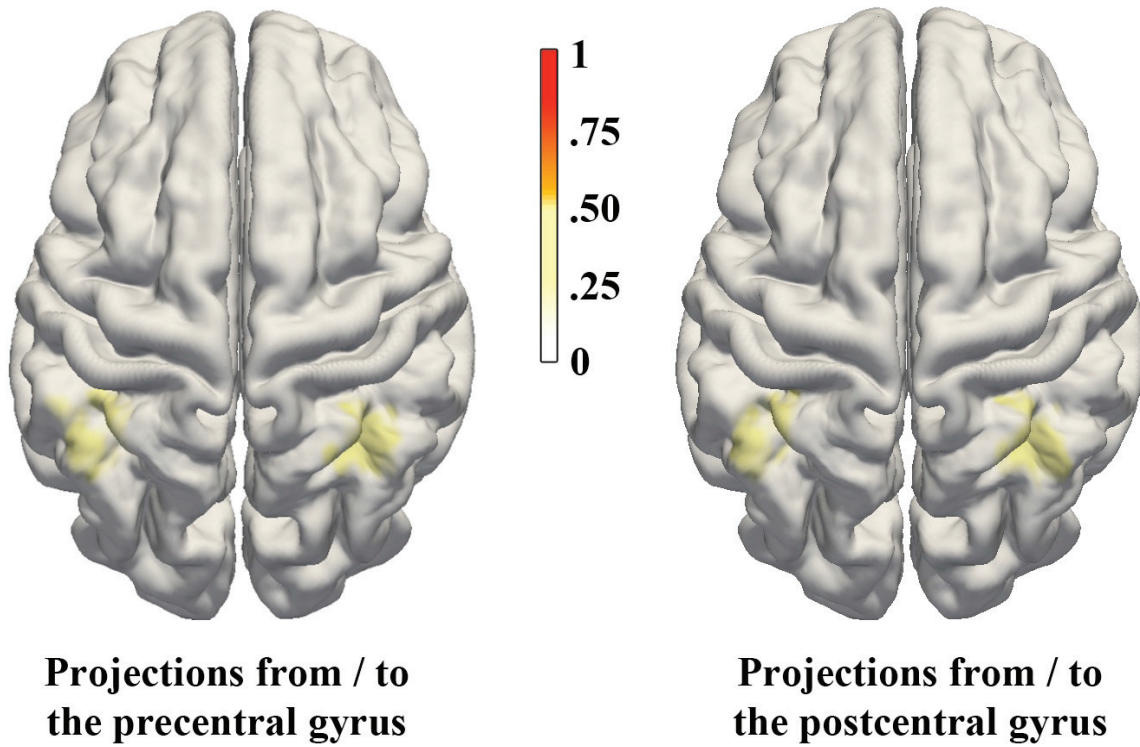
**Figure 1.** Confidence ellipsoid of the dorso-posterior parietal inhibitory region, computed from all the parietal sites which electrical stimulation was found to trigger a selective inhibition of hand movements (n=12). The yellow border displays the 95% confidence border of this ellipsoid. Adapted from (Desmurget *et al.*, 2018)



**Figure 2.** Putative anatomy of the parietal inhibitory network. S1: primary somatosensory cortex. M1: primary motor cortex. DPPr: dorso-posterior parietal region

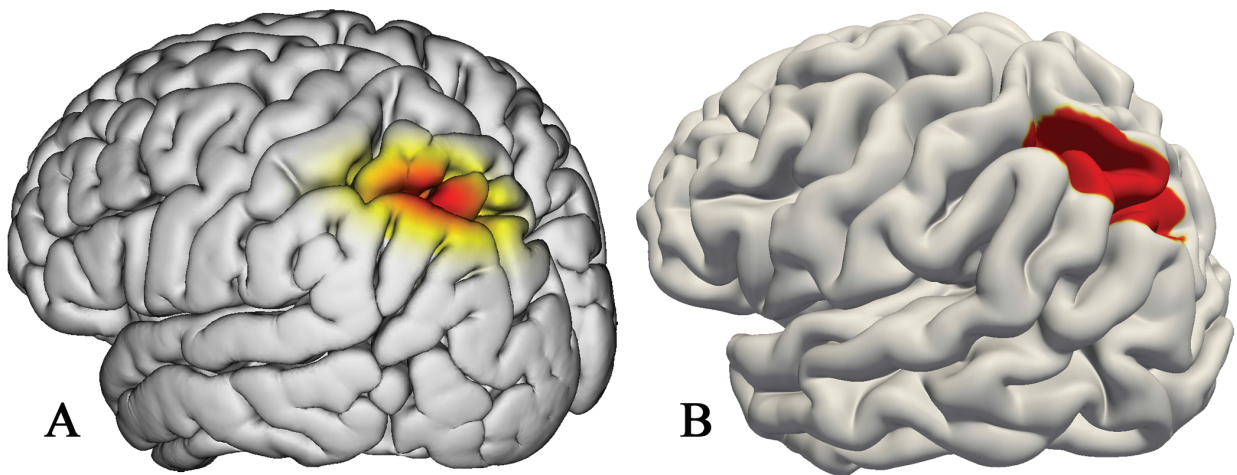


**Figure 3.** Normalized streamlines density maps for the pre and post central gyri (defined from Destrieux's parcellation (Destrieux *et al.*, 2010), projected on to the pial surface of an individual brain. Top line: left hemisphere. Bottom line: right hemisphere.

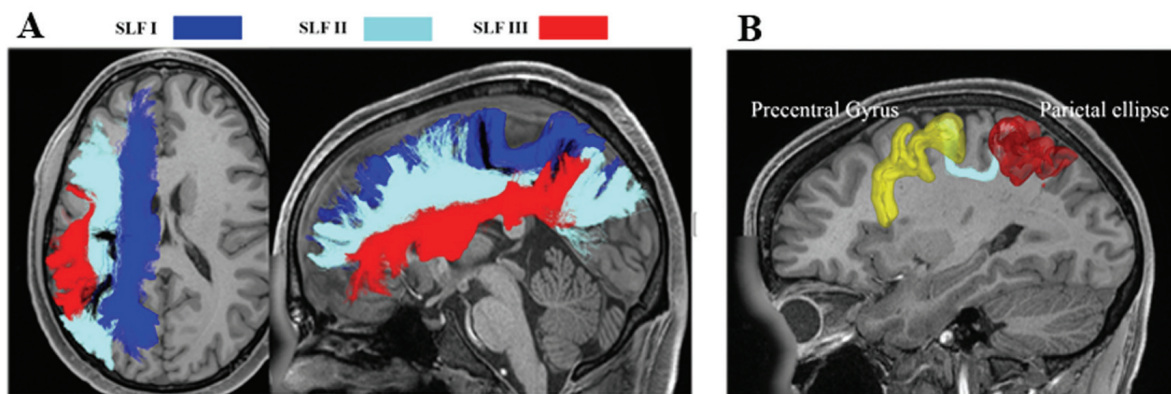


**Figure 4.** Normalized streamlines density maps identified within the dorso-posterior parietal cortex (DPPr; defined per-operatively, Desmurget *et al.*, 2018), projected on to the pial surface of an individual brain.

## 7) SUPPLEMENTAL DATA



**Figure S1.** (A) Dorso-posterior parietal inhibitory region (see also figure 1). (B) Corresponding confidence area projected onto the pial surface of an individual brain.



**Figure S2.** Virtual dissection of the SLF based on the Destrieux's parcellation (Destrieux *et al.*, 2010) and on the known projections of the SLF subcomponents (Hecht *et al.*, 2015). (A) the three main components of the SLF are represented: SLF-I, dark blue; SLF-II, light blue; and SLF-III, red. The black bundle shows the DPRR-M1 pathway. (B) Independent representation of the DPRR-M1 pathway (light blue).

## References

- Destrieux C, Fischl B, Dale A, Halgren E. Automatic parcellation of human cortical gyri and sulci using standard anatomical nomenclature. *Neuroimage* 2010; 53: 1-15.
- Hecht EE, Gutman DA, Bradley BA, Preuss TM, Stout D. Virtual dissection and comparative connectivity of the superior longitudinal fasciculus in chimpanzees and humans. *Neuroimage* 2015; 108: 124-37.



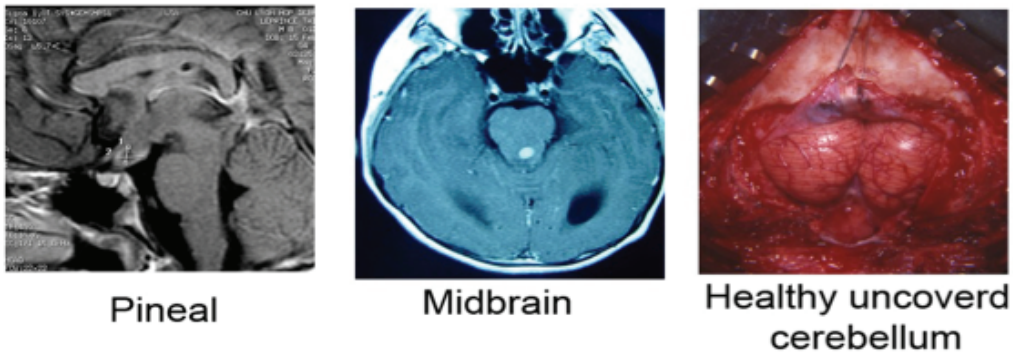
## **C) ROLE OF THE CEREBELLUM IN SENSORI-MOTOR AND HIGHER-LEVEL FUNCTIONS**

## C-1) Scientific Background

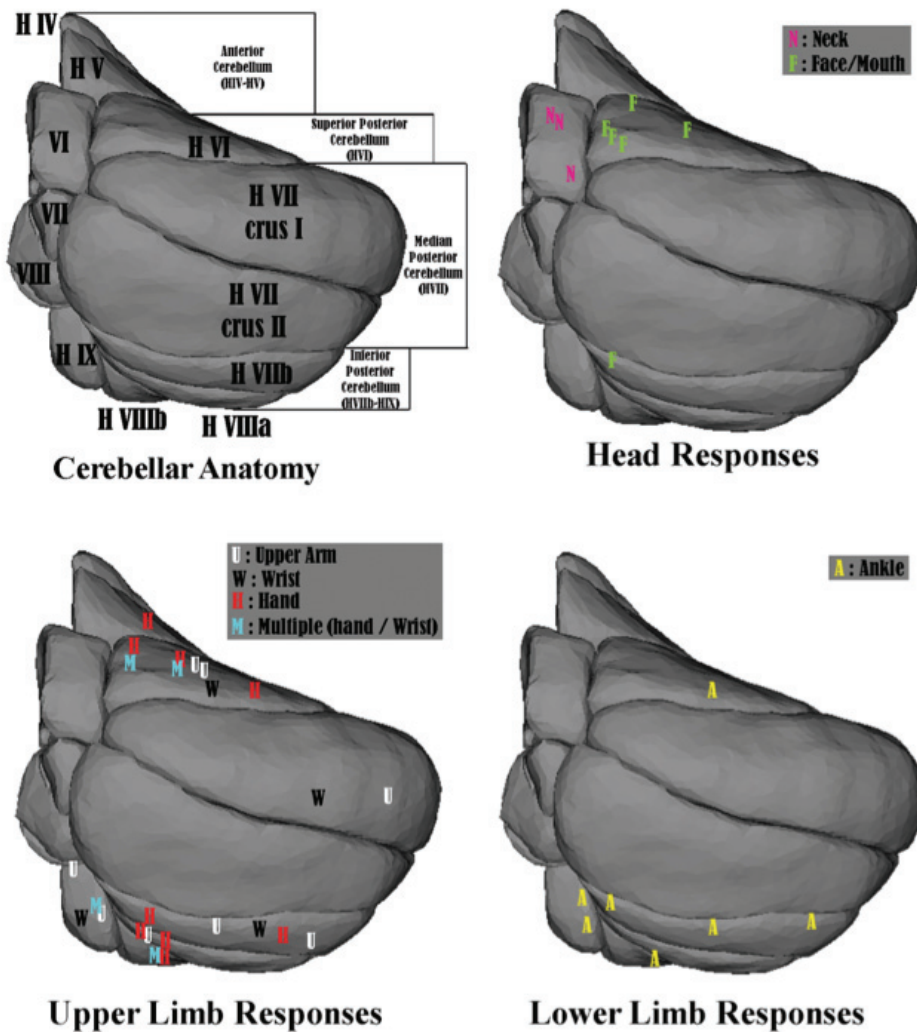
The cerebellum has been traditionally associated with motor control and coordination (Holmes 1939; Horne and Butler 1995; Bastian 2006; Ito 2006; Timmann et al. 2010; Manto et al. 2012; Lisberger 2013; Mottolese et al. 2013). However, more recent evidence has also revealed the link between cerebellar processing and high order cognitive functions, including learning and affective regulations (Schmahmann and Sherman 1998; Strick, Dum, and Fiez 2009; Schmahmann 2010; Stoodley 2012).

In a pioneering series of studies, our research group was the first to investigate motor (efferent) cerebellar somatotopy in patients harboring small extra-cerebellar tumors (i.e. tumors of small size located outside the cerebellum but that required uncovering the cerebellar cortex for their excision; e.g. figure 6 (Mottolese et al. 2013; Mottolese et al. 2015). DES evoked focal responses in the ipsilesional hemibody (figure 7) (Mottolese et al. 2013; Mottolese et al. 2015). Different body segments were represented in different cerebellar regions: head in the vermal lobule VI; face in the hemispheric lobule VI; lower limb in the hemispheric lobules VIIb-IX; and upper limb in the hemispheric lobule VI and hemispheric lobules VIIb-IX. The intermediate regions of the posterior cerebellum (crus) were essentially silent. Strikingly, our results failed to identify any intra or inter-limb somatotopy in the areas where body movements were evoked by stimulation. From a functional point of view, overlapping representations of the upper limb/mouth in the superior posterior lobe and upper limb/lower limb in the inferior posterior lobe might favor the production of integrated motor behaviors between these pairs of segments. Together with latency data existing electrophysiological evidence in animals suggest that these evoked responses were mediated by a descending brainstem pathway.

### Patients with extra-cerebellar tumours



**Figure 6 :** *left Panel : sagittal MRI post gadolinium T1 weighted image showing an extra-cerebellar tumor in the pineal region ; middle panel : axial MRI post gadolinium T1 weighted image showing an extra-cerebellar tumor in midbrain ; right panel : per-operative view of a healthy cerebellum uncover for surgical reason (tumor removal of an extra-cerebellar tumor)*



**Figure 7** : *Location of the evoked motor responses for the head (neck (N), face/mouth (F), upper limb (upper arm (U), wrist (W), hand (H), multi-joint hand/wrist (M)) and lower limb (ankle (A)). (Reprinted with permission from Mottolese et al 2013).*

To date, little is known about the involvement of the cerebellum in sensory functions. Anatomical evidence in primates showed that this structure receives cortical projections from the different sensory systems (Brodal 1978; Brodal 1981). Electrophysiological studies in non-human primate demonstrated the activation of the Purkinje cells and mossy fiber of the cerebellum during passive movement (Bauswein et al. 1983; Bauswein, Kolb, and Rubia 1984), in agreement with the fact that cerebellar neurons receive cortical inputs from all the sensory modalities (Brodal 1978; Brodal 1981). However, early clinical studies failed to report gross sensory deficits after cerebellar damages in humans (Holmes 1939), leading to the idea that the cerebellum did not have a major sensory function. Recently, functional neuroimaging studies have reinvestigated this issue. To say the least, evidence was mixed. A few studies confirmed that the cerebellum had no role in the sensory processing: they failed, for instance, to identify cerebellar activation during passive movement tasks (Seitz and Roland 1992; Tempel and Perlmutter 1992; Burton, Videen, and Raichle 1993; Casey et al. 1996; Mima et al. 1999; Weeks et al. 1999). By contrast, using similar paradigms (passive movement or tactile stimulation), other studies found significant responses not only in the cerebellar cortex but also in the deep cerebellar nuclei (Gao et al. 1996; Jueptner et al. 1997; Liu et al. 2000; Bushara et al. 2001; Takanashi et al. 2003; Thickbroom, Byrnes, and Mastaglia 2003; Habas, Axelrad, and Cabanis 2004; Ciccarelli et al. 2005; Guzzetta et al. 2007; Macaluso, Cherubini, and Sabatini 2007; Kavounoudias et al. 2008; Francis et al. 2009; Gentile, Petkova, and Ehrsson 2011; Wiestler, McGonigle, and Diedrichsen 2011; Van de Winckel et al. 2013; van der Zwaag et al. 2013; Boscolo Galazzo et al. 2014). However, these studies did not report a clear somatotopic organization and multiple (generally different) loci of activation were found in the anterior

and/or posterior lobe. In addition, while some studies found only ipsilateral activations, others found bilateral or even only contralateral responses (Macaluso, Cherubini, and Sabatini 2007; van der Zwaag et al. 2013; Boscolo Galazzo et al. 2014).

# C-2) Paper 4: Cerebellar lesions at a young age predict poorer long-term recovery

*Submitted*

Pierre-Aurélien Beuriat<sup>1,2,3,\*</sup>, Irene Cristofori<sup>1,2,\*</sup>, Nathalie Richard<sup>1,2</sup>, Lara Bardi<sup>1,2</sup>, Alexandru Szathmari<sup>1,2,3</sup>, Federico Di Rocco<sup>2,3</sup>, Pierre Leblond<sup>4</sup>, Didier Frappaz<sup>4</sup>, Cécile Faure-Contier<sup>4</sup>, Line Claude<sup>5</sup>, Carmine Mottolese<sup>1,2,3</sup> and Michel Desmurget<sup>1,2</sup>.

\* These authors contributed equally to this work

## **Author' Affiliations:**

<sup>1</sup> Institute of Cognitive Neuroscience Marc Jeannerod, CNRS / UMR 5229, 69500 Bron, France

<sup>2</sup> Université Claude Bernard, Lyon 1, 69100 Villeurbanne, France

<sup>3</sup> Department of Pediatric Neurosurgery, Hôpital Femme Mère Enfant, 69500, Bron, France

<sup>4</sup> Department of Pediatric Hematology and Oncology, Institut d'hématologie et d'oncologie Pédiatrique, 69008 Lyon

<sup>5</sup> Department of Radiotherapy, Centre Léon Bérard, 69008 Lyon

## 1) ABSTRACT

Early studies on long-term functional recovery after motor and premotor lesions showed better outcomes in younger than older monkeys. This finding led to the widespread belief that brain injuries cause less impairment in children than adults. However, this view has limitations and a large body of evidence now indicates that cerebral damages can be more harmful when inflicted at young age, during critical periods of neural development.

To date, this issue has been mainly investigated in the context of focal and diffuse cortical lesions. Much less is known about the potential influence of early cerebellar damages. Several studies exist in survivor of posterior fossa tumors. However, in these studies critical confounders were not always considered and contradictory conclusions were provided.

Here, we studied the impact of early cerebellar damage on long-term functional recovery in 3 groups of fifteen posterior fossa survivors, comparable with respect to their tumoural characteristics (nature size and location) but operated at different ages: young ( $\leq 7$  years), middle ( $> 7$  years and  $\leq 13$  years) and old ( $> 13$  years). Daily (Health-related Quality of Life - hrQoL-, Performance Status -PS-), motor (International Cooperative Ataxia Rating Scale - ICARS-, Pegboard Purdue Test -PegBoard-) and cognitive (Full Scale Intelligence Quotient - FSIQ-) functioning were measured. A General Linear Model controlling for age at surgery, radiotherapy, preservation of deep-cerebellar nuclei, tumor volume and delay between surgery and assessment, was used to investigate significant variations in outcome measures.

Early age at surgery, lesion of deep cerebellar nuclei and post-operative radiotherapy had a significant, independent negative influence on long term recovery. Tumor volume and delay between surgery and assessment had no statistically detectable impact. The negative influence of early age at surgery was significant in all domains: daily functioning (hrQoL; PS), motor functioning (ICARS; Pegboard) and cognitive functioning (FSIQ).

These results support the existence of an early critical period of development during which the cerebellar "learning machine" is of critical importance. Although the extent to which the early deficits here observed can be reversed needs now to be established, our data plead for the implementation of prompt and intense rehabilitation interventions in children operated before 7 years of age.

**Keywords.** Cerebellum; Kennard principle; posterior fossa tumor; cognitive recovery; sensorimotor recovery; quality of life; age at surgery.

## 2) INTRODUCTION

Eighty years ago, Margaret Kennard showed that long-term functional recovery was better in younger than older monkeys following experimental lesions of the motor and premotor cortices (Kennard, 1942). This finding, later coined the "Kennard principle", led to the widespread belief that brain injuries cause less impairment in children than adults (Webb *et al.*, 1996; Johnson *et al.*, 2003). However, as first emphasized by Kennard herself (Dennis, 2010), this view has limitations. Indeed, a large body of evidence now indicates that cerebral damages can actually be more harmful when inflicted at a young age, during critical periods of neural development (Taylor and Alden, 1997; Forsyth, 2010; Anderson *et al.*, 2011; Krageloh-Mann *et al.*, 2017).

To date, the impact of age on functional recovery has been mainly investigated in the context of focal and diffuse cortical injuries (Taylor and Alden, 1997; Forsyth, 2010; Anderson *et al.*, 2011; Krageloh-Mann *et al.*, 2017). Much less attention has been given to the issue whether the "Kennard Principle" holds for cerebellar lesions. This is regrettable for at least two reasons. First, the cerebellum is an essential motor and cognitive structure of the nervous



system (Horne and Butler, 1995; Ito, 2006; Strick *et al.*, 2009; Timmann *et al.*, 2010; Stoodley, 2012; Koziol *et al.*, 2014). Second, and perhaps more importantly, this structure is the most frequent surgical target for tumor removal in children (Kaye and Laws, 2001; McKean-Cowdin *et al.*, 2013).

Previous studies have reported that cerebellar surgeries performed at a young age tend to produce more severe, long-lasting deficits in both the motor and cognitive domains (Dennis *et al.*, 1996; von Hoff *et al.*, 2008; Robinson *et al.*, 2013; Hanzlik *et al.*, 2015). However, the origin of this observation remains debated. It is often claimed to reflect the more deleterious impact of post-operative radiation therapies in young children (Packer *et al.*, 1989; Hoppe-Hirsch *et al.*, 1990; Copeland *et al.*, 1999; Conklin *et al.*, 2008; Moxon-Emre *et al.*, 2014). Consistent with this explanation, several studies have identified either no effect (Steinlin *et al.*, 2003; Konczak *et al.*, 2005; Ronning *et al.*, 2005) or positive effects (Levisohn *et al.*, 2000) of age at surgery on long-term sensorimotor and cognitive functions, in non-irradiated patients. However, other studies have reported contradictory findings (Aarsen *et al.*, 2006; Aarsen *et al.*, 2009). In agreement with these studies, pioneering observations, in animals, have shown that early hemispherectomies predict higher levels of functional deficits than late hemispherectomies (Smith *et al.*, 1974; Gramsbergen, 1982); although contradictory conclusion have been reported (Molinari *et al.*, 1990).

Most probably, the inconsistencies above are related to experimental factors. Indeed, despite their major contribution to the field, most studies that have investigated the effect of age at surgery on functional recovery have either based their conclusions on very small samples of young patients (Konczak *et al.*, 2005) or have failed to control for important potential confounders, including tumor size, delay between surgery and assessment time, and/or damages to the deep cerebellar nuclei (Steinlin *et al.*, 2003; Ronning *et al.*, 2005; Aarsen *et al.*, 2006; Aarsen *et al.*, 2009).

Given the importance of developing the best intervention strategies in children and adults affected by cerebellar tumor, solving the existing contradictions in our current knowledge is highly desirable. This is the goal of the present study which aims to evaluate the validity of Kennard principle in the context of cerebellar injuries. In keeping with previous studies, we set the cutoff for "young age" at 7 years (Chin and Maruyama, 1984; Ellenberg *et al.*, 1987; Packer *et al.*, 1989; Chapman *et al.*, 1995; Riva *et al.*, 2002; Mitby *et al.*, 2003; Conklin *et al.*, 2008; Robinson *et al.*, 2013). Our results show that early damages ( $\leq 7$  years old) predict poorer recovery than late damage ( $> 7$  years old) independent of radiotherapy, tumor characteristics, delay between surgery and assessment time, and damages to the deep cerebellar nuclei.

### **3) PATIENTS AND METHODS**

#### **a) Patients**

Over a 18-month period, 45 patients were recruited. They were all operated under general anesthesia between 2001 and 2016 by the same neurosurgeons (CM, ASz). Within two weeks of their routine follow-up appointment (annual or bi-annual), these patients were contacted (or their legal guardians for minors) and invited to participate in a long-term follow-up study, in addition to their standard clinical evaluation. They were told that this additional evaluation would last around 2 hours and require the fulfillment of a series of non-invasive cognitive and motor tests (see below). If the patients (or their legal guardians for minors) agreed, testing was scheduled on the day of their appointment and, if not possible, within the following month. For all patients, formal consent was obtained (from the patients themselves or their legal guardians for minors) according to a protocol approved by our local institutional ethical committee and in agreement with the precepts of the Helsinki Declaration.

Patient recruitment was framed by a dual goal. First, investigating the effect of age on long-term recovery. Second, identifying potential interactions between age and other key factors that have been shown to affect recovery (e.g. as observed above it is possible that early age has a deleterious effect because post-operative radiotherapy or lesion of the deep-cerebellar nuclei is more damaging in younger children; if this is the case, statistical analyses should reveal a significant interaction between these factors -see below-). To achieve these goals, we tried to minimize clinical disparities between experimental groups of different ages while ensuring sufficient variations of the factors of interest within each group. Inclusion criteria reflected these constraints. They were as follows: (i) having been subjected to a surgical procedure for the removal of a cerebellar tumor, at least one year before evaluation; (ii) exhibiting a total tumor removal with no subsequent recurrence; (iii) being free of chronic or ongoing medical treatments; (iv) suffering no transient post-operative complications capable of interfering with recovery (including mutism); (v) being older than six years at the time of evaluation; (vi) speaking French as mother tongue.

First, all eligible patients younger than 7 years at the time of surgery were identified (n = 15). None declined to participate in the study. Second, we paired each of these young patients with a middle ( $> 7$  years and  $\leq 13$  years) and older age ( $> 13$  years) peer according to tumor characteristics (type, location, volume) and radiation therapy. In other words, as emphasized above, we recruited 3 groups of 15 patients that were both different according to their age (younger, middle, older) but as comparable as possible with respect to their clinical characteristics. The main demographic and clinical characteristics of these patients are summarized in supplementary table S1. This table also reports statistical analyses showing the comparability of the three age-groups for these characteristics.

To avoid ambiguity, it must be mentioned that the vast majority of cerebellar tumors, in young children, are located within the midline (vermal) area, with or without hemispheric

extension (Poretti *et al.*, 2012; Koob and Girard, 2014). Our clinical sample reflects this epidemiological "bias": all the patients of the young age group exhibited lesions encompassing the vermis with or without hemispheric extension. Due to the pairing procedure used for ensuring clinical comparability across age groups (see above), the same spatial distribution was observed in the older patients (middle, old). Supplementary figure S1 displays a lesion overlap map for the three age groups.

### **b) Clinical assessments**

Patients were first submitted to a series of clinical questionnaires to measure their overall quality of life, their ability to live an independent life and the intensity of their ataxic symptoms. These evaluations were carried out by a trained physician (PAB) who was blind to patients' clinical history and imaging results.

Health-related Quality of Life (hrQoL). This scale measures the self-perceived well-being of the patients. In patients older than 16 years, this dimension was assessed with a standardized questionnaire: the EORTC Quality of Life Questionnaire (EORTC QLQ-C30) (Aaronson *et al.*, 1993). In children younger than 16 years, hrQoL was assessed with the corresponding pediatric questionnaire: the Pediatric Quality of Life Inventory (PedQoL 4.0) (Varni *et al.*, 2001). In this case, self-reports were privileged, but parent proxy-report were sometimes used when the children were too young or too cognitively impaired to complete the questionnaire (Varni *et al.*, 2007). For both scales, final mean scores between 0 and 100 were obtained after linear normalization of raw scores. Based on previous studies in healthy adults and children populations, we used a conservative mean score of 60, as the threshold value for defining a "good quality of life" (Dancey *et al.*, 1997; van de Poll-Franse *et al.*, 2011).

Performance Status (PS). PS is a standardized scale designed to evaluate patients' ability to carry out (ordinary) daily activities. Depending on patient age, we used the Karnofsky

Performance Status ( $\geq 16$  years) (Sachsenheimer *et al.*, 1992) or Lansky Scale ( $< 16$  years) (Lansky *et al.*, 1987). The final score ranges from 0 to 100. A higher score reflects a better ability to live an independent life. The score of 70 is considered the threshold above which the patient can care for himself and is able to carry out normal daily activity independently.

*International Cooperative Ataxia Rating Scale (ICARS)*. ICARS is a standardized scale designed to measure severity of cerebellar ataxia in patients (Trouillas *et al.*, 1997). The final score grows with disease severity from 0 to 100. For healthy subjects ICARS score is typically below 7 (Storey *et al.*, 2004).

### **c) Cognitive and sensorimotor assessments**

These evaluations were carried out to measure fine sensorimotor functions and general intelligence of the patients. They were completed under the supervision of a licensed neuropsychologist (MD) who was blind to the patients' clinical history and imaging results.

*Pegboard Purdue Bimanual Assembly Task (PegBoard)*. *PegBoard* assesses upper-limb movements with a special emphasis on manual dexterity (Tiffin and Asher, 1948). The material consists of a wood board of two parallel rows of 25 holes each. The bimanual assembly task captures sensorimotor deficits irrespective of hand dominance and tumor laterality. The subject is instructed to use both hands alternatively to build as many object assemblies over a 60 s time period: put a pin in the hole with one hand, then a washer on the pin with the other hand, then a collar with the first hand, then another a washer with the other hand. The final score is obtained through averaging of 3 consecutive repetitions. For each participant, this score is then evaluated as a deviation (in percent) with respect to the mean expected performance (adjusted for age and sex).

*Intelligence Quotient (IQ)*. The Full Scale Intelligence Quotient (FSIQ) of the Wechsler Intelligence Scale was administered as a gold standard measure of cognitive functions. The

Wechsler Adult Intelligence Scale fourth edition (WAIS-IV, French version) (Wechsler, 2011) was used for patients older than 17 years. The Wechsler Intelligence Scale for Children fourth edition (WISC-IV, French version) (Wechsler, 2005) was used for patients younger than 17 years.

#### **d) Tumor volume and preservation of cerebellar nuclei**

For each patient, anatomical normalization of the cerebellum was performed on pre-operative high resolution magnetic resonance image (MRI) with the SUIIT toolbox of the SPM12b software (<http://www.diedrichsenlab.org/imaging/suit.htm>). Tumors were manually drawn on individual MRI and excluded from the normalization procedure. Damages within the deep cerebellar nuclei were automatically determined from normalized images by identifying areas of overlap between the tumors mesh and deep nuclei. Outcomes of this automatic procedure were visually reviewed on individual MRI images.

#### *Statistical analysis*

A General Linear Model was used to investigate the origin of significant variations in the outcome measures described above. The following predictors were entered in the model. *Age at surgery*, three levels: younger ( $\leq 7$  years); middle ( $> 7$  years and  $\leq 13$  years); older ( $> 13$  years). *Radiation therapy*, two levels: no; yes. *Deep cerebellar nuclei*, two levels: preserved (all nuclei intact); lesioned (nuclei lesioned). *Tumor volume* and *delay between surgery and assessment*, which could not be unambiguously categorized, were entered as continuous factors in the model. All analyses were performed with the statistical software Statistica (version 8.0; StatSoft®). Duncan significant difference test was used for post-hoc comparisons (Winer, 1971). Threshold for statistical significance was set at  $p = .05$ .

#### 4) RESULTS

From a clinical point of view, the patients of our sample fared quite well. In majority, they reported a good quality of life (hrQoL > 60; 80 %) and were able to carry out daily activities independently (PS > 70; 93 %). At the time of the evaluation, all children below 18 (n = 29) were enrolled in regular school programs (7 showed academic backwardness). Among adults (n = 16), 11 owned a driving license (in France, only adults older than 18 can have a driving license); 5 were working full time, 7 were enrolled in post-graduate programs (academic or vocational), 4 were unemployed. Severe cognitive impairments were relatively rare. Intellectual disabilities, characterized by a Full Scale IQ score below 70, were only observed in 9 % of the patients (3.9 times the proportion expected from the theoretical IQ distribution - 2.3 %-). Mild deficits, characterized by a Full Scale IQ score between 70 and 85, were found in 20 % of the patients (1.5 times the proportion expected from the theoretical IQ distribution - 13.6 %-). Still, more than half of the patients displayed detectable signs of cerebellar ataxia (ICARS > 7; 51 %). More than a third had difficulties performing fine distal motor tasks (PegBoard < Mean - 2\*SD of the norm; 36 %).

This general pattern of favorable outcomes was accompanied by a substantial level of inter-individual variability. Several factors accounted for this observation including age at surgery (see supplementary table S2 for statistical details). When surgery was performed before 7 years of age, all markers of functional recovery were significantly deteriorated (figure 1). As shown by post-hoc analyses, the performance average of the young age group was systematically degraded with respect to the performance of the middle and old age groups (all ps < .045). These latter two groups were not different from each other (all ps > .450). Overall, young patients experienced a lower quality of life (hrQoL;  $F_{(2,31)} = 4.50$ ,  $p = .019$ ) and a degraded ability to carry out common daily activities (PS;  $F_{(2,31)} = 3.68$ ,  $p = .037$ ). Also, these patients exhibited stronger ataxic symptoms (ICARS;  $F_{(2,31)} = 4.62$ ,  $p = .018$ ), a greater inability to

perform fine manual movements (PegBoard;  $F_{(2,31)}= 3.34$ ,  $p = .048$ ) and a lower intelligence quotient (FSIQ;  $F_{(2,31)}= 4.39$ ,  $p = .021$ ). The effect of age was statistically independent of the influence of the other factors included in the model (interactions, all  $ps > .130$ ).

Beyond age at surgery, lesion of the deep cerebellar nuclei was also an important negative, independent (no interactions; all  $ps > .240$ ) predictor of functional recovery (figure 2). When these nuclei were injured, patients' ability to perform regular daily activities was lessened (PS;  $F_{(1,31)}= 5.60$ ,  $p = .024$ ), ataxic symptoms were stronger (ICARS;  $F_{(1,31)}= 7.97$ ,  $p = .008$ ), manual dexterity was degraded (PegBoard;  $F_{(1,31)}= 16.00$ ,  $p = .0004$ ) and intelligence quotient was diminished (FSIQ;  $F_{(1,31)}= 16.66$ ,  $p = .0003$ ). Differences observed for the quality of life scale failed to reach statistical significance (hrQoL;  $F_{(1,31)}= 1.46$ ,  $p = .236$ ).

Finally, a significant, independent (no interactions; all  $ps > .130$ ) negative influence of post-operative radiotherapy was observed for fine motor abilities (PegBoard;  $F_{(1,31)}= 4.84$ ,  $p = .035$ ) and quality of life (hrQOL;  $F_{(1,31)}= 4.34$ ,  $p = .045$ ). Negative trends were also identified for cognitive outcomes (FSIQ), ataxic symptoms (ICARS) and regular daily activities (PS) (figure 3). However, none reached statistical significance (all  $F_{S(1,31)} < 2.43$ ,  $ps > .130$ ).

Tumor volume and the time elapsed from surgery to assessment had no statistically detectable impact on the measured variables (all  $F_{S(1,31)} < 3.61$ ,  $ps > .065$ ).

## **5) DISCUSSION**

To sum up, the main aim of the present study was to clarify the debated issue whether young age at surgery is, in itself, an independent predictive factor of poor functional recovery in survivors of posterior fossa tumors. Our results provide a positive answer to this question. Indeed, we observe that patients operated before 7 years of age show degraded outcomes with respect to patients operated after this age. This negative influence is observed across all the



dependent measures considered in this study: daily functioning (hrQoL, PS); motor functioning (ICARS, PegBoard); and cognitive functioning (FSIQ).

Two complementary lines of evidence may account for the identified relationship between early cerebellar lesions and impaired recovery: (i) the cerebellum plays a central role in motor and cognitive learning (Ito, 2006; Koziol *et al.*, 2014; Sokolov *et al.*, 2017); (ii) during early childhood, sensitive periods cascade to lay the foundations for future acquisitions (Anderson *et al.*, 2011). Within this framework, it may be speculated that early lesions of the cerebellum, a structure seen as a "*broad learning machine*" (Ito, 2006), damage the development of cardinal functional skills (motor and cognitive) upon which later acquisitions are built.

Although the extent to which this negative impact of early cerebellar lesions can be reversed needs now to be established, our results clearly plead for the implementation of heavy rehabilitation programs in children operated before 7 years of age. Evidence exist that these programs are efficient at remediating existing deficits and preventing gradual deterioration (Castellino *et al.*, 2014; Olson and Sands, 2016). With regard to this latter point, it is worth noting that we found no sign of functional worsening over time. A similar observation was reported in previous studies (Copeland *et al.*, 1999; Konczak *et al.*, 2005; von Hoff *et al.*, 2008). Others, however, have described a progressive worsening (Hoppe-Hirsch *et al.*, 1990; Dennis *et al.*, 1996; Aarsen *et al.*, 2006; Conklin *et al.*, 2008). We cannot rule out the possibility that our follow up-duration (5 years on average) was too short to allow for such a gradual deterioration to reach a detectable threshold. Alternatively, it is also possible that our study was not sensitive enough for identifying longitudinal changes, due to the high inter-subject variability inherent to cross-sectional designs.

Another interesting finding of the present study concerns the potential impact of tumor volume on functional recovery. The existing literature provides conflicting observations on this issue. Some studies have reported a significant relation (Catsman-Berrevoets *et al.*, 1999; Law

*et al.*, 2012) while others, like the present one, found no association (Steinlin *et al.*, 2003; Konczak *et al.*, 2005; Kuper *et al.*, 2013). It is tempting to speculate that this divergence reflects the failure of positive studies to control for the anatomical status of the deep cerebellar nuclei. Indeed, the risk for these nuclei to be damaged increases with tumor volume. Ours and previous studies that have taken this factor into account found no effect of tumor volume on recovery (Konczak *et al.*, 2005; Kuper *et al.*, 2013). This finding is not unexpected in light of ablation experiments showing, in monkeys, that large lesions involving different lobes of the cerebellar cortex produces very mild, often undetectable, deficits as long as the deep nuclei are spared (Dow and Moruzzi, 1958). From a surgical point of view, this observation supports aggressive gross-total resections as long as the cerebellar nuclei can be preserved. When this is not the case, the possibility of near total resections protecting these nuclei should be considered (ex: medulloblastomas (Thompson *et al.*, 2016)). When complete resections are advised (ex: ependymomas (Guyotat *et al.*, 2009)), a special emphasis should be put on post-surgical rehabilitation procedures.

Our results also confirm the well-established impact of post-surgical radiotherapy on functional recovery (see introduction). However, this effect was only significant for fine motor abilities (PegBoard) and the self-perceived well-being of the patients (hrQol). Only a trend was found for ICARS, FSIQ and PS. Radiotherapy protocols might explain these results. Indeed, past studies involving standard craniospinal irradiation have almost unanimously reported long term intellectual deficits after radiotherapy (Packer *et al.*, 1989; Hoppe-Hirsch *et al.*, 1990; Palmer *et al.*, 2003). However, more recent researches have described more favorable outcomes in the context of less aggressive protocols involving lower dose radiations (e.g., 25 Gy rather than 36 Gy) (Grill *et al.*, 1999; Moxon-Emre *et al.*, 2014), hyperfractionated radiations (Gupta *et al.*, 2012; Kennedy *et al.*, 2014) or radiations circumscribed to the posterior fossa (Fouladi

*et al.*, 2005; von Hoff *et al.*, 2008). In our cohort, 88 % of the 25 patients exposed to radiotherapy were submitted to these less aggressive protocols.

In summary, our results support the conclusion that cerebellar lesion have more negative impact on long-term functional recovery when inflicted at a young age. This finding pleads for the implementation of prompt and intense rehabilitation interventions in children with posterior fossa tumors, operated before 7 years of age. Further studies are now required to confirm this observation and extend it to more hemispheric lesions. Indeed, all our patients had tumors centered on the midline (vermal) region, either purely or with some degree of hemispheric extension. This bias reflects the over-representation of midline tumors in young children (Poretti *et al.*, 2012; Koob and Girard, 2014) and, in this sense, ensues directly from the goal of this study. Whether our findings can be generalized to other subpopulation of patients with more lateral lesion needs to be investigated.

### **Data availability**

The data supporting the findings of this study are available from the corresponding author upon reasonable request. They are not publicly available because of ethical restrictions.

### **Funding**

This work was supported by the Centre National de la Recherche Scientifique (CNRS), the Agence Nationale de la Recherche (ANR-12-BSV4-0018-01; ANR-16-CE37-0017-01) and the LABEX CORTEX (ANR-11-LABX-0042) of Université de Lyon, within the ANR program "Investissements d'Avenir" (ANR-11-IDEX-0007).

### **Conflict of Interest.**

The authors declare no conflict of interest.

## **REFERENCES**

- Aaronson NK, Ahmedzai S, Bergman B, Bullinger M, Cull A, Duez NJ, *et al.* The European Organization for Research and Treatment of Cancer QLQ-C30: a quality-of-life instrument for use in international clinical trials in oncology. *J Natl Cancer Inst* 1993; 85: 365-76.
- Aarsen FK, Paquier PF, Arts WF, Van Veelen ML, Michiels E, Lequin M, *et al.* Cognitive deficits and predictors 3 years after diagnosis of a pilocytic astrocytoma in childhood. *J Clin Oncol* 2009; 27: 3526-32.
- Aarsen FK, Paquier PF, Reddingius RE, Streng IC, Arts WF, Evera-Preesman M, *et al.* Functional outcome after low-grade astrocytoma treatment in childhood. *Cancer* 2006; 106: 396-402.
- Anderson V, Spencer-Smith M, Wood A. Do children really recover better? Neurobehavioural plasticity after early brain insult. *Brain* 2011; 134: 2197-221.
- Castellino SM, Ullrich NJ, Whelen MJ, Lange BJ. Developing interventions for cancer-related cognitive dysfunction in childhood cancer survivors. *J Natl Cancer Inst* 2014; 106.
- Catsman-Berrevoets CE, Van Dongen HR, Mulder PG, Paz y Geuze D, Paquier PF, Lequin MH. Tumour type and size are high risk factors for the syndrome of "cerebellar" mutism and subsequent dysarthria. *J Neurol Neurosurg Psychiatry* 1999; 67: 755-7.
- Chapman CA, Waber DP, Bernstein JH, Pomeroy SL, LaVally B, Sallan SE, *et al.* Neurobehavioral and neurologic outcome in long-term survivors of posterior fossa brain tumors: role of age and perioperative factors. *J Child Neurol* 1995; 10: 209-12.
- Chin HW, Maruyama Y. Age at treatment and long-term performance results in medulloblastoma. *Cancer* 1984; 53: 1952-8.

- Conklin HM, Li C, Xiong X, Ogg RJ, Merchant TE. Predicting change in academic abilities after conformal radiation therapy for localized ependymoma. *J Clin Oncol* 2008; 26: 3965-70.
- Copeland DR, deMoor C, Moore BD, 3rd, Ater JL. Neurocognitive development of children after a cerebellar tumor in infancy: A longitudinal study. *J Clin Oncol* 1999; 17: 3476-86.
- Dancey J, Zee B, Osoba D, Whitehead M, Lu F, Kaizer L, *et al.* Quality of life scores: an independent prognostic variable in a general population of cancer patients receiving chemotherapy. *Qual Life Res* 1997; 6: 151-8.
- Dennis M. Margaret Kennard (1899-1975): not a 'principle' of brain plasticity but a founding mother of developmental neuropsychology. *Cortex* 2010; 46: 1043-59.
- Dennis M, Spiegler BJ, Hetherington CR, Greenberg ML. Neuropsychological sequelae of the treatment of children with medulloblastoma. *J Neurooncol* 1996; 29: 91-101.
- Dow RS, Moruzzi G. *The physiology and Pathology of the Cerebellum*. Minneapolis: Minnesota University Press; 1958.
- Ellenberg L, McComb JG, Siegel SE, Stowe S. Factors affecting intellectual outcome in pediatric brain tumor patients. *Neurosurgery* 1987; 21: 638-44.
- Forsyth RJ. Back to the future: rehabilitation of children after brain injury. *Arch Dis Child* 2010; 95: 554-9.
- Fouladi M, Gilger E, Kocak M, Wallace D, Buchanan G, Reeves C, *et al.* Intellectual and functional outcome of children 3 years old or younger who have CNS malignancies. *J Clin Oncol* 2005; 23: 7152-60.
- Gramsbergen A. The effects of cerebellar hemispherectomy in the young rat. I. Behavioral sequelae. *Behav Brain Res* 1982; 6: 85-92.

- Grill J, Renaux VK, Bulteau C, Viguier D, Levy-Piebois C, Sainte-Rose C, *et al.* Long-term intellectual outcome in children with posterior fossa tumors according to radiation doses and volumes. *Int J Radiat Oncol Biol Phys* 1999; 45: 137-45.
- Gupta T, Jalali R, Goswami S, Nair V, Moiyadi A, Epari S, *et al.* Early clinical outcomes demonstrate preserved cognitive function in children with average-risk medulloblastoma when treated with hyperfractionated radiation therapy. *Int J Radiat Oncol Biol Phys* 2012; 83: 1534-40.
- Guyotat J, Metellus P, Giorgi R, Barrie M, Jouvét A, Fevre-Montange M, *et al.* Infratentorial ependymomas: prognostic factors and outcome analysis in a multi-center retrospective series of 106 adult patients. *Acta Neurochir (Wien)* 2009; 151: 947-60.
- Hanzlik E, Woodrome SE, Abdel-Baki M, Geller TJ, Elbabaa SK. A systematic review of neuropsychological outcomes following posterior fossa tumor surgery in children. *Childs Nerv Syst* 2015; 31: 1869-75.
- Hoppe-Hirsch E, Renier D, Lellouch-Tubiana A, Sainte-Rose C, Pierre-Kahn A, Hirsch JF. Medulloblastoma in childhood: progressive intellectual deterioration. *Childs Nerv Syst* 1990; 6: 60-5.
- Horne MK, Butler EG. The role of the cerebello-thalamo-cortical pathway in skilled movement. *Prog Neurobiol* 1995; 46: 199-213.
- Ito M. Cerebellar circuitry as a neuronal machine. *Prog Neurobiol* 2006; 78: 272-303.
- Johnson DA, Rose FD, Brooks BM, Eyers S. Age and recovery from brain injury: legal opinions, clinical beliefs and experimental evidence. *Pediatr Rehabil* 2003; 6: 103-9.
- Kaye AH, Laws ER. *Brain Tumors*. London: England Harcourt; 2001.
- Kennard MA. Cortical reorganization of motor function: Studies on series of monkeys of various ages from infancy to maturity. *Arch Neurol Psychiat* 1942; 48: 227-40.

- Kennedy C, Bull K, Chevignard M, Culliford D, Dorr HG, Doz F, *et al.* Quality of survival and growth in children and young adults in the PNET4 European controlled trial of hyperfractionated versus conventional radiation therapy for standard-risk medulloblastoma. *Int J Radiat Oncol Biol Phys* 2014; 88: 292-300.
- Konczak J, Schoch B, Dimitrova A, Gizewski E, Timmann D. Functional recovery of children and adolescents after cerebellar tumour resection. *Brain* 2005; 128: 1428-41.
- Koob M, Girard N. Cerebral tumors: specific features in children. *Diagn Interv Imaging* 2014; 95: 965-83.
- Koziol LF, Budding D, Andreasen N, D'Arrigo S, Bulgheroni S, Imamizu H, *et al.* Consensus paper: the cerebellum's role in movement and cognition. *Cerebellum* 2014; 13: 151-77.
- Krageloh-Mann I, Lidzba K, Pavlova MA, Wilke M, Staudt M. Plasticity during Early Brain Development Is Determined by Ontogenetic Potential. *Neuropediatrics* 2017; 48: 66-71.
- Kuper M, Doring K, Spangenberg C, Konczak J, Gizewski ER, Schoch B, *et al.* Location and restoration of function after cerebellar tumor removal-a longitudinal study of children and adolescents. *Cerebellum* 2013; 12: 48-58.
- Lansky SB, List MA, Lansky LL, Ritter-Sterr C, Miller DR. The measurement of performance in childhood cancer patients. *Cancer* 1987; 60: 1651-6.
- Law N, Greenberg M, Bouffet E, Taylor MD, Laughlin S, Strother D, *et al.* Clinical and neuroanatomical predictors of cerebellar mutism syndrome. *Neuro Oncol* 2012; 14: 1294-303.
- Levisohn L, Cronin-Golomb A, Schmahmann JD. Neuropsychological consequences of cerebellar tumour resection in children: cerebellar cognitive affective syndrome in a paediatric population. *Brain* 2000; 123 ( Pt 5): 1041-50.

- McKean-Cowdin R, Razavi P, Barrington-Trimis J, Baldwin RT, Asgharzadeh S, Cockburn M, *et al.* Trends in childhood brain tumor incidence, 1973-2009. *J Neurooncol* 2013; 115: 153-60.
- Mitby PA, Robison LL, Whitton JA, Zevon MA, Gibbs IC, Tersak JM, *et al.* Utilization of special education services and educational attainment among long-term survivors of childhood cancer: a report from the Childhood Cancer Survivor Study. *Cancer* 2003; 97: 1115-26.
- Molinari M, Petrosini L, Gremoli T. Hemicerebellectomy and motor behaviour in rats. II. Effects of cerebellar lesion performed at different developmental stages. *Exp Brain Res* 1990; 82: 483-92.
- Moxon-Emre I, Bouffet E, Taylor MD, Laperriere N, Scantlebury N, Law N, *et al.* Impact of craniospinal dose, boost volume, and neurologic complications on intellectual outcome in patients with medulloblastoma. *J Clin Oncol* 2014; 32: 1760-8.
- Olson K, Sands SA. Cognitive training programs for childhood cancer patients and survivors: A critical review and future directions. *Child Neuropsychol* 2016; 22: 509-36.
- Packer R, Sutton L, Atkins T, Radcliffe J, Bunin G, D'Angio G, *et al.* A prospective study of cognitive function in children receiving whole-brain radiotherapy and chemotherapy: 2-year results. *J Neurosurg Pediatr* 1989; 70: 707-13.
- Palmer SL, Gajjar A, Reddick WE, Glass JO, Kun LE, Wu S, *et al.* Predicting intellectual outcome among children treated with 35-40 Gy craniospinal irradiation for medulloblastoma. *Neuropsychology* 2003; 17: 548-55.
- Poretti A, Meoded A, Huisman TA. Neuroimaging of pediatric posterior fossa tumors including review of the literature. *J Magn Reson Imaging* 2012; 35: 32-47.

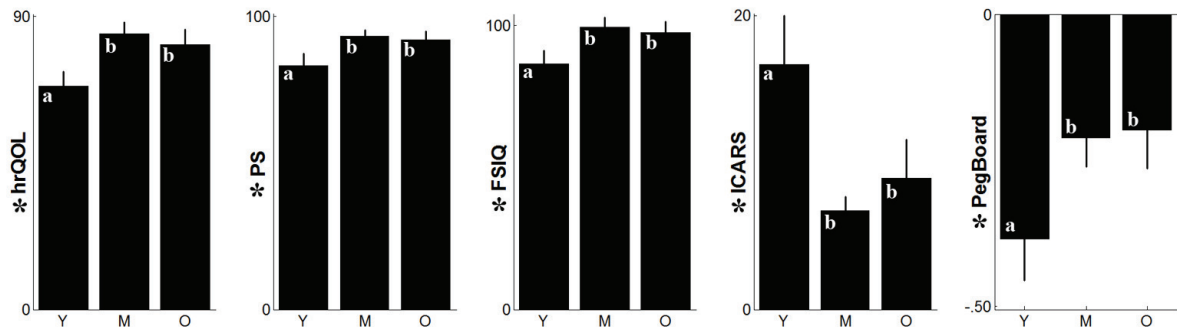


- Riva D, Giorgi C, Nichelli F, Bulgheroni S, Massimino M, Cefalo G, *et al.* Intrathecal methotrexate affects cognitive function in children with medulloblastoma. *Neurology* 2002; 59: 48-53.
- Robinson KE, Fraley CE, Pearson MM, Kuttesch JF, Jr., Compas BE. Neurocognitive late effects of pediatric brain tumors of the posterior fossa: a quantitative review. *J Int Neuropsychol Soc* 2013; 19: 44-53.
- Ronning C, Sundet K, Due-Tonnessen B, Lundar T, Helseth E. Persistent cognitive dysfunction secondary to cerebellar injury in patients treated for posterior fossa tumors in childhood. *Pediatr Neurosurg* 2005; 41: 15-21.
- Sachsenheimer W, Piotrowski W, Bimmler T. Quality of life in patients with intracranial tumors on the basis of Karnofsky's performance status. *J Neurooncol* 1992; 13: 177-81.
- Smith RL, Parks T, Lynch G. A comparison of the role of the motor cortex in recovery from cerebellar damage in young and adult rats. *Behav Biol* 1974; 12: 177-98.
- Sokolov AA, Miall RC, Ivry RB. The Cerebellum: Adaptive Prediction for Movement and Cognition. *Trends Cogn Sci* 2017; 21: 313-32.
- Steinlin M, Imfeld S, Zulauf P, Boltshauser E, Lovblad KO, Ridolfi Luthy A, *et al.* Neuropsychological long-term sequelae after posterior fossa tumour resection during childhood. *Brain* 2003; 126: 1998-2008.
- Stoodley CJ. The cerebellum and cognition: evidence from functional imaging studies. *Cerebellum* 2012; 11: 352-65.
- Storey E, Tuck K, Hester R, Hughes A, Churchyard A. Inter-rater reliability of the International Cooperative Ataxia Rating Scale (ICARS). *Mov Disord* 2004; 19: 190-2.
- Strick PL, Dum RP, Fiez JA. Cerebellum and nonmotor function. *Annu Rev Neurosci* 2009; 32: 413-34.

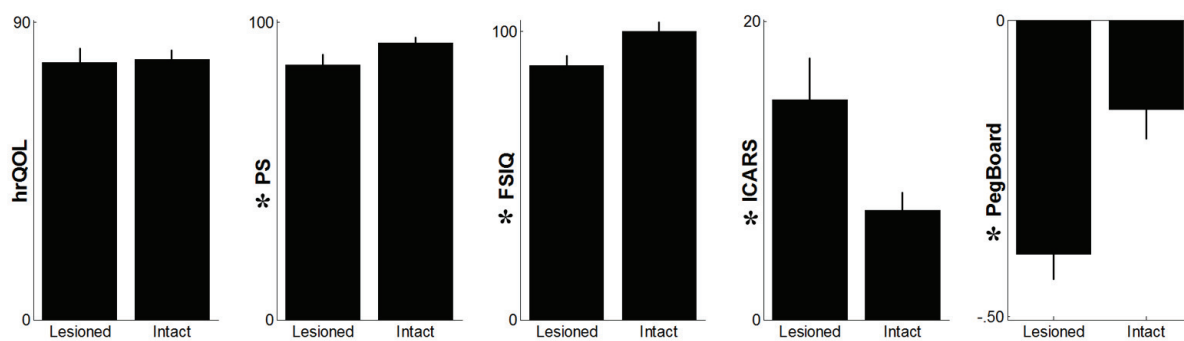
- Taylor HG, Alden J. Age-related differences in outcomes following childhood brain insults: an introduction and overview. *J Int Neuropsychol Soc* 1997; 3: 555-67.
- Thompson EM, Hielscher T, Bouffet E, Remke M, Luu B, Gururangan S, *et al.* Prognostic value of medulloblastoma extent of resection after accounting for molecular subgroup: a retrospective integrated clinical and molecular analysis. *Lancet Oncol* 2016; 17: 484-95.
- Tiffin J, Asher EI. The Purdue Pegboard : Norms and studies of reliability and validity. *J Appl Psychol* 1948; 32: 234-47.
- Timmann D, Drepper J, Frings M, Maschke M, Richter S, Gerwig M, *et al.* The human cerebellum contributes to motor, emotional and cognitive associative learning. A review. *Cortex* 2010; 46: 845-57.
- Trouillas P, Takayanagi T, Hallett M, Currier RD, Subramony SH, Wessel K, *et al.* International Cooperative Ataxia Rating Scale for pharmacological assessment of the cerebellar syndrome. The Ataxia Neuropharmacology Committee of the World Federation of Neurology. *J Neurol Sci* 1997; 145: 205-11.
- van de Poll-Franse LV, Mols F, Gundy CM, Creutzberg CL, Nout RA, Verdonck-de Leeuw IM, *et al.* Normative data for the EORTC QLQ-C30 and EORTC-sexuality items in the general Dutch population. *Eur J Cancer* 2011; 47: 667-75.
- Varni JW, Limbers CA, Burwinkle TM. Parent proxy-report of their children's health-related quality of life: an analysis of 13,878 parents' reliability and validity across age subgroups using the PedsQL (TM) 4.0 Generic Core Scales. *Health Qual Life Outcomes* 2007; 5.
- Varni JW, Seid M, Kurtin PS. PedsQL (TM) 4.0: Reliability and validity of the pediatric quality of life Inventory (TM) Version 4.0 generic core scales in healthy and patient populations. *Med Care* 2001; 39: 800-12.

- von Hoff K, Kieffer V, Habrand JL, Kalifa C, Dellatolas G, Grill J. Impairment of intellectual functions after surgery and posterior fossa irradiation in children with ependymoma is related to age and neurologic complications. *BMC Cancer* 2008; 8: 15.
- Webb C, Rose FD, Johnson DA, Attree EA. Age and recovery from brain injury: clinical opinions and experimental evidence. *Brain Inj* 1996; 10: 303-10.
- Wechsler D. Wechsler Intelligence Scale for Children -Fourth Edition. French version. Paris: ECPA/Pearson; 2005.
- Wechsler D. Wechsler Adult Intelligence Scale -Fourth Edition. French version. Paris: ECPA/Pearson; 2011.
- Winer BJ. *Statistical principles in experimental design*. New York: Mc Graw-Hill; 1971.

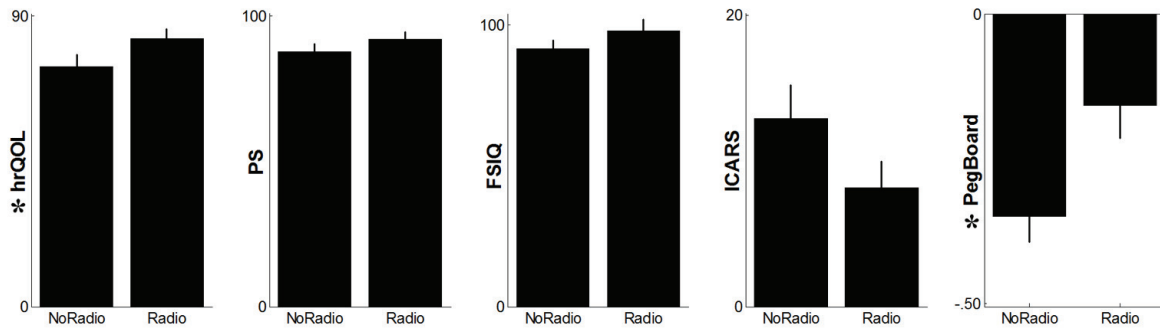
## 6) FIGURES



**Figure 1.** Effect of age at surgery on the different dependent outcome measures (one per column). Vertical lines display the standard errors of the means. Y: young age group; M: middle age group; O: old age group. hrQoL: Health-related Quality of Life; PS: Performance Status; ICARS: International Cooperative Ataxia Rating Scale; Pegboard Purdue Test: PegBoard; FSIQ: Full Scale Intelligence Quotient. For each panel, the symbol \* before the vertical labels indicate that the effect of age is statistically significant; letters on the bars identify significant (different letters) or non-significant (same letters) post-hoc difference between means.



**Figure 2.** Effect of anatomical damages to the deep cerebellar nuclei on the different dependent outcome measures (one per column). Vertical lines display the standard errors of the means. Lesioned: nuclei lesioned; Intact: nuclei intact. hrQoL: Health-related Quality of Life; PS: Performance Status; ICARS: International Cooperative Ataxia Rating Scale; Pegboard Purdue Test: PegBoard; FSIQ: Full Scale Intelligence Quotient. For each panel, the symbol \* before the vertical labels indicate that the effect of lesioning the deep cerebellar nuclei is statistically significant.



**Figure 3.** Effect of post-operative radiotherapy on the different dependent outcome measures (one per column). Vertical lines display the standard errors of the means. Radio: radiotherapy; NoRadio: no radiotherapy. hrQoL: Health-related Quality of Life; PS: Performance Status; ICARS: International Cooperative Ataxia Rating Scale; Pegboard Purdue Test: PegBoard; FSIQ: Full Scale Intelligence Quotient. For each panel, the symbol \* before the vertical labels indicate that the effect of post-operative radiotherapy is statistically significant.

## 7) SUPPLEMENTAL INFORMATION

<u>Parameters</u>	<u>Measures</u>	<u>Age-group differences</u>
<u>Sex</u> Male Female	<u>number (%)</u> 21 (47 %) 24 (53 %)	Maracuillo multiple proportion test non-significant (all $p > .05$ )
<u>Age at surgery (years)</u> Young ( $\leq 7$ ) Middle ( $> 7 \ \& \ \leq 13$ ) Old ( $> 13$ )	<u>number (%) / mean/ range</u> 15 (33 %) / 4.6 / 0.9 - 6.9 15 (33 %) / 10.0 / 7.3 - 12.5 15 (33%) / 20.9 / 13.5 - 39.8	ANOVA significant ( $F_{(2,42)} = 32.4$ ; $p < .00001$ )
<u>Follow-up</u> Delay from surgery to assessment (years)	<u>mean (SD) / median</u> 5.0 (2.9) / 4.2	ANOVA non-significant ( $F_{(2,42)} = 1.25$ ; $p > .25$ )
<u>Radiotherapy</u> Yes No	<u>number (%)</u> 25 (56 %) 20 (44 %)	Maracuillo multiple proportion test non-significant (all $p > .05$ )
<u>Tumor type</u> Malignant (medulloblastoma, ependymoma) Benign (pilocytic astrocytoma, hemangioblastoma, ganglioglioma)	<u>number (%)</u> 25 (56 %) 20 (44 %)	Maracuillo multiple proportion test non-significant (all $p > .05$ )
<u>Tumor volume and location</u> Volume ( $\text{mm}^3$ ) Location Vermis Vermis extending to the hemisphere	<u>mean (SD) / median</u> 42 (31) / 36  <u>number (%)</u> 11 (24 %) 34 (76 %)	ANOVA non-significant ( $F_{(2,42)} = 0.88$ ; $p > .42$ )  Maracuillo multiple proportion test* non-significant (all $p > .05$ )
<u>Deep Nuclei</u> Preserved Lesioned	<u>number (%)</u> 24 (53 %) 21 (47 %)	Maracuillo multiple proportion test non-significant (all $p > .05$ )

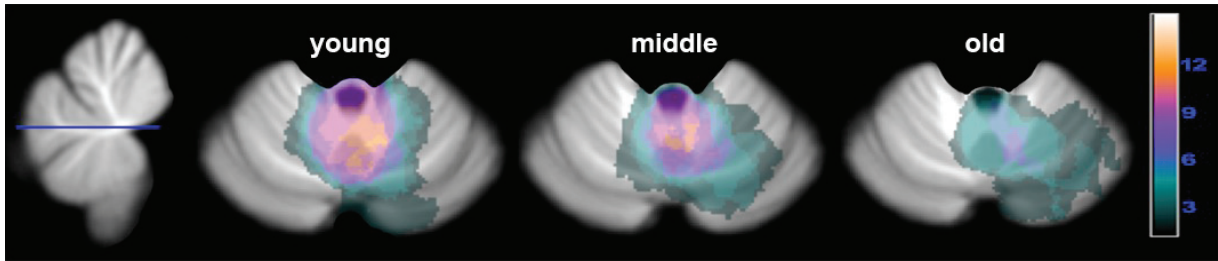
\* A MANOVA was also performed on the MNI coordinates (x, y, z) of the center of gravity of the lesions. Results failed to reveal any difference between age-groups ( $F_{(6,80)} = 1.57$ ,  $p = .17$ )

**Table S1.** Characteristics of the patients (N = 45) and statistical differences between the three age group for these characteristics (last column).

			hrQoL	PS	ICARS	PegBoard	FSIQ
Age at surgery	ANOVA		<b>F<sub>(2,31)</sub> = 4.50</b> <b>p = .019</b>	<b>F<sub>(2,31)</sub> = 3.68</b> <b>p = .037</b>	<b>F<sub>(2,31)</sub> = 4.62</b> <b>p = .018</b>	<b>F<sub>(2,31)</sub> = 3.34</b> <b>p = .048</b>	<b>F<sub>(2,31)</sub> = 4.39</b> <b>p = .021</b>
	post-hoc	<i>young vs middle</i>	<b>p = .008</b>	<b>p = .026</b>	<b>p = .006</b>	<b>p = .022</b>	<b>p = .010</b>
		<i>young vs old</i>	<b>p = .026</b>	<b>p = .043</b>	<b>p = .022</b>	<b>p = .019</b>	<b>p = .023</b>
		<i>middle vs old</i>	p = .533	p = .747	p = .498	p = .862	p = .671
Nuclei preserved	ANOVA		F <sub>(1,31)</sub> = 1.46 p = .236	<b>F<sub>(1,31)</sub> = 5.60</b> <b>p = .024</b>	<b>F<sub>(1,31)</sub> = 7.97</b> <b>p = .008</b>	<b>F<sub>(1,31)</sub> = 16.00</b> <b>p = .0004</b>	<b>F<sub>(1,31)</sub> = 16.66</b> <b>p = .0003</b>
Radiation therapy	ANOVA		<b>F<sub>(1,31)</sub> = 4.34</b> <b>p = .045</b>	F <sub>(1,31)</sub> = 1.31 p = .261	F <sub>(1,31)</sub> = 2.43 p = .130	<b>F<sub>(1,31)</sub> = 4.84</b> <b>p = .035</b>	F <sub>(1,31)</sub> = 0.02 p = .894
Lesion volume	ANOVA		F <sub>(1,31)</sub> = 2.99 p = .094	F <sub>(1,31)</sub> = 0.46 p = .502	F <sub>(1,31)</sub> = 0.01 p = .935	F <sub>(1,31)</sub> = 0.58 p = .451	F <sub>(1,31)</sub> = 3.61 p = .067
Delay to assessment	ANOVA		F <sub>(1,31)</sub> = 0.41 p = .526	F <sub>(1,31)</sub> = 0.41 p = .525	F <sub>(1,31)</sub> = 0.39 p = .535	F <sub>(1,31)</sub> = 0.01 p = .932	F <sub>(1,31)</sub> = 1.60 p = .216
Interactions	ANOVA		all ps > .335	all ps > .240	all ps > .245	all ps > .355	all ps > .130

**Table S2.** Summary of statistical results. Significant differences are highlighted in bold ( $p < .05$ ). Duncan significant difference test was used for post-hoc comparisons {Winer, 1971 #1846}. Interactions between factors were not detailed but summarized within a single line (interactions) considering that no interaction reached significance level. hrQoL: Health-related Quality of Life; PS: Performance Status; ICARS: International Cooperative Ataxia Rating Scale; Pegboard Purdue Test: PegBoard; FSIQ: Full Scale Intelligence Quotient.





**Figure S1.** Regional distribution of lesions for each age-group of the patient sample. Lesions have been mapped on cerebellar horizontal sections using the SUI Atlas (level of sections is shown by the blue line on the right sagittal view). For the sake of legibility, all left-sided lesions have been flipped to the right. The regional frequency of brain lesions in each cerebellar area is expressed by the color scale.

# C-3) Paper 5: Mapping somatosensory representation in the human cerebellum

*To be submitted*

Pierre-Aurélien Beuriat<sup>1,2,3</sup>, Nathalie Richard<sup>1,2</sup>, Alexandru Szathmari<sup>1,2,3</sup>, Federico Di Rocco<sup>2,3</sup>, Carmine Mottolese<sup>1,2,3</sup>, Angela Sirigu<sup>1,2</sup>, and Michel Desmurget<sup>1,2</sup>.

## **Author' Affiliations:**

<sup>1</sup> Institute of Cognitive Neuroscience Marc Jeannerod, CNRS / UMR 5229, 69500 Bron, France

<sup>2</sup> Université Claude Bernard, Lyon 1, 69100 Villeurbanne, France

<sup>3</sup> Department of Pediatric Neurosurgery, Hôpital Femme Mère Enfant, 69500, Bron, France

**Correspondence to:** Michel Desmurget

## 1) ABSTRACT

The cerebellum is a major sensorimotor structure. However, in humans, its somatosensory topographical organization remains controversial and indirectly inferred from neuroimaging and animal studies. To date, no map of cerebellar somatosensory inputs has been reported using direct recording of somatosensory evoked potentials (SEP). To address this lacunae, we recorded cerebellar SEP with cortical strip electrodes, in 10 patients undergoing surgery because of focal tumors located outside the cerebellum (e.g. pineal gland, quadrigeminal plate). Electrical stimulation was used to provoke active contractions in 9 muscles of the face (*orbicularis oris*), upper limb (*biceps*, *triceps*, *extensor digitorum communis*, *flexor carpi radialis*, *thenar eminence*, *hypothenar eminence*) and lower-limb (*tibialis anterior*, *gastrocnemius*). Results confirm that SEP reach the cerebellar cortex, but not homogeneously. The quasi-totality of body inputs were located (i) in the anterior / superior-posterior cerebellar region (lobules HV-HVI); and (ii) in the inferior posterior cerebellar region (lobules HVIIb-HVIII). Although most SEP were ipsilateral, a substantial fraction of contralateral afferences was found (around 30 %). No somatotopic arrangement was identified. Mouth and upper-limb signals, in particular, overlapped greatly in the anterior / superior-posterior cerebellar region. The potential role of this somatosensory afferent signals for fine motor control is discussed.

**Keywords:** Cerebellum; Sensory; Somatosensory evoked potentials; Per-operative mapping, Human.

## 2) INTRODUCTION

The cerebellum is a major structure of our nervous system. While accounting for only 10 % of the total brain mass, it houses more than 80 % of all neurons (Azevedo *et al.*, 2009). During the last century, numerous anatomical and functional studies have linked cerebellar integrity to sensorimotor performance (Holmes, 1939; Thach *et al.*, 1992; Horne and Butler, 1995; Wolpert *et al.*, 1998; Strick *et al.*, 2009). However, there is still no consensus on what the cerebellum exactly does (Manto *et al.*, 2012; Koziol *et al.*, 2014; Baumann *et al.*, 2015). Even basic questions related to the anatomic organization of this fundamental organ remain unanswered, in humans. For example, despite decades of intense research, a map of cerebellar somatosensory inputs is still lacking. In other words, in humans, we still do not know where afferent body signals reach the cerebellar cortex.

In animals, anatomical studies have demonstrated that the cerebellar cortex receives somatosensory inputs directly from muscles sensors (through spinocerebellar pathways) and indirectly from the main cortical sensorimotor regions (through cortico-cerebellar projections) (Ghez and Thach, 2000; Apps and Watson, 2013). These inputs have been reported to reach the anterior lobe and paramedian lobule in a somatotopically organized manner (Dow and Moruzzi, 1958; Manni and Petrosini, 2004). Strikingly, however, this somatotopic arrangement is only apparent in animals deeply anesthetized with sodium pentobarbital (Dow and Moruzzi, 1958; Manni and Petrosini, 2004). To account for this observation, it has been suggested that this anesthetic (widely used in past studies) affects either the diffusion of the sensory inputs over the cerebellar cortex or the conductivity of some specific components of the spinocerebellar pathways. According to this latter view, upcoming somatosensory signals would convey a dual body representation: one "local" with strong somatotopic attributes, insensitive to sodium pentobarbital; one "diffuse" with overlapping properties, inhibited by sodium pentobarbital (Bloedel, 1973).

The issue whether the observations above can be generalized to humans was only addressed recently, thanks to the development of neuroimaging techniques. Overall, evidence is mixed and controversial, despite the use of rather basic and comparable protocols relying on the investigation of externally-driven body movements (triggered either mechanically or through electrical muscle stimulation). Many studies failed to identify evoked responses in the cerebellar cortex (Seitz and Roland, 1992; Tempel and Perlmutter, 1992; Burton *et al.*, 1993; Mima *et al.*, 1999; Weeks *et al.*, 1999) and it was argued that this structure should no longer be considered a "sensory organ" (Weeks *et al.*, 1999). In opposition to this bold conclusion, other investigations, generally more recent, reported positive activations (Gao *et al.*, 1996; Jueptner *et al.*, 1997; Liu *et al.*, 2000; Bushara *et al.*, 2001; Takanashi *et al.*, 2003; Thickbroom *et al.*, 2003; Habas *et al.*, 2004; Ciccarelli *et al.*, 2005; Guzzetta *et al.*, 2007; Macaluso *et al.*, 2007; Kavounoudias *et al.*, 2008; Francis *et al.*, 2009; Gentile *et al.*, 2011; Wiestler *et al.*, 2011; Van de Winckel *et al.*, 2013; van der Zwaag *et al.*, 2013; Boscolo Galazzo *et al.*, 2014). However, as shown in figure 1 for hand/finger inputs, an astonishing level of variability was found regarding the location and laterality of somatosensory inputs. Based on these data, no clear conclusion could be reached regarding the somatosensory organization of the cerebellum and the existence of a somatotopic arrangement within this organization.

Here, we aim to address the uncertainties above. To this end, we recorded somatosensory evoked-potential per-operatively, in ten patients undergoing brain surgery for tumor removal. To minimize the possible impact of anatomic-functional adaptations induced by the tumoral invasion (Desmurget *et al.*, 2007; Mottolese *et al.*, 2013), we selected patients with focal extra-cerebellar tumors (e.g. pineal gland, quadrigeminal plate), i.e. patients for whom the cerebellar cortex and deep cerebellar nuclei are not injured. Four specific questions were addressed: (1) where are the somatosensory inputs from the upper-

limb (arm, hand), lower-limb (foot) and face processed in the cerebellum? (2) Are these inputs somatotopically organized within different cerebellar lobes or lobules? (3) How are they lateralized? (4) How fast do they reach the cerebellar cortex (and are those latencies similar across different lobules)? This latter question is important for determining whether somatosensory evoked-potentials (SEP) are routed through ascending spinocerebellar pathways or remote cortical sensorimotor regions areas, such as the primary sensorimotor cortex.

### **3) MATERIAL AND METHODS**

#### **a) Subjects**

Ten patients were recruited from the neurosurgical department of the neurological hospital in Lyon. All patients were operated under general anesthesia. Their lesions (mainly malformations and tumoral invasions) were located outside the cerebellum, in the posterior fossa. The mean age was 20 years (range 10 - 58). Before surgery all patients were informed about the surgical procedure by the senior surgeon (CM) and gave a formal consent (for minors, consent was obtained from the parents). The protocol was approved by the local ethics committee (CPP, Lyon Sud-Est IV, Centre Léon Berard, Lyon) and sponsored by CNRS.

#### **b) Peri-operative mapping**

During the pre-operative phase of the surgery, disposable surface Ag/AgCl electrodes (Viasys) were placed unilaterally over the face (orbicularis oris), upper limb (biceps, triceps, extensor digitorum communis, flexor carpi radialis, thenar eminence, hypothenar eminence) and lower-limb (tibialis anterior, gastrocnemius). These electrodes

were then electrically simulated to provoke muscle contractions. In this protocol, commonly employed in rehabilitation and research settings to mimic voluntary movements (Bickel *et al.*, 2011), the afferent signals collected in the sensorimotor regions reflect the recruitment of cutaneous and proprioceptive afferent fibers (group I and II) (Niddam *et al.*, 2002; Niddam *et al.*, 2005). Stimulations consisted in standard electrical trains (9 pulses, 500  $\mu$ s wide, 10 ms interpulse interval) delivered at a 2.7 Hz frequency. Intensity varied from 5 to 20 mA, depending on patients, target muscle and measured impedances. SEP were recorded on the cerebellar cortex in a bipolar way using cortex strip electrodes (1 to 4 grids of 4 to 6 contacts; figure 2). During surgery SEP were collected at a 10 kHz sampling rate and filtered within a 0.5 to 300 Hz frequency band. A period of 120 ms was considered after each stimulus onset. For each cortical site and peripheral muscle, mean curves were obtained in real time by averaging 200 individual trials. The resulting curves were displayed on a computer screen, and visually assessed. Then, they were saved for off-line processing.

Significance of stored SEP signals was determined, for each subject, using a standard procedure (Blair and Karniski, 1993; Carota *et al.*, 2010; Desmurget *et al.*, 2014). A baseline curve was first defined by averaging all individual signals. For each time sample, a t-test was then computed between the SEP and the baseline curves, using a 95% significance level. Periods showing more than 100 consecutive significant t-tests (corresponding to a 10 ms period) were considered significant. Latencies were computed from significant curves as the onset of the first 10 ms period above or below 3 standard deviations of the mean signal averaged from all non-significant curves. In a last step, SEP activities were filtered with a 100 Hz low-pass filter for display purpose.

All surgeries were performed in a seated position, using an infratentorial supracerebellar approach. This approach grants a bilateral access to the posterior (lobule VI to IX) and some part of the anterior (lobule V) lobes of the cerebellum (figure 2). During

surgery, anaesthesia was typically maintained with 1.5-2.5 vol% (minimum alveolar concentration -MAC-) sevoflurane without nitrous oxide and remifentanyl at 0.25 microgram per kilogram per minute. This protocol has been shown not to affect intraoperative recording of motor evoked potentials (Reinacher *et al.*, 2006). Completion of the stimulation protocol required around 15 minutes.

### **c) Localizing stimulation sites**

The procedure for localizing stimulation sites has been described in a previous publication (Mottolese *et al.*, 2013; Desmurget *et al.*, 2018). In brief, stimulation site localization was performed *a posteriori* using a home-build 3D interactive visualization tool. For each patient, a high resolution MR image was obtained before the surgery. From this image, we reconstructed a 3D view of the patient brain including meshes of the patient head, tumors and cerebellar lobules. Lesion areas were manually drawn from preoperative MR images to generate tumor meshes which were excluded from the normalization transformation (Brett *et al.*, 2001). Normalization of the Cerebellar areas was performed using the SUIT toolbox (Diedrichsen, 2006) of the SPM12 software. This toolbox provides a high-resolution atlas template of the human cerebellum and brainstem that preserves the anatomical detail of cerebellar structures, as well as dedicated procedures to automatically isolate patient cerebellar structures from the cerebral cortex and to normalize accurately patient cerebellar structures to this template. Using the inverse of the resulting normalization transform, a parcellation of patient cerebellum was obtained based on the probabilistic MR atlas of the human cerebellum (Diedrichsen *et al.*, 2009) provided within the SUIT toolbox. Meshes of patient anatomical structures included in the 3D view were computed using the Brainvisa software from previously computed masks for the tumors and the cerebellar lobules and from the MR image of the patient head using an automatic procedure. Masks were



controlled visually before meshing. The home-build visualization software for interactive localization of sites was developed using the ITK (<http://www.itk.org/>), VTK (<http://www.vtk.org/>) and FLTK (<http://www.fltk.org/>) C/C++ toolkits. It allows displaying the 3D brain view, to interactively cut the head mesh to recreate the bone flap opened during the surgery and to manually position stimulation sites displayed as small spheres on the cortical surface. Before surgery, the exact location of the four corners of the bone flap was determined using relative distances from the anatomical markers of the skull (anion, nasion, auriculars, CZ point), as is standardly done in electroencephalographic studies for electrode placement (Jurcak *et al.*, 2007). These locations were then used to place the surgical bone flap on the MRI-based 3D skull of the individual subject. DES locations were then reconstructed with respect to the edges of the bone flap using peri-operative images of the tags positioned on each stimulation sites during the mapping procedure and distance measures performed during the surgery from two small flexible rulers positioned at the edges of the bone flap, one vertically, one horizontally.

#### **4) RESULTS**

A total of 92 sites were studied in 10 patients. Among these sites, 16 (17 %) were found to receive somatosensory inputs from body muscles. Most of these inputs concerned the upper-limb (n = 10), with a larger representation, in this case, of the distal segments (wrist/hand, n = 7), than the proximal ones (arm, n = 3) (figure 3). Second to the upper-limb was the mouth with five positive identifications. The foot was the least represented segment, with only one significant response.

Anatomically, responsive sites were not homogeneously distributed across the cerebellar surface. As shown in figure 3, SEP reached the cerebellum in two main regions;

(i) the anterior / superior-posterior cerebellar region (lobules HV-HVI); (ii) in the inferior posterior cerebellar region (lobules HVIIb-HVIII). Only one isolated response was found in the median posterior cerebellum. No somatotopy emerged from these data, even as a trend. In particular, upper-limb and mouth inputs could not be anatomically segregated. They closely overlapped within the hemispheric lobules V and VI (figure 3B). Whether a somatotopic map exist in the inferior posterior region cannot be determined from the present data, due to the small number of responses recorded in this region.

For the upper and lower limb, most inputs were ipsilateral (figure 3B). However, 2 contralateral responses were recorded for the hand, which represents almost 30 % of the SEP recorded for this segment (figure 3C). In one single subject, we found one site with convergent inputs from the mouth and the ipsilateral hand.

On average, sensory inputs from the mouth reached the cerebellar cortex slightly faster than sensory inputs from the upper-limb (54 ms versus 61 ms). However, this difference did not reach statistical significance (t test,  $p > .10$ ). With respect to this point it may be worth noting that data are not compared within but between subjects. A substantial level of inter-individual variability (i.e. of statistical noise), together with a limited number of observations, may thus explain the non-significant nature of the observed differences in SEP latencies.

## **5) DISCUSSION**

To summarize, we used a peri-operative mapping procedure to study the somatosensory afferent organization of the cerebellum. Our results confirm that SEP reach the cerebellar cortex, but not homogeneously. The quasi-totality of body inputs were located (i) in the anterior / superior-posterior cerebellar region (lobules HV-HVI); and (ii) in the

inferior posterior cerebellar region (lobules HVIIb-HVIII). For the most part, the recorded signals were ipsilateral, although a substantial fraction (around 30 %) of contralateral inputs were observed for the hand. No somatotopic arrangement was identified, at least within the anterior / superior-posterior region where mouth and upper-limb representations overlapped without spatial segregation (or even a trend indicating that such a segregation may exist).

Functionally, these data support the contribution of the cerebellum to somatosensory processing. This conclusion seems to contradict clinical observations that did not find gross sensory deficits after cerebellar damage (Holmes, 1939). With respect to this point, it is now widely acknowledged that the ability to estimate either the location of the hand or the posture of the arm is not impaired in cerebellar patients, after externally-driven movements (Holmes, 1917; Maschke *et al.*, 2003; Bhanpuri *et al.*, 2012, 2013). However, these data should not be considered a proof that the cerebellum does not process somatosensory signals in the context of more complex sensorimotor tasks. In particular, while passive proprioception is not altered following anatomical damages to the cerebellum, the ability to determine the location of the hand after active movements is deteriorated in cerebellar patients (Bhanpuri *et al.*, 2012, 2013). This result fits well with the conclusion that the cerebellum is involved in dynamic state estimation and predictive sensorimotor control (Wolpert *et al.*, 1998; Therrien and Bastian, 2015; Sokolov *et al.*, 2017)

Of course, some limitations must be acknowledged with respect to the present study. The main one concerns the limited number of available observations. Patients with focal extra-cerebellar tumors are not common which explains the relative smallness of our sample. In the future, we expect to increase the present cohort to confirm and generalize our observations. This being said, it is unlikely that (i) the lack of somatosensory responses in the intermediate regions of the cerebellum, and (ii) the concentration of SEP in anterior / superior-posterior region and (to a lesser extent) in the inferior posterior, are meaningless

and observed by chance. Indeed, beyond the existence of conflicting conclusions (see introduction), several neuroimaging studies have related the two cerebellar regions here identified on the bases of SEP to somatosensory processing (Bushara *et al.*, 2001; Takanashi *et al.*, 2003; Thickbroom *et al.*, 2003; Guzzetta *et al.*, 2007; Kavounoudias *et al.*, 2008; Wiestler *et al.*, 2011; Van de Winckel *et al.*, 2013; van der Zwaag *et al.*, 2013). To substantiate this claim, we used permutation tests (1,000,000 permutations) (Good, 2000), with the aim of determining the probability that 12 responses or more (over 16) could be identified, by chance, in the anterior / superior posterior cerebellum. Two analyses were conducted for which the cerebellum was divided in two (anterior / superior-posterior; intermediate and inferior posterior together) or three (anterior / superior-posterior; intermediate; inferior posterior) distinct areas. Both hypotheses allowed to reject the null hypothesis at a 5% threshold (p values < .04 and .0001 respectively).

Another limitation of the present data concerns the identification of SEP pathways. Indeed, based on the present data it is not possible to determine whether cerebellar SEP were conveyed directly through the spinocerebellar tracts or indirectly through the main cortical sensorimotor areas (especially S1). To address this issue, SEP latencies observed in the present study will have to be compared with SEP latencies recorded in S1, under similar surgical conditions.

To summarize, the debate over cerebellar somatosensory organization has been going on for more than a century. Up to now most of the available knowledge has been associated with anatomico-physiological studies in various animal species and fMRI experiments in humans. Using peri-operative mapping in the posterior cerebellar cortex of human subjects, we were able to expand this existing literature by identifying the first "direct" map of cerebellar afferent projections. All our subjects had focal tumors outside the cerebellum. We found that SEP reached mainly the anterior / superior-posterior (lobules

HV-HVI) and (to a lesser extent) the inferior posterior (lobules HVIIb-HVIII) regions of the cerebellar cortex. Within these regions, no clear somatotopy was identified. The exact route from muscle sensors to the cerebellar cortex could not be determined from this study.

## ***REFERENCES***

- Apps R, Watson TC. Cerebro-Cerebellar Connections. In: Manto M, Schmahmann JD, Rossi F, Gruol DL, Koibuchi N, editors. Handbook of the Cerebellum and Cerebellar Disorders. Dordrecht: Springer Netherlands; 2013. p. 1131-53.
- Azevedo FA, Carvalho LR, Grinberg LT, Farfel JM, Ferretti RE, Leite RE, *et al.* Equal numbers of neuronal and nonneuronal cells make the human brain an isometrically scaled-up primate brain. *J Comp Neurol* 2009; 513: 532-41.
- Baumann O, Borra RJ, Bower JM, Cullen KE, Habas C, Ivry RB, *et al.* Consensus paper: the role of the cerebellum in perceptual processes. *Cerebellum* 2015; 14: 197-220.
- Bhanpuri NH, Okamura AM, Bastian AJ. Active force perception depends on cerebellar function. *J Neurophysiol* 2012; 107: 1612-20.
- Bhanpuri NH, Okamura AM, Bastian AJ. Predictive modeling by the cerebellum improves proprioception. *J Neurosci* 2013; 33: 14301-6.
- Bickel CS, Gregory CM, Dean JC. Motor unit recruitment during neuromuscular electrical stimulation: a critical appraisal. *Eur J Appl Physiol* 2011; 111: 2399-407.
- Blair RC, Karniski W. An alternative method for significance testing of waveform difference potentials. *Psychophysiology* 1993; 30: 518-24.
- Bloedel JR. Cerebellar afferent systems: a review. *Prog Neurobiol* 1973; 2: 3-68.
- Boscolo Galazzo I, Storti SF, Formaggio E, Pizzini FB, Fiaschi A, Beltramello A, *et al.* Investigation of brain hemodynamic changes induced by active and passive movements: a combined arterial spin labeling-BOLD fMRI study. *J Magn Reson Imaging* 2014; 40: 937-48.
- Brett M, Leff AP, Rorden C, Ashburner J. Spatial normalization of brain images with focal lesions using cost function masking. *Neuroimage* 2001; 14: 486-500.

- Burton H, Videen TO, Raichle ME. Tactile-vibration-activated foci in insular and parietal-occipital cortex studied with positron emission tomography: mapping the second somatosensory area in humans. *Somatosens Mot Res* 1993; 10: 297-308.
- Bushara KO, Wheat JM, Khan A, Mock BJ, Turski PA, Sorenson J, *et al.* Multiple tactile maps in the human cerebellum. *Neuroreport* 2001; 12: 2483-6.
- Carota F, Posada A, Harquel S, Delpuech C, Bertrand O, Sirigu A. Neural dynamics of the intention to speak. *Cereb Cortex* 2010; 20: 1891-7.
- Ciccarelli O, Toosy AT, Marsden JF, Wheeler-Kingshott CM, Sahyoun C, Matthews PM, *et al.* Identifying brain regions for integrative sensorimotor processing with ankle movements. *Exp Brain Res* 2005; 166: 31-42.
- Desmurget M, Bonnetblanc F, Duffau H. Contrasting acute and slow-growing lesions: a new door to brain plasticity. *Brain* 2007; 130: 898-914.
- Desmurget M, Richard N, Beuriat PA, Szathmari A, Mottolese C, Duhamel JR, *et al.* Selective Inhibition of Volitional Hand Movements after Stimulation of the Dorsoposterior Parietal Cortex in Humans. *Curr Biol* 2018; 28: 3303-9 e3.
- Desmurget M, Richard N, Harquel S, Baraduc P, Szathmari A, Mottolese C, *et al.* Neural representations of ethologically relevant hand/mouth synergies in the human precentral gyrus. *Proc Natl Acad Sci U S A* 2014; 111: 5718-22.
- Diedrichsen J. A spatially unbiased atlas template of the human cerebellum. *Neuroimage* 2006; 33: 127-38.
- Diedrichsen J, Balsters JH, Flavell J, Cussans E, Ramnani N. A probabilistic MR atlas of the human cerebellum. *Neuroimage* 2009; 46: 39-46.
- Dow RS, Moruzzi G. *The physiology and Pathology of the Cerebellum*. Minneapolis: Minnesota University Press; 1958.

- Francis S, Lin X, Aboushousah S, White TP, Phillips M, Bowtell R, *et al.* fMRI analysis of active, passive and electrically stimulated ankle dorsiflexion. *Neuroimage* 2009; 44: 469-79.
- Gao JH, Parsons LM, Bower JM, Xiong J, Li J, Fox PT. Cerebellum implicated in sensory acquisition and discrimination rather than motor control. *Science* 1996; 272: 545-7.
- Gentile G, Petkova VI, Ehrsson HH. Integration of visual and tactile signals from the hand in the human brain: an FMRI study. *J Neurophysiol* 2011; 105: 910-22.
- Ghez C, Thach WR. The Cerebellum. In: Kandel ER, Schwartz JH, Jessell TM, editors. *Principles of neural sciences* (4th edition). New York: McGraw-Hill; 2000.
- Good PI. *Permutation tests: a practical guide to resampling methods for testing hypotheses*. 2nd ed. Berlin: Springer-Verlag; 2000.
- Guzzetta A, Staudt M, Petacchi E, Ehlers J, Erb M, Wilke M, *et al.* Brain representation of active and passive hand movements in children. *PediatrRes* 2007; 61: 485-90.
- Habas C, Axelrad H, Cabanis EA. The cerebellar second homunculus remains silent during passive bimanual movements. *Neuroreport* 2004; 15: 1571-4.
- Holmes G. The symptoms of acute cerebellar injuries due to gunshot injuries. *Brain* 1917; 40: 461-535.
- Holmes G. The cerebellum of man. *Brain* 1939; 62: 1-30.
- Horne MK, Butler EG. The role of the cerebello-thalamo-cortical pathway in skilled movement. *Prog Neurobiol* 1995; 46: 199-213.
- Jueptner M, Ottinger S, Fellows SJ, Adamschewski J, Flerich L, Muller SP, *et al.* The relevance of sensory input for the cerebellar control of movements. *Neuroimage* 1997; 5: 41-8.
- Jurcak V, Tsuzuki D, Dan I. 10/20, 10/10, and 10/5 systems revisited: their validity as relative head-surface-based positioning systems. *Neuroimage* 2007; 34: 1600-11.

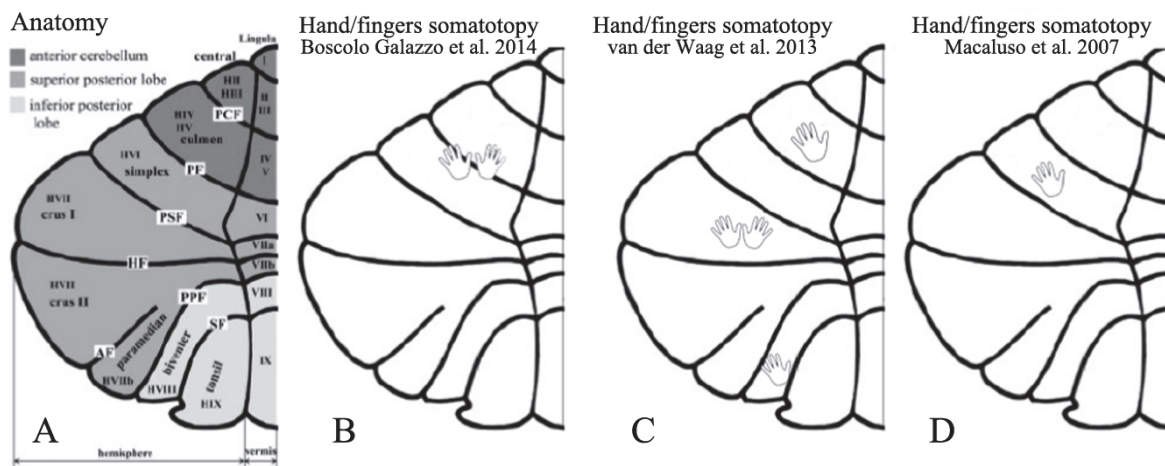


- Kavounoudias A, Roll JP, Anton JL, Nazarian B, Roth M, Roll R. Proprio-tactile integration for kinesthetic perception: an fMRI study. *Neuropsychologia* 2008; 46: 567-75.
- Koziol LF, Budding D, Andreasen N, D'Arrigo S, Bulgheroni S, Imamizu H, *et al.* Consensus paper: the cerebellum's role in movement and cognition. *Cerebellum* 2014; 13: 151-77.
- Liu Y, Pu Y, Gao JH, Parsons LM, Xiong J, Liotti M, *et al.* The human red nucleus and lateral cerebellum in supporting roles for sensory information processing. *Hum Brain Mapp* 2000; 10: 147-59.
- Macaluso E, Cherubini A, Sabatini U. Bimanual passive movement: functional activation and inter-regional coupling. *Front Integr Neurosci* 2007; 1: 5.
- Manni E, Petrosini L. A century of cerebellar somatotopy: a debated representation. *Nat Rev Neurosci* 2004; 5: 241-9.
- Manto M, Bower JM, Conforto AB, Delgado-Garcia JM, da Guarda SN, Gerwig M, *et al.* Consensus paper: roles of the cerebellum in motor control--the diversity of ideas on cerebellar involvement in movement. *Cerebellum* 2012; 11: 457-87.
- Maschke M, Gomez CM, Tuite PJ, Konczak J. Dysfunction of the basal ganglia, but not the cerebellum, impairs kinaesthesia. *Brain* 2003; 126: 2312-22.
- Mima T, Sadato N, Yazawa S, Hanakawa T, Fukuyama H, Yonekura Y, *et al.* Brain structures related to active and passive finger movements in man. *Brain* 1999; 122 ( Pt 10): 1989-97.
- Mottolese C, Richard N, Harquel S, Szathmari A, Sirigu A, Desmurget M. Mapping motor representations in the human cerebellum. *Brain* 2013; 136: 330-42.
- Niddam DM, Chen LF, Wu YT, Hsieh JC. Spatiotemporal brain dynamics in response to muscle stimulation. *Neuroimage* 2005; 25: 942-51.

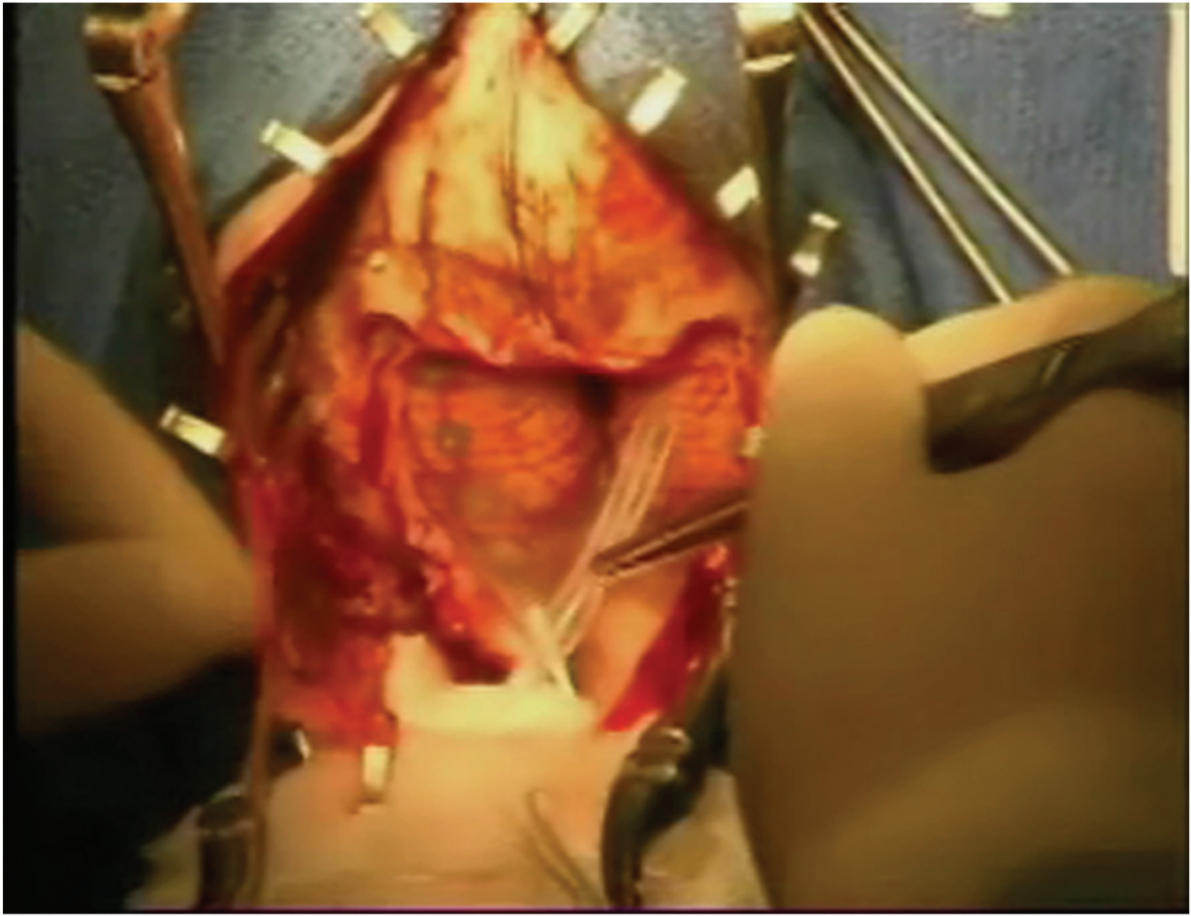
- Niddam DM, Yeh TC, Wu YT, Lee PL, Ho LT, Arendt-Nielsen L, *et al.* Event-related functional MRI study on central representation of acute muscle pain induced by electrical stimulation. *Neuroimage* 2002; 17: 1437-50.
- Reinacher PC, Priebe HJ, Blumrich W, Zentner J, Scheufler KM. The effects of stimulation pattern and sevoflurane concentration on intraoperative motor-evoked potentials. *Anesth Analg* 2006; 102: 888-95.
- Seitz RJ, Roland PE. Vibratory stimulation increases and decreases the regional cerebral blood flow and oxidative metabolism: a positron emission tomography (PET) study. *Acta Neurol Scand* 1992; 86: 60-7.
- Sokolov AA, Miall RC, Ivry RB. The Cerebellum: Adaptive Prediction for Movement and Cognition. *Trends Cogn Sci* 2017; 21: 313-32.
- Strick PL, Dum RP, Fiez JA. Cerebellum and nonmotor function. *Annu Rev Neurosci* 2009; 32: 413-34.
- Takanashi M, Abe K, Yanagihara T, Sakoda S, Tanaka H, Hirabuki N, *et al.* A functional MRI study of somatotopic representation of somatosensory stimulation in the cerebellum. *Neuroradiology* 2003; 45: 149-52.
- Tempel LW, Perlmutter JS. Vibration-induced regional cerebral blood flow responses in normal aging. *J Cereb Blood Flow Metab* 1992; 12: 554-61.
- Thach WT, Goodkin HP, Keating JG. The cerebellum and the adaptive coordination of movement. *AnnuRevNeurosci* 1992; 15: 403-42.
- Therrien AS, Bastian AJ. Cerebellar damage impairs internal predictions for sensory and motor function. *Curr Opin Neurobiol* 2015; 33: 127-33.
- Thickbroom GW, Byrnes ML, Mastaglia FL. Dual representation of the hand in the cerebellum: activation with voluntary and passive finger movement. *Neuroimage* 2003; 18: 670-4.

- Van de Winckel A, Klingels K, Bruyninckx F, Wenderoth N, Peeters R, Sunaert S, *et al.*  
How does brain activation differ in children with unilateral cerebral palsy compared to typically developing children, during active and passive movements, and tactile stimulation? An fMRI study. *Res Dev Disabil* 2013; 34: 183-97.
- van der Zwaag W, Kusters R, Magill A, Gruetter R, Martuzzi R, Blanke O, *et al.* Digit somatotopy in the human cerebellum: a 7T fMRI study. *Neuroimage* 2013; 67: 354-62.
- Weeks RA, Gerloff C, Honda M, Dalakas MC, Hallett M. Movement-related cerebellar activation in the absence of sensory input. *J Neurophysiol* 1999; 82: 484-8.
- Wiestler T, McGonigle DJ, Diedrichsen J. Integration of sensory and motor representations of single fingers in the human cerebellum. *J Neurophysiol* 2011; 105: 3042-53.
- Wolpert DM, Miall RC, Kawato M. Internal models in the cerebellum. *Trends Cogn Sci* 1998; 2: 338-47.

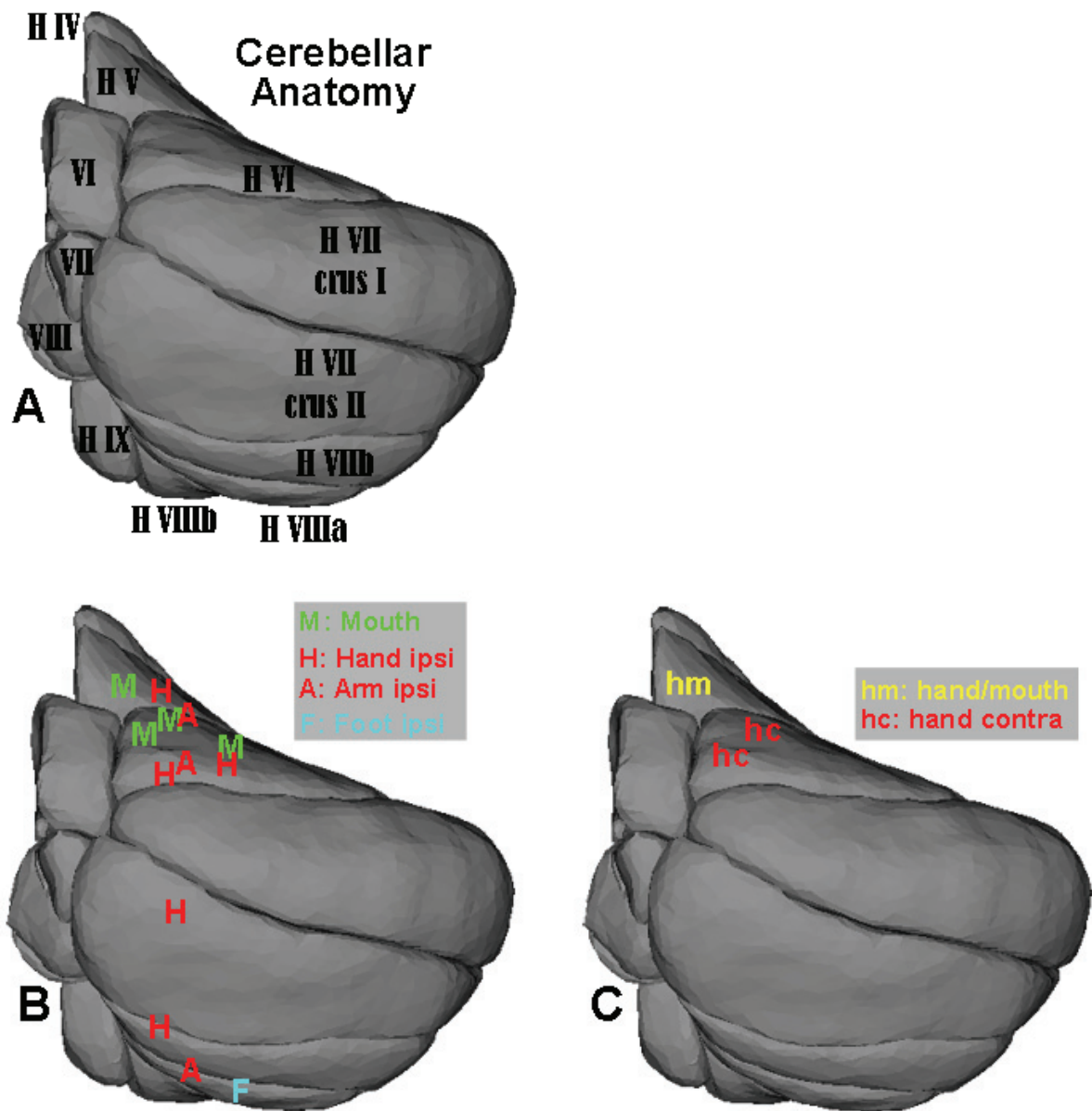
## 6) CAPTIONS:



**Figure 1.** (A) Unfolded view of the cerebellar cortex showing the main lobes, lobules and fissures. (B-D) Illustration of the variability of hand/finger somatosensory organization, for three representative neuroimaging studies (Macaluso *et al.*, 2007; van der Zwaag *et al.*, 2013; Boscolo Galazzo *et al.*, 2014). Single signs (one hand) illustrate ipsilateral activations. Double signs (two hands) illustrate bilateral activations. PCF: preculminate fissure. PF: Primary fissure. PSF: Posterior superior fissure. HF: Horizontal fissure AF: Ansoparamedian fissure. PPF: Prepyramidal fissure. SF: Secondary fissure.



**Figure 2.** Subdural grids used for SEP recording.



**Figure 3.** (A) Cerebellar anatomy. (B-C) Location and origin of the somatosensory inputs recorded in response to electrical stimulations of the body muscles.

# **GENERAL DISCUSSION**

The aim of the thesis was to investigate the mapping of the anatomofunctional organization of the human sensorimotor system and how volitional movements are produced and controlled in humans. Neuroimaging and especially DTI, fine anatomo-functional observations in patients and DES were considered. This multi-modal approach permitted us to improve our understanding of sensorimotor organization in humans. Indeed, our results show that: DES is a useful tool and has potential benefit for tumor resections and preservation of functions in a children; the posterior parietal cortex is involved in the control (and inhibition) of hand movements and has a close anatomo-functional connection with the primary motor and sensory cortex; sensory functions are somatotopically organized in the cerebellum and finally, cerebellar lesions at a young age predict poorer long-term recovery.

In the first study, we showed the use of DES during awake brain surgery is a safe and efficient procedure to decrease post-operative neurological deficits in children. DES improves accuracy in detecting eloquent areas in children, as previously shown in the adult population, with a relatively good tolerance from a neuropsychological and psychological perspective. Specific factors and age-related adaptations need to be considered such as an extensive pre-operative work-up of each individual patient, including psychological and neuropsychological assessment, essential for the success of the procedure. Age-adapted intensive preparation may enable offering ABS even to younger children on an individual basis. Subcortical stimulation ameliorates in our opinion the accuracy and extent of functional discrimination with respect to depth and vascular supply.

In a second series of two studies, we showed that the dorso-posterior part of the parietal cortex is a key structure in the complex organization of movements in human, with a S1-DPPr-M1 loop.



In the first study, DES over focal cortical sites in the dorso-posterior part of the parietal cortex triggered inhibition of movement production and blocked ongoing movement without producing muscle contraction or conscious movement sensations. Several hypotheses about the underlying mechanisms are discussed. However, only two hypotheses, in our view, deserve attention. The first one derives from recent data in monkeys, in which long cortical connections between different functional areas in PPC were shown to activate inhibitory neurons to block competing movements (Kaas and Stepniewska 2016). In effect, considering that our parietal inhibition sites receive short-latency sensory inputs, we can speculate that this inhibition is driven by an internal sensory-to-motor feedback-loop. The entry of the loop would be a sensory signal that generates an inhibitory signal to M1 from DPPr when an unwanted muscle response is detected. The second hypothesis would be that DES prevents the transmission of the real-time error-signal that drives motor activity in primary motor regions (or would cause these regions to interpret the disorganized upcoming signal as a null-error signal). As a consequence, the ongoing movement would promptly stop. Unfortunately, based on our clinical data, we cannot determine the respective validity of this hypothesis and the previously evoked possibility that movement inhibition relies on a dedicated circuit. Further investigation is needed to address this issue.

In the second study, we aimed to find a direct projection from the PRR, defined in the first study (Desmurget et al. 2018a), to the M1 and S1. Thanks to the DTI state-of-the-art tractography, we succeeded in finding such major ipsilateral streamlines projecting in the well-known hand knob region giving new insights of the white matter structures involved in the inhibition of volitional hand movements. These observations confirm clinical per-operative data showing that stimulating the counterpart of PRR in humans can disrupt hand movements ipsilaterally, irrespective of the hemisphere. Moreover, our results

shed light on the implication of the PRR for the volitional hand sensorimotor operating behavior.

In the last part of the thesis, we studied one of the major structures of our central nervous system yet far less known than the cerebrum: the cerebellum.

In the first one, we investigated the impact of early cerebellar damage on long-term functional recovery in 3 groups of fifteen posterior fossa survivors, comparable with respect to their tumoural characteristics (nature size and location), but operated at different ages: young ( $\leq 7$  years), middle ( $> 7$  years and  $\leq 13$  years) and old ( $> 13$  years). Daily (Health-related Quality of Life -hrQoL-, Performance Status -PS-), motor (International Cooperative Ataxia Rating Scale -ICARS-, Pegboard Purdue Test -PegBoard-) and cognitive (Full Scale Intelligence Quotient -FSIQ-) functioning were measured. A General Linear Model controlling for age at surgery, radiotherapy, preservation of deep-cerebellar nuclei, tumor volume and delay between surgery and assessment, was used to investigate significant variations in outcome measures. Early age at surgery, lesion of deep cerebellar nuclei and post-operative radiotherapy had a significant, independent negative influence on long-term recovery. Tumor volume and delay between surgery and assessment had no statistically detectable impact. The negative influence of early age at surgery was significant in all domains: daily functioning (hrQoL; PS), motor functioning (ICARS; Pegboard) and cognitive functioning (FSIQ). These results support the existence of an early critical period of development during which the cerebellar "learning machine" is of critical importance. Although the extent to which the early deficits here observed can be reversed needs now to be established, our data plead for the implementation of prompt and intense rehabilitation interventions in children operated before 7 years of age.

In the second study, we aimed to address the controversies regarding the somatosensory organization of the cerebellum and the existence of a somatotopic

arrangement within this organization. In that purpose, we recorded cerebellar SEP with cortical strip electrodes in 10 patients undergoing surgery because of focal tumors located outside the cerebellum (e.g. pineal gland, quadrigeminal plate). Peripheral electrical stimulation was used to induce contractions in 9 muscles of the face (*orbicularis oris*), upper limb (*biceps*, *triceps*, *extensor digitorum communis*, *flexor carpi radialis*, *thenar eminence*, *hypothenar eminence*) and lower-limb (*tibialis anterior*, *gastrocnemius*). We showed that electrical stimulation of peripheral muscles was able to trigger SEP on the cerebellar cortex, but not homogeneously. The quasi-totality of body inputs were located (i) in the anterior/superior-posterior cerebellar region (lobules HV-HVI); and (ii) in the inferior posterior cerebellar region (lobules HVIIb-HVIII). For the most part, the recorded signals were ipsilateral, although a substantial fraction (around 30%) of contralateral inputs were observed for the hand. No somatotopic arrangement was identified, at least within the anterior/superior-posterior region where mouth and upper-limb representations overlapped without spatial segregation (or even a trend indicating that such a segregation may exist). From a functional point of view, the present study does not allow us to determine the anatomical routes that convey the cerebellar SEP which could be the spinocerebellar tracts or indirectly through the main cortical sensorimotor areas (especially S1).

To summarize, in this thesis I used a multi-modal approach to investigate the human sensorimotor system. Significant advances were achieved at both the clinical (generalization of awake surgeries in children) and fundamental (better understanding of the anatomo-functional organization of the parietal and cerebellar cortex; identification of a critical period for post-lesional recovery in posterior fossa patients) levels. Of course, these results have now to be extended and generalized. Also, many issues remain to be studied. This sets exciting challenges and tracks to explore for the years to come.

# REFERENCES

Akay, Ali, Mete Rüksen, H. Yurday Çetin, H. Özer Seval, and Sertaç İşlekel 2016 Pediatric Awake Craniotomy for Brain Lesions. *Pediatric Neurosurgery* 51(2): 103–108.

Alkadhi, H., G. R. Crelier, S. H. Boendermaker, et al. 2002 Reproducibility of Primary Motor Cortex Somatotopy under Controlled Conditions. *American Journal of Neuroradiology* 23(9): 1524–1532.

Bastian, Amy J. 2006 Learning to Predict the Future: The Cerebellum Adapts Feedforward Movement Control. *Current Opinion in Neurobiology* 16(6): 645–649.

Bauswein, E., F. P. Kolb, B. Leimbeck, and F. J. Rubia 1983 Simple and Complex Spike Activity of Cerebellar Purkinje Cells during Active and Passive Movements in the Awake Monkey. *The Journal of Physiology* 339: 379–394.

Bauswein, E., F. P. Kolb, and F. J. Rubia 1984 Cerebellar Feedback Signals of a Passive Hand Movement in the Awake Monkey. *Pflugers Archiv: European Journal of Physiology* 402(3): 292–299.

Beez, Thomas, Kira Boge, Michel Wager, et al. 2013 Tolerance of Awake Surgery for Glioma: A Prospective European Low Grade Glioma Network Multicenter Study. *Acta Neurochirurgica* 155(7): 1301–1308.

Berger, Ms, and Ga Ojemann 1992 Intraoperative Brain Mapping Techniques in Neurooncology. *Stereotactic and Functional Neurosurgery* 58(1–4): 153–161.

Boetto, Julien, Luc Bertram, Gérard Moulinié, et al. 2015 Low Rate of Intraoperative Seizures During Awake Craniotomy in a Prospective Cohort with 374 Supratentorial Brain Lesions: Electrocorticography Is Not Mandatory. *World Neurosurgery* 84(6): 1838–1844.

Borchers, Svenja, Marc Himmelbach, Nikos Logothetis, and Hans-Otto Karnath 2011 Direct Electrical Stimulation of Human Cortex - the Gold Standard for Mapping Brain Functions? *Nature Reviews. Neuroscience* 13(1): 63–70.

Boscolo Galazzo, Ilaria, Silvia F. Storti, Emanuela Formaggio, et al. 2014 Investigation of Brain Hemodynamic Changes Induced by Active and Passive Movements: A Combined Arterial Spin Labeling-BOLD fMRI Study. *Journal of Magnetic Resonance Imaging: JMIR* 40(4): 937–948.

Branco, D. M., T. M. Coelho, B. M. Branco, et al. 2003 Functional Variability of the Human Cortical Motor Map: Electrical Stimulation Findings in Perirolandic Epilepsy Surgery. *Journal of Clinical Neurophysiology* 20(1): 17–25.

Broca, P 1865 Sur Le Siège de La Faculté Du Language Articulé. *Bull Soc Anthropol.* 6: 337–393.

Brodal, A. 1981 *Neurological Anatomy in Relation to Clinical Medicine.* Oxford University. New York.

Brodal, P. 1978 The Corticopontine Projection in the Rhesus Monkey. Origin and Principles of Organization. *Brain: A Journal of Neurology* 101(2): 251–283.

Burton, H., T. O. Videen, and M. E. Raichle 1993 Tactile-Vibration-Activated Foci in Insular and Parietal-Opercular Cortex Studied with Positron Emission Tomography: Mapping the Second Somatosensory Area in Humans. *Somatosensory & Motor Research* 10(3): 297–308.

Bushara, K. O., J. M. Wheat, A. Khan, et al. 2001 Multiple Tactile Maps in the Human Cerebellum. *Neuroreport* 12(11): 2483–2486.

Casey, K. L., S. Minoshima, T. J. Morrow, and R. A. Koeppe 1996 Comparison of Human Cerebral Activation Pattern during Cutaneous Warmth, Heat Pain, and Deep Cold Pain. *Journal of Neurophysiology* 76(1): 571–581.

Chang, Edward F., Aaron Clark, Justin S. Smith, et al. 2011 Functional Mapping-Guided Resection of Low-Grade Gliomas in Eloquent Areas of the Brain: Improvement of Long-Term Survival Clinical Article. *Journal of Neurosurgery* 114(3): 566–573.

Ciccarelli, O., A. T. Toosy, J. F. Marsden, et al. 2005 Identifying Brain Regions for Integrative Sensorimotor Processing with Ankle Movements. *Experimental Brain Research* 166(1): 31–42.

Desmurget, Michel, Nathalie Richard, Pierre-Aurélien Beuriat, et al. 2018a Selective

Inhibition of Volitional Hand Movements after Stimulation of the Dorsoposterior Parietal Cortex in Humans. *Current Biology* 28(20): 3303-3309.e3.

Desmurget, Michel, Nathalie Richard, Pierre-Aurélien Beuriat, et al. 2018b Selective Inhibition of Volitional Hand Movements after Stimulation of the Dorsoposterior Parietal Cortex in Humans. *Current Biology: CB* 28(20): 3303-3309.e3.

Desmurget, Michel, Nathalie Richard, Sylvain Harquel, et al. 2014 Neural Representations of Ethologically Relevant Hand/Mouth Synergies in the Human Precentral Gyrus. *Proceedings of the National Academy of Sciences of the United States of America* 111(15): 5718–5722.

Desmurget, Michel, and Angela Sirigu 2009 A Parietal-Premotor Network for Movement Intention and Motor Awareness. *Trends in Cognitive Sciences* 13(10): 411–419.

Desmurget, Michel, and Angela Sirigu 2015 Revealing Humans' Sensorimotor Functions with Electrical Cortical Stimulation. *Philosophical Transactions of the Royal Society of London. Series B, Biological Sciences* 370(1677): 20140207.

Desmurget, Michel, Zheng Song, Carmine Mottolise, and Angela Sirigu 2013 Re-Establishing the Merits of Electrical Brain Stimulation. *Trends in Cognitive Sciences* 17(9): 442–449.

Donoghue, Jp, S. Leibovic, and Jn Sanes 1992 Organization of the Forelimb Area in Squirrel-Monkey Motor Cortex - Representation of Digit, Wrist, and Elbow Muscles.

Experimental Brain Research 89(1): 1–19.

Elsberg, C. A. 1925 CRANIOTOMY UNDER LOCAL ANAESTHESIA. *Annals of Surgery* 81(1): 213–222.

Farrell, Donald F., Nicole Burbank, Ettore Lettich, and George A. Ojemann 2007 Individual Variation in Human Motor-Sensory (Rolandic) Cortex. *Journal of Clinical Neurophysiology* 24(3): 286–293.

Fogassi, L., V. Gallese, M. Gentilucci, et al. 1994 The Frontoparietal Cortex of the Prosimian Galago - Patterns of Cytochrome-Oxidase Activity and Motor Maps. *Behavioural Brain Research* 60(1): 91–113.

Francis, Susan, Xia Lin, Samia Aboushousah, et al. 2009 FMRI Analysis of Active, Passive and Electrically Stimulated Ankle Dorsiflexion. *NeuroImage* 44(2): 469–479.

Fritsch, G, and E Hitzig N.d. Ueber die elektrische Erregbarkeit des Grosshirns. *Arch. Anat. Physiol. Wiss. Med* 37: 300–332.

Galvani, L 1791 De Viribus Electricitatis in Motu Musculari Commentarius. *Bononiensi Sci. Artium Inst. Acad* 7: 363–418.

Gao, J. H., L. M. Parsons, J. M. Bower, et al. 1996 Cerebellum Implicated in Sensory Acquisition and Discrimination Rather than Motor Control. *Science (New York, N.Y.)* 272(5261): 545–547.



Gentile, Giovanni, Valeria I. Petkova, and H. Henrik Ehrsson 2011 Integration of Visual and Tactile Signals from the Hand in the Human Brain: An FMRI Study. *Journal of Neurophysiology* 105(2): 910–922.

Gould, HJ, CG Cusick, TP Pons, and JH Kaas 1986 The Relationship of Corpus-Callosum Connections to Electrical-Stimulation Maps of Motor, Supplementary Motor, and the Frontal Eye Fields in Owl Monkeys. *Journal of Comparative Neurology* 247(3): 297–325.

Grafton, ST, RP Woods, and JC Mazziotta 1993 Within-Arm Somatotopy in Human Motor Areas Determined by Positron Emission Tomography Imaging of Cerebral Blood-Flow. *Experimental Brain Research* 95(1): 172–176.

Gupta, Deepak Kumar, P. S. Chandra, B. K. Ojha, et al. 2007 Awake Craniotomy versus Surgery under General Anesthesia for Resection of Intrinsic Lesions of Eloquent Cortex--a Prospective Randomised Study. *Clinical Neurology and Neurosurgery* 109(4): 335–343.

Guzzetta, Andrea, Martin Staudt, Elisa Petacchi, et al. 2007 Brain Representation of Active and Passive Hand Movements in Children. *Pediatric Research* 61(4): 485–490.

Habas, C., H. Axelrad, and E.-A. Cabanis 2004 The Cerebellar Second Homunculus Remains Silent during Passive Bimanual Movements. *Neuroreport* 15(10): 1571–1574.

Haseeb, Ateeq, Eishi Asano, Csaba Juhasz, et al. 2007 Young Patients with Focal Seizures

May Have the Primary Motor Area for the Hand in the Postcentral Gyrus. *Epilepsy Research* 76(2–3): 131–139.

Hervey-Jumper, Shawn L., Jing Li, Darryl Lau, et al. 2015 Awake Craniotomy to Maximize Glioma Resection: Methods and Technical Nuances over a 27-Year Period. *Journal of Neurosurgery* 123(2): 325–339.

Histed, Mark H., Amy M. Ni, and John H. R. Maunsell 2013 Insights into Cortical Mechanisms of Behavior from Microstimulation Experiments. *Progress in Neurobiology* 103: 115–130.

Hlustik, P., A. Solodkin, R. P. Gullapalli, D. C. Noll, and S. L. Small 2001 Somatotopy in Human Primary Motor and Somatosensory Hand Representations Revisited. *Cerebral Cortex* 11(4): 312–321.

Holmes, G 1939 The Cerebellum of Man. *Brain* 62: 1–30.

Horne, M. K., and E. G. Butler 1995 The Role of the Cerebello-Thalamo-Cortical Pathway in Skilled Movement. *Progress in Neurobiology* 46(2–3): 199–213.

Ito, Masao 2006 Cerebellar Circuitry as a Neuronal Machine. *Progress in Neurobiology* 78(3–5): 272–303.

Jueptner, M., S. Ottinger, S. J. Fellows, et al. 1997 The Relevance of Sensory Input for the Cerebellar Control of Movements. *NeuroImage* 5(1): 41–48.

Kaas, Jon H., and Iwona Stepniewska 2016 Evolution of Posterior Parietal Cortex and Parietal-Frontal Networks for Specific Actions in Primates. *Journal of Comparative Neurology* 524(3): 595–608.

Kandel, ER, JH Schwartz, TM Jessel, SA Siegelbaum, and AJ Hudspeth 2013 2000 Principles of Neural Sciences. Fifth edition. New York: Mc-Graw-Hill Medical.

Karnath, Hans-Otto, Svenja Borchers, and Marc Himmelbach 2010 Comment on “Movement Intention after Parietal Cortex Stimulation in Humans.” *Science* (New York, N.Y.) 327(5970): 1200; author reply 1200.

Kavounoudias, A., J. P. Roll, J. L. Anton, et al. 2008 Proprio-Tactile Integration for Kinesthetic Perception: An fMRI Study. *Neuropsychologia* 46(2): 567–575.

Leeds, N. E., and S. A. Kieffer 2000 Evolution of Diagnostic Neuroradiology from 1904 to 1999. *Radiology* 217(2): 309–318.

Lisberger, S. 2013 The Cerebellum. *In* Principles of Neural Science Pp. 960–81.

Liu, Y., Y. Pu, J. H. Gao, et al. 2000 The Human Red Nucleus and Lateral Cerebellum in Supporting Roles for Sensory Information Processing. *Human Brain Mapping* 10(4): 147–159.

Logothetis, Nikos K., Mark Augath, Yusuke Murayama, et al. 2010 The Effects of Electrical

Microstimulation on Cortical Signal Propagation. *Nature Neuroscience* 13(10): 1283–1291.

Lohkamp, Laura-Nanna, Carmine Mottolese, Alexandru Szathmari, et al. 2019  
Awake Brain Surgery in Children-Review of the Literature and State-of-the-Art.  
*Child's Nervous System: ChNS: Official Journal of the International Society for Pediatric  
Neurosurgery.*

Lotze, M., M. Erb, H. Flor, et al. 2000 FMRI Evaluation of Somatotopic Representation in  
Human Primary Motor Cortex. *Neuroimage* 11(5): 473–481.

Macaluso, Emiliano, Andrea Cherubini, and Umberto Sabatini 2007 Bimanual Passive  
Movement: Functional Activation and Inter-Regional Coupling. *Frontiers in Integrative  
Neuroscience* 1: 5.

Manni, Ermanno, and Laura Petrosini 2004 A Century of Cerebellar Somatotopy: A  
Debated Representation. *Nature Reviews. Neuroscience* 5(3): 241–249.

Manto, Mario, James M. Bower, Adriana Bastos Conforto, et al. 2012 Consensus Paper:  
Roles of the Cerebellum in Motor Control--the Diversity of Ideas on Cerebellar  
Involvement in Movement. *Cerebellum (London, England)* 11(2): 457–487.

Matyas, Ferenc, Varun Sreenivasan, Fred Marbach, et al. 2010 Motor Control by Sensory  
Cortex. *Science* 330(6008): 1240–1243.

Meier, Jeffrey D., Tyson N. Aflalo, Sabine Kastner, and Michael S. A. Graziano 2008

Complex Organization of Human Primary Motor Cortex: A High-Resolution FMRI Study. *Journal of Neurophysiology* 100(4): 1800–1812.

Meng, Lingzhong, Mitchel S. Berger, and Adrian W. Gelb 2015 The Potential Benefits of Awake Craniotomy for Brain Tumor Resection: An Anesthesiologist's Perspective. *Journal of Neurosurgical Anesthesiology* 27(4): 310–317.

Mima, T., N. Sadato, S. Yazawa, et al. 1999 Brain Structures Related to Active and Passive Finger Movements in Man. *Brain: A Journal of Neurology* 122 ( Pt 10): 1989–1997.

Mottolese, C., A. Szathmari, P.-A. Beuriat, A. Sirigu, and M. Desmurget 2015 Sensorimotor Mapping of the Human Cerebellum during Pineal Region Surgery. *Neuro-Chirurgie* 61(2–3): 101–105.

Mottolese, Carmine, Nathalie Richard, Sylvain Harquel, et al. 2013 Mapping Motor Representations in the Human Cerebellum. *Brain: A Journal of Neurology* 136(Pt 1): 330–342.

Nii, Y., S. Uematsu, R. P. Lesser, and B. Gordon 1996 Does the Central Sulcus Divide Motor and Sensory Functions? Cortical Mapping of Human Hand Areas as Revealed by Electrical Stimulation through Subdural Grid Electrodes. *Neurology* 46(2): 360–367.

Paldor, Iddo, Katharine J. Drummond, Mohammed Awad, Yuval Z. Sufaro, and Andrew H. Kaye 2016 Is a Wake-up Call in Order? Review of the Evidence for Awake Craniotomy. *Journal of Clinical Neuroscience: Official Journal of the Neurosurgical Society of*

Australasia 23: 1–7.

Penfield, Wilder, and Edwin Boldrey 1937 SOMATIC MOTOR AND SENSORY REPRESENTATION IN THE CEREBRAL CORTEX OF MAN AS STUDIED BY ELECTRICAL STIMULATION. *Brain* 60(4): 389–443.

Plow, Ela B., Pooja Arora, Megan A. Pline, Meagan T. Binstock, and James R. Carey 2010 Within-Limb Somatotopy in Primary Motor Cortex - Revealed Using FMRI. *Cortex* 46(3): 310–321.

Preuss, T. M., I. Stepniewska, and J. H. Kaas 1996 Movement Representation in the Dorsal and Ventral Premotor Areas of Owl Monkeys: A Microstimulation Study. *Journal of Comparative Neurology* 371(4): 649–675.

Riquin, Elise, Mickael Dinomais, Jean Malka, et al. 2017 Psychiatric and Psychologic Impact of Surgery While Awake in Children for Resection of Brain Tumors. *World Neurosurgery* 102: 400–405.

Sanai, Nader, Zaman Mirzadeh, and Mitchel S. Berger 2008 Functional Outcome after Language Mapping for Glioma Resection. *The New England Journal of Medicine* 358(1): 18–27.

Sanes, J. N., and M. H. Schieber 2001 Orderly Somatotopy in Primary Motor Cortex: Does It Exist? *Neuroimage* 13(6): 968–974.

Sanes, Jn, Jp Donoghue, V. Thangaraj, Rr Edelman, and S. Warach 1995 Shared  
Neural Substrates Controlling Hand Movements in Human Motor Cortex. *Science*  
268(5218): 1775–1777.

Schieber, Mh, and Ls Hibbard 1993 How Somatotopic Is the Motor Cortex Hand  
Area. *Science* 261(5120): 489–492.

Schmahmann, J. D., and J. C. Sherman 1998 The Cerebellar Cognitive Affective  
Syndrome. *Brain: A Journal of Neurology* 121 ( Pt 4): 561–579.

Schmahmann, Jeremy D. 2010 The Role of the Cerebellum in Cognition and Emotion:  
Personal Reflections since 1982 on the Dysmetria of Thought Hypothesis, and Its Historical  
Evolution from Theory to Therapy. *Neuropsychology Review* 20(3): 236–260.

Scoville, William Beecher, and Brenda Milner 1957 LOSS OF RECENT MEMORY  
AFTER BILATERAL HIPPOCAMPAL LESIONS. *Journal of Neurology, Neurosurgery,  
and Psychiatry* 20(1): 11–21.

Seitz, R. J., and P. E. Roland 1992 Vibratory Stimulation Increases and Decreases the  
Regional Cerebral Blood Flow and Oxidative Metabolism: A Positron Emission  
Tomography (PET) Study. *Acta Neurologica Scandinavica* 86(1): 60–67.

Serletis, Demitre, and Mark Bernstein 2007 Prospective Study of Awake Craniotomy  
Used Routinely and Nonselectively for Supratentorial Tumors. *Journal of Neurosurgery*  
107(1): 1–6.

Stoodley, Catherine J. 2012 The Cerebellum and Cognition: Evidence from Functional Imaging Studies. *Cerebellum* (London, England) 11(2): 352–365.

Strick, Peter L. 2002 Stimulating Research on Motor Cortex. *Nature Neuroscience* 5(8): 714–715.

Strick, Peter L., Richard P. Dum, and Julie A. Fiez 2009 Cerebellum and Nonmotor Function. *Annual Review of Neuroscience* 32: 413–434.

Surbeck, Werner, Gerhard Hildebrandt, and Hugues Duffau 2015 The Evolution of Brain Surgery on Awake Patients. *Acta Neurochirurgica* 157(1): 77–84.

Takanashi, M., K. Abe, T. Yanagihara, et al. 2003 A Functional MRI Study of Somatotopic Representation of Somatosensory Stimulation in the Cerebellum. *Neuroradiology* 45(3): 149–152.

Tate, Matthew C., Guillaume Herbet, Sylvie Moritz-Gasser, Joseph E. Tate, and Hugues Duffau  
2014 Probabilistic Map of Critical Functional Regions of the Human Cerebral Cortex: Broca's Area Revisited. *Brain* 137: 2773–2782.

Taylor, Charlotte S. R., and Charles G. Gross 2003 Twitches versus Movements: A Story of Motor Cortex. *The Neuroscientist: A Review Journal Bringing Neurobiology, Neurology and Psychiatry* 9(5): 332–342.



Taylor, M. D., and M. Bernstein 1999 Awake Craniotomy with Brain Mapping as the Routine Surgical Approach to Treating Patients with Supratentorial Intraaxial Tumors: A Prospective Trial of 200 Cases. *Journal of Neurosurgery* 90(1): 35–41.

Tempel, L. W., and J. S. Perlmutter 1992 Vibration-Induced Regional Cerebral Blood Flow Responses in Normal Aging. *Journal of Cerebral Blood Flow and Metabolism: Official Journal of the International Society of Cerebral Blood Flow and Metabolism* 12(4): 554–561.

Thickbroom, Gary W., Michelle L. Byrnes, and Frank L. Mastaglia 2003 Dual Representation of the Hand in the Cerebellum: Activation with Voluntary and Passive Finger Movement. *NeuroImage* 18(3): 670–674.

Timmann, D., J. Drepper, M. Frings, et al. 2010 The Human Cerebellum Contributes to Motor, Emotional and Cognitive Associative Learning. A Review. *Cortex; a Journal Devoted to the Study of the Nervous System and Behavior* 46(7): 845–857.

Trevisi, Gianluca, Thomas Roujeau, and Hugues Duffau 2016 Awake Surgery for Hemispheric Low-Grade Gliomas: Oncological, Functional and Methodological Differences between Pediatric and Adult Populations. *Child's Nervous System: ChNS: Official Journal of the International Society for Pediatric Neurosurgery* 32(10): 1861–1874.

Van de Winckel, Ann, Katrijn Klingels, Frans Bruyninckx, et al. 2013 How Does Brain Activation Differ in Children with Unilateral Cerebral Palsy Compared to Typically

Developing Children, during Active and Passive Movements, and Tactile Stimulation? An FMRI Study. *Research in Developmental Disabilities* 34(1): 183–197.

Weeks, R. A., C. Gerloff, M. Honda, M. C. Dalakas, and M. Hallett 1999 Movement-Related Cerebellar Activation in the Absence of Sensory Input. *Journal of Neurophysiology* 82(1): 484–488.

Widener, G. L., and P. D. Cheney 1997 Effects on Muscle Activity from Microstimuli Applied to Somatosensory and Motor Cortex during Voluntary Movement in the Monkey. *Journal of Neurophysiology* 77(5): 2446–2465.

Wiestler, Tobias, David J. McGonigle, and Jörn Diedrichsen 2011 Integration of Sensory and Motor Representations of Single Fingers in the Human Cerebellum. *Journal of Neurophysiology* 105(6): 3042–3053.

Yang, Tt, Cc Gallen, Bj Schwartz, and Fe Bloom 1993 Noninvasive Somatosensory Homunculus Mapping in Humans by Using a Large-Array Biomagnetometer. *Proceedings of the National Academy of Sciences of the United States of America* 90(7): 3098–3102.

Zeharia, Noa, Uri Hertz, Tamar Flash, and Amir Amedi 2012 Negative Blood Oxygenation Level Dependent Homunculus and Somatotopic Information in Primary Motor Cortex and Supplementary Motor Area. *Proceedings of the National Academy of Sciences of the United States of America* 109(45): 18565–18570.

van der Zwaag, Wietske, Remy Kusters, Arthur Magill, et al. 2013 Digit Somatotopy in the

Human Cerebellum: A 7T fMRI Study. *NeuroImage* 67: 354–362.