



HAL
open science

Caractérisation de la plaque athérombotique à la phase aigüe de l'infarctus du myocarde en imagerie endocoronaire et marqueurs biologiques thrombotiques

Vincent Roule

► To cite this version:

Vincent Roule. Caractérisation de la plaque athérombotique à la phase aigüe de l'infarctus du myocarde en imagerie endocoronaire et marqueurs biologiques thrombotiques. Médecine humaine et pathologie. Normandie Université, 2019. Français. NNT : 2019NORMC414 . tel-02438192

HAL Id: tel-02438192

<https://theses.hal.science/tel-02438192>

Submitted on 14 Jan 2020

HAL is a multi-disciplinary open access archive for the deposit and dissemination of scientific research documents, whether they are published or not. The documents may come from teaching and research institutions in France or abroad, or from public or private research centers.

L'archive ouverte pluridisciplinaire **HAL**, est destinée au dépôt et à la diffusion de documents scientifiques de niveau recherche, publiés ou non, émanant des établissements d'enseignement et de recherche français ou étrangers, des laboratoires publics ou privés.



Normandie Université

THÈSE

Pour obtenir le diplôme de doctorat

Spécialité RECHERCHE CLINIQUE, INNOVATION TECHNOLOGIQUE, SANTE PUBLIQUE

Préparée au sein de l'Université de Caen Normandie

Caractérisation de la plaque athérotrombotique à la phase aiguë de l'infarctus du myocarde en imagerie endocoronaire et marqueurs biologiques thrombotiques.

**Présentée et soutenue par
Vincent ROULE**

**Thèse soutenue publiquement le 03/12/2019
devant le jury composé de**

M. NICOLAS MENEVEAU	Professeur des universités PraticienHosp, Université de Franche-Comté	Rapporteur du jury
M. GERAUD SOUTEYRAND	Professeur des universités PraticienHosp, CHU Clermont-Ferrand Gabriel-Montpied	Rapporteur du jury
Mme ANNIE BOREL-DERLON	Maître de conférences HDR, Université Caen Normandie	Membre du jury
M. JEAN-PHILIPPE COLLET	Professeur des universités PraticienHosp, CHU Salpêtrière Paris	Président du jury
M. FARZIN ESMAIL-BEYGUI	Professeur des universités PraticienHosp, Université Caen Normandie	Directeur de thèse

Thèse dirigée par FARZIN ESMAIL-BEYGUI, Signalisation, électrophysiologie et imagerie des lésions d'ischémie-reperfusion myocardique (Caen)



UNIVERSITÉ
CAEN
NORMANDIE



Normandie de Biologie Intégrative,
Santé, Environnement



Remerciements

A Monsieur le Professeur Farzin BEYGUI

Merci pour tes précieux conseils et ton accompagnement dans ce travail. C'est un réel plaisir d'apprendre à tes côtés en salle de cathétérisme et en dehors. Merci de m'avoir fait confiance et de transmettre ta passion pour la recherche et l'innovation.

Aux Professeurs Jean-Philippe COLLET, Nicolas MENEVEAU et Géraud SOUTEYRAND et à Madame le Docteur Annie BOREL-DERLON

Merci pour l'honneur que vous me faites de juger ce travail en y apportant votre expérience et votre expertise. Veuillez trouver ici l'expression de ma sincère gratitude.

A Monsieur le Professeur Paul MILLIEZ

Merci pour ton accompagnement dans mon cursus en tant que chef de service. C'est fort agréable de pouvoir échanger très librement avec toi. Je tiens à te témoigner ma chaleureuse gratitude.

A Monsieur le Professeur Alain MANRIQUE

Merci de m'avoir accueilli au sein de ton unité de recherche et de m'avoir initié à la recherche expérimentale. J'en garde un souvenir fort.

A la bande des coronarographistes

Merci les gars et la fille pour votre soutien dans les études « maison » et surtout merci pour les cafés, nos blagues et jeux de mots et cette ambiance sans laquelle ce ne serait pas pareil. Comme dit Grandmalcormalade, on n'est pas payé cher mais on se marre bien. Et non, mon cher AL, je ne désespère pas d'un gros papier incluant la CRP-US.

A l'ensemble des équipes de cardiologie et en particulier de coronarographie avec qui j'ai réellement plaisir à travailler et discuter. Aux internes, infirmières, manips qui ont fait partie de cette aventure. A mes collègues cardiologues et néanmoins amis.

A Katrien

Pour ton soutien et tes nombreuses relectures pour l'avant-veille (je peux désormais t'appeler relector). Et pour tout le reste.

A mes deux soleils Robin et Clément, et à mes parents, toujours là pour me soutenir.

Résumé

L'activité plaquettaire joue un rôle clé dans la physiopathologie de l'infarctus du myocarde avec sus-décalage du segment ST (IDM ST+). La réactivité plaquettaire est augmentée lors d'un IDM ST+, traité par angioplastie primaire ou par fibrinolyse avec succès. La relation entre la réactivité plaquettaire résiduelle après un pré-traitement, la charge athérombotique et la qualité de la reperfusion myocardique reste peu décrite dans le cadre des IDM ST+. La tomographie par cohérence optique et celle plus récente par domaine de fréquence offrent une imagerie de haute résolution permettant l'identification et la quantification précise de la charge athérombotique intracoronaire (CAT). La CAT résiduelle intra-stent peut aider à mieux comprendre la relation entre la réactivité plaquettaire et la reperfusion. Dans un premier temps, nous avons évalué la précision des tests VerifyNow et PFA en comparaison à l'agrégométrie optique pour la détection de l'hyperréactivité plaquettaire dans le contexte particulier des IDM ST+ traités par fibrinolyse avec succès. Nous avons aussi décrit les caractéristiques de la CAT avant et après angioplastie selon la présence d'une rupture de plaque ou d'une érosion coronaire chez des patients traités par fibrinolyse avec succès. Ensuite, nous avons étudié la relation entre la réactivité plaquettaire résiduelle (en réponse au ticagrelor et à l'aspirine) mesurée par VerifyNow et la reperfusion myocardique chez des patients traités par angioplastie primaire. En parallèle, nous avons décrit la relation entre la reperfusion myocardique et la CAT résiduelle intra-stent dans la même cohorte.

Mots-clés : Infarctus du myocarde avec sus-décalage du segment ST; tomographie par cohérence optique; thrombus; reperfusion myocardique; réactivité plaquettaire; fibrinolyse; angioplastie primaire

Abstract

Platelet activity plays a key role in the pathophysiology of ST-segment elevation myocardial infarction (STEMI). Platelet reactivity is enhanced after STEMI treated with primary percutaneous coronary intervention (PCI) or successful thrombolysis. The relationship between residual platelet reactivity after pre-treatment, the atherothrombotic burden and the quality of reperfusion remains poorly described in STEMI. Optical coherence tomography (OCT) and optical frequency domain imaging (OFDI) provide high resolution imaging allowing identification and accurate quantification of intracoronary atherothrombotic burden (ATB). Residual in-stent ATB may help to better understand the relation between platelet reactivity and reperfusion. First, we assessed the accuracy of the point-of-care tests VerifyNow and PFA in comparison to light transmittance aggregometry to detect high on-treatment platelet reactivity (HPR) in the particular setting of STEMI successfully treated with fibrinolysis. We also described the characteristics of ATB before and after PCI according to the underlying presence of rupture or erosion in patients successfully treated with fibrinolysis. Then, we assessed the relationship between residual platelet reactivity (in response to ticagrelor and aspirin) using VerifyNow and myocardial reperfusion in primary PCI patients. In parallel, we studied the relationship between myocardial reperfusion and residual in-stent ATB in the same cohort.

Keywords: ST-segment elevation myocardial infarction; Optical coherence tomography; thrombus; myocardial reperfusion; platelet reactivity; fibrinolysis; primary-PCI

SOMMAIRE

Liste des abréviations.....	6
I. INTRODUCTION	7
1. L'infarctus du myocarde avec sus-décalage du segment ST	7
1.1. Epidémiologie.....	7
1.2. Mécanismes physiopathologiques de l'IDM.....	8
<i>L'athérosclérose</i>	<i>8</i>
<i>Mécanismes de l'athérombose coronaire</i>	<i>10</i>
1.3. Prise en charge thérapeutique initiale	11
<i>Angioplastie primaire ou fibrinolyse</i>	<i>11</i>
<i>Traitements anti-thrombotiques.....</i>	<i>12</i>
<i>Moment d'administration des inhibiteurs du P2Y12</i>	<i>15</i>
2. Indices de reperfusion angiographiques	15
3. La tomographie par cohérence optique.....	18
3.1. Principes	18
3.2. Applications pratiques	18
3.3. OCT et charge athérombotique	21
4. Les tests d'agrégation plaquettaire	24
4.1. L'agrégométrie optique.....	24
4.2. Le Verify Now	24
4.3. PFA et autres tests	25
4.4. Hyperréactivité plaquettaire et pronostic	26
4.5. Impact de la réactivité plaquettaire à la phase aigüe de l'IDM ST+	27
II. OBJECTIFS.....	28
III. ARTICLES.....	29
1. Tests de VerifyNow P2Y12 et INNOVANCE PFA P2Y comparés à l'agrégométrie optique après fibrinolyse.....	29
2. Erosion versus rupture de plaque en analyse OFDI pré et post stenting dans les IDM ST+ reperfusés par fibrinolyse	54
3. Réactivité plaquettaire résiduelle au ticagrelor et à l'aspirine dans l'angioplastie primaire et reperfusion myocardique	78
4. Charge athérombotique résiduelle évaluée en OFDI et reperfusion myocardique dans l'angioplastie primaire	97
IV. SYNTHÈSE	116
V. CONCLUSION.....	124
VI. REFERENCES.....	125

Liste des abréviations

ADP : adenosine-5-diphosphate

AntiGPIIbIIIa : inhibiteurs de la glycoprotéine IIbIIIa

ARU : aspirin reaction units

CAT : charge athérothrombotique

ECG : électrocardiogramme

HPR : hyperréactivité plaquettaire aux inhibiteurs du P2Y12

HaPR : hyperréactivité plaquettaire à l'aspirine

IAP : inhibition de l'agrégation plaquettaire

IDM : infarctus du myocarde

IDM ST+ : infarctus du myocarde avec sus-décalage du segment ST

HBPM : héparines de bas poids moléculaire

IVUS : imagerie intravasculaire par ultrasons

LTA : agrégométrie optique ou Light transmission agregometry

MBG : grade de blush myocardique

OCT : tomographie par cohérence optique

OFDI : optical frequency domain imaging (tomographie par domaine de fréquence optique)

PFA : Platelet Function Analyzer

PRU: P2Y12 reaction units

TIMI : thrombolysis in myocardial infarction

VN : VerifyNow

I. INTRODUCTION

1. L'infarctus du myocarde avec sus-décalage du segment ST

1.1. Epidémiologie

La cardiomyopathie ischémique reste la première cause spécifique de mortalité dans le monde. Concernant les infarctus du myocarde (IDM), on distingue les infarctus avec ou sans sus-décalage du segment ST (IDM ST+ et ST- ou STEMI et NSTEMI en anglais) sur l'électrocardiogramme (ECG). La mortalité à court et long terme post-IDM a diminué avec l'utilisation de l'angioplastie primaire, les nouveaux traitements antithrombotiques et le raccourcissement des délais de prise en charge. L'IDM ST+ reste néanmoins grevé d'une mortalité hospitalière variant entre 3 et 12% en Europe [1]. Dans les registres, la mortalité à 1 an post-IDM ST+ est d'environ 10% [2]. En France, on observe toutefois une nette diminution de la mortalité à 1 an post-IDM ST+ passée de 11.9% en 1995 à 5.9% en 2015 chez ceux ayant bénéficié d'une stratégie thérapeutique de reperfusion coronaire [3]. De nombreux facteurs liés aux caractéristiques des patients (antécédents de diabète, insuffisance rénale, âge avancé), de l'IDM (artère coupable, coronaropathie multitrunculaire) mais aussi à la prise en charge thérapeutique (délai de prise en charge et de revascularisation coronaire) impactent le pronostic. Le traitement à la phase aigüe de l'IDM doit être rapide et efficace pour diminuer le risque de complication ainsi que la mortalité à court et long terme.

1.2. Mécanismes physiopathologiques de l'IDM

L'athérosclérose

L'athérosclérose est une maladie immunoinflammatoire, chronique, fibroproliférative et multifocale intéressant les artères de moyen et gros calibre. Même si sa physiopathologie précise est complexe et multifactorielle, elle est principalement liée à l'accumulation lipidique dans la paroi du vaisseau [4, 5]. L'athérosclérose engendre généralement une réduction progressive de la lumière artérielle avec le temps. La plupart des plaques d'athérosclérose restent asymptomatiques, certaines deviennent obstructives (responsable de l'angine de poitrine), plus rarement un phénomène thrombotique apparaît engendrant le plus souvent un syndrome coronarien aigu. Les lésions coronaires symptomatiques comprennent donc une part variable d'athérosclérose (chronique) et de thrombose (aigue) communément appelée athérothrombose.

Schématiquement le recrutement de cellules inflammatoires et l'accumulation de lipides dans l'intima va former le noyau lipidique. Il y a d'abord une accumulation des lipoprotéines de basse densité (LDL-cholestérol) dans l'intima suivie de modifications oxydatives des LDL et d'expression de molécules d'adhésion à la surface de l'endothélium. La deuxième phase implique les monocytes circulants qui adhèrent à la surface de l'endothélium, le traversent et se transforment en macrophages puis en cellules spumeuses. Les macrophages produisent de nombreuses cytokines pro-inflammatoires qui augmentent l'activation endothéliale favorisant l'adhésion de nouveaux monocytes. La chape fibreuse est composée de cellules musculaires lisses migrant depuis la média et se transformant en fibroblastes et de protéines de la matrice extracellulaire (collagène, élastine, protéoglycanes). Dans certains cas, cette chape est rendue vulnérable : les protéinases sécrétées par les leucocytes activés détruisent la matrice extracellulaire et des cytokines pro-inflammatoires type interféron limitent la synthèse de nouveau collagène. Ceci engendre une chape fibreuse amincie et donc « vulnérable » [6].

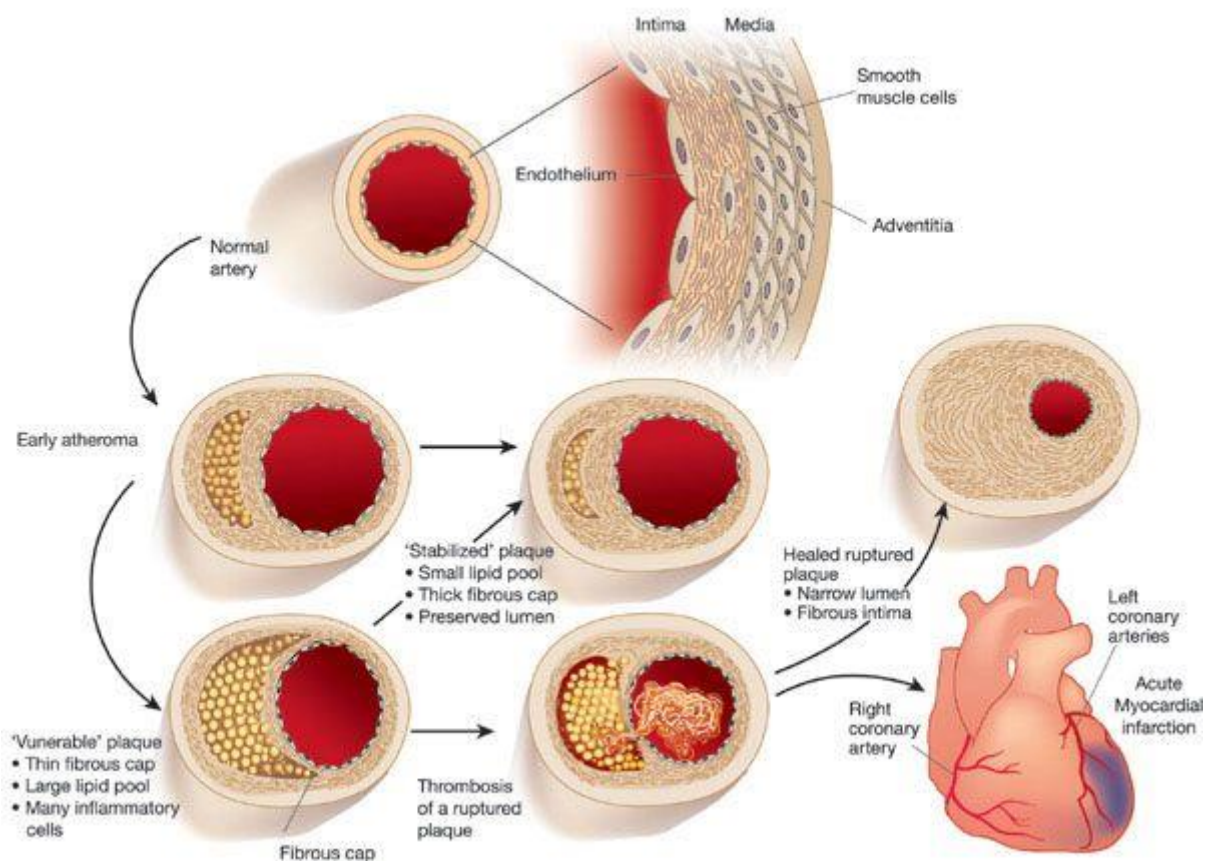


Figure 1: Evolution de l'athérosclérose (d'après Libby P, Nature, 2002).

La plaque vulnérable correspond à une plaque à risque de rupture/érosion donc de thrombose. Plusieurs caractéristiques participent à cette vulnérabilité : large cœur nécrotique, chape fibreuse fine (<65 μm), infiltration de cellules inflammatoires type macrophage, néovascularisation, hémorragie intra-plaque, calcification irrégulière, faible densité de cellules musculaires lisses [7, 8].

Mécanismes de l'athéromatose coronaire

Le mécanisme le plus fréquemment retrouvé, dans environ 2/3 des cas, est la rupture de plaque. La rupture survient classiquement sur un cœur nécrotique riche en lipides avec une chape fibreuse fine. Elle correspond à une rupture de la chape fibreuse à l'origine d'un défaut dans cette chape. Cela expose le cœur nécrotique lipidique aux éléments figurés du sang. Le cœur nécrotique est hautement thrombogène, en partie du fait du facteur tissulaire qu'il contient [9] et de microparticules prothrombotiques [10].

Le deuxième mécanisme le plus fréquent est l'érosion coronaire. Elle était classiquement évoquée en cas de thrombose coronaire sans rupture de plaque identifiée. Les études histologiques [11] ont montré un endothélium absent (dénudation endothéliale) ou lacéré, l'intima étant riche en cellules musculaires lisses. Il existe souvent un épaissement intimal ou fibroathérome avec une média intacte (à la différence des ruptures où la média est souvent détruite au site de rupture). L'inflammation observée est généralement moindre dans le cas des érosions et les thrombus générés souvent adhérent à la paroi dénudée.

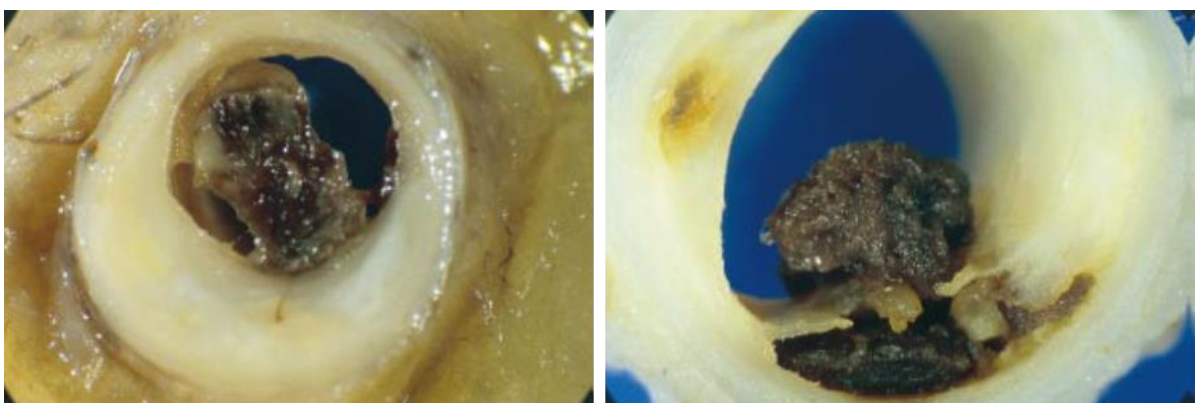


Figure 2 : Images anatomopathologiques de thromboses coronaires sur une érosion (à gauche) et une rupture de plaque (à droite). (D'après Davies MJ, Heart, 2000)

Beaucoup plus rarement que l'érosion et la rupture de plaque, le nodule calcaire est rapporté depuis les années 2000 comme un autre mécanisme pouvant être à l'origine d'athérombose. Cela correspond à la protrusion intra-luminale d'un spicule calcaire, généralement chez des sujets plus âgés ayant des calcifications coronaires importantes [11].

Le thrombus est un élément central de la physiopathologie de l'occlusion coronaire à l'origine des IDM ST+. L'obstruction initiale est classiquement liée à l'agrégation plaquettaire puis la fibrine intervient pour stabiliser le thrombus plaquettaire. On observe ainsi des thrombi riches en plaquettes (thrombus blanc), classiquement plus récents. Avec la stagnation des éléments sanguins et l'activation de la coagulation, des thrombi riches en érythrocytes (thrombus rouge) apparaissent généralement de façon plus tardive [8].

1.3. Prise en charge thérapeutique initiale

Angioplastie primaire ou fibrinolyse

La stratégie de reperfusion choisie dépend du délai estimé entre le temps zéro du diagnostic (ECG) et celui du début de l'angioplastie (arrivée en salle de cathétérisme cardiaque) : en deçà de 120 minutes, l'angioplastie primaire est privilégiée. Sinon se pose la question d'une fibrinolyse suivie dans les 2 à 24h d'une angioplastie secondaire (stratégie pharmacoinvasive). L'angioplastie primaire (coronarographie et angioplastie de l'artère coronaire coupable) est la stratégie de reperfusion préférée si elle peut être effectuée dans les délais recommandés [12, 13]. C'est aussi la stratégie recommandée quand les symptômes durent depuis plus de 12h et persistent.

Toutefois, l'angioplastie primaire n'est pas toujours réalisable dans les 2 heures suivant le diagnostic d'IDM ST+, en particulier dans les régions rurales comme la Basse-Normandie. Une stratégie pharmaco-invasive doit alors être envisagée. Elle consiste en une fibrinolyse, administrée à l'endroit de la prise en charge du patient (dite fibrinolyse pré-hospitalière) suivie d'une angioplastie de sauvetage (si échec de la reperfusion sur les critères cliniques et ECG à l'arrivée dans le centre de coronarographie) ou d'une angioplastie de routine dans les 24 heures suivant la fibrinolyse (succès de reperfusion par la fibrinolyse). Il faut noter que le délai recommandé pour l'angioplastie après un succès de fibrinolyse est passé de 3-24h dans les précédentes recommandations européennes à 2-24h dans les plus récentes [14]. Ce changement est basé sur les résultats d'une méta-analyse [15] et sur le délai médian (2 à 17h) des études ayant mesuré l'impact de l'angioplastie post-fibrinolyse en routine [16-21]. Notre méta-analyse des études randomisées ayant pris en charge des patients dont le début des symptômes datait de moins de 6h lors du diagnostic a montré que la thrombolyse pré-hospitalière -lorsqu'indiquée- est une alternative valable à l'angioplastie primaire avec une mortalité similaire [22].

Quel que soit la stratégie retenue, une stratégie invasive (le plus souvent par angioplastie avec mise en place d'un stent, parfois par pontage voire traitement médical lorsque la lésion coupable n'est pas accessible) systématique, y compris après un succès de fibrinolyse, a permis d'améliorer le pronostic et de réduire le risque d'événements cardiaques dont les revascularisations urgentes [18, 20].

Traitements anti-thrombotiques

Ce traitement comporte l'association d'un anticoagulant et d'une double anti-agrégation plaquettaire visant à stopper la cascade thrombotique et lyser le thrombus.

Plusieurs anticoagulants sont utilisables [14]. Notre protocole régional de prise en charge recommande l'utilisation d'Enoxaparine (à la dose de 0,5 mg/kg i.v. pour une angioplastie primaire ; ou en cas de fibrinolyse : bolus de 30 mg i.v. puis 1mg/kg/12h sous-cutané pour les patients < 75 ans et pas de bolus mais 0,75 mg/kg/12h si patients \geq 75 ans).

La double anti-agrégation plaquettaire repose sur l'aspirine et un inhibiteur du P2Y12. L'aspirine est administrée par voie i.v. dans notre protocole à la dose de 250 mg. L'inhibiteur du P2Y12 retenu dans notre pratique est préférentiellement le ticagrelor (180 mg en dose de charge puis 90 mg 2/jour ensuite, per os) ou le prasugrel (60 mg en dose de charge puis 10mg/jour ensuite, per os), le clopidogrel étant réservé aux contre-indications aux 2 autres, comme indiqué par les dernières recommandations européennes [14]. Dans notre pratique courante, et ce en rapport avec les habitudes et drogues disponibles des SAMU, le ticagrelor représente l'antiagrégant le plus utilisé.

La figure 3 résume les différentes cibles d'action des traitements anticoagulants et antiagrégants plaquettaires.

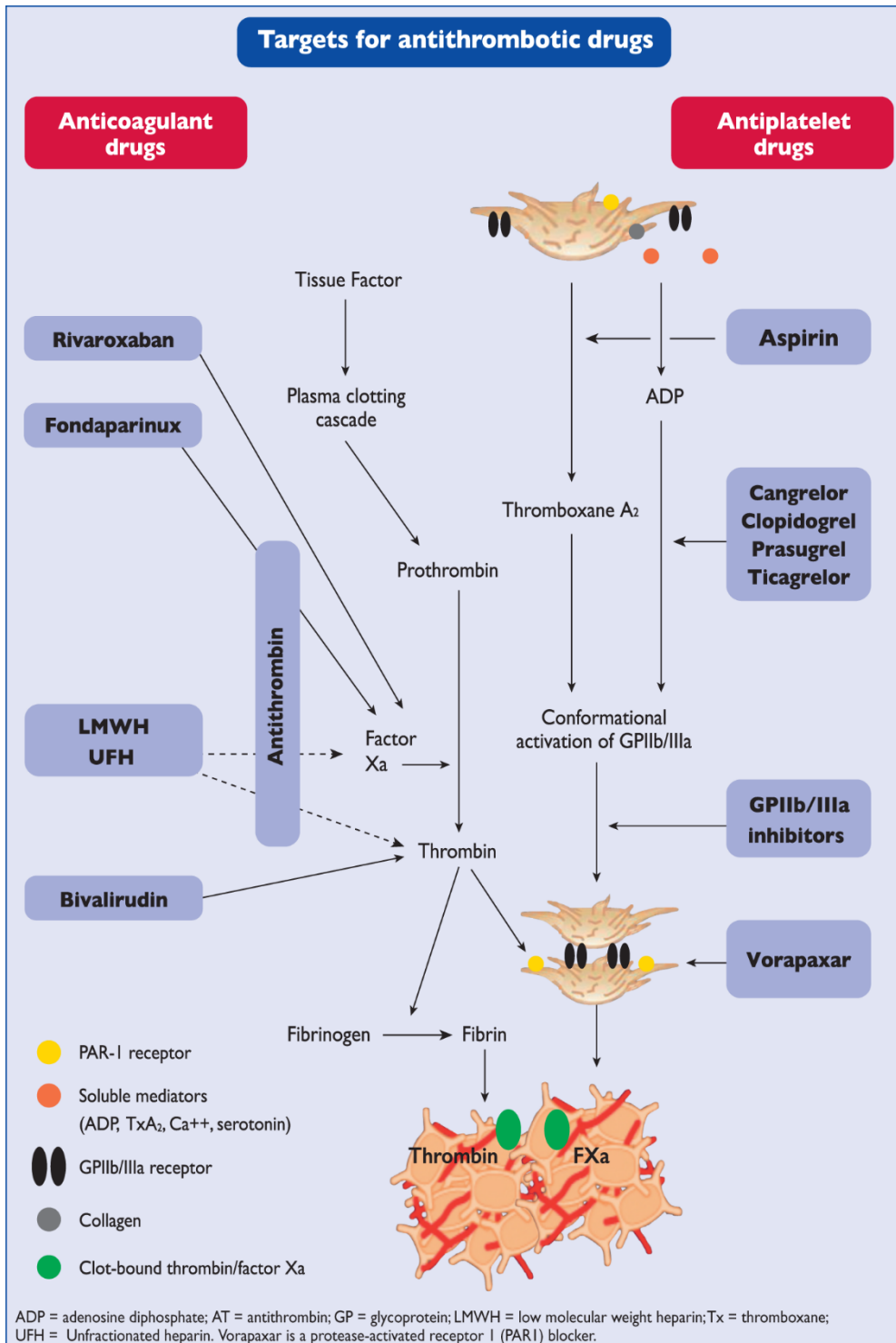


Figure 3: Cibles des différentes molécules anticoagulantes et antiagrégantes utilisées dans le traitement des IDM (D'après Roffi M, ESC Guidelines, EHJ, 2015).

Moment d'administration des inhibiteurs du P2Y12

Il existe peu de données sur le moment d'administration idéal des inhibiteurs du P2Y12 dans l'IDM ST+ traité par angioplastie primaire. Des études observationnelles ont retrouvé une diminution de la mortalité hospitalière et à 1 an chez les patients pré-traités par clopidogrel avant l'arrivée en salle de cathétérisme [23] en comparaison à ceux recevant le clopidogrel en salle. Une étude randomisée avec un faible effectif (166 patients pré-traités par clopidogrel vs 171 traités en salle de cathétérisme) n'a pas retrouvé de différence sur les événements cliniques ou le taux de flux TIMI 2/3 avant angioplastie [24]. L'étude plus récente ATLANTIC a comparé l'administration du ticagrelor en pré-hospitalier versus en salle de cathétérisme avant l'angiographie [25]. Les indices de reperfusion coronaire avant angioplastie (flux TIMI 3) n'étaient pas différents. Il y avait moins de thrombose de stent dans le groupe pré-traité. Même si les preuves d'un bénéfice du pré-traitement sont faibles, cette pratique est largement répandue en Europe.

2. Indices de reperfusion angiographiques

L'analyse des flux coronaires en angiographie est un outil couramment utilisé en pratique courante et dans les études pour juger du résultat de la revascularisation coronaire.

Le grade de flux TIMI, classé de 0 à 3, est utilisé depuis plus de 30 ans pour juger de la reperfusion épicaudique, comme suit [26]:

- Flux TIMI 0 : pas de perfusion. Pas de flux antérograde au-delà de l'occlusion
- Flux TIMI 1 : pénétration sans perfusion. Le produit de contraste franchit le site de l'obstruction coronaire mais n'opacifie pas le lit coronaire distal

- Flux TIMI 2 : perfusion partielle. Le produit de contraste franchit le site de l'obstruction coronaire et opacifie le lit coronaire distal. Cependant la vitesse de progression du contraste en distalité et sa disparition avec le cycle cardiaque se fait plus lentement que dans une autre artère épicaudique homo ou controlatérale en dehors du territoire de l'IDM

- Flux TIMI 3 : perfusion complète. La vitesse de progression du contraste en distalité et sa disparition avec le cycle cardiaque se fait aussi vite que dans une autre artère épicaudique homo ou controlatérale en dehors du territoire de l'IDM

En cas d'IDM, l'artère est considérée comme « ré-ouverte » en cas de flux TIMI basal grade 2 ou 3. Le flux TIMI 3 correspond à une reperfusion épicaudique normale. Le grade de flux TIMI est corrélé à la mortalité [27, 28]. La corrélation entre TIMI 3 et mortalité est cependant biaisée par le fait que la plupart des flux TIMI 2 sont observés dans le territoire de l'artère interventriculaire antérieure (zone à risque de l'IDM plus importante que pour la coronaire droite ou l'artère circonflexe). D'autres techniques de quantification des flux ont donc été développées.

Le nombre d'images TIMI corrigé (corrected TIMI frame count en anglais) mesure aussi le flux épicaudique et correspond au nombre d'images de ciné film pour que le contraste atteigne la distalité de l'artère coronaire coupable. Cette mesure quantitative simple est objective et reproductible [29]. Le nombre d'image est dit corrigé car divisé par 1,7 pour l'artère interventriculaire antérieure afin de prendre en compte la longueur plus importante de cette artère coronaire en comparaison aux 2 autres troncs coronaires. Le nombre d'images TIMI corrigé est corrélé au pronostic après fibrinolyse [30] et angioplastie primaire [31].

La restauration du flux épicaudique ne signifie pas pour autant qu'il existe une restauration du flux au niveau tissulaire (ou reperfusion myocardique). D'autres indices ont donc été développés, à savoir le grade de perfusion myocardique TIMI et plus récemment le grade de

« blush » myocardique (ou myocardial blush grade en anglais) afin de mesurer la reperfusion myocardique. Ce dernier est mesuré sur des acquisitions en 30 images/secondes dans le plan dégagant au mieux le territoire de l'artère coupable afin d'apprécier l'entrée et la sortie du produit de contraste dans la microcirculation. Il comprend 4 grades détaillés de 0 à 3, comme suit [32]:

- grade 0 : absence de blush ou de densité de contraste visible (aspect en verre dépoli). Cela signifie que le contraste n'entre pas dans la microcirculation

-grade 1 : densité de contraste minimale

- grade 2 : densité de contraste modérée avec apparition et/ou lavage moindre que celui observé dans une artère homo ou controlatérale en dehors du territoire de l'IDM

-grade 3 : densité de contraste normale, semblable à celle d'une artère homo ou controlatérale en dehors du territoire de l'IDM. Cela correspond à une pénétration et une sortie normale du produit de contraste dans la microcirculation.

Le blush myocardique a été corrélé à la taille de l'IDM, la fraction d'éjection ventriculaire gauche et la mortalité à long terme et ce, indépendamment du flux TIMI [32]. L'absence de reperfusion myocardique alors que l'artère épicaudique a été efficacement reperfusée correspond au phénomène dit de « no-reflow » en anglais. Ce phénomène multifactoriel a un impact pronostique important car associé à un risque de complications précoces post-IDM, un remodelage ventriculaire gauche négatif et une mortalité accrue [33, 34].

3. La tomographie par cohérence optique

3.1. Principes

La tomographie par cohérence optique (OCT en anglais) est une méthode invasive d'imagerie endocoronaire, fondée sur la réflexion et l'absorption d'une lumière proche des infrarouges sur les structures vasculaires environnantes. Les premières générations d'OCT (dite « time domain OCT » en anglais) nécessitaient une occlusion coronaire temporaire pour obtenir un milieu transparent, ce qui en limitait l'utilisation en pratique. L'OCT dernière génération (dite frequency domain OCT ou optical frequency domain imaging/OFDI) permet d'acquérir des images sans occlusion avec une vitesse d'acquisition plus rapide permettant un retrait rapide (pullback) et une meilleure résolution [35]. La sonde d'OCT est en pratique amenée en intracoronaire sur le guide d'angioplastie coronaire et l'acquisition se fait pendant un flush de produit de contraste iodé.

3.2. Applications pratiques

D'autres techniques d'imagerie comme l'imagerie intravasculaire par ultrasons (IVUS) permettent de visualiser la paroi coronaire. Toutefois, avec une résolution de l'ordre de 10 μm , proche de l'histologie et donc meilleure que l'IVUS, l'OCT est une imagerie de très haute résolution permettant de caractériser la plaque athéromateuse. Cette technique a déjà été utilisée en phase aigüe d'infarctus du myocarde où elle a démontré sa sécurité [36]. Des images de qualités sont obtenues chez la majorité des patients [37].

Elle permet de visualiser précisément la chape fibreuse, les calcifications, la composition de la plaque (lipidique, fibreuse, calcifications). L'OCT permet de distinguer les mécanismes causals de l'IDM : rupture de plaque, érosion, nodule calcaire, dissection coronaire.

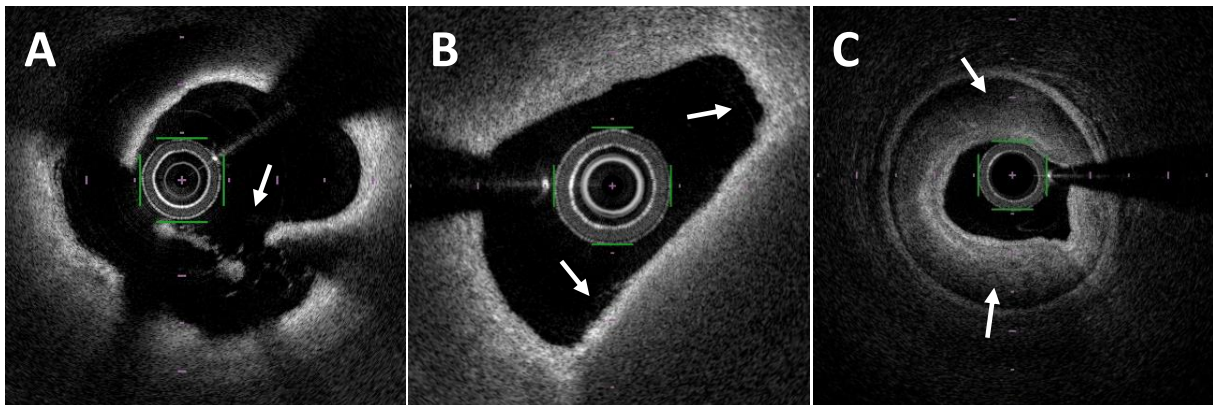


Figure 4: Images OFDI de rupture de plaque (A), érosion coronaire (B) et hématorne/dissection coronaire spontanée (C).

L'OCT permet d'apprécier le résultat d'angioplasties avec mise en place d'un stent (apposition, couverture incomplète, dissection de bord). L'OCT est ainsi recommandée dans l'évaluation des mécanismes à l'origine des resténoses et thromboses de stent [38]. Ces mécanismes de thrombose de stent ont été détaillés dans le registre français PESTO [39], dont les résultats sont présentés dans la figure 5.

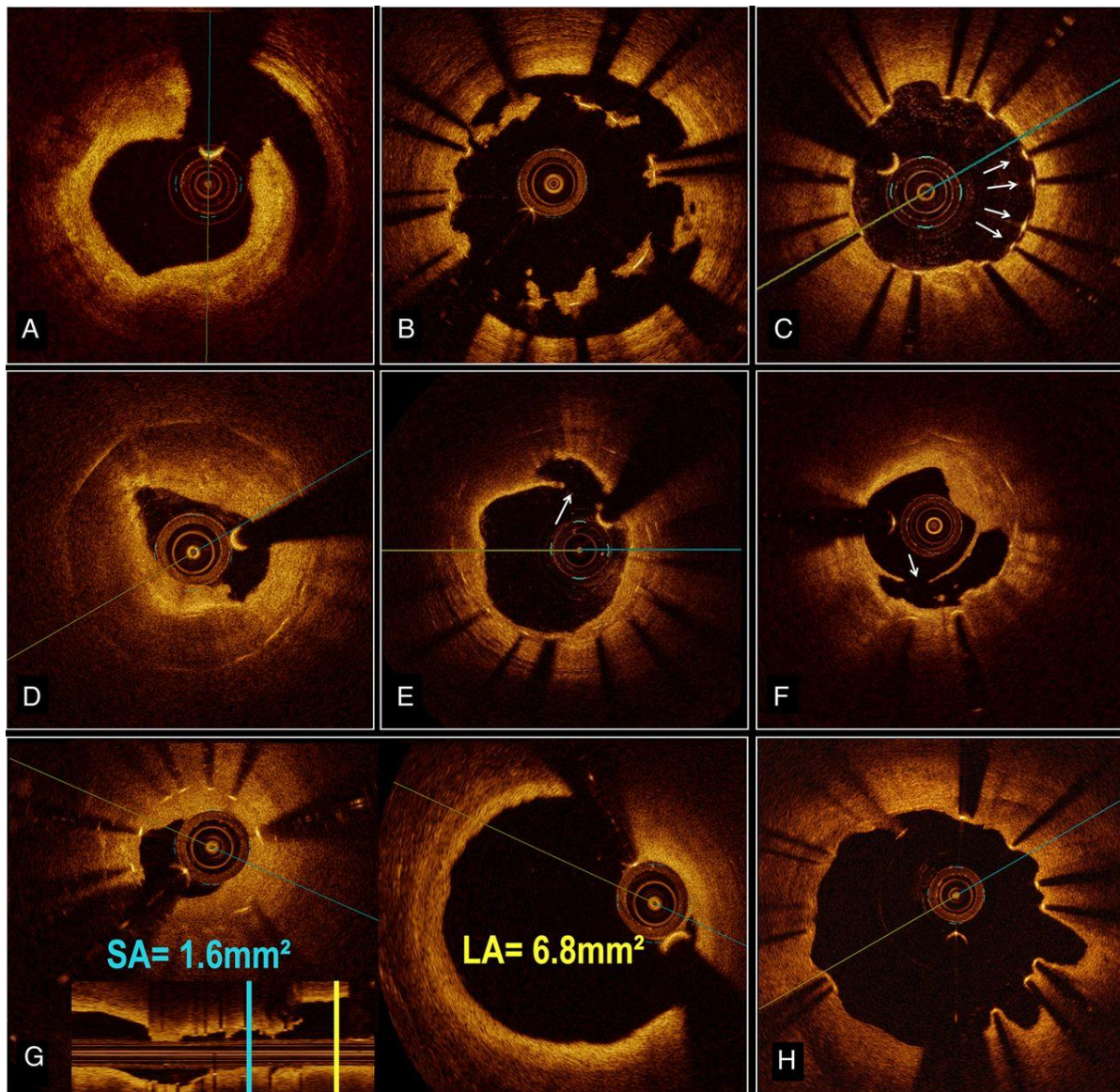


Figure 5 : Exemples d'images OCT sur les mécanismes à l'origine de thromboses de stent (après résorption du thrombus) : dissection de bord (A), malapposition majeure du stent (B), mailles non endothélialisées/couvertes sur thrombose de stent tardive (C), néoathérosclérose (D), rupture de plaque sur néoathérosclérose (E et F), sous-expansion du stent (SA= stent area ; LA=lumen area, figure G), évaginations coronaires sur remodelage positif (H). (D'après Souteyrand G, EHJ, 2016)

L'OCT permet également d'optimiser le résultat de l'angioplastie chez certains patients (stenting du tronc commun en particulier). L'étude multicentrique française DOCTORS [40] a montré que le fait de guider la procédure d'angioplastie par OCT vs angiographie seule était associé à un meilleur résultat (apprécié par une meilleure FFR). L'OCT a en effet permis, en guidant des post-dilatations au ballon de corriger des sous-expansions, défauts d'apposition ou couvertures incomplètes de la lésion par le stent.

3.3. OCT et charge athérombotique

La présence de thrombus angiographique a été associée à une reperfusion myocardique altérée et à un pronostic mauvais dans l'angioplastie primaire et en post fibrinolyse [41-43]. Mais l'angiographie n'est pas une méthode fiable pour visualiser la présence de thrombus, qui est souvent ainsi sous-estimée [44]. L'OCT est la meilleure technique endovasculaire pour visualiser et quantifier le thrombus en pratique courante en salle de cathétérisme lors des IDM [36]. Elle permet de caractériser le type de thrombus observé : thrombus rouge, légèrement hétérogène avec forte atténuation et cône d'ombre postérieur ; et thrombus blanc homogène avec faible atténuation postérieure. La quantité et le type de thrombus dépend du mécanisme causal de l'IDM à savoir rupture ou érosion [45]. La plupart des études ont décrit cela dans le cadre d'angioplasties primaires obligeant à une thromboaspiration ou une pré-dilatation au ballon préalable, ce qui a pu modifier les caractéristiques du thrombus et sa répartition. En post fibrinolyse, cela reste très peu décrit.

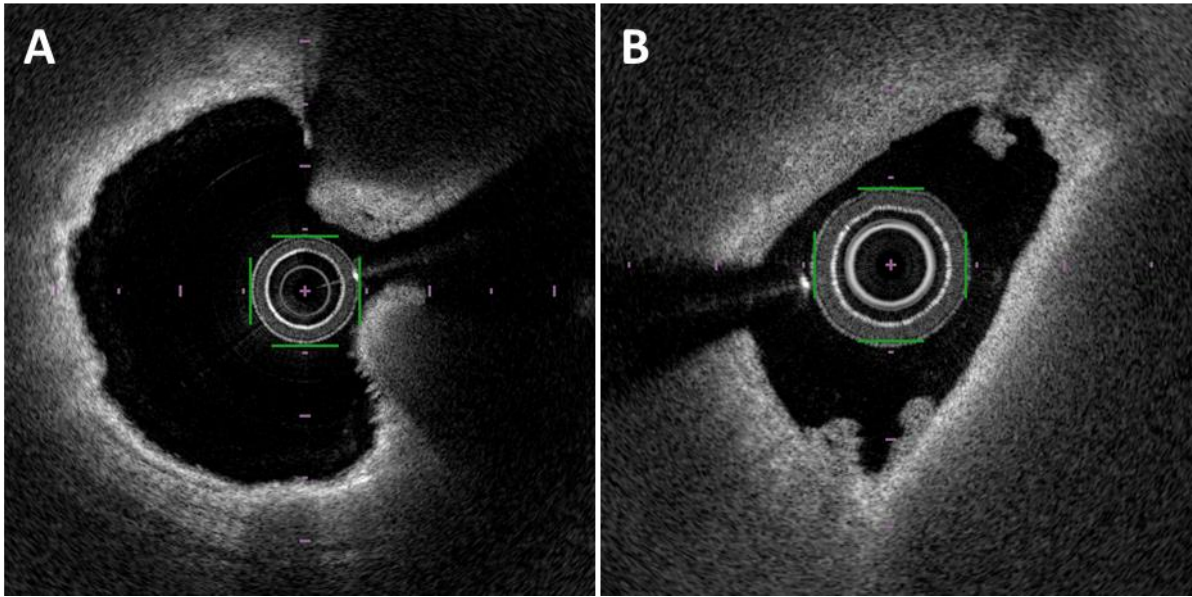


Figure 6: Images OFDI de thrombus dit « rouge » (A) ou « blanc » (B).

Plusieurs méthodes de quantification de la charge thrombotique ou athérombotique (mélange de thrombus et plaque d'athérome, difficiles à distinguer l'un de l'autre même en OCT) ont été utilisées dans la littérature [46]. Il existe des méthodes quantitatives utilisant l'aire de thrombus calculée sur les différentes coupes, ajoutées pour obtenir un volume ou un pourcentage global de thrombus sur l'ensemble de la lésion [47-49]. L'intervalle entre les coupes utilisées pour le calcul varie entre les études entre 0,2 et 1 mm. Un score thrombotique semi-quantitatif a aussi été utilisé : chaque coupe est divisée en 4 cadrans, 1 point est attribué à chaque cadran contenant du thrombus et un score total est ainsi calculé [50]. La comparaison des différentes méthodes de mesure OCT de la charge thrombotique reste peu décrite [48]. Enfin en post-stenting, on observe de manière quasi-systématique une protrusion de matériel dit athérombotique à travers les mailles du stent [51, 52] dont l'impact pronostic n'est pas clair dans la littérature.

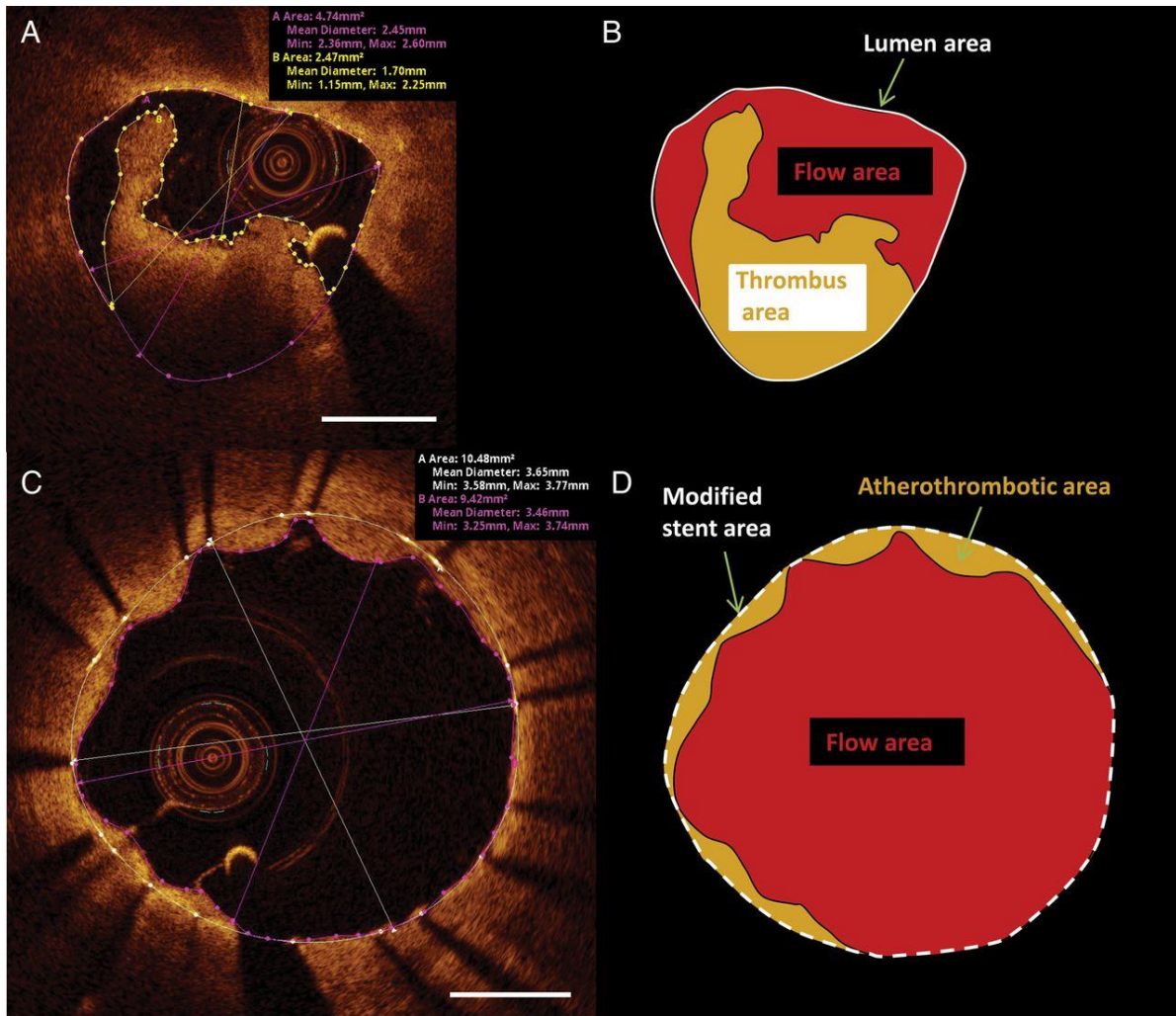


Figure 7: Exemples de quantification de thrombus pré (A et B) et post-stenting (C et D).
 (D'après Kajander OA, EHJ Cardiovasc. Imaging, 2015)

4. Les tests d'agrégation plaquettaire

L'inhibition plaquettaire par les inhibiteurs du P2Y₁₂ (clopidogrel, ticagrelor, prasugrel) et l'aspirine joue un rôle crucial dans la prévention des événements thrombotiques après angioplastie coronaire. Il existe plusieurs méthodes de mesure de la réponse aux traitements antiagrégants.

4.1. L'agrégométrie optique

Elle est considérée comme le gold standard pour évaluer la fonction plaquettaire dans son ensemble. L'agrégation plaquettaire est mesurée en analysant la transmission de la lumière à travers du plasma riche en plaquettes obtenu après centrifugation de sang complet citraté. Après l'adjonction d'un agoniste plaquettaire (usuellement adenosine-5-diphosphate ou ADP 10-20 µmol/l), la formation d'agrégats plaquettaires diminue la turbidité de la suspension et augmente ainsi la transmission lumineuse. Notre laboratoire utilise le modèle ATRACT® 4004 aggregometer (ELITechGroup, France). L'agrégation plaquettaire maximale est mesurée quelques minutes plus tard (temps t défini selon les laboratoires/études). L'inhibition de l'agrégation plaquettaire (IAP) est alors calculée par la formule : $IAP = [1 - (\text{agrégation plaquettaire max au temps } t / \text{agrégation plaquettaire max au temps } 0)] \times 100\%$. Cette technique est cependant onéreuse et nécessite les compétences spécifiques de techniciens spécialisés, ce qui ne la rend pas disponible directement en salle de cathétérisme.

4.2. Le Verify Now

Ce test se base sur la capacité des plaquettes à se lier au fibrinogène en utilisant des billes recouvertes de fibrinogène. Les mesures sont faites sur sang total par analyse optique

turbidimétrique. Ce système simple d'utilisation est utilisable directement en salle de cathétérisme. Le système, basé sur des cartouches, contient 20 $\mu\text{mol/L}$ d'ADP afin d'induire l'agrégation plaquettaire (activant à la fois les récepteurs P2Y1 et P2Y12) et 22 nmol/L de prostaglandine E1 pour supprimer la contribution indésirable des récepteurs P2Y1. Deux autres activateurs sont utilisés dans un deuxième canal de mesure (canal de référence) : le peptide activant le récepteur de la thrombine (Iso-TRAP, Iso-Thrombin receptor activating peptide) et le PAR4-AP (PAR4-activating peptide). Ils activent fortement les plaquettes malgré le blocage du récepteur P2Y12 par les thiénoxyridines et reflètent ainsi la réactivité plaquettaire basale, en l'absence de traitement [53]. La transmission lumineuse augmente lorsque les plaquettes activées agrègent les billes recouvertes de fibrinogène. Les résultats sont exprimés en fonction du changement du signal optique en « P2Y12 reaction units » (PRU en anglais), pourcentage d'inhibition et valeur de base (BASE). Le pourcentage d'inhibition est calculé par la formule : $[(1 - \text{PRU}/\text{BASE}) \times 100]$. L'hyperréactivité plaquettaire au P2Y12 (HPR en anglais) est définie par un PRU > 208 [54, 55]. Une autre cartouche permet de mesurer la réponse antiagrégante à l'aspirine, exprimée en « aspirin reaction units » (ARU en anglais). L'hyperréactivité plaquettaire à l'aspirine (HaPR en anglais) est définie par un ARU ≥ 550 [54].

Toutefois, le Verify Now n'a jamais été évalué et en particulier comparé à l'agrégométrie optique chez les patients traités par fibrinolyse à la phase aiguë de l'IDM ST+.

4.3. PFA et autres tests

Le PFA (Platelet Function Analyzer) simule in vitro les conditions hémodynamiques de l'adhésion et de l'agrégation plaquettaire suite à une lésion vasculaire. Ce système est utilisable directement en salle de cathétérisme. Le temps d'occlusion correspond au temps

nécessaire à l'obturation d'une membrane de collagène par le clou plaquettaire en présence d'agoniste plaquettaire dans des conditions de flux standardisé [56]. La membrane de la nouvelle cartouche INNOVANCE PFA P2Y que nous utilisons est recouverte avec 20µg ADP, 5 ng de prostaglandine E1 et 459µg de chlorure de calcium. L'hyperréactivité plaquettaire a été définie par un temps d'occlusion < 106 secondes par le fabricant.

Il existe d'autres tests évaluant la réactivité plaquettaire sous traitement (VASP, thromboélastographie, multiplate analyser) non détaillés ici car non utilisés pour nos travaux.

4.4. Hyperréactivité plaquettaire et pronostic

L'hyperréactivité plaquettaire sous traitement par un inhibiteur du P2Y₁₂, essentiellement le clopidogrel, est associée à un risque accru d'événements cardiaques récurrents et en particulier de thrombose de stent [54, 57]. A l'opposé une réponse trop marquée aux antiagrégants expose à un sur-risque de saignement [55]. Les IDM ST+ représentent toutefois une minorité des patients inclus dans les études précédentes.

L'impact de l'agrégation plaquettaire sur le pronostic après angioplastie a fait naître l'idée qu'un monitoring des patients et une adaptation du traitement antiagrégant selon ces tests pouvait améliorer le devenir des patients. Toutefois les grandes études publiées n'ont pas montré de bénéfice clinique d'une prescription personnalisée en fonction de la réactivité plaquettaire [58-60]. Il faut souligner que les IDM ST+ ont été exclus de ces études ou très peu représentés (< 0,5% dans GRAVITAS).

4.5. Impact de la réactivité plaquettaire à la phase aigüe de l'IDM ST+

De rares études se sont intéressées à la relation entre la réactivité plaquettaire mesurée à la phase aigüe d'un IDM ST+ et les indices de reperfusion angiographiques dans l'angioplastie primaire. Deux études ont retrouvé un plus faible taux de flux TIMI 2/3 chez les patients ayant une hyperréactivité plaquettaire [61, 62]. Une seule étude [61] a inclus des patients pré-traités avec les récents antiagrégants recommandés en 1^{ère} intention (Prasugrel et Ticagrelor) mais n'a pas retrouvé d'impact significatif de l'HPR sur la reperfusion myocardique (évaluée par le blush myocardique). L'impact de l'HPR sur les indices de reperfusion angiographiques n'a pas été décrit en post-fibrinolyse.

Une relation entre les volumineux thrombi visualisés en angiographie et la réactivité plaquettaire a été décrite dans 2 études observationnelles [61, 63]. Cependant cela n'a pas été décrit avec une évaluation précise de la charge athérombotique en OCT ou OFDI. L'impact de la charge athérombotique résiduelle évaluée en OCT sur la reperfusion myocardique reste peu étudié [49].

II. OBJECTIFS

Cette thèse avait pour but : (1) d'évaluer la pertinence du VerifyNow et du PFA en post fibrinolyse ; (2) de définir les déterminants de la charge athérombotique caractérisée en imagerie endocoronaire; et (3) d'évaluer les relations entre la réactivité plaquettaire, les indices de reperfusion angiographique et la charge athérombotique à la phase aigüe de l'IDM ST+.

Ces différents objectifs ont fait l'objet de 4 travaux de recherche visant à répondre aux objectifs précis suivants :

- Evaluer la validité des tests d'agrégation simples (Verify Now et PFA) en comparaison à l'agrégométrie optique en post-fibrinolyse
- Décrire les caractéristiques du thrombus en pré et post-stenting en OFDI en fonction du mécanisme causal de l'IDM chez les patients traités par fibrinolyse avec succès
- Evaluer la relation entre la réactivité plaquettaire résiduelle après dose de charge de ticagrelor et aspirine et la reperfusion myocardique dans l'angioplastie primaire
- Evaluer la relation entre la charge athérombotique post stenting mesurée par différentes méthodes en OFDI et la reperfusion myocardique dans l'angioplastie primaire

III. ARTICLES

1. Tests de VerifyNow P2Y12 et INNOVANCE PFA P2Y comparés à l'agrégométrie optique après fibrinolyse

La mesure de la réactivité plaquettaire par des tests réalisables au lit du malade n'a pas été validée en post fibrinolyse pour un IDM ST+. Cette première étude a évalué la précision des tests VerifyNow P2Y12 (VN) et INNOVANCE PFA P2Y (PFA) -réalisables facilement auprès du malade- en comparaison à l'agrégométrie optique (LTA) chez ces patients. Une hyperréactivité plaquettaire (HPR), à l'aide par un prélèvement réalisé juste avant l'angioplastie en salle de cathétérisme, a été retrouvée chez 10 (34.5%) patients, 15 (51.7%) patients et 14 (50%) patients en utilisant la LTA, le VN et le PFA, respectivement. Des discordances ont été observées entre les tests même s'il existait des corrélations significatives entre la réactivité plaquettaire obtenue par LTA et VN ($r=0.74$; $p<0.0001$) et celle obtenue par LTA et PFA ($r=0.75$; $p<0.0001$). En comparaison à la LTA, le VN et le PFA ont détecté une HPR avec une valeur prédictive positive (VPP) et négative (VPN) de 92% et 53%, et de 92% et 64%, respectivement. Lorsqu'on combinait VN et PFA, on obtenait une VPP de 90% et une VPN de 100% si l'on considérait les discordances entre ces deux tests comme l'absence d'HPR. Au total, en comparaison à la LTA, le VN et le PFA identifient correctement les patients sans HPR mais surestiment la proportion de patients avec HPR en post fibrinolyse. L'association de ces 2 tests permet d'améliorer la précision de la détection de l'HPR, si une HPR est détectée sur un de ces tests initialement.

ARTICLE 1

Point of Care Tests VerifyNow P2Y12 and INNOVANCE PFA P2Y Compared to Light Transmittance Aggregometry After Fibrinolysis.

Roule V, Ardouin P, Repessé Y, Le Querrec A, Blanchart K, Lemaitre A, Sabatier R, Borel-Derlon A, Beygui F.

Clin Appl Thromb Hemost. 2018 Oct;24(7):1109-1116. Epub 2018 May 2. PMID: 29719963

Abstract

Detection of high on-treatment platelet reactivity (HPR) by point of care tests has not been validated after successful fibrinolysis for ST-elevation myocardial infarction. We assessed the validity of the point-of-care VerifyNow P2Y12 (VN) and INNOVANCE PFA P2Y (PFA) tests on HPR compared to light transmittance aggregometry (LTA) in these patients. HPR was identified in 10 patients (34.5%), 15 patients (51.7%) and 14 patients (50%) using LTA, VN and PFA respectively. Discrepancies were observed between the tests despite significant correlations between platelet reactivity measures by LTA and VN ($r=0.74$; $p<0.0001$) and, LTA and PFA ($r=0.75$; $p<0.0001$). Compared to LTA, VN and PFA were associated with a 92% and 53% and, 92% and 64% positive (PPV) and negative predictive values (NPV) respectively in detecting HPR. When combined, VN and PFA results yielded 90% and 100% PPV and NPV values if discrepancies between the two tests were considered as non-HPR. VN or PFA identify patients without HPR correctly, but overestimate the proportion of HPR patients. The association of the two tests, in case of HPR, improves the accuracy of the detection of HPR.

Introduction

Primary percutaneous coronary intervention (PCI) is considered as the preferred reperfusion strategy in patients with ST-elevation myocardial infarction (STEMI), when performed within 2 hours following first medical contact [1]. However most patients present to non-PCI capable hospitals worldwide [2]. In patients with STEMI managed <12 hours after symptom-onset, pre-hospital fibrinolysis (FL) in association with routine angiography and percutaneous coronary intervention (PCI) performed 3 to 24h after FL, is a valuable alternative with similar early and late mortality rates compared with primary PCI [3]. Adjuvant antiplatelet therapy including aspirine and clopidogrel (loading dose of 300 mg in patients aged ≤ 75 years and 75 mg in those > 75 years) is recommended at the time of FL [4, 5].

Light transmittance aggregometry (LTA) is the gold standard for determining the on-treatment platelet reactivity, but it requires specific equipment and competence. Point-of-care (POC) platelet function assays were developed for use in routine clinical practice. VerifyNow P2Y12 (VN) and INNOVANCE PFA P2Y (PFA) are rapid, easy to perform and commonly used bedside tests, well correlated with LTA in different settings [6-10]. However they have not been validated in the detection of on-treatment high platelet reactivity (HPR) in the highly pro-thrombotic setting of post-FL, at the time of recommended PCI.

The paradoxical pro-thrombotic status observed after FL [11] associated with the variability of platelet response and slow onset of action of clopidogrel [12] could promote HPR which has been reported to be associated with increased risk of stent thrombosis [13] and ischemic events [14] after PCI. Few studies have reported HPR prevalence early post FL [15, 16]. All such studies have used the VN assay only despite the absence of validation of the test in comparison with the reference method. Moreover, the variability of the results of different platelet function tests in assessing response to clopidogrel as well as aspirin [17, 18] appears important in the setting of post-FL and justifies studies comparing such tests.

Our study aimed to assess the accuracy of HPR detected by VN and PFA at the time of PCI in STEMI patients successfully treated by FL in comparison with LTA.

Methods

Patient selection

We prospectively included consecutive STEMI patients successfully treated by FL admitted to our center between November 2014 and November 2016. Successful FL was defined as the resolution of both ST-segment elevation (>50%) and chest pain <90 min after FL [1]. All patients had early routine post-thrombolysis angiography with subsequent PCI if indicated. Patients were selected at the time of coronary angiography during modified opening hours (6 am-2 pm, Monday to Friday) as needed for access to LTA. Exclusion criteria were: contraindications or history of allergy to anticoagulant/antithrombotic therapy, hematocrit <30% or thrombocytopenia <100.000/dL, oral anticoagulation, use of glycoprotein IIb/IIIa inhibitors, clinical instability as well as the absence of reperfusion criteria leading to rescue PCI. All patients provided written informed consent and the study was approved by the institutional ethics committee.

Pharmacological regimen

All patients received 250 mg IV aspirin, PO clopidogrel (loading dose of 300 mg if age <75 years and 75 mg if age \geq 75 years), followed by 75 mg of clopidogrel and 75 mg of aspirin daily as recommended in the regional STEMI network protocol. Anticoagulation was performed with enoxaparin (30 mg i.v. bolus followed 15 min later by 1 mg/kg SC every 12 h in patients <75 years; no IV bolus and a SC dose of 0.75 mg/kg in patients \geq 75 years) or

unfractionated heparin (60 U/kg IV bolus with a maximum of 4000 U followed by an IV infusion of 12 U/kg with a maximum of 1000 U/h). The fibrinolytic agent was tenecteplase, administered with a weight and age-adjusted dose (half weight-adjusted dose in patients \geq 75 years) [19].

Platelet function tests

Blood samples were drawn at the beginning of the coronary angiogram directly from the arterial sheath for platelet reactivity analysis. A second VN test was performed 12 to 24 hours after the initial test, on a sample drawn by venipuncture, after a 5 ml discard sample to avoid spontaneous platelet activation. All blood samples were drawn into vacutainer tubes containing sodium citrate 3.2% (Becton-Dickinson, San Jose, CA) and analyzed within 2 hours after extraction.

Light transmission aggregometry (LTA)

Platelet-rich plasma (PRP) was obtained after blood centrifuging at 100g for 10 minutes. The remaining blood was further centrifuged at 2300g for 15 min to prepare platelet-poor plasma (PPP). LTA was performed using an ATRACT® 4004 aggregometer (ELITechGroup, France). PRP samples were pre-warmed in the instrument at 37°C for 5 min and 100% transmission was set using autologous PPP and 0% transmission was set with PRP. Platelet aggregation was measured in PRP after addition of adenosine-5-diphosphate (ADP; final concentration 10 μ mol/L). Testing was performed for exactly 496 seconds and the maximal platelet aggregation (MPA) was recorded as the highest value achieved during this observation period. Inhibition of platelet aggregation (IPA at time t = IPAt) was calculated using the formula IPAt

= $[1 - (\text{MPAt}/\text{MPA0})] \times 100\%$, where MPA0 is the MPA at baseline. HPR was defined as an IPAt < 30%.

VN

The VN assay (Accumetrics, San Diego, CA) is a whole-blood, cartridge-based, light transmission-based optical detection system designed to measure platelet aggregation. The method has been described elsewhere [20]. Results from the device are reported as P2Y12 reaction units (PRU), percent inhibition, and a baseline value (BASE) for platelet function, claimed by the manufacturer to be independent of the level of P2Y12 blockade. The percent inhibition (IPA) is calculated as: $[(1 - \text{PRU}/\text{BASE}) \times 100]$. HPR was defined as a PRU ≥ 208 [14].

PFA

The PFA-100 system (Siemens Healthcare Diagnostics Products GmbH, Marburg, Germany) is a system for the assessment of high shear stress dependent platelet function by a procedure simulating the complex process of primary hemostasis in vitro. This test has been previously described [7]. The time required to occlude the central aperture (diameter, 100 μ m) is defined as the closure time (CT). HPR was defined as a CT <106 sec as recommended by the manufacturer.

The mean coefficient of variation of test precision has been reported to be 3.2%, 6.8% and 9.3% in patients with coronary artery disease for VN, LTA and PFA, respectively [21].

Clinical follow-up

Patients or their general practitioner were contacted in December 2016 to assess clinical follow-up. Major adverse clinical events (MACE) were defined as the composite of all-cause death, new myocardial infarction, stroke and urgent revascularization. Minor and major bleedings were defined according to the TIMI definition [22].

Statistical analysis

The inclusion of 30 patients was considered to assume a normal distribution. Groups were defined as non HPR group or HPR group based on the results of each test at the beginning of the coronary angiography. Continuous variables' distribution was tested for normality using the Kolmogorov-Smirnov test. With the exception of the VN IPA and the PFA closure time all other variables were normally distributed. Continuous variables were expressed as mean \pm standard deviation or median (IQR) and compared between groups using the Student's t test or the Wilcoxon-Cox test when applicable. Categorical variables were expressed as n (%) and compared between groups using the Chi square test. The correlation between different measures was assessed using Pearson's or Spearman correlation tests when applicable. Sensitivity, specificity and, negative and positive predictive values were calculated based on binary definitions of HPR in comparison to LTA. Such parameters were calculated for VN, PFA and both VN and PFA with discrepancies considered as non-HPR.

A P-value of < 0.05 was considered statistically significant. R software version 3.4.1 (2017-06-30) for MacOS (R Foundation for Statistical Computing) was used for statistical analysis.

Results

A total of 30 patients were included but the measure with the VN assay failed in one patient due to a technical problem, LTA was not realized in one patient and PFA in two other patients because of a > 2 hour delay after sample collection.

HPR was identified in 10 (34.5%), 15 (51.7%) and 14 patients (50%) using LTA, VN and PFA respectively. Patients' clinical characteristics and treatments (Table 1) were comparable between groups identified by HPR on VN, except for a hemoglobin concentration lower in the HPR group (13.9 ± 1 vs 15.1 ± 1.1 g/dl; $p= 0.006$). Baseline characteristics of the patients were comparable between groups identified by HPR on PFA or LTA.

Table 1: Baseline characteristics with and without HPR according each platelet function test

Baseline patient characteristics	All	VN			PFA			LTA		
	(n = 30)	HPR (n = 15)	No HPR (n=14)	p	HPR (n = 14)	No HPR (n = 14)	p	HPR (n=10)	No HPR (n=19)	p
Age (years)	57.4 ± 12	56 ± 12.5	57.9 ± 11.5	0.67	56.5 ± 14.1	59.7 ± 10	0.5	61.2 ± 14.2	55.2 ± 10.8	0.26
Sex (Male)	26 (86.7%)	12 (80%)	13 (92.9%)	0.32	13 (92.9)	12 (85.7)	0.5	9 (90)	16 (84.2)	0.67
Systemic hypertension	10 (33.3%)	6 (40%)	4 (28.6%)	0.52	6 (42.9)	4 (28.6)	0.4	5 (50)	5 (26.3)	0.20
Hyperlipidemia	13 (43.3%)	7 (46.7%)	6 (42.9%)	0.84	5 (35.7)	7 (50)	0.4	3 (30)	9 (47.4)	0.37
Diabetes mellitus	3 (10%)	2 (13.3%)	0	0.16	3 (21.4)	0	0.07	1 (10)	2 (10.5)	0.96
Active smoker	19 (63.3%)	11 (73.3%)	8 (57.1%)	0.36	10 (71.4)	7 (50)	0.25	6 (60)	13 (68.4)	0.65
Body mass index (kg/m2)	25.5 ± 4.7	25.5 ± 5.8	25.5 ± 3.5	0.98	26.4 ± 5.6	24.9 ± 3.8	0.42	26.7 ± 6.4	24.8 ± 3.6	0.4
<u>Past History of</u>										
Myocardial infarction	2 (6.7%)	0	2 (14.3%)	0.13	0	2 (14.3)	0.14	1 (10)	1 (5.3)	0.63
PCI	2 (6.7%)	0	2 (14.3%)	0.13	0	2 (14.3)	0.14	1 (10)	1 (5.3)	0.63
<u>Treatment prior to index event</u>										
Aspirin	1 (3.3%)	0	1 (7.1%)	0.29	0	1 (7.1)	0.3	1 (10)	0	0.16
Clopidogrel	2 (6.7%)	0	2 (14.3%)	0.13	0	2 (14.3)	0.14	1 (10)	1 (5.3)	0.63
Proton-pump inhibitor	5 (16.7%)	2 (13.3%)	3 (21.4%)	0.56	2 (14.3)	3 (21.4)	0.6	3 (30)	2 (10.5)	0.19
Statins	6 (20%)	4 (26.7%)	2 (14.3%)	0.41	3 (21.4)	2 (14.3)	0.6	2 (20)	4 (21.1)	0.95
Anterior wall STEMI	5 (16.7%)	3 (20%)	2 (14.3%)	0.68	2 (14.3)	2 (14.3)	1	2 (20)	3 (15.8)	0.77
Inferior wall STEMI	23 (76.7%)	12 (80%)	10 (71.4%)	0.59	12 (85.7)	10 (71.4)	0.36	8 (80)	14 (73.7)	0.70
Other infarct location	3 (10%)	1 (6.7%)	2 (14.3%)	0.5	1 (7.1)	2 (14.3)	0.54	1 (10)	2 (10.5)	0.96
Left ventricular ejection fraction (%)	52.5 ± 8.7	51.7 ± 8.4	53.4 ± 9.5	0.61	51.8 ± 9.3	53.4 ± 8.6	0.6	51.5 ± 8.8	53.1 ± 8.9	0.65
Systolic blood pressure (mmHg)	146 ± 29	142.9 ± 31.4	147.9 ± 27.8	0.65	144.1 ± 31.8	149.6 ± 29	0.6	157.2 ± 23.5	139.8 ± 31.2	0.1
Heart rate (beats/min)	78 ± 18	79 ± 21	77 ± 16	0.76	78 ± 22	77 ± 15	0.9	84 ± 22	76 ± 16	0.35
Killip class ≥II	2 (6.7%)	1 (6.7%)	1 (7.1%)	0.96	1 (7.1)	1 (7.1)	1	1 (10)	1 (5.3)	0.63
GRACE score	129.6 ± 26.6	128.9 ± 27.6	129.4 ± 27.3	0.96	129.4 ± 28.8	130.1 ± 27.3	0.95	133.4 ± 30.5	127.3 ± 25.7	0.59
CRUSADE score	27.7 ± 12.5	26.3 ± 14.2	27.9 ± 10	0.73	30.1 ± 12.9	27 ± 12.2	0.5	30.6 ± 12.7	26.8 ± 12.5	0.45
<u>Timepoints (min)</u>										
Pain to FMC	112.5 ± 81	107.2 ± 60.2	109.6 ± 97.9	0.94	113 ± 71.5	107 ± 96.3	0.8	110.7 ± 73.8	116.8 ± 87.1	0.84
Pain to FL	156.1 ± 86.4	151 ± 65.3	154.1 ± 105.8	0.92	152.1 ± 75.8	156.4 ± 103.4	0.9	153.5 ± 73.9	159.4 ± 96	0.85
FL to PCI	1057.6 ± 563.4	1078 ± 648.8	1002.4 ± 484	0.72	1157.5 ± 659.9	1041.9 ± 443	0.6	1217.1 ± 703.4	941.4 ± 463.4	0.28
FMC to PCI	1101.1 ± 567	1121.6 ± 652.6	1046.9 ± 489	0.73	1196.3 ± 662.5	1091.1 ± 450.2	0.6	1259.6 ± 700.9	983.9 ± 470	0.28

Admission biological characteristics										
Hemoglobin (g/dL)	14.5 ± 1.2	13.9 ± 1	15.1 ± 1.1	0.006	14.2 ± 1.1	14.8 ± 1.2	0.20	14.2 ± 1.1	14.6 ± 1.3	0.46
Hematocrit (%)	40.1 ± 10.2	41.3 ± 2.5	38.4 ± 14.7	0.49	42.2 ± 2.6	37.8 ± 14.6	0.28	42.7 ± 3.2	38.4 ± 12.4	0.17
White blood cell count (G/L)	12.2 ± 4.5	12.6 ± 4.3	12 ± 5	0.74	13.8 ± 6.1	10.7 ± 1.8	0.08	12.5 ± 5.1	12.2 ± 4.5	0.88
Platelet count (G/L)	252.4 ± 72.7	262.7 ± 80.8	243.6 ± 66.9	0.49	269.4 ± 73.4	225 ± 44.2	0.07	250.9 ± 72.3	254.9 ± 76.4	0.89
Kaliemia (mmol/L)	4.3 ± 0.4	4.2 ± 0.4	4.3 ± 0.4	0.63	4.3 ± 0.4	4.3 ± 0.4	0.7	4.2 ± 0.5	4.3 ± 0.3	0.67
Creatinine clearance (mL/min)	91.2 ± 32.2	99.3 ± 40.2	85 ± 19.2	0.23	93.4 ± 41.8	86.6 ± 21.9	0.6	86.4 ± 39.2	93.7 ± 29.6	0.61
Prothrombin rate (%)	95.4 ± 6.9	96 ± 7.7	95.3 ± 6.4	0.8	95.4 ± 7.9	95.5 ± 6.6	0.9	95.8 ± 4.7	96.2 ± 6.9	0.86
aPTT (sec)	1.2 ± 0.3	1.2 ± 0.3	1.2 ± 0.3	0.77	1.2 ± 0.3	1.2 ± 0.3	0.9	1.1 ± 0.3	1.2 ± 0.3	0.76
Anti-Xa (IU)	0.5 ± 0.2	0.5 ± 0.2	0.6 ± 0.2	0.42	0.55 ± 0.2	0.49 ± 0.3	0.5	0.5 ± 0.2	0.55 ± 0.2	0.66
Adjunctive Therapy to FL										
Clopidogrel loading dose 300mg	28 (93.3%)	14 (93.3%)	13 (92.9%)	0.96	13 (92.9)	13 (92.9)	1	9 (90)	18 (94.7)	0.63
Enoxaparin	27 (90%)	12 (80%)	14 (100%)	0.08	12 (85.7)	13 (92.9)	0.5	8 (80)	18 (94.7)	0.21
Unfractionated heparin	3 (10%)	3 (20%)	0	0.08	2 (14.3)	1 (7.1)	0.5	2 (20)	1 (5.3)	0.21

aPPT=activated partial thromboplastin time; CRUSADE=Can Rapid risk stratification of Unstable angina patients Suppress ADverse outcomes with Early implementation of the ACC/AHA Guidelines, FMC=first medical contact; GRACE=Global Registry of Acute Coronary Events; HPR=high platelet reactivity; LTA=light transmittance aggregometry; PCI=Percutaneous coronary intervention; STEMI=ST-Elevation Myocardial Infarction; TL=thrombolysis; VN=Verify Now

Table 2 : Platelet reactivity

Platelet function test	All	VN			PFA			LTA		
	(n = 30)	HPR (n = 15)	No HPR (n=14)	p	HPR (n=14)	No HPR (n=14)	p	HPR (n=10)	No HPR (n=19)	p
At coronary angiography										
VerifyNow	n = 29	n = 15	n = 14		n = 14	n = 13		n = 9	n = 19	
PRU	195.8 ± 65.2	243.7 ± 25.3	144.6 ± 54.6	< 0.0001	238.5 ± 31.1	156.2 ± 65.7	< 0.0001	242.4 ± 35.4	178.1 ± 65.2	0.002
Base	214.5 ± 29.8	214.6 ± 24.3	214.3 ± 35.8	0.98	211.3 ± 25.4	217.1 ± 35.7	0.63	214.4 ± 28.8	216.3 ± 30.7	0.88
IPA (%)	2 (21)	0 (0)	25 (30.8)	< 0.0001	0 (0)	19 (29.5)	0.0002	0 (0)	11 (32.5)	0.014
PFA	n = 28	n = 14	n = 13		n = 14	n = 14		n = 10	n = 17	
Closure time (sec)	106.5 (243.3)	64.5 (35.3)	300 (0)	< 0.001	56.5 (15)	300 (0)	< 0.001	56 (13.3)	300 (205)	0.002
LTA	n = 29	n = 15	n = 13		n = 13	n = 14		n = 10	n = 19	
MPA	51.5 ± 15.4	59.6 ± 11.5	41.4 ± 14.1	0.001	63.3 ± 7.0	39.6 ± 13.2	< 0.0001	66.8 ± 4.4	43.5 ± 12.7	< 0.001
IPA (%)	38.2 ± 18.6	28.5 ± 14	50.6 ± 16.6	< 0.001	23.9 ± 8.8	52.6 ± 15.5	< 0.0001	19.5 ± 5.7	48.1 ± 14.9	< 0.001
At Day 1 (VerifyNow P2Y12)	n = 26	n = 15	n = 11		n = 11	n = 13		n = 9	n = 17	
PRU	189 ± 66.5	220.5 ± 46.9	146.1 ± 66.8	0.006	227.1 ± 36.3	147 ± 73.6	0.005	235.6 ± 35.2	164.3 ± 66.5	0.001
Base	216.5 ± 29.9	221.1 ± 29.5	210.4 ± 30.7	0.38	212.1 ± 31	222.8 ± 30.5	0.4	213.9 ± 33.3	217.9 ± 28.9	0.76
IPA (%)	2.5 (15.3)	0 (8.5)	16 (32)	0.035	0 (0)	16 (44.5)	0.003	0 (0)	13 (31)	0.005

HPR=high platelet reactivity; LTA=Light transmission aggregometry; IPA= Inhibition of platelet aggregation; MPA=Maximal platelet aggregation; PRU= P2Y12 reaction units

Platelet reactivity at the time of angiography and correlation of the tests

Overall, as awaited, significantly lower IPA and CT, and greater PRU were observed in the HPR group regardless of the test used to define HPR (Table 2).

There was a significant correlation between IPA and PRU ($r=0.74$; $p<0.0001$; Figure 1A), between IPA and CT ($r=0.75$; $p<0.0001$; Figure 1B) and, between CT and PRU ($r=0.74$; $p<0.0001$; Figure 1C).

The sensitivity, specificity and, positive (PPV) and negative predictive value (NPV) of VN to detect HPR as compared to LTA were 63%, 89 %, 92% and 53% respectively. Similarly, the sensitivity, specificity, PPV and NPV of PFA were 70%, 90%, 92% and 64% respectively. The accuracy to classify HPR/non-HPR patients as assessed by LTA was 71% and 78% with the VN and the PFA respectively.

When we combined both VN and PFA results considering the discrepancies between the two tests as non-HPR, PPV and NPV were increased to 90% and 100% (Table 3).

The concordance between the VN and the PFA was 81%.

Table 3: Sensitivity, specificity and predictive values of the VN and PFA compared to LTA

LTA versus	VN	PFA	VN + PFA	
			Discrepancies considered as no-HPR	Discrepancies considered as HPR
Sensitivity	0.63	0.70	0.53	0.75
Specificity	0.89	0.90	0.89	0.57
PPV	0.92	0.92	0.9	0.6
NPV	0.53	0.64	1	0.73
Accuracy	0.71	0.78	0.65	0.65

HPR= high platelet reactivity; NPV=negative predictive value ; PPV=positive predictive value

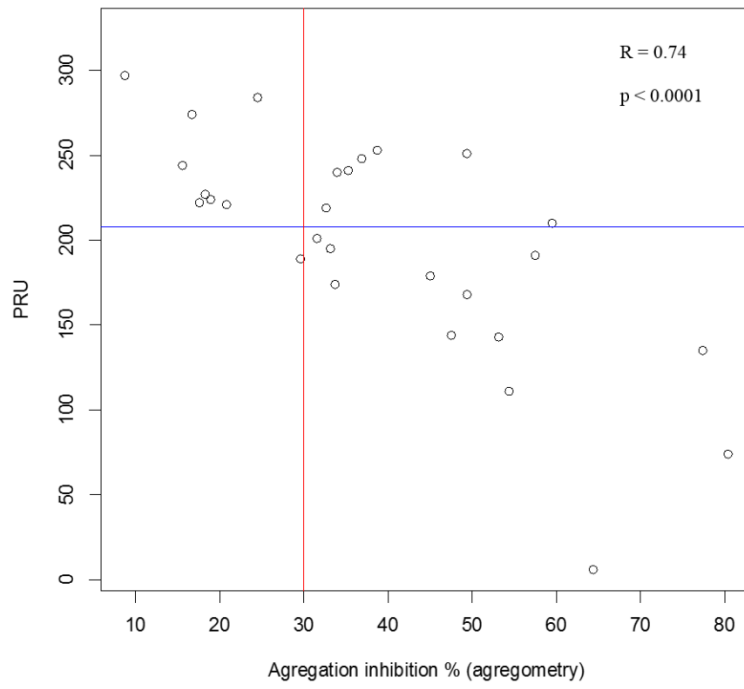


Figure 1A

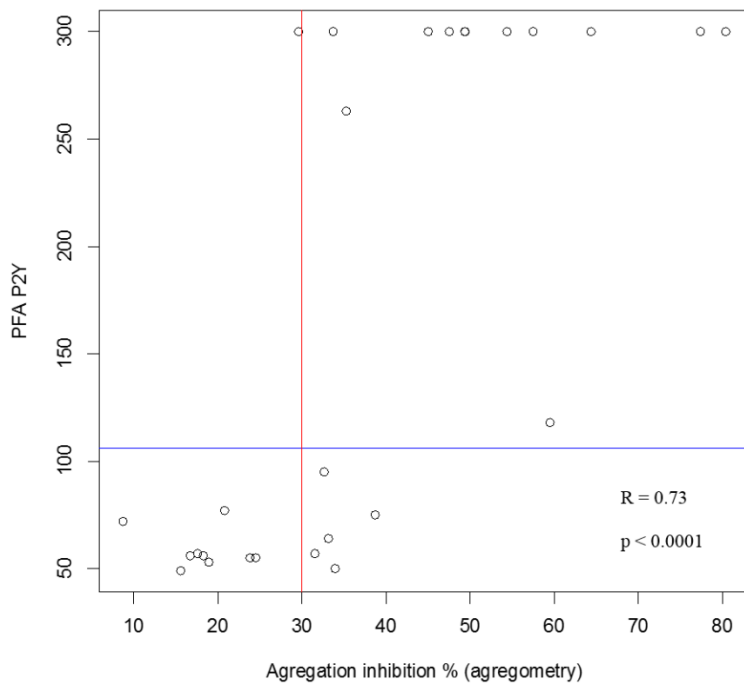


Figure 1B

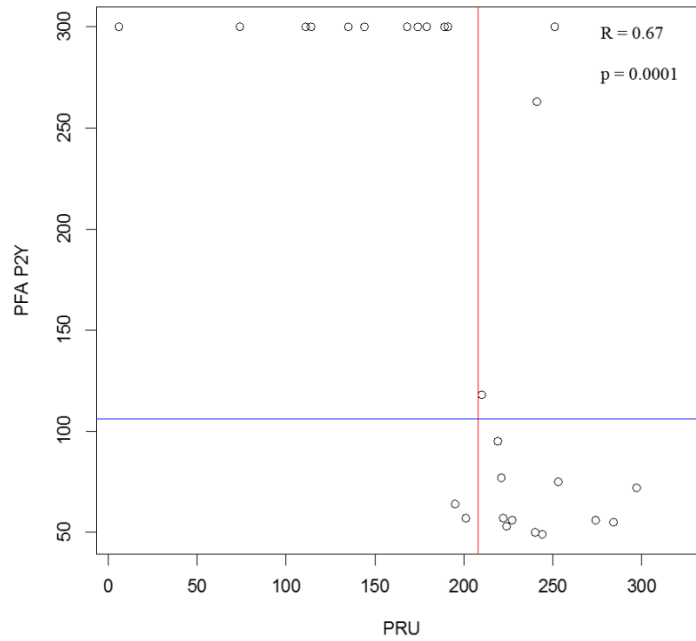


Figure 1C

Figure 1: Distribution and correlation of values derived from measurements between: A. LTA (inhibition of platelet aggregation, %) and VN (PRU); B. LTA and PFA (closure time, sec) and C. PFA and VN.

The lines indicate the cut-off values of each test determining high platelet reactivity (106 sec for PFA; 208 PRU for VN and 30% for LTA).

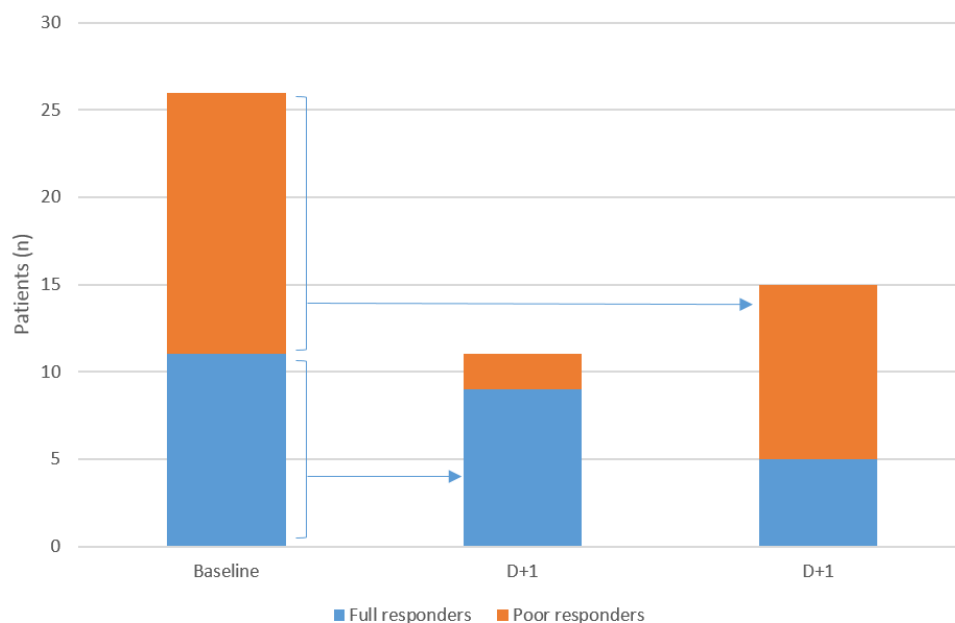


Figure 2: Responsiveness status of the patients at the time of angiography and day + 1 based on VerifyNow P2Y12

VN at day + 1 (D1)

Although on-clopidogrel platelet reactivity assessed by continuous PRU did not significantly differ between baseline and D1 (199.5 ± 65.5 vs 189 ± 66.5 ; $p=0.15$), as outlined in Figure 2, 7 out of 26 patients (26.9%) changed their responsiveness status: 5 initially HPR patients became full responders and 1 initially responder became HPR.

Outcomes

All patients were treated with coronary stenting except one who was referred for coronary artery bypass grafting. Clinical follow-up was performed with a median of 658.3 ± 129.6 days. No complications were recorded during hospitalization. Outcomes were comparable between groups, without any reported death or bleeding. Two patients had a MACE, one in each group, based on all tests.

Discussion

Our study showed that HPR is common after successful fibrinolysis, ranging from one-third to one-half of our cohort according to the test used. We found a significant correlation between LTA and both VN or PFA but also some discrepancies between POC tests and LTA in stratifying patients in HPR or non-HPR. Both, PFA and VN adequately identify patients without HPR but overestimate the proportion of HPR patients. A second different POC test seems to be a useful option to improve the accuracy of the patients' status in case of detected HPR with a first test.

Early routine angiography and PCI are recommended within a time window of 3-24h after successful FL [1]. At this time window (17.6 ± 9.4 hours), we found high rates of HPR ranging between 34.5% and 51.7% according the test used. Two previous studies have reported higher proportions of HPR early after FL reaching 67.5% [15] and 70.7% [16] of cases, as assessed by VN only. Enhanced platelet reactivity is reported in patients with acute coronary syndrome [23, 24] up to 48h following PCI [23]. The paradoxical pro-thrombotic status and thrombin-induced platelet activation within the early hours after FL [11, 25] is also likely to participate in increasing rates of HPR. The recommended adjunctive antiplatelet therapy with clopidogrel suffers from several drawbacks such as slow onset of action and variability of platelet response [12], especially with the lower doses [26] recommended with FL. Moreover the bioavailability of clopidogrel is impaired in STEMI patients [27]. These considerations explain the high prevalence of HPR in general and in our cohort. Our study is the first to report a simultaneous and head to-head comparison of platelet reactivity early post-FL with LTA - considered to be the gold standard test – VN and PFA. One third of our cohort had LTA-detected HPR, which represents only half of the previously published rates in this setting using VN [15, 16]. The prevalence of HPR using PFA was similar to that found with

VN in our patient population. As LTA is time-consuming and requires specialized equipment and technicians, POC platelet function tests have been developed for routine clinical practice. The VN and PFA can easily be used in the cathlab by a non-specific staff. Our study provides details on their validity in the early post-FL setting.

We found a significant and relatively strong correlation between IPA and PRU and between IPA and CT ($r=0.74$ and 0.75 respectively). The correlation between IPA and PRU is comparable to previous reports in elective PCI [9] or PCI in real-life practice including ACS [6] despite different study-specific LTA-ADP concentrations, cut-offs and populations. In reference to LTA, the accuracy to classify HPR/non-HPR patients was 71% for VN and 78% between for PFA. Such values are similar to those previously reported in other settings than FL [6-8]. Importantly, both VN and PFA correctly identified most patients without HPR but overestimated the proportion of HPR patients when compared to LTA. Some differences between the tests may explain these results. The PFA and VN add prostaglandin E1 to the ADP to suppress further activation of platelets through P2Y12 receptor. A variable degree of residual P2Y12 function can potentially persist despite P2Y12 inhibition and consequently modify the monitoring of clopidogrel therapy measured with ADP alone, such as in LTA. More-over LTA is performed in platelet-rich plasma whereas VN and PFA use whole-blood samples. Such differences may explain the higher concordance to classify HPR/non-HPR (81%) observed between VN and PFA as compared to POC tests and LTA (71%). The difference in hemoglobin levels between groups may also have influenced the VN results as patients with lower hemoglobin are more likely to have HPR [28]. Finally, shear stress which may influence platelet function [7] is lower in LTA unlike PFA.

Our findings imply that PCI following successful FL was performed without adequate P2Y12 inhibition in a high proportion of patients. Both the early post-STEMI setting and the HPR are high-risk situations for recurrent coronary events [13, 14]. Hence it is important to adequately

identify patients who may benefit from alternative or intensified antiplatelet therapy [29] especially in association with FL which is on the other hand associated with a higher risk of bleeding. A re-loading dose of clopidogrel distant from FL and 2h hours before PCI could enhance platelet inhibition [26, 30]. A delayed PCI to achieve full clopidogrel effect, although un-recommended, could also be considered. The selective use of glycoprotein IIb/IIIa inhibitors associated with reduced ischemic events without increased bleedings in poor clopidogrel-responders undergoing elective PCI [31] could also be an alternative. Finally, recent more potent antiplatelet therapy could be discussed after the acute phase, as proposed in the recent European guidelines [32]. Recently, ticagrelor was tested in patients with HPR post FL and provided a more effective antiplatelet inhibition than clopidogrel [15]. However, HPR was defined according only to a single VN measure in the latter study. Such strategy appears to be questionable considering our results. The bleeding risk associated with both FL and more intensive antiplatelet regimens warrant reliable identification of patients who truly benefit from such strategies.

The studied POC tests appear to be reliable in detecting non-HPR in the early post-FL setting. A single measure with any of the POC tests appears insufficient to tailor antiplatelet therapy in those with detected HPR. Considering that platelet reactivity is enhanced early after ACS [23, 24], a repetitive testing using the same device may be useful. We showed that a quarter of patients changed their responsiveness status at day 1, mostly HPR patients becoming full responders. After FL, the reported variations in the PRU levels between baseline and day 1 are discordant between studies [15, 16]. However a decrease of on-clopidogrel platelet reactivity over time was showed in a larger cohort of patients treated with PCI, mostly for non-STEMI [33]. Interestingly, we showed that a measure with a second different type of POC test might be useful when a first test detects HPR. Considering that the patient is HPR when the 2 tests are concordantly positive and is non-HPR when both tests are negative or

discordant, remarkably improves both NPV and PPV of the strategy. In clinical practice, POC tests are useful in tailoring antiplatelet treatment for patients at high bleeding and/or high ischemic risk. The latter situations include those with a history of stent thrombosis or complex PCI with numerous stents and/or complex bifurcation lesions. Considering the high bleeding and thrombotic risk associated with FL, and the fact that only clopidogrel can be used in concomitance with FL, the POC tests appear as ideally indicated in this setting.

Study limitation

Our study was not powered nor designed to detect potential relationship between HPR and clinical events. Additional studies are needed to assess the clinical benefit of testing platelet reactivity and further antiplatelet regimens in patients with HPR despite conventional recommended therapy in this setting. There was a rather lengthy period of patients recruitment due to the inclusion criteria. However, during the inclusion period FL, antithrombotic and interventional protocols were not modified in our center.

Conclusion

HPR is a common finding after successful FL but its rates vary according to the used tests. When compared to LTA, POC tests VN and PFA correctly identify patients without HPR but overestimate the proportion of HPR patients. Hence one measure of such POC tests detects optimally treated patients at the time of PCI following FL in a pharmaco-invasive strategy but not those requiring more aggressive antiplatelet therapy who may be more accurately identified by the association of two different POC test.

References Article 1:

1. Steg PG, James SK, Atar D, et al. ESC Guidelines for the management of acute myocardial infarction in patients presenting with ST-segment elevation. *Eur Heart J.* 2012; 33:2569-619.
2. Armstrong PW, Boden WE. Reperfusion paradox in ST-segment elevation myocardial infarction. *Ann Intern Med.* 2011; 155:389-91.
3. Roule V, Ardouin P, Blanchart K, et al. Prehospital fibrinolysis versus primary percutaneous coronary intervention in ST-elevation myocardial infarction: a systematic review and meta-analysis of randomized controlled trials. *Crit Care.* 2016; 20:359.
4. Chen ZM, Jiang LX, Chen YP, et al. Addition of clopidogrel to aspirin in 45,852 patients with acute myocardial infarction: randomised placebo-controlled trial. *Lancet.* 2005; 366:1607-21.
5. Sabatine MS, Cannon CP, Gibson CM, et al. Addition of clopidogrel to aspirin and fibrinolytic therapy for myocardial infarction with ST-segment elevation. *N Engl J Med.* 2005; 352:1179-89.
6. Kim IS, Jeong YH, Kang MK, et al. Correlation of high post-treatment platelet reactivity assessed by light transmittance aggregometry and the VerifyNow P2Y12 assay. *J Thromb Thrombolysis.* 2010; 30:486-95.
7. Linnemann B, Schwonberg J, Rechner AR, Mani H, Lindhoff-Last E. Assessment of clopidogrel non-response by the PFA-100 system using the new test cartridge INNOVANCE PFA P2Y. *Ann Hematol.* 2010; 89:597-605.
8. Tsantes A, Ikonomidis I, Papadakis I, et al. Evaluation of the role of the new INNOVANCE PFA P2Y test cartridge in detection of clopidogrel resistance. *Platelets.* 2012; 23:481-9.

9. Van Werkum JW, Van Der Stelt CA, Seesing TH, Hackeng CM, Ten Berg JM. A head-to-head comparison between the VerifyNow P2Y12 assay and light transmittance aggregometry for monitoring the individual platelet response to clopidogrel in patients undergoing elective percutaneous coronary intervention. *J Thromb Haemost*. 2006; 4:2516-8.
10. Varenhorst C, James S, Erlinge D, et al. Assessment of P2Y(12) inhibition with the point-of-care device VerifyNow P2Y12 in patients treated with prasugrel or clopidogrel coadministered with aspirin. *Am Heart J*. 2009; 157:562 e1-9.
11. Eisenberg PR, Sobel BE, Jaffe AS. Activation of prothrombin accompanying thrombolysis with recombinant tissue-type plasminogen activator. *J Am Coll Cardiol*. 1992; 19:1065-9.
12. O'donoghue M, Wiviott SD. Clopidogrel response variability and future therapies: clopidogrel: does one size fit all? *Circulation*. 2006; 114:e600-6.
13. Stone GW, Witzencbichler B, Weisz G, et al. Platelet reactivity and clinical outcomes after coronary artery implantation of drug-eluting stents (ADAPT-DES): a prospective multicentre registry study. *Lancet*. 2013; 382:614-23.
14. Price MJ, Angiolillo DJ, Teirstein PS, et al. Platelet reactivity and cardiovascular outcomes after percutaneous coronary intervention: a time-dependent analysis of the Gauging Responsiveness with a VerifyNow P2Y12 assay: Impact on Thrombosis and Safety (GRAVITAS) trial. *Circulation*. 2011; 124:1132-7.
15. Alexopoulos D, Perperis A, Koniari I, et al. Ticagrelor versus high dose clopidogrel in ST-segment elevation myocardial infarction patients with high platelet reactivity post fibrinolysis. *J Thromb Thrombolysis*. 2015; 40:261-7.

16. Diego A, De Prado AP, Cuellas C, et al. P2Y12 platelet reactivity after thrombolytic therapy for ST-segment elevation myocardial infarction. *Thromb Res.* 2012; 130:e31-6.
17. Gasparyan AY. Aspirin and clopidogrel resistance: methodological challenges and opportunities. *Vasc Health Risk Manag.* 2010; 6:109-12.
18. Gasparyan AY, Watson T, Lip GY. The role of aspirin in cardiovascular prevention: implications of aspirin resistance. *J Am Coll Cardiol.* 2008; 51:1829-43.
19. Armstrong PW, Gershlick AH, Goldstein P, et al. Fibrinolysis or primary PCI in ST-segment elevation myocardial infarction. *N Engl J Med.* 2013; 368:1379-87.
20. Luo Y, Li J, Liu X, et al. Combination of P2Y12 reaction unit and percentage of platelet inhibition assessed by VerifyNow P2Y12 assay is a useful predictor of long-term clinical outcomes in patients with acute coronary syndrome undergoing percutaneous coronary intervention. *Thromb Res.* 2016; 139:114-20.
21. Paniccia R, Antonucci E, Gori AM, et al. Different methodologies for evaluating the effect of clopidogrel on platelet function in high-risk coronary artery disease patients. *J Thromb Haemost.* 2007; 5:1839-47.
22. Mehran R, Rao SV, Bhatt DL, et al. Standardized bleeding definitions for cardiovascular clinical trials: a consensus report from the Bleeding Academic Research Consortium. *Circulation.* 2011; 123:2736-47.
23. Althoff TF, Fischer M, Langer E, Ziemer S, Baumann G. Sustained enhancement of residual platelet reactivity after coronary stenting in patients with myocardial infarction compared to elective patients. *Thromb Res.* 2010; 125:e190-6.

24. Geisler T, Kapp M, Gohring-Frischholz K, et al. Residual platelet activity is increased in clopidogrel- and ASA-treated patients with coronary stenting for acute coronary syndromes compared with stable coronary artery disease. *Heart*. 2008; 94:743-7.
25. Rasmanis G, Vesterqvist O, Green K, Edhag O, Henriksson P. Evidence of increased platelet activation after thrombolysis in patients with acute myocardial infarction. *Br Heart J*. 1992; 68:374-6.
26. Savcic M, Hauert J, Bachmann F, Wyld PJ, Geudelin B, Cariou R. Clopidogrel loading dose regimens: kinetic profile of pharmacodynamic response in healthy subjects. *Semin Thromb Hemost*. 1999; 25 Suppl 2:15-9.
27. Heestermans AA, Van Werkum JW, Taubert D, et al. Impaired bioavailability of clopidogrel in patients with a ST-segment elevation myocardial infarction. *Thromb Res*. 2008; 122:776-81.
28. Elsenberg EH, Van Werkum JW, Van De Wal RM, et al. The influence of clinical characteristics, laboratory and inflammatory markers on 'high on-treatment platelet reactivity' as measured with different platelet function tests. *Thromb Haemost*. 2009; 102:719-27.
29. Aradi D, Komocsi A, Price MJ, et al. Efficacy and safety of intensified antiplatelet therapy on the basis of platelet reactivity testing in patients after percutaneous coronary intervention: systematic review and meta-analysis. *Int J Cardiol*. 2013; 167:2140-8.
30. Gurbel PA, Bliden KP, Hayes KM, Yoho JA, Herzog WR, Tantry US. The relation of dosing to clopidogrel responsiveness and the incidence of high post-treatment platelet aggregation in patients undergoing coronary stenting. *J Am Coll Cardiol*. 2005; 45:1392-6.

31. Cuisset T, Frere C, Quilici J, et al. Glycoprotein IIb/IIIa inhibitors improve outcome after coronary stenting in clopidogrel nonresponders: a prospective, randomized study. *JACC Cardiovasc Interv.* 2008; 1:649-53.
32. Ibanez B, James S, Agewall S, et al. 2017 ESC Guidelines for the management of acute myocardial infarction in patients presenting with ST-segment elevation: The Task Force for the management of acute myocardial infarction in patients presenting with ST-segment elevation of the European Society of Cardiology (ESC). *Eur Heart J.* 2017;
33. Campo G, Parrinello G, Ferraresi P, et al. Prospective evaluation of on-clopidogrel platelet reactivity over time in patients treated with percutaneous coronary intervention relationship with gene polymorphisms and clinical outcome. *J Am Coll Cardiol.* 2011; 57:2474-83.

2. Erosion versus rupture de plaque en analyse OFDI pré et post stenting dans les IDM ST+ reperfusés par fibrinolyse

Le thrombus intracoronaire est un élément déterminant de la qualité de la reperfusion myocardique dans les infarctus du myocarde. Nous avons comparé les caractéristiques de la charge thrombotique pré et post stenting, évaluée en OFDI, selon le mécanisme identifié (érosion ou rupture de plaque) responsable de l'IDM ST+ traités avec succès par fibrinolyse. Sur les 27 patients inclus, 17 (63%) avaient une rupture de plaque et 10 (37%) une érosion. Avant angioplastie, les patients avec rupture de plaque présentaient un volume et une charge thrombotique plus importants que ceux avec érosion (13.4 ± 18.4 vs 2.8 ± 2.3 mm³; $p=0.03$ et 33.8 ± 17.5 vs 17.5 ± 9.9 %; $p=0.007$, respectivement). Le thrombus était majoritairement rouge et étalé de part et d'autre de la sténose dans les ruptures de plaque alors qu'il était plutôt blanc avec une distribution focale dans les érosions. Après mise en place du stent, il n'y avait pas de différence de volume de thrombus ni de sa distribution apparaissant globalement étalée le long du stent de manière homogène. Notre étude montre que le type de thrombus, son volume et sa distribution dépendent du mécanisme physiopathologique à l'origine de l'IDM ST+ mais ces différences ne sont pas retrouvées en post stenting.

ARTICLE 2

Plaque erosion versus rupture characterization by optical frequency domain imaging before and after coronary stenting following successful fibrinolysis for ST-segment elevation myocardial infarction.

Roule V, Briet C, Lemaitre A, Ardouin P, Bignon M, Sabatier R, Blanchart K, Beygui F.

Heart Vessels. 2019 Mar;34(3):401-409. Epub 2018 Sep 6. PMID: 30191317

Abstract

Objectives: Intracoronary thrombus burden affects the quality of myocardial reperfusion in the setting of ST-elevation myocardial infarction (STEMI). We aimed to study the characteristics of the plaque and thrombus assessed by intracoronary optical frequency domain imaging (OFDI) according the presence of plaque rupture or erosion in STEMI patients treated with successful fibrinolysis.

Methods: Pre-stenting thrombus and post-stenting atherothrombotic burden were compared between plaque rupture and erosion. Twenty-seven consecutive patients were included: 17 (63%) had OFDI-plaque rupture and 10 (37%) had OFDI-erosion.

Results: Thrombus volume and burden were significantly higher in case of rupture compared to erosion at baseline (13.4 ± 18.4 vs 2.8 ± 2.3 mm³; $p=0.03$ and 33.8 ± 17.5 vs 17.5 ± 9.9 %; $p=0.007$, respectively). In the rupture group, the core of the thrombus consisted dominantly of red thrombus evenly distributed along the entire culprit plaque. In the erosion group, it consisted dominantly of white thrombus with a focal distribution near the minimal lumen area zone. After stenting, the atherothrombotic volume, burden and its distribution, as well as angiographic estimators of myocardial reperfusion were similar between groups.

Conclusion: Our study showed that pre-PCI thrombus amount, typesetting and distribution are mainly linked to the underlying mechanism of STEMI. After stenting, the atherothrombotic burden and its distribution were similar between the groups.

Introduction

The most common underlying mechanisms of myocardial infarction are a rupture or erosion of an atherosclerotic plaque initiating intraluminal thrombus formation and the subsequent partial or complete occlusion of the coronary artery [1]. High thrombus burden is associated with the risk of distal embolization and microcirculatory impairment, reducing the efficacy of myocardial reperfusion by percutaneous coronary intervention (PCI) and increasing infarct size [2-4].

Optical coherence tomography (OCT) and optical frequency domain imaging (OFDI) provide high resolution imaging of the culprit lesion and thrombus [5]. Several studies have described the underlying plaque morphologies and the thrombus burden using OCT [6-9] in patients with ST-segment elevation myocardial infarction (STEMI) treated with primary PCI. However, in all latter studies, OCT has been performed after thrombectomy or balloon predilation as high thrombus burden or severe stenosis are the pitfalls of the technique in the acute phase of STEMI. Hence, features described by such studies may have been modified by such interventions prior to imaging.

In patients with STEMI managed early after symptom-onset, pre-hospital fibrinolysis (FL) within a pharmaco-invasive strategy is a valuable alternative to primary PCI with similar early and late mortality rates [10]. At the time of PCI -within 2-24h after thrombolytic therapy [11]-, the paradoxical pro-thrombotic post-FL status [12] associated with the variability of platelet response and slow onset of action of clopidogrel [13] especially with the low doses [14] recommended in association with FL increase the risk of thrombus formation. On the other hand, thrombus burden depends also on the underlying mechanism of myocardial infarction, plaque rupture being associated with higher thrombus burden as compared to erosion [9].

The aim of our study was to assess and compare the characteristics of thrombus between OFDI-plaque rupture (PR) and OFDI-plaque erosion (PE), before and after PCI following successful FL in STEMI patients treated using OFDI.

Methods

Study population

We investigated patients enrolled in the prospective AODIS study (Assessment of intracoronary thrombus by optical frequency domain imaging during percutaneous coronary intervention after successful fibrinolysis and its impact on myocardial reperfusion) between July 2015 and October 2016. The inclusion criteria were: patient ≥ 18 years admitted to our tertiary center for STEMI successfully treated by FL and PCI of a native coronary culprit lesion 3 to 24h after FL, with a pre and post-PCI OFDI imaging. Successful FL was defined as the resolution of both ST-segment elevation ($>50\%$) and chest pain <90 min after FL [15]. OFDI (Lunawave®, FastView®, Terumo Europe, Leuven, Belgium) was performed before PCI and any percutaneous intervention and at the end of the procedure. Exclusion criteria were: use of glycoprotein IIb/IIIa inhibitors, cardiogenic shock, stent thrombosis or restenosis, severe renal insufficiency (estimated glomerular filtration rate (eGFR) < 30 mL/min), coagulation disorders and severely calcified or tortuous arteries inaccessible to OFDI.

Informed consent was obtained from all individual participants included in the study and the study was approved by the local ethics committee. The study is registered on ClinicalTrials.gov under the identifier NCT02850315.

Pharmacological regimen

All patients received a 250 mg i.v. bolus of aspirin and a clopidogrel oral loading dose of 300 mg if aged ≤ 75 years or 75 mg if aged > 75 years, followed by 75 mg of clopidogrel and aspirin daily as recommended in our regional STEMI network protocol. Anticoagulation was performed with enoxaparin in all. The fibrinolytic agent was tenecteplase, administered in a weight-adjusted dose [16].

OFDI image analysis

The OFDI procedure was performed as previously described [17]. The images were analyzed by 2 investigators (VR and CB) using previously validated criteria for OCT plaque characterization [18-20]. OFDI-plaque rupture (PR) was defined by the presence of fibrous cap discontinuity with a clear cavity formed inside the plaque [7,19]. OFDI-plaque erosion (PE) was defined by the presence of attached thrombus overlying an intact plaque or luminal surface irregularity without thrombus and with no detectable signs of fibrous cap rupture. Culprit lesions that did not satisfy these criteria were classified as “other”. Stent malapposition was defined as a stent to adjacent vessel lumen distance $>200\mu\text{m}$.

For the thrombus quantification, the whole stented segment was analyzed at each frame on post-PCI images. The corresponding arterial segment on pre-PCI images was identified using anatomical landmarks and analyzed similarly at each frame. On pre-PCI images, thrombus was defined as an irregular intraluminal mass either attached to the vessel wall or floating into the lumen. Thrombus were categorized as either erythrocyte-rich (red) highly backscattering with high attenuation or, platelet-rich (white), less backscattering, homogeneous with low attenuation. At each frame, lumen area (LA) and flow-area (FA) were manually measured by planimetry as previously described [21] and thrombus area (TA) was defined as the difference

between LA and FA (Figure 1). The thrombus volume was calculated by numerical integration based on the disk summation method by the proprietary software [17]. Thrombus burden (TB) was calculated as thrombus volume divided by lumen volume multiplied by 100. We also calculated the thrombus burden of the thrombotic area (TB thrombotic area) by restricting the quantification only to the segment containing visible thrombus.

Post-stent atherothrombotic burden (ATB) included tissue prolapse and thrombus, either attached to the vessel wall or the struts or floating. The post-stent LA was measured using stents' struts as limits. In case of strut malapposition, a corresponding point in the vessel wall was traced instead [21]. The calculation of atherothrombotic burden and volume were similar to TB and thrombus volume. The semi-quantitative pre and post-PCI thrombus scores were calculated by summing the number of involved quadrants containing thrombus at 1 mm intervals [22]. Irregular protrusion was defined as previously described [23].

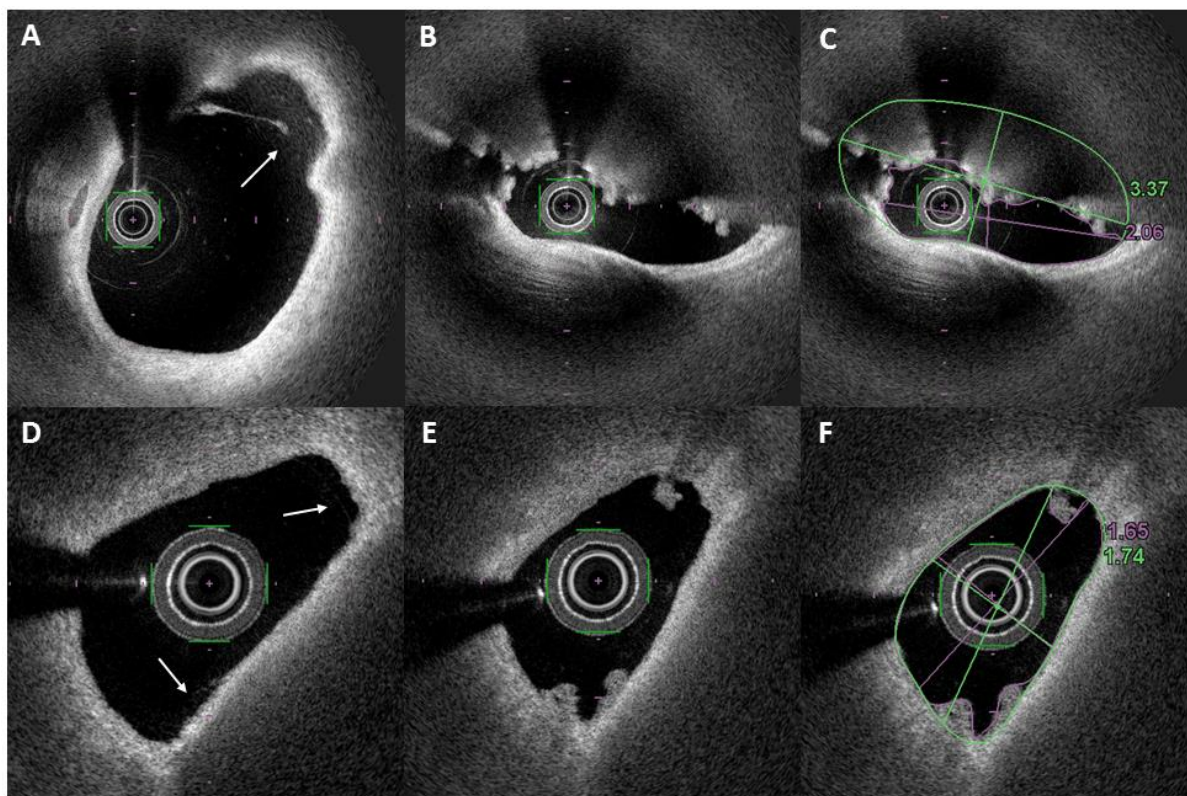


Figure 1: Optical frequency domain imaging examples of plaque analysis. Plaque rupture (white arrow, panel A) associated with red thrombus 5 mm more proximal (panel B); lumen and flow area delimitations (panel C; thrombus area 1.31 mm² or 38.9%). Plaque erosion with mild luminal surface irregularities (white arrow, panel D) and white thrombus 0.2 mm more distal (panel E); lumen and flow area delimitations (panel F; thrombus area 0.09 mm² or 5.2%).

Angiographic analysis

Coronary angiograms were analyzed before PCI and at the end of the procedure to evaluate basal and post-PCI Thrombolysis in Myocardial Infarction (TIMI) flow grade, angiographic thrombus grade and, post-PCI myocardial blush grade and corrected TIMI frame count (CTFC), as previously described [24,25].

Statistical analysis

Groups were defined by the identification of PR or PE. Continuous variables were expressed as mean \pm standard deviation and compared between groups using Student's t, Welch-Satterthwaite or Wilcoxon-Mann Whitney tests when adapted. Categorical variables were expressed as numbers (percentages) and compared between groups using Fisher's exact test. Univariate correlations were assessed by Pearson's correlation test. A P-value of < 0.05 was considered statistically significant. SAS 9.4 (SAS Institute Inc., Cary, NC, USA) was used for statistical analysis.

Results

A total of 31 patients underwent OCT evaluation after successful FL but 4 were excluded from the analysis because of poor pre-stent image quality in 2 and un-identification of plaque rupture or erosion in 2. Finally, 27 patients were included in the analysis, 17 (63%) with PR and 10 (37%) with PE.

Baseline demographic and angiographic characteristics (detailed in Table 1) were comparable between groups, except for the culprit coronary lesion which was more often located in the left circumflex in the erosion group ($p=0.04$). No patient had thrombus aspiration.

The OFDI analysis showed that rupture was associated with higher rates of lipid-rich plaque (Table 2). Baseline thrombus volume and burden of the thrombotic area were significantly higher in PR compared to PE (13.4 ± 18.4 vs 2.8 ± 2.3 mm³; $p=0.03$ and 33.8 ± 17.5 vs 17.5 ± 9.9 %; $p=0.007$, respectively).

Table 1: Baseline characteristics of the study population

Baseline patient characteristics	All n=27 (100%)	Rupture n=17 (63%)	Erosion n=10 (37%)	p
Age (years)	59.9 ± 13.9	63.2 ± 15.4	54.2 ± 9.2	0.1
Men	24 (88.9%)	15 (88.2%)	9 (90%)	0.46
Body mass index (kg/m ²)	26.7 ± 4.7	27.9 ± 5.1	24.6 ± 2.9	0.07
Systemic hypertension	11 (40.7%)	7 (41.2%)	4 (40%)	0.3
Hyperlipidemia	12 (44.4%)	7 (25.9%)	5 (50%)	0.3
Actif Smoker	14 (51.8%)	8 (47%)	6 (60%)	0.5
Diabetes mellitus	2 (7.4%)	1 (5.9%)	1 (10%)	0.5
History of Myocardial Infarction	1 (3.7%)	1 (5.9%)	0	0.6
Anterior wall STEMI	11 (40.7%)	9 (52.9%)	2 (20%)	0.1
Inferior wall STEMI	15 (55.5%)	7 (41.2%)	8 (80%)	0.1
Other infarct location	1 (3.7%)	1 (5.9%)	0	0.6
Systolic Blood Pressure (mmHg)	130.6 ± 14.9	132.2 ± 14.4	128 ± 16.1	0.5
Diastolic Blood Pressure (mmHg)	76.2 ± 13.8	75.8 ± 12.3	76.9 ± 16.8	0.8
Heart rate (beats/minute)	72.4 ± 14.2	73.2 ± 13.5	71.1 ± 16	0.7
Timepoints (min)				
Pain to first medical contact	122.3 ± 69.5	108.5 ± 64	145 ± 75.7	0.2
Pain to fibrinolysis	158.5 ± 79.6	143.1 ± 65	187.7 ± 97	0.16
Fibrinolysis to PCI	1026.5 ± 476.7	1001.1 ± 464.1	1069.8 ± 520	0.7
Biological characteristics				
Creatinine (µmol/L)	79.8 ± 15.9	80.1 ± 18.4	79.3 ± 11.2	0.9
Hemoglobin (g/dL)	14.2 ± 1.4	14	14.4	0.6
Adjunctive Therapy				
Clopidogrel loading dose 75mg	3 (11.1%)	3 (17.6%)	0	0.3
Clopidogrel loading dose 300mg	24 (88.9%)	14 (82%)	10 (100%)	0.2
Angiographic characteristics				
Culprit coronary artery				
Left anterior descending artery	12 (44.4%)	10 (58.8%)	2 (20%)	0.1
Left circumflex artery	3 (11.1%)	0	3 (30%)	0.04
Right coronary artery	12 (44.4%)	7 (41.2%)	5 (50%)	0.3
Angiographic thrombus grade				
Grade 0	4 (14.8%)	3 (17.6%)	1 (10%)	1
Grade 1	11 (40.7%)	6 (35.3%)	5 (50%)	0.7
Grade 2	4 (14.8%)	2 (11.8%)	2 (20%)	0.6
Grade 3	6 (22.2%)	5 (29.4%)	1 (10%)	0.4
Grade 4	2 (7.4%)	1 (5.9%)	1 (10%)	0.5
Basal TIMI flow grade				
Grade 2	5 (18.5%)	4 (23.5%)	1 (10%)	0.3
Grade 3	22 (81.5%)	13 (76.5%)	9 (90%)	0.3
Final TIMI flow grade				
Grade 2	3 (11.1%)	3 (17.6%)	0	0.23
Grade 3	24 (88.9%)	14 (82.3%)	10 (100%)	0.2
Basal corrected TIMI frame count	48.08 ± 21.7	52.3 ± 25.1	40.8 ± 11.9	0.2
Final corrected TIMI frame count	43.8 ± 22	47.4 ± 25.2	37.6 ± 13.9	0.3
Basal myocardial blush grade				
Grade 2	5 (18.5%)	4 (23.5%)	1 (10%)	0.3
Grade 3	22 (81.5%)	13 (76.5%)	9 (90%)	0.5
Final myocardial blush grade 3	27 (100%)	17 (100%)	10 (100%)	1
Stent diameter (mm)	3.2 ± 0.6	3.2 ± 0.6	3.1 ± 0.6	0.6
Total stent length (mm)	30.6 ± 13.8	31.9 ± 14.8	28.4 ± 12.2	0.5

PCI=percutaneous coronary intervention ; STEMI=ST-elevation myocardial infarction

Table 2: OFDI findings of culprit lesions at baseline and post-stenting

OFDI characteristics	All n=27 (100%)	Rupture n=17 (63%)	Erosion n=10 (37%)	p
Culprit plaque analysis				
Lipid rich plaque	21 (77.8%)	16 (94.1%)	5 (50%)	0.01
Cap thickness (µm)	76.1 ± 33.2	73.2 ± 36.2	86 ± 19.5	0.5
Thin-cap fibroatheroma	12 (54.6%)	11 (64.7%)	1(10%)	0.1
Fibrous plaque	6 (22.2%)	1 (5.9%)	5 (50%)	0.01
Calcification	10 (37%)	6 (35.3%)	4 (40%)	0.3
Microchannels	11 (40.7%)	9 (52.9%)	2 (20%)	0.08
Thrombus	27 (100%)	17 (100%)	10 (100%)	1
Red thrombus	18 (66.7%)	16 (94.1%)	1 (10%)	<0.0001
White thrombus	10 (37%)	1 (5.9%)	9 (90%)	<0.0001
Baseline analysis				
Reference lumen area (mm2)	7.4 ± 3.3	7.4 ± 3.6	7.2 ± 5.2	0.8
Reference narrowing	4 (14.8%)	2 (11.8%)	2 (20%)	0.6
Minimum lumen area (mm2)	1.43 ± 1.03	1.62 ± 1.18	1.08 ± 0.65	0.18
Area stenosis (%)	78.6 ± 13.7	76.6 ± 15.7	81.9 ± 9.4	0.34
Lumen volume (mm3)	110.6 ± 54.6	125.8 ± 60	84.9 ± 32.1	0.06
Thrombus length (mm)	5.8 ± 3.9	6.3 ± 4	5 ± 3	0.4
Thrombus volume (mm3)	9.47 ± 15.4	13.4 ± 18.4	2.8 ± 2.3	0.03
Thrombus burden (%)	7.67 ± 6.9	9.5±7.2	4.6 ± 5.4	0.07
Thrombus burden TA* (%)	27.8 ± 15.8	33.8 ± 17.5	17.5 ± 9.9	0.007
Thrombus score	15.3 ± 10.4	17.4 ± 11.1	11.7 ± 4.7	0.1
Post stenting analysis				
Instant dissection	1 (3.7%)	1 (5.9%)	0	0.6
Edge dissection	2 (7.4%)	1 (5.9%)	1 (10%)	0.5
Stent malapposition	6 (22.2%)	4 (23.5%)	2 (20%)	0.3
Instant minimal lumen area (mm2)	6.3 ± 2.7	6.6 ± 2.7	5.8 ± 2.7	0.5
Intrastent protrusion >500 µm	12 (44.4%)	8 (47.1%)	4 (40%)	0.3
Irregular protrusion	15 (55.6%)	11 (64.7%)	4 (40%)	0.15
Stent volume	180.7 ± 80.3	199.5 ± 86.3	148.7 ± 60.1	0.1
Atherothrombotic length (mm)	20.5 ± 6.9	21.2 ± 7	19.3 ± 6.9	0.5
Atherothrombotic volume (mm3)	13.2 ± 8.8	14.9 ± 9.9	10.3 ± 6.3	0.2
Atherothrombotic burden (%)	7.42 ± 3.9	7.44 ± 3.4	7.4 ± 4.8	1
Atherothrombotic burden TA* (%)	8.1 ± 3.5	8.3 ± 2.9	7.8 ± 4.5	0.7
Thrombus score	33.8 ± 13.6	35.7 ± 16	30.5 ± 8	0.3

TA*=thrombotic area (calculation of the thrombus burden was restricted to the area containing thrombus)

In the rupture group, the core of the thrombus primarily consisted of red thrombus which was evenly distributed over the entire culprit lesion (Figure 2A). In the erosion group, the core of the thrombus primarily consisted of white thrombus which remained concentrated around the minimal lumen area. After stenting, the atherothrombotic volume, burden and its distribution (Figure 2B) were similar between groups.

There was a significant but weak correlation between baseline thrombus volume and post-stenting atherothrombotic volume ($r=0.39$; $p=0.045$). In the rupture group, the distance between the minimal lumen area and site of rupture was 3 ± 2.3 mm.

During hospitalization, one patient presented major bleeding in the rupture group, related to intracranial hemorrhage.

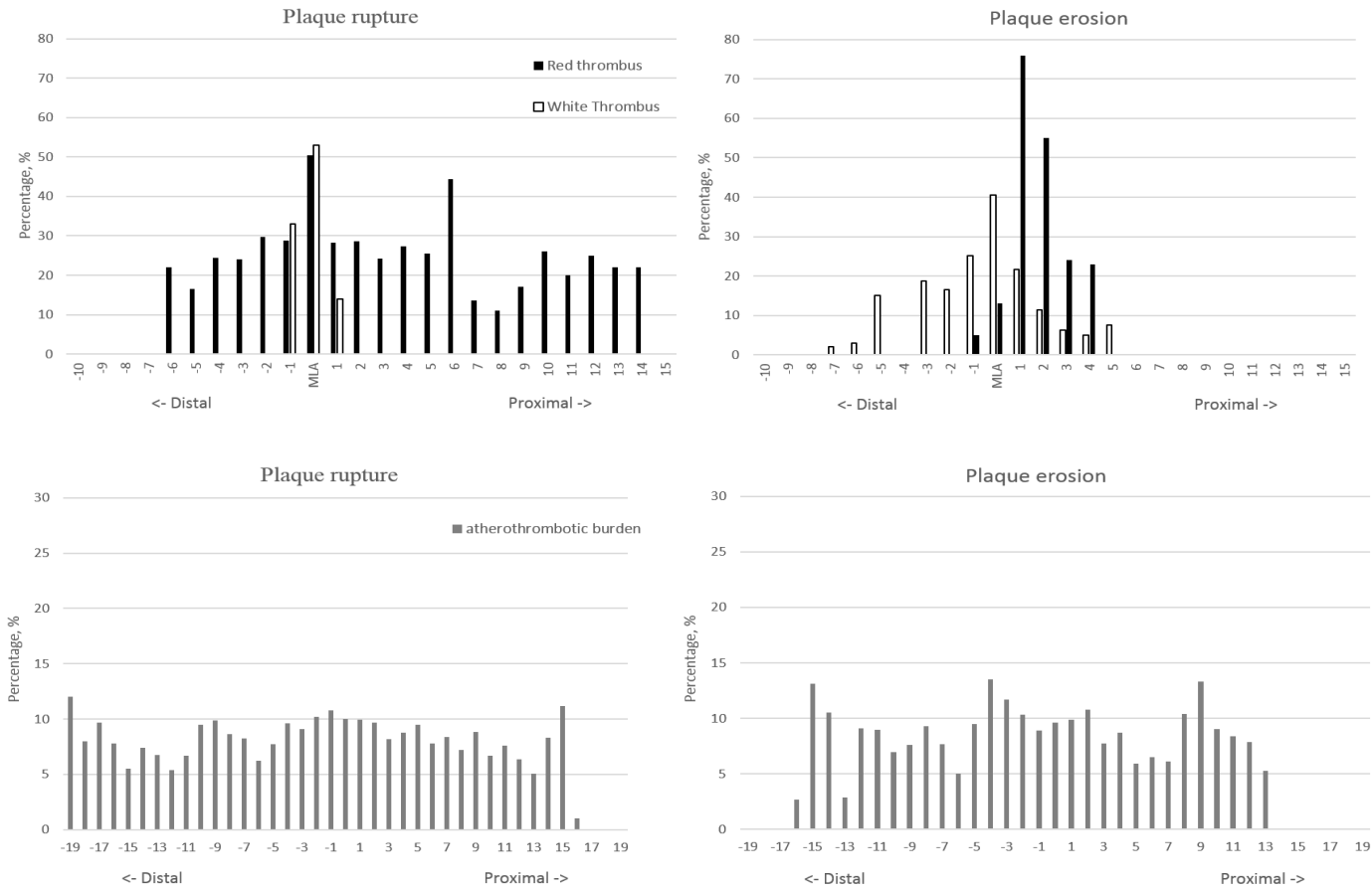


Figure 2: Distribution of pre-stenting thrombus burden (panel A) and post-stenting atherothrombotic burden (panel B) in patients with plaque rupture vs plaque erosion, from either side of the minimal lumen area (MLA) in frames containing thrombus.

Discussion

Our study showed that pre-stenting thrombus architecture, distribution and amount after successful FL are mainly linked to the underlying mechanism of myocardial infarction. Compared to PE, PR was associated with dominantly red -versus white- thrombus, evenly distributed across and afar the minimal lumen area -versus focal- and greater thrombus burden. After stenting the atherothrombotic burden features became however similar between PR and PE.

Plaque rupture remains the most common substrate for coronary thrombosis and was identified in 63% of our patients concordantly with prior reports [26,7,9]. Although the amount of thrombus was variable between patients, it was identified on all assessed lesions regardless of the underlying mechanism. Two previous studies assessed thrombus by OCT after successful thrombolysis and identified thrombus in 65 and 100% of patients [27,28]. PR was identified in half of their patients.

Our study outlined that PR was associated with greater thrombus burden, compared to PE. Post-thrombectomy OCT studies in STEMI patients treated with primary PCI did not all retrieve greater thrombus in the setting of rupture, based on the semi-quantitative thrombus score [7,9]. Using the same score, we only found a trend toward higher thrombus burden in PR. However, using a more accurate volumetric quantification, in agreement with the only previous post-thrombolysis OCT study [27] we found a significantly higher thrombus volume and burden in the setting of PR compared to PE. PR and PE present different atherosclerotic patterns that could explain thrombus differences. While eroded plaques are often rich in smooth muscle cells and proteoglycans, PR usually complicates lipid-rich plaques [29], as shown in our study. PR occurs most frequently where the fibrous cap is the thinnest and heavily infiltrated by macrophage foam cells. Such conditions are associated with high tissue factor activity [30]. The necrotic core which is exposed to the circulation by PR is known to

be the most thrombogenic component of atherosclerotic plaque [31]. The release of potent pro-thrombotic substances such as tissue factor and microparticles left behind after apoptotic cell death [32] may be one mechanistic explanation to higher thrombus volume associated with PR. Thrombi were also richer in erythrocyte in the rupture group and more platelet-rich in the erosion group, as previously described [27,33,9]. It is usually admitted that “red” thrombi correspond to old thrombi as opposed to recent platelet-rich “white” thrombi but ischemic times did not differ between groups in our cohort. Plaque haemorrhage and extravasation of erythrocytes play an important role in necrotic core expansion and plaque vulnerability [26]. This may participate into the higher proportion of red thrombi observed in PR. On the contrary in the erosion group, the less intense thrombotic stimuli and smaller area of endothelial injury may be associated with more limited coagulation leading to more platelet-rich thrombi. Finally, inflammation plays a key role in the setting of STEMI and could explain thrombus differences. A recent OCT study showed that matrix metalloproteinase 9 (MMP-9) within the culprit plaques could affect thrombus formation [34]. Autopsy studies have reported lower rates of inflammatory markers in PE, as outlined by sparse infiltration of macrophages [26]. On the other hand, PR is associated with higher concentrations of C-reactive protein [35] which may explain its increased thrombogenicity. A recent OCT study showed different intracoronary cytokine expression patterns between PR and PE [36]. While PE was associated with preferential expression of thrombospondin-1, implicated in platelet recruitment [37], the increased MMP-9 expression observed in PR may explain the predominance of red thrombus as MMP-9 indirectly enhances tissue factor activity [38]. Although numerically higher, the post stent atherothrombotic burden was not significantly different between both groups. A recent retrospective OCT study [39] including both STEMI and NSTEMI reported a higher incidence of thrombus after stenting with PR,

even if the thrombus score-based analysis was not significantly different. Their population was different and thrombus volumes were approximately 10 times lower than in our study.

Importantly, our study showed that pre-stenting thrombus' distribution differed according to the causal mechanism. The setting of successful FL allowed a precise evaluation of plaque and thrombus characteristics without the changes in the architecture and the distribution of the plaque and the thrombus generated by balloon predilation or thrombectomy. In case of PR, the thrombus was evenly distributed across and afar the plaque while it remained focal within the minimal lumen area in case of erosion. Eroded plaques expose the underlying collagen as one nidus for thrombus formation [40] leading to a more localized and mural thrombus. The strong pro-thrombotic stimuli associated with PR induce a rapid and important thrombus formation -usually floating into the lumen- which contributes to the thrombus mass spreading. Additionally, the exposure of the plaque content including local inflammatory markers to the blood flow may participate to the thrombus' extension. At the opposite, local thrombospondin-1 release in PE secures platelet tethering and thrombus adherence to injured endothelium [37]. Moreover autopsy studies have shown that more than 88% of coronary thrombi overlying plaque erosions exhibited late stages of healing, compared to 50% in plaque rupture [41]. This suggests repetitive less intense thrombotic stimuli in erosion, which may have left time to thrombus dissolution caused by spontaneous FL or by pharmacological FL in our patients. Then again, post stent atherothrombotic burden distribution was uniformly scattered in both groups, likely as a consequence of similar thrombus-plaque crushing spreading uniformly the atherothrombotic substrate along the stent. Hence pre-stenting but not post-stenting thrombus amount, typesetting and distribution seem to be mainly linked to the underlying mechanism of myocardial infarction. However we found a significant but relatively weak correlation between pre and post-stent thrombotic volume in the overall population as previously reported [6,21]. The precise OCT analysis of the composition of the

in-stent atherothrombotic burden is unreliable as the distinction between atheromatous tissue prolapse and thrombus is practically unfeasible after stenting. The clinical significance and the factors affecting the post-stenting atherothrombotic burden remain to be investigated by further adequately designed studies.

We did not find a significant association between the type of plaque and angiographic reperfusion indices. These results should be tempered by the small sample size and by the fact that all our patients had basal TIMI flow ≥ 2 . Indeed, PR has been reported to be associated with higher risk of distal embolization [39], higher rates of no-reflow phenomenon and impaired TIMI flow and, larger infarct size after FL. Impaired angiographic reperfusion indices have also been reported in patients with greater residual thrombus assessed by OCT after aspiration thrombectomy or after stenting [42,43]. Although our study may have lacked power to detect a significant difference, the numerically greater CTFC in the rupture group - pre and post-stenting- may be considered as consistent with these studies. The larger thrombus extent in PR may also be a potential risk factor for distal embolization after stenting. However one may also speculate that the use of OFDI may have influenced the choice of the diameter and the length of the stents and led to a more optimal plaque covering leading to both similar post-stenting atherothrombotic burden and myocardial reperfusion estimators in our study.

Limits

The findings of our study were based on a small cohort of patients who had successful FL and it may have lacked power to detect differences between some studied parameters. It could be difficult to differentiate PE from severe stenosis using OFDI but thrombus presence highlights an underlying endothelial injury process in this setting. Finally, it is possible that FL may be

more effective on white thrombus mostly caused by erosion. However, the difference of thrombus amount between PR and PE in our cohort is consistent with previous studies without FL.

Conclusion

In the setting of PCI after successful FL for STEMI, the pre-PCI thrombus amount, typesetting and distribution assessed by OFDI seem mainly linked to the underlying mechanism of myocardial infarction. Compared to PE, PR is associated with dominantly red thrombus, higher thrombus burden and a more important longitudinal extent of thrombus across and afar the stenosis. Despite such differences, angiographic estimators of reperfusion and post stenting atherothrombotic burden were similar between the two complicated plaque types.

References article 2:

1. Davies MJ, Thomas A. Thrombosis and acute coronary-artery lesions in sudden cardiac ischemic death. *N Engl J Med.* 1984; 310:1137-40.
2. Michaels AD, Gibson CM, Barron HV. Microvascular dysfunction in acute myocardial infarction: focus on the roles of platelet and inflammatory mediators in the no-reflow phenomenon. *Am J Cardiol.* 2000; 85:50B-60B.
3. Napodano M, Dariol G, Al Mamary AH, et al. Thrombus burden and myocardial damage during primary percutaneous coronary intervention. *Am J Cardiol.* 2014; 113:1449-56.
4. Topol EJ, Yadav JS. Recognition of the importance of embolization in atherosclerotic vascular disease. *Circulation.* 2000; 101:570-80.
5. Kubo T, Imanishi T, Takarada S, et al. Assessment of culprit lesion morphology in acute myocardial infarction: ability of optical coherence tomography compared with intravascular ultrasound and coronary angiography. *J Am Coll Cardiol.* 2007; 50:933-9.
6. Bhindi R, Kajander OA, Jolly SS, et al. Culprit lesion thrombus burden after manual thrombectomy or percutaneous coronary intervention-alone in ST-segment elevation myocardial infarction: the optical coherence tomography sub-study of the TOTAL (ThrOmbecTomy versus PCI ALone) trial. *Eur Heart J.* 2015; 36:1892-900.
7. Higuma T, Soeda T, Abe N, et al. A Combined Optical Coherence Tomography and Intravascular Ultrasound Study on Plaque Rupture, Plaque Erosion, and Calcified Nodule in Patients With ST-Segment Elevation Myocardial Infarction: Incidence, Morphologic Characteristics, and Outcomes After Percutaneous Coronary Intervention. *JACC Cardiovasc Interv.* 2015; 8:1166-76.

8. Ino Y, Kubo T, Tanaka A, et al. Difference of culprit lesion morphologies between ST-segment elevation myocardial infarction and non-ST-segment elevation acute coronary syndrome: an optical coherence tomography study. *JACC Cardiovasc Interv.* 2011; 4:76-82.
9. Wang L, Parodi G, Maehara A, et al. Variable underlying morphology of culprit plaques associated with ST-elevation myocardial infarction: an optical coherence tomography analysis from the SMART trial. *Eur Heart J Cardiovasc Imaging.* 2015; 16:1381-9.
10. Roule V, Ardouin P, Blanchart K, et al. Prehospital fibrinolysis versus primary percutaneous coronary intervention in ST-elevation myocardial infarction: a systematic review and meta-analysis of randomized controlled trials. *Crit Care.* 2016; 20:359.
11. Ibanez B, James S, Agewall S, et al. 2017 ESC Guidelines for the management of acute myocardial infarction in patients presenting with ST-segment elevation: The Task Force for the management of acute myocardial infarction in patients presenting with ST-segment elevation of the European Society of Cardiology (ESC). *Eur Heart J.* 2018; 39:119-77.
12. Eisenberg PR, Sobel BE, Jaffe AS. Activation of prothrombin accompanying thrombolysis with recombinant tissue-type plasminogen activator. *J Am Coll Cardiol.* 1992; 19:1065-9.
13. O'donoghue M, Wiviott SD. Clopidogrel response variability and future therapies: clopidogrel: does one size fit all? *Circulation.* 2006; 114:e600-6.
14. Rasmanis G, Vesterqvist O, Green K, Edhag O, Henriksson P. Evidence of increased platelet activation after thrombolysis in patients with acute myocardial infarction. *Br Heart J.* 1992; 68:374-6.

15. Steg PG, James SK, Atar D, et al. ESC Guidelines for the management of acute myocardial infarction in patients presenting with ST-segment elevation. *Eur Heart J*. 2012; 33:2569-619.
16. Armstrong PW, Gershlick AH, Goldstein P, et al. Fibrinolysis or primary PCI in ST-segment elevation myocardial infarction. *N Engl J Med*. 2013; 368:1379-87.
17. Garcia-Garcia HM, Muramatsu T, Nakatani S, et al. Serial optical frequency domain imaging in STEMI patients: the follow-up report of TROFI study. *Eur Heart J Cardiovasc Imaging*. 2014; 15:987-95.
18. Jang IK, Tearney GJ, Macneill B, et al. In vivo characterization of coronary atherosclerotic plaque by use of optical coherence tomography. *Circulation*. 2005; 111:1551-5.
19. Jia H, Abtahian F, Aguirre AD, et al. In vivo diagnosis of plaque erosion and calcified nodule in patients with acute coronary syndrome by intravascular optical coherence tomography. *J Am Coll Cardiol*. 2013; 62:1748-58.
20. Tearney GJ, Regar E, Akasaka T, et al. Consensus standards for acquisition, measurement, and reporting of intravascular optical coherence tomography studies: a report from the International Working Group for Intravascular Optical Coherence Tomography Standardization and Validation. *J Am Coll Cardiol*. 2012; 59:1058-72.
21. Kajander OA, Koistinen LS, Eskola M, et al. Feasibility and repeatability of optical coherence tomography measurements of pre-stent thrombus burden in patients with STEMI treated with primary PCI. *Eur Heart J Cardiovasc Imaging*. 2015; 16:96-107.

22. Prati F, Capodanno D, Pawlowski T, et al. Local delivery versus intracoronary infusion of abciximab in patients with acute coronary syndromes. *JACC Cardiovasc Interv.* 2010; 3:928-34.
23. Soeda T, Uemura S, Park SJ, et al. Incidence and Clinical Significance of Poststent Optical Coherence Tomography Findings: One-Year Follow-Up Study From a Multicenter Registry. *Circulation.* 2015; 132:1020-9.
24. Gibson CM, De Lemos JA, Murphy SA, et al. Combination therapy with abciximab reduces angiographically evident thrombus in acute myocardial infarction: a TIMI 14 substudy. *Circulation.* 2001; 103:2550-4.
25. Gibson CM, Schomig A. Coronary and myocardial angiography: angiographic assessment of both epicardial and myocardial perfusion. *Circulation.* 2004; 109:3096-105.
26. Falk E, Nakano M, Bentzon JF, Finn AV, Virmani R. Update on acute coronary syndromes: the pathologists' view. *Eur Heart J.* 2013; 34:719-28.
27. Hu S, Yonetsu T, Jia H, et al. Residual thrombus pattern in patients with ST-segment elevation myocardial infarction caused by plaque erosion versus plaque rupture after successful fibrinolysis: an optical coherence tomography study. *J Am Coll Cardiol.* 2014; 63:1336-8.
28. Toutouzas K, Tsiamis E, Karanasos A, et al. Morphological characteristics of culprit atheromatic plaque are associated with coronary flow after thrombolytic therapy: new implications of optical coherence tomography from a multicenter study. *JACC Cardiovasc Interv.* 2010; 3:507-14.
29. Fuster V, Moreno PR, Fayad ZA, Corti R, Badimon JJ. Atherothrombosis and high-risk plaque: part I: evolving concepts. *J Am Coll Cardiol.* 2005; 46:937-54.

30. Badimon L, Vilahur G. Thrombosis formation on atherosclerotic lesions and plaque rupture. *J Intern Med.* 2014; 276:618-32.
31. Fernandez-Ortiz A, Badimon JJ, Falk E, et al. Characterization of the relative thrombogenicity of atherosclerotic plaque components: implications for consequences of plaque rupture. *J Am Coll Cardiol.* 1994; 23:1562-9.
32. Sato Y, Hatakeyama K, Yamashita A, Marutsuka K, Sumiyoshi A, Asada Y. Proportion of fibrin and platelets differs in thrombi on ruptured and eroded coronary atherosclerotic plaques in humans. *Heart.* 2005; 91:526-30.
33. Jia H, Dai J, Hou J, et al. Effective anti-thrombotic therapy without stenting: intravascular optical coherence tomography-based management in plaque erosion (the EROSION study). *Eur Heart J.* 2017; 38:792-800.
34. Nishiguchi T, Tanaka A, Taruya A, et al. Local Matrix Metalloproteinase 9 Level Determines Early Clinical Presentation of ST-Segment-Elevation Myocardial Infarction. *Arterioscler Thromb Vasc Biol.* 2016; 36:2460-7.
35. Sano T, Tanaka A, Namba M, et al. C-reactive protein and lesion morphology in patients with acute myocardial infarction. *Circulation.* 2003; 108:282-5.
36. Chandran S, Watkins J, Abdul-Aziz A, et al. Inflammatory Differences in Plaque Erosion and Rupture in Patients With ST-Segment Elevation Myocardial Infarction. *J Am Heart Assoc.* 2017; 6:
37. Bonnefoy A, Daenens K, Feys HB, et al. Thrombospondin-1 controls vascular platelet recruitment and thrombus adherence in mice by protecting (sub)endothelial VWF from cleavage by ADAMTS13. *Blood.* 2006; 107:955-64.

38. Belaouaj AA, Li A, Wun TC, Welgus HG, Shapiro SD. Matrix metalloproteinases cleave tissue factor pathway inhibitor. Effects on coagulation. *J Biol Chem.* 2000; 275:27123-8.
39. Hu S, Zhu Y, Zhang Y, et al. Management and Outcome of Patients With Acute Coronary Syndrome Caused by Plaque Rupture Versus Plaque Erosion: An Intravascular Optical Coherence Tomography Study. *J Am Heart Assoc.* 2017; 6:e004730.
40. Partida RA, Libby P, Crea F, Jang IK. Plaque erosion: a new in vivo diagnosis and a potential major shift in the management of patients with acute coronary syndromes. *Eur Heart J.* 2018; 39:2070-6.
41. Kramer MC, Rittersma SZ, De Winter RJ, et al. Relationship of thrombus healing to underlying plaque morphology in sudden coronary death. *J Am Coll Cardiol.* 2010; 55:122-32.
42. Higuma T, Soeda T, Yamada M, et al. Does Residual Thrombus After Aspiration Thrombectomy Affect the Outcome of Primary PCI in Patients With ST-Segment Elevation Myocardial Infarction?: An Optical Coherence Tomography Study. *JACC Cardiovasc Interv.* 2016; 9:2002-11.
43. Magro M, Regar E, Gutierrez-Chico JL, et al. Residual atherothrombotic material after stenting in acute myocardial infarction--an optical coherence tomographic evaluation. *Int J Cardiol.* 2013; 167:656-63.

3. Réactivité plaquettaire résiduelle au ticagrelor et à l'aspirine dans l'angioplastie primaire et reperfusion myocardique

Le bénéfice clinique d'un pré traitement par un inhibiteur du P2Y12 dans l'angioplastie primaire reste peu documenté. La relation entre le degré d'inhibition plaquettaire obtenu au moment de l'angioplastie et la reperfusion myocardique –reconnue comme un facteur pronostic majeur- pourrait permettre de mieux appréhender le bénéfice du pré traitement. Nous avons inclus 61 patients pré-traités et chez qui la réactivité plaquettaire au ticagrelor (exprimée en « platelet reaction units » ou PRU) et à l'aspirine (exprimée en « aspirin reaction units » ou ARU) a été mesurée par VerifyNow juste avant l'angioplastie en salle de cathétérisme. L'hyperréactivité plaquettaire au ticagrelor (HPR) et à l'aspirine (HaPR) était définis par un PRU > 208 et un ARU \geq 550, respectivement. Nous avons comparé les patients avec blush myocardique final normal (MBG 3) aux autres. Un MBG normal a été retrouvé chez 28 (46%) patients. Le PRU était significativement plus faible chez ces patients comparativement à ceux ayant un MBG <3 (155.82 ± 90.91 vs 227.42 ± 65.18 ; $p=0.001$). L'ARU moyen n'était pas différent entre les 2 groupes. Une HPR et HaPR ont été observés chez 30 (49.2%) et 11 (18%) patients, respectivement. L'HPR était plus souvent présente dans le groupe avec un MBG<3 (66.7 vs 28.6%; $p=0.003$) mais pas l'HaPR (21.2 vs 14.3%; $p=0.48$). Au total, seule la réactivité plaquettaire au ticagrelor était corrélée à la reperfusion myocardique dans notre étude. Nos données sont en faveur d'un pré traitement par ticagrelor le plus précocement possible dans l'angioplastie primaire.

ARTICLE 3

Residual platelet reactivity after pre-treatment with ticagrelor prior to primary percutaneous coronary intervention is associated with suboptimal myocardial reperfusion.

Roule V, Heudel T, Lemaitre A, Bignon M, Ardouin P, Sabatier R, Blanchart K, Beygui F.

Eur Heart J Acute Cardiovasc Care. 2019 Aug [Epub ahead of print] PMID: 31402681

Abstract

Background: The evidence of a clinical benefit of P2Y12 inhibitor pre-treatment in primary percutaneous coronary intervention (PCI) and the relation between the level of platelet inhibition and myocardial reperfusion with newer potent P2Y12 inhibitors remain unclear. We aimed to assess the relationship between platelet reactivity at the time of primary PCI after pre-treatment with aspirin and ticagrelor and the post-PCI myocardial blush grade (MBG).

Methods: We prospectively included 61 patients. Platelet reaction units for ticagrelor (PRU) and aspirin reaction units (ARU) were measured using the point-of-care test VerifyNow before PCI. The high on-ticagrelor (PRU >208) and on-aspirin (ARU \geq 550) platelet reactivity (HPR and HaPR) were assessed. Patients were divided into two groups according to MBG 3 or <3.

Results: MBG 3 was identified in 28 (46%) patients. Mean PRU was lower in such patients as compared to those with MBG <3 (155.82 ± 90.91 vs 227.42 ± 65.18 ; $p=0.001$) while mean ARU was similar between groups. HPR and HaPR were observed in 30 (49.2%) and 11 patients (18%), respectively. HPR but not HaPR was more frequent in the group with impaired MBG (66.7 vs 28.6%; $p=0.003$ and 21.2 vs 14.3%; $p=0.48$ respectively).

Conclusion: Our study shows that higher PRU and the subsequent HPR at the time of primary PCI, after pretreatment with ticagrelor, are the only correlates of post PCI MBG. These findings support the earliest possible loading with ticagrelor prior to primary PCI.

Introduction

Platelet activity plays a key role in the pathophysiology of ST-segment elevation myocardial infarction (STEMI) [1]. Enhanced platelet reactivity is observed after STEMI [2, 3]. Both the early post-STEMI setting and the high on-treatment platelet reactivity (HPR) tested with clopidogrel are associated with recurrent acute coronary events [4, 5]. On the other hand, the prognostic impact of high on-aspirin platelet reactivity (HaPR) is controversial [6, 7]. Current European guidelines [8] and a position paper of the Acute Cardiovascular Care association [9] state that the earliest administration of aspirin and a potent P2Y12 inhibitor (prasugrel or ticagrelor) may be preferable in STEMI patients treated with primary percutaneous coronary intervention (PCI). While early initiation of a P2Y12 inhibitor is a common practice in Europe, the clinical benefit of such strategy remains unclear.

The prompt restoration of antegrade coronary blood flow in STEMI is necessary but not sufficient to achieve effective myocardial reperfusion. The so-called “no-reflow” phenomenon, is associated with poor left ventricular functional recovery and cardiac mortality [10, 11]. Myocardial reperfusion can be accurately assessed using myocardial blush grade (MBG) [11]. Although there is evidence connecting HPR and adverse outcome, the association between myocardial reperfusion and the degree of platelet inhibition provided by aspirin and new potent P2Y12 inhibitors, at the time of PCI, remains poorly studied in STEMI patients.

Our study aimed to assess the relationship between platelet reactivity at the time of primary PCI after pre-treatment with aspirin and ticagrelor and the post-PCI MBG.

Methods

Study population

We investigated platelet reactivity with VerifyNow® (Accumetrics, San Diego, CA) in the population of the prospective ODIPP study (optical frequency domain imaging-quantified intracoronary thrombus mass during primary percutaneous coronary intervention, relationship with antiplatelet pretreatment effect and impact on myocardial reperfusion) between September 2017 and May 2018. The inclusion criteria were: patient ≥ 18 years admitted to our tertiary center for STEMI, pre-treated (ie at the time of the first medical contact within the ambulance or the emergency room) with aspirin (250 mg i.v. bolus) and ticagrelor (180 mg oral loading dose), successfully treated by primary PCI of a native coronary culprit lesion. Exclusion criteria were: use of glycoprotein IIb/IIIa inhibitors before or during PCI, known hematocrit $< 30\%$ or thrombocytopenia $< 100.000/dL$, oral anticoagulation, cardiogenic shock, stent thrombosis or restenosis and severe renal insufficiency (estimated glomerular filtration rate (eGFR) $< 30mL/min$). Anticoagulation was performed with enoxaparin as recommended in our regional STEMI network protocol.

All patients provided written informed consent and the study was approved by the local ethics committee. The study is registered on ClinicalTrials.gov under the identifier NCT03342521.

VerifyNow (VN) P2Y12 and Aspirin

Blood samples were drawn on arrival at the cath lab directly from the arterial sheath for the assessment of platelet reactivity as well as usual biological parameters based on our routine practice. For VN measurements, blood samples were collected in vacutainer® (Becton-Dickinson, San Jose, CA) tubes containing sodium citrate 3.2% and analyzed within 2 hours after extraction. A second VN P2Y12 test was performed at day 1 on a sample drawn by

venipuncture, after a 5 ml discard sample to avoid spontaneous platelet activation. The VN assay is a whole-blood, cartridge-based, light transmission-based optical detection system designed to measure platelet aggregation. The method has been described elsewhere [12]. Results from the VN P2Y12-assay are reported as P2Y12 reaction units (PRU) and percent inhibition and, a baseline value (BASE) for platelet function, claimed by the manufacturer to be independent of the level of P2Y12 blockade. The percent inhibition is calculated as: $[(1 - \text{PRU}/\text{BASE}) \times 100]$. HPR was defined as a PRU > 208 [5, 13]. A second cartridge was used to measure the response to aspirin, expressed as aspirin reaction units (ARU). HaPR was defined as an ARU \geq 550 [5].

Angiographic analysis

Coronary angiograms were analyzed by two operators before PCI and at the end of the procedure to evaluate basal and post-PCI Thrombolysis in Myocardial Infarction (TIMI) flow grade, pre-PCI angiographic thrombus grade, post-PCI MBG and corrected TIMI frame count (CTFC), on angiography at 30 frames/sec using the best projection to assess the myocardial region of the infarct-related coronary artery, as previously described [14, 15]. Angiographic runs had to be long enough to allow filling of the venous coronary system. MBG were defined as follows: 0 = no myocardial blush (ground glass appearance) or contrast density which means that contrast fails to enter the microvasculature; 1 = minimal myocardial blush; 2 = moderate myocardial blush but less than that obtained during angiography of a contralateral or ipsilateral non–infarct-related coronary artery; and 3 = normal myocardial blush or contrast density, comparable with that obtained during angiography of a contralateral or ipsilateral non–infarct-related coronary artery. MBG 3 corresponds to a normal entry and exit of contrast from the microvasculature.

Since in angiographic thrombus score grade 5 there is total occlusion, patients initially presenting in this group were reclassified into one of the other four categories after vessel recanalization by either wire crossing or passage/dilatation of a small (1.5-mm diameter) balloon to correctly assess thrombus burden. In case of discordance a third operator's evaluation was considered to reach consensus.

Statistical analysis

Patients were separated into two groups defined by final MBG equal or inferior to 3. Continuous variables were expressed as mean \pm standard deviation and compared between groups using Student's t test after visual assessment of normality of distribution. Categorical variables were expressed as numbers of patients and percentages and compared between groups using The Chi-Squared test. A post hoc analysis using a logistic regression model adjusted on variables differently distributed between the two groups further assessed the relationship of platelet reactivity with MBG. A P-value of < 0.05 was considered statistically significant. R software version 3.5.2 for MacOS (R Foundation for Statistical Computing) was used for statistical analysis.

Results

A total of 63 patients fulfilled the inclusion criteria but two were excluded from the analysis because of poor image quality to assess final MBG. Finally, 61 patients were included in the analysis, 28 (46%) with final MBG 3 and 33 (54%) with MBG <3.

Baseline demographic characteristics (detailed in Table 1) were comparable between groups, except for heart rate which was higher in the MBG 3 group ($p=0.02$). Patients with a MBG 3 had higher rates of basal and final TIMI 3 flow grade (36% vs 9%; $p=0.01$ and 100% vs 63.6%; $p=0.0004$ respectively) than those with suboptimal reperfusion.

The mean PRU was significantly lower in the group with MBG 3 as compared to the group with MBG <3 (155.82 ± 90.91 vs 227.42 ± 65.18 ; $p=0.001$; Figure 1) but mean ARU did not significantly differ between groups (Table 2). After adjustment on heart rate and rates of basal TIMI 3 flow, the relationship between PRU and MBG remained statistically significant ($p=0.01$)

Based on the binary cutoff of PRU and ARU, HPR and HaPR were observed in 30 (49.2%) and 11 patients (18%), respectively. Rates of HPR but not HaPR were higher in the group with impaired MBG ($p=0.003$ and $p=0.48$ respectively). When considering the 55 patients who had PCI within 2 hours following ticagrelor loading dose, HPR was present in 29 (52.7%) and HaPR in 9 (16.4%). At day 1, no patient had HPR.

Table 1: Baseline characteristics of the study population

Baseline patients characteristics	All n=61 (100%)	Final Blush <3 n=33 (54%)	Final Blush 3 n=28 (46%)	p
Age (years)	60.3 ± 10.52	59.94 ± 11.87	60.71 ± 8.87	0.77
Men	49 (80%)	24 (72.7%)	25 (89.3%)	0.10
Body mass index (kg/m ²)	26.77 ± 4.32	26.98 ± 4.67	26.53 ± 3.94	0.68
Systemic hypertension	19 (31%)	10 (30.3%)	9 (32.1%)	0.87
Hyperlipidemia	21 (34%)	12 (36.4%)	9 (32.1%)	0.72
Active smoker	32 (52%)	18 (54.5%)	14 (50%)	0.72
Diabetes mellitus	5 (8%)	2 (6.1%)	3 (10.7%)	0.50
History of myocardial infarction	5 (8%)	3 (9.1%)	2 (7.1%)	0.78
History of PCI	4 (7%)	2 (6.1%)	2 (7.1%)	0.86
Morphine use	24 (39%)	15 (45.5%)	9 (32.1%)	0.29
Cardiac arrest before PCI	3 (5%)	2 (6.1%)	1 (3.6%)	0.65
Systolic blood pressure (mmHg)	131.69 ± 28.67	132.09 ± 28.69	131.21 ± 29.18	0.90
Diastolic blood pressure (mmHg)	78.61 ± 14.86	77.39 ± 14.86	80.04 ± 15	0.49
Heart rate (bpm)	74.79 ± 17.06	69.91 ± 15.24	80.54 ± 17.54	0.02
Timepoints (min)				
Pain to PCI	260 ± 180.58	258.91 ± 185	261.29 ± 178.6	0.95
Pain to ticagrelor loading dose	177.1 ± 163.6	177.3 ± 182.79	176.75 ± 140.97	0.99
ECG to PCI	105.38 ± 77.16	103.09 ± 48.42	108.07 ± 102.16	0.81
Ticagrelor loading dose to PCI	82.95 ± 72.9	81.61 ± 40.66	84.54 ± 99.22	0.88
Admission biological characteristics				
Creatinine (μmol/L)	72.21 ± 16.78	73.79 ± 15.16	70.36 ± 18.63	0.43
C reactive protein (mg/L)	5.28 ± 14.63	2.62 ± 3.54	8.36 ± 20.97	0.18
Troponin (pg/mL)	39.86 ± 28.12	39.67 ± 27.47	40.07 ± 29.39	0.95
Hemoglobin (g/dL)	14.39 ± 1.4	14.38 ± 1.26	14.4 ± 1.58	0.95
Hematocrit (%)	42.63 ± 3.69	42.51 ± 3.48	42.77 ± 3.98	0.78
Prothrombin rate (%)	94.66 ± 6.71	94.58 ± 6.77	94.75 ± 6.76	0.92
aPTT, seconds	1.19 ± 0.29	1.16 ± 0.21	1.23 ± 0.36	0.40
Enoxaparin Anti-Xa (IU/mL)	0.68 ± 0.36	0.64 ± 0.28	0.73 ± 0.45	0.44
Angiographic characteristics				
Culprit coronary artery				
Right coronary artery	27 (44%)	14 (42.4%)	13 (46.4%)	0.75
Left anterior descending artery	24 (39%)	13 (39.4%)	11 (39.3%)	0.99
Left circumflex artery	10 (16%)	6 (18.2%)	4 (14.3%)	0.68
Thrombus aspiration	9 (15%)	6 (18.2%)	3 (10.7%)	0.41
Stent diameter (mm)	3.01 ± 0.46	3 ± 0.48	3.02 ± 0.45	0.85
Total stent length (mm)	29.38 ± 11.27	29.39 ± 11.4	29.36 ± 11.31	0.98
Balloon dilation post PCI	46 (75%)	27 (81.8%)	19 (67.9%)	0.20
Basal TIMI flow grade				
Grade 0	30 (49%)	19 (57.6%)	11 (39.3%)	0.15
Grade 1	9 (15%)	5 (15.2%)	4 (14.3%)	0.92
Grade 2	9 (15%)	6 (18.2%)	3 (10.7%)	0.41
Grade 3	13 (21%)	3 (9.1%)	10 (35.7%)	0.01
Angiographic thrombus grade				
Grade 0	2 (3%)	0 (0%)	2 (7.1%)	0.11
Grade 1	20 (23%)	9 (27.3%)	11 (39.3%)	0.31
Grade 2	10 (16%)	7 (21.2%)	3 (10.7%)	0.26
Grade 3	17 (28%)	9 (27.3%)	8 (28.6%)	0.91
Grade 4	12 (20%)	8 (24.2%)	4 (14.3%)	0.32
Grade 5	30 (49%)	19 (57.6%)	11 (39.3%)	0.15
Final TIMI flow grade				
Grade 2	14 (23%)	13 (39.4%)	0 (0%)	0.0002
Grade 3	48 (79%)	21 (63.6%)	28 (100%)	0.0004
Final corrected TIMI frame count	40.34 ± 17.85	46.82 ± 19.15	32.71 ± 12.73	0.0011

aPPT=activated partial thromboplastin time; ECG=electrocardiogram ; PCI=percutaneous coronary intervention

Table 2: Platelet reactivity

Verify Now at admission	All n=61 (100%)	Final Blush <3 n=33 (54%)	Final Blush 3 n=28 (46%)	p
PRU P2Y12	194.56 ± 85.32	227.42 ± 65.18	155.82 ± 90.91	0.001
Base	193.54 ± 49.01	194.79 ± 45.68	192.07 ± 53.48	0.83
Inhibition of platelet aggregation (%)	15.61 ± 29.85	5.7 ± 17.55	27.29 ± 36.79	0.007
ARU	463.97 ± 76.45	472.58 ± 72.5	453.82 ± 81	0.34
PRU >208	30 (49.1%)	22 (66.7%)	8 (28.6%)	0.003
ARU ≥ 550	11 (18%)	7 (21.2%)	4 (14.3%)	0.48
Verify Now at day 1	n=57	n=30	n=27	p
PRU P2Y12	40.86 ± 41.43	47.27 ± 45.87	33.74 ± 35.35	0.21
Base	196.98 ± 36.19	193.67 ± 30.67	200.81 ± 41.97	0.47
Inhibition of platelet aggregation (%)	79.8 ± 17.96	76.37 ± 20.54	83.77 ± 13.78	0.11

ARU=Aspirin reaction units; PRU=P2Y12 reaction units

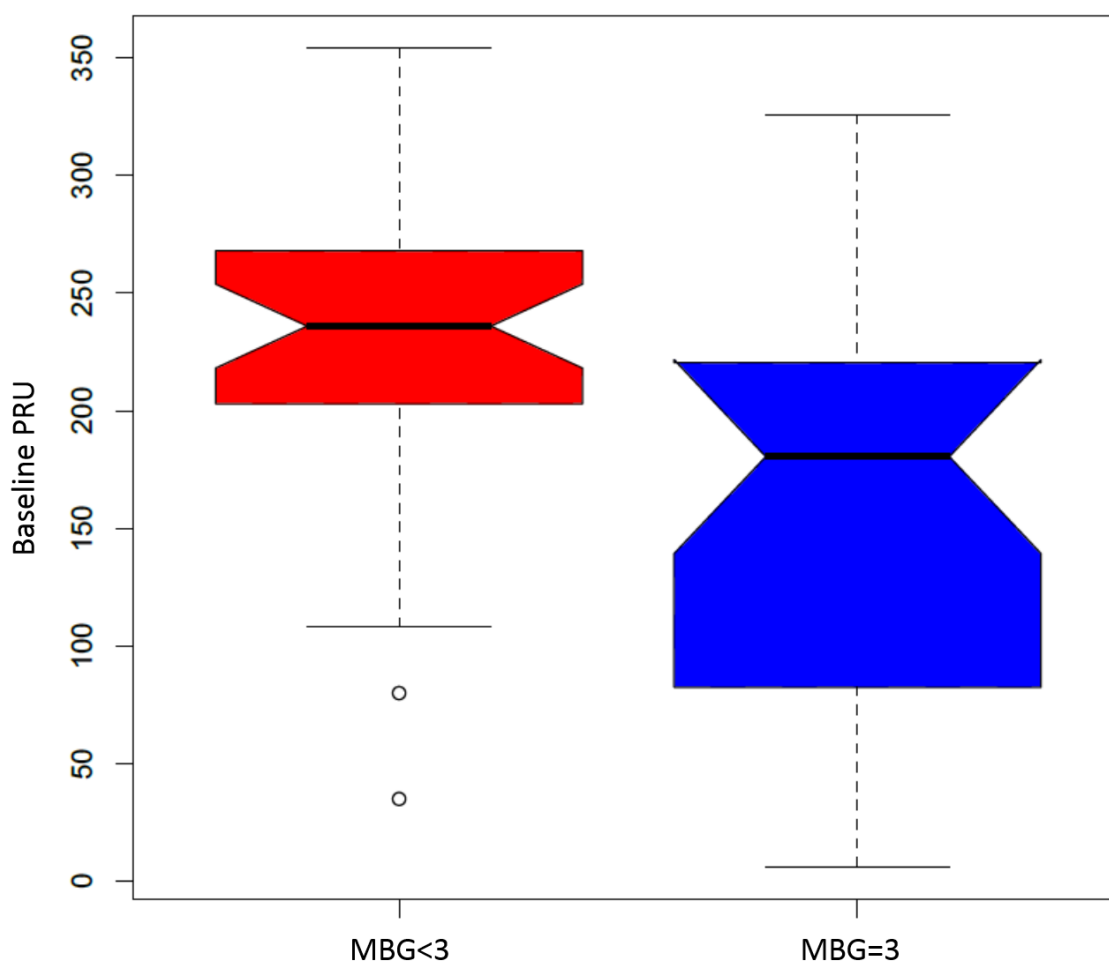


Figure 1: Baseline PRU levels according to final myocardial blush grade (MBG).

Discussion

Our study found that HPR and HaPR remain common at the time of primary PCI in STEMI patients pre-treated with ticagrelor and aspirin. Lower PRU at the time of primary PCI in such patients is a correlate of improved myocardial reperfusion as assessed by MBG. HPR, but not HaPR, is associated with impaired myocardial reperfusion.

Current European guidelines [8] state that the earliest administration of aspirin and a potent P2Y12 inhibitor may be preferable in STEMI patients treated with primary PCI. But there is still limited evidence to when the P2Y12 inhibitor should be initiated in these patients. The ATLANTIC study [16] showed that pre-hospital vs in-hospital administration of ticagrelor was not associated with an improvement of pre- nor post-PCI coronary reperfusion as assessed by the TIMI flow grade. But there was a trend towards higher rates of ST-segment elevation resolution $\geq 70\%$ after PCI ($p=0.05$), an electrocardiogram sign of myocardial reperfusion, in the pre-hospital group. Our study showed a negative association between HPR and myocardial reperfusion among patients pretreated by ticagrelor. A previous study in STEMI patients treated with clopidogrel [17] reported that patients with final MBG 3 had lower PRU levels compared to those with impaired MBG. Importantly, only patients that had a first medical contact to balloon time $>2h$ were included in their study. HPR was associated with lower pre-PCI coronary patency in two other studies after clopidogrel [18] or any of the oral P2Y12 antagonists [19] pretreatment. However, none reported a significant association between HPR and MBG, even if the only study including new potent P2Y12 inhibitors [19] found a trend ($p=0.08$) towards such association in a subgroup of patients tested using light transmission aggregometry. The longer transfer times, and the subsequent longer interval between P2Y12 inhibitor loading and PCI in our study, may explain these differences. In the same way, the proportion of patients with HPR was lower in our study (49.2% vs 71.3 to 88%). We did not include patients pre-treated with clopidogrel which has a known variability

of platelet response and slow onset of action [20]. Moreover, the previous studies [18, 19] used several anticoagulant regimens -mostly unfractionated heparin- which may have impacted their results. The lack of benefit of pre-treatment in the ATLANTIC trial may be explained by the very small difference in the loading doses to PCI time between the two groups, possibly insufficient to generate a significant difference in the level of platelet inhibition. Our findings suggest that adequate level of P2Y12-mediated platelet inhibition at the time of PCI may be beneficial, especially when transfer times are longer, as it is in semi-rural regions like ours, and supports early loading with a potent P2Y12 inhibitor in primary PCI.

The negative association between HPR and myocardial reperfusion may be related to the higher risk of thrombus embolization. Large thrombus burden assessed angiographically prior to PCI -associated with higher risk of distal embolization- has been reported to be also correlated with higher PRU levels [17, 19]. Distal embolization is also associated with enhanced platelet-induced vasospasm [21] which participates to microvascular obstruction and altered myocardial reperfusion.

In our study rates of HaPR (18%) were much lower than HPR and HaPR was not associated with the quality of myocardial reperfusion. This is in concordance with previous reports in patients treated with clopidogrel and aspirin [17, 18]. Post-STEMI setting is associated with increased residual platelet reactivity [2] and the rates of HaPR are reported to be more than twice higher in patients with STEMI compared to those with stable coronary artery disease [22]. The rates of HaPR in our study may be explained by the systematic use of intravenous loading dose of aspirin as both high loading doses [23, 24] and intravenous administration of aspirin [7] are associated with reduced incidence of HaPR. Additionally, the estimation of HaPR is assay-dependent and lower with assays using arachidonic acid [23] to stimulate platelet aggregation such as VerifyNow. However VerifyNow Aspirin is the most

reproducible and the only assay significantly correlated with serum thromboxane levels when comparing different platelet function tests[25]. The rates of HaPR in our study are concordant with previous studies in STEMI patients [7, 26]. Although the above-mentioned considerations and our sample size may have weakened a possible correlation between MBG and HaPR, other studies in the setting of primary PCI for STEMI also reported no difference in terms of post-PCI TIMI flow grade and distal embolization between “poor” and “good” responders to aspirin [27]. However good responders in the latter study were more likely to have ST-segment resolution of 70%, suggestive of better myocardial reperfusion but overall, the prognostic impact of HaPR after PCI remains controversial [6, 7, 28, 29]. Different study designs, timing of blood sampling and different assays used may explain these discrepancies between studies. The ADAPT-DES trial that included the largest cohort of patients with acute coronary syndrome, reported no relationship between HaPR and adverse clinical outcomes [6].

We found that patients with a MBG 3 had higher rates of basal and final TIMI 3 flow grades. This could question the choice of MBG as the main outcome parameter. The positive correlation between MBG and TIMI flow is already reported [11] but as outlined by our results, some patients presented final TIMI 3 flow grade yet abnormal MBG. Indeed, restoration of epicardial flow does not systematically lead to restoration of microvascular perfusion. Hence a further differentiation among patients with TIMI 3 flow is needed. Higher MBG has been associated with lower infarct size, higher left ventricular ejection fraction and decreased long-term mortality independently of TIMI 3 flow [11]. Knowing this gradual correlation, we compared patients with normal MBG to the others. We did not find a relationship between angiographic thrombus and MBG, unlike a previous study [30]. Different populations, antiplatelet regimens and the limits of angiography to detect thrombus may explain such differences.

Our study shows that despite the use of the more potent P2Y12 inhibitor ticagrelor [31], half of the patients presented HPR at the time of primary PCI as previously described [32]. Enhanced residual platelet reactivity may be due to the high degree of platelet activation observed in STEMI [33] but also to the possible delayed absorption of orally administered P2Y12 inhibitors in this setting [32]. Based on our results, platelet reactivity testing to tailor additional platelet inhibitors use, especially with rapid on-and-offset-agents such as intravenous antagonist of the P2Y12 receptor or Glycoprotein IIb/IIIa inhibitors, may be considered in future studies assessing optimization of myocardial reperfusion and its clinical impact. Our findings plead for loading with a potent P2Y12 inhibitor in STEMI as soon as possible. The crushed administration of ticagrelor providing earlier efficient platelet inhibition [34] may be useful if its benefit is demonstrated by further studies.

Limits

The findings of our study were based on a small cohort of patients and may have lacked power to detect differences between some studied parameters. Our conclusions are restricted to patients pre-treated with ticagrelor. Our center is the reference center of a semi-rural region with transfer times around 100 minutes and the results may not apply to centers with much shorter transfer times.

Conclusion

HPR and HaPR remain common at the time of primary PCI in STEMI patients pre-treated with ticagrelor and aspirin. Our results show that higher PRU and the subsequent HPR, but not HaPR, are associated with suboptimal myocardial reperfusion in this setting. Such findings support the use of potent P2Y12 inhibitors as soon as possible in primary PCI.

References article 3:

1. Ruggeri ZM. Platelets in atherothrombosis. *Nat Med.* 2002; 8:1227-34.
2. Althoff TF, Fischer M, Langer E, Ziemer S, Baumann G. Sustained enhancement of residual platelet reactivity after coronary stenting in patients with myocardial infarction compared to elective patients. *Thromb Res.* 2010; 125:e190-6.
3. Geisler T, Kapp M, Gohring-Frischholz K, et al. Residual platelet activity is increased in clopidogrel- and ASA-treated patients with coronary stenting for acute coronary syndromes compared with stable coronary artery disease. *Heart.* 2008; 94:743-7.
4. Price MJ, Angiolillo DJ, Teirstein PS, et al. Platelet reactivity and cardiovascular outcomes after percutaneous coronary intervention: a time-dependent analysis of the Gauging Responsiveness with a VerifyNow P2Y12 assay: Impact on Thrombosis and Safety (GRAVITAS) trial. *Circulation.* 2011; 124:1132-7.
5. Stone GW, Witzenbichler B, Weisz G, et al. Platelet reactivity and clinical outcomes after coronary artery implantation of drug-eluting stents (ADAPT-DES): a prospective multicentre registry study. *Lancet.* 2013; 382:614-23.
6. Chung CJ, Kirtane AJ, Zhang Y, et al. Impact of high on-aspirin platelet reactivity on outcomes following successful percutaneous coronary intervention with drug-eluting stents. *Am Heart J.* 2018; 205:77-86.
7. Gori AM, Grifoni E, Valenti R, et al. High on-aspirin platelet reactivity predicts cardiac death in acute coronary syndrome patients undergoing PCI. *Eur J Intern Med.* 2016; 30:49-54.
8. Ibanez B, James S, Agewall S, et al. 2017 ESC Guidelines for the management of acute myocardial infarction in patients presenting with ST-segment elevation: The Task Force for

the management of acute myocardial infarction in patients presenting with ST-segment elevation of the European Society of Cardiology (ESC). *Eur Heart J*. 2018; 39:119-77.

9. Beygui F, Castren M, Brunetti ND, et al. Pre-hospital management of patients with chest pain and/or dyspnoea of cardiac origin. A position paper of the Acute Cardiovascular Care Association (ACCA) of the ESC. *Eur Heart J Acute Cardiovasc Care*. 2015;

10. Morishima I, Sone T, Okumura K, et al. Angiographic no-reflow phenomenon as a predictor of adverse long-term outcome in patients treated with percutaneous transluminal coronary angioplasty for first acute myocardial infarction. *J Am Coll Cardiol*. 2000; 36:1202-9.

11. Van 'T Hof AW, Liem A, Suryapranata H, Hoorntje JC, De Boer MJ, Zijlstra F. Angiographic assessment of myocardial reperfusion in patients treated with primary angioplasty for acute myocardial infarction: myocardial blush grade. Zwolle Myocardial Infarction Study Group. *Circulation*. 1998; 97:2302-6.

12. Luo Y, Li J, Liu X, et al. Combination of P2Y₁₂ reaction unit and percentage of platelet inhibition assessed by VerifyNow P2Y₁₂ assay is a useful predictor of long-term clinical outcomes in patients with acute coronary syndrome undergoing percutaneous coronary intervention. *Thromb Res*. 2016; 139:114-20.

13. Tantry US, Bonello L, Aradi D, et al. Consensus and update on the definition of on-treatment platelet reactivity to adenosine diphosphate associated with ischemia and bleeding. *J Am Coll Cardiol*. 2013; 62:2261-73.

14. Gibson CM, De Lemos JA, Murphy SA, et al. Combination therapy with abciximab reduces angiographically evident thrombus in acute myocardial infarction: a TIMI 14 substudy. *Circulation*. 2001; 103:2550-4.

15. Gibson CM, Schomig A. Coronary and myocardial angiography: angiographic assessment of both epicardial and myocardial perfusion. *Circulation*. 2004; 109:3096-105.
16. Montalescot G, Van 'T Hof AW, Lapostolle F, et al. Prehospital ticagrelor in ST-segment elevation myocardial infarction. *N Engl J Med*. 2014; 371:1016-27.
17. Vavuranakis M, Vrachatis DA, Papaioannou TG, et al. Residual platelet reactivity after clopidogrel loading in patients with ST-elevation myocardial infarction undergoing an unexpectedly delayed primary percutaneous coronary intervention. - Impact on intracoronary thrombus burden and myocardial perfusion. *Circ J*. 2011; 75:2105-12.
18. Ferreiro JL, Homs S, Berdejo J, et al. Clopidogrel pretreatment in primary percutaneous coronary intervention: prevalence of high on-treatment platelet reactivity and impact on preprocedural patency of the infarct-related artery. *Thromb Haemost*. 2013; 110:110-7.
19. Capranzano P, Capodanno D, Bucciarelli-Ducci C, et al. Impact of residual platelet reactivity on reperfusion in patients with ST-segment elevation myocardial infarction undergoing primary percutaneous coronary intervention. *Eur Heart J Acute Cardiovasc Care*. 2016; 5:475-86.
20. O'donoghue M, Wiviott SD. Clopidogrel response variability and future therapies: clopidogrel: does one size fit all? *Circulation*. 2006; 114:e600-6.
21. Huczek Z, Filipiak KJ, Kochman J, et al. Baseline platelet reactivity in acute myocardial infarction treated with primary angioplasty--influence on myocardial reperfusion, left ventricular performance, and clinical events. *Am Heart J*. 2007; 154:62-70.
22. Poulsen TS, Jorgensen B, Korsholm L, Licht PB, Haghfelt T, Mickley H. Prevalence of aspirin resistance in patients with an evolving acute myocardial infarction. *Thromb Res*. 2007; 119:555-62.

23. Gurbel PA, Bliden KP, Dichiara J, et al. Evaluation of dose-related effects of aspirin on platelet function: results from the Aspirin-Induced Platelet Effect (ASPECT) study. *Circulation*. 2007; 115:3156-64.
24. Santos MT, Madrid I, Moscardo A, et al. The administration of a loading dose of aspirin to patients presenting with acute myocardial infarction while receiving chronic aspirin treatment reduces thromboxane A2-dependent platelet reactivity. *Platelets*. 2014; 25:268-73.
25. Grove EL, Hvas AM, Johnsen HL, et al. A comparison of platelet function tests and thromboxane metabolites to evaluate aspirin response in healthy individuals and patients with coronary artery disease. *Thromb Haemost*. 2010; 103:1245-53.
26. Godschalk TC, Byrne RA, Adriaenssens T, et al. Observational Study of Platelet Reactivity in Patients Presenting With ST-Segment Elevation Myocardial Infarction Due to Coronary Stent Thrombosis Undergoing Primary Percutaneous Coronary Intervention: Results From the European PREvention of Stent Thrombosis by an Interdisciplinary Global European Effort Registry. *JACC Cardiovasc Interv*. 2017; 10:2548-56.
27. Fefer P, Beigel R, Varon D, et al. Bimodal response to aspirin loading in acute ST-elevation myocardial infarction. *Platelets*. 2013; 24:435-40.
28. Chen WH, Lee PY, Ng W, Tse HF, Lau CP. Aspirin resistance is associated with a high incidence of myonecrosis after non-urgent percutaneous coronary intervention despite clopidogrel pretreatment. *J Am Coll Cardiol*. 2004; 43:1122-6.
29. Mayer K, Bernlochner I, Braun S, et al. Aspirin treatment and outcomes after percutaneous coronary intervention: results of the ISAR-ASPI registry. *J Am Coll Cardiol*. 2014; 64:863-71.

30. Kirtane AJ, Vafai JJ, Murphy SA, et al. Angiographically evident thrombus following fibrinolytic therapy is associated with impaired myocardial perfusion in STEMI: a CLARITY-TIMI 28 substudy. *Eur Heart J.* 2006; 27:2040-5.
31. Storey RF, Angiolillo DJ, Patil SB, et al. Inhibitory effects of ticagrelor compared with clopidogrel on platelet function in patients with acute coronary syndromes: the PLATO (PLATElet inhibition and patient Outcomes) PLATELET substudy. *J Am Coll Cardiol.* 2010; 56:1456-62.
32. Parodi G, Valenti R, Bellandi B, et al. Comparison of prasugrel and ticagrelor loading doses in ST-segment elevation myocardial infarction patients: RAPID (Rapid Activity of Platelet Inhibitor Drugs) primary PCI study. *J Am Coll Cardiol.* 2013; 61:1601-6.
33. Gawaz M, Neumann FJ, Ott I, Schiessler A, Schomig A. Platelet function in acute myocardial infarction treated with direct angioplasty. *Circulation.* 1996; 93:229-37.
34. Parodi G, Xanthopoulos I, Bellandi B, et al. Ticagrelor crushed tablets administration in STEMI patients: the MOJITO study. *J Am Coll Cardiol.* 2015; 65:511-2.

4. Charge athérombotique résiduelle évaluée en OFDI et reperfusion myocardique dans l'angioplastie primaire

La présence d'une protrusion athérombotique résiduelle intrastent est quasi systématiquement retrouvée dans la cadre des IDM ST+. Cependant la relation entre cette charge athérombotique (CAT) et la reperfusion myocardique reste mal définie dans le contexte de l'angioplastie primaire, en particulier avec les récents inhibiteurs du P2Y12. Il existe différentes méthodes de quantification de cette CAT rapportées en OCT ou OFDI. Soixante patients pré-traités par aspirine et ticagrelor avec analyse OFDI de la CAT ont été inclus. Une quantification volumétrique utilisant la planimétrie (avec une analyse à chaque coupe et une autre à chaque millimètre) et un score semi-quantitatif ont été utilisés pour quantifier la CAT. La CAT moyenne était de $10.08 \pm 5.21\%$. Cette CAT était significativement plus faible chez les patients ayant un blush myocardique final normal en comparaison à ceux ayant un blush <3 quel que soit la méthode de quantification utilisée (8.15 ± 5.58 vs $11.77 \pm 4.28 \%$; $p=0.007$ pour la quantification par coupe; 7.8 ± 5.19 vs $11.07 \pm 4.07 \%$; $p=0.009$ pour la quantification par mm et 11.21 ± 11.75 vs 22.91 ± 17.35 ; $p=0.003$ pour le score semi-quantitatif, respectivement). Au final, la CAT reste substantielle en post angioplastie primaire, même avec un pré-traitement par aspirine et ticagrelor. Cette CAT est corrélée à la reperfusion myocardique qui est un marqueur pronostique reconnu.

ARTICLE 4

Residual atherothrombotic burden after primary percutaneous coronary intervention and myocardial reperfusion-An optical frequency domain imaging study.

Roule V, Schwob L, Lemaitre A, Bignon M, Ardouin P, Sabatier R, Blanchart K, Beygui F.

Catheter Cardiovasc Interv. 2019 Aug 13. [Epub ahead of print] PMID: 31410965

Abstract

Objectives: We aimed to assess the relationship between residual in-stent atherothrombotic burden (ATB) after primary percutaneous coronary intervention (PCI) measured by optical frequency domain imaging (OFDI) using different measurement methods and myocardial blush grade (MBG).

Background: The impact of residual ATB after primary PCI on myocardial reperfusion remains unclear.

Methods: We prospectively included 60 ST-elevation myocardial infarction patients pre-treated with aspirin and ticagrelor. OFDI volumetric quantification using planimetry (with intervals every frame or every millimeter) and semi-quantitative score were used to determine ATB. Patients were divided into two groups according to final MBG 3 or <3.

Results: The mean ATB was $10.08 \pm 5.21\%$. ATB was lower in patients with final MBG 3 compared to those with impaired MBG, regardless of the measurement method (8.15 ± 5.58 vs $11.77 \pm 4.28\%$; $p=0.007$ for quantification per frame; 7.8 ± 5.19 vs $11.07 \pm 4.07\%$; $p=0.009$ for quantification per mm and 11.21 ± 11.75 vs 22.91 ± 17.35 ; $p=0.003$ for the semi-quantitative thrombus score, respectively).

Conclusion: Residual post-stenting ATB remains substantial after primary PCI in STEMI patients, even when pre-treated with ticagrelor and aspirin. ATB appears as a significant correlate of suboptimal myocardial reperfusion, a known surrogate of clinical outcome.

Introduction

Percutaneous coronary intervention (PCI) leads to plaque protrusion between stent struts in nearly all patients as initially observed in histopathological studies [1, 2]. Thrombus is also commonly identified around stent struts, especially early after stenting. Optical coherence tomography (OCT) and optical frequency domain imaging (OFDI) provide high resolution imaging allowing more accurate identification and quantification of intracoronary plaque burden and thrombus [3] as compared to other intravascular imaging modalities [4]. Residual in-stent atherothrombotic burden (ATB) has been previously reported using OCT in most patients both in the setting of stable coronary artery disease and myocardial infarction [5-8]. The clinical significance of these OCT findings remains unclear [5, 7, 9-11]. Moreover, the different methods for ATB quantification used in different studies may be a source of variability [8, 12-15]. Comparisons of these methods also remain limited [16, 17].

The prompt restoration of antegrade coronary blood flow in ST-Elevation Myocardial Infarction (STEMI) is necessary but not sufficient to achieve effective myocardial reperfusion. The so-called “no-reflow” phenomenon, an open epicardial artery without flow into the myocardium, predicts poor left ventricular functional recovery, larger infarct size and mortality [18, 19]. Myocardial reperfusion can be accurately assessed using myocardial blush grade (MBG) [19]. The association between the amount of residual in-stent ATB and myocardial reperfusion has not been assessed in the era of potent P2Y12 inhibitors.

Our study aimed to assess the relationship between MBG and in-stent ATB measured by OFDI using different methods in STEMI patients pre-treated with ticagrelor and aspirin.

Materials and Methods

Study population

We investigated patients enrolled in the prospective ODIPP study (optical frequency domain imaging-quantified intracoronary thrombus mass during primary percutaneous coronary intervention, relationship with antiplatelet pretreatment effect and impact on myocardial reperfusion) between September 2017 and May 2018. The inclusion criteria were: patient ≥ 18 years admitted to our tertiary center for STEMI pre-treated with aspirin (250 mg i.v. bolus) and ticagrelor (180 mg oral loading dose), successfully treated by primary PCI of a native coronary culprit lesion, with post-PCI OFDI imaging (Lunawave®, FastView®, Terumo Europe, Leuven, Belgium). Exclusion criteria were: use of glycoprotein IIb/IIIa inhibitors before or during PCI, known hematocrit $< 30\%$ or thrombocytopenia $< 100.000/dL$, oral anticoagulation, cardiogenic shock, stent thrombosis or restenosis and severe renal insufficiency (estimated glomerular filtration rate (eGFR) $< 30mL/min$). Anticoagulation was performed with enoxaparin as recommended in our regional STEMI network protocol. Intracoronary vasodilators (isosorbide dinitrate, 0.5 to 1 mg) were administrated before OFDI and final MBG analysis.

All patients provided written informed consent and the study was approved by the local ethics committee. The study is registered on ClinicalTrials.gov under the identifier NCT03342521.

OFDI image analysis

The OFDI procedure was performed as previously described [12]. The images were analyzed by 2 investigators (VR and LS) using previously validated criteria [3]. For the ATB quantification, the whole stented segment was analyzed at each frame on post-PCI images.

ATB included tissue prolapse and thrombus, either attached to the vessel wall or the struts or floating in the arterial lumen (Figure 1).

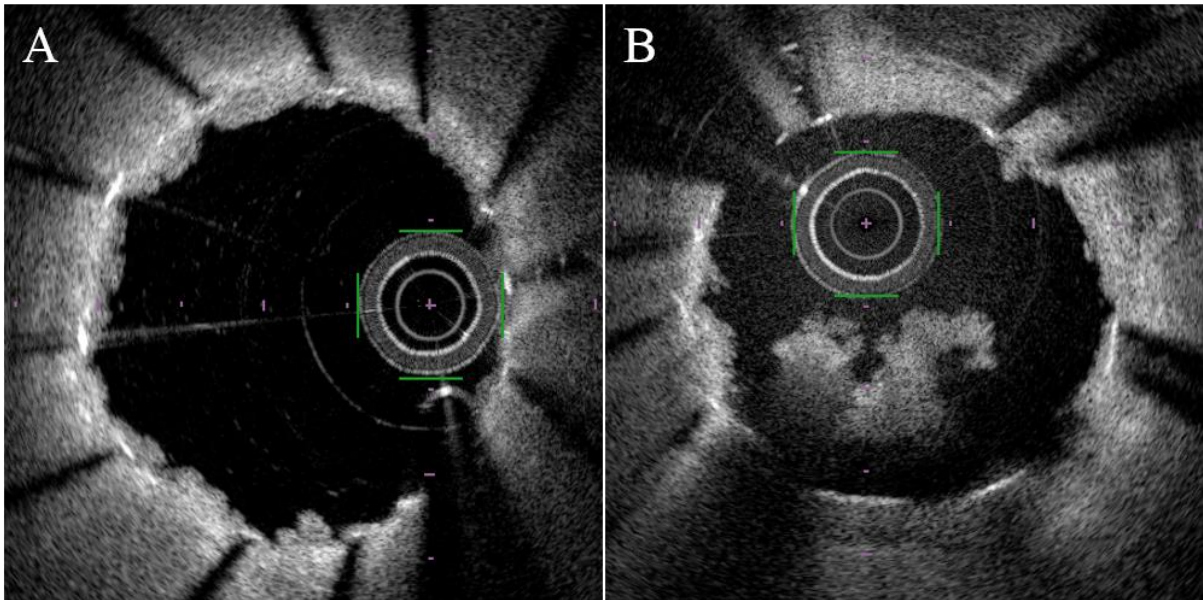


Figure 1: Optical frequency domain imaging examples of post-stent atherothrombotic burden attached to the vessel wall and the struts (panel A) or floating into the lumen (panel B)

At each frame, post-stent lumen area (LA) and flow-area (FA) were manually measured by planimetry as previously described [17] and atherothrombotic area (ATA) was defined as the difference between LA and FA. The LA was measured using stents' struts as limits. In case of strut mal-apposition, a corresponding point in the vessel wall was traced instead. The atherothrombotic volume (ATVol) was calculated by numerical integration based on the disk summation method of the dedicated console software [12]. ATB was calculated as the ATVol on lumen volume ratio (Figure 2). The second method of quantification used the previous

measures in 1 mm intervals to calculate the mean ATA and then the ATB (called ATB mm). Finally the semi-quantitative post-PCI thrombus score was calculated by summing the number of involved quadrants containing thrombus > 250 μ m in diameter, at 1 mm intervals [14].

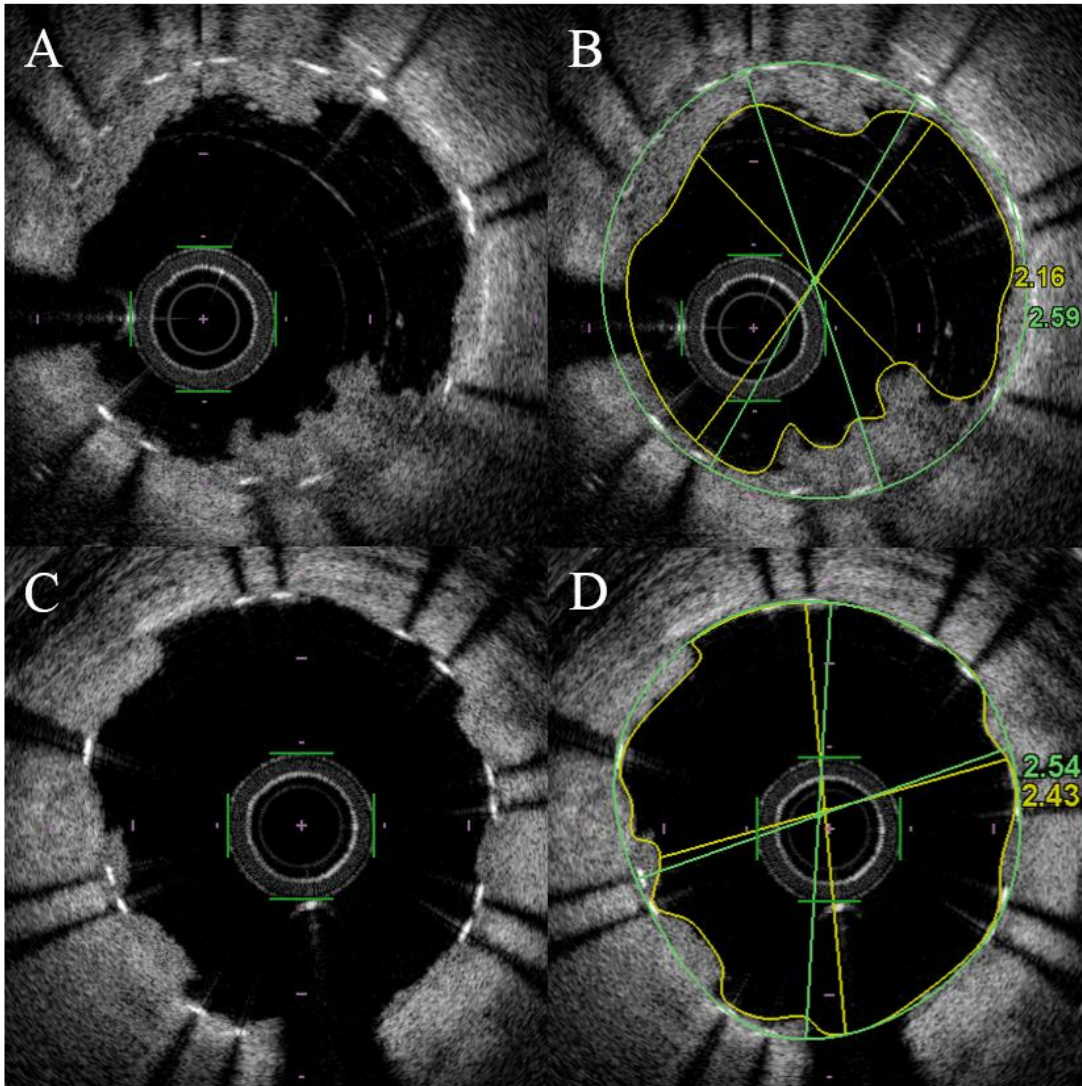


Figure 2: Optical frequency domain imaging examples of post-stent atherothrombotic burden (ATB) quantification. Lumen area using stents' struts (green line) and flow area (yellow line) were delimited to calculate ATB in a patient with final myocardial blush grade <3 (panel A and B; ATB = 0.43 mm² or 16.6%; thrombus score=4) and in another patient with normal final myocardial blush grade (panel C and D; ATB = 0.11 mm² or 4.3%; thrombus score=0).

Angiographic analysis

Coronary angiograms were analyzed before PCI and at the end of the procedure to evaluate basal and post-PCI Thrombolysis in Myocardial Infarction (TIMI) flow grade, pre-PCI angiographic thrombus grade, post-PCI MBG and corrected TIMI frame count (CTFC), as previously described [20, 21]. Digital angiograms, performed at 30 frames/sec and using the best projection to assess the myocardial region of the infarct-related coronary artery, were visually analyzed by 2 independent experienced interventional cardiologists blinded to OFDI results.

Since in angiographic thrombus score grade 5 there is total occlusion, patients initially presenting in this group were reclassified into one of the other four categories after vessel recanalization by either wire or balloon (1.5-mm diameter) crossing [22] to correctly assess thrombus burden.

Statistical analysis

Patients were separated into two groups defined by final MBG = or < 3. Continuous variables were expressed as means \pm standard deviation and compared between groups using Student's t test. Categorical variables were expressed as numbers (%) and compared between groups using Fisher's exact test. A P-value of <0.05 was considered statistically significant. R software version 3.5.2 for MacOS (R Foundation for Statistical Computing) was used for statistical analysis.

Results

A total of 63 patients fulfilled the inclusion criteria but three were excluded from the analysis because of poor image quality (one for OFDI quality and two others because of angiography quality limiting assessment of final MBG). Finally, 60 patients were included in the analysis, 28 (47%) with final MBG 3 and 32 (53%) with MBG <3.

Baseline characteristics, reported in Table 1, were comparable between groups, except for heart rate which was higher in the group with normal MBG ($p=0.02$). Patients with normal final MBG presented higher rates of basal and final TIMI 3 flow grade (35.7 vs 9.4%; $p=0.01$ and 96.4 vs 65.6%; $p=0.003$ respectively) than those with impaired MBG. Enoxaparin anti-Xa was within optimal therapeutic ranges (0.68 ± 0.36 IU/mL) and did not differ between groups. ST-segment elevation resolution $\geq 70\%$ after PCI was present in 51 (85%) patients and did not differ between groups (87.5 vs 82.1%, $p=0.56$ for final blush <3 vs blush 3, respectively).

Altogether, 13318 OFDI cross-sections were analyzed. The mean ATVol was 21.66 ± 16.81 mm³ corresponding to an ATB of $10.08 \pm 5.21\%$ (Table 2). ATB was lower in patients with final MBG 3, regardless of the method used (8.15 ± 5.58 vs $11.77 \pm 4.28\%$; $p=0.007$ for quantification per frame; 7.8 ± 5.19 vs $11.07 \pm 4.07\%$; $p=0.009$ for quantification per mm and 11.21 ± 11.75 vs 22.91 ± 17.35 ; $p=0.003$ for the thrombus score). There was no visible angiographic thrombus post-PCI.

Table 1: Baseline characteristics of the study population

Baseline patients characteristics	All n=60 (100%)	Final Blush <3 n=32 (53%)	Final Blush 3 n=28 (47%)	p
Age (years)	60.05 ± 10.44	59.47 ± 11.74	60.71 ± 8.87	0.64
Men	48 (80%)	23 (71.9%)	25 (89.3%)	0.09
Body mass index (kg/m ²)	26.6 ± 4.15	26.66 ± 4.38	26.53 ± 3.94	0.90
Systemic hypertension	18 (30%)	9 (28.1%)	9 (32.1%)	0.73
Hyperlipidemia	20 (33%)	11 (34.4%)	9 (32.1%)	0.85
Active smoker	32 (53%)	18 (56.2%)	14 (50%)	0.63
Diabetes mellitus	5 (8%)	2 (6.2%)	3 (10.7%)	0.53
History of myocardial infarction	5 (8%)	3 (9.4%)	2 (7.1%)	0.75
History of PCI	4 (7%)	2 (6.2%)	2 (7.1%)	0.89
Morphine use	24 (40%)	15 (46.9%)	9 (32.1%)	0.25
Systolic blood pressure (mmHg)	132.05 ± 28.78	132.78 ± 28.87	131.21 ± 29.18	0.84
Diastolic blood pressure (mmHg)	78.83 ± 14.88	77.78 ± 14.93	80.04 ± 15	0.56
Heart rate (bpm)	74.63 ± 17.16	69.47 ± 15.27	80.54 ± 17.54	0.01
Timepoints (min)				
Pain to PCI	260 ± 182.11	259 ± 187.96	261.29 ± 178.6	0.96
Pain to ticagrelor loading dose	178.33 ± 164.66	179.72 ± 185.18	176.75 ± 140.97	0.94
ECG to PCI	104.28 ± 77.33	100.97 ± 47.61	108.07 ± 102.16	0.74
Ticagrelor loading dose to PCI	81.73 ± 72.88	79.28 ± 39.02	84.54 ± 99.22	0.79
Admission biological characteristics				
Creatinine (µmol/L)	71.82 ± 16.63	73.09 ± 14.86	70.36 ± 18.63	0.54
C reactive protein (mg/L)	5.3 ± 14.77	2.57 ± 3.59	8.36 ± 20.97	0.18
Troponin (pg/mL)	39.16 ± 27.89	38.35 ± 26.96	40.07 ± 29.39	0.82
Hemoglobin (g/dL)	14.37 ± 1.4	14.33 ± 1.24	14.4 ± 1.58	0.85
Enoxaparin Anti-Xa (IU/mL)	0.68 ± 0.36	0.65 ± 0.29	0.73 ± 0.45	0.47
Angiographic characteristics				
Culprit coronary artery				
Right coronary artery	27 (45%)	14 (43.8%)	13 (46.4%)	0.84
Left anterior descending artery	23 (38%)	12 (37.5%)	11 (39.3%)	0.89
Left circumflex artery	10 (17%)	6 (18.2%)	4 (14.3%)	0.64
Thrombectomy use	8 (13%)	5 (15.6%)	3 (10.7%)	0.58
Balloon predilation	13 (21.7%)	7 (21.9%)	6 (21.4%)	1
Stent diameter (mm)	3 ± 0.46	2.98 ± 0.48	3.02 ± 0.45	0.76
Total stent length (mm)	29.38 ± 11.36	29.41 ± 11.59	29.36 ± 11.31	0.99
Balloon dilation post PCI	45 (75%)	26 (81.2%)	19 (67.9%)	0.23
Basal TIMI flow grade				
Grade 0	30 (50%)	19 (59.4%)	11 (39.3%)	0.12
Grade 1	8 (13%)	4 (12.5%)	4 (14.3%)	0.84
Grade 2	9 (15%)	6 (18.8%)	3 (10.7%)	0.38
Grade 3	13 (22%)	3 (9.4%)	10 (35.7%)	0.01
Angiographic thrombus grade				
Grade 0	2 (3%)	0 (0%)	2 (7.1%)	0.12
Grade 1	20 (23%)	9 (28.1%)	11 (39.3%)	0.36
Grade 2	10 (17%)	7 (21.9%)	3 (10.7%)	0.25
Grade 3	16 (27%)	8 (25%)	8 (28.6%)	0.75
Grade 4	12 (20%)	8 (25%)	4 (14.3%)	0.30
Grade 5	30 (50%)	19 (59.4%)	11 (39.3%)	0.12
Final TIMI flow grade				
Grade 2	12 (20%)	11 (34.4%)	1 (3.6%)	0.003
Grade 3	48 (80%)	21 (65.6%)	27 (96.4%)	0.003
Final corrected TIMI frame count	40.08 ± 17.89	46.53 ± 19.38	32.71 ± 12.73	0.002

ECG = electrocardiogram ; PCI = percutaneous coronary intervention ; TIMI = Thrombolysis In Myocardial Infarction

Table 2 : Post stenting OFDI findings

OFDI measures	All n=60 (100%)	Final Blush <3 n=32 (53%)	Final Blush 3 n=28 (47%)	p
Stent volume (mm ³)	219.42 ± 135.76	226.08 ± 168.69	211.82 ± 86.57	0.68
Evaluation per frame				
Atherothrombotic volume (mm ³)	21.66 ± 16.81	25.83 ± 18.86	16.89 ± 12.83	0.035
Atherothrombotic burden (%)	10.08 ± 5.21	11.77 ± 4.28	8.15 ± 5.58	0.007
Evaluation per millimeter				
Atherothrombotic volume (mm ³)	20.71 ± 16.16	24.57 ± 18.15	16.29 ± 12.43	0.042
Atherothrombotic burden (%)	9.5 ± 4.88	11.07 ± 4.07	7.8 ± 5.19	0.009
Thrombus score	17.45 ± 16	22.91 ± 17.35	11.21 ± 11.75	0.003

Discussion

Our study showed that residual post-stenting ATB was found after primary PCI in STEMI in all patients despite pre-treated with ticagrelor and aspirin. Higher volumes of ATB were associated with sub-optimal myocardial reperfusion assessed by MBG. The association was significant regardless of the method of ATB quantification.

Residual in-stent ATB is a commonly found after PCI by OCT. Frequently observed in stable coronary artery disease patients [5, 7, 8], it is almost systematically found after primary PCI for STEMI [13, 16, 17]. Higher quantities of ATB are reported in association with plaque rupture, lipid-rich plaque, thinner fibrous cap and longer stent length [8, 23, 24], conditions which are usually gathered in STEMI [25, 26]. The mean ATB of $10.08 \pm 5.21\%$ in our study is higher than the rates observed in previous studies [13, 16, 17], possibly explained by the higher use of thrombectomy (50% of the patients) in the previous studies. The clinical detrimental impact of residual ATB remains either unclear [5, 7, 10, 11], or restricted to ATB $>500 \mu\text{m}$ [11] or irregular protrusion [7].

The association between myocardial reperfusion and ATB found in our study may be the pathophysiological basis of such clinical impact as impaired myocardial reperfusion is a strong predictor of adverse cardiac events and long-term mortality [18, 27]. Impaired myocardial reperfusion is caused by a combination of distal atherothrombotic embolization, ischemic injury with cell swelling, reperfusion injury associated with inflammation and vasoconstriction [28]. Our results underline the importance of thrombus in microvascular obstruction in STEMI. The association between ATB and MBG was observed in 40 patients pre-treated with clopidogrel and unfractionated heparin [13]. However, they exclude patients with a very high angiographic thrombus load and those in whom thrombus aspiration was mandatory according to the treating interventional cardiologist, which could induce a bias. Our study confirmed the relationship between ATB and MBG in clinical practice in the era of

much more potent and rapidly effective P2Y12 inhibitor ticagrelor. Residual ATB may reflect a larger overall pre-PCI thrombotic burden even if a previous OCT study showed a minor correlation between pre and post-stent thrombotic burden [16]. Another possibility is that ATB may be a surrogate marker of enhanced thrombotic activity or even act as a trigger of thrombus formation. Indeed, an autopsy study showed that the extent of ATB prolapse was a risk factor for stent thrombosis [29].

Considering our findings, the methods for quantifying ATB are important. OCT remains the most accurate method to evaluate ATB. However, various methods of quantification were used in previous reports [8, 12-15]. The comparative value of different quantification methods remain limited, especially regarding to the semi-quantitative score which was only assessed pre-PCI in these studies [16, 17]. Our results showed for the first time that the different methods -ranging from volumetric quantification using planimetry (with intervals ranging from every frame to every millimeter) to semi-quantitative score- were all reliable in the post-stent setting. The semi-quantitative score was restricted to ATB > 250 μ m in diameter as small ATB is systematic in STEMI and in line with previous pre-PCI OCT studies [30, 31]. This score offers a faster method using simple visual evaluation. On the other way, intervals of 1 mm appear adequate to accurately measure ATB in practice. These methods were previously shown to be highly repeatable [17].

Limits

The findings of our study were based on a small cohort of patients and may have lacked power to detect differences between some studied parameters. The impact of ATB as an independent correlate of MBG may not be assessed by our study in absence of a large sample size needed for a multivariable analysis. Our conclusions are restricted to patients pre-treated with ticagrelor. The ATB measure included atheromatous tissue prolapse and thrombus which are difficult to distinguish in practice, even with the high OFDI resolution. However the ATB quantification was systematically and blindly done for all patients and this should not affect our results. We did not assess thrombus burden nor plaque characteristics pre-PCI but usually OFDI or OCT in STEMI patients with occluded or very severe stenoses as well as high thrombus load do not yield high quality images before PCI [13].

Conclusion

Residual post-stenting ATB remains substantial after primary PCI in STEMI patients despite pre-treatment with ticagrelor and aspirin. ATB is a major correlate of MBG, an important surrogate of clinical outcome. This association between ATB and MBG is found using different quantitative and semi-quantitative methods of measurement.

References article 4:

1. Anderson PG, Bajaj RK, Baxley WA, Roubin GS. Vascular pathology of balloon-expandable flexible coil stents in humans. *J Am Coll Cardiol.* 1992; 19:372-81.
2. Farb A, Sangiorgi G, Carter AJ, et al. Pathology of acute and chronic coronary stenting in humans. *Circulation.* 1999; 99:44-52.
3. Tearney GJ, Regar E, Akasaka T, et al. Consensus standards for acquisition, measurement, and reporting of intravascular optical coherence tomography studies: a report from the International Working Group for Intravascular Optical Coherence Tomography Standardization and Validation. *J Am Coll Cardiol.* 2012; 59:1058-72.
4. Kubo T, Imanishi T, Takarada S, et al. Assessment of culprit lesion morphology in acute myocardial infarction: ability of optical coherence tomography compared with intravascular ultrasound and coronary angiography. *J Am Coll Cardiol.* 2007; 50:933-9.
5. Gonzalo N, Serruys PW, Okamura T, et al. Optical coherence tomography assessment of the acute effects of stent implantation on the vessel wall: a systematic quantitative approach. *Heart.* 2009; 95:1913-9.
6. Meneveau N, Souteyrand G, Motreff P, et al. Optical Coherence Tomography to Optimize Results of Percutaneous Coronary Intervention in Patients with Non-ST-Elevation Acute Coronary Syndrome: Results of the Multicenter, Randomized DOCTORS Study (Does Optical Coherence Tomography Optimize Results of Stenting). *Circulation.* 2016; 134:906-17.
7. Soeda T, Uemura S, Park SJ, et al. Incidence and Clinical Significance of Poststent Optical Coherence Tomography Findings: One-Year Follow-Up Study From a Multicenter Registry. *Circulation.* 2015; 132:1020-9.

8. Sugiyama T, Kimura S, Akiyama D, et al. Quantitative assessment of tissue prolapse on optical coherence tomography and its relation to underlying plaque morphologies and clinical outcome in patients with elective stent implantation. *Int J Cardiol.* 2014; 176:182-90.
9. Kawamori H, Shite J, Shinke T, et al. Natural consequence of post-intervention stent malapposition, thrombus, tissue prolapse, and dissection assessed by optical coherence tomography at mid-term follow-up. *Eur Heart J Cardiovasc Imaging.* 2013; 14:865-75.
10. Prati F, Romagnoli E, Burzotta F, et al. Clinical Impact of OCT Findings During PCI: The CLI-OPCI II Study. *JACC Cardiovasc Imaging.* 2015; 8:1297-305.
11. Prati F, Romagnoli E, Gatto L, et al. Clinical Impact of Suboptimal Stenting and Residual Intrastent Plaque/Thrombus Protrusion in Patients With Acute Coronary Syndrome: The CLI-OPCI ACS Substudy (Centro per la Lotta Contro L'Infarto-Optimization of Percutaneous Coronary Intervention in Acute Coronary Syndrome). *Circ Cardiovasc Interv.* 2016; 9:
12. Garcia-Garcia HM, Muramatsu T, Nakatani S, et al. Serial optical frequency domain imaging in STEMI patients: the follow-up report of TROFI study. *Eur Heart J Cardiovasc Imaging.* 2014; 15:987-95.
13. Magro M, Regar E, Gutierrez-Chico JL, et al. Residual atherothrombotic material after stenting in acute myocardial infarction--an optical coherence tomographic evaluation. *Int J Cardiol.* 2013; 167:656-63.
14. Prati F, Capodanno D, Pawlowski T, et al. Local delivery versus intracoronary infusion of abciximab in patients with acute coronary syndromes. *JACC Cardiovasc Interv.* 2010; 3:928-34.

15. Yamaguchi T, Kubo T, Ino Y, et al. Optical coherence tomography assessment of efficacy of thrombus aspiration in patients undergoing a primary percutaneous coronary intervention for acute ST-elevation myocardial infarction. *Coron Artery Dis.* 2015; 26:567-72.
16. Bhindi R, Kajander OA, Jolly SS, et al. Culprit lesion thrombus burden after manual thrombectomy or percutaneous coronary intervention-alone in ST-segment elevation myocardial infarction: the optical coherence tomography sub-study of the TOTAL (ThrOmbecTomy versus PCI ALone) trial. *Eur Heart J.* 2015; 36:1892-900.
17. Kajander OA, Koistinen LS, Eskola M, et al. Feasibility and repeatability of optical coherence tomography measurements of pre-stent thrombus burden in patients with STEMI treated with primary PCI. *Eur Heart J Cardiovasc Imaging.* 2015; 16:96-107.
18. Morishima I, Sone T, Okumura K, et al. Angiographic no-reflow phenomenon as a predictor of adverse long-term outcome in patients treated with percutaneous transluminal coronary angioplasty for first acute myocardial infarction. *J Am Coll Cardiol.* 2000; 36:1202-9.
19. Van 'T Hof AW, Liem A, Suryapranata H, Hoorntje JC, De Boer MJ, Zijlstra F. Angiographic assessment of myocardial reperfusion in patients treated with primary angioplasty for acute myocardial infarction: myocardial blush grade. Zwolle Myocardial Infarction Study Group. *Circulation.* 1998; 97:2302-6.
20. Gibson CM, De Lemos JA, Murphy SA, et al. Combination therapy with abciximab reduces angiographically evident thrombus in acute myocardial infarction: a TIMI 14 substudy. *Circulation.* 2001; 103:2550-4.
21. Gibson CM, Schomig A. Coronary and myocardial angiography: angiographic assessment of both epicardial and myocardial perfusion. *Circulation.* 2004; 109:3096-105.

22. Capranzano P, Capodanno D, Bucciarelli-Ducci C, et al. Impact of residual platelet reactivity on reperfusion in patients with ST-segment elevation myocardial infarction undergoing primary percutaneous coronary intervention. *Eur Heart J Acute Cardiovasc Care*. 2016; 5:475-86.
23. Hong YJ, Jeong MH, Ahn Y, et al. Plaque prolapse after stent implantation in patients with acute myocardial infarction: an intravascular ultrasound analysis. *JACC Cardiovasc Imaging*. 2008; 1:489-97.
24. Qiu F, Mintz GS, Witzendichler B, et al. Prevalence and Clinical Impact of Tissue Protrusion After Stent Implantation: An ADAPT-DES Intravascular Ultrasound Substudy. *JACC Cardiovasc Interv*. 2016; 9:1499-507.
25. Ino Y, Kubo T, Tanaka A, et al. Difference of culprit lesion morphologies between ST-segment elevation myocardial infarction and non-ST-segment elevation acute coronary syndrome: an optical coherence tomography study. *JACC Cardiovasc Interv*. 2011; 4:76-82.
26. Wang L, Parodi G, Maehara A, et al. Variable underlying morphology of culprit plaques associated with ST-elevation myocardial infarction: an optical coherence tomography analysis from the SMART trial. *Eur Heart J Cardiovasc Imaging*. 2015; 16:1381-9.
27. Ndrepepa G, Tiroch K, Fusaro M, et al. 5-year prognostic value of no-reflow phenomenon after percutaneous coronary intervention in patients with acute myocardial infarction. *J Am Coll Cardiol*. 2010; 55:2383-9.
28. Niccoli G, Burzotta F, Galiuto L, Crea F. Myocardial no-reflow in humans. *J Am Coll Cardiol*. 2009; 54:281-92.

29. Nakano M, Yahagi K, Otsuka F, et al. Causes of early stent thrombosis in patients presenting with acute coronary syndrome: an ex vivo human autopsy study. *J Am Coll Cardiol.* 2014; 63:2510-20.
30. Higuma T, Soeda T, Yamada M, et al. Does Residual Thrombus After Aspiration Thrombectomy Affect the Outcome of Primary PCI in Patients With ST-Segment Elevation Myocardial Infarction?: An Optical Coherence Tomography Study. *JACC Cardiovasc Interv.* 2016; 9:2002-11.
31. Parodi G, Valenti R, Migliorini A, et al. Comparison of manual thrombus aspiration with rheolytic thrombectomy in acute myocardial infarction. *Circ Cardiovasc Interv.* 2013; 6:224-30.

IV. SYNTHÈSE

Dans la première partie de cette thèse, nous avons testé la validité des tests de réactivité plaquettaire simples VerifyNow et PFA en comparaison à la LTA dans le contexte particulier de la post fibrinolyse. En parallèle, une analyse de la plaque athérotrombotique à l'origine de l'IDM ST+ a été réalisée en imagerie endocoronaire par OFDI également en post-fibrinolyse et corrélée aux caractéristiques du thrombus pré et post stenting. Secondairement, nous avons étudié les relations entre la reperfusion myocardique et la réactivité plaquettaire résiduelle d'une part et la charge athérotrombotique post stenting d'autre part, chez des patients traités par angioplastie primaire.

La stratégie pharmacoinvasive associant fibrinolyse et angioplastie coronaire est le traitement recommandé si l'angioplastie primaire ne peut être réalisée dans les délais impartis [14]. Cette alternative est utilisée régulièrement dans notre région semi-rurale. Nous avons testé 3 différents tests d'agrégation plaquettaire dans ce contexte. Une hyperréactivité plaquettaire résiduelle (HPR) au moment de l'angioplastie a été retrouvée chez 34,5% à 51,7% des patients selon le test utilisé, la LTA donnant le taux le plus faible. L'HPR observée s'explique par le contexte aigu de l'IDM [64], le rebond prothrombotique post-fibrinolyse et l'activation plaquettaire médiée par une augmentation de l'activation de la prothrombine [65]. Il existe aussi une augmentation de la production de thromboxane expliquant les effets bénéfiques de l'adjonction d'aspirine à la thrombolyse [66]. La réactivité plaquettaire liée à l'aspirine n'a toutefois pas été mesurée dans notre étude. L'HPR au clopidogrel dans notre cohorte s'explique aussi par la variabilité individuelle dans la réponse au traitement et son long délai d'action en particulier aux faibles doses recommandées en aigu dans ce contexte [67, 68]. Toutefois les taux d'HPR mesurée pour la 1^{ère} fois par la LTA sont deux fois plus faible que

ceux observés précédemment avec le VN [69, 70]. Les différences entre les techniques (prostaglandine utilisée pour supprimer la contribution indésirable des récepteurs P2Y1 dans le VN et le PFA mais pas dans la LTA, test sur sang total ou sur plasma riche en plaquettes) peuvent expliquer les discordances. Concrètement, le VN et le PFA identifient correctement les patients sans HPR mais surestiment les taux de patients avec HPR. En cas d'HPR détectée par le VN ou le PFA, le fait d'associer ces 2 tests facilement réalisables en pratique permet d'améliorer nettement la valeur prédictive négative (mesurée alors à 100% dans notre cohorte). La LTA requiert un personnel qualifié et des techniques spécialisées ne la rendant pas accessible à toute heure. La mesure de la réactivité plaquettaire pour adapter le traitement antiplaquettaire n'est pas recommandée en pratique courante [38]. Cependant, une mesure par un test simple type VN ou PFA peut s'avérer utile dans certains cas particuliers (thrombose de stent, montage complexe de stents) combinant haut risque ischémique et hémorragique dans le contexte de la post fibrinolyse. Une nouvelle dose de charge en clopidogrel [71] ou le switch vers un inhibiteur plus puissant type ticagrelor permettant d'obtenir une inhibition plaquettaire plus adéquate y compris dans le contexte particulier de la fibrinolyse [72] [73] peuvent être envisagés. Nous n'avons pas inclus de patients ayant eu un échec de reperfusion par fibrinolyse. Pour des raisons pratiques (en particulier pour faire la LTA), les patients ont été inclus aux heures ouvrables en semaine. Une majoration du traitement antiplaquettaire chez ces patients pourrait exposer à un sur-risque hémorragique car l'angioplastie est réalisée assez précocement après la thrombolyse. D'autres études de mesures de réactivité plaquettaire chez ces patients seraient toutefois informatives.

Les patients traités avec succès par fibrinolyse ont une artère coronaire coupable perméable offrant la possibilité d'une évaluation OFDI avant l'angioplastie. Contrairement aux études dans l'angioplastie primaire [45, 74-76], l'analyse OFDI dans notre deuxième étude -chez des patients fibrinolisés avec succès- a pu être réalisée sans nécessité d'une pré-dilatation ou d'une

thromboaspiration préalable pouvant dénaturer la morphologie du thrombus. Les patients ayant une rupture de plaque présentaient une quantité de thrombus pré-stent plus importante, un thrombus majoritairement rouge en OFDI et réparti diffusément de part et d'autre de la sténose, comparativement à ceux ayant une érosion (thrombus moins volumineux, plutôt blanc et surtout localisé près de la sténose). La quantité de thrombus plus importante avec les ruptures de plaque est concordante avec les études antérieures [45, 77]. Les mécanismes physiopathologiques sous-jacents peuvent expliquer ces différences. La rupture de plaque expose le cœur nécrotique à la circulation et celui-ci qui est 6 fois plus thrombogène que les autres composantes de la plaque [9]. La libération du facteur tissulaire et des microparticules prothrombotiques, l'infiltration macrophagique et l'inflammation plus marquée dans les ruptures [8, 10, 78, 79] expliquent aussi la charge thrombotique basale plus importante observée dans ces cas. Les différentes cytokines exprimées participent aussi aux différences des types de thrombus observés [80] : la thrombospondine 1 impliquée dans le recrutement des plaquettes et la stabilisation des thrombi [81] est davantage exprimée dans les érosions ; la métalloprotéinase matricielle 9 davantage exprimée dans les ruptures est connue pour augmenter l'activité du facteur tissulaire [82]. Enfin, l'hémorragie intra plaque joue un rôle important dans l'expansion de plaque et son risque de rupture, pouvant expliquer le thrombus majoritairement rouge dans ce cas. Toutefois, en post stenting, nous avons observé une charge athérothrombotique répartie uniformément le long du stent et quantitativement similaire entre les deux groupes. Une étude ayant inclus des IDM ST+ et ST- et ayant exclu ceux thrombolysés a retrouvé une masse thrombotique post stent plus importante chez les patients ayant une rupture de plaque comparativement à ceux ayant une érosion [83] mais la corrélation entre masse thrombotique pré et post stent reste globalement faible [48, 74]. Le résultat post stenting était similaire dans nos 2 groupes ce qui suppose une efficacité comparable du stenting. Une étude dans l'IDM ST+ corrobore nos résultats avec une

protrusion intrastent immédiate et des résultats morphologiques OCT à 9 mois similaires entre rupture et érosion [84]. Le stenting est efficace quel que soit le mécanisme mais il faut rappeler que l'étude EROSION [85] a prouvé que le traitement anti thrombotique sans stenting était une option thérapeutique possible en cas d'érosion avec une sténose résiduelle inférieure à 70%.

Les 2 derniers travaux de cette thèse visaient à évaluer les relations entre la réactivité plaquettaire, les indices de reperfusion angiographique et la charge athérombotique à la phase aigüe de l'IDM ST+. L'HPR a été associée à un risque d'événement cardiaques et en particulier de thrombose de stent plus important [54, 57]. Cependant son impact à la phase aigüe de l'IDM ST+ en particulier avec les récents antiagrégants plaquettaires reste peu décrit. L'impact pronostic de l'hyperréactivité à l'aspirine diverge selon les études et apparait plus contrasté [86, 87]. Notre 3^{ème} article visait à étudier les déterminants d'une bonne reperfusion myocardique (blush myocardique 3) dans le cadre de l'angioplastie primaire chez des patients pré-traités par aspirine et ticagrelor. Nous avons retrouvé une réactivité plaquettaire au P2Y12 (exprimée en PRU) plus importante chez les patients avec une reperfusion altérée (blush <3) mais pas de différence entre les 2 groupes concernant la réactivité à l'aspirine. Nos résultats sont concordants avec une étude plus ancienne ayant retrouvé une corrélation entre la réactivité plaquettaire mesurée par PFA et l'élévation des marqueurs de nécrose myocardique (CPK-MB ou troponine T) dans l'IDM [88]. Les taux de troponine ne différaient cependant pas entre les groupes dans notre étude. Ceci est principalement expliqué par le fait que nous avons dosé le taux de troponine qu'à J1, sans cycle régulier de mesure. Il ne s'agissait donc pas forcément du pic de troponine pour nos patients. Le blush myocardique utilisé pour quantifier la reperfusion, a une valeur pronostique majeure car il est corrélé à la taille de l'IDM, la fraction d'éjection ventriculaire gauche, la mortalité cardiaque et globale et ce, indépendamment du flux TIMI [32, 89]. Une seule étude, qui avait inclus des IDM ST+ pré-

traités par clopidogrel avec un temps de transfert >2h, a retrouvé une association entre la réactivité plaquettaire au P2Y12 et la reperfusion [63]. D'autres études sur la réactivité plaquettaire à la phase aiguë de l'IDM n'ont pas retrouvé d'association significative avec le blush myocardique [61, 62]. Contrairement à nous, plusieurs régimes d'anticoagulants principalement de l'héparine non fractionnée qui présente un rapport dose/réponse moins prévisible que les HBPM [90] ont été utilisés ces études. L'intervalle de temps entre la dose de charge d'antiagrégant et l'angioplastie qui était plus long dans notre étude peut expliquer en partie ces discordances. En effet, dans l'IDM ST+, l'efficacité des inhibiteurs du P2Y12 est retardée y compris avec le ticagrelor ou le prasugrel [91] et il faut donc un temps nécessaire pour observer différents niveaux d'inhibition plaquettaire. Ainsi, dans la sous-étude angiographique de PLATO qui comparait clopidogrel et ticagrelor, il n'a pas été retrouvé de différence sur la reperfusion myocardique entre les 2 groupes mais l'intervalle de temps entre la randomisation et l'angioplastie était de seulement 41 minutes [92]. C'est bien la réactivité plaquettaire en aigu qui apparaît intéressante sous ticagrelor puisqu'à J1 aucun de nos patients n'avait d'HPR. Nous n'avons pas retrouvé de corrélation entre la réactivité à l'aspirine et la reperfusion myocardique, et ce de manière concordante avec les études préalables [62, 63]. Les taux peu élevés (18%) d'hyperréactivité à l'aspirine (HaPR) dans le contexte d'IDM s'expliquent par la dose de charge systématique, par voie veineuse, reçue par les patients [87, 93, 94]. Ces résultats apparaissent dans la lignée de l'étude ADAPT DES [54] qui n'a pas retrouvé de lien entre l'HaPR et les événements cardiaques. Les comparaisons entre les études restent limitées étant donné des patients (<10% des patients inclus dans ADAPT DES avaient un IDM ST+), des tests et des temps de mesure (à J1 post angioplastie dans ADAPT DES) différents. La relation entre la réactivité plaquettaire sous ticagrelor et la reperfusion myocardique pourrait être liée à la charge thrombotique intracoronaire, plus faible en l'absence d'HPR, et son embolisation distale.

Nous avons donc étudié les relations entre reperfusion myocardique et la charge athérombotique post-stent dans cette même cohorte d'angioplastie primaire. La protrusion athérombotique intrastent en fin d'angioplastie est presque systématiquement retrouvée dans le cadre des IDM ST+ [48, 49, 74]. La signification clinique de cette protrusion reste peu claire [52, 95-97]. Nous avons retrouvé qu'une masse athérombotique résiduelle plus importante était associée à une reperfusion myocardique altérée. Cette constatation est concordante avec une précédente étude OCT chez des patients traités par clopidogrel [49]. Plusieurs hypothèses peuvent expliquer nos résultats. La charge athérombotique résiduelle peut être le continuum d'une masse thrombotique pré-stent plus importante et possiblement de davantage de ruptures de plaque dans ce cas étant donné nos résultats préalables. Toutefois, la corrélation entre thrombus pré et post-stenting évaluée en OCT est faible [48, 74]. Il peut aussi s'agir d'un marqueur d'une activité prothrombotique augmentée. Une étude IVUS dans l'angioplastie primaire a montré que les protrusions importantes étaient associées à un risque accru de thrombose de stent précoce [98]. La relation entre masse athérombotique et blush myocardique souligne le rôle central du thrombus dans la reperfusion par le biais de l'embolisation distale dans la microcirculation. L'altération de la reperfusion myocardique souvent appelée « no-reflow » a une physiopathologie multifactorielle [34] au sein de laquelle les plaquettes jouent un rôle déterminant. L'embolisation distale de micro agrégats de plaquettes, le relargage de substances pro-inflammatoires et l'inflammation de l'endothélium induite, le recrutement de leucocytes par les plaquettes activées et le vasospasme participent à l'altération de la reperfusion myocardique médiée par les plaquettes [99]. Il apparaît donc important de pouvoir bien quantifier cette masse athérombotique résiduelle. Les différentes méthodes testées dans notre étude se sont montrées toutes reliées au blush myocardique. Ainsi, la quantification semi-quantitative ou quantitative par millimètre, moins fastidieuse et facilement accessible, apparaît suffisante.

Au total, la présence d'une HPR lors de la prise en charge par angioplastie d'un IDM ST+ reste très fréquente, même avec les inhibiteurs puissants du P2Y12 comme le ticagrelor [100]. Ceci est lié à l'augmentation de la réactivité plaquettaire dans l'IDM [64, 101] mais aussi au probable délai d'absorption retardé des drogues per os dans ce contexte [91]. Les recommandations européennes [14] concèdent que si l'administration précoce d'inhibiteurs du P2Y12 paraît préférable, les preuves cliniques restent limitées [23, 24] même si une large méta-analyse sur le prétraitement par clopidogrel retrouvait un bénéfice sur la mortalité et les événements cardiaques majeurs dans le sous-groupe IDM ST+ [102] traité par angioplastie. Concernant le ticagrelor, l'étude ATLANTIC sur le pré traitement par ticagrelor dans l'IDM ST+ n'a pas retrouvé de bénéfice du pré traitement sur la reperfusion épiscopardique avant angioplastie définie par un flux TIMI 3 [25]. L'écart moyen de temps entre la prise du ticagrelor et l'angiographie était seulement de 31 minutes entre les 2 stratégies (ticagrelor pré vs intra hospitalier). Ces temps étaient plus élevés dans notre étude permettant d'obtenir des niveaux d'inhibition plaquettaire différents par rapport à ATLANTIC et corrélés à la reperfusion. Nos études sont en faveur d'un pré-traitement par ticagrelor dans l'angioplastie primaire, en particulier dans des régions semi-rurales comme la Basse-Normandie où les temps de transferts sont plus longs. Le fait de mâcher les comprimés de ticagrelor permet d'accélérer son action sur l'inhibition plaquettaire [103] et peut donc être utilisé. Nos données soulèvent l'hypothèse de l'intérêt d'une intensification du traitement antiplaquettaire en salle de cathétérisme basée sur le résultat du VerifyNow. Le cangrelor, qui est un puissant inhibiteur du P2Y12, administré par voie intraveineuse avec un effet on/off rapide pourrait être utilisé. Son bénéfice en l'absence de pré traitement n'a cependant été démontré qu'en comparaison au clopidogrel [104]. L'utilisation d'inhibiteurs de la glycoprotéine IIb/IIIa (antiGPIIb/IIIa), puissant inhibiteurs plaquettaires administrés aussi par voie intraveineuse, peut aussi être évoquée. Ils ont été associés à davantage de flux TIMI 3 avant angioplastie

versus placebo dans l'IDM ST+ mais chez des patients non pré-traités par inhibiteurs du P2Y12 [105]. Les antiGPIIb/IIIa sont surtout utilisés en cas de forte charge thrombotique et de no-reflow [14] chez des patients avec un risque ischémique élevé [106]. La prescription personnalisée d'antiagrégants en fonction de la réactivité plaquettaire en post-angioplastie a échoué à démontrer un bénéfice clinique dans les études randomisées [58-60]. Toutefois, une méta-analyse sur l'intensification du traitement antiplaquettaire (principalement par une nouvelle dose de charge de clopidogrel) basée sur un test de réactivité plaquettaire biologique a montré que cela était associé à une réduction de la mortalité cardiovasculaire, des thromboses de stent et des IDM [107]. Il faut souligner que très peu de patients admis pour IDM ST+ ont été inclus dans ces études. L'utilisation d'inhibiteurs intraveineux du P2Y12, en plus d'antiagrégants per os puissants tel le ticagrelor, sur la base de tests biologiques d'antiagrégation n'a pas été testée à la phase aiguë de l'IDM et mérite d'autres études d'autant plus qu'il existe un surrisque hémorragique associé à ces molécules [106, 108].

V. CONCLUSION

Nos travaux soulignent l'importance de la réactivité plaquettaire résiduelle après pré-traitement par inhibiteurs du P2Y12 dans l'IDM ST+. Le taux d'HPR varie selon le test d'agrégation plaquettaire utilisé en post fibrinolyse. Nous avons observé que l'impact du mécanisme causal de l'IDM sur la charge thrombotique ou athérothrombotique était différent selon que l'on se situait avant ou après mise en place du stent. Dans l'angioplastie primaire, nous avons montré qu'une HPR était associée à une reperfusion myocardique altérée dont l'impact clinique est majeur. Nos résultats ont permis de préciser la signification de la charge athérothrombotique résiduelle observée en OFDI en post stenting. Ces données soulignent l'importance d'un pré-traitement le plus précocement possible chez ces patients et suggèrent l'évaluation de traitements intraveineux dans ce contexte par des études adaptées.

VI. REFERENCES

1. Kristensen SD, Laut KG, Fajadet J, et al. Reperfusion therapy for ST elevation acute myocardial infarction 2010/2011: current status in 37 ESC countries. *Eur Heart J*. 2014; 35:1957-70.
2. Fokkema ML, James SK, Albertsson P, et al. Population trends in percutaneous coronary intervention: 20-year results from the SCAAR (Swedish Coronary Angiography and Angioplasty Registry). *J Am Coll Cardiol*. 2013; 61:1222-30.
3. Puymirat E, Cayla G, Cottin Y, et al. Twenty-year trends in profile, management and outcomes of patients with ST-segment elevation myocardial infarction according to use of reperfusion therapy: Data from the FAST-MI program 1995-2015. *Am Heart J*. 2019; 214:97-106.
4. Libby P, Ridker PM, Hansson GK. Progress and challenges in translating the biology of atherosclerosis. *Nature*. 2011; 473:317-25.
5. Tabas I, Williams KJ, Boren J. Subendothelial lipoprotein retention as the initiating process in atherosclerosis: update and therapeutic implications. *Circulation*. 2007; 116:1832-44.
6. Libby P. Inflammation in atherosclerosis. *Nature*. 2002; 420:868-74.
7. Davies MJ. The pathophysiology of acute coronary syndromes. *Heart*. 2000; 83:361-6.
8. Falk E, Nakano M, Bentzon JF, Finn AV, Virmani R. Update on acute coronary syndromes: the pathologists' view. *Eur Heart J*. 2013; 34:719-28.
9. Fernandez-Ortiz A, Badimon JJ, Falk E, et al. Characterization of the relative thrombogenicity of atherosclerotic plaque components: implications for consequences of plaque rupture. *J Am Coll Cardiol*. 1994; 23:1562-9.
10. Rautou PE, Vion AC, Amabile N, et al. Microparticles, vascular function, and atherothrombosis. *Circ Res*. 2011; 109:593-606.
11. Virmani R, Kolodgie FD, Burke AP, Farb A, Schwartz SM. Lessons from sudden coronary death: a comprehensive morphological classification scheme for atherosclerotic lesions. *Arterioscler Thromb Vasc Biol*. 2000; 20:1262-75.
12. Andersen HR, Nielsen TT, Rasmussen K, et al. A comparison of coronary angioplasty with fibrinolytic therapy in acute myocardial infarction. *N Engl J Med*. 2003; 349:733-42.
13. Keeley EC, Boura JA, Grines CL. Primary angioplasty versus intravenous thrombolytic therapy for acute myocardial infarction: a quantitative review of 23 randomised trials. *Lancet*. 2003; 361:13-20.
14. Ibanez B, James S, Agewall S, et al. 2017 ESC Guidelines for the management of acute myocardial infarction in patients presenting with ST-segment elevation: The Task Force for the management of acute myocardial infarction in patients presenting with ST-segment elevation of the European Society of Cardiology (ESC). *Eur Heart J*. 2018; 39:119-77.
15. Madan M, Halvorsen S, Di Mario C, et al. Relationship between time to invasive assessment and clinical outcomes of patients undergoing an early invasive strategy after fibrinolysis for ST-segment elevation myocardial infarction: a patient-level analysis of the randomized early routine invasive clinical trials. *JACC Cardiovasc Interv*. 2015; 8:166-74.
16. Armstrong PW, Gershlick AH, Goldstein P, et al. Fibrinolysis or primary PCI in ST-segment elevation myocardial infarction. *N Engl J Med*. 2013; 368:1379-87.
17. Bohmer E, Hoffmann P, Abdelnoor M, Arnesen H, Halvorsen S. Efficacy and safety of immediate angioplasty versus ischemia-guided management after thrombolysis in acute myocardial infarction in areas with very long transfer distances results of the NORDISTEMI (NORwegian study on District treatment of ST-elevation myocardial infarction). *J Am Coll Cardiol*. 2010; 55:102-10.
18. Cantor WJ, Fitchett D, Borgundvaag B, et al. Routine early angioplasty after fibrinolysis for acute myocardial infarction. *N Engl J Med*. 2009; 360:2705-18.
19. Di Mario C, Dudek D, Piscione F, et al. Immediate angioplasty versus standard therapy with rescue angioplasty after thrombolysis in the Combined Abciximab REteplase Stent Study in Acute Myocardial Infarction (CARESS-in-AMI): an open, prospective, randomised, multicentre trial. *Lancet*. 2008; 371:559-68.

20. Fernandez-Aviles F, Alonso JJ, Castro-Beiras A, et al. Routine invasive strategy within 24 hours of thrombolysis versus ischaemia-guided conservative approach for acute myocardial infarction with ST-segment elevation (GRACIA-1): a randomised controlled trial. *Lancet*. 2004; 364:1045-53.
21. Le May MR, Wells GA, Labinaz M, et al. Combined angioplasty and pharmacological intervention versus thrombolysis alone in acute myocardial infarction (CAPITAL AMI study). *J Am Coll Cardiol*. 2005; 46:417-24.
22. Roule V, Ardouin P, Blanchart K, et al. Prehospital fibrinolysis versus primary percutaneous coronary intervention in ST-elevation myocardial infarction: a systematic review and meta-analysis of randomized controlled trials. *Crit Care*. 2016; 20:359.
23. Koul S, Smith JG, Schersten F, James S, Lagerqvist B, Erlinge D. Effect of upstream clopidogrel treatment in patients with ST-segment elevation myocardial infarction undergoing primary percutaneous coronary intervention. *Eur Heart J*. 2011; 32:2989-97.
24. Zeymer U, Arntz HR, Mark B, et al. Efficacy and safety of a high loading dose of clopidogrel administered prehospitally to improve primary percutaneous coronary intervention in acute myocardial infarction: the randomized CIPAMI trial. *Clin Res Cardiol*. 2012; 101:305-12.
25. Montalescot G, Van 'T Hof AW, Lapostolle F, et al. Prehospital ticagrelor in ST-segment elevation myocardial infarction. *N Engl J Med*. 2014; 371:1016-27.
26. Gibson CM, Schomig A. Coronary and myocardial angiography: angiographic assessment of both epicardial and myocardial perfusion. *Circulation*. 2004; 109:3096-105.
27. Simes RJ, Topol EJ, Holmes DR, Jr., et al. Link between the angiographic substudy and mortality outcomes in a large randomized trial of myocardial reperfusion. Importance of early and complete infarct artery reperfusion. GUSTO-I Investigators. *Circulation*. 1995; 91:1923-8.
28. Vogt A, Von Essen R, Tebbe U, Feuerer W, Appel KF, Neuhaus KL. Impact of early perfusion status of the infarct-related artery on short-term mortality after thrombolysis for acute myocardial infarction: retrospective analysis of four German multicenter studies. *J Am Coll Cardiol*. 1993; 21:1391-5.
29. Gibson CM, Cannon CP, Daley WL, et al. TIMI frame count: a quantitative method of assessing coronary artery flow. *Circulation*. 1996; 93:879-88.
30. Gibson CM, Murphy SA, Rizzo MJ, et al. Relationship between TIMI frame count and clinical outcomes after thrombolytic administration. Thrombolysis In Myocardial Infarction (TIMI) Study Group. *Circulation*. 1999; 99:1945-50.
31. Hamada S, Nishiue T, Nakamura S, et al. TIMI frame count immediately after primary coronary angioplasty as a predictor of functional recovery in patients with TIMI 3 reperfused acute myocardial infarction. *J Am Coll Cardiol*. 2001; 38:666-71.
32. Van 'T Hof AW, Liem A, Suryapranata H, Hoorntje JC, De Boer MJ, Zijlstra F. Angiographic assessment of myocardial reperfusion in patients treated with primary angioplasty for acute myocardial infarction: myocardial blush grade. Zwolle Myocardial Infarction Study Group. *Circulation*. 1998; 97:2302-6.
33. Henriques JP, Zijlstra F, Van 'T Hof AW, et al. Angiographic assessment of reperfusion in acute myocardial infarction by myocardial blush grade. *Circulation*. 2003; 107:2115-9.
34. Niccoli G, Burzotta F, Galiuto L, Crea F. Myocardial no-reflow in humans. *J Am Coll Cardiol*. 2009; 54:281-92.
35. Tearney GJ, Regar E, Akasaka T, et al. Consensus standards for acquisition, measurement, and reporting of intravascular optical coherence tomography studies: a report from the International Working Group for Intravascular Optical Coherence Tomography Standardization and Validation. *J Am Coll Cardiol*. 2012; 59:1058-72.
36. Kubo T, Imanishi T, Takarada S, et al. Assessment of culprit lesion morphology in acute myocardial infarction: ability of optical coherence tomography compared with intravascular ultrasound and coronary angiography. *J Am Coll Cardiol*. 2007; 50:933-9.
37. Amabile N, Hammas S, Fradi S, et al. Intra-coronary thrombus evolution during acute coronary syndrome: regression assessment by serial optical coherence tomography analyses. *Eur Heart J Cardiovasc Imaging*. 2015; 16:433-40.

38. Neumann FJ, Sousa-Uva M, Ahlsson A, et al. 2018 ESC/EACTS Guidelines on myocardial revascularization. *Eur Heart J*. 2019; 40:87-165.
39. Souteyrand G, Amabile N, Mangin L, et al. Mechanisms of stent thrombosis analysed by optical coherence tomography: insights from the national PESTO French registry. *Eur Heart J*. 2016; 37:1208-16.
40. Meneveau N, Souteyrand G, Motreff P, et al. Optical Coherence Tomography to Optimize Results of Percutaneous Coronary Intervention in Patients with Non-ST-Elevation Acute Coronary Syndrome: Results of the Multicenter, Randomized DOCTORS Study (Does Optical Coherence Tomography Optimize Results of Stenting). *Circulation*. 2016; 134:906-17.
41. Fokkema ML, Vlaar PJ, Svilaas T, et al. Incidence and clinical consequences of distal embolization on the coronary angiogram after percutaneous coronary intervention for ST-elevation myocardial infarction. *Eur Heart J*. 2009; 30:908-15.
42. Henriques JP, Zijlstra F, Ottervanger JP, et al. Incidence and clinical significance of distal embolization during primary angioplasty for acute myocardial infarction. *Eur Heart J*. 2002; 23:1112-7.
43. Kirtane AJ, Vafai JJ, Murphy SA, et al. Angiographically evident thrombus following fibrinolytic therapy is associated with impaired myocardial perfusion in STEMI: a CLARITY-TIMI 28 substudy. *Eur Heart J*. 2006; 27:2040-5.
44. White CJ, Ramee SR, Collins TJ, et al. Coronary thrombi increase PTCA risk. Angioscopy as a clinical tool. *Circulation*. 1996; 93:253-8.
45. Wang L, Parodi G, Maehara A, et al. Variable underlying morphology of culprit plaques associated with ST-elevation myocardial infarction: an optical coherence tomography analysis from the SMART trial. *Eur Heart J Cardiovasc Imaging*. 2015; 16:1381-9.
46. Porto I, Mattesini A, Valente S, Prati F, Crea F, Bolognese L. Optical coherence tomography assessment and quantification of intracoronary thrombus: Status and perspectives. *Cardiovasc Revasc Med*. 2015; 16:172-8.
47. Garcia-Garcia HM, Muramatsu T, Nakatani S, et al. Serial optical frequency domain imaging in STEMI patients: the follow-up report of TROFI study. *Eur Heart J Cardiovasc Imaging*. 2014; 15:987-95.
48. Kajander OA, Koistinen LS, Eskola M, et al. Feasibility and repeatability of optical coherence tomography measurements of pre-stent thrombus burden in patients with STEMI treated with primary PCI. *Eur Heart J Cardiovasc Imaging*. 2015; 16:96-107.
49. Magro M, Regar E, Gutierrez-Chico JL, et al. Residual atherothrombotic material after stenting in acute myocardial infarction--an optical coherence tomographic evaluation. *Int J Cardiol*. 2013; 167:656-63.
50. Prati F, Capodanno D, Pawlowski T, et al. Local delivery versus intracoronary infusion of abciximab in patients with acute coronary syndromes. *JACC Cardiovasc Interv*. 2010; 3:928-34.
51. Anderson PG, Bajaj RK, Baxley WA, Roubin GS. Vascular pathology of balloon-expandable flexible coil stents in humans. *J Am Coll Cardiol*. 1992; 19:372-81.
52. Gonzalo N, Serruys PW, Okamura T, et al. Optical coherence tomography assessment of the acute effects of stent implantation on the vessel wall: a systematic quantitative approach. *Heart*. 2009; 95:1913-9.
53. Luo Y, Li J, Liu X, et al. Combination of P2Y12 reaction unit and percentage of platelet inhibition assessed by VerifyNow P2Y12 assay is a useful predictor of long-term clinical outcomes in patients with acute coronary syndrome undergoing percutaneous coronary intervention. *Thromb Res*. 2016; 139:114-20.
54. Stone GW, Witzenbichler B, Weisz G, et al. Platelet reactivity and clinical outcomes after coronary artery implantation of drug-eluting stents (ADAPT-DES): a prospective multicentre registry study. *Lancet*. 2013; 382:614-23.
55. Tantry US, Bonello L, Aradi D, et al. Consensus and update on the definition of on-treatment platelet reactivity to adenosine diphosphate associated with ischemia and bleeding. *J Am Coll Cardiol*. 2013; 62:2261-73.

56. Linnemann B, Schwonberg J, Rechner AR, Mani H, Lindhoff-Last E. Assessment of clopidogrel non-response by the PFA-100 system using the new test cartridge INNOVANCE PFA P2Y. *Ann Hematol.* 2010; 89:597-605.
57. Price MJ, Angiolillo DJ, Teirstein PS, et al. Platelet reactivity and cardiovascular outcomes after percutaneous coronary intervention: a time-dependent analysis of the Gauging Responsiveness with a VerifyNow P2Y12 assay: Impact on Thrombosis and Safety (GRAVITAS) trial. *Circulation.* 2011; 124:1132-7.
58. Collet JP, Cuisset T, Range G, et al. Bedside monitoring to adjust antiplatelet therapy for coronary stenting. *N Engl J Med.* 2012; 367:2100-9.
59. Price MJ, Berger PB, Teirstein PS, et al. Standard- vs high-dose clopidogrel based on platelet function testing after percutaneous coronary intervention: the GRAVITAS randomized trial. *JAMA.* 2011; 305:1097-105.
60. Trenk D, Stone GW, Gawaz M, et al. A randomized trial of prasugrel versus clopidogrel in patients with high platelet reactivity on clopidogrel after elective percutaneous coronary intervention with implantation of drug-eluting stents: results of the TRIGGER-PCI (Testing Platelet Reactivity In Patients Undergoing Elective Stent Placement on Clopidogrel to Guide Alternative Therapy With Prasugrel) study. *J Am Coll Cardiol.* 2012; 59:2159-64.
61. Capranzano P, Capodanno D, Bucciarelli-Ducci C, et al. Impact of residual platelet reactivity on reperfusion in patients with ST-segment elevation myocardial infarction undergoing primary percutaneous coronary intervention. *Eur Heart J Acute Cardiovasc Care.* 2016; 5:475-86.
62. Ferreira JL, Homs S, Berdejo J, et al. Clopidogrel pretreatment in primary percutaneous coronary intervention: prevalence of high on-treatment platelet reactivity and impact on preprocedural patency of the infarct-related artery. *Thromb Haemost.* 2013; 110:110-7.
63. Vavuranakis M, Vrachatis DA, Papaioannou TG, et al. Residual platelet reactivity after clopidogrel loading in patients with ST-elevation myocardial infarction undergoing an unexpectedly delayed primary percutaneous coronary intervention. - Impact on intracoronary thrombus burden and myocardial perfusion. *Circ J.* 2011; 75:2105-12.
64. Althoff TF, Fischer M, Langer E, Ziemer S, Baumann G. Sustained enhancement of residual platelet reactivity after coronary stenting in patients with myocardial infarction compared to elective patients. *Thromb Res.* 2010; 125:e190-6.
65. Eisenberg PR, Sobel BE, Jaffe AS. Activation of prothrombin accompanying thrombolysis with recombinant tissue-type plasminogen activator. *J Am Coll Cardiol.* 1992; 19:1065-9.
66. Rasmanis G, Vesterqvist O, Green K, Edhag O, Henriksson P. Evidence of increased platelet activation after thrombolysis in patients with acute myocardial infarction. *Br Heart J.* 1992; 68:374-6.
67. O'donoghue M, Wiviott SD. Clopidogrel response variability and future therapies: clopidogrel: does one size fit all? *Circulation.* 2006; 114:e600-6.
68. Savcic M, Hauert J, Bachmann F, Wyld PJ, Geudelin B, Cariou R. Clopidogrel loading dose regimens: kinetic profile of pharmacodynamic response in healthy subjects. *Semin Thromb Hemost.* 1999; 25 Suppl 2:15-9.
69. Alexopoulos D, Perperis A, Koniari I, et al. Ticagrelor versus high dose clopidogrel in ST-segment elevation myocardial infarction patients with high platelet reactivity post fibrinolysis. *J Thromb Thrombolysis.* 2015; 40:261-7.
70. Diego A, De Prado AP, Cuellas C, et al. P2Y12 platelet reactivity after thrombolytic therapy for ST-segment elevation myocardial infarction. *Thromb Res.* 2012; 130:e31-6.
71. Gurbel PA, Bliden KP, Hayes KM, Yoho JA, Herzog WR, Tantry US. The relation of dosing to clopidogrel responsiveness and the incidence of high post-treatment platelet aggregation in patients undergoing coronary stenting. *J Am Coll Cardiol.* 2005; 45:1392-6.
72. Dehghani P, Lavoie A, Lavi S, et al. Effects of ticagrelor versus clopidogrel on platelet function in fibrinolytic-treated STEMI patients undergoing early PCI. *Am Heart J.* 2017; 192:105-12.
73. Berwanger O, Nicolau JC, Carvalho AC, et al. Ticagrelor vs Clopidogrel After Fibrinolytic Therapy in Patients With ST-Elevation Myocardial Infarction: A Randomized Clinical Trial. *JAMA Cardiol.* 2018; 3:391-9.

74. Bhindi R, Kajander OA, Jolly SS, et al. Culprit lesion thrombus burden after manual thrombectomy or percutaneous coronary intervention-alone in ST-segment elevation myocardial infarction: the optical coherence tomography sub-study of the TOTAL (Thrombectomy versus PCI Alone) trial. *Eur Heart J*. 2015; 36:1892-900.
75. Higuma T, Soeda T, Abe N, et al. A Combined Optical Coherence Tomography and Intravascular Ultrasound Study on Plaque Rupture, Plaque Erosion, and Calcified Nodule in Patients With ST-Segment Elevation Myocardial Infarction: Incidence, Morphologic Characteristics, and Outcomes After Percutaneous Coronary Intervention. *JACC Cardiovasc Interv*. 2015; 8:1166-76.
76. Ino Y, Kubo T, Tanaka A, et al. Difference of culprit lesion morphologies between ST-segment elevation myocardial infarction and non-ST-segment elevation acute coronary syndrome: an optical coherence tomography study. *JACC Cardiovasc Interv*. 2011; 4:76-82.
77. Hu S, Yonetsu T, Jia H, et al. Residual thrombus pattern in patients with ST-segment elevation myocardial infarction caused by plaque erosion versus plaque rupture after successful fibrinolysis: an optical coherence tomography study. *J Am Coll Cardiol*. 2014; 63:1336-8.
78. Sano T, Tanaka A, Namba M, et al. C-reactive protein and lesion morphology in patients with acute myocardial infarction. *Circulation*. 2003; 108:282-5.
79. Sato Y, Hatakeyama K, Yamashita A, Marutsuka K, Sumiyoshi A, Asada Y. Proportion of fibrin and platelets differs in thrombi on ruptured and eroded coronary atherosclerotic plaques in humans. *Heart*. 2005; 91:526-30.
80. Chandran S, Watkins J, Abdul-Aziz A, et al. Inflammatory Differences in Plaque Erosion and Rupture in Patients With ST-Segment Elevation Myocardial Infarction. *J Am Heart Assoc*. 2017; 6:
81. Bonnefoy A, Daenens K, Feys HB, et al. Thrombospondin-1 controls vascular platelet recruitment and thrombus adherence in mice by protecting (sub)endothelial VWF from cleavage by ADAMTS13. *Blood*. 2006; 107:955-64.
82. Belaouaj AA, Li A, Wun TC, Welgus HG, Shapiro SD. Matrix metalloproteinases cleave tissue factor pathway inhibitor. Effects on coagulation. *J Biol Chem*. 2000; 275:27123-8.
83. Hu S, Zhu Y, Zhang Y, et al. Management and Outcome of Patients With Acute Coronary Syndrome Caused by Plaque Rupture Versus Plaque Erosion: An Intravascular Optical Coherence Tomography Study. *J Am Heart Assoc*. 2017; 6:e004730.
84. Saia F, Komukai K, Capodanno D, et al. Eroded Versus Ruptured Plaques at the Culprit Site of STEMI: In Vivo Pathophysiological Features and Response to Primary PCI. *JACC Cardiovasc Imaging*. 2015; 8:566-75.
85. Jia H, Dai J, Hou J, et al. Effective anti-thrombotic therapy without stenting: intravascular optical coherence tomography-based management in plaque erosion (the EROSION study). *Eur Heart J*. 2017; 38:792-800.
86. Chung CJ, Kirtane AJ, Zhang Y, et al. Impact of high on-aspirin platelet reactivity on outcomes following successful percutaneous coronary intervention with drug-eluting stents. *Am Heart J*. 2018; 205:77-86.
87. Gori AM, Grifoni E, Valenti R, et al. High on-aspirin platelet reactivity predicts cardiac death in acute coronary syndrome patients undergoing PCI. *Eur J Intern Med*. 2016; 30:49-54.
88. Frossard M, Fuchs I, Leitner JM, et al. Platelet function predicts myocardial damage in patients with acute myocardial infarction. *Circulation*. 2004; 110:1392-7.
89. Morishima I, Sone T, Okumura K, et al. Angiographic no-reflow phenomenon as a predictor of adverse long-term outcome in patients treated with percutaneous transluminal coronary angioplasty for first acute myocardial infarction. *J Am Coll Cardiol*. 2000; 36:1202-9.
90. Montalescot G, Cohen M, Salette G, et al. Impact of anticoagulation levels on outcomes in patients undergoing elective percutaneous coronary intervention: insights from the STEEPLE trial. *Eur Heart J*. 2008; 29:462-71.
91. Parodi G, Valenti R, Bellandi B, et al. Comparison of prasugrel and ticagrelor loading doses in ST-segment elevation myocardial infarction patients: RAPID (Rapid Activity of Platelet Inhibitor Drugs) primary PCI study. *J Am Coll Cardiol*. 2013; 61:1601-6.

92. Kunadian V, James SK, Wojdyla DM, et al. Angiographic outcomes in the PLATO Trial (Platelet Inhibition and Patient Outcomes). *JACC Cardiovasc Interv.* 2013; 6:671-83.
93. Gurbel PA, Bliden KP, Dichiara J, et al. Evaluation of dose-related effects of aspirin on platelet function: results from the Aspirin-Induced Platelet Effect (ASPECT) study. *Circulation.* 2007; 115:3156-64.
94. Santos MT, Madrid I, Moscardó A, et al. The administration of a loading dose of aspirin to patients presenting with acute myocardial infarction while receiving chronic aspirin treatment reduces thromboxane A₂-dependent platelet reactivity. *Platelets.* 2014; 25:268-73.
95. Prati F, Romagnoli E, Burzotta F, et al. Clinical Impact of OCT Findings During PCI: The CLI-OPCI II Study. *JACC Cardiovasc Imaging.* 2015; 8:1297-305.
96. Prati F, Romagnoli E, Gatto L, et al. Clinical Impact of Suboptimal Stenting and Residual Intrastent Plaque/Thrombus Protrusion in Patients With Acute Coronary Syndrome: The CLI-OPCI ACS Substudy (Centro per la Lotta Contro L'Infarto-Optimization of Percutaneous Coronary Intervention in Acute Coronary Syndrome). *Circ Cardiovasc Interv.* 2016; 9:
97. Soeda T, Uemura S, Park SJ, et al. Incidence and Clinical Significance of Poststent Optical Coherence Tomography Findings: One-Year Follow-Up Study From a Multicenter Registry. *Circulation.* 2015; 132:1020-9.
98. Choi SY, Witzienbichler B, Maehara A, et al. Intravascular ultrasound findings of early stent thrombosis after primary percutaneous intervention in acute myocardial infarction: a Harmonizing Outcomes with Revascularization and Stents in Acute Myocardial Infarction (HORIZONS-AMI) substudy. *Circ Cardiovasc Interv.* 2011; 4:239-47.
99. Gawaz M. Role of platelets in coronary thrombosis and reperfusion of ischemic myocardium. *Cardiovasc Res.* 2004; 61:498-511.
100. Storey RF, Angiolillo DJ, Patil SB, et al. Inhibitory effects of ticagrelor compared with clopidogrel on platelet function in patients with acute coronary syndromes: the PLATO (PLATElet inhibition and patient Outcomes) PLATELET substudy. *J Am Coll Cardiol.* 2010; 56:1456-62.
101. Geisler T, Kapp M, Gohring-Frischholz K, et al. Residual platelet activity is increased in clopidogrel- and ASA-treated patients with coronary stenting for acute coronary syndromes compared with stable coronary artery disease. *Heart.* 2008; 94:743-7.
102. Bellemain-Appaix A, O'Connor SA, Silvain J, et al. Association of clopidogrel pretreatment with mortality, cardiovascular events, and major bleeding among patients undergoing percutaneous coronary intervention: a systematic review and meta-analysis. *JAMA.* 2012; 308:2507-16.
103. Parodi G, Xanthopoulou I, Bellandi B, et al. Ticagrelor crushed tablets administration in STEMI patients: the MOJITO study. *J Am Coll Cardiol.* 2015; 65:511-2.
104. Bhatt DL, Stone GW, Mahaffey KW, et al. Effect of platelet inhibition with cangrelor during PCI on ischemic events. *N Engl J Med.* 2013; 368:1303-13.
105. Montalescot G, Barragan P, Wittenberg O, et al. Platelet glycoprotein IIb/IIIa inhibition with coronary stenting for acute myocardial infarction. *N Engl J Med.* 2001; 344:1895-903.
106. De Luca G, Navarese E, Marino P. Risk profile and benefits from Gp IIb-IIIa inhibitors among patients with ST-segment elevation myocardial infarction treated with primary angioplasty: a meta-regression analysis of randomized trials. *Eur Heart J.* 2009; 30:2705-13.
107. Aradi D, Komocsi A, Price MJ, et al. Efficacy and safety of intensified antiplatelet therapy on the basis of platelet reactivity testing in patients after percutaneous coronary intervention: systematic review and meta-analysis. *Int J Cardiol.* 2013; 167:2140-8.
108. Steg PG, Bhatt DL, Hamm CW, et al. Effect of cangrelor on periprocedural outcomes in percutaneous coronary interventions: a pooled analysis of patient-level data. *Lancet.* 2013; 382:1981-92.

Caractérisation de la plaque athérombotique à la phase aigüe de l'infarctus du myocarde en imagerie endocoronaire et marqueurs biologiques thrombotiques

Intracoronary imaging characterization of atherothrombotic plaque in acute myocardial infarction and biological markers of thrombosis

Vincent ROULE

Résumé: L'activité plaquettaire joue un rôle clé dans la physiopathologie de l'infarctus du myocarde avec sus-décalage du segment ST (IDM ST+). La réactivité plaquettaire est augmentée lors d'un IDM ST+, traité par angioplastie primaire ou par fibrinolyse avec succès. La relation entre la réactivité plaquettaire résiduelle après un pré-traitement, la charge athérombotique et la qualité de la reperfusion myocardique reste peu décrite dans le cadre des IDM ST+. La tomographie par cohérence optique et celle plus récente par domaine de fréquence offrent une imagerie de haute résolution permettant l'identification et la quantification précise de la charge athérombotique intracoronaire (CAT). La CAT résiduelle intra-stent peut aider à mieux comprendre la relation entre la réactivité plaquettaire et la reperfusion. Dans un premier temps, nous avons évalué la précision des tests VerifyNow et PFA en comparaison à l'agrégométrie optique pour la détection de l'hyperréactivité plaquettaire dans le contexte particulier des IDM ST+ traités par fibrinolyse avec succès. Nous avons aussi décrit les caractéristiques de la CAT avant et après angioplastie selon la présence d'une rupture de plaque ou d'une érosion coronaire chez des patients traités par fibrinolyse avec succès. Ensuite, nous avons étudié la relation entre la réactivité plaquettaire résiduelle (en réponse au ticagrelor et à l'aspirine) mesurée par VerifyNow et la reperfusion myocardique chez des patients traités par angioplastie primaire. En parallèle, nous avons décrit la relation entre la reperfusion myocardique et la CAT résiduelle intra-stent dans la même cohorte.

Abstract: Platelet activity plays a key role in the pathophysiology of ST-segment elevation myocardial infarction (STEMI). Platelet reactivity is enhanced after STEMI treated with primary percutaneous coronary intervention (PCI) or successful thrombolysis. The relationship between residual platelet reactivity after pre-treatment, the atherothrombotic burden and the quality of reperfusion remains poorly described in STEMI. Optical coherence tomography (OCT) and optical frequency domain imaging (OFDI) provide high resolution imaging allowing identification and accurate quantification of intracoronary atherothrombotic burden (ATB). Residual in-stent ATB may help to better understand the relation between platelet reactivity and reperfusion. First, we assessed the accuracy of the point-of-care tests VerifyNow and PFA in comparison to light transmittance aggregometry to detect high on-treatment platelet reactivity (HPR) in the particular setting of STEMI successfully treated with fibrinolysis. We also described the characteristics of ATB before and after PCI according to the underlying presence of rupture or erosion in patients successfully treated with fibrinolysis. Then, we assessed the relationship between residual platelet reactivity (in response to ticagrelor and aspirin) using VerifyNow and myocardial reperfusion in primary PCI patients. In parallel, we studied the relationship between myocardial reperfusion and residual in-stent ATB in the same cohort.

Mots-clés : Infarctus du myocarde avec sus-décalage du segment ST; tomographie par cohérence optique; thrombus; reperfusion myocardique; réactivité plaquettaire; fibrinolyse; angioplastie primaire

Keywords: ST-segment elevation myocardial infarction; Optical coherence tomography; thrombus; myocardial reperfusion; platelet reactivity; fibrinolysis; primary-PCI