



**HAL**  
open science

## La chirurgie éveillée chez l'enfant

Matthieu Delion

► **To cite this version:**

Matthieu Delion. La chirurgie éveillée chez l'enfant. Chirurgie. Université d'Angers, 2016. Français.  
NNT : 2016ANGE0073 . tel-02613225

**HAL Id: tel-02613225**

**<https://theses.hal.science/tel-02613225>**

Submitted on 19 May 2020

**HAL** is a multi-disciplinary open access archive for the deposit and dissemination of scientific research documents, whether they are published or not. The documents may come from teaching and research institutions in France or abroad, or from public or private research centers.

L'archive ouverte pluridisciplinaire **HAL**, est destinée au dépôt et à la diffusion de documents scientifiques de niveau recherche, publiés ou non, émanant des établissements d'enseignement et de recherche français ou étrangers, des laboratoires publics ou privés.

# Thèse de Doctorat

Matthieu DELION

*Mémoire présenté en vue de l'obtention du  
grade de Docteur de l'Université d'Angers  
sous le sceau de l'Université Bretagne Loire*

École doctorale : *Biologie-Santé*

Discipline : *Neurosciences, section CNU 69*

Unité de recherche : *Service de neurochirurgie, CHU Angers*

Soutenu le *22 Mars 2016*

Thèse N° : *81437*

## La chirurgie éveillée chez l'enfant

### JURY

|                         |   |  |
|-------------------------|---|--|
| Rapporteurs :           | <b>Michel ZERAH</b><br><b>Patrick VAN BOGAERT</b>   | Professeur des Universités-Praticien hospitalier, Université Paris V<br>Professeur des Universités-Praticien hospitalier, Université de Bruxelles  |
| Examineurs :            | <b>Michel ZERAH</b><br><b>Patrick VAN BOGAERT</b><br><b>Philippe MENEI</b><br><b>Aram TER MINASSIAN</b> | Professeur des Universités-Praticien Hospitalier, Université Paris V<br>Professeur des Universités-Praticien Hospitalier, Université de Bruxelles<br>Professeur des Universités-Praticien Hospitalier, Université d'Angers<br>Praticien Hospitalier-HDR, Université d'Angers |
| Invité(s) :             | <b>Philippe MERCIER</b>   | Professeur des Universités-Praticien Hospitalier, Université d'Angers  |
| Directeur de Thèse :    | <b>Philippe MENEI</b>   | Professeur des Universités-Praticien Hospitalier, Université d'Angers  |
| Co-directeur de Thèse : | <b>Aram TER MINASSIAN</b>   | Praticien Hospitalier-HDR, Université d'Angers   |

## Remerciements:

Au Pr. Philippe Menei, merci de m'avoir encouragé et encadré durant cette Thèse,

Au Dr. Aram Ter Minassian, merci d'avoir accepté de m'encadrer pour ce projet, tes grandes connaissances en imagerie fonctionnelle ne cesseront jamais de m'impressionner,

Au Pr. Michel Zerah, cher Michel, merci de me faire l'honneur d'être rapporteur de ce travail de Thèse,

Au Pr. Van Bogaert, merci de me faire l'honneur d'être rapporteur de ce travail de thèse, je souhaite que cette première rencontre ouvre la voie d'une longue collaboration au sein du CHU d'Angers,

Au Pr. Philippe Mercier, merci de me faire l'honneur de participer à mon jury de thèse,

Au Dr. Thierry Lehoussé, mon cher Thierry, merci d'avoir accepté de participer à cette aventure de chirurgie éveillée chez les enfants, c'est grâce à toi que j'ai découvert notamment les bienfaits de l'hypnose... j'espère que cette collaboration continuera...

Au Dr. Mickael Dinomais, merci pour ton aide, tes stimulations régulières et tes nombreuses idées...

Au Dr. Elise Riquin et au Dr. Jean Malka, merci pour votre participation à ce travail et votre enthousiasme,

A Mme Laetitia Fortuny et Mr Pierre Martin pour leur participation, merci du cœur que vous mettez à cet ouvrage,

A Mme Patricia Corne, ta grande maîtrise de l'hypnose a été essentielle dans ce travail,

A tous mes collègues neurochirurgiens notamment angevins, merci pour votre soutien,

A ma femme Anne, merci de ton soutien et de ton aide, sans toi je n'en serais pas là,

A mes enfants Jeanne et Joseph, vous illuminez chaque instant de ma vie,

A mes Parents et ma Famille,

## Table des matières:

|          |  |           |
|----------|--|-----------|
| <b>1</b> | <b>Introduction .....</b>  | <b>5</b>  |
| <b>2</b> | <b>Etat des lieux de la chirurgie éveillée.....</b>  | <b>8</b>  |
| 2.1      | Rappel : chirurgie éveillée et cartographie corticale chez l'adulte.....   | 8         |
| 2.2      | La chirurgie éveillée chez l'enfant dans la littérature .....  | 16        |
| 2.3      | La chirurgie éveillée chez l'enfant en France : .....  | 20        |
| <b>3</b> | <b>La chirurgie éveillée avec cartographie corticale et sous corticale chez l'enfant : expérience clinique angevine.....</b>                               | <b>31</b> |
|          | ❖ <u>Article n°1</u> : Specificities of awake craniotomy and brain mapping in children for resection of supratentorial tumours in the language areas. .... | 32        |
| <b>4</b> | <b>Impact psychologique :.....</b>   | <b>41</b> |
|          | ❖ <u>Article n°2</u> : Psychiatric and psychological impact of surgery while awake in children for resection of brain tumors in the language area .....    | 42        |
| <b>5</b> | <b>IRMf de repos :.....</b>  | <b>58</b> |
|          | ❖ <u>Article N°3</u> : Resting state fMRI in children for preoperative language mapping. Comparison with intraoperative direct stimulation. ....           | 59        |
| <b>6</b> | <b>Discussion et perspectives :.....</b>   | <b>95</b> |
| 6.1      | Limitations .....  | 95        |
| 6.2      | Conditionnement préopératoire: .....   | 98        |
| 6.3      | La place de l'hypnose .....  | 99        |
| 6.4      | L'IRM fonctionnelle de repos : .....   | 101       |
| 6.5      | Perspectives :.....  | 105       |

|           |   |            |
|-----------|---|------------|
| <b>7</b>  | <b>Conclusion :</b> .....   | <b>105</b> |
| <b>8</b>  | <b>Publications et communications présentées au cours de la thèse : .....</b>                     | <b>107</b> |
| 8.1       | Publications : .....  | 107        |
| 8.2       | Articles soumis (1 <sup>ER</sup> et dernier auteur) : .....                                       | 108        |
| 8.3       | Publications didactiques dans revue avec comité de lecture : .....                                | 108        |
| 8.4       | Conférences orales sur invitation : .....   | 108        |
| 8.5       | Communications orales lors de congrès : .....   | 109        |
| <b>9</b>  | <b>Annexes :</b> .....  | <b>110</b> |
| 9.1       | Annexe 1 : items DO 80.....   | 110        |
| 9.2       | Annexe 2 : questionnaire de latéralité manuelle d'Edinburgh d'après<br>Oldfield 1971 (108) :..... | 111        |
| <b>10</b> | <b>Bibliographie.....</b>   | <b>112</b> |

# 1 Introduction

Chez l'enfant, les tumeurs cérébrales représentent la deuxième cause de cancer après les hémopathies et la première cause de décès par cancer. La prise en charge de cette pathologie apparaît donc comme un enjeu de santé publique. Le pronostic vital de ces enfants est intimement lié à la qualité de la résection chirurgicale de la tumeur cérébrale. En cas de proximité avec certaines aires éloquentes du cerveau (motricité et langage), le pronostic fonctionnel peut-être impacté par la chirurgie. Depuis un peu plus de dix ans, la chirurgie éveillée avec cartographie corticale et sous corticale per opératoire (CECCSC) s'est développée dans le monde de la neurochirurgie adulte. Ce type de procédure est maintenant réalisé en routine dans certains centres pour la prise en charge de tumeurs cérébrales sustentorielles localisées en régions éloquentes. Son intérêt a été largement démontré sur le plan fonctionnel. Cette stratégie permet en effet de réaliser une exérèse chirurgicale maximaliste mais respectueuse de la fonction. Pour des raisons épidémiologiques (faible incidence des tumeurs sustentorielles de l'enfant) mais aussi probablement par crainte, la CECCSC s'est très peu développée chez l'enfant. Elle pose en effet plusieurs problèmes, notamment de coopération, voire de communication chez les plus jeunes. Il existe bien sûr par ailleurs des limites liées à la maturation du système nerveux chez les tous petits pouvant poser des problèmes de paramétrage des outils d'électrostimulation. La notion de plasticité cérébrale, trop souvent surestimée chez les enfants, a quant à elle probablement constitué un frein au développement de la technique. Il existe quelques publications dans la littérature sur cette chirurgie en pédiatrie mais la plupart des articles concernent des adolescents ou des jeunes adultes.

L'objectif principal de cette thèse a été le transfert de la CECCSC de l'adulte à l'enfant. En effet ce type de procédure est pratiquée dans notre service chez l'adulte depuis 2007 et a fait d'ailleurs l'objet d'un travail préalable portant sur la CECCSC dans les tumeurs de l'aire motrice supplémentaire. Nous avons ainsi acquis une large expérience ce qui nous permet de réaliser cette procédure chez l'adulte en routine, de façon parfaitement réglée et sécurisée.

Dans un premier temps nous proposons un état des lieux de la CECCSC de l'enfant dans la littérature puis sur le terrain en France. Ce recensement en

France repose sur l'encadrement d'un mémoire pour le certificat de capacité d'orthophoniste (Université Paris VI) portant sur l'état des lieux de la CECCSC en France.

Le véritable travail de cette thèse se divise ensuite en trois parties :

La première partie de cette thèse est le fruit de notre expérience clinique chez l'enfant. Après avoir réuni une équipe pédiatrique pluridisciplinaire incluant anesthésiste-réanimateur, neuropsychologue, orthophoniste et pédopsychiatre, nous avons étudié la faisabilité de la CECCSC chez l'enfant à travers une cohorte de 7 jeunes patients âgés de 8 à 16 ans. Nous présentons dans cette première partie les spécificités et les adaptations nécessaires chez les enfants. Un certain nombre de précautions doivent en effet être respectées notamment en ce qui concerne la préparation de ces jeunes patients. Dans ce cadre, l'hypnose, en tant que technique de diversion mentale, nous est apparue comme un outil indispensable. Ce premier volet de ce travail de thèse nous a ainsi conduit à nous interroger sur certains aspects propres à l'enfant et en particulier leur degré de maturité qui pourrait constituer une limite infranchissable pour le bon déroulement de cette chirurgie mais aussi l'impact de la maturation et de la plasticité cérébrale.

La deuxième partie de cette thèse porte sur l'impact psychologique de cette chirurgie chez les enfants. Cette seconde partie a été réalisée en collaboration avec l'équipe de pédopsychiatrie grâce à des entretiens répétés.

La troisième partie de cette thèse a pour objectif de trouver un moyen de pallier à ce type de prise en charge en cas de contre indication à une chirurgie éveillée chez l'enfant. Dans notre expérience cette situation ne s'est présentée que très récemment, cependant il nous avait paru indispensable d'explorer cette éventualité. En effet, un enfant trop immature ou présentant des troubles du langage en préopératoire, ne peut bénéficier d'une CECCSC dans de bonnes conditions. L'axe majeur de cette réflexion repose sur l'utilisation de l'IRM fonctionnelle (IRMf) de repos chez l'enfant. A l'heure actuelle, même si la CECCSC reste le « gold standard » pour la résection d'une lésion en zones fonctionnelles, de nombreux travaux ont été publiés dans la littérature portant sur le bilan préchirurgical par IRMf chez l'adulte. Contrairement à l'IRMf d'activation qui nécessite la coopération du patient à travers la réponse à une tâche, l'IRMf de repos est basée sur la fluctuation spontanée de l'activité neuronale et ne nécessite

aucune coopération du patient. Le but ultime de cette troisième partie est de comparer le réseau du langage obtenu en préopératoire par IRMf de repos avec la cartographie du langage réalisée en peropératoire.



# 2 Etat des lieux de la chirurgie éveillée

## 2.1 Rappel : chirurgie éveillée et cartographie corticale chez l'adulte

La question de la CECCSC se pose lorsqu'on se trouve face à une tumeur cérébrale située en régions fonctionnelles ou « éloquentes » c'est à dire impliquées dans une fonction (motricité, langage, vision, somesthésie...). En effet, dans cette situation, en raisonnant comme pour une tumeur en zone non éloquente, le risque est de réaliser, sous anesthésie générale (AG), non seulement une résection incomplète mais surtout de provoquer des séquelles neurologiques. Ce risque de séquelles neurologique est très élevé puisqu'il est de 15 à 27,5% dans certaines séries récentes où l'intervention est réalisée sous AG sans cartographie corticale directe (1-3). Par ailleurs, il semble encore trop tôt pour se fier uniquement aux techniques d'imageries fonctionnelles et de tractographie préopératoire car en fonction des publications la corrélation n'est pas toujours suffisante (4). Le seul moyen à l'heure actuelle de pouvoir monitorer la fonction pendant une chirurgie en zone éloquente est donc la CECCSC. Cette technique repose sur la stimulation électrique corticale directe décrite dès les années 1930, qui représente encore à l'heure actuelle le « gold standard » en termes de cartographie corticale et sous corticale (5). Elle remonte à Cushing, Forester, Penfield et Boldrey. La technique a été proposée initialement par Penfield et Boldrey pour les fonctions motrices et sensibles (6) puis par Penfield et Rasmussen pour le langage (7). La technique princeps repose donc sur les travaux de Penfield mais aussi d'Ojemann. La technique de cartographie précise a été largement décrite dans la littérature par la suite (5,8,9) et plus récemment par Duffau (10-12)(13). Cette technique est résumée dans le tableau n°1.

Il existe en réalité plusieurs écoles selon les intervenants : endormi sous anesthésie générale (AG) puis réveillé au moment de l'ouverture durale jusqu'à la fin (14), éveillé du début à la fin avec hypnose (15), endormi-éveillé-endormi, cette dernière technique mise au point par Duffau a pour intérêt de réaliser toute la première partie jusqu'à l'ouverture de la dure-mère sous AG, puis de réaliser la

cartographie corticale et sous corticale et donc la déconnection sous corticale chez le patient réveillé puis de terminer l'exérèse et la fermeture sous AG (16,17).

| PARAMÈTRES DE STIMULATIONS  |
|---|
| <ul style="list-style-type: none"><li>— impulsions rectangulaires, courant biphasique</li><li>— fréquences de 50 à 60 Hz</li><li>— intensités de 1 à 6 mA (anesthésie locale) ou de 4 à 18 mA (anesthésie générale)</li><li>— augmentation progressive des intensités de 0,5 en 0,5 sur l'écran du générateur (soit de 1 en 1 mA)</li></ul>   |
| durée de stimulation : 1 seconde (sensori-moteur), 4 secondes (fonctions cognitives)  |
| <i>Attention</i> : l'impédance est augmentée chez l'enfant ; l'impédance peut varier dans, au voisinage immédiat et à distance de la tumeur ; l'impédance peut diminuer après exérèse lésionnelle   |
| MODALITÉS PRATIQUES DE STIMULATIONS   |
| <ul style="list-style-type: none"><li>— stimuler l'ensemble de la surface corticale exposée, tous les 5 mm<sup>2</sup> (puisque sonde de 5 mm d'espacement)</li><li>— stimuler chaque site au moins 3 fois</li><li>— ne jamais stimuler le même site cortical deux fois successivement</li><li>— toujours réaliser un test de vérification sans stimulation entre deux stimulations</li><li>— si tâche cognitive, toujours commencer la stimulation avant la présentation de l'item</li><li>— en sous-cortical : majorer les intensités de 2 mA, et répéter <i>très régulièrement</i> les stimulations</li><li>— toujours garder les surfaces à stimuler à peine humides</li><li>— en cas de crise : irriguer avec du sérum froid ; ne pas restimuler immédiatement après</li></ul> |
| <i>Attention</i> : ne pas se contenter d'un seul site éloquent, mais chercher les redondances possibles ; une cartographie négative ne protège pas, mais pose le problème de la fiabilité de l'exploration  |
| ENVIRONNEMENT   |
| <ul style="list-style-type: none"><li>— Anesthésie adaptée (propofol + analgésique)</li><li>— Surveillance par au moins deux observateurs de l'hémicorps controlatéral lors de cartographie motrice sous anesthésie générale (membres supérieur et inférieur ± face)</li><li>— Orthophoniste et/ou neuropsychologue si cartographie des fonctions cognitives</li><li>— Tâches per-opératoires adaptées (&lt; 4 secondes), sélectionnées en fonction du site lésionnel, du bilan neuropsychologique et de l'INF pré-opératoires</li></ul>  |

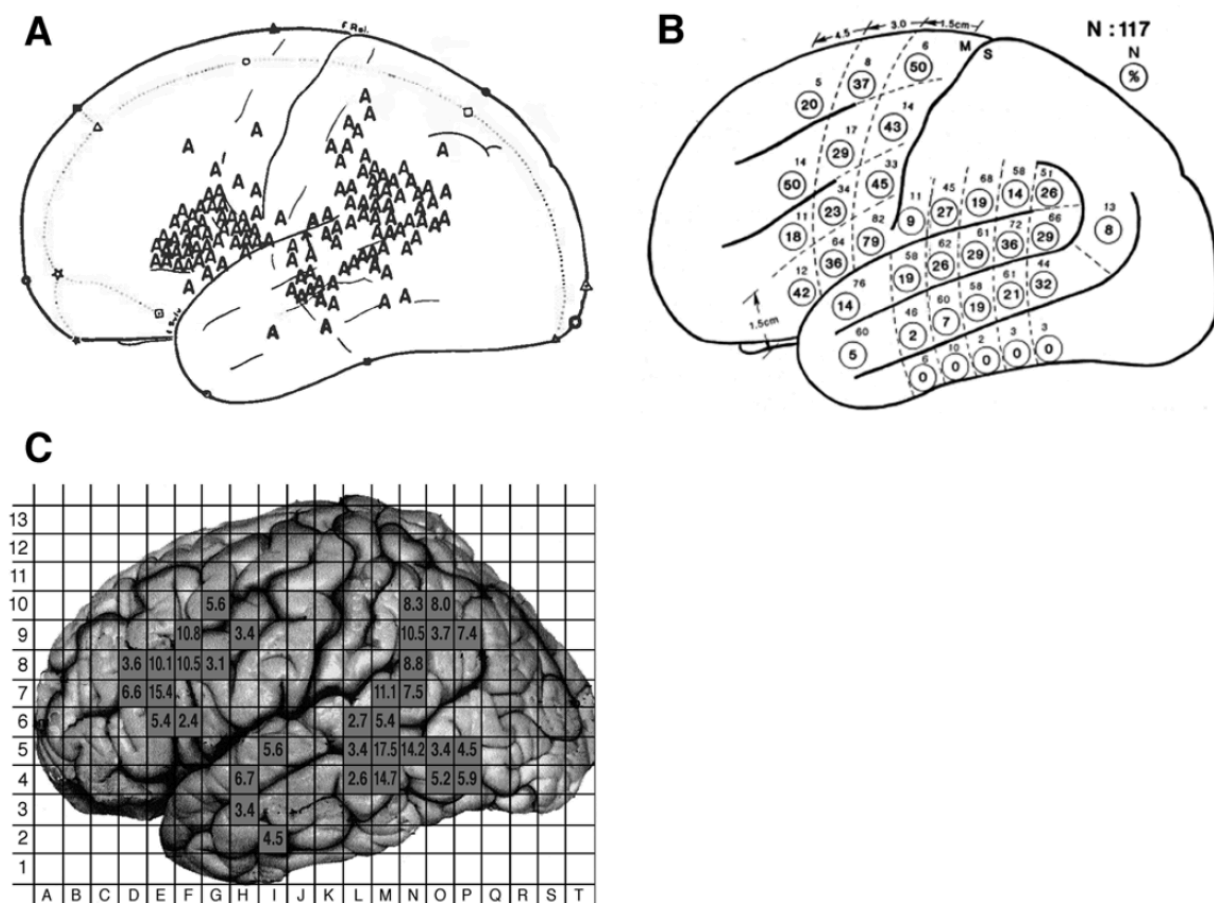
*Tableau 1 : Résumé des paramètres et modalités de stimulation selon Duffau. Extrait de Duffau, H. (2004). "[Peroperative functional mapping using direct electrical stimulations. Methodological considerations]." Neurochirurgie 50(4): 474-83 (10).*

En ce qui concerne la technique de la cartographie elle-même, tous les auteurs ont à peu près les mêmes pratiques. Il y a cependant des différences de considérations notamment en ce qui concerne l'EEG per opératoire qui selon certains auteurs n'est pas nécessaire (18).

Elle peut être pratiquée sous anesthésie générale en cas de chirurgie portant sur l'exérèse de tumeurs intéressant la région motrice cependant dans notre expérience même en cas de chirurgie en région motrice, il est beaucoup plus confortable d'opérer en conditions vigiles notamment en ce qui concerne le risque de déclencher des crises d'épilepsie lors de la stimulation électrique. Il semble en effet que le seuil épiléptogène soit beaucoup plus bas chez un patient sous AG.

En cas d'exérèse de tumeurs intéressant les régions impliquées dans le langage, la vision et la somesthésie, la chirurgie doit être réalisée chez un patient éveillé avec anesthésie locale. Selon H. Duffau, la CECCSC est aussi nécessaire pour opérer l'hémisphère mineur. Dans le cas du langage, la stimulation a une action

inhibitrice sur la fonction par désorganisation de l'influx nerveux (19). Elle induit ainsi en pratique des troubles du langage de différents types en fonction de la zone stimulée qu'elle soit corticale ou sous corticale (manque du mot, troubles de répétition, paraphasies...). Il semble que le test de dénomination d'images utilisé par la plupart des auteurs soit le plus robuste et permette de détecter la majorité des sites éloquentes impliqués dans le langage (20,21).



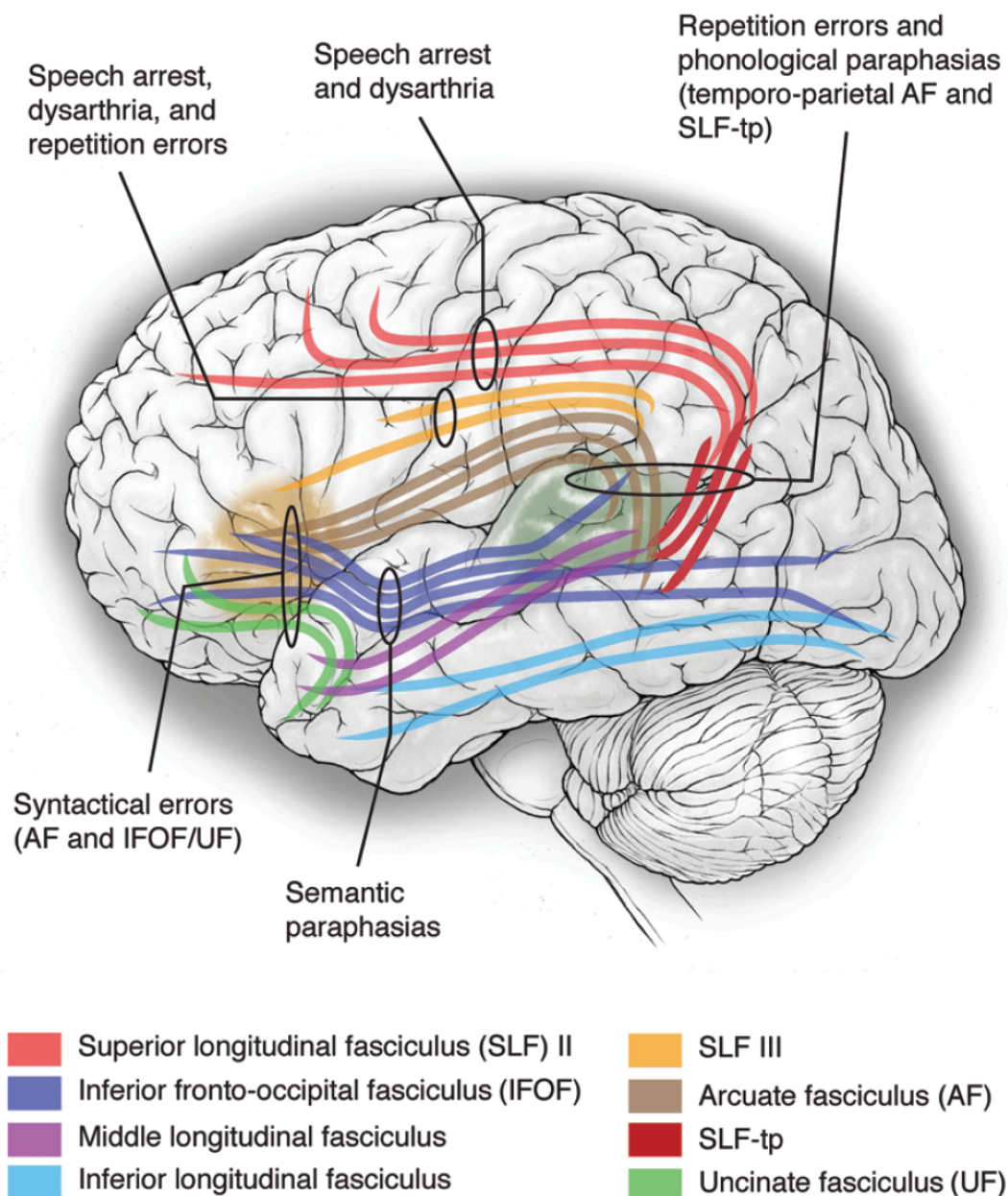
*Figure 1: Résultats de cartographies corticales du langage réalisées sur d'importantes séries de patients de la littérature. D'après Chang EF, Raygor KP, Berger MS. Contemporary model of language organization: an overview for neurosurgeons. J Neurosurg. 2015 Feb;122(2):250–61 (20). A: Représentation selon Penfield des sites corticaux (lettre "A") induisant des troubles phasiques lors de la stimulation (8). B: Représentation selon Ojemann des sites corticaux induisant des troubles phasiques lors de la stimulation sur une série de 117 patients. Le petit chiffre du haut dans chaque zone délimitée par des lignes brisées représente le nombre de patients stimulés à cet endroit; Le chiffre entouré correspond au pourcentage de patients dont la stimulation de cette zone a entraîné des troubles phasiques (5). C: Représentation selon Sanai et Al., des sites corticaux induisant des erreurs de dénomination lors de la stimulation (22).*

On connaît maintenant la plupart des sites impliqués dans le langage au niveau

cortical mais aussi au niveau des faisceaux sous-corticaux de substance blanche. On sait aussi approximativement quels types de troubles doivent être attendus en fonction des sites du langage explorés, qu'ils soient corticaux ou sous corticaux. Au niveau cortical, Penfield a ainsi décrit plusieurs types de troubles du langage lors de ses nombreuses cartographies corticales en fonction des sites stimulés sur l'hémisphère gauche (8) : ainsi, selon lui, les sites provoquant une anarthrie (absence totale de langage) étaient plutôt situés au niveau de la pars opercularis et du gyrus précentral, mais peuvent aussi être retrouvés au niveau de l'opercule frontal et des régions temporo-pariétales (cf. figure 1A). En revanche les sites provoquant les autres troubles du langage tels qu'une anomie (sans anarthrie) et plus globalement une erreur de dénomination ou une persévération sur un mot, se situaient plutôt au niveau de la partie postérieure du gyrus frontal inférieur, des aires temporales postérieures et des aires pariétales inférieures. Cette répartition a été confirmée depuis par d'autres grandes séries récentes notamment d'Ojemann (5) (cf. figure 1B) et Berger (22) (cf. figure 1C). Si cette répartition des sites éloquents semble robuste et reproductible sur ces grandes séries, il ne faut pas perdre de vue le fait que chaque patient présente une organisation particulière de son langage et que celle-ci reste totalement imprévisible en préopératoire (20). En effet, il existe une grande variabilité interindividuelle des sites éloquents (5) ; de plus, la présence d'une lésion et notamment d'un gliome infiltrant provoque une réorganisation locale ou controlatérale du réseau (23-26). Par ailleurs il faut tenir compte du fait qu'un site provoquant un trouble phasique correspond à une zone corticale très limitée d'environ 1cm<sup>2</sup>, souvent située juste à côté d'une zone non éloquente à la stimulation (5,8). Ces éléments constituent des arguments imparables rendant indispensable une cartographie corticale chez des patients opérés en zones fonctionnelles.

En ce qui concerne l'organisation sous corticale du langage, les récentes avancées majeures reposent essentiellement sur les résultats des travaux de H. Duffau et de quelques autres auteurs, obtenus lors de chirurgies éveillées (11,12,26-34). L'objectif est désormais de prendre pour limites d'exérèse les limites fonctionnelles et non plus tumorales. Un schéma de l'organisation sous corticale des réseaux du langage a été proposé récemment par l'équipe de Berger

reprenant les principaux faisceaux et les troubles attendus lors de leur stimulation (20)(cf. figure 2).



*Figure 2: Représentation schématique des principaux faisceaux de substance blanche impliqués dans le langage et des troubles du langage induits par leur stimulation électrique. D'après Chang EF, Raygor KP, Berger MS. Contemporary model of language organization: an overview for neurosurgeons. J Neurosurg. 2015 Feb;122(2):250-61(20).*

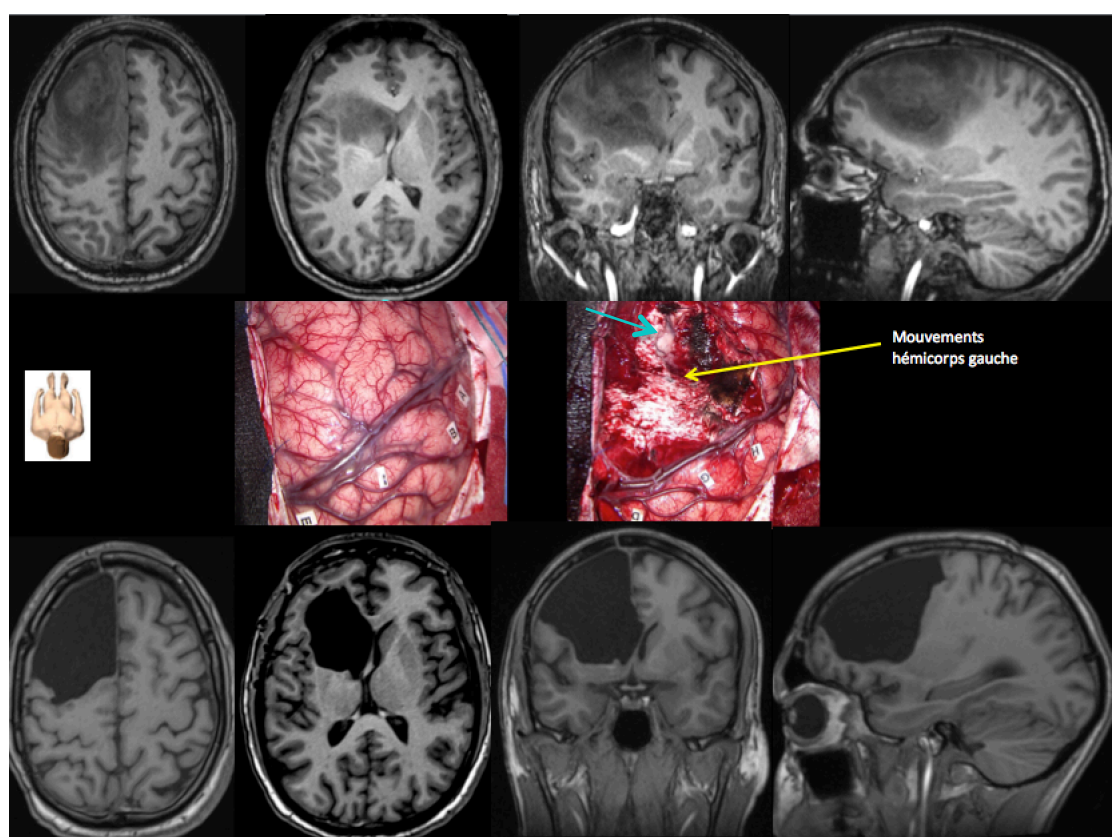
Dans les années 1990 et 2000, de plus en plus d'équipes se sont formées à la CECCSC pour l'exérèse de tumeurs en régions éloquentes (27,35-54).

A l'heure actuelle, l'intérêt de la CECCSC n'est plus à démontrer en terme de pronostic fonctionnel (22) mais aussi de pronostic vital y compris dans les

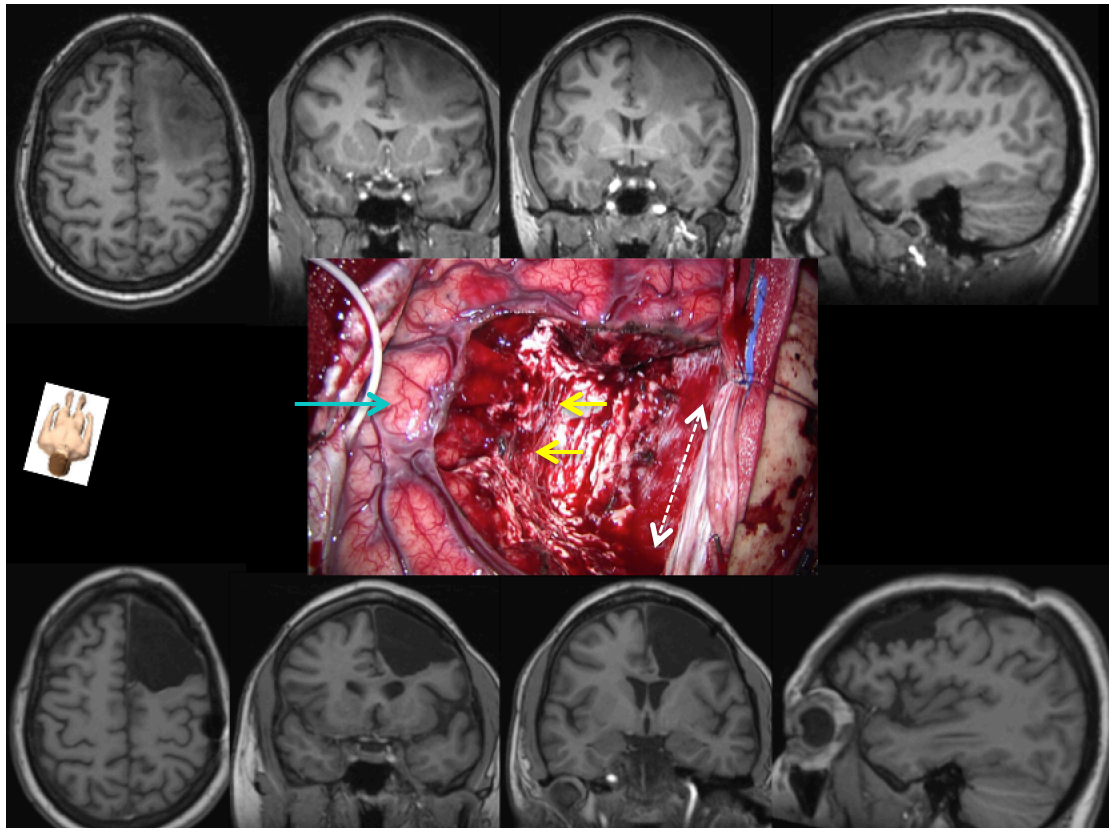
tumeurs malignes (48,55). En effet la CECCSC permet une résection plus importante des tumeurs situées en régions fonctionnelles (56), cette augmentation du volume tumoral réséqué améliore la survie des patients (57-60).

Nous avons commencé à réaliser cette chirurgie dans le service de neurochirurgie du CHU d'Angers en 2007. Elle nécessite un apprentissage théorique et pratique non négligeable. La CECCSC est maintenant pratiquée en routine dans le service avec des résultats de plus en plus satisfaisants et constitue un centre d'intérêt majeur dans mon activité de neurochirurgie.

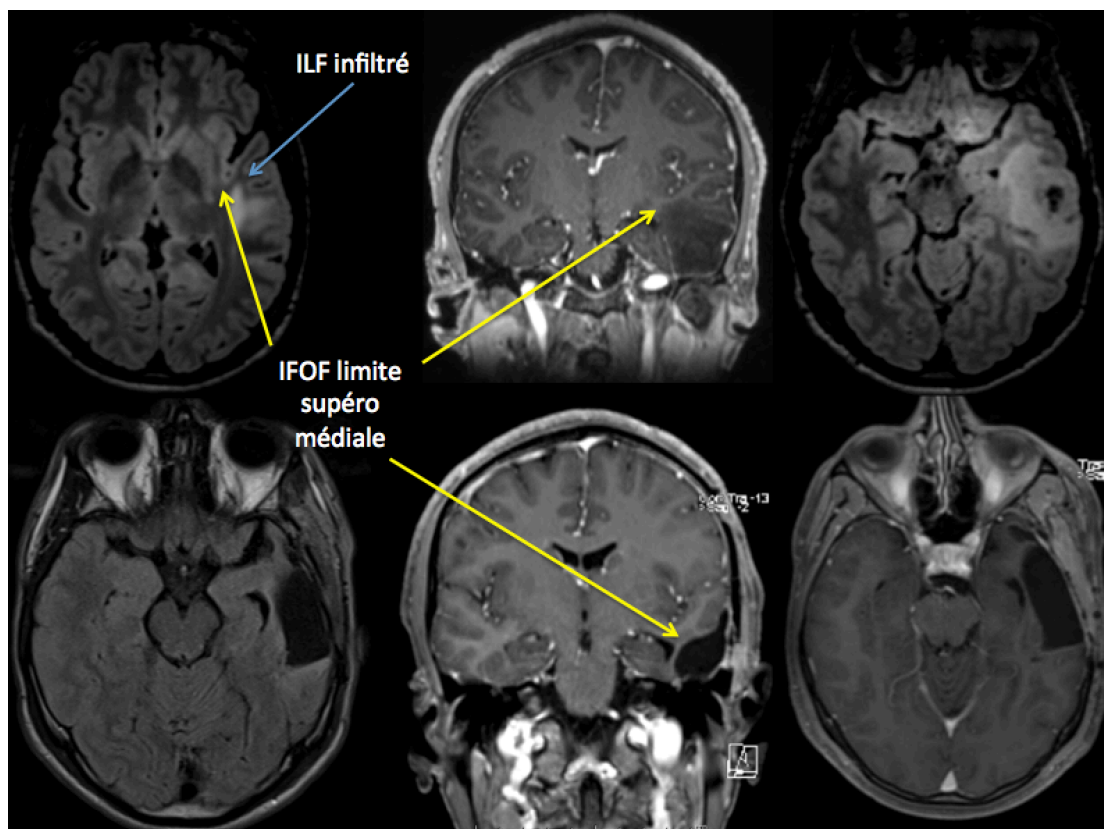
Les trois dossiers cliniques suivants illustrent notre expérience en CECCSC chez l'adulte avec des bons résultats fonctionnels sur la motricité et sur le langage. Il s'agit de trois dossiers tirés de mon expérience personnelle :



*Figure 3 : Exemple de chirurgie éveillée d'un gliome infiltrant frontal droit. La stimulation corticale chez ce patient a permis de délimiter l'aire motrice primaire droite repérée par les étiquettes corticales. L'intérêt dans ce cas était de déterminer la limite fonctionnelle postérieure motrice et donc de passer en zone saine. La stimulation sous corticale a permis de localiser le faisceau cortico-spinal et de le suivre jusqu'à la capsule interne en respectant le bras postérieur. La flèche jaune montre le bras postérieur de la capsule interne où la stimulation déclenchait des mouvements synchrones de l'ensemble de l'hémicorps gauche. La flèche verte montre le plancher du ventricule latéral droit dont la paroi est ouverte.*



*Figure 4 : Exemple de chirurgie éveillée d'un gliome infiltrant frontal gauche chez un patient droitier. La stimulation corticale dans ce cas a permis de localiser le gyrus frontal inférieur et plus particulièrement le pied de F3 (gyrus frontal inférieur : flèche verte). Dans la mesure où la tumeur infiltrait les gyri frontaux supérieurs et inférieurs, la limite de résection était le sillon frontal inférieur gauche (dissection sous-piale). La double flèche blanche désigne la faux du cerveau. La stimulation sous corticale (flèches jaunes) a permis dans ce cas de déterminer la position du faisceau longitudinal supérieur (portion supérieure du faisceau arqué) et du faisceau occipito-frontal supérieur qui constituaient la limite inférieure de la résection.*



*Figure 5: Exemple de chirurgie éveillée d'un gliome infiltrant de haut grade temporal gauche chez un patient droitier. Hormis l'intérêt évident du mapping cortical pour délimiter les limites d'exérèse, la stimulation sous corticale a permis d'identifier le faisceau occipito frontal inférieur (IFO) grâce à la mise en évidence de paraphrasies sémantiques. Ce faisceau constituait la limite supéro-médiale de notre exérèse. (ILF : faisceau longitudinal inférieur).*

Le challenge aujourd'hui n'est plus d'opérer à proximité des zones fonctionnelles mais bien dans les zones anatomiquement connues pour être fonctionnelles. Cette nouvelle vision remet en question la théorie localisationniste de la neuroanatomie dans laquelle une région cérébrale correspondait à une fonction précise (61). En effet, il semble que chaque cerveau soit différent avec une organisation en réseaux interconnectés propres à chacun reliés par des faisceaux de substance blanche (20). La situation d'une tumeur dans le pied de F3 par exemple ne doit pas constituer un frein et rendre un patient inopérable. De nombreuses publications récentes montrent que l'on peut opérer sans risque dans certaines régions éloquentes voire les réséquer sans provoquer de trouble du langage. Ces publications s'appuient sur la résection



partielle ou complète d'aires corticales comme Broca ou même de faisceaux d'association de substance blanche comme le faisceau unciné (20,62-67)(68).

## 2.2 La chirurgie éveillée chez l'enfant dans la littérature

Dans la littérature internationale, on trouve essentiellement quelques cas isolés ou petites cohortes d'enfants opérés en CECCSC (cf. tableau 2). La faisabilité de la CECCSC chez l'enfant a déjà été démontré à propos de ces quelques cas. Nous revoyons dans ce paragraphe, les principales publications de la littérature portant sur la chirurgie éveillée chez l'enfant:

| Journal, year, reference                   | Number of pediatric while awake surgical procedures | Age of the children (years)            | Use of hypnosis |
|--|---|--|-----------------|
| Neurosurgery 1989 (2)                      | 3   | Unspecified                            | No              |
| Paediatric Anesthesia 1997 (23)            | 1   | 12                                     | No              |
| Paediatric Anesthesia 2000 (22)            | 12  | 11 to 15 not detailed                  | No              |
| Journal of Neurosurgery 2003 (1)           | 8   | 10 to 16 not detailed                  | No              |
| Journal of Clinical Anesthesia 2004 (9)    | 3   | 11, 12, 16                             | No              |
| Anesthesia 2004 (21)                       | 1   | 9                                      | No              |
| Pediatric Anesthesia 2006 (20)             | 2   | 16, 16                                 | No              |
| Journal of Clinical Neuroscience 2014 (10) | 10  | 11, 11, 13, 13, 15, 16, 16, 17, 17, 17 | No              |
| Our study: World Neurosurgery 2015 (14)    | 7   | 11, 12, 14, 14, 15, 15, 16             | Yes             |

*Tableau 2 : revue de la littérature d'après Delion et al., World Neurosurg 2015 (14) .*

Dans leur publication « princeps » sur la CECCSC chez l'enfant, Ojemann et Berger rapportent une série de 26 enfants âgés de 4 à 16 ans, opérés de lésions cérébrales tumorales ou vasculaires situées en régions éloquentes et ayant nécessité une cartographie du langage (69). Parmi eux seulement 8 ont été opérés en CECCSC, les autres ont été explorés de façon extra opératoire après mise en place d'une électrode sous durale. Cette dernière technique était contributive mais nécessitait deux chirurgies et posait un certain nombre de difficultés, pas seulement infectieuses, chez des jeunes enfants pas toujours accessibles à une « discipline » suffisante.

Dans cette étude l'enfant le plus jeune opéré en CECCSC était âgé de 10 ans. Nous n'avons cependant pas de précision sur l'âge exact de chacun de ces enfants qui d'après les données de cet article ont un âge compris entre 10 et 16 ans. La technique opératoire était bien détaillée. Nous nous sommes d'ailleurs largement inspirés des travaux de Ojemann en ce qui concerne la technique de cartographie déjà décrite antérieurement (70). En ce qui concerne l'évaluation neuropsychologique du langage en per-opératoire, l'auteur utilisait le « object denomination task » jusqu'à l'âge de 10 ans, pour les plus jeunes enfants. Ce test de dénomination découle du « Boston Naming Test » mis au point en 1983 (71) qui constitue un des outils du « Boston Diagnosis Aphasia Examination », principale batterie de test d'évaluation de l'aphasie utilisée par les neuropsychologues du monde entier (72). Il s'agit à l'origine d'une série de 60 dessins réalisés avec uniquement des traits noirs sur fond blanc précédés d'une courte phrase « ceci est » qui permet de distinguer l'anomie de l'anarthrie (10). Dans notre pratique nous utilisons un équivalent tiré de la DO 80 (73) (cf. annexe 1).

Même si pour certains auteurs le modèle de représentation globale du langage est à peu près le même chez l'adulte et l'enfant (74), il semble d'après les quelques publications de la littérature qu'il y ait quelques précautions à prendre avec les enfants :

En comparant les résultats décrits ci-dessus avec ceux d'une importante série chez l'adulte (69,70), Ojemann a montré qu'il existait une grande variabilité interindividuelle dans la population pédiatrique concernant la localisation des sites éloquents du langage et que la fréquence des erreurs de dénomination

obtenues lors de la stimulation des mêmes sites corticaux était plus faible chez les enfants que chez les adultes (cf. figure 6).

Ceci était aussi observé en séparant le groupe pédiatrique en deux sous-groupes de plus et moins de huit ans. Il en allait de même pour Berger auparavant à propos d'une série de trois enfants (36). Ceci laissait supposer l'apparition de nouveaux sites impliqués dans le langage au fil de la croissance et des nouveaux apprentissages et donc de la maturation cérébrale.

Une publication récente rapporte de façon rétrospective une expérience de CECCSC chez l'enfant à propos de 10 cas âgés de 11 à 17 ans (75). L'âge moyen de cette cohorte était de 14,6 ans. L'auteur décrit la procédure qui semble s'être bien passée. Cependant cette étude comprend entre autres deux jeunes de 16 ans et trois jeunes de 17 ans pour lesquels selon nous la procédure ne requiert pas d'autre adaptation particulière par rapport à celle chez l'adulte. Par ailleurs la procédure n'a pas abouti chez un enfant de 13 ans qui a dû être ré-endormi compte tenu de difficultés de comportement. Cette étude porte donc véritablement après analyse sur 4 enfants âgés de 11 à 15 ans.

Les autres publications ont peu d'intérêt sur le plan scientifique. Elles concernent essentiellement l'aspect anesthésique, mais dans chaque cas les interventions semblent s'être bien déroulées (76-79), il n'y a cependant pas de précisions apportées. On notera que dans l'un des articles le test neuropsychologique est précisé : il s'agit du « aachen aphasia test » (77).

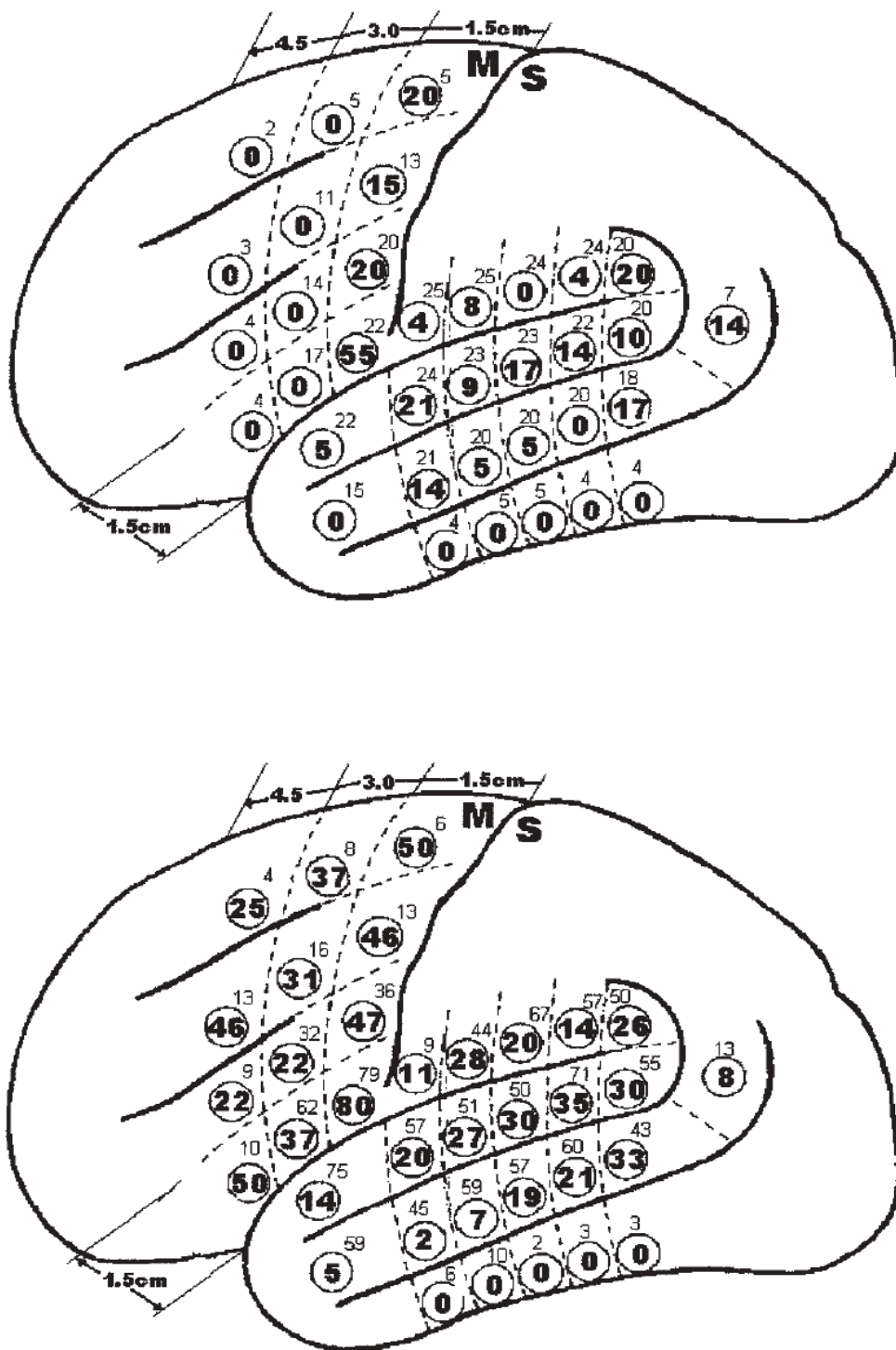


Figure 6: En haut: représentation des sites provoquant des erreurs de dénomination sur une série de 26 enfants. En bas: représentation des sites provoquant des erreurs de dénomination lors de la stimulation corticale sur une série de 114 adultes. Dans chaque zone corticale délimitée par des lignes brisées, le numéro du haut représente le nombre de patients stimulés sur ce site et le nombre entouré représente le pourcentage d'erreurs de dénominations induites. D'après Ojemann, S. G., M. S. Berger, et al. (2003). "Localization of language function in children: results of electrical stimulation mapping." *J Neurosurg* 98(3): 465-70 (69).

## 2.3 La chirurgie éveillée chez l'enfant en France :

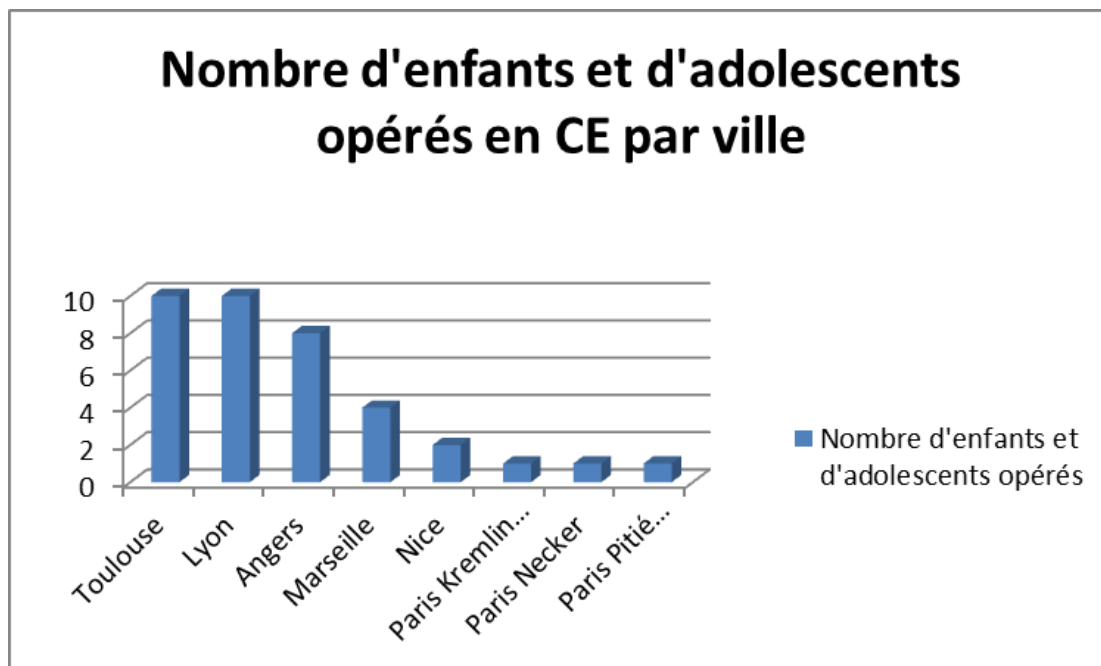
Dans le cadre d'un mémoire pour le certificat de capacité d'orthophoniste que j'ai encadré au cours de l'année universitaire 2014-2015 (80), nous avons recensé les centres français pratiquant la chirurgie éveillée chez l'enfant et analysé leurs pratiques :

Alors que la plupart des services de neurochirurgie français pratiquent de façon plus ou moins courante la chirurgie éveillée chez les adultes, peu de centres ont réalisé cette intervention chez les enfants. Ce recensement a été réalisé sous la forme de questionnaires adressés aux neurochirurgiens et neuropsychologues ou orthophonistes concernés de tous les CHU de France sans aucune limite de temps. Sur 31 services de neurochirurgie contactés, 23 pratiquent en routine la chirurgie éveillée chez l'adulte. 3 centres n'ont pas répondu. Cette chirurgie s'adresse aux gliomes infiltrants essentiellement mais aussi à d'autres types de lésions telles que les gliomes de haut grade, les cavernomes, les métastases, et même les malformations artérioveineuses.

Nous avons cherché à savoir pourquoi les services de neurochirurgie qui pratiquent la CECCSC en routine chez les adultes ne la proposent pas chez les enfants. Au delà de l'organisation sanitaire de la neurochirurgie pédiatrique et donc de l'habilitation des services de neurochirurgie à pratiquer la neurochirurgie pédiatrique, certains centres refusent d'opérer des enfants en CECCSC au prétexte que d'une part les gliomes infiltrants sont très peu courants chez les enfants et que d'autre part les tumeurs sustentorielles en général sont moins fréquentes. D'autres centres estiment que les enfants ont un tel potentiel de récupération que cette chirurgie n'est pas nécessaire pour leur éviter des déficits moteurs ou cognitifs définitifs. Ces différents arguments ne nous paraissent pas valables et seront abordés dans la discussion.

Nous avons répertorié huit centres pratiquant la chirurgie éveillée chez l'enfant avec par nombre d'interventions les CHU de Toulouse (10 interventions, 10 à 15 ans), Lyon (10 interventions, 7 à 15 ans), Angers (8 interventions, 8 à 16 ans), Marseille (4 interventions, 11 à 15 ans), Nice (2 interventions, 16 et 17 ans), Paris Kremlin-Bicêtre (1 intervention, 9 ans), Paris Pitié-Salpêtrière (1

intervention, 17 ans) et Necker (1 enfant). Ce qui représente une quarantaine de cas au total et donc une activité plutôt marginale.



*Figure 7 : tiré du mémoire de capacité d'orthophoniste de Suzon Chauvat et (80)*

En ce qui concerne le type de lésion, on retrouve dans les cas opérés en France, des astrocytomes pilocytiques, des gangliogliomes, des glioblastomes et des cavernomes.

Dans tous les centres impliqués, l'ensemble des acteurs de cette chirurgie sont parfaitement d'accord pour dire que la maturité et donc la coopération de l'enfant sont des facteurs limitants. Dans tous les cas, la préparation notamment psychologique préopératoire reste un des éléments les plus importants avec l'implication d'un psychologue dans certains centres. Plusieurs centres proposent des films ainsi qu'une visite du bloc opératoire aux patients et à leurs familles. Nous sommes le seul centre à proposer en routine un conditionnement par hypnose chez les enfants. Cette pratique sera détaillée ultérieurement.

En ce qui concerne le bilan neuropsychologique pré et post opératoire, sa composition est très hétérogène en fonction des centres. La plupart des tests utilisés restent des tests normés chez les adultes. Il n'y a aucune homogénéité.

On retrouve ainsi de nombreux tests :

Bilan RV, Alouette, Edinburgh, L2MA, DO80, DEN48, ELO, BDAE, Vol du PC, BALE, NEPSY, TLOCC, PELEA, Chronodicté.

En per opératoire, les tests employés restent par contre les mêmes et reposent dans tous les centres sur des épreuves de dénomination (adaptées du « object dénomination task » décrit précédemment), de langage spontané et de répétition. Ce sont les mêmes tests que ceux utilisés chez l'adulte. La durée des périodes éveillées en fonction des centres va de 15 minutes à deux heures. Un orthophoniste ou un neuropsychologue, voire les deux, sont systématiquement présents.

En ce qui concerne le suivi post-opératoire, nous notons encore une grande hétérogénéité : concernant l'évaluation neuropsychologique post opératoire notamment, celle-ci n'est pas réalisée au même moment, ou alors parfois en libéral avec probablement des méthodes différentes de celles utilisées en pré-opératoire, ou même pas du tout. Nous avons finalement peu d'idée précise sur l'évolution post-opératoire de ces enfants si l'on se base sur les résultats de cette enquête. Globalement, sont fréquemment retrouvés en post-opératoire, un ralentissement général, des troubles du langage plutôt fins et des difficultés attentionnelles et mnésiques.

Nous nous sommes enfin intéressés, à travers des questionnaires, à la qualité de vie de ces enfants et de leurs parents en pré per et post opératoire. Sept enfants et huit couples de parents pris en charge dans des centres différents ont répondu à ce questionnaire. En ce qui concerne les patients, Il semble que les explications fournies en préopératoire soient suffisantes mais plutôt stressantes et que le niveau de stress préopératoire des patients était plutôt important. En ce qui concerne le vécu per-opératoire, seulement un peu plus de la moitié des patients estimaient ne pas avoir eu de douleurs, tous les patients se sont sentis par contre bien entourés par l'équipe soignante. En ce qui concerne les parents, la majorité, sept sur huit, estiment avoir été bien informés. En ce qui concerne la perception d'un changement éventuel chez leurs enfants en post-opératoire, les parents décrivent l'apparition d'angoisses au coucher, d'une plus grande fatigue, de difficultés de mémoire, de langage, de changements physiques, intellectuels, psychologiques et d'une augmentation nette de maturité.

Ces quelques résultats reflètent un certain nombre de problèmes :

On s'aperçoit en effet à la lumière de ces éléments que cette pratique ne semble pas faire l'objet d'un consensus chez les enfants, que peu de centres s'y intéressent et que les pratiques sont plutôt hétérogènes suivant les rares centres impliqués.

C'est la raison pour laquelle nous avons proposé en 2014 un projet de PHRC national aux principaux centres de neurochirurgie pédiatrique français. La réponse de la plupart des centres avait été positive (7 centres avaient donné leur accord). Nous avons donc soumis une lettre d'intention (cf. dossier PHRC) qui n'a malheureusement pas été retenue (cf. réponse lettre d'intention).

L'objectif de ce PHRC n'était pas tant de démontrer l'intérêt ou même la faisabilité de la CECCSC chez l'enfant mais de mettre en évidence et protocoliser les nécessaires adaptations à prendre en compte afin d'harmoniser les pratiques et réaliser cette procédure dans de bonnes conditions chez les enfants.



ACADEMIE DE PARIS

UNIVERSITE PARIS VI PIERRE et MARIE CURIE

MEMOIRE POUR LE CERTIFICAT DE CAPACITE D'ORTHOPHONISTE

**ETAT DES LIEUX DE LA CHIRURGIE EVEILLEE PEDIATRIQUE :  
APPROCHE ORTHOPHONIQUE**

Directeurs de Mémoire : Monsieur Matthieu DELION et Madame Ghislaine AUBIN

Année universitaire : 2014-2015

Suzon CHAUVAT  
Née le : 15/02/1991

Mathilde GABORIEAU  
Née le : 02/07/1992



## État des lieux de la chirurgie éveillée pédiatrique : approche orthophonique

Suzon Chauvat, Mathilde Gaborieau

► **To cite this version:**

Suzon Chauvat, Mathilde Gaborieau. État des lieux de la chirurgie éveillée pédiatrique : approche orthophonique. Neurosciences [q-bio.NC]. 2015. <dumas-01212352>

**HAL Id: dumas-01212352**

<http://dumas.ccsd.cnrs.fr/dumas-01212352>

Submitted on 26 Oct 2015

**HAL** is a multi-disciplinary open access archive for the deposit and dissemination of scientific research documents, whether they are published or not. The documents may come from teaching and research institutions in France or abroad, or from public or private research centers.

L'archive ouverte pluridisciplinaire **HAL**, est destinée au dépôt et à la diffusion de documents scientifiques de niveau recherche, publiés ou non, émanant des établissements d'enseignement et de recherche français ou étrangers, des laboratoires publics ou privés.



## Appel à projets national en cancérologie 2014

### Lettre d'intention / Letter of intent

La lettre d'intention est à rédiger en anglais pour permettre l'évaluation internationale

Date limite de soumission en ligne : 3 avril 2014 avant Minuit

Veillez cocher l'appel pour lequel vous soumettez votre projet

**Si soumission PHRC-K :**

<http://www.e-cancer.fr/aap/recherche/phrck2014>

**Si soumission PRME-K :**

<http://www.e-cancer.fr/aap/recherche/prmek2014>

#### In the frame of DGOS calls for proposals:

First submission  Previous submission  (fill in section dedicated to previous submission in the last page):

| Titre de l'étude envisagée, précédé par son acronyme <sup>1</sup>   |  |
|---|--|
| CECE01 Faisabilité de la chirurgie éveillée avec cartographie corticale et sous corticale dans la prise en charge des tumeurs sustentorielles de l'enfant |  |
| Project title   |  |
| Feasibility of awake surgery in child with cortical and subcortical mapping for resection of supratentorial brain tumours                                 |  |

#### GENERAL INFORMATION

|  |   |
|--|---|
| First name and name of coordinator :         | Matthieu DELION                                   |
| Specialty                                    | PEDIATRIC NEUROSURGERY                            |
| Service ou département - Unit or department  | DEPARTMENT OF NEUROSURGERY                        |
| Name and adress of the hospital              | CHU of ANGERS<br>4 rue Larrey 49000 ANGERS france |
| Phone number                                 | +33241353893/+33241354846                         |
| E-mail                                       | Matthieu.Delion@chu-angers.fr                     |
| Physician, dental practitioner / Biologist / | physician   |

<sup>1</sup> L'acronyme sera formé d'un nombre de lettres inférieur à 15, suivi de 2 chiffres (01 le plus souvent, ou 02 s'il s'agit du 2<sup>ème</sup> projet dans la continuation d'un 1<sup>er</sup> projet portant le même titre, etc...

|                            |  |
|----------------------------|--|
| Nurse, other paramedical : |  |
|----------------------------|--|

|  |    |
|--|----|
| <b>Previous grants in the frame of DGOS calls (List with: year, ref number, state.):</b> | NO |
|--|----|

|   |   |
|---|---|
| <b>Research domain</b><br>Organ, tumor location :<br>Others :         | neurooncology, pediatrics neurosurgery, humanities and social sciences  |
| <b>Keywords</b><br>-Coordinator domain :<br>-Whished reviewer domain: | Paediatrics neurosurgery, neuro oncology, awake surgery, cortical and subcortical mapping, brain tumours of child, neuropsychological evaluation, anatomy |

|  |  |
|--|--|
| <b>Affiliated institution responsible for the budget from ministry of health</b> | CHU of ANGERS  |
| <b>Approximate level of funding required (K euros):</b>                          | <i>120 K euros: The study is based on current practice without extra cost. The funding required are limited to travel and accommodation costs of the teams (neuropsychologist, neuropaediatrician, neurosurgeons, anaesthetist) and to the upgrading costs (congress, publications).the approximate level of funding required are evaluated at 120000 euros (5000 euros par center and per year)</i> |

|  |  |
|--|--|
| <b>First name and name of the methodologist :</b>    | PAROT ELSA   |
| Name and adress of the hospital                      | CHU of ANGERS<br>4 rue Larrey 49000 ANGERS france                |
| Phone number   | +33241355855   |
| E-mail   | <a href="mailto:elparot@chu-angers.fr">elparot@chu-angers.fr</a> |
| <b>First name and name of the economist (if any)</b> |  |
| Name and address of the establishment:               |  |
| Phone number   |  |
| E-mail   |  |

|  |  |
|--|--|
| <b>Organization responsible for project management:</b>              | Department of neurosurgery<br>CHU of ANGERS  |
| <b>Organization responsible for quality assurance:</b>               | Clinical research center CHU ANGERS  |
| <b>Organization responsible for data management and statistics :</b> | Section of methodology and biostatistics of the delegation of clinical research and to innovation (DRCI) CHU of ANGERS |

|  |   |
|--|---|
| <b>Anticipated number of recruiting centers (NC)</b> | 8 |
|--|---|

| <b>Co-investigators (1 à n)</b> |            |           |                  |         |                  |  |              |                             |
|---------------------------------|------------|-----------|------------------|---------|------------------|--|--------------|-----------------------------|
| N°                              | Name       | Firstname | Town             | Country | Hospital         | E-mail   | Tel          | Speciality                  |
| 1                               | PUGET      | STEPHANIE | PARIS            | FRANCE  | NECKER           | <a href="mailto:stephanie.puget@gmail.com">stephanie.puget@gmail.com</a>             | +33144494025 | Pediatric neurosurgery      |
| 2                               | PECH GOURG | gregoire  | marseille        | france  | La timone        | <a href="mailto:Gregoire.PECHGOURG@ap-hm.fr">Gregoire.PECHGOURG@ap-hm.fr</a>         | +33491386677 | Pediatric neurosurgery      |
| 3                               | MOTTOLESE  | carmine   | lyon             | france  | wertheimer       | <a href="mailto:Carmine.mottolese@chu-lyon.fr">Carmine.mottolese@chu-lyon.fr</a>     | +33472357572 | Pediatric neurosurgery      |
| 4                               | GIMBERT    | edouard   | bordeaux         | france  | chu              | <a href="mailto:edouard.gimbert@chu-bordeaux.fr">edouard.gimbert@chu-bordeaux.fr</a> | +33556795679 | Pediatric neurosurgery      |
| 5                               | LISTRAT    | antoine   | TOURS            | FRANCE  | clocheville      | <a href="mailto:A.LISTRAT@chu-tours.fr">A.LISTRAT@chu-tours.fr</a>                   | +33247474747 | Pediatric neurosurgery      |
| 6                               | RIFFAUD    | leurent   | rennes           | france  | chu              | <a href="mailto:laurent.riffaud@chu-rennes.fr">laurent.riffaud@chu-rennes.fr</a>     | +33299282583 | Pediatric neurosurgery      |
| 7                               | COLL       | guillaume | Clermont ferrand | france  | Gabriel montpied | <a href="mailto:gcoll@chu-clermontferrand.fr">gcoll@chu-clermontferrand.fr</a>       | +33473752186 | Pediatric neurosurgery      |
| 8                               | MENEI      | philippe  | angers           | france  | chu              | phmenei@chu-angers.fr  | +33241354823 | neurosurgery                |
| 9                               | MERCIER    | philippe  | angers           | france  | chu              | phmercier@chu-angers.fr  | +33241353893 | Pediatric neurosurgery      |
| 10                              | PELLIER    | isabelle  | angers           | france  | chu              | ispellier@chu-angers.fr  | +33241354890 | Pediatric oncology          |
| 11                              | NGUYEN     | sylvie    | angers           | france  | chu              | synguyen@chu-angers.fr   | +33241354846 | Pediatric neurology         |
| 12                              | FORTUNY    | laetitia  | angers           | france  | chu              | lafortuny@chu-angers.fr  | +33241354846 | Pediatric neuropsychologist |
| 13                              | LEHOUSSE   | thierry   | angers           | france  | chu              | ThLehousse@chu-angers.fr   | +33241354440 | pediatricanaesthetic        |
| 14                              | MALKA      | jean      | angers           | france  | chu              | JeMalka@chu-angers.fr  | +33241354442 | Pediatrics psychiatrist     |
| 15                              | DINOMAI    | mickael   | angers           | france  | chu              | mdinomais@les-capucins-angers.fr]  | +33241351515 | Pediatric rehabilitation    |

|   |
|---|
| <b>References</b>   |
| <i>List of the main publications (5 maximum) justifying the project in the national and international context</i> |

- 1 Localization of language function in children : result of electrical stimulation mapping  
Steven G. Ojemann et Al., J Neurosurg 98 : 465-470, 2003
- 2 Awake craniotomy for glioblastoma in a 9-year-old child  
M. Klimek et Al., Anaesthesia 59 : 607-609, 2004
- 3 Language cortex representation : effects of developmental versus acquired pathology  
M. Duchowny et Al., Ann Neurol 1996; 40:31-38
- 4 Tolerance of awake surgery for gliomas : a prospective european low grade glioma network multicenter study; Beez T et Al., Acta Neurochir (Wien). 2013 Jul ;155(7) :1301-8
- 5 Awake mapping optimizes the extent of resection for low grade gliomas in eloquent areas  
De Benedictis A et Al., Neurosurgery, 2010 Jun ;66(6) :1074-84

## RESEARCH PROJECT

### Rational (Context and hypothesis, max 320 words)

*Resection of brain tumours near eloquent areas is based on a cortical and subcortical mapping using electrical stimulation during awake surgery. The aim of that surgery is to do the most complete resection without any sequelae.*

*This methodology, which is well managed in adults by several teams, needs a substantial training. We practice this surgery since 2007 with a cohorte of 150 operated patients. We now use awake surgery for cavernomas and epileptic lesions.*

*However, until now this approach was difficult to apply to children. The plasticity of brain has probably limited the development of this technique. Indeed young children with left cerebral insults or functional hemispherectomy in the first 5 years of life relocate language to the opposite hemisphere.*

*After 5 years, the brain plasticity is similar than for adults and every neurologic weakness could become a neurologic sequelae. A brain mapping of language areas seems extremely important before tumour resection.*

*In the paediatric population several difficulties are encountered like cooperation, anxiety, impact of maturation of the central nervous system on the electrical stimulation of brain and the need of adapted neuropsychological test usable during surgery. In our experience and in the literature, this surgery is feasible in children aged 9 to 18 years old without any major changes compared to the technique used in adults. This surgery would be theoretically feasible between 5 and 9 years.*

*Our experience as for the other teams remains limited (about 10 or 12 patients in France). The low incidence of supratentorial brain tumours in children explains the lack of validation of this technique in paediatrics patients and the lack of data in the literature. A multicentric study could facilitate the evaluation of the feasibility in children.*

### Originality and innovative aspects (max 160 words)

*To our knowledge, no major study has been conducted yet regarding children, and French neurosurgery is probably ahead on this theme through the strong development of adult awake surgery. Adjustment of this approach to the child will more allow us to explore new techniques for mental diversion as hypnosis or virtual reality which would facilitate the experience of children and develop more playful neuropsychological tests. Immersion in a virtual environment would allow us to take their attention, reduce pain and anxiety outside the period of test requiring full cooperation. We have already installed a collaboration with teams working on virtual reality to develop suitable glasses (School of Arts et Metiers, ESIA*

*Paris-Laval).*

**Focus of research**

Health technology (tick and then detail):

Drugs  Devices

Procedures and organizational systems used in health care (including Health services<sup>2</sup>)

If relevant: date of CE mark / market authorization

**Please detail :**

**Keywords (5):**

Paediatrics neurosurgery, awake surgery, cortical and subcortical mapping, supratentorial brain tumours of child, neuropsychological evaluation

**Main objective (Detail, max 48 words)**

*The main purpose is to measure the feasibility of awake surgery in children aged 5 to 18 years old i.e. to achieve an informative cortical and subcortical mapping in order to obtain complete surgical resection without resorting to general anaesthesia.*

**Tick one:**

Hypothesis  Description feasibility  Tolerance efficacy

Safety efficiency  Budget impact  Organization of care

**Tick one:**

Etiology Causality<sup>3</sup>  Diagnosis  Prognosis

Therapeutics (impact on clinical end-points<sup>4</sup>)

Therapeutics (impact on intermediate end-point<sup>5</sup>)

Compliance  Effective Practice  Research methodology

Qualitative Research  Others

<sup>2</sup> <http://htaglossary.net>

<sup>3</sup> Studies designed to determine the causes of a disease, the risk of being exposed to a drug, a pollutant etc

<sup>4</sup> Example : reduction of myocardial infarction incidence, of mortality

<sup>5</sup> Example : reduction of serum cholesterol, improvement of a pain scale

|  |
|--|
| <b>Secondary objectives (detail, max 160 words)</b>  |
| <p><i>Assessing the child's experience through a preoperative and mainly postoperative pedopsychiatric appraisal.</i></p> <p><i>Judging the interest of the techniques of mental diversion and promoting the hypnosis and virtual reality glasses for the child's comfort during surgery modelled on what is done in the refection of the bandages under local anaesthesia in severe burns</i></p> <p><i>Validation in the 9 to 18 years old children of the neuropsychological tests of object denomination task already used in adults during awake surgery and to establish neuropsychological adapted tests for 5 to 9 years old children usable during cortical mapping.</i></p> <p><i>Assessing the impact on the functional prognosis (language, motor ability and executive function)</i></p> <p><i>Evaluate the correlation between MRI preoperative functional mapping and cortical mapping in children</i></p> <p><i>Evaluate the quality of resection on the postoperative MRI</i></p> |
| <b>Primary end point (linked with the main objective)</b>  |
| <p>The feasibility will be evaluated on three points:</p> <ul style="list-style-type: none"> <li>- The ability to complete the surgery until the end of the resection of the tumour without resorting to general anaesthesia</li> <li>- The ability to obtain at least one full and reproducible positive answer during the mapping of an area involved in language</li> <li>- The ability to establish a cortical and subcortical informative mapping of the exposed brain area</li> </ul>  |
| <b>Secondary end points (linked with the secondary objectives)</b>   |
| <p>Improvement of the language disorder or at least stability</p> <p>Improvement of a motor weakness or at least stability</p> <p>Improvement of epilepsy</p> <p>Equivalence of preoperative MRI functional mapping and peroperative cortical mapping.</p> <p>Growth total or subtotal resection of the tumour on the postoperative MRI control scan.</p>  |
| <b>Study population</b>  |
| <p><b>Main inclusion criteria</b></p> <p><i>5 to 18 years old children</i></p> <p><i>supratentorial tumour or lesion located near or inside an eloquent area of the brain involved in language or motricity</i></p> <p><b>Main exclusion criteria</b></p> <p><i>Language disorder too important to allow peroperative neuropsychological exploration</i></p>   |

|   |
|---|
| <b>Design (tick + detail max 320 words)</b>   |
| <p>Meta analysis <input type="checkbox"/>      Randomized clinical trial <input type="checkbox"/>      if yes : Open <input type="checkbox"/> Single blind <input type="checkbox"/> Double blind <input type="checkbox"/></p> <p>Systematic reviews <input type="checkbox"/>                      Pragmatic studies <input type="checkbox"/></p> <p>Quasi-experimental studies (non randomized cohorts ...) <input type="checkbox"/>      Prospective cohort study <input type="checkbox"/></p> <p>Case-control study <input type="checkbox"/>                                      Cross-sectional study <input type="checkbox"/></p> <p>Retrospective cohort <input type="checkbox"/>                                      Administrative / hospital inpatient database research <input type="checkbox"/></p> <p>Modelisation <input type="checkbox"/>      Case series <input type="checkbox"/>                      Qualitative studies <input type="checkbox"/> Others <input checked="" type="checkbox"/></p> |



**Please detail :**

The experimental plan is based on **an opened and non randomized clinical trial of feasibility interesting a prospective and multicentric cohort of children aged 5 to 18 years old and suffering from supratentorial brain tumours located near or inside an eloquent area.**

The duration of the trial is fixed at three years. The trial also concerns cavernomas and epileptic lesions. An area is considered eloquent if it is near or inside a brain area involved in language, motor ability or both of them.

Preoperative evaluation:

Clinical neurological examination

Neuropsychological evaluation

Pedopsychiatric evaluation

Brain MRI with MR Tractography

Functional MRI (activation functional MRI and resting state functional MRI)

Surgery:

The anaesthetic methodology depends on the experience of the anaesthetic team but it seems interesting to evaluate hypnosis in the psychological conditioning of the patients outside the period of test.

Neuronavigation

Peroperative electrocorticography

Cortical and subcortical mapping of language and motricity

Peroperative neuropsychological test with a neuropsychologist

Resection of the lesion

Postoperative assessment:

Clinical neurological examination during the postoperative hospitalization. In case of surgery in the supplementary motor area the clinical examination must take place three month after the surgery.

Brain MRI within 48 hours after surgery to evaluate the quality of resection

Neuropsychological evaluation 3 month after surgery

Psychiatric evaluation 3 month after surgery

|   |
|---|
| <b>If health-economics analysis (tick + detail max 320 words) :</b>   |
| Cost-utility analysis <input type="checkbox"/> Cost-effectiveness analysis <input type="checkbox"/> Cost-benefit analysis <input type="checkbox"/><br>Budget impact analysis <input type="checkbox"/> Cost-minimization analysis <input type="checkbox"/> Cost-consequence analysis <input type="checkbox"/><br>Cost of illness analysis <input type="checkbox"/> Others <input type="checkbox"/><br><b>Please detail :</b> |
| <b>In the case of a drug trial:</b>   |
| Phase: I <input type="checkbox"/> phase: II <input type="checkbox"/> phase: I/II <input type="checkbox"/> phase: III <input type="checkbox"/> phase: IV <input type="checkbox"/>  |
| <b>If comparison groups :</b>   |
| NO  |
| <b>Experimental group (detail max 48 words)</b>   |
| NO  |
| <b>Control group (detail max 48 words)</b>  |
| NO  |

## INCLUSIONS

|   |
|---|
| <b>Duration of participation of each patient (days/months/years):</b>   |
| <i>3 months</i>   |
| <b>Anticipated duration of recruitment (DUR) (in months):</b>   |
| <i>39 months</i>  |
| <b>Total number of scheduled patients / observations to be recruited (NP) (3 digits + Justification of sample size max 80 words):</b>   |
| <i>According to epidemiologic analysis in the literature about supratentorial tumours of children and to the recruitment of each team, and by including cavernomas and epileptic lesions we propose to include 72 patients on the three years</i> |

| <b>Number of patients / observations to be recruited / month / center ((NP/DUR)/NC) (2 digits + Justification if more than 2 patients/month/center)</b> |
|---|
| BETWEEN 2 and 5 PATIENTS / YEAR / CENTER  |

| <b>Expected number of patients eligible in the centers</b> |           |           |                  |         |                            |       |
|--|-----------|-----------|------------------|---------|----------------------------|-------|
| N°   | Name      | Surname   | Town             | Country | Expected recruitment/month | Total |
| 1  | Puget     | Stéphanie | Paris            | France  | 5 / <u>YEAR</u>            | 15    |
| 2  | Pechgourg | Grégoire  | Marseille        | France  | 3 / <u>YEAR</u>            | 9     |
| 3  | Mottolèse | Carmine   | Lyon             | France  | 2 / <u>YEAR</u>            | 6     |
| 4  | Gimbert   | Edouard   | Bordeaux         | France  | 3 / <u>YEAR</u>            | 9     |
| 5  | Listrat   | Antoine   | Tours            | France  | 3 / <u>YEAR</u>            | 9     |
| 6  | Riffaud   | Laurent   | Rennes           | France  | 3 / <u>YEAR</u>            | 9     |
| 7  | Coll      | Guillaume | Clermont Ferrand | France  | 2 / <u>YEAR</u>            | 6     |
| 8  | Delion    | Matthieu  | Angers           | France  | 3 / <u>YEAR</u>            | 9     |

|   |
|---|
| <b>Participation of a research network (Detail max 32 words)</b>  |
| " Réseau gliome cancéropôle grand ouest"  |
| <b>Participation of industry (Detail max 64 words)</b>  |
| NO  |
| <b>Others aspects to insure the feasibility of the project (Detail max 64 words)</b>  |
| <p><i>Several teams have already the experience about a few cases in children, for the others a transfer of skill from adult to children would be easy, according to the fact that each team has an adult experience of awake surgery.</i></p> <p><i>The small number of cases in each team facilitates the perfect adherence to the protocol</i></p> <p><i>The follow-up is only of three months</i></p> |
| <b>Expected patient or public health benefit (Detail max 320 words)</b>   |
| <p><i>The central nervous system tumours are the second most common cancer of children. The prognosis very often depends on the quality of resection. It is therefore essential to operate the skill transfer of awake surgery from adult to child to ensure optimal management of them.</i></p>  |

|   |
|---|
| <b>In the case of a previous submission, mention the additional aspects relevant to the recommendations of the scientific committee (Experts comments and corresponding answers, max 320 words)</b> |
| NO PREVIOUS SUBMISSION  |

Date limite de soumission en ligne : 3 avril 2014 avant Minuit

Veuillez cocher l'appel pour lequel vous soumettez votre projet

**Si soumission PHRC-K :**

<http://www.e-cancer.fr/aap/recherche/phrck2014>

**Si soumission PRME-K :**

<http://www.e-cancer.fr/aap/recherche/prmek2014>

## Appel à Projets PHRC-K 2014 – Call for proposals

### Letter of intent - Evaluation form

cette fiche anonymisée sera adressée au coordonnateur de projet

This anonymized form will be sent to the project coordinator

|  |  |
|--|--|
| <b>N° dossier</b><br><b>Project reference</b>                | <b>PHRC-K14-161</b>  |
| <b>Titre du projet</b><br><b>Project Title</b>               | faisabilité de la chirurgie éveillée chez l'enfant avec cartographie corticale et sous corticale dans la prise en charge des tumeurs cérébrales sustentorielles<br><br>feasibility of awake surgery in child with cortical and subcortical mapping for resection of supratentorial tumours |
| <b>Coordonnateur du projet</b><br><b>Project coordinator</b> | <b>Matthieu DELION</b>   |

### RAPPORTEUR 1 – REVIEWER 1

#### **Points forts/Project strengths**

- This study explores the feasibility of awake surgery in child with cortical and subcortical mapping for resection of supratentorial brain tumours which is an important question. The aim of that surgery is to do the most complete resection without any sequelae.
- This methodology, well managed in adults by several teams was difficult to apply to children. However, after 5 years, every neurologic weakness in children could become a neurologic sequelae. A brain mapping of language areas seems extremely important before tumour resection.
- A multicentric study could facilitate the evaluation of the feasibility in children. The low incidence of supratentorial brain tumours in children explains the lack of validation of this technique in pediatric patients and the lack of data in the literature.
- Low cost because based on current practice

#### **Points faibles/ *Project's weaknesses***

- Low experience
- Open study may bias the recruitment by selection of a specific type of patients who seem to be more adequate for this technique
- Judging the interest of the techniques of mental diversion and promoting the hypnosis and virtual reality glasses for the child's comfort during surgery is well but the methodology of these different techniques of anesthesia should be well standardized and better designed

- The funding is limited to travel and accommodations costs of the teams, congress,...Is a funding necessary for these activities?

## **RAPPORTEUR 2 – REVIEWER 2**

### **Points forts/Project strengths**

- Childhood brain cancer is an area of unmet need.

### **Points faibles/ *Project's weaknesses***

- Is this more a training exercise rather than a research project?

## **Avis du Comité International de Recherche Clinique en cancérologie (CIR2C) Comité d'évaluation du 26 Juin 2014**

**Lettre d'intention non retenue**

### **3 La chirurgie éveillée avec cartographie corticale et sous corticale chez l'enfant : Expérience clinique angevine.**

Notre expérience clinique de la CECCSC chez l'enfant repose sur huit procédures réalisées sur une série de 7 enfants âgés de 8 à 16 ans. L'un des enfants a du être opéré à deux reprises en CECCSC. Une prise en charge par hypnose a été réalisée chez les cinq derniers patients. Dans tous les cas, la cartographie corticale et sous-corticale a pu être réalisée sans difficulté et a été très contributive, en utilisant les items de la DO80 (73) (cf. annexe 1) y compris à l'âge de huit ans avec une coopération tout à fait satisfaisante. Aucun des patients n'a été aggravé sur le plan neurologique. En termes de résection, l'exérèse a pu être complète dans tous les cas sauf dans un cas où il restait un résidu centimétrique en région non éloquente qui a pu être retiré en chirurgie conventionnelle secondairement. L'ensemble des résultats de cette étude sont présentés dans une publication (14). Il s'agit de la seule série française publiée.

Le patient le plus jeune dans notre expérience est une fillette de 8 ans prise en charge après la publication de cet article. Il s'agissait d'une tumeur de l'aire motrice supplémentaire gauche. Cette enfant a bénéficié de l'ensemble du bilan et de la prise en charge décrits dans l'article. L'exérèse complète d'une tumeur Dysembryoplasique Neuro Epithéliale (DNET) a permis de la guérir de son épilepsie. Malgré son âge, la coopération n'a posé aucun problème et le vécu per opératoire et à posteriori a été très bon.

❖ **Article n°1: Specificities of awake craniotomy and brain mapping in children for resection of supratentorial tumours in the language areas.**

M. Delion, A Terminassian, T Lehoussé, G Aubin, J Malka, S N'Guyen, P Mercier, P Menei

Publié dans *World Neurosurgery*

Rang SIGAPS C

IF 2015 : 2,88





## Specificities of Awake Craniotomy and Brain Mapping in Children for Resection of Supratentorial Tumors in the Language Area

Matthieu Delion<sup>1,2</sup>, Aram Terminassian<sup>3</sup>, Thierry Lehouste<sup>3</sup>, Ghislaine Aubin<sup>4</sup>, Jean Malka<sup>5</sup>, Sylvie N'Guyen<sup>6</sup>, Philippe Mercier<sup>1,2</sup>, Philippe Menei<sup>1</sup>

■ **BACKGROUND:** In the pediatric population, awake craniotomy began to be used for the resection of brain tumor located close to eloquent areas. Some specificities must be taken into account to adapt this method to children.

■ **OBJECTIVE:** The aim of this clinical study is to not only confirm the feasibility of awake craniotomy and language brain mapping in the pediatric population but also identify the specificities and necessary adaptations of the procedure.

■ **METHODS:** Six children aged 11 to 16 were operated on while awake under local anesthesia with language brain mapping for supratentorial brain lesions (tumor and cavernoma). The preoperative planning comprised functional magnetic resonance imaging (MRI) and neuropsychologic and psychologic assessment. The specific preoperative preparation is clearly explained including hypnosis conditioning and psychiatric evaluation. The success of the procedure was based on the ability to perform the language brain mapping and the tumor removal without putting the patient to sleep. We investigated the pediatric specificities, psychological experience, and neuropsychologic follow-up.

■ **RESULTS:** The children experienced little anxiety, probably in large part due to the use of hypnosis. We succeeded in doing the cortical-subcortical mapping and removing the tumor without putting the patient to sleep in all cases. The psychological experience was good, and the neuropsychologic follow-up showed a favorable evolution.

■ **CONCLUSIONS:** Preoperative preparation and hypnosis in children seemed important for performing awake craniotomy and contributing language brain mapping with

the best possible psychological experience. The pediatric specificities are discussed.

### INTRODUCTION

Intraoperative direct stimulation during awake surgery is considered to be the gold standard for identifying eloquent cortical sites (19). It was first described by Penfield for sensory motor function and language functions. The most common technique is based on the work of Berger and Ojemann (3, 19). Duffau reintroduced the technique more recently in France in adults and clearly showed the importance of the method in term of the quality of resection respecting eloquent areas (8-10). We can say that today awake craniotomy with intraoperative direct stimulation is routinely used all over the world to operate in eloquent areas of the brain in adults.

To the best of our knowledge, only small series have been conducted regarding children. The few existing studies often involved young adults and mainly focused on describing the technical side of the surgery. However, this procedure in children raises certain questions concerning ethics, psychologic experience, brain plasticity, cortical language area organization, and intraoperative direct cortical stimulation in maturing brains.

The main purpose of this publication is less to demonstrate the feasibility of surgery while awake in children than to expose, through our clinical experience, the specificities of the adaptation of this method in children with particular attention on the psychologic conditioning and psychologic experience of these patients. We propose using hypnosis to improve the cooperation and experience for the children. We also insist on the neuropsychologic follow-up for each patient. In the discussion we

#### Key words

- Awake craniotomy
- Children
- Hypnosis
- Language brain mapping
- Neuropsychology
- Supratentorial brain tumor

#### Abbreviations and Acronyms

**MRI:** Magnetic resonance imaging

From the Departments of <sup>1</sup>Neurosurgery, <sup>2</sup>Anesthesiology, <sup>3</sup>Neuropsychology, <sup>4</sup>Child Psychiatry, <sup>5</sup>Pediatric Neurology, Angers Teaching Hospital, Angers, France; and <sup>6</sup>Anatomy Laboratory, Medical Faculty, University of Angers, LUNAM, Angers, France

To whom correspondence should be addressed: Matthieu Delion, M.D.  
[E-mail: [matthieudelion@yahoo.com](mailto:matthieudelion@yahoo.com)]

Citation: *World Neurosurg.* (2015) 84, 6:1645-1652.  
<http://dx.doi.org/10.1016/j.wneu.2015.06.073>

Journal homepage: [www.WORLDNEUROSURGERY.org](http://www.WORLDNEUROSURGERY.org)

Available online: [www.sciencedirect.com](http://www.sciencedirect.com)

1878-8750/\$ - see front matter © 2015 Elsevier Inc. All rights reserved.

explain the specific points of brain mapping and awake craniotomy in the pediatric population.

## MATERIAL AND METHODS

This publication lies on a morally acceptable clinical study, which only involves current normal clinical practice. Furthermore, there are no additional risks for the patient and the benefit in terms of functional outcome, quality of resection, and survival is demonstrated and admitted by all.

### Population

Our experience is based on 7 procedures on 6 youth from 11 to 16 years old suffering from brain lesions in eloquent areas, operated on while awake between 2008 and 2015 (Table 1). Patients 2 and 3 were operated on twice while awake. Patient 2 just turned 18 years old for the second surgery, and patient 3 was 15 years old for the second surgery. In all cases the preoperative planning included functional MRI, neuropsychologic examination by a pediatric speech therapist, psychiatric evaluation (by a child psychiatrist), and psychological preparation. All but the fourth and the last of these patients were right-handed. Patient 4 and 6 were actually left-handed, but the neuropsychologic assessment and functional MRI concluded a bilateral representation of the cortical sites involved in language.

### Magnetic Resonance Imaging Preoperative Planning

Morphologic and functional MRI were performed for each patient. The functional MRI in our experience contributes to help shorten the duration of the preoperative neuropsychologic evaluation by directly targeting the eloquent areas to be stimulated. However, care must be taken: The functional MRI does not replace the electrical cortical mapping and certainly not the subcortical mapping.

### Psychologic Patient Preparation

A child psychiatrist examined each patient before and after surgery.

We used hypnosis conditioning in the last 5 procedures (including the second look of patient 3) for anesthetic induction, preoperative awakening, and during periods without stimulation.

The hypnosis conditioning was done by the anesthetic team. The patient had been seen in hypnosis clinics 1–3 weeks before surgery by the same trained team to establish communication. The purpose of this meeting with the hypnotist is intended to collect some themes about pleasant places and pleasant sensations including visual, hearing, kinesthesia, smell, and taste. Above the analgesic effect, the aim of this management is to recreate during the induction and during the awakening a relaxing environment. In our experience this approach allows an induction and an awakening in calm conditions. Hypnosis is also of major interest for the preoperative periods without stimulation, such as periods of tumor resection during which cooperation of the child is not necessary, in creating a spatio-temporal distortion based on the predefined themes identified from the initial encounter. In focusing the attention of the child on pleasing situations, the psychological experience and course of the operation are facilitated. Concerning the analgesic effect, hypnosis is obviously insufficient, so we add intravenous analgesic drugs.

In the last 4 procedures we offered the patient the chance to meet another child who had been operated on by awake craniotomy to explain his psychological experience. Among our patients, there is a 12-year-old girl (patient 4) operated on while awake and cured of a left parietal cavernoma. This young teenager is happy to meet other children who need to undergo awake craniotomy to speak about her psychological experience.

We show the patient pictures and a video describing the atmosphere of the operating room.

Patient 5 visited the operating room and met the surgical and anesthetic team before surgery to get acquainted with the atmosphere.

### Neuropsychologic Evaluation

A child language therapist examined the child in each case before, during and 3–6 months after the surgery. The preoperative and postoperative evaluation is based on the Boston Diagnosis Aphasia Examination (12).

The preoperative evaluation is based on the “object denomination task” described in Ojemann’s work on adults and children, corresponding to a black line drawing of an object together with the carrier phrase “this is ...” on a white slide (19, 20). We use a

**Table 1.** Pediatric Population Operated on by Awake Craniotomy

| Patient | Age | Sex<br>F/M | Handedness | Neurologic Presentation              | Tumor Location                               | Hypnosis<br>Preparation | Pathology             |
|---------|-----|------------|------------|--------------------------------------|--|-------------------------|-----------------------|
| 1       | 15  | F          | Right      | Seizure                              | Left precentral sulcus                       | No                      | Grade 1 ganglioglioma |
| 2       | 16  | M          | Right      | Seizure, right facial palsy          | Left parietal opercula                       | No                      | Grade 1 ganglioglioma |
| 3       | 14  | M          | Right      | Seizure                              | Left frontopolar area                        | Yes                     | Grade 3 ependymoma    |
| 4       | 12  | F          | Left       | Seizure, motor palsy, dysarthria     | Left parietal postcentral sulcus             | Yes                     | Cavernoma             |
| 5       | 11  | F          | Right      | Motor weakness, language disturbance | Left temporal, parietal, and occipital lobes | Yes                     | Grade 3 ependymoma    |
| 6       | 14  | M          | Left       | Seizure                              | Left temporal lobe                           | Yes                     | Cavernoma             |

F, female; M, male.

French equivalent test based on the DO 80 (denomination orale) (5).

### Anesthetic Technique

For the last 5 procedures realized in patients 3 (first and second look) to 6, the children were put to sleep by hypnosis in addition to intravenous remifentanyl and propofol. The anesthetic team used a conventional intratracheal intubation for patients 1 to 4, while for the last 2 patients an appropriately sized laryngeal airway mask was used. Indeed, in the literature, the use of a laryngeal mask airway appeared extremely useful in the pediatric population undergoing awake craniotomy (1, 14). The scalp incision, pin sites of the Mayfield head holder, scalp nerves, and dura were infiltrated with diluted 0.2 % ropivacain. The local nervous anesthetic block was done on the supraorbital, retroauricular, and occipital nerves.

Patients were woken and extubated after the completion of the bone flap and before opening the dura.

### Surgical Technique

Patients were positioned in the supine or lateral position according to the location of the tumor. The skin incision, bone flap, and infiltration of the dura were done under general anesthesia.

Magnetic resonance intraoperative neuronavigation (Brainlab AG, Munich, Germany) based on preoperative images was used in all the cases to assist in locating the brain lesion and facilitate the growth total removal of the lesion.

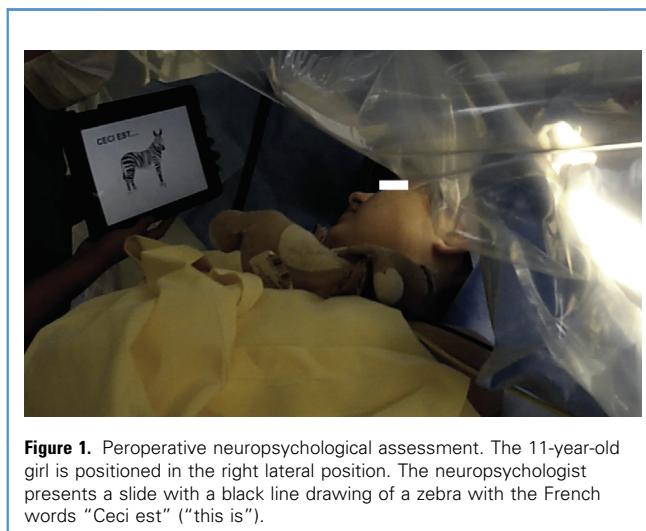
After the awakening and extubation of the child and when he was able to clearly communicate with the neuropsychologist, we opened the dura and started the electrical cortical mapping. For each patient we made a large bone flap with a large cortical exposure, including in each case a motor area to clearly determine the stimulation threshold, which is defined by the lowest intensity producing a movement. In practice, a bipolar electrode delivering a biphasic current is applied to the cortex before the resection, starting with a 1-mA intensity and increasing by one mA at a time. On a motor eloquent site this electrical stimulation can induce an involuntary motor response. For the sites involved in language function, an object denomination task is presented to the woken child during each stimulation, according to our adult experience and the literature (19). We look for transient language disturbances (aphasic arrest, paraphasia, naming delay). A speech therapist was present to interpret the kind of language disorder. During the surgical removal of a tumor, subcortical stimulation was also used to identify white matter language or motor tracts. Subcortical stimulation was continuously alternated with ultrasonic hover resection in a back-and-forth fashion as already described by some authors (2).

## RESULTS

### Neuropsychologic Evaluation

Concerning the peroperative language exploration, the use of the "object denomination task" was useful and clearly understood by all the children in our study (Figure 1).

Apart from the fourth and fifth patients, the preoperative assessment did not find any language disturbance: The fourth patient essentially presented a discreet dysarthria without aphasia,



**Figure 1.** Peroperative neuropsychological assessment. The 11-year-old girl is positioned in the right lateral position. The neuropsychologist presents a slide with a black line drawing of a zebra with the French words "Ceci est" ("this is").

and the fifth patient felt a subjective word finding, but no objective language disorder was identified. She still presented a mental clouding, which affected her language fluidity and resulted in global memory difficulties.

### Psychologic Preparation

To date, the pediatric psychiatrist did not contraindicate any child for this procedure. The psychological experience of this surgery was good for each patient.

Concerning hypnosis, it seemed helpful to facilitate the psychologic experience and cooperation of the children: We noticed that hypnosis conditioning constitutes an effective and easily performed method. In an emergency for patient 5 we succeeded in using hypnosis, too. This patient was examined by the hypnotist just before the surgery and was also sensitive to hypnosis during the anesthetic induction and the woken period, as well as the others. The best example of the efficiency of hypnosis concerns patient 4. She had an anxious personality, and the psychiatrist's assessment suggested slight depression. Thanks to hypnosis, we obtained good cooperation and the atmosphere was relaxed.

### Anesthetic Technique

The use of a laryngeal airway mask seemed ideal when compared with the conventional intratracheal intubation. The fifth child, who benefited from this technique, was more comfortable than the others. The intratracheal intubation often gives the patient, after extubation, the feeling of having a frog in the throat. It seems a minor problem, but it may be enough to undermine the cooperation of the child during the neuropsychologic examination and sometimes it makes them cough uncontrollably, causing in some adult cases acute intracranial hypertension in our experience.

Our global analgesic conditioning, including anesthetic drugs and local anesthesia, provided complete satisfaction and the children did not experience any pain during surgery.

### Surgical Technique

We confirmed that surgery while awake is feasible in children aged 11–16 years old. We succeeded in making an informative cortical-subcortical mapping with an efficient intensity of 1.5–6 mA for cortical mapping and 5–10 mA for subcortical mapping. The tumor was removed without putting the patient to sleep in all cases. This technique allowed us to do a total growth resection in 5 of the 6 presented cases without any new neurologic sequelae other than those present before surgery. The fifth child needed further surgery under general anesthesia for a 1-cm residue located in the noneloquent area. In this last case the size of the tumor preoperatively was estimated at 10 cm in diameter. This second operation allowed us to finally obtain a total growth resection. Children who presented a neurologic weakness before surgery had an improved neurologic status. The second patient presented a repeat tumor, which was again operated on in while awake.

Figures 2 through 7 illustrate the management of one of our cases.

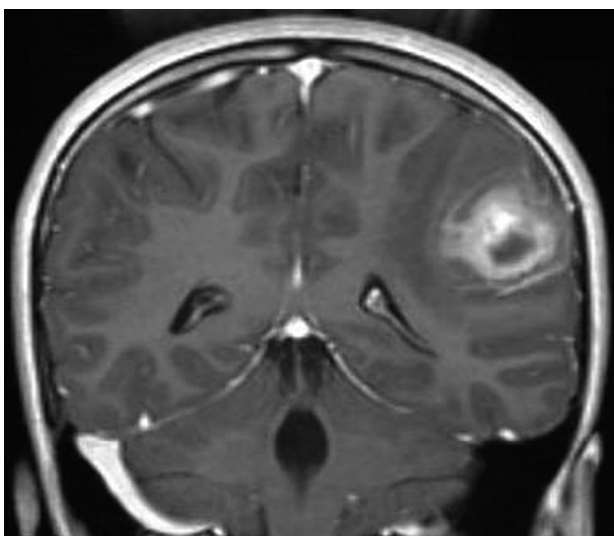
### Follow-up

The follow-up extends from 1 week for the most recent case to 74 months for the oldest case, with a mean follow-up of 24.3 months.

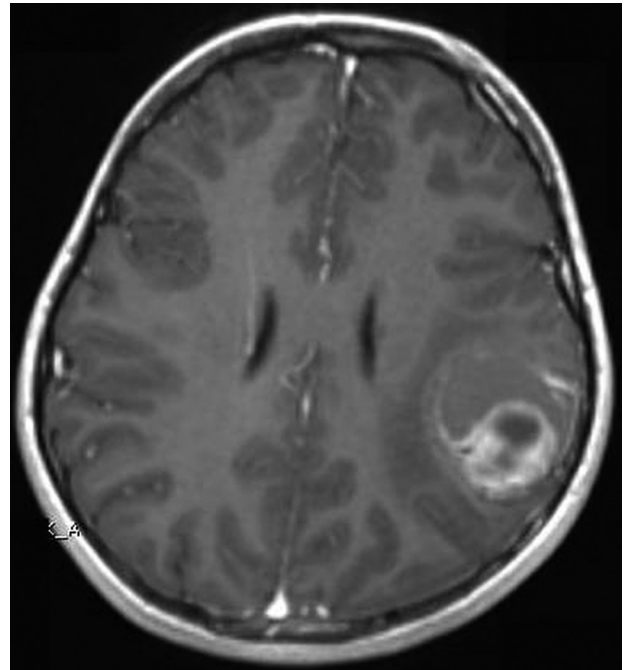
We present for each patient the neuropsychologic, neurologic, and radiologic evolution after surgery. The localization and histopathology for each patient are outlined in Table 1.

### First Case

From the neuropsychologic point of view, the 15-year-old young girl presented a moderate dysarthria after surgery, which rapidly improved. Concerning her neurologic evolution, the young girl presented a partial right brachial and facial palsy, which improved rapidly thanks to active rehabilitation with a physiotherapist at home. Furthermore, she did not suffer from any seizures after



**Figure 2.** Axial view of a preoperative magnetic resonance imaging scan showing a left parietal lesion in a child with language disturbance.

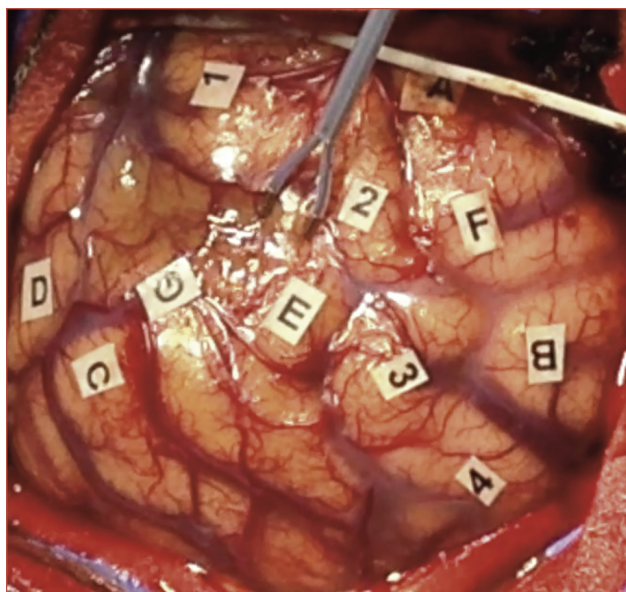


**Figure 3.** Coronal view of a preoperative magnetic resonance imaging scan showing a left parietal lesion in a child with language disturbance.

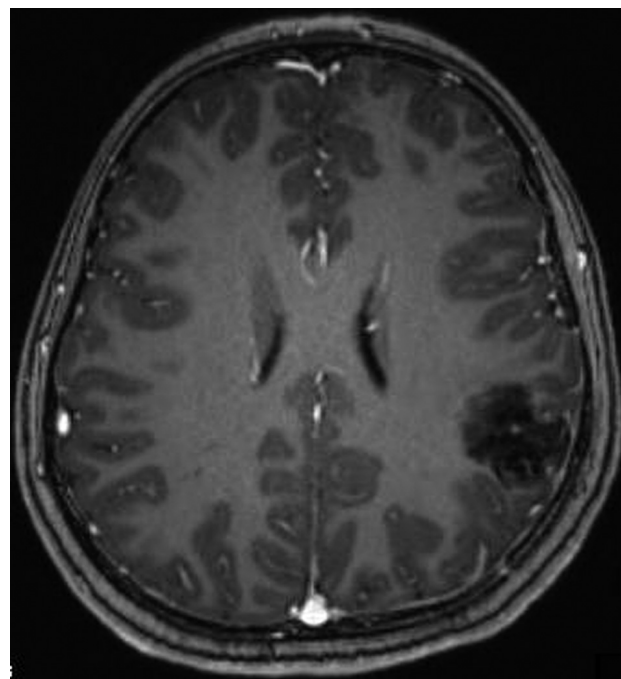
surgery. In terms of psychiatric impacts, the evolution was fully satisfactory. The postoperative MRI 3 months after surgery confirmed a growth total resection, and the other MRIs remained stable. She continued her education without any difficulties and received her high school diploma with the maximum result of “very good.” According to our latest update, she has started postsecondary education in medical school.

### Second Case

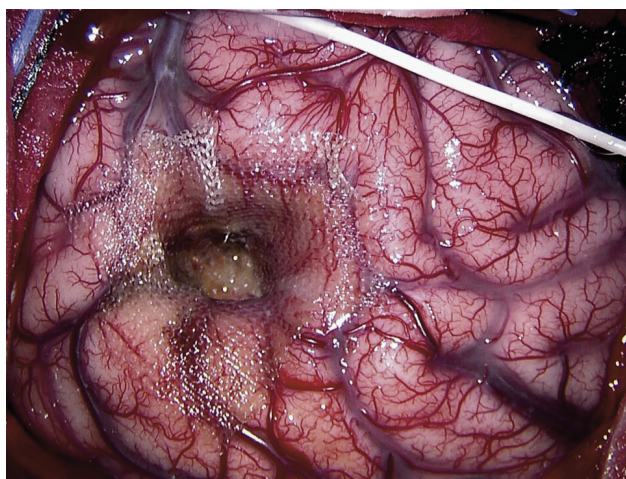
From a neuropsychologic point of view, after surgery on this 16-year-old boy we observed a slow ideation and word-finding problems, which quickly improved with orthophonic rehabilitation at home. The neuropsychologic evaluation 1 month after surgery did not reveal any difficulties in terms of language. The detailed assessment still showed some difficulties with the working memory, verbal learning, and planning process. He nevertheless partially returned to school and his basketball training less than 1 month after surgery and then full-time 3 months after surgery. At 3 months the only remaining problems affect the memory and executive functions. Concerning his neurologic status, just after surgery he suffered from right proprioceptive disorders. The facial palsy had disappeared after 1 month. The psychiatrist’s evaluation at 1 month did not highlight any psychopathologic disorder. The first MRI 3 months after surgery revealed a total growth removal, but 6 months after surgery the patient presented new epileptic seizure and the MRI scan 1 year after surgery showed the occurrence of a tumoral nodule, which required a surgical second look, again while awake 18 months after the first one without any difficulties and with



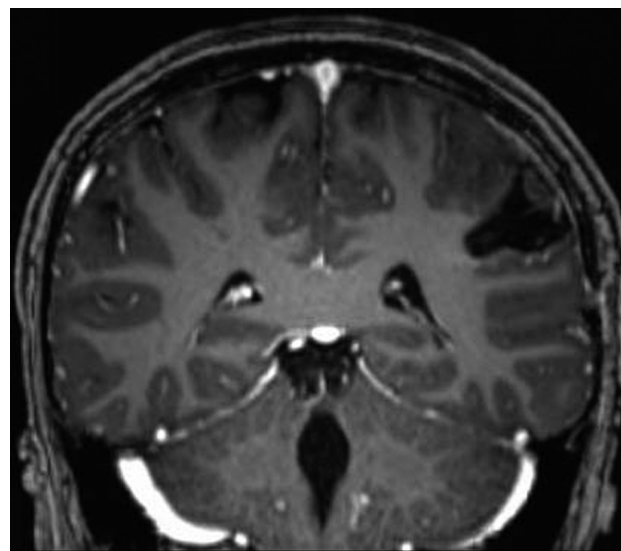
**Figure 4.** Surgical view of the cortical mapping on a left hemisphere in a child. The cortex is intact in front of the lesion. The vein in the top left corner corresponds to the end of the sylvian fissure. The letters A, B, and F correspond to the precentral gyrus identified by stimulation-induced movements. The numbers 1, 2, 3, and 4 correspond to the postcentral gyrus identified by stimulation-induced paresthesia. The other letters correspond to the sites of language disturbances induced by electrical stimulation. The cortical mapping permitted us to determine the transcortical approach. The top of the head is on the right of the photograph, and the face of the patient is at the top of the photograph.



**Figure 6.** Axial view of the postoperative magnetic resonance imaging scan.



**Figure 5.** Cortical view after resection of the lesion. The vein in the top left corner corresponds to the end of the sylvian fissure. We used a transparietal approach through the inferior parietal lobule. At the bottom of the cavity, we stopped resection after observing repetition disturbances induced by electrical stimulation. We were at the level of the arcuate fasciculus. The top of the head is on the right of the photograph, and the face of the patient is at the top of the photograph.



**Figure 7.** Coronal view of the postoperative magnetic resonance imaging scan.

total growth resection. He just turned 18 years old. It is important to note that between the two surgeries the patient received his high school diploma and started postsecondary education, reflecting the good neuropsychological status. The follow-up was

marked by school difficulties attributed to the epileptic treatment, which improved after the treatment was changed. Concerning the neuropsychologic evolution, the last evaluation 9 months after the second surgery showed a real improvement. Some discreet abnormalities persisted in terms of memory and word finding. The neurologic status was otherwise clearly normal.

### Third Case

In this 14-year-old boy the following operations were simple. The patient did not present any new neurologic or neuropsychologic weaknesses. The postoperative MRI confirmed the total growth resection. He returned to school part-time less than 1 month after surgery and then full-time 3 months after surgery. The neuropsychologic assessment 3 months after surgery was positive and showed only some minor difficulties concerning working memory, episodic verbal memory, and graphomotor treatment. He nevertheless had good school results. Unfortunately, 18 months after surgery, the MRI scan showed an asymptomatic tumor recurrence in the same place, which required a surgical while-awake second look. We performed a total growth resection confirmed by a postoperative MRI scan, and the following operations were simple. The examination after surgery did not reveal any difficulties in terms of language. However, we are waiting for the neuropsychologic assessment.

### Fourth Case

In terms of the psychologic experience the case of this 12-year-old girl was the most complicated to manage. She was anxious, and the psychiatric evaluation showed a slight case of depression. In addition to her preoperative weakness (right hemiparesis, proprioceptive troubles, dissociation between verbal and nonverbal skills, and graphomotor slowdown without language troubles in the neuropsychologic evaluation), she suffered from painful algodystrophy. We obtained a total growth resection, and the following operations were simple. The neurologic disorders persisted but were not exacerbated. She presented a reduced verbal fluency. She had to be admitted to a rehabilitation department for active rehabilitation. It is important to note that she returned to normal school 6 months after surgery. The neuropsychologic assessment 6 months after surgery showed a global improvement with a language considered normal, a homogenization of her intellectual competences, and the disappearance of the graphomotor slowdown. At 11 months post surgery, she is now independent in her daily life.

### Fifth Case

Immediately after surgery we observed the persistence of the hemiparesis but no major language disturbance. The following operations were marked by the persistence of right hemiparesis and the progressive appearance in the first week of language disturbance, mental clouding, and sedation due to postoperative hydrocephaly treated by a ventriculoperitoneal shunt. The neurologic and neuropsychologic status required admission to a rehabilitation department. Six months after surgery, minor hemiparesis and minor difficulties in finding words persisted and the neuropsychologic assessment showed a global improvement. She has not yet returned to school but is receiving school

teaching in the hospital. She is nevertheless now independent in her daily life.

### Sixth Case

The following operations were simple without any neurologic weakness. The psychologic experience was good in this anxious young boy. From the neuropsychologic point of view, the examination after surgery did not reveal any difficulties in terms of language. However, we await the detailed assessment in 3 months. The patient went home 1 week after surgery and was able to return directly to school.

## DISCUSSION

Childhood brain cancer is an area requiring work. Currently, central nervous system tumors are the second most common childhood malignancy and the first cause of cancer-related death in childhood. The mean annual incidence rate was 39 per million according to the French National Registry of Childhood Solid Tumor between 2000 and 2008 (6). Among these, only 30%–40% are supratentorial, 40% of which are on the midline. Furthermore, supratentorial tumors are more frequent in the 2 first years of life. This low incidence of supratentorial tumors in children probably explains the lack of validation of this technique in pediatric patients and the lack of data in the literature. We now know clearly that the child's survival depends on the quality of the tumor resection and the vicinity of eloquent areas in a non-negligible number of supratentorial cases explains the absolute necessity of using awake craniotomy in these children to obtain a total growth resection.

One of the other reasons that explains the lack of validation of this method is the "famous" notion of brain plasticity. We think that this "overvalued" brain plasticity of child has probably limited the development of the technique. Until recently it was admitted by most neurosurgeons that a child recovered much more easily than an adult from a neurologic weakness. Many publications explain the risk of a negative impact in childhood of brain tumor surgery on the functional outcome. Even if children probably recover more easily than adults from a motor point of view, the neuropsychologic side effect of surgery is difficult to avoid, causing real neurocognitive deficits (13, 17, 18, 23). The brain plasticity also does not involve the age range of 11–16 of the population in our study. It does not concern either the younger population. Indeed, according to the literature, it seems that young children can relocate language to the opposite hemisphere, but only during the first 5 years of life (7). After 5 years, the reality is that the brain plasticity is similar to adults and is limited to local and reduced plasticity in the area close to the tumor. On that basis, every neurologic weakness could become a neurologic sequela. The respect of eloquent areas by awake craniotomy and corticosubcortical mapping also seems essential from the age of 5.

The extraoperative mapping by implanted subdural electrodes constitutes an alternative attractive option in the case of young children to avoid awake craniotomy (4, 8, 20). This second way needs two surgeries under general anesthesia and can cause difficulties in young children, plus there is the risk of infection. It also does not allow exploration of the subcortical white matter

pathway. This technique, which has been used for a long time in epilepsy surgery, at least allows us to demonstrate the efficiency of brain stimulation in maturing brain in children up to the age of 2 (7).

Concerning cortical stimulation on maturing brain, each child operated on while awake in our experience underwent relevant cortical and subcortical mapping with involuntary stimulation-induced movement and stimulation-induced errors in naming. We were never restricted by a problem that could be attributed to a lack of brain maturation. This result could even be reproduced under general anesthesia for motor stimulation in each case until the age of 3. In our group, the stimulation threshold in all cases was determined on involuntary movements obtained by stimulating motor areas. The intensity used to obtain a positive response was not significantly different from the intensity used in adults. Contrary to Jayakar et al., we did not need to exceed the afterdischarge threshold to obtain a motor or language response (15). According to Duchowny, the template of language organization was similar in children and adults (7), but for Ojemann (20) and Berger (3) there is an important variability in language cortex localization among children and the abundance of the eloquent electrically objectified sites was reduced. In practice this cortical particularity was not a problem in our experience for the brain mapping of children.

In our opinion, the challenge for pediatric surgery while awake is to operate on children younger than 15. Currently there are only a few cases described in the literature and most of them concern children aged 16 or 17 (11). The main publications of prior childhood awake craniotomies are presented in Table 2. A recent publication reports the retrospective experience of awake craniotomy in 10 patients aged 11–17, with 5 patients aged 16 and 17 (a mean age of 14.6 years) (1). Awake craniotomy at 16 or 17 can be assimilated to awake craniotomy in adults and does not appear to require any particular approach or adaptation in particular with regard to the technical aspect of this surgery. Indeed, as demonstrated earlier, the principle of cortical and subcortical mapping in children is similar to that in adults apart from possibly some differences of stimulation intensity. However,

we think that a 16-year-old patient is not as mature as an adult and requires more psychologic conditioning. Theoretically, this technique should be used from the age of 5 if we consider the plasticity possibilities described earlier. In the younger population it seems important to explain and adapt the operative procedure. A few examples demonstrating the feasibility of awake craniotomy in patients aged 10–15 years (1, 20) are described in the literature. Other publications about younger children come from anesthetic reviews and often refer to isolated cases, without any information about the execution and adaptation of this technique in children (16, 21, 22). All these publications focused mainly on the technical aspect of the brain mapping. Beyond the question of feasibility, the most important point is to explain how to adapt this surgery for children. In this way we think that every possibility for improving the psychologic experience of this surgery should be applied.

Psychologic preparation starts before surgery: We show the child and parents pictures and videos of a previous procedure to precisely explain the operation. We observed that a meeting with a child already operated on while awake, as well as the family, and the child who is going to be operated on is useful for decreasing the stress of the operation. In addition, we schedule a visit to the operating room and nursing team.

Furthermore, the child needs to meet a pediatric psychiatrist. In our experience it is now always the same therapist who is involved in this protocol.

Good cooperation and psychologic experience require a total absence of pain. This is based on the anesthetic analgesic drugs given by the anesthetic team. It is also achieved by the use of an efficient local anesthesia and a local anesthetic nerve block of the entire scalp.

The use of a laryngeal airway mask seemed ideal compared with the conventional intratracheal intubation. The fifth child, who benefited from this technique, was more comfortable than the others.

We also noticed that hypnosis conditioning constitutes an effective and easily performed method even in an emergency. Balogun et al., in their recent study, deplore the rejection of the waking procedure for one patient aged 13 due to combative

**Table 2.** Prior Published Childhood Awake Craniotomy Series

| Journal, Year, Reference                           | Number of Pediatric-While-Awake Surgical Procedures | Age of Children (Years)                | Use of Hypnosis |
|--|---|--|-----------------|
| <i>Neurosurgery</i> , 1989 (3)                     | 3   | Unspecified                            | No              |
| <i>Paediatric Anesthesia</i> , 1997 (22)           | 1   | 12                                     | No              |
| <i>Paediatric Anesthesia</i> , 2000 (21)           | 12  | 11–15<br>not detailed                  | No              |
| <i>Journal of Neurosurgery</i> , 2003 (19)         | 8   | 10–16<br>not detailed                  | No              |
| <i>Journal of Clinical Anesthesia</i> , 2004 (14)  | 3   | 11, 12, 16                             | No              |
| <i>Anesthesia</i> , 2004 (16)                      | 1   | 9                                      | No              |
| <i>Pediatric Anesthesia</i> , 2006 (11)            | 2   | 16, 16                                 | No              |
| <i>Journal of Clinical Neuroscience</i> , 2014 (1) | 10  | 11, 11, 13, 13, 15, 16, 16, 17, 17, 17 | No              |
| Our study  | 7   | 11, 12, 14, 14, 15, 15, 16             | Yes             |

behavior. We think that hypnosis in this case might have facilitated the procedure (1).

This study has a few limitations. The number of children included is still low, and this small experiment needs to be evaluated on a larger pediatric population. We are limited, however, by the low incidence of supratentorial tumors in children as described earlier. The mean age still remains high, and this surgery should be broadened to younger children, in particular to assess the use of hypnosis in the younger population. Finally, we have to reflect on the elaboration of a newly adapted neuropsychologic peroperative test for children younger than 9 or 10.

## REFERENCES

- Balogun JA, Khan OH, Taylor M, Dirks P, Der T, Carter Snead III O, Weiss S, Ochi A, Drake J, Rutka JT: Pediatric awake craniotomy and intraoperative stimulation mapping. *J Clin Neurosci* 21:1891-1894, 2014.
- Bello L, Gallucci M, Fava M, Carrabba G, Giussani C, Acerbi F, Baratta P, Songa V, Conte V, Branca V, Stocchetti N, Papagno C, Gaini SM: Intraoperative subcortical language tract mapping guides surgical removal of gliomas involving speech areas. *Neurosurgery* 60:67-80; discussion 80-82, 2007.
- Berger MS, Kincaid J, Ojemann GA, Lettich E: Brain mapping techniques to maximize resection, safety, and seizure control in children with brain tumors. *Neurosurgery* 25:786-792, 1989.
- Bollo RJ, Carlson C, Schevon C, Wisoff JH, Devinsky O, Weiner HL: Extraoperative functional mapping and staged resection of supratentorial tumors near eloquent cortex in children. *Pediatr Neurosurg* 45:175-180, 2009.
- Deloche G, Hannequin D: Test de dénomination orale d'images: DO 80. Éd. du Centre de psychologie appliquée, 25 rue de la plaine, 75980, PARIS Cedex 20; 1997.
- Desandes E, Guissou S, Chastagner P, Lacour B: Incidence and survival of children with central nervous system primitive tumors in the French National Registry of Childhood Solid Tumors. *Neuro-Oncol* 16:975-983, 2014.
- Duchowny M, Jayakar P, Harvey AS, Resnick T, Alvarez L, Dean P, Levin B: Language cortex representation: effects of developmental versus acquired pathology. *Ann Neurol* 40:31-38, 1996.
- Duffau H: Contribution of cortical and subcortical electrostimulation in brain glioma surgery: methodological and functional considerations. *Neurophysiol Clin Clin Neurophysiol* 37:373-382, 2007.
- Duffau H: Perioperative functional mapping using direct electrical stimulations. *Methodological considerations. Neurochirurgie* 50:474-483, 2004.
- Duffau H, Peggy Gatignol ST, Mandonnet E, Capelle L, Taillandier L: Intraoperative subcortical stimulation mapping of language pathways in a consecutive series of 115 patients with grade II glioma in the left dominant hemisphere. *J Neurosurg* 109:461-471, 2008.
- Everett LL, van Rooyen IF, Warner MH, Shurtleff HA, Saneto RP, Ojemann JG: Use of dexmedetomidine in awake craniotomy in adolescents: report of two cases. *Paediatr Anaesth* 16:338-342, 2006.
- Goodglass H, Kaplan E: *The Assessment of Aphasia and Related Disorders*. Philadelphia: Lea & Febiger; 1972.
- Grill J, Viguier D, Kieffer V, Bulteau C, Sainte-Rose C, Hartmann O, Kalifa C, Dellatolas G: Critical risk factors for intellectual impairment in children with posterior fossa tumors: the role of cerebellar damage. *J Neurosurg* 101 (2 Suppl): 152-158, 2004.
- Hagberg CA, Gollas A, Berry JM: The laryngeal mask airway for awake craniotomy in the pediatric patient: report of three cases. *J Clin Anesth* 16: 43-47, 2004.
- Jayakar P, Alvarez LA, Duchowny MS, Resnick TJ: A safe and effective paradigm to functionally map the cortex in childhood. *J Clin Neurophysiol Off Publ Am Electroencephalogr Soc* 9:288-293, 1992.
- Klimek M, Verbrugge SJC, Roubos S, van der Most E, Vincent AJ, Klein J: Awake craniotomy for glioblastoma in a 9-year-old child. *Anaesthesia* 59: 607-609, 2004.
- Konczak J, Schoch B, Dimitrova A, Gizewski E, Timmann D: Functional recovery of children and adolescents after cerebellar tumour resection. *Brain J Neurol* 128 (Pt 6):1428-1441, 2005.
- Nazemi KJ, Butler RW: Neuropsychological rehabilitation for survivors of childhood and adolescent brain tumors: a view of the past and a vision for a promising future. *J Pediatr Rehabil Med* 4:37-46, 2011.
- Ojemann G, Ojemann J, Lettich E, Berger M: Cortical language localization in left, dominant hemisphere. An electrical stimulation mapping investigation in 117 patients. *J Neurosurg* 71: 316-326, 1989.
- Ojemann SG, Berger MS, Lettich E, Ojemann GA: Localization of language function in children: results of electrical stimulation mapping. *J Neurosurg* 98:465-470, 2003.
- Soriano SG, Eldredge EA, Wang FK, Kull L, Madsen JR, Black PM, Riviello JJ, Rockoff MA: The effect of propofol on intraoperative electrocorticography and cortical stimulation during awake craniotomies in children. *Paediatr Anaesth* 10:29-34, 2000.
- Tobias JD, Jimenez DF: Anaesthetic management during awake craniotomy in a 12-year-old boy. *Paediatr Anaesth* 7:341-344, 1997.
- Vago C, Bulgheroni S, Usilla A, Biassoni V, Serra A, Gentile S, Ajovalasit D, Leonardi M, Massimino M, Fidani P, Riva D: Adaptive functioning in children in the first six months after surgery for brain tumours. *Disabil Rehabil* 33:953-960, 2011.

*Conflict of interest statement: The author declares that the article content was composed in the absence of any commercial or financial relationships that could be construed as a potential conflict of interest.*

*Received 9 May 2015; accepted 30 June 2015*

*Citation: World Neurosurg. (2015) 84, 6:1645-1652.*

*http://dx.doi.org/10.1016/j.wneu.2015.06.073*

*Journal homepage: www.WORLDNEUROSURGERY.org*

*Available online: www.sciencedirect.com*

*1878-8750/\$ - see front matter © 2015 Elsevier Inc.*

*All rights reserved.*



## 4 Impact psychologique :

Forts de notre expérience clinique, nous avons voulu évaluer l'impact psychologique de la CECCSC chez ces enfants. Nous avons donc repris la même cohorte d'enfants. Ce travail initialement rétrospectif est devenu prospectif au cours de la prise en charge des enfants. Nous avons pour cela collaboré avec l'équipe de pédopsychiatrie. Des entretiens pédopsychiatriques répétés avant et après l'intervention ont eu lieu. En préopératoire, une évaluation pédopsychiatrique était réalisée. En post-opératoire les symptômes d'état de stress post-traumatique et de stress aigu selon le DSM V étaient recherchés.

Aucun des patients n'a été contre-indiqué sur le plan pédopsychiatrique. En post-opératoire, nous n'avons pas retrouvé de symptômes évocateurs d'un état de stress post-traumatique ou d'un état de stress aigu. Un des enfants a présenté en post-opératoire des symptômes de dépression qui ont nécessité une psychothérapie de soutien pendant 6 mois sans traitement psychotrope associé. Ces symptômes étaient surtout en rapport avec la peur d'une rechute et ont disparu avec l'IRM de contrôle montrant une absence de récurrence. On imagine que ces derniers symptômes auraient pu survenir de la même façon en cas de chirurgie conventionnelle.

Dans notre expérience, cette intervention s'avère donc inoffensive sur le plan de l'impact psychologique.

Les résultats de cette étude sont soumis dans « the journal of clinical psychiatry ».

❖ **Article n°2 : Psychiatric and psychological impact of surgery while awake in children for resection of brain tumors in the language areas**

Elise Riquin, Mickael Dinomais, Jean Malka, Thierry Lehouste, Philippe Duverger, Philippe Menei, Matthieu Delion

Soumis dans The journal of Clinical Psychiatry

Rang SIGAPS B

Impact factor : 5,847

Psychiatric and psychological impact of surgery while awake in children for resection of brain tumors in the language area.

Authors :

Elise Riquin MD <sup>1</sup>, Mickael Dinomais MD PhD <sup>2</sup>, Jean Malka MD <sup>1</sup>, Thierry Lehouste MD <sup>3</sup>, Philippe Duverger MD PhD <sup>1</sup>, Philippe Menei MD PhD <sup>4</sup>, Matthieu Delion MD <sup>4,5</sup>

1 LUNAM, CHU Angers, Université d'Angers, Département de Pédiopsychiatrie F-49933, Angers, France

2LUNAM, CHU Angers, Université d'Angers, Département de médecine physique et réadaptation, F-49933, Angers, France

3LUNAM, CHU Angers, Université d'Angers, Département d'Anesthésie-Réanimation , F-49933, Angers, France

4LUNAM, CHU Angers, Université d'Angers, Département de Neurochirurgie , F-49933, Angers, France

5 LUNAM, University of Angers, Medical Faculty, Anatomy Laboratory, F-49045, Angers, France

Corresponding author : RIQUIN E. Address: CHU Angers, Université d'Angers, Département de Pédiopsychiatrie, F-49933, Angers, France. Phone number: 02 41 35 44 42, fax number: 02 41 35 49 34, e-mail : [elise.riquin@chu-angers.fr](mailto:elise.riquin@chu-angers.fr)

Acknowledgements : The authors would like to thank Mrs Laetitia Guinefolleau, Mrs Ghislaine Aubin, Mrs Nolwenn Madec and Mr Pierre Martin for their work as child language therapists.

Conflict of interest : on behalf of all authors, the corresponding author states that there is no conflict of interest.

## Abstract

**Background:** Intraoperative direct stimulation during surgery while awake is considered to be the gold standard for identifying eloquent cortical sites. Only a few studies have referenced the psychological impact of this event, especially in the pediatric population.

**Objective :** The aim of this clinical study is to present the psychological aspects of surgery while awake in children. We question the psychiatric contraindications and age limits, but also the impact on children, with particular attention to the psychological conditioning and psychological experience of these patients.

**Methods :** Seven patients aged from 8 to 16 years old suffering from brain lesions in the eloquent area and operated on while awake between 2008 and 2015. The patients met a child psychiatrist before, immediately after surgery or at 3 months. Data collected included perception and memories of surgery and diagnosis and also their real-life experience after surgery. Symptoms of posttraumatic stress disorder or acute stress were investigated.

**Results :** None of the children had initial psychiatric problems. No psychiatric diagnosis was made before surgery. The child psychiatrist didn't contraindicate any child for this procedure. They experienced very little anticipatory anxiety. No child presented symptoms of posttraumatic stress disorder or acute stress.

**Conclusions :** Surgery while awake raises a lot of medical, ethical and psychological questions. The results are encouraging, allowing us to contemplate using brain surgery while awake for children without particular worries about the psychological aspect.

## Introduction

Brain cancer represents the second most common childhood malignancy and the first cause of death related to cancer in childhood. Surgery is often necessary and must be as complete as possible. However, a functional area located close to the tumor can limit the resection. Intraoperative direct stimulation surgery while awake is considered to be a gold standard for identifying the eloquent cortical sites (motor and language areas) in the adult population (1). Only small series have been published regarding children (2–10) Indeed, the mean annual incidence rate of supratentorial hemispheric tumors in children is very low (11). In our center, we estimate at about 3 children per year are eligible for this procedure while awake. This low incidence explains the lack of data in the literature. The few existing studies often concerned young adults and focused primarily on describing the technical aspect of the surgery but, currently, there is no specific international procedure for operating on such children. In a recent publication we presented our procedure relating to the unique nature of craniotomy while awake in children, but, as in the literature, psychological aspects still remain understudied (6).

The main purpose of this publication is to present the psychological aspects of surgery while awake in children. We question the psychiatric contraindications and age limits, but also the impact on children, with particular attention to psychological conditioning and the psychological experience of these patients. Few studies have dealt with the psychological aspects and the patients' perspective of surgery while awake (12–15), but only concern the adult population. We present here a pilot study on the psychiatric and psychological impact of surgery while awake in the pediatric population.

### Material and methods

Our experience is based on seven patients aged from 8 to 16 years old suffering from brain lesions in the eloquent area and operated on by while awake between 2008 and 2015 for six of whom the surgery has been described in another publication. (6). Two of these patients were operated on twice while awake. All pediatric patients and their parents gave their consent for surgery while awake.

#### Preoperative

Considering the psychological aspects, all children and their families met the child psychiatrist before the surgery. The data collected during the interview included basic demographic data, and real-life experience of the pre-operative symptoms. The main psychological facts were noticed in the medical record and a psychiatric diagnosis based on DSM 5 was carried out if necessary. Eventually any contraindications to surgery while awake were identified. The child psychiatrist's interviews were based on semi structured, open-ended, interviews. . A neuropsychological evaluation with a child language therapist was also carried out before the surgery. This evaluation allowed us to get to know the young patients before surgery and to appreciate the starting point of the young patients before surgery so as to adjust evaluation during the surgery. The children met the anesthetic team for hypnosis conditioning. Indeed, for the last five procedures, we used hypnosis conditioning for anesthetic induction, preoperative awakening and during periods without stimulation. The patient had been seen in hypnosis clinics 1 and 3 weeks before surgery. Over and above the analgesic effect, the aim of this management was to recreate a relaxing environment during both the induction and the awakening. In the last 4 procedures we offered the patient the chance to meet another child who had been operated on by a craniotomy while awake to explain their psychological experience. We showed the patient some pictures and a video describing the atmosphere of the operating room. The patient visited the operating room and met the surgical and anesthetic team before surgery to get acquainted with the atmosphere (16).

#### During the surgery:

A neuropsychological evaluation with a child language therapist was carried out during the surgery.

Hypnosis conditioning was used during the peroperative periods without stimulation, such as periods of tumor resection during which the cooperation of the child is not necessary. With regard to the anesthetic technique, the children were put to sleep. Conventional intratracheal intubation or an appropriate-sized laryngeal airway mask were used. Pin sites for the holder, scalp nerve and scalp incision were infiltrated with diluted ropivacain.

Considering the surgical aspects, patients were positioned in the supine or lateral position according to the location of the tumor as shown in figure 1. The patients were woken after the completion of the bone flap and the infiltration of the dura. After the awakening and the extubation of the child, and when he was able to clearly communicate with the neuropsychologist, we opened the dura and started the electrical cortical mapping. In practice, a bipolar electrode is applied to the cortex before the resection, starting with a 1 mA intensity and increasing by 1 mA at a time. On a motor eloquent site this electrical stimulation can induce an involuntary motor response. For the sites involved in language function, an object denomination task with the carrier phrase “this is” on a white slide, as shown in figure 1, is presented to the child during each stimulation, in line with our adult experience and the literature (1) . We looked for transient language disturbance (aphasic arrest, paraphasia, naming delay). During the surgical removal of a tumor, sub cortical stimulation was also used.

Postoperative :

Patients met the child psychiatrist immediately after surgery and at 3 months. Data collected included their perception and memories of surgery, diagnosis and also real-life experience after surgery. Symptoms of posttraumatic stress disorder (PTSD) or acute stress, based on DSM 5, were identified.

A neuropsychological evaluation with a child language therapist was carried out at 3 and 6 months after the surgery. These evaluations allowed us to specify post operative cognitive sequelae and to focus the rehabilitation process on objectives.

This publication involves current normal clinical practice and is based on a clinical study in compliance with Ethics.

## Results

### Preoperative

For five children, the symptoms leading to discovery of a brain tumor were seizures, generalized for four children and partial for 1 child. One child had a cerebral hemorrhage, with language problems and facial

palsy. 1 child had symptoms of high intra cranial pressure. Previously, none of them had a medical history, apart from 1 child who was operated by conventional surgery for his brain tumor a few months earlier.

All the children were provided with ordinary schooling. None of the children had initial psychiatric problems. No psychiatric diagnosis was made before surgery. The child psychiatrist didn't contraindicate any child for this procedure. The children asked a lot of questions before the surgery, searching for reassurance linked with moderate anxiety for five children and at a higher level for two children. These two children were anxious about surgery and for one of them symptoms of slight depression were found with a lack of self confidence and performance anxiety. This anticipatory anxiety never specifically concerned the fact of being awake during surgery, but more the surgery per se.

However, surgery was always considered a positive event and the family and child were expecting it. A young patient talked about his fear of having new symptoms of the brain tumors and was impatient for the surgery. For this child, surgery was considered to be an event which would allow him to no longer feel any anxiety.

#### During the surgery

All the children felt reassured and sustained by presence of the child language therapist they had met before surgery.

Concerning hypnosis, it was always helpful to facilitate the psychological experience and cooperation of the children: We noticed that hypnosis conditioning constitutes an effective and easily-performed method in creating a spatio-temporal distortion based on the predefined themes identified from the initial encounter.

Finally, thanks to this kind of management, we succeeded in making a very informative cortical-subcortical mapping. The tumor was removed without putting the patient to sleep in all cases. This technique allowed us to do a total growth resection in six of the seven-presented cases without any new neurological sequellae other than those present before surgery. The fifth child needed further surgery under general anesthesia for a one-centimeter residue located in the noneloquent area. This second operation allowed us to finally obtain a total growth resection. Children who presented a neurological weakness before surgery had an improved neurological status. No child recalled any pain during surgery.

#### Post operative

No child showed symptoms of PTSD or acute stress. The children talked about surgery without difficulty and one of the children had a strong memory of it. These memories were pleasant and the young patient talked about surgery without anxiety. This child was the patient who was very anxious before surgery.

For other patients, their memories were often vague and were based on a fantasy. One of the patients was quite anxious immediately after surgery, he was lucid and coherent, but seemed perplexed. This state ended a few days later. For this child, there was no hypnosis induction for surgery. One child had symptoms of depression just after surgery, which necessitated a psychotherapeutic follow up without any psychotropic medication and this went on for 6 months. The depression was principally about the fear of a relapse. This state ended when magnetic resonance imaging showed no recurrence.

### Discussion

No contraindications were listed in our cohort. Two children had a high level of preoperative anxiety. With this, surgery took place without any difficulty and in good conditions both for the child and for the medical team. After surgery, the child was capable of talking about it without fear. We consider that, based on the indisputable interest of surgery while awake in specific brain tumors, we have to envisage surgery while awake with no psychiatric exclusion as a rule.

We questioned our views on the minimal age for surgery while awake considering the psychological and psychiatric aspects. For some authors, craniotomy while awake is not feasible in children under 11 or 12 years of age (7). Nevertheless we found a publication about a craniotomy while awake on a 9-year-old child (2) and there are a few publications about young patients in the literature (2,3,5–10). According to our experience we can confirm that this surgical technique is feasible on a 8 year-old child with good cooperation (6). This younger patient was very relaxed and attentive during the surgery, even if she was very active before surgery and during the consultations. In this context, surgery while awake in early age seems to be based on an individual evaluation of comprehension capacity and the cooperation of the child. It cannot constitute a psychiatric contraindication as a rule, since the child has consented to it and has good psychological preparation, without further studies (5). Furthermore, there is no interest in operating them before the age of 5 year. In fact, young children can relocate language to the opposite hemisphere only during the first five years of life due to efficient neuroplasticity (19).

Related to the real-life experience from discovering the brain tumor to surgery, we think that the discovery and diagnosis of a brain tumor are psychologically extremely painful and the child psychiatrist has to support the child and their family with their expectations and worries. Patients describe the shock of discovering the first symptoms, often sudden and intense in a child who was healthy before. In fact, in our cohort, five



children had generalized seizures with residual symptoms such as seizures, headaches, visual problems or were aware of fluctuations.

The traumatic impact of surgery while awake was evaluated in interviews with the child psychiatrist. A traumatic situation depends on two points. First of all, the person must have experienced or faced or been a witness to a situation which has put their own life or the lives of others in severe danger. This situation must have provoked severe injuries or seriously endangered the physical integrity of the person or that of others. Then, reaction to this exposure must have created an intense fear, high levels of distress or a feeling of horror. The news of a disease affecting a vital organ, especially a brain tumor, carries the weight of a high lethal potential, corresponds to this definition. PTSD is defined by three clusters (re-experiencing, avoidance/numbing and increased arousal). However, these symptoms do not summarize the clinical presentation and course, and individual, familial, but also cultural dimensions have to be considered. For surgery or cancer diagnosis, the nature of the event is a chance encounter with death and takes on a severe traumatic potential. Brain surgery is linked with a high level of intrusion anxiety and a lot of fantasies and intense imagination about the surgical sequence. Surgery appears to be a solution (20), but also as an event which can induce new symptoms which are going to damage the child, first of all because of the scar, but also symbolically with the loss of the fantasy of a perfect child with no disease and no disabilities (21). The child's development may also induce specific symptoms. For patients over 6 years of age, we may observe anxiety, mood disorders or inhibition, but also expressions of guilt and academic problems. For adolescents, we can observe behavioral disorders and aggressiveness, but also substance abuse (22). In our cohort, the children didn't show these signs of PTSD or acute stress after surgery. The mental suffering seemed to be more linked to the first neurological symptoms and news of the disease, both for the family and for the child (20). In fact, during our interviews, these elements were the main points raised instead of the progress of the surgery. The risk of developing PTSD in children is linked with the seriousness of the event, the age of the child and the parental distress (22–24). We think that in these situations, parents represent for the child a major protective factor. We have to assess their capacity to be the main support for their child and offer psychotherapeutic follow-up when they seem vulnerable. In fact, parents who are suffering severely from the events can become the agents of a traumatic experience. Finally, we argue that an anticipatory anxiety is always present before any kind of surgery and that the anxiety before surgery while awake doesn't seem to be any higher. We need further studies to confirm this hypothesis.

Memories of surgery were frequently confused. This seems to be linked with hypnosis and anesthetic drugs, which could give that kind of feeling, such as a dreamlike experience. This kind of experience has already

been described in previously-published literature (20). Because of this, we think that surgery appeared to be a "psychological scotoma". With regard to hypnosis, by focusing the attention of the child on pleasing situations, the psychological experience and course of the operation are facilitated and with that, none of the children received any anxiolytic medication before the surgery.

Related to the psychological preparation, surgery while awake requires the perfect cooperation of the patient. Some authors evoke the necessity of a "state of a perfect harmony" between the patient, the surgeons, the child language therapist and the anesthetic team (25). This state requires optimal preparation and especially psychological preparation. We can therefore discuss these particular points.

We think that psychological preparation begins before surgery. This preoperative preparation with pictures and videos has been recommended by other studies in the adult population to give them an idea of what to expect during the actual surgery (20). We consider that information and a good understanding of the patient and their family on the rational behind craniotomy while awake is very important, as has already been shown in other studies (14,15,26). The information for the pediatric population is specific but we argue that it plays a very important role in good cooperation and in good outcomes both during and after surgery. The child, being a participant in this event may facilitate it, and isn't dispossessed of his body and mind even when surgery and illness are often linked with these types of feelings. Then the oral consent of all the children appears to be a main ethical, but also clinical, element.

We also consider that it is very important that children don't feel any pain during surgery. (20,26). In our cohort, no child reported pain during surgery,

Regarding the international literature, our study results have led to the same conclusions : craniotomy while awake is feasible in childhood (5). Considering the literature and our experience (6), craniotomy while awake in children is well tolerated by young patients. But nobody has evaluated the perception of the child and the psychiatric and psychological impact of that kind of surgery on the child. In the adult literature there are studies about perceptions of craniotomy while awake (12,13,15,20,27). These studies concluded that craniotomy while awake is well tolerated by patients and focused principally on such themes as recollections, pain or discomfort during surgery, satisfaction with surgery while awake or informing patients and didn't specifically examine the psychological or psychiatric aspects. Surgical questionnaires were often used excepted for one study (16) which focused on the traumatic impact of surgery while awake and psychiatrists were involved for only two studies (16, 27). We present these prior publications in table 1.

This study has certain limitations. The number of children included is still low and this small experiment needs to be re-evaluated on a larger pediatric population.

### Conclusion

Surgery while awake raises a lot of medical, ethical and psychological questions. It seems that the preliminary results are encouraging, allowing us to contemplate brain surgery while awake for children without any particular worries about the psychological effects. Age or psychiatric illnesses don't seem to constitute absolute contraindications as a rule in our knowledge. Some complementary studies are needed to pursue these innovative and promising procedures. A joint-project between surgeons, child psychiatrists, anesthetic doctors is a capital element of the follow up (5). A prospective study by the University of Angers is being undertaken at international pediatric scales. This new study may allow us to refine and clarify these preliminary results.

### Figure captions

Figure 1 : Peroperative neuropsychological assessment. The young girl is positioned in the right lateral position. The head is maintained in a Mayfield head holder. The neuropsychologist present a slide with a black line drawing of a dog with the mention « this is » in french. In the same time, the neurosurgeon stimulate the cortex with an electrode.

### References

1. Ojemann G, Ojemann J, Lettich E, Berger M. Cortical language localization in left, dominant hemisphere. An electrical stimulation mapping investigation in 117 patients. *J Neurosurg.* 1989;(71):316–26.
2. Klimek M, Verbrugge SJC, Roubos S, van der Most E, Vincent AJ, Klein J. Awake craniotomy for glioblastoma in a 9-year-old child. *Anaesthesia.* 2004 Jun;59(6):607–9.
3. Tobias JD, Jimenez DF. Anaesthetic management during awake craniotomy in a 12-year-old boy. *Paediatr Anaesth.* 1997;7(4):341–4.
4. Berger MS, Kincaid J, Ojemann GA, Lettich E. Brain mapping techniques to maximize resection, safety, and seizure control in children with brain tumors. *Neurosurgery.* 1989 Nov;25(5):786–92.
5. Balogun JA, Khan OH, Taylor M, Dirks P, Der T, Carter Snead Iii O, et al. Pediatric awake craniotomy and intra-operative stimulation mapping. *J Clin Neurosci Off J Neurosurg Soc Australas.* 2014 Nov;21(11):1891–4.

6. Delion M, Terminassian A, Lehouste T, Aubin G, Malka J, N'Guyen S, et al. Specificities of awake craniotomy and brain mapping in children for resection of supratentorial tumors in the language area. *World Neurosurg.* 2015 Jul 8;
7. Berger MS. The impact of technical adjuncts in the surgical management of cerebral hemispheric low-grade gliomas of childhood. *J Neurooncol.* 1996 Jun;28(2-3):129–55.
8. Hagberg CA, Gollas A, Berry JM. The laryngeal mask airway for awake craniotomy in the pediatric patient: report of three cases. *J Clin Anesth.* 2004 Feb;16(1):43–7.
9. Everett LL, van Rooyen IF, Warner MH, Shurtleff HA, Saneto RP, Ojemann JG. Use of dexmedetomidine in awake craniotomy in adolescents: report of two cases. *Paediatr Anaesth.* 2006 Mar;16(3):338–42.
10. Soriano SG, Eldredge EA, Wang FK, Kull L, Madsen JR, Black PM, et al. The effect of propofol on intraoperative electrocorticography and cortical stimulation during awake craniotomies in children. *Paediatr Anaesth.* 2000;10(1):29–34.
11. Desandes E, Guissou S, Chastagner P, Lacour B. Incidence and survival of children with central nervous system primitive tumors in the French National Registry of Childhood Solid Tumors. *Neuro-Oncol.* 2014 Jul;16(7):975–83.
12. Wrede KH, Stieglitz LH, Fiferna A, Karst M, Gerganov VM, Samii M, et al. Patient acceptance of awake craniotomy. *Clin Neurol Neurosurg.* 2011 Dec;113(10):880–4.
13. Bajunaid KM, Ajlan AM. Awake craniotomy. A patient's perspective. *Neurosci Riyadh Saudi Arab.* 2015 Jul;20(3):248–52.
14. Wahab SS, Grundy PL, Weidmann C. Patient experience and satisfaction with awake craniotomy for brain tumours. *Br J Neurosurg.* 2011 Oct;25(5):606–13.
15. Manchella S, Khurana VG, Duke D, Brussel T, French J, Zuccherelli L. The experience of patients undergoing awake craniotomy for intracranial masses: expectations, recall, satisfaction and functional outcome. *Br J Neurosurg.* 2011 May 26;
16. Zemmoura I, Fournier E, El-Hage W, Jolly V, Destrieux C, Velut S. Hypnosis for Awake Surgery of Low-grade Gliomas: Description of the Method and Psychological Assessment. *Neurosurgery.* 2015 Aug 25;
17. Duchowny M, Jayakar P, Harvey AS, Resnick T, Alvarez L, Dean P, et al. Language cortex representation: effects of developmental versus acquired pathology. *Ann Neurol.* 1996 Jul;40(1):31–8.
18. Khu KJ, Doglietto F, Radovanovic I, Taleb F, Mendelsohn D, Zadeh G, et al. Patients' perceptions of

- awake and outpatient craniotomy for brain tumor: a qualitative study. *J Neurosurg.* 2010 May;112(5):1056–60.
19. Brun D. *L'enfant donné pour mort : Parents, comment vivre une guérison.* Paris: Editions Aubier; 2013. 179 p.
  20. Taïeb O, Baubet T, Pradère J, Lévy K, Revah-Lévy A, Serre G, et al. Traumatismes psychiques chez l'enfant et l'adolescent. *EMC - Psychiatr.* 2004 Jan;1(1):23–32.
  21. David W, Foy BTM. Etiologic Factors in the Development of Posttraumatic stress disorder in children and adolescents. *J Sch Psychol.* 1996;34(2):133–45.
  22. Silva RR, Alpert M, Munoz DM, Singh S, Matzner F, Dummit S. Stress and vulnerability to posttraumatic stress disorder in children and adolescents. *Am J Psychiatry.* 2000 Aug;157(8):1229–35.
  23. Duffau H. [Awake surgery for brain gliomas: plea for an increased involvement of anesthesiologists]. *Ann Fr Anesthésie Réanimation.* 2012 Jun;31(6):e81–6.
  24. Potters J-W, Klimek M. Awake craniotomy: improving the patient's experience. *Curr Opin Anaesthesiol.* 2015 Aug 8;
  25. R. Andrew Danks MR. Patient Tolerance of Craniotomy Performed with the Patient under Local Anesthesia and Monitored Conscious Sedation. *Neurosurgery.* 1998;42(1):28–34; discussion 34–6.

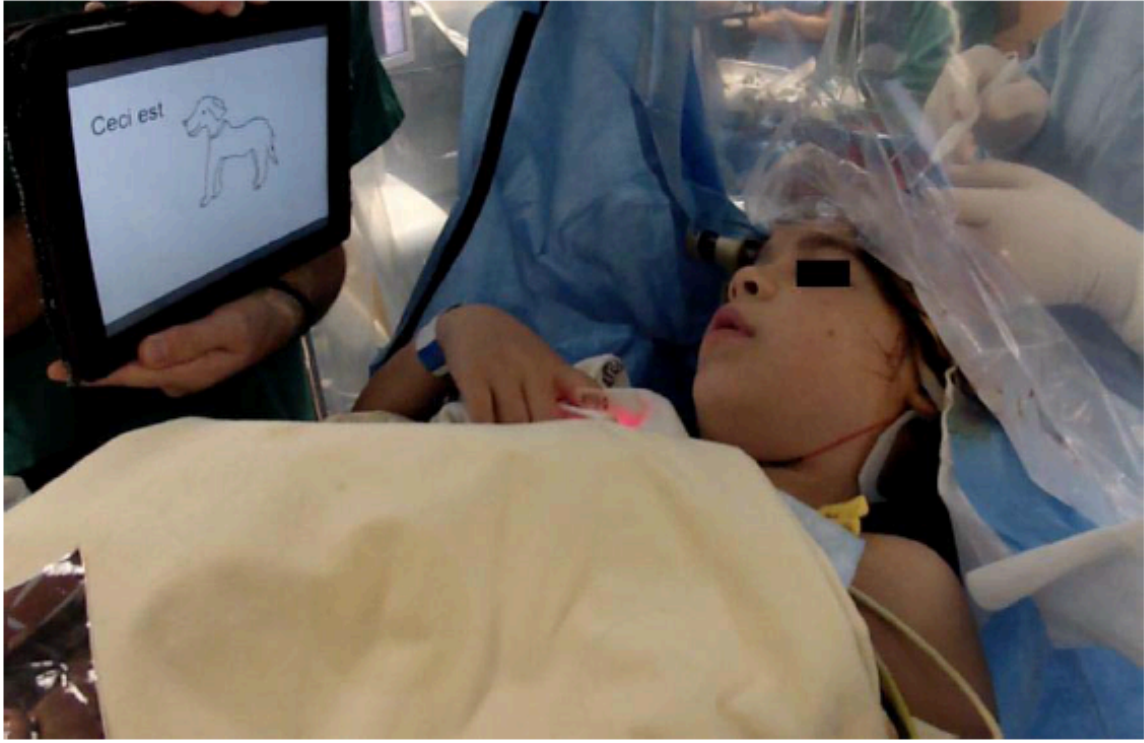

figure 1

| Authors, year, reference  | Population  | Questionnaire   | Psychiatrist | Themes  | Principal results  |
|---------------------------|---|---|--------------|---|--|
| Danks et al., 1998 (27)   | 21 adults   | Brief Profil of Mood State (POMS)                     | Yes          | Experience<br>Pain<br>Recollection  | AC is useful and safe  |
| Joy Khu et al., 2010 (20) | 27 adults   | Semi structured                                       | No           | Experience<br>Information<br>Satisfaction<br>Understanding<br>Confidence  | AC is well tolerated   |
| Wrede et al., 2011 (12)   | 48 AC<br>43 craniotomy with general anaesthesia<br>18 to 71 years old | Patient evaluation in the perioperative phase (PPP33) | Psychologist | Information<br>Autonomy<br>Communication<br>Physical disorders<br>Pain<br>Regeneration<br>Fear<br>Accommodation | Good acceptance for AC<br>Less post operative pain and physical disorders for AC |
| Wahab et al., 2011 (14)   | 45 adults   | Questionnaire designed with surgeons                  | No           | Implication of patients<br>Information  | High level of patient satisfaction   |

|                             |                                     |  |     |   |  |
|-----------------------------|-------------------------------------|--|-----|---|--|
|                             |                                     |  |     | Confidence<br><br>Discomfort during surgery<br><br>Post operative pain  |  |
| Manchella et al., 2011 (15) | 26 adults<br><br>16 to 78 years old | Semi structured questionnaire  | No  | Understanding<br><br>Confidence<br><br>Recollection<br><br>Satisfaction | AC is well tolerated   |
| Bajunaid et al., 2015 (13)  | 9 adults                            | Standard   | No  | Recollection<br><br>Pain  | AC is well tolerated<br><br>No pain during operation                             |
| Zemmoura et al., 2015 (16)  | 37 adults                           | Peritraumatic dissociative experience questionnaire<br><br>Perceived stress scale<br><br>Posttraumatic stress disorder checklist scale | Yes | Assessment of a new method for AC based on hypnosis                     | Effectiveness of hypnosis<br><br>Positive psychological impact of this technique |
| Our study                   | 7 patients<br><br>from 8 to 16      | Semi structured  | Yes | Understanding<br><br>Anxiety  | AC is feasible in children   |



|  |           |  |  |   |   |
|--|-----------|--|--|---|---|
|  | years old |  |  | Hypnosis<br>Pain<br>Recollection<br>Post operative<br>stress disorder | No Post<br>operative stress<br>disorder<br>Interest for<br>hypnosis |
|--|-----------|--|--|---|---|

AC : Awake Craniotomy

Table 1 : Prior publications on patient's experience in awake craniotomy

## 5 IRMf de repos :

Le point de départ de ce projet portant sur l'intérêt de l'IRMf en préopératoire provient de l'idée que les enfants peuvent être non seulement aphasiques mais surtout trop immatures pour coopérer. Il nous a donc paru indispensable de trouver un moyen de palier à la CECCSC.

Comme nous l'avons évoqué en introduction, l'axe majeur de cette réflexion repose sur l'utilisation de l'IRM fonctionnelle (IRMf) de repos chez l'enfant. A l'heure actuelle, même si la CECCSC reste le « gold standard » pour la résection d'une lésion en zones fonctionnelles, de nombreux travaux ont été publiés dans la littérature portant sur le bilan préchirurgical par IRMf chez l'adulte. Contrairement à l'IRMf d'activation qui nécessite la coopération du patient à travers la réponse à une tâche, l'IRMf de repos est basée sur la fluctuation spontanée de l'activité neuronale et ne nécessite aucune coopération du patient. Nous avons pu ainsi montrer non seulement la corrélation de ce bilan par IRM fonctionnelle de repos avec l'électrostimulation per opératoire mais aussi sa probable supériorité par rapport à l'IRMf d'activation en terme de sensibilité et de spécificité quant à la localisation des aires du langage. En effet l'IRMf de repos nous a permis d'isoler les réseaux attentionnels qui interfèrent souvent avec les réseaux du langage obtenus en IRMf d'activation, lors de la réalisation d'une tâche. De plus l'IRMf de repos apparaît plus performante que l'IRMf d'activation dans la détection des aires impliquées dans les aspects sémantiques du langage. D'après ces résultats, l'IRMf de repos préopératoire pourrait constituer une alternative à la CECCSC en cas d'immaturité ou même d'aphasie.

Ces résultats sont présentés dans un article soumis récemment dans la revue : « Human Brain Mapping ».

❖ **Article N°3 : Resting state fMRI in children for preoperative language mapping. Comparison with intraoperative direct stimulation.**

M. Delion<sup>1, 2</sup>, L.M. Leiber<sup>3</sup>, M. Labriffe<sup>3</sup>, P. Menei<sup>1</sup>, M. Dinomais<sup>4, 6</sup>, A. Ter Minassian<sup>5, 6</sup>

Soumis dans Human Brain Mapping  
Rang SIGAPS A  
Impact Factor : 5,969

**Resting state fMRI in children for preoperative language mapping.  
Comparison with intraoperative direct stimulation.**

M. Delion<sup>1,2</sup>, L.M. Leiber<sup>3</sup>, M. Labriffe<sup>3</sup>, P. Menei<sup>1</sup>, M. Dinomais<sup>4,6</sup>, A. Ter Minassian<sup>5,6</sup>

1. Department of Neurosurgery, Angers Teaching Hospital, F-49933

Angers, France

2. Anatomy Laboratory, Medical Faculty, rue haute de Reculée, F-49045

Angers Cedex 01, France

3. Department of Radiology, Angers Teaching Hospital, F-49933

Angers, France

4. Department of physical medicine and rehabilitation, C3RF-CHU

Angers, F-49933 Angers, France

5. Pole anesthésie-réanimation , Angers Teaching Hospital, F-49933

Angers, France.

6. LARIS EA 7315, Image Signal et Sciences du Vivant.

Corresponding author: Aram Ter Minassian

Address: Département d'Anesthésie Reanimation, CHU d'Angers 4 rue

Larrey, F-49933 Angers, France

Tel: +33 2 41 35 39 51

Fax: +33 2 41 35 52 24

E-mail address: arterminassian@chu-angers.fr

## **Abstract**

Preoperative language functional magnetic imaging (fMRI) aimed to identify eloquent areas in the vicinity of surgically resectable brain lesions. Primary fMRI methodology consist in imaging a task induced activity (TIA fMRI) and require a cooperation not always achievable in young children. Resting-state fMRI (rsfMRI) allow identification of language network (LANG) without performance of any explicit task. Such a method might be particularly useful in young patients unable to cooperate. The aim of this study was to compare preoperative language mapping by rsfMRI to TIA fMRI, and cortical mapping (CM) during awake craniotomies in children.

Six children aged from 8 to 15 and suffering from brain lesions, were enrolled in this study. They performed three fMRI sessions including one rsfMRI and two TIA fMRI sessions. Analysis was performed using a generalized linear model and a spatial independent component analysis approach for TIA and rSfMRI respectively.

For each patient at rest, we identify language (LANG), salience network and ventral attentional network (vATT). In all patients except one, TIA imaging included main nodes of salience network (SN). Such co-activation of SN together with LANG was never found at rest. In two of our six patients rsfMRI was able to detect eloquent areas during cortical stimulation not present in TIA mapping.

This study tends to indicate the superiority of resting state fMRI on TIA in detecting eloquent areas

## **Introduction:**

Currently, central nervous system tumors are the second most common childhood malignancy and the first cause of cancer related death in childhood [Desandes et al., 2014]. Children survival depends on the quality of the tumor resection. However, when eloquent areas are adjacent to the tumor as in a non-negligible number of supra-tentorial cases, an informative surgical mapping of brain areas involved in linguistic function is suitable. Therefore, intraoperative direct stimulation during awake surgery is considered as the gold standard to identify language cortical and subcortical sites [Ojemann et al., 2008]. This procedure common in adults has been seldomly reported in children aged from 9 to 17 years [Balogun et al., 2014; Berger et al., 1989; Delion et al., 2015; Everett et al., 2006; Hagberg et al., 2004; Klimek et al., 2004; Ojemann et al., 2003; Soriano et al., 2000; Tobias and Jimenez, 1997].

One reason for this paucity is the lack of cooperation achieved in young children. Functional magnetic resonance imaging (fMRI) performed preoperatively is suitable to provide topological information on brain areas involved in linguistic processes [FitzGerald et al., 1997; Hertz-Pannier et al., 2014; Mahdavi et al., 2015; Mahvash et al., 2014; de Ribaupierre et al., 2012; Roux et al., 2003; Shimony et al., 2009; Tie et al., 2014; Tomczak et al., 2000]. Thus, it may challenge conventional surgical mapping to take important surgical decisions. Classically fMRI is performed by contrasting the brain oxygen level dependent images of a period of task induced activity (TIA) alternating with a baseline period. TIA imaging by fMRI has been widely used for preoperative mapping of the resectable cerebral zones in patients suffering from brain tumor [FitzGerald et al., 1997; de Ribaupierre et al., 2012; Roux et al., 2003; Rutten et al., 2002; De Tiège et al., 2009]. Nevertheless, this non-invasive fMRI method requires a fair cooperation of the patient, which isn't always achievable in young children. Contrary to TIA fMRI, resting-state fMRI (rsfMRI) is based on the spontaneous fluctuation of intrinsic connectivity networks (ICNs) which may be defined as sets of brain areas that are synchronous in the low frequency range typically below 0.1 Hz [Biswal et al., 1995]. Although not fully understood, the correlation structure of ICNs reflects the neuroanatomical substrate of task-

induced activity[Fox et al., 2005; Smith et al., 2009]. These spontaneous slow waves could play a role in Hebbian learning and synaptic long-term shaping [Beggs and Plenz, 2003; Beggs and Plenz, 2004; Cabral et al., 2014; Duyn et al., 2005].

Among other networks the part of ICN corresponding to the language network has been successfully identified in adults at rest[Cordes et al., 2000; Hampson et al., 2002; Lee et al., 2013; Mitchell et al., 2013a; Ter Minassian et al., 2013; Tie et al., 2014], thus providing a method to identify brain areas involved in linguistic process without requiring explicit linguistic task. Furthermore, identifying ICNs by an independent component analysis represents a strictly data driven method not requiring prior knowledge [Mitchell et al., 2013a].

Such a method might be particularly useful in young patients with brain lesions unable to cooperate and who bear potentially atypical language networks. We present a pilot study about the use of resting state functional MRI (rsfMRI) for the preoperative mapping of children suffering from brain tumor in eloquent areas.

The purpose of this pilot study was to compare the efficacy of preoperative language mapping by rsfMRI to TIA fMRI, and electro cortical stimulation when available, before and during awake craniotomies in children. In addition to the validation of the technics in a pediatric population, we also aimed to individualize cognitive and attentional networks together with language network. Indeed, various cognitive and attentional process might be responsible of cerebral activations during linguistic tasks.

### **Methods:**

The study was approved by our local ethic committee (CPP OUEST II, autorisation date 15/11/2012). After written informed consent of both parents, six children aged from 8 to 15 were enrolled in this study. They were all French native speakers and handedness was determined by completing the Edinburgh handedness inventory scale [Oldfield, 1971].

Details of the population are presented in table 1.

| Patient     | Age | Sex | Pathology  | Language disturbance | Cortical mapping |
|-------------|-----|-----|--|----------------------|------------------|
| 1 (LB)      | 10  | F   | Parasitosis right superior frontal gyrus   | No                   | No               |
| 2 (TA1)     | 12  | M   | Anaplastic ependymoma left inferior frontal gyrus  | Yes                  | Yes              |
| 2 bis (TA2) | 14  | M   | Anaplastic ependymoma left inferior frontal gyrus  | No                   | Yes              |
| 3 (DS)      | 12  | F   | Cavernoma left supra marginal gyrus  | Transient dysarthria | Yes              |
| 4 (AL)      | 11  | F   | Anaplastic ependymoma extending to left hippocampus, left parietal and left occipital lobe | yes                  | Yes              |
| 5 (RD)      | 14  | M   | Cavernoma left inferior temporal gyrus   | No                   | Yes              |
| 6 (OS)      | 8   | F   | DNET left superior frontal gyrus   | No                   | Yes              |

*Table 1: Main characteristic of patients.*

*Note that patient 2 (TA) underwent a second surgical procedure 19 months after the first one. DNET = dysembryoplastic neuroepithelial tumor.*



### *fMRI acquisition*

All datasets were acquired on a 3.0 Tesla MR Scanner (Magnetom® Skyra Medical Systems™, Erlangen, Germany). The scanner room was kept dark during image acquisition. Patients laid supine with the head immobilized by foam pads and straps. They looked through a prism at a red fixation cross displayed on a screen at their feet. They were equipped with earphones.

Echo planar imaging sequences were used, covering the whole brain, including the cerebellum. The parameters were as follows: repetition time = 2280 ms, echo time = 30ms, flip angle= 90 °, 42 axial slices interleaved, 4 mm-thick, 0-mm-gap, in plane matrix= 64x64, yielding a voxel size of 3 x 3 x 4 mm<sup>3</sup>, field of view = 168 x 187 mm. A T1-weighted anatomical three-dimensional dataset covering the whole brain was also obtained (192 contiguous axial slices, in-plane matrix 256x256, yielding a voxel size of 1x1x1mm<sup>3</sup>) to coregister and normalize echo planar images.

### *Task design*

After completing the Edinburgh handedness inventory (Oldfield 1971), subjects performed three 10 minute consecutive sessions beginning with a resting state session followed by two consecutive blocked design sessions of 10 minutes each.

For TIA fMRI session, we used block paradigms, in which the patients had to perform the task repeatedly over interest and reference periods of 16 seconds each. Period of interest consisted of the covert generation of a short sentences (condition SG) semantically linked to a word heard in the earphones every 4 seconds. During reference period they listened two monotonous tones in alternance (condition TL) , every 4 seconds. Words and tones were presented using E-Prime software. Subjects were trained to perform the task beforehand overtly and then covertly.

For rsfMRI subjects were instructed to keep their eyes open and relax.

## *Images processing*

fMRI data were analyzed with SPM8 software (Wellcome department of Imaging neuroscience, University College, London, Unitedkingdom; [www.fil.ion.ucl.ac.uk/spm](http://www.fil.ion.ucl.ac.uk/spm)) running under Matlab (the MathWorks, Natick, MA). The three first acquisition volumes in each functional series were discarded to allow the longitudinal magnetization to stabilize.

Preprocessing was conducted as follows. First, each patient's native space images were corrected for time delays between different slices. Then they were realigned to the first volume and unwrapped to correct for head movement and susceptibility distortions. The anatomical dataset was segmented using VBM 8.0 toolbox for SPM®. Co-registration of images from different modalities was achieved using grey matter segmentation as a reference image and a mean echo planar of the slice-timed and motion-corrected unwrapped image as the source image. Normalization of echo-planar images to the standard template provided by the Montreal Neurological Institute (MNI-template) was then based on the co-registered grey matter segment. Functional images were transformed to a final resolution of 3x3x3 mm before being smoothed by an isotropic Gaussian kernel of 6 mm full-width at half-maximum.

For TIA analysis we used a generalized linear model approach. Regressors corresponding to each of the 2 conditions were convolved with a model of canonical hemodynamic response incorporated in SPM8 package. Each individual time series of pre-processed data sets were then analysed by a voxel-wise multiple regression. Low frequency noise was removed by a 128 seconds cut-off high pass filtering. No global signal normalization was applied. The conditions were the two successive epochs of a trial: tones listening and sentence generation. In order to obtain an overview of activation specifically related to sentences processing, elementary contrast SG > TL were individually determined by t-test. Images were corrected for multiple comparisons at the voxel level (FWE = 0.05, k extend = 5 voxels).

For rsfMRI data analysis, we used a spatial independent component analysis approach (sICA) using NetBrainWork™ (<http://www.imed.jussieu.fr/en/equips>

/e1/netbrainwork/netbrainwork.php) running under Matlab, for the identification of large-scale networks. We compute 55 spatial independent components (ICs) on pre-processed images of each individual run. Individual spatial components were thresholded at  $z = 2$ .

*Identification of language and attentional networks:*

Language network at rest (LANGrest) was identified using the same criteria used in a previous study [Ter Minassian et al., 2014] : network, presenting activity within subdivisions of the inferior frontal Gyrus (IFG) [Bozic et al., 2010; Marslen-Wilson and Tyler, 2007], angular gyrus (ANG) [Vigneau et al., 2006]; middle temporal gyrus (MTG) with a peak of activity in its mid-posterior part in the vicinity of superior temporal sulcus [Devlin et al., 2004; Dronkers and Ogar, 2004] ; temporal poles [Binder et al., 2011] ; bilateral caudate [Crosson et al., 2003]; cerebellum [Jansen et al., 2005] and dorsomedial prefrontal cortex [Alario et al., 2006].

However, the poor statistical level of individual analysis and inter individual variability justified to retain the presence of T2ml, IFG and ANG either uni or bilaterally as the main criteria for the identification of LANGrest .

Furthermore, due to the abnormal proportion of left handedness in our pathological population, we put less emphasis on the lateralization of the putative LANGrest. As a consequence, some ambiguities could arise. Indeed, the ventral attention network (vATT) presents similarities with LANG in the ventrolateral prefrontal cortex, inferior frontal cortex and temporal gyrus in the right hemisphere in right handed subjects. Noteworthy, activity in inferior parietal lobule is not the same within these two networks. Activity in inferior parietal lobule involves temporo parietal junction (TPJ) and supramarginal gyrus (SMG) for vATT in adults [Corbetta et al., 2008] and also in children [Sylvester et al., 2013] and the more posterior angular gyrus (ANG) for LANG [Vigneau et al., 2006]. Thus along with previously mentioned areas the presence of activity in ANG was a major criterion for the identification of LANGrest in case of left handedness.

Identification of the salience network was made on the presence of his cingulo-opercular components: dorsal anterior cingulate cortex (dACC) posterior pre-SMA and anterior insula/frontal operculum (AIFO) [Farrant and Uddin, 2015; Uddin et al., 2011].

For each patient we calculated the lateralization index (LI) from neuroimaging data using LI toolbox for SPM [Wilke and Lidzba, 2007; Wilke and Schmithorst, 2006].

To perform a second order group analysis, a one sample t-test was achieved using unthresholded MNI normalized contrast maps SG > TL, and on t maps of networks of interest for rsfMRI. Images were Monte Carlo corrected for multiple comparisons ( $p = 0.005$  uncorrected,  $p = 0.05$  corrected cluster extend  $k = 188$ ). A two sample t-test was performed between t maps of LANGrest and contrast maps sentences > tones. Maps of differences were cluster level corrected (FWE = 0.05).

#### *Surgical procedure and intraoperative direct stimulation*

Among these 6 children 5 were operated while awake with an electrical cortical and subcortical mapping performed intra-operatively. One child underwent two successive procedures for recurrent ependymoma.

Details of the surgical procedure can be found in supplementary material annexe1.

In a way to identify the sites involved in language function, the peroperative evaluation was based on the “object denomination task” described by Ojemann et al. in adults and children. It consisted into a black line drawing of an object together with the carrier phrase “this is...” appearing on a white slide presented during each stimulation [Ojemann et al., 2003; Ojemann et al., 2008]. We used a French equivalent test based on the DO 80 [Deloche and Hannequin, 1997]. We looked for transient language disturbances (aphasic arrest, paraphasia). A speech therapist was present to interpret any of language disorder. During the surgical removal of the tumor, sub cortical stimulation was also used to identify white matter language or motor tracts. Subcortical stimulation was continuously alternated with ultrasonic hover resection in a back-and-forth fashion.

## **Results:**

In all patients we identified the language network at rest and also the salience network and vATT. Concerning GLM analysis of TIA, we found in one patient a significant activity in only one of the two sessions.

Results of LI are presented in table 2.

| <b>Patient</b> | <b>Edinburgh</b> | <b>GLM</b> | <b>Rest</b> |
|----------------|------------------|------------|-------------|
| 1 (LB)         | -40              | 69         | 84          |
| 2 (TA)         | 64               | -6         | -67         |
| 2bis (TA )     | 67               | 68         | 79          |
| 3 (DS)         | -26              | -14        | 76          |
| 4 (AL)         | 90               | 62         | 75          |
| 5 (RD)         | -80              | -42        | -63         |
| 6 (SO)         | -60              | 19         | 48          |

*Table 2 : Laterality Indexes.*

*Edinburgh : handedness as determined by Edinburgh inventory scale.*

*GLM and Rest : laterality indexes as determined on individual fMRI data of the contrast sentences generation > tone listening and t-maps of language network isolated at rest, respectively. All indexes are scaled from -100 to +100. Positive values indicate right handedness on Edinburgh and left hemispheric dominance on GLM and Rest.*

In the right-handed patients there was an agreement between the Edinburgh test and the LI obtained by GLM and resting state except for the first session of the patient n°2. Noteworthy, among the four left handed patients, only the patient n°5 (RD) has a right lateralized fMRI LI (right hemispheric dominance). In the others, the fMRI LI was left lateralized (left hemispheric dominance) except the LI obtained by GLM in patient n°3 (DS) which is moderately right lateralized.

In the patient n°1 (BL), we observe major overlaps between language network obtained by task induced activity (TIA) and a component we identified in rsfMRI as LANGrest. This child was moderately left handed on Edimburgh laterality test (ELT). However, language network was left lateralized on both TIA and Rest on Lateralization Index. This patient presented a neurocysticercosis and was medically treated : no cortical mapping was available

The patient n°2 suffering left frontal ependymoma (TA), underwent two fMRI explorations and two awake surgeries. In the first fMRI exploration the patient presented moderate speech disturbances and the TIA showed nodes of the language network on the left hemisphere: T2ml, IFGop and IFGtri. Despite right lateralization on ELT, TIA was slightly right lateralized as a consequence of a peak of activity in the right posterior part of superior temporal sulcus i.e. the counterpart of T2ml ordinary found in left hemisphere in right handed. We identified LANG at rest as a moderately right lateralized network overlapping TIA in IFG, bilateral T2ml and other areas of MTG. During the cortical mapping, we clearly obtained a reproducible language disturbances on the left pars triangularis and orbitalis corresponding to the overlapping areas of TIA and LANGrest (paraphasia and anomia).

On the second fMRI, the patient presented no more speech disturbance. Peak of activity in T2ml was found in the left hemisphere. At Rest we identified the language network.

Both TIA and Rest included activity in left F3op. The involvement of this area in the language network was confirmed by the cortical stimulation with language disturbance.

For the patient n°3 (DS), which is moderately left handed on ELT, we observed a massive bilateral TIA with a slightly right LI. The peak of activity was found on right T2ml.

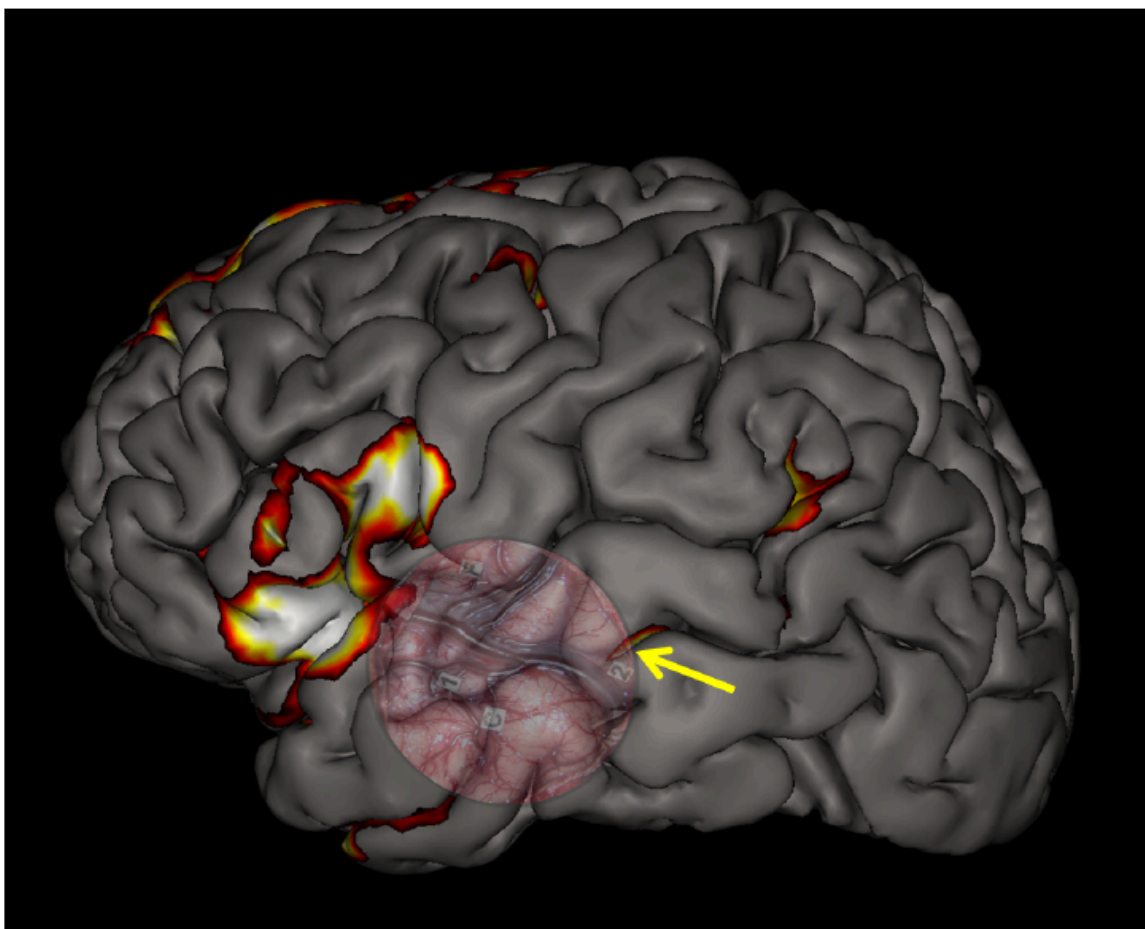
At rest we identified a slightly left lateralized LANG network with main overlaps with TIA in left hemisphere including ANG but also in right hemisphere where T2ml was also active.

The cortical stimulation produced an aphasic arrest within the overlap between TIA and LANGrest on the left ANG.

For the patient 4 (AL), ELT indicated strong right handedness and she presented with aphasic disorders. TIA included left nodes of language network, T2ml included. However, no activity was detected in left ANG. LI of TIA indicated a moderate left dominance. The LANGrest we identified was left lateralized and

included left ANG and T2ml. These two areas were eloquent under electrical stimulation during the cortical mapping: stimulation of left ANG produced semantic paraphasia whereas stimulation of T2ml induced anomia.

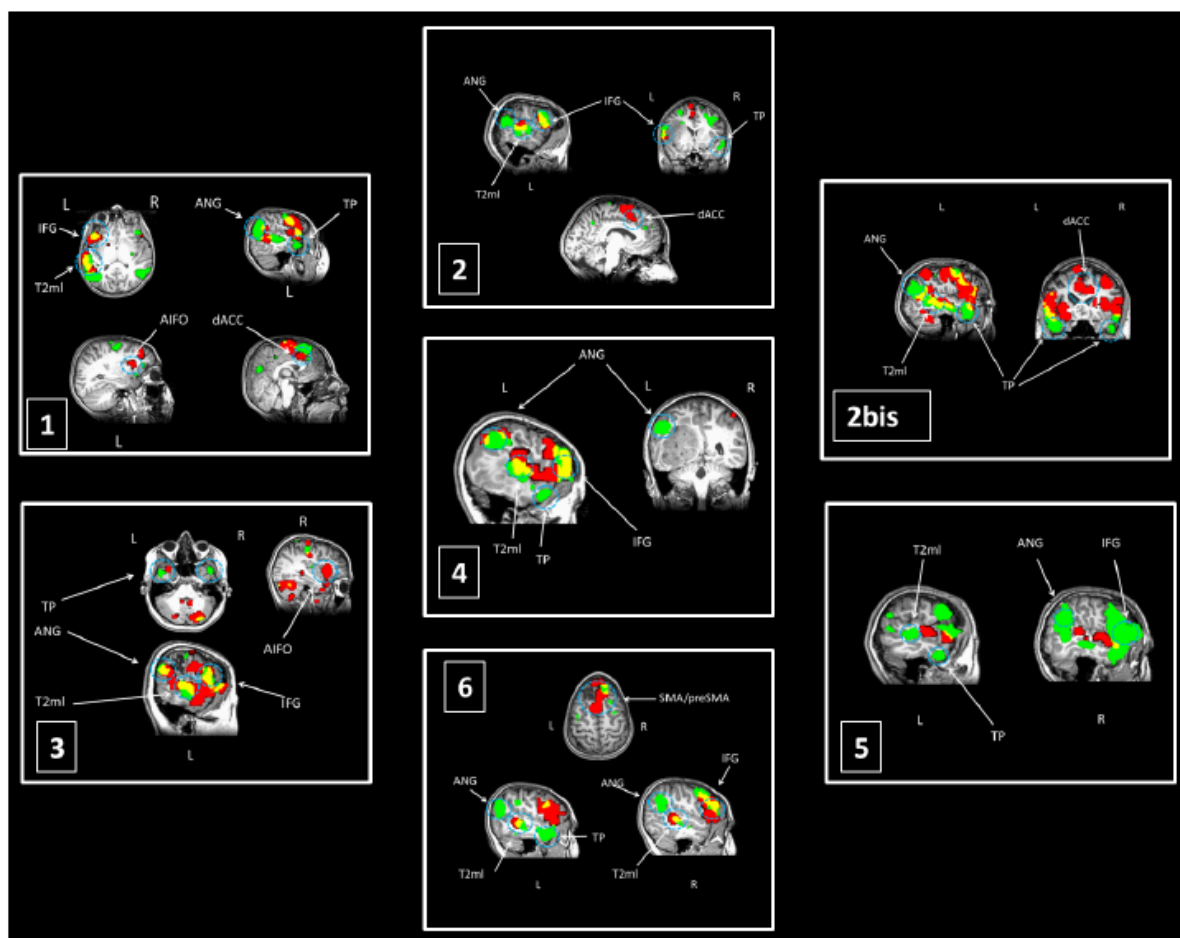
For the patient 5 (RD), who appeared strongly left handed on ELT, the GLM analysis showed a bilateral activation of the temporal planum demonstrating the lack of cooperation of the patient in TIA. At rest, we identified LANG as a right lateralized network. Despite this lateralization T2ml was dominant in the left hemisphere. During surgical mapping of this area by electrical stimulation speech was suspended. (Supplementary figure).



*Supplementary figure: Patient 5 (RD). Per-operative caption of brain surface superimposed on the fusion in native space of brain mesh with language network as identified at rest by spatial independent component analysis (LANGrest). LANGrest is shown at voxel-level  $z > 2$ , cluster-size threshold 5 voxels. The yellow arrow indicates the site where electrical stimulation elicited speech arrest. Note at this site the activity of T2ml.*

For the patient 6 (OS), left handed on ELT, TIA was poorly contributive. No activity was found in one of the two sessions. In the other one, TIA presented a

trend to left dominance and involved bilaterally T2ml and inferior frontal gyrus. Activations were found on bilateral posterior preSMA, immediately posterior to the lesion. At rest, we identified LANGrest as a bilateral network moderately left lateralized. No activity was found on left pre SMA. ANG and T2ml were dominant on left hemisphere whereas IFG dominated in right hemisphere. LANGrest overlapped into TIA bilateral T2ml, IFGtri and dorsal IFGop. Electrical stimulation of left posterior preSMA induced no aphasia or anomia but a clear and reproducible speech delay. Overlaps of contrast sentences > tones and LANGrest are shown for each patient in Figure 1.



*Figure 1: Individual imaging data of all patients in native space. The left side of the brain is on the left of the images.*

*Language network as identified at rest by spatial independent component analysis (LANGrest) appears in green. Contrast sentences generation > Tone listening of task induced activity (TIA) appears in red. Overlaps between LANGrest and TIA appears in yellow. LANGrest is shown at voxel-level  $z > 2$  cluster-size threshold 5 voxels. TIA is shown FWE corrected at voxel level  $p < 0.05$ , cluster-size threshold 5 voxels. AIFO : anterior insula/frontal operculum; ANG : angular gyrus ; dACC : dorsal anterior cingulate cortex ; IFG : inferior frontal gyrus ; SMA/preSMA :*



supplementary and pre-supplementary motor area ; T2ml : postero-superior part of middle temporal gyrus ; TP : temporal pole.

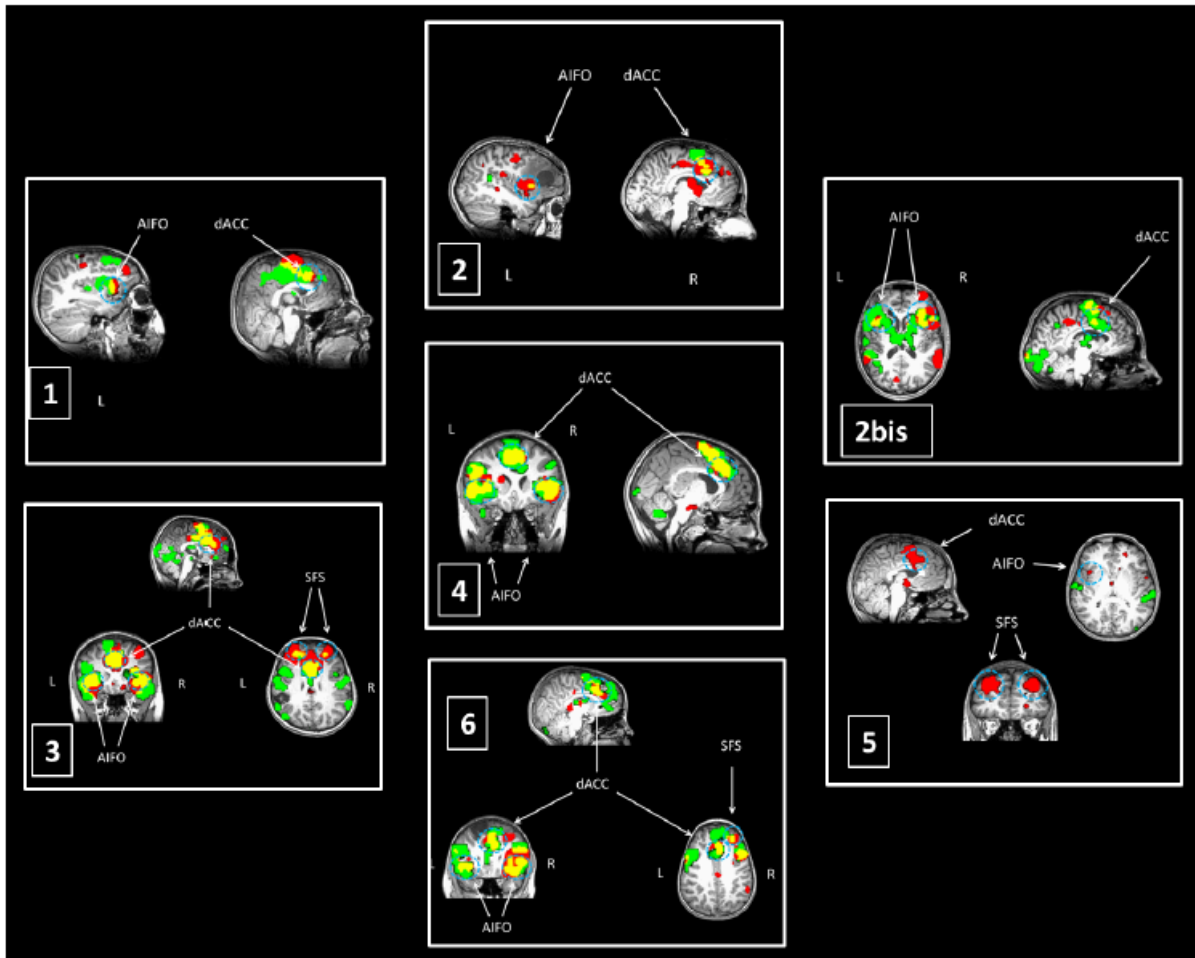
Table 3 summarizes main findings of fMRI and cortical mapping data.

| Patient            |  | 1(BL) | 2(TA)    | 2bis(TA) | 3(DS)    | 4(AL)                         | 5(RD)            | 6(SO)                        |
|--------------------|--|-------|----------|----------|----------|-------------------------------|------------------|------------------------------|
| <b>TIA (GLM)</b>   | <b>T2ml</b>                                  | left  | left     | left     | right    | left                          | <i>no</i>        | right                        |
|                    | <b>ANG</b>                                   | no    | no       | no       | left     | <i>no</i>                     | no               | no                           |
|                    | <b>TP</b>                                    | no    | no       | no       | bi       | no                            | bi               | no                           |
|                    | <b>IFG</b>                                   | left  | left     | left     | left     | left                          | no               | left                         |
|                    | <b>SMA/preSMA</b>                            | bi    | left     | bi       | bi       | bi                            | no               | <i>bi</i>                    |
|                    | <b>dACC</b>                                  | yes   | yes      | yes      | yes      | yes                           | no               | yes                          |
|                    | <b>AIFO</b>                                  | left  | no       | bi       | bi       | bi                            | no               | bi                           |
| <b>Rest (sICA)</b> | <b>T2ml</b>                                  | left  | right    | left     | bi       | left                          | <i>left</i>      | bi                           |
|                    | <b>ANG</b>                                   | left  | left     | left     | left     | <i>left</i>                   | right            | left                         |
|                    | <b>TP</b>                                    | left  | right    | left     | bi       | left                          | right            | left                         |
|                    | <b>IFG</b>                                   | left  | left     | left     | left     | left                          | right            | right                        |
|                    | <b>SMA/preSMA</b>                            | left  | no       | no       | left     | left                          | bi               | <i>right</i>                 |
|                    | <b>dACC</b>                                  | no    | no       | no       | no       | no                            | no               | no                           |
|                    | <b>AIFO</b>                                  | no    | no       | no       | no       | no                            | no               | no                           |
| <b>CM</b>          | <b>Site of induced aphasia or paraphasia</b> | NA    | left IFG | left IFG | left ANG | left T2 ml<br><i>left ANG</i> | <i>left T2ml</i> | <i>no on left SMA/preSMA</i> |

*Table 3: Main findings obtained on fMRI data and by electrical cortical mapping during awake craniotomy. TIA (GLM): task induced activity analysed by generalized linear modelling. Rest (sICA) : resting state fMRI analyzed by spatial independent components analysis. CM : cortical mapping.*

*T2ml : posterior superior temporal sulcus. ANG : angular gyrus. TP : temporal pole. IFG : inferior frontal gyrus. SMA/preSMA : supplementary and pre-supplementary motor area. dACC : dorsal anterior cingulate cortex. AIFO : anterior insula-frontal operculum. Anatomic areas in bold italic indicate either eloquent areas identified at rest but not by TIA, or false positive eloquent area identified by TIA not present at rest.*

In all patients except one (subject 5 RD), TIA included main nodes of salience network as shown by the large overlap of this network identified at rest with TIA (Figure 2).

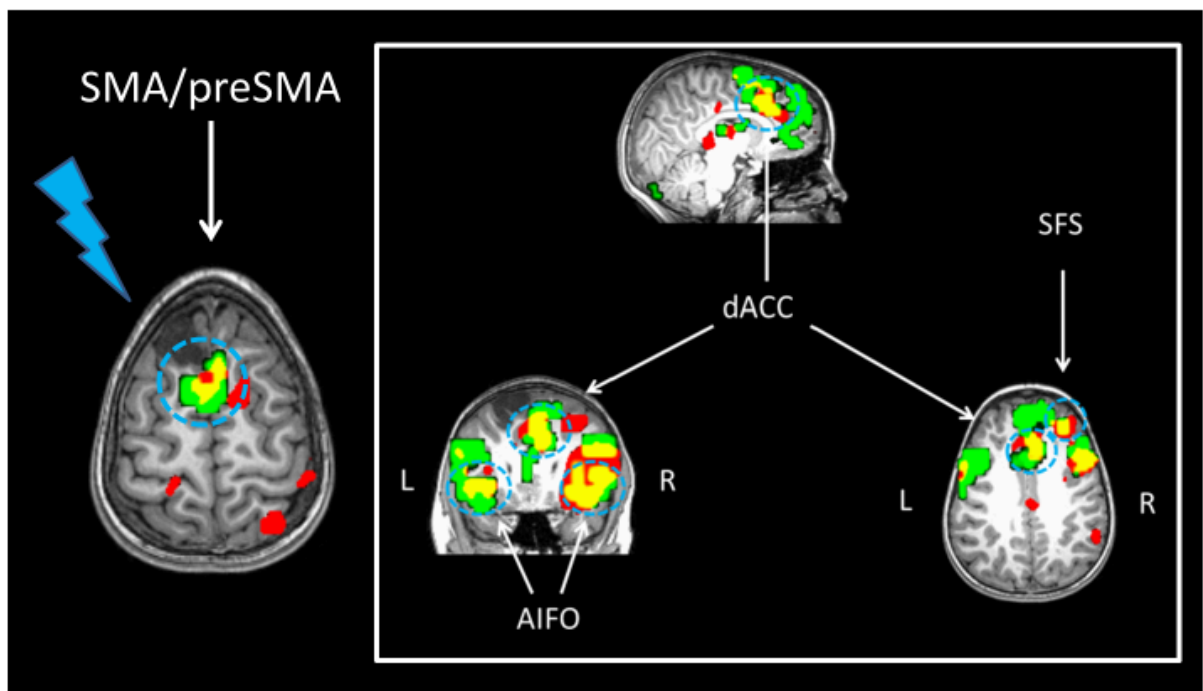


*Figure 2: Individual imaging data of all patients in native space. The left side of the brain is on the left of the images.*

*Contrast sentences generation > Tone listening of task induced activity (TIA) appears in green. Salience network as identified at rest by spatial independent component analysis (SN) appears in red. Overlaps between TIA and SN appears in yellow. TIA is shown FWE corrected at voxel level  $p < 0.05$ , cluster-size threshold 5 voxels. SN is shown at voxel-level  $z > 2$  cluster-size threshold 5 voxels. AIFO : anterior insula/frontal operculum; dACC : dorsal anterior cingulate cortex ; SFS : superior frontal sulcus.*

These nodes comprised dACC in all patients and in most cases bilateral AIFO. In patient 6 (OS) posterior pre SMA associated to SN and TIA activation overlapped at the site where electrical stimulation induced speech delay (Figure 3).

The pattern of co-activation of SN together with LANG was not found at rest. Conversely, an activity in AG and TPs was observed at rest in all patients. This pattern was apparent in TIA in only one patient.



*Figure 3: Individual imaging data of patient 6 (SO) in native space. The left side of the brain is on the left of the images.*

*Contrast sentences generation > Tone listening of task induced activity (TIA) appears in green. Saliency network as identified at rest by spatial independent component analysis (SN) appears in red. Overlaps between TIA and SN appears in yellow. TIA is shown FWE corrected at voxel level  $p < 0.05$ , cluster-size threshold 5 voxels. SN is shown at voxel-level  $z > 2$  cluster-size threshold 5 voxels. AIFO : anterior insula/frontal operculum; dACC : dorsal anterior cingulate cortex ; SFS : superior frontal sulcus. TIA and SN overlapped at the junction of supplementary and pre-supplementary motor area. Electrical stimulation of this area adjacent to the lesion (indicated by the blue flash) elicited no anomia or paraphasia but a slight naming delay.*

Table 4 and Table 5 indicate the coordinates of peak of differences between TIA and LANGrest at the group level. This analysis confirms the evidence found at the individual level : LANGrest presents greater activity in areas involved in semantic processing [Binder et al., 2009; Binder et al., 2011; Vigneau et al., 2006], TIA presents greater activity in nodes of SN.

| Area                                    | k           | T <sup>6</sup> | x   | y   | z   |
|---|-------------|----------------|-----|-----|-----|
| <i>L Cuneus</i>                         | <b>1067</b> | 7.27           | 2   | -69 | 24  |
| <i>R Precuneus</i>                      |             | 5.17           | 14  | -58 | 42  |
| <i>L Angular Gyrus</i>                  | <b>702</b>  | 6.43           | -45 | -52 | 31  |
| <i>L Superior Frontal Gyrus</i>         | <b>394</b>  | 7.29           | -12 | 66  | 24  |
| <i>L Superior Medial Gyrus (DMPFC)</i>  |             | 6.29           | -6  | 59  | 40  |
| <i>R Angular Gyrus</i>                  | <b>306</b>  | 6.67           | 66  | -49 | 27  |
| R SMA                                   | <b>233</b>  | 5.02           | 6   | -16 | 55  |
| R MCC                                   |             | 4.98           | 12  | -10 | 51  |
| L MCC                                   |             | 4.93           | -3  | -10 | 43  |
| <i>L PrF3op</i>                         | <b>226</b>  | 6.37           | -33 | 18  | 31  |
| <i>L Middle Temporal Gyrus</i>          | <b>115</b>  | 5.02           | -60 | -28 | -8  |
| R Paracentral Lobule                    | <b>114</b>  | 6.58           | 8   | -25 | 63  |
| <i>R Middle Temporal Gyrus</i>          | <b>107</b>  | 5.01           | 58  | -67 | 18  |
| <i>L Inferior Temporal Gyrus</i>        | <b>75</b>   | 7.93           | -57 | -21 | -32 |
| <i>R Temporal Pole</i>                  | <b>61</b>   | 5.21           | 41  | 23  | -30 |
| <i>L Superior Medial Gyrus (DMPFC)</i>  | <b>59</b>   | 4.67           | -2  | 48  | 40  |
| <i>R IFG (p. Triangularis)</i>          | <b>57</b>   | 5.37           | 63  | 32  | 21  |
| R Superior Parietal Lobule              | <b>53</b>   | 4.59           | 23  | -55 | 61  |
| <i>L Middle Temporal Gyrus</i>          | <b>48</b>   | 5.66           | -71 | -37 | 4   |
| <i>R Superior Medial Gyrus (DMPFC)</i>  | <b>48</b>   | 4.33           | 11  | 59  | 40  |
| <i>R Superior Frontal Gyrus (DMPFC)</i> |             | 4.11           | 15  | 56  | 39  |

**Table 4 :** Two samples t-test, greater activity in LANGrest compared to TIA.

The significant local peak maxima were obtained under a threshold of  $p_{FWEcorr} < 0.05$  at the cluster level, cluster-size threshold 48 voxels;  $T^6 = T$  value for 6 degrees of freedom ; anatomical labels were derived from the anatomy toolbox for SPM ; k = cluster extend in voxels, in case of multiple peaks in the same anatomic area of a cluster, only the maximal peak is reported for this anatomic area ; x,y,z = the original SPM coordinates of the MNI space in millimetres.

Italics indicate areas involved in semantic processing [Binder et al., 2009; Binder et al., 2011; Vigneau et al., 2006]

DMPFC : dorso-medial prefrontal cortex. MCC : middle cingulate cortex. PrF3op : pre-inferior frontal gyrus opercularis. IFG : inferior frontal gyrus ; SMA : supplementary motor area.

| <b>Area</b>                 | <b>k</b>    | <b>T<sup>6</sup></b> | <b>x</b> | <b>y</b> | <b>z</b> |
|-----------------------------|-------------|----------------------|----------|----------|----------|
| <i>R dACC</i>               | <b>3264</b> | 10.27                | 17       | 32       | 25       |
| <i>R Caudate /Putamen</i>   |             | 8.33                 | 20       | 23       | -5       |
| <i>R Insula Lobe (AIFO)</i> |             | 7                    | 31       | 24       | 12       |
| L IFG (p. Triangularis)     |             | 5.94                 | -35      | 30       | 7        |
| R Precuneus                 | <b>809</b>  | 4.95                 | 14       | -43      | 13       |
| R ParaHippocampal Gyrus     | <b>265</b>  | 6.05                 | 35       | -30      | -15      |
| R Hippocampus               |             | 5.46                 | 38       | -33      | -6       |
| <i>R Thalamus</i>           |             | 4.36                 | 24       | -22      | -5       |
| <i>R Lobule VI</i>          | <b>75</b>   | 5.34                 | 30       | -49      | -38      |
| R Lingual Gyrus             | <b>60</b>   | 5.49                 | 24       | -82      | -2       |

**Table 5 :** Two samples *t*-test, greater activity in TIA compared to LANGrest.

The significant local peak maxima were obtained under a threshold of  $p_{FWEcorr} < 0.05$  at the cluster level, cluster-size threshold 48 voxels;  $T^6 = T$  value for 6 degrees of freedom ; anatomical labels were derived from the anatomy toolbox for SPM ;  $k$  = cluster extend in voxels, in case of multiple peaks in the same anatomic area of a cluster, only the maximal peak is reported for this anatomic area ;  $x,y,z$  = the original SPM coordinates of the MNI space in millimetres.

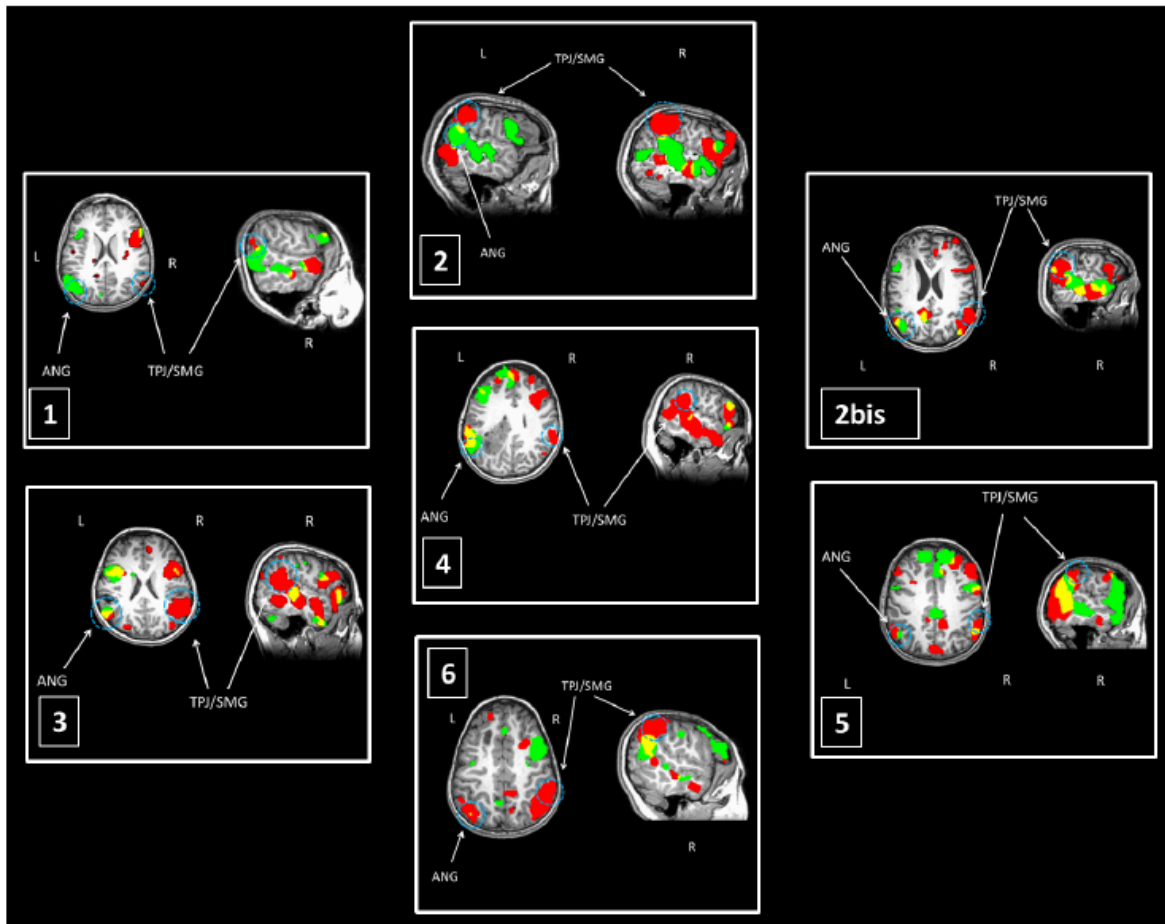
*Italics indicate nodes of the salience network.*

*dACC : dorsal anterior cingulate cortex. AIFO : anterior insula/frontal operculum.*

*IFG : inferior frontal gyrus.*

Coordinates of peaks of TIA, LANGrest, SN and vATT at the group level are shown in Supplementary Table 1-4.

At rest, in all patients, a network quite similar to LANG was identified as the vATT in the right hemisphere. Both networks comprise activity in inferior frontal cortex, middle temporal gyrus and superior temporal sulcus. Apart from lateralization, a major difference between LANGrest and vATT was the involvement of the angular gyrus in LANG network, but a more anterior activity of TPJ within the SMG for vATT (Figure 4, supplementary tables 2 and 4)



*Figure 4: Individual imaging data of all patients in native space. The left side of the brain is on the left of the images.*

*Language network as identified at rest by spatial independent component analysis (LANGrest) appears in green. Ventral attention network as identified at rest by spatial independent component analysis (vATT) appears in red. Overlaps between LANGrest and TIA appears in yellow. LANGrest and vATT are shown at voxel-level  $z > 2$  cluster-size threshold 5 voxels. ANG : angular gyrus ; TPJ/SMG : temporo-parietal junction/supra-marginal gyrus.*

### **Discussion:**

We showed in this pilot study that despite a pitfall due to similarities between LANG rest and vATT it is possible to isolate LANG at rest even in patients with atypical lateralization. To our knowledge, this work is the first to identify LANG by rsfMRI in order to map preoperatively language areas in children. rsfMRI detected all eloquent areas which were present in the contrast maps SG > TL. Furthermore, in two of our six patients rsfMRI was able to detect eloquent areas during cortical stimulation not present in TIA mapping. In one

case (patient 5) rsfMRI could detect an important eloquent area T2ml which has been shown to be an obligatory entry in language network for auditory and visual modality [Devlin et al., 2004]. As T2ml lesion is known to be accompanied by profound and irreversible aphasia, detection of this area in the vicinity of the left temporal cavernoma appeared crucial. Noteworthy, despite a rightward LI, this left handed patient presented a bi-hemispheric representation of language : T2ml being dominant on left hemisphere and ANG and IFG on right hemisphere. However, superiority of rsfMRI on TIA in this patient for the detection of eloquent area appeared somewhat trivial. Indeed the poor contribution of TIA is most probably due to the poor performance of the linguistic task by this patient.

#### *Identification of semantic areas in the language network*

More interestingly in the second case (patient 4), eloquent left ANG in a right handed patient with strong leftward LIs was detected by rsfMRI but not by TIA. Indeed, our data showed that LANGrest included ANG and TPs in all cases. These areas are known to be involved in semantic processing [Binder et al., 2009; Binder et al., 2011; Vigneau et al., 2006]. It has been emphasized that TIA obtained by contrasting linguistic task to a low level baseline, has poor sensibility in detecting semantic areas. Indeed mind wandering is likely to occur during a low level baseline. The semantic system being active during linguistic task and baseline, the contrast is no more visible in the contrast image of these two conditions [Binder et al., 2011]. Thus, rsfMRI detecting systematically semantic areas appears as a good alternative to task requiring a high level of attentional control. This condition may allow enhancement of semantic contrast [Binder et al., 2011] but may be difficult to perform by young patients with brain lesions.

#### *Saliency network and language.*

In this study we observed systematic co activation of the main nodes of SN together with the language network during TIA. We observed a systematic stronger LI activity in LANG rest compared to TIA. The co activation of SN, which is slightly right lateralized, explains this difference.

A co-activation of SN is not surprising according to the difficult acoustic condition inherent to MRI and the challenge imposed to our young patients.

Indeed, co-activation of the SN during a linguistic task supports word identification in difficult condition [Vaden et al., 2013].

Interestingly, during cortical mapping in patient 6 (SO), stimulation of the left posterior pre-SMA common to SN and TIA, induced no anomia or paraphasia but a reproducible naming delay. It has been shown that lesions of SMA/ preSMA promote syndromes such the urge to move or akinesia. These apparently contradictory syndromes have in common the impairment of volitional selection [Nachev et al., 2008]. Furthermore, since the late 90s it is known that lesions of ACC, a key node of SN are accompanied by akinesia, alteration of self-initiated actions and poor utterance [Allman et al., 2011; Cohen et al., 1999]. More recently, clinical observations confirmed the implication of SN in the “will to persevere” [Parvizi et al., 2013]. Thus, in patient 6, the naming delay without paraphasia we observed when mapping left post pre SMA appears to be compatible with a behavioral disturbance elicited by interfering with a node of SN rather than with a node of LANrest.

#### *LANGrest, vATT and lateralisation.*

A major criterion for identifying LANGrest in healthy volunteers is the expected left lateralization in right handed subjects. Indeed, 82–96% of right handed ones use their left hemisphere for language processing [Knecht et al., 2000a; Knecht et al., 2000b; Springer et al., 1999] This criterion remains true in left handed ones but is weaker. Moreover, the incidence of right hemisphere dominance is linearly correlated with the degree of handedness on ELT, ranging from 4 % when ELT = 100 to 27% when ELT = -100 [Knecht et al., 2000b].

Considering an incidence of left handedness of 10 % [de Leon et al., 1986], we observed an abnormal proportion of left handed ( 66%) in our pathological patients. This abnormal proportion suggests an adaptative modification of handedness and possibly of language lateralization due to alterations provoked by the tumor. Thus, we put little emphasis on LI for the identification of LANGrest but much more on strict anatomic criterions. As exposed previously,



vATT presents similarities in the right hemisphere with LANGrest notably in the IFG, and temporal gyrus. This is particularly confounding when LI of LANGrest is a priori unknown. Thus, we suggest that when attempting to identify LANGrest by ICA, identification of vATT should also be performed in such a way to discriminate these two networks by their different activity in IPL.

#### *Ventral attention and salience network*

In this study we referred to vATT and SN [Seeley et al., 2007] as distinct networks. However literature is quite confusing when defining these networks. Indeed differences in nomenclature can explain such a confusion. As emphasized by Farrant et al [Farrant and Uddin, 2015], vATT as an ICN has been historically defined [Fox et al., 2006] by its correlation structure to a region of interest that has been later shown to be part of SN [Uddin et al., 2011]. As a consequence, Sridharan et al. indiscriminately referred to vATT and SN for the same network [Sridharan et al., 2007; Sridharan et al., 2008]. This was also put forth in an important paper on neurolinguistics [Vaden et al., 2013] and in a previous study on language network connectivity [Ter Minassian et al., 2013]. However, a recent connectivity study showed that vATT and SN constitute distinct entities in adults and children: the TPJ being a key node of the former and dACC a key node of the latter [Farrant and Uddin, 2015]. Our finding of distinct networks identified by sICA linked to these areas is in line with the results of Farrant et al.

#### *Previous studies of fMRI imaging for surgical planning*

Previous studies of pre surgical fMRI imaging for motor mapping by TIA confirm the good quality of data obtained with fMRI in toddlers and children [De Tiège et al., 2009]. However, regarding TIA, results are mitigated in comparison to intraoperative cortical mapping. In all these studies, the sensibility of fMRI varied from 38 to 100 % and the specificity from 65 to 97 % [de Ribaupierre et al., 2012]. Hertzpannier et al., claimed that fMRI imaging does not provide hierarchical information on the activated areas, which may not all be essential to

language, thus explaining the low specificity of this technique [Hertz-Pannier et al., 2014]. A recent report has shown the good correspondence between fMRI and intraoperative direct stimulation in detecting all the critical language areas in children, provided that an appropriate “broad” task was chosen [de Ribaupierre et al., 2012]. However, these techniques are feasible in cooperative patients only, contrarily to rsfMRI, which allows an assessment of brain language network independently of task performance in deficient, asleep, or even sedated young children. Furthermore, such all the data can be collected within 5 minutes [Van Dijk et al., 2010].

In adults, there are few studies on presurgical motor and language mapping by rsfMRI [Kamran et al., 2014; Lee et al., 2013; Shimony et al., 2009; Zhang et al., 2009]. Two studies report comparison to direct intraoperative stimulation with encouraging sensitivity and specificity [Mitchell et al., 2013b]. In newborn, resting state networks driven by spontaneous signal fluctuation are already present [Fransson et al., 2009] and are relatively stable in children and adolescents [Thomason et al., 2011]. Moreover, it has been shown that by an age of 7 to 9, children manifest a functional architecture similar to the adults’ one [Fair et al., 2008; Supekar et al., 2009]. Despite these facts, rsfMRI has not yet been evaluated in children for presurgical planning.

### *Limitations of the study*

This study bears some limitations. The number of children included is low and our findings should be replicated on a larger pediatric population even if the low incidence of supratentorial tumors in children limits possible patient inclusion.

The mean age of our patient remains high even if one patient in our series is the youngest ever described as having undergone a successful awake surgery, according to literature.

### **Conclusion**

Resting fMRI for pre-surgical language mapping is a technique easy to implement that appears feasible in children. This pilot study tends to indicate the superiority of resting state fMRI on TIA in detecting eloquent areas. Sensitivity and specificity of resting state fMRI for language mapping in children remains to be assessed in a larger cohort.

## References

- Alario F-X, Chainay H, Lehericy S, Cohen L (2006): The role of the supplementary motor area (SMA) in word production. *Brain Res* 1076:129–143.
- Allman JM, Tetreault NA, Hakeem AY, Manaye KF, Semendeferi K, Erwin JM, Park S, Goubert V, Hof PR (2011): The von Economo neurons in the fronto-insular and anterior cingulate cortex. *Ann N Y Acad Sci* 1225:59–71.
- Balogun JA, Khan OH, Taylor M, Dirks P, Der T, Carter Snead Iii O, Weiss S, Ochi A, Drake J, Rutka JT (2014): Pediatric awake craniotomy and intra-operative stimulation mapping. *J Clin Neurosci* 21:1891–1894.
- Beggs JM, Plenz D (2003): Neuronal avalanches in neocortical circuits. *J Neurosci Off J Soc Neurosci* 23:11167–11177.
- Beggs JM, Plenz D (2004): Neuronal avalanches are diverse and precise activity patterns that are stable for many hours in cortical slice cultures. *J Neurosci Off J Soc Neurosci* 24:5216–5229.
- Berger MS, Kincaid J, Ojemann GA, Lettich E (1989): Brain mapping techniques to maximize resection, safety, and seizure control in children with brain tumors. *Neurosurgery* 25:786–792.
- Binder JR, Desai RH, Graves WW, Conant LL (2009): Where is the semantic system? A critical review and meta-analysis of 120 functional neuroimaging studies. *Cereb Cortex N Y N* 1991 19:2767–2796.
- Binder JR, Gross WL, Allendorfer JB, Bonilha L, Chapin J, Edwards JC, Grabowski TJ, Langfitt JT, Loring DW, Lowe MJ, Koenig K, Morgan PS, Ojemann JG, Rorden C, Szaflarski JP, Tivarus ME, Weaver KE (2011): Mapping anterior temporal lobe language areas with fMRI: a multicenter normative study. *NeuroImage* 54:1465–1475.
- Biswal B, Yetkin FZ, Haughton VM, Hyde JS (1995): Functional connectivity in the motor cortex of resting human brain using echo-planar MRI. *Magn Reson Med* 34:537–541.
- Bozic M, Tyler LK, Ives DT, Randall B, Marslen-Wilson WD (2010): Bihemispheric foundations for human speech comprehension. *Proc Natl Acad Sci U S A* 107:17439–17444.
- Cabral J, Luckhoo H, Woolrich M, Joensson M, Mohseni H, Baker A, Kringelbach ML, Deco G (2014): Exploring mechanisms of spontaneous functional connectivity in MEG: how delayed network interactions lead to structured amplitude envelopes of band-pass filtered oscillations. *NeuroImage* 90:423–435.
- Cohen RA, Kaplan RF, Zuffante P, Moser DJ, Jenkins MA, Salloway S, Wilkinson H (1999): Alteration of intention and self-initiated action associated with bilateral anterior cingulotomy. *J Neuropsychiatry Clin Neurosci* 11:444–453.
- Corbetta M, Patel G, Shulman GL (2008): The reorienting system of the human brain: from environment to theory of mind. *Neuron* 58:306–324.
- Cordes D, Haughton VM, Arfanakis K, Wendt GJ, Turski PA, Moritz CH, Quigley MA, Meyerand ME (2000): Mapping functionally related regions of brain with functional connectivity MR imaging. *AJNR Am J Neuroradiol* 21:1636–1644.

- Crosson B, Benefield H, Cato MA, Sadek JR, Moore AB, Wierenga CE, Gopinath K, Soltysik D, Bauer RM, Auerbach EJ, Gökçay D, Leonard CM, Briggs RW (2003): Left and right basal ganglia and frontal activity during language generation: contributions to lexical, semantic, and phonological processes. *J Int Neuropsychol Soc JINS* 9:1061–1077.
- Delion M, Terminassian A, Lehouste T, Aubin G, Malka J, N'Guyen S, Mercier P, Menei P (2015): Specificities of Awake Craniotomy and Brain Mapping in Children for Resection of Supratentorial Tumors in the Language Area. *World Neurosurg* 84:1645–1652.
- Deloche G, Hannequin D (1997): Test de dénomination orale d'images: DO 80. Éd. du Centre de psychologie appliquée.
- Desandes E, Guissou S, Chastagner P, Lacour B (2014): Incidence and survival of children with central nervous system primitive tumors in the French National Registry of Childhood Solid Tumors. *Neuro-Oncol* 16:975–983.
- Devlin JT, Jamison HL, Matthews PM, Gonnerman LM (2004): Morphology and the internal structure of words. *Proc Natl Acad Sci U S A* 101:14984–14988.
- Van Dijk KRA, Hedden T, Venkataraman A, Evans KC, Lazar SW, Buckner RL (2010): Intrinsic functional connectivity as a tool for human connectomics: theory, properties, and optimization. *J Neurophysiol* 103:297–321.
- Dronkers N, Ogar J (2004): Brain areas involved in speech production. *Brain J Neurol* 127:1461–1462.
- Duyn JH, van Gelderen P, Talagala L, Koretsky A, de Zwart JA (2005): Technological advances in MRI measurement of brain perfusion. *J Magn Reson Imaging JMRI* 22:751–753.
- Everett LL, van Rooyen IF, Warner MH, Shurtleff HA, Saneto RP, Ojemann JG (2006): Use of dexmedetomidine in awake craniotomy in adolescents: report of two cases. *Paediatr Anaesth* 16:338–342.
- Fair DA, Cohen AL, Dosenbach NUF, Church JA, Miezin FM, Barch DM, Raichle ME, Petersen SE, Schlaggar BL (2008): The maturing architecture of the brain's default network. *Proc Natl Acad Sci U S A* 105:4028–4032.
- Farrant K, Uddin LQ (2015): Asymmetric development of dorsal and ventral attention networks in the human brain. *Dev Cogn Neurosci* 12:165–174.
- FitzGerald DB, Cosgrove GR, Ronner S, Jiang H, Buchbinder BR, Belliveau JW, Rosen BR, Benson RR (1997): Location of language in the cortex: a comparison between functional MR imaging and electrocortical stimulation. *AJNR Am J Neuroradiol* 18:1529–1539.
- Fox MD, Corbetta M, Snyder AZ, Vincent JL, Raichle ME (2006): Spontaneous neuronal activity distinguishes human dorsal and ventral attention systems. *Proc Natl Acad Sci U S A* 103:10046–10051.
- Fox MD, Snyder AZ, Vincent JL, Corbetta M, Van Essen DC, Raichle ME (2005): The human brain is intrinsically organized into dynamic, anticorrelated functional networks. *Proc Natl Acad Sci U S A* 102:9673–9678.
- Fransson P, Skiöld B, Engström M, Hallberg B, Mosskin M, Aden U, Lagercrantz H, Blennow M (2009): Spontaneous brain activity in the newborn brain during natural sleep--an fMRI study in infants born at full term. *Pediatr Res* 66:301–305.

- Hagberg CA, Gollas A, Berry JM (2004): The laryngeal mask airway for awake craniotomy in the pediatric patient: report of three cases. *J Clin Anesth* 16:43–47.
- Hampson M, Peterson BS, Skudlarski P, Gatenby JC, Gore JC (2002): Detection of functional connectivity using temporal correlations in MR images. *Hum Brain Mapp* 15:247–262.
- Hertz-Pannier L, Noulhiane M, Rodrigo S, Chiron C (2014): Pretherapeutic functional magnetic resonance imaging in children. *Neuroimaging Clin N Am* 24:639–653.
- Jansen A, Flöel A, Van Randenborgh J, Konrad C, Rotte M, Förster A-F, Deppe M, Knecht S (2005): Crossed cerebro-cerebellar language dominance. *Hum Brain Mapp* 24:165–172.
- Kamran M, Hacker CD, Allen MG, Mitchell TJ, Leuthardt EC, Snyder AZ, Shimony JS (2014): Resting-state blood oxygen level-dependent functional magnetic resonance imaging for presurgical planning. *Neuroimaging Clin N Am* 24:655–669.
- Klimek M, Verbrugge SJC, Roubos S, van der Most E, Vincent AJ, Klein J (2004): Awake craniotomy for glioblastoma in a 9-year-old child. *Anaesthesia* 59:607–609.
- Knecht S, Deppe M, Dräger B, Bobe L, Lohmann H, Ringelstein E, Henningsen H (2000a): Language lateralization in healthy right-handers. *Brain J Neurol* 123 ( Pt 1):74–81.
- Knecht S, Dräger B, Deppe M, Bobe L, Lohmann H, Flöel A, Ringelstein EB, Henningsen H (2000b): Handedness and hemispheric language dominance in healthy humans. *Brain J Neurol* 123 Pt 12:2512–2518.
- Lee MH, Smyser CD, Shimony JS (2013): Resting-state fMRI: a review of methods and clinical applications. *AJNR Am J Neuroradiol* 34:1866–1872.
- De Leon MJ, la Regina ME, Ferris SH, Gentes CI, Miller JD (1986): Reduced incidence of left-handedness in clinically diagnosed dementia of the Alzheimer type. *Neurobiol Aging* 7:161–164.
- Mahdavi A, Azar R, Shoar MH, Hooshmand S, Mahdavi A, Kharrazi HH (2015): Functional MRI in clinical practice: Assessment of language and motor for pre-surgical planning. *Neuroradiol J* 28:468–473.
- Mahvash M, Maslehaty H, Jansen O, Mehdorn HM, Petridis AK (2014): Functional magnetic resonance imaging of motor and language for preoperative planning of neurosurgical procedures adjacent to functional areas. *Clin Neurol Neurosurg* 123:72–77.
- Marslen-Wilson WD, Tyler LK (2007): Morphology, language and the brain: the decompositional substrate for language comprehension. *Philos Trans R Soc Lond B Biol Sci* 362:823–836.
- Mitchell TJ, Hacker CD, Breshears JD, Szrama NP, Sharma M, Bundy DT, Pahwa M, Corbetta M, Snyder AZ, Shimony JS, Leuthardt EC (2013a): A novel data-driven approach to preoperative mapping of functional cortex using resting-state functional magnetic resonance imaging. *Neurosurgery* 73:969–982; discussion 982–983.
- Mitchell TJ, Hacker CD, Breshears JD, Szrama NP, Sharma M, Bundy DT, Pahwa M, Corbetta M, Snyder AZ, Shimony JS, Leuthardt EC (2013b): A novel data-driven approach to preoperative mapping of functional cortex using

- resting-state functional magnetic resonance imaging. *Neurosurgery* 73:969–982; discussion 982–983.
- Nachev P, Husain M, Kennard C (2008): Volition and eye movements. *Prog Brain Res* 171:391–398.
- Ojemann G, Ojemann J, Lettich E, Berger M (2008): Cortical language localization in left, dominant hemisphere. An electrical stimulation mapping investigation in 117 patients. 1989. *J Neurosurg* 108:411–421.
- Ojemann SG, Berger MS, Lettich E, Ojemann GA (2003): Localization of language function in children: results of electrical stimulation mapping. *J Neurosurg* 98:465–470.
- Oldfield RC (1971): The assessment and analysis of handedness: the Edinburgh inventory. *Neuropsychologia* 9:97–113.
- Parvizi J, Rangarajan V, Shirer WR, Desai N, Greicius MD (2013): The will to persevere induced by electrical stimulation of the human cingulate gyrus. *Neuron* 80:1359–1367.
- De Ribaupierre S, Fohlen M, Bulteau C, Dorfmüller G, Delalande O, Dulac O, Chiron C, Hertz-Pannier L (2012): Presurgical language mapping in children with epilepsy: clinical usefulness of functional magnetic resonance imaging for the planning of cortical stimulation. *Epilepsia* 53:67–78.
- Roux F-E, Boulanouar K, Lotterie J-A, Mejdoubi M, LeSage JP, Berry I (2003): Language functional magnetic resonance imaging in preoperative assessment of language areas: correlation with direct cortical stimulation. *Neurosurgery* 52:1335–1345; discussion 1345–1347.
- Rutten GJM, Ramsey NF, van Rijen PC, Alpherts WC, van Veelen CWM (2002): fMRI-determined language lateralization in patients with unilateral or mixed language dominance according to the Wada test. *NeuroImage* 17:447–460.
- Seeley WW, Menon V, Schatzberg AF, Keller J, Glover GH, Kenna H, Reiss AL, Greicius MD (2007): Dissociable intrinsic connectivity networks for salience processing and executive control. *J Neurosci Off J Soc Neurosci* 27:2349–2356.
- Shimony JS, Zhang D, Johnston JM, Fox MD, Roy A, Leuthardt EC (2009): Resting-state spontaneous fluctuations in brain activity: a new paradigm for presurgical planning using fMRI. *Acad Radiol* 16:578–583.
- Smith SM, Fox PT, Miller KL, Glahn DC, Fox PM, Mackay CE, Filippini N, Watkins KE, Toro R, Laird AR, Beckmann CF (2009): Correspondence of the brain's functional architecture during activation and rest. *Proc Natl Acad Sci U S A* 106:13040–13045.
- Soriano SG, Eldredge EA, Wang FK, Kull L, Madsen JR, Black PM, Riviello JJ, Rockoff MA (2000): The effect of propofol on intraoperative electrocorticography and cortical stimulation during awake craniotomies in children. *Paediatr Anaesth* 10:29–34.
- Springer JA, Binder JR, Hammeke TA, Swanson SJ, Frost JA, Bellgowan PS, Brewer CC, Perry HM, Morris GL, Mueller WM (1999): Language dominance in neurologically normal and epilepsy subjects: a functional MRI study. *Brain J Neurol* 122 ( Pt 11):2033–2046.

- Sridharan D, Levitin DJ, Chafe CH, Berger J, Menon V (2007): Neural dynamics of event segmentation in music: converging evidence for dissociable ventral and dorsal networks. *Neuron* 55:521–532.
- Sridharan D, Levitin DJ, Menon V (2008): A critical role for the right fronto-insular cortex in switching between central-executive and default-mode networks. *Proc Natl Acad Sci U S A* 105:12569–12574.
- Supekar K, Musen M, Menon V (2009): Development of large-scale functional brain networks in children. *PLoS Biol* 7:e1000157.
- Sylvester CM, Barch DM, Corbetta M, Power JD, Schlaggar BL, Luby JL (2013): Resting state functional connectivity of the ventral attention network in children with a history of depression or anxiety. *J Am Acad Child Adolesc Psychiatry* 52:1326–1336.e5.
- Ter Minassian A, Ricalens E, Humbert S, Duc F, Aubé C, Beydon L (2013): Dissociating anticipation from perception: Acute pain activates default mode network. *Hum Brain Mapp* 34:2228–2243.
- Ter Minassian A, Ricalens E, Nguyen The Tich S, Dinomais M, Aubé C, Beydon L (2014): The presupplementary area within the language network: a resting state functional magnetic resonance imaging functional connectivity analysis. *Brain Connect* 4:440–453.
- Thomason ME, Dennis EL, Joshi AA, Joshi SH, Dinov ID, Chang C, Henry ML, Johnson RF, Thompson PM, Toga AW, Glover GH, Van Horn JD, Gotlib IH (2011): Resting-state fMRI can reliably map neural networks in children. *NeuroImage* 55:165–175.
- De Tiège X, Connelly A, Liégeois F, Harkness W, Clark CA, Chong WK, Gadian DG, Cross JH (2009): Influence of motor functional magnetic resonance imaging on the surgical management of children and adolescents with symptomatic focal epilepsy. *Neurosurgery* 64:856–864; discussion 864.
- Tie Y, Rigolo L, Norton IH, Huang RY, Wu W, Orringer D, Mukundan S, Golby AJ (2014): Defining language networks from resting-state fMRI for surgical planning--a feasibility study. *Hum Brain Mapp* 35:1018–1030.
- Tobias JD, Jimenez DF (1997): Anaesthetic management during awake craniotomy in a 12-year-old boy. *Paediatr Anaesth* 7:341–344.
- Tomczak RJ, Wunderlich AP, Wang Y, Braun V, Antoniadis G, Görlich J, Richter HP, Brambs HJ (2000): fMRI for preoperative neurosurgical mapping of motor cortex and language in a clinical setting. *J Comput Assist Tomogr* 24:927–934.
- Uddin LQ, Supekar KS, Ryali S, Menon V (2011): Dynamic reconfiguration of structural and functional connectivity across core neurocognitive brain networks with development. *J Neurosci Off J Soc Neurosci* 31:18578–18589.
- Vaden KI, Kuchinsky SE, Cute SL, Ahlstrom JB, Dubno JR, Eckert MA (2013): The cingulo-opercular network provides word-recognition benefit. *J Neurosci Off J Soc Neurosci* 33:18979–18986.
- Vigneau M, Beaucoisin V, Hervé PY, Duffau H, Crivello F, Houdé O, Mazoyer B, Tzourio-Mazoyer N (2006): Meta-analyzing left hemisphere language areas: phonology, semantics, and sentence processing. *NeuroImage* 30:1414–1432.
- Wilke M, Lidzba K (2007): LI-tool: a new toolbox to assess lateralization in functional MR-data. *J Neurosci Methods* 163:128–136.



- Wilke M, Schmithorst VJ (2006): A combined bootstrap/histogram analysis approach for computing a lateralization index from neuroimaging data. *NeuroImage* 33:522-530.
- Zhang D, Johnston JM, Fox MD, Leuthardt EC, Grubb RL, Chicoine MR, Smyth MD, Snyder AZ, Raichle ME, Shimony JS (2009): Preoperative sensorimotor mapping in brain tumor patients using spontaneous fluctuations in neuronal activity imaged with functional magnetic resonance imaging: initial experience. *Neurosurgery* 65:226-236.

## Supplementary material

**Annexe 1** :In all patients hypnotic preparation was performed the days preceding surgery. Patients were positionned in the supine or lateral position according to the location of the tumor. The scalp incision, the pin sites of the Mayfield holder were infiltrated with diluted ropivacaine. Local anesthetic blocks were also performed on the supraorbital, temporal, retro auricular and occipital nerve. The skin incision, the bone flap and the infiltration of the dura with ropivacaine were done under general anesthesia with intravenous remifentanyl and propofol and controlled ventilation through laryngeal airway mask. MR intraoperative neuronavigation (Brainlab AG Munich Germany) based on preoperative images was used in all the cases to assist in locating the brain lesion and to facilitate the total removal of the lesion.

After the awakening, hypnotic suggestion was performed and when the child was able to clearly communicate with the neuropsychologist the dura was opened and electrical cortical mapping was performed.

For each operated patient a large cortical exposure including motor area was performed. This was done in way to define the stimulation threshold delivering a biphasic current, which is the lowest intensity of a biphasic current delivered by a bipolar electrode producing a movement.

### Supplementary tables:

| Area                      | k           | T <sup>0</sup> | x   | y   | z   |
|---------------------------|-------------|----------------|-----|-----|-----|
| L Middle Temporal Gyrus   | <b>4932</b> | 16.4           | -66 | -19 | -12 |
| L Insula Lobe             |             | 12.69          | -38 | 11  | -14 |
| L Temporal Pole           |             | 11.82          | -36 | 11  | -23 |
| L Medial Temporal Pole    |             | 11.32          | -44 | 8   | -27 |
| R Thalamus                |             | 10             | 3   | -4  | -2  |
| R Superior Temporal Gyrus | <b>2652</b> | 16.5           | 58  | -16 | 3   |
| R Middle Temporal Gyrus   |             | 11.58          | 60  | -28 | -5  |

|                          |             |      |     |     |     |
|--------------------------|-------------|------|-----|-----|-----|
| R ACC                    | <b>2121</b> | 7.98 | 11  | 32  | 24  |
| L ACC                    |             | 6.08 | -6  | 33  | 19  |
| L Superior Medial Gyrus  |             | 5.93 | -14 | 41  | 19  |
| R Caudate Nucleus        | <b>559</b>  | 6.04 | 18  | 18  | 3   |
| R Putamen                |             | 5.95 | 20  | 20  | -5  |
| L Superior Medial Gyrus  | <b>505</b>  | 6.14 | -11 | 30  | 54  |
| L Pre-SMA                |             | 6.09 | -9  | 18  | 63  |
| L Superior Frontal Gyrus |             | 5.26 | -9  | 27  | 48  |
| L Hippocampus            | <b>351</b>  | 6.26 | -14 | -37 | 1   |
| L Thalamus               |             | 4.52 | -8  | -30 | 6   |
| R Temporal Pole          | <b>288</b>  | 9.45 | 51  | 6   | -17 |
| R Middle Temporal Gyrus  |             | 5.49 | 45  | 5   | -27 |
| R Medial Temporal Pole   |             | 4.71 | 54  | 8   | -30 |

**Supplementary table 1** : one sample t-test, second order analysis at the group level of the contrast sentences generation > listen tones.

The significant local peak maxima were obtained under a threshold of  $p < 0.005$  at the voxel level Monte-Carlo corrected for multiple comparisons at the cluster level cluster-size threshold 185;  $T^6 = T$  value for 6 degrees of freedom ; anatomical labels were derived from the anatomy toolbox for SPM ;  $k$  = cluster extend in voxels, in case of multiple peaks in the same anatomic area of a cluster, only the maximal peak is reported for this anatomic area ;  $x,y,z$  = the original SPM coordinates of the MNI space in millimetres.

ACC : anterior cingulate cortex. ; Pre-SMA : pre-supplementary motor area.

Note that activity within angular gyri failed to reach significance.

| Area                      | k    | $T^6$        | x   | y   | z   |
|---------------------------|------|--------------|-----|-----|-----|
| L Superior Medial Gyrus   | 2257 | <b>18.86</b> | -9  | 48  | 18  |
| L Superior Frontal Gyrus  |      | <b>7.41</b>  | -12 | 66  | 24  |
| R Superior Medial Gyrus   |      | <b>5.67</b>  | 6   | 48  | 40  |
| L Inferior Temporal Gyrus | 2197 | <b>11.34</b> | -59 | -21 | -32 |
| L Middle Temporal Gyrus   |      | <b>7.39</b>  | -57 | -27 | -5  |
| L Temporal Pole           | 1188 | <b>7.39</b>  | -26 | 14  | -29 |

|                            |     |              |     |     |     |
|----------------------------|-----|--------------|-----|-----|-----|
| L Medial Temporal Pole     |     | <b>5.09</b>  | -36 | 26  | -35 |
| L IFG (p. Orbitalis)       |     | <b>4.86</b>  | -44 | 29  | -9  |
| R Middle Temporal Gyrus    | 840 | <b>8.81</b>  | 56  | -37 | -2  |
| L Middle Frontal Gyrus     | 825 | <b>13.59</b> | -32 | 15  | 42  |
| L IFG (p. Triangularis)    |     | <b>7.33</b>  | -50 | 18  | 21  |
| L Angular Gyrus            | 783 | <b>4.84</b>  | -45 | -64 | 48  |
| L Calcarine Gyrus          | 598 | <b>10.49</b> | 2   | -70 | 16  |
| R Precuneus                |     | <b>5.52</b>  | 5   | -67 | 25  |
| R Pre-SMA                  | 563 | <b>6.41</b>  | 15  | 11  | 61  |
| R Cerebellum (Crus 2)      | 442 | <b>5.13</b>  | 29  | -87 | -39 |
| R Middle Temporal Gyrus    | 415 | <b>7.46</b>  | 57  | -7  | -23 |
| R Medial Temporal Pole     | 384 | <b>6.39</b>  | 47  | 11  | -44 |
| R Paracentral Lobule       | 361 | <b>18.23</b> | 6   | -25 | 61  |
| R Posterior-Medial Frontal |     | <b>9.3</b>   | 3   | -18 | 57  |
| R Angular Gyrus            | 308 | <b>6.72</b>  | 64  | -51 | 28  |
| L MCC                      | 300 | <b>7.18</b>  | 0   | -10 | 34  |
| R MCC                      |     | <b>6.32</b>  | 9   | -19 | 39  |
| R Cerebellum (VI)          | 269 | <b>7.17</b>  | 17  | -73 | -24 |
| L Pre-SMA                  | 190 | <b>4.71</b>  | -9  | 23  | 67  |
| L Superior Frontal Gyrus   |     | <b>4.62</b>  | -11 | 26  | 64  |
| R Middle Temporal Gyrus    | 185 | <b>5.31</b>  | 57  | -67 | 19  |

**Supplementary table 2** : one sample t-test, second order analysis at the group level of the independent component identified at rest as the language network

The significant local peak maxima were obtained under a threshold of  $p < 0.005$  at the voxel level, Monte-Carlo corrected for multiple comparisons at the cluster level cluster-size threshold 185;  $T^6 = T$  value for 6 degrees of freedom ; anatomical labels were derived from the anatomy toolbox for SPM ;  $k$  = cluster extend in voxels, in case of multiple peaks in the same anatomic area of a cluster, only the maximal peak is reported for this anatomic area ;  $x,y,z$  = the original SPM coordinates of the MNI space in millimetres.

IFG : inferior frontal gyrus ; MCC : Middle cingulate cortex ; Pre-SMA : pre-supplementary motor area.

Note the important clusters within angular gyri

| Area                       | k           | T <sup>6</sup> | x   | y   | z   |
|----------------------------|-------------|----------------|-----|-----|-----|
| L pre-SMA                  | <b>3526</b> | 12.32          | -12 | 14  | 67  |
| L Superior Medial Gyrus    |             | 11.61          | -5  | 29  | 51  |
| R pre-SMA                  |             | 8.39           | 3   | 15  | 51  |
| L SMA                      |             | 6.48           | -9  | 3   | 78  |
| L dACC                     |             | 4.49           | -4  | 20  | 28  |
| L Insula Lobe              | <b>2926</b> | 21.79          | -45 | 15  | 0   |
| L Medial Temporal Pole     |             | 7.73           | -50 | 21  | -29 |
| L IFG (p. Triangularis)    |             | 7.12           | -38 | 21  | 7   |
| L Temporal Pole            |             | 6.66           | -48 | 20  | -24 |
| R Putamen                  | <b>2025</b> | 6.89           | 24  | 8   | 1   |
| R IFG (p. Orbitalis)       |             | 4.93           | 53  | 33  | -9  |
| R Middle Frontal Gyrus     | <b>1239</b> | 8.64           | 34  | 41  | 27  |
| R IFG (p. Triangularis)    |             | 4.89           | 43  | 26  | 31  |
| R dACC                     | <b>1192</b> | 6.07           | 8   | 0   | 31  |
| R MCC                      |             | 6.03           | 2   | -12 | 42  |
| L MCC                      |             | 5.75           | -3  | -22 | 40  |
| L Cerebellum (VI)          | <b>864</b>  | 9.47           | -18 | -75 | -17 |
| L Cerebellum (Crus 1)      |             | 9.41           | -36 | -61 | -38 |
| L Cerebellum (VIII)        |             | 7.47           | -33 | -54 | -44 |
| L Fusiform Gyrus           |             | 5.39           | -26 | -63 | -15 |
| R Cerebellum (VI)          | <b>631</b>  | 7.84           | 30  | -73 | -23 |
| R Cerebellum (Crus 1)      |             | 6.31           | 44  | -64 | -35 |
| R Fusiform Gyrus           |             | 6.14           | 33  | -64 | -17 |
| R Inferior Occipital Gyrus | <b>528</b>  | 10.1           | 45  | -76 | -11 |
| L Cerebellum (Crus 1)      | <b>397</b>  | 9.38           | -3  | -81 | -17 |
| L Calcarine Gyrus          |             | 6.87           | 2   | -87 | -9  |
| R Inferior Occipital Gyrus | <b>217</b>  | 6.26           | 27  | -93 | -5  |
| R Calcarine Gyrus          |             | 5.24           | 21  | -99 | -5  |
| L IFG (p. Opercularis)     | <b>193</b>  | 10.78          | -51 | 11  | 25  |

**Supplementary table 3** : one sample t-test, second order analysis at the group level of the independent component identified at rest as the salience network.

The significant local peak maxima were obtained under a threshold of  $p < 0.005$  at the voxel level, Monte-Carlo corrected for multiple comparisons at the cluster level cluster-size threshold 185;  $T^6 = T$  value for 6 degrees of freedom ; anatomical labels were derived from the anatomy toolbox for SPM ;  $k$  = cluster extend in voxels, in case of multiple peaks in the same anatomic area of a cluster, only the maximal peak is reported for this anatomic area ;  $x,y,z$  = the original SPM coordinates of the MNI space in millimetres. dACC : dorsal anterior cingulate cortex; IFG : inferior frontal gyrus ; MCC : Middle cingulate cortex ; Pre-SMA : pre-supplementary motor area ; SMA : supplementary motor area

| Area                       | k           | T <sup>6</sup> | x   | y   | z   |
|----------------------------|-------------|----------------|-----|-----|-----|
| R Superior Temporal Gyrus  | <b>2358</b> | 6.98           | 65  | -43 | 12  |
| R SupraMarginal Gyrus      |             | 5.15           | 65  | -43 | 24  |
| R Pre-SMA                  | <b>1703</b> | 14.52          | 12  | 15  | 55  |
| R Superior Medial Gyrus    |             | 7.55           | 12  | 33  | 61  |
| R Middle Frontal Gyrus     |             | 7.31           | 28  | 20  | 48  |
| R Middle Frontal Gyrus     |             | 7.26           | 28  | 21  | 45  |
| R Superior Frontal Gyrus   |             | 6.4            | 20  | 14  | 51  |
| R Inferior Temporal Gyrus  | <b>964</b>  | 13.3           | 53  | -6  | -30 |
| R Middle Temporal Gyrus    |             | 6.35           | 53  | -9  | -17 |
| R Medial Temporal Pole     |             | 4.95           | 50  | 3   | -17 |
| L SupraMarginal Gyrus      | <b>692</b>  | 6.87           | -60 | -54 | 25  |
| L Middle Temporal Gyrus    |             | 4.95           | -45 | -57 | 13  |
| L Cerebelum (Crus 1)       | <b>678</b>  | 11.15          | -23 | -69 | -33 |
| L Middle Temporal Gyrus    | <b>652</b>  | 8.64           | -65 | -43 | 4   |
| R IFG (p. Triangularis)    | <b>586</b>  | 14.04          | 42  | 23  | 15  |
| R Middle Temporal Gyrus    | <b>476</b>  | 8.14           | 65  | -27 | -11 |
| R Precuneus                | <b>365</b>  | 9.73           | 8   | -60 | 36  |
| R IFG (p. Orbitalis)       | <b>303</b>  | 6.21           | 53  | 33  | -8  |
| L IFG (p. Orbitalis)       | <b>250</b>  | 13.18          | -23 | 12  | -21 |
| L ParaHippocampal Gyrus    |             | 12.45          | -18 | 6   | -24 |
| L Inferior Parietal Lobule | <b>209</b>  | 8.23           | -48 | -46 | 58  |
| R ACC                      | <b>194</b>  | 7.18           | 6   | 48  | 19  |

**Supplementary table 4:** one sample t-test, second order analysis at the group level of the independent component identified at rest as the ventral attention network

The significant local peak maxima were obtained under a threshold of  $p < 0.005$  at the voxel level, Monte-Carlo corrected for multiple comparisons at the cluster level cluster-size threshold 185;  $T^6 = T$  value for 6 degrees of freedom ; anatomical labels were derived from the anatomy toolbox for SPM ;  $k$  = cluster extend in voxels, in case of multiple peaks in the same anatomic area of a cluster, only the maximal peak is reported for this anatomic area ;  $x,y,z$  = the original SPM coordinates of the MNI space in millimetres.

ACC : anterior cingulate cortex. Pre-SMA : pre-supplementary motor area.

Note the important cluster in right temporo-parietal junction/ supramarginal gyrus and the absence of significant activity within angular gyri.

## 6 Discussion et perspectives :

Comme nous l'avons déjà évoqué dans l'introduction, les tumeurs cérébrales chez l'enfant représentent la deuxième cause de cancer après les hémopathies et la première cause de décès par cancer (81). La prise en charge de cette pathologie apparaît donc comme un enjeu de santé publique. Le pronostic vital et fonctionnel de ces enfants est intimement lié à la qualité de la résection. En effet, en cas de proximité avec certaines aires éloquentes du cerveau (motricité et langage), le pronostic fonctionnel peut-être impacté par la chirurgie. Cette problématique peut être réglée chez l'enfant aussi par la CECCSC. La faisabilité de cette technique n'est plus à démontrer comme nous l'avons indiqué. Il n'y a cependant que peu de cas décrits dans la littérature et nous avons réalisé dans la première partie de ce travail la revue de la littérature la plus exhaustive possible. Nous avons donc choisi d'articuler notre discussion d'abord sur l'analyse des limitations qui ont pu empêcher le développement de la technique, nous insistons ensuite sur le conditionnement préopératoire et notamment la place de l'hypnose, et enfin nous revenons sur l'IRMf de repos à propos du cas récent d'un jeune patiente aphasique.

### 6.1 Limitations

Plusieurs paramètres ont probablement limité le développement de la technique chez l'enfant:

- La première raison est très probablement éthique. En effet inconsciemment il existe une certaine réticence des professionnels à réaliser ce type d'intervention chez un enfant, par rapport à la gestion de la douleur et du vécu. C'est la raison pour laquelle nous avons choisi d'étudier le vécu et l'impact psychologique de la CECCSC chez l'enfant. Ceci a fait l'objet d'un article spécifique soumis et présenté dans la deuxième partie de ce travail de thèse.
- La question de la coopération des enfants en cas de CECCSC a souvent été citée comme facteur limitant la mise en place de cette prise en charge par l'ensemble des neurochirurgiens refusant de la proposer chez l'enfant (80). Cela rejoint aussi le problème lié à l'absence de tests spécifiques per opératoires pour les enfants et à la compréhension des tests proposés. Il n'y a à l'heure actuelle aucune publication sur le sujet. Dans notre expérience, nous avons observé une très bonne

participation des enfants lors de l'évaluation neuropsychologique per opératoire. Ceci était permis par un conditionnement faisant intervenir l'ensemble des professionnels de santé impliqués: neurochirurgien, pédopsychiatre, neuropsychologue, anesthésiste, infirmière de bloc opératoire, infirmière anesthésiste et en particulier praticien de l'hypnose. En ce qui concerne les tests neuropsychologiques utilisés en per opératoire, nous avons longtemps réfléchi à l'élaboration de tests adaptés aux jeunes enfants. Au final il semble surtout important de ne pas compliquer la situation et la plupart du temps les tests de dénomination et de répétition nous semblent parfaitement suffisants (20,82) et complètement adaptés aux enfants et ce jusqu'à un âge minimum de 8 ans. Nous avons en effet pu opérer une enfant de 8 ans avec un très bon vécu et une cartographie corticale et sous corticale très contributive. Les tests de dénomination utilisés reposaient sur la D080 (73) et étaient parfaitement compréhensibles par cette petite fille. La répétition de mot ne posait pas non plus de problème de compréhension. Ces données s'accordent tout à fait avec les constatations faites lors de l'enquête nationale réalisée au cours du mémoire d'orthophonie (80). Sur la quarantaine de patients opérés en France, tous ont été évalués avec le même type de batterie d'items pour la dénomination. En fonction du degré de maturité la situation peut évidemment varier; quoiqu'il en soit, on pourra toujours modifier les items pour les adapter à l'enfant voire réaliser des tests de confrontation d'objets en montrant les objets à l'enfant comme cela a été utilisé par Duchowny jusqu'à l'âge de 2 ans en extra-opératoire (74).

- D'un point de vue épidémiologique, le manque de données dans la littérature est probablement aussi lié au faible nombre de tumeurs sustentorielles chez l'enfant. En effet, on estime à environ 39 par million l'incidence moyenne annuelle des tumeurs du système nerveux central de l'enfant d'après le registre français des tumeurs solides de l'enfant sur la période 2000-2008 (81). Sur la totalité de ces tumeurs, seulement 30 à 40 % sont supratentorielles avec parmi elles 40 % de tumeurs de la ligne médiane. En outre, les tumeurs sustentorielles de l'enfant sont plus fréquentes avant l'âge de deux ans. Ceci est d'ailleurs illustré d'une part par le nombre de cas estimés éligibles par chaque centre lors de la proposition de PHRC national qui est évalué à 24 enfants par an pour un total de 8 CHU, et d'autre part par le nombre de cas d'enfants opérés en chirurgie éveillée recensés lors de



l'enquête réalisée sur le territoire dans le cadre du mémoire d'orthophonie qui était d'environ 40 enfants (80)(sans fourchette de temps précisée).

- Par ailleurs, la fameuse notion de plasticité cérébrale chez l'enfant, trop souvent surestimée a probablement constitué un frein dans le développement de la technique. En effet, il est encore communément admis dans le corps des neurochirurgiens que les enfants récupèrent souvent mieux que les adultes d'un déficit neurologique, et donc, que par conséquent, il n'y aurait pas de place pour la chirurgie éveillée chez les enfants. Cette vision est sûrement erronée, car si les enfants récupèrent probablement mieux d'un déficit moteur que les adultes, de nombreuses publications rapportent les effets néfastes de la chirurgie des tumeurs intracérébrales sur le pronostic fonctionnel des enfants, notamment sur le plan neuropsychologique avec des risques réels de séquelles neurocognitives (83-86) . En réalité, cette plasticité ne concerne absolument pas la tranche d'âge éligible de prime abord à une chirurgie éveillée. En effet, d'après la littérature, il semble exister un seuil de 5 ans, en dessous duquel la plasticité cérébrale est la plus efficace (74). Ceci a été démontré par plusieurs auteurs et est parfaitement illustré par le fait que chez le nourrisson voire chez le nouveau-né, l'apparition d'une lésion ou d'un AVC n'entrave pas forcément l'acquisition du langage (87-89). De la même façon, une hémisphérectomie fonctionnelle gauche notamment dans le traitement chirurgical de l'épilepsie n'empêche pas le développement du langage (90-92). Il semble donc qu'après 5 ans, la plasticité est similaire à celle de l'adulte et est donc réduite à une plasticité post-lésionnelle et péri-lésionnelle décrite par Duffau (24-26). Le risque de déficit séquellaire existe donc autant chez un enfant de plus de 5 ans que chez un adulte. Le respect des aires éloquentes chez l'enfant éligible à la chirurgie éveillée apparaît donc essentiel pour préserver le pronostic fonctionnel.

- Certains auteurs ont évoqué des limitations liées à la cartographie corticale et sous corticale par stimulation électrique directe sur un cerveau en cours de maturation. Dans notre expérience, toutes les cartographies par stimulation électrique directe corticale ou sous corticale réalisées chez des enfants endormis ou éveillés ont été informatives. Les intensités de stimulation utilisées n'étaient pas forcément plus élevées que chez l'adulte contrairement à ce qui a été écrit par certains auteurs dans la littérature (93) . Nous avons ainsi pu observer des troubles phasiques (erreurs de dénomination, manque du mot...) induits par stimulation

électrique corticale ou sous corticale jusqu'à un âge minimum de 8 ans en chirurgie éveillée, mais aussi des mouvements et ce jusqu'à un âge minimum de 3 ans. Ces données sont compatibles avec celles de la littérature puisque la plupart des auteurs s'accordent pour dire que la stimulation électrique directe est parfaitement efficace chez le jeune enfant. Ceci a non seulement été démontré dans les quelques publications portant sur la chirurgie éveillée de l'enfant (concernant essentiellement des adolescents) (14,69,75,94) mais a surtout été confirmé dans le cadre de la chirurgie de l'épilepsie par implantation d'électrodes sous-durales chez des enfants très jeunes y compris pour l'exploration du langage (11,69,95) et notamment jusqu'à un âge minimum de deux ans (74).

- Enfin même si la CECCSC a été initialement décrite puis utilisée chez l'adulte pour la prise en charge des gliomes infiltrants qui par définition n'ont pas de limite nette, cette procédure doit cependant pouvoir intéresser tout type de lésion située dans ou à proximité de régions éloquentes. En effet, une lésion même bien limitée sous corticale nécessite de déterminer la meilleure voie d'abord pour y accéder, afin de respecter les différentes fonctions. Ceci est parfaitement démontré dans la littérature chez l'adulte où l'on retrouve cette technique pour la prise en charge des cavernomes (14,96) et même des malformations artérioveineuses (97). Les cavernomes constituent en outre, à notre avis, une très bonne indication de chirurgie éveillée lorsqu'ils sont situés en zone fonctionnelle. Ils présentent en effet la particularité d'être associés à une gliose périlésionnelle, que l'on pourrait comparer à une infiltration de la substance blanche, et dont l'exérèse conditionne la guérison de l'épilepsie lésionnelle. Cette procédure nous paraît donc indiquée voire indispensable dans la prise en charge des tumeurs sustentorielles de l'enfant situées en zones fonctionnelles.

## **6.2 Conditionnement préopératoire:**

Le conditionnement préopératoire de l'enfant constitue un des éléments les plus importants pour réussir cette chirurgie. En effet la coopération de l'enfant dépend bien évidemment de son degré de maturité mais aussi et surtout de son stress et de l'atmosphère qui règne au bloc opératoire. Nous avons donc réuni une équipe pluridisciplinaire afin de pouvoir répondre à cette problématique. Au delà de la présentation de film, de la visite du bloc opératoire et de la rencontre de l'équipe soignante, nous avons mis en place un parcours de soin spécifique pour

cette prise en charge qui devra être réalisée le plus complètement possible en fonction du degré d'urgence.

Nous avons ainsi mis en place, chez ces enfants, en dehors de la consultation neurochirurgicale une consultation pédopsychiatrique systématique, une consultation neuropsychologique, une consultation pré-anesthésique et une consultation pré-hypnose.

Nous proposons de développer dans le paragraphe suivant la question de l'hypnose qui dans notre expérience apparaît réellement bénéfique pour ces enfants non seulement pour la gestion de la douleur mais aussi en terme d'apaisement et donc de coopération.

### **6.3 La place de l'hypnose**

Dans notre pratique, en dehors des situations d'urgence, l'enfant est vu en consultation pré-hypnose environ trois semaines avant l'intervention afin de faire connaissance et d'établir la communication. Cette consultation avant l'intervention semble réduire la douleur et le stress post-opératoire comme cela a été décrit dans la littérature dans d'autres situations (98). Sur le plan pratique, un questionnaire est proposé à l'enfant. L'objectif est de colliger quelques thèmes à propos de situations et de sensations plaisantes pour l'enfant, incluant des sensations visuelles, auditives, kinesthésiques, gustatives et olfactives.

L'hypnose est déjà utilisée en médecine pour la prise en charge de la douleur en complément de l'anesthésie. Cette technique peut être utilisée chez la quasi-totalité de la population, le problème de la sensibilité à l'hypnose étant en réalité secondaire pour la prise en charge et l'atténuation de la douleur. En effet, selon Montgomery et Al., 45% de la population présenterait une faible sensibilité à l'hypnose (99), mais cela suffirait pour réduire significativement la douleur pendant une intervention (100). L'efficacité de l'hypnose chez les patients opérés n'est plus à démontrer (15,101)

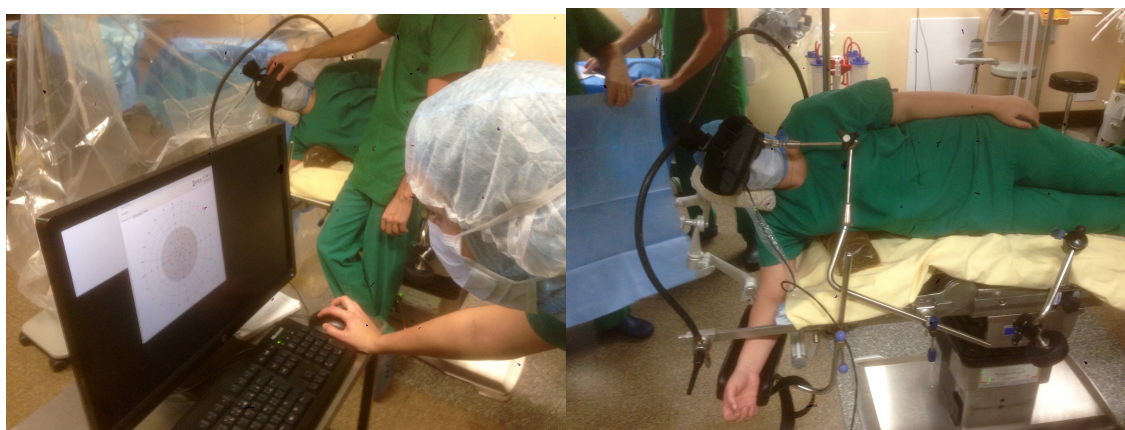Au delà de la gestion de la douleur, l'objectif de cette prise en charge vise à recréer à travers une distorsion spatio-temporelle en per opératoire une atmosphère apaisante pour l'enfant, en focalisant son attention sur ces situations plaisantes. Notre objectif était de voir si son utilisation était utile tout en étant compatible avec la CECCSC chez les enfants. En effet, dans notre expérience,

l'hypnose facilite la phase initiale d'induction mais aussi de réveil en permettant à l'enfant de se réveiller dans un environnement similaire à celui qu'il vient de quitter au moment de l'induction. Cette « transe » hypnotique permet aussi d'atténuer les moments plus difficiles à supporter, parfois douloureux pendant lesquels le chirurgien n'a pas besoin de la coopération du patient. Dans notre expérience chez l'enfant, nous n'avons pas souhaité remplacer totalement l'anesthésie générale par l'hypnose, celle-ci intervient plutôt comme une technique facilitante et complémentaire de l'anesthésie générale. En effet la première partie de l'intervention comporte des gestes qui peuvent être douloureux voire traumatisants pour l'enfant (mise en place de la têtère à pointe, infiltration du scalp, incision cutanée, réalisation du volet osseux, incision de la dure-mère).

L'utilisation de l'hypnose seule sans anesthésie générale lors de la chirurgie éveillée a cependant été récemment décrite chez l'adulte sur une série de 43 patients opérés en CECCSC. L'auteur en comparant cette série à une série antérieure opérée selon la technique de référence « asleep-awake-asleep »(16) montre ainsi que cette technique peut parfaitement suffire pour la totalité de l'intervention depuis l'installation du patient jusqu'à « la fermeture » (15). L'un des principaux avantages de l'hypnose par rapport à la technique de référence selon cet article étant de surseoir aux contre-indications anesthésiques. Cet argument n'est cependant pas valable chez l'enfant chez qui les contre-indications anesthésiques sont très rares. L'autre avantage selon le même auteur étant de permettre un retour à la conscience plus rapide et donc une évaluation neuropsychologique de meilleure qualité. Comme nous l'avons évoqué un peu plus haut, dans notre prise en charge, l'hypnose permet lorsqu'elle est utilisée pour l'induction et le réveil un retour à la conscience plus rapide, même lorsqu'elle est associée à l'anesthésie générale.

Des variantes de l'hypnose sont aussi utilisées en médecine pour la réalisation des pansements très douloureux chez les grands brûlés en utilisant des techniques de diversion mentale reposant sur la réalité virtuelle. L'immersion de ces patients dans un environnement de réalité virtuelle sur une banquise, grâce à la projection d'un film sur un écran, permet de créer une ambiance confortable pour le patient et de réaliser les soins quotidiens sans anesthésie (102-104) y compris chez les enfants. Nous sommes en train de réfléchir en collaboration avec l'ESIEA (école d'ingénieur en sciences et technologies du numérique) à des lunettes de réalité

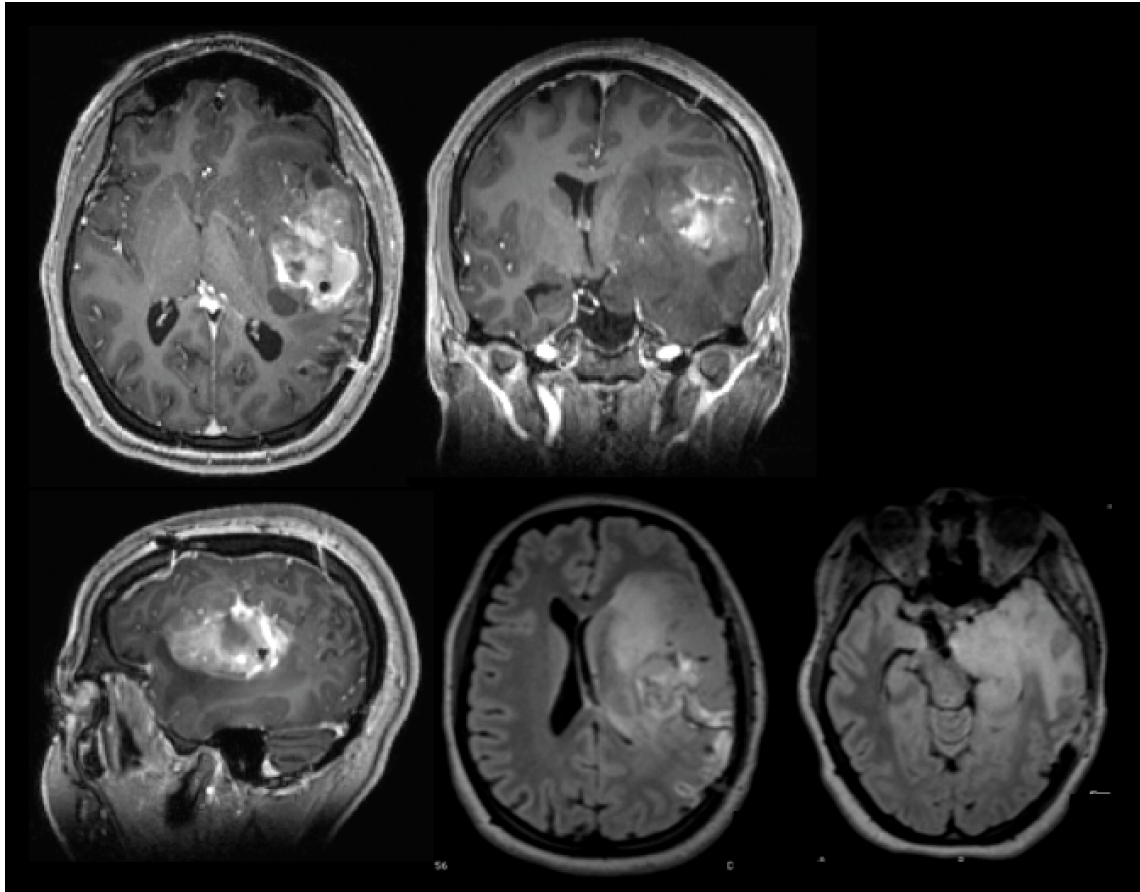
virtuelle pour projeter à l'enfant un environnement apaisant. Nous avons déjà mis au point avec cette équipe une technique permettant d'explorer le champ visuel au bloc opératoire grâce à l'utilisation d'un casque de réalité virtuelle dans lequel on peut par ailleurs intégrer les images de la DO80 (73). Le casque utilisé est le « OCULUS RIFT » (cf. figure 8). Nous l'avons déjà utilisé chez les adultes pour réaliser l'exérèse d'une tumeur cérébrale située à proximité des voies visuelles. L'idée à terme est d'y intégrer un environnement apaisant en réalité virtuelle ou augmentée, à l'image de ce que font les chirurgiens plasticiens pour les grand brûlés (sur des écrans). Ceci permettra probablement de régler les problèmes de distraction causés par l'utilisation d'un simple écran posé à distance du patient comme cela a déjà été proposé dans la littérature (105).



*Figure 8 : Essai en situation opératoire, avec un sujet témoin, du casque oculus rift. Le technicien examine le champ visuel du sujet en projetant des « spots lumineux » dans le casque.*

#### **6.4 L'IRM fonctionnelle de repos :**

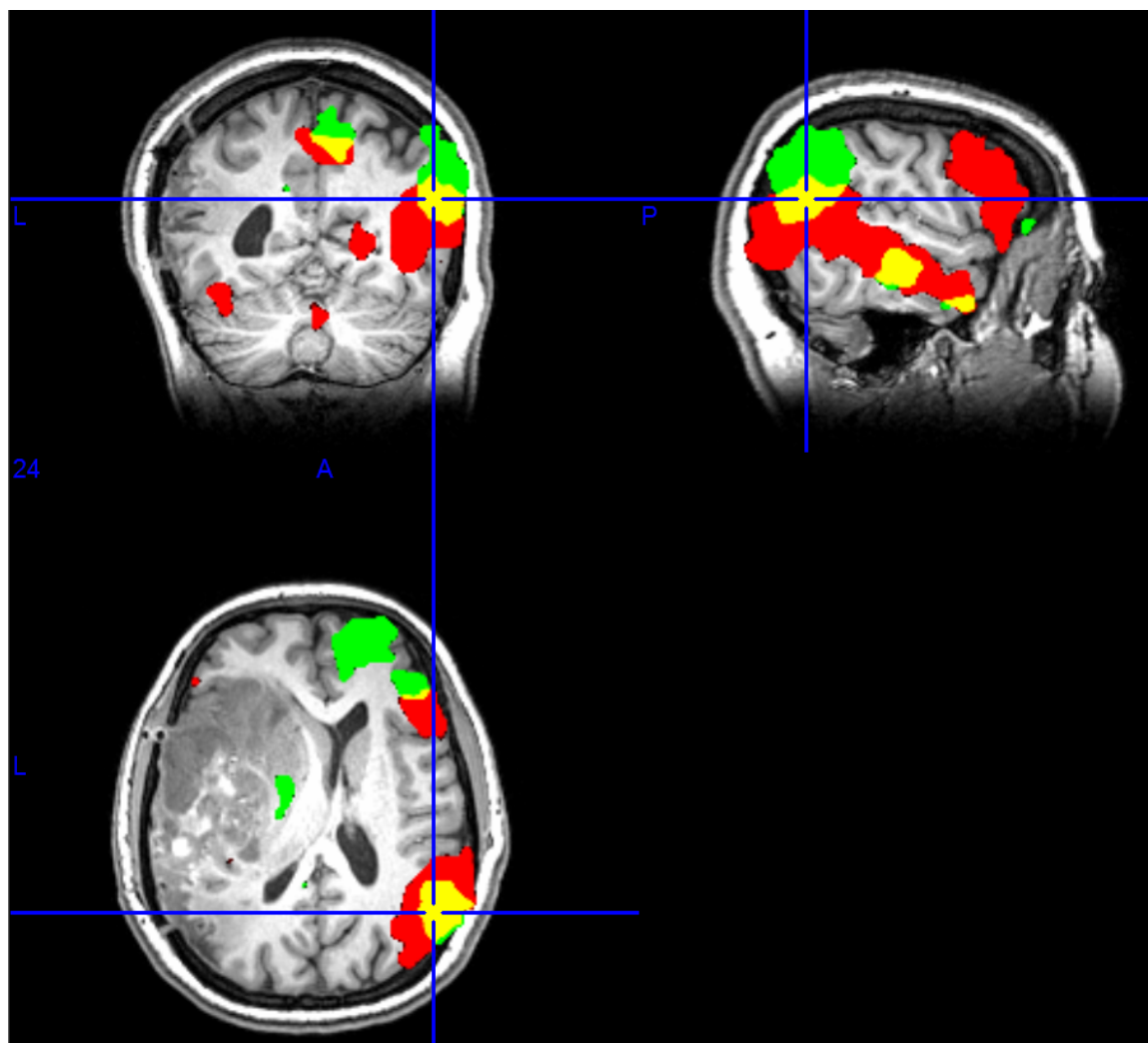
Nous avons montré que contrairement à l'IRMf d'activation, l'IRMf de repos avait une meilleure sensibilité en terme de prédiction de la localisation des aires éloquentes du langage et une meilleure spécificité dans la mesure où elle permettait d'isoler le réseau attentionnel qui interfère souvent avec le réseau du langage obtenu lors de la réalisation d'une tâche en IRMf d'activation. La question est de savoir si cela est suffisant pour se fier uniquement à cette technique en cas d'aphasie notamment. Nous avons tout récemment été confronté à cette situation puisque nous avons pris en charge une jeune fille de 15 ans, gauchère, présentant une volumineuse tumeur fronto-temporo-insulaire gauche responsable d'une aphasie (cf. figure 9).



*Figure 9: Glioblastome fronto temporo insulaire gauche chez une jeune fille de 15 ans gauchère présentant des troubles phasiques. Convention radiologique.*

Cette aphasie n'est pas surprenante chez un patient gaucher, puisqu'une bonne partie des gauchers gardent un langage latéralisé au niveau de l'hémisphère gauche. En effet, d'après la littérature, l'incidence de la dominance hémisphérique droite est linéairement corrélée à la latéralisation obtenue au test de latéralité d'Edinburgh; ainsi pour les patients évalués comme droitiers francs au test d'Edinburgh (ELT = 100) seulement 4% ont un hémisphère droit dominant, alors que pour les patients évalués comme gauchers vrais (ELT = -100), 27% ont un hémisphère droit dominant (106). Autrement dit, parmi les gauchers vrais, 73% gardent un hémisphère dominant à gauche. Cette jeune patiente présentait un langage spontané plutôt adapté et cohérent malgré des paraphrasies, avec cependant, un manque du mot très important. Elle présentait en effet lors des tests de dénomination, une aphasie de production tout à fait majeure rendant impossible la réalisation des tests per-opératoires. En pré-opératoire, lors de l'épreuve de dénomination de la DO80, la patiente ne dénommait correctement que 30 items et ces réponses n'étaient que partiellement reproductibles lors de la réévaluation à

quelques jours d'intervalle. Une IRMf de repos été réalisée chez cette patiente (cf. figure 10). Nous avons pu ainsi mettre en évidence entre autres trois réseaux cognitifs : un réseau modifié que nous identifions comme le réseau du langage, le réseau ventral de l'attention et le réseau du mode par défaut.



*Figure 10: IRMf de repos chez une patiente de 15 ans, gauchère, présentant un glioblastome fronto-temporo-insulaire gauche. rouge : langage rest rsfMRI; vert : vATT rsfMRI (réseau ventral de l'attention comprenant le gyrus supra marginal) ; jaune : overlap entre vATT et LANG rest. Convention neurologique : la droite est à droite de l'image. Incidences coronale, sagittale (hémisphère droit) et axiale.*

L'IRMf de repos, chez cette adolescente gauchère, nous montrait cependant un réseau du langage prédominant au niveau de l'hémisphère droit. Or chez cette patiente on ne peut imaginer une dominance hémisphérique droite dans la mesure où elle présente des troubles phasiques francs. Est-ce le témoignage d'une compensation de son réseau du langage dans l'hémisphère controlatéral sain ou simplement d'une décompensation de son réseau du langage dans l'hémisphère

lésé chez une patiente présentant une représentation bilatérale ? La question reste ouverte. On constate en effet qu'il n'y a que très peu d'activations correspondant au réseau du langage dans l'hémisphère gauche, alors même que la patiente est aphasique. On retrouve juste une modeste activation au niveau du gyrus frontal inférieur gauche au sein du réseau du langage. De façon notable, le réseau du mode par défaut, qui est particulièrement robuste, était largement amputé de ses composantes gauches évoquant donc une déstructuration hémisphérique gauche majeure. Ceci est compatible avec le fait que la patiente présentait lors de l'examen neuropsychologique des troubles de dénomination majeurs et un manque du mot. On retrouve par ailleurs un réseau ventral de l'attention distinct, comprenant le gyrus supra marginal, comme cela a été montré dans le dernier article soumis.

En pratique, nous avons « tenté l'expérience » en se disant qu'on pourrait utiliser uniquement la vingtaine d'items reconnus. En peropératoire, les tests de dénomination ne se sont pas du tout révélés fiables. Nous avons donc essayé de nous baser uniquement sur le langage spontané. Cette solution s'avère en réalité très « bancable » dans la mesure où elle reste très dépendante du débit de parole. Ceci était en outre aggravé par les quelques paraphasies retrouvées dans le langage spontané. L'intervention s'est par ailleurs très bien déroulée suivant notre protocole habituel avec notamment un bon vécu.

En se basant sur cette imagerie fonctionnelle et sur les résultats décrits dans le dernier article, nous aurions pu approfondir l'exérèse en résectionnant notamment le lobe temporal gauche et une partie du lobe frontal gauche. Il est d'ailleurs intéressant de noter, que lors de la cartographie corticale par électrostimulation, nous n'avons pas provoqué de modification de son état de base lors des tests neuropsychologiques peropératoires. Nous avons bien entendu recherché et obtenu auparavant le seuil de stimulation efficace en zone motrice. Nous avons finalement réalisé une exérèse très limitée. La patiente n'a pas été aggravée en post-opératoire. Quoiqu'il en soit, nous n'avons pas « osé » nous baser uniquement sur les résultats de l'IRMf de repos pour réaliser une résection plus complète, compte tenu notamment de la situation clinique qui correspondait à une tumeur gliale maligne et du pronostic vital probablement limité de cette patiente, mais aussi du fait que les résultats préliminaires que nous avons obtenus et décrits dans la dernière soumission portent sur une petite cohorte et ne sont donc pas suffisants. Ils méritent en effet d'être vérifiés sur un nombre de patients plus important avant de pouvoir tirer des conclusions et des applications cliniques.



S'il apparaît délicat, à l'heure actuelle, de se baser uniquement sur l'IRMf pour opérer en zone fonctionnelle, il ne faut pas oublier en outre que cet examen ne permet d'explorer que le cortex cérébral et de façon inévitable ne prédit ni la localisation ni le caractère fonctionnel des faisceaux de substance blanche sous corticaux. On peut cependant imaginer que si les aires corticales ne sont pas éloquentes, les faisceaux qui les relient peuvent être interrompus voire réséqués, de la même façon que l'on opère dans les zones non éloquentes du cerveau. Cette question ne peut en outre pas être résolue par l'imagerie de tenseur de diffusion et la tractographie qui, au delà de leur problème d'interprétation en présence d'une tumeur ou d'un oedème péritumoral, n'analysent pas le caractère fonctionnel du faisceau exploré.

## **6.5 Perspectives :**

Après réflexion, il est probable qu'un Protocole Hospitalier de Recherche Clinique n'était probablement pas le bon cadre pour mettre en place une étude de ce type, qui ne nécessite en réalité que peu de moyens financiers, dans la mesure où il s'agit essentiellement d'un projet reposant sur des soins courants. Je souhaite donc proposer à nouveau de travailler de façon multicentrique sur ce sujet plutôt dans le cadre d'un projet réalisé sous l'égide d'une société savante. Il semble en effet important de démocratiser cette pratique afin d'apporter aux enfants la meilleure prise en charge possible, quelque soit la situation.

Je souhaite enfin profiter de cette expérience grandissante dans le domaine de la neurochirurgie en zones fonctionnelles pour développer la chirurgie de l'épilepsie de l'enfant en collaboration avec l'équipe de neuropédiatrie du CHU d'Angers.

## **7 Conclusion :**

Ce travail de thèse montre bien la faisabilité de la CECCSC chez l'enfant jusqu'à un âge minimum de huit ans d'après notre expérience. Il s'agit d'une technique qui donne des résultats satisfaisants à la fois sur le plan neurologique et oncologique en terme de pronostic respectivement fonctionnel et vital. En outre, la CECCSC est bien vécue et n'a pas d'impact psychologique négatif à court ou moyen

terme sur les enfants. En ce qui concerne l'utilisation de l'IRMf de repos, nous avons démontré sur des résultats préliminaires que cette méthode était non seulement faisable chez les enfants mais qu'elle donnait des résultats meilleurs que l'IRMf d'activation en terme de sensibilité et de spécificité. Ces résultats restent cependant préliminaires et nécessitent d'être évalués sur une cohorte plus importante avant d'être utilisables en clinique.

## 8 Publications et communications présentées au cours de la thèse :

### 8.1 Publications :

- Perivier M, **Delion M**, Chinier E, Lousteau S, Nguyen S, Ter Minassian A, Richard I, Dinomais M. relations between somatosensory deficit and brain somatosensory system after early brain lesion : A morphometric study. *European Journal of Paediatric Neurology* 2016
- Bernard F, lemeé JM, **Delion M**, Fournier HD, lower third clivus and foramen magnum intradural tumor removal : the plea for a simple posterolateral approach. *Neurochirurgie* 2016
- Lambron J, Kakotonjanahary J, Loisel D, Frampas E, De Carli E, **Delion M**, Rialland X, Toulgoat F. Can we improve accuracy and reliability of MRI interpretation in children with optic pathway glioma? Proposal for a reproducible imaging classification. *Neuroradiology* 2015
- Dinomais M, Hertz-Pannier, Groeschel S, Chabrier S, **Delion M**, Husson B, Kossorotof M, Renaud C, Nguyen The Tich, S. Long term motor function after neonatal stroke : lesion localization above all. *Human Brain Mapping* 2015 Decembre, vol 36(12) pp 4793-4807.
- **M Delion**, P Mercier, G Brassier. Arteries and veins of the sylvian fissure and the insula: microsurgical anatomy. *Advances and technical standards in Neurosurgery*, 2016 vol 43 pp. 185-216.
- **Delion M**, Terminassian A, Lehoussé T, Aubin, G, Malka J, N'Guyen S, Mercier P, Menei P. Specificities of Awake Craniotomy and Brain Mapping in children for resection of supratentorial tumors in the language area. *World Neurosurgery*, 2015 vol. 84(6) pp1645-52
- Josué Rakotonjanahary, Emilie De Carli, **Matthieu Delion**, Chantal Kalifa, Jacques Grill, François Doz, Pierre Leblond, Anne-Isabelle Bertozzi, Xavier Rialland. Mortality in children with optic pathway glioma treated with up front BBSFOP chemotherapy. *PLOS ONE* 2015, vol. 10(6) pp.e0127676
- **M Delion**, P Mercier, M Dinomais. The long insular perforating arteries are essential cerebral perforating vessels too. Letter to the editor. DOI: 10.1007 :s00701-015-2464-y. *Acta Neurochirurgica Acta Neurochir (Wien)* 2015 vol.157(8) pp.1391-2
- Magro E, **Delion M**, Abed-Rabbo F, Mercier P, Seizeur R. Comparaison of injection:dissection and injection:corrosion methods: example of vertebral veins in the transverse canal. *Surgical and Radiologic Anatomy* 2015 vol 37(3) pp.273-9.
- **M. Delion**, P.Mercier. Microanatomical study of the insular perforating arteries. *Acta Neurochirurgica. Acta Neurochir (Wien)*. 2014 Oct;156(10):1991-7.
- Grignon B, Mainard L, **Delion M**, Hodez C, Oldirini G. Recent advances in medical imaging: anatomical and clinical applications. *Surg Radiol Anat*. 2012 Oct; vol 34(8) pp.675-86.

- Stéphanie Proust Houdemont, Emilie De Carli, **Matthieu Delion**, Benedicte Ringuier, Catherine Chapotte, Catherine Jeudy, Philippe Mercier, Jean-Claude Granry, Xavier Rialland. Short-term neurological outcome of children after surgery for brain tumors: incidence and characteristics in a pediatric intensive care unit. Childs Nerv Syst 2011 jan 6.

## 8.2 Articles soumis (1<sup>ER</sup> et dernier auteur) :

- **M Delion**, M Dinomais, P Mercier. Arteries and veins of the cerebellum. The Cerebellum. Rang Sigaps D, IF 2,717.
- **M Delion**, LM Leiber, M Labriffe, P Menei, M Dinomais, A Terminassian. The use of RSfMRI in children for preoperative planning of supratentorial lesion located in the language area. Comparison with the intraoperative direct stimulation. Human Brain Mapping Rang sigaps A, IF 5 ,9.
- Elise Riquin, Mickael Dinomais, Jean Malka, Thierry Lehouste, Philippe Duverger, Philippe Menei, **Matthieu Delion**. Psychiatric and psychological impact of awake surgery in children for resection of brain tumors in the language area. Journal of Clinical Psychiatry, Rang Sigaps B, IF 5,5.
- **M Delion**, A Terminassian, M Perivier, S Loustau, E Chinier, S Nguyen, I Richard, M Dinomais. (Re)organization of the somatosensory system after early brain lesion: a lateralization index fMRI study. Neuroimage Clinical. Rang Sigaps C, IF 2,5.

## 8.3 Publications didactiques dans revue avec comité de lecture :

- **M Delion**, M Dinomais, A Ter Minassian, P Mercier. Magnetic resonance imaging: from morphological imaging to functional imaging. Part I: Investigation methods, Chapter 3, page 91, in Stereotaxy and Epilepsy Surgery, Jean-Marie Scarabin Edition John Libbey 2012.
- JM.Scarabin, Ph.Mercier, **M.Delion**, C.Barillot, P.Janin, B.Gibaud, E.Berton From bourgery anatomy to brain multiparameter, 3D digital imaging, individual for each patient. Part I: Investigation methods, Chapter 2, page 41, in Stereotaxy and Epilepsy Surgery, Jean-Marie Scarabin Edition John Libbey 2012.

## 8.4 Conférences orales sur invitation :

- **M Delion**. Les tumeurs cérébrales de l'enfant, le point de vue du neurochirurgien. DES oncopediatrie inter région ouest, janvier 2016 , Nantes.
- **M Delion**. Craniosténoses. FMC pédiatrie, Octobre 2015, Nantes.
- **M Delion**. Les tumeurs cérébrales de l'enfant. DES pédiatrie inter-région ouest. Mai 2015, Angers.
- **M Delion**. Hydrocéphalie de l'enfant. DES neurochirurgie inter région ouest. Octobre 2014, Nantes.
- **M Delion**. Chirurgie éveillée et cartographie corticale chez l'enfant : les spécificités. Journées nationales d'enseignement de neurochirurgie. Septembre 2014, Paris.

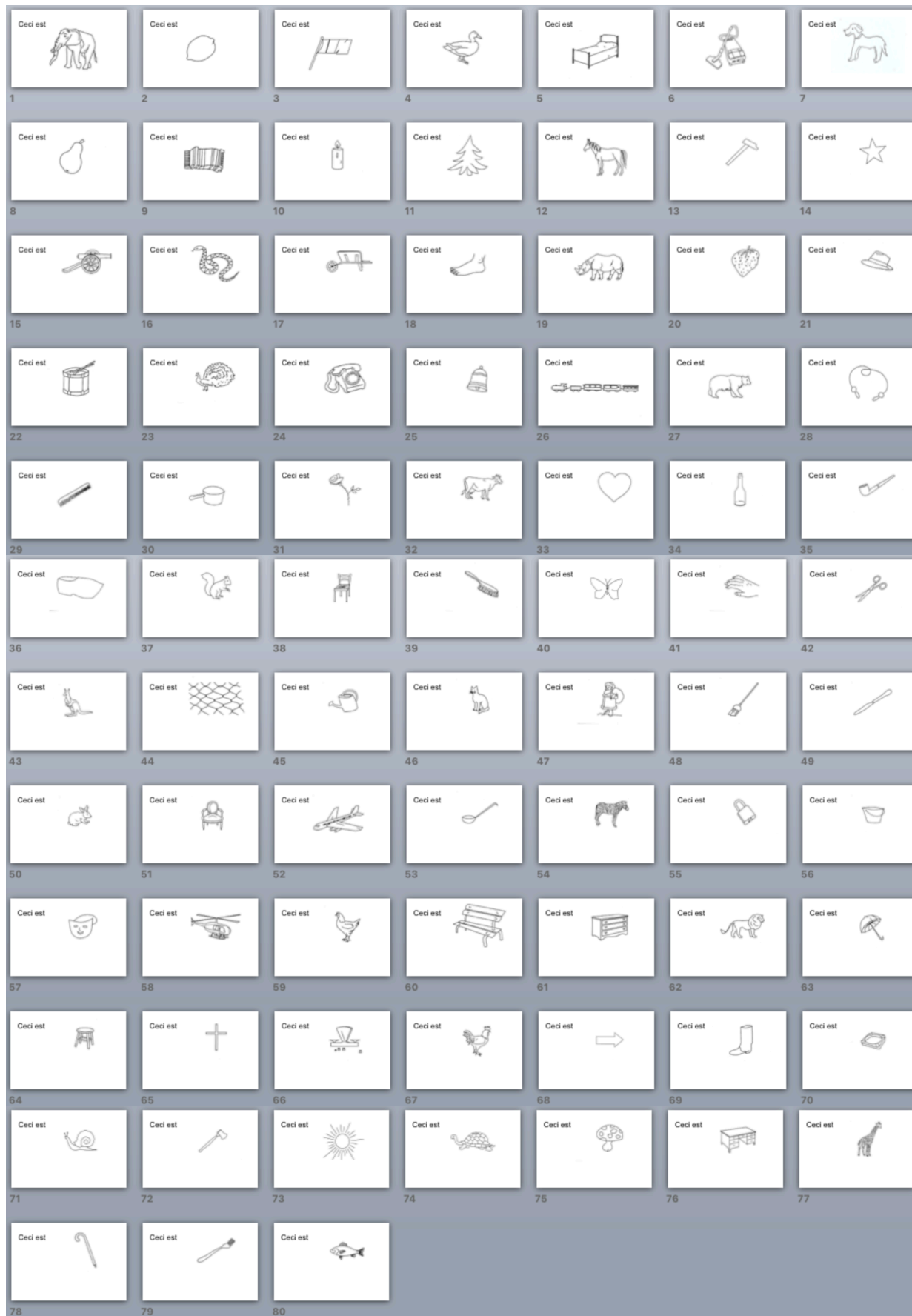- **M Delion**. La place de la neurochirurgie dans la prise en charge des tumeurs cérébrales. DIU neuro-oncologie. Février 2013. Angers.

## 8.5 Communications orales lors de congrès :

- **M Delion**, P.Mercier, Etude microanatomique des artères perforantes insulaires. Société française de neurochirurgie. Nantes 2015
- **M Delion**, P Mercier. Stimulation vagale : la technique chirurgicale. Société de neurophysiologie clinique de langue française. Angers Juin 2014.
- Luc Le Fournier, **M Delion**, P Menei, P Mercier. Chirurgie éveillée chez l'enfant à propos de 4 cas. Société française de neurochirurgie. Clermont Ferrand Mai 2014
- **M Delion**, P Mercier, G Brassier Anatomie de l'angle ponto cérébelleux. Cours francophone société de langue française de neurochirurgie. Bucarest 2013
- **M Delion**, M Braun, G Brassier, P Mercier. Vascularisation artérielle et veineuse du corps calleux. Congrès de l'association des morphologistes. Amiens 2014
- **M Delion**, P Mercier. Anatomie microchirurgicale des artères perforantes insulaires. Congrès de l'association des morphologistes. Clermont Ferrand. Mars 2012.
- **M. Delion**, G. Hayek, A. Terminassian, G. Aubin, P. Mercier, P. Menei. Awake surgery and cortical sub cortical mapping in a child: case report. Congrès de la société française de neurochirurgie. Marseille 2009.

# 9 Annexes :

## 9.1 Annexe 1 : items DO 80



**9.2 Annexe 2 : questionnaire de latéralité manuelle d'Edinburgh d'après Oldfield 1971 (107) :**

| Quelle main utilisez-vous ?              | Droite | Gauche |
|--|--------|--------|
| 1. Pour écrire                           |        |        |
| 2. Pour dessiner                         |        |        |
| 3. Pour lancer une balle                 |        |        |
| 4. Pour utiliser une paire de ciseaux    |        |        |
| 5. Pour vous peigner                     |        |        |
| 6. Pour vous servir d'une brosse à dents |        |        |
| 7. Pour tenir un couteau                 |        |        |
| 8. Pour manger avec une cuillère         |        |        |
| 9. Pour frapper avec un marteau          |        |        |
| 10. Pour vous servir d'un tournevis      |        |        |

Coefficient de latéralisation manuelle :  $D-G/D+G =$

Le score obtenu, multiplié par 100, donne la dominance manuelle :

+100 : Droitier

-100 : Gaucher homogène

## 10 Bibliographie

1. Brell M, Ibáñez J, Caral L, Ferrer E. Factors influencing surgical complications of intra-axial brain tumours. *Acta Neurochir (Wien)*. 2000;142(7):739–50.
2. Sawaya R, Hammoud M, Schoppa D, Hess KR, Wu SZ, Shi WM, et al. Neurosurgical outcomes in a modern series of 400 craniotomies for treatment of parenchymal tumors. *Neurosurgery*. 1998 May;42(5):1044–55; discussion 1055–6.
3. Tandon P, Mahapatra AK, Khosla A. Operations on gliomas involving speech centres. *Acta Neurochir Suppl (Wien)*. 1993;56:67–71.
4. Roux F-E, Boulanouar K, Lotterie J-A, Mejdoubi M, LeSage JP, Berry I. Language functional magnetic resonance imaging in preoperative assessment of language areas: correlation with direct cortical stimulation. *Neurosurgery*. 2003 Jun;52(6):1335–45; discussion 1345–7.
5. Ojemann G, Ojemann J, Lettich E, Berger M. Cortical language localization in left, dominant hemisphere. An electrical stimulation mapping investigation in 117 patients. *J Neurosurg*. 1989 Sep;71(3):316–26.
6. Penfield W, Boldrey E. Somatic motor representation in the cerebral cortex of man as studied by electrical stimulation. *Brain J Neurol*. 1937;60:389–443.
7. Penfield W, Rasmussen T. *The Cerebral Cortex of Man*. In: New York: Macmillan Co. 1950.
8. Penfield W, Roberts L. *Speech and brain mechanisms*. In: Princeton University Press. 1959.
9. Ojemann JG, Ojemann GA, Lettich E. Cortical stimulation mapping of language cortex by using a verb generation task: effects of learning and comparison to mapping based on object naming. *J Neurosurg*. 2002 Jul;97(1):33–8.
10. Duffau H. [Peroperative functional mapping using direct electrical stimulations. Methodological considerations]. *Neurochirurgie*. 2004 Sep;50(4):474–83.
11. Duffau H. Contribution of cortical and subcortical electrostimulation in brain glioma surgery: methodological and functional considerations. *Neurophysiol Clin Clin Neurophysiol*. 2007 Dec;37(6):373–82.
12. Duffau H, Peggy Gatignol ST, Mandonnet E, Capelle L, Taillandier L. Intraoperative subcortical stimulation mapping of language pathways in a consecutive series of 115 patients with Grade II glioma in the left dominant hemisphere. *J Neurosurg*. 2008 Sep;109(3):461–71.
13. Szelényi A, Bello L, Duffau H, Fava E, Feigl GC, Galanda M, et al. Intraoperative electrical stimulation in awake craniotomy: methodological aspects of current practice. *Neurosurg Focus*. 2010 Feb;28(2):E7.



14. Delion M, Terminassian A, Lehouste T, Aubin G, Malka J, N'Guyen S, et al. Specificities of Awake Craniotomy and Brain Mapping in Children for Resection of Supratentorial Tumors in the Language Area. *World Neurosurg.* 2015 Dec;84(6):1645–52.
15. Zemmoura I, Fournier E, El-Hage W, Jolly V, Destrieux C, Velut S. Hypnosis for Awake Surgery of Low-grade Gliomas: Description of the Method and Psychological Assessment. *Neurosurgery.* 2016 Jan;78(1):53–61.
16. Duffau H. The usefulness of the asleep-awake-asleep glioma surgery. *Acta Neurochir (Wien).* 2014 Aug;156(8):1493–4.
17. Duffau H. The reliability of asleep-awake-asleep protocol for intraoperative functional mapping and cognitive monitoring in glioma surgery. *Acta Neurochir (Wien).* 2013 Oct;155(10):1803–4.
18. Boetto J, Bertram L, Moulinié G, Herbet G, Moritz-Gasser S, Duffau H. Low Rate of Intraoperative Seizures During Awake Craniotomy in a Prospective Cohort with 374 Supratentorial Brain Lesions: Electrocorticography Is Not Mandatory. *World Neurosurg.* 2015 Dec;84(6):1838–44.
19. Tharin S, Golby A. Functional brain mapping and its applications to neurosurgery. *Neurosurgery.* 2007 Apr;60(4 Suppl 2):185–201; discussion 201–2.
20. Chang EF, Raygor KP, Berger MS. Contemporary model of language organization: an overview for neurosurgeons. *J Neurosurg.* 2015 Feb;122(2):250–61.
21. Duffau H, Moritz-Gasser S, Mandonnet E. A re-examination of neural basis of language processing: proposal of a dynamic hodotopical model from data provided by brain stimulation mapping during picture naming. *Brain Lang.* 2014 Apr;131:1–10.
22. Sanai N, Mirzadeh Z, Berger MS. Functional outcome after language mapping for glioma resection. *N Engl J Med.* 2008 Jan 3;358(1):18–27.
23. Krainik A, Duffau H, Capelle L, Cornu P, Boch A-L, Mangin J-F, et al. Role of the healthy hemisphere in recovery after resection of the supplementary motor area. *Neurology.* 2004 Apr 27;62(8):1323–32.
24. Duffau H. Brain plasticity: from pathophysiological mechanisms to therapeutic applications. *J Clin Neurosci Off J Neurosurg Soc Australas.* 2006 Nov;13(9):885–97.
25. Duffau H. Brain plasticity and tumors. *Adv Tech Stand Neurosurg.* 2008;33:3–33.
26. Duffau H. Does post-lesional subcortical plasticity exist in the human brain? *Neurosci Res.* 2009 Oct;65(2):131–5.
27. Duffau H, Gatignol P, Mandonnet E, Peruzzi P, Tzourio-Mazoyer N, Capelle L. New insights into the anatomo-functional connectivity of the semantic system:

- a study using cortico-subcortical electrostimulations. *Brain J Neurol.* 2005 Apr;128(Pt 4):797–810.
28. De Benedictis A, Sarubbo S, Duffau H. Subcortical surgical anatomy of the lateral frontal region: human white matter dissection and correlations with functional insights provided by intraoperative direct brain stimulation: laboratory investigation. *J Neurosurg.* 2012 Dec;117(6):1053–69.
  29. Duffau H. Intraoperative cortico-subcortical stimulations in surgery of low-grade gliomas. *Expert Rev Neurother.* 2005 Jul;5(4):473–85.
  30. Duffau H, Capelle L, Sichez N, Denvil D, Lopes M, Sichez J-P, et al. Intraoperative mapping of the subcortical language pathways using direct stimulations. An anatomo-functional study. *Brain J Neurol.* 2002 Jan;125(Pt 1):199–214.
  31. Freyschlag CF, Duffau H. Awake brain mapping of cortex and subcortical pathways in brain tumor surgery. *J Neurosurg Sci.* 2014 Dec;58(4):199–213.
  32. Maldonado IL, Moritz-Gasser S, Duffau H. Does the left superior longitudinal fascicle subserve language semantics? A brain electrostimulation study. *Brain Struct Funct.* 2011 Sep;216(3):263–74.
  33. Martino J, De Witt Hamer PC, Berger MS, Lawton MT, Arnold CM, de Lucas EM, et al. Analysis of the subcomponents and cortical terminations of the perisylvian superior longitudinal fasciculus: a fiber dissection and DTI tractography study. *Brain Struct Funct.* 2013 Jan;218(1):105–21.
  34. Zemmoura I, Herbet G, Moritz-Gasser S, Duffau H. New insights into the neural network mediating reading processes provided by cortico-subcortical electrical mapping. *Hum Brain Mapp.* 2015 Jun;36(6):2215–30.
  35. Black PM, Ronner SF. Cortical mapping for defining the limits of tumor resection. *Neurosurgery.* 1987 Jun;20(6):914–9.
  36. Berger MS, Kincaid J, Ojemann GA, Lettich E. Brain mapping techniques to maximize resection, safety, and seizure control in children with brain tumors. *Neurosurgery.* 1989 Nov;25(5):786–92.
  37. Walsh AR, Schmidt RH, Marsh HT. Cortical mapping and local anaesthetic resection as an aid to surgery of low and intermediate grade gliomas. *Br J Neurosurg.* 1992;6(2):119–24.
  38. Ebeling U, Schmid UD, Ying H, Reulen HJ. Safe surgery of lesions near the motor cortex using intra-operative mapping techniques: a report on 50 patients. *Acta Neurochir (Wien).* 1992;119(1-4):23–8.
  39. Berger MS, Deliganis AV, Dobbins J, Keles GE. The effect of extent of resection on recurrence in patients with low grade cerebral hemisphere gliomas. *Cancer.* 1994 Sep 15;74(6):1784–91.
  40. Reulen HJ, Schmid UD, Ilmberger J, Eisner W, Bise K. [Tumor surgery of the speech cortex in local anesthesia. Neuropsychological and neurophysiological

- monitoring during operations in the dominant hemisphere]. *Nervenarzt*. 1997 Oct;68(10):813–24.
41. Wagner W, Tschiltshcke W, Niendorf WR, Schroeder HW, Gaab MR. Infrared-based neuronavigation and cortical motor stimulation in the management of central-region tumors. *Stereotact Funct Neurosurg*. 1997;68(1-4 Pt 1):112–6.
  42. Danks RA, Aglio LS, Gugino LD, Black PM. Craniotomy under local anesthesia and monitored conscious sedation for the resection of tumors involving eloquent cortex. *J Neurooncol*. 2000 Sep;49(2):131–9.
  43. Krombach GA, Spetzger U, Rohde V, Gilsbach JM. Intraoperative localization of functional regions in the sensorimotor cortex by neuronavigation and cortical mapping. *Comput Aided Surg Off J Int Soc Comput Aided Surg*. 1998;3(2):64–73.
  44. Duffau H, Capelle L, Sichez J, Faillot T, Abdennour L, Law Koune JD, et al. Intraoperative direct electrical stimulations of the central nervous system: the Salpêtrière experience with 60 patients. *Acta Neurochir (Wien)*. 1999;141(11):1157–67.
  45. Ebel H, Ebel M, Schillinger G, Klimek M, Sobesky J, Klug N. Surgery of intrinsic cerebral neoplasms in eloquent areas under local anesthesia. *Minim Invasive Neurosurg MIN*. 2000 Dec;43(4):192–6.
  46. Fukaya C, Katayama Y, Yoshino A, Kobayashi K, Kasai M, Yamamoto T. Intraoperative wake-up procedure with propofol and laryngeal mask for optimal excision of brain tumour in eloquent areas. *J Clin Neurosci Off J Neurosurg Soc Australas*. 2001 May;8(3):253–5.
  47. Lanier WL. Brain tumor resection in the awake patient. *Mayo Clin Proc*. 2001 Jul;76(7):670–2.
  48. Signorelli F. The value of cortical stimulation applied to the surgery of malignant gliomas in language areas. *Neurol Sci Off J Ital Neurol Soc Ital Soc Clin Neurophysiol*. 2001 Jun;22(3):217–8.
  49. Peraud A, Meschede M, Eisner W, Ilmberger J, Reulen H-J. Surgical resection of grade II astrocytomas in the superior frontal gyrus. *Neurosurgery*. 2002 May;50(5):966–75; discussion 975–7.
  50. Reithmeier T, Krammer M, Gumprecht H, Gerstner W, Lumenta CB. Neuronavigation combined with electrophysiological monitoring for surgery of lesions in eloquent brain areas in 42 cases: a retrospective comparison of the neurological outcome and the quality of resection with a control group with similar lesions. *Minim Invasive Neurosurg MIN*. 2003 Apr;46(2):65–71.
  51. Sarang A, Dinsmore J. Anaesthesia for awake craniotomy--evolution of a technique that facilitates awake neurological testing. *Br J Anaesth*. 2003 Feb;90(2):161–5.
  52. Signorelli F, Guyotat J, Mottolese C, Schneider F, D'Acunzi G, Isnard J. Intraoperative electrical stimulation mapping as an aid for surgery of

- intracranial lesions involving motor areas in children. *Childs Nerv Syst ChNS Off J Int Soc Pediatr Neurosurg*. 2004 Jun;20(6):420–6.
53. Whittle IR, Borthwick S, Haq N. Brain dysfunction following “awake” craniotomy, brain mapping and resection of glioma. *Br J Neurosurg*. 2003 Apr;17(2):130–7.
  54. Bello L, Gallucci M, Fava M, Carrabba G, Giussani C, Acerbi F, et al. Intraoperative subcortical language tract mapping guides surgical removal of gliomas involving speech areas. *Neurosurgery*. 2007 Jan;60(1):67–80; discussion 80–2.
  55. Signorelli F, Guyotat J, Isnard J, Schneider F, Mohammedi R, Bret P. The value of cortical stimulation applied to the surgery of malignant gliomas in language areas. *Neurol Sci Off J Ital Neurol Soc Ital Soc Clin Neurophysiol*. 2001 Feb;22(1):3–10.
  56. De Benedictis A, Moritz-Gasser S, Duffau H. Awake mapping optimizes the extent of resection for low-grade gliomas in eloquent areas. *Neurosurgery*. 2010 Jun;66(6):1074–84; discussion 1084.
  57. Duffau H. Preserving quality of life is not incompatible with increasing overall survival in diffuse low-grade glioma patients. *Acta Neurochir (Wien)*. 2015 Feb;157(2):165–7.
  58. Duffau H. Long-term outcomes after supratotal resection of diffuse low-grade gliomas: a consecutive series with 11-year follow-up. *Acta Neurochir (Wien)*. 2016 Jan;158(1):51–8.
  59. Chang EF, Clark A, Smith JS, Polley M-Y, Chang SM, Barbaro NM, et al. Functional mapping-guided resection of low-grade gliomas in eloquent areas of the brain: improvement of long-term survival. Clinical article. *J Neurosurg*. 2011 Mar;114(3):566–73.
  60. Sacko O, Lauwers-Cances V, Brauge D, Sesay M, Brenner A, Roux F-E. Awake craniotomy vs surgery under general anesthesia for resection of supratentorial lesions. *Neurosurgery*. 2011 May;68(5):1192–8; discussion 1198–9.
  61. Duffau H, Duchatelet C. *L’erreur de Broca*. Michel Lafon; 2016. 281 p.
  62. Duffau H, Gatignol P, Moritz-Gasser S, Mandonnet E. Is the left uncinate fasciculus essential for language? A cerebral stimulation study. *J Neurol*. 2009 Mar;256(3):382–9.
  63. De Witt Hamer PC, Moritz-Gasser S, Gatignol P, Duffau H. Is the human left middle longitudinal fascicle essential for language? A brain electrostimulation study. *Hum Brain Mapp*. 2011 Jun;32(6):962–73.
  64. Benzagmout M, Gatignol P, Duffau H. Resection of World Health Organization Grade II gliomas involving Broca’s area: methodological and functional considerations. *Neurosurgery*. 2007 Oct;61(4):741–52; discussion 752–3.

65. Plaza M, Gatignol P, Leroy M, Duffau H. Speaking without Broca's area after tumor resection. *Neurocase*. 2009 Aug;15(4):294–310.
66. Tate MC, Herbet G, Moritz-Gasser S, Tate JE, Duffau H. Probabilistic map of critical functional regions of the human cerebral cortex: Broca's area revisited. *Brain J Neurol*. 2014 Oct;137(Pt 10):2773–82.
67. Rolston JD, Englot DJ, Benet A, Li J, Cha S, Berger MS. Frontal operculum gliomas: language outcome following resection. *J Neurosurg*. 2015 Apr;122(4):725–34.
68. Sarubbo S, Le Bars E, Moritz-Gasser S, Duffau H. Complete recovery after surgical resection of left Wernicke's area in awake patient: a brain stimulation and functional MRI study. *Neurosurg Rev*. 2012 Apr;35(2):287–92; discussion 292.
69. Ojemann SG, Berger MS, Lettich E, Ojemann GA. Localization of language function in children: results of electrical stimulation mapping. *J Neurosurg*. 2003 Mar;98(3):465–70.
70. Ojemann G, Ojemann J, Lettich E, Berger M. Cortical language localization in left, dominant hemisphere. An electrical stimulation mapping investigation in 117 patients. 1989. *J Neurosurg*. 2008 Feb;108(2):411–21.
71. Kaplan E, Goodglass H, Weintraub S. Boston Naming Test. Lea & Febiger; 1983. 120 p.
72. Goodglass H, Kaplan E. The Assessment of Aphasia and Related Disorders. Lea & Febiger; 1972. 120 p.
73. Deloche G, Hannequin D. Test de dénomination orale d'images: DO 80. Éd. du Centre de psychologie appliquée; 1997. 25 p.
74. Duchowny M, Jayakar P, Harvey AS, Resnick T, Alvarez L, Dean P, et al. Language cortex representation: effects of developmental versus acquired pathology. *Ann Neurol*. 1996 Jul;40(1):31–8.
75. Balogun JA, Khan OH, Taylor M, Dirks P, Der T, Carter Snead Iii O, et al. Pediatric awake craniotomy and intra-operative stimulation mapping. *J Clin Neurosci*. 2014 Nov;21(11):1891–4.
76. Soriano SG, Eldredge EA, Wang FK, Kull L, Madsen JR, Black PM, et al. The effect of propofol on intraoperative electrocorticography and cortical stimulation during awake craniotomies in children. *Paediatr Anaesth*. 2000;10(1):29–34.
77. Klimek M, Verbrugge SJC, Roubos S, van der Most E, Vincent AJ, Klein J. Awake craniotomy for glioblastoma in a 9-year-old child. *Anaesthesia*. 2004 Jun;59(6):607–9.
78. Tobias JD, Jimenez DF. Anaesthetic management during awake craniotomy in a 12-year-old boy. *Paediatr Anaesth*. 1997;7(4):341–4.

79. Everett LL, van Rooyen IF, Warner MH, Shurtleff HA, Saneto RP, Ojemann JG. Use of dexmedetomidine in awake craniotomy in adolescents: report of two cases. *Paediatr Anaesth*. 2006 Mar;16(3):338–42.
80. Chauvat S, Gaborieau M, Delion M, Aubin G. *Etat des lieux de la chirurgie éveillée pédiatrique: approche orthophonique*. Paris, France: Université Pierre et Marie Curie. UFR de médecine Pierre et Marie Curie; 2016.
81. Desandes E, Guissou S, Chastagner P, Lacour B. Incidence and survival of children with central nervous system primitive tumors in the French National Registry of Childhood Solid Tumors. *Neuro-Oncol*. 2014 Jul;16(7):975–83.
82. Ilmberger J, Ruge M, Kreth F-W, Briegel J, Reulen H-J, Tonn J-C. Intraoperative mapping of language functions: a longitudinal neurolinguistic analysis. *J Neurosurg*. 2008 Oct;109(4):583–92.
83. Duchowny M. Language localization, the developing brain and childhood epilepsy: back to the future. *J Int Neuropsychol Soc JINS*. 2007 May;13(3):501–4.
84. Grill J, Viguier D, Kieffer V, Bulteau C, Sainte-Rose C, Hartmann O, et al. Critical risk factors for intellectual impairment in children with posterior fossa tumors: the role of cerebellar damage. *J Neurosurg*. 2004 Nov;101(2 Suppl):152–8.
85. Konczak J, Schoch B, Dimitrova A, Gizewski E, Timmann D. Functional recovery of children and adolescents after cerebellar tumour resection. *Brain J Neurol*. 2005 Jun;128(Pt 6):1428–41.
86. Nazemi KJ, Butler RW. Neuropsychological rehabilitation for survivors of childhood and adolescent brain tumors: a view of the past and a vision for a promising future. *J Pediatr Rehabil Med*. 2011;4(1):37–46.
87. Vago C, Bulgheroni S, Usilla A, Biassoni V, Serra A, Gentile S, et al. Adaptive functioning in children in the first six months after surgery for brain tumours. *Disabil Rehabil*. 2011;33(11):953–60.
88. Rausch R, Walsh GO. Right-hemisphere language dominance in right-handed epileptic patients. *Arch Neurol*. 1984 Oct;41(10):1077–80.
89. Vargha-Khadem F, O’Gorman AM, Watters GV. Aphasia and handedness in relation to hemispheric side, age at injury and severity of cerebral lesion during childhood. *Brain J Neurol*. 1985 Sep;108 ( Pt 3):677–96.
90. Woods RP, Dodrill CB, Ojemann GA. Brain injury, handedness, and speech lateralization in a series of amobarbital studies. *Ann Neurol*. 1988 May;23(5):510–8.
91. Vargha-Khadem F, Carr LJ, Isaacs E, Brett E, Adams C, Mishkin M. Onset of speech after left hemispherectomy in a nine-year-old boy. *Brain J Neurol*. 1997 Jan;120 ( Pt 1):159–82.

92. Boatman D, Freeman J, Vining E, Pulsifer M, Miglioretti D, Minahan R, et al. Language recovery after left hemispherectomy in children with late-onset seizures. *Ann Neurol*. 1999 Oct;46(4):579–86.
93. Devlin AM, Cross JH, Harkness W, Chong WK, Harding B, Vargha-Khadem F, et al. Clinical outcomes of hemispherectomy for epilepsy in childhood and adolescence. *Brain J Neurol*. 2003 Mar;126(Pt 3):556–66.
94. Jayakar P, Alvarez LA, Duchowny MS, Resnick TJ. A safe and effective paradigm to functionally map the cortex in childhood. *J Clin Neurophysiol Off Publ Am Electroencephalogr Soc*. 1992 Apr;9(2):288–93.
95. Berger MS, Kincaid J, Ojemann GA, Lettich E. Brain mapping techniques to maximize resection, safety, and seizure control in children with brain tumors. *Neurosurgery*. 1989 Nov;25(5):786–92.
96. Bollo RJ, Carlson C, Schevon C, Wisoff JH, Devinsky O, Weiner HL. Extraoperative functional mapping and staged resection of supratentorial tumors near eloquent cortex in children. *Pediatr Neurosurg*. 2009;45(3):175–80.
97. Matsuda R, Coello AF, De Benedictis A, Martinoni M, Duffau H. Awake mapping for resection of cavernous angioma and surrounding gliosis in the left dominant hemisphere: surgical technique and functional results: clinical article. *J Neurosurg*. 2012 Dec;117(6):1076–81.
98. Gamble AJ, Schaffer SG, Nardi DJ, Chalif DJ, Katz J, Dehdashti AR. Awake Craniotomy in Arteriovenous Malformation Surgery: The Usefulness of Cortical and Subcortical Mapping of Language Function in Selected Patients. *World Neurosurg*. 2015 Nov;84(5):1394–401.
99. Montgomery GH, Weltz CR, Seltz M, Bovbjerg DH. Brief presurgery hypnosis reduces distress and pain in excisional breast biopsy patients. *Int J Clin Exp Hypn*. 2002 Jan;50(1):17–32.
100. Montgomery GH, DuHamel KN, Redd WH. A meta-analysis of hypnotically induced analgesia: how effective is hypnosis? *Int J Clin Exp Hypn*. 2000 Apr;48(2):138–53.
101. Milling LS. Is high hypnotic suggestibility necessary for successful hypnotic pain intervention? *Curr Pain Headache Rep*. 2008 Apr;12(2):98–102.
102. Montgomery GH, David D, Winkel G, Silverstein JH, Bovbjerg DH. The effectiveness of adjunctive hypnosis with surgical patients: a meta-analysis. *Anesth Analg*. 2002 Jun;94(6):1639–45, table of contents.
103. Gregoretta C, Decaroli D, Piacevoli Q, Mistretta A, Barzaghi N, Luxardo N, et al. Analgo-sedation of patients with burns outside the operating room. *Drugs*. 2008;68(17):2427–43.
104. Van Twillert B, Bremer M, Faber AW. Computer-generated virtual reality to control pain and anxiety in pediatric and adult burn patients during wound dressing changes. *J Burn Care Res Off Publ Am Burn Assoc*. 2007 Oct;28(5):694–702.

105. Brown NJ, Rodger S, Ware RS, Kimble RM, Cuttle L. Efficacy of a children's procedural preparation and distraction device on healing in acute burn wound care procedures: study protocol for a randomized controlled trial. *Trials*. 2012;13:238.
106. Askay SW, Patterson DR, Sharar SR. VIRTUAL REALITY HYPNOSIS. *Contemp Hypn J Br Soc Exp Clin Hypn*. 2009 Mar;26(1):40-7.
107. Knecht S, Dräger B, Deppe M, Bobe L, Lohmann H, Flöel A, et al. Handedness and hemispheric language dominance in healthy humans. *Brain J Neurol*. 2000 Dec;123 Pt 12:2512-8.
108. Oldfield RC. The assessment and analysis of handedness: the Edinburgh inventory. *Neuropsychologia*. 1971 Mar;9(1):97-113.



# Thèse de Doctorat

Matthieu DELION

La chirurgie éveillée chez l'enfant

Awake craniotomy in children

## Résumé

Chez l'enfant, la chirurgie éveillée avec cartographie corticale et sous corticale per opératoire (CECCSC) est peu réalisée et très peu décrite dans littérature. Il s'agit cependant de la technique de référence pour optimiser la résection chirurgicale d'une tumeur sustentorielle située en zone « éloquente ». Le pronostic vital et fonctionnel de ces enfants est en effet intimement lié à la qualité de l'exérèse chirurgicale. Le fil rouge de ma thèse a donc été de transférer la CECCSC de l'adulte à l'enfant.

Le premier travail de cette thèse a été d'étudier, à travers notre expérience clinique, la faisabilité de cette procédure chez les enfants. Nous avons montré que la CECCSC était réalisable dans cette population avec un bon résultat fonctionnel et radiologique. Certaines spécificités doivent cependant être prises en compte notamment en ce qui concerne le conditionnement de l'enfant.

Le deuxième travail a été d'évaluer en collaboration avec les pédopsychiatres, l'impact psychologique, de ce type d'intervention chez l'enfant. Nous avons constaté que le vécu avait été bon pour tous les patients. Nous n'avons pas retrouvé d'état de stress post-traumatique après la chirurgie.

Le troisième objectif a été d'évaluer l'IRM fonctionnelle (IRMf) de repos chez l'enfant en préopératoire. Nous avons pu montrer non seulement sa corrélation avec l'électrostimulation per opératoire mais aussi sa supériorité par rapport à l'IRMf d'activation en termes de sensibilité et de spécificité quant à la localisation des aires du langage. En effet l'IRMf de repos nous a permis d'isoler les réseaux attentionnels des réseaux du langage qui interfèrent avec les résultats de l'IRMf d'activation.

## Mots clés

Chirurgie éveillée, tumeur sustentorielle, cartographie corticale et sous corticale, enfants, impact psychologique, hypnose, IRM fonctionnelle de repos, réseau attentionnel.

## Abstract

Intraoperative cortical and subcortical direct stimulation surgery while awake (CSCSSA) is rarely used to operate in functional areas of the brain in children. Only small series have been published regarding children. However, this procedure is considered to be a gold standard for identifying and preserving the eloquent cortical and subcortical sites. Indeed the child's survival and the quality of life depend on the quality of the tumor resection. The unifying idea of my thesis was the transfer of the CSCSSA from adults to children.

The first work of this thesis was to study the feasibility of the CSCSSA in children through our clinical experience. We also showed that CSCSSA could be applied in children in a safe way with good clinical and radiological results. Some precautions should also be observed, notably concerning the preparation of these young patients.

The second step of this thesis was to evaluate the psychological impact of this kind of procedure in children, thanks to the cooperation of the child psychiatrists. The child's experience was good in every case. None of our patients presented symptoms of post-traumatic stress disorder after the surgery.

The third objective was to evaluate the use of resting state functional MRI (rsfMRI) in children for the preoperative planning. We demonstrated not only the strong correlation between rsfMRI and brain electrical mapping, but also the superiority in terms of sensibility and specificity of rsfMRI compared to task based functional MRI. Indeed rsfMRI allowed us to isolate the attentional networks, which interfere with the results of task based functional MRI.

## Key Words

Awake craniotomy, supratentorial tumor, cortical and subcortical mapping, children, psychological impact, hypnosis, resting state functional MRI, attentional network.