



**HAL**  
open science

# Development of novel therapeutic strategies for periodontal regeneration by modulation of inflammatory response

Fareeha Batool

► **To cite this version:**

Fareeha Batool. Development of novel therapeutic strategies for periodontal regeneration by modulation of inflammatory response. Bioengineering. Université de Strasbourg, 2019. English. NNT : 2019STRAJ068 . tel-02885068

**HAL Id: tel-02885068**

**<https://theses.hal.science/tel-02885068>**

Submitted on 30 Jun 2020

**HAL** is a multi-disciplinary open access archive for the deposit and dissemination of scientific research documents, whether they are published or not. The documents may come from teaching and research institutions in France or abroad, or from public or private research centers.

L'archive ouverte pluridisciplinaire **HAL**, est destinée au dépôt et à la diffusion de documents scientifiques de niveau recherche, publiés ou non, émanant des établissements d'enseignement et de recherche français ou étrangers, des laboratoires publics ou privés.

*École Doctorale des Sciences de la Vie et de la Santé*

Unité de recherche INSERM UMR 1260 « Nanomédecine Régénérative »

# THÈSE

Présentée et soutenue publiquement le **16 septembre 2019** par

**Fareeha BATOOL**

Pour obtenir le grade de **Docteur de l'Université de Strasbourg**

Discipline / Spécialité : **Sciences du Vivant / Nanomédecine Régénérative et Ingénierie  
Tissulaire Ostéoarticulaire**

**Développement de stratégies innovantes de régénération  
parodontale via la modulation de la réponse inflammatoire**

*Directeur de Thèse*

**Pr Olivier HUCK**

*Rapporteurs Externes*

**Pr Marjolaine GOSSET  
Pr Kerstin GRITSCH**

*Rapporteur Interne*

**Dr Nicolas ANTON**

*Membres invités*

**Pr Henri TENENBAUM  
Dr Nadia BENKIRANE-JESSEL**



*Dedicated to my father (Abbu)*

*I wish you were here with me but wherever you are, I hope this makes you smile!*

## Acknowledgements

*I would like to express my sincere gratitude to my thesis committee. I would like to thank Pr. Marjolaine Gosset, Pr. Kerstin Gritsch and Dr. Nicolas Anton for their kind approval to be a part of my jury, sparing time out to review my work and accepting my thesis. I am truly honored to have a jury with such established names in the field.*

*I would like to extend my heartfelt thanks to Dr. Nadia Benkirane-Jessel for welcoming me warmly into the wonderful family of INSERM UMR1260. Your insight into my research work and your appreciation towards Pakistani food and culture is highly admirable.*

*I thank Pr. Henri Tenenbaum from the core of my heart for accepting my request to work with his team and gracing my PhD defense with his presence. His positive aura and a highly encouraging demeanor have inspired me throughout my PhD journey. I would thank Pr. Jean-Luc Davideau for familiarizing me with in vivo techniques in my master internship that helped me a great deal during my PhD research.*

*Above all, I would thank my supervisor, my mentor and my inspiration, Pr. Olivier Huck, whose charismatic personality and scientific acumen inculcated in me the spirit of research and hard work. I cannot thank you enough for being patient towards my blunders and always encouraging me to achieve more. I would never have completed this journey without your tremendous support.*

*I would take this opportunity to thank the Higher Education Commission (HEC) of Pakistan for granting me the scholarship to pursue my masters and doctoral studies in France.*

*I whole-heartedly thank all my colleagues and team members specially David, Quentin, Max, Marion, Lindah, Arielle, Sabine and Hervé. Despite the initial language barrier, you have been a fantastic family. I would also thank my Pakistani friends in France for being a great company away from home.*

*I thank my friend and collaborator from Lille, Kevimy, for being my partner during in vivo experiments. I would specially thank my friend-cum-sister Catherine without whom working late in the lab would have never been so much fun.*

*Thank you, Ammi, for your prayers and unwavering support. Thank you Ali bhai for keeping Abbu's legacy alive and bestowing me with your trust and support. Thank you Wajeaha, Alia bhabi and Sakina for the bundles of joy you sent my way.*

*Thank you to the two PhDs in my family; Madeeha baji and Monis bhai whose tough struggle and eventual success was a constant reassurance that I could do it.*

*Thanks a million Hassan for your unflinching support through thick and thin that has been invaluable throughout this journey.*

## Summary

Control of periodontal infection and inflammation is crucial for optimal periodontal wound healing and regeneration. For this purpose, three different and novel strategies were developed and tested for their impact on periodontal wound healing parameters *in vitro* and *in vivo*. Firstly, an ibuprofen-functionalized polycaprolactone (IBU-PCL) membrane was developed as an anti-inflammatory barrier membrane that successfully reduced inflammatory markers expression in gingival cells *in vitro* and decreased soft tissue inflammation, thus, improving periodontal tissue healing in an experimental periodontitis model *in vivo*. Secondly, chlorhexidine and ibuprofen containing *in-situ* forming implant (CHX-IBU ISFI) was developed to target both infection and inflammation that successfully reduced *Porphyromonas gingivalis* growth and inflammatory response of gingival cells *in vitro* as well as improved soft tissue periodontal wound healing *in vivo*. Lastly, a thermosensitive chitosan-based hydrogel functionalized with atorvastatin encapsulated in a nano-emulsion (ATV-KELP NE) was characterized and used to treat an induced bone defect *in vivo* that resulted in improved soft and hard tissue healing by counteracting infection and modulation of immuno-inflammatory response.

**Keywords:** Periodontal regeneration, *Porphyromonas gingivalis*, controlled-release scaffolds, inflammation

## Résumé

Le contrôle de l'infection et de l'inflammation est crucial dans les traitements parodontaux de régénération tissulaire. Dans cet objectif, trois stratégies novatrices ont été développées et évaluées *in vitro* et *in vivo* en se focalisant sur les paramètres associés à la cicatrisation. Dans un premier temps, une membrane de polycaprolactone (IBU-PCL) fonctionnalisée avec de l'ibuprofène a été développée. Ce nouveau biomatériau aux propriétés anti-inflammatoires et utilisé comme barrière permettant l'exclusion tissulaire a permis de réduire significativement l'expression des marqueurs de l'inflammation au niveau des cellules épithéliales gingivales *in vitro* et l'inflammation des tissus mous *in vivo*. Dans un second temps, un implant se formant *in situ* (ISFI) fonctionnalisé par ibuprofène et chlorhexidine a été développé pour cibler l'infection et l'inflammation. Ce biomatériau a permis de réduire la croissance bactérienne de *Porphyromonas gingivalis* et d'optimiser la cicatrisation des tissus parodontaux par réduction de l'inflammation. Enfin, un hydrogel thermosensible fonctionnalisé par atorvastatine encapsulée dans des nano-émulsions a été synthétisé (ATV-KELP NE) et a induit une amélioration de la néoformation osseuse dans un modèle de calvaria.

**Mot clés :** Régénération parodontale, *Porphyromonas gingivalis*, système à libération contrôlée, inflammation

# Table of Contents

Acknowledgements .....	1
Summary.....	3
Résumé .....	3
List of Abbreviations .....	5
List of Figures and Tables.....	7
<b>I. INTRODUCTION .....</b>	<b>8</b>
<b>1.1. Periodontal diseases .....</b>	<b>10</b>
1.1.1. Classification of periodontal diseases .....	12
1.1.2. Prevalence.....	13
1.1.3. Periodontal diseases and systemic health .....	14
1.1.4. Etiopathogenesis .....	15
1.1.4.1. Role of bacteria.....	17
1.1.4.2. Role of inflammatory-immune cross-talk .....	18
1.1.4.2.1. Pro-inflammatory mediators .....	21
1.1.4.2.2. Anti-inflammatory mediators .....	22
1.1.4.2.3. Pro-resolution mediators.....	22
1.1.5. Management of periodontal diseases: current concepts .....	23
1.1.5.1. Non-surgical therapy.....	23
1.1.5.2. Surgical therapy .....	26
1.1.6. Periodontal wound healing .....	26
1.1.6.1. Phases of periodontal wound healing .....	27
1.1.6.1.1. Hemostasis .....	27
1.1.6.1.2. Inflammatory phase.....	27
1.1.6.1.3. Proliferation.....	27
1.1.6.1.4. Remodeling .....	28
1.1.6.2. Repair versus regeneration.....	29
1.1.6.3. Guided tissue regeneration (GTR).....	30
1.1.7. Adjunctive periodontal therapy .....	32
1.1.7.1. Modulation of inflammation .....	32
1.1.7.2. Anti-inflammatory drugs.....	33
1.1.7.3. Antibiotics and antimicrobials .....	34
1.1.7.4. Pleiotropic drugs: the case of statins .....	34
1.1.8. Novel spatial and time-controlled drug delivery scaffolds.....	35
1.1.8.1. In-situ forming implants (ISFI) .....	36
<b>II. AIMS AND HYPOTHESES.....</b>	<b>38</b>
<b>III. RESULTS .....</b>	<b>41</b>
<b>CHAPTER 1 .....</b>	<b>42</b>
<b>Development of a novel strategy to modulate periodontal inflammation and to promote periodontal wound healing based on synthesis of a novel electrospun functionalized scaffold</b>	
<b>CHAPTER 2 .....</b>	<b>63</b>
<b>Development of a novel biomaterial targeting both infection and inflammation to improve periodontal treatment</b>	
<b>CHAPTER 3 .....</b>	<b>93</b>
<b>Development of a thermosensitive statin–functionalized chitosan-based hydrogel and evaluation of bone healing</b>	
<b>IV. DISCUSSION .....</b>	<b>143</b>
<b>V. CONCLUSION .....</b>	<b>150</b>
<b>REFERENCES .....</b>	<b>152</b>
<b>APPENDIX .....</b>	<b>168</b>
<b>List of Publications .....</b>	<b>169</b>
<b>List of Communications .....</b>	<b>170</b>
<b>Periodontal Tissues, Maxillary Jaw Bone, and Tooth Regeneration Approaches: From Animal Models Analyses to Clinical Applications .....</b>	<b>172</b>

## List of Abbreviations

- Aa:** *Aggregatibacter actinomycetemcomitans*
- AA:** Arachadonic acid
- ALP:** Alkaline phosphatase
- ATBC:** Acetyltributyl citrate
- ATV:** Atorvastatin
- bFGF:** Basic fibroblast growth factor
- BI:** Bleeding index
- BOP:** Bleeding on probing
- CAL:** Clinical attachment level
- ChiG:** Chitosan gel
- CHX:** Chlorhexidine
- COX:** Cyclo-oxygenase
- EC:** Epithelial cells
- ECM:** Extracellular matrix
- EDTA:** Ethylene diamine tetra acetic acid
- EGF:** Epidermal growth factor
- EMD:** Enamel matrix derivatives
- FB:** Fibroblasts
- GCF:** Gingival crevicular fluid
- GTR:** Guided tissue regeneration
- HMG-CoA:** Reductase Inhibitors of 3-hydroxy- 3-methylglutaryl coenzyme A reductase
- HPMC:** Hydroxy propyl methylcellulose
- IBU:** Ibuprofen
- IFN- $\gamma$ :** Interferon gamma
- IL-1 $\beta$ :** Interleukin-1 beta
- ISFI:** *In situ* forming implants
- ITR:** Induced tissue regeneration
- KELP:** Kolliphor ELP
- MMPs:** Matrix metalloproteinases
- NE:** Nano-emulsion
- NMP:** N-methyl-pyrrolidone
- NSAIDs:** Non-steroidal anti-inflammatory drugs

**OCN:** Osteocalcin  
**OFD:** Open flap debridement  
**OPN:** Osteopontin  
**PBS:** Phosphate-buffered saline  
**PCL:** Polycaprolactone  
**PDGF:** Platelet-derived growth factor  
**PDL:** Periodontal ligament  
**PFA:** Paraformaldehyde  
*Pg: Porphyromonas gingivalis*  
*Pg-LPS: Porphyromonas gingivalis* lipopolysaccharide  
**PGE2:** Prostaglandin E2  
**PI:** Plaque index  
**PLGA:** Poly(lactic-co-glycolic) acid  
**PMNs:** Polymorphonuclear neutrophils  
**PPD:** Periodontal pocket depth  
**PRF:** Platelet-rich plasma/ fibrin  
**PSD:** Polymicrobial synergy and dysbiosis  
**RANKL:** Receptor activator of nuclear factor kappa-B ligand  
**ROS:** Reactive oxygen species  
**RvD1-6:** D-series resolvins  
**RvE1-3:** E-series resolvins  
**SEM:** Scanning electron microscopy  
**SPMs:** Specialized pro-resolving mediators  
**SRP:** Scaling and root planing  
**TEM:** Transmission electron microscopy  
**TGF- $\beta$ 1:** Transforming growth factor beta 1  
**TH:** T-helper lymphocytes  
**TNF- $\alpha$ :** Tumor necrosis factor-alpha  
**Treg:** Regulatory T lymphocytes  
**VEGF:** Vascular endothelial growth factor

## List of Figures and Tables

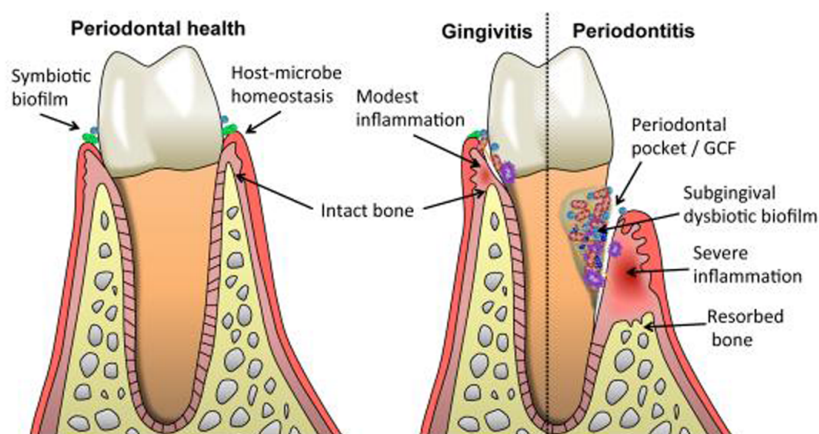
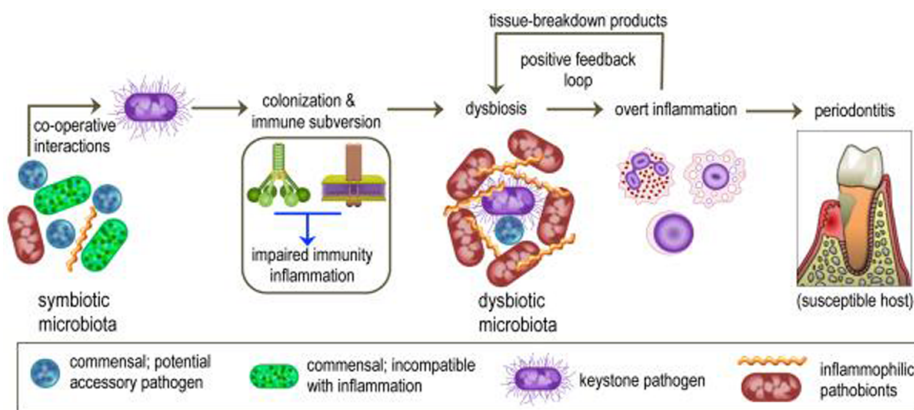
<i>Figure 1: Periodontal health and development of periodontal diseases (gingivitis and periodontitis).....</i>	10
<i>Figure 2: The main stages of periodontal diseases .....</i>	11
<i>Figure 3: Healthy and diseased periodontium.....</i>	12
<i>Figure 4: A model explaining the pathogenesis of periodontitis. ....</i>	16
<i>Figure 5: The polymicrobial synergy and dysbiosis (PSD) model of periodontal disease etiology.....</i>	18
<i>Figure 6: Immuno-inflammatory cross-talk leading to periodontal tissue destruction. ....</i>	20
<i>Figure 7: Inflammation-mediated periodontal tissue damage. ....</i>	22
<i>Figure 8: Transition from initiation to resolution of periodontal inflammation .....</i>	23
<i>Figure 9: Decision algorithm for the therapeutic management of chronic periodontitis....</i>	25
<i>Figure 10: Phases of periodontal wound healing.....</i>	29
<i>Figure 11: Patterns of periodontal wound healing. ....</i>	30
<i>Figure 12: Guided tissue regeneration (GTR). ....</i>	31
<i>Figure 13: The “tug of war” between periodontal inflammation and resolution. ....</i>	33
<i>Figure 14: Mechanism of action of ISFI.....</i>	37
<i>Table 1: Classification of periodontal diseases and conditions 2017 .....</i>	12
<i>Table 2: Classification of periodontitis based on stages defined by severity (according to the level of interdental clinical attachment loss, radiographic bone loss and tooth loss), complexity, extent and distribution. ....</i>	13
<i>Table 3: “Towards a Common Language for Functioning, Disability and Health: The International Classification of Functioning, Disability and Health World Health Organization” .....</i>	15



# I. INTRODUCTION

## 1. Introduction

*Periodontium* refers to the entire complex of the tooth supporting tissues comprising gingiva (epithelium and connective tissue), cementum, alveolar bone, and periodontal ligament (PDL) (Barczyk et al., 2013; Cho and Garant, 2000; Kinane et al., 2017). The *periodontium* mainly attaches the teeth to the jaw bone, maintains teeth vitality and provides a barrier to the tooth supporting structures against the continuous insult by the oral microflora (Katancik et al., 2016; Mariotti, 2007). The gingiva (soft tissue) represents the superficial *periodontium* and acts as the first line of defense against any foreign aggression. Profound *periodontium* is composed mainly by hard tissues including cementum and alveolar bone. Cementum is a thin, avascular, mineralized tissue that covers the root surface and allows attachment of PDL to the root surface, whereas, PDL is composed of collagen fibers, blood vessels and nerves and supports tooth attachment to the jaw bone, especially through alveolar bone (Goudouri et al., 2017). The different components of *periodontium* vary in their cellular composition, types, protein content, degree of mineralization, rate of metabolic activity and disease susceptibility (Mariotti, 2007). Periodontal health is defined by absence of clinically detectable inflammation in these periodontal tissues, and a homeostasis between the oral microbiota and the immune response of the host (Chapple et al., 2018) (Figure 1).

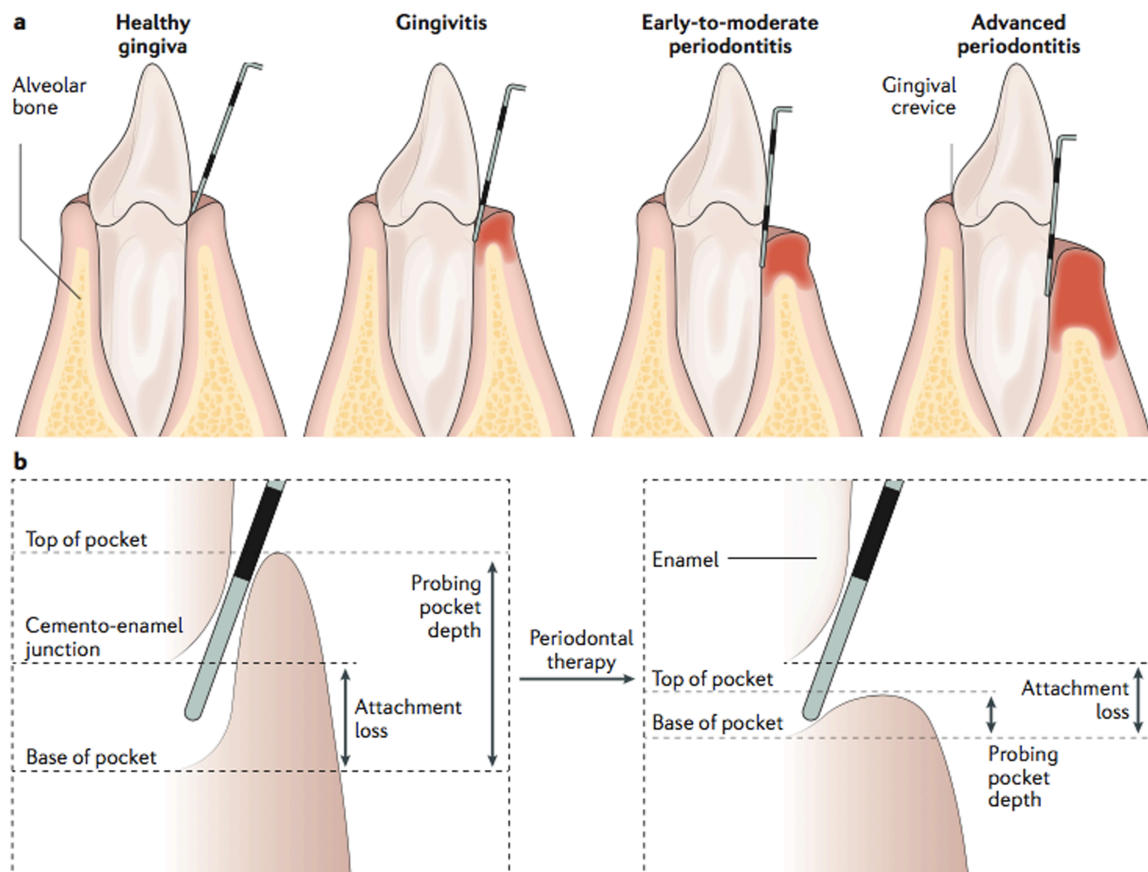


**Figure 1: Periodontal health and development of periodontal diseases (gingivitis and periodontitis).** The upper panel depicts the colonization of the keystone periodontal pathogen, *Porphyromonas gingivalis* (*Pg*), that shifts the balance of the symbiotic microflora to dysbiotic microbiota that triggers host inflammatory-immune response. Dysbiosis and inflammation reinforce each other and lead to periodontal tissue breakdown. The lower panel compares periodontal health (with no sign of inflammation) to periodontal diseases. In gingivitis, the inflammation is restricted to the gingival compartment, however, in periodontitis, the inflammation damages the underlying bone and PDL as well (Hajishengallis, 2015).

## 1.1. Periodontal diseases

Periodontal diseases entail a broad range of inflammatory pathologies affecting tooth-supporting tissues in response to bacterial challenge, notably the keystone periodontal pathogen, *Porphyromonas gingivalis* (*Pg*) (Kinane et al., 2017). Periodontal diseases are mainly induced by bacterial plaque accumulation that can initially manifest itself as superficial gingival inflammation, referred to as gingivitis (Kinane et al., 2017). Gingivitis symptoms include redness, swelling and bleeding of gums. It is the most common form of gingival inflammation and is reversible upon the disruption or removal of the dental bacterial biofilm formed over the teeth and gingiva (Chapple et al., 2018; Jin et al., 2016). Clinically, the presence of chronic inflammation in the periodontal tissues is exhibited by bleeding on probing (BOP)

(Papapanou and Susin, 2017). If left untreated, gingivitis progresses to periodontitis which is characterized by chronic inflammation of infectious origin that leads to progressive destruction of the profound *periodontium* (gingiva, alveolar bone, cementum and PDL) resulting in gingival bleeding, increased periodontal pocket depth (PPD), reduction in clinical attachment (CAL), abscess formation, tooth mobility, and eventual tooth loss (Ivanovski, 2009; Jin et al., 2016; Tonetti et al., 2017a). Its symptoms vary with the severity or extent of periodontal destruction (Sanz et al., 2010). This destruction of the tooth attachment apparatus (both soft and hard tissues) is usually irreversible (Chapple et al., 2018) and periodontitis is considered the main cause of tooth loss (Tonetti et al., 2017b). Deep periodontal pockets are the hallmark of periodontitis (Kinane et al., 2017) while CAL mostly characterizes history of the destruction and is a major determinant of the prognosis of tooth loss (Nunn et al., 2012; Park et al., 2017) (Figure 2).



**Figure 2: The main stages of periodontal diseases: a) Schematics of healthy gingiva, gingivitis, early-to-moderate periodontitis and advanced periodontitis, b) Measurement of periodontal pocket depth (PPD). Probing is performed by gently passing a narrow-diameter graduated periodontal probe. The probing depth can diminish after successful treatment as a result of reduced inflammation and gingival swelling, and tightening of the gingival attachment to the tooth (Kinane et al., 2017).**

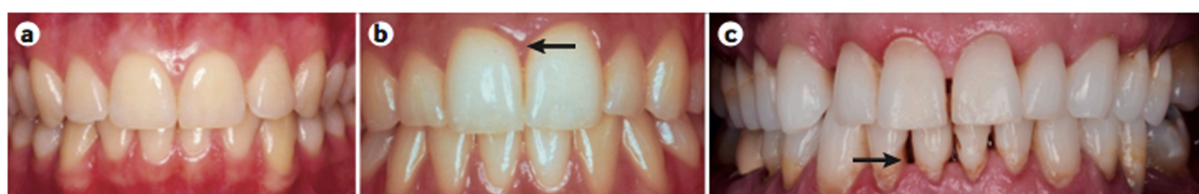### 1.1.1. Classification of periodontal diseases

Periodontal diseases are classified into different categories to ensure uniformity and ease in diagnosis and treatment. Recently, a new classification of periodontal diseases has been adopted (Table 1).

CLASSIFICATION OF PERIODONTAL AND PERI-IMPLANT DISEASES AND CONDITIONS 2017										
Periodontal Diseases and Conditions										
Periodontal Health, Gingival Diseases and Conditions Chapple, Mealey, et al. 2018 Consensus Rept <a href="#">link</a> Trombelli et al. 2018 Case Definitions <a href="#">link</a>			Periodontitis Papapanou, Sanz et al. 2018 Consensus Rept <a href="#">link</a> Jepsen, Caton et al. 2018 Consensus Rept <a href="#">link</a> Tonetti, Greenwell, Kornman. 2018 Case Definitions <a href="#">link</a>			Other Conditions Affecting the Periodontium Jepsen, Caton et al. 2018 Consensus Rept <a href="#">link</a> Papapanou, Sanz et al. 2018 Consensus Rept <a href="#">link</a>				
Periodontal Health and Gingival Health	Gingivitis: Dental Biofilm-Induced	Gingival Diseases: Non-Dental Biofilm-Induced	Necrotizing Periodontal Diseases	Periodontitis	Periodontitis as a Manifestation of Systemic Disease	Systemic diseases or conditions affecting the periodontal supporting tissues	Periodontal Abscesses and Endodontic-Periodontal Lesions	Mucogingival Deformities and Conditions	Traumatic Occlusal Forces	Tooth and Prosthesis Related Factors

**Table 1: Classification of periodontal diseases and conditions 2017.** Gingivitis has been subdivided into plaque-induced and non-plaque induced gingivitis. Necrotizing periodontal disease, periodontitis and periodontitis as a manifestation of systemic disease have been grouped under “periodontitis”. Other conditions affecting periodontium are grouped together in a separate category (Caton et al., 2018).

A patient with intact *periodontium* having a BOP score  $\geq 10\%$  of teeth, further classified as localized (BOP score  $\geq 10\%$  and  $\leq 30\%$ ) or generalized (BOP score  $> 30\%$ ) would be regarded as a gingivitis case (Trombelli et al., 2018). Clinically, a patient is a “periodontitis case” if the interdental clinical attachment loss is detectable at  $\geq 2$  non-adjacent teeth, or the buccal (or oral) clinical attachment loss  $\geq 3$  mm with pocketing  $\geq 3$  mm is detectable at  $\geq 2$  teeth (Papapanou et al., 2018) (Figure 3).



**Figure 3: Healthy and diseased periodontium.** a) Healthy periodontal tissues, b) Early gingival inflammation (arrow) can be seen in the gingiva between the central incisors, c) Clinical appearance of periodontitis, with tissue loss and deep periodontal ‘pockets’ that are a hallmark of disease (arrow) (Kinane et al., 2017).

Persistence of inflammation is the key feature of periodontitis. Periodontitis is regarded as generalized periodontitis if more than >30% of teeth are affected and is termed localized when < 30% teeth are involved (Kinane et al., 2017). Initial and moderate periodontitis are ranked as stage 1 and 2 respectively with mostly horizontal bone loss involved, while, stage 3 and 4 encompass severe periodontitis with vertical bone loss (infrabony defects), complex lesions and functional impairment (Caton et al., 2018) (Table 2).

Periodontitis stage		Stage I	Stage II	Stage III	Stage IV
Severity	Interdental CAL at site of greatest loss	1 to 2 mm	3 to 4 mm	≥5 mm	≥5 mm
	Radiographic bone loss	Coronal third (<15%)	Coronal third (15% to 33%)	Extending to middle or apical third of the root	Extending to middle or apical third of the root
	Tooth loss	No tooth loss due to periodontitis		Tooth loss due to periodontitis of ≤4 teeth	Tooth loss due to periodontitis of ≥5 teeth
Complexity	Local	Maximum probing depth ≤4 mm Mostly horizontal bone loss	Maximum probing depth ≤5 mm Mostly horizontal bone loss	In addition to stage II complexity: Probing depth ≥6 mm Vertical bone loss ≥3 mm Furcation involvement Class II or III Moderate ridge defect	In addition to stage III complexity: Need for complex rehabilitation due to: Masticatory dysfunction Secondary occlusal trauma (tooth mobility degree ≥2) Severe ridge defect Bite collapse, drifting, flaring Less than 20 remaining teeth (10 opposing pairs)
		For each stage, describe extent as localized (<30% of teeth involved), generalized, or molar/incisor pattern			
Extent and distribution	Add to stage as descriptor	For each stage, describe extent as localized (<30% of teeth involved), generalized, or molar/incisor pattern			

**Table 2: Classification of periodontitis based on stages defined by severity (according to the level of interdental clinical attachment loss, radiographic bone loss and tooth loss), complexity, extent and distribution. At stage 1 and 2, only horizontal bone loss occurs, whereas, at the advanced stages 3 and 4, vertical bone loss can lead to tooth loss (Papapanou et al., 2018).**

### 1.1.2. Prevalence

Periodontal diseases, comprising gingivitis and periodontitis, are probably the most common diseases of mankind (Tonetti et al., 2017b). The prevalence of gingivitis varies between 50 and 90% of the world population (Pihlstrom et al., 2005). Despite being less common compared to gingivitis, periodontitis remains a public health concern owing to its impact on quality of life including its socio-economic aspect (Tonetti et al., 2017b).

Severe periodontitis is the sixth most prevalent disease worldwide with an overall prevalence of 11.2% affecting around 743 million people aged between 15-99 years (Frencken



et al., 2017; Jin et al., 2016). The prevalence of periodontitis is reported to be between 20 and 50% of the worldwide population (Albandar and Rams, 2002) with an average of 5% to 20% of any population suffering from severe periodontitis, while mild to moderate periodontitis affecting majority of adults (Dye, 2012; Petersen and Ogawa, 2012). The prevalence of periodontitis increases with age, especially, a drastic rise between the third and fourth decades of life is observed reaching a peak prevalence at 40 years. Epidemiological studies highlighted the variations by geographical regions and countries. In, 2010, the lowest prevalence of severe periodontitis (4.5%) was recorded in Oceania, whereas, the highest (20.4%) in Southern Latin America (Frencken et al., 2017). Moreover, periodontitis affects more males than females (Eke et al., 2012; Kassebaum et al., 2014). Interestingly, the global patterns did not change between the 1990-2010, however, the global burden of periodontal disease was increased by 57.3% from 1990 to 2010 (Kassebaum et al., 2014; Marcenes et al., 2013; Murray et al., 2012). In France, nearly one adult in two exhibit severe periodontal attachment loss ( $\geq 5\text{mm}$ ) (Bourgeois et al., 2007).

### 1.1.3. Periodontal diseases and systemic health

Several systemic conditions such as diabetes mellitus (Lalla and Papapanou, 2011), rheumatoid arthritis (Huck et al., 2018), atherosclerosis (Linden et al., 2013; Tonetti et al., 2013), renal disorders (Deschamps-Lenhardt et al., 2019), sexual hormones imbalance (Akcalı et al., 2018), pre-term birth complications (Huck et al., 2011) and stress (Akcalı et al., 2013) have been reported to have a bidirectional association with periodontal diseases and even the possible mechanisms establishing these systemic conditions as the risk-factors for periodontal diseases have also been explored. For instance, diabetes mellitus contributes to the initiation and progression of periodontal diseases as a high inflammatory mediators content in the gingival crevicular fluid (GCF) and saliva of diabetic patients causes PDL breakdown and eventual tooth loss (Casanova et al., 2014; Chapple et al., 2013; Patel et al., 2013; Preshaw and Bissett, 2013). Likewise, stress reduces salivary flow leading to plaque accumulation (Reners and Brex, 2007) and high cortisol levels in GCF of patients suffering from stress are linked to poor periodontal treatment outcomes (Akcalı et al., 2013; Rai et al., 2011). Moreover, a study conducted on Mexican Americans demonstrated that patients with low kidney function were more likely to have periodontal diseases compared to those with a normal kidney function (Ioannidou et al., 2013).

On the other hand, the locally secreted pro-inflammatory cytokines produced in periodontitis, can enter the systemic circulation and induce systemic inflammation by increasing the level of C-reactive protein, fibrin and amyloid A (Hajishengallis, 2015a). Moreover, the systemic dissemination of periodontal bacteria through gingival ulceration in periodontal pockets or swallowing can also cause or exacerbate systemic inflammation as the dysbiotic microbiota has the ability to invade and modulate the immune response of the host (Alshammari et al., 2017; Bugueno et al., 2018; Elkaïm et al., 2008). *Pg* has been detected in circulating leukocytes and in atherosclerotic lesions, where they may act as pro-atherogenic stimuli (Hajishengallis, 2015a; Huck et al., 2015).

Furthermore, periodontitis has been listed in the World Health Organization International Classification of Functioning, Disability and Health framework highlighting its importance in influencing the quality of life. Periodontitis compromises both facial esthetics and masticatory function, thereby, affecting both personal and professional lives of the patients (Papapanou and Susin, 2017) (Table 3).

Condition	Impairment	Activity limitations	Participation restrictions
Periodontitis	Loss of periodontal tissues (loss of periodontal attachment and alveolar bone; gingival recession)	Difficulties in chewing, eating, speaking and smiling	Personal/professional relationships may be affected

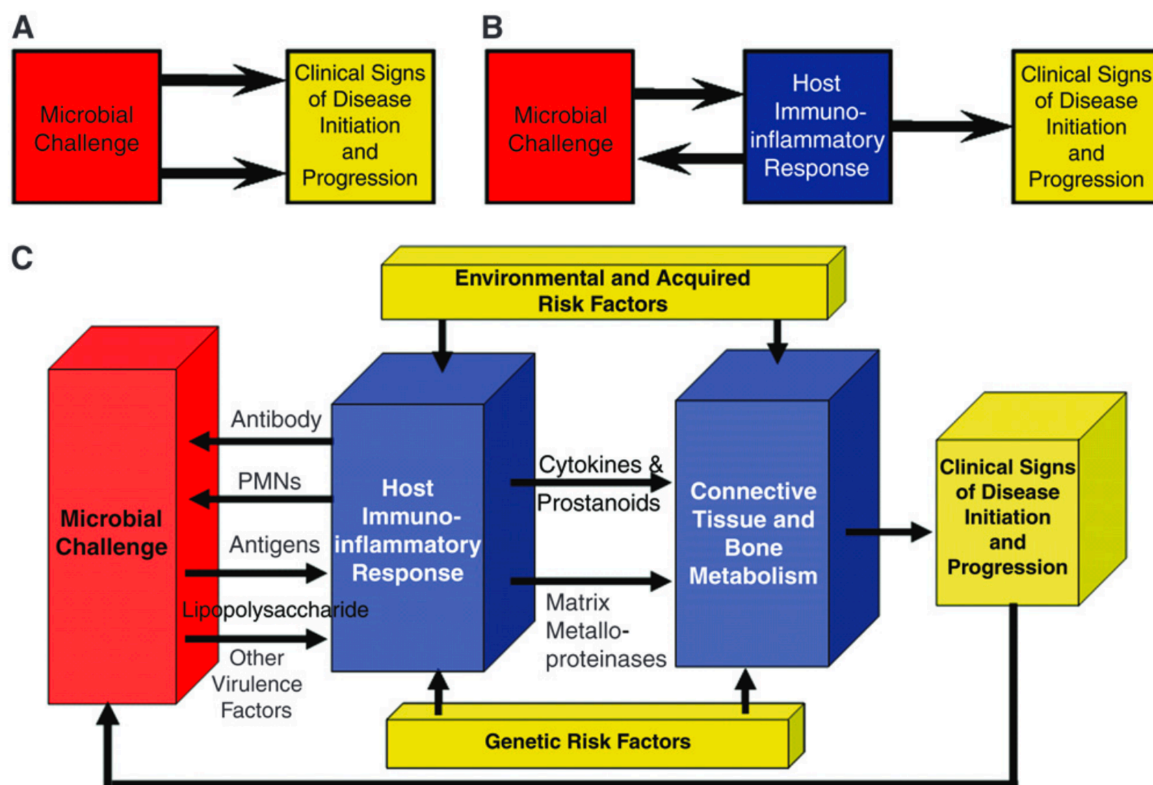
**Table 3: “Towards a Common Language for Functioning, Disability and Health: The International Classification of Functioning, Disability and Health World Health Organization”.** Periodontitis is associated with compromised esthetics, phonetics and masticatory function, thereby, negatively impacting the personal and professional lives of periodontitis patients (Papapanou and Susin, 2017).

#### 1.1.4. Etiopathogenesis

To date, the mechanisms that explain the transition from health to disease are only partially understood. Current concepts are based on complex interactions between a commensal flora and the host's immune response within a particular environment (Bartold and Van Dyke, 2013). Microbial aggression activates host immuno-inflammatory response that leads to tissue destruction (Sanz et al., 2010). Although gingivitis and periodontitis are initiated and sustained by the microbial biofilm or the dental plaque, nevertheless, genetic and environmental host



factors also influence the rate of the disease (Kinane et al., 2017) (Figure 4). Indeed, risk factors are categorized as either modifiable or non-modifiable based on their possibility of amendment. Dental anatomy or morphology promoting plaque retention, smoking, age, stress, systemic diseases, poor nutritional status and socio-economic background are some of the risk factors which may negatively influence the immune-inflammatory response to microbial biofilm burden, resulting in exaggerated or “hyper” inflammation (Akcalı et al., 2013; Chapple et al., 2018; Dye, 2012). Despite the polygenic nature of periodontitis, environmental factors and patient related factors also greatly impact the disease onset and progression. Moreover, the contribution of the genetic factor cannot be undermined (Divaris et al., 2013).



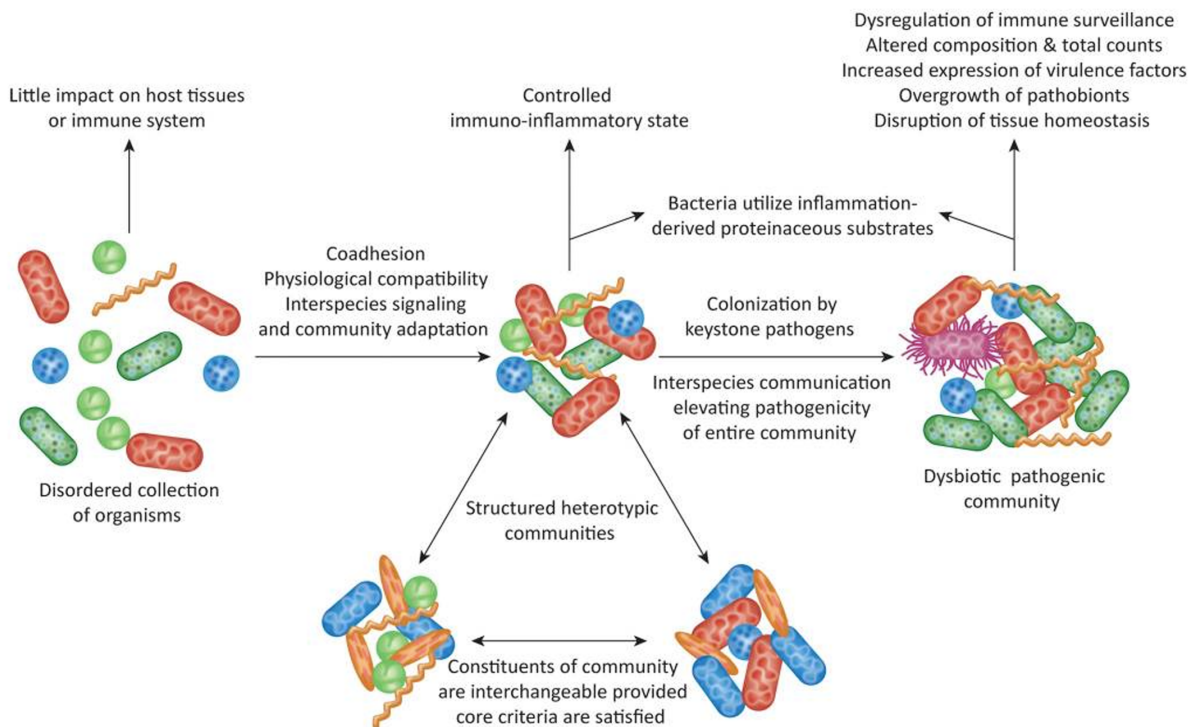
**Figure 4: A model explaining the pathogenesis of periodontitis.** Microbial challenge is the main etiological factor leading to periodontal tissue destruction. The bacterial toxins and other virulence factors trigger a host immuno-inflammatory response producing inflammatory cytokines and matrix metalloproteinases (MMPs) that lead to a dysregulation of the connective tissue and bone metabolism that contribute to the initiation and progression of the disease. This response is influenced by both genetic and environmental risk factors (Kornman, 2008).

#### 1.1.4.1. Role of bacteria

The development and progression of gingivitis and periodontitis is attributed to the microorganisms residing in the thin pellicle-like biofilm, also referred to as dental plaque, over the teeth and periodontal tissues. Interestingly, the oral microbial biofilm can comprise around 150 species in a single person, and more than 500 different species have been identified in human dental plaque so far (Darveau, 2010). Dental plaque is present in both uncalcified (soft) and calcified (calculus) forms. The supragingival plaque is usually uncalcified. However, subgingival plaque could be calcified, dark in color and more difficult to remove (Akcalı and Lang, 2018).

Periodontitis has a multifactorial pathogenesis, but its main etiological factor is associated with dysbiosis of the periodontal flora resulting in increased proportions of anaerobic bacteria such as *Pg*, a gram-negative anaerobe. *Pg* is considered the keystone pathogen in causing periodontal diseases, acting through several virulence factors such as lipopolysaccharide (*Pg*-LPS) and gingipains (Bozkurt et al., 2017; Hajishengallis, 2015a; Kinane et al., 2017). About 30 other bacteria associated with periodontal disease have been grouped into microbial complexes according to their pathogenic ability. Among these bacteria, *Pg*, *Tannerella forsythia* and *Treponema denticola* are specifically distinguished by their virulence factors (proteases, toxins etc.) and their ability to induce experimental periodontitis in animals (Alshammari et al., 2017; Batool et al., 2018 (see Appendix); Holt et al., 1988; Saadi-Thiers et al., 2013). The triad of the "red complex" is also strongly implicated in disease progression in humans (Byrne et al., 2009; Socransky and Haffajee, 2005).

Recent studies have established a better understanding regarding the role of bacteria in the development of periodontal diseases emphasizing the new concept based on polymicrobial synergy and dysbiosis (PSD) model of periodontal disease etiology (Figure 5). A diverse microbiota resides in the gingival pocket and these communities are in *equilibrium* with the host. However, colonization by keystone pathogens such as *Pg* creates the shift from a symbiotic microbial flora to a pro-inflammatory dysbiotic community that impairs host immune system (through its virulence factors and toxins) causing periodontal tissue destruction (Darveau, 2010; Hajishengallis, 2014; Hajishengallis and Lamont, 2012).



**Figure 5: The polymicrobial synergy and dysbiosis (PSD) model of periodontal disease etiology.** Colonization of the keystone pathogen, *Pg*, in the oral biofilm shifts the balance of the microenvironment from symbiotic microflora to dysbiotic pathogenic community that produces toxins and impairs host inflammatory and immune response (Lamont and Hajishengallis, 2015).

#### 1.1.4.2. Role of inflammatory-immune cross-talk

The severity of periodontal disease varies between individuals. Besides other factors, the susceptibility to periodontal inflammation and subsequent disease has been partly attributed to the variability in the host defense mechanisms (Trombelli et al., 2004).

Epithelial cells (EC) function as a physical barrier against pathogens and elicit innate and acquired immune responses (Benakanakere and Kinane, 2012; Bugueno et al., 2017; Kocgozlu et al., 2009). Fibroblasts (FB) also participate in the local defense system (Sorsa et al., 2016). Virulence factors (lipopolysaccharides, toxins, proteases etc.) produced by periodontopathogens trigger the EC, FB, alveolar bone cells and immune cells to release pro-inflammatory mediators such as interleukin-1 beta (IL-1 $\beta$ ), tumor necrosis factor-alpha (TNF- $\alpha$ ), prostaglandin E2 (PGE2), Receptor activator of nuclear factor kappa-B ligand (RANKL) and reactive oxygen species (ROS) to initiate the periodontal tissue-destruction pathways (Alshammari et al., 2017; Huck et al., 2018; Lapérine et al., 2016; Singh et al., 2018). The complement system is a network of interacting channels or molecules that trigger, amplify, and

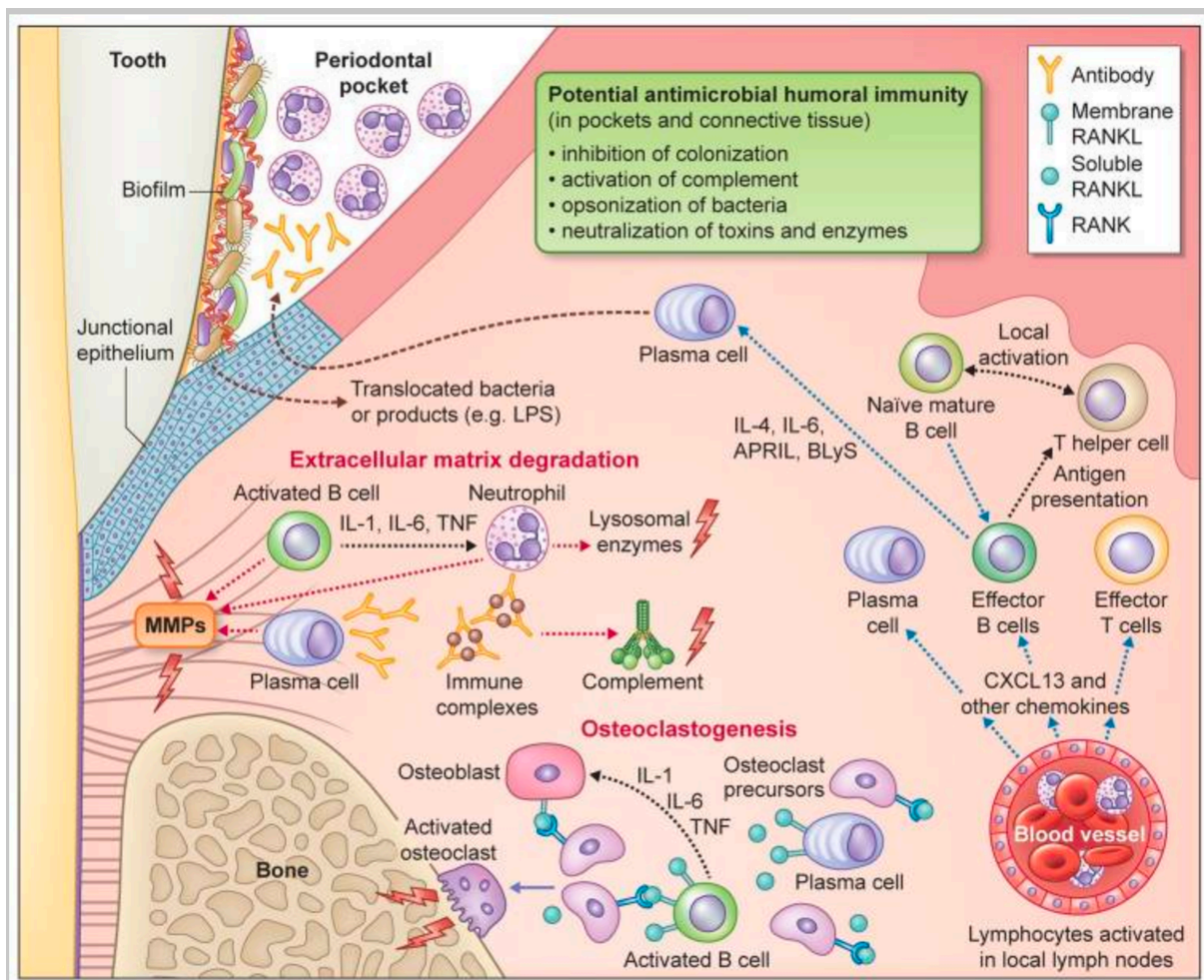
regulate immune and inflammatory signaling pathways (Hajishengallis et al., 2015). Dendritic Langerhans cells within the epithelium take up microbial antigenic material and bring it to the lymphoid tissue for presentation to lymphocytes. Neutrophils, granulocytes and lymphocytes infiltration into the periodontal lesion ensues where neutrophils attempt to engulf and kill bacteria (Bostanci et al., 2013). However, the severity and persistence of the periodontal infection causes severe chronic inflammatory response that leads to alveolar bone resorption by osteoclasts and degradation of PDL fibers by MMPs, consequently, forming the granulation tissue. This pathophysiological cascade continues tissue damage leading to tooth loss unless the treatment successfully removes the microbial biofilm and granulation tissue (Graves, 2008; Sorsa et al., 2016).

The coordinated recruitment of neutrophils is crucial for periodontal tissue homeostasis as they can cause periodontal tissue destruction if their recruitment is not properly regulated or the microbial challenge in the *periodontium* cannot be controlled. Moreover, macrophages are detected in great numbers in gingival tissues of patients with gingivitis and chronic periodontitis, as confirmed by biopsy studies, and produce pro-inflammatory molecules like IL-1, TNF- $\alpha$ , MMPs and PGE2. The subset M1 of macrophages has a pro-inflammatory role, whereas, M2 produces IL-10 and transforming growth factor beta 1 (TGF- $\beta$ 1) (Hajishengallis and Korostoff, 2017; Huck et al., 2017).

Once lymphocytes reach the site of damage, B cells transform to antibody-producing plasma cells. The amount and avidity of the antibodies are instrumental in protection against periodontitis. Besides the antibody response, T-cells contribute to cell-mediated immune response by stimulating various T-helper (TH) cell responses: TH1, TH2 and TH17. Although the exact timing of their involvement and importance are still not fully elucidated, TH1 and TH2 cells are considered important during the early and late stages of chronic periodontitis respectively (Gemmell and Seymour, 2004). Moreover, recent studies have demonstrated that regulatory T (Treg) cells and other TH cell subsets (Kagami et al., 2009) as well as various cytokines (such as IL-17, IL-33) are also important in periodontal disease immuno-pathology (Lapérine et al., 2016; Schmitz et al., 2005). The phenomenon of osteoclastogenesis leading to bone resorption is regulated by several proteins including TNF/TNF receptor family. One of such group of proteins is called RANKL with its functional receptor called RANK. RANKL is expressed by EC, FB, osteoblasts and activated T cells, B cells and Treg cells. The RANK/RANKL binding activates osteoclastogenesis leading to bone resorption (Chen et al., 2014; Hassan et al., 2017; Lapérine et al., 2016; Wei et al., 2005).



The host response plays a crucial role in periodontitis that has been demonstrated in several studies involving animal models (Delima et al., 2001; Eskan et al., 2012). An optimally regulated host response can provide homeostatic immunity and thus be protective (Hajishengallis and Korostoff, 2017). The understanding of the molecular mechanisms involving cytokines and complement systems for innate-adaptive immune crosstalk, activation and regulation of leukocytes and immune regulation of osteoclastogenesis have highlighted novel therapeutic targets for human periodontitis (Hajishengallis and Korostoff, 2017) (Figure 6).

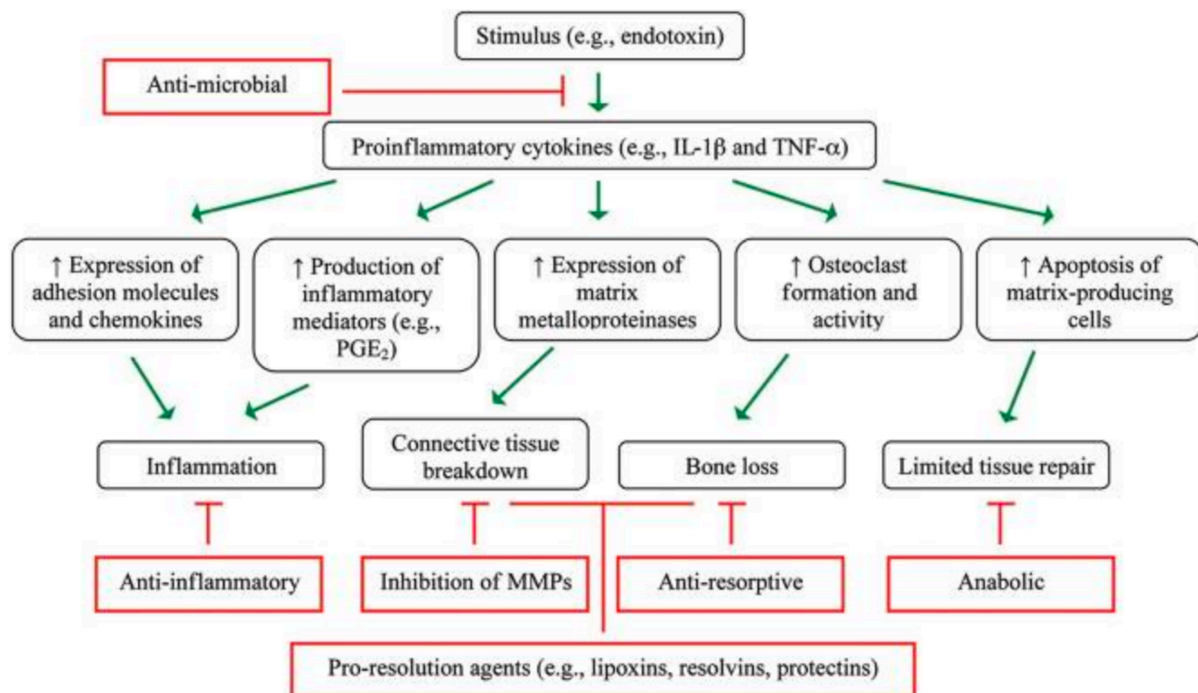


**Figure 6: Immuno-inflammatory cross-talk leading to periodontal tissue destruction.** Microbial dysbiosis induces innate immune signaling pathways that lead to the development of an adaptive immune response within the junctional epithelium and gingival connective tissue. Regarding the humoral component of the response, pathogen-specific antibody that diffuses into the gingival sulcus (or pocket) or remains in the connective tissue can, in principle, inhibit the bacterial challenge via a number of potential mechanisms (indicated). Antibody-mediated activation of complement and innate immune cells can enhance gingival inflammation and contribute to tissue breakdown. Recent evidence has demonstrated the potential for B-lineage cells to express pro-inflammatory cytokines, MMPs, and RANKL. B-lineage cells therefore directly and indirectly participate in the degradation of the soft and hard tissue components of the periodontium (Hajishengallis and Korostoff, 2017).

#### 1.1.4.2.1. Pro-inflammatory mediators

Pro-inflammatory mediators are the key players not only in disease development and progression but also in initiating the repair process following tissue injury. TNF- $\alpha$  and IL-1 $\beta$  are produced immediately after injury at high concentrations and increase the expression of adhesion molecules, chemokines, other pro-inflammatory mediators including prostaglandins (PGs) specially PGE2 and MMPs. Moreover, they stimulate the activation of osteoclasts, T, and B cells. Several studies confirmed that the absence of pro-inflammatory mediators can impair or delay wound healing (epithelialization, bone formation) (Graves et al., 2001; Heo et al., 2011; Ueda et al., 2014; Zhang et al., 2002), however, their over secretion after their due time or in concentrations higher than required can be detrimental for the healing phenomenon (Thomas and Puleo, 2011).

*In vivo*, the “dual-edged sword” like role of pro-inflammatory mediators has demonstrated that the blockade of TNF- $\alpha$  and IL-1 $\beta$  at the early stage of the inflammation promotes wound healing, whereas, their prolonged blockade may have negative consequences (Zhang et al., 2002). Several studies highlighted the instrumental role played by TNF- $\alpha$  and IL-1 $\beta$  in both the initiation and resolution of inflammation as well as in the regulation of osteoclastogenesis (Darveau, 2010; Morand et al., 2017a) (Figure 7). Studies have described many pro-inflammatory mediators that play a role in disease pathogenesis and healing such as IL-1 $\beta$ , IL-2, IL-6, IL-7, IL-8, IL-12, IL-17, IL-21, IL-23, IL-33, interferon gamma (IFN- $\gamma$ ), and TNF- $\alpha$  (Cetinkaya et al., 2013; Lapérine et al., 2016; Miranda et al., 2019).



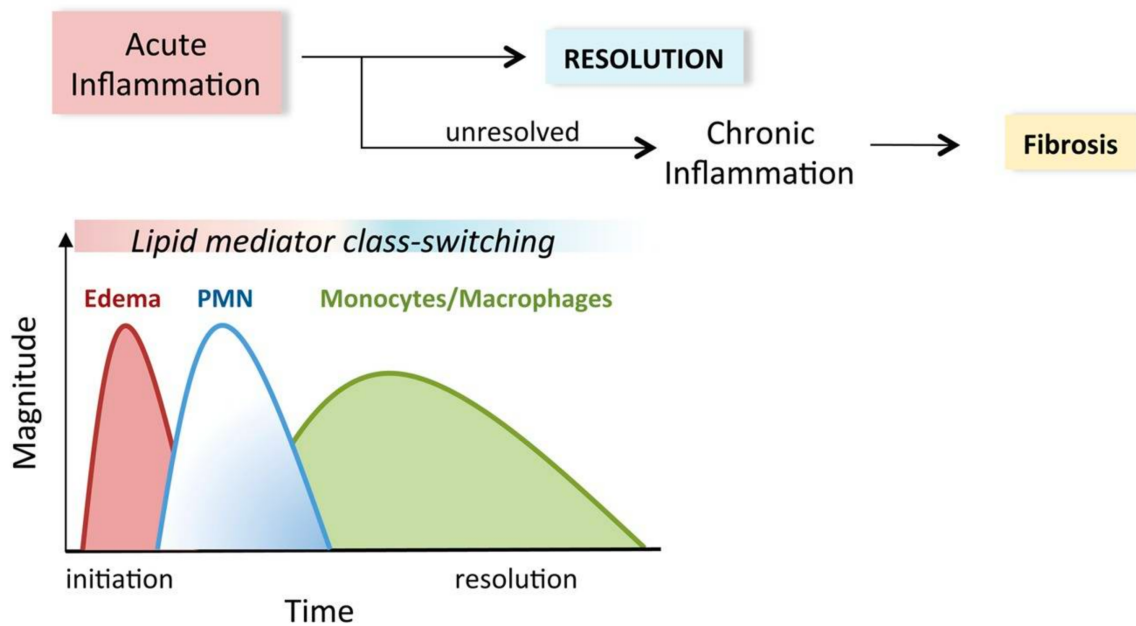
**Figure 7: Inflammation-mediated periodontal tissue damage.** In periodontitis, bacteria produce a variety of virulence factors that elicit a host response consisting of the expression of various signaling molecules and mediators, and the recruitment of inflammatory cells. This process may culminate in tissue destruction and interfere with tissue regeneration and repair. The different pathways involved in the development and progression of periodontitis act as potential therapeutic targets for disease management (Thomas and Puleo, 2011).

#### 1.1.4.2.2. Anti-inflammatory mediators

To counter-balance the effect of the pro-inflammatory cytokines and chemokines, certain anti-inflammatory (IL-4, IL-5, IL-10, IL-13, and TGF- $\beta$ ) cytokines are also secreted and their role is critical in the transition from inflammation to resolution phase (Bozkurt et al., 2006; Cetinkaya et al., 2013; Miranda et al., 2019).

#### 1.1.4.2.3. Pro-resolution mediators

The pro-inflammatory mediators signal the generation of specialized pro-resolving mediators (SPMs) or induce their receptor targets (Spite et al., 2014). Various arachidonic acid (AA) derived metabolites (PGs, leukotrienes, lipoxins), D-series resolvins (RvD1-6), maresins, protectins and E-series resolvins (RvE1-3) are the key players in the resolution of inflammation preventing fibrosis (Balta et al., 2017; Kantarci and Van Dyke, 2005; Spite et al., 2014; Van Dyke, 2017) (Figure 8).



**Figure 8: Transition from initiation to resolution of periodontal inflammation.** Unresolved acute inflammation progresses to chronic inflammation that can, eventually, lead to fibrosis. In the initial inflammatory phase, polymorphonuclear neutrophils (PMNs) are recruited to the lesion. The monocyte/macrophage ratio is critical to achieve the resolution of inflammation (Spite et al., 2014).

### 1.1.5. Management of periodontal diseases: current concepts

The aim of the periodontal therapy is to control inflammation and disease progression so that the patient can maintain a healthy and functional dentition at long term. Gingivitis is mainly treated by scaling that involves the removal of plaque or calculus deposits from teeth and surrounding tissues and the removal or reduction of risk factors, followed by daily home care and professional prophylaxis at follow-up visits (Petit et al., 2019a).

#### 1.1.5.1. Non-surgical therapy

In mild to moderate periodontitis, the patient management usually involves scaling and root planing (SRP) for the removal of both supra-gingival and sub-gingival plaque, and calculus deposits. SRP is performed manually with hand scalers and curettes, through power-driven ultrasonic instruments, or using a combination of both. Manual scalers and curettes are sharp instruments with one or two cutting edges used for the removal of plaque and calculus. Subgingival cleaning or root planing is crucial in periodontal therapy and is more efficiently carried out with the ultrasonic scalers that vibrate at an ultrasonic range (approximately 25,000–30,000 cycles per second) with stream of water ejected to remove adherent deposits from teeth (Adriaens and Adriaens, 2004; Kinane et al., 2017; Lea et al., 2004; Van der Weijden and

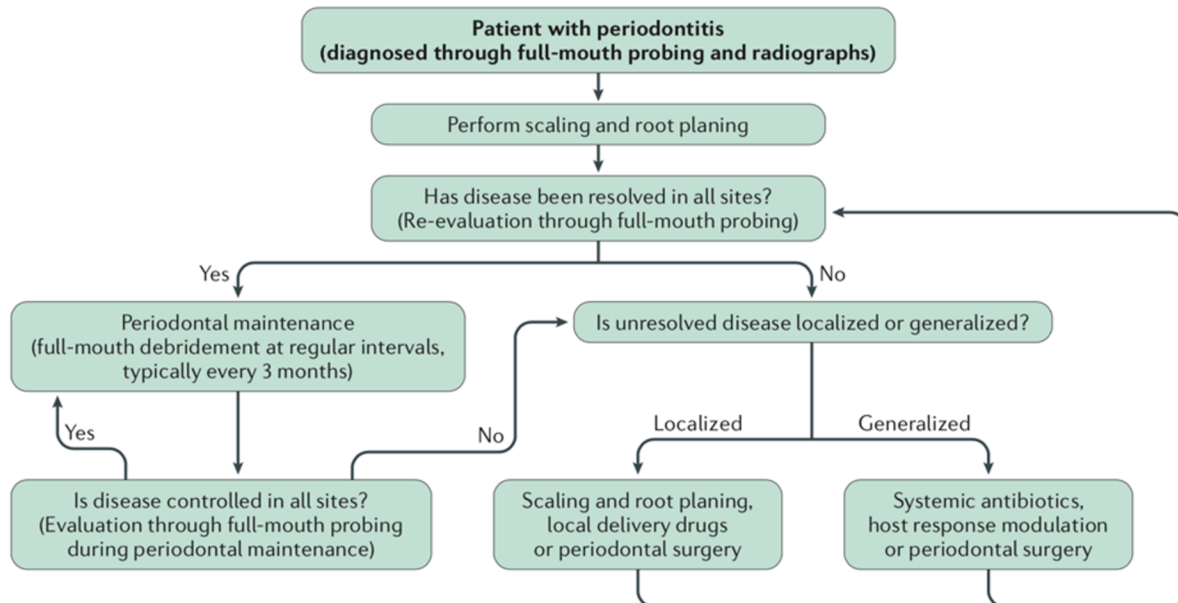


Timmerman, 2002). Following the initial SRP, adequate healing of the connective tissue requires about 4 to 12 weeks. Afterwards, the patient is recalled for a re-evaluation and the response to initial therapy is reassessed by recording clinical parameters.

If no residual inflammation and pockets exist, then the patient is placed on periodontal maintenance therapy. However, if there are signs of active disease, additional therapy is required, which could be either localized or generalized and either non-surgical or surgical, depending on the extent and severity of the residual inflammation (Graziani et al., 2017). In non-surgical periodontal therapy, adjunctive chemotherapeutic agents, for instance, antimicrobial mouth-rinses and/or toothpastes with agents such as fluorides, chlorhexidine or triclosan are also incorporated to ensure and maintain plaque control (Kinane et al., 2017). Since supragingival plaque reappears within hours or days after its removal, it is important that patients have access to effective alternative chemotherapeutic products that could help them achieve adequate supragingival plaque control (Drisko, 2001). Moreover, complete sub-gingival plaque removal is rather unrealistic to achieve, especially in deep periodontal pockets (Adriaens and Adriaens, 2004; Kocher et al., 2000).

SRP with oral hygiene instructions is the most effective therapy to control periodontal infection and subsequent gingival inflammation (Tunkel et al., 2002; Van der Weijden and Timmerman, 2002). Long-term randomized controlled trials have shown that, when these basic conditions are met, non-surgical therapy can be an effective strategy, with no difference observed between non-surgical and surgical therapy when mean values of clinical measures are compared (PPD, CAL) (Apatzidou and Kinane, 2010; Goodson, 1986; Goodson et al., 2012).

Clinically, the periodontal treatment is targeted at reducing BOP and PPD, thereby, improving CAL as a result of tightened gingival attachment to the tooth due to decreased inflammation (Heitz-Mayfield and Lang, 2013). The choice of treatment strategy depends on several factors such as severity of the condition, patient's age and systemic status (Figure 9).



**Figure 9: Decision algorithm for the therapeutic management of periodontitis.** Once diagnosed, patients with periodontitis undergo SRP, in addition to basic motivation and education on personal plaque control and reducing modifiable risk factors, such as smoking. If this approach proves successful at resolving the disease, patients should be offered regular maintenance therapy comprising debridement (SRP). If the disease is not controlled, additional treatment is needed and can comprise antibiotic, host modulation or surgical therapy (Kinane et al., 2017).

Although non-surgical periodontal therapy, with or without adjunctive therapies, is an effective treatment for periodontitis as it reduces PPD and results in the formation of some new attachment (Cobb, 2002) it also has several limitations. For instance, in non-surgical SRP, the periodontal curettes have a limited access (up to approximately 5.5 mm) and the mean PPD in which a plaque-free and calculus-free surface can be established is <4 mm, therefore, the efficacy of non-surgical SRP is reduced, especially in deep pockets (PPD >5 mm). In such deep pockets, the feasibility to successfully remove calculus increases with surgical access for SRP (Deas et al., 2016). In several cases, local anatomical factors that contribute to plaque retention may at the same time interfere with the non-surgical SRP, hence, necessitating the gain of surgical access or adjuvant therapy to eliminate plaque and calculus at these sites (Harmouche et al., 2019; Wang and Greenwell, 2001). Smoking habit and poor plaque control following non-surgical therapy also negatively impacts its outcomes (Tomasi et al., 2007). Therefore, in severe periodontitis cases, surgical therapy may be necessary to control inflammation and improve the treatment outcomes.

### 1.1.5.2. Surgical therapy

The primary aim of the periodontal surgery is to gain sufficient access for SRP to ensure efficient sub-gingival plaque control, especially, in case of deep pockets or furcation involvement (Fickl et al., 2009; Serino et al., 2001; Wachtel et al., 2003). Several surgical approaches have been developed and modified for improvement over the years such as gingivectomy, gingivoplasty, open flap debridement (OFD), modified Widman flap, gingival curettage, minimally invasive surgery and regenerative surgery (Fickl et al., 2009; Serino et al., 2001; Wachtel et al., 2003). In OFD, a section of the gingiva is surgically separated from the underlying tissues to provide visibility and access to the lesion. Pocket reduction surgery includes resection of soft and hard tissue using various techniques (Kinane et al., 2017; Wang and Greenwell, 2001). The excision of the soft tissue wall of the pocket is carried out in gingivectomy followed by gingivoplasty to contour the soft tissue (Deas et al., 2016). Conventional surgical approaches such as OFD are still considered reliable methods to access root surfaces, reduce PPD, and improve CAL gain. Combined SRP and surgery yielded greater PPD reduction as compared to periodontal surgery without initial SRP (Aljateeli et al., 2014; Graziani et al., 2017). However, the conventional surgical techniques offer only limited potential towards regenerating tissues destroyed by disease. Recently, surgical procedures have been developed and tested that aim at greater regeneration of periodontal tissues by achieving clinical attachment close to their original level (Bartold et al., 2016; Bottino and Thomas, 2015; Ivanovski, 2009; Wang et al., 2005). Regenerative surgery such as guided tissue regeneration (GTR) or induced tissue regeneration (ITR) with the use of biological agents or growth factors (Emdogain) and grafting are being carried out in clinical settings and have shown to improve significantly the clinical parameters. Moreover, further optimization and improvement of such pro-regenerative procedures is being tested by *in vitro* and *in vivo* approaches (Larsson et al., 2016; Sanz et al., 2019; Sculean et al., 2000, 2011).

### 1.1.6. Periodontal wound healing

The periodontal wound healing involves a complex interplay of several cell types, chemokines, cytokines, growth factors and extracellular matrix (ECM) factors. This process can be categorized into different phases based on the predominant chemical mediators and cellular events taking place in each (Chen et al., 2010; Hämmerle et al., 2014; Morand et al., 2017) (Figure 10) .

### **1.1.6.1. Phases of periodontal wound healing**

#### **1.1.6.1.1. Hemostasis**

Hemostasis is the first phase of wound healing following an injury which is characterized by the formation of a clot or a hemostatic plug formed of activated platelets, neutrophils, and red blood cells entangled in a matrix of fibrin that fills the lesion site and initiates recruitment of inflammatory cells (Gurtner et al., 2008). This process usually lasts for about 3 to 6 hours. Various chemokines, cytokines, and growth factors such as epidermal growth factor (EGF), basic fibroblast growth factor (bFGF), TGF- $\beta$ , platelet-derived growth factor (PDGF) and vascular endothelial growth factor (VEGF) are also secreted that drive the following phases (Qu and Chaikof, 2010):

#### **1.1.6.1.2. Inflammatory phase**

Inflammatory phase is initiated concomitant with hemostasis and lasts 4 to 6 days. Neutrophils and macrophages are the predominant cell types that eliminate pathogens at the lesion site (Susin et al., 2015). Several cell types such as gingival FB, PDL cells, EC, macrophages, and neutrophils secrete cytokines, such as TNF- $\alpha$  IL-1 $\beta$ , IL-6, and TGF- $\beta$ , to promote proliferative activity of EC and gingival FB and activate immune cells (T cells, B cells) (Kim et al., 2009; Noh et al., 2013). Certain enzymes like collagenases are secreted to degrade the ECM components, for instance, collagen and fibronectin. Later in this phase, lymphocytes infiltrate the lesion site influencing gingival FB proliferation and collagen formation (Morand et al., 2017; Trindade et al., 2014). The decrease in the pro-inflammatory precursors/stimuli is reflected by reduced numbers of neutrophils and macrophages switch from pro-inflammatory to pro-resolutive type (Fujishiro et al., 2008). This phase plays a major role in the process of periodontal wound healing and regeneration (Diegelmann and Evans, 2004).

#### **1.1.6.1.3. Proliferation**

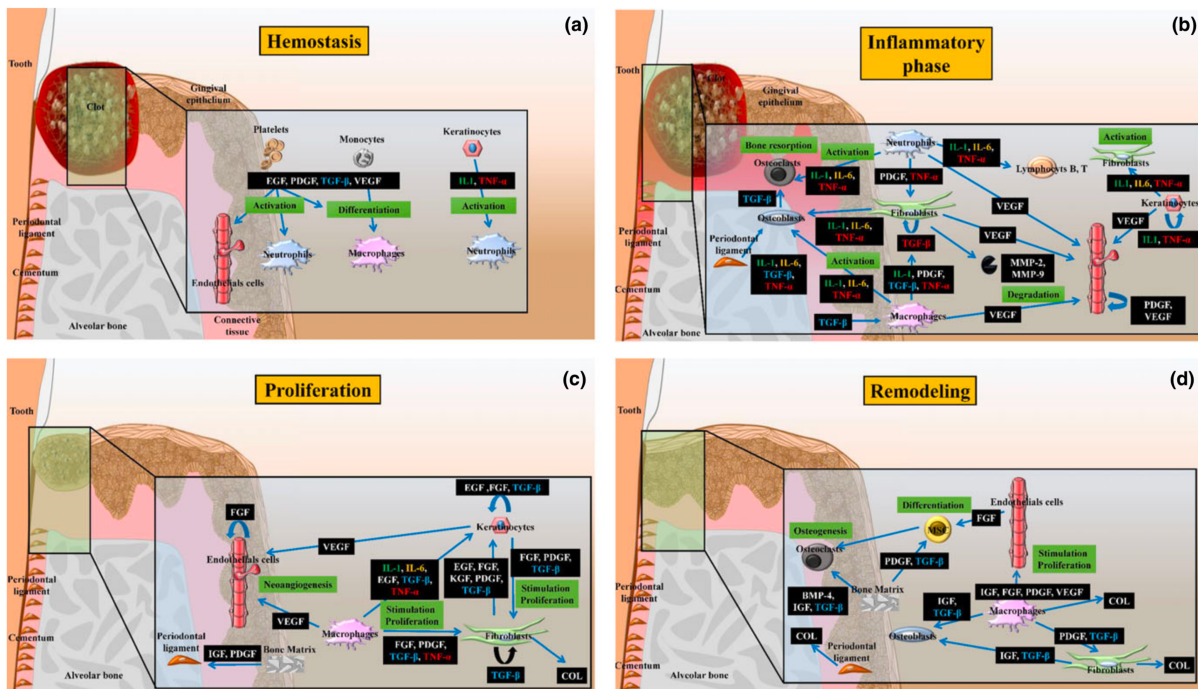
The aftermath of inflammatory phase involves the formation of the granulation tissue (a highly vascularized tissue rich in FB) (Brancato and Albina, 2011). This period is regarded as the proliferative phase that usually spans between 4 to 14 days. This phase is dominated by the recruitment of EC, gingival FB and endothelial cells and decrease in wound size due to the contraction of myofibroblasts (Velnar et al, 2009; Morand et al., 2017). EC, gingival FB and macrophages secrete TNF- $\alpha$ , IL-1 $\beta$ , IL-6, and TGF- $\beta$  (Brancato and Albina,

2011) that induce their activation, proliferation, migration and differentiation (Morand et al., 2017; Werner et al., 2007). Later, EC secrete MMPs that causes degradation of the ECM (Hackam and Ford, 2002). These chemical mediators stimulate and modulate ECM biosynthesis, epithelialization, and angiogenesis (Robson, 2003). Proliferation rate varies among cells types. Epithelial cells exhibit the highest proliferative rate explaining the development of a long junctional epithelium during conventional periodontal wound healing (Alpiste-Illueca et al., 2006; Bosshardt and Lang, 2005; Susin et al., 2015).

### 1.1.6.1.4. Remodeling

The final phase of wound healing involves the development of a new epithelium, elimination of granulation tissue and ECM remodeling (Velnar et al., 2009). This phase leads to complete wound closure and appearance of a scar as a result of fibrosis (Brancato and Albina, 2011). Gingival FB and PDL reorganize ECM by synthesizing collagen (types I, III, V, VI, XII, and XIV), elastin, proteoglycans, MMPs, and their inhibitors (Sarrazay et al., 2011). This phase is regulated by several cytokines such as PDGF and TGF- $\beta$  released by macrophages that stimulate gingival FB proliferation and synthesis of matrix components such as glycosaminoglycan and fibronectin leading to the contraction of provisional wound matrix (Morand et al., 2017). Furthermore, PDGF and TGF- $\beta$  released during osteoclastic bone resorption also regulate osteoblast migration during bone remodeling and differentiation (Zagai et al., 2003).

Epithelial healing is achieved between 7 and 14 days following periodontal surgical therapy (Hämmerle et al., 2014). However, persistence of several factors such as infection and inflammation at the lesion site reduces healing rate and leads to greater scarring (Martin and Leibovich, 2005; Morand et al., 2017). The inflammatory response can either lead to chronic inflammation, scarring and fibrosis or complete resolution (Serhan and Chiang, 2008). These possibilities may be influenced by many factors, such as the type or site of injury and the host response. The resolution of inflammation is initiated by anti-inflammatory and pro-resolution lipid mediators, such as the lipoxins, resolvins, and protectins that promote the return to tissue homeostasis (Serhan and Chiang, 2008). Persistent inflammation or derangement of the resolution phase leads to chronic inflammation and, consequently tissue fibrosis and scar formation (Maskrey et al., 2011; Morand et al., 2017).



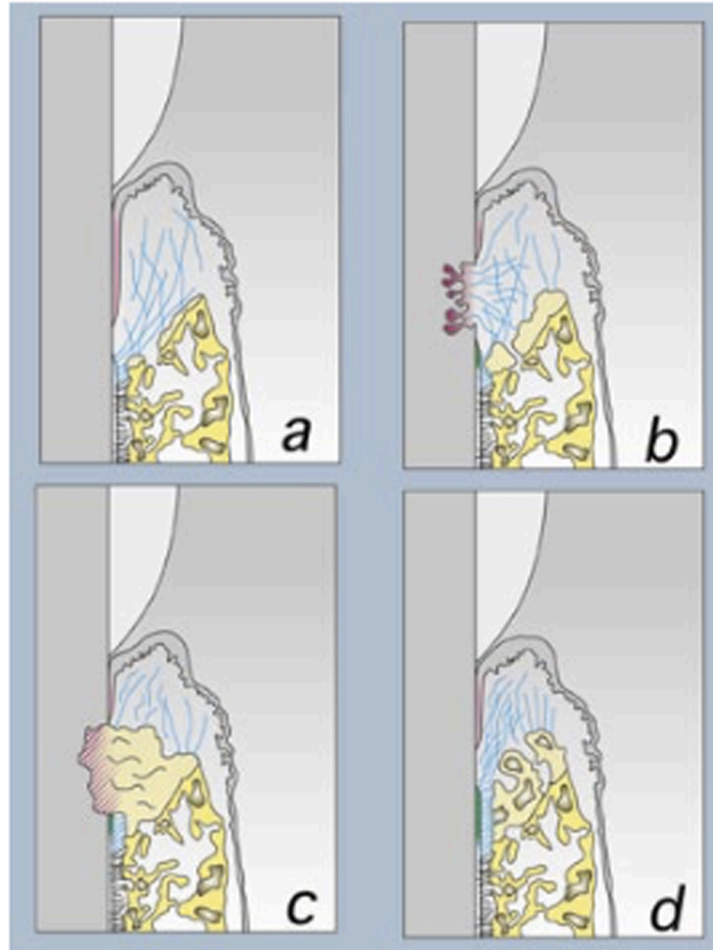
**Figure 10: Phases of periodontal wound healing.** Following an injury, the hemostasis phase is characterized by clot formation to maintain hemostasis. Then, inflammatory phase ensues which involves inflammatory cell recruitment and wound contraction. Angiogenesis, ECM synthesis and epithelialization occur during proliferative phase. Finally, epithelial and bone maturation and remodeling takes place in the remodeling phase of periodontal wound healing (Morand et al., 2017).

### 1.1.6.2. Repair versus regeneration

After the control of inflammation, regeneration of the degraded tissues remains the ultimate goal of periodontal therapy. Periodontal regeneration is defined as the reproduction or reconstitution of the lost or damaged tissues to their pre-existing and ideal form and function. Periodontal regeneration can only be fully demonstrated histologically (Ivanovski, 2009). The unique anatomy and composition of the *periodontium* comprising of both soft and hard tissues make periodontal wound healing a complex process as it demands a well-coordinated interaction between hard and soft tissues (Morand et al., 2017). Conventional periodontal therapy most commonly results in repair by collagenous scar tissue and is accompanied by the apical migration of gingival epithelium between the gingival connective tissue and the root surface forming long junctional epithelium (Alpiste-Illueca et al., 2006; Bosshardt and Lang, 2005). This healing process does not fully restore either the form or the function of the lost structures and, hence, cannot be regarded as regeneration (Ivanovski, 2009). At contrary, periodontal regeneration refers to the restoration of periodontal tissues to their original form and function and its achievement requires a coordinated wound healing response of hard and



soft tissues (Alpiste Illueca et al., 2006; Bosshardt and Sculean, 2009; Ivanovski, 2009) (Figure 11). Several animal models have also been developed to study periodontal wound healing and regeneration at a pre-clinical level (Batoool et al., 2018 (see appendix); Kantarci et al., 2015).

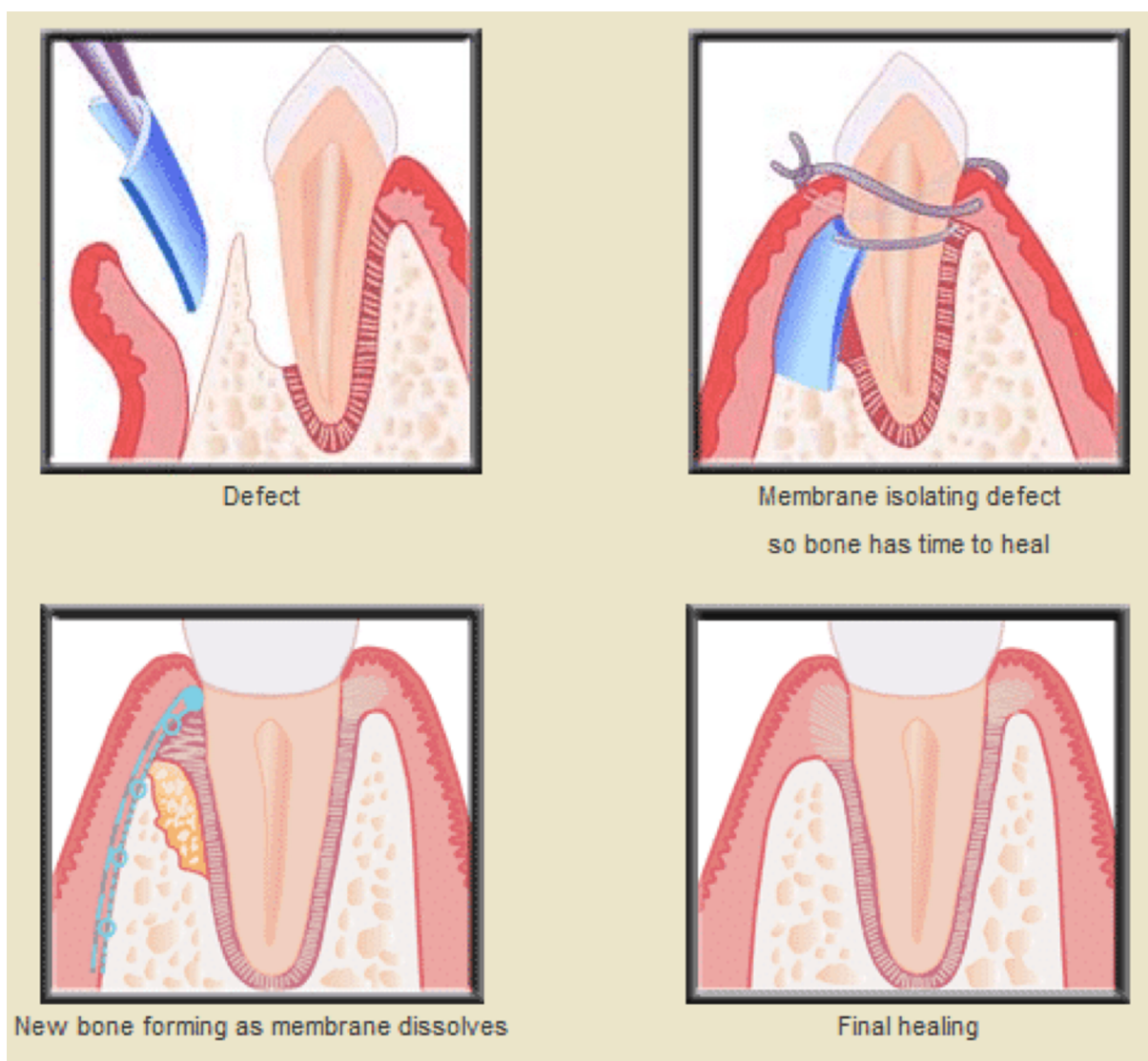


**Figure 11: Patterns of periodontal wound healing.** Periodontal healing can involve a) formation of long junctional epithelium b) root resorption c) ankylosis d) periodontal regeneration (Alpiste-Illueca et al., 2006).

### 1.1.6.3. Guided tissue regeneration (GTR)

The concept of GTR was first introduced by Melcher in 1976 (Melcher, 1976). GTR is based on the principle of selective cell exclusion or selective cell repopulation. EC migrate approximately 10 times faster than other periodontal cells types. The exclusion of EC and gingival connective tissue cells from the wound for a period of time long enough to allow other cell types with regenerative potential to form cementum, bone and PDL can prevent the formation of the undesirable long junctional epithelium formed as a result of the premature epithelial down growth, consequently, promoting regeneration. This can be achieved by using

various barrier membranes with or without bone grafts (Alpiste-Illueca et al., 2006; Bosshardt, 2018). The physical separation with the membrane creates a secluded place for the PDL, cementoblast and bone cells underneath to populate the site and create the neo-attachment of the tooth (Alpiste-Illueca et al., 2006; Bosshardt and Sculean, 2009; Ivanovski, 2009) (Figure 12). GTR application in humans was first reported in 1982, utilizing a bacterial filter made of cellulose acetate (Millipore) as the barrier membrane with histology demonstrating the new attachment (Nyman et al., 1982). Several pre-clinical and clinical studies have shown improved treatment outputs with the application of GTR (Sculean et al., 2008).



**Figure 12: Guided tissue regeneration (GTR).** The placement of a barrier membrane prevents the pre-mature epithelial downgrowth and allows space and time for the underlying bone and PDL to mature. This phenomenon leads to periodontal regeneration (Bhavsar et al., 2018).



Several factors like defect morphology, plaque index (PI), smoking, patient's systemic condition play an important role in determining the healing response to GTR (Alpiste-Illueca et al., 2006; Cortellini et al., 2017; Reynolds et al., 2003). Moreover, membrane exposure owing to infection or persistent inflammation constitutes the major limitation of this procedure (Ivanovski, 2009; Ling et al., 2003).

### **1.1.7. Adjunctive periodontal therapy**

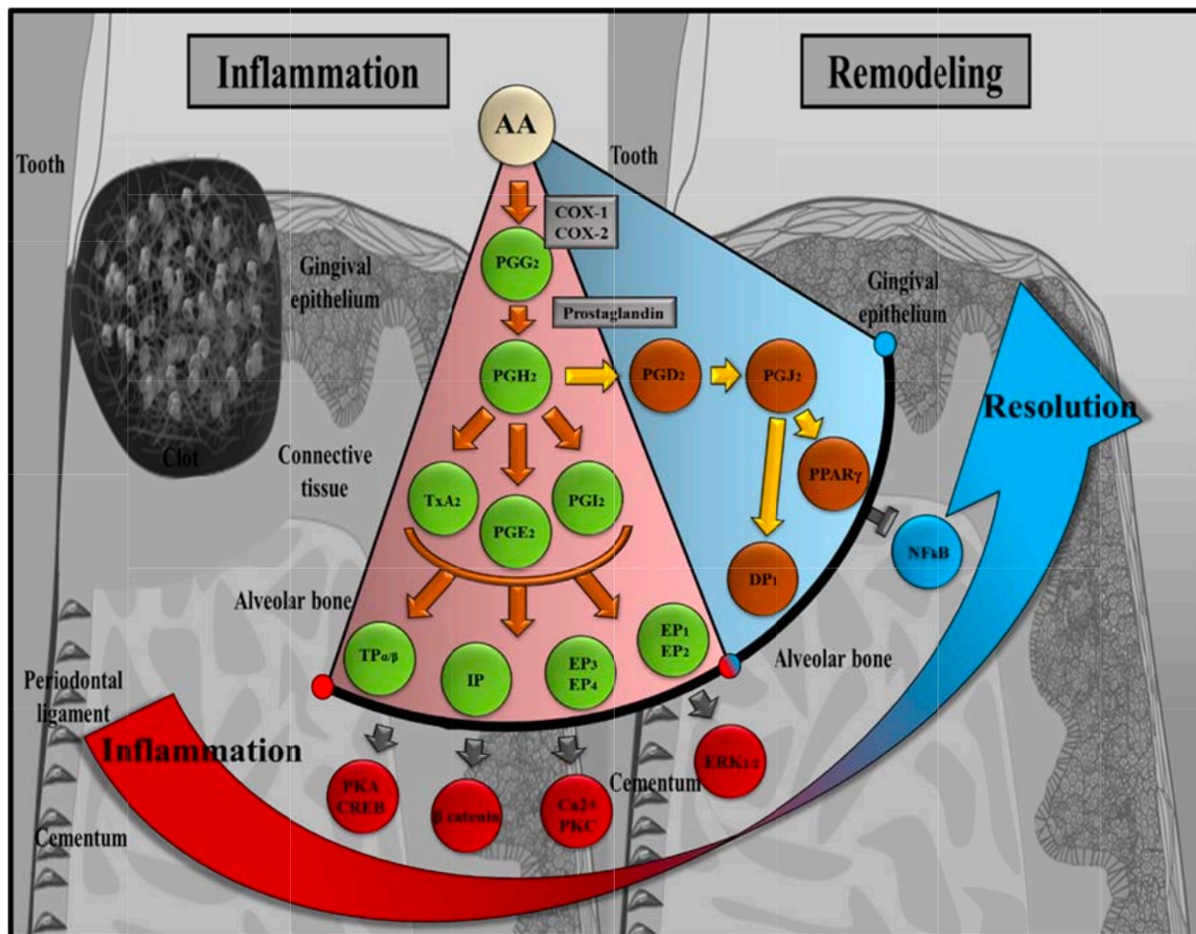
Several drugs have been proposed as adjuncts to non-surgical and surgical periodontal therapies for improving treatment outcomes. These include drugs targeting pathways involving infection, inflammation, host-immune system and bone metabolism such as antimicrobials (antibiotics/antiseptics) (Mombelli et al., 2011), anti-inflammatory (non-steroidal anti-inflammatory drugs (NSAIDs)) (Agossa et al., 2015) and immune-modulatory drugs such as statins (Petit et al., 2019b; Zhang et al., 2014). The drugs are either administered systemically or locally. Systemic drug delivery is effective; however, it requires a very high dose to achieve an optimal concentration in the periodontal pocket after the initial hepatic bypass. The use of such high systemic dose results in several side-effects. At contrary, local drug administration has demonstrated greater efficacy because of its at-site delivery. Moreover, it requires a much lower dose, thereby, decreasing the risk of systemic side-effects and cost (Herrera et al., 2012; Joshi et al., 2016; Zhang et al., 2014).

#### **1.1.7.1. Modulation of inflammation**

Several cytokines are considered as key molecules during periodontal destruction process. The AA metabolite, cyclo-oxygenase-2 enzyme (COX-2) plays a dual role in the initiation and resolution of inflammation. During the inflammatory phase, the temporal switch from pro- to anti-inflammatory eicosanoids is a key event in the resolution of the inflammation. The PGs (PGD<sub>2</sub> and PGE<sub>2</sub>) synthesis occurs by AA through COX-2 activity. The pro-inflammatory effect of PGE<sub>2</sub> is counter-balanced by the anti-inflammatory effect of PGD<sub>2</sub>. The shift towards the anti-inflammatory signaling causes blockade of the NFκB pathway, consequently, reducing the inflammatory response and progressing towards the resolution phase (Agossa et al., 2015) (Figure 13).

The achievement of a fine balance between pro-inflammatory and anti-inflammatory/pro-resolution mediators is crucial for periodontal wound healing and regeneration. The control and modulation of the inflammatory response and, especially, the activation/inhibition of

cytokines in a time- and spatial-controlled manner can be a potential therapeutic target for periodontal tissue engineering (Morand et al., 2017).



**Figure 13: The “tug of war” between periodontal inflammation and resolution.** AA is metabolized by COX-1 and COX-2 leading to the production of several PGs. PGE2 initiates a pro-inflammatory response. At contrary, PGD2 is involved in the resolution of inflammation (Agossa et al., 2015).

### 1.1.7.2. Anti-inflammatory drugs

Several studies have demonstrated the beneficial impact of anti-inflammatory agents against gingivitis (with reduction in PI, BOP and PPD), either as a single treatment modality or as an adjunctive therapy. Since gingivitis leads to the development of periodontitis, the use of anti-inflammatory drugs could be effective to control gingival inflammation in periodontitis as well (Polak et al., 2015; Rosin et al., 2005). NSAIDs are non-selective inhibitors of COX enzymes (COX-1 and COX-2). COX-1 (expressed in cells and tissues) is the precursor of PG biosynthesis, whereas, COX-2 is induced by inflammatory triggers (cytokines, hormones and growth factors) and produces PGs in the inflammatory and proliferative phase of wound

healing (Agossa et al., 2015; Rouzer and Marnett, 2009). NSAIDs such as aspirin, ibuprofen, flurbiprofen, and naproxen are amongst the most commonly prescribed drugs worldwide. NSAIDs have been tested for decades to ameliorate periodontal inflammation, consequently, improving periodontal wound healing (Agossa et al., 2015; Meek et al., 2010). Ibuprofen is one of the most frequently prescribed NSAIDs in clinic as well as tested in several pre-clinical and clinical trials (Cavagni et al., 2016; Su et al., 2013). Ibuprofen is a selective COX-2 inhibitor and has a slight ability to inhibit COX-1 (Agossa et al., 2015).

#### **1.1.7.3. Antibiotics and antimicrobials**

Poor control of bacterial plaque or lack of maintenance visits are major risk factors for periodontal treatment and lead to a reduction in the formation of new attachment and bone tissue (Lang and Bartold, 2018, Petit et al, 2019a). The *de novo* accumulation of plaque provokes a relapse of periodontal diseases, even when a significant attachment level has been achieved by the treatment (Alpiste-Illueca et al., 2006). The use of anti-plaque chemical agents as adjunctive therapy is well established, especially, in treating gingivitis and for the maintenance phase of periodontal therapy (Serrano et al., 2015). The administration (both local and systemic) of antibiotics and antimicrobials as an adjunct to periodontal therapy has shown significant improvement in periodontal parameters (PPD reduction and CAL gain) (Herrera et al., 2012). However, the long-term use of systemic antibiotics poses the risk of developing bacterial resistance and potential side-effects, therefore, the use of probiotics or other antimicrobials is considered as a safer alternative (Martin-Cabezas et al., 2016; Tomasi et al., 2008).

#### **1.1.7.4. Pleiotropic drugs: the case of statins**

Statins, or inhibitors of 3-hydroxy- 3-methylglutaryl coenzyme A reductase (HMG-CoA reductase) have demonstrated pleiotropic properties that could be beneficial as an adjunct to periodontal therapy for improving the treatment outcomes. Statins possess anti-inflammatory, anti-bacterial characteristics, can modulate the host-immune response and regulate bone metabolism (Petit et al., 2019b; Zhang et al., 2014). Several pre-clinical and clinical trials have endorsed their effectiveness in improving periodontal parameters through systemic as well as local delivery (Bradley et al., 2016; Fentoğlu et al., 2012; Özdoğan et al., 2018; Pradeep and Thorat, 2010; Pradeep et al., 2015).

### 1.1.8. Novel spatial and time-controlled drug delivery scaffolds

According to the American Society for Testing Materials (ASTM—F2150), a scaffold is defined as “the support, delivery vehicle, or matrix for facilitating the adhesion, migration, or transport of cells or bioactive molecules used to replace, repair, or regenerate tissues”. It should precisely replicate the features of the native ECM at the nanoscale to regulate cell function and encourage and regulate specific events at the cellular and tissue levels. Moreover, scaffolds should be synthesized from biocompatible and biodegradable materials to avoid immune responses (Bottino et al., 2017).

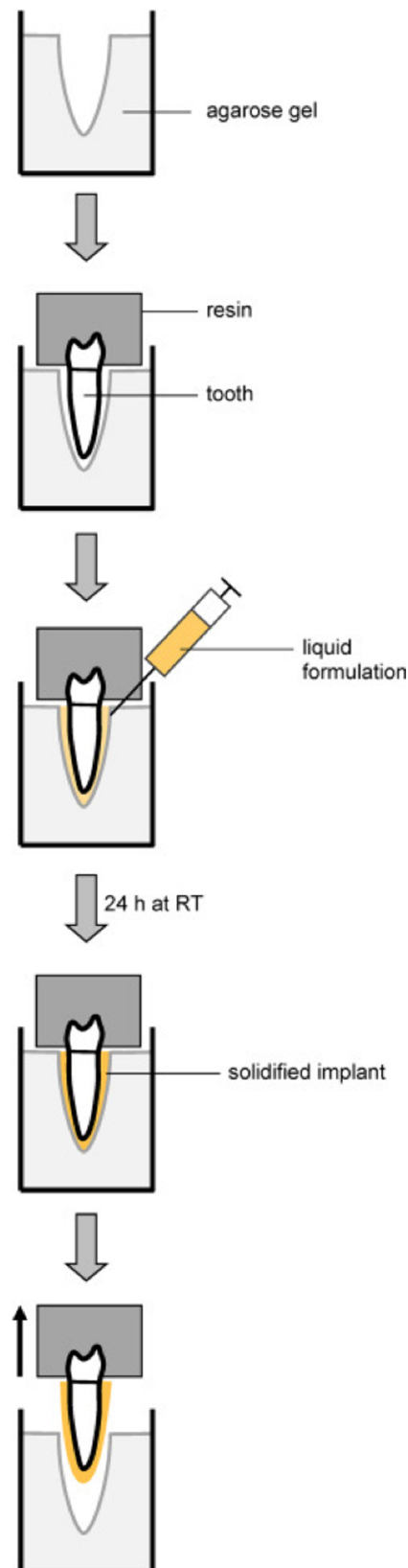
Several scaffolds have been developed for the local delivery of active molecules in a time-controlled manner that could be optimized for future clinical use. Functionalized membranes (Bottino and Thomas, 2015; Farooq et al., 2015; Morand et al., 2015; Yar et al., 2016), gels such as hydrogels, nano-emulsions (Anton and Vandamme, 2009, 2011), *in-situ* forming implants (Agossa et al., 2017; Aithal et al., 2018; Do et al., 2014; Prateeksha et al., 2019), nano-particles (Khodir et al., 2013), liposomes (Sugano et al., 2014) and 3D matrices (Eap et al., 2012; Rasperini et al., 2015; Rusu et al., 2019) are some of the major scaffolding strategies. These strategies directly deliver the drug at the treatment site enhancing its quick absorption and retention, thus, improving its efficiency. The sustained delivery of the active molecule promotes wound healing. Furthermore, the low dose of locally delivered drug reduces the risk of systemic side-effects. Interestingly, such scaffolds can be optimized to deliver a combination of active molecules such as antimicrobial agents, anti-inflammatory and growth factors in a time-dependent manner (Ivanovski et al., 2014; Sundararaj et al., 2013).

Several characteristics, for instance, chemical and physical properties, morphology, porosity and rate of degradation must be considered while designing a scaffold. An ideal scaffold is biocompatible, biodegradable and has a three-dimensional architecture, initial mechanical strength and appropriate rigidity. Moreover, a high porosity facilitates attachment, proliferation, migration, differentiation of cells and also allows the transport of nutrients and metabolic waste. However, the scaffold’s rate of degradation must be precisely controlled and coordinated to follow the regenerated neo-tissues during their stages of growth, remodeling, and maturation (Alsberg et al., 2003). Different techniques or a combination of techniques are used for the fabrication of scaffolds such as solvent exchange, emulsion freeze-drying, salt leaching, electrospinning and 3D printing (Agossa et al., 2017; Ivanovski et al., 2014; Loh and Choong, 2013). Furthermore, functionalization of scaffolds with active molecules or drugs could be obtained by methods like impregnation, incorporation, encapsulation, coating, and

grafting. Nevertheless, the use of membranes for periodontal regeneration requires surgical administration of the membrane and a subsequent risk of infection or membrane exposure besides other surgery-associated complications (Ling et al., 2003). The incorporation of conventional gels into periodontal therapy is convenient, however, their easy dislodgement from the periodontal pocket limits their efficacy (Kempe and Mäder, 2012; Kranz and Bodmeier, 2008).

### 1.1.8.1. *In-situ* forming implants (ISFI)

Recently, ISFI have been developed and characterized as poly(lactic-co-glycolic acid) (PLGA) based controlled-release local drug delivery systems containing hydroxypropyl methylcellulose (HPMC) as adhesive polymer. They have been tested for local administration of drugs such as doxycycline or metronidazole for periodontitis treatment (Do et al., 2014, 2015a). However, since the long-term use of antibiotics can lead to bacterial resistance, a safer alternative of ISFI using antiseptic drug chlorhexidine has been developed and tested for local periodontitis treatment. These formulations possess a liquid consistency at the time of injection that hardens within the periodontal pocket through solvent exchange process and acquires the 3-dimensional shape of the lesion, thus ensuring a full lesion coverage and greater retention. These properties make ISFI a very convenient and efficient intra-pocket therapy as an adjunct to periodontal treatment (Agossa et al., 2017) (Figure 14).



**Figure 14: Mechanism of action of ISFI.** The ISFI are liquid formulations and can, therefore, be easily injected into the periodontal pocket where they harden upon contact with saliva and gingival fluid (through solvent exchange) and achieve the 3D shape of the pocket, thus, enhancing the ISFI retention and efficiency (Agossa et al., 2017).

## **II. AIMS AND HYPOTHESES**

Persistence of inflammation and infection are the major hinderances in achieving optimal periodontal wound healing and regeneration, and their control is crucial to avoid inflammation-mediated degradation of periodontal tissues. Therefore, our aim was to develop and optimize novel therapeutic strategies for promoting periodontal wound healing and regeneration by the modulation of inflammatory response. The co-ordinated healing response of the soft and hard periodontal tissues is difficult to achieve, and the following therapeutic strategies were developed and tested for their pro-regenerative potential:

### **I. Development of a novel membrane targeting inflammation to improve periodontal treatment outcomes.**

As persistence of a chronic inflammation impaired GTR, we hypothesized that the control of inflammation through local delivery of anti-inflammatory drug will be of interest to improve GTR outcomes. Indeed, we wanted to combine the principle of cellular exclusion through the physical properties of a membrane with the pharmacological control of the inflammation through ibuprofen delivery. Therefore, we selected to synthesize a polycaprolactone membrane functionalized with ibuprofen through electrospinning technique due to its physical and biological properties, and we aimed to evaluate its biocompatibility, anti-inflammatory and pro-regenerative effects in *Pg* stimulated periodontal cells (EC and FB) *in vitro* and in an experimental model of periodontitis *in vivo*.

### **II. Development of a novel ISFI targeting both infection and inflammation to improve periodontal treatment outcomes.**

As demonstrated previously, non-surgical periodontal treatment outcomes could be impaired by local risk factors associated to the depth of the lesion or to the 3D configuration of the periodontal lesion. Indeed, persistence of biofilms on the tooth surface or within pocket could trigger chronic inflammation and reduce healing potential. To address these problems, we hypothesized that the local delivery of both antiseptic and anti-inflammatory drugs in addition to SRP will overcome such limitations. ISFI could be an interesting option as it is easy to inject within the lesion and fits to its 3D shape. Therefore, we decided to develop an ISFI loaded with chlorhexidine and ibuprofen, as a proof of concept, and to evaluate its anti-microbial and anti-inflammatory properties *in vitro* and *in vivo*.



### **III. Development of a novel hydrogel targeting infection, inflammation, immune response and bone metabolism to improve periodontal treatment outcomes.**

The knowledge of periodontal disease pathogenesis, involving infection triggered-immuno-inflammatory response leading to dysregulation of bone metabolism, highlights potential therapeutic targets. Statins have demonstrated pleiotropic effects including anti-bacterial activity, modulation of inflammatory-immune response and bone metabolism. Therefore, we hypothesized that the local delivery of atorvastatin could improve periodontal treatment outcomes and could induce a co-ordinated healing response of soft and hard periodontal tissues. Since, statins are poorly soluble in aqueous solvents, we decided to synthesize a thermosensitive atorvastatin-functionalized chitosan hydrogel. Furthermore, we conjectured that encapsulation of atorvastatin within nano-emulsion particles could enhance their intracellular drug delivery. Thus, in a preliminary study, we decided to explore the efficacy of local atorvastatin nano-emulsion delivery *in vitro* as well as *in vivo* in a murine calvarial bone defect model.

# **III. RESULTS**

# **CHAPTER 1**

**Development of a novel strategy to modulate periodontal inflammation and to promote periodontal wound healing based on synthesis of a novel electrospun functionalized scaffold**

**Publication 1:** Synthesis of a Novel Electrospun Polycaprolactone Scaffold Functionalized with Ibuprofen for Periodontal Regeneration: An *In Vitro* and *In Vivo* Study. (Batool et al., Materials, 2018)

**Résumé :**

La persistance d'une inflammation chronique parodontale est le facteur majeur impliqué dans la destruction des tissus parodontaux. De plus, il a été observé que celle-ci peut également réduire le potentiel de régénération au niveau d'un site parodontal traité. A l'heure actuelle, l'utilisation de membrane permettant l'exclusion cellulaire est une technique largement utilisée dans le traitement des lésions infra-osseuses. Cependant, les résultats obtenus peuvent varier en fonction de facteurs de risque mais également de la réponse inflammatoire et de son intensité notamment au niveau des tissus mous, ceci du fait principalement des interactions moléculaires entre parodonte superficiel et profond (soft tissues/bone crosstalk) mais également du fait de la prolifération des tissus mous au sein du défaut. L'objectif de cette étude a été de développer une nouvelle membrane synthétique fonctionnalisée par un anti-inflammatoire et d'évaluer son effet sur la réponse inflammatoire cellulaire au niveau des tissus mous et sur la régénération parodontale.

Une membrane a ainsi été synthétisée à base de polycaprolactone par la technique d'électrospinning et a été fonctionnalisée par ibuprofène. La membrane a par la suite été caractérisée par microscopie électronique à balayage et à transmission. Ces analyses ont permis de valider la structure de la membrane obtenue. Celle-ci est formée de fibres régulières interconnectés d'un diamètre moyen de 374nm reproduisant la structure de la matrice extracellulaire. De plus, l'encapsulation de l'ibuprofène a pu être observée au sein des fibres de la membrane. Enfin, il a été observé un relargage à court terme de l'ibuprofène dans le milieu permettant d'atteindre rapidement une dose active au niveau tissulaire.

Afin d'évaluer les propriétés anti-inflammatoires de cette membrane, une analyse *in vitro* de la viabilité, de la prolifération (scratch assay) et de l'expression des gènes (Rt-qPCR) associées à l'inflammation a été réalisée au niveau de cellules épithéliales gingivales et de fibroblastes stimulés par le LPS de *Pg*. Les résultats ont pu mettre en évidence une réduction de la vitesse de prolifération des cellules épithéliales stimulées par le LPS lorsque les cellules étaient en contact avec la membrane fonctionnalisée. De plus, une réduction de l'expression des gènes pro-inflammatoires COX-2 et IL-8 a été observée au niveau des cellules stimulées par le LPS et au contact de la membrane fonctionnalisée. L'ensemble de ces données nous ont



permis de valider le biomatériau synthétisé et d'évaluer ses effets *in vivo* sur la cicatrisation parodontale.

Dans un modèle murin de parodontite expérimentale induite par le placement répété de ligatures infectées par *Pg*, les membranes fonctionnalisées par l'ibuprofène ont pu être testées après mise en place chirurgicale. L'impact sur la cicatrisation a été mesuré après 22 jours de cicatrisation par mesures histomorphométriques. Il a ainsi été observé une amélioration qualitative de l'attache parodontale au niveau des sites traités par membrane fonctionnalisée caractérisée par un épithélium de jonction plus court que celui observé au niveau des sites contrôles (traitement mécanique seul). Bien qu'aucune différence significative n'ait été mise en évidence en ce qui concerne le niveau osseux, une réduction du nombre d'ostéoclastes (TRAP positive) au niveau des sites traités par membrane fonctionnalisée a été observé.

Cette étude nous a permis de valider l'intérêt de l'utilisation de telle membrane fonctionnalisée par un anti-inflammatoire dans le contexte parodontal. Cependant, des améliorations notamment relatives à la dégradation de la membrane dans le temps mais également sur le temps et la période de libération du médicament doivent être entrepris afin de faciliter son utilisation et optimiser les résultats. De plus, la démonstration de la faisabilité du placement d'une membrane dans un modèle murin de parodontite expérimentale a également pu être effectuée.

Article

# Synthesis of a Novel Electrospun Polycaprolactone Scaffold Functionalized with Ibuprofen for Periodontal Regeneration: An In Vitro and In Vivo Study

Fareeha Batool <sup>1,2,†</sup>, David-Nicolas Morand <sup>1,2,†</sup>, Lionel Thomas <sup>3</sup>,  
Isaac Maximiliano Bugueno <sup>1,2</sup>, Javier Aragon <sup>4</sup> , Silvia Irusta <sup>4,5</sup>, Laetitia Keller <sup>1,2</sup>,  
Nadia Benkirane-Jessel <sup>1,2</sup>, Henri Tenenbaum <sup>1,2</sup> and Olivier Huck <sup>1,2,6,\*</sup> 

- <sup>1</sup> INSERM (French National Institute of Health and Medical Research), UMR 1260, Regenerative Nanomedicine (RNM), FMTS, 67000 Strasbourg, France; s\_fareeha\_b@hotmail.com (F.B.); davidnicolas.morand@gmail.com (D.-N.M.); isaacmaxi@gmail.com (I.M.B.); lkeller@unistra.fr (L.K.); nadia.jessel@inserm.fr (N.B.-J.); htenen@gmail.com (H.T.)
- <sup>2</sup> Université de Strasbourg, Faculté de Chirurgie-dentaire, 67000 Strasbourg, France
- <sup>3</sup> Institute Pluridisciplinaire Hubert CURIEN (IPHC), Strasbourg 67000, France; lionel.thomas@iphc.cnrs.fr
- <sup>4</sup> Department of Chemical Engineering, Nanoscience Institute of Aragon (INA), University of Zaragoza, 50018 Zaragoza, Spain; javier.aragon@unizar.es (J.A.); sirusta@unizar.es (S.I.)
- <sup>5</sup> Networking Research Center on Bioengineering, Biomaterials and Nanomedicine, CIBER-BBN, 28029 Madrid, Spain
- <sup>6</sup> Hopitaux Universitaires de Strasbourg, Pôle de médecine et chirurgie bucco-dentaire, Department of Periodontology, 67000 Strasbourg, France
- \* Correspondence: huck.olivier@gmail.com; Tel.: +33-3-88-116947
- † Authors contribute equally to this work.

Received: 16 February 2018; Accepted: 9 April 2018; Published: 10 April 2018



**Abstract:** Ibuprofen (IBU) has been shown to improve periodontal treatment outcomes. The aim of this study was to develop a new anti-inflammatory scaffold by functionalizing an electrospun nanofibrous poly- $\epsilon$ -caprolactone membrane with IBU (IBU-PCL) and to evaluate its impact on periodontal inflammation, wound healing and regeneration in vitro and in vivo. IBU-PCL was synthesized through electrospinning. The effects of IBU-PCL on the proliferation and migration of epithelial cells (EC) and fibroblasts (FB) exposed to *Porphyromonas gingivalis* lipopolysaccharide (Pg-LPS) were evaluated through the AlamarBlue test and scratch assay, respectively. Anti-inflammatory and remodeling properties were investigated through Real time qPCR. Finally, the in vivo efficacy of the IBU-PCL membrane was assessed in an experimental periodontitis mouse model through histomorphometric analysis. The results showed that the anti-inflammatory effects of IBU on gingival cells were effectively amplified using the functionalized membrane. IBU-PCL reduced the proliferation and migration of cells challenged by Pg-LPS, as well as the expression of fibronectin-1, collagen-IV, integrin  $\alpha 3 \beta 1$  and laminin-5. In vivo, the membranes significantly improved the clinical attachment and IBU-PCL also reduced inflammation-induced bone destruction. These data showed that the IBU-PCL membrane could efficiently and differentially control inflammatory and migratory gingival cell responses and potentially promote periodontal regeneration.

**Keywords:** regeneration; periodontitis; membrane; GTR; NSAIDs

## 1. Introduction

Periodontal diseases are a group of inflammatory diseases, comprising gingivitis and periodontitis, induced by bacterial infection. Gingivitis is a reversible disease affecting gingival tissues, while periodontitis is irreversible and affects the profound periodontium. Severe periodontitis is the sixth most prevalent disease worldwide affecting around 743 million people [1] and is considered the main cause of tooth loss with an impact on systemic health and quality of life [2]. Periodontitis leads to a progressive destruction of the periodontal tissues including alveolar bone, periodontal ligament and connective tissues. This destructive phenomenon results in periodontal pocket formation defined as the space between pathologically-detached gingiva and tooth surface clinically measured by increased pocket depth (PPD) and decreased clinical attachment level (CAL) [3]. CAL refers to the estimated attachment of tooth-supporting tissues and is directly linked to the prognosis of tooth loss [4].

The main etiological factor of periodontitis is associated with dysbiosis of the periodontal flora resulting in increased proportions of anaerobic bacteria such as *Porphyromonas gingivalis* (*Pg*), a Gram-negative anaerobe often found in severe periodontal lesions, acting through virulence factors such as lipopolysaccharide (*Pg*-LPS) [5]. Periodontal destruction results from the disruption of host-pathogens balance, characterized by sustained inflammation orchestrated by the activation of innate immune response leading to massive recruitment of immune cells, the release of inflammatory mediators including cytokines such as Tumor necrosis factor-alpha (TNF- $\alpha$ ) and proteases such as matrix metalloproteinases (MMPs) [6].

The aim of periodontal treatment is to reduce bacterial load and suppress inflammation. It consists of oral hygiene instructions, modification of local or systemic risk factors, scaling and root planing (SRP) with, in some clinical scenarios, adjunctive therapeutics such as antimicrobials (antibiotics, antiseptics), probiotics or surgical approaches aiming to reduce bacterial load and sustained tissue inflammation [7–9]. The conventional treatment achieves the repair of degraded tissue with some recovery of CAL and reduction in PPD; however, periodontal regeneration still remains elusive [10]. Periodontal regeneration refers to the restoration of destructed tissue to its original state of both form and function [11]. It is of clinical interest to achieve regeneration as it has been associated with long-term benefits including tooth retention, less periodontitis recurrence and less expense for re-intervention [12]. Guided tissue regeneration (GTR) has been considered to be the gold standard for periodontal regeneration for decades and is still considered effective in improving the clinical and radiographic parameters of patients with chronic periodontitis [13,14]. The use of a membrane, as a barrier, prevents early epithelial downgrowth, allowing maturation of bone and periodontal ligament [15]. The use of non-resorbable membranes allows better space maintenance and clinical outcomes; however, it requires a second surgery for removal, increasing the risk of infection. In contrast, the ease of use, gradual degradation and reduced chances of infection render bioresorbable membranes better candidates for GTR [16]. Nevertheless, GTR outcomes could also be impaired by persistent inflammation [17], and the use of new functionalized membranes has been proposed to overcome inflammation and infection-related challenges [18–20].

The phases during periodontal wound healing are under the control of several growth factors and cytokines. An imbalance between pro- and anti-regenerative molecules can be induced by sustained release of prostaglandins (PGs) and arachidonic acid (AA) metabolites [21]. Therefore, the use of non-steroidal anti-inflammatory drugs (NSAIDs) has been proposed in this regard. NSAIDs block cyclooxygenase (COX), which converts AAs to PGs [22], and previous clinical studies have shown that their use during periodontal treatment leads to PPD reduction and improvement of CAL gain [23], as demonstrated for ibuprofen (IBU) or flurbiprofen. However, their long-term use, especially through systemic delivery, is associated with potential side-effects [24].

Currently, multiphasic scaffolds represent one of the newest and very promising nanomaterials in the field of drug delivery, wound healing and tissue engineering. Immediate or modified drug release can be achieved by varying the choice of polymer and the manner of drug loading for nanofiber production [25]. These strategies tend to facilitate the controlled release and local delivery of drugs



in a time-dependent manner, rendering it possible to overcome the side-effects of systemic delivery of certain drugs [26]. The functionalization of scaffolds with drugs could be obtained with several methods such as impregnation, incorporation, encapsulation, coating and grafting, hence imparting different advantageous characteristics to the membrane [27]. In this context, a poly- $\epsilon$ -caprolactone (PCL) membrane was evaluated and demonstrated for its pro-regenerative ability in periodontal applications [28]. The PCL membrane has been reported to be biodegradable and biocompatible with enhanced mechanical properties to stabilize the initial clot [29]. Interestingly, functionalization with anti-inflammatory compounds such as alpha-melanocyte-stimulating hormone ( $\alpha$ -MSH) has already displayed amplified anti-inflammatory effects associated with anti-soft tissue invasion and anti-fibrotic characteristics [28]. Fascinated by this concept, NSAID-loaded electrospun membranes (ketoprofen/PCL and piroxicam/chitosan) have also been successfully tested for periodontal regeneration in vitro with promising results [30–32].

The aim of our study was to develop an efficient anti-inflammatory scaffold to overcome the post-operative inflammation after GTR, through localized delivery of IBU from electrospun PCL nanofibers thus, integrating the barrier technique with anti-inflammatory therapy, to assess the biocompatibility and anti-inflammatory properties of the IBU-functionalized PCL membrane (IBU-PCL) and to study its potential pro-regenerative role during periodontal wound healing in vitro and in vivo. The primary expected goal of our synthesized scaffold was to control inflammation and migration of soft tissue-associated cell types and to achieve a short epithelial attachment reinforced by an underlying connective tissue support, thereby eliminating the undesirable long junctional epithelial attachment hindering ad integrum periodontal regeneration.

## 2. Results

### 2.1. Release of IBU from IBU-PCL Membrane

The release profile showed that IBU exhibited a burst release. The optimal therapeutic concentration of IBU (98%) was achieved after 2 h (Figure 1A). Moreover, it confirmed the encapsulation of the IBU within the PCL phase (Figure 1B). The morphology and fiber diameter distributions of the IBU-PCL membrane exhibited no beads in the fibrous structure, and the fibers were uniform in size and interconnected in order to mimic the natural extracellular matrix (ECM) (Figure 1C). The diameter of fibers was  $374 \pm 89$  nm for the IBU-PCL electrospun fibrous membrane.

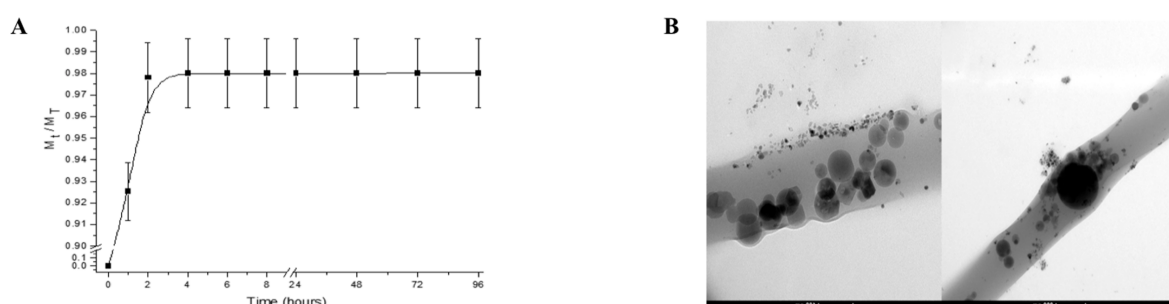



Figure 1. Cont.

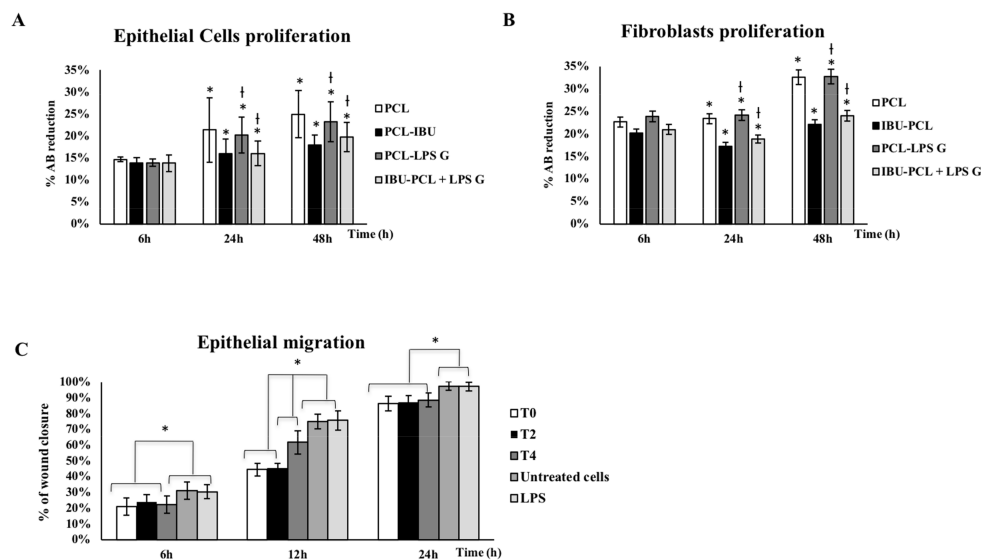


**Figure 1.** Morphology and analyses (quantitative and qualitative) of IBU-PCL electrospun fibrous scaffolds. In vitro IBU release profile (A) and localization of IBU (B) within PCL electrospun fibers. 98% of IBU was released from PCL electrospun fibers during the first two hours in PBS. Analysis was determined by UV spectroscopy and transmission electron microscopy observation (TEM). The scale bar of the TEM images represents 100 and 200 nm. The fiber size distribution was obtained by measuring at least 200 fibers in different scanning electron microscopy (SEM) images (C) of the IBU-PCL electrospun fibrous membrane. The fiber solution was constituted by 10% of PCL, 20% of non-commercial hydroxyapatite (HANc), 10% of IBU and 10% of polyvinyl acetate (PVAc) (*w/w*), and the fiber diameter was of 374 nm. The scale bar of the SEM images represents 10, 3 and 1  $\mu\text{m}$ .

## 2.2. IBU-PCL Membrane Reduces Proliferation of Pg-LPS-Stimulated Cells

To assess if the IBU-PCL membrane influences EC and FB proliferation in an inflammatory context, cells were challenged by Pg-LPS during 6–48 h. Exposure to Pg-LPS induced an increased proliferation of both EC and FB seeded on the PCL membrane at 24 and 48 h (Figure 2A,B). Interestingly, these increments were not observed for cells seeded on the IBU-PCL membrane.

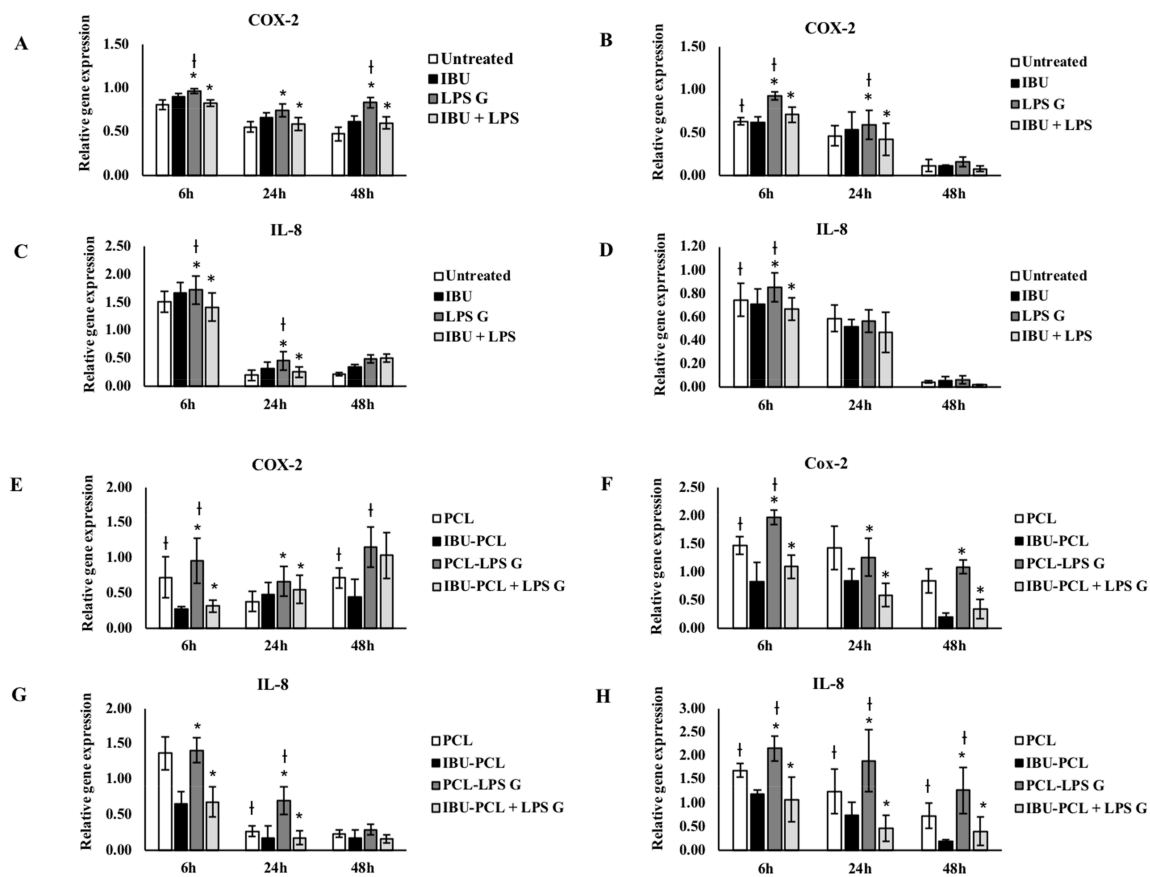
To evaluate the impact of IBU on EC migration, a scratch assay has been performed. Data showed that early treatment of Pg-LPS-stimulated EC with IBU significantly reduced their migration rate (42% decrease at 12 h;  $p < 0.05$ ) (Figure 2C).



**Figure 2.** Proliferation of EC (A) and FB (B) after 6, 24 and 48h and EC migration after 6–24 h (C). These different conditions have been measured by using the AlamarBlue test (A,B). EC and FB proliferation has been evaluated on PCL and IBU-PCL membranes and with or without Pg-LPS stimulation. Data are expressed as the mean  $\pm$  SD. \* Difference between cells with or without IBU,  $p < 0.05$ , † difference between stimulated cells with or without IBU,  $p < 0.05$ . Epithelial migration has been evaluated through the in vitro scratch assay (C) after injection of IBU (50  $\mu\text{g}/\text{mL}$ ) at baseline (T0), 2 h (T2) and 4 h (T4) at 6, 12 and 24 h in EC stimulated with Pg-LPS. Data are expressed as the % of wound closure  $\pm$  SD; \*  $p < 0.05$ .

### 2.3. IBU-PCL Membrane Modulates mRNA Expression in Stimulated Cells

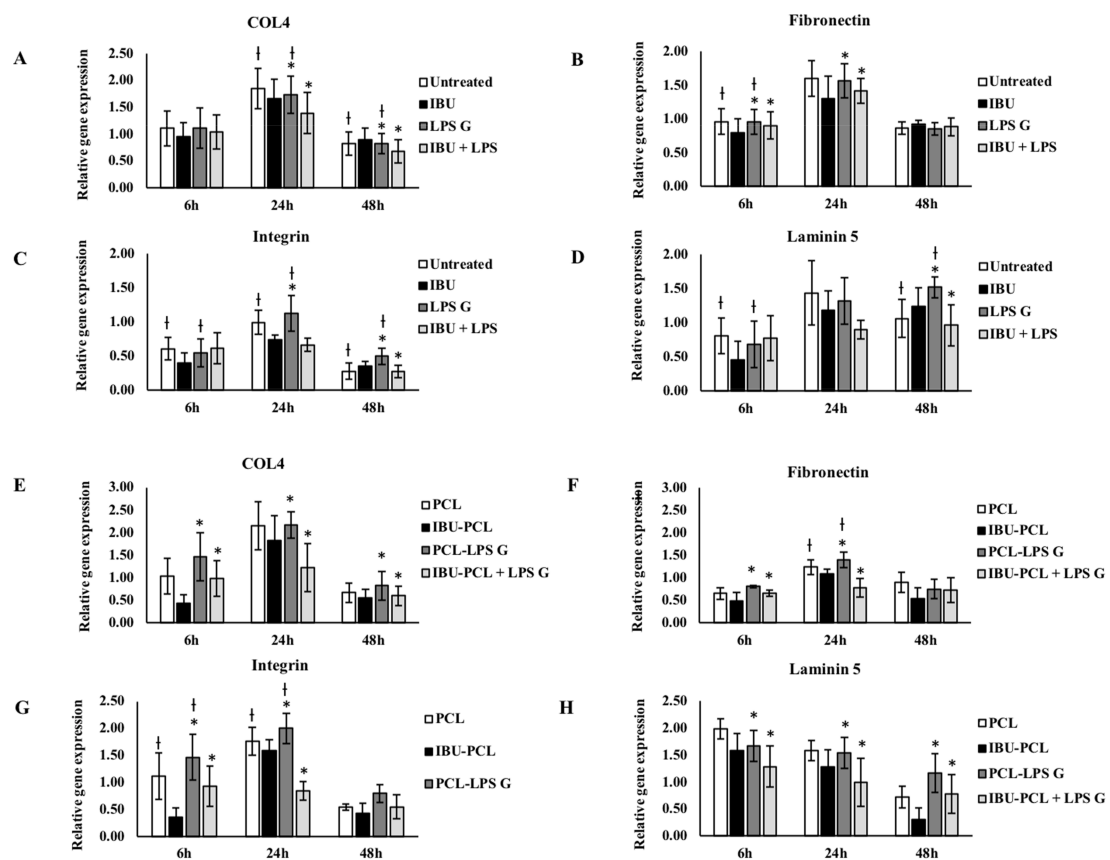
In order to evaluate the anti-inflammatory and pro-regenerative properties of the IBU-PCL membrane, gene expression of COX-2, IL-8 and extracellular matrix (ECM)-related molecules (fibronectin-1, collagen-IV, integrin  $\alpha3\beta1$  and laminin-5) was measured in cells stimulated by *Pg*-LPS. As expected, exposure to *Pg*-LPS significantly increased gene expression of inflammatory mediators, COX-2 and IL-8 in EC and FB seeded on plastic and on the PCL membrane (Figure 3). Such an increase was counteracted in *Pg*-LPS-stimulated cells seeded on the IBU-PCL membrane emphasizing the anti-inflammatory effect associated with the release or contact between cells and IBU.



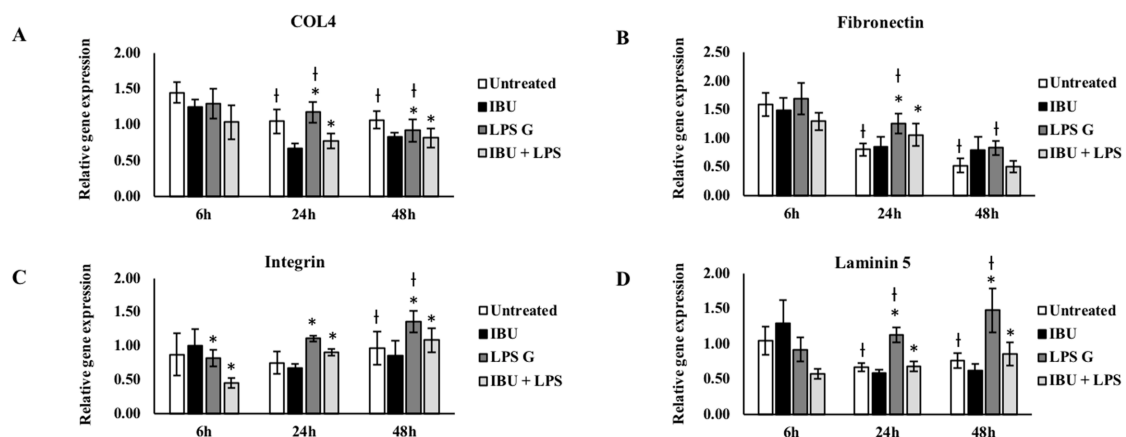
**Figure 3.** Gene expression of COX-2, IL-8 in EC (A,C,E,G) and FB (B,D,F,H) cultured on plastic (A–D) and PCL membrane (E–H). Relative mRNA levels were analyzed by real-time RT-qPCR for COX-2, IL-8 in EC and FB after 6 h and 24 h. Data are expressed as mean  $\pm$  SD. † Difference between non-stimulated and stimulated cells,  $p < 0.05$ ; \* difference between stimulated cells with or without IBU,  $p < 0.05$ .

ECM factor expression was also modulated by *Pg*-LPS challenge, and this exposure significantly enhanced fibronectin and laminin-5 expression in FB seeded on plastic and membrane (Figure 4). IBU had no significant effect on mRNA expression of ECM factors in EC and FB not exposed to *Pg*-LPS (Figures 4 and 5) and cultured on plastic compared to their respective controls, whereas, in the presence of *Pg*-LPS, IBU significantly decreased integrin  $\alpha3\beta1$  expression in EC (Figure 5) and fibronectin-1 expression in FB (Figure 4). In contrast to the cell cultures on plastic, the IBU-PCL membrane decreased mRNA expression of collagen-IV, fibronectin-1, integrin  $\alpha3\beta1$  and laminin-5 in both non-stimulated and stimulated EC and FB at 6 h. These results showed that embedding of IBU within PCL membrane enhanced its effects on gene expression in a cell-dependent manner. Furthermore, negligible decrease

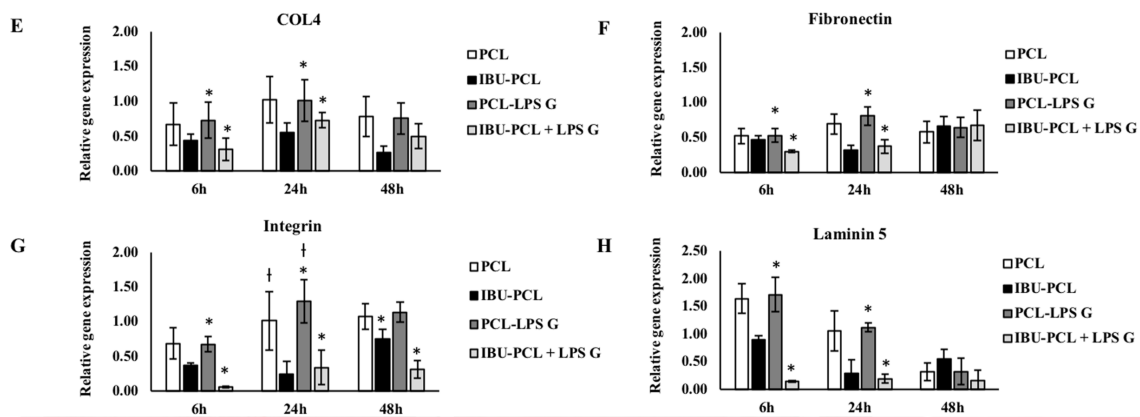
of mRNA expression of COX-2, IL-8 and ECM factors by PCL membrane in cells, both non-stimulated and stimulated with *Pg*-LPS, revealed the non-toxic/non-inflammatory nature of the membrane.



**Figure 4.** Gene expression of collagen-IV, fibronectin-1, integrin  $\alpha 3\beta 1$  and laminin-5 in FB cultured on plastic (A–D) and PCL membrane (E–H). Relative mRNA levels were analyzed by real-time RT-qPCR for collagen-IV, fibronectin-1, integrin  $\alpha 3\beta 1$  and laminin-5 in FB after 6 and 24 h. Data are expressed as the mean  $\pm$  SD. † Difference between non-stimulated and stimulated cells,  $p < 0.05$ ; \* difference between stimulated cells with or without IBU,  $p < 0.05$ .



**Figure 5.** Cont.



**Figure 5.** Gene expression of collagen-IV, fibronectin-1, integrin  $\alpha3\beta1$  and laminin-5 in EC cultured on plastic (A–D) and PCL membrane (E–H). Relative mRNA levels were analyzed by real-time RT-qPCR of collagen-IV, fibronectin-1, integrin  $\alpha3\beta1$  and laminin-5 in EC after 6 and 24 h. Data are expressed as the mean  $\pm$  SD. † Difference between non-stimulated and stimulated cells,  $p < 0.05$ ; \* difference between stimulated cells with or without IBU,  $p < 0.05$ .

2.4. IBU-PCL Membrane Improves Wound Healing in an Induced Periodontitis Mouse Model

IBU-PCL membrane was surgically placed in an experimental periodontitis mouse model to evaluate its therapeutic potential in vivo (Figure 6). Epithelial attachment (EA) and bone level (BL) were evaluated 22 d after membrane placement. A qualitative improvement of CAL was observed in membrane-treated sites exhibiting a more important connective tissue attachment and a corresponding shorter junctional epithelium in comparison with sites treated with SRP only ( $p < 0.05$  for PCL and IBU-PCL vs. control) (Figure 6F). Regarding BL, no improvement was measured in sites treated with either of the membranes in comparison with SRP-treated sites. However, no osteoclastic activity was observed on alveolar bone margins at IBU-PCL-treated sites, while some was detected at PCL-treated sites (Figure 6G,H). Interestingly, some inflammatory cell infiltrate was observed surrounding the membrane (both IBU-PCL and PCL) visibly persistent in the tissue (connective tissue zone) (Figure 6E). In some cases, a space in the fibrous connective tissue organization indicated the presence of a membrane (IBU-PCL) that may have stayed intact for a short duration of time.

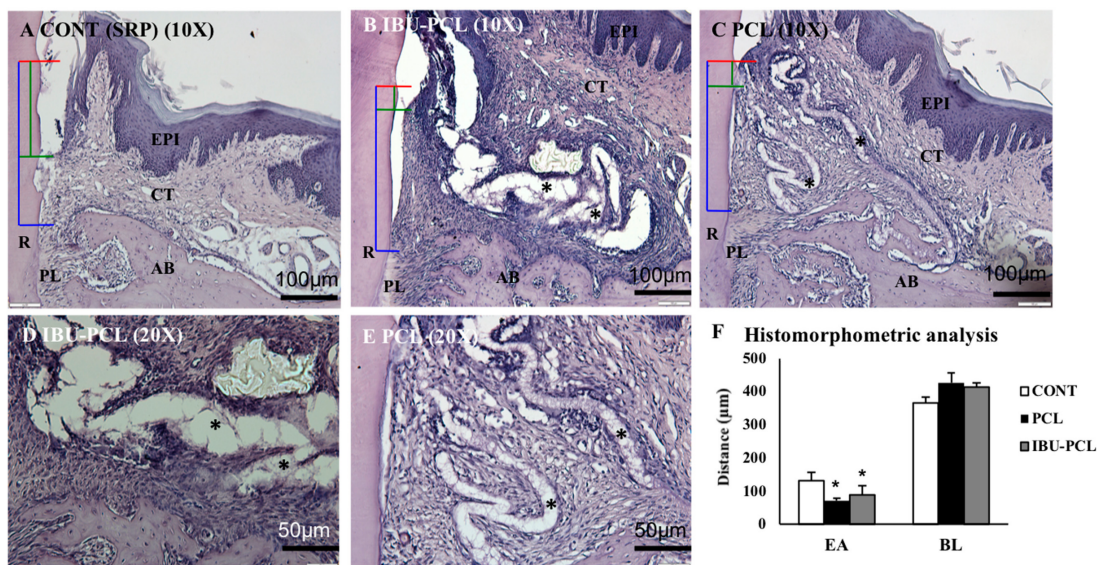
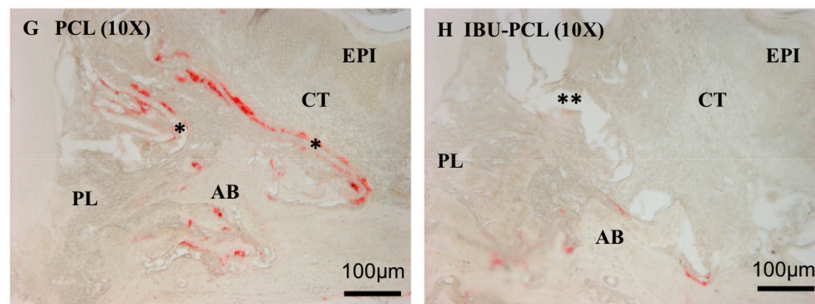


Figure 6. Cont.





**Figure 6.** Periodontal wound healing at 22 days. Corresponding histological sections scaling and root planning (SRP) (A), IBU-PCL (B,D), and PCL (C,E). Red lines = cemento-enamel junction (CEJ); green lines = epithelial attachment level; yellow lines = bone level. PCL and the IBU-PCL membrane are highlighted (\*). Histomorphometric analysis (F). EA and BL have been measured on histological sections. Distances are expressed as the mean  $\pm$  SD in  $\mu\text{m}$ ; \*  $p < 0.05$ . TRAP expression: Few TRAP-positive cells (red staining) were observed on the bone surface at 22 days (G,H). Numerous TRAP-positive cells were observed around PCL membrane (\*), but not around the IBU-PCL membrane (\*\*). EPI: gingival epithelium, CT: gingival connective tissue, AB: alveolar bone, PL: periodontal ligament, R: root, EA: epithelial attachment level, BL: bone loss.

### 3. Discussion

Achievement of periodontal regeneration is the ideal goal of periodontal treatment. In this study, an NSAID-loaded scaffold was developed to combine both mechanical properties of a barrier membrane and anti-inflammatory effects of IBU. Herein, we demonstrated the anti-inflammatory and anti-migratory effects of IBU-PCL membrane and its positive effects on periodontal wound healing parameters.

Inflammation is a necessary component of wound healing, which if persists, may hinder tissue regeneration. Excessive inflammation may lead to wound non-closure or development of granulation tissue [32]. Furthermore, activation of COX-2 by bacterial stressors or cytokines (IL-1 $\alpha$ , TNF- $\alpha$ ) will induce production of PGE<sub>2</sub>, which has been demonstrated to be involved in the regulation of bone metabolism through activation of related molecular pathways in FB or periodontal ligament cells [33]. Therefore, development of immunomodulatory strategies may be of interest to improve periodontal regeneration outcomes, and several drugs or compounds from synthetic or natural origin have been tested, aiming to reduce inflammatory markers' levels [20,34,35]. However, systemic delivery may reduce their efficacy and may increase the risk of side-effects. Therefore, new scaffolds based on nanotechnologies were developed to deliver drug to particular tissues or cells [36].

PCL membranes have been previously used to promote periodontal ligament, bone healing [37,38], as a scaffold for periodontal cells [39] and as a drug carrier [40,41]. Biocompatibility of PCL has also been extensively demonstrated with osteoblasts in vitro [42,43] or in vivo [38] and medical-grade PCL is already available [41]. The PCL membrane exhibited a fiber distribution and diameter similar to the ECM combining high infiltration and integration with mechanical properties such as low resorbability and space maintenance [44].

Here, IBU was selected and loaded into PCL core-shelled nanofibers, protecting it during the electrospinning process [45]. IBU is a well-described anti-inflammatory drug that has been evaluated in the context of periodontitis [46]. Here, we selected the dose of 50  $\mu\text{g}/\text{mL}$  based on the low cytotoxicity and its capability to reduce EC migration. Herein, this dose was able to reduce the expression of inflammatory markers induced by *Pg*-LPS stimulation in both cell types significantly. *Pg*-LPS is a strong inducer of pro-inflammatory responses in gingival EC and FB [28,47]. In this inflammatory model, *Pg*-LPS increased COX-2 and IL-8 expression as previously observed in a cell-dependent manner [48–50]. This cell-specific response was also observed in keratinocytes and fibroblasts in skin substitutes [51] and may be explained by the type of Toll-like receptor (TLR) activated [52,53]. In the

present study, the IBU-PCL membrane amplified and/or extended over time the anti-inflammatory effect of IBU depending on cell type emphasizing the role of the progressive release by the scaffold as observed for the association with the PLGA membrane [54].

The proliferation rate of EC and FB cultured on PCL membranes showed that PCL membranes were biocompatible for gingival cells. Interestingly, the use of PCL membranes delayed cell proliferation, and this effect appeared to be less pronounced in EC than in FB [55]. This reduction of proliferation was amplified with the same dose of IBU in PCL membranes. This difference in proliferation between EC and FB may be due to the surface chemistry and topography, microstructure and mechanical properties of the cultures. Furthermore, PCL membranes functionalized with IBU tend to decrease EC and FB proliferation stimulated by *Pg*-LPS. These results suggest that the use of IBU-PCL membranes may prevent or delay gingival cell migration in an inflammatory context.

Concerning the ECM molecule expressions, IBU downregulated collagen-IV, fibronectin-1, integrin  $\alpha 3\beta 1$  and laminin-5 expressions in EC and FB cultured on plastic and PCL membrane. Compared to plastic culture, downregulation of genes was also amplified with the same dose of IBU in PCL. Fibronectin-1 and laminin-5 are essential for periodontal wound healing. Fibronectin-1 constitutes a provisional wound matrix (clot), and laminin-5 is a key ECM component of the intact basement membrane and hemi-desmosomes [56]. Integrin  $\alpha 3\beta 1$  is the main molecule by which cells communicate with the ECM mainly through binding to laminin-5 and fibronectin-1 [57]. Collagen-IV constitutes a new matrix that replaces the clot and leads to restoration of both the structure and function of the periodontal basement membrane [58]. These molecules were expressed by keratinocytes, FB [56] and involved in adhesion, migration, proliferation and interaction between the epithelial and connective tissues [54–58]. Furthermore, previous *in vivo* studies have shown that NSAIDs could significantly inhibit collagen deposition in granulation tissue [59]. Taken together, these data showed anti-inflammatory, anti-proliferative and anti-fibrotic effects of IBU in a time- and cell-dependent manner.

The electrospun PCL nanofibrous scaffold architecturally mimics the ECM in living tissues, but its poor hydrophilicity caused a reduction of its ability of cell adhesion, migration, proliferation and differentiation [60]. However, by combining two or more classes of materials into composites, such as a crystalline ceramic (e.g., HA) and a synthetic polymer (e.g., PCL), scaffolds with improved mechanical properties can be expected [61]. Electrospun composite PCL/nHA (nanohydroxyapatite) nanofibrous membranes improve mineralization of mesenchymal stem cells to promote bone tissue regeneration. nHA is the major inorganic component of the bone matrix, and its specific affinity toward many adhesive proteins and direct involvement in the bone cell differentiation and mineralization processes make nHA especially appealing for applications in the bone regeneration field [62]. nHA has been incorporated in PCL by electrospinning in several studies *in vitro* [63] and *in vivo* in a calvarial defect mouse model where association with HA significantly improved bone healing induced by PCL [64]. The HA-coated PCL membrane has favorable effects on proliferation and differentiation of human periodontal ligament cells and might be a candidate material for periodontal tissue regeneration [65]. Similarly, the properties of PCL have also been enhanced by the use of silica [66], and other pretreatments enhancing mineralization would be of interest for bone tissue mineralization and regeneration as demonstrated for cellulose-based porous matrix [67].

Establishment of periodontal destruction in mice is a well-described phenomenon [68], and its use will confer several advantages over the use of large animals in the context of periodontal treatment such as a large number of available kits for analysis, transgenic strains and laboratory considerations (housing, cost). Additionally, it will allow us to investigate the molecular mechanisms regulating the wound healing process or drug application. Infected ligature-induced periodontitis is considered to be a reliable and reproducible model of experimental periodontitis so far as it is site-specific and results, as observed in humans, in rupture and apical migration of the junctional epithelium, inflammatory cell infiltration and time-dependent alveolar bone resorption. In this model, connective tissue and bone loss occur predictably over a period of 7–15 days [69,70]. The ligatures can be inserted and



removed on an “as and when required” basis; therefore, using ligatures is a flexible and optimizable method for disease induction [71]. Moreover, the use of *Pg*-infected ligatures supported a long-lasting infection of *Pg* in mice, resulting in alveolar bone breakdown as seen in humans [72]. In our study, we demonstrated, to the best of our knowledge, the feasibility of membrane placement in such an experimental periodontitis model. In vivo, the positive impact of membrane placement on periodontal wound healing and its biocompatibility were observed. However, it is mandatory to understand and control the scaffold degradation process. As tissue ingrowth and maturation are tissue-specific phenomena, a defect filled with immature tissue should not be considered “regenerated”. Hence, many scaffold-based strategies have failed in the past, as the scaffold degradation was more rapid than tissue remodeling or maturation. It is important that the scaffold remains intact as the tissue matures in the scaffold pores, with bulk degradation occurring later [10]. Here, membrane persistence in the connective tissue zone may have hindered bone regeneration, and an optimization of its degradation rate is required. However, the use of bioresorbable PCL membrane at 22 d of periodontal wound healing maintained its primary focus on the soft tissue healing response, whereas a longer time point needs to be evaluated to study the healing response of the bone and periodontal ligament after the resorption of the membrane. As a perspective, combination with specific bone pro-regenerative molecules such as BMP-2 could be performed to improve regeneration of profound periodontium, as it was demonstrated that electrospun PCL functionalized with BMP-2 enhanced bone healing and regeneration [73,74]. Such a combination will be of interest to obtain a better bone healing response, thereby reaching a coordinated soft and hard tissue healing response.

GTR membranes often suffer exposure to consequent infection and inflammation. The post-operatively persisting inflammation after GTR can worsen the treatment outcomes [17]. Therefore, application of this IBU-loaded anti-inflammatory GTR membrane (IBU-PCL) could be a judicious choice to prevent local post-operative inflammation after further optimization with in vivo and pre-clinical models. In the future, an appropriate combination of antibiotic or growth factors with an anti-inflammatory drug could be ideal to overcome post-operative GTR complications and could be beneficial in striding towards improved periodontal wound healing and regeneration.

## 4. Materials and Methods

### 4.1. Cell Culture

Human oral epithelial cells (TERT-2 OKF-6, BWH Cell Culture and Microscopy Core, Boston, MA, USA) (EC) were cultivated in Keratinocyte-SFM medium (Life Technologies, Saint-Aubin, France) supplemented with growth supplementation mix and antibiotics (10 U/mL penicillin and 100 µg/mL streptomycin) (Lonza, Levallois-Perret, France). Human oral fibroblasts (FB) were cultivated in RPMI 1640 medium supplemented with 10% fetal bovine serum (Life Technologies, Saint-Aubin, France), 2 mM glutamine, 250 U/mL fungizone and 10 U/mL antibiotics (10 U/mL penicillin and 100 µg/mL streptomycin) at 37 °C in a humidified atmosphere with 5% CO<sub>2</sub>, and the culture medium was changed every 2–3 days as described in Morand et al. [17].

### 4.2. Bacterial Culture

The *Pg* strain (ATCC 33277) was purchased from the American Type Culture Collection (ATCC, Manassas, VA, USA). Bacterial culture was performed under strict anaerobic conditions at 37 °C in brain-heart infusion medium supplemented with hemin (5 mg/mL) and menadione (1 mg/mL) purchased from Sigma (St. Louis, MO, USA). For each experiment, bacteria were grown in anaerobic conditions at 37 °C for 4 days, and before use, the bacterial culture was centrifuged, bacteria were washed twice with phosphate buffer saline (PBS) and counted as previously described [51]. Commercial ultrapure *Pg*-LPS was purchased from InvivoGen (San Diego, CA, USA).

#### 4.3. Stimulation of Cells with *Porphyromonas Gingivalis*-Lipopolysaccharide

Twenty-four hours before the experiment,  $5 \cdot 10^4$  EC or  $2 \cdot 10^4$  FB were seeded in each well of a 24-well plate. On the day of the experiment, cells were washed twice with PBS and exposed to *Pg*-LPS stimulation at a concentration of  $1 \mu\text{g}/\text{mL}$ . Ibuprofen sodium salt (Sigma, St-Quentin, France) was used as the experimental drug at a concentration of  $50 \mu\text{g}/\text{mL}$ .

#### 4.4. Electrospinning and Functionalization

IBU-PCL membranes were prepared by electrospinning process using a Yflow 2.2.D-500 electrospinner (Coaxial Electrospinning Machines/R&D Microencapsulation, Malaga, Spain). PCL pellets were dissolved at 10% *w/w* (PCL/solvents) in dichloromethyl/dimethyl formamide (DCM/DMF) (1:1), and polyvinyl acetate (PVAc) was dissolved at 10% *w/w* (PVAc/solvents) in DMF; these two solutions were stirred overnight at room temperature. To prepare PCL-HAnC-IBU (20% of non-commercial hydroxyapatite (HAnC) and 10% of IBU *w/w*) scaffolds, PCL pellets were dissolved in DCM/DMF by stirring overnight at room temperature; then, HAnC and IBU powders were weighed and dispersed with the help of TWEEN<sup>®</sup> 80 by stirring overnight at room temperature. Both solutions were loaded into 20-mL plastic syringes connected to a coaxial spinneret by plastic tubes having inner needle and outer needle diameters of 0.9 mm and 1.7 mm, respectively, with the outer needle connected to a positive voltage power supply at 13.26 kV. The shell and core flow rates and the spinning distance were fixed at 0.5 mL/h and 19 cm. The spun fibers were collected on a static plate connected to a negative voltage power supply at  $-2.7$  kV.

#### 4.5. Scanning and Transmission Electron Microscopy

In vitro release of IBU was carried out at  $37^\circ\text{C}$  in phosphate buffer saline (PBS) at  $\text{pH} = 7.4$ . The materials loaded with IBU were immersed in 3 mL of PBS. At predetermined time intervals, aliquots of the dissolution medium were withdrawn, and an equivalent amount of fresh medium was added to maintain a constant dissolution volume. IBU concentration in the aliquots was determined by UV spectroscopy using a Varian Cary 50 PROBE UV-Visible spectrophotometer (Agilent Technologies, Santa Clara, CA, USA) at 221 nm from the standard calibration curve. The prepared fibers were studied by scanning electron microscopy (SEM; CSEM-FEG INSPECT 50, Thermo Fisher Scientific, Waltham, MA, USA) and transmission electron microscopy (TEM; FEI Tecnai F30 and probe aberration-corrected FEI-Titan 60-30, Thermo Fisher Scientific) to characterize fibers' size and morphology. The size distribution statistics were obtained by measuring at least 200 fibers in different images. Samples for SEM were mounted on metal stubs and sputter-coated with platinum.

#### 4.6. Cell Viability Assay

The effect of different doses of IBU on EC and FB viability was analyzed by the AlamarBlue assay (Life Technologies, Saint-Aubin, France). After 6, 24 and 48 h of stimulation, 200  $\mu\text{L}$  of incubation media were transferred to a 96-well plate and measured at 590 and 630 nm in order to determine the percentage of AlamarBlue reduction.

#### 4.7. Wound Closure Assay

Cell migration was assessed by the wound-healing "scratch" assay. EC were seeded in 48-well plates at  $2.5 \times 10^4$  cells/mL and grown until confluence. Cells were washed with PBS. In each well, a scratch was made with the tip of a sterile pipette point (200  $\mu\text{L}$ ). Cells were washed again with PBS in order to remove cell debris. In each well, 500  $\mu\text{L}$  of medium containing IBU or only medium were added. The scratch was captured immediately and after 24 h with an optical microscope (Nikon inverted microscope, Eclipse TS100, Nikon, Champigny-sur-Marne, France), and the area of the scratch was calculated with Photoshop CS4. The closure percentage of the scratch was calculated as  $((\text{surface of the scratch at time 0 h} - \text{surface of the scratch at time 24 h}) / (\text{surface of the scratch at time 0 h} \times 100))$ ,

as described in [28]. Only ECs, being the first cell type to migrate to the periodontal wound and hindering tissue regeneration owing to their high proliferation rate, were selected for performing the scratch test.

#### 4.8. Real-Time qPCR

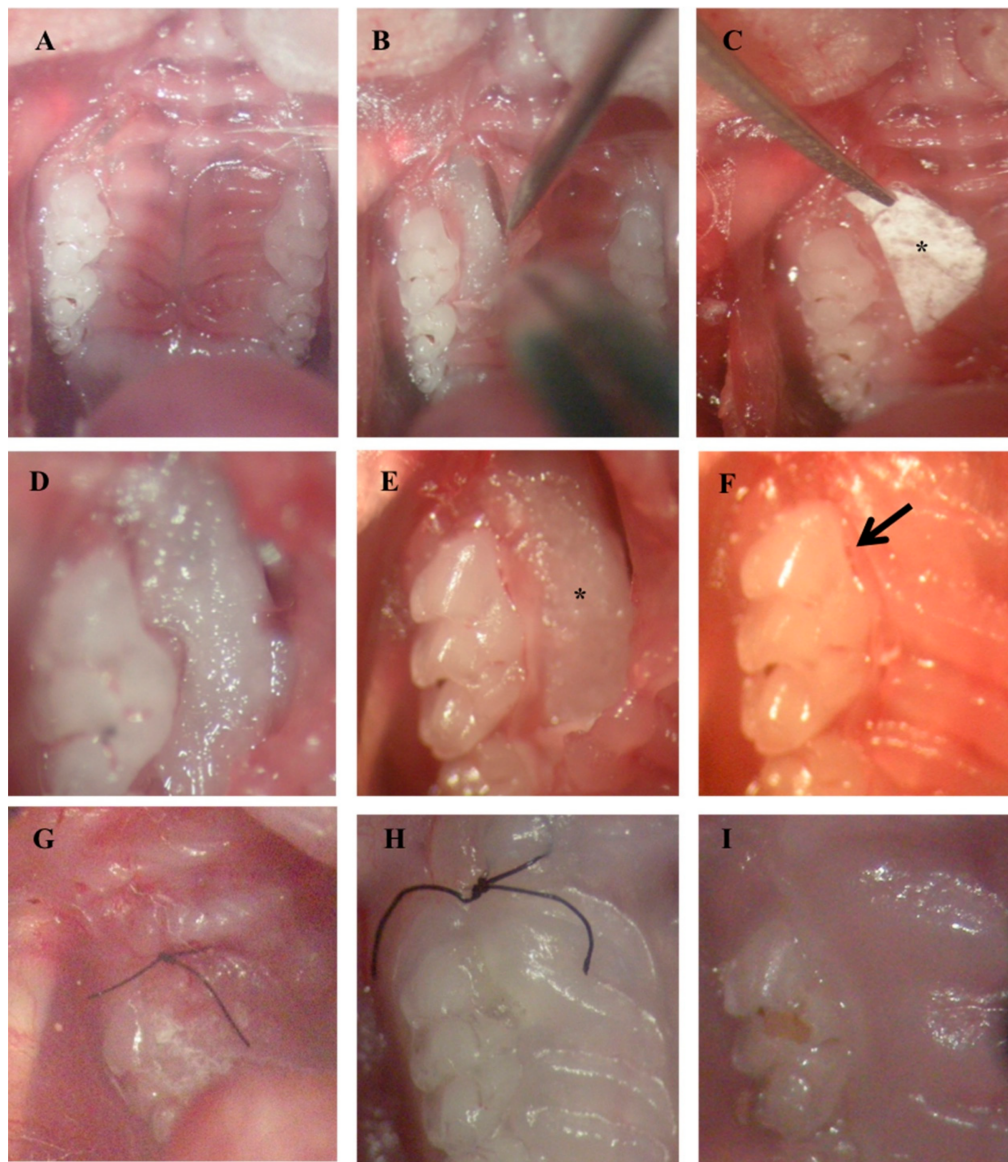
To quantify RNA expression, qPCR was performed on the cDNA samples. PCR amplification and analysis were achieved using the CFX Connect™ Real-Time PCR Detection System (Bio-Rad, Miltry-Mory, France). Amplification reactions have been performed using iTaq Universal SYBR Green Supermix (Bio-Rad, Miltry-Mory, France). Beta-actin was used as the endogenous RNA control (housekeeping gene) in the samples. Primer sequences were synthesized by Life Technologies (Saint-Aubin, France). The specificity of the reaction was controlled using melting curve analysis. The expression level was calculated using the comparative Ct method ( $2^{-\Delta\Delta C_t}$ ) after normalization to the housekeeping gene. All PCR assays were performed in triplicate, and the results are represented by the mean values. All primers sequences are listed in Supplemental File S1.

#### 4.9. Experimental Periodontitis Induction in Mouse Model

To avoid any potential effects of estrogen, only male mice C57BL/6J (n = 9) aged 8 weeks were used in this study. All animals were regularly fed and kept in separate cages. All procedures were approved by the local ethics committee and performed according to the regulations for animal experimentation. Mice were examined to evaluate pain and stress, and their weights were monitored daily. Periodontitis was induced in mice by *Pg*-infected ligatures to simulate disease condition comparable to human periodontitis as described previously [68,75]. Briefly, after anesthesia, *Pg*-infected silk ligatures (6-0) were placed repeatedly in the palatal sulcus of the first molar (bilaterally) thrice a week for up to 40 days. The placement of *Pg*-infected ligatures was facilitated by sulcular incisions bilaterally and a drop of a thin mix of Glass Ionomer Cement (Ketac™ Cem radiopaque, 3M ESPE) to retain the ligatures in the sulcus around the cervical areas of the maxillary molars. Infected ligatures were renewed every two days. Gradually, after carrying out a few inductions, the periodontal pocket was well established, and therefore, the ligatures could be retained within the pocket without any need of cement to block them. To ensure uniformity and standardization of the defects, the same procedures were performed bilaterally each time by the same operator to overcome operator bias. After induction, the periodontal lesion was characterized by periodontal pocket formation, soft tissue inflammation associated with bleeding on probing and bone destruction assessed through micro-CT to ensure the uniformity and standardization of defects in terms of the size and morphology before initiating the treatment (average BL = 485  $\mu$ m) (Supplemental File S2).

#### 4.10. Treatment of Periodontal Defect

Sulcular incisions were performed bilaterally, along the cervical margins of the maxillary 1st and 2nd molars and extended a little anteriorly on the mesial aspect of the 1st molar to raise the flap efficiently to gain surgical access (Figure 7A,B). SRP was performed at all sites, and PCL or IBU-PCL membranes were surgically placed along the right molars (test sides) in mice (n = 4 and n = 5, respectively). Left molars were treated only by SRP and constituted control sides. Membranes were punched with a 3 mm-diameter cutter. The cut circular pieces of membrane were further cut into two halves. The cut membrane was then placed over the bony defect under the raised flap in such a way that the concave part of the membrane faced and covered the necks of the crowns of the teeth, entering the interdental area, as well, and the rest of the bulk of the membrane was placed flat beneath the flap with its convex side facing towards the palatal midline (Figure 7C–F). The membrane was then sutured to ensure its retention under the flap (Figure 7G). Post-operative wound healing was assessed at 7 and 15 days (Figure 7 H,I). Mice were euthanized with an intraperitoneal lethal injection of pentobarbital (100 mg/kg) (Centravet) 22 days after the treatment.



**Figure 7.** Surgical placement of membrane in the induced periodontitis mice model. Incision (A) followed by flap raising for periodontal lesion access and debridement (B,D). Membrane (\*) calibration (C) and placement (\*) beneath the palatal flap (E). Palatal flap covering membrane (arrow) (F). Sutures (G). Post-surgical views at 7 days (H) and 15 days (I).

#### 4.11. Tissue Preparation

Tissue fixation was performed by intra-cardiac perfusion with a solution containing 4% paraformaldehyde (PFA) in PBS (pH 7.4). Afterwards, maxillae were dissected and post-fixed by immersion in the same fixative solution overnight at 4 °C. After rinsing with PBS for 24 h, the specimens were demineralized at 4 °C in 15% EDTA at pH 7.4 for 3 weeks with a regular change of solution every 2 days. After extensive washing in PBS, the samples were dehydrated in increasing concentrations of ethanol and toluene before finally embedding in paraffin (Paraplast plus, Sigma). Seven micrometer-thick serial frontal paraffin sections of the maxilla were cut with a microtome.

#### 4.12. Histomorphometric Analysis

For histomorphometric evaluation, prepared sections were deparaffinized, rehydrated and stained with hematoxylin. After dehydration, slides were mounted with Distrene-plasticizer-xylene



(DPX) resin (Sigma), and computerized images were captured on a microscope (RM 2145 DMRB microscope, Leica, Rueil-Malmaison, France). Palatal root areas of the first molars were analyzed to examine the extension of epithelial downgrowth, connective tissue attachment and alveolar bone loss. For histomorphometric analysis: epithelial attachment (EA) was measured from the cemento-enamel junction (CEJ) to the apical limit of the epithelium, and the alveolar bone level (BL) was measured from CEJ to alveolar bone crest (ABC) using imaging software (ImageJ, 1.46r, National Institute of Mental health (NIMH), Bethesda, Maryland, USA).

#### 4.13. Tartrate-Resistant Acid Phosphatase Activity Assay (TRAP)

Paraffin frontal sections were rehydrated, placed in a fixative solution for 5 minutes and rinsed with water before staining with acetate buffer (at pH 5.2) containing 2.5 mM naphthol AS-TR-phosphate, 0.36 M *N,N*-dimethylformamide, 0.1 M sodium tartrate and 4 mM 1,5-naphthalenedisulfonate salt. After staining, sections were rinsed with water and mounted with mounting medium. Using imaging software, TRAP-positive cells were analyzed on the ABC surface at the palatal root and the mesial and distal furcation aspects of the first molar using standardized views.

#### 4.14. Statistical Analysis

All experiments were repeated at least three times (technical and biological replicates), and statistical analysis was performed using the Mann–Whitney test (XLSTAT, Addinsoft France, Paris, France). A probability of a *p*-value < 0.05 was considered significant.

## 5. Conclusions

We developed an efficient anti-inflammatory GTR membrane. Hence, electrospun biodegradable IBU-PCL nanofiber membranes could be an optimal choice for the local prevention of post-surgical inflammation and improved wound healing. Besides, this scaffold may also be used for localized drug delivery of bioactive molecules such as antimicrobials or growth factors, in a dose- and spatially-controlled manner.

**Supplementary Materials:** The following are available online at <http://www.mdpi.com/1996-1944/11/4/580/s1>, File S1: Primers' sequences, File S2: In vivo micro-computed tomography (micro-CT) analyses.

**Acknowledgments:** The authors are very grateful to the ANR (The French National Research Agency) (No. ANR-14-CE16-0025-01) for their valuable support.

**Author Contributions:** Fareeha Batool and David-Nicolas Morand contributed to the design of the study, the experiments, the results' analysis and manuscript writing. Lionel Thomas facilitated the micro-CT analysis. Javier Aragon and Sylvia Irueta synthesized and characterized the functionalized membrane. Isaac Maximiliano Bugueno, Laetitia Keller and Nadia Benkirane-Jessel critically revised the manuscript. Olivier Huck and Henri Tenenbaum contributed to the design of the study, the results' analysis and the manuscript writing.

**Conflicts of Interest:** The authors declare that they have no conflicts of interest related to this study.

## References

1. Jin, L.J.; Lamster, I.B.; Greenspan, J.S.; Pitts, N.B.; Scully, C.; Warnakulasuriya, S. Global burden of oral diseases: Emerging concepts, management and interplay with systemic health. *Oral Dis.* **2016**, *22*, 609–619. [[CrossRef](#)] [[PubMed](#)]
2. Tonetti, M.S.; Jepsen, S.; Jin, L.; Otomo-Corgel, J. Impact of the global burden of periodontal diseases on health, nutrition and wellbeing of mankind: A call for global action. *J. Clin. Periodontol.* **2017**, *44*, 456–462. [[CrossRef](#)] [[PubMed](#)]
3. Bosshardt, D.D. The periodontal pocket: Pathogenesis, histopathology and consequences. *Periodontology.* **2018**, *76*, 43–50. [[CrossRef](#)] [[PubMed](#)]
4. Nunn, M.E.; Fan, J.; Su, X.; Levine, R.A.; Lee, H.-J.; McGuire, M.K. Development of prognostic indicators using classification and regression trees for survival. *Periodontology* **2012**, *58*, 134–142. [[CrossRef](#)] [[PubMed](#)]

5. Kinane, D.F.; Stathopoulou, P.G.; Papapanou, P.N. Periodontal diseases. *Nat. Rev. Dis. Primer* **2017**, *3*, 17038. [[CrossRef](#)] [[PubMed](#)]
6. Olsen, I.; Lambris, J.D.; Hajishengallis, G. *Porphyromonas gingivalis* disturbs host-commensal homeostasis by changing complement function. *J. Oral Microbiol.* **2017**, *9*, 1340085. [[CrossRef](#)] [[PubMed](#)]
7. Feres, M.; Figueiredo, L.C.; Soares, G.M.S.; Favari, M. Systemic antibiotics in the treatment of periodontitis. *Periodontology* **2015**, *67*, 131–186. [[CrossRef](#)] [[PubMed](#)]
8. Martin-Cabezas, R.; Davideau, J.-L.; Tenenbaum, H.; Huck, O. Clinical efficacy of probiotics as an adjunctive therapy to non-surgical periodontal treatment of chronic periodontitis: A systematic review and meta-analysis. *J. Clin. Periodontol.* **2016**, *43*, 520–530. [[CrossRef](#)] [[PubMed](#)]
9. Heitz-Mayfield, L.J.A.; Lang, N.P. Surgical and nonsurgical periodontal therapy. Learned and unlearned concepts. *Periodontology* **2013**, *62*, 218–231. [[CrossRef](#)] [[PubMed](#)]
10. Ivanovski, S.; Vaquette, C.; Gronthos, S.; Hutmacher, D.W.; Bartold, P.M. Multiphasic scaffolds for periodontal tissue engineering. *J. Dent. Res.* **2014**, *93*, 1212–1221. [[CrossRef](#)] [[PubMed](#)]
11. Bosshardt, D.D.; Sculean, A. Does periodontal tissue regeneration really work? *Periodontology* **2009**, *51*, 208–219. [[CrossRef](#)] [[PubMed](#)]
12. Cortellini, P.; Buti, J.; Pini Prato, G.; Tonetti, M.S. Periodontal regeneration compared with access flap surgery in human intra-bony defects 20-year follow-up of a randomized clinical trial: Tooth retention, periodontitis recurrence and costs. *J. Clin. Periodontol.* **2017**, *44*, 58–66. [[CrossRef](#)] [[PubMed](#)]
13. Ravi, S.; Malaiappan, S.; Varghese, S.; Jayakumar, N.D.; Prakasam, G. Additive Effect of Plasma Rich in Growth Factors with Guided Tissue Regeneration in Treatment of Intrabony Defects in Patients with Chronic Periodontitis: A Split-Mouth Randomized Controlled Clinical Trial. *J. Periodontol.* **2017**, *88*, 839–845. [[CrossRef](#)] [[PubMed](#)]
14. Jenabian, N.; Haghanifar, S.; Ehsani, H.; Zahedi, E.; Haghpanah, M. Guided tissue regeneration and platelet rich growth factor for the treatment of Grade II furcation defects: A randomized double-blinded clinical trial—A pilot study. *Dent. Res. J.* **2017**, *14*, 363–369.
15. Bottino, M.C.; Thomas, V. Membranes for Periodontal Regeneration—A Materials Perspective. *Front. Oral Biol.* **2015**, *17*, 90–100. [[CrossRef](#)] [[PubMed](#)]
16. Parrish, L.C.; Miyamoto, T.; Fong, N.; Mattson, J.S.; Cerutis, D.R. Non-bioabsorbable vs. bioabsorbable membrane: Assessment of their clinical efficacy in guided tissue regeneration technique. A systematic review. *J. Oral Sci.* **2009**, *51*, 383–400. [[CrossRef](#)] [[PubMed](#)]
17. Yoshinari, N.; Tohya, T.; Mori, A.; Koide, M.; Kawase, H.; Takada, T.; Inagaki, K.; Noguchi, T. Inflammatory cell population and bacterial contamination of membranes used for guided tissue regenerative procedures. *J. Periodontol.* **1998**, *69*, 460–469. [[CrossRef](#)] [[PubMed](#)]
18. Ranjbar-Mohammadi, M.; Zamani, M.; Prabhakaran, M.P.; Bahrami, S.H.; Ramakrishna, S. Electrospinning of PLGA/gum tragacanth nanofibers containing tetracycline hydrochloride for periodontal regeneration. *Mater. Sci. Eng. C Mater. Biol. Appl.* **2016**, *58*, 521–531. [[CrossRef](#)] [[PubMed](#)]
19. Yamano, S.; Haku, K.; Yamanaka, T.; Dai, J.; Takayama, T.; Shohara, R.; Tachi, K.; Ishioka, M.; Hanatani, S.; Karunakaran, S.; et al. The effect of a bioactive collagen membrane releasing PDGF or GDF-5 on bone regeneration. *Biomaterials* **2014**, *35*, 2446–2453. [[CrossRef](#)] [[PubMed](#)]
20. Yar, M.; Farooq, A.; Shahzadi, L.; Khan, A.S.; Mahmood, N.; Rauf, A.; Chaudhry, A.A.; Rehman, I.U. Novel meloxicam releasing electrospun polymer/ceramic reinforced biodegradable membranes for periodontal regeneration applications. *Mater. Sci. Eng. C Mater. Biol. Appl.* **2016**, *64*, 148–156. [[CrossRef](#)] [[PubMed](#)]
21. Morand, D.N.; Davideau, J.-L.; Clauss, F.; Jessel, N.; Tenenbaum, H.; Huck, O. Cytokines during periodontal wound healing: Potential application for new therapeutic approach. *Oral Dis.* **2017**, *23*, 300–311. [[CrossRef](#)] [[PubMed](#)]
22. Cekici, A.; Kantarci, A.; Hasturk, H.; Van Dyke, T.E. Inflammatory and immune pathways in the pathogenesis of periodontal disease. *Periodontology* **2014**, *64*, 57–80. [[CrossRef](#)] [[PubMed](#)]
23. Brägger, U.; Mühle, T.; Fourmoussis, I.; Lang, N.P.; Mombelli, A. Effect of the NSAID flurbiprofen on remodelling after periodontal surgery. *J. Periodontol. Res.* **1997**, *32*, 575–582. [[CrossRef](#)] [[PubMed](#)]
24. Agossa, K.; Morand, D.-N.; Tenenbaum, H.; Davideau, J.-L.; Huck, O. Systemic Application of Anti-inflammatory Agents in Periodontal Treatment. *Clin. Anti-Inflamm. Anti-Allergy Drugs* **2015**, *2*, 3–13. Available online: <http://www.eurekaselect.com/142258/article> (accessed on 30 November 2017). [[CrossRef](#)]

25. Potrč, T.; Baumgartner, S.; Roškar, R.; Planinšek, O.; Lavrič, Z.; Kristl, J.; Kocbek, P. Electrospun polycaprolactone nanofibers as a potential oromucosal delivery system for poorly water-soluble drugs. *Eur. J. Pharm. Sci. Off. J. Eur. Fed. Pharm. Sci.* **2015**, *75*, 101–113. [[CrossRef](#)] [[PubMed](#)]
26. Sundararaj, S.C.; Thomas, M.V.; Peyyala, R.; Dziubla, T.D.; Puleo, D.A. Design of a Multiple Drug Delivery System Directed at Periodontitis. *Biomaterials* **2013**, *34*, 8835–8842. [[CrossRef](#)] [[PubMed](#)]
27. He, M.; Jiang, H.; Wang, R.; Xie, Y.; Zhao, C. Fabrication of metronidazole loaded poly ( $\epsilon$ -caprolactone)/zein core/shell nanofiber membranes via coaxial electrospinning for guided tissue regeneration. *J. Colloid Interface Sci.* **2017**, *490*, 270–278. [[CrossRef](#)] [[PubMed](#)]
28. Morand, D.-N.; Huck, O.; Keller, L.; Jessel, N.; Tenenbaum, H.; Davideau, J.-L. Active Nanofibrous Membrane Effects on Gingival Cell Inflammatory Response. *Materials* **2015**, *8*, 7217–7229. [[CrossRef](#)] [[PubMed](#)]
29. Shi, R.; Xue, J.; He, M.; Chen, D.; Zhang, L.; Tian, W. Structure, physical properties, biocompatibility and in vitro/vivo degradation behavior of anti-infective polycaprolactone-based electrospun membranes for guided tissue/bone regeneration. *Polym. Degrad. Stable* **2014**, *109*, 293–306. [[CrossRef](#)]
30. Basar, A.O.; Castro, S.; Torres-Giner, S.; Lagaron, J.M.; Turkoglu Sasmazel, H. Novel poly( $\epsilon$ -caprolactone)/gelatin wound dressings prepared by emulsion electrospinning with controlled release capacity of Ketoprofen anti-inflammatory drug. *Mater. Sci. Eng. C Mater. Biol. Appl.* **2017**, *81*, 459–468. [[CrossRef](#)] [[PubMed](#)]
31. Farooq, A.; Yar, M.; Khan, A.S.; Shahzadi, L.; Siddiqi, S.A.; Mahmood, N.; Rauf, A.; Qureshi, Z.-A.; Manzoor, F.; Chaudhry, A.A.; et al. Synthesis of piroxicam loaded novel electrospun biodegradable nanocomposite scaffolds for periodontal regeneration. *Mater. Sci. Eng. C Mater. Biol. Appl.* **2015**, *56*, 104–113. [[CrossRef](#)] [[PubMed](#)]
32. Hortensius, R.A.; Harley, B.A. Naturally derived biomaterials for addressing inflammation in tissue regeneration. *Exp. Biol. Med.* **2016**, *241*, 1015–1024. [[CrossRef](#)] [[PubMed](#)]
33. Noguchi, K.; Ishikawa, I. The roles of cyclooxygenase-2 and prostaglandin E2 in periodontal disease. *Periodontology* **2007**, *43*, 85–101. [[CrossRef](#)] [[PubMed](#)]
34. Van Dyke, T.E.; Hasturk, H.; Kantarci, A.; Freire, M.O.; Nguyen, D.; Dalli, J.; Serhan, C.N. Proresolving nanomedicines activate bone regeneration in periodontitis. *J. Dent. Res.* **2015**, *94*, 148–156. [[CrossRef](#)] [[PubMed](#)]
35. Yuan, H.; Gupte, R.; Zelkha, S.; Amar, S. Receptor activator of nuclear factor kappa B ligand antagonists inhibit tissue inflammation and bone loss in experimental periodontitis. *J. Clin. Periodontol.* **2011**, *38*, 1029–1036. [[CrossRef](#)] [[PubMed](#)]
36. Zupancic, S.; Kocbek, P.; Baumgartner, S.; Kristl, J. Contribution of Nanotechnology to Improved Treatment of Periodontal Disease. *Curr. Pharm. Des.* **2015**, *21*, 3257–3271. [[CrossRef](#)] [[PubMed](#)]
37. Eap, S.; Ferrand, A.; Palomares, C.M.; Hébraud, A.; Stoltz, J.-F.; Mainard, D.; Schlatter, G.; Benkirane-Jessel, N. Electrospun nanofibrous 3D scaffold for bone tissue engineering. *Biomed. Mater. Eng.* **2012**, *22*, 137–141. [[CrossRef](#)] [[PubMed](#)]
38. Vaquette, C.; Fan, W.; Xiao, Y.; Hamlet, S.; Hutmacher, D.W.; Ivanovski, S. A biphasic scaffold design combined with cell sheet technology for simultaneous regeneration of alveolar bone/periodontal ligament complex. *Biomaterials* **2012**, *33*, 5560–5573. [[CrossRef](#)] [[PubMed](#)]
39. Farag, A.; Vaquette, C.; Theodoropoulos, C.; Hamlet, S.M.; Hutmacher, D.W.; Ivanovski, S. Decellularized periodontal ligament cell sheets with recellularization potential. *J. Dent. Res.* **2014**, *93*, 1313–1319. [[CrossRef](#)] [[PubMed](#)]
40. Eap, S.; Keller, L.; Schiavi, J.; Huck, O.; Jacomine, L.; Fioretti, F.; Gauthier, C.; Sebastian, V.; Schwinté, P.; Benkirane-Jessel, N. A living thick nanofibrous implant bifunctionalized with active growth factor and stem cells for bone regeneration. *Int. J. Nanomed.* **2015**, *10*, 1061–1075. [[CrossRef](#)]
41. Mathew, A.; Vaquette, C.; Hashimi, S.; Rathnayake, I.; Huygens, F.; Hutmacher, D.W.; Ivanovski, S. Antimicrobial and Immunomodulatory Surface-Functionalized Electrospun Membranes for Bone Regeneration. *Adv. Healthc. Mater.* **2017**, *6*. [[CrossRef](#)] [[PubMed](#)]
42. Ferrand, A.; Eap, S.; Richert, L.; Lemoine, S.; Kalaskar, D.; Demoustier-Champagne, S.; Atmani, H.; Mély, Y.; Fioretti, F.; Schlatter, G.; et al. Osteogenetic properties of electrospun nanofibrous PCL scaffolds equipped with chitosan-based nanoreservoirs of growth factors. *Macromol. Biosci.* **2014**, *14*, 45–55. [[CrossRef](#)] [[PubMed](#)]
43. Ren, K.; Wang, Y.; Sun, T.; Yue, W.; Zhang, H. Electrospun PCL/gelatin composite nanofiber structures for effective guided bone regeneration membranes. *Mater. Sci. Eng. C Mater. Biol. Appl.* **2017**, *78*, 324–332. [[CrossRef](#)] [[PubMed](#)]



44. Lam, C.X.F.; Savalani, M.M.; Teoh, S.-H.; Hutmacher, D.W. Dynamics of in vitro polymer degradation of polycaprolactone-based scaffolds: Accelerated versus simulated physiological conditions. *Biomed. Mater.* **2008**, *3*, 034108. [[CrossRef](#)] [[PubMed](#)]
45. Liang, D.; Hsiao, B.S.; Chu, B. Functional electrospun nanofibrous scaffolds for biomedical applications. *Adv. Drug Deliv. Rev.* **2007**, *59*, 1392–1412. [[CrossRef](#)] [[PubMed](#)]
46. Salvi, G.E.; Lang, N.P. The effects of non-steroidal anti-inflammatory drugs (selective and non-selective) on the treatment of periodontal diseases. *Curr. Pharm. Des.* **2005**, *11*, 1757–1769. [[CrossRef](#)] [[PubMed](#)]
47. Bozkurt, S.B.; Hakki, S.S.; Hakki, E.E.; Durak, Y.; Kantarci, A. *Porphyromonas gingivalis* Lipopolysaccharide Induces a Pro-inflammatory Human Gingival Fibroblast Phenotype. *Inflammation* **2017**, *40*, 144–153. [[CrossRef](#)] [[PubMed](#)]
48. Ara, T.; Kurata, K.; Hirai, K.; Uchihashi, T.; Uematsu, T.; Imamura, Y.; Furusawa, K.; Kurihara, S.; Wang, P.-L. Human gingival fibroblasts are critical in sustaining inflammation in periodontal disease. *J. Periodontol. Res.* **2009**, *44*, 21–27. [[CrossRef](#)] [[PubMed](#)]
49. Hu, P.; Huang, P.; Chen, M.W. Curcumin attenuates cyclooxygenase-2 expression via inhibition of the NF- $\kappa$ B pathway in lipopolysaccharide-stimulated human gingival fibroblasts. *Cell Biol. Int.* **2013**, *37*, 443–448. [[CrossRef](#)] [[PubMed](#)]
50. McClure, R.; Massari, P. TLR-Dependent Human Mucosal Epithelial Cell Responses to Microbial Pathogens. *Front. Immunol.* **2014**, *5*, 386. [[CrossRef](#)] [[PubMed](#)]
51. Spiekstra, S.W.; Breetveld, M.; Rustemeyer, T.; Scheper, R.J.; Gibbs, S. Wound-healing factors secreted by epidermal keratinocytes and dermal fibroblasts in skin substitutes. *Wound Repair Regen. Off. Publ. Wound Heal. Soc. Eur. Tissue Repair Soc.* **2007**, *15*, 708–717. [[CrossRef](#)] [[PubMed](#)]
52. Kocgozlu, L.; Elkaim, R.; Tenenbaum, H.; Werner, S. Variable cell responses to *P. gingivalis* lipopolysaccharide. *J. Dent. Res.* **2009**, *88*, 741–745. [[CrossRef](#)] [[PubMed](#)]
53. Wang, P.-L.; Ohura, K. *Porphyromonas gingivalis* lipopolysaccharide signaling in gingival fibroblasts—CD14 and Toll-like receptors. *Crit. Rev. Oral Biol. Med. Off. Publ. Am. Assoc. Oral Biol.* **2002**, *13*, 132–142.
54. Cantón, I.; Mckean, R.; Charnley, M.; Blackwood, K.A.; Fiorica, C.; Ryan, A.J.; MacNeil, S. Development of an Ibuprofen-releasing biodegradable PLA/PGA electrospun scaffold for tissue regeneration. *Biotechnol. Bioeng.* **2010**, *105*, 396–408. [[CrossRef](#)] [[PubMed](#)]
55. Kasaj, A.; Reichert, C.; Götz, H.; Röhrig, B.; Smeets, R.; Willershausen, B. In vitro evaluation of various bioabsorbable and nonresorbable barrier membranes for guided tissue regeneration. *Head Face Med.* **2008**, *4*, 22. [[CrossRef](#)] [[PubMed](#)]
56. Larjava, H.; Koivisto, L.; Häkkinen, L.; Heino, J. Epithelial integrins with special reference to oral epithelia. *J. Dent. Res.* **2011**, *90*, 1367–1376. [[CrossRef](#)] [[PubMed](#)]
57. Gräber, H.G.; Conrads, G.; Wilharm, J.; Lampert, F. Role of interactions between integrins and extracellular matrix components in healthy epithelial tissue and establishment of a long junctional epithelium during periodontal wound healing: A review. *J. Periodontol.* **1999**, *70*, 1511–1522. [[CrossRef](#)] [[PubMed](#)]
58. Preeja, C.; Janam, P.; Nayar, B.R. Fibrin clot adhesion to root surface treated with tetracycline hydrochloride and ethylenediaminetetraacetic acid: A scanning electron microscopic study. *Dent. Res. J.* **2013**, *10*, 382–388.
59. Fairweather, M.; Heit, Y.I.; Buie, J.; Rosenberg, L.M.; Briggs, A.; Orgill, D.P.; Bertagnolli, M.M. Celecoxib inhibits early cutaneous wound healing. *J. Surg. Res.* **2015**, *194*, 717–724. [[CrossRef](#)] [[PubMed](#)]
60. Kim, C.H.; Khil, M.S.; Kim, H.Y.; Lee, H.U.; Jahng, K.Y. An improved hydrophilicity via electrospinning for enhanced cell attachment and proliferation. *J. Biomed. Mater. Res. B Appl. Biomater.* **2006**, *78*, 283–290. [[CrossRef](#)] [[PubMed](#)]
61. Fabbri, P.; Bondioli, F.; Messori, M.; Bartoli, C.; Dinucci, D.; Chiellini, F. Porous scaffolds of polycaprolactone reinforced with in situ generated hydroxyapatite for bone tissue engineering. *J. Mater. Sci. Mater. Med.* **2010**, *21*, 343–351. [[CrossRef](#)] [[PubMed](#)]
62. Chen, J.-P.; Chang, Y.-S. Preparation and characterization of composite nanofibers of polycaprolactone and nanohydroxyapatite for osteogenic differentiation of mesenchymal stem cells. *Colloids Surf. B Biointerfaces* **2011**, *86*, 169–175. [[CrossRef](#)] [[PubMed](#)]
63. Hassan, M.I.; Sultana, N. Characterization, drug loading and antibacterial activity of nanohydroxyapatite/polycaprolactone (nHA/PCL) electrospun membrane. *Biotech* **2017**, *7*. [[CrossRef](#)] [[PubMed](#)]

64. Groppo, M.F.; Caria, P.H.; Freire, A.R.; Figueroba, S.R.; Ribeiro-Neto, W.A.; Bretas, R.E.S.; Prado, F.B.; Haiter-Neto, F.; Aguiar, F.H.; Rossi, A.C. The effect of a hydroxyapatite impregnated PCL membrane in rat subcritical calvarial bone defects. *Arch. Oral Biol.* **2017**, *82*, 209–215. [[CrossRef](#)] [[PubMed](#)]
65. Park, S.-H.; Kim, T.-I.; Ku, Y.; Chung, C.-P.; Han, S.-B.; Yu, J.-H.; Lee, S.-P.; Kim, H.-W.; Lee, H.-H. Effect of hydroxyapatite-coated nanofibrous membrane on the responses of human periodontal ligament fibroblast. *J. Ceram. Soc. Jpn.* **2008**, *116*, 31–35. [[CrossRef](#)]
66. Plazas Bonilla, C.E.; Trujillo, S.; Demirdögen, B.; Perilla, J.E.; Murat Elcin, Y.; Gómez Ribelles, J.L. New porous polycaprolactone–silica composites for bone regeneration. *Mater. Sci. Eng. C* **2014**, *40*, 418–426. [[CrossRef](#)] [[PubMed](#)]
67. Petrauskaitė, O.; Gomes, P.D.S.; Fernandes, M.H.; Juodzbalytė, G.; Stumbras, A.; Maminskas, J.; Liesiene, J.; Ciccì, M. Biomimetic mineralization on a macroporous cellulose-based matrix for bone regeneration. *BioMed. Res. Int.* **2013**, *2013*, 452750. [[CrossRef](#)] [[PubMed](#)]
68. Saadi-Thiers, K.; Huck, O.; Simonis, P.; Tilly, P.; Fabre, J.-E.; Tenenbaum, H.; Davideau, J.-L. Periodontal and systemic responses in various mice models of experimental periodontitis: Respective roles of inflammation duration and *Porphyromonas gingivalis* infection. *J. Periodontol.* **2013**, *84*, 396–406. [[CrossRef](#)] [[PubMed](#)]
69. De Molon, R.S.; Mascarenhas, V.I.; de Avila, E.D.; Finoti, L.S.; Toffoli, G.B.; Spolidorio, D.M.P.; Scarel-Caminaga, R.M.; Tetradis, S.; Cirelli, J.A. Long-term evaluation of oral gavage with periodontopathogens or ligature induction of experimental periodontal disease in mice. *Clin. Oral Investig.* **2016**, *20*, 1203–1216. [[CrossRef](#)] [[PubMed](#)]
70. Karimbux, N.Y.; Ramamurthy, N.S.; Golub, L.M.; Nishimura, I. The expression of collagen I and XII mRNAs in *Porphyromonas gingivalis*-induced periodontitis in rats: The effect of doxycycline and chemically modified tetracycline. *J. Periodontol.* **1998**, *69*, 34–40. [[CrossRef](#)] [[PubMed](#)]
71. Abe, T.; Hajishengallis, G. Optimization of the ligature-induced periodontitis model in mice. *J. Immunol. Methods* **2013**, *394*, 49–54. [[CrossRef](#)] [[PubMed](#)]
72. Kimura, S.; Nagai, A.; Onitsuka, T.; Koga, T.; Fujiwara, T.; Kaya, H.; Hamada, S. Induction of experimental periodontitis in mice with *Porphyromonas gingivalis*-adhered ligatures. *J. Periodontol.* **2000**, *71*, 1167–1173. [[CrossRef](#)] [[PubMed](#)]
73. Noordijk, M.; Davideau, J.-L.; Eap, S.; Huck, O.; Fioretti, F.; Stoltz, J.-F.; Bacon, W.; Benkirane-Jessel, N.; Clauss, F. Bone defects and future regenerative nanomedicine approach using stem cells in the mutant Tabby mouse model. *Biomed. Mater. Eng.* **2015**, *25*, 111–119. [[CrossRef](#)] [[PubMed](#)]
74. Ciccì, M. Real Opportunity for the Present and a Forward Step for the Future of Bone Tissue Engineering. *J. Craniofac. Surg.* **2017**, *28*, 592–593. [[CrossRef](#)] [[PubMed](#)]
75. Bugueno, I.M.; Batool, F.; Korah, L.; Benkirane-Jessel, N.; Huck, O. *Porphyromonas gingivalis* differentially modulates apoptosome APAF-1 in epithelial cells and fibroblasts. *Am. J. Pathol.* **2017**. [[CrossRef](#)]



# CHAPTER 2

**Development of a novel biomaterial targeting both infection and inflammation to improve periodontal treatment**

**Publication 2:** *In-situ* forming implants loaded with chlorhexidine and ibuprofen for periodontal treatment: proof of concept study in vivo (Batoool et al., accepted, International Journal of Pharmaceutics, 2019; <https://doi.org/10.1016/j.ijpharm.2019.118564>)

**Résumé :**

Afin de pallier les difficultés pouvant être associées au placement chirurgical d'un biomatériau, telle qu'une membrane, les traitements adjuvants pouvant être utilisés de manière simplifiée sont privilégiés. Ainsi, l'utilisation de gel ou de biomatériau injectable représente une alternative d'intérêt pour le clinicien. De ce fait, nous avons souhaité développer une nouvelle formulation permettant la délivrance locale d'un anti-inflammatoire et d'un antiseptique, ceci afin de réduire l'inflammation et de contribuer à la réduction de la charge bactérienne par voie chimique.

Un implant se formant *in situ* (ISFI) chargé en ibuprofène et en chlorhexidine a ainsi été synthétisé et caractérisé. Ce type de biomatériau injectable, biocompatible et biodégradable possède la capacité de se conformer à la situation tridimensionnelle de la lésion et permet ainsi le relargage des molécules thérapeutiques. Son utilisation est facile et peu chronophage. Il est constitué d'acide polylactique-co-glycolique (PLGA) et de N-méthyl-pyrrolidone (NMP). L'ibuprofène et la chlorhexidine ont été incorporés aux doses suivantes : 1.5% or 5.3% (w/w). La caractérisation du relargage des molécules actives à partir de l'ISFI dans de la salive artificielle par HPLC a mis en évidence un relargage progressif au cours du temps. Cependant, celui-ci est plus important lors des 5 premiers jours.

Afin d'évaluer les propriétés anti-microbiennes et anti-inflammatoires de cet ISFI, une analyse *in vitro* a été effectuée. Concernant les propriétés anti-microbiennes, des échantillons provenant du relargage de l'ISFI dans la salive artificielle ont été mis en contact avec une culture de *Pg*. Les échantillons provenant des 2 types d'ISFI testés ont permis une réduction significative du taux de croissance bactérien après 6, 24 et 48h de mise en contact validant l'efficacité de la chlorhexidine mais démontrant également un effet antiseptique intrinsèque de l'ISFI. Les propriétés anti-inflammatoires de l'ISFI ont également pu être mises en évidence. Le milieu de relargage provenant de l'ISFI a été mis en contact de cellules épithéliales gingivales stimulées par le LPS de *Pg*. L'analyse par ELISA des surnageants a mis en évidence que la concentration de TNF- $\alpha$  sécrétée par les cellules stimulées traitées par l'ISFI était significativement réduite en comparaison avec les cellules contrôles stimulées et non traitées après 24h. Ces résultats encourageants obtenus *in vitro* nous ont permis d'entreprendre une

évaluation *in vivo*. Celle-ci a été effectuée en utilisant la concentration de 1,5% car présentant le moins de toxicité cellulaire.

Dans un modèle murin de parodontite expérimentale induite par placement de ligatures infectées par *Pg*, l'ISFI a été placé au niveau d'une lésion parodontale. L'impact de ce traitement sur le degré d'inflammation au niveau des tissus mous a été effectuée après 7 et 15 jours et a mis en évidence une réduction significative de degré d'inflammation post-traitement en comparaison avec les sites contrôles. Cette réduction du degré d'inflammation se caractérise par une diminution du nombre de cellules inflammatoires retrouvées au niveau du site de la lésion. Sur le plan histologique, l'analyse histomorphométrique a permis de mettre en évidence, à court terme, un impact sur la cicatrisation parodontale puisqu'un épithélium de jonction court ainsi qu'une attache fibreuse plus importante a pu être mesurée au niveau des sites traités.

Ces résultats ont permis de valider l'utilisation de l'ISFI chargé en ibuprofène et chlorhexidine au niveau cellulaire et au niveau tissulaire. Ils confirment les possibilités d'utilisation de ce type de biomatériau comme adjuvant au traitement parodontal mécanique. Cependant, une optimisation des temps de relargage ainsi que des doses doit être entrepris. Ce type de biomatériau peut également servir de vecteur pour la délivrance d'autres molécules actives immuno-modulatrices ou antiseptiques ciblées sur certaines molécules ou pathogènes clés impliqués dans le développement de la lésion parodontale ou la cicatrisation.

# **CHAPTER 3**

**Development of a thermosensitive statin–functionalized chitosan-based hydrogel and evaluation of bone healing**

**Résumé :**

Les premières parties de ce travail de thèse nous ont permis de développer deux types de biomatériaux adaptés à une utilisation dans le cadre du traitement des lésions parodontales. Ces travaux nous ont également permis de valider l'intérêt de l'utilisation d'un anti-inflammatoire dans la gestion de l'inflammation chronique et sur la cicatrisation tissulaire. Dans cette troisième partie, nous nous sommes intéressés à l'utilisation de molécules plus complexes, les statines. Ces molécules sont utilisées de manière extensive pour leurs propriétés anti-inflammatoires, anti-oxidantes, anti-bactériennes et sur la réponse immune (Petit et al., 2019b). Plusieurs études se sont intéressées à leur impact sur le traitement parodontal, cependant, malgré des effets positifs sur les résultats de celui-ci, leur administration systémique de manière prolongée est associée à un risque d'effets secondaires systémiques. De ce fait, différentes stratégies de délivrance locale sont développées à l'heure actuelle.

Dans ce travail, nous avons souhaité développer un gel permettant la délivrance locale, au sein des lésions parodontales, d'une dose efficace de statines. Afin d'atteindre cet objectif, nous avons développé un hydrogel à base de chitosan, ce polymère étant utilisable dans des applications médicales et présentant des propriétés de biocompatibilité et de biodégradabilité compatibles avec les objectifs du traitement. Afin d'intégrer les statines, ici l'atorvastatine, au gel, celles-ci ont été incorporées dans des nano-émulsions permettant leur délivrance.

Dans un premier temps, nous avons caractérisé par différentes méthodes (zeta-sizer, microscopie électronique, immunofluorescence, ...), les caractéristiques physico-chimiques du gel et des nano-émulsions. Nous avons ainsi pu valider la méthode de synthèse, celle-ci aboutissant à la synthèse de nano-émulsions homogènes en taille et permettant leur internalisation et l'endocytose de la molécule active. Une analyse du profil de relargage de l'atorvastatine a également permis d'observer que celui-ci aboutit à un relargage rapide et continu de la molécule.

Afin de valider les potentiels effets de la molécule et la faisabilité de son application, nous avons testé celui-ci dans un modèle de lésion induite par forage au niveau de la calvaria. Dans des défauts de 2mm de diamètre, nous avons ainsi pu administrer le gel fonctionnalisé par l'atorvastatine et comparer les résultats obtenus en termes de néo-formation osseuse après 15j. Dans ce modèle pré-clinique, le traitement par gel fonctionnalisé par atorvastatine a accéléré la néo-formation osseuse par rapport au groupe non traité (cicatrisation naturelle) mais également par rapport au groupe traité par voie systémique.

Ces résultats valident l'utilisation de ce gel fonctionnalisé par l'atorvastatine *in vivo*. Des expériences complémentaires restent cependant nécessaires pour valider son utilisation



dans le domaine parodontal. En effet, le modèle de calvaria est un modèle intéressant pour aborder la régénération osseuse mais ne reflète pas la complexité du système parodontal. De ce fait, l'évaluation de ce type de traitement devra être envisagé dans un modèle de parodontite expérimentale.

## Review Article

# Contribution of Statins towards Periodontal Treatment: A Review

Catherine Petit,<sup>1,2,3</sup> Fareeha Batool,<sup>1,2</sup> Isaac Maximiliano Bugueno,<sup>1,2</sup> Pascale Schwinté,<sup>1,2</sup>  
Nadia Benkirane-Jessel,<sup>1,2</sup> and Olivier Huck<sup>1,2,3</sup> 

<sup>1</sup>INSERM (French National Institute of Health and Medical Research), UMR 1260, Regenerative Nanomedicine, Fédération de Médecine Translationnelle de Strasbourg (FMTS), Strasbourg, France

<sup>2</sup>Université de Strasbourg, Faculté de Chirurgie-dentaire, 8 rue Sainte-Elisabeth, 67000 Strasbourg, France

<sup>3</sup>Hôpitaux Universitaires de Strasbourg, Pôle de Médecine et Chirurgie Bucco-dentaire, Department of periodontology, 1 place de l'Hôpital, 67000 Strasbourg, France

Correspondence should be addressed to Olivier Huck; o.huck@unistra.fr

Academic Editor: Maria Jose Alcaraz

Copyright © 2019 Catherine Petit et al. This is an open access article distributed under the Creative Commons Attribution License, which permits unrestricted use, distribution, and reproduction in any medium, provided the original work is properly cited.

The pleiotropic effects of statins have been evaluated to assess their potential benefit in the treatment of various inflammatory and immune-mediated diseases including periodontitis. Herein, the adjunctive use of statins in periodontal therapy *in vitro*, *in vivo*, and in clinical trials was reviewed. Statins act through several pathways to modulate inflammation, immune response, bone metabolism, and bacterial clearance. They control periodontal inflammation through inhibition of proinflammatory cytokines and promotion of anti-inflammatory and/or proresolution molecule release, mainly, through the ERK, MAPK, PI3-Akt, and NF- $\kappa$ B pathways. Moreover, they are able to modulate the host response activated by bacterial challenge, to prevent inflammation-mediated bone resorption and to promote bone formation. Furthermore, they reduce bacterial growth, disrupt bacterial membrane stability, and increase bacterial clearance, thus averting the exacerbation of infection. Local statin delivery as adjunct to both nonsurgical and surgical periodontal therapies results in better periodontal treatment outcomes compared to systemic delivery. Moreover, combination of statin therapy with other regenerative agents improves periodontal healing response. Therefore, statins could be proposed as a potential adjuvant to periodontal therapy. However, optimization of the combination of their dose, type, and carrier could be instrumental in achieving the best treatment response.

## 1. Introduction

Periodontitis is an inflammatory disease of infectious origin characterized by progressive destruction of periodontal soft and hard tissues leading to tooth loss. The main symptoms comprise gingival inflammation, formation of periodontal pocket, alveolar bone loss, abscess, or tooth mobility [1]. The pathogenesis of periodontitis involves a complex interaction of immune and inflammatory cascades initiated by bacteria of the oral biofilm [2]. Persistent inflammation and dysbiosis worsen periodontal tissue damage, and the host response plays a vital role in this phenomenon contributing to tissue destruction [3].

The conventional treatment comprising scaling and root planing (SRP) presents limitations in certain cases involving deep periodontal pockets, inaccessible areas, or severe

periodontitis [4]. Therefore, several adjunctive pharmacological therapeutics have been tested to improve its outcomes. In this context, systemic and local deliveries of drugs such as antibiotics, bisphosphonates, anti-inflammatory drugs, anticytokines, probiotics, and prebiotics have been tested so far to reduce bacterial load and to control inflammation [5–9]. Likewise, the use of statins in periodontal treatment has been explored recently [10]. Statins, or inhibitors of 3-hydroxy-3-methylglutaryl coenzyme A reductase (HMG-CoA reductase), are a group of drugs, used primarily to treat hyperlipidemia and to prevent cardiovascular diseases [11]. After their discovery in the 70s, they have been widely prescribed worldwide [12]. They differ mainly in their ring structure, and these structural differences modify their pharmacological properties including hydrophilicity and lipophilicity. The lactone ring is present in an active form (already hydrolyzed)

TABLE 1: Physical properties of different types of statins.

Drug	Source	Solubility	Molecular mass (Da)
Atorvastatin	Synthetic	Lipophilic	1209.42
Simvastatin	Natural	Lipophilic	418.6
Lovastatin	Natural	Lipophilic	404.5
Mevastatin	Natural	Lipophilic	390.52
Pravastatin	Natural	Hydrophilic	446.52
Fluvastatin	Synthetic	Lipophilic	411.47
Cerivastatin	Synthetic	Lipophilic	459.56
Pitavastatin	Synthetic	Lipophilic	421.46
Rosuvastatin	Synthetic	Hydrophilic	481.54

in all statins except for simvastatin, lovastatin, and mevastatin, in which the lactone ring is activated (hydrolyzed) in the liver. The lactone form of the statins enables their transport, metabolism, and clearance [13] (Table 1).

Apart from their lipid-lowering properties, statins possess pleiotropic effects due to their anti-inflammatory, antioxidative, antibacterial, and immunomodulatory properties [14–17]. Statins have also been reported to have anabolic effects on the bone by augmenting bone morphogenetic protein-2 (BMP-2) expression, thus contributing towards the differentiation and activity of osteoblasts (OBs) [18]. In view of their beneficial properties, statins have been presented as new potential candidates for improving periodontal therapy outcomes [19, 20].

In several preclinical and clinical studies, statins have exhibited contradictory results [21–23] depending on the mode of delivery (local vs systemic), anatomy and severity of the lesions, type of disease, and treatment approach (nonsurgical vs surgical). Therefore, the aim of this literature review was to establish a better understanding of the prophylactic and therapeutic effects of all statin types administered locally or systemically as adjuvant to nonsurgical/surgical periodontal treatment in existing preclinical models and clinical settings and to explore the biological mechanisms underlying these healing and proregenerative effects in the management of periodontitis.

## 2. Methods

**2.1. Literature Search.** Studies published in English language only were included, and the last search was carried out in September 2018. Regarding studies performed on animal models and clinical trials, a systematic literature search was performed in the PubMed/MEDLINE and ScienceDirect databases. A hand search has also been performed after checking references of the identified articles. Concerning *in vivo* studies, the following keywords were used for the search: periodontitis OR periodontal disease OR alveolar bone loss OR periodontal attachment loss OR periodontal pocket AND simvastatin OR statin OR rosuvastatin OR atorvastatin OR cerivastatin OR mevastatin OR lovastatin OR pravastatin OR Fluvastatin OR pitavastatin OR Hydroxymethylglutaryl-CoA Reductase Inhibitors AND mouse OR dog OR pig OR rat OR rodent OR rabbit OR

monkey OR *in vivo*. A study was considered eligible if it met the following criteria: (1) experimentally induced periodontitis (EIP) and/or acute/chronic periodontal defects (ACP), (2) treatment of EIP and/or ACP with statins (local or systemic or combination) with or without SRP or other periodontal treatment modalities, and (3) at least one periodontal parameter assessed as outcome. Exclusion criteria for *in vivo* studies were the following: (1) periapical lesions, (2) tooth extraction models, (3) orthodontic movements, (4) calvarial models, (5) long bone defects, and (6) drug-induced gingival enlargement.

Concerning clinical studies, the following keywords were used for the search: periodontitis OR periodontal disease OR alveolar bone loss OR periodontal attachment loss OR periodontal pocket AND simvastatin OR statin OR rosuvastatin OR atorvastatin OR cerivastatin OR mevastatin OR lovastatin OR pravastatin OR Fluvastatin OR pitavastatin OR Hydroxymethylglutaryl-CoA Reductase Inhibitors. A study was considered eligible if it met the following criteria: (1) randomized and controlled clinical trials, (2) cohort clinical studies, (3) longitudinal studies, (4) patients with diagnosis of chronic or aggressive periodontitis, (5) systemic or local administration of statins with nonsurgical or surgical periodontal treatment, and (6) at least one periodontal parameter: pocket depth (PD), clinical attachment level (CAL), bone loss (BL), or tooth loss (TL) assessed as outcome. Exclusion criteria for clinical studies were the following: (1) no follow-up, (2) no periodontal treatment, and (3) reviews, letters, and case reports.

**2.2. Study Selection.** Titles and abstracts of the studies were screened independently by two reviewers (CP and FB) and categorized as suitable or not for inclusion. Full reports were reviewed independently for studies appearing to meet the inclusion criteria or for which there was insufficient information in the title and abstract to allow a clear decision. Disagreements between the authors were resolved after discussion with a third reviewer (OH).

**2.3. Risk of Bias Assessment.** Risk of bias was assessed using the Cochrane Collaboration's tool for assessing risk of bias which provided guidelines for the following parameters: sequence generation, allocation concealment method, blinding of the examiner, address of incomplete outcome data, and free of selective outcome reporting. The degree of bias was categorized as follows: low risk if all the criteria were met, moderate risk when only one criterion was missing, and high risk if two or more criteria were missing. Two reviewers (FB and CP) independently performed the quality assessment, and any disagreement was resolved by a third investigator (OH) (Supplemental Table 1).

## 3. Results

**3.1. Effect of Statins on the Inflammatory-Immune Crosstalk.** Localization of *periodontium* at the interface between the teeth and jaws exposes periodontal tissues to continuous bacterial challenge which could contribute to exacerbation of the immune response during periodontal

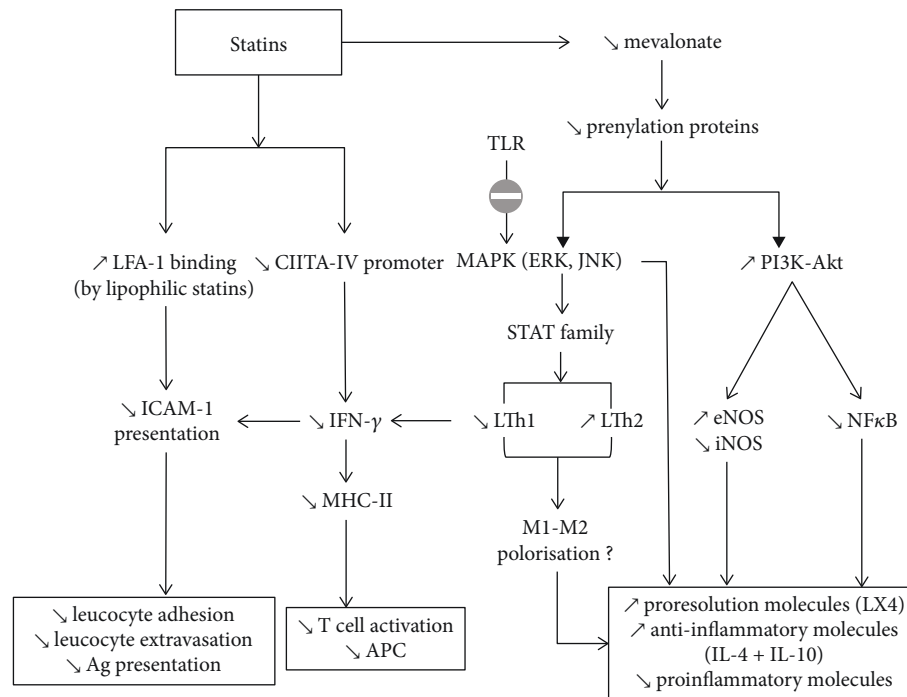


FIGURE 1: Effect of statins on the inflammatory-immune crosstalk. Direct LFA1 site binding by lipophilic statins decreases ICAM-1 presentation leading to reduced leukocyte chemotaxis and antigen presentation. Statins inhibit MHC-II induction by IFN- $\gamma$  leading to decreased T-cell activation. Statins lower mevalonate release, leading to resolution of inflammation via the ERK, MAPK, and PI3K-Akt pathways.

wound healing. Recruitment of inflammatory cells at the periodontal site, including polymorphonuclear (PMN) leukocytes, macrophages, and lymphocytes, is associated to the release of a complex nexus of cytokines. When the inflammatory front migrates toward the alveolar bone, it stimulates osteoclastogenesis and subsequent alveolar bone destruction [24]. Therefore, the importance of inflammation control at the soft tissue level cannot be undermined.

The effects of statins on the inflammatory-immune crosstalk involved in the periodontal wound healing have been evaluated. Statins decrease the levels of proinflammatory cytokines (interleukin-1 beta (IL-1 $\beta$ ), interleukin-8 (IL-8), interleukin-6 (IL-6), and tumor necrosis factor-alpha (TNF- $\alpha$ )) and increase the release of anti-inflammatory mediators (IL-10) and chemokines [25, 26]. There are several pathways implicated in the action of statins, notably suppression of HMG-CoA reductase, thereby inhibiting Rac and p21Ras phosphorylation. As Rac and p21Ras are coupled to the transcription of proinflammatory molecules via MAP kinase (MAPK) pathways, therefore, statins also suppress nuclear factor kappa B (NF- $\kappa$ B) activation, thus reducing the expression of proinflammatory molecules [27] (Figure 1).

**3.1.1. Effect of Statins on Inflammatory Molecules.** *In vitro*, the effect of statins on inflammatory mediators' secretion was demonstrated to be cell specific. For instance, in human oral epithelial cells [15] and OBs [28], statins reduced IL-6, IL-8 release, whereas, in T-cells [29, 30], statins increased the expression of IL-4, IL-5, IL-10 and IL-13. *In vivo*, statins confirmed the reduction of cyclooxygenase-2 (COX-2),

prostaglandin E<sub>2</sub> (PGE<sub>2</sub>), IL-1 $\beta$ , IL-6, IL-8, TNF- $\alpha$ , interferon-gamma (IFN- $\gamma$ ), C-reactive protein (CRP), colony-stimulating factors (CSF2, CSF3), recruitment of mononuclear inflammatory cells, and several Toll-like receptors (TLRs) in various EIP or ACP models [26, 31–35]. Clinical trials also corroborated the downregulation of inflammation by the use of statins, as demonstrated by increased IL-10 level in gingival crevicular fluid (GCF) from hyperlipidemic patients treated with statins [19].

**3.1.2. Effect of Statins on Proresolution Molecules.** Periodontal wound healing and regeneration involve a constant “tug-of-war” between the proinflammatory and anti-inflammatory/proresolution mediators [36, 37]. Anti-inflammatory effects of statins enhancing resolution of periodontal inflammation, that is, initiated by several endogenous chemical and lipid mediators, such as the lipoxins (LXs), resolvins (RVs), protectins, and maresins, could possibly explain the positive treatment outcomes [38, 39]. However, further studies need to explore the exact effect of statins on the proresolution mediators.

**3.1.3. Effect of Statins on Host Modulation.** Literature reports contradictory results regarding the effect of statins on different types of immune cells. For instance, in an ACP model, simvastatin did not change circulating white blood cell (WBC) counts in a study [33], whereas leukocyte infiltration was decreased by atorvastatin gavage in an EIP model [40]. Similarly, regulatory T (Treg) cells that control adaptive immunity against pathogens and activate other effector

immune cells were reported to be regulated by statins. In this regard, atorvastatin and simvastatin demonstrated an increase in the number of human Treg cells and differentiation of CD4 into Treg *in vitro* [41, 42].

Furthermore, TLRs have an important role in the immune-inflammatory crosstalk with a consequent impact on periodontal wound healing response. In the context of periodontal treatment, targeting TLRs has been proposed as it could enhance antimicrobial properties, suppress adverse inflammation, or activate tissue repair [43]. Interestingly, simvastatin inhibited the stimulation of several TLRs (1, 2, 3, 4, 6, 7, and 9) by *Aggregatibacter actinomycetemcomitans* (A.a) LPS *in vivo*, reducing its capability to escape innate immune response [33]. Hence, statins play an instrumental role in the modulation of inflammatory and immune responses.

**3.1.4. Inhibition of Major Histocompatibility Complex Class II (MHC-II) by Statins.** In case of nonresolving periodontal lesions, bacterial antigens are processed and presented by antigen-presenting cells and macrophages. Such process is associated to massive immune cell recruitment implicated in tissular destruction [2]. In this regard, statins are able to inhibit MHC-II expression due to inhibition of the inducible promoter IV of the class II transactivator (CIITA) as observed in several cell types, including monocytes and macrophages [44]. This effect renders statins to have a potential host-modulating impact on periodontal treatment.

**3.1.5. Lymphocyte Function-Associated Antigen-1 LFA1 Site Binding by Statins.** Lymphocyte function-associated antigen-1 (LFA-1), an integrin with its main ligand intercellular adhesion molecule-1 (ICAM-1), is activated on the surface of fibroblasts (FBs) by IFN- $\gamma$  and represents a critical phase in the early stage of inflammation. ICAM-1 regulates LFA-1-dependent neutrophil transmigration and recruitment to the inflammation site [45]. Several studies have demonstrated the inhibition of LFA-1 by statins in many inflammatory and immune diseases other than periodontitis. Statins inhibit ICAM-1 upregulation and chemotaxis of monocytes [46]. Lovastatin, simvastatin, and mevastatin, but not pravastatin, were able to inhibit the LFA-1/ICAM-1 interaction *in vitro* by binding to the L-site of LFA-1 [47]. In this way, statins limit the exacerbation of immune-mediated inflammatory response at the lesion site. However, the impact of statins on LFA-1 binding in the context of periodontal wound healing remains unexplored.

**3.1.6. Effect of Statins on Nitric Oxide Synthase (NOS).** NOS plays an important role in host defence and homeostasis and has been implicated in the pathogenesis of periodontitis, where it is expressed in FBs, epithelial cells, rests of Malassez, macrophages, osteoclasts (OC), and vascular endothelial cells [48, 49]. In chronic periodontitis, bacterial challenge induces proinflammatory cytokine release and a higher expression of inducible NOS (iNOS) and NOS derived from FBs and WBCs that migrate to the periodontal lesion [50–52] leading to inflammation-mediated bone resorption [53]. Various studies demonstrated a NOS-inhibiting effect by the use

of statins. For instance, *in vivo*, rosuvastatin significantly reduced inflammation-mediated tissue destruction and gingival iNOS expression [54].

Concerning the underlying mechanism of action, statins attenuate the production of reactive oxygen species (ROS) induced by NADPH oxidase by suppressing Rac's geranylation. Phosphatidylinositol-3 active kinase (PI3-Akt) is a kinase that phosphorylates and stimulates eNOS. Mevalonate is able to inhibit PI3-Akt; therefore, by reducing the concentration of mevalonate, statins upregulate eNOS-derived NO production resulting in vasorelaxation that leads to improved angiogenesis and wound healing response [27].

**3.1.7. Effect of Statins on Matrix Metalloproteinases (MMPs).** MMPs degrade extracellular matrix proteins, especially collagen, contributing to the degradation of periodontal tissue including alveolar bone [55]. Most statins have been reported to potently inhibit the expression of MMP-1, MMP-8, and MMP-9 upregulated by LPS as demonstrated for simvastatin in mononuclear cells *in vitro* [56]. Moreover, *in vivo*, a decrease of MMP-1, MMP-2, MMP-8, and MMP-9 was observed by the use of statins [31, 57–59]. Thus, statins prevent periodontal tissue and alveolar bone destruction by inhibiting the release of MMPs.

**3.2. Effect of Statins on Bone Metabolism.** Statins have an impact on bone metabolism through increase of osteogenesis, decrease of OB apoptosis, and osteoclastogenesis [60]. Statins allow periodontal regeneration via the Ras/Smad/extracellular signal-regulated kinase (Erk)/BMP-2 pathway that enhances bone formation [61] and by antagonizing TNF- $\alpha$  through Ras/Rho/mitogen-activated protein kinase (MAPK) that causes osteoclastic differentiation [62]. Moreover, they significantly increase OB differentiation factors such as alkaline phosphatase (ALP), osteocalcin (OCN), bone sialoprotein (BSP), BMP-2 [63], osteopontin (OPN), and vascular endothelial growth factor (VEGF) [64] (Figure 2).

**3.2.1. Role of Statins in the Promotion of Osteogenesis.** Inhibition of HMG-CoA by statins decreases prenylation of farnesyl pyrophosphate (FPP) and geranylgeranyl pyrophosphate (GPP) leading to increased levels of BMP-2 and VEGF through the PI3-Akt pathway. Interestingly, both VEGF and BMP-2 regulate OB differentiation and bone formation during bone repair and regeneration [65, 66]. Concerning BMP, simvastatin and lovastatin increased the levels of BMP-2, consequently, increasing OB activity *in vitro* [58, 63]. Statins present a cost-effective option when compared with growth factors such as BMP-2 [67, 68].

Hydrophobic statins (simvastatin, atorvastatin, and cerivastatin) also increased mRNA expression of VEGF in OBs [69]. Likewise, simvastatin increased osteoprotegerin (OPG) expression in periodontal tissue [58] and enhanced matrix calcification in human bone marrow stem cells by diminishing the mean size of the fibroblastic colony-forming units (CFU-Fs) [70]. *In vivo*, statins stimulated bone growth and repair by increasing angiogenesis [71]. In particular, the lactone-form statins (lovastatin and simvastatin) stimulated OB differentiation of mouse periodontal ligament cells



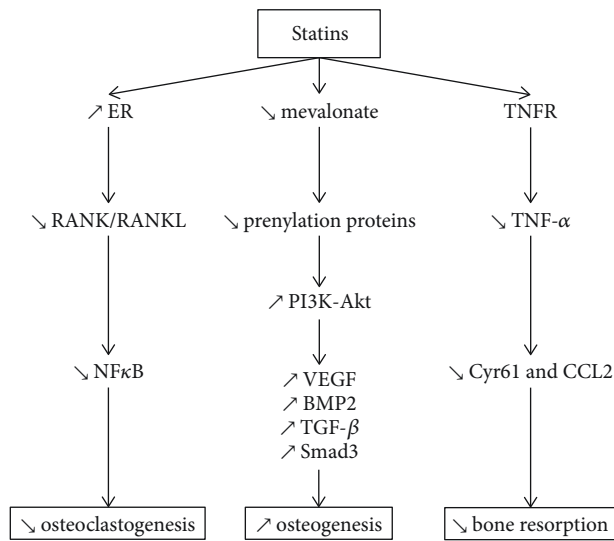


FIGURE 2: Effects of statins on several pathways involved in bone metabolism. Statins decrease osteoclastogenesis via RANK/RANKL and NF- $\kappa$ B signaling. Statins promote osteogenesis by increasing VEGF, BMP2, and TGF- $\beta$  expression through the PI3-Akt pathway. Statins prevent inflammation-mediated bone resorption by decreasing TNF- $\alpha$ , via TNFR.

(PDLs) via the ERK1/2 pathway (phosphorylation) and enhanced intercellular matrix mineralization [63].

**3.2.2. Role of Statins in the Inhibition of Bone Destruction.** Statins act through certain pathways that avert bone degradation. Several clinical trials confirm the reduction of alveolar bone loss by statins, as an adjunct to SRP [72]. Many studies reported significantly decreased bone resorption by the use of simvastatin, rosuvastatin, and atorvastatin [26, 28, 32, 73]. Interestingly, simvastatin reduced TNF- $\alpha$ -induced synthesis of Cysteine-rich 61 (Cyr61) and chemokine ligand 2 (CCL2) [74] that are potential osteolytic mediators in inflammatory bone diseases, in human OB, thereby decreasing bone loss. Besides, statins increase bone formation by inhibiting OB apoptosis, augmenting TGF- $\beta$  against the Smad3 signaling pathway. As an evidence, pitavastatin, mevastatin, and simvastatin induced the expression of Smad3 in non-transformed OBs (MC3T3-E1) [75]. Consequently, statins prevent bone destruction and also promote bone healing and regeneration.

**3.2.3. Role of Statins in the Inhibition of Osteoclastogenesis.** Statins suppress osteoclastogenesis through the OPG/receptor activator of the nuclear factor kappa-B ligand (RANKL)/RANK signaling pathway. Statins (simvastatin, atorvastatin, and fluvastatin) inhibited, *in vitro* and *in vivo*, the expression of the receptor activator of RANK which along with RANKL is required for the differentiation of OC precursors [26, 31, 33, 58, 76]. Nevertheless, IL-10 is also implicated in inhibiting bone resorption by preventing the RANK/RANKL pathway ([77]); hence, statins could potentially reduce the inflammation-mediated bone resorption [25]. Another mechanism for osteoclastogenesis involving unprenylated Rap GTP-binding protein 1A (Rap-1A), a RAS super family

of small GTP-binding protein member, has been studied in the context of statins. Rosuvastatin, pravastatin, cerivastatin, and simvastatin caused accumulation of unprenylated Rap-1A in rabbit osteoclast-like cells and macrophages, inhibiting osteoclast-mediated resorption. Interestingly, hydrophilic statin (cerivastatin) was more effective than hydrophobic statin (rosuvastatin) to inhibit OC prenylation [78]. Additionally, the mRNA expression of cathepsin K, a key marker of OC differentiation, is reduced by simvastatin through inhibition of Src signaling and modulation of MAPK including ERK1/ERK2. Moreover, upregulation of AKT leads to a decrease of OC activity via RANKL and BMP-2 [79].

**3.3. Antibacterial Effect of Statins.** Periodontitis is a polymicrobial disease involving keystone pathogen such as *Porphyromonas gingivalis* (*P.g*) that is able to hijack the adaptive immune response. Therefore, elimination of the periodontal pathogens is the cornerstone of periodontal treatment. Uncontrolled infection hinders periodontal wound healing and may worsen the therapeutic outcome by reducing the clinical attachment gain. Statins exhibit antimicrobial effects attributed to an increased bacterial clearance from the infection site as demonstrated in a model of sepsis (Figure 3) ([80]). Hence, statins could provide an additional benefit during periodontal wound healing (Table 2).

Cholesterol is an integral component needed by bacteria for maintaining their membrane integrity. Statins can counter bacteria by inhibiting the intermediate in the isoprenoid biosynthesis pathway necessary for membrane stability, which is substituted by cholesterol and protects bacteria from the toxic effect of statins. Statins, therefore, kill bacteria directly and by lowering accessible host cholesterol content for bacterial growth and protection. Such effects may be due to the disruption of teichoic acid structures reducing biofilm formation ([81]). Statins display antibacterial activity towards anaerobic bacteria, including periodontal pathogens such as *A.a* and *P.g*. For instance, low concentration of simvastatin was proven to be effective against *A.a* and *P.g* even if *A.a* was more sensitive (MIC < 1  $\mu$ g/mL) than *P.g* (MIC until 2  $\mu$ g/mL dilution) [82]. The hydrophobic nature of simvastatin may explain its antibacterial activity against periodontal pathogens where it disrupts the bacterial membrane in a “soap-like” manner causing its death [83]. Nevertheless, not all statins exhibit antibacterial activity. The degree of HMG-CoA reductase inhibition corresponds directly to the cholesterol-lowering capabilities of statins [84] but it does not seem commensurate with their antibacterial potency [85].

Some other mechanisms are modulated by the action of statins on lipoxin A4 (LXA4) production, a proresolving lipid mediator that enhances bacterial clearance, consequently reducing the severity of periodontal disease [86, 87]. Furthermore, the mechanistic target of rapamycin (mTOR) signaling, regulated principally by TLRs via two major pathways (NF- $\kappa$ B-dependent pathway and a PI3-Akt-dependent pathway), is also involved in bacterial clearance [88]. It is known that statins inhibit isoprenoid synthesis, impeding intracellular signaling molecules like Rho or Rac [89].

Therefore, it is plausible that statins possess certain antibacterial properties that could facilitate periodontal

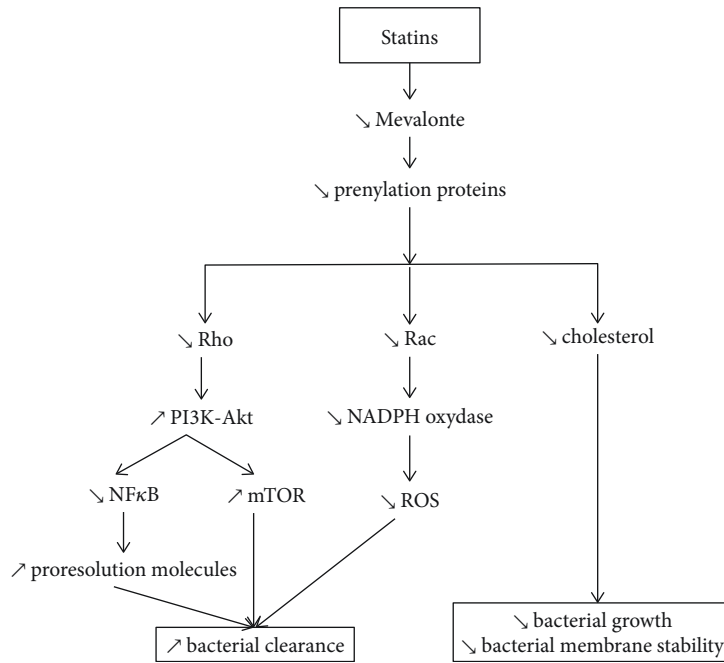


FIGURE 3: Antibacterial effect of statins. Statins arrest bacterial growth and disrupt their membrane stability by decreasing cholesterol. Statins increase bacterial clearance by decreasing NF- $\kappa$ B and ROS signaling (via the PI3K-Akt and NADPH oxidase pathways, respectively) and by enhancing proresolution molecule release.

TABLE 2: Representative *in vitro* studies evaluating the impact of statins on periodontal pathogens.

Reference	Experimental design	Local drug delivery Type of statin dose	Results	Periodontal consideration
[82]	MIC was determined against <i>P.g</i> (ATCC 33277) and <i>A.a</i> (ATCC 25586) using serial dilution method	Simvastatin, 1 $\mu$ g/mL to 500 $\mu$ g/mL	$\searrow$ <i>P.g</i> $\searrow$ <i>A.a</i>	Simvastatin had an antibacterial effect against the keystone pathogens involved in periodontal disease
[138]	<i>A.a</i> (ATCC 43719), <i>P. nigrescens</i> (ATCC 33563), or <i>P.g</i> (ATCC 33277) were cultured on a trilayer functional CS membrane with EGCG and lovastatin	Lovastatin 0.1, 0.5, 1, and 2 mg	$\searrow$ <i>P.g</i> $\searrow$ <i>A.a</i>	Lovastatin had an antibacterial effect against periodontopathogenic bacteria

treatment. However, since periodontitis is a polymicrobial disease, the susceptibility of various other periodontal pathogens to statins must also be evaluated.

**3.4. Effects of Statins in Induced Periodontitis Models.** Statins have been tested in several induced periodontitis models to evaluate improvement in periodontal parameters and their underlying biological mechanisms. *In vivo*, 35 studies were identified based on the inclusion criteria (Figure 4), out of which 16 involved local statin delivery (Table 3), 17 used systemic route (Table 4), and 2 employed a combination of both modes (Table 5). In the studies evaluating local statin application, 8 studies involved the treatment of EIPs while the remaining 8 investigated the treatment of ACP models, one of which was induced by LPS injection of *Escherichia coli* (*E. coli*) [90]. Concerning the systemic administration of statins (Table 4), 14 out of the total 17 studies treated EIPs, whereas the 3 remaining studies

involved ACP models by LPS injections of *A.a* [32, 33] and *P.g* into the gingiva [76].

Regarding the mode of periodontitis induction, in total, 24 out of 35 studies had EIP with ligatures (cotton, nylon, or silk), whereas 11 used ACP including the 4 studies where periodontitis was induced by bacterial LPS. Studies were mostly performed in rodents (Tables 3, 4, and 5). In ACP models, the surgically created lesions were mainly intrabony defects, fenestration defects, dehiscence defects, furcation class II defects, and 3-walled intrabony defects.

In 6 studies, animals with systemic diseases (i.e., osteoporosis [26, 91, 92], metabolic syndrome [32], cyclosporine A-associated alveolar bone loss [35], hyperlipidemia [54], or hypertension [93]) were used to evaluate the effect of statins treatment. Overall, 22 studies involved treatment with simvastatin, 7 with atorvastatin, 3 with rosuvastatin, 2 with lovastatin, and only one with fluvastatin. Some studies investigated more than one type of statin. *In vivo*, the systemic



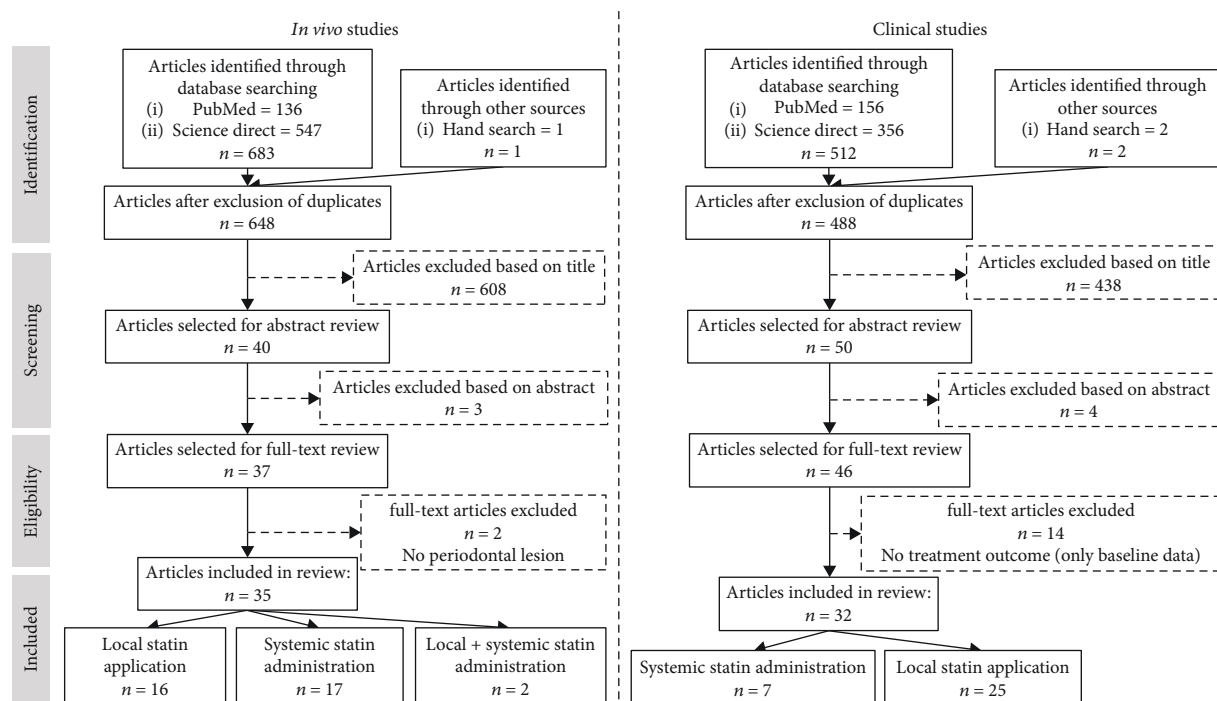


FIGURE 4: Selection of the studies.

dosage used ranged from 0.3 to 30 mg/kg with 20 mg/kg as the most commonly tested dose. The dose of locally delivered statins varied with the type of carrier/scaffold used (Table 3). Five studies demonstrated insignificant improvements [94–98]. Interestingly, 3 of them involved surgical treatment of ACP models by local statin application [94, 96, 98] and one study employed nonsurgical local statin therapy [95], whereas only one EIP was treated with systemic statin delivery [97]. One study even demonstrated a negative impact of statin use [99].

**3.5. Clinical Outcomes.** The selected studies evaluating the effect of statins in the context of periodontal treatment included 23 controlled and randomized clinical trials, 8 cohort studies, and 1 longitudinal study (Figure 4). Primary outcomes varied between improvement of clinical attachment level (CAL), reduction of pocket depth (PD), tooth loss, radiographic bone defect depth, periodontal inflamed surface area (PISA), and serum and/or GCF proinflammatory cytokines level. Most of the studies focused on the local administration ( $n = 25$ ) of statins (Table 6), while 7 investigated the impact of systemic route (Table 7). Essentially, effects of statins have been evaluated as an adjunct to both nonsurgical and surgical treatments, mainly in the context of chronic periodontitis in healthy patients.

**3.6. Statins as a Local Adjunct to Nonsurgical Periodontal Treatment.** The effect of local delivery of statins as an adjunct to nonsurgical periodontal therapy (SRP) was studied in 20 clinical trials (Table 6). Atorvastatin and simvastatin have been the most commonly studied statins. Amongst the identified studies, 13 demonstrated a significant PD reduction, CAL gain, and IBD fill in healthy patients, 2 in

well-controlled type II diabetes patients, and 3 in smokers. At contrary, in 2 studies, the test groups using atorvastatin or simvastatin did not show any significant differences when compared with the control [21, 100]. For instance, with simvastatin, the mean PD gain was  $1.23 \pm 0.57$  mm for the control group versus  $1.83 \pm 0.07$  mm for the test group ( $p = 0.112$ ) and the mean CAL gain was  $2.09 \pm 0.08$  mm for the control group versus  $2.43 \pm 0.01$  mm for the test group ( $p = 0.889$ ) after 45 days. Nevertheless, authors found a statistically significant reduction of PI, BOP, IL-6, and IL-8 levels [21].

Only 4 studies compared the outcomes obtained with more than one statin; however, contradictory results were observed. For instance, one study did not show any significant difference between atorvastatin and simvastatin [100], whereas better results were obtained with atorvastatin in another study [101]. Nevertheless, two studies highlighted greater efficacy with rosuvastatin in comparison with atorvastatin [20, 102].

Interestingly, studies that have investigated the effects of statin treatment on the biological markers from GCF showed that simvastatin administration reduced significantly IL-6, IL-8 and increased the anti-inflammatory IL-10 [21, 100, 103].

**3.7. Statins as a Local Adjunct to Surgical Periodontal Treatment.** Statins have also been inspected for their role in the surgical treatment outcomes. In all identified studies where statins (simvastatin, atorvastatin, and rosuvastatin) were locally administered concomitant to surgical approach (including the use of biomaterials or PRF), a significant reduction of PD, improvement of CAL, and bone defect fill was achieved in the test group in comparison to the control

TABLE 3: *In vivo* studies evaluating the impact of local statin administration on periodontal wound healing.

Reference	Experimental periodontitis induction model (i) Animal (ii) Method (iii) Site	Periodontitis treatment (i) Type of treatment (ii) Type and dose of statin (iii) Mode and time of statin delivery	Local drug delivery	Results	Periodontal considerations
[139]	Rats (retired female breeder) EIP by ligatures Maxillary right M2	Nonsurgical treatment (therapeutic) Simvastatin prodrug 0.5 mg, 1.0 mg, and 1.5 mg Local injections of the drug/SIM/SIM-mPEG carrier 10 $\mu$ L into the palatal gingiva between maxillary M1 and M2 Three weekly injections until euthanasia		<ul style="list-style-type: none"> <li>↗ amount of uninflamed connective tissue in the M1-M2 interproximal area</li> <li>↘ bone loss, especially with 1.5 mg SIM/SIM-mPEG</li> <li>↘ percentage of neutrophils</li> </ul>	Simvastatin limited periodontal breakdown by reducing bone loss and the extent of gingival inflammation
[73]	Rats (male) ACP (maxillary bone defect) Maxillary M1 extraction followed by socket healing, preparation of a critical-sized periodontal defect (2.0 mm diameter and 1.0 mm depth) on the mesial aspect of the M2, and manual removal of the residual bone and cementum on mesial aspect of M2	Surgical treatment (therapeutic) Simvastatin 1 mg Encapsulated in double-walled PDLLA-PLGA microspheres Combinations: simvastatin-BSA, simvastatin-PDGF, simvastatin		<ul style="list-style-type: none"> <li>↗ neo-osteogenesis</li> <li>↗ bone mineral density</li> <li>↗ bone volume fraction</li> <li>↗ number and thickness of trabeculae</li> <li>↘ trabecular separation</li> <li>↗ cementogenesis of the periodontal apparatus</li> <li>↘ inflammatory cell infiltration</li> </ul>	Simvastatin promoted osteogenic differentiation, reduced inflammation, and facilitated osteogenesis. Sequential PDGF-simvastatin delivery was able to accelerate osteogenesis, bone maturation, fiber realignment, and cementogenesis of the periodontal apparatus, thus accelerating periodontal regeneration
[94]	Rats (male) ACP (tooth-associated alveolar bone defect model) extraction of M1 followed by 4 weeks of socket healing, preparation of a critical-sized intrabony periodontal defect in the M1 edentulous ridge next to the mesial aspect of the M2 finished by a 2.6 mm diameter and 1.0 mm deep osteotomy (completely removing the mesial wall of the osteotomy), and cementum removal (to expose the mesial aspect of M2)	Surgical treatment (therapeutic) Simvastatin 1 mg PDLLA-PLGA hybrid microspheres encapsulating simvastatin/PDGF/BSA to fill the defects		<ul style="list-style-type: none"> <li>↗ neo-osteogenesis (histologically)</li> <li>PDL fibers not inserted on the root surface (mainly parallel)</li> <li>↗ bone volume fraction % (not significant)</li> </ul>	Simvastatin histologically improved bone healing but better healing response was observed in the group receiving PDGF
[95]	Rats (female) ACP (fenestration defects) Defects 2 mm high, 4 mm wide, and 1.5 mm deep over mandibular molar roots	Nonsurgical treatment (therapeutic) Simvastatin 0.5 mg Local injection of 0.5 mg SIM per site dissolved in 70% ethanol or as SIM-ALN-CD Three weekly injections		<ul style="list-style-type: none"> <li>↗ insignificant improvement of bone fill compared to other groups</li> <li>New cementum formation (not significant)</li> <li>But better bone healing</li> </ul>	Simvastatin had a local bone healing effect which can be augmented by addition of certain other regenerative molecules like ALN

TABLE 3: Continued.

Reference	Experimental periodontitis induction model (i) Animal (ii) Method (iii) Site	Periodontitis treatment (i) Type and dose of statin (ii) Type and dose of statin (iii) Mode and time of statin delivery	Local drug delivery	Results	Periodontal considerations
[138]	Dogs (male) ACP (maxillary bone defect) Extraction of all maxillary PM2 followed by healing and preparation of one-walled intrabony defects (4 × 5 × 4 mm: buccolingual, mesiodistal, and depth, respectively) on the mesial and distal sides of maxillary bilateral PM1 Removal of residual cementum by SRP	Treatment started 15 days after the defect preparation		response after systemic ALN administration followed by simvastatin injections ↗ new bone formation in the EGCG14-CS-lovastatin 1 group (62.03%) > BioMend® group (46.07%) > control group (42.32%) Evidence of new cementum deposition observed on the root surface No inflammatory cell infiltrate was noted in the EGCG <sub>14</sub> -CS-lovastatin 1 group Fibrous connective tissue approximated to the surgical defect	The trilayer functional CS membrane with EGCG and lovastatin enhanced periodontal regeneration and bone formation rate
[140]	Dogs (male) ACP (maxillary bone defect) Extraction of maxillary 2 <sup>nd</sup> and 3 <sup>rd</sup> incisors followed by 8 weeks of socket healing and, later, preparation of three-walled intrabony defects (4 × 4 × 5 mm: buccolingual, mesiodistal, and depth, respectively) on the mesial side of maxillary bilateral canines Removal of residual cementum by SRP	Nonsurgical treatment (therapeutic) Lovastatin 4 mg dissolved in chloroform to form a 3 wt % PLGA solution Local injections of PLGA-lovastatin-CS-tetracycline 0.3% nanoparticles prepared as a hydrogel by mixing with gelatin (10 mg/100 mm <sup>3</sup> ) to fill the defects		↗ new deposits of cementum on the root surface ↗ active plasmacytoid osteoblastic rimming along the trabecular surface of the bone adjacent to the defect ↗ percentage of new bone formation (41.32%) No evident inflammation	PLGA-lovastatin-chitosan-tetracycline nanoparticles showed a good osteogenic potential. They promoted new bone and cementum formation
[96]	Rats (male) ACP (mandibular bone defect) Preparation of surgical defects 0.8 mm in diameter through the alveolar bone over the mesiobuccal root of the mandibular M1 bilaterally	Surgical treatment (therapeutic) Simvastatin 2.5% gel Defect was filled with 2.5% simvastatin gel Single topical application		↘ marrow spaces in simvastatin-treated defects ↗ collagen fibril organization ↗ OPN in bone matrix ↗ alveolar bone regeneration	Simvastatin gel improved the quality of the new bone and decreased bone resorption

TABLE 3: Continued.

Reference	Experimental periodontitis induction model (i) Animal (ii) Method (iii) Site	Periodontitis treatment (i) Type of treatment (ii) Type and dose of statin (iii) Mode and time of statin delivery	Local drug delivery	Results	Periodontal considerations
[99]	Dogs (males and females) ACP (mandibular bone defect) Preparation of bilateral 3-walled intrabony defects (4 × 4 × 4 mm) distal of the mandibular PM2 and mesial of the PM4 and class II furcation defects at the buccal furcation of the mandibular M1 measuring 4 mm occlusal apically and 4 mm buccolingually followed by healing and SRP of defect sites	Nonsurgical treatment (therapeutic) Simvastatin 0.5 mg or 2.0 mg in 30 µL methylcellulose gel Three weekly injections		<ul style="list-style-type: none"> <li>↗ edentulous ridge thickness (29% greater with simvastatin)</li> <li>↗ bone loss in class II furcation defects</li> <li>↗ length of new cementum in the interproximal intrabony defect</li> <li>↗ bone height with simvastatin (2 mg)</li> <li>No new cementum was observed in furcations</li> </ul>	Simvastatin was not appropriate for the treatment of class II furcation defects. However, it improved bone healing in intrabony defects and edentulous ridges significantly
[22]	Rats (male) EIP by ligatures Maxillary M2 bilaterally	Nonsurgical treatment (therapeutic) Atorvastatin 2% w/v containing CS gel Local 100 µL volume application every other day until euthanasia		<ul style="list-style-type: none"> <li>↘ IL-1β, IL-6, and IL-8</li> <li>↗ IL-10 (time dependent)</li> <li>↘ alveolar bone resorption</li> <li>(significantly with ATV + CS application and insignificantly with ATV alone)</li> <li>↘ attachment loss</li> <li>Improvement of inflammatory and osteoclastic activity score over time</li> </ul>	Atorvastatin with chitosan downregulated inflammation-mediated bone resorption
[90]	Rats (female) EIP by injection of <i>E. coli</i> LPS 10 µL of endotoxin injection (1 mg/mL of LPS in PBS) between M1 and M2	Nonsurgical treatment (preventative) Simvastatin 0.5 mg of simvastatin and 3.75 mg of SIM-ALN-CD in H2O Three weekly 12 µL injection bilaterally into the palatal/interproximal gingiva of M1 and M2 Treatment started one week before induction		<ul style="list-style-type: none"> <li>↗ bone preservation during experimental periodontitis by prophylactic SIM-ALN-CD injection</li> <li>↘ subulcular inflammation</li> <li>↘ alveolar bone loss</li> <li>↘ OC number</li> </ul>	Simvastatin protected against alveolar bone loss and soft tissue inflammation
[98]	Dogs (female) ACP (mandibular bone defect) Preparation of dehiscence defects (5 × 3 mm) bilaterally on the lateral aspect of the mandibular PM2 mesial roots and removal of	Surgical treatment (therapeutic) Simvastatin Graft surgery with HA grafts bilaterally covered with resorbable bilayer collagen membranes hydrated with 10 mg simvastatin		<ul style="list-style-type: none"> <li>↗ width of new bone in edentulous ridge</li> <li>Distance between CEJ and the alveolar crest was more coronal in dehiscence defects treated</li> </ul>	Simvastatin improved new bone formation where periosteum existed and did not induce severe side effects except for moderate swelling that, eventually, subsided

TABLE 3: Continued.

Reference	Experimental periodontitis induction model (i) Animal (ii) Method (iii) Site	Periodontitis treatment (i) Type of treatment (ii) Type and dose of statin (iii) Mode and time of statin delivery	Results	Periodontal considerations
	root cementum Split-mouth design	Local drug delivery (graft surgery performed at the time of defect preparation) Local injection 10 mg SIM (0.5 mg/kg) in ethanol (100 µL) Three weekly injections (one week after the graft surgery and defect preparation)	with simvastatin (insignificant) Three weeks post-op after simvastatin injection (firm swelling about 1 × 1 cm to 3.5 × 3.5 cm in size), disappeared in 2 months	
[59]	Rats (male) EIP by ligatures Left mandibular M1	Nonsurgical treatment (therapeutic) Simvastatin 1 mg/mL (Natrosol + simvastatin gel solution) into the periodontal pocket SRP and irrigation with simvastatin Single injection	↘ MMP-8 expression ↘ bone loss	Simvastatin reduced periodontal bone loss
[141]	Rats (male) EIP by ligatures Maxillary M2	Nonsurgical treatment (therapeutic) Simvastatin 0.2 mg in 50 µL PBS topically injected into the buccal gingivae Twice a week for 70 days	↗ ALP activity ↗ bone nodule formation No inflammatory cells around the new bone ↘ bone loss Simvastatin recovered the ligature-induced alveolar bone resorption (46% reversal of bone height)	Simvastatin increased bone regeneration and reduced inflammation
[142]	Rats (male) EIP by ligatures Mandibular left M1	Nonsurgical treatment (preventative) Simvastatin 0.5 mg/kg body weight orally Followed by laser therapy Treatment started 1 day before induction and daily until euthanasia	↘ bone loss ↘ carbonylated proteins in gingiva	Simvastatin reduced bone loss
[91]	Rats (female ovariectomized) EIP by ligatures Mandibular right M1	Nonsurgical treatment (protective) Simvastatin 10 <sup>-6</sup> M, 3 × 10 <sup>-7</sup> M, 10 <sup>-7</sup> M subperiosteal injections (0.05 mL)	↘ periodontal breakdown ↘ bone loss in alveolar bone crest zone in a dose-dependent manner (10 <sup>-7</sup> > 10 <sup>-6</sup> > 3 × 10 <sup>-7</sup> )	Simvastatin reduced bone loss in a dose-dependent manner

TABLE 3: Continued.

Reference	Experimental periodontitis induction model (i) Animal (ii) Method (iii) Site	Periodontitis treatment (i) Type of treatment (ii) Type and dose of statin (iii) Mode and time of statin delivery	Local drug delivery	Results	Periodontal considerations
[143]	Rat (female) EIP (ligature) Maxillary M2 bilaterally	Twice a week since the first day of ligature insertion to the 25th day Nonsurgical treatment (therapeutic) Simvastatin SIM-PPi conjugate Different treatments including SIM-PPi (dissolved in 25%, 2.56 mg, equivalent to 1.56 mg SIM) and SIM acid (dissolved in PBS, 1.56 mg, equivalent to 1.5 mg of SIM) locally injected (10 $\mu$ L) into the palatal gingiva between the maxillary M1 and M2 On the first day of weeks 1, 2 and 3 after ligature placement		$\nearrow$ alveolar bone crest preservation with SIM-PPi $\nearrow$ bone volume $\nearrow$ trabecular thickness $\nearrow$ trabecular number $\searrow$ trabecular separation $\searrow$ neutrophil and lymphocyte score $\searrow$ OC score	Simvastatin improved periodontal bone regeneration and decreased periodontal inflammation

TABLE 4: *In vivo* studies evaluating the impact of systemic statin administration on periodontal wound healing.

Experimental periodontitis induction model		Systemic drug delivery	
Reference	(i) Animal (ii) Method (iii) Site	(i) Type of treatment (ii) Type and dose of statin (iii) Mode and time of statin delivery	Results
[31]	Rats (male) EIP by ligatures Maxillary left M2	Nonsurgical treatment (protective) Atorvastatin 1 mg/kg, 5 mg/kg, and 10 mg/kg 1 hour before induction and thereafter once daily	<ul style="list-style-type: none"> <li>➢ MMP-2, MMP-9</li> <li>➢ RANK-L, RANK</li> <li>➢ OPG</li> <li>➢ GSH levels</li> <li>➢ IL-1<math>\beta</math>, TNF-<math>\alpha</math>, and MPO (dose dependent)</li> <li>➢ COX-2 level</li> <li>➢ MDA activity</li> <li>➢ alveolar bone loss is dose dependent</li> </ul> <p>Atorvastatin protected against alveolar bone loss in a dose-dependent manner</p>
[58]	Rats (female) EIP by ligatures Maxillary left M2	Nonsurgical treatment (protective) Simvastatin 3, 10, and 30 mg/kg/day 1 hour before induction and thereafter once daily	<ul style="list-style-type: none"> <li>➢ BMP-2 and OPG levels</li> <li>➢ TRAP activity</li> <li>➢ MPO activity (dose dependent)</li> <li>➢ IL-1<math>\beta</math> and TNF-<math>\alpha</math></li> <li>➢ IL-10</li> <li>➢ gingival GSH</li> <li>➢ gingival MDA and NOX</li> <li>➢ iNOS, MMP-1, MMP-8, RANK, and RANKL expression</li> <li>No differences in AST and ALT levels</li> <li>Inhibition of alveolar bone loss</li> </ul> <p>Simvastatin prevented inflammatory bone resorption and possessed antioxidant properties</p>
[144]	Rats (male) EIP by ligatures Maxillary left M2	Nonsurgical treatment (protective) Atorvastatin 1, 3, and 9 mg/kg Atorvastatin mixed in sterile saline by gavage 30 min before ligature placement and then daily until euthanasia	<ul style="list-style-type: none"> <li>➢ alveolar bone loss in the furcation area as well as in proximal faces of upper M2 (47% reduction with 9 mg dose compared to that with the control)</li> <li>Insignificant bone loss protection with 1 and 3 mg doses</li> </ul> <p>Atorvastatin had protective effect against alveolar bone loss</p>
[40]	Rats (male) EIP by ligatures Maxillary left M2	Nonsurgical treatment (protective + therapeutic) Atorvastatin 0.3 mg/kg or 27 mg/kg by gavage In combination with ALN 30 min before ligature placement and thereafter once daily until euthanasia or 5 days after the start of periodontitis induction and then daily until euthanasia	<ul style="list-style-type: none"> <li>➢ TRAP and MPO activity</li> <li>➢ cementum resorption</li> <li>➢ neutrophilia and lymphomonocytosis</li> <li>➢ alveolar bone loss both prophylactically (39%) and therapeutically (53.4%) with lower dose of ALN + ATV (0.01 mg/kg+0.3 mg/kg, respectively)</li> <li>Prevented BALP reduction with lower dose of ALN + ATV</li> <li>No effect on serum transaminases</li> </ul> <p>Atorvastatin reduced alveolar bone loss, cemental resorption, and inflammatory cell infiltration both prophylactically and therapeutically</p>



TABLE 4: Continued.

Systemic drug delivery			
Reference	Experimental periodontitis induction model (i) Animal (ii) Method (iii) Site	Periodontitis treatment (i) Type of treatment (ii) Type and dose of statin (iii) Mode and time of statin delivery	Results  Periodontal considerations
[145]	Rats (male) EIP by ligatures Maxillary left M2	Nonsurgical treatment (protective) Atorvastatin 0.3, 3, and 27 mg/kg by gavage 30 min before ligature placement and thereafter once daily until euthanasia	<ul style="list-style-type: none"> <li>➤ alveolar bone in a dose-dependent manner (39% for 3 mg/kg and 56% for 27 mg/kg doses)</li> <li>➤ Prevented the reduction of BALP serum levels (27 mg/kg)</li> <li>➤ Prevented leukocytosis (27 mg/kg)</li> </ul> <p>Atorvastatin prevented alveolar bone loss with both prophylactic and therapeutic doses</p>
[32]	Rats (female with metabolic syndrome) ACP (injection of 20 µg of <i>A.a</i> LPS in PBS) into the palatal gingiva between the maxillary M1 and M2, thrice per week for 4 weeks	Nonsurgical treatment (protective) Simvastatin 20 mg/kg/day Daily via gavage for 4 weeks Treatment started on the same day as injection of LPS	<ul style="list-style-type: none"> <li>➤ LPS induced alveolar bone loss in both lean and fat rats (significantly)</li> <li>➤ infiltration of mononuclear cells</li> <li>➤ inflammatory score</li> <li>➤ LPS stimulated RANKL and CSF2 expression in both lean and fat rats</li> <li>➤ bone resorption</li> </ul> <p>Simvastatin downregulated inflammation-mediated bone resorption</p>
[33]	Rats (female) ACP injection of 20 µg/rat of <i>A.a</i> LPS through the palatal gingiva between the maxillary M1 and M2 thrice per week for 8 weeks	Nonsurgical treatment (protective) Simvastatin (20 mg/kg/day) daily via oral gavage for 8 weeks	<ul style="list-style-type: none"> <li>➤ LPS induced alveolar bone loss (31%)</li> <li>➤ LPS induced osteoclastogenesis</li> <li>➤ TNF-α, IL-1α, IL-1β, IL-6, CSF-2, CSF-3, MCP-1, and MMP-9</li> <li>➤ LPS induced TLR family members' expression</li> </ul> <p>Simvastatin downregulated inflammation-mediated bone resorption</p>
[25]	Rats (male) EIP by ligatures Maxillary M2	Nonsurgical treatment (protective) Rosuvastatin 20 mg/kg in water by gavage 1 h before ligation and then once daily until euthanasia	<ul style="list-style-type: none"> <li>➤ IL-10</li> <li>➤ IL-1β</li> <li>➤ MDA</li> <li>➤ GSH</li> <li>➤ inflammatory infiltrate</li> <li>➤ OC number</li> <li>➤ OB number</li> <li>➤ alveolar bone loss (significantly)</li> </ul> <p>Rosuvastatin protected against alveolar bone loss</p>
[54]	Rats (male) EIP by ligatures Hyperlipidemia induction through diet Maxillary M2	Nonsurgical treatment (protective) Rosuvastatin 20 mg/kg in water by gavage 1 h before ligation and then once daily until euthanasia	<ul style="list-style-type: none"> <li>➤ gingival iNOS (significantly)</li> <li>➤ inflammation and hyperemia</li> <li>➤ alveolar bone loss</li> </ul> <p>Rosuvastatin protected against inflammation-induced bone degradation</p>
[34]	Rats (male) EIP by ligatures Mandibular M1 and maxillary M2 bilaterally	Nonsurgical treatment (therapeutic) Simvastatin 10 mg/kg in water once daily orally until euthanasia Treatment started 8 days after periodontitis induction	<ul style="list-style-type: none"> <li>➤ alveolar bone loss</li> <li>➤ IL-6</li> <li>➤ CRP</li> </ul> <p>Simvastatin decreased inflammation and alveolar bone loss</p>

TABLE 4: Continued.

Reference	Experimental periodontitis induction model (i) Animal (ii) Method (iii) Site	Periodontitis treatment (i) Type of treatment (ii) Type and dose of statin (iii) Mode and time of statin delivery	Systemic drug delivery	Results	Periodontal considerations
[93]	Rats (male hypertensive) EIP by ligatures Mandibular M1 bilaterally	Nonsurgical treatment (protective) Rosuvastatin 2 mg/kg oral gavage Treatment started since the day of induction daily until euthanasia		<ul style="list-style-type: none"> <li>↳ bone loss in furcation area</li> <li>↳ attachment loss</li> <li>↳ TRAP-positive multinucleated cells</li> </ul>	Rosuvastatin reduced alveolar bone loss and osteoclastogenesis
[97]	Rats EIP by ligatures Mandibular M1	Nonsurgical treatment (protective + therapeutic) Simvastatin Different treatments: simvastatin-simvastatin: aqueous suspension of simvastatin by gavage (35 mg/kg/day) administration before and after periodontitis induction; simvastatin-water: simvastatin administration before and filtered water after periodontitis induction; and water-simvastatin: water administration before and simvastatin after periodontitis induction		<ul style="list-style-type: none"> <li>No significant differences between groups receiving simvastatin before the induction of periodontitis and those that received water</li> <li>No protective effect of simvastatin against the development of periodontitis</li> </ul>	Simvastatin did not possess protective or therapeutic effects against periodontitis development
[146]	Rats (male) EIP by ligatures Mandibular left M1	Nonsurgical treatment (therapeutic) Simvastatin 25 mg/kg Dissolved in saline Treatment started 14 days after the initiation of periodontitis induction		<ul style="list-style-type: none"> <li>↗ TG levels</li> <li>↳ MDA level</li> <li>↗ IL-10</li> <li>↳ MMP-9</li> <li>↳ bone loss</li> <li>No difference on TNF-<math>\alpha</math> levels</li> </ul>	Simvastatin promoted the anti-inflammatory mediators to counter alveolar bone loss
[35]	Rats (male, cyclosporine A-induced alveolar bone loss) EIP by ligatures Mandibular right M1	Nonsurgical treatment (protective) Simvastatin 20 mg/kg orally daily for 30 days The treatment and induction started on the same day		<ul style="list-style-type: none"> <li>↗ Ca<sup>2+</sup> concentrations (significantly)</li> <li>No effect of simvastatin treatment in the presence of periodontal disease on serum ALP levels but it blocked the cyclosporine A-mediated decrease of ALP</li> <li>No significant effect on alveolar bone turnover but with concomitant cyclosporine A and simvastatin delivery</li> <li>Simvastatin completely inhibited cyclosporine A-induced bone loss</li> </ul>	Simvastatin did not prevent alveolar bone loss in periodontitis but it completely countered the cyclosporine A-induced bone loss
[147]	Rats (male) EIP by ligatures Mandibular right M1	Nonsurgical treatment (protective) Simvastatin 20 mg/kg The treatment and induction started on the same day		<ul style="list-style-type: none"> <li>↗ ALP activity in periodontal inflammation</li> <li>↳ alveolar bone loss</li> </ul>	Simvastatin protected against alveolar bone loss

TABLE 4: Continued.

Reference	Experimental periodontitis induction model		Systemic drug delivery		Results	Periodontal considerations
	(i) Animal	(ii) Method	(i) Type of treatment	(ii) Type and dose of statin		
			(iii) Mode and time of statin delivery			
[76]	Mice (male) ACP ( <i>P.g</i> LPS injection) 1 mg/kg <i>P.g</i> LPS injection at the gingiva of left mandibular M2 on days 4 and 7		Nonsurgical treatment (protective) Fluvastatin 3 mg/kg IP injections on days 1, 4, and 7		<ul style="list-style-type: none"> <li>↳ LPS induced OC (by &gt;50%)</li> <li>↳ LPS-induced bone erosion</li> <li>↳ RANKL</li> </ul>	Fluvastatin prevented inflammation-induced bone erosion
[26]	Rats (male, GIOP) EIP by ligatures Maxillary left M2		Nonsurgical treatment (protective) Atorvastatin 27 mg/kg ATV orally 30 min before induction and once daily afterwards		<ul style="list-style-type: none"> <li>↳ bone loss</li> <li>↳ MPO, TNF-<math>\alpha</math>, IL-1<math>\beta</math>, IL-6, and IL-8</li> <li>↳ IL-10, GSH, SOD, and CAT levels</li> <li>↳ RANKL and DKK-1</li> <li>↳ OPG, WNT10 <math>\beta</math>, and <math>\beta</math>-catenin expressions and BALP activity</li> </ul>	Atorvastatin prevented alveolar bone loss in periodontitis and reduced inflammation

TABLE 5: *In vivo* studies evaluating the impact of a combination of local and systemic statin administration on periodontal wound healing.

Reference	Experimental periodontitis induction model (i) Animal (ii) Method (iii) Site	Local + systemic drug delivery		Periodontal considerations
		Periodontitis treatment (i) Type of treatment (ii) Type and dose of statin (iii) Mode and time of statin delivery	Results	
[57]	Rats (male) EIP by ligatures mandibular M1	Nonsurgical treatment (therapeutic) Atorvastatin Systemically (5 mg/kg in a volume of 0.5 mL) and locally (0.1 mg/kg in a volume of 0.05 mL) at a dose of 0.1 mg/kg in a volume of 0.05 mL	↗ alveolar bone area % ↗ VEGF ↘ MMP-9 ↘ alveolar bone and attachment loss Local application showed better results on periodontium healing	Atorvastatin increased the alveolar bone regeneration while decreasing the periodontal inflammation and attachment loss
[92]	Rats (female ovariectomized) EIP by ligatures Maxillary M1 and M2 bilaterally	Nonsurgical treatment (therapeutic) Simvastatin Local injection (0.8 mg/0.05 mL) Oral (25 mg/kg) For two months until euthanasia	↗ alveolar crest height (28% with local & oral and 27% with local) ↗ BV/TV ↗ trabecular thickness ↘ trabecular separation	Simvastatin reduced bone degradation when administered locally, systemically, or both locally and systemically together

The animals included in the studies are healthy unless stated otherwise. Treatment was considered (i) “preventative” when it started at least one day before the start of EIP/ACP induction, (ii) “protective” when it started the same day as that of EIP/ACP induction, and (iii) “therapeutic” when it started at least one day after the start of EIP/ACP induction.

group [104–108] (Table 6). Amongst these studies, the mean difference of PD between the test and control groups ranged from  $1.3 \pm 0.21$  mm to  $2.51 \pm 0.22$  mm ( $p < 0.001$ ). Thus, the mean difference of CAL between the test and control groups ranged from  $1.16 \pm 0.09$  mm to  $2.35 \pm 0.08$  ( $p < 0.001$ ). Moreover, the mean difference of bone defect fill between the test and control groups ranged from  $1.336 \pm 0.714$  to  $3.08 \pm 0.07$  ( $p < 0.001$ ).

**3.8. Impact of Systemic Administration of Statins on Nonsurgical Periodontal Treatment Outcomes.** The impact of systemic administration of statins on nonsurgical periodontal treatment outcomes was evaluated in a few studies (Table 7). From the 7 studies identified, 4 demonstrated significant improvements regarding reduction of PD, CAL gain, and/or tooth loss in comparison to the control group [56, 109–111]. At contrary, 3 other studies did not show any significant differences in periodontal outcomes between the statin-treated and control groups [112–114]. These discrepancies could be due to the very short follow-up of the abovementioned 3 studies (3 months) compared to the other ones (from 3 months to 7 years follow-up). Moreover, one of the studies did not compare the treatment group with a control group [110].

#### 4. Discussion

Statins exhibit multiple effects, including modulation of inflammatory-immune crosstalk, bone regeneration, and antibacterial activity, to promote periodontal wound healing and regeneration (Figure 5). They act through several closely interrelated pathways highlighting potential therapeutic targets. The hydrophobic or hydrophilic nature of statins determines their efficacy, action on periodontal pathogens, and

treatment response and appears to be largely cell and tissue dependent [69, 78]. Further insight into this may help selecting the best statin.

Moreover, the mode of statin delivery also affects the treatment outcomes. Oral systemic administration of statins reduces periodontal inflammation and consequent tooth loss [111] but the low resultant dose available to the tissues after hepatic bypass renders them relatively less efficacious [60]. On the other hand, a higher dose to enhance efficacy can manifest systemic side effects such as statin-induced myopathy, hepatotoxicity, nephrotoxicity, pulmonary manifestations, ophthalmological manifestations, gastrointestinal hemorrhage risk, and oral manifestations (dryness, itch, bitterness, and cough) [115, 116]. Therefore, to avoid these side effects, various local application strategies have been tested that allow site-specific delivery reducing the required dose, frequency of application, and bioavailability in the blood [60, 117, 118], concomitantly improving patient compliance [119].

The development and selection of an optimal statin delivery carrier are crucial as it enhances the statin retention on the lesion and acts as a scaffold for cell growth and differentiation [120]; therefore, it should be capable to withstand the oral environment, continuous fluid exchange inside the pocket, and salivary influx.

Several studies demonstrate that anti-inflammatory properties of statins vary according to the type and dose of statin used [121]. On a cellular level, modulation of macrophage polarization from a proinflammatory M1 to a proresolution M2 phenotype by systemic delivery of immune modulatory drugs resolved persistent inflammation associated with chronic periodontitis [122]. In this context, statins' ability to switch M1 to M2 to promote periodontal wound healing and regeneration needs to be explored. Furthermore,

TABLE 6: Clinical studies evaluating the impact of local statin administration on periodontal wound healing.

Reference Study area Type of study	Drug		Local drug delivery		Number of patients Periodontal status Type of patients	Type of treatment Study design (groups) Follow-up	Results	Periodontal considerations
	Mode of delivery	Dose	Number of patients	Study design (groups) Follow-up				
[130] (India) RCT with split-mouth design	Simvastatin in methylcellulose gel	1.2 g of SIM	Periodontitis (Armitage 1999) Healthy patients (nonsmokers) Sites with periodontal pocket measuring $\geq 5$ mm and vertical bone loss $\geq 2$ mm in different quadrants of the mouth	Nonsurgical treatment Group I: SRP + placebo gel Group II: SRP + SIM gel 6 months follow-up	30	All subjects tolerated the drug $\nearrow$ periodontal parameters with or without SIM $\nearrow$ CAL ( $p = 0.02$ ) $\nearrow$ INFRA 2 ( $p < 0.01$ ) $\searrow$ PD significantly ( $p = 0.04$ ) $\searrow$ INFRA 1 ( $p < 0.01$ )	Simvastatin increased periodontal regeneration and CAL gain	
[23] (India) RCT	Rosuvastatin 1.2% rosuvastatin (RSV) gel		Chronic periodontitis Healthy patients (nonsmokers)	Nonsurgical treatment Groups I: SRP + placebo gel Group II: SRP + 1.2% RSV gel Group III: SRP + 1% MF gel 12 months follow-up	90	$\nearrow$ CAL $\searrow$ PD significant $\nearrow$ bone fill $\searrow$ PI $\searrow$ mSBI $\searrow$ DDR	Rosuvastatin increased periodontal regeneration and CAL gain	
[102] (India) RCT	Atorvastatin and rosuvastatin 1.2% atorvastatin or 1.2% rosuvastatin gel local drug delivery (1.2 mg/0.1 mL)		No data Healthy patients (nonsmokers) Mandibular class II furcation defects with PD $\geq 5$ mm and horizontal PD $\geq 3$ mm	Nonsurgical treatment Group I: SRP + placebo Group II: SRP + 1.2% RSV gel Group III: SRP + 1.2% ATV gel 9 month follow-up	90	$\searrow$ PI and mSBI in all groups The 2 statins lead to the following: $\searrow$ PD $\nearrow$ mean gain in CAL $\nearrow$ mean percentage of DDR Statistically greater results for RSV than for ATV	Statins increased periodontal regeneration and CAL gain	
[103] (India) Cohort study	Simvastatin SIM gel (1.2 mg/0.1 mL)		Chronic periodontitis Healthy patients (nonsmokers)	Nonsurgical treatment Group I: SRP alone Group II: SRP + SIM gel 3 months follow-up	50	$\searrow$ IL-6 and IL-8 $\nearrow$ IL-10 significantly $\searrow$ PI, mSBI, and PD No effect on CAL $\searrow$ PI, GI, and SBI No significant difference for PD and CAL $\searrow$ mean IL-6 levels No significant difference for IL-8 levels	Simvastatin gel decreased periodontal inflammation and promote periodontal regeneration	
[21] (India) RCT	Simvastatin 1.2% simvastatin gel		Chronic periodontitis Healthy patients (nonsmokers)	Nonsurgical treatment Group I: SRP Group II: SRP + SIM gel 45 days follow-up	46		Simvastatin gel decreased periodontal inflammation	

TABLE 6: Continued.

Reference Study area Type of study	Drug		Number of patients Periodontal status Type of patients	Local drug delivery		Results	Periodontal considerations
	Mode of delivery Dose	Type of treatment Study design (groups) Follow-up					
[104] (India) Cohort study with split-mouth design	Simvastatin Combination of DFDBA and a 10 <sup>-8</sup> M solution of the drug simvastatin	Surgical treatment (Kirkland flap) Group A: DFDBA alone Group B: DFDBA + SIM 24 weeks follow-up	15 No data Healthy patients (nonsmokers) Identical bilateral infrabony defect			<ul style="list-style-type: none"> <li>↘ PD</li> <li>↗ mean gain in CAL (better with DFDBA + SIM)</li> <li>↘ infrabony defect depth (greater reduction with DFDBA + SIM)</li> <li>↗ linear defect fill (better with DFDBA + SIM)</li> </ul>	Simvastatin increased periodontal regeneration and CAL gain
[148] (India) RCT	Atorvastatin 1.2% atorvastatin gel (ATV gel (1.2 mg/0.1 mL))	Nonsurgical treatment Group 1: SRP + ATV Group 2: SRP + placebo 9 months follow-up	75 Well-controlled type 2 diabetic patients (nonsmokers) Chronic periodontitis			<ul style="list-style-type: none"> <li>↗ mSBI</li> <li>↘ PD</li> <li>↗ CAL gain</li> <li>↘ IBD depth and DDR</li> <li>No significant difference for PI at all time intervals evaluated</li> </ul>	Atorvastatin increased periodontal regeneration
[125] (India) RCT	Atorvastatin 1.2% atorvastatin gel (ATV gel (1.2 mg/0.1 mL))	Nonsurgical treatment Group 1: SRP + ATV Group 2: SRP + placebo 9 months follow-up	71 Smokers Chronic periodontitis			<ul style="list-style-type: none"> <li>↘ PD</li> <li>↗ mean CAL gain</li> <li>↘ mean percentage of DDR</li> <li>↘ mSBI</li> <li>↘ IBD depth</li> <li>No statistically significant difference in the site-specific PI score and full-mouth PI score between the groups at any visit</li> </ul>	Atorvastatin increased periodontal regeneration and CAL gain
[105] (India) Cohort	Atorvastatin 1.2% ATV gel	Surgical treatment Group I: OFD + PRF Group II: OFD + PRF + 1.2% ATV Group III: OFD alone 9 months follow-up	96 Healthy patients (nonsmokers) Chronic periodontitis			<ul style="list-style-type: none"> <li>ATV gel and PRF alone showed significantly the following:</li> <li>↘ PD</li> <li>↗ mean CAL gain</li> <li>↘ IBD depth</li> </ul>	Atorvastatin increased periodontal regeneration and CAL gain

TABLE 6: Continued.

Reference Study area Type of study	Drug Mode of delivery Dose	Number of patients Periodontal status Type of patients	Local drug delivery		Results	Periodontal considerations
			Type of treatment Study design (groups) Follow-up	Follow-up		
[101] (India) RCT	Atorvastatin and simvastatin 10 mL of 1.2% ATV gel (1.2 mg/0.1 mL) and 10 mL of 1.2% SIM gel (1.2 mg/0.1 mL)	96 Healthy patients (nonsmokers) Chronic periodontitis	Nonsurgical treatment Group I: SRP + 1.2% ATV Group II: SRP + 1.2% SIM Group III: SRP + placebo 9 months follow-up		No statistically significant difference in PI and mSBI scores between the groups at 9 months  The 2 statins lead to the following: ↘ PD ↘ mSBI ↘ IBD depth ↗ mean CAL gain Statistically greater results for ATV than for SIM for PD reduction, CAL gain and percentage of IBD reduction	Atorvastatin increased periodontal regeneration and CAL gain
[149] (India) RCT	Simvastatin Single topical transmucosal injection 1.2 mg SIM	60 Chronic periodontitis Healthy patients (nonsmokers)	Nonsurgical treatment Group I: SRP + placebo Group II: SRP + SIM 6 months follow-up		↘ mSBI ↘ mean PD ↗ mean CAL ↗ IBD fill ↘ GI	Simvastatin increased periodontal regeneration and CAL gain
[126] (India) RCT	Simvastatin SIM 1.2 µg/inj. (0.12 µg/mm <sup>3</sup> ) Methylcellulose gel	72 Chronic periodontitis Healthy patients (nonsmokers) Mandibular buccal class II furcation defects	Nonsurgical treatment Group I: SRP + placebo Group II: SRP + 1.2 mg SIM 6 months follow-up		↘ SBI and PB ↗ CAL ↗ IBD fill	Simvastatin increased periodontal regeneration and CAL gain
[150] (India) RCT	Atorvastatin 1.2% ATV methyl cellulose gel	60 patients Chronic periodontitis Healthy patients (nonsmokers)	Nonsurgical treatment Group I: SRP + 1.2% ATV Groups II: SRP + placebo gel 9 months follow-up		↘ PD ↘ mSBI ↗ mean CAL gain ↗ IBD fill	Simvastatin increased periodontal regeneration and CAL gain
[151] (India) RCT	Simvastatin 1.2% SIM gel	38 Chronic periodontitis Well-controlled type II diabetes Nonsmokers	Nonsurgical treatment Group I: SRP + SIM Group II: SRP + placebo 9 months follow-up		↘ PD ↗ mean CAL gain ↗ mean radiographic bone fill ↘ mSBI	Simvastatin increased periodontal regeneration and CAL gain



TABLE 6: Continued.

Reference Study area Type of study	Drug Mode of delivery Dose	Number of patients Periodontal status Type of patients	Local drug delivery		Results	Periodontal considerations
			Type of treatment Study design (groups) Follow-up	Follow-up		
[152] (India) RCT	Rosuvastatin 1.2% rosuvastatin (RSV) gel	65 Chronic periodontitis Healthy (nonsmokers)	Nonsurgical treatment Group I: SRP + RSV Group II: SRP + placebo 6 months follow-up	6 months follow-up	<ul style="list-style-type: none"> <li>↘ mSBI</li> <li>↘ PD</li> <li>↗ mean CAL gain</li> <li>↗ IBD fill</li> </ul>	Rosuvastatin increased periodontal regeneration and CAL gain
[20] (India) RCT	Atorvastatin + rosuvastatin 1.2% RSV and 1.2% ATV gel	90 Chronic periodontitis Healthy (nonsmokers)	Nonsurgical treatment Group I: SRP + placebo Group II: SRP + 1.2% RSV gel Group III: SRP + 1.2% ATV gel 9 months follow-up	9 months follow-up	<p>The 2 statins lead to the following:</p> <ul style="list-style-type: none"> <li>↘ mSBI</li> <li>↘ PD</li> <li>↗ mean CAL gain</li> <li>↗ IBD fill</li> <li>Statistically greater results for RSV than for ATV for PD reduction, CAL gain, IBD reduction, and mSBI reduction</li> </ul>	Atorvastatin and rosuvastatin increased periodontal regeneration and CAL gain
[106] (India) RCT	Rosuvastatin 1.2% RSV gel	90 Chronic periodontitis Healthy (nonsmokers)	Surgical treatment 2/3-walled intrabony defects Group I: OFD alone Group II: OFD + PRF Group III: OFD + PRF + 1.2% RSV gel 9 months follow-up	9 months follow-up	<ul style="list-style-type: none"> <li>↘ PD</li> <li>↗ mean CAL gain</li> <li>↗ IBD fill</li> </ul>	Rosuvastatin increased periodontal regeneration and CAL gain
[107] (India) RCT	Rosuvastatin 1.2% RSV gel	110 Chronic periodontitis Healthy (nonsmokers) Mandibular degree II furcation defects	Surgical treatment Group I: OFD + placebo gel Group II: OFD + PRF + HA Group III: OFD + RSV 1.2 mg/gel + PRF + HA 9 months follow-up	9 months follow-up	<ul style="list-style-type: none"> <li>↘ PD</li> <li>↗ mean CAL gain</li> <li>↗ IBD fill</li> <li>↘ PI and mSBI</li> </ul>	Rosuvastatin increased periodontal regeneration and CAL gain
[153] (India) RCT	Atorvastatin 1.2% atorvastatin gel	90 Chronic periodontitis Healthy patients (nonsmokers) Intrabony defect	Nonsurgical treatment Group I: SRP + ALN Group II: SRP + 1.2% ATV Group III: SRP + placebo group 9 months follow-up	9 months follow-up	<ul style="list-style-type: none"> <li>↘ PD</li> <li>↗ mean CAL gain</li> <li>↗ IBD fill</li> <li>↘ mSBI</li> </ul>	Local delivery of atorvastatin increased periodontal regeneration

TABLE 6: Continued.

Reference Study area Type of study	Local drug delivery		Number of patients Periodontal status Type of patients	Type of treatment Study design (groups) Follow-up		Results	Periodontal considerations
	Drug Mode of delivery Dose						
[154] (India) RCT	Simvastatin 0.1 mL SIM gel (1.2 mg/0.1 mL)		24 Aggressive periodontitis Healthy patients (nonsmokers) Intrabony defect	Nonsurgical treatment Group I: SRP + placebo gel Group II: SRP + SIM gel 6 months follow-up		<p>↘ PD</p> <p>↗ mean CAL gain</p> <p>↗ IBD fill</p> <p>↘ mSBI</p> <p>All patients tolerated the drug with no postapplication complications</p> <p>Simvastatin increased periodontal regeneration</p>	
[108] (India) RCT	Simvastatin 1.2 mg Simvastatin gel		20 Chronic periodontitis Healthy patients (nonsmokers)	Surgical treatment PD ≥ 5 mm in the mandibular molar region bilaterally Group I: OFD + SIM Group II: OFD + placebo gel 9 months follow-up		<p>↗ IBD fill for group I</p> <p>Significant results at 9 months in both groups:</p> <p>↘ GI, PD</p> <p>↗ mean CAL gain</p>	Simvastatin increased periodontal regeneration
[155] (India) RCT	Simvastatin 10 µL prepared SIM gel (1.2 mg/0.1 mL)		40 Chronic periodontitis Healthy patients Smokers only	Nonsurgical treatment Group I: SRP + SIM 1.2% Group II: SRP + placebo 9 months follow-up		<p>↘ mSBI</p> <p>↘ PD</p> <p>↗ mean CAL gain</p> <p>↗ IBD fill</p>	Simvastatin increased periodontal regeneration and CAL gain
[156] (India) RCT	Simvastatin 1.2% simvastatin gel		60 Chronic periodontitis Healthy (nonsmokers)	Nonsurgical treatment Group A: SRP + placebo Group B: SRP + SIM gel 6 months follow-up		<p>↘ mSBI and PD</p> <p>↗ mean CAL gain</p> <p>↗ IBD fill</p> <p>↘ IL-6 levels</p>	This study showed the efficacy of SIM as a local drug delivery system in the treatment of chronic periodontitis not only in clinical but also in molecular levels
[137] (Chile) RCT	Atorvastatin 2% atorvastatin dentifrice		36 Chronic periodontitis Controlled diabetic only All types of smoking status	Nonsurgical treatment Group I: SRP + ATV dentifrice Group II: SRP + placebo dentifrice 1 month follow-up		<p>↘ PISA</p> <p>↘ mean PD</p> <p>↘ % of sites with PD ≥ 5 mm</p>	Simvastatin increased periodontal regeneration and CAL gain

TABLE 6: Continued.

Reference Study area Type of study	Local drug delivery		Number of patients Periodontal status Type of patients	Type of treatment Study design (groups) Follow-up	Results	Periodontal considerations
	Drug Mode of delivery Dose	Study design (groups) Follow-up				
[100] (India) Cohort study	Atorvastatin + simvastatin Drug in sodium alginate suspension administered with calcium chloride solution, subgingival delivery 1.2% simvastatin, or 1.2% atorvastatin	Nonsurgical treatment Group I: SRP alone Group II: SRP + 1.2% SIM Group III: SRP + 1.2% ATV 6 months follow-up	45 Moderate to severe chronic periodontitis Healthy (nonsmokers)		<ul style="list-style-type: none"> <li>↗ mean CAL gain</li> <li>↘ % of sites with CAL ≥ 5 mm</li> <li>↘ BOP</li> <li>↘ GI</li> </ul>	No significant benefit for periodontal regeneration with the use of statin

TABLE 7: Clinical studies evaluating impact of systemic statin administration on periodontal wound healing.

Reference Study area Type of study	Drug		Systemic drug delivery		Results	Periodontal considerations
	Mode of delivery Dose	Number of patients Periodontal status Type of patients	Type of treatment Study design (groups) Follow-up	Number of patients Periodontal status Type of patients		
[109] (USA) Retrospective cohort study	Not reported	1021 Chronic periodontal disease All types of patients (diabetic, smokers, antibiotic users, anti-inflammatory users...)	Nonsurgical treatment Hyperlipidemic vs healthy Mean follow-up = 7.1 years	Any statin use during the first 3 years after the initial periodontal exam was associated with a 48% decreased tooth loss rate in year 4 and subsequent years	Statin reduced tooth loss in chronic periodontitis	
[112] (Mexico) RCT	Atorvastatin 20 mg/day	38 Chronic periodontitis Healthy (all types of smoking status)	Nonsurgical treatment Group I: SRP + ATV Group II: SRP + placebo 3 months follow-up	<ul style="list-style-type: none"> <li>↘ dental mobility</li> <li>↘ distance from the crestal alveolar bone to the cemento-enamel junction</li> </ul>	Atorvastatin reduced tooth mobility and bone loss	
[110] (Turkey) No control group Longitudinal	Atorvastatin 10 or 20 mg	20 Chronic periodontitis Hyperlipidemic patients (nonsmokers)	Nonsurgical treatment SRP 6 months follow-up	<ul style="list-style-type: none"> <li>↘ median values for the PI, GI, PD, and BOP (%)</li> <li>↗ median value of CAL gain</li> <li>All lipid parameters decreased after the periodontal treatment</li> <li>No comparison with the control group</li> </ul>	Atorvastatin reduced periodontal breakdown Improved periodontal health may influence metabolic control of hyperlipidemia	
[113] (Turkey) Cohort study	Atorvastatin 10 or 20 mg	80 Chronic periodontitis Healthy or hyperlipidemic patients (nonsmokers)	Nonsurgical treatment Group I: healthy patient + SRP Group II: hyperlipidemic patients + prescribed diet (HD) Group III: hyperlipidemic patients + atorvastatin (HS) 3 months follow-up	<ul style="list-style-type: none"> <li>↗ BOP</li> <li>↘ IL-6 (serum and GCF)</li> <li>↘ TNF-<math>\alpha</math> (GCF) levels</li> </ul>	Systemic atorvastatin had beneficial effects on periodontal inflammation	
[111] (Germany) Cohort study	Simvastatin ( $n = 87$ ), lovastatin ( $n = 27$ ), pravastatin ( $n = 53$ ), fluvastatin ( $n = 37$ ), atorvastatin ( $n = 34$ ), and cerivastatin ( $n = 42$ )	2689 All types of periodontal disease Hyperlipidemic vs normolipidemic All types of smoking status	All types of periodontal treatment Group I: participants undergoing statin treatment Group II: patients without statins 5.3 years mean follow-up	No effect on PD and CAL tooth loss	Statin had the beneficial effect of protecting against tooth loss	
[56] (USA) Cohort study	Simvastatin Not reported	117 Chronic periodontitis Diabetic vs healthy All types of smoking status	Nonsurgical treatment Group I: nondiabetic patients not taking statin Group II: nondiabetic patients taking statin Group III: diabetic patients not taking statin	<ul style="list-style-type: none"> <li>↘ PD in diabetic patients</li> <li>↗ CAL in nondiabetic patients</li> <li>↘ MMP-1 level in GCF of nondiabetic and diabetic patients</li> <li>No difference was found for</li> </ul>	Statin intake was associated with reduced PD in diabetic patients and MMP-1 level in GCF in either nondiabetic or diabetic patients	

TABLE 7: Continued.

Reference Study area Type of study	Drug Mode of delivery Dose	Systemic drug delivery			Results	Periodontal considerations
		Number of patients Periodontal status Type of patients	Type of treatment Study design (groups) Follow-up			
[114] (India) Cohort study	Atorvastatin 20 mg/day	107 Chronic periodontitis Hyperlipidemic vs normolipidemic Nonsmokers	Group IV: diabetic patients taking statin 6 weeks follow-up	MMP-8 and MMP-9 levels in GCF	Patients with hyperlipidemia were more prone to periodontal disease Statin intake had beneficial effects on periodontal inflammation	
			Nonsurgical periodontal treatment	> GI		
			Group 1: hyperlipidemic + SIM Group 2: hyperlipidemic + diet Group 3: normolipidemic patients 3 months follow-up	Mean change in PD is negatively associated with LDL-C Mean change in GI is positively associated with HDL-C		

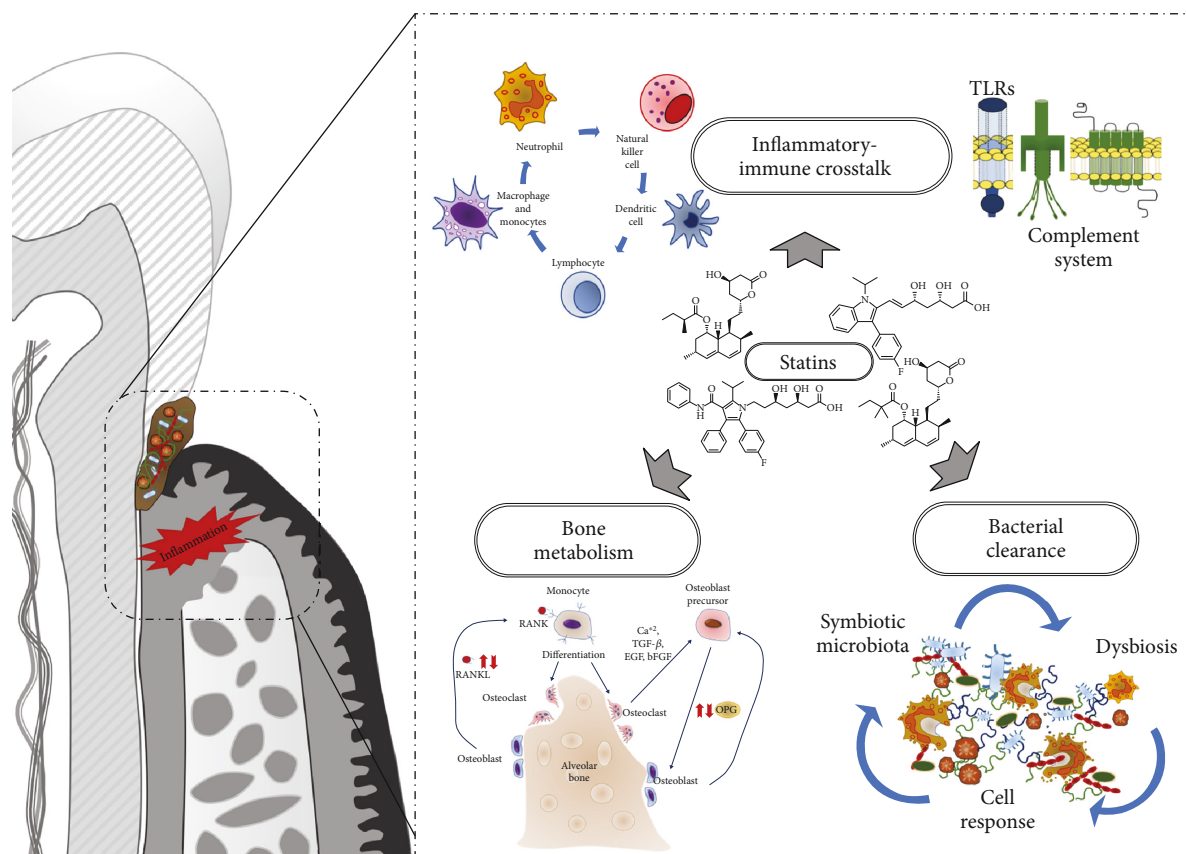


FIGURE 5: Pleiotropic effects of statins in the context of periodontitis management. Statin biological properties might be of interest for the management of periodontitis as they act on each tissular compartment and mechanisms including inflammatory-immune crosstalk, bone metabolism and bacterial clearance.

it is yet to be established if statin-induced reduction in plasma total cholesterol and LDL cholesterol levels in the periodontal space could decrease macrophage recruitment to improve the treatment outcome.

Despite the documented anti-inflammatory properties of statins, a local high-dose statin application causes considerable soft tissue inflammation [123]. Accordingly, studies determined that reducing the simvastatin dose from 2.2 mg to 0.5 mg reduced inflammation without compromising its bone growth potential [67]. A 10 mg/kg/day dose in rats is equivalent to 70 mg/day for humans, so it is a high systemic dose compared to that commonly used in clinical practice (20-40 mg/day) [124].

Concerning locally applied statins, most clinical studies investigated the 1.2% dose (mainly atorvastatin, simvastatin, and rosuvastatin) [20, 23, 125, 126]. Therefore, other doses should be tested to compare efficacy.

Most of the review articles have focused on the use of statins as adjunct to the nonsurgical SRP in clinical settings [127-129]. Here, this review encompasses the use of statins (local, systemic, or combination), alone or in addition to other drugs or scaffolds, in nonsurgical or surgical periodontal treatment *in vitro*, *in vivo*, and in clinical trials. However, the potential of statins in surgical periodontal therapy remains relatively less explored except for a few studies where treatment outcomes were improved, primarily, with the

combination of some other regenerative agents such as allograft or PRF [105, 106]. Cognizant of the numerous studies involving statins, not all statin types have been studied so far; thus, exploring all natural and synthetic statins to compare their efficacy and safety could be instrumental.

Notably, 17 out of 32 clinical studies were carried out by the same group of researchers on similar population; therefore, generalizations should be drawn with caution. Additionally, in most studies involving statins, the follow-up period was no longer than 9 months [103, 130]. Hence, it is imperative to follow clinical studies for periods longer than those commonly investigated so as to achieve a deeper and more genuine insight into their long-term benefits. Discrepancies amongst outcomes between time points are of importance to clearly conclude. For instance, the meta-analysis performed by Sinjab et al. [131] declared the outcomes of the control group of a study [20] to be better by considering the data up to 6 months follow-up, whereas the meta-analysis performed by Ambrósio et al. regarded the treatment group of the same study to have better outcomes as the follow-up data until 9 months was taken into account [132].

Moreover, the studies carried out so far mainly involved hyperlipidemic patients, diabetic patients, or smokers. Systemic diseases, such as obesity or metabolic syndrome, have been linked with periodontitis [133]. It has been demonstrated that such conditions modify significantly the host



response to periodontal pathogens [134] but also could impair treatment response. For instance, in a rat model of metabolic syndrome, the effects induced by statins in rats with metabolic syndrome were different in comparison with rats without [32] highlighting the potential modulation of pharmacologic effect due to the systemic condition. Even if clinical trials performed in diabetes patients or exhibiting hyperlipidemia showed promising results when statins were administered concomitantly to nonsurgical periodontal treatment [56, 110, 113, 114], more studies are required to better understand the differential biological mechanisms modulated by statin's administration. It would also be of importance to assess statins' tolerance and efficacy in subjects with different systemic conditions where periodontal treatment response is impaired (e.g., liver diseases, kidney dysfunction, and immunocompromised states).

In clinical trials, the local application of statins with surgical periodontal treatment always showed significant improvements in periodontal parameters [105, 106]. However, *in vivo*, statin application in ACP models showed contradictory results [99] which could be explained by the limitations of animal models to simulate conditions identical to human periodontal disease. Nevertheless, as a direct optimization of treatment protocols in humans is not ethically permissible, the utility of preclinical models to get directions and overall assessment of the expected treatment outcomes in clinical scenarios cannot be undermined.

Concerning the systemic administration of statins, a study reported that using a combination of two pharmacokinetically different statins (20 mg/day of atorvastatin plus 40 mg/day of pravastatin) in hyperlipidemic patients for one year improved their lipid profiles compared to those on monotherapies [135]. Besides, a case of a hyperlipidemic patient experiencing certain side effects with a high dose of systemic simvastatin who could well tolerate a combination of reduced doses of simvastatin and rosuvastatin instead has also been reported [136]. To the best of our knowledge, no two statins have been combined for periodontal treatment so far; nonetheless, combination of two statins could be tested for its impact on periodontal treatment response.

Likewise, the impact of incorporating statins with antimicrobial agents, growth factors, or other proregenerative molecules within a local application system could be studied as adjunct to SRP. Statin integration into gels [21] or dentifrice [137] could enhance ease of application and patient's compliance and could be potentially beneficial in the maintenance phase to counter periodontal breakdown that persists after conventional periodontal treatment. The literature does not report the impact of statins on patients with extremely poor oral hygiene; nonetheless, it could be interesting to explore the impact of statins on oral hygiene indicators.

## 5. Conclusion

Statins have been studied in depth in the context of bone regeneration, but soft tissue healing remains relatively less explored. Further research into it could present statins as a potential adjunctive therapeutic strategy with a positive impact on both hard and soft periodontal tissue healing.

Furthermore, the impact of statins on proresolution molecules has not been investigated in the context of periodontal wound healing and regeneration. This could unveil new vistas for statins as regenerative therapeutics. Since all available statins have not been tested yet, new studies need to evaluate the impact of other statins on antibacterial, inflammatory, immune, and osteoprogenitor responses. To conclude, choosing an optimum dose of statins, based on the mode of drug delivery and the carrier employed, may enhance the positive impact of statins on the periodontal treatment outcomes. Moreover, combining statins with growth factors or other drugs in an efficient carrier system may be beneficial to promote periodontal regeneration.

## Abbreviations

M1:	First molar
M2:	Second molar
M3:	Third molar
mPEG:	Polyethylene glycol monomethyl ether
PDLLA-PLGA:	Poly-(d,l-lactide) and poly-(d,l-lactide-co-glycolide)
BSA:	Bovine serum albumin
PDGF:	Platelet-derived growth factor
PM:	Premolar
PDL:	Periodontal ligament cells
EGCG:	Epigallocatechin-3-gallate
CS:	Chitosan
BALP:	Bone alkaline phosphatase
LPS:	Lipopolysaccharide
PBS:	Phosphate buffered saline
ALN-CD:	Alendronate- $\beta$ -cyclodextrin
SIM:	Simvastatin
CEJ:	Cemento-enamel junction
HA:	Hydroxyapatite
TGF- $\beta$ :	Transforming growth factor beta
<i>E. coli</i> :	<i>Escherichia coli</i>
PPi:	Isopropyl alcohol
TRAP:	Tartrate-resistant acid phosphatase
GSH:	Glutathione
MDA:	Malondialdehyde
MPO:	Myeloperoxidase
GIOP:	Glucocorticoid-induced osteoporosis
DKK1:	Dickkopf-related protein
CAT:	Enzyme catalase
SOD:	Enzyme superoxide dismutase
MMPs:	Matrix metalloproteinases
MCP:	Monocyte chemotactic protein
CSF:	Colony-stimulating factor
<i>A.a</i> :	<i>Aggregatibacter actinomycetemcomitans</i>
<i>P.g</i> :	<i>Porphyromonas gingivalis</i>
COX:	Cyclooxygenase
ALP:	Alkaline phosphatase
AST:	Aspartate aminotransferase
ALT:	Alanine aminotransferase
IP:	Intraperitoneal
TG:	Triglyceride
ATV:	Atorvastatin
PD:	Pocket depth

RANKL:	Receptor activator of the NF- $\kappa$ B ligand
RANK:	Receptor activator of NF- $\kappa$ B
OPG:	Osteoprotegerin
OPN:	Osteopontin
BV/TV:	Bone volume/tissue volume
CAL:	Clinical attachment level
SRP:	Scaling and root planing
INFRA:	Radiographic infrabony defect fill
MF:	Metformin
DDR:	Defect depth reduction
DFDBA:	Deminerlized freeze-dried bone allograft
OFD:	Open flap debridement
BOP:	Bleeding on probing
GI:	Gingival index
PI:	Plaque index
mSBI:	Modified sulcus bleeding index
IBD:	Intrabony defect
PRF:	Platelet-rich fibrin
PISA:	Periodontal inflamed surface area
LDL-C:	Low-density lipoprotein cholesterol
HDL-C:	High-density lipoprotein cholesterol
OB:	Osteoblasts
OC:	Osteoclasts
EIP:	Experimentally induced periodontitis
ACP:	Acute/chronic periodontal defect
NOX:	Nitrate/nitrite levels
VEGF:	Vascular endothelial growth factor.

## Conflicts of Interest

The authors declare no conflicts of interest related to this study.

## Authors' Contributions

CP and FB performed the electronic search and drafted the manuscript. OH drafted and critically revised the manuscript. IB, PS, and NB-J critically revised the manuscript. All authors reviewed the final version of the manuscript. Catherine Petit and Fareeha Batool contributed equally to this work.

## Acknowledgments

The authors are very grateful to the Agence Nationale de la Recherche (The French National Research Agency) (nos. ANR-14-CE16-0025-04 and ANR-17-CE17-0024-01) for their valuable support.

## Supplementary Materials

Risk of bias assessment of included clinical studies. (*Supplementary Materials*)

## References

[1] D. F. Kinane, P. G. Stathopoulou, and P. N. Papapanou, "Periodontal diseases," *Nature Reviews Disease Primers*, vol. 3, article 17038, 2017.

- [2] A. Cekici, A. Kantarci, H. Hasturk, and T. E. van Dyke, "Inflammatory and immune pathways in the pathogenesis of periodontal disease," *Periodontology 2000*, vol. 64, no. 1, pp. 57–80, 2014.
- [3] I. Olsen, J. D. Lambris, and G. Hajishengallis, "*Porphyromonas gingivalis* disturbs host-commensal homeostasis by changing complement function," *Journal of Oral Microbiology*, vol. 9, no. 1, article 1340085, 2017.
- [4] C. M. Cobb, "Clinical significance of non-surgical periodontal therapy: an evidence-based perspective of scaling and root planing," *Journal of Clinical Periodontology*, vol. 29, Supplement 2, pp. 22–32, 2002.
- [5] K. Agossa, D. N. Morand, H. Tenenbaum, J. L. Davideau, and O. Huck, "Systemic application of anti-inflammatory agents in periodontal treatment," *Clinical Anti-Inflammatory & Anti-Allergy Drugs*, vol. 2, no. 1, pp. 3–13, 2016.
- [6] Z. Akram, T. Abduljabbar, S. V. Kellesarian, M. I. Abu Hassan, F. Javed, and F. Vohra, "Efficacy of bisphosphonate as an adjunct to nonsurgical periodontal therapy in the management of periodontal disease: a systematic review," *British Journal of Clinical Pharmacology*, vol. 83, no. 3, pp. 444–454, 2017.
- [7] A. Alshammari, J. Patel, J. al-Hashemi et al., "Kava-241 reduced periodontal destruction in a collagen antibody primed *Porphyromonas gingivalis* model of periodontitis," *Journal of Clinical Periodontology*, vol. 44, no. 11, pp. 1123–1132, 2017.
- [8] S. R. Gokhale and A. M. Padhye, "Future prospects of systemic host modulatory agents in periodontal therapy," *British Dental Journal*, vol. 214, no. 9, pp. 467–471, 2013.
- [9] R. Martin-Cabezas, J. L. Davideau, H. Tenenbaum, and O. Huck, "Clinical efficacy of probiotics as an adjunctive therapy to non-surgical periodontal treatment of chronic periodontitis: a systematic review and meta-analysis," *Journal of Clinical Periodontology*, vol. 43, no. 6, pp. 520–530, 2016.
- [10] I. M. G. Estanislau, I. R. C. Terceiro, M. R. P. Lisboa et al., "Pleiotropic effects of statins on the treatment of chronic periodontitis - a systematic review," *British Journal of Clinical Pharmacology*, vol. 79, no. 6, pp. 877–885, 2015.
- [11] E. Martin-Ruiz, A. Olry-de-Labry-Lima, R. Ocaña-Riola, and D. Epstein, "Systematic review of the effect of adherence to statin treatment on critical cardiovascular events and mortality in primary prevention," *Journal of Cardiovascular Pharmacology and Therapeutics*, vol. 23, no. 3, pp. 200–215, 2018.
- [12] L. Pasin, G. Landoni, M. L. Castro et al., "The effect of statins on mortality in septic patients: a meta-analysis of randomized controlled trials," *PLoS One*, vol. 8, no. 12, article e82775, 2013.
- [13] C. W. Fong, "Statins in therapy: understanding their hydrophilicity, lipophilicity, binding to 3-hydroxy-3-methylglutaryl-CoA reductase, ability to cross the blood brain barrier and metabolic stability based on electrostatic molecular orbital studies," *European Journal of Medicinal Chemistry*, vol. 85, pp. 661–674, 2014.
- [14] M. Margaritis, F. Sanna, and C. Antoniadis, "Statins and oxidative stress in the cardiovascular system," *Current Pharmaceutical Design*, vol. 23, no. 46, pp. 7040–7047, 2017.
- [15] K. Sakoda, M. Yamamoto, Y. Negishi, J. K. Liao, K. Node, and Y. Izumi, "Simvastatin decreases IL-6 and IL-8 production in epithelial cells," *Journal of Dental Research*, vol. 85, no. 6, pp. 520–523, 2006.

- [16] E. J. Whitaker and A. Alshammari, "Bacteriostatic effect of simvastatin on selected oral streptococci in vitro," *Contemporary Clinical Dentistry*, vol. 8, no. 1, pp. 59–63, 2017.
- [17] R. Zeiser, "Immune modulatory effects of statins," *Immunology*, vol. 154, no. 1, pp. 69–75, 2018.
- [18] H. Zhou, Y. Xie, Z. Baloch, Q. Shi, Q. Huo, and T. Ma, "The effect of atorvastatin, 3-hydroxy-3-methylglutaryl coenzyme A reductase inhibitor (HMG-CoA), on the prevention of osteoporosis in ovariectomized rabbits," *Journal of Bone and Mineral Metabolism*, vol. 35, no. 3, pp. 245–254, 2017.
- [19] V. Cicek Ari, Y. D. Ilarslan, B. Erman et al., "Statins and IL-1 $\beta$ , IL-10, and MPO levels in gingival crevicular fluid: preliminary results," *Inflammation*, vol. 39, no. 4, pp. 1547–1557, 2016.
- [20] A. R. Pradeep, V. Garg, D. Kanoriya, and S. Singhal, "1.2% rosuvastatin versus 1.2% atorvastatin gel local drug delivery and redelivery in treatment of intrabony defects in chronic periodontitis: a randomized placebo-controlled clinical trial," *Journal of Periodontology*, vol. 87, no. 7, pp. 756–762, 2016.
- [21] G. Gunjiganur Vemanaradhya, S. Emani, D. S. Mehta, and S. Bhandari, "Effect of 1.2% of simvastatin gel as a local drug delivery system on gingival crevicular fluid interleukin-6 & interleukin-8 levels in non surgical treatment of chronic periodontitis patients," *Archives of Oral Biology*, vol. 82, pp. 55–61, 2017.
- [22] A. I. Özdoğan, Y. D. Ilarslan, K. Kösemehmetoğlu et al., "In vivo evaluation of chitosan based local delivery systems for atorvastatin in treatment of periodontitis," *International Journal of Pharmaceutics*, vol. 550, no. 1–2, pp. 470–476, 2018.
- [23] D. Pankaj, I. Sahu, I. G. Kurian, and A. R. Pradeep, "Comparative evaluation of subgingivally delivered 1.2% rosuvastatin and 1% metformin gel in treatment of intrabony defects in chronic periodontitis: a randomized controlled clinical trial," *Journal of Periodontology*, vol. 89, no. 11, article 16, pp. 1318–1325, 2018.
- [24] D. T. Graves, J. Li, and D. L. Cochran, "Inflammation and uncoupling as mechanisms of periodontal bone loss," *Journal of Dental Research*, vol. 90, no. 2, pp. 143–153, 2011.
- [25] F. Y. Kirzioğlu, M. Tözüm Bulut, B. Doğan et al., "Anti-inflammatory effect of rosuvastatin decreases alveolar bone loss in experimental periodontitis," *Journal of Oral Science*, vol. 59, no. 2, pp. 247–255, 2017.
- [26] L. H. Sousa, E. V. M. Linhares, J. T. Alexandre et al., "Effects of atorvastatin on periodontitis of rats subjected to glucocorticoid-induced osteoporosis," *Journal of Periodontology*, vol. 87, no. 10, pp. 1206–1216, 2016.
- [27] K. Pahan, "Lipid-lowering drugs," *Cellular and Molecular Life Sciences*, vol. 63, no. 10, pp. 1165–1178, 2006.
- [28] P. E. Lazzarini, C. Capperucci, A. Spreafico et al., "Rosuvastatin inhibits spontaneous and IL-1 $\beta$ -induced interleukin-6 production from human cultured osteoblastic cells," *Joint, Bone, Spine*, vol. 80, no. 2, pp. 195–200, 2013.
- [29] M. Arora, L. Chen, M. Paglia et al., "Simvastatin promotes Th2-type responses through the induction of the chitinase family member Ym1 in dendritic cells," *Proceedings of the National Academy of Sciences of the United States of America*, vol. 103, no. 20, pp. 7777–7782, 2006.
- [30] E. Mira, B. Leon, D. F. Barber et al., "Statins induce regulatory T cell recruitment via a CCL1 dependent pathway," *The Journal of Immunology*, vol. 181, no. 5, pp. 3524–3534, 2008.
- [31] R. Fernandes de Araújo, T. Oliveira Souza, L. Moreno de Moura et al., "Atorvastatin decreases bone loss, inflammation and oxidative stress in experimental periodontitis," *PLoS One*, vol. 8, no. 10, article e75322, 2013.
- [32] J. Jin, E. R. Machado, H. Yu et al., "Simvastatin inhibits LPS-induced alveolar bone loss during metabolic syndrome," *Journal of Dental Research*, vol. 93, no. 3, pp. 294–299, 2014.
- [33] J. Jin, X. Zhang, Z. Lu et al., "Simvastatin inhibits lipopolysaccharide-induced osteoclastogenesis and reduces alveolar bone loss in experimental periodontal disease," *Journal of Periodontal Research*, vol. 49, no. 4, pp. 518–526, 2014.
- [34] W. M. Machado, A. P. Prestes, T. P. Costa et al., "The effect of simvastatin on systemic inflammation and endothelial dysfunction induced by periodontitis," *Journal of Periodontal Research*, vol. 49, no. 5, pp. 634–641, 2014.
- [35] P. O. Nassar, C. A. Nassar, M. R. Guimarães et al., "Simvastatin therapy in cyclosporine A-induced alveolar bone loss in rats," *Journal of Periodontal Research*, vol. 44, no. 4, pp. 479–488, 2009.
- [36] D.-N. Morand, J. L. Davideau, F. Clauss, N. Jessel, H. Tenenbaum, and O. Huck, "Cytokines during periodontal wound healing: potential application for new therapeutic approach," *Oral Diseases*, vol. 23, no. 3, pp. 300–311, 2017.
- [37] T. E. Van Dyke, H. Hasturk, A. Kantarci et al., "Proresolving nanomedicines activate bone regeneration in periodontitis," *Journal of Dental Research*, vol. 94, no. 1, pp. 148–156, 2015.
- [38] H. Hasturk, A. Kantarci, T. Ohira et al., "RvE1 protects from local inflammation and osteoclast-mediated bone destruction in periodontitis," *The FASEB Journal*, vol. 20, no. 2, pp. 401–403, 2006.
- [39] M. Spite and C. N. Serhan, "Novel lipid mediators promote resolution of acute inflammation: impact of aspirin and statins," *Circulation Research*, vol. 107, no. 10, pp. 1170–1184, 2010.
- [40] P. Goes, I. M. Melo, L. M. C. M. Silva et al., "Low-dose combination of alendronate and atorvastatin reduces ligature-induced alveolar bone loss in rats," *Journal of Periodontal Research*, vol. 49, no. 1, pp. 45–54, 2014.
- [41] S.-I. Kagami, T. Owada, H. Kanari et al., "Protein geranylgeranylation regulates the balance between T<sub>H</sub>17 cells and Foxp3<sup>+</sup> regulatory T cells," *International Immunology*, vol. 21, no. 6, pp. 679–689, 2009.
- [42] K. Mausner-Fainberg, G. Luboshits, A. Mor et al., "The effect of HMG-CoA reductase inhibitors on naturally occurring CD4<sup>+</sup>CD25<sup>+</sup> T cells," *Atherosclerosis*, vol. 197, no. 2, pp. 829–839, 2008.
- [43] G. Hajishengallis, "Toll gates to periodontal host modulation and vaccine therapy," *Periodontology 2000*, vol. 51, no. 1, pp. 181–207, 2009.
- [44] S. J. Lee, H. Qin, and E. N. Benveniste, "The IFN- $\gamma$ -induced transcriptional program of the CIITA gene is inhibited by statins," *European Journal of Immunology*, vol. 38, no. 8, pp. 2325–2336, 2008.
- [45] G. Hajishengallis and S. E. Sahingur, "Novel inflammatory pathways in periodontitis," *Advances in Dental Research*, vol. 26, no. 1, pp. 23–29, 2014.
- [46] F. Montecucco, F. Burger, G. Pelli et al., "Statins inhibit C-reactive protein-induced chemokine secretion, ICAM-1 upregulation and chemotaxis in adherent human monocytes," *Rheumatology*, vol. 48, no. 3, pp. 233–242, 2009.



- [47] G. Weitz-Schmidt, K. Welzenbach, V. Brinkmann et al., "Statins selectively inhibit leukocyte function antigen-1 by binding to a novel regulatory integrin site," *Nature Medicine*, vol. 7, no. 6, pp. 687–692, 2001.
- [48] Y. Korkmaz, W. Bloch, S. Behrends, H. Schroder, K. Addicks, and M. A. Baumann, "NO-cGMP signaling molecules in the rat epithelial rests of Malassez," *European Journal of Oral Sciences*, vol. 112, no. 1, pp. 55–60, 2004.
- [49] L. u. Tóthová and P. Celec, "Oxidative stress and antioxidants in the diagnosis and therapy of periodontitis," *Frontiers in Physiology*, vol. 8, p. 1055, 2017.
- [50] A. C. Batista, T. A. Silva, J. H. Chun, and V. S. Lara, "Nitric oxide synthesis and severity of human periodontal disease," *Oral Diseases*, vol. 8, no. 5, pp. 254–260, 2002.
- [51] Y.-S. Kim, S. H. Pi, Y. M. Lee, S. I. Lee, and E. C. Kim, "The anti-inflammatory role of heme oxygenase-1 in lipopolysaccharide and cytokine-stimulated inducible nitric oxide synthase and nitric oxide production in human periodontal ligament cells," *Journal of Periodontology*, vol. 80, no. 12, pp. 2045–2055, 2009.
- [52] V. L. Popkov, I. A. Fil'chukova, N. V. Lapina, V. P. Galenko-Yaroshevskii, and A. S. Dukhanin, "Activity of nitric oxide synthase and concentration of nitric oxide end metabolites in the gingiva under experimental pathological conditions," *Bulletin of Experimental Biology and Medicine*, vol. 140, no. 4, pp. 391–393, 2005.
- [53] B. S. Herrera, R. Martins-Porto, A. Maia-Dantas et al., "iNOS-derived nitric oxide stimulates osteoclast activity and alveolar bone loss in ligature-induced periodontitis in rats," *Journal of Periodontology*, vol. 82, no. 11, pp. 1608–1615, 2011.
- [54] F. Y. Kirzioğlu, Ö. Özmen, B. Doğan, M. T. Bulut, Ö. Fentoğlu, and M. Özdem, "Effects of rosuvastatin on inducible nitric oxide synthase in rats with hyperlipidaemia and periodontitis," *Journal of Periodontal Research*, vol. 53, no. 2, pp. 258–266, 2018.
- [55] C. Franco, H.-R. Patricia, S. Timo, B. Claudia, and H. Marcela, "Matrix metalloproteinases as regulators of periodontal inflammation," *International Journal of Molecular Sciences*, vol. 18, no. 2, p. 440, 2017.
- [56] C. J. Poston, T. C. Pierce, Y. Li et al., "Statin intake is associated with MMP-1 level in gingival crevicular fluid of patients with periodontitis," *Oral Diseases*, vol. 22, no. 5, pp. 438–444, 2016.
- [57] U. Balli, G. C. Keles, B. O. Cetinkaya, U. Mercan, B. Ayas, and D. Erdogan, "Assessment of vascular endothelial growth factor and matrix metalloproteinase-9 in the periodontium of rats treated with atorvastatin," *Journal of Periodontology*, vol. 85, no. 1, pp. 178–187, 2014.
- [58] R. Dalcico, A. M. A. de Menezes, O. B. Deocleciano et al., "Protective mechanisms of simvastatin in experimental periodontal disease," *Journal of Periodontology*, vol. 84, no. 8, pp. 1145–1157, 2013.
- [59] B. F. E. Santos, E. Q. M. Souza, M. R. P. L. Brigagão, D. C. d. Lima, and L. A. Fernandes, "Local application of statins in the treatment of experimental periodontal disease in rats," *Journal of Applied Oral Science*, vol. 25, no. 2, pp. 168–176, 2017.
- [60] Y. Zhang, A. D. Bradley, D. Wang, and R. A. Reinhardt, "Statins, bone metabolism and treatment of bone catabolic diseases," *Pharmacological Research*, vol. 88, pp. 53–61, 2014.
- [61] P.-Y. Chen, J.-S. Sun, Y.-H. Tsuang, M.-H. Chen, P.-W. Weng, and F.-H. Lin, "Simvastatin promotes osteoblast viability and differentiation via Ras/Smad/Erk/BMP-2 signaling pathway," *Nutrition Research*, vol. 30, no. 3, pp. 191–199, 2010.
- [62] M. Yamashita, F. Otsuka, T. Mukai et al., "Simvastatin antagonizes tumor necrosis factor- $\alpha$  inhibition of bone morphogenetic proteins-2-induced osteoblast differentiation by regulating Smad signaling and Ras/Rho-mitogen-activated protein kinase pathway," *Journal of Endocrinology*, vol. 196, no. 3, pp. 601–613, 2008.
- [63] I. S. Kim, B. C. Jeong, O. S. Kim et al., "Lactone form 3-hydroxy-3-methylglutaryl-coenzyme A reductase inhibitors (statins) stimulate the osteoblastic differentiation of mouse periodontal ligament cells via the ERK pathway," *Journal of Periodontal Research*, vol. 46, no. 2, pp. 204–213, 2011.
- [64] T. Maeda, A. Matsunuma, I. Kurahashi, T. Yanagawa, H. Yoshida, and N. Horiuchi, "Induction of osteoblast differentiation indices by statins in MC3T3-E1 cells," *Journal of Cellular Biochemistry*, vol. 92, no. 3, pp. 458–471, 2004.
- [65] K. Hu and B. R. Olsen, "Osteoblast-derived VEGF regulates osteoblast differentiation and bone formation during bone repair," *Journal of Clinical Investigation*, vol. 126, no. 2, pp. 509–526, 2016.
- [66] R. Reyes, J. A. Rodríguez, J. Orbe, M. R. Arnau, C. Évora, and A. Delgado, "Combined sustained release of BMP2 and MMP10 accelerates bone formation and mineralization of calvaria critical size defect in mice," *Drug Delivery*, vol. 25, no. 1, pp. 750–756, 2018.
- [67] D. Stein, Y. Lee, M. J. Schmid et al., "Local simvastatin effects on mandibular bone growth and inflammation," *Journal of Periodontology*, vol. 76, no. 11, pp. 1861–1870, 2005.
- [68] Z. Wang, Y. Li, F. Zhou, Z. Piao, and J. Hao, "Effects of statins on bone mineral density and fracture risk: a PRISMA-compliant systematic review and meta-analysis," *Medicine*, vol. 95, no. 22, article e3042, 2016.
- [69] T. Maeda, T. Kawane, and N. Horiuchi, "Statins augment vascular endothelial growth factor expression in osteoblastic cells via inhibition of protein prenylation," *Endocrinology*, vol. 144, no. 2, pp. 681–692, 2003.
- [70] K. H. Baek, W. Y. Lee, K. W. Oh et al., "The effect of simvastatin on the proliferation and differentiation of human bone marrow stromal cells," *Journal of Korean Medical Science*, vol. 20, no. 3, pp. 438–444, 2005.
- [71] Y.-S. Liu, M. E. Ou, H. Liu et al., "The effect of simvastatin on chemotactic capability of SDF-1 $\alpha$  and the promotion of bone regeneration," *Biomaterials*, vol. 35, no. 15, pp. 4489–4498, 2014.
- [72] E. de Monès, S. Schlaubitz, S. Catros, and J. C. Fricain, "Statins and alveolar bone resorption: a narrative review of preclinical and clinical studies," *Oral Surgery, Oral Medicine, Oral Pathology and Oral Radiology*, vol. 119, no. 1, pp. 65–73, 2015.
- [73] P.-C. Chang, A. S. Dovban, L. P. Lim, L. Y. Chong, M. Y. Kuo, and C. H. Wang, "Dual delivery of PDGF and simvastatin to accelerate periodontal regeneration *in vivo*," *Biomaterials*, vol. 34, no. 38, pp. 9990–9997, 2013.
- [74] L.-D. Lin, S. K. Lin, Y. L. Chao et al., "Simvastatin suppresses osteoblastic expression of Cyr61 and progression of apical periodontitis through enhancement of the transcription factor Forkhead/winged helix box protein O3a," *Journal of Endodontics*, vol. 39, no. 5, pp. 619–625, 2013.

- [75] H. Kaji, J. Naito, Y. Inoue, H. Sowa, T. Sugimoto, and K. Chihara, "Statin suppresses apoptosis in osteoblastic cells: role of transforming growth factor- $\beta$ -Smad3 pathway," *Hormone and Metabolic Research*, vol. 40, no. 11, pp. 746–751, 2008.
- [76] N. K. Pokhrel, Y. G. Kim, J. Y. Kim, H. H. Kim, and Y. Lee, "Fluvastatin inhibits osteoclast differentiation and *Porphyromonas gingivalis* lipopolysaccharide-induced alveolar bone erosion in mice," *Journal of Periodontology*, vol. 88, no. 4, pp. 390–398, 2017.
- [77] K. E. Evans and S. W. Fox, "Interleukin-10 inhibits osteoclastogenesis by reducing NFATc1 expression and preventing its translocation to the nucleus," *BMC Cell Biology*, vol. 8, no. 1, p. 4, 2007.
- [78] A. Hughes, M. J. Rogers, A. I. Idris, and J. C. Crockett, "A comparison between the effects of hydrophobic and hydrophilic statins on osteoclast function in vitro and ovariectomy-induced bone loss in vivo," *Calcified Tissue International*, vol. 81, no. 5, pp. 403–413, 2007.
- [79] M. Yamashita, F. Otsuka, T. Mukai et al., "Simvastatin inhibits osteoclast differentiation induced by bone morphogenetic protein-2 and RANKL through regulating MAPK, AKT and Src signaling," *Regulatory Peptides*, vol. 162, no. 1–3, pp. 99–108, 2010.
- [80] M. Z. Chaudhry, J. H. Wang, S. Blankson, and H. P. Redmond, "Statin (cerivastatin) protects mice against sepsis-related death via reduced proinflammatory cytokines and enhanced bacterial clearance," *Surgical Infections*, vol. 9, no. 2, pp. 183–194, 2008.
- [81] H. H. T. Ko, R. R. Lareu, B. R. Dix, and J. D. Hughes, "In vitro antibacterial effects of statins against bacterial pathogens causing skin infections," *European Journal of Clinical Microbiology & Infectious Diseases*, vol. 37, no. 6, pp. 1125–1135, 2018.
- [82] S. Emani, G. V. Gunjiganur, and D. S. Mehta, "Determination of the antibacterial activity of simvastatin against periodontal pathogens, *Porphyromonas gingivalis* and *Aggregatibacter actinomycetemcomitans*: an *in vitro* study," *Contemporary Clinical Dentistry*, vol. 5, no. 3, pp. 377–382, 2014.
- [83] P. Bergman, C. Linde, K. Pütsep et al., "Studies on the antibacterial effects of statins - *in vitro* and *in vivo*," *PLoS One*, vol. 6, no. 8, article e24394, 2011.
- [84] J. K. Liao and U. Laufs, "Pleiotropic effects of statins," *Annual Review of Pharmacology and Toxicology*, vol. 45, no. 1, pp. 89–118, 2005.
- [85] H. H. T. Ko, R. R. Lareu, B. R. Dix, and J. D. Hughes, "Statins: antimicrobial resistance breakers or makers?," *PeerJ*, vol. 5, article e3952, 2017.
- [86] C. D. Russell and J. Schwarze, "The role of pro-resolution lipid mediators in infectious disease," *Immunology*, vol. 141, no. 2, pp. 166–173, 2014.
- [87] C. N. Serhan, A. Jain, S. Marleau et al., "Reduced inflammation and tissue damage in transgenic rabbits overexpressing 15-lipoxygenase and endogenous anti-inflammatory lipid mediators," *The Journal of Immunology*, vol. 171, no. 12, pp. 6856–6865, 2003.
- [88] M. Abdel-Nour, J. Tsalikis, D. Kleinman, and S. E. Girardin, "The emerging role of mTOR signalling in antibacterial immunity," *Immunology and Cell Biology*, vol. 92, no. 4, pp. 346–353, 2014.
- [89] U. Laufs, H. Kilter, C. Konkol, S. Wassmann, M. Böhm, and G. Nickenig, "Impact of HMG CoA reductase inhibition on small GTPases in the heart," *Cardiovascular Research*, vol. 53, no. 4, pp. 911–920, 2002.
- [90] U. Price, H. . O. T. le, S. E. Powell et al., "Effects of local simvastatin-alendronate conjugate in preventing periodontitis bone loss," *Journal of Periodontal Research*, vol. 48, no. 5, pp. 541–548, 2013.
- [91] H. Vaziri, R. Naserhojjati-Roodsari, N. Tahsili-Fahadan et al., "Effect of simvastatin administration on periodontitis-associated bone loss in ovariectomized rats," *Journal of Periodontology*, vol. 78, no. 8, pp. 1561–1567, 2007.
- [92] X.-C. Xu, H. Chen, X. Zhang et al., "Simvastatin prevents alveolar bone loss in an experimental rat model of periodontitis after ovariectomy," *Journal of Translational Medicine*, vol. 12, no. 1, p. 284, 2014.
- [93] M. R. Messora, G. H. Apolinário Vieira, J. M. T. M. M. Vanderlei et al., "Rosuvastatin promotes benefits on induced periodontitis in hypertensive rats," *Journal of Periodontal Research*, vol. 52, no. 4, pp. 734–744, 2017.
- [94] L. Y. Chong, L. Y. Chien, M. C. Chung et al., "Controlling the proliferation and differentiation stages to initiate periodontal regeneration," *Connective Tissue Research*, vol. 54, no. 2, pp. 101–107, 2013.
- [95] A. C. Killeen, P. A. Rakes, M. J. Schmid et al., "Impact of local and systemic alendronate on simvastatin-induced new bone around periodontal defects," *Journal of Periodontology*, vol. 83, no. 12, pp. 1463–1471, 2012.
- [96] N. Maciel-Oliveira, V. Bradaschia-Correa, and V. E. Arana--Chavez, "Early alveolar bone regeneration in rats after topical administration of simvastatin," *Oral Surgery, Oral Medicine, Oral Pathology, Oral Radiology, and Endodontics*, vol. 112, no. 2, pp. 170–179, 2011.
- [97] R. M. Moraes, "Effects of simvastatin on prevention and progression of induced periodontitis in rats," *Journal of Dental Health, Oral Disorders & Therapy*, vol. 8, no. 1, 2017.
- [98] J. Rutledge, M. D. Schieber, J. M. Chamberlain et al., "Simvastatin application to augment facial jaw bone in a dog model: pilot study," *Journal of Periodontology*, vol. 82, no. 4, pp. 597–605, 2011.
- [99] M. S. Morris, Y. Lee, M. T. Lavin et al., "Injectable simvastatin in periodontal defects and alveolar ridges: pilot studies," *Journal of Periodontology*, vol. 79, no. 8, pp. 1465–1473, 2008.
- [100] S. M. Surve, A. B. Acharya, and S. L. Thakur, "Efficacy of subgingivally delivered atorvastatin and simvastatin as an adjunct to scaling and root planing," *Drug Metabolism and Personalized Therapy*, vol. 30, no. 4, pp. 263–269, 2015.
- [101] S. S. Martande, M. Kumari, A. R. Pradeep, S. P. Singh, and D. K. Suke, "Comparative evaluation of efficacy of subgingivally delivered 1.2% atorvastatin and 1.2% simvastatin in the treatment of intrabony defects in chronic periodontitis: a randomized controlled trial," *Journal of Dental Research, Dental Clinics, Dental Prospects*, vol. 11, no. 1, pp. 18–25, 2017.
- [102] S. Garg and A. R. Pradeep, "1.2% rosuvastatin and 1.2% atorvastatin gel local drug delivery and redelivery in the treatment of class II furcation defects: a randomized controlled clinical trial," *Journal of Periodontology*, vol. 88, no. 3, pp. 259–265, 2017.
- [103] H. S. Grover, S. Kapoor, and A. Singh, "Effect of topical simvastatin (1.2 mg) on gingival crevicular fluid interleukin-6,

- interleukin-8 and interleukin-10 levels in chronic periodontitis – a clinicobiochemical study,” *Journal of Oral Biology and Craniofacial Research*, vol. 6, no. 2, pp. 85–92, 2016.
- [104] P. Kinra, H. Gupta, S. Khan, and M. S. Ahmad, “Evaluation of the relative efficacy of an allograft used alone and that in combination with simvastatin in the treatment of human periodontal Infrabony defects – a clinical and radiological study,” *Journal of Taibah University Medical Sciences*, vol. 5, no. 2, pp. 75–88, 2010.
- [105] S. S. Martande, M. Kumari, A. R. Pradeep, S. P. Singh, D. K. Suke, and C. N. Guruprasad, “Platelet-rich fibrin combined with 1.2% atorvastatin for treatment of intrabony defects in chronic periodontitis: a randomized controlled clinical trial,” *Journal of Periodontology*, vol. 87, no. 9, pp. 1039–1046, 2016.
- [106] A. R. Pradeep, V. Garg, D. Kanoriya, and S. Singhal, “Platelet-rich fibrin with 1.2% rosuvastatin for treatment of Intrabony defects in chronic periodontitis: a randomized controlled clinical trial,” *Journal of Periodontology*, vol. 87, no. 12, pp. 1468–1473, 2016.
- [107] A. R. Pradeep, S. Karvekar, K. Nagpal, K. Patnaik, A. Raju, and P. Singh, “Rosuvastatin 1.2 mg in situ gel combined with 1:1 mixture of autologous platelet-rich fibrin and porous hydroxyapatite bone graft in surgical treatment of mandibular class II furcation defects: a randomized clinical control trial,” *Journal of Periodontology*, vol. 87, no. 1, pp. 5–13, 2016.
- [108] R. Ranjan, S. R. Patil, and H. R. Veena, “Effect of in-situ application of simvastatin gel in surgical management of osseous defects in chronic periodontitis—a randomized clinical trial,” *Journal of Oral Biology and Craniofacial Research*, vol. 7, no. 2, pp. 113–118, 2017.
- [109] J. Cunha-Cruz, B. Saver, G. Maupome, and P. P. Hujoel, “Statin use and tooth loss in chronic periodontitis patients,” *Journal of Periodontology*, vol. 77, no. 6, pp. 1061–1066, 2006.
- [110] Ö. Fentoğlu, T. Sözen, S. G. Öz et al., “Short-term effects of periodontal therapy as an adjunct to anti-lipemic treatment,” *Oral Diseases*, vol. 16, no. 7, pp. 648–654, 2010.
- [111] P. Meisel, H. K. Kroemer, M. Nauck, B. Holtfreter, and T. Kocher, “Tooth loss, periodontitis, and statins in a population-based follow-up study,” *Journal of Periodontology*, vol. 85, no. 6, pp. e160–e168, 2014.
- [112] M. E. Fajardo, M. L. Rocha, F. J. Sánchez-Marin, and E. J. Espinosa-Chávez, “Effect of atorvastatin on chronic periodontitis: a randomized pilot study,” *Journal of Clinical Periodontology*, vol. 37, no. 11, pp. 1016–1022, 2010.
- [113] Ö. Fentoğlu, F. Y. Kırzioğlu, M. Özdem, H. Koçak, R. Sütçü, and T. Sert, “Proinflammatory cytokine levels in hyperlipidemic patients with periodontitis after periodontal treatment,” *Oral Diseases*, vol. 18, no. 3, pp. 299–306, 2012.
- [114] A. Sangwan, S. Tewari, H. Singh, R. K. Sharma, and S. C. Narula, “Effect of hyperlipidemia on response to nonsurgical periodontal therapy: statin users versus nonusers,” *European Journal of Dentistry*, vol. 10, no. 1, pp. 69–76, 2016.
- [115] H. S. Grover, S. Luthra, and S. Maroo, “Are statins really wonder drugs?,” *Journal of the Formosan Medical Association*, vol. 113, no. 12, pp. 892–898, 2014.
- [116] A. I. Martinez, P. R. Freeman, and D. C. Moga, “Statin use and gastrointestinal hemorrhage: a large retrospective cohort study,” *American Journal of Cardiovascular Drugs*, vol. 46, pp. 107–110, 2018.
- [117] H. A. Da Rocha, C. F. Silva, F. L. Santiago, L. G. Martins, P. C. Dias, and D. De Magalhães, “Local drug delivery systems in the treatment of periodontitis: a literature review,” *Journal of the International Academy of Periodontology*, vol. 17, no. 3, pp. 82–90, 2015.
- [118] D. Joshi, T. Garg, A. K. Goyal, and G. Rath, “Advanced drug delivery approaches against periodontitis,” *Drug Delivery*, vol. 23, no. 2, pp. 363–377, 2016.
- [119] A. Mombelli and L. P. Samaranayake, “Topical and systemic antibiotics in the management of periodontal diseases,” *International Dental Journal*, vol. 54, no. 1, pp. 3–14, 2004.
- [120] J.-B. Park, “The use of simvastatin in bone regeneration,” *Medicina Oral, Patología Oral y Cirugía Bucal*, vol. 14, no. 9, pp. e485–e488, 2009.
- [121] P. Schwinté, A. Mariotte, P. Anand et al., “Anti-inflammatory effect of active nanofibrous polymeric membrane bearing nanocontainers of atorvastatin complexes,” *Nanomedicine*, vol. 12, no. 23, pp. 2651–2674, 2017.
- [122] C. Sima and M. Glogauer, “Macrophage subsets and osteoimmunology: tuning of the immunological recognition and effector systems that maintain alveolar bone,” *Periodontology 2000*, vol. 63, no. 1, pp. 80–101, 2013.
- [123] M. R. Thylin, J. C. McConnell, M. J. Schmid et al., “Effects of simvastatin gels on murine calvarial bone,” *Journal of Periodontology*, vol. 73, no. 10, pp. 1141–1148, 2002.
- [124] J. W. Wang, S. W. Xu, D. S. Yang, and R. K. Lv, “Locally applied simvastatin promotes fracture healing in ovariectomized rat,” *Osteoporosis International*, vol. 18, no. 12, pp. 1641–1650, 2007.
- [125] M. Kumari, S. S. Martande, and A. R. Pradeep, “Subgingivally delivered 1.2% atorvastatin in the treatment of chronic periodontitis among smokers: a randomized, controlled clinical trial,” *Journal of Investigative and Clinical Dentistry*, vol. 8, no. 2, article e12213, 2017.
- [126] A. R. Pradeep, N. Priyanka, N. Kalra, S. B. Naik, S. P. Singh, and S. Martande, “Clinical efficacy of subgingivally delivered 1.2-mg simvastatin in the treatment of individuals with class II furcation defects: a randomized controlled clinical trial,” *Journal of Periodontology*, vol. 83, no. 12, pp. 1472–1479, 2012.
- [127] Z. Akram, F. Vohra, and F. Javed, “Efficacy of statin delivery as an adjunct to scaling and root planing in the treatment of chronic periodontitis: a meta-analysis,” *Journal of Investigative and Clinical Dentistry*, vol. 9, no. 2, article e12304, 2018.
- [128] J. Meza-Mauricio, D. Soto-Peñaloza, D. Peñarrocha-Oltra, J. M. Montiel-Company, and D. C. Peruzzo, “Locally applied statins as adjuvants to non-surgical periodontal treatment for chronic periodontitis: a systematic review and meta-analysis,” *Clinical Oral Investigations*, vol. 22, no. 7, pp. 2413–2430, 2018.
- [129] F. W. M. G. Muniz, K. Taminski, J. Cavagni, R. K. Celeste, P. Weidlich, and C. K. Rösing, “The effect of statins on periodontal treatment—a systematic review with meta-analyses and meta-regression,” *Clinical Oral Investigations*, vol. 22, no. 2, pp. 671–687, 2018.
- [130] S. Agarwal, K. K. Chaubey, A. Chaubey, V. Agarwal, E. Madan, and M. C. Agarwal, “Clinical efficacy of subgingivally delivered simvastatin gel in chronic periodontitis patients,” *Journal of Indian Society of Periodontology*, vol. 20, no. 4, pp. 409–416, 2016.
- [131] K. Sinjab, N. Zimmo, G. H. Lin, M. P. Chung, L. Shaikh, and H. L. Wang, “The effect of locally delivered statins on treating periodontal intrabony defects: a systematic review and



- meta-analysis," *Journal of Periodontology*, vol. 88, no. 4, pp. 357–367, 2017.
- [132] L. M. B. Ambrósio, E. S. Rovai, D. I. Sendyk, M. Holzhausen, and C. M. Pannuti, "Does the adjunctive use of statins provide additional benefits to nonsurgical periodontal treatment? A systematic review and meta-analysis," *Journal of Periodontal Research*, vol. 53, no. 1, pp. 12–21, 2018.
- [133] G. J. Linden, A. Lyons, and F. A. Scannapieco, "Periodontal systemic associations: review of the evidence," *Journal of Periodontology*, vol. 84, no. 4-s, pp. S8–19, 2013.
- [134] Q. Zhou, S. E. Leeman, and S. Amar, "Signaling mechanisms in the restoration of impaired immune function due to diet-induced obesity," *Proceedings of the National Academy of Sciences of the United States of America*, vol. 108, no. 7, pp. 2867–2872, 2011.
- [135] V. G. Athyros, A. A. Papageorgiou, D. S. Dimitriadis, and A. G. Kontopoulos, "Atorvastatin plus pravastatin for the treatment of heterozygous familial hypercholesterolaemia—a pilot study," *Current Medical Research and Opinion*, vol. 17, no. 4, pp. 267–272, 2001.
- [136] Y. A. Ogai, T. A. Banks, and S. M. Gada, "Statin allergy: clinical experience and structural relation as a framework for evaluation," *The Journal of Allergy and Clinical Immunology: In Practice*, vol. 3, no. 6, pp. 993–995, 2015.
- [137] D. R. Rosenberg, C. X. Andrade, A. P. Chaparro et al., "Short-term effects of 2% atorvastatin dentifrice as an adjunct to periodontal therapy: a randomized double-masked clinical trial," *Journal of Periodontology*, vol. 86, no. 5, pp. 623–630, 2015.
- [138] B.-S. Lee, C. C. Lee, H. P. Lin et al., "A functional chitosan membrane with grafted epigallocatechin-3-gallate and lovastatin enhances periodontal tissue regeneration in dogs," *Carbohydrate Polymers*, vol. 151, pp. 790–802, 2016.
- [139] A. D. Bradley, Y. Zhang, Z. Jia et al., "Effect of simvastatin prodrug on experimental periodontitis," *Journal of Periodontology*, vol. 87, no. 5, pp. 577–582, 2016.
- [140] B. S. Lee, C. C. Lee, Y. P. Wang et al., "Controlled-release of tetracycline and lovastatin by poly(D,L-lactide-co-glycolide acid)-chitosan nanoparticles enhances periodontal regeneration in dogs," *International Journal of Nanomedicine*, vol. 11, pp. 285–297, 2016.
- [141] H. Seto, H. Ohba, K. Tokunaga, H. Hama, M. Horibe, and T. Nagata, "Topical administration of simvastatin recovers alveolar bone loss in rats," *Journal of Periodontal Research*, vol. 43, no. 3, pp. 261–267, 2008.
- [142] A. A. Swerts, B. F. E. Santos, S. R. Bruzadelli, M. R. P. L. Brigagão, D. C. . Lima, and L. A. Fernandes, "Treatment of experimental periodontal disease by laser therapy in simvastatin-modified rats," *Journal of Applied Oral Science*, vol. 25, no. 4, pp. 387–395, 2017.
- [143] X. Wang, Z. Jia, Y. Almoshari, S. M. Lele, R. A. Reinhardt, and D. Wang, "Local application of pyrophosphorylated simvastatin prevents experimental periodontitis," *Pharmaceutical Research*, vol. 35, no. 8, p. 164, 2018.
- [144] P. Goes, A. P. S. Lima, I. M. Melo, R. O. C. C. Rêgo, and V. Lima, "Effect of atorvastatin in radiographic density on alveolar bone loss in Wistar rats," *Brazilian Dental Journal*, vol. 21, no. 3, pp. 193–198, 2010.
- [145] P. Goes, N. A. Lima, J. A. G. Rodrigues, N. M. B. Benevides, G. A. C. Brito, and V. Lima, "Anti-inflammatory and anti-resorptive effects of atorvastatin on alveolar bone loss in Wistar rats," *Brazilian Dental Journal*, vol. 27, no. 3, pp. 267–272, 2016.
- [146] J. C. E. Mouchrek Júnior, C. G. Macedo, H. B. Abdalla et al., "Simvastatin modulates gingival cytokine and MMP production in a rat model of ligature-induced periodontitis," *Clinical, Cosmetic and Investigational Dentistry*, vol. 9, pp. 33–38, 2017.
- [147] C. A. Nassar, G. D. Battistetti, F. P. Nahsan et al., "Evaluation of the effect of simvastatin on the progression of alveolar bone loss in experimental periodontitis—an animal study," *Journal of the International Academy of Periodontology*, vol. 16, no. 1, pp. 2–7, 2014.
- [148] M. Kumari, S. S. Martande, A. R. Pradeep, and S. B. Naik, "Efficacy of subgingivally delivered 1.2% atorvastatin in the treatment of chronic periodontitis in patients with type 2 diabetes mellitus: a randomized controlled clinical trial," *Journal of Periodontology*, vol. 87, no. 11, pp. 1278–1285, 2016.
- [149] A. R. Pradeep and M. S. Thorat, "Clinical effect of subgingivally delivered simvastatin in the treatment of patients with chronic periodontitis: a randomized clinical trial," *Journal of Periodontology*, vol. 81, no. 2, pp. 214–222, 2010.
- [150] A. R. Pradeep, M. Kumari, N. S. Rao, S. S. Martande, and S. B. Naik, "Clinical efficacy of subgingivally delivered 1.2% atorvastatin in chronic periodontitis: a randomized controlled clinical trial," *Journal of Periodontology*, vol. 84, no. 7, pp. 871–879, 2013.
- [151] A. R. Pradeep, N. S. Rao, P. Bajaj, and M. Kumari, "Efficacy of subgingivally delivered simvastatin in the treatment of patients with type 2 diabetes and chronic periodontitis: a randomized double-masked controlled clinical trial," *Journal of Periodontology*, vol. 84, no. 1, pp. 24–31, 2013.
- [152] A. R. Pradeep, S. Karvekar, K. Nagpal, K. Patnaik, C. N. Guruprasad, and K. M. Kumaraswamy, "Efficacy of locally delivered 1.2% rosuvastatin gel to non-surgical treatment of patients with chronic periodontitis: a randomized, placebo-controlled clinical trial," *Journal of Periodontology*, vol. 86, no. 6, pp. 738–745, 2015.
- [153] A. R. Pradeep, D. Kanoriya, S. Singhal, V. Garg, B. Manohar, and A. Chatterjee, "Comparative evaluation of subgingivally delivered 1% alendronate versus 1.2% atorvastatin gel in treatment of chronic periodontitis: a randomized placebo-controlled clinical trial," *Journal of Investigative and Clinical Dentistry*, vol. 8, no. 3, article e12215, 2017.
- [154] N. Priyanka, A. Abhilash, S. Saquib et al., "Clinical efficacy of subgingivally delivered 1.2 mg simvastatin in the treatment of patients with aggressive periodontitis: a randomized controlled clinical trial," *The International Journal of Periodontics & Restorative Dentistry*, vol. 37, no. 2, pp. e135–e141, 2017.
- [155] N. S. Rao, A. R. Pradeep, P. Bajaj, M. Kumari, and S. B. Naik, "Simvastatin local drug delivery in smokers with chronic periodontitis: a randomized controlled clinical trial," *Australian Dental Journal*, vol. 58, no. 2, pp. 156–162, 2013.
- [156] A. Rath, J. Mahendra, L. Thomas, M. Sandhu, A. Namasi, and T. Ramakrishna, "A clinical, radiological and il-6 evaluation of subgingivally delivered simvastatin in the treatment of chronic periodontitis," *International Journal of Drug Delivery*, vol. 4, pp. 70–81, 2012.

## **Development of a thermosensitive statin–functionalized chitosan-based hydrogel and evaluation of bone healing**

### **1. Introduction**

Periodontitis is a chronic inflammatory disease of infectious origin characterized by a progressive destruction of tooth-supporting tissues (Hajishengallis, 2015b). The main symptoms include gingival inflammation, periodontal pocket formation, alveolar bone loss, abscess, tooth mobility and eventual tooth loss. Periodontitis is a risk factor for several systemic conditions and also negatively impacts the quality of life (Linden et al., 2013). The pathogenesis of periodontitis involves a complex interaction of immune and inflammatory cascades initiated by oral biofilm bacteria (Cekici et al., 2014). It involves a disturbance of homeostasis between the host's immune response and the dysbiotic microbial flora at the site of the lesion (Hajishengallis, 2015b).

Non-surgical therapy, that consist of scaling and root planing (SRP), has a positive impact on periodontal health in most cases, however, some limitations related to type of disease, specific flora, presence of systemic or local risks factors such as inflammatory pathologies, smoking or unadapted dental fillings may decrease the rate of response to these non-surgical procedures leading to the need of adjunctive therapies or surgical treatments (Graziani et al., 2017).

Risk factors for optimal healing of periodontal lesions include exacerbation of bacterial infection at the site of periodontal injury leading to persistent inflammation characterized by increased levels of inflammatory markers such as cytokines, chemokines and matrix metalloproteinases (MMPs) or an imbalance with their antagonists/inhibitors promoting the activity of pro-inflammatory mediators (Agossa et al., 2015; Morand et al., 2017).

Statins, or inhibitors of 3-hydroxy-3-methylglutaryl coenzyme A reductase, are a group of drugs used primarily to treat hyperlipidemia and to prevent cardiovascular disease. However, in recent years, various pleiotropic properties of statins such as anti-inflammatory, antioxidant, antibacterial and immunomodulatory have paved their path to periodontal treatment (Petit et al., 2019b).

With regards to their action on the immune and inflammatory response involved in periodontal healing, statins reduce the pro-inflammatory cytokine levels (IL-1 $\beta$ , IL-8, IL-6, TNF- $\alpha$ ) and increase the release of anti-inflammatory mediators (IL-10, IL-12), chemokines, cytokines such as IFN- $\gamma$  (Estanislau et al., 2015; Grover et al., 2016; Petit et al., 2019b). In addition, statins impede periodontal destruction by inhibiting the expression of MMPs such as

MMP-1, MMP-8 and MMP-9 (Poston et al., 2016). Statins can also regulate bone metabolism through three major mechanisms: the promotion of osteogenesis, the suppression of osteoblast apoptosis and the inhibition of osteoclastogenesis (Petit et al., 2019b; Zhang et al., 2014). Statins allow periodontal regeneration by increasing Smad signaling, which accelerates bone formation, and by antagonizing TNF- $\alpha$  via Ras/Rho/MAPK, initiators of osteoclastic differentiation. They also significantly increase the levels of osteoblast (OBs) differentiation factors such as alkaline phosphatase (ALP), osteopontin (OPN), osteocalcin (OCN) and VEGF (Vascular Endothelial Growth Factor) (Sousa et al., 2016). Nevertheless, statins have also demonstrated interesting antibacterial properties against key periodontopathogens such as *Porphyromonas gingivalis* (*Pg*) and *Aggregatibacter actinomycetemcomitans* (*Aa*) (Emani et al., 2014; Lee et al., 2016). Furthermore, they improve epithelialization and wound healing through the regulation of inflammation (Schwinté et al., 2017).

Several epidemiological studies have demonstrated a beneficial effect of systemic statin administration on SRP response (Norata and Catapano, 2014). However, the application of local statins as an adjunct to the SRP results in a significantly greater reduction in clinical periodontal probing depth (PPD), depth of the radiographic defect, bleeding index (BI) and, hence, periodontal inflammation compared to that with their systemic administration (Saxlin et al., 2009). Thus, the systemic status of the patient and the mode of administration of statins are important factors that influence SRP outcomes and also determine the risk of side effects (Katz et al., 2005).

Among the statins family, the effect of both systemic and local simvastatin on periodontitis treatment with both systemic and local administration has been extensively studied in several *in vitro*, *in vivo* and clinical studies (Muniz et al., 2018; Petit et al., 2019b). However, atorvastatin (ATV) and some other statin family members, despite showing similar efficiency towards bone metabolism and immune-inflammatory response involved in periodontal healing, have been less studied (de Araújo et al., 2013; Bertl et al., 2017; Goes et al., 2016; Sousa et al., 2016).

Since statins are insoluble in aqueous solutions, the addition of a surfactant is crucial for achieving statins solubility. In this regard, the use of a nano-emulsion (NE) is considered instrumental for the local delivery of such drugs or compounds (Anton and Vandamme, 2009; Anton et al., 2016). The emulsions are characterized by the dispersion of two immiscible liquids where a liquid is dispersed in the form of droplets in the continuous phase of another liquid and when the size of the droplets reaches a scale below 1  $\mu\text{m}$ , these emulsions are called NE (Ganta et al., 2010). NE is a heterogeneous system in which the oily phase is dispersed as droplets in

an aqueous phase and stabilized by emulsifying agents. Emulsifying agents are surfactants that can reduce the interface voltage between two immiscible liquid phases (oil and water) by adsorbing preferentially at their interfaces. The solubilization capacity in water ( $W_{max}$ ) is reached with a water / oil-surfactant-statin ratio of 60:40. This ratio is used for the formulation of vitamin E-based NEs associated with, for instance, Kolliphor ELP (KELP). The interest of formulating NEs is to increase the concentration of the molecule of interest in a given volume and to facilitate the endocytosis of the molecule of interest by the target cells (Martínez-Ballesta et al., 2018).

The aim of this study was to synthesize, characterize and evaluate, *in vitro* and *in vivo*, the potential pro-regenerative effect of a thermosensitive and muco-adhesive hydrogel functionalized by ATV on the control of inflammation.

## 2. Materials & Methods

### 2.1. Characterization of thermosensitive chitosan-based hydrogel (ChiG)

2.5% ChiG solutions were prepared by dissolving 125 mg of chitosan (Sigma, St-Quentin, France) in 5 ml of a 1% aqueous acetic acid solution. After cooling the chitosan solution to 4°C, 600 mg of glycerophosphate (Gp) salt powder (Sigma, St-Quentin, France) was added. This concentration of Gp at 0.56M ensures a thermo-irreversible chitosan gel at 37°C. The mixture is maintained for 15 minutes with constant stirring. The resulting transparent ChiG solution was stored at 4°C (Ganji et al., 2007; Madi and Kassem, 2018).

### 2.2. Solubility tests for ATV

Since statins display low solubility in ChiG, an oil or co-solvent must be added to ensure its solubility. The solubility of ATV was visually tested in 7 surfactant or co-surfactant oils: KELP, capmul, castor oil, labrafil M, tetraglycol, transcutool P or D- $\alpha$ -Tocopherol polyethylene glycol succinate (TPGS). 5 mg of ATV were mixed with 1 ml of surfactant oil or co-surfactant before being vortexed for 30 seconds, passed through an ultrasound bath for 1 minute and then heated at 50°C for 5 minutes. The oils or co-solvents that could dissolve statins upon visual verification were tested again with the increasing concentration of statins ATV. Accordingly, KELP was selected for further experimentations due to its interesting physical and chemical properties.

### **2.3. Characterization of NE**

Vitamin E was used as a base with KELP for preparing the statins functionalized NE. This statin-vitamin E mixture and surfactant was heated to 80°C and vortexed until the dissolution of ATV. The mixture was then cooled down to 25°C and distilled water (MilliQ) was added in increasing concentrations to achieve the solubilizing limit of water which is detected visually as the clear/ transparent NE formulation becomes cloudy/turbid.

#### **2.3.1. Scanning and Transmission Electron Microscopy SEM and TEM**

The statin functionalized with NE was characterized for size and surface charge. Measurement of the size of ATV- KELP NE was performed using the Zetasizer® software that measures the particle size using dynamic light scattering. These measurements were confirmed by TEM analysis. Measurement of the surface charge of ATV-functionalized NE was performed using Zetasizer® Zeta potential software that measures surface charge by Doppler laser electrophoresis.

#### **2.3.2. pH**

The pH measurement of ChiG, ChiG mixed with ATV and ChiG containing ATV-KELP NE was performed using an electronic pH meter and confirmed by the use of pH paper.

#### **2.3.3. Release profile**

ATV release profile in ChiG was performed using a 6-wells plate. The vitamin E KELP based NE was labeled with a fluorescent dye NR668. This Dye is excited around 488-530nm and emits in the visible (600nm). 500µL of ChiG functionalized with the labeled ATV-KELP NE was deposited in each well. Then, the plate was heated for 10 min at 40 °C to gel the preparation. Finally, 5 mL of MilliQ water was added to each well and the wells were stirred constantly in the dark. Aliquots of 1 mL were taken at regular time intervals and were returned to the wells after analysis. A standard range was achieved by diluting increasing concentrations of labeled NE in a constant volume of deionized water.

### **2.4. Cell culture**

TERT-2 OKF-6 Human Oral Epithelial Cells (EC) (BWH Cell Culture and Microscopy Core, Boston, MA, USA) were cultured in Keratinocyte-SFM medium (Life Technologies, Saint-Aubin, France) supplemented with a mixture growth supplement and antibiotics (10 U/ml penicillin and 100 µg/ml streptomycin) (Lonza, Levallois-Perret, France).

The cells were cultured at 37°C in a humidified atmosphere with 5% CO<sub>2</sub> and the culture medium was changed every 2 to 3 days.

### ***2.5. Immunofluorescence- uptake of drug by cells***

The endocytic capacity of ATV-KELP NE was tested on EC by optical microscopic observation of Dye NR668, fluorescent in red in the visible (emission spectrum = 600nm). A sterile glass plate was placed in the bottom of each well of a 24-wells plate before seeding  $2 \times 10^5$  cells per well. After 24h, a NR668-labeled ATV-KELP NE preparation diluted in the cell culture medium replaced the culture medium of each well after thorough rinsing with PBS. The cells remained in culture for 24h in contact with the NE before recovering the glass plates on which the cells were cultured in order to observe them under an optical microscope.

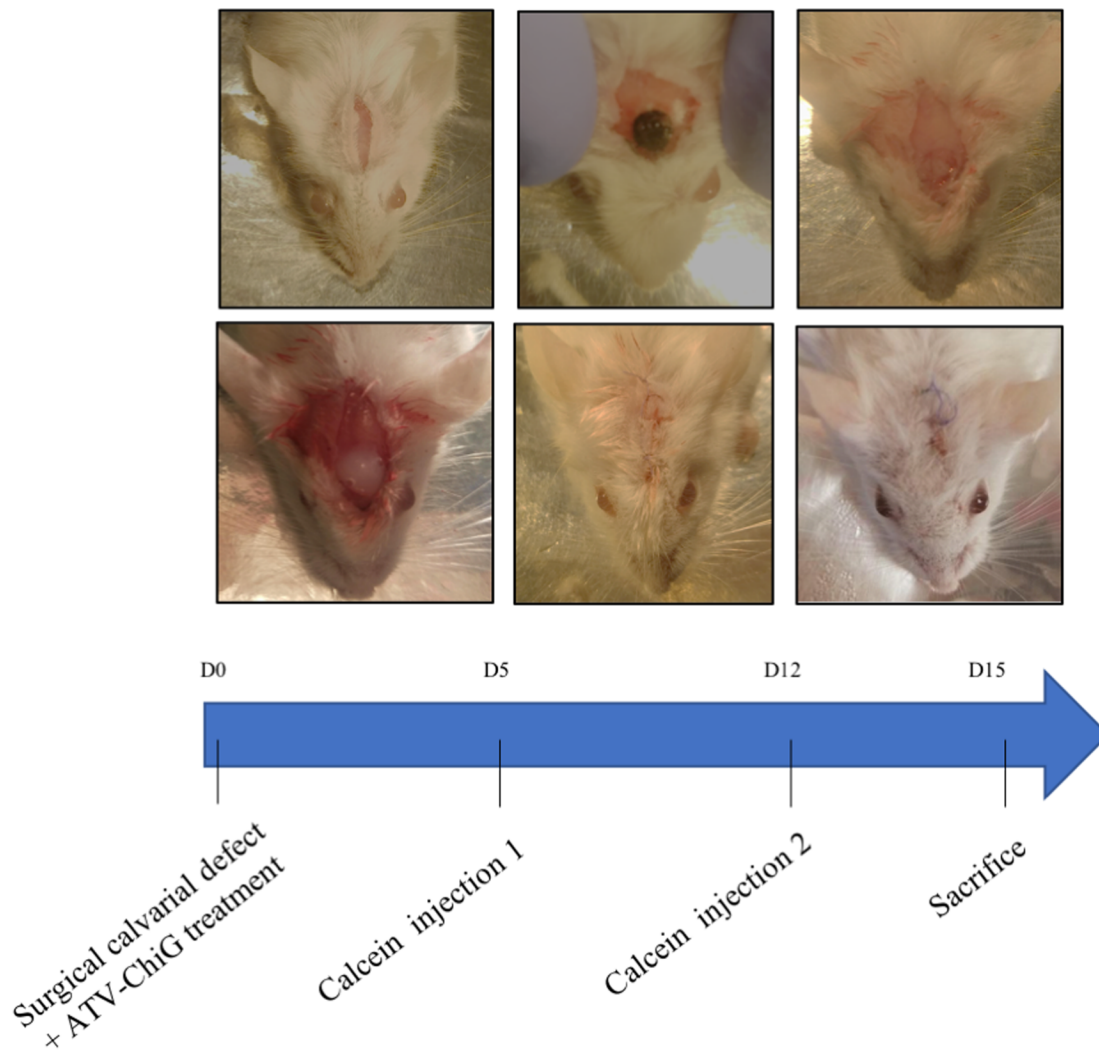
### ***2.6. Treatment of calvarial bone defect***

The mice were anesthetized intraperitoneally with a mixture of ketamine (80 mg/kg) and xylazine (10 mg/kg) as a function of body weight of the mouse (approximately 0.1 ml /10 g of body weight). The top of the head was shaved before making a single vertical incision of about 1.5 cm in the middle of the skull until bone contact. Then, a calvarial defect of 2 mm diameter was made by drilling with appropriate round bur. After cleaning the surgical wound with physiological saline and drying by tamponade, a drop of 50 µL of statin-functionalized or non-functionalized gels were deposited on the calvarial defect. Finally, a continuous suture of calvarial skin (silk suture 6-0) allowed surgical wound closure hermetically. The healing was evaluated after 15 days. As a control, ATV was also administered systemically by oral gavage (10mg/kg/day) for 15 days.

#### ***2.6.1. In vivo calcein injection***

Injections of calcein in phosphate-buffered saline (10 mg/kg, Sigma-Aldrich Co.) were performed intra-peritoneally 10 days and 3 days before the sacrifice (Figure 1).





**Figure 1: Surgical preparation of calvarial defect (2mm) treated with local ATV ChiG NE.** The bone defect was carefully drilled with a round bur using constant irrigation to avoid overheating. The defect was cleaned with physiological saline, dried with a gauze and treated with local application of ChiG containing ATV-KELP NE. The wound was sutured hermetically. Calcein was injected 10 and 3 days before sacrifice.

### 2.6.2. Tissue preparation

The mice were euthanized by a lethal intraperitoneal injection of pentobarbital (100 mg/kg). The calvaria were then dissected and post-fixed by immersing in a solution of 4% paraformaldehyde diluted in PBS before being placed overnight at 4°C. After careful washing in PBS, the samples were included in OCT (Tissue-Tek) cryostat medium and stored at -20 °C. Then, 10µm thick serial sections of the calvaria were cut with a cryostat at -30°C. The computerized images were analyzed using imaging software.



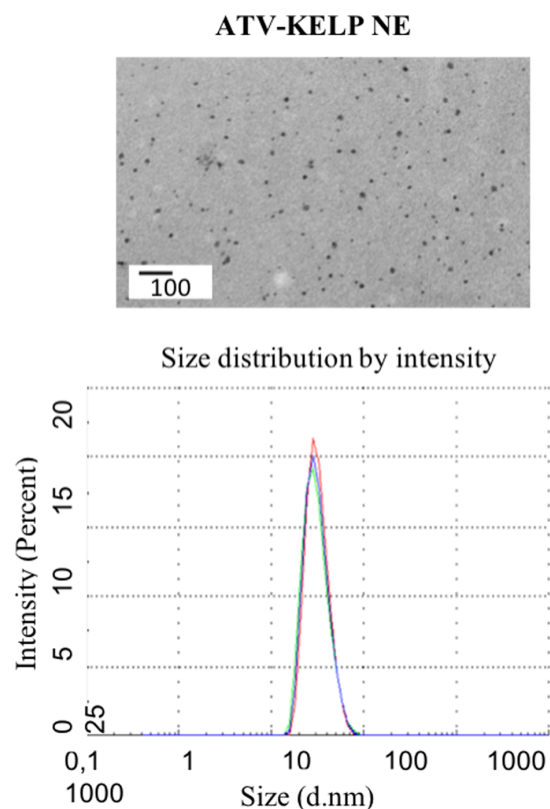
### 2.6.3. Histological and immunofluorescence analyses

The sections to be observed were then immersed for 10 minutes in paraformaldehyde before being rinsed and stained for 5 minutes in alizarin red. Slides were mounted using DAKO mounting medium prior to examination under microscope (RM 2145 DMRB microscope, Leica, Rueil-Malmaison, France). The immunofluorescent calcein staining was followed using fluorescent microscope (RM 2145 DMRB microscope, Leica, Rueil-Malmaison, France). The circumference of neo-bone area was marked and measured by Olympus cellSens Entry imaging software. At least 3 samples per mouse were considered for each condition tested.

## 3. Results

### 3.1. Characterization of NE and NE loaded chitosan- based hydrogel

After measuring with Zetasizer device and its Zetasizer® software, the NE droplets average size was estimated: 42.51 nm (KELP NE) and 37.96 nm (ATV-KELP NE functionalized with ATV) with the range being between 40-100nm (Figure 2). The NE surface charge was on average -26.7 mV (KELP NE) and -21.4 mV (ATV-KELP NE).



**Figure 2:** Analysis of droplet size of ATV-KELP NE by SEM and TEM. For TEM, the samples were labeled with uranyl acetate. A heterogeneity of the observed droplets is noted by measurements on the images captured during the observation under the microscope. These data are consistent with those found by measurement with Zetasizer®, 37.96nm for KELP-ATV.

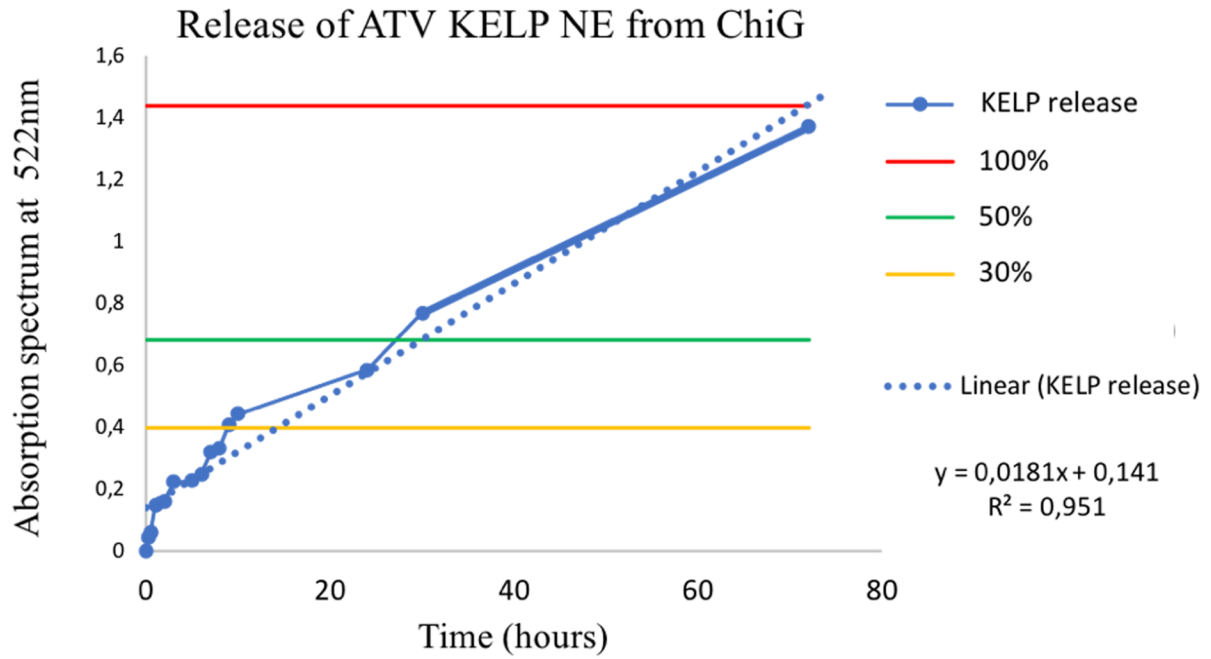
All synthesized formulations have a pH between 6.3 and 6.8, thus, potentially cytocompatible and usable in clinic (Table 1).

<b>Preparation</b>	<b>pH</b>
Chitosan gel	6.3
ATV Chitosan gel	6.5
Chitosan gel + ATV-KELP NE	6.4

*Table 1: pH of different ChiG preparations.*

### **3.2. Release profile**

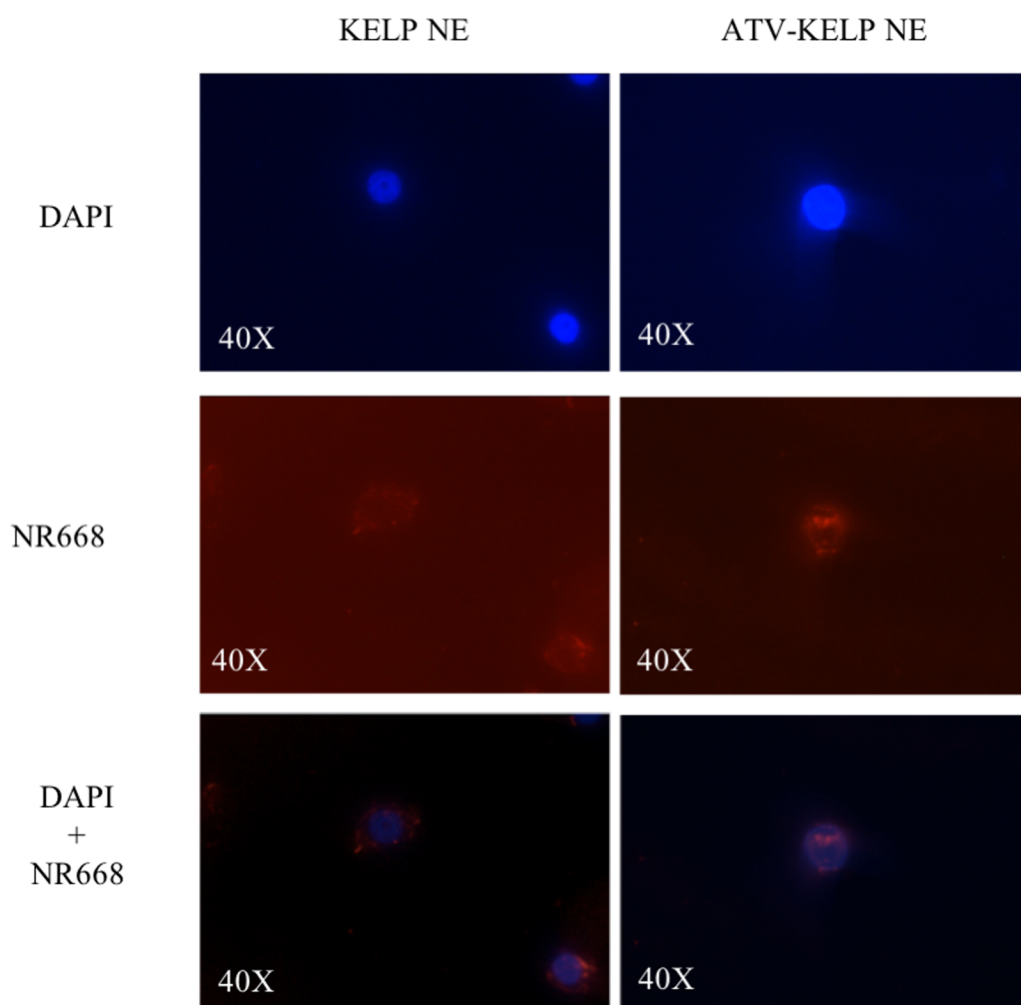
The results of spectrophotometric analysis of the release over 72 hours of KELP NE containing ATV were measured using a spectrophotometer (Uviline 9400) (Figure 3). The release in the ChiG follows a linear curve with a coefficient of determination greater than 0.95. At 24h, about 45% of the NE is released and it takes a little more than 72 hours for the ChiG to escape almost all of the NE. The release curve of ATV-KELP NE shows a semblance of plateau between 10 and 24h that can be explained by a quick release of the NE at the periphery of the gel while a latency time of the NE in the core of the gel to reach the periphery before being released.



**Figure 3:** Release curve of NR668 labeled ATV-KELP NE. It follows a linear curve with a semblance of plateau between 10 and 24h.

### 3.3. NE endocytosis

The endocytosis capacity of ATV-KELP NE was tested at 24h on EC by fluorescence microscopic observation of dye NR668 fluorescent in red in the visible (emission spectrum = 600nm). The internalization of the NR668 dye (red) around the DAPI stained nuclei (in blue) shows that the NE is able to penetrate and deliver the drug into the EC (Figure 4).

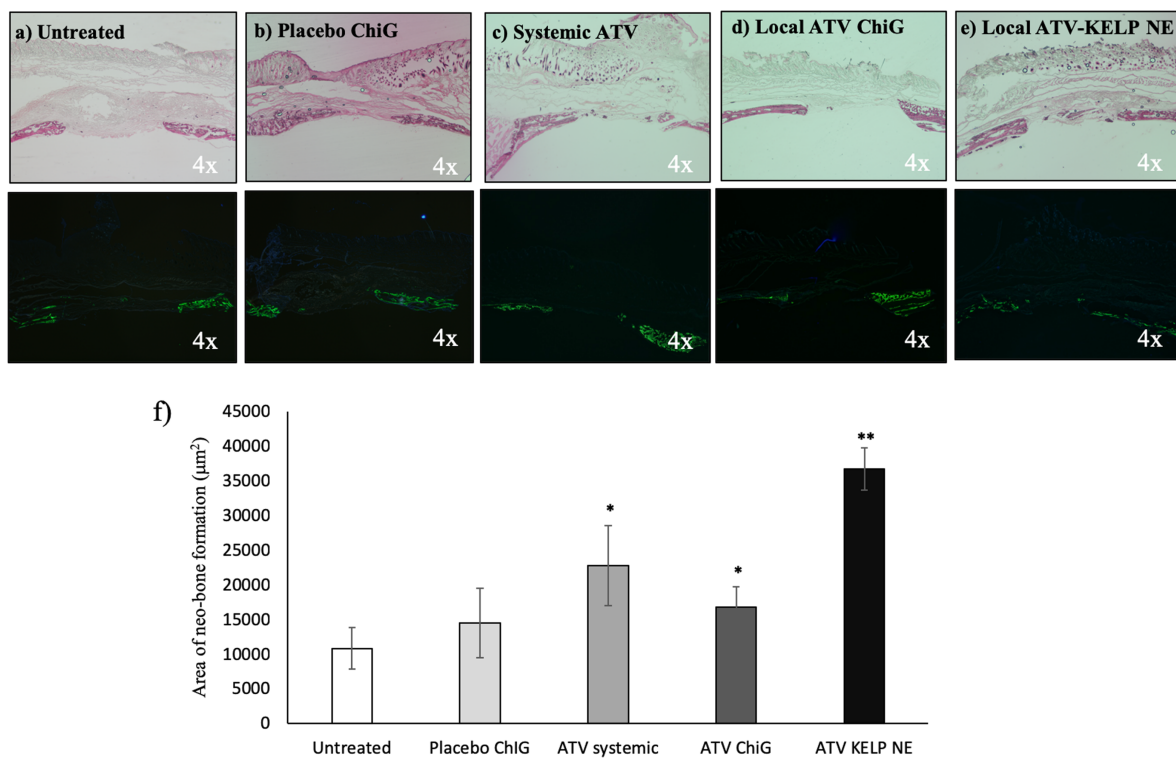


**Figure 4: Endocytosis of drug from statins functionalized NE by EC.** The internalization of the NR668 dye (red) around the DAPI stained nuclei (in blue) shows that the NE is able to penetrate and deliver the statin into the EC.

### 3.4. Statins functionalized NE induce neo-bone formation *in vivo*

Histomorphometric and immunofluorescence analyses confirmed neo-bone formation in the area of induced bone defect *in vivo*. The new bone area was measured in  $\mu\text{m}^2$  and was shown to be significantly greater in mice treated with local ATV-KELP NE application

compared to other groups. Interestingly, systemic and ATV ChiG also showed better healing response compared to the untreated control and the placebo ChiG. However, their new bone formation was still less in comparison with that formed in ATV-KELP NE group. Moreover, the immunofluorescent calcein staining confirmed the presence of speckled areas of new bone within the defect area (Figure 5). In addition to the bone formation, the surrounding soft tissue of the treated subjects demonstrated significantly decreased inflammation at 15 days of wound healing compared to that in the untreated/control mice characterized by reduced PMN infiltration.



**Figure 5: Histological and corresponding immunofluorescent sections of induced bone defect at 15 days of wound healing a) untreated and treated with b) placebo ChiG, c) systemic ATV, d) local ATVChiG, e) local ATV-KELP NE, f) graph representing the area of new bone formed ( $\mu\text{m}^2$ ) within the induced calvarial bone defect. \*  $p < 0.05$  compared to untreated control, \*\*  $p < 0.05$  compared to systemic ATV, placebo and ATV ChiG.**

#### 4. Discussion

In this study, we demonstrated the neo-bone forming properties of ATV that promote wound healing and regeneration. Several *in vivo* studies have corroborated that statins, especially ATV, are effective in reducing inflammation (de Araújo et al., 2013) and promoting osteogenesis by inhibiting osteoclastic activity (Zhang et al., 2014). However, the improvement of statin-induced bone regeneration *in vivo* largely depends on the at-site concentration of the drug (Zhang et al., 2014). In local drug administration, the delivery system plays an important role. Here, we selected to develop a chitosan-based hydrogel. ChiG has a low viscosity at low temperature and gels at 37°C. This property will be of interest as we aim, in the future, to use it in the context of periodontitis, allowing its convenient application and *in situ* retention within periodontal pockets (Sheshala et al., 2019). The gel is biocompatible, biodegradable and mucoadhesive. Its liquid consistency allows easy intra-pocket injection and becomes irreversibly hard within the periodontal pocket (in 4 min at 37°C) (Ganji et al., 2007). Moreover, the use of a thermosensitive ChiG ensures the delivery of an effective statin concentration directly to the lesion site. Furthermore, the gel completely resorbs on its own without generating any toxic byproducts that can interfere with the healing process. The sustained drug delivery of statins in a controlled manner maintains optimal drug dose necessary for the modulation of inflammatory process. A similar chitosan-based hydrogel containing hyaluronic acid has already been developed for periodontal tissue engineering (Miranda et al., 2016).

In order to increase aqueous solubility and improve the bioavailability of statins, an NE-based drug delivery system was successfully developed using vitamin E-based KELP-to encapsulate statins in nanodroplets. The NE size below 200nm ensures good endocytosis by cells of interest as shown by our *in vitro* results of oral EC endocytosis.

TEM revealed a certain degree of heterogeneity in the sizes of NE droplets, however, the average size was found similar to that recorded by Zetasizer®. Indeed, NEs are a type of nanoparticles generally defined as dynamic structures formed of surfactants encapsulating an internal phase containing a molecule of interest. The integrity of the particles can be maintained by a complex mixture of small molecular weight, surfactants (emulsifiers) (Sarker, 2005).

The loading of any drug delivery system is an important property that governs its suspension stability due to electrostatic interactions as well as its *in vivo* performance (Ganta et al., 2014). However, the properties of the NE depend on the composition of the material at the interface between the droplets and the dispersion medium. It was, therefore, important to measure the surface charge of the NE prepared. Thermodynamically stable particles possess

very low surface tension (Sarker, 2005) while a low surface charge of these NE droplets enhances their stability in the gel. Thus, the size of KELP-based NE used in this study and its non-neutral surface charge ensure better intracellular uptake of the drug. At the cellular level, NE uptake can occur via phagocytosis, macropinocytosis or endocytosis. The endocytosed molecules can accumulate in lysosomes, intracellular vacuoles or cytoplasm (Ganta et al., 2014).

pH is one of the many important physicochemical properties to evaluate for any product intended for local application. It is one of the factors playing an important role in the transition from a healthy gingiva to a pathological *periodontium* (Socransky and Haffajee, 2005) as the development of periodontitis is associated with an increase in pH in the gingival sulcus (around 8.5). It is due to the degradation of the proteins present in the GCF, which results in the production of ammonium ( $\text{NH}_4$ ). The latter promotes the precipitation of calcium salts from GCF or saliva resulting in the formation of sub- or juxta-gingival calculus, thereby, contributing to the development and exacerbation of periodontal disease. In addition, a localized increase in pH facilitates the emergence of acid-sensitive and more proteolytic species, such as *Pg* (Barros et al., 2016). However, all tested ChiG preparations have a pH between 6.3 and 6.8, and therefore, compatible with periodontal healing.

*In vitro*, our release profile exhibits a sustained and gradual statins delivery from the ChiG over period of 3 days. Thus, this pattern is expected to aid in the initial phase of healing and avert inflammation-mediated tissue destruction. In the context of periodontitis management, this sustained release pattern allows prolonged use of statins by periodontal cells on the days following SRP.

An *in vivo* evaluation was performed in a mouse calvarial model as a proof of concept to validate the usability of the ChiG and to ensure of potential biological effects with the selected dose of ATV. Rodents have periodontal, anatomical, bacterial and pathogenic characteristics similar to humans (Saadi-Thiers et al., 2013; Batoool et al., 2018). However, the tiny size of the murine oral cavity presents a technical challenge in the placement of ligatures loaded with the periodontopathogenic bacteria necessary for the induction of periodontitis. To overcome this difficulty, a relatively faster and easier model of induced bone defect in mouse calvaria was chosen. The compressive force exerted on murine calvaria is similar to that of intraoral wounds (Choi et al., 2010). The calvaria model, although not a true periodontal system, can be used in a wide variety of pathological applications relevant to dental research. This model is frequently used in the evaluation of bone healing *in vivo*, specially, for studying bone turnover and the anti-inflammatory effects of a molecule (Graves et al., 2008). It presents



several advantages such as easy surgical access to bone, faster induction of bone defect and convenient suture placement. Nevertheless, this murine model of calvaria can be used as a preliminary model to optimize dose and delivery system in the study of bone regeneration before advancing to the more complicated induced periodontitis models (Batoool et al., 2018) (see appendix).

Histological analysis showed increased neo-bone formation and decreased soft tissue inflammation in the mice treated with ATV-KELP NE compared to the untreated controls. These results suggest that an application of 50  $\mu$ L of gel containing 0.1 mg of ATV is a suitable dose for topical application in a mouse model. In the context of periodontal treatment, the control of soft tissue inflammation is instrumental to achieve an optimized wound healing and hard tissues regeneration. Therefore, this reduced inflammation score characterized by reduced PMN recruitment will be of interest as it will promote bone healing as demonstrated with others pharmacological treatments (Alshammari et al., 2017; Huck et al., 2018; Yuan et al., 2011). Moreover, the local application of ATV-KELP NE showed better healing response compared to systemic ATV through oral gavage. This finding is consistent with the literature and will be of interest to reduce the risk of side effects associated with long-term administration of statins (Estanislau et al., 2015; Petit et al., 2019b).

Despite the convenience associated with the use of calvarial model, it has limitations in simulating a real periodontal lesion caused by periodontopathogens' infection. In future, it would be mandatory to assess the regenerative potential of such statin functionalized ChiG and NE in an experimental periodontitis mouse model associated with bacterial inoculation, for instance *Pg*, in order to study the antibacterial, anti-inflammatory, immune system and bone metabolism modulatory properties of statins and to consider the complexity of the periodontal lesion. Furthermore, the incorporation of other pro-regenerative agents to the statins functionalized NE, for instance, growth factors such as BMP2 or other pro-resolution agents such as resolvins, could further enhance its efficiency to promote periodontal wound healing and regeneration.

## **5. Conclusion**

The thermosensitive statins functionalized ChiG and ATV-KELP NE are efficient controlled drug delivery systems with potential regenerative effect. The preliminary results are promising. However, evaluation of its impact in an experimental periodontitis model could give beneficial insights into their efficiency in promoting periodontal wound healing and regeneration in particular.

## **IV. DISCUSSION**

Control of periodontal inflammation is the main goal of periodontal therapy. However, as mentioned previously, its outcomes could be reduced by risk factors such as sustained inflammation and recurrent infection (Goodson et al., 2012; Kinane et al., 2017; Van Dyke, 2008). Therefore, we aimed to develop several therapeutic strategies targeted against these two major biological processes to improve periodontal treatment outcomes.

In our first study, we synthesized IBU-PCL membrane as an anti-inflammatory barrier membrane to overcome local post-op inflammation associated with GTR surgery. For this purpose, IBU-PCL membrane was synthesized by electrospinning core-shell technique. This biomaterial displays interesting physical and chemical properties allowing the consideration of its use in the periodontal field. Indeed, such functionalization of active molecules with PCL membranes has been reported in several studies (Liang et al., 2007; Morand et al., 2015). The core-shell method protected within the core the active molecule (IBU) inside the shell (PCL). Several studies have confirmed the desirable properties of PCL membrane such as biocompatibility, similar fiber distribution and diameter as that of ECM *in vitro* (Ferrand et al., 2014; Lam et al., 2008; Morand et al., 2015) and *in vivo* (Vaquette et al., 2012). Interestingly, our results also showed decreased proliferation rate of EC and FB cultured on PCL membrane as suggested in literature (Kasaj et al., 2008). This effect was amplified in the presence of IBU with a consequent delay in cellular proliferation and migration. This characteristic is instrumental in achieving selective cellular exclusion that could be beneficial in an inflammatory context. The IBU dose used (50 $\mu$ g/mL) was non-cytotoxic and its local and controlled release induced an efficient anti-inflammatory effect without any risk of side-effects associated with systemic IBU delivery. IBU-PCL reduced ECM factors (collagen-IV, fibronectin-1, integrin  $\alpha$ 3 $\beta$ 1 and laminin-5) gene expressions in EC and FB. These molecules are key players in wound healing as they are involved in orchestrating intra-cellular and inter-cellular interactions such as adhesion, migration and proliferation (Cantón et al., 2010; Kasaj et al., 2008; Larjava et al., 2011). However, their precise roles need to be further explored in the context of periodontal wound healing (Jakhu et al., 2018).

Our *in vitro* results were validated by treatment of experimental periodontitis with IBU-PCL membrane *in vivo* in a well-established *Pg*-infected ligature-induced periodontitis mouse model (Batoool et al., 2018 (see appendix); Saadi-Thiers et al., 2013). This animal model mimics the disease pathology and GTR using IBU-PCL membrane demonstrated reduced pre-mature epithelial downgrowth reflected by shorter EA in treated sites compared to that of control. The formation of long junctional epithelium is undesirable for ideal periodontal wound healing and regeneration (Alpiste-Illueca et al., 2006; Bosshardt and Lang, 2005). Furthermore, IBU

decreased inflammation-mediated bone resorption as shown by reduced osteoclast number in treated sites. IBU-PCL membrane successfully improved the soft tissue healing response, however, a longer follow-up (not incorporated in our study) was necessary to anticipate bone healing.

Despite cost-effective housing, easy availability of strains and analyses kits and ethical reasons, the small oral cavity of mice renders this surgery rather challenging for the operator. Moreover, a limited quantity and size of sample is achieved. Nevertheless, the biocompatibility and feasibility of surgical membrane placement in a mouse model was presented. At the same time, we also developed an interesting surgical model to overcome issues associated to the long-term ligature placement through the drilling of a standardized maxillary defect (Batoool et al., 2018, see Appendix). However, it needs more technical improvement to ensure the reproducible size of the defect and allows an easy membrane placement. Such model would be of interest to evaluate biomaterials in the context of guided bone regeneration or alveolar socket preservation. Although our IBU-PCL membrane helped in achieving a local post-op inflammation control, addition of antimicrobials, growth factors or pro-resolution molecules could further optimize periodontal wound healing and regeneration.

Our second study involved the development of ISFI containing CHX and IBU to target both inflammation and infection simultaneously. PLGA based ISFI have been well-described for different therapeutic applications (Bode et al., 2018) including periodontal disease management (Agossa et al., 2017; Do et al., 2015b). CHX-IBU ISFI presents an antibiotic free strategy, thus, overcoming the problem of bacterial resistance associated with long-term antibiotic use as adjunct to periodontal treatment as demonstrated earlier (Agossa et al., 2017). The solvent exchange method enables preparation of liquid formulations that are easily injectable into the periodontal pocket and harden only inside the pocket, acquiring a 3D shape of the periodontal lesion. This prevents their accidental dislodgement from the lesion site, thereby, ensuring better efficacy and retention of active molecules. The biocompatibility of CHX-IBU ISFI was established in EC. The IBU released by the developed ISFI reduced significantly the TNF- $\alpha$  levels that were up-regulated as a result of *Pg*-exposure *in vitro*.

*In vivo*, the CHX-IBU ISFI was injected directly into the periodontal pocket created by *Pg*-infected ligatures-induced mouse model as described previously (Batoool et al., 2018; Saadi-Thiers et al., 2013). This resulted in significantly decreased inflammatory score of the treated sites in comparison to those treated with placebo ISFI or untreated controls. Furthermore, an improved periodontal wound healing response was demonstrated by reduced EA and improved FA along the root. Nonetheless, the bone healing did not show improvement indicating the need

of a longer follow-up or an addition of other pro-regenerative molecules or growth factors capable of inducing bone regeneration.

In the third study, statins containing thermosensitive chitosan-based hydrogel and nano-emulsion were synthesized and characterized. ATV was functionalized with ChiG. The ChiG was formulated as described earlier (Ganji et al., 2007; Madi and Kassem, 2018). However, to further enhance the solubility of hydrophobic ATV, a vitamin E-KELP based NE was synthesized to encapsulate ATV within its nanodroplets and act as a spatial and controlled-release drug delivery system. The ATV-KELP NE was characterized for its size, pH and release profile. The average size of NE particles prepared (37.96nm) was in correspondence to the reported size range of NE particles (Anton and Vandamme, 2011). The release profile confirmed a sustained release of ATV from ATV-KELP NE. The endocytosis of the NE by EC confirmed intracellular uptake of the encapsulated drug released by ChiG. Our *in vitro* findings were corroborated by the results obtained from *in vivo* in a calvarial model of induced bone defect treated with local ATV ChiG, local ATV-KELP NE and systemic ATV. The results demonstrated neo-bone formation in treated sites compared to the untreated controls.

Taken together, all these results need to be evaluated and compared according to several parameters related to technology required for their synthesis, cost-effectiveness and most importantly, their applicability at the clinical level. The electrospinning technique can create unique fibers by mixing various polymer solutions with other polymers, chemical agents, drugs, growth factors and nanoparticles. It can synthesize gels or membranes that can also be used for stem cell transplantation (Galler et al., 2012). However, it is difficult to control the pore size/shape within the scaffold or to maintain sufficient mechanical properties with this technique (Reneker and Yarin, 2008; Zhang et al., 2012). To overcome this shortcoming, an alternative method, known as thermally-induced phase separation has shown to improve macro/micro pore networks within 3D nanofibrous scaffolds fabrication (Gupte and Ma, 2012).

Various therapeutic approaches, including guided tissue regeneration (GTR) (Alpiste-Illueca et al., 2006; Tonetti et al., 2004), platelet-rich fibrin (PRF) (Martande et al., 2016), and enamel matrix derivatives (EMD) (Sculean et al., 2000, 2011), have achieved success in the regeneration of lost periodontal tissues, but the treatment outcomes remain highly variable. Cell therapy has also been extensively explored to optimize therapeutic management of periodontal diseases (Bassir et al., 2016; Du et al., 2015; Trofin et al., 2013). Moreover, several recombinant human cytokines and growth factors have been investigated regarding their ability to stimulate periodontal tissue regeneration. The results of pre-clinical and clinical studies have shown that the application of fibroblast growth factor-2 (FGF-2) facilitates cell proliferation of resident

progenitor cells from surrounding bone marrow and PDL and enhances angiogenesis, and bone formation in 2 or 3 wall defects to induce periodontal tissue regeneration (Chen and Jin, 2010; Du et al., 2015; Nagayasu-Tanaka et al., 2015). Nevertheless, the outcomes of these regenerative procedures carried out in animal models and clinical studies remain limited to the three bony wall periodontal defects, and the results are highly unpredictable in the case of advanced periodontal defects in which resident progenitor cells are reduced or destroyed (Nagayasu-Tanaka et al., 2015). Therefore, these therapies need to be improved based on stem cell biology, especially those involved in the differentiation of stem cells into PDL, cementum and alveolar bone.

The effect of autologous mesenchymal stem cells (MSC) transplantation has been investigated in clinical trials for periodontal regeneration of systemically healthy patients (Baba et al., 2016; Chen et al., 2016). However, this strategy cannot be used in patients with systemic diseases, such as diabetes, rheumatoid arthritis or advanced age in whom the intrinsic properties of MSCs are altered. Hence, there is a need for an allogeneic transplantation approach for patients who experience difficulty with autologous transplantation for periodontal regeneration therapy. Pre-clinical studies involving allogeneic MSCs such as adipose-derived multi-lineage progenitor cells (ADMPC) have demonstrated their efficacy, safety and favorable periodontal-regenerative potential (Du et al., 2014; Fu et al., 2014; Venkataiah et al., 2019). Current evidence suggests that the periodontal microenvironment may induce ADMPC to grow and differentiate into periodontal tissues and that the ADMPC themselves might secrete various factors that stimulate resident progenitor cells (Lemaitre et al., 2017). These unique properties make ADMPC a lucrative cell source for stem cell-based therapeutic approaches for periodontal diseases.

Recently an injectable and thermosensitive chitosan/gelatin/glycerol phosphate hydrogel has been successfully tested *in vivo*, to provide a 3D environment for transplanted induced pluripotent stem cells (iPSC) and to enhance stem cell delivery and engraftment for periodontal regeneration. Interestingly, the results exhibited enhanced osteogenic potential due to its functionalization with BMP-6 and caused regeneration of PDL. This also minimized the exacerbation of inflammation resulting in potential periodontal regeneration (Chien et al., 2018). Therefore, iPSCs and trans-differentiated cells may be promising cell sources for periodontal tissue regeneration (Cho et al., 2019).

Several encapsulation strategies such as liposomes (Di Turi et al., 2012; Sugano et al., 2014), micelles (Wang et al., 2019) and nano-particles/ nano-emulsions (Kaur et al., 2017; Lee et al., 2016) have been investigated to optimize spatial- and controlled-delivery of active



molecules like growth factors (Wang et al., 2017) or pharmacological agents (Lee et al., 2016) for periodontal regeneration. These techniques improve the intracellular uptake of the active molecules, enhancing their efficiency and decreasing their resultant systemic availability.

The synchronization of the rate of scaffold resorption with that of healing tissues is crucial for optimizing the periodontal treatment outcomes (Bresaola et al., 2017; Hoornaert et al., 2016; Ivanovski et al., 2014). Thus, it is very important to precisely follow the rate of drug release and degradation of the drug carrier. Several advanced techniques such as matrix-assisted laser desorption-ionization time-of-flight mass-spectrometry (MALDI-TOF MS) are used to evaluate the release of active drug within tissues could be extremely beneficial. Furthermore, MALDI-TOF technique can allow phenotypic identification of periodontopathogens from periodontal disease patients, improving accuracy of diagnosis and efficiency of the corresponding treatment plan (Rams et al., 2018; Yeh et al., 2019).

The precise mapping of cell response through cutting-edge techniques involving transcriptomic and proteomics analyses has widened the horizon of periodontal diagnostics and therapeutic targeting. For instance, microRNAs (miRNAs) are short, noncoding RNAs involved in the regulation of several processes associated with inflammatory diseases and infection. Bacterial infection modulates their expression to subvert any innate immune response. The impact of miRNA expression induced by infection with common periodontal pathogens such as *Pg* has been evaluated in gingival tissue samples (Stoecklin-Wasmer et al., 2012). Several miRNAs are differentially expressed in healthy and diseased gingival tissues and impact inflammatory cytokine release (such as TNF- $\alpha$  and IL-10), thereby, potentially helping both in diagnosis as well as in delineating targets for modulation of inflammation (Simões et al., 2019). Several mimics and inhibitors of such miRNA have been evaluated recently for control of inflammation mediated bone resorption (Fujimori et al., 2019; Huck et al., 2017). Gingival biopsies of periodontitis patients or samples collected from experimental periodontitis animal models can undergo transcriptome analyses (RNA sequencing/microarrays) to reveal the expression and splicing pattern of genes involved in periodontitis pathogenesis. These beneficial insights into the mechanisms underlying the disease could be highly instrumental in highlighting the precise therapeutic targets and improving the periodontal treatment strategies (Kim et al., 2016). More recently, spatial-transcriptomics have made it possible to map gene activity in different compartments of the gingival tissues, hence, providing more precise information on the cell types and specific genes regulating inflammation in specific tissues within the periodontium. Further exploration into this could help in optimizing the harmonized and coordinated healing response of all tissue compartments

within *periodontium* (Lundmark et al., 2018). With advancing research, attempts are aimed at a better understanding of the mechanisms underlying bacterial invasion, involvement of defense barriers, receptors inducing different signaling pathways and inflammatory-immune responses. Recently, the use of intestinal epithelial cell line (CACO-2) has rendered it possible to evaluate the effect of bacterial invasion through epithelial and intestinal barriers to improve our understanding of local and systemic dissemination of periodontopathogenic bacteria (Bugueno et al., 2018; Yamada et al., 2018). Such developments also aid in establishing dose responses at a systemic level.

*In vivo*, to reduce the technical challenge associated with the conventional ligature model, a simplified method has been described to enhance feasibility of placing a bacterially retentive ligature between two molars for inducing experimental periodontitis. This model can induce gingival tissue inflammation and alveolar bone loss within 18 days after ligature placement. Furthermore, it can also be used on germ-free mice to investigate the role of human oral bacteria in periodontitis (Marchesan et al., 2018). In addition, very recently, an injection of a cocktail of type II collagen antibodies along with an oral gavage of *Pg* in mice has shown to induce adequate periodontal destruction in a shorter time, thus, serving as a time-saving alternative to conventional periodontitis induction methods (Alshammari et al., 2018). Therefore, the identification of the key factors associated to each phase of the wound healing and the regeneration process, will be instrumental to develop new regenerative strategies based on the controlled delivery of specific drug or molecules. Interestingly, laser capture microdissection (LCM) will be helpful to isolate specific tissue compartments of the *periodontium* and will also allow such precise identification (Nakamura et al., 2007).

The use of combination therapies such as autogenous connective tissue grafts with EMD (Nemcovsky and Beitlitum, 2018), combination of pro-regenerative agents/ drugs (Lee et al., 2016; Martande et al., 2016), stem cells and growth factors (Chien et al., 2018) have shown better potential of periodontal wound healing and regeneration compared to monotherapies.

# V. CONCLUSION

Periodontal diseases have a high impact on public health due to their high prevalence worldwide. Periodontal regeneration is the ultimate goal of periodontal treatment; however, it is not fully achieved despite effective, costly and time-consuming treatments. Therefore, new, easy to use, inexpensive and low side effect causing therapeutic strategies need to be developed.

Strategies that minimize infection and inflammation at the periodontal lesion site contribute successfully towards the promotion of periodontal wound healing and regeneration. The development of spatial- dose and time-controlled release scaffolds has shown to be more efficient with rapid recovery of diseased tissues and decreased risk of systemic side effects. Interestingly, such local drug delivery systems supplying therapeutic active agents can be incorporated as adjuncts to periodontal therapy to improve the treatment outcomes. In this context, as our first strategy, we developed IBU-PCL membrane to counter local post-op inflammation associated with GTR therapy in periodontal treatment that improved periodontal parameters by significantly decreasing inflammation *in vitro* and *in vivo*. However, the resolution of inflammation was observed mainly at the soft tissue level *in vivo*. This strategy will be of interest as adjunctive to surgical approach especially if more specific drugs could be included.

Our second strategy constituted the development of a CHX-IBU ISFI that successfully counteracted periodontal infection and inflammation simultaneously *in vitro*. *In vivo*, its easy intra-pocket administration resulted in significant amelioration of periodontal treatment outcomes with a marked improvement in soft tissue healing response. The easy use of this treatment strategy will allow its development especially in the context of adjuvant to non-surgical periodontal treatment and/or in the management of at-risk patients.

The two above mentioned approaches failed to significantly enhance alveolar bone healing *in vivo* at the time points tested. However, as our third strategy, we synthesized a thermosensitive hydrogel ATV-ChiG and encapsulated ATV within nano-droplets ATV-KELP NE to further enhance its cellular uptake. This approach led to a decrease in infection-triggered inflammation-mediated tissue degradation *in vivo*. It is noteworthy that this approach improved the healing response of both soft and hard tissues. Nevertheless, in the future, optimization of the combination of pro-regenerative agents (such as drugs, growth factors, stem cells etc.) for their doses and rate of release with appropriate scaffolds adapted for their rate of degradation with rate of neo-tissue formation is crucial for achieving periodontal regeneration. The addition of pro-resolution agents to such approaches can help prevent or avert inflammation-mediated periodontal tissue breakdown and establish periodontal tissue homeostasis, thus, leading to optimal periodontal wound healing and regeneration.

## REFERENCES

- Adriaens, P.A., and Adriaens, L.M. (2004). Effects of nonsurgical periodontal therapy on hard and soft tissues. *Periodontol. 2000* 36, 121–145.
- Agossa, K., Morand, D.-N., Tenenbaum, H., Davideau, J.-L. and Huck, O. (2015). Systemic Application of Anti-inflammatory Agents in Periodontal Treatment. *Clin Anti-Infl Anti-All Drugs* 2, 3–13.
- Agossa, K., Lizambard, M., Rongthong, T., Delcourt-Debruyne, E., Siepmann, J., and Siepmann, F. (2017). Physical key properties of antibiotic-free, PLGA/HPMC-based in-situ forming implants for local periodontitis treatment. *Int J Pharm* 521, 282–293.
- Aithal, G.C., Nayak, U.Y., Mehta, C., Narayan, R., Gopalkrishna, P., Pandiyan, S., and Garg, S. (2018). Localized In Situ Nanoemulgel Drug Delivery System of Quercetin for Periodontitis: Development and Computational Simulations. *Molecules* 23.
- Akcalı, A., Huck, O., Tenenbaum, H., Davideau, J.L., and Buduneli, N. (2013). Periodontal diseases and stress: a brief review. *J Oral Rehabil* 40, 60–68.
- Akcalı, A., and Lang, N.P. (2018). Dental calculus: the calcified biofilm and its role in disease development. *Periodontol. 2000* 76, 109–115.
- Akcalı, A., Akcalı, Z., Batool, F., Petit, C., and Huck, O. (2018). Are Sex Steroid Hormones Influencing Periodontal Conditions? A Systematic Review. *Curr Oral Health Rep* 5, 33–38.
- Albandar, J.M., and Rams, T.E. (2002). Global epidemiology of periodontal diseases: an overview. *Periodontol. 2000* 29, 7–10.
- Aljateeli, M., Koticha, T., Bashutski, J., Sugai, J.V., Braun, T.M., Giannobile, W.V., and Wang, H.-L. (2014). Surgical periodontal therapy with and without initial scaling and root planing in the management of chronic periodontitis: a randomized clinical trial. *J. Clin. Periodontol.* 41, 693–700.
- Alpiste-Illueca, F.M., Buitrago Vera, P., de Grado Cabanilles, P., Fuenmayor Fernandez, V., and Gil Loscos, F.J. (2006). Periodontal regeneration in clinical practice. *Med Oral Patol Oral Cir Bucal* 11, E382-392.
- Alsberg, E., Kong, H.J., Hirano, Y., Smith, M.K., Albeiruti, A., and Mooney, D.J. (2003). Regulating bone formation via controlled scaffold degradation. *J. Dent. Res.* 82, 903–908.
- Alshammari, A., Patel, J., Al-Hashemi, J., Cai, B., Panek, J., Huck, O., and Amar, S. (2017). Kava-241 Reduced Periodontal Destruction in a Collagen Antibody Primed Porphyromonas gingivalis Model of Periodontitis. *J Clin Periodontol* 44, 1123–1132.
- Anton, N., and Vandamme, T.F. (2009). The universality of low-energy nano-emulsification. *Int J Pharm* 377, 142–147.
- Anton, N., and Vandamme, T.F. (2011). Nano-emulsions and micro-emulsions: clarifications of the critical differences. *Pharm. Res.* 28, 978–985.
- Anton, N., Hallouard, F., Attia, M.F., and Vandamme, T.F. (2016). Nano-emulsions for Drug Delivery and Biomedical Imaging. *Intracellular Delivery III*, 273–300.
- Apatzidou, D.A., and Kinane, D.F. (2010). Nonsurgical mechanical treatment strategies for periodontal disease. *Dent. Clin. North Am.* 54, 1–12.
- de Araújo, R.F., Souza, T.O., de Moura, L.M., Torres, K.P., de Souza, L.B., Alves, M. do S.C.F., Rocha, H.O., and de Araújo, A.A. (2013). Atorvastatin Decreases Bone Loss, Inflammation and Oxidative Stress in Experimental Periodontitis. *PLoS One* 8.
- Baba, S., Yamada, Y., Komuro, A., Yotsui, Y., Umeda, M., Shimuzutani, K., and Nakamura, S. (2016). Phase I/II Trial of Autologous Bone Marrow Stem Cell Transplantation with

- a Three-Dimensional Woven-Fabric Scaffold for Periodontitis. *Stem Cells Int.*, 2016:6205910
- Balta, M.G., Loos, B.G., and Nicu, E.A. (2017). Emerging Concepts in the Resolution of Periodontal Inflammation: A Role for Resolvin E1. *Front Immunol* 8.
- Barczyk, M., Bolstad, A.I., and Gullberg, D. (2013). Role of integrins in the periodontal ligament: organizers and facilitators. *Periodontol* 2000 63, 29–47.
- Barros, S.P., Williams, R., Offenbacher, S., and Morelli, T. (2016). Gingival crevicular fluid as a source of biomarkers for periodontitis. *Periodontol.* 2000 70, 53–64.
- Bartold, P.M., and Van Dyke, T.E. (2013). Periodontitis: a host-mediated disruption of microbial homeostasis. Unlearning learned concepts. *Periodontol.* 2000 62, 203–217.
- Bartold, P.M., Gronthos, S., Ivanovski, S., Fisher, A., and Hutmacher, D.W. (2016). Tissue engineered periodontal products. *J. Periodont. Res.* 51, 1–15.
- Bassir, S.H., Wisitrasameewong, W., Raanan, J., Ghaffarigarakani, S., Chung, J., Freire, M., Andrada, L.C., and Intini, G. (2016). Potential for Stem Cell-Based Periodontal Therapy. *J. Cell. Physiol* 231, 50–61.
- Batool, F., Strub, M., Petit, C., Bugueno, I.M., Bornert, F., Clauss, F., Huck, O., Kuchler-Bopp, S., and Benkirane-Jessel, N. (2018). Periodontal Tissues, Maxillary Jaw Bone, and Tooth Regeneration Approaches: From Animal Models Analyses to Clinical Applications. *Nanomaterials* 8, 337.
- Benakanakere, M., and Kinane, D.F. (2012). Innate cellular responses to the periodontal biofilm. *Front Oral Biol* 15, 41–55.
- Bertl, K., Parllaku, A., Pandis, N., Buhlin, K., Klinge, B., and Stavropoulos, A. (2017). The effect of local and systemic statin use as an adjunct to non-surgical and surgical periodontal therapy—A systematic review and meta-analysis. *J Dent* 67, 18–28.
- Bhavsar, A.K., Parween, S., Karthikeyan, B.V., and Prabhuji, M.L.V. (2018). Critical Issues in Periodontal Regeneration - A Review. *J Oral Health Dent* 2, 204.
- Bode, C., Kranz, H., Siepmann, F., and Siepmann, J. (2018). In-situ forming PLGA implants for intraocular dexamethasone delivery. *Int J Pharm* 548, 337–348.
- Bosshardt, D.D. (2018). The periodontal pocket: pathogenesis, histopathology and consequences. *Periodontol.* 2000 76, 43–50.
- Bosshardt, D.D., and Lang, N.P. (2005). The junctional epithelium: from health to disease. *J. Dent. Res* 84, 9–20.
- Bosshardt, D.D., and Sculean, A. (2009). Does periodontal tissue regeneration really work? *Periodontol.* 2000 51, 208–219.
- Bostanci, N., Thurnheer, T., Aduse-Opoku, J., Curtis, M.A., Zinkernagel, A.S., and Belibasakis, G.N. (2013). Porphyromonas gingivalis regulates TREM-1 in human polymorphonuclear neutrophils via its gingipains. *PLoS One* 8, e75784.
- Bottino, M.C., and Thomas, V. (2015). Membranes for Periodontal Regeneration--A Materials Perspective. *Front Oral Biol* 17, 90–100.
- Bottino, M.C., Pankajakshan, D., and Nör, J.E. (2017). Advanced Scaffolds for Dental Pulp and Periodontal Regeneration. *Dent Clin North Am* 61, 689–711.
- Bourgeois, D., Bouchard, P., and Mattout, C. (2007). Epidemiology of periodontal status in dentate adults in France, 2002-2003. *J. Periodont. Res.* 42, 219–227.
- Bozkurt, F.Y., Yetkin Ay, Z., Berker, E., Tepe, E., and Akkuş, S. (2006). Anti-inflammatory cytokines in gingival crevicular fluid in patients with periodontitis and rheumatoid arthritis: a preliminary report. *Cytokine* 35, 180–185.
- Bozkurt, S.B., Hakki, S.S., Hakki, E.E., Durak, Y., and Kantarci, A. (2017). Porphyromonas gingivalis Lipopolysaccharide Induces a Pro-inflammatory Human Gingival Fibroblast Phenotype. *Inflammation* 40, 144–153.



- Bradley, A.D., Zhang, Y., Jia, Z., Zhao, G., Wang, X., Pranke, L., Schmid, M.J., Wang, D., and Reinhardt, R.A. (2016). Effect of Simvastatin Prodrug on Experimental Periodontitis. *J. Periodontol.* 87, 577–582.
- Brancato, S.K., and Albina, J.E. (2011). Wound macrophages as key regulators of repair: origin, phenotype, and function. *Am. J. Pathol.* 178, 19–25.
- Bresaola, M.D., Matsumoto, M.A., Zahoui, A., Biguetti, C.C., and Nary-Filho, H. (2017). Influence of rapid- and slow-rate resorption collagen membrane in maxillary sinus augmentation. *Clin Oral Implants Res* 28, 320–326.
- Bugueno, I.M., Batool, F., Korah, L., Benkirane-Jessel, N., and Huck, O. (2017). Porphyromonas gingivalis differentially modulates apoptosome APAF-1 in epithelial cells and fibroblasts. *Am. J. Pathol* 188,404-416.
- Bugueno, I.M., Batool, F., Keller, L., Kuchler-Bopp, S., Benkirane-Jessel, N., and Huck, O. (2018). Porphyromonas gingivalis bypasses epithelial barrier and modulates fibroblastic inflammatory response in an in vitro 3D spheroid model. *Scientific Reports* 8, 14914.
- Byrne, S.J., Dashper, S.G., Darby, I.B., Adams, G.G., Hoffmann, B., and Reynolds, E.C. (2009). Progression of chronic periodontitis can be predicted by the levels of Porphyromonas gingivalis and Treponema denticola in subgingival plaque. *Oral Microbiol. Immunol* 24, 469–477.
- Cantón, I., Mckean, R., Charnley, M., Blackwood, K.A., Fiorica, C., Ryan, A.J., and MacNeil, S. (2010). Development of an Ibuprofen-releasing biodegradable PLA/PGA electrospun scaffold for tissue regeneration. *Biotechnol. Bioeng* 105, 396–408.
- Casanova, L., Hughes, F.J., and Preshaw, P.M. (2014). Diabetes and periodontal disease: a two-way relationship. *Br Dent J* 217, 433–437.
- Caton, J.G., Armitage, G., Berglundh, T., Chapple, I.L.C., Jepsen, S., S Kornman, K., L Mealey, B., Papapanou, P.N., Sanz, M., and Tonetti, M.S. (2018). A new classification scheme for periodontal and peri-implant diseases and conditions - Introduction and key changes from the 1999 classification. *J. Clin. Periodontol* 45 Suppl 20, S1–S8.
- Cavagni, J., Muniz, F.W.M.G., Rösing, C.K., Cavagni, J., Muniz, F.W.M.G., and Rösing, C.K. (2016). The effect of inflammatory response modulator agents on gingivitis and periodontitis. *Revista Gaúcha de Odontologia* 64, 312–319.
- Cekici, A., Kantarci, A., Hasturk, H., and Van Dyke, T.E. (2014). Inflammatory and immune pathways in the pathogenesis of periodontal disease. *Periodontol* 2000 64, 57–80.
- Cetinkaya, B., Guzeldemir, E., Ogus, E., and Bulut, S. (2013). Proinflammatory and anti-inflammatory cytokines in gingival crevicular fluid and serum of patients with rheumatoid arthritis and patients with chronic periodontitis. *J. Periodontol* 84, 84–93.
- Chapple, I.L.C., Genco, R., and working group 2 of the joint EFP/AAP workshop (2013). Diabetes and periodontal diseases: consensus report of the Joint EFP/AAP Workshop on Periodontitis and Systemic Diseases. *J. Periodontol* 84, S106-112.
- Chapple, I.L.C., Mealey, B.L., Dyke, T.E.V., Bartold, P.M., Dommisch, H., Eickholz, P., Geisinger, M.L., Genco, R.J., Glogauer, M., Goldstein, M., et al. (2018). Periodontal health and gingival diseases and conditions on an intact and a reduced periodontium: Consensus report of workgroup 1 of the 2017 World Workshop on the Classification of Periodontal and Peri-Implant Diseases and Conditions. *J Clin Periodontol* 45, S68–S77.
- Chen, F.-M., and Jin, Y. (2010). Periodontal tissue engineering and regeneration: current approaches and expanding opportunities. *Tissue Eng Part B Rev* 16, 219–255.
- Chen, B., Wu, W., Sun, W., Zhang, Q., Yan, F., and Xiao, Y. (2014). RANKL Expression in Periodontal Disease: Where Does RANKL Come from? *Biomed Res Int* 2014:731039.

- Chen, F.-M., Zhang, J., Zhang, M., An, Y., Chen, F., and Wu, Z.-F. (2010). A review on endogenous regenerative technology in periodontal regenerative medicine. *Biomaterials* 31, 7892–7927.
- Chen, F.-M., Gao, L.-N., Tian, B.-M., Zhang, X.-Y., Zhang, Y.-J., Dong, G.-Y., Lu, H., Chu, Q., Xu, J., Yu, Y., et al. (2016). Treatment of periodontal intrabony defects using autologous periodontal ligament stem cells: a randomized clinical trial. *Stem Cell Res Ther* 7:33.
- Chien, K.-H., Chang, Y.-L., Wang, M.-L., Chuang, J.-H., Yang, Y.-C., Tai, M.-C., Wang, C.-Y., Liu, Y.-Y., Li, H.-Y., Chen, J.-T., et al. (2018). Promoting Induced Pluripotent Stem Cell-driven Biomineralization and Periodontal Regeneration in Rats with Maxillary-Molar Defects using Injectable BMP-6 Hydrogel. *Sci Rep* 8, 114.
- Cho, M.I., and Garant, P.R. (2000). Development and general structure of the periodontium. *Periodontol.* 2000 24, 9–27.
- Cho, Y.-D., Kim, K.-H., Ryoo, H.-M., Lee, Y.-M., Ku, Y., and Seol, Y.-J. (2019). Recent Advances of Useful Cell Sources in the Periodontal Regeneration. *Curr Stem Cell Res Ther* 14, 3–8.
- Choi, J.-Y., Jung, U.-W., Kim, C.-S., Eom, T.-K., Kang, E.-J., Cho, K.-S., Kim, C.-K., and Choi, S.-H. (2010). The effects of newly formed synthetic peptide on bone regeneration in rat calvarial defects. *J Periodontal Implant Sci* 40, 11–18.
- Cobb, C.M. (2002). Clinical significance of non-surgical periodontal therapy: an evidence-based perspective of scaling and root planing. *J. Clin. Periodontol.* 29 Suppl 2, 6–16.
- Cortellini, P., Buti, J., Pini Prato, G., and Tonetti, M.S. (2017). Periodontal regeneration compared with access flap surgery in human intra-bony defects 20-year follow-up of a randomized clinical trial: tooth retention, periodontitis recurrence and costs. *J Clin Periodontol* 44, 58–66.
- Darveau, R.P. (2010). Periodontitis: a polymicrobial disruption of host homeostasis. *Nat. Rev. Microbiol* 8, 481–490.
- Deas, D.E., Moritz, A.J., Sagun, R.S., Gruwell, S.F., and Powell, C.A. (2016). Scaling and root planing vs. conservative surgery in the treatment of chronic periodontitis. *Periodontol.* 2000 71, 128–139.
- Delima, A.J., Oates, T., Assuma, R., Schwartz, Z., Cochran, D., Amar, S., and Graves, D.T. (2001). Soluble antagonists to interleukin-1 (IL-1) and tumor necrosis factor (TNF) inhibits loss of tissue attachment in experimental periodontitis. *J. Clin. Periodontol* 28, 233–240.
- Deschamps-Lenhardt, S., Martin-Cabezas, R., Hannedouche, T., and Huck, O. (2019). Association between periodontitis and chronic kidney disease: Systematic review and meta-analysis. *Oral Dis* 25, 385–402.
- Di Turi, G., Riggio, C., Vittorio, O., Marconcini, S., Briguglio, F., Funel, N., Campani, D., Barone, A., Raffa, V., and Covani, U. (2012). Sub-micrometric liposomes as drug delivery systems in the treatment of periodontitis. *Int J Immunopathol Pharmacol* 25, 657–670.
- Diegelmann, R.F., and Evans, M.C. (2004). Wound healing: an overview of acute, fibrotic and delayed healing. *Front. Biosci* 9, 283–289.
- Divaris, K., Monda, K.L., North, K.E., Olshan, A.F., Reynolds, L.M., Hsueh, W.-C., Lange, E.M., Moss, K., Barros, S.P., Weyant, R.J., et al. (2013). Exploring the genetic basis of chronic periodontitis: a genome-wide association study. *Hum. Mol. Genet* 22, 2312–2324.
- Do, M.P., Neut, C., Delcourt, E., Seixas Certo, T., Siepmann, J., and Siepmann, F. (2014). In situ forming implants for periodontitis treatment with improved adhesive properties. *Eur J Pharm Biopharm* 88, 342–350.

- Do, M.P., Neut, C., Metz, H., Delcourt, E., Mäder, K., Siepmann, J., and Siepmann, F. (2015a). In-situ forming composite implants for periodontitis treatment: How the formulation determines system performance. *Int J Pharm* 486, 38–51.
- Do, M.P., Neut, C., Metz, H., Delcourt, E., Siepmann, J., Mäder, K., and Siepmann, F. (2015b). Mechanistic analysis of PLGA/HPMC-based in-situ forming implants for periodontitis treatment. *Eur J Pharm Biopharm* 94, 273–283.
- Drisko, C.H. (2001). Nonsurgical periodontal therapy. *Periodontol.* 2000 25, 77–88.
- Du, J., Shan, Z., Ma, P., Wang, S., and Fan, Z. (2014). Allogeneic bone marrow mesenchymal stem cell transplantation for periodontal regeneration. *J. Dent. Res* 93, 183–188.
- Du, M., Duan, X., and Yang, P. (2015). Induced Pluripotent Stem Cells and Periodontal Regeneration. *Curr Oral Health Rep* 2, 257–265.
- Dye, B.A. (2012). Global periodontal disease epidemiology. *Periodontology* 2000 58, 10–25.
- Eap, S., Ferrand, A., Palomares, C.M., Hébraud, A., Stoltz, J.-F., Mainard, D., Schlatter, G., and Benkirane-Jessel, N. (2012). Electrospun nanofibrous 3D scaffold for bone tissue engineering. *Biomed Mater Eng* 22, 137–141.
- Eke, P.I., Dye, B.A., Wei, L., Thornton-Evans, G.O., Genco, R.J., and CDC Periodontal Disease Surveillance workgroup (2012). Prevalence of periodontitis in adults in the United States: 2009 and 2010. *J. Dent. Res* 91, 914–920.
- Elkaïm, R., Dahan, M., Kocgozlu, L., Werner, S., Kanter, D., Kretz, J.G., and Tenenbaum, H. (2008). Prevalence of periodontal pathogens in subgingival lesions, atherosclerotic plaques and healthy blood vessels: a preliminary study. *J. Periodont. Res* 43, 224–231.
- Emani, S., Gunjiganur, G.V., and Mehta, D.S. (2014). Determination of the antibacterial activity of simvastatin against periodontal pathogens, *Porphyromonas gingivalis* and *Aggregatibacter actinomycetemcomitans*: An in vitro study. *Contemp Clin Dent* 5, 377–382.
- Eskan, M.A., Jotwani, R., Abe, T., Chmelar, J., Lim, J.-H., Liang, S., Ciero, P.A., Krauss, J.L., Li, F., Rauner, M., et al. (2012). The leukocyte integrin antagonist Del-1 inhibits IL-17-mediated inflammatory bone loss. *Nat. Immunol* 13, 465–473.
- Estanislau, I.M.G., Terceiro, I.R.C., Lisboa, M.R.P., Teles, P. de B., Carvalho, R. de S., Martins, R.S., and Moreira, M.M.S.M. (2015). Pleiotropic effects of statins on the treatment of chronic periodontitis--a systematic review. *Br J Clin Pharmacol* 79, 877–885.
- Farooq, A., Yar, M., Khan, A.S., Shahzadi, L., Siddiqi, S.A., Mahmood, N., Rauf, A., Qureshi, Z.-A., Manzoor, F., Chaudhry, A.A., et al. (2015). Synthesis of piroxicam loaded novel electrospun biodegradable nanocomposite scaffolds for periodontal regeneration. *Mater Sci Eng C Mater Biol Appl* 56, 104–113.
- Fentoğlu, O., Kirzioğlu, F.Y., Ozdem, M., Koçak, H., Sütçü, R., and Sert, T. (2012). Proinflammatory cytokine levels in hyperlipidemic patients with periodontitis after periodontal treatment. *Oral Dis* 18, 299–306.
- Ferrand, A., Eap, S., Richert, L., Lemoine, S., Kalaskar, D., Demoustier-Champagne, S., Atmani, H., Mély, Y., Fioretti, F., Schlatter, G., et al. (2014). Osteogenetic properties of electrospun nanofibrous PCL scaffolds equipped with chitosan-based nanoreservoirs of growth factors. *Macromol Biosci* 14, 45–55.
- Fickl, S., Thalmeier, T., Keschull, M., Böhm, S., and Wachtel, H. (2009). Microsurgical access flap in conjunction with enamel matrix derivative for the treatment of intra-bony defects: a controlled clinical trial. *J. Clin. Periodontol* 36, 784–790.
- Frencken, J.E., Sharma, P., Stenhouse, L., Green, D., Laverty, D., and Dietrich, T. (2017). Global epidemiology of dental caries and severe periodontitis – a comprehensive review. *J. Clin. Periodontol* 44, S94–S105.

- Fu, X., Jin, L., Ma, P., Fan, Z., and Wang, S. (2014). Allogeneic stem cells from deciduous teeth in treatment for periodontitis in miniature swine. *J. Periodontol.* 85, 845–851.
- Fujimori, K., Yoneda, T., Tomofuji, T., Ekuni, D., Azuma, T., Maruyama, T., Mizuno, H., Sugiura, Y., and Morita, M. (2019). Detection of Salivary miRNAs Reflecting Chronic Periodontitis: A Pilot Study. *Molecules* 24.
- Fujishiro, N., Anan, H., Hamachi, T., and Maeda, K. (2008). The role of macrophages in the periodontal regeneration using Emdogain gel. *J. Periodont. Res* 43, 143–155.
- Galler, K.M., Hartgerink, J.D., Cavender, A.C., Schmalz, G., and D’Souza, R.N. (2012). A customized self-assembling peptide hydrogel for dental pulp tissue engineering. *Tissue Eng Part A* 18, 176–184.
- Ganji, F., Abdekhodaie, M.J., and S.a, A.R. (2007). Gelation time and degradation rate of chitosan-based injectable hydrogel. *J Sol-Gel Sci Technol* 42, 47–53.
- Ganta, S., Deshpande, D., Korde, A., and Amiji, M. (2010). A review of multifunctional nanoemulsion systems to overcome oral and CNS drug delivery barriers. *Mol. Membr. Biol* 27, 260–273.
- Ganta, S., Talekar, M., Singh, A., Coleman, T.P., and Amiji, M.M. (2014). Nanoemulsions in translational research-opportunities and challenges in targeted cancer therapy. *AAPS PharmSciTech* 15, 694–708.
- Gemmell, E., and Seymour, G.J. (2004). Immunoregulatory control of Th1/Th2 cytokine profiles in periodontal disease. *Periodontol.* 2000 35, 21–41.
- Goes, P., Lima, N.A., Rodrigues, J.A.G., Benevides, N.M.B., Brito, G.A.C., Lima, V., Goes, P., Lima, N.A., Rodrigues, J.A.G., Benevides, N.M.B., et al. (2016). Anti-inflammatory and Anti-resorptive Effects of Atorvastatin on Alveolar Bone Loss in Wistar Rats. *Braz Dent J* 27, 267–272.
- Goodson, J.M. (1986). Clinical measurements of periodontitis. *J. Clin. Periodontol.* 13, 446–460.
- Goodson, J.M., Haffajee, A.D., Socransky, S.S., Kent, R., Teles, R., Hasturk, H., Bogren, A., Van Dyke, T., Wennstrom, J., and Lindhe, J. (2012). Control of periodontal infections: a randomized controlled trial I. The primary outcome attachment gain and pocket depth reduction at treated sites. *J. Clin. Periodontol* 39, 526–536.
- Goudouri, O.-M., Kontonasaki, E., and Boccaccini, A.R. (2017). 17 - Layered scaffolds for periodontal regeneration. *Biomaterials for Oral and Dental Tissue Engineering* 279–295.
- Graves, D. (2008). Cytokines that promote periodontal tissue destruction. *J. Periodontol* 79, 1585–1591.
- Graves, D.T., Nooh, N., Gillen, T., Davey, M., Patel, S., Cottrell, D., and Amar, S. (2001). IL-1 plays a critical role in oral, but not dermal, wound healing. *J. Immunol* 167, 5316–5320.
- Graziani, F., Karapetsa, D., Alonso, B., and Herrera, D. (2017). Nonsurgical and surgical treatment of periodontitis: how many options for one disease? *Periodontol.* 2000 75, 152–188.
- Grover, H.S., Kapoor, S., and Singh, A. (2016). Effect of topical simvastatin (1.2 mg) on gingival crevicular fluid interleukin-6, interleukin-8 and interleukin-10 levels in chronic periodontitis – A clinicobiochemical study. *J Oral Biol Craniofac Res* 6, 85–92.
- Gupte, M.J., and Ma, P.X. (2012). Nanofibrous Scaffolds for Dental and Craniofacial Applications. *J Dent Res* 91, 227–234.
- Gurtner, G.C., Werner, S., Barrandon, Y., and Longaker, M.T. (2008). Wound repair and regeneration. *Nature* 453, 314–321.

- Hackam, D.J., and Ford, H.R. (2002). Cellular, biochemical, and clinical aspects of wound healing. *Surg Infect 3 Suppl 1*, S23-35.
- Hajishengallis, G. (2014). Immunomicrobial pathogenesis of periodontitis: keystones, pathobionts, and host response. *Trends Immunol 35*, 3–11.
- Hajishengallis, G. (2015). Periodontitis: from microbial immune subversion to systemic inflammation. *Nature Reviews Immunology 15*, 30.
- Hajishengallis, G., and Korostoff, J.M. (2017). Revisiting the Page & Schroeder model: the good, the bad and the unknowns in the periodontal host response 40 years later. *Periodontol. 2000 75*, 116–151.
- Hajishengallis, G., and Lamont, R.J. (2012). Beyond the red complex and into more complexity: the polymicrobial synergy and dysbiosis (PSD) model of periodontal disease etiology. *Mol Oral Microbiol 27*, 409–419.
- Hajishengallis, G., Maekawa, T., Abe, T., Hajishengallis, E., and Lambris, J.D. (2015). Complement involvement in periodontitis: molecular mechanisms and rational therapeutic approaches. *Adv Exp Med Biol 865*, 57–74.
- Hämmerle, C.H.F., Giannobile, W.V., and Working Group 1 of the European Workshop on Periodontology (2014). Biology of soft tissue wound healing and regeneration--consensus report of Group 1 of the 10th European Workshop on Periodontology. *J. Clin. Periodontol. 41 Suppl 15*, S1-5.
- Harmouche, L., Courval, A., Mathieu, A., Petit, C., Huck, O., Severac, F., and Davideau, J.-L. (2019). Impact of tooth-related factors on photodynamic therapy effectiveness during active periodontal therapy: A 6-months split-mouth randomized clinical trial. *Photodiag Photodyn Ther 27*, 167–172.
- Hassan, B., Fouilloux, I., Baroukh, B., Llorens, A., Biosse Duplan, M., Gosset, M., Cherruau, M., and Saffar, J.-L. (2017). Coordination of early cellular reactions during activation of bone resorption in the rat mandible periosteum: An immunohistochemical study. *Heliyon 3*, e00430.
- Heitz-Mayfield, L.J.A., and Lang, N.P. (2013). Surgical and nonsurgical periodontal therapy. Learned and unlearned concepts. *Periodontol. 2000 62*, 218–231.
- Heo, S.C., Jeon, E.S., Lee, I.H., Kim, H.S., Kim, M.B., and Kim, J.H. (2011). Tumor necrosis factor- $\alpha$ -activated human adipose tissue-derived mesenchymal stem cells accelerate cutaneous wound healing through paracrine mechanisms. *J. Invest. Dermatol 131*, 1559–1567.
- Herrera, D., Matesanz, P., Bascones-Martínez, A., and Sanz, M. (2012). Local and systemic antimicrobial therapy in periodontics. *J Evid Based Dent Pract 12*, 50–60.
- Holt, S.C., Ebersole, J., Felton, J., Brunsvold, M., and Kornman, K.S. (1988). Implantation of *Bacteroides gingivalis* in nonhuman primates initiates progression of periodontitis. *Science 239*, 55–57.
- Hoornaert, A., d'Arros, C., Heymann, M.-F., and Layrolle, P. (2016). Biocompatibility, resorption and biofunctionality of a new synthetic biodegradable membrane for guided bone regeneration. *Biomed Mater 11*, 045012.
- Huck, O., Tenenbaum, H., and Davideau, J.-L. (2011). Relationship between periodontal diseases and preterm birth: recent epidemiological and biological data. *J Pregnancy 2011*, 164654.
- Huck, O., Elkaim, R., Davideau, J.-L., and Tenenbaum, H. (2015). Porphyromonas gingivalis-impaired innate immune response via NLRP3 proteolysis in endothelial cells. *Innate Immun 21*, 65–72.
- Huck, O., Al-Hashemi, J., Poidevin, L., Poch, O., Davideau, J.-L., Tenenbaum, H., and Amar, S. (2017). Identification and Characterization of MicroRNA Differentially Expressed in Macrophages Exposed to Porphyromonas gingivalis Infection. *Infect. Immun 85*.

- Huck, O., You, J., Han, X., Cai, B., Panek, J., and Amar, S. (2018). Reduction of Articular and Systemic Inflammation by Kava-241 in a *Porphyromonas gingivalis*-Induced Arthritis Murine Model. *Inf Immun* 86, e00356-18.
- Ioannidou, E., Hall, Y., Swede, H., and Himmelfarb, J. (2013). Periodontitis associated with chronic kidney disease among Mexican Americans. *J Public Health Dent* 73, 112–119.
- Ivanovski, S. (2009). Periodontal regeneration. *Aust Dent J* 54 Suppl 1, S118-128.
- Ivanovski, S., Vaquette, C., Gronthos, S., Hutmacher, D.W., and Bartold, P.M. (2014). Multiphasic scaffolds for periodontal tissue engineering. *J. Dent. Res* 93, 1212–1221.
- Jakhu, H., Gill, G., and Singh, A. (2018). Role of integrins in wound repair and its periodontal implications. *J Oral Biol Craniofac Res* 8, 122–125.
- Jin, L.J., Lamster, I.B., Greenspan, J.S., Pitts, N.B., Scully, C., and Warnakulasuriya, S. (2016). Global burden of oral diseases: emerging concepts, management and interplay with systemic health. *Oral Dis* 22, 609–619.
- Joshi, D., Garg, T., Goyal, A.K., and Rath, G. (2016). Advanced drug delivery approaches against periodontitis. *Drug Deliv* 23, 363–377.
- Kagami, S., Owada, T., Kanari, H., Saito, Y., Suto, A., Ikeda, K., Hirose, K., Watanabe, N., Iwamoto, I., and Nakajima, H. (2009). Protein geranylgeranylation regulates the balance between Th17 cells and Foxp3<sup>+</sup> regulatory T cells. *Int. Immunol* 21, 679–689.
- Kantarci, A., and Van Dyke, T.E. (2005). Resolution of Inflammation in Periodontitis. *J. Periodontol* 76, 2168–2174.
- Kantarci, A., Hasturk, H., and Van Dyke, T.E. (2015). Animal models for periodontal regeneration and peri-implant responses. *Periodontol* 2000 68, 66–82.
- Kasaj, A., Reichert, C., Götz, H., Röhrig, B., Smeets, R., and Willershausen, B. (2008). In vitro evaluation of various bioabsorbable and nonresorbable barrier membranes for guided tissue regeneration. *Head Face Med* 4, 22.
- Kassebaum, N.J., Bernabé, E., Dahiya, M., Bhandari, B., Murray, C.J.L., and Marcenes, W. (2014). Global burden of severe periodontitis in 1990-2010: a systematic review and meta-regression. *J. Dent. Res* 93, 1045–1053.
- Katancik, J.A., Kumarswamy, A., Branch-Mays, G., and Califano, J.V. (2016). 11 - Infections of the Periodontal Apparatus. *Head, Neck, and Orofacial Infections* 189–202.
- Katz, J., Bhattacharyya, I., Farkhondeh-Kish, F., Perez, F.M., Caudle, R.M., and Heft, M.W. (2005). Expression of the receptor of advanced glycation end products in gingival tissues of type 2 diabetes patients with chronic periodontal disease: a study utilizing immunohistochemistry and RT-PCR. *J. Clin. Periodontol* 32, 40–44.
- Kaur, A., Gupta, S., Tyagi, A., Sharma, R.K., Ali, J., Gabrani, R., and Dang, S. (2017). Development of Nanoemulsion Based Gel Loaded with Phytoconstituents for the Treatment of Urinary Tract Infection and in Vivo Biodistribution Studies. *Advanced Pharmaceutical Bulletin* 7, 611.
- Kempe, S., and Mäder, K. (2012). In situ forming implants — an attractive formulation principle for parenteral depot formulations. *J Controlled Release* 161, 668–679.
- Khodir, W.W.A., Guarino, V., Alvarez-Perez, M., Cafiero, C., and Ambrosio, L. (2013). Trapping tetracycline-loaded nanoparticles into polycaprolactone fiber networks for periodontal regeneration therapy. *J Bioact Compat Polymers* 28, 258–273.
- Kim, J.H., Jin, H.M., Kim, K., Song, I., Youn, B.U., Matsuo, K., and Kim, N. (2009). The mechanism of osteoclast differentiation induced by IL-1. *J. Immunol* 183, 1862–1870.
- Kim, Y.-G., Kim, M., Kang, J.H., Kim, H.J., Park, J.-W., Lee, J.-M., Suh, J.-Y., Kim, J.-Y., Lee, J.-H., and Lee, Y. (2016). Transcriptome sequencing of gingival biopsies from chronic periodontitis patients reveals novel gene expression and splicing patterns. *Hum. Genomics* 10, 28.



- Kinane, D.F., Stathopoulou, P.G., and Papapanou, P.N. (2017). Periodontal diseases. *Nature Reviews Disease Primers* 3, 17038.
- Kocgozlu, L., Elkaim, R., Tenenbaum, H., and Werner, S. (2009). Variable cell responses to *P. gingivalis* lipopolysaccharide. *J. Dent. Res* 88, 741–745.
- Kocher, T., Langenbeck, M., Rühling, A., and Plagmann, H.C. (2000). Subgingival polishing with a teflon-coated sonic scaler insert in comparison to conventional instruments as assessed on extracted teeth. (I) Residual deposits. *J. Clin. Periodontol* 27, 243–249.
- Kornman, K.S. (2008). Mapping the pathogenesis of periodontitis: a new look. *J. Periodontol* 79, 1560–1568.
- Kranz, H., and Bodmeier, R. (2008). Structure formation and characterization of injectable drug loaded biodegradable devices: In situ implants versus in situ microparticles. *European Journal of Pharmaceutical Sciences* 34, 164–172.
- Lalla, E., and Papapanou, P.N. (2011). Diabetes mellitus and periodontitis: a tale of two common interrelated diseases. *Nature Reviews Endocrinology* 7, 738–748.
- Lam, C.X.F., Savalani, M.M., Teoh, S.-H., and Hutmacher, D.W. (2008). Dynamics of in vitro polymer degradation of polycaprolactone-based scaffolds: accelerated versus simulated physiological conditions. *Biomed Mater* 3, 034108.
- Lamont, R.J., and Hajishengallis, G. (2015). Polymicrobial synergy and dysbiosis in inflammatory disease. *Trends Mol Med* 21, 172–183.
- Lang, N.P., and Bartold, P.M. (2018). Periodontal health. *J Periodontol* 89, S9–S16.
- Lapérine, O., Cloitre, A., Caillon, J., Huck, O., Bugueno, I.M., Pilet, P., Sourice, S., Tilly, E.L., Palmer, G., Davideau, J.-L., et al. (2016). Interleukin-33 and RANK-L Interplay in the Alveolar Bone Loss Associated to Periodontitis. *PLOS One* 11, e0168080.
- Larjava, H., Koivisto, L., Häkkinen, L., and Heino, J. (2011). Epithelial integrins with special reference to oral epithelia. *J. Dent. Res.* 90, 1367–1376.
- Larsson, L., Decker, A.M., Nibali, L., Pilipchuk, S.P., Berglundh, T., and Giannobile, W.V. (2016). Regenerative Medicine for Periodontal and Peri-implant Diseases. *J. Dent. Res.* 95, 255–266.
- Lea, S.C., Landini, G., and Walmsley, A.D. (2004). Thermal imaging of ultrasonic scaler tips during tooth instrumentation. *J. Clin. Periodonto.* 31, 370–375.
- Lee, B.-S., Lee, C.-C., Wang, Y.-P., Chen, H.-J., Lai, C.-H., Hsieh, W.-L., and Chen, Y.-W. (2016). Controlled-release of tetracycline and lovastatin by poly(d,l-lactide-co-glycolide acid)-chitosan nanoparticles enhances periodontal regeneration in dogs. *Int J Nanomedicine* 11, 285–297.
- Lemaitre, M., Monsarrat, P., Blasco-Baque, V., Loubières, P., Burcelin, R., Casteilla, L., Planat-Bénard, V., and Kémoun, P. (2017). Periodontal Tissue Regeneration Using Syngeneic Adipose-Derived Stromal Cells in a Mouse Model. *Stem Cells Transl Med* 6, 656–665.
- Liang, D., Hsiao, B.S., and Chu, B. (2007). Functional electrospun nanofibrous scaffolds for biomedical applications. *Adv. Drug Deliv. Rev* 59, 1392–1412.
- Linden, G.J., Lyons, A., and Scannapieco, F.A. (2013). Periodontal systemic associations: review of the evidence. *J. Clin. Periodontol* 40 Suppl 14, S8-19.
- Ling, L.-J., Hung, S.-L., Lee, C.-F., Chen, Y.-T., and Wu, K.-M. (2003). The influence of membrane exposure on the outcomes of guided tissue regeneration: clinical and microbiological aspects. *J. Periodont. Res* 38, 57–63.
- Loh, Q.L., and Choong, C. (2013). Three-Dimensional Scaffolds for Tissue Engineering Applications: Role of Porosity and Pore Size. *Tissue Eng Part B Rev* 19, 485–502.
- Lundmark, A., Gerasimcik, N., Båge, T., Jemt, A., Mollbrink, A., Salmén, F., Lundberg, J., and Yucel-Lindberg, T. (2018). Gene expression profiling of periodontitis-affected gingival tissue by spatial transcriptomics. *Sci Rep* 8, 9370.

- Madi, M., and Kassem, A. (2018). Topical simvastatin gel as a novel therapeutic modality for palatal donor site wound healing following free gingival graft procedure. *Acta Odontol. Scand* 76, 212–219.
- Marcenes, W., Kassebaum, N.J., Bernabé, E., Flaxman, A., Naghavi, M., Lopez, A., and Murray, C.J.L. (2013). Global burden of oral conditions in 1990-2010: a systematic analysis. *J. Dent. Res* 92, 592–597.
- Marchesan, J., Girnary, M.S., Jing, L., Miao, M.Z., Zhang, S., Sun, L., Morelli, T., Schoenfisch, M.H., Inohara, N., Offenbacher, S., et al. (2018). An experimental murine model to study periodontitis. *Nat Protoc* 13, 2247–2267.
- Mariotti, A. (2007). Periodontal Diseases. *XPharm*, 1–5.
- Martande, S.S., Kumari, M., Pradeep, A.R., Singh, S.P., Suke, D.K., and Guruprasad, C.N. (2016). Platelet-Rich Fibrin Combined With 1.2% Atorvastatin for Treatment of Intrabony Defects in Chronic Periodontitis: A Randomized Controlled Clinical Trial. *J. Periodontol* 87, 1039–1046.
- Martin, P., and Leibovich, S.J. (2005). Inflammatory cells during wound repair: the good, the bad and the ugly. *Trends Cell Biol* 15, 599–607.
- Martin-Cabezas, R., Davideau, J.-L., Tenenbaum, H., and Huck, O. (2016). Clinical efficacy of probiotics as an adjunctive therapy to non-surgical periodontal treatment of chronic periodontitis: a systematic review and meta-analysis. *J. Clin. Periodontol* 43, 520–530.
- Martínez-Ballesta, Mc., Gil-Izquierdo, Á., García-Viguera, C., and Domínguez-Perles, R. (2018). Nanoparticles and Controlled Delivery for Bioactive Compounds: Outlining Challenges for New “Smart-Foods” for Health. *Foods* 7, pii: E72.
- Maskrey, B.H., Megson, I.L., Whitfield, P.D., and Rossi, A.G. (2011). Mechanisms of resolution of inflammation: a focus on cardiovascular disease. *Arterioscler. Thromb. Vasc Biol.* 31, 1001–1006.
- Meek, I.L., van de Laar, M.A.F.J., and Vonkeman, H.E. (2010). Non-Steroidal Anti-Inflammatory Drugs: An Overview of Cardiovascular Risks. *Pharmaceuticals* 3, 2146–2162.
- Melcher, A.H. (1976). On the repair potential of periodontal tissues. *J. Periodontol* 47, 256–260.
- Miranda, T.S., Heluy, S.L., Cruz, D.F., da Silva, H.D.P., Feres, M., Figueiredo, L.C., and Duarte, P.M. (2019). The ratios of pro-inflammatory to anti-inflammatory cytokines in the serum of chronic periodontitis patients with and without type 2 diabetes and/or smoking habit. *Clin Oral Investig* 23, 641–650.
- Miranda, D.G., Malmonge, S.M., Campos, D.M., Attik, N.G., Grosogeat, P., and Gritsch, K., (2016). A chitosan-hyaluronic acid scaffold for periodontal tissue engineering. *J. Biomed. Mater Res. B. Appl. Biomater* 104, 1691–1702.
- Mombelli, A., Cionca, N., and Almaghouth, A. (2011). Does adjunctive antimicrobial therapy reduce the perceived need for periodontal surgery? *Periodontol.* 2000 55, 205–216.
- Morand, D.-N., Huck, O., Keller, L., Jessel, N., Tenenbaum, H., and Davideau, J.-L. (2015). Active Nanofibrous Membrane Effects on Gingival Cell Inflammatory Response. *Materials* 8, 7217–7229.
- Morand, D.N., Davideau, J.-L., Clauss, F., Jessel, N., Tenenbaum, H., and Huck, O. (2017). Cytokines during periodontal wound healing: potential application for new therapeutic approach. *Oral Dis* 23, 300–311.
- Muniz, F.W.M.G., Taminski, K., Cavagni, J., Celeste, R.K., Weidlich, P., and Rösing, C.K. (2018). The effect of statins on periodontal treatment-a systematic review with meta-analyses and meta-regression. *Clin Oral Investig* 22, 671–687.

- Murray, C.J.L., Vos, T., Lozano, R., Naghavi, M., Flaxman, A.D., Michaud, C., Ezzati, M., Shibuya, K., Salomon, J.A., Abdalla, S., et al. (2012). Disability-adjusted life years (DALYs) for 291 diseases and injuries in 21 regions, 1990-2010: a systematic analysis for the Global Burden of Disease Study 2010. *Lancet* 380, 2197–2223.
- Nagayasu-Tanaka, T., Anzai, J., Takaki, S., Shiraishi, N., Terashima, A., Asano, T., Nozaki, T., Kitamura, M., and Murakami, S. (2015). Action Mechanism of Fibroblast Growth Factor-2 (FGF-2) in the Promotion of Periodontal Regeneration in Beagle Dogs. *PLoS One* 10, e0131870.
- Nakamura, Y., Nomura, Y., Arai, C., Noda, K., Oikawa, T., Kogure, K., Kawamoto, T., and Hanada, N. (2007). Laser capture microdissection of rat periodontal ligament for gene analysis. *Biotech Histochem* 82, 295–300.
- Nemcovsky, C.E., and Beitlitum, I. (2018). Combination Therapy for Reconstructive Periodontal Treatment in the Lower Anterior Area: Clinical Evaluation of a Case Series. *Dent J* 6, pii: E50.
- Noh, M.K., Jung, M., Kim, S.H., Lee, S.R., Park, K.H., Kim, D.H., Kim, H.H., and Park, Y.G. (2013). Assessment of IL-6, IL-8 and TNF- $\alpha$  levels in the gingival tissue of patients with periodontitis. *Exp Ther Med* 6, 847–851.
- Norata, G.D., and Catapano, A.L. (2014). Statins and periodontal inflammation: a pleiotropic effect of statins or a pleiotropic effect of LDL-cholesterol lowering? *Atherosclerosis* 234, 381–382.
- Nunn, M.E., Fan, J., Su, X., Levine, R.A., Lee, H.-J., and McGuire, M.K. (2012). Development of prognostic indicators using classification and regression trees for survival. *Periodontol.* 2000 58, 134–142.
- Nyman, S., Lindhe, J., Karring, T., and Rylander, H. (1982). New attachment following surgical treatment of human periodontal disease. *J. Clin. Periodontol* 9, 290–296.
- Özdoğan, A.I., İlarıslan, Y.D., Kösemehmetođlu, K., Akca, G., Kutlu, H.B., Comerđov, E., Iskit, A.B., and řenel, S. (2018). In vivo evaluation of chitosan based local delivery systems for atorvastatin in treatment of periodontitis. *Int J Pharm* 550, 470–476.
- Papapanou, P.N., and Susin, C. (2017). Periodontitis epidemiology: is periodontitis under-recognized, over-diagnosed, or both? *Periodontol* 2000 75, 45–51.
- Papapanou, P.N., Sanz, M., Buduneli, N., Dietrich, T., Feres, M., Fine, D.H., Flemmig, T.F., Garcia, R., Giannobile, W.V., Graziani, F., et al. (2018). Periodontitis: Consensus report of workgroup 2 of the 2017 World Workshop on the Classification of Periodontal and Peri-Implant Diseases and Conditions. *J Clin Periodontol* 45, S162–S170.
- Park, S.-B., An, S.-Y., Han, W.-J., and Park, J.-T. (2017). Three-dimensional measurement of periodontal surface area for quantifying inflammatory burden. *J Periodontal Implant Sci* 47, 154–164.
- Patel, M.H., Kumar, J.V., and Moss, M.E. (2013). Diabetes and tooth loss: an analysis of data from the National Health and Nutrition Examination Survey, 2003-2004. *J Am Dent Assoc* 144, 478–485.
- Petersen, P.E., and Ogawa, H. (2012). The global burden of periodontal disease: towards integration with chronic disease prevention and control. *Periodontol.* 2000 60, 15–39.
- Petit, C., Schmeltz, S., Burgy, A., Tenenbaum, H., Huck, O., and Davideau, J.-L. (2019a). Risk factors associated with long-term outcomes after active and supporting periodontal treatments: impact of various compliance definitions on tooth loss. *Clin Oral Investig.*
- Petit, C., Batool, F., Bugueno, I.M., Schwinté, P., Benkirane-Jessel, N., and Huck, O. (2019b). Contribution of Statins towards Periodontal Treatment: A Review. *Mediators Inflamm* 2019:6367402.

- Pihlstrom, B.L., Michalowicz, B.S., and Johnson, N.W. (2005). Periodontal diseases. *Lancet* 366, 1809–1820.
- Polak, D., Martin, C., Sanz-Sánchez, I., Beyth, N., and Shapira, L. (2015). Are anti-inflammatory agents effective in treating gingivitis as solo or adjunct therapies? A systematic review. *J Clin Periodontol* 42, S139–S151.
- Poston, C.J., Pierce, T.C., Li, Y., Brinson, C.W., Lu, Z., Lauer, A.W., Leite, R.S., and Huang, Y. (2016). Statin intake is associated with MMP-1 level in gingival crevicular fluid of patients with periodontitis. *Oral Dis* 22, 438–444.
- Pradeep, A.R., and Thorat, M.S. (2010). Clinical effect of subgingivally delivered simvastatin in the treatment of patients with chronic periodontitis: a randomized clinical trial. *J. Periodontol* 81, 214–222.
- Pradeep, A.R., Karvekar, S., Nagpal, K., Patnaik, K., Guruprasad, C.N., and Kumaraswamy, K.M. (2015). Efficacy of locally delivered 1.2% rosuvastatin gel to non-surgical treatment of patients with chronic periodontitis: a randomized, placebo-controlled clinical trial. *J. Periodontol* 86, 738–745.
- Prateeksha, Barik, S.K., and Singh, B.N. (2019). Nanoemulsion-loaded hydrogel coatings for inhibition of bacterial virulence and biofilm formation on solid surfaces. *Sci Rep* 9, 6520.
- Preshaw, P.M., and Bissett, S.M. (2013). Periodontitis: oral complication of diabetes. *Endocrinol. Metab. Clin. North Am* 42, 849–867.
- Qu, Z., and Chaikof, E.L. (2010). Interface between hemostasis and adaptive immunity. *Curr Opin Immunol* 22, 634–642.
- Rai, B., Kaur, J., Anand, S.C., and Jacobs, R. (2011). Salivary stress markers, stress, and periodontitis: a pilot study. *J. Periodontol* 82, 287–292.
- Rams, T.E., Sautter, J.D., Hsiao, C.Y., and van Winkelhoff, A.J. (2018). Phenotypic identification of periodontal *Prevotella intermedia/nigrescens* group isolates validated by MALDI-TOF mass spectrometry. *Anaerobe* 54, 201–204.
- Rasperini, G., Pilipchuk, S.P., Flanagan, C.L., Park, C.H., Pagni, G., Hollister, S.J., and Giannobile, W.V. (2015). 3D-printed Bioresorbable Scaffold for Periodontal Repair. *J Dent Res* 94, 153S–157S.
- Reneker, D.H., and Yarin, A.L. (2008). Electrospinning jets and polymer nanofibers. *Polymer* 49, 2387–2425.
- Reners, M., and Brex, M. (2007). Stress and periodontal disease. *Int J Dent Hyg* 5, 199–204.
- Reynolds, M.A., Aichelmann-Reidy, M.E., Branch-Mays, G.L., and Gunsolley, J.C. (2003). The efficacy of bone replacement grafts in the treatment of periodontal osseous defects. A systematic review. *Ann. Periodontol* 8, 227–265.
- Robson, M.C. (2003). Cytokine manipulation of the wound. *Clin Plast Surg* 30, 57–65.
- Rosin, M., Kähler, S.T., Hessler, M., Schwahn, C., Kuhr, A., and Kocher, T. (2005). The effect of a dexibuprofen mouth rinse on experimental gingivitis in humans. *J. Clin. Periodontol* 32, 617–621.
- Rouzer, C.A., and Marnett, L.J. (2009). Cyclooxygenases: structural and functional insights. *J Lipid Res* 50, S29–S34.
- Rusu, D., Boariu, M., Stratul, Ștefan-I., Bojin, F., Paunescu, V., Calniceanu, H., Surlin, P., Roman, A., Milicescu, Ștefan, Caruntu, C., et al. (2019). Interaction between a 3D collagen matrix used for periodontal soft tissue regeneration and T-lymphocytes: An in vitro pilot study. *Exp Ther Med* 17, 990–996.
- Saadi-Thiers, K., Huck, O., Simonis, P., Tilly, P., Fabre, J.-E., Tenenbaum, H., and Davideau, J.-L. (2013). Periodontal and systemic responses in various mice models of experimental periodontitis: respective roles of inflammation duration and *Porphyromonas gingivalis* infection. *J. Periodontol* 84, 396–406.

- Sanz, M., D’Aiuto, F., Deanfield, J., and Fernandez-Avilés, F. (2010). European workshop in periodontal health and cardiovascular disease—scientific evidence on the association between periodontal and cardiovascular diseases: a review of the literature. *Eur Heart J Suppl* 12, B3–B12.
- Sanz, M., Dahlin, C., Apatzidou, D., Artzi, Z., Bozic, D., Calciolari, E., De Bruyn, H., Dommisch, H., Donos, N., Eickholz, P., et al. (2019). Biomaterials and regenerative technologies used in bone regeneration in the craniomaxillofacial region: Consensus report of group 2 of the 15th European Workshop on Periodontology on Bone Regeneration. *J. Clin. Periodontol* 46 Suppl 21, 82–91.
- Sarker, D.K. (2005). Engineering of nanoemulsions for drug delivery. *Curr Drug Deliv* 2, 297–310.
- Sarrazy, V., Billet, F., Micallef, L., Coulomb, B., and Desmoulière, A. (2011). Mechanisms of pathological scarring: role of myofibroblasts and current developments. *Wound Repair Regen* 19 Suppl 1, s10-15.
- Saxlin, T., Suominen-Taipale, L., Knuutila, M., Alha, P., and Ylöstalo, P. (2009). Dual effect of statin medication on the periodontium. *J. Clin. Periodontol* 36, 997–1003.
- Schmitz, J., Owyang, A., Oldham, E., Song, Y., Murphy, E., McClanahan, T.K., Zurawski, G., Moshrefi, M., Qin, J., Li, X., et al. (2005). IL-33, an Interleukin-1-like Cytokine that Signals via the IL-1 Receptor-Related Protein ST2 and Induces T Helper Type 2-Associated Cytokines. *Immunity* 23, 479–490.
- Schwinté, P., Mariotte, A., Anand, P., Keller, L., Idoux-Gillet, Y., Huck, O., Fioretti, F., Tenenbaum, H., Georgel, P., Wenzel, W., et al. (2017). Anti-inflammatory effect of active nanofibrous polymeric membrane bearing nanocontainers of atorvastatin complexes. *Nanomedicine* 12, 2651–2674.
- Sculean, A., Chiantella, G.C., Windisch, P., and Donos, N. (2000). Clinical and histologic evaluation of human intrabony defects treated with an enamel matrix protein derivative (Emdogain). *Int J Periodontics Restorative Dent* 20, 374–381.
- Sculean, A., Nikolidakis, D., and Schwarz, F. (2008). Regeneration of periodontal tissues: combinations of barrier membranes and grafting materials - biological foundation and preclinical evidence: a systematic review. *J. Clin. Periodontol* 35, 106–116.
- Sculean, A., Alessandri, R., Miron, R., Salvi, G.E., and Bosshardt, D.D. (2011). Enamel Matrix Proteins and Periodontal Wound Healing and Regeneration. *Clin Adv Periodontics* 1, 101–117.
- Serhan, C.N., and Chiang, N. (2008). Endogenous pro-resolving and anti-inflammatory lipid mediators: a new pharmacologic genus. *Br. J. Pharmacol* 153 Suppl 1, S200-215.
- Serino, G., Rosling, B., Ramberg, P., Socransky, S.S., and Lindhe, J. (2001). Initial outcome and long-term effect of surgical and non-surgical treatment of advanced periodontal disease. *J. Clin. Periodontol* 28, 910–916.
- Serrano, J., Escribano, M., Roldán, S., Martín, C., and Herrera, D. (2015). Efficacy of adjunctive anti-plaque chemical agents in managing gingivitis: a systematic review and meta-analysis. *J. Clin. Periodontol* 42 Suppl 16, S106-138.
- Sheshala, R., Quah, S.Y., Tan, G.C., Meka, V.S., Jnanendrapa, N., and Sahu, P.S. (2019). Investigation on solution-to-gel characteristic of thermosensitive and mucoadhesive biopolymers for the development of moxifloxacin-loaded sustained release periodontal in situ gels. *Drug Deliv Transl Res* 9, 434–443.
- Simões, A., Chen, L., Chen, Z., Zhao, Y., Gao, S., Marucha, P.T., Dai, Y., DiPietro, L.A., and Zhou, X. (2019). Differential microRNA profile underlies the divergent healing responses in skin and oral mucosal wounds. *Sci Rep* 9.

- Singh, S.P., Huck, O., Abraham, N.G., and Amar, S. (2018). Kavain Reduces Porphyromonas gingivalis–Induced Adipocyte Inflammation: Role of PGC-1 $\alpha$  Signaling. *J Immunol* 1;201(5):1491-1499.
- Socransky, S.S., and Haffajee, A.D. (2005). Periodontal microbial ecology. *Periodontol. 2000* 38, 135–187.
- Sorsa, T., Gursoy, U.K., Nwhator, S., Hernandez, M., Tervahartiala, T., Leppilahti, J., Gursoy, M., Könönen, E., Emingil, G., Pussinen, P.J., et al. (2016). Analysis of matrix metalloproteinases, especially MMP-8, in gingival crevicular fluid, mouthrinse and saliva for monitoring periodontal diseases. *Periodontol. 2000* 70, 142–163.
- Sousa, L.H., V M Linhares, E., Trycia Alexandre, J., Roberto Lisboa, M., Furlaneto, F., Freitas, R., Ribeiro, I., Val, D., Marques, M., Chaves, H., et al. (2016). Effects of Atorvastatin on Periodontitis of Rats Subjected to Glucocorticoid-induced Osteoporosis. *J. Periodontol* 87, 1206–1216.
- Spite, M., Clària, J., and Serhan, C.N. (2014). Resolvins, specialized proresolving lipid mediators, and their potential roles in metabolic diseases. *Cell Metab* 19, 21–36.
- Stoecklin-Wasmer, C., Guarnieri, P., Celenti, R., Demmer, R.T., Kebschull, M., and Papapanou, P.N. (2012). MicroRNAs and their target genes in gingival tissues. *J. Dent. Res* 91, 934–940.
- Su, J., Gu, J., Dong, Z., and Mei, B. (2013). Ibuprofen rescues abnormalities in periodontal tissues in conditional presenilin 1 and presenilin 2 double knockout mice. *Int J Mol Sci* 14, 18457–18469.
- Sugano, M., Negishi, Y., Endo-Takahashi, Y., Hamano, N., Usui, M., Suzuki, R., Maruyama, K., Aramaki, Y., and Yamamoto, M. (2014). Gene delivery to periodontal tissue using Bubble liposomes and ultrasound. *J. Periodont. Res.* 49, 398–404.
- Sundararaj, S.C., Thomas, M.V., Peyyala, R., Dziubla, T.D., and Puleo, D.A. (2013). Design of a Multiple Drug Delivery System Directed at Periodontitis. *Biomaterials* 34, 8835–8842.
- Susin, C., Fiorini, T., Lee, J., De Stefano, J.A., Dickinson, D.P., and Wikesjö, U.M.E. (2015). Wound healing following surgical and regenerative periodontal therapy. *Periodontol. 2000* 68, 83–98.
- Thomas, M.V., and Puleo, D.A. (2011). Infection, inflammation, and bone regeneration: a paradoxical relationship. *J. Dent. Res* 90, 1052–1061.
- Tomasi, C., Leyland, A.H., and Wennström, J.L. (2007). Factors influencing the outcome of non-surgical periodontal treatment: a multilevel approach. *J. Clin. Periodontol* 34, 682–690.
- Tomasi, C., Koutouzis, T., and Wennström, J.L. (2008). Locally delivered doxycycline as an adjunct to mechanical debridement at retreatment of periodontal pockets. *J. Periodontol* 79, 431–439.
- Tonetti, M.S., Cortellini, P., Lang, N.P., Suvan, J.E., Adriaens, P., Dubravec, D., Fonzar, A., Fourmoussis, I., Rasperini, G., Rossi, R., et al. (2004). Clinical outcomes following treatment of human intrabony defects with GTR/bone replacement material or access flap alone. A multicenter randomized controlled clinical trial. *J. Clin. Periodontol* 31, 770–776.
- Tonetti, M.S., Van Dyke, T.E., and working group 1 of the joint EFP/AAP workshop (2013). Periodontitis and atherosclerotic cardiovascular disease: consensus report of the Joint EFP/AAP Workshop on Periodontitis and Systemic Diseases. *J. Periodontol* 84, S24–29.
- Tonetti, M.S., Christiansen, A.L., and Cortellini, P. (2017a). Vertical subclassification predicts survival of molars with class II furcation involvement during supportive periodontal care. *J. Clin. Periodontol* 44, 1140–1144.



- Tonetti, M.S., Jepsen, S., Jin, L., and Otomo-Corgel, J. (2017b). Impact of the global burden of periodontal diseases on health, nutrition and wellbeing of mankind: A call for global action. *J. Clin. Periodontol* 44, 456–462.
- Trindade, F., Oppenheim, F.G., Helmerhorst, E.J., Amado, F., Gomes, P.S., and Vitorino, R. (2014). Uncovering the molecular networks in periodontitis. *Proteomics Clin Appl* 8, 748–761.
- Trofin, E.A., Monsarrat, P., and Kémoun, P. (2013). Cell therapy of periodontium: from animal to human? *Front Physiol* 4.
- Trombelli, L., Tatakis, D.N., Scapoli, C., Bottega, S., Orlandini, E., and Tosi, M. (2004). Modulation of clinical expression of plaque-induced gingivitis. II. Identification of “high-responder” and “low-responder” subjects. *J. Clin. Periodontol* 31, 239–252.
- Trombelli, L., Farina, R., Silva, C.O., and Tatakis, D.N. (2018). Plaque-induced gingivitis: Case definition and diagnostic considerations. *J. Clin. Periodontol* 45, S44–S67.
- Tunkel, J., Heinecke, A., and Flemmig, T.F. (2002). A systematic review of efficacy of machine-driven and manual subgingival debridement in the treatment of chronic periodontitis. *J. Clin. Periodontol* 29 Suppl 3, 72–81.
- Ueda, M., Fujisawa, T., Ono, M., Hara, E.S., Pham, H.T., Nakajima, R., Sonoyama, W., and Kuboki, T. (2014). A short-term treatment with tumor necrosis factor-alpha enhances stem cell phenotype of human dental pulp cells. *Stem Cell Res Ther* 5, 31.
- Van der Weijden, G.A., and Timmerman, M.F. (2002). A systematic review on the clinical efficacy of subgingival debridement in the treatment of chronic periodontitis. *J. Clin. Periodontol* 29 Suppl 3, 55–71.
- Van Dyke, T.E. (2008). The Management of Inflammation in Periodontal Disease. *J. Periodontol* 79, 1601–1608.
- Van Dyke, T.E. (2017). Pro-resolving Mediators in the Regulation of Periodontal Disease. *Mol Aspects Med* 58, 21–36.
- Vaquette, C., Fan, W., Xiao, Y., Hamlet, S., Huttmacher, D.W., and Ivanovski, S. (2012). A biphasic scaffold design combined with cell sheet technology for simultaneous regeneration of alveolar bone/periodontal ligament complex. *Biomaterials* 33, 5560–5573.
- Velnar, T., Bailey, T., and Smrkolj, V. (2009). The wound healing process: an overview of the cellular and molecular mechanisms. *J. Int. Med. Res* 37, 1528–1542.
- Venkataiah, V.S., Handa, K., Njuguna, M.M., Hasegawa, T., Maruyama, K., Nemoto, E., Yamada, S., Sugawara, S., Lu, L., Takedachi, M., et al. (2019). Periodontal Regeneration by Allogeneic Transplantation of Adipose Tissue Derived Multi-Lineage Progenitor Stem Cells in vivo. *Sci Rep* 9, 921.
- Wachtel, H., Schenk, G., Böhm, S., Weng, D., Zühr, O., and Hürzeler, M.B. (2003). Microsurgical access flap and enamel matrix derivative for the treatment of periodontal intrabony defects: a controlled clinical study. *J. Clin. Periodontol* 30, 496–504.
- Wang, H.-L., and Greenwell, H. (2001). Surgical periodontal therapy. *Periodontology* 2000 25, 89–99.
- Wang, H.-L., Greenwell, H., Fiorellini, J., Giannobile, W., Offenbacher, S., Salkin, L., Townsend, C., Sheridan, P., Genco, R.J., and Research, Science and Therapy Committee (2005). Periodontal regeneration. *J. Periodontol* 76, 1601–1622.
- Wang, Y., Li, H., Feng, Y., Jiang, P., Su, J., and Huang, C. (2019). Dual micelles-loaded gelatin nanofibers and their application in lipopolysaccharide-induced periodontal disease. *Int J Nanomedicine* 14, 963–976.

- Wang, Z., Wang, Z., Lu, W.W., Zhen, W., Yang, D., and Peng, S. (2017). Novel biomaterial strategies for controlled growth factor delivery for biomedical applications. *NPG Asia Materials* 9, e435.
- Wei, X., Zhang, X., Zuscik, M.J., Drissi, M.H., Schwarz, E.M., and O'Keefe, R.J. (2005). Fibroblasts express RANKL and support osteoclastogenesis in a COX-2-dependent manner after stimulation with titanium particles. *J. Bone Miner. Res* 20, 1136–1148.
- Werner, S., Krieg, T., and Smola, H. (2007). Keratinocyte-fibroblast interactions in wound healing. *J. Invest. Dermatol* 127, 998–1008.
- Yamada, M., Takahashi, N., Matsuda, Y., Sato, K., Yokoji, M., Sulijaya, B., Maekawa, T., Ushiki, T., Mikami, Y., Hayatsu, M., et al. (2018). A bacterial metabolite ameliorates periodontal pathogen-induced gingival epithelial barrier disruption via GPR40 signaling. *Sci Rep* 8, 9008.
- Yar, M., Farooq, A., Shahzadi, L., Khan, A.S., Mahmood, N., Rauf, A., Chaudhry, A.A., and Rehman, I.U. (2016). Novel meloxicam releasing electrospun polymer/ceramic reinforced biodegradable membranes for periodontal regeneration applications. *Mater Sci Eng C Mater Biol Appl* 64, 148–156.
- Yeh, H.-C., Lu, J.-J., Chang, S.-C., and Ge, M.-C. (2019). Identification of microbiota in peri-implantitis pockets by matrix-assisted laser desorption/ionization time-of-flight mass spectrometry. *Sci Rep* 9, 774.
- Yuan, H., Gupte, R., Zelkha, S., and Amar, S. (2011). Receptor activator of nuclear factor kappa B ligand antagonists inhibit tissue inflammation and bone loss in experimental periodontitis. *J. Clin. Periodontol* 38, 1029–1036.
- Zagai, U., Fredriksson, K., Rennard, S.I., Lundahl, J., and Sköld, C.M. (2003). Platelets stimulate fibroblast-mediated contraction of collagen gels. *Respir Res* 4, 13.
- Zhang, H., Liu, S., Zhou, Y., Tan, J., Che, H., Ning, F., Zhang, X., Xun, W., Huo, N., Tang, L., et al. (2012). Natural mineralized scaffolds promote the dentinogenic potential of dental pulp stem cells via the mitogen-activated protein kinase signaling pathway. *Tissue Eng Part A* 18, 677–691.
- Zhang, X., Schwarz, E.M., Young, D.A., Puzas, J.E., Rosier, R.N., and O'Keefe, R.J. (2002). Cyclooxygenase-2 regulates mesenchymal cell differentiation into the osteoblast lineage and is critically involved in bone repair. *J. Clin. Invest* 109, 1405–1415.
- Zhang, Y., Bradley, A.D., Wang, D., and Reinhardt, R.A. (2014). Statins, bone metabolism and treatment of bone catabolic diseases. *Pharmacological Research* 88, 53–61.

# APPENDIX

## List of Publications

- 1. Synthesis of a novel electrospun polycaprolactone scaffold functionalized with ibuprofen for periodontal regeneration: an *in vitro* and *in vivo* study**, *Materials*, 2018; doi: 10.3390/ma11040580  
**Fareeha Batool**, David-Nicolas Morand, Lionel Thomas, Isaac Maximiliano Bugueno, Javier Aragon, Silvia Irusta, Laetitia Keller, Nadia Benkirane-Jessel, Henri Tenenbaum, Olivier Huck
- 2. Periodontal tissues, maxillary jaw bone, and tooth regeneration approaches: from animal models analyses to clinical applications**, *Nanomaterials*, 2018; doi: 10.3390/nano8050337.  
**Fareeha Batool**, Marion Strub, Catherine Petit, Isaac Maximiliano Bugueno, Fabien Bornert, François Clauss, Olivier Huck, Sabine Kuchler-Bopp and Nadia Benkirane-Jessel
- 3. Contribution of statins towards periodontal treatment: a review**, *Mediators of inflammation*, 2019, <https://doi.org/10.1155/2019/6367402>  
Catherine Petit\*, **Fareeha Batool\***, Isaac Maximiliano Bugueno, Nadia Benkirane-Jessel, Olivier Huck  
\* Authors contributed equally to the work.
- 4. *In-situ* forming implants loaded with chlorhexidine and ibuprofen for periodontal treatment: proof of concept study *in vivo*** (Accepted by *International Journal of Pharmaceutics*; <https://doi.org/10.1016/j.ijpharm.2019.118564>)  
**Fareeha Batool**, Kevimy Agossa, Martin Lizambard, Nadia Benkirane-Jessel, Henri Tenenbaum, Jurgen Siepmann, Florence Siepmann, Olivier Huck
- 5. Porphyromonas gingivalis differentially modulates apoptosome apoptotic peptidase activating factor 1 in epithelial cells and fibroblasts**, *American Journal of Pathology*, 2018, doi: 10.1016/j.ajpath.2017.10.014  
Isaac Maximiliano Bugueno, **Fareeha Batool**, Lindah Korah, Nadia Benkirane-Jessel, Olivier Huck
- 6. Porphyromonas gingivalis bypasses epithelial barrier and modulates fibroblastic inflammatory response in an *in vitro* 3D spheroid model**, *Scientific Reports*, 2018, doi: 10.1038/s41598-018-33267-4  
Isaac Maximiliano Bugueno, **Fareeha Batool**, Laetitia Keller, Sabine Kuchler-Bopp, Nadia Benkirane-Jessel, Olivier Huck
- 7. Are sex steroid hormones influencing periodontal conditions: a systematic review**, *Current Oral Health Reports*, 2018, doi: 10.1007/s40496-018-0168  
Aliye Akcalı, Zeynep Akcalı, **Fareeha Batool**, Catherine Petit, Olivier Huck

## List of Communications

### 1. Poster presentation at CED-IADR, 2017, Vienna Austria- 1st prize

**Title:** *In vitro* and *in vivo* assessment of poly- $\epsilon$ -caprolactone membrane functionalized with ibuprofen on periodontal wound healing.

**Authors:** Fareeha Batool, David-Nicolas Morand, Lionel Thomas, Isaac Maximiliano Bugueno, Javier Aragon, Silvia Irusta, Laetitia Keller, Nadia Benkirane-Jessel, Henri Tenenbaum, Olivier Huck

### 2. Oral presentation of American Academy of Periodontology; 2017, Boston USA

**Title:** Development of 3D gingival microtissues.

**Authors:** Isaac Maximiliano Bugueno, Fareeha Batool, Laetitia Keller, Sabine Bopp-Kuchler, Nadia Benkirane-Jessel, Olivier Huck

### 3. Oral presentation at symposium Fédération de Médecine Translationnelle de Strasbourg (FMTS), 2017, Strasbourg France

**Title:** Modulation of inflammatory response in periodontal wound healing: Perspectives in periodontal regeneration

**Authors:** Fareeha Batool, Olivier Huck

### 4. Electronic-poster presentation at EuroPerio9, 2018, Amsterdam Netherlands

**Title:** Anti-inflammatory functionalized membrane for periodontal regeneration: *in vivo* evaluation in periodontitis-induced mouse model

**Authors:** Fareeha Batool, David-Nicolas Morand, Lionel Thomas, Isaac Maximiliano Bugueno, Javier Aragon, Silvia Irusta, Laetitia Keller, Nadia Benkirane-Jessel, Henri Tenenbaum, Olivier Huck

### 5. Electronic-poster presentation at EuroPerio9, 2018, Amsterdam, Netherlands

**Title:** A new 3D *in vitro* model of gingival tissue to assess host-pathogen interactions.

**Authors:** Isaac Maximiliano Bugueno, Fareeha Batool, Laetitia Keller, Sabine Bopp-Kuchler, Nadia Benkirane-Jessel, Olivier Huck

### 6. Poster presentation at IADR 2018, London, United Kingdom.

**Title:** A novel chlorhexidine and ibuprofen *in-situ* forming depot for periodontal regeneration: a proof of concept study

**Authors:** Fareeha Batool, Kevimy Agossa, Martin Lizambard, Nadia Benkirane-Jessel, Henri Tenenbaum, Jurgen Siepmann, Florence Siepmann, Olivier Huck

### 7. Oral presentation at Symposium Strasbourg-Jerusalem 2018, Strasbourg France

**Title:** Modulation of inflammation and new perspectives in periodontal regeneration

**Authors:** Fareeha Batool, Olivier Huck

### 8. Poster presentation at Journées postgraduate-universitaires, Faculté de chirurgie-dentaire 2018, Strasbourg France- 1st prize

**Title:** *In vitro* and *in vivo* assessment of poly- $\epsilon$ -caprolactone membrane functionalized with ibuprofen on periodontal wound healing.

**Authors:** Fareeha Batool, David-Nicolas Morand, Lionel Thomas, Isaac Maximiliano Bugueno, Javier Aragon, Silvia Irusta, Laetitia Keller, Nadia Benkirane-Jessel, Henri Tenenbaum, Olivier Huck

**9. Oral presentation at Doctoral School days 2018, Strasbourg, France.**

**Title:** Anti-inflammatory functionalized membrane for periodontal regeneration: *in vivo* evaluation in periodontitis-induced mouse model

**Authors:** Fareeha Batool, David-Nicolas Morand, Lionel Thomas, Isaac Maximiliano Bugueno, Javier Aragon, Silvia Irusta, Laetitia Keller, Nadia Benkirane-Jessel, Henri Tenenbaum, Olivier Huck

**10. Poster presentation at SFPIO, 2019, Paris France- 1<sup>st</sup> prize.**

**Title:** A novel chlorhexidine and ibuprofen in-situ forming implant for periodontal regeneration: a proof of concept study

**Authors:** Fareeha Batool, Kevimy Agossa, Martin Lizambard, Nadia Benkirane-Jessel, Henri Tenenbaum, Jurgen Siepmann, Florence Siepmann, Olivier Huck

**Periodontal Tissues, Maxillary Jaw Bone, and Tooth  
Regeneration Approaches: From Animal Models Analyses to  
Clinical Applications**





Review

# Periodontal Tissues, Maxillary Jaw Bone, and Tooth Regeneration Approaches: From Animal Models Analyses to Clinical Applications

Fareeha Batool <sup>1,†</sup>, Marion Strub <sup>1,2,3,†</sup>, Catherine Petit <sup>1,2,4</sup>, Isaac Maximiliano Bugueno <sup>1</sup>, Fabien Bornert <sup>1,2,5</sup>, François Clauss <sup>1,2,3</sup>, Olivier Huck <sup>1,2,4</sup> , Sabine Kuchler-Bopp <sup>1,\*</sup> and Nadia Benkirane-Jessel <sup>1,2</sup>

<sup>1</sup> INSERM (French National Institute of Health and Medical Research), UMR 1260, Regenerative NanoMedicine (RNM), FMTS, 67000 Strasbourg, France; s\_fareeha\_b@hotmail.com (F.B.); marion.strub@chru-strasbourg.fr (M.S.); catherin.petit@gmail.com (C.P.); isaacmaxi@gmail.com (I.M.B.); bornertfabien@gmail.com or fabien.bornert@chru-strasbourg.fr (F.B.); francois\_clauss@hotmail.com or francois.clauss@chru-strasbourg.fr (F.C.); huck.olivier@gmail.com or o.huck@unistra.fr (O.H.); nadia.jessel@inserm.fr (N.B.-J.)

<sup>2</sup> Faculty of Dentistry, University of Strasbourg (UDS), 8 rue Ste Elisabeth, 67000 Strasbourg, France

<sup>3</sup> Departement of Pediatric Dentistry, Pôle de Médecine et Chirurgie Bucco-Dentaires, Hôpitaux Universitaires de Strasbourg (HUS), 1 place de l'Hôpital, 67000 Strasbourg, France

<sup>4</sup> Department of Periodontology, Pôle de Médecine et Chirurgie Bucco-Dentaires, Hôpitaux Universitaires de Strasbourg (HUS), 1 place de l'Hôpital, 67000 Strasbourg, France

<sup>5</sup> Department of Oral Surgery, Pôle de Médecine et Chirurgie Bucco-Dentaires, Hôpitaux Universitaires de Strasbourg (HUS), 1 place de l'Hôpital, 67000 Strasbourg, France

\* Correspondence: kuchler@unistra.fr; Tel.: +33-061-961-0523

† Those authors contributed equally to this work.

Received: 24 April 2018; Accepted: 15 May 2018; Published: 16 May 2018



**Abstract:** This review encompasses different pre-clinical bioengineering approaches for periodontal tissues, maxillary jaw bone, and the entire tooth. Moreover, it sheds light on their potential clinical therapeutic applications in the field of regenerative medicine. Herein, the electrospinning method for the synthesis of polycaprolactone (PCL) membranes, that are capable of mimicking the extracellular matrix (ECM), has been described. Furthermore, their functionalization with cyclosporine A (CsA), bone morphogenetic protein-2 (BMP-2), or anti-inflammatory drugs' nanoreservoirs has been demonstrated to induce a localized and targeted action of these molecules after implantation in the maxillary jaw bone. Firstly, periodontal wound healing has been studied in an induced periodontal lesion in mice using an ibuprofen-functionalized PCL membrane. Thereafter, the kinetics of maxillary bone regeneration in a pre-clinical mouse model of surgical bone lesion treated with BMP-2 or BMP-2/Ibuprofen functionalized PCL membranes have been analyzed by histology, immunology, and micro-computed tomography (micro-CT). Furthermore, the achievement of innervation in bioengineered teeth has also been demonstrated after the co-implantation of cultured dental cell reassociations with a trigeminal ganglia (TG) and the cyclosporine A (CsA)-loaded poly(lactic-co-glycolic acid) (PLGA) scaffold in the jaw bone. The prospective clinical applications of these different tissue engineering approaches could be instrumental in the treatment of various periodontal diseases, congenital dental or cranio-facial bone anomalies, and post-surgical complications.

**Keywords:** bioengineered tooth; BMP-2; cyclosporine A; electrospun polycaprolactone; ibuprofen; innervation; nanoreservoirs; periodontitis

## 1. Introduction

Tooth loss undermines oral health, affecting both function and aesthetics, compromising oral health related quality of life [1]. Periodontitis, a group of inflammatory diseases of infectious origin, is considered as the main cause of tooth loss. It is characterized by progressive destruction of the tooth-supporting tissues (gingiva, cementum, alveolar bone, and periodontal ligament) resulting in gingival bleeding, increased periodontal pocket depth, abscess formation, tooth mobility, and—consequently—tooth loss [2]. Besides the conventionally employed therapy, mainly comprising scaling and root planing to reduce bacterial load, regeneration of destructed tissues is the ultimate objective of periodontal treatment as it has been demonstrated to improve function and long-term retention of the tooth [3]. Currently, for the restoration of missing tooth, implant placement is a widely used therapeutic modality. However, in some cases, there is low residual bone height or volume, caused by local trauma, tumor resection, or systemic conditions, necessitating bone regeneration prior to implant placement [4].

Over the last few decades, many different techniques and biomaterials, including guided tissue regeneration (GTR), guided bone regeneration (GBR), bone grafts of human, xenogenic or allogenic origins, growth factors, and various pharmacological agents, have been tested with the aim of regenerating periodontium and maxillary bone in vitro, in vivo, and in clinical settings but the results of the clinical trials have been, by and large, variable [5–11]. Current strategies for periodontal and bone regeneration are based on the fabrication of scaffolds which are biocompatible and can act as suitable vehicles for delivery of bioactive molecules (growth factors, drugs) or stem cells [12]. Not only does the scaffold material provide bulk mechanical support to the regenerating tissues but it also mimics the extracellular matrix (ECM) of tissues which directs the cell behavior to contribute towards the regenerative process [13]. In this context, control of inflammatory process has been suggested as sustained inflammation may impair regenerative therapeutic outcomes [14]. Membranes loaded with drugs such as ibuprofen (Ibu) and growth factors such as bone morphogenetic protein-2 (BMP-2) have already been tested in mice and have exhibited beneficial effects on wound healing and tissue regeneration [15,16]. Pre-clinical and clinical studies in the treatment of jaw bone defects are focused on bone substitution and regenerative approaches, the latter requiring novel experimental development and functionalization of bioactive molecules, different types of stem cells with synthetic biomembranes or scaffolds.

The association of transforming growth factor-beta 3 (TGF- $\beta$ 3) and dental pulp stem cells for peri-implant bone regeneration in an animal model of anterior implant repair showed promising results compared to mere bone substitution with bone powder [17]. Moreover, the trabecular bone was found to be having a superior bone density in the control group with surrounding osteoblasts arranged in clusters. Different types of stem cells (stem cells of human exfoliated deciduous teeth, human dental pulp stem cells, and bone marrow mesenchymal stem cells) have been compared for their ability to stimulate bone response in a model of calvarial defect in immunodeficient mice [18]. These stem cells were transplanted with a polylactic-polyglycolic acid (PLGA) scaffold and exerted similar bone regeneration abilities after 12 weeks of transplantation [18].

In humans, a recent study demonstrated positive results of a collagen-enriched xenogenic bovine bone mineral on post-operative volumetric bone alterations [19]. Another clinical technique for alveolar ridge preservation has been based on the association of xenogenic bone substitute with 10% collagen and covered with native bilayer collagen membrane [20]. Although a significant reduction of radiographic bone loss was observed with this technique. Nevertheless, these methods seem limited by the absence of biological bone and vascularization. To overcome this limitation, the use of mesenchymal stem cells (MSC) was clinically evaluated to treat maxillary bone defects following biopsies or osteolytic odontogenic benign tumors. Results showed promising outcome in terms of bone volume or density with MSC from autologous bone marrow on bone regeneration after biopsies or osteolytic lesions [21]. As the kinetics of in situ stem cells' release cannot be controlled,

functionalization of a synthetic PCL biomembrane with mesenchymal stem cells, as we proposed for the treatment of a maxillary bone lesion, may overcome such limitation.

Replacement of missing tooth by tooth tissue engineering has recently attracted much attention [22]. Therefore, besides periodontal tissue engineering, regenerating the entire missing tooth has also been attempted by tooth bioengineering. Vascularization and innervation are essential factors for homeostasis and response to noxious stimuli, determining the success of the bioengineered tooth [23]. Previous studies have shown that reassociations between dissociated mesenchymal cells and an intact epithelium from embryonic mouse molars (14th embryonic day, ED14) rendered it possible to obtain dental germs [24]. Their subcutaneous implantation in the mouse resulted in the formation and morphogenesis of molars that were vascularized but not innervated [25]. In 2014, Eap et al. synthesized  $\epsilon$ -polycaprolactone (PCL) membranes by electrospinning and functionalized them with nerve growth factor (NGF) nanoreservoirs. By adding a trigeminal ganglion (TG) to the functionalized membrane and the germ, peripheral axons were detected in the pulp cavity as early as two weeks after implantation [26]. In another study, a TG was implanted with the germ to constitute a supply of nerve fibers, in conjunction with a systemic treatment with cyclosporine A (CsA) in the drinking water of mice [27]. This treatment allowed the subcutaneous development of vascularized and innervated molars as early as two weeks after implantation. CsA has immunomodulatory properties and stimulates nerve growth [28]. The side effects of the systemic administration of CsA, including renal dysfunction and cancers, have been widely reported and, thus, not negligible. To overcome this issue, local delivery of the molecule is more desirable, therefore, development of scaffold, such as biomembrane functionalized with nanoreservoirs of CsA, is of clinical interest with multiple therapeutic targets and has been successfully tested [29].

The objective of this review is to present new regenerative strategies based on controlled local delivery of active anti-inflammatory drugs and growth factors through functionalized membranes targeting each component of tooth and its supporting tissues.

## 2. Materials and Methods

### 2.1. Materials

Poly (D, L-lactic acid/glycolic acid) 50/50 polymer (PLGA; MW 24–38 KDa), under the commercial name Resomer<sup>®</sup> RG 503, was purchased from Evonik Industries AG (Darmstadt, Germany). Polycaprolactone (PCL; MW 80 KDa) analytical grade, cyclosporine A (0.1 mg/mL), dexamethasone (used as HPLC internal standard), Pluronic<sup>®</sup> F-68 surfactant, ethyl acetate (Class 3 solvent according to the pharmacopeia), acetonitrile, methanol (HPLC grade), and Ibuprofen (50  $\mu$ g/mL) were all purchased from Sigma-Aldrich (St. Louis, MO, USA). BMP-2 (200 ng/mL) was acquired from Euromedex (Souffelweyersheim, France) and chitosan (Protasan UPCL 113, 500  $\mu$ g/mL) from NovaMatrix (Sandvika, Norway).

### 2.2. Synthesis and Characterization of Cyclosporine A (CsA) Loaded PLGA Nanoparticles

Cyclosporine A loaded PLGA (PLGA/CsA) nanoparticles were prepared in a continuous microfluidic reactor using a PEEK-made interdigital micromixer (SIMM-V2, Slit Interdigital Micro Mixer, IMM, Mainz, Germany) by carrying out an oil-in-water (O/W) emulsification process followed by a solvent evaporation procedure as previously described [29]. Scanning electron microscopy (SEM, Inspec F50, FEI, Eindhoven, The Netherlands) was employed to determine the shape of the synthesized PLGA NPs.

### 2.3. PCL Scaffold Synthesis and Functionalization

PCL was dissolved in a mixture of dichloromethane/dimethylformamide (DCM/DMF 50/50 *v/v*) at 15% *w/v* and stirred overnight before use. A standard electrospinning set-up (EC-DIG apparatus, IME Technologies, Eindhoven, Netherlands) was used to fabricate the PCL scaffolds as described

earlier [30]. The objective was to achieve nanoreservoirs distributed randomly on the surface of PCL nanofibers as shown in another study [30]. In our study, for some experiments, PCL scaffolds were incubated in a chitosan solution (chitosan, 500 µg/mL) for 15 min and rinsed with the buffer for 15 min. These scaffolds were then incubated in PLGA or PLGA/CsA NPs solution for another 15 min and, finally, thoroughly washed for 15 min, thus, constructing a 'bilayer' (chitosan/PLGA/CsA) on the fiber surface. Repetition of this protocol five times allowed the construction of (chitosan/PLGA/CsA)<sub>5</sub>, respectively. Even though this buffer solution provided high ionic strength to the media, the NPs remained strongly bound to the PCL electrospun nanofibers. For other experiments, (BMP-2/chitosan)<sub>10</sub> and (Ibuprofen/chitosan)<sub>3</sub> were built up on the PCL scaffold as described recently [15]. BMP-2 and ibuprofen remain protected and available for cellular activity due to their encapsulation in the nanoreservoirs of chitosan. Finally, Ibuprofen-functionalized PCL membranes (PCL/Ibu) were synthesized by mixing PCL pellets dissolved in DCM/DMF and Ibuprofen (10% of Ibu *w/w*) with TWEEN<sup>®</sup> 80 and electrospinning process in a Yflow 2.2.D-500 electrospinner (Coaxial Electrospinning Machines/R&D Microencapsulation, Malaga, Spain) using the shell–core technique as described recently [16].

Scanning electron microscopy (SEM) was used to characterize fibers size and morphology of the different scaffolds as described earlier [15].

#### 2.4. In Vivo Micro-Surgical Protocols

All experimental protocols fulfilled the authorization of the “Ministère de l'Enseignement Supérieur et de la Recherche” under the agreement numbers 01715.01 and 01715.02. The Ethics Committee of Strasbourg named “Comité Régional d'Ethique en Matière d'Expérimentation Animale de Strasbourg (CREMEAS)” specifically approved this study.

First, periodontitis was induced in mice by *Porphyromonas gingivalis*-infected ligatures to simulate disease condition comparable to human periodontitis as described previously [31]. To surgically treat the periodontal lesion, the test sites were treated with PCL/Ibu membrane [16].

Secondly, an intrabony periodontal lesion was created with a 0.5 mm round bur and a PCL/Ibu membrane was placed on the created bone lesion in such a manner that its ends could be blocked beneath the vestibular and palatal flaps. Bone level was evaluated by manual probing of the pocket depth and with the micro-computed tomography (micro-CT) analysis to confirm bone loss before initiating the treatment plan.

Thirdly, a maxillary bone lesion was created, under general anesthesia, in the diastemal area with a dental bur (0.8 mm) after gingival incision. On one side, bi-functionalized BMP-2/Ibuprofen or functionalized BMP-2 scaffold was implanted while the other side served as a control without scaffold or with non-functionalized scaffold for 30 and 90 days. The gingiva was closed with biological glue composed of enbucrilate (Histoacryl<sup>®</sup>, B. Braun, Rubi, Spain). To study the evolution of bone response, a longitudinal post-operative follow-up using micro-CT was conducted.

Finally, first mandibular molars were dissected from ICR mice (Charles River Laboratories, l'Arbresle, France) embryos at embryonic day 14 (ED14). Germs cultured on semi-solid medium reached the bell stage. For the innervation experiments, molars were cultured for six days on semi-solid medium as previously described [27], associated with a TG on PCL scaffolds (functionalized by chitosan/PLGA or chitosan/PLGA/CsA) for one night and implanted in the diastemal area. An incision was made up to the bone contact at the top of the alveolar crest in diastemal zone, in front of the first maxillary molar (M1). The bone lesion was obtained using a round bur (diameter 0.8 mm). Then, the cultured germ associated with TG on the CsA biomembrane was implanted and the lesion was closed with fibrin biological glue composed of enbucrilate (Histoacryl<sup>®</sup>, B. Braun, Rubi, Spain) for two and four weeks.



### 2.5. Histology and Indirect Immunofluorescence

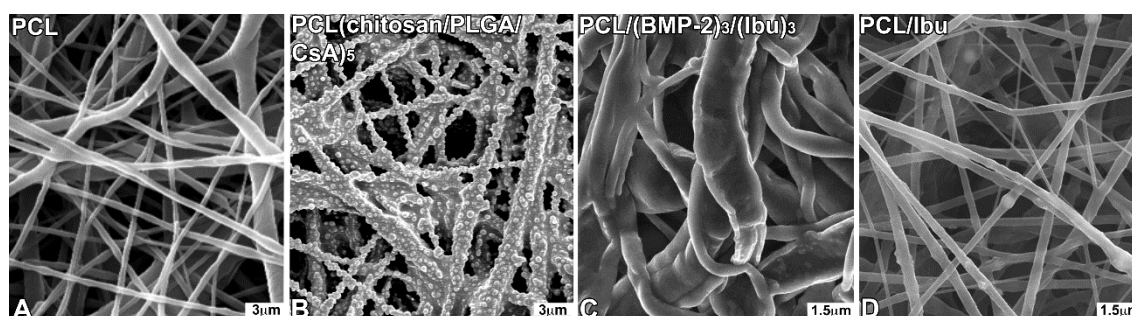
For histology, samples were fixed for 24 h in 4% paraformaldehyde, decalcified in ethylenediaminetetraacetic acid (EDTA) at 37 °C for one week and embedded in paraffin. Serial sections (10 µm) were stained with hematoxylin/eosin or Gomori trichrome stain and observed on a Leica DM4000B microscope.

For the immunofluorescence, some samples were embedded in Tissue-Tek, frozen at −20 °C and sectioned (10 µm) using a cryostat (Leica, CM3000). Serial sections were rinsed with phosphate buffered saline (PBS), fixed for 10 min with 4% paraformaldehyde at 4 °C and treated as previously described [27], using anti-peripherin, anti-CD31 and anti-osteocalcin antibodies. Sections were observed with a fluorescence microscope (Leica DM4000B).

## 3. Results

### 3.1. Characterization of the Biomembrane

The control nanofibrous structure (Figure 1A), the distribution of CsA (Figure 1B), BMP-2/Ibu nanoreservoirs (Figure 1C) and the PCL-Ibuprofen structure (Figure 1D) were characterized by SEM. The PCL scaffolds exhibited a nonwoven mesh like structure with a large surface area per volume ratio (Figure 1 A). The distribution of nanoreservoirs was random (Figure 1B). The morphology and fiber diameter distribution of the ibuprofen electrospun fibrous membrane showed that there were no beads in the fibrous structure and the fibers were uniform in size and interconnected in order to mimic the natural extracellular matrix (Figure 1D). The diameter of fibers was  $374 \pm 89$  nm for the PCL/Ibu electrospun fibrous membrane.



**Figure 1.** Scanning electron microscopy (SEM) observations of non-functionalized PCL scaffolds consisting of non-woven electrospun nanofibers (A), PCL scaffolds grafted with CsA-loaded PLGA nanoparticles (chitosan/PLGA/CsA)<sub>5</sub> (B), with BMP-2/Ibuprofen (PCL/(BMP-2)<sub>3</sub>/(Ibu)<sub>3</sub>) nanoreservoirs (C) or with Ibuprofen (D). For the morphological study by SEM, the different scaffolds were fixed with 4% paraformaldehyde, dehydrated in successive baths of ethanol (25, 50, 75, 90, 100%) and treated with hexamethyldisilazane (HDMS). They were mounted on a supporting sample holder using carbon conductive adhesive, then, silver-coated and observed with a Philips XL-30 ESEM scanning electron microscope in conventional mode (high vacuum) with a Everhart-Thornley secondary electron detector.

### 3.2. Assessment of PCL Membrane Functionalized with Ibuprofen on Periodontal Wound Healing in Periodontitis-Induced Mouse Model

In periodontal wound healing at seven days (Figure 2E,H,I), inflammatory infiltrate could be observed in the control. Moreover, fibrous attachment primarily remained dominant but new cementum formation was also initiated (Figure 2I). More cementum formation was visualized in the test using PCL/Ibu (Figure 2K) compared to that in the control. The test also exhibited a better organization of the gingival tissue (Figure 2F,G). In fact, separate zones comprising dense cellular zone and collagen zone could be distinctively observed in the test. Membrane interposed between

the cells and surrounded by inflammatory cells was shown in the test (Figure 2G). In the control, an increase in the cementum and bone formation was seen at 15 days of wound healing (Figure 2L–M) compared to that at seven days (Figure 2E–G). Epithelial attachment level was found to be improving while the fibrous attachment was observed to be replaced by epithelium and newly formed cementum. The differences between the control and test were less pronounced when the membrane persisted. Inflammation on the cervical margins of the persistent membrane could still be seen. Dense collagen bundles inserted on the bone away from the root surface were observed.

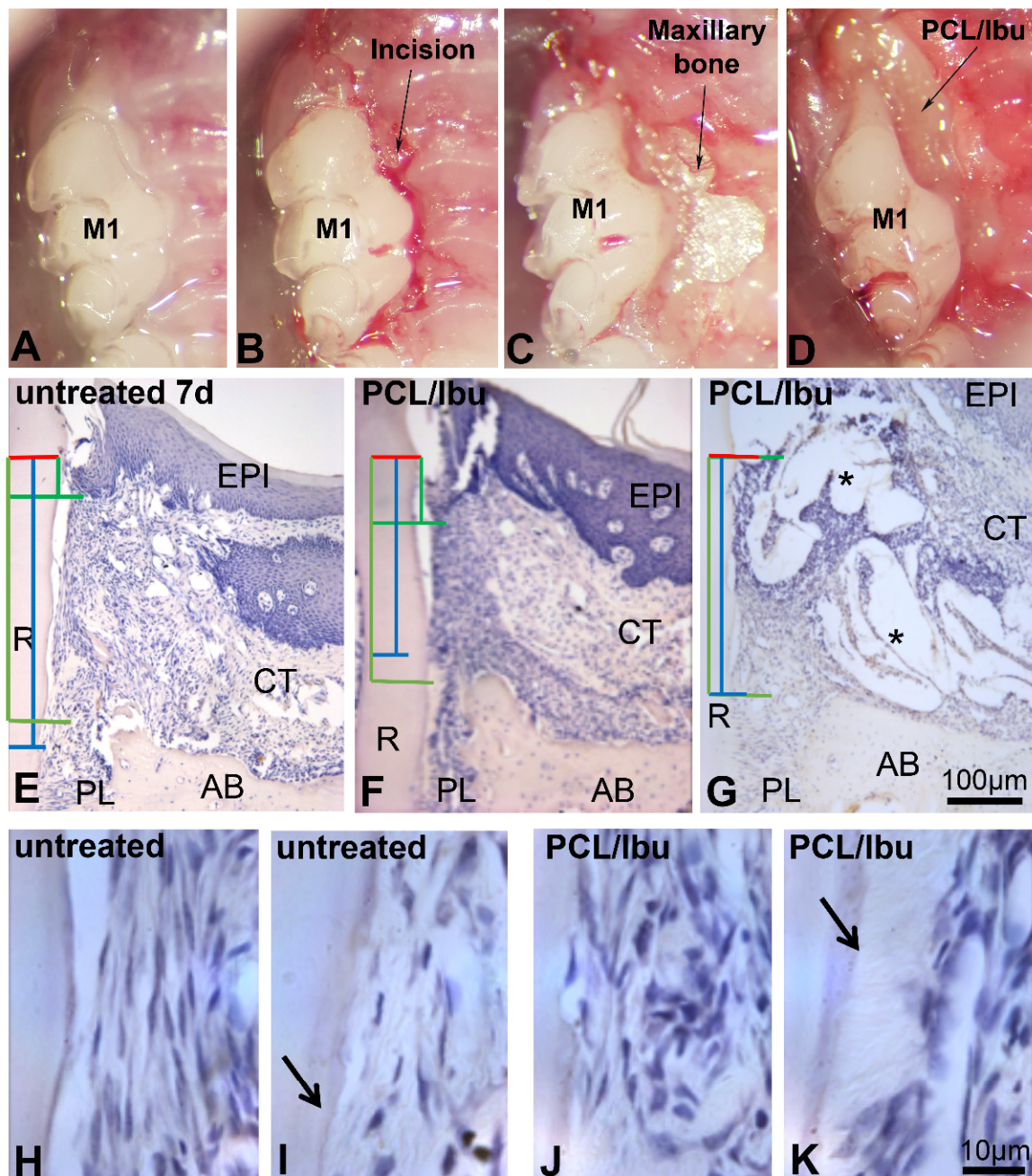
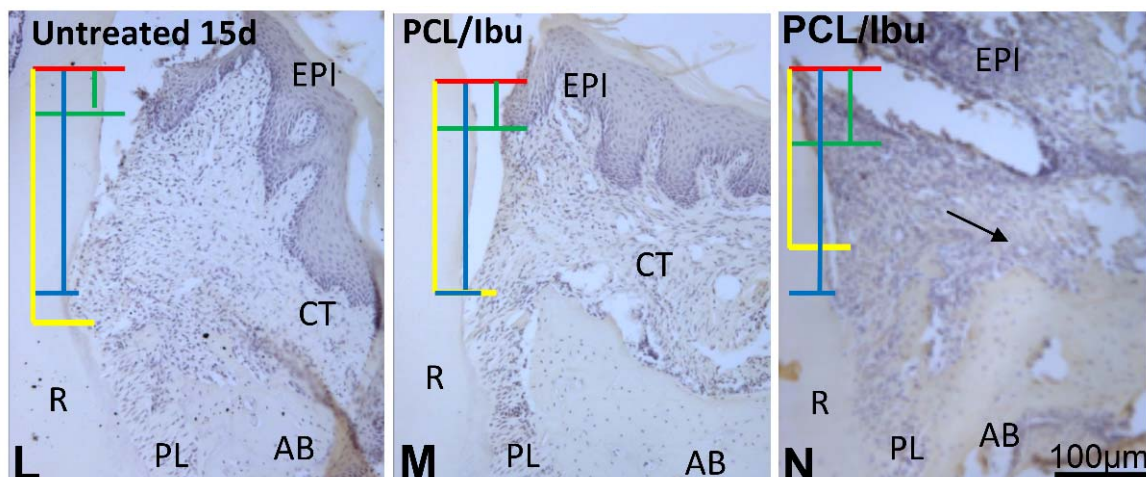


Figure 2. Cont.



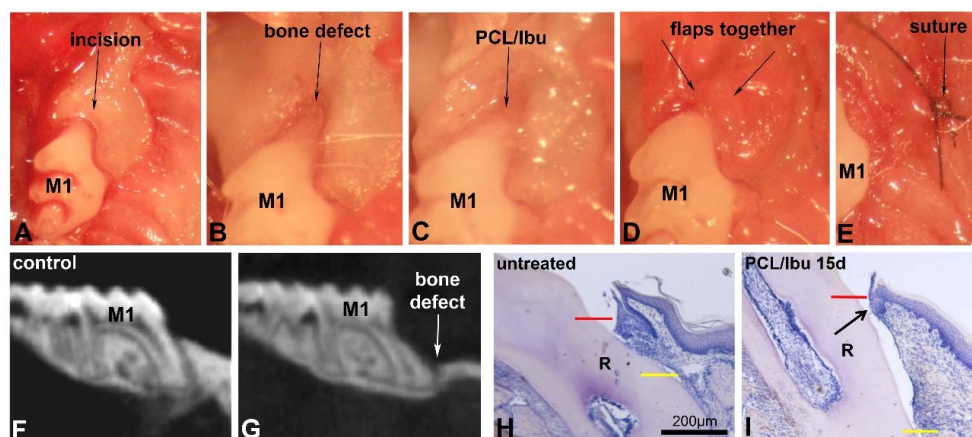


**Figure 2.** Periodontitis induced with *Porphyromonas gingivalis*-infected ligatures and treatment with PCL/Ibu membrane (A–D). (B) sulcular incision along the first and second maxillary molars, (C) raising the flaps for exposure and access, (D) surgical placement of PCL/Ibu membrane on the periodontal lesion, (E–N) histological view at 7 and 15 days. (E–K) histology of periodontal wound healing at 7 days and (L–N) at 15 days. Red line = cemento-enamel junction, blue line = fibrous connective tissue attachment, green line = epithelial attachment, yellow line = bone level. After anesthesia, a slight incision to the bone crest contact was made to facilitate the first ligature placement at the junction between the gum and the tooth along the first and second molars (M1-M2) as previously described [16]. The thread was then blocked with a drop of glass ionomer (Fuji IIGC, GC, France, Bonneuil sur Marne, France). Sterilized black braided 6.0 silk threads (Ethicon, Auneau, France) were incubated in culture medium containing *P.gingivalis* in an anaerobic chamber for one day. *P.gingivalis*-soaked ligatures were placed around maxillary first and second molars. The ligatures were inspected and replaced (with freshly infected ones) thrice a week for a period of 40 days. An incision was performed along the sulcular margins of the first and second molars and extended anteriorly on the mesial aspect of the first molar to efficiently raise the flap to gain access. Ibuprofen-functionalized PCL membrane was punched with a 3 mm diameter cutter. The circular pieces of membrane were further divided into half to achieve a size appropriate enough to cover the lesion. The cut membrane was then placed into the periodontal pocket after raising the flap such that the membrane stays flat beneath the flap covering the lesion fully and the necks of the crowns (molars) partially, entering the inter-dental area as well. The flap was nicely repositioned to perform a suture on the flap while maintaining the membrane underneath [16]. AB: alveolar bone, CT: connective tissue, EPI: epithelium, PL: periodontal ligament, R: root. Stars showing PCL/Ibu membrane.

### 3.3. Assessment of PCL Membrane Functionalized with Ibuprofen on Periodontal Wound Healing in a Mesial Bone Defect Model

A good bulk of the bone over and around the mesial root of the first molar was removed (Figure 3A–E) as confirmed by the micro-CT's sagittal view (Figure 3F,G). Sagittal views of the histological sections compare the bone level and epithelial attachment level in the control (Figure 3H) and test (Figure 3I). Long junctional epithelium was found to be formed in the test (Figure 3I, arrow).



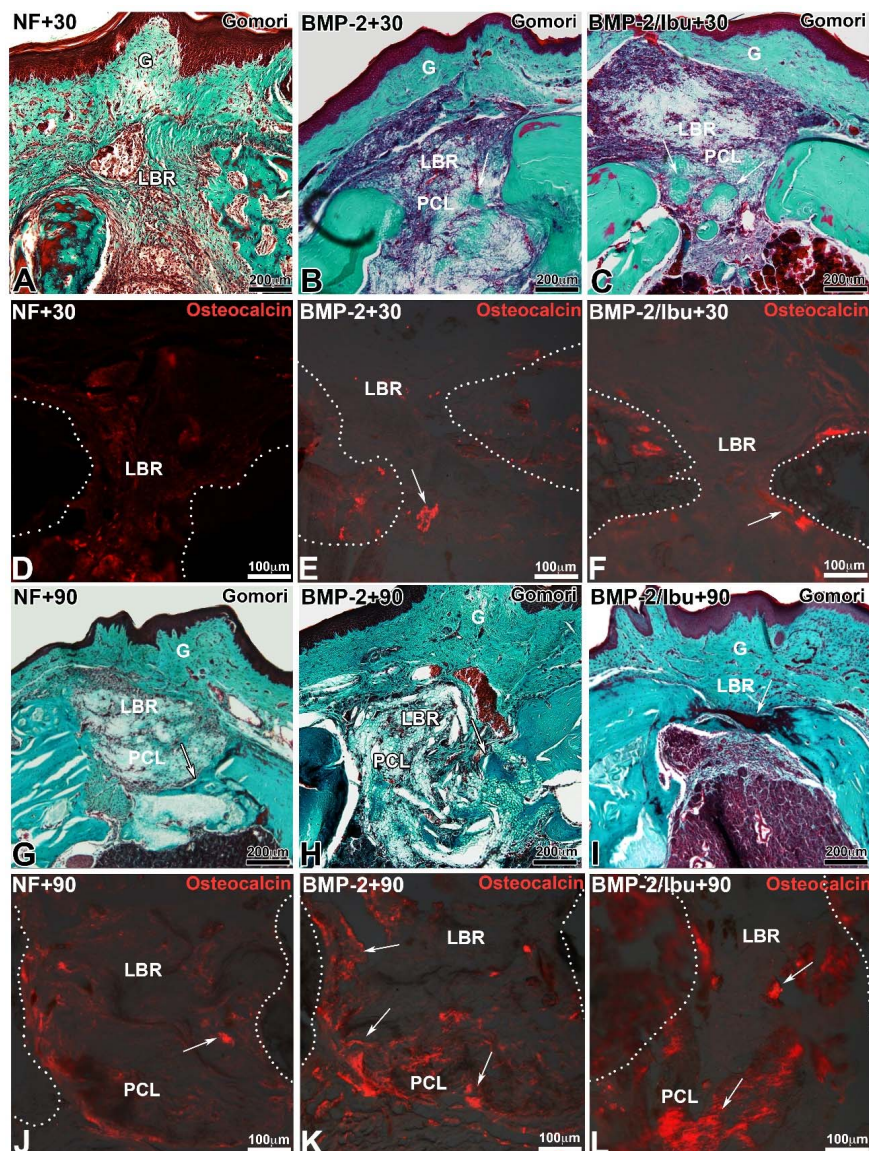


**Figure 3.** Surgical bone defect model and treatment with PCL/Ibu membrane (A–I). (A–E) demonstrate the surgical procedure for creating the mesial bone defect. After anesthesia, sulcular incision (A) was given along maxillary first molar and extended anteriorly on the mesial aspect of the first molar for efficient raising of palatal and vestibular flaps so that they do not hinder the bone drilling procedure. The exposed bone was drilled to create the intrabony defect (B). The bone over and around the mesial root of the first molar was removed. Constant irrigation with physiological saline was maintained to avoid overheating of the bur and the bone area concerned. The drilled bone was, later, nicely irrigated, cleaned, and dried to remove all the bone chips and debris. PCL/Ibu functionalized membrane was placed on the created bone lesion (C) in such a manner that its ends could be blocked beneath the vestibular and palatal flaps. Palatal and vestibular flaps were approximated covering the PCL/Ibu membrane underneath and sutured (9-0 ETHILON\* Polyamide 6/6) or glued to retain the membrane underneath (D,E). (F) micro-CT view before the bony defect and (G) after bony defect. (H,I) Histology of periodontal wound healing at 15 days. Red line = cemento-enamel junction, yellow line = bone level. (I) Arrow showing short epithelial attachment in test. M1: first upper molar, R: root.

#### 3.4. Maxillary Bone Regeneration Based on Nanoreservoirs Functionalized PCL with BMP-2 and BMP-2/Ibu

Surgery to study bone regeneration is the same as that depicted later in the text (Section 3.5). The only difference is that on one side, bi-functionalized BMP-2/Ibuprofen or functionalized BMP-2 scaffolds were implanted while the contra-lateral bone lesion served as a control without scaffold or with non-functionalized PCL scaffold for 30 and 90 days.

Trichrome of Gomori stain and immunofluorescence for osteocalcin showed the degree of bone neoformation and closure of the bone lesion (Figure 4). At 30 days, the membrane is largely colonized by the cells (Figure 4A–C). For the mice treated with a non-functionalized membrane, little neoformed bone was observed at day 30 compared to the lesions treated with the membranes functionalized with BMP-2 or BMP-2/ibuprofen (Figure 4A). At 90 days, the bone bridge was thicker (Figure 4G–I). Neoformed bone showed trabeculations in different directions from the original bone. In lesions treated with PCL membrane or with PCL/BMP-2 (Figure 4G,H), areas of mineralization extended further and further tending to join the osseous banks at day 90 with BMP-2/ibuprofen (Figure 4I). A greater number of red blood cells was found around the functionalized PCL/BMP-2-treated lesion (Figure 4H) than the PCL/BMP-2/Ibu-treated lesion (Figure 4I). The control lesion appeared to be the least vascularized area. Osteocalcin antibody was used to demonstrate osteoblastic activity and bone neoformation (Figure 4D–F,J–L). After 30 days, immunofluorescence showed differences in bone formation according to the different scaffolds tested. Osteoblasts were visualized in the bone/scaffold interface (Figure 4E,F white arrows) for PCL/BMP-2 and PCL/BMP-2/Ibu scaffolds while with unfunctionalized PCL very few osteoblasts were detected (Figure 4D). After 90 days, there was a massive expression of this protein (Figure 4K,L, white arrows), allowing clear observation of distinctly differentiated osteoblasts in almost all microscopic fields within the scaffold area. These results corroborated the efficiency of biocompatible scaffolds in promoting new bone regeneration to repair maxillary bone defects.

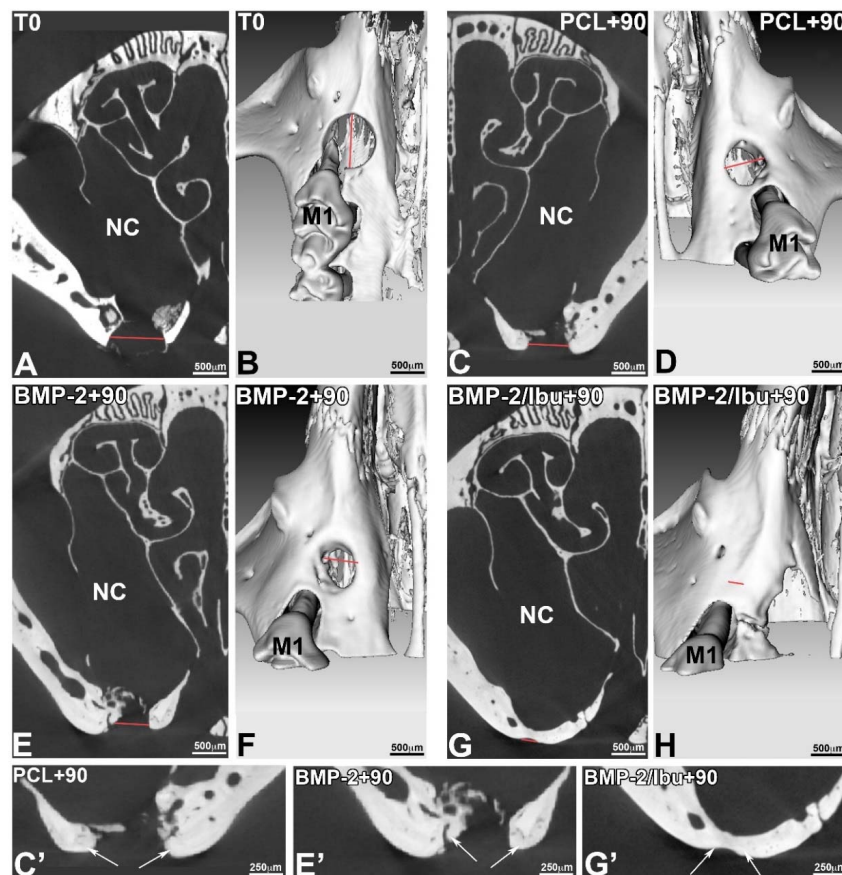


**Figure 4.** Trichrome of Gomori staining (A–C,G–I) and immunofluorescence for osteocalcin (D–F,J–L) after 30 (A–F) and 90 days (G–L) implantation of PCL (A,D,G,J), PCL/(BMP-2)<sub>10</sub> (B,E,H,K) and PCL/(BMP-2)<sub>10</sub>/(Ibu)<sub>3</sub> (C,F,I,L). Arrows indicated neoformed bone positive for osteocalcin. White dots indicate the limit of the maxillary bone. For the immunofluorescence, samples were embedded in Tissue-Tek, frozen at  $-20^{\circ}\text{C}$  and sectioned ( $10\ \mu\text{m}$ ) using a cryostat (Leica, CM3000). Serial sections were rinsed with PBS, fixed for 10 min with 4% paraformaldehyde at  $4^{\circ}\text{C}$  and treated as previously described [27] using the rabbit anti-osteocalcin antibodies (Santa Cruz Biotechnology, dilution 1/200). Sections were observed with a fluorescence microscope (Leica DM4000B). G: gingiva, LBR: lesion with bone regeneration, PCL: scaffold.

The micro-CT (phoenix/X-ray, GE sensing & Inspection Technologies GmbH, Wunstorf, Germany) validated the position of the standardized lesion on the bone crest, in close proximity to the first molar. The sections acquired in micro-CT allowed visualizing the periosteal reaction at the base of the lesion, with regards to the nasal cavity (Figure 5C,E). This mechanism corresponds to a physiological osteoformation activity in response to the experimental surgical trauma. This micro-CT analysis confirmed that the bridge connecting the bone banks was mineralized (Figure 5G,G'). The micro-CT also measured the size of the initial bone defect (T<sub>0</sub>), which in this case corresponded to the diameter of the drilling bur used. On the 3D volume micro-CT reconstructions, the bony margins of the lesion were



clear at T0 (Figure 5B), whereas at 90 days, the banks were more rounded, showing bone remodelling. We assessed the initial size of the lesion (Figure 5B) and observed the progressive bone response at 90 days with the BMP2-functionalized membranes and the non-functionalized PCL (Figure 5D,F) which does not lead to a closure of the bone banks. The 3D micro-CT reconstruction at 90 days in case of a bifunctionalized membrane with BMP-2 and ibuprofen (BMP-2/Ibu) showed a closure of the lesion, but the sections still showed that the bone formed was not as mineralized as the bone at the edges of the lesion (Figure 5C',E',G'). The thickness of the neoformed bone bridge formed was smaller compared to the initial situation (Figure 5G').

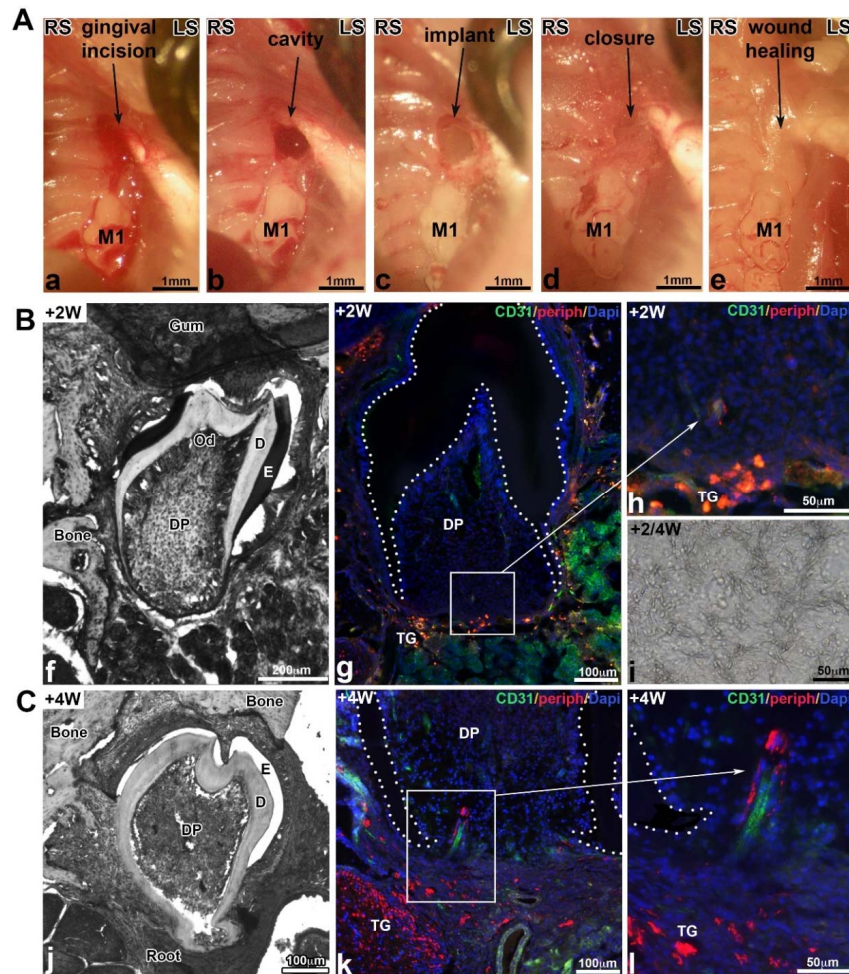


**Figure 5.** Micro-CT sections (A,C,E,G,C',E',G') and 3D reconstructions (B,D,F,H) at T0 (A,B) and after 90 days of implantation of PCL (C,D,C'), PCL/BMP-2 (E,F,E'), and PCL/BMP-2/Ibu (G,H,G'). To study the evolution of bone response, we conducted an ex vivo longitudinal post-operative follow-up using micro-CT. The X-ray microtomography acquisitions were performed after 0 and 90 days. The size of the reconstructed isotropic voxel was 8 μm. M1: first upper molar, NC: nasal cavity.

### 3.5. Molar Bioengineering and Innervation After Bone Implantation Using CsA Functionalized Membrane

An incision was made up to the bone contact at the top of the alveolar crest in diastemal area, in front of the M1 (Figure 6(Aa)). The bone lesion was obtained using a round bur (diameter 0.8 mm) (Figure 6(Ab)). Then, the cultured germ associated with a TG on the CsA biomembrane was implanted (Figure 6(Ac)) and the lesion was closed with a biological glue (Figure 6(Ad)), which allowed to cover the whole surgical site and promoted the wound healing. Two weeks after implantation, the mucosa was macroscopically and histologically closed (Figure 6(Ae)). Samples were recovered after two and four weeks of implantation (Figure 6(B,C)). Well-formed teeth were developed in the maxillary bone. The crown presented a normal morphogenesis with several cusps (Figure 6(Bf)) and the root formation was initiated after two weeks (Figure 6(Bf)) and further developed after four

weeks (Figure 6(Cj)). Odontoblasts and ameloblasts were functional, they secreted predentin/dentin and enamel organic matrix, respectively (Figure 6(Bf),(Cj)). The PCL membrane was detected in contact with the bioengineered tooth (Figure 6(Bi)). Indirect immunofluorescence analysis two weeks after implantation revealed the presence of blood vessels positive for CD31 (Figure 6(Bg)) in the dental pulp and some nervous filaments positive for peripherin at the base of the tooth (Figure 6(Bh)). Four weeks following implantation, nerve fibers penetrated the dental pulp in the most apical region (Figure 6(Ck),(Cl)). In both cases, nerve fibers were associated with the blood vessels. After implantation with control PCL membranes ((chitosan/PLGA)<sub>5</sub>), bioengineered teeth were vascularized but not innervated (not shown) [22].



**Figure 6.** (A) Different stages of the microsurgery: incision of the gingiva (Aa), maxillary bone lesion obtained with a dental bur (500  $\mu\text{m}$ ) (Ab), implantation of the membrane with the bioengineered tooth and TG (Ac), closing of the gingiva with biological glue (Ad), and wound healing of the mucosa two weeks after implantation (Ae). (B,C) Histology, vascularization and innervation of bioengineered tooth implanted on PCL scaffolds functionalized with CsA-loaded PLGA nanoparticles (chitosan/PLGA/CsA)<sub>5</sub> after two (B) or four (C) weeks of implantation. Samples were embedded in Tissue-Tek, frozen at  $-20\text{ }^{\circ}\text{C}$  and sectioned (10 $\mu\text{m}$ ) using a cryostat (Leica, CM3000). Serial sections were rinsed with PBS, fixed for 10 min with 4% paraformaldehyde at  $4\text{ }^{\circ}\text{C}$ . Some were stained with hematoxylin/eosin ((Cf),(Ci),(Cj)) or for the immunofluorescence as previously described using rabbit anti-peripherin (Abcam, dilution 1/600) and rat anti-CD31 (BD Pharmingen, dilution 1/100) antibodies [22] ((Bg),(Bh),(Ck),(Cl)). Cell nuclei were stained with 200 nM DAPI (Sigma-Aldrich Co, Darmstadt, Germany). D: dentin, DP: dental pulp, E: enamel, M1: first upper molar, Od: odontoblasts, TG: trigeminal ganglion.

#### 4. Discussion

Tissue regeneration is a pivotal field of research in dentistry, especially in regenerative endodontics or periodontology. The aim of the current therapeutic approaches is to regenerate lost tissues and several strategies have been developed and tested in this regard. Particularly, the use of bioactive scaffolds, such as membranes, has been widely studied [32].

In the context of periodontal and bone regeneration, synthetic membranes should combine both mechanical and biological properties to prevent their collapse within the defect and, ultimately, being capable of delivering 'at-site', the biomolecules or cells with controlled release to promote regeneration. To achieve this goal, electrospinning technique has been used to synthesize membranes from PCL [14–16,33]. PCL membranes are biocompatible, bioresorbable, and non-toxic [34,35]. Furthermore, they mimic efficiently the extracellular matrix supporting adhesion, differentiation, and cell proliferation. Interestingly, not only does their synthetic origin overcome the use of animal derived products but also exhibits desirable mechanical properties such as rigidity and low rate of resorption [36].

PCL membrane could also be utilized as an efficient drug delivery vehicle as described in this review with several interesting therapeutic applications for local delivery of certain bioactive agents such as anti-inflammatory or osteogenic molecules. Several strategies have been proposed to functionalize such scaffolds. Drugs, peptides, or other active molecules could be either inserted within the synthesized fibers through core-shell loading technique allowing a passive release of the compound during resorption of the fibers or by direct contact with the cells [16]. Nanoreservoir technology could also be used to deliver the active compounds to cells reaching tissues/organs in a controlled active manner as demonstrated for BMP2-PCL membrane [37]. In the context of periodontal diseases, evaluation of therapeutic efficacy should be assessed in both septic and aseptic conditions. Periodontitis is an inflammatory disease of infectious origin; therefore, it can be argued that concomitant to anti-inflammatory treatment, delivery of antimicrobial such as antibiotics would be of interest [38]. Here, we described two different models of periodontal destruction, one induced by infected ligature allowing to take into consideration the infectious nature of the disease, and the second one, where the lesion is mechanically induced by drilling in a depth-controlled manner. Thereafter, the test of new biomaterials or scaffolds for active compound delivery could be performed in a well-described environment.

The feasible synthesis of such PCL-membrane by electrospinning technique combining both core-shell and nanoreservoirs functionalization will open new perspectives in the field of regenerative medicine. In this regard, combination of a passive anti-inflammatory drug release and nanoreservoir containing pro-regenerative molecules such as growth factors would be of great interest. The passive release of anti-inflammatory molecules may reduce the risk of persistent inflammation with concomitant active release of pro-regenerative drugs, promoting specific regeneration of the tissues. For instance, if combined in a such scaffold as described earlier, passive release of ibuprofen will decrease the inflammation leading to increased BMP-2 secretion by macrophages [39] while active loading of BMP-2 or other growth factor will directly promote in a specific manner, the regeneration of targeted tissue such as alveolar bone. This strategy could be developed with other growth factors combining osteogenic, osteoinductive, and angiogenic molecules such as vascular endothelial growth factor (VEGF) [40] or other signaling molecules such as hepatocyte growth factor (HGF), as an upregulation of VEGF and BMP-2 receptor via nuclear factor kappa B (NF- $\kappa$ B) has been shown for HGF, in cultured osteocytes and in vivo, promoting osteogenesis and neo-vascularization of tissue-engineered bone [41].

As described previously, the use of such scaffolds leads to the regeneration of small defects such as periodontal lesion as well as more significant bone destruction such as observed in the bone regeneration of critical size defect. However, the combination with stem cells, such as bone-marrow derived stromal cells, may be of interest to improve clinical outcomes [42]. Such strategies have already been evaluated and are already used clinically in orthopedic surgery, with functionalization based on multipotent mesenchymal stem cells [43]. However, it is of importance to describe the



significant impact of the surgical technique used for membrane placement on regeneration related outcomes. Exposure of membrane has a potential detrimental influence on the outcome as observed for bone regeneration [44]. The full coverage of membrane by the flap is, therefore, mandatory. To our knowledge, no data are available regarding the effect of functionalized-PCL membrane exposure on the outcome of the therapy. Such parameters should be evaluated in the future to determine, more precisely, the potential of use of this type of biomaterial.

Tooth engineering has been the ultimate goal of regenerative dentistry for decades and many successful protocols have been described [45]. PCL membrane has been successfully tested to improve vascularization and innervation of the germ. For example, stem cells have the ability to stimulate axonal growth and are characterized by immunomodulatory properties. The concentration of nanoreservoirs can be adapted and the CsA release kinetics have already been the subject of a previous study [29]. In other medical domains, CsA has been used in the form of microspheres in hydrogel, which could be explored for tooth bioengineering [46].

In a previously reported work, we tried to implant reassociations in alveolar bone on M1 or M2 extraction sites but the tooth germ did not develop and was resorbed. We assume that this failure was due to a difference in bone type and bone healing metabolism. The hypothesis established that natural bone healing occurred more rapidly at the extraction site (pulp bleeding, alveolar bone, presence of mesodermal cells, and odontogenic mesenchymal stem cells) than at the level of a diastemal bone lesion in the diastemal zone (basal bone with poor vascularization). Hence, it was necessary to combine tooth regeneration techniques with bone regeneration strategies to prepare the implant site in the best manner possible. Besides its effect on osteogenesis, the membrane allowed isolation of the lesion from the nasal cavity, which was otherwise mostly approached during the milling process, in this murine model. This exposure of the lesion to bacteria of the nasal cavity could slow bone healing and this risk is greater in the absence of the membrane. Interestingly, in such model, fibrin glue could be used to protect the surgical site and maintain the membrane on site since it does not interfere with the underlying bone healing [47].

## 5. Conclusions

The development of regenerative nanomedicine illustrated by the synthesis and characterization of bioactive scaffolds such as membranes will open new therapeutic conservative approaches aiming to maintain, at long-term, the existing teeth and also, when required, to restore esthetics and function of missing teeth without exogenous devices such as dental implants.

**Author Contributions:** F.C., O.H. and S.K.-B. conceived and designed the experiments; F.Ba., M.S. and I.M.B. performed the experiments; F.Bo., O.H., and N.B.-J. analyzed the data; F.C., C.P., O.H. and S.K.-B. wrote the paper.

**Funding:** This research was funded by the INSERM, the Fondation des Gueules Cassées (grant number 55-2017) and the ANR-14-CE16-0025-01.

**Acknowledgments:** The authors thank Hervé Gegout for histology and Georg Schulz (University of Basel) for the micro-CT acquisitions.

**Conflicts of Interest:** The authors declare no conflict of interest with respect to the authorship and/or publications of this article. The founding sponsors had no role in the design of the study; in the collection, analyses, or interpretation of data; in the writing of the manuscript, or in the decision to publish the results.

## References

1. Tan, H.; Peres, K.G.; Peres, M.A. Retention of Teeth and Oral Health-Related Quality of Life. *J. Dent. Res.* **2016**, *95*, 1350–1357. [[CrossRef](#)] [[PubMed](#)]
2. Tonetti, M.S.; Christiansen, A.L.; Cortellini, P. Vertical subclassification predicts survival of molars with class II furcation involvement during supportive periodontal care. *J. Clin. Periodontol.* **2017**, *44*, 1140–1144. [[CrossRef](#)] [[PubMed](#)]

3. Cortellini, P.; Buti, J.; Pini Prato, G.; Tonetti, M.S. Periodontal regeneration compared with access flap surgery in human intra-bony defects 20-year follow-up of a randomized clinical trial: Tooth retention, periodontitis recurrence and costs. *J. Clin. Periodontol.* **2017**, *44*, 58–66. [[CrossRef](#)] [[PubMed](#)]
4. Buser, D.; Sennerby, L.; De Bruyn, H. Modern implant dentistry based on osseointegration: 50 years of progress, current trends and open questions. *Periodontol 2000* **2017**, *73*, 7–21. [[CrossRef](#)] [[PubMed](#)]
5. Agossa, K.; Morand, D.N.; Tenenbaum, H.; Davideau, J.L.; Huck, O. Systemic Application of Anti-inflammatory Agents in Periodontal Treatment. *Clin. Anti-Inflamm. Anti-Allergy Drugs* **2015**, *2*. [[CrossRef](#)]
6. Feres, M.; Figueiredo, L.C.; Soares, G.M.; Faveri, M. Systemic antibiotics in the treatment of periodontitis. *Periodontol 2000* **2015**, *67*, 131–186. [[CrossRef](#)] [[PubMed](#)]
7. Heitz-Mayfield, L.J.; Lang, N.P. Surgical and nonsurgical periodontal therapy. Learned and unlearned concepts. *Periodontol 2000* **2013**, *62*, 218–231. [[CrossRef](#)] [[PubMed](#)]
8. Karring, T.; Nyman, S.; Gottlow, J.; Laurell, L. Development of the biological concept of guided tissue regeneration—Animal and human studies. *Periodontol 2000* **1993**, *1*, 26–35. [[CrossRef](#)] [[PubMed](#)]
9. Martin-Cabezas, R.; Davideau, J.L.; Tenenbaum, H.; Huck, O. Clinical efficacy of probiotics as an adjunctive therapy to non-surgical periodontal treatment of chronic periodontitis: A systematic review and meta-analysis. *J. Clin. Periodontol.* **2016**, *43*, 520–530. [[CrossRef](#)] [[PubMed](#)]
10. Noordijk, M.; Davideau, J.L.; Eap, S.; Huck, O.; Fioretti, F.; Stoltz, J.F.; Bacon, W.; Benkirane-Jessel, N.; Clauss, F. Bone defects and future regenerative nanomedicine approach using stem cells in the mutant Tabby mouse model. *Biomed. Mater. Eng.* **2015**, *25* (Suppl. 1), 111–119. [[CrossRef](#)] [[PubMed](#)]
11. Reynolds, M.A.; Aichelmann-Reidy, M.E.; Branch-Mays, G.L.; Gunsolley, J.C. The efficacy of bone replacement grafts in the treatment of periodontal osseous defects: A systematic review. *Ann. Periodontol.* **2003**, *8*, 227–265. [[CrossRef](#)] [[PubMed](#)]
12. Bartold, P.M.; McCulloch, C.A.; Narayanan, A.S.; Pitaru, S. Tissue engineering: A new paradigm for periodontal regeneration based on molecular and cell biology. *Periodontol 2000* **2000**, *24*, 253–269. [[CrossRef](#)] [[PubMed](#)]
13. Huebsch, N.; Mooney, D.J. Inspiration and application in the evolution of biomaterials. *Nature* **2009**, *462*, 426–432. [[CrossRef](#)] [[PubMed](#)]
14. Morand, D.N.; Davideau, J.L.; Clauss, F.; Jessel, N.; Tenenbaum, H.; Huck, O. Cytokines during periodontal wound healing: Potential application for new therapeutic approach. *Oral Dis.* **2017**, *23*, 300–311. [[CrossRef](#)] [[PubMed](#)]
15. Strub, M.; Van Bellinghen, X.; Fioretti, F.; Bornert, F.; Benkirane-Jessel, N.; Idoux-Gillet, Y.; Kuchler-Bopp, S.; Clauss, F. Maxillary Bone Regeneration Based on Nanoreservoirs Functionalized  $\epsilon$ -Polycaprolactone Biomembranes in a Mouse Model of Jaw Bone Lesion. *BioMed Res. Int.* **2018**. [[CrossRef](#)] [[PubMed](#)]
16. Batool, F.; Morand, D.N.; Thomas, L.; Bugueno, I.M.; Aragon, J.; Irusta, S.; Keller, L.; Benkirane-Jessel, N.; Tenenbaum, H.; Huck, O. Synthesis of a Novel Electrospun Polycaprolactone Scaffold Functionalized with Ibuprofen for Periodontal Regeneration: An In Vitro and In Vivo Study. *Materials* **2018**, *11*, 580. [[CrossRef](#)] [[PubMed](#)]
17. Guزالinuer, A.; Muhetaer, H.; Wu, H.; Paerhati, A. Experimental study on the transforming growth factor  $\beta$ 3 combined with dental pulp stem cells in early bone integration of implant. *Zhonghua Kou Qiang Yi Xue Za Zhi* **2018**, *53*, 259–263. [[CrossRef](#)] [[PubMed](#)]
18. Nakajima, K.; Kunimatsu, R.; Ando, K.; Ando, T.; Hayashi, Y.; Kihara, T.; Hiraki, T.; Tsuka, Y.; Abe, T.; Kaku, M.; et al. Comparison of the bone regeneration ability between stem cells from human exfoliated deciduous teeth, human dental pulp stem cells and human bone marrow mesenchymal stem cells. *Biochem. Biophys. Res. Commun.* **2018**, *497*, 876–882. [[CrossRef](#)] [[PubMed](#)]
19. Tomasi, C.; Donati, M.; Cecchinato, D.; Szathvary, I.; Corrà, E.; Lindhe, J. Effect of socket grafting with deproteinized bone mineral: An RCT on dimensional alterations after 6 months. *Clin. Oral Implants Res.* **2018**. [[CrossRef](#)] [[PubMed](#)]
20. Jung, R.E.; Sapata, V.M.; Hämmerle, C.H.F.; Wu, H.; Hu, X.L.; Lin, Y. Combined use of xenogeneic bone substitute material covered with a native bilayer collagen membrane for alveolar ridge preservation: A randomized controlled clinical trial. *Clin. Oral Implants Res.* **2018**. [[CrossRef](#)] [[PubMed](#)]
21. Colangeli, W.; Riccelli, U.; Giudice, A.; Barca, I.; Caruso, D.; Novembre, D.; Tortosa, C.; Cordaro, R.; Cristofaro, M.G. Jaw bones regeneration using mesenchymal stem cells: A single-center experience. *Ann. Ital. Chir.* **2018**, *89*, 20–23. [[PubMed](#)]



22. Peng, L.; Ye, L.; Zhou, X.D. Mesenchymal stem cells and tooth engineering. *Int. J. Oral Sci.* **2009**, *1*, 6–12. [[CrossRef](#)] [[PubMed](#)]
23. Keller, L.; Kuchler-Bopp, S.; Mendoza, S.A.; Poliard, A.; Lesot, H. Tooth engineering: Searching for dental mesenchymal cells sources. *Front. Physiol.* **2011**, *2*, 7. [[CrossRef](#)] [[PubMed](#)]
24. Hu, B.; Nadiri, A.; Bopp-Kuchler, S.; Perrin-Schmitt, F.; Lesot, H. Dental epithelial histomorphogenesis in vitro. *J. Dent. Res.* **2005**, *84*, 521–525. [[CrossRef](#)] [[PubMed](#)]
25. Nait Lechguer, A.; Kuchler-Bopp, S.; Hu, B.; Haïkel, Y.; Lesot, H. Vascularization of engineered teeth. *J. Dent. Res.* **2008**, *87*, 1138–1143. [[CrossRef](#)] [[PubMed](#)]
26. Eap, S.; Bécavin, T.; Keller, L.; Kökten, T.; Fioretti, F.; Weickert, J.L.; Deveaux, E.; Benkirane-Jessel, N.; Kuchler-Bopp, S. Nanofibers implant functionalized by neural growth factor as a strategy to innervate a bioengineered tooth. *Adv. Healthc. Mater.* **2014**, *3*, 386–391. [[CrossRef](#)] [[PubMed](#)]
27. Kökten, T.; Bécavin, T.; Keller, L.; Weickert, J.L.; Kuchler-Bopp, S.; Lesot, H. Immunomodulation stimulates the innervation of engineered tooth organ. *PLoS ONE* **2014**, *9*, e86011. [[CrossRef](#)]
28. Roozbehi, A.; Joghataie, M.T.; Mehdizadeh, M.; Mirzaei, A.; Delaviz, H. The effects of cyclosporin-A on functional outcome and axonal regrowth following spinal cord injury in adult rats. *Acta Med. Iran.* **2012**, *50*, 226–232. [[PubMed](#)]
29. Kuchler-Bopp, S.; Larrea, A.; Petry, L.; Idoux-Gillet, Y.; Sebastian, V.; Ferrandon, A.; Schwinté, P.; Arruebo, M.; Benkirane-Jessel, N. Promoting bioengineered tooth innervation using nanostructured and hybrid scaffolds. *Acta Biomater.* **2017**, *50*, 493–501. [[CrossRef](#)] [[PubMed](#)]
30. Mendoza-Palomares, C.; Ferrand, A.; Facca, S.; Fioretti, F.; Ladam, G.; Kuchler-Bopp, S.; Regnier, T.; Mainard, D.; Benkirane-Jessel, N. Smart hybrid materials equipped by nanoreservoirs of therapeutics. *ACS Nano* **2012**, *6*, 483–490. [[CrossRef](#)] [[PubMed](#)]
31. Saadi-Thiers, K.; Huck, O.; Simonis, P.; Tilly, P.; Fabre, J.E.; Tenenbaum, H.; Davideau, J.L. Periodontal and systemic responses in various mice models of experimental periodontitis: Respective roles of inflammation duration and Porphyromonas gingivalis infection. *J. Periodontol.* **2013**, *84*, 396–406. [[CrossRef](#)] [[PubMed](#)]
32. Bottino, M.C.; Thomas, V. Membranes for Periodontal Regeneration—A Materials Perspective. *Front. Oral Biol.* **2015**, *17*, 90–100. [[CrossRef](#)] [[PubMed](#)]
33. Wei, S.; Jian, C.; Xu, F.; Bao, T.; Lan, S.; Wu, G.; Qi, B.; Bai, Z.; Yu, A. Vancomycin-impregnated electrospun polycaprolactone (PCL) membrane for the treatment of infected bone defects: An animal study. *J. Biomater. Appl.* **2018**, *32*, 1187–1196. [[CrossRef](#)] [[PubMed](#)]
34. Beachley, V.; Wen, X. Polymer nanofibrous structures: Fabrication, biofunctionalization, and cell interactions. *Prog. Polym. Sci.* **2010**, *35*, 868–892. [[CrossRef](#)] [[PubMed](#)]
35. Vaquette, C.; Fawzi-Grancher, S.; Lavalle, P.; Frochot, C.; Viriot, M.L.; Muller, S.; Wang, X. In vitro biocompatibility of different polyester membranes. *Biomed. Mater. Eng.* **2006**, *16* (Suppl. 4), S131–S136. [[PubMed](#)]
36. Deng, M.; James, R.; Laurencin, C.T.; Kumbar, S.G. Nanostructured polymeric scaffolds for orthopaedic regenerative engineering. *IEEE Trans. Nanobiosci.* **2012**, *11*, 3–14. [[CrossRef](#)] [[PubMed](#)]
37. Ferrand, A.; Eap, S.; Richert, L.; Lemoine, S.; Kalaskar, D.; Demoustier-Champagne, S.; Atmani, H.; Mély, Y.; Fioretti, F.; Schlatter, G.; et al. Osteogenetic properties of electrospun nanofibrous PCL scaffolds equipped with chitosan based nanoreservoirs of growth factors. *Macromol. Biosci.* **2014**, *14*, 45–55. [[CrossRef](#)] [[PubMed](#)]
38. Jepsen, K.; Jepsen, S. Antibiotics/antimicrobials: Systemic and local administration in the therapy of mild to moderately advanced periodontitis. *Periodontol 2000* **2016**, *71*, 82–112. [[CrossRef](#)] [[PubMed](#)]
39. Champagne, C.M.; Takebe, J.; Offenbacher, S.; Cooper, L.F. Macrophage cell lines produce osteoinductive signals that include bone morphogenetic protein-2. *Bone* **2002**, *30*, 26–31. [[CrossRef](#)]
40. Sharma, S.; Sapkota, D.; Xue, Y.; Rajthala, S.; Yassin, M.A.; Finne-Wistrand, A.; Mustafa, K. Delivery of VEGFA in bone marrow stromal cells seeded in copolymer scaffold enhances angiogenesis, but is inadequate for osteogenesis as compared with the dual delivery of VEGFA and BMP2 in a subcutaneous mouse model. *Stem Cell Res. Ther.* **2018**, *9*, 23. [[CrossRef](#)] [[PubMed](#)]
41. Zhen, R.; Yang, J.; Wang, Y.; Li, Y.; Chen, B.; Song, Y.; Ma, G.; Yang, B. Hepatocyte growth factor improves bone regeneration via the bone morphogenetic protein-2-mediated NF- $\kappa$ B signaling pathway. *Mol. Med. Rep.* **2018**, *17*, 6045–6053. [[CrossRef](#)] [[PubMed](#)]

42. Wang, D.; Lin, Y.; Chen, L.; Mo, Y.; Huang, P.; Ma, R. Guided bone regeneration using a bone tissue engineering complex consisting of a poly-*dl*-lactide membrane and bone mesenchymal stem cells. *Oncotarget* **2017**, *9*, 16380–16388. [[CrossRef](#)] [[PubMed](#)]
43. Guo, W.; Zheng, X.; Zhang, W.; Chen, M.; Wang, Z.; Hao, C.; Huang, J.; Yuan, Z.; Zhang, Y.; Wang, M.; et al. Mesenchymal stem cells in oriented PLGA/ACECM composite scaffolds enhance structure-specific regeneration of hyaline cartilage in a rabbit model. *Stem Cells Int.* **2018**, *2018*, 6542198. [[CrossRef](#)] [[PubMed](#)]
44. Garcia, J.; Dodge, A.; Luepke, P.; Wang, H.L.; Kapila, Y.; Lin, G.H. Effect of membrane exposure on guided bone regeneration: A systematic review and meta-analysis. *Clin. Oral Implants Res.* **2018**, *29*, 328–338. [[CrossRef](#)] [[PubMed](#)]
45. Li, G.; Zhou, T.; Lin, S.; Shi, S.; Lin, Y. Nanomaterials for Craniofacial and Dental Tissue Engineering. *J. Dent. Res.* **2017**, *96*, 725–732. [[CrossRef](#)] [[PubMed](#)]
46. Caicco, M.J.; Cooke, M.J.; Wang, Y.; Tuladhar, A.; Morshead, C.M.; Shoichet, M.S. A hydrogel composite system for sustained epi-cortical delivery of Cyclosporin A to the brain for treatment of stroke. *J. Control. Release* **2013**, *166*, 197–202. [[CrossRef](#)] [[PubMed](#)]
47. Cortellini, P.; Pini Prato, G.P.; Tonetti, M.S. No detrimental effect of fibrin glue on the regeneration of intrabony defects. A controlled clinical trial. *J. Clin. Periodontol.* **1995**, *22*, 697–702. [[CrossRef](#)] [[PubMed](#)]



© 2018 by the authors. Licensee MDPI, Basel, Switzerland. This article is an open access article distributed under the terms and conditions of the Creative Commons Attribution (CC BY) license (<http://creativecommons.org/licenses/by/4.0/>).

## Développement de stratégies innovantes de régénération parodontale via la modulation de la réponse inflammatoire

### Summary:

Control of periodontal infection and inflammation is crucial for optimal periodontal wound healing and regeneration. For this purpose, three different and novel strategies were developed and tested for their impact on periodontal wound healing parameters *in vitro* and *in vivo*. Firstly, an ibuprofen-functionalized polycaprolactone (IBU-PCL) membrane was developed as an anti-inflammatory barrier membrane that successfully reduced inflammatory markers expression in gingival cells *in vitro* and decreased soft tissue inflammation, thus, improving periodontal tissue healing in an experimental periodontitis model *in vivo*. Secondly, chlorhexidine and ibuprofen containing *in-situ* forming implant (CHX-IBU ISFI) was developed to target both infection and inflammation that successfully reduced *Porphyromonas gingivalis* growth and inflammatory response of gingival cells *in vitro* as well as improved soft tissue periodontal wound healing *in vivo*. Lastly, a thermosensitive chitosan-based hydrogel functionalized with atorvastatin encapsulated in a nano-emulsion (ATV-KELP NE) was characterized and used to treat an induced bone defect *in vivo* that resulted in improved soft and hard tissue healing by counteracting infection and modulation of immuno-inflammatory response.

**Keywords:** Periodontal regeneration, *Porphyromonas gingivalis*, controlled-release scaffolds, inflammation

### Résumé en français

Le contrôle de l'infection et de l'inflammation est crucial dans les traitements parodontaux de régénération tissulaire. Dans cet objectif, trois stratégies novatrices ont été développées et évaluées *in vitro* et *in vivo* en se focalisant sur les paramètres associés à la cicatrisation. Dans un premier temps, une membrane de polycaprolactone (IBU-PCL) fonctionnalisée avec de l'ibuprofène a été développée. Ce nouveau biomatériau aux propriétés anti-inflammatoires et utilisé comme barrière permettant l'exclusion tissulaire a permis de réduire significativement l'expression des marqueurs de l'inflammation au niveau des cellules épithéliales gingivales *in vitro* et l'inflammation des tissus mous *in vivo*. Dans un second temps, un implant se formant *in situ* (ISFI) fonctionnalisé par ibuprofène et chlorhexidine a été développé pour cibler l'infection et l'inflammation. Ce biomatériau a permis de réduire la croissance bactérienne de *Porphyromonas gingivalis* et d'optimiser la cicatrisation des tissus parodontaux par réduction de l'inflammation. Enfin, un hydrogel thermosensible fonctionnalisé par atorvastatine encapsulée dans des nano-émulsions a été synthétisé (ATV-KELP NE) et a induit une amélioration de la néoformation osseuse dans un modèle de calvaria.

**Mot clés :** Régénération parodontale, *Porphyromonas gingivalis*, système à libération contrôlée, inflammation