



HAL
open science

Effets de facteurs exogènes sur les gamètes masculins et leur génome : conséquences potentielles d'une élévation modérée de la température des testicules et des épидидymes sur la qualité du gamète

Mohamed Hadi Mohamed Abdelhamid

► To cite this version:

Mohamed Hadi Mohamed Abdelhamid. Effets de facteurs exogènes sur les gamètes masculins et leur génome : conséquences potentielles d'une élévation modérée de la température des testicules et des épидидymes sur la qualité du gamète. Reproduction sexuée. Université Paul Sabatier - Toulouse III, 2019. Français. NNT : 2019TOU30054 . tel-02896373v1

HAL Id: tel-02896373

<https://theses.hal.science/tel-02896373v1>

Submitted on 10 Jul 2020 (v1), last revised 10 Nov 2020 (v2)

HAL is a multi-disciplinary open access archive for the deposit and dissemination of scientific research documents, whether they are published or not. The documents may come from teaching and research institutions in France or abroad, or from public or private research centers.

L'archive ouverte pluridisciplinaire **HAL**, est destinée au dépôt et à la diffusion de documents scientifiques de niveau recherche, publiés ou non, émanant des établissements d'enseignement et de recherche français ou étrangers, des laboratoires publics ou privés.

Université Fédérale



Toulouse Midi-Pyrénées

THÈSE

En vue de l'obtention du

DOCTORAT DE L'UNIVERSITÉ DE TOULOUSE

Délivré par : l'Université Toulouse 3 - Paul Sabatier

Discipline ou spécialité : Physiopathologie, Biologie et Médecine du
Développement et de la Reproduction

Présentée et soutenue par : Mohamed Hadi Mohamed ABDELHAMID

Le : 9 juillet 2019

Titre :

**Effets de facteurs exogènes sur les gamètes masculins et leur génome:
conséquences potentielles d'une élévation modérée de la température
des testicules et des épидидymes sur la qualité du gamète.**

Jury

Pr. Catherine GUILLEMAIN

Rapporteuse

Pr. Hervé LEJEUNE

Rapporteur

Pr. Eric HUYGHE

Examineur

Dr. Hanaé PONS

Examinatrice

Pr. Louis BUJAN

Directeur de thèse

Dr. Safouane HAMD

Co-directeur de thèse

Ecole doctorale : BSB - Biologie, Santé, Biotechnologies

Unité de recherche : Groupe de Recherches en Fertilité Humaine (EA 3694)

Directeur de thèse : Pr. Louis BUJAN

Co-directeur de thèse : Dr. Safouane HAMD

Rapporteurs : Pr. Catherine GUILLEMAIN, Pr. Hervé LEJEUNE, Pr. Clément JIMENEZ

قال الإمام الشافعي

"لا تحسبن المجد تمر أنتم أكله لن تبلغ المجد حتى تلعق صبرا"

وقال:

"تَعَرَّبَ عَنِ الْأَوْطَانِ فِيهِ طَلَبُ الْعُلَا وَسَافِرٍ فِيهِ الْأَسْفَارِ خَمْسُ فَوَائِدٍ تَفَرُّجٌ هُمْ وَاکْتِسَابُ

مَعِيشَةٍ وَعِلْمٌ وَأَدَابٌ وَصُحْبَةٌ مَاجِدٌ وَإِنْ قِيلَ فِيهِ الْأَسْفَارُ ذُلٌّ وَمِحْنَةٌ وَقَطْعُ الْفِيَاضِ

وَاکْتِسَابُ الشَّدَائِدِ فَمَوْتٌ الْفَتَى خَيْرٌ لَهُ مِنْ حَيَاتِهِ بِدَارِ هَوَانٍ بَيْنَ وَاشٍ وَحَاسِدٍ"

This thesis is dedicated to,

My parents (Hadi and Laila) who have given me the opportunity of an education from the best institutions and support throughout my life.

My wife Najwan Nabil, for her great patience, waiting for me to finish this task, who has always supported me stood by me and dealt with all my absence from many family occasions and with love and smile.

My sisters, (Aml, Lubna, Reem, Fatema, Alaa and Heba) the heart of our spring in our family, they have given me the love, tenderness and happiness in my life.

My uncle (Lutfi Layas) who was my friend, godfather, guide and philosopher.

Finally, to my best friends and soulmates (Saadeddin, Abdul Aziz, Rudwan, and Mohamed) who have always helped me and believed that I could do it.

Acknowledgements

My director,

I wish to thank, first and foremost, my advisor **Pr. Louis BUJAN** who provided me an opportunity to join his team, for his patience, motivation and immense knowledge, without his guidance this study would not have been possible.

Co-director,

Dr. Safouane Hamdi co-director of my thesis, I express my profound gratitude for his competitive and vast expertise on the subject which I learned and tried to apply during my PhD work. His critical insight and exceptional command on the project really helped me a lot to think and judge scientifically.

Research group and team,

This thesis would have remained a dream had it not been for **Dr. Roger Mieusset** who give me the keys to the success of this work, **Dr. Myriam Daudin**, for her amical attachment and kindness that she really practiced during my study period. I gratefully acknowledge the able guidance of **Camille Esquerré, Marie Walschaerts** and **Dr. Nathalie Moinard** to helping me when needed and for her great friendly gesture.

Jury members,

Furthermore, I would like to thank the jury members; **Pr. Catherine GUILLEMAIN, Pr. Hervé LEJEUNE, Pr. Clément JIMENEZ, Pr. Eric HUYGHE** and **Dr. Hanaé PONS** for accepting to evaluate my thesis.

Staff of laboratory,

These acknowledgments would be incomplete if I do not pay thanks to all the members of **EA 3694**, whole staff of **CECOS**, they are helping me to find my way in CHU- Toulouse, improving my French and answering my endless questions and showing me the basics.

Finally, this dissertation is based on a three - year programme of research conducted by me at the Department of Andrology, Hospital Center University Toulouse. My studies there were facilitated by a scholarship awarded by **Biotechnology Research Center** through the ministry of higher education and scientific research - Libya, I am conscious of the enormous debt I owe these institutions for the opportunity so afforded for the enrichment of my academic career it is with a deeply felt sense of gratitude and thanks.

Contents

Résumé.....	10
Abstract	12
Introduction.....	14
1. Anatomy and physiology of the male reproductive system.....	19
1.1. Testes.....	19
1.1.1. Interstitial compartment	20
1.1.2. Tubular compartment	20
1.1.3. Different type of testicular cells	20
1.2. Epididymis	24
1.3. Scrotum	27
1.3.1. Skin	27
1.3.2. Dartos	28
1.3.3. Cremasteric	29
1.4. Testicular blood circulation system.....	30
1.4.1. Testicular artery	30
1.4.2. Testicular veins.....	30
1.5. Vas deferens	31
1.6. Glands.....	32
1.6.1. Seminal Vesicles	32
1.6.2. Prostate	33
1.6.3. Bulbourethral Glands (Cowper's)	34
2.1. Spermatogenesis	38
2.1.2. Mitosis	39
2.1.3. Meiosis	40
2.1.4. Spermiogenesis	45
2.1.5. Spermiation	50
2.2. Regulation of spermatogenesis process.....	52
2.2.1. Hypothalamic-Pituitary-Testicular Axis	52
2.2.2. Thermic regulation	55
2.2.2.1. Exchange testicular arterial and venous blood streams	56
2.2.2.2. Scrotum and surfaces area heat lost.....	59
3.1. Sperm morphology.....	64

3.1.1. Sperm (description, function and morphology)	64
3.2. Classifications sperm form and sperm morphology.....	67
3.3. Normal and abnormal sperm forms.....	68
3.3.1. Normal sperm form	70
3.3.2. Abnormal sperm form	74
3.3.3. Sperm form pathology.....	74
4.1. Sperm aneuploidy.....	80
4.1.1. Testis temperature, lifestyle related to sperm aneuploidy.....	83
5.1 Testis temperature	90
5.1.1. Measuring genital temperature	90
5.1.1.1. Mercury thermometer	91
5.1.1.2. Needle thermistor	92
5.1.1.3. Microwave technology	92
5.1.1.4. Scrotal skin surface temperature by infrared thermometry.....	93
5.1.1.5. Skin thermocouple	93
5.1.2 Testis temperature at various locations.....	96
6.1. Temperature and male fertility	103
6.1.1. Factors and situations that could cause an increase of testicular temperature.....	103
6.1.1.1. Sitting and sleeping posture	103
6.1.1.2. Environment and seasonal variation.....	105
6.1.1.3. Underwear.....	106
6.1.1.4. Occupation in high temperature	107
6.1.1.5. Car driving	108
6.1.1.6. Laptop computer users	109
6.1.1.7. Hot bath and sauna	109
6.1.1.8. Sports.....	111
6.1.1.9. Fever	112
6.1.1.10. Cryptorchidism	113
6.1.1.11. Varicocele	113
6.1.1.12. Obesity.....	116
7.1. Effect of temperature on the physiology of male reproduction	124
7.2. Effect of temperature on testis and epididymis.....	124
7.3. Effect of temperature on spermatogenesis	126
7.3.1. Spermatogonia (mitosis)	127

7.3.2. Spermatocyte and Spermatid (Meiosis).....	128
7.4. Effect of temperature on sperm in epididymis	129
7.5. Effect of temperature on sperm quality.....	130
7.5.1. Scrotal exposure to temperatures below core body physiological temperature	131
7.5.2. Scrotal exposure to temperatures above core body physiological temperature	136
8. What are physiological and pathophysiological mechanisms of testicular heating? What happens to testicular function during and after heating?	142
9. Clinical Applications.....	147
9.1. Use of testicular heating as a method for male contraception	147
9.2. Infertile situation.....	152
10.1. The main objective	157
10.1.1. Method of increase in testicular and epididymal temperature	159
10.1.1.1. Study Population	159
10.1.1.1.2. Techniques of testicular exposure to heat.....	160
10.1.1.1.3. Part I: A study the effect of a mild testicular and epididymal temperature on human sperm morphology	162
Periods of sampling	162
Semen collection	164
Sperm morphology.....	164
Statistical Analysis	165
10.1.1.1.4. Part II: Effect of a mild induced increase in testicular and epididymal temperature on sperm aneuploidy.....	166
Sperm concentration evaluation.....	166
Sperm Fluorescence in situ Hybridization (FISH).....	166
Statistical Analysis	169
Articles.....	170
Part I. Mild experimental increase in testis and epididymis temperature in men: Effects on sperm morphology according to spermatogenesis stages.....	171
Part II. Experimental mild increase in testicular temperature has drastic, but reversible, effect on sperm aneuploidy in men: a pilot study.....	212
11.1. Discussion.....	245
11.1.1. First part of the study previously published by our group (Ahmad et al., 2012)	246
11.1.2. Effect of heating on epididymal sperm	250
11.1.3. Effect of heating on testis spermatogenesis	252

11.2. Conclusions and prospective 261

 11.2.1. Conclusions..... 261

 11.2.2. Prospective 262

12. Reference 263

List of figures

Figure 1 Section of the germinal epithelium in the seminiferous tubule.	23
Figure 2 Anatomy of the testis and epididymis.....	26
Figure 3 Anatomy of the male reproductive system.....	35
Figure 4 Schematic overview of meiotic process in spermatogenesis. SC, synaptonemal complex	42
Figure 5 Differentiation of a human diploid germ cell into a fully functional spermatozoon	44
Figure 6 An extended diagram of the components in the midpiece of a mammalian spermatozoon tail.....	48
Figure 7 Schematic representation of the differentiation of human spermatid	49
Figure 8 Schematic representation different steps development of spermatogenesis.....	51
Figure 9 Diagram of the hypothalamic–pituitary–testis axis	54
Figure 10 Model of counter-current transfer of heat or a substance from the venous blood in the pampiniform plexus to the blood in the testicular artery.....	58
Figure 11 Scrotum and surfaces area heat lost.	61
Figure 12 Diagram of a typical mammalian spermatozoon. Cross-sectional insets show the orientation of the internal cell structure. Anatomy and physiology of the male reproductive system by	66
Figure 13 Sperm morphology: classifications of normal and abnormal human spermatozoa	77
Figure 14 Schematic representation of chromosome non-disjunction	82
Figure 15 Testis temperature in a different location.	100
Figure 16 Schematic representation of possible changes induced by potential exogenous and endogenous thermic factors on testicular and scrotal temperature in human.....	120
Figure 17 Minimum and maximum mean scrotal temperature in different situations.....	121
Figure 18 Two techniques of heating the testis to use for male contraception	150
Figure 19 Schematic representation of testicular and epididymal heat increase from 34°C in scrotal to 36°C into the inguinal canals.	161

Figure 20 Schematic representation of the timing of semen sampling during the three study periods before, during and after heating (phase I, phase II), B) Location and evolutionary stages of sperm during the spermatogenic process at heat induction 163

Figure 21 Schematic representation of semen sampling timing during the four study periods; Before D0, During H34, after (PH45 and PH180) 168

Figure 22. Percentage of sperm viability, motility, mean (SEM) sperm count (millions per ejaculate) and semen volume (mL per ejaculate) before, during and after a mild induced testicular and epididymal temperature increase in healthy men. 248

List of tables

Table 1 Values for sperm morphology in the different WHO manuals	73
Table 2 presents different methods of measuring genital temperature	95
Table 3 Testis temperature in a different location	99
Table 4 Factors and situation associated with an increase in scrotal/testicular temperature	119
Table 5 Effects of scrotal exposure to temperatures below core body physiological temperature on sperm parameter.....	135
Table 6 Testicular heating as a method for male contraception	151
Table 7 Sperm parameters during and after a mild induced testicular and epididymal temperature increase in healthy men.....	249

Abbreviations

ART	Assisted reproductive techniques
DAC	Diurnal artificial cryptorchidism
DFI	DNA fragmentation index
DNA	Deoxyribonucleic acid
DPBS	Dulbecco's phosphate buffer saline
E2	Estradiol
FISH	Fluorescence in situ hybridization
FSH	Follicle stimulating hormone
GnRH	Gonadotropin releasing hormone
hCG	Human chorionic gonadotropin
HDS	High DNA stainability
HOST	Hypoosmotic swelling test
HSPs	Heat shock proteins
ICSI	Intracytoplasmic sperm injection
INSL3	Insulin-like factor 3
IVF	In vitro fertilization
LH	Luteinizing hormone
MAI	Multiple anomalies index
NADPH	Nicotinamide adenine dinucleotide phosphate

NAG	Neutral α -glucosidase
NaOH	Sodium hydroxide
NGS	Next Generation Sequencing
PFA	Paraformaldehyde
RNA	Ribonucleic acid
ROS	Reactive oxygen species
RT	Rectal temperature
SCSA	Sperm chromatin structure assay
SDI	Sperm deformity index
TSP	Testis suprascrotal Position
T	Testosterone
TUNEL	Terminal deoxynucleotidyl transeferase dUTP nick end labelling assay
TZI	Teratozoospermia index
WHO	World Health Organization

Résumé:

L'impact des expositions de la vie courante, et en particulier de la température, sur la reproduction masculine est très étudié. Dans ce projet, nous avons étudié deux principaux paramètres liés à l'infertilité après une exposition testiculaire à une augmentation modérée de température (+2°C) chez des hommes sains : la morphologie et l'aneuploïdie du spermatozoïde et exploré leur potentielle réversibilité. Nous avons conçu un protocole expérimental qui a impliqué 5 hommes fertiles et une population témoin de 27 autres hommes fertiles. L'augmentation de température testiculaire et épидидymaire a été obtenue en maintenant les testicules dans une position supra-scrotale au moyen de sous-vêtements spécialement conçus, portés 15 +/- 1 heure par jour pendant 120 jours consécutifs.

La première partie de ma thèse a été consacrée à l'étude de l'augmentation de température sur la morphologie des spermatozoïdes et l'indice des anomalies multiples (IAM). Nous avons observé un impact significatif sur la morphologie du sperme et l'IAM entre le 20ème et 34ème jour reflétant un effet sur les stades de spermiogenèse et de méiose. Cet effet drastique a été présent pendant toute la période de chauffage et la récupération des valeurs initiales a été observée au 73ème jour.

Dans une deuxième partie, les aneuploïdies des chromosomes X,Y, 18 ont été analysées par hybridation in situ par la fluorescence (FISH) avant, pendant et

après l'augmentation modérée de température. Nous avons constaté une augmentation significative de l'aneuploïdie totale du sperme, de la disomie sexuelle et de la nullisomie au 45ème jour après chauffage. Ces effets ont été complètement inversés après deux cycles de spermatogenèse après l'exposition à la chaleur.

Ces résultats confirment l'impact de la température sur la spermatogenèse et peuvent avoir des implications cliniques dans l'infertilité masculine et notamment le concept de réversibilité après au moins deux cycles de spermatogenèse sans exposition à la chaleur.

Mots clés : Température, Testicule, Morphologie, spermocytogramme, Aneuploïdie, hommes, Spermatogenèse, Epididyme.

Abstract:

Lifestyle exposures including temperature have been studied in relationship to male reproductive health. In this project, we focused on two main parameters linked to infertility after testicular exposure of temperature. We evaluated the effects of a mild testis temperature increase (+2°C) on sperm morphology and sperm aneuploidy in five healthy men and examined its potential reversibility. We used 27 fertile men for comparison of results (control group), and designed an experimental protocol that induced in five healthy fertile men, an increase of testicular and epididymal temperature by maintained the testes in a supra-scrotal position by means of specially designed underwear worn 15 ± 1 hours daily consecutive days.

The first part of my thesis was dedicated to the study of the effects of a mild testis temperature increase (+2°C) on sperm morphology and multiple anomalies index (MAI). We observed that a significant impact on sperm morphology and MAI as early as days 20 and 34 reflecting an effect on the spermiogenesis and meiosis stages. This drastic effect was present during the entire heated period and recovery of the values before heating was observed at day193.

In the second part, sperm aneuploidies of chromosomes X, Y, 18 were analyzed by fluorescence in situ hybridization (FISH) before, during and after a mild testis temperature increase. We found that a significant increase in total

sperm aneuploidy, sex disomy and nullisomy at 45 days post-heating. Moreover, since increased abnormal sex disomy XY18, sex nullisomy and total sperm aneuploidy values were observed at the same time, these effects were completely reversed at least two spermatogenesis cycles after heat exposure.

Our results may have clinical implications in male infertility, the effect of a mild testis temperature increase was reversible but it seems advisable to allow at least one or two cycles of spermatogenesis to pass in order to recover normal exacting function.

Keywords: Temperature, testis, sperm morphology, MAI, aneuploidy, men, spermatogenesis, epididymis

Introduction:

Knowledge of the relationship between reproductive biology and the environment or exogenous factors will give us an excellent understanding of factors controlling fertility, reproduction and conservation of species. Sexual reproduction requires two parents and produces genetically distinct offspring. The male sex gamete (sperms) fuses with the female sex gamete (eggs) to create a zygote. The process of the male and female sex cells fusing is called fertilization. However, the medical definition of infertility is the failure to conceive following twelve months of unprotected intercourses.

Male reproductive health has deteriorated in many countries during the last few decades. In the 1990s, declining semen quality has been reported from Belgium, Denmark, France, and Great Britain (Toppari et al., 1996). Furthermore, in the world there is between 8 and 12% infertile couples (WHO 2010), affecting between 50 and 80 million people; both partners (male and female) contribute significantly in infertility disturbances. Moreover, it should be recalled that social and environmental factors, as well as physiological and genetic ones, contribute to the condition. Also, lifestyle conditions like smoking, alcohol consumption and exposure to chemical material are risk factors of infertility (Sharma et al., 2013).

What we do know is that spermatogenesis depends on two physiological factors; hypothalamic-pituitary-testicular axis and testicular thermoregulatory systems. The temperature was one of the most important impacts on male fertility; the high-temperature exposure adds an additional challenge to physiological spermatogenesis processes. The temperature, coupled with high relative humidity, can be taxing on the efficiency of sweating and other mechanisms responsible for cooling the testis. Maintenance of a lower testicular temperature relative to core body temperature is achieved by means of the thermoregulatory tissues of the testes; namely, the pampiniform plexus, and scrotum (Wallach et al., 1988).

In many mammals, including human, it is established that testis must be 4–6 °C below core body temperature to sustain physiological production of sperm (Mieusset et Bujan 1995). The testis, epididymal and scrotal are acutely sensitive to an increase of only a very few degrees, and much effort has been devoted to the analysis of this response (Bedford 1991). Dysfunction of thermoregulatory systems or conditions exceeding the efficiency of these systems results in an increase of testis temperature (Candas et al., 1993). Any variation in testicular temperature, high or low, may change the output of testicular functions. Daily life behaviors may be the cause of the increase of testis temperature for example; taking hot baths or sauna, sitting for longer periods, during driving, wearing tight underwear, occupation in higher

temperature. Pathological conditions like fever, cryptorchidism and varicocele are also involved in testicular temperature increase.

Moreover, if we look at it we find numerous animal and human studies that described the effect of an increase in testicular temperature on sperm characteristics and spermatogenesis processes. But very few ones have been performed to investigate the effect of temperature on sperm characteristics according to the physiological time of spermatogenesis and epididymis transit in men.

The main objective of this research work was to investigate the effects of the mild increase of testicular temperature on sperm morphology and changes in sperm aneuploidy chromosomes according to the physiological chronology of spermatogenesis in human.

To begin this work, a brief overview of the anatomy and physiology of male reproductive systems, testes and epididymis is presented.

Chapter I

Anatomy and physiology of the male reproductive system

(Testes, Epididymis, Different type of testicular cells, Scrotum, Glands, Testicular blood circulation system)

1. Anatomy and physiology of the male reproductive system

1.1. Testes

Testes are glandular organs suspended by a spermatic cord in a cutaneous pouch-like structure called scrotum. At early fetal life they are contained in the abdominal cavity, before birth each testis moves through the abdominal musculature to descend into the scrotal cavity. In human, testicular size depends on age and stage of sexual development. At birth, the testes measure approximately 1.5 cm in length and 1 cm in width, before the age of 12 years testicular volume is around 1–2 cm³. On average, testes of adults measure 15–25 cm³ in volume, measure 3.6–5.5 cm in length and 2.1–3.5 cm in width (Leung et al., 1984), and are compartmentalized by septal divisions into individual lobules (Cheng et al., 2016; Niederberger, 2011). They are surrounded by a fibrous capsule, the *tunica albuginea*, from which septations extend toward the testicular mediastinum, dividing the testis into 200–300 lobules. Each of these lobules contains several highly convoluted seminiferous tubules. These tubules consist of a basement membrane lined by Sertoli cells, interspersed with germ cells at various stages of maturation.

The testes are responsible for the production of sperm cells and the male sex hormone testosterone. The testes are comprised of two compartments:

1.1.1. Interstitial compartment

The most important cells of this compartment are the Leydig cells. In the human testis the interstitial compartment represents about 12–15% of the total testicular volume, 10–20% of which is occupied by Leydig cells. These cells are the source of testicular testosterone and of insulin-like factor 3 (INSL3). They also contain immune cells, blood and lymph vessels, nerves, fibroblasts and loose connective tissue (Weinbauer et al., 2010).

1.1.2. Tubular compartment

This compartment represents about 60–80% of the total testicular volume. It contains the germ cells and two different types of somatic cells, the peritubular cells and the Sertoli cells. The testis is divided by connective tissue septa into 250-300 lobules, each containing 1-3 profoundly tangled seminiferous tubules. Each human testis contains around 600 seminiferous tubules. The process of spermatogenesis takes place in the tubular compartment (Niederberger, 2011; Weinbauer et al., 2010) (Fig 1).

1.1.3. Different type of testicular cells

Testicular cells such as; Leydig, peritubular and Sertoli cells, secrete a large variety of factors (proteins, cytokines, growth factors, opioids, steroids,

prostaglandins, modulators of cell division) and support the structure of the germinal epithelium (Foster & Lamb, 1988).

1.1.3.1. Leydig Cells

The interstitial compartment contains about 200×10^6 Leydig cells, that produce and secrete the most important male sexual hormone, testosterone. There are the different types of Leydig cells: stem Leydig cells as founder cell, progenitor Leydig cells as a committed stem cell, fetal Leydig cells as a terminally differentiated cell in the fetus, and adult Leydig cells as the terminally differentiated Leydig cell (Christensen, 1975; Kaler et al., 1978).

1.1.3.2. Peritubular Cells

The seminiferous tubules are covered by a *lamina propria*, which consists of a basal membrane, a layer of collagen and the peritubular cells (myofibroblasts). The role of peritubular cells produce several factors that are involved in cellular contractility: panactin, desmin, gelsolin, smooth muscle myosin and actin (Holstein et al., 1996). These cells also secrete extracellular matrix and factors typically expressed by connective tissue cells: collagen, laminin, vimentin, fibronectin, growth factors, fibroblast protein and adhesion molecules (Albrecht et al., 2006; Schell et al., 2008). An important and accepted role of peritubular cells is the active transport of immotile sperm.

1.1.3.3. Sertoli Cells

Human Sertoli cells are located on the basal membrane and extend into the lumen of the tubular seminiferous and supporting structure of the germinal epithelium. Sertoli cells occupy a 30% of the volume of the seminiferous tubules of mammals with active spermatogenesis (Russell et al., 1990) and present elongated or irregularly-shaped nuclei. Testis with complete spermatogenesis contains $800\text{--}1200 \times 10^6$ Sertoli cells. Along the cell body extending over the entire height of the germinal epithelium, all morphological and physiological differentiation and maturation of the germinal cell up to the mature sperm take place (Weinbauer et al., 2010). Moreover, Sertoli cells assist in the translocation of early meiotic cells from the basal to the adluminal compartment during the epithelial cycle in the seminiferous epithelium. Sertoli cells also play an important secretory function: cytokines, growth factors, opioids, steroids, prostaglandins, modulators of cell division. They also produce testicular fluid, including ABP, a protein that binds to and concentrates androgens, which are essential for the development of the spermatozoa. They finally help for translocating the differentiating cells to the lumen, and phagocytosing degenerating germ cells and surplus cytoplasm remaining from spermiogenesis (Sharpe et al., 2003).

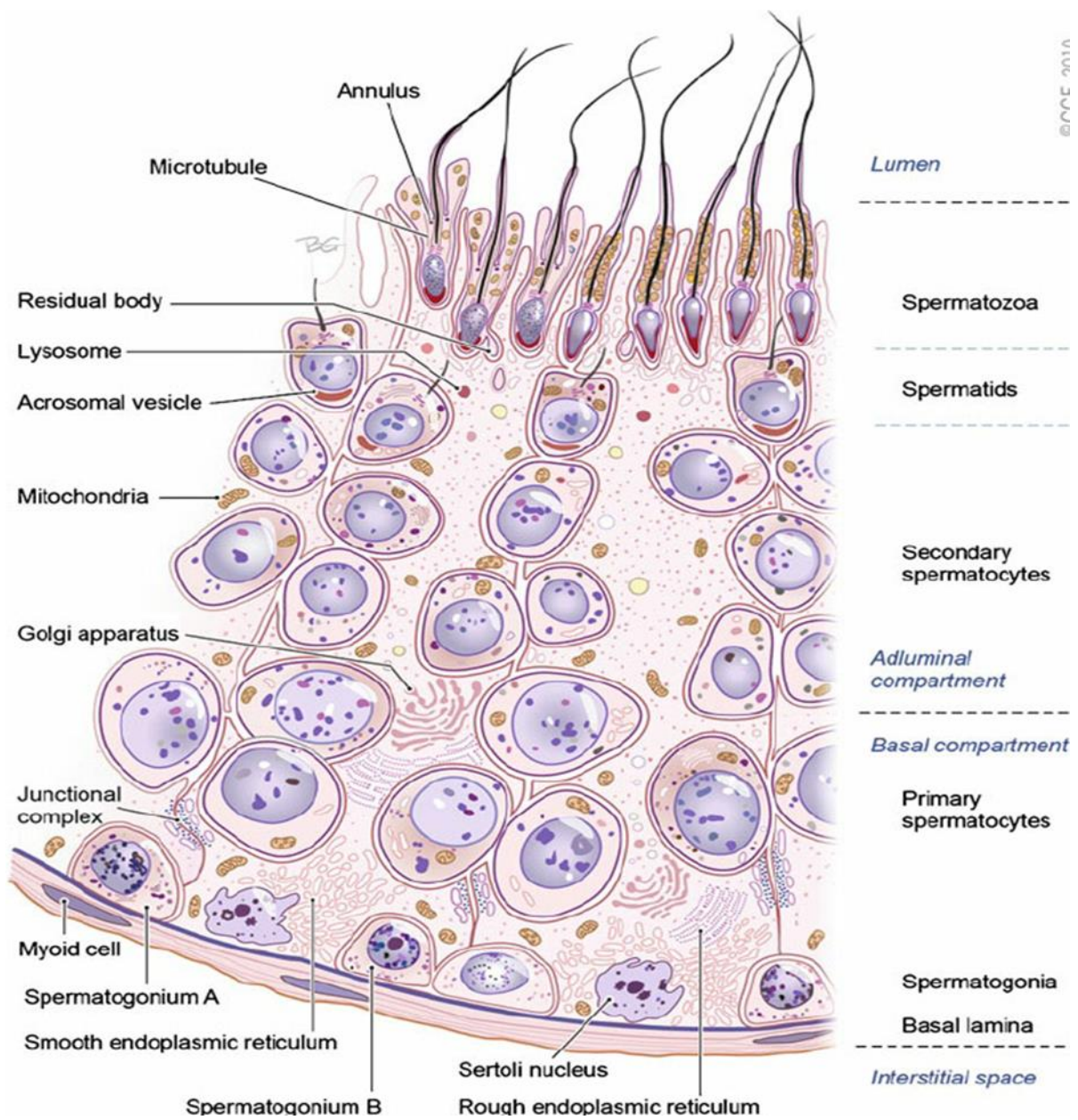


Figure 1 Section of the germinal epithelium in the seminiferous tubule. (Sharma & Agarwal., 2014)

1.2. Epididymis

The epididymis is a tubular organ which receives spermatozoa from testis. They are two in number, one on each testis. The major component parts of the epididymis are customarily referred to as head (caput), body (corpus) and tail (cauda) (Fig2). Each epididymid region supports distinctive functions with the caput and corpus carrying out early and late sperm maturational events, respectively, while the cauda region primarily serves as a storage site for functionally mature spermatozoa. The cauda epididymis is poorly developed in humans (Johnson and Varner, 1988). This correlates with the very limited sperm reservoir capacity in our species as confirmed after performing semen analyses on successive ejaculates from healthy young men (Johnson and Varner, 1988). Moreover, transit along the human epididymis takes 2–4 days (Bedford, 1990; 1991), as spermatozoa passing from the proximal to distal regions of the epididymis, they undergo a series of physiologic, biochemical, and morphologic changes with the end result being spermatozoa that have acquired the function of progressive motility and the ability to fertilize an ovum (Yeung et al., 1993; Soler et al., 2000; Cooper and Yeung, 2006). A distal part of epididymis plays an important role in acquiring the spermatozoa binding capacity (Moore et al., 1992). The chromatin of sperm becomes more condensed during epididymal transit (Haidl et al., 1994; Golan et al., 1996).

Principal functions of the epididymis are:

- (i) Producing the epididymal plasma, thus providing the spermatozoa with a fluid environment of a very special composition; where the fixed cells are both resorptive and secretory in nature and sperm can survive for 2 weeks in this environment.
- (ii) Promoting the maturation of spermatozoa, which are prerequisite for sperm motility and fertilizing abilities.
- (iii) Aiding the disposal of ageing and superfluous spermatozoa.
- (iv) Acting as a sperm reservoir (Cornwall, 2009; Belleannée et al., 2012).

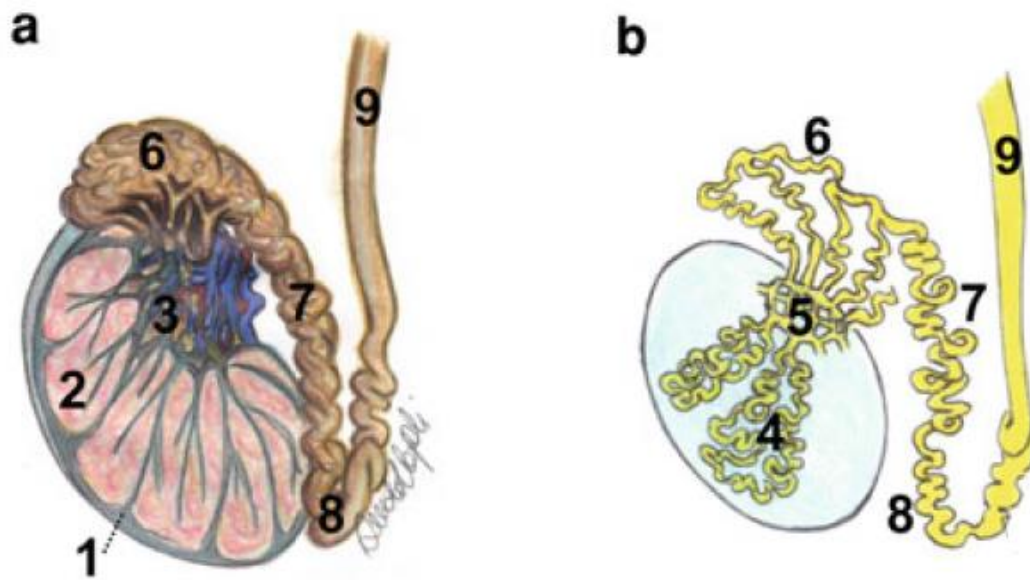


Figure 2 Anatomy of the testis and epididymis A) Longitududnal anatomical section. B) Inner structure of the spermatic route. 1 tunica albuginea, 2 lobules, 3 mediastinum testis, 4 seminiferous tubules, 5, rete testis, 6 head of the epididymis, 7 body of the epididymis, 8 tail of the epididymis, 9 vas deferens. (Liguori et al., 2012).

1.3. Scrotum

The testes are located in a skin-covered, highly pigmented, muscular sack called the scrotum that extends from the body behind the penis. This location is very important to keep the testes 2 to 4°C below core body temperature (Mieusset & Bujan, 1995; Liu, 2010). The scrotum divides into two compartments, each housing one testis. In the higher environment temperature or increase in testicular temperature, the scrotum relaxes from the body core with an increase of scrotal surface area, which promotes heat loss. On the contrary, there are the dartos and cremaster muscles to moving are the testes closer to the body and decrease the surface area when testes exposed to cold weather (Shafik, 1973). It varies from 2 to 8 mm in thickness (Leung et al., 1984). The system of different membranes inside the scrotum avoids testes from being injured due to blows or squeezes and acts as a covering and a protection to the testes: the testes lies suspended and loose in their cavity and are surrounded by several different layers in order to allow them a better mobility (Bertolotto et al., 2012).

1.3.1. Skin

The skin of the scrotum is a brownish layer, usually thrown into folds or rugæ, which contains roots of scattered, crisp hairs that cover the scrotum surface. It is very elastic and capable of great distension, and on account of the looseness

and amount of subcutaneous tissue, the scrotum becomes greatly enlarged in cases of edema, The skin of scrotum have special characteristics such as ; sweat glands, little subcutaneous fat, connective tissue, an abundance of thermoreceptors (Bertolotto et al., 2012; Wallach et al., 1988).

1.3.2. Dartos

The tunica dartos is a fat-free thin layer of smooth muscular fibers: it is a continuation of Scarpa's fascia which is a membranous layer of the subcutaneous tissue in the abdominal wall. The dartos divides the scrotum into two cavities, each containing one testis, through an inward septum that extends between the raphe and the under surface of the penis. In older males, the dartos muscle loses its tone, and tends to cause the scrotum to be smoother and to hang down further. The tunica dartos's role is to regulate the temperature of the testicles (Shafik, 1973). It does this by expanding or contracting to wrinkle the scrotal skin. The dartos is closely united to the skin externally, but connected with the subjacent parts by delicate areolar tissue, upon which it glides with the greatest facility.

Moreover, there is other physiological function of this muscle (Shafik et al., 2007), A dartos contraction have a role in testicular temperature elevation. During erection, the recorded dartos muscle (DM) contraction appears to elevate the testicular temperature by two mechanisms: (a) testicular elevation

bringing the testicle closer to the warm abdominal wall, and (b) closure of the fenestrae between the DM bundles thus transforming the scrotal compartment into a closed cavity (Shafik, 1973).

1.3.3. Cremasteric

Prolonged down ward around the surface of the cord and testis, the external spermatic fascia is a thin membrane, derived from the aponeurosis of the external oblique muscle. It is separated from the dartos by loose areolar tissue (Redman, 1996). The cremaster muscle consists of scattered bundles of muscular fibers connected together into a continuous covering by intermediate areolar tissue. It is a thin layer of skeletal muscle found in the inguinal canal and scrotum between the external and internal layers of spermatic fascia, surrounding the testis and spermatic cord. The cremaster muscle is a paired structure, there being one on each side of the body. Anatomically, the lateral cremaster muscle originates from the internal oblique muscle, just superior to the inguinal canal, and the middle of the inguinal ligament. The medial cremaster muscle, which sometimes is absent, originates from the pubic tubercle and sometimes the lateral pubic crest. Both insert into the tunica vaginalis underneath the testis (Bertolotto et al., 2012).

1.4. Testicular blood circulation system

The testicular arteries and veins play major roles in the thermo-regulation that is essential for the efficient functioning of this organ.

1.4.1. Testicular artery

It originates from the aorta, runs obliquely through the abdominal wall via the inguinal canal (Asala et al., 2001). Then it becomes flexuous from the deep inguinal ring. In all eutherian mammals with scrotal testes, the artery is unique, except for the branches to the epididymis, two in man, superior to the head and inferior to the body and tail (Harrison & Barclay, 1948).

1.4.2. Testicular veins

The testicular vascularization play an important role in reducing scrotal/testicular temperature by acting as a counter-current heat exchange, where the venous return from the testis is described as including three groups of veins (Wishahi, 1992) that intercommunicate and form the spermatic venous plexus “pampiniform plexus” :

1) Testicular vein (internal spermatic), which drains into the left renal vein or inferior vena cava on the right side.

2) Vassal vein (deferential), which follows the vas deferens and ends in the superior or inferior vesical vein.

3) Cremasteric vein (external spermatic), which drains into the inferior epigastric vein and then to the external iliac vein.

The testes are drained by a plexus of veins (pampiniform plexus), which continue as the testicular veins. The function of pampiniform plexus is to act as a heat exchanger, cooling the arterial blood before it reaches the testes (See chapter II, Fig 10). The right testicular vein directly drains into the inferior vena cava and the left testicular vein drains into the left renal vein (Labranche et al., 2018).

1.5. Vas deferens

The vas deferens is a thick muscular tube that measures approximately 35 to 40 cm from the cauda epididymis to the point of fusion with the seminal vesicle and ejaculatory ducts. Five portions have been previously described: epididymal, scrotal, inguinal, pelvic, and ampulla. The vas deferens, like the epididymis and seminal vesicle, is derived from the mesonephric duct. The ability to propel sperm forcefully is dependent on a three-layered muscular coat, with an inner and outer longitudinal layer and a middle circular layer. While the vas deferens receives nerve fibers from the sympathetic and parasympathetic nervous system, the rich supply of adrenergic fibers contributes to the efficiency of sperm transport. The vas deferens receives its

blood supply from the deferential artery via the inferior vesical artery, and the deferential vein accompanies it (Niederberger, 2011; Goldstein, 2013).

1.6. Glands

The male accessory sex glands vary considerably in mammals with respect to their topographical location, size, morphology, and functions, thus reflecting the diversity of species-specific requirements of these glands for reproduction that may be due to differences in environment and sexual habits (Aumuller & Seitz, 1990). The accessory glands of the male reproductive system are the seminal vesicles, prostate gland, and the bulbourethral glands, this glands secretion that aid in sperm transport, maintenance of stored sperm and fertilization processes (Nieschlag et al., 1992) (Fig 3).

1.6.1. Seminal Vesicles

The paired seminal vesicles are saccular glands posterior to the urinary bladder. Each gland has a short duct that joins with the ductus deferens at the ampulla to form an ejaculatory duct, which then empties into the urethra (Zhang, 1999). While, contributing to approximately 60% of the fluids passed from the human male during ejaculation, this fluid from the seminal vesicles is viscous and contains fructose, which provides an energy source for the sperm, also they secrete acid, inorganic phosphorus, potassium, prostaglandins, which contribute to the mobility and viability of the sperm; and proteins that cause

slight coagulation reactions in the semen after ejaculation (Aumuller & Riva, 1992).

1.6.2. Prostate

The prostate gland that is divided into two compartments muscular and glandular structures surround the neck of the male urinary bladder and urethra. The prostate gland in normal adult men weighs 15 to 20 g and length 4 to 6 cm. In human, development of the prostate begins with the growth of prostatic buds from the urogenital sinus at about 10 weeks of fetal development (Hayward & Cunha, 2000). In general, the prostate produces a variety of substances such as zinc (Zn), citric acid (citrate), acid phosphatase and gamma-glutamyltransferase, enzymes, and fibrinolytic. These elements have been considered reliable markers of the prostate gland. Zinc has a tendency to bind with other elements of semen; it can sometimes be bound to the surface of the sperm cells. Zn is an essential trace element for the maintenance of germ cells, the progression of spermatogenesis, and the regulation of sperm motility. (Aumuller & Seitz, 1990). Moreover, the most seminal plasma content of zinc comes from this gland.

1.6.3. Bulbourethral Glands (Cowper's)

A bulbourethral gland, also called a Cowper's gland are small, pea-sized glands, located inferior to the prostate gland near the base of the penis between the two layers of the fascia of the urogenital diaphragm in the male reproductive system. A short duct from each gland enters the proximal end of the penile urethra (Schattman et al., 2015). In response to sexual stimulation, the Cowper's glands secrete an alkaline mucus-like fluid. This fluid neutralizes the acidity of the urine residue in the urethra, helps to neutralize the acidity of the vagina, and provides some lubrication for the tip of the penis during intercourse (Chughtai et al., 2005)

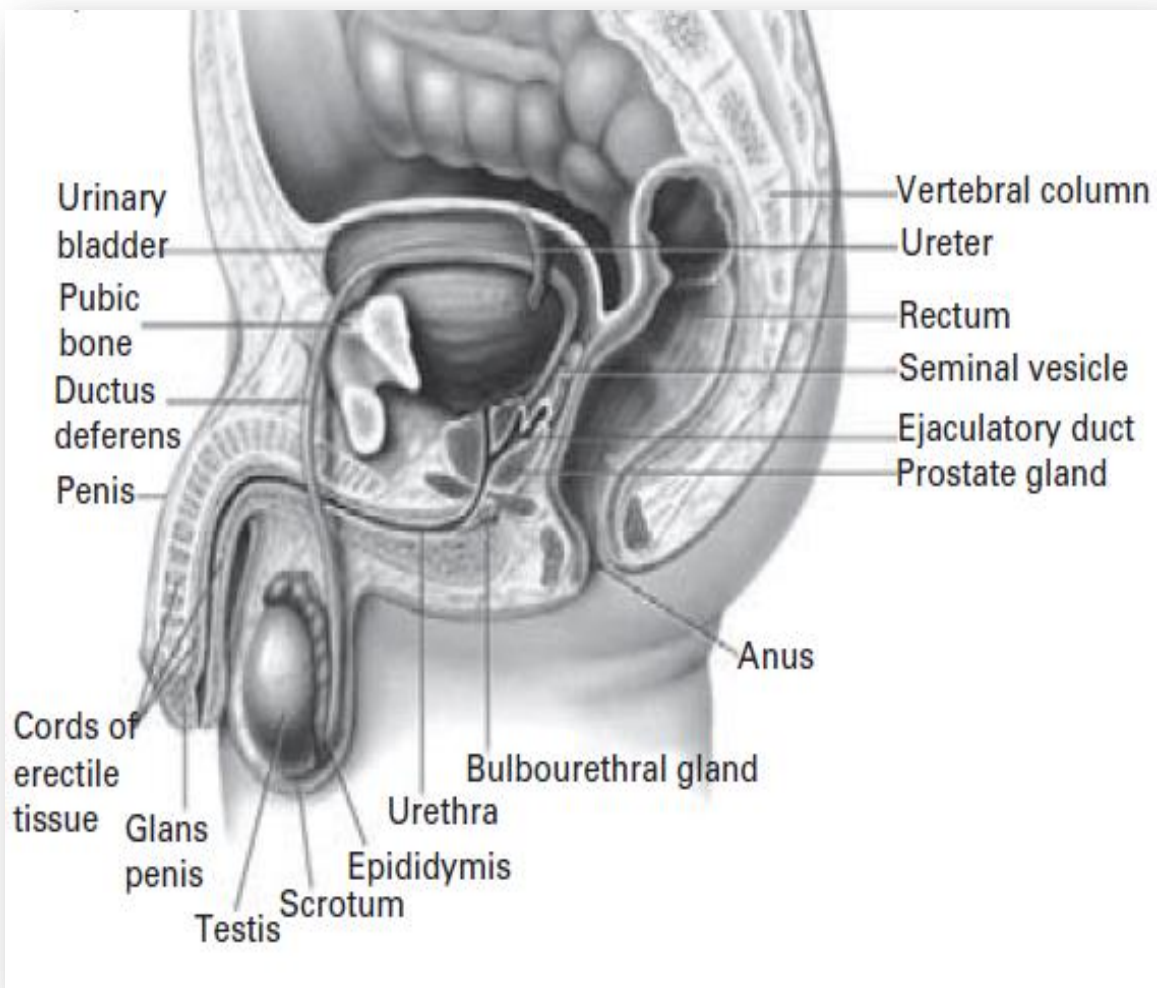


Figure 3 Anatomy of the male reproductive system (Niederberger, 2011).

Chapter II

Spermatogenic cells

(Mitosis, meiosis, spermiogenesis, spermiation)

2.1. Spermatogenesis

Spermatogenesis is a dynamic process whereby undifferentiated stem cells (spermatogonia) develop into highly specialized spermatozoa. The process can be divided into three distinct phases (Lamb & Foster, 1988, Niederberger, 2011):

- A. Spermatogonial proliferation, differentiation, and their division to form preleptotene spermatocytes.
- B. Meiosis of spermatocytes to preleptotene spermatocytes and second meiotic divisions to form spermatids.
- C. Spermiogenesis, which is transformation of a round spermatid to a sperm-like mature spermatid.

Spermatogenesis occurs in the seminiferous tubules that form the bulk of each testis. The process begins at puberty, after which time sperm are produced constantly throughout a man's life. One production cycle, from spermatogonia through formed sperm, takes approximately 74 days (Johnson et al., 1986). A new cycle starts approximately every 16 days, although this timing is not synchronous across the seminiferous tubules. During this process, the number of chromosomes (44,XY) present in spermatogonia is reduced to the haploid number (22,X or 22,Y) characteristic of spermatids.

2.1.2. Mitosis

Mitosis involves the proliferation and maintenance of spermatogonia. This phase can also be named spermatogoniogenesis, it is a precise, well-orchestrated sequence of events in which the genetic material (chromosomes) is duplicated, with a breakdown of the nuclear envelope and formation of two daughter cells as a result of the equal division of the chromosomes and cytoplasm. Broadly, spermatogonia divide by mitosis into types A and B. Type A_p spermatogonia function to undergo self-renewing divisions serving as stem cells but also undergo amplification by mitotic proliferation and transition into type B spermatogonia. Type B spermatogonia divide by mitosis and then progress to become primary spermatocytes. A continuous self-renewal process is then required, provided by stem cells that can undergo either mitosis (leading to daughter stem cells) or differentiate. Clermont reported that the stem cells are a subgroup of type A spermatogonia that also comprise A_d (dark) spermatogonia (that may represent the reserve or non-proliferative spermatogonial population, which can give rise to A_p) and A_p (pale) spermatogonia (which are probably the precursors of B spermatogonia) (Clermont, 1963) (Fig 5).

Spermatogonia do not separate completely after mitosis due to incomplete cytokinesis and remain joined by intercellular bridges. These intercellular bridges persist throughout all stages of spermatogenesis and are thought to

facilitate biochemical interactions allowing synchrony of germ cell maturation. Division of B spermatogonia leads to the development of preleptotene spermatocytes before the beginning of meiotic division. The B spermatogonia lose their contact with the basement membrane to form preleptotene primary spermatocytes $4n$ (Niederberger, 2011).

2.1.3. Meiosis

Meiosis is a key process in spermatogenesis, with the final goal of production of gametes with haploid genetic content. A significant number of exhaustive revisions of this process have been published in the specialized literature (Petronczki et al., 2003). The meiosis stage undergoes changes in the nuclear chromatin configuration after the last spermatogonial division. This stage is comprised of two divisions, meiosis I and meiosis II, this division to yield four haploid spermatids from one diploid primary spermatocyte. After the first meiotic division (reduction division), each daughter cell contains one partner of the homologous chromosome pair, and they are called secondary spermatocytes ($2n$). Each meiotic division is characterized by 4 steps: prophase, metaphase, anaphase, and telophase.

The prophase of first meiotic division lasts 3 weeks and the other phases of first meiotic division and whole of the second meiotic divisions take 1-2 days (Weinbauer et al., 2010). The process starts when type B spermatogonia lose

contact with the basement membrane and form preleptotene primary spermatocytes. Prophase itself is subdivided into five phases (Fig 4, 5):

(1) leptotene, wherein thread-type chromosomes can be observed; (2) zygotene, wherein the pairing of homologous chromosomes occurs; (3) pachytene, wherein the paired chromosomes thicken and undertake crossing over; (4) diplotene, wherein paired chromosomes decondense and partially separate; and (5) diakinesis, wherein chromosomes recondense.

Following prophase, spermatocytes enter into metaphase, wherein the highly condensed chromosomes become aligned on a metaphase spindle. During anaphase, the chromosome pairs move to opposite poles of the cell. During telophase, the cells finally separate into daughter cells, termed secondary spermatocytes in the process of cytokinesis. (Sharma & Agarwal, 2011).

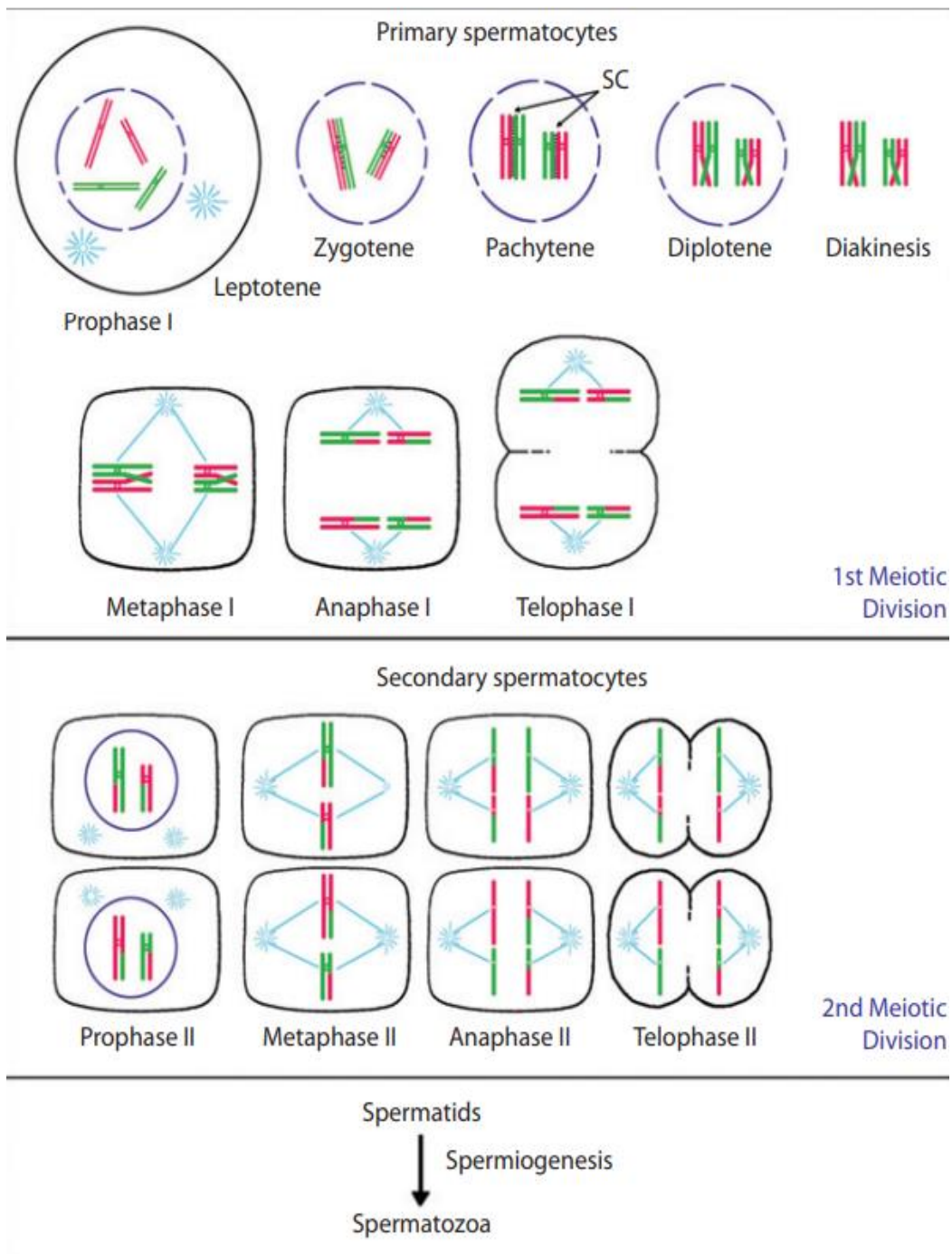


Figure 4 Schematic overview of meiotic process in spermatogenesis. SC, synaptonemal complex (Simon & Rubio, 2017)

The second meiotic division is very short, and in this phase (metaphase - anaphase), the DNA content is reduced to half as the two chromatids of each chromosome separate and move to the opposite poles. At the end of telophase (Fig 4), the spermatids do not separate completely but remain interconnected by fine bridges for synchronous development (Sharma & Agarwal, 2011). Moreover, not surprisingly, errors in the meiotic program have severe consequences for the fertility of an animal. These consequences range from azoospermia to oligospermia, depending on the degree of meiotic failure and the associated germ cell's death (usually apoptosis), to aneuploidy and elevated fetal loss (Pellestor et al., 2011).

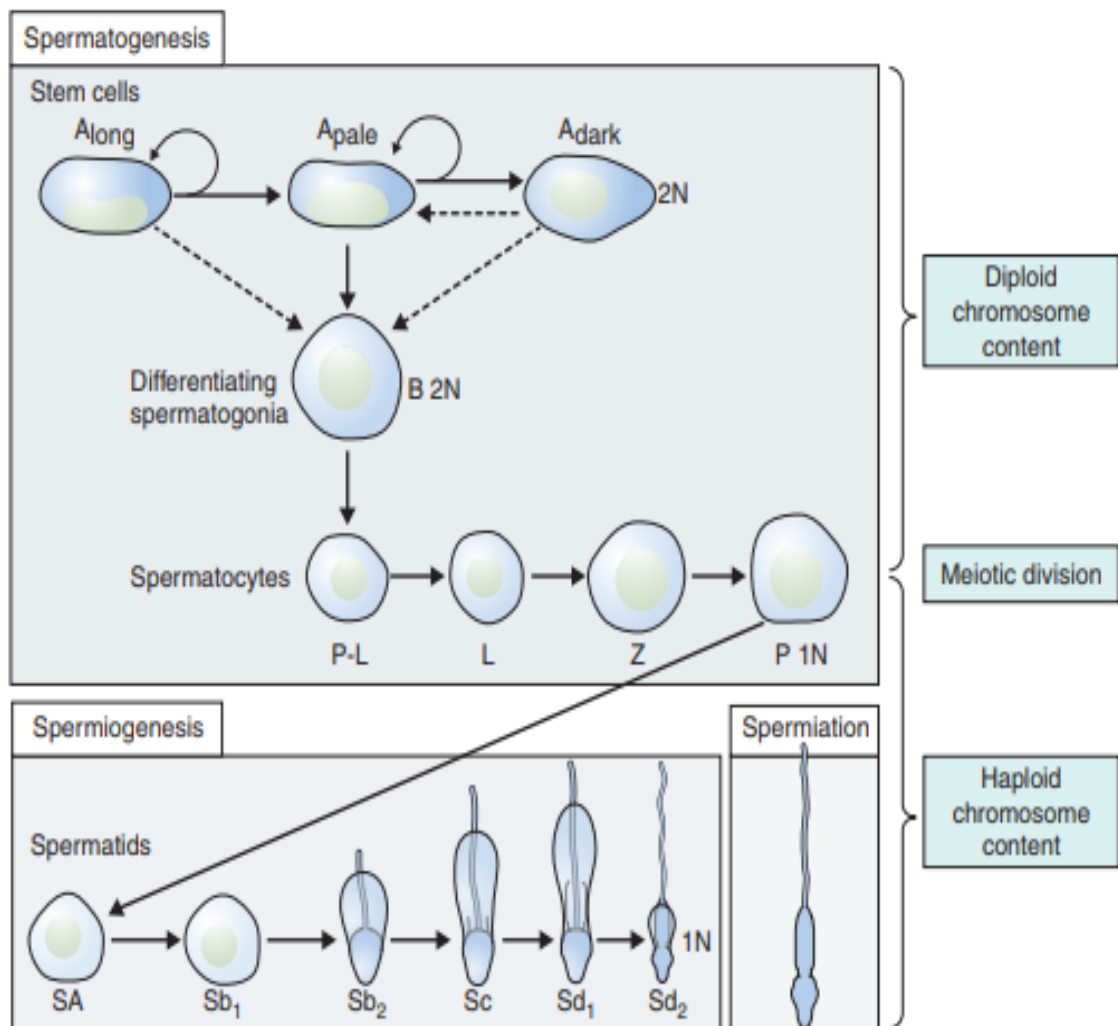


Figure 5 Differentiation of a human diploid germ cell into a fully functional spermatozoon, (Huckins C, 1975).

2.1.4. Spermiogenesis

Spermiogenesis is the third stage of spermatogenesis and is the morphological differentiation of spermatids into spermatozoa, which is the process by which spermatids acquire condensation and structural shaping of the nucleus, lose its cytoplasm and develop several organelles and accessory structures such as the acrosome and the flagellum. They begin after spermatocytes complete 2 quick successive meiotic reductive divisions to produce haploid round spermatids.

In humans, six different stages have been described in the process of spermatid maturation; (Sharma & Agarwal, 2011) these are termed as (Sa-1 and Sa-2, Sb-1 and Sb-2, and Sc-1 and Sc-2), each stage can be identified by morphological characteristics over the following phases (see figure 7); Golgi phase, cap phase, acrosomal phase and maturation phase. However, in a recent study reported by Muciaccia et al. (2013) the process of spermatid maturation can be divided into 12 stages on basis of acrosomal development made visible by immunohistochemistry (IHC) for (pro) acrosin. This new classification has been described as has been already done for many other mammals, including monkeys and mice.

At Golgi phase acrosomal bubbles and craniocaudal symmetry appear. While, in the cap phase the spermatids become elongated and the acrosome develops, covering the cranial half to two-thirds of the spermatid. During the fertilization process enzymes are released by the acrosome (Weinbauer et al.,

2010). The centrioles start to migrate to a position beneath the nucleus that is opposite the acrosomic vesicle. The proximal centriole (PC) will give rise to the attachment point of the tail, whereas distal centriole (DC) will give rise to the developing axoneme.

In the acrosomal phase the cell nucleus becomes further condensed and elongation of the cell continues. During condensation the majority of histones are lost and gene transcription stops. Nuclear chromatin is now extremely condensed, implying that the proteins necessary for spermiogenesis have to be transcribed before this time point and justifying the finding of RNA species with very long half-life and RNA binding proteins. This is the case for transition proteins and protamine. At the chromosomal level, chromatin condensation begins with the replacement of histones, the predominant chromatin proteins of somatic cells, by the basic low molecular weight transition proteins (TNPs). These proteins are then replaced with protamines (PRMs) in the nuclear matrix producing a tightly compacted nucleus with extensive disulfide bridge crosslinking (Bukowska et al., 2013).

A delicate fibrillary structure appears in the cytoplasm and extends from a close association with the nucleus to surround the flagellum for some distance; the chromatoid body approaches the flagellum near the centrioles and partly surrounds it; a delicate ring appears and closely surrounds the

flagellum. Fawcett et al. (1975) clearly demonstrated that the chromatoid body contributed material to the ring. This ring eventually slides down the flagellum for a given distance and comes to rest at the caudal extremity of the middle piece. The middle piece is that portion of the flagellum between the modified centrioles and the ring around which the mitochondria accumulate in a regular covering (Fig 6). The period during which the nucleus and covering acrosomic system undergo the most dramatic morphological transformation was referred to as the acrosome phase.

The principal event during the maturation phase of the spermatids is the extrusion of the rest of the cytoplasm as the so-called residual body. Residual bodies are phagocytosed by Sertoli cells and have a regulatory role. Elongated spermatids and their residual bodies influence the secretory function of Sertoli cells (production of tubular fluid, inhibin, androgen-binding protein and interleukin-1 and 6). In parallel with degradation of the residual bodies, a new spermatogenic cycle begins (Clermont, 1963; Weinbauer et al. 2010).

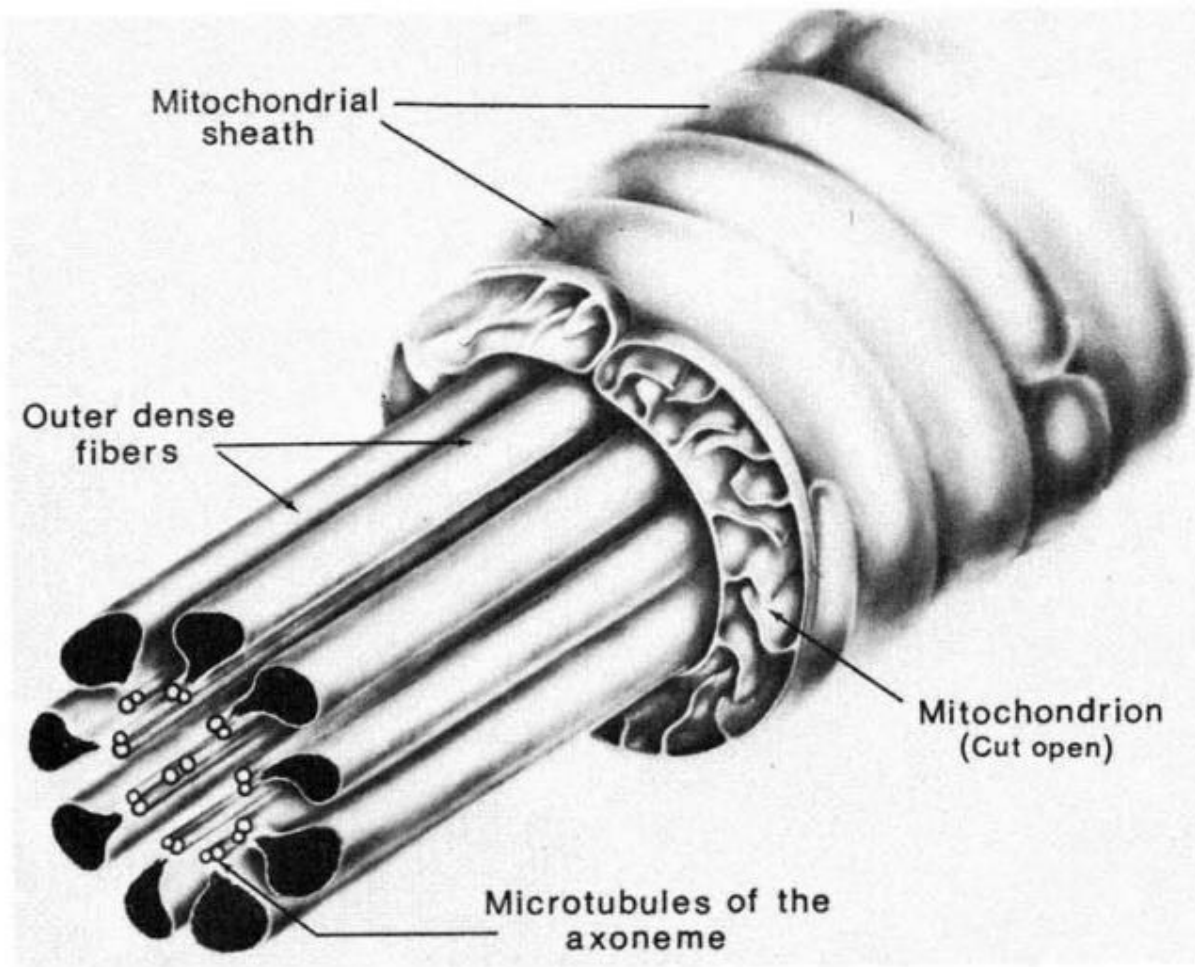


Figure 6 An extended diagram of the components in the midpiece of a mammalian spermatozoon tail (Fawcett, 1975)

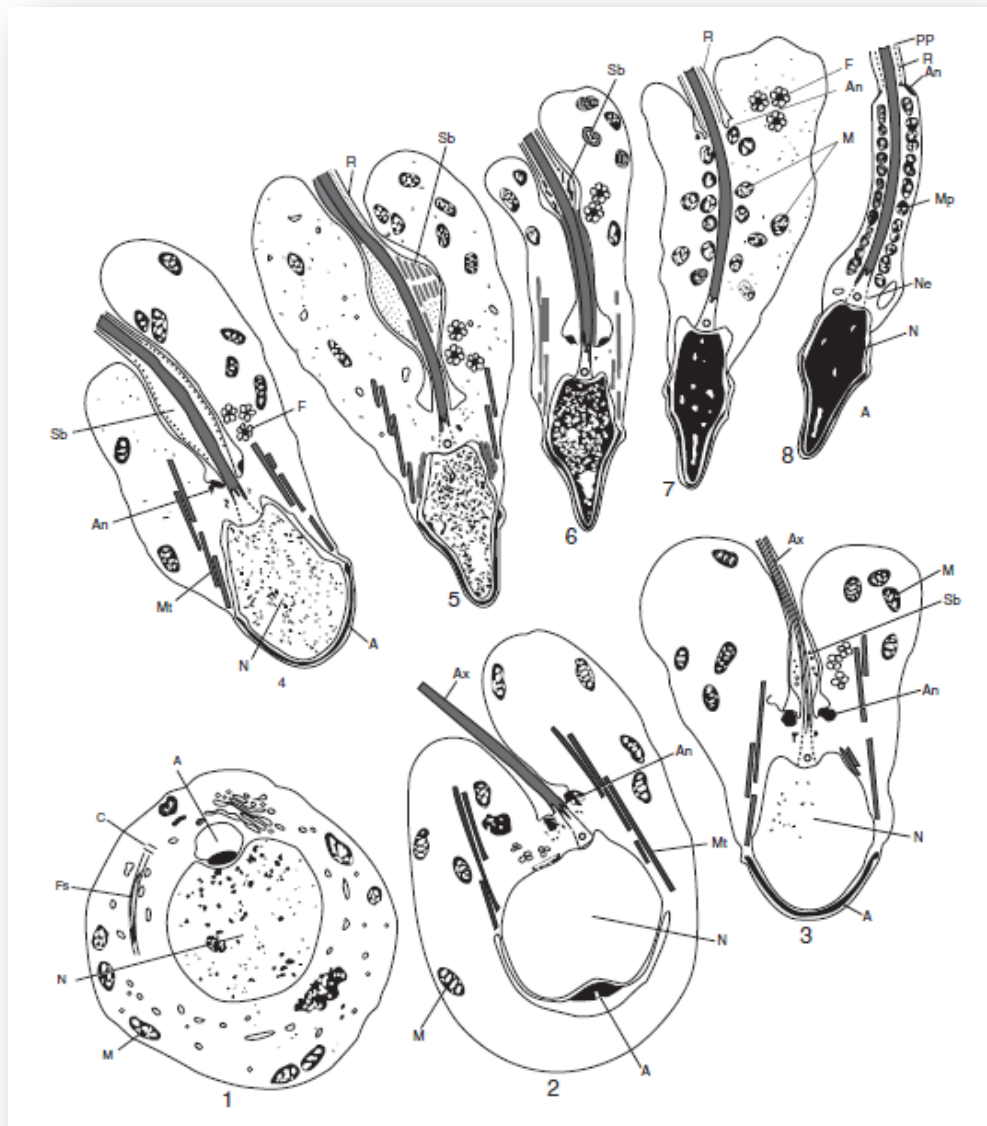


Figure 7 Schematic representation of the differentiation of human spermatid 1, Golgi phase; 2–4, cap phase; 5–6, acrosome phase; 7–8, maturation phase; A, acrosome; An, annulus; Ax, axoneme; C, centriole; F, flower-like structures; Fs, flagellar substructures; M, mitochondria; Mp, middle piece; Mt, manchette; Ne, neck; N, nucleus; PP, principal piece; R, ring fibers; Sb, spindle-shaped body (Holdstein & Roosen-Runge 1981).

2.1.5. Spermiation

Spermiation is a multi-step process involving changes in both the spermatid and the Sertoli cell that ready the elongated spermatid, at the end of spermatogenesis, for its final Sertoli cells into the seminiferous tubule lumen prior to their passage to the epididymis. It takes place over several days at the apical edge of the seminiferous epithelium and involves several discrete steps including remodeling of the spermatid head and cytoplasm, removal of specialized adhesion structures and the final disengagement of the spermatid from the Sertoli cell (O'Donnell., et al 2011; Russell, 1984). However, the contribution of defects in the spermiation process to abnormal sperm forms in the ejaculate is potentially clinically significant, where variety of environmental exposures in humans could adversely affect spermiation and sperm output, whether it be a transient or long-term effect (O'Donnell., et al 2011).

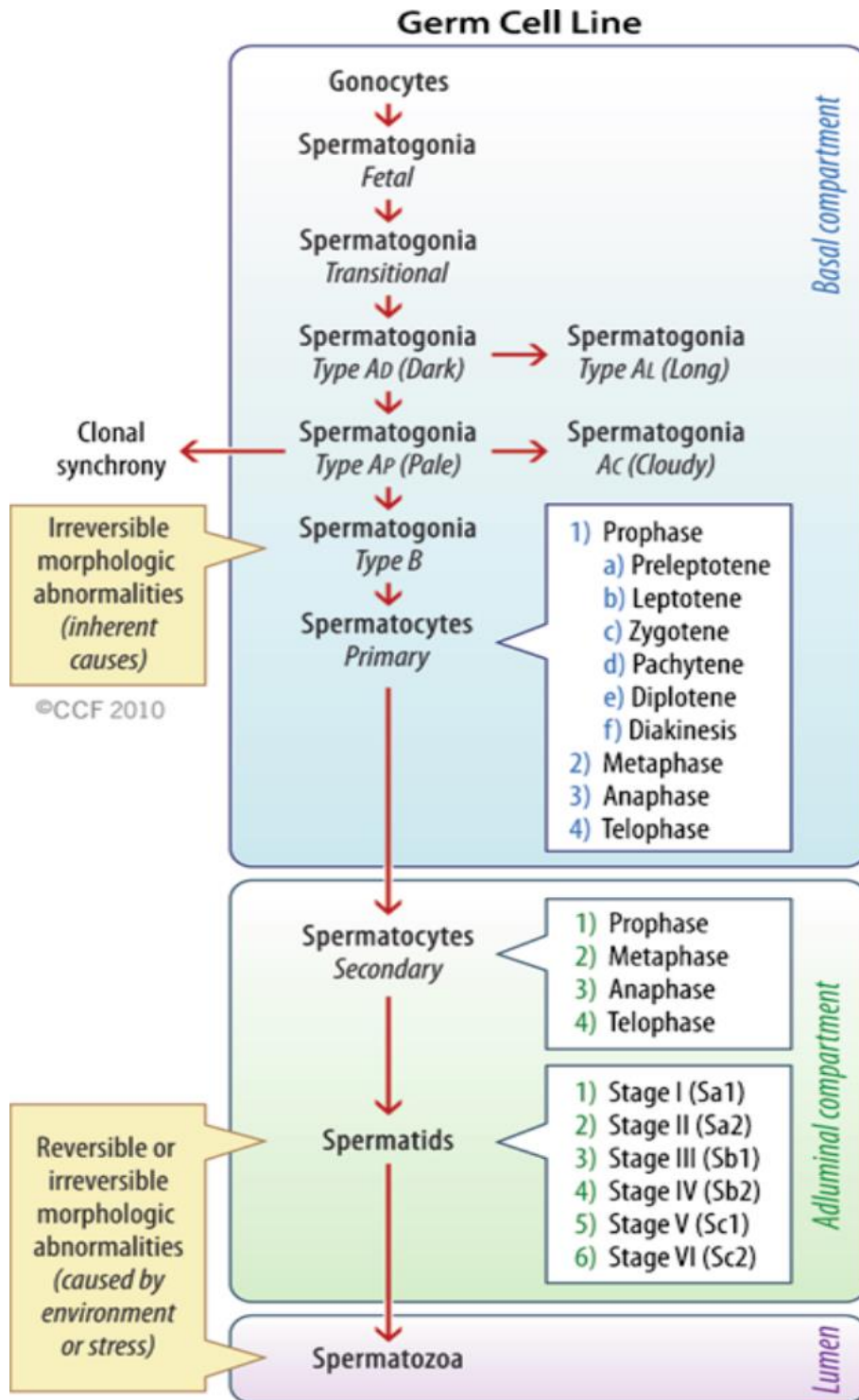


Figure 8 Schematic representation different steps development of spermatogenesis (Sharma & Agarwal, 2014).

2.2. Regulation of spermatogenesis process

Spermatogenesis is highly dependent upon optimal conditions for the process to occur correctly. Two important factors have been implicated in the regulation of this process:

- Endocrine regulation: Hypothalamic-Pituitary-Testicular Axis
- Thermic systems.

2.2.1. Hypothalamic-Pituitary-Testicular Axis

The endocrine control of spermatogenesis is governed by the neuroendocrine activity along the hypothalamic-pituitary-testicular axis. Gonadotropin Releasing Hormone (GnRH) is released in a pulsatile pattern into the pituitary portal blood system from neuroendocrine cells in the basal hypothalamus and acts to stimulate gonadotrope cells in the anterior pituitary to synthesize and release two proteic hormones, follicle-stimulating hormone (FSH) and luteinizing hormone (LH) into the circulation (Fig 9). Once in the bloodstream, these hormones reach the testis, where LH stimulates testosterone production by the Leydig cells in the interstitium while FSH supports spermatogenesis in the seminiferous epithelium by stimulation of the Sertoli cells. A focused network of negative feedback relationships finesses testosterone secretion and sperm production. Both testosterone and estrogens play important roles in the regulation of reproductive function at the cellular and tissue levels. This

cascade is maintained by steroid and peptide feedback within the testis as well as the hypothalamic and pituitary gland (see Figure 9) (Dhole & Kumar, 2017).

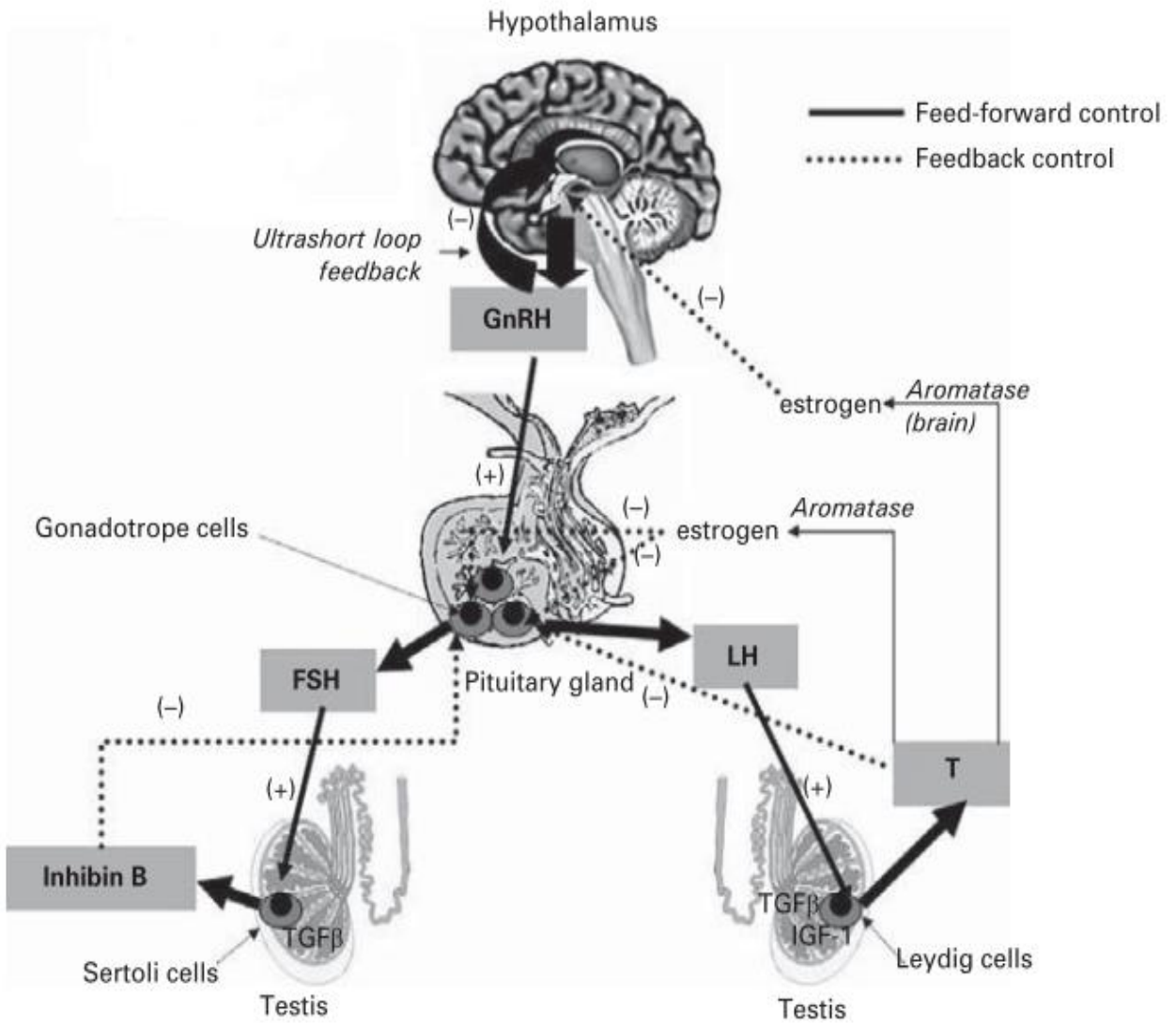


Figure 9 Diagram of the hypothalamic–pituitary–testis axis (Adapted from Niederberger, 2011).

2.2.2. Thermic regulation

In scrotal mammals, testicular thermoregulation is achieved by local and central mechanisms that are independent of the temperature regulatory mechanisms of the body core. The scrotum plays this important role in thermoregulation via several structural and functional adaptations, including the contraction of the cremaster and the dartos muscles, the presence of a large number of apocrine sweat glands, the absence of subcutaneous fat and the activity of the counter-current heat exchange system in the pampiniform plexus. The tunica dartos is a smooth muscle found in the subdermal layer of the scrotal skin, Contraction of the dartos reduces the surface area of the scrotum and blood flow to the scrotal skin, preventing heat loss (Shafik, 1974). Dartos relaxation causes excess heat to be removed. Therefore, the dartos plays an important role in the thermoregulation of the testes and congenital absence of this mechanism leads to infertility. The scrotum is not simply a pouch that houses the testis; it plays an active role in providing the necessary thermal environment for the testis. There are five main anatomical features that contribute to the maintenance of the testicular temperature lower than that of the body core. They are:

- a) the tunica dartos smooth muscle the striated cremaster muscle
- b) a counter-current heat exchange system.

C) the absence of a subcutaneous fat layer.

d) an abundance of sweat glands.

The physiological lower temperature for human testis results from two thermoregulatory systems (Waites & Moule, 1961). Both systems maintain the testicular temperature lower than core body temperature in a range of 32 and 34.5 C° (*i.e.* 2- 4 °C below core body temperature) (Mieusset & Bujan, 1995).

2.2.2.1. Exchange testicular arterial and venous blood streams

The first system reduces temperature of the testicular arterial blood which cools then the testis. The venous blood is therefore also cooler than the body temperature. The venous blood cools the arterial, as a result of a special vascular arrangement (the highly coiled pampiniform plexus) in which the artery winds in and out through venous sinuses within the inguinal canal (Fig 10) (Harrison, 1948). Nevertheless, study by Hsiung et al. (Zorgniotti, 1991) reported that any heating of the scrotal skin increases the venous blood temperature, inducing a reduction of the arteriovenous gradient and thus the efficiency of the thermoregulatory system. In cases of very high thermic conditions, this can induce a reversion of the pampiniform heat exchange resulting in a dramatic increase of the testicular temperature. Dahl and Herrick (1959) examined the gradient in temperature of the blood supplying the testis and scrotum: internal spermatic arterial blood temperature was lower than

that of the aorta by 3°C and the gradient fell markedly when venous drainage through the pampiniform plexus was interrupted.

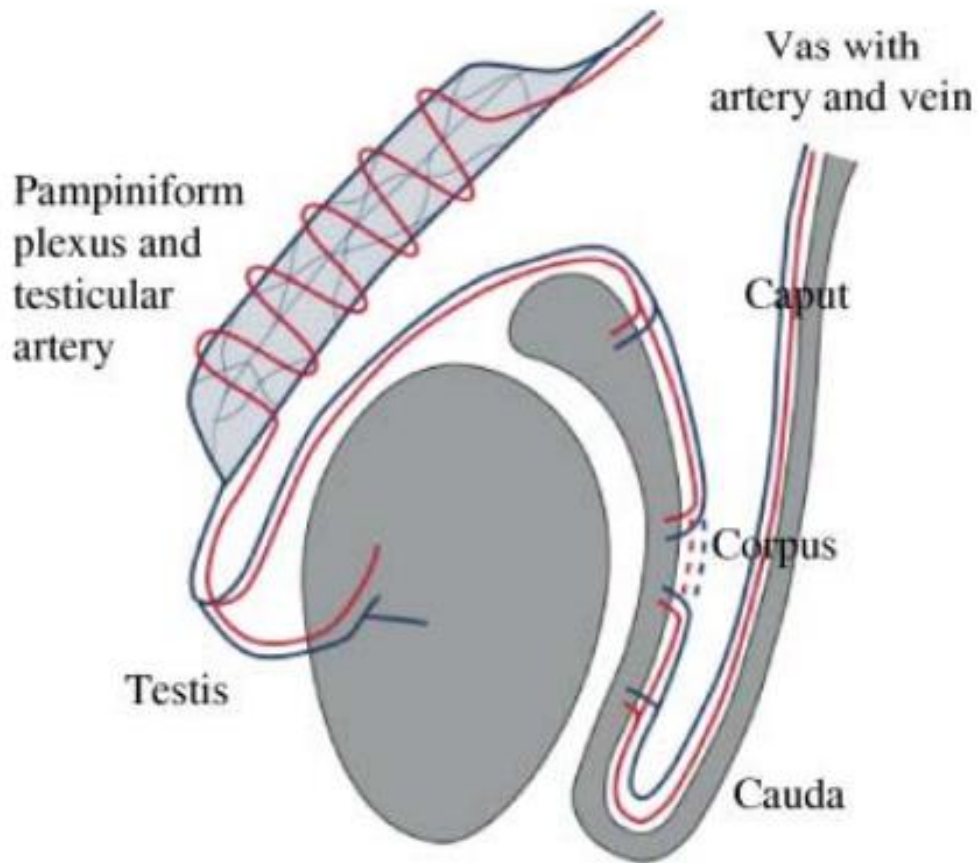


Figure 10 Model of counter-current transfer of heat or a substance from the venous blood in the pampiniform plexus to the blood in the testicular artery (Einer-Jensen & Hunter, 2005).

2.2.2.2. Scrotum and surfaces area heat lost

The second system induces losing heat outside of the testis through passive convection and radiation by the scrotum (Shafik, 1974; Einer-Jensen & Hunter, 2005; Mieusset & Bujan, 1995; Wallach et al., 1988); the role and function of this system are dependent to changes in body and environment temperature and other factors like varicocele.

Moore and Quick (1923) reported that physiologically the scrotum is a local thermo-regulator for the testes, and they see the possibilities of its having contributed materially to the evolution of the mammalian group. The special characteristics of scrotal skin anatomically such as; sweat glands, little subcutaneous fat, connective tissue, an abundance of thermoreceptors and the presence of the readily responsive dartos and cremasteric muscles to changes in environmental temperature are involved to lower temperature for human testis (Wallach et al., 1988). The musculature and vasculature in the genitals play a role in regulating testicular temperature as well. To maximize heat loss, the cremaster muscle that surrounds the testes and spermatic cords and the dartos muscle that lies beneath the scrotal skin relax, causing the testes to hang away from the abdomen and the scrotal skin to slacken, increasing the total surface area for easy heat dissipation (Fig 11) (Durairajanayagam et al., 2015). Further, vasodilation of scrotal vessels and activation of sweat glands promote heat loss when temperatures increase. If it is colder, these structures

pull the testes closer to take advantage of body heat and if it gets hotter muscles relax to allow the testes to get further from the warmth of the body, increasing the exposed surface area for a faster dispersion of heat excess increasing the total surface area for easy heat dissipation (Kleisner et al., 2010; Zoragniotti, 1982; Durairajanayagam et al., 2015).

Moreover, when external temperatures rise and cause the scrotal temperature to increase beyond a threshold value, cutaneous receptors on the scrotal skin are activated, initiating secretions of the scrotal sweat glands and active heat loss occurs through the evaporation of sweat (Waites, 1991; Candas et al., 1993). One or the other half of the scrotal sac hangs at a lower level than the other. The testes, housed within the sacs are also situated, suspended, one slightly lower than its other, this form to increase in surface area lost temperature (Deralakatte & Nithyanandanagar, 2008). Further, vasodilation of scrotal vessels and activation of sweat glands promote heat loss when temperatures increase.

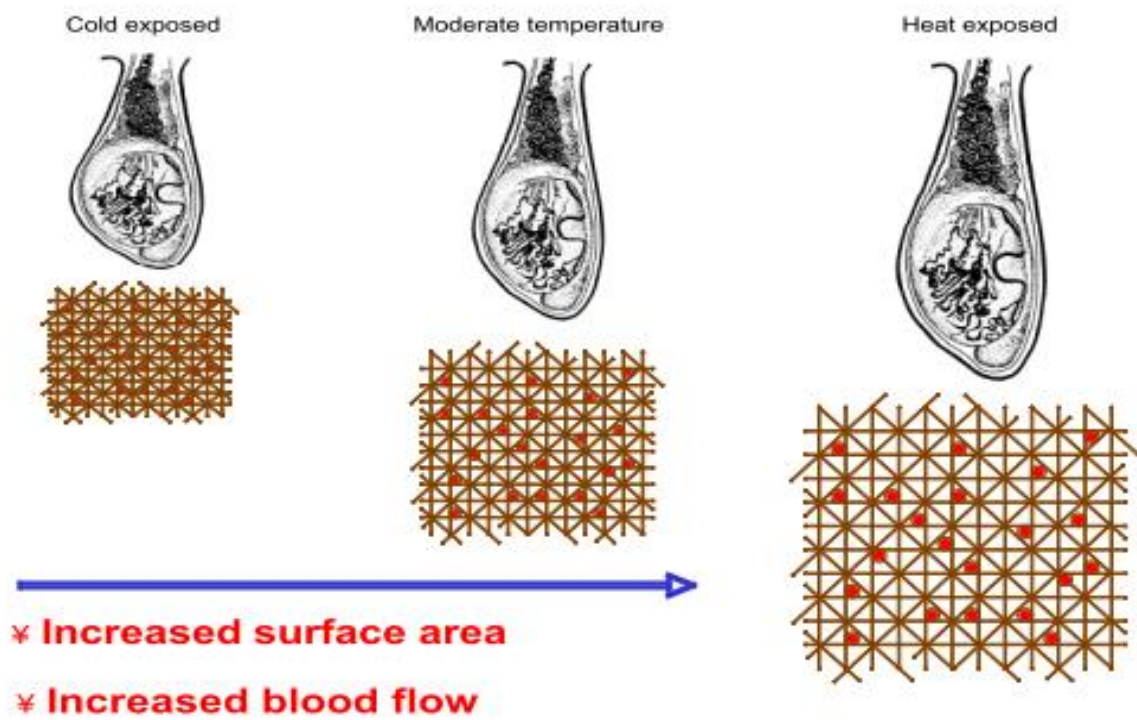


Figure 11 Scrotum and surfaces area heat lost (Nanayakkara, 2011)

Chapter III

Sperm morphology

(Description, Classifications, Pathology)

3.1. Sperm morphology

3.1.1. Sperm (description, function and morphology)

Spermatozoa, or formed sperm is the end result of the spermatogenesis process, and is smaller than most cells in the body; the human sperm divide to three main parts; head, neck and tail [midpiece (anterior portion), principal piece, and end piece (posterior portion)] is about 60 μm long. A typical human spermatozoon has a distinct structure with an oval-shaped head (3–5 μm length and 2–3 μm width), a midpiece (7–8 μm), and a tail (45 μm) (Sedo et al., 2012; Baccetti, 1984) (Fig 12). In addition, this structure called the acrosome covers most of the head of the sperm cell as a “cap” that is filled with lysosomal enzymes important for preparing sperm to participate in fertilization. Moreover, the head is the most important part of the mature male gamete as it contains a nucleus, which is composed of packed chromosomal paternal genetic material (mostly DNA) containing 23 chromosomes. The nucleus comprises about 65% of the head, but unlike most somatic cells, lacks a large cytoplasm to match. The neck of spermatozoa is the site of articulation between the head and tail, and comprises the sperm centriole and connecting piece. During spermiogenesis, the axoneme of the tail grows from the distal centriole while the proximal centriole migrates to the caudal pole of the nucleus and attaches to it. Around the centriolar pair assembles the complex

structure of the connecting piece, a dense protein cylinder formed by nine longitudinal columns closed cranially by the capitulum that articulates with the sperm nucleus. At the final stages of sperm maturation, the distal centriole degenerates and only the proximal one remains at the cranial end of the connecting piece. The tail gives the sperm cell movement and responsible for sperm motility. After spermatogenesis process, the sperm is released into the lumen and is moved along a series of ducts in the testis toward a structure called the epididymis for the next step of sperm maturation, Midpiece contained tightly packed mitochondria for the production of ATP to the power of the flagellum (tail) (Kruger et al., 1986).

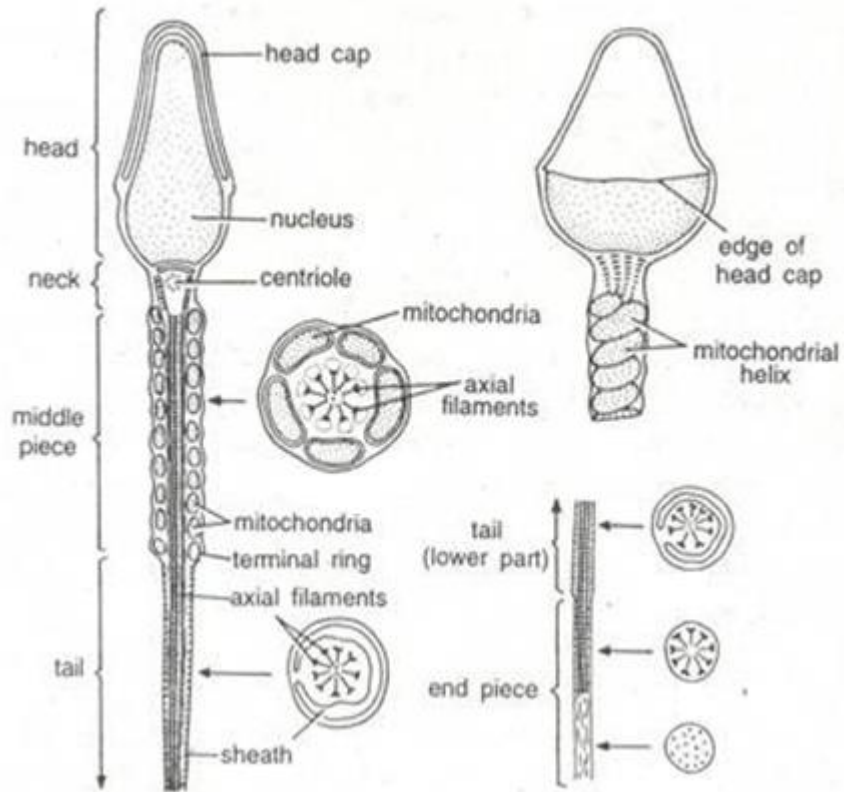


Figure 12 Diagram of a typical mammalian spermatozoon. Cross-sectional insets show the orientation of the internal cell structure (Holstein & Roosen-Runge, 1981)

3.2. Classifications sperm form and sperm morphology

Sperm morphology is described by the size and shape of sperm, and its morphology assessment has been one of the most common tests in evaluation of fertility (Gatimel et al., 2017). Sperm morphology results are reported as the percentage of sperm that appear normal when semen is viewed under a microscope. Moreover, there are three different indices that have been proposed and defined (WHO 1992; 2010; Jouannet et al., 1988; David et al., 1975).

- The multiple abnormalities index (MAI), used in the French modified David classification, is the average number of abnormalities per abnormal spermatozoon.
- The teratozoospermia index (TZI) is similar to the MAI, but a maximum of four abnormalities per abnormal spermatozoon are counted: one each for the head, the midpiece, the principal tail piece, and the residual cytoplasm, regardless of the real number of abnormalities per abnormal spermatozoon.
- The sperm deformity index (SDI) is the number of abnormalities divided by the total number of spermatozoa (normal and abnormal).

3.3. Normal and abnormal sperm forms

Sperm morphology is currently examined in semen smears with the main criteria for normalcy relying on morphometric parameters of the sperm head, mid-piece, and flagellum (Chemes & Rawe, 2003). Morphological analysis of spermatozoa is currently assessed in the stained smears under a light microscope at 1000x magnification (WHO, 2010). Studies on scanning electron microscopy (SEM) and transmission electron microscopy (TEM) facilitated a better understanding of phenotypical abnormalities of human spermatozoa and their cytological details that represented certain functional abilities to an extent (Visco et al., 2010). World Health Organization (WHO) has described the percentage of normal sperm morphology forms through different versions, it was recommended in the last version (5th edition) that the lower reference limit to normal sperm forms is 4% (Table 1). However, this limit is lower than the recommendation in the 4th edition, and the recommended criteria for spermatozoa morphology assessment are also different from that of the 4th edition (see the Table 1). Menkveld (2010) showed that the new proposal of a very low normal value may not provide a strong predictive value for male's fertility potential, as originally reported for sperm morphology evaluated according to strict criteria.

In an another classification (French modified David classification) the reference value for the percentage of normal forms was first 30% and was then

reassessed by Auger et al. (2016) to 23% in a study that described the frequency of the various sperm abnormalities of the head, midpiece and tail principal piece in a large group of fertile men (Gatimel et al., 2017; Auger et al., 2016).

Two classifications exist for the results of the spermocytogram; the modified David classification and the Kruger classification, international, recommended by the World Health Organization (WHO, 2010). Both systems list all the anomalies found on a minimum of 100 spermatozoa, but with a different system are: The Kruger's classification lists four classes of abnormal type: acrosome (front part of the head), head, midpiece, and flagellum anomalies. While, David's modified classification lists 7 types of head anomalies, 3 types midpiece anomalies and 5 types flagellar anomalies. The typical shape threshold also differs between the two classifications. According to Kruger's classification, sperm morphology is considered normal when at least 4% of typical sperm are present, compared to 15% according to David's modified classification, an abnormality of the sperm that can reduce the chances of pregnancy. In general, David's classification was better to describe the type of abnormal tail (flagellum) than Kruger's classification.

3.3.1. Normal sperm form

Normal sperm cell is about 60 μm in length and consists of a head, neck and tail. A morphologically normal head should be smooth and symmetrically oval in shape with a broad base and tapering apex.

Head and acrosome region

The sperm head measures between 3–5 μm in length and 2–3 μm in width, with a length-to-width ratio of between 1.5 and 1.7 (Menkveld et al., 2011). However, Menkveld (2010) reported that the head length for normal spermatozoa may vary between 4.0 and 4.5 μm , with a mean of $4.07 \pm 0.19 \mu\text{m}$ and a mean width of $2.98 \pm 0.14 \mu\text{m}$, as measured with a built-in microscope eye-piece micrometer. The head also contains a well-defined acrosome region, a cap-like covering of the anterior two thirds of the head (40– 70% of the apex). The acrosome derived from the Golgi complex. Among the common abnormalities of the sperm head are defective shape or size and the presence of numerous vacuoles (>20%) within the head surface. Shape defects include large, small, tapering, pyriform, amorphous, double heads, and various other combinations.

Tail

The tail measures 40–50 μm in length (nearly ten times the length of the head) and provides motility for the cell. The sperm cell's entire motility

apparatus is contained in the tail, propelling the sperm body via waves generated in the neck region that pass along distally in a whiplash manner. The tail can be divided into the midpiece (anterior portion), principal piece, and end piece (posterior portion). Ideally, the midpiece supports the head at exactly the center position. It should be slender as well (maximum width of 1 μm), yet thicker than the rest of the tail and between 7.0 and 8.0 μm in length. The tail diameter should be between 0.4 and 0.5 μm , measuring about 50 μm in length. The tail should have a well-defined end piece, without any coiling or abnormal bending (over 90°).

The mid-piece consists of tightly packed mitochondria surrounded by a sheath. The mitochondria in the mid-piece supply energy in the form of ATP for tail movement. The principal piece is the longest part of the tail and comprises most of the propellant machinery. Common abnormalities of the neck and mid-piece region are the absence of the regions themselves, thickened neck, distended or irregular/bent mid-piece, abnormally thin mid-piece (no mitochondrial sheath), or a combination of these abnormalities.

The presence of excess residual cytoplasm (a cytoplasmic droplet greater than one third the area of normal sperm head) at the posterior portion of the mid-piece is another common abnormality. The cytoplasmic droplet is released during ejaculation as long as the sperm has sufficiently matured in the

epididymis, Common tail defects include short or multiple hairpins broken tails, irregular widths, coiled tails with terminal droplets, or a combination of these defects (Katz et al., 1986; Hafez et al., 1976; Kruger et al., 1986).

Table 1 Values for sperm morphology in the different WHO manuals (Adapted from Gatimel et al 2017)

WHO edition	Year	Cut- off for normal forms (%)
1 st	1980*	80.5
2 nd	1987*	≥ 50
3 rd	1992**	≥ 30
4 th	1999***	14
5 th	2010****	4

* No clear description of normal forms, and classification based on MacLeod's description.

** Clear description of normal spermatozoa according to strict criteria with well-defined sperm head lengths and widths and qualitative descriptions.

*** List of various abnormalities without accurate description.

**** Precise definition of normal spermatozoa and of different abnormalities.

3.3.2. Abnormal sperm form

Based on the structural parts of spermatozoa the morphological abnormalities are named according to David's classification (Fig 13) (David et al., 1975).

Head defects

Tapered head, thin head, microcephalic, macrocephalic, multiple heads, abnormal post-acrosomal region and abnormal acrosomal region.

Midpiece defects

excess residual cytoplasm, thin midpiece and bent misaligned midpiece.

Tail defects

No tail, short tail, irregularly shaped tail, coiled tail and multiple tails.

It is well established that the percentage of normal sperm has prognostic value of fertility (Jouannet et al., 1988; Eggert-Kruse et al., 1996; Bonde et al., 1998).

3.3.3. Sperm form pathology

Two main forms of abnormal spermatozoa can be distinguished. In the first and more frequent variety, a heterogeneous combination of different alterations is found randomly distributed in each individual and among

different patients. These alterations can be referred to as nonspecific or non-systematic sperm defects.

The second variety presents with a characteristic anomaly that involves the vast majority of spermatozoa in a semen sample. These alterations may be called systematic in the sense that there is a common sperm phenotype that predominates in a given patient and resembles similar defects in other individuals suffering from the same condition. Moreover, the first variety is usually secondary to various pathologies that affect the normal function of the testis or the seminal pathway. Systematic alterations tend to show family clustering and have proven or suspected genetic origin (affecting 99 or 100% of spermatozoa) such as globozoospermia, sperm macrocephaly syndrome, multiple tail abnormalities, or headless spermatozoa (Chemes & Rawe, 2003). However, some sperm morphology defects may be associated with functional abnormalities such as changes in chromatin condensation, defects in the acrosome reaction, problems with tail motility or even an increase in phenomena of apoptosis or necrosis (Menkveld et al., 1990; Bastiaan et al., 2003).

Teratospermia is the production of morphologically abnormal sperm, which are often functionally deficient as well. This lesion can follow exposure to some toxicants (Rousseaux & Bolon, 2018). Direct actions of compounds on sperm

may alter their cytoarchitecture and/or their function. The aberrant functional attributes are reported more frequently, and likely are of greater consequence. Examples of functional deficits include altered sperm motility, reduced ribosomal activity (often with decreased RNA content), and impaired protein synthesis. The induction of chromosomal damage is indicative of substantial genetic damage that may be passed to the progeny, and that may result in malformations (Rousseaux & Bolon, 2018).

Sutovsky and Manandhar (2006) reported that any alteration of normal spermiogenesis may lead to the production of pathological forms of spermatozoa with head anomalies, defective neck alignment, midpiece defects with cytoplasmic residues, and tail defects. As the spermiogenesis is a complex process involving mostly 2300 genes (Massart et al., 2012).

















Morphologically normal			34
<i>Head Anomalies</i>	Tapered		0
	Thin	 ◆	3
	Microcephalous		3
	Macrocephalous		2
	Multiple		0
	Abnormal post-acrosomal region	 ◆	26
	Abnormal or absent acrosome	 ◆	53
<i>Midpiece Anomalies</i>	Cytoplasmic droplet		2
	Thin		0
	Bent	 ◆	3
<i>Tail Anomalies</i>	Absent		2
	Short		0
	Irregular		0
	Coiled		9
	Multiple		0
Total number of isolated and associated anomalies = T			103
◆ Multiple Anomalies Index (MAI) = T / number of abnormal sperm (66 for 100 spermatozoa assessed)			1.56

Figure 13 Sperm morphology: classifications of normal and abnormal human spermatozoa (David et al., 1975) (MAI interpreted by Jouannet et al., 1988).

Chapter IV

Sperm aneuploidy

(Temperature, lifestyle related)

4.1. Sperm aneuploidy

Sperm aneuploidy is an abnormality in the chromosome number and is the most prevalent type of genetic abnormality and a major type of chromosome aberration in humans (Härkönen et al., 1999). Sperm aneuploidy screening has been used as a tool in the diagnosis and determining treatment options for male factor infertility since the development of human sperm karyotyping by injection into hamster and mouse oocytes in the 1970s (Emery, 2013). Aneuploidy can have major health consequences when it occurs in germinal or somatic cells (Hassold & Hunt, 2001). It has been reported that approximately one in 300 live births are aneuploid (Jacobs, 1992). A substantial proportion of aneuploidy which occurs in embryos and newborns is of paternal origin (Hassold et al., 1996). The aneuploidy rate in human sperm samples is between 1% and 4%; the incidence of aneuploidy in human oocytes is between 20% and 70% (Templado et al., 2013; 2011).

In fact, any alteration of the intra-testicular micro-environment not only impairs spermatogenesis but may also disturb the fine-tuned mechanisms that regulate chromosomal segregation during meiosis (see Figure 14), leading to the production of aneuploidy gametes (Calogero et al ., 2003). Theoretically, improper chromosome segregation in male meiosis may be results from:

(a) Errors in homologous pairing or synapsis during early prophase I.

(b) Altered recombination at pachytene.

(c) Failures in chromosome cohesion maintenance.

(d) And /or in centromeric orientation in the anaphase stage (Templado et al., 2011).

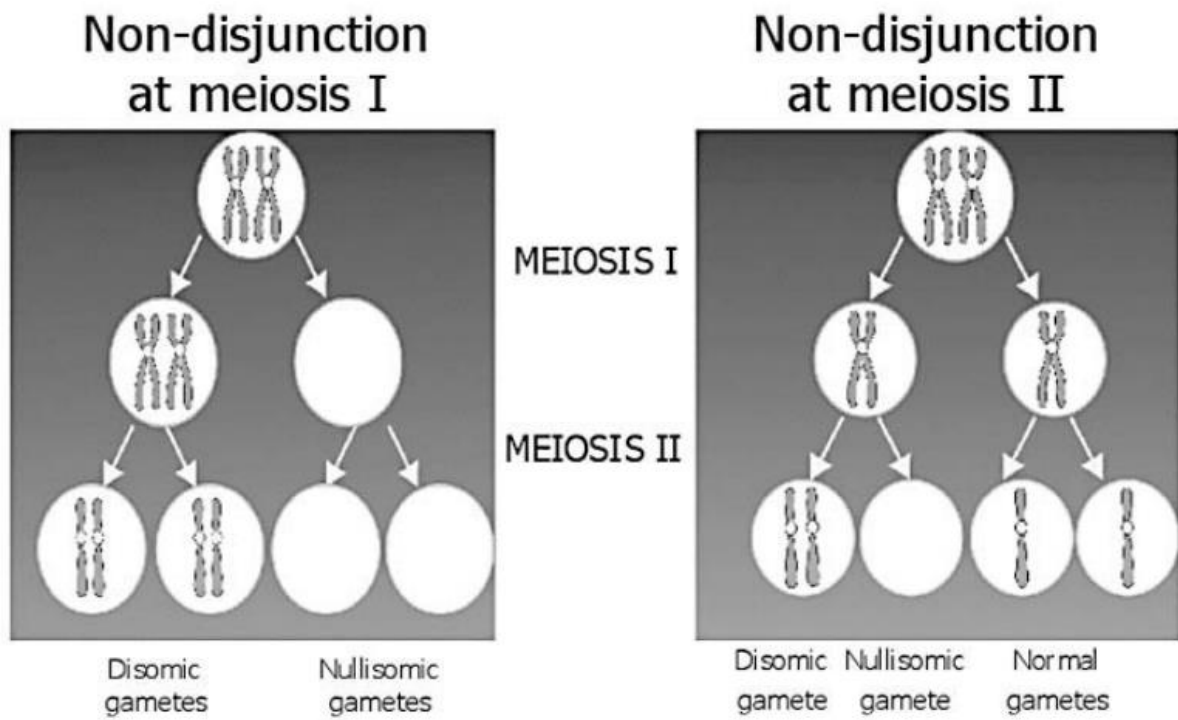


Figure 14 Schematic representation of chromosome non-disjunction All gametes produced from a cell line with a non-disjunction occurring during the first meiotic division are aneuploid (left panel), whereas only half of the gametes produced by a cell line with non-disjunction occurring during the second meiotic division are aneuploid (right panel) (Calogero et al., 2003)

4.1.1. Testis temperature, lifestyle related to sperm aneuploidy

To date no study had investigated the effect of a mild testis temperature increase (testis temperature below core temperature) on sperm aneuploidy in men. A recently published study examined sperm aneuploidy in 10 men before and during scrotal heating using an electric warming bag to increase the testis temperature to 43°C for 30-40 min two days per week for 3 months [Zhang et al. 2018]. Compared with pre-heating values, a significant increase in the sum rate of sperm chromosomal 13, 18, 21, and sum of X and Y sperm was reported at the end of the 3 months of heating. In this last study, the increase of sum rate of aneuploidy for X and Y at the end of the 3-month period of heating was 14.2-fold greater than before heating. The findings of Zhang et al. could indicate that the effects of an increase in testis temperature (43°C), even only 2 days/week but repeated every week for 3 months, results in such increased aneuploidy that reversibility could require a longer period than in the present study. However, the aneuploidy values after cessation of heating were not reported in the study by Zhang et al (2018). Another limitation in this study was the very low number of sperm studied by FISH (only 200 cells).

The precise mechanisms of aneuploidy induction in man following mild testis temperature increase are not known. However, meiosis is a dynamic structural process, broadly conserved across eukaryotes, and temperature appears to be a major challenge for chromosome segregation during the meiosis stage where

the temperature increase was associated with failure of synapsis and reduced chiasma frequency in plant and animals at both high and low temperatures (Bomblies et al., 2015).

In humans, sperm aneuploidy may result in a risk for the embryo, fetus and offspring (Templado et al., 2013; 2011). The majority of these embryos are not viable but several chromosomal abnormalities, such as autosomal trisomy or sex chromosome aneuploidy, could be non-lethal and compatible with survival (Eskenazi et al., 2002).

Moreover, more studies have investigated to establish a relationship between sperm parameters and sperm aneuploidy. Rives et al. (1999), Vegetti et al. (2000) and Calogero et al. (2001b) reported a negative correlation between aneuploidy rate and sperm concentration. Likewise, the present authors found a strong negative correlation between sperm total aneuploidy and the percentage of normal forms; Bernardini et al. (1998) showed a 15–30-fold increase of aneuploidy rate in chromosomes 1 and 17 for morphologically abnormal spermatozoa compared with that for germ cells with normal morphology in controls and patients with OAT. Also, the aneuploidy rate increased from 17% among spermatozoa with normal morphology to 61% in those with an abnormal shape (Estop et al., 1998).

Daily life behaviors for example; smoking, coffee drinking, wearing tight fitting underwear, consumption alcohol, also pathological conditions like cryptorchidism and varicocele may interfere with the normal sperm aneuploidy rate during meiosis (Jurewicz et al.,2014). Whereas a high level of leisure time activity was negatively associated with copy number changes in the whole chromosome 18 as compared to men who reported that they did not perform any leisure time physical activity. Also, wearing boxer shorts result to the decrease in the copy number changes in whole chromosome 18. There was a statistically significant positive association between smoking and additional chromosome 13 as compared to non-smokers and negative association between using boxer shorts and the lack of chromosome 13 (Jurewicz et al.,2014).

It is noteworthy that in patients with varicocele, the frequency of meiotic abnormalities such as partial asynapsis, chromosome breaks, and a high rate of sex vesicle-autosome association were higher than in a control group [North et al. 2004]. Moreover, in this study abnormal temperature was correlated with meiotic abnormalities and after varicocele surgery no meiotic abnormalities were noted, suggesting the meiosis alterations due to increased temperature were reversible. In the same way, a comparison of sperm aneuploidy frequency before and after varicolectomy (Acar et al., 2009) showed that varicolectomy resulted in a decrease of sperm aneuploidy frequency, which

although not statistically significant due to the low number of subjects, suggests that the possible effect of the abnormally elevated testis temperature was reversible. Only one study reported increased sperm aneuploidy in patients with a history of cryptorchidism, but without any temperature evaluation, which was not statistically significant due to the low number of studied patients but indicating a severe disturbance of meiotic segregation in this case (Moretti et al., 2007).

Further meiotic studies carried out in spermatocytes and spermatozoa will contribute to determine the mechanisms leading to meiotic missegregation and to accurately evaluate the environmental effects on aneuploidy in human spermatozoa.

Chapter V

Literature Review

Testis temperature

(Measuring temperature, testis location)

5.1 Testis temperature

5.1.1. Measuring genital temperature

Testicular temperature may be taken as single or continuous measurements. Single measurements of intra-scrotal temperature are made using a **mercury thermometer** (clinical thermometers are inadequate for this purpose), **skin surface thermocouples** for measurement in a clothed state, provided the thermocouples stay in place (Bujan et al., 2000; Jockenhovel et al., 1990) , **thermistor needles** an invasive method that directly measures testis, scrotal cavity temperatures (Kitayama, 1965), **infrared thermometry** and **thermography** a noncontact method measuring scrotal skin heat emission or thermal radiation and not deep scrotal temperature (Zorgniotti, 1982), and **liquid crystal thermometry** (Zorgniotti et al., 1982) (Table 2) .

In an experimental study, Jockenhovel et al (1990) introduced a portable digital data recorder, which was connected with two scrotal thermistor sensors allowing measurement of temperatures under daily-life conditions in a dynamic way. Rock and Robinson (1965) placed under local anesthesia a thermistor subcutaneously near the upper pole of the testis. The thermistor was connected with a cord to a tele thermometer. Brindley (1982) used a temperature sensor implant (radio-interrogation method) for the mid-sagittal plane of the scrotum on himself as single volunteer and published scrotal

temperature data for several dynamic exposure conditions. Kitayama (1965) evaluated the temperature of rectum, testis, scrotal cavity and external inguinal ring region for 141 male urological patients; age ranged from 10 to 76 years old by a different method. The patients were, kept quiet at the supine position in operation room, mainly under spinal or general anesthesia, and then a hypodermic needle with a thermistor device was used to measure to temperatures.

5.1.1.1. Mercury thermometer

For a long time, the most preferred method to measure genital heating was the scrotal invagination of a mercury thermometer (Zorgniotti & MacLeod, 1973). This method was compared in 10 subjects with intra-scrotal temperature measurements according to Rock and Robinson (1965) with good correlation of values. However, for such procedure volunteers must be undressed and variation of the time necessary to undress represents an important confounder of the measurements. Moreover, this method delivers only reproducible results under static conditions such as lying in a supine position or standing undressed for several minutes. Hence, this method cannot be employed to evaluate dynamic processes (Zorgniotti et al., 1979).

5.1.1.2. Needle thermistor

Kurz and Goldstein (1986) measured in 34 men with a needle thermistor the intra-testicular temperature and additionally with a further thermistor the scrotal skin temperature, and observed a good correlation between both values. Thus, it became feasible to measure scrotal skin temperature under dynamic conditions as read-out parameter for genital heat stress. However, placement of a thermistor needle within the testis or scrotum is to be condemned as barbaric and unnecessary because indirect methods give entirely satisfactory results. This method can also be inaccurate because intra-testicular temperature is higher at the mediastinum than anteriorly, which would make needle placement critical. (Zorgniotti, 1982).

5.1.1.3. Microwave technology

Gazvani et al 2000 presented the method using microwave technology for reliable assessment of inguinal canal and testicular temperature in scrotal position in men with varicocele and normal men. He reported that temperature of the inguinal canal was around 36-36.3°C. However, the accurate of this method are $\pm 0.25^\circ\text{C}$. To date, no study has compared invasive and non-invasive methods in order to measure testis core temperatures in scrotal and inguinal position and the efficiency superiority of modern methods was not demonstrated.

5.1.1.4. Scrotal skin surface temperature by infrared thermometry

The thermometer must be accurate to within 0.1°C. A pistol type digital readout thermometer with a small aperture is preferred. Aimed perpendicularly at the skin over the most prominent portion of the testis, triplicate readings give a satisfactory estimation of the temperature of the underlying organ. It is advisable to calibrate these thermometers using the black body furnished by the manufacturer (Zorgniotti, 1982). Moreover, infrared thermometry proved to be useful for evaluating patients with varicocele. It is a rapid, noninvasive, simple and cost-effective method that is applicable to clinical practice (Takada et al 1996). However, from 0 to 100°C the infrared thermometry accuracy is plus or minus 0.5-1°C comparison to temperatures measured by the thermocouple temperature ranged from ≈ 31 to $\approx 36.5^\circ\text{C}$ (Matsukawa et al., 2000).

5.1.1.5. Skin thermocouple

A thermocouple attached to the scrotal skin using an adhesive butterfly strip is of value when temperatures are to be obtained under certain experimental conditions such as in the clothed state, where the scrotum is inaccessible and the cables to the electrodes are draped over the waistband of the trousers. Displacement of the thermocouple in relation to the underlying testis and slight movements of the scrotum can alter readings (Zorgniotti, 1982).

In conclusion, the best mode to measure testicular temperature would be to insert a temperature sensor to an intra-testicular location delivering data under dynamic exposure conditions. However, such a procedure would cause major ethical concerns and human volunteers are not likely to give their consent. To date, no study has compared the different methods for give us which the best and accurate thermometer to measure testicular and scrotal temperature with approving the medical ethics committees.

Table 2 presents different methods of measuring genital temperature

Reference	n	situation	Location measured	Type of thermometer	Scrotal mean T°
Zorgniotti & MacLeod, 1973	35	Normal	Scrotal skin	Mercury thermometer	Left 33.4-33.6 Right 33.4 -33.5 34.6
Mieusset et al., 1989	64				
Zorgniotti & Sealfon, 1988	30				
Zorgniotti et al., 1979;	7	Normal	Scrotal skin	Infrared thermometry	Left 31.8 Right 32.2
Zorgniotti et al., 1982	7	Normal	Scrotal skin	Skin thermocouple	Left 32-33 Right 32.5-33.2 32.04-36.21*
Kurz & Goldstein, 1986	34				
Jockenhovel et al., 1990	8				
Gazvani et al., 2000	20	Normal	Scrotal neck	Microwave technology	35.8

* During sleep n: Number of subjects

5.1.2 Testis temperature at various locations

The fetal testis develops in the abdomen, but moves into the scrotum, where it is normally located at birth. In most mammals, including man, some key testicular and epididymal functions occur within a thermal range of which the upper value is always lower than normal core body temperature.

Authors evaluated the testis temperature in a different location such as; in scrotal, superficial inguinal canal, inguinal canal and cryptorchidism (Kitayama, 1965; Zorngiotti, 1982; Shafik 1991; Mieusset., et al 1993) observed that the testis temperature in the range 33 to 36 °C (see figure 15).

Here there is a very important question, why are these variations to testis temperature by every different situation and position?

In man, as in most mammals with scrotal testis, the physiological migration of the testis is associated with a considerable cooling of its thermal environment. This action result to scrotal temperature which is about 2- 4 °C lower than in the rest of the body. This temperature is required for the process of sperm development, or spermatogenesis, to proceed normally.

Moreover, any lifting of testis position result to increase in the testis temperature of higher than the normal range, and if such exposure is repeated

daily for a long enough time, this will result in some adverse changes to response of thermoregulation testicular system (Mieusset et al., 1993).

Furthermore, the location of the testis high in the inguinal pouch close to the warm abdomen elevates its temperature and decreases the recorded testicular–rectal temperature below normal range (Shafik, 2000). Hence, the mean difference between rectal and testicular temperature was $3 \pm 0.2^{\circ}\text{C}$ in the pre-suspension period and dropped $1.1 \pm 0.1^{\circ}\text{C}$ in the post-suspension period. The constantly and significantly elevated testicular temperature seems to be responsible for the diminished spermatogenesis.

The temperature in the testis can therefore be considered as a reading of the energy state derived from the difference between the heat input which is primarily arterial blood flow and heat losses from conduction (primarily venous return blood), surface skin convection, sweat evaporation, and radiation. In any clinical temperature measurement, the complete thermodynamic system in which the temperature measurement is performed must be considered (Zorgniotti, 1991).

To date, few studies have examined the testis temperature in different locations in men (table 3). Testicular temperatures in scrotal position (normal position) are $33.1 \pm 0.12^{\circ}\text{C}$ in the right side and $33.2 \pm 0.13^{\circ}\text{C}$ in the left, those of scrotal cavity temperature are $32.6 \pm 0.12^{\circ}\text{C}$ in the right and $32.6 \pm 0.12^{\circ}\text{C}$ in the

left (Kitayama, 1965). However, the testis was suspended in the superficial inguinal pouch close to the scrotal neck using stitch suspension (Shafik, 1991), which recorded that the testicular temperature in this location is 35.5 – 36 °C.

In 8 cases where testis located in the inguinal canal, testicular, scrotal cavity and external inguinal ring region temperatures were 35.7 ± 0.36 °C, 34.9 ± 0.18 °C and 35.1 ± 0.08 °C respectively, therefore testicular temperature was higher than that of in normal testicular group among 2.6-2.4°C (Kitayama, 1965).

Moreover, temperature of the undescended testis, measured in its cryptorchid location during surgical procedure for orchidopexy in 46 boys, 13- to 180-months-old (Mieusset et al., 1993), was significantly higher (34.4 ± 0.9 C°) than that of the contralateral normally descended testicle (33.2 ± 1.2 C°; $P < 0.001$). Addition, temperature significantly declined from the Bogros' space (35.3 ± 0.5 °C) to the inguinal canal (34.7 ± 0.7 °C) and from the latter to the empty scrotal cavity (31.1 ± 1.8 °C) (Mieusset et al., 1993).

Harrenstein (1928) performed experiments on 16 children, between the ages of 1 and 11 years, on whom an operation for inguinal hernia or retained testis was being done. He found a considerable difference between the intraperitoneal and scrotal temperatures in each case, the average being 3.5 to 4.9 C°.

Table 3 Testis temperature in different locations

<i>Researcher</i>	<i>Situation</i>	<i>Testis location</i>	
<i>Badenoch 1945; Tessler & Krahn, 1966</i>	Normal	Scrotal	2- 4 C° below body core T°
			Average of T° above normal values
<i>Shafik, 1991</i>	Stitch suspension	Superficial inguinal canal	1.5-2 C°
<i>Kitayama, 1965</i>	Surgery with anesthesia	Inguinal canal	1.7-2.6 C°
<i>Mieusset et al., 1993</i>	Surgery with anesthesia	Cryptorchid location in child	1.4 C°

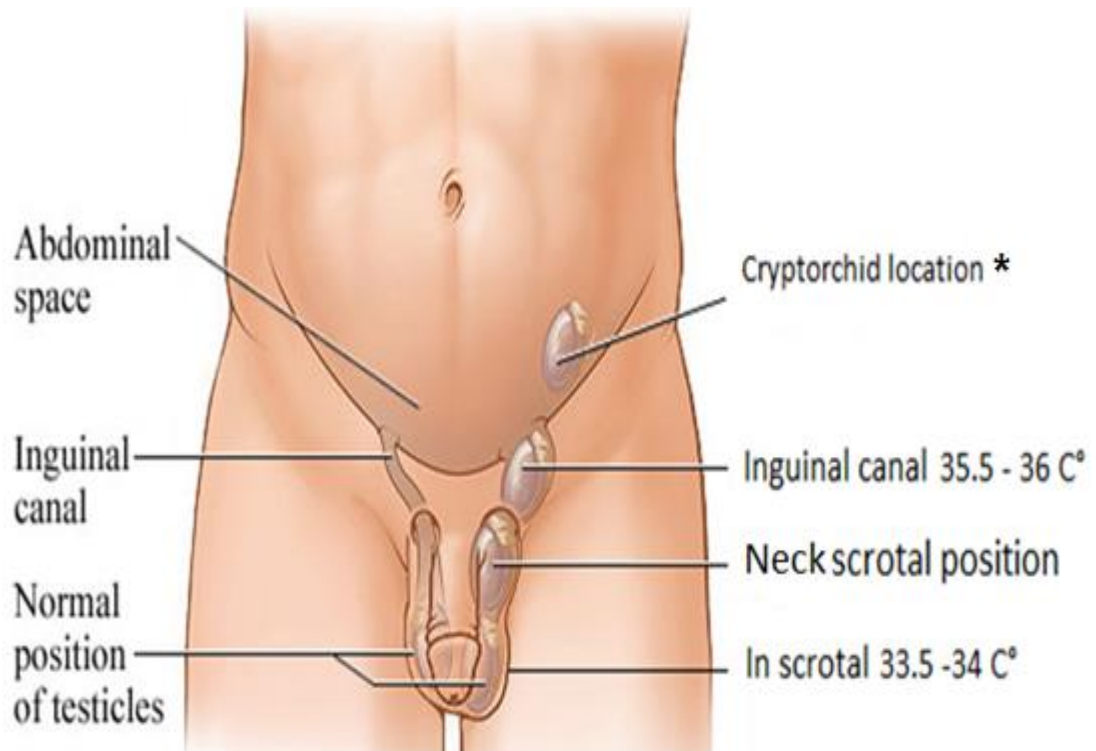


Figure 15 Testis temperature in different locations. (Adapted from Healthwise Staff, 2018)

* No data available to testis temperature in abdominal location “cryptorchid” in adults

Chapter VI

Temperature and male fertility

(Factors and situations that could cause an increase of testicular temperature)

6.1. Temperature and male fertility

In men, there are two groups of factors that may cause an increase of testicular and epididymal temperature; these thermogenic factors can be broadly grouped into lifestyle and behavioral factors such as occupational and environmental and/or clinical factors resulting from pathophysiological conditions (Table 4) (Fig 16; 17) (Gat et al., 2005; Jung et al., 2005; Magnusdottir et al., 2005; Shiraishi et al., 2009).

6.1.1. Factors and situations that could cause an increase of testicular temperature

6.1.1.1. Sitting and sleeping posture

In studies by Rock & Robinson (1965), Zoragniotti & MacLeod (1973), Brindley (1982) and Jockenhovel et al., (1990) the value of scrotal temperature was examined by different techniques in naked normal men in at least two of the following postures: supine, sitting with legs either together or apart, and standing. They observed the lowest scrotal temperature whilst standing, with a mean lowering of 0.3 to 0.6°C when changing from supine to a standing posture. When sitting with legs together, scrotal temperature was higher than with legs apart, but in both situations, the temperature is higher than that when standing (Mieusset & Bujan, 1995). Moreover, during sleep, scrotal temperature profiles are significantly higher than during wake periods. This

was consistently found in studies dealing with this object (Jung et al., 2001a; 2003).

Also, Jung et al., 2005 reported that walking is associated with significantly lower scrotal temperatures than sitting. In addition, nocturnal scrotal temperatures were significantly higher during sleeping on the side compared with periods lying on the back with a rise of + 0.65 °C right scrotum and + 0.54 °C left scrotum (Jung et al., 2003).

On other hand, Koskelo et al. (2005) examined the influence of six different chair types on scrotal temperatures in eight volunteers and found significantly lower scrotal temperatures for a so-called saddle chair compared with a cushioned office chair. Also, sitting position with closely brought together legs is the major cause of scrotal hyperthermia (Sheynkin et al., 2011). Sitting directly on heated floors is a well-known habit of Korean people. Song & Seo (2006) analyses the influence of the floor surface temperature on scrotal temperature in six volunteers. Men sitting on the floor and reading a book at a maximum surface floor temperature of 42.2°C showed a mean scrotal temperature of 35.0°C after 50min of exposure. Playing a card game in sitting posture over 180 min at a floor temperature of 35.9°C induced scrotal temperature of 35.6°C in the mean.

Generally, the scrotal temperatures are lower when walking compared with sitting; because scrotal movement during ambulation provides better air circulation and heat dispersion.

6.1.1.2. Environment and seasonal variation

Ambient temperature exerts an effect on scrotal temperature; as demonstrated experimentally in one subject (Brindley, 1982), scrotal temperature increases with elevation of the environmental temperature from 1°C to 20°C, a change which was independent of clothing or activity. Moreover, elevation of body temperature in man in conjunction with a simultaneous elevation of the environmental temperature (the cabinet was pre-heated to 43°C; humidity level between 95 and 100%) results in a marked drop in spermatozoa production (Macleod & Hotchkiss, 1941). There is correlation between the ambient temperature and heat flux on the scrotum (Song & Seo 2008). In early study by Newman and Wilhelm (1950), it was reported that it is impossible to determine the average testicular temperature without taking into account the environmental temperature. They found that the lowest recorded testicular temperature was 81.5°F (27.5°C) and the highest 101°F (37.5°C). While, the average testicular temperature was 6.5°F lower than the rectal temperature over an environmental temperature span of from 73°F (22.5°C) to 87.5°F (30.8°C).

Hjollund (2000) reported that when scrotal temperature was measured in the summer, it was only significantly increased with respect to the most extreme high temperatures.

6.1.1.3. Underwear

Layers of clothing and bedding trap additional layers of air and impede air exchange, thus conserving heat and increasing scrotal temperatures. Being clothed elevates scrotal temperatures by 1.5–2°C when standing or supine, compared with an unclothed state (Mieusset et al., 2007). A study started that mean scrotal temperature was increased by 1.8°C and 1.5°C on the right and left sides respectively, in seven euspermic men wearing underpants and trousers when compared to the unclothed state (Zorgniotti et al., 1982). Brindley (1982) reported an intra-scrotal temperature of 0.5°C lower when wearing loose rather than tight shorts in the same man, it was found that scrotal temperatures increased by 1.8°C as a result of wearing polyester-lined athletic supports.

In lightly clothed, resting men clothing isolates a layer of air between skin and clothes, which temperature of is on average 3.5°C higher than that of the ambient air when the latter is between 21°C and 32°C, (Elebute, 1976).

Moreover, Jung et al. (2005) showed that wearing tight fitting underwear is associating with significantly higher scrotal and consequently testicular temperatures than wearing loose fitting underwear or none.

In the other vain, one study shows (Partsch et al., 2000) that scrotal temperature, which closely reflects testicular temperature, is increased in boys wearing disposable plastic lined nappies. The physiological testicular cooling mechanism is blunted and often completely abolished during plastic nappy use.

6.1.1.4. Occupation in high temperature

Heat is one of the physical risks that can cause health problems in the workplace, also to may be caused to increase in scrotal temperature.

In a recent study by Hamerezaee et al (2018), the mean value of heat exposure was 5.6 hours per days for a group employed in steel industry, that of and their scrotal temperature was measured at 35.85 °C (SD= 1.26) comparing with non-exposed group 34.97 °C (SD= 0.41).

Likewise, sedentary work which is work in sitting posture, lead to an increase in scrotal temperature, the prevalence of sedentary work has been increasing in the last decade (Hjollund et al., 2000; 2002a). Men sitting at work for 8 h a day have on average 0.7°C increased scrotal temperature during the day in

comparison with employees with <8 h in the sedentary body position (Hjollund et al.,2002).

Bonde (1992) examined skin temperature during a work-shift and showed average temperature increases of 1- 4 °C in the groin and 3.0°C on the back during periods of exposure to radiant heat. However, Momen et al (2010) did not observe that a significant difference between the two groups regarding their scrotal temperature not regarding semen analysis parameters which remained in the normozoospermic range.

6.1.1.5. Car driving

Long duration car driving has an impact on testis and scrotal temperature, Jung et al (2008) reported that temperature after the end of the sitting periods were significantly higher using the heated car seat versus the un-heated seat (left scrotal side: 0.5° C; right scrotal side: 0.6 °C) and the maximum values recorded during sitting alone were exceeded on the heated seat already after one-third of the exposure time.

In another study, Bujan et al. (2000) examined the influence of sitting while driving a car on scrotal temperatures by k- type thermocouple, they found after 2 h a mean value of 36.2 °C on the left and 36.4 °C on the right scrotal side.

Furthermore, the effect of long-term driving upon spermiogenesis was investigated in 281 patients professional drivers. The incidence of pathospermia was significantly increased among the 281 occupational drivers as 9.4% compared to other professionals (3.8%). The ratio of severe pathospermia was increased in proportion to the number of years of driving (Sas & Szollsi, 1979).

6.1.1.6. Laptop computer users

In other conditions, using the laptop computer may increase scrotal temperatures when put near to scrotal - testis region or on the thighs. Scrotal median temperatures with a laptop computer were recorded at 36.2°C (right side) and 36.0 °C (left side) while scrotal temperatures without a laptop computer were significantly lower - 0.8 and -0.5°C respectively (Sheynkin et al., 2005).

6.1.1.7. Hot bath and sauna

Rock and Robinson (1965) reported changes in scrotal-rectal temperature differential in eight normal subjects during immersion of the body below the neck in baths at temperatures of 38 to 43°C. At a bath temperature of 38°C, median rectal (body) and scrotal temperatures were 37.7 and 36.1°C, respectively. As water became progressively hotter, both temperatures

remained fairly constant until water temperature reached 39°C, when rectal temperature rose gradually, whereas scrotal temperatures began a steep incline, and exceeded that of the rectum at about 40°C. At 43°C, median scrotal temperature was 40.5°C, which was higher than that of the rectum by 1.2°C. Thus, heat caused a reversal in the scrotal-rectal differential, indicating a rapid thermal exchange across the scrotal wall that could overwhelm the regulatory mechanism responsible for maintenance of the normal negative scrotal-rectal (body) differential.

These are plenty experimental evidence that intensive and frequent use of saunas increases testes temperature. During sauna sessions, mean scrotal temperatures of 10 normal men were increased from $32.72 \pm 0.23^\circ\text{C}$ to $37.53 \pm 0.38^\circ\text{C}$ (Jockenhovel et al., 1990). Procope (1965) examined the effect of repeated increase of body temperature on 12 fertile men after exposure to hot saunas. For a mean total time of 2 hours and 24 minutes over a 2-week period, he found an average increase in rectal temperatures induced by heat treatment of 0.93°C . It should be noted that there is a positive correlation between the rectal temperature and increased scrotal temperature (Rock & Robinson 1965).

In a further study, Brown-Woodman (1984) has shown that twenty minutes in sauna increased the rectal temperature of 3 subjects by 0.7°C and one

subject 0.4°C. Moreover, Garolla et al (2013) reported that mean scrotal temperatures from 10 subjects exposed to Finnish sauna sessions (consisting of full body exposure to 80 – 90°C with humidity level ranging from 20 to 30% for 15 min) raised from 34.5±0.68°C before treatment to 37.5±0.48°C after treatment (i.e. temperature measurements were taken on the subjects before and immediately after each sauna session).

In an experimental study, Saikhun et al (1998) found a significant increase in scrotal temperature ($p < 0.005$) during and after sauna exposure. The average increase in scrotal temperature was 2.4 °C during sauna exposure and 1.7 °C after sauna. In addition, during and after sauna the rectal temperature increased by an average of 1.1 and 0.8 °C, respectively.

6.1.1.8. Sports

Different type of sports like the marathon, cycling and running may have an effect on reproductive function through an increase in intra-scrotal and testicular temperature; however data regarding the impact of sports during and after exercise on scrotal and testicular temperature have not been provided.

Arce et al (1993) suggested that the effects of exercise on spermatogenesis might not be as a result of hormonal changes but might, in fact, be as a result

of increased scrotal temperature. This increase may be as a result of wearing tight, supportive clothing during periods of strenuous exercise. However, two studies examined that the extended periods of cycling in form-fitting spandex outfits and being seated for long hours on a saddle seat is likely to cause elevated scrotal temperatures (Lucia et al., 1996; Jung et al., 2008b)

6.1.1.9. Fever

Fever has been reported as a factor that may increase testis temperature by French et al (1973), Evenson et al (2000) and Sergerie et al (2007). For an acute fever (39.9- 40 °C) of one to four days, they found a negative different impact in sperm parameters such as sperm output, motility, morphology, and DNA fragmentation. This defect may be due to an increased testicular temperature. When intra-scrotal temperature was compared to rising body temperature in febrile patients, (Lazarus & Zoragniotti, 1975) it remained unchanged until the fever reached 37.8°C., at which point intra-scrotal temperature rose sharply. This critical point (37.6-37.9°C.) was the same for all subjects, suggesting a clearly defined limit upon the capacity of the scrotal mechanism to deal with increased heat load.

6.1.1.10. Cryptorchidism

The risk of infertility in adulthood is more significant in patients with bilateral undescended testes (Chung Brock, 2011). Approximately 10% of the infertile men have a history of cryptorchidism (Fawzy et al., 2015).

Mieusset and Bujan (1995) reported that among infertile men with a cryptorchidism history, 45% had an abnormally high scrotal temperature. This abnormal temperature represented a pejorative risk factor for fertility in this situation, since it was associated with a more severely impaired spermatogenesis and a higher incidence of primary infertility than in infertile men with a history of cryptorchidism but normal scrotal temperatures. Additionally, the temperature of the undescended testis, measured in its cryptorchid location during surgical procedure for orchidopexy in 46 boys, age from 13 to 180 months, was significantly higher ($34.4 \pm 0.9^{\circ}\text{C}$) than that of the contralateral normally descended testicle ($33.2 \pm 1.2^{\circ}\text{C}$; $P < 0.001$) (Mieusset et al., 1993).

6.1.1.11. Varicocele

Varicocele is another pathological condition which also increases the testicular temperature and may affect the sperm parameters. Varicocele is the most common and treatable cause of male infertility and it affects 15 % of the

male population. Gorelick and Goldstein, 1993 reported that it is implicated in 40 % of men with primary infertility and in 80 % of men with secondary infertility.

Further, intra testicular temperature and scrotal skin surface temperature are elevated significantly in humans with varicocele at (i.e. ambient temperature was $22.7 \pm 1.58^{\circ}\text{C}$ and mean body temperature was $36.92 \pm 0.60^{\circ}\text{C}$ $p < 0.001$) (Goldstein & Eid, 1989). They also, found that left intra-testicular temperature was $31.91 \pm 2.48^{\circ}\text{C}$ for the controls and $34.62 \pm 2.40^{\circ}\text{C}$ for the left varicocele group; as well the right intra-testicular temperature was $31.54 \pm 2.47^{\circ}\text{C}$ for the controls and $34.07 \pm 2.73^{\circ}\text{C}$ for the right varicocele group (Goldstein & Eid, 1989).

Moreover, mean right and left scrotal surface temperatures in men with unilateral varicocele were $34.00 \pm 0.91^{\circ}\text{C}$ and $34.37 \pm 0.87^{\circ}\text{C}$, respectively and $34.07 \pm 0.83^{\circ}\text{C}$ and $34.34 \pm 0.85^{\circ}\text{C}$, respectively in men with bilateral varicocele, (Wright et al., 1997). However, they also reported that drop in temperature was highly significant after varicocelectomy (right side $33.03 \pm 0.85^{\circ}\text{C}$, left side $32.84 \pm 1.0^{\circ}\text{C}$ in the unilateral group and right side $33.27 \pm 1.0^{\circ}\text{C}$, left side $33.54 \pm 1.2^{\circ}\text{C}$ for bilateral). In the same vein, there was a significantly higher intra-scrotal temperature (0.6-0.8°C.) in infertile subjects with varicocele than in a control group (Zorgniotti & Macleod, 1973). In a study measuring the

scrotal temperature of 6 normally fertile volunteers and 48 infertile patients with unilateral varicocele (Lerchl et al., 1993), researchers used a portable data recorder for 24-hour periods while the patients carried out their regular daily activities. The experiment found that temperatures during sleep were typically higher and that diurnal variations were less dramatic in the infertile patients than in the normal volunteers. Scrotal temperatures at night were similar between groups but statistically varied during the daytime hours (Lerchl et al., 1993). However, thermoregulatory defect contributes to the pathophysiology of varicocele and is corrected with surgical repair. Some studies also show a discrepancy in these results, Lund and Nilsen (1996), Tessler and Krahn (1966) reported there was no difference in scrotal skin temperature in men with or without a varicocele. A more recent study supports these findings that (Gat et al., 2005; Shiraishi et al., 2009) that varicocele is able to induce testicular hyperthermia leading to ischemic and heating damage to both testes.

Heat stress (elevated scrotal temperature), which has been documented to occur with varicocele (Agger, 1971; Yamaguchi et al., 1989; Wright et al., 1997), one of the suggested explanations for the pathophysiology of varicocele is an increase in testicular temperature due to impaired heat transfer in the spermatic cord and/or decreased testicular blood flow (Young, 1956; Hanley & Harrison, 1962; Takihara et al., 1991).

Also, the occurrence of testicular damage with varicocele has alternatively been attributed to (Brown et al., 1967):

- Increased scrotal (intra-testicular) temperature
- Venous stasis
- Reduced oxygen tension
- Toxic metabolites from the adrenals or kidney.

6.1.1.12. Obesity

Obesity is on the rise globally, and men with an above normal body mass index (BMI) ≥ 25 have an average to scrotal temperature more than normal body mass men (Kort et al., 2006). Where obese men have compromised testicular thermoregulation owing to several factors: decreased physical activity and prolonged sedentary periods, increased fat deposition in the abdominal, suprapubic, spermatic cord (scrotal lipomatosis) and upper thigh areas, which leads to suppressed spermatogenesis and change in scrotal temperature.

Garolla et al., (2013) reported that a significant increase in 24-h for mean scrotal temperature (left scrotal 35.48°C and right scrotal 35.29°C) in 20 men have BMI ≥ 30 Kg/m² (obese men) compared with controls group (left scrotal 34.80°C and right scrotal 34.66°C). Moreover, possible explanations for

increase in scrotal and testis temperature with obese men; (Durairajanayagam et al., 2014) are that obesity:

- Provides insulation that could disrupt the radiation of testicular heat.
- Compresses blood vessels, leading to testicular congestion (venous stasis) and impaired heat exchange.
- Compresses the testicular artery leading to ischemia of the testis.
- Hampers the cord's ability to reposition the testes in response to temperature changes.
- Finally, disrupts local thermoregulation due to excess fat in the suprapubic region.

Conclusion: A moderate increase in testicular temperature (lower than core body temperature) induces a reversible decrease in sperm output and quality (motility, normal morphology) as well as in fertility when daily exposure ranges up to 14h. In addition, it is documented that exposure to strong ambient temperatures, such as in certain occupations, induces both a decrease in spermatogenesis and an increased incidence of infertility. In this case, repeated exposure to strong ambient temperature is to be considered in all cases as a real risk factor for infertility in humans (Fig 16, 17). Meanwhile, both fertile and infertile men who are looking to start or continue their family may do well to refrain from as many different types of factors that induce heat stress as

possible, so that harmful effects of hyperthermia on sperm quality can be minimized.

Note: In Figure (17), different methods were used to measure scrotal temperature in previous studies. In addition, only the mean values were used to collect the scrotal temperature.

Table 4 Factors and situation associated with an increase in scrotal/testicular temperature

Authors	Source of genital heat stress	Scrotal/testicular temperature
Wright et al., 1997; Goldstein and Eid, 1989	Varicocele	Increase
Garolla et al., 2013	Obesity	Increase
Mieusset et al., 1993	Cryptorchidism	Increase
Sheynkin et al., 2011 Jung et al., 2001a, 2003, 2005 Rock & Robinson 1965, Zorgniotti & MacLeod 1973, Brindley 1982 Jockenhovel et al, 1990	Sitting and sleeping posture	Increase
Jung et al, 2008, Bujan et al. 2000,	Car seat or professional drivers	Increase
Sheynkin et al. 2005	Sitting with portable computers in a laptop position	Increase
Jung et al 2005, Mieusset et al, 2007, Zorgniotti et al, 1982, Brindley 1982, Elebute, 1976, Shafik 1992	Underwear	Increase
Robinson and Rock, 1965, Jockenhovel et al., 1990, Brown-woodman 1984, Garolla et al 2013	Sauna sessions and genital heat exposure in a water-bath	Increase
Brindley, 1982	Environment and seasonal variation	Insufficient data
Hjollund et al, 2002, Bonde 1992, Hamerezaee et al 2018	Occupational exposure to high temperatures	Increase
Lucia et al., 1996, Jung et al., 2008b	Sport or cycling	Insufficient data
lazarus and Zorgniotti . 1975	Fever	Increase

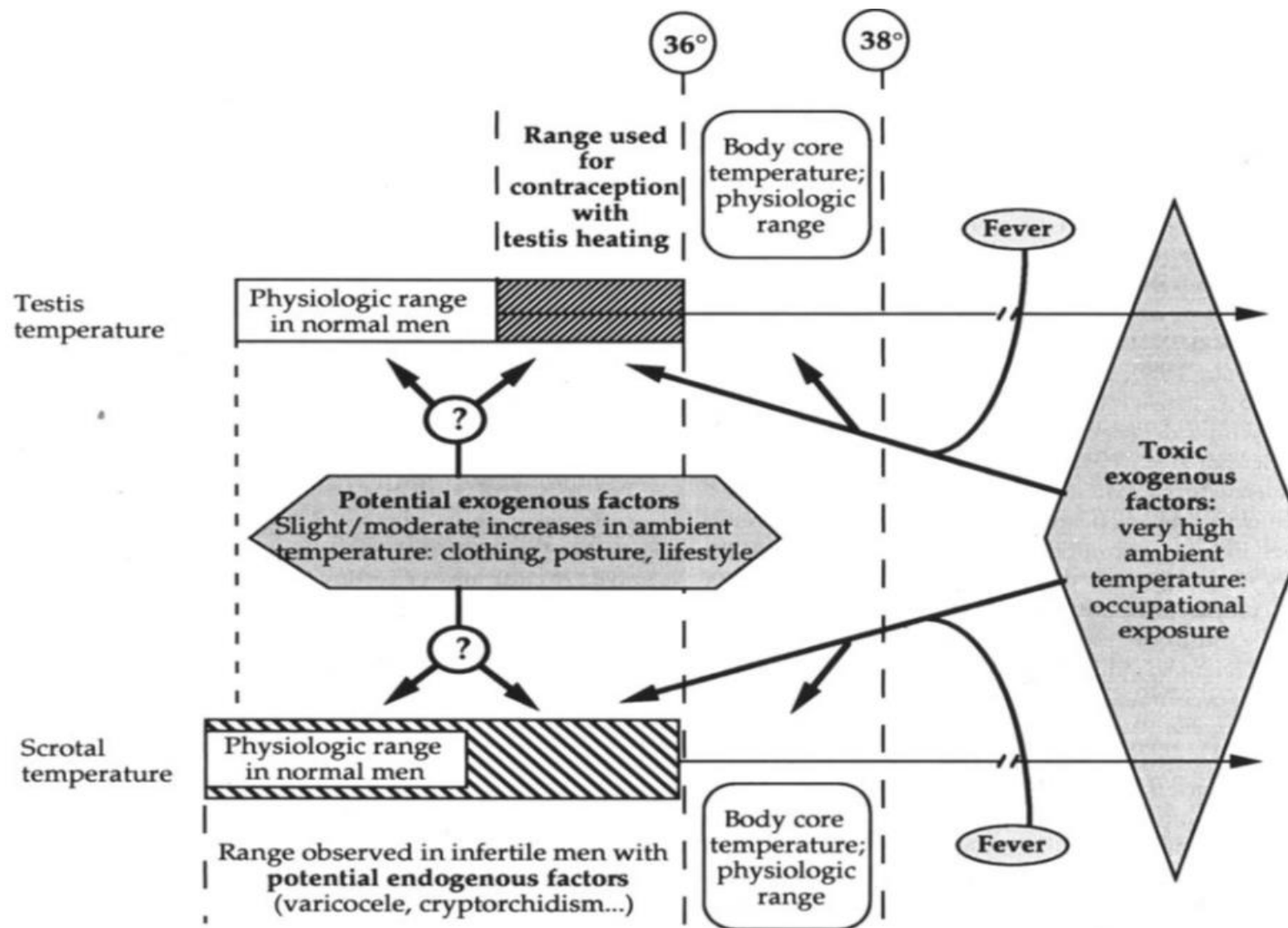


Figure 16 Schematic representation of possible changes induced by potential exogenous and endogenous thermic factors on testicular and scrotal temperature in human (Miesusset & Bujan 1995)

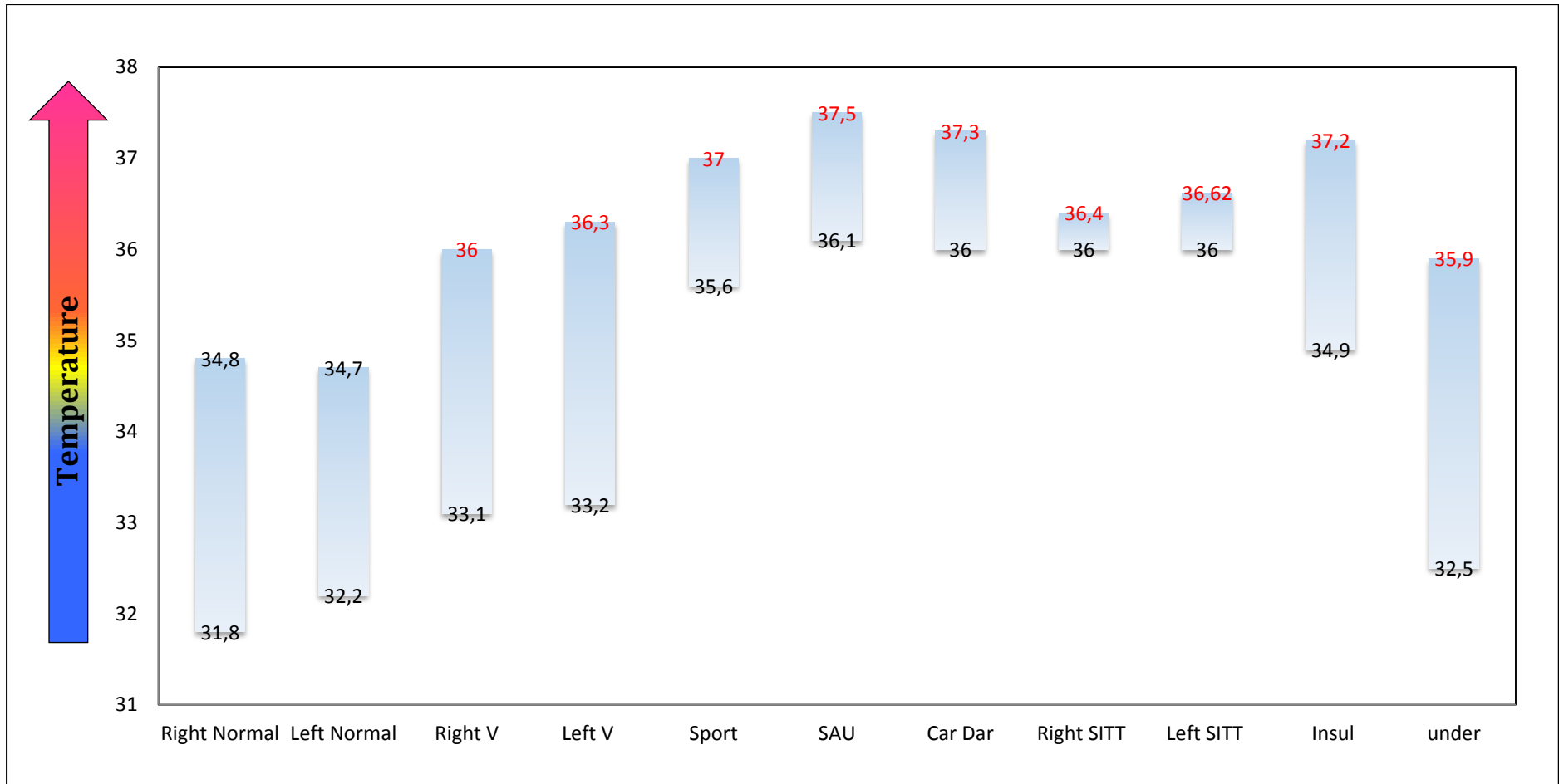


Figure 17 Minimum and maximum mean scrotal temperature in different situations. Right Normal: Normal right scrotal T° Left Normal: Normal left scrotal T° Right S V: Right scrotal T° with Varicocele Left S V: Left scrotal T° with Varicocele Sport: Scrotal T° during sport SAU: Scrotal T° during sauna Car Dar: Scrotal T° after car driving Right SITT: Right scrotal T° during sitting Left SITT: Left scrotal T° during sitting Inus: scrotal insulation Under: scrotal T with underwear Black number: Minimum mean values Red number: Maximum mean values.

Chapter VII

Effect of temperature on the physiology of male reproduction

**(Testis, epididymis, spermatogenesis, spermatogonia, spermatocyte and
spermatid, sperm in epididymis, sperm quality)**

7.1. Effect of temperature on the physiology of male reproduction

In this paragraph, I will review some testicular and epididymis responses to temperature elevation that have been reported, and describe the effects of physiological temperature elevation on testicular, epididymis and different sperm parameters.

Before starting this section it is very important to know that testicular temperature may range between 31°C and 35 °C depending on the measurement method and the presence of any underlying pathology (Zorgniotti, 1982). Also, significant differences in temperature between normal subjects and those with poor semen can be demonstrated by different methods. Moreover, the difference between abdominal and testicular temperature is not the same among mammal species and pointed out that it was greatest in the rat and mouse (mean values being 8.3 and 8.5°C, respectively); intermediate in the rabbit and ram (6.2 and 7.1 °C) and least in the macaque monkey (2.0°C), while, in man this temperature difference is between 2.0 and 2.5°C (Glover & Young, 1963).

7.2. Effect of temperature on testis and epididymis

Steinberger cited by (Zorgniotti, 1991) found that there is sufficient evidence that most cell types in the testis are either directly or indirectly affected by high scrotal temperatures. The changes noted after acute heat exposure (40-43°C)

are more dramatic and have provided valuable clues regarding relative heat sensitivity of different testicular cell types. The more meaningful biologically experiments are those using subtle temperature changes that are closer to normal body temperature. This reduction in testicular weight can be ascribed to germ cell loss, mainly by apoptosis (Durairajanayagam et al., 2015).

Some studies suggested that altered spermatogenesis, due to exposure of the testis to high temperature, could be derived from insufficient blood supply and the consequent hypoxic stress of the testis tissue (Galil & Setchell, 1988; Setchell et al., 1998).

In continuation to the work on effect of temperature on testis and epididymis, there is some reason to suspect that the storage capacity of the human cauda epididymidis may often be subtly suppressed by the scrotal temperatures that are present in modern men. In the cauda region, this heat imposition hastens epididymal sperm transport, modifies the ionic, protein profile of the caudal milieu and compromising its ability to prolong sperm viability (Bedford et al., 1973; 2015). The difference of epididymal response to heat exposure between species may be due to different of length of the epididymis, where being more than 70 m in the stallion, about 40 m in the bull, and roughly 6 m in man (Glover & Young, 1965).

However, namely that epididymis and sex gland functions were not severely affected, this indicated that the deterioration of semen quality was not caused by post-testicular factors, but mainly by testicular factors (Rao et al., 2015).

7.3. Effect of temperature on spermatogenesis

Many studies during the last 40 years have been carried out to investigate the effect of temperature on spermatogenesis process; I will review in this paragraph the effect of temperature by different methods on spermatogenesis stage by stage; beginning from spermatogonia to spermatozoa in epididymis (mitosis to sperm maturation).

In human, complete spermatogenic cycle can be divided into three stages, spermatogonia mitosis (about 28 days), spermatocyte meiosis stage (about 23 days for meiosis I and 1 day for meiosis II), and spermiogenesis stage (about 22 days) followed by 12 days of epididymal maturation (Ahmad et al., 2012).

Previous studies dealing with the potential source of testicular heating (posture, clothing, lifestyle factors and varicocele) clearly indicate a deleterious effect of strong or moderate heating upon spermatogenesis, this effect are depends on two important factors; temperature exposure rate (high or mild) and/or the period of heat exposure (Mieusset & Bujan, 1995).

Many studies reported that scrotal exposure to temperatures of several degrees above core body physiological temperature (Garolla et al., 2013; Roa et al., 2015; Rock & Robinson, 1965; Zhang et al., 2015; 2018 a;b ; Love & Kenney, 1999; Sailer et al .,1997) and/or below core body temperature (Ahmad et al., 2012; Shafik, 1991 ; 1992; Mieusset et al., 1985; 1987a,b; Mieusset & Bujan, 1994; Rock & Robinson, 1967) may induce a disruption of spermatogenesis.

7.3.1. Spermatogonia (mitosis)

Previous studies have shown that heat stress-induced stage-specific damage to germ cells, those at the spermatocyte and spermatid stages were more susceptible than cells at other stages while spermatogonia were not sensitive to heat stress in human at all (Ahmed et al., 2012).

Rao et al., (2015) confirmed these statements in an experimental study that observed that the sperm count at week 10 and week 12 recovered gradually after testicular warming at 43°C in a water bath 10 times, for 30 min each time, due to the relatively low sensitivity to heat stress of spermatogonian mitosis (about 58–86 days before ejaculation). Moreover, with cryptorchidism testes a marked decrease in spermatogonia was observed in the undescended (Lipshultz, 1976), as compared with normal scrotal testes of patients with unilateral cryptorchidism. In the same vein, all cryptorchid males (17 [94%] of

18 [72.7–99.9%]) whose germ cells had completed the second maturational step, independent of the time of early surgery, had a normal sperm count. By contrast, an abnormal sperm count was recorded in 12 (92%) of 13 (64.0–99.8%) cryptorchid males who had gonocytes, multinuclear germ cells, and no Ad spermatogonia, indicating an incomplete maturation of germ cells. Four in this group had azoospermia; and five had severe oligospermia (Hadziselimovic and Herzog 2001). This disproportionate reduction in Ad spermatogonia is correlated directly to spermiograms and represents the fundamental abnormality in germ cell development in cryptorchidism.

Roque and Esteves reported that spermatogonia B and developing spermatozoa are highly vulnerable to heat stress. On the contrary, spermatogonia A, Leydig and Sertoli cells are thermo-resistant (Zini & Agarwal, 2018). However, the cause in the differential response of spermatogonia cells in several studies was due to the duration and location or situation to testicular heat exposure.

7.3.2. Spermatocyte and Spermatid (Meiosis)

Most previously studies in animal (Chowdhury & Steinberger, 1970; Waldbieser & Chrisman, 1986) and human (Carlsen et al., 2003) reported that among the germ cells, the types that are most vulnerable to heat are the

pachytene and diplotene spermatocytes and the early round spermatids. Also, the numbers of spermatids and spermatozoa in fragments of human testes were lower when they were cultured at 37°C, rather than 31 °C, whereas the numbers of spermatogonia and spermatocytes were not affected (Nakamura et al., 1987)

Further, Ahmad et al (2012) showed that the major decrease in sperm output at D34 during heated by supra-scrotal position suggests that a +2°C increase in testicular temperature has an active impact mainly on the meiosis stage. Also Rao et al (2015) recorded the same result at week 8 after testicular warming in a 43°C water bath 10 times, for 30 min each time.

7.4. Effect of temperature on sperm in epididymis

In previously study Ahmad et al (2012) reported that spermatozoa collected at D4 and D9 of heating were more probably in the epididymis when a temperature increase of +2°C was induced. They found no changes in total sperm count or percentage of motile and viable spermatozoa.

Further, testis temperature may range between 31 and 36 °C depending on the method used for the measurement of temperature and the presence of any underlying pathology. Accuracy and reproducibility of the temperature are important as temperature differences in a normal (euthermic) and pathologic

(hyperthermic) testis may be as small as 0.6–1.4°C. Even these small increases can hamper spermatogenesis and epididymal maturation (Zorgniotti, 1982).

A recent study by Zhang et al (2018), recorded lower levels of neutral α -glucosidase (NAG) activity in the semen during transient scrotal heating, therefore the effect of scrotal heating not only effects on the testis but also the epididymis, causing a reduction in seminal quality measures and impaired quality of the sperm membrane and nucleus. Addition, NAG has repeatedly been described as an important parameter to test epididymal potency and is correlated with greater DNA fragmentation index (DFI) and human sperm concentration and motility (Zhang et al., 2018).

7.5. Effect of temperature on sperm quality

Sperm parameters less than the normal limit values are the result of the spermatogenic cycle reaction to many factors exposure like temperature elevation conditions. The majority of experimental protocols inducing an increase in testicular temperature in human by different methods reported that the effects of heat exposure are reversible (Rock & Robinson, 1965; Rock & Robinson, 1967; Mieusset et al., 1985 ;1987; Shafik, 1991 ; 1992; Mieusset & Bujan, 1994; Ahmad et al., 2012; Garolla et al., 2013; Roa et al., 2015; Zhang et al.,2015; 2018a,b), which means recover to normal values when the influence factor is recovered .

The bulk of available evidence suggests that the magnitude of spermatozoa damage after exposure to heat is determined by the following:

- The location of spermatozoa in the excretory system (seminiferous tubule to the vas deferens).
- Species susceptibility to the effect of heat.
- Degree and period of heat exposure.

There are two studies methods have been carried out to investigate the effect of testicular temperature; the first is scrotal exposure to temperatures degrees above core body physiological temperature (hyperthermia). The second is scrotal exposure to temperatures degrees below core body temperature (mild hyperthermia). Therefore, I will describe the effect of temperature on human sperm parameter through this division:

7.5.1. Scrotal exposure to temperatures below core body physiological temperature

In experimental studies (Robinson et al., 1967; Wang et al., 1997; Ahmad et al., 2012) showed no change to semen volume during and after testicular and epididymal exposition to different temperature elevation and conditions. However, Mieusset et al (1985) and Shafik et al (1992) observed that semen volume significant decrease during heat exposure.

In the other hand, the effect of a mild testicular heating by a testis Supra-scrotal Position method (TSP) which localizes the testes near the respective inguinal canals by worn polyester-lined underwear, resulted in a significant decrease in total sperm output (Robinson et al., 1967; Mieusset et al., 1985; 1987a+b; Shafik, 1991; 1992; Mieusset & Bujan, 1994, Ahmad et al 2012) and sperm motility (Mieusset et al., 1985;1987a+b; Shafik, 1991; Mieusset & Bujan, 1994; Ahmad et al 2012) (See Table 5).

Moreover, studies by (Mieusset et al 1985; 1987a+b; Shafik, 1991; Wang et al 2007) have examined the effects of mild heating on sperm morphology in human; Mieusset et al (1985; 1987a+b) using supra-scrotal position (SP) method found an increase in the percentage of abnormal morphological sperm 2 months after heat induction. Also, abnormal sperm morphology increased to 180% of baseline values during the SP period and recovered normal values 10-12 months after heating was stopped (Mieusset et al., 1987b). Other study by Shafik (1991), in 28 male volunteers the testes were suspended in the superficial inguinal pouch close to the scrotal neck 24h/days for 12 months. During suspension the percentage of sperm morphology dropped from (60%) before heating to (27%, 12%) at 3 and 12 months respectively. However, 6-12 months after suspension release percentage of sperm morphology returned to baseline (Shafik, 1991).

In an experimental study (Sanger & Friman, 1990), two euspermic men alternated from wearing tight-fitting to loose-fitting underwear, each condition lasting for 3 months and being alternated twice within a 1 -year period. Weekly semen analysis showed that sperm parameters decreased gradually when wearing tight underwear and increased gradually during the wearing of loose underwear, but in this study no scrotal or testicular temperature measurement was performed. However, Wang et al 1997 reported no effects on sperm parameters including sperm morphology, but in this last study the temperature increase was very low (scrotal testis temperature increases by 0.8-1C°).

Hjollund et al (2002b) was investigating the impact heat sedentary work positions have on increasing scrotal temperature. Semen and blood samples from 99 healthy men were analyzed in relation to scrotal skin temperature with 24-hour continuous monitoring, along with a questionnaire about sedentary work environments. Finding a negative correlation between high scrotal temperature and sperm output, results showed that sperm concentration decreased 40% per 1°C increase of median daytime scrotal temperature.

Only one study was using testis supra-scrotal position method (TSP) to increase testes and epididymides temperature, and reported a drastic decline

in sperm production and an increase on sperm DNA fragmentation (Ahmad et al.,2012).

Table 5 Effects of scrotal exposure to temperatures below core body physiological temperature on sperm parameter

<i>Research group</i>	Method of Heating	N	H/days	Period	Started effects	Recovery normal	Parameter
Robinson 1967	Cloth - insulation	10 fertile men	11 H	10 W	3 W During T	11W After T	Count (↓)
⁽¹⁾ Mieusset a 1985; b 1987	STP	14 fertile men	15H	12M	2M During T	6-8 M After T	volume(↓) Count(↓) Morphology(↓) Motility(↓)
⁽²⁾ Mieusset 1987 C	STP	6 fertile men	15H	6-24M	2M During T	6-15 After T	Count(↓) Morphology(↓) Motility(↓)
Shafik 1991	Polyester - insulation	28 couple	24H	12 M	3M During T	6 M After T	Count(↓) Morphology(↓) Motility(↓)
Shafik 1992	Polyester - insulation	14 couple	24H	12 M	3M	6 M After T	Count(↓) Testicular Volume (↓)
Wang 1997	Polyester-lined	21 fertile men	Daily	52 W	No	No	No
Ahmad 2012	STP	5 fertile men	15H	4M	34 D During T	93 D after T	Count (↓) Motility(↓) Round Cell (↑) Viability (↓) DFI (↑) HDS (↑)

(1)Ensure the permanent localization of the testes close to the inguinal canal but testicles were relatively free to travel due to the elasticity of the fabric. (2) Add to the device a ring of soft material for ensured that the testicles were kept permanently in an inguinal position. STP: supra-scrotal position. N: subject number. W: week. M: Month. D: days. T: temperature. DFI: DNA fragmentation index. HDS: High DNA stainability

7.5.2. Scrotal exposure to temperatures above core body physiological temperature

A series of studies was then carried out to analyze the adverse effects of induced heating above core body physiological temperature on sperm quality. In man, experimentally induced increase in testis temperature through electric warming bag has resulted in a decrease in sperm count and in percentage of motility, associated with an increase of abnormal sperm morphology (Zhang et al., 2015; 2018 a, b). Statistically significant differences of sperm DNA fragmentation, normal sperm membrane, vitality, and caspase-3 activity were observed between the groups of before heating and 1, 2- and 3-months during heating (Zhang et al., 2015).

In a case report investigating the effect of acute fever (38-39°C) on sperm characteristics, Andrade-Rocha et al (2013) reported a decrease of sperm quality. Moreover, Sergerie et al (2007) reported changes in sperm parameters (total sperm count, motility and vitality) and DNA fragmentation index (DFI) after febrile illness in a fertile man. Semen parameters were analysed before the episode of febrile illness and until 180 days after the fever. Total sperm count significantly decreased at 15, 37 and 58 after fever and returned to normal by day 79 post fever. Percentage motility significantly decreased by day 15 and 37 and returned to normal by day 58

post fever. In the same vein, sperm concentration significantly decreased by 32.6% following fever during meiosis and by 35.0% following fever during the post-meiotic period of spermatogenesis (spermiogenesis). The percentage of morphologically normal sperm was decreased by 7.4% (-11.6; -3.0) and the percentage of immotile sperm was increased by 20.4% (6.0; 36.8) by fever during spermiogenesis. The number of days the men experienced fever significantly affected their semen parameters (Carlsen et al., 2003). Buch and Havlovec (1991) also found decreased sperm count in a case report of a semen donor who suffered an acute viral illness with fever (38.3C for 24 hours). On the other hand, MacLeod and Hotchkiss (1941) exposed six volunteers in a fever room 45 min with 43 °C, sperm count, motility, and morphology parameters decreased after the febrile episode. Recovery of morphology and motility parameters occurred 4 weeks after normalization of the temperature. However, sperm count parameters only returned to normal 8 weeks after normalization of the temperature. In a study by Jung et al (2007), volunteers increased their body temperatures to 40.5°C for 32 min, and demonstrated a decrease of total sperm counts after 4–8 weeks by approximately 50 %. All results of papers about febrile episode impacts were reported without regard to the scrotum or testis temperature.

In saunas with temperatures ranging from 80–90°C, and at different frequency and duration of exposure, the use of saunas could disrupt spermatogenesis and cause abnormal sperm count and motility (Brown-Woodman et al., 1984; Garolla et al., 2013; Saikhun et al., 1998). Further, regular sauna exposure over an entire spermatogenic cycle also modified mitochondrial function, chromatin protamination and condensation in the sperm and percentage of sperm DNA fragmentation increases (Garolla et al., 2013). On contrary, Saikhun et al (1998) observed that all sperm characteristics (semen values, sperm count, percentage of motility, normal sperm morphology, sperm penetration assay) were not changed after sauna exposure at 30 min per day for 2 weeks.

Moreover, full-body immersion in a warm bath, hot tub, heated Jacuzzi or whirlpool at temperatures over 36.9°C for 30 min or more a week for 3 months or more leads to wet hyperthermia, which could have a reversible negative effect on sperm motility (Shefi et al., 2007). Likewise, 10 volunteers received testicular warming in a 43°C water bath 10 times, for 30 min each time (Rao et al., 2015), and results indicated that sperm parameters (sperm concentration and sperm motility) reversibly decreased at 6 or 8 week after treatment , while serum sexual hormone levels, epididymis, and accessory

sex gland function were not affected. In addition, intermittent heat exposure can more seriously damage spermatogenesis.

Wang et al (2007) treated 18 of healthy male volunteer by scrotal submersion at 43 °C in water for 30 min/day for 6 consecutive days, and found that mean sperm concentration after heat treatment decreased maximally at 6 week and then gradually returned to baseline levels by week 12. At the second week, a significantly greater germ cell apoptosis was recorded.

Rachootin and Olsen (1983) reported a significantly increased odds ratio for occupational exposure to heat among men with sperm abnormalities. In the Italian ceramic industry (Figa-Talania et al., 1992), individuals exposed to high temperature had a higher incidence of childlessness and of self-reported difficulty in conceiving than did controls. Overall evaluation of the semen parameters indicated a higher prevalence of pathological sperm profiles in heat-exposed workers. Finally, in a longitudinal study of 17 welders exposed to moderate radiant heat, the proportion of spermatozoa with normal forms declined significantly after 6 weeks of exposure, but increased after a break from heat exposure (Bonde, 1992).

Chapter VIII

What are physiological and pathophysiological mechanisms of testicular heat stress? What happens to testicular function during and after heating?

8. What are physiological and pathophysiological mechanisms of testicular heating? What happens to testicular function during and after heating?

Human and animals studies and reviews on different cases reported that these were different hypotheses for physiological and pathophysiological mechanisms of testicular heating on testis – epididymis function and sperm quality (Young, 1956; Hanley & Harrison, 1962; Waites et al., 1964; Chowdhury & Steinberger, 1970; Galil & Setchell, 1988; Takihara et al., 1991; Setchell et al., 1998; Sutovsky & Manandhar, 2006; Zhu et al., 2010; Bomblies et al., 2015; Widlak & Vydra, 2017). Therefore, I will try to summarize those hypotheses in some points:

- Exposure of the testis to high temperature could be derived from insufficient blood supply and consequent hypoxic stress of the testis tissue (Galil & Setchell, 1988; Setchell et al., 1998).
- The uptake of oxygen and glucose by the testis and epididymis increased over the control after the testes had been above 39°C for 100 to 144 min (Waites et al., 1964).
- The pathophysiology of varicocele is an increase in testicular temperature due to impaired heat transfer in the spermatic cord and/or decreased testicular

blood flow in male infertility (Young, 1956; Hanley & Harrison, 1962; Takihara et al., 1991). However, the mechanism of elevated intra-scrotal temperature is a failure to precool testicular artery blood because of reflux induced failure of counter-current heat exchange and concomitant inability of the scrotal wall to correct this abnormality (Zorgniotti, 1982).

- Death of germ cells (Widlak & Vydra, 2017) could be induced by mild heating (37°C) extended elevation of temperature exemplified by cryptorchidism (massive apoptosis observed after three and /or four days) or acute heat shock at 42–43°C (massive apoptosis observed after a few hours).
- Pachytene spermatocytes and round spermatids are the most testicular cells sensitive to heat stress (Chowdhury & Steinberger, 1970). Whereas, any alteration in spermiogenesis may lead to the production of pathological forms of spermatozoa with head anomalies, defective neck alignment, midpiece defects with cytoplasmic residues, and tail defects (Sutovsky & Manandhar, 2006).
- Temperature appears to be a major challenge for chromosome segregation during the meiosis stage where the temperature increase was associated with failure of synapsis and reduced chiasma frequency in animals at high temperatures (Bomblies et al., 2015).

- Heat shock proteins (HSPs) play a protective role in response to cell stress and several HSPs were induced mainly in spermatocytes and round spermatids when testis temperature increased (Widlak & Vydra, 2017).
- Damage to the seminiferous epithelium after the end of local heating treatment and impaired expression of several proteins mainly expressed during germ cell proliferation, survival, as well as in apoptosis (Zhu et al., 2010; Lue et al., 2002).
- Finally, a disproportionate increase in ROS may lead to oxygen species (OS) that can cause damage to nuclear and mitochondrial sperm DNA (Roque & Esteves in Zini & Agarwal 2018).

Conclusion: To date, consequences of heat stress on germ cells, however, are not thoroughly understood. This warrants further genetic studies to shed more light on pathways that regulate heat stress responses of male germ cells and discover new genes that may be involved. Understanding the molecular mechanisms of testicular heat stress would aid in developing targeted male infertility therapies and contraception.

Chapter IX

Clinical Applications

(Male contraception, infertile situation)

9. Clinical Applications

9.1. Use of testicular heating as a method for male contraception

The world's population is estimated to be 6.8 billion and is rising rapidly. Still, safe, effective, reversible and affordable contraception are asked by many couples (Cheng & Mruk, 2010). About 10 % of reproductive age rang used method male contraception (Wang & Swerdloff, 2002) such as; condoms and vas occlusion. However, the male contraception failure of condoms in general use is about 12% (Trussell et al., 1987).

Testicular heating was one of the methods of male contraception considered safe alternative compared with other contraceptive methods such as hormonal, withdrawal and spermicides and/or vasectomy. Therefore, a recent study by Amouroux et al (2018) reported that at 30% of the new fathers and 45% of the female new providers would be interested in thermal male contraception method.

The potential use of testicular heating through scrotal heating or insulation for contraceptive purposes in men is a possibility that has been investigated for more than 60 years, an early study by Watanabe (1959) suggested can be used the thermal contraceptive method for men through immersion of the scrotum in water at 44 - 46°C at 30 min for 1-12 days.

In the same vein, many authors have shown that a prolonged increase in scrotal heating of just 1–1.5°C is able to induce germ cell apoptosis and reduction in testis size leading to reduced sperm production and altered sperm morphology (Mieusset et al., 1987; 1991; Jung & Schuppe, 2007). Even, on the basis of these observations, a mild but continuous testicular heating has been proposed as a noninvasive method of male contraception (Wallach et al., 1988). The mild testicular heating method included perfecting four characteristics (Mieusset & Bujan, 1994):

- Safety for the user and his partner.
- Reversibility of the contraceptive effect.
- High efficacy as a means of birth control.
- Acceptability for the user.

Mild testicular heating was assessed as a potential male contraceptive by two different studies (Shafik, 1991; Mieusset & Bujan, 1994). In both studies, the testes were elevated to the superficial pouch close to the scrotal neck. In such a position intra-testicular temperature was increased by about 2°C (Shafik, 1991). Differences between the two studies were in the methods used for maintaining the testes in a supra scrotal position and in the duration of daily exposure to heat in this position. Immobilization of the testis was achieved either by surgical fixation or by use of a special suspensory sling made of non-stretchable

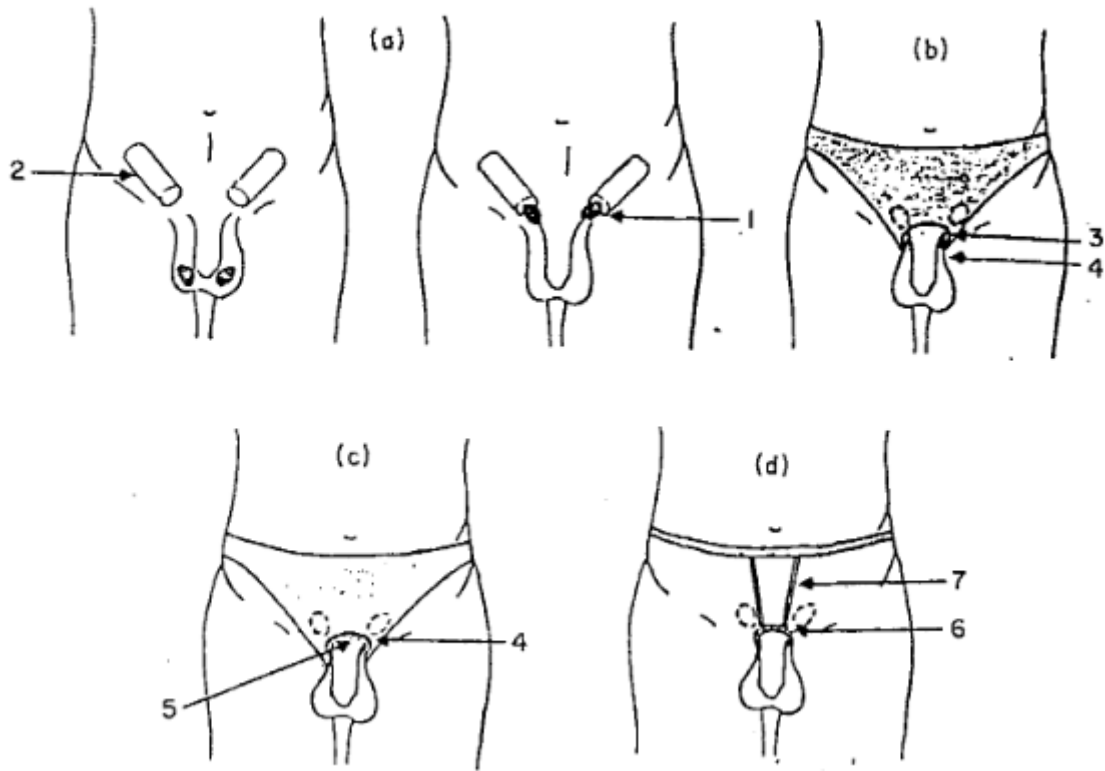
fabric with a ball fixed in its bottom (Shafik, 1991), or by the use of close-fitting underwear in which a hole was made through which the penis and empty scrotum were passed, or by use of a ring of smooth rubber surrounding the hole of the previous underwear or worn alone and maintained with traps (Mieusset & Bujan, 1994). Daily exposure was for either 24 h (Shafik, 1991) or only during waking hours, i.e. approximately 15h per days (Mieusset & Bujan, 1994).

The results of these studies (see table 6) are summarized below:

- Shafik 1991: 28 couples, 252 cycles of exposure to pregnancy: 0 pregnancies.
- Shafik 1992: 9 couples, 126 cycles of exposure to pregnancy: 0 pregnancies.
- Mieusset and Bujan 1994 *T1: 3 couples, 42 cycles of exposure to pregnancy: 1
- Mieusset and Bujan 1994 *T2: 6 couples, 117 cycles of exposure to pregnancy: 0

(*) T1= Immobilization of the testis was achieved by the use of close-fitting underwear in which a hole was made, through which the penis and the empty scrotum were passed.

(*) T2= A ring of soft material made of smooth rubber was either added to the underwear surrounding the hole or was worn without underwear but maintained with thin straps. (See figure 18).



(a) Testes are lifted up (1) close to the inguinal canal (2). (b) With technique 1, testes are maintained in the previous location by means of underwear in which a hole (3) was made at the level of the root of the penis. The penis and the scrotal skin are passed through this hole (4). (c) With technique 2, either a ring of soft rubber (5) was added to the hole in the underwear (4) or (d) this ring was worn alone (6), but maintained with thin straps (7).

Figure 18 Two techniques of heating the testis to use for male contraception (Mieusset & Bujan, 1994)

Table 6 Testicular heating as a method for male contraception

Technique	Count (10^6 /ml)	N° of cycles were exposure	Pregnancy	Recovery
15H per days T1⁽¹⁾	2.4	42	1	6-12M
15H per days T2⁽²⁾	0.2	117	0	5-8 M
24H per days⁽³⁾	0.15	252	0	6-12 M

(1 +2) Mieuseset & Bujan 1994, (3) Shafik 1991.

9.2. Infertile situation

Previous experimental studies reported that lowering scrotal temperatures or hypothermia can be used to correct abnormal spermatogenesis, either in varicocele or in oligozoospermic patients in whom scrotal temperatures had been found to be abnormally elevated (Jung et al. 2001; Zoragniotti et al. 1982; Zoragniotti & Sealfon, 1984). In addition, avoidance of exposure to heat has been reported to prevent infertility (Hendry et al. 1973; Jung et al. 2005; Lynch et al. 1986).

Jung et al (2001) found that semen quality could be improved by lowering scrotal temperatures by using a simple cooling device (continuous air stream) at night in men with oligoasthenoteratozoospermia of idiopathic nature or caused by varicocele. He observed that a highly significant increase in sperm concentration and total sperm output was achieved after nocturnal scrotal cooling for 12 weeks together with a moderate decrease in factors leading to genital heat stress. Likewise, applying chronic scrotal hypothermia to 25 patients with infertility and elevated testis temperature resulted in varying degrees of improvement over their pretreated poor semen in 16/25. Pregnancy occurred in 6/25 infertile couples (mean period of infertility 6.0 years) after wearing an evaporative scrotal cooling device for sixteen hours daily for a mean of 14.5 weeks (Zoragniotti et al, 1982). In other vein, Lynch et al (1986)

performed an interventional study with 128 infertile men with a history of at least two hot baths per week and the use of tight-fitting underwear. After avoiding hot baths and wearing loose-fitting boxer shorts for three months, semen quality of men with oligozoospermia significantly improved. In same recommend using loose underpants resulted in 25 cases, either a normal seminal analysis (13 patients) or pregnancy in the spouse (12 patients) without any need for further treatment (Hendry et al., 1973).

Davidson (1954) reported an improvement of semen quality in three infertile men with oligozoospermia by means of cold sponging of the scrotum twice daily and avoidance of tight-fitting underwear. These measures were followed by an increase of sperm density by 7-fold of pre-treatment values.

Moreover, effects of scrotal cooling ice packs on 50 men with reduced sperm motility were exposed (Mulcahy, 1984). Every night, jockey shorts held the cooling mechanism in place and resulted in at least a 2-fold increase in sperm quantity as well as an increase in motility for 65% of the patients. Success in treatment was independent of whether a varicocele was present or not.

Another study reported that application of an ice bag to the scrotum for a mean of about 30 minutes cooled the testicular environment by a mean of 6.9°C and such cold treatment on 14 consecutive days, stimulated spermatogenesis without initial inhibition (Robinson et al., 1968).

Chapter X

10. Our studies

Studies Objectives

10.1. The main objective

In this work, the main objective was to investigate the effects of the mild increase of testicular and epididymal temperature (*i.e.* testis temperature below core body temperature) on two sperm parameters:

- Sperm morphology defect including multiple anomalies index (MAI).
- Total sperm aneuploidy chromosomes including sperm aneuploidy for Chromosomes X, Y, 18.

These investigations were performed according to the physiological chronology of spermatogenesis and epididymal transit in human.

Materials & Methods

10.1.1. Method of increase in testicular and epididymal temperature

10.1.1.1. Study Population

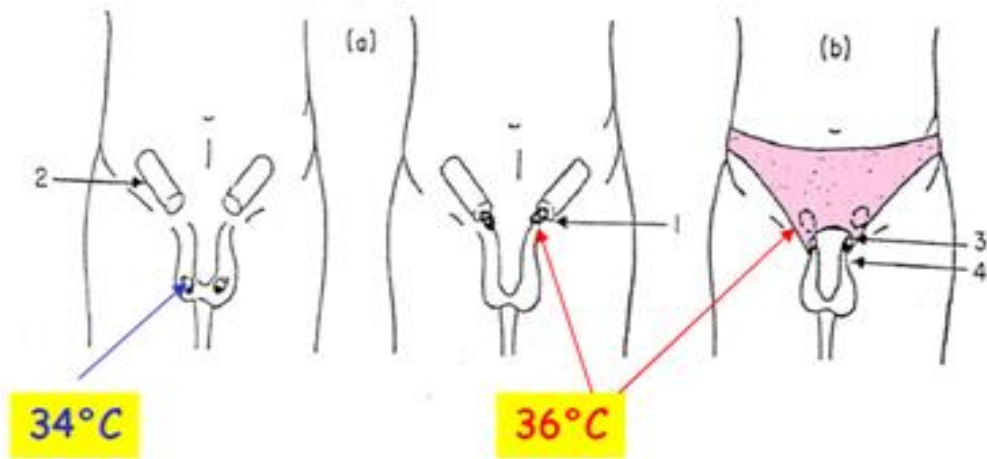
The study was approved by the Ethics Committee (Comité de Protection des Personnes Sud-Ouest et Outre Mer I) and the protocol has been previously described (Ahmad et al., 2012). The volunteers were recruited through advertisement in the press and hospital communication. A total of 34 men volunteered for the study. After exclusion criteria and financial limitations 6 volunteers (aged 25-35 years) were selected. These men, who had fathered at least one child, had a normal clinical andrological examen and had no current pathology, no medical or surgical history. They had no or moderate and occasional alcohol intake. They are not exposed to toxic agents and have no particular professional risk for fertility. One volunteer dropped the study at day 73 of heating due to personal reasons hence the data of this volunteer were excluded. Remaining five volunteers followed the instructions and the protocol and continued till the completion of study. None of the volunteer reported any discomfort during the entire period of study. The aneuploidy results of 27 fertile men were used as control values to compare with aneuploidy values of experimental volunteers (n=5).

One volunteer smokes 20 cigarettes a day in experimental group and 7 men smoke more than 10 cigarettes a day in control group.

10.1.1.1.2. Techniques of testicular exposure to heat

Increased testicular and epididymal temperature was induced by maintaining the testes in a supra-scrotal position by means of specially designed underwear worn 15 ± 1 hours daily for 120 consecutive days. The method was developed by (Mieusset et al., 1985; Ahmed et al., 2012) is well tolerated and reversible. Each volunteer was provided specific underwear. A comprehensive demonstration was given to the volunteers explaining how to push up and maintain the testicles at the upper part of the root of the penis (Fig 18).

All volunteers were able to push and maintain the testicles easily in this position. The testicles were pushed up into the inguinal canals and maintained their daily for waking. The support to the testes was ensured by the briefs (underwear) provided with an orifice allowing the penis and scrotum to be exteriorized and specifically made for each volunteers. This testis supra-scrotal position (TSP) resulted in a 1.5 to 2°C increase in testicular temperature (Kitayama, 1965; Shafik, 1991).



15h/day

Techniques of heating the testes. (a) Testes are lifted up (1) close to the inguinal canal (2). (b) With technique 1, testes are maintained in the previous location by means of underwear in which a hole (3) was made at the level of the root of the penis. The penis and the scrotal skin are passed through this hole (4). (c) With technique 2, either a ring of soft rubber (5) was added to the hole in the underwear (4) or (d) this ring was worn alone (6), but maintained with thin straps (7).

Figure 19 Schematic representation of testicular and epididymal heat increase from 34°C in scrotal to 36°C into the inguinal canals (Adapted from Mieusset et al., 1985)

10.1.1.1.3. Part I: A study the effect of a mild testicular and epididymal temperature on human sperm morphology

Periods of sampling

This experimental prospective study was divided into three periods: “before heating” (-40, -15 and 0 days), “during heating” (4, 9, 20, 34,45,73,95 and 120 days) and when heating was stopped “after heating” (124, 129, 140, 154, 165, 193, 215 and 300 days). The days of semen collection were defined according to the physiological chronology of spermatogenesis and epididymal transit. According to these physiological times and so to the exposition of testicular germinal cells to heat we divided the “after heating” period in two phases: 1) Phase I (when some of the germ cells and different stages of spermatogenesis cycle have been heated, corresponding to 124,129, 140,154,165,193 days); 2) phase II (when no germ cells nor any stage of spermatogenesis cycle have been heated, corresponding to days from 215 to 300) (Fig 20). According to spermatogenesis and epididymal physiologies spermatozoa collected at D20 were at the elongated spermatid stage in the testis when heating was induced. Those collected at D34 were at the late spermatocytes stage (end of meiosis) or at spermiogenesis stage, those collected at D45 were in meiosis stage and finally those collected from D56 to D86 at mitosis stage of spermatogenesis.

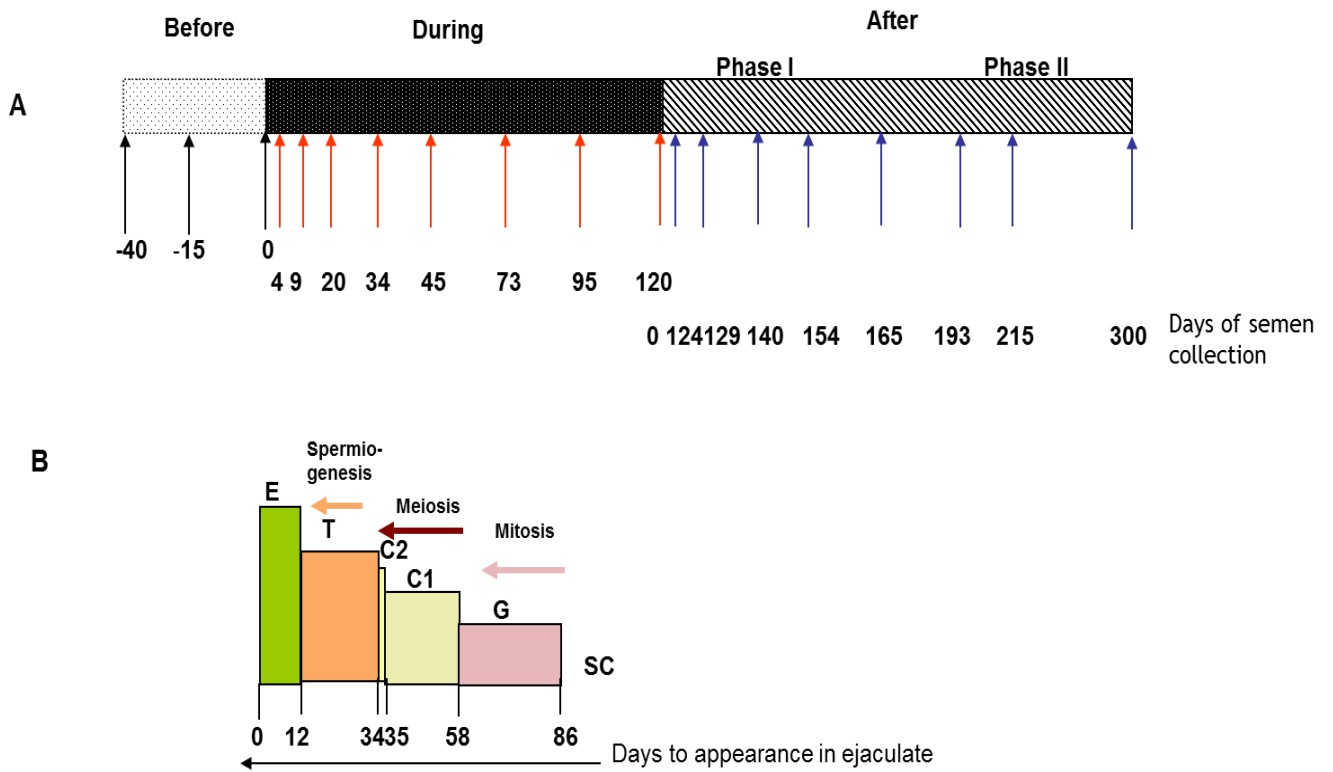


Figure 20 Schematic representation of the timing of semen sampling during the three study periods before, during and after heating (phase I, phase II), B) Location and evolutionary stages of sperm during the spermatogenic process at heat induction (Adapted from Ahmad et al., 2012)

Semen collection

Semen samples were collected by masturbation after a median sexual abstinence of 4.1 ± 1 days. The samples were examined after liquefaction 37 C° for 30 minutes. Semen volume, sperm count were analyzed according to the previous method (Ahmad et al., 2012).

Sperm morphology

Sperm morphology was assessed by observing 100 spermatozoa per sample according to the classification of David et al (1975) modified by Jouannet et al (1988). The type of sperm morphology defects were categorized into head, mid-piece and tail i.e.: Head defects (tapered head, thin head, microcephalic, macrocephalic, multiple heads, abnormal post-acrosomal region and abnormal acrosomal region), Midpiece defects (excess residual cytoplasm, thin midpiece, and bent misaligned midpiece) and Tail defects (no tail, short tail, irregularly shaped tail, coiled tail and multiple tails).

Multiple anomalies index (MAI) is the mean numbers of anomalies per abnormal spermatozoon (Jouannet et al., 1988). All the head, midpiece, and tail anomalies are included in the calculation.

In order to minimize inter-observer variability, sperm morphology was assessed by a single technician in the experimental as well as in the control group.

Statistical Analysis

Data are presented as median and interquartile range Q1–Q3 due to the number of patients for tables, and as mean and standard deviation for graphic representation.

Sperm morphology and MAI data were compared before and during and after mild induced testicular and epididymal heating by the Wilcoxon signed rank-sum test, with a p-value of 0.50% after a Bonferroni correction.

Due to the limited number of men included in the experimental protocol, we also carried out statistical comparison with a control group of 27 fertile men (a single time point evaluation of sperm morphology for each man) using a non-parametric Mann-Whitney analysis. As there were multiple comparisons, a Bonferroni correction was used and a p-value of 0.38 % was considered significant.

Statistical analyses were performed using SAS software (9.3, SAS Institute). A P-value of 5% was considered significant in the case of no Bonferroni correction.

10.1.1.1.4. Part II: Effect of a mild induced increase in testicular and epididymal temperature on sperm aneuploidy

The present work is the second part of a study of the effects of mild induced testis temperature increase on gamete quality (Ahmad et al., 2012). We used the biological specimens which had been frozen during the first part of the study.

Sperm concentration evaluation

Semen analyses were performed within 1 hour of sample collection. Sperm count ($\times 10^6/\text{ml}$) was assessed with the use of a Malassez cell (Rogo Sanlab) as published previously (Mieusset et al., 1985).

Sperm Fluorescence in situ Hybridization (FISH)

We used FISH for sperm chromosome study at four time points: before heating (day 0), at day 34 of the heating period (H34), and after the end of the heating period at post-heating day 45 (PH45) and day 180 (PH180) (Fig. 1). No investigation was possible between days H34 and H120 due to the insufficient number of spermatozoa in ejaculates.

Semen samples were collected during the experimental study (Ahmad et al. 2012) and mixed with a cryoprotectant, frozen in straws within 1 hour of

collection and stored in liquid nitrogen according to the standard procedures used for sperm banking in our laboratories. All samples were stored in the Germethèque Biobank (BB-0033-00081, France) until aneuploidy examination according to our previously published method (Esquerré et al., 2018).

Briefly, cells were thawed and then washed twice with 5 ml PBS and centrifugation at 630g. Samples were then fixed with a fixation solution (acetic acid and methyl alcohol) for 30 min at 4°C. After centrifugation at 1500g, the supernatant was discarded and the pellet resuspended. 10 µl were dropped on a slide and cell density was verified by microscopy and adjusted accordingly. Slides were incubated for a minimum of 2h at -20°C. DNA was decondensed by incubating slides in 1M NaOH for 1 min, washed twice in SSC, then dehydrated in 70%, 90% and 100% ethyl alcohol baths (2 min each). Each slide was then incubated overnight with the different probes at 37°C (Vysis probes (Abbott), CEP X spectrum green, CEP Y spectrum orange and CEP 18 spectrum aqua). After a 2 min wash in 2SSC 0.4% NP40 at 73°C followed by a 1 min wash in 2SSC 0.3% NP40, slides were incubated with 1/2000e Hoechst for 3 min and washed for 3 min in PBS. Slides were finally mounted with Antifade mounting medium (Promega, Germany) and stocked at -20°C until reading. A mean of 5149 ± 218 cells per subject at each time were read by a single reader for experimental group and 5232 ± 190 for control group.

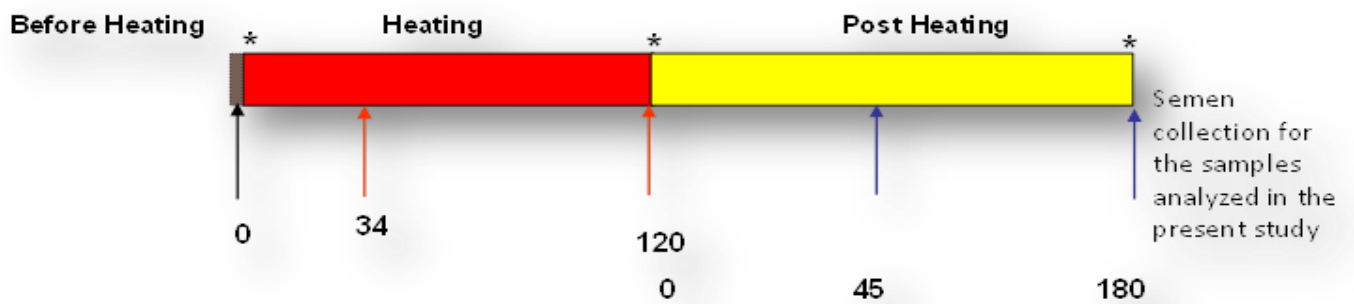


Figure 21 Schematic representation of semen sampling timing during the four study periods; Before D0, During H34, after (PH45 and PH180)

Statistical Analysis

Data are presented in the Tables as median and interquartile range Q1–Q3 due to the number of patients and as mean and standard deviation in graphic representations.

Sperm aneuploidy data were compared before, during and after mild induced increase in testicular and epididymal temperature by the Wilcoxon signed rank-sum test. Due to the small number of men included in the experimental protocol, we also carried out statistical comparison with a control group of 27 fertile men (a single evaluation of sperm aneuploidy for each man) using the non-parametric Mann-Whitney test. As there were multiple comparisons, a Bonferroni correction was used. P-values of 1.66% were considered significant for the Wilcoxon test and of 1.25% for the Mann-Whitney test.

Statistical analyses were performed using SAS software (9.3, SAS Institute). A p-value of 5% was considered significant without Bonferroni correction.

Articles

Part I. Mild experimental increase in testis and epididymis temperature in men: Effects on sperm morphology according to spermatogenesis stages.

**Mild experimental increase in testis and epididymis temperature in men:
Effects on sperm morphology according to spermatogenesis stages.**

Short title: Testis heating and sperm morphology in men

Mohamed Hadi Mohamed Abdelhamid¹, Marie Walschaerts^{1,2}, Gulfam Ahmad^{1#}, Roger Mieusset^{1,4}, Louis Bujan^{1,5*} and Safouane Hamdi^{1,6}

¹ Groupe de Recherche en Fertilité Humaine (EA 3694, Human Fertility Research Group), Université de Toulouse; UPS, Toulouse, France

² Germéthèque, Groupe d'activité de médecine de la reproduction, Hôpital Paule de Viguier, CHU Toulouse, Toulouse, France

⁴ Unité d'Andrologie, Groupe d'activité de médecine de la reproduction, Hôpital Paule de Viguier, CHU Toulouse, Toulouse, France

⁵ CECOS, Groupe d'activité de médecine de la reproduction, Hôpital Paule de Viguier, CHU Toulouse, Toulouse, France

⁶ Laboratoire de biochimie, Institut Fédératif de Biologie, CHU Toulouse, Toulouse, France

Current address: School of Medical Sciences, Sydney Medical School, Discipline of Pathology, Sydney University, Sydney, Australia

***Corresponding author**

E-mail: bujan.l@chu-toulouse.fr (LB)

Abstract

A mild increase in testicular and epididymal temperatures in men, bulls and rams (pendulous scrotum) induces spermatogenesis inhibition associated with increased percentages of sperm with an abnormal morphology. However, knowledge about the stages of spermatogenesis that are most sensitive to a mild increase in testicular temperature in men is still missing. The aim of the present study was to explore the effects of a mild induced testicular and epididymal temperature increase (*i.e.* testis temperature sustained below core body temperature) on sperm morphology in humans according to the physiological time of spermatogenesis and epididymal transit. Five healthy volunteers were enrolled in an experimental study in which testicular and epididymal temperatures were increased by maintaining the testes in a supascrotal position with a specially designed underwear worn 15 ± 1 hours daily for 120 consecutive days. Semen collection was scheduled on specific days according to spermatogenic stages and epididymal transit. Sperm morphology and multiple anomalies index (MAI) were analyzed before, during and after heating. This mild induced increase in testicular and epididymal temperatures resulted in a significant increase in the percentage of morphologically abnormal spermatozoa on day 34 of heating, which remained higher throughout the heating period and persisted until 45 days after

cessation of heating. The MAI was significantly increased on day 20 throughout the heating period and persisted 45 days after cessation of heating. Increase in the percentage of anomalies in the sperm head, acrosome or tail occurred at days 34 and/or 45 of heating. Abnormal sperm morphology and MAI reverted to control values 73 days after cessation of heating. Thus, the increased percentage of sperm with abnormal morphology induced by mild and sustained increase in testicular and epididymal temperatures results first from alterations during spermiogenesis which are later compounded by alterations during meiosis.

Introduction

In men and in most mammalian species, normal physiological spermatogenesis requires a testis temperature that is 2–6°C below the core body temperature [1, 2]. In humans two thermoregulatory systems are responsible for this lower physiological testis temperature. The first system consists of a countercurrent heat exchange between arterial blood and spermatic vein blood through the pampiniform plexus. The second system is external heat loss outside the body through passive convection and radiation by the scrotum [2, 3]. Dysfunctions in thermoregulatory systems or conditions that exceed the efficiency of these systems result in an increase in testis temperature [4].

In mammal studies that included men, testis and epididymis functions were shown to be acutely sensitive to temperature increase of only a few degrees [5], and much effort has been devoted to the analysis of this response. The majority of experimental protocols that induce an increase in testicular temperature in humans by different methods (electric warming bag, polyester-lined supports, testis suprascrotal localization, sauna, water bath) have a negative impact on spermatogenesis [6-11] and the quality of sperm parameter in most cases. However, according to the body temperature, temperature intensity in experimental increase could be classified into two categories: mild increase when

testis temperature remains below body temperature and high increase when it reaches values above body temperature.

To date, four studies have examined the effects of a mild experimental increase in scrotal and testicular temperature on sperm morphology in humans. In the first study, mild testicular heating was performed using the Testis Suprascrotal Position method (TSP) which positions the testes near the respective inguinal canals [7, 12]. This method resulted in a reversible decrease in total sperm output and sperm motility and a reversible increase in morphologically abnormal spermatozoa. In the second study, an improvement in the TSP method resulted in a more intensive effect on sperm characteristics [13]. Abnormal sperm morphology increased to 180% of baseline values during the TSP period (15 ± 1 hour daily, 6 to 24 months) and recovered normal values 10-12 months after cessation of the TSP. The aim of these studies was to prove that a sustained and repeated mild increase in testicular temperature systematically sufficed to induce a drastic reduction in sperm output and was therefore a viable means of male contraception. They were not intended to decipher the various stages of germ cells that were affected.

This view has been amply confirmed by Shafik [14], who described the reversible effect of an increase in testis temperature by testicular suspension. In 28 male volunteers the testes were suspended in the superficial inguinal pouch

close to the scrotal neck for 12 months. During suspension the percentage of normal sperm morphology dropped in 12 months. However, 6-12 months after release sperm morphology returned to normal [14].

Wang et al [15] reported no significant increase in the percentage of spermatozoa with abnormal morphology in men wearing polyester-lined supports to increase scrotal temperature by 0.8 to 1 C°. The absence of negative effects in this study was attributed to an insufficient temperature increase.

In animals, experimental studies explored the effects of a mild temperature increase on sperm morphology in bulls and rams, particularly by the use of scrotal insulation. In these models (scrotal insulation), increase in testes and epididymis temperatures induced negative effects on sperm parameters and sperm morphology [16-20].

To date, no study has investigated the effects of a mild increase in testicular temperature on sperm morphology in humans, according to the precise chronology of spermatogenesis and epididymal transit in order to decipher at least the initiation of morphological alterations in sperm.

In this context, the aim of the present study was to explore the effects of a mild induced testicular and epididymal temperature increase (*i.e.* testis temperature sustained below core body temperature) on sperm morphology in humans

according to the physiological time of spermatogenesis and epididymal transit. This work is the continuation of our previously published experimental study in which the deleterious effects of testis temperature on sperm production and DNA fragmentation were explored [21].

Material and methods

Study Population

Five healthy fertile volunteers were recruited (men aged 25-35 years who had fathered at least one child by natural conception). The study was approved by the Ethics Committee (Comité de Protection des Personnes Sud-Ouest et Outre Mer I) and the protocol has been previously described [21]. The volunteers were recruited through advertisement in the press and hospital communication. A total of 34 men volunteered for the study. After exclusion criteria and financial limitations 6 volunteers were selected. These men, who had fathered at least one child, had a normal clinical andrological examen and had no current pathology, no medical or surgical history. They had no or moderate and occasional alcohol intake. They are not exposed to toxic agents and have no particular professional risk for fertility. One volunteer dropped the study at day 73 of heating due to personal reasons hence the data of this volunteer were excluded. Remaining five volunteers followed the instructions and the protocol and continued till the completion of study. None of the volunteer reported any discomfort during the entire period of study.

In the present study semen samples of 27 healthy fertile men were analyzed to serve as controls before applying the protocol of mild increase in testicular and epididymal temperature on experimental volunteers (n=5).

Study Design

Techniques of testicular exposure to heat

Increased testicular and epididymal temperatures were induced by maintaining the testes in a suprascrotal position by means of specially designed underwear worn 15 ± 1 hours daily [7, 21] for 120 consecutive days. This testis suprascrotal position (TSP) resulted in 1.5 to 2°C increase in testicular temperature [14, 22].

Sampling periods

This experimental prospective study was divided into three periods: “before heating” (-40, -15 and 0 days), “during heating” (4, 9, 20, 34, 45, 73, 95 and 120 days) and when heating was stopped “after heating” (124, 129, 140, 154, 165, 193, 215 and 300 days). The days of semen collection were scheduled according to the physiological chronology of spermatogenesis and epididymal transit. According to these physiological times and the exposition of testicular germinal cells to heat we divided the “after heating” period into two phases: 1) phase I when some of the germ cells and different stages of spermatogenesis cycle have been heated, corresponding to 124, 129, 140, 154, 165 and 193 days; 2) phase II when no germ cell or stage of spermatogenesis cycle have been heated, corresponding to 215 to 300 days) (Fig. 1).

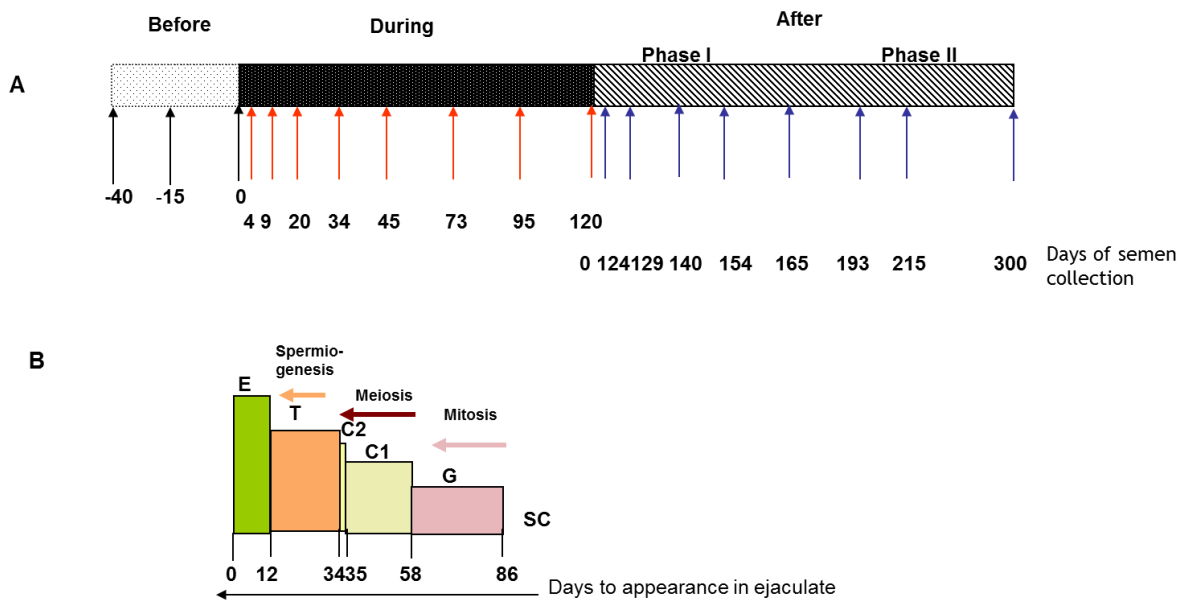


Fig. 1 A) Schematic representation of the timing of semen sampling during the three study periods before, during and after heating (phase I, phase II), **B)** Location and evolutionary stages of sperm during the spermatogenic process at heat induction (D0) and their expected appearance in ejaculates. E = epididymal sperm; T = spermatids; C2 = spermatocytes II; C1 = spermatocytes I; G = spermatogonia; SC = stem cells (adapted from Ahmad et al [21]).

Semen collection

Semen samples were collected by masturbation after a median sexual abstinence of 4.1 ± 1 day. The samples were examined after liquefaction at 37°C for 30 minutes. Semen volume and sperm count were analyzed according to the WHO ([23] recommendations as in our previous study [21].

Sperm morphology

Sperm morphology was assessed by observing 100 spermatozoa per sample according to the classification by [24] modified by [25]. The type of sperm morphology defects were categorized into head, mid-piece and tail i.e. : Head defects (tapered head, thin head, microcephalic, macrocephalic, multiple heads, abnormal post-acrosomal region and abnormal acrosomal region), Midpiece defects (excess residual cytoplasm, thin midpiece, and bent misaligned midpiece) and Tail defects (no tail, short tail, irregularly shaped tail, coiled tail and multiple tails).

The multiple anomalies index (MAI) is the mean numbers of anomalies per abnormal spermatozoon [25]. All the head, midpiece, and tail anomalies were included in the MAI calculation.

In order to minimize inter-observer variability, sperm morphology was assessed by a single technician in the experimental as well as in the control group.

Statistical Analysis

Data are presented as median and interquartile ranges Q1–Q3 due to the number of patients for tables, and as mean and standard deviation for graphs. Sperm morphology and MAI data were compared before, during and after mild induced testicular and epididymal heating by the Wilcoxon signed rank-sum test, with a p-value of 0.50% after a Bonferroni correction. Because of the limited number of men included in the experimental protocol, we also made a statistical comparison with a control group of 27 fertile men (a single time point evaluation of sperm morphology for each man) using a non-parametric Mann-Whitney analysis. Considering that there were multiple comparisons, a Bonferroni correction was used and a p-value of 0.38% was considered significant. Statistical analyses were performed using SAS software (9.3, SAS Institute). A P-value of 5% was considered significant in case of no Bonferroni correction

Results

The experimental protocol effectively reduced sperm concentration during heating periods and all men became severely oligozoospermic at D45 and two of the five volunteers presented azoospermia at D95 and D120 respectively. From D95 until D154, two men had fewer spermatozoa in their ejaculates while others were either azoospermic or had rare spermatozoa which rendered morphological analysis invaluable at these time points. Therefore, the result of sperm morphology at time points was presented when the number of volunteers (n=5) was constant during the three periods of the study (Fig. 2).

Percentage of normal spermatozoa and multiple anomalies index (MAI)

Before heating, the percentage of normal spermatozoa and the multiple anomalies index (MAI) were not statistically different between the control group (n=27) and the experimental group (n=5) (Table 1A). Therefore, we compared all experimental values with the values of the control group (see material and methods). The percentage of normal spermatozoa significantly decreased at D34 (during heating), remained significantly lower throughout the heating period until D165 (45 days after cessation of heating) and reverted to control values at D193 (73 days after cessation of heating) (Fig. 2). The percentage of morphologically normal sperm was 5-fold reduced during

heating. The multiple anomalies index (MAI) was significantly increased at D20 (during heating) and returned to the normal mean at D193. Likewise, a drastic decrease in sperm count was observed from D34 until D165 (Fig. 2). However, semen volume did not change during the follow-up.

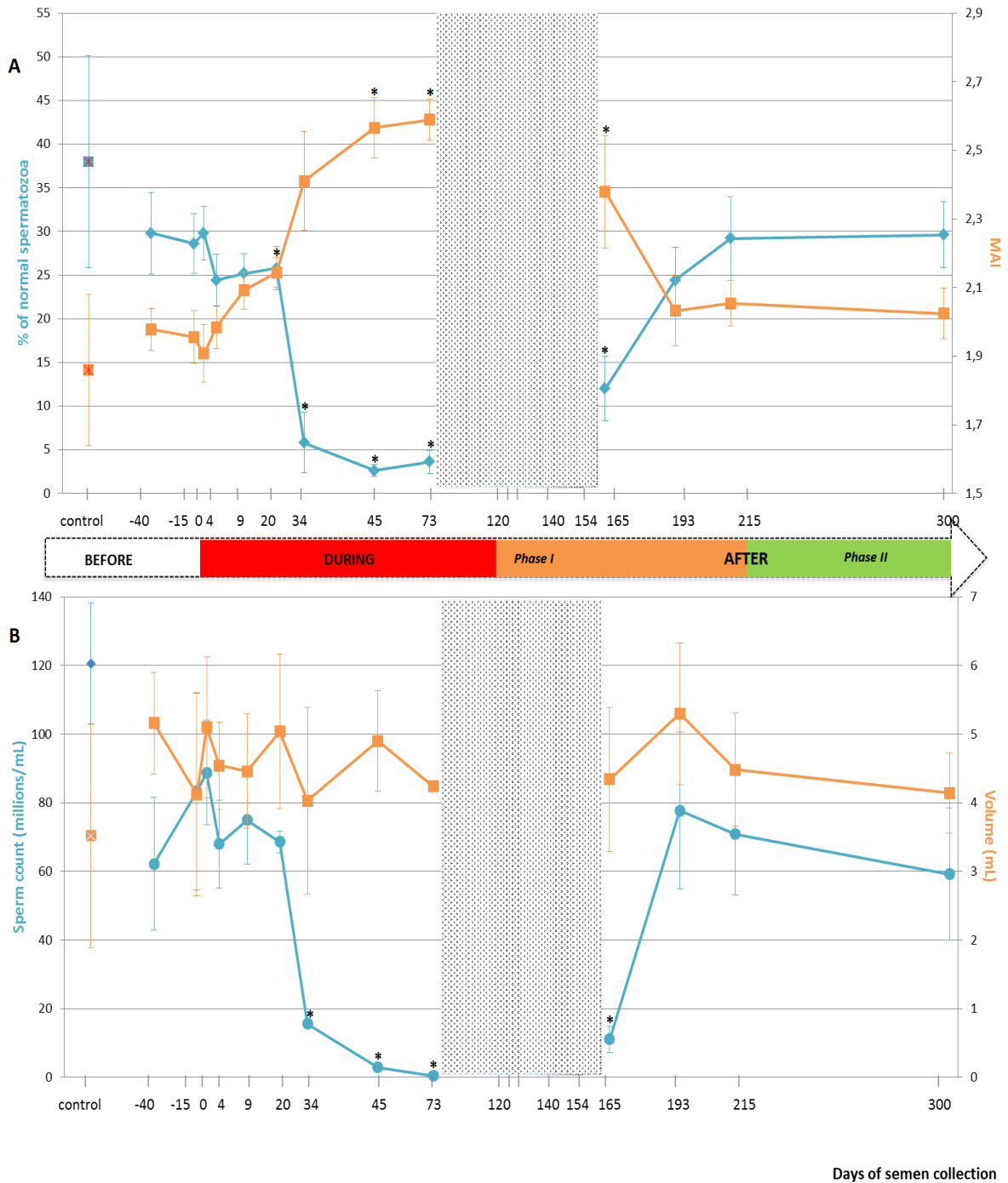


Fig. 2 Percentages of spermatozoa with normal morphology, multiple anomalies index (MAI), sperm count (millions/ml) and semen volume (ml) before, during, and after (phase I and phase II) mild induced testicular and epididymal heating in men (n=5). A) Percentages of spermatozoa with normal morphology, multiple anomalies index (MAI). B) Sperm count (millions/ml) and semen volume (ml). Means \pm SEM were represented compared with the control group (control; n=27). *: $p < 0.05$. Grey zona: sperm morphology study not possible (see results).

Details of sperm morphology changes

Before heating

Before heating, controls (n=27) and volunteers (n=5) had comparable results for sperm morphology.

Table 1A. Sperm morphology (%) at follow-up time points, before induced testicular and epididymal heating in volunteers, and in control group.

	Controls	BEFORE HEATING		
		-40 D	-15 D	0 D
		n=5	n=5	n=5
Tapered head	1 [0-3]	0 [0-3]	1 [0-1]	0 [0-3]
Thin head	5 [3-7]	6 [6-7]	9 [2-12]	6 [6-8]
Microcephalic	10 [7-15]	25 [13-26]	20 [19-21]	16 [12-21]
Macrocephalic	1 [0-2]	0 [0-0]	1 [0-2]	1 [1-1]
Multiple heads	1 [0-2]	1 [0-1]	0 [0-1]	1 [0-1]
Abnormal post-acrosomal region	25 [12-31]	20 [14-26]	17 [13-32]	21 [21-22]
Abnormal acrosomal region	36 [25-47]	45 [38-48]	41 [40-54]	42 [38-47]
Excess residual cytoplasm	3 [2-6]	3 [2-4]	4 [2-4]	4 [3-7]
Thin midpiece	2 [0-3]	1 [1-2]	1 [0-4]	0 [0-1]
Bent or misaligned midpiece	17 [11-21]	19 [17-24]	15 [14-20]	18 [17-22]
No tail	1 [0-2]	0 [0-2]	1 [0-1]	1 [1-2]
Short tail	0 [0-1]	1 [0-1]	1 [1-1]	1 [0-2]
Irregularly shaped tail	0 [0-1]	1 [0-1]	2 [0-2]	1 [1-2]
Coiled tail	9 [4-13]	13 [9-17]	15 [14-17]	9 [5-11]
Multiple tails	1 [0-2]	0 [0-1]	1 [1-1]	1 [1-1]
Normal spermatozoa (%)	38 [26-44]	30 [25-34]	26 [25-30]	28 [25-31]
MAI	1.86 [1.68-1.94]	2.00 [1.98-2.06]	1.97 [1.84-2.02]	1.86 [1.76-1.98]

Values are expressed as median with interquartile range [q1-q3].

During heating

Testicular and epididymal heat exposure led to an increase in the percentage of sperm head anomalies compared to the control group (n=27) as early as D34. A notable increase was noted for thin head ((27% [10-31], microcephalic (29% [29-33]) and abnormal acrosomal region (79% [78-88]) (Table 1b). The percentage of spermatozoa with either thin head or microcephalic head was 3 times higher than the baseline mean values (D0, - 15 and - 40) (Fig. 3).

Similarly, the percentage of spermatozoa with short or irregular tails were significantly higher (2% [1-4] and 1% [1-5] respectively) than values for the control group at day 34 whereas the percentage of coiled ((29% [21-30]) or multiple tailed (4% [4-4]) spermatozoa were significantly higher at D45 and D73 respectively (Table 1B). Mean percentages of spermatozoa with short or coiled tails were 2 times higher than the baseline mean values at D45 (Fig. 3).

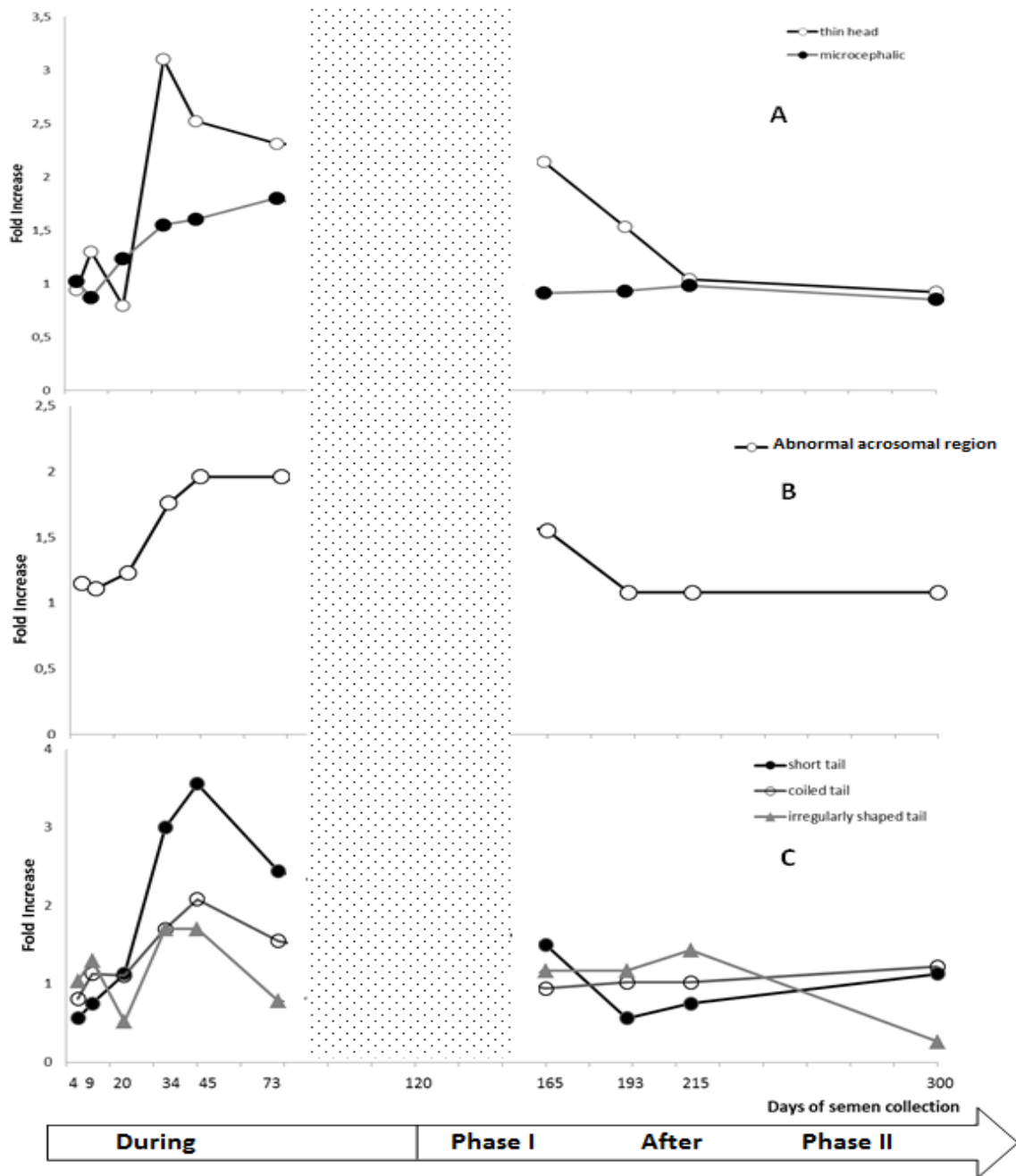


Fig. 3 Description of fold increase in some specific anomalies in sperm morphology during and after (phase I and phase II) mild induced testicular and epididymal heating in men: **A)** Head abnormalities. **B)** Acrosome-related abnormalities. **C)** Tail abnormalities. Data concerning fold increase in sperm anomalies during and after heating were compared with baseline mean values at -40,-15 and 0 day before heating. Grey zona: analyses between day 73 and day 154 were not possible (see results).

After the heating period (phase I)

D165, i.e. 45 days after cessation of heat exposure, was the first time point when ejaculates had an adequate number of sperm to perform a morphology analysis. The percentages of spermatozoa with thin heads (14% [10-18]) or abnormal acrosomal regions (72% [54-80]) remained significantly higher (Table 1C) than in the control group (n=27) until D165.

All morphological characteristics and the overall sperm morphology returned to normal values at D193, i.e. 73 days after cessation of heat exposure (Table 1C).

After the heating period (phase II)

At D215 (95 days after cessation of heat exposure) sperm morphology and percentage of sperm anomalies returned to the baseline values (Table 1C) which indicates that the effects of heat exposure were reversible but a minimum of one cycle of spermatogenesis is required before sperm morphological characteristics return to normal.

Table 1B. Sperm morphology (%) at follow-up time points, during induced testicular and epididymal heating in t volunteers, and in control group.

	DURING HEATING						
	Controls	4 D	9 D	20 D	34 D	45 D	73 D
	n=27	n=5	n=5	n=5	n=5	n=5	n=5*
Tapered head	1 [0-3]	0 [0-0]	1 [0-1]	0 [0-1]	0 [0-0]	0 [0-1]	2 [2-2]
Thin head	5 [3-7]	3 [3-10]	6 [6-12]	8 [7-9]	27 [10-31] *	22 [16-23] *	14 [14-22] *
Microcephalic	10 [7-15]	17 [15-24]	18 [17-19]	23 [18-28]	29 [29-33] *	29 [28-44]	41 [34-44]
Macrocephalic	1 [0-2]	0 [0-1]	0 [0-1]	1.5 [0-2]	1 [0-1]	0 [0-2]	0 [0-1]
Multiple heads	1 [0-2]	1 [1-2]	2 [1-4]	1.5 [0-2]	2 [1-2]	4 [4-5]	2 [2-5]
Abnormal post-acrosomal region	25 [12-31]	26 [20-28]	20 [19-32]	18.5 [17-26]	24 [21-26]	32 [17-38]	24 [22-46]
Abnormal acrosomal region	36 [25-47]	50 [48-55]	47 [45-50]	53 [46-54]	79 [78-88] *	90 [85-90] *	88 [76-90]
Excess residual cytoplasm	3 [2-6]	4 [2-7]	4 [2-6]	3 [2-4]	4 [3-6]	3 [3-5]	4 [0-5]
Thin midpiece	2 [0-3]	2 [1-4]	2 [2-2]	2.5 [0-3]	0 [0-1]	1 [0-5]	2 [0-4]
Bent or misaligned midpiece	17 [11-21]	14 [13-22]	22 [12-26]	21.5 [21-28]	29 [25-29]	26 [26-30]	23 [22-26]
No tail	1 [0-2]	2 [1-2]	1 [0-1]	0 [0-2]	3 [2-4]	4 [4-7]	4 [4-8]
Short tail	0 [0-1]	0 [0-1]	1 [0-1]	1.5 [0-2]	2 [1-4] *	3 [1-4] *	3 [2-5] *
Irregularly shaped tail	0 [0-1]	1 [1-1]	1 [0-3]	1 [0-1]	1 [1-5] *	2 [1-4]	2 [0-2]
Coiled tail	9 [4-13]	10 [9-12]	15 [10-17]	16.5 [14-19]	25 [14-26]	29 [21-30] *	21 [18-34] *
Multiple tails	1 [0-2]	1 [0-1]	3 [2-4]	1 [0-1]	2 [1-2]	3 [1-3]	4 [4-4] *
Normal spermatozoa (%)	38 [26-44]	27 [22-29]	26 [21-30]	26 [24-27]	5 [0-19] *	3 [3-3] *	5 [1-6] *
MAI	1.86 [1.68-1.94]	1.97 [1.95-2.07]	2.10 [2.04-2.16]	2.14 [2.09-2.2] *	2.50 [2.42-2.58]	2.46 [2.42-2.75] *	2.52 [2.49-2.68] *

Values are expressed as median with interquartile range [q1-q3].

- at T73, 50 spermatozoa were analyzed instead of 100 for 3 patients. * Values are significant different from control group.

Table 1C. Sperm morphology (%) at follow-up time points, after induced testicular and epididymal heating volunteers and in control group.

	AFTER HEATING				
	Controls	165 D	193 D	215 D	300 D
	n=27	n=5	n=5	n=5	n=5
Tapered head	1 [0-3]	3 [2-6]	1 [0-2]	1 [0-1]	0 [0-1]
Thin head	5 [3-7]	14 [10-18] *	7 [7-16]	6 [5-9]	6 [5-10]
Microcephalic	10 [7-15]	14 [8-26]	18 [18-21]	15 [13-25]	14 [9-21]
Macrocephalic	1 [0-2]	3 [1-4]	1 [0-1]	0 [0-0]	1 [1-1]
Multiple heads	1 [0-2]	2 [2-3]	2 [1-2]	1 [0-3]	2 [0-3]
Abnormal post-acrosomal region	25 [12-31]	36 [34-39]	22 [22-32]	21 [20-21]	21 [21-29]
Abnormal acrosomal region	36 [25-47]	72 [54-80] *	42 [41-54]	41 [39-54]	46 [40-56]
Excess residual cytoplasm	3 [2-6]	8 [8-12]	5 [4-5]	5 [5-6]	2 [2-5]
Thin midpiece	2 [0-3]	2 [1-2]	2 [1-2]	1 [1-2]	3 [1-4]
Bent or misaligned midpiece	17 [11-21]	25 [21-27]	23 [18-28]	19 [16-24]	16 [14-22]
No tail	1 [0-2]	2 [2-3]	1 [0-1]	1 [1-1]	1 [1-5]
Short tail	0 [0-1]	1 [1-3]	0 [0-1]	0 [0-1]	1 [1-1]
Irregularly shaped tail	0 [0-1]	1 [0-4]	0 [0-3]	1 [1-2]	0 [0-1]
Coiled tail	9 [4-13]	13 [11-13]	11 [9-17]	10 [10-18]	17 [9-22]
Multiple tails	1 [0-2]	3 [3-4]	2 [2-3]	1 [1-1]	2 [1-3]
Normal spermatozoa (%)	38 [26-44]	11 [4-20] *	26 [18-29]	33 [21-37]	33 [23-33]
MAI	1.86 [1.68-1.94]	2.42 [2.1-2.73] *	2.10 [1.84-2.16]	2 [1.97-2.08]	1.98 [1.91-2.04]

Values are expressed as median with interquartile range [q1-q3]. * Values are significantly different from control group.

The incidence of men with abnormal sperm morphology values

In this study, we specified that men have abnormal morphology parameters when the observed value was superior to the maximum value observed before the initiation of experimental heating. This allowed us to calculate the frequencies of men with abnormal values. The results (Fig. 4) indicate an increase in the number of volunteers with abnormal sperm head morphology during heat exposure which started at D34 for thin head, microcephalic, abnormal acrosomal region and coiled tail.

There was no observed difference in the number of volunteers with abnormal Midpiece morphology at any time point (4 to 300 days). However, an excess of residual cytoplasm was noted in 4/5 men at Days 165. More volunteers showed abnormal sperm tail morphology after 34 days and throughout the heat exposure period, except for irregularly shaped tail defects.

As indicated in (Fig. 4) most of volunteers showed abnormal sperm morphology and the multiple anomalies index (MAI) as early as D34 which persisted through heat exposure until D165 (45 daysafter cessation of the temperature increase).

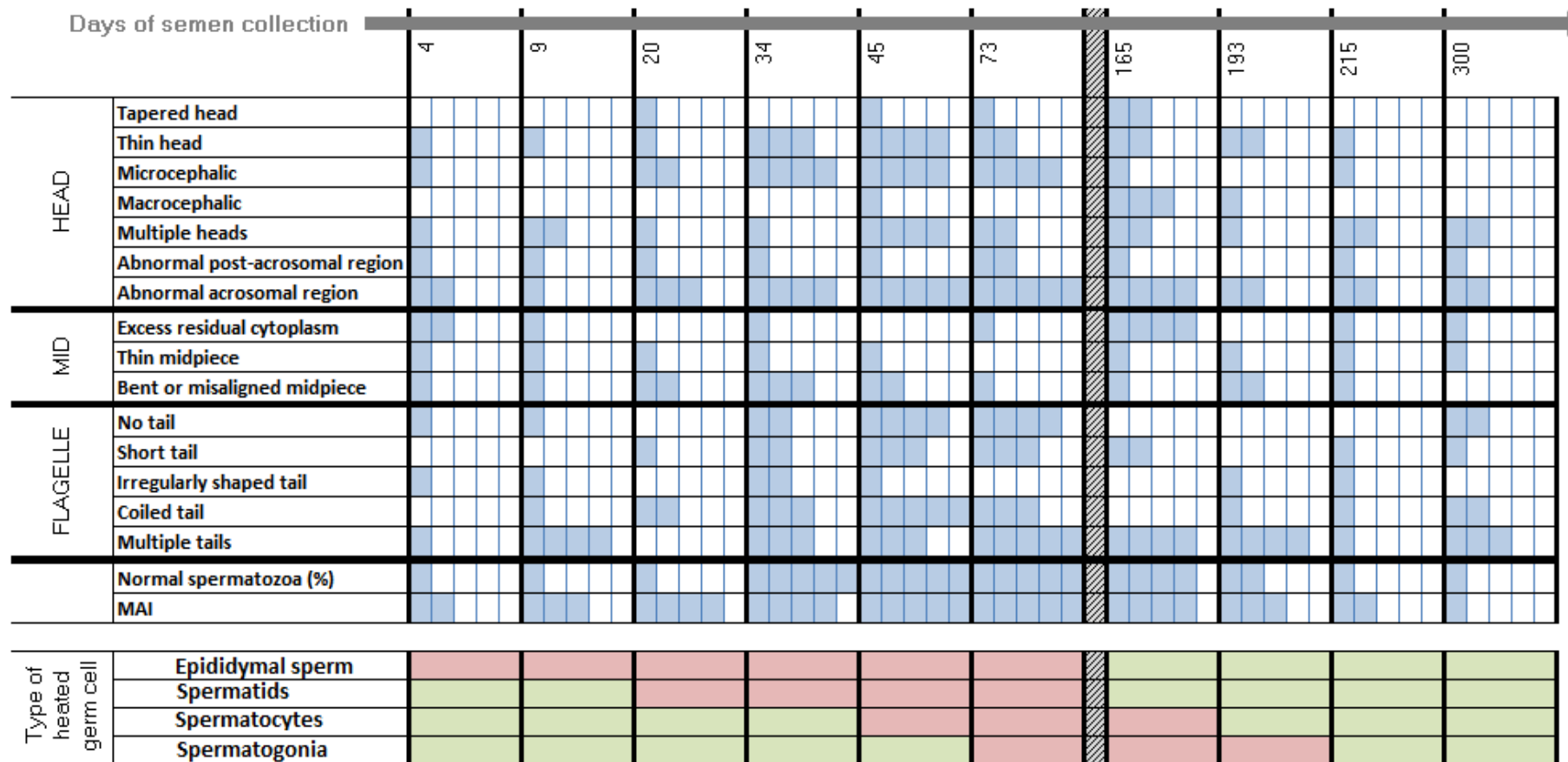


Fig. 4 Schematic presentation of the number of volunteers with a higher percentage of abnormalities during and after mild induced testicular and epididymal heating than at baseline before heating (see results) and which correspond with the spermatogenesis stage and the epididymal transit heating chronology. Each cell represents a volunteer. For one anomaly, a blue cell means that a volunteer has an abnormal percentage. A white cell means that a volunteer has a normal percentage. A green cell means that the stages of spermatogenesis or epididymis were not heated. A red cell means that the stages of spermatogenesis or epididymis were heated.

Discussion

To date, this is the first study that reports detailed changes in the morphological characteristics of sperm induced by a mild testis and epididymis temperature increase according to the physiological chronology of spermatogenesis and epididymal transit in humans. The key feature of the testis suprascrotal position method (TSP) is that the increase in testis and epididymis temperature is mild and remains below the body temperature. With this method we previously reported a drastic decline in sperm production and an increase in sperm DNA fragmentation [21]. In this study we focus on the effects of a mild induced increase (1.5 - 2°C) in testicular and epididymal temperature on sperm morphology.

The effect of heating on sperm morphology during epididymal transit

According to epididymal transit, spermatozoa collected at D4 and D9 of heating were more likely to have been in the epididymis when temperature increase was induced. In this study, sperm morphology was not affected at these time points (D4, D9) by this mild increase in epididymis temperature. There is a lack of information in the literature and to date, no study in men is

available that reports the effect on sperm morphology while spermatozoa are transiting through epididymis exposed to a mild temperature increase.

Nonetheless, in bulls and rams (Fig. 5), two species with a pendulous scrotum, a mild increase in scrotal temperature has been obtained through scrotal insulation or by controlling room temperature (ambient). In bulls, two out of eight studies have reported an effect on sperm morphology when sperm were in the epididymis at the time of heating introduction [26, 27]. However, we can explain the discrepancy between these results and other studies by differences in heat exposure (see Fig. 5), bag materials used for insulation and/or the breed of bulls.

Likewise, studies by Junior et al [17] and Rocha et al [28] on rams have reported the effect of an increase in testis temperature by scrotal insulation, on sperm morphology while sperm is transiting through epididymis. Rocha et al [28] observed a significant decrease in the percentage of morphologically normal sperm from $92 \pm 2.7\%$ on day 0 (pre-insulation) to $39 \pm 4.2\%$ on day 8 of scrotal insulation. These effects were caused by a temperature increase in scrotal skin from 31.2 ± 0.2 °C pre-insulation to 35.2 ± 0.3 °C during insulation for 24h/day for 8 consecutive days. Similarly, Junior et al [17] reported that an increase in testis temperature by scrotal insulation caused an increase in the percentage of sperm with abnormal morphology in the first week post-

insulation. The main defects observed were: bent tail (35%), coiled tail (16.25%), distal cytoplasmic droplet (14%) and normal detached head (20%).

The possible reasons for a discrepancy between our study and animal studies might be the variability in the physiology of species, and/or in the methods and duration of heating. It seems that the epididymis of rams is more sensitive to temperature increases than human epididymis. This might be due to two physiological factors: i) in humans the body core -testicular temperature gradient is approximately 2.8°C [29] in contrast to 6-8°C in rams with a body temperature that has been modified by scrotal insulation [30] ii) ram epididymis has a significantly longer tail [29, 31] . However, while no modifications in sperm morphology have been observed in spermatozoa localized in the epididymis during heating, we should remember that epididymal sperm maturation is a heat-sensitive process and alterations in sperm functions such as embryo development, without modifications in classical sperm parameters, have been reported as soon as Day 4 of mild scrotal heating in rams [30].

The effects of heating on testicular germ cells

Beginning of heating

According to spermatogenesis and epididymal physiologies [21], spermatozoa collected at D20 were at the elongated spermatid stage in the testes when heating was induced. Those collected at D34 were at the late spermatocyte

stage (end of meiosis) or the spermiogenesis stage, those collected at D45 were in the meiosis stage and finally those collected from D56 to D86 at the mitosis stage of spermatogenesis.

The significant increase in the MAI, which is an integrated index of sperm morphological anomalies and a good predictive value in fertility assessment for couples [25], at D20 suggests that late spermiogenesis was affected by heat induction. However, the drastic fall (fivefold) in the percentage of normal sperm at D34 might be the consequence of effects on early spermiogenesis and the late stage of meiosis. These results correspond with the fact that pachytene spermatocytes and round spermatids are the testicular cells most sensitive to heat stress [32].

To date, no human study has reported such an early effect (before 34 days during heat induction) of mild increase in testis temperature on sperm morphology. Using a similar method of heat induction (TSP) in 10 men, a significant increase in the percentage of sperm with abnormal morphology was observed in semen collected between weeks 5 and 8 after the start of heating, i.e. at meiosis stage [7]. In 28 male volunteers the testes were suspended in the superficial inguinal pouch close to the scrotal neck 24h/days for 12 months [14]. The percentage of sperm with a normal morphology dropped from 60% before heating to 27%, with 12% at 3 and 12 months respectively during

heating. However, 6-12 months after release the percentage of sperm morphology returned to normal [14]. Three other studies have reported the effects of scrotal insulation on semen parameters in men [10, 15, 33]. Two reported a significant decrease in sperm count [10, 33]. However, sperm morphology was not analyzed. The other study did not report any change in sperm count or morphology; however the temperature increase in this study was very low (increase in scrotal temperature of 0.8-1 C°) [15].

A recent study examined the sperm morphology in fertile men before, during and after scrotal heating with an electric warming bag to increase testis temperature to 43°C for 30-40 min two days per week for 3 months [11, 34], which is not a mild testicular increase but a high one. The percentage of sperm with normal morphology was significantly decreased at 1, 2, and 3 months of scrotal heating compared with the percentage before heating. Together, the results of Zhang et al [11, 34] and our previous studies [7, 12, 13] indicate that both a mild sustained induced increase in testis temperature or a high short-duration induced increase in testicular temperature result in a decline in normal sperm morphology which is consistent with the results of the present study.

One important aspect of our study is the description of abnormalities induced by the mild testicular-epididymal temperature increase. It is noteworthy that in

the present study, thin heads, microcephalic heads, and sperm with abnormal acrosomal regions were the head anomalies induced by the mild temperature increase. Tails anomalies such as short tail - an irregular shaped tail which could represent anomalies of per-axonemal structures [35, 36] were significantly increased from D34. These modifications at D34 suggested an alteration of spermiogenesis processes. A significant increase in the percentage of sperm with coiled tails was found at D45 and multiple tails at D73 suggesting that germ cells in earlier stages of spermatogenesis were further affected.

Abnormal sperm morphology has been connected to sperm DNA damage [37-39], and we previously [21] reported significant increase in sperm DFI and mean sperm HDS after 20 to 45 days of heat exposure. Moreover, in bulls, scrotal exposure to heat (scrotal insulation method) is related to defective nuclear chromatin condensation during the acrosome and Golgi phases of spermiogenesis [16, 18]. The significant increase of protamine deficient sperm cells during this period (spermiogenesis and spermatocytes) indicates that scrotal insulation, at least partially causes defective chromatin protamination [40]. The same results of protamine modifications were also found after an episode of fever in men [41].

Cessation of heating

The percentage of normal sperm remained significantly decreased and the MAI increased until D165 which corresponds to 45 days after the cessation of heat (post heating phase I). The recovery of sperm morphological values comparable to the control group was observed at D193. These results indicate that normal sperm morphology values did not reappear until one spermatogenesis cycle after the cessation of heating. In contrast, Mieusset et al [13] reported recovery of a percentage of normal sperm only at 10-12 months after the end of TSP. However, in their study the duration of experimental heating was very long (24 months). With another scrotal heating method through an electric warming bag ($43.0^{\circ}\text{C} \pm 0.5^{\circ}\text{C}$, 30-40 min two days per week for 3 months), Zhang et al [11, 34] observed that the percentage of sperm with a normal morphology gradually returned to normal levels two month after scrotal heating.

In bulls (Fig. 5), significantly higher percentages of sperm abnormalities such as head abnormalities, acrosome defects, pyriform-shaped heads, micro- and macro-cephalic heads and tail defects were observed from 14 to 42 days after heating in the majority of the studies[16, 18-20, 42] and 10 to 11 days in two studies [27, 43]. These results were compatible with the effect of heating in the spermiogenesis and meiosis stages.

In rams, the effects lasted longer; up to 77 days (more than one spermatogenesis cycle) were reported after heat induction while the duration of heat exposure was brief (duration of exposure: 3 to 8 days; [17, 28, 44]. The mechanism of a long-term effect must be elicited.

In humans such a mild increase in temperature could be caused by several conditions. Fever or occupational heat exposure has been connected to an increase in anomalies in sperm morphology. Andrade-Rocha [45] found a decrease in sperm concentration and increase in the percentage of abnormal forms, particularly small-head sperm following high fever (38-39°C). Working conditions such as welding also affect the percentage of normal forms. Bond [46] observed a decrease in normal sperm morphology in men four to six weeks after exposure to heat (on average, the skin temperature in the groin increased 1.4°C) which is consistent with the notion that an induced increase in testis temperature has an effect on spermiogenesis - meiosis stages. Similarly, Figa-Talamanca et al [47] reported an increase in abnormalities in sperm morphology in workers exposed to high temperature in the ceramics industry.

In general, human sperm morphology assessment is regarded as an important semen parameter that is correlated with fertility potential, the probability of conception and pregnancy outcome and pregnancy loss in *in vivo*

and *in vitro* studies [48-51]. Therefore, abnormal sperm morphology can lead to delayed and/or failed conception.

The first striking feature of our study is the experimentally controlled mild increase in testis and epididymal temperature which remains below core body temperature and to which men are exposed during daily life activities. The second strength is the precise chronological analysis of sperm morphology throughout the spermatogenic cycle and epididymal transit. However, one major limitation of this study is the low number of volunteers included.

It is noteworthy that in our current study and those reported by others in men and animals modifications in sperm morphology induced by a mild temperature increase were always reversible.

Conclusion

This experimental study shows that even a mild induced increase in testicular and epididymal temperature can severally compromise sperm morphology which is an integral sperm parameter in fertility assessment and in the prediction of the outcome of assisted reproductive technologies. Continuous and long-term occupational/environmental exposure to slightly higher temperature could impair sperm morphology and consequently the likelihood of natural conception. Therefore, in fertility assessment, the history of occupational and environmental exposure to increased temperature should be considered. Patients in a situation that represents a risk of increase in testis temperature, even mild, must be advised to avoid such a situation.

On the other hand, owing to the reversibility and safety of this experimental method, a mild testicular and epididymal temperature increase may be considered as an alternative approach to male contraception.

Acknowledgements

The authors thank all of the participants involved in this study and Jean Michel Borthayre for text editing. Ms. M. Daudin, M.D., Ms N. Moinard, D Pharm. and the technicians of the CECOS laboratory, particularly Ms. Francoise Cendres, are also acknowledged for their assistance.

References

1. Liu Y. Temperature control of spermatogenesis and prospect of male contraception. *Front Biosci (Scholar edition)*. 2010;2:730-55.
2. Mieusset R, Bujan L. Testicular heating and its possible contributions to male infertility: a review. *Int J Androl*. 1995;18(4):169-84.
3. Wallach EE, Kandeel FR, Swerdloff RS. Role of temperature in regulation of spermatogenesis and the use of heating as a method for contraception. *Fertil Steril*. 1988;49(1):1-23.
4. Candas V, Becmeur F, Bothorel B, Hoeft A. Qualitative assessment of thermal and evaporative adjustments of human scrotal skin in response to heat stress. *Int J Androl*. 1993;16(2):137-42.
5. Bedford JM. Effects of elevated temperature on the epididymis and testis: experimental studies. *Adv Exp Med Biol*. 1991;286:19-32.
6. Garolla A, Torino M, Sartini B, Cosci I, Patassini C, Carraro U, et al. Seminal and molecular evidence that sauna exposure affects human spermatogenesis. *Hum Reprod*. 2013;28(4):877-85.
7. Mieusset R, Grandjean H, Mansat A, Pontonnier F. Inhibiting effect of artificial cryptorchidism on spermatogenesis. *Fertil Steril*. 1985;43(4):589-94.
8. Rao M, Zhao X-L, Yang J, Hu S-F, Lei H, Xia W, et al. Effect of transient scrotal hyperthermia on sperm parameters, seminal plasma biochemical markers, and oxidative stress in men. *Asian J Androl*. 2015;17(4):668.
9. Rock J, Robinson D. Effect of induced intrascrotal hyperthermia on testicular function in man. *Ame J Obstet Gynecol*. 1965;93(6):793-801.
10. Shafik A. Contraceptive efficacy of polyester-induced azoospermia in normal men. *Contraception*. 1992;45(5):439-51.
11. Zhang MH, Zhai LP, Fang ZY, Li AN, Xiao W, Qiu Y. Effect of scrotal heating on sperm quality, seminal biochemical substances, and reproductive hormones in human fertile men. *J Cell Biochem*. 2018;119(12):1-11.
12. Mieusset R, Bujan L, Mansat A, Pontonnier F, Grandjean H. Effects of artificial cryptorchidism on sperm morphology. *Fertil Steril*. 1987;47(1):150-5.
13. Mieusset R, Bujan L, Mansat A, Pontonnier F, Grandjean H. Hyperthermia and human spermatogenesis: enhancement of the inhibitory effect obtained by artificial cryptorchidism. *Int J Androl*. 1987;10(4):571-80.
14. Shafik A. Testicular suspension as a method of male contraception: technique and results. *Adv Contracept Deliv Syst: CDS*. 1991;7(3-4):269.
15. Wang C, McDonald V, Leung A, Superlano L, Berman N, Hull L, et al. Effect of increased scrotal temperature on sperm production in normal men. *Fertil Steril*. 1997;68(2):334-9.
16. Fernandes C, Dode M, Pereira D, Silva A. Effects of scrotal insulation in Nellore bulls (*Bos taurus indicus*) on seminal quality and its relationship with in vitro fertilizing ability. *Theriogenology*. 2008;70(9):1560-8.
17. Junior CC, Lucci C, Peripolli V, Silva A, Menezes A, Morais S, et al. Effects of testicle insulation on seminal traits in rams: preliminary study. *Small Rumin Res*. 2015;130:157-65.
18. Rahman MB, Vandaele L, Rijsselaere T, Maes D, Hoogewijs M, Frijters A, et al. Scrotal insulation and its relationship to abnormal morphology, chromatin protamination and nuclear shape of spermatozoa in Holstein-Friesian and Belgian Blue bulls. *Theriogenology*. 2011;76(7):1246-57.
19. Ross A, Entwistle K. The effect of scrotal insulation on spermatozoal morphology and the rates of spermatogenesis and epididymal passage of spermatozoa in the bull. *Theriogenology*. 1979;11(2):111-29.
20. Vogler C, Bame J, DeJarnette J, McGilliard M, Saacke R. Effects of elevated testicular temperature on morphology characteristics of ejaculated spermatozoa in the bovine. *Theriogenology*. 1993;40(6):1207-19.

21. Ahmad G, Moinard N, Esquerré-Lamare C, Mieusset R, Bujan L. Mild induced testicular and epididymal hyperthermia alters sperm chromatin integrity in men. *Fertil Steril.* 2012;97(3):546-53.
22. Kitayama T. Study on testicular temperature in men. *Hinyokika Kiyo Acta Urologica Japonica.* 1965;11(6):435-7.
23. WHO. WHO laboratory manual for the examination of human semen and sperm-cervical mucus interaction. Cambridge: Cambridge University Press; 2010.
24. David G, Bisson J, Czyglik F, Jouannet P, Gernigon C. Anomalies morphologiques du spermatozoïde de humain. 1) Propositions pour un système de classification. *J Gynecol Obstet Biol Reprod.* 1975;4(suppl 1):17-36.
25. Jouannet P, Ducot B, Feneux D, Spira A. Male factors and the likelihood of pregnancy in infertile couples. I. Study of sperm characteristics. *Int J Androl.* 1988;11(5):379-94.
26. Kastelic J, Cook R, Coulter G, Saacke R. Insulating the scrotal neck affects semen quality and scrotal/testicular temperatures in the bull. *Theriogenology.* 1996;45(5):935-42.
27. Wildeus S, Entwistle K. Spermogram and sperm reserves in hybrid *Bos indicus* x *Bos taurus* bulls after scrotal insulation. *J Reprod Fertil.* 1983;69(2):711-6.
28. Rocha DR, Martins JAM, van Tilburg MF, Oliveira RV, Moreno FB, Monteiro-Moreira ACO, et al. Effect of increased testicular temperature on seminal plasma proteome of the ram. *Theriogenology.* 2015;84(8):1291-305.
29. Glover T, Young D. Temperature and the production of spermatozoa. *Fertil Steril.* 1963;14(4):441-50.
30. Mieusset R, Casares PQ, Sanchez•Partida L, Sowerbutts S, Zupp J, Setchell B. The effects of moderate heating of the testes and epididymides of rams by scrotal insulation on body temperature, respiratory rate, spermatozoa output and motility, and on fertility and embryonic survival in ewes inseminated with frozen semen. *Ann N Y Acad Sci* 1991;637(1):445-58.
31. Dott H, Glover T. Sperm production and delivery in mammals, including man. In: Glover TD, Barratt LR, eds. Cambridge University Press, Cambridge;1999. 34-55.
32. Chowdhury A, Steinberger E. Early changes in the germinal epithelium of rat testes following exposure to heat. *J Reprod Fertil.* 1970;22(2):205-12.
33. Robinson D, Rock J. Intrascrotal hyperthermia induced by scrotal insulation: effect on spermatogenesis. *Obstet Gynecol.* 1967;29(2):217-23.
34. Zhang MH, Zhai LP, Fang ZY, Li AN, Qiu Y, Liu YX. Impact of a mild scrotal heating on sperm chromosomal abnormality, acrosin activity and seminal alpha•glucosidase in human fertile males. *Andrologia.* 2018;50(4):e12985.
35. Auger J. Assessing human sperm morphology: top models, underdogs or biometrics? *Asian J Androl.* 2010;12(1):36.
36. Chemes HE, Rawe VY. Sperm pathology: a step beyond descriptive morphology. Origin, characterization and fertility potential of abnormal sperm phenotypes in infertile men. *Hum Reprod Update.* 2003;9(5):405-28.
37. He M, Tan L. Correlation between sperm ultrastructure in infertile patients with abnormal sperm morphology and DNA damage. *Genet Mol Res.* 2015;14:17000-6.
38. Rao M, Xia W, Yang J, Hu LX, Hu SF, Lei H, et al. Transient scrotal hyperthermia affects human sperm DNA integrity, sperm apoptosis, and sperm protein expression. *Andrology.* 2016;4(6):1054-63.
39. Sheikh N, Amiri I, Farimani M, Najafi R, Hadeie J. Correlation between sperm parameters and sperm DNA fragmentation in fertile and infertile men. *Iranian J Reprod Med.* 2008;6(1):13-8.
40. Rahman MB, Schellander K, Luceno NL, Van Soom A. Heat stress responses in spermatozoa: Mechanisms and consequences for cattle fertility. *Theriogenology.* 2018;113:102-12.
41. Evenson DP, Jost LK, Corzett M, Balhorn R. Characteristics of human sperm chromatin structure following an episode of influenza and high fever: a case study. *J Androl.* 2000;21(5):739-46.
42. Newton LD, Kastelic JP, Wong B, Van der Hoorn F, Thundathil J. Elevated testicular temperature modulates expression patterns of sperm proteins in Holstein bulls. *Mol Reprod Dev: Incorporat Gam Res.* 2009;76(1):109-18.

43. Brito LF, Silva AE, Barbosa RT, Unanian MM, Kastelic JP. Effects of scrotal insulation on sperm production, semen quality, and testicular echotexture in *Bos indicus* and *Bos indicus* x *Bos taurus* bulls. *Anim Reprod Sci.* 2003;79(1-2):1-15.
44. Alves MBR, de Andrade AFC, de Arruda RP, Batissaco L, Florez-Rodriguez SA, de Oliveira BMM, et al. Recovery of normal testicular temperature after scrotal heat stress in rams assessed by infrared thermography and its effects on seminal characteristics and testosterone blood serum concentration. *Theriogenology.* 2016;86(3):795-805. e2.
45. Andrade-Rocha FT. Temporary impairment of semen quality following recent acute fever. *Ann Clin Lab Sci.* 2013;43(1):94-7.
46. Bonde JP. Semen quality in welders exposed to radiant heat. *Br J Ind Med.* 1992;49(1):5-10.
47. Figa-Talamanca I, Dell'Orco V, Pupi A, Dondero F, Gandini L, Lenzi A, et al. Fertility and semen quality of workers exposed to high temperatures in the ceramics industry. *Reprod Toxicol.* 1992;6(6):517-23.
48. Coetzee K, Kruger TF, Lombard CJ. Predictive value of normal sperm morphology: a structured literature review. *Hum Reprod Update.* 1998;4(1):73-82.
49. Guzick DS, Overstreet JW, Factor-Litvak P, Brazil CK, Nakajima ST, Coutifaris C, et al. Sperm morphology, motility, and concentration in fertile and infertile men. *N Engl J Med.* 2001;345(19):1388-93.
50. Kihaille P, Hirotsuru K, Kumasako Y, Misumi J, Utsunomiya T. Fertilization rates of small-head sperm in conventional IVF and ICSI. *Arch Androl.* 2003;49(5):327-9.
51. Slama R, Eustache F, Ducot B, Jensen TK, Jorgensen N, Horte A, et al. Time to pregnancy and semen parameters: a cross-sectional study among fertile couples from four European cities. *Hum Reprod.* 2002;17(2):503-15.
52. Armengol ML, Sabino G, Forquera J, de La Casa A, Aisen EG. Sperm head ellipticity as a heat stress indicator in Australian Merino rams (*Ovis aries*) in Northern Patagonia, Argentina. *Theriogenology.* 2015;83(4):553-9. e2.
53. Kastelic J, Wilde R, Rizzoto G, Thundathil J. Hyperthermia and not hypoxia may reduce sperm motility and morphology following testicular hyperthermia. *Vet Med.* 2017;62(8).
54. Moule G, Waites G. Seminal degeneration in the ram and its relation to the temperature of the scrotum. *J Reprod Fertil.* 1963;5(3):433-46.

Part II. Experimental mild increase in testicular temperature has drastic, but reversible, effect on sperm aneuploidy in men: a pilot study



Contents lists available at ScienceDirect

Reproductive Biology

journal homepage: www.elsevier.com/locate/repbio

Experimental mild increase in testicular temperature has drastic, but reversible, effect on sperm aneuploidy in men: A pilot study

Mohamed Hadi Mohamed Abdelhamid^a, Camille Esquerre-Lamare^a, Marie Walschaerts^{a,b},
Gulfam Ahmad^c, Roger Mieusset^{a,d}, Safouane Hamdi^{a,e}, Louis Bujan^{a,f,*}

^a Université de Toulouse, UPS, Groupe de Recherche en Fertilité Humaine (EA 3694, Human Fertility Research Group), 330 avenue de Grande Bretagne, 31059 Toulouse, France

^b GERMETHIQUE, Groupe d'activité de médecine de la reproduction, Hôpital Paule de Viguier, CHU Toulouse, 330 avenue de Grande Bretagne, 31059 Toulouse, France

^c School of Medical Sciences, Sydney Medical School, Discipline of Pathology, Sydney University, Australia

^d Unité d'Andrologie, Groupe d'activité de médecine de la reproduction, Hôpital Paule de Viguier, CHU Toulouse, 330 avenue de Grande Bretagne, 31059 Toulouse, France

^e Laboratoire de biochimie, Institut Fédératif de Biologie, CHU Toulouse, 330 avenue de Grande Bretagne, 31059 Toulouse, France

^f CECOS, Groupe d'activité de médecine de la reproduction, Hôpital Paule de Viguier, CHU Toulouse, 330 avenue de Grande Bretagne, 31059 Toulouse, France

ARTICLE INFO

Keywords:

Sperm aneuploidy
Spermatogenesis alteration
Testis temperature increase
Male infertility
Fluorescence In Situ Hybridization (FISH)

ABSTRACT

In mammals testicular and epididymal temperature increase impairs spermatogenesis. This experimental study investigates the effects of a mild testis temperature increase (i.e. testis temperature remains below core body temperature) on sperm aneuploidy in men. In 5 fertile volunteers a testicular temperature increase was induced by maintaining the testes at suprascrotal position using specially designed underwear for 15 ± 1 h daily for 120 consecutive days. After heating men were followed for next 180 days. A control group (27 men) was recruited. Semen samples were collected before, during and after heating period and analyzed for chromosomes X, Y and 18 for aneuploidy using FISH. A total of 234,038 spermatozoa were studied by FISH. At day 34 of heating, mean sperm aneuploidy values were not modified. From day 34 of heating until day 45 post heating, FISH evaluation was not possible due to the drastic fall of sperm count. At day 45 post-heating total sperm aneuploidy percentage was twice higher than before heating whereas. Sex disomy (sperm XY18), sex chromosome nullisomy (sperm 18) were significantly higher than controls. These effects were completely reversed at 180 days post heat exposure. Conclusion: A mild rise in testicular temperature significantly increases sperm aneuploidies, reflecting an effect on the meiosis stage of spermatogenesis. The effect of heating was reversible and suggests that recovery of aneuploidy to normal values requires at least two cycles of spermatogenesis. Nonetheless, the low number of volunteers was a limitation of this pilot study and warrants further research on larger population.

1. Introduction

The adverse effects of increased testicular temperature on spermatogenesis in mammals have been investigated and established for many years. In most mammals, testes are located in the scrotum outside the body, which provides anatomical location that offers lower testicular temperature than core body. In a thermoneutral environment, the scrotal testes are appreciably cooler than the body, but this does not mean that they are kept at a constantly lower temperature [1]. In man as in most other mammals, optimal spermatogenesis requires 2–6 °C lower testicular temperature than body and any rise above the physiological temperature of the testes has adverse impact on spermatogenesis [2,3].

Several pathological conditions are associated with an increase in testicular temperature which include cryptorchidism [4], varicocele [5–7] and febrile diseases [8,9]. Exogenous factors such as occupational exposure to high temperatures [10,11], car driving [12] or sauna exposure [13–15] also increase the testicular temperature. Notably, some living conditions such as wearing tight clothing [16] or sitting and sleeping postures [17] are also associated with an increase in testicular temperature which remains in the physiological range [18]. The relation between lifestyle factors or exposure to environmental risk factors and sperm aneuploidy was investigated in several studies [19–22], but to our knowledge, only one epidemiological study has reported the possible link between circumstances known to improve testicular temperature, such as sauna use or type of underwear, and sperm

* Corresponding author at: Groupe de Recherche en Fertilité Humaine (EA 3694, Human Fertility Research Group), UPS, Université de Toulouse and CECOS, CHU Paule de Viguier, 31059 Toulouse Cedex 09, France.

E-mail address: bujan.l@chu-toulouse.fr (L. Bujan).

<https://doi.org/10.1016/j.repbio.2019.06.001>

Received 5 December 2018; Received in revised form 1 June 2019; Accepted 6 June 2019

1642-431X/ © 2019 Published by Elsevier B.V. on behalf of Society for Biology of Reproduction & the Institute of Animal Reproduction and Food Research of Polish Academy of Sciences in Olsztyn.

Experimental mild increase in testicular temperature has drastic, but reversible, effect on sperm aneuploidy in men : a pilot study

Mohamed Hadi Mohamed Abdelhamid^a, Camille Esquerre-Lamare^a, Marie Walschaerts^{a,b}, Gulfam Ahmad^c, Roger Mieusset^{a,d}, Safouane Hamdi^{a,e} and Louis Bujan^{a,f}

^a Université de Toulouse; UPS; Groupe de Recherche en Fertilité Humaine (EA 3694, Human Fertility Research Group), 330 avenue de Grande Bretagne, 31059 Toulouse, France

email:

Mohamed Hadi Abdelhamid: moh9363@gmail.com

Camille Esquerre-Lamare: camille_lamare@hotmail.com

Marie Walschaerts: walschaertsm@gmail.com

Roger Mieusset: mieusset.r@chu-toulouse.fr

Safouane Hamdi: hamdi.s@chu-toulouse.fr

^b Germethèque, Groupe d'activité de médecine de la reproduction, Hôpital Paule de Viguié, CHU Toulouse, 330 avenue de Grande Bretagne, 31059 Toulouse, France

^c School of Medical Sciences, Sydney Medical School, Discipline of Pathology, Sydney University, Australia

Gulfam Ahmad: gulfam.ahmed@sydney.edu.au

^d Unité d'Andrologie, Groupe d'activité de médecine de la reproduction, Hôpital Paule de Viguié, CHU Toulouse, 330 avenue de Grande Bretagne, 31059 Toulouse, France

^e Laboratoire de biochimie, Institut Fédératif de Biologie, CHU Toulouse, 330 avenue de Grande Bretagne, 31059 Toulouse, France

^f CECOS, Groupe d'activité de médecine de la reproduction, Hôpital Paule de Viguier, CHU Toulouse, 330 avenue de Grande Bretagne, 31059 Toulouse, France

Corresponding author: Louis Bujan, Groupe de Recherche en Fertilité Humaine (EA 3694, Human Fertility Research Group), UPS, Université de Toulouse and CECOS, CHU Paule de Viguier, 31059 Toulouse Cedex 09, France; e-mail: bujan.l@chu-toulouse.fr; phone: 00 33 567771046; fax: 00 33 567771049

Short title: Testis heating and sperm aneuploidy in men

Acknowledgments:

This study was supported by a grant from CHU de Toulouse N° 09 161 02.

We would like to thank Nina Crowte for text editing.

Abstract

In mammals, including men, testicular and epididymal temperature increase impairs spermatogenesis. In the present experimental study, we investigate the effects of a mild testis temperature increase (i.e. testis temperature remains below core body temperature) on sperm aneuploidy in men. In healthy fertile volunteers (n=5) a testicular and epididymal temperature increase was induced by maintaining the testes at supascrotal position using specially designed underwear for 15 ± 1 hours daily for 120 consecutive days. After 120 days, heating was stopped and men were followed for next 180 days. A group of 27 fertile men was recruited as control group. Semen samples were collected before, during and after heating period and analyzed for chromosomes X, Y and 18 for aneuploidy using fluorescence in situ hybridization (FISH). A total of 234,038 spermatozoa were studied by FISH. At day 34 of heating mean sperm aneuploidy values were not different than sperm collected before heating or from controls. From day 34 of heating until day 45 post heating, FISH evaluation was not possible due to the drastic fall of sperm count. At day 45 post heating total sperm aneuploidy percentage was twice higher than before heating whereas. Sex disomy (sperm XY18), sex chromosome nullisomy (sperm 18) were significantly higher than controls. These effects were completely reversed at 180 days post heat exposure. Conclusion: A mild rise in testicular temperature significantly increases

sperm aneuploidies, reflecting an effect on the meiosis stage of spermatogenesis. The effect of heating was reversible and suggests that full recovery of aneuploidy to normal values requires at least two cycles of spermatogenesis after heating is removed. Nonetheless, the low number of included volunteers was a limitation of this pilot study and warrants further research on larger population.

Keywords

Sperm aneuploidy; spermatogenesis alteration; testis temperature increase; male infertility; Fluorescence In Situ Hybridization (FISH).

1. Introduction

The adverse effects of increased testicular temperature on spermatogenesis in mammals have been investigated and established for many years. In most mammals, testes are located in the scrotum outside the body which provides anatomical location that offers lower testicular temperature than core body. In a thermoneutral environment, the scrotal testes are appreciably cooler than the body, but this does not mean that they are kept at a constantly lower temperature [1]. In man as in most other mammals, optimal spermatogenesis requires 2-6°C lower testicular temperature than body and any rise above the physiological temperature of the testes has adverse impact on spermatogenesis [2, 3].

Several pathological conditions are associated with an increase in testicular temperature which include cryptorchidism [4], varicocele [5-7] and febrile diseases [8, 9]. Exogenous factors such as occupational exposure to high temperatures [10, 11], car driving [12] or sauna exposure [13-15] also increase the testicular temperature. Notably, some living conditions such as wearing tight clothing [16] or sitting and sleeping postures [17] are also associated with an increase in testicular temperature which remains in the physiological range [18]. The relation between lifestyle factors or exposure to environmental risk factors

and sperm aneuploidy was investigated in several studies [19-22], but to our knowledge only one epidemiological study has reported the possible link between circumstances known to improve testicular temperature such as sauna use or type of underwear with sperm aneuploidy and have shown decrease in sperm aneuploidy in men wearing boxer shorts compared to those wearing tight underwear [23].

In man, different experimentally methods increasing testicular temperature resulted in a drastic, but reversible, inhibition of spermatogenesis with decrease in sperm count [13, 24-28] sperm motility [13, 24-27] and sperm normal morphology [13, 25, 26]. In addition to conventional sperm parameters (count, motility, morphology) the adverse effects of testicular hyperthermia on sperm DNA damage have also been reported [13, 24].

It has been suggested that a modification of testicular temperature could be used in two ways: increasing testes temperature to inhibit spermatogenesis or decreasing it to improve spermatogenesis in infertile men who have abnormally elevated testes temperatures. Experimental studies [29-31] and reviews [32-34] have reported that a mild testis temperature increase could be used as a male contraceptive approach. On the other hand, reducing the testicular temperature using application of an ice bag for 30 min per day for 14 days improves

spermatogenesis outcome [35]. Various devices have been used to decrease testicular temperature and improve spermatogenesis, either in varicocele or in oligozoospermic patients having higher scrotal temperatures [36-38] . In addition, avoidance of exposure to heat has been reported to prevent infertility [39-41].

We have previously demonstrated that a mild increase in testicular and epididymal temperature (+2°C, i.e. a testicular temperature below core body temperature), induced by maintaining the testes in a suprascrotal position, had drastic effects not only on sperm output and quality but also on sperm DNA fragmentation in humans [24].

While a study in mice [42] reported X-Y dissociation increase in spermatocytes from animals that were exposed to an environmental temperature of 35°C for 2-5 days (whole body exposure), to date no study has investigated the effect of a mild testicular temperature increase (testicular temperature below core temperature) on sperm aneuploidy in men. A recent study in man reported increased sperm aneuploidy after testicular exposure to 43°C for two successive days per week for 3 months. [43]. Noteworthy, 43°C is very high temperature compared to physiological temperature of testes ($\approx 34.5^\circ\text{C}$) and sperm aneuploidy is more likely to occur at this higher temperature threshold.

Sperm aneuploidy can be a risk to the embryonic and fetal development and the offspring [44, 45]. The majority of the aneuploidy embryos are not viable resulting into miscarriages but several chromosomal abnormalities, such as autosomal trisomy or sex chromosome aneuploidy, could be non-lethal and compatible with survival resulting in birth and developmental defects [44-47].

In this context, the objective of this study was to evaluate the effects of a mild testicular temperature increase (+2°C) on sperm aneuploidy in fertile men and to examine its potential reversibility.

2. Materials and methods

2.1. Study Design

The present study is the second part of a study of the effects of mild induced testes temperature increase on gamete quality [24]. We used the biological specimens that had been frozen during the first part of the study.

2.2. Study Population

The study was approved by the Ethics Committee (Comité de Protection des Personnes Sud-Ouest et Outre Mer I) and the protocol has been previously described [24]. The volunteers were recruited through advertisement in the press and local hospital communication portal. A total of 34 men volunteered for the study. After exclusion criteria and financial limitations 6 volunteers (aged 25-35 years) were selected. Only the men who had fathered at least one child, had a normal clinical andrological examination, no current pathology, medical or surgical history, had either no, moderate or occasional alcohol intake were included. None of the participating volunteer was exposed to toxic agents and had no particular professional risk to fertility. One volunteer smoke 20 cigarettes a day in experimental group and 7 men smoke more than 10 cigarettes a day in control group.

One volunteer dropped the study at day 73 of heating due to personal reasons hence the data of this volunteer were excluded. Remaining five volunteers followed the instructions and the protocol and continued until the completion of study. None of the volunteer reported any discomfort during the entire period of study. The aneuploidy results of 27 fertile men were used as control values to compare with aneuploidy values of experimental volunteers (n=5).

2.3. Technique for Increasing Testicular Temperature

Increased testicular and epididymal temperature was induced by maintaining the testes in a suprascrotal position by means of specially designed underwear worn 15 ± 1 hours daily [3, 24, 29] for 120 consecutive days. The method was developed by our group and has been tested safe, reversible and reproducible. Before, commencement of heating participating volunteers of experimental group were trained on how to put the underwear by lifting the testes up at the root of the penis during waking hours. The support to the testes keeping them at suprascrotal position was ensured with the underwear provided with an orifice allowing the scrotum and penis to be exteriorized specifically designed for each volunteer as we previously described [25]. The suprascrotal position of the testes results in $1.5 - 2^{\circ}\text{C}$ increase in testicular temperature. Notably, the testicular

temperature remains below core human body temperature in this heating method [30, 48].

Semen analysis

Semen samples were collected, after mean sexual abstinence of 4.1 (± 1.0) days, at specific times according to spermatogenesis chronology as we previously described [24]. After liquefaction at 37°C for minimum of 30 minutes, semen analysis was done according to WHO guidelines [49] on an aliquot (200 μ L) by a trained technician. The characteristics considered were sexual abstinence (days), ejaculate volume (ml), sperm concentration (SC, 10^6 spermatozoa/ml) and total sperm count (volume \times SC = TSC, 10^6 spermatozoa/ejaculate). Total sperm count was the only sperm parameter presented as it is the true reflect of sperm production.

After initial analysis a part of each sample was frozen in liquid nitrogen in the Germethèque Biobank (BB-0033-00081, France) using routine freezing method currently practiced in our laboratory [50] and stored until FISH analysis.

Sperm Fluorescence in situ Hybridization (FISH)

FISH analysis was performed at four time points i.e. before heating at D0, D34, post heating at PH45 and PH180 (Fig. 1). Between day 34 of heating and day 45

post heating total sperm count was drastically reduced due to heating method and did not recover sufficiently until day 45 post heating which rendered the FISH analysis impossible (Figure 1). Frozen cells were thawed and washed twice with 5 ml phosphate buffer saline (PBS) and centrifugation performed at 630g for 10 minutes. Samples were then fixed with fixation solution (acetic acid and methyl alcohol) for 30 min at 4°C. After centrifugation at 1500g for 10 minutes, the supernatant was discarded and the pellet re-suspended. A volume of 10 µl was dropped on a slide and cell density was verified by microscopy and adjusted accordingly. Slides were incubated for a minimum of 2h at -20°C. DNA was decondensed by incubating slides in 1M NaOH for 1 min, washed twice in saline sodium citrate (SSC) buffer, then dehydrated in 70%, 90% and 100% ethyl alcohol baths (2 min each). Each slide was then incubated overnight with the different probes at 37°C (Vysis probes (Abbott), CEP X spectrum green, CEP Y spectrum orange and CEP 18 spectrum aqua). After a 2 min wash in 2SSC 0.4% NP40 at 73°C followed by a 1 min wash in 2SSC 0.3% NP40, slides were incubated with 1/2000e Hoechst for 3 min and washed for 3 min in PBS. Slides were finally mounted with Antifade mounting medium (Promega, Germany) and stocked at -20°C until reading. Slides were analyzed under a Leica DM 6000 B microscope system.

At each time, a mean of 5149 ± 218 and 5232 ± 190 cells, per subject, were read respectively in experimental group and control group.

2.4. Statistical Analysis

Data are presented in the Tables as median and interquartile range Q1–Q3 due to the number of patients and as mean and standard deviation in graphic representations.

Sperm aneuploidy data were compared before, during and after mild induced increase in testicular and epididymal temperature by the Wilcoxon signed rank-sum test. Due to the small number of men included in the experimental protocol, we also carried out statistical comparison with a control group of 27 fertile men (a single evaluation of sperm aneuploidy for each man) using the non-parametric Mann-Whitney test. As there were multiple comparisons, a Bonferroni correction was used. P-values of 1.66% were considered significant for the Wilcoxon test and of 1.25% for the Mann-Whitney test.

Statistical analyses were performed using SAS software (9.3, SAS Institute). A p-value of 5% was considered significant without Bonferroni correction.

3. Results

The number of volunteers (n=5) was constant during the three study periods (before, during and after heating). Due to technical problems, at D0 and PH45 four volunteers underwent FISH analyses instead of five.

Total sperm count decreased significantly as early as day 34 during heat exposure (Fig. 1) and remained persistently low (azoospermia or severe oligospermia) throughout the heating period (days 0-120). FISH analysis was not possible until day 45 after cessation of heating (PH45).

A total of 234,038 spermatozoa were analyzed by FISH. Before commencement of experimental heating (Day 0), no significant differences were found for aneuploidy percentages between the control group (n = 27) and the five volunteers except for median frequencies of XXY18. However, the range of frequencies difference was very small, ranging from 0.00 to 0.02 (Table 1).

Table 1 represents sperm aneuploidy percentages at the different time points of the study. The major significant results were an increased total aneuploidy, sex disomy (sperm XY18) and sex chromosome nullisomy (sperm 18) at day 45 post heating (PH45). The percentages of sperm with sex disomy and sex nullisomy were two and three times more elevated, respectively, than before heating

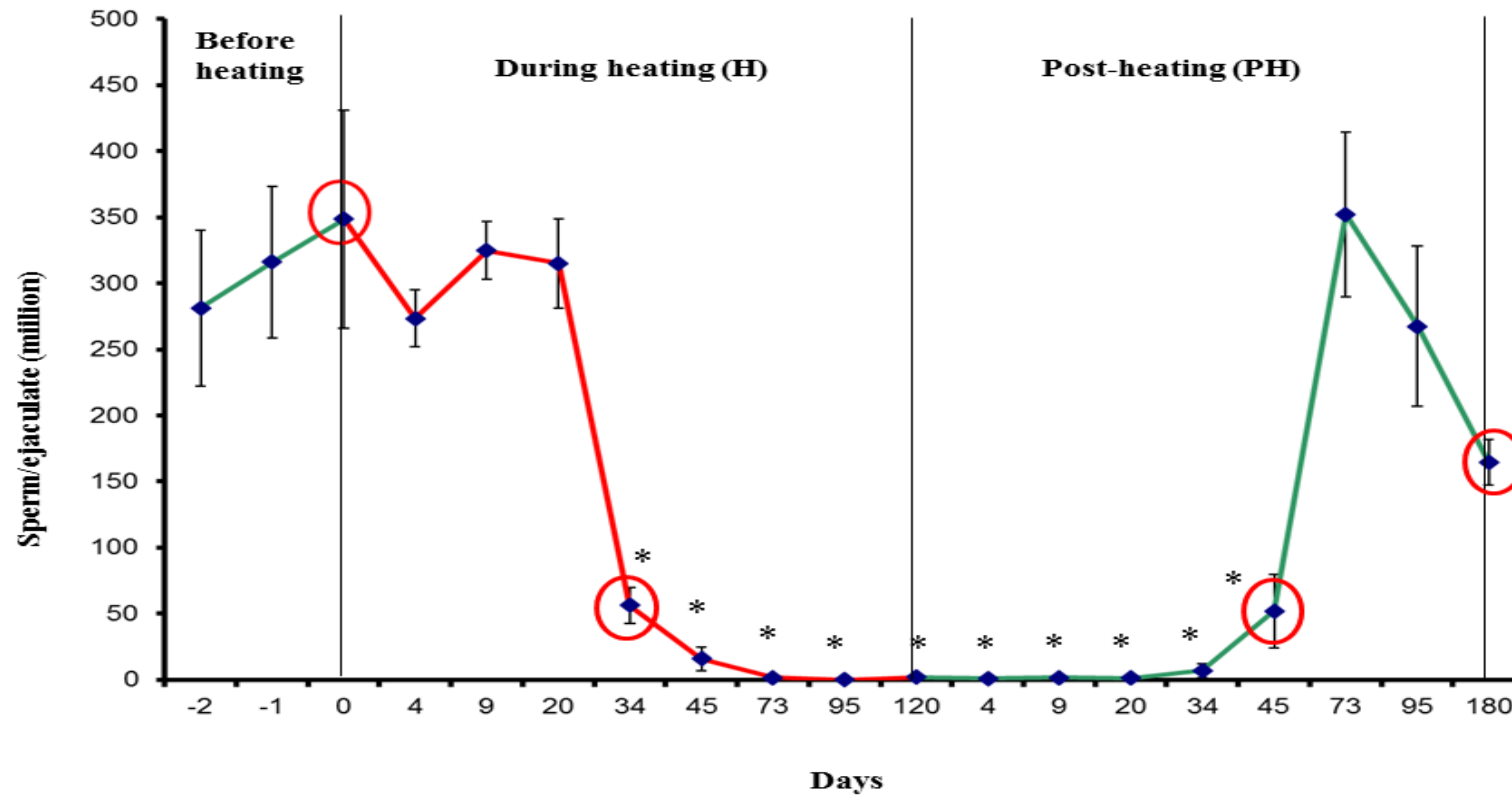


Figure 1 Mean (SEM) total sperm count (millions per ejaculate) before, during and after a mild induced testicular and epididymal temperature increase in healthy men. Red circles: semen probes used for sperm aneuploidy study: before heating (day 0), during heating (day 34) and during post heating period (day 45 and day 180). * $p < 0.016$.

Table 1. Sperm aneuploidies (%) in controls and before (Day 0), during (H34) and after (PH45, 180) testicular and epididymidal heating in healthy men.

	Controls (n=27)	Day 0 (n=4)	H 34 (n=5)	PH 45 (n=4)	PH 180 (n=5)
	median [Q1-Q3]	median [Q1-Q3]	median [Q1-Q3]	median [Q1-Q3]	median [Q1-Q3]
Number of spermatozoa counted per subject	5231 [5092-5335]	5082.5 [5048.5-5191.5]	5085 [5083-5143]	5076 [5047-5089.5]	5117 [5047-5120]
Y 18	49.43 [47.67-50.6]	49.96 [49.16-50.55]	50.39 [49.78-51.34]	49.15 [48.47-50.32]	48.89 [48.21-49.64]
X 18	49.82 [48.85-51.3]	49.44 [48.72-49.8]	48.98 [47.92-49.09]	48.97 [47.93-49.47]	49.66 [49.28-51.23]
XX 18	0.06 [0.04-0.06]	0.04 [0.01-0.06]	0.02 [0.02-0.04]	0.03 [0.02-0.04]	0.02 [0.02-0.02]
YY 18	0.04 [0-0.06]	0 [0-0.04]	0.02 [0-0.04]	0.04 [0.03-0.06]	0.02 [0-0.02]
XY 18	0.21 [0.13-0.31]	0.35 [0.21-0.72]	0.34 [0.32-0.49]	0.85 [0.68-1.03] (p=0.001)*	0.18 [0.16-0.8]
Sex disomy	0.30 [0.19-0.38]	0.35 [0.24-0.80]	0.45 [0.35-0.53]	0.93 [0.76-1.10] (p=0.001)*	0.22 [0.18-1.04]
X 1818	0 [0-0.02]	0 [0-0.02]	0 [0-0.02]	0.01 [0-0.02]	0.02 [0-0.04]
Y 1818	0.02 [0-0.04]	0.01 [0-0.03]	0.02 [0-0.02]	0.04 [0.04-0.05]	0.02 [0-0.02]
Disomy 18	0.04 [0-0.06]	0.01 [0-0.05]	0.02 [0.02-0.03]	0.05 [0.04-0.07]	0.02 [0.02-0.04]
XX 1818	0 [0-0]	0 [0-0]	0 [0-0]	0 [0-0]	0 [0-0.02] (p=0.001)*
YY 1818	0 [0-0]	0 [0-0]	0 [0-0]	0 [0-0.01]	0 [0-0]
XY 1818	0 [0-0]	0 [0-0.03]	0 [0-0.02] (p=0.010)*	0.01 [0-0.03] (p=0.003)*	0 [0-0.02] (p=0.010)*
Diploidy	0 [0-0]	0 [0-0.03]	0 [0-0.02]	0.02 [0-0.04]	0 [0-0.08]
XXY 18	0 [0-0]	0.01 [0-0.02] (p=0.003)*	0 [0-0]	0 [0-0.01]	0 [0-0]
YYX 18	0 [0-0]	0 [0-0]	0 [0-0]	0 [0-0.01]	0 [0-0]
18	0.24 [0.17-0.33]	0.29 [0.23-0.37]	0.26 [0.25-0.31]	0.91 [0.76-0.99] (p=0.001)*	0.41 [0.34-0.46]
X	0.06 [0-0.23]	0.01 [0-0.03]	0 [0-0]	0 [0-0.03]	0 [0-0.04]
Y	0 [0-0]	0 [0-0]	0 [0-0]	0 [0-0]	0 [0-0]
Nullisomy 18	0.06 [0-0.23]	0.01 [0-0.03]	0 [0-0]	0 [0-0.03]	0 [0-0.06]
Total aneuploidy	0.65 [0.46-0.81]	0.73 [0.58-1.19]	0.73 [0.64-0.87]	1.93 [1.62-2.19] (p=0.002)*	0.7 [0.67-1.84]
Meiosis I	0.28 [0.17-0.32]	0.35 [0.21-0.79]	0.37 [0.34-0.51]	0.91 [0.74-1.11] (p=0.001)*	0.20 [0.20-1.19]
Meiosis II	0.08[0.06-0.11]	0.04 [0.01-0.10]	0.039 [0.038-0.039]	0.08 [0.07-0.09]	0.04 [0.02-0.08]

* $p < 0.0125$ between controls and volunteers at time 0, H34, PH 45 and PH180. Values are expressed as median with interquartile range [q1-q3]. Day 0: before heating, H: heating period, PH: post heating period. Sex disomy: sum of XX18, YY18, XY18. Disomy 18: sum of X1818 and Y1818. Diploidy: sum of XX1818, YY1818 and XY1818. Nullisomy 18: sum of X and Y. Meiosis I: sum of frequencies of XY18 and XY1818. Meiosis II: sum of XX18, YY18, XX1818 and YY18.

period (D0). Percentage of total aneuploidy was twofold higher at PH45 than before heating (D0) (Table 1, Fig. 2).

At day 180 post heating (PH180), sperm aneuploidy percentages did not differ from the values before heating (Fig. 2), which suggests that the effects of heating were reversible.

In this study, we defined an abnormal aneuploidy rate as a rate above the 90th percentile of control group values. This enabled us to calculate the number of volunteers who had an abnormal aneuploidy rate at different time points.

The results indicate that at 45 post heating, all volunteers had a higher number of abnormal sperm with sex disomy XY18, sex nullisomy and total sperm aneuploidy (Fig. 3) which did not recover to values before heating period until day 180 post heating suggesting that minimum of two cycles of spermatogenesis and epididymal transit after discontinuation of heating are required in order to restore normal spermatogenesis with no risk of aneuploidy (Fig.3).

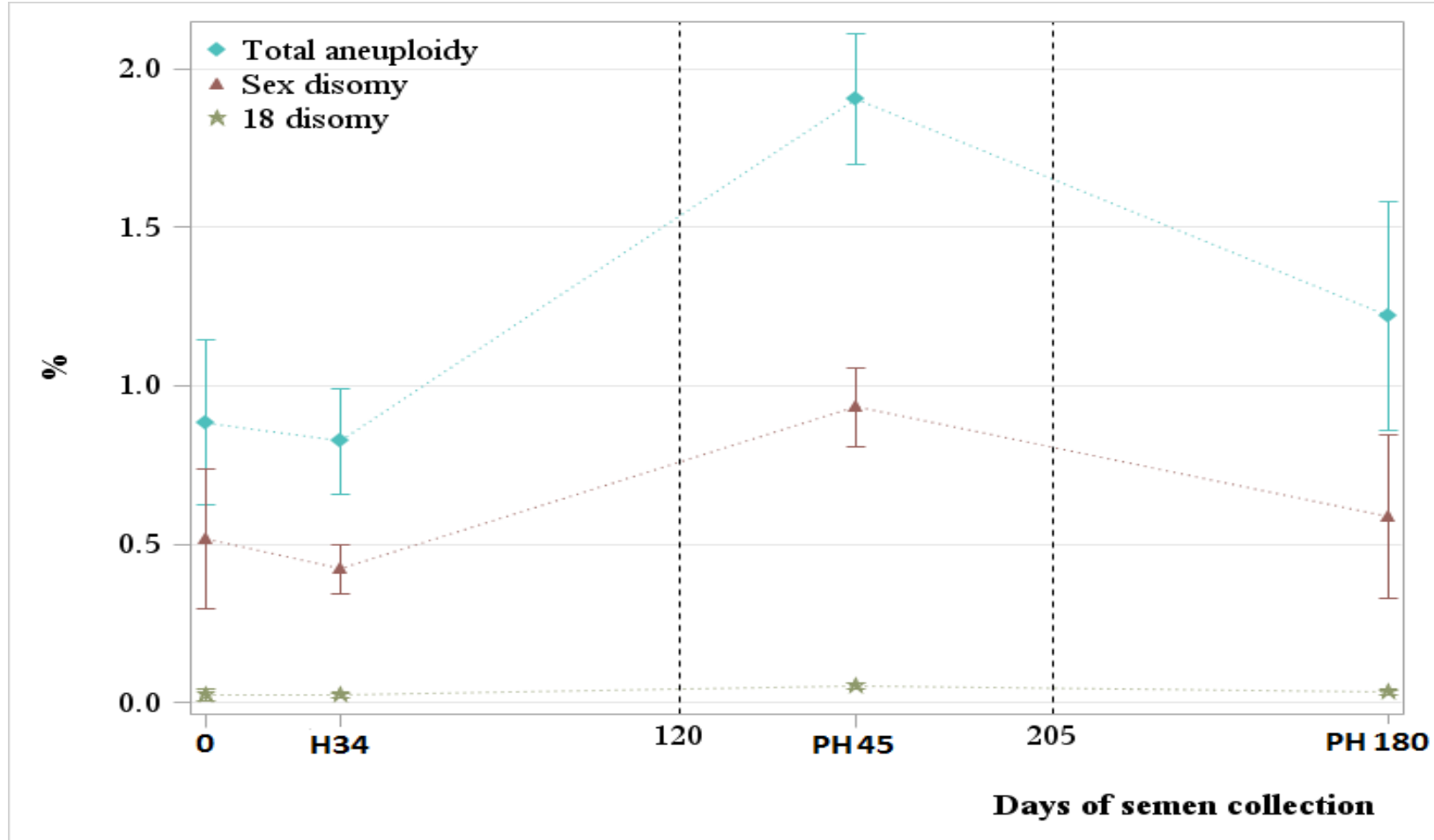


Figure 2 Sperm aneuploidies (%) before, during and after a mild increase in testicular and epididymal temperature in men. Sperm chromosomal abnormalities (%) measured at the four time points: before heating (D0), during heating (H34), and after heating (PH45 and PH180). Means \pm SEM are represented. Mild induced testicular and epididymal heating was discontinued at D120.

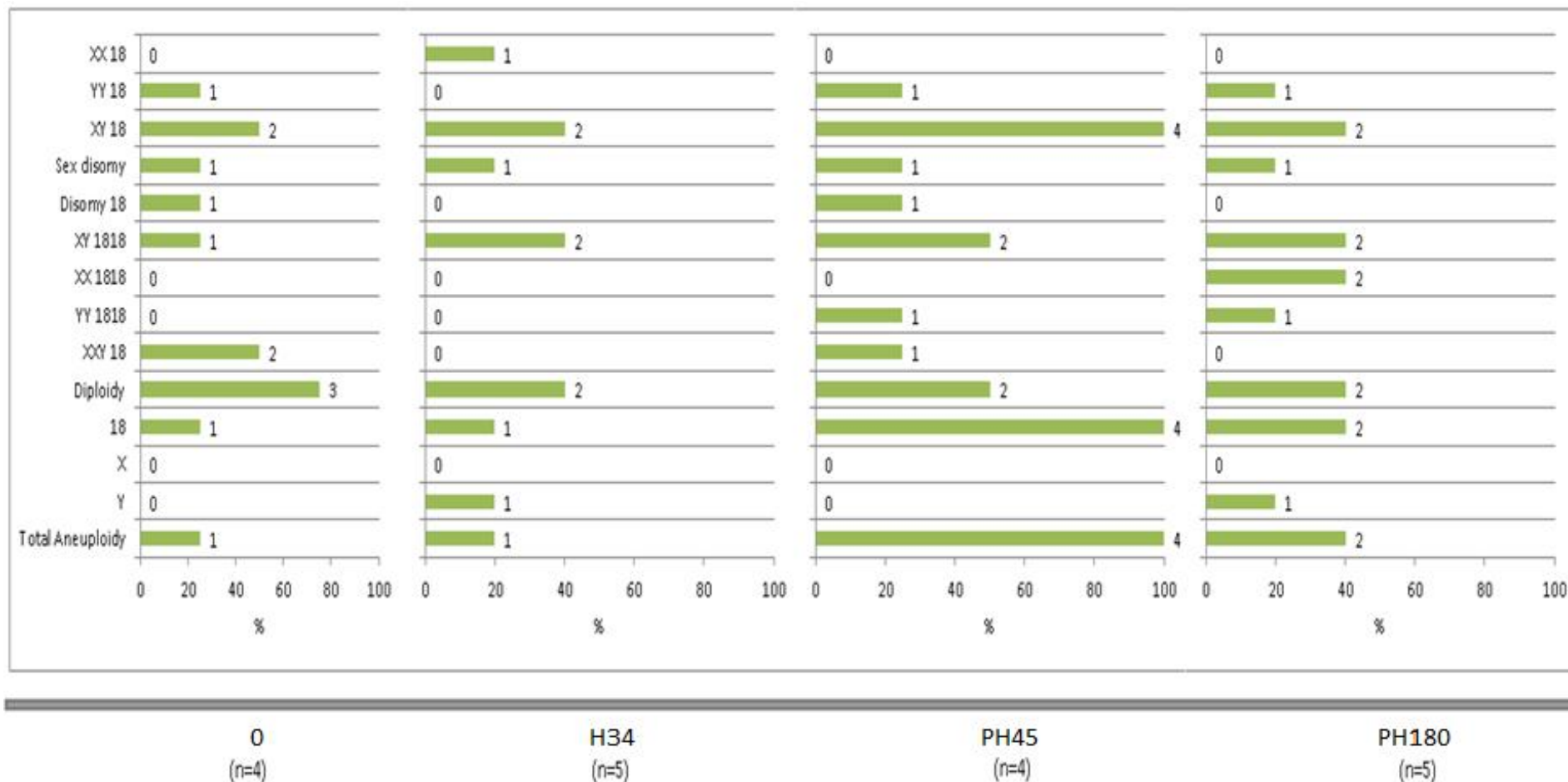


Figure 3 Number of volunteers whose percentage of sperm aneuploidies before, during and after a mild induced increase in testicular and epididymal temperature was greater than the 90e percentile of the control group.

4. Discussion

The negative impact on spermatogenesis after testicular exposure to a mild or high temperatures increase has been demonstrated by numerous experimental human and animal studies. A recent study reported an increases sperm aneuploidy rate when testes were exposed to 43°C [43]. However, these findings were taken at one-point time and reversibility was not evaluated. Moreover, 43°C is a pathological temperature which is much higher than testes and core body temperature and sperm aneuploidies are more likely to occur at this high threshold. No study has investigated the effect of a mild increase in testicular temperature (<37°C) on the frequency of sperm chromosomal abnormalities.

In present study by inducing a mild increase in testes and epididymal temperature for 15 ± 1 hours daily for 120 consecutive days, we show that this temperature threshold is sufficient to increase sperm aneuploidy in men and that this effect is reversible after cessation of heating which suggests that testicular heating is the cause of sperm aneuploidy.

At day 34 of heating, the percentage of chromosomal abnormalities were not affected by the mild temperature increase. In accordance with the physiology of the spermatogenesis process and epididymal transit timing, spermatozoa

collected at D34 were at the late spermatocyte stage (end of meiosis) or early round spermatids in the testes when heat was induced: i.e. they were subjected to heat but were released from progenitor germ cells that were not exposed to heating. This is in agreement with previous reports indicating that most chromosomal abnormalities in sperm result from meiotic errors during the spermatogenesis process [51, 52].

At day 45 post heating (PH45) we found a significant increase of disomic sperm (XY18 sperm: non-disjunction of the sexual chromosome at meiosis I) or nullisomic sperm (18) and a slight increase of diploidy sperm (XY1818), consequently total aneuploidy increased at this time. It is noteworthy that spermatozoa collected at day 45 after heating were more probably affected by heating at the meiosis stage, according to spermatogenesis and epididymis physiology as previously published [24].

The effects of a mild increase in testes temperature are reversible, as indicated by recovery of aneuploidy values to pre-heating values at PH180. The time require to recover the aneuploidy to control values suggest that reversibility requires more than two cycles of spermatogenesis.

A recently published study examined sperm aneuploidy in 10 men before and during scrotal heating using an electric warming bag to increase the testes

temperature to 43°C for 30-40 min two days per week for 3 months [43]. Compared to pre-heating values, a significant increase in the sum rate of sperm chromosomal 13, 18, 21, and sum of X and Y sperm was reported at the end of the 3 months of heating. In this last study, the increase of sum rate of aneuploidy for X and Y at the end of the 3-month period of heating was 14.2-fold higher than before heating values. This is much higher than the 2 to 3-fold increase we observed in the present study where temperature increase was very mild. However, the aneuploidy values after cessation of heating were not reported in the study by Zhang et al [43] which lacks information about the reversibility. Further, only 200 sperm cells were analyzed by Zhang et al [43] compared to present study which report analysis of 5149 ± 218 and 5232 ± 190 cells in experimental volunteers and controls respectively.

Relation of lifestyle factors, such clothing, with sperm aneuploidy has also been reported. Jurewicz et al [53] reported that use of boxer short decreases sperm aneuploidy rate compared to tight underwear.

In animal models, only three studies have reported the effect of induced increased temperatures on germ cell chromosomal abnormalities and abnormal chromosome configurations [42]. Exposing mice to an environment of approximately $35 \pm 1^\circ\text{C}$ and 65% relative humidity for 2-5 days led to significant peaks of X-Y dissociation 5 days after the end of heat stress which

recovered to control levels 50-70 days after cessation of heat stress (≈ 1.5 to 2 cycles of spermatogenesis in mice).

In another study [54], testes of mice and rats under anesthesia were heated in a water bath at 42°C for 20 min which resulted in an increase in the percentage of X-Y univalents after 6 days of heat exposure in mice and 12 days in rats. These results suggest an action of heating in pre-meiotic or early prophase I stages of spermatogenesis, which was also suggested by Garriott and Chrisman [55].

The precise mechanism of aneuploidy induction in man following mild testis temperature increase is not known. However, meiosis is a structural dynamic process, broadly conserved across eukaryotes, and temperature appears to be a major challenge for chromosome segregation during the meiosis stage. Temperature increase was associated with failure of synapsis and reduced chiasma frequency in plant and animals at both high and low temperatures [56]. Heat shock proteins (HSPs) play a protective role in response to cell stress and several HSPs were induced mainly in spermatocytes and round spermatids when testis temperature was increased [57]. The HSP70 gene is expressed during the meiosis prophase, and HSP70 protein is present in the synaptonemal complex and in attachment plaques at the ends of chromosomes. Desynapsis is disrupted in male mice lacking this protein [58, 59]. Moreover, heat stress

following experimental cryptorchidism in rats resulted in modifications in the expression of 594 genes in pachytene spermatocytes [60].

Some cases of varicoceles are associated with abnormally elevated testes temperature. It is noteworthy that in patients with varicocele, the frequency of meiotic abnormalities such as partial asynapsis, chromosome breaks and a high rate of sex vesicle-autosome association were higher than in a control group [59]. Further analysis after varicocele surgery showed no abnormalities suggesting that the meiotic alterations were due to increased temperature and were reversible. Likewise, a comparison of sperm aneuploidy frequency before and after varicocelectomy showed decrease, though not significant, in the sperm aneuploidy frequency [61].

One of the limitations of our study is the small number of volunteers included in this experimental protocol. The other limitation is the small number of chromosomes studied by FISH (X, Y, 18). However, the inter-chromosomal effect has been reported using CGH array [62, 63] and it has been suggested that the results obtained by studying one set of chromosomes could be extended to others [64]. The absence of longitudinal follow-up of the control group could be another limitation of our study. Testicular temperature was not measured in this study owing to invasive approach and was based on the existing literature [30, 48].

While further studies are needed to clarify the relationship between sperm aneuploidy and various circumstances resulting in testes temperature increase, findings of current study may have clinical implications. In infertile men, it seems reasonable to avoid or treat situations (fever, varicocele, ascending testis or mispositioning of testis, and occupational or professional exposure) which can result in increased scrotal or testicular temperature. If such circumstances are unavoidable, FISH analysis of sperm may be advised to identify aneuploidy which can pose possible risk to the future embryo.

In conclusion, this study shows that a mild induced increase ($\approx 2^{\circ}\text{C}$) in testicular and epididymal temperature (15 ± 1 hour daily for 120 consecutive days) results in increased sperm aneuploidy in men which reflects an effect of temperature on the meiosis stage of spermatogenesis. This effect was reversible and suggests waiting period of minimum 2 cycles of spermatogenesis if a couple is planning to conceive allowing cells sufficient time to recover from heat stress. Nevertheless, the current results are based on a smaller population which does warrant validation of these findings on larger cohort of men.

Conflicts of Interest: The authors declare that there is no conflict of interest that could be perceived as prejudicing the impartiality of the research reported

REFERENCES

- [1] Setchell BP. The parkes lecture heat and the testis. *J Reprod Fertil.* 1998;114:179-94.
- [2] Liu Y. Temperature control of spermatogenesis and prospect of male contraception. *Front Biosci (Scholar edition).* 2010;2:730-55.
- [3] Mieusset R, Bujan L. Testicular heating and its possible contributions to male infertility: a review. *Int J Androl.* 1995;18:169-84.
- [4] Mieusset R, Fouda PJ, Vaysse P, Guitard J, Moscovici J, Juskiewenski S. Increase in testicular temperature in case of cryptorchidism in boys. *Fertil Steril.* 1993;59:1319-21.
- [5] Agger P. Scrotal and testicular temperature: its relation to sperm count before and after operation for varicocele. *Fertil Steril.* 1971;22:286-97.
- [6] Lund L, Nielsen K. Varicocele testis and testicular temperature. *Br J Urol.* 1996;78:113-5.
- [7] Wright EJ, Young GP, Goldstein M. Reduction in testicular temperature after varicocelectomy in infertile men. *Urology.* 1997;50:257-9.
- [8] Evenson DP, Jost LK, Corzett M, Balhorn R. Characteristics of human sperm chromatin structure following an episode of influenza and high fever: a case study. *J Androl.* 2000;21:739-46.
- [9] Sergerie M, Mieusset R, Croute Fo, Daudin M, Bujan L. High risk of temporary alteration of semen parameters after recent acute febrile illness. *Fertil Steril.* 2007;88:970. e1-. e7.
- [10] Bonde JP. Semen quality in welders exposed to radiant heat. *Br J Ind Med.* 1992;49:5-10.
- [11] Hjollund NHI, Storgaard L, Ernst E, Bonde JP, Olsen Jr. Impact of diurnal scrotal temperature on semen quality. *Reprod Toxicol.* 2002;16:215-21.
- [12] Bujan L, Daudin M, Charlet J-P, Thonneau P, Mieusset R. Increase in scrotal temperature in car drivers. *Hum Reprod.* 2000;15:1355-7.
- [13] Garolla A, Torino M, Sartini B, Cosci I, Patassini C, Carraro U, et al. Seminal and molecular evidence that sauna exposure affects human spermatogenesis. *Hum Reprod.* 2013;28:877-85.
- [14] Jockenhovel F, Grawe A, Nieschlag E. A portable digital data recorder for long-term monitoring of scrotal temperatures. *Fertil Steril.* 1990;54:694-700.
- [15] Saikhun J, Kitiyanant Y, Vanadurongwan V, Pavasuthipaisit K. Effects of sauna on sperm movement characteristics of normal men measured by computer-assisted sperm analysis. *Int J Androl.* 1998;21:358-62.
- [16] Rock J, Robinson D. Effect of induced intrascrotal hyperthermia on testicular function in man. *Amer J Obstet Gynecol.* 1965;93:793-801.
- [17] Hjollund NHI, Bonde JPE, Jensen TK, Olsen Jr, Team DFPPS. Diurnal scrotal skin temperature and semen quality. *Int J Androl.* 2000;23:309-18.
- [18] Mieusset R, Bengoudifa B, Bujan L. Effect of posture and clothing on scrotal temperature in fertile men. *J Androl.* 2007;28:170-5.
- [19] Jurewicz J, Radwan M, Sobala W, Polanska K, Radwan P, Jakubowski L, et al. The relationship between exposure to air pollution and sperm disomy. *Environ Mol Mutagen.* 2015;56:50-9.
- [20] Robbins W, Elashoff D, Xun L, Jia J, Li N, Wu G, et al. Effect of lifestyle exposures on sperm aneuploidy. *Cytogen Genome Res.* 2005;111:371-7.
- [21] Shi Q, Ko E, Barclay L, Hoang T, Rademaker A, Martin R. Cigarette smoking and aneuploidy in human sperm. *Mol Reprod Dev.* 2001;59:417-21.
- [22] Young HA, Meeker JD, Martenies SE, Figueroa ZI, Barr DB, Perry MJ. Environmental exposure to pyrethroids and sperm sex chromosome disomy: a cross-sectional study. *Environ Health.* 2013;12:111.
- [23] Jurewicz J, Radwan M, Sobala W, Radwan P, Jakubowski L, Hawula W, et al. Lifestyle factors and sperm aneuploidy. *Reprod Bio.* 2014;14:190-9.
- [24] Ahmad G, Moinard N, Esquerre-Lamare C, Mieusset R, Bujan L. Mild induced testicular and epididymal hyperthermia alters sperm chromatin integrity in men. *Fertil Steril.* 2012;97:546-53.

- [25] Mieusset R, Bujan L, Mansat A, Pontonnier F, Grandjean H. Hyperthermia and human spermatogenesis: enhancement of the inhibitory effect obtained by artificial cryptorchidism. *Int J Androl.* 1987;10:571-80.
- [26] Mieusset R, Grandjean H, Mansat A, Pontonnier F. Inhibiting effect of artificial cryptorchidism on spermatogenesis. *Fertil Steril.* 1985;43:589-94.
- [27] Rao M, Zhao X-L, Yang J, Hu S-F, Lei H, Xia W, et al. Effect of transient scrotal hyperthermia on sperm parameters, seminal plasma biochemical markers, and oxidative stress in men. *Asian J Androl.* 2015;17:668.
- [28] Robinson D, Rock J. Intrascrotal hyperthermia induced by scrotal insulation: Effect on spermatogenesis. *Obstet Gynecol.* 1967;29:217-23.
- [29] Mieusset R, Bujan L. The potential of mild testicular heating as a safe, effective and reversible contraceptive method for men. *Int J Androl.* 1994;17:186-91.
- [30] Shafik A. Testicular suspension as a method of male contraception: technique and results. *Advances in contraceptive delivery systems: CDS.* 1991;7:269.
- [31] Shafik A. Contraceptive efficacy of polyester-induced azoospermia in normal men. *Contraception.* 1992;45:439-51.
- [32] Anderson RA, Baird D. Male contraception. *Endocr Rev.* 2002;23:735-62.
- [33] Setchell B. Contraception: Possible physiological bases for contraceptive techniques in the male. *Hum Reprod.* 1994;9:1081-7.
- [34] Soufir J-C. Hormonal, chemical and thermal inhibition of spermatogenesis: contribution of French teams to international data with the aim of developing male contraception in France. *Basic Clin Androl.* 2017;27:3.
- [35] Robinson D, Rock J, Menkin MF. Control of human spermatogenesis intrascrotal temperature. *Jama.* 1968;204:290-7.
- [36] Jung A, Eberl M, Schill W. Improvement of semen quality by nocturnal scrotal cooling and moderate behavioural change to reduce genital heat stress in men with oligoasthenoteratozoospermia. *Reproduction.* 2001;121:595-603.
- [37] Zornigotti A, Sealfon A, Toth A. Further clinical experience with testis hypothermia for infertility due to poor semen. *Urology.* 1982;19:636-40.
- [38] Zornigotti AW, Sealfon AI. Scrotal Hypothermia: New therapy for poor semen. *Urology.* 1984;23:439-41.
- [39] Hendry W, Sommerville I, Hall R, Pugh R. Investigation and treatment of the subfertile male. *Br J Urol.* 1973;45:684-92.
- [40] Jung A, Leonhardt F, Schill W-B, Schuppe H-C. Influence of the type of undertrousers and physical activity on scrotal temperature. *Hum Reprod.* 2005;20:1022-7.
- [41] Lynch R, Lewis-Jones DI, Machin DG, Desmond AD. Improved seminal characteristics in infertile men after a conservative treatment regimen based on the avoidance of testicular hyperthermia. *Fertil Steril.* 1986;46:476-9.
- [42] Waldbieser G, Chrisman C. X Y chromosome univalency in the testes of hyperthermic mice: I. Concomitant formation of multinucleated giant cells. *Gamete Res.* 1986;15:153-60.
- [43] Zhang MH, Zhai LP, Fang ZY, Li AN, Qiu Y, Liu YX. Impact of a mild scrotal heating on sperm chromosomal abnormality, acrosin activity and seminal alpha glucosidase in human fertile males. *Andrologia.* 2018;50:e12985.
- [44] Templado C, Uroz L, Estop A. New insights on the origin and relevance of aneuploidy in human spermatozoa. *Mol Hum Reprod.* 2013;19:634-43.
- [45] Templado C, Vidal F, Estop A. Aneuploidy in human spermatozoa. *Cytogenet Genome Res.* 2011;133:91-9.
- [46] Eskenazi B, Wyrobek A, Kidd S, Lowe X, Moore D, 2nd, Weisiger K, et al. Sperm aneuploidy in fathers of children with paternally and maternally inherited Klinefelter syndrome. *Hum Reprod.* 2002;17:576-83.

- [47] Hassold T, Hunt P. To err (meiotically) is human: the genesis of human aneuploidy. *Nat Rev Genet.* 2001;2:280.
- [48] Kitayama T. Study on testicular temperature in men. *Hinyokika Kyo Acta Urologica Japonica.* 1965;11:435.
- [49] WHO. WHO laboratory manual for the examination and processing of human semen. Geneva: World Health Organisation; 2010.
- [50] Esquerré-Lamare C, Walschaerts M, Debordeaux LC, Moreau J, Bretelle F, Isus F, et al. Sperm aneuploidy and DNA fragmentation in unexplained recurrent pregnancy loss: a multicenter case-control study. *Basic Clin Androl.* 2018;28:4.
- [51] Griffiths A, Miller J, Suzuki D, Lewontin R, Gelbart W. Chromosome mutation II: Changes in chromosome number. In: Griffiths AJF MJ, Suzuki DT, editor. *An Introduction to genetic analysis.* New York: WH Freeman; 2000.
- [52] Uroz L, Templado C. Meiotic non-disjunction mechanisms in human fertile males. *Hum Reprod.* 2012;27:1518-24.
- [53] Jurewicz J, Radwan M, Sobala W, Radwan P, Jakubowski L, Hawula W, et al. Lifestyle factors and sperm aneuploidy. *Reprod Biol.* 2014;14:190-9.
- [54] Van Zelst S, Zupp J, Hayman D, Setchell B. XY chromosome dissociation in mice and rats exposed to increased testicular or environmental temperatures. *Reprod Fertil Dev.* 1995;7:1117-21.
- [55] Garriott M, Chrisman C. Hyperthermia induced dissociation of the X Y bivalent in mice. *Environ Mutagen.* 1980;2:465-71.
- [56] Bomblies K, Higgins JD, Yant L. Meiosis evolves: adaptation to external and internal environments. *New Phytol.* 2015;208:306-23.
- [57] Widlak W, Vydra N. *The role of heat shock factors in mammalian spermatogenesis. The role of heat shock proteins in reproductive system development and function:* Springer; 2017. p. 45-65.
- [58] Eddy EM. Role of heat shock protein HSP70-2 in spermatogenesis. *Rev Reprod.* 1999;4:23-30.
- [59] North M, Lellei I, Rives N, Erdei E, Dittmar A, Barbet J, et al. Reversible meiotic abnormalities in azoospermic men with bilateral varicocele after microsurgical correction. *Cell Mol Biol (Noisy-le-Grand, France).* 2004;50:281-9.
- [60] Yadav SK, Pandey A, Kumar L, Devi A, Kushwaha B, Vishvkarma R, et al. The thermo-sensitive gene expression signatures of spermatogenesis. *Reprod Biol Endo.* 2018;16:56.
- [61] Acar H, Kilinc M, Guven S, Yurdakul T, Celik R. Comparison of semen profile and frequency of chromosome aneuploidies in sperm nuclei of patients with varicocele before and after varicolectomy. *Andrologia.* 2009;41:157-62.
- [62] Hornak M, Vozdova M, Musilova P, Prinosilova P, Oracova E, Linkova V, et al. Comprehensive meiotic segregation analysis of a 4-breakpoint t (1; 3; 6) complex chromosome rearrangement using single sperm array comparative genomic hybridization and FISH. *Reprod Biomed Online.* 2014;29:499-508.
- [63] Patassini C, Garolla A, Bottacin A, Menegazzo M, Speltra E, Foresta C, et al. Molecular karyotyping of human single sperm by array-comparative genomic hybridization. *PLoS One.* 2013;8:e60922.
- [64] Frias S, Van Hummelen P, Meistrich ML, Lowe XR, Hagemester FB, Shelby MD, et al. NOVP chemotherapy for Hodgkins disease transiently induces sperm aneuploidies associated with the major clinical aneuploidy syndromes involving chromosomes X, Y, 18, and 21. *Cancer Res.* 2003;63:44-51.

Chapter XI

General discussion

And

Conclusions

11.1. Discussion

The negative impact of exogenous scrotal mild or high heat exposure in sperm production has been demonstrated by numerous experimental human and animal studies. However, very few studies have been performed to investigate the effect of a mild temperature on sperm morphology and sperm aneuploidy in men. This is the first study that reports detailed changes in sperm morphological characteristics induced by mild testis temperature increase according to the physiological chronology of spermatogenesis in human. Using the diurnal artificial cryptorchidism method our group have reported previously, the effects of this mild temperature increase the sperm production in the first part of this study (Ahmad et al., 2012). Here we focus the study on the effects of experimentally induced mild testicular and epididymal temperature increase on sperm morphology and sperm aneuploidy. Testis temperature, where testis are located on inguinal canal (supra-scrotal position), was previously reported in two studies (Kitayama, 1965 and Shafik, 1991). Consequently, according to the need of invasive approach in order to measure testis temperature in inguinal canal we have not performed testis measure temperature in our studies. The ethic board (Comité de Protection des Personnes) pays great attention to the benefice – risk ratio particularly in this case where published papers are measuring temperature.

11.1.1. First part of the study previously published by our group (Ahmad et al., 2012)

Our thesis work is the continuation of a previously published experimental study in which the deleterious effects of mild testis and epididymal temperature on sperm parameter were reported (Ahmad et al., 2012). In this study, a mild increase on testicular and epididymal temperature (i.e. Testis temperature below the core body temperature), induced by maintaining the testes at supra scrotal position, had not only reversible drastic effects on sperm production and quality but also in sperm DNA fragmentation in human. According to spermatogenesis and epididymal physiologies, spermatozoa collected at D4, 9 and 20 corresponding to epididymis transit were not affected. However, percentages of motile and viable sperm decreased significantly ($P < .05$) compared with baseline values as early as D20 and D34, respectively, and the difference remained significant until D120 (Fig 22). Sperm concentration decreased significantly as early as D34 and remained low during the entire period of hyperthermia (Fig 22). Baseline total sperm count was $315.2 \pm 19.4 \times 10^6$, which significantly decreased to $56.0 \pm 13 \times 10^6$ at D34 and to $16.0 \pm 8 \times 10^6$ at D45. One of the five volunteers presented with azoospermia at D95, a second at D120, and the remainder had rare spermatozoa in their ejaculates at D120 (Ahmad et al., 2012). Moreover, total round cell count started to increase at D20 and to be significantly higher than

baseline values at D34, and then decreased to baseline values until the end of hyperthermia (D120) with the exception of a low significant value at D73.

Sperm DNA fragmentation index (DFI) and high DNA stainability (HDS), sperm DFI (%) were significantly increased at D20 (16.7 ± 3.9), D34 (23.8 ± 2.9), and D45 (31.3 ± 5.4) compared with baseline (11.9 ± 1.5). Mean sperm HDS started to increase as early as D20 (7.4 ± 1.5) and was significantly higher than the baseline value (5.9 ± 0.3) at D34 (10.9 ± 1.0) and D45 (13.0 ± 1.1). Moreover, the percentage values of sperm DFI (27.8 ± 4.3) and HDS (14.9 ± 2.3) remained higher at D73 but appeared statistically nonsignificant, most probably owing to the smaller number of volunteers ($n = 4$) at this time point (see Table 7).

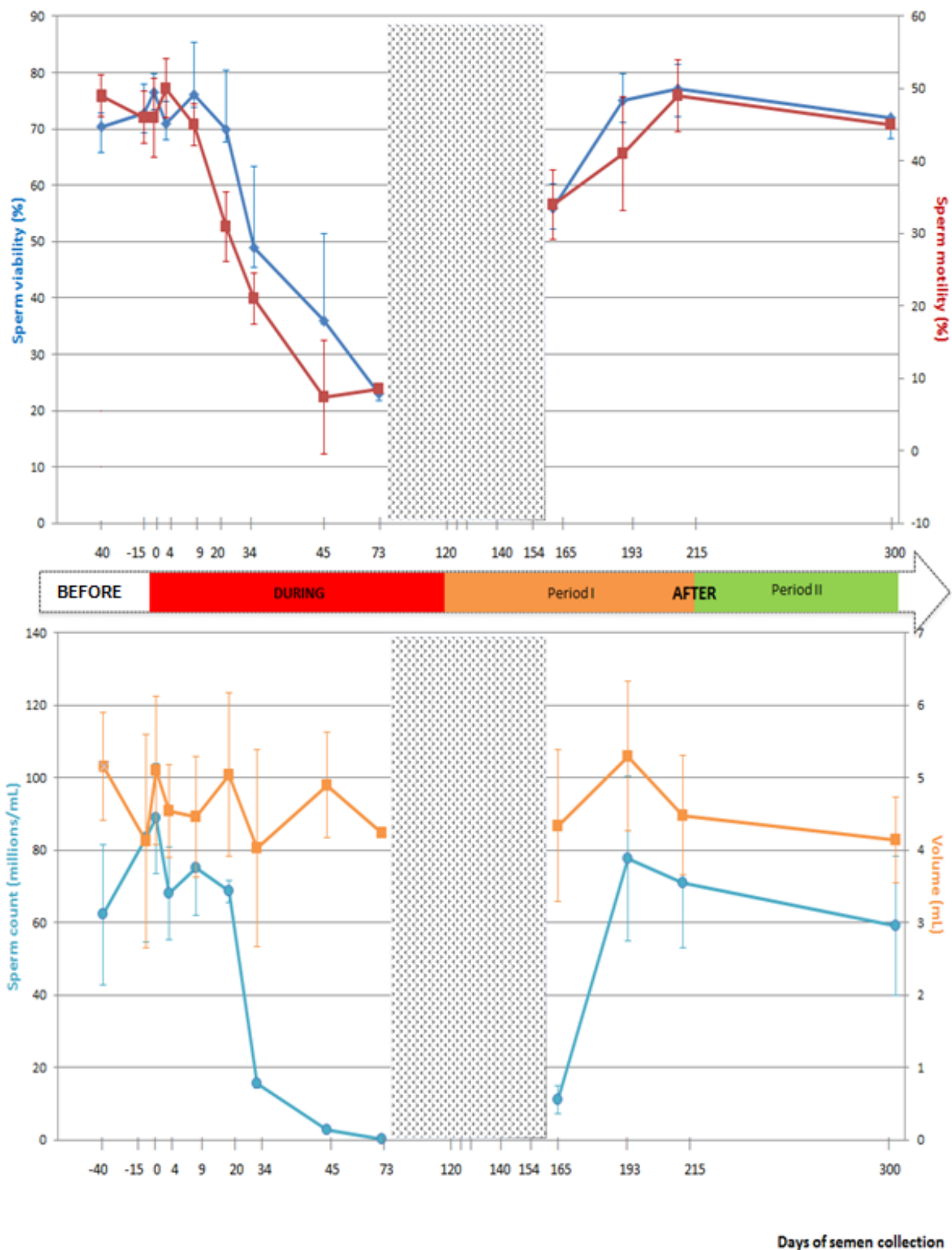


Figure 22. Percentage of sperm viability, motility, mean (SEM) sperm count (millions per ejaculate) and semen volume (mL per ejaculate) before, during and after a mild induced testicular and epididymal temperature increase in healthy men. (Adapt form Ahmad et al., 2012)

Table 7 Sperm parameters during and after a mild induced testicular and epididymal temperature increase in healthy men

Parameters	During heat (Beginning effect)	After heat (Recovery)
Volume (ml)	↔	↔
Sperm count (x10 ⁶ /ml)	↘ D 34	↗ D 193
Sperm viability (%)	↘ D 34	↗ D 193
Progressive motility (%)	↘ D 20	↗ D 193
Round cell count (x10 ⁶ /ml)	↗ D 34	↘ D 193
DFI	↗ D 20	↘ D 193
HDS	↗ D 34	↘ D 193

(↔) No change (↘) significant decrease (↗) significant increase (Adapt form Ahmad et al., 2012)

11.1.2. Effect of heating on epididymal sperm

According to epididymal transit, spermatozoa collected at D4 and D9 of heating were more probably in the epididymis when temperature increase was induced. In the present study, sperm morphology was not affected at these time points (D4, D9) by this mild increase in epididymis temperature. Literature lacks information and till date, no study in men is available to report effect on sperm parameter while spermatozoa are transiting through epididymis exposed to a mild temperature increase.

Nonetheless, in animals (bull and ram), two species having a pendular scrotum, mild increase in scrotal temperature has been obtained through scrotal insulation or controlling the room temperature (ambient). In bull, two out of eight studies have reported an effect on sperm morphology when sperm were in epididymis at the time of heating induction (Kastelic et al., 1996; Wildeus & Entwistle, 1983). The discrepant results between these studies could be explained by differences in heat exposure, bag materials using for insulation and/or by bulls breeds.

Likewise, in ram, studies by Junior et al (2015) and Rocha et al (2015) have reported effect of testis temperature increase, by scrotal insulation, on sperm morphology while sperm is transiting through epididymis. Rocha et al (2015) observed a significant decrease in the percentage of morphologically

normal sperm from $92 \pm 2.7\%$ on day 0 (pre-insulation) to $39 \pm 4.2\%$ on day 8 of scrotal insulation; these effects were caused by a temperature increase in scrotal skin from 31.2 ± 0.2 °C pre-insulation to 35.2 ± 0.3 °C during insulation for 24h/day for 8 consecutive days. In the same way, Junior et al (2015) reported that the testis temperature increase, by scrotal insulation, caused an increase in the percentage of sperm morphology at first week post-insulation, the main defect observed: bent tail (35%), coiled tail (16.25%), distal cytoplasmic droplet (14%), and normal detached head (20%).

The possible reasons of discrepancy between our study and animal studies could be the variability in the physiology of species, and/or in the methods and duration of heating. It seems that the epididymis of ram is more sensitive to temperature increase than human epididymis; this could be supported by two physiological factors:

- In man the body-core-testis temperature gradient is about 2.8°C (Glover and Young 1963); in contrast to 6-8°C in ram, in which body temperature is modified in cases of scrotal insulation (Mieusset et al., 1991).
- An extensively longer tail of ram epididymis (Dott & Glover, 1999; Glover & Young, 1963).

11.1.3. Effect of heating on testis spermatogenesis

According to spermatogenesis and epididymal physiologies (Ahmad et al., 2012), spermatozoa collected at D20 were at the elongated spermatid stage in the testis when heating was induced. Those collected at D34 were at the late spermatocytes stage (end of meiosis) or at spermiogenesis stage, those collected at D45 were in meiosis stage and finally those collected from D56 to D86 at mitosis stage of spermatogenesis.

The significant increase of MAI, which is an integrated index of sperm morphological anomalies and good predictive value in fertility assessment of couples (Jouannet et al., 1988), at D20, suggests that late spermiogenesis was affected by heat induction. However, the drastic fall (fivefold) of the percentage of normal sperm at D34 might be the consequence of effects on early spermiogenesis and late stage of meiosis. These results are in agreement with the fact that pachytene spermatocytes and round spermatids are the testicular cells most sensitive to heat stress (Chowdhury & Steinberger, 1970). To date, no human study has reported such an early effect (before 34 days during heat induction) of a mild increase in testis temperature on sperm morphology. Using a similar method of heating induction (testis located in supra-scrotal position) in 10 men, a significant increase in the percentage of sperm with abnormal morphology was

observed in semen collected between weeks 5 to 8 after the start of heating; i.e. between D29 to D56 of heating (Mieusset et al., 1985).

In 28 male volunteers the testes were suspended in the superficial inguinal pouch close to the scrotal neck 24h/days for 12 months (Shafik, 1991). The percentage of normal sperm morphology dropped from 60% before heating to 27%, 12% at 3 and 12 months respectively during heating. However, 6-12 months after suspension release percentage of sperm morphology returned to normal (Shafik, 1991). Three other studies have reported the effects of scrotal insulation on semen parameters in men (Robinson & Rock, 1967; Shafik, 1992; Wang et al., 1997). Two of them report significant decline in sperm count (Robinson & Rock, 1967; Shafik, 1992) but sperm morphology was not analyzed.

The other study did not report any change in sperm count including morphology; however the temperature rise in this study was of very low grade (increase of scrotal temperature is 0.8-1 C°) (Wang et al., 1997).

A recent study examined the sperm morphology in fertile men before, during and after scrotal heating using an electric warming bag to increase the testis temperature to 43°C for 30-40 min two days per week for 3 months (Zhang et al., 2018 a, b), which is not a mild testicular increase but a

high one. The percentage of sperm with normal morphology was significantly decreased at 1, 2, and 3 months of scrotal heating compared with pre-scrotal heating.

Together, the results of Zhang et al (2018a, b) and our previous studies (Mieusset et al., 1985; 1987a, b) indicate that both a mild sustained induced increase in testis temperature and a high short duration increase induced of testicular temperature result in a decline in normal sperm morphology which is in accordance with results of the present study.

One important aspect of our study is the description of abnormalities induced by the mild testicular-epididymal temperature increase. It is noteworthy that, in the present study, thin head, microcephalic heads, and sperm with abnormal acrosomal region were the head anomalies induced by the mild temperature increase. Tails anomalies such as the short tail, an irregular shaped tail which could represent anomalies of per-axonemal structures (Chemes & Rawe, 2003, Auger, 2010) were significantly increased from D34. These modifications at D34 suggested an alteration of spermiogenesis processes. Significant increase in the percentage of sperm with coiled tail was found at D45 and multiple tails at D73 suggested that germ cells in earlier stages of spermatogenesis were further affected.

Abnormal sperm morphology has been related to sperm DNA damage (He & Tan, 2015; Sheikh et al. 2008; Rao et al. 2016), and previously we have reported significant increase in sperm DFI and mean sperm HDS after 20 to 45 days of heat exposure (Ahmad et al., 2012). Moreover, in bulls, heat scrotal exposure (scrotal insulation method) is related to defective nuclear chromatin condensation during the acrosome and the Golgi phase of spermiogenesis (Rahman et al., 2011, Fernandes et al., 2008). The significant increase of protamine deficient sperm cells at this period (spermiogenesis and spermatocytes) indicates that scrotal insulation, at least in part, causes defective chromatin protamination (Rahman et al., 2018). Also, the same results, of protamine modifications, were found after an episode of fever in man (Evenson et al., 2000). Indeed, no significant changes in semen characteristics (motility, sperm morphology) on day 9 which are explained by the fact that sperm collected were outside the testis (tail of the epididymis and ampulla of ductus deferens) when thermal insult was initiated (Fernandes et al., 2008) and sperm head and nuclear structures were more resistant in epididymis than in testis (Karabinus et al., 1997).

In animals models, a study of five bulls submitted to a scrotal insulation (10 or 20h) demonstrates an increase in the percentage of abnormal spermatozoa, after three (21 days) and nine weeks post-treatment (Ross &

Entwistle, 1979). Furthermore, negative changes in the mean percentage of abnormal spermatozoa during scrotal insulation (48h) started at 15 days of insulation and peaked on a day 18 and increase of abnormal head and tails percentage after 15 days (Vogler et al., 1993). In a study conducted by Fernandes et al (2008), it was shown that significant decreases in normal sperm morphology at day 14 and day 21 after the scrotal insulation of bulls, and percentage of acrosome, midpiece defects were higher in the same period.

Induction of mild hyperthermia using scrotal insulation for 48 h in Holstein-Friesian and Belgian Blue bull resulted on significantly higher percentages of sperm abnormalities such as head abnormalities (acrosome defects, pyriform-shaped heads, micro- and macro-cephalic heads), nuclear vacuoles, and tail defects at ejaculates collected 14 to 42 days (action on spermiogenesis and meiosis stages) (Rahman et al., 2011). In the bull, increased pyriform sperm was observed 15-20 days after scrotal insulation (Newton et al., 2009) with alteration of several spermatid specific functional and structural proteins. In other scrotal insulation protocols in bull an increase of head abnormalities (Rahman et al., 2011) and pyriform sperm was observed. Moreover, scrotal insulation in bull (Saadi et al., 2013) results on adverse effects on testicular germ cells leading to pyriform sperm,

abnormality occurring in the late spermiogenesis stage. Addition altered expression of several spermatid-specific functional and structural proteins in pyriform sperm. In ram, Armengol et al (2015) found that heat stress made by climate round 8h/day during 5 days increased elliptical sperm heads in Australian Merino rams between Days 43 to 49 after treatment. Notwithstanding, the uptake of oxygen and glucose by the testis and epididymis increased over the control after the testes had been above 39°C for 100 to 144 min (Waites et al., 1964). In the other hand, Kastelic et al 2017 found that heat-stress after 30 h (ram scrotal insulation) instigated damage to sperm morphology and motility that was due to increased temperature per se and not due to testicular hypoxia. Rocha et al (2015) observed a rise of abnormal sperm defect following 2 weeks of scrotal insulation at 15- 22 days, with, head (pyriform heads: 4.6% and heads with abnormal contour: 4.2%) and midpiece defects (bent tail: 4%).

We investigate, in a second time, the impact of the mild increase in epididymis temperature on human sperm aneuploidy. At day 34 of heating, the percentages of chromosomal abnormalities were not affected by the mild temperature increase as no change in sperm aneuploidy characteristics was observed at this time point. In accordance with the physiology of the spermatogenesis process and epididymal transit, spermatozoa collected at

D34 were at the late spermatocyte stage (end of meiosis) or early round spermatids in the testis when temperature increase was induced: i.e. they were subjected to heat but issued from progenitor germ cells that had not been exposed to an increased temperature. This finding is in agreement with reports indicating that most chromosomal abnormalities in sperm result from meiotic errors during the spermatogenesis process (Griffiths et al. 2000; Uroz & Templado 2012).

Due to the drastic inhibiting effects of the present mild increase in testis temperature on sperm output during heating (H34 to day H120) which results in severe oligo or azoospermia (Ahmad et al., 2012), FISH analysis was not possible after day 34 of heating or during the first days after heating. The first analysis was done at day 45 after cessation of heating (PH45).

After cessation of heat exposure, percentage of normal sperm remained significantly decreased and MAI increased until D165 which corresponds to 45 days post-heating. The recovery of sperm morphological values comparable to control group was observed at D193. These results indicate that sperm morphologically normal values did not appear until one spermatogenesis cycle after the cessation of heating had been completed.

In contrast, Mieuxset et al. (1987) reported recovery of percentage of normal sperm only at 10-12 months after the end of TSP, but in their study the duration of the experimental heating was very long (24 months). On the other hand, Zhang et al (2018 a,b) observed that the percentage of sperm morphology gradually returned to normal levels two month after scrotal heating.

Moreover, we found a significant increase of disomic sperm (XY18 sperm: non-disjunction of the sexual chromosome at meiosis I) or nullisomic sperm (18) and a slight increase of diploidy sperm (XY1818), consequently total aneuploidy increased at this time. It is noteworthy that spermatozoa collected at day 45 post-heating (PH) were more probably affected by heating at the meiosis stage, according to spermatogenesis and epididymis physiology (Ahmad et al., 2012): “ejaculated sperm at PH45 were germ cells that escaped apoptosis and went through the meiosis process”.

The effects of a mild increase in testis temperature are reversible, as indicated by recovery of preheating values at PH180 after the end of heating except for the values of diploidy XX1818 and XY1818 sperm, which were significantly different from pre-heating values but remained at a very low level. It seems that reversibility could require more than two cycles of

spermatogenesis, but this must be confirmed on a larger sample of men as no analysis was made between PH45 and PH180.

Zhang et al (2018) was examined sperm aneuploidy in 10 men before and during scrotal heating. Compared with pre-heating values, a significant increase in the sum rate of sperm chromosomal 13, 18, 21, and sum of X and Y sperm was reported at the end of the 3 months of heating. In this last study, the increase of sum rate of aneuploidy for X and Y at the end of the 3-month period of heating was 14.2-fold greater than before heating. This is higher than the 2 to 3-fold increase in the present study, where temperature increase was lower. However, the aneuploidy values after cessation of heating were not reported in the study by Zhang et al (2018). Another limitation in this last study was the very low number of sperm studied by FISH (only more than 200 cells).

11.2. Conclusions and prospective

11.2.1. Conclusions

Our experimental study showed that even a mild increase in testicular and epididymal temperature can severally compromise the sperm quality (sperm count, morphology and aneuploidy) which is important in fertility assessment and in the prediction of assisted reproductive technologies outcome.

Therefore, in fertility assessment, history of occupational and environmental exposure to increased temperature should be considered. It is mean that any situation which push the temperature of the testis higher than the normal range, and if such exposure is repeated daily for a long enough time, results in significant adverse effect to spermatogenesis and/or fertility. As we have shown in this work that abnormal sperm parameters returns to normal after cessation of heat exposure, patients must be counselled to minimize the heat exposure and should take protective measures when expecting such a risk.

On the other hand, owing to the reversibility and safety of this experimental method, testicular and epididymal mild temperature increase may be considered as an alternative male contraceptive approach.

11.2.2. Prospective

The present studies have confirmed that the experimental testis and epididymal mild temperature increase using the supra-scrotal position method is an effective experimental model of spermatogenesis disruption. Therefore, this model could be useful for clinical and physiopathology researches.

It is noteworthy that sperm genome and epigenome are important for conceptus development and quality. Further studies could be carried out using the recent molecular technologies as for examples next generation sequencing or array-comparative genome hybridization. Probably, these further researches will improve the knowledge of the links between testis heat stress, spermatogenesis impairment and gamete quality in human. Moreover, such researches allow the identification of bio molecular markers of spermatogenesis alterations (Example: miRNA, DNA methylation) which were relevant for innovations and for environment studies in the field of the reproductive medicine.

12. References

- Acar, H., Kilinc, M., Guven, S., Yurdakul, T. & Celik, R. (2009) Comparison of semen profile and frequency of chromosome aneuploidies in sperm nuclei of patients with varicocele before and after varicocelectomy. *Andrologia*, 41, 157-162.
- Agger, P. (1971) Scrotal and testicular temperature: Its relation to sperm count before and after operation for varicocele. *Fertil Steril*, 22, 286-297.
- Ahmad, G., Moinard, N., Esquerre-Lamare, C., Mieusset, R. & Bujan, L. (2012) Mild induced testicular and epididymal hyperthermia alters sperm chromatin integrity in men. *Fertil Steril*, 97, 546-553.
- Albrecht, M., Raïmsch, R., Koïhn, F. M., Schwarzer, J. U. & Mayerhofer, A. (2006) Isolation and cultivation of human testicular peritubular cells: A new model for the investigation of fibrotic processes in the human testis and male infertility. *J Clin Endocri Metabol*, 91, 1956-1960.
- Alves, M. B. R., de Andrade, A. F. C., de Arruda, R. P., Batissaco, L., Florez-Rodriguez, S. A., de Oliveira, B. M. M., Torres, M. A., Lanoni, R., Ravagnani, G. M. & do Prado Filho, R. R. (2016) Recovery of normal testicular temperature after scrotal heat stress in rams assessed by infrared thermography and its effects on seminal characteristics and testosterone blood serum concentration. *Theriogenology*, 86, 795-805.

- Amann, R. P. (2008) The cycle of the seminiferous epithelium in humans: A need to revisit? *J Androl*, 29, 469-487.
- Amouroux, M., Mieusset, R., Desbriere, R., Opinel, P., Karsenty, G., Paci, M., Fernandes, S., Courbiere, B. & Perrin, J. (2018) Are men ready to use thermal male contraception? Acceptability in two french populations: New fathers and new providers. *PloS one*, 13, e0195824.
- Anderson, R. A. & Baird, D. (2002) Male contraception. *Endocrinol Rev*, 23, 735-762.
- Andrade-Rocha, F. T. (2013) Temporary impairment of semen quality following recent acute fever. *Ann Clin Lab Sci*, 43, 94-97.
- Armengol, M. L., Sabino, G., Forquera, J., de La Casa, A. & Aisen, E. G. (2015) Sperm head ellipticity as a heat stress indicator in australian merino rams (*ovis aries*) in northern Patagonia, Argentina. *Theriogenology*, 83, 553-559. e552.
- Asala, S., Chaudhary, S. C., Masumbuko-Kahamba, N. & Bidmos, M. (2001) Anatomical variations in the human testicular blood vessels. *Ann Anat*, 183, 545-549.
- Auger, J. (2010) Assessing human sperm morphology: Top models, underdogs or biometrics? *Asian J Androl*, 12, 36.

- Auger, J., Eustache, F., Andersen, A., Irvine, D., Jargensen, N., Skakkebaek, N., Suominen, J., Toppari, J., Vierula, M. & Jouannet, P. (2001) Sperm morphological defects related to environment, lifestyle and medical history of 1001 male partners of pregnant women from four european cities. *Hum Reprod*, 16, 2710-2717.
- Auger, J., Jouannet, P. & Eustache, F. (2015) Another look at human sperm morphology. *Hum Reprod*, 31, 10-23.
- Aumuller, G. & Riva, A. (1992) Morphology and functions of the human seminal vesicle. *Andrologia*, 24, 183-196.
- Aumuller, G. & Seitz, J. (1990) Protein secretion and secretory processes in male accessory sex glands. *Int Rev Cytol*, 121, 127–231.
- Bastiaan, H. S., Windt, M.-L., Menkveld, R., Kruger, T. F., Oehninger, S. & Franken, D. R. (2003) Relationship between zona pellucida-induced acrosome reaction, sperm morphology, spermzona pellucida binding, and in vitro fertilization. *Fertil Steril*, 79, 49-55.
- Bedford, J. (1973) The maturation of spermatozoa in the human epididymis. *J Reprod Fertil* 18, 199-213.
- Bedford, J. (1990) Sperm dynamics in the epididymis. *Game Physiol*, 53-68.

- Bedford, J. (1994) Epididymal physiology: Its implications for epididymal microsurgery. In: *Microsurgery of Male Infertility*. Fondazione per gli studi sulla riproduzione umana, 71-100, Palermo, Italy.
- Bedford, J. M. (1978) Influence of abdominal temperature on epididymal function in the rat and rabbit. *Amer J Anat*, 152, 509-521.
- Bedford, J. M. (1991) Effects of elevated temperature on the epididymis and testis: Experimental studies. In: *Temperature and environmental effects on the testis*, 19-32. Springer, Boston, MA.
- Bedford, J. M. (2015) The epididymis re-visited: A personal view. *Asian J Androl*, 17, 693-698.
- Belleannée, C., Thimon, V. & Sullivan, R. (2012) Region-specific gene expression in the epididymis. *Cell Tissue Res*, 349, 717-731.
- Bernardini, L., Borini, A., Preti, S., Conte, N., Flamigni, C., Capitanio, G. & Venturini, P. (1998) Study of aneuploidy in normal and abnormal germ cells from semen of fertile and infertile men. *Hum Reprod*, 13, 3406-3413.
- Bertolotto M, Trombetta C & Baert AL. (2012) *Scrotal pathology*. 27-34, Springer, Berlin Heidelberg.
- Bomblies, K., Higgins, J. D. & Yant, L. (2015) Meiosis evolves: Adaptation to external and internal environments. *New Phytol*, 208, 306-323.

- Bonde, J. P. (1992) Semen quality in welders exposed to radiant heat. *Occup Environ Med*, 49, 5-10.
- Brindley, G. (1982) Deep scrotal temperature and the effect on it of clothing, air temperature, activity, posture and paraplegia. *Br J Urol*, 54, 49-55.
- Brito, L. F., Silva, A. E., Barbosa, R. T., Unanian, M. M. & Kastelic, J. P. (2003) Effects of scrotal insulation on sperm production, semen quality, and testicular echotexture in *Bos indicus* and *Bos indicus* x *Bos taurus* bulls. *Animal Reprod Sci*, 79, 1-15.
- Brown-Woodman, P., Post, E., Gass, G. & White, I. (1984) The effect of a single sauna exposure on spermatozoa. *Arch Androl*, 12, 9-15.
- Brown, J. S., Dubin, L. & Hotchkiss, R. S. (1967) The varicocele as related to fertility. *Fertil Steril*, 18, 46-56.
- Bujan, L., Daudin, M., Charlet, J.-P., Thonneau, P. & Mieusset, R. (2000) Increase in scrotal temperature in car drivers. *Hum Reprod*, 15, 1355-1357.
- Bukowska, D., Kempisty, B., Piotrowska, H., Sosinska, P., Wozna, M., Ciesiolka, S., Antosik, P., Jaskowski, J., Brussow, K. & Nowicki, M. (2013) The structure and role of mammalian sperm rna: A review. *Vet Med*, 2, 57-64.

- Calogero, A. E., De Palma, A., Grazioso, C., Barone, N., Romeo, R., Rappazzo, G. & D'Agata, R. (2001) Aneuploidy rate in spermatozoa of selected men with abnormal semen parameters. *Hum Reprod*, 16, 1172-1179.
- Calogero, A. E., Burrello, N., De Palma, A., Barone, N., D'Agata, R. & Vicari, E. (2003) Sperm aneuploidy in infertile men. *Reprod Biomed Online*, 6, 310-317.
- Candas, V., Becmeur, F., Bothorel, B. & Hoeft, A. (1993) Qualitative assessment of thermal and evaporative adjustments of human scrotal skin in response to heat stress. *Int J Androl*, 16, 137-142.
- Carlsen, E., Andersson, A. M., Petersen, J. r. H. & Skakkebaek, N. E. (2003) History of febrile illness and variation in semen quality. *Hum Reprod*, 18, 2089-2092.
- Chemes, H. E. & Rawe, V. Y. (2003) Sperm pathology: A step beyond descriptive morphology. Origin, characterization and fertility potential of abnormal sperm phenotypes in infertile men. *Hum Reprod Update*, 9, 405-428.
- Cheng, J. W. C., Myklak, K., & Ko, E. Y. (2016). Physiology of Spermatogenesis: Opportunities for Disruption. In *Cancer and Fertility*, 21-47. Humana Press, Cham.

- Chowdhury, A. & Steinberger, E. (1970) Early changes in the germinal epithelium of rat testes following exposure to heat. *J Reprod Fertil*, 22, 205-212.
- Chughtai, B., Sawas, A., O'malley, R. L., Naik, R. R., Ali Khan, S. & Pentyala, S. (2005) A neglected gland: A review of Cowper's gland. *Int J Androl*, 28, 74-77.
- Chung, E. & Brock, G. B. (2011) Cryptorchidism and its impact on male fertility: A state of art review of current literature. *Can Urol Assoc J*, 5, 210-214.
- Clermont, Y. (1963) The cycle of the seminiferous epithelium in man. *Amer J Anat*, 112, 35-51.
- Coetzee, K., Kruger, T. F. & Lombard, C. J. (1998) Predictive value of normal sperm morphology: A structured literature review. *Hum Reprod Update*, 4, 73-82.
- Cooper TG, Yeung C-H. (2006) Sperm maturation in the human epididymis. In: De Jonge C, Barratt C, editors. The sperm cell production, maturation fertilization regeneration, 72–107. Cambridge University Press, Cambridge.
- Cornwall, G. A. (2009) New insights into epididymal biology and function. *Hum Reprod Update*, 15, 213-227.

- David, G., Bisson, J., Czyglik, F., Jouannet, P. & Gernigon, C. (1975) Anomalies morphologiques du spermatozoïde de humain. 1) propositions pour un système de classification. *J Gynecol Obstet Biol Reprod*, 4, 17-36.
- Davidson, H. (1954) Treatment of male subfertility; testicular temperature and varicoceles. *Practitioner*, 173, 703-708.
- Deralakatte, N. P. (2008) Swinging high and low: Why do the testes hang at different levels? A theory on surface area and thermoregulation. *Med hypoth*, 70, 698-708.
- Dhole, B. & Kumar, A. (2017) Hypothalamic-pituitary-testicular axis. In: *Basi Hum Androl*, 117-134. Springer, Singapore.
- Durairajanayagam, D., Sharma, R. K., du Plessis, S. S., & Agarwal, A. (2014). Testicular heat stress and sperm quality. In *Male Infertility*, 105-125. Springer, New York.
- Durairajanayagam, D., Agarwal, A. & Ong, C. (2015) Causes, effects and molecular mechanisms of testicular heat stress. *Reprod Biomed Online*, 30, 14-27.
- Eggert-Kruse, W., Schwarz, H., Rohr, G., Demirakca, T., Tilgen, W. & Runnebaum, B. (1996) Sperm morphology assessment using strict criteria and male fertility under in-vivo conditions of conception. *Hum Reprod*, 11, 139-146.

- Einer-Jensen, N. & Hunter, R. (2005) Counter-current transfer in reproductive biology. *Reproduction*, 129, 9-18.
- Elebute, E. (1976) The relationship of skin temperatures of clothed adults to ambient temperature in a warm environment. *Afr J Med Medical Sci*, 5, 175-178.
- Emery, B. R. (2013) Sperm aneuploidy testing using fluorescence in situ hybridization. In: *Spermatogenesis*, 167-173. Humana Press, Totowa.
- Eskenazi, B, Wyrobek, A., Kidd, S., Lowe, X., Moore, D., 2nd, Weisiger, K. & Aylstock, M. (2002) Sperm aneuploidy in fathers of children with paternally and maternally inherited Klinefelter syndrome. *Hum Reprod*, 17, 576-583.
- Esponda, P. & Bedford, J. (1986) The influence of body temperature and castration on the protein composition of fluid in the rat cauda epididymidis. *J Reprod Fertil*, 78, 505-514.
- Esquerré-Lamare, C., Walschaerts, M., Debordeaux, L. C., Moreau, J., Bretelle, F., Isus, F. (2018). Sperm aneuploidy and DNA fragmentation in unexplained recurrent pregnancy loss: a multicenter case-control study. *Basic and clinical andrology*, 28, 4-10.

- Esteves, S. C., Verza Jr, S., Sharma, R. K., Gosajlvez, J. & Agarwal, A. (2015) Role and significance of sperm function in men with unexplained Infertility: Pathophysiology, *Evalu Treat*, 12, 91-101.
- Estop, A. M., Munna, S., Cieply, K. M., Vandermark, K. K., Lamb, A. N. & Fisch, H. (1998) Meiotic products of a klinefelter 47, XXY male as determined by sperm fluorescence in-situ hybridization analysis. *Hum Reprod*, 13, 124-127.
- Evenson, D. P., Jost, L. K., Corzett, M. & Balhorn, R. (2000) Characteristics of human sperm chromatin structure following an episode of influenza and high fever: A case study. *J Androl*, 21, 739-746.
- Fawcett , D. W. (1975) The mammalian spermatozo on. A review. *Dev. Biol.* 44,394-436.
- Fawzy, F., Hussein, A., Eid, M. M., Kashash, A. M. E. & Salem, H. K. (2015) Cryptorchidism and fertility. *Clinical Medicine Insights: Reprod Health*, 9, 39-43.
- Fernandes, C., Dode, M., Pereira, D. & Silva, A. (2008) Effects of scrotal insulation in nellore bulls (*Bos taurus indicus*) on seminal quality and its relationship with in vitro fertilizing ability. *Theriogenology*, 70, 1560-1568.

- Figa-Talamanca, I., Dell'Orco, V., Pupi, A., Dondero, F., Gandini, L., Lenzi, A., Lombardo, F., Scavalli, P. & Mancini, G. (1992) Fertility and semen quality of workers exposed to high temperatures in the ceramics industry. *Reprod Toxicol*, 6, 517-523.
- French, J. G., Lowrimore, G., Nelson, W. C., Finklea, J. F., English, T. & Hertz, M. (1973) The effect of sulfur dioxide and suspended sulfates on acute respiratory disease. *Arch Environ Health*, 27, 129-133.
- Galil, K. & Setchell, B. (1988) Effects of local heating of the testis on testicular blood flow and testosterone secretion in the rat. *Int J Androl*, 11, 73-85.
- Garolla, A., Torino, M., Miola, P., Caretta, N., Pizzol, D., Menegazzo, M., Bertoldo, A. & Foresta, C. (2015) Twenty-four-hour monitoring of scrotal temperature in obese men and men with a varicocele as a mirror of spermatogenic function. *Hum Reprod*, 30, 1006-1013.
- Garolla, A., Torino, M., Sartini, B., Cosci, I., Patassini, C., Carraro, U. & Foresta, C. (2013) Seminal and molecular evidence that sauna exposure affects human spermatogenesis. *Hum Reprod*, 28, 877-885.
- Gat, Y., Zukerman, Z., Chakraborty, J. & Gornish, M. (2005) Varicocele, hypoxia and male infertility. Fluid mechanics analysis of the impaired testicular venous drainage system. *Hum Reprod*, 20, 2614-2619.

- Gatimel, N., Moreau, J., Parinaud, J. & Léandri, R. (2017) Sperm morphology: Assessment, pathophysiology, clinical relevance, and state of the art in 2017. *Andrology*, 5, 845-862.
- Gazvani MR, Wood SJ, Thomson AJ, Kingsland CR & Lewis-Jones DI. (2000) Assessment of testicular core temperatures using microwave thermography. *Hum Reprod*, 15, 1723-1726.
- Golan, R., Cooper, T., Oschry, Y., Oberpenning, F., Schulze, H., Shochat, L. & Lewin, L. (1996) Andrology: Changes in chromatin condensation of human spermatozoa during epididymal transit as determined by flow cytometry. *Hum Reprod*, 11, 1457-1462.
- Goldstein, M. & Eid, J.-F. (1989) Elevation of intratesticular and scrotal skin surface temperature in men with varicocele. *J Urol*, 142, 743-745.
- Goldstein, M. & Schlegel, P. N. (2013) Anatomy and physiology of the male. Surgical and medical management of male infertility. 4-7, Cambridge University Press, Cambridge.
- Gorelick, J. I. & Goldstein, M. (1993) Loss of fertility in men with varicocele. *Fertil Steril*, 59, 613-616.
- Griffiths, A., Miller, J., Suzuki, D., Lewontin, R. & Gelbart, W. (2000) Chromosome mutation ii: Changes in chromosome number. An introduction to genetic analysis. 89-95, WH Freeman, New York.

- Guzick, D. S., Overstreet, J. W., Factor-Litvak, P., Brazil, C. K., Nakajima, S. T., Coutifaris, C., Carson, S. A., Cisneros, P., Steinkampf, M. P. & Hill, J. A. (2001) Sperm morphology, motility, and concentration in fertile and infertile men. *N Engl J Med*, 345, 1388-1393.
- Hadziselimovic, F. & Herzog, B. (2001) Importance of early postnatal germ cell maturation for fertility of cryptorchid males. *Horm Res Paedia*, 55, 6-10.
- Hafez, E. S. E. (1976) Human semen and fertility regulation in men. Mosby.
- Haidl, G., Badura, B. & Schill, W. B. (1994) Function of human epididymal spermatozoa. *J Androl*, 15, 23-27.
- Hamerezaee, M., Dehghan, S. F., Golbabaee, F., Fathi, A., Barzegar, L. & Heidarnejad, N. (2018) Assessment of semen quality among workers exposed to heat stress: A cross-sectional study in a steel industry. *Safe Health Work*, 9, 232-235.
- Hanley, H. G. & Harrison, R. (1962) The nature and surgical treatment of varicocele. *Br J Surg*, 50, 64-67.
- Harkonen, K., Viitanen, T., Larsen, S. B., Bonde, J. P. & Lahdetie, J. (1999) Aneuploidy in sperm and exposure to fungicides and lifestyle factors. *Environ Mol Mutagen*, 34, 39-46.
- Harrison, R. & Barclay, A. (1948) The distribution of the testicular artery (internal spermatic artery) to the human testis. *Br J Urol*, 20, 57-66.

- Hassold, T., Abruzzo, M., Adkins, K., Griffin, D., Merrill, M., Millie, E., Saker, D., Shen, J. & Zaragoza, M. (1996) Human aneuploidy: Incidence, origin, and etiology. *Environ Mol Mutagen*, 28, 167-175.
- Hassold, T. & Hunt, P. (2001) To err (meiotically) is human: The genesis of human aneuploidy. *Nature Rev Genet*, 2, 280.
- Hayward, S. W. & Cunha, G. R. (2000) The prostate: Development and physiology. *Radiologic Clin North Am*, 38, 1-14.
- He, M. & Tan, L. (2015) Correlation between sperm ultrastructure in infertile patients with abnormal sperm morphology and DNA damage. *Genet Mol Res*, 14, 17000-17006.
- Hendry, W., Sommerville, I., Hall, R. & Pugh, R. (1973) Investigation and treatment of the subfertile male. *Br J Urol*, 45, 684-692.
- Hjollund, N. H. I., Bonde, J. P. E., Jensen, T. K., Olsen, J. r. & Team, D. F. P. P. S. (2000) Diurnal scrotal skin temperature and semen quality. *Int J Androl*, 23, 309-318.
- Hjollund, N. H. I., Storgaard, L., Ernst, E., Bonde, J. P. & Olsen, J. r. (2002) Impact of diurnal scrotal temperature on semen quality. *Reprod Toxicol*, 16, 215-221.
- Holstein, A. F., Maekawa, M., Nagano, T. & Davidoff, M. S. (1996) Myofibroblasts in the lamina propria of human seminiferous tubules are

- dynamic structures of heterogeneous phenotype. *Arch Histol Cytol*, 59, 109-125.
- Holstein, A. F. & Roosen-Runge, E. C. (1981) Atlas of human spermatogenesis. 8 -244, Grosse Verlag, Berlin.
- Huckins, C (1975) Adult spermatogenesis, Characteristics, kinetics, and control. In Lipshultz & LI,Howards S.S. (eds): Infertility in the Male. 76-108, Churchill Linvingstone, New York.
- Johnson, L. (1986) Spermatogenesis and aging in the human. *J Androl*, 7, 331-354.
- Johnson, L. & Varner, D. D. (1988) Effect of daily spermatozoan production but not age on transit time of spermatozoa through the human epididymis. *Biol Reprod*, 39, 812-817.
- Jouannet, P., Ducot, B., Feneux, D. & Spira, A. (1988) Male factors and the likelihood of pregnancy in infertile couples. I. Study of sperm characteristics. *Int J Androl*, 11, 379-394.
- Jung, A., Eberl, M. & Schill, W. (2001) Improvement of semen quality by nocturnal scrotal cooling and moderate behavioural change to reduce genital heat stress in men with oligoasthenoteratozoospermia. *Reproduction*, 121, 595-603.

- Jung, A., Leonhardt, F., Schill, W.-B. & Schuppe, H.-C. (2005) Influence of the type of undertrousers and physical activity on scrotal temperature. *Hum Reprod*, 20, 1022-1027.
- Jung, A., Strauss, P., Lindner, H. & Schuppe, H. (2008) Influence of moderate cycling on scrotal temperature. *Int J Androl*, 31, 403-407.
- Junior, C. C., Lucci, C., Peripolli, V., Silva, A., Menezes, A., Morais, S., Araujo, M., Ribeiro, L., Mattos, R. & McManus, C. (2015) Effects of testicle insulation on seminal traits in rams: Preliminary study. *Small Rumin Res*, 130, 157-165.
- Jurewicz, J., Radwan, M., Sobala, W., Radwan, P., Jakubowski, L., Hawula, W., Ulanska, A. & Hanke, W. (2014) Lifestyle factors and sperm aneuploidy. *Reprod Biol*, 14, 190-199.
- Kaler, L. W. & Neaves, W. B. (1978) Attrition of the human Leydig cell population with advancing age. *Anat Rec*, 192, 513-518.
- Karabinus, D. S., Vogler, C. J., Saacke, R. G. & Evenson, D. P. (1997) Chromatin structural changes in sperm after scrotal insulation of holstein bulls. *J Androl*, 18, 549-555.
- Kastelic, J., Cook, R., Coulter, G. & Saacke, R. (1996) Insulating the scrotal neck affects semen quality and scrotal/testicular temperatures in the bull. *Theriogenology*, 45, 935-942.

- Kastelic, J., Wilde, R., Rizzoto, G. & Thundathil, J. (2017) Hyperthermia and not hypoxia may reduce sperm motility and morphology following testicular hyperthermia. *Vet Med*, 62.
- Katz, D. F., Overstreet, J. W., Samuels, S. J., Ninswander, P. W., Bloom, T. D. & Lewis, E. L. (1986) Morphometric analysis of spermatozoa in the assessment of human male fertility. *J Androl*, 7, 203-210.
- Kihaile, P., Hirotsuru, K., Kumasako, Y., Misumi, J. & Utsunomiya, T. (2003) Fertilization rates of small-head sperm in conventional IVF and ICSI. *Arch Androl*, 49, 327-329.
- Kitayama, T. (1965) Study on testicular temperature in men. *Hinyokika Kiyo. Acta Urologica Japonica*, 11, 435.
- Kleisner, K., Ivell, R. & Flegr, J. The evolutionary history of testicular externalization and the origin of the scrotum. *J Biosci*, 35, 27-37.
- Kort, H. I., Massey, J. B., Elsner, C. W., Mitchell•Leef, D., Shapiro, D. B., Witt, M. A. & Roudebush, W. E. (2006) Impact of body mass index values on sperm quantity and quality. *J Androl*, 27, 450-452.
- Kruger, T. F., Menkveld, R., Stander, F. S., Lombard, C. J., Van der Merwe, J. P., van Zyl, J. A. & Smith, K. (1986) Sperm morphologic features as a prognostic factor in in vitro fertilization. *Fertil Steril*, 46, 1118-1123.

- Ku, J. H., Son, H., Kwak, C., Lee, S. E., Lee, N. K. & Park, Y. H. (2002) Impact of varicocele on testicular volume in young men: Significance of compensatory hypertrophy of contralateral testis. *J Urol*, 168, 1541-1544.
- Labranche, L., Sweeney, S., Storti, S. & Kalmey, J. (2018) Identification of an aberrant testicular vein draining the right kidney. *Int J Anat Var*, 11.
- Lamb, J. C. & Foster, P. M. (1988) Physiology and toxicology of male reproduction. 7-31, Academic Press, London.
- Lazarus, B. A. & Zorgniotti, A. W. (1975) Thermoregulation of the human testis. *Fertil Steril*, 26, 757-759.
- Lerchl, A., Keck, C., Spiteri•Grech, J., Nieschlag, E. & Bergh, A. (1993) Diurnal variations in scrotal temperature of normal men and patients with varicocele before and after treatment. *Int J Androl*, 16, 195-200.
- Leung, M. L., Gooding, G. & Williams, R. D. (1984) High-resolution sonography of scrotal contents in asymptomatic subjects. *Amer J Roentgenol*, 143, 161-164.
- Liguori G, Ollandini G, Napoli R, Mazzon G, Petrovic M, Trombetta C (2012) Anatomy of the scrotum. In: Bertolotto M, Trombetta C (eds) *Scrotal pathology*. 27–34, Springer, Berlin, Heidelberg.

- Lipshultz, L. (1976) Cryptorchidism in the subfertile male. *Fertil Steril*, 27, 609-620.
- Liu, Y. (2010) Temperature control of spermatogenesis and prospect of male contraception. *Front Biosci (Scholar edition)*, 2, 730-755.
- Love, C. C. & Kenney, R. M. (1999) Scrotal heat stress induces altered sperm chromatin structure associated with a decrease in protamine disulfide bonding in the stallion. *Biol Reprod*, 60, 615-620.
- Lucia, A., Chicharro, J. L., Pérez, M., Serratos, L., Bandrés, F. & Legido, J. C. (1996) Reproductive function in male endurance athletes: Sperm analysis and hormonal profile. *J Appl Physiol*, 81, 2627-2636.
- Lue, Y. H., Lasley, B. L., Laughlin, L. S., Swerdloff, R. S., Hikim, A. P. S., Leung, A., Overstreet, J. W. & Wang, C. (2002) Mild testicular hyperthermia induces profound transitional spermatogenic suppression through increased germ cell apoptosis in adult *Cynomolgus* monkeys (*Macaca fascicularis*). *J Androl*, 23, 799-805.
- Lund, L. & Nielsen, K. (1996) Varicocele testis and testicular temperature. *Br J Urol*, 78, 113-115.
- Lynch, R., Lewis-Jones, D. I., Machin, D. G. & Desmond, A. D. (1986) Improved seminal characteristics in infertile men after a conservative treatment

- regimen based on the avoidance of testicular hyperthermia. *Fertil Steril*, 46, 476-479.
- MacLeod, J. & Hotchkiss, R. S. (1941) The effect of hyperpyrexia upon spermatozoa counts in men. *Endocrinology*, 28, 780-784.
- Magnusdottir, E. V., Thorsteinsson, T., Thorsteinsdottir, S., Heimisdottir, M. & Olafsdottir, K. (2005) Persistent organochlorines, sedentary occupation, obesity and human male subfertility. *Hum Reprod*, 20, 208-215.
- Massart, A., Lissens, W., Tournaye, H. & Stouffs, K. (2012) Genetic causes of spermatogenic failure. *Asian J Androl*, 14, 40-48.
- Matsukawa T, Ozaki M, Nishiyama T, Imamura M & Kumazawa T. (2000) Comparison of infrared thermometer with thermocouple for monitoring skin temperature. *Critical Care Med*, 28, 532-536.
- Menkveld, R. (2010) Clinical significance of the low normal sperm morphology value as proposed in the fifth edition of the who laboratory manual for the examination and processing of human semen. *Asian J Androl*, 12, 47-58.
- Menkveld, R., Holleboom, C. A. & Rhemrev, J. P. (2011) Measurement and significance of sperm morphology. *Asian J Androl*, 13, 59-68.

- Menkveld, R., Stander, F. S., Kotze, T. J. v., Kruger, T. F. & Zyl, J. A. v. (1990) The evaluation of morphological characteristics of human spermatozoa according to stricter criteria. *Hum Reprod*, 5, 586-592.
- Mieusset, R., Bengoudifa, B. & Bujan, L. (2007) Effect of posture and clothing on scrotal temperature in fertile men. *J Androl*, 28, 170-175.
- Mieusset, R. & Bujan, L. (1994) The potential of mild testicular heating as a safe, effective and reversible contraceptive method for men. *Int J Androl*, 17, 186-191.
- Mieusset, R. & Bujan, L. (1995) Testicular heating and its possible contributions to male infertility: A review. *Int J Androl*, 18, 169-184.
- Mieusset, R., Bujan, L., Mansat, A., Pontonnier, F. & Grandjean, H. I. n. (1987) Effects of artificial cryptorchidism on sperm morphology. *Fertil Steril*, 47, 150-155.
- Mieusset, R., Bujan, L., Mansat, A., Pontonnier, F. & Grandjean, H. L. N. (1987) Hyperthermia and human spermatogenesis: Enhancement of the inhibitory effect obtained by artificial cryptorchidism. *Int J Androl*, 10, 571-580.
- Mieusset, R., Casares, P. Q., Sanchez•Partida, L., Sowerbutts, S., Zupp, J. & Setchell, B. (1991) The effects of moderate heating of the testes and epididymides of rams by scrotal insulation on body temperature,

respiratory rate, spermatozoa output and motility, and on fertility and embryonic survival in ewes inseminated with frozen semen a. *Ann New Acad Sci*, 637, 445-458.

Mieusset, R., Fouda, P. J., Vaysse, P., Guitard, J., Moscovici, J. & Juskiewenski, S. (1993) Increase in testicular temperature in case of cryptorchidism in boys. *Fertil Steril*, 59, 1319-1321.

Mieusset, R., Grandjean, H. I. n., Mansat, A. & Pontonnier, F. (1985) Inhibiting effect of artificial cryptorchidism on spermatogenesis. *Fertil Steril*, 43, 589-594.

Momen, M. N., Ananian, F. B., Fahmy, I. M. & Mostafa, T. (2010) Effect of high environmental temperature on semen parameters among fertile men. *Fertil Steril*, 93, 1884-1886.

Moore, C. R. & Quick, W. J. (1923) A comparison of scrotal and peritoneal temperatures. *Proc Soc Zool Anat Rec*, 26, 344-351.

Moore, H. D., Curry, M. R., Penfold, L. M. & Pryor, J. P. (1992) The culture of human epididymal epithelium and in vitro maturation of epididymal spermatozoa. *Fertil Steril*, 58, 776-783.

Moretti, E., Di Cairano, G., Capitani, S., Scapigliati, G., Baccetti, B. & Collodel, G. (2007) Cryptorchidism and semen quality: A tem and molecular study. *J Androl*, 28, 194-199.

- Moule, G. & Waites, G. (1963) Seminal degeneration in the ram and its relation to the temperature of the scrotum. *J Reprod Fertil*, 5, 433-446.
- Nanayakkara, S.D.I (2011) The physiological mechanisms of scrotal temperature regulation and the effects of its dysregulation on endocrine function of the testes, 20-23. Doctoral dissertation, University of Western Australia.
- Newman, H. F. & Wilhelm, S. F. (1950) Testicular temperature in man. *J Urol*, 63, 349-352.
- Newton, L. D., Kastelic, J. P., Wong, B., Van der Hoorn, F. & Thundathil, J. (2009) Elevated testicular temperature modulates expression patterns of sperm proteins in Holstein Bulls. *Mol Reprod Dev: Incorporating Gamete Res*, 76, 109-118.
- Niederberger, C. (2011) An introduction to male reproductive medicine, 2-19. Cambridge University Press, Cambridge.
- Nieschlag, E. & Behre, H. (1992) Male infertility due to testicular dysfunction. In: *Infertility*, 65-79. Springer, London.
- O'Donnell, L., Nicholls, P. K., O'Bryan, M. K., McLachlan, R. I. & Stanton, P. G. (2011) Spermiation: The process of sperm release. *Spermatogenesis*, 1, 14-35.
- Partsch, C., Aukamp, M. & Sippell, W. (2000) Scrotal temperature is increased in disposable plastic lined nappies. *Arch Diseases Child*, 83, 364-368.

- Pellestor, F., Anahory, T., Lefort, G., Puechberty, J., Liehr, T., Hedon, B., & Sarda, P. (2011). Complex chromosomal rearrangements: origin and meiotic behavior. *Human reproduction update*, 17, 476-494.
- Petronczki, M., Siomos, M. F. & Nasmyth, K. (2003) Un menage a quatre: The molecular biology of chromosome segregation in meiosis. *Cell*, 112, 423-440.
- Rachootin, P. and Olsen, J. (1983) The risk of infertility and delayed conception associated with exposures in the Danish workplace. *J Occup Med*, 25, 394-402.
- Rahman, M. B., Schellander, K., Luceno, N. L. & Van Soom, A. (2018) Heat stress responses in spermatozoa: Mechanisms and consequences for cattle fertility. *Theriogenology*, 113, 102-112.
- Rahman, M. B., Vandaele, L., Rijsselaere, T., Maes, D., Hoogewijs, M., Frijters, A., Noordman, J., Granados, A., Dernelle, E. & Shamsuddin, M. (2011) Scrotal insulation and its relationship to abnormal morphology, chromatin protamination and nuclear shape of spermatozoa in Holstein-Friesian and Belgian Blue bulls. *Theriogenology*, 76, 1246-1257.
- Rao, M., Xia, W., Yang, J., Hu, L. X., Hu, S. F., Lei, H., Wu, Y. Q. & Zhu, C. H. (2016) Transient scrotal hyperthermia affects human sperm DNA

- integrity, sperm apoptosis, and sperm protein expression. *Andrology*, 4, 1054-1063.
- Rao, M., Zhao, X.-L., Yang, J., Hu, S.-F., Lei, H., Xia, W. & Zhu, C.-H. (2015) Effect of transient scrotal hyperthermia on sperm parameters, seminal plasma biochemical markers, and oxidative stress in men. *Asian J Androl*, 17, 668-675.
- Redman, J. F. (1996) Applied anatomy of the cremasteric muscle and fascia. *J Urol*, 156, 1337-1340.
- Regalado, F., Esponda, P. & Nieto, A. (1993) Temperature and androgens regulate the biosynthesis of secretory proteins from rabbit cauda epididymidis. *Mol Reprod Dev*, 36, 448-453.
- Rives, N., Saint Clair, A., Mazurier, S., Sibert, L., Simon, N., Joly, G. r. & Mac, B. (1999) Relationship between clinical phenotype, semen parameters and aneuploidy frequency in sperm nuclei of 50 infertile males. *Hum Genet*, 105, 266-272.
- Robinson, D. & Rock, J. (1967) Intrascrotal hyperthermia induced by scrotal insulation: Effect on spermatogenesis. *Obstet Gynecol*, 29, 217-223.
- Robinson, D., Rock, J. & Menkin, M. F. (1968) Control of human spermatogenesis intrascrotal temperature. *JAMA*, 204, 290-297.

- Rocha, D. R., Martins, J. A. M., van Tilburg, M. F., Oliveira, R. V., Moreno, F. B., Monteiro-Moreira, A. C. O., Moreira, R. A., Araujo, A. A. & Moura, A. A. (2015) Effect of increased testicular temperature on seminal plasma proteome of the ram. *Theriogenology*, 84, 1291-1305.
- Rock, J. & Robinson, D. (1965) Effect of induced intrascrotal hyperthermia on testicular function in man. *Amer J Obstet Gynecol*, 93, 793-801.
- Ross, A. & Entwistle, K. (1979) The effect of scrotal insulation on spermatozoal morphology and the rates of spermatogenesis and epididymal passage of spermatozoa in the bull. *Theriogenology*, 11, 111-129.
- Rousseaux, C. G., & Bolon, B. (2018). Embryo, Fetus, and Placenta. In *Fundamentals of Toxicologic Pathology*, 823-853. Academic Press, London.
- Russell, L. (1990) Mammalian spermatogenesis. histological and histopathological evaluation of the testis, 1-40. Cache River Press, Clearwater.
- Russell, L. D. (1984) Spermiation the sperm release process: Ultrastructural observations and unresolved problems. In: *Ultrastructure of reproduction*, 46-66. Springer, Boston.

- Sailer, B. L., Sarkar, L. J., Bjordahl, J. A., Jost, L. K. & Evenson, D. P. (1997) Effects of heat stress on mouse testicular cells and sperm chromatin structure. *J Androl*, 18, 294-301.
- Sanger, W. G. & Friman, P. C. (1990) Fit of underwear and male spermatogenesis: A pilot investigation. *Reprod Toxicol*, 4, 229-232.
- Schatte, E. C., Hirshberg, S. J., Fallick, M. L., Lipshultz, L. I. & Kim, E. D. (1998) Varicocelelectomy improves sperm strict morphology and motility. *J Urol*, 160, 1338-1340.
- Schell, C., Albrecht, M., Mayer, C., Schwarzer, J. U., Frungieri, M. B. & Mayerhofer, A. (2008) Exploring human testicular peritubular cells: Identification of secretory products and regulation by tumor necrosis factor- α . *Endocrinology*, 149, 1678-1686.
- Sealfon, A. I. & Zorngiotti, A. W. (1991) Temperature and environmental effects on the testis, 123-135. Springer, New York.
- Sergerie, M., Mieusset, R., Croute, F. o., Daudin, M. & Bujan, L. (2007) High risk of temporary alteration of semen parameters after recent acute febrile illness. *Fertil Steril*, 88, 970.e1 - 970.e7.
- Setchell, B. (1994) Contraception: Possible physiological bases for contraceptive techniques in the male. *Hum Reprod*, 9, 1081-1087.

- Setchell, B. P. (1998) The parkes lecture heat and the testis. *J Reprod Fertil*, 114, 179-194.
- Shafik, A. (1973) The cremasteric muscle. Role in varicocelogenesis and in thermoregulatory function of the testicle. *Invest Urol*, 11, 92-97.
- Shafik, A. (1973) The dartos muscle. A study of its surgical anatomy and role in varicocelogenesis: A new concept of its thermoregulatory function. *Invest Urol*, 11, 98-100.
- Shafik, A. (1974) Thermoregulatory apparatus of the testicle: A review. *Urologia J*, 41, 473-479.
- Shafik, A. (1991) Testicular suspension as a method of male contraception: Technique and results. *Advances in contraceptive delivery systems: CDS*, 7, 269-279.
- Shafik, A. (1992) Contraceptive efficacy of polyester-induced azoospermia in normal men. *Contraception*, 45, 439-451.
- Shafik, A., Shafik, I. A., El Sibai, O. & Shafik, A. A. (2007) The effect of external urethral sphincter contraction on the cavernosus muscles and its role in the sexual act. *Int Urol Nephrol*, 39, 541-546.
- Sharma, R. & Agarwal, A. (2011) Spermatogenesis: An overview. In: *Sperm chromatin*, 19-44. Springer, New York.

- Sharma, R., Biedenharn, K. R., Fedor, J. M. & Agarwal, A. (2013) Lifestyle factors and reproductive health: Taking control of your fertility. *Reprod Biol Endocrinol*, 11, 66.
- Sharpe, R. M., McKinnell, C., Kivlin, C. & Fisher, J. S. (2003) Proliferation and functional maturation of Sertoli cells, and their relevance to disorders of testis function in adulthood. *Reproduction*, 125, 769-784.
- Shefi, S., Tarapore, P. E., Walsh, T. J., Croughan, M. & Turek, P. J. (2007) Wet heat exposure: A potentially reversible cause of low semen quality in infertile men. *Int Bra J Urol*, 33, 50-57.
- Sheikh, N., Amiri, I., Farimani, M., Najafi, R. & Hadeie, J. (2008) Correlation between sperm parameters and sperm DNA fragmentation in fertile and infertile men. *Iran J Reprod Med*, 6, 13-18.
- Sheynkin, Y., Jung, M., Yoo, P., Schulsinger, D. & Komaroff, E. (2005) Increase in scrotal temperature in laptop computer users. *Hum Reprod*, 20, 452-455.
- Shiraishi, K., Takihara, H. & Matsuyama, H. (2010) Elevated scrotal temperature, but not varicocele grade, reflects testicular oxidative stress-mediated apoptosis. *World J Urol*, 28, 359-364.
- Simon, C. & Rubio, C. (2017) Handbook of new genetic diagnostic technologies in reproductive medicine. 20-67, CRC Press, New York.

- Slama, R., Eustache, F., Ducot, B., Jensen, T. K., Jorgensen, N., Horte, A., Irvine, S., Suominen, J., Andersen, A. & Auger, J. (2002) Time to pregnancy and semen parameters: A cross-sectional study among fertile couples from four european cities. *Hum Reprod*, 17, 503-515.
- Soler, A. J., Pérez-guzman, M. D. & Garde, J. J. (2003) Storage of red deer epididymides for four days at 5 c: Effects on sperm motility, viability, and morphological integrity. *Journal of Experimental Zoology Part A: Comp Exp Biol*, 295, 188-199.
- Song, G. S. & Seo, J. T. (2006) Changes in the scrotal temperature of subjects in a sedentary posture over a heated floor. *Int J Androl*, 29, 446-457.
- Sutovsky, P. & Manandhar, G. (2006) Mammalian spermatogenesis and sperm structure: Anatomical and compartmental analysis. *The Sperm Cell: Production, Maturation, Fertilization, Regeneration*, 1-30. Cambridge University Press, Cambridge.
- Takada, T., Kitamura, M., Matsumiya, K., Miki, T., Kiyohara, H., Namiki, M. & Okuyama, A. (1996) Infrared thermometry for rapid, noninvasive detection of reflux of spermatic vein in varicocele. *J Urol*, 156, 1652-1654.
- Takahara, H., Yamaguchi, M., Ishizu, K., Ueno, T. & Sakatoku, J. (1991) Deep body temperature measurement for the noninvasive diagnosis of

- varicocele. In: Temperature and environmental effects on the testis, 253-260. Springer, Boston.
- Templado, C., Uroz, L. & Estop, A. (2013) New insights on the origin and relevance of aneuploidy in human spermatozoa. *Mol Hum Reprod*, 19, 634-643.
- Templado, C., Vidal, F. & Estop, A. (2011) Aneuploidy in human spermatozoa. *Cytogen Genom Res*, 133, 91-99.
- Toppari, J., Larsen, C., Christiansen, P., Giwercman, A., Grandjean, P., Guillette, Jr., Jegou, B., Jensen, K., Jouannet, P., Keiding, N., Leffers, H., McLachlan, A., Meyer, O., Muller, J., Rajpert-De, E., Scheike, T., Sharpe, R., Sumpter, J. & Skakkebaek, E. (1996) Male reproductive health and environmental xenoestrogens. *Environ Health Perspect*, 104, 741–803.
- Trussell, J. & Kost, K. (1987) Contraceptive failure in the United States: A critical review of the literature. *Stud Fam Plann*, 18, 237-283.
- Vegetti, W., Van Assche, E., Frias, A., Verheyen, G., Bianchi, M. M., Bonduelle, M., Liebaers, I. & Van Steirteghem, A. (2000) Correlation between semen parameters and sperm aneuploidy rates investigated by fluorescence in-situ hybridization in infertile men. *Hum Reprod*, 15, 351-365.

- Visco, V., Raffa, S., Elia, J., Delfino, M., Imbrogno, N., Torrisi, M. R. & Mazzilli, F. (2010) Morphological sperm defects analyzed by light microscopy and transmission electron microscopy and their correlation with sperm motility. *Int J Urol*, 17, 259-266.
- Vivas-cevedo, G., Lozano-Hernandez, R. & Camejo, M. I. (2014) Varicocele decreases epididymal neutral α -glucosidase and is associated with alteration of nuclear DNA and plasma membrane in spermatozoa. *BJU Int*, 113, 642-649.
- Vogler, C., Bame, J., DeJarnette, J., McGilliard, M. & Saacke, R. (1993) Effects of elevated testicular temperature on morphology characteristics of ejaculated spermatozoa in the bovine. *Theriogenology*, 40, 1207-1219.
- Waites, G. & Moule, G. (1961) Relation of vascular heat exchange to temperature regulation in the testis of the ram. *J Reprod Fertil*, 2, 213-224.
- Waites, G. M. (1991) Thermoregulation of the scrotum and testis: Studies in animals and significance for man. In: *Temperature and environmental effects on the testis*, 9-17. Springer, Boston.
- Waldbieser, G. & Chrisman, C. (1986) X Y chromosome univalency in the testes of hyperthermic mice: I. Concomitant formation of multinucleated giant cells. *Gamet Res*, 15, 153-160.

- Wallach, E. E., Kandeel, F. R. & Swerdloff, R. S. (1988) Role of temperature in regulation of spermatogenesis and the use of heating as a method for contraception. *Fertil Steril*, 49, 1-23.
- Wang, C., Cui, Y.-G., Wang, X.-H., Jia, Y., Sinha Hikim, A., Lue, Y.-H., Tong, J.-S., Qian, L.-X., Sha, J.-H. & Zhou, Z.-M. (2007) Transient scrotal hyperthermia and levonorgestrel enhance testosterone-induced spermatogenesis suppression in men through increased germ cell apoptosis. *J Clin Endocrinol Metabol*, 92, 3292-3304.
- Wang, C., McDonald, V., Leung, A., Superlano, L., Berman, N., Hull, L. & Swerdloff, R. S. (1997) Effect of increased scrotal temperature on sperm production in normal men. *Fertil Steril*, 68, 334-339.
- Wang, C. & Swerdloff, R. S. (2002) Male contraception. *Best Pract Res Clin Obstet Gynaecol*, 16, 193-203.
- Watanabe, A. (1959) The effect of heat on the human spermatogenesis. *Kyushu J Med Sci*, 10, 17.
- Weinbauer, G. F., Luetjens, C. M., Simoni, M. & Nieschlag, E. (2010) Physiology of testicular function. In: *Andrology*, 11-59. Springer, Berlin, Heidelberg.
- WHO. (2010) WHO laboratory manual for the examination of human semen and sperm-cervical mucus interaction, Cambridge University Press. Cambridge

- Widlak, W. & Vydra, N. (2017) The role of heat shock factors in mammalian spermatogenesis. In: The role of heat shock proteins in reproductive system development and function, 45-65. Springer, Cham.
- Wildeus, S. & Entwistle, K. (1983) Spermogram and sperm reserves in hybrid bos indicus x bos taurus bulls after scrotal insulation. *J Reprod Fertil*, 69, 711-716.
- Wishahi, M. M. (1992) Anatomy of the spermatic venous plexus (pampiniform plexus) in men with and without varicocele: Intraoperative venographic study. *The J Urol*, 147, 1285-1289.
- Wojciech, R., Lucjusz, R., Wanda, J., Anna, H. & Wojciech, U. (2014) Lifestyle factors and sperm aneuploidy. *Reprod Biol*, 14, 190-199.
- Wong, P., Au, C. & Bedford, J. (1982) Biology of the scrotum. II. Suppression by abdominal temperature of transepithelial ion and water transport in the cauda epididymidis. *Biol Reprod*, 26, 683-689.
- Wright, E. J., Young, G. P. & Goldstein, M. (1997) Reduction in testicular temperature after varicolectomy in infertile men. *Urology*, 50, 257-259.
- <https://www.healthwise.org/> (2018) Health wise Staff.

- Yamaguchi, M., Sakatoku, J. & Takihara, H. (1989) The application of intrascrotal deep body temperature measurement for the noninvasive diagnosis of varicoceles. *Fertil Steril*, 52, 295-301.
- Yeung, C., Cooper, T., Oberpenning, F., Schulze, H. & Nieschlag, E. (1993) Changes in movement characteristics of human spermatozoa along the length of the epididymis. *Biol Reprod*, 49, 274-280.
- Young, D. (1956) The influences of varicocele on human spermatogenesis . *Br J Urol*, 28, 426-427.
- Zhang, M. H., Zhai, L. P., Fang, Z. Y., Li, A. N., Qiu, Y. & Liu, Y. X. (2018) Impact of a mild scrotal heating on sperm chromosomal abnormality, acrosin activity and seminal alpha•glucosidase in human fertile males. *Andrologia*, 50, e12985, 1-12.
- Zhang, M. H., Zhai, L. P., Fang, Z. Y., Li, A. N., Xiao, W. & Qiu, Y. (2018) Effect of scrotal heating on sperm quality, seminal biochemical substances, and reproductive hormones in human fertile men. *J cell Biochem*, 12, 10228-10238 .
- Zhang, S.-x. (1999) An atlas of histology, 187-251. Springer Science & Business Media, Springer, New York.
- Zidi-Jrah, I., Hajlaoui, A., Mougou-Zerelli, S., Kammoun, M., Meniaoui, I., Sallem, A., Brahem, S., Fekih, M., Bibi, M. & Saad, A. (2016) Relationship

between sperm aneuploidy, sperm DNA integrity, chromatin packaging, traditional semen parameters, and recurrent pregnancy loss. *Fertil Steril*, 105, 58-64.

Zorgniotti, A. (1991) Hypothesis to explain subfertile semen. *Advances in experimental medicine and biology*, 286, 221-223.

Zorgniotti, A. (1982) Elevated intrascrotal temperature. In: Indirect testis and intrascrotal temperature measurement for clinical and research use. *Bull N Y Acad Med*, 58, 541-544.

Zorgniotti, A., Sealfon, A. & Toth, A. (1982) Further clinical experience with testis hypothermia for infertility due to poor semen. *Urology*, 19, 636-640.

Zorgniotti, A. W. & Macleod, J. (1973) Studies in temperature, human semen quality, and varicocele. *Fertil Steril*, 24, 854-863.

Zorgniotti, A. W. & Sealfon, A. I. (1984) Scrotal hypothermia: New therapy for poor semen. *Urology*, 23, 439-441.

Zorgniotti, A. W., Toth, A. & Macleod, J. (1979) Infrared thermometry for testicular temperature determinations. *Fertil Steril*, 32, 347-348.