



Evaluation and validation of new techniques of facial nerve preservation during cerebellopontine angle (CPA) tumor surgery

Mohamed Ahmed Magdiel Elsayed

► To cite this version:

Mohamed Ahmed Magdiel Elsayed. Evaluation and validation of new techniques of facial nerve preservation during cerebellopontine angle (CPA) tumor surgery. *Neurons and Cognition [q-bio.NC]*. Sorbonne Université, 2020. English. NNT : 2020SORUS047 . tel-03254595

HAL Id: tel-03254595

<https://theses.hal.science/tel-03254595>

Submitted on 9 Jun 2021

HAL is a multi-disciplinary open access archive for the deposit and dissemination of scientific research documents, whether they are published or not. The documents may come from teaching and research institutions in France or abroad, or from public or private research centers.

L'archive ouverte pluridisciplinaire **HAL**, est destinée au dépôt et à la diffusion de documents scientifiques de niveau recherche, publiés ou non, émanant des établissements d'enseignement et de recherche français ou étrangers, des laboratoires publics ou privés.



Sorbonne Université

Ecole doctorale 394:

<<Physiologie, Physiopathologie et thérapeutique >>

Thèse de doctorat

**Evaluation and validation of new techniques of facial
nerve preservation during CPA tumor surgery**

Par

Mohamed Ahmed Magdiel Elsayed

Directeurs : *Prof. Olivier Sterkers et Prof. Yann Nguyen*

<<Réhabilitation chirurgicale mini-invasive et robotisée de l'audition>>

Inserm/Sorbonne Université

Présentée et soutenue publiquement le **27 Mars 2020**

Devant un jury composé de:

- Professeur Philippe Cornu
- Professeur Mathieu Marx
- Professeur Hani Elgarem
- Professeur Mohamed Badr-Eldine
- Professeur Daniele De Seta

**Le Président
Rapporteurs
Rapporteurs
Examineur
Examineur**



Sorbonne Université

Ecole doctorale 394:

<<Physiologie, Physiopathologie et thérapeutique >>

PhD thesis entitled

**Evaluation and validation of new techniques of facial
nerve preservation during CPA tumor surgery**

Presented by

Mohamed Ahmed Magdiel Elsayed

Supervised by: *Prof. Olivier Sterkers and Prof. Yann Nguyen*

<<Réhabilitation chirurgicale mini-invasive et robotisée de l'audition>>

Inserm/Sorbonne Université

Presented and defended at Paris on the **27 March 2020**

Dissertation committee:

- | | |
|---------------------------------|------------------|
| • Professor Philippe Cornu | President |
| • Professor Mathieu Marx | Reviewer |
| • Professor Hani Elgarem | Reviewer |
| • Professor Mohamed Badr-Eldine | Examiner |
| • Professor Daniele De Seta | Examiner |

To Yasmin, my amazing wife.

To Saleem, my son & my best friend.

To Zain, Maya, Yassin, Adam and Youssef, my little children.

To all my beloved family.

Acknowledgement

Completing this PhD has been a truly life-changing experience for me and it would not have been possible to do without the support and guidance that I received from many people.

First and foremost, my utmost gratitude my supervisor ***Professor Olivier Sterkers*** for all the support and encouragement he gave me since the first day I arrived at Paris. His dynamism, vision, sincerity and motivation have deeply inspired me. Without his guidance and constant feedback this PhD would not have been achievable.

Many thanks and gratitude is due to ***Dr Yann Nguyen*** for his patience, supervisory role, and steadfast encouragement and shared valuable insights in the relevance of the research work. I do believe that this research work could not be carried out with him being available for any question or problem. I would also like to thank him for his friendship, empathy and great sense of humor.

I would like to express my special gratitude and appreciation to ***Professor Michel Kalamarides*** and all the surgical team at ***Groupe Hospitalier Pitié-Salpêtrière, Paris, France*** for sharing their expertise and support in order to complete the clinical work.

I would like to pay my special regards to ***Dr Evelyne Ferrary*** and my colleagues ***Dr Renato Torres, Dr Ghizlene Lahlou and Dr Huan Jia***. I would like to recognize the invaluable assistance that you all provided during my study.

Special thanks to ***Anirudhan Narasimhan***, Global Product Manager, H&N therapies, ***Medtronic ENT, Jacksonville, FL, USA*** for their materials and technical support during the research work. *Without their support and funding, this project could not have reached its goal.*

I gratefully acknowledge as well the funding received towards my PhD from ***the Ministry of Higher Education, Mission sector, Egypt (<http://www.mohe-casm.edu.eg>) and the Ministry of Scientific Research, Egypt***. We gratefully acknowledge as well the ***“Association de Recherche du service d’ORL de l’hôpital Beaujon”*** for its support for travel and housing.

Many thanks and appreciation to the distinguished members of the Jury headed by ***Professor Philippe CORNU*** and all members of the Jury ; ***Professor Mathieu Marx ,Professor Hani Elgarem , Professor Mohamed Badr-Eldin and Professor Daniele De Seta*** for their approval and recognition of my work.

Finally, I am extremely grateful and indebted to my Family for their love, prayers, understanding and continuous support to complete this research work.

Table of Content

Acknowledgement	II
Table of Content.....	IV
List of Figures.....	VII
List of Abbreviations	VIII
Chapter 1 INTRODUCTION	1
▪ Development and Anatomy of the Facial Nerve.....	3
▪ Challenges of facial nerve preservation during CPA tumor surgery	5
▪ Intraoperative neuromonitoring (IONM) for facial nerve	7
▪ Historical review of FN-IONM.....	8
▪ State of art of Electromyography (EMG) monitoring devices	8
▪ Current Facial nerve IONM practice at our institute.....	13
▪ References.....	21
Chapter 2 OBJECTIVES.....	23
Chapter 3 RESULTS.....	24
3.1 Pig as a Large Animal Model for Posterior Fossa Surgery in Oto-Neurosurgery: A Cadaveric Study	25
3.1.1 Abstract.....	26
3.1.2 Introduction.....	26
3.1.3 Methods.....	27
3.1.4 Results.....	27
3.1.5 Discussion	29

3.1.6 Conclusion	33
3.1.7 References.....	33
3.2 In vivo porcine model for posterior fossa surgery in oto-neurosurgery: a preliminary experience.....	35
3.2.1 In vivo porcine model for posterior fossa surgery in oto-neurosurgery: a preliminary experience.....	36
3.2.2 Abstract.....	37
3.2.3 Introduction.....	38
3.2.4 Methods.....	40
3.2.5 Results.....	46
3.2.6 Discussion.....	50
3.2.7 Conclusions.....	54
3.2.8 Acknowledgments.....	55
3.2.9 References.....	55
3.3 Optimization of facial nerve outcome by intraoperative electromyography guided microsurgical resection of large vestibular schwannomas.....	57
3.3.1 Optimization of facial nerve outcome by intraoperative electromyography guided microsurgical resection of large vestibular schwannomas.....	58
3.3.2 Abstract.....	59
3.3.3 Introduction.....	60
3.3.4 Materials and Methods.....	61
3.3.5 Statistical analysis.....	64
3.3.6 Results.....	64

3.3.7 Discussion	72
3.3.8 Conclusions	75
3.3.9 Acknowledgment	75
3.3.10 References	76
Chapter 4 DISCUSSION	78
I. Animal models and surgical training	79
II. Animal models and IONM research.....	81
III. Intraoperative neuromonitoring of FN	84
▪ Change of paradigm for surgical decision and strategy	84
▪ Dual Facial nerve monitoring technique	86
▪ Continuous intraoperative Facial nerve monitoring technique	87
IV. Recent advances in FN preservation during CPA surgery	90
▪ Preoperative visualization of the facial nerve	90
▪ Intraoperative use of endoscopy.....	90
▪ Peri-operative Neuro-protective agents.....	92
V. References	94
Chapter 5 CONCLUSION AND FUTURE PERSPECTIVES.....	97
Chapter 6 ANNEXES	98
Annex 1	98
Annex 2.....	104

List of Figures

Figure 1-1 Illustrative Course and relationships of the right facial nerve from the pontomedullary junction to the stylomastoid foramen.	4
Figure 1-2 An example of ventral and inferior displacement of the facial nerve.	6
Figure 1-3 Illustrative examples of three types of EMG activity often seen during vestibular schwannoma (VS) surgery.	11
Figure 1-4 The StimBurGard (black arrow) system with Visao drill.	20
Figure 3-1 Operating room set-up.	40
Figure 3-2 Pig positioning and setting up of NIM 3.0 subdermal needle electrodes.	41
Figure 3-3 Incision, soft tissue dissection and skull base anatomy.	43
Figure 3-4 Lateral view of craniotomy of a pig's ear on the left side.	44
Figure 3-5 The acoustic-facial bundle (cranial nerves VII/VIII) in the IAC.	45
Figure 3-6 Different views of the facial nerve (FN) in the IAC and CPA.	45
Figure 3-7 APS electrode.	48
Figure 3-8 Example of APS electrode placement on the facial nerve in the CPA.	49
Figure 3-9 Example of APS electrode placement on the facial nerve in the CPA.	50
Figure 3-10 Postoperative FN function according to HB staging,	71
Figure 3-11 Optimization of facial nerve outcome by reducing the nervous conduction blockage severity.	73
Figure 4-1 Comparison between new pledget electrode on the left and APS electrode on the right.	83
Figure 4-2 The ball-type, continuous facial nerve stimulating electrode (SE) that is placed intraoperatively on the REZ of FN (arrow).[19]	88
Figure 4-3 Intraoperative CPA view of vestibular schwannoma (*) and Facial nerve (white Arrow) on the left side and Positioning of the APS electrode on Facial nerve on the right side.	89

List of Abbreviations

APS	Automatic periodic stimulation
BBB	Blood-brain barrier
CMAP	compound muscle action potential
C-IONM	Continuous intraoperative neurophysiological monitoring
CN	Cranial nerve
CPA	Cerebellopontine angle
CSF	Cerebrospinal fluid
DES	Direct electrical stimulation
DTT	Diffusion tensor tractography
FNMEPs	Facial nerve motor evoked potentials
FN	Facial nerve
GTR	Gross total resection
H-B	House-Brackmann
IAC	Internal acoustic canal
IGF-I	Insulin-like growth factor 1
IONM	Intraoperative neurophysiological monitoring
I-IONM	Intermittent Intraoperative neurophysiological monitoring
MRI	Magnetic resonance imaging
NTR	Near-total resection
REZ	Root Exit zone
STR	Subtotal resection
VS	Vestibular schwannoma

Chapter 1 INTRODUCTION

Otologic surgery emerged during the 19th century, with a major breakthrough occurring in the middle of the 20th century. In 1952 Wullstein first used a surgical microscope in an otological operation, laying a foundation for otomicrosurgery. Subsequently, surgical microscopes were used extensively; allowing the continuing evolution of microsurgical techniques in the middle ear. When microsurgical techniques reached the inner ear and cerebellopontine angle (CPA) area, allowing access to the skull base and lateral skull base, the era of micro-otoneurosurgery dawned.[1] Otoneurosurgeons are challenged with eradicating pathology while preserving preoperative functional status. Minimally invasive techniques have arisen to meet the need to preserve function and promote quick recovery.

Thus, the aims of surgery in the cerebellopontine angle (CPA) have changed from tumor resection and prolongation of life to the anatomical and functional preservation of the cranial nerves (CNs). Dealing with CPA tumors has developed from almost a death sentence at the beginning of the 20th century to the current concept of functional microsurgery. In this interim, several developments regarding radiological diagnosis, the introduction of the operative microscope and microsurgical techniques, advances in the field of neuroanesthesia, as well as intraoperative neuromonitoring were responsible for significant reductions in the morbidity and mortality in patients suffering from CPA tumors.[2]

Pathologies common to the CPA include acoustic neuroma, facial neural tumors, meningioma and dysfunctional cranial nerves. Among these, acoustic neuroma accounts for a great portion. In the past 10 years, with rapid development of otoneurosurgery and imaging technologies, early diagnosis of CPA pathologies has improved, broadening scope of surgical practices for otologists. Acoustic neuroma or vestibular schwannoma (VS) is a benign, slow-growing tumor of the Schwann cells originating from the vestibular branch of the eighth cranial nerve, with an incidence of 12.4 tumors per million persons per year. They are extra-axial brain tumors developing near the internal auditory canal (IAC). When manifested in the internal auditory canal (IAC), they may grow in the direction of least mechanical resistance: the cerebellopontine angle (CPA). The vast majority of VS are sporadic and unilateral. [2]

Therapeutic options include an active wait-and-scan policy, stereotactic radio-surgery, and microsurgery. Although there is no general consensus for the treatment of small and medium-sized lesions, surgery still remains the preferred option for large tumors. Advances in treatment modalities have popularized the application of less invasive management methods such as radiotherapy and radiosurgery, which carry high efficacy and low morbidity. However, many acoustic neuromas, particularly those that are large in size, necessitate surgical intervention.

Surgical approaches to CPA lesions, especially acoustic neuroma, require gaining access to the CPA and maximal exposure of the internal acoustic meatus, all while attempting to maintain facial and auditory nerve function. Microscopy coupled with functional facial nerve monitoring greatly reduces both the mortality and the incidence of facial nerve paralysis in acoustic neuroma surgeries. Preserving auditory function remains a challenge because removal of the tumor often damages the cochlear nerve, and ischemia-induced deafness can happen due to damage to or spasm of the fragile internal auditory artery. Other CPA surgeries share this difficult bargain between tumor excision and preservation of function.[3]

Generally, the primary operative goals are gross tumor debulking while safeguarding the adjacent cranial nerves. Neural preservation is particularly imperative in the contemporary management of VS. By virtue of their location, these tumors are close to the facial and vestibulocochlear cranial nerves and can thus severely impair the nerve function at the time of initial presentation. The VS can directly impinge, tightly adhere to, or overtly damage the nerves. These goals require good preservation of both facial nerve (FN) and cochlear nerve (CN) function if the patient had functional hearing preoperatively. However, preserving these neurological functions is often challenging, especially when a large tumor must be removed [3].

CPA tumors often present as operative challenges, as resection may cause nerve irritation or injury leading to neurapraxia, axonotmesis, or neurotmesis. The various options of surgical approaches (translabyrinthine vs. middle fossa vs. retrosigmoid) for VS and their respective patterns of postoperative cranial nerve preservation have been described. Although significant advances have been observed in the recent era, facial nerve (FN) anatomical preservation during VS surgery is currently around the range of 95% and FN functional

preservation is in the low range of 70%. FN injury is not exclusively related to VS surgery and may also occur postoperatively in several tumors of the CPA.[2]

▪ **Development and Anatomy of the Facial Nerve**

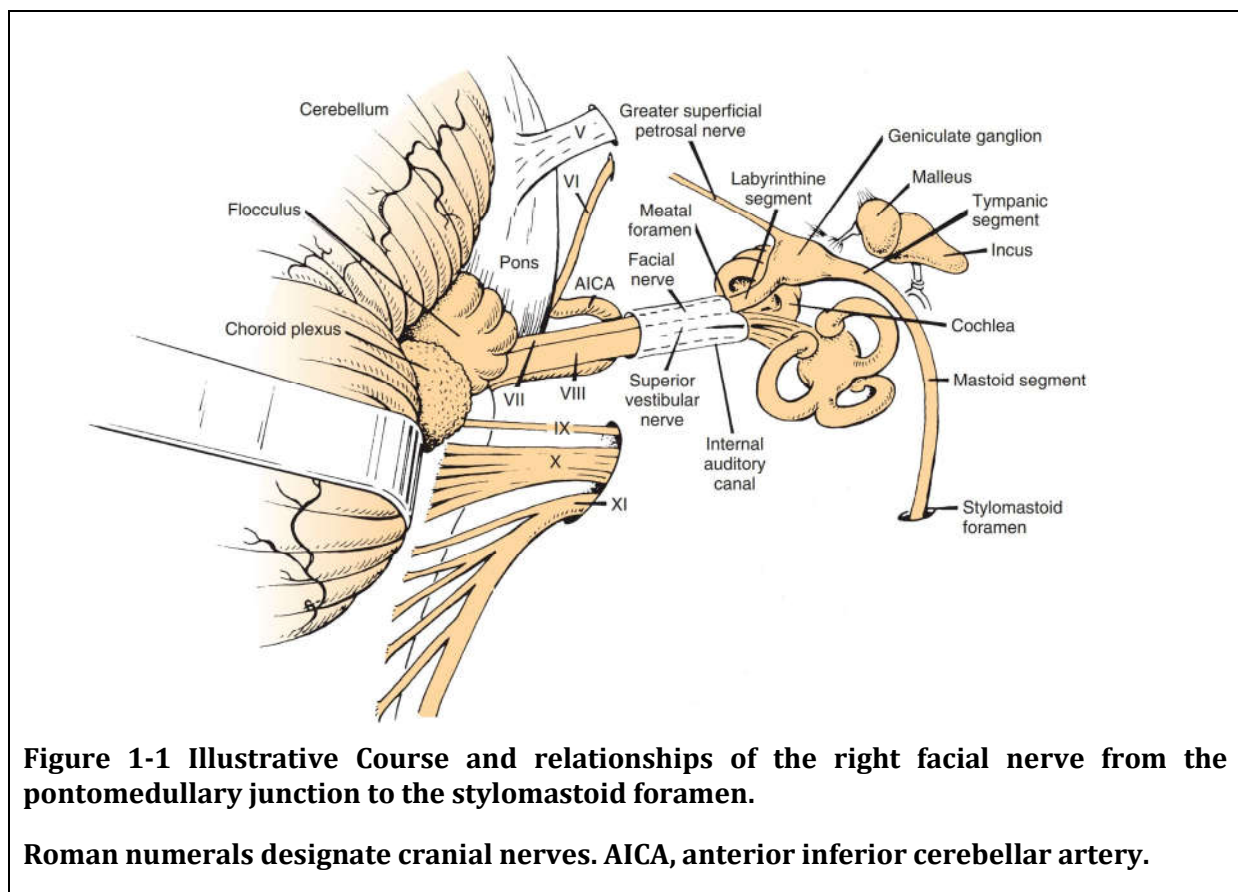
The facial nerve is composed of motor, sensory, and parasympathetic fibers. Complete separation of the facial and acoustic nerves and development of the nervus intermedius (or nerve of Wrisberg) occurs by 6 weeks of gestation. By the 16th week, the neural connections are completely developed. The bony facial canal develops until birth, enclosing the facial nerve in bone throughout its course except at the facial hiatus (the site of the geniculate ganglion) in the floor of the middle cranial fossa. The only difference between the anatomies of the facial nerve in infants compared with adults is in the region of the stylomastoid foramen. As the mastoid tip develops, the extratemporal facial nerve is positioned in a more inferior and medial position.

Facial motor fibers originate from cell bodies located in the precentral and postcentral gyri of the frontal motor cortex. These fibers travel in the posterior limb of the internal capsule inferiorly to the caudal Pons. There, the motor fibers supplying the facial musculature beneath the brows cross the midline to reach the contralateral motor nucleus in the reticular formation of the lower pons (anterior to the fourth ventricle). The majority of motor fibers that supply the musculature of the forehead also cross the midline; however, a few fibers do not, instead travel in the ipsilateral motor nucleus. Thus, muscles of the forehead receive innervations from both sides of the motor cortex, and so forehead-sparing facial paralyses can be indicative of a central etiology. The motor fibers pass dorsally, loop medial-to-lateral around the abducens nucleus, and create the facial colliculus, which bulges into the floor of the fourth ventricle. This loop of the facial nerve forms the internal genu of the facial nerve.

The nervus intermedius contains sensory, special sensory and parasympathetic fibers. It provides sensation to the posterior concha and external auditory canal. The nervus intermedius' special sensory fibers supply taste sensation to the anterior two-thirds of the tongue. The afferent fibers synapse with cell bodies in the geniculate ganglion at the first genu of the facial nerve. These sensory afferents then join the parasympathetic fibers, passing via the nervus intermedius to the nucleus tractus solitarius in the medulla. The parasympathetic portion of the nervus intermedius originates in the superior salivatory

nucleus in the dorsal pons and provides the secretomotor function of the ipsilateral lacrimal gland, submandibular glands, sublingual glands, and minor salivary glands.

Both the motor root of the facial nerve and the nervus intermedius leave the brainstem near the dorsal Pons at the pontomedullary junction (the cisternal segment of the facial nerve). Within the cerebellopontine angle (CPA), the nerve travels anterolaterally into the porus acousticus of the internal auditory canal (IAC), anterior to the vestibulocochlear nerve. This segment is 24 mm. The nervus intermedius either joins the motor root as it emerges from the brainstem or near the meatus of the IAC. The facial nerve runs in the anterior-superior quadrant of the IAC. At the lateral end of the IAC, a horizontal segment of bone (the transverse of falciform crest) separates the facial nerve from the cochlear nerve inferiorly. Within this area of the IAC, a vertical segment of bone (Bill's bar) separates the facial nerve from the posteriorly located superior vestibular nerve. (Figure 1-1)



The anterior inferior cerebellar artery (AICA) arises from the basilar artery near the junction of the pons and medulla. The AICA can have a variable course and territory. The AICA runs within the IAC and is frequently in proximity with the nerve within the IAC. In some cases, the AICA may run in the IAC between the facial and vestibulocochlear nerve.

The blood supply to this region of the facial nerve is the labyrinthine artery, a branch of AICA.[4]

▪ **Challenges of facial nerve preservation during CPA tumor surgery**

Facial palsy is one of the most serious morbidities because loss of facial expression is a functionally and psychologically debilitating condition. It is a debilitating condition that may lead to difficulties in several areas of daily life, including speaking, eating, and blinking (which may lead to dry eyes and corneal damage). Facial palsy is also a movement disorder and an emotional and communication disorder. Many patients with facial palsy experience social isolation and develop depression because of their difficulty in emotionally connecting or communicating with others. Reducing the high risk of facial palsy after surgery has become a major issue in treatment of VS.[5]

The factors causing FN impairment could be divided into three general aspects, according to our experience:

- (1) Mechanical injury: when the FN was compressed, stretched, or even cut;
- (2) Heat injury: when electro coagulation was used frequently near the FN;
- (3) Ischemic injury: when supply arteries or drainage veins of the FN were damaged

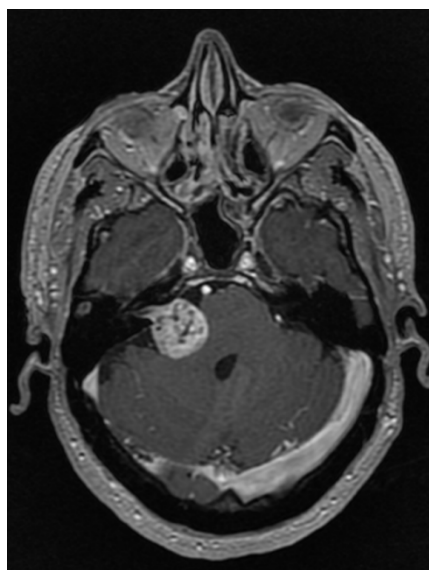
The key to improved protection of the facial nerve during surgery includes a complete understanding of the anatomy of the cerebellopontine angle, proper use of microsurgical techniques, and intraoperative electrophysiological monitoring of the status of facial nerve functions to avoid damage to the nerves. [6]

Anatomical and functional preservation of FN in VS surgery is still challenging even for experienced neurosurgeons (**Figure 1-2**):

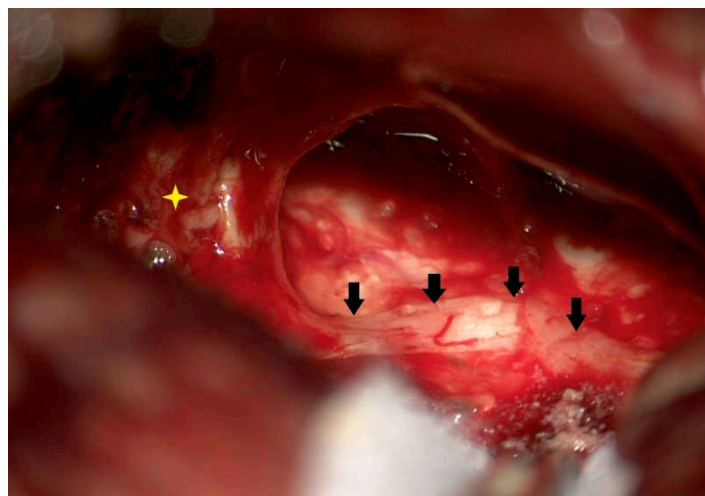
First, the FN near VS tends to be compressed and flattened, and the FN can even become membranous, adopting a color similar to that of the surrounding tissue. It is then easily injured during separation because it has become extraordinarily thin or is adherent to the VS.

Second, variations in the locations of the FN and CN are frequently encountered. The FN and CN typically travel separately because of tumor enlargement. Although the FN is typically positioned on the anterior side of the tumor, anterosuperior, anteroinferior, superior or other positions are also possible reported to have penetrated the tumor in a small number of cases.[7]

Due to this variability in the fiber positions, the anatomical preservation of the FN has become an important consideration in VS therapy. The surgeon's experience appears to be an important factor governing the ability to preserve FN and CN function despite this anatomical variability. Identification and visualization of facial nerve is a key step for its preservation. In large tumors, FNs are always displaced and morphologically changed in an unpredictable manner. Some are even indistinguishable from the tumor capsule under microscope. There have no models for predicting FN course in VS cases so far, although stimulated FN EMG monitoring is desirable.[8]



A



B

Figure 1-2 An example of ventral and inferior displacement of the facial nerve.

A: Preoperative magnetic resonance image. B: A microphotograph taken after removal of the tumor (yellow*) shows that the facial nerve (black arrows) is flattened and displaced ventrally and inferiorly.

▪ **Intraoperative neuromonitoring (IONM) for facial nerve**

Since the introduction of intraoperative neuromonitoring (IONM) for facial nerve in 1979, electromyography (EMG) is widely used in microsurgery to aid the identification as well as dissection of the FN. EMG is especially useful for removal of large VS, in which the facial nerve is displaced and tends to be very thin due to the mass effect of the tumor and its close relationship with the vestibular nerve.[9]

The main purpose of intraoperative monitoring is to make the surgical team aware of the ongoing changes in the neural function, thereby permitting modifications in surgical strategies that can ultimately avoid neural damage.

Effective neurophysiologic monitoring requires knowledge of pertinent anatomy and physiology; selection of the appropriate monitoring techniques based on the structures at risk for each surgical procedure; and appropriate interpretation of the evoked responses based on knowledge of the normal activity.

Thus, the objectives of IOFNM include:

1. Identifying precociously the FN in soft tissue, tumor, and bone;
2. Warning the surgeon of an unexpected facial stimulation;
3. Mapping the course of the FN in the temporal bone or tumor by using electrical stimulation;
4. Enhancing neural preservation by reducing mechanical trauma to the FN during rerouting or tumor dissection;
5. Assessing the prognosis of the FN function at the end of tumor removal.

The percentage of severe postoperative facial dysfunction has fallen from some 15%---59% in the era before monitoring to approximately 10%---33% with the use of facial nerve monitoring. Facial nerve monitoring has been established as an essential part of cranial base surgery.

▪ **Historical review of FN-IONM**

Monitoring of cranial nerve function during posterior fossa surgery was first applied almost a century ago. Dr Fedor Krause, on July 14th, 1898, performed a cochlear nerve section for tinnitus and reported that "unipolar faradic irritation of the nerve trunk with the weakest possible current of the induction apparatus resulted in contractions of the ipsilateral facial muscles, especially of the orbicularis oculi, as well as of the branches supplying the nose and mouth.

Describing a similar technique used in 1912, Frazier pointed out the importance of preserving the facial nerve (FN) and possibility of identifying it by "galvanic current". These early techniques of observing the face for visible contractions induced by electrical stimulation remained the state of the art for intraoperative identification of the FN until facial electromyography (EMG) was introduced in 1979.

In 1979, Delgado et al. introduced the use of intraoperative electromyography (EMG) surface electrodes for FN monitoring during CPA surgeries to improve identification and to facilitate the dissection of the FN. a new device that consisted of a pair of accelerometers attached to the Orbicularis oculi and oris that converted facial movements into audible sounds through a loudspeaker to provide acoustic feedback to the surgeons. Thereby the surgeons were able to recognize facial responses without the necessity of having a member of the surgical staff observing the patients face.

▪ **State of art of Electromyography (EMG) monitoring devices**

Electromyography (EMG) enables the recording of electrical activity produced by skeletal muscles. EMG device consists of a stimulator probe and a "sensor" that detects contractions of the facial muscles. Formerly, most operations used a minimum of 2 channels to observe the activity of the Orbicularis oris and Orbicularis oculi muscles, although the use of additional channels to observe other facial muscles may provide further benefit. When considering a 2-channel system, a pair of needle electrodes are usually planted in the Orbicularis oris and Orbicularis oculi muscles while another is placed on the forehead or shoulder for grounding. Another essential requirements for facial EMG monitoring are a stimulator that can be precisely controlled at low levels, one or more low noise amplifiers

capable of amplifying microvolt level signals ,an oscilloscope ,and an audio monitor with a squelch circuit to mute the output during electrocautery.

Intraoperative electromyography (EMG) detection (neurotonic discharge in response to metabolic or mechanical stimulus) or a stimulation method (discharge induced by an electrical stimulation) may be used to assess facial nerve function. Measuring the stimulation threshold by the latter technique evaluates the excitability of the nerve fibers but yields partial information on the functional integrity of the fibers because at the threshold level, only a limited number of large nerve fibers adjacent to the probe will be stimulated. On the other hand, supramaximal stimulation induces depolarization of all the functional fibers and is largely used to evaluate nerve lesions in neurophysiology

A) Free-running EMG detects mechanical and/or metabolic irritation of the nerve. It can be recorded in the innervated muscles without electrical stimulation of the nerve. Two types of discharge, each with different clinical significance, can be observed using free-running EMG monitoring: **tonic discharge and phasic discharge**.

Train (tonic) activity:

consists of repetitive and steady episodes of activity from grouped motor units that can last from several seconds to minutes; it can be observed in nerve ischemia due to traction, heat spread from electrocautery, or irrigation with saline. Tonic or “train” activity consists of episodes of *prolonged, asynchronous* grouped motor unit discharges that lasted up to several minutes. Romstock and coworkers[10] classified train activity into three distinct patterns:

a) **A-train (dense train)**: symmetrical sequence of high-frequency and low-amplitude signals that have a sudden onset.

b) **B-train (interrupted train, popcorn train)**: less dense, lower frequency, regular, sustained discharge, usually in the form of interrupted spikes or bursts.

c) **C-train**: characterized by continuous irregular EMG responses that have many overlapping components.

Although B- and C-trains did not correlate with postoperative function, the authors suggested a relation between the occurrence of A trains and poor postoperative FN function.

In contrast, **Phasic (burst) discharge:**

Are short and relatively synchronous burst of motor unit potentials, which is mostly associated with blunt mechanical trauma. When burst activity occurs, it usually indicates that the FN is being stimulated enough to result in depolarization and production of EMG response but not necessarily to the point of injury. It generally is accepted that the occurrence of burst activity of small amplitude (less than 500 μ V in amplitude) is not of major concern, and accordingly, the surgeon need not be warned each time such activity occurs. On the other hand, the occurrence of large-amplitude burst activity (greater than 500 μ V in amplitude) during the critical stages of dissection or final stages of drilling usually indicates a degree of FN injury, the extent of which differs with the force and number of impacts. **(Figure 1-3).**[11]

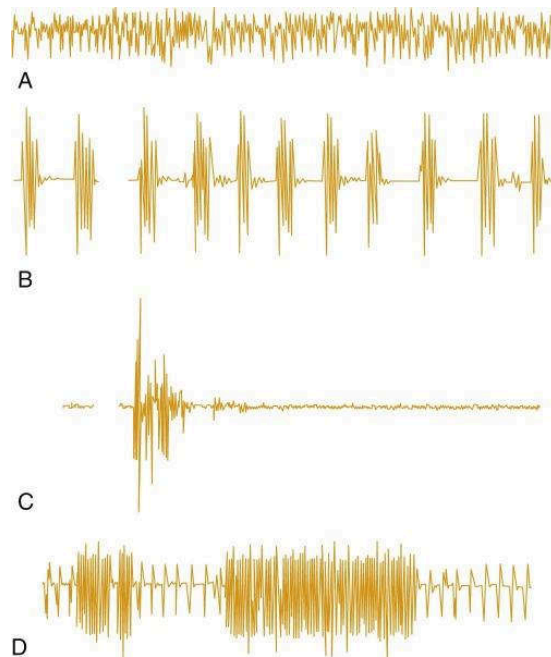


Figure 1-3 Illustrative examples of three types of EMG activity often seen during vestibular schwannoma (VS) surgery.

A, Dense *tonic (sustained) activity*, often associated with nerve stretch and demonstrating a sinusoidal pattern. **B**, Lower *tonic activity*, called popcorn activity. **C**, *Phasic (transient) burst activity* typically associated with direct contact with the nerve. Such events are not of major significance unless they involve large-amplitude trains and occur during critical stages of dissection. **D**, *Burst activity* superimposed on ongoing small-amplitude train; it is important not to overlook such events overlapping on background activity, because they may pass unnoticed despite their significance.

B) Stimulated EMG is performed by electrically stimulating the nerves and recording the resulting compound muscle action potentials in the innervated muscle. Stimulated EMG is advantageous for the following reasons:

1. Operating surgeons can be informed of the anatomical variation of the motor nerves in individual patients;
2. Functions of the nerves can be identified, i.e., motor or sensory;
3. And the proximity of the surgical procedures or device, such as a pedicle screw of the spine, to the endangered nerves can be observed.[12]

The use of direct electrical stimulation (**DES**) is very simple in its concept. A stimulating probe is used to apply DES over the posterior fossa structures and to generate the compound muscle action potentials (CMAP) that are recorded through paired electrodes placed on the patients face in the ipsilateral facial muscles, whereas a ground electrode is positioned at the forehead. The response of the facial muscles is monitored acoustically through a loudspeaker, and the magnitude of the muscle contractions is visually observed on the monitor. It is important to recognize that the stimulus intensity required to evoke CMAPs is higher in injured nerves or nerve roots. DES may be used as an adjunct during surgical exploration within the anatomical regions traversed by FN, providing real-time information about the nerve status. The safety of nerve stimulation has been well established, in both animal models and clinical practice.

The stimulator probe is applied to determine the location of the facial nerve. During an operation, the ideal location for applying the probe on the facial nerve is near the brainstem because it is proximal to the area of resection. Distal stimulation, while possible, yields limited data, as stimulation is being directed on the portion of the nerve that is virtually unaffected by resection. However, distal stimulation is not to be ignored, as several studies have found that higher proximal-to-distal EMG amplitude ratios successfully predict postoperative facial nerve function. When delivering the stimulus, the amount of current that is administered by the probe can be adjusted. Once the amount of current applied exceeds the action potential threshold of the patient's facial nerve, an action potential is fired that causes twitching of the facial muscles. The sensor detects these facial movements and emits a sound alarm, thereby providing direct, immediate, and real-time feed-back. The facial muscle MUPs corresponding to this stimulation are also projected onto an oscilloscope to facilitate visualization.

Both monopolar and bipolar stimulating probes have been employed. Theoretically a bipolar electrode should show more specificity and precision of localization because there would be less likelihood of spread of current to adjacent structures than with a distant reference monopolar configuration. In practice, however, this appears not to be the case. The effectiveness of bipolar stimulation is highly dependent on the orientation of the two tips of the probe with respect to the axis of the nerve. The increased bulk of a bipolar electrode makes maintenance of the desired orientation difficult in the close confines of the posterior

fossa. A monopolar electrode does not have this disadvantage and if the stimulus intensity is kept at the appropriate level can provide spatial resolution of less than 1 mm.[2]

Nerve monitoring is used in surgical procedures where nerves are at risk. A system including a nerve integrity monitor and a hand held stimulator probe having an electrode provides intermittent stimulation only when the surgeon probes the nerve. Nerves can be at risk, however, in between stimulations due to surgical incision “blind” trauma caused by manipulation and stretching during tumor removal, and cumulative trauma or damage that may result in neurapraxia. Automatic periodic stimulation (APS) provides continuous intraoperative nerve monitoring (CIONM). The electrode provides continuous, periodic stimulation of nerve used for trending amplitude and latency in real time which includes adjustable alarm limits for significant baseline changes. This early warning helps alert the surgeon to stop surgical trauma as most injury is immediacy reversible but can become permanent if prolonged. Recording the EMG responses is typically conducted by recording EMG from innervated muscle with an EMG tube (end tracheal tube with integrated recording electrodes) or invasive needle electrodes placed in the muscles of the larynx percutaneously or intraorally. The present inventors have discovered current methods have shortcomings. The APS electrodes need to place circumferentially around the stimulated nerve which is invasive and presents risk for neurological damage without careful dissection surgical skill. EMG tubes are specialty electrodes are complex and expensive. Both conventional devices are dependent on operator placement to be effective and time consuming to reposition.

▪ **Current Facial nerve IONM practice at our institute**

At our tertiary academic referral center, Otolaryngology-Head and Neck Surgery Department, Pitié Salpêtrière Hospital, AP-HP, Paris, Intraoperative neuromonitoring has been established as one of the methods by which our oto-neurosurgery team can improve surgical results while reducing morbidity of patients who underwent surgery for CPA tumors over the past 2 decades. our oto-neurosurgical team has been performing more than 100 surgical procedures for sporadic VS per year .

▪ **Device**

Intraoperative four-channel facial electromyography (EMG) monitoring (NIM Response3.0, Medtronic Xomed, and Jacksonville, FL, U.S.A.) was used in all cases.

Four bipolar-paired sub-dermal needle electrodes were placed in the Frontalis, O. oculi, O. oris, and mentalis Muscles. The difference between electrode impedances remained less than 1 K Ω during the recordings for all channels. A monopolar probe with a 0.5-mm tip electrically stimulated the facial nerve. Square current waves of 100-msduration at 4-Hz frequency were applied as stimulation. The availability of more channels allows simultaneous monitoring of multiple divisions of the facial nerve independently as well as other cranial motor nerves such as V and XI, which are often involved in acoustic tumor surgery. [13]

The Stim Bur Guard system (Medtronic, Xomed) is used for the translabyrinthine approach. In the case of a middle cranial fossa approach, the Digi-pointeur computer-assisted navigation system (Collin, Bagneux, France) is used to help identify the position of the internal auditory canal with a titanium screw as an invasive landmark and a bone anchored receptor. Surgery is performed with VISAO otologic drill (Medtronic, Xomed) with the continuous stimulating burr (SBG) system (Medtronic Xomed)) connected to the FN monitor (4-channel NIM-Response 3; Medtronic Xomed). The SBG system delivers a continuous stimulating monopolar current on the tip and handle of the drill and the intensity of such current can be varied as for the nerve stimulator monopolar probe. All measures are performed with a diamond burr with a diameter varying from 6 to 4 mm, depending on the size of the mastoid, under a continuous saline serum irrigation provided through both suction and drill to avoid heating the FN. The measured values obtained with the burr are compared with those obtained with a monopolar probe. In case of a retrosigmoid approach, an INDIGO otologic drill is preferred as the thinner hand piece allows a better exposure of the surgical field in case of IAC drilling.[14]

▪ **Anesthetic considerations**

Fortunately, the EMG are not affected by routine concentrations of common anesthetics, such as nitrous oxide, opiates, or halogenated agents, so no other constraints on anesthetic technique are necessary. Short-acting agents such as succinylcholine may be given to facilitate intubation, but it must be verified that such agents have cleared before any

manipulations that might affect the facial nerve are undertaken. For a suboccipital approach, this would be the time of opening the dura and retraction of the cerebellum; in a translabyrinthine approach, the facial nerve is first at risk during skeletonization of the horizontal portion in the temporal bone. Fortunately these events typically occur far enough into the procedure that any relaxants given at intubation will have cleared in time.[13]

For all patients, general anesthesia is induced with a mixture of sufentanil (0.15–1.3 µg/kg), propofol (2–3 mg/kg), and atracurium (0.5 mg/kg) before endotracheal intubation. In order to avoid confounding electrophysiological issues, anesthesia was maintained during the procedure with sevoflurane (1.5%–2.5%) and intravenous infusion of sufentanil (0.1–0.2 µg/kg/h), without any myorelaxant. FN dissection is performed after checking that myorelaxation was abolished with more than 90% train-of-four response. Body temperature is monitored and maintained between 36°C and 37°C with a warming blanket. Mean blood pressure is maintained between 65 and 75 mm Hg and end-tidal CO₂ between 30 and 35 mm Hg to preserve brain perfusion.

All patients receive an intravenous bolus of methylprednisolone (1 mg/kg) during surgery. In the case of impaired facial nerve function at postoperative day 1, corticosteroid therapy (methylprednisolone, 1 mg/kg/ d) was administered for 1 week. No antiviral therapy was administered as prophylaxis or in the case of facial palsy.

▪ *Surgical procedure*

All patients were operated on in the supine position under general anesthesia through a translabyrinthine, retrosigmoid or middle cranial fossa approach.

Patients' positioning on the operating table and opening up to the dura mater were performed by the otologists through a retro-auricular incision that allowed a 3-cm craniotomy limited by the sigmoid and transverse sinus in retrosigmoid approach. When necessary, mastoid air cells were obliterated with bone wax. Then, the neurosurgeon access the CPA through an anterior and superior-based dural flap. After opening the dura mater, the VS is initially de-bulked intra-tumorally with tumor capsule preservation using the ultrasonic aspirator, the proximal segment of the FN at the brainstem always being rapidly identified.

The FN is then stimulated supramaximally using a 2-mA stimulating current, and the peak response obtained from the channel having the greatest amplitude response was

recorded as a baseline. Then, dissection of the FN proceeds laterally toward the porus with tumor reduction performed under constant visual observation of the FN. The initial recorded value was considered as a baseline. If necessary, IAC bone was drilled by the otologist to remove the intra-meatal VS root. After sectioning the vestibular nerves (superior and inferior), the tumor was removed. In the case of strong FN adherence or a decrease in the supramaximal amplitude response at the proximal segment by more than 40% compared to the baseline value, FN dissection from the tumor was stopped and a near (strong adherence on a short distance) or subtotal (strong adherence on a long distance) resection was performed. In selected patients (large VS in elderly, anatomical considerations, or NF2), a partial resection could be planned preoperatively.

▪ *Postoperative Facial nerve outcome*

Even if the rate of good FN function outcomes has increased over time, facial palsy is still a complication of major concern for patients undergoing VS surgery [15-16]. Intraoperative neuromonitoring has been established as one of the methods by which modern neuro-otological surgery can improve surgical results while reducing morbidity. Despite routine use of intraoperative facial nerve (FN) monitoring, FN injury still is a complication of major concern due to severe negative impact on patient's quality of life. It should be remembered that regardless of the monitoring technique, IOFNM is merely a technical adjunct that can aid both the experienced and the inexperienced surgeon and does not replace surgical skills and experience. Furthermore, IOFNM may also improve hearing preservation outcomes because of the likelihood of reducing surgical trauma that may jeopardize both nerves.[2]

Intraoperative electromyographic FN monitoring can not only supply the surgical team for the FN location in CPA and on the tumor capsule but also provide information on the occurrence of a conductive nervous blockage during FN dissection from the tumor surface. Intraoperative electromyography (EMG) detection (neurotonic discharge in response to metabolic or mechanical stimulus) or a stimulation method (discharge induced by an electrical stimulation) may be used to assess facial nerve function. Measuring the stimulation threshold by the latter technique evaluates the excitability of the nerve fibers but yields partial information on the functional integrity of the fibers because at the threshold level, only a limited number of large nerve fibers adjacent to the probe will be stimulated. On the other hand, supramaximal stimulation induces depolarization of all the functional fibers

and is largely used to evaluate nerve lesions in neurophysiology. Indeed, among several parameters, the decrease of amplitude responses at the brain stem by supramaximal stimulation of the nerve is a marker of the onset of a conductive nervous block [17-18]. If so, decision to shift from a total to near/subtotal VS resection can be taken to avoid postoperative facial palsy [19].

The first report of intraoperative monitoring with a 4-channel recording device of the Frontalis, chin muscles, and the 2 orbiculari muscles described using the 4-channel facial nerve EMG monitor, NIM response 2.0 (Medtronic Xomed). The addition of the chin muscles (CM) allowed studying a greater number of facial nerve fibers because the CM group contains the *depressor labii inferioris*, *depressor anguli inferioris*, and *mentalis* muscles, which represent the bulkiest facial muscle groups with significant electrical response amplitude. From November 2005 to July 2007, 140 patients with no facial palsy who underwent VS surgery with continuous facial nerve monitoring were enrolled, and 120 were included in this study.[17] The most significant prognostic indicators were after VS resection, the combination of a low stimulation threshold intensity (<0.04 mA), a maximal CM response amplitude greater than 800 KV, and a proximal/distal ratio of the maximal response amplitudes of greater than 0.6 predicts a good facial outcome (Grade 1 or 2) with a 90% sensitivity, a 78% specificity, a 93% positive predictive value, and a 70% negative predictive value. Additional predictive parameters of postoperative facial nerve paralysis included the course of the facial nerve in the IAM and CPA.

Several reports were continuously published in order to analyse the evolution in surgical outcomes of VSs operated by a neurotological team by different approaches. Zhang et al [15], conducted a monocentric retrospective review performed on medical charts of 1006 consecutive patients operated for sporadic VS removal between January 1990 and December 2006. Mean follow-up was 5.9 ± 2.4 years. Overall, complete VS removal was achieved in 99.4% of cases. Mortality rate was 0.3%, meningitis and CSF leaks were observed in 1.2 % and 9 % of the cases, respectively. Facial nerve was anatomically preserved in 97.7% of cases. At one year, a good facial nerve function was observed in 85.1% of patients (grade I and II of House-Brackmann grading scale). At one year, hearing preservation was obtained in 61.6% of patients (class A+B+C from the AAO-HNS classification). Useful hearing (class A+B) was observed in 33.5% of cases overall. FN anatomical integrity does not necessarily correspond to good FN function. In our series, with 97.7% of FN anatomical integrity, good

FN function was achieved only in 85.1% of patients. The good FN function rate varied from 91.7% to 79.9%, and it was inversely proportional to the tumor size. Thus, a larger tumor size implies a worse postoperative functional outcome. Many factors influence the surgical outcomes of sporadic VS. Our experience in a large series of 1006 sporadic VS treated over a 17-year period revealed that good functional outcomes depend on several critical variables, including tumor size, surgical approach, surgeon's experience and development of technique.

In addition, Torres et al.[14], performed a retrospective study from January 2009 to December 2011 on 272 consecutive patients who had undergone vestibular schwannoma surgery. We observed that 74% and 84% of patients had good facial function (House-Brackmann [HB] I-II) at day 8 and 1 year, respectively. Of 60 patients, 26 (43%) who had impaired facial function (HB III-VI) at day 8 recovered good facial function (HB I-II) 1 year after surgery. A structured equation model showed that advanced tumor stage and strong facial nerve adhesion were independently associated with facial nerve conduction block at day 8. Our results showed that only stage 3 and 4 tumors and a strong nerve adhesion to the tumor were associated with impaired facial nerve function at day 8. We presumed that medium-sized and large lesions lead to chronic nerve injury as a result of stretching or compression. In addition, strong nerve adhesion makes surgical dissection of the nerve difficult and would also independently contribute to postoperative nerve injury. At day 8, our study showed that 16 mm was the cutoff value for extracanalicular tumor diameter to minimize risk to facial nerve function. Henceforward, the importance of Near/Subtotal resection strategy in larger tumors to improve facial nerve outcome have been taken into consideration by our surgical team.

Bernardeschi et al.[19], discussed the FN outcome and radiological results in patients undergoing near/Subtotal VS resection guided by electromyographic supramaximal stimulation of the FN at the brainstem. In large vestibular schwannoma (VS) surgery, the facial nerve (FN) is at high risk of injury. Near-total resection has been advocated in the case of difficult facial nerve dissection, but the amount of residual tumor that should be left and when dissection should be stopped remained controversial factors. In this study, VS surgery was guided primarily by electrophysiological responses rather than just surgical observation. Twenty five patients with large solitary VS (Stage III or IV) between January 2014 and December 2014 with electrophysiological monitoring, normal preoperative FN function, and interruption of dissection of the FN from the tumor because of loss

of around 50% of the response of the nerve to a supramaximal stimulation (2 mA) at the brainstem associated with strong adherence of the tumor to the FN. They have been able to document Grade I or II FN function in 64% of patients at Day 8 and 84% at 1 year after surgery.

During the last decade, our oto-neurosurgical team has been performing about 100 surgical procedures for sporadic VS per year mainly through TL, especially for stage III and IV tumors. Recently, the proportion of VS resection through RS has increased over the last 5 years from 30% (2013–16) to 60 % (2017) and to 85% in the last 2 years. RS was more and more performed to attempt to preserve hearing, even in large VS. On the other hand, the authors' surgical strategies have recently shifted; using a retrosigmoid (RS) approach even in large VS, with resection guided by facial nerve (FN) monitoring in order to minimize the risk of facial nerve injury.

Despite all these data, the most important limitation in FN monitoring is that during drilling, the system does not alert the surgeon if he is drilling close to the FN, and the electromyographic (EMG) responses could be elicited when injury of the FN has already been done; furthermore, with a direct trauma or progressive heating, the IOM could fail to alert the surgeon. Moreover, the intermittently working conventional handheld stimulation electrode is potentially limited because the nerve is still at risk for damage between two FN stimulations. The inability to monitor nerve function between two stimulation cycles puts the nerve at risk during unmonitored dissection intervals, and remains to be the most significant disadvantage of intermittent intraoperative neuromonitoring (IIONM).

Therefore, the implementation of a continuous facial nerve (FN) stimulating burr (the StimBurGard) during our otologic/neurotologic procedures when drilling in contact with the Fallopian canal (FC) of the mastoid segment of the FN has been effected by our team for over a decade now .[20] We found that the value of 1 mA stimulation corresponded approximately at 1 mm of the remaining bone over the FN. Hence, the value of 1 mA was recommended for a safe drilling near the FN because it guarantees the integrity of the FC during TL or during drilling the IAC in RS approach without limitation in the exposure of the CPA. **(Figure 1-4)**

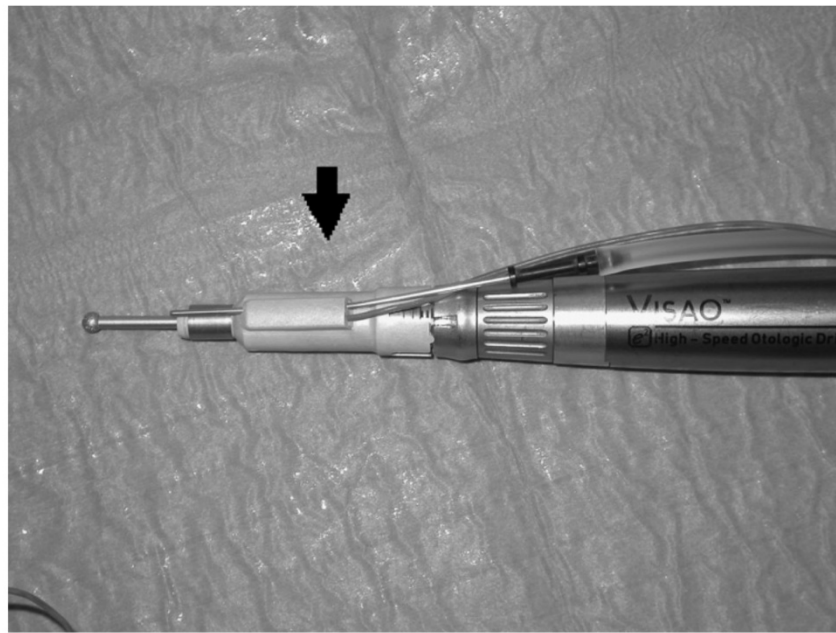


Figure 1-4 The StimBurGard (black arrow) system with Visao drill.

Because of anatomical integrity of FN does not guarantee its functional integrity. In clinical practice of CPA surgery, FN palsies can be caused by transection, thermal injury, pressure, and traction. There are different strategies to avoid these lesions: Transection may be omitted by consequent application of nerve identification tools, i.e., intermittent intraoperative nerve monitoring (I-IONM). Pressure and tensile stress to the nerve may be prevented by the continuous intraoperative neuromonitoring (C-IONM). C-IONM is thought to recognize emerging trauma, thus enabling the surgeon to react instantly when the signal decreases.

■ References

1. House WF. Acoustic neuroma. Case summaries. Arch Otolaryngol. 1968 Dec;88(6):586-91.
2. Acioly MA, Liebsch M, de Aguiar PH, Tatagiba M. Facial nerve monitoring during cerebellopontine angle and skull base tumor surgery: a systematic review from description to current success on function prediction. World Neurosurg. 2013 Dec;80(6):e271-300.
3. Shi-Ming Y, Li-Mei Y, Yi-Hui Z, Li-Ming Y, Fei J, Wei-Yan Y, et al. Endoscope-assisted cerebellopontine angle surgery. Journal of Otology. 2009;4(1):44-9.
4. Gupta S, Mends F, Hagiwara M, Fatterpekar G, Roehm PC. Imaging the facial nerve: a contemporary review. Radiol Res Pract. 2013;2013:248039.
5. Lee S, Seol HJ, Park K, Lee JI, Nam DH, Kong DS, et al. Functional Outcome of the Facial Nerve After Surgery for Vestibular Schwannoma: Prediction of Acceptable Long-Term Facial Nerve Function Based on Immediate Postoperative Facial Palsy. World neurosurgery. 2016 May;89:215-22.
6. You YP, Zhang JX, Lu AL, Liu N. Vestibular schwannoma surgical treatment. CNS neuroscience & therapeutics. 2013 May;19(5):289-93.
7. Esquia-Medina GN, Grayeli AB, Ferrary E, Tubach F, Bernat I, Zhang Z, et al. Do facial nerve displacement pattern and tumor adhesion influence the facial nerve outcome in vestibular schwannoma surgery? Otol Neurotol. 2009 Apr;30(3):392-7.
8. Zhang Y, Chen Y, Zou Y, Zhang W, Zhang R, Liu X, et al. Facial nerve preservation with preoperative identification and intraoperative monitoring in large vestibular schwannoma surgery. Acta neurochirurgica. 2013 Oct;155(10):1857-62.
9. Liu SW, Jiang W, Zhang HQ, Li XP, Wan XY, Emmanuel B, et al. Intraoperative neuromonitoring for removal of large vestibular schwannoma: Facial nerve outcome and predictive factors. Clinical neurology and neurosurgery. 2015 Jun;133:83-9.
10. Romstock J, Strauss C, Fahlbusch R. Continuous electromyography monitoring of motor cranial nerves during cerebellopontine angle surgery. J Neurosurg. 2000 Oct;93(4):586-93.
11. Yingling C, Ashram Y. Intraoperative monitoring of cranial nerves in neurotologic surgery. Otolaryngology Head and Neck Surgery Elsevier Mosby St Louis. 2005:3877-910.
12. Kim SM, Kim SH, Seo DW, Lee KW. Intraoperative neurophysiologic monitoring: basic principles and recent update. J Korean Med Sci. 2013 Sep;28(9):1261-9.
13. Yingling CD, Gardi JN. Intraoperative monitoring of facial and cochlear nerves during acoustic neuroma surgery. 1992. Neurosurg Clin N Am. 2008 Apr;19(2):289-315, vii.
14. Torres R, Nguyen Y, Vanier A, Smail M, Ferrary E, Sterkers O, et al. Multivariate Analysis of Factors Influencing Facial Nerve Outcome following Microsurgical Resection of Vestibular Schwannoma. Otolaryngol Head Neck Surg. 2017 Mar;156(3):525-33.

15. Zhang Z, Nguyen Y, De Seta D, Russo FY, Rey A, Kalamarides M, et al. Surgical treatment of sporadic vestibular schwannoma in a series of 1006 patients. *Acta Otorhinolaryngol Ital.* 2016 Oct;36(5):408-14.
16. Sterkers JM, Morrison GA, Sterkers O, El-Dine MM. Preservation of facial, cochlear, and other nerve functions in acoustic neuroma treatment. *Otolaryngol Head Neck Surg.* 1994 Feb;110(2):146-55.
17. Bernat I, Grayeli AB, Esquia G, Zhang Z, Kalamarides M, Sterkers O. Intraoperative electromyography and surgical observations as predictive factors of facial nerve outcome in vestibular schwannoma surgery. *Otol Neurotol.* 2010 Feb;31(2):306-12.
18. Goldbrunner RH, Schlake HP, Milewski C, Tonn JC, Helms J, Roosen K. Quantitative parameters of intraoperative electromyography predict facial nerve outcomes for vestibular schwannoma surgery. *Neurosurgery.* 2000 May;46(5):1140-6; discussion 6-8.
19. Bernardeschi D, Pyatigorskaya N, Vanier A, Bielle F, Smail M, Lamas G, et al. Role of electrophysiology in guiding near-total resection for preservation of facial nerve function in the surgical treatment of large vestibular schwannomas. *J Neurosurg.* 2018 Mar;128(3):903-10.
20. Bernardeschi D, Meskine N, Otaibi NA, Ablonczy R, Kalamarides M, Grayeli AB, et al. Continuous facial nerve stimulating burr for otologic surgeries. *Otol Neurotol.* 2011 Oct;32(8):1347-51.

Chapter 2 **OBJECTIVES**

This thesis had an objective of evaluating new methods and parameters of facial nerve preservation during CPA surgery. Our main objective was to analyze and implement the state of art of continuous-IONM (C-IONM) in our oto-neurosurgical procedure.

A new animal model has been proposed and outlined where a complete exposure of FN has been achieved successfully. Furthermore, our preliminary experience on FN testing in the living animal model has been evaluated. That was essential for evaluating the safety and reliability of the new intraoperative technique. Its applicability in future research and clinical work has been discussed.

Also, we have been able to highlight our current experience with Intraoperative neuromonitoring (IONM) technique of Facial nerve.

Ultimately, this has been satisfactory accomplished through:

- Establishing a porcine model for posterior fossa surgery with exposure of the course of the facial and vestibulocochlear nerves emerging from the brain stem in the CPA and then within the IAC.
- Reproducing the Porcine mode in vivo where its advantages and pitfalls are described.
- Highlighting our preliminary experience with Intraoperative neuromonitoring technique in the identification and dissection of the FN in the CPA and IAC in the porcine model.
 - The NIM 3.0 – Nerve Integrity Monitoring Systems (Medtronic, Jacksonville, FL, USA) is currently routinely used in our oto-neurosurgical daily practice.
 - We evaluated the conventional intermittent-IONM (I-IONM) using a hand-held probe. In addition, we evaluated the applicability of the more recently developed technique; continuous-IONM (C-IONM), using the Automated Periodic Stimulation (APS) Electrode Stimulator probe (Medtronic) and how it could be further implemented in future research work.
- Investigating and refining the predictive value of present and new intraoperative FN monitoring parameters clinically, to determine if they could prognosticate FN outcome.

Chapter 3 RESULTS

In the coming sections we are going to represent our results as following:

- I. ***Section 3.1 "Pig as a large animal model for posterior fossa surgery in otoneurosurgery: A cadaveric study."***
Demonstrates the development of the porcine animal model of posterior fossa surgery in cadavers.
- II. ***Section 3.2 "In vivo porcine model for posterior fossa surgery in otoneurosurgery: a preliminary experience."***
Discusses the reproducibility of the former porcine model in living animals and highlights the feasibility of this approach and preliminary experience on FN monitoring and testing.
- III. ***Section 3.3." Optimization of facial nerve outcome by intraoperative electromyography guided microsurgical resection of large vestibular schwannomas. "***
Reviews the clinical peri-operative parameters that can predict the postoperative facial nerve function .in addition, reinvestigating some new intraoperative monitoring value that could predict the postoperative outcome especially in large tumors.

3.1 Pig as a Large Animal Model for Posterior Fossa Surgery in Oto-Neurosurgery: A Cadaveric Study


This work has been published as : *Mohamed Elsayed, Renato Torres, Olivier Sterkers, Daniele Bernardeschi, and Yann Nguyen. "Pig as a large animal model for posterior fossa surgery in oto-neurosurgery: A cadaveric study." PloS one 14, no. 2 (2019).*

RESEARCH ARTICLE

Pig as a large animal model for posterior fossa surgery in oto-neurosurgery: A cadaveric study

Mohamed Elsayed^{1,2,3*}, Renato Torres^{1,2}, Olivier Sterkers^{1,2}, Daniele Bernardeschi^{1,2}, Yann Nguyen^{1,2}

1 Sorbonne Université, Inserm, Unité "Réhabilitation chirurgicale mini-invasive et robotisée de l'audition", Paris, France, **2** AP-HP, GHU Pitié-Salpêtrière, Service ORL, Otologie, implants auditifs et chirurgie de la base du crâne, Paris, France, **3** Alexandria University, Faculty of Medicine, ORL Department, Alexandria, Egypt

* Mohamed.Elsayed@inserm.fr

OPEN ACCESS

Citation: Elsayed M, Torres R, Sterkers O, Bernardeschi D, Nguyen Y (2019) Pig as a large animal model for posterior fossa surgery in oto-neurosurgery: A cadaveric study. PLoS ONE 14(2): e0212855. <https://doi.org/10.1371/journal.pone.0212855>

Editor: Johannes Boltze, Fraunhofer Research Institution of Marine Biotechnology, GERMANY

Received: July 2, 2018

Accepted: February 11, 2019

Published: February 26, 2019

Copyright: © 2019 Elsayed et al. This is an open access article distributed under the terms of the [Creative Commons Attribution License](https://creativecommons.org/licenses/by/4.0/), which permits unrestricted use, distribution, and reproduction in any medium, provided the original author and source are credited.

Data Availability Statement: All relevant data are within the manuscript.

Funding: This work was supported by the Ministry of higher education, Mission sector, Egypt (<http://www.mohe-casm.edu.eg>) and the Ministry of Scientific Research, Egypt to ME. The funders had no role in study design, data collection and analysis, decision to publish, or preparation of the manuscript.

Competing interests: The authors have declared that no competing interests exist.

Abstract

This study proposes a practical model for a new approach to the posterior fossa in common domestic pigs. Several surgical procedures can be simulated in the nonliving pig model, including soft tissue dissection, drilling of temporal bone, dural incision, access to the cerebellopontine angle, exposure of cranial nerves and drilling of the internal auditory canal. The pig model perfectly simulates standard otological and neurosurgical procedures, and we highlight the feasibility of our approach for further experiments in a living pig model with the possibility of reproducing the model for research on cranial nerves in pigs to study their electrophysiological behavior.

Introduction

Many models have been described in the literature for otological and neurosurgical training and education including cadaveric dissection of human temporal bone, synthetic materials such as artificial temporal bones, animal models and recently, computer-based simulation models. The gold standard training is still human cadaveric temporal bone as this represents the most realistic model. Unfortunately, the availability of human temporal bone is becoming increasingly difficult and limited for legal, economic, and ethical reasons. Thus, temporal bones of animals, which are readily available at low cost, represent an excellent alternative [1, 2].

Additionally, living animal models are excellent candidates for investigation and electrophysiological evaluation of injury and regeneration processes of peripheral and cranial nerves. In our oto-neurosurgical daily practice, when we are dealing with pathologies located in the cerebellopontine angle (CPA) or at the skull base, surgical manipulations involving the facial and vestibulocochlear nerves carry a high risk of iatrogenic traumatic insult. This may result in severe functional loss of hearing and facial nerve palsy even though the nerves remain morphologically intact. Today, many animal models are well established for the investigation of peripheral nerve lesions; however, only a few studies have investigated cranial nerve injury [3].

Animal models involving small mammals such as rabbits, guinea pigs and rodents have been widely used. However, there is need for an animal model that better matches the human in size. Large animals such as the domestic pig and sheep are strong candidates. They can be used for practicing various procedures and also to improve our understanding of the basic anatomical structures and topography [4, 5].

Over the past few decades, several authors have studied and described the temporal bones and brain anatomy of pigs with the emergence of a pig experimental model that reflects the considerable resemblance to human anatomy and physiology [1, 4, 6–9]. Generally, pig brain is comparable to the human brain in gross anatomy. Homology exists in the relationship between pig and human skull base with a similar comparative anatomy with regard to brain, and upper and lower cranial nerves [10]. In addition, the weight of the adult pig brain ranges from 80 to 180 g which is more than 50 times greater than that of rat brain. Thus, the pig model can facilitate ideal and real life scenarios during neurosurgical training [7].

Therefore, studies have also described an in vivo pig model for general neurosurgical training. Surgical procedures have included craniotomy, dural opening, brain surgery and excision of an artificial tumor. Microscopy and bleeding management were also an integral part of training with the aim of developing a laboratory setting imitating an almost realistic operating room [11–13].

Despite this volume of available background data concerning pig temporal bones and pig brain anatomy, little attention has been paid to the possibility of using the pig as a surgical model in skull base surgery and specifically the posterior fossa. In 1999, Jarrahy et al. evaluated the anatomy of the CPA through a retro-sigmoid approach in a pig specimen but mainly to demonstrate its usefulness as a model for the use of endoscopy in skull base surgery [10].

Accordingly, our study aimed to assess the pig as a surgical model to access the posterior fossa with full exposure of the facial and vestibulocochlear nerves in the CPA and within the internal auditory canal (IAC) by establishing a detailed approach in pig specimens.

Our experiment highlights the feasibility of this approach for exposure of cranial nerves in the CPA and IAC in pigs which can subsequently be used as a possible in vivo model not only for oto-neurosurgical training but also for investigation and electrophysiological evaluation of cranial nerve injury.

Methods

Seven adult heads of common domestic pigs (*Sus scrofa domestica*) were acquired from a regional slaughterhouse and dissected within 12 hours postmortem at our INSERM-UMR-S 1159 Laboratory, and two heads were dissected directly postmortem at the anatomy laboratory at Fer a Moulin Animal Hospital, Paris, France.

The aim of our approach was to expose the course of the facial and vestibulocochlear nerves emerging from the brain stem in the CPA and then within the IAC.

In all specimens, we performed the following steps: a skin incision, soft tissue dissection, craniotomy, dural opening in order to expose the CPA and visualize the acoustic-facial bundle, and finally drilling of the IAC to complete the exposure.

These steps were performed using an operating microscope (OpMi-1 Zeiss Inc., Jena, Germany), microsurgical instruments, suction, and a surgical drill.

Results

Purpose of the approach

Anatomically, the temporal bone in pigs is located in the same position as in humans; however, landmarks usually found in humans are missing. In our approach, the following structures could be identified: the posterior wall of the external auditory canal (EAC), the atlanto-

occipital joint, the posterior arcade (which is synonymous with the posterior semicircular canal in humans [6]), the dura of the posterior cranial fossa, the posterior wall of the IAC and the acoustic-facial bundle.

The approach also allowed the drilling of the posterior wall of the EAC, the posterior arcade and the IAC, which are important surgical steps during surgery to remove tumors in the CPA.

Because of its relative simplicity, minimal invasiveness and satisfactory exposure of cranial nerves, this approach can be used in experimental animal studies specifically to access the CPA and IAC.

Surgical procedure

a. Incision and soft tissue dissection. The pig's head was positioned in the prone position. A midline vertical incision of skin and subcutaneous tissue was made between the eyes and extending posteriorly at the sloping crest of the occipital bone then laterally in a semilunar fashion through the post-auricular groove (Fig 1). Dissection of the skin flap continued laterally until the cartilaginous part of the EAC had been cut through.

Then, dissection of muscles overlying the occipital bone, temporal fossa and mastoid area in a sub-periosteal plane could be achieved easily. Separating muscle attachment on the occipital bone was done superiorly, laterally and at the midline. At the temporal fossa, we separated temporal muscle from its superior, posterior and inferior attachments until we had sufficiently exposed the parietal bone. We noted that, at the mastoid plane, this bone was partially covered by the atlanto-occipital joint [9]. Thus, it was necessary to dissect the muscle overlying it to expose part of the joint in order to facilitate subsequent drilling.

b. Craniotomy. Using different cutting and diamond burs, we started drilling following the direction of the posterior wall of the EAC as a landmark. The EAC is very long, narrow and oriented strictly upward and backward [9].

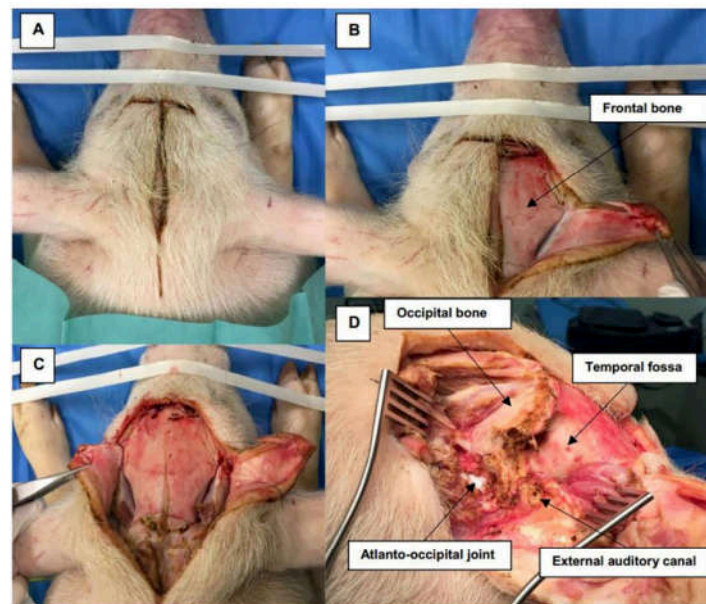


Fig 1. Incision and soft tissue dissection. (A) The pig's head is in the prone position with a midline skin incision extending posteriorly then laterally into the post-auricular area. (B, C, D) Dissection of soft tissue over the frontal bone, temporal fossa (TF), occipital bone (OB), external auditory canal (EAC) and mastoid area, which is partially covered by the atlanto-occipital joint (AOJ).

<https://doi.org/10.1371/journal.pone.0212855.g001>

An important landmark was the posterior arcade, which could be easily identified following drilling of the EAC. It is the first arcade identified, not the lateral one as in humans. It is well and easily identified by the typical yellow color similar to the human otic capsule [6].

Medially, in a close anatomical relationship with the posterior arcade, the sigmoid sinus and the dura of the posterior fossa are in direct contact. Skeletonization of the dura was performed next using a diamond burr medially to the occipital bone and inferiorly to the atlanto-occipital joint. The mastoid air cells cannot be found in the pig because they are poorly pneumatized [5, 6], and are hidden under the atlanto-occipital joint (Figs 2 and 3).

c. Access to CPA and IAC exposure. After skeletonizing the dura over the posterior fossa, a dural incision was carefully performed with a posterior-based flap and brain tissue was exposed. The cerebellum was immediately identified and retracted posteriorly (Fig 4).

The acoustic-facial bundle (Cranial nerves VII/VIII) could be identified easily emerging from the pons and entering the IAC. As in humans, nerve bundles can be separated and the facial nerve lies anteriorly to the vestibulocochlear nerve.

Further exposure of the facial and vestibulocochlear nerve bundle in the IAC could be achieved by first, careful drilling of the posterior arcade in order to allow more exposure and a better angle of view of the posterior wall of the IAC. Then, drilling of the IAC was performed slowly and deliberately using a diamond bur drill at low speed from a medial to lateral direction (Figs 5 and 6).

Discussion

In the current literature, many studies have tried to find alternatives to human temporal bone in otological and neurosurgical training and research. Several models have been described,

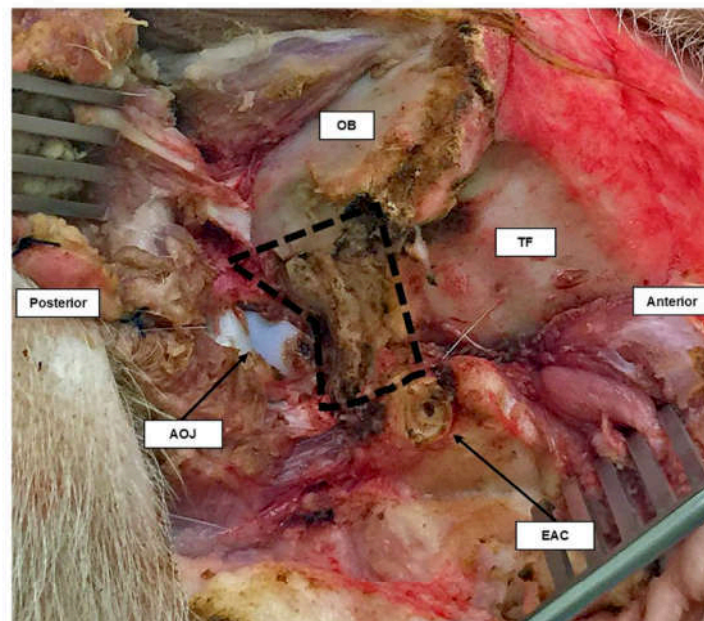


Fig 2. Lateral view of the right temporal bone of the pig. The area inside the black dashed line is the part of temporal bone covering the posterior fossa. It lies between the external auditory canal (EAC), occipital bone (OB) and atlanto-occipital joint (AOJ).

<https://doi.org/10.1371/journal.pone.0212855.g002>

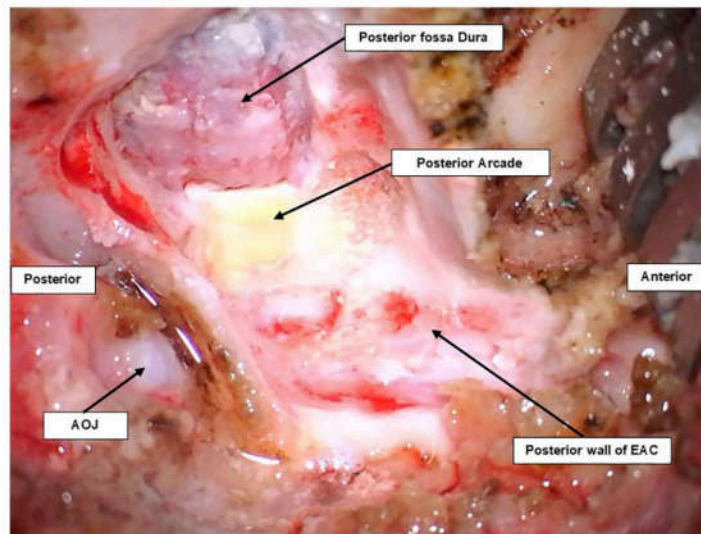


Fig 3. Lateral view of craniotomy of a pig's ear on the right side. The posterior arcade can be seen as a yellow bone beside the dura of the posterior fossa. Both can be seen after drilling following the posterior wall of the EAC.

<https://doi.org/10.1371/journal.pone.0212855.g003>

including nonliving animal models [1, 2, 6, 13–15]. These are readily available at low cost and may also offer a very realistic similarity to human anatomy in comparison to other synthetic materials. Temporal bones of sheep and pigs have been proposed by many authors as alternatives for otological education because the middle ear and tympanic membrane of both animals are morphologically similar to the structures found in human ears [2, 5].

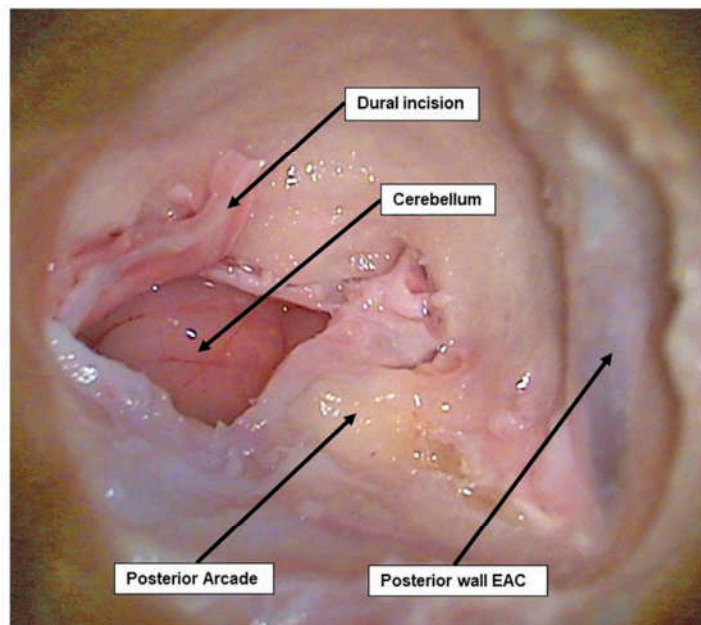


Fig 4. Dural incision and CPA exposure. Dural incision of the posterior fossa where the cerebellum can be easily identified and retracted.

<https://doi.org/10.1371/journal.pone.0212855.g004>

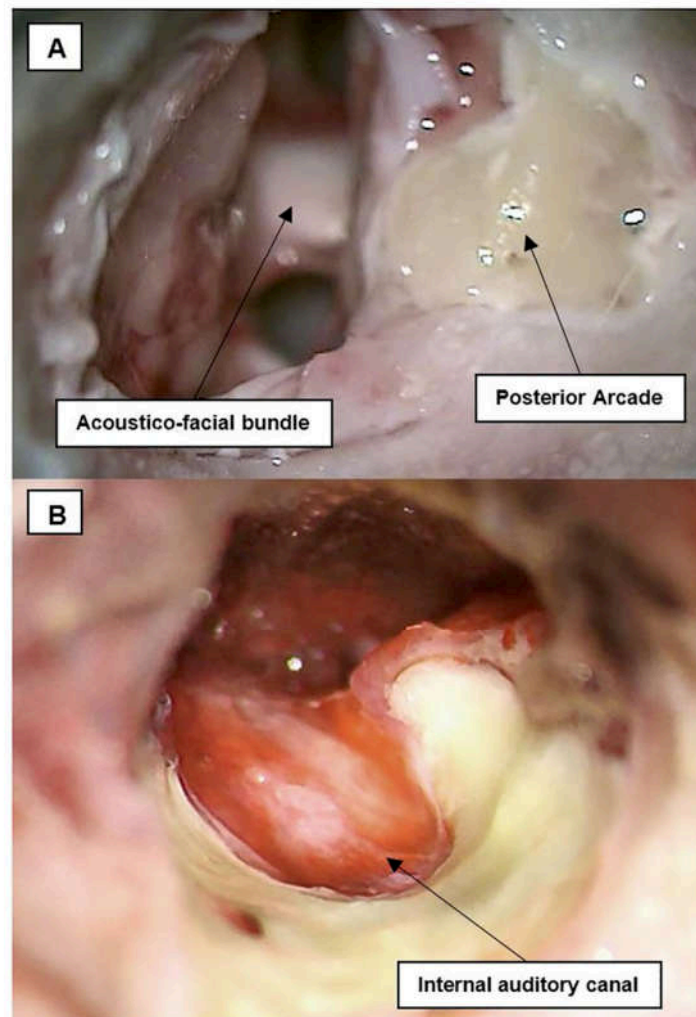


Fig 5. Acoustic-facial bundle in CPA and IAC exposure. (A) The acoustic-facial bundle (CN VII/VIII) could be seen emerging from the medulla, and entering the internal auditory canal (IAC). (B) After drilling of the posterior arcade and the posterior wall of the IAC, CN VII/VIII could be completely exposed.

<https://doi.org/10.1371/journal.pone.0212855.g005>

Neurosurgical training models using pigs, sheep and cows have also been reported [1, 7, 10–12, 14–16]. Both nonliving and living models have been used extensively mainly because of their relatively large size and the similarity of their brains to the human brain. In fact, the differences between the anatomy of the posterior fossa of these brains are negligible under microscopic view regarding microsurgical techniques for cranial nerves around the brain stem [10, 14]. Moreover, these models are very satisfactory when familiarizing trainees with surgical techniques used in cranial approaches, especially around the CPA [15].

Despite all available data on animal models in otological and neurosurgical experiments and education, few publications can be found with an oto-neurosurgical background, especially the approach to the posterior fossa with cranial nerve exposure in the CPA and IAC [10, 13]. In humans, neurosurgical procedures for pathologies located at the CPA, such as

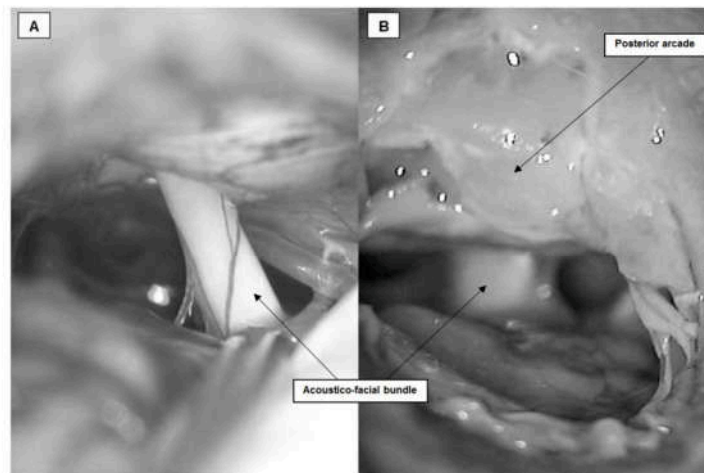


Fig 6. Comparison between CPA microscopic view and acoustic-facial bundle in (A) human (courtesy of Dr Y. Nguyen) and (B) pigs.

<https://doi.org/10.1371/journal.pone.0212855.g006>

meningioma or acoustic neuroma, always involve manipulations of the acoustic-facial bundle. These manipulations can carry a high risk of injury with functional loss postoperatively.

In our experiment, we used the pig as a nonliving model to demonstrate the feasibility of our approach to access cranial nerves, specifically, the facial and vestibulocochlear nerves in the CPA and IAC. The availability and low cost of the pig, combined with the ease of preparation made it a strong candidate. Also, the fact that we can reproduce this model *in vivo* later at our facility made the pig more convenient than other models such as sheep or cows. It is easy to obtain and maintain living pigs and to anesthetize them.

After a first look at the temporal bone of pigs, one may note that it has a completely different appearance from human temporal bone. The position and length of the EAC are markedly different in pigs, it is very long and narrow. In addition, the mastoid is difficult to identify in pigs, as it is poorly pneumatized and partially hidden beneath the atlanto-occipital joint. However, we used the pig's cadavers as a model and after a closer look at the middle ear structures and tympanic membrane, we can observe that they are morphologically similar to the structures found in human ears, as has been described by several authors [4–6].

Skin incision and soft tissue dissection were performed in a posterior and inferior direction to the EAC, much as in humans, although thicker skin and massive muscle mass could be observed in the occipital and temporal area. This could be a technical disadvantage in the living model.

Regarding the anatomy of the skull base, it is highly similar to that of humans especially when it comes to the anatomy of cranial nerves and vessels in the posterior fossa [10–12]. Yet, drilling of that part of temporal bone covering the posterior fossa is difficult because the classic landmarks that are used in humans are either missing or have a different orientation. These include the linea temporalis (temporal line), EAC and mastoid cells which are used to define the correct location for the surgical procedure. We used other simple and easily identifiable landmarks instead, starting with the posterior wall of the EAC, the posterior arcade and the dura of the posterior fossa.

Access to the CPA, drilling of the IAC, and exposure of the complete course of the acoustic-facial bundle (CN VII/VIII) were accomplished in all specimens. The facial and vestibulocochlear nerves could be successfully exposed from their emergence in the CPA until they

entered the IAC. These surgical manipulations represent important steps in all surgery involving the posterior fossa and CPA.

The strong similarities of the middle ear and its structures between humans and pigs recommend it as a possible model for otological research and education. The pig can be a strong candidate for oto-neurosurgical training concerning the CPA and IAC. Furthermore, this approach offers satisfactory exposure of the acoustic-facial-cranial nerve bundle with relatively straightforward and easily identifiable landmarks. Great similarities under the microscope could be noticed between the acoustic facial bundle in human and pigs (Fig 6). Hence, it can be further developed and used as a useful biological living animal model in research work concerning investigation and electrophysiological evaluation of cranial nerve injury.

Conclusions

The outer appearance of the temporal bone of pigs differs markedly from that of humans; however, using our approach, the pig can offer a modeled surgical environment that can be used as an outline for surgical training of otologists and neurosurgeons using nonliving and living models. It can also be used in further research work on facial and cochlear nerve testing and the study of their neurophysiological behavior.

Author Contributions

Conceptualization: Mohamed Elsayed, Yann Nguyen.

Investigation: Mohamed Elsayed.

Methodology: Mohamed Elsayed.

Supervision: Renato Torres, Olivier Sterkers, Daniele Bernardeschi, Yann Nguyen.

Writing – original draft: Mohamed Elsayed.

Writing – review & editing: Mohamed Elsayed, Renato Torres, Yann Nguyen.

References

1. Aurich LA, Silva Junior LF, Monteiro FM, Ottoni AN, Jung GS, Ramina R. Microsurgical training model with nonliving swine head. Alternative for neurosurgical education. *Acta cirurgica brasileira*. 2014; 29(6):405–9. PMID: [24919051](#)
2. Gurr A, Stark T, Probst G, Dazert S. [The temporal bone of lamb and pig as an alternative in ENT-education]. *Laryngo-rhino-otologie*. 2010; 89(1):17–24. <https://doi.org/10.1055/s-0029-1224158> PMID: [19691010](#)
3. Oertel J, Tschan CA, Keiner D. Animal Models for Experimental Neurosurgery of Peripheral and Cranial Nerves. *Experimental Neurosurgery in Animal Models*. 2016:151–63.
4. Hoffstetter M, Lugauer F, Kundu S, Wacker S, Perea-Saveedra H, Lenarz T, et al. Middle ear of human and pig: a comparison of structures and mechanics. *Biomedizinische Technik Biomedical engineering*. 2011; 56(3):159–65. <https://doi.org/10.1515/BMT.2011.011> PMID: [21657989](#)
5. Singh V, Chaitanya DK, Chauhan B, Kumar IDV. A comparative study of pneumatization of Temporal bone. *Journal of the Anatomical Society of India*. 2017; 66(1):78–81.
6. Gurr A, Kevenhorster K, Stark T, Pearson M, Dazert S. The common pig: a possible model for teaching ear surgery. *European archives of oto-rhino-laryngology: official journal of the European Federation of Oto-Rhino-Laryngological Societies*. 2010; 267(2):213–7.
7. Lind NM, Moustgaard A, Jelsing J, Vajta G, Cumming P, Hansen AK. The use of pigs in neuroscience: modeling brain disorders. *Neuroscience and biobehavioral reviews*. 2007; 31(5):728–51. <https://doi.org/10.1016/j.neubiorev.2007.02.003> PMID: [17445892](#)
8. Lovell JM, Harper GM. The morphology of the inner ear from the domestic pig (*Sus scrofa*). *Journal of microscopy*. 2007; 228(Pt 3):345–57. <https://doi.org/10.1111/j.1365-2818.2007.01852.x> PMID: [18045329](#)

9. Garcia Lde B, Andrade JS, Testa JR. Anatomical study of the pigs temporal bone by microdissection. *Acta cirurgica brasileira*. 2014; 29 Suppl 3:77–80.
10. Jarrahy R, Shahinian HK, Young J, Berci G. Endoscopic skull base surgery II: a new animal model for surgery of the posterior fossa. *Journal of investigative surgery: the official journal of the Academy of Surgical Research*. 1999; 12(6):335–9.
11. Regelsberger J, Eicker S, Siasios I, Hanggi D, Kirsch M, Horn P, et al. In vivo porcine training model for cranial neurosurgery. *Neurosurgical review*. 2015; 38(1):157–63; discussion 63. <https://doi.org/10.1007/s10143-014-0572-4> PMID: 25240530
12. Regelsberger J, Heese O, Horn P, Kirsch M, Eicker S, Sabel M, et al. Training microneurosurgery—four years experiences with an in vivo model. *Central European neurosurgery*. 2011; 72(4):192–5. <https://doi.org/10.1055/s-0030-1261906> PMID: 20635313
13. PARSAK T. Posterior fossa approach: microneurosurgical training model in cadaveric sheep. *Turkish Neurosurgery*. 2006; 16(3):111–4.
14. Hamamcioglu MK, Hicdonmez T, Tiryaki M, Cobanoglu S. A laboratory training model in fresh cadaveric sheep brain for microneurosurgical dissection of cranial nerves in posterior fossa. *British journal of neurosurgery*. 2008; 22(6):769–71. <https://doi.org/10.1080/02688690802477573> PMID: 19085361
15. Turan Suslu H, Ceylan D, Tatarli N, Hicdonmez T, Seker A, Bayri Y, et al. Laboratory training in the retrosigmoid approach using cadaveric silicone injected cow brain. *British journal of neurosurgery*. 2013; 27(6):812–4. <https://doi.org/10.3109/02688697.2013.772095> PMID: 23458576
16. Sauleau P, Lapouble E, Val-Laillet D, Malbert CH. The pig model in brain imaging and neurosurgery. *Animal: an international journal of animal bioscience*. 2009; 3(8):1138–51.

3.2 In vivo porcine model for posterior fossa surgery in oto-neurosurgery: a preliminary experience.

This Manuscript has been submitted as: *Mohamed Elsayed, Fabienne Carré, Vittoria Sykopenrites, Renato Torres, Olivier Sterkers, and Yann Nguyen. “In vivo porcine model for posterior fossa surgery in oto-neurosurgery: a preliminary experience.” PloS one, February 2020.*

3.2.1 In vivo porcine model for posterior fossa surgery in otoneurosurgery: a preliminary experience

Mohamed Elsayed^{1,2,3*}, Fabienne Carré², Vittoria Sykopezites^{2,4}, Renato Torres^{1,2,5}, Olivier Sterkers^{1,2}, and Yann Nguyen^{1,2}

¹ Sorbonne Université, Inserm, Unité "Réhabilitation chirurgicale mini-invasive et robotisée de l'audition", Paris, France

² AP-HP, GHU Pitié-Salpêtrière, Service ORL, Otologie, implants auditifs et chirurgie de la base du crâne, Paris, France

³ Alexandria University, Faculty of Medicine, Otorhinolaryngology Department, Alexandria, Egypt

⁴ Department of Otorhinolaryngology and Neuro-Otology, Gruppo Otologico, Piacenza, Rome, Italy

⁵ Universidad Nacional de San Agustín, Facultad de Medicina, Centro de Investigación y Desarrollo Científico (CIDECA), Arequipa, Peru

Short title: Large living animal model for posterior fossa surgery

***Corresponding author**

Email: Mohamed.Elsayed@inserm.fr

3.2.2 Abstract

Porcine living experimental models have been essential not only for surgical training but also for investigation and electrophysiological evaluation of injury and regenerative processes of the peripheral and cranial nerves. Accordingly, our study seeks to establish a porcine living model for posterior fossa surgery. Our recent experience with this in vivo porcine model is outlined, and its advantages and pitfalls are described. Moreover, our preliminary experience with intraoperative facial nerve neuromonitoring is highlighted, indicating where it could be successfully implemented in future research work.

Key words (MeSH): In vivo model, Posterior fossa surgery, Facial nerve, Porcine neuroanatomy

3.2.3 Introduction

At present, supplemental surgical education models are desirable and essential for oto-neurosurgical training. The routine use of human cadaver specimens and virtual reality models has been widely described in the literature [1-4]; however, with regard to soft tissue, and in particular, brain parenchyma and cranial nerve manipulations after fixation, these models do not fulfill the properties of vital tissue with regard to texture and haptic perceptions [4].

Therefore, a number of authors have described an in vivo porcine model for general neurosurgical training. Surgical procedures included craniotomy, dural opening, brain surgery and excision of an artificial tumor. Microscopy and bleeding management were also an integral part of training with the aim of developing a laboratory setting imitating an operating room as closely as possible [4-6].

The porcine experimental model has considerable similarities to human anatomy and physiology [2, 7-11]. Generally, pig brain is comparable to the human brain in gross anatomy. Much likeness exists in the relationship between pig and human skull base with a similar comparative anatomy with regard to brain and cranial nerves [12]. In fact, the differences between the anatomies of the posterior fossa in the two brains are negligible under microscopic view with regard to microsurgical techniques involving the cranial nerves around the brain stem [12-13]. In addition, the pig is a widely available and relatively cheap experimental animal.

Living animal models are excellent candidates for the investigation and electrophysiological evaluation of injury and regenerative processes of the peripheral and cranial nerves. Intraoperative neural monitoring (IONM) has gained wide acceptance as an adjunct technique in cranial surgery. For instance, in our oto-neurosurgical daily practice, when we are dealing with pathologies located in the cerebellopontine angle (CPA) or at the skull base, surgical manipulations involving the facial and vestibulocochlear nerves carry a high risk of iatrogenic traumatic insult [14-15].

In general, the objectives of IONM include: (1) identifying the nerve in soft tissue, tumor, and bone as early as possible; (2) warning the surgeon of an unexpected nerve stimulation; (3) mapping the course of the nerve in temporal bone, soft tissue or tumor using

electrical stimulation; (4) enhancing neural preservation by reducing mechanical trauma during rerouting or tumor dissection; (5) detecting, and understanding the mechanisms of nerve injury, and predicting the outcome at the end of tumor removal [14]. Although it does not replace the knowledge of surgical anatomy or excellent surgical technique, IONM has added a new functional dynamic to surgery as it empowers the surgeon beyond what is available to them through visual information alone thereby permitting modifications in surgical strategies that can ultimately avoid neural damage [16]. The porcine model has been widely used in IONM research for many years and in many studies, and as a result, it is now considered to be a reliable and reproducible model for evaluating the electrophysiologic correlates of electromyography (EMG) during IONM [16-18].

In our previous work [1], we used the pig as a nonliving model to outline a detailed surgical approach to the posterior fossa and to demonstrate that this approach can be used to access the cranial nerves, specifically, the facial and vestibulocochlear nerves in the CPA and the internal auditory canal (IAC). We have focused our attention on the pig's posterior fossa as this is an important anatomical area that is implicated in many lesions, which, while extremely debilitating, are very susceptible to surgical resection [12].

Accordingly, the main goal of our study was to establish a porcine living model for posterior fossa surgery with exposure of the course of the facial and vestibulocochlear nerves emerging from the brain stem in the CPA and then within the IAC. Our recent experience with this in vivo porcine model is outlined, and its advantages and pitfalls are described. The porcine anatomy and approach with respect to oto-neurosurgical requirements are illustrated in detail for the first time and might help others to reproduce the model for training purposes.

Our second goal was to highlight our preliminary experience with IONM in the identification and dissection of the FN in the CPA and IAC. The NIM 3.0 – Nerve Integrity Monitoring Systems (Medtronic, Jacksonville, FL, USA) is currently routinely used in our oto-neurosurgical daily practice. We evaluated the conventional intermittent-IONM (I-IONM) using a hand-held probe. In addition, we evaluated the applicability of the more recently developed technique, continuous-IONM (C-IONM), using the Automated Periodic Stimulation (APS) Electrode Stimulator probe (2.0 mm; Medtronic) and how it could be further implemented in future research work.

3.2.4 Methods

Permission to perform this study was approved by the Ethics Committee on animal testing (Paris Descartes University, PROJET APAFIS #13860 N° 2018020112434493) under supervision from the French Ministry of Research. The experiments took place at Fer a Moulin Animal Hospital (APHP, Paris, France). This facility offered full veterinary and anesthetic support for practical training purposes in the laboratory. An operating surgical microscope (Zeiss, Germany), bipolar and monopolar coagulation, suction, and microsurgical instruments provided as realistic an experience as possible of the daily situation in the operating room [Fig. 3-1].

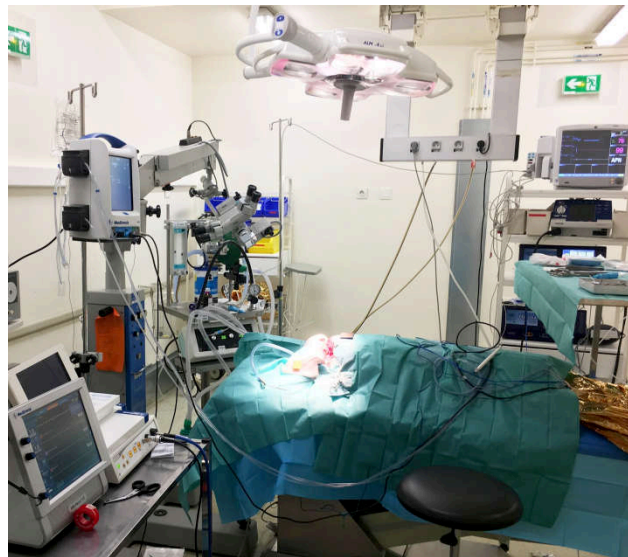


Figure 3-1 Operating room set-up.

3.2.4.1 Animals and anesthesia

Six live pigs weighing 30–40 kg were used in this prospective experiment. The pigs were fasted for 8 hours but were allowed water before the experiment. Thirty minutes after intramuscular administration of pre-anesthetic medication (STRESNIL® solution – Azapérone 2 mg/kg, Atropine 1 mg, Diazepam 10 mg, ketamine 20 mg/kg), the pigs were placed on an operating table in the prone position. An intravenous catheter was placed in a superficial vein in one of the lower limbs through which the animal received a continuous intravenous infusion of lactated Ringer's solution (5 mL/kg/h) throughout the operation. Anesthesia was supplemented with Thiopental (Nesdonal): 2 mg/kg. Analgesics were given in the form of Nalbuphine 0.4 mg/kg. General anesthesia was induced and maintained by

Isoflurane (Forene, Abbott, France) in oxygen after endotracheal intubation. No neuromuscular blocking agents were allowed. Heart rate and oxygen saturation were monitored during the entire surgical procedure. Body core temperature was stabilized by a heating mattress and covering blankets. At the end of each experiment, the pigs were sacrificed by an intravenous injection of DOLÉTHAL® (pentobarbital) (1 mL/kg).

3.2.4.2 Intraoperative neuro-monitoring equipment and setting

For EMG monitoring, we used NIM 3.0 (Medtronic). Paired, four bipolar subdermal needle 25-mm electrodes were placed in the frontalis, orbicularis oculi, orbicularis oris, and chin muscles [Fig. 3-2].

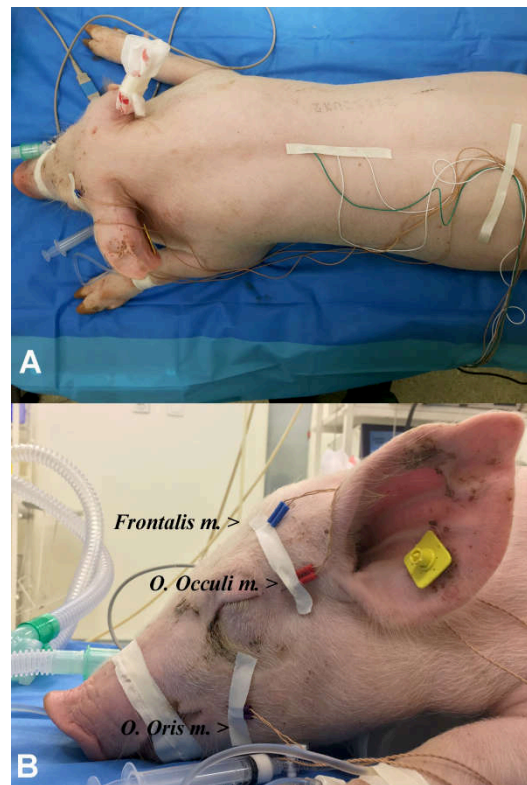


Figure 3-2 Pig positioning and setting up of NIM 3.0 subdermal needle electrodes.

(A) The pig was placed in the prone position. (B) Set-up of subdermal needle paired electrodes attached to the NIM 3.0 (Medtronic). Frontalis, orbicularis oculi (o. oculi), and orbicularis oris (o. oris) electrodes are shown in the figure.

We used the VISAO otologic drill (Medtronic) with the continuous stimulating bur (Stim Bur Gard, SBG) system (Medtronic) connected to the NIM 3.0. The SBG system delivers a continuous stimulating monopolar current on the tip and handle of the drill and the intensity of such current can be varied with the same way like the nerve stimulator monopolar probe. This stimulation system allows a precise and reliable localization and stimulation of the FN during drilling.

In order to investigate the real-time EMG changes in the facial nerve more accurately and efficiently during the procedure, we also tried continuous monitoring via automated periodic stimulation (APS; APS Electrode Stimulator probe [2.0 mm; Medtronic]). APS is a pulse generator for continuous stimulation (1 pulse/6 s, 100 μ s, 1 mA). The conventional monopolar stimulation probe (4 pulses/s, 100 μ s, 1 mA; Medtronic) was used for identification and intermittent stimulation of the facial nerve.

3.2.4.3 Design

In our previous work [1], we established a detailed surgical approach to access the posterior fossa in pigs' specimens using very simple and easily identifiable landmarks. Full exposure of the acoustic-facial-cranial nerve bundle in the CPA and within the IAC was accomplished.

A midline skin incision was made extending in a curvilinear fashion in the postauricular area on both sides. Soft tissue dissection was performed to expose the temporal bone including the external bony canal and mastoid area. It was necessary to partially dissect the muscle overlying the atlanto-occipital joint (AOJ) to facilitate subsequent drilling during craniotomy. The surgical field was maintained bloodless using monopolar or bipolar diathermy [Fig. 3-3].

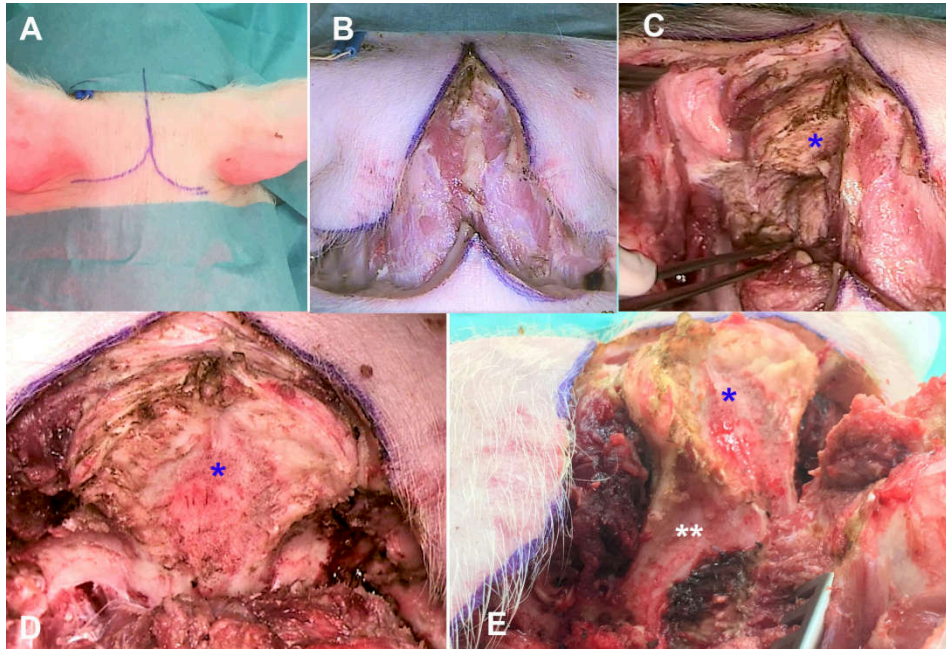


Figure 3-3 Incision, soft tissue dissection and skull base anatomy.

(A,B) In the prone position, a midline skin incision was made extending in a curvilinear fashion into the postauricular area. (C–E) Dissection of soft tissue exposed the occipital bone (blue *), part of the temporal bone and mastoid area covering the posterior fossa (white **) on both sides of the pig.

Craniotomy was performed to skeletonize the posterior fossa dura on both sides using the otologic drill and different diamond burs with a diameter varying from 5 to 3 mm. Continuous saline serum irrigation was provided throughout the drilling to avoid heating. Drilling started along the direction of the posterior wall of the external auditory canal (EAC) which was used as a landmark. Next, an important landmark, the posterior arcade, could be easily identified by its typical yellow color similar to the otic capsule in humans. Skeletonization of the dura was performed medially to the occipital bone and inferiorly to the AOJ. Bone wax and bipolar electrocautery were used to control bleeding from the bony surfaces and from the dura.

A dural incision was carefully performed and brain tissue was exposed. Cerebrospinal fluid (CSF) was gently suctioned from the operating field. The cerebellum was immediately identified and retracted posteriorly [Fig 3-4].

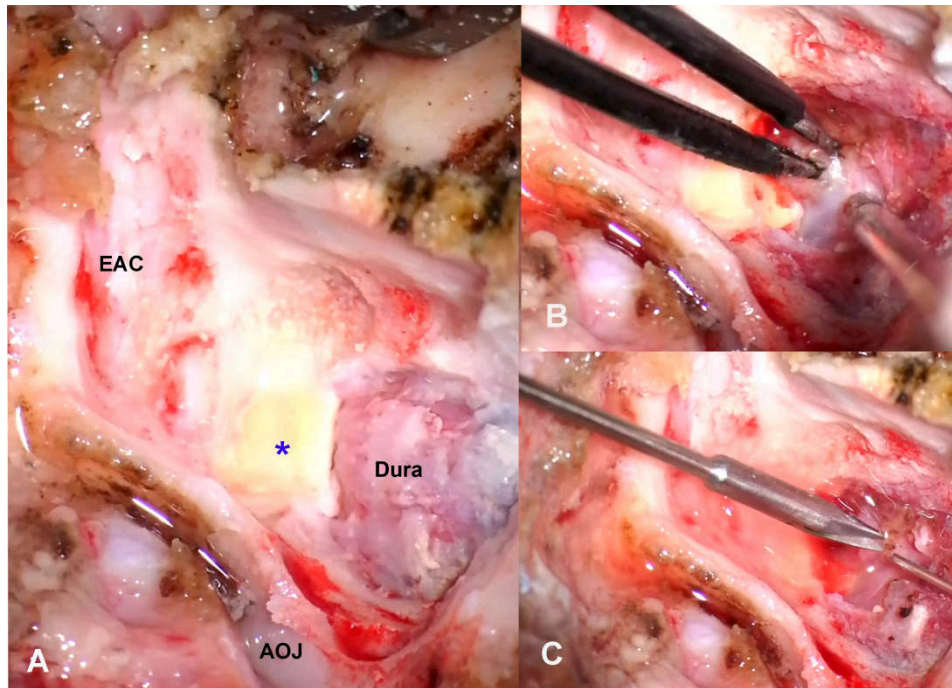


Figure 3-4 Lateral view of craniotomy of a pig's ear on the left side.

(A) Drilling of the posterior wall of the external auditory canal (EAC) as far as the posterior arcade can be identified as a yellow bone (*) beside the dura of the posterior fossa. The mastoid area is partially covered by the atlanto-occipital joint (AOJ).

(C,D) Dural opening and hemostasis using bipolar electrocautery.

The acoustic-facial bundle (cranial nerves VII/VIII) could easily be identified emerging from the pons and entering the IAC. Further exposure of the facial and vestibulocochlear nerve bundle in the IAC could be achieved by careful drilling of the posterior arcade and IAC. Drilling was performed slowly and deliberately using a diamond bur drill at low speed under continuous irrigation. Accordingly, exposure of the complete course of the acoustic-facial bundle (CN VII/VIII) was effected from their emergence in the CPA until they entered the IAC.

The facial/vestibulocochlear nerve complex could be separated from each other. The facial nerve was successfully localized and identified using microsurgical instruments and the conventional hand-held monopolar stimulation probe of the NIM 3 (Medtronic) [Figs 3-5, 6].

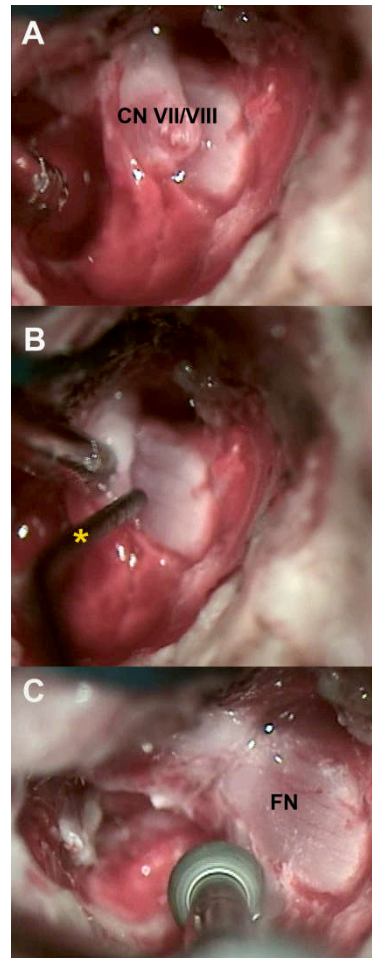


Figure 3-5 The acoustic-facial bundle (cranial nerves VII/VIII) in the IAC.

(A) The facial/vestibulocochlear nerve complex (VII/VIII). (B) Dissection and separation of the facial nerve (FN) guided by the conventional hand-held monopolar probe of the NIM 3 (yellow *). (C) Drilling of the bony IAC around the facial nerve (FN) could be performed to improve nerve exposure and manipulation.

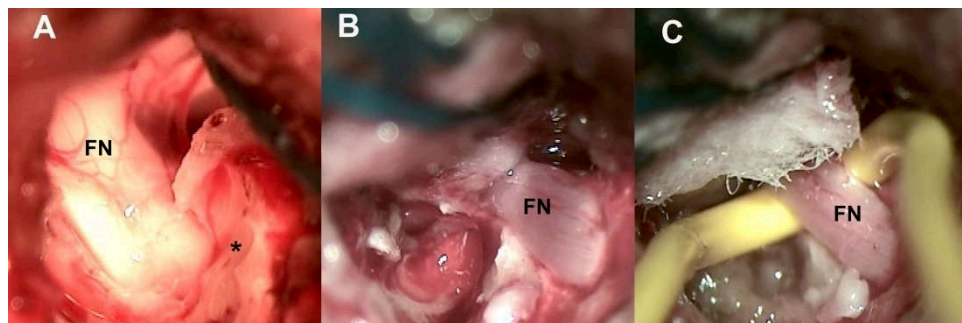


Figure 3-6 Different views of the facial nerve (FN) in the IAC and CPA.

3.2.5 Results

A total of six animals (12 sides) were operated (**Table 1**). Average duration for skin incision, soft tissue dissection of neck muscles and exposure of that part of the temporal bone covering the posterior fossa bilaterally was 38.7 ± 5 min (mean \pm SD).

Table 1. Summary of posterior fossa surgical procedures performed in six animals (total of 12 sides)

Animal	Side	Dural opening (n=12)	FN/Vestibulocochlear nerve identification (n=10)	FN identification and separation (n=9)	APS electrode placement (n=6)	Complication
1	Right	+	-	-	-	Sever Bleeding
	Left	+	+	+	-	-
2	Right	+	+	-	-	Injury to acoustic-facial bundle during drilling of IAC
	Left	+	-	-	-	Sever Bleeding
3	Right	+	+	+	+	-
	Left	+	+	+	+	
4	Right	+	+	+	+	-
	Left	+	+	+	-	FN transected during dissection
5	Right	+	+	+	+	-
	Left	+	+	+	-	FN transected during dissection
6	Right	+	+	+	+	-
	Left	+	+	+	+	
APS, automated periodic stimulation; FN, facial nerve; IAC, internal auditory canal.						

In total, 12 craniotomies were performed as described earlier. Care was taken because thin dura might easily be injured during craniotomy. Venous bleeding from bone or violated sinuses had to be managed by compression or the early use of bone wax and other hemostatics. In fact, severe bleeding was experienced in two sides; hence we had to abandon further work there. The dura was opened in a U-shaped fashion using a scalpel and micro-scissors. If required, a suture was made in the dura to lift it up.

Careful microscopic dissection was performed to expose the acoustic-facial bundle entering the IAC. Experienced use of suction, bipolar cautery, cottonoids, microsurgical instruments and microscope is essential during this step.

After this, exposure of the bundle in the IAC was achieved by slow, deliberate drilling of the posterior arcade and IAC. Injury to the bundle was only encountered once during this study. Microdissection was performed to separate the FN using microsurgical instruments and guided by the NIM 3 conventional hand-held probe as realized in our daily practice during oto-neurosurgical procedures for pathology in the CPA and IAC. Unfortunately, the FN was transected in two sides during dissection.

Electrophysiological testing of the FN in the IAC was performed by supramaximal stimulation at 2 mA and values for both amplitude and latency were recorded. The average maximal amplitude of the responses at 2 mA at the IAC was 4458.7 ± 1604 μ V. The latency value at 2 mA was 5.1 ± 0.98 ms (mean \pm SD).

In order to evaluate the minimal stimulation threshold, an increasing intensity of stimulation was applied in increments of 0.01 mA between 0.03 and 0.10 mA, and in increments of 0.05 mA between 0.10 and 3.0 mA, until a response greater than 100 μ V was obtained on at least 1 channel. The average minimal stimulation threshold was 0.037 ± 0.011 mA.

The first trials to position the APS electrode on the facial nerve in the CPA were performed by keeping the enclosure tabs open with a microforceps; however, some modification to the 2.0 mm APS electrode size was essential for proper handling, insertion, and placement of electrodes and probes on the FN proximally in the CPA. Successful placement of the electrode was accomplished in 6 sides out of the 12 nerves [Figs 3-7, 8].




Figure 3-7 APS electrode.

(A) The original 2 mm APS electrode; a vertical cut was made on each side of the probe parallel to the electrode knob, as indicated by the dashed lines. (B) The shape of the APS after the recommended adjustment.

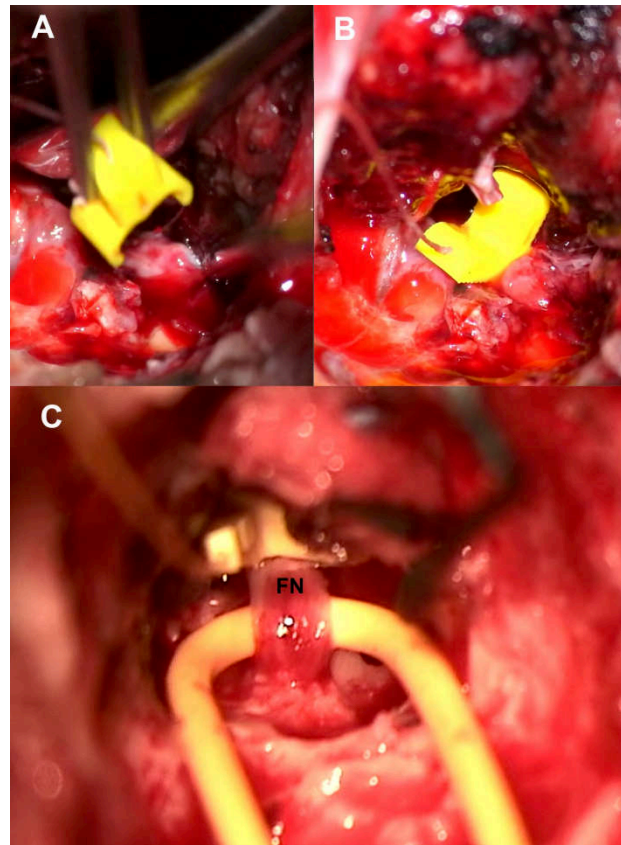


Figure 3-8 Example of APS electrode placement on the facial nerve in the CPA.

(A) Using a microforceps, the APS electrode was positioned by keeping the enclosure tabs open. (B, C) APS electrode after placement on the FN in two different models.

After determining the APS baseline for amplitude and latency of the evoked response, continuous stimulated EMG signals were recorded. An upper threshold for latency (+10%) and a lower threshold for amplitude (−50%) were set as separate alarm thresholds. In addition, acoustic and optical signals alerted the surgeon if a preset threshold had been crossed or if an electrode had been dislodged. Throughout the procedure, we encountered intermittent difficulties associated with excessive CSF production and accumulation, blood accumulation, and the relatively strongly pulsating brain which restricted reliable recording of continuous EMG signals for sufficient time [Fig 9].

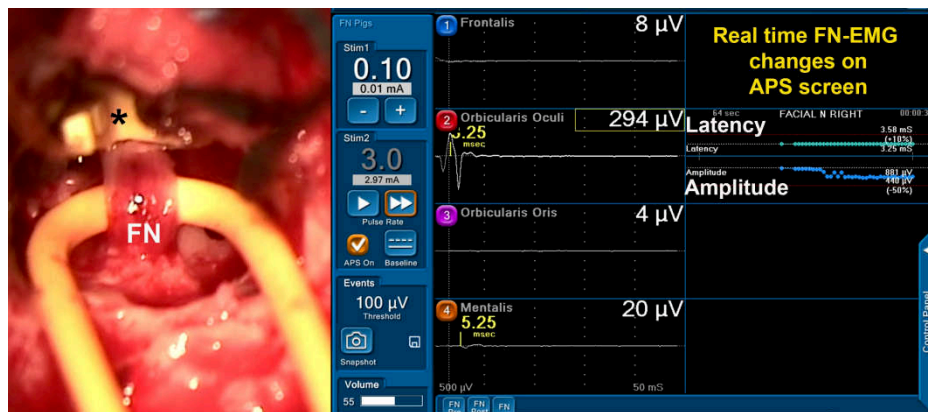


Figure 3-9 Example of APS electrode placement on the facial nerve in the CPA.

FN, facial nerve; APS, a circumferential clip electrode that is placed around the FN for “Automated Periodic Stimulation” with real-time EMG signals of amplitude and latency on the right side.

3.2.6 Discussion

Oto-neurosurgical porcine models, both nonliving and living, are well established for familiarizing trainees with surgical techniques used in cranial approaches, especially around the CPA [4-5, 19]. Cadavers allow the study of neuro-anatomy in a practical way. Identification of anatomical landmarks, skull base anatomy, and training in surgical approaches are strong advantages of using cadaveric specimens. The neuro-anatomy of pigs differs from but remains similar to humans, and allows neurosurgical trainees to quickly focus on their practical skills [2, 4-5, 8, 12-13, 19-20].

Despite all available data on porcine models, few published studies can be found with an oto-neurosurgical background. In an earlier study, we outlined a practical detailed model for a new approach to the posterior fossa in pig cadavers [1]. This unique approach offered satisfactory exposure of the acoustic-facial-cranial nerve bundle with relatively minimally invasive steps and easily identifiable landmarks. Several surgical procedures and manipulations could be simulated on cadavers which represent important steps in all surgical procedures involving the posterior fossa and CPA.

In this study, we were able to reproduce this approach in living animals at our facility. This novel and unique experience ideally mimics daily microneurosurgical practice. Cadaver training allows the trainee to focus more quickly on surgical skills. However, microsurgical

dissection and bleeding management of a pulsating brain under the microscope are particularly challenging skills which can only be acquired or mastered on a living model.

Skin incision and soft tissue dissection were performed in a fashion much as in humans, although thicker skin and massive muscle mass could be observed in the occipital and temporal area. The surgical field could easily be maintained bloodless using compression, hemostatics and monopolar diathermy.

Furthermore, the in vivo model presented here has major advantages in regard to bleeding management, craniotomy, dura opening and appropriate CSF suction without damaging brain tissue, suctioning while bleeding, and finally handling the microscope and microsurgical instruments. These skills are major components of cranial surgery, and, using this in vivo model, it is possible to train without risk to the patient (Table 2).

Table 2. Comparison between in vivo and cadaveric porcine model specimen related to the surgical skills which can be obtained		
Surgical skills and learning objectives	Cadaver	In vivo
Set-up compared to real operating room	0	++
Skin incision, soft tissue preparation and dissection	+	++
Hemostasis and bleeding management (compression, hemostatics and bipolar coagulation)	0	+
Identification of anatomical landmarks and skull base anatomy	+	+
Craniotomy, bone drilling	+	++
Dura opening	+	++
Brain parenchyma and CPA anatomy	+	++
Bipolar cautery and suction in CPA	0	++
Cranial nerve microsurgical manipulation (identification, dissection, electrophysiological testing)	0	++
CPA, cerebellopontine angle. 0, ineligible 0; +, appropriate+; ++, ideal.		

A valuable advantage of this study is the adequate exposure of the acoustic-facial bundle in the CPA and IAC. For otologists and neurosurgeons, this porcine model offers surgical landmarks that are directly analogous to those encountered in current microsurgical practice in the posterior fossa during removal of pathology such as acoustic neuroma or meningioma.

In contrast to cadavers, this in vivo model permitted us to implement IONM using conventional hand-held stimulation electrodes to guide the dissection and exposure of the FN. IONM helped in FN dissection in about 75% of specimens.

The C-IONM system has become an area of keen interest as it offers advantages over conventional I-IONM. The main drawback of the intermittently working conventional hand-held stimulation electrodes is that the FN is still at risk of damage between the two

stimulation cycles. A continuous neuromonitoring system would be able to test the functional integrity of the recurrent laryngeal nerve (RLN) in real time and might prevent nerve damage. Thus, ongoing animal and clinical studies have been trying to improve our understanding of IONM technology and the electrophysiology of nerve injury specifically in thyroid surgery to avoid RLN injury. Consequently, several varieties of electrodes have been designed for C-IONM for stimulation of the vagus nerve, which is reported to offer more seamless monitoring of the nerve's functional integrity during surgery [16, 21-23].

Despite all the available data in the literature, the current status of C-IONM of the FN during CPA surgery has not yet been elaborated. In this study, we tried to show the feasibility of placement of the APS electrode on the FN and recording satisfactory EMG signals. The 2.0 mm APS electrode is relatively large in comparison to the more limited dimensions of the porcine posterior fossa. Hence, the commercially available electrode was modified as described earlier to safely position the electrode on the FN. Subsequent successful trials of implantation and removal of the electrode were achieved atraumatically.

Another challenge was encountered after electrode placement; that the duration of stimulation by APS was not stable or continuous for sufficient time to evaluate the continuous monitoring of the nerve. Recurrent incidental dislocation of the electrode or instability due to excessive CSF and/or blood accumulation was evident. Moreover, the pulsating brain might cause electrode displacement in the relatively small surgical field.

The main goal of our study was effectively accomplished. The *in vivo* model and approach to the posterior fossa presented here appears technically feasible in regard to otoneurosurgical daily practice. It could complement other surgical educational programs for young surgeons such as using cadavers or virtual reality models. In addition, preliminary experience with electrophysiological testing of the FN was highlighted using combined intermittent and continuous IONM systems.

This study had several limitations. This is an animal model with small sample size. The specific data in this study concerning electrophysiological evaluation of the FN cannot be completely generalized. First, anesthetic factors such as mean blood pressure, end-tidal CO₂ and core body temperature should be controlled in future experiments to allow a more extended duration of stimulation by APS without excessive pulsation, bleeding and CSF accumulation. Another limitation was the APS electrode size. Modification of the electrode

was mandatory for it to fit in the posterior fossa without injury to the FN. Finally, another drawback was the limited histopathological analysis of the FN after electrode placement.

3.2.7 Conclusions

The present study is the first attempt to develop a simple in vivo surgical model specifically to approach the CPA and IAC that can be used as an outline for complementary surgical training of otologists and neurosurgeons with successful implementation of IONM of the FN. Further research is needed on facial nerve testing and on its neurophysiological behavior. Trials of different electrodes for C-IONM of the FN and under different controlled stresses to the nerve will be implemented in future work. This may lead to new concepts in operative strategy on the basis of real-time C-IONM data during CPA surgery and hence, reduce the risk of inadvertent iatrogenic injury of the FN.

3.2.8 Acknowledgments

We would like to gratefully thank Medtronic Xomed (Jacksonville, FL, USA) for their materials and technical support.

3.2.9 References

1. Elsayed M, Torres R, Sterkers O, Bernardeschi D, Nguyen Y. Pig as a large animal model for posterior fossa surgery in oto-neurosurgery: A cadaveric study. *PLoS One*. 2019;14(2):e0212855.
2. Aurich LA, Silva Junior LF, Monteiro FM, Ottoni AN, Jung GS, Ramina R. Microsurgical training model with nonliving swine head. Alternative for neurosurgical education. *Acta cirurgica brasileira*. 2014 Jun;29(6):405-9.
3. Gurr A, Stark T, Probst G, Dazert S. [The temporal bone of lamb and pig as an alternative in ENT-education]. *Laryngo- rhino- otologie*. 2010 Jan;89(1):17-24.
4. Regelsberger J, Eicker S, Siasios I, Hanggi D, Kirsch M, Horn P, et al. In vivo porcine training model for cranial neurosurgery. *Neurosurgical review*. 2015 Jan;38(1):157-63; discussion 63.
5. Regelsberger J, Heese O, Horn P, Kirsch M, Eicker S, Sabel M, et al. Training microneurosurgery - four years experiences with an in vivo model. *Cent Eur Neurosurg*. 2011 Nov;72(4):192-5.
6. Parsak T. Posterior fossa approach: microneurosurgical training model in cadaveric sheep. *Turkish Neurosurgery*. 2006;16(3):111-4.
7. Gurr A, Kevenhorster K, Stark T, Pearson M, Dazert S. The common pig: a possible model for teaching ear surgery. *European archives of oto-rhino-laryngology : official journal of the European Federation of Oto-Rhino-Laryngological Societies*. 2010 Feb;267(2):213-7.
8. Lind NM, Moustgaard A, Jelsing J, Vajta G, Cumming P, Hansen AK. The use of pigs in neuroscience: modeling brain disorders. *Neuroscience and biobehavioral reviews*. 2007;31(5):728-51.
9. Hoffstetter M, Lugauer F, Kundu S, Wacker S, Perea-Saveedra H, Lenarz T, et al. Middle ear of human and pig: a comparison of structures and mechanics. *Biomedizinische Technik Biomedical engineering*. 2011 Jun;56(3):159-65.
10. Lovell JM, Harper GM. The morphology of the inner ear from the domestic pig (*Sus scrofa*). *Journal of microscopy*. 2007 Dec;228(Pt 3):345-57.
11. Garcia Lde B, Andrade JS, Testa JR. Anatomical study of the pigs temporal bone by microdissection. *Acta cirurgica brasileira*. 2014;29 Suppl 3:77-80.

12. Jarrahy R, Shahinian HK, Young J, Berci G. Endoscopic skull base surgery II: a new animal model for surgery of the posterior fossa. *Journal of investigative surgery : the official journal of the Academy of Surgical Research*. 1999 Nov-Dec;12(6):335-9.
13. Hamamcioglu MK, Hicdonmez T, Tiryaki M, Cobanoglu S. A laboratory training model in fresh cadaveric sheep brain for microneurosurgical dissection of cranial nerves in posterior fossa. *British journal of neurosurgery*. 2008 Dec;22(6):769-71.
14. Acioly MA, Liebsch M, de Aguiar PH, Tatagiba M. Facial nerve monitoring during cerebellopontine angle and skull base tumor surgery: a systematic review from description to current success on function prediction. *World Neurosurg*. 2013 Dec;80(6):e271-300.
15. Oertel J, Tschan CA, Keiner D. Animal Models for Experimental Neurosurgery of Peripheral and Cranial Nerves. *Experimental Neurosurgery in Animal Models*. 2016:151-63.
16. Wu CW, Randolph GW, Lu IC, Chang PY, Chen YT, Hun PC, et al. Intraoperative neural monitoring in thyroid surgery: lessons learned from animal studies. *Gland Surg*. 2016 Oct;5(5):473-80.
17. Knight MJ, McDonald SE, Birchall MA. Intrinsic muscles and distribution of the recurrent laryngeal nerve in the pig larynx. *Eur Arch Otorhinolaryngol*. 2005 Apr;262(4):281-5.
18. Tanaka H, Kobayashi E. Education and research using experimental pigs in a medical school. *J Artif Organs*. 2006;9(3):136-43.
19. Turan Suslu H, Ceylan D, Tatarli N, Hicdonmez T, Seker A, Bayri Y, et al. Laboratory training in the retrosigmoid approach using cadaveric silicone injected cow brain. *British journal of neurosurgery*. 2013 Dec;27(6):812-4.
20. Sauleau P, Lapouble E, Val-Laillet D, Malbert CH. The pig model in brain imaging and neurosurgery. *Animal : an international journal of animal bioscience*. 2009 Aug;3(8):1138-51.
21. Schneider R, Przybyl J, Pliquett U, Hermann M, Wehner M, Pietsch UC, et al. A new vagal anchor electrode for real-time monitoring of the recurrent laryngeal nerve. *Am J Surg*. 2010 Apr;199(4):507-14.
22. Lee HY, Cho YG, You JY, Choi BH, Kim JY, Wu CW, et al. Traction injury of the recurrent laryngeal nerve: Results of continuous intraoperative neuromonitoring in a swine model. *Head Neck*. 2016 Apr;38(4):582-8.
23. Lin YC, Dionigi G, Randolph GW, Lu IC, Chang PY, Tsai SY, et al. Electrophysiologic monitoring correlates of recurrent laryngeal nerve heat thermal injury in a porcine model. *Laryngoscope*. 2015 Aug;125(8):E283-90.

3.3 Optimization of facial nerve outcome by intraoperative electromyography guided microsurgical resection of large vestibular schwannomas.

This Manuscript has been submitted as: *Mohamed Elsayed , Huan Jia, Baptiste Hochet, Olivier Sterkers, Renato Torres, Yann Nguyen, Isabelle Bernat, Ghizlene Lahlou , Michel Kalamarides."* *Optimization of facial nerve outcome by intraoperative electromyography guided microsurgical resection of large vestibular schwannomas. "Otology & Neurotology, February 2020.*

3.3.1 Optimization of facial nerve outcome by intraoperative electromyography guided microsurgical resection of large vestibular schwannomas

Running title: Optimization of facial nerve outcome in vestibular schwannoma surgery

Mohamed Elsayed MD^{1,2,4}, Huan Jia MD, PhD^{1,2,5}, Baptiste Hochet MD^{1,2}, Olivier Sterkers MD, PhD^{1,2}, Renato Torres MD, PhD^{1,6}, Yann Nguyen MD, PhD^{1,2}, Isabelle Bernat MD^{1,2}, Ghizlene Lahlou MD^{1,2}, Michel Kalamarides MD, PhD^{1,3}

1 Sorbonne Université-APHP, Groupe Hospitalier Pitié-Salpêtrière, Department of Otolaryngology, Auditory Implants and Skull Base Surgery, 75013, Paris, France

2 Sorbonne Université-APHP, Groupe Hospitalier Pitié-Salpêtrière, Department of Clinical Neurophysiology, Paris

3 Sorbonne Université-APHP, Groupe Hospitalier Pitié-Salpêtrière, Department of Neurosurgery, Paris, France

4 Alexandria University, Faculty of Medicine, ORL Department, Alexandria, Egypt

5 Shanghai Key Laboratory of Translational Medicine on Ear and Nose Diseases (14DZ2260300), Shanghai, China; Sino-francais joint clinic research center on Otolaryngology and Neuro-Otolaryngology, Shanghai 9th People's Hospital, Shanghai Jiatong University School of Medicine, Shanghai, China

6. Universidad Nacional de San Agustín, Facultad de Medicina, Centro de Investigación y Desarrollo Científico, Arequipa, Peru

Conflicts of Interest and Source of Funding: The authors report no conflict of interest concerning the materials or methods used in this study or the findings specified in this paper. This work was supported by the Ministry of Higher Education, Mission sector, Egypt (<http://www.mohe-casm.edu.eg>) and the Ministry of Scientific Research, Egypt to Mohamed Elsayed; and was supported by the Shanghai Scientific and Technological

Innovation Action Plan (17441903600) to Huan Jia. The funders had no role in study design, data collection and analysis, decision to publish, or preparation of the manuscript.

3.3.2 Abstract

Objective: Decision making for large sporadic vestibular schwannomas (VS) guided by the intraoperative change in supramaximal facial nerve (FN) amplitude and latency response to optimize FN outcome.

Study Design: Monocentric prospective study.

Setting: Tertiary referral care center.

Patients: From January to December 2018, 43 large sporadic VS and 2 neurinoma-like meningiomas with preoperative normal FN function were included.

Intervention(s): Tumors were removed through retrosigmoid (84%) or translabyrinthine (16%) approaches with FN monitoring.

Main Outcome Measure(s): Intraoperative pre- and post-VS resection supramaximal (2 mA) amplitude and latency responses and post-resection threshold at 100 μ V at the proximal FN root were recorded.

Results: Total, near-/subtotal VS resections (TR, NTR, STR) were achieved in 51%, 38%, and 11% of tumors, respectively, guided by no more than a 30–40% decrease in supramaximal amplitude. Pre- and post-resection supramaximal amplitude and latency responses were lower and longer, respectively, in NTR+STR than in TR. At day 8, FN function was grade I-II in 78% of patients and grade III-V in 22%, and after 6 months to 1 year, it was in grade I-II in 96% and grade III in 4%, and there was no significant difference between TR and NTR+STR. Facial palsy occurred in older patients and in the case of severe FN adhesion. At day 8, pre- and post-resection supramaximal amplitude but not latency responses were different between FN grade III-V and grade I-II. Serviceable hearing was preserved in 27% of large VS.

Conclusions: Intraoperative FN monitoring guided VS resection in large VS so that 49% retained some residual tumor. Accordingly, 96% good postoperative FN function and significant hearing preservation were achieved.

Keywords (MeSH): Vestibular schwannoma, Intraoperative facial nerve monitoring, Electromyography supramaximal amplitude and latency responses, Total and near-/sub-total surgical resection, Facial nerve outcome, Hearing preservation

3.3.3 Introduction

Vestibular schwannoma (VS) is a benign, slow-growing tumor of the Schwann cells originating from the vestibular branch of the eighth cranial nerve, with an incidence of 12.4 tumors per million persons per year. Therapeutic options include an active wait-and-scan policy, stereotactic radiosurgery, and microsurgical resection [1].

The generally accepted goals of VS surgery are gross total removal of the tumor and maintenance of a good postoperative quality of life. Facial nerve function preservation is a primary goal because postoperative facial palsy is a devastating complication. Loss of facial expression is a functionally and psychologically debilitating condition [2].

FN preservation, both anatomically and functionally, is often challenging because anatomical integrity of the nerve does not necessarily imply functional neural integrity. FN in contact with VS tends to be compressed and flattened, and it can even become membranous, adopting a color similar to that of the surrounding tissue. Moreover, variations in the location of the FN and other cranial nerves are frequently encountered during surgery [3,4]. Despite major advances in the field of VS diagnosis and surgery, 6–20% of poor facial function (grade III–VI in the House-Brackmann [HB] classification [5]) can occur after surgery [6].

Prognostic factors influencing the early and long-term FN postoperative outcomes have been widely studied. For instance, the tumor size and characteristics, adhesion of the FN to surrounding tissue, and electromyography (EMG) responses have all been recognized as significant prognostic factors influencing FN function [6,7].

Perhaps the most significant advancement in FN preservation came in the 1980s with the widespread use of intraoperative FN-EMG. Routine monitoring during microsurgical resection has now become an essential part of cranial base surgery [8]. Intraoperative monitoring aims to make the surgical team aware of the ongoing changes in neural function, thereby permitting modifications in surgical strategies that can ultimately avoid neural damage.[3]

Intraoperative electrophysiological responses that can accurately predict postoperative FN outcome would improve the ability to perform tailored resections, such as sub-total resection (STR) and near-total resection (NTR), which are now being performed more frequently to minimize the risk of FN injury [1,8].

In this context, we conducted a prospective study of patients who were operated for microsurgical resection of VS with anatomic preservation of the facial nerve. The primary goal of this study was to identify the clinical peri-operative factors that could determine the occurrence of an immediate postoperative impaired facial function and recovery in the long-term. Secondly, to refine the predictive value of intraoperative monitoring, we thought it would be interesting to investigate FN monitoring parameters (i.e. pre- and post-surgical resection ratios of amplitude and latency values at supramaximal stimulation) to determine if either value could prognosticate FN outcome.

3.3.4 Materials and Methods

The work was designed as a monocentric prospective study from January to December 2018 in a tertiary referral center. Institutional review board approval was obtained from the Ethics Committee of our institution (CPP-Ile de France VI, Groupe Hospitalier Pitié-Salpêtrière) for analysis of medical records and imaging data.

The study included 45 patients who had surgery for solitary VS or neurinoma-like meningioma with normal preoperative facial palsy. Pre- and intraoperative factors that could influence immediate FN outcome at day 1 and day 8 (maximal nervous conduction block [7]), and subsequent FN function recovery at 1 month, and 6 months to 1 year were studied in all patients.

Exclusion criteria were preoperative facial palsy, neurofibromatosis type 2 (NF2), recurrent VS, and interruption of the facial nerve during surgery.

In all cases, written informed consent was obtained for the surgery and the research studies (CNIL#2211758). Data was analyzed anonymously and consideration was given to confidentiality.

Intraoperative monitoring of facial nerve function was achieved with a four-channel nerve monitoring system (NIM® 3.0, Medtronic, Jacksonville, FL, USA). For the translabyrinthine approach, a StimBurr guard system (Medtronic) was used. Electrophysiological monitoring of the facial nerve requires avoidance of neuromuscular blockade during the intervention. Subdermal needle electrodes were placed in optimal locations to record activity from the facial muscles, typically in the four muscle areas innervated by the facial nerve: *frontal*, *orbicularis oculi*, *orbicularis ori*, and *mentalis*.

Ground and stimulator anode electrodes were also placed. A monopolar probe with a 0.5-mm tip was included in the sterile operating field. All electrode wires were connected to an interface circuit box. Stimulus intensity, duration, rate, and event threshold were set. Typical parameters used at our institution were: stimulus intensity ranging from 0.01 mA to 3 mA; duration, 100 μ s; and event threshold, 100 μ V.

All patients received an intravenous bolus of methylprednisolone (1 mg/kg) at anesthesia induction. In the case of impaired FN function at postoperative day 1, corticosteroid therapy (methylprednisolone, 1 mg/kg/day) was administered for 1 week. No antiviral therapy was administered as prophylaxis or in the case of facial palsy.

3.3.4.1 Clinical characteristics

Patient characteristics included age, sex, symptoms at diagnosis, and delay between the first diagnostic MRI until the time of surgery.

3.3.4.2 Audiometric evaluation

Pre- and postoperative hearing was assessed by pure tone average (PTA) at 0.5, 1, 2, and 3 kHz, and speech discrimination score (SDS) with monosyllabic lists (*Lafon list*). Audiometric tests were performed in a soundproof booth. PTA was combined with SDS to report hearing using the 4-class system according to the recommendations of the AAO-HNS hearing loss scale [9] as class A (pure-tone thresholds (PTA) \leq 30 dB, and speech discrimination (SD) \geq 70%), class B (30 dB < PTA \leq 50 dB, and SD \geq 50%), class C (PTA > 50 dB, and SD \geq 50%), and class D (whatever the PTA value, and SD < 50%).

3.3.4.3 Radiological characteristics

Tumors were categorized according to the largest diameter in the axial or coronal view, and if necessary, in the magnetic resonance imaging (MRI) view of the cerebellopontine angle (CPA) on gadolinium-enhanced sequences as already described [1,4,6,7,10] in four functional stages: stage 1 (intracanalicular), stage 2 (\leq 15 mm maximal extracanalicular diameter), stage 3 (15–30 mm), or stage 4 (>30 mm); the cystic character of the tumor was defined on the preoperative MRI and classified as solid or cystic vestibular schwannoma. Fundus involvement was determined by considering the tumor extension

toward the lateral end of the internal auditory meatus (IAM), as A (fundus invasion), B (fundus free of tumor), and C (internal auditory meatus free) [6].

3.3.4.4 Intraoperative surgical data

All patients were operated on in the supine position under general anesthesia through a translabyrinthine (TL) or retrosigmoid (RS) approach. When the VS totally invaded the IAM fundus with no direct microscopic visualization, dissection of the tumor from the FN was performed under endoscopic view. The facial nerve position relative to the tumor was identified [4] (type 1: anterior-inferior; type 2: anterior; type 3: superior; or type 4: posterior). Tumor adhesion was defined by the senior surgeons as: weak (the dissection plane between the tumor capsule and the facial nerve was easily recognized and detachable), moderate (the dissection plane was recognizable but adhesion to the facial nerve sheath was significant), and strong (the dissection plane was not recognizable).

3.3.4.5 Intraoperative FN monitoring parameters

A mono-polar probe with a 0.5-mm tip electrically stimulated the FN at constant current. Before tumor excision, the FN was stimulated at its root entry zone (proximal-pre), at a sufficient distance of the adhesion zone of the FN to the tumor capsule to avoid concomitant stimulation of its distal axons. The FN was exposed either immediately after opening the cisterna for middle-sized VS or after first debulking its posterior extension for larger VS. Then, during VS removal, the FN was stimulated either to locate the course of the nerve on the VS capsule at 0.8–1 mA or to identify a significant amplitude response decrease at a supramaximal value of 2 mA. After VS excision, the FN was stimulated again at the root entry zone (proximal post), and when possible in the IAM (distal post). The following parameters were measured:

1) *Maximal amplitude of the responses* (in microvolts; μV) after supramaximal stimulation at 2 mA before and after tumor excision to determine if it had decreased by not more than 30–40% of its initial value throughout the surgical procedure.

2) *Latency values* (in milliseconds; ms) after supramaximal stimulation at 2 mA before and after tumor excision to disclose an increase in responses.

3) *Stimulation threshold* (in milliamperes; mA), with increasing intensity of stimulation in increments of 0.01 mA between 0.03 and 0.10 mA, and of 0.05 mA further, if necessary, until a response greater than 100 μ V on at least one channel was obtained at the end of VS resection.

3.3.4.6 Assessment of FN function

FN function was clinically determined by a senior ENT surgeon at day 1, day 8 (during the subsequent week), 1 month, and between 6 months and 1 year after surgery. Day 8 was identified as being, in most cases, the time of maximal nervous conduction block in the early postoperative period [7]. In a few cases, the day 8 outcome deteriorated later, and this was indicated as delayed facial palsy. The House–Brackmann facial nerve grading scale (HB) [5] was used to assess FN function. Good FN function was defined as HB I–II and impaired FN function as HB III–V.

3.3.5 Statistical analysis

All statistical analyses were performed with IBM SPSS statistical software package version 20.0 (Armonk, NY: IBM Corp.). Qualitative data were described using numbers and percentages. The Kolmogorov–Smirnov test was used to verify the normality of the distribution. Descriptive data were reported using mean \pm SD, range [minimum and maximum], and median value. Univariate logistic regression models were performed to assess the association between baseline characteristics and facial function at day 8 and 1-year postoperatively. All differences between groups with a p-value \leq 0.05 were considered to be significant.

3.3.6 Results

3.3.6.1 Population and intraoperative data (Table 1)

In total, 45 patients hosting 43 unilateral VS and 2 neurinoma-like CPA meningioma (considered to be VS) were included in this study with a mean age of 51 \pm 11.4 years (range 20–78 years), equally distributed below and above 50 years, 20 males and 25 females.

At diagnosis, hearing loss was the prevalent symptom (93% of cases), with a sudden onset in 16% of patients, and then tinnitus (24%), trigeminal hypoesthesia (21%), and

instability (12%) or vertigo (10%); all symptoms observed in large tumors. Indeed, tumors were almost all stage 3 and 4 with frequent invasion of the fundus of the IAM (58%).

Surgery was performed at least 1 year after the diagnosis was made (mean \pm SD, 15 \pm 24.5 months; range, 1 month to 10 years), 73% being operated on during the first post-diagnosis year. VS were resected mainly through a RS approach (84%), a TL approach being reserved for VS with poor hearing. In this large VS population, hearing was generally preserved preoperatively, and still serviceable in 78% of patients. Intraoperatively, the FN was more frequently located anteriorly to the VS (73%) than superiorly (20%), and its adhesion to the VS capsule was distributed equally between weak (40%), moderate (31%), and severe (29%). VS resection was considered to be total, near-total or sub-total in 51%, 38%, and 11% of cases, respectively. No major complications were observed, apart from a retro-auricular hematoma in a wound and a CSF leakage, both cured by revision surgery.

The pre- and post-resection supramaximal amplitude responses were 2212 \pm 1368.9 and 1572 \pm 1044.4 μ V, respectively, with a mean amplitude decrease of 28 \pm 23.7%. The supramaximal latency values remained stable at 6.3 ms.

Table 1. Patients' characteristics and general outcomes

		No.	%
Gender	Male	20	44
	Female	25	56
Age(year)	51±11.4[20-78]		
Symptoms	Progressive HL	35	78
	Tinnitus	24	53
	Trigeminal defect	21	47
	Instability	12	27
	Vertigo	10	23
	Sudden HL	7	16
	Headache	3	7
	Caudal nerve defect	1	2
Hearing (AAO-HNS)	A	21	47
	B	14	31
	C	1	2
	D	9	20
VS volume (Functional staging)	I	0	0
	II	2	5
	III	28	62
	IV	15	33
IAM invasion	A	26	58
	B	12	27
	C	7	15
Cystic VS (n=43)	No	26	60
	Yes	17	40
Approach	RS	38	84
	TL	7	16
Origin of VS	Inf. Vest. N	20	45
	Sup. Vest. N	19	42
	unsure	6	13
FN positioning	Anterior-inferior	3	7
	Anterior	33	73
	Superior	9	20
FN adherence to VS	Weak	18	40
	Moderate	14	31
	Severe	13	29
VS type of resection	Total	23	51
	Near-total	17	38
	Sub-total	5	11
Proximal supramaximal FN amplitude response (µV)	Pre-resection	2212±1386.9 [170- 6446]	
	Post-resection	1572±1044.4 [122- 4519]	
	Amplitude loss	28±23. 7 %	

Proximal	supramaximal	Pre-resection	6.3±1.32	[4.4-10.0]
FN latency (ms)		Post-resection	6.3±1.48	[4.4-10.9]

3.3.6.2 Type of VS resection (Table 2)

Tumors were removed using an RS approach in the majority of patients (84%) to attempt to preserve hearing whatever the preoperative state of hearing or VS size, and a TL approach (16%) was used only if anacusis (n=6) or a rapidly growing stage 4 VS (n=1) invaded the IAM fundus.

Gross-total resection was performed in 23 cases (51%), and in the remaining cases, VS were partially resected leaving a small piece of tumor adherent to the FN considered as a function of the length of the adherent zone as near- or sub-total resection in 17 and 5 patients, respectively. Stage 3 VS were more frequently totally resected and stage 4 partially resected ($p<0.05$). Accordingly, all small tumors were completely removed, but this dropped to 60% for mid-sized tumors while only 27% of large tumors were completely removed. Adhesion was estimated to be weak in the majority of TR ($p<0.005$) and severe in the majority of NTR/STR ($p<0.005$). Moderate adhesion was distributed equally between the two groups.

Decision making for a partial (NTR/STR) resection was guided by both intraoperative evaluation of severe FN adhesion to the VS and a decrease of at least 30–40% of the supramaximal amplitude response. Before dissection of the tumor from the FN, the supramaximal amplitude responses were lower for partial resections than for total resections ($p<0.05$) and latencies were higher for partial resections than for total resections ($p=0.05$). In the group with partial resections, amplitude responses less than 1000 μ V were recorded (n=3) but not in the group with total resections. For pre-VS resection latencies longer than 8 ms (n=6), TR was performed for only 1 VS. At variance with this, resection had been total when the pre-VS resection amplitude responses were higher than 3500 μ V (n=5). Nevertheless, supramaximal amplitude response losses between pre- and post-VS resection were similar in both groups, from 24% to 34% in total and partial excision groups. No changes in supramaximal stimulation latencies were noted in the two groups. The 100 μ V threshold could be obtained at low stimulation values in both groups.

For NTR, in most cases, the residual tumor was not enhanced on early postoperative contrast MRI although it was enhanced for STR. MRI scans performed from 1 week to 1 year

postoperatively were available in only 18 cases. They were all negative (n=5) among 23 TR, either negative (n=7) or with residual tumor (n=4; mean volume 492 mm³ [25–756]) among 17 NTR, and with residual tumor (n=2; 245 and 3366 mm³) among 5 STR.

Table 2: Factors influencing decision making for VS resection type

Surgical decision			Total resection (n=23)	Partial resection (n=22)	P-value
Tumor Stage		II	2 (9%)	-	-
		III	17 (74%)	11(50%)	< 0.05
		IV	4 (17%)	11(50%)	
FN adhesion to VS		Weak	14 (61%)	4(18%)	< 0.05
		Moderate	7 (30%)	7(32%)	n.s.
		Severe	2 (9%)	11(50%)	< 0.05
Proximal supramaximal FN amplitude response (μV)		Pre-resection	2659±1624.1 [1000–6446]	1744±904.9 [170–3197]	< 0.05
		Post-resection	1951±1158,1 [835-4519]	1175±746,9 [122–3009]	< 0.001
Proximal supramaximal FN latency (ms)		Pre-resection	5.9±1,17 [4.4-8.7]	6.7±1.37 [4.9-10.0]	< 0.05
		Post-resection	5.8±1.14 [4.4-8.6]	6.9±1.64 [4.6-10.9]	< 0.02
Post-resection threshold at 100μV (mA)			0.06±0.14[0.03-0.7]	0.05±0.10 [0.03-0.5]	n.s.
FN outcome	Day 8	I – II	19(82.6%)	16(72.7%)	
		III – VI	4(17.4%)	6(22.9%)	
		V	-	1(4.4)	
	1 year	I – II	22(95.7%)	21(95.5%)	
		III – VI	1(4.3%)	1(4.5%)	
Hearing preservation (n=36)		A/B/C	5/21 (24%)	7/15 (47%)	
FN: facial nerve; Proximal supramaximal (2mA) FN amplitude responses or latencies, and threshold at 100μV determined at cerebellopontine FN root.					

3.3.6.3 Facial nerve function outcome (Table 3, and Fig. 3-10)

The day after surgery, FN function was considered to be good in 91% of patients (19 and 22 patients with Grade I and Grade II, respectively). Only 4 of them were evaluated as Grade III. At day 8, when nervous conduction block is known to be maximal, a good FN function was achieved in 78% and distributed as follows: Grade I in 20 patients, Grade II in

15, Grade III in 6, Grade IV in 3, and Grade V in 1 patient. Facial paralysis (FP) was observed in 6 more patients than at day 1 (Fig. 1); no further delayed FP was noted. FP occurred in older patients compared with those with good FN function (58 ± 8.5 years vs. 49 ± 11.5 years, respectively; $p < 0.05$).

The symptoms at diagnosis, VS volume, IAM invasion, hearing level, surgical approach, FN position, vestibular nerve origin, and resection type did not influence the onset of FP. At variance with this, severe FN adhesion to the VS capsule was a negative factor (7/35 Grade I–II vs 6/10 Grade III–V, $p < 0.02$), but this was not the case with either weak or moderate FN adhesion.

Pre- and post-resection supramaximal FN amplitude responses were lower when FN function was maximally altered at day 8 than in the absence of major FN impairment. The decrease in responses was similar in the two groups (Table 3). However, the ratio between distal, as recorded at the fundus or nearby, and proximal post-resection supramaximal FN amplitude responses reached higher values in the presence of FP ($62 \pm 20.2\%$ [32–85], $n = 8$ Grade III–V vs $39 \pm 13.1\%$ [15–59], $n = 23$ Grade I–II $p < 0.01$). The supramaximal FN latencies and the threshold at $100 \mu V$ were not different between the two groups (Table 3).

The electrophysiological parameters influencing the onset of a nervous conduction block were evaluated at day 8 by analyzing separately Grade I considered to be a normal nerve, Grade II as weakly altered, and Grade III–V as a moderately to severely injured nerve. Pre- and postoperative supramaximal amplitude responses were similar in the two former groups but lower in the latter group indicating that Grade I and Grade II could be analyzed together.

As shown in Fig. 1, the FN recovered with 89% Grade I–II at 1 month, and 96% after more than 6 months (35 Grade I and 8 Grade II). Only two patients still had Grade III FP after 6 months to 1 year of postoperative follow-up, one in each of the two groups, total and partial VS resections. Neither clinical, nor radiological, nor intraoperative observations nor EMG recordings were found to influence FN recovery.

Table 3. EMG parameters influencing FN function (HB scaling) at post-operative day 8

		FN function at D8		P-value
		Grade I-II (n=35)	Grade III-V (n=10)	
Proximal	Pre-resection	2433±11436.7	1436±924.3	<0.05
supramaximal		[753-6446]	[170-3029]	
FN amplitude	Post-resection	1746±1069.2	960±691.4	<0.01
response (μV)		[393-4519]	[122-2547]	
Proximal	Pre-resection	6.3±1.37	6.2±1.15	n.s.
supramaximal		[4.5-10.0]	[4.4-8.0]	
FN latency (ms)	Post-resection	6.4±1.57	6.3±1.16	n.s.
		[4.4-10.9]	[4.5-7.5]	
Post-resection threshold at 100μV (mA)		0.03±0.0	0.15±0.24	<0.01
		[0.03-0.04]	[0.03-0.7]	

FN: facial nerve; Proximal supramaximal (2mA) FN amplitude responses or latencies, and threshold at 100μV determined at cerebellopontine FN root.

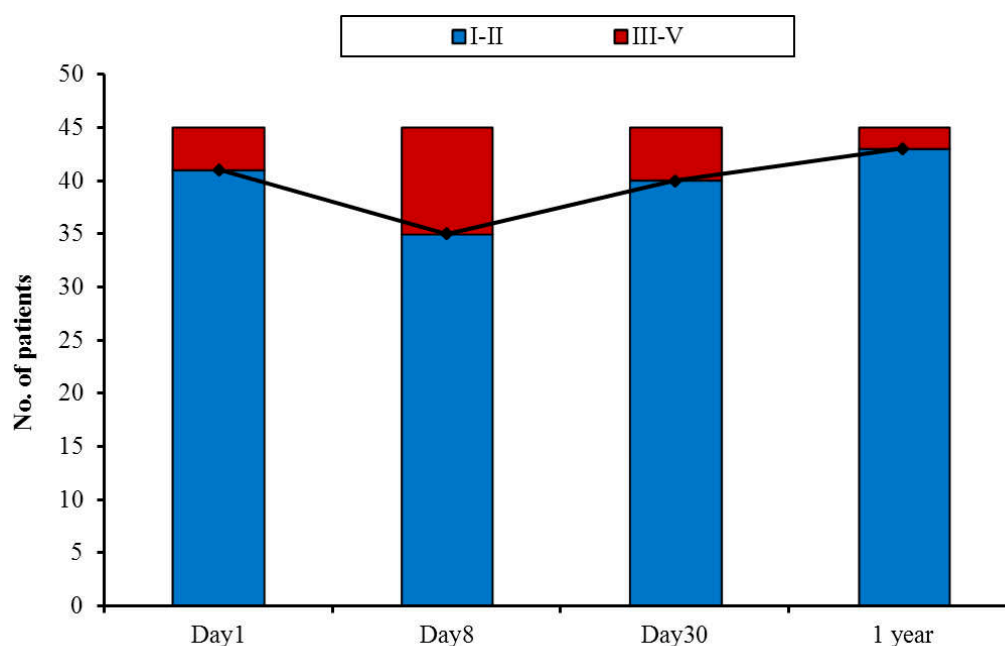


Figure 3-10 Postoperative FN function according to HB staging,

Stage 1-2 and stage 3-5 were considered as good and poor, respectively (n = 45).

3.3.6.4 Hearing preservation

An attempt was made to preserve hearing using an RS approach in patients with a large VS whatever the preoperative hearing level and VS size, apart from when there was a preoperative dead ear. Among 38 VS operated on through RS, 2 audiograms were missing postoperatively (2 class B). Preoperative hearing was classified as 20 class A, 12 class B, and 3 class D (persisting PTA with no intelligibility). Serviceable hearing (class A+B) was preserved in 9 among 33 patients (27%; 8 class A and 1 class B) and measurable hearing in 12 among all 36 VS operated on through an RS approach (33%; 1 class A and 1 class B decreased to class C, although 1 class D improved to class C). Thus, hearing was preserved in 50% of preoperative class A patients, and was at the same class level in 40% of them. Hearing was serviceable in 5 stage 3 patients with 2 TR and 3 NTR, and 4 stage 4 patients with 1 TR and 3 NTR. Hearing was measurable in 3 additional class C patients with stage 3 VS (2 TR and 1 STR). Among 21 cases of TR, measurable hearing was preserved in 5 cases (24%), but among 15 cases of NTR and STR, this rate increased to 47%.

The interval between VS diagnosis and surgery was shorter in the 9 patients with preserved serviceable hearing than in the remaining 26 class C+D patients (7 ± 16.0 months [1–50] vs 16 ± 22.3 months [1–87]; $p < 0.01$). Preoperative normal hearing was more frequent

when hearing could be retained (4 out of 9 in the former group versus 21 out of 26 in the latter group; $p < 0.05$). No other clinical, radiological, intraoperative observational or electrophysiological factors could account for the preservation of serviceable hearing.

3.3.7 Discussion

This prospective study was aimed at minimizing the onset of FN conduction nervous blockage while managing surgically sporadic VS. We have previously shown that the occurrence of a postoperative FP was maximal at the end of the first week and then gradually recovered, in many cases in a few weeks although it may last for up to several months in some others [7]. These different FP recovery patterns may be accounted for not only by the severity of FN injury during the surgical manipulations, which results mainly from FN adherence to the tumor capsule, but also by the preoperative FN impairment due to its stretching induced by the VS volume [4,7]. Accordingly these two factors, VS volume and FN adherence, were found to be independently predictive of FP occurrence in a multivariate analysis [6]. Indeed, in most studies, patients with a preoperative facial weakness were excluded although a normal facial function does not preclude some FN damage. Previous studies have demonstrated that intraoperative monitoring by FN electromyography, regardless of the stimulation level, could be predictive of FN function at 1 year, which results from combined factors including preoperative FN status, severity of initial postoperative FN blockage, and quality of recovery, depending also on complex mechanisms [3]. After total VS resection, a good FN recovery was achieved at 6 months if amplitude responses $\geq 100 \mu\text{V}$ could be obtained by stimulation of the proximal root of the nerve at $\leq 0.04 \text{ mA}$ [11]. In addition, conduction nervous blockage resulting in postoperative Grade III–VI FP at day 8 emerged if either the nerve pre-resection amplitude responses were under $800 \mu\text{V}$ or the post-/pre-resection amplitude response ratio had declined by $\geq 40\%$ after supramaximal stimulation (2 mA) of the proximal root [7]. According to this last parameter and/or because of severe adherence of the FN to the VS capsule, instead of performing the usual total VS removal, a small tongue of tumor was left adherent to the nerve yielding a near-/subtotal resection depending on the length and width of the nerve–tumor adherence, especially in large VS [1]. Although partial resections of large VS have been reported, there is no clear definition of the residual volume for near- or sub-total resection [1, 8, 12].

In this study, decision making for a total or partial resection depended on both intraoperative evaluation of FN to VS adherence and intraoperative FN electromyography parameters before and during VS resection. It was concluded that a partial resection was indicated if FN adherence to the VS was severe and/or there was a 30–40% decrease in post-/pre supramaximal amplitude response ratio at the proximal FN root in the CPA. As shown in **Figure 3-11**, the markers of a severe adherence between FN and VS were pre-resection supramaximal low amplitude responses ($<1200 \mu\text{V}$) or high latencies ($>8 \text{ ms}$) as in all cases except 2 ($n=13$), partial resections were performed. At variance with this, high amplitude responses ($>3500 \mu\text{V}$, $n=5$) but not low latencies indicated a weak adherence allowing a total resection. Although for weak and severe FN adhesions to the VS capsule, more TR and NTR/STR were achieved, respectively, moderate adherence had an intermediate status which needs to be further evaluated presumably by its length and its width as intraoperative recordings did not provide valuable markers.

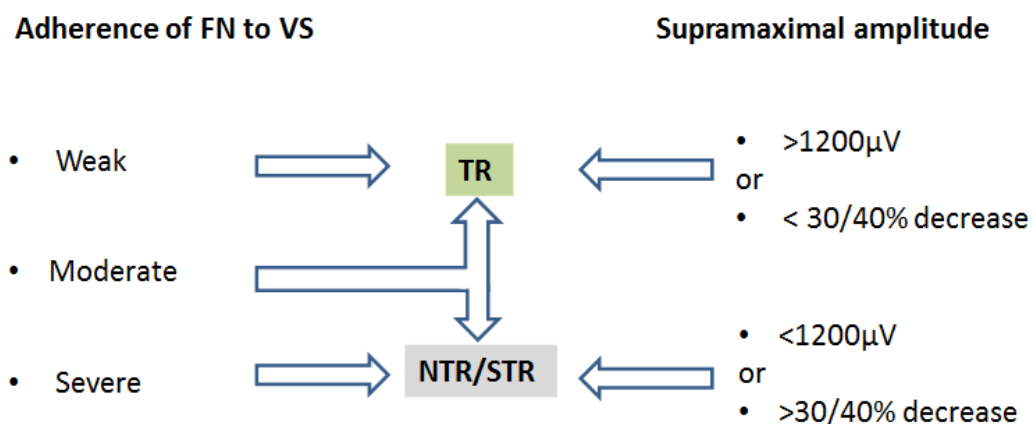


Figure 3-11 Optimization of facial nerve outcome by reducing the nervous conduction blockage severity.

FN: facial nerve; VS: vestibular schwannoma; TR: total resection; NTR: near-total resection; STR: subtotal resection.

FN function outcomes are generally reported 1 year after surgical gross-total or partial VS removal and are greatly dependent on VS volume: the smaller the tumor, the better the FN function [13–15]. The cutoff value for extra-canal tumor diameter to minimize the risk of impaired facial function was 16 mm after gross-total resection [6], which nicely corresponded to the limit between stages 2 and 3 in our classification [1,4,7,11,13]. In the present series of

large VS managed surgically with an equal proportion of total or partial tumor removal, a good FN function was achieved in 96% of cases after 6 months to 1 year, and the only two poor outcome cases were evaluated as Grade 3 at the last visit. Previously, we reported that good FN function at 1 year ranged from 80% to 85% after gross-total resection of large tumors (139 stage 4 and 192 stage 3, respectively) [13]. Indeed, intraoperative monitoring provides information on the functional status of the nerve at the beginning of the surgical procedure, and then on its evolution during VS dissection from the nerve. An initial impaired FN can be suspected if the supramaximal amplitude responses and/or latencies were low and high, respectively, assuming axon fiber and/or myelin sheath alterations related to both VS volume and FN adhesion to the tumor capsule. During VS resection, only the decrease in supramaximal amplitude responses indicated the development of a conductive nervous blockage which may lead to a Grade 3 or more FP. Taking this marker into account could preclude the onset of a severe conductive nerve blockage as 71% of VS had no or only a slight FN impairment at day 8 and, then it recovered to 89% and 96% after 1 month and at the last visit after at least 6 months, respectively. Less than a 40% decrease in the supramaximal amplitude responses at the proximal FN root seems to be critical since we reported previously 64% and 84% Grade I–II FN outcome at day 8 and 1 year, respectively, in 25 consecutive NTR/STR for large VS based on 50% loss of the initial value [1].

Hearing preservation is one of the most challenging goals of VS removal. Most of these large VS were resected through an RS approach with 27% and 33% of postoperative serviceable and measurable hearing, respectively. Thus, the intraoperative FN monitoring criteria used to minimize the occurrence of FN blockage could also provide benefit for hearing preservation. Many factors have been found to influence the preservation of hearing such as the tumor size, tumor growth rate, preoperative hearing level, etc. [13,16,17]. Herein a short interval between the diagnosis and surgical treatment was a good prognostic factor together with normal hearing.

Residual tumor volumes after NTR and STR were evaluated by gadolinium injected MRI performed during the months following microsurgery only in some instances, and showing that the residual tumor was not enhanced by the contrast in most NTR. This suggests that the residual tumor adherent to the FN had been substantially devascularized during microsurgery with a limited risk of regrowth. In a previous series of large partially resected VS, regrowth was observed in 2 out 25 tumors [1]. The need for subsequent complementary

radiotherapy treatment depends on the regrowth rate and the volume achieved. In these cases, revision surgery should not be performed when adherence between the FN and VS capsule was not relieved after the first surgery.

3.3.8 Conclusions

Supramaximal stimulation of the FN proximal to the VS is mandatory during VS surgery because, on the one hand, the values of amplitude responses and latencies provide information on the pre-resection nerve status, and on the other hand, the amplitude responses should not decrease by more than 30–40% so as to avoid a severe conduction nervous blockage. Following these indicators, half of the large VS were totally removed and half near-/sub-totally removed with 96% of normal/sub-normal FN function after 6 months to 1 year. In addition, this guidance could allow hearing to be preserved in one-third of patients. Continuous intraoperative monitoring of the FN would help the surgeon to make an immediate decision on a partial VS resection if a decrease in amplitude responses occurred, and to modify his procedure to preserve a good FN function as well as hearing in most cases.

3.3.9 Acknowledgment

We gratefully thank Amgad Hamza (S&S for Biostatistical Analysis, Alexandria, Egypt) for assistance with statistical analysis.

3.3.10 References

- 1 Bernardeschi D, Pyatigorskaya N, Vanier A, et al. Role of electrophysiology in guiding near-total resection for preservation of facial nerve function in the surgical treatment of large vestibular schwannomas. *J Neurosurg* 2018 Mar;128(3):903-10.
- 2 Bloch O, Sughrue ME, Kaur R, et al. Factors associated with preservation of facial nerve function after surgical resection of vestibular schwannoma. *J Neurooncol* 2011 Apr;102(2):281-6.
- 3 Acioly MA, Liebsch M, de Aguiar PH, Tatagiba M. Facial nerve monitoring during cerebellopontine angle and skull base tumor surgery: a systematic review from description to current success on function prediction. *World Neurosurg* 2013 Dec;80(6):e271-300.
- 4 Esquia-Medina GN, Grayeli AB, Ferrary E, et al. Do facial nerve displacement pattern and tumor adhesion influence the facial nerve outcome in vestibular schwannoma surgery? *Otol Neurotol* 2009 Apr;30(3):392-7.
- 5 House JW, Brackmann DE. Facial nerve grading system. *Otolaryngol Head Neck Surg* 1985 Apr;93(2):146-7.
- 6 Torres R, Nguyen Y, Vanier A, et al. Multivariate analysis of factors influencing facial nerve outcome following microsurgical resection of vestibular schwannoma. *Otolaryngol Head Neck Surg* 2017 Mar;156(3):525-33.
- 7 Bernat I, Grayeli AB, Esquia G, Zhang Z, Kalamarides M, Sterkers O. Intraoperative electromyography and surgical observations as predictive factors of facial nerve outcome in vestibular schwannoma surgery. *Otol Neurotol* 2010 Feb;31(2):306-12.
- 8 Schmitt WR, Daube JR, Carlson ML, et al. Use of supramaximal stimulation to predict facial nerve outcomes following vestibular schwannoma microsurgery: results from a decade of experience. *J Neurosurg* 2013 Jan;118(1):206-12.
- 9 Committee on Hearing and Equilibrium guidelines for the evaluation of hearing preservation in acoustic neuroma (vestibular schwannoma). American Academy of Otolaryngology-Head and Neck Surgery Foundation, INC. *Otolaryngol Head Neck Surg* 1995 Sep;113(3):179-80.
- 10 Grayeli AB, Kalamarides M, Bouccara D, Rey A, Sterkers O. Functional staging of acoustic neuromas. In: Kanzaki J, Tos M, Sanna M, et al. eds. *Acoustic Neuroma. Consensus on Systems for Reporting Results*. Tokyo: Springer, 2003; 141-6.

- 11 Grayeli AB, Guindi S, Kalamarides M, et al. Four-channel electromyography of the facial nerve in vestibular schwannoma surgery: sensitivity and prognostic value for short-term facial function outcome. *Otol Neurotol*. 2005 Jan;26(1):114-20.
- 12 Gurgel RK, Theodosopoulos PV, Jackler RK. Subtotal/near-total treatment of vestibular schwannomas. *Curr Opin Otolaryngol Head Neck Surg* 2012 Oct;20(5):380-4.
- 13 Zhang Z, Nguyen Y, De Seta D, et al. Surgical treatment of sporadic vestibular schwannoma in a series of 1006 patients. *Acta Otorhinolaryngol Ital* 2016 Oct;36(5):408-14.
- 14 Liu SW, Jiang W, Zhang HQ, et al. Intraoperative neuromonitoring for removal of large vestibular schwannoma: Facial nerve outcome and predictive factors. *Clin Neurol Neurosurg* 2015 Jun;133:83-9.
- 15 Taha I, Hyvarinen A, Ranta A, et al. Facial nerve function and hearing after microsurgical removal of sporadic vestibular schwannomas in a population-based cohort. *Acta Neurochir (Wien)* 2019 Sep 7. doi: 10.1007/s00701-019-04055-4. [Epub ahead of print]
- 16 Yang J, Grayeli AB, Barylyak R, Elgarem H. Functional outcome of retrosigmoid approach in vestibular schwannoma surgery. *Acta Otolaryngol* 2008 Aug;128(8):881-6.
- 17 Zhu W, Chen H, Jia H, et al. Long-term hearing preservation outcomes for small vestibular schwannomas: retrosigmoid removal versus observation. *Otol Neurotol* 2018 Feb;39(2):e158-e65.

Chapter 4 **DISCUSSION**

Along with the improvement of surgical techniques, the acquiring importance of radio-surgery and the advancement of diagnostic equipment led to a change in the objectives of VS treatment. Modern CPA surgery is reaching the goal of preservation of function. Although facial nerve preservation was the major concern in the past decades, currently hearing preservation is the main challenge. To date, the choice of the surgical strategy depends on tumor size, hearing and facial nerve function, patient age and the presence of other disabling symptoms. The challenge and the matter of the actual debate are to achieve major tumor removal, with a minimal impairment of these functions.

Over years, we were able to achieve 97.7% of FN anatomical integrity, although, good FN function was achieved only in 85.1% of patients. Surgical outcome depends on several critical variables, including tumor size, surgical approach, surgeon's experience and development of technique.[1-4]

In order to minimize FN injury and improve hearing preservation, a strategic shift in our surgical approach, decision making and improved operative techniques and parameters has been successfully implemented.

Ultimately, Continuous intra-operative monitoring of nerve function is becoming an essential tool of cranial base surgery because of the problem of the conventional handheld intraoperative monitoring probe and how the surgical team is completely blind between 2 cycles of stimulations with quite long unmonitored dissection intervals. Therefore, the continuous intraoperative neuromonitoring (C-IONM) is thought to recognize emerging trauma, thus enabling the surgeon to change his strategy and operative technique in real time before nerve injury.

I. Animal models and surgical training

Developing and establishing a porcine model for posterior fossa surgery was a primary goal of our study. Despite all available data on porcine models, a large animal model with an oto-neurosurgical background was not described before. The availability and low cost of the pig, combined with the ease of preparation made it a strong candidate. Also, the fact that we can reproduce this model in vivo later at our facility made the pig more convenient than other models such as sheep or cows. It is easy to obtain and maintain living pigs and to anesthetize them.

The anatomy of the skull base, it is highly similar to that of humans especially when it comes to the anatomy of cranial nerves and vessels in the posterior fossa. Yet, drilling of that part of temporal bone covering the posterior fossa is difficult because the classic landmarks that are used in humans are either missing or have a different orientation. Following many trials on cadavers, we were able to use other simple and easily identifiable landmarks instead, starting with the posterior wall of the EAC, the posterior arcade and the dura of the posterior fossa.[5]

The use of animal models is very important for providing the education and training needed to master clinical skills. They can be used for practicing various procedures and also to improve our understanding of the basic anatomical structures and topography. Many Surgical procedures could be simulated aiming at developing a laboratory setting imitating an almost realistic operating room. Oto-neurosurgical porcine models, both nonliving and living, are well established for familiarizing trainees with surgical techniques used in cranial approaches, especially around the CPA .The porcine experimental model has considerable similarities to human anatomy and physiology.[5]

Several surgical procedures and manipulations could be simulated in vivo, in regard to bleeding management, craniotomy, dura opening and appropriate CSF suction without damaging brain tissue, suctioning while bleeding, and finally handling the microscope and microsurgical instruments. These skills are major components of cranial surgery, however with this model; it is possible to train without risk to the patient.

We have successfully developed a simple surgical model specifically to approach the CPA and IAC that can be used as an outline for complementary surgical training of otologists and neurosurgeons.

II. Animal models and IONM research

Many animal studies have attempted to solve common pitfalls of intraoperative neuromonitoring (IONM) and to investigate new applications. The advent of animal studies has substantially improved understanding of IONM technology. Lessons learned from animal studies have immediate clinical applications in establishing reliable strategies for preventing intraoperative nerve injury.

Several studies and reports have described the use of several varieties of C-IONM electrodes that simulate the vagus nerve during thyroid surgery and that offer seamless monitoring of the functional integrity of the vagus and the recurrent laryngeal nerve (RLN) throughout the course of the operation. The feasibility, safety and reliability of the new C-IONM technique were studied and analyzed over years using well established in vivo animal models that allowed for nerve testing and electrophysiological evaluation.[6-10]

The Automatic Periodic Stimulation (APS) provides continuous intraoperative nerve monitoring (CIONM). The electrode provides continuous, periodic stimulation of nerve used for trending amplitude and latency in real time which includes adjustable alarm limits for significant baseline changes. This early warning helps alert the surgeon to stop surgical trauma as most injury is immediacy reversible but can become permanent if prolonged. Quantitative measurements of amplitude, latency, and wave duration in healthy and injured nerves are feasible. Eventually, improved understanding of distinguishing EMG characteristics of different nerves and normative data for different stimulation devices, different recording devices, and different conditions serves to optimize the efficacy of IONM performed by surgeons, but would also improve their ability to predict the pathologic neural states.

In animal studies, researchers and surgeons can repeatedly stimulate or intentionally injure target nerves to compare the relative strengths or shortcomings of different stimulation or recording techniques and different IONM devices. We are able to compare either different recording electrode configurations or different methods of stimulation.

Specifically, the combination of IONM technology and living animal models is a valuable tool for studying the pathophysiology of nerve injury. The real strength of animal

modeling is in models of nerve injury which occur rarely in humans and can't be accurately quantified in human.

For instance, elucidating the mechanisms of RLN injury not only enabled further refinement of surgical techniques, but also reduced RLN palsy rates. Researchers and surgeons could successfully induce RLN injuries of varying severity and with varying causal mechanisms (e.g. thermal injury, traction, compression). Real-time EMG evolutions were then recorded and correlated with vocal cord function outcome and histopathology results. Therefore, combining IONM technology with animal models provides a valuable tool for studying electrophysiology, severity, and recovery in various RLN injuries.[7, 9-12]

Respectively, our particular surgical model offered satisfactory exposure of the acoustic-facial-cranial nerve bundle with relatively minimally invasive steps and easily identifiable landmarks. Later, this valuable merit in living surgical models enabled to use the IONM using The NIM 3.0 – Nerve Integrity Monitoring Systems (Medtronic) which is currently routinely used in our oto-neurosurgical daily practice. The conventional hand-held stimulation electrode is used to guide the dissection and exposure of the FN both in CPA and IAC in most of specimens simulating microsurgical resection in patients.

Nevertheless, the APS electrodes need to place circumferentially around the stimulated nerve which is invasive and presents risk for neurological damage without careful dissection surgical skill. Consequent trials of placement of the APS electrode on the FN and recording satisfactory EMG signals were performed in our study. The 2.0 mm APS electrode was found to be relatively large in comparison to the more limited dimensions of the porcine posterior fossa. Another challenge was encountered after electrode placement; that the duration of stimulation by APS was not stable or continuous for sufficient time to evaluate the continuous monitoring of the nerve. Recurrent incidental dislocation of the electrode or instability due to excessive CSF and/or blood accumulation was evident. Moreover, the pulsating brain might cause electrode displacement in the relatively small surgical field.

Hence, Subsequent trials of recently developed C-IONM electrodes, pledget stimulation / recording electrode were explored. **(Figure 4-1)** They are particularly useful for automatic periodic stimulation. The pledget substrate is applied to the tissue. Therefore, no dissection of the nerve or tissue on which the pledget substrate is secured is required. Such application can include optionally wetting the pledget substrate with saline and then wrapping

the pledget substrate around the tissue. In architecture where micro hooks or micro needles are provided on the pledget substrate, they may be applied to be inserted within the tissue. These pledgets can be sewn or stapled into the tissue through the apertures. Due to its hydrophilic nature, the pledget substrate will naturally absorb moisture present at the target tissue, which will retain the pledget substrate to the nerve .

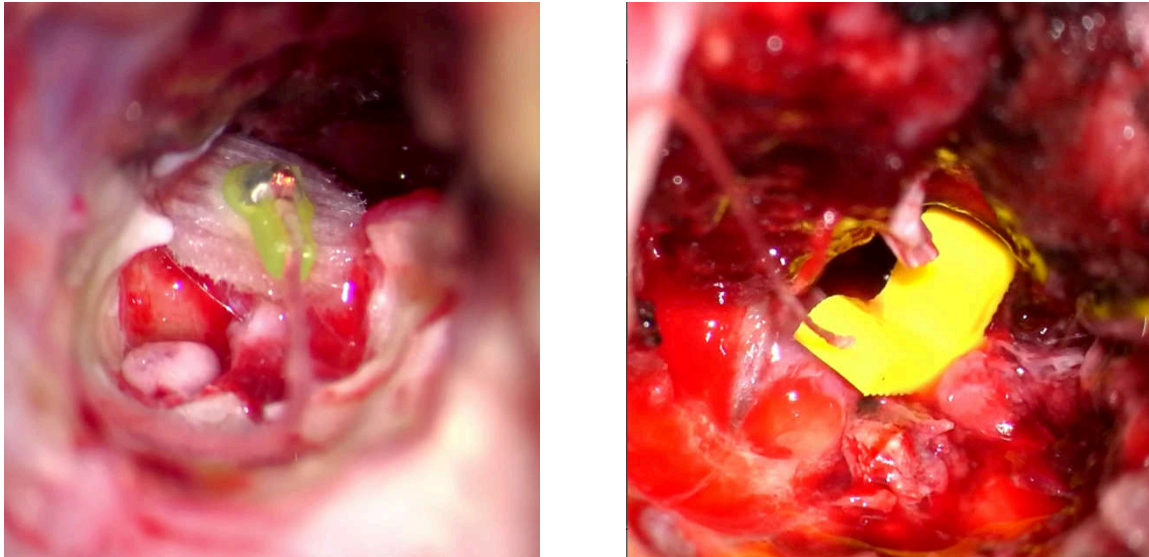


Figure 4-1 Comparison between new pledget electrode on the left and APS electrode on the right.

Once applied, methods can include recording bioelectric responses of the tissue sensed from one or more electrodes of the electrode assembly. The bioelectric response can include EMG activity or direct nerve recording. In some embodiments the stimulation is therapeutic stimulation applied to the tissue. It can also be used in evoked potential intraoperative monitoring systems during surgical procedures and are an alternative which simplifies stimulation of tissue over current methods including cuffed APS electrodes or needle electrodes used for stimulation.[13]

III. Intraoperative neuromonitoring of FN

Neurophysiologic monitoring of the facial nerve was first introduced into the operating theatre in the 1970s. Monitoring techniques were subsequently refined by other investigators with the addition of free-running electromyography (EMG), the use of different stimulating and recording electrodes, and with the addition of audible feedback signifying facial EMG activities. The use of EMG monitoring has been shown to improve the outcome of facial nerve function in surgery of the lateral skull base and cerebellopontine angle and is currently the gold standard in neurophysiologic monitoring of the facial nerve in lateral skull base surgery. However, there are limitations to these techniques. For example, in free-running EMG, non-injurious maneuvers can produce irritation and neurotonic discharges, which do not necessarily indicate permanent facial nerve injury. The proximal facial nerve may be inaccessible in the early stage of the surgery with large tumors making the use of stimulus-triggered compound muscle action potential (CMAP) difficult. Furthermore, stimulus-triggered CMAP is intermittently requiring the surgeon to stop the surgical manipulation of the tumor from time to time and may not provide the desired ongoing functional assessment.[14-15]

▪ Change of paradigm for surgical decision and strategy

During the last decade, our oto-neurosurgical team has been performing about 100 surgical procedures for sporadic VS per year mainly through TL, especially for stage III and IV tumors. Recently, the proportion of VS resection through RS has increased over the last 5 years from 30% (2013–16) to 60 % (2017) and to 85% in the last 2 years. RS was more and more performed to attempt to preserve hearing, even in large VS. On the other hand, the authors' surgical strategies have recently shifted; using a retrosigmoid (RS) approach even in large VS, with resection guided by facial nerve (FN) monitoring in order to minimize the risk of facial nerve injury. Accumulated surgical experience often allows the complete removal of large VSs with functional preservation of the FN. This remains the best treatment because it is definitive.[1-3]

A good FN function was observed for 89% of patients with stage III and IV which reached similar values than those previously reported by our team either after total VS removal through RS (91%) of smaller tumors, or after VS resection guided by FN monitoring through TL (84%) of larger VS stage IV. The improvement in postoperative facial outcomes may be accounted for by the absence of dissection of FN from a strongly adherent tumor capsule as indicated by a decrease by at most 40% of the supramaximal FN amplitude responses at in CPA in near-/subtotal resections mostly performed for large VS. It appears that NTR is optimal in cases in which the facial nerve is threatened (strong adhesion) with disappearance of the plane between the nerve, pia mater, and tumor). In this way, the patient should be able to retain normal facial function with a very small tumor remnant, which could require additional treatment by stereotactic radio-surgery.

Generally, the treatment paradigm for large VS, which has traditionally focused on total excision of the tumor, but with a consequent important risk of facial and cochlear nerve damage, has recently changed with an increased emphasis on preservation of facial function and hearing. A combined approach with planned subtotal removal followed by GKS has been increasingly adopted as the main strategy for preserving cranial nerve functions along with long-term tumor control, as a paradigm shift in the past decade. The mechanical stress related with direct dissection can be reduced or avoided in case of subtotal resection and represents the “nerve-centered” tumor surgery approach inherent in this treatment philosophy. This surgical perspective reintegrates the preservation of auditory function as an essential part of the treatment strategy, often neglected because of the need of total resection.[16]

Our strategy adopted the use of electrophysiology that help to maximize the extent of resection while preserving good postoperative FN function in the case of surgical difficulties when dissecting the FN from the tumor. The value of supramaximal stimulation of the FN as a prognostic factor for early and long-term FN function has been recognized in other retrospective and prospective studies. Since this stimulation allows depolarization of all of the nerve fibers, the responses give a more precise status of the FN than stimulation at threshold. We can speculate whether a 50% loss of response is an appropriate value. We have used a 50% cutoff. It is possible that adopting a 30% drop as the criterion for stopping dissection of the VS from the FN could improve our results even more, especially in older patients. Using a 50% cutoff, we have documented Grade I or II FN function in 64% of patients at Day 8 and 84% at 1 year after surgery.[3] In this study we improved our strategy

and decision making for a partial (NTR/STR) resection that was guided by both intraoperative evaluation of severe FN adhesion to the VS and a decrease of at least 30–40% of the supra-maximal amplitude response not 50%. Accordingly, Tumors were removed using an RS approach in the majority of patients (84%) to attempt to preserve hearing. The sub-total or near-total removal rate increased to 49%, yet, about 95% of good postoperative FN function and significant hearing preservation were achieved.

Nevertheless, the use of the supramaximal response during surgery has some difficulties. First of all, the range of response is wide, because it depends on the concentration of endplates near the recording electrodes, and this varies from patient to patient. Then, in patients with large tumors, the FN is not immediately accessible at the brainstem, and some minor damage could be done during the debulking or during dissection of the tumor from the brainstem before identification of the FN. To overcome this drawback, Fukuda et al. proposed transcranial stimulation of the FN rather than stimulation at the brainstem to obtain an earlier response; but with this method, the value obtained is only one-fifth of what is routinely obtained with direct stimulation of the FN at the brainstem, limiting the stimulation to a few axons.[3, 17]

▪ **Dual Facial nerve monitoring technique**

Facial muscle motor evoked potential (MEP) monitoring is an established method for assessment of the corticospinal system. This technique could be extended to the corticobulbar pathway for facial nerve monitoring that may allow us to circumvent the limitations of standard EMG method. The event-to-baseline FMEPs could provide ongoing functional assessment of the facial nerve during surgery and a >0.60 FMEP ratio accurately predicted satisfactory postoperative facial function. Furthermore, because of continuous monitoring throughout VS surgery, intraoperative FMEP ratio can also be used to allow intraoperative warning. FMEP can be used to be conservative on the one hand but more aggressive on the other in tumor resection. If the FMEP drops more than 50 to 60% compared with the baseline during tumor dissection and does not recover after a surgical pause further dissection should be avoided. FMEP allows monitoring FN before being able to identifying the nerve, especially during the initial stages, and in large tumors. Therefore, if the FMEP continues to be normal despite difficulty obtaining stimulus-triggered CMAPs, dissection can continue with the knowledge of physiologically intact FN.[17]

Recent reports discussed improved early facial nerve outcome by a dual monitoring technique of motor cranial nerves. In addition to EMG monitoring, mainly useful for nerve localization and mechanic reactivity of fiber groups, facial nerve motor evoked potentials (FNMEPs), by transcranial activation, gives feedback on the integrity of the whole facial motor tract at any time, independent of the surgical exposure of the nerves and therefore independent of tumor size. By this multimodality monitoring technique, the rate of useful early function is increased significantly from 75 to 82%. Complete eye closure 1 week after surgery is the best predictor for long-term normal facial nerve function and good quality of life.

▪ **Continuous intraoperative Facial nerve monitoring technique**

The monitoring by transcranial facial motor-evoked potentials (FMEP) is surely effective, particularly until the surgeon finds the REZ of the facial nerve. However, body movement at electrical stimulation is considered a problem. In FMEP, as they point out, it is necessary to stop microsurgical procedures to record electromyograms from the viewpoint of safety. We consider FMEP to be a different type of monitoring compared to our method, which allows us to assess the condition of the facial nerve continuously during the process of dissecting the tumor from the facial nerve in real-time without stopping microsurgical procedures.

Tokimura et al.,[18-19] have been using intraoperative continuous monitoring of evoked FN electromyography (EMG) in addition to conventional methods. This technique involves continuous electrical stimulation with a ball type stimulating electrode (SE) that is placed on the root exit zone (REZ). **(Figure 4-2)**

Nevertheless, concerns about movement of the electrode for continuous stimulation are expressed and replacement of the electrode could take place most twice or three times in a surgery. A small cotton pad is used to fix the electrode in place.

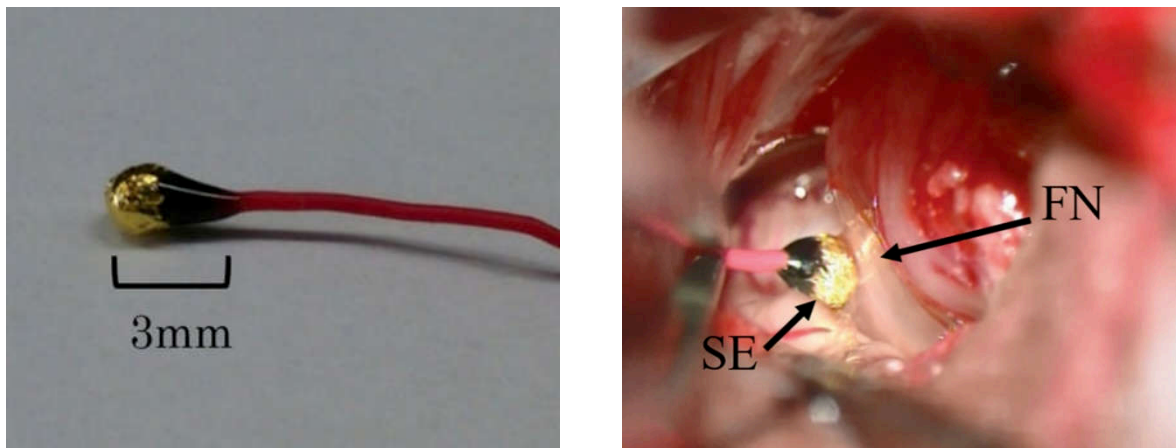


Figure 4-2 The ball-type, continuous facial nerve stimulating electrode (SE) that is placed intraoperatively on the REZ of FN (arrow).[19]

An important part of developing new surgical methodologies is to keep them simple, effective and easy to perform. For a new method to become popular and widely used over time, however, certain techniques and tips are required for every operation in the neurosurgical field. In particular with acoustic neuroma surgery, our team has gained a very wide experience in the field of Facial nerve intraoperative neuromonitoring using The NIM 3.0 – Nerve Integrity Monitoring Systems (Medtronic) which is currently routinely used in our oto-neurosurgical daily practice.

Accordingly, the use of the C-IONM during CPA surgery combined with free running facial electromyography and occasional stimulation of the facial nerve will be superior in our surgical results. The NIM 3.0 – Nerve Integrity Monitoring Systems (Medtronic,) provide two important modalities of C-IONM.

- **The StimBurGar system** which is continuous facial nerve (FN) stimulating burr. It delivers a continuous stimulating monopolar current on the tip and handle of the drill that offer real time feedback when drilling in contact facial nerve has overcome the drawback of former monitoring systems that could not alert the surgeon during drilling close to FN.

That system is safe and easy to use and time saving during surgery. It does allow a precise and reliable localization and stimulation of the FN during mastoidectomy. Obviously, the advantage of using such a system seems especially in revision cases, where the anatomy is distorted by previous operation, or in malformation cases. It

helps residents to be more confident during mastoid bone work, and for more trained surgeons, it could reduce the operative time.[20]

- **The Automatic periodic stimulation (APS)** provides continuous intraoperative nerve monitoring (CIONM). The electrode provides continuous, periodic stimulation of nerve used for trending amplitude and latency in real time which includes adjustable alarm limits for significant baseline changes.

One of the most important trends in intraoperative neural monitoring (IONM) in thyroid surgery is currently the real-time monitoring of the vagus nerve (VN) in order to prevent RLN iatrogenic damages. However, and to the best of our knowledge, trials of APS electrode in CPA surgery for continuous monitoring of FN has not been elaborated before. Accordingly, we have tried as proof of concept to clinically implement the use of APS in patient undergoing CPA surgery. **(Figure 4-3)**

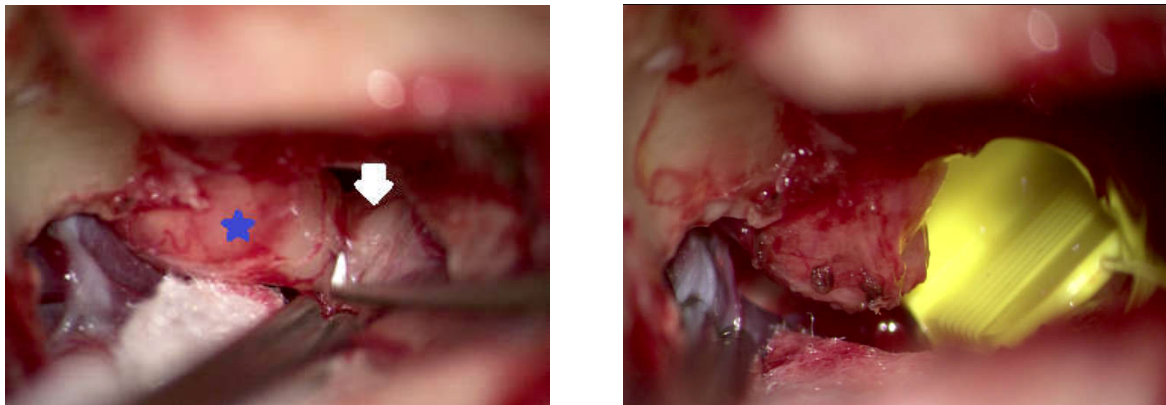


Figure 4-3 Intraoperative CPA view of vestibular schwannoma (*) and Facial nerve (white Arrow) on the left side and Positioning of the APS electrode on Facial nerve on the right side.

IV. Recent advances in FN preservation during CPA surgery

As a consequence of conservative strategies such as watchful waiting or radio-surgical management, surgeons are faced mainly with medium to large vestibular schwannomas. Preservation of facial nerve function still remains the most important goal.

Over years, many advances in operative tools, imaging techniques and surgical strategy are constantly developing in order to improve functional outcome. Our study reviews other technological amendments in intraoperative neuromonitoring, imaging, drug therapy and strategic shift in our surgical planning and tools.

▪ Preoperative visualization of the facial nerve

Preoperative visualization of the facial nerve location is a long-desired wish of otoneurosurgeons. Fortunately, the application of diffusion tensor tractography in VS surgery has turned it into reality. In recent years, many authors have reported their experience with preoperative identification of the facial nerve in VS surgery using DTT. However, their methods and results have varied.

Diffusion tensor imaging is an MRI technique based on the principle that water molecule diffusion is anisotropic in white matter tracts. DTT uses this information to reconstruct the white matter tracts three dimensionally. DTT has been widely used to trace several fibers such as the pyramidal tract, medial lemniscuses, optic radiation, etc. Hodaie [21] first introduced DTT to the field of cranial nerve tracing. Taoka [22], first demonstrated the use of tracing the facial nerve with diffusion tensor tractography in patients with VS. This technique provides a new noninvasive method to predict the location of the facial nerve. Since then, several authors have reported their experience of applying this technique to reconstruct the facial nerve tract in VS patients. Nevertheless, the ability to estimate degree of adherence of tumor capsule to FN cannot be achieved.[23]

▪ Intraoperative use of endoscopy

The main drawback of the posterior fossa approach using the retrosigmoid corridor is the inadequate control over the fundus of the internal auditory canal (IAC) increasing the chances of leaving residual disease in this anatomical site. The use of the endoscope in the retrosigmoid approach was introduced in recent decades as an adjunctive tool in microsurgery

to overcome this problem. The advantages of the endoscope are its improved visualization of anatomical structures of the CPA, minimizing cerebellar retraction, and a reduction in the rate of complications. [24]

More recently, a minimally invasive approach has been proposed with a fully endoscopic resection of the tumor via a retrosigmoid keyhole craniotomy. [25-26] Furthermore, in recent years, a transcanal transpromontorial approach was developed to reach the inner ear and the CPA through the external auditory canal. Despite the advent of endoscopic approaches in the otological field, the microscope is still the dominant tool in vestibular schwannoma surgery. Although the procedures for vestibular schwannoma surgery are well codified, there is a possibility of leaving residual diseases in the IAC fundus, porus, or CPA.[24]

Corrivetti et al. [27], demonstrated that flexible endoscope appears to be particularly suitable for IAC inspection. The main advantages consist in endoscopic tip orientation and in the appropriate dimensions (4-mm × 65- cm, Karl Storz Endoscopy, Germany.) in order to be inserted and directed towards the fundus of the IAC. In addition, flexible endoscope carries further advantages when introduced along the corridors between the cranial nerves. Particularly, it is appreciated because of the possibility to arrange the shape in order to obtain a safe corridor between the neurovascular structures of the CPA. Furthermore, it can be easily adapted in a comfortable position allowing keeping the microscope in place in order to be inserted and manipulated under direct microscopic view, avoiding injuries to neurovascular structures of CPA during in-and-out movements. They proposed that this technique provides a tandem endoscopic and microscopic view improving the safety of endoscope manipulation in the surgical field. Flexible endoscope was shown to provide more surgical freedom comparing to the rigid endoscope, during parasellar region dissection, limiting the conflict between instruments, and a remarkable working area and angle of attack during transphenoidal surgery.

▪ Peri-operative Neuro-protective agents

Routine use of **glucocorticoids** intraoperatively and postoperatively aims at reducing cerebral edema and to suppress inflammatory responses. Many other neuroprotective agents and drugs have been described in literature in order to enhance neural preservation during and after surgery.[28]

The postoperative facial palsy can be immediate or delayed .It can occur in spite of preserved nerve continuity .The mechanisms involved in this complication are thought to be ischemia, inflammation, neurotmesis or a combination of all these factor .Steroid therapy after facial nerve trauma is extensively prescribed even if its efficacy has not been demonstrated .This widespread attitude is based on the observation that high-dose methylprednisolone is effective in the treatment of Bell's palsy. . Both facial nerve trauma and Bell's palsy are associated with inflammation and edema of the labyrinthine portion of the nerve.

Grayeli et al., [28] conducted a multicenter, prospective, randomized, double-blind and versus-placebo study between 2006 and 2010. Three hundred and ten patients operated on for a CPA tumor. They investigated the effect of **Methylprednisolone** administered intraoperatively and on the 5 following postoperative days on the incidence of Facial palsy. They showed that high-dose methylprednisolone administered intra and postoperatively after CPA tumor surgery does not affect the facial function outcome. They concluded that administration of intravenous methylprednisolone 1 mg/kg/day intra- and postoperatively for 6 days did not reduce the facial palsy rate significantly at day 8, but a much larger study would be needed to statistically prove no effect. Moreover, they the use of steroids for 6 days did not increase the postoperative complications.

Previous experimental and clinical studies demonstrated the neuroprotective potency of the calcium channel blocker **Nimodipine**. For instance, intra- and postoperative application of **hydroxyethylstarch** and **nimodipine** showed a beneficial effect on hearing preservation in a subgroup of patients. Prevention of intracellular calcium overload seems to have antiapoptotic effects. Nimodipine also improves resprouting, axonal growth, and re-myelination of cranial nerves. The reduction of the hematocrit by using hydroxyethylstarch and the vasoactive effect of nimodipine may improve the intraneural microcirculation of the facial and cochlear nerves. Because of these two different effects, the combination of cellular

mechanisms (calcium channel blockade) and improvement of the intraneural microcirculation may be superior to a monotherapy. Prophylactic vasoactive treatment consisting of nimodipine and hydroxyethylstarch shows significantly better results concerning preservation of the facial and cochlear nerve function in vestibular schwannoma surgery. Therefore, prophylactic medication protects neuronal cells from intraoperative injury. It is obvious that the efficiency of an intraoperative start of treatment is worse than prophylactic treatment.[29]

Somatomedin C or IGF-I (Insulin-like growth factor 1), is an insulin analog, protein macromolecule (hormone). The potential neuroprotective role of IGF-I has been confirmed in many studies. IGF-I has potent neurotrophic and neuroprotective effects, and extensive preclinical evidence supports the hypothesis of attenuation of motor neuron loss and maintenance of neuronal synapses and neuromuscular junctions by IGF-I.

Recent study showed that there was a correlation between elevated IGF-I levels and postoperative hearing and/or facial nerve impairment in large VS cases. Thus, the association of good surgical plan and equipments, with possible IGF-I-mediated myelin stimulation in injured nerves, could help achieve a better result. It is also possible that increased IGF-I levels hold a key role in nerve recovery.[30]

Bevacizumab is a humanized monoclonal antibody against VEGF and inhibits the blood-brain barrier (BBB) permeability and over-pruning of blood vessels. Despite proven efficacy, *Bevacizumab* still remains a controversial drug and there are only level II studies approving its benefit. It has been reported to induce both tumor regression and hearing improvement in patients with NF2 associated VS. Chemotherapy with Bevacizumab has been shown to reduce the growth of vestibular schwannoma. Apart from it, it has also been reported to be a useful drug for the management of radiation induced brain edema and radiation necrosis. Early intervention with *Bevacizumab* has been shown to revert the complications of sudden hearing and facial nerve dysfunction to a significant extent.[31-32]

V. References

1. Zhang Z, Nguyen Y, De Seta D, Russo FY, Rey A, Kalamarides M, et al. Surgical treatment of sporadic vestibular schwannoma in a series of 1006 patients. *Acta Otorhinolaryngol Ital.* 2016 Oct;36(5):408-14.
2. Torres R, Nguyen Y, Vanier A, Smail M, Ferrary E, Sterkers O, et al. Multivariate Analysis of Factors Influencing Facial Nerve Outcome following Microsurgical Resection of Vestibular Schwannoma. *Otolaryngol Head Neck Surg.* 2017 Mar;156(3):525-33.
3. Bernardeschi D, Pyatigorskaya N, Vanier A, Bielle F, Smail M, Lamas G, et al. Role of electrophysiology in guiding near-total resection for preservation of facial nerve function in the surgical treatment of large vestibular schwannomas. *J Neurosurg.* 2018 Mar;128(3):903-10.
4. Bernat I, Grayeli AB, Esquia G, Zhang Z, Kalamarides M, Sterkers O. Intraoperative electromyography and surgical observations as predictive factors of facial nerve outcome in vestibular schwannoma surgery. *Otol Neurotol.* 2010 Feb;31(2):306-12.
5. Elsayed M, Torres R, Sterkers O, Bernardeschi D, Nguyen Y. Pig as a large animal model for posterior fossa surgery in oto-neurosurgery: A cadaveric study. *PLoS One.* 2019;14(2):e0212855.
6. Wu CW, Randolph GW, Lu IC, Chang PY, Chen YT, Hun PC, et al. Intraoperative neural monitoring in thyroid surgery: lessons learned from animal studies. *Gland Surg.* 2016 Oct;5(5):473-80.
7. Schneider R, Przybyl J, Pliquet U, Hermann M, Wehner M, Pietsch UC, et al. A new vagal anchor electrode for real-time monitoring of the recurrent laryngeal nerve. *Am J Surg.* 2010 Apr;199(4):507-14.
8. Lin YC, Dionigi G, Randolph GW, Lu IC, Chang PY, Tsai SY, et al. Electrophysiologic monitoring correlates of recurrent laryngeal nerve heat thermal injury in a porcine model. *Laryngoscope.* 2015 Aug;125(8):E283-90.
9. Lee HY, Cho YG, You JY, Choi BH, Kim JY, Wu CW, et al. Traction injury of the recurrent laryngeal nerve: Results of continuous intraoperative neuromonitoring in a swine model. *Head Neck.* 2016 Apr;38(4):582-8.
10. Wu CW, Dionigi G, Sun H, Liu X, Kim HY, Hsiao PJ, et al. Intraoperative neuromonitoring for the early detection and prevention of RLN traction injury in thyroid surgery: a porcine model. *Surgery.* 2014 Feb;155(2):329-39.
11. Dionigi G, Wu CW, Kim HY, Rausei S, Boni L, Chiang FY. Severity of Recurrent Laryngeal Nerve Injuries in Thyroid Surgery. *World J Surg.* 2016 Jun;40(6):1373-81.
12. Chiang FY, Lu IC, Kuo WR, Lee KW, Chang NC, Wu CW. The mechanism of recurrent laryngeal nerve injury during thyroid surgery--the application of intraoperative neuromonitoring. *Surgery.* 2008 Jun;143(6):743-9.

13. Cantwell ML, Hacker DC, Prisco JR, Narasimhan A. Pledget stimulation and recording electrode assemblies. Google Patents; 2019.
14. Acioly MA, Liebsch M, de Aguiar PH, Tatagiba M. Facial nerve monitoring during cerebellopontine angle and skull base tumor surgery: a systematic review from description to current success on function prediction. *World Neurosurg*. 2013 Dec;80(6):e271-300.
15. Bhimrao SK, Le TN, Dong CC, Makarenko S, Wongprasartsuk S, Westerberg BD, et al. Role of Facial Nerve Motor-Evoked Potential Ratio in Predicting Facial Nerve Function in Vestibular Schwannoma Surgery Both Immediate and at 1 Year. *Otol Neurotol*. 2016 Sep;37(8):1162-7.
16. Daniel RT, Tuleasca C, Rocca A, George M, Pralong E, Schiappacasse L, et al. The Changing Paradigm for the Surgical Treatment of Large Vestibular Schwannomas. *J Neurol Surg B Skull Base*. 2018 Oct;79(Suppl 4):S362-S70.
17. Fukuda M, Oishi M, Hiraishi T, Saito A, Fujii Y. Intraoperative facial nerve motor evoked potential monitoring during skull base surgery predicts long-term facial nerve function outcomes. *Neurol Res*. 2011 Jul;33(6):578-82.
18. Tokimura H, Sugata S, Yamahata H, Yunoue S, Hanaya R, Arita K. Intraoperative continuous monitoring of facial motor evoked potentials in acoustic neuroma surgery. *Neurosurg Rev*. 2014 Oct;37(4):669-76.
19. Torihashi K, Sora S, Sato H, Kohno M. The Method for Placement of an Intraoperative Continuous Facial Nerve Stimulating Electrode in Acoustic Neuroma Surgery: Technical Note. *Neurol Med Chir (Tokyo)*. 2018 Nov 15;58(11):477-80.
20. Bernardeschi D, Meskine N, Otaibi NA, Ablonczy R, Kalamarides M, Grayeli AB, et al. Continuous facial nerve stimulating burr for otologic surgeries. *Otol Neurotol*. 2011 Oct;32(8):1347-51.
21. Hodaie M, Quan J, Chen DQ. In vivo visualization of cranial nerve pathways in humans using diffusion-based tractography. *Neurosurgery*. 2010 Apr;66(4):788-95; discussion 95-6.
22. Taoka T, Hirabayashi H, Nakagawa H, Sakamoto M, Myochin K, Hirohashi S, et al. Displacement of the facial nerve course by vestibular schwannoma: preoperative visualization using diffusion tensor tractography. *J Magn Reson Imaging*. 2006 Nov;24(5):1005-10.
23. Li H, Wang L, Hao S, Li D, Wu Z, Zhang L, et al. Identification of the Facial Nerve in Relation to Vestibular Schwannoma Using Preoperative Diffusion Tensor Tractography and Intraoperative Tractography-Integrated Neuronavigation System. *World Neurosurg*. 2017 Nov;107:669-77.
24. Marchioni D, Gazzini L, Boaria F, Pinna G, Masotto B, Rubini A. Is endoscopic inspection necessary to detect residual disease in acoustic neuroma surgery? *European Archives of Oto-Rhino-Laryngology*. 2019;276(8):2155-63.

25. Setty P, D'Andrea KP, Stucken EZ, Babu S, LaRouere MJ, Pieper DR. Endoscopic Resection of Vestibular Schwannomas. *J Neurol Surg B Skull Base*. 2015 Jun;76(3):230-8.
26. Sun JQ, Sun JW. Endoscope-assisted retrosigmoid keyhole approach for cerebellopontine angle: cadaveric study. *Acta Otolaryngol*. 2013 Nov;133(11):1154-7.
27. Corrivetti F, Cacciotti G, Scavo CG, Roperto R, Stati G, Sufianov A, et al. Flexible endoscopic assistance in the surgical management of vestibular schwannomas. *Neurosurgical review*. 2019:1-9.
28. Bozorg Grayeli A, Ferrary E, Tubach F, Bernat I, Deguine O, Darrouzet V, et al. Effect of corticosteroids on facial function after cerebellopontine angle tumor removal: a double-blind study versus placebo. *Audiol Neurotol*. 2015;20(4):213-21.
29. Scheller C, Richter HP, Engelhardt M, Koenig R, Antoniadis G. The influence of prophylactic vasoactive treatment on cochlear and facial nerve functions after vestibular schwannoma surgery: a prospective and open-label randomized pilot study. *Neurosurgery*. 2007 Jul;61(1):92-7; discussion 7-8.
30. Fotakopoulos G, Fountas K, Tsianaka E, Kotlia P, Pachatouridis D, Paschalis T, et al. Could IGF-I levels play a neuroprotective role in patients with large vestibular schwannomas? *Future Sci OA*. 2018 Feb;4(2):FSO260.
31. Tripathi M, Deora H, Kumar N, Batish A, Dutta P, Gurnani J, et al. Role of Bevacizumab as a prophylactic and rehabilitative treatment modality in cases of sporadic and syndromic vestibular schwannoma: Fifty shades of grey! *Interdisciplinary Neurosurgery*. 2020;19:100607.
32. Jia H, Elsayed M, Smail M, Mosnier I, Wu H, Sterkers O, et al. Neurofibromatosis type 2: Hearing preservation and rehabilitation. *Neurochirurgie*. 2018 Nov;64(5):348-54.

Chapter 5 CONCLUSION AND FUTURE PERSPECTIVES

The aims of surgery in the cerebellopontine angle (CPA) have changed from tumor resection and prolongation of life to the anatomical and functional preservation of the cranial nerves (CNs). The challenge and the matter of the actual debate are to achieve major tumor removal, with a minimal impairment of these functions.

We do believe that implementation of the state of art of C-IONM during CPA surgery combined with the conventional method of free running facial electromyography and occasional stimulation of the facial nerve will have a superior outcome in our surgical results. The use of APS or the pledget electrode in CPA surgery is still under further study for its safety and efficacy.

The advent of animal studies can improve our understanding of this technology and have immediate clinical applications. Our particular surgical animal model offered satisfactory exposure of the acoustic-facial-cranial nerve bundle with relatively minimally invasive steps and easily identifiable landmarks. The feasibility, safety and reliability of the new C-IONM technologies could be easily studied and analyzed through our well established in vivo animal models that allowed for future nerve testing and electrophysiological evaluation.

Meanwhile, our animal model is very important for providing supplementary surgical education and training needed to master clinical skills based specifically on an otoneurosurgery background. Several surgical procedures and manipulations could be simulated in vivo, which are major components of daily cranial surgery, however in animals; it is possible to train without risk to the patient.


Chapter 6 ANNEXES

Annex 1

This article has been published as: *Mohamed Elsayed; Baptiste Hochet; Renato Torres; Olivier Sterkers; Yann Nguyen, Ghizlene Lahlou; and Michel Kalamarides . "Metachronous bilateral vestibular schwannomas," The Laryngoscope, 17 Feb., 2020. DOI: 10.1002/lary.28571*

Case Report

Metachronous Bilateral Vestibular Schwannomas

Mohamed Elsayed, MD; Baptiste Hochet, MD; Renato Torres, MD, PhD; Olivier Sterkers, MD, PhD;
Yann Nguyen, MD, PhD; Ghizlene Lahlou, MD ; Michel Kalamarides, MD, PhD

Bilateral vestibular schwannoma (BVS) is the hallmark of neurofibromatosis type 2 (NF2), both of them being present at diagnosis. We report four cases of metachronous BVS, a contralateral intracanalicular vestibular schwannomas (VS) being visible 2 to 13 years after resection of a unilateral VS. NF2 workup was negative except in one case where two NF2 gene mutations were found in tumor analysis. These cases raise the questions of whether the contralateral VS occurred by chance and how to manage it on the only hearing ear. Otolologists should be aware of this rare eventuality for decision making of the first unilateral VS.

Key Words: Bilateral vestibular schwannoma, sporadic vestibular schwannoma, neurofibromatosis type 2, metachronous benign tumors.

Laryngoscope, 00:1–5, 2020

INTRODUCTION

Bilateral vestibular schwannoma (BVS) is rare, occurring mainly in the context of neurofibromatosis type 2 (NF2), an autosomal-dominant disease.¹ However, sporadic BVS occurring by chance has been reported, especially in elderly patients.² NF2 has an incidence of 1/33,000 births and a prevalence of 1/56,000. Multiple benign nervous system tumors, such as BVS, represent the hallmark of the disease.³ NF2 diagnostic criteria include the presence of BVS according to the Manchester diagnostic criteria. These criteria expand on the original National Institutes of Health criteria with additional criteria.²

Approximately half of NF2 mutations occur in patients with a family history, and the newly diagnosed cases are spontaneous (de novo mutation in the *NF2* gene.) Such spontaneous mutations may be present in all cells if they occur in the gametes (germline mutation) or lead to mosaicism if they occur during the postzygotic stages of embryogenesis.

We report herein four cases of unilateral vestibular schwannoma (VS) operated on with subsequent

anacusis, which developed a contralateral VS later on, raising the questions of its nature, NF2 versus sporadic, and of its management on the only hearing ear (TABLE I).

CASE REPORTS

Case 1

A 42-year-old male presented with a left unilateral VS removed through a retrosigmoid approach with postoperative normal facial nerve function (FNF) and anacusis. No recurrence was observed at the 5-year magnetic resonance imaging (MRI) follow-up. A contralateral 8-mm intracanalicular VS was diagnosed 13 years later (Fig. 1A) when the patient presented vertigo. No other NF2 features (personal, familial, or gene mutation in the blood) were present, but analysis of the removed VS revealed two mutations in one *NF2* gene. Right sudden sensorineural hearing loss (SNHL) occurred 1 year later, which recovered under intravenous steroid therapy. The VS grew from 8 to 12 mm during the 3 following years (Fig. 1B). Hearing remained stable, and bevacizumab treatment was started (5 mg/kg every 2 weeks). Under chemotherapy, the VS did not grow (Fig. 1C), but hearing declined moderately (Fig. 1D, E).

Case 2

A 36-year-old female presented a right unilateral VS excised through a translabyrinthine (TL) approach in 2004 in another hospital. Postoperative FNF was grade II (House-Brackmann scale⁴). MRI follow-up showed neither recurrence nor contralateral VS 5 years postoperatively (Fig. 2A). Twelve years later, MRI performed for persistent headaches revealed a contralateral asymptomatic 5-mm intracanalicular VS (Fig. 2B). NF2 workup was

From the Sorbonne University (M.E., B.H., R.T., O.S., Y.N., G.L., M.K.), Paris, France; Otolaryngology, Hearing Implants, and Skull Base Surgery Unit, AP-HP Pitié-Salpêtrière University Hospital (M.E., B.H., R.T., O.S., Y.N., G.L.), Paris, France; Faculty of Medicine, Otorhinolaryngology Department (M.E.), Alexandria University, Alexandria, Egypt; Faculty of Medicine, Research and Scientific Development Center (R.T.), National University of Saint Augustine, Arequipa, Peru; and theNeurosurgery Department (M.K.), AP-HP Pitié-Salpêtrière University Hospital, Paris, France.

Editor's Note: This Manuscript was accepted for publication on January 27, 2020.

The authors have no funding, financial relationships, or conflicts of interest to disclose.

Send correspondence to Ghizlene Lahlou, MD, Otolaryngology, Hearing Implants, and Skull Base Surgery Unit, AP-HP Pitié-Salpêtrière University Hospital, 47-83 Boulevard de l'Hôpital, 75651 Paris, Cedex 13, France. E-mail: ghizlene.lahlou@aphp.fr

DOI: 10.1002/lary.28571

TABLE I.
Characteristics of the Four Patients.

	Patient 1	Patient 2	Patient 3	Patient 4
Sex	M	F	M	M
Age at first presentation, yr	42	36	44	68
Symptoms revealing the first VS	Progressive SNHL, dizziness, and tinnitus	Progressive SNHL, dizziness, and tinnitus	Sudden SNHL and tinnitus	Progressive SNHL
Preoperative first-side hearing level*	Class B	Class C	Class C	Class B
Surgical approach for the first side	RS	TL	TL	TL
First preoperative VS stage†	2	3	2	4
Interval between first VS surgery and occurrence of the contralateral VS, yr	13	12	2	2
Symptoms revealing the second VS	Vertigo	No	No	Sudden SNHL
Hearing in only hearing ear	Class A	Class A	Class A	Class C
Management of contralateral VS	Chemotherapy	Proposed chemotherapy	Observation	Surgery (TL) and cochlear implantation

*Hearing is evaluated by audiometry according to the guidelines of the American Academy of Otolaryngology–Head and Neck Surgery Foundation.¹⁴

†Tumor size was evaluated by magnetic resonance imaging and classified as follows: stage I (intracanalicular), stage II (≤ 15 mm maximal extracanalicular diameter), stage III (16–30 mm), or stage IV (>30 mm).¹⁵

F = female; M = male; RS = retrosigmoid; SNHL = sensorineural hearing loss; TL = translabyrinthine; VS = vestibular schwannoma.

negative with no family history. The tumor grew from 5 to 7.6 mm (Fig. 2C) in 2 years follow-up with normal hearing (Fig. 2D). Treatment with bevacizumab is being considered.

Case 3

A 44-year-old male presented a left unilateral VS (Fig. 3A) removed through a TL approach in 2009 with normal postoperative FNF. Two years later, MRI showed

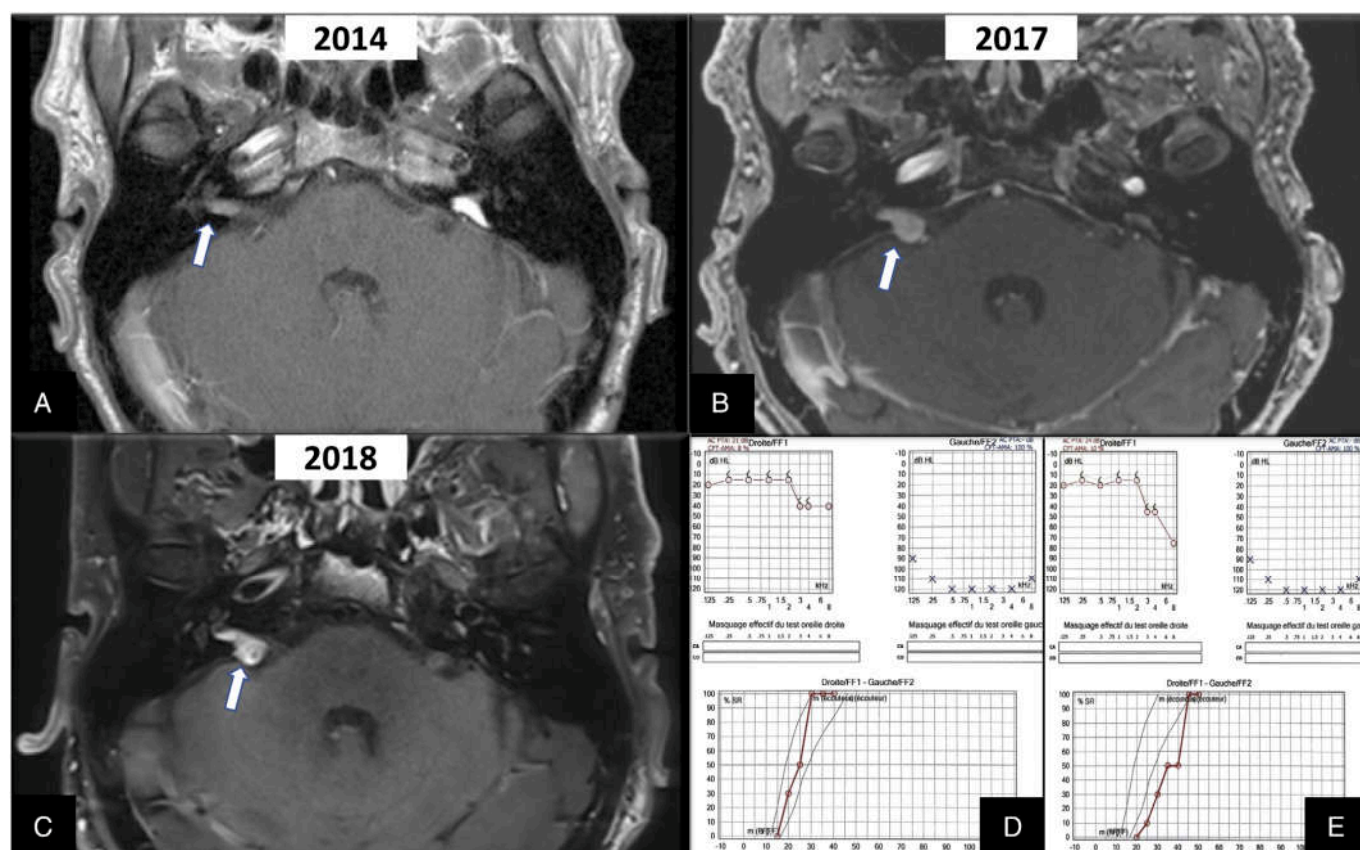


Fig. 1. Case 1. (A) Postoperative axial T1-weighted gadolinium-enhanced magnetic resonance imaging (MRI) showing contralateral right-side intracanalicular vestibular schwannoma (VS) (white arrow) 14 years after left VS removal. (B) MRI showing growth of the tumor (stage II) in 3 years (white arrow). (C) Follow-up MRI after chemotherapy with no VS evolution (white arrow). (D, E) Audiometric evaluations before (D) and after (E) treatment with bevacizumab showing slight high frequencies and speech recognition threshold decline. [Color figure can be viewed in the online issue, which is available at www.laryngoscope.com.]

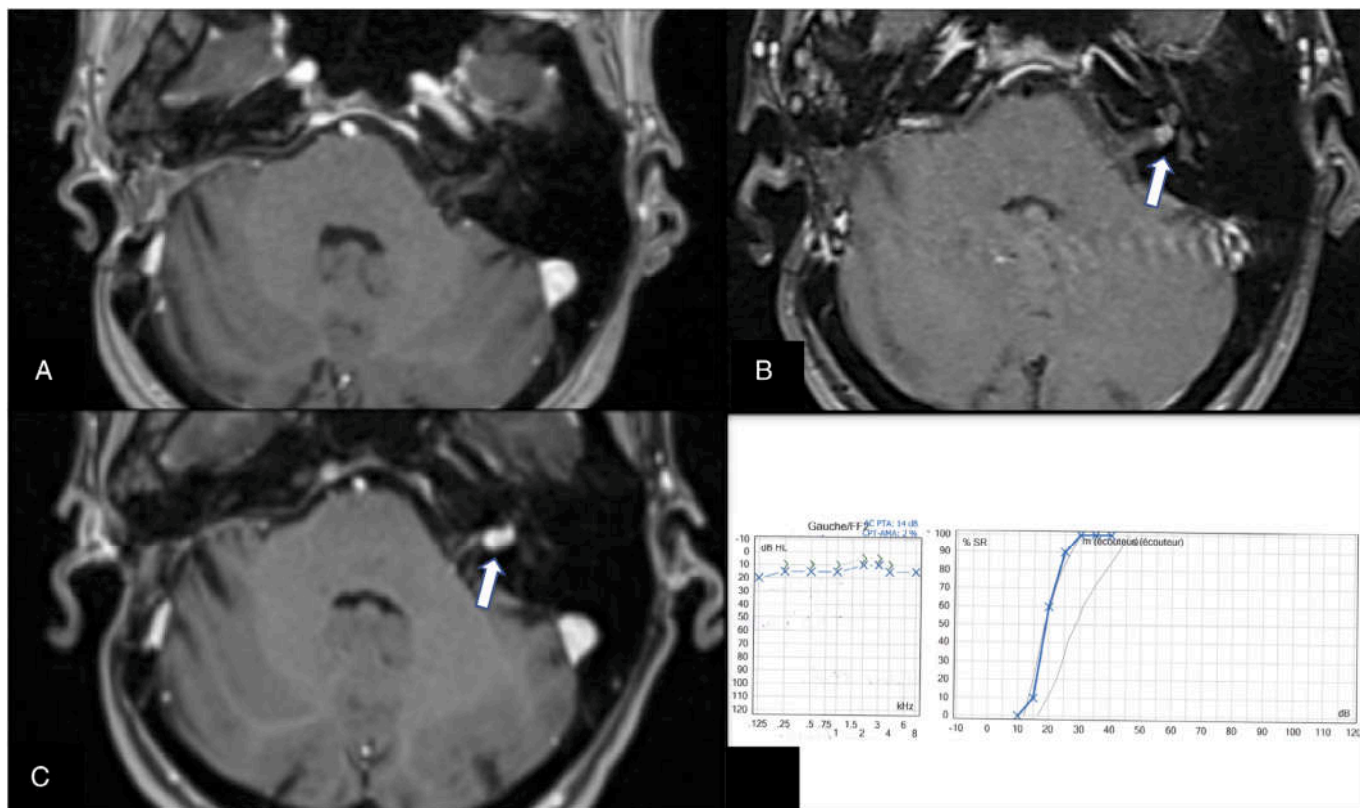


Fig. 2. Case 2. (A) Axial T1-weighted gadolinium-enhanced magnetic resonance imaging (MRI) 5 years after vestibular schwannoma (VS) removal on the right side showing no enhancement on both sides. (B) Follow-up gadolinium-enhanced MRI T1 image showing a left-side

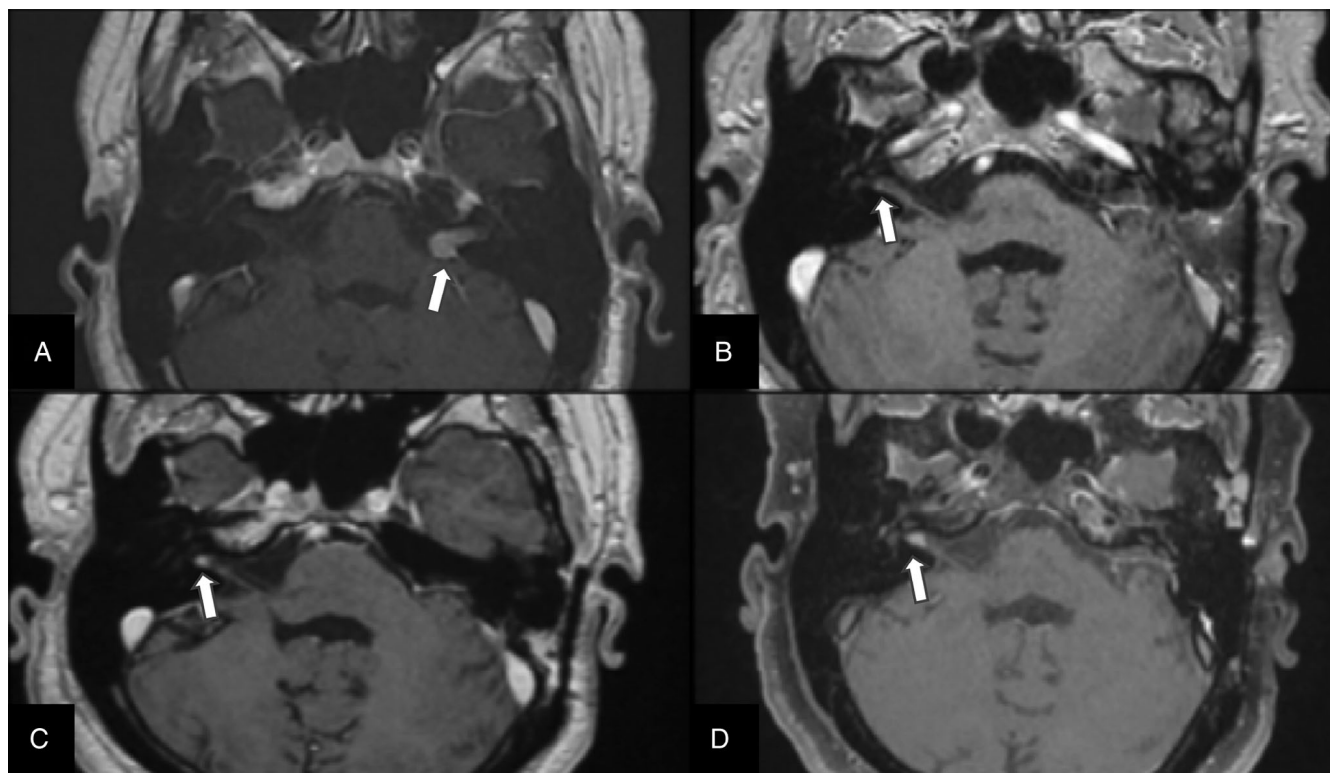


Fig. 3. Case 3. (A) Preoperative axial T1-weighted gadolinium-enhanced magnetic resonance imaging (MRI) showing left-side vestibular schwannoma (VS) (white arrow). (B–D) Postoperative axial T1-weighted gadolinium-enhanced MRI scans showing the initial growth (B, C) and secondary stabilization (C, D) of the contralateral right side VS in (whites arrows).

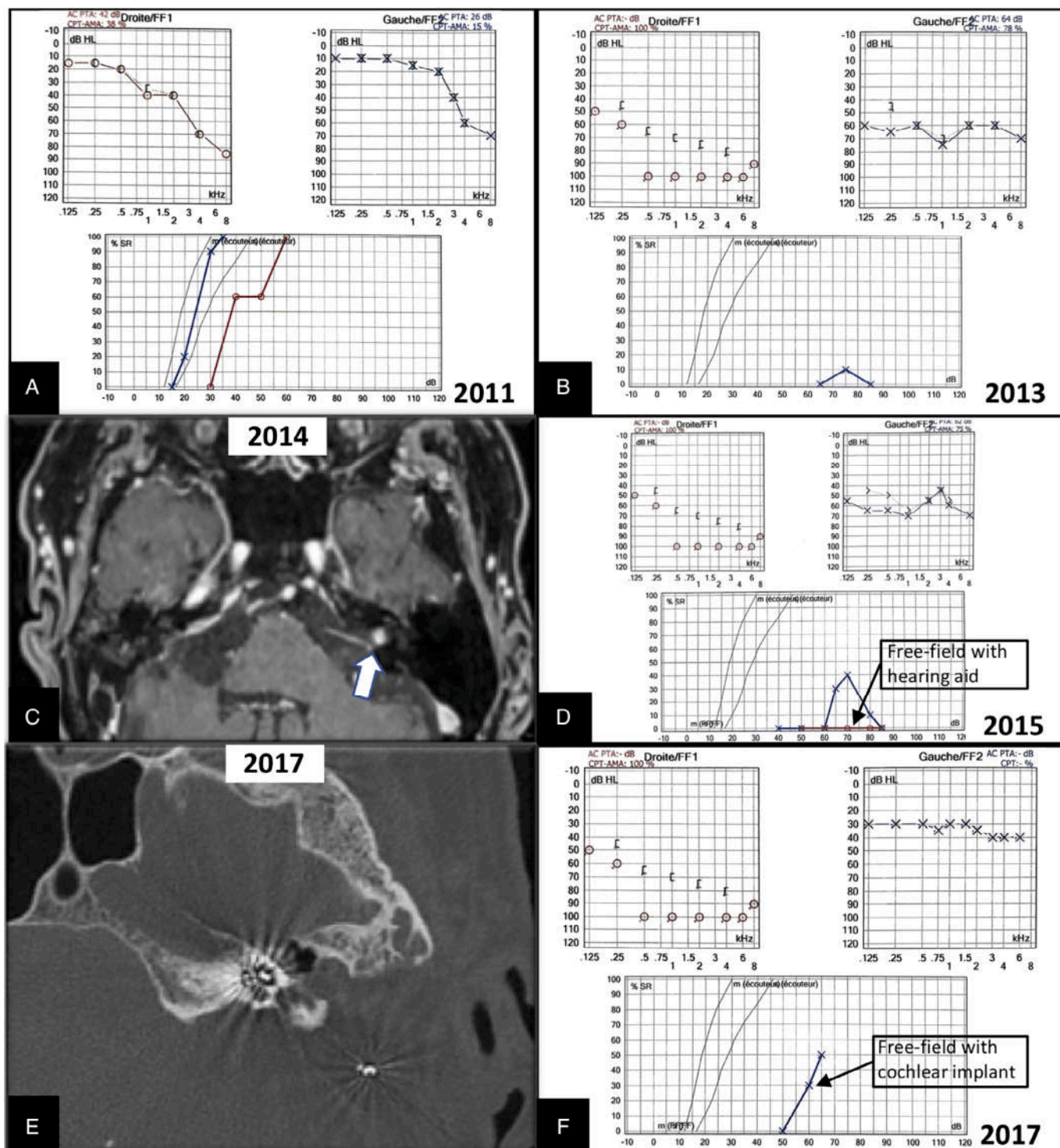


Fig. 4. Case 4. (A) Audiogram showing the hearing loss before right vestibular schwannoma removal through a translabyrinthine approach. (B–D) Audiograms showing sudden left sensorineural hearing loss (SNHL) 2 years later (B) with partial recovery after intravenous steroid therapy and no benefit of hearing aid (D). (C) Postoperative axial T1-weighted gadolinium-enhanced magnetic resonance imaging showing evolution of a contralateral left side vestibular schwannoma (VS) (white arrow) revealed by sudden SNHL. (E) Postoperative computed tomography (CT) scan of the patient after removal of the left-sided VS through a translabyrinthine approach and insertion of a cochlear implant at the same side. (F) Patient's moderate left cochlear implant performance 1 year after implantation. [Color figure can be viewed in the online issue, which is available at www.laryngoscope.com.]

incidentally a 1-mm enhancement of the contralateral vestibular nerve (Fig. 3B). A 3-mm intracanalicular VS was confirmed 4 years later (Fig. 3C), that grew to 6.5 mm in

2016 (Fig. 3D), and then remained stable. NF2 workup was negative with no family history. The patient remained asymptomatic and is under annual observation.

Case 4

A 67-year-old male presented with a right unilateral VS (Fig. 4A) removed in 2011 through a TL approach in another hospital. Sudden SNHL occurred 2 years later on the contralateral ear with partial recovery under intravenous steroid therapy (Fig. 4B), revealing a small intracanalicular left VS (Fig. 4C). No other NF2 features or family history were found. Because VS was slowly growing (1 mm/yr) with a nonserviceable hearing loss (Fig. 4D), TL excision with simultaneous cochlear implantation was performed in 2015 (Fig. 4E). MRI follow-up disclosed a right small recurrence 1 year later and the patient underwent radiosurgery in 2016 with no further growth. The patient is a daily cochlear implant user with moderate cochlear implant performance (Fig. 4F).

DISCUSSION

The wide use of MRI explains the increase of VS incidence in the last decades (1.9/100,000 annually⁵). This is consistent with a 1/1,000 lifetime incidence and a potential 1 in 2 million risk of chance of BVS, assuming a 1/2,000 chance on the contralateral side.²

NF2 predominant feature remains BVS development, although 12% to 18% of NF2 patients present an unilateral tumor.⁶ Atypical forms of NF2 with low growth potential of tumors are usually encountered in the elderly. Frequent occurrence of somatic mosaicism in NF2⁷ explains why germline mutation is rarely found. Alternatively, when BVS appears with no other NF2 features, the two tumors could have developed sporadically with no molecular event in common between them, especially in the elderly,^{8,9} or after radiation treatment.¹⁰ Evans et al. has estimated that 25% of BVS in those over 50 years old and 50% in those over 70 years old, with no other features of NF2, represent a chance occurrence rather than the expression of NF2.² That implies an extended monitoring by MRI for 10 years after an initial unilateral surgery to search for an eventual recurrence, and a new MRI if any new symptom appears.

The risk of familial NF2 in de novo NF2 patients after negative blood analysis is below the 7% and 5% for patients presenting BVS tumors after 40 years old. Nevertheless, these numbers did not take into account the possibility of sporadic VS occurring by chance.²

Although rare, if a contralateral VS occurs after removal of a first VS considered initially as sporadic, it will appear as a small intracanalicular VS on the only hearing ear. A wait-and-scan policy enables the evaluation of the

VS growth and hearing evolution. Rarely, a bilateral severe-to-profound hearing loss may require removal of the contralateral VS with concomitant cochlear implantation (case 4).^{11,12} If hearing declines and/or tumor extends into cerebellopontine angle, chemotherapy (bevacizumab) is strongly advocated to control VS growth and preserve hearing.^{12,13}

CONCLUSION

A low but true risk of occurrence of a delayed contralateral VS exists, which may define either an NF2 or bilateral sporadic VS. Active monitoring for new symptoms and the analysis of the postoperative imaging on the contralateral side should be performed. If a contralateral VS appears, the treatment strategy should be carefully tailored to each case, especially if the first VS led to anacusis.

BIBLIOGRAPHY

1. Evans DGR, Ramsden RT, Gokhale C, Bowers N, Huson SM, Wallace A. Should NF2 mutation screening be undertaken in patients with an apparently isolated vestibular schwannoma? *Clin Genet* 2007;71:354-358.
2. Evans DGR, Freeman S, Gokhale C, et al. Bilateral vestibular schwannomas in older patients: NF2 or chance? *J Med Genet* 2015;52:422-424.
3. Peyre M, Goutagny S, Bah A, et al. Conservative management of bilateral vestibular schwannomas in neurofibromatosis type 2 patients: hearing and tumor growth results. *Neurosurgery* 2013;72:907-913.
4. House J, Brackmann D. Facial nerve grading system. *Otolaryngol Head Neck Surg* 1985;93:146-147.
5. Stangerup S-E, Caye-Thomasen P. Epidemiology and natural history of vestibular schwannomas. *Clin Otolaryngol* 2012;45:257-268.
6. Evans DGR, Lye R, Neary W, et al. Probability of bilateral disease in people presenting with a unilateral vestibular schwannoma. *J Neurol Neurosurg Psychiatry* 1999;66:764-767.
7. Goutagny S, Bah AB, Parfait B, Sterkers O, Kalamarides M. Neurofibromatosis type 2 in the elderly population: clinical and molecular features. *Am J Med Genet A* 2013;161:667-670.
8. Evans DGR, Baser ME, O'Reilly B, et al. Management of the patient and family with neurofibromatosis 2: a consensus conference statement. *Br J Neurosurg* 2005;19:5-12.
9. Rao A, Lawrie A, Bodkin P, Tighe J, Kamel M. Bilateral cerebellopontine angle lesions not always NF2: diagnostic pitfall. *Br J Neurosurg* 2012;26:275-277.
10. Carlson M, Gompel J. Multiple unilateral vestibular schwannomas: segmental NF2 or sporadic occurrence? *J Neurol Surg Rep* 2016;77:e106-e108.
11. Jia H, Nguyen Y, De Seta D, et al. Management of sporadic vestibular schwannoma with contralateral nonserviceable hearing [published online October 23, 2019]. *Laryngoscope*. <https://doi.org/10.1002/lary.28369>.
12. Jia H, El Sayed MME, Smail M, et al. Neurofibromatosis type 2: hearing preservation and rehabilitation. *Neurochirurgie* 2018;64:348-354.
13. Goutagny S, Kalamarides M. Medical treatment in neurofibromatosis type 2. Review of the literature and presentation of clinical reports. *Neurochirurgie* 2018;64:370-374.
14. American Academy of Otolaryngology-Head and Neck Surgery Foundation. Committee on hearing and equilibrium guidelines for the evaluation of hearing preservation in acoustic neuroma (vestibular schwannoma). *Otolaryngol Head Neck Surg* 1995;113:179-180.
15. Torres R, Nguyen Y, Vanier A, et al. Multivariate analysis of factors influencing facial nerve outcome following microsurgical resection of vestibular schwannoma. *Otolaryngol Neck Surg* 2017;156:525-533.

Annex 2

Jia H, Elsayed M, Smail M, Mosnier I, Wu H, Sterkers O, Kalamarides M, Bernardeschi D. “*Neurofibromatosis type 2: Hearing preservation and rehabilitation.*” *Neurochirurgie*. 2018 Nov 1; 64(5):348-54.



Disponible en ligne sur

ScienceDirect
www.sciencedirect.com

Elsevier Masson France

EM|consulte
www.em-consulte.com


Original article

Neurofibromatosis type 2: Hearing preservation and rehabilitation

H. Jia^{a,c,e,f}, M. Elsayed^{a,b}, M. Smail^{a,b,c}, I. Mosnier^{b,c}, H. Wu^{e,**}, O. Sterkers^{a,b,c,f},
M. Kalamarides^{b,d,f,*}, D. Bernardeschi^{a,b,c}
^a Inserm, UMRS 1159, “unité de réhabilitation chirurgicale mini-invasive robotisée de l'audition”, Sorbonne Universités, université Pierre et Marie-Curie Paris 6, 75013 Paris, France

^b CMR neurofibromatosis type 2, GHU Pitié Salpêtrière, AP-HP, 75651 Paris, France

^c Service d'ORL, otologie, implants auditifs et chirurgie de la base du crâne, GHU Pitié Salpêtrière, AP-HP, 75651 Paris, France

^d Service de neurochirurgie, GHU Pitié Salpêtrière, Sorbonne Université, AP-HP, 75651 Paris, France

^e Department of Otolaryngology Head and Neck Surgery, Shanghai Ninth People's Hospital, Shanghai Jiaotong University School of Medicine, 200011 Shanghai, PR China

^f Sino-French Joint Clinical Research Center of Otolaryngology and Neuro-otology, 200011 Shanghai, PR China


ARTICLE INFO

Article history:

Received 1st March 2018

Received in revised form 4 August 2018

Accepted 7 September 2018

Available online 9 October 2018

Keywords:

Vestibular schwannoma

Hearing loss

Cochlear implant

Auditory brainstem implant

ABSTRACT

The main manifestation of neurofibromatosis type 2 (NF2) is the development of bilateral vestibular schwannomas (VS). Consequently, one of the most severe functional sequelae is bilateral sensorineural hearing loss, caused by spontaneous tumor progression and/or treatment-related damage (surgery or radiosurgery). Preserving or restoring hearing is still challenging in NF2 no matter the strategy applied to each individual based on the natural history of VS. In this review, the different strategies for hearing preservation or rehabilitation are discussed and illustrated by several cases. A decisional algorithm for NF2 patients with VS is proposed that takes into consideration the tumor size and hearing level.

© 2018 Elsevier Masson SAS. All rights reserved.

1. Introduction

Neurofibromatosis type 2 (NF2) is a genetic disorder that occurs with a birth incidence of approximately 1 in 25,000 with a dominant pattern of inheritance. Bilateral vestibular schwannomas (VS) appear in 90–95% of NF2 patients, as well as a predisposition to other benign nervous system tumors [1]. Various strategies have been used, including “wait and scan” (periodic radiological and audiological evaluations), surgical treatment (decompression of internal auditory meatus, partial removal, total removal), radiation-based therapy (single-fraction stereotactic radiosurgery, fractionated stereotactic radiation therapy), and chemotherapy (Bevacizumab). Because most patients suffer bilateral sensorineural hearing loss (SNHL), hearing preservation by acoustic amplification (hearing aid, HA) or rehabilitation by electrical stimulation to the remaining auditory structures (cochlear

implant, CI) or the cochlear nucleus (auditory brainstem implant, ABI) is also an essential element of treatment [2–14].

Analyzing and comparing different therapeutic strategies for NF2 patients is difficult because of the existence of multiple classifications. These classifications induce and perpetuate knowledge silos and references used only by certain specialists [15]. To evaluate hearing, neuro-otologists normally use the AAOHNS classifications, neuro-oncologists commonly use the Gardner Robertson classification, and some surgeons directly use the SDS. Similarly, there are several classifications available for tumor size depending on the author's preference. For example, the Koos classification takes into account indirectly the volume of the posterior fossa which tends to over-evaluate the tumor volume and results in more Grade IV tumors.

To make a better decision for each individual patient by considering the symptoms, tumor size and invasiveness, surgical risks, and natural history of tumor growth, a multidisciplinary medical team has been set up at NF2 reference centers composed of an otologist, neurosurgeon, audiologist, speech therapist, neuroradiologist and psychologist [16,17]. In this article, we present a short and thus non-exhaustive review of the literature on the subject of hearing and NF2, and a summary of the extensive experience of our National NF2 Reference Center, which is similar to that of most the large international expert centers on NF2.

* Corresponding author. Service neurochirurgie, hôpital Pitié-Salpêtrière, AP-HP, 47–83, boulevard de l'hôpital, 75651 Paris cedex 13, France.

** Co-corresponding author. Department of Otolaryngology Head and Neck Surgery, Shanghai Ninth People's Hospital, Shanghai Jiaotong University School of Medicine, 639 Zhizaoju Road, 200011 Shanghai, PR China.

E-mail addresses: wuhao622@sina.cn (H. Wu), michel.kalamarides@aphp.fr (M. Kalamarides).

1.1. Hearing preservation strategies

1.1.1. Wait and scan

VS in NF2 are usually slow growing tumors, although there is a wide individual range (0.4–10 mm/year) [18–20]. In our series, 25% of 92 VS in 46 patients had fast growth (>3 mm/year), and rapid tumor growth was more frequent in younger patients [19]. This suggests that the first magnetic resonance imaging (MRI) scan should be performed 6 months after the diagnosis and then annually. Meanwhile, spontaneous VS shrinkage or no growth was observed in some cases (14% in our series). It should be emphasized that, after removing a large one-sided VS, the contralateral VS may grow quicker. This may be due to repositioning of the brainstem to operated side where the cerebellopontine angle (CPA) space was released, which releases the compression on the tumor of the non-operated side [21].

Although a correlation between tumor growth and hearing deterioration was observed in sporadic VS, it seems that VS in NF2 has a special feature and this correlation has not been confirmed in small NF2 patient cohorts [18,22,23]. Relative to tumor growth observed in 31% cases at 1 year, 64% at 2 years, and 79% at 3 years, hearing deterioration was observed in 5% cases at 1 year, 13% at 2 years, and 16% at 3 years [24]. Some authors thought that profound SNHL would present approximately 3–5 years after the diagnosis of NF2 [25], but others demonstrated that useful hearing was still present in 65% to 74% of NF2 patients after 6–7 years [18,19]. This hearing deterioration may develop as a result of cochlear aperture obstruction and accumulation of intralabyrinthine protein [26]; it might be also due to a compression injury of the cochlear nerve and/or vascular occlusion of the auditory artery by the intracanalicular part

of the tumor, or stretching of the nerve by the extension of the CPA part of the tumor [22].

As a consequence, the “wait and scan” strategy can be recommended as a natural hearing preservation strategy, especially in middle-age or older patients with small- or mid-sized tumors, because the VS might not grow quickly and hearing may continue to be at a useful level for a long time in the majority of these NF2 patients (Case 1, Fig. 1).

1.1.2. Radiosurgery

Radiation therapy is an alternative treatment for NF2, including two main techniques, single-fraction stereotactic radiosurgery (SRS) and fractionated stereotactic radiation therapy (FSRT), whose radiation schedules and doses are different. Up to now, their outcomes are controversial. Some institutions reported that small- and mid-sized tumors were well controlled, with a 5-year local control rate between 75% and 87% [27–32]. However, there is some concern because in most cases, natural growth of the VS was not documented before treatment and was not analyzed in results [33]. The hearing preservation rate was inconsistent, depending on the chosen articles, all of which had shortcomings. Krut et al. reported a 5-year hearing preservation rate of 59% [30], and Lloyd et al. concluded that generally 41.1% patients maintained serviceable hearing long-term with a mean tumor control rate of 81.4% [34]. Increasing of the marginal dose led to better control of NF2-related VS but resulted in a higher rate of hearing loss. No prospective and randomized studies comparing the hearing outcomes of SRS and FSRT have been completed in the NF2 reference centers because of the small numbers of patients, tumor size bias and physician preferences. The risk of VS malignant transformation as well as

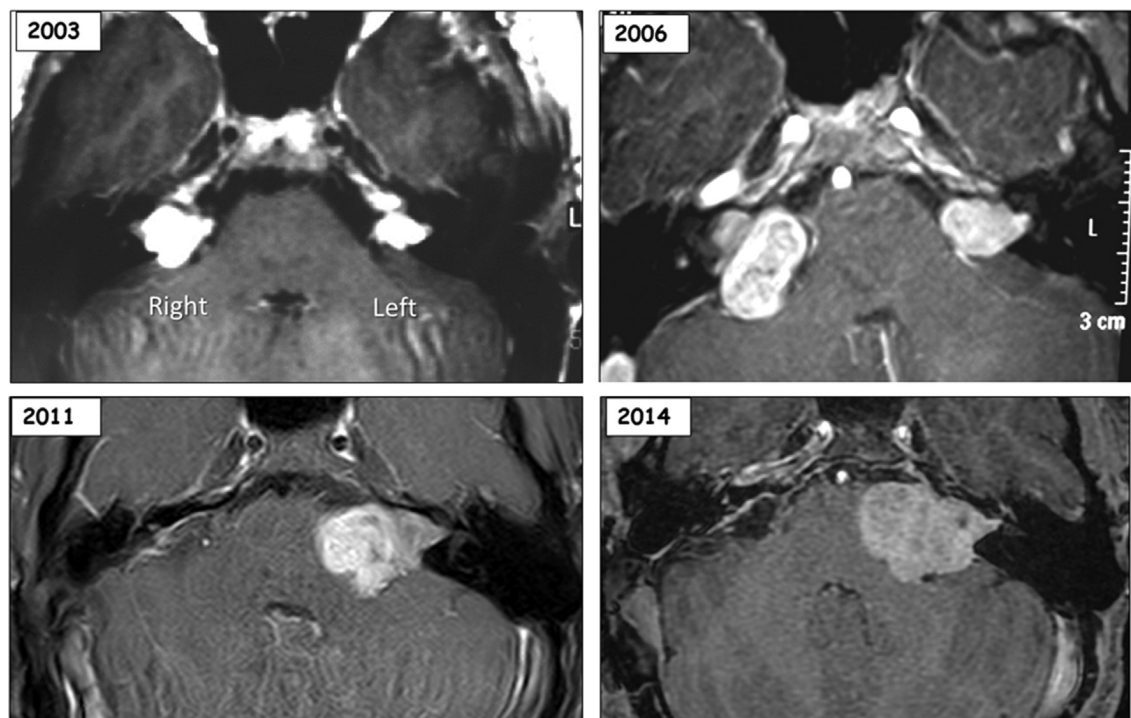


Fig. 1. Hearing maintenance by decompression of internal auditory meatus. A 14-year-old male patient was diagnosed with NF2 in 2003 because of a familial history of NF2. He had an 11 mm tumor (maximum diameter) on the left and an 8 mm tumor on the right side. Because of Class A hearing (AAOHS Classification) of both sides, the “wait and scan” strategy was used initially. Three years later (2006), his right tumor grew quickly (22 mm) with hearing deterioration (Class C) while his left tumor grew slowly (12 mm) with stable hearing (Class A), so his right tumor was removed through a translabyrinthine approach and the right hearing was sacrificed. Five years after the surgery (2011), his left hearing showed signs of deterioration but was still useful (Class B) when the tumor grew to 23 mm, so a decompression of the internal auditory meatus was performed to recover or delay hearing loss. His left hearing was successful preserved and was still useful (Class C) for 3 years (2014), despite the tumor growing slowly (28 mm). Later, he suffered a sudden hearing loss in his only functioning ear and did not recover with corticosteroid therapy. Therefore, cochlear implantation was performed in 2017 on the left side with the tumor in situ. Good auditory performance was achieved which was useful for daily conversation.

meningioma induction cannot be ignored since the NF2 gene is a tumor suppressor gene predisposing to the development of tumors, which is accelerated after radiation therapy [35,36]. Nevertheless, late malignant transformation can occur in the absence of irradiation [37] and no malignant transformation was observed in some long-term follow-up studies [38].

1.1.3. Microsurgical resection

The availability of high-definition stereo-microscopes, safer high-speed drills with integrated nerve stimulation, efficient local hemostatic agents, navigation and intraoperative nerve monitoring with better anti-interference capabilities have contributed to the goals of microsurgery for VS evolving from preserving life to preserving neurological functions. Microsurgical resection with hearing preservation can be performed through two approaches: middle cranial fossa approach (MFA) and retrosigmoid (RS). MFA is indicated for small- or mid-sized tumors, and standard RS approach is proposed for VS without IAM fundus involvement. Recently, endoscopes are becoming widely used in skull base surgery, and since the relationship in the IAM fundus can be viewed, it has eliminated the major drawbacks of RS. With the development of intraoperative facial nerve monitoring [39], the risk of facial nerve paralysis remains low (inferior to 10%) in these small or mid-sized VS 1 year after surgery [40].

With modern intraoperative cochlear nerve monitoring, the rate of hearing preservation is higher than before. The rate was 60–70% via MFA and 30–40% via RS [31], but the two approaches could not be compared directly because the tumor size and location differed. Further, the risk of recurrence was higher with MCF than RS in the

cases without tumor involvement of IAM fundus [41]. In some cases of NF2-related VS, postoperative hearing might be lost even if auditory monitoring showed a preserved response at the end of surgery. Destruction of the auditory nerve's blood supply is the main reason despite the nerve being preserved. No predictive factors for hearing preservation following microsurgery have been identified in sporadic VS, but the hearing preservation rates seemed higher in cases of stable PTA with normal ABR during follow-up, in cases without cochlear fossa tumors for MFA, or in cases without fundus tumors for RS [42,43].

1.1.4. Decompression of internal auditory meatus

As hearing preservation by MSR varied and could not be predicted accurately, a surgical technique with less trauma to the auditory nerve and its surroundings was proposed: decompression of the IAM via MFA. Image-guided navigation systems have been used more and more in this technique, helping to precisely locate and open the IAM roof [44]. This surgical technique results in a good rate of hearing preservation (approximately 90% short-term) and is accepted as a safe procedure to maintain useful hearing in NF2 patients with monoaural hearing, which becomes paramount to their quality of life [45,46]. Furthermore, a cochlear implant could be used when these patients lose their hearing later in life, because the auditory nerve was not damaged by the surgical manipulations (Case 2, Fig. 2). Thus, IAM decompression is proposed to NF2 patients with an objective hearing modification (progressive, fluctuating, or sudden hearing loss); this treatment could be combined with chemotherapy if the VS is fast growing. Some teams have proposed operating on patients before the hearing

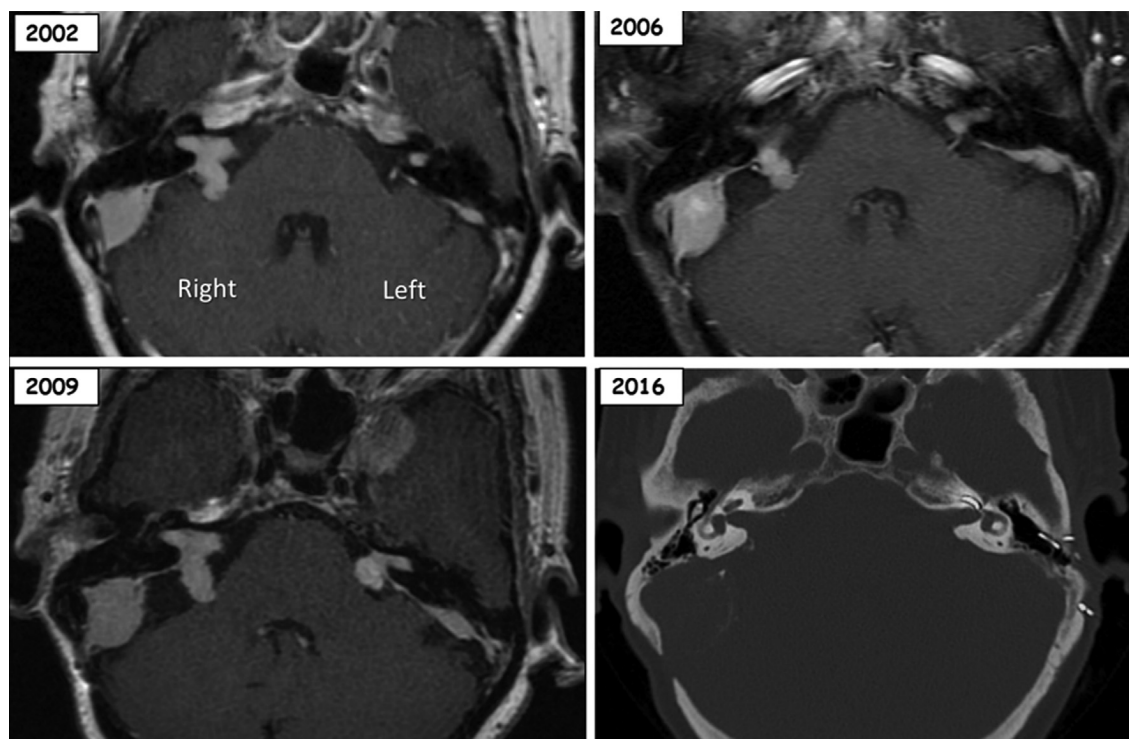


Fig. 2. Hearing rehabilitation by cochlear implantation without tumor removal. A female patient (born in 1944) was diagnosed as having NF2 when she was young. She was operated on twice for a left coronal meningioma (1982) and posterior fossa meningioma (1998). In 2002, her left hearing was normal (Class A, 4 mm intracanalicular tumor) and right hearing was moderately altered (Class B, 12 mm tumor). The “wait and scan” strategy was initially adopted for her. In 2006, her right tumor was stable (12 mm) with slight deterioration of hearing (Class B), but the left one grew (11 mm) with progressive hearing loss (Class C). “Wait and scan” was continued. In 2009, she had total hearing loss on the left and Class C hearing on the right, which meant her hearing level was insufficient for day-to-day life. Considering her age (65 years old) and slow growth of the tumor, cochlear implantation into her left ear was proposed without tumor removal. The auditory brainstem response was confirmed to be evoked by electric stimulation on the promontory before implantation. Seven years after her cochlear implantation (2016), the hearing in her right non-implanted ear was still Class C. With a hearing aid in her right ear and a cochlear implant in her left ear, the intelligibility in free field measurement was quite good (SRT 65 dB, SDS 80%). CT follow-up imaging did not show any evident tumor growth.

impairment develops, making their decision on the alteration of EABR. To date, no study has shown the validity of this approach.

1.1.5. Chemotherapy

Nearly all VS express vascular endothelial growth factor (VEGF, MGF-A). bevacizumab, a human IgG monoclonal antibody, which binds to VEGF with high specificity, was given to NF2 patients in clinical trials. Short-term studies showed good efficacy for controlling tumor growth as well as preserving useful hearing, although side effects appeared with long-term use [47–49]. Additionally, it seems the treatment effect was temporary and the beneficial effects subsided when the treatment was discontinued. A

prospective 14-patient study aimed at minimizing side effects with a lower bevacizumab dosage found a hearing response in at least one-third of patients for 3 months [50]. This hearing response was correlated to biomarkers indicating reduced tumor-associated edema and improved oxygenation that impact on tumor volume. In some patients, hearing was preserved during long-term treatment with everolimus [51,52]. The number of patients treated with other drugs is too small to reach a conclusion.

Currently, it appears that bevacizumab has significantly reduced the number of surgeries on the contralateral VS and consequently decreased the number of ABI implantations at NF2 reference centers around the world.

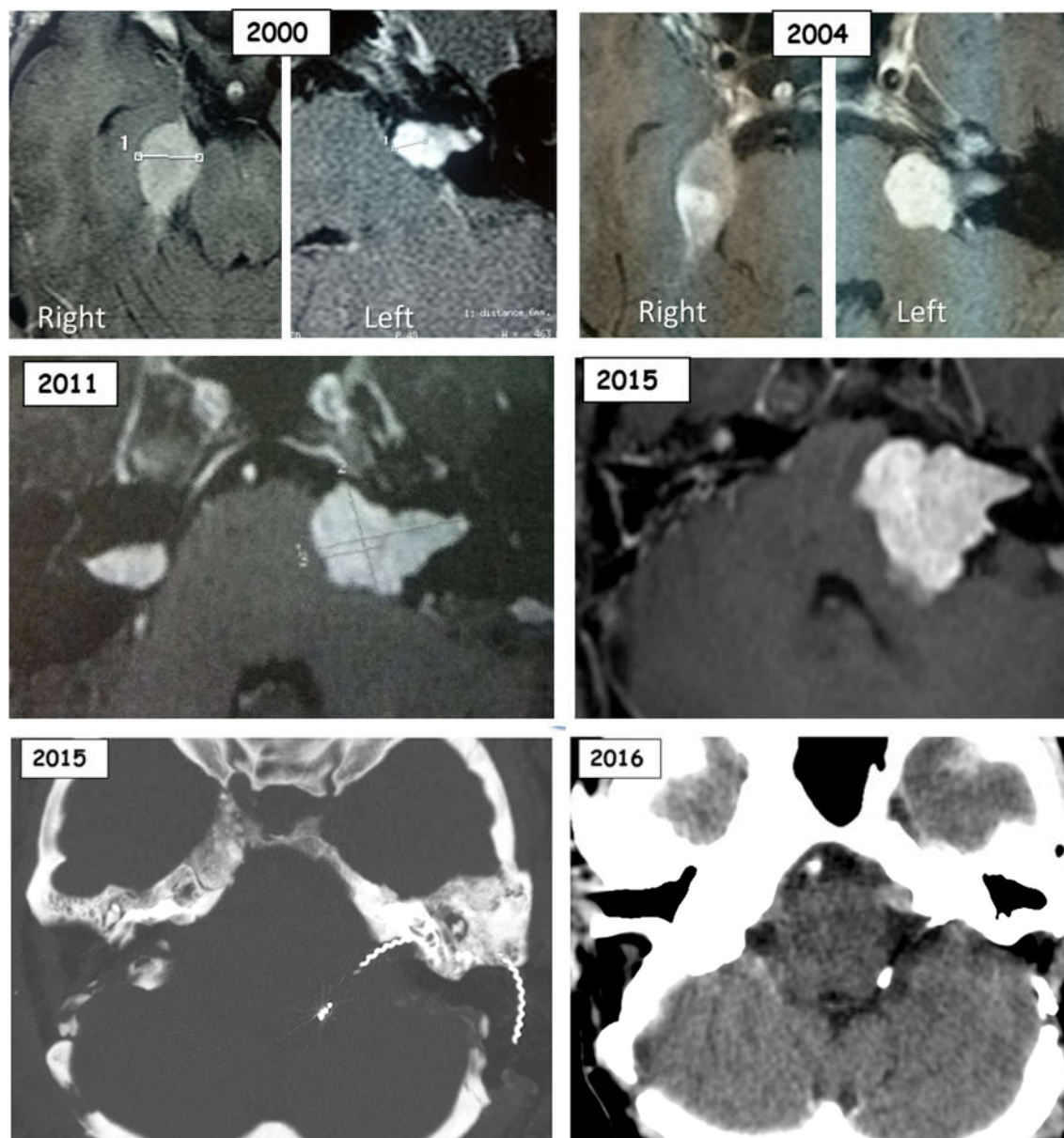


Fig. 3. Hearing rehabilitation by auditory brainstem implantation. A female patient (born in 1973) was diagnosed as NF2 in 1997, presenting bilateral vestibular schwannomas and right middle fossa meningioma. In 1998, her right schwannoma was removed via RS at another hospital but the hearing was not preserved. During the follow-up, she had several sudden hearing loss episodes on the left side but all finally recovered (Class A). Decompression of the left internal auditory meatus (8 mm tumor in CPA) was proposed in 2004 to reduce the frequency and risk of hearing loss, and her hearing was stable for about 7 years (Class A, 2011) although the left tumor was growing slowly (22 mm, 2011). Meanwhile, a recurrence of the tumor was observed in the right internal auditory meatus in 2011; it was removed at the same hospital that performed the previous removal. In 2015, her left hearing was totally lost with a growing tumor (31 mm), so the tumor was removed via TL and an ABI was implanted to restore her hearing. One year later (2016), there was no recurrence on the left side, and the patient was satisfied with the ABI outcome (word and sentence recognition score with lip-reading were both 60%).

1.2. Hearing rehabilitation strategy

1.2.1. Hearing aids

Hearing aids deliver amplified sound through the damaged cochlea and nerves to brain. In NF2 patients with mild to severe hearing loss, conventional hearing aids could be proposed as a temporary but low risk and atraumatic strategy. The type of hearing loss in NF2 patients is retrocochlear, which causes a decrease in the speech intelligibility score and desynchronization of auditory brainstem responses. Consequently, the real benefit of sound amplification by a hearing aid is uncertain. Most patients prefer not to wear it because sounds appear distorted and intelligibility in noisy conditions is relatively poor.

1.2.2. Cochlear implant (CI)

A cochlear implant is an implanted device that provides direct electrical stimulation into the inner ear, which requires a functional auditory nerve as a traditional indication. Because the integrity or function of the auditory nerve cannot be guaranteed, cochlear implantation in NF2-related VS was not considered until recently. The main reasons may be the insufficient benefit and weak performance achieved with ABI, and lack of ABI support in some medical centers or countries. In this situation, the cochlear nerve was preserved as best possible. Anatomical preservation of the cochlear nerve is sometimes very difficult in NF2, particularly because of the variety of lesions. The recent use of intraoperative monitoring with DNAP and CNAP (dorsal nucleus and cochlear nerve action potentials, respectively) may be to be a solution to improving the number of functional, and also electrical, cochlear nerve preservations, allowing CI placement at the same time or secondarily. In any case, the peak performance of ABI is generally lower than that achievable with cochlear implantation [53]. The promontory test evaluating the electrical integrity of the cochlear nerve has a

good positive predictive value notwithstanding many false negatives. Therefore, some centers prefer to implant a CI first instead of an ABI [54]. Because of the uncertainty of hearing preservation via the RS approach, some authors suggest removing tumor via a translabyrinthine (TL) approach that can identify the cochlear nerve early and expose it entirely, no matter the preoperative hearing level, and simultaneously perform cochlear implantation [12,13,55]. In order to ensure maximum integrity of the auditory nerve, cochlear implantation without tumor removal was proposed and applied in older patients whose tumors were stable or increased slowly in volume [12,56–58] (Case 2, Fig. 2). CI might be also proposed to patients whose tumor is controlled by Bevacizumab but there are no published study on this topic. Because some patients obtained better long-term audition with CI, cochlear implantation has been the main alternative for hearing restoration in NF2 patients [12–14,58,59].

Indeed, CI in NF2 patients performs better than ABI, but the audiological features, tumor features and age of the two populations differs. With recent technological developments, radiological evaluation by MRI at 1.5 T or 3.0 T can still be performed for some CI or ABI devices. Furthermore, previous SRS does not contraindicate the placement of CI or ABI [2,60].

1.2.3. Auditory brainstem implant (ABI)

The ABI was developed by House and Hitselberger in the 1980s. This device uses technology similar to that of cochlear implants, but instead of electrical stimulation to the cochlea, ABI stimulates the cochlear nucleus of the brainstem which bypasses the damaged auditory nerve. The implanted electrode should be placed on and/or inserted into the cochlear nucleus in the lateral recess of the 4th ventricle; this could be performed in the same surgical procedure as intracranial tumor resection. In most cases, ABI was implanted on the second side (Case 3, Fig. 3), but in some cases it was also

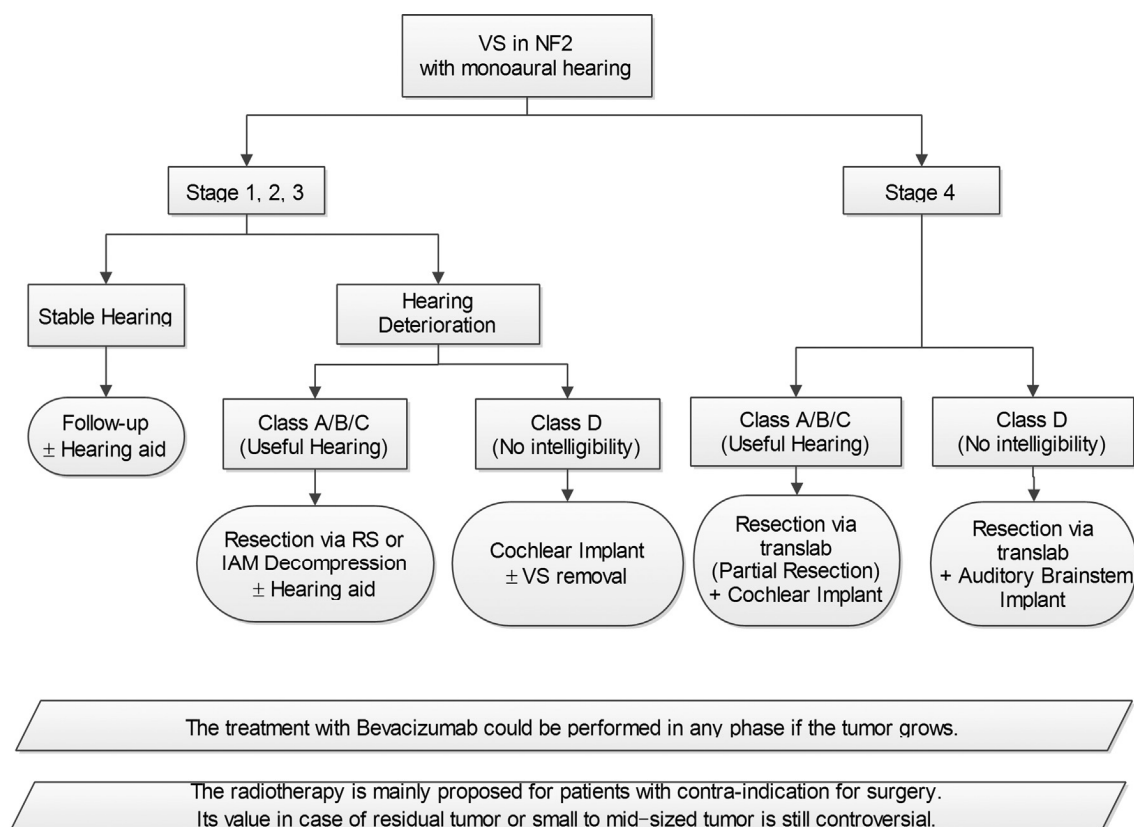


Fig. 4. Decisional algorithm for NF2 patients with vestibular schwannomas and monaural hearing.

implanted on the first side with the device switched off until total contralateral hearing loss has developed (Sleeper ABI) [61]. The ABI achieved the expected auditory benefit with lip-reading in most cases. But the intelligibility remains uncertain and few NF2 patients had good open set performance without lip-reading [3,5,6,8,9]. In order to improve the performance of ABI, many studies have been undertaken, such as penetrating electrodes designed to improve the contact between the electrodes and the coding areas of the nucleus, but this technique did not produce better outcomes [7]. Positron emission tomography scans showed the auditory cortex could be activated though ABI [62]; this result meant that the coding strategies developed for CI might not be suitable for the cochlear nucleus mapping for ABI [63].

However ABI could be recommended in young NF2 patients whose VS are growing rapidly and often large, because there is no other choice. ABI performs better here than in other populations, probably due to the high brain plasticity in younger people.

2. Conclusion

A combination of different treatment options should now be considered for hearing preservation and tumor volume control (Fig. 4), if there are no other indications for surgical intervention such as encephalic stage or spinal tumor. These different treatment strategies are to be tailored to each patient, in particular to the severity of the illness, the rate of tumor progression and the personal history of the illness and sometimes, the family history. Decompression of the IAM and chemotherapy, principally Bevacizumab, are now the best options to preserve or improve useful hearing in NF2 patients especially as the VS is growing. The presence of artificial hearing by electrical stimulation (ABI, CI) could impact the synchronism of binaural signals in auditory cortex when contralateral natural hearing is present. Hence, when the devices are implanted during the initial surgery, they are usually switched off until patients lose their bilateral useful hearing. Generally, older patients with no or slow growth of small- and mid-sized VS are candidates for CI without tumor resection, and young patients with large progressive VS are candidates for ABI with tumor resection. Because of small sample sizes and large individual differences, no prospective and randomized studies have been completed in NF2 patients. Further study are needed to allow us to draw a conclusion with high confidence.

Grant Support

The authors from China were supported by the projects of Shanghai Science and Technology Committee (17441903600) in this work.

Disclosure of interest

The authors declare that they have no competing interest.

References

- [1] Evans DG, Moran A, King A, Saeed S, Gurusinge N, Ramsden R. Incidence of vestibular schwannoma and neurofibromatosis 2 in the North West of England over a 10-year period: higher incidence than previously thought. *Otol Neurotol* 2005;26(1):93–7.
- [2] Kalamarides M, Grayeli AB, Bouccara D, Dahan EA, Sollmann WP, Sterkers O, et al. Hearing restoration with auditory brainstem implants after radiosurgery for neurofibromatosis type 2. *J Neurosurg* 2001;95(6):1028–33.
- [3] Nevison B, Laszig R, Sollmann WP, Lenarz T, Sterkers O, Ramsden R, et al. Results from a European clinical investigation of the Nucleus multichannel auditory brainstem implant. *Ear Hear* 2002;23(3):170–83.
- [4] Kanowitz SJ, Shapiro WH, Golfinos JG, Cohen NL, Roland Jr JT. Auditory brainstem implantation in patients with neurofibromatosis type 2. *Laryngoscope* 2004;114(12):2135–46.
- [5] Vincenti V, Pasanisi E, Guida M, Di Trapani G, Sanna M. Hearing rehabilitation in neurofibromatosis type 2 patients, cochlear versus auditory brainstem implantation. *Audiol Neurotol* 2008;13(4):273–80.
- [6] Grayeli AB, Kalamarides M, Bouccara D, Ambert-Dahan E, Sterkers O. Auditory brainstem implant in neurofibromatosis type 2 and non-neurofibromatosis type 2 patients. *Otol Neurotol* 2008;29(8):1140–6.
- [7] Otto SR, Shannon RV, Wilkinson EP, Hitselberger WE, McCreery DB, Moore JK, Brackmann DE. Audiologic outcomes with the penetrating electrode auditory brainstem implant. *Otol Neurotol* 2008;29(8):1147–54.
- [8] Maini S, Cohen MA, Hollow R, Briggs R. Update on long-term results with auditory brainstem implants in NF2 patients[J]. *Cochlear Implants Int* 2009;10(Suppl 1):33–7.
- [9] Sanna M, Di Lella F, Guida M, Merkus P. Auditory brainstem implants in NF2 patients, results and review of the literature. *Otol Neurotol* 2012;33(2):154–64.
- [10] Behr R, Colletti V, Matthies C, Morita A, Nakatomi H, Dominique L, et al. New outcomes with auditory brainstem implants in NF2 patients. *Otol Neurotol* 2014;35(10):1844–51.
- [11] Ramsden RT, Freeman SR, Lloyd SK, King AT, Shi X, Ward CL, et al. Auditory Brainstem Implantation in Neurofibromatosis Type 2. Experience from the Manchester programme. *Otol Neurotol* 2016;37(9):1267–74.
- [12] Carlson ML, Breen JT, Driscoll CL, Link MJ, Neff BA, Gifford RH. Experience from the Manchester Programme. Cochlear implantation in patients with neurofibromatosis type 2, variables affecting auditory performance. *Otol Neurotol* 2012;33(5):853–62.
- [13] Lloyd SK, Glynn FJ, Rutherford SA, King AT, Mawman DJ, O'Driscoll MP. Experience from the Manchester Programme. Ipsilateral cochlear implantation after cochlear nerve preserving vestibular schwannoma surgery in patients with neurofibromatosis type 2. *Otol Neurotol* 2014;35(1):43–51.
- [14] Neff BA, Wiet RM, Lasak JM, Cohen NL, Pillsbury HC, Ramsden RT, Welling DB. Cochlear implantation in the neurofibromatosis type 2 patient, long-term follow-up. *Laryngoscope* 2007;117(6):1069–72.
- [15] Schnurman Z, Golfinos JG, Roland Jr JT, Kondziolka D. Knowledge silos: assessing knowledge sharing between specialties through the vestibular schwannoma literature. *J Neurosurg* 2017;1:1–8.
- [16] Aboukais R, Bonne NX, Baroncini M, Zairi F, Schapira S, Vincent C, et al. Management of multiple tumors in neurofibromatosis type 2 patients. *Neurochirurgie* 2015 [pii: S0028-3770(15)00055-7].
- [17] Lloyd SK, Evans DG. Neurofibromatosis type 2 service delivery in England. *Neurochirurgie* 2016 [pii: S0028-3770(15)00279-9].
- [18] Kontorinis G, Nichani J, Freeman SR, Rutherford SA, Mills S, King AT, et al. Progress of hearing loss in neurofibromatosis type 2, implications for future management. *Eur Arch Otorhinolaryngol* 2015;272(11):3143–50.
- [19] Peyre M, Goutagny S, Bah A, Bernardeschi D, Larroque B, Sterkers O, et al. Conservative management of bilateral vestibular schwannomas in neurofibromatosis type 2 patients, hearing and tumor growth results. *Neurosurgery* 2013;72(6) [discussion 914; quiz 914].
- [20] Harris GJ, Plotkin SR, Maccollin M, Bhat S, Urban T, Lev MH, et al. Three-dimensional volumetrics for tracking vestibular schwannoma growth in neurofibromatosis type II. *Neurosurgery* 2008;62(6):1314–9 [discussion 1319–20].
- [21] Peyre M, Goutagny S, Imbeaud S, Bozorg-Grayeli A, Felce M, Sterkers O, et al. Increased growth rate of vestibular schwannoma after resection of contralateral tumor in neurofibromatosis type 2. *Neuro Oncol* 2011;13(10):1125–32.
- [22] Peyre M, Bernardeschi D, Sterkers O, Kalamarides M. Natural history of vestibular schwannomas and hearing loss in NF2 patients. *Neurochirurgie* 2015 [pii: S0028-3770(15)00090-9].
- [23] Fisher LM, Doherty JK, Lev MH, Slattery WH. Concordance of bilateral vestibular schwannoma growth and hearing changes in neurofibromatosis 2, neurofibromatosis 2 natural history consortium. *Otol Neurotol* 2009;30(6):835–41.
- [24] Plotkin SR, Merker VL, Muzikansky A, Barker FG, Slattery W. Natural history of vestibular schwannoma growth and hearing decline in newly diagnosed neurofibromatosis type 2 patients. *Otol Neurotol* 2014;35(1):e50–6.
- [25] Masuda A, Fisher LM, Oppenheimer ML, Iqbal Z, Slattery WH. Natural History Consortium. Hearing changes after diagnosis in neurofibromatosis type 2. *Otol Neurotol* 2004;25(2):150–4.
- [26] Asthagiri AR, Vasquez RA, Butman JA, Wu T, Morgan K, Brewer CC, et al. Mechanisms of hearing loss in neurofibromatosis type 2. *PLoS One* 2012;7(9):e46132.
- [27] Sun S, Liu A. Long-term follow-up studies of Gamma Knife surgery for patients with neurofibromatosis Type 2. *J Neurosurg* 2014;121 Suppl:143–9.
- [28] Mallory GW, Pollock BE, Foote RL, Carlson ML, Driscoll CL, Link MJ. Stereotactic radiosurgery for neurofibromatosis 2-associated vestibular schwannomas, toward dose optimization for tumor control and functional outcomes. *Neurosurgery* 2014;74(3):292–300 [discussion 300–1].
- [29] Chung LK, Nguyen TP, Sheppard JP, Lagman C, Tenn S, Lee P, et al. A Systematic Review of Radiosurgery Versus Surgery for Neurofibromatosis Type 2 Vestibular Schwannomas. *World Neurosurg* 2018;109:47–58.
- [30] Krut J, Verheul JB, Hanssens PEJ, Kunst HPM. Gamma Knife radiosurgery for treatment of growing vestibular schwannomas in patients with neurofibromatosis Type 2: a matched cohort study with sporadic vestibular schwannomas. *J Neurosurg* 2018;128(1):49–59.
- [31] Combs SE, Welzel T, Kessel K, Habermehl D, Rieken S, Schramm O, et al. Hearing preservation after radiotherapy for vestibular schwannomas is comparable to hearing deterioration in healthy adults and is accompanied by local tumor control and a highly preserved quality of life (QOL) as patients' self-reported outcome. *Radiother Oncol* 2013;106(2):175–80.

- [32] Andrews DW, Suarez O, Goldman HW, Downes MB, Bednarz G, Corn BW, et al. Stereotactic radiosurgery and fractionated stereotactic radiotherapy for the treatment of acoustic schwannomas: comparative observations of 125 patients treated at one institution. *Int J Radiat Oncol Biol Phys* 2001;50: 1265–78.
- [33] Miller T, Lau T, Vasan R, Danner C, Youssef AS, van Loveren H, et al. Reporting success rates in the treatment of vestibular schwannomas: are we accounting for the natural history? *J Clin Neurosci* 2014;21(6):914–8.
- [34] Lloyd SKW, King AT, Rutherford SA, Hammerbeck-Ward CL, Freeman SRM, Mawman DJ, et al. Hearing optimisation in neurofibromatosis type 2. A systematic review. *Clin Otolaryngol* 2017.
- [35] Hilton DA, Hanemann CO. Schwannomas and their Pathogenesis. *Brain Pathol* 2014;24(3):205–20.
- [36] Evans DG, Birch JM, Ramsden RT, Sharif S, Baser ME. Malignant transformation and new primary tumours after therapeutic radiation for benign disease, substantial risks in certain tumour prone syndromes. *J Med Genet* 2006;43(4):289–94.
- [37] Bashir A, Poulsen L, Broholm H, Fugleholm K. Late malignant transformation of vestibular schwannoma in the absence of irradiation: case report. *J Neurosurg* 2016;125(2):372–7.
- [38] Birkhead B, Sio TT, Pollock BE, Link MJ, Laack NN. Gamma Knife radiosurgery for neurofibromatosis type 2-associated meningiomas: a 22-year patient series. *J Neurooncol* 2016;130(3):553–60.
- [39] Bernardeschi D, Meskine N, Otaibi NA, Ablonczy R, Kalamarides M, Grayeli AB, et al. Continuous facial nerve stimulating burr for otologic surgeries. *Otol Neurotol* 2011;32(8):1347–51.
- [40] Torres R, Nguyen Y, Vanier A, Smail M, Ferrary E, Sterkers O, et al. Multivariate analysis of factors influencing facial nerve outcome following microsurgical resection of vestibular Schwannoma. *Otolaryngol Head Neck Surg* 2017;156(3):525–33.
- [41] Friedman RA1, Goddard JC, Wilkinson EP, Schwartz MS, Slattery WH, 3rd, et al. Hearing preservation with the middle cranial fossa approach for neurofibromatosis type 2. *Otol Neurotol* 2011;32(9):1530–7.
- [42] Kari E, Friedman RA. Hearing preservation microsurgery. *Curr Opin Otolaryngol Head Neck Surg* 2012;20(5):358–66.
- [43] Wang ZY, Jia H, Yang J, Tan HY, Wu H. A combination use of endoscope and microscope in cerebral pontine angle surgery. *Zhonghua Er Bi Yan Hou Tou Jing Wai Ke Za Zhi* 2017;52(2):85–8.
- [44] Bernardeschi D, Nguyen Y, Villepelet A, Ferrary E, Mazalaigue S, Kalamarides M, et al. Use of bone anchoring device in electromagnetic computer-assisted navigation in lateral skull base surgery. *Acta Otolaryngol* 2013;133(10): 1047–52.
- [45] Slattery WH, Hoa M, Bonne N, Friedman RA, Schwartz MS, Fisher LM, et al. Middle fossa decompression for hearing preservation, a review of institutional results and indications. *Otol Neurotol* 2011;32(6): 1017–24.
- [46] Bernardeschi D, Peyre M, Collin M, Smail M, Sterkers O, Kalamarides M. Internal Auditory Canal Decompression for Hearing Maintenance in Neurofibromatosis Type 2 Patients. *Neurosurgery* 2016;79(3):370–7.
- [47] Plotkin SR, Merker VL, Halpin C, Jennings D, McKenna MJ, Harris GJ, et al. 2nd. Bevacizumab for progressive vestibular schwannoma in neurofibromatosis type 2, a retrospective review of 31 patients. *Otol Neurotol* 2012;33(6):1046–52.
- [48] Slusarz KM, Merker VL, Muzikansky A, Francis SA, Plotkin SR. Long-term toxicity of bevacizumab therapy in neurofibromatosis 2 patients. *Cancer Chemother Pharmacol* 2014;73(6):1197–204.
- [49] Farschtschi S, Kollmann P, Dalchow C, Stein A, Mautner VF. Reduced dosage of bevacizumab in treatment of vestibular schwannomas in patients with neurofibromatosis type 2. *Eur Arch Otorhinolaryngol* 2015;272(12):3857–60.
- [50] Blakeley JO, Ye X, Duda DG, Halpin CF, Bergner AL, Muzikansky A, et al. Efficacy and biomarker study of bevacizumab for hearing loss resulting from neurofibromatosis type 2-associated vestibular schwannomas. *J Clin Oncol* 2016;34(14):1669–75.
- [51] Goutagny S, Raymond E, Esposito-Farese M, Trunet S, Mawrin C, Bernardeschi D, et al. Phase II study of mTORC1 inhibition by everolimus in neurofibromatosis type 2 patients with growing vestibular schwannomas. *J Neurooncol* 2015;122(2):313–20.
- [52] Goutagny S, Giovannini M, Kalamarides M. A 4-year phase II study of everolimus in NF2 patients with growing vestibular schwannomas. *J Neurooncol* 2017;133(2):443–5.
- [53] Peng KA, Lorenz MB, Otto SR, Brackmann DE, Wilkinson EP. Cochlear implantation and auditory brainstem implantation in neurofibromatosis type 2. *Laryngoscope* 2018.
- [54] Harris F, Tysome JR, Donnelly N, Durie-Gair J, Crundwell G, Tam YC, et al. Cochlear implants in the management of hearing loss in Neurofibromatosis Type 2. *Cochlear Implants Int* 2017;18(3):171–9.
- [55] Ahsan S, Telischi F, Hodges A, Balkany T. Cochlear implantation concurrent with translabyrinthine acoustic neuroma resection. *Laryngoscope* 2003;113(3):472–4.
- [56] Huo Z, Zhang Z, Huang Q, Yang J, Wang Z, Li Y, Huang M, Wu H. Hearing Restoration for Adults with Vestibular Schwannoma in the Only Hearing Ear: Ipsilateral or Contralateral Cochlear Implantation? *ORL J Otorhinolaryngol Relat Spec* 2016;78(5):281–8.
- [57] Roehm PC, Mallen-St Clair J, Jethanamest D, Golfinos JG, Shapiro W, Waltzman S, et al. Auditory rehabilitation of patients with neurofibromatosis Type 2 by using cochlear implants. *J Neurosurg* 2011;115(4):827–34.
- [58] North HJ, Mawman D, O'Driscoll M, Freeman SR, Rutherford SA, King AT, et al. Outcomes of cochlear implantation in patients with neurofibromatosis type 2. *Cochlear Implants Int* 2016;17(4):172–7.
- [59] Lassaletta L, Aristegui M, Medina M, Aranguiz G, Pérez-Mora RM, Falcioni M, et al. Ipsilateral cochlear implantation in patients with sporadic vestibular schwannoma in the only or best hearing ear and in patients with NF2. *Eur Arch Otorhinolaryngol* 2016;273(1):27–35.
- [60] Wu H, Kalamarides M, Bouccara D, Dahan EA, Viala P, Sollmann WP, et al. Auditory brainstem implant (Nucleus 21-channel) in neurofibromatosis type 2 patients previously operated on: preliminary results. *Adv Otorhinolaryngol* 2000;57:236–9.
- [61] Ramsden RT, Freeman SRM, Lloyd Simon Kingsley Wickham, et al. Auditory brainstem implantation in neurofibromatosis type 2: experience from the Manchester Programme. *Otol Neurotol* 2016;37(9):1267–74.
- [62] Miyamoto RT, Wong D, Pisoni DB, Hutchins G, Sehgal M, Fain R. Positron emission tomography in cochlear implant and auditory brain stem implant recipients. *Am J Otol* 1999;20(5):596–601.
- [63] Coez A, Zilbovicius M, Ferrary E, Bouccara D, Mosnier I, Ambert-Dahan E, et al. Processing of voices in deafness rehabilitation by auditory brainstem implant. *Neuroimage* 2009;47(4):1792–6.

Sujet : Evaluation des nouvelles techniques pour améliorer les résultats de la fonction postopératoire du nerf facial pendant la chirurgie des tumeurs de l'angle cérébelleux (APC).

Résumé : Une lésion du nerf facial (entraînant une paralysie faciale) entraîne des conséquences graves sur la qualité de vie des patients avec une perte de maîtrise des expressions faciales avec des retentissements sur les fonctions du visage et des conséquences psychologiques. Elle peut conduire à des difficultés dans plusieurs domaines de la vie quotidienne, avec des difficultés pour parler, manger et cligner (ce qui peut conduire à une sécheresse oculaire, les lésions cornéennes voire une perte de la vision de l'œil atteint). Ainsi, beaucoup de patients atteints de paralysie faciale éprouvent un isolement social et développent une dépression à cause de leurs difficultés à communiquer avec les autres sur le plan émotionnel.

Les tumeurs de l'angle ponto-cérébelleux (L'APC) peuvent comprimer le nerf facial et les autres nerfs dans cette région ainsi perturber leur fonctionnements. Le traitement de référence actuel reste l'exérèse chirurgicale. Environ, cinq cents personnes sont opérées chaque année en France de ce type de lésion. Ainsi la préservation anatomique et fonctionnelle du nerf facial pendant l'opération est toujours difficile, même pour des chirurgiens expérimentés : Tout d'abord, le nerf facial au contact de la tumeur a tendance à être comprimé et aplati. Il peut ainsi avoir une couleur similaire à celle de la tumeur au contact qui le rend impossible à reconnaître visuellement, même avec un microscope opératoire. Ensuite, le nerf peut être refoulé d'un côté de la tumeur qui ne peut pas être anticipé. Cela rend d'autant plus difficile la zone dans laquelle il doit rechercher le nerf.

Afin d'aider le chirurgien, un monitoring peropératoire du nerf facial est systématiquement utilisé dans cette indication. Avec une sonde de stimulation, le chirurgien peut ensuite rechercher le nerf facial par exploration des régions anatomiques. L'inconvénient de cette technique est qu'elle apporte des informations partielles au chirurgien car cette sonde de stimulation ne sert pas à réséquer la tumeur. Lors de la dissection de la tumeur entre deux utilisations de la sonde, la qualité du monitoring de la fonction du nerf est donc diminuée. C'est la limite majeure des outils à disposition du chirurgien actuellement. Lors d'une prise en charge par une équipe experte de cette chirurgie, on observe 26% de patients ayant une paralysie postopératoire huit jours après l'intervention.

La sonde de stimulation classique travaille par intermittence et a un usage potentiellement limité parce que le nerf est toujours à risque de dommages entre deux stimulations de repérage. L'incapacité de surveiller la fonction nerveuse entre deux cycles de stimulation met le nerf en danger pendant les intervalles de dissection surveillés par le

monitorage passif, et reste une limitation importante de la technique de monitoring actuel. Ainsi, un nouveau système qui propose une surveillance étroite et continue des nerfs pendant toute la procédure chirurgicale a été conçu. Ce système a fait ses preuves dans la préservation de la fonction des nerfs innervant les muscles des cordes vocales au cours de la chirurgie de la thyroïde. Il n'a jamais été testé et validé pour surveiller le nerf facial dans la chirurgie des tumeurs de l'angle ponto-cérébelleux. Le but est ainsi d'obtenir une surveillance continue en temps réel de l'intégrité de la fonction du nerf facial afin de permettre des mesures correctives rapides avant que des dommages permanents soient constitués sur le nerf facial. Ce système est constitué par l'électrode APS (Automated Periodic Stimulation, Medtronic, Jacksonville, USA) est un élément circonférentiel qui est placé autour du nerf d'intérêt. La stimulation électrique est assurée par un petit anneau qui est placé à la surface intérieure de l'attache circonférentielle, et des potentiels d'action musculaire composites sont enregistrées dans le muscle (s) innervé par le nerf.

Le but du travail est aussi de mieux décrire l'abord de l'angle ponto cérébelleux sur le cochon pour des projets scientifiques ultérieurs. Le protocole prévoit des stimulations mécaniques et thermiques telles que celles réalisées pendant la chirurgie et pouvant conduire à une paralysie faciale. La réalisation du protocole nécessite donc le recours à un modèle animal vivant. Cela nécessite le recours à un gros animal tel que le cochon car les structures anatomiques étudiées sont de petites tailles millimétriques (technique microchirurgicale). Le cerveau de porc est différent du cerveau humain. Cependant, les différences entre l'anatomie de la fosse postérieure de ces cerveaux sont négligeables sous un microscope opérationnel en termes de manipulation microchirurgicales des nerfs crâniens autour du tronc cérébral. De plus il est envisagé d'utiliser le même matériel que celui qui sera utilisé en clinique afin de réduire les délais de translation de la recherche vers l'application vers le patient. Pour cette raison, un animal possédant des structures anatomiques de dimensions proches de celle de l'homme est nécessaire.

Parallèlement, une étude prospective clinique a été réalisée des patients qui ont été opérés pour la résection microchirurgicale de schwannome vestibulaire avec la préservation anatomique du nerf facial. Le but de cette étude était d'identifier les facteurs peropératoire cliniques qui pourraient déterminer les résultats de la fonction faciale postopératoire. De plus, il vise à améliorer et affiner la valeur prédictive de la surveillance peropératoire, nous avons pensé qu'il serait intéressant d'étudier les paramètres de surveillance nerf facial et si la valeur pouvait pronostiquer avec précision le résultat de la fonction faciale postopératoire.

Mots clés : [Nerf facial - modèle animal - tumeurs de l'angle ponto-cérébelleux- monitoring peropératoire]

Title : Evaluation and validation of new techniques of facial nerve preservation during cerebellopontine angle (CPA) tumor surgery.

Abstract: The aims of surgery in the cerebellopontine angle (CPA) have changed from tumor resection and prolongation of life to the anatomical and functional preservation of the cranial nerves. Facial palsy is one of the most serious morbidities because loss of facial expression is a functionally and psychologically debilitating condition. It is a debilitating condition that may lead to difficulties in several areas of daily life, including speaking, eating, and blinking (which may lead to dry eyes and corneal damage). Anatomical and functional preservation of FN in VS surgery is still challenging even for experienced neurosurgeons. In large VS cases, FNs are always displaced and morphologically changed in an unpredictable manner. Some are even indistinguishable from the tumor capsule under microscope. There have no models for predicting FN course in VS cases so far. The main purpose of intraoperative monitoring is to make the surgical team aware of the ongoing changes in the neural function, thereby permitting modifications in surgical strategies that can ultimately avoid neural damage. For the purpose of risk minimization, a monitoring system is required that continuously monitors the integrity of nerve function during the operation. Continuous intraoperative neuromonitoring (C-IONM) affords close monitoring in real time of the functional integrity of the entire facial so that impending nerve injury can be detected on time, enabling quick corrective action. A cadaveric animal model was proposed to allow access to Facial nerve in pigs and then reproduced in vivo with trials of the C-IONM electrodes. In parallel, a clinical prospective study was performed of patients who were operated for microsurgical resection of VS with anatomic preservation of the facial nerve. The primary goal of this study was to identify the clinical peri-operative factors that could determine the occurrence of an immediate postoperative impaired facial function and recovery in the long-term. Secondly, to refine the predictive value of intraoperative monitoring, we thought it would be interesting to investigate FN monitoring parameters (i.e. pre- and post-surgical resection ratios of amplitude and latency values at supra-maximal stimulation) to determine if either value could prognosticate FN outcome.

Keywords: [Facial nerve preservation- CPA surgery - Neuromonitoring- Animal study]