



HAL
open science

Hepatocellular carcinoma on non cirrhotic liver : comparative analysis of histological and genomic determinants in two cohorts (Peruvian and European)

Luis Rodolfo Cano Ayestas

► **To cite this version:**

Luis Rodolfo Cano Ayestas. Hepatocellular carcinoma on non cirrhotic liver : comparative analysis of histological and genomic determinants in two cohorts (Peruvian and European). Human health and pathology. Université de Rennes, 2019. English. NNT : 2019REN1B044 . tel-03418307

HAL Id: tel-03418307

<https://theses.hal.science/tel-03418307v1>

Submitted on 7 Nov 2021

HAL is a multi-disciplinary open access archive for the deposit and dissemination of scientific research documents, whether they are published or not. The documents may come from teaching and research institutions in France or abroad, or from public or private research centers.

L'archive ouverte pluridisciplinaire **HAL**, est destinée au dépôt et à la diffusion de documents scientifiques de niveau recherche, publiés ou non, émanant des établissements d'enseignement et de recherche français ou étrangers, des laboratoires publics ou privés.

THESE DE DOCTORAT DE

L'UNIVERSITE DE RENNES 1
COMUE UNIVERSITE BRETAGNE LOIRE

ECOLE DOCTORALE N° 605

Biologie Santé

Spécialité : « "Physiologie, physiopathologie, biologie systémique médicale" »

Par

Luis Rodolfo CANO AYESTAS

CARCINOME HEPATOCELLULAIRE SUR FOIE NON CIRRHOTIQUE

Analyse comparative des déterminants histologiques et génomiques dans deux cohortes (Péruvienne et Européenne)

Thèse présentée et soutenue à « Rennes », le « 06 de Novembre 2019 »
Unité de recherche : INSERM UMR 1241 – NUMECAN

Rapporteurs avant soutenance :

Brigitte LE BAIL PU-PH - CHU Bordeaux
Laurent CHAVATTE CR - CNRS-ENS Lyon

Composition du Jury :

Président :	Véronique Loustaud-Ratti	PUPH – CHU Limoges
Examineurs :	Brigitte Le Bail	PU-PH - CHU Bordeaux
	Laurent Chavatte	CR - CNRS-ENS Lyon
	Stéphane Bertani	CRCN – IRD Toulouse
	Olivier Lóreal	DR – NUMECAN Rennes
Dir. de thèse :	Bruno Turlin	MCU-PH – NUMECAN Rennes
Co-dir. de thèse :	Pascal Pineau	DR – Institut Pasteur Paris

A few words

I am not an artist, although I must confess that I would like to be, not to write songs, much less symphonies, but at the dawn of these lines I will try, even for a moment to approach them by sharing with you the fruit of 3 years of my life.

There have been easy times to cope with, the distance, although shorter and shorter, always accompanies the silent nights of those who left everything they knew behind.

The greatest fear is not outside, on the contrary, it accompanies us whenever life reminds us of the way we are, not helpless, not alone, but struggling with ourselves to take the next step.

The spirit is broken, tears are born, hands tremble, the voice is silenced, but we still move forward, because we do not know that it will come later, but we trust that when the night is over, the dawn will illuminate in front of us all that we have lived

Many times, we want the suffering to end, but in our most intimate moments, when we can talk with him, we reach an agreement and understand that despite everything we need to know that we are alive.

Our humanity is now defined by what we have done and we are able to do. Because from this moment we can control the time itself at our whim, the barriers fall when we see ourselves pass, the spirit ignites and burns so strong that it illuminates everything around.

From this moment, the meanings are over, the questions are silent, stunned by our presence, not because of fear, on the contrary. We have earned their respect and just like us, we wait for patients the precise moment where they can approach us to talk.

Accompanied by friends or my own shadow, I walk in the direction of the sun, leaving behind stories, but looking for new ones, I don't miss what I lost, but I pay tribute to it, because thanks to what went away something new could come.

In this eternal return, where each end is succeeded by a beginning, I am free to leave and enter at will.

To my parents, teachers and Friends

Gratitude

With simple words I will try to be neat, it has never been my will to overwhelm others with redundant sounds.

I have so many thanks to give as stars in the sky, there are so many people who have contributed to this work, that naming them all would be impossible for me. However, I hope in these lines not to forget the most important.

Every adventure has a beginning and every beginning the first day I opened my eyes to the world, my parents were responsible for awakening in me the flame of knowledge that burns with much more force today.

The right people come to you when you least expect it, that's what I thought when Dr. Oswaldo García told me one day during a semiology class in Chimbote, get out of here, go try the world and if you like it then conquer it. At first with fear, but also with curiosity, it was like a 22-year-old boy leaving a beach behind, he decided to travel to discover everything the world had to show him.

I am French, the first sentence I heard of who is one of the articles of this story today, my friend Stephane Bertani, without his support and above all patience I would never have dared to cross an ocean looking for new adventures and above all have the courage to expand my limits.

You did well, my director, Bruno Turlin, told me, after my first thesis committee, while stammering in a new language such a simple answer, but with so much meaning: Merci chef.

Hug, is the last line of the message of my thesis director, Pascal Pineau, what, although here is not the constitute to do it, a hug can be the most comforting thing in the world besides making you feel that there is no loneliness when you have people who esteem you.

It must be precise, Olivier Loréal, one of my adoptive parents in this country, told me in front of the others in a meeting, highlighting a characteristic of mine, which pleased the rest, for being a well-valued quality.

You are welcome!; It was the first thing I heard from Alain Fautrel, there are no words to describe what it feels like not to be a stranger in an unknown land.

And life is not complete without friends, what I say to all those to whom I do not dedicate a paragraph, but they have a well-earned place in the pages of my history book, Moussa, Patricia, Isabelle, Elise, Catherine, Anne, Thomas, Patricia, Michelle, Bruno, Marinne, Valérie, Guevorg, Pascal, Roselyn.

For you and me, in the today and yesterday of this story, during the night and in the day, moving on to the end.

I wouldn't be here today if it wasn't for all of you.

Unas breves palabras

No soy artista, aunque debo confesar que me gustaría serlo, no escribo canciones ni mucho menos sinfonías, pero en el amanecer de estas líneas trataré, aunque sea por un momento de aproximarme a ellos al compartir con ustedes el fruto de 3 años de mi vida.

No han sido tiempos fáciles de sobrellevar, la distancia, aunque cada vez mas corta, siempre acompaña las noches silenciosas de aquellos que dejaron todo lo que conocían atrás.

El miedo más grande no esta fuera, al contrario, nos acompaña siempre que la vida nos recuerda el camino en el que estamos, no desamparados, no solos, pero si luchando con nosotros mismos por dar el siguiente paso.

El espíritu se quiebra, la lagrimas nacen, las manos tiemblan, la voz se hace pedazos, pero aún así seguimos avanzando, porque no sabemos que vendrá después, pero confiamos en que cuando la noche se acabe, el alba iluminará frente a nosotros todo lo que hemos vivido.

Muchas veces queremos que el sufrimiento se acabe, pero en nuestros momentos más íntimos, cuando podemos dialogar con él, llegamos a un acuerdo y entendemos que a pesar de todo lo necesitamos para saber que estamos vivos.

Nuestra humanidad, ahora se define por lo que hemos hecho y somos capaces de hacer. Porque desde este momento podemos controlar el tiempo mismo a nuestro antojo, las barreras caen al vernos pasar, el espíritu se enciende y arde tan fuerte que ilumina todo alrededor.

Desde este momento, los significados sobran, las preguntas están calladas, atónitas ante nuestra presencia, no por miedo, al contrario. Nos hemos ganado su respeto y así como nosotros, esperan pacientes el momento preciso donde puedan acercarse a platicar.

Acompañado de amigos o de mi propia sombra, camino en dirección al sol, dejando atrás historias, pero buscando nuevas, no añoro lo que perdí, pero si le rindo homenaje, ya que gracias a lo que se fue pudo venir algo nuevo.

En este eterno retorno, donde cada final es sucedido por un inicio, soy libre de salir y entrar a voluntad.

A mis padres, maestros y amigos

Agradecimiento

Con palabras simples trataré de ser prolijo, nunca ha sido mi voluntad abrumar a los demás con sonidos redundantes.

Tengo tantas gracias que dar como estrellas en el cielo, son tantas las personas que han contribuido a realizar esta obra, que nombrarlos a todos se me haría imposible. Sin embargo, espero en estas líneas no olvidarme de los más importantes.

Toda aventura tiene un inicio y todo inició el primer día que abrí los ojos al mundo, mis padres fueron los encargados de despertar en mí la llama del conocimiento que hoy arde con mucha más fuerza.

La gente adecuada llega a ti cuando menos te lo esperas, fue lo que pensé cuando el Dr. Oswaldo García, me dijo un día durante una clase de semiología en Chimbote, sal de aquí, ve a probar el mundo y si te gusta pues conquístalo. Al principio con miedo, pero también con curiosidad, fue como un chico de 22 años dejó atrás una playa, decidió viajar a descubrir todo lo que el mundo tenía que mostrarle.

Yo soy francés, la primera frase que escuché de quien es hoy uno de los artífices esta historia, mi amigo Stephane Bertani, sin su apoyo y sobretodo paciencia nunca me hubiera atrevido a cruzar un océano buscando nuevas aventuras y sobretodo tener el coraje para expandir mis límites.

Lo hiciste bien, me dijo mi director, Bruno Turlin, después de de mi primer comité de tesis, mientras balbuceaba en un lenguaje nuevo una respuesta tan simple, pero con tanto significado: Merci chef.

Abrazo, es la última línea del mensaje de mi director de tesis, Pascal Pineau, qué, aunque aquí no sea la costumbre hacerlo, un abrazo puede ser lo más reconfortante del mundo además de hacerte sentir que no hay soledad cuando tienes gente que te estima.

Debe ser preciso me dijo Olivier Loréal, uno de mis padres adoptivos en este país, delante de los demás en una reunión, resaltando una característica mía, que causo beneplácito al resto, por ser una cualidad bien valorada.

Bienvenido!; fue lo primero que escuche de Alain Fautrel, no existen palabras para describir que es lo que se siente no ser un extraño en una tierra desconocida.

Y la vida no esta completa sin amigos, lo que yo digo a todos aquellos a quienes no dedico un párrafo, pero tienen un lugar bien ganado en las páginas del libro de mi historia, Moussa, Patricia, Isabelle, Elise, Catrine, Anne, Thomas, Patricia, Michelle, Bruno, Marinne, Valérie, Guevorg, Pascal, Roselyn.

Para ti y para mí, en el hoy y el ayer de esta historia, durante la noche y en el día, avanzando hasta el final.

Hoy no estaría aquí si no fuera por todos ustedes.

It's all about precision

On ne savait pas comment ça allait terminer, mais nous avons quand même essayé de le faire

Eres y serás la más grande de mis Victorias

Résumé

Le carcinome hépatocellulaire (CHC) est au niveau mondial le 6^{me} cancer par ordre de fréquence, mais le 4^{me} en termes de mortalité. Il se développe dans près de 80 % des cas sur une cirrhose constituée, qui correspond à la séquelle – parfois encore évolutive - d'une pathologie hépatique chronique. Les étiologies possibles des cirrhoses sont dominées par les infections virales – virus de l'hépatite B (VHB) et virus de l'hépatite C (VHC). La fréquence de l'infection virale – chez les patients porteurs d'une cirrhose – est très variable en fonction de la zone géographique d'origine du patient. Notamment il existe une incidence élevée des infections virales dans les régions d'Asie du sud est, d'Europe de l'Est et d'Amérique du Sud.

Les autres facteurs étiologiques des cirrhoses incluent la consommation chronique d'alcool, les maladies stéatosiques du foie (elles-mêmes secondaires aux pathologies métaboliques comme l'obésité et le diabète de type 2). D'autres pathologies moins fréquentes peuvent être à l'origine d'une cirrhose hépatique, comme des maladies héréditaires (hémochromatose génétique ou certaines glycoséose), mais aussi des maladies non héréditaires de surcharge en fer telle l'hémochromatose bantoue, très courante en Afrique subsaharienne. Toutefois, il existe des CHC qui se développent sur un foie non cirrhotique (CHC NC). Il existe, là aussi, une grande variabilité de fréquence du CHC NC dans le monde.

Une forme particulière de CHC NC est le carcinome fibrolamellaire : cette tumeur, qui se développe en l'absence de maladie hépatique chronique, est retrouvée chez des patients jeunes (< 40 ans) et comporte des caractéristiques spécifiques, tant au niveau clinique (taille de la tumeur, absence d'élévation du taux sérique de l'alpha-fœtoprotéine (AFP)) que morphologique (cellules hexagonales avec cytoplasme abondant et granuleux et présence de bandes de fibrose lamellaire au sein de la tumeur).

Plus récemment, un autre type de CHC NC a été décrit, qui ne répond pas aux caractéristiques du carcinome fibrolamellaire. Ce type de CHC, qui a été décrit au Pérou - Amérique du Sud par Bertani et al., présente des caractéristiques particulières telles que :

- Un jeune âge de survenu (moyenne de 44 ans) avec une répartition bimodale des âges.
- Des niveaux élevés d'AFP, (moyenne de 29.124 +/- 3.382 ng/mL).
- Une tumeur de grande taille (moyenne de 15 cm) ;
- Une fréquente positivité sérologique pour l'hépatite B, mais sans lésions hépatique chronique.

La population péruvienne est particulière et présente des caractéristiques spécifiques qui pourraient favoriser le développement de cette maladie, comme l'existence de zones d'endémie de l'infection par le VHB, avec des régions – telle que l'Apurimac - présentant des taux de infection atteignant 59,7%, et l'augmentation des taux d'obésité et de diabète de type 2.

L'analyse de la répartition géographique de la population péruvienne porteuse d'un CHC NC montre une corrélation entre l'incidence de la maladie et la présence d'une activité minière. Ce résultat pose la question d'un potentiel rôle des métaux dans le développement du CHC NC au Pérou.

Par conséquent, les objectifs de notre étude sont les suivants :

- Effectuer une analyse pathologique du foie – concernant les composantes tumorale et non tumorale.
- Analyser les relations potentielles entre les facteurs environnementaux (métaux) et le développement de cette maladie

Analyse pathologique du foie

Notre premier objectif a constitué en l'analyse du foie non tumoral.

Pour cela, nous avons effectué une étude comparative du foie non tumoral de patients atteints de CHC NC et de patients subissant une chirurgie hépatique pour métastases de différents cancers.

Les deux cohortes de patients (CHC et contrôles) comportaient respectivement de 50 et 75 personnes. L'analyse a porté sur des échantillons tissulaires fixés au formol et inclus en paraffine ou congelés. Les techniques histologiques utilisées comprenaient le HES (hématoxyline, éosine et safran), la coloration de Perls (pour évaluer la présence de fer dans les tissus), le trichrome de Masson (pour évaluer le niveau de fibrose), la réticuline (analyse du dessin trabéculaire) et la coloration de PAS après digestion par l'amylase.

Une étude immunohistochimique a été entreprise avec les marqueurs suivant : actine du muscles lisses (pour montrer la présence d'une activation des cellules étoilées du foie) ; CD 34 (marqueur endothélial), glutamine synthétase (marqueur des hépatocytes centrolobulaire) et CD 163 (marqueur des macrophages). Une analyse transcriptomique a également été effectuée sur le tissu congelé à partir de sous-groupes de patients de chaque cohorte. Une détection du VHB au sein du foie a aussi été entreprise.

L'analyse des données montre, comme décrit par Bertani et al. la présence d'une distribution bimodale de l'âge pour la cohorte CHC. La comparaison histologique entre les deux cohortes, ne montre aucune différence en termes de fibrose, de stéatose ou de présence de fer. Cependant, l'examen histologique a mis en évidence - dans la cohorte CHC - des foyers d'hépatocytes de grande taille, d'aspect clarifiés et entourés par une discrète composante inflammatoire. Ces foyers cellulaires présentent également une altération de l'architecture trabéculaire normale (travées hépatocytaires épaissies) et une positivité cytoplasmique avec la coloration de PAS après digestion par l'amylase.

Les analyses transcriptomiques - entre les sous-groupes des deux cohortes - ont montrées que les foies, des patients présentant ces foyers cellulaires altérés, présentent également une surexpression des gènes associés au métabolisme des glucides, tels que IGF1 et PDK4, par rapport aux foies des autres patients. Enfin, nous devons souligner que dans le groupe de patients avec une sérologie négative pour le VHB, une positivité de 52% a été trouvée dans les tests de

quantification de l'ADN, ce qui révèle un statut d'infection occulte dans ce groupe de patients.

Ces foyers de cellules claires se trouvent uniquement dans le foie des patients péruviens porteur d'un CHC. Mais nous ne pouvons pas déterminer si ces lésions sont en elles-mêmes des précurseurs du CHC ou simplement un marqueur d'une atteinte hépatique qui conduira ultérieurement à la génèse d'un CHC.

Notre deuxième objectif était l'analyse histologique de la composante tumorale. Nous avons sélectionné une cohorte de 101 patients porteurs d'un CHC et analysé, sur les blocs de paraffine et des fragments congelés, les caractéristiques tumorales. Les données obtenues ont été mises en relation avec les données cliniques et biologiques (notamment avec les données de survie). L'étude immunohistochimique réalisée a utilisé des marqueurs hépatocytaires (Glypican 3 et AFP), d'une composant de cellules souches (cytokératine 19, Epithelial Cellular Adherens Molecule, CD 133, CD 117) et de l'altération des voies moléculaires (béta-Caténine, P53, Glutamine synthétase).

Une analyse transcriptomique, réalisée sur les fragments congelés, a été entreprise sur un sous-groupe de patients (66 patients, 18 femmes et 48 hommes).

De nouveau la répartition bimodale des âges précédemment décrite par Bertani et al. a été mise en évidence dans cette population. L'analyse histologique des tumeurs révèle un pattern non décrit dans la classification OMS des CHC. Ce nouveau pattern a été identifié chez 14 patients. Il est constitué d'une architecture macrotrabéculaire, dont la particularité est d'être composée de deux populations cellulaires de répartition spécifique :

- a) La première population, située à la périphérie des travées, est composée par cellules petites à moyennes, de forme cubique, avec un cytoplasme acidophile et de disposition palissadique. Les noyaux sont orientés vers le centre des travées.

- b) La deuxième population de cellules de taille moyenne, située au centre des travées, comporte un cytoplasme clair abondant. Son noyau est de petite taille et central.

L'analyse immunohistochimique ne montre pas de différence d'expression entre ce pattern et les formes classiques. Cependant, l'expression de la Glutamine synthétase est volontiers restreinte à la composante cellulaire périphérique au sein des CHC avec ce nouveau pattern. La comparaison de l'expression de gènes – entre les CHC de formes classiques et ce nouveau pattern, montre une sur expression de la LPA (lipoprotéine A), la MBL2 (lectine de liaison au mannose 2), du CD 74 et du CD 97. Ce groupe de gènes a déjà été associé à un pronostic péjoratif dans le CHC et aussi dans d'autres tumeurs (sarcome pléomorphe indifférencié et cancer du rein).

La survie des patients est différente entre les CHC de formes classiques et le nouveau pattern avec – respectivement - une survie moyenne de 132 semaines contre 48 semaines.

Analyse du contenu métallomique du foie

Le troisième objectif était de déterminer le profil métallomique du foie.

Nous avons réalisé chez des patients porteur d'un cHC NC, une analyse comparative du profil métallomique entre une cohorte de patients péruviens (n=38) et une cohorte de patients français (n=45). Le dosage des concentrations de métaux (foies non tumoral et tumoral) a été réalisé grâce à la technique ICP-MS (spectrométrie de masse à plasma à couplage induit).

Les résultats ont été analysés pour étudier les relations entre les données cliniques (notamment la survie), biologiques et histopathologiques et les concentrations de métaux dans les deux cohortes. Les patients péruviens sont plus jeunes que les patients français (< de 40 ans vs > 50 ans ; $p < 0.05$) et présentent une infection virale B plus fréquentes (50 % vs 5 % ; $p < 0.01$).

Le profil métallomique au sein du foie non tumoral révèle des concentrations plus élevées de métaux toxiques considérés comme cancérigènes (As, Cd, Co) chez

les patients péruviens. En particulier l'arsenic, qui n'a été dosable que dans la cohorte péruvienne.

Dans le tissu tumoral, nous avons trouvé – pour tous les métaux sauf le cuivre - une quantité inférieure de métaux par rapport au tissu non tumoral correspondant, et ceux pour les deux cohortes. Il existe donc des différences nettes entre les profils métallomiques au sein des deux cohortes. L'analyse des relations entre profils métallomiques et survie montre que des concentrations élevées de sélénium dans le tissu tumoral sont associées à une survie plus longue, mais uniquement pour les patients péruviens.

La synthèse des résultats obtenus au cours de ces travaux montre que la CHC NC au Pérou est particulier par des caractéristiques pathologiques :

- Présence de lésions du foie non tumoral, foyers de cellules claires, associées à des modifications du transcriptome ;
- La présence d'un nouveau pattern histologique du CHC, constitué de deux populations cellulaires, dont le pronostic est péjoratif ;
- Un profil métallomique différent de celui d'une cohorte française de CHC NC, avec un potentiel rôle délétère de certains des métaux mais aussi un rôle protecteur du sélénium sur la survie des patients.

Ces résultats ouvrent des perspectives intéressantes concernant le rôle potentiels des métaux sur la genèse du CHC NC et donc l'implication de facteurs environnementaux dans ce processus.

INDEX

I)	INTRODUCTION	21
1)	The Liver	21
1.1)	Celullar components	22
1.2)	Mechanisms of liver injury	24
1.2.1)	Apoptosis	25
1.2.2)	Necrosis	25
1.2.3)	Regeneration	25
1.2.4)	Fibrosis	26
1.2.5)	Cirrhosis	26
2)	The Hepatocellular Carcinoma	27
2.1)	Epidemiology	27
2.2)	Risk factors for hepatocellular carcinoma	28
2.2.1)	Hepatitis B virus infection	29
2.2.2)	Hepatitis C virus infection	30
2.2.3)	Alcohol	33
2.2.4)	Aflatoxin	33
2.2.5)	Diabetes, obesity, steatosis and non-alcoholic steatohepatitis	34
2.2.6)	Iron overload diseases	36
2.3)	Molecular mechanisms in the development of hepatocellular carcinoma	37
2.3.1)	Hepatitis B infection	37
2.3.2)	Hepatitis C virus infection	40
2.3.3)	Alcohol	41
2.3.4)	Associated mechanisms NASH, obesity and HCC	42
2.3.5)	Genetic and epigenetic changes in carcinogenesis of HCC	43
2.4)	Preneoplastic lesions	48
2.4.1)	Dysplastic foci: small or large dysplasia	48
2.4.2)	Dysplastic nodules	50
2.4.3)	Regenerative nodules	50
2.4.4)	Iron-free foci	51
2.4.5)	Foci of altered hepatocytes, rich in glycogen / oncocytes	51
2.4.6)	Hepatocellular adenoma	53
2.5)	Histopathology of Hepatocellular carcinoma	55
2.5.1)	Architectural patterns	56
2.5.2)	Cytological variants	56
		14

2.5.3)	Peculiar Histological subtypes	57
2.6)	Molecular classification of hepatocellular carcinoma	61
2.7)	Clinical manifestations	63
2.7.1)	Paraneoplastic Syndromes	64
2.7.2)	Serum AFP	65
2.8)	Treatment	66
2.8.1)	Liver resection	66
2.8.2)	Abaltive treatments	67
2.8.3)	Targeted Therapies	70
3)	The non – cirrhotic hepatocellular carcinoma (NC – HCC)	71
3.1)	Demographic characteristics	72
3.2)	Molecular profile	72
4)	Hepatocellular Carcinoma in Peru	73
4.1)	Possible causes	76
4.1.1)	Infectious	76
4.1.2)	Environmental pollution	80
II)	WORK OBJECTIVES	101
1)	Section 1	102
1.1)	Description of the phenotype of the non-tumor liver of patients with NC- HCC	102
2)	Section 2	115
2.1)	Description of the tumor phenotype of patients with NC-HCC	115
2.1.1)	Material and methods	116
3)	Section 3	133
3.1)	Analyze the relationship between environmental exposure to heavy metals in two cohorts and the clinical manifestations of the disease as well as in survival	133
III)	GENERAL DISCUSSION	163
IV)	PERSPECTIVES	167
V)	REFERENCES	168

Figure List

FIGURE 1: LIVER SEGMENTATION.	22
FIGURE 2: LIVER ZONATION.	24
FIGURE 3: WORLDWIDE DISTRIBUTION OF LIVER CANCER FOR MALES - WHO	31
FIGURE 4: WORLDWIDE DISTRIBUTION OF LIVER CANCER FOR FEMALES - WHO	32
FIGURE 5: DYSPLASTIC FOCI	49
FIGURE 6: IRON FREE FOCI.	51
FIGURE 7: GLYCOGENIC HEPATOCYTES	52
FIGURE 8: HISTOLOGICAL PATTERNS OF HCC.	57
FIGURE 9: FIBROLAMELLAR HCC.	58
FIGURE 10: HCC MACROTRABECULAR MASSIVE TYPE.	59
FIGURE 11: COMBINED HEPATOCELLULAR CARCINOMA-CHOLANGIOCARCINOMA	60
FIGURE 12: TRANSITIONAL LIVER CELL TUMOR (TLCT).	61
FIGURE 13: MOLECULAR CLASSIFICATION OF HCC.	63
FIGURE 14: PREVALENCE OF HEPATITIS B INFECTION IN SOUTH AMERICA.	77
FIGURE 15: ENDEMIC LEVELS OF HBV IN PERU.	78
FIGURE 16: PERU MAPS. HCC-MINING-HEPATITIS B	83
FIGURE 17: PERIODIC TABLE OF ELEMENTS.	100
FIGURE 18: HEMATOXYLIN-EOSIN SLIDES FOR NEW PATTERN	124
FIGURE 19: EXPRESSION OF IHC IN "NEW PATTERN" TUMOR	126
FIGURE 20: TRANSCRIPTOMIC ANALYSIS.	128
FIGURE 21: SAMPLE ENRICHMENT SCORE (SES) ANALYSIS OF HISTOLOGICAL PATTERNS.	129
FIGURE 22: SURVIVAL ANALYSIS FOR "NEW PATTERN".	130

TABLE LIST

TABLE 1: HEPATOCELLULAR "PRENEOPLASTIC" LESSIONS	48
TABLE 2: SIGNS AND SYMPTOMS OF HCC ACCORDING TO FREQUENCY OF PRESENTATION	63
TABLE 3: ABSOLUTE AND RELATIVE CONTRAINDICATIONS FOR ABLATIVE THERAPY IN HCC	70
TABLE 4: SELENOPROTEINS AND HUMAN CARCINOGENESIS	98
TABLE 5: ANTIBODY LIST FOR IMMUNOHISTOCHEMICAL PROFILE IN NEW PATTERN HCC	119
TABLE 6: CLINICAL FEATURES OF PERUVIAN PATIENTS	122
TABLE 7: LABORATORY TEST FOR HISTOLOGICAL PATTERN	124
TABLE 8: ANTIBODY'S LIST USED FOR ANALYSIS OF HISTOLOGICAL PATTERNS	125

LIST OF ABBREVIATIONS

AFB1	Aflatoxin B1
AFB1-FABY	AFB1-formamidopyrimidine
ATP	Adenosine triphosphate
BMI	Body mass index
CP	Ceruloplasmin
cHCC-CC	Combined hepatocellular carcinoma cholangiocarcinoma
COXIII	Cytochrome c oxidase subunit III
ALAD	Delta-aminolevulinic acid dehydrogenase
DCP	Des-gamma-carboxy-prothrombin
DNMT	DNA methyltransferases
ER	Endoplasmic reticulum dysfunction
EGFR	Epidermal growth factor receptor
ERK	Extracellular signal-regulated kinases
HCC-FL	Fibrolamellar hepatocellular carcinoma
FAH	Foci of altered hepatocytes
GSF	Foci that store glycogen
G6PD	Glucose-6-phosphate dehydrogenase
GSH	Glutathione
GSH	Glutathione antioxidant enzymes
GSSG	Glutathione disulfide
Gpx	Glutathione peroxidase
GSH-Px	Glutathione peroxidase
GST	Glutathione S-transferase
GDP	Gross domestic product
HBV	Hepatitis B virus
HCV	Hepatitis c virus
HBsAg	Hepatitis B surface antigen
HA	Hepatocellular Adenoma
HCC	Hepatocellular carcinoma
HH	Hereditary hemochromatosis
HIFU	High intensity ultrasound

HIF	Hipoxia inducible factor
HNE	4-hydroxynonenal
HIV	Human immunodeficiency virus
H ₂ O ₂	Hydrogen peroxide
• OH	Hydroxyl radical
IR	Insulin resistance
IHC	Immunohistochemistry
IGF1	Insulin-like growth factor 1
IL-6	Interleukin 6
IARC	International agency for research on cancer
LCD	Large cell dysplasia
LPO	Lipid peroxidation
L-FABP	Liver fatty acid binding protein
LOH	Loss of heterozygosity
mtDNA	Mitochondrial DNA
MTC-HCC	Macrotrabecular massive hepatocellular carcinoma
mTOR	Mammalian rapamycin pathway
MS	Metabolic syndrome
MT	Metallothioneins
MWA	Microwave ablation
NK	Natural killer cells
NO	Nitric oxide
NAFLD	Non-alcoholic fatty liver disease
NC-HCC	Non-cirrhotic hepatocellular carcinoma
NASH	Nonalcoholic steatohepatitis
ORF	Open reading frame
PTP	Permeability transition pore
PDH	Piruvato dehydrogenase
PDGF	Platelet derived growth factor
PVTT	Portal vein tumoral thrombosis
PTEN	Protein and tumor suppressor tensin
RFA	Radiofrequency ablation
MAPK	Ras-mitogen-activated protein kinase

ROS	Reactive oxygen species
RUNX3	Runt-related transcription factor 3
1O ₂ -	Singlet oxygen
SIRT1	Sirtuin 1
SCD	Small cell dysplasia
SOR	Sorafenib
SREBP-1c	Sterol regulatory and element binding protein 1c
O ₂ •-	Superoxide
SOD	Superoxide dismutase
TERT	Telomerase reverse transcriptase
RSH	Thiol radicals
TNF- α	Tumor necrosis factor- α
TRAILr	Ligand inducer of apoptosis related to TNF
TGF- β 1	Transforming growth factor beta 1
TLCT	Transitional Liver Cell Tumor
M1	Type 1 macrophages
TP2D	Type 2 diabetes
M2	Type 2 macrophages
UPR	Unfolded protein response
VEGF	Vascular endothelial growth factor
VEGFA	Vascular endothelial growth factor A
VLDL	Very low-density lipoprotein
VDAC3	Voltage-dependent anion channel 3 protein

I) INTRODUCTION

1) The Liver

The liver is considered as the most noble and multifaceted organ of the economy. Also characterized by an important capacity for regeneration which has been recognized since ancient times as the legend of Prometheus tells it.

This intra-abdominal location organ represents 2% of the body weight, being its largest dimension, the transverse one, which can measure up to 28cm. Anatomically located in the upper right quadrant of the abdomen, this organ is closely related to the diaphragm, being held in this location by the falciform ligament which in turn divides it into two lobes, the right and the left. A particular thing in liver is its irrigation. Since the arterial supplement is provided by the hepatic artery, meanwhile the venous irrigation consists of: the portal vein system and suprahepatic veins.

The portal vein is responsible for collecting all the venous supply from the superior mesenteric vein and the transverse splenomesenteric trunk. Thus, contributing with 80% of liver irrigation. This system provides blood from the digestive tract, allows the liver to fulfill its function as a filter of nutrients and toxins from the digestive tract. Then return the blood to the general circulation through the hepatic vein, which will end up anastomosing with the inferior vena cava (1).

In addition, the portal vein provides the anatomical principles for liver segmentation (2) (figure 1), that is, a functional liver distribution that allows the development of the surgical technique called segmentectomy (3) which is able to isolate the segments compromised by diseases, mainly by tumors.

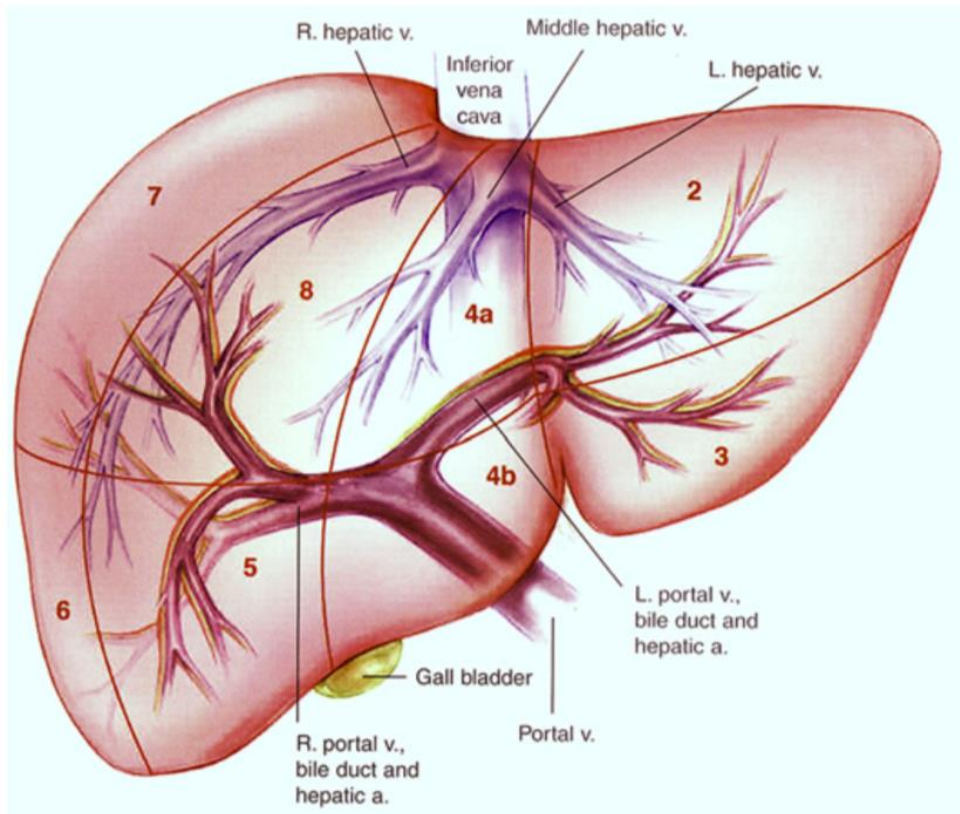


Figure 1: Liver segmentation.

Segmentation according to the branches of the portal vein. From Sakamoto *et al.* *Clinical Anatomy of the Liver: Review of the 19th Meeting of the Japanese Research Society of Clinical Anatomy*

1.1) Cellular components

The liver, from the histological point of view, is composed of various cell types, which coexist harmoniously, allowing it to develop its complex functions, the following allows us to have an overview of the different cell types that make it up, which are:

- **Hepatocytes:** Hepatocytes are responsible for most of the synthetic functions and many of the liver's metabolic functions. With an average size of approximately 20-30mm in cross section. They are relatively large polygonal cells, represent approximately 60-70% of all cells of this organ and make up approximately 80% of their mass / volume.

- Endothelial cells: they are flat cells that form the lining of the sinusoidal wall of the liver. They comprise 3% of the total volume of the liver. They are characterized by fenestrations and lack of basement membrane.
- Kupffer cells: Understand about 2% of the volume of the liver. They are found within the lumen of the hepatic sinusoids. Kupffer cells have a great phagocytic capacity through the C3 and Fc receptors, whose main function is the cleaning of sinusoidal blood from bacteria, degraded erythrocytes or dead hepatocytes.
- Star cells: Located in the Disse space (space between hepatocytes and hepatic sinusoid endothelial cells) comprise approximately 1.5% of liver volume. They are characterized by participating together with hepatocytes in the metabolism of vitamin A. In addition, these cells are responsible for synthesizing, secreting and degrading components of the perisinusoidal extracellular matrix.
- Cholangiocytes: Cholangiocytes are biliary epithelial cells responsible for forming the bile network and transporting bile.
- Liver associated lymphocytes (Pit cells): the natural killer cells (NK) associated with the liver are called pit cells. Presenting a functionally modified morphological compared to peripheral blood NK cells. We find within this group, different types of T, NK, NKT and dendritic cells.

All these cells are components of a liver-centered immune system. Which is responsible - along with kupffer cells - for the elimination of numerous harmful agents from the intestine.

All these cells are organized forming hexagonal structures characterized in whose center we find a centrallobular vein and whose corners are formed by the so-called portal triads consisting of a branch of the portal vein, a branch of the hepatic artery and a bile duct. In the lobe, hepatocytes are connected to each

other, following a distribution of cords, whose arrangement goes from the central vein to the portal spaces. These cords are upholstered by blood vessels called sinusoids (4,5).

The functional unit of the liver, called hepatic acini, (figure 2). In this configuration we can differentiate 3 functional zones. The first around the portal (periportal) triads, a second around the central (perivenous) vein and an intermediate between both zones.

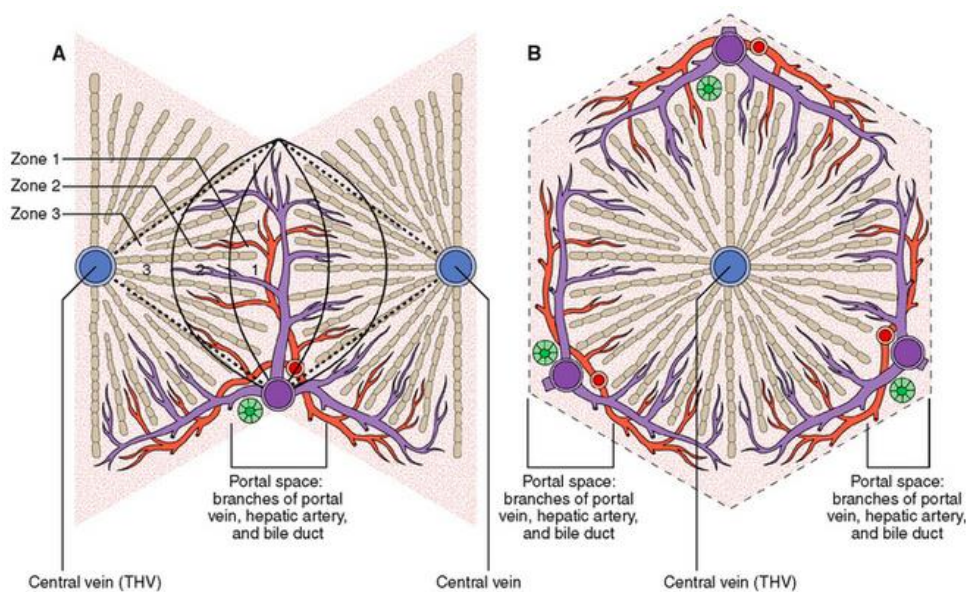


Figure 2: Liver zonation.

A. Representation of a liver acini, showing the distribution by zones of the acini. B. Representation of hepatic lobule. From Underwood JCE: General and Systemic Pathology, 4th ed. Edinburgh, Churchill Livingstone, 2004, p. 402

Each of which fulfills almost exclusive subcellular, biochemical and physiological functions. As for example the synthesis of localized bile acids, glutamine and the glycolysis process are mainly in the perivenous zone, while the catabolism of histidine and serine, the gluconeogenesis process is mainly located in the periportal zone (6,7).

1.2) Mechanisms of liver injury

It is thanks to this zoning that the liver can efficiently fulfill its various functions, however due to the complex tasks that it performs, within which detoxification is

found, this organ can be affected by various viruses, toxins, coming from the apparatus digestive. Therefore, there are patterns of liver injury that we consider convenient to mention.

1.2.1) Apoptosis

The apoptosis type of programmed cell death caused by the same organism, in order to control its development and growth. It is characterized by cellular contraction, cell membrane alterations, plasma membrane budding, chromatin aggregation to the nuclear membrane, pore formation in the mitochondrial membrane, nuclear and cytoplasm fragmentation in smaller bodies called apoptotic bodies. These morphological changes are the result of the activation of receptors on the cell surface caused by extrinsic stimuli, among which we can find tumor necrosis factor-alpha (TNF- α), Fas ligand (FasL) and TRAIL receptors (ligand inducer of apoptosis related to TNF- α) or also by the mitochondrial signaling pathway induced by intrinsic stimuli (8,9).

1.2.2) Necrosis

Morphologically, necrosis is characterized by oncosis (cell swelling), karyolysis and plasma membrane rupture. Which is the result of a metabolic lesion that leads to total consumption of ATP. Obtaining as a result the death of the cell, which triggers an inflammatory response - which is another characteristic of the necrosis process - since the internal cell component released causes neutrophil invasion (9).

1.2.3) Regeneration

The lesion of any of the cell lines found in the liver can be completely regenerated as long as the inflammatory and fibrogenic pathways are not initiated. Although the human liver slowly recovers its mass after a massive injury or surgical resection, liver function can be maintained despite significantly reduced tissue mass.

We must also emphasize that mesenchymal cells, star cells, hepatocytes, cholangiocytes and liver cells or liver progenitors maintain the potential to multiply throughout adulthood. Two mechanisms of hepatic regeneration have been indicated. The first, where differentiated mature hepatocytes and cholangiocytes can undergo division and replication, remaining within their tissue compartment and responding rapidly to liver damage. And the second, the stimulation of the proliferation of progenitor cells within the periportal region, which implies a ductular reaction and differentiation through intermediate hepatocytes to new hepatocytes; and through intermediate cholangiocytes to new elements of the bile duct (10,11).

1.2.4) Fibrosis

While regeneration can be seen as a beneficial step for recovery, it is also a damaging and perhaps defining process in the progression of chronic liver disease. Fibrosis can be considered as the healing of a repeated lesion on the liver parenchyma. Faced with a persistent liver injury, liver regeneration may not restore lost tissue, with the consequent extracellular matrix deposition, becoming more extensive and forming "scars" in the liver.

As chronic liver disease progresses, excess type I and III collagen is deposited not only in the portal pathways but also around the lobe, creating both fibrous septal pathways and severe alterations of the sinusoidal ultrastructure (11,12).

1.2.5) Cirrhosis

Cirrhosis is defined anatomically by the presence throughout the liver of fibrous septa that subdivide the parenchyma into nodules. These fibrous partitions cover a broad spectrum of presentation which ranges from minimal to severe and are formed by extending by connecting the portal tracts and lobular center veins. The nodules produced as a result of these fibrous deposits can vary from micronodules (<3 mm in diameter) to macronodules (3 mm to several centimeters in diameter) (4).

In this context, the convergence of several harmful factors in the liver simultaneously activates the pathways of necrosis, apoptosis, regeneration and fibrosis, resulting in the development of chronic liver disease or also called liver cirrhosis, which offers a suitable microenvironment for development of hepatocellular carcinoma.

2) The Hepatocellular Carcinoma

2.1) Epidemiology

Hepatocellular carcinoma (HCC) is the most common primary liver tumor. It occupies 90% of all reported cases from primary liver tumors. It is currently the sixth most common tumor in the world, with an incidence of 5.7% and has become the third leading cause of death by cancer in the world (13,14).

In 2012, 782,000 new cases of HCC were diagnosed worldwide. Causing approximately 746,000 deaths around the world (13). The geographical distribution of this disease mainly comprises Asia-Pacific region, Southeast and sub-Saharan Africa, all of these account for approximately 83% of the total reported cases. However, only China represents 50% of all cases worldwide, whose incidence rate was 22.3 / 100,000 person-years in 2012 (15).

Similarly, their continental neighbors present as Mongolia (78.1 / 100,000), or Lao People's Democratic Republic (52.6 / 100,000), they also have very high rates. On the other hand, the African regions of the Gambia (25.8 / 100,000) and Egypt (25.6 / 100,000) have reported rates that resemble those found in the Asian continent. As part of the disparity associated with the extension of the disease, we can find rates as low as Spain (5.9 / 100,000) or the Netherlands (1.1/100.000), just to cite examples of the situation of the European continent (16).

HCC mainly affects middle-aged adults and older adults, with a clear predilection for males, with a global incidence four times higher than in women (15).

With male:female ratios that fluctuate between 2:1 and 4:1. However, it is important to mention that there are much lower ratios such as those found in Zimbabwe where the ratio is 1.2:1 and also much higher, as in France where the ratio is 5:1(17). As consequence the HCC is considered the second cause of cancer mortality in men and the ninth cause in women (18).

The reasons that may explain the elevation of these rates in men are related to gender-specific differences in exposure to risk factors. Men are more likely to be infected with Hepatitis B virus (HBV), they are more exposed to chronic consume alcohol, smoke cigarettes.

In addition, a question has aroused interest in relation to the possible relationship between gender and the development of HCC. Since, in studies conducted in animal models, where under the same exposure to risk factors, the rate of HCC development was always higher in the male gender. Therefore, a probable influence of estrogens or androgens as protective agents or contributors to the development of HCC is postulated (19,20).

2.2) Risk factors for hepatocellular carcinoma

Within the pathogenic process of the disease we find a common pathway between different risk factors and the development of HCC, we specifically talk about liver cirrhosis, since between 70 and 90% of cases of HCC develop on a cirrhotic liver (21).

Hepatic cirrhosis is a form of chronic disease of hepatic parenchyma, characterized histologically by a diffuse nodulation of the liver due to the fibrous bands that subdivide the hepatic parenchyma into regenerative nodules (22).

The two major global causes of cirrhosis development are hepatitis B and C virus infection (21). However, other risk factors well related to the development of HCC are: chronic alcohol consumption, chronic tobacco use, exposure to aflatoxins, obesity, diabetes (23).

The distribution and impact of risk factors in the development of HCC varies geographically, for example chronic alcohol consumption, chronic infection with hepatitis virus and non-alcoholic fatty liver disease (NAFLD) they are the most common causes in Western countries. While chronic hepatitis B is the leading cause of liver cirrhosis in the Asia-Pacific region.

2.2.1) Hepatitis B virus infection

HBV is a virus that contains a partial double strand of DNA belonging to the family of "*Hepadnaviridae*" (24). It is estimated that 1 in 3 people around the world has been infected with HBV (18), of which only 5% will develop chronic carrier status (25). However, 25% of chronic carriers will develop cirrhosis or HCC. Currently in places like China and sub-Saharan Africa where there is the highest amount of HCC associated with chronic HBV infection, China alone accounts for 73% of global cases. As the main means of transmission in Asia, the mother-child infection, while in Africa we find the sibling-to-sibling transmission (26).

Several epidemiological studies have established that the prevalence levels for HBV infection are highly variable and location-dependents. For example, we found:

- Low prevalence rates, <2% positivity for surface antigen B (HBsAg) in countries such as North America, Northern Europe, Western Europe, and Europe East, Australia and New Zealand.
- Intermediate rates, 2-7% of HBsAg positive in Japan, the Middle East, Eastern Europe, Southern Europe and parts of South America.
- High prevalence rate, > 8% HBsAg in sub-Saharan Africa, the Amazon Basin, China, Korea, and Taiwan (27,28). (figures 3,4)

Actually there are 8 HBV genotypes designated A to H, which take as a basis a variation of more than 8% of the nucleotides of the entire genome (29,30). Several studies have attempted to establish a relationship between HBV genotype and the risk of developing HCC. Genotypes B and C were mainly

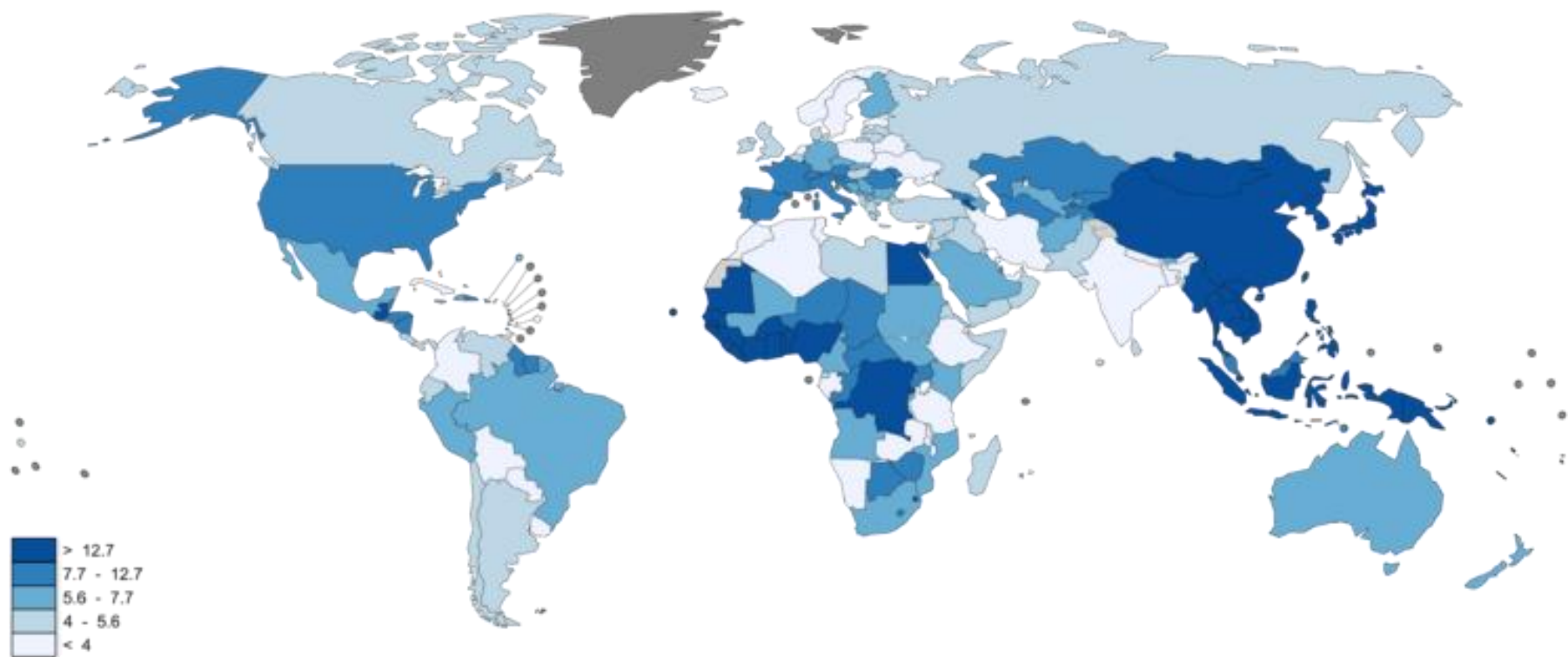
evaluated, highlighting a strong relationship between genotype C and HCC development (31,32).

It has been documented that in the course of the natural history of chronic HBV virus infection, the development of antibodies against HBsAg and HBeAg are associated with a marked reduction in the risk of developing HCC (33). However, we must mention that there is a large percentage of affected patients; who, despite being serologically negative, develop a hidden HBV infection due to the persistence of HBV DNA (34). To date there is no clear association between the status of hidden infection and to the risk of developing HCC. Therefore, it is recommended that cities with endemic HBV infection develop large-scale vaccination programs.

2.2.2) Hepatitis C virus infection

Hepatitis C virus (HCV) infection is the second cause of the development of HCC worldwide. The overall prevalence of HCV is estimated at 185 million infected (35), which demonstrates an increase in it in the last 15 years. Genotypes 1 (46.2% infected) and 3 (30.1% infected) being the most prevalent (36). HCV infection is mainly carried out in adult life, in contrast to what is established for HBV. Being the main form of infection, intravenous (37).

HCV infection is strongly associated with the development of HCC, this because HCV increases the development of cirrhosis by 30% in patients with chronic infection. The rate of development of HCC in cirrhotic patients is 2-5%. However, higher rates (7%) have been reported in countries such as Japan (38). It should be mentioned that in patients with HCV infection, the progression towards the development of cirrhosis depends mainly on factors of the host and the environment like characteristic, of the virus itself, characteristics of the patient (advanced age, male gender, duration of infection) and associated diseases (chronic alcohol consumption, obesity, diabetes and HBV or Human immunodeficiency virus (HIV) coinfection) (39).



No data
 Not applicable

The boundaries and names shown and the designations used on this map do not imply the expression of any opinion whatsoever on the part of the World Health Organization concerning the legal status of any country, territory, city or area or of its authorities, or concerning the delimitation of its frontiers or boundaries. Dotted and dashed lines on maps represent approximate border lines for which there may not yet be full agreement.

Data source: GLOBOCAN 2012
 Map production: IARC
 World Health Organization



Figure 3: Worldwide distribution of liver cancer for males - WHO

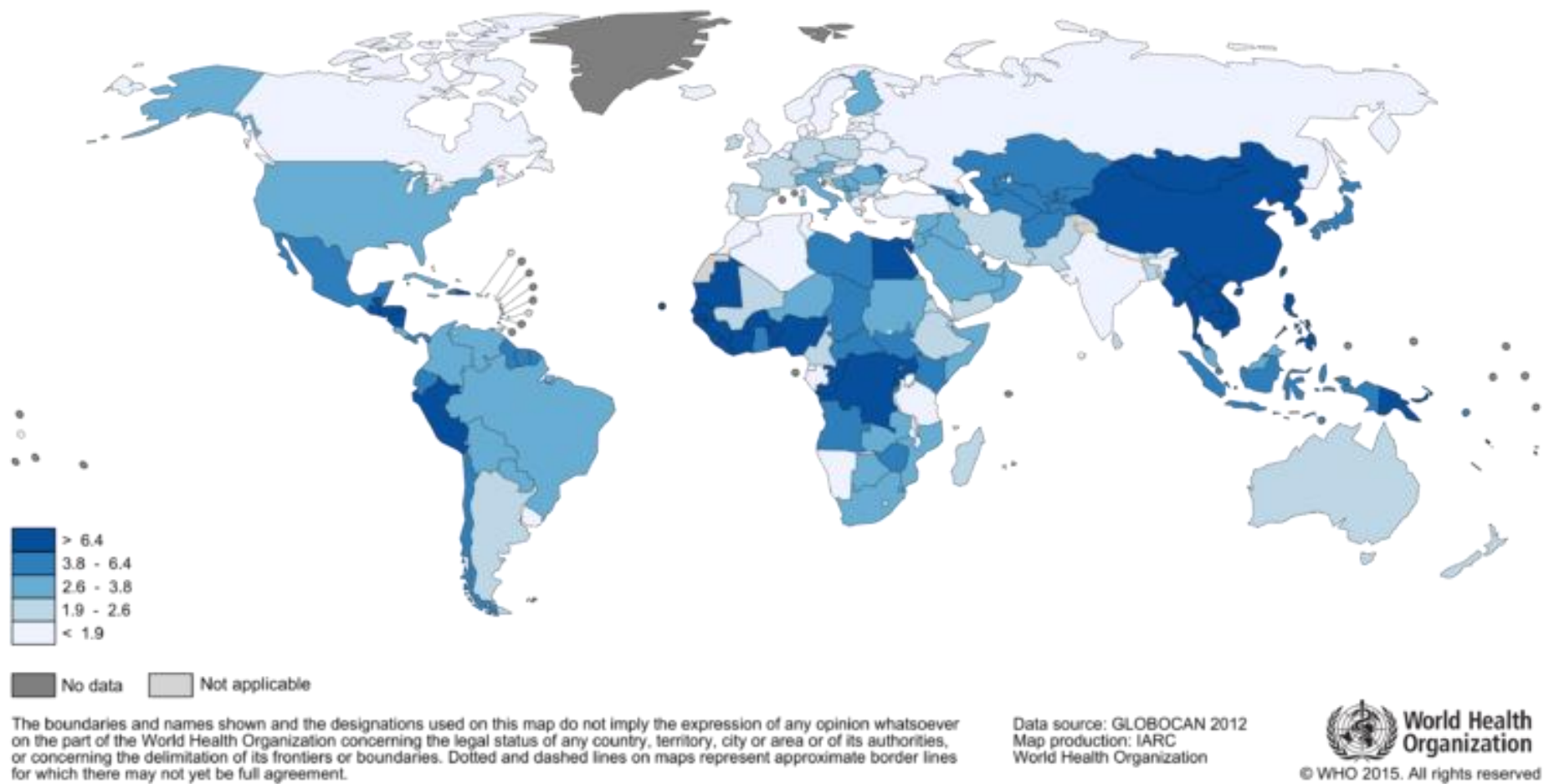


Figure 4: Worldwide distribution of liver cancer for females - WHO

2.2.3) Alcohol

Chronic consumption of alcohol is defined as the intake of amounts greater than 50-70g/day for prolonged periods. This behavior was cataloged by the international agency for research on cancer (IARC) as hepatocarcinogenic (40). The prevalence of alcohol consumption varies according to geographical location, for example, higher rates are recorded in the northern hemisphere compared to the southern hemisphere (41). Gender is an important factor in the development of this behavior, since it develops mainly in men compared to women. However, a dramatic increase in the number of women who consume alcohol chronically has recently been demonstrated (42). There is also evidence that suggests a synergistic effect on the part of alcohol, by increasing the risk for HCC, when it interacts with other known risk factors, among them we have obesity and viral hepatitis (43,44).

2.2.4) Aflatoxin

Aflatoxins are mycotoxins produced by the fungi *Aspergillus flavus* and *Aspergillus parasiticus*. These products derived from difuranocoumarin are produced under certain environmental conditions. They are considered contaminants of many staple foods such as corn, nuts and rice (45). It is estimated that around 4.5 to 5.5 million people worldwide are at risk of exposure to this toxin (46). The main regions of exposure are sub-Saharan Africa, East Asia and parts of South America, with cities located between 40 ° North and 40 ° South of equator where the highest risk indices are found (47,48).

A strong correlation between chronic exposure to aflatoxins and the risk of developing HCC was observed while ago (49). B1 toxin (AFB1) is the most potent of all, the most commonly found as a pollutant in foods and the one with the strongest association in the process of carcinogenesis (50). This is promoted by the fact that the main site of its metabolism is the liver where are expressed enzymes of the cytochrome p450 family (CYP 3A4, 3A5, 3A7 and 1A2) responsible of its oxydation.

In the liver, the cytochrome p450 family of enzymes metabolizes aflatoxin primarily to aflatoxin-8,9-exo-epoxide and, to a lesser extent, an aflatoxin-8,9-endo-epoxide compound. Aflatoxin exo-epoxide is highly reactive and can form derivatives with DNA, RNA and proteins. It can notably react with specific sequences of the p53-encoding gene (47,48).

Similarly, it can bind to the DNA to form the 8,9-dihydro-8- (N7 guanyl) -9-hydroxy AFB1 (AFB1-N7-Gua) pro-mutagenic compound. AFB1-N7-Gua, can produce two others compounds, an apurinic site and AFB1-formamidopyrimidine (AFB1-FABY), the latter being most stable of the two. AFB1-FABY causes mutations of guanine (G) in thymine (T) six times higher than that of AFB1-N7-Gua. AFB1-FABY is capable to incorporate into double-stranded DNA and develop mutagenic effects that may cause changes that, over time, promote the malignant transformation of hepatocytes into HCC (51).

2.2.5) Diabetes, obesity, steatosis and non-alcoholic steatohepatitis

Type 2 diabetes mellitus has been proposed as a risk factor for the development of HCC, being 1.5 - 3.5 times higher, compared to a patient not affected by diabetes (52,53). The mechanism by which diabetes contributes is through the development of hepatic statorsis, then steatohepatitis, fibrosis and cirrhosis. In addition, there is evidence that diabetes favors DNA damage by generating reactive oxygen species (ROS), derived from an increase in the levels of inflammatory cytokines such as IL-6 and TNF- α (54). There are also interesting associations between the development of liver cirrhosis and the presence of diabetes. It has been found that between 10-20% of patients with cirrhosis have diabetes(55).

Similarly, a considerable decrease in the risk of developing HCC has been demonstrated in diabetic patients treated with metformin (56,57). These findings indicate a possible role of glucose metabolism in the development of HCC (58).

On the other hand, obesity is closely linked to insulin resistance and type 2 diabetes, and like this, obesity has been proposed as a risk factor for developing HCC (59,60). It has been shown that there is a higher level of development and progression to hepatic fibrosis in obese patients in relation to patients with normal BMI. Several studies suggest that obesity is related to the increase in epigenetic aging in hepatocytes, and also altering the intestinal flora with the consequent increase in the formation of hepatotoxins. There are studies where it has been shown that a body mass index (BMI) > 30 is associated with an increased risk of developing HCC by 1.89-fold compared to patients who are below that measure (61,62).

Likewise, NAFLD is composed of an evolutionary spectrum that begins with abnormal retention of lipids within hepatocytes (steatosis) then these changes evolve towards nonalcoholic steatohepatitis (NASH), later progresses to fibrosis and finally to cirrhosis (63). Several studies have shown a strong association between the presence of NAFLD and the development of HCC (64,65).

Within the spectrum of NAFLD, co-morbidities are strongly associated, such as type 2 diabetes (T2D) and metabolic syndrome (MS). These conditions are responsible for promoting a cascade of pathophysiological events that entail a facilitator for the development HCC (64). A common feature of these diseases is insulin resistance (IR) (66), which induces in the adipocytes an increase in the biosynthesis of fatty acids accompanied by a decrease in adiponectin levels and the release of leptin, TNF- α and interleukin 6 (IL-6) (67). Both TNF- α and IL-6 favor steatosis and hepatic inflammation, in addition to stimulate pathways such as NF- κ B, JNK, mTOR (68). It is also known that IL-6 and TNF- α activate pro-oncogenic effectors such as STAT3 (69).

IR is also capable of generating an increase in the amount of reactive ROS and carcinogenic metabolites derived from lipid peroxidation (70). This is due to the effect of steatosis on the mitochondria, which become vulnerable to stress due to a change in the depolarization of the internal mitochondrial membrane or by depletion of the ATP reserves (71). In addition, it has been shown that in the

mitochondria of fatty livers, there is a chronic increase in the production of O₂- and H₂O₂ in vitro, which eventually leads to a state of chronic oxidative stress (66).

In such circumstances, it is considered that the impact of NAFLD in the process of liver carcinogenesis, is mainly due to the effect of ROS and inflammatory mediators which alter the mechanisms of normal cellular repair. As well as the defense against carcinogenic agents such as viruses or environmental pollutants.

2.2.6) Iron overload diseases

Iron overload is defined as an increase in total body iron greater than 5gr (72). The main iron storage center is the liver. Which is why when the level of safe metal storage is exceeded the storage protein becomes denatured, releasing large amounts of iron in the hepatocyte cytoplasm (73).

Excess iron in the liver was documented for the first time in two human diseases: hereditary hemochromatosis (HH) (74) and iron overload in the African diet (previously called Bantu visceral siderosis) (75).

The harmful effects on the liver in other conditions that affect iron storage such as thalassemia major, sideroblastic anemia and spherocytosis have received less attention. However, the evidence suggests that, regardless of any underlying liver disease, the accumulation of iron in the liver is an important risk factor for the development of HCC (76).

HH was the first condition in which it was demonstrated that hepatic iron overload predisposes to the development of HCC (77). Hereditary predisposition to excessive iron absorption in the HH diet is almost always the result of the homozygosity of the C282Y mutation of the HFE gene, which causes a low secretion of hepcidin. It is known that HCC is responsible for 45% of deaths in patients affected with HH (78,79).

Also, it has been shown that there is a link between iron overload and insulin resistance and metabolic syndrome. Both factors for the development of HCC (80).

The mechanisms by which iron is capable of generating injury are related to its ability to generate ROS and oxidative stress, which damage DNA, lipids and proteins, producing necrosis and apoptosis of hepatocytes (81). Iron-catalyzed oxidative stress causes lipid peroxidation, protein modification and DNA damage, as well as the decrease in antioxidant defenses and the promotion of mutagenesis (82).

2.3) Molecular mechanisms in the development of hepatocellular carcinoma

2.3.1) Hepatitis B infection

The role of the HBx protein

The development of HCC caused by HBV is mainly due to the development of chronic inflammation and cirrhosis. The main pathogenic mechanism responsible for the damage caused by HBV is through the HBx protein. HBx is a small protein of 154 amino acids, which plays a transcriptional and regulatory activity (83).

It has been shown in in vitro models that HBx up-regulates the expression of transforming growth factor beta 1 (TGF- β 1) (84). In the normal liver TGF- β 1 plays a role by regulating SMADS proteins, which inhibit the growth of liver cells and maintenance of homeostasis. Likewise, TGF- β 1 has a fibrosis promoting effect by activating hepatic stellate cells, transforming them into fibroblasts (85). It is also known that, an important up-regulation in the expression of TGF- β 1 stimulates the expression of platelet derived growth factor (PDGF); thus, constitutively activating the activation of β -catenin, which can act as an oncoprotein (86).

On the other hand, the SMAD protein - in the presence of HBx - increases its transcriptional activity, achieving an increase in the activity of genes related to extracellular matrix production (87). Other effects related to the HBx protein are the activation of other signaling molecules such as NF- κ B, PI3K, AP-1 and ras/raf/MAPK (88).

A poor role of the immune system has been reported in patients with chronic HBV infection, the main mechanism being a defect in clearance of HBV mediated by CD4 + and CD8 + T cells (89). Some hypotheses to explain this immune system failure propose the role that HBV plays in altering the toll-like receptor-mediated signaling pathway (TLR) (90), which plays an important role in the control of the immune system. Another hypothesis points to a mechanism of resistance to TNF- α by the immune system, mediated by the trans-activation of HBx (91).

Reactive oxygen species and HBV

Patients with chronic hepatitis B exhibit signs of pronounced oxidative stress. The levels of ROS in the liver samples of these patients exceed from 1.5 to 4 times the levels in healthy people (92). In addition, the theory of cellular injury associated with oxidative damage during chronic infection is supported by the fact that antioxidant therapy improved liver injury caused by viral infection (93).

In the same way, it has been demonstrated by means of immunohistochemical techniques that there are products derived from injury by ROS, as are the products of lipid peroxidation and 8-oxoG, produced by DNA oxidation in patients with HBV active (94). Finally, it is known that the presence of chronic infection with HBV is associated with a decrease in antioxidant elements such as glutathione (GSH) (95).

Within the context of acute hepatitis, hidden infection and also in asymptomatic infections, ROS have been established as markers of the evolution of the disease. The ROS profile in cases of occult hepatitis is characterized by an increase in its levels in lymphocytes with the consequent DNA damage (96).

In patients with non-active infection, a considerable decrease in antioxidant status and changes in numerous markers of oxidative stress have also been reported (97). The production of ROS directly mediated by HBV is associated with the presence of; i) HBx, ii) HBsAg and iii) HBcAg (94). This statement has been validated thanks to the finding of high levels of superoxide anions and products of DNA oxidation in the mitochondria (98) In addition, HBx triggers oxidation of a homologous phosphatase protein and tumor suppressor tensin (PTEN), leading to its inactivation and, subsequently, to the permanent activation of the PI3K/AKT pathway, with potentially important metabolic consequences on lipid homeostasis (99).

The HBx protein can also alter carbohydrate fluxes. By activating Nrf2, HBx is known to induce glucose-6-phosphate dehydrogenase (G6PD) (100) and increases the levels of ATP, NADPH and the oxidation of fatty acids, which can promote cell survival by conferring a resistance to glucose deprivation to infected cells (101). Two proteins have been recognized as the starting points to understand the mechanism between HBx and mitochondria. The first is the voltage-dependent anion channel 3 protein (VDAC3), VDAC3 forms an ion channel located in the outer mitochondrial membrane, participating in turn in the formation of permeability transition pore (PTP). The PTPs are responsible for the correct passage of calcium ions through the outer mitochondrial membrane. HBx directly affects VDAC3 and generates a significant increase in calcium both in the cytoplasm and in the mitochondria, causing a malfunction of the PTP, which triggers the induction of oxidant stress (102,103). The second is the cytochrome c oxidase subunit III (COXIII), which increases its expression and stimulates the activity of the IV complex in response to the interaction with HBx (104)

Finally, it is also known that HBx suppresses the production of proteins that are directly related to the maintenance of antioxidant defense, such as selenoprotein P, whose malfunction decreases the effectiveness of glutathione peroxidase (Gpx), glutathione S-transferase (GST) and thioredoxin reductases (105).

The next protein associated with ROS production is HBsAg. Which is encoded by open reading frame (ORF), which encodes the formation of three variants of the surface antigen; i) small (domain-S), ii) media (domains preS2-S) and iii) large (domains preS1 -preS2-S). It is known that a mutant of the large variant of the surface antigen called "premutante S" accumulates within the endoplasmic reticulum generating stress and initiating unfolded protein response (UPR). Which induces the release of calcium in the cytoplasm with the consequent increase in ROS production. This mechanism of calcium release is also shared by the HBcAg protein (106).

ROS as an enhancer of the pathogenesis of HBV

The oxidative stress induced by HBV is an important factor to establish a state of chronic inflammation which will lead to liver inflammation and later cancer (94). A well-known mechanism is the integration of the HBV genome into DNA of hepatocytes, thus causing its malignant transformation. It is known that both oxidative stress and H₂O₂ favor this mechanism of integration. In addition, the integration often modifies the genes that control carcinogenesis and triggers the signaling pathways related to cancer (107).

HBV also induces a series of cascades of pro-carcinogenic signaling through ROS. The oxidative stress induced by HBV in tissues with HCC increases the promoter methylation of the runt-related transcription factor 3 (RUNX3), which is involved in the development of solid tumors (108). In addition HBV also causes a ROS-dependent translocation of the Raf-1 kinase in the mitochondria (109).

2.3.2) Hepatitis C virus infection

HCV is an RNA virus, which contains approximately a 10-kilobase genome, is responsible for most cases of HCC in the world (110). The HCV genome organization includes structural (core, E1, E2/p7) and non-structural (NS2, NS3, NS4A, NS4B, NS5A and NS5B) proteins (111). The mechanism by which HCV causes injury is the integration of viral elements into the host genome, which leads to direct oncogenic transformation of hepatocytes. The central HCV protein activates STAT3 through an autocrine pathway mediated by IL-6 (112), and also

increases the activity of telomerases, which can induce oncogenic changes in hepatocytes. In addition, the NS3 and NS4A proteins improve cell proliferation by activating phosphorylation of extracellular signal-regulated kinases (ERK) and inhibiting p53-mediated apoptosis (113).

Other mechanisms by which HCV induces oncogenic transformation are: a continuous inflammatory process by activating the NF- κ B pathway (114); the increase of oxidative stress, inducing DNA mutagenesis (115); alteration of tumor suppressor genes; misfunction of wnt / β -catenin pathway mediated by NS5A; and blocking the signaling of TGF- β , thanks to interaction between TGF- β receptor I (T β R-I) and NS5A (116). In addition, HCV proteins regulate the transcription of genes responsible for signal translation and suppression of apoptosis such as p53 and p21, triggering proliferation and transformation of hepatocytes (117).

2.3.3) Alcohol

Although the pathogenic mechanisms underlying the initiation of alcohol-induced tumorigenesis have been well defined (118,119) , the alcohol-related signaling pathways involved in tumor promotion and progression are poorly understood. Induction of cytochrome p450 2E1 (CYP2E1), by chronic alcohol consumption induces many biological effects, such as increases in alcohol metabolism, over production of ROS, as well as interactions with various drugs and carcinogens (120).

Recent studies have described the association between CYP2E1 polymorphisms and alcohol-related disorders (121). It has been shown that chronic alcohol consumption is significantly related to the activation of the Wnt/ β -catenin signaling pathway (122), which leads to an increase in hepatocyte proliferation and the promotion of tumorigenesis after an initial injury to liver.

In addition, alcohol has been shown to reduce the hepatic expression of Sirtuin 1 (SIRT1) (123). Which suggests that, the loss of SIRT1 activity can initiate an

alcoholic liver disease (124). However, the role of SIRT1 in the development and progression of tumors remains controversial. The proposed mechanism of SIRT1 are by inhibition of cell transformation and tumor progression or by tumor-promoting roles (125,126). In the context of HCC, the existence of a positive feedback regulation between c-myc and SIRT1 has been demonstrated (127), which promotes the proliferation of tumor cells and predicts poor survival in patients with HCC.

2.3.4) Associated mechanisms NASH, obesity and HCC

The progression of non-alcoholic steatohepatitis towards fibrosis and finally cirrhosis has been studied. Among 15-20% of NASH cases progress to cirrhosis, the latter being a recognized risk factor for the development of HCC (128).

In NASH, the main mechanisms of liver lesions are associated with endoplasmic reticulum dysfunction (ER), mitochondrial dysfunction and impaired autophagy in intrahepatic NKT and CD8+ cells and increased oxidative stress (129). During the inflammatory process in NASH, several cytokines, adipokines and lymphokines contribute to hepatic fibrogenesis through the regenerative process of hepatocytes (130). Recent studies have shown that positive regulation of the insulin-like growth factor 1 (IGF1)/insulin substrate 1 pathway caused by hyperinsulinemia (68) as well as increased levels of IL-6 and TNF- α due to obesity (69) contribute to the development of hepatocarcinogenic mechanisms.

It has also been shown that obese patients experience an increase in the relative number of macrophages type 1 and 2 (131). Obesity generates a state of mild inflammation of the adipose tissue, in addition to increasing the inflammatory component mainly due to macrophages (132). Type 1 macrophages (M1), are an essential component of humoral immunity, in states of overactivation the M1 secrete large amounts of proinflammatory factors, including nitric oxide (NO) proinflammatory cytokines such as TNF- α , IL-1, IL-2, IL-6 and reactive ROS (133).

On the other hand, type 2 macrophages (M2) are stimulated by the presence of IL-4, IL-10, IL-13, consequently stimulating tissue remodeling and repair (134). Both M1 and M2 act synergistically contributing to the development of a pro-inflammatory state capable of triggering carcinogenic events. A side effect caused by the activation of M1 and M2 is insulin resistance (135), which in turn triggers an inflammatory cascade that includes the secretion of leptin and adiponectin (136).

High levels of circulating insulin stimulate hepatic sterol regulatory element binding protein 1c (SREBP-1c), related to the induction of hepatic lipogenesis and overexpression of very low-density lipoprotein (VLDL) (137,138). High levels of VLDL exert a negative effect on high-density lipoprotein levels and an intrahepatic increase in triglycerides (138). All these factors contribute to the increase in insulin resistance and the consequent liver inflammation. Within this process, other pathways such as c-Jun N-terminal kinase / activator protein 1, cyclic adenosine monophosphate responsive element binding protein H (CREB-H), the JAK/STAT pathway, and the nuclear factor κ B (NF κ B) have been involved (139).

The effect of the increase in fatty acids, acting over the ER, inducing the accumulation of unfolded or misfolded proteins in the ER should also be considered (140). Finally, the stress produced on the ER increases the production of TNF- α , IL-6 and finally ROS (141).

2.3.5) Genetic and epigenetic changes in carcinogenesis of HCC

2.3.5.1) Genetic mutations

It has been determined that HBV infection is associated with a relatively high frequency of mutations as it replicates through RNA-mediated reverse transcription (142). However, HCV can cause double stranded DNA breaks and increase the frequency of mutations. HCV-infected cells exhibit an increased

mutation frequency in genes such as immunoglobulin genes, BCL-6, TP53 and β -catenin (CTNNB1) (143).

Telomerase promoter mutations

Telomerase is an enzyme protein complex formed by telomerase reverse transcriptase (TERT) and the RNA component of telomerase (TERC). Telomerase maintains the length of telomeres by synthesizing specific telomeric DNA sequences and adding them at the end of the chromosome. However, in chronic liver injury where there is a high rate of cell regeneration, telomere shortening is accentuated, due to telomerase suppression in mature adult cells(144). The progressive shortening of telomeres leads to the activation of a DNA damage program that results in apoptosis or cellular senescence, resulting in a liver unable to completely regenerate its normal architecture, triggering the development of fibrosis and eventually cirrhosis (145).

Because cirrhosis is a precursor to HCC, the hypothesis argues that the shortening of telomeres causes chromosomal instability that drive cancer onset. Mutations in the TERT promoter region occur in 30 to 60% of HCC (142) also, mutations in the TERT promoter have been found not only in 59% of CHCs but also in 25% of cirrhotic preneoplastic lesions, suggesting that this is probably a conductive mutation (146).

TP53 mutations

The frequency of the p53 gene mutation in HCC varies between 18% and 50%, depending on the underlying etiology and geographic location (147,148). Within the spectrum of mutations of p53 there are some that are particular to certain types of diseases. For example, the one associated with AFB1, which reports a mutation of codon 249 of p53 (45).

On the other hand, patients infected with HBV develop a mutation linked to the presence of HBx which is characterized by the G/C to T/A transversion (149).

It is also known that the integration of HBV into the hepatocyte genome affects the TERT, MLL4, RAR β , CCNE1, Cyclin A2, FN1, ROCK1, SENP5, ANGPT1, PDGF genes, genes related to calcium signaling, ribosomal protein genes, epidermal growth factor receptor (EGFR). Some of the other common mutations in HCC involve the Wnt/ β -catenin pathway, including mutations in β -catenin (18–40%), AXIN1 and AXIN2 genes. Additional mutations recently identified in HCC include members of the chromatin remodeling pathway (ARID1A and ARID2) and STAT/JAK and IL6ST ubiquitination, genes involved in RAS/MAPK signaling (RPS6KA3) and genes in the path of oxidative stress NFE2L2 (147,148,150).

2.3.5.2) Epigenetic modifications

Epigenetics is defined by the presence of heritable states of gene expression without alteration in DNA sequences. Epigenetic deregulation could contribute to carcinogenesis by influencing mechanisms such as gene transcription, chromosomal stability and cell differentiation (151).

DNA methylation

DNA methylation is a process by which methyl groups are added to DNA. Modifying the function of DNA when it is in the promoter gene (151). Two types of alteration are found within this process, hypo and hypermethylation. The first is associated with problems in nuclear and structural function in promoting genetic and chromosomal instability, while hypermethylation is frequently associated with the silencing of tumor suppressor genes. It has been identified to date that chronic HBV and HCV infection are causing methylation dysregulation in the hepatic carcinogenesis process (152,153).

Also, it has been disclosed about a subset of 15 genes that were found to be preferentially methylated in the HCV related to HCC; methylated genes belong to signaling pathways such as RAS/RAF/ERK and the Wnt/ β -catenin pathways (154). Another epigenetic mechanism for HBV tumorigenesis is the directed deregulation of DNA methyltransferases (DNMT) by HBx, which promotes both specific regional hypermethylation and global hypomethylation (152).

In addition, hypermethylation of the CDKN2A promoter that leads to suppression of p16 is an event commonly observed in HCC (155). P16 is a cell cycle regulator and a tumor suppressor; Therefore, its suppression promotes tumor progression. Other genes commonly methylated in HCC include RASSF1A56, GSTP157.58, SOCS-359 and MGMT60 (142).

2.3.5.3) Altered pathways in HCC

WNT / β -catenin pathway

The functions of the WNT/ β -catenin pathway are multiples, since we find it in processes such as: embryogenesis, differentiation, cell proliferation. In addition, it is present in processes linked to tumorigenesis and is one of the most commonly disrupted pathways in HCC (1). Nineteen Wnt ligands have been described, which bind to 10 transmembrane frizzled receptors, leading to activation of the pathway of canonical Wnt (β -catenin dependent) or non-canonical (independent of β -catenin). Activation of the canonical Wnt pathway results in the accumulation of β -catenin in the cytoplasm and its subsequent translocation into the nucleus. Genetic mutations that activate WNT/ β -catenin signaling are observed in 40 – 60 % of HCC (156). The most common being those due to activation in CTNNB1, which result in the stabilization of β -catenin (157). In addition, we can find the mutations in AXIN1 (in 3 to 16% of HCC) and AXIN 2 (3% of HCC), which exert a negative regulatory effect of the Wnt pathway, and also the inactivation of the tumor suppressor gene adenomatous polyposis coli (APC) (156) .

There is an interesting difference between HCCs that exhibit activation of the Wnt/ β -catenin pathway without CTNNB1 mutation, of those that possess the CTNNB1 mutation. HCCs with activation of the Wnt/ β -catenin CTNNB1 (-) pathway are preferably observed in HBV-infected patients and are associated with high chromosomal instability and an aggressive phenotype(158). In contrast, CTNNB1 (+) HCCs are usually tumors low grade associated with a favorable prognosis (159).

Tyrosine-kinase's receptor pathway

Approximately 50% of cases of HCC presented with an alteration of the Ras-mitogen-activated protein kinase (MAPK) and PI3K-Akt kinase pathways (160). The activation of these pathways is linked to the binding of ligands and phosphorylation of several tyrosine kinase receptors of growth factors such as EGFR, FGFR, HGFR/c-MET, the stem cell growth factor receptor (c-kit) and VEGFR. In addition, the activation of the Ras/Raf/MEK/ERK (MAPK) pathway in turn activates the cFos protooncogene and the AP-1/c-Jun transcription factor, which induce cell proliferation, thanks to gene transcription (161).

In addition, insulin receptors or IGF receptors (such as IGFR1) cause activation of the PI3K-Akt kinase pathway, which is involved in the alteration of the mammalian rapamycin pathway (mTOR), which occurs in approximately 40% to 50% of cases of HCC (162). Likewise, the mTOR pathway is capable of deregulating PI3K, by losing the function of the PTEN gene by mutation or epigenetic silencing.

Angiogenic pathways

One of the most important characteristics of HCC is the abundant concentration of blood vessels it possesses. Therefore, vascular endothelial growth factor (VEGF) and angiopoetins play a prominent role in the promotion and maintenance of neoangiogenesis (163). This principle has been used as a basis for the development of new drugs for the treatment of HCC, such as sorafenib, which inhibits the angiogenic effects of VEGF.

However, hypoxia levels are also present in the HCC, due to the disorganization of the neo-vessels and the ineffectiveness of an adequate oxygen transport. The increase in hypoxia levels promotes the induction of factors inducible by hypoxia 1 and 2 (HIF 1 and 2) and IGF that promote greater tumor angiogenesis by transcriptional activation of genes that respond to hypoxia, leading to tumor progression and metastasis (164).

2.4) Preneoplastic lesions

HCC could be preceded by morphologically distinct lesions, called "preneoplastic," even though these lesions are associated with the development and evolution of the disease, there is no evidence of its precursor character.

Table 01 summarize the most common lesions inside category

Lesions called foci

Dysplastic foci	Less than 1 mm which can only be recognized by microscopic observation
Small cell foci	
Large cell foci	
Iron free foci	Iron free hepatocytes in liver parenchyma with overload
Foci of altered hepatocytes	Hepatocyte's foci with particular histological characteristics

Lesions called nodules

Dysplastic nodules	Nodular region of hepatocytes at least 1 mm in diameter with dysplasia
Regenerative nodules	Minimum size of 5 mm and do not exhibit cytological or architectural atypia

Lesions called tumors

Hepatocellular adenoma	Bening tumor, represent 2% of all hepatic neoplasms
-------------------------------	---

Table 1: Hepatocellular "Preneoplastic" lesions

2.4.1) Dysplastic foci: small or large dysplasia

The term refers to small foci less than 1 mm which can only be recognized by microscopic observation. Here we find two types: small cell dysplasia and large cell dysplasia (figure5) (165).

Small cell dysplasia (SCD) refers to a group of hepatocytes with reduced cytoplasmic volume, moderate nuclear pleomorphism, and an increased cytoplasmic nucleus ratio (166). In addition, the SCD has histological and cytological similarities with well-differentiated HCC (167). For example, at the macro level, the involved hepatic trabeculae can reach 2 to 3 layers or form pseudo-glandular structures that resemble those often observed in the well-differentiated HCC originally described by Edmondson and Steiner (168). SCD foci also contain chromosome gains and losses that are also present in HCC but not in the underlying hepatic parenchyma (169). It has also been shown that about half of SCDs foci are composed of cells almost exclusively with the immunophenotypic profile of hepatic progenitor cells and hepatocyte-like intermediate cells, suggesting that hepatic progenitor cells may cause HCC in the human liver through the formation of SCD foci (170).

Large cell dysplasia (LCD) is defined as a group of hepatocytes with nuclear and cellular growth, a normal cytoplasmic nucleus ratio, nuclear pleomorphism, multinucleation, nuclear pseudoinclusions and a prominent nucleolus (171). LCD was initially considered a "precursor" lesion of HCC, due to the abnormal amount of DNA found. However, the DNA concentration does not correspond to histological changes, such as the low rate of proliferation (172), the low nucleus cytoplasm ratio and the strong apoptotic activity (166).

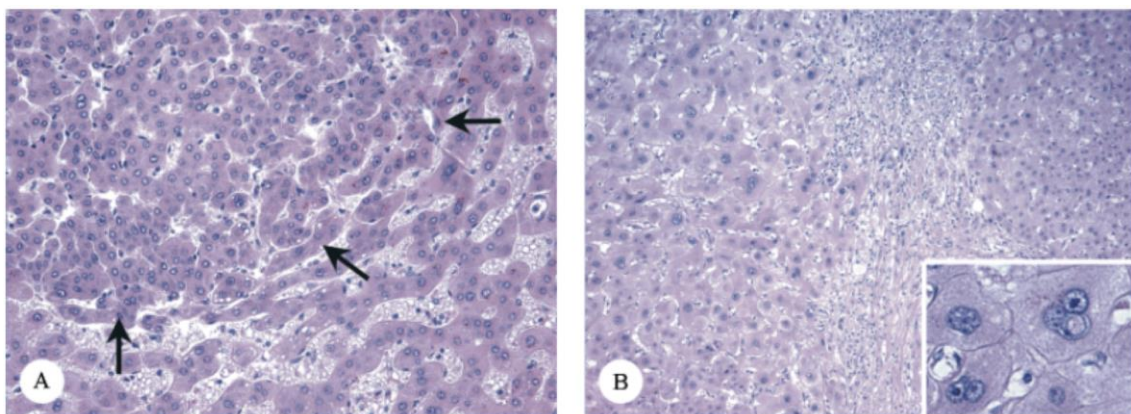


Figure 5: Dysplastic Foci

A) Small hepatocytes with an increased nucleocytoplasmic ratio form in SCD focus (arrows) and compress the surrounding parenchyma. Magnification 200x (B) A focus of LCD consisting of hepatocytes that show nuclear and cellular enlargement (left half of figure) compared with the surrounding parenchyma (right half of figure). Magnification 100x and 200x. From: Libbrecht, Preneoplastic lesions in human hepatocarcinogenesis.

It has also been shown that LCD foci are due to hepatocytes pushed into a replicative senescence process caused by persistent necro-inflammation and hepatocellular regeneration. The genetic alterations of these differentiated polypoid hepatocytes modify normal cell division and lead to the formation of a large cell dysplastic focus with increased and abnormal DNA content. Because they are in the last stage of differentiation, the LCD cannot progress to the HCC. Therefore, and according to current hypotheses, LCD are pathologically related and associated with HCC, but they are not *bona fide* precursor lesions (173). In addition, it was found that the LCD foci did not have the characteristics of the progenitor cells. However, the LCD foci strongly express the senescence marker p16 (174).

2.4.2) Dysplastic nodules

Dysplastic nodules are defined as a nodular region of hepatocytes at least 1 mm in diameter with dysplasia, but without defined histological criteria of malignancy. There are two types of low-grade nodules, characterized by slight atypia and high grade nodules, with at least moderate but not enough for the diagnosis of malignancy (175). The most important morphological criteria to assess dysplastic nodules are the nucleo-cytoplasmic ratio, the nuclear contour and the thickness of the trabeculae of hepatocytes (165).

2.4.3) Regenerative nodules

According to the classification proposed in 1995 by Wanless *et al.*, the regenerative nodules are lesions of a minimum size of 5 mm and do not exhibit cytological or architectural atypia (175). They can also be located mainly next to the largest portal spaces. A debate emerged though concerning the presence of the monoclonality of these lesions and their relationship with the development of HCC. It has been shown by some investigators that a percentage of these lesions are monoclonal, but these results have not been fully replicated. Therefore, additional studies are still needed to show whether or not regenerative nodules might represent precursor lesion (176–178).

2.4.4) Iron-free foci

A study in patients with hemochromatosis revealed a type of lesion called *iron-free foci* (179). Histologically, this lesion is defined as lesions of more than 20 iron-free hepatocytes, in a parenchyma with overload (180). The mechanism by which these hepatocytes avoid overload is not known until now. However, it is known that these iron-free foci are strongly associated with the appearance of HCC (figure 6) (181).

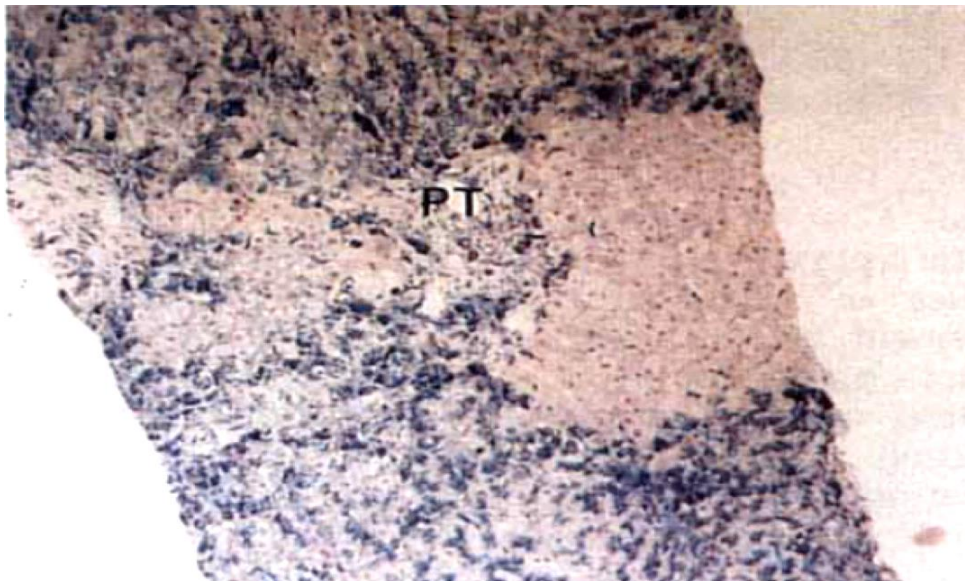


Figure 6: Iron Free Foci.

We can show the absence of positivity for Pearls Stain. (PT = Portal tract). From: Deugnier, Preneoplastic significance of hepatic iron-free foci in genetic hemochromatosis: A study of 185 patients

2.4.5) Foci of altered hepatocytes, rich in glycogen / oncocytes

Pre-neoplastic foci of altered hepatocytes (FAH) were originally found in the liver of rats treated with hepatocarcinogenic nitrosamines. Since then, different animals have been observed, including primates in the early stages of hepatocarcinogenesis induced by genotoxic or non-genotoxic chemicals (182). Currently they are considered as precursors lesions of HCC (182). Because of their histological characteristics, 8 different varieties of these FAH have been described, the most considered are; i) foci that store glycogen (GSF) and ii) oncocytic foci (174,183).

GSFs are characterized by a relatively clear cytoplasm with only a hint of very pale eosinophilic staining and thin rows of cytoplasm that make the cytoplasmic vacuoles have an indistinct edge. The cells that make up a GSF are characterized by the central nucleus (183). There are just some reports of GSF in the human liver. GSF are present in the majority of cirrhotic livers with HCC and some of them contain SCD foci, suggesting a probable evolution path from GSF to SCD with the final development of HCC.(183–185). At present, there is insufficient evidence that the important role played by GSF in certain animal models of hepatocarcinogenesis can find its equivalence in the human liver (figure 7).

Oncocytic changes in hepatocytes are characterized by a granular eosinophilic cytoplasm, due to the large number of mitochondria distributed compactly in the cytoplasm (186). In the human liver affected by a chronic disease, oncocyte foci occur quite frequently, which is why they have been studied extensively (187). According to the current hypothesis an environment characterized by chronic inflammation contributes to lesions and depletion of mitochondrial DNA (mtDNA), mainly due to ROS released by inflammatory infiltrate (165).

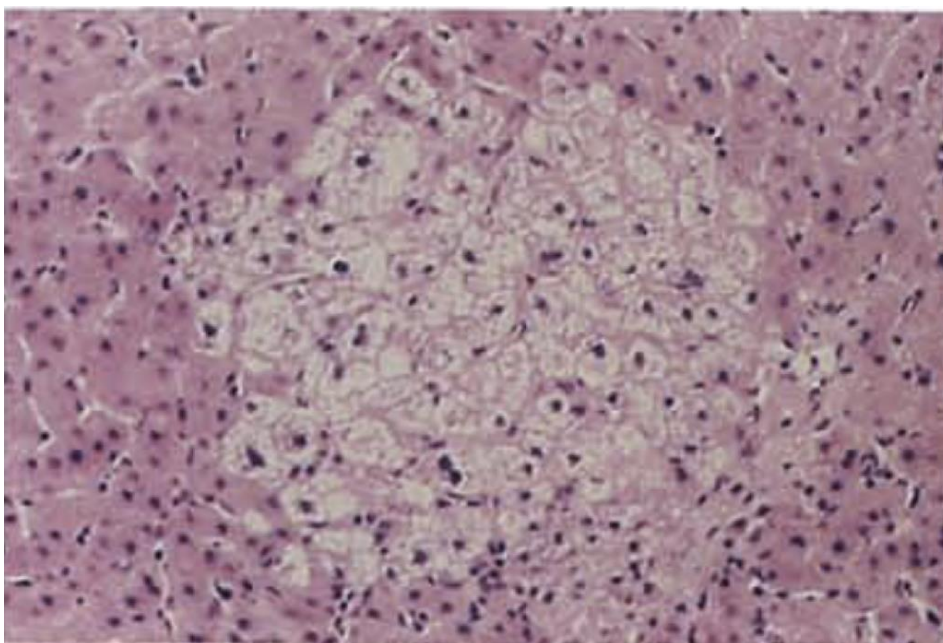


Figure 7: Glycogenic hepatocytes
Focal zone of glycogenic hepatocytes in liver 100x. From: Bannasch, Focal hepatic glycogenesis: a putative preneoplastic lesion associated with neoplasia and cirrhosis in explanted human livers

This depletion in mtDNA causes defects in the respiratory chain, and a compensation by increasing the number of mitochondria, yielding thereby the typical color of the cytoplasm under the microscope (188). However, for the moment, there is not enough evidence to establish a link between oncocytic changes and the onset of HCC.

2.4.6) Hepatocellular adenoma

Hepatocellular adenoma (HA), it is a rare benign tumor, accounting for 2% of all hepatic neoplasms and occurs mostly, but not exclusively, in middle-aged women with a history of oral contraceptive use for a long time (189). Clinically they are characterized by being a unique lesion, located mainly in the right lobe of the liver, with measures ranging from 1 to 30 cm (189). At clinical examination the presence of a palpable mass or hepatomegaly is the initial symptom in 30% of the cases (190). Patients with large tumors also show vague abdominal pain.

The macroscopic characteristics of the tumor include a single lesion, well delimited, not encapsulated with occasional necrosis and intratumoral hemorrhage. At the microscopic level, HA's show hepatocytes without signs of dysplasia, arranged in plates of slightly thickened cells, with preservation of the reticulin network. The arterial vascular supply is characterized by thin walls. There is a lack of portal spaces or the elements that compose them. Other less common features include steatosis, inflammatory infiltrate, ductular reaction, hemorrhage and abnormal blood vessels (191).

At the molecular level, 4 types are distinguished:

- HA-H: characterized by the presence of steatosis, absence of inflammatory component. In addition, a loss of expression of liver fatty acid binding protein (L-FABP) is observed at the immunohistochemical level (192), which is conserved in the adjacent parenchyma. The molecular findings show mutation of HNF1A in 85% of cases (191).

- HA-B: histologically characterized by the predominant presence of a pseudoacinar pattern and mild cytologic atypia. The aberrant expression of β -catenin located in the nucleus is the characteristic of this subtype. In addition, a diffuse cytoplasmic expression of glutamine synthetase can also be found. Molecularly, an activation of the β -catenin gene is found (193).
- HA-I: Also called inflammatory adenoma, this subtype is characterized by inflammatory component mainly mononuclear, tracts of arteries surrounded by a fibrous area, called pseudoportal tracts. We also find multifocal sinusoidal dilatation and peliosis (194).
- HA-U: category created to encompass all adenomas that do not present any of the above characteristics in a well-defined manner (191).

The potential of the HA to transform into HCC has been mentioned in more than 35 years ago, when a tumor composed of HA and HCC was found in a female patient (195). The percentage of transformation is estimated at 4.5%, according to the series reviewed (189). The risk factors being the presence of a size larger than 6 cm, the prolonged use of steroids, the male gender, the type I glycogen storage disease, the presence of multiple HA and the molecular subtype (190).

The presence of HA-B adenomas has been associated with an increased risk of malignant transformation. Up to 46% mutations of β -catenin in HCC associated with HA have been found (193). Therefore, the theory of an adenoma carcinoma evolution is postulated. This theory is reinforced by the presence of foci of dysplasia within the hepatic adenoma which once developed will invariably progress towards an HCC (196). Genomic studies have revealed chromosomal aberrations, loss of heterozygosity (LOH) for the M6P/IGFRII receptor, LOH in hMLH1, both in HCA and in HCC (197). Other studies suggesting evidence as the monoclonality of HA as a hypothesis for a possible process of malignant transformation (198).

To date, there are few reported cases of non-cirrhotic hepatocellular carcinoma (NC-HCC) from an HA. However, cases have been reported where the transformation of an HA has been favored by underlying liver disease, such as glycogen storage disease, Fanconi's anemia (199).

2.5) Histopathology of Hepatocellular carcinoma

Just as the structure and different cell groups in the normal liver have been initially described, A careful microscopic analysis of H&E slides of the tumor tissue gives us a better understanding of their nature and the changes to which they are subjected.

The analysis of the structural pattern, that is to say the predominant or often unique histological pattern of HCC, is the first step towards a better understanding of the nature of the disease, since some of them are related to the prognosis and survival of patients.

WHO has proposed a structural classification that comprises three major histological patterns (200). There are, however, other classifications where additional classifications have been proposed(201), but for the purposes of this review, we will only consider those identified by the WHO.

We also want to emphasize that there are several cytological variants of HCC. Several studies have tried to point out the clinical relevance of these cell variants, however a clear consensus to date has not been possible. However, we must recognize that, its use brings benefits when discerning between the presence of HCC and potential mimic neoplasms.

Finally, special types of HCC have also been described, which have unique characteristics within their architecture, as well as in the population groups they affect.

2.5.1) Architectural patterns

2.5.1.1) Trabecular

Characterized by the formation of cords of neoplastic cells of variable thickness, separated by sinusoidal spaces, the trabecular pattern is the most frequent presentation in well and moderately differentiated tumors (200). This pattern is the most common presentation in tumors developed in both cirrhotic and non-cirrhotic liver, accounting for between 41 and 76% of all cases (202) (figure 8A).

2.5.1.2) Acinar

This type of pattern is named after the presence of a central space or "acini" formed of a single layer of cells or a dilatation of a structure similar to a biliary canaliculus. These "acini" often contain a positive PAS protein material (203) (figure 8B).

2.5.1.3) Compact

This pattern is characterized by abundant cellularity with almost imperceptible sinusoidal spaces (200,204) (figure 8C).

2.5.1.4) Macrotrabecular

The new classification of the liver tumors of the oms, published in 2019 mentions this new architectural pattern whose main characteristic is the presence of macrotrabeculae with a thickness greater than 10 cells in each of them (205)

2.5.2) Cytological variants

2.5.2.1) Pleomorphic cells

Characterized by cells with marked variation in nuclear and cellular size. It is common to find also multinucleated giant cells, giant cells of the osteoclast type (less frequently) (200).

2.5.2.2) Clear cells

Characterized by cells with clear cytoplasm occasionated by the presence of abundant glycogen. This variant has to be distinguished from : metastatic clear cell renal cell carcinoma, angiomyolipomas and adrenocortical carcinomas (201).

2.5.2.3) Ground glass inclusions

Tumor cells with inclusions equal to those found in hepatocytes infected with hepatitis b virus. Paradoxically this type of variant is not found in HCC developed from an infection with HBV (200).

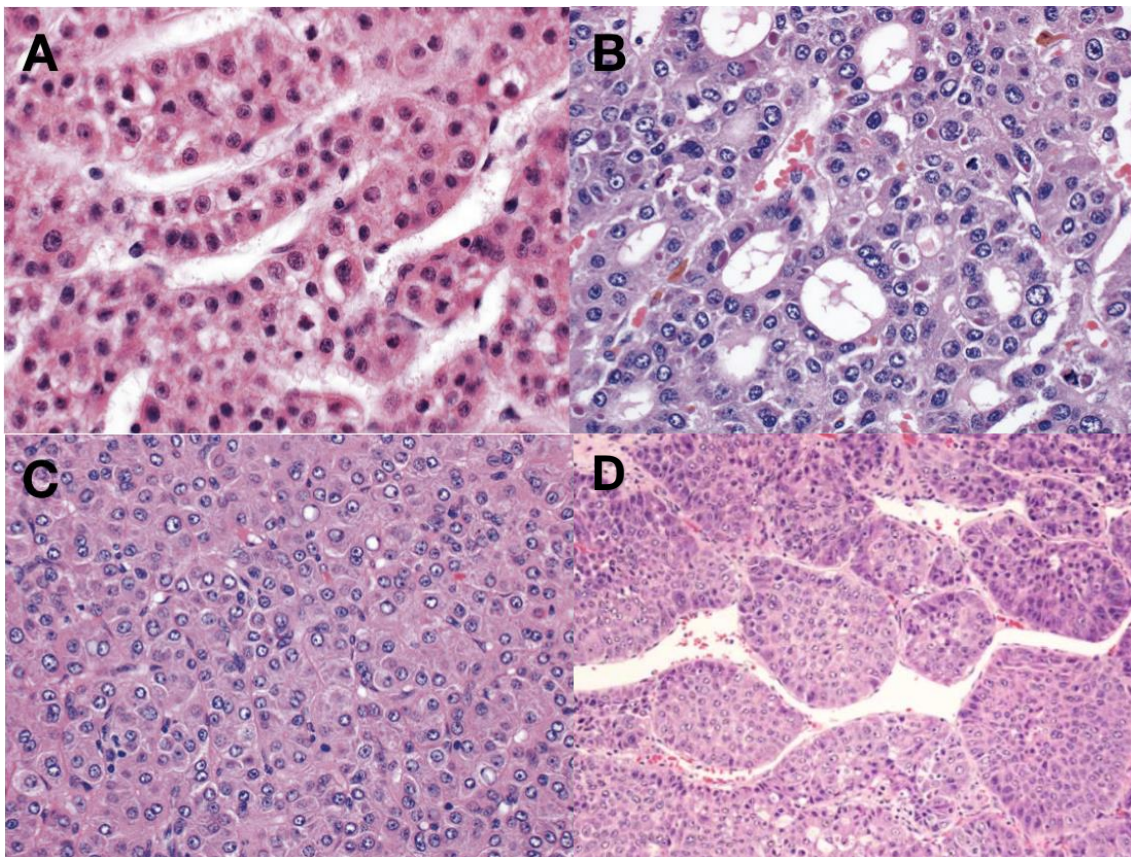


Figure 8: Histological patterns of HCC.
A) Trabecular pattern, B) Acinar pattern C) Solid pattern. D) Macrotrabecular pattern. Magnification 200x. From: Torbenson, Surgical Pathology of Liver Tumors

2.5.3) Peculiar Histological subtypes

2.5.3.1) Fibrolamellar (HCC-FL)

Considered as a rare and peculiar variant of HCC, this type of tumor is mainly characterized by development in young patients in the context of a non-cirrhotic

liver (206). In the spectrum of clinical manifestations, this type of tumor does not have a clear predilection for sex. AFP levels are almost normal, however elevations are between 10 - 15% of cases (204).

Histologically, this tumor is defined by a triad of characteristics, such as;

i) large polygonal cells, with abundant eosinophilic cytoplasm of granular appearance, ii) prominent and eosinophilic nucleoli and iii) collagen bands in plate form (lamellar fibrosis) which must be present in at least 50% of the tumor. HCC-FL has been associated with aggressive behavior, as lymphatic and peritoneal metastases are much more common than in conventional HCC (207,208). Recent studies show that the survival of HCC-FL is similar to that of HCC developed on non-cirrhotic liver, surgical resection being the most important prognostic factor (figure 9) (209).

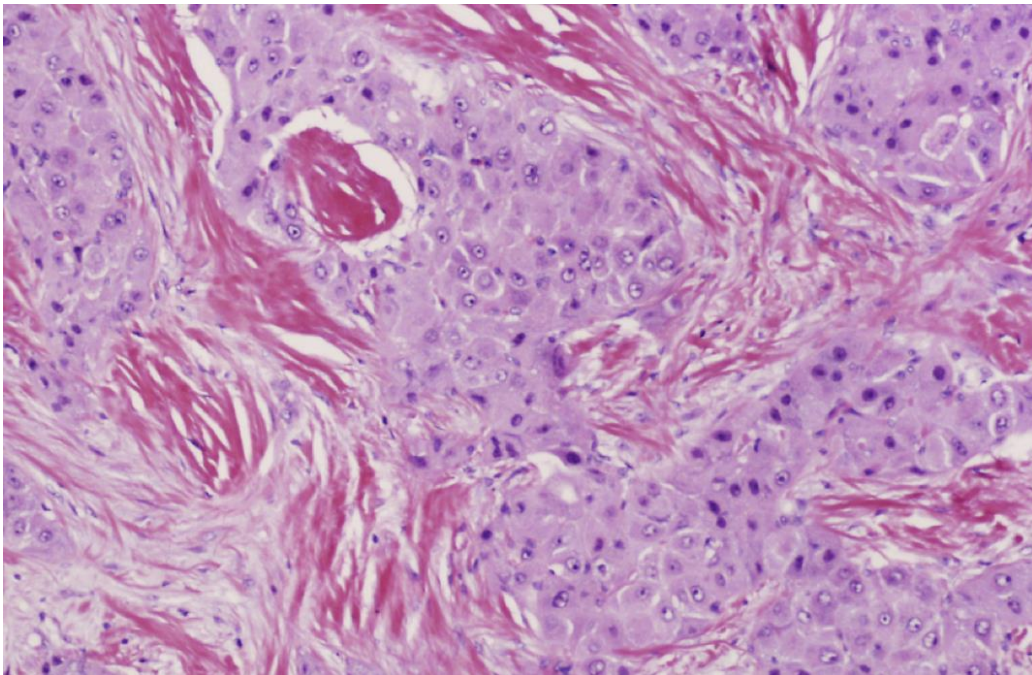


Figure 9: Fibrolamellar HCC.
We can show collagen bands in plate form; cellular characteristics show macronuclei and polygonal cells. From: Shafizadeh, Hepatocellular Carcinoma. Histologic Subtypes

2.5.3.2) Macrotrabecular massive (MTM-HCC)

Recently described by Calderaro (210) this type of tumor is characterized by the presence of large trabeculae of more than 20 cells each one, in at least 50% of the totality of the tumor (figure 10).

At the molecular level, this tumor presents P53 mutation and amplification of FGF19. Endothelial markers such as angiopoietin 2 (Ang2) and vascular endothelial growth factor A (VEGFA) are also overexpressed. Clinically, this type of tumor is associated with a large size (> 50mm), high levels of alpha fetoprotein, satellite nodules, as well as macro and microvascular invasion, which is why overall survival is diminished compared to other histological types (211).

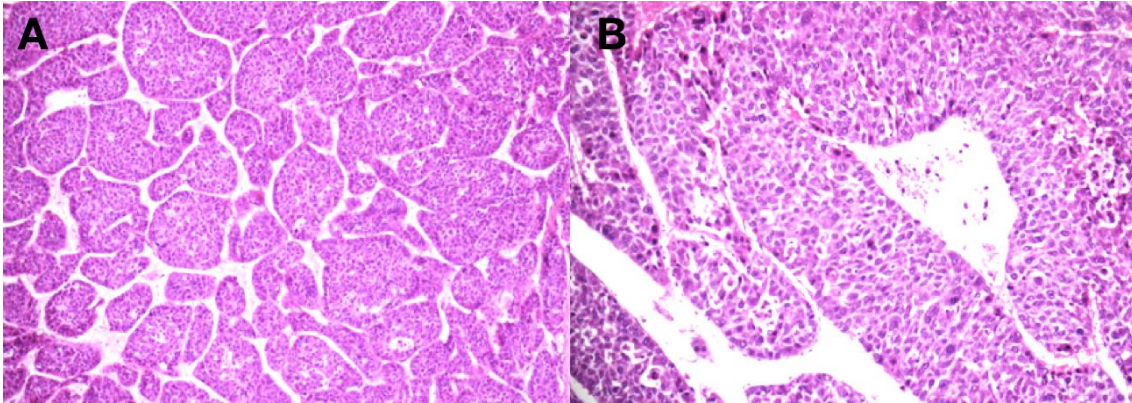


Figure 10: HCC macrotrabecular massive type. A) Macrotrabecular pattern 100x and B) 200x magnification. From: Calderaro, Histological subtypes of hepatocellular carcinoma are related to gene mutations and molecular tumour classification

2.5.3.3) Combiend Hetapocellular carcinoma – Cholangiocarcinoma (cHCC-CC)

Described for the first time in 1903 (204), WHO considers this type of tumor to be a tumor containing both HCC and CC elements intimately combined (200). The separate nodules of HCC and CC in the same tumor should be considered colliding tumors. To date, two subtypes of cHCC-CC are recognized: i) the classical type and ii) the type exhibiting the characteristics of the stem cells.

The classic type

This type of tumor contains classic areas of HCC and CC. The HCC component can vary according to the degrees of differentiation, the most commonly observed pattern is the trabecular type. The presence of CC component can be differentiated from features such as: glandular formation, desmoplastic stroma and mucin production. It is suggested that confirmation of the HCC component

as CC must be performed by immunohistochemical techniques (figure 11a) (212,213).

The stem cell type

Characterized by the presence of a small cell population, oval-shaped, hyperchromatic nucleus, rare cytoplasm and mild to moderate atypia. The immunohistochemistry (IHC) markers expressed in this cell subpopulation are: CK19 and MOC-31(epitope of EpCAM) together with a variety of stem cell markers such as NCAM, KIT and CD133 (figure 11b) (212).

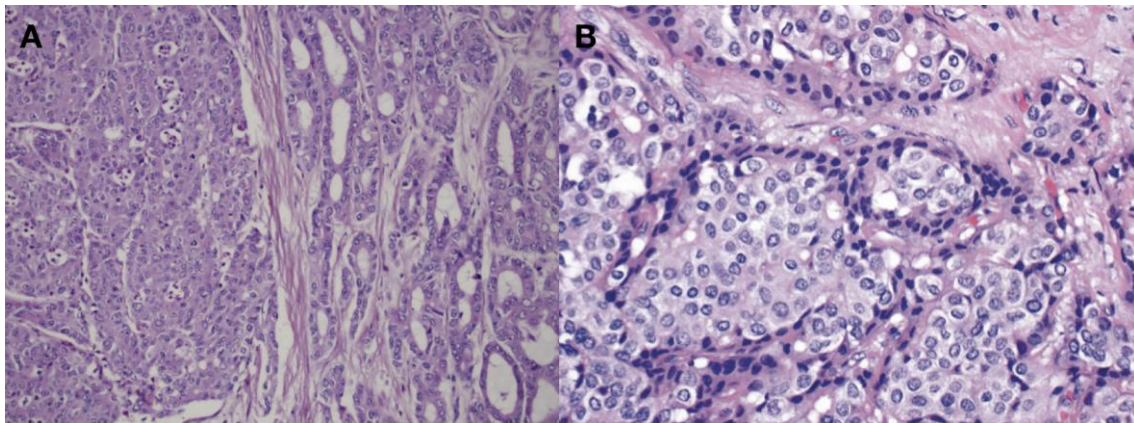


Figure 11: Combined Hepatocellular Carcinoma-Cholangiocarcinoma
A) Classic Type: we can show two components of tumor. right colangio component, left HCC component. B) Stem cell type Magnification, we can show the small “stem” cells around the nests. 100x. From: Shafizadeh, Hepatocellular Carcinoma. Histologic Subtypes.

2.5.3.4) Transitional Liver Cell Tumor

The Transitional Liver Cell Tumor (TLCT) was initially reported by Prokurat (214), after conducting a study in older children and adolescents with a diagnosis of hepatoblastoma. This tumor has mostly areas consistent with HCC but there are also areas with poorly differentiated small cells that resemble the embryonic component of hepatoblastoma explaining its “transitional” naming, there would be an apparent transition between both cell types (203).

The causes of these transitional characteristics are still unknown but the hypothesis postulates that it is due to a secondary mechanism of maturation.

Clinically, tumors show a marked elevation of alpha fetoprotein levels, in addition to behavior similar to that of HCC (214,215). It has also been reported that these tumors present an expression of β -catenin of mainly nuclear and cytoplasmic localizations (no plasma membrane pool) (figure 12).

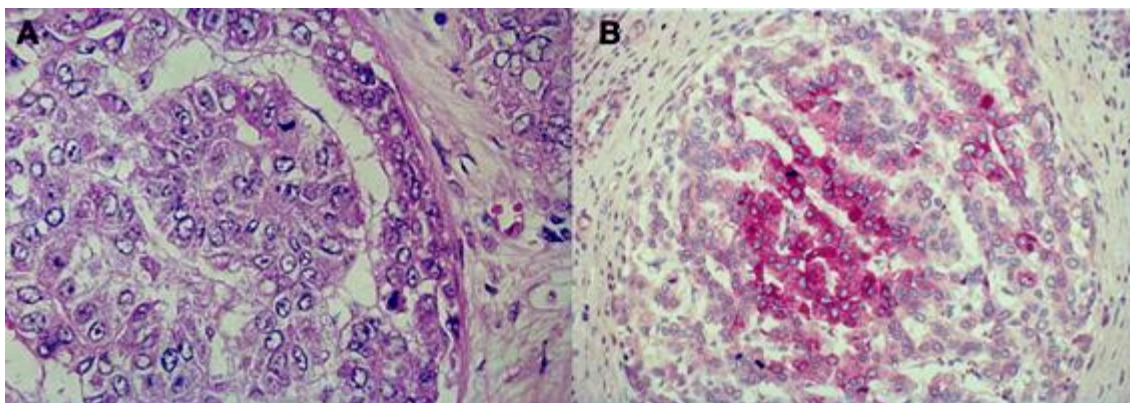


Figure 12: Transitional liver cell tumor (TLCT).

A) large cells with granular aspect of cytoplasm, in acinar like disposition. B) Reactive for AFP is positive in central cells of nest. From: Prokurat, Transitional liver cell tumors (TLCT) in older children and adolescents: A novel group of aggressive hepatic tumors expressing β -catenin

2.5.3.5) Undifferentiated

Corresponding to < 2% of epithelial liver tumors (200), undifferentiated carcinomas are defined as primary tumors of the liver, which cannot be diagnosed as primary cancers by the use of immunohistochemical techniques (216). This type of tumor has a predilection for the male sex, being also associated with a worse prognosis compared to conventional HCC (204)

2.6) Molecular classification of hepatocellular carcinoma

Several studies, carried out on dozens of molecular signatures in HCC samples, have shown a variety of molecular subclasses and genetic signatures that are associated with biological phenotypes and / or clinical outcomes (158,210,217,218).

HCC tumors can be classified first into two main groups. The first group, with more aggressive biological / clinical characteristics, which include greater genetic

instability, cell proliferation, ubiquitination, activation of survival signals such as the E2F1 and MET pathways, in addition to a marked deterioration in the TP53 gene. Likewise, these tumors can also express a positive KRT19, a larger and less differentiated tumor size, a higher incidence of tumor recurrence and a worse prognosis. The second group of HCC comprises tumors with aggressive features, including preserved hepatocyte function, a smaller and differentiated tumor and a better prognosis.

There are also subdivisions within each group, this due to the result of various meta-analyses, which establish the following qualification. For the group of aggressive tumors, there is subgroup 1, whose main characteristics are: shows relatively higher activation of TGF- β pathway and cholangioma-like gene signature. Subgroup 2 is characterized by: by positivity EPCAM, high levels of AFP (protein and seric level) and activation of GPC3, IGF2, in addition to a higher expression of genes associated with vascular invasion.

Also, within the group of less aggressive tumors, we find a subgroup, characterized by mutations in exon 3 of the CTNNB1 gene which are accompanied by the induction of specific target genes, GLUL, LGR5 and SLC1A2 (217).

It should also be mentioned that recently different studies mention new groups identified, considering a total number of 6 subdivisions, however this topic is still a subject of study (210). Figure 13 illustrates the 3 classifications mentioned, as well as the 3 proposals currently. The spectrum of clinical presentations of the HCC varies from asymptomatic conditions to those where the tumor and hemoperitoneum rupture is debut (219). The asymptomatic presentation of the HCC is mainly related to the early and early detection of the disease, due to a routine examination. Currently, the HCC incidence uncovered by routine exams is still in place. On the other hand, the classic triad of the presentation of HCC includes pain in the upper right quadrant, weight loss and hepatomegaly (4).

2.7) Clinical manifestations

Table 2 summarizes the most frequent signs and symptoms of HCC.

Sympton	Frequency (%)	Sign	Frequency (%)
Abdmonal pain	59 – 95	Hepatomegaly	54 – 98
Weight loss	34 – 71	Hepatic bruit	6 – 25
Weakness	22 – 53	Ascites	35 – 61
Abdominal swelling	28 – 43	Splenomegaly	27 – 42
Nonspecific gastrointestinal symptoms	25 – 28	Jaundice	4 – 35
Jaundice	5 – 26	Fever	11 – 54

Table 2: Signs and symptoms of HCC according to frequency of presentation. From: Carr, Hepatocellular Carcinoma: Diagnosis and Treatment

Noteworthy is that most HCC develop on a cirrhotic liver, so HCC contributes to the decompensation of an established disease. Within the decompensation of a cirrhotic liver due to HCC, we find the development of abrupt onset ascites, bleeding from esophageal varices, progressive encephalopathy and jaundice (16).

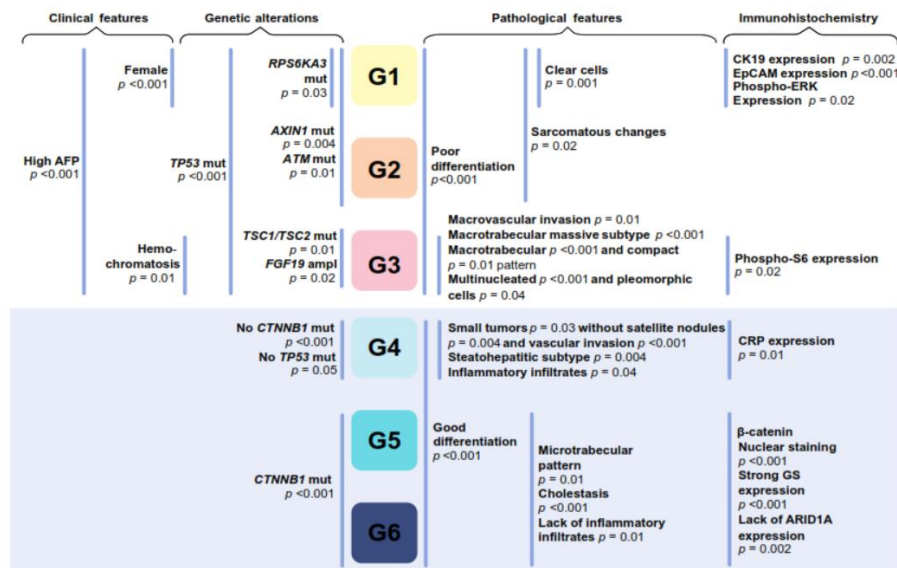


Figure 13: Molecular classification of HCC.

Classification proposed by Calderaro. 6 Molecular classification were proposed according to clinical, genetic, pathological and immunohistochemistry. From. Histological subtypes of hepatocellular carcinoma are related to gene mutations and molecular tumour classification. Calderaro *et al.*

A complication frequently found in patients with HCC - which is represented in 30 - 40% of cases - is the portal vein tumoral thrombosis (PVTT), whose appearance is associated with a worse prognosis (220). Indeed the presence of PVTT is a contraindication for liver transplantation (221). Another complication presented in 10% of cases of HCC is gastrointestinal bleeding, which in many cases is the presenting symptom. In most cases, 45%, the bleeding comes from esophageal varices caused by problems of redistribution of the portal flow (222).

Finally, a fatal complication in HCC patients is tumor rupture, which can occur spontaneously or as a side effect of abdominal trauma. It has been reported that patients with large tumor size, PVTT and a contour protrusion have a higher risk of tumor rupture (223).

2.7.1) Paraneoplastic Syndromes

An interesting and florid clinical picture, due to the secretion of hormones or hormones-like by the tumor, are the so-called paraneoplastic syndromes. Due to the rarity of this type of presentation, there is not much literature available, however we find:

- Hypoglycemia, whose spectrum encompasses two types. Type A hypoglycemia, which occurs in the context of rapid tumor growth and abrupt loss of muscle mass. The proposed mechanism is an inability of the liver to meet glucose levels by the tumor and other tissues. Type B hypoglycemia, which manifests as severe hypoglycemia and difficult treatment that goes hand in hand with the development of the disease. This result due to a defect in IGF2 processing by hepatocytes (224).
- More rarely, cases of polycythemia have been reported, which is caused by the increased synthesis of an erythropoietin-like hormone for tumor cells (225).
- And less frequent syndromes, there are: hypercalcemia, high blood pressure, feminization, hypercholesterolemia and watery diarrhea (224,226,227).

2.7.2) Serum AFP

In 1956 Bergstrand first mentioned AFP like the presence of a protein found in the serum of human fetuses. which presented characteristics similar to albumin and globulin. Being found only in the fetus, but not in the mother (228).

The synthesis of AFP can be detected 29 days after conception. Its initial production is carried out in the yolk sac and the liver (229). However, liver production increases steadily until, at the end of the first trimester, it is the main source of production. However, smaller amounts of AFP can be produced also in the gastrointestinal tract. A study conducted by Gitlin, it was found that the secretion of AFP disappears a few weeks after birth. remarking that except in pregnancy, the production of AFP in adults is abnormal (228).

Abelev (230) first described AFP as as a diagnostic marker in hepatomas, establishing a relationship between the secretion of this marker and liver tumors. Later it was discovered that oval cells, a type of liver stem cells, also express this marker in circumstances of hepatic regeneration (231) and in models of chemical carcinogenesis, which is why several hypotheses raise a possible role of stem cells in the process of carcinogenesis in AFP hyperproductive tumors (229).

Actually, we know that almost 80% of hepatocellular carcinomas, all teratocarcinomas of the testis and ovary that contain analogues of the yolk sac, and also in some cases of gastric and colon cancers may present high levels of AFP(232). However, unexplained elevations of serum AFP in certain non-malignant conditions have been reported as for example in patients with ataxia telangiectasia(233).

AFP values represent a useful tool in the early diagnosis of HCC, however it lacks good sensitivity (41-65%) but high specificity (80-94%) (234). WHO has established that a rapid elevation of > 400 ng / ml or a continuous elevation > 100 ng/ml is highly suggestive of the presence of HCC (200,235). It is interesting to note also the variability of the range of secretion of this protein according to the type of liver tumor. Not all tumors secrete high amounts of this hormone, AFP

levels are, for example normal in FL-HCC (236), whereby the range of values fluctuates between 10ng/ml up to 500 ng/ml.

A gray area in relation to the benefits of afp in the diagnosis of HCC is found in cases of NC-HCC, where the elevation of this marker only occurs between 31-67% of all cases (237), where AFP levels hardly exceed 20 ng/ml (202). compared to its counterpart developed on cirrhotic liver, where we can find it between 59-84% of cases with values greater than 400 mg / ml.

2.8) Treatment

2.8.1) Liver resection

Surgery is the best therapeutic option for patients with HCC (202). Hepatic resection and hepatic transplantation are considered as the only two curative methods for HCC (238), offering a survival of 60 - 80% at 5 years (239). In addition, surgical resection is considered the first line of treatment in patients with HCC developed on non-cirrhotic liver.

The current guidelines for the selection of patients who are candidates for surgery are governed by the Barcelona consensus (BCLC) (240), which considers:

- Patients with solitary and small tumors
- Well preserved liver function
- Hepatic venous pressure gradient <10 mmHg

The BCLC has shown survival rates of up to 70% at 5 years in patients with bilirubin levels were <1 and hepatic venous pressure gradient <10 mmHg. However, the strict application of these criteria only allows 10% of the total patients with HCC to undergo surgery (240).

Surgery must comply with principles aimed at improving survival as much as possible. The techniques used are strictly linked to the decrease in blood loss during the operation. Since it has been shown that large losses of blood volume

are associated with increased post-surgical mortality. So also, for multiple blood transfusions (241).

The surgery is performed following the anatomical principles, removing the compromised liver segments as much as possible, always considering - especially in patients with advanced liver disease - to leave enough “healthy” liver to avoid liver failure.

Another important factor to considering in surgery is the state of the surgical margin. Several studies have indicated that the commitment of surgical margins is a factor of capital importance in the recurrence of the disease. It is currently estimated that a surgical margin considered as optimal is 1cm. However, a recent study has shown that the margins of 2cm have a significant advantage in decreasing recurrence and long-term survival compared to those of 1cm (242).

2.8.2) Abaltive treatments

2.8.2.1) Percutaneous ablation therapies – Alcohol injection

Percutaneous ablation therapies have as their principle to destroy the tumor tissue by chemical or physiological means. Within the gamma of agents used, we find: ethanol, acetic acid, in the first case; and radiofrequency, microwave or use of laser in the second (243).

Among percutaneous ablation therapies, the most widely used and widespread is percutaneous ethanol injection, which is developed under ultrasound guidance. Due to its real-time control, it is possible to specify the adequate location of the lesion, an adequate distribution of ethanol as well as the necessary and sufficient quantity to be injected (244).

The mechanisms of action of ethanol can be divided into cellular and vascular. Within the cellular effect, we found a diffusion of ethanol within the cells, causing immediate cellular dehydration, with a subsequent coagulative necrosis to finely end up in fibrosis of the injured tissue. Vascular effects are due to the entry of

alcohol into the circulation, which induces endothelial cell necrosis and platelet aggregation, leading to thrombosis and ischemia of the neoplastic tissue (245). Both effects act favorably on HCC due to hypervascularization and a different consistency compared to adjacent healthy tissue.

This technique is used according to the following criteria (243):

- Solitary HCC < 4-5cm in diameter
- Multiple HCC with 2 or 3 nodules, all less than or equal to 3cm in diameter
- HCC in advanced stages as long as the tumor size does not exceed 30% of the hepatic parenchyma and there are no neoplastic thrombi in branches of the portal vein or hepatic veins.

For the evaluation of the effectiveness of the therapy, a combination of serologicals markers are used, which include the levels of AFP and des-gamma-carboxy-prothrombin (DCP). In addition, the use of ultrasound and spiral multi-slice computed tomography is recommended (246). Complications of this therapy include intraperitoneal hemorrhage, cholangitis, jaundice secondary to bile duct injury, hepatic abscess, shock and hepatic (segmental) infarction. The increase in complications is directly associated with the number of sessions performed (247).

2.8.2.2) Local ablation

Local ablation is the first line of treatment for patients in the early stages of the disease, whose decision is not surgery or liver transplantation. Ablative treatments are classified as hyperthermic (temperature between 60 - 100 C °) where we find radiofrequency ablation (RFA), microwave ablation (MWA), high intensity ultrasound (HIFU) and laser therapy. Within the group of hypothermic (tissue freezing at - 20 ° C) we find cryoablation (248). Of all the aforementioned, the RFA is currently the most widely used. We must also consider that all these procedures are usually developed percutaneously. However, laparoscopic ablation is recommended if the lesion is located in areas of difficult access.

These types of treatments are indicated as long as they are patients with HCC where the tumor is located in a deep area or if it is a multinodular HCC, it can also be used in very early stages of the disease, according to established by BCLC (240). There are also a series of absolute and / or relative contraindications for this type of therapy, which have been summarized in (Table 3).

The mechanism of action of the radiofrequency is mainly based on the application of alternating current, generating an injury within the tumor tissue due to the heat produced by the friction of the ionic agitation of particles (249). Whose objective is not only to detach the tumor mass, but also to ensure the destruction of the surrounding tissue by ensuring a margin of 1cm, thereby obtaining destruction of possible microsattelites and preventing local recurrence.

2.8.2.3) Transarterial chemoembolization (TACE)

One method classified as a reference therapy for the treatment of unresectable hcc is the transarterial chemoembolization (TACE). The method bases its operation on the vascular supply of arterial predominance, which is characteristic of hcc. Offering a semi-selective way to attack only the tumor and respecting as far as possible the non-tumor hepatic parenchyma (250,251). The main agents used in this type of treatment are: cisplatin, doxorubicin, 5-FUdr, mitomycin c and gencitabine. Which are often used as sole agents or in combination with each other. In addition to the use of these chemotherapeutic agents, agents that facilitate contact between the drug are also used, as well as reducing the blood supply to the tumor through vascular occlusion. Lipiodol and gelaton slurry are respectively the most used (252).

After the injection of the aforementioned medications, an inflammatory-ischemic response is triggered at the liver level, which has been described as the post-embolization syndrome. Which is characterized by the presence of fever, nausea and pain within 24 hours of the procedure. It should be mentioned that the post-embolization syndrome has a self-limited nature (253).

Absolute contraindications

Extrahepatic disease
Altered mental status
Active infection
Tumor abutting a major hepatic duct
Liver descompensation

Relative contraindications

Lesions > 5 cm
More than 4 lesions
Severe pulmonary or cardiac disease
Refractory coagulopathy

Table 3: Absolute and relative contraindications for ablative therapy in HCC. From: Faccioruso, Local ablative treatments for hepatocellular carcinoma: An updated review

2.8.3) Targeted Therapies

2.8.3.1) Sorafenib

Sorafenib (SOR) is a kinase inhibitor, it is currently the only drug approved by the FDA for the treatment of HCC. Several studies have shown some effectiveness of the drug in cases of advanced HCC. For example, the SHARP study showed that the average overall survival with sorafenib was 10.7 months compared with 7.9 months for patients treated only with placebo (254). In the same way, the GIDEON study showed a mean survival in child A patients treated with SOR of 10.3 months compared to 4.8 months in patients in the child B group (255).

2.8.3.2) Linifanib

Linifanib is a targeted inhibitor of the VEGFR and PDGFR pathways. Phase II studies showed that the average survival in patients with HCC treated with this medicine was 9.7 months (256). However, in a phase III trial comparing the efficacy between linifanib and sorafenib, no significant differences were found between them. In addition, linifanib was shown to be associated with increased toxicity compared to sorafenib (257).

2.8.3.3) Erlotinib

Erlotinib is an EGFR inhibitor, whose action develops on the tyrosine kinase domain. It has been used for the treatment of unresectable HCC, obtaining a survival of 13 months, as evidenced by the phase II study of Thomas (258) . However, it has not shown any benefit compared to the use of sorafenib. In addition, like linifanib, it has shown a toxicity greater than sorafenib (259).

3) The non – cirrhotic hepatocellular carcinoma (NC – HCC)

The non – cirrhotic hepatocellular carcinoma (NC – HCC) occurs in approximately 20% of all HCC cases (260). The mechanisms of hepatocarcinogenesis for this particular type of clinical presentation of HCC remain unclear. A possible strong association principally of HBV viruse in the tumorigenesis of this type of neoplasia has been reported (261,262). The proposed carcinogenic effect is given by the ability of viral proteins to modulate gene transcription, cell proliferation and cell death (31,263,264).

In addition, it is also considered that the origins of NC-HCC may be associated with exposure to carcinogenic chemicals (265). As has been proposed in models of experimental chemical hepatocarcinogenesis and could involve liver stem cells. By respecting the concept of blocked ontogenesis, hepatic stem cells or "oval cells" can participate directly in the histogenesis of NC-HCC by stopping their maturation (266).

Other hypotheses postulate a possible malignant transformation of a hepatocellular adenoma from a non-fibrotic liver. Mainly in the context of inherited metabolic diseases, such as glycogenosis, although cases of NC-HCC outside of this context have also been described (267). However, detailed histopathological reports on non-tumor "normal liver" are difficult to find direct causal relationship, and a direct cause between preneoplastic lesions and tumors has not been established (260,268,269).

3.1) Demographic characteristics

The distribution of this particular type of disease varies according to geographical location. In Japan, for example, we found rates of 10.7% (268), in Italy, an incidence of 21.47% (262), the United States presents 42.6% (260) and finally, in Peru, we found that of the total HCC cases, 89% were NC-HCC (270). The male to female ratio (M:F) according to some studies are to 1:6 to 3.1:1 (260,262,270), which is much weaker compared to its counterpart developed on the cirrhotic liver 8:1 where we observe a marked predilection on the male sex (202).

NC-HCC has an unusual distribution with respect to the age of the affected individuals, which has not been observed in its cirrhotic counterpart. This distribution is usually bimodal, with a first peak in the second decade of life and a second between the sixth and seventh (262,270).

It is interesting to note that about one-third of NC-HCCs, exclusively those in the first peak of the bimodal distribution, belong to the fibrolamellar variant of hepatocellular carcinoma (FL-HCC) (271). FL-HCC is a subtype with well-defined histological and molecular characteristics, as well as typical clinical signs characterized by: the predilection to develop on a liver without chronic disease, affecting as much men as women and with a predilection for early onset, because it is develops exclusively in individuals under 40 years (200).

3.2) Molecular profile

A particular mutation profile has been described for this type of tumor, noting that there is a strong presence of insertion/deletion mutations for TP53 and AXIN1. Mutations associated with CTNNB1 have been reported lower than usually found in HCCs developed on cirrhotic liver. Likewise, the alteration of the Wnt pathway has been reported in 26% of cases, of this type of HCC (272)

Due to the clinical characteristics, such as its large size, various molecular pathways have been evaluated, such as the Hippo axis, which has shown a repression in its functioning (272). Other studies reveal that NC-HCCs show microsatellite instability (MSI) in 43% of cases. Of which, 16% corresponds to high

MSI and 27% low MSI. Interestingly high MSI has been associated with large tumor size, absence of the tumor capsule and a short time until recurrence after surgery (273).

4) Hepatocellular Carcinoma in Peru

Peru is a country located on the south of American continent, in the north-west of South America. It is naturally divided into three geographical regions: coastal, Andean Highlands, and tropical rainforest, each region with unique characteristics such as climate, culture and, above all, the socioeconomic level.

These differences are also found when making an epidemiological evaluation of the country in the last 50 years, for example: the total population has doubled in size from 1961 to 2015, the percentage of urbanization grew by 23%, there has been a decrease in the fertility rate of 4.3 in 1986 to 2.5 in 2015, a fall in poverty rates from 48.7 to 22.7% (274). However, despite some clear improvements, a frequent problem whose solution has motivated the development of new policies in the field of health is the increase in the incidence of cancer within the country.

Cancer represents a serious growing problem of public health, due to its high levels of incidence and mortality, it also causes a high social and economic impact. In this context, developing countries, such as Peru are the most affected. Peru currently allocates a 5.3 of GDP to public spending on health, a low amount compared to its continental neighbors such as Brazil or Chile, which means that the health needs of 32 million inhabitants are incompletely satisfied (275).

As an example, according to the Instituto Nacional de Enfermedades Neoplásicas (INEN) only 1 in 3 Peruvians with cancer manages to be diagnosed in time (276).

But the social and political problems of health services for the treatment of cancer have been dissected by the Lancet Oncology Commission in 2013 (277), indicating; i) the fragmentation of health services, ii) restricted health coverage,

not all oncological disease have all the treatments, iii) insufficient money to cover the necessary human and logistic resources and also a poor distribution of them and finally iv) a poor implementation of oncological records.

According to the estimated data of the 2018 – Globocan, in Peru, a total of 66 627 new cases of cancer were presented, which caused a total of 33 098 deaths (278). In Peru, without considering the therapeutic costs, cancer causes approximately the loss of 900 million dollars per year, being the main responsible: stomach, cervix, breast, leukemia, liver and lung cancers (279).

In this context, Peru began in 2011, with the development of policies whose goal was to unlock access to health services in cancer, said plan began with the construction of two national reference centers IREN-North and IREN-South located in strategic geographic points in the north and south of the country.

However, a significant change in health policy arrived in 2012, with the implementation of the PLAN ESPERANZA, with the main objective being to reduce the mortality and morbidity of patients with oncological diagnoses. For which a total of US \$ 30 million was destined for treatment coverage as well as a total of PEN147 million for the acquisition of new equipment and infrastructure (280).

In addition, the *PLAN ESPERANZA* encourages social commitment, through the promotion of beneficial behaviors for health, such as the reduction of tobacco consumption, the importance of regular medical check-ups, reduction of exposure to ultraviolet rays, responsible sexual behavior and the promotion of universal vaccination in areas of high prevalence for HBV just to name a few. This multidisciplinary approach has been well received by the general population, with scenarios showing an increase in the early detection of lung cancer, breast, colon, cervix and stomach cancers (280). However, much remains to be done concerning other neoplasms such as glioblastoma, renal carcinoma and hepatocellular carcinoma.

Liver cancer has shown a clear incidence, especially in the Latin American region, as described by Wong (281). Actually, liver cancer in Peru is the 10th most frequent neoplasm. However, it is the second cause of death by cancer nationwide (282).

Peru, like many other countries in Latin America, shares an important population characteristic. Since between 36 to 50% of its population belongs to indigenous communities. Several studies have shown that these communities are more exposed to risk factors to develop cancer. A particular case is found, for example, in the indigenous communities that belongs to the Amazonian watershed, where significant rates of HBV virus infection have been recorded (283).

Moore (283) reported that the communities of the Amazon are also over-exposed to environmental pollutants dumped into the waters of the Amazon River.

Recently Bertani *et al.* (270) developed a study in the INEN, collecting information on 1541 patients diagnosed with HCC treated between the period of 1997 - 2010 and found very specific clinical characteristics for this entity, such as:

- A bimodal distribution, two affected population groups whose average age is 44 years. Being the average age 25.5 for the group of young patients and 64.5 for the group of elderly patients. Contrary to unimodal distribution seen in conventional HCC.
- A large tumor size (15 cm on average).
- Stratospheric levels of alpha fetoprotein (greater than 10 million), not previously reported in the context of HCC disease.
- A strong relationship with hepatitis B virus infection, since most patients come from hyperendemic areas of hepatitis B.
- Absence of underlying chronic disease in the surrounding hepatic parenchyma, that is, an HCC developed on a non-cirrhotic liver.
- A pattern of geographical distribution for the youngest patients affected by this disease which is distributed mainly between the regions of andean highlands and tropical rainforest such as: Amazonas, Apurimac, Cuzco, Huanuco, Junin, Ucayali, San Martin and Loreto.

4.1) Possible causes

4.1.1) Infectious

Hepatitis B in Peru

Peru tropical rainforest is located in the east of the country, occupies 60% of the entire national territory. It is in turn divided into two regions: high forest and low forest or Amazon rainforest, the latter belonging to the watershed of the Amazon (284).

WHO estimates that the seroprevalence of HBsAg, marker of chronic infection, is between 0.5% and 3% for the South American region, with a total of about 11 million carriers (27). However, atypical models of high incidence of HBsAg are also observed in countries belonging to the Amazon watershed, with rates still higher than 8% (figure 1) (285).

Peru, because of its geographical contrasts, has different levels of prevalence depending on the region studied. There is also great variation among the different communities of the same region, for example in the city of Iquitos, located in the Peruvian jungle has a prevalence rate ranging from 2.5% for population of the city at 83% in the indigenous populations of the same region. These levels contrast diametrically with those of the coastal region, whose ranks range from 1 to 3.5% (286,287). From these Peruvian endemic areas for HBV, several studies have been conducted highlighting the strong if not exclusive presence of the F genotype know in addition for its emplications in the development of fulminant liver disease, as well as HCC (29,288)

However, studies of Peruvian indigenous populations are more alarming. Cabezas *et al.* conducted a study of 12 Amazon watersheds comprising 37 Aboriginal communities, determining that the average age of chronically infected subjects was 22.7 years (range: 1 to 94 years), previous infection rates of 59.7%, a recent infection of 1.8%; being the total of the subjects studied in this study 870.

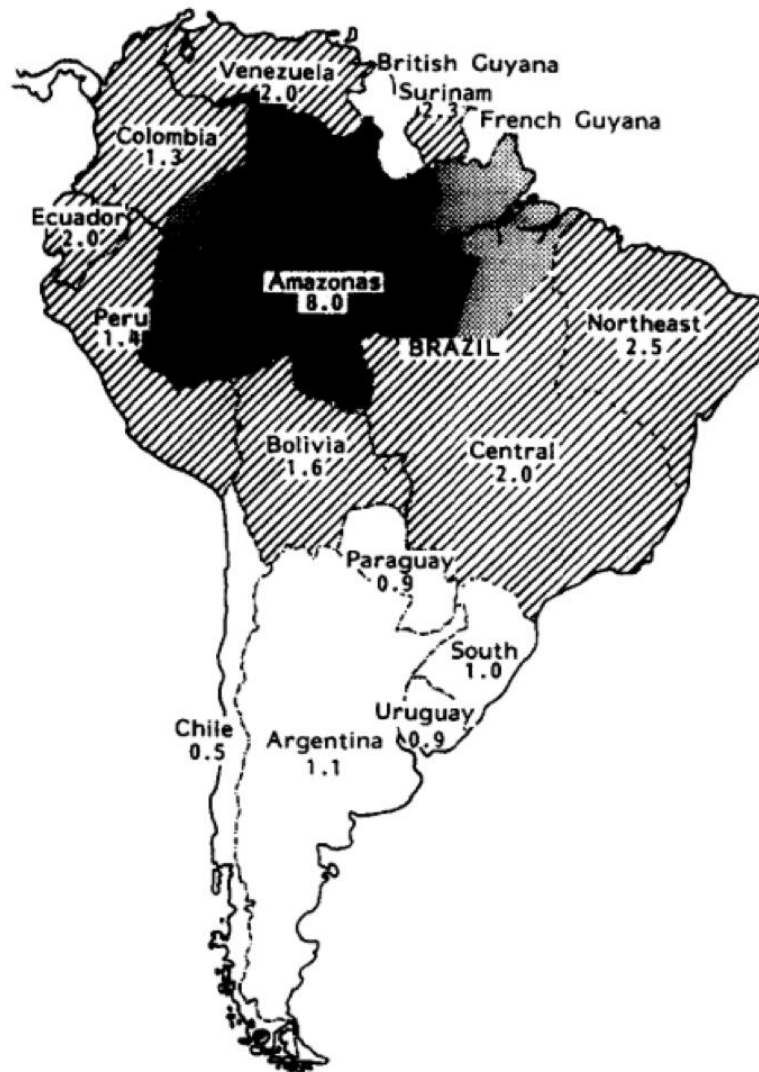

Figure 14: Prevalence of Hepatitis B infection in South America. The number represent the (%) total of population. Source: Fay. Hepatitis B in Latin America: epidemiological patterns and eradication strategy

It is worth mentioning that the rate of HBV infection has increased gradually according with age, reaching 82.5% in people over 45 years of age. (figure 15) (289).

Transmission mechanisms

Blood transfusion

The levels of blood donation in Peru correspond grossly to prevalence of the majority of the population. In hyperendemic areas (low and high forests areas), 80 to 90% of the population capable to donate present positive HBV markers (286)

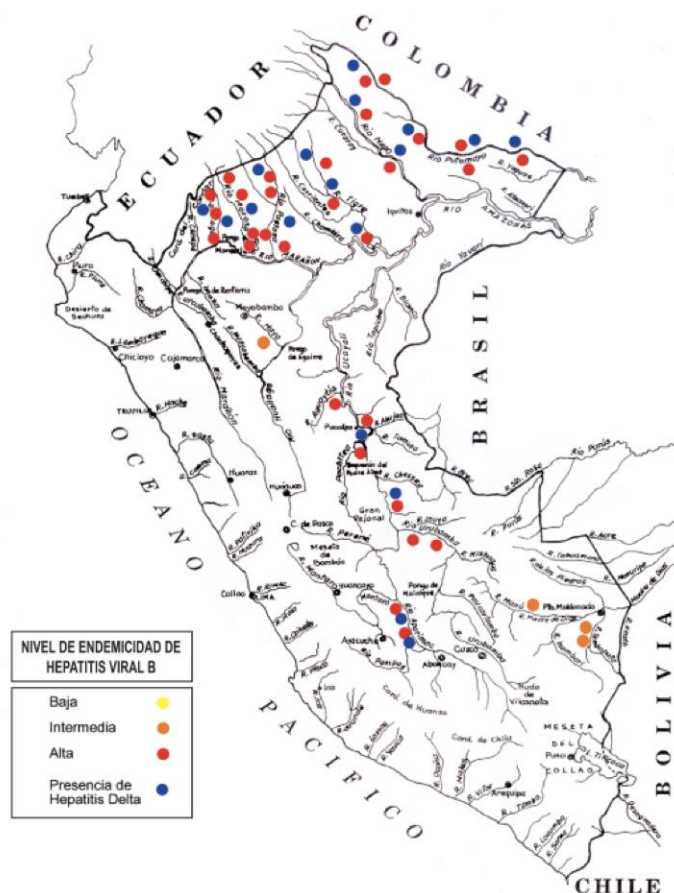


Figure 15: Endemic levels of HBV in Peru. Yellow circles represent low endemic zones, orange circle middle endemic zones, red circles high endemic zones. Blue circles represent hepatitis delta co-infection zones. From: Cabezas, Hiperendemicidad de Hepatitis Viral

Sexual transmission

The risk of infection through sexual contact is directly related to the number of sexual partners; In addition, sex workers are at risk of contracting this disease, as cited by Mayca *et al.* (290). The prevalence rates of seropositivity for HBsAg vary from region to region but remain at high levels, above 60% in most instances.

Vertical, pseudo-vertical and horizontal transmission

Vertical materno-fetal transmission is defined as a positive serology for HBsAg or HBV-DNA at 6 or 12 months of life of a child born to an infected mother (291). Besides, it is estimated that half of the world's population chronically infected by the virus has been contaminated during the perinatal period or early childhood, particularly in endemic areas (292,293). These latter routes of virus transmission do not correspond to the definition of vertical transmission

Mother-to-child transmission can occur in three ways; i) intrauterine transmission (rare) , ii) transmission during delivery ie pseudo-vertical route, iii) postpartum or perinatal transmission (291), the last being the most frequent and is not always due to the mother. It is rather a horizontal transmission through casual contacts within the household. The transmitter can be one of the arents or siblings.

In Peru, several studies have been conducted to assess the prevalence of this virus in the population of less than one year, obtaining figures below 0.1% (289). On the other hand, multicenter studies developed in Peru show a low prevalence of the "e" antigen in women with HBsAg, corroborating the low prevalence rate in children. Therefore, it is postulated that infection in high incidence areas occurs primarily in infancy in a horizontal manner (294).

Since HBV infection at an early age is correlated with an increased risk of chronic carriage and subsequent development of chronic forms of the disease, such as HCC. The risk of chronicity in children contaminated younger than 1 year of age is 70-90%, between 2 and 3 years is 40 - 70% and if it occurs between 4 and 6 years is 10 to 40% (295).

A study in Peru found a high incidence of HBV carriers in the infant population of indigenous Amazon watershed populations. In these communities, a history of HBV infection is found in up to 37.5% in children under 5 years and 44.2% among children under 10 years old. Finally, 14% of children under 5 years of age have been diagnosed with chronic infection (289).

Horizontal transmission is defined as the transmission of a virus-associated disease through non-sexual, perinatal or parenteral contact. This is a form of transmission known mainly in children under 10 years (296).

This form has been widely recognized as a means of transmitting diseases especially in endemic areas, saliva can be an important means of transmission (297). In Amazonian communities there is a habit of feeding children with food chewed by the mother, which may be an important route for transmitting the

disease. In addition, there is a strong correlation between the consumption of "masato" (a drink prepared from the pre-mastication of cassava, which is then fermented) and the chronic carrier status of HBsAg (289).

Other possible transmission routes

Studies in indigenous populations as well as military residents in parts of the Amazon show an association between acute or chronic HBV infection and the bite of the hematophagous common vampire (*Desmodus Rotondus Phyllostomidae*) (289).

Tattooing, a typical practice of Peru's indigenous cultures, is another possible postulated mechanism. However, more studies are needed to support this claim.

4.1.2) Environmental pollution

4.1.2.1) Mycotoxins

As described above, AFB1, produced by the fungus *Aspergillus flavus*, is closely related to the development of HCC due to the ability to induce mutations in the p53 gene (45).

The presence of *Aspergillus flavus*, in general, is found in tropical and subtropical regions of the world where and due to the climatic and storage conditions that fluctuate between warm and humid promote the growth of these toxin-producing fungi, being able to contaminate food products, such as cereals, nuts, spices, figs and nuts (298).

This type of pollution is found mainly in Africa and Asia. However, in Peruvian reality we find recent studies that have determined high concentrations of mycotoxins, in products of daily consumption, such as soybeans. Guerrero (299) determined that 100% of the samples analyzed in the Chincha community were contaminated with AFB1. However, it is worth mentioning that although all samples were contaminated, they did not exceed the maximum levels allowed.

Other studies have found similar results in countries such as Argentina and Guatemala (300).

4.1.2.2) Mining

Peru is a country with a great natural wealth and above all minerals. Mining has been part of the Peruvian history from its origins with the Mochica culture until its time of maximum apogee in the times of the Incas (301). Currently as a developing country, Peru is a major producer of ores (copper, 2nd in the world, silver 2nd, tin, 4th, etc).

One of the cornerstones of the Peruvian economy is based on mining extraction, which represents 15% of Peru's gross domestic product (GDP) and corresponds to 60% of the country's total exports (302).

Peruvian polymetallic wealth includes metals such as gold, silver, tin, zinc, copper, iron, bismuth, tellurium, cadmium, selenium, molybdenum, lead, arsenic and finally rare earths (303).

All these products are extracted by large corporations, but also by small producers that correspond to a percentage of mining called informal. The informal sector developed without the conditions to provide workers with the necessary protection that prevents damage to health due to exposure to toxic agents (304). We must also emphasize that 90% of formal and informal mining sites are found mainly in the Peruvian jungle and mountain regions (305).

Several studies have shown that overexposure to heavy metals has the ability to produce deleterious effects on health in general, being among all, the most serious, the ability to induce the process of carcinogenesis (306). The association with metal exposure and the increase of breast cancer has been demonstrated (307), also for lung, skin (308), prostate (309) and liver (310). In Peru, a recent study showed a high degree of contamination by lead (Pb) in the soil of villages near the mining sites of the Cerro de Pasco region (305), where we can find that

the HCC represents 3.1% of the oncological cases reported. This incidence of HCC is even higher in regions such as Apurimac (5.6%), Huanuco (5.4%), Cuzco (4.6%) and Junin (4.4%) (282).

The confluence of factors: sociocultural, geographical and economic, causes that the inhabitants of certain communities of the country are in a situation vulnerable to noxas capable of producing complex interactions among themselves, causing irreparable damage in the organs of the body associated with atypical clinical symptoms like the Peruvian NC-HCC (figure16).

As a product of the complex interaction between the various factors discussed above, we want to highlight the well-known role of metals, whose main mechanism of injury is through the generation of ROS.

The overload of metals not originated by genetic diseases, act as co-carcinogenic factors for the development of NC-HCC, this phenomenon has been reported in patients with iron overload, associated with chronic consumption of contaminated beer (75,202). The explanation that supports this hypothesis is overproduction of ROS. In controlled quantities, ROS play a role in physiological pathways, such as signal transduction and redox regulation of cell proliferation and apoptosis (311). Due to their short half-life, small size and highly diffusible nature, ROS are also excellent candidates for develop second messenger function (312).

But if one observes an increase of the steady-state ROS levels beyond the antioxidant capacity of the body, an oxidative stress becomes present, causing the oxidation of the proteins, the lipid peroxidation of the membrane and the modification nucleic acids. Several studies have reported a state of significant oxidative stress as a cause of the genesis of various disease entities, such as: atherosclerosis, cancers, arthritis, heart attack, hepatitis and liver damage, chronic inflammation, ischemia, re-perfusion injury or neurodegeneration (313,314).

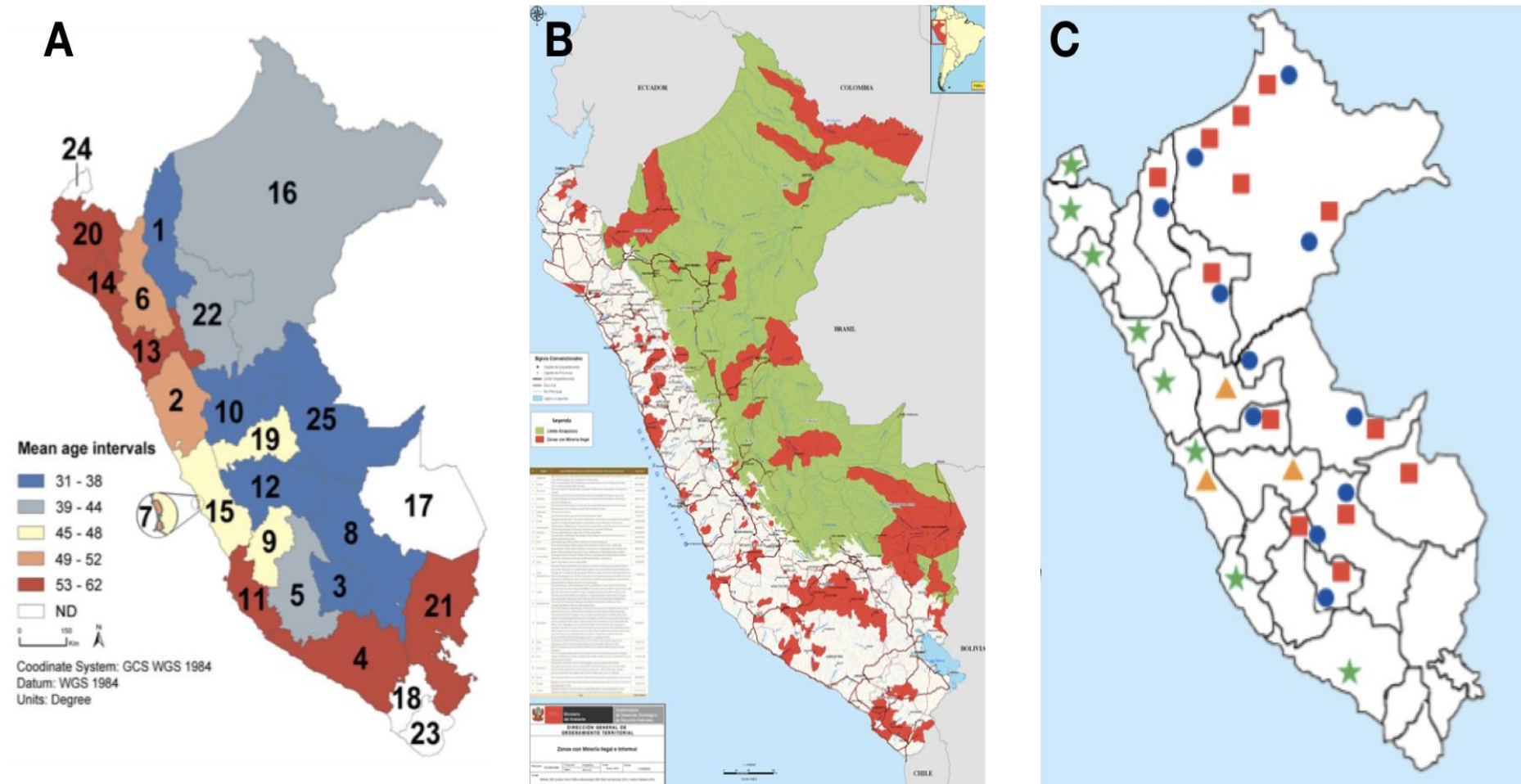
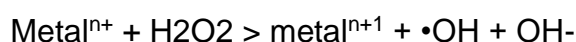

Figure 16: Peru maps. HCC-Mining-Hepatitis B

A) HCC distribution according regions in Peru, we show a particular distribution for young patients, we can observe the over-position pattern with (B) informal mining zones (in red) and (C) Hepatitis B and D distribution. Green stars means: low endemic areas HBsAg < 1%, Yellow triangles: Middle endemic areas, HBsAg 2 - 7%, Red square: High endemic areas, HBsAg > 8%. Blue points: Presence of Delta Hepatitis zones.

Metals and ROS production

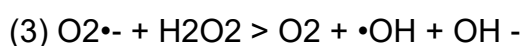
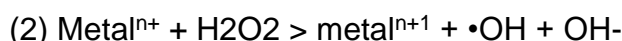
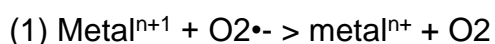
Metallic ions can produce intracellular ROS of direct and indirect forms, the Fenton reaction being the best known and studied mechanism to date. For which a transition metal and H₂O₂ are required, this reaction produces a highly toxic hydroxyl radical (\bullet OH) and an oxidized metal ion.



General scheme of Fenton reaction

The Fenton reaction occurs with metals such as iron (Fe (II)), copper (Cu), chromium (Cr (III), Cr (IV) and Cr (V)), cobalt (Co). (II)), nickel (Ni (II)) and vanadium (V (IV)), but the ability of each to generate ROS is not the same (315,316).

Another key mechanism in the induction of ROS is the Haber-Weiss reaction. In this reaction, an oxidized metal ion is reduced by O₂^{•-} and reacts with H₂O₂ to generate a radical \bullet OH (317).



General scheme of Haber-Weiss reaction

The metals involved in the Haber-Weiss reaction are: chromium (Cr (III), Cr (IV), Cr (V) and Cr (VI)), vanadium (V (IV)) and cobalt (Co (I) and Co (II)) (316). This reaction plays a particularly important role in macrophage-mediated phagocytosis processes. It has been reported that a significant amount of oxygen consumed by macrophages is converted to O₂^{•-} (318). It is worth noting that the conversion of O₂^{•-} to H₂O₂ is very slow to be considered physiologically important unless a metal acts as a catalyst. This presents a significant risk because, if the metal is used to catalyze the reaction, large amounts of OH radicals can be obtained from small amounts of metal.

A third mechanism by which metals can generate ROS is the direct interaction with cellular molecules, to generate free radicals or activate signaling pathways. For example, the reaction between chromium (IV) and cysteine generates thiol radicals (RSH). RSH can cause direct cell damage or react with other molecules to generate $O_2^{\bullet-}$.

In addition, flavoenzymes, glutathione reductase, lipoyl dehydrogenase and ferroxine-NADP reductase can reduce chromate or vanadate to generate vanadium and chromium intermediates. During this process, cellular oxygen is reduced to $O_2^{\bullet-}$ using NADPH as a cofactor (317). In addition, metals such as arsenic, at low concentrations, have an activating effect on NADH oxidase producing superoxide radicals. It also exerts a factor on NADPH oxidase to produce high concentrations of superoxide (319).

Metals responsible for the production of ROS

Arsenic

Arsenic (As) is an environmental pollutant considered by IARC in group 1 carcinogens for humans. It is commonly found in many natural resources such as water, land, air and even food (320). Arsenic exists mainly in two forms: trivalent arsenite [As (III)] and pentavalent arsenate [As (V)]. The trivalent form is the most toxic and reacts with the thiol groups of the proteins, while the pentavalent form owes its toxicity to the reduction which suffers in the tetravalent form (321).

Chronic exposure to arsenic has been correlated with the development of various neoplasms of the kidneys, lungs, liver and prostate, as well as other non-oncological diseases such as diabetes, coronary heart disease, of reproduction and neuropathies (322).

Arsenic can induce oxidative stress by alternating oxidation states in metals such as Fe, notably because of its interaction with antioxidants, which produces an

increase in inflammation, causing an increase in the accumulation free radicals in the cell. The main arsenic-induced ROS are: superoxide ($O_2^{\bullet-}$), hydroxyl ($\bullet OH$), hydrogen peroxide (H_2O_2), singlet oxygen (1O_2) and lastly the peroxide radical (323).

The induction of oxidative stress by Arsenic is the most accepted mechanism as a cause of carcinogenesis, the main determinant of DNA damage induced by arsenic-induced oxidative stress is always the valence state of the arsenic species. Intermediate metabolites of Arsenic form free radicals that interact directly with cellular macromolecules (324).

DNA damage caused by Arsenic includes modifications such as aneuploidy, micronucleus formation, chromosomal aberrations, deletion mutations, and sister chromatid exchange (325). In addition, an association between arsenic concentrations and expression of the DNA damage marker, 8-hydroxydesoxyguanosine (8-OHdG), was found (326). It is also known that the increase in ROS due to As is inversely related to a decrease in the ratio between glutathione antioxidant enzymes (GSH)/glutathione disulfide (GSSG) (327).

Arsenic is also known to affect transcription factors involved in the activation or inhibition of cell proliferation processes differently. For example, activation of NF- κ B has been reported at low concentrations of Arsenic and is associated with activation of many anti-apoptotic genes, induction of proliferation, and onset or acceleration of tumorigenesis (328). We can also find an indirect interaction of Arsenic with genes products such as p53, by regulating the expression of its regulators such as the MDM2 protein, leading the cell to the replication of damaged (due to Arsenic) DNA (329).

In addition, Arsenic can potentiate the carcinogenic effects of other substances, through the inhibition of DNA ligase (330). Recent studies have shown that the ROS generated by Arsenic have a decremental effect in basal and total liver Piruvato dehydrogenase (PDH) activities. This enzyme plays an important role in

carbohydrate metabolism and whose dysfunction can generate alterations within this metabolic pathway (331,332).

There is a strong association between Arsenic and HCC development (326,333,334). Animal models show that chronic exposure to Arsenic affects ROS-mediated antioxidant levels and lipid peroxidation prior to the onset of histomorphologic lesions and liver fibrosis (335). Fetal exposure to arsenic has been shown to cause tumors in various organs, including the liver (336).

Cadmium

Cadmium (Cd) is an abundant, non-essential element that accumulates continuously in the environment as a result of industrial activities. Cadmium has a very long elimination half-life of about 20 to 35 years in human body due to the lack of excretion system for this element. This situation causes its accumulation and concomitant toxicity to cells and tissues. Cd accumulates mainly in the lungs, liver, pancreas, kidneys (337,338)

Cadmium is a bivalent cation that cannot directly generate free radicals. However, the production of ROS after exposure to cadmium has been reported in several studies (339–341). It has been shown that Cd increases the concentration of metals such as Fe and Cu, probably because of its replacement in several cytoplasmic and membrane proteins, thus increasing the cellular availability of metals (342). These "free" metals directly increase the production of \bullet OH and $O_2\text{-}\bullet$ ions thanks to their participation in the Fenton and Haber-Weiss reactions (315).

Superoxide dismutase (SOD) is a metalloenzyme that could be affected by Cd as shown by Yalin (343). In addition, because of the existence of different isoforms of SOD, each of them may present a different response to aggression of Cd, it is thought that this response is due to the metal cofactor of each of them. For example, high levels of Cd inhibit Cu/ZnSOD gene expression, whereas mitochondrial MnSOD levels remain unchanged (344). Enzymes such as

catalases (CAT), whose function is to catalyze the degradation of H₂O₂ to H₂O and divalent O₂, are also modified after exposure to Cd (345).

Besides, it is also known that glutathione peroxidase (GSH-Px) exhibits behaviors depending on the time of exposure to cadmium. For example, its activity is increased in cases of acute exposure and decreased in cases of chronic exposure, a possible mechanism that would explain this behavior would be the depletion of selenium (Se) and the decrease of the Cd-Se-cys complex of which the function is to form the core of the active site of GSH-Px (346).

Thiols (SH) are vital agents in redox detection and regulation. During Cd stress, thiols play a major role in the mobilization and detoxification of Cd through the formation of Cd-thiol complexes within the cell. Like that SH reduce the oxidative stress induced by Cd (347,348).

The failure of regulation of gene expression is considered an important factor in a multi-step model of chemical carcinogenesis. In processes related to cadmium carcinogenesis, we find; i) modification of the immediate response genes (IEG). IEGs are proto-oncogenes that code for transcription factors and play an important role in chemical carcinogenesis by influencing the expression of target genes, including those controlling growth and cell division. These genes are often overexpressed in tumors. The most studied IEGs are c-fos, c-jun and c-myc (349,350). The overexpression of Cd-induced IEG is a mitogenic growth signal that stimulates cell proliferation and is considered a major player at the promotion stage in a multistage carcinogenesis model. ii) Cd also affects induction of expression in several stress response genes, such as those encoding MT synthesis, genes that encode heat shock proteins (HSPs), genes involved in stress response, and genes involved in glutathione synthesis (341).

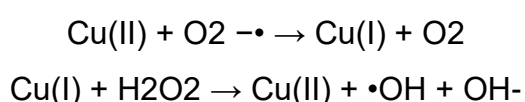
Finally, iii) It is also known that E-cadherin, a transmembrane Ca (II) binding glycoprotein, which plays an important role in cell adhesion, can bind Cd to Ca (II) binding regions, by changing the conformation of the glycoprotein. Interruption of cell-cell adhesion caused by Cd binding to replace Ca in E-cadherin may play an important role in tumor induction and promotion (351).

Copper

Copper (Cu) is an essential trace element, Cu (I) and Cu (II) being the primary forms found in living organisms. Cu is a cofactor for many enzymes, such as cytochrome c oxidase, ascorbate oxidase or SOD, all involved in cellular redox mechanisms (352). 40% of Cu resulting from ingestion is absorbed in the small intestine (about 2 mg / day), another small percentage in the stomach. Copper is mainly absorbed by the so-called amino acid transport system, mainly by histidine, methionine and cysteine. The absorbed copper binds to the albumin to be transported in the blood vessels or stored in the liver. Copper is imported into hepatocytes via the high-affinity copper transporter (hCTR1) located in the cell membrane (353).

Once inside the cell, the copper is transferred into; i) a metallothionein pool, or ii) into mitochondria for incorporation into cytochrome c oxidase, or iii) to be supplied to Cu, Zn -SOD emerge. or iv) transported to ATP-ase P-type Wilson disease in the trans-golgi network for subsequent incorporation into ceruloplasmin (CP), which contains 6 copper atoms in cuprous and cupric states (354–356). CP contains 95% of all available copper in the serum. The main route of excretion of copper stored in the liver is via the bile ducts (approximately 80%).

Copper can induce oxidative stress by two mechanisms; i) It can directly catalyze the formation of ROS by a Fenton type reaction. ii) Exposure to high levels of copper significantly decreases GSH's reserves (357). Cu (II) cupric ion, in the presence of the superoxide radical and / or biological reducers such as ascorbic acid or GSH, can be reduced to cuprous Cu (I) ion, capable of catalyzing the formation of reactive hydroxyl radicals (\bullet OH) by the decomposition of hydrogen peroxide (H₂O₂) thanks to the reaction of Fenton (81,358).



Copper is also able to cause breaks in DNA chains by base oxidation, thanks to the production of ROS. Copper in the two oxidation states (cupric or cuprous) is

more active than iron in promoting DNA breakage induced by the genotoxic metabolite of benzene, 1,2,4-benzenetriol. It has also been shown that Cu results in dose-dependent modifications of DNA oligonucleotide conformation(81,359).

Glutathione is a substrate for several enzymes that removes ROS and is also a potent cellular antioxidant. Glutathione can eliminate the toxicity of copper by chelating it directly and keeping it in a reduced state, making it unavailable for the redox cycle. However, an interruption of Cu homeostasis, as in the case of overload, helps to alter the redox balance towards a more oxidative environment, which reduces glutathione levels (357). This leads to increase the cytotoxic effect of ROS and to allow greater catalytic activity of Cu, which produces higher levels of ROS.

The role of ROS in the ability of copper to activate MAPK signaling pathways has already been demonstrated through the use of PKC, p38, ERK and JNK inhibitors. The results obtained by adjusting the level of intracellular copper-induced oxidative stress showed altered levels of protein binding to AP-1 and ARE. This clearly demonstrates a role in the activation of copper-induced MAPK signaling pathways induced by ROS (360).

Copper-induced ROS formation can cause lipid peroxidation, which in turn leads to increased levels of 4-HNE signaling molecule. 4-HNE acts as a second messenger and can increase levels of phosphorylation and activation of the c-Jun kinase/stress-activated protein kinase as well as p38 pathways. Similarly, the production of 4-HNE is correlated with an increase in AP-1 activity and the expression of several genes, including type I collagen, transforming growth factor B1, and gamma-glutamylcysteine synthetase is also able to increase c-Jun expression and enable PKC and JNK/SAPK (360).

Lead

Lead is a persistent metal and, because of its unusual physical and chemical properties, is used in a variety of industrial applications. Lead is a toxic metal for humans and animals. Due to its durability, it is present for a long time in

environments such as water, soil, dust as well as in manufactured products containing lead (361). Due to its toxicity, it has been established that concentrations of 10 ug/dl Pb (equivalent to 0.48 mmol/L) can cause cancer, cardiovascular diseases, neurological disorders, cognitive disorders, hypertension (362).

Lead exposure occurs mainly through the respiratory and gastrointestinal tract. About 30 to 40% of the inhaled lead is absorbed into the blood (363). Gastrointestinal absorption (GI) varies with nutritional status and age. As a result, GI absorption of lead is greater during childhood; babies can absorb up to 50% of the lead in food, water, dust or contaminated soil, while adults absorb only 10 to 15%. Iron is thought to impair the absorption of lead in the intestine, whereas iron deficiency is associated with increased blood lead levels in children (364).

In adults, about 80 to 95% of the stored lead is in the bone, while in children about 70% is stored in the bone, resulting in a greater amount of lead in the soft tissues of the child. comparison with adults. Lead is stored in bone for long periods, with an estimated half-life of 20-30 years (363).

There are two mechanisms by which Pb generates lesions; i) the generation of ROS, such as hydrogen peroxides, singlet oxygen and hydroperoxides, and also ii) the depletion of antioxidant stores. One of the effects of lead exposure is at the level of GSH metabolism. The Sulfidril-GSH complex is directly linked to metals having affinity or sulfhydryl groups, such as mercury, arsenic and lead. As a side effect to this union, the GSH molecule loses its availability to participate as an antioxidant in hepatic metabolism (365).

Pb also binds to enzymes with functional sulfhydryl groups, transforming them, like GSH in nonfunctional enzymes, breaking the antioxidant equilibrium. Two enzymes with sulfhydryl functions were particularly affected in cases of Pb poisoning, delta-aminolevulinic acid dehydrogenase (ALAD) and glutathione reductase (GR) (366–368).

The ALAD enzyme is the most affected by lead, because of its interaction with lead, which leads to an increase in the substrate ALA (aminolevulinic acid), which generates large amounts of hydrogen peroxide and superoxide radicals. ALA also becomes oxidized to 4,5-dioxovaleric acid. The generation of this potentially carcinogenic compound has been the proposed mechanism by which lead induces DNA damage and triggers the genesis of the tumor (369).

In addition, GR is an enzyme responsible for the recycling of oxidized glutathione (GSSG) to reduce it to GSH. Lead has been shown to have direct interference in this cycle, resulting in low levels of GSH. A similar trend has been observed in other enzymes such as catalase, SOD and glutathione peroxidase, thus providing insight into the deleterious effects of Pb (370).

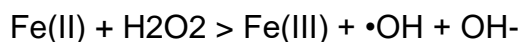In blood, it is known that erythrocytes have a strong affinity for lead, since they bind up to 99% of Pb in the blood. Lead has a destabilizing effect on cell membranes and, in red blood cells, causes a decrease in the fluidity of the cell membrane and increases the rate of erythrocyte hemolysis. Hemolysis appears to be the end result of lipid peroxidation generated by ROS in the red blood cell membrane (371).

Iron

Due to its ability to participate in redox reactions, iron is a powerful catalyst for the formation of hydroxyl radicals from reduced forms of O₂. Under normal conditions, mitochondria, microsomes and peroxisomes produce significant amounts of ROS species. The cellular concentration of ROS remains well regulated by activities that convert ROS into non-toxic sub-products. In addition to cellular and plasma antioxidants, the modulation of iron availability is the main mechanism to maintain ROS levels under strict control (372).

Iron overload results in the generation of toxic hydroxyl radicals, as has been demonstrated by Kadiiska (373). Several mechanisms may explain the subsequent loss of activity of the respiratory chain enzymes in cells exposed to iron overload.

The direct binding of Fe (II) to a metal binding site in the respiratory enzyme and its reaction with H₂O₂, by the Fenton reaction, produces a highly toxic hydroxyl radical (•OH) and an oxidized metal ion.



General scheme of "iron" Fenton reaction

This leads to the conversion of some amino acid residues into carbonyl derivatives, in addition to the loss of catalytic activity and greater susceptibility to proteolytic degradation (374). A vicious circle can also be established due to the oxidative inactivation of the enzymes involved in the mitochondrial respiratory chain where the loss of enzymatic activity can lead to an incomplete reduction of molecular oxygen and to a greater formation of free radicals.

Free radicals can interact with the lipid components of the mitochondrial membrane, such as cardiolipin, which are particularly rich in polyunsaturated fatty acids and, therefore, very susceptible to peroxidative damage, which would produce mitochondrial damage at the level of the respiratory chain (375).

The peroxidation of polyunsaturated fatty acids results in the formation of highly reactive aldehydes, such as malonyldialdehyde and 4-hydroxynonenal. These reactive aldehydes form covalent bonds with proteins or protein adducts (376). They mainly involve the amino group of the lysine residues and the sulfhydryl groups, which results in an altered enzymatic activity.

The increase in lipid peroxidation (LPO) apparently contributes to hepatocarcinogenesis in cases of iron overload (377,378).

Oxidative stress leads to LPO of unsaturated fatty acids in cell membranes and organelles. Obtaining as a result chain breaks in fatty acids with the insertion of hydrophobic groups and cis-trans isomerization. Which causes the production of cytotoxic sub-products such as malondialdehyde (MDA), thiobarbituric reactive substances and 4-HNE (379). In addition, LPO can also occur through the

autooxidation of unsaturated lipids by free radicals, the lipoxygenase pathway, or the oxidation of unsaturated lipids by non-heme iron enzymes, catalyzing the dioxygenation of polyunsaturated fatty acids.

In addition to participating in the initial and propagation steps of LPO, it is believed that iron is involved in the cleavage of lipid hydroperoxides, producing biogenic aldehydes that interact with DNA to form exocyclic products. The cytotoxic aldehydic byproducts and reagents of the LPO affect cell function and protein synthesis(76,380).

In addition, LPO products, such as 4-HNE, MDA and acrolein, are capable of diffusing from their production sites to more distant sites within the cell to interact with DNA nucleophiles, proteins or proteins. Both MDA and 4-HNE are cytotoxic and genotoxic and are involved in carcinogenesis. 4-HNE, for example, can be metabolized further into an epoxide that can interact with DNA to form exocyclic enteno-guanine, adenine and cytosine adducts.

Possible mechanisms of action include LPO and poor DNA repair. Experimental evidence in animals has shown that cyclin D1 is overexpressed in the liver overloaded with iron. Probably contributing to cell cycle abnormalities and could play a role in iron-induced hepatocarcinogenesis (381).

Zinc

Zinc (Zn) is an essential trace element for humans, it is present in all organs and tissues of the body in the form of complexes, being the only metal that acts as a cofactor of almost 300 enzymes (382), besides being an important part in 70 of them which are involved in the cellular metabolism of lipids, carbohydrates and proteins. In addition, Zn plays an important role in the metabolism of glucose and is a necessary component for the proper functioning of the immune system (383). On the other hand, its deficiency generates disorders such as growth disorder, hypogonads, loss of appetite, dermatitis, poor wound healing. The main cause of

the deficits of Zn are associated a diminished intake, an over-ingestion of phytates, chronic diseases or an over-ingestion of Fe and Cu.

Zinc is an inert metal from the redox point of view, therefore it does not participate in the oxidation-reduction reactions, unlike the other metals previously seen. However, Zn plays an important role as an antioxidant with acute and chronic effects (341). While long-term chronic exposure of an organism to zinc results in an improved synthesis of metallothioneins, chronic zinc deprivation generally results in greater sensitivity to some oxidative stress (384).

The acute effect of zinc function as an antioxidant involves two distinct mechanisms; i) protection of sulfhydryl groups of proteins and enzymes against free radical attack, or oxidation, and ii) reduction of OH formation from of H₂O₂ by preventing the formation of free radicals or also, the antagonism of redox-active transition metals, such as iron and copper (385).

The protection of the sulfhydryl groups, one of the mechanisms that Zn plays as an antioxidant, comprises "isolating" the sulfhydryl groups of certain oxidation enzymes that could be toxic to them (386). The reduction of the formation of free radicals implies the antagonism of Zn in redox active transition metals. It is well established that in the process of protein oxidation, as well as oxidative modifications occur predominantly around the metal binding site (374).

The beneficial effects of long-term zinc administration can be linked to the induction of some other species that serve as final antioxidants, with MT being the most effective. Recent studies have proposed that MTs represent a connection between cellular Zn and the redox state of the cell. Under conditions of high oxidative stress, for example, changes in the redox state cause the release of zinc from metallothionein as a result of the sulfide / disulfide exchange, thus mitigating the effects caused by ROS (384,387).

Zn deficiency has been associated with higher than normal levels of tissue oxidative damage, including increased lipids (388), the oxidation of proteins and

DNA (389). Experiments in animals confirmed that chronic or prolonged Zn deprivation makes an organism more susceptible to injury induced by oxidative stress (390).

The levels of zinc in the serum and malignant tissues of patients with various types of cancer are abnormal, which supports the participation of zinc in the development of cancer. Studies have shown that serum zinc levels are reduced in patients with breast cancer, gallbladder, lung, colon, head and neck and bronchi (391).

Interestingly, while serum zinc levels are low in the context of most cancers, the tumor tissue in breast and lung cancer has elevated levels of zinc compared to the corresponding normal tissues. In addition, the peripheral tissue surrounding the hepatic, renal and pulmonary metastases have a higher zinc content than the corresponding normal tissue or the tumor tissue itself. It has been widely recognized that ZIP, cellular zinc importers are up-regulated in most tumoral cells, indicating an increase in Zn concentrations in most tumors (392).

The expression levels of Zn transporters in human tumors correlate with their malignancy, suggesting that the alteration of intracellular Zn homeostasis may contribute to the severity of the cancer. Specific Zn importers are upregulated in most types of cancer, perhaps allowing tumor cells to escape apoptosis and activate cell survival through autophagic processes (393).

Selenium

Selenium (Se) is an essential trace element with a narrow range between toxic and therapeutic doses, therefore, its activity is highly dependent on the dose (394). For example, at very high doses the toxicity is caused in animals that produce conditions such as "blind staggering" and "alkaline disease." A correct doses, animal testing has shown that Se is a protective factor against liver necrosis (395). And its decline has been linked to an increased risk of developing colon, prostate and lung cancer (396).

There are two amino acids that use Se for its conformation; i) selenomethionine (Se-meth/SeM) and ii) selenocysteine (Se-cyst/SeC). These amino acids, in particular Se-meth, are the predominant form of Se in food. The inorganic Se (selenite and selenate with valences of +4 and +6 respectively) is generally included only in the diet through supplements. Most of the biological functions of Se are carried out through selenoproteins that contain Se-cyst, the so-called amino acid number 21 (397).

It has been known mainly in recent years to be due to its alleged preventive properties against some types of cancer, mainly due to its antioxidant action. Selenium's ability to reduce the incidence of spontaneous cancer induced by carcinogens has been widely investigated over the past 20 years, in both animal and human models, in most organs and against a wide range of forms of cancer. The main mechanism by which Se acts as an antineoplastic agent is through the Selenoproteins. Currently it is known that there are 25 "selenoproteins" in humans, but the function of many of them is still unknown (398).

The relationship between selenoproteins and the risk of cancer was initially based on their antioxidant activities, such as the enzymes like glutathione peroxidase (Gpx), thioredoxin reductases (TrxR) iodothyronine deionidase (Dio), methionine sulfoxide reductase (Msr), selenoproteins of endoplasmic reticulum (SelK, Sel15, SelM, SelN, SelS) (399) and selenoprotein P (SelP), which provide antioxidant protection against ROS, which are responsible for inducing persistent oxidative stress states contributing to the expression of the malignant phenotype of cancer cells by genetic changes in oncogenes and tumor suppressor genes (400).

In the table 4 we can find the main Se-proteins that play a role in human carcinogenesis. It is known that Se, regardless of its form, alters the expression of several genes in a way that may explain the prevention of cancer. It can regulate genes related to phase II detoxification enzymes, in addition to certain genes that encode Se-binding proteins and apoptotic genes, while downregulating genes related to phase I activating enzymes and cell proliferation.

<i>Selenoprotein</i>	<i>Gene</i>	<i>Transcript expression</i>	<i>Associated cancer type</i>
Glutathione peroxidase 1 (Gpx1)	GPX1	Ubiquitous in cytosol and mitochondria	Bladder, breast, prostate, lung
Glutathione peroxidase 2 (Gpx2)	GPX2	Gastrointestinal tract	Colorectal adenoma
Selenoprotein P (SeP)	SEPP1	Ubiquitous predominant in liver	Colorectal adenoma, prostate
Selenoprotein 15 (Sep15)	SEP15	Prostate, thyroid, parathyroid, liver, brain and kidney	Breast, head and neck lung
Thioredoxin reductase	TXNRD1	Ubiquitous	Numerous

Table 4: Selenoproteins and human carcinogenesis. From: Brozmanová, Selenium: a double-edged sword for defense and offence in cancer.

Phase I activating enzymes include members of the cytochrome P450 system responsible for converting chemical carcinogens into reactive adducts that can attack DNA. It has been reported that regardless of the type of tissue, the expression of CYCLIN A, CYCLIN D, CDC25A, CDK4, PCNA and E2F genes is inhibited, whereas it induces the expression of P19, P21, P53, GST, SOD, NQO1, GADD153 and certain CASPASAS (401).

Effects on DNA repair

It is known that around 10,000 DNA lesions arise in a cell every day (402). Therefore, a general ability to repair DNA seems to be one of the key determinants of cancer predisposition. It should be noted that the cells are equipped with a range of DNA repair systems to maintain the integrity of the genome and the human population shows considerable variability in their ability to repair DNA (400). It has also been shown that SeMet has the potential to activate the p53 tumor suppressor protein by a redox mechanism (403).

Accordingly, it was shown that DNA damage and the repair response induced by pretreatment with SeMet in UV-irradiated mouse embryo fibroblasts are dependent on p53. It has been shown that it offers beneficial properties by decreasing oxidative DNA damage and decreasing the adduct formation of highly mutagenic 8-hydroxy-2-deoxyguanosine (8-oxodG) (404). An additional link has been demonstrated between Se and the effectiveness of DNA repair in relation

to the BRCA1 gene product that plays a role in the maintenance of genome integrity and repair of double-strand break of the DNA (405).

Toxic effects of Selenium

It was found that the Se can induce DNA damage (406), by producing oxidative stress, increasing lipid peroxidation, generating neurotoxicity in mice and not providing protection against adverse actions induced by other compounds such as arsenic (407–409). However, the aforementioned effects depend on the level of Se and the chemical form in which it is found.

Tests have been conducted to determine the ability of selenium compounds to induce chromosomal aberrations in cultured human leukocytes, all showed a chromosome rupture activity, being significantly higher in compounds with fewer amounts of valencies (410). So inorganic Se compounds like sodium selenite and sodium selenate increase the amount of aberrations in different cell lines, likewise these compounds have the ability to induce exchanges of sister chromatids(411). Prooxidant responses of Se compounds have also been reported, it has been shown that selenite induces oxidative stress and apoptosis, these effects were significantly attenuated by superoxide dismutase, catalase and deferoxamine (412).

The effect of Se alone or in combination with other compounds is able to exert a negative effect on cell growth and proliferation, it has been shown that sodium selenite inhibits growth of hepatoma cells, this response follows a dose-dependent mechanism, obtaining the opposite effect when stopping the administration (413).

1		Atomic #																2																																																																																																																																																																																																																																																																																																																																															
1		Name																2																																																																																																																																																																																																																																																																																																																																															
1		Symbol																2																																																																																																																																																																																																																																																																																																																																															
1		Atomic Mass																2																																																																																																																																																																																																																																																																																																																																															
1	H	Hydrogen	1.00794	2	He	Helium	4.002602	3	Li	Lithium	6.941	4	Be	Beryllium	9.012182	5	B	Boron	10.811	6	C	Carbon	12.0107	7	N	Nitrogen	14.0067	8	O	Oxygen	15.9994	9	F	Fluorine	18.9984032	10	Ne	Neon	20.1797	11	Na	Sodium	22.98976928	12	Mg	Magnesium	24.3050	13	Al	Aluminium	26.9815386	14	Si	Silicon	28.0855	15	P	Phosphorus	30.973762	16	S	Sulfur	32.065	17	Cl	Chlorine	35.453	18	Ar	Argon	39.948	19	K	Potassium	39.0983	20	Ca	Calcium	40.078	21	Sc	Scandium	44.955912	22	Ti	Titanium	47.867	23	V	Vanadium	50.9415	24	Cr	Chromium	51.9961	25	Mn	Manganese	54.938045	26	Fe	Iron	55.845	27	Co	Cobalt	58.933195	28	Ni	Nickel	58.6934	29	Cu	Copper	63.546	30	Zn	Zinc	65.38	31	Ga	Gallium	69.723	32	Ge	Germanium	72.64	33	As	Arsenic	74.92160	34	Se	Selenium	78.96	35	Br	Bromine	79.904	36	Kr	Krypton	83.798	37	Rb	Rubidium	85.4678	38	Sr	Strontium	87.62	39	Y	Yttrium	88.90585	40	Zr	Zirconium	91.224	41	Nb	Niobium	92.90638	42	Mo	Molybdenum	95.96	43	Tc	Technetium	(97.9072)	44	Ru	Ruthenium	101.07	45	Rh	Rhodium	102.90550	46	Pd	Palladium	106.42	47	Ag	Silver	107.8682	48	Cd	Cadmium	112.411	49	In	Indium	114.818	50	Sn	Tin	118.710	51	Sb	Antimony	121.760	52	Te	Tellurium	127.60	53	I	Iodine	126.90447	54	Xe	Xenon	131.293	55	Cs	Caesium	132.9054519	56	Ba	Barium	137.327	57-71	72	Hf	Hafnium	178.49	73	Ta	Tantalum	180.94788	74	W	Tungsten	183.84	75	Re	Rhenium	186.207	76	Os	Osmium	190.23	77	Ir	Iridium	192.217	78	Pt	Platinum	195.084	79	Au	Gold	196.966569	80	Hg	Mercury	200.59	81	Tl	Thallium	204.3833	82	Pb	Lead	207.2	83	Bi	Bismuth	208.98040	84	Po	Polonium	(209.9824)	85	At	Astatine	(209.9871)	86	Rn	Radon	(222.0176)	87	Fr	Francium	(223)	88	Ra	Radium	(226)	89-103	104	Rf	Rutherfordium	(261)	105	Db	Dubnium	(262)	106	Sg	Seaborgium	(266)	107	Bh	Bohrium	(264)	108	Hs	Hassium	(277)	109	Mt	Mitnium	(268)	110	Ds	Darmstadtium	(271)	111	Rg	Roentgenium	(272)	112	Uub	Ununbium	(285)	113	Uut	Ununtrium	(284)	114	Uuq	Ununquadium	(289)	115	Uup	Ununpentium	(288)	116	Uuh	Ununhexium	(292)	117	Uus	Ununseptium	(289)	118	Uuo	Ununoctium	(294)

For elements with no stable isotopes, the mass number of the isotope with the longest half-life is in parentheses.

Design and Interface Copyright © 1997 Michael Dayah (michael@dayah.com). <http://www.ptable.com/>



57	La	Lanthanum	138.90547	58	Ce	Cerium	140.116	59	Pr	Praseodymium	140.90785	60	Nd	Neodymium	144.242	61	Pm	Promethium	(145)	62	Sm	Samarium	150.36	63	Eu	Europium	151.964	64	Gd	Gadolinium	157.25	65	Tb	Terbium	158.92535	66	Dy	Dysprosium	162.500	67	Ho	Holmium	164.93032	68	Er	Erbium	167.259	69	Tm	Thulium	168.93421	70	Yb	Ytterbium	173.054	71	Lu	Lutetium	174.9668	89	Ac	Actinium	(227)	90	Th	Thorium	232.03806	91	Pa	Protactinium	231.03688	92	U	Uranium	238.02891	93	Np	Neptunium	(237)	94	Pu	Plutonium	(244)	95	Am	Americium	(243)	96	Cm	Curium	(247)	97	Bk	Berkelium	(247)	98	Cf	Californium	(251)	99	Es	Einsteinium	(252)	100	Fm	Fermium	(257)	101	Md	Mendelevium	(258)	102	No	Nobelium	(259)	103	Lr	Lawrencium	(262)
----	----	-----------	-----------	----	----	--------	---------	----	----	--------------	-----------	----	----	-----------	---------	----	----	------------	-------	----	----	----------	--------	----	----	----------	---------	----	----	------------	--------	----	----	---------	-----------	----	----	------------	---------	----	----	---------	-----------	----	----	--------	---------	----	----	---------	-----------	----	----	-----------	---------	----	----	----------	----------	----	----	----------	-------	----	----	---------	-----------	----	----	--------------	-----------	----	---	---------	-----------	----	----	-----------	-------	----	----	-----------	-------	----	----	-----------	-------	----	----	--------	-------	----	----	-----------	-------	----	----	-------------	-------	----	----	-------------	-------	-----	----	---------	-------	-----	----	-------------	-------	-----	----	----------	-------	-----	----	------------	-------

Figure 17: Periodic table of elements.

The elements in red square are considered as harmful for human health. Elements in blue square can become harmful dose-depending

II) Work objectives

NC-HCC represents a small proportion of HCC cases worldwide, due to their poor presentation. However, recent studies have shown that Peruvian patients present almost exclusively this hepatic neoplasm.

In light of the question arises: what may be the possible factors that lead to this outcome? an initial response has been the strong presence of the HBV; however, we must also consider the particularities of the socio-cultural concept of the Peruvian population which is exposed to various pollutants such as those produced by mining.

Therefore, we have decided to develop a study that allows us to better understand and characterize the phenotype of this pathology, as well as evaluate the role of heavy metals in the disease process.

Thus, we have chosen two cohorts, one Peruvian and one French to develop our analysis, considering the diversity of characteristics between both, we hope to represent in the most faithful way possible the true role of heavy metals in the development or clinical presentation of the NC-HCC

We have considered it pertinent to separate our main objective in three specific objectives:

- a) Description of the phenotype of the non-tumor liver of patients with NC-HCC.
- b) Description of the tumor phenotype of patients with NC-HCC.
- c) Analyze the relationship between environmental exposure to heavy metals in two cohorts and the clinical manifestations of the disease as well as in survival.

1) Section 1

1.1) Description of the phenotype of the non-tumor liver of patients with NC- HCC

In 2013, a study published by Bertani *et al* (270). referred to a particular HCC feature in Peruvian patients. Peruvian HCC develops on a liver without the presence of underlying chronic disease, that is, free of cirrhosis.

NC-HCC is a disease described above, however its frequency does not exceed 20% in the largest series. However, the NC-HCC in the Peruvian population is the most common presentation of liver cancer, with an incidence of 80%.

Several studies have published that, there is not enough data on the non-tumor liver of these patients, as explained by tresivssani in 2010.

Therefore, we have developed a comparative study of non-tumor liver between two groups of patients. A first with the diagnosis of NC-HCC and a control group of patients without NC-HCC. Which allows us to have a better understanding of the phenomena that occur in the non-tumor liver of these patients.

Article published in Scientific Reports

“Liver clear cell foci and viral infection are associated with non-cirrhotic, non-fibrolamellar hepatocellular carcinoma in young patients from South America”

SCIENTIFIC REPORTS

OPEN

Liver clear cell foci and viral infection are associated with non-cirrhotic, non-fibrolamellar hepatocellular carcinoma in young patients from South America

Luis Cano¹, Juan Pablo Cerapio², Eloy Ruiz³, Agnès Marchio⁴, Bruno Turlin¹, Sandro Casavilca⁵, Luis Taxa⁵, Guillaume Marti⁶, Eric Deharo⁶, Pascal Pineau⁴ & Stéphane Bertani⁶

We previously described a divergent clinical and molecular presentation of hepatocellular carcinoma (HCC) in Peru. The present study aimed to further characterize the tissue features associated with this singular nosological form of HCC in order to gain insight into the natural history of the disease. We performed an exploratory analysis of the histology of both tumor and non-tumor liver (NTL) tissues from 50 Peruvian HCC patients, and compared with that of 75 individuals with non-HCC liver tumor or benign liver lesions as a baseline for NTL features. We complemented this approach with a transcriptome analysis in a subset of NTL tissue samples and also performed an ultra-sensitive hepatitis B virus (HBV) detection in liver tissues of the patients. Overall, results highlighted the low rate of liver parenchymal alterations in a young patient cohort (median age: 40 years old), despite a strong prevalence of underlying HBV infection (c. 67%). Withal, liver clear cell foci of cellular alteration were genuinely associated with HCC and appended to some changes in immune and G protein-coupled receptor gene expression ontologies. Our findings confirm the occurrence of a particular setting of HCC in South America, a region where the pathophysiology of liver cancer remains largely unexplored.

The development of hepatocellular carcinoma (HCC) is frequently associated with a chronic insult of the liver and long-lasting hepatic diseases that trigger over time the induction of a carcinogenic process^{1–3}. One of the prevailing patterns of the natural history of the disease is the string of pathophysiological events driving liver disorders, such as chronic liver inflammation and steatohepatitis, towards hepatic fibrosis⁴. Liver cirrhosis represents often the final stage of this sequence that drastically enhances the risk of developing HCC⁵. Thus, a larger number of HCC cases described hitherto are found in cirrhotic patients, whereas non-cirrhotic liver tumor presentation is more rarely described.

We previously described a peculiar clinical epidemiology of HCC among patients attending the National Cancer Institute of Peru (INEN) in Lima, Peru⁶. These HCC patients displayed notable clinical features: (i) 50% of them were relatively young with a median age below 40 years old; (ii) the large majority of the patients presented with advanced-stage HCC and large tumors exceeding 10 cm diameter; and last but not least, (iii) only 11% of HCCs occurred in the context of cirrhosis, whereas the proportion of cirrhotic patients with HCC in relevant literature chiefly ranges from 80% to 90%^{7–9}. We then consolidated this peculiar clinical presentation at the molecular genetic level with a unique mutation spectrum, in which the major class of alterations was epitomized

¹Université de Rennes 1, INSERM, CNRS, U 1241 NUMECAN, Rennes, France. ²Sorbonne Universités, UPMC Univ Paris 06, Institut Pasteur, Unité Organisation Nucléaire et Oncogénèse, Paris, France. ³Instituto Nacional de Enfermedades Neoplásicas, Departamento de Cirugía en Abdomen, Lima, Peru. ⁴Institut Pasteur, Unité Organisation Nucléaire et Oncogénèse, INSERM, U 993, Paris, France. ⁵Instituto Nacional de Enfermedades Neoplásicas, Departamento de Patología, Lima, Peru. ⁶Université de Toulouse, IRD, UPS, UMR 152 PHARMADEV, Toulouse, France. Pascal Pineau and Stéphane Bertani contributed equally to this work. Correspondence and requests for materials should be addressed to S.B. (email: stephane.bertani@ird.fr)

Received: 22 March 2018

Accepted: 19 June 2018

Published online: 02 July 2018

by genomic short indels¹⁰. This mutation spectrum is not only unprecedented for HCC, but also unique among solid tumors in which indels are a marginal subset of genetic alterations^{11,12}. Thus, while consistent detection of advanced clinical stages of HCC may reflect both the lack of screening program and a deficient access to health care in Peru, the situation encountered in the country is also most likely due to some biological features intrinsic to the natural history of the disease in the population of Peru, and more broadly from South America¹³.

As the very large majority of the Peruvian HCC patients attending INEN intriguingly do not present with full-fledged cirrhosis, we decided to determine, from a histological point of view, the detailed pathological status of the non-tumor liver (NTL) parenchyma of these patients. To address this issue, we performed a comprehensive study examining retrospectively liver sections from a cohort that complied with the HCC patient population structure from INEN in terms of gender and age distribution. In parallel, we contrasted this HCC patient population with a second cohort of Peruvian individuals with primary or secondary, non-HCC liver tumor or benign liver lesions as a baseline for NTL features in order to gain insight into the tissue alterations associated with the development of non-fibrolamellar HCC in young, non-cirrhotic individuals.

Results

Details of the study are presented extensively in the Supplementary Information file.

Clinical demography. Table 1 shows an overview of the demographical, clinical features of the 50 patients with HCC (Patient Group) included in the present study. The mean and median ages of the Patient Group were respectively 46.5 ± 20.9 and 40 years old, ranging from age 10 to age 96. The structure of the Patient Group regarding age was fitting with the bimodal distribution previously described among the patient population with HCC in Peru, displaying 52% of individuals below or equal to age 40 ($n = 26$) and 48% of individuals above age 40 ($n = 24$) (Fig. 1)^{6,10,14–16}. The ratio of males to females was 1.5 with 60% of men ($n = 30$) and 40% of women ($n = 20$), once again, in accordance with the clinical epidemiological pattern reported hitherto for HCC in Peru. Chronic infection with hepatitis B virus (HBV) was found in 52% of HCC patients ($n = 26$), whereas only one patient was recorded positive for infection with hepatitis C virus (HCV). Overall, the average level of alpha-fetoprotein (AFP) in serum was exceedingly elevated with $76,255.9 \pm 140,085.6$ ng/mL (median 5,286.5 ng/mL), which is a persistent hallmark in younger Peruvian HCC patients⁶.

A second group consisting of 75 individuals with primary or secondary, non-HCC liver tumor or benign liver lesions (Comparative Group) was included in the design of the study in order to approximate a baseline for NTL features among Peruvian people who underwent a hepatectomy. The ratio of males to females in the Comparative Group was 0.8 with 44% of men ($n = 33$) and 56% of women ($n = 42$). The mean and median ages of the Comparative Group were respectively 57.6 ± 17.7 and 60 years old, ranging from age 6 to age 90 (Fig. 1). Intra-hepatic neoplasms from the Comparative Group included metastatic colorectal cancer ($n = 39$); gallbladder cancer ($n = 10$); breast cancer ($n = 6$); neuroendocrine tumor ($n = 5$); renal cancer and undifferentiated tumor ($n = 2$); and angiosarcoma, gastrointestinal stromal tumor, leiomyosarcoma, diffuse large B-cell lymphoma, and melanoma (all $n = 1$). In addition, Comparative Group also included individuals with benign liver lesions such as chronic liver inflammation ($n = 2$) and primary sclerosing cholangitis, focal nodular hyperplasia, peliosis hepatis, and inflammatory pseudotumor of the liver (all $n = 1$).

Clinical presentation of hepatocellular carcinoma. The mean diameter of HCCs was 13.9 ± 6.2 cm with a median of 14 cm diameter (Table 1). Tumors were well differentiated (G1) in 28% of the cases ($n = 14$), moderately differentiated (G2) in 48% of the cases ($n = 24$), and poorly differentiated (G3) in 24% of the cases ($n = 12$); no tumor was graded undifferentiated (G4). The histological growth pattern of HCC was trabecular in 54% of the cases ($n = 27$), mixed in 38% ($n = 19$), compact in 4% ($n = 2$), and acinar in 4% ($n = 2$). These features were in accordance with those reported hitherto¹⁴. Classical and steatohepatic histological types represented the very large majority of the HCCs scrutinized with 56% ($n = 28$) and 42% ($n = 21$), respectively. A single fibrolamellar carcinoma variant (2%) was observed. Macro- and/or micro-vascular invasion was observed in 24% of the cases ($n = 12$), and 28% of the patients had developed distant metastasis ($n = 14$).

Histology of the non-tumor liver parenchyma. Table 2 presents descriptive statistical results for hepatic fibrosis staging in both the Patient and Comparative Groups. In the Patient Group, the large majority of the NTLs, i.e. 72%, presented with null to moderate Stages 1 and 2 fibrosis ($n = 36$). In addition, 12% of the NTLs were recorded at Stage 3 fibrosis ($n = 6$); and 16% displayed cirrhosis, i.e. eight patients including merely two males less than 50 years of age. There was no statistical trend towards higher fibrosis stage in the Patient Group compared to the Comparative Group ($P = 6.20E-02$), using the Cochran–Armitage test for trend.

About 26% of HCC patients ($n = 14$) and 30.7% of comparative individuals ($n = 23$) displayed macro- and micro-vesicular hepatic steatosis that, in any case, did not exceed 50% of parenchymal involvement (Table 3). There was no statistical trend towards a higher grade of steatosis in the Patient Group compared to the Comparative Group ($P = 0.28$). Lobular activity was slightly significantly contrasted with a trend toward mild inflammation in HCC patients ($P = 4.70E-02$); whereas the portal/periportal inflammation level was not statistically different between both groups ($P = 0.30$) (see Supplementary Table S1). Definite steatohepatitis was scored in 8% of HCC cases ($n = 4$) and 6.7% of the comparative individuals ($n = 5$). Once again, there was no significant difference regarding fatty liver changes between both groups ($P = 1.00$).

Table 4 details the descriptive statistical results for ferric iron overload in NTL in both the Patient and Comparative Groups. A certain degree of parenchymal siderosis was recorded in half of the HCC-associated NTLs with 50% of the samples ($n = 25$) scoring in histological Grades 1+ to 4+. On the same hand, 40% of the NTLs from the Comparative Group ($n = 30$) scored histological Grades 1+ to 4+. As a result, no differential trend in iron accumulation was statistically revealed between the Patient Group and the Comparative Group ($P = 0.58$).

Feature	Parameter	Number	Percentage
Cohort	Patient	50	100
Age (years)	Mean \pm s.d.	46.5 \pm 20.9	n/a
	Median	40	n/a
	Range	[10–96]	n/a
	Interquartile range	38.5	n/a
Gender	Female	20	40
	Male	30	60
HBsAg	Negative	23	46
	Positive	26	52
Anti-HCV	Negative	49	98
	Positive	1	2
Tumor size (cm)	Mean \pm s.d.	13.9 \pm 6.2	n/a
	Median	14	n/a
	Range	[2.5–29]	n/a
	Interquartile range	7.6	n/a
	Less than 5 cm	3	6
	Between 5 and 10 cm	12	24
	More than 10 cm	35	70
Tumor nodule	Single	46	92
	Multinodular	4	8
Vascular invasion	Absent	38	76
	Macro	4	8
	Micro	3	6
	Macro and micro	5	10
Tumor grade	G1	14	28
	G2	24	48
	G3	12	24
Tumor growth pattern	Acinar	2	4
	Compact	2	4
	Mixed growth pattern	19	38
	Trabecular	27	54
AFP (ng/mL)	Mean \pm s.d.	76,255.9 \pm 140,085.6	n/a
	Median	5,286.5	n/a
	Range	[1–481,050]	n/a
	Interquartile range	72,455.7	n/a

Table 1. Baseline demographical and clinical features of the Peruvian HCC patients. Percentages are expressed as a ratio of the 50 patients investigated for the considered parameter. Tumor architecture and grading (G1–G4) were defined according to established classifications^{50,51}. Mean values are presented with \pm standard deviation (s.d.). AFP, alpha-fetoprotein; HBsAg, HBV surface antigen; HCV, hepatitis C virus; n/a, not applicable.

Data mining and exploratory multivariate data analysis. Principal component analysis (PCA) was applied as an exploratory data analysis to provide an unsupervised overview of clinical and histological data. No discrimination was highlighted between the Patient Group and the Comparative Group on the PCA score plot (Fig. 2a). Some people were characterized by the prevalence of hepatocellular ballooning and steatohepatitis, but this subset of individuals was indistinctly found in both groups. Orthogonal projection to latent structure-discriminant analysis (OPLS-DA) was then employed to disjoin HCC patients from comparative individuals (Fig. 2b). According to coefficient plot, there was no dramatic difference between the Patient Group and the Comparative Group for most clinical, biochemical, and histological features scrutinized, with the notable exceptions of periodic acid–Schiff (PAS) positive [PAS(+)] hepatic foci of cellular alteration ($P = 4.46E-13$) and HBV surface antigen (HBsAg) carriage ($P = 1.06E-08$), as well as, albeit to a significantly lesser extent, macrophage (CD163) and hematopoietic stem cell (CD34) counts ($P = 6.43E-06$ and $3.31E-05$, respectively) (Fig. 2c) (see Supplementary Fig. S1a,b and Supplementary Table S2).

Histological features of the hepatic foci of cellular alteration. As pointed out by OPLS-DA, much more hepatic foci of cellular alteration were strongly marked positively by PAS staining in NTL sections of Peruvian HCC patients, in a significant manner [62% ($n = 31$) in Patient Group versus 4% ($n = 3$) in Comparative Group; $P = 4.46E-13$] (Fig. 2c). When scored positive, these foci were found abundantly in liver parenchyma with a density of 2.19 ± 2.37 ind./cm² in NTL section and were preferentially observed in Zones 2 and 3 of the hepatic acinus (Fig. 3a). Under PAS staining, these foci featured a massive accumulation of cytoplasmic glycogen storage compared

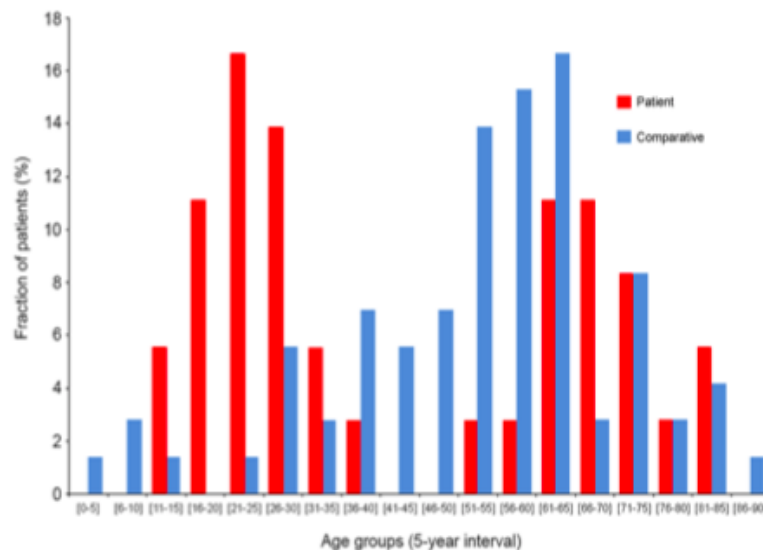


Figure 1. Age distribution of both Patient Group and Comparative Group. Histogram shows the age distribution of HCC patients (red) and comparative individuals (blue). X-axis shows age (5-year interval); Y-axis shows percentage of HCC patients (n = 50) and comparative individuals (n = 75) for a given age group.

Fibrosis stage	Contingency in Patient Group (n)	Percentage in Patient Group (%)	Contingency in Comparative Group (n)	Percentage in Comparative Group (%)
Stage 0	17	34	33	44
Stage 1	14	28	21	28
Stage 2	5	10	11	14.6
Stage 3	6	12	6	8
Stage 4	8	16	4	5.4
Total	50	100	75	100

Table 2. Fibrosis staging of non-tumor liver parenchyma from both Peruvian patients with hepatocellular carcinoma and comparative individuals. Scheuer staging system was used to determine the stage of hepatic fibrosis⁵⁴. Stage 0, no fibrosis and normal amount of connective tissue; Stage 1, enlarged, fibrotic portal tracts; Stage 2, periportal or portal-portal septa, but intact architecture; Stage 3, bridging fibrosis with architectural distortion, but no obvious cirrhosis; Stage 4, probable or definite cirrhosis.

Steatosis grade	Contingency in Patient Group (n)	Percentage in Patient Group (%)	Contingency in Comparative Group (n)	Percentage in Comparative Group (%)
Grade 0	37	74	52	69.3
Grade 1	11	22	13	17.3
Grade 2	1	2	8	10.7
Grade 3	1	2	2	2.7
Total	50	100	75	100

Table 3. Steatosis grading of non-tumor liver parenchyma from both Peruvian patients with hepatocellular carcinoma and comparative individuals. Hepatic steatosis was graded using the system established by the Non-alcoholic Steatohepatitis Clinical Research Network⁵². Grade 0, less than 5% of parenchymal involvement by steatosis; Grade 1, from 5% to 33% of parenchymal involvement by steatosis; Grade 2, from 33% to 66% of parenchymal involvement by steatosis; Grade 3, more than 66% of parenchymal involvement by steatosis.

to the adjacent parenchymal hepatocytes (Fig. 3b). While being observed under hematoxylin–eosin staining, these clear cell foci were well defined and presented a disorganized rearrangement of the hepatic plates in a parenchymal area of 0.14 mm² on average, with a distortion of the trabecular architecture (Fig. 3c,d). Within a focus, cells were reduced in size compared to surrounding hepatocytes. They exhibited an altered nuclear–cytoplasmic ratio with a centrally positioned nucleus and cytoplasm with pale eosinophilic staining, without intracytoplasmic inclusions. A discrete inflammation was monitored within the nearby perisinusoidal spaces. In addition, it could be observed some steatotic hepatocytes in the surrounding tissue microenvironment, but this was not always consistent. It was registered some degree of *in situ* congruence between these foci and focal glutamine synthetase (GS) expression found in NTL parenchyma of Peruvian HCC patients (Fig. 3e). No statistical correlation was observed between PAS(+) and the prevalence of steatosis ($P = 0.19$) and steatohepatitis ($P = 0.28$).

Iron overload grade	Occurrence in Patient Group (n)	Percentage in Patient Group (%)	Occurrence in Comparative Group (n)	Percentage in Comparative Group (%)
Grade 0	25	50	45	60
Grade 1+	9	18	9	12
Grade 2+	8	16	11	14.7
Grade 3+	6	12	6	8
Grade 4+	2	4	4	5.3
Total	50	100	75	100

Table 4. Histological grading of ferric iron overload in non-tumor liver parenchyma from both Peruvian patients with hepatocellular carcinoma and comparative individuals. Ferric iron accumulation was graded using the system established by LeSage and colleagues³⁵. Grade 0, no stainable iron; Grade 1+, less than 25% of hepatic cells positive; Grade 2+, between 25% and 50% of hepatic cells positive; Grade 3+, between 50% and 75% of hepatic cells positive; Grade 4+, more than 75% of hepatic cells positive.

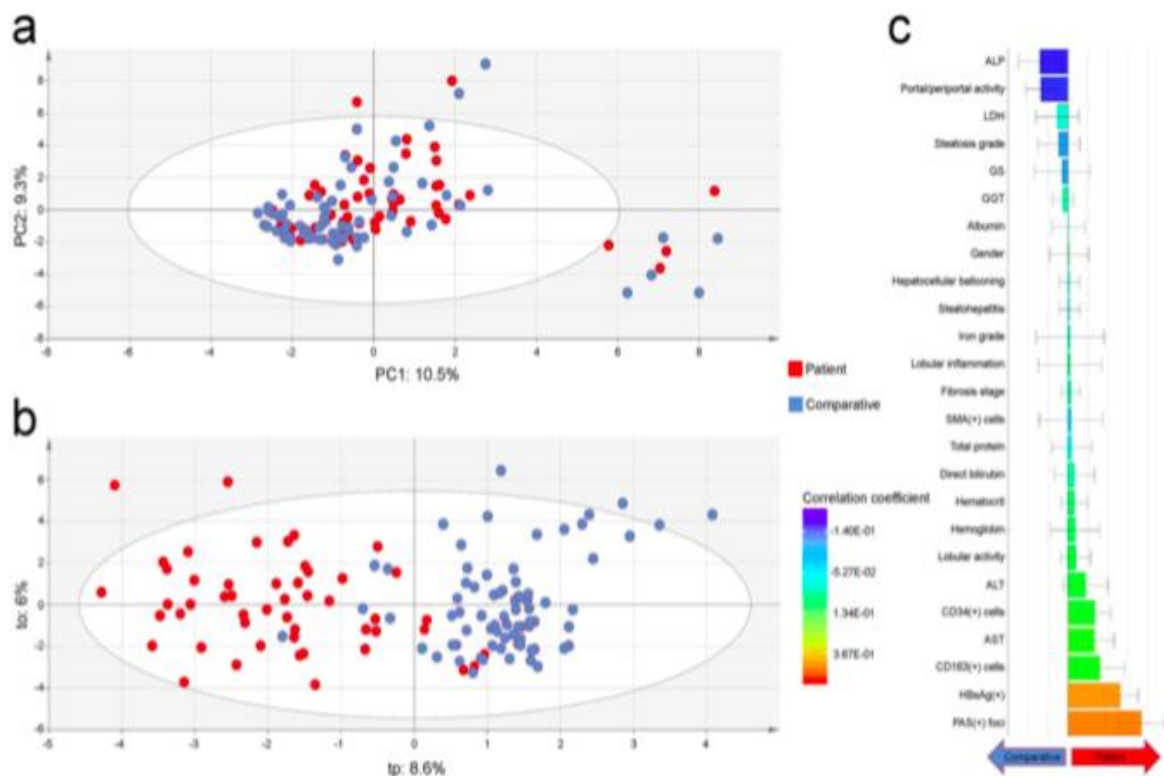


Figure 2. Exploratory multivariate data analysis of non-tumor liver features in both Peruvian patients with hepatocellular carcinoma and comparative individuals. **(a)** Unsupervised PCA score plot (PC1: 10.5% versus PC2: 9.3%) displaying a blended assemblage of HCC patients and comparative individuals. The scattered cluster located outside the Hotelling's T^2 limits on the lower right corner plots individuals with hepatocellular ballooning and steatohepatitis. **(b)** OPLS-DA score plot for the first predictive (tp: 8.6%) versus orthogonal (to: 6%) components showing dissociation between HCC patients and comparative individuals. The performance of the prediction model was satisfactory ($R^2Y = 0.68$; $Q^2Y = 0.53$). **(a,b)** HCC patients and comparative individuals are plotted in red and blue, respectively. **(c)** Regression coefficient plot for the OPLS-DA model with biomedical features of both HCC patients and comparative individuals. Right coefficient boxes indicate a correlation with Patient Group and left coefficient boxes indicate a correlation with Comparative Group; coefficient box color gives an indication about the degree of correlation; and error bars represent the Jack-knife standard error of the Y loading weight vector computed from the rounds of cross validation.

Differential gene expression analysis. Gene expression profiling was performed in a subset of NTLs from individuals of the Patient Group for whom we had high quality RNA, i.e. six PAS(+) patients and three patients with no such hepatic lesion [PAS(-)] (see Supplementary Table S1). Interestingly, differential analysis revealed contrasts in gene expression between PAS(+) and PAS(-) NTLs. At first sight, the immune status of PAS(+) NTLs appeared to be altered at the transcriptional level compared to PAS(-) NTLs, as the gene expression of multiple immune-related ontologies were significantly mitigated (Fig. 4a). Conversely, some genes of the olfactory receptor superfamily were significantly overexpressed in PAS(+) NTLs compared to PAS(-) NTLs (Fig. 4b). In addition, we purposely focused on genes involved in carbohydrate metabolic process, as PAS stains

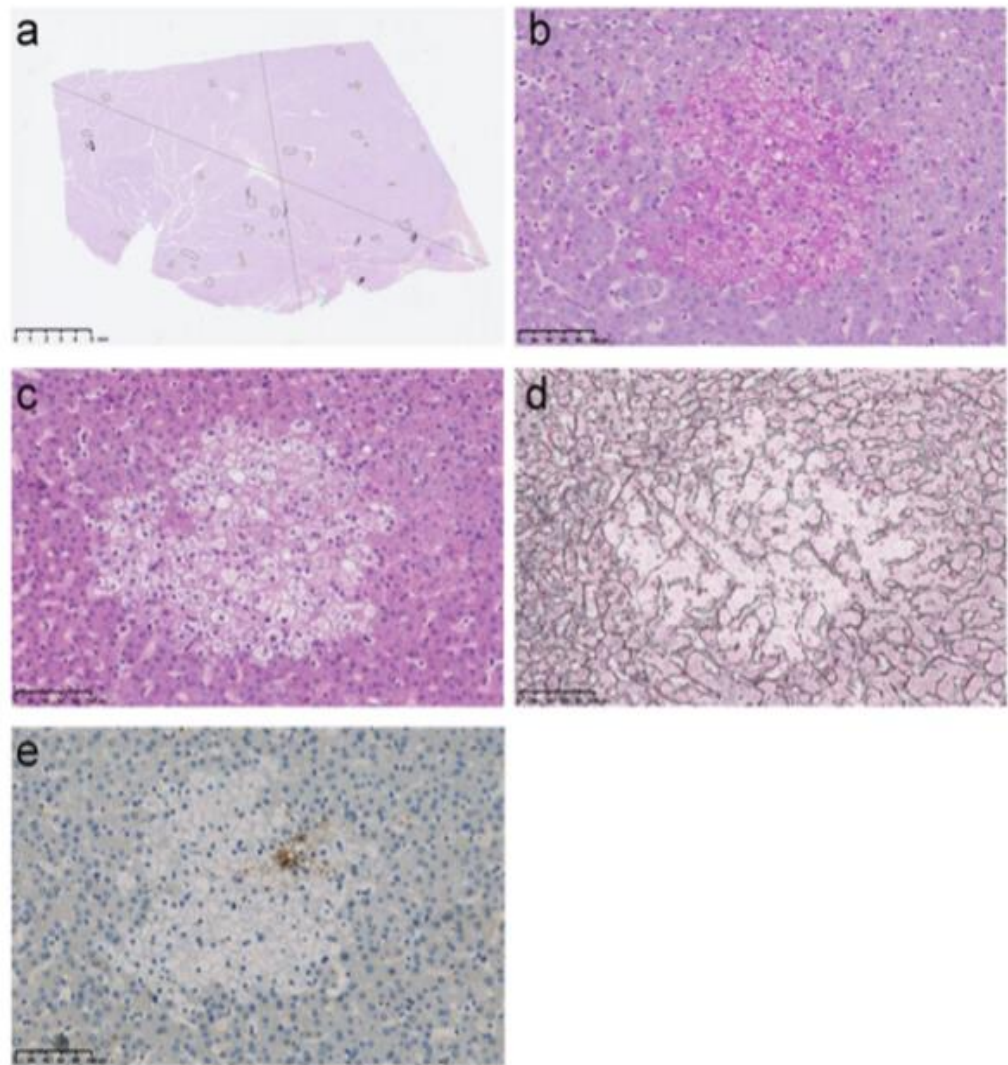


Figure 3. Illustration of the hepatic foci of cellular alteration observed in non-tumor liver parenchyma of Peruvian patients with hepatocellular carcinoma. **(a)** NTL section from a 37-year-old Peruvian male individual with a 16-cm-diameter well differentiated (G1), trabecular growth pattern HCC. The surrounded areas indicate location and size of liver clear cell foci within the section. NTL section dimension; 25.5 mm-length, 15.1 mm-width. Scale bar; 5 mm. **(b–e)** Representative features in a series of serial NTL sections from a 32-year-old Peruvian male individual with a 14-cm-diameter moderately differentiated (G2), trabecular growth pattern HCC under medium power magnification (30x). Scale bars; 100 μ m. **(b)** A hepatic focus of cellular alteration under PAS staining. This histological feature was significantly associated with Patient Group by OPLS-DA (Fig. 2b). **(c)** The same focus than in (b) under hematoxylin–eosin staining. The focus is displaying a clear cell-like appearance. **(d)** The same focus than in (b,c) under G&M reticulin staining. It is observed a distortion of the trabecular architecture over the focal area. **(e)** GS immunohistochemistry on the same focus than in (b–d). GS expression is observed heterogeneously in some cells of the hepatic focus of cellular alteration.

tissue structures containing a high proportion of carbohydrates, e.g. glycogen, glycoproteins, and proteoglycans¹⁷. We found that several genes, which are key players for carbohydrate anabolism, were transcriptionally overexpressed in PAS(+) NTLs compared to PAS(–) NTLs, such as insulin-like growth factor 1 (*IGF1*) ($P = 6.17E-03$), insulin receptor substrate 1 (*IRS1*) ($P = 2.26E-02$), forkhead box O1 (*FOXO1*) ($P = 1.11E-02$), or even pyruvate dehydrogenase kinase 4 (*PDK4*) ($P = 1.73E-03$) (see Supplementary Table S3). However, other genes involved in carbohydrate catabolism, like galactosidase alpha (*GLA*), were down regulated ($P = 4.95E-02$). Finally, *SERPINA1* gene linked to alpha-1-antitrypsin deficiency was not statistically differentially expressed between PAS(+) and PAS(–) NTLs ($P = 0.96$), whereas differential transcription of few other genes of the serine proteinase inhibitor (serpin) superfamily, i.e. *SERPIND1*, *SERPINE1*, and *SERPINF2*, were monitored ($P = 3.55E-02$, $3.88E-02$, and $4.62E-02$, respectively) (see Supplementary Table S3).

Evaluation of the burden of hepatitis B virus in tumor and non-tumor liver tissues. As revealed by OPLS-DA, HBsAg carriage was significantly found in 52% of HCC patients ($n = 26$), whereas merely 6.7% comparative individuals were recorded positive for HBV infection ($n = 5$) ($P = 1.06E-08$). A comprehensive molecular detection of HBV was then performed in a subset of 30 HCC and parent NTL matched pairs for which

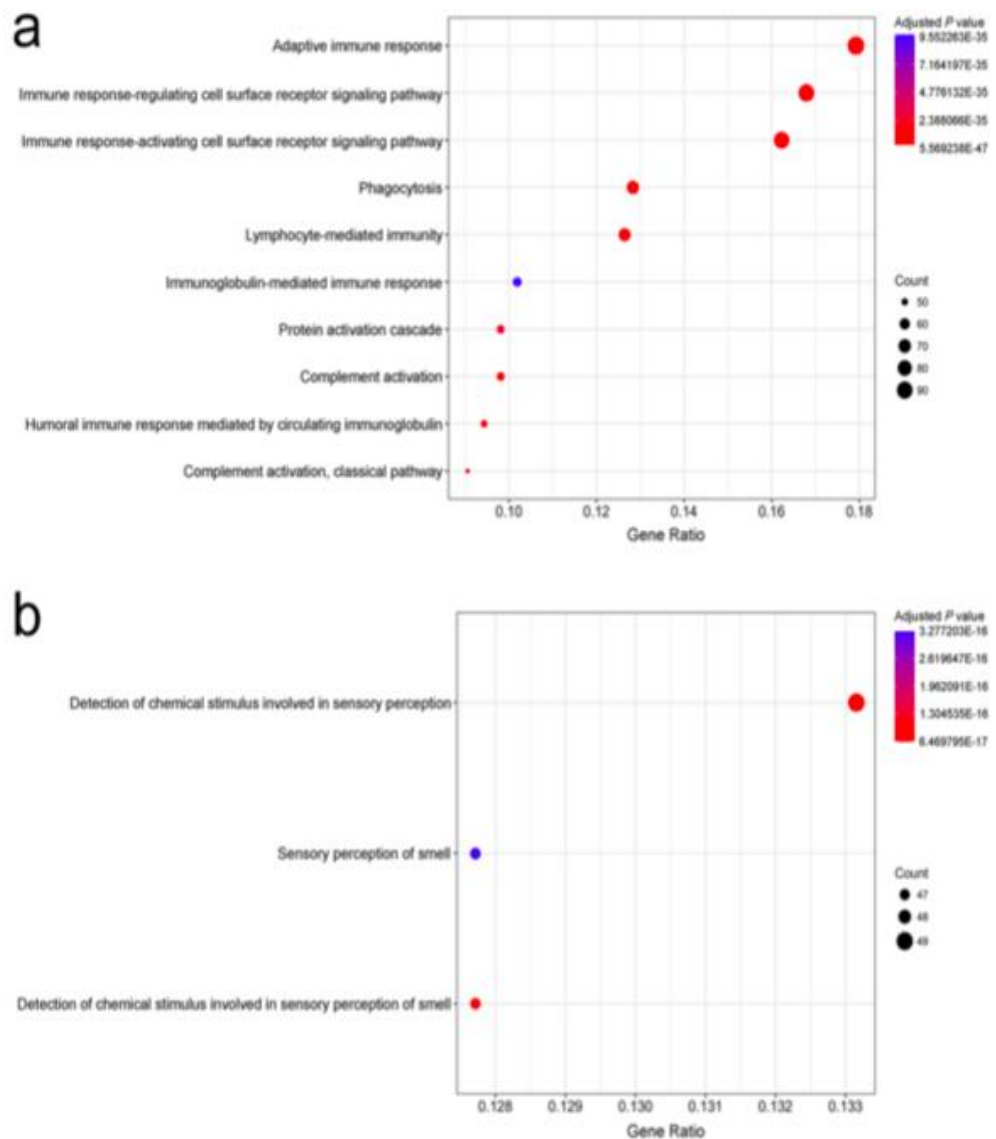


Figure 4. Gene ontology enrichment analysis on expression dataset of non-tumor livers with and without PAS positive hepatic foci of cellular alteration. **(a)** Point plot representation of the ontologies downregulated in PAS(+) NTL compared to PAS(-) NTL of Peruvian HCC patients. **(b)** Point plot representation of the ontologies upregulated in PAS(+) NTL compared to PAS(-) NTL of Peruvian HCC patients. **(a,b)** X-axis shows Gene Ratio of each term and Y-axis shows the Gene Ontology pathway terms; point size scales the gene count; and point color illustrates the adjusted P value.

we had total DNA extracted from fresh frozen tissues. In this sub-cohort, prevalence of HBsAg carriage was 43.3% ($n = 13$). The presence of HBV DNA was monitored in at least one sample of the matched pairs of liver tissues in 66.7% of the cases ($n = 20$), which implies that 23.3% of HBV DNA-positive patients was initially monitored negative for HBsAg serology ($n = 7$) (see Supplementary Table S1). Total HBV DNA burden was very low with median values of $6.01E-01$ viral genome equivalent copy per cell in HCC and $2.89E-01$ in NTL, with no statistical difference between the two types of tissues ($P = 0.08$) (see Supplementary Fig. S2). Likewise, no correlation was established between prevalence of HBsAg carriage and/or HBV DNA in NTL with PAS(+) NTL ($P = 0.70$).

Discussion

HCC arising in non-cirrhotic liver displays several histopathological and clinical features that distinguish it from HCC occurring in the setting of cirrhosis¹⁸. Epidemiologically, the age distribution of non-cirrhotic HCC patients delineates a bimodal pattern, with two peaks at the third and the seventh decades^{18,19}. We previously reported this very specific incidence in Peru where non-cirrhotic individuals represent the vast majority of HCC patients attending INEN and age distribution displays bimodality with two maximums at age 25 and age 64 (Fig. 1 and Table 1)⁶. This peculiar clinical epidemiology is associated with a singular mutation spectrum, in which has recorded a low rate of alterations in HCC-related gene mutation hotspots and short indels as the prominent class of genetic defects¹⁰. This has some implications for the clinical management strategy pertaining to HCC patients with no cirrhosis in Peru and elsewhere^{13,14,20}. Despite this intriguing clinicopathological presentation of the

tumor, no study had been conducted so far to precisely characterize the histopathological status of NTL from Peruvian patients with HCC. Hence, we assembled a cohort of HCC patients attending INEN that matched the structure of the Peruvian population of HCC patients both in terms of gender and age distribution, in order to investigate the histology of both their liver tumor and their non-tumor parenchyma.

Some features observed were noteworthy. Over 76% of HCCs were categorized as well to moderately differentiated (G1 and G2), despite the fact that histological assessment was performed on surgical specimens that generally grade higher compared to needle core biopsies²¹. Interestingly, younger HCC patients presented with virtually no fibrolamellar carcinomas, a histotype occurring almost exclusively in non-cirrhotic liver and allegedly earlier than age 40^{22–24}. This observation coincides with the results obtained previously in a cohort of 256 Peruvian HCC patients, who were around 40 years old on average and predominantly non-cirrhotic, which yielded only 1.6% of fibrolamellar variant¹⁴. Furthermore, a significant fraction of the liver tumors scrutinized in the present cohort were steatohepatic HCC, a relatively rare histological variant that has been associated hitherto with non-alcoholic fatty liver diseases and HCV-related cirrhosis^{25,26}.

Data indicate that Peruvian HCC is arising mostly in NTL with low to mild degrees of fibrosis, independently of the tumor histological architecture and grade. Three-quarters of the patients were still in low to moderate Stages 0–2 of hepatic fibrosis, whereas merely one-tenth displayed the severe Stage 3 and eight cases a full-fledged cirrhosis Stage 4 (Table 2). This figure is utterly at odds with the current literature on the topic, as HCC in non-cirrhotic, non-fibrotic livers is generally claimed to represent a small minority of the cases unselected for their NTL features^{19,27}.

In order to deepen our understanding of the natural history of the disease, we assessed the levels of fatty liver and steatohepatitis in NTL, as they represent, in some circumstances, a path towards fibrosis and thus enhance the risk of HCC^{28–30}. While our results confirmed the low prevalence of severe fibrosis, the fractions of patients with steatosis and steatohepatitis were also relatively low within the cohort, with about a quarter and one-tenth of the patients being affected, respectively (Table 3). These data concur with what was previously described in a large multicenter study pertaining exclusively to HCC occurring in non-cirrhotic livers³¹; whereas our results were obtained within a single-center cohort, unsupervised from a histopathological point of view for the status of the non-tumor liver parenchyma. Above all, multivariate analysis (PCA) did not discriminate NTL features of the Patient Group from those of the Comparative Group, therefore emphasizing the relatively healthy status of the liver in Peruvian HCC patients (Fig. 2a).

It has been reported that parenchymal and parenchymal–mesenchymal-mixed iron overload in NTL is associated with HCC, regardless the cirrhotic status of the liver^{32–34}. We thus assessed the level of iron accumulation in NTL from Peruvian HCC patients and compared the results to the data obtained with a comparative group. The very large majority of NTLs were scored with low to moderate grades of iron overload (Grades 0–3+), mostly parenchymal (Table 4). Some degree of iron overload in the liver is relatively common in patients with chronic liver disease, such as alcoholic liver disease and non-alcoholic fatty liver disease^{35,36}. Also, iron accumulation has been monitored in the liver of a significant fraction of patients with chronic HCV infection³⁷. None of these hepatic affections were observed to be truly prevalent in our cohort of patients; and the mild degree of iron accumulation observed in NTL was not correlated either with fibrosis staging nor fatty liver and steatohepatitis grading of HCC patients. Whether the siderosis monitored in NTL of HCC patients is a confounding factor, a consequence of the liver tumor development, or is related to its etiology remains to be investigated.

When comparing both Patient Group and Comparative Group using discriminant multivariate analysis (OPLS-DA), PAS positive hepatic foci of cellular alteration observed in NTL were strikingly associated with the occurrence of HCC (Figs 2b,c and 3a–e). From a morpho-histological point of view, these hepatic foci are highly reminiscent of liver lesions described hitherto in some animal models that have been exposed to genotoxic chemicals (Fig. 3b–d)^{38,39}. This type of liver clear cell foci has also been recently described in human non-cirrhotic liver parenchyma by Ribback and colleagues⁴⁰. However, the authors were not able to assess whether or not, in humans, these lesions were *in fine* precancerous or benign, since they recorded a lower frequency of foci in NTL associated with HCC. Yet, the exact brunt of these hepatic foci of cellular alteration and their alleged role in liver carcinogenesis in animal models has to be elucidated, as well as kinship with what has been observed in human has to be ascertained. Nonetheless, it can be suspected that such foci may have potential to progress to neoplasia, as there is a significant association with HCC as well as some degree of congruence with the co-expression of precancerous marker GS⁴¹, and thus, that they could be active players in the natural history of the disease in a significant proportion of HCC patients (Fig. 3e).

In order to gain further insights into the burden of these hepatic foci of cellular alteration, we performed a differential gene expression analysis between PAS(+) and PAS(–) NTLs of Peruvian HCC patients. Because hepatic foci represent only a smaller fraction in PAS(+) NTL, there is a strong distortion in disfavor of these foci, lowering the discriminating power of the analysis when directly comparing whole PAS(+) to PAS(–) tissues; so results of such analysis should be viewed cautiously. It is interesting to note, though, some divergent gene expression between NTLs from two sets of Peruvian HCC patients stratified on the presence/absence of these hepatic foci. Indeed, Gene Ontology analysis suggests that the immune system's activity in PAS(+) NTL is comprehensively modified compared to PAS(–) NTL (Fig. 4a). Concerning olfactory receptors, which are members of a large family of G-protein-coupled receptors also found to be expressed in different non-olfactory tissues, their overexpression has been previously reported to participate in the processes of cancer cell proliferation, metastasis, invasiveness, as well as angiogenesis (Fig. 4b)⁴².

HBV is regarded as a prominent causative agent of HCC, playing an instrumental role in liver carcinogenesis either by oncogene product expression, viral DNA integration into host genes, or through an active viral replication supporting a persistent inflammatory microenvironment that fosters tumor onset². Peruvian HCC develops in an epidemiological context where prevalence of overt chronic HBV infection is intermediate with around 50% of HBsAg carriers and very few HVC-infected cases^{6,10,14,43}. This situation implies that a significant fraction of

Peruvian patients would have cryptogenic HCC, which is commonly characterized by a well-conserved architecture of the liver parenchyma and absence of a *bona fide* risk factor, such as overt HBV or HCV infections. It has been previously reported that occult HBV infection (OBI), defined by the presence of HBV DNA in blood or liver tissue without detectable levels of HBsAg, can be associated with non-cirrhotic HCC⁴⁴. This is why we undertook a comprehensive molecular detection of HBV in tumor and non-tumor liver tissues. Prevalence of HBV within the cohort was thus initially underestimated as some patients had OBI, disclosing an alternative risk factor for HCC. However, we could not establish a clear-cut correlation between overt and/or occult HBV infection and the occurrence of PAS positive foci of cellular alteration in liver parenchyma, despite the fact that these biomedical features predominate in Peruvian HCC. Given the whole landscape for Peruvian HCC, the potential cooperative role of overt or OBI HBV infection, iron overload, and genotoxic chemicals in liver carcinogenesis etiology has to be further explored, as previously suggested for Chinese HCC cases by Ming and colleagues⁴⁵.

Altogether, our findings uphold the peculiarity of the clinicopathological context of HCC encountered among the patients from South America, especially in Peru^{6,13}. It emerges that, in this relatively young patient population, non-cirrhotic, non-fibrolamellar HCC is prevailing. This clinical presentation coincides with the presence of remarkable hepatic foci of cellular alteration in the liver parenchyma that could be the hallmark of liver tissue injury caused by exposure to genotoxic substances^{38–40}. In addition, Peruvian HCC displays a unique mutation spectrum for HCC in which short indels are the major class of mutations, what might suggest deficiency in DNA repair mechanisms⁴⁰. It also displays a low rate of alterations in tumor protein p53 (*TP53*) gene and a high prevalence of aberrations affecting genes of the Wnt family [e.g. axin 1 (*AXIN1*) and catenin beta 1 (*CTNBI*) genes]. The latter are features of a molecular signature reported hitherto for HCC arising in non-cirrhotic livers^{46,47}.

Indeed, several studies have already pointed out the occurrence of non-cirrhotic, non-fibrotic HCCs, but not to the extent described in the present study, and with the difference that fibrolamellar carcinomas were herein underrepresented in a relatively young patient population^{18,19,22,27,48,49}. According to current views, these non-cirrhotic, non-fibrotic HCCs delineate a distinct nosological entity that displays some noticeable features, all spotted in the clinicopathological context encountered in Peru: (i) a bimodal age distribution with a rather balanced sex-ratio; (ii) an advanced tumor stage at the time of the diagnosis, as it is usually detected due to the onset of cancer-related symptoms with no prodromal period; (iii) relatively moderate distant invasiveness properties; and (iv) a good amenability to liver resection even in cases of major hepatectomy. In addition to this, Trevisani and colleagues specified that the overall and disease-free survivals after resection of these HCCs are equal to those obtained with liver transplantation in cirrhotic patients with early stage tumor, that overall survival depends on HCC burden and is poorly affected by liver function¹⁹. This information is particularly relevant regarding surgical outcomes in a clinical situation of low- and middle-income countries, where a significant fraction of HCC patients are dismissed from the chain of care due to a poor prognosis empirically determined by canonical staging systems designed elsewhere in an utterly different clinico-epidemiological context¹⁴.

Methods

Ethics approval and consent to participate. Written informed consent was provided by participants for their information and samples to be stored in the INEN Department of Cancer Statistics and Epidemiology (for medical charts) and the INEN Department of Pathology (for tissue specimens) and used for research. When the patient was non-adult, a parent provided the informed consent on his behalf. The present study was carried out in strict accordance with the ethical principles contained in the up-to-date Declaration of Helsinki and was approved by the INEN Human Subjects Committee, protocol numbers #008-2010-CRP-DI/INEN and #113-2014-CIE/INEN.

Study design and patient selection. The present study was conducted retrospectively within a cohort assembled by analyzing medical charts and surgical specimens of liver resection of 50 patients with HCC (Patient Group) and 75 individuals with primary or secondary, non-HCC liver tumor or benign liver lesions (Comparative Group) who were hospitalized at INEN between October 2012 and August 2017. As a public hospital, INEN accommodates individuals regardless of age, sex, ethnicity, residence, economic status, and health care coverage. Participants were selected on the basis of their pathology report, i.e. whether they had developed intra-hepatic tumors and had undergone surgery. Information on age and gender was checked in order to comply with the clinical epidemiology of HCC patient population in Peru, as previously described^{6,10,14–16}.

Patient management and diagnosis. Patients with malignant liver neoplasms were managed through the INEN Department of Abdominal Surgery. The patients included in the present study were treated by anatomic liver resection, i.e. systematic removal of the tumoral liver segments confined by portal branches to ensure tumor-free margins¹⁴. After the surgical intervention, pathologists determined primarily tumor size (i.e. longest chord measured), nodule number and presence of macro-vascular invasion, and then assessed the type of cancer cells on hematoxylin–eosin-stained liver sections⁵⁰. In case of HCC, histopathological architecture and grading (G1–G4) were recorded according to the classifications of the World Health Organization and of the American Joint Committee on Cancer, respectively^{50,51}. All blood tests were performed at the clinical laboratory of INEN. Tumor marker AFP was monitored for its serum concentration by radioimmunoassay (Roche Diagnostics). Infections with HBV and HCV were monitored in patients' sera using Elecsys® HBsAg II and Elecsys® anti-HCV II assays (both Roche Diagnostics).

Histology. Parent NTLs were obtained from tumor-free margins of the resected surgical pieces. Tissues were formalin-fixed, paraffin-embedded (FFPE) in the INEN Department of Pathology according to an established procedure. All tissue staining and immunohistochemistry were performed on the Histo Pathology High Precision

(H2P2) platform - certified to ISO 9001 - of the University of Rennes, France. Hepatic steatosis was estimated on hematoxylin-eosin-stained FFPE sections under medium power magnification (x40) and graded (0–3) in accordance with the Non-alcoholic Steatohepatitis Clinical Research Network staging system⁵². Steatohepatitis in NTLs was diagnosed according to the American Association for the Study of Liver Diseases criteria⁵³. In addition, possible steatohepatitic HCC variant was assessed using the combination of histopathological features described by Salomao and colleagues²⁵. FFPE NTL slices from HCC patients were colored using the Masson's Trichrome Stain Kit, Artisan™ (Dako), according to the manufacturer's instructions. Liver fibrosis stage (0–4) was then scored in accordance with the scoring system for fibrosis and cirrhosis described by Scheuer⁵⁴. In parallel, FFPE NTL slices from HCC patients and comparative individuals were stained for the visualization of ferric iron in tissues (Perls' method) using the Iron Stain Kit, Artisan™ (Dako), according to the manufacturer's instructions. Histological grade of iron accumulation in NTLs was then scored (0–4+) in accordance with the grading system previously described by LeSage and colleagues⁵⁵. PAS Staining Kit (MilliporeSigma) was used to stain carbohydrates in FFPE NTLs, according to the manufacturer's instructions (with no diastase treatment). Finally, anti-CD163 (from Abcam), anti-CD34 (from Leica), anti-GS (from BD Biosciences), and anti-smooth muscle actin (from Dako) antibodies were used for immunohistochemistry in FFPE NTLs, conforming to established protocols of the H2P2 platform.

Transcriptomic analysis. About 50 mg of both HCC and parent NTL matched pair were harvested from the resected surgical pieces, flash-frozen in liquid nitrogen, and stored at -80 °C (INEN Cancer Research Biobank). Total RNA was later isolated from flash-frozen NTLs using TRI Reagent® (Sigma-Aldrich) and Lysin Matrix D homogenization system (MP Biomedicals), according to manufacturer's instructions. RNA integrity and quantity were assessed using the RNA 6000 Nano LabChip® Kit (Agilent Technologies) and a 2100 Bioanalyzer System (Agilent Technologies), as well as with the Qubit® RNA Broad-Range Assay Kit (Invitrogen). About 100 ng of total RNA [with RNA integrity number (RIN) >7] were used to evaluate gene expression using GeneChip™ Human Transcriptome Array 2.0 (Applied Biosystems), according to the manufacturer's instructions. Gene expression analysis was performed using the limma software standard pipeline (R/Bioconductor) at a significance level of 0.05 with no false discovery rate controlling procedure^{56,57}. Genes differentially expressed were selected in order to complete a gene enrichment analysis using clusterProfiler software (R/Bioconductor) and the Gene Ontology database (Gene Ontology Consortium) for biological process, with a 0.05 significance level⁵⁸.

Hepatitis B virus DNA detection. Flash-frozen HCC and NTL samples were pounded under liquid nitrogen and then digested at 37 °C for 8 hours in tissue lysis buffer containing proteinase K and SDS. Total DNA was extracted twice with phenol and once with chloroform, precipitated in ethanol, and resuspended in TE buffer (10 mM Tris; 0.1 mM EDTA; pH 8.0). DNA concentrations were measured using the Qubit® dsDNA Broad-Range Assay Kit (Invitrogen). About 50 ng of total DNA were screened by PCR for presence of HBV DNA, using a nested procedure when appropriate, on at least three different regions of the viral genome, i.e. preS, S, and X/preC. PCRs were carried out with 35 cycles at 95 °C for 1 min, 59 °C for 1 min, and 72 °C for 1–2 min. Subsequently, HBV DNA was quantified by qPCR in 100 ng of total DNA on a CFX96™ Real-Time PCR Detection System (Bio-Rad) using the TaqMan® Pathogen Detection Assay Pa03453406_s1 (Thermo Fisher Scientific). Covalently closed circular DNA (cccDNA) was measured with primers overlapping with the nick of the minus strand, in accordance with Ducroux and colleagues⁵⁹. Amplification specificity for cccDNA was checked by melt-curve analysis. HBV genome equivalent copies were determined on a standard curve generated with known copy numbers of a plasmid containing HBV genome (pFC80). In addition, droplet digital PCRs were performed on a QX100™ Droplet Digital™ PCR System (Bio-Rad) using the TaqMan® Pathogen Detection Assay Pa03453406_s1 and the Human TaqMan® Copy Number Reference Assay (Thermo Fisher Scientific) as a reference. Reaction mixtures consisted in 10 µl of ddPCR™ Supermix (Bio-Rad), 1x primers, and 100 ng of total DNA in a final volume of 20 µl. About 70 µl of Droplet Generation Oil (Bio-Rad) was used to create an emulsion of monodispersed droplets using QX100™ Droplet Generator (Bio-Rad), and emulsified samples were transferred to a 96-well PCR plate. Duplex PCRs were performed on a CM1000 Touch™ Thermal Cycler (Bio-Rad) with the following thermal cycling protocol: denaturation at 95 °C for 10 min, followed by 40 cycles at 94 °C for 30 s with a 2.5 °C/sec ramp rate, 59 °C for 1 min with a 2.5 °C/sec ramp rate, 98 °C for 5 min, and hold at 4 °C. After PCR, 96-well plates were scanned in a QX100 Droplet Reader (Bio-Rad). Data were analyzed using QuantaSoft™ software (Bio-Rad) with autoanalysis settings for duplex experiment.

Statistics. Medical information was inputted on Microsoft Excel® software version 16.9 (Microsoft Corporation). Statistical tests, i.e. Fisher's exact test and Student's *t*-test, were performed two-tailed with a 0.05 significance level using R statistical software version 3.4.3 (R Foundation). One- and two-sided Cochran–Armitage test for trend were performed with Monte Carlo simulation ($n = 5,000$). For multivariate data analysis, data were imported to SIMCA-P+ multivariate tool version 14.0 (Umetrics) and scaled to unit variance for PCA and OPLS-DA. For OPLS-DA, the model fit was assessed by leave-one-subject-out cross-validation. The validity of the discriminant model was checked using permutation test (Y-scrambling; $n = 100$).

Data availability. All data generated or analyzed during this study are included in this published article and its Supplementary Information file, as well as in the NCBI's Gene Expression Omnibus repository (for microarray data), accessible through GEO series accession number GSE111580 (<https://www.ncbi.nlm.nih.gov/geo/query/acc.cgi?acc=GSE111580>).

References

- Hajarizadeh, B., Grebely, J. & Dore, G. J. Epidemiology and natural history of HCV infection. *Nat. Rev. Gastroenterol. Hepatol.* **10**, 553–562 (2013).
- Busch, K. & Thimme, R. Natural history of chronic hepatitis B virus infection. *Med. Microbiol. Immunol.* **204**, 5–10 (2015).
- Calzadilla Bertot, L. & Adams, L. A. The natural course of non-alcoholic fatty liver disease. *Int. J. Mol. Sci.* **17**, E774 (2016).
- Bishayee, A. The role of inflammation and liver cancer. *Adv. Exp. Med. Biol.* **816**, 401–435 (2014).
- Ringelhan, M., Pfister, D., O'Connor, T., Pikarsky, E. & Heikenwalder, M. The immunology of hepatocellular carcinoma. *Nat. Immunol.* **19**, 222–232 (2018).
- Bertani, S. *et al.* An atypical age-specific pattern of hepatocellular carcinoma in Peru: a threat for Andean populations. *Plos One* **8**, e67756 (2013).
- Yang, J. D. & Roberts, L. R. Hepatocellular carcinoma: a global view. *Nat. Rev. Gastroenterol. Hepatol.* **7**, 448–458 (2010).
- El-Serag, H. B. Hepatocellular carcinoma. *N. Engl. J. Med.* **365**, 1118–1127 (2011).
- Forner, A., Llovet, J. M. & Bruix, J. Hepatocellular carcinoma. *Lancet* **379**, 1245–1255 (2012).
- Marchio, A. *et al.* A peculiar mutation spectrum emerging from young Peruvian patients with hepatocellular carcinoma. *Plos One* **9**, e114912 (2014).
- Vogelstein, B. *et al.* Cancer Genome Landscapes. *Science* **339**, 1546–1558 (2013).
- Gröbner, S. N. *et al.* The landscape of genomic alterations across childhood cancers. *Nature* **555**, 321–327 (2018).
- Debes, J. D. *et al.* Hepatocellular carcinoma in South America: evaluation of risk factors, demographics and therapy. *Liver Int.* **38**, 136–143 (2018).
- Ruiz, E. *et al.* Hepatocellular carcinoma surgery outcomes in the developing world: a 20-year retrospective cohort study at the National Cancer Institute of Peru. *Heliyon* **2**, e00052 (2016).
- Rojas Rojas, T. *et al.* Herbal medicine practices of patients with liver cancer in Peru: a comprehensive study toward integrative cancer management. *Integr. Cancer Ther.* **17**, 52–64 (2016).
- Machicado, C. *et al.* Negative serology of Fasciola hepatica infection in patients with liver cancer in Peru: a preliminary report. *Rev. Soc. Bras. Med. Trop.* **51**, 231–233 (2018).
- Fu, D. A. & Campbell-Thompson, M. Periodic acid-Schiff staining with diastase. In *Alpha-1 antitrypsin deficiency* 145–149 (Humana Press, 2017).
- Gaddikeri, S. *et al.* Hepatocellular carcinoma in the noncirrhotic liver. *AJR Am. J. Roentgenol.* **203**, W34–47 (2014).
- Trevisani, F., Frigerio, M., Santi, V., Grignaschi, A. & Bernardi, M. Hepatocellular carcinoma in non-cirrhotic liver: a reappraisal. *Dig. Liver Dis.* **42**, 341–347 (2010).
- Schütte, K. *et al.* Characterization and prognosis of patients with hepatocellular carcinoma (HCC) in the non-cirrhotic liver. *BMC Gastroenterol.* **14**, 117 (2014).
- Pawlik, T. M. *et al.* Preoperative assessment of hepatocellular carcinoma tumor grade using needle biopsy: implications for transplant eligibility. *Ann. Surg.* **245**, 435–442 (2007).
- Okuda, K. Natural history of hepatocellular carcinoma including fibrolamellar and hepato-cholangiocarcinoma variants. *J. Gastroenterol. Hepatol.* **17**, 401–405 (2002).
- El-Serag, H. B. & Davila, J. A. Is fibrolamellar carcinoma different from hepatocellular carcinoma? A US population-based study. *Hepatology* **39**, 798–803 (2004).
- Kakar, S. *et al.* Clinicopathologic features and survival in fibrolamellar carcinoma: comparison with conventional hepatocellular carcinoma with and without cirrhosis. *Mod. Pathol.* **18**, 1417–1423 (2005).
- Salomao, M., Yu, W. M., Brown, R. S., Emond, J. C. & Lefkowitz, J. H. Steatohepatic hepatocellular carcinoma (SH-HCC): a distinctive histological variant of HCC in hepatitis C virus-related cirrhosis with associated NAFLD/NASH. *Am. J. Surg. Pathol.* **34**, 1630–1636 (2010).
- Benedict, M. & Zhang, X. Non-alcoholic fatty liver disease: an expanded review. *World J. Hepatol.* **9**, 715–732 (2017).
- Lubrano, J. *et al.* Long-term outcome of liver resection for hepatocellular carcinoma in noncirrhotic nonfibrotic liver with no viral hepatitis or alcohol abuse. *World J. Surg.* **32**, 104–109 (2008).
- Satapathy, S. K. & Sanyal, A. J. Epidemiology and natural history of nonalcoholic fatty liver disease. *Semin. Liver Dis.* **35**, 221–235 (2015).
- Goh, G. B. B. & McCullough, A. J. Natural history of nonalcoholic fatty liver disease. *Dig. Dis. Sci.* **61**, 1226–1233 (2016).
- Marengo, A., Jouness, R. I. K. & Bugianesi, E. Progression and natural history of nonalcoholic fatty liver disease in adults. *Clin. Liver Dis.* **20**, 313–324 (2016).
- Alexander, J., Torbenson, M., Wu, T. T. & Yeh, M. M. Non-alcoholic fatty liver disease contributes to hepatocarcinogenesis in non-cirrhotic liver: a clinical and pathological study. *J. Gastroenterol. Hepatol.* **28**, 848–854 (2013).
- Deugnier, Y. Iron and liver cancer. *Alcohol* **30**, 145–150 (2003).
- Deugnier, Y. & Turlin, B. Pathology of hepatic iron overload. *Semin. Liver Dis.* **31**, 260–271 (2011).
- Turlin, B. *et al.* Increased liver iron stores in patients with hepatocellular carcinoma developed on a noncirrhotic liver. *Hepatology* **22**, 446–450 (1995).
- Ko, C. *et al.* Prevalence of hepatic iron overload and association with hepatocellular cancer in end-stage liver disease: results from the National Hemochromatosis Transplant Registry. *Liver Int.* **27**, 1394–1401 (2007).
- Kowdley, K. V. *et al.* Serum ferritin is an independent predictor of histologic severity and advanced fibrosis in patients with nonalcoholic fatty liver disease. *Hepatology* **55**, 77–85 (2012).
- Price, L. & Kowdley, K. V. The role of iron in the pathophysiology and treatment of chronic hepatitis C. *Can. J. Gastroenterol.* **23**, 822–828 (2009).
- Hailey, J. R. *et al.* Classification of proliferative hepatocellular lesions in Harlan Sprague-Dawley rats chronically exposed to dioxin-like compounds. *Toxicol. Pathol.* **33**, 165–174 (2005).
- Thoolen, B. *et al.* Comparative histomorphological review of rat and human hepatocellular proliferative lesions. *J. Toxicol. Pathol.* **25**, 189–199 (2012).
- Ribback, S. *et al.* Molecular and metabolic changes in human liver clear cell foci resemble the alterations occurring in rat hepatocarcinogenesis. *J. Hepatol.* **58**, 1147–1156 (2013).
- Fleming, K. E. & Wanless, I. R. Glutamine synthetase expression in activated hepatocyte progenitor cells and loss of hepatocellular expression in congestion and cirrhosis. *Liver Int.* **33**, 525–534 (2013).
- Chen, Z., Zhao, H., Fu, N. & Chen, L. The diversified function and potential therapy of ectopic olfactory receptors in non-olfactory tissues. *J. Cell. Physiol.* **233**, 2104–2115 (2018).
- El-Serag, H. B. Epidemiology of viral hepatitis and hepatocellular carcinoma. *Gastroenterology* **142**, 1264–1273.e1 (2012).
- Shim, C. W. *et al.* Noncirrhotic hepatocellular carcinoma: etiology and occult hepatitis B virus infection in a hepatitis B virus-endemic area. *Ther. Adv. Gastroenterol.* **10**, 529–536 (2017).
- Ming, L. *et al.* Dominant role of hepatitis B virus and cofactor role of aflatoxin in hepatocarcinogenesis in Qidong, China. *Hepatology* **36**, 1214–1220 (2002).
- Tannapfel, A. & Wittekind, C. Genes involved in hepatocellular carcinoma: deregulation in cell cycling and apoptosis. *Virchows Arch. Int. J. Pathol.* **440**, 345–352 (2002).

47. Chiappini, F. *et al.* Microsatellite instability mutator phenotype in hepatocellular carcinoma in non-alcoholic and non-virally infected normal livers. *Carcinogenesis* **25**, 541–547 (2004).
48. Smalley, S. R. *et al.* Hepatoma in the noncirrhotic liver. *Cancer* **62**, 1414–1424 (1988).
49. Trevisani, F. *et al.* Etiologic factors and clinical presentation of hepatocellular carcinoma. Differences between cirrhotic and noncirrhotic Italian patients. *Cancer* **75**, 2220–2232 (1995).
50. Tumours of the liver and intrahepatic bile ducts. In *WHO Classification of Tumours of the Digestive System. Third Volume.* (eds Bosman, F. T. *et al.*) 157–202 (IARC, 2010).
51. Liver. In *AJCC cancer staging manual* (eds Edge, S. B. *et al.*) 191–195 (Springer, 2010).
52. Kleiner, D. E. *et al.* Design and validation of a histological scoring system for nonalcoholic fatty liver disease. *Hepatology* **41**, 1313–1321 (2005).
53. Neuschwander-Tetri, B. A. & Caldwell, S. H. Nonalcoholic steatohepatitis: summary of an AASLD Single Topic Conference. *Hepatology* **37**, 1202–1219 (2003).
54. Scheuer, P. J. Classification of chronic viral hepatitis: a need for reassessment. *J. Hepatol.* **13**, 372–374 (1991).
55. LeSage, G. D. *et al.* Hemochromatosis: genetic or alcohol-induced? *Gastroenterology* **84**, 1471–1477 (1983).
56. Ritchie, M. E. *et al.* limma powers differential expression analyses for RNA-sequencing and microarray studies. *Nucleic Acids Res.* **43**, e47 (2015).
57. Phipson, B., Lee, S., Majewski, I. J., Alexander, W. S. & Smyth, G. K. Robust hyperparameter estimation protects against hypervariable genes and improves power to detect differential expression. *Ann. Appl. Stat.* **10**, 946–963 (2016).
58. Yu, G., Wang, L. G., Han, Y. & He, Q. Y. clusterProfiler: an R package for comparing biological themes among gene clusters. *Omic J. Integr. Biol.* **16**, 284–287 (2012).
59. Ducroux, A. *et al.* The Tudor domain protein Spindlin1 is involved in intrinsic antiviral defense against incoming hepatitis B virus and herpes simplex virus type 1. *PLoS Pathog.* **10**, e1004343 (2014).

Acknowledgements

This study was funded by the Third Cancer Plan, ITMO Cancer of the French National Alliance for Life Sciences and Health (ENV201408); L.C. was a recipient of a doctoral fellowship from French National Research Institute for Sustainable Development (IRD) (EMHE-ARTS-2016-878573B); J.P.C. was a recipient of a doctoral fellowship from the Peruvian National Council for Science and Technology (212-2015-FONDECYT); and L.C., E.R., and S.C. were supported by the Young Research Teams Associated with IRD Program (INCancer). The funders had no role in study design, data collection and analysis, decision to publish, or preparation of the manuscript. The authors wish to acknowledge all patients whose participation was essential to the achievement of this study. The authors are grateful to Karina Cancino, Juan Jose Contreras, Dany Cordova, Franco Doimi, Macarena Farias, Ruddy Liendo, and Maricarmen Valera from the INEN Cancer Research Biobank for their leadership in aggregating medical information; Alain Fautrel and staff members from the H2P2 platform for their technical support; Jamila Faivre from the Paris-Sud University and Benoît Terris from the Paris University Hospitals Centre for their critical discussions; and Elizabeth Elliott and Brian Gadd for their valuable editorial assistance.

Author Contributions

E.R., E.D., P.P. and S.B. contributed to conception and design of the study. L.C., J.P.C., E.R., A.M., S.C., L.T., P.P. and S.B. contributed to the data acquisition. L.C., J.P.C., B.T., A.M., G.M., P.P. and S.B. contributed to the analysis of the data. L.C., B.T., P.P. and S.B. contributed to interpretation of the data. L.C., E.D., P.P. and S.B. contributed to writing and editing the manuscript. All authors reviewed the manuscript.

Additional Information

Supplementary information accompanies this paper at <https://doi.org/10.1038/s41598-018-28286-0>.

Competing Interests: The authors declare no competing interests.

Publisher's note: Springer Nature remains neutral with regard to jurisdictional claims in published maps and institutional affiliations.



Open Access This article is licensed under a Creative Commons Attribution 4.0 International License, which permits use, sharing, adaptation, distribution and reproduction in any medium or format, as long as you give appropriate credit to the original author(s) and the source, provide a link to the Creative Commons license, and indicate if changes were made. The images or other third party material in this article are included in the article's Creative Commons license, unless indicated otherwise in a credit line to the material. If material is not included in the article's Creative Commons license and your intended use is not permitted by statutory regulation or exceeds the permitted use, you will need to obtain permission directly from the copyright holder. To view a copy of this license, visit <http://creativecommons.org/licenses/by/4.0/>.

© The Author(s) 2018

2) Section 2

2.1) Description of the tumor phenotype of patients with NC-HCC

The NC-HCC developed in Peruvian patients, is characterized by:

- Age's bimodal distribution, with a preference for young people
- A large tumor size
- High levels of AFP
- A strong presence of HBV infection

However, beyond the clinical and molecular spectrum, new histological patterns associated with a particular spectrum of mutations that have a clinical representation have recently been reported, such as the massive trabecular type described by Calderaro *et al.*(211). Due to this, we have decided to investigate the histological component of the tumor itself, for which we have performed a histological review of the tumors of Peruvian patients diagnosed with NC-HCC

2.1.1) Material and methods

2.1.1.1) Ethics approval and consent to participate

Written informed consent was provided by participants for their information and samples to be stored in the INEN Department of Cancer Statistics and Epidemiology (for medical records), the INEN Department of Pathology (for paraffin embedded tissues specimens) and INEN Cancer Research Biobank (for frozen tissues) used for research. When the patient was non-adult, a parent provided the informed consent on his behalf. The present study was carried out in strict accordance with the ethical principles contained in the up-to-date Declaration of Helsinki and was approved by the INEN Human Subjects Committee, protocol numbers #008-2010-CRP-DI/INEN and #113-2014-CIE/INEN.

2.1.1.2) Patients

Our retrospective study collected samples of patients undergoing liver surgery at the National Institute of Cancer (Lima-Peru) between the years 2010-2015. To perform a correct histological analysis, the following inclusion criteria were considered:

- Patients with diagnosis of HCC
- Patients with HCC developed in non cirrhotic liver, fibrosis stages 0 – 3
- Tumor samples with less than 50% necrosis

Finally, 66 patients met the inclusion criteria, and which their clinical records were obtained for collection of epidemiological information (age, sex, place of origin, date of diagnosis, date of operation) and laboratory (levels of alpha fetoprotein, serology for HBV and HCV, total bilirubin, AST, ALT, GGTP, LDH, albumin, and prothrombin time)

2.1.1.3) Paraffin-embedded blocks, H&E slides and frozen tissues

Samples of tissue embedded in paraffin and slides of H&E stain were collected from pathology department from INEN, for each selected patient.

Histo-morphological examination of the tumor was developed from entire case, considering all H&E slides and the following criteria was taking for the analysis:

- I. The histological grade, according to WHO scale
- II. Architectural patterns were described according WHO patterns.
- III. Tumor extension, lymph-vascular invasion, perineural invasion and surgical margins were considered according College of American Pathologist checklist.

The review of the histopathological material was carried out by two pathologists (LC and BT).

2.1.1.4) Preparation of the TMA

After histopathological analysis, a tissue microarray (TMA) was performed from the 66 selected cases. A previous selection of the most representative area of each tumor was made from the H&E slides. For the preparation of the TMA two spots were considered for each sample, with a diameter of 2 mm for each one, in addition to a control spot at the start of each TMA was added for the subsequent orientation of the same. The TMA was elaborated using MiniCore® Version 1.1.0.0, Alphelys SAS. The creation of the template with the spots of each fabric was developed with EasyTMACreaton 1.0.0.12® Excilone SARL software. A block of TMA was obtained as a result of this process, TMA was used just for immunohistochemical analysis.

2.1.1.5) Immunohistochemical antibodies protocols for TMA stain

As a first step in our study, we decided to carry out an immunohistochemical analysis, using markers to determine if this type of tumor is of liver strain (Glypican, AFP), the presence of a stem cell component (CK19, Epcam, CD133, CD117) and the presence of altered molecular pathways (p53, β -catenin, Glutamine Synthetase)

The protocol for processing every slide was, as follow: paraffin-embedded tissue was cut at 4 μ m thichness, mounted on positively charged slides and dried at 58°C for 60 minutes. The table 6 summarizes the procedures performed for each antibody.

Every antibody was tested according positive and negative control for evaluate this correct function and avoid false postivie results.

Antibody	Stainer Kit	Buffer solution (pH)	Incubation time and temperature	Primary antibody (Distributor)	Dillution	Secondary antibody
<u>Hepatic profile</u>						
AFP	Ventana CHROMO MAP	Tris pH6	32' – 37°	Anti AFP (ABCAM)	1/500	Rabbit
Glutamine Synthetase	Ventana DAB MAP	Tris pH6	60' – 37°	Anti-GS (BD BIOSCIENCE)	1/50	Mouse
Glypican	Ventana CHROMO MAP	Tris pH8	60' – 37°	Anti-Glypican (CELL MARQUE)	1/50	Mouse
<u>Stem cells markers</u>						
CK19	Ventana DAB MAP	Tris pH8	60' – 37°	Anti cd117 (Dako)	1/200	Goat/Rabbit
CD133	Ventana DAB MAP	Tris pH8	60' – 37°	Anti-CD133 (PROMAB)	1/200	Goat/Mouse
CD117	Ventana DAB MAP	Tris pH8	60' – 37°	Anti-CD117 (DAKO)	1/200	Rabbit
EpCAM	Ventana OMNI-MAP	Tris pH8	32' – 37°	Anti-Epcam (BIOSCIENCES)	1/50	Mouse
<u>Molecular pathways</u>						
P53	Ventana CHROMO MAP	Tris pH8	60' – 58°	Anti P53 (Santa Cruz)	1/200	Rabbit
β-catenin	Ventana CHROMO MAP	Tris pH8	60' – 37°	Anti β -catenin (BD BIOSCIENCE)	1/100	Mouse

Table 5: Antibody list for immunohistochemical profile in of peruvian HCC

2.1.1.6) Transcriptomic analysis

About 50 mg of both HCC and parent NTL matched pair were harvested from the resected surgical pieces, flash-frozen in liquid nitrogen, and stored at - 80 °C (INEN Cancer Research Biobank). Total RNA was later isolated from flash-frozen NTLs using TRI Reagent® (Sigma-Aldrich) and Lysin Matrix D homogenization system (MP Biomedicals), according to manufacturer's instructions. RNA integrity and quantity were assessed using the RNA 6000 Nano LabChip® Kit (Agilent Technologies) and a 2100 Bioanalyzer System (Agilent Technologies), as well as with the Qubit® RNA Broad-Range Assay Kit (Invitrogen). About 100 ng of total RNA [with RNA integrity number (RIN) >7] were used to evaluate gene expression using GeneChip™ Human Transcriptome Array 2.0 (Applied Biosystems), according to the manufacturer's instructions. Gene expression analysis was performed using the limma software standard pipeline (R/Bioconductor) at a significance level of 0.05 with no false discovery rate controlling procedure. Genes differentially expressed were selected in order to complete a gene enrichment analysis using clusterProfiler software (R/Bioconductor) and the Gene Ontology database (Gene Ontology Consortium) for biological process, with a 0.05 significance level.

2.1.1.7) Pathway-centric approach of transcriptomic data

Gene expression data were normalized using Robust Multichip Average (RMA) algorithm. RMA normalized data was collapsed using a collapse microarray software (collapse_genes-09, Fred's Softwares). The pathways-centric approach was performed using the Sample Enrichment Score (SES) algorithm, following the recommended workflow (414). As recommended, SES control experiments were performed using developers proposed gene sets: 1000 Random Gene Set (1000_RGS) and, gender gene sets (female and male).

Using SES, we evaluated four publicly available and curate databases compiled by the algorithm developers: Kegg, Reactome (reactome_2018803), Gene

Ontology - Cellular component (C5_CC) and MsigDB Hallmarks (H). Obtained scores for each sample were classed in Known-pattern (Acinar, Solid and Trabecular) and New-pattern, and compared. The significant different (T-student) pathways/gene sets were defined after applying a threshold of $p < 0.05$ and fold change of < 0.7 and > 1.5 .

2.1.1.8) Analysis of data

Medical information was inputted on Numbers[®] software version 5.3 (Apple Corporation). All statistical analyses were performed in R version 3.5.1, "Feather Spray"(R Foundation) with a 0.05 significance level.

An analysis of principal components was initially developed to obtain the most important variables for histological categories. The architectural patterns were considered as a grouping criterion. Forward an analysis of an unsupervised hierarchical cluster was carried out at first to determine if there was a pattern of grouping between the different patterns. In order to classify if the different parameters corresponded to some type of particular pattern. Values of p less than 0.05 were accepted as significant results.

Survival analysis, by Kaplan-Meier method, was done between all histological patterns.

2.1.1.9) Results

Patients

A total of 66 patients were enrolled in this study. This group of patients presented with the bimodal distribution already described by Bertani *et al.* (270) in Peruvian patients with HCC.

Table 6 summarized clinical data for both group of patients

Variable	Group < 40 years N = 40	Group > 40 years N = 26	P.value
Sex			0.53
<i>M</i>	28	20	
<i>F</i>	12	6	
HBV			0.001
<i>Positive</i>	31	9	
<i>Negative</i>	6	7	
AFP (mg/dl)			0.9
<i>Mean</i>	163446.9	217225.2	
<i>Sd</i>	+/- 242719.8	+/- 325176.6	
Alkaline phosphatase (U/L)			0.02
<i>Mean</i>	195.29	329.95	
<i>Sd</i>	139.32	292.51	
Albumin (gr/l)			0.06
<i>Mean</i>	42.82	38.78	
<i>Sd</i>	6.70	9.67	
Prothrombin Time (sec)			0.6
<i>Mean</i>	13.39	13.42	
<i>Sd</i>	1.51	1.40	

Table 6: Clinical features of Peruvian patients

Histological analysis

Of the cases examined, 11 patients (16%) presented with acinar histological pattern (19%), 13 with solid pattern (19%), 28 with trabecular pattern (42%) and 14 with an undescribed pattern (21%). No preferential histological pattern was found according to the distribution of age groups ($p = 0.94$). We would like to emphasize that no cases were found, especially in young patients, with the histological characteristics described for the fibrolamellar variant of HCC.

Of the 14 patients who presented this "undescribed pattern" 9 were of under 40 group (64.28%) and 5 (35.71%) belonged to the group of over 40 ($p=0.28$).

The pattern not yet described, which we have called "new pattern" is characterized by presenting a macrotrabecular architecture, its most outstanding feature being the presence of two cell populations arranged in a characteristic manner within each trabecula (figure 18).

- A population of cells of medium size, elongated - cubic, with acidophilus cytoplasm, whose nuclei are oriented towards the center of the trabecula. This population is located on the periphery of the trabecula and follows a palisade distribution (figure 18 C)
- A central cell population, medium to large in size, with abundant light-colored cytoplasm, in many of them we can find intracytoplasmic lipid inclusions. Their nuclei are of moderate to small size, basophilic and central location. However, in cases where intracytoplasmic inclusions are found, nuclei can be pushed to the periphery. This population is organized irregularly in the center of the trabecula (figure 18 D)

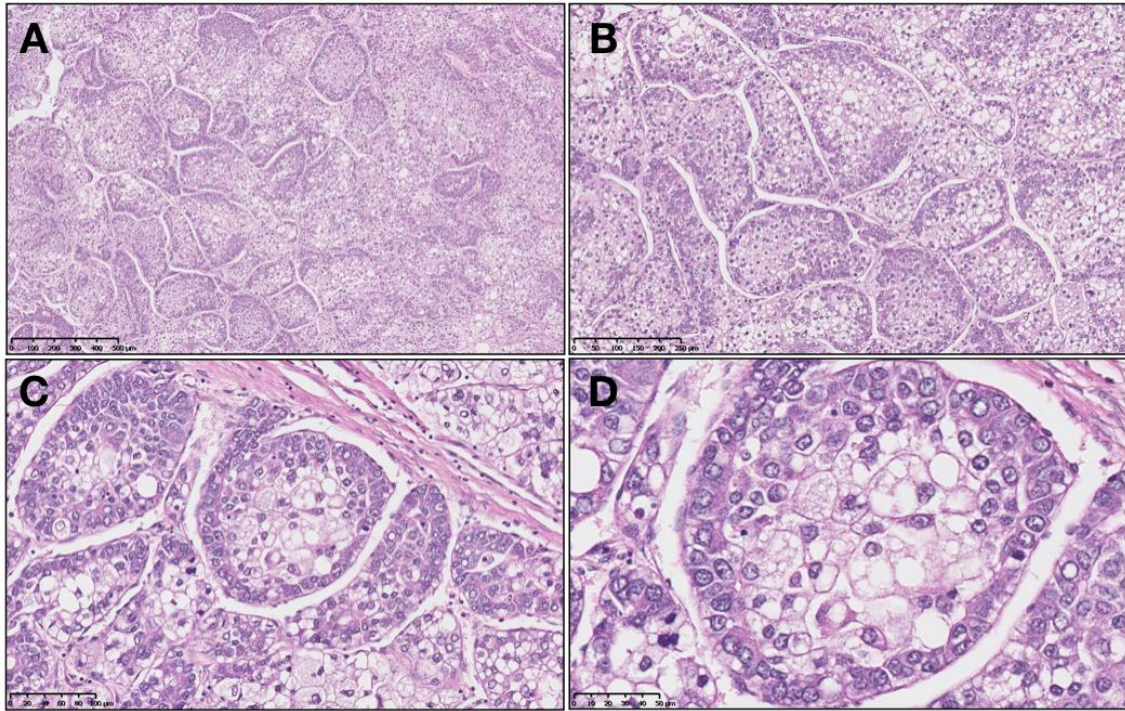


Figure 18: Hematoxylin-Eosin slides for New Pattern

A) 40x resolution, we can observe the macrotrabecular architecture. B) 100x the presence of 2 cellular populations, one peripheral and the other central, is accurately observed. C) 200x we observe in better detail the cellular disposition of the periphery, characterized by an eosinophilic cytoplasm, cytoplasm nucleus ratio 1: 1 D) 400x we observe in better detail the cellular characteristics of the central population, of clear cytoplasm, lateralized nucleus and the presence of intra-cytoplasmic vesicles

Clinical variables and histologic patterns were studied, table 7 summarized the results

<i>Variable</i>	<i>Acinar</i>	<i>New Pattern</i>	<i>Solid</i>	<i>Trabecular</i>	<i>P.value</i>
AFP					0.68
Mean	111106.9	373308.5	71158.14	167655.6	
Sd	+/- 204417	+/-423532.2	+/-158656.6	+/-217933.2	
AP					0.18
Mean	362.5	244.6	208.16	222.56	
Sd	+/-355	+/-183.6	+/-111.3	+/-202.9	
Albumin					0.20
Mean	41.2	36.2	42.6	42.8	
Sd	+/-5.80	+/-12.8	+/-5.28	+/-7.05	
PT					0.34
Mean	14.2	13.5	13	13.3	
Sd	+/-1.52	+/-1.68	+/-1.32	+/-1.35	

Table 7: Laboratory test according histological patter

Inmunohistochemical analysis

IHC results for all patterns are summarized in table 8, and expression of IHC markers in new pattern tumors are show in figure 19.

<i>Antibody</i>		<i>Acinar</i> (n=11)	<i>Trabecular</i> (n=28)	<i>Solid</i> (n=13)	<i>New pattern</i> (n=14)	<i>P.value</i>
<i>AFP</i>	<i>Positive</i>	2 (18.18%)	4 (14.28%)	6 (46.15%)	3 (21.42%)	0.16
	<i>Negative</i>	9 (81.81%)	23 (82.14%)	7 (53.84%)	11 (78.57%)	
<i>Glutamine Synthase</i>	<i>Positive</i>	8 (72.72%)	20 (71.42%)	7 (53.84%)	12 (85.71%)	0.38
	<i>Negative</i>	3 (27.27%)	5 (17.85%)	5 (38.46%)	2 (14.28%)	
<i>Glypican3</i>	<i>Positive</i>	9 (81.81%)	15 (38.18%)	8 (61.53%)	8 (57.14%)	0.32
	<i>Negative</i>	1 (9.09%)	11 (39.28%)	5 (38.46%)	4 (28.57%)	
<i>CK19</i>	<i>Positive</i>	0	0	0	0	N.A
	<i>Negative</i>	11 (100 %)	27 (96.42%)	12 (92.30%)	11 (84.61%)	
<i>CD133</i>	<i>Positive</i>	0	0	0	0	N.A
	<i>Negative</i>	11 (100%)	27 (96.42%)	13 (100%)	14 (100%)	
<i>CD117</i>	<i>Positive</i>	1 (9.09%)	1 (3.57%)	1 (7.69%)	0	0.74
	<i>Negative</i>	9 (81.81%)	25 (89.28%)	12 (92.30%)	9 (64.28%)	
<i>EpCAM</i>	<i>Positive</i>	8 (72.72%)	15 (38.38%)	7 (53.84%)	8 (57.14%)	0.14
	<i>Negative</i>	1 (9.09%)	11 (39.28%)	5 (38.46%)	1 (7.14%)	
<i>p53</i>	<i>Positive</i>	2 (18.18%)	2 (7.14%)	1 (7.69%)	2 (14.28%)	0.73
	<i>Negative</i>	9 (81.81%)	25 (89.28%)	11 (84.61%)	11 (78.57%)	
<i>β-catenin (membrane)</i>	<i>Positive</i>	10 (90.90%)	20 (71.42%)	10 (76.92%)	11 (78.57%)	0.59
	<i>Negative</i>	0	4 (14.28%)	2 (15.38%)	2 (14.28%)	

Table 8: Antibody's list used for analysis of histological patterns

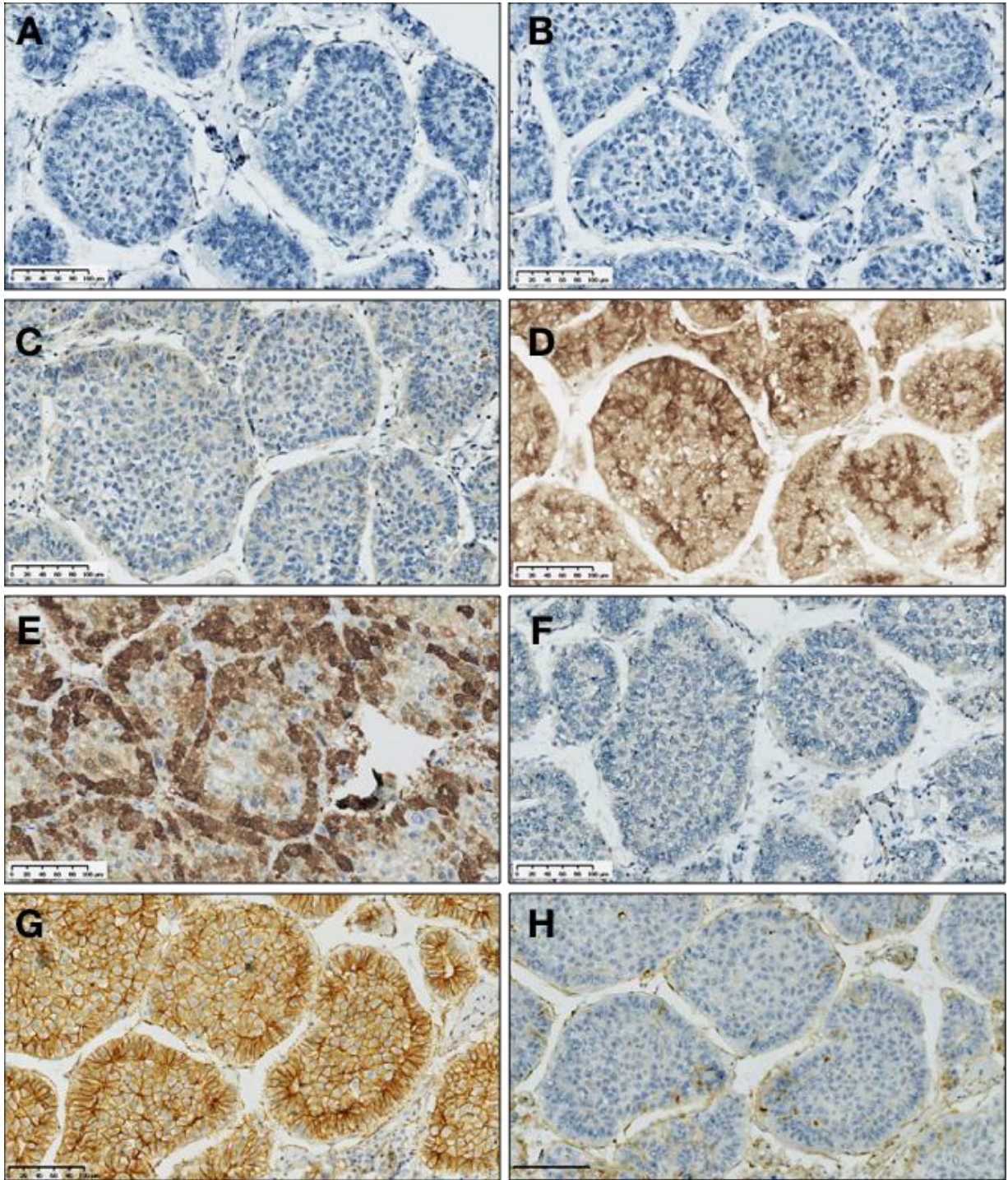


Figure 19: Expression of IHC in "New pattern" tumor

A) CK19 is totally negative. B) CD117 is not expressed in the tumor cells. C) P53 presents a nuclear expression in some cells. D) Glypican3 is completely positive. E) Glutamine Synthetase is expressed in the cell population of the periphery. F) CD133 is not expressed in the tumor cells. G) Expression of β -catenin in the cell membrane, without nuclear expression of the marker has been evidenced. H) AFP does not express possibility in tumor cells. Magnification 20x

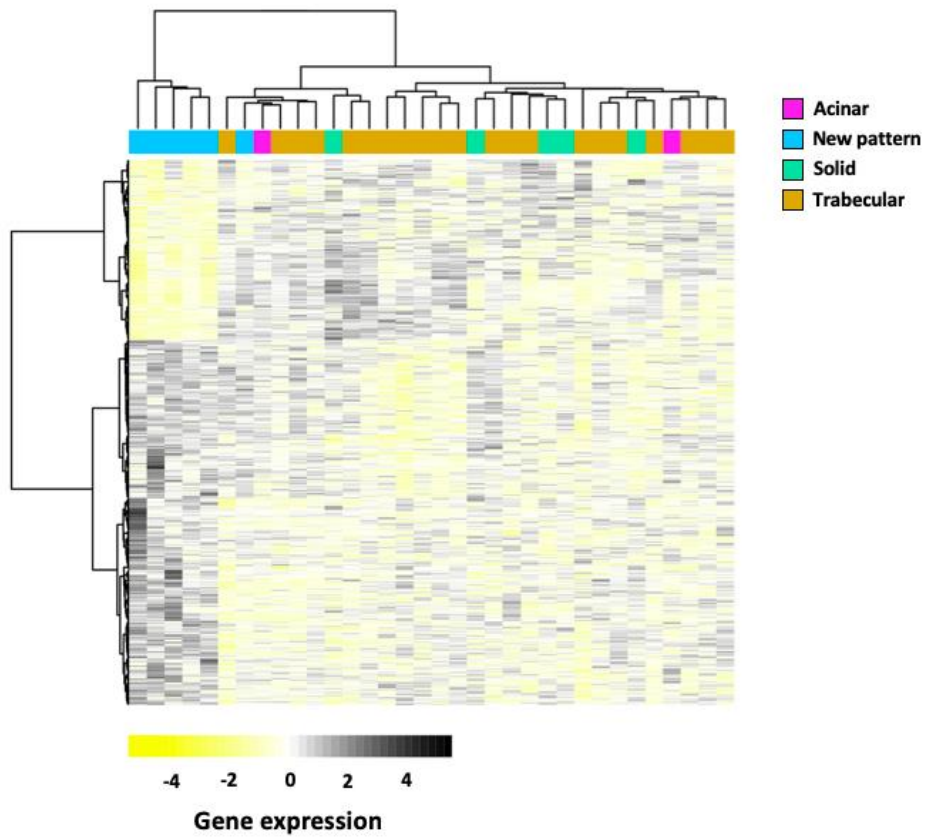
Transcriptomic analysis

34 patients had frozen samples, and good RNA quality. Of the total of patients 6 were classified as "New Pattern". Interestingly, differential analysis reveals a contrast in gene expression for both groups (figure 20A). As up-regulated genes we found the LPA (Lipoprotein A) gene ($p = 0.008$), which is related to the development of diseases such as pancreatic sarcoma and peripheral vascular disease, in addition the expression of this marker is commonly decreased in patients with chronic liver diseases, as well as in patients with hepatitis B virus infection, becoming undetectable in cases of liver cirrhosis. The MBL2 gene (Mannose Binding Lectin 2) ($p = 0.04$) expressed too in the New pattern. This gene is associated with regulatory mechanisms in immune processes, as well as within the complement pathway.

While, within the set of down-regulated genes we find very interesting a whole subgroup of the HLA family. Likewise, other genes such as CD74 ($p = 0.002$), and CD97 ($p = 0.002$) both related in immune processes and also in the development of undifferentiated pleomorphic sarcoma, mucinous carcinoma of the lung and thyroid cancer have been found altered between both groups. The GeneOntology analysis found groups of genes corresponding to the pathways of Alograft rejection, Graf-vs-host disease, diabetes mellitus type 1, which are down-regulated in the New pattern compared to the other histological types (figure 20B).

Similarly, the gene set analysis found that groups of genes associated with immunity, vitamin A metabolism, oxidative stress and RUNX1 which are differentially expressed between the new pattern and the other histological types (figure 21).

A



B

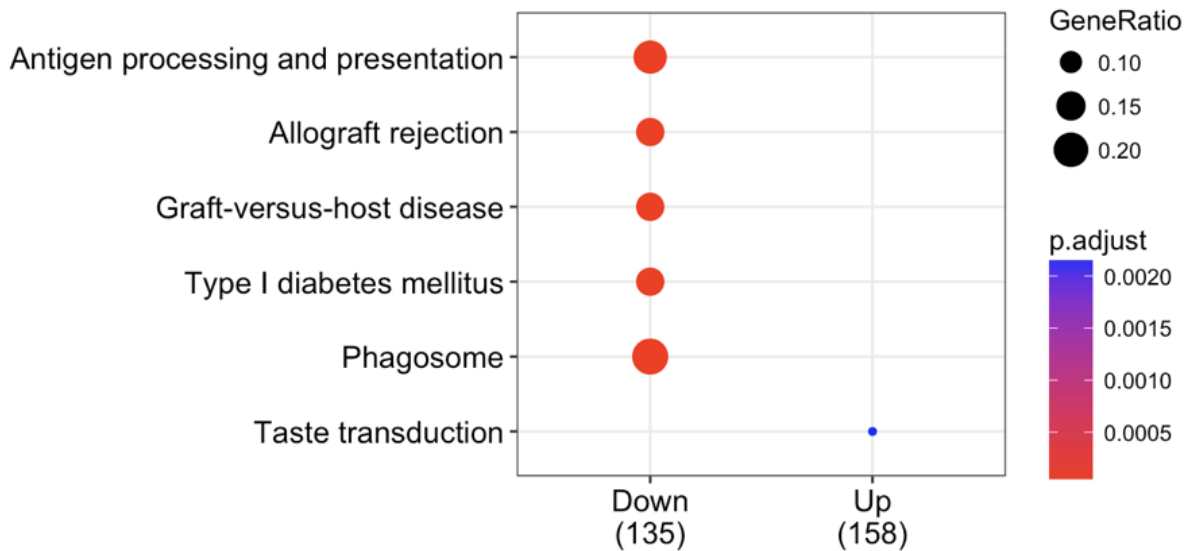


Figure 20: Transcriptomic analysis.

A) Hierarchical cluster - Heatmap for gene expression, between New and conventional patterns. A significant group of genes is down-regulated (yellow) in a New pattern compared to traditional patterns. B) GeneOntology analysis, we observe the principal sets that are downregulated in in New pattern.

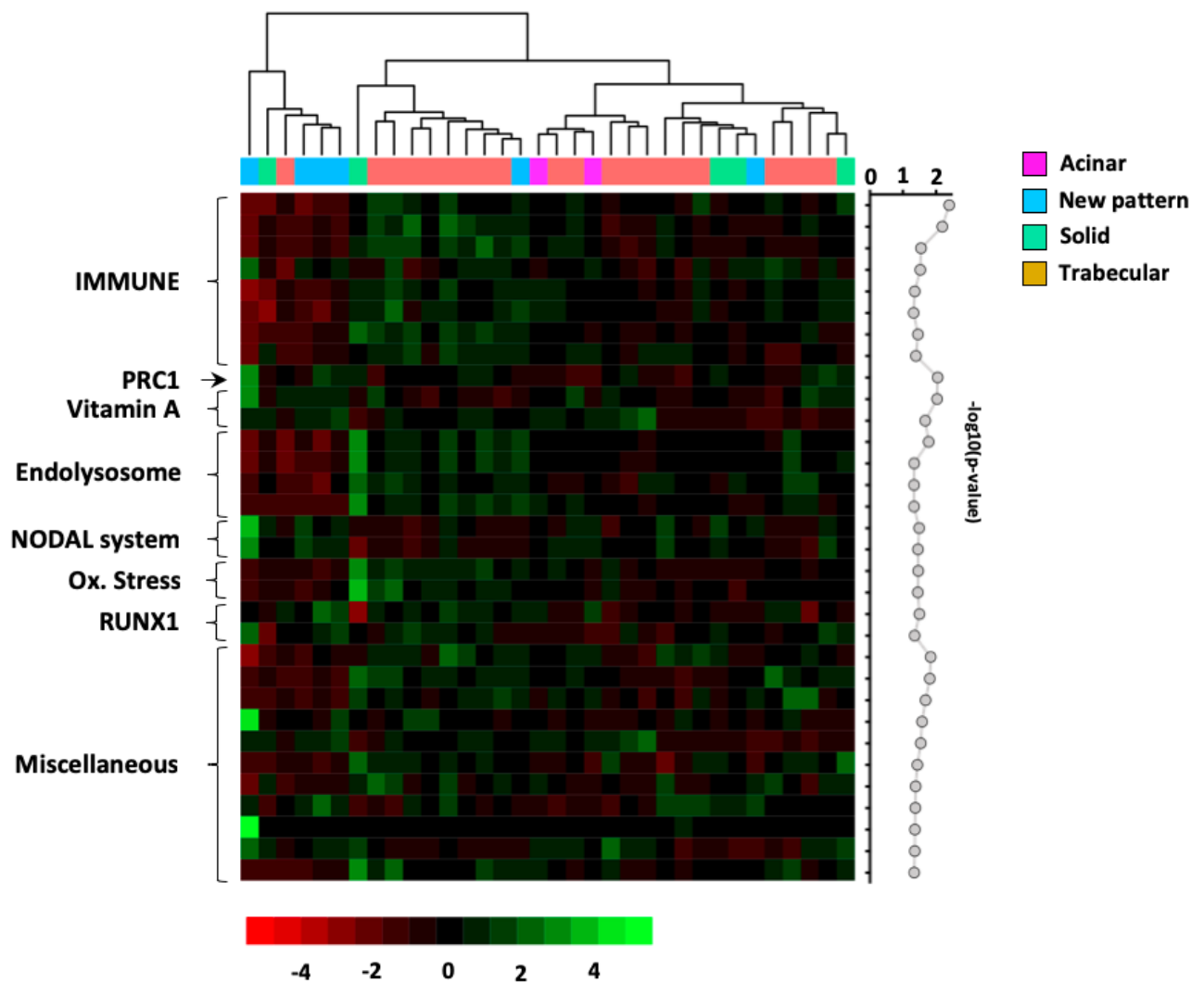


Figure 21: Sample Enrichment Score (SES) analysis of histological patterns.

In order to investigate if some Gene sets are principally affected in New pattern. We established a comparison between patterns. Finally, we showed 33 gene sets with significant values ($p < 0.05$). However, the most significant values were found for PCRA, Vitamin A and immune system gene set.

Survival analysis

Patients with diagnosis of new pattern of NC-HCC had a half-life of 48 weeks, compared to 132 weeks for patients with others patterns ($p=0.0022$) (figure 22). By Kaplan-Meier analysis, this the new pattern was associated with a lower survival in relation to three the others patterns ($p = 0.008$)

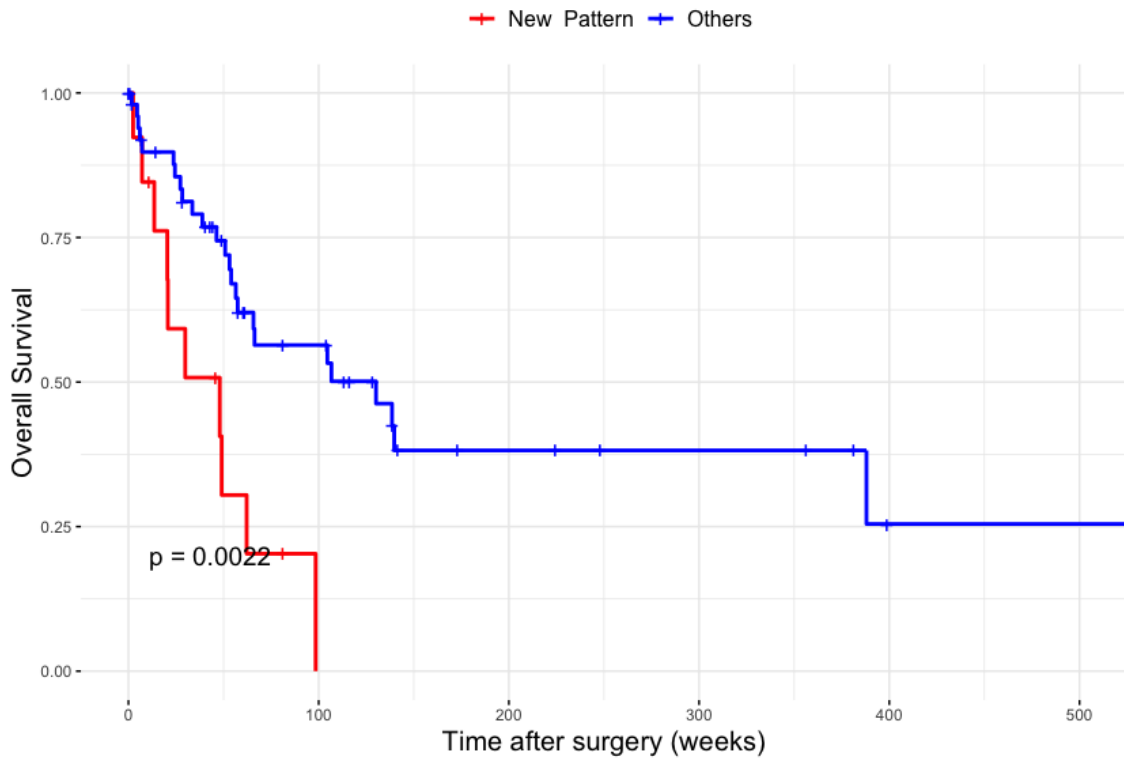


Figure 22: Survival Analysis for “New pattern”.

“New pattern” vs others histological patterns. A significant decrease in survival is observed, approximately 100 weeks, for those affected with the New pattern.

Discussion

Hepatocellular carcinoma not associated with a chronic disease, that is, free of cirrhosis (NC-HCC), has an overall incidence of only 20% (202). However, recently it has been described that the NC-HCC on the Peruvian population, represents 80% of all cases of HCC (270,415).

As already report by Bertani *et al.*(270). This group of patients is clinically peculiar as it presented with i) a bimodal age distribution whose cut-off point is 40 years. ii) very high levels of AFP (mean = 337.777 ng/ml), iii) a large tumor size, whose average diameter is 14 cm.

Our work offers, for the first time, a histopathological perspective of the Peruvian NC-HCC. This study shows a new histologica pattern with a specific behavior. It is noteworthy that none of features correspond to fibrolamellar HCC (200). In the same way, these tumors did not correspond to hepatoblasoma, as non blastematous tissue was found despite representative sampling of the tumors.

Two types of hepatocytic liver tumor shared some features with our new pattern tumors: macrotrabecular massive tumor (MTMT) and transitional liver cell tumors (TLCT). The MTMT were recently described by Calderaro (210), and have been associated with p53 mutations in 50% of cases, levels of AFP more than 100 ng/ml in 50% of cases, and presence of HBV infection in 35%.

An important feature, in our new pattern tumors, is the presence of two cell populations in the same trabeculae. This has been reported in the stem cells variant of combinend hepatocellular and cholangiocellular carcinoma. Indeed, this type of tumor presents a peripeheral small cells component (positive to stem cell markers such as EpCAM, CK19, and CD56 (416), and a central cell population characterized by negative expression to all markers. However, if we have obtained a positive staining for EpCAM in isolated cases, there is no specific staining of peripheral cells. In the same way, the stains for CD133 and CK19 were negative.

This new histological pattern of NC-HCC, found in Peruvian patients, is not associated with clinical or biological specific data, but it showed a worse prognosis than classical patterns. This bad behavior is associated with pathological data such as tumor size and vascular invasion. Immunohistochemical study showed a specific feature, ie positive staining of the peripheral cells of trabeculae with anti GS antibody.

Integrative genomics conducted under the supervision of Dr. Pascal Pineau and Dr. Juan Pablo Cerapio established that Peruvian NC-HCC fell into the progenitor-like cluster of the proliferative class based on prognostic gene signature. In that respect, Peruvian NC-HCC was singularly enriched in genes involved in the Wnt/ β -catenin, Hippo/YAP1, and MYC signaling pathways, as well as in Polycomb epigenetic repressors and DNA repair effectors (e.g. TP53, BRCA1, and FANCD2). Overall, Peruvian NC-HCC is characterized by a significant gain of stem cell-like features at the transcriptomic level involving epigenome regulators, concomitant with massive loss in hepatocyte markers.

In addition, our results show that this new pattern presents a dysregulation of genes associated with the immune system such as CD97 and CD74, which have been described by Yin (417) and Lu (418) as factors of poor prognosis in patients with hcc. However, these studies have reported histologically specific characteristics such as those indicated

In conclusion, in this specific population composed of peruvian NC-HCC, we have identified a new histological pattern characterized by large trabeculae with two well-defined cells populations. This histological pattern is associated to a worse prognosis compared to others patterns.

3) Section 3

3.1) Analyze the relationship between environmental exposure to heavy metals in two cohorts and the clinical manifestations of the disease as well as in survival

As is well known, one of the main risk factors for the development of HCC is HBV infection. However, it is also known that various environmental agents such as heavy metals are capable of inducing carcinogenesis (419). In addition to having a synergistic effect on other pathogens. All this is thanks to the ability to generate ROS and break the antioxidant balance.

We also know that there is a preferential geographical distribution in young Peruvian patients with NC-HCC which overlaps with areas where mining activity is extensively developed.

In this context, the question: ¿do metals play a role in the carcinogenesis process of NC-HCC? it is mandatory. To answer this question, we have developed a study with two cohorts: a Peruvian and a French one of patients diagnosed with NC-HCC. Which present a clear difference in their socio-cultural contexts. We have performed an analysis using the ICP-MS technique to determine the concentration of metals in the samples of tumor and non-tumor tissue and to study the possible relationships of metals with clinical, histological and survival variables.

Currently in edition

The differential metallomic profiles of two cohorts of patients with non-cirrhotic liver hepatocellular carcinoma suggest the potential role of contaminating metals in the liver carcinogenesis process.

Luis Cano¹, Stephane Bertani², Marie Laure Island¹, Juan Pablo Cerapio³, Eloy Ruiz⁴, Pascal Pineau⁵, Valérie Monbet⁶, Martine Ropert¹, Bruno Turlin^{1§}, Olivier Loreal^{1§}.

¹ INSERM, Univ Rennes, INRA, CHU Pontchaillou, UMR 1241 NUMECAN, Rennes, France

² Université de Toulouse, IRD, UPS, UMR 152 PHARMADEV, Toulouse, France

³ Sorbonne Universités, UPMC Univ Paris 06, Institut Pasteur, Unité Organisation Nucléaire et Oncogénèse, Paris, France

⁴ Institut Pasteur, Unité Organisation Nucléaire et Oncogénèse, INSERM, U 993, Paris, France

⁵ Instituto Nacional de Enfermedades Neoplásicas, Departamento de Patología, Lima, Peru

⁶ IRMAR, INRIA/ASPI, Université de Rennes 1, Rennes, France.

§ correspondence: olivier.loreal@univ-rennes1.fr and bruno.turlin@univ-rennes.fr

Abstract

Hepatocellular carcinoma (HCC) may occur in non-cirrhotic liver (NC-HCC). Our goal was to characterize the relationships between NC-HCC and the metallomic profile in two cohorts of patients, one of which being more exposed to mining activity. **Patients and methods:** Tumor and non-tumor biopsies of 38 peruvian and 45 french patients were studied. Twelve metals were assayed using ICP-MS: Mn, Fe, Cu, Co, Zn, As, Se, Rb, Mo, Cd, Pb and Sn. Clinical data were collected and histopathological analysis performed. **Results.** The mean age of peruvian and french patients was 41 ± 20 and 68 ± 9 years respectively and a bimodal repartition was found in peruvian population. The sex ratio (M:F) was 2.1 / 1 and 8/1, respectively. 80% of peruvian patients were positive for the hepatitis B virus, without chronic hepatitis lesions, compared to only 9% of French patients. Consumption of alcohol was difficult to specify retrospectively. Higher concentrations of Cd, Co, Cu, Mn, Mo, Rb, Se, Zn and As were found in the non-tumor livers (NTL) of the peruvians patients ($p < 0.05$), As being only significantly detected in Peruvians. In the tumor areas of both cohorts, metal concentrations were lower compared to NTL, except for Cu, which was in higher concentration ($p < 0.05$). Survival study using a Cox model showed that the survival time, in the Peruvian population who did not benefit from treatment complementary to surgery, was associated with a higher concentration of Se in the tumor. Conclusion: Our results show that : i) the concentration of metals is higher in the non-tumor liver of the peruvian compared to frenchs; The role of exposure to metals in this mining zone is possible, and ii) the process of tumorigenesis

similarly affects the cell metabolism of metals, regardless the origin of the population and the pathological associations.

Introduction

Hepatocellular carcinoma (HCC) is the most frequent primary liver cancer, the sixth most common cancer in worldwide (13) , and the third cause of death by cancer. Many factors are involved in the genesis of HCC, most of them being related to chronic liver insult. Thus, HCC is multistep pathogenic process leading to inflammatory damage and hepatocyte necrosis, that provoke hepatic fibrosis and finally cirrhosis (420). However, 20 % of HCC cases may occur in patients not exhibiting a cirrhotic liver.

These “non-cirrhotic HCC” (NC-HCC) have a particular “bimodal” age distribution, with peaks at 2nd and 6-7th decades of life, male predilection, and low levels of alpha fetoprotein (AFP) (237). In Peruvian population, it has been recently described a high incidence of NC-HCC occurring in young patients with positivity of hepatitis B serologic markers. NH-HCC are characterized by are a very large tumor size (>10 cm), extremely high levels of AFP and a unique spectrum of genetic mutations (272,421). Despite the potential role of viral hepatitis B in the HCC occurrence, the absence of inflammation and cirrhosis in the liver of Peruvian patients developing NC-HCC direct us to search additional factors that could participate in the carcinogenesis process.

Metals have been reported being cofactors that may favor the occurrence of HCC. Thus, during iron overload diseases related to genetic causes in hereditary hemochromatosis the occurrence of HCC is a major complication that may occur on non-cirrhotic liver. (422). The role of oxidative stress and reactive oxygen species is strongly suggested. Arsenic is also a metal associated with the development of HCC and more globally in carcinogenesis(423). In the other hand there are metals that are required for the activity of antioxidant defense system, such as Zn, Mn, Fe and Se (424,425).

The Peru is a country whose gross domestic product (GDP) depends on mining, that is carried out in a large part of the country, often illegally, leading to expose miners to reagents, such as As, that is used in mining without the necessary protection conditions for workers. Moreover, effluents of mining activity are released in nature and potentially contaminate ground, including crop areas and water in rivers

Therefore, our objective was to investigate the relationship between hepatic metal concentrations, and non-tumoral and tumoral HCC phenotype in a peruvian group of patients exhibiting a NC-HCC in comparison with a group of patients with NC-HCC of an independent geographic area.

Materials and methods

Study design, patient selection and ethical agreement

The present study was developed retrospectively on 2 cohorts, one Peruvian and one French. All patients included in the present study exhibited a NC-HCC, and were treated by surgical hepatic resection. For both cohorts, collected cryopreserved tissues and paraffin embedded tissues of tumor and non-tumor liver were evaluated. Bioclinical parameters were collected from clinical records. Finally, follow-up data for survival analysis were obtained from the national registry of identification (RENIEC) in the case of the Peruvian cohort. For French cohort the information was obtained from national obituary system.

The Peruvian cohort consisted of 38 patients who were hospitalized in the INEN between 2010 and 2016. The French cohort was made up of 45 patients hospitalized in the Rennes University hospital between 2014 and 2017. Participants from both cohorts were selected on their histopathological report, considering the diagnosis of NC-HCC. For peruvian cohort paraffin samples were obtained from INEN Pathology department and INEN Cancer Research Biobank. For French cohort samples were obtained from the Pathology department and Biological Ressources Center (CRB) in Rennes.

This study was carried out in strict accordance with the ethical principles contained in the up-to-date Declaration of Helsinki. The peruvian collection was approved by the INEN Human Subjects Committee, protocol numbers #008-2010-CRP-DI/INEN and #113-2014-CIE/INEN. Written informed consent was provided and signed by participants. Samples were stored in the INEN

Department of Pathology (for paraffin embedded tissues specimens) and INEN Cancer Research Biobank (for frozen tissues) in Lima, Peru. For the French cohort, the biological material used as well as the clinical records data complied with the norms established by the legislation and of French Ethic Committee.

Histological analysis

Formalin-fixed, paraffin-embedded tissues (FFPE) and hematoxylin–eosin (H&E) slides were obtained from INEN Department of Pathology and CHU Rennes. We get new slides from non tumor FFPE which were colored using the Masson's Trichrome Stain Kit, Artisan™ (Dako), according to the manufacturer's instructions, stain was performed on the Histo- Pathology High Precision (H2P2) platform - ISO 9001 certified – UMS Biosit, within of the University of Rennes, France.

Histopathological analysis of tumor comprises architecture and grading (G1-G4) according to the World Health Organization (200) and of the American Joint Committee on Cancer (426) classifications, respectively. Liver fibrosis stage (0–4) was then scored in accordance with the scoring system for fibrosis and cirrhosis described by Scheuer (427). All histopathological parameters were independently evaluated by two pathologists (LC, BT). In case of divergence a consensus was adopted.

Trace elements quantification

All samples were treated to avoid environmental metal contamination. Tumor and no tumor samples were desiccated for overnight at 120°C in oven. Then, dried samples were weighed and mineralized by nitric acid solution in Teflon PFA-lined

digestion vessels. Acid digestion was carried out at 180°C using ultrapure concentrated HNO₃ (69%) (Fisher Chemical Optima Grade) in microwave oven device (Mars 6, CEM®). The elements studied were: manganese (⁵⁵Mn), iron (⁵⁶Fe), copper (⁶³Cu), cobalt (⁵⁹Co), zinc (⁶⁶Zn), arsenic (⁷⁵As), selenium (⁷⁹Se), rubidium (⁸⁵Rb), molybdenum (⁹⁶Mo), cadmium (¹¹²Cd), tin (¹¹⁹Sn), lead (²⁰⁷Pb). All these were measured by Inductively Coupled Plasma Mass Spectrometry (ICP-MS) in a X-Series II from Thermo Scientific® equipped with collision cell technology (Platform AEM2, Biochemical Laboratory, Rennes1 University/–Rennes hospital). The source of plasma was argon (purity degree >99.99%) (428).

The collision/reaction cell used was pressurized with a mixture of helium (93%) and hydrogen (7%) ; argon and hydrogen are were provided for Messer®. Ultra-pure water was provided from Milipore Direct-Q® 3 water station. Nitric acid solution utilized at 69% (Fisher Chemical – Optima Grade®). The rhodium was used like internal standard (Fisher Scientific®). Calibration ranges were realized using a multi-element solution (SCP Science® Plasma Cal). The performance was calibrated using multi-element solutions, tune F and tune A (Thermo®). Certified reference materials (bovine liver ZC71001 were obtained from NCS Testing Technology (Beijing, China).

Statistics.

Data collected were inputted on Numbers® software version 5.3 (Apple Corporation). All statistical analyses were performed in R version 3.5.1, "Feather Spray" (R Foundation). The comparative analyzes between both populations

were performed with the Mann-Whitney test. For survival analysis surgery date was considered as the starting parameter for the calculation of survival. The date presence of active disease by tomography or analysis was considered for criteria of date of recurrence. Univariate COX regression model was done with all variables. Later all variables with significant values were used in multivariate model, the resulting model was improved with backward and forward stepwise regression. Finally, evaluation between all models was done with AIC index. Best model was selected from lower AIC value. Finally, we used metal's concentration average for create groups (over and under the average) and develop comparative analysis of survival between them.

Results

Clinical data and histological data

Table 1 summarizes all the clinical and histopathological findings between both cohorts. At diagnosis, the average age for Peruvian cohort was 40.6 years (sd +/- 20.14). The characteristic expected bimodal distribution was found in peruvian's patient group. The average of age for the French cohort was 67.9 years, (sd +/- 9.34). A significant difference was found for the age of diagnosis between both cohorts ($p < 0.001$).

The Peruvian cohort presented a total of 26 men (68.4%) and 12 women (31.6%) with sex ratio (M:F) of 2.1/1, whereas in the French cohort there are 5 women (11.1%) and 40 men (88.9%), with a sex ratio of 8/1. A significant difference was found for gender between both cohorts ($p = 0.02$)

The presence of hepatitis B in the Peruvian cohort was reported for 15 patients (48.38 %), whereas in the French cohort we found only 2 (5 %) with serology positive for HBV, a significant difference was found between both cohorts ($p < 0.001$).

From the pathological point of view, significant differences were found: in the tumor size ($p < 0.001$) that was greater in peruvian cohort. The French cohort presented many more cases of undifferentiated HCC compared to the Peruvian cohort, where no undifferentiated cases were observed ($p < 0.01$).

Determination of hepatic metal concentrations

Table 2 summarizes the concentration of metals in the non-tumor liver for both cohorts. Within the 12 metals evaluated, 9 of them (As, Cd, Co, Cu, Mn, Mo, Rb, Se, Zn) had higher concentrations in Peruvian patients. Among those metals the presence of known toxic metals such as cadmium and arsenic were found, the latter being found only in the Peruvian cohort. One metal whose concentrations were highest in French patient group was tin. Also, iron and lead are also elevated in the non-tumor tissue of the French cohort in relation to Peruvian. However, no significant differences were found between both cohorts.

Table 3 summarizes the concentration of metals in tumor between both cohorts. As in the non-tumor counterpart, Peruvian patients had a higher concentration of metals in their tumor tissue. The arsenic was found again exclusively in the Peruvian cohort. Lead and tin concentrations were higher in the French cohort. The iron concentrations in the tumor tissues of French patients were triple the value found in Peruvian patients.

In general, we have showed that metal concentrations are much higher in non-tumor tissues. Except for copper, which is always higher in the tumor tissue of both cohorts. It is noteworthy that, although copper concentrations are higher in tumor tissue (49.40 ± 87.5 ug/gr) compared to non-tumor (25.27 ± 31.11 ug/gr) we have not found a significant difference in the French cohort ($p = 0.22$).

In addition, metals such as rubidium and lead are also higher in non-tumor tissue, but there is no significant difference within the French cohort also. (figure 2 and 3)

Survival analysis

Initially we developed comparative Kaplan-Meier analysis between both cohort, 7 patients from French cohort were retired from this analysis because their received pre-operative treatment.

Peruvian patients have a survival average of 65.7 week, whereas French have 148.4 weeks of survival average ($p=0.0071$).

A Multivariate cox proportional hazard ratio model was developed with all metals concentration, in tumoral and non tumoral tissues. Our results show that higher Se concentration was associated as protective factor ($p < 0.004$) and Pb as detrimental factor ($p = 0.011$), but in Peruvian cohort only.

Finally, based on the results of the COX regression model, we performed an analysis to assess the impact of metals on survival. For this, we use the values of selenium and lead, in the tumor and non-tumor tissue, to create two groups from the average concentration of each one (above and below the average). Our results show that, the group of patients with a selenium concentration greater than $1.49 \mu\text{g} / \text{gr}$ had an average survival of 323 weeks versus 49 weeks for patients below this threshold ($p = 0.033$). However, this result was significant only in the Peruvian group.

Discussion

Our study presents, for the first time, a comparative study of hepatic metallomic profiles among patients from different geographical locations, affected by NC-HCC, that is a disease escaping the conventional profile of HCC and representing only 20% of cases of HCC (202). However for the Peruvian reality, NC-HCC represents 80% of total cases of liver cancer (421). In addition, these tumors present another particular features as: bimodal distribution of age, large tumor size and elevated levels of AFP(421).

The impact of metals on cellular process is a phenomenon very studied but not completely understood. They are involved in many beneficial functions like maintenance of pH, enzymatic cofactor, metabolism trigger, and reactive oxygen species formation as a product of normal metabolism (429–432). However, present in excess, metals may have harmful effects. The principal effect caused by metals is the disruption of intracellular redox balance, debt to increase of ROS production (316).

Our data shows that concentrations of metals was higher in non-tumor liver of peruvian patients. In addition, among those metals we found some with harmful effects on health such as arsenic and cadmium. Arsenic and cadmium are considered as carcinogenic to human according to WHO (333). The mechanism by which arsenic contributes to the process of carcinogenesis is through damage caused to DNA, such chromosomal aberrations, deletion mutations and aneuploidy (322,433). A strong link between exposure to arsenic and the

development of HCC has been demonstrated in animal models, which also evidenced an increase in lipid peroxidation levels, prior to the onset of the fibrosis process and subsequent development of HCC (327,433,434). The mechanism of cadmium injury involve the interaction and possible inactivation of thiol groups, altered functioning of the metalloenzymes of the SOD family and depletion of antioxydant agents such as glutathion (337,344).

Peru is a country, where mining extraction occupies an important part of its GDP, representing 14% (302). This activity is developed in most of the regions of the Peruvian jungle and highlands, many without the necessary conditions to provide adequate protection to workers regarding metals including those used during the extraction and mainly during leaching's procedure (304,435). Recently a study developed by the university of Cajamarca in Peru, showed that the main sources of water supply (rivers and lakes) for agriculture, had high concentrations of lead and arsenic (436). Also, Elwakil (310) described too high concentrations of Cd, Pb, As, and Hg in sanguineous samples from patients with HCC who were exposed to the consumption of plants contaminated.

In addition, we cannot assess whether NC-HCC and its spectrum of particular genes mutated are directly caused by the presence of heavy metals. It is likely they could play an enhancing role in the carcinogenic process in association with hepatic carcinogenic agents, such the hepatitis B virus exposure in peruvian patients (94).

A second highlight of the study is the common metallome profile of liver tumors compared to the non tumoral areas in both cohorts, with lower concentrations of

metals in tumor tissue. Such findings suggest that whatever the etiological factors, the geographic origin or other different parameters between cohorts, the tumor cell has similar adaptive process regarding metal metabolisms. Whether the concentration decrease of most of these metals are related to a lower uptake, an increase release or an increase needs related especially to the enhanced cell cycle and cell metabolism is not known.

The increase of copper concentration, mainly in the tumor tissue, was already reported in HCC (437) and others tumors affecting especially breast, cervical, ovarian, and lung (434,438–440). A theory that aims to explain the behavior of copper in tumor tissues, was proposed by Fisher (441), who states that the increase of copper is due to a decrease in the catabolism in tumoral cells of Ceruloplasmin (Cp), a multicopper protein, caused by a sialylation of cleaved sialic acid in Cp from the cell membrane of neoplastic cells. This hypothesis was later supported by Bernacki (442) in an animal model. However, no further studies have been developed deepening on this statement. Another theory that has aroused the interest of numerous research groups(443–445) is related to the role of copper as an angiogenic agent. This effect of copper was first described by McAuslan (446), who showed that copper act as promotor for the migration of endothelial cells, subsequently Ziche (447) described an increase in copper levels in the cornea after an exposure of PGE1. However, it was Martin (448) whose consolidated both theories, he described the link between Cu, ceruloplasmin and HIF-1a. Its result shows that copper acts as a stabilizer of the HIF-1a molecule mediates the inhibition of prolyl-4-hydroxylation. The HIF-1A is finally responsible for regulating a dependent promoter which is related to the

expression of the ceruloplasmin regulatory gene. Besides Himoto (449) proposed a possible mechanism whereby Cu is required for binding HIF-1a to p300 and inhibit the effect of Factor Inhibiting HIF-1 (FIH-1).

Another finding is the relationship between selenium concentration in tumors and survival that is only found in the Peruvian group. Se plays a major role in homeostasis, mainly through selenoproteins which may have anti-inflammatory, chemo preventive and antiviral effects, as well as improvement of immune response (429). Our COX Regression Model, suggest a beneficial effect in overall survival for patients with higher levels of se in tumor tissues. This data is corroborated by one meta-analysis displayed the negative correlation between selenium and HCC (450). Indeed, low levels of selenium have been associated with high risk to develop HCC. Our model, developed on a relatively small number of patients is only applicable to the Peruvian cohort. This could be explained by the fact that in those patients a “natural evolution of the disease” is observed (415), since this group of patients only undergo surgery as the only treatment, unlike patients the French cohort where additional local or systemic treatments could modify this relationship (451,452). In addition, our findings should be validated in larger cohorts to be able to determine their possible significance.

Conclusion

Our data shows that the two cohort have different metallomic profiles in the non tumoral areas suggesting the impact of environmental factors in this picture. The role of illegal mining activity must be evoked as potential source of contamination in the Peruvian population. Whether these elements play a role in the very

peculiar phenotype of HCC in Peru should be explored. In addition, the modulation of metal concentration that is shared by the two cohort suggests a coordinated modulation of metal metabolism in hepatic tumoral cells during the carcinogenesis. Further studies will permit to progress in the understanding of the place of metal metabolisms alterations in the carcinogenic process.

Acknowledgments

This study was funded by the French National Alliance for Life Sciences and Health (ENV201408); LC was a recipient of a doctoral fellowship from French National Research Institute for Sustainable Development (IRD) (EMHE-ARTS-2016-878573B); JPC was a recipient of a doctoral fellowship from the Peruvian National Council for Science and Technology (212-2015-FONDECYT); and LC, ER, and SC were supported by the Young Research Teams Associated with IRD Program (INCAnce). The authors are grateful to Karina Cancino, Danny Cordova from the INEN Cancer Research Biobank, Patricia Leroyer from NUMECAN, Alain Fautrel, Marine Seffals, Gevorg Ghukasyan from H2P2 for logistic and technical support.

Author contributions

O.L., B.T., M.R. contributed to conception and design of the study; L.C., J.P.C., S.C., M.L.I., E.R., S.B. and M.R., contributed to the data acquisition; L.C., J.P.C. contributed to the analysis of the data; O.L., B.T., L.C. contributed to interpretation of the data; L.C., O.L., B.T., S.B., contributed to writing and editing the manuscript. All authors reviewed the manuscript.

Competing interests

The authors declare that they have no competing interests.

References

1. Ferlay J, Soerjomataram I, Dikshit R, Eser S, Mathers C, Rebelo M, et al. Cancer incidence and mortality worldwide: sources, methods and major patterns in GLOBOCAN 2012. *Int J Cancer*. 2015;136(5):E359-86.
2. Forner A, Reig M, Bruix J. Hepatocellular carcinoma. *The Lancet*. 2018 Mar;391(10127):1301–14.
3. Gaddikeri S, McNeeley MF, Wang CL, Bhargava P, Dighe MK, Yeh MMC, et al. Hepatocellular Carcinoma in the Noncirrhotic Liver. *Am J Roentgenol*. 2014 Jul;203(1):W34–47.
4. Bertani S, Pineau P, Loli S, Moura J, Zimic M, Deharo E, et al. An Atypical Age-Specific Pattern of Hepatocellular Carcinoma in Peru: A Threat for Andean Populations. *PLoS ONE*. 2013;8(6).
5. Marchio AS, Phane Bertani S, Rojas TR, Doimi F, Terris B, Deharo E, et al. A Peculiar Mutation Spectrum Emerging from Young Peruvian Patients with Hepatocellular Carcinoma. 2014; Available from: <https://journals.plos.org/plosone/article/file?id=10.1371/journal.pone.0114912&type=printable>
6. Deugnier YM, Guyader D, Crantock L, Lopez J-M, Turlin B, Yaouanq J, et al. Primary liver cancer in genetic hemochromatosis: A clinical, pathological, and pathogenetic study of 54 cases. *Gastroenterology*. 1993 Jan;104(1):228–34.
7. Lu S-N, Chow N-H, Wu W-C, Chang T-T, Huang W-S, Chen S-C, et al. Characteristics of Hepatocellular Carcinoma in a High Arsenicism Area in Taiwan: A Case-Control Study. *J Occup Environ Med*. 2004 May;46(5):437–41.
8. Riordan JF. The Role of Metals in Enzyme Activity. :11.
9. Al-Fartusie FS, Mohssan SN. Essential Trace Elements and Their Vital Roles in Human Body. *Indian J Adv Chem Sci*. 2017;10.
10. Bosman FT, World Health Organization, International Agency for Research on Cancer, editors. WHO classification of tumours of the

- digestive system. Lyon: IARC Press; 2010. 417 p. (World Health Organization classification of tumours, 4th edition).
11. Amin MB, Edge S, Greene F, Byrd DR, Brookland RK, Washington MK, et al., editors. AJCC Cancer Staging Manual [Internet]. 8th ed. Springer International Publishing; 2017 [cited 2019 Jun 30]. Available from: <https://www.springer.com/gp/book/9783319406176>
 12. Scheuer PJ. Classification of chronic viral hepatitis: a need for reassessment. *J Hepatol.* 1991;13(3):372–374.
 13. Cavey T, Ropert M, de Tayrac M, Bardou-Jacquet E, Island M-L, Leroyer P, et al. Mouse genetic background impacts both on iron and non-iron metals parameters and on their relationships. *Biometals Int J Role Met Ions Biol Biochem Med.* 2015 Aug;28(4):733–43.
 14. Trevisani F, Frigerio M, Santi V, Grignaschi A, Bernardi M. Hepatocellular carcinoma in non-cirrhotic liver: A reappraisal. *Dig Liver Dis.* 2010 May;42(5):341–7.
 15. Zoidis E, Seremelis I, Kontopoulos N, Danezis GP. Selenium-Dependent Antioxidant Enzymes: Actions and Properties of Selenoproteins. *Antioxidants* [Internet]. 2018 May 14 [cited 2018 Nov 1];7(5). Available from: <https://www.ncbi.nlm.nih.gov/pmc/articles/PMC5981252/>
 16. Daher R, Karim Z. Iron metabolism: State of the art. *Transfus Clin Biol.* 2017 Sep 1;24(3):115–9.
 17. Maret W. Zinc Biochemistry: From a Single Zinc Enzyme to a Key Element of Life. *Adv Nutr.* 2013 Jan 1;4(1):82–91.
 18. Jennette KW. The role of metals in carcinogenesis: biochemistry and metabolism. *Environ Health Perspect.* 1981 Aug;40:233–52.
 19. Lee J-C, Son Y-O, Pratheeshkumar P, Shi X. Oxidative stress and metal carcinogenesis. *Free Radic Biol Med.* 2012 Aug;53(4):742–57.
 20. Centeno JA, Mullick FG, Martinez L, Page NP, Gibb H, Longfellow D, et al. Pathology related to chronic arsenic exposure. *Environ Health Perspect.* 2002 Oct;110 Suppl 5(Suppl 5):883–6.
 21. Arita A, Costa M. Epigenetics in metal carcinogenesis: Nickel, Arsenic, Chromium and Cadmium. *Met Integr Biometal Sci.* 2009;1:222–8.
 22. Bjørklund G, Aaseth J, Chirumbolo S, Urbina MA, Uddin R. Effects of

- arsenic toxicity beyond epigenetic modifications. *Environ Geochem Health*. 2018 Jun;40(3):955–65.
23. Chen CJ, Chen CW, Wu MM, Kuo TL. Cancer potential in liver, lung, bladder and kidney due to ingested inorganic arsenic in drinking water. *Br J Cancer*. 1992;66(5):888.
 24. Flora SJS, Bhadauria S, Pant SC, Dhaked RK. Arsenic induced blood and brain oxidative stress and its response to some thiol chelators in rats. *Life Sci*. 2005 Sep;77(18):2324–37.
 25. Casalino E, Calzaretti G, Sblano C, Landriscina C. Molecular inhibitory mechanisms of antioxidant enzymes in rat liver and kidney by cadmium. *Toxicology*. 2002 Sep;179(1–2):37–50.
 26. Cuypers A, Plusquin M, Remans T, Jozefczak M, Keunen E, Gielen H, et al. Cadmium stress: an oxidative challenge. Available from: <https://link.springer.com/content/pdf/10.1007%2Fs10534-010-9329-x.pdf>
 27. Inversión minera creció 142% en últimos cuatro años y suma US\$ 34,020 millones | Economía | Gestion [Internet]. [cited 2019 May 30]. Available from: <https://gestion.pe/economia/inversion-minera-crecio-142-ultimos-cuatro-anos-suma-us-34-020-millones-96239>
 28. Minería Informal: ¿Qué hacer? | Blogs | Gestión [Internet]. [cited 2019 May 30]. Available from: <https://gestion.pe/blog/mineria-2021/2018/02/mineria-informal-que-hacer.html?ref=gesr>
 29. Huamán Paredes E, Vicuña Puente D, Visitación Figueroa L, Flores del Pino L. Efecto tóxico y ecotoxicológico de arenas negras de la minería artesanal en Madre de Dios. *Rev Soc Quím Perú*. 2017 Oct;83(4):403–11.
 30. Lozano HHF. Evaluación de la concentración de metales pesados en las aguas del río Grande y su relación con la actividad minera. [Cajamarca - Perú]: Universidad Nacional de Cajamarca; 2016.
 31. Elwakil MA, Abo-Hashem EM, Shabana YM, El-Metwally MA, El-Kannishy G, El-Adl AM, et al. Hepatocellular Carcinoma in Populations Consuming Heavy Metals Contaminated Plants in North Delta, Egypt. Available from: <http://docsdrive.com/pdfs/academicjournals/rjet/2017/55-61.pdf>
 32. Ivanov AV, Valuev-Elliston VT, Tyurina DA, Ivanova ON, Kochetkov SN, Bartosch B, et al. Oxidative stress, a trigger of hepatitis C and B virus-

- induced liver carcinogenesis. *Oncotarget*. 2016;8(3):3895–932.
33. Gurusamy K. Trace Element Concentration in Primary Liver Cancers—A Systematic Review. *Biol Trace Elem Res*. 2007 Sep 4;118(3):191–206.
 34. Huang Y-L, Sheu J-Y, Lin T-H. Association between oxidative stress and changes of trace elements in patients with breast cancer. *Clin Biochem*. 1999 Mar;32(2):131–6.
 35. Chan A, Wong F, Arumanayagam M. Serum Ultrafiltrable Copper, Total Copper and Caeruloplasmin Concentrations in Gynaecological Carcinomas. *Ann Clin Biochem Int J Biochem Lab Med*. 1993 Nov;30(6):545–9.
 36. Chanvorachote P, Luanpitpong S. Iron induces cancer stem cells and aggressive phenotypes in human lung cancer cells. *Am J Physiol-Cell Physiol*. 2016 May;310(9):C728–39.
 37. Fisher GL, Shifrine M. Hypothesis for the Mechanism of Elevated Serum Copper in Cancer Patients. *Oncology*. 1978;35(1):22–5.
 38. Bernacki RJ, Kim U. Concomitant elevations in serum sialyltransferase activity and sialic acid content in rats with metastasizing mammary tumors. *Science*. 1977 Feb 11;195(4278):577–80.
 39. Finney L, Vogt S, Fukai T, Glesne D. COPPER AND ANGIOGENESIS: UNRAVELLING A RELATIONSHIP KEY TO CANCER PROGRESSION. *Clin Exp Pharmacol Physiol*. 2009 Jan;36(1):88–94.
 40. Xie H, Kang YJ. Role of copper in angiogenesis and its medicinal implications. *Curr Med Chem*. 2009;16(10):1304–14.
 41. Urso E, Maffia M. Behind the Link between Copper and Angiogenesis: Established Mechanisms and an Overview on the Role of Vascular Copper Transport Systems. *J Vasc Res*. 2015;52(3):172–96.
 42. McAuslan BR, Reilly W. Endothelial cell phagocytosis in response to specific metal ions. *Exp Cell Res*. 1980 Nov;130(1):147–57.
 43. Ziche M, Jones J, Gullino PM. Role of prostaglandin E1 and copper in angiogenesis. *J Natl Cancer Inst*. 1982 Aug;69(2):475–82.
 44. Martin F. Copper-dependent activation of hypoxia-inducible factor (HIF)-1: implications for ceruloplasmin regulation. *Blood*. 2005 Jun 15;105(12):4613–9.

45. Himoto T, Fujita K, Nomura T, Tani J, Miyoshi H, Morishita A, et al. Roles of Copper in Hepatocarcinogenesis via the Activation of Hypoxia-Inducible Factor-1 α . *Biol Trace Elem Res*. 2016 Nov;174(1):58–64.
46. Zhang Z, Bi M, Liu Q, Yang J, Xu S. Meta-analysis of the correlation between selenium and incidence of hepatocellular carcinoma. *Oncotarget*. 2016 Oct 21;7(47):77110–6.
47. Ruiz E, Rojas TR, Berrospi F, Chávez I, Luque C, Cano L, et al. Hepatocellular carcinoma surgery outcomes in the developing world: A 20-year retrospective cohort study at [3 _ T D \$ D I F F] the National Cancer Institute of Peru. 2015; Available from: <http://dx.doi.org/10.1016/j.heliyon.2015.e000522405-8440/>
48. Cadier B, Bulsei J, Nahon P, Seror O, Laurent A, Rosa I, et al. Early detection and curative treatment of hepatocellular carcinoma: A cost-effectiveness analysis in France and in the United States. *Hepatology*. 2017;65(4):1237–48.
49. Goutté N, Sogni P, Bendersky N, Barbare JC, Falissard B, Farges O. Geographical variations in incidence, management and survival of hepatocellular carcinoma in a Western country. *J Hepatol*. 2017 Mar;66(3):537–44.

<i>Variable</i>	<i>French Cohort</i>	<i>Peruvian Cohort</i>	<i>P. Value</i>
<i>Age (years)</i>			<i>< 0.001</i>
Mean	67.87 (+/-9.34)	40.63 (+/-20.14)	
Range	37 - 85	13 - 94	
<i>Sex</i>			<i>0.021</i>
M	5	12	
F	40	26	
<i>Tumor size (cm)</i>			<i>< 0.001</i>
Mean	8.69 (+/-5.49)	14.33 (+/-5.12)	
Range	1 - 21	4.50 - 27	
<i>Hepatitis B</i>			<i>< 0.001</i>
Positive	2 (2.8 %)	15 (21.12 %)	
Negative	38 (53.52 %)	16 (22.53 %)	
<i>Fibrosis Grade</i>			<i>0.145</i>
Absent	5	7	
Grade 1	12	12	
Grade 2	20	8	
Grade 3	8	11	
Grade 4	0	0	
<i>Histological grade</i>			<i>0.010</i>
Well differentiated	9	3	
Moderately differentiated	28	28	
Poorly differentiated	2	7	
Undifferentiated	6	0	
<i>Vascular invasion</i>			<i>0.104</i>
Yes	27	16	
No	18	22	

Table 1: Clinical and histological variables from both cohorts. For numerical variables mean values are presented with \pm standard deviation. For categorial variables, data is presented as number of cases.

<i>Metal (ug/gr)</i>	<i>Non Tumor Tissues - French Cohort</i>	<i>Non Tumor Tissues - Peruvian Cohort</i>	<i>P. Value</i>
<i>Arsenic (As)</i>			<i>< 0.001</i>
Mean (Sd)	0	0.12 (+/-0.16)	
Range	0	0.00 - 0.41	
<i>Cadmium (Cd)</i>			<i>0.002</i>
Mean (Sd)	2.42 (+/- 2.73)	4.20 (+/- 4.10)	
Range	0.0 - 13.35	0.22 - 21.34	
<i>Cobalt (Co)</i>			<i>0.05</i>
Mean (Sd)	0.11 (+/- 0.08)	0.15 (+/-0.07)	
Range	0.00 - 0.27	0.00 - 0.30	
<i>Copper (Cu)</i>			<i>0.001</i>
Mean (Sd)	25.27 (+/-31.11)	27.30 (+/-11.96)	
Range	6.90 - 204.10	9.00 - 75.00	
<i>Iron (Fe)</i>			<i>0.395</i>
Mean (Sd)	873.82 (+/-1024.90)	698.58 (+/-721.45)	
Range	56.20 - 6275.40	87.00 - 3973.00	
<i>Manganese (Mn)</i>			<i>< 0.001</i>
Mean (Sd)	4.58 (+/-2.37)	7.54 (+/-3.95)	
Range	0.00 - 11.96	0.95 - 26.67	
<i>Molybdenum (Mo)</i>			<i>< 0.001</i>
Mean (Sd)	2.05 (+/-1.27)	3.26 (+/-1.54)	
Range	0.00 - 6.51	0.32 - 9.44	
<i>Lead (Pb)</i>			<i>0.283</i>
Mean (Sd)	0.34 (+/-1.21)	0.16 (+/-0.24)	
Range	0.00 - 8.04	0.00 - 1.34	
<i>Rubidium (Rb)</i>			<i>0.002</i>
Mean (Sd)	17.24 (+/-5.96)	22.15 (+/-8.50)	
Range	0.90 - 35.60	2.40 - 40.70	
<i>Selenium (Se)</i>			<i>0.019</i>
Mean (Sd)	1.74 (+/-0.75)	2.07 (+/- 0.85)	
Range	0.00 - 4.06	0.53 - 5.41	

<i>Tin (Sn)</i>			<i>0.006</i>
Mean (Sd)	0.34 (+/-0.40)	0.14 (+/-0.11)	
Range	0.00 - 1.76	0.00 - 0.47	
<i>Zinc (Zn)</i>			<i>< 0.001</i>
Mean (Sd)	167.56 (+/-68.88)	258.14 (+/-103.33)	
Range	46.20 - 385.50	71.90 - 553.70	

Table2. Comparative data for metals quantifiacion in non tumor tissues between both cohorts. Data are presented as mean, standar deviation (sd) and range.

<i>Metal (ug/gr)</i>	<i>Tumor Tissues - French Cohort</i>	<i>Tumor Tissues - Peruvian Cohort</i>	<i>P. Value</i>
<i>Arsenic (As)</i>			<i>< 0.001</i>
Mean	0	0.11 (+/-0.15)	
Range	0	0.00 - 0.52	
<i>Cadmium (Cd)</i>			<i>0.304</i>
Mean	0.90 (+/- 1.96)	1.10 (+/- 2.97)	
Range	0.0 - 9.92	0.00 - 13.11	
<i>Cobalt (Co)</i>			<i>0.157</i>
Mean	0.03 (+/- 0.08)	0.02 (+/-0.07)	
Range	0.00 - 0.39	0.00 - 0.34	
<i>Copper (Cu)</i>			<i>0.496</i>
Mean	49.40 (+/-87.54)	64.98 (+/-123.70)	
Range	0.00 - 345.20	4.00 - 543.20	
<i>Iron (Fe)</i>			<i>< 0.001</i>
Mean	689.62 (+/-1537.99)	255.87 (+/-511.75)	
Range	55.40 - 9941.00	24.00 - 3026.00	
<i>Manganese (Mn)</i>			<i>0.140</i>
Mean	2.99 (+/-2.86)	2.59 (+/-3.58)	
Range	0.10 - 13.00	0.13 - 18.46	
<i>Molybdenum (Mo)</i>			<i>0.121</i>
Mean	1.02 (+/-1.00)	0.79 (+/-1.06)	
Range	0.00 - 4.73	0.00 - 5.45	
<i>Lead (Pb)</i>			<i>0.840</i>
Mean	0.19 (+/-0.49)	0.03 (+/-0.05)	
Range	0.00 - 2.67	0.00 - 0.19	
<i>Rubidium (Rb)</i>			<i>0.938</i>
Mean	16.64 (+/-7.03)	16.23 (+/-8.79)	
Range	4.40 - 42.00	2.70 - 41.80	
<i>Selenium (Se)</i>			<i>0.851</i>
Mean	1.47 (+/-0.77)	1.49 (+/-0.67)	

Range	0.00 - 4.50	0.66 - 3.91	
<i>Tin (Sn)</i>			<i>0.152</i>
Mean	0.10 (+/-0.20)	0.03 (+/-0.06)	
Range	0.00 - 0.96	0.00 - 0.26	
<i>Zinc (Zn)</i>			<i>0.440</i>
Mean	99.40 (+/-53.90)	322.09 (+/-1344.17)	
Range	17.40 - 318.90	23.40 - 8369.90	

Table 3. Comparative data for metals quantification in non tissues between both cohorts. Data are presented as mean, standard deviation (sd) and range.

Free disease survival for Peruvian and French population

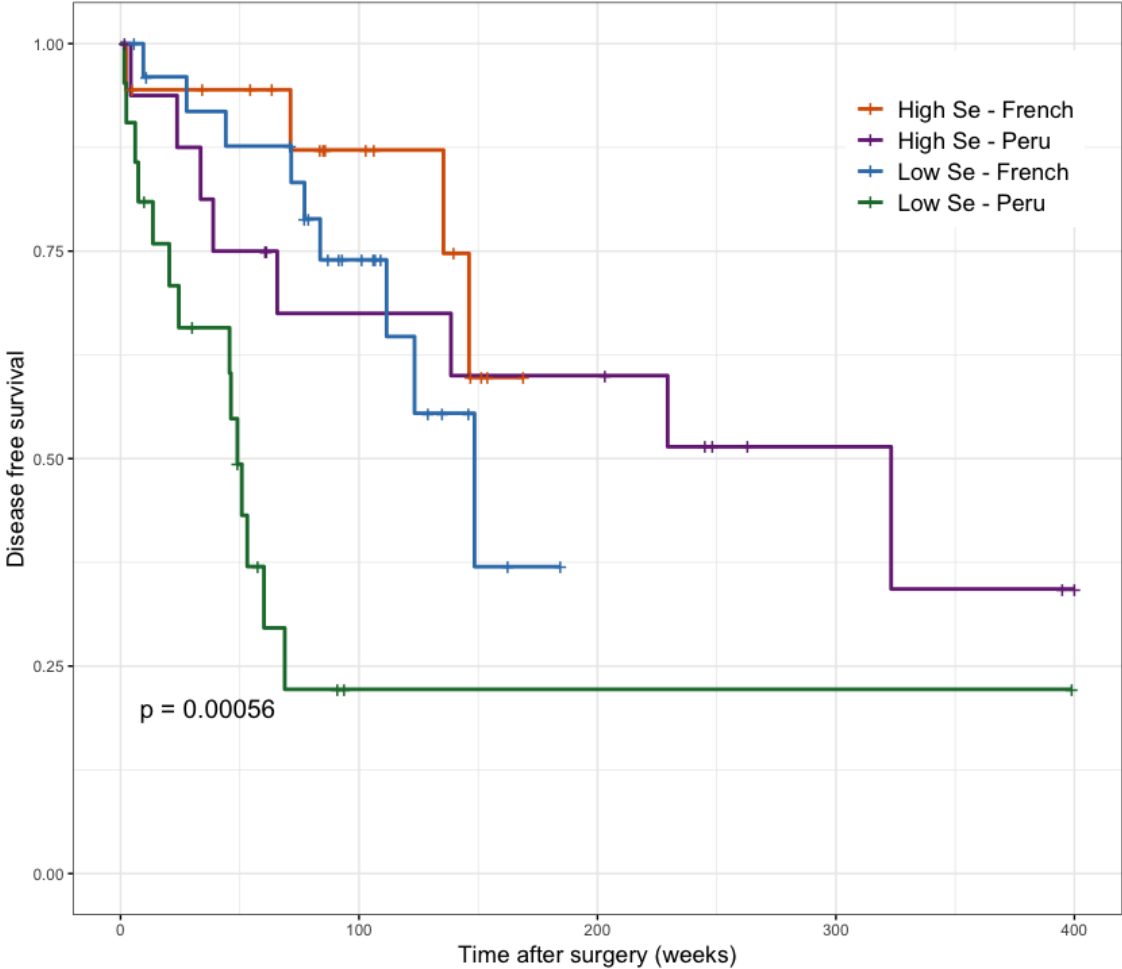


Figure 1. Comparative disease free survival plot for mean of selenium in both cohorts. We can observe a significant value in peruvian cohort (selenium's mean = 1.49). Not same result was found for french cohort.

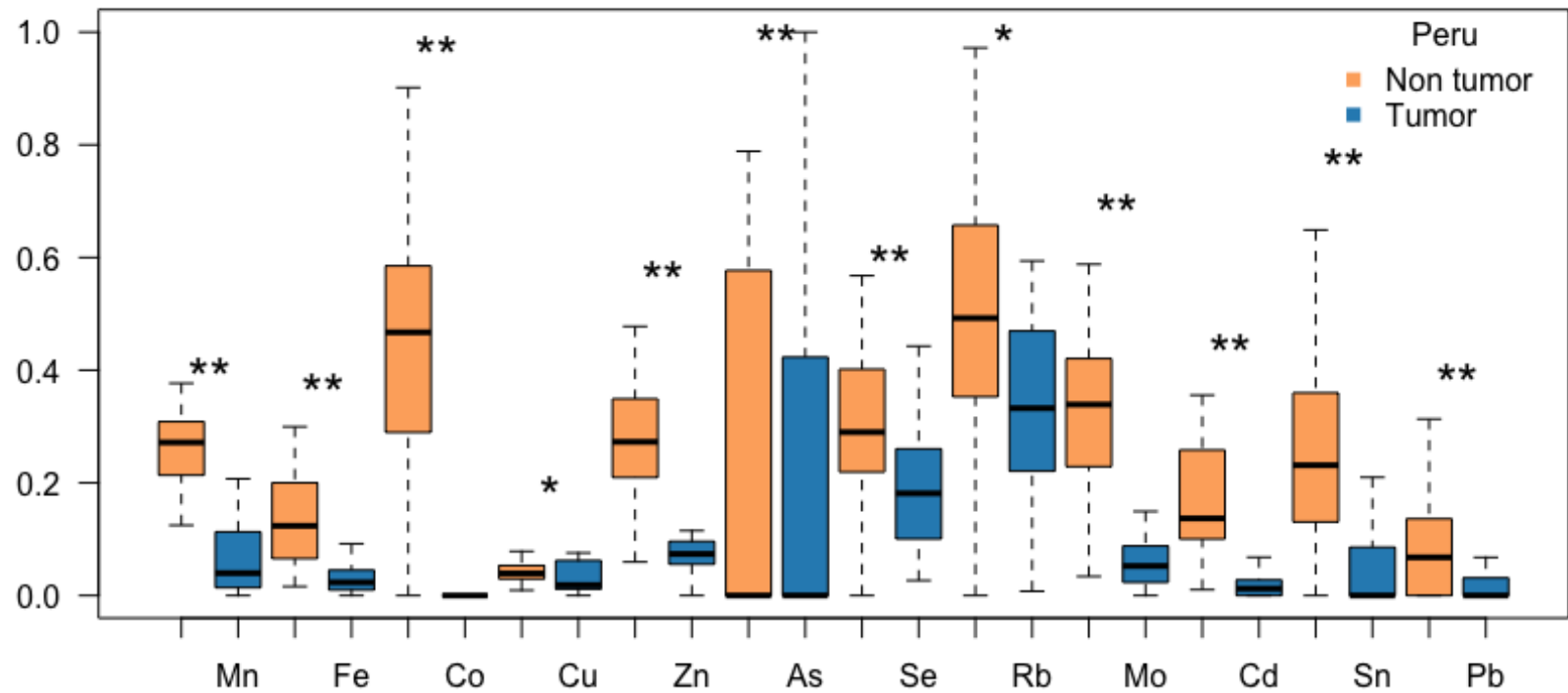


Figure 2: Non-tumor tissue and tumor tissue metals' concentration for peruvian patients
 Barplots, graphic representation of metal concentrations in non-tumor tissue (orange) compared to tumor tissue (blue).
 The concentration values in ug / gr have been scaled (from 0 to 1) to create a single graph with all metals. the value of p is represented by the asterisks (* = 0.01; ** = 0.001)

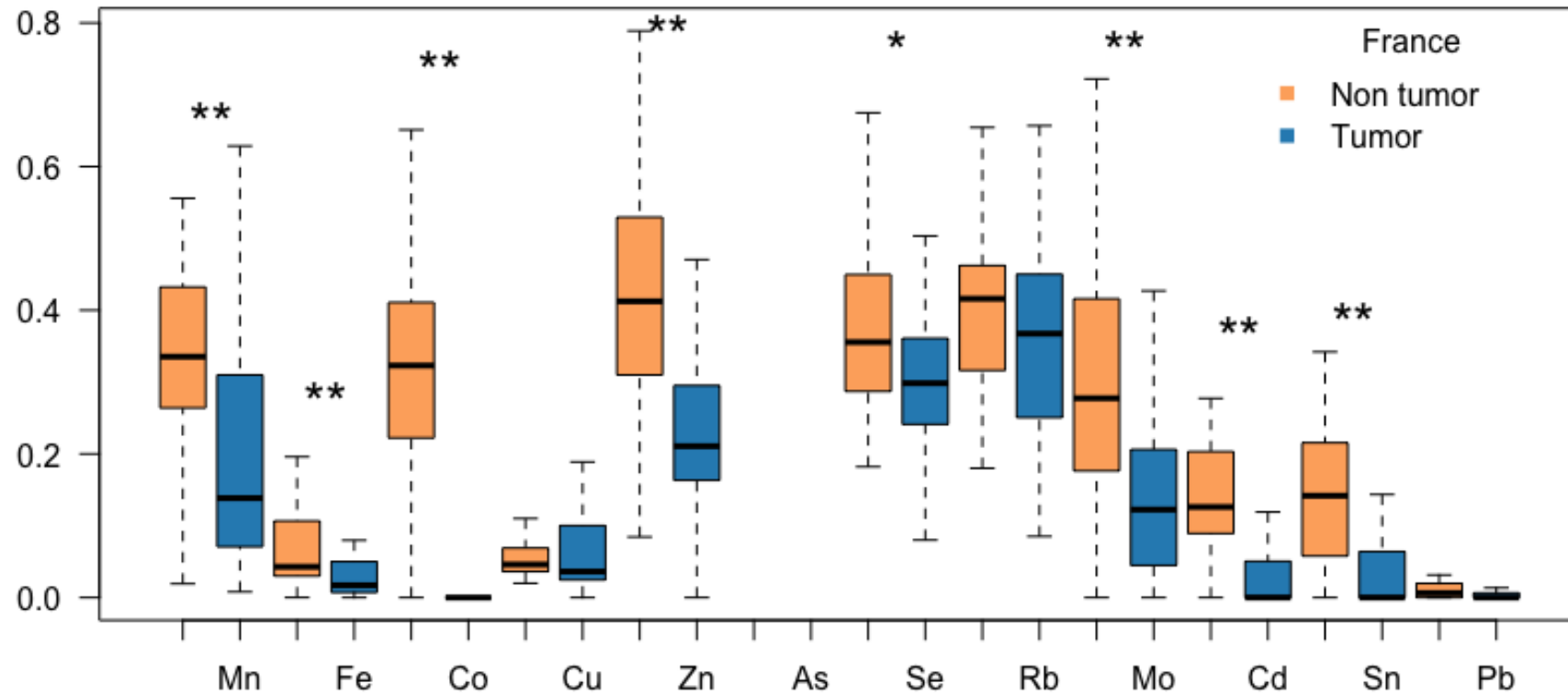


Figure 3: Non-tumor tissue and tumor tissue metals' concentration for french patients
 Barplots, graphic representation of metal concentrations in non-tumor tissue (orange) compared to tumor tissue (blue).
 Arsenic was not detected in the French cohort. The concentration values in ug/gr have been scaled (from 0 to 1) to create a single graph with all metals. The value of p is represented by the asterisks (* = 0.01; ** = 0.001)

III) General Discussion

Our aim was to better characterize the phenotype of CHC occurring in Peruvian patients, and to explore potential mechanisms involved. Indeed, previous works have highlighted clinical features (270) as a bimodal distribution, high levels of AFP, and large tumor size. A particular mutation spectrum characterized by insertions/deletion alterations, and over-expression of NANOG stemness factor (272). Finally, the surgical treatment options for a different reality (415) - tumors mostly larger than 10 cm - differ from the international recommendations made by the Barcelona group.

The data that we obtained provide additional information concerning factors contributing potentially in HCC development and evolution such as pathological and metabolic characteristics of non-tumor liver, especially the presence clear cell foci that potentially represent pre-neoplastic lesions and metals concentration. In addition, we found a new histological type of liver tumor. In the non-tumor area of liver, the absence of cirrhosis is the main characteristic, since more than 80% of Peruvian patients with HCC develop the disease on a liver without histological sings of underlying disease (270). Which indicates that the mechanisms of carcinogenesis are probably not related to the classic sequence: tissue aggression with necrosis, repair, fibrosis, cirrhosis and finally HCC. The presence of clear cell foci in the non-tumor area of patients with NC-HCC as opposed to the control group - which is composed of patients with non-primary liver tumors - is an important point. In fact, this indicates that, in patients who have developed NC-HCC, there are important metabolic changes in these lesions. This hypothesis is supported by the modification of glycogen metabolism illustrated by PAS staining, as well as the profile of up-regulated genes such as IGF1, IRS1, FOXO1 and PDK4 and the down-regulated as Galactosidase alpha (420). In addition, considering in a global way the non-tumor liver area of patients with PAS + staining, we also found, through ontological studies, that mRNA expression of some genes associated with immune system function, as well as receptor genes coupled to protein G are modulated compared to the control

group. This suggests that clear cell foci in patients with NC-HCC could be an emerging part of the iceberg of the carcinogenesis process.

A hypothesis that could explain this phenomenon, could be the overexposure of metals found in the non-tumor liver of the Peruvian population. Indeed, the non-tumor areas of the liver of Peruvian patients with NC-HCC compared to those of French patients, have a higher concentration of different metals. within which we can find arsenic, cadmium which are considered by the WHO as carcinogenic agents for humans. Several studies (306,421) have shown that the waste produced by mining mainly affects the populations that live in the surroundings of the mining settlements and in the basins of the adjacent rivers, this problem is mainly found in developing countries where health policies are not fully implemented.

Additionally, *in vivo* studies have shown that chronic exposure to metals such as arsenic or cadmium generates liver damage characterized by sinusoidal dilation and cytoplasmic vacuolization (422). Moreover, recently it has been demonstrated in groups of Asian patients that overexposure to heavy metals, such as lead and cadmium, is associated with the development of NAFLD (423,424), which is a clear risk factor for the development of hepatocellular carcinoma (425). Paradoxically and despite recent studies showing obesity rates of 60.9% (426) throughout the Peruvian territory and an incidence of type 2 diabetes of 40% in some districts of the capital. Peruvian patients with NC-HCC, as published by Cano *et al* (420), do not have high frequency of NAFLD or NASH.

A prominent feature of Peruvian patients with NC-HCC is the very high levels of AFP concentration in serum (270,272). This peptide was initially described in 1956, whose production is in charge of the yolk sack and the liver (228). Its main functions include i) protection of the fetus against the mother's immune system, ii) participating in the development of the central nervous system (229). However, several studies indicate elevations of AFP in circumstances such as: hepatic regeneration processes -especially after partial hepatectomies- and injury

processes produced by chemical agents (229,231). The secretion of this peptide is associated with proliferation process in liver. Nevertheless, we found also elevation of this marker in liver tumors mainly those that expressing a stem cell phenotype.

The concentration of AFP, secreted by hepatocytes from liver tumors is also related to the prognosis of the disease (427). Thus, values greater than 400 mg / ml have been associated with a higher risk of recurrence (428). However, peruvian patients with NC-HCC exhibits frequently very high concentration, often exceeding 100.000 ng/ml (272). It is noteworthy that those very high AFP values are consistent with the values found during hepatoblastoma, another liver neoplasm of childs, (429). For this tumor the secretion of AFP in serum is clearly related to the immature component - "blastic" - of the liver tumor (430). The high concentrations of serum AFP in Peruvian patients with NC-HCC suggest that this tumor probably has a stem cell component, however the IHC analyzes we report do not correspond to this statement. However, molecular biology analyzes suggest that the Peruvian NC-HCC has a molecular signature that corresponds to the progenitor-type.

Architecturally the macrotrabecular pattern of the pattern that we have described, shares a characteristic with the massive macrotrabecular type described by Calderaro (210). However, the double population- central and peripheral cells- present in each macrotrabecula of our new type is a unique feature so far not described. On the other hand, more studies are needed to demonstrate the differences between both cell populations.

Two interesting hypotheses are evident in relation to the development of this new tumor pattern. The first is to show if there is a relationship between the presence of the clear cell foci and the new pattern. The second, to determine if the histological changes found respond to a particular effect of metals on the tumor. Recent studies have demonstrated the effect that metals develop on tumor tissue, an example of this is arsenic-induced lung cancer (431), where it has been

found that metal directly modulates the EGFR, PI3K/AKT and NRF2/KEAP1 pathways, which causes more aggressive tumors, which in turn have particular histological characteristics. Other examples of metals associated with histological changes in the tumor are: the effect of selenium at the level of the gastric mucosa, characterized by metaplastic changes and in addition to promoting the formation of leiomyomas associated with the carcinogenesis process (432). It has also been reported that elevated levels of cadmium in the urine are associated with an increased risk of specifically developing HER2+ breast cancer (433).

As a final fact, we want to highlight the impact of the new pattern on survival, which, as we have shown, is much lower in relation to the other histological patterns. Within the features that explain the aggressiveness of the peruvian tumors, we find the large tumor size at the time of diagnosis (270,415), characteristic that these tumors share with the NC-HCC reported around the world (202,237,269,434,435).

It is important to note that, we have shown that both selenium and lead have positive and negative effects on the survival of patients respectively. It is known what is the role of selenium within the redox balance in the intra and extracellular compartments, so a possible hypothesis to explain its beneficial effect is an increase in antioxidant agents reducing the damage mediated by oxidative stress in the tumor microenvironment as in the non-tumor.

IV) Perspectives

Our data presents an interesting panorama for the development of future studies in relation to the NC-HCC. Some of which we describe below

The existence of clear cell foci and the possible preneoplastic potential that they present within the hepatic carcinogenesis process, which is why we propose to deepen their study at the molecular level and to analyze the possible relationships with the new histological pattern described.

We also hope to understand the effect of environmental pollutants, mainly metals, on the development and progression of liver disease. since as we have seen they play an important role in the development of carcinogenesis. Therefore, we would like to develop a study to analyze the synergistic effects of metal overload on the hepatitis B virus and also on a NAFLD model.

Finally, we hope to deepen the development of clinical tools, such as a nomogram, considering the characteristics of the Peruvian population, such as AFP levels, tumor size, selenium levels, presence of the new pattern, presence of light cell foci, whose purpose is to provide better treatment and follow-up to patients diagnosed with NC-HCC.

V) References

1. Rouvière H, Delmas A. Rouvière, H., Anatomía Humana Descriptiva, topográfica y funcional, 11a ed. ©2005 Últ. Reimpr. 2006. Elsevier España; 2005. 793 p.
2. Abdel-Misih SRZ, Bloomston M. Liver Anatomy. Surg Clin North Am. 2010 Aug;90(4):643–53.
3. Germain T, Favelier S, Cercueil J-P, Denys A, Krausé D, Guiu B. Liver segmentation: Practical tips. Diagn Interv Imaging. 2014 Nov 1;95(11):1003–16.
4. Burt AD, Portmann BC, Ferrell LD, MacSween RNM, editors. MacSween's pathology of the liver: expert consult activate at expertconsult.com, searchable full text online. 6. ed. Edinburgh: Churchill Livingstone Elsevier; 2012. 1020 p.
5. Muriel P, editor. Liver pathophysiology: therapies and antioxidants. London, United Kingdom: Academic Press, an imprint of Elsevier; 2017. 881 p.
6. Gebhardt R, Matz-Soja M. Liver zonation: Novel aspects of its regulation and its impact on homeostasis. World J Gastroenterol WJG. 2014 Jul 14;20(26):8491–504.
7. Kietzmann T. Metabolic zonation of the liver: The oxygen gradient revisited. Redox Biol. 2017 Apr;11:622–30.
8. Guicciardi ME, Gores GJ. Apoptosis: a mechanism of acute and chronic liver injury. Gut. 2005 Jul 1;54(7):1024–33.
9. Wang K. Molecular mechanisms of liver injury: Apoptosis or necrosis. Exp Toxicol Pathol. 2014 Oct;66(8):351–6.
10. Rmilah AA, Zhou W, Nelson E, Lin L, Amiot B, Nyberg SL. Understanding the marvels behind liver regeneration. Wiley Interdiscip Rev Dev Biol. 2019 May;8(3):e340.
11. Cordero-Espinoza L, Huch M. The balancing act of the liver: tissue regeneration versus fibrosis. J Clin Invest. 2018 Jan 2;128(1):85–96.
12. Elpek GÖ. Cellular and molecular mechanisms in the pathogenesis of liver fibrosis: An update. World J Gastroenterol. 2014;20(23):7260.

13. Ferlay J, Soerjomataram I, Dikshit R, Eser S, Mathers C, Rebelo M, et al. Cancer incidence and mortality worldwide: sources, methods and major patterns in GLOBOCAN 2012. *Int J Cancer*. 2015;136(5):E359-86.
14. Lee DH, Lee JM. Primary malignant tumours in the non-cirrhotic liver. *Eur J Radiol*. 2017 Oct;95:349–61.
15. Baecker A, Liu X, La Vecchia C, Zhang Z-F. Worldwide incidence of hepatocellular carcinoma cases attributable to major risk factors. *Eur J Cancer Prev Off J Eur Cancer Prev Organ ECP*. 2018;27(3):205–12.
16. Carr BI, editor. *Hepatocellular Carcinoma: Diagnosis and Treatment* [Internet]. 3rd ed. Springer International Publishing; 2016 [cited 2019 Jun 20]. (Current Clinical Oncology). Available from: <https://www.springer.com/gp/book/9783319342122>
17. Forman D, International Agency for Research on Cancer, World Health Organization, International Association of Cancer Registries. *Cancer incidence in five continents: Volume X*. 2014.
18. Lozano R, Naghavi M, Foreman K, Lim S, Shibuya K, Aboyans V, et al. Global and regional mortality from 235 causes of death for 20 age groups in 1990 and 2010: a systematic analysis for the Global Burden of Disease Study 2010. *Lancet Lond Engl*. 2012 Dec 15;380(9859):2095–128.
19. Kohi MP. Gender-Related Differences in Hepatocellular Carcinoma: Does Sex Matter? *J Vasc Interv Radiol*. 2016 Sep;27(9):1338–41.
20. Liu P, Xie S-H, Hu S, Cheng X, Gao T, Zhang C, et al. Age-specific sex difference in the incidence of hepatocellular carcinoma in the United States. *Oncotarget*. 2017 Jul 12;8(40):68131–7.
21. Ramakrishna G, Rastogi A, Trehanpati N, Sen B, Khosla R, Sarin SK. Viral hepatitis and hepatocellular carcinoma: etiology and management *Liver Cancer* 2013;2:367-383. 2013; Available from: www.karger.com/lic
22. Pathology Outlines - Cirrhosis [Internet]. [cited 2019 Jun 20]. Available from: <http://www.pathologyoutlines.com/topic/livercirrhosis.html>
23. Gomaa AI, Khan SA, Toledano MB, Waked I, Taylor-Robinson SD. Hepatocellular carcinoma: Epidemiology, risk factors and pathogenesis. *World J Gastroenterol WJG*. 2008 Jul 21;14(27):4300–8.

24. Kay A, Zoulim F. Hepatitis B virus genetic variability and evolution. *Virus Res.* 2007 Aug;127(2):164–76.
25. Sharma SK, Saini N, Chwla Y. Hepatitis B Virus: Inactive carriers. *Viol J.* 2005 Sep 28;2:82.
26. Shimakawa Y, Bottomley C, Njie R, Mendy M. The association between maternal hepatitis B e antigen status, as a proxy for perinatal transmission, and the risk of hepatitis B e antigenaemia in Gambian children. *BMC Public Health.* 2014 May 30;14:532.
27. Custer B, Sullivan SD, Hazlet TK, Iloeje U, Veenstra DL, Kowdley KV. Global Epidemiology of Hepatitis B Virus. *J Clin Gastroenterol.* 2004;38(December):S158–68.
28. Oh J-K, Weiderpass E. Infection and Cancer: Global Distribution and Burden of Diseases. *Ann Glob Health.* 2014 Sep;80(5):384–92.
29. Von Meltzer M, Vásquez S, Sun J, Wendt UC, May A, Gerlich WH, et al. A new clade of hepatitis B virus subgenotype F1 from Peru with unusual properties. *Virus Genes.* 2008;37(2):225–30.
30. Kramvis A, Arakawa K, Yu MC, Nogueira R, Stram DO, Kew MC. Relationship of Serological Subtype, Basic Core Promoter and Precore Mutations to Genotypes/Subgenotypes of Hepatitis B Virus. *J Med Virol.* 2008;80:27–46.
31. Wang J, Chenivresse X, Henglein B, Bréchet C. Hepatitis B virus integration in a cyclin A gene in a hepatocellular carcinoma. *Nature.* 1990 Feb;343(6258):555–7.
32. Mahmood S, Niiyama G, Kamei A, Izumi A, Nakata K, Ikeda H, et al. Influence of viral load and genotype in the progression of hepatitis B-associated liver cirrhosis to hepatocellular carcinoma. *Liver Int.* 2005;25(2):220–5.
33. Cammà C, Giunta M, Andreone P, Craxì A. Interferon and prevention of hepatocellular carcinoma in viral cirrhosis: an evidence-based approach. *J Hepatol.* 2001 Apr 1;34(4):593–602.
34. Torbenson M, Thomas DL. Occult hepatitis B. *Lancet Infect Dis.* 2002 Aug 1;2(8):479–86.

35. Hanafiah KM, Groeger J, Flaxman AD, Wiersma ST. Global epidemiology of hepatitis C virus infection: New estimates of age-specific antibody to HCV seroprevalence. *Hepatology*. 2013;57(4):1333–42.
36. Messina JP, Humphreys I, Flaxman A, Brown A, Cooke GS, Pybus OG, et al. Global distribution and prevalence of hepatitis C virus genotypes. *Hepatology*. 2015;61(1):77–87.
37. Moosavy SH, Davoodian P, Nazarnezhad MA, Nejatizadeh A, Eftekhari E, Mahboobi H. Epidemiology, transmission, diagnosis, and outcome of Hepatitis C virus infection. *Electron Physician*. 2017 Oct 25;9(10):5646–56.
38. El-Serag HB. Epidemiology of Viral Hepatitis and Hepatocellular Carcinoma. *Gastroenterology*. 2012 May 1;142(6):1264-1273.e1.
39. Sherman KE, Rouster SD, Chung RT, Rajcic N. Hepatitis C Virus Prevalence among Patients Infected with Human Immunodeficiency Virus: A Cross-Sectional Analysis of the US Adult AIDS Clinical Trials Group. *Clin Infect Dis*. 2002 Mar 15;34(6):831–7.
40. IARC Working Group on the Evaluation of Carcinogenic Risks to Humans, World Health Organization, International Agency for Research on Cancer, editors. Alcohol consumption and ethyl carbamate. Lyon, France: Geneva: International Agency for Research on Cancer; Distributed by WHO Press; 2010. 1424 p. (IARC monographs on the evaluation of carcinogenic risks to humans).
41. World Health Organization, editor. Global status report on alcohol and health. Geneva, Switzerland: World Health Organization; 2011. 286 p.
42. World Health Organization, World Health Organization, World Health Organization, Management of Substance Abuse Team. Global status report on alcohol and health 2018. 2018.
43. Loomba R, Yang H-I, Su J, Brenner D, Barrett-Connor E, Iloeje U, et al. Synergism Between Obesity and Alcohol in Increasing the Risk of Hepatocellular Carcinoma: A Prospective Cohort Study. *Am J Epidemiol*. 2013 Feb 15;177(4):333–42.
44. Hassan MM, Hwang L-Y, Hatten CJ, Swaim M, Li D, Abbruzzese JL, et al. Risk factors for hepatocellular carcinoma: Synergism of alcohol with viral hepatitis and diabetes mellitus. *Hepatology*. 2002;36(5):1206–13.

45. Kew MC. Aflatoxins as a Cause of Hepatocellular Carcinoma. *J Gastrointest Liver Dis.* 2013;22(3):6.
46. Strosnider H, Azziz-Baumgartner E, Banziger M, Bhat RV, Breiman R, Brune M-N, et al. Workgroup Report: Public Health Strategies for Reducing Aflatoxin Exposure in Developing Countries. *Environ Health Perspect.* 2006 Dec;114(12):1898–903.
47. Strosnider H, Azziz-Baumgartner E, Banziger M, Bhat RV, Breiman R, Brune M-N, et al. Workgroup report: public health strategies for reducing aflatoxin exposure in developing countries. *Environ Health Perspect.* 2006 Dec;114(12):1898–903.
48. Liu Y, Chang C-CH, Marsh GM, Wu F. Population attributable risk of aflatoxin-related liver cancer: Systematic review and meta-analysis q. 2012; Available from: [https://www.ejancer.com/article/S0959-8049\(12\)00146-3/pdf](https://www.ejancer.com/article/S0959-8049(12)00146-3/pdf)
49. Chen C, Wang L, You S, Zhang Y, Wang L, Santella RM. Elevated Aflatoxin Exposure and Increased Risk of Hepatocellular Carcinoma acteristics, cigarette smoking, alcohol drinking, betel nut chewing, consumption frequency of various food items, and personal and fam-ily history of major diseases. Questionnaire [Internet]. 1996. Available from: <https://aasldpubs.onlinelibrary.wiley.com/doi/pdf/10.1002/hep.510240108>
50. McLean M, Dutton MF. Cellular interactions and metabolism of aflatoxin: an update. *Pharmacol Ther.* 1995 Feb;65(2):163–92.
51. Johannesburg W, Kew MC. Aflatoxins as a Cause of Hepatocellular Carcinoma [Internet]. 2013 p. 305–310. Available from: <http://www.jgld.ro/2013/3/13.pdf>
52. Li X, Wang X, Gao P. Diabetes Mellitus and Risk of Hepatocellular Carcinoma. *BioMed Res Int* [Internet]. 2017 [cited 2019 Aug 4];2017. Available from: <https://www.ncbi.nlm.nih.gov/pmc/articles/PMC5742888/>
53. Mantovani A, Targher G. Type 2 diabetes mellitus and risk of hepatocellular carcinoma: spotlight on nonalcoholic fatty liver disease. *Ann Transl Med* [Internet]. 2017 Jul [cited 2019 Aug 4];5(13). Available from: <https://www.ncbi.nlm.nih.gov/pmc/articles/PMC5515814/>

54. Singh MK, Das BK, Choudhary S, Gupta D, Patil UK. Diabetes and hepatocellular carcinoma: A pathophysiological link and pharmacological management. *Biomed Pharmacother*. 2018 Oct;106:991–1002.
55. Garcia-Compean D, Jaquez-Quintana JO, Gonzalez-Gonzalez JA, Maldonado-Garza H. Liver cirrhosis and diabetes: Risk factors, pathophysiology, clinical implications and management. *World J Gastroenterol WJG*. 2009 Jan 21;15(3):280–8.
56. Donadon V, Balbi M, Mas MD, Casarin P, Zanette G. Metformin and reduced risk of hepatocellular carcinoma in diabetic patients with chronic liver disease. *Liver Int*. 2010 May;30(5):750–8.
57. Tseng C-H. Metformin and risk of hepatocellular carcinoma in patients with type 2 diabetes. *Liver Int*. 2018 Nov;38(11):2018–27.
58. Shang R-Z, Qu S-B, Wang D-S. Reprogramming of glucose metabolism in hepatocellular carcinoma: Progress and prospects. *World J Gastroenterol*. 2016 Dec 7;22(45):9933–43.
59. Henry ZH, Caldwell SH. Obesity and Hepatocellular Carcinoma: A Complex Relationship. *Gastroenterology*. 2015 Jul;149(1):18–20.
60. Jang BK. Does obesity increase the risk of hepatocellular carcinoma in chronic hepatitis B patients? *Clin Mol Hepatol*. 2016 Sep;22(3):336–8.
61. Kim K, Choi S, Park SM. Association of High Body Mass Index and Hepatocellular Carcinoma in Patients With Chronic Hepatitis B Virus Infection: A Korean Population-Based Cohort Study. *JAMA Oncol*. 2018 May 1;4(5):737.
62. Wang Y, Wang B, Shen F, Fan J, Cao H. Body Mass Index and Risk of Primary Liver Cancer: A Meta-Analysis of Prospective Studies. *The Oncologist*. 2012 Nov;17(11):1461–8.
63. Desai A, Sandhu S, Lai J-P, Sandhu S. Hepatocellular carcinoma in non-cirrhotic liver: A comprehensive review. *World J Hepatol*. 2019;11(1):1–18.
64. Perumpail RB, Liu A, Wong RJ, Ahmed A, Harrison SA. Pathogenesis of hepatocarcinogenesis in non-cirrhotic nonalcoholic fatty liver disease: Potential mechanistic pathways. *World J Hepatol*. 2015 Oct 8;7(22):2384–8.
65. Piñero F, Costa P, Boteon YL, Duque SH, Marciano S, Anders M, et al. A changing etiologic scenario in liver transplantation for hepatocellular carcinoma

in a multicenter cohort study from Latin America. *Clin Res Hepatol Gastroenterol*. 2018 Oct;42(5):443–52.

66. Yang S, Zhu H, Li Y, Lin H, Gabrielson K, Trush MA, et al. Mitochondrial Adaptations to Obesity-Related Oxidant Stress. *Arch Biochem Biophys*. 2000 Jun 15;378(2):259–68.

67. Hotamisligil GS. Inflammation and metabolic disorders. *Nature*. 2006 Dec;444(7121):860.

68. Stickel F, Hellerbrand C. Non-alcoholic fatty liver disease as a risk factor for hepatocellular carcinoma: mechanisms and implications. *Gut*. 2010 Oct 1;59(10):1303–7.

69. Park EJ, Lee JH, Yu G-Y, He G, Ali SR, Holzer RG, et al. Dietary and Genetic Obesity Promote Liver Inflammation and Tumorigenesis by Enhancing IL-6 and TNF Expression. *Cell*. 2010 Jan 22;140(2):197–208.

70. Leung C, Yeoh SW, Patrick D, Ket S, Marion K, Gow P, et al. Characteristics of hepatocellular carcinoma in cirrhotic and non-cirrhotic non-alcoholic fatty liver disease. *World J Gastroenterol WJG*. 2015 Jan 28;21(4):1189–96.

71. Diehl AM, Hoek JB. Mitochondrial Uncoupling: Role of Uncoupling Protein Anion Carriers and Relationship to Thermogenesis and Weight Control “The Benefits of Losing Control.” :14.

72. Zacharski LR, Ornstein DL, Woloshin S, Schwartz LM. Association of age, sex, and race with body iron stores in adults: Analysis of NHANES III data. *Am Heart J*. 2000 Jul 1;140(1):98–104.

73. Wang CY, Babitt JL. Liver iron sensing and body iron homeostasis. *Blood*. 2019;133(1):18–29.

74. Pietrangelo A. Genetics, Genetic Testing, and Management of Hemochromatosis: 15 Years Since Heparidin. *Gastroenterology*. 2015 Oct;149(5):1240-1251.e4.

75. Kew MC, Asare GA. Dietary iron overload in the African and hepatocellular carcinoma. *Liver Int*. 2007 Aug 1;27(6):735–41.

76. Kew MC. Hepatic iron overload and hepatocellular carcinoma. *Cancer Lett*. 2009 Dec;286(1):38–43.

77. Kowdley KV. Iron, hemochromatosis, and hepatocellular carcinoma. *Gastroenterology*. 2004 Nov 1;127(5, Supplement 1):S79–86.
78. Strohmeyer G, Niederau C, Stremmel W. Survival and Causes of Death in Hemochromatosis.: Observations in 163 Patients. *Ann N Y Acad Sci*. 1988 Jun;526(1 Hemochromatos):245–57.
79. Fracanzani AL, Conte D, Fraquelli M, Taioli E, Mattioli M, Losco A, et al. Increased cancer risk in a cohort of 230 patients with hereditary hemochromatosis in comparison to matched control patients with non-iron-related chronic liver disease. *Hepatology*. 2001;33(3):647–51.
80. Siegel AB, Zhu AX. Metabolic Syndrome and Hepatocellular Carcinoma: Two Growing Epidemics with a Potential Link. *Cancer*. 2009 Dec 15;115(24):5651–61.
81. Jomova K, Valko M. Advances in metal-induced oxidative stress and human disease. *Toxicology*. 2011 May;283(2–3):65–87.
82. Valko M, Rhodes CJ, Moncol J, Izakovic M, Mazur M. Free radicals, metals and antioxidants in oxidative stress-induced cancer. *Chem Biol Interact*. 2006 Mar;160(1):1–40.
83. Wei Y, Neuveut C, Tiollais P, Buendia M-A. Molecular biology of the hepatitis B virus and role of the X gene. *Pathol Biol*. 2010 Aug;58(4):267–72.
84. Yoo YD, Ueda H, Park K, Flanders KC, Lee YI, Jay G, et al. Regulation of transforming growth factor-beta 1 expression by the hepatitis B virus (HBV) X transactivator. Role in HBV pathogenesis. *J Clin Invest*. 1996 Jan 15;97(2):388–95.
85. Fabregat I, Caballero-Díaz D. Transforming Growth Factor- β -Induced Cell Plasticity in Liver Fibrosis and Hepatocarcinogenesis. *Front Oncol* [Internet]. 2018 [cited 2019 Aug 4];8. Available from: <https://www.frontiersin.org/articles/10.3389/fonc.2018.00357/full>
86. PDGF essentially links TGF- β signaling to nuclear β -catenin accumulation in hepatocellular carcinoma progression | *Oncogene* [Internet]. [cited 2019 Aug 4]. Available from: <https://www.nature.com/articles/1210121>

87. Henkler F, Koshy R. Hepatitis B virus transcriptional activators: mechanisms and possible role in oncogenesis. *J Viral Hepat.* 1996 May;3(3):109–21.
88. Feitelson MA, Duan LX. Hepatitis B virus X antigen in the pathogenesis of chronic infections and the development of hepatocellular carcinoma. *Am J Pathol.* 1997 Apr;150(4):1141–57.
89. Bauer T, Sprinzl M, Protzer U. Immune Control of Hepatitis B Virus. *Dig Dis.* 2011;29(4):423–33.
90. Ma Z, Cao Q, Xiong Y, Zhang E, Lu M. Interaction between Hepatitis B Virus and Toll-Like Receptors: Current Status and Potential Therapeutic Use for Chronic Hepatitis B. *Vaccines* [Internet]. 2018 Jan 16 [cited 2019 Aug 4];6(1). Available from: <https://www.ncbi.nlm.nih.gov/pmc/articles/PMC5874647/>
91. Pan J, Lian Z, Wallet S, Feitelson MA. The hepatitis B x antigen effector, URG7, blocks tumour necrosis factor -mediated apoptosis by activation of phosphoinositol 3-kinase and beta-catenin. *J Gen Virol.* 2007 Dec 1;88(12):3275–85.
92. Valgimigli L, Valgimigli M, Gaiani S, Pedulli GF, Bolondi L. Measurement of oxidative stress in human liver by EPR spin-probe technique. *Free Radic Res.* 2000 Aug;33(2):167–78.
93. Marotta F, Yoshida C, Barreto R, Naito Y, Packer L. Oxidative-inflammatory damage in cirrhosis: Effect of vitamin E and a fermented papaya preparation. *J Gastroenterol Hepatol.* 2007 Apr;22(5):697–703.
94. Ivanov AV, Valuev-Elliston VT, Tyurina DA, Ivanova ON, Kochetkov SN, Bartosch B, et al. Oxidative stress, a trigger of hepatitis C and B virus-induced liver carcinogenesis. *Oncotarget.* 2016;8(3):3895–932.
95. Dikici I, Mehmetoglu I, Dikici N, Bitirgen M, Kurban S. Investigation of oxidative stress and some antioxidants in patients with acute and chronic viral hepatitis B and the effect of interferon- α treatment. *Clin Biochem.* 2005 Dec;38(12):1141–4.
96. Bhargava A, Khan S, Panwar H, Pathak N, Punde RP, Varshney S, et al. Occult hepatitis B virus infection with low viremia induces DNA damage,

apoptosis and oxidative stress in peripheral blood lymphocytes. *Virus Res.* 2010 Oct;153(1):143–50.

97. Duygu F, Karsen H, Aksoy N, Taskin A. Relationship of Oxidative Stress in Hepatitis B Infection Activity with HBV DNA and Fibrosis. *Ann Lab Med.* 2012 Mar;32(2):113–8.

98. Ren J-H, Chen X, Zhou L, Tao N-N, Zhou H-Z, Liu B, et al. Protective Role of Sirtuin3 (SIRT3) in Oxidative Stress Mediated by Hepatitis B Virus X Protein Expression. *PloS One.* 2016;11(3):e0150961.

99. Ha H-L, Yu D-Y. HBx-induced reactive oxygen species activates hepatocellular carcinogenesis via dysregulation of PTEN/Akt pathway. *World J Gastroenterol.* 2010 Oct;16(39):4932–7.

100. Liu B, Fang M, He Z, Cui D, Jia S, Lin X, et al. Hepatitis B virus stimulates G6PD expression through HBx-mediated Nrf2 activation. *Cit Cell Death Dis* [Internet]. 1980;6. Available from: www.nature.com/cddis

101. Wang Z, Li Z, Ye Y, Xie L, Li W. Oxidative Stress and Liver Cancer: Etiology and Therapeutic Targets. *Oxid Med Cell Longev.* 2016 Nov;2016:1–10.

102. Rahmani Z, Huh KW, Lasher R, Siddiqui A. Hepatitis B virus X protein colocalizes to mitochondria with a human voltage-dependent anion channel, HVDAC3, and alters its transmembrane potential. *J Virol.* 2000 Mar;74(6):2840–6.

103. Hoppe UC. Mitochondrial calcium channels. *FEBS Lett.* 2010 May;584(10):1975–81.

104. Li D, Wang X-Z, Yu J-P, Chen Z-X, Huang Y-H, Tao Dan Li Q-M. Cytochrome C oxidase III interacts with hepatitis B virus X protein in vivo by yeast two-hybrid system. *World J Gastroenterol* *World J Gastroenterol.* 2345;10:86–96.

105. Yi Y-S, Park SG, Byeon SM, Kwon Y-G, Jung G. Hepatitis B virus X protein induces TNF-alpha expression via down-regulation of selenoprotein P in human hepatoma cell line, HepG2. *Biochim Biophys Acta.* 2003 Jul;1638(3):249–56.

106. Hsieh Y-H, Su I-J, Wang H-C, Chang W-W, Lei H-Y, Lai M-D, et al. Pre-S mutant surface antigens in chronic hepatitis B virus infection induce oxidative stress and DNA damage. Available from: <https://academic.oup.com/carcin/article-abstract/25/10/2023/2475823>

107. Murakami Y, Saigo K, Takashima H, Minami M, Okanoue T, Bréchet C, et al. Large scaled analysis of hepatitis B virus (HBV) DNA integration in HBV related hepatocellular carcinomas. *Gut*. 2005;54:1162–8.
108. Chuang L, Ito Y. RUNX3 is multifunctional in carcinogenesis of multiple solid tumors. *Oncogene*. 2010;29:2605–15.
109. Chen J, Siddiqui A. Hepatitis B Virus X Protein Stimulates the Mitochondrial Translocation of Raf-1 via Oxidative Stress. *J Virol*. 2007;81(12):6757–60.
110. Axley P, Ahmed Z, Ravi S, Singal AK. Hepatitis C Virus and Hepatocellular Carcinoma: A Narrative Review. *J Clin Transl Hepatol*. 2018 Mar 28;6(1):79–84.
111. Manns MP, Buti M, Gane E, Pawlotsky J-M, Razavi H, Terrault N, et al. Hepatitis C virus infection. *Nat Rev Dis Primer* [Internet]. 2017 Dec [cited 2019 Aug 4];3(1). Available from: <http://www.nature.com/articles/nrdp20176>
112. Irshad M, Gupta P, Irshad K. Molecular basis of hepatocellular carcinoma induced by hepatitis C virus infection. *World J Hepatol*. 2017 Dec 28;9(36):1305–14.
113. Kwun HJ, Jang KL, Lee MN, Jung EY, Ahn JY. p53-dependent transcriptional repression of p21waf1 by hepatitis C virus NS3. *J Gen Virol*. 2001 Sep 1;82(9):2235–41.
114. Yu G-Y, He G, Li C-Y, Tang M, Grivennikov S, Tsai W-T, et al. Hepatic Expression of HCV RNA-Dependent RNA Polymerase Triggers Innate Immune Signaling and Cytokine Production. *Mol Cell*. 2012 Oct;48(2):313–21.
115. Korenaga M, Wang T, Li Y, Showalter LA, Chan T, Sun J, et al. Hepatitis C Virus Core Protein Inhibits Mitochondrial Electron Transport and Increases Reactive Oxygen Species (ROS) Production. *J Biol Chem*. 2005 Nov 11;280(45):37481–8.
116. Yoon SK. Molecular mechanism of hepatocellular carcinoma. *Hepatoma Res*. 2018 Aug 8;4(8):42.
117. Bahnassi AA, Zekri A-RN, El-Houssini S, Mokhtar NM, Abdel-Aziz AO, Sherif GM, et al. Hepatitis C virus-NS3P in relation to p53, p21waf, mdm2, p21-ras and c-erbB2 in hepatocarcinogenesis. *J Gastroenterol Hepatol*. 2005 Nov;20(11):1731–40.

118. Sidharthan S, Kottlil S. Mechanisms of alcohol-induced hepatocellular carcinoma. *Hepatol Int*. 2014 Sep;8(S2):452–7.
119. Ratna A, Mandrekar P. Alcohol and Cancer: Mechanisms and Therapies. *Biomolecules* [Internet]. 2017 Aug 14 [cited 2019 Sep 1];7(3). Available from: <https://www.ncbi.nlm.nih.gov/pmc/articles/PMC5618242/>
120. Neuman MG, Malnick S, Maor Y, Nanau RM, Melzer E, Ferenci P, et al. Alcoholic liver disease: Clinical and translational research. *Exp Mol Pathol*. 2015 Dec;99(3):596–610.
121. Polonikov AV, Ivanov VP, Solodilova MA. CYP2E1 Gene Promoter Polymorphism -1293G>C Increases the Risk of Essential Hypertension in Men with Alcohol Abuse. *Bull Exp Biol Med*. 2013 Oct;155(6):734–7.
122. Mercer KE, Hennings L, Ronis MJJ. Alcohol consumption, Wnt/ β -catenin signaling and hepatocarcinogenesis. *Adv Exp Med Biol*. 2015;815:185–95.
123. McKillop IH, Schrum LW, Thompson KJ. Role of alcohol in the development and progression of hepatocellular carcinoma. *Hepatic Oncol*. 2016 Jan;3(1):29–43.
124. Thompson KJ, Humphries JR, Niemeyer DJ, Sindram D, McKillop IH. The effect of alcohol on Sirt1 expression and function in animal and human models of hepatocellular carcinoma (HCC). *Adv Exp Med Biol*. 2015;815:361–73.
125. Yeung F, Hoberg JE, Ramsey CS, Keller MD, Jones DR, Frye RA, et al. Modulation of NF- κ B-dependent transcription and cell survival by the SIRT1 deacetylase. *EMBO J*. 2004 Jun 16;23(12):2369–80.
126. Stünkel W, Peh BK, Tan YC, Nayagam VM, Wang X, Salto-Tellez M, et al. Function of the SIRT1 protein deacetylase in cancer. *Biotechnol J*. 2007 Nov;2(11):1360–8.
127. Jang KY, Noh SJ, Lehwald N, Tao G-Z, Bellovin DI, Park HS, et al. SIRT1 and c-Myc Promote Liver Tumor Cell Survival and Predict Poor Survival of Human Hepatocellular Carcinomas. Man K, editor. *PLoS ONE*. 2012 Sep 14;7(9):e45119.
128. Wong VW-S, Wong GL-H, Choi PC-L, Chan AW-H, Li MK-P, Chan H-Y, et al. Disease progression of non-alcoholic fatty liver disease: a prospective study with paired liver biopsies at 3 years. *Gut*. 2010 Jul 1;59(7):969–74.

129. Wu J. Utilization of animal models to investigate nonalcoholic steatohepatitis-associated hepatocellular carcinoma. *Oncotarget* [Internet]. 2016 Jul 5 [cited 2019 Aug 4];7(27). Available from: <http://www.oncotarget.com/fulltext/8641>
130. Wu J. Epigenetic regulation of hepatic tumor-initiating cells. *Front Biosci*. 2015;20(6):946–63.
131. Chylikova J, Dvorackova J, Tauber Z, Kamarad V. M1/M2 macrophage polarization in human obese adipose tissue. *Biomed Pap*. 2018 Jun 25;162(2):79–82.
132. Castoldi A, Naffah de Souza C, Câmara NOS, Moraes-Vieira PM. The Macrophage Switch in Obesity Development. *Front Immunol* [Internet]. 2016 Jan 5 [cited 2019 Aug 4];6. Available from: <https://www.ncbi.nlm.nih.gov/pmc/articles/PMC4700258/>
133. Labonte AC, Tosello-Tramont A-C, Hahn YS. The Role of Macrophage Polarization in Infectious and Inflammatory Diseases. *Mol Cells*. 2014 Apr 30;37(4):275–85.
134. Gordon S, Plüddemann A. Tissue macrophages: heterogeneity and functions. *BMC Biol* [Internet]. 2017 Jun 29 [cited 2019 Aug 4];15. Available from: <https://www.ncbi.nlm.nih.gov/pmc/articles/PMC5492929/>
135. Shoelson SE, Lee J, Goldfine AB. Inflammation and insulin resistance. *J Clin Invest*. 2006 Jul 3;116(7):1793–801.
136. Frühbeck G, Catalán V, Rodríguez A, Ramírez B, Becerril S, Salvador J, et al. Involvement of the leptin-adiponectin axis in inflammation and oxidative stress in the metabolic syndrome. *Sci Rep* [Internet]. 2017 Jul 26 [cited 2019 Aug 4];7. Available from: <https://www.ncbi.nlm.nih.gov/pmc/articles/PMC5529549/>
137. Moslehi A, Hamidi-zad Z. Role of SREBPs in Liver Diseases: A Mini-review. *J Clin Transl Hepatol*. 2018 Sep 28;6(3):332–8.
138. Donnelly KL, Smith CI, Schwarzenberg SJ, Jessurun J, Boldt MD, Parks EJ. Sources of fatty acids stored in liver and secreted via lipoproteins in patients with nonalcoholic fatty liver disease. :10.
139. Lefterova MI, Lazar MA. New developments in adipogenesis. *Trends Endocrinol Metab*. 2009 Apr;20(3):107–14.

140. Wei Y, Wang D, Topczewski F, Pagliassotti MJ. Saturated fatty acids induce endoplasmic reticulum stress and apoptosis independently of ceramide in liver cells. *Am J Physiol-Endocrinol Metab.* 2006 Aug;291(2):E275–81.
141. Lumeng CN, Saltiel AR. Inflammatory links between obesity and metabolic disease. *J Clin Invest.* 2011 Jun 1;121(6):2111–7.
142. Dhanasekaran R, Bando S, Roberts LR. Molecular pathogenesis of hepatocellular carcinoma and impact of therapeutic advances. *F1000Research.* 2016 May 12;5:879.
143. Machida K, Cheng KT-N, Sung VM-H, Shimodaira S, Lindsay KL, Levine AM, et al. Hepatitis C virus induces a mutator phenotype: Enhanced mutations of immunoglobulin and protooncogenes. *Proc Natl Acad Sci U S A.* 2004 Mar 23;101(12):4262–7.
144. Zvereva MI, Shcherbakova DM, Dontsova OA. Telomerase: structure, functions, and activity regulation. *Biochem Biokhimiia.* 2010 Dec;75(13):1563–83.
145. Hartmann D, Srivastava U, Thaler M, Kleinhans KN, N'kontchou G, Scheffold A, et al. Telomerase gene mutations are associated with cirrhosis formation. *Hepatology Baltim Md.* 2011 May;53(5):1608–17.
146. Nault JC, Mallet M, Pilati C, Calderaro J, Bioulac-Sage P, Laurent C, et al. High frequency of telomerase reverse-transcriptase promoter somatic mutations in hepatocellular carcinoma and preneoplastic lesions. *Nat Commun.* 2013;4:2218.
147. Cleary SP, Jeck WR, Zhao X, Chen K, Selitsky SR, Savich GL, et al. Identification of Driver Genes in Hepatocellular Carcinoma by Exome Sequencing. *Hepatology Baltim Md.* 2013 Nov;58(5):1693–702.
148. Kan Z, Zheng H, Liu X, Li S, Barber TD, Gong Z, et al. Whole-genome sequencing identifies recurrent mutations in hepatocellular carcinoma. *Genome Res.* 2013 Sep;23(9):1422–33.
149. Ali A, Abdel-Hafiz H, Suhail M, Al-Mars A, Zakaria MK, Fatima K, et al. Hepatitis B virus, HBx mutants and their role in hepatocellular carcinoma. *World J Gastroenterol WJG.* 2014 Aug 14;20(30):10238–48.

150. Villanueva A, Llovet JM. Mutational landscape of HCC—the end of the beginning. *Nat Rev Clin Oncol*. 2014 Feb;11(2):73–4.
151. Wahid B, Ali A, Rafique S, Idrees M. New Insights into the Epigenetics of Hepatocellular Carcinoma. *BioMed Res Int*. 2017;2017:1–16.
152. Park IY, Sohn BH, Yu E, Suh DJ, Chung Y, Lee J, et al. Aberrant Epigenetic Modifications in Hepatocarcinogenesis Induced by Hepatitis B Virus X Protein. *Gastroenterology*. 2007 Apr 1;132(4):1476–94.
153. Lim JS, Park S-H, Jang KL. Hepatitis C virus Core protein overcomes stress-induced premature senescence by down-regulating p16 expression via DNA methylation. *Cancer Lett*. 2012 Aug 28;321(2):154–61.
154. Deng Y-B, Nagae G, Midorikawa Y, Yagi K, Tsutsumi S, Yamamoto S, et al. Identification of genes preferentially methylated in hepatitis C virus-related hepatocellular carcinoma. *Cancer Sci*. 2010;101(6):1501–10.
155. Narimatsu T, Tamori A, Koh N, Kubo S, Hirohashi K, Yano Y, et al. p16 Promoter Hypermethylation in Human Hepatocellular Carcinoma with or without Hepatitis Virus Infection. *Intervirol*. 2004;47(1):26–31.
156. Khalaf AM, Fuentes D, Morshid AI, Burke MR, Kaseb AO, Hassan M, et al. Role of Wnt/ β -catenin signaling in hepatocellular carcinoma, pathogenesis, and clinical significance. *J Hepatocell Carcinoma*. 2018 Jun 27;5:61–73.
157. Guichard C, Amaddeo G, Imbeaud S, Ladeiro Y, Pelletier L, Maad IB, et al. Integrated analysis of somatic mutations and focal copy-number changes identifies key genes and pathways in hepatocellular carcinoma. *Nat Genet*. 2012 Jun;44(6):694–8.
158. Hoshida Y, Nijman SMB, Kobayashi M, Chan JA, Brunet J-P, Chiang DY, et al. Integrative Transcriptome Analysis Reveals Common Molecular Subclasses of Human Hepatocellular Carcinoma. *Cancer Res*. 2009 Sep 15;69(18):7385–92.
159. Lachenmayer A, Alsinet C, Savic R, Cabellos L, Toffanin S, Hoshida Y, et al. Wnt-pathway activation in two molecular classes of hepatocellular carcinoma and experimental modulation by sorafenib. *Clin Cancer Res Off J Am Assoc Cancer Res*. 2012 Sep 15;18(18):4997–5007.

160. Villanueva A, Newell P, Chiang D, Friedman S, Llovet J. Genomics and Signaling Pathways in Hepatocellular Carcinoma. *Semin Liver Dis.* 2007 Feb;27(1):055–76.
161. Roberts LR, Gores GJ. Hepatocellular carcinoma: molecular pathways and new therapeutic targets. *Semin Liver Dis.* 2005;25(2):212–25.
162. Bhat M, Sonenberg N, Gores G. The mTOR Pathway in Hepatic Malignancies. *Hepatology Baltim Md.* 2013 Aug;58(2):810–8.
163. Park YN, Kim Y-B, Yang KM, Park C. Increased Expression of Vascular Endothelial Growth Factor and Angiogenesis in the Early Stage of Multistep Hepatocarcinogenesis. *Arch Pathol Lab Med.* 2000 Jul 1;124(7):1061–5.
164. Kim K-W, Bae S-K, Lee O-H, Bae M-H, Lee M-J, Park BC. Insulin-like Growth Factor II Induced by Hypoxia May Contribute to Angiogenesis of Human Hepatocellular Carcinoma. *Cancer Res.* 1998 Jan 15;58(2):348–51.
165. Libbrecht L, Desmet V, Roskams T. Preneoplastic lesions in human hepatocarcinogenesis. *Liver Int.* 2005;25(1):16–27.
166. Watanabe S, Okita K, Harada T, Kodama T, Numa Y, Takemoto T, et al. Morphologic studies of the liver cell dysplasia. *Cancer.* 1983 Jun 15;51(12):2197–205.
167. Su Q, Bannasch P. Relevance of Hepatic Preneoplasia for Human Hepatocarcinogenesis. *Toxicol Pathol.* 2003;31(1):126–33.
168. Edmondson HA, Steiner PE. Primary carcinoma of the liver. A study of 100 cases among 48,900 necropsies. *Cancer.* 1954 May 1;7(3):462–503.
169. Marchio A, Terris B, Meddeb M, Pineau P, Duverger A, Tiollais P, et al. Chromosomal abnormalities in liver cell dysplasia detected by comparative genomic hybridisation. *Mol Pathol MP.* 2001 Aug;54(4):270–4.
170. Dumble ML, Croager EJ, Yeoh GCT, Quail EA. Generation and characterization of p53 null transformed hepatic progenitor cells: oval cells give rise to hepatocellular carcinoma. *Carcinogenesis.* 2002 Mar;23(3):435–45.
171. Anthony PP, Vogel CL, Barker LF. Liver cell dysplasia: a premalignant condition. *J Clin Pathol.* 1973 Mar;26(3):217–23.
172. Cohen C, Berson SD. Liver cell dysplasia in normal, cirrhotic, and hepatocellular carcinoma patients. *Cancer.* 1986 Apr;57(8):1535–8.

173. Lee RG, Tsamandas AC, Demetris AJ. Large cell change (liver cell dysplasia) and hepatocellular carcinoma in cirrhosis: Matched case-control study, pathological analysis, and pathogenetic hypothesis. *Hepatology*. 1997 Dec;26(6):1415–22.
174. Libbrecht L, Desmet V, Van Damme B, Roskams T. The immunohistochemical phenotype of dysplastic foci in human liver: correlation with putative progenitor cells. *J Hepatol*. 2000 Jul;33(1):76–84.
175. Wanless IR. Terminology of nodular hepatocellular lesions. *Hepatology*. 1995 Sep 1;22(3):983–93.
176. Aihara T, Noguchi S, Sasaki Y, Nakano H, Imaoka S. Clonal analysis of regenerative nodules in hepatitis C virus-induced liver cirrhosis. *Gastroenterology*. 1994 Dec;107(6):1805–11.
177. Paradis V, Laurendeau I, Vidaud M, Bedossa P. Clonal analysis of macronodules in cirrhosis. *Hepatology*. 1998 Oct;28(4):953–8.
178. Tiniakos DG, Brunt EM. Proliferating cell nuclear antigen and Ki-67 labeling in hepatocellular nodules: a comparative study. *Liver*. 1999 Feb;19(1):58–68.
179. Deugnier YM, Lorgal O, Turlin B, Guyader D, Jouanolle H, Moirand R, et al. Liver Pathology in Genetic Hemochromatosis: A Review of 135 Homozygous Cases and Their Bioclinical Correlations [Internet]. 1992 p. 2050–9. Available from: [https://www.gastrojournal.org/article/0016-5085\(92\)90331-R/pdf?referrer=https%3A%2F%2Fwww.ncbi.nlm.nih.gov%2F](https://www.gastrojournal.org/article/0016-5085(92)90331-R/pdf?referrer=https%3A%2F%2Fwww.ncbi.nlm.nih.gov%2F)
180. Deugnier YM, Charalambous P, Quilleuc DL, Turlin B, Searle J, Brissot P, et al. Preneoplastic significance of hepatic iron-free foci in genetic hemochromatosis: A study of 185 patients. *Hepatology*. 1993 Dec 1;18(6):1363–9.
181. Deugnier YM, Charalambous P, Quilleuc DL, Turlin B, Searle J, Brissot P, et al. Preneoplastic significance of hepatic iron-free foci in genetic hemochromatosis: A study of 185 patients. *Hepatology*. 1993;18(6):1363–9.
182. Bannasch P, Klimek F, Mayer D. Early bioenergetic changes in hepatocarcinogenesis: preneoplastic phenotypes mimic responses to insulin and thyroid hormone. *J Bioenerg Biomembr*. 1997 Aug;29(4):303–13.

183. Su Q, Benner A, Hofmann WJ, Otto G, Pichlmayr R, Bannasch P. Human hepatic preneoplasia: phenotypes and proliferation kinetics of foci and nodules of altered hepatocytes and their relationship to liver cell dysplasia. *Virchows Arch Int J Pathol.* 1997 Dec;431(6):391–406.
184. Evert M, Dombrowski F. Hepatozelluläre Karzinome in der nicht-zirrhotischen Leber. 2007; Available from: <https://link.springer.com/content/pdf/10.1007%2Fs00292-007-0953-3.pdf>
185. Bannasch P, Jahn U, Hacker HJ, Hofmann W, Pichlmayr R, Otto G. Focal hepatic glycogenosis : a putative preneoplastic lesion associated with neoplasia and cirrhosis in explanted human livers. 1997;261–8.
186. Chang A, Harawi SJ. Oncocytes, oncocytosis, and oncocytic tumors. *Pathol Annu.* 1992;27 Pt 1:263–304.
187. Lefkowitz JH, Arborgh BA, Scheuer PJ. Oxyphilic granular hepatocytes. Mitochondrion-rich liver cells in hepatic disease. *Am J Clin Pathol.* 1980 Oct;74(4):432–41.
188. Tanji K, Bhagat G, Vu TH, Monzon L, Bonilla E, Lefkowitz JH. Mitochondrial DNA dysfunction in oncocytic hepatocytes. *Liver Int Off J Int Assoc Study Liver.* 2003 Oct;23(5):397–403.
189. Stoot JHMB, Coelen RJS, De Jong MC, Cornelis &, Dejong HC. Malignant transformation of hepatocellular adenomas into hepatocellular carcinomas: a systematic review including more than 1600 adenoma cases. 2010; Available from: <https://www.ncbi.nlm.nih.gov/pmc/articles/PMC2997656/pdf/hpb0012-0509.pdf>
190. Vijay A, Elaffandi A, Khalaf Adarsh Vijay H, Khalaf H, Hepatocellular KH. Hepatocellular adenoma: An update. *World J Hepatol.* 2015;7(25):2603–9.
191. Dhingra S, Fiel ; M Isabel. Update on the New Classification of Hepatic Adenomas Clinical, Molecular, and Pathologic Characteristics. Available from: <https://www.archivesofpathology.org/doi/pdf/10.5858/arpa.2013-0183-RA>
192. Bioulac-Sage P, Cubel G, Balabaud C, Zucman-Rossi J. Revisiting the Pathology of Resected Benign Hepatocellular Nodules Using New Immunohistochemical Markers. *Semin Liver Dis.* 2011 Feb;31(01):091–103.

193. Bioulac-Sage P, Rebouissou S, Thomas C, Blanc J-F, Saric J, Sa Cunha A, et al. Hepatocellular adenoma subtype classification using molecular markers and immunohistochemistry. *Hepatology*. 2007 Sep;46(3):740–8.
194. Lo RC-L, Ng IO-L. Hepatocellular tumors: Immunohistochemical analyses for classification and prognostication. *Chin J Cancer Res*. 2011 Dec;23(4):245–53.
195. Davis M, Portmann B, Searle M, Wright R, Williams R. Histological evidence of carcinoma in a hepatic tumour associated with oral contraceptives. *BMJ*. 1975 Nov;4(5995):496–8.
196. Liau S-S, Qureshi MS, Praseedom R, Huguet E. Molecular Pathogenesis of Hepatic Adenomas and Its Implications for Surgical Management. *J Gastrointest Surg*. 2013 Oct;17(10):1869–82.
197. Macdonald GA, Greenson JK, Saito K, Cherian SP, Appelman HD, Boland CR. Microsatellite instability and loss of heterozygosity at DNA mismatch repair gene loci occurs during hepatic carcinogenesis. *Hepatology*. 1998 Jul;28(1):90–7.
198. Paradis V, Laurent A, Flejou J, Vidaud M, Bedossa P. Evidence for the polyclonal nature of focal nodular hyperplasia of the liver by the study of X-chromosome inactivation. *Hepatology*. 1997 Oct;26(4):891–5.
199. Farges O, Dokmak S. Malignant Transformation of Liver Adenoma: An Analysis of the Literature. *Dig Surg* [Internet]. 2010; Available from: www.karger.com
200. Bosman FT, World Health Organization, International Agency for Research on Cancer, editors. WHO classification of tumours of the digestive system. Lyon: IARC Press; 2010. 417 p. (World Health Organization classification of tumours, 4th edition).
201. Jain D. Tissue Diagnosis of Hepatocellular Carcinoma. *J Clin Exp Hepatol*. 2014 Aug;4(Suppl 3):S67.
202. Trevisani F, Frigerio M, Santi V, Grignaschi A, Bernardi M. Hepatocellular carcinoma in non-cirrhotic liver: A reappraisal. *Dig Liver Dis*. 2010 May;42(5):341–7.
203. Torbenson MS. *Surgical Pathology of Liver Tumors*. 2015.

204. Shafizadeh N, Kakar S. Hepatocellular Carcinoma. Histologic Subtypes. *Surg Pathol Clin*. 2013;6(2):367–84.
205. Board WC of TE. Digestive System Tumours [Internet]. [cited 2019 Oct 28]. Available from: <http://publications.iarc.fr/Book-And-Report-Series/Who-Iarc-Classification-Of-Tumours/Digestive-System-Tumours-2019>
206. El-Serag HB, Davila JA. Is Fibrolamellar Carcinoma Different from Hepatocellular Carcinoma? A US Population-Based Study. *Hepatology*. 2004;
207. Stevens WR, Johnson CD, Stephens DH, Nagorney DM. Fibrolamellar hepatocellular carcinoma: Stage at presentation and results of aggressive surgical management. *Am J Roentgenol*. 1995;
208. Stipa F, Yoon SS, Liau KH, Fong Y, Jarnagin WR, D'Angelica M, et al. Outcome of patients with fibrolamellar hepatocellular carcinoma. *Cancer*. 2006;
209. Kakar S, Burgart LJ, Batts KP, Garcia J, Jain D, Ferrell LD. Clinicopathologic features and survival in fibrolamellar carcinoma: Comparison with conventional hepatocellular carcinoma with and without cirrhosis. *Mod Pathol*. 2005;
210. Calderaro J, Couchy G, Imbeaud S, Amaddeo G, Letouzé E, Blanc J-F, et al. Histological subtypes of hepatocellular carcinoma are related to gene mutations and molecular tumour classification. *J Hepatol*. 2017 Oct;67(4):727–38.
211. Ziol M, Poté N, Amaddeo G, Laurent A, Nault JC, Oberti F, et al. Macrotrabecular-massive hepatocellular carcinoma: A distinctive histological subtype with clinical relevance. *Hepatology*. 2018;68(1):103–12.
212. Gera S, Ettl M, Acosta-Gonzalez G, Xu R. Clinical features, histology, and histogenesis of combined hepatocellular-cholangiocarcinoma. *World J Hepatol*. 2017 Feb;9(6):300–9.
213. Taguchi J, Nakashima O, Tanaka M, Hisaka T, Takazawa T, Kojiro M. A clinicopathological study on combined hepatocellular and cholangiocarcinoma. *J Gastroenterol Hepatol*. 1996 Aug;11(8):758–64.
214. Prokurat A, Kluge P, Kołczyńska A, Perek D, Kappeler A, Zimmermann A. Transitional liver cell tumors (TLCT) in older children and adolescents: A novel

group of aggressive hepatic tumors expressing beta-catenin. *Med Pediatr Oncol*. 2002 Nov;39(5):510–8.

215. Ozcan HN, Oguz B, Salim T, Talim B, Haliloglu M. A rare malignant hepatic tumor of childhood: transitional liver cell tumor revisited. *JBR-BTR Organe Soc R Belge Radiol SRBR Orgaan Van K Belg Ver Voor Radiol KBVR*. 2015 Apr 1;98(2):79–81.

216. Maeda T, Kayashima H, Imai D, Takeishi K, Harada N, Tsujita E, et al. Undifferentiated carcinoma of the liver: a case report with immunohistochemical analysis. *Surg Case Rep [Internet]*. 2017 Jan 10 [cited 2019 Jul 16];3. Available from: <https://www.ncbi.nlm.nih.gov/pmc/articles/PMC5225379/>

217. Goossens N, Sun X, Hoshida Y. Molecular classification of hepatocellular carcinoma: potential therapeutic implications. *Hepatic Oncol*. 2015 Oct;2(4):371–9.

218. Zucman-Rossi J. Molecular classification of hepatocellular carcinoma. *Dig Liver Dis*. 2010 Jul;42:S235–41.

219. Kew MC, Dos Santos HA, Sherlock S. Diagnosis of Primary Cancer of the Liver. *Br Med J*. 1971 Nov 13;4(5784):408–11.

220. del Carmen Manzano-Robleda M, Barranco-Fragoso B, Uribe M, Méndez-Sánchez N. Portal vein thrombosis: What is new? *Ann Hepatol*. 2015 Jan;14(1):20–7.

221. Quirk M, Kim YH, Saab S, Lee EW. Management of hepatocellular carcinoma with portal vein thrombosis. *World J Gastroenterol WJG*. 2015 Mar 28;21(12):3462–71.

222. Yeo W, Sung JY, Ward SC, Chung SC, Lee WY, Li AK, et al. A prospective study of upper gastrointestinal hemorrhage in patients with hepatocellular carcinoma. *Dig Dis Sci*. 1995 Dec;40(12):2516–21.

223. Kim HC, Yang DM, Jin W, Park SJ. The various manifestations of ruptured hepatocellular carcinoma: CT imaging findings. *Abdom Imaging*. 2008 Nov 1;33(6):633–42.

224. Kew MC. Paraneoplastic Phenomena in Patients with Hepatocellular Carcinoma. *J Liver Res Disord Ther [Internet]*. 2016 Jan 28 [cited 2019 Aug 5];2(1). Available from: <http://medcraveonline.com/JLRDT/JLRDT-02-00017.php>

225. Kew MC, Fisher JW. Serum erythropoietin concentrations in patients with hepatocellular carcinoma. *Cancer*. 1986 Dec 1;58(11):2485–8.
226. Kew MC, Kirschner MA, Abrahams GE, Katz M. Mechanism of Feminization in Primary Liver Cancer. *N Engl J Med*. 1977 May 12;296(19):1084–8.
227. Steiner E. Hepatocellular Carcinoma Presenting With Intractable Diarrhea: A Radiologic-Pathologic Correlation. *Arch Surg*. 1986 Jul 1;121(7):849.
228. Crandall BF, Lau HL. Alpha-fetoprotein: a review. *CRC Crit Rev Clin Lab Sci*. 1981;15(2):127–185.
229. Sell S. Alpha-Fetoprotein, Stem Cells and Cancer: How Study of the Production of Alpha-Fetoprotein during Chemical Hepatocarcinogenesis Led to Reaffirmation of the Stem Cell Theory of Cancer. *Tumor Biol*. 2008;29(3):161–80.
230. ABELEV GI, PEROVA SD, KHRAMKOVA NI, POSTNIKOVA ZA, IRLIN IS. Production of embryonal alpha-globulin by transplantable mouse hepatomas. *Transplantation*. 1963 Apr;1:174–80.
231. KUHLMANN W. Alpha-fetoprotein: origin of a biological marker in rat liver under various experimental conditions. *Int J Exp Path*. 2006;87:343–359.
232. Naz Z, Usman S, Saleem K, Ahmed S, Bashir H, Bilal M, et al. Alpha-fetoprotein: A fabulous biomarker in hepatocellular, gastric and rectal cancer diagnosis. *Biomed Res [Internet]*. 2018 [cited 2019 Sep 6];29(12). Available from: <http://www.alliedacademies.org/abstract/alphafetoprotein-a-fabulous-biomarker-in-hepatocellular-gastric-and-rectal-cancer-diagnosis-10484.html>
233. Stray-Pedersen A, Borresen-Dale AL, Paus E, Lindman CR, Burgers T, Abrahamsen TG. Alpha fetoprotein is increasing with age in ataxia–telangiectasia. *Eur J Paediatr Neurol*. 2007 Nov 1;11(6):375–80.
234. Li G-C. Tumor markers for hepatocellular carcinoma (Review). *Mol Clin Oncol [Internet]*. 2013 May 13 [cited 2017 Jul 26]; Available from: <http://www.spandidos-publications.com/10.3892/mco.2013.119>
235. Bruix J, Sherman M, Llovet JM, Beaugrand M, Lencioni R, Burroughs AK, et al. Clinical Management of Hepatocellular Carcinoma. Conclusions of the Barcelona-2000 EASL Conference. *J Hepatol*. 2001 Sep;35(3):421–30.

236. Chagas A, Kikuchi L, Herman P, Alencar R, Tani C, Diniz M, et al. Clinical and pathological evaluation of fibrolamellar hepatocellular carcinoma: a single center study of 21 cases. *Clinics*. 2015 Mar 30;70(3):207–2013.
237. Gaddikeri S, McNeeley MF, Wang CL, Bhargava P, Dighe MK, Yeh MMC, et al. Hepatocellular Carcinoma in the Noncirrhotic Liver. *Am J Roentgenol*. 2014 Jul;203(1):W34–47.
238. Fong Y, Sun RL, Jarnagin W, Blumgart LH. An Analysis of 412 Cases of Hepatocellular Carcinoma at a Western Center. *Ann Surg*. 1999 Jun;229(6):790.
239. Llovet JM, Fuster J, Bruix J, Barcelona Clinic Liver Cancer (BCLC) Group. Intention-to-treat analysis of surgical treatment for early hepatocellular carcinoma: Resection versus transplantation. *Hepatology*. 1999 Dec;30(6):1434–40.
240. Clasificación Barcelona Clinic Liver Cancer (BCLC) de carcinoma hepatocelular [Internet]. *Gastroenterología Latinoamericana*. 2015 [cited 2019 Aug 5]. Available from: <https://gastrolat.org/clasificacion-barcelona-clinic-liver-cancer-bclc-de-carcinoma-hepatocelular/>
241. Liu L, Wang Z, Jiang S, Shao B, Liu J, Zhang S, et al. Perioperative Allogeneic Blood Transfusion Is Associated with Worse Clinical Outcomes for Hepatocellular Carcinoma: A Meta-Analysis. *PLoS ONE* [Internet]. 2013 May 31 [cited 2019 Aug 5];8(5). Available from: <https://www.ncbi.nlm.nih.gov/pmc/articles/PMC3669337/>
242. Shi M, Guo R-P, Lin X-J, Zhang Y-Q, Chen M-S, Zhang C-Q, et al. Partial Hepatectomy With Wide Versus Narrow Resection Margin for Solitary Hepatocellular Carcinoma. *Ann Surg*. 2007 Jan;245(1):36–43.
243. Huo T-I, Huang Y-H, Wu J-C. Percutaneous Ablation Therapy for Hepatocellular Carcinoma: Current Practice and Future Perspectives. *J Chin Med Assoc*. 2005 Apr 1;68(4):155–9.
244. Shiina S, Tateishi R, Imamura M, Teratani T, Koike Y, Sato S, et al. Percutaneous ethanol injection for hepatocellular carcinoma: 20-year outcome and prognostic factors. *Liver Int*. 2012 Oct;32(9):1434–42.

245. Shiina S, Tagawa K, Unuma T, Takanashi R, Yoshiura K, Komatsu Y, et al. Percutaneous ethanol injection therapy for hepatocellular carcinoma. A histopathologic study. *Cancer*. 1991 Oct 1;68(7):1524–30.
246. Crissien AM, Frenette C. Current management of hepatocellular carcinoma. *Gastroenterol Hepatol*. 2014;10(3):153.
247. Di Stasi M, Buscarini L, Livraghi T, Giorgio A, Salmi A, De Sio I, et al. Percutaneous ethanol injection in the treatment of hepatocellular carcinoma. A multicenter survey of evaluation practices and complication rates. *Scand J Gastroenterol*. 1997 Nov;32(11):1168–73.
248. Facciorusso A, Serviddio G, Muscatiello N. Local ablative treatments for hepatocellular carcinoma: An updated review. *World J Gastrointest Pharmacol Ther*. 2016 Nov 6;7(4):477–89.
249. McDermott S, Gervais DA. Radiofrequency Ablation of Liver Tumors. *Semin Interv Radiol*. 2013 Mar;30(1):49–55.
250. Sacco R, Tapete G, Simonetti N, Sellitri R, Natali V, Melissari S, et al. Transarterial chemoembolization for the treatment of hepatocellular carcinoma: a review [Internet]. *Journal of Hepatocellular Carcinoma*. 2017 [cited 2019 Oct 28]. Available from: <https://www.dovepress.com/transarterial-chemoembolization-for-the-treatment-of-hepatocellular-ca-peer-reviewed-article-JHC>
251. Kennedy A, Nag S, Salem R, Murthy R, McEwan AJ, Nutting C, et al. Recommendations for radioembolization of hepatic malignancies using yttrium-90 microsphere brachytherapy: a consensus panel report from the radioembolization brachytherapy oncology consortium. *Int J Radiat Oncol Biol Phys*. 2007 May 1;68(1):13–23.
252. Precision molecular pathology of liver cancer. New York, NY: Springer Science+Business Media, LLC; 2017.
253. Lewandowski RJ, Mulcahy MF, Kulik LM, Riaz A, Ryu RK, Baker TB, et al. Chemoembolization for Hepatocellular Carcinoma: Comprehensive Imaging and Survival Analysis in a 172-Patient Cohort 1. *Radiology*. 2010 Jun;255(3):955–65.

254. Llovet JM, Hilgard P, de Oliveira AC, Forner A, Zeuzem S, Galle PR, et al. Sorafenib in Advanced Hepatocellular Carcinoma. *N Engl J Med*. 2008;13.
255. Kim DY, Kim HJ, Han K-H, Han SY, Heo J, Woo HY, et al. Real-Life Experience of Sorafenib Treatment for Hepatocellular Carcinoma in Korea: From GIDEON Data. *Cancer Res Treat Off J Korean Cancer Assoc*. 2016 Oct;48(4):1243–52.
256. Toh HC, Chen P-J, Carr BI, Knox JJ, Gill S, Ansell P, et al. Phase 2 trial of linifanib (ABT-869) in patients with unresectable or metastatic hepatocellular carcinoma. *Cancer*. 2013 Jan 15;119(2):380–7.
257. Cainap C, Qin S, Huang W-T, Chung IJ, Pan H, Cheng Y, et al. Linifanib versus Sorafenib in patients with advanced hepatocellular carcinoma: results of a randomized phase III trial. *J Clin Oncol Off J Am Soc Clin Oncol*. 2015 Jan 10;33(2):172–9.
258. Thomas MB, Chadha R, Glover K, Wang X, Morris J, Brown T, et al. Phase 2 study of erlotinib in patients with unresectable hepatocellular carcinoma. *Cancer*. 2007 Sep 1;110(5):1059–67.
259. SEARCH: A Phase III, Randomized, Double-Blind, Placebo-Controlled Trial of Sorafenib Plus Erlotinib in Patients With Advanced Hepatocellular Carcinoma | *Journal of Clinical Oncology* [Internet]. [cited 2019 Oct 28]. Available from: <https://ascopubs.org/doi/10.1200/JCO.2013.53.7746>
260. Nzeako UC, Goodman ZD, Ishak KG. Hepatocellular Carcinoma in Cirrhotic and Noncirrhotic Livers A Clinico-Histopathologic Study of 804 North American Patients [Internet]. 1996 p. 65–75. Available from: <https://academic.oup.com/ajcp/article-abstract/105/1/65/1756419>
261. Kalayci C, Johnson PJ, Davies SE, Williams R. Hepatitis B virus related hepatocellular carcinoma in the non-cirrhotic liver. *J Hepatol*. 1991 Jan;12(1):54–9.
262. Trevisani F, D'Intino PE, Caraceni P, Pizzo M, Stefanini GF, Mazziotti A, et al. Etiologic factors and clinical presentation of hepatocellular carcinoma. Differences between cirrhotic and noncirrhotic Italian patient. *Cancer*. 1995 May 1;75(9):2220–32.

263. De Mitri MS, Poussin K, Baccharini P, Pontisso P, D'Errico A, Simon N, et al. HCV-associated liver cancer without cirrhosis. *Lancet Lond Engl*. 1995 Feb;345(8947):413–5.
264. Dejean A, Bougueleret L, Grzeschik K-H, Tiollais P. Hepatitis B virus DNA integration in a sequence homologous to v-erb-A and steroid receptor genes in a hepatocellular carcinoma. *Nature*. 1986 Jul;322(6074):70–2.
265. Sell S. Cellular origin of cancer: dedifferentiation or stem cell maturation arrest? *Environ Health Perspect*. 1993 Dec;101 Suppl 5(Suppl 5):15–26.
266. Sell S, Dunsford HA. Evidence for the stem cell origin of hepatocellular carcinoma and cholangiocarcinoma. *Am J Pathol*. 1989 Jun;134(6):1347–63.
267. Ferrell LD. Hepatocellular carcinoma arising in a focus of multilobular adenoma. A case report. *Am J Surg Pathol*. 1993 May;17(5):525–9.
268. Okuda K, Nakashima T, Kojiro M, Kondo Y, Wada K. Hepatocellular carcinoma without cirrhosis in Japanese patients. *Gastroenterology*. 1989 Jul 1;97(1):140–6.
269. Bismuth H, Chiche L, Castaing D. Surgical treatment of hepatocellular carcinomas in noncirrhotic liver: experience with 68 liver resections. *World J Surg*. 19(1):35–41.
270. Bertani S, Pineau P, Loli S, Moura J, Zimic M, Deharo E, et al. An Atypical Age-Specific Pattern of Hepatocellular Carcinoma in Peru: A Threat for Andean Populations. Lee JW, editor. *PLoS ONE*. 2013 Jun 28;8(6):e67756.
271. Houben KW, McCall JL. Liver transplantation for hepatocellular carcinoma in patients without underlying liver disease: A systematic review. *Liver Transpl Surg*. 1999 Mar;5(2):91–5.
272. Marchio AS, Phane Bertani S, Rojas TR, Doimi F, Terris B, Deharo E, et al. A Peculiar Mutation Spectrum Emerging from Young Peruvian Patients with Hepatocellular Carcinoma. 2014; Available from: <https://journals.plos.org/plosone/article/file?id=10.1371/journal.pone.0114912&type=printable>
273. Togni R, Bagla N, Muiesan P, Miquel R, O'Grady J, Heaton N, et al. Microsatellite instability in hepatocellular carcinoma in non-cirrhotic liver in patients older than 60 years. *Hepatol Res*. 2009;39(3):266–73.

274. Piñeros M, Ramos W, Antoni S, Abriata G, Medina LE, Miranda JJ, et al. Cancer patterns, trends, and transitions in Peru: a regional perspective. *Lancet Oncol.* 2017 Oct;18(10):e573–e586.
275. Human Development Reports [Internet]. [cited 2019 May 30]. Available from: <http://hdr.undp.org/en/countries/profiles/PER>
276. Perú, Instituto Nacional de Enfermedades Neoplásicas. Datos estadísticos. Lima: INEN; 2013 [Internet]. 2013 [cited 2019 May 30]. Available from:
http://www.inen.sld.pe/portal/documentos/pdf/estadistica/datos_estadisticos/20052011_INEN_NM_FRECUENTES_2000_2009_vf.pdf
277. Strasser-Weippl K, Chavarri-Guerra Y, Villarreal-Garza C, Bychkovsky BL, Debiasi M, Liedke PER, et al. Progress and remaining challenges for cancer control in Latin America and the Caribbean. *Lancet Oncol.* 2015 Oct;16(14):1405–38.
278. Peru - Globocan 2018 [Internet]. Available from: <https://gco.iarc.fr/today/data/factsheets/populations/604-peru-fact-sheets.pdf>
279. Pinillos-Ashton L, Limache G A. CONTRIBUCIONES DE LA COALICIÓN MULTISECTORIAL PERÚ CONTRA EL CÁNCER CONTRIBUTION. *Rev Peru Med Exp Salud Publica.* 2013;30(1):99–104.
280. López M, Regalado R, Manrique J, Calderón M, Mas L, Neciosup S, et al. Cancer in Peru 3 The implementation of the Plan Esperanza and response to the imPACT Review [Internet]. 2017 p. 595–606. Available from: www.thelancet.com/oncology
281. Wong MCS, Jiang JY, Goggins WB, Liang M, Fang Y, Fung FDH, et al. International incidence and mortality trends of liver cancer: a global profile. *Sci Rep* [Internet]. 2017 Apr [cited 2019 Jun 23];7(1). Available from: <http://www.nature.com/articles/srep45846>
282. Análisis de la situación del cáncer en el Perú 2013 Dirección General de Epidemiología [Internet]. Available from: <http://www.dge.gob.pe>
283. Moore SP, Forman D, Piñeros M, Fernández SM, Oliveira Santos M, Bray F. Cancer in indigenous people in Latin America and the Caribbean: a review. *Cancer Med.* 2014 Feb;3(1):70–80.

284. Davies TM, Burr RN, Moore JP, Pulgar-Vidal J. Peru - Amazonia. Encycl Br [Internet]. 2018; Available from: <https://www.britannica.com/place/Peru/Amazonia>
285. Fay OH, American L, Group RS. Hepatitis B in Latin America: epldemlological patterns and eradication strategy. 1990;8:100–6.
286. Cabezas C. Hepatitis viral B Y Delta en el Perú : Epidemiología Y Bases para su control. Rev Peru Med Exp Salud Pública. 2007;24(4):378–97.
287. Vildoza H Victor;Cambilli, Emma;Torres, Juan;Flores, Maria;Ramos, Elizabeth. Prevalencia de la infección y factores de riesgo para Hepatitis B en dos grupos de gestantes adolescentes en relación al número de parejas sexuales. Rev Gastroenterol Perú. 2006;26(3):242–58.
288. Casey JL, Niro GA, Engle RE, Vega A, Gomez H, McCarthy M, et al. Hepatitis B virus (HBV)/hepatitis D virus (HDV) coinfection in outbreaks of acute hepatitis in the Peruvian Amazon basin: the roles of HDV genotype III and HBV genotype F. J Infect Dis. 1996 Nov;174(5):920–6.
289. Cabezas S. C, Suárez J M, Romero C G, Carrillo P C, García MP, Reátegui S J, et al. Hiperendemicidad de Hepatitis Viral B y Delta en pueblos indígenas de la Amazonía Peruana. Rev Peru Med Exp Salud Pública. 2006;23(2):114–22.
290. P JM, R RV. HEPATITIS B EN EL PERÚ: REVISIÓN 1970 - 2002. Rev Peru Med Exp Salud Publica. 2004;21:261–8.
291. Gentile I, Borgia G. vertical transmission of hepatitis B virus: challenges and solutions. 2014; Available from: <http://dx.doi.org/10.2147/IJWH.S51138>
292. Borgia G, Carleo MA, Gaeta GB, Gentile I. Hepatitis B in pregnancy. World J Gastroenterol WJG. 2012 Sep 14;18(34):4677–83.
293. Alter MJ. Epidemiology of hepatitis B in Europe and worldwide. J Hepatol. 2003;39:64–9.
294. Cabezas Sánchez C. Artículo de Revisión Situación y control de la hepatitis B y Delta en el Perú Hepatitis B and Delta in Peru: Current Status and Control [Internet]. Adaptado de Fung; 2008 p. 790–2. Available from: <http://www.scielo.org.pe/pdf/amp/v25n2/a10v25n2.pdf>

295. Shapiro CN. Epidemiology of Hepatitis B. *Pediatr Infect Dis.* 1993;12(5):433–7.
296. Gray Davis L, Weber DavidJ, Lemon StanleyM. HORIZONTAL TRANSMISSION OF HEPATITIS B VIRUS. *The Lancet.* 1989 Apr;333(8643):889–93.
297. El Valle EN, Río D, Segovia G, Galván K, García V, Huamaní L, et al. PREVALENCIA DE MARCADORES SEROLÓGICOS PARA HEPATITIS B Y DELTA E INFECCIÓN INTRAFAMILIAR [Internet]. 2002. Available from: <http://www.scielo.org.pe/pdf/rins/v19n2/a02v19n2.pdf>
298. HAMID AS, TESHAMARIAM IG, ZHANG Y, ZHANG ZG. Aflatoxin B1-induced hepatocellular carcinoma in developing countries: Geographical distribution, mechanism of action and prevention. *Oncol Lett.* 2013 Apr;5(4):1087.
299. Guerrero Canelo A, Parreño Tipian J. Determination of mycotoxins by the ELISA method in soybeans for poultry in production in the province of Chincha, 2016. *Rev Soc Quím Perú.* 2018 Jan;84(1):27–40.
300. Torres O, Matute J, Gelineau-van Waes J, Maddox J r., Gregory S g., Ashley-Koch A e., et al. Human health implications from co-exposure to aflatoxins and fumonisins in maize-based foods in Latin America: Guatemala as a case study. *World Mycotoxin J.* 2014 Jun 17;8(2):143–59.
301. Guerra MF, Núñez-Regueiro P. La orfebrería de los Andes en la época inca (siglos XV-XVI). *Bull Inst Fr Détudes Andin.* 2017 Apr;(46 (1)):1–3.
302. Inversión minera creció 142% en últimos cuatro años y suma US\$ 34,020 millones | Economía | Gestion [Internet]. [cited 2019 May 30]. Available from: <https://gestion.pe/economia/inversion-minera-crecio-142-ultimos-cuatro-anos-suma-us-34-020-millones-96239>
303. Producción Minera [Internet]. [cited 2019 May 30]. Available from: <http://www.minagri.gob.pe/portal/44-sector-agrario/recurso-mineral/336-produccion-minera>
304. Minería Informal: ¿Qué hacer? | Blogs | Gestión [Internet]. [cited 2019 May 30]. Available from: <https://gestion.pe/blog/mineria-2021/2018/02/mineria-informal-que-hacer.html?ref=gesr>

305. van Geen A, Bravo C, Gil V, Sherpa S, Jack D. Lead exposure from soil in Peruvian mining towns: a national assessment supported by two contrasting examples. *Bull World Health Organ.* 2012 Dec;90(12):878–886.
306. Plumlee GS, Morman SA. Mine Wastes and Human Health. *Elements.* 2011 Dec;7(6):399–404.
307. Romaniuk A, Lyndin M, Sikora V, Lyndina Y, Romaniuk S, Sikora K. Heavy metals effect on breast cancer progression. *J Occup Med Toxicol Lond Engl.* 2017;12:32.
308. Matthews NH, Fitch K, Li W-Q, Morris JS, Christiani DC, Qureshi AA, et al. Exposure to Trace Elements and Risk of Skin Cancer: A Systematic Review of Epidemiologic Studies. *Cancer Epidemiol Biomark Prev Publ Am Assoc Cancer Res Cosponsored Am Soc Prev Oncol.* 2019 Jan;28(1):3–21.
309. Shah S. Trace Minerals and Heavy Metals: Implications in Prostate Cancer. *Bangladesh J Med Biochem.* 2017;8(1):27–32.
310. Elwakil MA, Abo-Hashem EM, Shabana YM, El-Metwally MA, El-Kannishy G, El-Adl AM, et al. Hepatocellular Carcinoma in Populations Consuming Heavy Metals Contaminated Plants in North Delta, Egypt. Available from: <http://docsdrive.com/pdfs/academicjournals/rjet/2017/55-61.pdf>
311. Gray MW. Mitochondrial DNA. *Brenners Encycl Genet Second Ed.* 2013;554:436–8.
312. Ullah Khan A, Wilson T. Reactive oxygen species as cellular messengers. *Chem Biol.* 1995;2(7):437–45.
313. Cohen JH, Kristal AR, Stanford JL. Fruit and vegetable intakes and prostate cancer risk. *J Natl Cancer Inst.* 2000 Jan;92(1):61–8.
314. Sena LA, Chandel NS. Physiological roles of mitochondrial reactive oxygen species. 2012; Available from: <https://www.ncbi.nlm.nih.gov/pmc/articles/PMC3484374/pdf/nihms412463.pdf>
315. Desurmont M. [Carcinogenic effect of metals]. *Sem Hopitaux Organe Fonde Par Assoc Enseign Med Hopitaux Paris.* 1983 Sep;59(29–30):2097–9.
316. Lee J-C, Son Y-O, Pratheeshkumar P, Shi X. Oxidative stress and metal carcinogenesis. *Free Radic Biol Med.* 2012 Aug;53(4):742–57.

317. Leonard SS, Harris GK, Shi X. Metal-induced oxidative stress and signal transduction. *Free Radic Biol Med.* 2004 Dec;37(12):1921–42.
318. Freeman BA, Crapo JD. Biology of disease: free radicals and tissue injury. *Lab Investig J Tech Methods Pathol.* 1982 Nov;47(5):412–26.
319. Smith KR, Klei LR, Barchowsky A. Arsenite stimulates plasma membrane NADPH oxidase in vascular endothelial cells. *Am J Physiol-Lung Cell Mol Physiol.* 2017;280(3):L442–9.
320. Tchounwou PB, Centeno JA, Patlolla AK. Arsenic toxicity, mutagenesis, and carcinogenesis - A health risk assessment and management approach. *Mol Cell Biochem.* 2004;255(1–2):47–55.
321. Ferrario D, Croera C, Brustio R, Collotta A, Bowe G, Vahter M, et al. Toxicity of inorganic arsenic and its metabolites on haematopoietic progenitors “in vitro”: Comparison between species and sexes. *Toxicology.* 2008 Jul;249(2–3):102–8.
322. Bjørklund G, Aaseth J, Chirumbolo S, Urbina MA, Uddin R. Effects of arsenic toxicity beyond epigenetic modifications. *Environ Geochem Health.* 2018 Jun;40(3):955–65.
323. Flora SJS. Arsenic-induced oxidative stress and its reversibility. *Free Radic Biol Med.* 2011;51(2):257–81.
324. Cantor KP, Lubin JH. Arsenic, internal cancers, and issues in inference from studies of low-level exposures in human populations. *Toxicol Appl Pharmacol.* 2007 Aug;222(3):252–7.
325. Huang C, Ke Q, Costa M, Shi X. Molecular mechanisms of arsenic carcinogenesis. *Mol Cell Biochem.* 2004;
326. Liu J, Waalkes MP. Liver is a target of arsenic carcinogenesis. *Toxicol Sci Off J Soc Toxicol.* 2008 Sep;105(1):24–32.
327. Flora SJS, Bhadauria S, Pant SC, Dhaked RK. Arsenic induced blood and brain oxidative stress and its response to some thiol chelators in rats. *Life Sci.* 2005 Sep;77(18):2324–37.
328. Guttridge DC, Albanese C, Reuther JY, Pestell RG, Baldwin AS. NF-kappaB controls cell growth and differentiation through transcriptional regulation of cyclin D1. *Mol Cell Biol.* 1999 Aug;19(8):5785–99.

329. Tapio S, Grosche B. Arsenic in the aetiology of cancer. *Mutat Res Mutat Res*. 2006 Jun;612(3):215–46.
330. Maier A, Schumann BL, Chang X, Talaska G, Puga A. Arsenic co-exposure potentiates benzo[a]pyrene genotoxicity. *Mutat Res*. 2002 May;517(1–2):101–11.
331. Aposhian HV, Aposhian MM. ReViews Arsenic Toxicology: Five Questions †. 2006; Available from: <https://pubs.acs.org/sharingguidelines>
332. Paul DS, Hernández-Zavala A, Walton FS, Adair BM, Dědina J, Matoušek T, et al. Examination of the effects of arsenic on glucose homeostasis in cell culture and animal studies: Development of a mouse model for arsenic-induced diabetes. *Toxicol Appl Pharmacol*. 2007 Aug;222(3):305–14.
333. Centeno JA, Mullick FG, Martinez L, Page NP, Gibb H, Longfellow D, et al. Pathology related to chronic arsenic exposure. *Environ Health Perspect*. 2002 Oct;110 Suppl 5(Suppl 5):883–6.
334. Guha Mazumder DN. Effect of chronic intake of arsenic-contaminated water on liver. *Toxicol Appl Pharmacol*. 2005 Aug;206(2):169–75.
335. Santra A, Maiti A, Das S, Lahiri S, Charkaborty SK, Mazumder DN. Hepatic damage caused by chronic arsenic toxicity in experimental animals. *J Toxicol Clin Toxicol*. 2000;38(4):395–405.
336. Waalkes MP, Liu J, Diwan BA. Transplacental arsenic carcinogenesis in mice. *Toxicol Appl Pharmacol*. 2007 Aug;222(3):271–80.
337. Cuypers A, Plusquin M, Remans T, Jozefczak M, Keunen E, Gielen H, et al. Cadmium stress: an oxidative challenge. Available from: <https://link.springer.com/content/pdf/10.1007%2Fs10534-010-9329-x.pdf>
338. Nath R, Prasad R, Palinal VK, Chopra RK. Molecular basis of cadmium toxicity. *Prog Food Nutr Sci*. 1984;8(1–2):109–63.
339. Belyaeva EA, Dymkowska D, Więckowski MR, Wojtczak L. Reactive oxygen species produced by the mitochondrial respiratory chain are involved in Cd²⁺-induced injury of rat ascites hepatoma AS-30D cells. *Biochim Biophys Acta BBA - Bioenerg*. 2006 Dec;1757(12):1568–74.
340. Wang L, Cao J, Chen D, Liu X, Lu H, Liu Z. Role of Oxidative Stress, Apoptosis, and Intracellular Homeostasis in Primary Cultures of Rat Proximal

Tubular Cells Exposed to Cadmium. 2008; Available from: <https://link.springer.com/content/pdf/10.1007%2Fs12011-008-8223-7.pdf>

341. Valko M, Morris H, Cronin MTD. Metals, toxicity and oxidative stress. *Curr Med Chem*. 2005;12(10):1161–208.

342. Dorta DJ, Leite S, DeMarco KC, Prado IMR, Rodrigues T, Mingatto FE, et al. A proposed sequence of events for cadmium-induced mitochondrial impairment. *J Inorg Biochem*. 2003 Nov;97(3):251–7.

343. Yalin S, Comelekoglu U, Bagis S, Sahin NO, Ogenler O, Hatungil R. Acute effect of single-dose cadmium treatment on lipid peroxidation and antioxidant enzymes in ovariectomized rats. *Ecotoxicol Environ Saf*. 2006 Sep;65(1):140–4.

344. Casalino E, Calzaretti G, Sblano C, Landriscina C. Molecular inhibitory mechanisms of antioxidant enzymes in rat liver and kidney by cadmium. *Toxicology*. 2002 Sep;179(1–2):37–50.

345. Gong P, Chen FX, Ma GF, Feng Y, Zhao Q, Wang R. Endomorphin 1 effectively protects cadmium chloride-induced hepatic damage in mice. *Toxicology*. 2008 Sep;251(1–3):35–44.

346. Ognjanović BI, Marković SD, Pavlović SZ, Žikić RV, Štajn AŠ, Saičić ZS, et al. Effect of Chronic Cadmium Exposure on Antioxidant Defense System in Some Tissues of Rats: Protective Effect of Selenium. *Physiol Res*. 2008;57:403–11.

347. JONES DP, GO Y-M, ANDERSON CL, ZIEGLER TR, KINKADE JM, KIRLIN WG. Cysteine/cystine couple is a newly recognized node in the circuitry for biologic redox signaling and control. *FASEB J*. 2004 Aug;18(11):1246–8.

348. Vairavamurthy MA, Goldenberg WS, Ouyang S, Khalid S. The interaction of hydrophilic thiols with cadmium: investigation with a simple model, 3-mercaptopropionic acid. *Mar Chem*. 2000 May;70(1–3):181–9.

349. Matsuoka M, Call KM. Cadmium-induced expression of immediate early genes in LLC-PK1 cells. *Kidney Int*. 1995 Aug;48(2):383–9.

350. Wang Z, Templeton DM. Induction of c-fos proto-oncogene in mesangial cells by cadmium. *J Biol Chem*. 1998 Jan;273(1):73–9.

351. Pearson CA, Prozialeck WC. E-Cadherin, β -Catenin and cadmium carcinogenesis. *Med Hypotheses*. 2001 May;56(5):573–81.

352. Linder MC, Hazegh-Azam M. Copper biochemistry and molecular biology. *Am J Clin Nutr.* 1996 May;63(5):797S-811S.
353. Zhou B, Gitschier J. hCTR1: A human gene for copper uptake identified by complementation in yeast [Internet]. 1997 p. 7481–6. Available from: www.pnas.org.
354. van den Berghe PVE, Klomp LWJ. Posttranslational regulation of copper transporters. *JBIC J Biol Inorg Chem.* 2010 Jan;15(1):37–46.
355. Kuo MT, Chen HHW, Song I-S, Savaraj N, Ishikawa T. The roles of copper transporters in cisplatin resistance. *Cancer Metastasis Rev.* 2007 Mar;26(1):71–83.
356. Shim H, Harris ZL. Genetic Defects in Copper Metabolism. *J Nutr.* 2003 May;133(5):1527S-1531S.
357. Speisky H, Gómez M, Carrasco-Pozo C, Pastene E, Lopez-Alarcón C, Olea-Azar C. Cu(I)–Glutathione complex: A potential source of superoxide radicals generation. *Bioorg Med Chem.* 2008 Jul;16(13):6568–74.
358. Barbusiński K. FENTON REACTION-CONTROVERSY CONCERNING THE CHEMISTRY REAKCJA FENTONA-KONTROWERSJE DOTYCZĄCE CHEMIZMU [Internet]. Available from: [http://tchie.uni.opole.pl/freeECE/S_16_3/Barbusinski_16\(3\).pdf](http://tchie.uni.opole.pl/freeECE/S_16_3/Barbusinski_16(3).pdf)
359. Moriwaki H, Osborne MR, Phillips DH. Effects of mixing metal ions on oxidative DNA damage mediated by a Fenton-type reduction. *Toxicol In Vitro.* 2008 Feb;22(1):36–44.
360. Mattie MD, McElwee MK, Freedman JH. Mechanism of Copper-Activated Transcription: Activation of AP-1, and the JNK/SAPK and p38 Signal Transduction Pathways. *J Mol Biol.* 2008 Nov;383(5):1008–18.
361. Kumar A, Scott Clark C. Lead loadings in household dust in Delhi, India. *Indoor Air.* 2009;19(5):414–20.
362. Jakubowski M. Low-level environmental lead exposure and intellectual impairment in children — The current concepts of risk assessment. *Int J Occup Med Environ Health.* 2011 Jan;24(1):1–7.
363. Philip AT, Gerson B. Lead poisoning--Part I. Incidence, etiology, and toxicokinetics. *Clin Lab Med.* 1994 Jun;14(2):423–44.

364. Ziegler EE, Edwards BB, Jensen RL, Mahaffey KR, Fomon SJ. Absorption and Retention of Lead by Infants. *Pediatr Res*. 1978 Jan;12(1):29–34.
365. Christie NT, Costa M. In vitro assessment of the toxicity of metal compounds. *Biol Trace Elem Res*. 1984 Apr;6(2):139–58.
366. Gurer-Orhan H, Sabir HU, Ozgüneş H. Correlation between clinical indicators of lead poisoning and oxidative stress parameters in controls and lead-exposed workers. *Toxicology*. 2004 Feb;195(2–3):147–54.
367. Sandhir R, Julka D, Gill KD. Lipoperoxidative damage on lead exposure in rat brain and its implications on membrane bound enzymes. *Pharmacol Toxicol*. 1994 Feb;74(2):66–71.
368. Farant JP, Wigfield DC. Biomonitoring lead exposure with delta-aminolevulinic acid dehydratase (ALA-D) activity ratios. *Int Arch Occup Environ Health*. 1982;51(1):15–24.
369. Bechara EJ. Oxidative stress in acute intermittent porphyria and lead poisoning may be triggered by 5-aminolevulinic acid. *Braz J Med Biol Res Rev Bras Pesqui Medicas E Biol*. 1996 Jul;29(7):841–51.
370. Sugawara E, Nakamura K, Miyake T, Fukumura A, Seki Y. Lipid peroxidation and concentration of glutathione in erythrocytes from workers exposed to lead. *Br J Ind Med*. 1991 Apr;48(4):239–42.
371. Lawton LJ, Donaldson WE. Lead-Induced Tissue Fatty Acid Alterations and Lipid Peroxidation [Internet]. 1991. Available from: <https://link.springer.com/content/pdf/10.1007/BF02863075.pdf>
372. Hershko C. Mechanism of iron toxicity. *Food Nutr Bull*. 2007;28(4 SUPPL.):500–9.
373. Kadiiska MB, Burkitt MJ, Xiang QH, Mason RP. Iron supplementation generates hydroxyl radical in vivo. An ESR spin-trapping investigation. *J Clin Invest*. 1995 Sep;96(3):1653–7.
374. Stadtman ER. Metal ion-catalyzed oxidation of proteins: biochemical mechanism and biological consequences. *Free Radic Biol Med*. 1990;9(4):315–25.

375. Richter C, Gogvadze V, Laffranchi R, Schlapbach R, Schweizer M, Suter M, et al. Oxidants in mitochondria: from physiology to diseases. *Biochim Biophys Acta*. 1995 May;1271(1):67–74.
376. Houglum K, Filip M, Witztum JL, Chojkier M. Malondialdehyde and 4-hydroxynonenal protein adducts in plasma and liver of rats with iron overload. *J Clin Invest*. 1990 Dec;86(6):1991–8.
377. Esterbauer H, Schaur RJ, Zollner H. Chemistry and biochemistry of 4-hydroxynonenal, malonaldehyde and related aldehydes. *Free Radic Biol Med*. 1991;11(1):81–128.
378. Cheeseman KH. Mechanisms and effects of lipid peroxidation. *Mol Aspects Med*. 1993 Jan;14(3):191–7.
379. Esterbauer H. Cytotoxicity and genotoxicity of lipid-oxidation products. *Am J Clin Nutr*. 1993 May;57(5):779S-786S.
380. Cadenas E. Biochemistry of Oxygen Toxicity. *Annu Rev Biochem*. 1989 Jun;58(1):79–110.
381. Troadec M-B, Courselaud B, D tivaud L, Haziza-Pigeon C, Leroyer P, Brissot P, et al. Iron overload promotes Cyclin D1 expression and alters cell cycle in mouse hepatocytes. *J Hepatol*. 2006 Feb;44(2):391–9.
382. Rink L, Gabriel P. Zinc and the immune system. *Proc Nutr Soc*. 2000 Nov;59(4):541–52.
383. Chien XX, Zafra-Stone S, Bagchi M, Bagchi D. Bioavailability, antioxidant and immune-enhancing properties of zinc methionine. *BioFactors Oxf Engl*. 2006;27(1–4):231–44.
384. Powell SR. The Antioxidant Properties of Zinc. *J Nutr*. 2000 May;130(5):1447S-1454S.
385. Bray TM, Bettger WJ. The physiological role of zinc as an antioxidant. *Free Radic Biol Med*. 1990;8(3):281–91.
386. Gibbs PN, Gore MG, Jordan PM. Investigation of the effect of metal ions on the reactivity of thiol groups in human 5-aminolaevulinatase. *Biochem J*. 1985 Feb;225(3):573–80.
387. Jiang LJ, Maret W, Vallee BL. The ATP-metallothionein complex. *Proc Natl Acad Sci U S A*. 1998 Aug;95(16):9146–9.

388. Kraus A, Roth H-P, Kirchgessner M. Supplementation with Vitamin C, Vitamin E or β -Carotene Influences Osmotic Fragility and Oxidative Damage of Erythrocytes of Zinc-Deficient Rats. *J Nutr.* 1997 Jul;127(7):1290–6.
389. Oteiza PI, Clegg MS, Zago MP, Keen CL. Zinc deficiency induces oxidative stress and AP-1 activation in 3T3 cells. *Free Radic Biol Med.* 2000 Apr;28(7):1091–9.
390. Taylor CG, Bettger WJ, Bray TM. Effect of Dietary Zinc or Copper Deficiency on the Primary Free Radical Defense System in Rats. *J Nutr.* 1988 May;118(5):613–21.
391. Chasapis CT, Loutsidou AC, Spiliopoulou CA, Stefanidou ME. Zinc and human health: an update. *Arch Toxicol.* 2012 Apr;86(4):521–34.
392. Costello LC, Franklin RB. The clinical relevance of the metabolism of prostate cancer; zinc and tumor suppression: connecting the dots. *Mol Cancer.* 2006 May 15;5:17.
393. John E, Laskow TC, Buchser WJ, Pitt BR, Basse PH, Butterfield LH, et al. Zinc in innate and adaptive tumor immunity. *J Transl Med.* 2010 Nov 18;8:118.
394. Mishra S, Dwivedi SP, Singh RB. A Review on Epigenetic Effect of Heavy Metal Carcinogens on Human Health [Internet]. 2010 p. 188–93. Available from: <https://benthamopen.com/contents/pdf/TONUTRAJ/TONUTRAJ-3-188.pdf>
395. Daniels LA. Selenium Metabolism and bioavailability. 1996;54(1):185–99.
396. Touat-Hamici Z, Bulteau A-L, Bianga J, Jean-Jacques H, Szpunar J, Lobinski R, et al. Selenium-regulated hierarchy of human selenoproteome in cancerous and immortalized cells lines. *Biochim Biophys Acta BBA - Gen Subj.* 2018 Nov 1;1862(11):2493–505.
397. Lockitch G. Selenium: Clinical Significance and Analytical Concepts. *Crit Rev Clin Lab Sci.* 1989 Jan;27(6):483–541.
398. Moghadaszadeh B, Beggs AH. Selenoproteins and Their Impact on Human Health Through Diverse Physiological Pathways. *Physiology.* 2006 Oct;21(5):307–15.
399. Bulteau A-L, Chavatte L. Update on Selenoprotein Biosynthesis. *Antioxid Redox Signal.* 2015 Oct;23(10):775–94.

400. Brozmanová J, Mániková D, Viera Vlčková •, Chovanec M. Selenium: a double-edged sword for defense and offence in cancer. Available from: <https://link.springer.com/content/pdf/10.1007%2Fs00204-010-0595-8.pdf>
401. El-Bayoumy K. The protective role of selenium on genetic damage and on cancer. *Mutat Res.* 2001 Apr;475(1–2):123–39.
402. Ames BN, Gold LS. The causes and prevention of cancer: gaining perspective. *Environ Health Perspect.* 1997 Jun;105 Suppl 4(Suppl 4):865–73.
403. Fischer JL, Mihelc EM, Pollok KE, Smith ML. Chemotherapeutic selectivity conferred by selenium: a role for p53-dependent DNA repair. *Mol Cancer Ther.* 2007 Jan;6(1):355–61.
404. Laffon B, Valdiglesias V, Pásaro E, Méndez J. The Organic Selenium Compound Selenomethionine Modulates Bleomycin-Induced DNA Damage and Repair in Human Leukocytes. *Biol Trace Elem Res.* 2010 Jan;133(1):12–9.
405. Kowalska E, Narod SA, Huzarski T, Zajaczek S, Huzarska J, Gorski B, et al. Increased Rates of Chromosome Breakage in BRCA1 Carriers Are Normalized by Oral Selenium Supplementation. *Cancer Epidemiol Biomarkers Prev.* 2005 May;14(5):1302–6.
406. Biswas S, Talukder G, Sharma A. Chromosome damage induced by selenium salts in human peripheral lymphocytes. *Toxicol In Vitro.* 2000 Oct;14(5):405–8.
407. Wycherly BJ, Moak MA, Christensen MJ. High Dietary Intake of Sodium Selenite Induces Oxidative DNA Damage in Rat Liver. *Nutr Cancer.* 2004 Jan;48(1):78–83.
408. Barbosa DJ, Capela JP, Oliveira JM, Silva R, Ferreira LM, Siopa F, et al. Pro-oxidant effects of Ecstasy and its metabolites in mouse brain synaptosomes. *Br J Pharmacol.* 2012 Feb;165(4b):1017–33.
409. Hasgekar N, Beck JP, Dunkelberg H, Hirsch-Ernst KI, Gebel TW. Influence of Antimonite, Selenite, and Mercury on the Toxicity of Arsenite in Primary Rat Hepatocytes. *Biol Trace Elem Res.* 2006;111(1–3):167–84.
410. Nakamuro K, Yoshikawa K, Sayato Y, Kurata H, Tonomura M. Studies on selenium-related compounds. V. Cytogenetic effect and reactivity with DNA. *Mutat Res.* 1976 Jul;40(3):177–84.

411. Ray JH, Altenburg LC. Dependence of the sister-chromatid exchange-inducing abilities of inorganic selenium compounds on the valence state of selenium. *Mutat Res.* 1980 Jul;78(3):261–6.
412. Stewart MS, Spallholz JE, Neldner KH, Pence BC. Selenium compounds have disparate abilities to impose oxidative stress and induce apoptosis. *Free Radic Biol Med.* 1999 Jan;26(1–2):42–8.
413. LeBoeuf RA, Laishes BA, Hoekstra WG. Effects of selenium on cell proliferation in rat liver and mammalian cells as indicated by cytokinetic and biochemical analysis. *Cancer Res.* 1985 Nov;45(11 Pt 1):5496–504.
414. Tosolini M, Algans C, Pont F, Ycart B, Fournié J-J. Large-scale microarray profiling reveals four stages of immune escape in non-Hodgkin lymphomas. *Oncoimmunology* [Internet]. 2016 May 19 [cited 2019 Jun 28];5(7). Available from: <https://www.ncbi.nlm.nih.gov/pmc/articles/PMC5006906/>
415. Ruiz E, Rojas TR, Berrospi F, Chávez I, Luque C, Cano L, et al. Hepatocellular carcinoma surgery outcomes in the developing world: A 20-year retrospective cohort study at [3 _ T D \$ D I F F] the National Cancer Institute of Peru. 2015; Available from: <http://dx.doi.org/10.1016/j.heliyon.2015.e000522405-8440/>
416. O'Connor K, Walsh JC, Schaeffer DF. Combined hepatocellular-cholangiocarcinoma (cHCC-CC): a distinct entity. *Ann Hepatol.* 2014 May 1;13(3):317–22.
417. Yin Y, Xu X, Tang J, Zhang W, Zhangyuan G, Ji J, et al. CD97 Promotes Tumor Aggressiveness Through the Traditional G Protein-Coupled Receptor-Mediated Signaling in Hepatocellular Carcinoma. *Hepatol Baltim Md.* 2018;68(5):1865–78.
418. Lu M, Xu Y, He G, Liu Q, Zhu J, Zhang C. The expression of CD74 and macrophage migration inhibitory factor protein is upregulated in hepatitis B virus-related hepatocellular carcinoma. *Transl Cancer Res.* 2018 Dec 3;7(6):1537-1547–1547.
419. Chen QY, DesMarais T, Costa M. Metals and Mechanisms of Carcinogenesis. *Annu Rev Pharmacol Toxicol.* 2019;59:537–537.

420. Cano L, Cerapio JP, Ruiz E, Marchio A, Turlin B, Casavilca S, et al. Liver clear cell foci and viral infection are associated with non-cirrhotic, non-fibrolamellar hepatocellular carcinoma in young patients from South America. *Sci Rep*. 2018 Jul 30;8(1):9945.
421. von der Goltz J, Barnwal P. Mines: The local wealth and health effects of mineral mining in developing countries. *J Dev Econ*. 2019 Jun;139:1–16.
422. Baiomy AA, Mansour AA. Genetic and Histopathological Responses to Cadmium Toxicity in Rabbit's Kidney and Liver: Protection by Ginger (*Zingiber officinale*). *Biol Trace Elem Res*. 2016 Apr;170(2):320–9.
423. Zhai H, Chen C, Wang N, Chen Y, Nie X, Han B, et al. Blood lead level is associated with non-alcoholic fatty liver disease in the Yangtze River Delta region of China in the context of rapid urbanization. *Environ Health [Internet]*. 2017 Aug 31 [cited 2019 Sep 7];16. Available from: <https://www.ncbi.nlm.nih.gov/pmc/articles/PMC5580229/>
424. Lin Y-C, Lian I-B, Kor C-T, Chang C-C, Su P-Y, Chang W-T, et al. Association between soil heavy metals and fatty liver disease in men in Taiwan: a cross sectional study. *BMJ Open [Internet]*. 2017 Jan 23 [cited 2019 Sep 7];7(1). Available from: <https://www.ncbi.nlm.nih.gov/pmc/articles/PMC5278238/>
425. Ohata K, Hamasaki K, Toriyama K, Matsumoto K, Saeki A, Yanagi K, et al. Hepatic steatosis is a risk factor for hepatocellular carcinoma in patients with chronic hepatitis C virus infection. *Cancer*. 2003 Jun 15;97(12):3036–43.
426. Pajuelo Ramírez J, Torres Aparcana L, Agüero Zamora R, Bernui Leo I. El sobrepeso, la obesidad y la obesidad abdominal en la población adulta del Perú. *An Fac Med*. 2019 Jan;80(1):21–7.
427. Bai D-S, Zhang C, Chen P, Jin S-J, Jiang G-Q. The prognostic correlation of AFP level at diagnosis with pathological grade, progression, and survival of patients with hepatocellular carcinoma. *Sci Rep [Internet]*. 2017 Oct 9 [cited 2019 Sep 8];7. Available from: <https://www.ncbi.nlm.nih.gov/pmc/articles/PMC5634482/>
428. Lu Y, Zhu M, Li W, Lin B, Dong X, Chen Y, et al. Alpha fetoprotein plays a critical role in promoting metastasis of hepatocellular carcinoma cells. *J Cell Mol Med*. 2016 Mar;20(3):549–58.

429. Czauderna P, Garnier H. Hepatoblastoma: current understanding, recent advances, and controversies. *F1000Research* [Internet]. 2018 Jan 15 [cited 2019 Sep 8];7. Available from: <https://www.ncbi.nlm.nih.gov/pmc/articles/PMC5770992/>
430. Spyridakis I. Embryonal/Fetal Subtype Hepatoblastoma: A Case Report. *J Clin Diagn Res* [Internet]. 2014 [cited 2019 Sep 8]; Available from: http://jcdr.net/article_fulltext.asp?issn=0973-709x&year=2014&volume=8&issue=9&page=ND01&issn=0973-709x&id=4823
431. Hubaux R, Becker-Santos DD, Enfield KS, Rowbotham D, Lam S, Lam WL, et al. Molecular features in arsenic-induced lung tumors. *Mol Cancer*. 2013 Mar 19;12:20.
432. Su Y-P, Tang J-M, Tang Y, Gao H-Y. Histological and ultrastructural changes induced by selenium in early experimental gastric carcinogenesis. *World J Gastroenterol WJG*. 2005 Aug 7;11(29):4457–60.
433. Strumylaite L, Kregzdyte R, Bogusevicius A, Poskiene L, Baranauskiene D, Pranys D. Cadmium Exposure and Risk of Breast Cancer by Histological and Tumor Receptor Subtype in White Caucasian Women: A Hospital-Based Case-Control Study. *Int J Mol Sci*. 2019 Jun 21;20(12):3029.
434. Bralet M-P, Régimbeau J-M, Pineau P, Dubois S, Loas G, Degos FO, et al. Hepatocellular Carcinoma Occurring in Nonfibrotic Liver: Epidemiologic and Histopathologic Analysis of 80 French Cases. *HEPATOLOGY*. 2000;32:200–4.
435. Calvet X, Bruix J, Brú C, Ginés P, Vilana R, Solé M, et al. Natural history of hepatocellular carcinoma in Spain: Five year's experience in 249 cases. *J Hepatol*. 1990 May;10(3):311–7.

Titre : CARCINOME HEPATOCELLULAIRE SUR FOIE NON CIRRHOTIQUE, Analyse comparative des déterminants histologiques et génomiques dans deux cohortes (Péruvienne et Européenne)

Mots clés : carcinome hépatocellulaire, métaux lourds, foie non cirrhotique, type histologique, lésion paranéoplasique

Résumé : Le carcinome hépatocellulaire développé sur foie non cirrhotique (NC-HCC) est une tumeur mal connue, ne comprenant que 20% du total des cas de carcinome hépatocellulaire. Cependant, une prévalence élevée de cette tumeur a été décrite chez des patients péruviens.

Une relation a été établie entre le développement du NC-HCC et la surexposition aux métaux lourds, un produit de l'activité minière au Pérou.

Afin de valider ou d'exclure cette hypothèse, nous avons entrepris ce travail, qui inclut une analyse histologique du tissu hépatique non tumoral et de la tumeur. Nous avons aussi mesurés les concentrations en métaux dans les deux tissus à l'aide de la technique ICP-MS.

Nos travaux montrent, dans le foie adjacent à la tumeur, la présence d'un état pathologique spécifique constitué de lésions à potentiel de malignité incertain et à une surexpression de gènes du métabolisme des glucides.

Au niveau de la tumeur, nous avons décrit un nouveau sous-type histologique, associé à un pronostic défavorable.

Enfin, le profil métallomique révèle de plus la présence de mécanisme régulant les métaux avec une concentration de métaux dans les tissus non tumoraux, parmi lesquels on trouve l'arsenic et le cadmium. En revanche, le cuivre est plus abondant dans les tissus tumoraux.

De même, nous avons montré que les concentrations tissulaires de sélénium étaient corrélées à la survie

Titre : HEPATOCELLULAR CARCINOMA ON NON-CIRRHOTIC LIVER, Comparative analysis of histological and genomic determinants in two cohorts (Peruvian and European)

Keywords : liver cancer, heavy metals, non-cirrhotic liver, histological subtype, preneoplastic lesion

Abstract : Hepatocellular carcinoma developed on non-cirrhotic liver (NC-HCC) is a poorly known tumor, comprising only 20% of the total cases of hepatocellular carcinoma. However, a high prevalence of this tumor has been described in Peruvian patients. A relationship has been established between the development of NC-HCC and overexposure to heavy metals, a product of mining activity in Peru.

In order to validate or exclude this hypothesis, we undertook this work, which includes a histological analysis of non-tumor liver tissue and tumor. We also measured metal concentrations in both tissues using the ICP-MS technique.

Our work shows, in the liver adjacent to the tumor, the presence of a specific pathological condition consisting of lesions with uncertain malignant potential and overexpression of carbohydrate metabolism genes. At the level of the tumor, we described a new histological subtype, associated with an unfavorable prognosis.

Finally, the metallomic profile further reveals the presence of a mechanism regulating metals with a concentration of metals in non-tumor tissues, among which we find arsenic and cadmium. In contrast, copper is more abundant in tumor tissues. Similarly, we have shown that tissue selenium concentrations correlate with survival.