



HAL
open science

Caractérisation clinique, iconographique et pronostique des atteintes des gros vaisseaux dans l'artérite à cellules géantes

Hubert De Boysson

► To cite this version:

Hubert De Boysson. Caractérisation clinique, iconographique et pronostique des atteintes des gros vaisseaux dans l'artérite à cellules géantes. Médecine humaine et pathologie. Normandie Université, 2019. Français. NNT : 2019NORMC425 . tel-03498280

HAL Id: tel-03498280

<https://theses.hal.science/tel-03498280v1>

Submitted on 21 Dec 2021

HAL is a multi-disciplinary open access archive for the deposit and dissemination of scientific research documents, whether they are published or not. The documents may come from teaching and research institutions in France or abroad, or from public or private research centers.

L'archive ouverte pluridisciplinaire **HAL**, est destinée au dépôt et à la diffusion de documents scientifiques de niveau recherche, publiés ou non, émanant des établissements d'enseignement et de recherche français ou étrangers, des laboratoires publics ou privés.



Normandie Université

THÈSE

Pour obtenir le diplôme de doctorat

Spécialité RECHERCHE CLINIQUE, INNOVATION TECHNOLOGIQUE, SANTE PUBLIQUE

Préparée au sein de l'Université de Caen Normandie

Caractérisation clinique, iconographique et pronostique des atteintes des gros vaisseaux dans l'artérite à cellules géantes.

**Présentée et soutenue par
Hubert DE BOYSSON**

**Thèse soutenue publiquement le 20/12/2019
devant le jury composé de**

| | | |
|-----------------------------|---|--------------------|
| Mme LAURENCE BOUILLET | Professeur des universités PraticienHosp, CHU de Grenoble site Nord | Rapporteur du jury |
| Mme SOPHIE GEORGIN-LAVIALLE | Professeur des universités PraticienHosp, Hôpital Tenon Groupe Hospitalier APHP | Rapporteur du jury |
| M. JEAN-CHRISTOPHE LEGA | Professeur des universités PraticienHosp, Hôpital Lyon Sud, | Membre du jury |
| M. ALAIN MANRIQUE | Professeur des universités, Université Caen Normandie | Président du jury |
| M. ACHILLE ERIC AOUBA | Professeur des universités, Université Caen Normandie | Directeur de thèse |

Thèse dirigée par ACHILLE ERIC AOUBA, Signalisation, électrophysiologie et imagerie des lésions d'ischémie-reperfusion myocardique (Caen)



UNIVERSITÉ
CAEN
NORMANDIE



Normandie de Biologie Intégrative,
Santé, Environnement




REMERCIEMENTS

- Merci à mon Jury de thèse:
 - Achille AOUBA : mon mentor et un ami cher. Merci pour ton soutien et ton accompagnement sans faille. Je te dois mon développement et épanouissement professionnel. Reçois ma plus profonde gratitude et amitié. Je suis enchanté des nombreuses perspectives en cours et à venir.
 - Alain MANRIQUE, Merci pour votre disponibilité et bienveillance inconditionnelles depuis tant d'années. Je suis heureux de continuer nos collaborations.
 - Sophie GEORGIN-LAVIALLE, Merci d'avoir accepté d'être rapporteur de ce travail et de délaissier l'auto-inflammation pour une autre maladie (peut-être auto-inflammatoire aussi ??). Je me demande si tu auras tes chaussures de running dans ton sac à main le 20 décembre prochain....
 - Laurence BOUILLET, Merci d'avoir accepté d'être rapporteur de ce travail provenant d'un coin sans montagne à l'horizon et pour lequel le dosage du C1 inhibiteur est peu utile (en même temps, en est-on sûr ?). Merci d'avoir fait le déplacement.
 - Jean-Christophe LEGA, Merci d'être examinateur de ce travail. Je suis ravi d'avoir ton regard critique sur cette maladie que tu connais bien. En espérant de tout cœur que nous puissions continuer à collaborer par la suite sur d'autres travaux. Merci d'avoir fait le déplacement.

- A mes amis et collègues de travail: Alexandra Audemard-Verger, Jonathan Boutemy, Samuel Deshayes, Anael Dumont, Benjamin Lelièvre, Gwénola Maigné, Nicolas Martin Silva. Le quotidien est tellement plus lumineux avec vous.

- A mes collègues internistes qui ont participé à ces travaux et qui ont toujours été disponibles : Eric Liozon, Marc Lambert, Olivier Espitia, Christian Agard, Maxime Samson, Mathieu Vautier, David Saadoun, Arsene Mékinian, Aurélie Daumas....

- A ma petite femme Ali qui me supporte au quotidien et qui, à force de corriger tous mes articles en anglais, est devenue une vraie experte du Horton....
- A mes 3 enfants qui pensent encore que Horton est un éléphant....



Introduction, problématique, périmètre et objectifs du travail

L'artérite à cellules géantes (ACG, ou maladie de Horton) est la plus fréquente des vascularites systémiques chez les patients âgés de plus de 50 ans. Elle concerne essentiellement les vaisseaux de gros calibre selon la nomenclature de Chappell Hill, c'est-à-dire l'aorte et ses branches [1, 2].

Historiquement, elle fut décrite pour la première fois en 1880 [3], puis détaillée en 1932 par Morbus Horton [4]. La dénomination d'artérite giganto-cellulaire provient des analyses histologiques réalisées en 1941 [5]. Toutes ces descriptions historiques de la maladie font mention de l'atteinte prédominante des vaisseaux temporaux, d'où son autre dénomination initiale d'artérite temporale. En effet, l'ACG touche préférentiellement les artères à destinées céphaliques, en particulier les branches de la carotide externe. Cette atteinte explique les symptômes crâniens « typiques » de la maladie, plus particulièrement les céphalées, à prédominance temporale, la claudication de la mâchoire, l'hyperesthésie du cuir chevelu, ou encore les atteintes ischémiques en particulier ophtalmologiques, constituant la gravité fonctionnelle la plus sévère de la maladie.

Cependant, dès les années 70, quelques rares publications rapportent des patients avec une ACG ayant développé une atteinte de l'aorte et de ses branches. En 1975, la publication d'une série de 248 patients suivis à la Mayo Clinic aux Etats-Unis rapportait l'existence d'atteintes symptomatiques de l'aorte et de ses branches se traduisant par une claudication de membre, un phénomène de Raynaud, ou une abolition de pouls chez 34 (14%) patients de leur cohorte. Trois de ces patients décédaient d'une dissection aortique. L'analyse histologique de l'aorte révélait alors l'existence de lésions giganto-cellulaires [6]. Ainsi, l'atteinte des gros vaisseaux est connue de longue date mais elle a été considérée pendant des décennies comme exceptionnelle et finalement peu analysée jusqu'à peu. En dehors de complications plutôt rares de la maladie, le plus souvent tardives mais parfois révélatrices, représentées par les sténoses vasculaires symptomatiques, les thromboses vasculaires ou les dissections aortiques, l'atteinte des gros vaisseaux est le plus souvent asymptomatique et nécessite l'utilisation d'examens d'imagerie pour être mise en évidence. D'autres atteintes asymptomatiques telles que des dilatations ou anévrysmes artériels peuvent se développer à bas bruit sur une paroi artérielle inflammatoire [7-10]. Ainsi, avant les années 2000, la recherche radiologique d'une aortite ou d'une atteinte inflammatoire des branches de l'aorte était exceptionnelle et quasi-exclusivement guidée par une symptomatologie clinique évocatrice [11, 12].

Afin d'homogénéiser les patients décrits dans les études sur l'ACG, le collège américain de rhumatologie (ACR, American College of Rheumatology) a édité en 1990 des critères de classification. Ces critères stipulent que la probabilité du diagnostic d'ACG est supérieure à 80% chez un patient ayant au moins 3 des 5 critères suivants : 1) âge >50 ans ; 2) VS>50 mm à la première heure (et par extension un syndrome inflammatoire biologique) ; 3) céphalées inhabituelles ; 4) anomalies sur le trajet de l'artère temporale ; et 5) positivité de la biopsie d'artère temporale montrant des signes typiques d'ACG [13]. Outre les 2 critères démographique et biologique, les 3 autres critères font référence à l'atteinte temporale. L'atteinte inflammatoire des gros vaisseaux ou la pseudo-polyarthrite rhizomélique (PPR) – rhumatisme inflammatoire des ceintures scapulaires et pelviennes présent chez un tiers des patients avec une ACG – ne sont pas inclus dans ces critères de classification.

A partir des années 2000, les divers développements techniques et l'accès plus aisé de l'imagerie des gros vaisseaux ont permis de mener des études focalisées sur ces atteintes spécifiques. En dehors de l'écho-Doppler de l'artère temporale, trois techniques d'imagerie sont particulièrement décrites dans l'ACG, s'axant essentiellement sur l'exploration des gros vaisseaux: *l'angioscanner de l'aorte, la tomographie par émission de positons au ¹⁸FDG couplées à un scanner conventionnel (TEP-TDM) ou l'angiographie par résonance magnétique (ARM)*. En fonction des études, des critères d'inclusion, et des techniques d'imagerie utilisées, 30 à 80% des patients avec une ACG auraient une atteinte de l'aorte et de ses branches au diagnostic de la maladie [14-36]. De manière intéressante, la plupart de ces études regroupent sous un même terme générique – « aorto-artérite », « vascularites des gros vaisseaux » (« large-vessel vasculitis »), « atteinte des gros vaisseaux » (« large-vessel involvement ») – différentes formes d'atteinte des gros vaisseaux, quel que soit le site vasculaire concerné et le type d'atteinte vasculaire. Cependant une analyse de l'atteinte des gros vaisseaux doit prendre en compte deux niveaux de catégorisation radiologiques. Le premier niveau correspond à une analyse topographique distinguant l'atteinte de l'aorte, de ses principales branches, et des artères plus périphériques des membres. Le deuxième niveau correspond à une analyse structurale du type de modification pariétale artérielle. L'imagerie morphologique détaille les aspects diversement associés d'épaississement pariétal, de dissection pariétale essentiellement aortique, de perte du parallélisme pariétal à type de dilatation ou d'anévrisme ou même encore de sténoses vasculaires. L'imagerie morphologique se couple également à une imagerie fonctionnelle favorisée par les injections de ¹⁸FDG, d'iode, ou de gadolinium qui apporte un renseignement sur l'éventuelle activité inflammatoire

vasculaire. Pour chacune des possibles combinaisons morphologiques et fonctionnelles, peu d'information et très peu d'études existent pour préciser les fréquences, sites préférentiels, durée de survenue par rapport au diagnostic, pronostic et réponses au traitement.

Ainsi, bien qu'il soit bien connu que l'ACG puisse toucher l'aorte et ses branches, la très grande majorité des séries publiées sur cette vascularite décrit des patients satisfaisant au moins 3 des critères de l'ACR, en cours depuis 1990, ces derniers se focalisant sur l'atteinte céphalique prédominante de la maladie et occultant ses autres composantes macrovasculaires mais aussi rhumatologique. La description des patients avec des atteintes de l'aorte et de ses branches, qu'elles soient symptomatiques ou non, était jusqu'à maintenant rare parce que non systématiquement recherchées. Cette attitude historique occasionne ainsi une sélection des patients essentiellement « céphaliques » sur la base des critères de l'ACR de 1990.

Depuis une dizaine d'années, plusieurs bouleversements sont intervenus et ont totalement modifié la perception, le diagnostic, la prise en charge et les publications concernant les patients avec une ACG :

- Tout d'abord, pour la première fois en 2017, un essai international prospectif – Giacta portant sur l'utilisation du Tocilizumab (anticorps monoclonal anti-Interleukine 6) dans l'ACG – considérait comme unique critère d'inclusion l'existence d'une histologie artérielle positive ou d'une atteinte des gros vaisseaux à l'imagerie, et sans prise en compte des critères de l'ACR 1990 [37].
- Il est aujourd'hui pressenti que l'existence d'une atteinte des gros vaisseaux pourrait être associée à un pronostic plus péjoratif, en particulier du fait d'un risque accru de développer une dilatation aortique et une dissection aortique, importante cause de mortalité dans la maladie [7-9, 12, 38-43]. Ainsi, sous l'égide d'experts européens – membres de l'EULAR (european league against rheumatism) – des recommandations officielles ont été éditées sur la nécessité de dépister et surveiller radiologiquement l'atteinte potentielle des gros vaisseaux en raison de l'implication pronostique que cela peut avoir [44].
- Des recommandations actualisées françaises et européennes ont été publiées afin de standardiser la prise en charge diagnostique et thérapeutique [45-47].

Ainsi, à la lumière des publications de ces dernières années, beaucoup de changements sont intervenus dans l'ACG, mais il faut l'avouer très souvent avec peu de données épidémiologiques solides ni définitives. Le spectre clinique et radiologique de la maladie s'est

étouffé, les moyens de diagnostic et de suivi se sont enrichis, et les possibilités de traitements se sont améliorées notamment avec la récente autorisation de mise sur le marché du Tocilizumab dans l'ACG.

Néanmoins, beaucoup de questions restent en suspens, et des incertitudes demeurent concernant la valeur de la détection d'une atteinte des gros vaisseaux infra-clinique, que ce soit en termes de pronostic, de traitement ou de surveillance. Les récents résultats fournis sur l'efficacité du Tocilizumab dans l'ACG sont globaux et ne permettent pas de situer précisément les sous-groupes de patients chez qui le traitement serait plus profitable. Par ailleurs, certains travaux fondamentaux stipulent que les patterns d'ACG avec une atteinte des gros vaisseaux pourraient procéder d'un substratum cytokinique différent des formes sans. Des compositions cytokiniques différentes (notamment la signature interféron) ou encore des polarisations lymphocytaires différentes (TH1 ou TH17) ont été observées au sein des parois vasculaires temporales ou aortiques, suggérant des mécanismes d'atteinte possiblement différents [12, 48, 49]. Ainsi, à la lumière de ces données, il semble qu'une meilleure connaissance des différentes formes d'ACG soit indispensable car pourrait conditionner le pronostic, le suivi et le traitement des patients.

La rareté de la maladie limite par ailleurs les effectifs dans les cohortes publiées, en particulier celles se rapportant aux formes rares ou atypiques de la maladie. Ainsi, il est exceptionnel qu'une étude comporte plus de 200 patients. D'autre part, beaucoup d'études, rétrospectives ou prospectives, sont limitées par des biais d'inclusion ou de sélection. Les études n'ayant inclus que des patients avec ≥ 3 critères ACR n'ont par définition pas analysé les patients ayant une forme atypique de la maladie; les études n'ayant inclus que des patients avec une biopsie d'artère temporale positive s'affranchissent des patients « de vraies vies » avec une biopsie négative ou les patients sans atteintes céphaliques. Ainsi, même dans l'étude Giacta qui est aujourd'hui l'étude la plus aboutie dans l'ACG, les patients rapportés étaient sélectionnés et ne correspondaient pas aux patients « tout venants » de la pratique clinique quotidienne.

Il reste ainsi encore de la place pour mener des études « de vraie vie » au sein de larges cohortes de patients. A ce titre, et grâce à des travaux collaboratifs, nous avons aujourd'hui la capacité de mener de telles études sous l'égide de notre service de Médecine Interne du CHU de Caen.

Le service de Médecine Interne du CHU de Caen est historiquement le service d'adressage et de prise en charge des patients suspects d'ACG dans un périmètre d'environ 50 à 100 kilomètres autour de Caen. L'adressage préférentiel et le recrutement singulièrement élevé de notre centre

à l'échelle nationale (environ 30 nouveaux cas par an à Caen, contre 10-15 par centre à l'échelle nationale) nous a permis de constituer une cohorte monocentrique unique de plus de 460 patients sur une période allant de 2005 à aujourd'hui. Ces patients sont inclus au fil de l'eau dans une base de données. Nous disposons ainsi pour chaque patient des données démographiques, cliniques, biologiques, histologiques, radiologiques, thérapeutiques et évolutives. Depuis 2014, tous les patients adressés dans notre centre pour suspicion d'ACG bénéficient d'une prise en charge standardisée. Ces patients sont ainsi inclus prospectivement dans la base de données.

Par ailleurs, notre service a pu développer des collaborations fructueuses avec plusieurs services de Médecine Interne (Limoges, Lille, Marseille, Nantes, Dijon, Paris-La Pitié Salpêtrière, Saint-Antoine) permettant d'enrichir la base de données à plus de 1300 patients. Le recours fréquent à la TEP-TDM dans notre centre, ainsi que dans les centres de Limoges, Lille et Marseille, nous a permis de recueillir un grand nombre de données d'imagerie et à nous intéresser naturellement à l'atteinte des gros vaisseaux.

En somme, avec la reconsidération de l'ACG, non plus comme une artérite temporale avec des signes céphaliques et oculaires, mais selon le nouveau paradigme de vascularite systémique des gros vaisseaux, l'atteinte de l'aorte et de ses branches se replace au cœur de la maladie. L'atteinte des gros vaisseaux pourrait par ailleurs conditionner les pronostics évolutifs tardifs et vitaux de la maladie, via un risque accru de rechutes, de complications anévrysmales et/ou de dissections.

Les objectifs généraux de cette thèse sont ainsi de déterminer plus précisément les caractéristiques épidémio-cliniques, radiologiques (morphologiques et fonctionnelles) et évolutives de l'atteinte de l'aorte et de ses branches, en remplaçant et évaluant le poids de cette atteinte dans les critères diagnostiques et pronostiques de l'ACG sur une cohorte de taille jusque-là inégalée.

Les préalables ayant inspiré ces objectifs se déclinent à travers une série coordonnée et hiérarchisée de travaux publiés en 2016 et 2017, visant à:

1) Evaluer si l'atteinte inflammatoire de l'aorte et de ses branches favorisait le développement de complications morphologiques aortiques ultérieures au cours de l'ACG et dans quel délai.

A partir d'une analyse de 130 patients ayant bénéficié d'une TEP-TDM, nous avons observé que 9 patients, tous ayant une TEP-TDM positive sur les gros vaisseaux,

avaient développé une complication aortique (dilatation et/ou dissection aortique) après un délai médian de 33 mois, suggérant que l'atteinte inflammatoire segmentaire des gros vaisseaux augmentait le risque de complications aortiques [7]. Ce travail rapportait la plus grosse série de patients ayant bénéficié d'une TEP-TDM et confortait les quelques données publiées sur le risque accru de développer une complication aortique en cas d'atteinte inflammatoire des gros vaisseaux. Néanmoins, l'échantillon de patients avec une complication aortique était petit et les analyses statistiques (notamment pour effectuer des analyses multivariées) étaient limitées.

2) Evaluer l'impact du traitement sur l'imagerie fonctionnelle de l'aorte et de ses branches.

Nous avons analysé l'utilité des TEP-TDM répétitives chez les patients ayant une atteinte des gros vaisseaux et en rémission clinico-biologique. Nous montrions que 80% des patients, bien qu'en rémission clinique et biologique, conservaient une TEP-TDM positive au suivi [50]. Ce résultat a depuis été conforté dans d'autres études, que ce soit avec la TEP-TDM [51, 52], l'angioscanner aortique [53] ou avec l'ARM [54]. La persistance d'un rehaussement ou d'un épaissement aortique à l'imagerie chez un patient en rémission clinico-biologique pourrait indiquer l'existence de phénomènes de cicatrisation, de remodelage, ou d'une inflammation persistante à un stade infra-clinique et infra-biologique. Quoi qu'il en soit, ces mécanismes pourraient expliquer pourquoi les patients avec une atteinte des gros vaisseaux développent une fragilité de la paroi aortique les exposant à un risque accru de dilatation ou dissection. Cette constatation ouvre aussi la réflexion au recours d'autres thérapeutiques, potentiellement plus efficaces sur l'atteinte inflammatoire des gros vaisseaux.

3) Evaluer la concordance et les performances diagnostiques en analyse globale et par segments de deux techniques d'imagerie usuelles des gros vaisseaux dans l'ACG.

En raison de l'implication médico-économique, nous avons comparé la TEP-TDM à l'angioscanner aortique pour rechercher une atteinte des gros vaisseaux. Dans ce travail, nous montrions que les deux techniques d'imagerie avaient une sensibilité similaire pour démontrer l'atteinte inflammatoire de l'aorte et de ses branches mais

que la TEP-TDM permettait une cartographie vasculaire plus détaillée [55]. Ce travail permettait ainsi de préconiser le recours à l'angioscanner aortique en première intention pour chercher une atteinte des gros vaisseaux, cet examen étant moins onéreux et plus facile d'accès que la TEP-TDM.

4) Evaluer les pratiques thérapeutiques en cas d'atteinte des gros vaisseaux au cours de l'ACG

Nous avons effectué une analyse des pratiques concernant les traitements utilisés selon qu'il existe ou non une atteinte des gros vaisseaux. Ainsi, en comparant 40 patients avec et 40 patients sans atteinte des gros vaisseaux, nous n'avons pas mis en évidence de différences sur la gestion de la corticothérapie (dose d'introduction, schéma de décroissance, durée de traitement) ou le recours aux traitements d'épargne cortisonique [56].

Forts de ces premiers travaux et du nombre conséquent de patients inclus dans notre cohorte, nous avons souhaité approfondir cette recherche sur l'atteinte et le remodelage des gros vaisseaux au cours de l'ACG. C'est ainsi que le projet de thèse « Caractérisation clinique, iconographique et pronostique des atteintes des gros vaisseaux dans l'artérite à cellules géantes » est né.

Ainsi, au cours de ces trois dernières années, nous avons voulu, comme objectifs opérationnels spécifiques successifs :

- 1) Décrire les différents spectres clinico-radiologiques de l'ACG dans une cohorte de patients consécutifs. L'objectif de ce travail était d'avoir une photographie des différents visages de l'ACG et de pouvoir mieux situer les patients avec une atteinte des gros vaisseaux.**
- 2) Faire un focus sur les patients développant une atteinte symptomatique des gros vaisseaux sans signes crâniens. Cette forme de la maladie est particulièrement rare, peu décrite et de diagnostic difficile.**
- 3) Confirmer à plus grande échelle l'observation initiale du risque accru de complications aortiques chez les patients avec une atteinte des gros vaisseaux.**

4) Décrire les différentes formes d'atteinte des gros vaisseaux et analyser leur pronostic cardio-vasculaire.

5) Démontrer la limite des critères de classification de l'ACR 1990 et émettre des propositions pour actualiser ces critères en intégrant les différents spectres d'atteinte de l'ACG.

6) Faire une revue générale sur l'imagerie des gros vaisseaux au diagnostic et au suivi de l'ACG, tout en discutant leurs intérêts et limitations respectives.

Chacun des points précédents a fait l'objet d'une publication (acceptée ou en cours de soumission).

1 – Quelles sont, en intégrant le nouveau paradigme d'aorto-artérite, les différentes présentations clinico-radiologiques de l'artérite à cellules géantes ?

Fort du constat que l'ACG n'est pas une maladie monomorphe et au vu des disparités de présentation décrites dans la littérature, il apparaissait indispensable en premier lieu de décrire rigoureusement les différentes présentations cliniques observées au diagnostic d'ACG dans une cohorte conséquente de patients consécutifs et d'en estimer les fréquences respectives. L'atteinte des gros vaisseaux est ainsi ici particulièrement analysée à la lumière de ces différents groupes.

La cohorte de l'étude est composée de tous les patients consécutivement suivis dans le service de médecine interne du CHU de Caen entre 2000 et 2017, et de tous les patients consécutivement suivis dans le service de médecine interne du CHU de Limoges entre 1976 et 2017 (travail réalisé avec la collaboration du Dr Eric Liozon). Afin de garantir une certitude du diagnostic chez tous les patients, nous n'avons analysé que les patients avec une histologie positive ou avec une démonstration de vascularite à l'imagerie des gros vaisseaux. La cohorte permettait ainsi l'analyse des données radio-cliniques de 693 patients.

Inspirés des données antérieurement publiées, nous distinguons 4 formes principales d'ACG [12, 30, 49, 57, 58]. La forme crânienne définissait la présentation la plus typique de la maladie, et concernait les patients souffrant de symptômes crâniens (céphalées, claudication de mâchoire, hyperesthésie du cuir chevelu, signes ophtalmologiques...). Nous classions le patient dans cette forme si un seul symptôme crânien évocateur existait et cela, qu'il y ait ou non des signes de PPR ou d'atteinte asymptomatique des gros vaisseaux. La seconde forme définissait les patients ayant des symptômes évocateurs d'une atteinte des gros vaisseaux, qu'il y ait ou non des signes crâniens. Ces patients avaient donc une présentation initiale à type de dissection aortique, de claudication artérielle périphérique, d'acrosyndrome ou d'évènement ischémique en lien avec l'atteinte vasculaire inflammatoire. La troisième forme de la maladie était la forme systémique, c'est-à-dire celle correspondant aux patients ne souffrant d'aucun symptôme céphalique ou extra-céphalique. Tout au plus, ces patients avaient une fièvre isolée et/ou un syndrome inflammatoire biologique isolé. Enfin, la quatrième présentation concernait les patients souffrant d'une PPR d'allure isolée mais pour laquelle les explorations démontraient des signes de vascularite (sur une biopsie ou sur une imagerie des gros vaisseaux), classant alors le patient comme ACG. Chacune des 4 formes étaient comparées.

Parmi les 693 patients, la forme crânienne, c'est-à-dire celle typique ou encore historique, concernait 80% des effectifs, tandis que les 20% restant correspondaient aux formes atypiques. Une atteinte symptomatique des gros vaisseaux et la forme systémique asymptomatique étaient observées chez respectivement 9% des patients. La présentation sous forme de PPR isolée mais avec une démonstration de vascularite concernait les 2% restants. Une imagerie de l'aorte et de ses branches était disponible au diagnostic chez 310 patients et objectivait une inflammation vasculaire chez 173 d'entre eux, soit un taux d'atteinte des gros vaisseaux de 55.8%.

Hubert de Boysson, Eric Liozon, Kim Heang Ly, Anael Dumont, Claire Delmas, Achille Aouba.

The different clinical patterns of giant cell arteritis.

Clin Exp Rheumatol. 2019;37 Suppl 117(2):57-60

The different clinical patterns of giant cell arteritis

H. de Boysson^{1,2}, E. Liozon³, K.H. Ly³, A. Dumont¹, C. Delmas¹, A. Aouba^{1,2}

¹Department of Internal Medicine, Caen University Hospital;

²University of Normandy, Caen;

³Department of Internal Medicine and Clinical Immunology, Limoges University Hospital, France.

Hubert de Boysson, MD, MSc

Eric Liozon, MD

Kim Heang Ly, MD, PhD

Anael Dumont, MD

Claire Delmas, MD

Achille Aouba, MD, PhD

Please address correspondence to:

Hubert de Boysson, MD, MSc,
Department of Internal Medicine,
Caen University Hospital,
University of Caen-Normandie,
Avenue de la Côte de Nacre,
14000 Caen, France.

E-mail: deboysson-h@chu-caen.fr

Received on August 23, 2018; accepted in revised form on November 19, 2018.

Clin Exp Rheumatol 2019; 37 (Suppl. 117): S57-S60.

© Copyright CLINICAL AND EXPERIMENTAL RHEUMATOLOGY 2019.

Key words: giant-cell arteritis, pattern, clinical phenotypes, large-vessel vasculitis

ABSTRACT

Objective. To estimate the frequency of different clinical patterns in giant-cell arteritis (GCA) at onset.

Methods. All GCA patients consecutively followed-up in two referral centers for GCA with a biopsy-proven diagnosis and/or large-vessel vasculitis (LVV) demonstrated on imaging were analysed.

Results. We analysed the initial clinical presentation of 693 patients with a median age of 75 [48-94] years and including 486 (70%) women. We identified four different clinical patterns: isolated cranial GCA (in 80%), symptomatic LVV with or without associated cranial signs (9%), isolated fever or inflammatory response (9%), and isolated polymyalgia rheumatica with vasculitis (2%). A silent LVV was found in 110 (45%) out of the 247 patients without large-vessel symptoms who underwent imaging at GCA diagnosis. Symptomatic LVV patients were more frequently GC-dependent compared to other patterns ($p=0.03$) and showed the longest treatment duration (median: 37 [15-212] months versus <30 months for other clinical phenotypes; $p=0.001$).

Conclusion. This study suggests that 80% of GCA patients display a typical presentation, whereas the other 20% showed rarer presentations. Patients with symptomatic LVV required longer treatment duration.

Introduction

Giant-cell arteritis (GCA) is the most frequent systemic vasculitis in Western countries. Since its first description, multiple clinical and/or radiological sub-phenotypes of the disease have been described. In addition to the typical and pure cranial presentation on which the criteria from the American College of Rheumatology are based (1), other less frequent patterns of the disease have been described (2-4). Large-vessel vasculitis (LVV) has been

extensively described in recent years, especially due to the increasing use of whole body imaging such as CT angiography (CTA), magnetic resonance angiography (MRA), and positron emission tomography with computed tomography (PET/CT) (5). Ultrasound is also more widely used in the diagnosis of LVV (6). Other GCA phenotypes, more anecdotally reported and more challenging to diagnose, include GCA with isolated increased inflammatory parameters and/or fever of unknown origin (FUO), GCA with isolated large-vessel involvement without cranial symptoms, and isolated polymyalgia rheumatica (PMR) with LVV or positive temporal artery biopsy (TAB) (2, 7-9). Studies dealing with the frequency of each clinical pattern are scarce, and current knowledge on infrequent spectrums of the disease relies only on small selected series.

In this study, we aimed to determine the frequency of different clinical disease patterns at onset in a large-cohort of consecutive patients with GCA.

Patients and methods

Study population

We enrolled a cohort of newly diagnosed GCA patients recruited from the Internal Medicine departments of two French referral centres for GCA (Limoges and Caen). Patients from Limoges were prospectively enrolled from 1976 until 2017. Records of patients from Caen were retrospectively retrieved from 2000 to 2017 using the hospital diagnostic code database and the register of all temporal artery biopsy (TAB) performed in the hospital. All patients in this cohort were consecutively diagnosed and followed in the departments of Internal Medicine.

All included patients had a biopsy-proven diagnosis (on TAB or extra-temporal artery sample) and/or demonstration of large-vessel vasculitis (LVV) on imaging (without any other cause of LVV).

Competing interests: none declared.

S-57

This study was conducted in compliance with good clinical practices and the Declaration of Helsinki principles. At the time of this study, in accordance with French public health law (Art. L 1121-1-1, Art. L 1121-1-2), formal approval from an ethics committee was not required for this type of observational study that was initiated prior to August 2016.

Study variables and definition

We recorded for each patient demographics, clinical manifestations at onset, laboratory tests at diagnosis, biopsy results, and, when available, the results of large-vessel imaging. Data regarding treatment, the rate of relapses, glucocorticoids (GC)-dependence, GC discontinuation and deaths were retrieved for each patient.

We defined relapse as reoccurrence of symptoms and increased C-reactive protein level that responded to a sustained increase in GC dose. GC-dependence was defined as a daily prednisone dose >0.30 mg/kg after 6 months or >0.20 mg/kg after 12 months, or failure to withdraw GC treatment after 24 months.

In light of published series, we distinguished four main clinical patterns according to the clinical manifestations at onset (1, 2, 7, 9). Cranial GCA involved patients with isolated cranial symptoms affecting the cranial area (e.g. headaches, scalp tenderness or jaw claudication), i.e. without extracranial vascular features suggesting LVV. Patients with cranial symptoms and clinically silent LVV on imaging were classified as having cranial CGA. The 2nd clinical pattern included patients with symptomatic LVV such as limb claudication or pulseless limb. Patients with isolated raised inflammatory markers and/or fever of unknown origin (inflammation or fever of unknown origin: IFUO) formed the 3rd pattern. The 4th pattern included patients with clinically isolated PMR but with vasculitis demonstrated on TAB or imaging.

Statistical analyses

Categorical variables were expressed as numbers (%), and quantitative

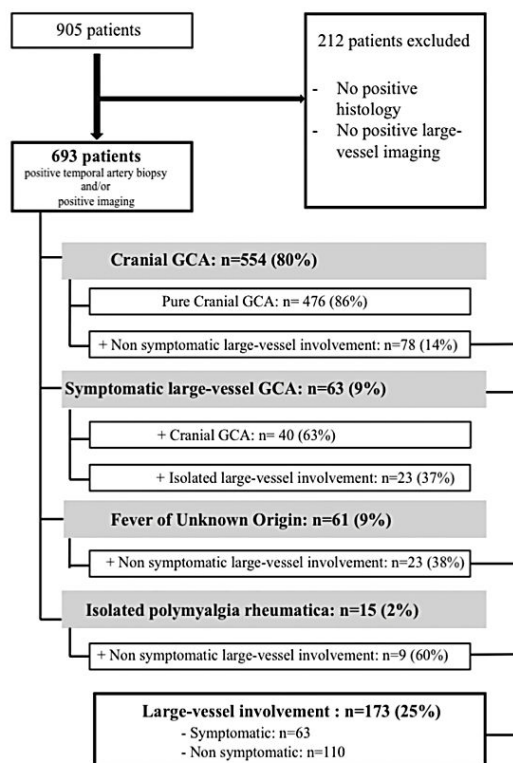


Fig. 1. Flow-chart of patients' selection and details of the four identified clinical patterns.

variables were expressed as medians [range]. Quantitative variables among the four subgroups were analysed using the Kruskal-Wallis test. For categorical analysis, the Chi-square for trend was used. The statistical analyses were computed using JMP 9.0.1 (SAS Institute Inc., Cary, NC, USA). A $p \leq 0.05$ defined statistical significance.

Results

Description of the four clinical patterns

We analysed the initial clinical presentation of 693 patients with a median age of 75 [48–94] years and including 486 (70%) women. Figure 1 depicts the flow-chart of patients' selection and sub-grouping. GCA diagnosis was made on biopsy in 632 (91%) patients. The 61 remaining patients without biopsy-proven diagnosis had demonstra-

tion of LVV on imaging (aortic CTA, MRA and/or PET/CT imaging).

Figure 1 and Table I show the main characteristics of the four clinical patterns at diagnosis, namely, isolated cranial GCA (in 80%), symptomatic LVV (in 9%) with or without associated cranial signs, GCA as IFUO (in 9%) and GCA as isolated PMR (in 2%).

A silent LVV was found in 110 (45%; 78 with cranial GCA + 23 with IFUO + 9 with isolated PMR) out of the 247 patients without large-vessel symptoms who underwent imaging. The proportions of the four clinical patterns between patients from both centers did not differ ($p=0.45$).

Treatment and outcomes

The initial GC doses or the relapse rates did not differ between the four groups. Symptomatic LVV patients were more

Table I. Disease patterns in 693 patients with giant-cell arteritis.

| | Isolated cranial GCA (n=554) | Symptomatic large-vessel GCA (n=63) | GCA as isolated IFUO (n=61) | GCA as clinically isolated PMR (n=15) | p-value |
|---|------------------------------|-------------------------------------|-----------------------------|---------------------------------------|---------|
| <i>Demographics</i> | | | | | |
| Female | 378 (68) | 52 (83) | 45 (74) | 11 (73) | 0.11 |
| Age | 76 [51-94] | 70 [53-92] | 72 [48-89] | 77 [58-83] | <0.0001 |
| <i>Cardiovascular risk factors</i> | | | | | |
| Hypertension | 258 (47) | 32 (51) | 22 (36) | 9 (60) | 0.24 |
| Tobacco use | 62 (11) | 10 (16) | 8 (13) | 0 | 0.34 |
| Diabetes mellitus | 55 (10) | 3 (5) | 8 (13) | 2 (13) | 0.43 |
| Dyslipidaemia | 85 (15) | 7 (11) | 12 (20) | 4 (27) | 0.37 |
| Delay to diagnosis, days | 45 [2-580] | 100 [0-1825] | 95 [21-380] | 165 [50-420] | <0.0001 |
| <i>Clinical manifestations at onset</i> | | | | | |
| Fever | 168 (30) | 22 (35) | 37 (63) | 2 (13) | <0.0001 |
| Headaches | 491 (89) | 35 (56) | - | - | <0.0001 |
| Scalp tenderness | 291 (53) | 14 (22) | - | - | <0.0001 |
| Jaw claudication | 255 (46) | 12 (19) | - | - | <0.0001 |
| Ophthalmic troubles | 207 (37) | 8 (13) | - | - | <0.0001 |
| Unilateral blindness | 106 (19) | 4 (6) | - | - | <0.001 |
| Bilateral blindness | 26 (5) | 0 | - | - | 0.08 |
| Polymyalgia rheumatica | 206 (37) | 18 (29) | - | 15 (100) | <0.0001 |
| Limb claudication | 0 | 56 (89) | - | - | <0.0001 |
| C-reactive protein, mg/l | 83 [1-535] | 58 [3-300] | 119 [18-382] | 66 [22-229] | 0.004 |
| <i>Mean to diagnose GCA</i> | | | | | |
| Positive histology | 528 (95) | 44 (70) | 50 (82) | 10 (67) | <0.0001 |
| LVV on imaging | 78/199 (39) | 63 (100) | 23/39 (59) | 9/9 (100) | <0.0001 |

Except where indicated otherwise, values are displayed as absolute number (%) or median [range].

GCA: giant-cell arteritis; IFUO: inflammation or fever of unknown origin; PMR: polymyalgia rheumatica; TA: temporal artery; LVV: large-vessel vasculitis.

Table II. Treatment and outcomes of patients with GCA according to different disease patterns.

| | Isolated cranial GCA (n=554) | Symptomatic large-vessel GCA (n=63) | GCA as isolated IFUO (n=61) | GCA as clinically isolated PMR (n=15) | p-value |
|-------------------------|------------------------------|-------------------------------------|-----------------------------|---------------------------------------|---------|
| GC dose, mg/k | | | | | |
| At onset | 0.73 [0.25-1.6] | 0.7 [0.38-1.15] | 0.7 [0.3-1.1] | 0.7 [0.63-1] | 0.56 |
| At month 12 | 0.1 [0.01-0.36] | 0.12 [0.03-0.53] | 0.14 [0.06-0.29] | 0.13 [0.04-0.29] | 0.11 |
| Discontinuation of GC | 296 (53) | 33 (52) | 26 (43) | 5 (33) | 0.20 |
| Duration of GC, month | 23 [3-133] | 37 [15-212] | 27 [10-97] | 30 [19-71] | 0.001 |
| Relapse | 276 (50) | 40 (63) | 31 (51) | 7 (47) | 0.23 |
| GC-dependence | 161 (29) | 29 (46) | 15 (25) | 4 (27) | 0.03 |
| Use of GC-sparing agent | 92 (17) | 16 (25) | 13 (22) | 3 (20) | 0.31 |
| Follow-up, months | 50 [0-279] | 76 [0-264] | 28 [0-139] | 27 [1-142] | 0.0008 |
| Death | 163 (29) | 18 (29) | 20 (31) | 1 (7) | 0.25 |

Except where indicated otherwise, values are displayed as absolute number (%) or median [range].

GCA: giant-cell arteritis; IFUO: inflammation or fever of unknown origin; PMR: polymyalgia rheumatica; GC: glucocorticoids

frequently GC-dependent compared to other patterns ($p=0.03$) and showed the longest treatment duration (median: 37 [15-212] months vs. <30 months for other clinical phenotypes; $p=0.001$). At last follow-up, 360 (52%) patients had discontinued their treatment permanently (Table II).

Discussion

Distinguishing and comparing GCA patients according to these four clinical

patterns at onset had not been reported previously. This classification appears clinically relevant and practical. Isolated cranial form remains the most frequent and typical clinical pattern (80% of patients) with the highest risk for early ischaemic complications, especially visual loss, as previously described (10, 11).

Our study is the first to report such a high number of patients with symptomatic LVV in a cohort of consecutive

GCA patients. Owing to the study design without selection bias, the proportion of patients with symptomatic LVV is probably representative of a clinically relevant subgroup of the disease. In a well-defined cohort of 168 consecutive patients diagnosed with GCA in Olmsted County (Minnesota) between 1950 and 1999, 21 (13%) incident cases of large-artery stenosis occurred, without focus of the initial clinical pattern (12). LVV was observed in all four clinical

patterns but was often non symptomatic, as in the literature where 30% to 80% of assessed patients are described with silent LVV (2, 13). Herein, we found a 45%-rate of silent LVV in GCA patients who underwent large-vessel imaging at diagnosis. Previous studies highlighted the need to revisit and re-define the concept of the disease, especially regarding the inclusion of LVV in ACR criteria (2).

The link between PMR and GCA is not fully elucidated, although many studies suggest a strong relationship between the two conditions (8, 13, 14). There are several reports of patients diagnosed with PMR without any signs of GCA who subsequently developed GCA many months to years after (14, 15). Blockmans *et al.* showed, in a PET/CT study performed in patients with isolated PMR, that large vessels were involved in 31% of the cases (14). Whether patients with initial PMR and subsequent vasculitis must be retrospectively upgraded in GCA at disease onset remains unclear. Indeed, our 15 patients with clinically isolated PMR did not respond to low GC doses usually able to control PMR and required at least 0.7 mg/kg/day of prednisone to achieve complete and durable control. These findings suggest that the end of the spectrum of PMR may be GCA.

Our study has several limitations, including its retrospective design. The different times of diagnosis between both centers are probably another limitation as patients included before 2000 might have had less easy access to imaging. Recruitment of patients in internal medicine departments may have led to overestimate the proportion

of patients with atypical presentations such as IFUO and symptomatic LVV. Only 45% of the patients underwent routine large-vessel imaging, which may have introduced selection biases. Moreover, as most of our patients had a biopsy-proven diagnosis, the proportion of LVV in our cohort may be underestimated as some studies suggested a lower rate of positive TAB in patients with LVV (7).

In conclusion, according to our study design, typical GCA and atypical presentations of GCA account for 80% and 20% of the cases, respectively. Further pathophysiological studies are needed to analyse whether different mechanisms support these different phenotypes. Finally, therapeutic studies are required to determine whether these different clinical patterns warrant different therapeutic approaches.

References

- HUNDER GG, BLOCH DA, MICHEL BA *et al.*: The American College of Rheumatology 1990 criteria for the classification of giant cell arteritis. *Arthritis Rheumatol* 1990; 33: 1122-8.
- DEJACO C, DUFTNER C, BUTTGEREIT F, MATTESON EL, DASGUPTA B: The spectrum of giant cell arteritis and polymyalgia rheumatica: revisiting the concept of the disease. *Rheumatology (Oxford)* 2017; 56: 506-15.
- KERMANI TA, WARRINGTON KJ, CROWSON CS *et al.*: Large-vessel involvement in giant cell arteritis: a population-based cohort study of the incidence-trends and prognosis. *Ann Rheum Dis* 2013; 72: 1989-94.
- ELEFANTE E, BOND M, MONTI S *et al.*: One year in review 2018: systemic vasculitis. *Clin Exp Rheumatol* 2018; 36 (Suppl. 111): S12-32.
- BLOCKMANS D, DE CEUNINCK L, VANDER-SCHUEREN S, KNOCKAERT D, MORTELMANS L, BOBBAERS H: Repetitive 18F-fluorodeoxyglucose positron emission tomography in giant cell arteritis: a prospective study of 35 patients. *Arthritis Rheumatol* 2006; 55: 131-7.
- GERMANÒ G, MONTI S, PONTE C *et al.*: The role of ultrasound in the diagnosis and follow-up of large-vessel vasculitis: an update. *Clin Exp Rheumatol* 2017; 35 (Suppl. 103): S194-8.
- BRACK A, MARTINEZ-TABOADA V, STANSON A, GORONZY JJ, WEYAND CM: Disease pattern in cranial and large-vessel giant cell arteritis. *Arthritis Rheumatol* 1999; 42: 311-7.
- CID MC, PRIETO-GONZALEZ S, ARGUIS P *et al.*: The spectrum of vascular involvement in giant-cell arteritis: clinical consequences of detrimental vascular remodelling at different sites. *APMIS Suppl* 2009; 10-20.
- LIOZON E, BOUTROS-TONI F, LY K, LOUSTAUD-RATTI V, SORIA P, VIDAL E: Silent, or masked, giant cell arteritis is associated with a strong inflammatory response and a benign short term course. *J Rheumatol* 2003; 30: 1272-6.
- GROSSMAN C, BARSHACK I, KOREN-MORAG N, BEN-ZVI I, BORNSTEIN G: Risk factors for severe cranial ischaemic events in patients with giant cell arteritis. *Clin Exp Rheumatol* 2017; 35 (Suppl. 103): S88-93.
- LIOZON E, DALMAY F, LALLOUE F *et al.*: Risk factors for permanent visual loss in biopsy-proven giant cell arteritis: a study of 339 patients. *J Rheumatol* 2016; 43: 1393-9.
- NUENNINGHOFF DM, HUNDER GG, CHRISTIANSON TJ, MCCLELLAND RL, MATTESON EL: Incidence and predictors of large-artery complication (aortic aneurysm, aortic dissection, and/or large-artery stenosis) in patients with giant cell arteritis: a population-based study over 50 years. *Arthritis Rheumatol* 2003; 48: 3522-31.
- MURATORE F, PAZZOLA G, PIPITONE N, BOIARDI L, SALVARANI C: Large-vessel involvement in giant-cell arteritis and polymyalgia rheumatica. *Clin Exp Rheumatol* 2014; 32 (Suppl. 82): S106-11.
- BLOCKMANS D, MAES A, STROOBANTS S *et al.*: New arguments for a vasculitic nature of polymyalgia rheumatica using positron emission tomography. *Rheumatology (Oxford)* 1999; 38: 444-7.
- YAMASHITA H, KUBOTA K, TAKAHASHI Y *et al.*: Whole-body fluorodeoxyglucose positron emission tomography/computed tomography in patients with active polymyalgia rheumatica: evidence for distinctive bursitis and large-vessel vasculitis. *Mod Rheumatol* 2012; 22: 705-11.

2 – Quelles sont les caractéristiques des patients avec une artérite à cellules géantes dont le territoire vasculaire touché ne correspond qu’au réseau artériel des membres ?

A l’issue du travail précédent [59], parmi les 63 (=9%) patients ayant une atteinte symptomatique des gros vaisseaux, un sous-groupe de patients avait un délai diagnostique prolongé (supérieur à 100 jours), témoignant de probables difficultés diagnostiques. En analysant en détail ces patients, ils s’avéraient que 23 d’entre eux avaient une présentation tout à fait atypique avec une atteinte isolée et symptomatique des gros vaisseaux, sans aucun signe céphalique. Le tableau clinique de ces patients était en pratique plus proche d’une artérite de Takayasu que d’une ACG.

L’objectif de ce deuxième travail était donc d’analyser en détail ces patients ayant une présentation topographique vasculaire atypique et, en conséquence, des conduites diagnostique et/ou thérapeutique retardées.

Afin d’augmenter le nombre de patients à analyser, nous avons fait un appel à observations dans trois autres centres (services de Médecine Interne de Nantes, Marseille – AP—HM, et Paris La Pitié-Salpêtrière), cela nous permettant de colliger 4 observations supplémentaires. L’ensemble de ces 27 patients avec une atteinte artérielle isolée et symptomatique des membres étaient comparés à 81 patients contrôles issus de la base commune Caen-Limoges et ayant tous 5/5 critères ACR, c’est-à-dire ayant une forme tout à fait typique de la maladie.

Nous observons que les patients avec une atteinte artérielle isolée et symptomatique des membres étaient significativement plus jeunes et de sexe féminin, et avaient un délai diagnostique significativement plus long (263 contre 25 jours pour les patients témoins). Sur le plan paraclinique, les marqueurs biologiques inflammatoires étaient moins élevés chez les patients avec une atteinte isolée et symptomatique des membres que chez les patients contrôles. Tous les patients avec une atteinte artérielle isolée et symptomatique des membres avaient une imagerie des gros vaisseaux pathologique avec une surreprésentation d’atteinte des artères périphériques à destinée des membres (artères axillaires, humérales et des membres inférieurs). L’aorte thoracique était aussi atteinte dans 80% des cas chez ces patients.

De manière intéressante, alors que ces mêmes patients n’avaient strictement aucun signe crânien, 69% des biopsies d’artère temporale systématiquement pratiquées étaient revenues positives.

Nous n'observons pas de différences en termes de gestion de la corticothérapie ni de recours à un traitement immunosuppresseur entre les deux groupes de patients, mais les patients avec une atteinte artérielle isolée et symptomatique des membres étaient traités plus longtemps que les patients témoins.

Enfin, sur une durée de suivi d'environ 4 ans, plus de deux tiers des patients avec une atteinte isolée et symptomatique des artères des membres souffraient d'une complication cardiovasculaire, contre seulement 21% des témoins ($p < 0.0001$). Ces complications concernaient des événements ischémiques (AVC, syndrome coronariens, ischémie de membre), mais également des complications aortiques (dilatation et dissection de l'aorte). Une chirurgie vasculaire était aussi requise chez 44% d'entre eux.

Hubert de Boysson, Olivier Espitia, Eric Liozon, Aurélie Daumas, Mathieu Vautier, Anael Dumont, Brigitte Granel, David Saadoun, Gaétane Planchard, Kim Heang Ly, Achille Aouba.

Vascular Presentation and Outcomes of Patients With Giant Cell Arteritis and Isolated Symptomatic Limb Involvement

J Clin Rheumatol.2019. doi: 10.1097/RHU.0000000000001051

Vascular Presentation and Outcomes of Patients With Giant Cell Arteritis and Isolated Symptomatic Limb Involvement

Hubert de Boysson, MD, MSc,* Olivier Espitia, MD, MSc,† Eric Liozon, MD,‡ Aurélie Daumas, MD, MSc,§ Mathieu Vautier, MD,|| Anael Dumont, MD,* Brigitte Granel, MD,§ David Saadoun, MD, PhD,||¶**†† Gaétane Planchard, MD,‡‡ Kim Heang Ly, MD,† and Achille Aouba, MD, PhD*

Objective: The aims of this study were to describe and assess the vascular outcomes of patients with giant cell arteritis (GCA) presenting with only symptomatic isolated limb involvement (LI-GCA).

Methods: We retrospectively recruited patients from 5 tertiary centers who were diagnosed with GCA based on histology or vasculitis demonstration on imaging and who presented with isolated symptomatic limb involvement at diagnosis. For each included patient, we randomly selected 3 control patients who satisfied the 5 criteria from the American College of Rheumatology at diagnosis.

Results: We included 27 LI-GCA patients and 81 control patients. Compared with the controls, the patients with LI-GCA were younger ($p = 0.005$), exhibited a more delayed diagnosis ($p = 0.006$), and had lower C-reactive protein levels ($p = 0.001$), but they did not show more cardiovascular risk factors. Glucocorticoid use (starting and tapering doses) and relapse rates did not differ in the 2 groups, but the patients with LI-GCA received longer treatment ($p = 0.02$). Cardiovascular complications occurred in 67% of the patients with LI-GCA versus 21% of the control patients ($p < 0.0001$), especially ischemic events ($p < 0.0001$) including stroke ($p = 0.03$) and myocardial infarction ($p = 0.01$). Vascular surgery was required in 44% of the patients with LI-GCA versus 2% of the controls ($p < 0.0001$). Excluding vascular surgery, the cumulative incidence of cardiovascular complications was higher in the patients with LI-GCA (log-rank test: $p < 0.0001$) than in the controls (hazard ratio, 5.73; 95% confidence interval, 2.94–11.28; $p < 0.0001$).

Conclusions: Compared with the typical cranial form of GCA, LI-GCA has a worse cardiovascular-related prognosis. Further studies are required to determine the best management of these patients.

Key Words: cardiovascular events, giant cell arteritis, large-vessel vasculitis, limb involvement, outcomes

(*J Clin Rheumatol* 2019;00: 00–00)

From the *Department of Internal Medicine, Caen University Hospital, University of Caen—Basse Normandie, Caen; †Department of Internal Medicine, Nantes University Hospital, Nantes; ‡Department of Internal Medicine, Limoges University Hospital, Limoges; §Department of Internal Medicine, Marseille University Hospital, Marseille; ||AP-HP, Groupe Hospitalier Pitié-Salpêtrière, Département de Médecine Interne et Immunologie Clinique, National Center for Autoimmune and Systemic Rare Disease, and National Center for Autoinflammatory Diseases and Amyloidosis, F-75013; ¶Département Hospitalo-Universitaire Inflammation-Immunopathologie-Biothérapie (DHU 2B), F-75005; **INSERM, UMR_S 959, F-75013; ***CNRS, FRE3632, F-75005; and ††Sorbonne Universités, UPMC Université Paris 06, UMR 7211, Paris; and ‡‡Department of Pathology, Caen University Hospital, University of Caen—Basse Normandie, Caen, France.

The authors declare no conflict of interest.

Correspondence: Hubert de Boysson, MD, MSc, Department of Internal Medicine, Caen University Hospital, Avenue de la Côte de Nacre, 14000 Caen, France. E-mail: deboysson-h@chu-caen.fr

Supplemental digital content is available for this article. Direct URL citation appears in the printed text and is provided in the HTML and PDF versions of this article on the journal's Web site (www.jclinrheum.com).

Copyright © 2019 Wolters Kluwer Health, Inc. All rights reserved.

ISSN: 1076-1608

DOI: 10.1097/RHU.0000000000001051

Giant cell arteritis (GCA) is a systemic vasculitis affecting people older than 50 years.¹ According to the Chapel Hill classification,² GCA and Takayasu arteritis (TAK) are the 2 main systemic vasculitides affecting large vessels, namely, the aorta and its main branches. Both diseases share pathogenic, clinical, radiological, and histological features and thus have been proposed by some authors to represent different phenotypes on a spectrum of a single disease.^{3,4}

Giant cell arteritis mainly affects elderly patients and is commonly and easily recognized by its typical involvement of external carotid branches with subsequent cranial signs. Large-vessel vasculitis (LVV) may affect 30% to 80% of GCA patients and is most often asymptomatic at disease diagnosis, especially when the aorta is solely involved among the whole large arterial segments.^{5–10} In association with the presence of typical cranial signs (e.g., headaches or scalp tenderness), the demonstration of large-vessel involvement on imaging is currently becoming a diagnostic criterion.^{11–13} Symptomatic limb involvement has been reported to be associated with other typical signs of GCA but very rarely as an isolated and inaugural clinical involvement of the disease.^{10,14–21} Therefore, this clinical pattern of GCA may represent a diagnostic challenge with atherosclerosis or with other LVV diseases, especially TAK.^{10,15,16,22–29} Some studies on GCA and TAK indicated a worse cardiovascular prognosis in patients with large-vessel involvement.^{22,24,28–30}

In this study, we aimed to describe the characteristics of GCA patients with symptomatic and isolated limb involvement (LI-GCA), that is, without any other GCA-related symptoms. We also questioned whether these patients would carry poorer cardiovascular outcomes than those with a typical presentation.

METHODS

Study Population

Patients with LI-GCA were retrospectively enrolled from the departments of internal medicine at 5 university hospitals (Caen, Limoges, Nantes, Marseille, and Paris—La Pitié Salpêtrière). To be included in this cohort, patients had to show isolated and symptomatic limb involvement with demonstration of vascular inflammation on imaging. They did not show any signs of cranial GCA or polymyalgia rheumatica (PMR) but could have associated constitutional symptoms (fever, weight loss, and/or fatigue).

Giant cell arteritis was diagnosed between 2010 and 2016 in all these patients based on a positive temporal artery biopsy (TAB) or demonstration of LVV by imaging (providing that other causes of LVV were ruled out). They also have an age at disease onset above 50 years old (except a 49-year-old patient with a typical positive TAB). Finally, each patient had a follow-up with experienced physicians in the field of GCA.

The control patients were selected from a common database from Caen and Limoges that includes 905 patients. The patients from Limoges were prospectively enrolled in a registry since 1976 and were consecutively followed in the department of internal medicine

until 2017. The records of patients from Caen were retrospectively retrieved using the hospital diagnostic code database, as well as the registry of all TAB procedures performed in the hospital. All of the patients from the Caen cohort were consecutively diagnosed and followed in the department of internal medicine from 2000 to 2017. Some control patients without peripheral vascular symptoms underwent a systematic LVV research at diagnosis since experience in the imaging of LVV showed that LVV is often silent.⁵⁻⁹

For each patient with LI-GCA included, 3 random patients without symptomatic LVV but with 5 of 5 of the criteria from the American College of Rheumatology (ACR) for GCA,³¹ that is, exhibiting typical cranial signs along with positive TAB and with or without PMR, were also selected from the common database and included in the control group.

This study was conducted in compliance with good clinical practices and the Declaration of Helsinki principles. At the time of this study, in accordance with French public health law (Art. L 1121-1-1 and Art. L 1121-1-2), formal approval from an ethics committee was not required for this type of observational study. Our local ethics committee confirmed the observational, noninterventive, retrospective nature of our cohort.

Study Parameters and Definition

By definition, cranial symptoms (including headaches, scalp tenderness, jaw claudication, abnormalities on temporal artery, and ophthalmic signs) should not be present in patients with LI-GCA but should be present in control patients.

In all of the included patients, data regarding demographics, medical history, initial presentation, laboratory tests, TAB status, imaging, and treatments were collected. During follow-up, the occurrences of relapse and death were also noted.

In patients with LI-GCA, we recorded the delay (in days) elapsed between the first peripheral vascular signs and the glucocorticoid (GC) introduction.

In the absence of a positive biopsy, as defined in previous studies,^{7,24,32} patients had LVV evidenced on positron emission tomography coupled with computed tomography (CT) scan (positron emission tomography [PET]/CT), aorta CT angiography (CTA), or aorta magnetic resonance angiography (MRA). On PET/CT, a circumferential and homogeneous fluorodeoxyglucose vascular uptake superior to the liver uptake, as defined by Hautzel et al,³³ indicated vascular inflammation. On CTA or MRA, aortitis was defined as a circumferential wall thickening/edema of the aorta by more than 2 mm, with or without contrast enhancement.

In all of the patients with LI-GCA, the aorta branches were analyzed and searched for stenosis (i.e., thickening causing a narrowing of the vascular lumen) and/or occlusion (i.e., total blockage of the vascular lumen). We differentiated GCA-related limb involvement from atherosclerosis in our patients on the following points: isolated lower limb involvement was related to GCA when a vascular sample showed vasculitis, no atheromatous plaque was observed within vascular thickening or vascular uptakes on imaging, and a circumferential and homogeneous vascular thickening or uptake was observed on the large-vessel imaging.

Relapse was defined as a reoccurrence of clinical signs attributable to GCA along with increased acute phase reactants that required an increase in treatment. In patients with LI-GCA, a relapse of limb involvement was suspected if an acute or subacute vascular deterioration occurred (e.g., new or worsening of a stenosis or occlusion, occlusion of a stent or a vascular bypass) clinically and/or on imaging along with an increase of acute phase reactants.

When doses of GCs could not be tapered below 0.30 mg/kg after 6 months or below 0.20 mg/kg after 12 months or should

have been maintained over 2 years to ensure a permanent disease control, we defined the disease as GC dependent.

We assessed the vascular outcomes of patients with LI-GCA and controls and analyzed the occurrence of acute ischemic events during the follow-up (stroke, myocardial infarction, and limb ischemia) and/or new aortic dilation/dissection. We also recorded vascular surgeries performed during the follow-up. Adapted from previous reports, the aortic root, aortic arch, and descending aorta were considered to be dilated when the aortic diameter was ≥ 4.5 , ≥ 4 , and ≥ 3.5 cm, respectively.^{8,24}

Statistical Analyses

Categorical variables are expressed as the number (%), and quantitative variables are expressed as the median (range). Categorical variables were analyzed using the χ^2 test or Fisher exact test, as appropriate, and quantitative variables were analyzed using the Wilcoxon rank-sum test. The cumulative incidence of cardiovascular events in the 2 groups of patients was analyzed using life tables and the Kaplan-Meier method, and these were compared using the log-rank test. Univariate Cox proportional hazards regression model was used to estimate hazard ratio for cardiovascular events according to the groups. The statistical analyses were computed using JMP 9.0.1 (SAS Institute Inc, Cary, NC). A $p \leq 0.05$ defined statistical significance.

RESULTS

Characteristics of Patients With Isolated and Symptomatic GCA-Related Limb Involvement

We enrolled 27 patients with LI-GCA (23 women [85%]; median age at diagnosis, 68 [49–80] years). Detailed characteristics of the patients with LI-GCA are shown in Supplemental Table 1, <http://links.lww.com/RHU/A148>. Only 1 patient was younger than 50 years (49 years old) and showed a typical positive TAB (patient 14 in Supplemental Table 1, <http://links.lww.com/RHU/A148>). They all showed peripheral vascular signs, especially limb claudication (upper limbs in 20 and lower limbs in 13), before being diagnosed with GCA. The diagnosis of GCA was made at a median delay of 263 (60–584) days after the onset of the limb symptoms. As defined, none of the patients displayed cranial GCA symptoms or PMR.

A morphological assessment of the vascular lumen of limb arteries was available in all of patients with LI-GCA and showed long vascular stenoses that explained limb claudication in all of them, including 2 patients who showed a total occlusion of the vascular lumen on the axillary and tibial arteries. In patients with lower limb claudication and vascular stenosis of iliofemoral arteries, other vascular segments (i.e., aorta or other aorta branches) were also inflamed on imaging. Among the 27 patients with LI-GCA, concomitant inflammatory involvement of the aorta was observed in 23 (85%) and was demonstrated on several procedures in some of them (on CTA in 19, on PET/CT in 10, and MRA in 1).

All but 3 patients showed increased acute phase reactants at diagnosis. A TAB was performed in 26 patients and was positive in 18 (69%). The 3 patients who did not exhibit increased acute phase reactants had a positive TAB. One patient did not have a TAB but showed giant cell vasculitis on a tibial vascular sample obtained during surgery for acute leg ischemia 4 months after GCA diagnosis.

The prevalence of LI-GCA in the database of Caen and Limoges hospitals was 2% (9 of 420 patients) and 1.5% (7 of 450 patients), respectively.

Comparison of Patients With LI-GCA and Controls

Eighty-one patients were included as control patients. The comparison of patients with LI-GCA and controls is described in Table 1.

At GCA diagnosis, patients with LI-GCA were younger than controls (68 [49–80] vs. 74 [52–91] years, $p = 0.005$). They also showed a more delayed diagnosis (263 [60–584] vs. 25 [13–120] days, $p = 0.006$). No difference was observed in the 2 groups regarding cardiovascular risk factors. Patients with LI-GCA showed lower acute phase reactants at diagnosis, including the erythrocyte sedimentation rate (60 [22–120] vs. 90 [16–131] mm, $p = 0.01$) and levels of C-reactive protein (55 [3–160] vs. 92 [15–424] mg/L, $p = 0.001$).

In the control group, 56 patients (69%), without any peripheral vascular signs, underwent 1 or 2 large-vessel imaging(s) at diagnosis to search a large-vessel involvement (a PET/CT in 42 and a CTA in 28), and LVV was demonstrated in 27 of them (48%). Besides the wall thickening, none of them showed vascular stenosis or occlusion. A qualitative comparison of involved vascular territories on imaging (i.e., large-vessel involvement or not) between the 2 groups showed that arteries supplying limbs were more frequently involved in patients with LI-GCA, namely, the axillary (74% vs. 19%, $p < 0.0001$) and humeral (33% vs. 4%, $p = 0.01$) arteries and arteries of the lower limbs (48% vs. 15%, $p = 0.008$) (Table 2).

Treatment and Outcomes

Treatments of the 2 groups are shown and compared in Table 3. While the GC duration was longer in patients with LI-GCA ($p = 0.02$), the median GC dose at onset, as well as that at months 3, 6, and 12, the rates of relapse, deaths, GC

TABLE 2. Comparison of the Vascular Territories Involved in the Patients With GCA With Isolated Limb Involvement and Control Patients (GCA With Typical Cranial Form) at Diagnosis on Imaging

| | LI-GCA (n = 27) | Control Patients With LVV (n = 27) | p value |
|-----------------------|-----------------|------------------------------------|---------|
| Thoracic aorta | 22 (81) | 22 (81) | 1 |
| Abdominal aorta | 14 (52) | 16 (59) | 0.58 |
| Subclavian arteries | 20 (74) | 19 (70) | 1 |
| Axillary arteries | 20 (74) | 5 (19) | <0.001 |
| Carotid arteries | 7 (26) | 12 (44) | 0.25 |
| Humeral arteries | 9 (33) | 1 (4) | 0.01 |
| Iliofemoral arteries | 12 (44) | 7 (26) | 0.15 |
| Lower limbs' arteries | 13 (48) | 4 (15) | 0.008 |

Values are number (%).

dependence, the use of immunosuppressant, and GC discontinuation did not differ between the 2 groups. Among the 19 patients with LI-GCA who relapsed, 7 (37%, all with a positive TAB) developed cranial symptoms at 11 (7–19) months after diagnosis.

Three deaths were recorded among LI-GCA patients, which were related to cardiovascular complications, including a stroke, a myocardial infarction, and a lower limb ischemia with rapid deterioration.

During the follow-up, vascular surgery was required in 12 patients (44%) with LI-GCA (see Supplemental Table 1,

TABLE 1. Comparison of Patients With GCA With Isolated Limb Involvement and Control Patients (GCA With Typical Cranial Form) at Diagnosis

| | LI-GCA (n = 27) | Control Patients (n = 81) | p value |
|------------------------------------|-----------------|---------------------------|---------|
| Demographics | | | |
| Age | 68 (49–80) | 74 (52–91) | 0.005 |
| Female | 23 (85) | 53 (65) | 0.05 |
| Diagnostic delay, ^a d | 263 (60–584) | 25 (13–120) | 0.006 |
| Cardiovascular risk factors | | | |
| Hypertension | 12 (44) | 38 (47) | 0.82 |
| Diabetes mellitus | 2 (7) | 9 (11) | 0.58 |
| Dyslipidemia | 3 (11) | 14 (17) | 0.45 |
| Tobacco use | 7 (26) | 17 (21) | 0.59 |
| Previous stroke | 1 (4) | 9 (11) | 0.25 |
| Previous myocardial infarct | 2 (7) | 9 (11) | 0.58 |
| Clinical manifestations | | | |
| Fever | 6 (22) | 26 (32) | 0.33 |
| PMR | 0 | 34 (42) | <0.0001 |
| Limb claudication | 27 (100) | 5 (6) | <0.0001 |
| Vascular bruits | 16 (59) | 7 (9) | <0.0001 |
| Paraclinical workup | | | |
| Erythrocyte sedimentation rate, mm | 60 (22–120) | 90 (16–131) | 0.01 |
| C-reactive protein, mg/L | 55 (3–160) | 92 (15–424) | 0.001 |
| Positive histology ^b | 19 (73) | 81 (100) | <0.0001 |
| Positive TAB | 18/26 (69) | 81 (100) | <0.0001 |
| LVV on imaging | 27 (100) | 27/56 (48) | <0.0001 |

Values are number (%) or median (range).

^aTime elapsed between the first signs and the GC introduction.

^bIncludes evidence of giant cell vasculitis on TAB and any other extratemporal vascular sample.

TABLE 3. Treatment and Outcomes of Patients With GCA-Related Isolated Limb Involvement and Controls (GCA With Typical Cranial Form)

| | LI-GCA (n = 27) | Control Patients (n = 81) | p value |
|--|-------------------|---------------------------|---------|
| GC dose, mg/kg per day | | | |
| At onset | 1 (0.70–1.15) | 0.71 (0.40–1.09) | 0.06 |
| At month 3 | 0.40 (0.16–0.58) | 0.29 (0.16–0.88) | 0.62 |
| At month 6 | 0.17 (0.09–0.40) | 0.18 (0.07–0.62) | 0.91 |
| At month 12 | 0.135 (0.07–0.18) | 0.11 (0.03–0.53) | 0.34 |
| Total follow-up duration, mo | 43 (8–234) | 59 (6–183) | 0.12 |
| GC discontinuation | 10 (37) | 37 (46) | 0.43 |
| GC duration, mo | 36 (24–212) | 23 (14–111) | 0.02 |
| Relapse | 19 (70) | 45 (56) | 0.17 |
| GC dependence | 12 (44) | 29 (36) | 0.42 |
| Immunosuppressant use | 11 (41) | 22 (27) | 0.18 |
| Death | 3 (11) | 14 (17) | 0.45 |
| New cardiovascular events ^a | 18 (67) | 17 (21) | <0.0001 |
| Any ischemic event | 13 (48) | 9 (11) | <0.0001 |
| Myocardial infarction | 5 (19) | 3 (4) | 0.01 |
| Stroke | 6 (22) | 6 (7) | 0.03 |
| New aortic dilation | 8 (30) | 8 (10) | 0.02 |
| Aortic dissection | 2 (7) | 0 | 0.01 |
| Vascular surgery | 12 (44) | 2 (2) | <0.0001 |

Values are number (%) or median (range).

^aExcluding vascular surgery but including acute ischemic events (stroke, myocardial infarction, and limb ischemia) or new aortic dilation/dissection.

<http://links.lww.com/RHU/A148>), including 5 who had an emergency context (acute leg ischemia in 2, aortic dissection in 2, and mesenteric infarction in 1). Seven vascular surgeries were for revascularization (vascular bypasses in 3; vascular stenting in 4, including 1 patient who also had a vascular bypass; and artery dilation in 1). The other 5 vascular surgeries were for a replacement of the ascending thoracic aorta in a patient who exhibited a rapid-onset aortic dilation, and the last 4 included a femoral amputation in 1, an aorta surgery for aortic dissection in 2, and a partial small bowel resection for mesenteric infarction in another. Vascular biopsy was performed during the surgical procedure in 4 patients, and 3 of them exhibited histologic features suggestive of GCA, including giant cell vasculitis on tibial, aortic, and mesenteric samples. The arterial sample of the last patient showed nonspecific inflammatory infiltrate without giant cells.

All 12 of the surgical patients with LI-GCA were under GC during the procedure, and all of them showed secondarily good vascular evolution during the follow-up, even though 2 patients showed a new occlusion—1 on a subclavian stent and 1 on an axillary bypass.

Cardiovascular Events During Follow-up

The median follow-up duration did not differ between the 2 groups (43 [8–234] months in the patients with LI-GCA vs. 59 [6–183] months in the controls, $p = 0.12$).

In addition to vascular surgery, which was more frequent in LI-GCA patients (44% vs. 2%, $p < 0.0001$), more of these patients also showed new cardiovascular events (67% in the LI-GCA patients vs. 21% in the control group, $p = <0.0001$) during follow-up. These last events corresponded especially to ischemic events (48% in the LI-GCA patients vs. 11% in the control patients, $p < 0.0001$), including myocardial infarction (19% in the LI-GCA patients vs. 4% in the control patients, $p = 0.01$) and stroke (22% in the LI-GCA patients vs. 7% in the control patients, $p = 0.03$). Five of the 6 strokes observed in the patients with LI-GCA affected

the vertebrobasilar territory. Aortic dilation (30% in the LI-GCA patients vs. 10% in the control patients, $p = 0.02$) and aortic dissections (observed in only 2 patients with LI-GCA, $p = 0.01$) also occurred more in patients with LI-GCA. Seven patients (26%) with LI-GCA experienced 2 or more vascular complications.

In the Supplemental Table 2, <http://links.lww.com/RHU/A148>, we compared patients with LI-GCA to the controls excluding the 27 patients demonstrating LVV. We observed the same results regarding outcomes, especially more cardiovascular events, including new ischemic events, aortic dilation, or aortic dissection in patients with LI-GCA. However, the occurrence of stroke and myocardial infarction was no longer different between the 2 groups ($p = 0.06$ and $p = 0.07$, respectively).

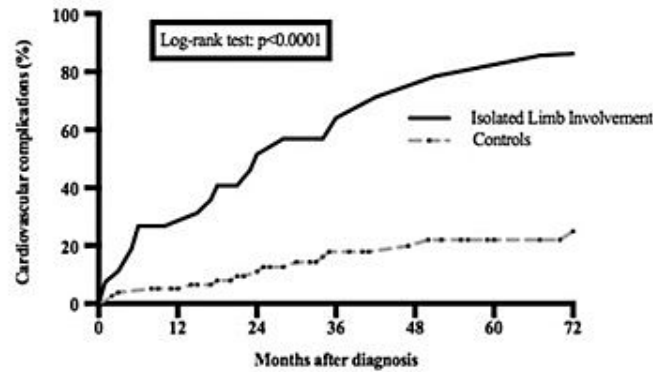
As new cardiovascular events occur more frequently in patients with previous cardiovascular disease and to show the GCA-specific effect of increasing the risk of new cardiovascular events, we analyzed the rate of these events excluding 3 and 15 patients with previous stroke and/or myocardial infarction in the LI-GCA and control groups, respectively (Supplemental Table 3, <http://links.lww.com/RHU/A148>). Similar results were still observed with more frequent new cardiovascular events noted in the group of LI-GCA patients (63% in LI-GCA patients and 17% in the controls, $p < 0.0001$).

The cumulative incidence of new cardiovascular events (excluding vascular surgery), as shown in the Figure, was higher in patients with LI-GCA (log-rank test: $p < 0.0001$) than in controls (hazard ratio, 5.73; 95% confidence interval, 2.94–11.28; $p < 0.0001$).

At the last follow-up, 16 (67%) of the 24 LI-GCA survivors did not complain of any vascular claudication.

DISCUSSION

Giant cell arteritis revealed by symptomatic and isolated limb involvement, without cranial symptoms, represents an infrequent and challenging diagnosis with a poor vascular prognosis when



| No. at risk | | | | | | | |
|---------------------------|----|----|----|----|----|----|----|
| Isolated Limb Involvement | 27 | 17 | 10 | 6 | 5 | 4 | 3 |
| Controls | 81 | 72 | 62 | 49 | 39 | 30 | 27 |

FIGURE. Cumulative incidence of cardiovascular complications in GCA patients with isolated and symptomatic limb involvement and in control patients with typical cranial form. Patients with isolated limb involvement showed the higher incidence of cardiovascular complications (log-rank test: $p < 0.001$).

compared with the typical cranial form. The absence of cranial, ophthalmic, and/or PMR signs makes the GCA diagnosis unlikely, and more frequently, mimickers, such as atherosclerosis, are discussed at first. The persistence of increased inflammatory parameters, as well as the presence of LVV on imaging, finally led to the GCA diagnosis. The design of our study allows for a pragmatic comparison of 2 forms of the disease, namely, the typical and most common cranial form with and without LVV and the LI-GCA form, which is poorly known. Only few studies are dedicated to limb involvement in GCA, and most of them include patients with concomitant cranial symptoms.^{10,15,16,28} The present study did not allow determining the real frequency of this pattern among all of the GCA patients as our patients were selected. However, this pattern of the disease is probably very rare, given the relatively small number of patients retrieved in our 5 centers. Nueninghoff et al.,²⁸ in a population-based study of all residents of Olmsted County, MN, found incident cases of large-artery stenosis in 13% of patients, most of them on cervical arteries. In another retrospective study, Assie et al.¹⁵ identified limb involvement in 10.25% of GCA patients. However, in both of these studies, the patients also exhibited other symptoms suggestive of GCA, such as cranial signs or PMR, suggesting that isolated limb involvement affects only a small percentage of patients. In our study, we found that LI-GCA more likely affected women and younger patients. We did not have a clear explanation for these data, but these differences were also observed in other studies where more than 80% of patients with LI-GCA were female younger than 70 years.^{10,15} Whether different pathophysiological mechanisms or hormonal influences contribute to these differences remains to be determined.

New stroke and myocardial infarctions affected approximately 20% of our patients with LI-GCA during the follow-up, while these patients did not show more cardiovascular risk factors than the controls at GCA onset, suggesting the participation of the vasculitic process in these events, which is also demonstrated in TAK.^{22,34,35} Moreover, 5 of the 6 strokes observed in the patients with LI-GCA affected the vertebrobasilar territory, which is known to more likely occur in GCA patients with stroke.^{36,37} The high rate of ischemic complications in this subgroup of patients is probably linked to different factors. First, ischemic events are the consequence of vascular occlusion and stenosis, which were more prevalent in this subgroup. Second, a delayed diagnosis, especially due to

the absence of cranial symptoms, can lead to a vascular progression with a worsening of stenosis leading to occlusion and subsequent ischemic events. Finally, the longer duration of treatment also may be a worsening factor because GC can accelerate atherosclerosis that can participate in these ischemic events.³⁸

In elderly patients with isolated lower limb ischemic signs and moreover exhibiting cardiovascular risk factors, atherosclerosis would be the first diagnosis evoked. However, increased inflammatory parameters on laboratory tests and vascular thickening or stenosis of other vascular segments on imaging should draw attention and suggest a vasculitis process. In addition, long and bilateral vascular stenosis, especially on certain territories such as the axillary or superficial femoral arteries, is less likely to be linked to atherosclerosis. Restenosis of a vascular stent or bypass is also suspected for vasculitis.

The historical descriptions of typical GCA and TAK present the 2 diseases as being clearly different and with a clear cutoff regarding the age at onset. However, our study and others highlight a small subset of younger GCA patients, namely, those with LI-GCA, in which the clinical distinction with TAK is more challenging.⁴ In some cohort studies comparing GCA and TAK, patients showed similar rates of lower and upper limb claudication, which may suggest a true overlap between TAK and GCA.^{3,4,39,40}

In the study analyzing ACR criteria in TAK, 16 of the 744 control patients were misclassified as having TAK, 11 of whom had a final diagnosis of GCA.⁴¹ In another study, Yoshida et al.⁴² classified late-onset TAK in all patients older than 40 years who failed to fulfill the GCA criteria. The comparison of typical early-onset TAK and late-onset TAK showed many different features, especially a higher rate of aortic dilation in late-onset TAK, which is what we also observed in the LI-GCA patients in our study. Moreover, the LI-GCA patients in our study showed younger age and lower acute phase reactants at onset, which is consistent with what is also observed in TAK. Indeed, biological inflammatory parameters are not included in the ACR criteria for TAK because they show poor sensitivity and specificity, with erythrocyte sedimentation rate or C-reactive protein being less reliable for determining disease activity in TAK. Finally, histopathologic findings can be indistinguishable in both diseases.⁴³ Interestingly, 44% of patients with LI-GCA required vascular surgery, which is more typical of TAK than GCA, where vascular surgery is exceptional. Noteworthy, none

of the patients in our study exhibited renal arterial stenosis or successive aneurysmal and stenosis lesions of the same arterial segment, which are highly characteristic of TAK.

Some limitations of this study have to be acknowledged, including that it is a retrospective study with some missing data, such as the value of Doppler ultrasonography in assisting the diagnosis and the potential presence of blood pressure asymmetry. Moreover, all of the patients in our study were selected. However, the control group is probably representative of the high majority of GCA patients recruited in practice, at least in the setting of a hospital-based recruitment. Of note, some control patients showed nonsymptomatic LVV demonstrated by imaging and thus may overlap with the group with LI-GCA. However, analyses conducted without these control patients with LVV displayed the same outcomes, especially regarding new cardiovascular events. We did not analyze and compare characteristics and outcomes of other clinical groups of GCA, such as those with PMR with LVV or GCA patients with systemic presentation. Moreover, a question may be whether patients with a negative TAB and demonstration of LVV might have idiopathic aortitis. Symptomatic involvement of the aorta branches, especially of the limb arteries, is exceptional in idiopathic aortitis and is also rarely associated with cardiovascular complications.⁴⁴ Taken together, the clinical presentation and vascular evolution of our patients reasonably preclude the diagnosis of idiopathic aortitis. The follow-up duration in the present study might have been too short to capture late cardiovascular events. Although we observed a significant rate of complications within the study time frame, to strengthen the value of our results, prospective studies with a longer follow-up duration are required to confirm these findings.

The objective of this study was to show the diagnosis challenge of patients with LI-GCA, and although we have high confidence in the diagnosis of GCA, some patients might have atypical TAK. However, we believe that the value of this study is to describe these patients with overlapping and challenging diagnosis. Although we attempted to exclude atherosclerosis on imaging within vascular stenoses, there remains a risk that a limited number of patients suffered from both inflammatory and atherosclerotic lesions. Finally, the low number of cardiovascular events did not allow for multivariate analyses.

In conclusion, symptomatic and isolated involvement of limbs in GCA affects a small subset of patients, who exhibit more new cardiovascular events despite a more prolonged treatment, in comparison to the classical form of the disease. The worst prognosis of LI-GCA may be related to an intrinsic most aggressive phenotype and/or to the delayed and challenging diagnosis, especially with atherosclerosis or TAK. Further studies are required to determine the best management of these patients.

KEY POINTS

Isolated limb involvement in GCA is a challenging diagnosis. Although our patients with isolated limb involvement did not show more cardiovascular risk factors than controls, cardiovascular complications occur in two-thirds of them, especially ischemic events. Vascular surgery was required in 44% of them.

REFERENCES

- Salvarani C, Cantini F, Hunder GG. Polymyalgia rheumatica and giant cell arteritis. *Lancet*. 2008;372:234–245.
- Jennette JC, Falk RJ, Bacon PA, et al. 2012 Revised International Chapel Hill consensus conference nomenclature of vasculitides. *Arthritis Rheum*. 2013;65:1–11.
- Grayson PC, Maksimowicz-McKinnon K, Clark TM, et al. Distribution of arterial lesions in Takayasu's arteritis and giant cell arteritis. *Ann Rheum Dis*. 2012;71:1329–1334.
- Maksimowicz-McKinnon K, Clark TM, Hoffman GS. Takayasu arteritis and giant cell arteritis: a spectrum within the same disease? *Medicine (Baltimore)*. 2009;88:221–226.
- Agard C, Barrier JH, Dupas B, et al. Aortic involvement in recent-onset giant cell (temporal) arteritis: a case-control prospective study using helical aortic computed tomodensitometric scan. *Arthritis Rheum*. 2008;59:670–676.
- Blockmans D, de Ceuninck L, Vanderschueren S, et al. Repetitive ¹⁸F-fluorodeoxyglucose positron emission tomography in giant cell arteritis: a prospective study of 35 patients. *Arthritis Rheum*. 2006;55:131–137.
- De Broysson H, Liozon E, Lambert M, et al. ¹⁸F-fluorodeoxyglucose positron emission tomography and the risk of subsequent aortic complications in giant-cell arteritis: a multicenter cohort of 130 patients. *Medicine (Baltimore)*. 2016;95:e3851.
- Prieto-Gonzalez S, Arguis P, Garcia-Martinez A, et al. Large vessel involvement in biopsy-proven giant cell arteritis: prospective study in 40 newly diagnosed patients using CT angiography. *Ann Rheum Dis*. 2012;71:1170–1176.
- Prieto-Gonzalez S, Depetris M, Garcia-Martinez A, et al. Positron emission tomography assessment of large vessel inflammation in patients with newly diagnosed, biopsy-proven giant cell arteritis: a prospective, case-control study. *Ann Rheum Dis*. 2014;73:1388–1392.
- Berti A, Campochiano C, Cavalli G, et al. Giant cell arteritis restricted to the limb arteries: an overlooked clinical entity. *Autoimmun Rev*. 2015;14:352–357.
- Tuckwell K, Collinson N, Dimonaco S, et al. Newly diagnosed vs. relapsing giant cell arteritis: baseline data from the GiACTA trial. *Semin Arthritis Rheum*. 2017;46:657–664.
- Stone JH, Tuckwell K, Dimonaco S, et al. Trial of tocilizumab in giant-cell arteritis. *N Engl J Med*. 2017;377:317–328.
- Dejaco C, Dufner C, Buttgerit F, et al. The spectrum of giant cell arteritis and polymyalgia rheumatica: revisiting the concept of the disease. *Rheumatology (Oxford)*. 2017;56:506–515.
- Aschwanden M, Kesten F, Stern M, et al. Vascular involvement in patients with giant cell arteritis determined by duplex sonography of 2x11 arterial regions. *Ann Rheum Dis*. 2010;69:1356–1359.
- Assie C, Janvresse A, Plissonnier D, et al. Long-term follow-up of upper and lower extremity vasculitis related to giant cell arteritis: a series of 36 patients. *Medicine (Baltimore)*. 2011;90:40–51.
- Brack A, Martinez-Taboada V, Stanson A, et al. Disease pattern in cranial and large-vessel giant cell arteritis. *Arthritis Rheum*. 1999;42:311–317.
- Czihal M, Piller A, Schroettle A, et al. Outcome of giant cell arteritis of the arm arteries managed with medical treatment alone: cross-sectional follow-up study. *Rheumatology (Oxford)*. 2013;52:282–286.
- Czihal M, Tato F, Rademacher A, et al. Involvement of the femoropopliteal arteries in giant cell arteritis: clinical and color duplex sonography. *J Rheumatol*. 2012;39:314–321.
- Kermani TA, Matteson EL, Hunder GG, et al. Symptomatic lower extremity vasculitis in giant cell arteritis: a case series. *J Rheumatol*. 2009;36:2277–2283.
- Le Hello C, Auboire L, Berger L, et al. Symptomatic lower-limb giant-cell arteritis: characteristics, management and long-term outcome. *J Med Virol*. 2017;42:148–156.
- Sigl M, Hsu E, Scheffel H, et al. Lower extremity vasculitis in giant cell arteritis: important differential diagnosis in patients with lower limb claudication. *Vasa*. 2014;43:326–336.
- Comarmond C, Baird L, Lambert M, et al. Long-term outcomes and prognostic factors of complications in Takayasu arteritis: a multicenter study of 318 patients. *Circulation*. 2017;136:1114–1122.
- Kim ESH, Beckman J. Takayasu arteritis: challenges in diagnosis and management. *Heart*. 2018;104:558–565.

24. De Boysson H, Dazmas A, Vautier M, et al. Large-vessel involvement and aortic dilation in giant-cell arteritis. A multicenter study of 549 patients. *Autoimmun Rev*. 2018;17:391–398.
25. Evans JM, O'Fallon WM, Hunder GG. Increased incidence of aortic aneurysm and dissection in giant cell (temporal) arteritis. A population-based study. *Ann Intern Med*. 1995;122:502–507.
26. García-Martínez A, Hernández-Rodríguez J, Arguís P, et al. Development of aortic aneurysm/dilatation during the followup of patients with giant cell arteritis: a cross-sectional screening of fifty-four prospectively followed patients. *Arthritis Rheum*. 2008;59:422–430.
27. Kermani TA, Warrington KJ, Crowson CS, et al. Large-vessel involvement in giant cell arteritis: a population-based cohort study of the incidence-trends and prognosis. *Ann Rheum Dis*. 2013;72:1989–1994.
28. Nuerninghoff DM, Hunder GG, Christianson TJ, et al. Incidence and predictors of large-artery complication (aortic aneurysm, aortic dissection, and/or large-artery stenosis) in patients with giant cell arteritis: a population-based study over 50 years. *Arthritis Rheum*. 2003;48:3522–3531.
29. Seyahi E. Takayasu arteritis: an update. *Curr Opin Rheumatol*. 2017;29:51–56.
30. Kermani TA, Warrington KJ, Crowson CS, et al. Predictors of dissection in aortic aneurysms from giant cell arteritis. *J Clin Rheumatol*. 2016;22:184–187.
31. Hunder GG, Bloch DA, Michel BA, et al. The American College of Rheumatology 1990 criteria for the classification of giant cell arteritis. *Arthritis Rheum*. 1990;33:1122–1128.
32. De Boysson H, Dumont A, Liozon E, et al. Giant-cell arteritis: concordance study between aortic CT angiography and FDG-PET/CT in detection of large-vessel involvement. *Eur J Nucl Med Mol Imaging*. 2017;44:2274–2279.
33. Hautzel H, Sander O, Heinzl A, et al. Assessment of large-vessel involvement in giant cell arteritis with ¹⁸F-FDG PET: introducing an ROC-analysis-based cutoff ratio. *J Nucl Med*. 2008;49:1107–1113.
34. Park MC, Lee SW, Park YB, et al. Clinical characteristics and outcomes of Takayasu's arteritis: analysis of 108 patients using standardized criteria for diagnosis, activity assessment, and angiographic classification. *Scand J Rheumatol*. 2005;34:284–292.
35. Park SJ, Kim HJ, Park H, et al. Incidence, prevalence, mortality and causes of death in Takayasu arteritis in Korea—a nationwide, population-based study. *Int J Cardiol*. 2017;235:100–104.
36. Samson M, Jacquin A, Audia S, et al. Stroke associated with giant cell arteritis: a population-based study. *J Neurol Neurosurg Psychiatry*. 2015;86:216–221.
37. De Boysson H, Liozon E, Larivière D, et al. Giant cell arteritis-related stroke: a retrospective multicenter case-control study. *J Rheumatol*. 2017;44:297–303.
38. Souverein PC, Berand A, Van Stuij TP, et al. Use of oral glucocorticoids and risk of cardiovascular and cerebrovascular disease in a population based case-control study. *Heart*. 2004;90:859–865.
39. Furuta S, Cousins C, Chaudhry A, et al. Clinical features and radiological findings in large vessel vasculitis: are Takayasu arteritis and giant cell arteritis 2 different diseases or a single entity? *J Rheumatol*. 2015;42:300–308.
40. Koster MJ, Matteson EL, Warrington KJ. Recent advances in the clinical management of giant cell arteritis and Takayasu arteritis. *Curr Opin Rheumatol*. 2016;28:211–217.
41. Arend WP, Michel BA, Bloch DA, et al. The American College of Rheumatology 1990 criteria for the classification of Takayasu arteritis. *Arthritis Rheum*. 1990;33:1129–1134.
42. Yoshida M, Watanabe R, Ishii T, et al. Retrospective analysis of 95 patients with large vessel vasculitis: a single center experience. *Int J Rheum Dis*. 2016;19:87–94.
43. Homme JL, Aubry MC, Edwards WD, et al. Surgical pathology of the ascending aorta: a clinicopathologic study of 513 cases. *Am J Surg Pathol*. 2006;30:1159–1168.
44. Espitia O, Samson M, Le Gallou T, et al. Comparison of idiopathic (isolated) aortitis and giant cell arteritis-related aortitis. A French retrospective multicenter study of 117 patients. *Autoimmun Rev*. 2016;15:571–576.

Supplemental Table 1. GCA patients with isolated and symptomatic limb involvement

| Patient | Sex, age | Positive histology | Peripheral vascular signs | Vascular Imaging | Vascular complications during follow-up |
|---------|----------|--------------------|---|---|---|
| 1 | F, 59 | Yes, TAB | Upper limbs' claudication. Axillary bruits | CTA: thoracic aortitis + subclavian and axillary stenoses | Myocardial infarction |
| 2 | F, 71 | Yes, TAB | Upper and lower limbs' claudication, Axillary bruits | CTA: subclavian, axillary, humeral, ilio-femoral and femoral stenoses | Myocardial infarction and posterior stroke |
| 3 | M, 64 | Yes, TAB | Lower limbs' claudication, femoral bruits | CTA: stenosis of iliac and femoral arteries PET/CT: uptakes of the subclavian, iliac and femoral arteries | Myocardial infarction |
| 4 | F, 68 | No | Upper limbs' claudication. Axillary bruits | CTA: subclavian and axillary stenoses | Bilateral axillary-humeral bypass, Myocardial infarction |
| 5 | F, 70 | Yes, TAB | Upper and lower limbs' claudication, multiple vascular bruits | CTA: thoracic and abdominal aortitis, stenoses of the subclavian, axillary and femoral arteries | Right subclavian stent + bilateral aorta-femoral bypasses |
| 6 | F, 66 | Yes, TAB | Lower limbs' claudication. Femoral bruits | CTA: abdominal aortitis, iliac and femoral stenoses | Supra-renal aortic dilation |
| 7 | F, 64 | Yes, tibial artery | Lower limbs' claudication and acute left leg ischemia 4 months after diagnosis. Femoral bruits | CTA: thoracic and abdominal aortitis, stenoses of the left femoral and tibial arteries. Tibial occlusion at month 4 | Acute left leg ischemia. Surgical femoral and tibial artery dilation |

| | | | | | |
|----|-------|------------------------------------|--|---|---|
| 8 | F, 75 | Yes, TAB | Upper limbs' claudication | CTA: thoracic and abdominal aortitis, stenoses of the subclavian, axillary and humeral arteries | Thoracic aorta dilation Myocardial infarction |
| 9 | F, 68 | Yes, TAB | Upper limbs' claudication | CTA and PET/CT: thoracic aortitis and subclavian stenoses on CTA | Subclavian stents |
| 10 | F, 71 | Yes, TAB | Upper limbs' claudication, multiple vascular bruits | PET/CT: thoracic aortitis, and uptakes of the subclavian and axillary arteries US: thickening of carotid, axillary and femoral arteries | Sylvian stroke |
| 11 | F, 65 | No | Upper limb's claudication, humeral vascular bruits | CTA: thoracic and abdominal aortitis, right axillary occlusion | Right axillary-humeral bypass |
| 12 | F, 58 | Yes, TAB + aorta sample | Upper and lower limbs' claudication. Multiples vascular bruits | CTA: thoracic aortitis, stenoses of the subclavian, axillary, humeral, iliac and femoral arteries | Thoracic aorta dilation Surgical replacement of the ascendant thoracic aorta |
| 13 | F, 64 | No | Raynaud phenomenon, upper limbs' claudication. Multiples vascular bruits | CTA: thoracic and abdominal aortitis, stenoses of the subclavian, axillary and carotid arteries | Posterior stroke |
| 14 | M, 49 | Yes, TAB + mesenteric sample | Mesenteric claudication, upper limbs' claudication and pulseless right radial artery | PET/CT and CTA: thoracic and abdominal aortitis, stenoses and FDG uptakes of the subclavian, axillary, carotid, humeral, iliac and femoral arteries | Mesenteric surgery Thoracic aorta dilation |

| | | | | | |
|----|-------|----------|---|--|--|
| 15 | M, 52 | Yes, TAB | Lower limbs' claudication | PET/CT and CTA: thoracic aortitis, stenoses and uptakes of the iliac and femoral arteries | Thoracic aorta dilation |
| 16 | F, 76 | No | Upper limbs' claudication Axillary bruits | CTA: thoracic and abdominal aortitis, stenoses of subclavian and axillary arteries | No |
| 17 | F, 76 | No | Lower limbs' claudication | CTA: thoracic and abdominal aortitis, stenoses of the iliac and femoral arteries | Thoracic aorta dilation |
| 18 | F, 61 | No | Upper and lower limbs' claudication. Axillary and carotid bruits | CTA: Thoracic aortitis and stenoses of the subclavian, axillary, carotid, iliac and femoral arteries. | Posterior stroke |
| 19 | F, 61 | No | Lower limbs' claudication | Angiography: long and filiform stenoses of the ilio-femoral arteries PET/CT: thoracic and abdominal aortitis, uptakes of the iliac and femoral arteries | No |
| 20 | F, 80 | Yes, TAB | Upper limbs' claudication | MRA: stenoses of the subclavian, axillary and humeral arteries PET/CT: thoracic aortitis, and uptakes of the subclavian, axillary and humeral arteries | Right subclavian stent. Restenosis of the stent |
| 21 | M, 78 | Yes, TAB | Lower limbs' claudication | CTA: thoracic and abdominal aortitis, stenoses of the iliac and femoral arteries | Acute left right ischemia. Femoral amputation |
| 22 | F, 66 | Yes, TAB | Upper limbs' claudication | CTA: thoracic aortitis and stenoses of the subclavian arteries | No |

| | | | | | |
|----|-------|----------|---|--|---|
| 23 | F, 73 | Yes, TAB | Upper limbs' claudication | PET/CT: thoracic aortitis, and uptakes of the subclavian, axillary and humeral arteries CTA: thoracic and abdominal aortitis, stenoses of the subclavian and axillary arteries | Thoracic aorta dilation and aortic dissection |
| 24 | F, 68 | Yes, TAB | Upper limbs' claudication. Axillary and carotid bruits | CTA: thoracic aortitis and stenoses of the subclavian, carotid, axillary and humeral arteries PET/CT: thoracic aortitis, and uptakes of the subclavian, axillary, carotid and humeral arteries | Posterior stroke Thoracic aorta dilation and aortic dissection |
| 25 | F, 79 | Yes, TAB | Upper limbs' claudication. Axillary bruits | CTA: stenoses of the subclavian and axillary arteries | Right subclavian stent |
| 26 | F, 72 | Yes, TAB | Upper and lower limbs' claudication. Multiples vascular bruits | MRA: thoracic and abdominal aortitis, stenoses of the subclavian, axillary, carotid, humeral, iliac and femoral arteries PET/CT: thoracic and abdominal aortitis, uptakes of the subclavian, axillary, carotid, humeral, iliac and femoral arteries | Posterior stroke |
| 27 | F, 65 | No | Upper and lower limbs' claudication. Multiples vascular bruits | CTA: thoracic and abdominal aortitis, stenoses of the subclavian, axillary, carotid, humeral and ilio-femoral arteries | No |

| | | | | | | |
|--|--|--|--|--|--|--|
| | | | | | <p>PET/CT: thoracic and abdominal aortitis, stenoses of the subclavian, axillary, carotid, humeral and ilio-femoral arteries</p> | |
|--|--|--|--|--|--|--|

3 – L’atteinte des gros vaisseaux au diagnostic est-elle associée à un risque de complications aortiques accrues ?

En 2016, sur une cohorte de 130 patients bénéficiant d’une TEP-TDM dont 69 étaient positives, nous avons identifié 9 patients qui développaient secondairement une complication aortique, tous ayant précédemment une inflammation des gros vaisseaux à l’imagerie [7]. Le faible effectif ne permettait pas de réaliser une analyse des facteurs prédictifs de complications aortiques. Le travail plus récent sur les atteintes isolées des artères à destination des membres semblait également indiquer un risque accru de complications cardio-vasculaires chez ces patients par rapport à des témoins [60].

Nous avons donc rétrospectivement recruté dans 6 services de médecine interne (Caen, Limoges, Lille, Marseille, Dijon et Paris La Pitié-Salpêtrière) tout patient ayant un diagnostic d’ACG et ayant bénéficié d’une imagerie de l’aorte et de ses branches au diagnostic. Nous avons alors individualisé deux groupes, un premier de 248 patients avec une atteinte de l’aorte et de ses branches au diagnostic et un second de 301 patients sans atteinte macrovasculaire initiale. Ces patients étaient comparés au diagnostic et pendant le suivi. Chez les patients bénéficiant d’une autre imagerie de l’aorte durant le suivi (154 dans le groupe avec inflammation initiale des gros vaisseaux et 123 dans le groupe sans atteinte macrovasculaire initiale), nous analysons le taux de complications aortiques (dilatation et/ou dissection). Une régression logistique était réalisée pour identifier les facteurs de risque de complications aortiques.

La comparaison initiale des patients en fonction de l’existence ou non d’une atteinte des gros vaisseaux révélait de nombreuses différences. Les patients avec une atteinte des gros vaisseaux étaient plus jeunes, plus souvent des femmes, n’avaient pas plus de facteurs de risque cardio-vasculaires, avaient moins souvent une PPR et des signes céphaliques mais plus souvent des signes vasculaires extra-céphaliques au diagnostic. En terme de traitements, nous ne retrouvons pas de différences de posologies de cortisone sur les 12 premiers mois, mais au 18^e mois les patients avec une atteinte des gros vaisseaux avaient des doses de glucocorticoïdes significativement plus importantes.

Avec près de 5 ans de suivi, 21% des patients avec une atteinte initiale des gros vaisseaux et bénéficiant d’une nouvelle imagerie avaient développé une dilatation aortique qui n’existait pas sur la première imagerie, contre 7% des patients sans atteinte macrovasculaire inflammatoire initiale ($p=0.0008$). En analyse multivariée, l’existence d’une atteinte inflammatoire de l’aorte

et de ses branches au diagnostic étaient ainsi indépendamment associée au risque de développer ultérieurement une dilatation aortique durant le suivi (95% HR 3.16 [1.34—7.48], $p=0.009$).

Hubert de Boysson, Aurélie Dumas, Mathieu Vautier, Jean-Jacques Parienti, Eric Liozon, Marc Lambert, Maxime Samson, Mikael Ebbo, Anael Dumont, Audrey Sultan, Bernard Bonnotte, Alain Manrique, Boris Bienvenu, David Saadoun, Achille Aouba

Large-vessel involvement and aortic dilation in giant-cell arteritis. A multicenter study of 549 patients

Autoimmun Rev. 2018 Apr;17(4):391-398. doi: 10.1016/j.autrev.2017.11.029



Contents lists available at ScienceDirect

Autoimmunity Reviews

journal homepage: www.elsevier.com/locate/autrev

Review

Large-vessel involvement and aortic dilation in giant-cell arteritis. A multicenter study of 549 patients

Hubert de Boysson^{a,b,*}, Aurélie Daumas^c, Mathieu Vautier^d, Jean-Jacques Parienti^e, Eric Liozon^f, Marc Lambert^g, Maxime Samson^h, Mikael Ebbo^c, Anael Dumont^a, Audrey Sultan^a, Bernard Bonnotte^h, Alain Manriqueⁱ, Boris Bienvenu^a, David Saadoun^{d,j,k,l}, Achille Aouba^{a,b}

^a Department of Internal Medicine, Caen University Hospital, Caen, France

^b University of Normandy, Caen, France

^c Department of Internal Medicine and Therapeutics, Timone Hospital, Marseille, France

^d AP-HP, Groupe Hospitalier Pitié-Salpêtrière, Department of Internal Medicine and Clinical Immunology, Centre de Référence des Maladies Auto-Immunes et Systémiques Rares, Centre de Référence des Maladies Auto-Inflammatoires, Paris, France

^e Biostatistics and Clinical Research Unit, Caen University Hospital, France

^f Department of Internal Medicine and Clinical Immunology, Limoges University Hospital, Limoges, France

^g Department of Internal Medicine, Lille University Hospital, Lille, France

^h Department of Internal Medicine and Clinical Immunology, Dijon University Hospital, Dijon, France

ⁱ Department of Nuclear Medicine, Caen University Hospital, Caen, France

^j Sorbonne Universités, UPMC Univ Paris 06, Inflammation-Immunopathology-Biotherapy Department, France

^k INSERM, Paris, France

^l CNRS, Paris, France

ARTICLE INFO

Article history:

Received 15 November 2017

Accepted 21 November 2017

Available online xxxxx

Keywords:

Giant-cell arteritis

Aortitis

Large-vessel involvement

Aortic dilation

ABSTRACT

Objectives: Large-vessel involvement (LVI) can occur in giant-cell arteritis (GCA) and may represent a distinct disease subgroup with a higher risk for aortic dilation. This study aimed to better characterize the presentation and evolution of LVI in patients with GCA.

Patients and methods: A retrospective multicenter study enrolled 248 GCA patients with LVI and 301 GCA patients without LVI on imaging. Factors associated with aortic dilation were identified in a multivariable model.

Results: The patients with LVI were younger ($p < 0.0001$), more likely to be women ($p = 0.01$), and showed fewer cephalic symptoms ($p < 0.0001$) and polymyalgia rheumatica ($p = 0.001$) but more extracranial vascular symptoms ($p = 0.05$) than the patients without LVI. Glucocorticoids (GC) management did not differ between the two groups, but the GC discontinuation rate was lower in the patients with LVI ($p = 0.0003$). Repeated aortic imaging procedures were performed at 19 months [range: 5–162 months] and 17 months [range: 6–168 months] after diagnosis in 154 patients with LVI and 123 patients without LVI, respectively, of whom 21% and 7%, respectively, presented new aortic dilations ($p = 0.0008$). In the patients with LVI, aortic dilation occurred on an aorta segment shown to be inflammatory on previous imaging in 94% of patients. In the multivariate analysis, LVI was the strongest predictor of aortic dilation (hazard ratio: 3.16 [range: 1.34–7.48], $p = 0.009$).

Conclusions: LVI represents a distinct disease pattern of GCA with an increased risk of aortic dilation. Control of the aortic morphology during follow-up is required.

© 2018 Elsevier B.V. All rights reserved.

Contents

| | |
|-----------------------------------|---|
| 1. Introduction | 0 |
| 2. Patients and methods | 0 |

Abbreviations: ACR, American college of rheumatology; CRP, C-reactive protein; CTA, computed tomography angiography; ESR, erythrocyte sedimentation rate; FDG, fluorodeoxyglucose; GC, glucocorticoids; GCA, giant-cell arteritis; LVI, large-vessel involvement; MRA, magnetic resonance angiography; PET/CT, positron emission tomography with computed tomography; TAB, temporal artery biopsy.

* Corresponding author at: Department of Internal Medicine, Caen University Hospital, University of Caen-Normandie, Avenue de la Côte de Nacre, 14000 Caen, France.

E-mail address: deboysson-h@chu-caen.fr (H. de Boysson).

<https://doi.org/10.1016/j.autrev.2017.11.029>

1568–9972/© 2018 Elsevier B.V. All rights reserved.

Please cite this article as: de Boysson H, et al, Large-vessel involvement and aortic dilation in giant-cell arteritis. A multicenter study of 549 patients, *Autoimmun Rev* (2018), <https://doi.org/10.1016/j.autrev.2017.11.029>

| | |
|---|---|
| 2.1. Patients | 0 |
| 2.2. Study parameters and definitions | 0 |
| 2.3. Statistical analyses | 0 |
| 3. Results | 0 |
| 3.1. Study population | 0 |
| 3.2. Comparison of patient characteristics according to the presence of LVI | 0 |
| 3.3. Analysis of patient characteristics according to the time of the performance of the vascular imaging | 0 |
| 3.4. Imaging details of patients with LVI | 0 |
| 3.5. Treatments and outcomes (Table 4) | 0 |
| 3.6. Aortic complications (Table 4) | 0 |
| 3.7. Factors associated with aortic dilation | 0 |
| 4. Discussion | 0 |
| 5. Conclusions | 0 |
| Funding sources | 0 |
| Disclosures | 0 |
| Ethics and consent | 0 |
| Appendix A. Supplementary data | 0 |
| References | 0 |

1. Introduction

Giant-cell arteritis (GCA) is a systemic vasculitis affecting patients older than 50 years [1]. In addition to the mainly affected branches of the external carotid that explain the polymorphic and typical cephalic manifestations of GCA, the aorta and its main branches are also affected in 40% to 80% of cases, even though they do not frequently induce symptoms [2–9]. The 1990 criteria from the American College of Rheumatology (ACR) are still used in clinical practice to classify the disease [10]. GCA diagnosis is highly probable in the presence of at least 3 of the 5 following criteria: 1) age > 50 years; 2) an erythrocyte sedimentation rate (ESR) > 50 mm (and, by extension, high inflammatory parameters such as increased C-reactive protein (CRP)); 3) recent onset of headaches; 4) abnormalities of the temporal artery; and 5) a positive temporal artery biopsy (TAB) showing transmural inflammation with the presence of giant cells. These criteria do not take into consideration the presence of clinical or radiological large-vessel involvement (LVI).

Over the past few decades, the proportion of GCA patients described with LVI has increased, mainly because of a wider use of imaging methods such as computed tomography angiography (CTA) [2,8], magnetic resonance angiography (MRA) of the aorta [11–13], or positron emission tomography with computed tomography (PET/CT) [3,9,14–17]. Previous studies indicate some differences regarding the clinical presentations [5,6,18–22] and outcomes [5,15] in patients with LVI, especially a higher risk for cardiovascular events such as aortic dilation. Although no guidelines have defined which type of GCA patients require large-vessel screening, the research of LVI in the setting of GCA is currently performed and is even used in some large studies as a means to affirm the diagnosis instead of using TAB [23,24].

To better identify patients who may require large-vessel exploration, we conducted a retrospective multicenter study and compared patients with LVI demonstrated on imaging at diagnosis or during follow-up to patients without LVI. We also compared the long-term outcomes of both of the subgroups, focusing on the development of aortic dilation and factors associated with this development.

2. Patients and methods

2.1. Patients

We retrospectively enrolled patients from the departments of internal medicine at 6 tertiary hospitals located in 6 large cities in France (Paris, Marseille, Lille, Dijon, Limoges and Caen).

All of the patients were diagnosed with GCA between 2000 and 2016 based on the presence of at least 3 criteria of the ACR [10] or 2 criteria

associated with the demonstration of LVI on imaging. For the purpose of this study, we enrolled GCA patients who performed at least one large-vessel imaging scan (aorta CTA, PET/CT or aorta MRA) at diagnosis or during follow-up. Patients who had at least one imaging scan showing large-vessel inflammation (“positive imaging”) were considered to be in the LVI subgroup. GCA patients with normal imaging comprised the control subgroup without LVI. In the absence of recommendations, large-vessel imaging is performed in practice either for atypical GCA presentation or evolution, depending on the choice and habits of the treating physician.

Among the patients with LVI, we distinguished patients with a positive PET/CT from those with a positive CTA or a positive MRA. As we previously showed that PET/CT may have a slightly higher sensitivity than CTA to detect large-vessel involvement [25], we classified patients with both positive PET/CT and CTA or those with both positive PET/CT and MRA into the positive PET/CT subgroup.

This study was conducted in compliance with good clinical practices and the Declaration of Helsinki principles. At the time of this study, in accordance with French public health law (Art. L 1121-1-1, Art. L 1121-1-2), formal approval from an ethics committee was not required for this type of observational study. Our local ethics committee confirmed the observational non-interventional retrospective nature of our cohort.

2.2. Study parameters and definitions

A standardized form was sent to the physicians who included the patients. We retrieved the following for all of the included patients: demographics, cardiovascular risk factors, clinical manifestations at diagnosis, laboratory tests (including CRP, ESR, hemoglobin and platelet levels), TAB status when available, and the results from imaging and administered treatments [including the dose of glucocorticoids (GC) per kilogram of body weight at treatment initiation and at months 3, 6, 12, and 18, if ongoing]. Cephalic manifestations included headaches, scalp tenderness, jaw claudication, ophthalmic troubles, pulseless or painful temporal artery. Extracranial vascular symptoms included heart or peripheral vascular bruits and pulseless or painful limbs. Ophthalmic symptoms included troubles linked to GCA.

Imaging results were extracted from the Nuclear Medicine and Radiology reports. In all procedures 8 vascular territories were analyzed, namely, the thoracic and abdominal aorta and subclavian, carotid, axillary, upper limb, ilio-femoral and lower limb arteries. A vascular territory was considered to be affected on aortic CTA or MRA when showing a circumferential and homogeneous thickening ≥ 2 mm of the vascular wall, associated with a parietal edema for MRA. On FDG-PET/

CT, all vascular uptakes of equal or superior intensity to that of liver physiologic uptake were considered positive [16]. Circumferential and homogeneous vascular uptakes were suggestive of vasculitis. In contrast, focal (non-circumferential) FDG uptakes were considered to be atherosclerotic lesions and were thus classified as negative PET/CT in the setting of GCA. Isolated uptake from the infrarenal abdominal aorta and/or from the iliac/femoral and/or lower limb arteries was arbitrarily considered to indicate a negative result, as atherosclerosis is a more prevalent mimicker in these locations. Imaging was considered to be performed at diagnosis if the procedure was performed before or within the first 7 days of the treatment. All the other procedures performed after 7 days were considered to be done during follow-up.

The outcomes and follow-up data for all the patients were retrieved. We defined relapse as a reoccurrence of symptoms and/or inflammatory parameters on laboratory findings without any other cause identified than GCA and that required a sustained increase in the GC dose and/or the addition of a GC-sparing agent.

The endpoint of our study was the analysis of patients who developed an aortic dilation during follow-up. Therefore, we analyzed the results of repeated imaging in patients who underwent another aortic imaging procedure (PET/CT, CTA, MRA or cardiac echography). Adapted from previous reports, the aortic root, aortic arch, and descending aorta were considered to be dilated when the aortic diameter was ≥ 4.5 cm, ≥ 4 cm and ≥ 3.5 cm, respectively [5,8].

We did not analyze other large-vessel complications, such as stenosis or thrombosis, because their analysis is poorly reproducible on CTA, MRA and PET/CT.

2.3. Statistical analyses

Categorical variables were expressed as numbers (%), and quantitative variables were expressed as medians [range]. Categorical variables were analyzed using the Chi-square test or Fisher's exact test, as appropriate, and quantitative variables were analyzed using Wilcoxon's rank-sum test. A Cox proportional hazards model was used to assess factors associated with aortic dilation, using variables that reached $p < 0.2$ in univariate analyses. We analyzed the cumulative incidence of aortic dilations in both groups of patients using life tables and the Kaplan-Meier

method, and these were compared using the log-rank test. The statistical analyses were computed using JMP 9.0.1 (SAS Institute Inc., Cary, NC, USA). A $p \leq 0.05$ defined statistical significance.

3. Results

3.1. Study population

Five hundred forty-nine patients [385 (70%) women; median age: 72 years [range: 50–91 years]] were enrolled, including 248 patients with LVI.

GCA diagnosis was proven by biopsy in 324 (59%) patients, and all of them had high inflammatory parameters, except for eight (who had a positive TAB).

Fig. 1 shows the types of imaging methods that demonstrated LVI. These imaging methods were performed at diagnosis in 398 patients and during follow-up in the 151 others (median duration of delay between diagnosis and imaging: 199 days [range: 14 days–13 months] and 46 days [range: 13 days–23 months] in patients with LVI and in those without LVI, respectively). Imaging was performed during follow-up for a systematic screening of the aorta in 118 patients in clinical and biological remission of their disease and for a relapse in the others.

Baseline characteristics of the patients are shown in Table 1. Table 2 indicates the features of the 398 patients who had large-vessel imaging at GCA diagnosis.

3.2. Comparison of patient characteristics according to the presence of LVI

Considering the whole cohort of patients, regardless of the time of the LVI assessment (Table 1), patients with LVI and those without LVI showed many distinct features.

In patients with LVI, 48 (19%) only satisfied 2 of the ACR criteria but had demonstration of vascular inflammation on imaging. Forty-five patients without any cephalic signs but with LVI on imaging underwent a TAB that was positive in 28 (62%) of them.

LVI more likely affected women (75% versus 66%, $p = 0.001$) and those of younger ages (65 years [range: 50–89 years] versus 75 years

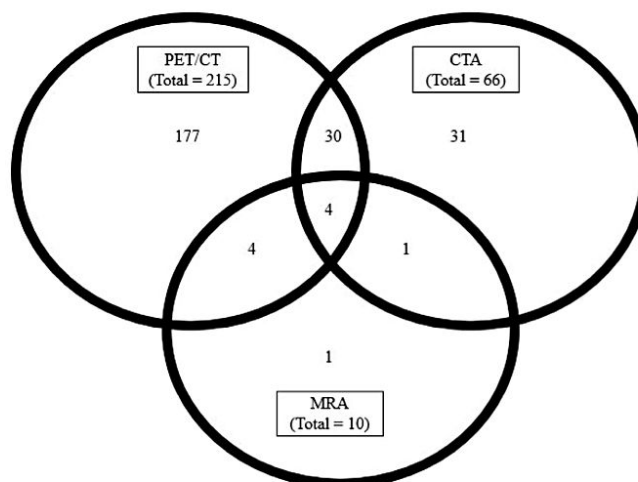


Fig. 1. Imaging used to demonstrate large-vessel involvement in giant-cell arteritis patients. 248 patients underwent an imaging procedure demonstrating large-vessel involvement. PET/CT: positron emission tomography with computed tomography; CTA: computed tomography angiography; MRA: magnetic resonance angiography.

Please cite this article as: de Boysson H, et al, Large-vessel involvement and aortic dilation in giant-cell arteritis. A multicenter study of 549 patients, *Autoimmun Rev* (2018), <https://doi.org/10.1016/j.autrev.2017.11.029>

Table 1

Characteristics of the whole cohort of giant-cell arteritis patients with and without large-vessel involvement.

| | Large-vessel involvement (n = 248) | No large-vessel involvement (n = 301) | p |
|--|------------------------------------|---------------------------------------|---------|
| Demographics | | | |
| Age | 68 [50–89] | 75 [50–91] | <0.0001 |
| <70 years | 147 (59.5) | 81 (27) | <0.0001 |
| 70–80 years | 78 (31.5) | 142 (47) | 0.0002 |
| >80 years | 23 (9) | 78 (26) | <0.0001 |
| Women | 187 (75) | 198 (66) | 0.01 |
| Cardiovascular risk factors^a | | | |
| No | 79 (32) | 83 (28) | 0.27 |
| 1 | 105 (42) | 115 (38) | 0.33 |
| ≥2 | 64 (26) | 103 (34) | 0.03 |
| Hypertension | 104 (42) | 168 (56) | 0.0012 |
| Diabetes mellitus | 22 (9) | 41 (14) | 0.08 |
| Dyslipidemia | 59 (24) | 99 (33) | 0.02 |
| Tobacco use | 64 (26) | 52 (17) | 0.015 |
| Weight (kg) | 65 [41–98] | 63 [37–109] | 0.37 |
| Body Mass Index (kg/m ²) | 25.15 [15.4–36.9] | 24.25 [16–42] | 0.22 |
| Clinical manifestations | | | |
| ACR criteria | 3 [2–5] | 4 [3–5] | 0.01 |
| Fever | 76 (31) | 81 (27) | 0.34 |
| Polymyalgia rheumatica | 78 (31) | 136 (45) | 0.001 |
| Cephalic signs | 179 (72) | 280 (93) | <0.0001 |
| Headaches | 152 (61) | 240 (80) | <0.0001 |
| Scalp tenderness | 69 (28) | 151 (50) | <0.0001 |
| Jaw claudication | 71 (29) | 129 (43) | 0.0006 |
| Sensitive temporal artery | 51 (21) | 112 (37) | <0.0001 |
| Ophthalmologic signs | 26 (10) | 84 (28) | <0.0001 |
| Extracranial vascular signs | 53 (21) | 45 (15) | 0.05 |
| Vascular and heart bruits | 43 (17) | 45 (15) | 0.45 |
| Limb claudication | 27 (11) | 4 (1) | <0.0001 |
| Laboratory tests | | | |
| Erythrocyte sedimentation rate (mm) | 84 [9–134] | 73 [7–141] | 0.06 |
| C-reactive protein (mg/l) | 83 [3–401] | 71 [3–426] | 0.13 |
| Hemoglobin level (g/dl) | 11 [7.4–14.8] | 11.6 [7.4–16.2] | 0.006 |
| Platelet count (G/mm ³) | 416 [121–896] | 391 [164–792] | 0.16 |
| Positive temporal artery biopsy | 130 ^b /228 (57) | 194/298 (65) | 0.06 |

Except where indicated otherwise, values are displayed as absolute number (%) or median [range].

^a Excluding age.

^b Including 3 patients who had a positive histology on vascular samples other than temporal artery.

[range: 50–91 years], $p < 0.0001$). The proportions of patients under 70 years old were 59.5% and 27% in patients with and without LVI ($p < 0.0001$), respectively. Regarding usual cardiovascular risk factors, only tobacco use was more frequently observed in the LVI subgroup ($p = 0.015$), whereas the absence or presence of only one of these factors was not significantly different between the two subgroups. By contrast, the presence of at least 2 associated factors ($p = 0.03$), including dyslipidemia ($p = 0.02$) or hypertension ($p = 0.0012$), was significantly rarer in the subgroup of LVI patients.

LVI patients more often exhibited extra-cephalic vascular signs ($p = 0.05$), especially limb claudication ($p < 0.0001$), but they complained from cephalic signs less frequently ($p < 0.0001$), including ophthalmic involvement, and presented less polymyalgia rheumatica ($p = 0.001$). Finally, LVI was associated with a lower hemoglobin level ($p = 0.006$).

The same trends were observed in the 398 patients who had imaging performed at GCA diagnosis (Table 2), except a more frequent TAB positivity in patients who underwent imaging at diagnosis and who did not present with LVI ($p = 0.005$).

3.3. Analysis of patient characteristics according to the time of the performance of the vascular imaging

We analyzed the characteristics of patients with LVI according to the time of the performance of the vascular imaging, i.e., at diagnosis or

Table 2

Characteristics of giant-cell arteritis patients with and without large-vessel involvement assessed at diagnosis (before or within the first 10 days of treatment).

| | Large-vessel involvement (n = 188) | No large-vessel involvement (n = 210) | p |
|--|------------------------------------|---------------------------------------|---------|
| Demographics | | | |
| Age | 67 [50–89] | 75 [48–91] | <0.0001 |
| <70 years | 112 (60) | 54 (25.5) | <0.0001 |
| 70–80 years | 61 (32) | 104 (50) | 0.0006 |
| >80 years | 15 (8) | 52 (24.5) | <0.0001 |
| Women/men | 140 (74) | 135 (64) | 0.01 |
| Cardiovascular risk factors^a | | | |
| No | 60 (32) | 61 (29) | 0.53 |
| 1 | 81 (43) | 84 (40) | 0.56 |
| ≥2 | 47 (25) | 65 (31) | 0.19 |
| Hypertension | 76 (40) | 114 (54) | 0.006 |
| Diabetes mellitus | 14 (7) | 26 (12) | 0.10 |
| Dyslipidemia | 43 (23) | 67 (32) | 0.04 |
| Tobacco use | 53 (28) | 27 (13) | 0.0001 |
| Weight (kg) | 65 [41–98] | 63.5 [41–95] | 0.47 |
| Body Mass Index (kg/m ²) | 25.1 [15.4–34.3] | 24 [16–33.6] | 0.32 |
| Clinical manifestations | | | |
| ACR criteria | 3 [2–5] | 4 [3–5] | 0.003 |
| Fever | 62 (33) | 68 (32) | 0.9 |
| Polymyalgia rheumatica | 50 (27) | 91 (43) | 0.0005 |
| Cephalic signs | 127 (68) | 196 (93) | <0.0001 |
| Headaches | 106 (56) | 166 (79) | <0.0001 |
| Scalp tenderness | 41 (22) | 105 (50) | <0.0001 |
| Jaw claudication | 44 (23) | 94 (45) | <0.0001 |
| Sensitive temporal artery | 31 (16) | 87 (41) | <0.0001 |
| Ophthalmologic signs | 15 (8) | 55 (26) | <0.0001 |
| Extra-cephalic vascular signs | 40 (21) | 26 (12) | 0.02 |
| Vascular and heart bruits | 32 (17) | 26 (12) | 0.19 |
| Limb claudication | 23 (12) | 1 (0.5) | <0.0001 |
| Laboratory tests | | | |
| Erythrocyte sedimentation rate (mm) | 90 [9–134] | 80 [7–141] | 0.38 |
| C-reactive protein (mg/l) | 81 [3–401] | 73 [3–426] | 0.73 |
| Hemoglobin level (g/dl) | 11 [7.4–14.6] | 11.5 [7.4–16.2] | 0.005 |
| Platelet count (G/mm ³) | 418 [121–896] | 397 [164–792] | 0.13 |
| Positive temporal artery biopsy | 89 ^b /169 (53) | 140/209 (67) | 0.005 |
| Aortic dilation at diagnosis on imaging | 20 (11) | 14 (7) | 0.16 |

Except where indicated otherwise, values are displayed as absolute number (%) or median [range].

^a Excluding age.

^b Including 3 patients who had a positive histology on vascular samples other than temporal artery.

during follow-up (Online Table 1). This analysis showed no significant difference between the two groups, except for less frequent cephalic signs in patients who underwent the imaging at diagnosis rather than during follow-up ($p = 0.004$).

In the same way, patients without LVI showed no significant difference according to the time when the imaging was performed, except for less frequent tobacco use ($p = 0.002$) and more frequent fever ($p = 0.01$) in those who had imaging at diagnosis rather than during follow-up (Online Table 2).

3.4. Imaging details of patients with LVI

The details of LVI are shown in Table 3. Among the eight segments that were screened, the thoracic aorta (shown in 89% of patients) and the abdominal aorta (shown in 73% of patients) portions were the more frequently involved vascular segments, followed by the subclavian arteries (shown in 67% of patients). Except for ilio-femoral involvement, which was more frequently observed on PET/CT ($p = 0.007$), a similar proportion of vascular involvement was observed between PET/CT, and CTA or MRA.

Please cite this article as: de Boysson H, et al, Large-vessel involvement and aortic dilation in giant-cell arteritis. A multicenter study of 549 patients, *Autoimmun Rev* (2018), <https://doi.org/10.1016/j.autrev.2017.11.029>

Table 3
Detailed characteristics of giant-cell arteritis patients with large-vessel involvement at diagnosis and/or follow-up.

| | Total (248 patients) | On PET/CT (215 patients) | On CTA or MRA (33 patients) | p |
|---|-------------------------|-----------------------------|-----------------------------------|-------|
| Total number of vascular territories involved | 3 [1–5] | 4 [1–8] | 3 [1–6] | 0.06 |
| Thoracic aorta | 220 (89) | 191 (89) | 29 (88) | 0.87 |
| Abdominal aorta | 180 (73) | 155 (72) | 25 (76) | 0.66 |
| Subclavian arteries | 166 (67) | 148 (69) | 18 (55) | 0.10 |
| Carotid arteries | 111 (45) | 101 (47) | 10 (30) | 0.07 |
| Axillary arteries | 79 (32) | 69 (32) | 10 (30) | 0.84 |
| Upper limb arteries | 30 (12) | 26 (12) | 4 (12) | 0.99 |
| Ilio-femoral arteries | 80 (32) | 76 (35) | 4 (12) | 0.007 |
| Lower limb arteries | 30 (12) | 29 (13) | 1 (3) | 0.08 |

Values are displayed as absolute number (%) or median [range]. PET/CT: fluorodeoxyglucose positron emission tomography with computed tomography; CTA: computed tomography angiography.

3.5. Treatments and outcomes (Table 4)

The median oral GC dosage at initiation was 0.8 mg/kg/day [range: 0.25–1.45 mg/kg/day] and 0.76 mg/kg/day [range: 0.37–1.60 mg/kg/day] in patients with and without LVI, respectively ($p = 0.22$). In the LVI group, the lowest daily dosage was 0.25 mg/kg/day (in an 80-kg diabetic patient who also received methotrexate at diagnosis), and 3 patients received initial dosages that were ≤ 0.5 mg/kg/day. In patients without LVI, the lowest daily dose was 0.37 mg/kg/day (in a 108-kg diabetic patient), and 5 patients received initial doses that were ≤ 0.5 mg/kg/day.

Six patients with LVI and 13 patients without LVI received a GC dosage ≥ 1.1 mg/kg/day at the start of treatment. The patient without LVI who received 1.60 mg/kg/day received an anti-tuberculous treatment along with GC, and the dosage was increased for the enzymatic inductor effect of rifampicin.

The GC tapering of the two groups was not different, except at 18 months, where patients with LVI received a significantly higher GC dosage than did those without LVI ($p = 0.02$).

Outcomes are shown in Table 4. At the time of this analysis, more patients without LVI had discontinued GC (47% versus 32%, $p = 0.0003$), and the median GC duration of these patients was lower than that of

Table 4
Treatment and outcomes in GCA patients with and without large-vessel involvement.

| | Large-vessel involvement (n = 248) | No large-vessel involvement (n = 301) | p |
|--------------------------------------|---------------------------------------|--|--------|
| Glucocorticoids doses (mg/kg) | | | |
| Initially | 0.80 [0.25–1.45] | 0.76 [0.37–1.60] | 0.22 |
| At month 3 | 0.32 [0.08–0.88] | 0.37 [0.12–1.04] | 0.15 |
| At month 6 | 0.19 [0.1–1] | 0.18 [0.06–0.70] | 0.89 |
| At month 12 | 0.11 [0.01–0.46] | 0.10 [0.01–0.56] | 0.67 |
| At month 18 | 0.10 [0.01–0.19] | 0.08 [0.01–0.50] | 0.02 |
| Outcomes | | | |
| Discontinuation of glucocorticoids | 79 (32) | 142 (47) | 0.0003 |
| Duration of glucocorticoids (months) | 29 [8–212] | 24 [5–113] | 0.05 |
| Relapse | 96 (39) | 133 (44) | 0.20 |
| Steroid-sparing agents | 69 (28) | 55 (18) | 0.008 |
| Death | 11 (4) | 32 (11) | 0.007 |
| Occurrence of aortic complications | | | |
| New aortic dilation | 32/154 ^a (21) | 8/123 ^a (7) | 0.0008 |
| Aortic dissection | 6/248 (2) | 2/301 (0.7) | 0.15 |
| Follow-up (months) | 54 [4–234] | 60 [1–262] | 0.83 |

Values are displayed as absolute number (%) or median [range].

^a Repeated aortic imaging was performed in 154 and 123 patients with and without large-vessel involvement.

the patients with LVI (24 months [range: 5–113 months] versus 29 months [range: 8–212 months], $p = 0.05$).

While the relapse rates of the two subgroups were not different (39% versus 44% in patients with and without LVI, respectively; $p = 0.20$), a significantly higher proportion of LVI patients received GC-sparing agents (28% versus 18%, $p = 0.008$). After median follow-ups of 54 and 60 months in the patients with and without LVI, respectively, 43 (8%) patients died, most of whom were in the group without LVI ($p = 0.007$). The causes of death were infections ($n = 10$), cardiovascular events ($n = 10$), malignancies ($n = 5$), stroke ($n = 3$), aortic dissections ($n = 3$) and other causes ($n = 12$).

3.6. Aortic complications (Table 4)

Among the 398 patients who had imaging performed at diagnosis, 20 (11%) patients with LVI and 14 (7%) patients without LVI had aortic dilation ($p = 0.16$). The thoracic segment was involved in 30 patients, while the suprarenal abdominal aorta was involved in the other four patients.

During follow-up, 154 patients with LVI and 123 patients without LVI repeated the imaging (PET/CT in 90 patients, CTA in 116 patients, echocardiography in 54 patients and MRA in 17 patients) at 19 months [range: 5–162 months] and 17 months [range: 6–168 months] after diagnosis ($p = 0.31$). New aortic dilation, i.e., aortic dilation not observed on the first aortic imaging, was diagnosed in 32 (21%) of the patients with LVI and in 8 (7%) of the patients without LVI ($p = 0.0008$). The thoracic segment was involved in 35 patients, while the suprarenal abdominal aorta was involved in 4, and both segments were involved in another one. Delay in the detection of the dilations after diagnosis was 33 months [range: 5–144 months] and 72 months [range: 22–168 months] in patients with LVI and in those without LVI, respectively ($p = 0.04$). The cumulative incidence of aortic dilations in both groups is shown in Fig. 2 (log-rank test: $p = 0.0015$).

In the LVI patients, aortic dilation occurred on a previous inflammatory aorta segment demonstrated on imaging in 30 (94%) patients.

Aortic dissection occurred in 8 patients, including 6 with previous aortitis. Three died before or during the aorta replacement.

Nine patients, all of whom had previous aortitis, had surgical replacement of the aorta root (a diameter > 50 mm in all of them). Four of them showed some persistent active signs of vasculitis on histology, while 3 showed fibrous tissue. Meanwhile, two of them did not have histologic analysis performed.

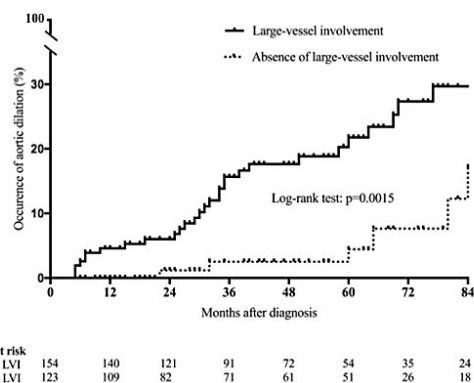


Fig. 2. Cumulative incidence of aortic dilations in giant-cell arteritis patients with and without large-vessel involvement. Patients with giant-cell arteritis-related large-vessel involvement showed more aortic dilations than patients without. Log-rank test was used to calculate the statistical difference between both groups. LVI: Large-vessel involvement.

Please cite this article as: de Boysson H, et al, Large-vessel involvement and aortic dilation in giant-cell arteritis. A multicenter study of 549 patients, Autoimmun Rev (2018), <https://doi.org/10.1016/j.autrev.2017.11.029>

3.7. Factors associated with aortic dilation

The results from the univariate and multivariate analyses of baseline variables associated with aortic dilations in the 277 patients who underwent a second aortic imaging procedure (154 patients with LVI and 123 patients without LVI) are shown in Table 5. In the multivariate analysis, LVI was the strongest predictive factor of aortic dilation (hazard ratio (HR): 3.16 [range: 1.34–7.48] $p = 0.009$). We also observed that the presence of cephalic signs at onset was protective against the occurrence of aortic dilation (HR: 0.39 [range: 0.18–0.83], $p = 0.01$).

4. Discussion

Our study provides new insights regarding GCA-related LVI. We identified and confirmed some demographical and clinical factors that are more frequently associated with LVI. Moreover, LVI was the strongest independent predictor for aortic dilation in multivariate analysis, regardless of the clinical status of the disease or the time of the aortic morphology assessment. Aortic dilation in patients with LVI occurred on a previously affected inflammatory segment in >90% of the patients.

GCA is a polymorphic disease with a wide spectrum of manifestations. Different disease subgroups have been identified according to the predominant or absent signs [6,18,20,26–30]. Patients with typical cephalic manifestations remain the most frequent and representative subgroup of the GCA spectrum. Our study confirms prior research showing that LVI in the setting of GCA represents another subgroup of the disease with different characteristics [5–9,20,28]. There were twice the number of patients with LVI under 70 years than those without LVI under 70 years, and only a tenth of the patients with LVI were >80 years old. Patients with LVI showed fewer cephalic symptoms, which did not seem to be a result of a selection bias (i.e., these patients might be addressed more easily to imaging for atypical presentations), as we observed the same differences in the subgroup of patients who had the imaging performed at diagnosis, which included patients with typical cephalic presentation. In the absence of recommendations regarding which patients should be addressed for large-vessel screening, our study suggests first addressing younger patients with atypical GCA manifestations, as they are more prone to LVI. A contrast imaging method, such as CTA, PET/CT or MRA, can be used in this setting because previous studies have shown its high sensitivity for the detection of LVI [2,3,5,8,9].

Table 5
Baseline variables associated with aortic dilation in giant-cell arteritis in uni- or multivariate Cox proportional hazards models.

| | Univariate HR [95% CI] | p | Multivariate HR [95% CI] | p |
|-----------------------------|---------------------------|--------|-----------------------------|-------|
| Female sex | 0.57 [0.29–1.20] | 0.13 | | |
| Age < 70 | 1.61 [0.85–3.14] | 0.15 | | |
| Tobacco use | 2.13 [1.07–4.12] | 0.03 | | |
| Hypertension | 1.08 [0.58–2.03] | 0.81 | | |
| Diabetes | 0.91 [0.22–2.53] | 0.87 | | |
| Dyslipidemia | 1.51 [0.73–2.97] | 0.26 | | |
| Cephalic signs | 0.39 [0.20–0.79] | 0.01 | 0.39 [0.18–0.83] | 0.01 |
| Headache | 0.63 [0.33–1.27] | 0.19 | | |
| Scalp tenderness | 1.25 [0.65–2.52] | 0.51 | | |
| Jaw claudication | 0.62 [0.29–1.25] | 0.19 | | |
| Temporal artery abnormality | 1.21 [0.58–2.86] | 0.63 | | |
| Ophthalmic signs | 0.59 [0.20–1.39] | 0.25 | | |
| Polymyalgia rheumatica | 0.64 [0.32–1.22] | 0.18 | | |
| Extra-cephalic signs | 0.65 [0.24–1.47] | 0.32 | | |
| Limb claudication | 1.03 [0.40–3.54] | 0.94 | | |
| Vascular bruits | 0.68 [0.23–1.59] | 0.40 | | |
| Positive histology | 1.12 [0.57–2.33] | 0.75 | | |
| LVI on imaging | 3.46 [1.62–8.54] | 0.0009 | 3.16 [1.34–7.48] | 0.009 |

95% CI: 95% confidence interval; HR: hazard ratio; LVI: large-vessel involvement.

Our study also underlines the limited usefulness of the ACR criteria in GCA patients with LVI, as nearly 20% of them only satisfied 2 of the criteria. In the recent GIACATA trial, 115/251 (46%) patients had a diagnosis of vasculitis based on imaging and 95 (38%) of them had negative or no TAB [23]. This trial emphasizes that the working diagnosis of GCA has evolved over the last three decades and that LVI is now considered a highly valuable finding for GCA diagnosis. In the absence of biopsy-proven vasculitis, the demonstration of LVI on imaging combined with other ACR criteria may probably replace TAB. Further studies are required to redefine the ACR criteria, which should take into consideration the presence of LVI. Interestingly, even in the absence of cephalic symptoms, TAB remains useful and can demonstrate vasculitis, suggesting that it should be included in the diagnostic work-up of aortitis in patients older than 50 years.

It is known in the general population that cardiovascular risk factors favor the occurrence of aortic dilations [31,32]. Approximately 10% of our patients in both groups had aortic dilation at diagnosis. While the number of cardiovascular risk factors was higher in the patients without LVI, we observed 3.5 times more patients with new aortic dilation in the LVI group. This suggests that different mechanisms may account for aortic dilation and that inflammation may act as a contributing factor. This statement is strengthened by the occurrence of aortic dilation within the first two years after diagnosis in some patients with LVI. In addition, aortic dilation occurred mostly on the vascular segment that was previously inflamed. Persistent post-therapeutic parietal inflammation and subsequently healed lesions could weaken the aorta vessel wall and may explain why the risk for aortic dilation still continues for a long time, even after the discontinuation of GC. Further studies are required to determine whether LVI patients warrant a more intense initial treatment regimen in order to rapidly control the vessel wall inflammation and thus avoid local fibrosclerosing of healed but weakened lesions that are more prone to dilate. Our results suggest that aortic morphology should be controlled during follow-up in patients with GCA-related LVI, especially the vascular segment that was previously inflamed. Since the thoracic aorta segment is the main segment affected by dilation, echocardiography, and especially colour-Doppler sonography, can be used [30]. Collaboration with cardiologists and radiologists is thus required in order to better monitor the thoracic aorta and better care for cardiovascular risk factors.

Few data exist about the treatment and outcomes of patients with LVI, especially regarding the long-term aortic morphology. In smaller series, it has been shown that patients with and without LVI did not receive different treatments [33]. Our present study confirms in a multicenter practice analysis that GC management did not differ at the initiation of treatment, regardless of the presence of LVI. Interestingly, our study challenges some published results, especially the relapse and death rate results in patients with LVI [6,18]. In our study, more patients without LVI died, mainly because over a quarter of them were >80 years. Regarding relapse, our patients with LVI did not show higher relapse rates. Since the LVI patients in our study showed a longer duration of treatment and a more frequent use of GC-sparing agents, no firm conclusion can be drawn for comparing final treatment outcomes in both subgroups. Such cautious attitude from our physicians in regard to LVI is probably related to previously reported findings highlighting that large-vessel imaging often remains positive during follow-up, even in the absence of clinical or biological disease activity [3,34,35].

Our study has limitations. First, the retrospective design limits the completeness of the retrieved data, especially follow-up data. The included patients were selected and were not included consecutively at each center. The choice to include patients who underwent imaging may be a source for selection bias, as many of these patients might have been referred for imaging for an atypical presentation. However, as discussed above, this bias is limited by the large number of patients with typical, i.e., cephalic presentations and without LVI. On the basis of negative imaging at diagnosis, some patients may have been included in the GCA group of patients without LVI, with a risk of developing LVI

Please cite this article as: de Boysson H, et al, Large-vessel involvement and aortic dilation in giant-cell arteritis. A multicenter study of 549 patients, *Autoimmun Rev* (2018), <https://doi.org/10.1016/j.autrev.2017.11.029>

later on. In addition, some patients only underwent an imaging procedure during follow-up under treatment, which might have provided negative results despite the possible earlier presence of LVI. However, these limitations are downplayed by the subgroup analysis that we conducted in patients according to the time when the imaging was performed and this showed similar results. We thus believe that the differences that we observed in patients according to the presence of LVI are relevant and meaningful.

Patients who previously presented with LVI are probably more likely referred for aortic morphology control, which may overestimate the proportion of aortic dilation in the LVI group. However, a large number of patients without LVI also performed another aortic imaging procedure and did not show a similar proportion of aortic dilation. Moreover, our results are concordant with others [5,15]. A large proportion of our patients underwent echocardiography during the follow-up, which is sensitive in detecting thoracic aorta dilation but does not detect abdominal aortic involvement. However, the proportion of abdominal aortic dilation was low in our study, even in the patients who performed a complete aortic imaging procedure. The times of the repeated aortic imaging are different among our patients, which is also a limitation of this study. Some patients might have undergone a repeat imaging procedure before occurrence of aortic dilation.

5. Conclusions

This study suggests that LVI in GCA represents a distinct epidemiologic, clinical and prognostic spectrum of the disease with a higher risk of aortic dilation, especially in previously inflamed vascular segments. Prospective studies should help confirm these findings and define the best rhythm, type and duration of aortic morphology follow-up. Additionally, further work is necessary to identify the most adapted therapeutic strategy in this pattern of the disease.

Funding sources

None.

Disclosures

None.

Ethics and consent

This study was conducted in compliance with good clinical practices and the Declaration of Helsinki principles. At the time of this study, in accordance with French public health law (Art. L 1121-1-1, Art. L 1121-1-2), formal approval from an ethics committee was not required for this type of observational study. Our local ethics committee confirmed the observational non-interventional retrospective nature of our cohort.

Appendix A. Supplementary data

Supplementary data to this article can be found online at <https://doi.org/10.1016/j.autrev.2017.11.029>.

References

- [1] Borchers AT, Gershwin ME. Giant cell arteritis: a review of classification, pathophysiology, geoepidemiology and treatment. *Autoimmun Rev* 2012;11:A544–554.
- [2] Agard C, Barrier JH, Dupas B, Ponge T, Mahr A, Fradet G, et al. Aortic involvement in recent-onset giant cell (temporal) arteritis: a case-control prospective study using helical aortic computed tomodensitometric scan. *Arthritis Rheum* 2008;59:670–6.
- [3] Blockmans D, de Ceuninck L, Vanderschueren S, Knockaert D, Mortelmans L, Bobbaers H. Repetitive 18F-fluorodeoxyglucose positron emission tomography in giant cell arteritis: a prospective study of 35 patients. *Arthritis Rheum* 2006;55:131–7.
- [4] Salvarani C, Soriano A, Muratore F, Shoenfeld Y, Blockmans D. Is PET/CT essential in the diagnosis and follow-up of temporal arteritis? *Autoimmun Rev* 2017;16:1125–30.
- [5] de Boysson H, Liozon E, Lambert M, Parienti J, Artigues N, Geffray L, et al. 18F-fluorodeoxyglucose positron emission tomography and the risk of subsequent aortic complications in giant-cell arteritis: a multicenter cohort of 130 patients. *Medicine* 2016;95:e3851.
- [6] Kermani TA, Warrington KJ, Crowson CS, Ytterberg SR, Hunder GG, Gabriel SE, et al. Large-vessel involvement in giant cell arteritis: a population-based cohort study of the incidence-trends and prognosis. *Ann Rheum Dis* 2013;72 (1989–1894).
- [7] Muratore F, Kermani TA, Crowson CS, Green AB, Salvarani C, Matteson EL, et al. Large-vessel giant cell arteritis: a cohort study. *Rheumatology (Oxford)* 2015;54:463–70.
- [8] Prieto-Gonzalez S, Arguis P, Garcia-Martinez A, Espigol-Frigole G, Tavera-Bahillo I, Butjosa M, et al. Large vessel involvement in biopsy-proven giant cell arteritis: prospective study in 40 newly diagnosed patients using CT angiography. *Ann Rheum Dis* 2012;71:1170–6.
- [9] Prieto-Gonzalez S, Depetris M, Garcia-Martinez A, Espigol-Frigole G, Tavera-Bahillo I, Corbera-Bellalta B. Positron emission tomography assessment of large vessel inflammation in patients with newly diagnosed, biopsy-proven giant cell arteritis: a prospective, case-control study. *Ann Rheum Dis* 2014;73:1388–92.
- [10] Hunder GG, Bloch DA, Michel BA, Stevens MB, Arend WP, Calabrese LH, et al. The American College of Rheumatology 1990 criteria for the classification of giant cell arteritis. *Arthritis Rheum* 1990;33:1122–8.
- [11] Adler S, Sprecher M, Wermelinger F, Kilink T, Bonel H, Villiger PM. Diagnostic value of contrast-enhanced magnetic resonance angiography in large-vessel vasculitis. *Swiss Med Wkly* 2017;21:w14397.
- [12] Bley TA, Uhl M, Carew J, Markle M, Schmidt D, Peter HH, et al. Diagnostic value of high-resolution MR imaging in giant cell arteritis. *AJNR Am J Neuroradiol* 2007;28:1722–7.
- [13] Narvaez J, Narvaez JA, Nolla JM, Sirvent E, Reina D, Valverde J. Giant cell arteritis and polymyalgia rheumatica: usefulness of vascular magnetic resonance imaging studies in the diagnosis of aortitis. *Rheumatology* 2005;44:479–83.
- [14] Besson FL, Parienti JJ, Bienvu B, Prior JO, Costo S, Bouvard G, et al. Diagnostic performance of (1)F-fluorodeoxyglucose positron emission tomography in giant cell arteritis: a systematic review and meta-analysis. *Eur J Nucl Med Mol Imaging* 2011;38:1764–72.
- [15] Blockmans D, Coudyzer W, Vanderschueren S, Stroobants S, Loeckx D, Heye S, et al. Relationship between fluorodeoxyglucose uptake in the large vessels and late aortic diameter in giant cell arteritis. *Rheumatology* 2008;47:1179–84.
- [16] Meller J, Strutz F, Siefker U, Scheel A, Sahlmann CO, Lehmann K, et al. Early diagnosis and follow-up of aortitis with [(18)F]FDG PET and MRI. *Eur J Nucl Med Mol Imaging* 2003;30:730–6.
- [17] Hommada M, Mekinian A, Brillet PY, Abad S, Larroche C, Dhôte R, et al. Aortitis in giant cell arteritis: diagnosis with FDG PET/CT and agreement with CT angiography. *Autoimmun Rev* 2017;16:1131–7.
- [18] Espitia O, Neel A, Leux C, Connault J, Espitia-Thibault A, Ponge T, et al. Giant cell arteritis with or without aortitis at diagnosis. A retrospective study of 22 patients with longterm followup. *J Rheumatol* 2012;39:2157–62.
- [19] Evans JM, O'Fallon WM, Hunder GG. Increased incidence of aortic aneurysm and dissection in giant cell (temporal) arteritis. A population-based study. *Ann Intern Med* 1995;122:502–7.
- [20] Nueninghoff DM, Hunder GG, Christianson TJ, McClelland RL, Matteson EL. Incidence and predictors of large-artery complication (aortic aneurysm, aortic dissection, and/or large-artery stenosis) in patients with giant cell arteritis: a population-based study over 50 years. *Arthritis Rheum* 2003;48:3522–31.
- [21] Robson JC, Kiran A, Maskell J, Hutchings A, Arden N, Dasgupta B, et al. The relative risk of aortic aneurysm in patients with giant cell arteritis compared with the general population of the UK. *Ann Rheum Dis* 2015;74:129–35.
- [22] Garcia-Martinez A, Hernandez-Rodriguez J, Arguis P, Paredes P, Segarra M, Lozano E, et al. Development of aortic aneurysm/dilatation during the followup of patients with giant cell arteritis: a cross-sectional screening of fifty-four prospectively followed patients. *Arthritis Rheum* 2008;59:422–30.
- [23] Stone JH, Tuckwell K, Dimonaco S, Klearman M, Aringer M, Blockmans D, et al. Trial of tocilizumab in giant-cell arteritis. *N Engl J Med* 2017;377:317–28.
- [24] Villiger PM, Adler S, Kuchen S, Wermelinger F, Dan D, Fiege V, et al. Tocilizumab for induction and maintenance of remission in giant cell arteritis: a phase 2, randomised, double-blind, placebo-controlled trial. *Lancet* 2016;387:1921–7.
- [25] de Boysson H, Dumont A, Liozon E, Lambert M, Boutemy J, Maigné G, et al. Giant-cell arteritis: concordance study between aortic CT angiography and FDG-PET/CT in detection of large-vessel involvement. *Eur J Nucl Med Mol Imaging* 2017. <https://doi.org/10.1007/s00259-017-3775-5>.
- [26] Brack A, Martinez-Taboada V, Stanson A, Goronzy JJ, Weyand CM. Disease pattern in cranial and large-vessel giant cell arteritis. *Arthritis Rheum* 1999;42:311–7.
- [27] Czirhal M, Tato F, Forster S, et al. Fever of unknown origin as initial manifestation of large vessel giant cell arteritis: diagnosis by colour-coded sonography and 18-FDG-PET. *Clin Exp Rheumatol* 2010;28:549–52.
- [28] Bertl A, Campochiaro C, Cavalli G, Pepe G, Praderio L, Sabbadini MG, et al. Giant cell arteritis restricted to the limb arteritis: an overlooked clinical entity. *Autoimmun Rev* 2015;14:352–7.
- [29] de Boysson H, Lambert M, Liozon E, Boutemy J, Maigné G, Olivier Y, et al. Giant-cell arteritis without cranial manifestations: working diagnosis of a distinct disease pattern. *Medicine* 2016;95:e3818.
- [30] Ghinoi A, Pipitone N, Nicolini A, Boiardi L, Silingardi M, Germano G, et al. Large-vessel involvement in recent-onset giant cell arteritis: a case-control colour-Doppler sonography study. *Rheumatology* 2012;51:730–4.

Please cite this article as: de Boysson H, et al. Large-vessel involvement and aortic dilation in giant-cell arteritis. A multicenter study of 549 patients. *Autoimmun Rev* (2018), <https://doi.org/10.1016/j.autrev.2017.11.029>

- [31] Meszaros I, Morocz J, Szlavi J, Schmidt J, Tornoci L, Nagy L, et al. Epidemiology and clinicopathology of aortic dissection. *Chest* 2000;117:1271-8.
- [32] Senaratne JM, Raggi P. Screening for aortic aneurysms in patients with coronary artery disease: should it be done? *Exp Rev Cardiovasc Ther* 2015;13:735-7.
- [33] de Boysson H, Liozon E, Lambert M, Dumont A, Boutemy J, Maigné G, et al. Giant-cell arteritis: do we treat patients with large-vessel involvement differently? *Am J Med* 2017;130:992-5.
- [34] de Boysson H, Aide N, Liozon E, Lambert M, Parienti JJ, Monteil J, et al. Repetitive 18F-FDG-PET/CT in patients with large-vessel giant-cell arteritis and controlled disease. *Eur J Intern Med* 2017. <https://doi.org/10.1016/j.ejim.2017.08.013>.
- [35] Prieto-Gonzalez S, Garcia-Martinez A, Tavera-Bahillo I, Hernandez-Rodriguez J, Gutierrez-Chacoff J, Alba MA, et al. Effect of glucocorticoid treatment on computed tomography angiography detected large-vessel inflammation in giant-cell arteritis. A prospective, longitudinal study. *Medicine* 2015;94:e486.

Please cite this article as: de Boysson H, et al, Large-vessel involvement and aortic dilation in giant-cell arteritis. A multicenter study of 549 patients, *Autoimmun Rev* (2018), <https://doi.org/10.1016/j.autrev.2017.11.029>

Online Table 1. Characteristics of patients with large-vessel involvement identified at diagnosis or during follow-up.

| | Large-vessel involvement at diagnosis (n=188) | Large-vessel involvement during follow-up (n=60) | P |
|--|--|---|----------|
| Demographics | | | |
| Age | 67 [50-89] | 68 [50-89] | 0.11 |
| Women | 140 (74) | 47 (78) | 0.54 |
| Cardiovascular risk factors* | | | |
| No | 60 (32) | 19 (32) | 0.84 |
| 1 | 81 (43) | 24 (40) | 0.67 |
| ≥2 | 47 (25) | 17 (28) | 0.61 |
| Hypertension | 76 (40) | 28 (47) | 0.39 |
| Diabetes mellitus | 14 (7) | 8 (13) | 0.16 |
| Dyslipidemia | 43 (23) | 16 (27) | 0.55 |
| Tobacco use | 53 (28) | 11 (18) | 0.13 |
| Weight (kg) | 65 [41-90] | 64 [45-98] | 0.95 |
| Body Mass Index (kg/m ²) | 25.1 [15.4-34.3] | 25.32 [18-36.9] | 0.24 |
| Clinical manifestations | | | |
| ACR criteria | 3 [2-5] | 3 [2-5] | 0.72 |
| Fever | 62 (33) | 14 (23) | 0.16 |
| Polymyalgia rheumatica | 50 (27) | 28 (47) | 0.004 |
| Cephalic signs | 127 (68) | 52 (87) | 0.004 |
| Headaches | 106 (56) | 46 (77) | 0.02 |
| Scalp tenderness | 41 (22) | 28 (47) | 0.0002 |
| Jaw claudication | 44 (23) | 27 (45) | 0.001 |
| Sensitive temporal artery | 31 (16) | 20 (33) | 0.005 |
| Ophthalmologic signs | 15 (8) | 11 (18) | 0.02 |
| Extra-cephalic vascular signs | 40 (21) | 13 (22) | 0.95 |
| Vascular and heart bruits | 32 (17) | 11 (18) | 0.81 |
| Limb claudication | 23 (12) | 4 (7) | 0.23 |
| Laboratory tests | | | |
| Erythrocyte sedimentation rate (mm) | 90 [9-134] | 80 [15-130] | 0.32 |
| C-reactive protein (mg/l) | 81 [3-401] | 100 [3-390] | 0.18 |
| Hemoglobin level (g/dl) | 11 [7.4-14.6] | 11.3 [8-14.7] | 0.27 |
| Platelet count (G/mm ³) | 418 [121-896] | 416 [230-848] | 0.97 |
| Positive temporal artery biopsy | 89 [†] /169 (53) | 41/59 (69) | 0.02 |

Except where indicated otherwise values are displayed as absolute number (%) or median [range].

*excluding age; [†]including 3 patients who had a positive histology on vascular samples other than temporal artery.

Online Table 2. Characteristics of patients without demonstration of large-vessel involvement at diagnosis or during follow-up.

| | No large-vessel involvement at diagnosis (n=210) | No large-vessel involvement during follow-up (n=91) | <i>P</i> |
|--|--|---|----------|
| Demographics | | | |
| Age | 75 [48-91] | 74 [56-90] | 0.70 |
| Women/Men | 135 (64) | 63 (69) | 0.41 |
| Cardiovascular risk factors* | | | |
| No | 61 (29) | 22 (24) | 0.39 |
| 1 | 84 (40) | 31 (34) | 0.33 |
| ≥2 | 65 (31) | 38 (42) | 0.07 |
| Hypertension | 114 (54) | 54 (59) | 0.42 |
| Diabetes mellitus | 26 (12) | 15 (16) | 0.34 |
| Dyslipidemia | 67 (32) | 32 (35) | 0.58 |
| Tobacco use | 27 (13) | 25 (27) | 0.002 |
| Weight (kg) | 63.5 [41-95] | 64 [37-109] | 0.88 |
| Body Mass Index (kg/m ²) | 24 [16-33.6] | 25 [16.9-42] | 0.33 |
| Clinical manifestations | | | |
| ACR criteria | 4 [3-5] | 4 [3-5] | 0.67 |
| Fever | 68 (32) | 13 (14) | 0.001 |
| Polymyalgia rheumatica | 91 (43) | 45 (49) | 0.33 |
| Cephalic signs | 196 (93) | 84 (92) | 0.75 |
| Headaches | 166 (79) | 74 (81) | 0.65 |
| Scalp tenderness | 105 (50) | 46 (51) | 0.93 |
| Jaw claudication | 94 (45) | 35 (38) | 0.31 |
| Sensitive temporal artery | 87 (41) | 25 (27) | 0.02 |
| Ophthalmologic signs | 55 (26) | 29 (32) | 0.31 |
| Extra-cephalic vascular signs | 26 (12) | 19 (21) | 0.06 |
| Vascular and heart bruits | 26 (12) | 19 (21) | 0.06 |
| Limb claudication | 1 (0.5) | 3 (3) | 0.08 |
| Laboratory tests | | | |
| Erythrocyte sedimentation rate (mm) | 80 [7-141] | 67 [16-130] | 0.11 |
| C-reactive protein (mg/l) | 73 [3-426] | 67 [4-424] | 0.08 |
| Hemoglobin level (g/dl) | 11.5 [7.4-16.2] | 11.7 [8.9-14.7] | 0.31 |
| Platelet count (G/mm ³) | 397 [164-792] | 380 [187-725] | 0.71 |
| Positive temporal artery biopsy | 140/209 (67) | 54/89 (61) | 0.30 |

Except where indicated otherwise values are displayed as absolute number (%) or median [range].

*excluding age.

Online Table 3. Detailed characteristics of giant-cell arteritis patients with large-vessel involvement at diagnosis and/or follow-up.

| | Total (248 patients) | On PET/CT (215 patients) | On CTA or MRA (33 patients) | <i>P</i> |
|---|---------------------------------|---|--|-----------------|
| Total number of vascular territories involved | 3 [1-5] | 4 [1-8] | 3 [1-6] | 0.06 |
| Thoracic aorta | 220 (89) | 191 (89) | 29 (88) | 0.87 |
| Abdominal aorta | 180 (73) | 155 (72) | 25 (76) | 0.66 |
| Subclavian arteries | 166 (67) | 148 (69) | 18 (55) | 0.10 |
| Carotid arteries | 111 (45) | 101 (47) | 10 (30) | 0.07 |
| Axillary arteries | 79 (32) | 69 (32) | 10 (30) | 0.84 |
| Upper limb arteries | 30 (12) | 26 (12) | 4 (12) | 0.99 |
| Ilio-femoral arteries | 80 (32) | 76 (35) | 4 (12) | 0.007 |
| Lower limb arteries | 30 (12) | 29 (13) | 1 (3) | 0.08 |

Values are displayed as absolute number (%) or median [range]. PET/CT: fluorodeoxyglucose positron emission tomography with computed tomography; CTA: computed tomography angiography.

4 – Est-ce que les différentes formes d'atteinte des gros vaisseaux dans l'ACG influencent le pronostic vasculaire au long cours ?

Les deux études précédentes indiquaient d'une part que l'existence d'une inflammation de l'aorte et de ses branches était associée à un risque accru de dilatation/dissection aortique, et d'autre part que les atteintes isolées des artères à destination des membres s'associaient plus fréquemment à la survenue de complications cardio-vasculaires notamment ischémiques [60, 61]. Forts de ce constat, nous avons voulu analyser sur un nombre conséquent de patients le pronostic cardio-vasculaire des différentes atteintes inflammatoires de l'aorte et de ses branches, c'est-à-dire en distinguant l'inflammation pariétale isolée des gros vaisseaux, les dilatations aortiques initiales attribuées à l'ACG et les lésions sténosantes des branches de l'aorte. Nous n'avons pas intégré dans cette analyse les dissections aortiques inaugurales compte tenu de leur pronostic cardio-vasculaire péjoratif dès le diagnostic. Néanmoins un travail est en cours sur ce sous-groupe de patients.

Dans cette étude, les 6 mêmes centres français ont été sollicités pour inclure tout patient avec :

- 1) un diagnostic d'ACG associé à une atteinte initiale des gros vaisseaux à l'imagerie (angioscanner aortique chez tous),
- 2) ayant au minimum un nouveau contrôle évolutif des gros vaisseaux au cours du suivi et
- 3) ayant été suivi au moins 6 mois.

Nous avons recruté 183 patients satisfaisant ces critères. Ces 183 patients avaient au minimum à l'imagerie une atteinte inflammatoire de l'aorte et/ou de ses branches. Nous notions parmi ces patients ceux qui avaient en plus une dilatation de l'aorte et/ou des lésions vasculaires sténosantes. Aucun patient n'avait une dilatation aortique initiale isolée ou une atteinte vasculaire sténosante isolée sans inflammation de l'aorte et/ou de ses branches afin de ne pas inclure des dilatations ou sténoses liées à l'athérosclérose.

Un groupe contrôle de 105 patients était constitué, tous ayant un diagnostic d'ACG formel à la biopsie d'artère temporale et n'ayant pas, ni au diagnostic ni pendant le suivi, développé d'atteinte des gros vaisseaux.

Parmi les 183 patients avec une atteinte inflammatoire de l'aorte et/ou de ses branches, 104 (57%) n'avaient qu'une inflammation isolée des gros vaisseaux, tandis que 27 (15%) avaient aussi une dilatation aortique et 55 (30%) des sténoses vasculaires. Trois patients avaient les 3 atteintes.

Un nouvel évènement cardio-vasculaire survenait chez 49% des patients avec une atteinte des gros vaisseaux contre 11% des témoins ($p < 0.0001$). L'analyse des sous-groupes d'atteinte des

gros vaisseaux révélait que c'était les patients avec des lésions sténosantes qui faisaient le plus de complications cardio-vasculaires (67% d'entre eux, principalement des complications ischémiques). Plus de 80% des nouvelles dilatations aortiques ont été observées dans le groupe des patients avec une inflammation isolée des gros vaisseaux. Enfin, toutes les dissections aortiques (n=8) survinrent sur des segments inflammatoires antérieurement et, cela pour la moitié d'entre elles sur des aortes initialement dilatées.

De manière intéressante, cette étude indiquait que la prescription d'un immunosuppresseur avait un effet protecteur de la survenue d'une complication cardio-vasculaire (95% HR 0.44 [0.29—0.66], $p < 0.0001$).

Hubert de Boysson, Eric Liozon, Olivier Espitia, Aurélie Daumas, Mathieu Vautier, Marc Lambert, Jean-Jacques Parienti, Brigitte Granel, Anael Dumont, Audrey Sultan, Alain Manrique, David Saadoun, Kim Heang Ly, Christian Agard, Achille Aouba

Different patterns and specific outcomes of large-vessel involvements in giant cell arteritis

J Autoimmun. 2019 Sep;103:102283. doi: 10.1016/j.jaut.2019.05.011.



Contents lists available at ScienceDirect

Journal of Autoimmunity

journal homepage: www.elsevier.com/locate/jautimm

Different patterns and specific outcomes of large-vessel involvements in giant cell arteritis

Hubert de Boysson^{a,b,*}, Eric Liozon^c, Olivier Espitia^d, Aurélie Dumas^e, Mathieu Vautier^f, Marc Lambert^g, Jean-Jacques Parienti^h, Brigitte Granel^e, Anael Dumont^a, Audrey Sultan^a, Alain Manriqueⁱ, David Saadoun^{f,j,k,l}, Kim Heang Ly^c, Christian Agard^d, Achille Aouba^{a,b}

^a Department of Internal Medicine, Caen University Hospital, Caen, France

^b Normandie Univ, UNICAEN, CHU de Caen Normandie, 14000, Caen, France

^c Department of Internal Medicine and Clinical Immunology, Limoges University Hospital, Limoges, France

^d Department of Internal Medicine, Nantes University Hospital, Nantes, France

^e Department of Internal Medicine and Therapeutics, Timone Hospital, Marseille, France

^f AP-HP, Groupe Hospitalier Pitié-Salpêtrière, Department of Internal Medicine and Clinical Immunology, Centre de Référence des Maladies Auto-Immunes et Systémiques

Rares, Centre de Référence des Maladies Auto-Inflammatoires, Paris, France

^g Department of Internal Medicine, Lille University Hospital, Lille, France

^h Biostatistics and Clinical Research Unit, Caen University Hospital, France

ⁱ Department of Nuclear Medicine, Caen University Hospital, Caen, France

^j Sorbonne Universités, UPMC Univ Paris 06, Inflammation-Immunopathology-Biotherapy Department, France

^k INSERM, Paris, France

^l CNRS, Paris, France

ARTICLE INFO

Keywords:

Giant-cell arteritis
Imaging patterns
Aortic dilation
Large-vessel stenosis
Aortic dissection
Cardiovascular outcomes

ABSTRACT

Large-vessel involvement (LVI) in giant cell arteritis (GCA) includes different clinical and imaging patterns that are rarely described separately at diagnosis and whose specific cardiovascular outcomes are unknown.

We conducted a nationwide retrospective study and included GCA patients with LVI demonstrated on imaging at diagnosis between 2007 and 2017. We analyzed the prognosis of three different imaging patterns of LVI present at diagnosis, with some of them overlapping but with the first one present in all patients: 1) inflammation of the aorta and/or its branches; 2) dilation of the aorta; and 3) stenosis of the aortic branches. A control group of GCA patients without LVI was constituted.

We included 183 patients with LVI and 105 controls without LVI. Altogether, among the 183 patients who all showed inflammation of the aorta and/or its main branches, concomitant aortic dilation and large-vessel stenosis were observed in 27 (15%) and 55 (30%) patients, respectively. During the follow-up period, new cardiovascular events occurred in 49% and 11% of LVI patients and controls, respectively ($p < 0.0001$). Inflammation of the aorta and/or its branches (HR: 3.42 [2.09–5.83], $p < 0.0001$) and large-artery stenosis (HR: 2.75 [1.80–4.15], $p < 0.0001$) were independent predictive factors of new cardiovascular events. Conversely, the use of an immunosuppressant besides corticosteroids was a protective factor against new cardiovascular events (HR: 0.44 [0.29–0.66], $p < 0.0001$) and the development of aortic dilation (HR: 0.43 [0.23–0.77], $p = 0.005$).

This study suggests different forms of cardiovascular events according to the initial imaging pattern of LVI.

1. Introduction

Giant cell arteritis (GCA) is a systemic vasculitis that typically affects cranial vessels in patients over 50. However, in addition to the cranial presentation, proximal large vessels, i.e., the aorta and its main branches, can be affected in 30%–80% of GCA patients [1–9], whereas

the involvement of peripheral limb arteries is more rarely reported [10–13]. Radiological assessment of large vessels is currently widely performed in GCA to demonstrate vasculitis, even replacing the histological criterion in some large-scale studies [14]. Imaging patterns of vascular changes on imaging described in GCA include inflammation of the aorta and/or of its main branches, solely or in association with

* Corresponding author. Department of Internal Medicine, Caen University Hospital, University of Caen-Normandie, Avenue de la Côte de Nacre, 14000, Caen, France.

E-mail address: deboysson-h@chu-caen.fr (H. de Boysson).

<https://doi.org/10.1016/j.jaut.2019.05.011>

Received 26 February 2019; Received in revised form 6 May 2019; Accepted 14 May 2019
0896-8411/ © 2019 Published by Elsevier Ltd.

aortic dilation or large-vessel stenosis [4,8,12,15–19]. Subsequent clinical consequences of these large-vessel involvements (LVI) range from acute symptomatic vascular events (e.g., aortic dissection or vascular occlusions) to non-symptomatic presentations (inflammation of the aorta and/or of its main branches or aortic dilation detected on systematic radiologic assessment) [5,20,21]. Therefore, LVI in GCA covers a large spectrum of different clinical and radiological patterns that are often pooled together in the published cohorts (often under the generic term “large-vessel vasculitis”).

Previous studies reported a worse vascular outcome in patients with LVI, especially more cardiovascular events and lower survival, due to early or late aortic dissections [5,19,22,23]. It has been suggested that late aortic dilation – increasing the risk of aortic dissection – occurs more readily in patients with demonstration of aortic inflammation [3,15,24,25]. However, the analysis of the different imaging patterns in GCA patients with LVI and their relationships with patients’ prognosis have been poorly investigated.

In this retrospective multicenter study, we analyzed the patients’ characteristics and subsequent prognosis according to the imaging patterns of LVI at GCA diagnosis.

2. Patients and methods

2.1. Patients and subgrouping

We conducted a nationwide retrospective study in six referral centers for GCA (Caen, Limoges, Nantes, Marseille, Lille, and Paris - La Pitié Salpêtrière) and included patients if they satisfied the three following criteria: 1) a diagnosis of GCA with LVI demonstrated on imaging made between 2007 and 2017; 2) at least one large-vessel imaging was repeated during the follow-up period; and 3) patients had to be followed-up at least 6 months, unless they died earlier.

LVI was demonstrated in all patients on a CT angiography (CTA) or a magnetic resonance angiography (MRA) to have a morphological assessment of the large vessels’ lumen and these procedures were performed at diagnosis, i.e., no later than 10 days after the start of treatment. Some patients also underwent, besides CTA or MRA, a positron emission tomography with ¹⁸F-fluorodeoxyglucose (FDG) coupled with computed tomography (PET/CT) but this imaging was not sufficient for patient inclusion in this study as it is not suitable for assessing the morphology of the arterial walls.

A standardized electronic form was used to collect data in each center, and the main investigator of the study gathered the forms from the 6 centers to constitute a common database.

Based on previous publications [6–8,12,13], we distinguished three different imaging patterns of LVI present at diagnosis, some of them overlapping but the first one being present in all patients: 1) inflammation of the aorta and/or of its branches; 2) dilation of the aorta; and 3) stenosis of the aortic branches. We decided to include only patients with demonstration of inflammation on the aorta and/or its branches on imaging to reduce the risk of considering other causes of vascular abnormalities, especially atherosclerosis, in those with aortic dilation or large-vessel stenosis. We considered that aortic dilation or vascular stenosis were related to GCA only if there existed a concomitant parietal inflammation on the same considered or the adjacent arterial segments. We therefore noted in each patient which pattern(s) of LVI was observed on imaging. We did not include in this study patients with initial aortic dissection as they represent a small subset of patients with a poor vascular prognosis at diagnosis. Moreover, in most cases, GCA is fortuitously diagnosed after the aortic dissection.

Finally, a control group was constituted with patients from Caen and Limoges. We included in this control group all patients diagnosed with GCA between 2007 and 2017 with a positive temporal artery biopsy (TAB) and negative large-vessel imaging performed at diagnosis. All of them also performed at least one other imaging of the aorta during the follow-up period that did not show occurrence of large-

vessel inflammation. However, we noted in these patients if an aortic dilation or dissection appeared on imaging as well as large-vessel stenosis.

In the six centers, since many studies have shown LVI in 30–80% of GCA patients, large-vessel imaging is performed in a high proportion of patients at diagnosis, even in the absence of LVI-related symptoms. Each imaging was specifically asked to search for LVI.

This study was conducted in compliance with good clinical practices and the Declaration of Helsinki principles. In accordance with French public health law (Art. L 1121-1-1, Art. L 1121-1-2), written consent from the patient is not required for this type of retrospective study. Our local ethics committee confirmed the observational non-interventional retrospective nature of our cohort.

2.2. Studied parameters and definitions

In each patient, we analyzed demographics, cardiovascular risk factors, past history of cardiovascular ischemic disease (myocardial infarction and stroke), clinical manifestations including cranial symptoms (headaches, scalp tenderness, jaw claudication, abnormalities on the temporal artery, and visual ischemic signs), extracranial signs (limb claudication or distal limb ischemic signs, pulseless limb and vascular murmurs) and polymyalgia rheumatica (PMR). The delay between the first symptoms/signs and the diagnosis of GCA was also recorded in each group. We also recorded whether or not patients satisfied the criteria from the American College of Rheumatology (ACR) [26].

Laboratory tests and histology findings (on TAB or on extratemporal vascular sample), when available, were also recorded.

Imaging results were recorded from the initial radiological reports. Adapted from previous reports, large-vessel inflammation (i.e., aortitis and/or inflammation of aortic branches) corresponded on CTA and MRA to a circular vascular thickening ≥ 2.2 mm [1,8,27,28] +/- with contrast enhancements, and on PET/CT to a vascular uptake superior to the physiologic uptake of the liver (grade 3 according to the classification from Meller et al.) [29]. Stenotic lesions were analyzed on morphologic procedures, such as CTA or MRA, and corresponded to a reduced vascular lumen $> 50\%$. We differentiated on imaging vascular inflammation from atherosclerosis on the following points: no atheromatous plaque was observed within vascular thickening or vascular uptakes on the considered arterial segment and vascular thickening or uptakes had to be circumferential and homogeneous on imaging. Adapted from previous reports, the aortic root, aortic arch, and descending aorta were considered to be dilated when the aortic diameter was ≥ 4.5 cm, ≥ 4 cm and ≥ 3.5 cm, respectively [15]. Repetitive imaging during the follow-up period were CTA, MRA or PET/CT, and were performed in patients with initial LVI and in controls.

Treatments were analyzed, especially glucocorticoid (GC) management (starting dose, GC tapering schedule, and duration) and the use of a GC-sparing agent. The GC tapering schedule in France is not strictly standardized. However, in the absence of ischemic complications, a starting dose of 0.7 mg/kg/day is consensual and a progressive tapering is planned within the following months with the aim to discontinue GC at 12 months. However, many patients continue a maintenance prednisone dose < 5 mg/day thereafter [30]. Outcomes included the GC discontinuation rate, the occurrence of a relapse (defined as a re-occurrence of clinical signs attributable to GCA along with increased acute phase reactants that required an increase in treatment and with a subsequent clinical and biological improvement) or a GC-dependence (defined when GC dose could not be tapered below 0.30 mg/kg after 6 months or 0.20 mg/kg after 12 months and was maintained without a decrement over 2 years to assure a permanent disease control and avoid a relapsing course).

All patients included in this study were longitudinally followed-up at each hospital in a department of internal medicine and were regularly seen for medical controls by their treating physician at a frequency left to their own choice (from two to six visits per year).

Repeated imaging were performed during follow-up at time intervals left to the choice of the treating physician. No patient was lost during follow-up. In each patient (including patients with initial LVI and controls), we analyzed the occurrence of new cardiovascular complications during the follow-up period, namely, stroke, myocardial infarctions, limb or any other organ ischemia (e.g., mesenteric infarction), aortic dilation (not observed on the first imaging), aortic dissection and any vascular surgery. We differentiated vascular surgeries performed for an aortic complication (aortic root surgery or valvular surgery) from those performed for a revascularization (arterial bypass, stenting or vascular surgery for an ischemic complication). We did not analyze the progression of aortic dilations present at diagnosis but we recorded whether an aortic dissection occurred or whether a vascular surgery was required.

2.3. Statistical analyses

Categorical variables are expressed as numbers (%), and quantitative variables are expressed as medians [range]. To compare two groups, categorical variables were analyzed using the Pearson or Fisher Chi-square test, as appropriate, and quantitative variables were analyzed using Wilcoxon's rank-sum test. To compare the three subgroups of imaging patterns, we used the Chi-square for homogeneity for the categorical analyses and the Kruskal-Wallis test for quantitative variables.

A Cox proportional hazards model was used to assess predictive factors associated with new cardiovascular complications, ischemic events and aortic dilation. Hazard ratios (HRs) and 95% confidence intervals (CI) were computed for each predictor in the univariate analysis and in the multivariate model using the backward stepwise approach using variables that reached $p < 0.1$ in univariate analyses. We analyzed the cardiovascular event-free survival in patients with LVI and in controls, as well as in each different pattern of LVI using life tables and the Kaplan-Meier method, and these were compared using the log-rank test. To account for death as a possible competing event, we also compared the cumulative incidence function of cardiovascular events between LVI (and different LVI subgroups) and controls using Gray's test in a sensitivity analysis.

The statistical analyses were computed using JMP 9.0.1 (SAS Institute Inc., Cary, NC, USA). A $p \leq 0.05$ defined statistical significance, except for the survival curves pairwise comparisons between each LVI pattern and controls, in which we applied a Bonferroni correction ($p < 0.016$).

3. Results

3.1. Characteristics and imaging patterns of patients with large-vessel involvement at diagnosis

One hundred and eighty-three patients with LVI were included in this study and were compared to 105 control patients without LVI on imaging at diagnosis. Their characteristics are described and compared in Table 1. An arterial biopsy was performed in 169 patients with LVI that showed giant cell vasculitis in 110 (65%) of them, including 103/165 (62%) on TAB and 7 on large-vessel samples obtained during a vascular surgery. Among the last 7 patients, three also underwent a TAB that was negative. Twenty-nine (16%) patients with LVI on imaging had 2 ACR criteria.

At GCA diagnosis, when compared to controls, patients with LVI were younger ($p < 0.0001$) and showed less frequent cranial signs ($p < 0.0001$) but more frequent disease-related limb claudication ($p < 0.0001$). The LVI was evidenced on CTA in 101, on CTA and PET/CT in 81 and on MRA in one of them. In the control group, no LVI was evidenced on PET/CT performed in 68 patients and on CTA performed in the 37 others. Control patients underwent at least one other aorta imaging procedure at a median delay of 11 [6–134] months after GCA

Table 1

Characteristics of patients with giant cell arteritis-related large-vessel involvement compared to GCA controls without large-vessel involvement.

| | GCA patients with large-vessel involvement at diagnosis (n = 183) | GCA control patients (n = 105) | P |
|------------------------------------|---|--------------------------------|----------|
| Demographics | | | |
| Female | 128 (70) | 69 (66) | 0.46 |
| Age | 69 [50–92] | 76 [49–90] ^a | < 0.0001 |
| Cardiovascular risk factors | | | |
| Hypertension | 89 (49) | 52 (50) | 0.88 |
| Diabetes mellitus | 19 (10) | 13 (12) | 0.60 |
| Dyslipidemia | 46 (25) | 37 (35) | 0.07 |
| Tobacco use | 52 (28) | 17 (16) | 0.02 |
| Previous stroke | 5 (3) | 5 (5) | 0.37 |
| Previous coronary disease | 10 (5) | 6 (6) | 0.93 |
| Aspirin use | 144 (80) | 79 (75) | 0.50 |
| Delay of diagnosis, days | 82 [5–410] | 33 [13–180] | 0.02 |
| Clinical manifestations | | | |
| Fever | 60 (33) | 31 (30) | 0.57 |
| Any cranial sign | 121 (66) | 97 (92) | < 0.0001 |
| Headaches | 101 (55) | 79 (75) | 0.0007 |
| Jaw claudication | 38 (21) | 46 (44) | < 0.0001 |
| Scalp tenderness | 36 (20) | 52 (50) | < 0.0001 |
| Abnormalities on TA | 35 (19) | 39 (37) | 0.0008 |
| Ophthalmological signs | 28 (15) | 23 (22) | 0.16 |
| Polymyalgia rheumatica | 57 (31) | 41 (39) | 0.17 |
| Limb claudication | 48 (26) | 0 | < 0.0001 |
| ESR, mm | 80 [18–140] | 91 [11–138] | 0.53 |
| CRP, mg/l | 73 [3–312] | 89 [3–421] | 0.043 |
| Hemoglobin, g/dl | 11.1 [7.5–15.1] | 11.5 [7.4–14.7] | 0.18 |
| Positive histology | 110/169 (65) | 105 (100) | < 0.0001 |
| On TAB | 103/165 (62) | 105 (100) | < 0.0001 |

Values are number (%) or medians [range]. GCA: giant cell arteritis; TA: temporal artery; ESR: erythrocyte sedimentation rate; CRP: C-reactive protein; TAB: temporal artery biopsy.

^a The 49-year-old patient showed typical features of GCA and a positive TAB.

diagnosis that did not show inflammation of the aorta and/or its branches.

Supplementary Fig. 1 depicts the different imaging patterns observed in the 183 patients with LVI at diagnosis. All of them showed inflammation of the aorta and/or its main branches. The aorta and its main branches were affected in 117 (64%) patients, while only the aorta and only the main aortic branches were involved in 49 (27%) and 17 (9%), respectively. Isolated inflammation of the aorta and/or of its branches was the only pattern observed in 104 (57%) patients, whereas the 79 (43%) other patients also exhibited another imaging pattern (76 and 3 patients presented two and three concomitant imaging patterns, respectively). Altogether, among these 183 patients, a concomitant aortic dilation was observed in 27 (24 on the thoracic aorta and 3 on the suprarenal abdominal aorta) patients (15%), and large-vessel stenosis in 55 (30%). Locations of large-vessel stenosis are indicated in (Supplemental Table 1). Subclavian and axillary arteries were more frequently involved, both in 54% of patients. Among the 55 patients with vascular stenosis, 27 (49%) showed multiple stenoses affecting different non-adjacent arteries.

Only 3 (1.6%) of the 183 patients with LVI showed concomitant aortic dilatation and large-vessel stenosis.

When comparing the characteristics at diagnosis of the 104 patients with the pattern of isolated inflammation of the aorta and/or its branches to each other pattern (aortic dilation and large-vessel stenosis, Supplementary Fig. 1), patients with isolated inflammation of the aorta and/or of its branches presented more frequently with fever than the other patterns ($p = 0.0008$). Moreover, patients with large-vessel stenosis showed more frequent limb claudication ($p < 0.0001$) and lower

Table 2
Outcomes of patients with giant cell arteritis according to the presence of a large-vessel involvement at diagnosis.

| | Patients with large-vessel involvement at diagnosis (n = 183) | GCA control patients (n = 105) | P |
|---|---|--------------------------------|-----------------|
| GC doses, mg/kg | | | |
| At onset | 0.82 [0.50-1] | 0.73 [0.60-1.2] | 0.63 |
| At month 6 | 0.2 [0.08-0.45] | 0.18 [0.07-0.70] | 0.20 |
| At month 12 | 0.135 [0.05-0.21] | 0.115 [0.01-0.59] | 0.59 |
| Relapse | 125 (68) | 52 (50) | 0.002 |
| GC-dependence | 89 (49) | 38 (36) | 0.04 |
| GC duration, months | 28 [0-212] ^a | 23 [8-84] | 0.15 |
| Use of immunosuppressant | 54 (30) | 19 (18) | 0.03 |
| Follow-up, months | 49 [0-243] ^a | 43 [1-158] | 0.56 |
| New cardiovascular events | 89 (49) | 12 (11) | < 0.0001 |
| Delay after diagnosis, months | 30 [1-134] | 46 [1-64] | 0.68 |
| New events in the first-year post-diagnosis | 21/89 (24) | 2/12 (17) | 0.59 |
| Events occurring after 12 months | 68/89 (76) | 10/12 (83) | 0.59 |
| Any ischemic event | 39 (21) | 7 (7) | 0.001 |
| Stroke | 19 (10) | 3 (3) | 0.02 |
| Myocardial infarction | 12 (7) | 2 (2) | 0.08 |
| New aortic dilation during follow-up | 42 (23) | 4 (4) | < 0.0001 |
| New aortic dissection | 8 (4) | 0 | 0.03 |
| Vascular surgery | 34 (19) | 0 | < 0.0001 |
| Aortic surgery | 14/34 | - | - |
| Revascularization | 22/34 | - | - |
| Death | 26 (14) | 17 (16) | 0.65 |

Values are number (%) or medians [range]; GC: glucocorticoids.

^a Two patients died during the first month.

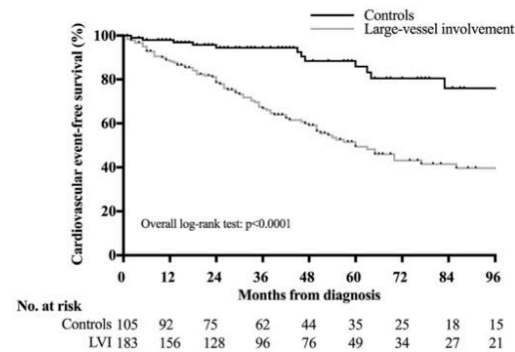


Fig. 1. Kaplan-Meier curves of cardiovascular event-free survival in patients with giant cell arteritis-related large-vessel involvement on imaging at diagnosis (gray line) and in control patients without large-vessel involvement on imaging at diagnosis (black line).

inflammatory parameters (lower CRP levels and higher hemoglobin levels, $p = 0.0002$ and $p = 0.003$, respectively). Their demographics, especially their age at GCA diagnosis, and previous cardiovascular risk factors were not different. The delay of diagnosis was not different in the three groups (data not shown).

3.2. Outcomes of patients with large-vessel involvement at diagnosis compared to control patients and according to the different imaging patterns

In Table 2, we compared the treatment regimen and the outcomes of patients with LVI to those of controls. GC doses at initiation and at months 6 and 12 were not different in both groups, nor were the GC durations. However, patients with LVI showed more frequent relapses ($p = 0.002$) and more GC-dependent disease ($p = 0.04$) than control patients, although their follow-up durations were not different (49 [0-243] months versus 43 [1-158] months, $p = 0.56$). In our study, 73 patients (54 with LVI and 19 without) were prescribed an immunosuppressant during follow-up, as a GC-sparing agent in 70 of them

(median delay of introduction: 8 [5-122] months after diagnosis). The three other patients received an immunosuppressant at GCA diagnosis following severe stenosis of the limbs. Methotrexate was the most commonly used agent, prescribed to 58 patients (79%). Tocilizumab was used in 8 patients, dapsone in 4, a TNF-alpha blocker in 2 and anakinra in 1.

New cardiovascular events occurred during the follow-up period in 89 (49%) and 12 (11%) of patients with initial LVI and controls, respectively ($p < 0.0001$), at a median delay of 30 [1-134] months after diagnosis in the former group and 46 [1-64] months in the latter ($p = 0.68$). Among all patients who experienced a new cardiovascular event, GCA was relapsing at that time in 31 (35%) out of the 89 patients with initial LVI and in one (8%) of the 12 control patients ($p = 0.06$). In patients with LVI, 13 (15%) out of the 89 patients who experienced a new cardiovascular event and 36 (38%) out of the 94 remaining patients without a cardiovascular event were receiving an immunosuppressant at the time of the event ($p = 0.0003$). The comparison of patients with LVI according to whether or not they experienced a new cardiovascular event is shown in Supplemental Table 2. Patients with new cardiovascular events were older ($p = 0.001$), showed more hypertension ($p = 0.0005$), more limb claudication ($p = 0.01$) and died more frequently (25% versus 4% in patients without cardiovascular events, $p < 0.0001$).

Fig. 1 shows poorer cardiovascular event-free survival in patients with LVI than in controls (log-rank test: $p < 0.0001$). The results of the sensitivity analyses considering death as a competing rather than censored event were consistent ($p < 0.0001$, by Gray's test) for the comparison between LVI and controls (Supplemental Fig. 2).

Ischemic events (21% in patients with LVI versus 7% in controls, $p = 0.001$), especially stroke (10% in patients with LVI versus 3% in controls, $p = 0.02$), were more frequent in patients with initial LVI. Among the 19 patients with initial LVI who experienced a stroke, the vertebrobasilar territory was affected in 14 (74%) of them. Patients with initial LVI also showed more frequently a new aortic dilation (23% in patients with LVI versus 4% in controls, $p < 0.0001$) and more frequently a new aortic dissection during follow-up (4% in patients with LVI versus none in controls, $p = 0.03$) than controls. A vascular surgery was required in 19% of the patients with initial LVI versus none in the control group ($p < 0.0001$). Histological evidence of active vasculitis was obtained in 8 of the 15 available surgical vascular samples.

Table 3
Outcomes of patients with GCA-related large-vessel involvement according to their imaging pattern.

| | Isolated inflammation of the aorta and/or its branches (n = 104) | Aortic dilation (n = 24) | Large-vessel stenoses (n = 55) | p |
|---|---|--------------------------|-----------------------------------|--------------------|
| GC doses, mg/kg | | | | |
| At onset | 0.80 [0.50–1] | 0.82 [0.52–1] | 0.82 [0.7–1] | 0.6 |
| At month 6 | 0.25 [0.09–0.44] | 0.2 [0.08–0.44] | 0.28 [0.08–0.45] | 0.35 |
| At month 12 | 0.12 [0.05–0.45] | 0.14 [0.06–0.21] | 0.15 [0.08–0.20] | 0.36 |
| Relapse | 71 (68) | 17 (71) | 37 (67) | 0.95 |
| GC-dependence | 45 (43) | 15 (63) | 29 (53) | 0.18 |
| GC duration, months | 27 [7–82] | 25 [0–118] ^a | 30 [10–212] | 0.82 |
| Immunosuppressant use | 30 (29) | 11 (46) | 13 (24) | 0.13 |
| Aspirin use | 77 (74) | 18 (75) | 49 (89) | 0.08 |
| Follow-up, months | 49 [2–190] | 48 [0–172] ^a | 50 [1–243] | 0.77 |
| New cardiovascular events | 46 (44) | 6 (25) | 37 (67) | 0.001 |
| Delay after diagnosis, months | 35 [3–134] | 117 [1–131] | 21 [1–132] | 0.07 |
| New events in the first-year post-diagnosis | 8/46 (17) | 2/6 (33) | 11/37 (30) | 0.36 |
| Events occurring after 12 months | 38/46 (83) | 4/6 (67) | 26/37 (70) | 0.36 |
| Stroke | 8 (8) | 1 (4) | 10 (18) | 0.07 |
| Myocardial infarction | 4 (4) | 0 | 8 (15) | 0.01 |
| Limb ischemia | 0 | 0 | 14 (25) | < 0.0001 |
| New aortic dilation during follow-up | 35 (34) | 0 | 7 (13) | 0.0002 |
| New aortic dissection | 2 (2) | 4 (17) | 2 (4) | 0.006 |
| Vascular surgery | 10 (10) | 3 (13) | 21 (38) | < 0.0001 |
| Aortic surgery | 8/10 (80) | 3/3 (100) | 3/21 (14) | 0.0002 |
| Revascularization | 3/10 (30) | 0 | 19/21 (90) | 0.0002 |
| Death | 10 (10) | 4 (17) | 12 (22) | 0.10 |

Values are number (%) or medians [range]; GC: glucocorticoids.

^a Two patients died during the first month.

Aspirin use at the time of the cardiovascular event did not differ between the groups.

Finally, the death rate did not differ between the groups ($p = 0.65$). Three patients with LVI died during the first month.

3.3. Clinical and radiologic outcomes of the different LVI patterns

Outcomes of patients according to the initial imaging pattern are detailed in Table 3. We included the 3 patients with concomitant aortic dilation and vascular stenosis in the group of patients with vascular stenosis (Supplementary Fig. 1). GC management did not differ between the three groups.

Regarding the occurrence of new cardiovascular events during follow-up, patients with initial large-vessel stenosis experienced a higher rate of vascular complications (in 67% of them versus $\leq 44\%$ in all other groups, $p = 0.001$), especially limb ischemia in the territory of the stenosis (25% versus none in all other groups, $p < 0.0001$) and the need for vascular surgery (38% in patients with vascular stenosis versus $\leq 13\%$ in other patients, $p < 0.0001$). Revascularization was the most frequent vascular surgery in patients with vascular stenosis (in 19 out of the 21 patients who underwent surgery). The cardiovascular event-free survival in the three patterns and in controls is shown in Fig. 2. Patients with large-vessel stenosis showed the worst outcomes (log-rank test: $p < 0.0001$). The results of the sensitivity analyses considering death as a competing rather than censored event were consistent ($p < 0.0001$, by Gray's test) for the comparison between different LVI subgroups and controls (Supplemental Fig. 3).

Patients with isolated inflammation of the aorta and/or of its branches developed more frequently new aortic dilations during the follow-up period (in 34% of them versus $\leq 13\%$ in other groups, $p = 0.0002$) on a previous inflammatory segment in 33 out of the 35 involved patients at a median delay of 33 [3–120] months after GCA diagnosis. Patients with aortic dilations at diagnosis developed more aortic dissections during the follow-up period (17% versus $\leq 4\%$ in the other groups, $p = 0.006$), at a median delay of 116 [8–131] months after GCA diagnosis and always on the previously dilated segment. At the last follow-up, the death rate was not different in the different subgroups.

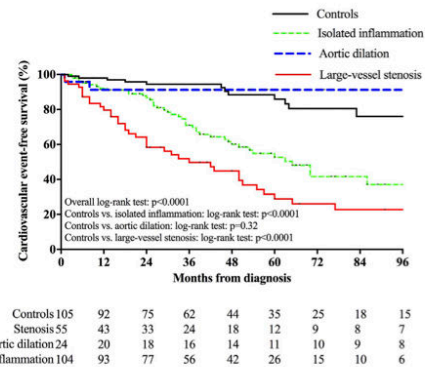


Fig. 2. Kaplan-Meier curves of cardiovascular event-free survival in patients with three patterns of giant cell arteritis-related large-vessel involvement on imaging at diagnosis and in control patients without large-vessel involvement on imaging at diagnosis.

3.4. Predictive factors associated with new cardiovascular events

Table 4 shows the uni- and multivariate analyses conducted to identify predictive factors associated with the occurrence of new cardiovascular events during the follow-up period. Diabetes (hazard ratio (HR): 2.03 [1.14–3.41], $p = 0.02$), inflammation of the aorta and/or its branches (HR: 3.42 [2.09–5.83], $p < 0.0001$) and large-artery stenosis (HR: 2.75 [1.80–4.15], $p < 0.0001$) were independent predictors. Conversely, the use of an immunosuppressant (HR: 0.44 [0.29–0.66], $p < 0.0001$) and the presence of cranial signs at diagnosis (HR: 0.64 [0.42–0.98], $p = 0.04$) were protective factors against new cardiovascular events.

Supplemental Table 3 shows the uni- and multivariate analyses conducted to identify predictive factors associated with the occurrence of new ischemic events during the follow-up. GCA-related large-artery stenosis at diagnosis (HR: 6.08 [3.44–10.87], $p < 0.0001$), previous

Table 4
Factors associated with the occurrence of new cardiovascular events in patients with GCA.

| | Univariate analysis | | Multivariate analysis | |
|---|---------------------|----------|-----------------------|----------|
| | HR [95% CI] | P | HR [95% CI] | P |
| Female | 0.90 [0.60–1.38] | 0.63 | | |
| Age | 2.25 [0.84–6.23] | 0.11 | | |
| Hypertension | 1.70 [1.14–2.55] | 0.009 | | |
| Diabetes mellitus | 1.64 [0.93–2.73] | 0.08 | 2.03 [1.14–3.41] | 0.02 |
| Dyslipidemia | 1.40 [0.92–2.11] | 0.12 | | |
| Tobacco use | 1.03 [0.64–1.59] | 0.90 | | |
| Previous stroke | 1.97 [0.60–4.75] | 0.23 | | |
| Previous coronary disease | 2.44 [1.08–4.74] | 0.03 | | |
| Aspirin use | 0.85 [0.57–1.27] | 0.14 | | |
| Delay of diagnosis | 0.54 [0.03–2.80] | 0.54 | | |
| Any cranial signs | 0.49 [0.32–0.74] | 0.001 | 0.64 [0.42–0.98] | 0.04 |
| Limb claudication | 2.03 [1.30–3.10] | 0.002 | | |
| Polymyalgia rheumatica | 0.70 [0.45–1.06] | 0.097 | | |
| C-reactive protein level | 0.71 [0.22–2.16] | 0.56 | | |
| Inflammation of aorta and/or its branches | 3.44 [2.15–5.77] | < 0.0001 | 3.42 [2.09–5.83] | < 0.0001 |
| Large-artery stenosis at diagnosis | 2.74 [1.80–4.11] | < 0.0001 | 2.75 [1.80–4.15] | < 0.0001 |
| Initial aortic dilation | 0.75 [0.35–1.42] | 0.40 | | |
| Glucocorticoid dose at diagnosis | 1.02 [0.56–1.87] | 0.76 | | |
| Glucocorticoid duration ^a | 1.57 [0.03–12.95] | 0.77 | | |
| Glucocorticoid dependency | 0.69 [0.41–1.07] | 0.13 | | |
| Immunosuppressant use | 0.61 [0.40–0.91] | 0.08 | 0.44 [0.29–0.66] | < 0.0001 |
| Total patient's follow-up duration | 0.998 [0.993–1.001] | 0.34 | | |

HR: Hazard ratio; CI: confidence interval.

^a At glucocorticoid discontinuation or at last follow-up if treatment is ongoing.

coronary disease (HR: 5.10 [2.02–11.21], $p = 0.001$), diabetes mellitus (HR: 3.61 [1.70–7.17], $p = 0.001$) and inflammation of the aorta and/or its branches at diagnosis (HR: 1.86 [1.01–3.59], $p = 0.045$) were independent predictors.

Inflammation of the aorta and/or its branches was the unique independent predictive factor associated with the occurrence of an aortic dilation during the follow-up period (HR: 9.30 [3.74–31.05], $p < 0.0001$), whereas the use of an immunosuppressant was protective (HR: 0.43 [0.23–0.77], $p = 0.005$) (Supplemental Table 4).

The small number of aortic dissections that occurred during the follow-up period did not allow a multivariate analysis to be run. However, among the eight patients with LVI who developed an aortic dissection, all of them had a previous aortitis, and 4 had an aortic dilation at onset.

Finally, multivariate analyses failed to identify predictive factors associated with complications occurring before 12 months after diagnosis (data not shown).

4. Discussion

Large-vessel involvement in GCA is proteiform and includes different clinical and imaging patterns. This distinction between the different patterns of LVI has been poorly studied, and we found some relevant findings suggesting different cardiovascular outcomes in patients with LVI. New cardiovascular events were significantly more frequently observed in patients with initial LVI when compared to control patients without LVI at diagnosis. Interestingly, GCA was relapsing, i.e., vasculitis was active, in 35% of patients with initial LVI who experienced new cardiovascular events, suggesting a possible role of GCA in the vascular event. Our study suggests a protective role of immunosuppressants in the occurrence of cardiovascular events. In patients with LVI, those who were taking an immunosuppressant showed less new cardiovascular events.

This study exhibited different subsets of new cardiovascular events according to the pattern of the initial LVI. Indeed, in accordance with previous works, we showed that aortic complications, especially aortic dilation, mainly occurred in patients with isolated inflammation of the aorta and/or its branches [15,24,25]. In addition, aortic dissection

during the follow-up period always occurred in this study in patients with previous aortic inflammation and mainly in patients with previous aortic dilation. On the other hand, ischemic events affecting visceral or limb arteries occurred mainly in patients with large-vessel stenosis and required more frequent revascularization surgeries in addition to the medical treatment. Except in patients with a vascular sample showing active vasculitis on the site of the cardiovascular event, the differential diagnosis between GCA and atherosclerosis remains difficult in front of an ischemic event in a GCA patient. However, all limb ischemia during follow-up occurred on the side where vascular stenosis was observed, and imaging showed inflammatory vascular findings rather than atherosclerosis signs. Moreover, most strokes occurring during the follow-up period in these patients affected the posterior territory, which is most often affected in GCA [31]. Interestingly, we found in multivariate analysis that the use of an immunosuppressant was a protective factor against new cardiovascular events, suggesting an effect against vascular inflammation that may favor these new vascular events in GCA. Little is known about the link and interaction between inflammation, atherosclerosis and cardiovascular complications. Although we did not observe more cardiovascular risk factors in patients with initial LVI in comparison with controls at diagnosis, diabetes mellitus and previous coronary disease were both independent predictive factors of new ischemic events, suggesting a possible pathogenic role of atherosclerosis in the occurrence of such complications. Some studies have indicated a higher risk of vascular calcifications in large-vessel vasculitis, especially in Takayasu arteritis (TAK), in areas of vascular inflammation [32–34]. Altogether, these studies support the existence of a probable link between vascular inflammation and the development of vascular calcifications. Patients with vasculitis-related large-vessel stenosis might thus have developed accelerated fibrosing atherosclerosis that leads to ischemic events. However, we did not analyze the link between microcalcifications within vessels and inflammation in this study. Our study did not analyze the impact of aspirin or statin use on the occurrence of cardiovascular events, and most of our patients already received aspirin at the time of the complication. Altogether, this observational study showed an increased risk of cardiovascular events in patients with LVI, but no conclusion can be made on the individual impact of GCA, treatments (including GCs,

immunosuppressants and cardiovascular protective drugs) and atherosclerosis in the occurrence of such events. To date, immunosuppressants are mainly used in GCA as GC-sparing agents or in the setting of a GC-dependency.

Further studies are required to determine whether treatments can be adapted according to these patterns, especially the use of immunosuppressants in the setting of LVI. Recent prospective studies dealing with anti-interleukin-6 receptors [14,35,36] or CTLA-4Ig [37] showed different outcomes, with some patients being unresponsive to these drugs. This suggests, as shown in some biological studies [12] that different cytokine networks are involved in GCA patients with LVI. Thus, a more personalized therapeutic strategy is probably required in patients with GCA, especially in those with LVI. Our finding regarding the protective impact of immunosuppressants on the occurrence of cardiovascular events in patients with LVI should be replicated in other studies.

We did not observe an increased mortality in patients with LVI when compared to controls, as already suggested in other studies [5,23,38]. The younger age of patients with LVI and the relatively short follow-up duration might explain this absence of differences.

Some limitations should be discussed. The retrospective design and the selection of patients do not allow any determination of the prevalence of the different patterns. The retrospective retrieval of data on imaging reports did not include the presence of vessels' dilation on sites other than aorta, although some studies indicated different outcomes in patients with subclavian arteries' dilations [25]. Moreover, our study did not analyze the beneficial value of Doppler ultrasonography at diagnosis and during follow-up. There probably still remains some slight differences among the different centers regarding the interpretation of imaging, especially the positivity criteria for large-vessel vasculitis. However, we used positivity criteria already used and validated in other studies [1,8,9,27,28]. Although the results from imaging were retrospectively retrieved on imaging reports and no central reviewing of imaging was performed, radiologists who performed the procedures were specifically asked to search for a GCA-related LVI. They were thus aware of the need to assess the large vessels. The absence of consensual guidelines regarding the frequency and the means of large-vessel screenings have led to heterogeneity regarding the control of aorta morphology during the follow-up period. Some cardiovascular complications were probably not captured given the relatively short follow-up period or because the repetitive imaging was performed too early to detect a complication. Some complications are described as occurring nearly 10 years after GCA diagnosis. Except in patients with vasculitis demonstration on the vascular area responsible for cardiovascular complications, the link between new cardiovascular events and GCA is uncertain. However, the different frequency of complications in different groups remains of clinical significance and is probably relevant. The mandatory criteria of inflammation of the aorta and/or its branches in the LVI group did not allow us to analyze GCA patients with isolated initial aortic dilation and those with isolated vascular stenosis. However, in the absence of any evidence of vascular inflammation, the link between GCA and aortic dilation or vascular stenosis is difficult to prove.

In the absence of recommendations regarding steroids' tapering schedule, some slight differences might exist in our patients, with a possible subsequent influence on outcomes. However, at onset, and at month 6 and 12, no significant differences of steroid doses were observed in the different groups. Given the retrospective retrieval of data, we did not record the cumulative dose of GC at the time of cardiovascular complications and one can hypothesize that patients with such complications might have higher cumulative doses.

Defining relapses by both clinical reoccurrence and increase of acute phase reactants could lead to an underestimation as some flares can occur without clinical symptoms or without increase of acute phase reactants [39].

Finally, further studies are needed to analyze patients who develop

LVI during the follow-up period, as our study only focused on patients with LVI at diagnosis. Moreover, other imaging studies dedicated to vascular outcomes under treatment are needed to assess the evolution of LVI.

In conclusion, this study highlights that large-vessel involvement in GCA includes different clinical and imaging patterns that might influence cardiovascular outcomes. In this study, the use of immunosuppressants in patients with LVI showed a protective impact on the occurrence of new cardiovascular events. A validation of this finding in other studies is required.

Sources of funding

The authors declare that they have no funding sources to disclose.

Disclosures

None.

Appendix A. Supplementary data

Supplementary data related to this article can be found at <https://doi.org/10.1016/j.jaut.2019.05.011>.

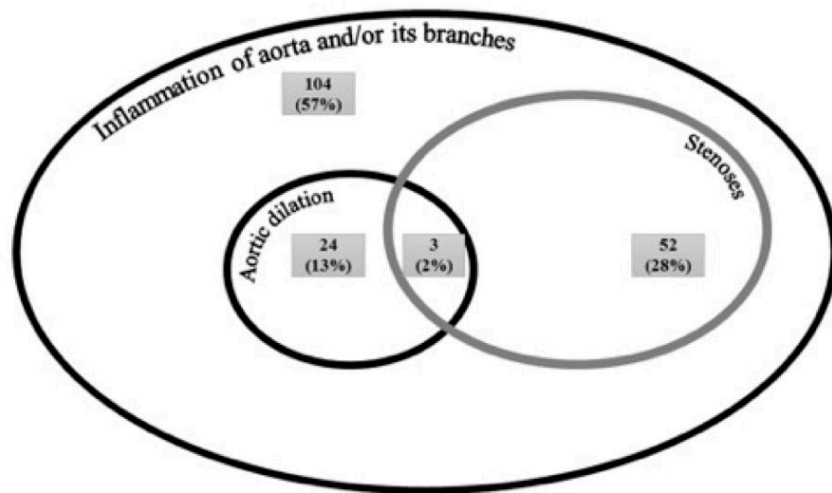
References

- [1] C. Agard, J.H. Barrier, B. Dupas, et al., Aortic involvement in recent-onset giant cell (temporal) arteritis: A case-control prospective study using helical aortic computed tomodensitometric scan, *Arthritis Rheum.* 59 (5) (2008) 670–676.
- [2] D. Blockmans, L. de Ceuninck, S. Vanderschueren, D. Knockaert, L. Mortelmans, H. Bobbaers, Repetitive 18F-fluorodeoxyglucose positron emission tomography in giant cell arteritis: A prospective study of 35 patients, *Arthritis Rheum.* 55 (1) (2006) 131–137.
- [3] H. de Boysson, E. Liozon, M. Lambert, et al., 18F-fluorodeoxyglucose positron emission tomography and the risk of subsequent aortic complications in giant-cell arteritis: A multicenter cohort of 130 patients, *Medicine* 95 (26) (2016) e3851.
- [4] A. Ghinoi, N. Pipitone, A. Nicolini, et al., Large-vessel involvement in recent-onset giant cell arteritis: A case-control colour-Doppler sonography study, *Rheumatology* 51 (4) (2012) 730–734.
- [5] T.A. Kermani, K.J. Warrington, C.S. Crowson, et al., Large-vessel involvement in giant cell arteritis: A population-based cohort study of the incidence-trends and prognosis, *Ann. Rheum. Dis.* 72 (12) (2013) 1989–1994.
- [6] R.G. Klein, G.G. Hunder, A.W. Stanson, S.G. Sheps, Large artery involvement in giant cell (temporal) arteritis, *Ann. Intern. Med.* 83 (6) (1975) 806–812.
- [7] F. Muratore, T.A. Kermani, C.S. Crowson, et al., Large-vessel giant cell arteritis: A cohort study, *Rheumatology* 54 (3) (2015) 463–470.
- [8] S. Prieto-Gonzalez, P. Arguis, A. Garcia-Martinez, et al., Large vessel involvement in biopsy-proven giant cell arteritis: Prospective study in 40 newly diagnosed patients using CT angiography, *Ann. Rheum. Dis.* 71 (7) (2012) 1170–1176.
- [9] S. Prieto-Gonzalez, M. Depetris, A. Garcia-Martinez, G. Espigol-Frigole, I. Tavera-Bahillo, B. Corbera-Bellalta, Positron emission tomography assessment of large vessel inflammation in patients with newly diagnosed, biopsy-proven giant cell arteritis: A prospective, case-control study, *Ann. Rheum. Dis.* 73 (2014) 1388–1392.
- [10] C. Assie, A. Janvresse, D. Plissonnier, H. Levesque, I. Marie, Long-term follow-up of upper and lower extremity vasculitis related to giant cell arteritis: A series of 36 patients, *Medicine* 90 (1) (2011) 40–51.
- [11] A. Bert, C. Campochiario, G. Cavalli, et al., Giant cell arteritis restricted to the limb arteries: An overlooked clinical entity, *Autoimmun. Rev.* 14 (4) (2015) 352–357.
- [12] A. Brack, V. Martinez-Taboada, A. Stanson, J.J. Goronzy, C.M. Weyand, Disease pattern in cranial and large-vessel giant cell arteritis, *Arthritis Rheum.* 42 (2) (1999) 311–317.
- [13] M.C. Cid, S. Prieto-Gonzalez, P. Arguis, et al., The spectrum of vascular involvement in giant-cell arteritis: Clinical consequences of detrimental vascular remodelling at different sites, *APMIS Suppl.* (2009) 10–20.
- [14] J.H. Stone, K. Tuckwell, S. Dimonaco, et al., Trial of tocilizumab in giant-cell arteritis, *N. Engl. J. Med.* 377 (4) (2017) 317–328.
- [15] H. de Boysson, A. Daumas, M. Vautier, et al., Large-vessel involvement and aortic dilation in giant-cell arteritis. A multicenter study of 549 patients, *Autoimmun. Rev.* 17 (4) (2018) 391–398.
- [16] C. Dejaco, C. Duftner, F. Buttgerit, E.L. Matteson, B. Dasgupta, The spectrum of giant cell arteritis and polymyalgia rheumatica: Revisiting the concept of the disease, *Rheumatology* 56 (4) (2017) 506–515.
- [17] S. Forster, F. Tato, M. Weiss, et al., Patterns of extracranial involvement in newly diagnosed giant cell arteritis assessed by physical examination, colour coded duplex sonography and FDG-PET, *Vasa* 40 (3) (2011) 219–227.
- [18] I. Marie, A. Proux, P. Duhaut, et al., Long-term follow-up of aortic involvement in giant cell arteritis: A series of 48 patients, *Medicine* 88 (3) (2009) 182–192.
- [19] D.M. Nuenninghoff, G.G. Hunder, T.J. Christianson, R.L. McClelland, E.L. Matteson,

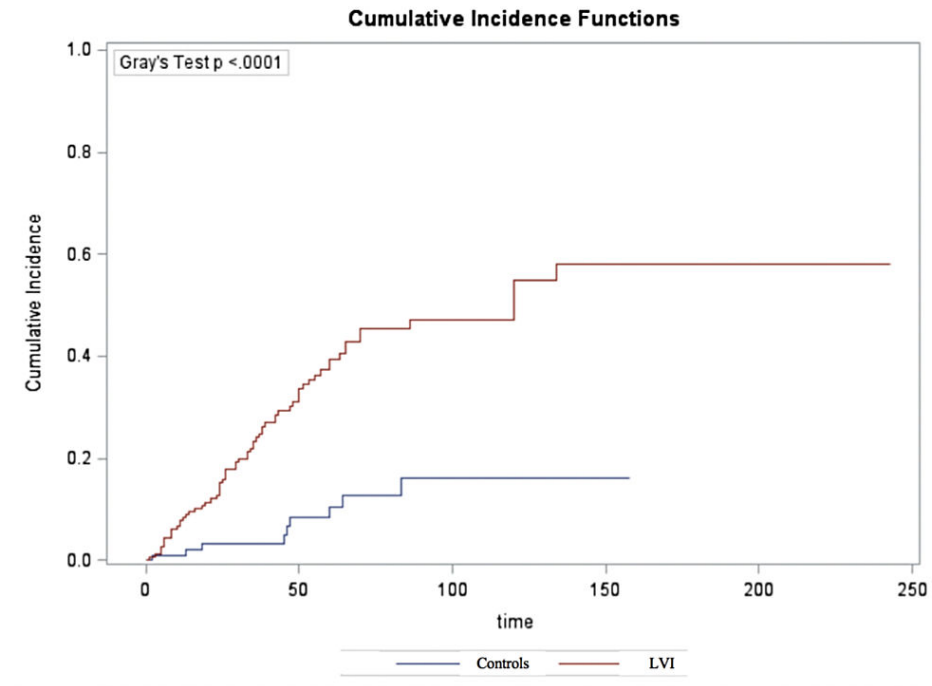
- Incidence and predictors of large-artery complication (aortic aneurysm, aortic dissection, and/or large-artery stenosis) in patients with giant cell arteritis: A population-based study over 50 years, *Arthritis Rheum.* 48 (12) (2003) 3522–3531.
- [20] J.M. Evans, C.A. Bowles, J. Bjornsson, C.J. Mullany, G.G. Hunder, Thoracic aortic aneurysm and rupture in giant cell arteritis. A descriptive study of 41 cases, *Arthritis Rheum.* 37 (10) (1994) 1539–1547.
- [21] M.A. Gonzalez-Gay, C. Garcia-Porrúa, A. Pineiro, R. Pego-Reigosa, J. Llorca, G.G. Hunder, Aortic aneurysm and dissection in patients with biopsy-proven giant cell arteritis from northwestern Spain: A population-based study, *Medicine* 83 (6) (2004) 335–341.
- [22] O. Espitia, A. Neel, C. Leux, et al., Giant cell arteritis with or without aortitis at diagnosis. A retrospective study of 22 patients with longterm followup, *J. Rheumatol.* 39 (11) (2012) 2157–2162.
- [23] J.C. Robson, A. Kiran, J. Maskell, et al., The relative risk of aortic aneurysm in patients with giant cell arteritis compared with the general population of the UK, *Ann. Rheum. Dis.* 74 (1) (2015) 129–135.
- [24] D. Blockmans, W. Coudyzer, S. Vanderschueren, et al., Relationship between fluorodeoxyglucose uptake in the large vessels and late aortic diameter in giant cell arteritis, *Rheumatology* 47 (8) (2008) 1179–1184.
- [25] F. Muratore, T.A. Kermani, C.S. Crowson, et al., Large-vessel dilatation in giant cell arteritis: A different subset of disease? *Arthritis Care Res.* 70 (9) (2018) 1406–1411.
- [26] G.G. Hunder, D.A. Bloch, B.A. Michel, et al., The American College of Rheumatology 1990 criteria for the classification of giant cell arteritis, *Arthritis Rheum.* 33 (8) (1990) 1122–1128.
- [27] P.E. Berthod, S. Aho-Gielele, P. Ornetti, et al., CT analysis of the aorta in giant-cell arteritis: A case-control study, *Eur. Radiol.* 28 (9) (2018) 3676–3684.
- [28] S. Adler, M. Sprecher, F. Wermelinger, T. Kilink, H. Bonel, P.M. Villiger, Diagnostic value of contrast-enhanced magnetic resonance angiography in large-vessel vasculitis, *Swiss Med. Wkly.* 21 (147) (2017) w14397.
- [29] J. Meller, F. Strutz, U. Siefker, et al., Early diagnosis and follow-up of aortitis with [(18)F]FDG PET and MRI, *Eur. J. Nucl. Med. Mol. Imaging* 30 (5) (2003) 730–736.
- [30] B. Bienvenu, K.H. Ly, M. Lambert, et al., Management of giant cell arteritis: Recommendations of the French study group for large vessel vasculitis (GEFA), *Rev. Med. Interne* 37 (3) (2016) 154–165.
- [31] H. de Boysson, E. Liozon, D. Larivière, et al., Giant cell arteritis-related stroke: A retrospective multicenter case-control study, *J. Rheumatol.* 44 (3) (2017) 297–303.
- [32] E. Seyahi, A. Uçul, D.C. Olgun, et al., Aortic and coronary calcifications in Takayasu arteritis, *Semin. Arthritis Rheum.* 43 (1) (2013) 96–104.
- [33] A. Gujadhur, E.R. Smith, L.P. McMahon, M. Spanger, J. Chuen, S.G. Holt, Large vessel calcification in Takayasu arteritis, *Intern. Med. J.* 43 (5) (2013) 584–587.
- [34] S. Banerjee, M. Bagheri, V. Sandfort, et al., Vascular calcification in patients with large-vessel vasculitis compared to patients with hyperlipidemia, *Semin. Arthritis Rheum.* S0049-172 (18) (2018) 30409-8.
- [35] M. Samson, H. Devilliers, K.H. Ly, et al., Tocilizumab as an add-on therapy to glucocorticoids during the first 3 months of treatment of Giant cell arteritis: A prospective study, *Eur. J. Intern. Med.* 57 (2018) 96–104.
- [36] P.M. Villiger, S. Adler, S. Kuchen, et al., Tocilizumab for induction and maintenance of remission in giant cell arteritis: A phase 2, randomised, double-blind, placebo-controlled trial, *Lancet* 387 (10031) (2016) 1921–1927.
- [37] C.A. Langford, D. Cuthbertson, S.R. Ytterberg, et al., A randomized, double-blind trial of abatacept (CTLA-4Ig) for the treatment of giant cell arteritis, *Arthritis Rheum.* 69 (4) (2017) 837–845.
- [38] A. Aouba, G.S. Chiappe, M. Eb, et al., Mortality causes and trends associated with giant cell arteritis: Analysis of the French national death certificate database (1980–2011), *Rheumatology* 57 (6) (2018) 1047–1055.
- [39] J.H. Stone, K. Tuckwell, S. Dimonaco, et al., Glucocorticoid doses and acute-phase reactants at giant cell arteritis flare in a randomized trial of tocilizumab, *Arthritis Rheum.* (2019), <https://doi.org/10.1002/art.40876>.

Supplemental material

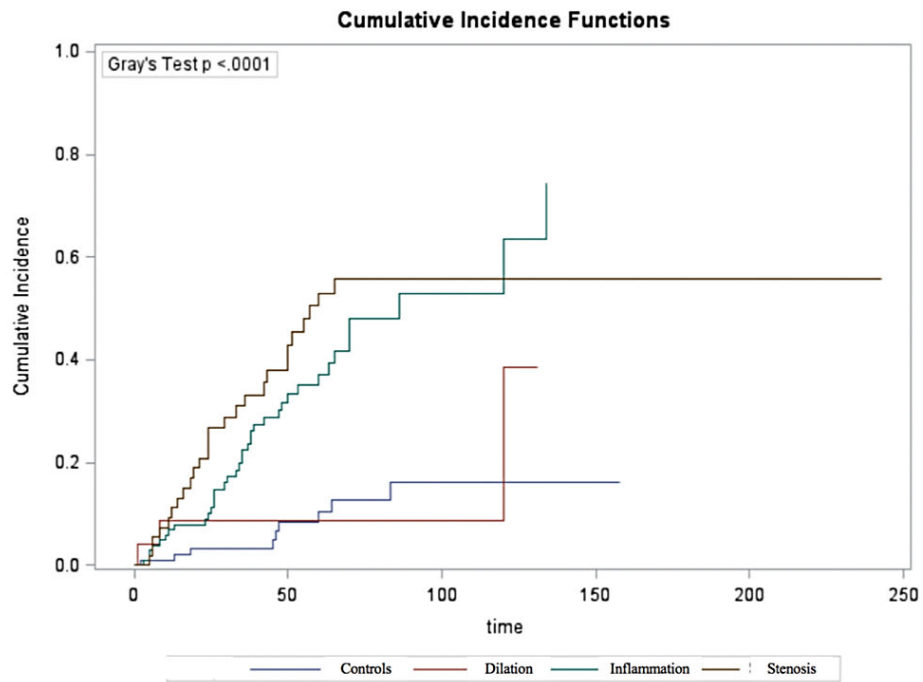
Supplementary Figure 1. The different imaging patterns of large-vessel involvement in patients with giant cell arteritis.



Supplementary Figure 2. Cumulative incidence function of cardiovascular events between LVI and controls using the Gray's test in a sensitivity analysis



Supplementary Figure 3. Cumulative incidence function of cardiovascular events between the different LVI subgroups and controls using the Gray's test in a sensitivity analysis



Supplemental Table 1. Location of large-vessel stenosis in 55 patients with GCA.

| | |
|--|---------|
| Subclavian arteries | 30 (54) |
| Axillary arteries | 30 (54) |
| Humeral arteries | 19 (35) |
| Carotids/vertebrobasilar arteries | 15 (27) |
| Iliofemoral arteries | 26 (47) |
| Lower limb arteries | 19 (35) |

Values are number (%)

Supplemental Table 2. Characteristics of patients with giant cell arteritis-related large-vessel involvement according to whether or not they experienced cardiovascular complications.

| | Cardiovascular complications during the follow-up (n=89) | No cardiovascular complications during the follow- up (n=94) | P |
|------------------------------------|--|---|---------------|
| Demographics | | | |
| Female | 61 (69) | 67 (71) | 0.69 |
| Age | 71 [49—92] | 66 [52—7] | 0.001 |
| Cardiovascular risk factors | | | |
| Hypertension | 55 (62) | 34 (36) | 0.0005 |
| Diabetes mellitus | 13 (15) | 6 (6) | 0.07 |
| Dyslipidemia | 28 (31) | 18 (19) | 0.06 |
| Tobacco use | 25 (28) | 27 (29) | 0.92 |
| Previous stroke | 4 (4) | 1 (1) | 0.15 |
| Previous coronary disease | 7 (8) | 3 (3) | 0.16 |
| Aspirin use | 71 (80) | 73 (78) | 0.73 |
| Clinical manifestations | | | |
| Fever | 25 (28) | 35 (37) | 0.19 |
| Any cranial sign | 56 (63) | 65 (69) | 0.37 |
| Ophthalmological signs | 20 (22) | 8 (9) | 0.009 |
| Polymyalgia rheumatica | 27 (30) | 30 (32) | 0.82 |
| Limb claudication | 31 (35) | 17 (18) | 0.01 |
| ESR, mm | 74 [18—140] | 92 [18—130] | 0.03 |
| CRP, mg/l | 77 [3—292] | 71 [3—312] | 0.96 |
| Positive histology | 61/85 (72) | 49/84 (58) | 0.07 |
| On TAB | 61/85 (72) | 42/80 (53) | 0.01 |
| GC doses, mg/kg | | | |
| At onset | 0.84 [0.50—1] | 0.81 [0.60—1] | 0.77 |
| At month 6 | 0.2 [0.09—0.44] | 0.21 [0.08—0.45] | 0.29 |
| At month 12 | 0.145 [0.06—0.21] | 0.125 [0.05—0.20] | 0.32 |
| Relapse | 59 (66) | 66 (70) | 0.57 |

| | | | |
|----------------------------------|------------|------------------------|-------------------|
| GC-dependence | 39 (44) | 50 (53) | 0.20 |
| GC duration, months | 25 [7—212] | 31 [0—83] ⁺ | 0.06 |
| Use of immunosuppressant* | 17 (19) | 37 (39) | 0.003 |
| Death | 22 (25) | 4 (4) | <0.0001 |

Values are number (%) or medians [range]. GCA: giant cell arteritis; TA: temporal artery; ESR: erythrocyte sedimentation rate; CRP: C-reactive protein; TAB: temporal artery biopsy;

* at lost follow-up; ⁺ Two patients died during the first month

Supplemental Table 3. Factors associated with the occurrence of ischemic events.

| | Univariate analysis | | Multivariate analysis | |
|---|----------------------|---------|-----------------------|---------|
| | HR [95% CI] | P | HR [95% CI] | P |
| Female | 0.80 [0.44—1.52] | 0.49 | | |
| Age | 4.49 [0.95—21.56] | 0.05 | | |
| Hypertension | 2.19 [1.20—4.17] | 0.01 | | |
| Diabetes mellitus | 2.72 [1.31—5.18] | 0.009 | 3.61 [1.70—7.17] | 0.001 |
| Dyslipidemia | 1.64 [0.88—2.97] | 0.12 | | |
| Tobacco use | 0.66 [0.28—1.34] | 0.26 | | |
| Previous stroke | 2.15 [0.35—7.11] | 0.35 | | |
| Previous coronary disease | 5.33 [2.16—11.39] | 0.0009 | 5.10 [2.02—11.21] | 0.001 |
| Aspirin use | 0.82 [0.56—1.27] | 0.27 | | |
| Delay of diagnosis | 0.999 [0.998—1.0003] | 0.22 | | |
| Any cranial signs | 0.66 [0.35—1.30] | 0.22 | | |
| Limb claudication | 2.70 [1.44—4.92] | 0.003 | | |
| Polymyalgia rheumatica | 0.75 [0.39—1.38] | 0.36 | | |
| C-reactive protein level | 0.44 [0.07—2.36] | 0.35 | | |
| Inflammation of aorta and/or its branches | 1.95 [1.06—3.78] | 0.03 | 1.86 [1.01—3.59] | 0.045 |
| Large-artery stenosis at diagnosis | 6.84 [3.80—12.54] | <0.0001 | 6.08 [3.44—10.87] | <0.0001 |
| Initial aortic dilation | 0.34 [0.06—1.10] | 0.08 | | |
| Glucocorticoid dose at diagnosis | 1.17 [0.85—1.58] | 0.62 | | |
| Glucocorticoid duration* | 0.997 [0.990—1.002] | 0.38 | | |
| Glucocorticoid dependency | 0.59 [0.26—1.21] | 0.16 | | |
| Immunosuppressant use | 0.56 [0.31—1.02] | 0.06 | | |
| Total patient's follow-up duration | 0.991 [0.98—0.999] | 0.03 | | |

HR: Hazard ratio; CI: confidence interval;

* at glucocorticoid discontinuation or at last follow-up if treatment is ongoing.

Supplemental Table 4. Factors associated with the occurrence of aortic dilation.

| | Univariate analysis | | Multivariate analysis | |
|---|---------------------|---------|-----------------------|---------|
| | HR [95% CI] | P | HR [95% CI] | P |
| Female | 0.73 [0.41—1.36] | 0.31 | | |
| Age | 1.21 [0.28—5.40] | 0.82 | | |
| Hypertension | 1.31 [0.74—2.39] | 0.35 | | |
| Diabetes mellitus | 1.71 [0.62—7.07] | 0.33 | | |
| Dyslipidemia | 1.04 [0.53—1.94] | 0.90 | | |
| Tobacco use | 1.42 [0.73—2.61] | 0.29 | | |
| Previous stroke | 1.18 [0.07—5.48] | 0.87 | | |
| Previous coronary disease | 1.31 [0.73—2.67] | 0.24 | | |
| Aspirin use | 0.92 [0.72—1.42] | 0.64 | | |
| Delay of diagnosis | 2.03 [0.11—11.84] | 0.54 | | |
| Any cranial signs | 0.56 [0.31—1.08] | 0.08 | | |
| Limb claudication | 1.46 [0.69—2.85] | 0.31 | | |
| Polymyalgia rheumatica | 0.62 [0.31—1.16] | 0.14 | | |
| C-reactive protein level | 0.82 [0.15—3.85] | 0.82 | | |
| Inflammation of aorta and/or its branches | 8.16 [3.30—27.14] | <0.0001 | 9.30 [3.74—31.05] | <0.0001 |
| Large-artery stenosis at diagnosis | 1.12 [0.40—2.07] | 0.97 | | |
| Glucocorticoid dose at diagnosis | 1.27 [0.80—1.47] | 0.41 | | |
| Glucocorticoid duration* | 4.77 [0.04—4249] | 0.41 | | |
| Glucocorticoid dependency | 0.66 [0.30—1.62] | 0.25 | | |
| Immunosuppressant use | 0.54 [0.30—0.98] | 0.03 | 0.43 [0.23—0.77] | 0.005 |
| Total patient's follow-up duration | 4.56 [0.03—43.36] | 0.43 | | |

HR: Hazard ratio; CI: confidence interval;

* at glucocorticoid discontinuation or at last follow-up if treatment is ongoing.

5 – Comment les critères de classification de l’ACG édités en 1990 pourraient-ils être améliorés en considérant le nouveau paradigme d’aorto-artérite ?

Les travaux que nous avons menés auparavant indiquent que 20% des patients ont une présentation atypique de la maladie et qu’environ 50% des patients auraient une atteinte, plus ou moins symptomatique, des gros vaisseaux [59, 62]. Les critères de classification de l’ACR, parfaitement adaptés aux présentations historiques typiques de la maladie, ne permettent pas d’intégrer les manifestations atypiques, en particulier les atteintes symptomatiques ou non des gros vaisseaux. Bien que chacun des items des critères de l’ACR 1990 ait théoriquement le même poids, le critère histologique, c’est-à-dire de démonstration de la vascularite, reste le critère le plus fort.

Dans ce travail, nous avons appliqué les critères de l’ACR 1990 aux 111 patients prospectivement diagnostiqués et suivis pour une ACG dans notre service entre 2015 et 2018. Nous avons pu analyser l’inadéquation de ces critères pour les patients avec une présentation atypique de la maladie ou ceux avec une atteinte inflammatoire des gros vaisseaux. Ces patients ont tous bénéficié d’une prise en charge standardisée avec recueil de données homogénéisées et bilan paraclinique pré-établi, notamment incluant une imagerie systématique des gros vaisseaux. Les différents sous-groupes de patients individualisés dans nos travaux précédents ont été analysés à la lumière de ces critères ACR 1990.

Nous proposons dans ce travail une version actualisée des critères de classification permettant d’intégrer les différents spectres clinico-radiologiques de l’ACG et de renforcer la démonstration de l’inflammation vasculaire à l’histologie ou à l’imagerie (temporale ou des gros vaisseaux).

La présentation de l’ACG était typique, c’est-à-dire crânienne chez 76% des patients. Appliqués à toute la cohorte, ≥ 3 critères ACR étaient présents chez 93 (84%) patients, dont 70 (63%) avec le critère histologique. Il en résulte que 23 patients avec ≥ 3 critères ACR n’avaient pas le critère histologique et que les 18 autres patients avaient moins de 3 critères de l’ACR. Parmi ces 18 patients, 13 avaient une démonstration de vascularite, notamment une histologie aortique chez 2, une imagerie des gros vaisseaux chez 12 et un Doppler des artères temporales évocateur chez 2. Pour les 24% des patients avec une présentation initiale atypique, les critères de l’ACR étaient satisfaits chez moins de 56% d’entre eux.

Afin de réduire le nombre de patients avec ≥ 3 critères ACR mais sans preuve de vascularite (n=23, 21% de la cohorte) et le nombre de patients ne satisfaisant pas les critères ACR alors

qu'il existait à l'évidence une inflammation vasculaire sur un examen non pris en compte dans les critères ACR 1990 (n=13, 12% de la cohorte), nous proposons les critères actualisés suivants :

- 1) Age > 50 ans et présence d'un syndrome inflammatoire biologique. Cette condition était remplie chez 109/111 patients
- 2) Présence d'un symptôme crânien, incluant ceux relatifs à une atteinte ophtalmologique, et/ou présence de signes de PPR. Cette condition était remplie chez 92% des patients
- 3) Démonstration d'une vascularite temporale à la biopsie ou au Doppler. Ce critère était observé chez 69% des patients
- 4) Démonstration d'une vascularite des gros vaisseaux à l'imagerie ou à l'histologie. Ce critère était satisfait chez 36% des patients.

Appliqués à la cohorte, 90/111 (81%) des patients avaient une preuve de vascularite (critère 3 et/ou 4). Les 21 autres patients combinaient les critères 1 et 2, sauf un patient avec une forme systémique. Au moins deux critères étaient observés chez 110/111 patients.

En analysant les différents spectres cliniques de l'ACG, plus des trois quarts des patients dans chaque sous-groupe avaient une démonstration de vascularite, à l'histologie ou à l'imagerie.

Hubert de Boysson, Anael Dumont, Samuel Deshayes, Alexandra Audemard-Verger, Jonathan Boutemy, Nicolas Martin Silva, Gwénola Maigné, Audrey Sultan, Alain Manrique, Achille Aouba

Integration of clinical patterns and imaging in the classification criteria of giant-cell arteritis:
Propositions from a monocentric prospective real-life cohort

J Autoimmun. 2019 Nov ; *Submitted*

Manuscript Details

| | |
|--------------------------|---|
| Manuscript number | YJAUT_2019_637 |
| Title | Integration of clinical and imaging patterns in the classification criteria of giant-cell arteritis: Propositions from a monocentric prospective real-life cohort |
| Article type | Research Paper |

Abstract

The 1990 classification criteria from the American College of Rheumatology (ACR) for giant-cell arteritis (GCA) appears outdated and insufficient in light of the different patterns of the disease. An update of this classification is thus required. We analysed a monocentric prospective cohort of 111 consecutive patients diagnosed with GCA between 2015 and 2018 who underwent a standardized diagnostic work-up including temporal artery biopsy (TAB), large-vessel vasculitis (LVV) research on imaging and temporal artery sonography. The different disease patterns were thereby confronted to the ACR criteria and were used to propose updated classification criteria. The >3 ACR criteria were satisfied in 80/84 (95%) patients with cranial presentation, 1/3 (33%) patients with isolated limb involvement, 3/8 (38%) patients with isolated PMR and vasculitis demonstration, and 9/16 (56%) patients with systemic presentation. Among the 93 patients with >3 ACR criteria, 70 (75%) had vasculitis demonstration on TAB. Subsequently, 23 patients with >3 ACR criteria had negative TAB and the remaining 18 only satisfied 2 ACR criteria, including 13 with vasculitis demonstration other than TAB. The updated classification criteria we propose are: 1) Age>50 and increased acute phase reactants; 2) Cranial symptoms and/or polymyalgia rheumatica; 3) Temporal vasculitis on TAB or Doppler sonography; 4) LVV on imaging or histology. Using this classification, 90/111 (81%) patients showed a vasculitis demonstration (at least the third and/or the fourth criterion) and 110/111 (99%) had at least 2 criteria. The satisfaction of the ACR criteria is problematic in patients with atypical presentations. We therefore propose 4 updated criteria that cover a broader spectrum of GCA patterns.

| | |
|---|---|
| Keywords | Giant-cell arteritis; ACR criteria; clinical patterns; large-vessel vasculitis; updated criteria |
| Manuscript category | Research paper |
| Corresponding Author | Hubert de Boysson |
| Corresponding Author's Institution | Caen University Hospital |
| Order of Authors | Hubert de Boysson, Anael Dumont, Samuel Deshayes, Alexandra Audemard-Verger, Jonathan Boutemy, Nicolas Martin Silva, Gwénola Maigné, Audrey Sultan, Alain Manrique, Achille Aouba |

Submission Files Included in this PDF

File Name [File Type]

Cover letter.docx [Cover Letter]

Highlights.docx [Highlights]

Manuscript.docx [Manuscript File]

Figure 1.tif [Figure]

Figure 2.tif [Figure]

Figure 3.tif [Figure]

To view all the submission files, including those not included in the PDF, click on the manuscript title on your EVISE Homepage, then click 'Download zip file'.

Research Data Related to this Submission

There are no linked research data sets for this submission. The following reason is given:
Data will be made available on request

Integration of clinical and imaging patterns in the classification criteria of giant-cell arteritis: Propositions from a monocentric prospective real-life cohort

Hubert de Boysson^{1,2,3}, MD, MSc, Anael Dumont^{1,2}, MD, MSc, Samuel Deshayes^{1,2}, MD, MSc, Alexandra Audemard-Verger^{1,2}, MD, PhD, Jonathan Boutemy¹, MD, Nicolas Martin Silva¹, MD, Gwénola Maigné¹, MD, Alain Manrique^{3,4}, MD, PhD, Achille Aouba^{1,2,3}, MD, PhD

¹Department of Internal Medicine, Caen University Hospital, Caen, France.

²Normandie University, UNICAEN, Caen, France.

³Normandie University, UNICAEN, EA 4650, GIP Cyceron, Caen, France.

⁴Department of Nuclear Medicine, Caen University Hospital, Caen, France.

Address for correspondence: Hubert de Boysson, MD, MSc, Department of Internal Medicine, Caen University Hospital, Avenue de la Côte de Nacre, 14000 Caen, France. (Tel.): +33 2 31 06 45 79; (Fax): +33 2 31 61 49 54; (e-mail address): deboysson-h@chu-caen.fr

Source of funding

The authors declare that they have no funding sources to disclose.

Disclosures

None

ABSTRACT

The 1990 classification criteria from the American College of Rheumatology (ACR) for giant-cell arteritis (GCA) appears outdated and insufficient in light of the different patterns of the disease. An update of this classification is thus required.

We analysed a monocentric prospective cohort of 111 consecutive patients diagnosed with GCA between 2015 and 2018 who underwent a standardized diagnostic work-up including temporal artery biopsy (TAB), large-vessel vasculitis (LVV) research on imaging and temporal artery sonography. The different disease patterns were thereby confronted to the ACR criteria and were used to propose updated classification criteria.

The ≥ 3 ACR criteria were satisfied in 80/84 (95%) patients with cranial presentation, 1/3 (33%) patients with isolated limb involvement, 3/8 (38%) patients with isolated PMR and vasculitis demonstration, and 9/16 (56%) patients with systemic presentation. Among the 93 patients with ≥ 3 ACR criteria, 70 (75%) had vasculitis demonstration on TAB. Subsequently, 23 patients with ≥ 3 ACR criteria had negative TAB and the remaining 18 only satisfied 2 ACR criteria, including 13 with vasculitis demonstration other than TAB. The updated classification criteria we propose are: 1) Age > 50 and increased acute phase reactants; 2) Cranial symptoms and/or polymyalgia rheumatica; 3) Temporal vasculitis on TAB or Doppler sonography; 4) LVV on imaging or histology. Using this classification, 90/111 (81%) patients showed a vasculitis demonstration (at least the third and/or the fourth criterion) and 110/111 (99%) had at least 2 criteria.

The satisfaction of the ACR criteria is problematic in patients with atypical presentations. We therefore propose 4 updated criteria that cover a broader spectrum of GCA patterns.

KEYWORDS

Giant-cell arteritis; ACR criteria; clinical patterns; large-vessel vasculitis; updated criteria

1. INTRODUCTION

Giant cell arteritis (GCA) is the more frequent systemic vasculitis in patients over 50. Involvement of cephalic vessels explains the typical cranial signs, such as headache, scalp tenderness, jaw claudication, or visual symptoms. Polymyalgia rheumatica (PMR) is frequently associated and affects around one third of patients with GCA. Involvement of the aorta and its branches on imaging affects 30 to 80% of patients, often silently [1-14]. Histological evidence of vasculitis, typically on temporal artery biopsy (TAB), or more rarely on an extra-temporal arterial sample, bolsters confidence in the diagnosis. In patients with negative or absent biopsy, GCA diagnosis relies on clinical symptoms and the response to glucocorticoids. Doppler sonography of the temporal arteries and large-vessel imaging are more widely used to evidence vasculitis, even replacing the histological criterion in some studies [15].

Historically, to ensure a consensual and homogeneous definition of patients with GCA in studies, the classification criteria from the American College of Rheumatology (ACR) established in 1990 were edited and are still used in studies [16]. However, only clinical and histological features affecting the cranial area are considered in these criteria and some patients can satisfy 3 of the criteria required to be diagnosed with GCA despite the absence of any vasculitis demonstration.

Given the high diagnostic value of vasculitis demonstration on TAB or large-vessel imaging, some studies do not use the ACR criteria and only include patients with biopsy-proven diagnosis or with signs of vasculitis on imaging, especially on temporal arteries or large vessels [17, 18].

ACR classification criteria do not take into consideration some frequent cranial and extra-cranial involvements, especially ophthalmologic signs, PMR or large-vessel vasculitis (LVV), although these are very suggestive of GCA in a patient over 50 with increased acute phase

reactants. This classification thus appears outdated and insufficient in light of the different patterns of GCA, especially the atypical forms of the disease, including the new paradigm of aorto-arteritis, or clinically isolated PMR or systemic presentations of GCA, i.e. isolated fever and/or biologic inflammatory syndrome of unknown origin, that can be associated with clinically silent LVV [8, 19].

In this monocentric prospective study, we included every new GCA patient within a timeframe of 4 years (2015-2018). All patients had a broad work-up including large-vessel imaging at diagnosis. We thus aimed to produce a real-life picture of GCA, detailing the different clinical and radiological patterns of the disease. We analysed the application of the ACR criteria within the cohort and discussed their limitations. Finally, we brainstormed ways to modify the ACR criteria in a near future to cover the spectrum of the disease.

2. PATIENTS AND METHODS

2.1 Study population

Since 2015, in our tertiary referral center for GCA in Northwestern France (Caen University Hospital), all patients admitted in our department with suspected GCA undergo a standardized work-up. Every patient undergoes at least a TAB (unless a sample on an extra-temporal area showed giant cell vasculitis), a large-vessel imaging and a sonography of the temporal arteries. Given the medical emergency to start glucocorticoids in patients with ischemic complications, some procedures might be performed after treatment initiation. From January 2015 to December 2018, 111 patients were diagnosed and followed-up with GCA in our department.

GCA was diagnosed in each patient after a clinical examination and based on the results of laboratory tests, TAB or large-vessel imaging, and treatment response. In patients with

negative TAB, diagnosis was reassessed during follow-up and was not eventually modified in any patient from the cohort. No patient was lost to follow-up.

2.2 Studied parameters

Since 2015, at GCA diagnosis in our department, a standardized database is used to collect the following data: demographics, age at diagnosis, cardio-vascular risk factors including previous stroke or coronary disease, clinical symptoms at onset including at least headaches, scalp tenderness, jaw claudication, abnormalities on the temporal artery, visual symptoms, polymyalgia rheumatica (PMR), fever, symptoms suggestive of large-vessel involvement (limb claudication, extra-cardiac vascular bruit). Laboratory tests included at least the values of erythrocyte sedimentation rate (ESR), C-reactive protein (CRP) and hemoglobin level. Histology results were recorded. Imaging performed included temporal artery sonography and a research of LVV on at least one of the 3 following imaging tools: CT angiography (CTA) of the aorta and its branches, positron emission tomography coupled to a CT scan (PET/CT) or aortic MR angiography (MRA).

Adapted from previous studies, we considered four different patterns of GCA at diagnosis: 1) the typical cranial presentation, provided that at least one of the cephalic symptoms, including ophthalmologic signs were present, whether extracranial signs were present or not; 2) the systemic presentation when patients had isolated fever and/or increased acute phase reactants without cranial or extra-cranial signs; 3) the isolated involvement of peripheral large-vessels without cranial symptoms; and 4) isolated PMR but with demonstration of vasculitis on TAB or imaging [19].

Finally, in patients demonstrating LVV findings on imaging, idiopathic aortitis, idiopathic retroperitoneal fibrosis, IgG4 disease, Erdheim-Chester disease, syphilis, tuberculosis, and chronic infections, especially *Coxiella*, were systematically ruled out.

This study was conducted in compliance with good clinical practices and the Declaration of Helsinki principles. In accordance with French public health law (Art. L 1121-1-1, Art. L 1121-1-2), written consent from the patient is not required for this type of retrospective study. Our local ethics committee confirmed the observational non-interventional retrospective nature of our cohort.

2.3 Statistical analyses

Categorical variables were expressed as the number (%) and quantitative variables as median (range). No statistical analyses were performed in this study.

3. RESULTS

3.1 Description of the GCA population

The characteristics of the 111 patients are shown in Table 1. The typical cranial presentation of the disease was observed in 84 (76%) patients, while the 27 (24%) others showed other patterns: isolated peripheral large-vessel involvement without cranial signs (n=3), isolated PMR with vasculitis demonstration on TAB or on imaging (n=8) or systemic presentation, i.e., isolated fever and/or increased inflammatory parameters without other symptoms (n=16).

Diagnosis of vasculitis was evidenced on histology in 72 (65%) patients, including on TAB in 70 and on an aorta samples in 2 others. Among the 39 patients without positive

histology, 13 (33%) demonstrated LVV on imaging. In the other 26 patients without positive histology or LVV on imaging, 20 satisfied at least 3 ACR criteria and 6 satisfied only 2 ACR criteria. Among these last six patients who were >50 years old and had increased acute phase reactants, 4 had ophthalmologic involvement without headaches and the 2 others had jaw claudication without other cranial symptoms. These 6 patients with 2 ACR criteria responded to glucocorticoids. Of note, 3 out of these 6 patients relapsed with secondary occurrence of headaches and increased inflammatory parameters.

A temporal artery sonography was performed in 105/111 patients and showed a typical halo sign in 46 (44%). TAB was positive in 39/46 (85%) patients with a halo sign, and in 29/59 (49%) with negative sonography.

All patients had LVV research on imaging. The procedure was performed before or in the 15 days following treatment initiation in 91 (82%) of them, and showed LVV in 32 (35%). The 20 others underwent imaging at a delay of 45 [35—96] days after diagnosis, and 8 (40%) showed LVV. Altogether, 40 (36%) patients demonstrated LVV in our study.

3.2 Application and limitations of the ACR criteria in our cohort

The application of the ACR criteria is shown in Table 2. All patients were >50 years old and showed increased acute phase reactants except two patients with a biopsy proven diagnosis who had normal ESR and CRP at diagnosis.

The satisfaction of at least 3 ACR criteria was observed in 93 (84%) patients including 70 (63%) who had a vasculitis demonstration on TAB (Figure 1, patients in grey boxes). Subsequently, 23 patients with ≥ 3 ACR criteria did not have a positive TAB and the remaining 18 patients only satisfied 2 ACR criteria. The ≥ 3 ACR criteria were satisfied in 80 (95%) patients with cranial presentation, in 1 (33%) patient with isolated limb involvement, in 3 (38%)

patients with isolated PMR with vasculitis demonstration and in 9 (56%) patients with systemic presentation.

Among the 23 (21%) patients with ≥ 3 ACR criteria but negative TAB, 7 had a vasculitis demonstration, including 5 with a bilateral halo sign on the temporal artery Doppler sonography and 3 with LVV on imaging (one patient had both). Among the 18 (16%) patients with 2 ACR criteria, 13 had a vasculitis demonstration: 2 had a positive histology on an aorta sample, 12 had LVV on imaging and 2 showed abnormal temporal sonography findings.

3.3 Toward updated criteria

In order to reduce the number of patients without positive TAB but who satisfied the ACR criteria for GCA classification (n=23, 21% of our cohort) or patients who did not satisfy the ACR criteria for GCA classification although they showed vasculitis on imaging or histology (n=13, 12% of our cohort), we computed modified criteria for classification. For this purpose, we took into consideration: 1) the actual tools used to demonstrate vasculitis, especially histology, large-vessel imaging or temporal artery sonography; 2) the frequent symptoms suggestive of GCA (visual signs, jaw claudication and PMR). We thus proposed four modified criteria that are shown in Table 3 and Figure 2.

The first criterion pools together the age above 50 and the increased inflammatory parameters, considering that both criteria should be mandatory for GCA classification. In the present cohort, only two patients did not satisfy this requirement.

The second updated and composite criteria is clinical and includes at least one of the following clinical signs: a cranial sign (namely headaches, temporal artery abnormalities, scalp tenderness, jaw claudication, or visual signs) and/or PMR. This criterion was observed in 92 (83%) of our patients.

The third updated criterion corresponds to the demonstration of a temporal vasculitis on TAB and/or on sonography. This criterion was observed in 77 (69%) of our patients.

Finally, the fourth updated criterion regards the demonstration of LVV on imaging and/or on histology (on aorta or large-vessel biopsy). This criterion was observed in 40 (36%) of our patients.

Altogether, using these classification criteria, 81% (90/111 patients), versus 63% when using the ACR criteria, of patients showed a vasculitis demonstration on histology or imaging, i.e. had the third and/or the fourth criterion (Figure 2, patients in grey boxes). The 21 (19%) other patients without vasculitis demonstration satisfied the first two updated criteria (except one patient who met only one criterion), i.e. age>50, increased acute phase reactants and cranial or PMR signs. The patient with only one criterion had a systemic presentation of GCA with negative initial work-up, responded to glucocorticoids and developed LVV 3 years after diagnosis. Of note, 16/21 patients without vasculitis demonstration satisfied at least 3 ACR criteria.

Using these updated criteria, vasculitis was demonstrated in 64 (76%) patients with cranial presentation, in 3 (100%) patients with isolated limb involvement, in 8 (100%) with isolated PMR with vasculitis demonstration and in 15 (94%) patients with systemic presentation (Figure 3).

The diagnosis of GCA may thus be considered in all patients with at least two of the four updated criteria. In our cohort, 110 (99%) patients satisfied this condition.

4. DISCUSSION

The need to update the ACR criteria for GCA has been discussed for years, notably to include the clinical and radiological spectrum of the disease, as different patterns were not individualized in 1990 [6, 8, 19-21]. The present study highlights that ACR criteria are often satisfied in patients with typical cranial patterns, but not in most patients with other patterns. For the last few years, the demonstration of vasculitis on TAB or imaging of temporal arteries and aorta has become more relevant than the ACR criteria for inclusion in studies [18].

Our study therefore highlights, in a real-life cohort of GCA patients, that ACR criteria are not adapted for all patients. The updated classification for GCA we propose is especially focused on the demonstration of vasculitis and integrated current imaging tools used in practice. Herein, 16% (18/111) of patients only had 2 ACR criteria and would not have been included in previous studies although 13 of them had demonstration of vasculitis. Conversely, up to 21% (23/111) would be included as they satisfied ≥ 3 ACR classification criteria, although they did not show positive TAB. Applying the ACR classification criteria to the whole cohort, 84% (93/111) of patients had a high probability of suffering from GCA but only 63% (70/111) had a certain diagnosis as they demonstrated vasculitis on TAB. Using the proposed updated criteria diagnostic certainty increased up to 81%. The four updated criteria we suggest also offer the possibility to consider every different clinical and radiological pattern of GCA. Moreover, they include other typical symptoms observed in GCA such as jaw claudication, ophthalmologic signs or PMR, that were not considered in the initial ACR criteria. These updated criteria also include the results of imaging tools commonly used in practice such as temporal artery Doppler sonography or large-vessel imaging.

Histological evidence of vasculitis remains the gold-standard for GCA diagnosis. However, in a patient >50 with increased acute phase reactants, GCA diagnosis is highly probable when imaging demonstrates a halo sign on Doppler sonography or LVV on large-

vessel imaging. The value of the halo sign can be controversial as false positives can be observed but 85% of patients with a positive halo sign also had a positive TAB in our study [22].

However, 19% of our patients lacked vasculitis demonstration on histology or imaging. The diagnosis in these patients is less certain but the clinical presentation, response to glucocorticoids and follow-up was very suggestive of GCA. Moreover, more than three quarters of these patients would satisfy the ≥ 3 ACR criteria.

Some limitations should be discussed. This cohort only enrolled patients with a certain GCA diagnosis and did not include patients with suspected diagnosis. Subsequently, the sensitivity, specificity and predictive values of these updated criteria cannot be calculated. Although all our patients underwent a large-vessel imaging, some procedures were performed after treatment initiation, which might reduce the ability to detect LVV in some of them [23].

To conclude, we propose updated GCA classification criteria that include a wide spectrum of GCA patterns with more or less typical clinical and radiological presentations and specifically focus on the demonstration of vasculitis, on histology or imaging. This monocentric prospective study remains preliminary but opens the way to further brainstorming on a homogenization of criteria defining the new aspects of GCA. Further international efforts are required to validate these results.

REFERENCES

1. Agard C, Barrier JH, Dupas B, Ponge T, Mahr A, Fradet G, et al. Aortic involvement in recent-onset giant cell (temporal) arteritis: a case-control prospective study using helical aortic computed tomodensitometric scan. *Arthritis Rheum*. 2008;59(5):670-6.
2. Berthod PE, Aho-Glele S, Ornetti P, Chevallier O, Devilliers H, Ricolfi F, et al. CT analysis of the aorta in giant-cell arteritis: a case-control study. *Eur Radiol*. 2018;28(9):3676-84.
3. Blockmans D. Diagnosis and extension of giant cell arteritis. Contribution of imaging techniques. *Presse Med*. 2012;41(10):948-54.
4. Bongartz T, Matteson EL. Large-vessel involvement in giant cell arteritis. *Current opinion in rheumatology*. 2006;18(1):10-7.
5. Brack A, Martinez-Taboada V, Stanson A, Goronzy JJ, Weyand CM. Disease pattern in cranial and large-vessel giant cell arteritis. *Arthritis and rheumatism*. 1999;42(2):311-7.
6. Cid MC, Prieto-Gonzalez S, Arguis P, Espigol-Frigole G, Butjosa M, Hernandez-Rodriguez J, et al. The spectrum of vascular involvement in giant-cell arteritis: clinical consequences of detrimental vascular remodelling at different sites. *APMIS Suppl*. 2009:10-20.
7. Conway R, Smyth AE, Kavanagh RG, O'Donohoe RL, Purcell Y, Heffernan EJ, et al. Diagnostic Utility of Computed Tomographic Angiography in Giant-Cell Arteritis. *Stroke*. 2018;49(9):2233-6.
8. Dejaco C, Duftner C, Buttgereit F, Matteson EL, Dasgupta B. The spectrum of giant cell arteritis and polymyalgia rheumatica: revisiting the concept of the disease. *Rheumatology*. 2017;56(4):506-15.
9. Duftner C, Dejaco C, Sepriano A, Falzon L, Schmidt WA, Ramiro S. Imaging in diagnosis, outcome prediction and monitoring of large vessel vasculitis: a systematic literature review and meta-analysis informing the EULAR recommendations. *RMD Open*. 2018;4(1):e000612.
10. Ghinoi A, Pipitone N, Nicolini A, Boiardi L, Silingardi M, Germano G, et al. Large-vessel involvement in recent-onset giant cell arteritis: a case-control colour-Doppler sonography study. *Rheumatology*. 2012;51(4):730-4.
11. Hautzel H, Sander O, Heinzl A, Schneider M, Muller HW. Assessment of large-vessel involvement in giant cell arteritis with 18F-FDG PET: introducing an ROC-analysis-based cutoff ratio. *J Nucl Med*. 2008;49(7):1107-13.
12. Kermani TA, Warrington KJ, Crowson CS, Ytterberg SR, Hunder GG, Gabriel SE, et al. Large-vessel involvement in giant cell arteritis: a population-based cohort study of the incidence-trends and prognosis. *Annals of the rheumatic diseases*. 2013;72(12):1989-94.
13. Klein RG, Hunder GG, Stanson AW, Sheps SG. Large artery involvement in giant cell (temporal) arteritis. *Annals of internal medicine*. 1975;83(6):806-12.
14. de Boysson H, Liozon E, Espitia O, Daumas A, Vautier M, Lambert M, et al. Different patterns and specific outcomes of large-vessel involvements in giant cell arteritis. *J Autoimmun*. 2019;103:102283.
15. Schmidt WA. Doppler ultrasonography in the diagnosis of giant cell arteritis. *Clin Exp Rheumatol*. 2000;18(4 Suppl 20):S40-2.
16. Hunder GG, Bloch DA, Michel BA, Stevens MB, Arend WP, Calabrese LH, et al. The American College of Rheumatology 1990 criteria for the classification of giant cell arteritis. *Arthritis and rheumatism*. 1990;33(8):1122-8.
17. Gonzalez-Gay MA, Miranda-Filloo JA, Lopez-Diaz MJ, Perez-Alvarez R, Gonzalez-Juanatey C, Sanchez-Andrade A, et al. Giant cell arteritis in northwestern Spain: a 25-year epidemiologic study. *Medicine*. 2007;86(2):61-8.
18. Stone JH, Tuckwell K, Dimonaco S, Klearman M, Aringer M, Blockmans D, et al. Trial of Tocilizumab in Giant-Cell Arteritis. *N Engl J Med*. 2017;377(4):317-28.
19. de Boysson H, Liozon E, Ly KH, Dumont A, Delmas C, Aouba A. The different clinical patterns of giant cell arteritis. *Clin Exp Rheumatol*. 2019;37 Suppl 117(2):57-60.

20. Seeliger B, Sznajd J, Robson JC, Judge A, Craven A, Grayson PC, et al. Are the 1990 American College of Rheumatology vasculitis classification criteria still valid? *Rheumatology*. 2017;56(7):1154-61.
21. Neshar G. The diagnosis and classification of giant cell arteritis. *J Autoimmun*. 2014;48-49:73-5.
22. Neshar G, Shemesh D, Mates M, Sonnenblick M, Abramowitz HB. The predictive value of the halo sign in color Doppler ultrasonography of the temporal arteries for diagnosing giant cell arteritis. *The Journal of rheumatology*. 2002;29(6):1224-6.
23. Nielsen BD, Gormsen LC, Hansen IT, Keller KK, Therkildsen P, Hauge EM. Three days of high-dose glucocorticoid treatment attenuates large-vessel 18F-FDG uptake in large-vessel giant cell arteritis but with a limited impact on diagnostic accuracy. *European journal of nuclear medicine and molecular imaging*. 2018;45(7):1119-28.

TABLES

Table 1. Characteristics of 111 consecutive patients with giant cell arteritis

| Characteristics | Total (n=111) |
|--|----------------------|
| Demographics | |
| Female/male | 80/31 |
| Age | 72 [52—90] |
| Cardiovascular risk factors | |
| Tobacco use | 36 (32) |
| Hypertension | 55 (50) |
| Diabetes mellitus | 13 (12) |
| Dyslipidemia | 37 (33) |
| Previous stroke | 5 (5) |
| Coronary disease | 8 (7) |
| Clinical manifestations | |
| Headaches | 70 (63) |
| Scalp tenderness | 46 (41) |
| Jaw claudication | 41 (37) |
| Temporal artery abnormality | 25 (23) |
| Visual symptom | 31 (28) |
| Polymyalgia rheumatica | 42 (38) |
| Extra-cardiac vascular bruit | 14 (13) |
| Limb claudication | 5 (5) |
| Fever | 24 (22) |
| Laboratory Tests | |
| Erythrocyte sedimentation rate, mm | 64 [18—130] |
| C-reactive protein, mg/l | 89 [1—424] |
| Hemoglobin level, g/dl | 11.4 [7.4—15.9] |
| Positive histology | |
| Temporal artery biopsy | 72/111 (65) |
| Surgical aortic sample | 70/109 (64) |
| Surgical aortic sample | 2 (2) |
| Positive Doppler ultrasound on TA | |
| | 46/105 (44) |
| Large-vessel vasculitis on imaging* | |
| | 40 (36) |

Values are numbers (%) or medians [range]; TA: temporal artery; * CT angiography, PET-CT and/or MRA

Table 2. Criteria from the American College of Rheumatology applied to the 111 patients with GCA

| | | |
|--------------------------|--|----------------|
| ACR criteria : | | |
| | Age>50 | 111 (100) |
| | Increased acute phase reactants | 109 (98) |
| | New onset headaches | 70 (63) |
| | Temporal artery abnormality | 25 (23) |
| | Positive TAB | 70/109 (64) |
| Satisfaction of : | | |
| | 2 ACR criteria | 18 (16) |
| | 3 ACR criteria | 40 (36) |
| | 4 ACR criteria | 36 (32) |
| | 5 ACR criteria | 17 (15) |
| | ≥ 3 ACR criteria | 93 (84) |
| | ≥ 3 criteria including a positive TAB | 70 (64) |

Values are numbers (%). TAB: temporal artery biopsy

Table 3. Suggestion of modified criteria for giant cell arteritis classification applied to 111 patients with GCA

| Suggested modified criteria | | |
|---|--|-----------------|
| 1 – Mandatory criterion | | |
| | Age>50 | 109 (98) |
| | and | |
| | Increased acute phase reactants | |
| 2 – Clinical criterion | | |
| | Cranial signs (headaches, scalp tenderness, abnormalities on TA, jaw claudication or visual signs) | 92 (83) |
| | and/or | |
| | PMR | |
| 3 – Demonstration of temporal vasculitis | | |
| | Positive TAB | 77 (69) |
| | and/or | |
| | Vascular abnormalities on US examination | |
| 4 – Demonstration of LVV | | |
| | Demonstration of LVV on imaging | 40 (36) |
| | and/or | |
| | Positive histology on large-vessel biopsy | |
| Satisfaction of : | | |
| | 1 criterion | 1 (1) |
| | 2 criteria | 32 (29) |
| | 3 criteria | 59 (53) |
| | 4 criteria | 19 (17) |
| | Vasculitis demonstration on histology or imaging | 90 (81) |
| | ≥ 2 criteria | 110 (99) |

Values are numbers (%).TA: temporal artery; TAB: temporal artery biopsy; PMR: polymyalgia rheumatica; US: ultrasound; LVV: large-vessel vasculitis

Figure 1. Number of patients satisfying each criterion from the classification of the American College of Rheumatology for giant-cell arteritis. Grey boxes represent patients with vasculitis demonstration.

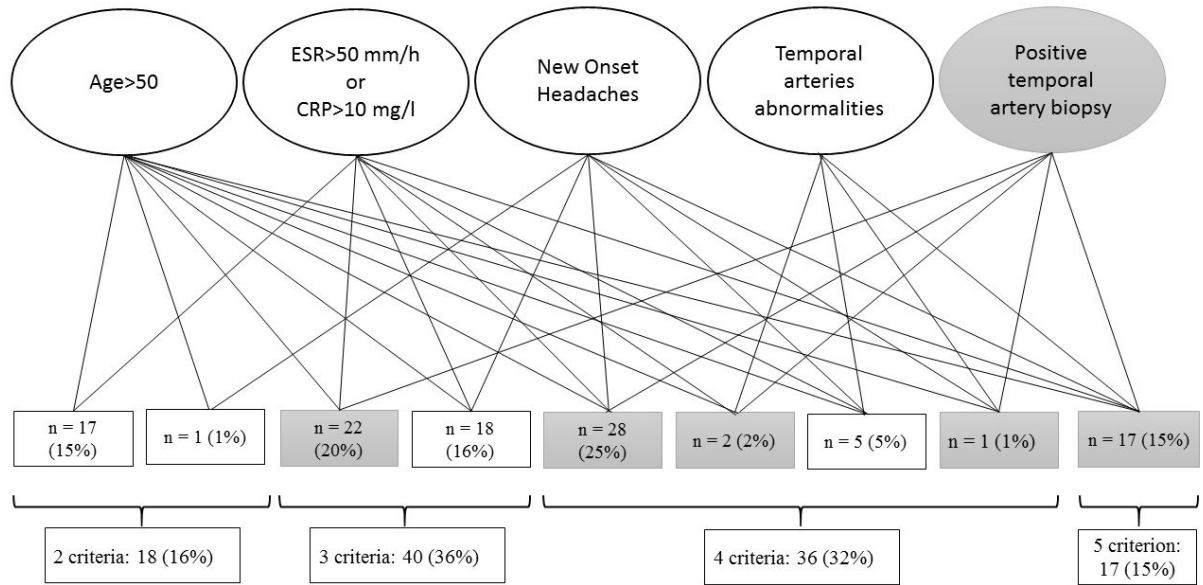


Figure 2. Number of patients satisfying each updated criterion. Grey boxes represent patients with vasculitis demonstration.

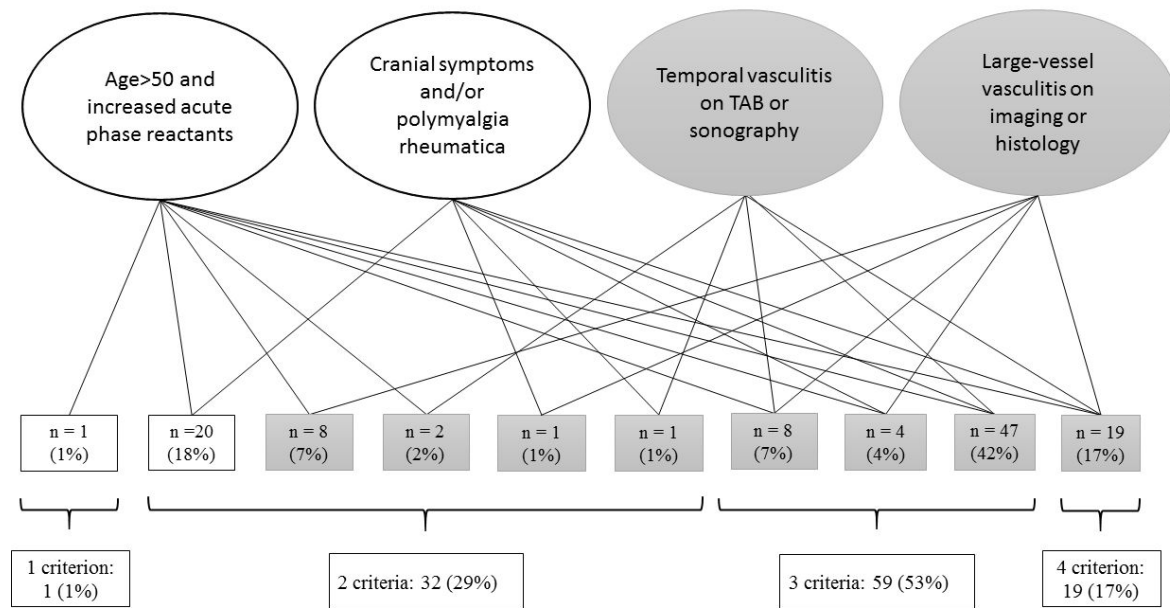
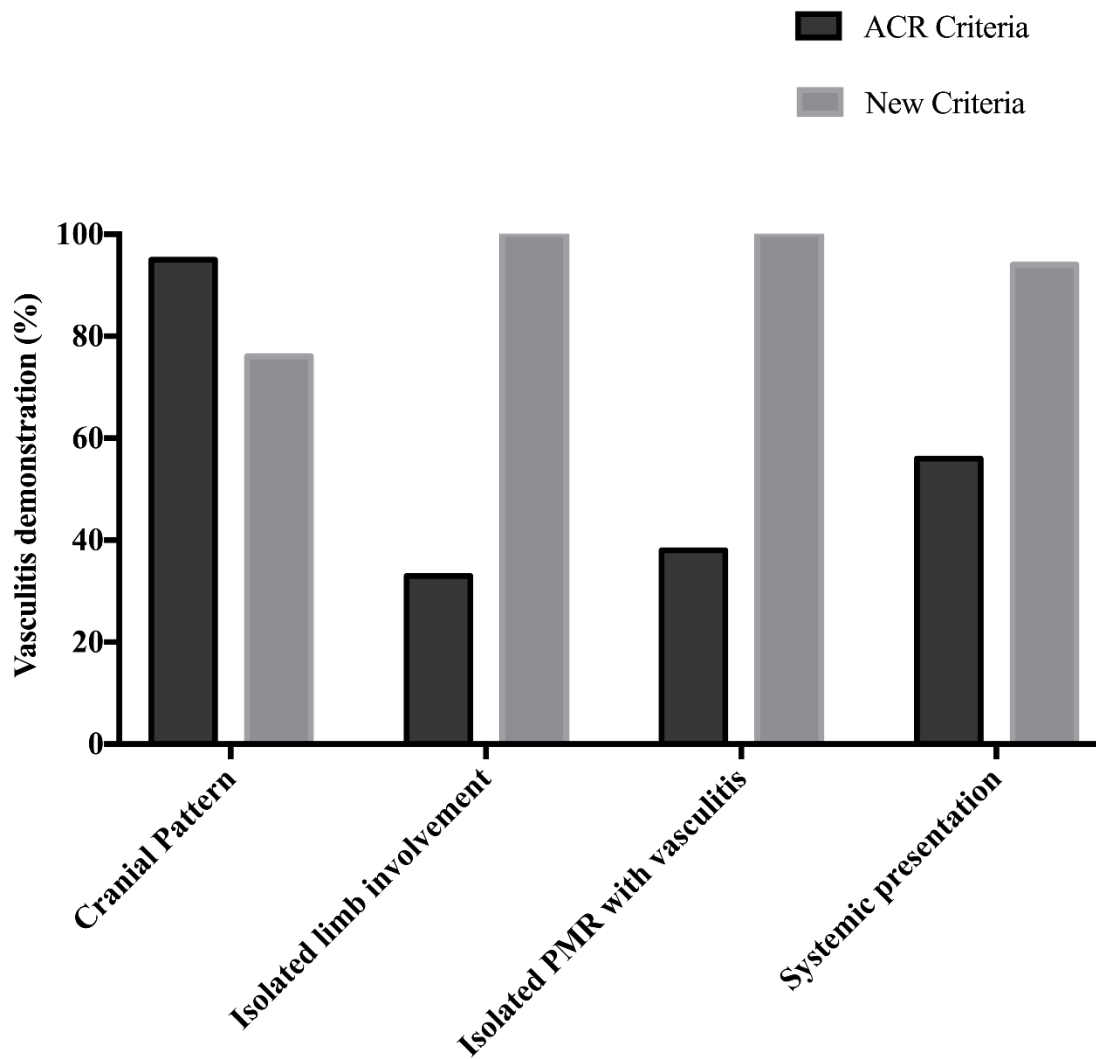


Figure 3. Proportion of patients with vasculitis demonstration within different patterns of giant-cell arteritis according to the two classification criteria.



6 – Quelle imagerie réaliser pour détecter une éventuelle atteinte des gros vaisseaux ?

En raison du poids croissant que la démonstration d'une atteinte des gros vaisseaux peut avoir sur la classification du patient, son traitement et sa surveillance, le groupe européen – EULAR (european league against rheumatism) – a édité des recommandations préconisant de détecter une éventuelle atteinte de l'aorte chez tout patient avec une ACG. Ces recommandations citent sans préférence l'angioscanner aortique, la TEP-TDM et l'ARM de l'aorte [44].

Il nous apparaissait alors intéressant de faire une revue générale de ces 3 modalités d'examen afin d'en analyser les avantages et inconvénients, et d'y intégrer la dimension médico-économique.

Chaque examen, à la lumière des connaissances actuelles relativement limitées, a été analysé pour une utilisation au diagnostic d'ACG mais aussi au cours du suivi.

Hubert de Boysson, Achille Aouba

Apport de l'imagerie (hors Doppler) pour le diagnostic et le suivi de l'artérite à cellules géantes.

Presse Med. 2019. <https://doi.org/10.1016/j.lpm.2019.07.032>

Pour citer cet article : de Boysson H, Aouba A. Apport de l'imagerie (hors Doppler) pour le diagnostic et le suivi de l'artérite à cellules géantes. Presse Med. (2019), <https://doi.org/10.1016/j.lpm.2019.07.032>

Presse Med. 2019; 00: 000
en ligne sur / on line on
www.em-consulte.com/revue/lpm
www.sciencedirect.com

ARTÉRITE À CELLULES GÉANTES

Dossier thématique

Mise au point

Apport de l'imagerie (hors Doppler) pour le diagnostic et le suivi de l'artérite à cellules géantes

Hubert de Boysson, Achille Aouba

Disponible sur internet le :

CHU de Caen, service de médecine interne, avenue de la Côte-de-Nacre,
14000 Caen, France

Correspondance :

Hubert de Boysson, CHU de Caen, service de médecine interne, avenue de la
Côte-de-Nacre, 14000 Caen, France.
deboysson-h@chu-caen.fr

■ Points essentiels

Depuis les années 2000, le recours à l'imagerie pour le diagnostic et le suivi évolutif de l'artérite à cellules géantes (ACG) est devenu coutumier.

Au diagnostic, la démonstration d'une atteinte des artères temporales à l'imagerie apporte une aide précieuse, que ce soit pour guider la biopsie d'artère temporale ou éventuellement, pour quelques équipes, remplacer cette dernière.

L'imagerie des gros vaisseaux a plus récemment pris une importance majeure, puisque selon les études et les techniques d'imagerie utilisées, 30 à 80 % des patients avec une ACG aurait une atteinte, le plus souvent silencieuse, de l'aorte et/ou de ses branches.

L'angioscanner de l'aorte, la tomographie par émission de positons et l'angiographie par résonance magnétique ont tous trois montré leur grande sensibilité pour détecter ces atteintes macro-vasculaires, devenant ainsi en pratique courante et dans les études récentes, un critère supplémentaire de classification et/ou de diagnostic de l'ACG.

De nombreuses études semblent par ailleurs indiquer un pronostic différent chez les patients avec une atteinte des gros vaisseaux, ce qui justifie la nécessité de dépister ces atteintes.

L'imagerie des gros vaisseaux est ainsi cruciale dans le suivi des patients pour à la fois, estimer l'évolution sous traitement de l'inflammation de l'aorte et de ses branches, et dépister les complications morphologiques (dilatations, dissections ou plus rarement sténoses) auxquelles les patients avec une atteinte macro-vasculaire seraient plus exposés.

Des recommandations européennes récentes présentent et évaluent les différents examens d'imagerie disponibles pour le diagnostic et le suivi des patients avec une ACG.

tome xx > n°x > xx 2019
<https://doi.org/10.1016/j.lpm.2019.07.032>
© 2019 Elsevier Masson SAS. Tous droits réservés.

la Presse
Médicale

ARTICLE IN PRESS

LPM-3878

Pour citer cet article : de Boysson H, Aouba A. Apport de l'imagerie (hors Doppler) pour le diagnostic et le suivi de l'artérite à cellules géantes. Presse Med. (2019), <https://doi.org/10.1016/j.lpm.2019.07.032>

H. de Boysson, A. Aouba

■ Key points

The additional value of imaging (excluding Doppler) for the diagnosis and follow-up of giant cell arteritis

Since 2000, imaging is frequently used for the diagnosis and follow-up of giant cell arteritis (GCA). At diagnosis, the demonstration on imaging of an involvement of the temporal arteries is useful to guide the temporal artery biopsy, or, sometimes, to replace it.

Large-vessel imaging is nowadays currently performed as some studies indicate that 30 to 80% of patients might demonstrate involvement of the aorta and its branches, often silently.

Aorta CT angiography, positron emission tomography or magnetic resonance angiography show a high sensibility to detect large-vessel inflammation, and have become in current practice and recent studies a supplementary criteria to classify or diagnose GCA.

Many studies indicate a different prognosis in patients with large-vessel inflammation, highlighting the need to diagnose such involvement.

Large-vessel imaging is important in the patients' follow-up to analyze how large-vessel inflammation evolves under treatment and to detect morphologic changes (dilations, dissections, or stenoses) that are more frequent in these patients.

Recent European recommendations analyze the different imaging procedures available for diagnosis and follow-up of patients with GCA.

L'artérite à cellules géantes (ACG) est une vascularite des gros vaisseaux aux multiples facettes. Si les critères du collègue américain de rhumatologie, datant de 1990, ne définissent la maladie que sur des critères histologiques et cliniques relatifs à l'atteinte du réseau artériel crânien et notamment à « l'artérite temporale » (céphalées inhabituelles, anomalies sur le trajet de l'artère temporale et positivité de la biopsie d'artère temporale [BAT]), il est aujourd'hui admis que le concept de la maladie doit être élargi pour intégrer les atteintes extracrâniennes, en particulier celles des gros vaisseaux, c'est-à-dire l'aorte et ses branches [1]. De nombreuses études d'imagerie utilisant l'échographie-Doppler, l'angioscanner de l'aorte et de ses branches, l'angiographie par résonance magnétique (ARM) et/ou la tomographie par émission de positons couplée à un scanner conventionnel (TEP-TDM) ont démontré que les gros vaisseaux seraient atteints chez 30 à 80 % des patients au diagnostic d'ACG, et ce parfois en l'absence de tout signe céphalique, incluant les signes ophtalmologiques [1]. Certains auteurs proposent même de retenir le diagnostic d'ACG en l'absence ou en cas de négativité de la BAT chez des patients de plus de 50 ans démontrant une atteinte inflammatoire des gros vaisseaux à l'imagerie et en l'absence d'autre étiologie évidente [2,3]. Le recours à l'imagerie s'est aussi développé dans l'évaluation de l'atteinte des artères temporales. Ainsi, si la BAT demeure à ce jour le *gold standard* pour démontrer la vascularite, cet examen reste invasif et sa rentabilité incertaine. Il en résulte le développement et la recherche de solutions alternatives, en particulier le recours à l'imagerie, à la fois pour aider le diagnostic et/ou guider la biopsie.

Ces examens d'imagerie deviennent aujourd'hui plus aisément accessibles, que ce soit en médecine hospitalière ou en médecine de ville, et les développements technologiques permettent d'accroître régulièrement leur résolution (scanners multi-barrettes, IRM 3-Tesla, nouvelles sondes d'échographie-Doppler) et d'augmenter ainsi leur pouvoir diagnostique. Il en résulte un questionnement croissant sur la place de l'imagerie dans l'évaluation des gros vaisseaux dans l'ACG. Cette réflexion a d'ailleurs été menée par un groupe d'experts européens permettant d'aboutir en 2018 à la publication de recommandations officielles sous l'égide de l'European League Against Rheumatism (EULAR) [2,4].

Dans cette revue systématique et actualisée, nous abordons les avancées des différents examens d'imagerie, hors échographie-Doppler (abordé dans un autre chapitre), dans l'évaluation des artères temporales et des gros vaisseaux, en discutant leurs intérêts et limites respectifs. Nous nous focaliserons sur le recours à ces examens pour le diagnostic d'ACG et pour le suivi. Enfin, nous citerons les principales recommandations de l'EULAR.

Imagerie des artères crâniennes (hors échographie-Doppler) au diagnostic

La démonstration d'une inflammation des vaisseaux crâniens superficiels à l'imagerie dans un contexte de suspicion d'ACG est un élément diagnostique fort. En dehors de l'échographie-Doppler, certaines études ont montré que l'IRM, l'angioscanner et même la TEP-TDM permettaient d'évaluer les artères crâniennes. Cependant, à ce jour, il est encore trop tôt pour utiliser ces

examens comme des alternatives à la BAT. En dehors d'une expérience encore limitée, l'accès et le coût de ces imageries sont des freins à leur utilisation en routine.

L'IRM des artères crâniennes superficielles

L'IRM est probablement la technique d'imagerie, en dehors de l'échographie-Doppler, pour laquelle il existe le plus d'études. Dès 2004, sur des IRM 1.5 Tesla, Bley et al. montraient qu'il existait un œdème intra-mural au sein des artères temporales sur les séquences T1 avec injection de gadolinium analysées en écho de spin chez des patients atteints d'ACG. Il existait une bonne corrélation entre le résultat de l'imagerie et les données clinico-histologiques [5]. Une récente méta-analyse réalisée pour éditer les recommandations de l'EULAR a montré à partir de 6 études et de 509 patients que la sensibilité et la spécificité de l'IRM des artères temporales en comparaison avec le diagnostic clinique d'ACG étaient respectivement de 73 % et 88 % [4]. En utilisant la BAT comme référence, l'IRM aurait une sensibilité et une spécificité de 93 % et 81 %, respectivement [6]. Cette étude démontrait également que la sensibilité de l'IRM des artères temporales diminuait au-delà de 5 jours de corticothérapie.

Avec la généralisation des IRM 3-Tesla, la résolution spatiale de l'imagerie s'est considérablement améliorée permettant également d'évaluer d'autres artères du scalp [7].

Le scanner des artères temporales

Une récente étude a démontré, au sein d'une cohorte de 14 patients avec une ACG consécutivement inclus et ayant bénéficié d'un angiostandard cervical et cérébral pour une suspicion d'accident vasculaire cérébral, que les artères temporales pouvaient être analysées. Ces 14 patients n'avaient pas encore commencé les glucocorticoïdes, n'avaient pas encore eu de BAT et n'avaient pas de signe clinique évident d'atteinte des artères temporales. Le diagnostic d'ACG a été porté par la suite. Ces patients ont été comparés à 14 contrôles, appariés sur le sexe et l'âge, ayant bénéficié d'un même angiostandard pour suspicion d'AVC sans contexte d'ACG. Un aspect flou de la paroi des artères temporales associé à un rehaussement périvasculaire était observé chez 10 (71 %) patients avec une ACG et seulement chez 2 (14 %) contrôles. Ces anomalies au scanner des artères temporales étaient corrélées à des anomalies histologiques chez 4 des 6 patients ayant une BAT positive et à des anomalies au Doppler chez 4 des 6 patients ayant un échographie-Doppler des artères temporales anormal. L'angiostandard avec évaluation des artères temporales aurait donc une sensibilité de 71,4 % (IC95 % : 41,9 %-91,6 %), une spécificité de 85,7 % (IC95 % : 57,2 %-98 %), une valeur prédictive positive de 83,3 % (IC95 % : 57,1 %-95 %) et une valeur prédictive négative de 75 % (IC95 % : 56,1 %-87,6 %). Rapportées aux sensibilités et spécificités de l'échographie-Doppler des artères temporales (sensibilité : 54 %, spécificité : 81 %) ou de l'IRM des artères temporales (sensibilité : 73 %, spécificité : 88 % [4]),

l'évaluation des artères temporales à l'angiostandard semble être un outil potentiellement utile [8].

La TEP-TDM des artères temporales

Jusqu'à peu, il était considéré que la résolution spatiale de la TEP-TDM et le bruit de fond du cerveau en lien avec une fixation avide du fluorodésoxyglucose (FDG) empêchaient l'évaluation des artères superficielles crâniennes. Dans un récent travail de preuve de concept, une équipe danoise a montré que l'évaluation des artères temporales, maxillaires et vertébrales était possible à la TEP-TDM. Dans cette étude, 44 patients avec une ACG étaient sélectionnés et bénéficiaient d'une TEP-TDM avant toute corticothérapie. Ils étaient comparés à 44 contrôles. Au total, 36 patients avec une ACG avaient un hypermétabolisme sur au moins une des artères crâniennes tandis qu'aucun contrôle ne montrait un tel rehaussement (sensibilité à 82 % et spécificité à 100 %). Alors que les spécificités restaient à 100 %, les sensibilités chutaient à 36 %, 61 % et 80 % lorsqu'étaient analysées séparément les artères temporales, maxillaires et vertébrales, respectivement. Chez les patients avec une ACG, une BAT était réalisée chez 41 patients et était positive chez 35 (80 %). La BAT était réalisée avant la TEP chez 3 patients ; la TEP était positive dans les 3 cas. L'analyse du résultat de la BAT par rapport au résultat de la TEP montrait que 31 des 36 patients ayant au moins un des 3 territoires vasculaires inflammatoires à la TEP avaient également une BAT positive. La sensibilité de la TEP est ainsi à 89 %, lorsque les 3 territoires sont analysés par rapport à la BAT servant de méthode de référence. Par contre en ne se référant qu'aux seuls territoires temporaux, 18 patients avec une TEP positive sur les artères temporales avaient concomitamment une BAT positive, et 17 autres avaient une TEP négative sur les artères temporales alors que la BAT était positive (sensibilité de la TEP par rapport à la BAT servant de référence à 51 %). Cette étude est ainsi la première montrant l'éventuelle utilité de la TEP-TDM, utilisée selon un protocole standard, dans l'évaluation des artères superficielles crâniennes [9].

Imagerie de l'aorte et de ses branches au diagnostic

L'augmentation du nombre d'études dédiées à l'analyse des gros vaisseaux au moyen de l'imagerie est exponentielle depuis 15 ans. Cet « engouement » s'explique particulièrement par deux points fondamentaux. Le premier concerne le changement de paradigme qui s'est opéré ces dernières années. Les études d'imagerie ont montré que l'atteinte de l'aorte et de ses branches était plus fréquente que ce qui était initialement cru, en particulier avant 2000. L'atteinte de l'aorte et de ses branches est le plus souvent asymptomatique, expliquant que le recours à l'imagerie initialement anecdotique est devenu plus fréquent et plus systématique. L'autre point fondamental concerne la différence de pronostic qui existerait chez les patients ayant une



Pour citer cet article : de Boysson H, Aouba A. Apport de l'imagerie (hors Doppler) pour le diagnostic et le suivi de l'artérite à cellules géantes. Presse Med. (2019), <https://doi.org/10.1016/j.lpm.2019.07.032>

H. de Boysson, A. Aouba

TABLEAU I
Caractéristiques des 3 techniques d'imagerie (hors Doppler) utilisées dans l'artérite à cellules géantes pour évaluer l'aorte et ses branches

| Imagerie | Sensibilité/spécificité | Avantages | Inconvénients | Coût |
|-----------------------|---|---|--|-------------|
| Angioscanner aortique | Sensibilité à 67 % Spécificité à 98 % [13] | Accessibilité Coût moindre Évaluation morphologique précise | Irradiant Injection de produit de contraste | ≈ 120 euros |
| Angio-IRM | Sensibilité à 80,6 % Spécificité à 97 % [5] | Non irradiant Évaluation morphologique précise | Acquisition longue Disponibilité moindre | ≈ 200 euros |
| TEP/TDM | Sensibilité entre 80 et 89 % Spécificité entre 90 et 98 % [22] | Bonne sensibilité Évaluation métabolique et morphologique Diagnostics différentiels | Accessibilité Coût plus élevé Radiotracer radioactif Faible sensibilité pour évaluer les artères distales (membres) Bruit de fond (cérébral, cardiaque) Faible reproductibilité de l'interprétation | ≈ 800 euros |

atteinte des gros vaisseaux. Plusieurs études ont suggéré que l'atteinte des gros vaisseaux était associée, d'une part, à des maladies de traitement plus difficile avec plus de rechutes, plus de dépendance aux glucocorticoïdes et un recours aux immunosuppresseurs plus fréquent [10], et d'autre part, à un pronostic vasculaire plus péjoratif avec plus de dilatation/anévrisme de l'aorte, plus de dissection aortique et finalement une mortalité accrue [11,12].

Nous allons analyser séparément la valeur de l'angioscanner de l'aorte, de la TEP-TDM et de l'angio-IRM de l'aorte au diagnostic d'ACG. Le *tableau I* indique les principales caractéristiques, en termes de sensibilité/spécificité, avantages/inconvénients et coûts de ces trois techniques. L'angiographie conventionnelle n'ayant plus sa place dans l'évaluation des gros vaisseaux, nous n'aborderons pas son utilisation dans ce chapitre.

L'angioscanner de l'aorte et de ses branches

L'inflammation vasculaire sur un angioscanner de l'aorte et de ses branches apparaît typiquement comme un épaississement pariétal circonférentiel, continu, homogène et sur un long segment. Une prise de contraste de la paroi vasculaire peut être observée. Outre l'inflammation vasculaire, l'angioscanner peut aussi mettre en évidence les dommages structuraux tels que dilatations, anévrismes, dissections ou sténoses vasculaires (*figure 1*). Récemment, une étude a montré qu'un épaississement de l'aorte $\geq 2,2$ mm était pathologique et très suggestif d'une inflammation vasculaire (sensibilité à 67 %, spécificité à 98 %) [13].

Une attention toute particulière doit être portée sur l'aspect de l'épaississement vasculaire et son éventuel lien avec des plaques athéromateuses calcifiées. L'existence d'un épaississement non circonférentiel et en regard de calcifications doit

être interprétée comme non inflammatoire mais plutôt d'origine athéroscléreuse. La localisation d'un épaississement en dessous des artères rénales doit aussi être interprétée avec précaution, l'athérosclérose étant spécifiquement très fréquente au niveau des bifurcations des artères iliaques ou au niveau des membres inférieurs, notamment chez les patients âgés.

Des études prospectives ont montré qu'une atteinte aortique était mise en évidence sur l'angioscanner de l'aorte chez 45,4 % [14] à 67,5 % [15] des patients.

L'angioscanner aortique reste plus facilement accessible que la TEP-TDM ou l'ARM de l'aorte, ce qui le rend particulièrement intéressant lorsqu'une évaluation des gros vaisseaux est souhaitée le plus tôt possible, avant ou au début du traitement. Aucune étude bien conduite n'a déterminé comment évoluaient les anomalies morphologiques de l'aorte et de ses branches une fois le traitement débuté. Cependant, ces anomalies, en particulier l'épaississement vasculaire semblent persister longtemps après l'introduction des corticoïdes [16].

Comparé à la TEP-TDM utilisée comme méthode référence, une étude a montré que l'angioscanner aortique avait une excellente sensibilité (95 %) et une excellente spécificité (100 %) pour montrer l'existence ou non d'une atteinte des gros vaisseaux. Par contre, la TEP-TDM permettait quant à elle d'obtenir une cartographie vasculaire plus détaillée des territoires atteints [17].

La tomographie par émission de positons couplée à un scanner conventionnel

La fixation vasculaire du FDG en cas de vascularite des gros vaisseaux est connue depuis la fin des années 90 et les premières séries de patients avec une ACG testés et suivis avec une

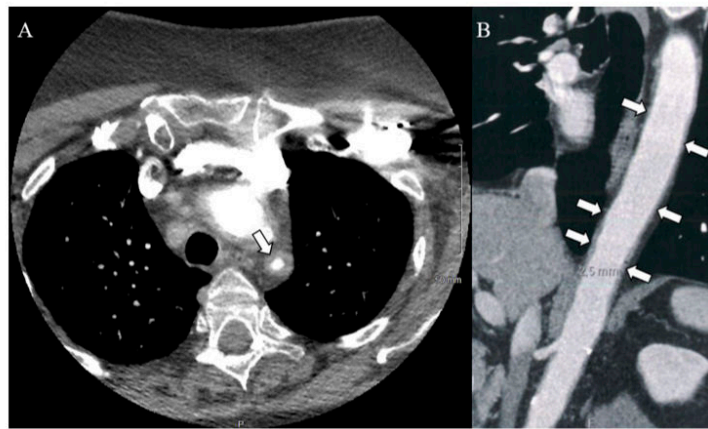


FIGURE 1

Angioscanner de l'aorte chez une patiente de 71 ans ayant une artérite à cellules géantes prouvée à la biopsie d'artère temporale et ayant développé une atteinte inflammatoire sténosante de l'artère sous-clavière gauche (A, flèche) et une aortite (B)

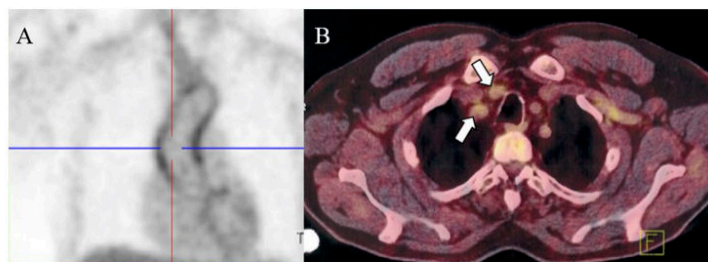


FIGURE 2

Tomographie par émission de positons, couplée à un scanner montrant un hypermétabolisme de l'aorte thoracique (A) et des tronc supra aortique (B) chez une patiente de 66 ans ayant une artérite à cellules géantes prouvée à la biopsie d'artère temporale

TEP-TDM datent du début des années 2000 [18]. En 2006, Blockmans et al. publie la première série prospective de 35 patients avec une ACG naïfs de traitement. Une atteinte des gros vaisseaux fut observée chez 83 % d'entre eux, principalement au niveau des artères sous-clavières [19]. Depuis, de nombreuses études prospectives [15,20,21] ou rétrospectives [10] ont trouvé des taux d'atteinte des gros vaisseaux allant de 30 à 80 % des patients, selon les études (figure 2). La sensibilité de la TEP-TDM pour détecter l'atteinte des gros vaisseaux dans l'ACG serait comprise entre 80 et 89 %, et sa spécificité entre 90 et 98 % [22].

Actuellement, la TEP-TDM est utilisée au diagnostic d'ACG, principalement dans deux situations. La première concerne la recherche systématique d'une atteinte des gros vaisseaux chez un patient pour lequel le bilan d'ACG est en cours. Cependant, l'accès à cette imagerie devenant de plus en plus difficile, la réalisation d'une TEP-TDM avant tout traitement devient plus problématique et la corticothérapie est souvent débutée lorsque l'examen est réalisé, avec alors un risque non négligeable de faux négatif.

Le second cas de figure où la TEP-TDM est aisément demandée concerne les présentations atypiques de la maladie, telles que



les formes systémiques. En effet, la découverte d'une vascularite des gros vaisseaux, chez un patient en cours d'exploration pour une fièvre et/ou syndrome inflammatoire biologique isolés, permet d'orienter le diagnostic d'ACG. Cet examen permet aussi d'écartier les diagnostics alternatifs comme les pathologies malignes ou les infections chroniques.

Peu d'informations existent sur la rentabilité de la TEP-TDM chez les patients recevant déjà une corticothérapie. La découverte d'une vascularite des gros vaisseaux lors du suivi d'un patient devenu dépendant aux corticoïdes ou devant une pseudo-polyarthrite rhizomélique réfractaire n'est pas rare, démontrant ainsi que la TEP-TDM a une place de choix dans ces contextes. Néanmoins, il est difficile d'émettre des recommandations sur le recours à la TEP-TDM lors du suivi des patients, car certaines études ont montré qu'après quelques jours de cortisone, un nombre conséquent d'exams se normalisait. Une étude prospective récente sur un petit contingent de patients avec une atteinte des gros vaisseaux a montré qu'après 3 jours de corticoïdes, 100 % des TEP-TDM restaient positives mais qu'à 10 jours du traitement, seules 36 % des recontrôles de ces exams restaient encore positifs. Les analyses semi-quantitatives montraient une diminution des hypermétabolismes de 10-15 % à j3 et de 30-40 % à j10. Aucune corrélation n'était observée entre, d'une part, les hypermétabolismes initiaux et leur devenir, et d'autre part, les taux de CRP [23]. Une analyse plus détaillée de la TEP-TDM au cours du suivi des patients est proposée dans le chapitre 3.a (Évaluation de l'efficacité du traitement sur l'atteinte des gros vaisseaux).

Outre sa difficulté d'accès et son prix élevé, la TEP-TDM a une autre importante limitation qui concerne les méthodes d'analyse et d'interprétation des hypermétabolismes. L'étude prospective princeps de Blockmans et al. utilisait par exemple un score vasculaire total. Ce score analysait sur 7 territoires vasculaires (aorte thoracique, aorte abdominale, artères sous-clavières, artères axillaires, artères carotides, artères iliofémorales et artères fémorales) l'intensité du rehaussement vasculaire (0, pas de rehaussement ; 1, faible rehaussement ; 2, fort rehaussement ; 3, très fort rehaussement), son total se situant entre 0 et 21 points [19]. Par contre depuis 2008, la méthode la plus souvent utilisée est semi-quantitative, basée sur la comparaison ou le rapport entre la fixation vasculaire et la fixation physiologique du foie [24]. Dans cette dernière, toute fixation vasculaire homogène d'intensité supérieure ou égale à celle du foie est ainsi considérée comme potentiellement liée à une inflammation. Cette méthode simple et relativement reproductible reste celle la plus souvent utilisée. D'autres approches semi-quantitatives ont également émergé comme celles analysant le ratio entre les fixations vasculaires maximales ou moyennes, rapportées à celles de tissus neutres comme le foie, le pool sanguin veineux ou encore le poumon [24].

Ainsi, à ce jour, il existe une multitude de techniques différentes, rendant l'interprétation des résultats plus difficiles et compliquant également la reproductibilité des études.

C'est pour cette raison qu'en 2018 un travail collaboratif international a été réalisé pour centraliser les avis d'experts et essayer d'homogénéiser les pratiques [25]. Ce travail se focalisait sur le recours à la TEP-TDM pour l'évaluation des vascularites des gros vaisseaux associés ou non à la PPR, et incluant aussi l'artérite de Takayasu. Comme cela est reconnu par les auteurs eux-mêmes, ces recommandations reposent sur de faibles niveaux de preuve. Néanmoins, le document a le mérite d'exister. De manière synthétique, les principales recommandations ou consensus relatifs à la réalisation d'une TEP-TDM dans ce contexte sont les suivants :

- maintenir le jeun depuis au moins 6 heures avant l'examen et avoir une glycémie < 7 mmol/L (< 1,26 g/L) ;
- privilégier pour le jour même de l'examen, la prise de corticoïdes, si déjà débutés, après la réalisation de ce dernier sauf si le risque ischémique est élevé. Idéalement, réaliser l'examen avant ou dans les 3 jours suivant l'introduction des corticoïdes ;
- d'autres études sont nécessaires pour déterminer les critères les plus relevant et reproductibles pour définir la présence d'une vascularite des gros vaisseaux. Les experts ne privilégient pas clairement une méthode d'analyse des hypermétabolismes par rapport à une autre ;
- les hypermétabolismes vasculaires inflammatoires apparaissent homogènes et circonférentiels, alors que les lésions d'athérosclérose sont plutôt « patchy », souvent non circonférentielles ;
- le couplage de la TEP à un angioscanner apporte une information morphologique complémentaire et permet de détecter les dommages structuraux. Le groupe d'experts définit l'inflammation vasculaire à l'angioscanner par un épaississement pariétal circonférentiel et régulier, de 2-3 mm, dépourvu de calcifications évocatrices d'athérosclérose et éventuellement associé à une prise de contraste.

Enfin, il est important de noter que les TEP-TDM de nouvelle génération permettent d'évaluer les artères céphaliques, notamment temporales. Comparée à la BAT, il semble que la sensibilité des nouvelles machines avoisine les 92 %, amenant ainsi certains auteurs à reconsidérer la TEP-TDM en première intention dans l'évaluation d'un patient suspect d'ACG [26].

L'angiographie par résonance magnétique (ARM) aortique

L'utilisation de l'angiographie par résonance magnétique de l'aorte et de ses branches n'a été rapportée que chez quelques patients [27]. L'injection de gadolinium est requise pour détecter l'œdème intra-mural qui apparaît alors en hypersignal sur les coupes tardives post-injection. Tout comme l'angioscanner, l'ARM permet d'évaluer la morphologie aortique et rechercher des épaississements ou sténoses vasculaires. La localisation des

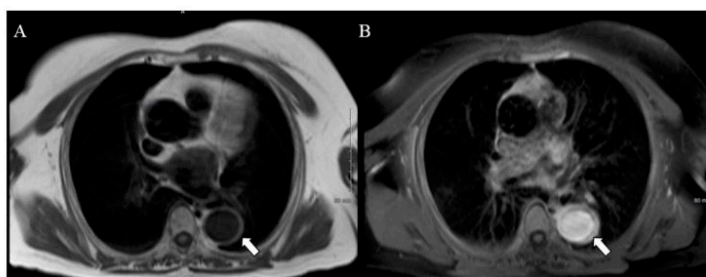


FIGURE 3

Angio-IRM de l'aorte montrant une aortite dans sa portion thoracique chez une patiente de 56 ans ayant une artérite à cellules géantes prouvée à la biopsie d'artère temporale. La paroi de l'aorte est épaissie de manière circonférentielle (A : séquence T1 en sang noir) et prend le contraste (B : séquence en T1 + injection de gadolinium)

épaississements vasculaires par rapport à d'éventuelles plaques d'athérome est également nécessaire pour différencier inflammation et remodelages vasculaires liés à l'athérosclérose [27]. Les caractéristiques de l'inflammation vasculaire à l'ARM associent des signes directs et indirects. L'épaississement vasculaire avec une prise de contraste représente le signe direct le plus évident d'inflammation vasculaire. Les séquences d'ARM de choix sont le T1 avec atténuation de graisse ou les séquences en sang noir (figure 3). Les séquences en T2 sont plus à risque d'artéfacts. Certaines études suggèrent que les signes directs d'inflammation s'atténuent dès 5 jours de cortisone [6]. Les rétrécissements vasculaires ou sténoses avec des conséquences hémodynamiques d'aval représentent des signes indirects d'inflammation, mais ils peuvent être difficiles à différencier de l'athérosclérose.

Quelques études ont comparé l'ARM aortique à la TEP-TDM, avec des résultats discordants [28]. Plus récemment, dans une étude prospective, il a été montré que l'ARM aortique permettait de détecter plus de territoires vasculaires inflammatoires que la TEP-TDM. Néanmoins, en termes de concordance entre activité clinique et anomalies radiologiques, la TEP-TDM était supérieure à l'ARM [28].

L'accès et le coût de l'IRM restent encore des freins réels à son utilisation en routine.

Place de l'imagerie de l'aorte et de ses branches au cours du suivi

La question de la place de l'imagerie des gros vaisseaux au cours du suivi reste encore non résolue. La plupart du temps, l'imagerie est discutée au cas par cas en fonction de la situation clinique et/ou des équipes médicales.

L'imagerie de l'aorte et de ses branches peut être discutée au cours du suivi lorsqu'il persiste par exemple un syndrome inflammatoire biologique sans signe clinique évident de

rechute, ou encore dans les cas plus rares de corticodépendance. La découverte dans ce contexte d'une aortite ou d'une inflammation des branches aortiques est fréquente.

La place de l'imagerie se discute surtout au cours du suivi des patients ayant une atteinte connue des gros vaisseaux. Cette imagerie a en théorie deux objectifs : déterminer l'efficacité du traitement sur l'inflammation des gros vaisseaux et dépister d'éventuelles complications macro-vasculaires, connues pour être plus fréquentes chez les patients avec une telle atteinte au diagnostic [11,12].

Une dernière situation concerne le recours à l'imagerie à la rechute de la maladie. En théorie, l'imagerie peut mettre en évidence une atteinte des gros vaisseaux, non dépistée ou non connue, ou montrer une aggravation d'une atteinte connue des gros vaisseaux. Cependant, comme il n'existe pas à notre connaissance d'études dédiées spécifiquement à l'analyse de l'imagerie des gros vaisseaux lors des rechutes, nous ne développerons pas plus ce point.

Évaluation de l'efficacité du traitement sur l'atteinte des gros vaisseaux

L'évaluation clinique de l'atteinte des gros vaisseaux est souvent difficile. L'inflammation aortique ou des branches aortiques est le plus souvent asymptomatique. Lorsque l'inflammation vasculaire a un retentissement hémodynamique en raison notamment de sténoses vasculaires serrées, la constatation d'une asymétrie tensionnelle, d'une absence de pouls, d'un souffle vasculaire ou d'une claudication ne permet pas d'évaluer convenablement l'activité de la maladie, ces éléments pouvant s'observer au stade cicatriciel, comme cela l'est souvent dans l'artérite de Takayasu. Outre les marqueurs biologiques d'inflammation, l'imagerie peut être une aide à l'appréhension de l'activité de la maladie. À cet effet, peu d'études ont analysé le rôle de la TEP-TDM, de l'angioscanner aortique ou de l'ARM aortique au cours du suivi [16,20,23,29-31]. Malheureusement,



les résultats des différentes études ne sont pas unanimes. Alors même que la clinique et la biologie se sont normalisées, certaines études montrent la persistance de signes, parfois indirects, d'inflammation iconographique des gros vaisseaux, alors que d'autres montrent une totale normalisation de l'imagerie. Dans un travail multicentrique et rétrospectif réalisé sur une série de 25 patients avec une atteinte des gros vaisseaux et en rémission clinicobiologique, nous avons analysé les résultats de 34 nouvelles TEP-TDM pratiquées au cours d'un suivi médian de 4 ans. Alors même que tous les patients étaient en rémission, 80 % gardaient une TEP-TDM positive, bien que le nombre de territoires vasculaires atteints soit moins important chez la plupart d'entre eux [30]. D'autres études sur la TEP-TDM semblent indiquer des résultats similaires avec une persistance d'hypermétabolismes chez 50 à 80 % des patients sur une maladie pourtant parfaitement contrôlée sur les critères cliniques et biologiques [19,28,30]. Néanmoins, lorsque des scores quantitatifs ou que le nombre de territoires vasculaires sont analysés à la TEP-TDM au cours du suivi chez des patients recevant des corticoïdes, il semble que le traitement ait toujours un effet bénéfique avec une diminution du score d'activité et/ou du nombre de territoires atteints [29].

Une autre étude a montré une bonne corrélation entre les rehaussements vasculaires à la TEP-TDM et les modifications thérapeutiques. Ainsi, les majorations thérapeutiques par rehaussement des doses et/ou adjonction d'autres traitements s'accompagnaient d'une amélioration clinique, biologique et une diminution des marqueurs d'activité à la TEP-TDM. Inversement, lorsque le traitement était diminué, l'activité vasculaire mesurée à la TEP-TDM augmentait alors même que la clinique et la biologie restaient normales, cela suggérant que la TEP-TDM pourrait être une aide pour dépister précocement les patients à risque de rechute [29]. Cette même équipe a d'ailleurs observé que la persistance d'un hypermétabolisme vasculaire chez un patient en rémission clinique et biologique serait associée à un risque accru de rechute clinique [20].

En ce qui concerne l'angioscanner aortique, après l'instauration des corticoïdes, un épaississement de l'aorte à l'angioscanner était toujours observé à un délai médian de 13 mois chez deux tiers des patients, pourtant en rémission clinicobiologique [16].

L'impact du tocilizumab sur l'imagerie des gros vaisseaux est encore moins bien connu et demeure une question d'actualité. Après 52 semaines de traitement par tocilizumab, un tiers des patients avec une atteinte des gros vaisseaux surveillés à l'ARM et en rémission clinique et biologique gardait un rehaussement tardif persistant de la paroi vasculaire. À noter cependant que cette étude n'analysait que 9 patients [31]. Plus récemment, une étude a montré que seuls 18 % des patients (soit 3 sur 17 patients) avec une atteinte des gros vaisseaux traitée par tocilizumab avaient une totale normalisation de leur TEP-TDM à 6 mois. Plusieurs études montrent cependant une diminution

de l'intensité des hypermétabolismes vasculaires chez les patients recevant du tocilizumab [29,32].

Ainsi, aux vues des données actuelles, parfois discordantes ou contradictoires, il est difficile de déterminer la place de l'imagerie des gros vaisseaux dans l'évaluation de l'activité de la maladie. L'utilisation de scores composites (utilisant une approche quantitative et visuelle) à la TEP-TDM peut permettre d'améliorer l'évaluation des hypermétabolismes vasculaires au cours du suivi. Néanmoins, la juste valeur d'un hypermétabolisme vasculaire persistant au long cours à la TEP-TDM ou d'un épaississement vasculaire à l'angioscanner ou à l'ARM chez un patient en rémission clinique et biologique reste inconnue. La distinction entre inflammation à bas bruit, phénomènes cicatriciels ou de remodelage reste pour le moment difficile.

Dépistage des complications vasculaires au cours du suivi

Il existe maintenant de nombreuses études montrant que l'atteinte des gros vaisseaux serait associée à un moins bon pronostic cardiovasculaire. L'inflammation aortique favoriserait le développement de dilatations aortiques [11], augmentant ainsi le risque de dissection aortique [33]. D'autres études ont montré aussi plus d'événements cardiovasculaires chez les patients avec une atteinte des gros vaisseaux [34]. Cela suggère que l'inflammation vasculaire même éteinte, ainsi que les processus de remodelage/cicatrisation locales pourraient faire le lit de fragilisations pariétales ultérieures. Ainsi, au vue de ces données, il semble nécessaire de surveiller la morphologie aortique parallèlement au suivi clinique. Par contre, la fréquence, les modalités et la durée optimales de ce suivi sont inconnues. Il semble que la plupart des dilatations/dissections aortiques concernent l'aorte thoracique et peuvent survenir jusqu'à 10 ans après le diagnostic d'ACG. Une surveillance échocardiographique annuelle pendant plusieurs années nous semble ainsi être le bilan minimal requis pendant le suivi. Néanmoins, en cas de dilatation avérée, une surveillance plus rapprochée ou le recours à d'autres techniques d'imagerie doivent bien évidemment être discutés au cas par cas.

Recommandations européennes

En 2018, l'EULAR a émis des recommandations sur la place de l'imagerie dans le diagnostic et le suivi des patients suspects de vascularite des gros vaisseaux. Ces recommandations sont essentiellement basées sur une revue détaillée de la littérature [4].

Voici un résumé des principales recommandations concernant l'imagerie dans l'ACG [2] :

- l'imagerie des gros vaisseaux doit de préférence être réalisée avant la mise en route du traitement ou, à défaut, le plus tôt possible. Néanmoins, l'initiation du traitement ne doit pas être retardée en raison des délais d'obtention de l'imagerie ;

- l'imagerie des artères temporales doit reposer en premier lieu sur l'échographie-Doppler. Mais à défaut, une IRM haute résolution des artères crâniennes peut être utilisée. Le scanner et la TEP-TDM n'ont pas de place dans l'évaluation des artères crâniennes ;
- l'évaluation des gros vaisseaux peut se faire indifféremment par angioscanner, ARM, TEP-TDM ou échographie (ce dernier étant néanmoins limité pour l'exploration des vaisseaux profonds) ;
- l'angiographie conventionnelle ne doit plus être utilisée ;
- dans le cadre d'une suspicion de rechute de l'ACG, une imagerie des gros vaisseaux peut être utile, sans préférence affirmée pour une procédure particulière ;
- par contre, l'imagerie des gros vaisseaux n'est pas indiquée en routine chez un patient en rémission clinique et biologique, l'interprétation d'éventuelles anomalies étant pour le moment incertaine ;
- chez les patients avec une atteinte des gros vaisseaux, une imagerie peut être réalisée pendant le suivi pour évaluer les dommages structuraux (occlusions, dilatations). L'angioscanner, l'ARM et l'échographie sont conseillés. Néanmoins, le choix de la technique et la fréquence de surveillance doivent être adaptés à chaque situation.

Déclaration d'intérêts : les auteurs déclarent ne pas avoir de liens d'intérêts.

Références

- [1] Dejaco C, Duftner C, Buttgerit F, Matteson EL, Dasgupta B. The spectrum of giant cell arteritis and polymyalgia rheumatica: revisiting the concept of the disease. *Rheumatology* 2017;56:506-15.
- [2] Dejaco C, Ramiro S, Duftner C, Besson FL, Bley TA, Blockmans D, et al. EULAR recommendations for the use of imaging in large-vessel vasculitis in clinical practice. *Ann Rheum Dis* 2018;77:636-43.
- [3] Stone JH, Tuckwell K, Dimonaco S, Kleerman M, Aninger M, Blockmans D, et al. Trial of tocilizumab in giant cell arteritis. *N Engl J Med* 2017;377:317-28.
- [4] Duftner C, Dejaco C, Sepriano A, Falzon L, Schmidt WA, Ramiro S. Imaging in diagnosis, outcome prediction and monitoring of large-vessel vasculitis: a systematic literature review and meta-analysis informing the EULAR recommendations. *RMD Open* 2018;4:e000612.
- [5] Bley TA, Uhl M, Carew J, Markl M, Schmidt D, Peter HH, et al. Diagnostic value of high-resolution MR imaging in giant cell arteritis. *AJNR Am J Neuroradiol* 2007;28:1722-7.
- [6] Klink T, Geiger J, Both M, Ness T, Heinzlmann S, Reinhard M, et al. Giant cell arteritis: diagnostic accuracy of MR imaging of superficial cranial arteries in initial diagnosis—results from a multicenter trial. *Radiology* 2014;273:844-52.
- [7] Rheaume M, Rebello R, Pagnoux C, Carrette S, Clements-Baker M, Cohen-Hallaleh V, et al. High-resolution magnetic resonance imaging of scalp arteries for the diagnosis of giant cell arteritis: results of a prospective cohort study. *Arthritis Rheumatol* 2017;69:161-8.
- [8] Conway R, Smyth AE, Kavanagh RG, O'Donoghue RL, Purcell Y, Heffernan EJ, et al. Diagnostic utility of computed tomographic angiography in giant cell arteritis. *Stroke* 2018;49:2233-6.
- [9] Nielsen BD, Hansen IT, Kramer S, Haraldsen A, Hjorthaug K, Bogsrud TV, et al. Simple dichotomous assessment of cranial artery inflammation by conventional 18F-FDG-PET/CT shows high accuracy for the diagnosis of giant cell arteritis: a case-control study. *Eur J Nucl Med Mol Imaging* 2019;46:184-93.
- [10] Dumont A, Parienti JJ, Delmas C, Boutemy J, Maigne G, Silva NM, et al. Factors associated with relapse and dependence to glucocorticoids in giant cell arteritis. *J Rheumatol* 2019. <http://dx.doi.org/10.3899/jrheum.181127>.
- [11] de Boysson H, Daumas A, Vautier M, Parienti JJ, Liozon E, Lambert M, et al. Large-vessel involvement and aortic dilation in giant cell arteritis. A multicenter study of 549 patients. *Autoimmun Rev* 2018;17:391-8.
- [12] Kermani TA, Warrington KJ, Crowson CS, Ytterberg SR, Hunder GG, Gabriel SE, et al. Large-vessel involvement in giant cell arteritis: a population-based cohort study of the incidence-trends and prognosis. *Ann Rheum Dis* 2013;72:1989-94.
- [13] Berthod PE, Aho-Giele S, Ornetti P, Chevallier O, Devilliers H, Ricolfi F, et al. CT analysis of the aorta in giant cell arteritis: a case-control study. *Eur Radiol* 2018;28:3676-84.
- [14] Agard C, Barrier JH, Dupas B, Ponge T, Mahr A, Fradet G, et al. Aortic involvement in recent-onset giant cell (temporal) arteritis: a case-control prospective study using helical aortic computed tomodensitometric scan. *Arthritis Rheum* 2008;59:670-6.
- [15] Prieto-Gonzalez S, Arguis P, Garcia-Martinez A, Espigol-Frigole G, Tavera-Bahillo I, Butjosa M, et al. Large-vessel involvement in biopsy-proven giant cell arteritis: prospective study in 40 newly diagnosed patients using CT angiography. *Ann Rheum Dis* 2012;71:1170-6.
- [16] Prieto-Gonzalez S, Garcia-Martinez A, Tavera-Bahillo I, Hernandez-Rodriguez J, Gutierrez-Chacoff J, Alba MA, et al. Effect of glucocorticoid treatment on computed tomography angiography detected large-vessel inflammation in giant cell arteritis. A prospective, longitudinal study. *Medicine* 2015;94:e486.
- [17] de Boysson H, Dumont A, Liozon E, Lambert M, Boutemy J, Maigne G, et al. Giant cell arteritis: concordance study between aortic CT angiography and FDG-PET/CT in detection of large-vessel involvement. *Eur J Nucl Med Mol Imaging* 2017;44:2274-9.
- [18] Blockmans D, Stroobants S, Maes A, Mortelmans L. Positron emission tomography in giant cell arteritis and polymyalgia rheumatica: evidence for inflammation of the aortic arch. *Am J Med* 2000;108:246-9.
- [19] Blockmans D, de Ceuninck L, Vanderschueren S, Knockaert D, Mortelmans L, Bobbaers H. Repetitive 18F-fluorodeoxyglucose positron emission tomography in giant cell arteritis: a prospective study of 35 patients. *Arthritis Rheumatol* 2006;55:131-7.
- [20] Grayson PC, Alehashemi S, Bagheri AA, Civelek AC, Cupps TR, Kaplan MJ, et al. (18)F-Fluorodeoxyglucose-positron emission tomography as an imaging biomarker in a prospective, longitudinal cohort of patients with large-vessel vasculitis. *Arthritis Rheumatol* 2018;70:439-49.
- [21] Larivière D, Benali K, Coustet B, Pasi N, Hyafil F, Klein I, et al. Positron emission tomography and computed tomography angiography for the diagnosis of giant cell arteritis: a real-life prospective study. *Medicine* 2016;95:e4146.
- [22] Soussan M, Nicolas P, Schramm C, Katsahian S, Pop G, Fain O, et al. Management of large-vessel vasculitis with FDG-PET: a systematic literature review and meta-analysis. *Medicine* 2015;94:e622.
- [23] Nielsen BD, Gormsen LC, Hansen IT, Keller KK, Therkildsen P, Hauge EM. Three days of high-dose glucocorticoid treatment attenuates large-vessel 18F-FDG uptake in large-vessel giant cell arteritis but with a limited impact on diagnostic accuracy. *Eur J Nucl Med Mol Imaging* 2018;45:1119-28.



Pour citer cet article : de Boysson H, Aouba A. Apport de l'imagerie (hors Doppler) pour le diagnostic et le suivi de l'artérite à cellules géantes. *Presse Med.* (2019), <https://doi.org/10.1016/j.lpm.2019.07.032>

H. de Boysson, A. Aouba

- [24] Hautzel H, Sander O, Heinzel A, Schneider M, Müller HW. Assessment of large-vessel involvement in giant cell arteritis with 18F-FDG-PET: introducing an ROC-analysis-based cutoff ratio. *J Nucl Med* 2008;49:1107-13.
- [25] Slart R, Writing g, Reviewer g, Members of EC, Members of EI, Inflammation. et al. FDG-PET/CT(A) imaging in large-vessel vasculitis and polymyalgia rheumatica: joint procedural recommendation of the EANM, SNMMI, and the PET Interest Group (PIG), and endorsed by the ASNC. *Eur J Nucl Med Mol Imaging* 2018;45:1250-69.
- [26] Sammel AM, Hsiao E, Schembri G, Nguyen K, Brewer J, Schrieber J, et al. Diagnostic accuracy of positron emission tomography/computed tomography of the head, neck, and chest for giant cell arteritis: a prospective, double-blind, cross-sectional study. *Arthritis Rheumatol* 2019. <http://dx.doi.org/10.1002/art.40864>.
- [27] Adler S, Sprecher M, Wermelinger F, Kilink T, Bonel H, Villiger PM. Diagnostic value of contrast-enhanced magnetic resonance angiography in large-vessel vasculitis. *Swiss Med Wkly* 2017;21:w14397.
- [28] Quinn KA, Ahlman MA, Malayeri AA, Marko J, Civelek AC, Rosenblum JS, et al. Comparison of magnetic resonance angiography and (18F)-fluorodeoxyglucose positron emission tomography in large-vessel vasculitis. *Ann Rheum Dis* 2018;77:1165-71.
- [29] Banejee S, Quinn KA, Gibbons KB, Rosenblum JS, Civelek AC, Novakovich E, et al. Effect of treatment on imaging, clinical, and serologic assessments of disease activity in large-vessel vasculitis. *J Rheumatol* 2019. <http://dx.doi.org/10.3899/jrheum.181222>.
- [30] de Boysson H, Aide N, Liozon E, Lambert M, Parienti JJ, Monteil J, et al. Repetitive (18F)-FDG-PET/CT in patients with large-vessel giant cell arteritis and controlled disease. *Eur J Intern Med* 2017;46:66-70.
- [31] Reichenbach S, Adler S, Bonel H, Cullmann JL, Kuchen S, Butikofer L, et al. Magnetic resonance angiography in giant cell arteritis: results of a randomized controlled trial of tocilizumab in giant cell arteritis. *Rheumatology* 2018;57:982-6.
- [32] Vitiello G, Orsi Battaglini C, Carli G, Radice A, Maturi A, Vultaggio A, et al. Tocilizumab in giant cell arteritis: a real-life retrospective study. *Angiology* 2018;69:763-9.
- [33] Kermani TA, Warrington KJ, Crowson CS, Hunder GG, Ytterberg SR, Gabriel SE, et al. Predictors of dissection in aortic aneurysms from giant cell arteritis. *J Clin Rheumatol* 2016;22:184-7.
- [34] Espitia O, Neel A, Leux C, Connault J, Espitia-Thibault A, Ponge T, et al. Giant cell arteritis with or without aortitis at diagnosis. A retrospective study of 22 patients with long-term follow-up. *J Rheumatol* 2012;39:2157-62.

Discussion

Au terme de ces travaux, il apparaît que l'atteinte des gros vaisseaux fait partie intégrante des atteintes fréquentes de l'ACG et implique donc la nécessité de leur recherche systématique au diagnostic, comme en témoigne d'ailleurs les recommandations européennes récentes [44]. Nous avons pu déterminer qu'entre un tiers et la moitié des patients développaient une atteinte de l'aorte et de ses branches, le plus souvent de manière asymptomatique. Notre approche clinico-radiologique de l'atteinte des gros vaisseaux apparaît totalement inédite, et la distinction de ces différentes formes d'atteinte semble adaptée à la description des différents profils évolutifs observés dans l'ACG. D'une part, nous avons pu observer que l'atteinte des gros vaisseaux s'accompagnait d'un risque accru de rechutes, de corticodépendance et de recours aux immunosuppresseurs. D'autre part, il semble que ces patients avec une atteinte de l'aorte et de ses branches développeraient davantage de complications cardio-vasculaires, dont la nature dépendrait du spectre clinico-radiologique initial. L'inflammation de l'aorte et de ses branches prédisposerait ainsi au développement *in situ* de dilatations aortiques, tandis que les atteintes vasculaires sténosantes favoriseraient les complications ischémiques. Les dissections aortiques, dont il a été montré qu'elles occasionnaient une importante mortalité cardio-vasculaire [40, 41, 63, 64], étaient observées surtout chez les patients connus pour avoir une dilatation de l'aorte.

A la lumière de nos analyses, des récentes publications internationales et des changements qui se sont opérés ces dernières années dans la compréhension, la prise en charge diagnostique et thérapeutique de la maladie, nous avons trouvé intéressant et novateur, quoique très ambitieux et audacieux, de proposer une première ébauche d'actualisation, qui du reste devient éminemment nécessaire, des critères de classification de l'ACG. Cette entreprise s'intègre pleinement dans l'ère du temps puisque plusieurs auteurs influents sur la thématique de l'ACG soulignaient la nécessité de revoir ces critères [58, 65]. Bien entendu, ce travail n'est qu'une réflexion préliminaire, modestement construite sur une petite cohorte monocentrique. Néanmoins, il se veut être une première pierre à un édifice que seul un travail européen et/ou outre-Atlantique pourra valider, améliorer et finaliser de manière pérenne.

Beaucoup de nos résultats viennent conforter et valider des études antérieures sur l'ACG, mais surtout certaines apportent des données et perspectives nouvelles sur le sujet. Il est important de souligner que nos résultats reposent sur l'analyse d'une série conséquente de patients, souvent avec un nombre d'effectifs inégaux. Ainsi, nos études furent les premières à proposer une analyse de plusieurs centaines de patients avec une atteinte des gros vaisseaux. Bien que

des changements se soient opérés ces dernières années avec un dépistage plus systématique de l'atteinte des gros vaisseaux, beaucoup de patients ne bénéficiaient d'aucune imagerie en l'absence de point d'appel. La description isolée de patients avec une atteinte des gros vaisseaux était donc rare et ne concernait jamais plus que quelques dizaines de patients [12, 29, 31, 32, 42, 43, 66-68]. Le travail collaboratif avec des équipes médicales habituées à la prise en charge de l'ACG et ayant intégré l'imagerie des gros vaisseaux dans le bilan initial, mais aussi parfois le suivi de la maladie, nous a permis de sélectionner un nombre conséquent de patients avec une atteinte des gros vaisseaux.

Depuis 2015, la standardisation de la démarche diagnostique dans notre service avec l'intégration de l'imagerie au diagnostic nous a permis de déterminer une prévalence de l'atteinte des gros vaisseaux au diagnostic autour de 35%. Ce chiffre s'intègre dans la fourchette basse des taux décrits dans la littérature, certaines équipes décrivant des taux allant jusqu'à 85% des patients [22]. Il est important de noter que l'importante variabilité observée dans la littérature s'explique par la disparité des techniques d'imagerie utilisées, des critères de sélection (patients tout venant, consécutifs ou patients sélectionnés ; recrutement dans un service de médecine ou d'imagerie...Etc) et même des critères de positivité utilisés à l'interprétation de l'imagerie. Dans notre série, bien que tous les patients aient bénéficié d'une imagerie au diagnostic, il existait une disparité entre les patients, selon qu'ils aient bénéficié d'un angioscanner ou d'une TEP-TDM, et selon qu'ils aient commencé ou non le traitement (même si l'imagerie était pratiquée dans les 10-15 jours suivant l'introduction des corticoïdes chez les patients ayant démarré un traitement lors de l'imagerie). En tout cas, nous avons pu déterminer dans une série de patients consécutifs que l'atteinte des gros vaisseaux était symptomatique chez moins de 10% des patients, renforçant le message de faire un dépistage de l'inflammation de l'aorte et de ses branches chez tous les patients et pas uniquement sur point d'appel clinique. Les recommandations européennes vont d'ailleurs en ce sens [44]. La meilleure modalité d'examen n'est pas connue et dépend probablement des centres, de l'accessibilité et des habitudes. Les quelques études comparatives sont trop discordantes pour pouvoir privilégier un examen par rapport à un autre. En terme médico-économique, l'angioscanner de l'aorte reste la technique la moins onéreuse pour dépister une atteinte aortique ou de ses branches. Dans un précédent travail, nous avons montré que l'angioscanner aortique et la TEP-TDM avaient une sensibilité voisine pour dépister une atteinte des gros vaisseaux mais que la TEP-TDM permettait d'avoir une cartographie vasculaire plus détaillée [55].

Nos données confortent des publications antérieures montrant que l'existence d'une atteinte des gros vaisseaux semble associée à une présentation clinique différente, notamment avec moins de signes crâniens. Par exemple, Brack et coll ont décrit deux formes d'ACG, en l'occurrence les formes céphaliques et les formes extra-céphaliques impliquant les gros vaisseaux. En comparant les deux groupes, ils ont constaté que les patients ayant une atteinte des gros vaisseaux (axillaires et sous-claviers dans l'étude) documentée par une angiographie conventionnelle étaient plus souvent des femmes, moins âgées, avec moins de signes céphaliques (moins de céphalées, moins de claudication de la mâchoire, moins de troubles visuels) et avaient moins de biopsies d'artères temporales positives [12]. Nueninghoff et coll ont également constaté qu'il existait une corrélation négative entre les signes céphaliques classiques et les complications des gros vaisseaux [43]. De même, pour Assie et coll, les patients ayant une atteinte des gros vaisseaux avaient moins de céphalées, moins de claudication de la mâchoire, moins d'hyperesthésie du cuir chevelu et moins de BAT positives [69].

A contrario, nous avons observé de manière inédite un taux conséquent de BAT positives chez des patients sans signes céphaliques : dans le travail sur les atteintes isolées des membres, 69% des BAT pratiquées étaient positives [60]; dans un autre travail sur les formes systémiques, 82% des BAT pratiquées étaient positive [70]. Ces données rappellent la grande rentabilité de la BAT chez des patients suspects d'ACG, et ce même en l'absence de signes crâniens.

La constatation d'un moins bon pronostic vasculaire chez les patients avec une atteinte des gros vaisseaux représente également un des résultats importants de ce travail. Quelques études antérieures [9, 40, 41, 43, 64, 71, 72] suggéraient qu'il existait un risque accru de dilatations et dissections aortiques chez les patients souffrant d'ACG. Nos travaux, confortés aussi par d'autres équipes [43, 71, 73] montrent que ce risque est plus important lorsqu'il existe une inflammation préalable de l'aorte et de ses branches. De manière intéressante, le délai d'apparition de ces complications est habituellement décrit entre 5 et 10 ans après le diagnostic [8-11, 40, 43, 71, 73]. Nous avons en réalité pu observer que certaines complications survenaient plus précocement, parfois dès la deuxième année, et ce majoritairement sur un territoire antérieurement inflammatoire. Cela implique donc une vigilance constante et une surveillance régulière de la morphologie aortique. En ce qui concerne les anomalies morphologiques tardives notamment anévrysmales, l'effet délétère additif de l'athérosclérose et de l'hypertension artérielle se discute et reste à être démontré.

A ce titre, il n'existe pas à ce jour de recommandations officielles sur la meilleure modalité de surveillance de l'aorte et de ses branches dans l'ACG. De même, le parfait contrôle des facteurs

de risque d'athérosclérose ne peut qu'être qu'empiriquement encouragé. Il semble que les dilatations de l'aorte survenant au cours du suivi se développent le plus souvent au niveau thoracique [7, 8, 11, 61]. Dans notre expérience, une échocardiographie thoracique annuelle semble être un bon examen de dépistage. Il semble d'autant plus légitime qu'un cardiologue soit consulté une fois par an que la population cible est souvent âgée et cumule souvent plusieurs facteurs de risque cardio-vasculaire.

Alors que certaines études de registre ont montré une mortalité accrue des patients avec une atteinte des gros vaisseaux, nous n'avons pas constaté de telles données dans nos différentes études [40, 63, 64, 72]. Plusieurs explications peuvent se discuter. D'abord, le suivi de nos différentes séries ne dépasse que rarement les 4 ou 5 ans, délai pouvant être trop court pour capturer les décès. D'autre part, il est possible que dans nos centres, le suivi des patients avec une atteinte des gros vaisseaux soit plus rapproché et qu'une vigilance accrue ait permis de limiter la mortalité, en proposant notamment une prise en charge interventionnelle chirurgicale. Enfin, un possible biais de sélection des études de registre de mortalité est également possible. La mortalité cardio-vasculaire attribuée à l'ACG décrite dans les registres de mortalité est possiblement surestimée, les autres causes de mortalité n'étant pas forcément adéquatement attribuées à l'ACG sur les certificats de décès. A ce titre, nous prévoyons une analyse détaillée de la mortalité dans notre cohorte.

L'observation d'un effet possiblement protecteur des immunosuppresseurs sur la survenue des complications cardio-vasculaires est intéressante pour plusieurs raisons :

- D'un point de vue physiopathologique, il a été montré dans plusieurs études que des lésions inflammatoires pouvaient persister à l'histologie sur des aortes opérées (pour remplacement de valve ou dissection) ou sur des analyses nécropsiques [6, 72, 74], alors même qu'il n'y avait plus de symptômes cliniques ou de syndrome inflammatoire biologique. Certaines études cytokiniques ont montré que les lésions aortiques étaient riches en Interféron-gamma. Ces lésions semblaient de fait moins sensibles aux glucocorticoïdes [12, 48, 49]. Enfin, les récentes études d'imagerie montrant la persistance au long cours de prise de contraste de la paroi de l'aorte [22, 50-54] alors même que la maladie semble en rémission d'un point de vue clinico-biologique, semblent également indiquer la persistance infra-clinique et infra-biologique d'une inflammation pariétale persistante au sein des gros vaisseaux. Toutes ces constatations questionnent sur la possible nécessité de traiter différemment (plus lourdement ou plus longtemps ?) ces patients avec une atteinte des gros vaisseaux. A ce titre, adjoindre un immunosuppresseur aux glucocorticoïdes apparaît alors être une option tout à fait légitime.

- D'un point de vue pratique. La récente indication du Tocilizumab dans l'ACG repose sur l'étude Giacta dont la moitié des patients étaient porteurs d'une atteinte des gros vaisseaux. A ce jour, il n'existe pas encore d'analyse de sous-groupes de ces patients et de l'efficacité potentielle de l'anti-IL6 dans ce cadre-là. Cependant, d'autres études avec de petits effectifs semblent confirmer l'intérêt de cette molécule lorsqu'il existe une atteinte des gros vaisseaux, avec un nombre conséquent d'amélioration d'imagerie [51, 52, 54, 75].

Certains de nos travaux ont montré que les patients avec une atteinte des gros vaisseaux souffraient davantage de rechute et de corticodépendance [76]. Dans ce contexte, la prescription d'immunosuppresseur à visée d'épargne cortisonique est fréquente. L'élargissement de l'arsenal thérapeutique disponible ouvre la voie à un traitement plus personnalisé. Nos travaux pourraient ainsi ouvrir la voie à une adaptation du traitement en fonction du pattern d'ACG, et l'atteinte des gros vaisseaux pourrait justifier d'emblée une association de glucocorticoïdes et d'un immunosuppresseur, avec le double objectif théorique d'éviter le développement d'une corticodépendance et la survenue de complications cardio-vasculaires. Bien sûr, des études à large échelle seront nécessaires pour confirmer ces données.

Nos travaux amènent nécessairement d'autres études, certaines étant déjà en cours, les autres étant planifiées dans les 12 à 24 mois à venir.

- L'arrivée du Tocilizumab sur le marché a laissé de nombreuses questions en suspens (population cible, modalité d'arrêt, surveillance du traitement par exemple). A ce titre, des études de vraies vies manquent. C'est pourquoi nous avons mis en place un registre national recueillant, sur déclaration, tous les patients avec une ACG ayant reçu du Tocilizumab. Une analyse des patients ayant reçu le médicament pour une atteinte des gros vaisseaux est en cours, portant sur une soixantaine de patients.

- L'athérosclérose représente un piège et un diagnostic différentiel lors de l'analyse d'un épaissement vasculaire à l'imagerie. D'ailleurs, la population concernée par l'ACG étant effectivement souvent âgée, il est fréquent d'observer une association de lésions inflammatoires et d'athérosclérose à l'imagerie. Certaines études ont suggéré que les lésions d'athérosclérose pourraient faire le lit aux lésions inflammatoires par un phénomène de réaction à corps étranger [77-79]. A ce titre, nous souhaitons refaire une analyse centralisée de notre base de données d'imagerie et confronter les lésions d'athérosclérose et les lésions inflammatoires.

- La collaboration avec l'unité de recherche SELIRM offre la possibilité d'étudier des techniques d'imageries inédites et possiblement adaptées à l'ACG. Ainsi, nous avons la possibilité de tester l'IRM de flux, technique d'imagerie visant à analyser le flux sanguin dans l'aorte et les contraintes pariétales s'exerçant sur la paroi. L'identification précoces des patients qui développeront des dilatations de l'aorte semble en théorie possible en analysant les contraintes pariétales aortiques, que l'on peut supposer plus importantes lorsqu'il existe une dilatation. A ce titre, nous avons obtenu un financement nous permettant de réaliser l'examen à des patients sélectionnés.

- Les dissections aortiques favorisées par l'ACG sont rares et peu décrites. Nous avons lancé un appel à observations et avons recueilli une cinquantaine d'observations. Ces patients seront prochainement décrits dans un article spécifique.

- Les analyses de registres indiquent une surmortalité cardio-vasculaire, notamment par dissection aortique, chez les patients souffrant d'une ACG [40, 63, 64, 72]. Néanmoins, il existe un probable biais, l'ACG étant citée comme cause du décès dans certaines situations évidentes, mais probablement pas dans d'autres situations (cancer, infections...). Nous sommes donc en train de conduire une étude sur la mortalité dans notre base de données et analyseront en détail les causes de décès dans les différents patterns d'ACG.

Quelques limitations, communes aux différents travaux doivent être discutées. Tout d'abord, un grand nombre d'analyses réalisées dans ces travaux concernent des données rétrospectivement récupérées, incluant donc nécessairement des données manquantes ou incomplètes. Une autre importante limitation concerne la généralisation de nos résultats. Quelques travaux ont concerné des patients rigoureusement sélectionnés. Par exemple, le travail publié dans *Clinical and Experimental Rheumatology* sur les patterns cliniques au diagnostic de l'ACG concernait 693 patients avec une biopsie d'artère temporale positive [59]. Cela exclue donc les patients avec une BAT négative qui sont pourtant des patients régulièrement vus et suivis, et qui pourraient correspondre à un pattern distinct, comme le suggère quelques études [80-82]. Dans l'étude sur les patterns d'atteinte des gros vaisseaux, le choix de n'inclure que des patients qu'avec une inflammation de l'aorte peut avoir surestimé le poids de cette atteinte dans le développement des complications cardio-vasculaires des différents patterns (dilatation, lésions sténosantes, ou atteinte aortique isolée) [62]. Néanmoins, en l'absence d'un épaissement homogène concomitant de la paroi vasculaire à l'imagerie, il n'est pas possible de préciser si une dilatation

vasculaire ou si une lésion sténosante est liée à l'inflammation pariétale ou liée à un phénomène dégénératif comme l'athérosclérose. C'est pour cette raison que nous avons fait le choix de ne sélectionner que des patients ayant une inflammation macro-vasculaire évidente.

En dehors de nos patients caennais diagnostiqués et suivis à partir de 2015, il est important de souligner que tous les autres patients n'ont pas eu une imagerie des gros vaisseaux systématiquement. Un biais peut donc exister concernant les patients ayant bénéficié d'une imagerie, ces derniers pouvant avoir une présentation ou une évolution atypique qui a motivé l'examen. D'autre part, nos patients proviennent de service de Médecine Interne habitués à la prise en charge de l'ACG. Le recrutement des patients peut être biaisé par l'adressage de patients "atypiques" dans un service de Médecine Interne (formes systémiques ou aortites isolées par exemple). D'autres spécialités non représentées dans ces travaux prennent en charge des patients peut être moins représentés dans nos séries (formes ophtalmologiques, PPR...).

L'atteinte des gros vaisseaux dans nos études étaient documentées chez la plupart des patients soit sur un angioscanner de l'aorte, soit sur une TEP-TDM. Même si plusieurs études suggèrent qu'il existe une bonne concordance entre les deux procédures pour démontrer l'atteinte des gros vaisseaux [55, 83], l'absence d'harmonisation sur la technique utilisée, les différentes machines et techniques d'analyses propres à chaque centre et la réalisation de certains examens quelques jours après l'introduction des glucocorticoïdes peuvent avoir induits des faux positifs ou des faux négatifs. D'autre part, une relecture centralisée des imageries permettrait d'en renforcer l'analyse. Cependant, les radiologues en charge d'analyser les imageries étaient avertis de la nécessité de regarder les gros vaisseaux, les examens étant demandés en ce sens.

Conclusion

Au terme de ces différents travaux, trois grands messages se dégagent et ouvrent la voie à des réflexions ultérieures :

- L'atteinte des gros vaisseaux n'est pas rare, reste souvent asymptomatique et doit ainsi être dépistée chez tout patient avec une ACG. La sinon les meilleures modalités d'imagerie restent à être déterminées sur une maladie apparaissant finalement plus inhomogène qu'il n'y paraissait, leur accessibilité dépendant cependant aussi des centres de soins concernés.
- Une attention toute particulière doit être portée au cours du suivi des patients avec une atteinte des gros vaisseaux, en raison notamment d'un risque accru de complications cardio-vasculaires. Ces complications pourraient dépendre du type d'atteinte initiale des gros vaisseaux. Un contrôle strict des facteurs de risque cardio-vasculaire et un suivi de la morphologie aortique semble indispensable au cours du suivi. Même si cette donnée nécessite une validation par d'autres études, les patients avec une atteinte des gros vaisseaux pourraient justifier d'un traitement plus lourd sinon plus spécifique. Le recours aux immunosuppresseurs ou aux thérapeutiques plus ciblées semble à ce titre prometteur avec l'objectif d'éradiquer plus rapidement l'inflammation et possiblement limiter le remodelage pariétal inadapté, lit des complications qui restent possibles même en cas de guérison clinique de la maladie. Cela pourrait conduire à considérer, par analogie à la maladie post-phlébitique, au paradigme de maladie post aorto-artéritique par remodelage inflammatoire via d'autres processus inflammatoires infra-cliniques de type athérosclérose accélérée.
- En raison du polymorphisme clinique et radiologique de l'ACG ainsi démontré et remettant l'atteinte artérielle des gros vaisseaux au centre des challenges diagnostiques, pronostiques et peut-être thérapeutiques, à côté des signes systémiques, céphaliques et de la possible PPR associée, les critères usuels de l'ACR 1990 sont aujourd'hui dépassés. De nouveaux critères de classifications doivent être édictés en reconsidérant l'ACG comme une vascularite primitive des gros vaisseaux, non uniquement localisée à la sphère crânienne.

Dans les années à venir, des études doivent être menées pour satisfaire l'impérieuse nécessité de mieux définir le cadre d'utilisation des biothérapies en fonction de la présence ou non d'une atteinte clinique ou radiologique des gros vaisseaux, en ayant ainsi recours possiblement à des prescriptions personnalisées. Une meilleure identification des patients à risque de complications

est aussi indispensable. A ce titre, des progrès sont nécessaires en imagerie pour mieux surveiller ces patients avec une atteinte des gros vaisseaux. Enfin, à l'instar des récentes recommandations européennes sur le traitement des vascularites des gros vaisseaux ou sur l'utilisation de l'imagerie, une concertation européenne voire internationale est nécessaire pour homogénéiser les critères de classification prenant en compte les différentes formes de la maladie, considérations de nos jours indispensables pour coller à la réalité de la vraie vie, de la pratique clinique et pour assurer une reproductibilité des travaux scientifiques.

References

- [1] Jennette JC, Falk RJ, Andrassy K, Bacon PA, Churg J, Gross WL, et al. Nomenclature of systemic vasculitides. Proposal of an international consensus conference. *Arthritis Rheum.* 1994;37:187-92.
- [2] Salvarani C, Cantini F, Hunder GG. Polymyalgia rheumatica and giant-cell arteritis. *Lancet.* 2008;372:234-45.
- [3] Hutchinson J. Diseases of the arteries. On a peculiar form of thrombotic arteritis of the aged which is sometimes productive of gangrene. *Arch Surg.* 1890;1:323-9.
- [4] Horton M. An undescribed form of arteritis of the temporal vessels. . *Proc Staff Meet Mayo Clin* 1. 1932;932:700.
- [5] Gilmore JR. Giant cell arteritis. *J Pathol Bacteriol.* 1941;53:262-77.
- [6] Klein RG, Hunder GG, Stanson AW, Sheps SG. Large artery involvement in giant cell (temporal) arteritis. *Ann Intern Med.* 1975;83:806-12.
- [7] de Boysson H, Liozon E, Lambert M, Parienti JJ, Artigues N, Geffray L, et al. 18F-fluorodeoxyglucose positron emission tomography and the risk of subsequent aortic complications in giant-cell arteritis: A multicenter cohort of 130 patients. *Medicine.* 2016;95:e3851.
- [8] Evans JM, O'Fallon WM, Hunder GG. Increased incidence of aortic aneurysm and dissection in giant cell (temporal) arteritis. A population-based study. *Ann Intern Med.* 1995;122:502-7.
- [9] Garcia-Martinez A, Hernandez-Rodriguez J, Arguis P, Paredes P, Segarra M, Lozano E, et al. Development of aortic aneurysm/dilatation during the followup of patients with giant cell arteritis: a cross-sectional screening of fifty-four prospectively followed patients. *Arthritis Rheumatol.* 2008;59:422-30.
- [10] Gonzalez-Gay MA, Garcia-Porrúa C, Pineiro A, Pego-Reigosa R, Llorca J, Hunder GG. Aortic aneurysm and dissection in patients with biopsy-proven giant cell arteritis from northwestern Spain: a population-based study. *Medicine.* 2004;83:335-41.
- [11] Evans JM, Bowles CA, Bjornsson J, Mullany CJ, Hunder GG. Thoracic aortic aneurysm and rupture in giant cell arteritis. A descriptive study of 41 cases. *Arthritis Rheumatol.* 1994;37:1539-47.
- [12] Brack A, Martinez-Taboada V, Stanson A, Goronzy JJ, Weyand CM. Disease pattern in cranial and large-vessel giant cell arteritis. *Arthritis Rheumatol.* 1999;42:311-7.
- [13] Hunder GG, Bloch DA, Michel BA, Stevens MB, Arend WP, Calabrese LH, et al. The American College of Rheumatology 1990 criteria for the classification of giant cell arteritis. *Arthritis Rheumatol.* 1990;33:1122-8.
- [14] Adler S, Sprecher M, Wermelinger F, Kilink T, Bonel H, Villiger PM. Diagnostic value of contrast-enhanced magnetic resonance angiography in large-vessel vasculitis. *Swiss Med Wkly.* 2017;21:w14397.
- [15] Agard C, Barrier JH, Dupas B, Ponge T, Mahr A, Fradet G, et al. Aortic involvement in recent-onset giant cell (temporal) arteritis: a case-control prospective study using helical aortic computed tomodensitometric scan. *Arthritis Rheum.* 2008;59:670-6.
- [16] Berthod PE, Aho-Glele S, Ornetti P, Chevallier O, Devilliers H, Ricolfi F, et al. CT analysis of the aorta in giant-cell arteritis: a case-control study. *Eur Radiol.* 2018;28:3676-84.
- [17] Besson FL, de Boysson H, Parienti JJ, Bouvard G, Bienvenu B, Agostini D. Towards an optimal semiquantitative approach in giant cell arteritis: an (18)F-FDG PET/CT case-control study. *Eur J Nucl Med Mol Imaging.* 2014;41:155-66.
- [18] Besson FL, Parienti JJ, Bienvenu B, Prior JO, Costo S, Bouvard G, et al. Diagnostic performance of (1)(8)F-fluorodeoxyglucose positron emission tomography in giant cell arteritis: a systematic review and meta-analysis. *Eur J Nucl Med Mol Imaging.* 2011;38:1764-72.
- [19] Bley TA, Uhl M, Carew J, Markl M, Schmidt D, Peter HH, et al. Diagnostic value of high-resolution MR imaging in giant cell arteritis. *AJNR Am J Neuroradiol.* 2007;28:1722-7.
- [20] Bley TA, Wieben O, Vaith P, Schmidt D, Ghanem NA, Langer M. Magnetic resonance imaging depicts mural inflammation of the temporal artery in giant cell arteritis. *Arthritis Rheumatol.* 2004;51:1062-3; author reply 4.

- [21] Blockmans D. Diagnosis and extension of giant cell arteritis. Contribution of imaging techniques. *Presse Med.* 2012;41:948-54.
- [22] Blockmans D, de Ceuninck L, Vanderschueren S, Knockaert D, Mortelmans L, Bobbaers H. Repetitive 18F-fluorodeoxyglucose positron emission tomography in giant cell arteritis: a prospective study of 35 patients. *Arthritis Rheumatol.* 2006;55:131-7.
- [23] Blockmans D, Stroobants S, Maes A, Mortelmans L. Positron emission tomography in giant cell arteritis and polymyalgia rheumatica: evidence for inflammation of the aortic arch. *Am J Med.* 2000;108:246-9.
- [24] Conway R, Smyth AE, Kavanagh RG, O'Donohoe RL, Purcell Y, Heffernan EJ, et al. Diagnostic Utility of Computed Tomographic Angiography in Giant-Cell Arteritis. *Stroke.* 2018;49:2233-6.
- [25] Guggenberger KV, Bley TA. Magnetic resonance imaging and magnetic resonance angiography in large-vessel vasculitides. *Clin Exp Rheumatol.* 2018;36 Suppl 114:103-7.
- [26] Hautzel H, Sander O, Heinzl A, Schneider M, Muller HW. Assessment of large-vessel involvement in giant cell arteritis with 18F-FDG PET: introducing an ROC-analysis-based cutoff ratio. *J Nucl Med.* 2008;49:1107-13.
- [27] Henes JC, Muller M, Krieger J, Balletshofer B, Pfannenbergl AC, Kanz L, et al. [18F] FDG-PET/CT as a new and sensitive imaging method for the diagnosis of large vessel vasculitis. *Clin Exp Rheumatol.* 2008;26:S47-52.
- [28] Lariviere D, Benali K, Coustet B, Pasi N, Hyafil F, Klein I, et al. Positron emission tomography and computed tomography angiography for the diagnosis of giant cell arteritis: A real-life prospective study. *Medicine.* 2016;95:e4146.
- [29] Muratore F, Kermani TA, Crowson CS, Green AB, Salvarani C, Matteson EL, et al. Large-vessel giant cell arteritis: a cohort study. *Rheumatology.* 2015;54:463-70.
- [30] Muratore F, Kermani TA, Crowson CS, Koster MJ, Matteson EL, Salvarani C, et al. Large-Vessel Dilatation in Giant Cell Arteritis: A Different Subset of Disease? *Arthritis Care Res (Hoboken).* 2018;70:1406-11.
- [31] Prieto-Gonzalez S, Arguis P, Garcia-Martinez A, Espigol-Frigole G, Tavera-Bahillo I, Butjosa M, et al. Large vessel involvement in biopsy-proven giant cell arteritis: prospective study in 40 newly diagnosed patients using CT angiography. *Ann Rheum Dis.* 2012;71:1170-6.
- [32] Prieto-Gonzalez S, Depetris M, Garcia-Martinez A, Espigol-Frigole G, Tavera-Bahillo I, Corbera-Bellalta B. Positron emission tomography assessment of large vessel inflammation in patients with newly diagnosed, biopsy-proven giant cell arteritis: a prospective, case-control study. *Ann Rheum Dis.* 2014;73:1388-92.
- [33] Puppo C, Massollo M, Paparo F, Camellino D, Piccardo A, Shoushtari Zadeh Naseri M, et al. Giant cell arteritis: a systematic review of the qualitative and semiquantitative methods to assess vasculitis with 18F-fluorodeoxyglucose positron emission tomography. *BioMed research international.* 2014;2014:574248.
- [34] Quinn KA, Ahlman MA, Malayeri AA, Marko J, Civelek AC, Rosenblum JS, et al. Comparison of magnetic resonance angiography and (18)F-fluorodeoxyglucose positron emission tomography in large-vessel vasculitis. *Ann Rheum Dis.* 2018;77:1165-71.
- [35] Walter MA, Melzer RA, Schindler C, Muller-Brand J, Tyndall A, Nitzsche EU. The value of [18F]FDG-PET in the diagnosis of large-vessel vasculitis and the assessment of activity and extent of disease. *Eur J Nucl Med Mol Imaging.* 2005;32:674-81.
- [36] Yamashita H, Kubota K, Takahashi Y, Minaminoto R, Morooka M, Ito K, et al. Whole-body fluorodeoxyglucose positron emission tomography/computed tomography in patients with active polymyalgia rheumatica: evidence for distinctive bursitis and large-vessel vasculitis. *Mod Rheumatol.* 2012;22:705-11.
- [37] Stone JH, Tuckwell K, Dimonaco S, Klearman M, Aringer M, Blockmans D, et al. Trial of Tocilizumab in Giant-Cell Arteritis. *N Engl J Med.* 2017;377:317-28.
- [38] Aschwanden M, Kesten F, Stern M, Thalhammer C, Walker UA, Tyndall A, et al. Vascular involvement in patients with giant cell arteritis determined by duplex sonography of 2x11 arterial regions. *Ann Rheum Dis.* 2010;69:1356-9.

- [39] Espitia O, Samson M, Le Gallou T, Connault J, Landron C, Lavigne C, et al. Comparison of idiopathic (isolated) aortitis and giant cell arteritis-related aortitis. A French retrospective multicenter study of 117 patients. *Autoimmun Rev*. 2016;15:571-6.
- [40] Kermani TA, Warrington KJ, Crowson CS, Hunder GG, Ytterberg SR, Gabriel SE, et al. Predictors of Dissection in Aortic Aneurysms From Giant Cell Arteritis. *J Clin Rheumatol*. 2016;22:184-7.
- [41] Kermani TA, Warrington KJ, Crowson CS, Ytterberg SR, Hunder GG, Gabriel SE, et al. Large-vessel involvement in giant cell arteritis: a population-based cohort study of the incidence-trends and prognosis. *Ann Rheum Dis*. 2013;72:1989-94.
- [42] Marie I, Proux A, Duhaut P, Primard E, Lahaxe L, Girszyn N, et al. Long-term follow-up of aortic involvement in giant cell arteritis: a series of 48 patients. *Medicine*. 2009;88:182-92.
- [43] Nuenninghoff DM, Hunder GG, Christianson TJ, McClelland RL, Matteson EL. Incidence and predictors of large-artery complication (aortic aneurysm, aortic dissection, and/or large-artery stenosis) in patients with giant cell arteritis: a population-based study over 50 years. *Arthritis Rheumatol*. 2003;48:3522-31.
- [44] Dejaco C, Ramiro S, Duftner C, Besson FL, Bley TA, Blockmans D, et al. EULAR recommendations for the use of imaging in large vessel vasculitis in clinical practice. *Ann Rheum Dis*. 2018;77:636-43.
- [45] Bienvenu B, Ly KH, Lambert M, Agard C, Andre M, Benhamou Y, et al. Management of giant cell arteritis: Recommendations of the French Study Group for Large Vessel Vasculitis (GEFA). *La Revue de medecine interne / fondee par la Societe nationale francaise de medecine interne*. 2016;37:154-65.
- [46] géantes. Pdlàc.
http://www.sfm.org/upload/consensus/RPC_arterite_a_cellules_geantes2017pdf.
- [47] Hellmich B, Agueda A, Monti S, Buttgerit F, de Boysson H, Brouwer E, et al. 2018 Update of the EULAR recommendations for the management of large vessel vasculitis. *Ann Rheum Dis*. 2019.
- [48] Deng J, Younge BR, Olshen RA, Goronzy JJ, Weyand CM. Th17 and Th1 T-cell responses in giant cell arteritis. *Circulation*. 2010;121:906-15.
- [49] Weyand CM, Tetzlaff N, Bjornsson J, Brack A, Younge B, Goronzy JJ. Disease patterns and tissue cytokine profiles in giant cell arteritis. *Arthritis Rheumatol*. 1997;40:19-26.
- [50] de Boysson H, Aide N, Liozon E, Lambert M, Parienti JJ, Monteil J, et al. Repetitive (18)F-FDG-PET/CT in patients with large-vessel giant-cell arteritis and controlled disease. *Eur J Intern Med*. 2017;46:66-70.
- [51] Banerjee S, Quinn KA, Gribbons KB, Rosenblum JS, Civelek AC, Novakovich E, et al. Effect of Treatment on Imaging, Clinical, and Serologic Assessments of Disease Activity in Large-Vessel Vasculitis. *J Rheumatol*. 2019.
- [52] Grayson PC, Alehashemi S, Bagheri AA, Civelek AC, Cupps TR, Kaplan MJ, et al. (18) F-Fluorodeoxyglucose-Positron Emission Tomography As an Imaging Biomarker in a Prospective, Longitudinal Cohort of Patients With Large Vessel Vasculitis. *Arthritis Rheumatol*. 2018;70:439-49.
- [53] Prieto-Gonzalez S, Garcia-Martinez A, Tavera-Bahillo I, Hernandez-Rodriguez J, Gutierrez-Chacoff J, Alba MA, et al. Effect of glucocorticoid treatment on computed tomography angiography detected large-vessel inflammation in giant-cell arteritis. A prospective, longitudinal study. *Medicine*. 2015;94:e486.
- [54] Reichenbach S, Adler S, Bonel H, Cullmann JL, Kuchen S, Butikofer L, et al. Magnetic resonance angiography in giant cell arteritis: results of a randomized controlled trial of tocilizumab in giant cell arteritis. *Rheumatology*. 2018;57:982-6.
- [55] de Boysson H, Dumont A, Liozon E, Lambert M, Boutemy J, Maigné G, et al. Giant-cell arteritis: concordance study between aortic CT angiography and FDG-PET/CT in detection of large-vessel involvement. *Eur J Nucl Med Mol Imaging*. 2017;doi: 10.1007/s00259-017-3775-5.
- [56] de Boysson H, Liozon E, Lambert M, Dumont A, Boutemy J, Maigné G, et al. Giant-Cell Arteritis: Do We Treat Patients with Large-Vessel Involvement Differently? *Am J Med*. 2017;130:992-5.
- [57] Cid MC, Prieto-Gonzalez S, Arguis P, Espigol-Frigole G, Butjosa M, Hernandez-Rodriguez J, et al. The spectrum of vascular involvement in giant-cell arteritis: clinical consequences of detrimental vascular remodelling at different sites. *APMIS Suppl*. 2009:10-20.

- [58] Dejaco C, Duftner C, Buttgereit F, Matteson EL, Dasgupta B. The spectrum of giant cell arteritis and polymyalgia rheumatica: revisiting the concept of the disease. *Rheumatology*. 2017;56:506-15.
- [59] de Boysson H, Liozon E, Ly KH, Dumont A, Delmas C, Aouba A. The different clinical patterns of giant cell arteritis. *Clin Exp Rheumatol*. 2019;37 Suppl 117:57-60.
- [60] de Boysson H, Espitia O, Liozon E, Daumas A, Vautier M, Dumont A, et al. Vascular Presentation and Outcomes of Patients With Giant Cell Arteritis and Isolated Symptomatic Limb Involvement. *J Clin Rheumatol*. 2019.
- [61] de Boysson H, Daumas A, Vautier M, Parienti JJ, Liozon E, Lambert M, et al. Large-vessel involvement and aortic dilation in giant-cell arteritis. A multicenter study of 549 patients. *Autoimmun Rev*. 2018;17:391-8.
- [62] de Boysson H, Liozon E, Espitia O, Daumas A, Vautier M, Lambert M, et al. Different patterns and specific outcomes of large-vessel involvements in giant cell arteritis. *J Autoimmun*. 2019;103:102283.
- [63] Aouba A, Gonzalez Chiappe S, Eb M, Delmas C, de Boysson H, Bienvenu B, et al. Mortality causes and trends associated with giant cell arteritis: analysis of the French national death certificate database (1980-2011). *Rheumatology*. 2018;57:1047-55.
- [64] Robson JC, Kiran A, Maskell J, Hutchings A, Arden N, Dasgupta B, et al. The relative risk of aortic aneurysm in patients with giant cell arteritis compared with the general population of the UK. *Ann Rheum Dis*. 2015;74:129-35.
- [65] Seeliger B, Sznajd J, Robson JC, Judge A, Craven A, Grayson PC, et al. Are the 1990 American College of Rheumatology vasculitis classification criteria still valid? *Rheumatology*. 2017;56:1154-61.
- [66] Berti A, Campochiaro C, Cavalli G, Pepe G, Praderio L, Sabbadini MG, et al. Giant cell arteritis restricted to the limb arteries: An overlooked clinical entity. *Autoimmun Rev*. 2015;14:352-7.
- [67] Ghinoi A, Pipitone N, Nicolini A, Boiardi L, Silingardi M, Germano G, et al. Large-vessel involvement in recent-onset giant cell arteritis: a case-control colour-Doppler sonography study. *Rheumatology*. 2012;51:730-4.
- [68] Kermani TA, Matteson EL, Hunder GG, Warrington KJ. Symptomatic lower extremity vasculitis in giant cell arteritis: a case series. *J Rheumatol*. 2009;36:2277-83.
- [69] Assie C, Janvresse A, Plissonnier D, Levesque H, Marie I. Long-term follow-up of upper and lower extremity vasculitis related to giant cell arteritis: a series of 36 patients. *Medicine*. 2011;90:40-51.
- [70] de Boysson H, Liozon E, Ly KH, Dumont A, Delmas C, Sultan A, et al. Giant cell arteritis presenting as isolated inflammatory response and/or fever of unknown origin: a case-control study. *Clin Rheumatol*. 2018;37:3405-10.
- [71] Blockmans D, Coudyzer W, Vanderschueren S, Stroobants S, Loeckx D, Heye S, et al. Relationship between fluorodeoxyglucose uptake in the large vessels and late aortic diameter in giant cell arteritis. *Rheumatology*. 2008;47:1179-84.
- [72] Nuenninghoff DM, Hunder GG, Christianson TJ, McClelland RL, Matteson EL. Mortality of large-artery complication (aortic aneurysm, aortic dissection, and/or large-artery stenosis) in patients with giant cell arteritis: a population-based study over 50 years. *Arthritis Rheumatol*. 2003;48:3532-7.
- [73] Daumas A, Rossi P, Bernard-Guervilly F, Frances Y, Berbis J, Durand JM, et al. [Clinical, laboratory, radiological features, and outcome in 26 patients with aortic involvement amongst a case series of 63 patients with giant cell arteritis.]. *Rev Med Interne*. 2013.
- [74] Miller DV, Isotalo PA, Weyand CM, Edwards WD, Aubry MC, Tazelaar HD. Surgical pathology of noninfectious ascending aortitis: a study of 45 cases with emphasis on an isolated variant. *Am J Surg Pathol*. 2006;30:1150-8.
- [75] Samson M, Devilliers H, Ly KH, Maurier F, Bienvenu B, Terrier B, et al. Tocilizumab as an add-on therapy to glucocorticoids during the first 3 months of treatment of Giant cell arteritis: A prospective study. *Eur J Intern Med*. 2018;57:96-104.
- [76] Dumont A, Parienti JJ, Delmas C, Boutemy J, Maigne G, Silva NM, et al. Factors Associated with Relapse and Dependence to Glucocorticoids in Giant-Cell Arteritis. *J Rheumatol*. 2019.
- [77] Nordborg E, Nordborg C. The inflammatory reaction in giant cell arteritis: an immunohistochemical investigation. *Clin Exp Rheumatol*. 1998;16:165-8.

- [78] Nordborg C, Nordborg E, Petursdottir V. The pathogenesis of giant cell arteritis: morphological aspects. *Clin Exp Rheumatol*. 2000;18:S18-21.
- [79] Nordborg C, Johansson H, Petursdottir V, Nordborg E. The epidemiology of biopsy-positive giant cell arteritis: special reference to changes in the age of the population. *Rheumatology*. 2003;42:549-52.
- [80] Gonzalez-Gay MA, Garcia-Porrúa C, Llorca J, Gonzalez-Louzao C, Rodriguez-Ledo P. Biopsy-negative giant cell arteritis: clinical spectrum and predictive factors for positive temporal artery biopsy. *Semin Arthritis Rheum*. 2001;30:249-56.
- [81] Breuer GS, Neshet R, Neshet G. Negative temporal artery biopsies: eventual diagnoses and features of patients with biopsy-negative giant cell arteritis compared to patients without arteritis. *Clin Exp Rheumatol*. 2008;26:1103-6.
- [82] Bornstein G, Barshack I, Koren-Morag N, Ben-Zvi I, Furie N, Grossman C. Negative temporal artery biopsy: predictive factors for giant cell arteritis diagnosis and alternate diagnoses of patients without arteritis. *Clin Rheumatol*. 2018;37:2819-24.
- [83] Hommada M, Mekinian A, Brillet PY, Abad S, Larroche C, Dhote R, et al. Aortitis in giant cell arteritis: diagnosis with FDG PET/CT and agreement with CT angiography. *Autoimmun Rev*. 2017;16:1131-7.

Résumé

Les travaux concernant les atteintes des gros vaisseaux dans l'artérite à cellules géantes sont rares et ne concernent rarement plus que quelques dizaines de patients. Dans des travaux précédents, nous montrions que l'atteinte des gros vaisseaux était associée à un risque accru de dilatation aortique. Grâce à un recrutement inédit et des collaborations fructueuses, nous avons pu constituer une cohorte conséquente de patients et avons pu déterminer la fréquence et la présentation clinico-radiologique des patients avec une atteinte des gros vaisseaux. Nous avons pu confirmer que cette atteinte était associée à un pronostic cardio-vasculaire plus sombre et avons pu individualiser différentes formes d'atteinte des gros vaisseaux, chacune ayant un pronostic cardio-vasculaire différent. L'adjonction d'un traitement immunosuppresseur aux glucocorticoïdes semble avoir un effet protecteur sur le développement des complications cardio-vasculaires. Nos travaux nous ont également amené à discuter la place des différentes imageries disponibles pour dépister l'atteinte des gros vaisseaux, et à proposer des nouveaux critères de classification actualisés prenant en compte l'atteinte des gros vaisseaux.

Abstract

Studies analyzing giant cell arteritis (GCA)-related large-vessel involvement are rare and only describe less than 100 patients. In previous studies, we showed that large-vessel involvement was associated with an increased risk of aortic dilation. Thanks to an unedited enrollment of GCA patients and collaborations with other teams, we created a large-sampled cohort. We analyzed the frequency and the clinical and radiological presentations of patients with large-vessel involvement. We confirmed poorer cardiovascular outcomes in patients with GCA-related large-vessel involvement. We also individualized different patterns of large-vessel involvement, with different cardiovascular prognoses. Combination of an immunosuppressant with glucocorticoids decreased the risk of cardiovascular complications in GCA patients with large-vessel involvement. We discussed in our studies the place of each imaging tool available to detect large-vessel involvement. Finally, we proposed updated classification criteria including large-vessel involvement in order to integrate the different disease patterns.

Mots-clés: artérite à cellules géantes; maladie de Horton; atteinte des gros vaisseaux; aortite; pronostic cardio-vasculaire; imagerie; classification.