



HAL
open science

Anatomie fonctionnelle de la cognition visuo-spatiale : de l'anatomie morphologique et fonctionnelle à la réalité virtuelle en chirurgie éveillée

Florian Bernard

► **To cite this version:**

Florian Bernard. Anatomie fonctionnelle de la cognition visuo-spatiale : de l'anatomie morphologique et fonctionnelle à la réalité virtuelle en chirurgie éveillée. Médecine humaine et pathologie. Université d'Angers, 2020. Français. NNT : 2020ANGE0043 . tel-03692137

HAL Id: tel-03692137

<https://theses.hal.science/tel-03692137>

Submitted on 9 Jun 2022

HAL is a multi-disciplinary open access archive for the deposit and dissemination of scientific research documents, whether they are published or not. The documents may come from teaching and research institutions in France or abroad, or from public or private research centers.

L'archive ouverte pluridisciplinaire **HAL**, est destinée au dépôt et à la diffusion de documents scientifiques de niveau recherche, publiés ou non, émanant des établissements d'enseignement et de recherche français ou étrangers, des laboratoires publics ou privés.

Thèse de Doctorat

Florian Bernard

Mémoire présenté en vue de l'obtention du
grade de Docteur de l'Université d'Angers
sous le label de L'Université Nantes Angers Le Mans

École doctorale : *Biologie-Santé*

Discipline : *Neurosciences, section CNU 69*

Unité de recherche :

- Département de Neurochirurgie, CHU d'Angers
- CRCINA- Unité INSERM U1232 équipe 17

Soutenu le 08/07/2020

Thèse N° : 211718

Anatomie fonctionnelle de la cognition visuo- spatiale

De l'anatomie morphologique et
fonctionnelle à la réalité virtuelle
en chirurgie éveillée

JURY

Rapporteurs :

Emmanuel Mandonnet
Marc Braun

Professeur des Universités – Praticien hospitalier - Université de Paris
Professeur des Universités - Praticien hospitalier - HDR, Université de Nancy

Examineurs :

Stéphane Velut
Thimothée Jacquesson
Ilyess Zemmoura

Professeur des Universités -Praticien hospitalier – université de Tours
Maitre de conférences -Praticien hospitalier – université de Lyon
Praticien hospitalier - HDR, Université de Tours

Directeur de Thèse :

Philippe MENEI

Professeur des Universités – Praticien hospitalier - HDR, Université d'Angers

Co-encadrant :

Aram Ter Minassian
Henri-Dominique Fournier

Praticien hospitalier – université d'Angers

Professeur des Universités – Praticien hospitalier - Université d'Angers

L'auteur du présent document vous autorise à le partager, reproduire, distribuer et communiquer selon les conditions suivantes :



- Vous devez le citer en l'attribuant de la manière indiquée par l'auteur (mais pas d'une manière qui suggérerait qu'il approuve votre utilisation de l'œuvre).
- Vous n'avez pas le droit d'utiliser ce document à des fins commerciales.
- Vous n'avez pas le droit de le modifier, de le transformer ou de l'adapter.

Consulter la licence creative commons complète en français :
<http://creativecommons.org/licences/by-nc-nd/2.0/fr/>

REMERCIEMENTS

Au Pr Philippe Menei, merci de m'avoir encadré durant cette thèse de Sciences. Merci de m'avoir guidé sur le chemin universitaire depuis mon arrivée dans votre équipe en 2012. J'ai eu le plaisir d'être un des témoins de vos avancées dans le développement de la chirurgie éveillée de l'hémisphère droit. Merci de m'avoir permis de travailler au sein de votre équipe universitaire. J'ai ainsi pu monter à bord d'un navire serein tout au long de mes trois années de thèse d'université.

Au Dr Aram Ter Minassian, merci de m'avoir aidé sur ce sujet du premier jour (rédaction du projet de master 2 en 2016), aux derniers jours de ma thèse. Travailler à vos côtés m'a permis de découvrir la complexité et les challenges que représentent les neurosciences. C'est avec joie et une grande humilité que je présente aujourd'hui un reflet de votre travail.

Au Pr Henri-Dominique Fournier, merci de me faire l'honneur de faire partie de mon jury de thèse et de m'encadrer dans ma formation. Nous avons bati ensemble une relation de confiance et de réel compagnonnage. Merci de me guider sur vos pas. Même si la tâche est hardie, je le vis comme une entreprise humaine exaltante.

Au Pr Emmanuel Mandonnet. Merci de me faire l'honneur d'être jury de ma thèse d'université.

Au Pr Marc Braun. Merci de me faire l'honneur d'être jury de ma thèse d'université.

Au Pr Stéphane Velut. Merci de compter une nouvelle foi parmi les membres de mon jury. J'espère que ce travail vous plaira. Merci de m'avoir aidé, accompagné, conseillé depuis mon stage dans votre laboratoire en 2015. Ce stage a changé ma vie professionnelle et m'a conforté dans la volonté d'apprendre et de transmettre l'anatomie.

Au Dr Thimothée Jacquesson. Merci de me faire l'honneur d'évaluer ce travail de neuroanatomie. J'espère pouvoir suivre tes pas dans la carrière anatomique.

Au Dr Ilyess Zemmoura, merci de me faire l'honneur d'être les rapporteurs de ce travail de Thèse. Merci de m'avoir conseillé dans la direction de ces travaux.

Au Dr Jean-Michel Lemée, merci de m'avoir tendu la main au début de l'internat, de m'avoir expliqué la marche à suivre et de m'avoir accompagné pour l'écriture de mes papiers. Tu restes toujours disponible et de bon conseil. Merci pour l'aide précieuse que tu m'a fourni pour l'écriture de cette thèse également. Je vois en toi toutes les qualités nécessaires pour devenir un excellent universitaire.

A ma compagne, Amandine. Merci de ton soutien et de ton aide en toute circonstance.

A ma famille, mes parents et ma soeur,

A ma belle-famille,

A mes collègues passés et présents,

A mes collègues du laboratoire d'anatomie,

A mes amis triathlètes, indispensables compagnons de route, et de soirées...

A mes amis granvillais.

Table des matières

Table des matières.....	4
Abréviations.....	6
Introduction.....	7
1. Contexte.....	7
1.1. Gliomes et chirurgie éveillée.....	7
1.2. Gliomes et altération des fonctions cognitives de l'HND.....	8
1.3. Évaluation des fonctions cognitives de l'HND.....	10
2. L'apport des neurosciences dans l'exploration de l'hémisphère non dominant.....	12
2.1. Méthodes d'études de l'HND.....	12
2.2. Synthèse des résultats de neuro-imagerie concernant l'héminégligence spatiale.....	14
2.3. Organisation des fibres blanches cérébrales.....	15
3. Objectifs de la thèse.....	16
4. Travaux réalisés.....	17
Revue de la littérature.....	20
1. État de l'art des fonctions cognitives de l'hémisphère droit : des bases anatomo-cliniques à la stimulation électrique corticale en chirurgie éveillée.....	21
1.1. Anatomie structurale et fonctionnelle de l'hémisphère non-dominant.....	21
Right Hemisphere Cognitive Functions: From Clinical and Anatomic Bases to Brain Mapping During Awake Craniotomy Part I: Clinical and Functional Anatomy.....	21
1.2. Tests neuropsychologiques et stimulation électrique en chirurgie éveillée de l'hémisphère non-dominant.....	22
Right Hemisphere Cognitive Functions: From Clinical and Anatomic Bases to Brain Mapping During Awake Craniotomy Part II: Neuropsychological tasks and Brain mapping.....	22
2. Anatomie des fibres blanches cérébrales. Le débat concernant la distinction entre SLF III et faisceau arqué.....	23
Anatomical variability of the arcuate fasciculus: a systematical review.....	23
Travail expérimental.....	24
The ventral attention network: the mirror of the language network in the right brain hemisphere.....	25
Oncology meets Art: a way to understand patient's symptoms.....	26

Using a VR social network during awake craniotomy to map the social cognition: Prospective Trial.....	27
Immersing patients in a virtual reality environment for brain mapping during awake surgery. Safety study	31
<i>Discussion générale, Perspectives</i>.....	32
Enter “The Matrix” for Brain mapping during awake brain surgery	33
<i>Publications et communications présentées au cours de la Thèse</i>.....	36
1. Publications :.....	34
2. Communications orales ou affichées.....	35
2.1. Communications orales lors de congrès.....	35
2.2. Communication par poster lors de congrès	35
<i>Bibliographie</i>.....	37
<i>Table des illustrations</i>.....	42
<i>Table des tableaux</i>.....	43

Abréviations

DAN	<i>Réseau dorsal de l'attention</i>
HD	<i>Hémisphère dominant</i>
HND	<i>Hémisphère non-dominant</i>
ICN	<i>Réseau de connectivité intrinsèque</i>
ILF	<i>Faisceau longitudinal inférieur</i>
IFOF	<i>Faisceau occipito-frontal inférieur</i>
IRMf	<i>Imagerie par résonance magnétique fonctionnelle</i>
SLF	<i>Faisceau longitudinal supérieur</i>
VAN	<i>Réseau ventral de l'attention</i>

Introduction

1. Contexte

1.1. Gliomes et chirurgie éveillée

Les tumeurs primitives gliales, communément appelées gliomes, représentent l'entité la plus fréquente des tumeurs cérébrales chez l'adulte (70%) (1). Elles sont, de par leurs évolutions, schématiquement divisées en deux groupes : les gliomes dits de haut grade d'évolution rapide et de mauvais pronostic en l'absence de traitement ; et les gliomes dits de bas grade d'évolution lente, présentant un risque de dégénérescence à long terme. La chirurgie est la première étape du traitement des patients porteurs de gliomes. Chez ces patients, dont la médiane de survie se situe entre 14 mois et 13 ans en fonction du grade du gliome, il est essentiel de préserver la qualité de vie et d'éviter de nouveaux déficits neurologiques ou d'aggraver ceux déjà existants.

Afin d'éviter des séquelles neurologiques lors de l'ablation des gliomes, la chirurgie éveillée a été développée (2). Cette technique chirurgicale consiste à réveiller les patients pendant l'intervention et à réaliser une cartographie cérébrale (corticale et sous-corticale) en inactivant temporairement des régions circonscrites du cerveau (environ 5 mm²) avec des stimulations électriques alors que le patient réalise une tâche (Figure 1). Si le patient montre des troubles comme un trouble du langage lors d'une tâche de dénomination, cela signifie que la région stimulée est élocutoire et doit être préservée. Dans la pratique, pour réduire le risque épileptique, l'utilisation de cette technique est soumise à des contraintes strictes : la stimulation électrique ne doit pas excéder 4 secondes et ne doit pas être appliquée plus de deux ou trois fois sur la même zone cérébrale. Les stimuli présentés dans les épreuves doivent alors obligatoirement être simples et brefs. La preuve que la chirurgie éveillée permet d'optimiser la résection chirurgicale tout en minimisant le risque de séquelles neurologiques a été apportée par de nombreuses publications (3-6).

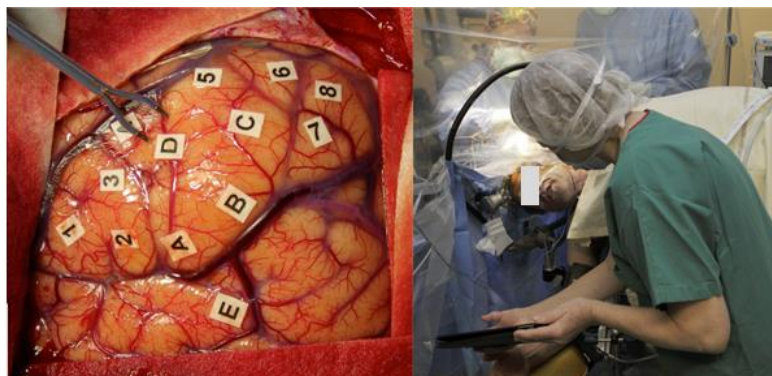


Figure 1 : Cartographie cérébrale par stimulation électrique en chirurgie éveillée

Actuellement, le protocole de chirurgie éveillée évalue principalement les fonctions du langage qui sont préférentiellement sous-tendues par l'hémisphère dominant (HD), localisé à gauche chez la plupart des patients,

notamment les droitiers. Ainsi, seuls les patients présentant une tumeur de l'HD, sans troubles phasiques ou ayant récupérés sous traitement par corticoïdes, et dont l'exérèse de la tumeur pourrait induire une aphasie, bénéficient d'une chirurgie éveillée. Ce protocole est aussi proposé chez les patients atteints de tumeurs dans l'hémisphère controlatéral dit non-dominant (HND), lorsque la tumeur est localisée à proximité d'une zone fonctionnelle motrice (lobe frontal), mais dans ce cas, l'évaluation langagière n'est pas requise. En l'absence de risques moteurs dans l'HND, le protocole de chirurgie éveillée est peu proposé pour l'exérèse de la tumeur.

Or, Il est aujourd'hui avéré que l'HND possède un rôle prépondérant dans de grandes fonctions cognitives, comme la cognition visuo-spatiale à laquelle on rattache les processus attentionnels et la cognition sociale (7-9). Des déficits de ces fonctions après une chirurgie de gliomes de l'HND sont connus. Ils peuvent avoir un impact significatif sur les relations sociales et la qualité de vie du patient. Leur préservation per-opératoire est délicate, notamment en chirurgie sous anesthésie générale. Une attitude séduisante serait d'effectuer une chirurgie éveillée pour préciser l'anatomie fonctionnelle per-opératoire et optimiser les résections chirurgicales. Différents tests neuropsychologiques évaluant ces fonctions sont disponibles en clinique courante. Contrairement à ceux utilisés pour l'évaluation langagière, ils ne sont pas adaptés aux contraintes strictes de la chirurgie éveillée. Cela explique pourquoi cette technique chirurgicale est peu proposée pour identifier et préserver les fonctions cognitives de l'HND.

1.2. Gliomes et altération des fonctions cognitives de l'HND

Une atteinte de la cognition visuo-spatiale et de la cognition sociale per-opératoire peut être à l'origine de déficits neurologiques polymorphes, impactant la qualité de vie des patients.

1.2.1. Troubles de la cognition spatiale et des processus attentionnels

Le trouble le plus connu de la cognition spatiale et des processus attentionnels est une négligence spatiale unilatérale, aussi appelée héminégligence (7). Selon la définition de Heilman & Valenstein, 1979, le syndrome d'héminégligence est défini comme « l'impossibilité de décrire verbalement, de répondre et de s'orienter aux stimulations controlatérales à la lésion hémisphérique, sans que ce trouble puisse être attribué à un déficit sensoriel ou moteur. ». Ce trouble doit donc être dissocié des troubles visuels purs (comme l'hémianopsie latérale homonyme) par le fait qu'il peut concerner différentes modalités sensorielles : visuelle, auditive, olfactive ou somesthésique(11). En raison du rôle majeur de l'HND dans les processus attentionnels, ce trouble apparaît quasiment exclusivement suite à des lésions de cet hémisphère. IL s'agit essentiellement d'une héminégligence gauche chez les patients droitiers.

Avant même une évaluation « papier-crayon » pour diagnostiquer cette négligence, on peut repérer certains signes cliniques grâce à la seule observation des patients (Li & Malhotra, 2015). En effet, les patients atteints de ces troubles se comportent de manière caricaturale en ignorant la moitié gauche de l'environnement. Ils ne mangent pas ce qui se trouve dans la moitié gauche de l'assiette, ne se rasent pas la partie gauche du visage et ne répondent pas quand ils sont interrogés du côté gauche. En dessinant de mémoire ou en copie une fleur ou une maison, ils omettent les détails de gauche. Si on leur demande de marquer le milieu d'une ligne horizontale, ils le déplacent vers la droite.

Alors qu'il est généralement admis que l'héminégligence résulte d'une atteinte de l'HND, il n'y a pas de consensus quant à la localisation anatomique intra-hémisphérique des lésions. Des études ont utilisé la stimulation électrique per-opératoire avec un test de bissection de ligne modifié sur l'HND pour explorer les fonctions visuo-spatiales (7,13–15). Ces études signalent le rôle du gyrus temporal supérieur et du lobule pariétal inférieur, et plus particulièrement de sa portion contigüe avec le lobe temporal. Les neuroscientifiques désignent d'ailleurs souvent cette région comme « la jonction temporopariétale droite », témoignant ainsi leur difficulté dans la définition précise de ce carrefour fonctionnel (Figure 2). Ces études ont aussi montré par l'utilisation de la tractographie cérébrale par IRM en tenseur de diffusion, que des lésions des faisceaux blancs d'association sont fortement corrélés au symptômes d'héminégligence spatiale. On peut citer de nombreux faisceaux impliqués, comme des lésions du faisceau longitudinal supérieur III (SLF pour « superior longitudinal fasciculus »), du faisceau arqué, du faisceau fronto-occipital inférieur (IFOF pour « inferior fronto-occipital fasciculus) et du faisceau longitudinal inférieur (ILF pour « inferior longitudinal fasciculus) (Figure 2).

Certaines équipes ont évalué l'impact d'une chirurgie cérébrale dans l'HND sur la cognition visuospatiale. Emanuele et al. (16) ont évalué les fonctions visuo-spatiales en pré- et post-opératoire chez 14 patients porteurs d'une tumeur cérébrale dans l'HND. Ils ont observé une prévalence des troubles visuo-spatiaux de 42,86% avant chirurgie qui a augmenté à 57,14% après la chirurgie. Cette morbidité ne peut être prédite de manière fiable sur les données d'imagerie pré et per-opératoires. Ces résultats soulignent l'importance potentielle de la chirurgie éveillée dans l'HND. Tester l'attention visuo-spatiale en per-opératoire pourrait permettre de minimiser ces troubles post-opératoires. Ainsi on pourrait diminuer l'impact fonctionnel de la prise en charge chirurgicale.

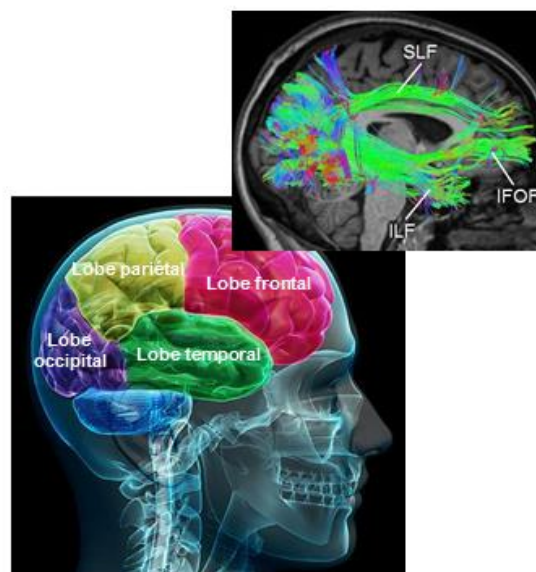


Figure 2 : Principaux faisceaux de la substance blanche impliqués dans les deux importantes fonctions cognitives de l'HND : cognition spatiale et cognition sociale (SLF : superior longitudinal fasciculus, IFOF : inferior fronto-occipital fasciculus, ILF : inferior longitudinal fasciculus).

1.2.2. Troubles de la cognition sociale

La cognition sociale sous-tend le succès de toute interaction sociale. Elle regroupe trois grandes fonctions : le langage non verbal, la théorie de l'esprit et l'empathie (17). Comprendre les émotions exprimées par les

visages nous permet de préciser les états affectifs de nos interlocuteurs. Une mauvaise identification, une fausse reconnaissance ou une mauvaise interprétation des émotions peuvent générer des attitudes inadaptées. De ce fait, l'analyse des visages sont dotés d'une importance sociale considérable.

Les techniques d'imagerie médicales telles que l'IRM fonctionnelle et la méthode de « voxel-based lesion symptom mapping » (VSLM) ont permis de mettre en évidence que la reconnaissance des émotions met en jeu un réseau de structures très largement distribuées dans le cerveau incluant le cortex occipito-temporal, l'amygdale, le cortex orbito-frontal et le cortex fronto-pariétal (Figure 2) (7,17–20). La reconnaissance de la peur se ferait en particulier par l'amygdale, celle du dégoût par le cortex insulaire et les ganglions de la base. Unger et al. (21) ont montré par tractographie que l'ILF et l'IFOF jouent tous deux un rôle important dans la reconnaissance des émotions (Figure 2). La latéralisation de ce réseau dans l'HND fait par contre encore débat (22). Des études récentes, impliquant spécifiquement des patients atteints de tumeurs cérébrales, n'ont pas observé d'effets de la latéralisation sur la reconnaissance des émotions faciales (17,18). Par contre, une relation entre les déficiences dans la reconnaissance des émotions faciales et la localisation de la tumeur a été rapportée par Campanella et al., 2014. Ils ont observé que les patients présentant des tumeurs cérébrales temporales étaient significativement plus déficients que des patients présentant des tumeurs cérébrales frontales et pariétales. De même, deux études ont rapporté que la procédure chirurgicale entraînait une majoration des déficiences dans la reconnaissance des émotions faciales en particulier pour les patients porteurs de gliomes de bas grade (18,23). Ces résultats soulignent, là encore, la nécessité d'évaluer en peropératoire la reconnaissance des émotions faciales pour éviter un déficit du langage non verbal qui entraînerait des difficultés sociales et professionnelles.

1.3. Évaluation des fonctions cognitives de l'HND

La principale condition pour réaliser une chirurgie éveillée dans l'hémisphère droit est d'obtenir un test rapide (inférieur à 4 secondes), fiable, reproductible et sans ambiguïté. Hors les tests d'évaluations neuropsychologiques utilisés en clinique courante ne sont pas adaptés à la stimulation électrique en chirurgie éveillée.

1.3.1. Tests d'évaluation des fonctions cognitives de l'HND en pré- et post-opératoire

Une variété de tests standardisés et non standardisés existe pour évaluer les fonctions cognitives de l'HND en pré- et post-opératoire. Les principaux utilisés pour détecter les troubles de l'attention visuo-spatiale et de reconnaissance émotionnelle sont présentés ci-dessous.

a) Évaluation de l'attention visuo-spatiale.

Les tests de bissection de lignes et les tests de barrage sont des tests couramment utilisés pour évaluer les déficits visuo-attentionnels.

Le test des cloches semble être le plus susceptible de détecter la présence d'une négligence (24). Ce test créé par (25) présente 35 cloches parmi 280 autres objets de distraction sur une page (Figure 3 A).

La distribution des cloches semble aléatoire, mais il y a en fait 5 cloches dans chacune des 7 colonnes (Figure 3B). Le but de ce test est d'évaluer le balayage visuel et d'identifier les personnes qui ont soit un déficit attentionnel ou une héménégligence visuelle.

Un score total de moins de 32 (plus de 3 omissions) suggère un déficit attentionnel. Une omission de 6 cloches ou plus dans la moitié droite ou dans la moitié gauche de la page indiquera une négligence spatiale unilatérale.




Figure 3 : Test des cloches. A) Feuille de passation, B) Feuille de score

b) Évaluation de la reconnaissance émotionnelle.

Le test d'Ekman, élaboré en 1976 (Ekman & Friesen, 1976), est le test le plus connu pour l'évaluation de la reconnaissance faciale des émotions dite « en situation statique ou unimodale ». Il comporte 60 photographies en noir et blanc représentant les 6 émotions de base (joie, surprise, tristesse, colère, peur, dégoût) et la neutralité exprimées par 10 acteurs (6 femmes et 4 hommes) (Figure 4A). Le patient doit désigner le nom de l'émotion faciale exprimée sur chaque photographie sur une carte réponse (Figure 4B).

Cet outil a été validé aux Etats-Unis, mais pas en France. En regard de l'étude de Diehl-Schmid et al. (27), il est considéré que tout score inférieur à 46/60 est pathologique. Le Greco (Groupe de Réflexion sur les Evaluations Cognitives) normalise et valide actuellement en France, dans le cadre des travaux du Grefex 2, une batterie de tests d'évaluation des fonctions socio-émotionnelles. Cette batterie de tests inclut notamment une version modifiée et abrégée du test d'Ekman contenant 36 photographies et un test pour la reconnaissance émotionnelle dite « en situation dynamique ou multimodale », le FEET [« French Emotion Evaluation Test », (28)]. Ce test, plus représentatif du quotidien du fait de sa caractéristique dynamique, est une adaptation française de l'« Emotion Evaluation Test » appartenant au TASIT [« The Awareness of Social Inference Test » ; (29)]. Il comprend 35 courtes séquences audio/vidéo (durée de chaque vidéo < 1 minute) dans lesquelles des acteurs professionnels jouent des scripts ambigus (texte) se référant à 7 émotions de base (peur, joie, tristesse, dégoût, surprise, colère, neutre). Le patient doit désigner le nom de l'émotion de base jouée dans chaque film sur une carte réponse.

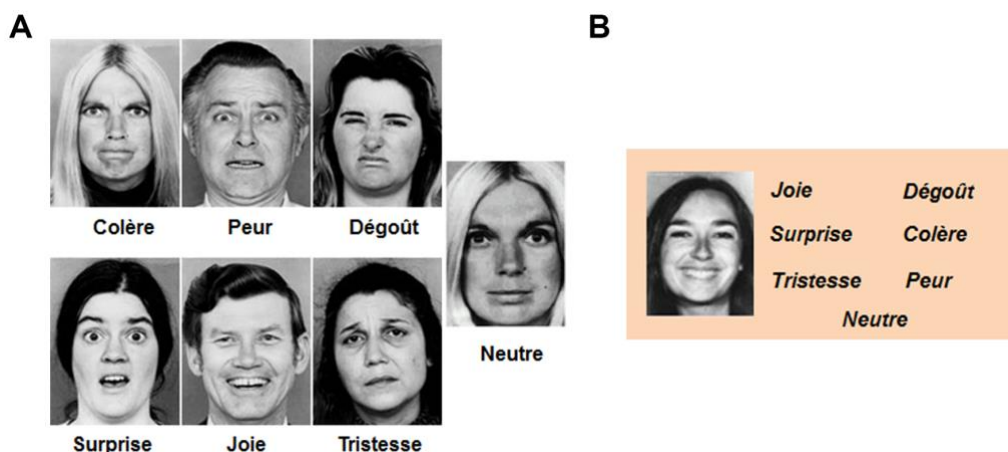


Figure 4 : Test d'Ekman. A) Exemple de photographies représentant les 6 émotions de base (colère, peur, dégoût, surprise, joie, tristesse) et la neutralité, B) Exemple d'une carte réponse

c) Tests d'évaluation des fonctions cognitives de l'HND en per-opérateur

Comme indiqué précédemment, les tests standardisés et non standardisés évaluant les fonctions cognitives de l'HND en pré- et post-opérateur ne sont pas adaptés au cahier des charges de la chirurgie éveillée. Celui-ci exige des tests rapides, réalisables le temps d'une stimulation électrique du cortex (environ 4 secondes), et entraînant une réponse non ambiguë. Certains auteurs ont modifié des tests standardisés pour une utilisation en per-opérateur comme le test de bissection de lignes pour évaluer les fonctions-visuo-spatiales (7,13-15) et le test « Reading the Mind in the Eyes » pour évaluer la théorie de l'esprit affective (30,31). A notre connaissance, aucun test évaluant en per-opérateur la reconnaissance faciale des émotions n'a été développé.

Nous avons initié dans le service de neurochirurgie, avec l'unité INSERM 1066 et l'équipe d'accueil EA7315 (Laboratoire Angevin de Recherche en Ingénierie des Systèmes) un programme sur la cartographie per opératoire des fonctions de l'hémisphère mineur. Une partie de ce programme repose sur la création d'un test per-opérateur en réalité virtuelle utile pour tester la cognition visuo-spatiale ou sociale. L'autre partie repose sur un travail d'anatomie et de neuro-imagerie visant à mieux connaître les faisceaux blancs à préserver en per-opérateur. C'est ici que s'inscrit cette thèse d'université.

2. L'apport des neurosciences dans l'exploration de l'hémisphère non dominant

Les neurosciences ont utilisé les moyens d'imagerie moderne et de dissection pour explorer l'HND. Après un bref rappel des méthodes d'études de l'HND, nous ferons mention du principal réseau d'IRM de repos impliqué dans l'héminégligence spatiale et les processus attentionnel : le réseau ventral de l'attention.

2.1. Méthodes d'études de l'HND

2.1.1. ANATOMIE MACROSCOPIQUE DESCRIPTIVE

La méthode de Klingler est une technique de dissection permettant d'explorer les fibres blanches cérébrales. La cristallisation de l'eau obtenue par congélation des hémisphères formolés, déstructure la substance grise (fortement hydraté à l'état normal), permettant de l'enlever en fine couche de la surface cérébrale. La congélation favorise également la dissociation mécanique des faisceaux de fibres blanches tout en respectant l'anatomie des principaux faisceaux permettant leur étude macroscopique (74). Les réseaux de fibres blanches connectant les gyri peuvent ainsi étudiés par cette méthode de Klingler. Il s'agit d'une méthode ex-vivo d'exploration des fibres blanches.

2.1.2. TRACTOGRAPHIE

La tractographie est une technique in-vivo d'étude des fibres blanches. Elle se propose de visualiser en trois dimensions le trajet des différents faisceaux composant la substance blanche du système nerveux. Cette méthode y parvient indirectement en étudiant la mobilité des molécules d'eau contrainte par l'anisotropie du milieu intra- et extracellulaire. En effet, ces molécules d'eau « piégées » entre les cellules se déplacent préférentiellement selon

l'axe principal des fibres nerveuses en raison notamment de la présence de la membrane plasmique et de la gaine de myéline qui s'opposent à leur mouvement. Ce coefficient d'anisotropie de diffusion de l'eau, dans un volume donné, variera en fonction des différentes directions, reflétant la trajectoire des fibres. Les faisceaux de substance blanche se composent d'un ensemble d'axones qui cheminent de manière compacte et cohérente de leur origine vers leurs cibles.

2.1.3. IRM D'ACTIVATION

L'IRM fonctionnelle d'activation détecte l'activation cérébrale par les variations du signal BOLD secondaires à la modification du rapport oxyhémoglobine sur désoxyhémoglobine. En effet, l'activation neuronale s'accompagne d'une augmentation locale de la consommation en oxygène porté par l'hémoglobine et d'une augmentation du débit sanguin artériel (couplage neuro-vasculaire). L'activation neuronale se traduit par une augmentation relative en oxyhémoglobine par rapport à la désoxyhémoglobine. Cette baisse de désoxyhémoglobine, agent paramagnétique, est accompagnée par une hausse transitoire du signal en pondération T2*.

Lors de l'acquisition en IRM fonctionnelle d'activation, le sujet exécute une succession de tâches répétées selon un paradigme d'activation. L'activité cérébrale des zones d'intérêt impliquées dans le paradigme d'activation entraîne des modifications hémodynamiques détectables en IRM : c'est le principe du contraste BOLD. L'analyse des variations du signal BOLD selon le modèle linéaire généralisé permet ensuite d'identifier les zones cérébrales spécifiquement activées par le paradigme de bloc (47,49,80). Il n'existe pas à l'heure actuelle de paradigme d'activation spécifique de l'HND, ce qui rend impossible son utilisation dans l'exploration de l'HND.

2.1.4. IRM FONCTIONNELLE DE REPOS

Le principe général de l'IRM repose sur la résonance magnétique nucléaire qui utilise les propriétés physiques des noyaux d'hydrogène. L'IRM nécessite un champ magnétique B0 puissant et stable afin de créer une aimantation tissulaire. Le signal de résonance magnétique nucléaire est enregistré lors du retour à l'équilibre de l'aimantation.

L'IRMf de repos (« resting state MRI ») met en évidence les fluctuations spontanées du signal. Il s'agit d'une technique permettant de récupérer le signal reflétant l'activité neuronale basale, en l'absence de tout stimulus. En pratique clinique, elle est adaptée aux populations ne pouvant pas réaliser de paradigme d'activation dans l'IRM (patients confus, présentant des troubles cognitifs, psychiatriques et enfants). Elle est également particulièrement utile pour explorer des fonctions cognitives non « stimulable » par des tests d'activation spécifiques, comme les fonctions cognitives supportées par l'HND.

L'acquisition est réalisée lorsque le sujet est au repos (ne réalisant aucune tâche). Différents réseaux de connectivité présentent différents signaux BOLD basses fréquences (<0.1 Hz) (49,66). Les zones cérébrales fonctionnellement connectées présentent ainsi une activation synchrones dans les basses fréquences, et peuvent être ainsi distinguées d'autres régions indépendantes (67). La découverte de ces réseaux de connectivité intrinsèque (ICN) par l'étude en IRMf de repos revient à Biswal (68). Les réseaux fonctionnels ont pu être isolés : l'audition, le réseau sensori-moteur, l'ensemble des réseaux attentionnels et cognitifs(48,69), dont le réseau du langage(70–72) et le réseau ventral de l'attention(73). Ces réseaux de connectivité intrinsèques sont supposés connectés par des fibres blanches intrahémisphériques.

Les études d'IRM fonctionnelle de repos chez des sujets sains(48) ont montré deux réseaux impliqués dans l'attention et l'orientation spatiale (46,49): le réseau ventral de l'attention (VAN) et le réseau dorsal de l'attention (DAN). Le DAN, bilatéral est impliqué dans le contrôle volontaire de l'attention, alors que le VAN latéralisé à droite serait principalement actif pour des stimuli involontaires (47). Les composants pariétaux, frontaux, et temporaux des VAN et DAN sont structurellement connectés par des fibres d'association de la substance blanche périventriculaire (50,51).

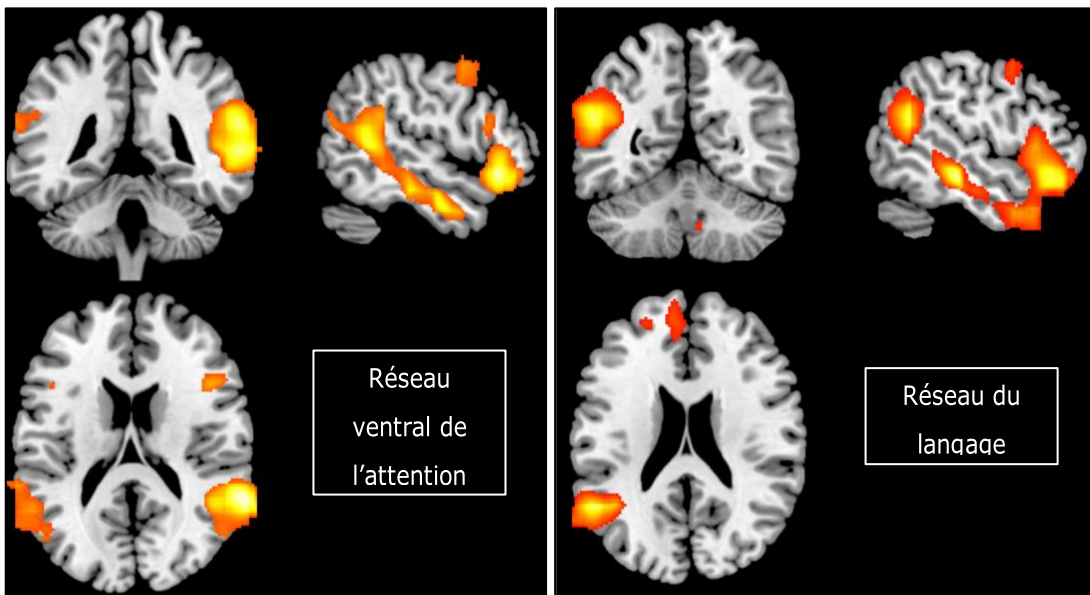
2.2. Synthèse des résultats de neuro-imagerie concernant l'héminégligence spatiale

L'héminégligence est un concept hétérogène, à la fois anatomiquement et en terme de manifestation clinique (37). Les patients peuvent montrer des signes d'héminégligence sur un test mais pas sur d'autres (38-40). En pratique clinique, l'héminégligence spatiale est habituellement diagnostiquée par une batterie de test explorant une grande variété de symptômes cliniques (par exemple l'épreuve de bissection de lignes, le dessin, la lecture et l'écriture). L'idée que l'héminégligence spatiale est un syndrome aux composantes multiples (34) est compatible avec les découvertes d'imageries qui ont révélées différents sites lésionnels (36,40) (théorie localisationniste). Alors que l'héminégligence est typiquement associée aux lésions du lobe pariétal(33), elle peut apparaître pour les lésions frontales(41), temporale (42), thalamique(41,43) ou des noyaux gris centraux(42). Cette diversité anatomique a été expliquée par une récente méta-analyse suggérant que les différentes formes de négligence peuvent être associées à des sites lésionnels distincts connectés à la fois dans la substance grise et blanche(44,45) (théorie de la connectivité cérébrale).

Ces symptômes d'héminégligences reflètent une interruption des systèmes cérébraux responsables de la conscience spatiale et du contrôle de l'attention, connus pour être reliés à des réseaux d'aires corticales et sous corticales, comme l'ont montré des recherches récentes après des AVC de l'hémisphère droit (46,47). À la lumière des études de « lesions mapping » (40,46) et de méta-analyses (44,45), il existe un rôle important de la déconnexion des fibres pariéto-frontale et occipito-frontales dans l'hémisphère droit des patients héminégligents. Des recherches récentes ont montré que les faisceaux de fibres blanches connectant le réseau ventral de l'attention (VAN) sont souvent lésés chez les patients héminégligents. Thiebaut de Schotten et al.(46) ont montrés que pour deux patients avec le même dommage cortical, la déconnexion du SLF III était prédictif de la présence d'une héminégligence. Il a aussi montré que la déconnexion du SLF III était corrélée aux performances de bissection de ligne. La compréhension des données de neuro-imagerie sur l'héminégligence spatiale nécessite une intégration des données corticales (obtenues à partir de l'IRM de repos) et de leur connexion en fibres blanches (obtenue par IRM en tractographie).

Dans le cadre d'une étude préliminaire en IRM fonctionnelle de repos, on a montré que l'activation du réseau ventral de l'attention (VAN) était fortement latéralisée dans l'hémisphère droit. Le VAN présentait de fortes similarités dans ses localisations corticales avec le réseau du langage dans l'HND (Figure 5).

Figure 5. Données préliminaires : identification du réseau ventral de l'attention (VAN) dans l'hémisphère droit comparable au réseau du langage chez 30 sujets.



Le SLF III et le faisceau arqué étant le principal support anatomique du réseau du langage dans l'HD, une hypothèse est formulée quant aux rôles de ces mêmes faisceaux dans l'héminégligence spatiale. Il est possible que les faisceaux d'association de substance blanche entre les régions corticales constitutives de la VAN présentent des similarités avec les faisceaux homologues du réseau cortical du langage dans l'hémisphère dominant.

2.3. Organisation des fibres blanches cérébrales

L'exploration de l'anatomie fonctionnelle de l'HND nécessite une connaissance des fibres blanches d'association intra-hémisphérique. Pour définir un réseau de fibres blanches appartenant au même faisceau il faut en définir ses points d'ancrages corticaux, la direction de ses fibres, sa profondeur et son rôle présumé. Il existe de nombreux débats de nomenclature concernant la description de ces faisceaux. Nous avons résumé les principaux faisceaux sur le tableau 1. Ainsi obtenir une analyse fine des ancrages corticaux du réseau ventral de l'attention, permettrait de mieux comprendre l'anatomie structurale et fonctionnelle de l'HND. Une meilleure connaissance des réseaux de fibres blanches impliqués dans la cognition visuo-spatiale permettrait d'affiner les tests réalisés au bloc opératoire en chirurgie éveillée.

Tableau 1: données anatomique des faisceaux d'association SLFs et du faisceau arqué.

Faisceaux d'association du SLF et Faisceau arqué	Régions inter-connectées	Rôle fonctionnel	
		Hémisphère dominant	Hémisphère non dominant
SLF I	Précunéus avec le gyrus cingulaire antérieur	Régulation de l'activité motrice, initiation motrice(53,58,59), activation au repos	Régulation de l'activité motrice, initiation motrice, activation au repos
SLF II	Partie antérieure du lobe occipital moyen ou du gyrus angulaire avec le gyrus frontal moyen	Orientation visuo-spatiale et attention(60,61)	Orientation visuo-spatiale et attention(60,61)
Segment indirect postérieur du SLFIII	Gyrus supra-marginal et gyrus angulaire avec le gyrus temporal moyen dans sa partie postérieure	lecture(56,62)	prosodie(56,62)
Segment indirect antérieur du SLF III	Partie postérieure et moyenne du gyrus temporal supérieur et partie moyenne du gyrus temporal moyen avec le cortex prémoteur ventral, la pars opercularis et triangularis	Traitement du langage phonologique (56,62)	Traitement du langage phonologique (56,62)
Faisceau arqué	Partie postérieure du gyrus temporal moyen et supérieur avec la partie postérieure du gyrus frontal inférieur (cortex prémoteur ventral, pars opercularis) et du gyrus frontal moyen	Traitement lexical et sémantique du langage (56,62)	Attention visuospatiale, prosodie, et traitement de la musicalité phonologique(60,63-65)

3. Objectifs de la thèse

Le parallélisme entre connectivité fonctionnelle et anatomie morphologique est peu connue dans l'HND. Le but de cette thèse est donc d'étudier le support structural du principal réseau fonctionnel de l'HND : le VAN.

Comprendre le lien entre anatomie structurale et fonctionnelle de l'HND est un prérequis indispensable à son exploration peropératoire en chirurgie éveillée. L'objectif secondaire de cette thèse est de créer un test peropératoire explorant les principales fonctions cognitives de l'hémisphère non dominant.

4. Travaux réalisés

L'objectif principal étant d'étudier le support structural et fonctionnel du VAN, nous avons d'abord étudié les métadonnées de la littérature concernant l'anatomie de l'hémisphère droit en intégrant les travaux de dissections, les articles anatomo-cliniques et les données de neurosciences (principalement de neuro-imagerie). Ainsi nous avons réalisé plusieurs travaux de revues de la littérature préliminaires :

1. Une étude d'anatomie fonctionnelle (**Right Hemisphere Cognitive Functions: From Clinical and Anatomic Bases to Brain Mapping During Awake Craniotomy. Part I: Clinical and Functional Anatomy** , *World Neurosurgery*, IF 1,924, **Article 1**, page 20) visant à proposer une taxonomie des fonctions cérébrales supportées par l'hémisphère droit. Les différentes zones corticales et faisceaux de fibres blanches impliqués dans chacune des fonctions cognitives de l'hémisphère droit (la cognition visuo-spatiale, la cognition sociale dont la reconnaissance faciale par exemple) ont été classées pour faciliter la compréhension de leur anatomie fonctionnelle.
2. Une étude d'anatomie clinique (**Right Hemisphere Cognitive Functions: From Clinical and Anatomic Bases to Brain Mapping During Awake Craniotomy. Part II : Neuropsychological task and Brain mapping**, *World Neurosurgery*, IF 1,924, **Article 2**, page 21) harmonisant les données d'anatomie fonctionnelle précédemment étudiées avec les données neuropsychologiques et de sémiologie clinique.
3. Une étude d'anatomie structurale permettant d'harmoniser la nomenclature anatomique entre les études de dissections et d'imagerie de l'hémisphère droit (**articles 1 et 2**, pages 20-21). Les études de dissection et d'imagerie structurale n'utilisaient pas nécessairement la terminologia anatomica concernant la disposition sulcogyrale et les fibres blanches intrahémisphériques. De même dans les études d'IRM fonctionnelle, la nomenclature anatomique est rarement appropriée : les auteurs utilisent parfois une terminologie floride concernant les zones d'activations corticales et la tractographie. Cet écueil, rend l'analyse des données de la littérature confusogène. Cette constatation nous a poussé à réaliser un travail inédit de revue systématique du principal faisceau de substance blanche : le faisceau arqué (**Anatomical variability of the arcuate fasciculus: a systematical review**, *Surgical and Radiological Anatomy*, IF 1,039, **Article 3**, page 23). Ce travail nous a permis d'extraire les métadonnées issues de 3 siècles de publications permettant de mieux définir le faisceau arqué dans sa disposition modale et ses variations décrites.
4. Ces travaux visaient également à harmoniser les connaissances entre les travaux d'anatomie fonctionnelle, clinique et structurale en utilisant la taxonomie précédemment décrite (cognition visuo-spatiale et cognition sociale dont la reconnaissance faciale, l'empathie, la théorie de l'esprit et la prosodie) en se basant sur la terminologia anatomica. Ces revues des connaissances ont soulevé une problématique concernant la disposition des réseaux fonctionnels dans l'hémisphère non dominants, suggérant une potentielle organisation en miroir entre le langage (dans l'hémisphère dominant) et la cognition visuo-spatiale (dans l'HND). Cette observation issue des données de la littérature, confrontée à nos données

préliminaires concernant l'organisation du réseau ventral de l'attention (VAN) suggérait une possible organisation en miroir.

5. Nous avons ainsi publié un travail anatomique expérimental (**The ventral attention network : the mirror of the language network in the right brain hemisphere**, *Journal of Anatomy*, IF 2,638, **Article 4**, page 25) explorant le réseau ventral de l'attention dont les ancrages corticaux pourraient répondre de manière contralatérale à ceux du réseau du langage. Ce principal réseau cognitif de l'hémisphère droit est impliqué dans la cognition visuospatiale. La connexion de ses ancrages corticaux (en miroir du réseau du langage) par des réseaux de fibres blanches était supposée. L'anatomie structurale du VAN a été étudiée par la comparaison de trois approches : en IRM fonctionnelle de repos, en macroscopie (étude anatomique des fibres blanches *ex-vivo* selon la technique de Klingler, et en IRM en tenseur de diffusion (pour une étude des fibres blanches *in-vivo* par tractographie). Réaliser cette étude nous a aussi permis d'en discuter les implications neurologiques et neurochirurgicales.

La principale implication chirurgicale concerne l'application à la chirurgie éveillée de l'hémisphère droit, ce qui rejoint l'objectif secondaire de la thèse (« créer un test per-opératoire explorant les principales fonctions cognitives de l'hémisphère non dominant »). Une préservation du SLF III et du faisceau arqué droit pourrait permettre d'éviter une altération de la cognition visuospatiale.

6. Notre expérience en cartographie peropératoire de l'hémisphère droit nous a permis de rapporter un symptôme rare mais typique de l'altération de la cognition visuo-spatiale : l'autoscopie (**Oncology meets Art : a way to understand patients' symptoms**, *Lancet Oncology*, IF 35,38, **Article 5**, page 26)
7. Utiliser la chirurgie éveillée pour préserver l'HND, comme pour le langage dans l'HD, apparaît être une idée réaliste. Pourtant ce champ thérapeutique se heurte à une contrainte : celle du test neuropsychologique peropératoire. En effet le développement d'un test neuropsychologique spécifique stimulant la cognition visuo-spatiale reste à développer pour pouvoir réaliser cette chirurgie éveillée. Dans ce sens, j'ai participé à un quatrième travail visant à l'utilisation des lunettes de réalité virtuelle en condition de chirurgie éveillée, pour réaliser de nouveaux tests neuropsychologiques dédiés à l'exploration des fonctions cognitives de l'hémisphère droit (**Using a Virtual Reality social network during awake craniotomy to map the social cognition**, *Journal of Medical Internet Research*, IF 4,8, **Article 6**, page 27). Il a été étudié l'apport de la réalité virtuelle dans l'exploration de la cognition sociale en chirurgie éveillée. Cette publication utilisant un réseau social virtuel et un casque de réalité virtuelle nous a permis de mieux orienter le développement d'un test rapide et sensible adapté à la chirurgie éveillée.
8. L'utilisation de la réalité virtuelle pour stimuler des fonctions cognitives de l'hémisphère droit en chirurgie éveillée a été pour notre équipe une solution potentielle nécessitant un développement d'application spécifique (software dédié en réalité virtuelle). Pour cela les comités de protection des personnes nous ont demandé d'effectuer d'abord une étude de tolérance de la technologie étudiée auprès des patients opérés en chirurgie éveillée (**Immersing patients in a virtual reality environment for brain mapping during awake surgery. Safety study**, *World Neurosurgery*, IF 1,924, **Article 7**, page 31).

Il a donc fallu prouver l'innocuité de l'utilisation de casques de réalité virtuelle (hardware, mis en place au bloc opératoire), notamment en terme d'inconfort pour le patient (« maladie de la réalité virtuelle »/« virtual reality disease » en anglais), ou de potentiel risque comitial. Ma participation à ce travail a été mineure, puisqu'initiée avant le début de ma thèse d'université. Il me paraît important cependant d'en faire mention pour mettre en exergue l'innocuité de cette démarche.

9. Les perspectives sont nombreuses. Intégrer les dernières avancées neuro-anatomiques, d'imagerie par IRM de repos et tractographie, chirurgicales et technologiques pourrait permettre d'explorer et de préserver la cognition visuospatiale de nos patients. Nous avons discuté les perspectives d'utilisation de la réalité virtuelle pour l'HND dans un essai scientifique (**Replay « the Matrix for brain mapping during awake surgery**, *Behavioral and Brain sciences*, IF 17,194, **Article 8**, page 33). Nous avons ainsi pu replacer les travaux présentés dans cette thèse d'université dans une stratégie d'équipe centrée sur le développement d'une application dédiée à la chirurgie éveillée de l'hémisphère droit.

Revue de la littérature

1. État de l'art des fonctions cognitives de l'hémisphère droit : des bases anatomo-cliniques à la stimulation électrique corticale en chirurgie éveillée.

1.1. Anatomie structurale et fonctionnelle de l'hémisphère non-dominant.

❖ Article n°1 :

Right Hemisphere Cognitive Functions: From Clinical and Anatomic Bases to Brain Mapping During Awake Craniotomy Part I: Clinical and Functional Anatomy

Bernard F, Lemée JM, Ter Minassian A, Menei P

World Neurosurgery, (publié IF= 1,924)

Right Hemisphere Cognitive Functions: From Clinical and Anatomic Bases to Brain Mapping During Awake Craniotomy Part I: Clinical and Functional Anatomy

Florian Bernard^{1,3}, Jean-Michel Lemée^{1,4}, Aram Ter Minassian^{2,5}, Philippe Menei^{1,4}

Key words

- Awake surgery
- Nondominant hemisphere
- Social cognition
- Unilateral neglect
- Visuospatial cognition

Abbreviations and Acronyms

AG: Angular gyrus
DAN: Dorsal attentional network
fMRI: Functional magnetic resonance imaging
FN: Face network
IFG: Inferior frontal gyrus
IFOF: Inferior fronto-occipital fasciculus
ILF: Inferior longitudinal fasciculus
IPL: Inferior parietal lobule
mvPFC: Medial ventral prefrontal cortex
MFG: Middle frontal gyrus
MTG: Middle temporal gyrus
SLF: Superior longitudinal fasciculus
SMG: Supramarginal gyrus
STG: Superior temporal gyrus
STS: Superior temporal sulcus
TOM: Theory of mind
TPJ: Temporoparietal junction
UN: Unilateral neglect
VAN: Ventral attentional network
VFC: Ventral frontal cortex

From the ¹Service de Neurochirurgie and ²Département d'Anesthésie-Réanimation, CHU d'Angers; ³Laboratoire d'Anatomie, Faculté de Médecine d'Angers; ⁴CRCINA, INSERM, Université de Nantes, Université d'Angers; and ⁵LARIS EA 7315, Image Signal et Sciences du Vivant, Angers Teaching Hospital, Angers, France

To whom correspondence should be addressed:
 Philippe Menei, M.D., Ph.D.
 [E-mail: phmenei@chu-angers.fr]

Citation: *World Neurosurg.* (2018).
<https://doi.org/10.1016/j.wneu.2018.05.024>

Journal homepage: www.WORLDNEUROSURGERY.org

Available online: www.sciencedirect.com

1878-8750/\$ - see front matter © 2018 Elsevier Inc. All rights reserved.

INTRODUCTION

In terms of function, the dominant (usually the left) cerebral hemisphere is traditionally regarded as the more important side of the brain. Neurosurgical decisions regarding surgical approaches in clinical practice are influenced by this paradigm. Nevertheless, the notion of a minor right hemisphere is now being challenged.¹

The nondominant hemisphere (usually the right) is responsible for primary cognitive functions such as visuospatial and social cognition. Awake surgery using direct electric stimulation for right cerebral tumor removal remains challenging because of the complexity of the functional anatomy and difficulties in adapting standard bedside tasks to awake surgery conditions. An understanding of semiology and anatomic bases, along with an analysis of the available cognitive tasks for visuospatial and social cognition per operative mapping allow neurosurgeons to better appreciate the functional anatomy of the right hemisphere and its relevance to tumor surgery. In this article, the first of a 2-part review, we discuss the anatomic and functional basis of right hemisphere function. Whereas part II of the review focuses primarily on semiology and surgical management of right-sided tumors under awake conditions, this article provides a comprehensive review of knowledge underpinning awake surgery on the right hemisphere.

Neurosurgeons are focusing more and more on elaborate right-lateralized cerebral functions, rather than on the patient as a whole. As they did few decades ago with the executive and left lateralized functions, they are trying to bring new insights to right hemisphere mapping.

The nondominant hemisphere (usually the right) is responsible for primary cognitive functions such as visuospatial and social cognition. Visuospatial cognition supports spatial awareness, perception, and representation of space. It allows sensory events and spatial relationships to be perceived and reported. Lesions on the network underpinning visuospatial cognition are associated with different symptoms, the most significant of these being unilateral neglect (UN). Social cognition is the other main function of the right hemisphere. Social cognition includes all cognitive processes involved in social interaction using nonverbal language (such as facial emotion recognition and emotional prosody), empathy, and theory of mind (TOM).

Compared with language mapping in the left hemisphere, few accounts of right hemisphere per operative mapping have been published.²⁻¹⁷ This lack of interest could be explained by underestimation of the cognitive role of the right hemisphere

but could also be caused by the complexity of the functional anatomy and the difficulties inherent in adapting standard bedside tasks to awake surgery conditions. It is possible to suggest a new model of visuospatial and social cognition based on parallel and interactive large-scale distributed networks, similar to that previously developed for language. Just as in the language model, these functions cannot be reliably localized on anatomic criteria alone, mostly because of variation between individuals. For this reason, individual brain mapping using direct electric stimulation during awake craniotomy is essential when looking to preserve these functions.

An understanding of semiology and anatomic bases, along with an analysis of the available cognitive tasks for visuospatial and social cognition per operative mapping, allow neurosurgeons to better appreciate the functional anatomy of the right hemisphere and its relevance to tumor surgery. In the first part of this 2-part review, we discuss the anatomic and functional basis of right hemisphere function.

THE COGNITIVE RIGHT HEMISPHERE: A MIRROR SYSTEM?

In the right hemisphere, the cortical areas and white matter fascicles involved in

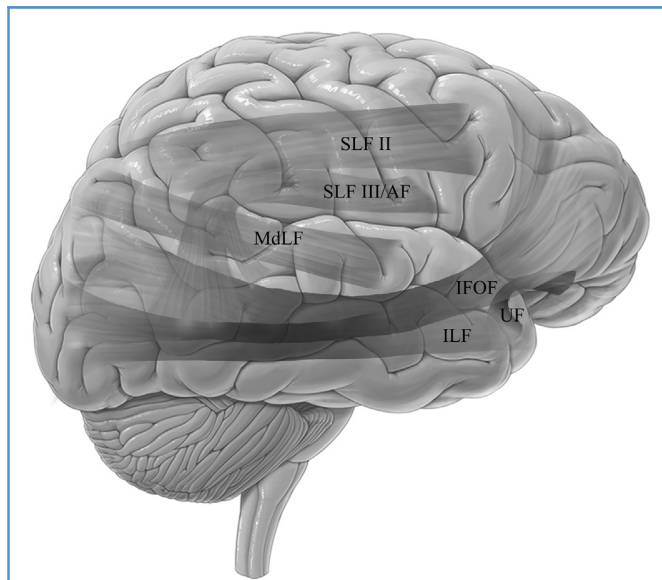


Figure 1. White matter fiber tract involved in right hemisphere cognitive functions. In the perisylvian area, the main long association fiber pathway is the superior longitudinal fasciculus (SLF), which has 3 parts: SLF I (dorsal), II (middle), and III (ventral). The SLF I (dorsal pathway) is positioned within the superior frontal gyrus, the SLF II (middle pathway) within the middle frontal gyrus, and the SLF III (ventral pathway) within the inferior frontal gyrus. Starting at the lateral surface and moving medially, the components of the SLF are encountered in reverse order: SLF III, SLF II, and then SLF I. The SLF III (so-called arcuate fasciculus [AF]) is the most superficial. The SLF III generally extends from the supramarginal gyrus to the pars opercularis. The inferior occipitofrontal fasciculus (IFOF) forms part of the extreme and external capsule and travels under the ventral insular cortex from the posterotemporal to the prefrontal regions. The middle longitudinal fasciculus (MdLF) travels from the upper portions of the occipital lobe to the superior temporal gyrus.²² MdLF covers the IFOF, which is situated deeper and slightly inferiorly. Whereas MdLF fibers continue at a relatively superficial level to reach anterior portions of the temporal lobe, the IFOF penetrates the deep temporal white matter to reach the insular lobe. The uncinate fasciculus (UF) connects the anterotemporal lobe with the orbitofrontal area. The inferior-longitudinal fasciculus (ILF) connects the occipital lobe and anterior temporal lobe, running along the lateral walls of the temporal horn of the lateral ventricle.

visuospatial and social cognition are almost symmetric to those involved in language with a perisylvian network.¹⁸ Is this apparent symmetry total or partial? This question has been a topic of debate and has also raised some interesting questions regarding determinism and brain anatomy. Several diffusion tensor imaging studies^{19,20} have reported a heightened prevalence of leftward asymmetry of perisylvian white matter volumes. On the other hand, some investigators have reported the presence of the right arcuate fasciculus in only 40% of their patients, whereas others have reported it in all patients.²¹ Anatomically, the white matter structure

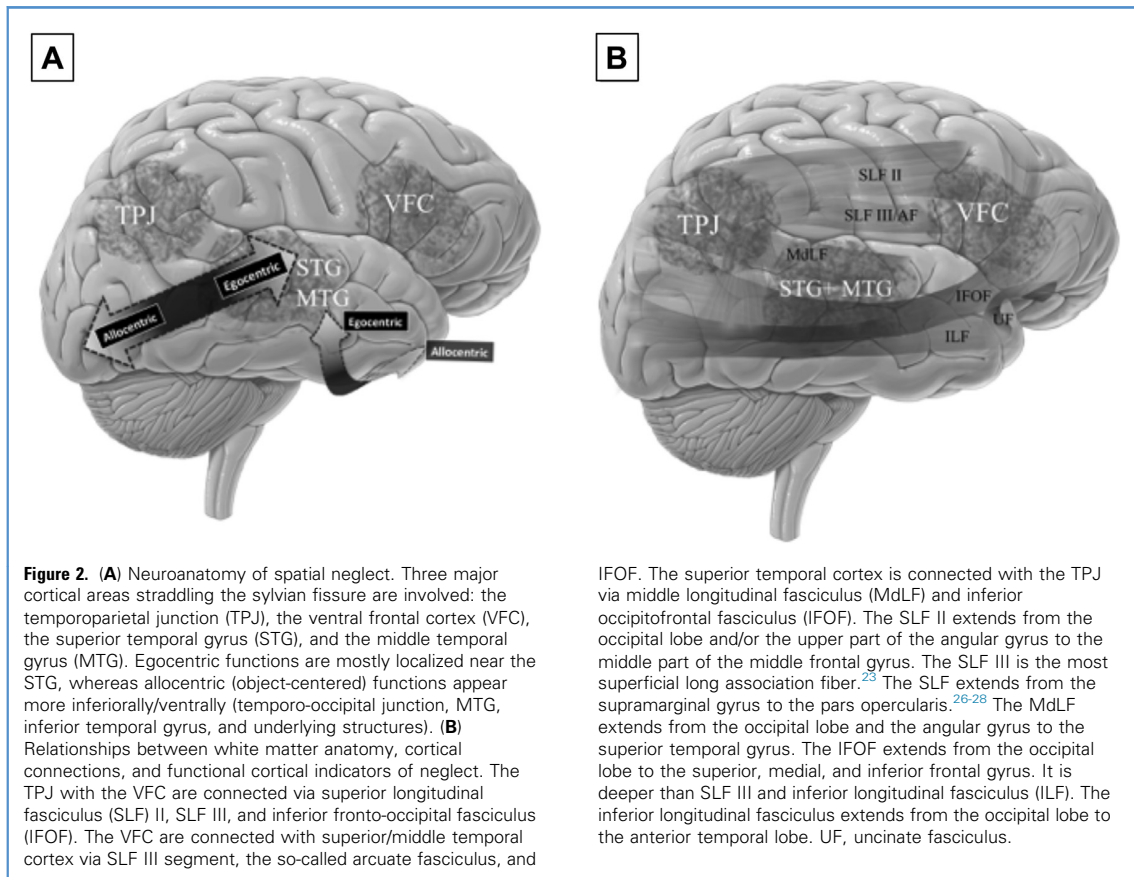
can be considered mostly symmetric. The same white matter fascicles as found in the left hemisphere have been identified (Figure 1). Most postmortem fiber dissection studies have not reported a significant difference between the left and right white matter fascicles, either in terms of the cortical connections²³ or in terms of fascicles volumes.²³⁻²⁵

Most of our knowledge about the neuroanatomy of visuospatial and social cognition has come from imaging studies of patients with UN or from functional magnetic resonance imaging (fMRI) studies. As for language in the dominant side, the right temporoparietal junction (TPJ) and ventral frontal cortex (VFC) both

seem to play a significant role in all these studies (Figure 2A). This anatomically ambiguous terminology reminds us of pioneering work in language anatomy using the Broca-Wernicke-Lichtheim-Geschwind model.²⁹⁻³¹ The medial ventral prefrontal cortex (mvPFC) is involved too. No standardized anatomic definitions exist for the localization of TPJ, VFC, and mvPFC.²⁴ Before describing the anatomic substrate of the cognitive right hemisphere, we propose to replace these terms with more precise anatomic definitions, based on standardized terminologia anatomica nomenclature (Table 1).³²

The VFC is involved in visuospatial cognition (see section on Neuroanatomy). According to Vessel (Figure 2), the VFC corresponds anatomically to the middle frontal gyrus (MFG) and inferior frontal gyrus (IFG), which is composed of the precentral gyrus, pars opercularis, triangularis, and orbitalis. The mvPFC is involved in social cognition (facial emotion recognition, empathy, and TOM; see sections on Facial Emotion Recognition, Emotional Prosody, and Empathy and Theory of Mind). The mvPFC is an anteromedial and inferior part of the frontal lobe (Figure 3). Although there is no universal agreement on how it should be demarcated, it is equivalent to the anterior cingulate gyrus, the gyrus rectus, and the medial aspect of the superior frontal gyrus in most sources.³³⁻³⁵

Providing an anatomic definition of the TPJ is more challenging, because it is not a single unitary structure; rather, it consists of multiple subregions with different connectivity patterns.^{25,29} One of these subregions is the inferior parietal lobule (IPL), which consists of 2 major gyri: the supramarginal gyrus (SMG) and the angular gyrus (AG) (Figure 4A). The sulcal patterns in the IPL vary greatly between individuals, with the superior temporal sulcus (STS) extending its caudal branches into the IPL, and the SMG and AG usually separated by the intermediate parietal sulcus of Jensen.^{30,31} The TPJ is a variably defined region located approximately where the IPL meets the superior temporal gyrus (STG) and is not associated with any objective landmarks. The term TPJ has been used for activations observed in the IPL as well as



in dorsal parts of the posterior STG. Occasionally, activations extending as far as the middle temporal gyrus (MTG) and lateral occipital lobe have also been labeled TPJ. Most investigators would probably define the TPJ as a small region that overlaps only the most ventral part of the IPL at the true intersection of the AG, SMG, and posterior part of the STG (Figure 4B). There is no consensus on the anatomic definition of the extent and precise location of the TPJ, and many other labels are used to describe activations around this region (e.g., IPL, ventral parietal cortex, lateral parietal cortex, AG, SMG, and posterior STS). Also, although the IPL and TPJ overlap, they are not synonymous with each other even in the most conservative definition of the TPJ. This situation may be explained by the insufficient spatial resolution of fMRI, lack of precision in tasks relating to the computation of that region, variations between individuals, and the application of spatial

normalization techniques. It may also be because higher-order cognitive activity may not subdivide cleanly along anatomic borders.³⁶ Although these differences can seem small from study to study, they have played a critical role in the debate on functional specialization.³⁶

VISUOSPATIAL COGNITION

Semiology

UN is highly heterogeneous in terms of severity and in its manifestations (for details, see Part II of the review).³² It does not constitute a unitary syndrome but a complex set of signs and symptoms. In most fMRI studies of right hemisphere strokes, UN could be defined as a common set of core symptoms, including biased gaze orientation and search (gaze direction, exploration, and cancellation biases), combined with an anosognosia regarding these symptoms. UN has been used in several studies as a

generic term and is not representative of the heterogeneity and variability of symptoms observed after a lesion of the visuospatial cognition anatomic substrate.

Neuroanatomy

Most knowledge about the neuroanatomy of visuospatial cognition comes from imaging studies of patients with UN, mostly after a stroke. Studies based on structural brain imaging suggest that 3 major cortical areas straddling the sylvian fissure may be responsible for the core deficit described in section on Semiology (Figure 2A, Table 2):

- the VFC³³⁻³⁵
- the TPJ³⁵⁻³⁷⁻⁴⁰
- the STG, MTG, and underlying insula.^{35,37,38}

These cortical areas also play a role in the human left hemisphere when patients

Table 1. Relationships Between Right Hemisphere Functional Areas, Their Anatomic Definitions and Functions

Functional Area	Terminologia Anatomica: Gyral Definition	Right Hemisphere Function
Ventral frontal cortex	MFG IFG	Visuospatial cognition
Temporo-parietal Junction (Figure 4)	SMG AG STG	Visuospatial cognition Social cognitions (empathy, theory of mind)
Medial ventral pre-frontal cortex (Figure 3A, B)	Antero-medial and inferior part of the frontal lobe: Anterior cingulate gyrus Gyrus rectus Medial SFG	Social cognition (facial emotion recognition, empathy and TOM)
Facial network (Figure 6)	Bilateral occipito-temporal cortex (fusiform gyrus and inferior occipital area) Right posterior part of the superior temporal sulcus ⁵⁷⁻⁶⁰ IFG, orbitofrontal gyrus ⁶² mvPFC ⁶¹ (anterior cingulate gyrus, gyrus rectus and medial SFG)	Facial emotion recognition
Emotional prosody network (Figure 7)	IFG Right SMG STG	Emotional prosody
Empathy network	Bilateral mvPFC (see above) Bilateral TPJ (see above) STS Other: paracingulate IFG, cingulate gyrus and amygdala	Empathy
Theory of mind network	Bilateral mvPFC (see above) Bilateral TPJ (see above) STS Lateral orbitofrontal gyrus Other: MFG, cuneus precuneus and STG	Theory of mind

MFG, middle frontal gyrus; IFG, inferior frontal gyrus; AG, angular gyrus; STG, superior temporal gyrus; TOM, theory of mind; SFG, superior frontal gyrus; mvPFC, medial ventral prefrontal cortex; SMG, supramarginal gyrus; TPJ, temporoparietal junction; STS, superior temporal sulcus.

show spatial neglect after a left-hemisphere stroke.

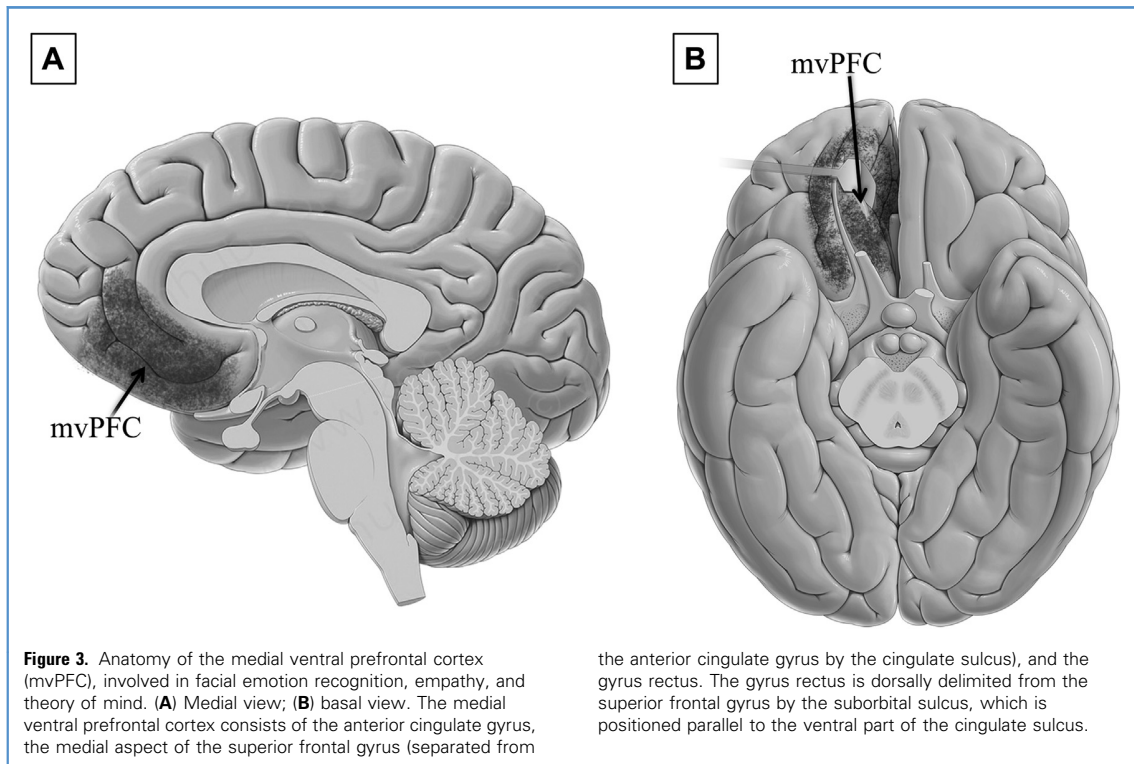
Tract tracing, myelin staining, and diffusion tensor imaging techniques suggest the presence of a dense perisylvian network interconnecting these 3 cortical sites³⁷ (Figure 2B, Table 2): the VFC with the STG and MTG cortex (via superior longitudinal fasciculus [SLF] III and inferior fronto-occipital fasci [IFOF]), the VFC with the TPJ (via SLF II, SLF III, and IFOF), and the STG with the TPJ (via posterior parts of the middle longitudinal fasciculus and IFOF). The role of these connections (in particular the SLF III and IFOF) in the brain

lesions of patients with spatial UN has been reported in single or small sample case studies^{26,55-57} as well as in a recent group study³⁷ that applied a statistical voxelwise lesion-behavior mapping approach to a large cohort of patients with an acute right-hemispheric stroke. As previously described in relation to language in the left hemisphere, network dysfunction induced by damage to white matter tracts could provide a more detailed explanation of why UN develops as a disconnection syndrome in large networks of connected brain areas.⁵⁸

Neurons in these perisylvian cortical regions provide information about the

position and motion of our body in space, playing an essential role in adjusting body position relative to external space.⁵⁹⁻⁶² The right perisylvian neural network is thus important for the neural transformation of converging vestibular, auditory proprioceptive, and visual inputs into higher-order (egocentric) spatial representations.^{60,63} It has been suggested⁶⁴ that other additional functions may be associated with lesions of these brain regions, such as a bias in spatial attention and deficits in arousal, reorienting, and detection.

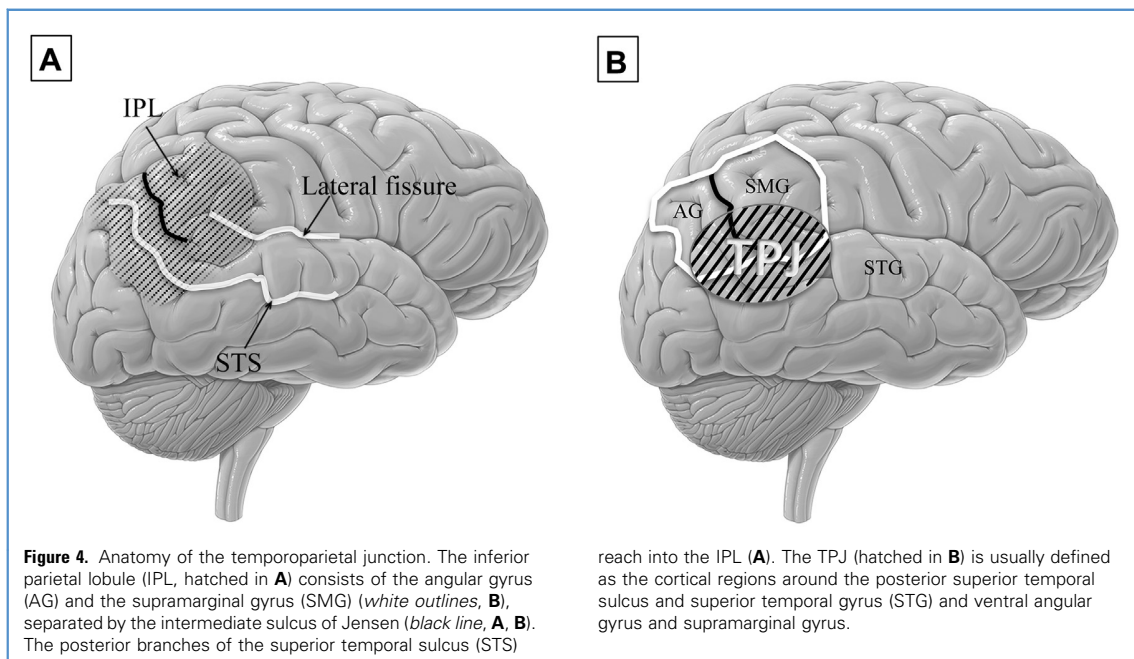
Recently, a functional model of visuospatial attention, deduced from resting



state fMRI, has been suggested. This model represents the connectivity of visuospatial attention and should not be

interpreted as an anatomic substrate (**Figure 5**). This functional model is composed of:

- The dorsal attentional network (DAN), which rostrocaudally includes the frontal eye field, the precuneus, the superior



parietal lobule, and the intraparietal sulcus. The DAN is represented bilaterally.

- The ventral attentional network (VAN), which rostrocaudally includes the MFG and IFG and the TPJ. The VAN is lateralized to the nondominant hemisphere.

The SLF anatomically supports these 2 frontoparietal functional networks. The SLF I connects brain regions within the DAN. The SLF III connects regions within the VAN network. The SLF II connects parietal regions of the VAN with the prefrontal regions of the DAN, allowing these 2 networks to communicate.

Spatial neglect can also be observed after injury of other deep structures. Specifically, lesions of the caudate nucleus,^{65,66} the putamen,⁶⁷ and the thalamic pulvinar⁶⁷ have been associated with spatial neglect. It has long been debated whether damage to these subcortical structures directly causes the disturbance, whether these injuries disrupt the subcortical-cortical projections, or whether the relationship is indirect, with subcortical damage leading to knock-on functional or metabolic abnormalities in cortical areas. Using perfusion-weighted imaging, recent studies have shown that cognitive disorders after such subcortical lesions are induced by the dysfunction of structurally intact but abnormally perfused cortical tissue.⁶⁸ Perfusion-weighted imaging showed that strokes centering on the right basal ganglia, which cause spatial neglect, induce abnormal perfusion in circumscribed areas of intact cortex, typically involving regions known to cause spatial neglect when damaged directly by cortical infarction. The data thus suggest that spatial neglect after a right basal ganglia lesion is typically caused by dysfunction of (part of) the cortical perisylvian network.

There is increasing evidence that the behaviorally dissociating symptoms observed after right hemisphere injury correlate with changes to underlying anatomy. Any lesion of the perisylvian network described earlier could induce the core egocentric symptoms termed spatial neglect. Nevertheless, studies of patients who have had both acute and chronic cortical injury have yielded differing results; egocentric deficits appeared near the STG, whereas allocentric (object-centered)

deficits appeared more frequently in posterior and inferior areas (temporo-occipital junction)^{11,38,69-71} (Figure 2A). Moreover, allocentric deficits seemed to correlate with cortical injury to the MTG and inferior temporal gyrus and underlying structures (including parahippocampal gyrus).⁷² This observation is consistent with suggestions by Medina et al.⁷¹ that object-based deficits may result from more ventral injury and supports findings that injury near the parahippocampal area is associated with spatial neglect³⁹ (Figure 2A). A recent study⁵⁸ showed that the white matter pathways are also associated with functionally dissociable neglect components, explaining the polymorphism of the neglect even as a disconnection syndrome. However, these observations are still limited by anatomic imprecision.

SOCIAL COGNITION

Neuroanatomy of Social Cognition

Facial Emotion Recognition. As described previously, social cognition includes nonverbal language, empathy, and TOM. Among the nonverbal cues involved in the TOM process, facial emotion recognition is considered one of the most important (Table 2). Lesion and functional imaging studies have connected the ability to recognize emotion in facial expressions to several cortical and subcortical structures, aptly named the face network (FN).⁷³

This large-scale FN includes (Figure 6, Table 2):

- right and left sectors of the occipito-temporal cortex
- the right posterior part of the STS
- the right IFG, orbitofrontal, and mvPFC.

Regarding the occipitotemporal cortex, neuroimaging studies have identified at least 2 bilateral areas of the visual cortex that respond more to pictures of faces than objects in normal human individuals. These areas include the middle fusiform gyrus (the fusiform face area) and, more posteriorly, the inferior occipital cortex (occipital face area), with right-hemisphere dominance.

The right posterior part of the STS plays a hublike role in facial expression recognition.⁴¹ The right posterior part of the STS has been highlighted as a key neural locus for perception of biological motion, particularly eye or mouth movement and body language. Previous neuroimaging studies have suggested the existence of a distinct neural substrate for the processing of static and dynamic facial stimuli.^{42,43} Inhibition of the right posterior part of the STS by transcranial magnetic stimulation in healthy volunteers disrupts their natural tendency to focus on the eyes, thus indirectly affecting their gaze perception. Conversely, stimulation of the right posterior part of the STS using transcranial direct current stimulation improves the recognition of emotional states, but only those showing negative emotions (e.g., sadness and anger).⁴⁴

Although their relative functions in face processing remain unclear, these regions provide outputs to (laterally to medially) the right IFG, orbitofrontal, and mvPFC.⁴⁵ It has been suggested that the right IFG may contribute to the ability to recognize facial expressions via a mechanism involving mimicking the other person's facial expression through mirror neurons. Anodal transcranial direct current stimulation of the right orbitofrontal cortex enhances facial expression recognition.⁴⁶

Other deeper structures have been implicated in the FN, such as the basal ganglia, the insula, and the amygdala. Older studies have reported that some of these structures making up the FN could be specifically involved in the analysis of a given emotion (e.g., there are connections between angry faces and the orbitofrontal cortex,⁷⁴ fearful faces and the amygdala,^{75,76} disgusted faces, and the insular and/or basal ganglia).⁷⁷

As with language and visuospatial cognition, the FN supporting facial emotion recognition is made up of cortical areas connected by white matter tracts. Recent studies suggest that the fiber tracts connecting visual and emotion-related structures also play a role, specifically the IFOF and the inferior longitudinal fasciculus (ILF).⁴⁷⁻⁴⁹ A combined transcranial magnetic stimulation/fMRI study⁷⁸ confirmed the existence, already shown in nonhuman primates, of a

Table 2. Functional and Structural Anatomic Support of Right Hemisphere Functions

Right Hemisphere Function	Functional Anatomic Area (Structural Magnetic Resonance Imaging)	Terminologia Anatomica Gyral Definition	Fiber Tracts (Tract Tracing, Myelin Staining, Diffusion Tensor Imaging Tractography)
Visuospatial cognition (Figure 2A and B)	Ventral frontal cortex ³³⁻³⁵	MFG, IFG	SLF II, SLF III, MdLF, IFOF ³⁷
	Temporoparietal junction ^{35,37-40}	SMG, AG, STG	
	Other areas ^{35,37,38}	STG, MTG, insula	
Social cognition			
Facial emotion recognition	Facial network	Bilateral occipitotemporal cortex (fusiform gyrus and inferior occipital area) Right posterior part of the superior temporal sulcus ⁴¹⁻⁴⁵ Right IFG, orbitofrontal gyrus ⁴⁶ mvPFC ⁴⁵ (anterior cingulate gyrus, gyrus rectus and medial SFG)	IFOF, ILF, ⁴⁷⁻⁴⁹ UF ⁵⁰
Emotional prosody	Emotional prosody network	Right SMG, STG, and IFG	Dorsal pathway (SLF III/AF) ⁵¹⁻⁵³ Ventral pathway (ILF/IFOF) ⁵⁴
Empathy	Empathy network	Bilateral mvPFC (see Table 1) Bilateral TPJ (see Table 1) STS Other: paracingulate IFG, cingulate gyrus, and amygdala	—
Theory of mind	Theory of mind network	Bilateral mvPFC (see Table 1) Bilateral TPJ (see Table 1) STS Lateral orbitofrontal gyrus Other: MFG, cuneus precuneus and STG	—
MFG, middle frontal gyrus; IFG, inferior frontal gyrus; SLF, superior longitudinal fasciculus; MdLF, middle longitudinal fasciculus; IFOF, inferior fronto-occipital fasciculus; SMG, supramarginal gyrus; AG, angular gyrus; STG, superior temporal gyrus; MTG, middle temporal gyrus; ILF, inferior longitudinal fasciculus; UF, uncinata fasciculus; SFG, superior frontal gyrus; AF, arcuate fasciculus; mvPFC, medial ventral prefrontal cortex; TPJ, temporoparietal junction; STS, superior temporal sulcus.			

corticoamygdala pathway for processing face information, projecting from the right posterior part of STS, via the right anterior part of STS, into the amygdala. A recent fMRI study⁵⁰ indicated that uncinate fasciculus is related to the ability to decode facial emotion expressions.

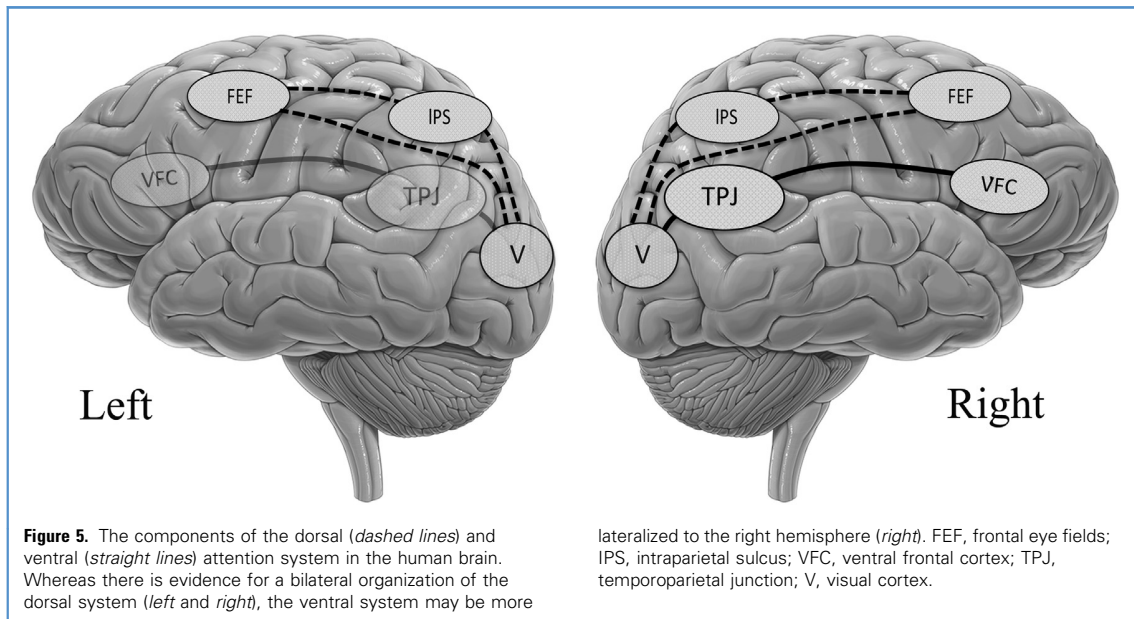
Emotional Prosody. Emotional prosody is another important nonverbal cue involved in social cognition. If emotional prosody is lateralized on the right hemisphere, linguistic prosody (which allows us to determine whether a sentence is a statement or a question, for instance) is processed in both hemispheres, with a left predominance.⁷⁹ In imagery studies, emotional prosody strongly but not exclusively activates the region around the right STG and IFG (Figure 7, Table 2). A study using

functional near-infrared spectroscopy⁸⁰ examined the brain response of neonates as they listened passively to fearful, angry, happy, and neutral prosodies. It was found that whereas the right temporal cortex (mainly located in the MTG and STG) showed enhanced response to emotional, as opposed to neutral, prosody, a right parietal area (located in the SMG) showed a heightened sensitivity to fearful, as opposed to happy and neutral, prosody.

These cortical areas communicate through a dorsal and a ventral white matter pathway.^{51-53,81,82} Using a fiber tracking approach, the dorsal pathway was identified as fibers belonging to the SLF III/arcuate fasciculus, connecting the posterior part of the STG to the pars opercularis (IFG); the ventral pathway was identified as the ILF/IFOF in the posterior part and the

extreme capsule in the anterior part, connecting the anterior part of the STG to the IFG. A study of traumatic brain injury⁵⁴ has confirmed the importance of these ventral paths (ILF and IFOF) but also of the cingulate gyrus in emotional prosody performance. Further work is needed for a conclusive assessment of these anatomofunctional hypotheses.

Empathy and Theory of Mind. TOM, also known as mentalizing, draws on the ability to understand and predict the mental states of others, based on 1) their emotions and feelings (affective TOM) and/or 2) their intentions, thoughts, and beliefs (cognitive TOM).⁸³⁻⁸⁶ TOM is a key aspect of social cognition and constitutes an important prerequisite for adequate social interactions.⁸⁷ The 2 extremes of TOM abnormalities are known as undermentalizing (insufficient



TOM) and overmentalizing (excessive TOM), which, respectively, refer to deficits commonly encountered in patients with autism⁸⁴ and schizophrenia.⁸⁸ Empathy lies in the individual's ability to reason, predict the consequences of emotions, and to produce a compassionate response accordingly.^{86,89-91} This skill requires them to view a situation from another person's perspective (other-oriented emotions), which often leads to altruistic behavior. In contrast, self-oriented emotions, such as personal distress, primarily focus on the empathizer's feelings in a way that might interfere with prosocial behavior. Therefore, they are not considered to constitute empathy.⁹²

Empathy and TOM are complex processes correlating with bihemispheric corticolimbic activations involved in emotional cue processing, self-other/same-different discrimination, assuming another person's perspective, emotional arousal, and decision making. Obviously, isolating a precise network supporting these functions is difficult, if not impossible. Nevertheless, attempts have been made to do so using fMRI (Table 2). One fMRI study⁹³ suggested that TOM and empathy stimuli are associated with overlapping but distinct neuronal networks. Common areas of activation included the mvPFC the TPJ and STS

(see section on "The Cognitive Right Hemisphere: A Mirror System"). Compared with the empathy condition, TOM stimuli showed increased activations in the lateral orbitofrontal cortex, MFG, cuneus, and STG. The cuneus is 1 of the 2 occipital gyri visible at the medial aspect of the brain, along with the lingual gyrus. It forms a triangle located between the parieto-occipital fissure anteriorly and the calcarine sulcus ventrally.⁹⁴ Empathy, on the other hand, was associated with enhanced activations of the paracingulate IFG, anterior and posterior cingulate gyrus, and amygdala. It was therefore suggested by the investigators that TOM and empathy both rely on networks associated with making inferences about the mental states of others. However, empathetic responses require the use of additional networks involved in emotional processing.

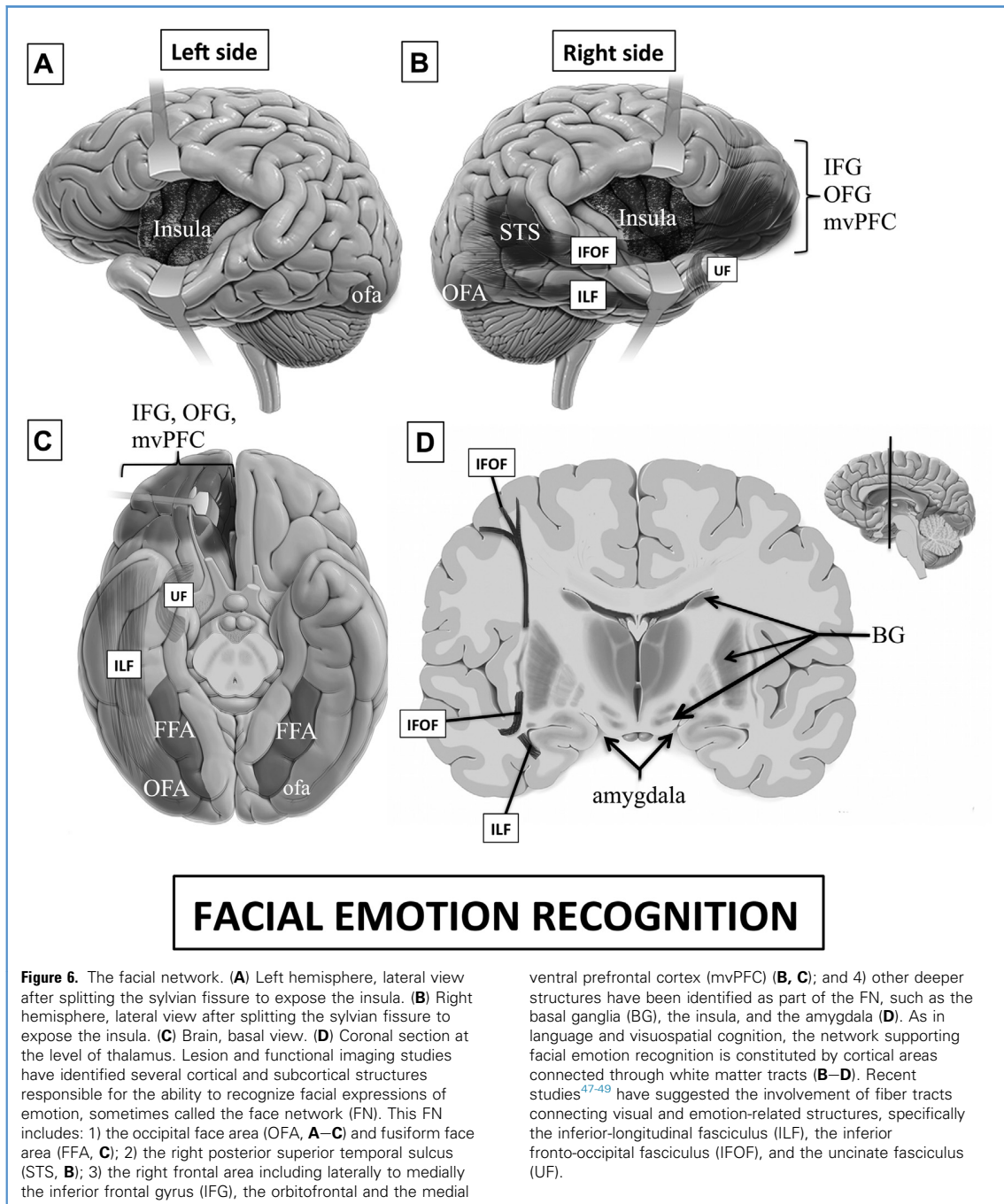
More recently, meta-analyses of fMRI studies for different paradigm-classes or experiments have suggested an interesting way of identifying a core network.^{95,96} Three cortical areas have been identified for TOM:

- The right and left TPJ. The right TPJ could constitute a relay between the VAN and the TOM networks.⁹⁷

However, some studies have suggested that the right TPJ contains 2 functionally fractionated subregions: whereas the posterior part of the right TPJ seems exclusively involved in the social domain, the anterior part of the right TPJ is involved in both attention and TOM, indicating an attentional shift in the role of this region.⁹⁸

- The bilateral mvPFC. Strong activation of the mvPFC was previously recognized in early studies on TOM, which led to the initial assumption that it was specifically linked to forming reasoned opinions.

The precuneus (also called the parietal lobe or medial Pr) is located dorsally to the subparietal sulcus, posteriorly to the marginal part of the cingulate sulcus, and anterodorsally to the parieto-occipital fissure.⁹⁴ Little evidence concerning the precuneus exists from patient and brain stimulation research, mainly because of its hidden location along the falx. Despite strong agreement that activation of the precuneus is one of the most robust correlates of TOM, the area has received relatively little attention in functional accounts. Convergent research shows that the precuneus is involved in visuospatial mental imagery. Based on these findings, it has been suggested



that a main function of the precuneus in TOM is mental imagery used to represent the perspective of another person.⁹⁹ Remarkably, available data suggest that distinct frontal circuits modulate TOM subcomponents, whereas the mvPFC appears to be particularly involved in processing affective TOM,¹⁰⁰ the

ventrolateral prefrontal and dorsolateral prefrontal cortices seem to be chiefly implicated in mediating cognitive TOM.¹⁰⁰

CONCLUSIONS

We reviewed current models of visuospatial and social cognition based on parallel

and interactive large-scale distributed networks that show the complexity of functional anatomy of the nondominant hemisphere. As in the left hemisphere with language, eloquent cortical and subcortical structures involved in visuospatial and social cognition vary between patients. A broad field of research that

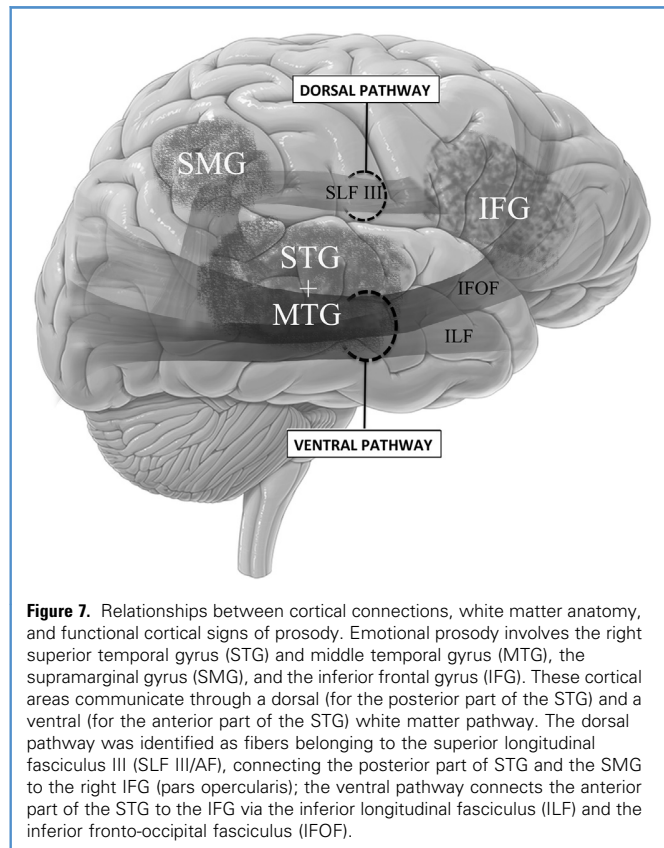


Figure 7. Relationships between cortical connections, white matter anatomy, and functional cortical signs of prosody. Emotional prosody involves the right superior temporal gyrus (STG) and middle temporal gyrus (MTG), the supramarginal gyrus (SMG), and the inferior frontal gyrus (IFG). These cortical areas communicate through a dorsal (for the posterior part of the STG) and a ventral (for the anterior part of the STG) white matter pathway. The dorsal pathway was identified as fibers belonging to the superior longitudinal fasciculus III (SLF III/AF), connecting the posterior part of STG and the SMG to the right IFG (pars opercularis); the ventral pathway connects the anterior part of the STG to the IFG via the inferior longitudinal fasciculus (ILF) and the inferior fronto-occipital fasciculus (IFOF).

would allow a better understanding of the behaviorally and anatomically dissociable right hemisphere syndromes using awake surgery is opening up for neurosurgeons.

REFERENCES

- Carota A, Bogousslavsky J. Minor hemisphere major syndromes. *Front Neurol Neurosci.* 2018;41:1-13.
- Charras P, Herbet G, Deverduin J, de Champfleur NM, Duffau H, Bartolomeo P, et al. Functional reorganization of the attentional networks in low-grade glioma patients: a longitudinal study. *Cortex J Devoted Study Nerv Syst Behav.* 2015;63:27-41.
- Conner AK, Glenn C, Burks JD, McCoy T, Bonney PA, Chema AA, et al. The use of the target cancellation task to identify eloquent visuospatial regions in awake craniotomies: technical note. *Cureus.* 2016;8:e883.
- Fried I, Mateer C, Ojemann G, Wohns R, Fedio P. Organization of visuospatial functions in human cortex. Evidence from electrical stimulation. *Brain J Neurol.* 1982;105:349-371.
- Giussani C, Pirillo D, Roux F-E. Mirror of the soul: a cortical stimulation study on recognition of facial emotions. *J Neurosurg.* 2010;112:520-527.
- Kitabayashi T, Nakada M, Kinoshita M, Sakurai H, Kobayashi S, Okita H, et al. [Awake surgery with line bisection task for two cases of parietal glioma in the non-dominant hemisphere]. *No Shinkei Geka.* 2012;40:1087-1093 [in Japanese].
- Kleinman JT, Sepkuty JP, Hillis AE, Lenz FA, Heidler-Gary J, Gingis L, et al. Spatial neglect during electrocortical stimulation mapping in the right hemisphere. *Epilepsia.* 2007;48:2365-2368.
- Manning L, Halligan PW, Marshall JC. Individual variation in line bisection: a study of normal subjects with application to the interpretation of visual neglect. *Neuropsychologia.* 1990;28:647-655.
- Mazerand E, Le Renard M, Hue S, Lemée J-M, Klinger E, Menei P. Intraoperative subcortical electrical mapping of the optic tract in awake surgery using a virtual reality headset. *World Neurosurg.* 2017;97:424-430.
- Plummer P, Morris ME, Dunai J. Assessment of unilateral neglect. *Phys Ther.* 2003;83:732-740.
- Rorden C, Fruhmann Berger M, Karnath H-O. Disturbed line bisection is associated with posterior brain lesions. *Brain Res.* 2006;1080:17-25.
- Roux F-E, Dufor O, Lauwers-Cances V, Boukhatem L, Brauge D, Draper L, et al. Electrostimulation mapping of spatial neglect. *Neurosurgery.* 2011;69:1218-1231.
- Sallard E, Duffau H, Bonnetblanc F. Ultra-fast recovery from right neglect after "awake surgery" for slow-growing tumor invading the left parietal area. *Neurocase.* 2012;18:80-90.
- Schenkenberg T, Bradford DC, Ajax ET. Line bisection and unilateral visual neglect in patients with neurologic impairment. *Neurology.* 1980;30:509-517.
- Talacchi A, Squintani GM, Emanuele B, Tramontano V, Santini B, Savazzi S. Intraoperative cortical mapping of visuospatial functions in parietal low-grade tumors: changing perspectives of neurophysiological mapping. *Neurosurg Focus.* 2013;34:E4.
- Vallar G, Bello L, Bricolo E, Castellano A, Casarotti A, Falini A, et al. Cerebral correlates of visuospatial neglect: a direct cerebral stimulation study. *Hum Brain Mapp.* 2014;35:1334-1350.
- Vilasboas T, Herbet G, Duffau H. Challenging the myth of right nondominant hemisphere: lessons from corticosubcortical stimulation mapping in awake surgery and surgical implications. *World Neurosurg.* 2017;103:449-456.
- Chang EF, Raygor KP, Berger MS. Contemporary model of language organization: an overview for neurosurgeons. *J Neurosurg.* 2015;122:250-261.
- Dorsaint-Pierre R, Penhune VB, Watkins KE, Neelin P, Lerch JP, Bouffard M, et al. Asymmetries of the planum temporale and Heschl's gyrus: relationship to language lateralization. *Brain J Neurol.* 2006;129:1164-1176.
- Parker GJM, Luzzi S, Alexander DC, Wheeler-Kingshott CAM, Ciccarelli O, Lambon Ralph MA. Lateralization of ventral and dorsal auditory-language pathways in the human brain. *Neuroimage.* 2005;24:656-666.
- Gharabaghi A, Kunath F, Erb M, Saur R, Heckl S, Tatagiba M, et al. Perisylvian white matter connectivity in the human right hemisphere. *BMC Neurosci.* 2009;10:15.
- Maldonado IL, de Champfleur NM, Velut S, Destrieux C, Zemmoura J, Duffau H. Evidence of a middle longitudinal fasciculus in the human brain from fiber dissection. *J Anat.* 2013;223:38-45.
- Yagmurlu K, Middlebrooks EH, Tanriover N, Rhoton AL. Fiber tracts of the dorsal language stream in the human brain. *J Neurosurg.* 2016;124:1396-1405.
- Geng JJ, Vossel S. Re-evaluating the role of TPJ in attentional control: contextual updating? *Neurosci Biobehav Rev.* 2013;37:2608-2620.
- Mars RB, Jbabdi S, Sallet J, O'Reilly JX, Croxson PL, Olivier E, et al. Diffusion-weighted imaging tractography-based parcellation of the human parietal cortex and comparison with human and macaque resting-state functional connectivity. *J Neurosci.* 2011;31:4087-4100.
- Thiebaut de Schotten M, Urbanski M, Duffau H, Volle E, Lévy R, Dubois B, et al. Direct evidence

- for a parietal-frontal pathway subserving spatial awareness in humans. *Science*. 2005;309:2226-2228.
27. Makris N, Kennedy DN, McInerney S, Sorensen AG, Wang R, Caviness VS Jr, et al. Segmentation of subcomponents within the superior longitudinal fascicle in humans: a quantitative, in vivo, DT-MRI study. *Cereb Cortex N Y N*. 2005;15:854-869.
 28. Schmahmann JD, Pandya DN, Wang R, Dai G, D'Arceuil HE, de Crespigny AJ, et al. Association fibre pathways of the brain: parallel observations from diffusion spectrum imaging and autoradiography. *Brain J Neurol*. 2007;130:630-653.
 29. Mars RB, Sallet J, Schüffelgen U, Jbabdi S, Toni I, Rushworth MFS. Connectivity-based subdivisions of the human right "temporoparietal junction area": evidence for different areas participating in different cortical networks. *Cereb Cortex N Y N*. 2012;22:1894-1903.
 30. Segal E, Petrides M. The morphology and variability of the caudal rami of the superior temporal sulcus. *Eur J Neurosci*. 2012;36:2035-2053.
 31. Zlatkina V, Petrides M. Morphological patterns of the intraparietal sulcus and the anterior intermediate parietal sulcus of Jensen in the human brain. *Proc Biol Sci*. 2014;281. <https://doi.org/10.1098/rspb.2014.1493>.
 32. Halligan PW, Marshall JC. Left visuo-spatial neglect: a meaningless entity? *Cortex J Devoted Study Nerv Syst Behav*. 1992;28:525-535.
 33. Committeri G, Pitzalis S, Galati G, Patria F, Pelle G, Sabatini U, et al. Neural bases of personal and extrapersonal neglect in humans. *Brain J Neurol*. 2007;130:431-441.
 34. Husain M, Kennard C. Visual neglect associated with frontal lobe infarction. *J Neurol*. 1996;243:652-657.
 35. Rengachary J, He BJ, Shulman GL, Corbetta M. A behavioral analysis of spatial neglect and its recovery after stroke. *Front Hum Neurosci*. 2011;5:29.
 36. Kubit B, Jack AI. Rethinking the role of the rTPJ in attention and social cognition in light of the opposing domains hypothesis: findings from an ALE-based meta-analysis and resting-state functional connectivity. *Front Hum Neurosci*. 2013;7:323.
 37. Karnath H-O, Rennig J, Johannsen L, Rorden C. The anatomy underlying acute versus chronic spatial neglect: a longitudinal study. *Brain J Neurol*. 2011;134:903-912.
 38. Chechlacz M, Rotshtein P, Humphreys GW. Neuroanatomical dissections of unilateral visual neglect symptoms: ALE meta-analysis of lesion-symptom mapping. *Front Hum Neurosci*. 2012;6:230.
 39. Mort DJ, Malhotra P, Mannan SK, Rorden C, Pambakian A, Kennard C, et al. The anatomy of visual neglect. *Brain J Neurol*. 2003;126:1986-1997.
 40. Vallar G, Perani D. The anatomy of unilateral neglect after right-hemisphere stroke lesions. A clinical/CT-scan correlation study in man. *Neuropsychologia*. 1986;24:609-622.
 41. Wang X, Song Y, Zhen Z, Liu J. Functional integration of the posterior superior temporal sulcus correlates with facial expression recognition. *Hum Brain Mapp*. 2016;37:1930-1940.
 42. Allison T, Puce A, McCarthy G. Social perception from visual cues: role of the STS region. *Trends Cogn Sci*. 2000;4:267-278.
 43. Hein G, Knight RT. Superior temporal sulcus—it's my area: or is it? *J Cogn Neurosci*. 2008;20:2125-2136.
 44. Vonck S, Swinnen SP, Wenderoth N, Alaerts K. Effects of transcranial direct current stimulation on the recognition of bodily emotions from point-light displays. *Front Hum Neurosci*. 2015;9:438.
 45. Sorger B, Goebel R, Schiltz C, Rossion B. Understanding the functional neuroanatomy of acquired prosopagnosia. *Neuroimage*. 2007;35:836-852.
 46. Willis ML, Murphy JM, Ridley NJ, Vercammen A. Anodal tDCS targeting the right orbitofrontal cortex enhances facial expression recognition. *Soc Cogn Affect Neurosci*. 2015;10:1677-1683.
 47. Genova HM, Rajagopalan V, Chiaravalloti N, Binder A, Deluca J, Lengenfelder J. Facial affect recognition linked to damage in specific white matter tracts in traumatic brain injury. *Soc Neurosci*. 2015;10:27-34.
 48. Philippi CL, Mehta S, Grabowski T, Adolphs R, Rudrauf D. Damage to association fiber tracts impairs recognition of the facial expression of emotion. *J Neurosci*. 2009;29:15089-15099.
 49. Unger A, Alm KH, Collins JA, O'Leary JM, Olson IR. Variation in white matter connectivity predicts the ability to remember faces and discriminate their emotions. *J Int Neuropsychol Soc*. 2016;22:180-190.
 50. Coad BM, Postans M, Hodgetts CJ, Muhlert N, Graham KS, Lawrence AD. Structural connections support emotional connections: Uncinate Fasciculus microstructure is related to the ability to decode facial emotion expressions. *Neuropsychologia*. 2017. <https://doi.org/10.1016/j.neuropsychologia.2017.11.006>. [Epub ahead of print]
 51. Frühholz S, Gschwind M, Grandjean D. Bilateral dorsal and ventral fiber pathways for the processing of affective prosody identified by probabilistic fiber tracking. *Neuroimage*. 2015;109:27-34.
 52. Frühholz S, Ceravolo L, Grandjean D. Specific brain networks during explicit and implicit decoding of emotional prosody. *Cereb Cortex N Y N*. 2012;22:1107-1117.
 53. Frühholz S, Grandjean D. Towards a fronto-temporal neural network for the decoding of angry vocal expressions. *Neuroimage*. 2012;62:1658-1666.
 54. Schmidt AT, Hanten G, Li X, Wilde EA, Ibarra AP, Chu ZD, et al. Emotional prosody and diffusion tensor imaging in children after traumatic brain injury. *Brain Inj*. 2013;27:1528-1535.
 55. He BJ, Snyder AZ, Vincent JL, Epstein A, Shulman GL, Corbetta M. Breakdown of functional connectivity in frontoparietal networks underlies behavioral deficits in spatial neglect. *Neuron*. 2007;53:905-918.
 56. Shinoura N, Suzuki Y, Yamada R, Tabei Y, Saito K, Yagi K. Damage to the right superior longitudinal fasciculus in the inferior parietal lobe plays a role in spatial neglect. *Neuropsychologia*. 2009;47:2600-2603.
 57. Urbanski M, Thiebaut de Schotten M, Rodrigo S, Catani M, Oppenheim C, Touzé E, et al. Brain networks of spatial awareness: evidence from diffusion tensor imaging tractography. *J Neurol Neurosurg Psychiatry*. 2008;79:598-601.
 58. Bartolomeo P, Thiebaut de Schotten M, Doricchi F. Left unilateral neglect as a disconnection syndrome. *Cereb Cortex N Y N*. 2007;17:2479-2490.
 59. Bottini G, Karnath HO, Vallar G, Sterzi R, Frith CD, Frackowiak RS, et al. Cerebral representations for egocentric space: functional-anatomical evidence from caloric vestibular stimulation and neck vibration. *Brain J Neurol*. 2001;124:1182-1196.
 60. Dieterich M, Brandt T. Global orientation in space and the lateralization of brain functions. *Curr Opin Neurol*. 2018;31:96-104.
 61. Kahane P, Hoffmann D, Minotti L, Berthoz A. Reappraisal of the human vestibular cortex by cortical electrical stimulation study. *Ann Neurol*. 2003;54:615-624.
 62. Stephan T, Deuschländer A, Nolte A, Schneider E, Wiesmann M, Brandt T, et al. Functional MRI of galvanic vestibular stimulation with alternating currents at different frequencies. *Neuroimage*. 2005;26:721-732.
 63. Karnath H-O, Himmelbach M, Küker W. The cortical substrate of visual extinction. *Neuroreport*. 2003;14:437-442.
 64. Corbetta M, Shulman GL. Spatial neglect and attention networks. *Annu Rev Neurosci*. 2011;34:569-599.
 65. Caplan LR, Schmahmann JD, Kase CS, Feldmann E, Baquis G, Greenberg JP, et al. Caudate infarcts. *Arch Neurol*. 1990;47:133-143.
 66. Kumral E, Eyyapan D, Balkir K. Acute caudate vascular lesions. *Stroke*. 1999;30:100-108.
 67. Karnath HO, Himmelbach M, Rorden C. The subcortical anatomy of human spatial neglect: putamen, caudate nucleus and pulvinar. *Brain J Neurol*. 2002;125:350-360.
 68. Hillis AE, Wityk RJ, Barker PB, Beauchamp NJ, Gailloud P, Murphy K, et al. Subcortical aphasia and neglect in acute stroke: the role of cortical hypoperfusion. *Brain J Neurol*. 2002;125:1094-1104.

69. Binder J, Marshall R, Lazar R, Benjamin J, Mohr JP. Distinct syndromes of hemineglect. *Arch Neurol.* 1992;49:1187-1194.
70. Grimsen C, Hildebrandt H, Fahle M. Dissociation of egocentric and allocentric coding of space in visual search after right middle cerebral artery stroke. *Neuropsychologia.* 2008;46:902-914.
71. Medina J, Kannan V, Pawlak MA, Kleinman JT, Newhart M, Davis C, et al. Neural substrates of visuospatial processing in distinct reference frames: evidence from unilateral spatial neglect. *J Cogn Neurosci.* 2009;21:2073-2084.
72. Verdon V, Schwartz S, Lovblad K-O, Hauert C-A, Vuilleumier P. Neuroanatomy of hemispatial neglect and its functional components: a study using voxel-based lesion-symptom mapping. *Brain J Neurol.* 2010;133:880-894.
73. Uono S, Sato W, Kochiyama T, Sawada R, Kubota Y, Yoshimura S, et al. Neural substrates of the ability to recognize facial expressions: a voxel-based morphometry study. *Soc Cogn Affect Neurosci.* 2017;12:487-495.
74. Blair RJ, Cipolotti L. Impaired social response reversal. A case of "acquired sociopathy." *Brain J Neurol.* 2000;123:1122-1141.
75. Adolphs R, Tranel D, Damasio H, Damasio A. Impaired recognition of emotion in facial expressions following bilateral damage to the human amygdala. *Nature.* 1994;372:669-672.
76. Marstaller L, Burianová H, Reutens DC. Individual differences in structural and functional connectivity predict speed of emotion discrimination. *Cortex J Devoted Study Nerv Syst Behav.* 2016;85:65-74.
77. Calder AJ, Keane J, Manes F, Antoun N, Young AW. Impaired recognition and experience of disgust following brain injury. *Nat Neurosci.* 2000;3:1077-1078.
78. Pitcher D, Japee S, Rauth L, Ungerleider LG. The superior temporal sulcus is causally connected to the amygdala: a combined TBS-fMRI study. *J Neurosci.* 2017;37:1156-1161.
79. Kreitewolf J, Friederici AD, von Kriegstein K. Hemispheric lateralization of linguistic prosody recognition in comparison to speech and speaker recognition. *Neuroimage.* 2014;102:332-344.
80. Zhang D, Zhou Y, Hou X, Cui Y, Zhou C. Discrimination of emotional prosodies in human neonates: a pilot fNIRS study. *Neurosci Lett.* 2017;658:62-66.
81. Klaas HS, Frühholz S, Grandjean D. Aggressive vocal expressions—an investigation of their underlying neural network. *Front Behav Neurosci.* 2015;9:121.
82. Sammler D, Grosbras M-H, Anwander A, Bestelmeyer PEG, Belin P. Dorsal and ventral pathways for prosody. *Curr Biol.* 2015;25:3079-3085.
83. Stone VE, Baron-Cohen S, Knight RT. Frontal lobe contributions to theory of mind. *J Cogn Neurosci.* 1998;10:640-656.
84. Baron-Cohen S. Theory of mind and autism: a review. In: *International Review of Research in Mental Retardation.* Vol. 23. Autism. San Diego, CA: Academic Press; 2000:169-184.
85. Uekermann J, Channon S, Winkel K, Schlebusch P, Daum I. Theory of mind, humour processing and executive functioning in alcoholism. *Addict Abingdon Engl.* 2007;102:232-240.
86. Uekermann J, Channon S, Lehmkämpfer C, Abdel-Hamid M, Vollmoeller W, Daum I. Executive function, mentalizing and humor in major depression. *J Int Neuropsychol Soc.* 2008;14:55-62.
87. Chalah MA, Ayache SS. Deficits in social cognition: an unveiled signature of multiple sclerosis. *J Int Neuropsychol Soc.* 2017;23:266-286.
88. Frith CD. Schizophrenia and theory of mind. *Psychol Med.* 2004;34:385-389.
89. Decety J, Jackson PL. The functional architecture of human empathy. *Behav Cogn Neurosci Rev.* 2004;3:71-100.
90. Ruby P, Decety J. How would you feel versus how do you think she would feel? A neuroimaging study of perspective-taking with social emotions. *J Cogn Neurosci.* 2004;16:988-999.
91. Uekermann J, Kraemer M, Abdel-Hamid M, Schimmelmann BG, Hebebrand J, Daum I, et al. Social cognition in attention-deficit hyperactivity disorder (ADHD). *Neurosci Biobehav Rev.* 2010;34:734-743.
92. Tangney JP, Stuewig J, Mashek DJ. Moral emotions and moral behavior. *Annu Rev Psychol.* 2007;58:345-372.
93. Völlm BA, Taylor ANW, Richardson P, Corcoran R, Stirling J, McKie S, et al. Neuronal correlates of theory of mind and empathy: a functional magnetic resonance imaging study in a nonverbal task. *Neuroimage.* 2006;29:90-98.
94. Destrieux C, Terrier LM, Andersson F, Love SA, Cottier JP, Duvernoy H, et al. A practical guide for the identification of major sulcogyral structures of the human cortex. *Brain Struct Funct.* 2017;222:2001-2015.
95. Carrington SJ, Bailey AJ. Are there theory of mind regions in the brain? A review of the neuroimaging literature. *Hum Brain Mapp.* 2009;30:2313-2335.
96. Schurz M, Tholen MG, Perner J, Mars RB, Sallet J. Specifying the brain anatomy underlying temporo-parietal junction activations for theory of mind: a review using probabilistic atlases from different imaging modalities. *Hum Brain Mapp.* 2017;38:4788-4805.
97. Schuerk T, Schurz M, Müller F, Rupprecht R, Sommer M. The rTPJ's overarching cognitive function in networks for attention and theory of mind. *Soc Cogn Affect Neurosci.* 2017;12:157-168.
98. Krall SC, Rottschy C, Oberwelling E, Bzdok D, Fox PT, Eickhoff SB, et al. The role of the right temporoparietal junction in attention and social interaction as revealed by ALE meta-analysis. *Brain Struct Funct.* 2015;220:587-604.
99. Cavanna AE, Trimble MR. The precuneus: a review of its functional anatomy and behavioural correlates. *Brain J Neurol.* 2006;129:564-583.
100. Shamay-Tsoory SG, Aharon-Peretz J. Dissociable prefrontal networks for cognitive and affective theory of mind: a lesion study. *Neuropsychologia.* 2007;45:3054-3067.

Conflict of interest statement: The authors declare that the article content was composed in the absence of any commercial or financial relationships that could be construed as a potential conflict of interest.

Received 16 February 2018; accepted 2 May 2018

Citation: World Neurosurg. (2018).

https://doi.org/10.1016/j.wneu.2018.05.024

Journal homepage: www.WORLDNEUROSURGERY.org

Available online: www.sciencedirect.com

1878-8750/\$ - see front matter © 2018 Elsevier Inc. All rights reserved.

1.2. Tests neuropsychologiques et stimulation électrique en chirurgie éveillée de l'hémisphère non-dominant.

❖ Article n°2 :

Right Hemisphere Cognitive Functions: From Clinical and Anatomic Bases to Brain Mapping During Awake Craniotomy Part II: Neuropsychological tasks and Brain mapping

Lemée JM, Bernard F, Ter Minassian A, Menei P

World Neurosurgery, (publié IF= 1,924)

Right Hemisphere Cognitive Functions: From Clinical and Anatomical Bases to Brain Mapping During Awake Craniotomy. Part II: Neuropsychological Tasks and Brain Mapping

Jean-Michel Lemée^{1,3}, Florian Bernard^{1,4}, Aram Ter Minassian^{2,5}, Philippe Menei^{1,3}

Key words

- Awake surgery
- Nondominant hemisphere
- Social cognition
- Unilateral neglect
- Visuospatial cognition

Abbreviations and Acronyms

- DES:** Direct electric stimulation
fMRI: Functional magnetic resonance imaging
IFOF: Inferior fronto-occipital fasciculus
MTG: Middle temporal gyrus
SLF: Superior longitudinal fasciculus
SMG: Supramarginal gyrus
STG: Superior temporal gyrus
TOM: Theory of mind
TPJ: Temporoparietal junction
UN: Unilateral neglect

From the ¹Service de Neurochirurgie, and ²Département d'Anesthésie-Réanimation, CHU d'Angers; ³CRCINA, INSERM, Université de Nantes, Université d'Angers; ⁴Laboratoire d'Anatomie, Faculté de Médecine d'Angers; and ⁵LARIS EA 7315, Image Signal et Sciences du Vivant, Angers Teaching Hospital, Angers, France

To whom correspondence should be addressed:
 Philippe Menei, M.D., Ph.D.
 [E-mail: pmmenei@chu-angers.fr]

Citation: *World Neurosurg.* (2018).
<https://doi.org/10.1016/j.wneu.2018.07.099>

Journal homepage: www.WORLDNEUROSURGERY.org

Available online: www.sciencedirect.com

1878-8750/\$ - see front matter © 2018 Elsevier Inc. All rights reserved.

INTRODUCTION

Traditionally, the dominant (usually left) cerebral hemisphere is regarded as the most important side in terms of functionality. Current neurosurgical decisions regarding the surgical approach in clinical practice are influenced by this paradigm. Nevertheless, the view of a “minor” right hemisphere is now being challenged by postoperative neuropsychological evaluations revealing very often cognitive and behavioral deficits after right hemisphere surgery.¹⁻³ Neurosurgeons are more sensitized to these defects and the better understanding of anatomical basis of the brain connectome and focus on elaborate

The nondominant hemisphere (usually right) is determinant for main cognitive functions such as visuospatial and social cognitions. Awake surgery using direct electrical stimulation for right cerebral tumor removal remains challenging due to the complexity of the functional anatomy and the difficulties in adapting the classical bedside tasks for awake surgery conditions. An understanding of semiology, anatomical bases, and an analysis of the available cognitive tasks for visuospatial and social cognition per operative mapping will allow neurosurgeons to better appreciate the functional anatomy of the right hemisphere and its application to tumor surgery. In this second review of 2 parts, we discuss the pertinence of the neuropsychological tests available for the study of nondominant hemisphere functions for the surgery on right-sided tumors in awake surgery conditions. In conjunction with part I of the review, which focuses primarily on the anatomical, functional, and semiological basis of the right hemisphere function, this article provides a comprehensive review of current knowledge supporting the awake surgery in the right hemisphere.

right-lateralized cerebral functions replacing the patient as a whole. As they did few decades ago with the executive and left lateralized functions, they are trying to bring new insights to the right hemisphere mapping with the aim of preserving cognitive function to achieve an optimal postoperative quality of life.

The nondominant hemisphere (usually right) is determinant for main cognitive functions such as visuospatial and social cognitions. The visuospatial cognition supports spatial awareness, perception, and representation of space. It allows perceiving, reporting, and orienting to sensory events towards one side of space to take place. Lesions of the network supporting the visuospatial cognition are associated with different symptoms; the most important one is the unilateral neglect (UN). The social cognition is the other main function of this hemisphere. It includes all cognitive processes involved in social interaction such as nonverbal language (like facial emotion recognition and emotional prosody), empathy, and theory of mind (TOM).

An understanding of semiology, anatomical bases, and an analysis of the

available cognitive tasks for visuospatial and social cognition per operative mapping will allow neurosurgeons to better appreciate the functional anatomy of the right hemisphere and its application to tumor surgery, which was the subject of the first part of this review.⁴

Compared with language mapping in the left hemisphere, very few procedures of the right hemisphere per operative mapping have been published.⁵⁻²⁰ This disinterest could be explained not only by the underestimation of the cognitive role of the right hemisphere but also by the complexity of the functional anatomy as much as the difficulties to adapt the classical bedside tasks to awake surgery conditions. As for language, these functions cannot be reliably localized on anatomical criteria alone, mostly due to the interindividual variation.

The neuroplasticity is present before the surgery in a slow-developing lesion such as low-grade gliomas, during the surgery, and continues in the postoperative period.²¹⁻²³ Neural plasticity is itself a source of interindividual variability, with different cortical mapping of brain function identified in the same patient over

time and must be taken into account the neuroplasticity and the capacity to recover after surgical damage to maintain these cognitive functions.^{24,25} The knowledge of the patient's neuroplasticity allows an optimal resection of a tumor even in traditionally "inoperable" localization, based on functional boundaries identified through direct electric cortical stimulation in awake surgery conditions while minimizing the risk of postoperative deficit.²⁶ In surgical series of low-grade gliomas, more than 95% of patients recovered a normal neurological examination and almost all patients returned to a normal socioprofessional life.²⁶⁻²⁸

In the second part of this review on the nondominant hemisphere, we propose a comprehensive review regarding previous experiences in cortical mapping for awake surgery focusing on the visuospatial and social cognitions, with reflections on the available neuropsychological tasks and their validity for awake surgery. Other right hemisphere functions such as calculation, nonverbal semantic cognition, and the motor control network will not be detailed in this review.^{20,29-33}

THE VISUOSPATIAL COGNITIONS

Semiology

The most important visuospatial impairment is UN, which is highly heterogeneous in its severity and its manifestations.³⁴ Severity can vary from a minor increase in the reaction time of stimuli detection in the neglected space to the total disappearance of this hemispace. UN represents a gradient across space, and severe neglect may be difficult to differentiate from hemianopia.

UN can also involve all sensorial modalities, a remembered scene or mental image ranging to the non-use of the contralesional limb, called motor neglect. Anosognosia is the unawareness of a specific deficit. Besides UN, lesions of the nondominant hemisphere can also induce several other neuropsychological disorders such as somatoparaphrenia (a monothematic delusion where one denies ownership of a limb or an entire side of their body), allochiria (responding to a stimulus to one side of the body as if it had been to the other side), and constructional apraxia (inability to draw or

copy complex diagrams). Another specific trait in lesions of the nondominant hemisphere is anosognosia, which is often associated and directed towards UN.

The degree of UN can fluctuate depending on the complexity of the task, the presence of distractor in the ipsilateral space (which corresponds to the extinction phenomenon), the emotional charge, and the patient's motivation. UN could also involve independently the far personal, peripersonal, and personal spaces. UN may also vary depending on the referential space such as egocentric and allocentric spatial referentials, where objects are located relative to their spatial configuration within a scene or to one another.

In summary, UN is polymorphic and does not constitute a unitary syndrome, but rather a complex set of signs and symptoms that is better represented on a continuous scale. Nevertheless, a common core set of symptoms, including biased gaze orientation and search, combined with an anosognosia regarding these symptoms, could be defined for clinical and functional magnetic resonance imaging (fMRI) studies of patients suffering from a lesion of the nondominant hemisphere.

Tasks and Perioperative Mapping

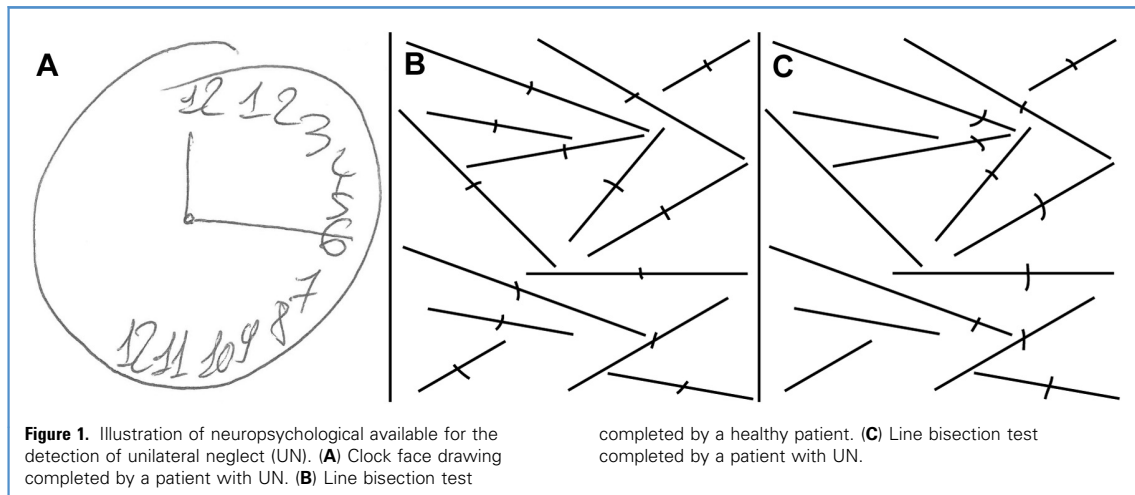
UN does not constitute a unitary syndrome and is highly polymorphic, and the use of single tests can fail to diagnose UN and differentiate it from general cognitive impairment or constructional apraxia. To detect UN at the bedside, clinicians use different pen-and-paper tests.¹³ Test objects considered to be sensitive to detecting UN are a clock face, the human form, and a butterfly drawing (Figure 1A). Unfortunately, these tests do not seem suitable for the perioperative detection of induced UN with direct electric stimulation (DES) because of the time needed to complete the task. Formal evaluation test batteries are better suited to identify UN, but it is evident that these batteries are not compatible with brain mapping.

Two neuropsychological tests currently used to detect UN are more suitable for perioperative use. The line bisection task requires people to estimate and indicate the midpoint of a horizontal line presented on a piece of paper placed in front

of them with respect to the patient's midline and aligned with the subject's horizontal line of vision (Figure 1B and C). Care should be taken to maintain each visual field within the corresponding half of the line to avoid visual field crossover that may result in inaccurate results. An ipsilateral deviation to the brain lesion is usually regarded as being indicative of neglect, although the magnitude can vary. There are many pen-and-paper or computerized versions of the line bisection task. Procedures are rarely standardized, except when used in a standardized test battery. For use as a bedside task, the line bisection task in spatial awareness seems to have a very good feasibility, a specificity of 90%, and a lower sensitivity of 60%.¹⁷ It is interesting to note for surgery that rightward deviations seem to be less pronounced when patients are lying down than standing.³⁵ The line bisection test was used in all the published series of patients operated in awake surgery, not only because of its simplicity, but also for the speed of the test and its reproducibility.^{9,15,18,19}

Interestingly, the line bisection task can dissociate visuospatial deficit from the core neglect disorder and fail to identify UN. For example, Ferber and Karnath (2001)³⁶ observed that 40% of patients with core symptoms of spatial neglect were unimpaired in the line bisection task. Moreover, lesion mapping demonstrates that patients with line bisection deficits have more posterior injury than those with only spatial neglect.^{14,37-39} Indeed, this anatomical dissociation was observed in publications that did not explicitly attempt to differentiate these symptoms.⁴⁰ Therefore, although the line bisection task does appear to identify a profound perceptual disorder, it appears to be anatomically and behaviorally independent from the core symptoms of neglect. One possible explanation for this dissociation is that the line bisection task draws on allocentric representation whereas the core deficit in spatial neglect is egocentric.^{14,41}

The perioperative observations described in the literature are in accordance with the previous studies on a visuospatial cognition anatomical substrate as described in part I of this review.⁴ An important precursor work on 2 patients showed a rightward deviation on the line



bisection task during the DES of 2 right cortical sites belonging to the right temporoparietal junction (TPJ) (especially the supramarginal gyrus [SMG] and the posterior part of the superior temporal gyrus [STG]) and a subcortical area corresponding to the superior longitudinal fasciculus (SLF) III.^{42,43} Another small study using the line bisection task found that preservation of the positive areas resulted in a lack of persisting neglect.¹⁸

The largest study published reports the use of a paper line bisection task in combination with the DES of the right hemisphere in 50 cases.¹⁵ Curiously, both rightward and leftward deviations were induced, sometimes in the same patient but for different stimulation sites. Group analysis showed that specific and reproducible line deviations were induced by stimulation of discrete cortical areas located in the TPJ and in the ventral frontal cortex. They obtained a leftward deviation in 1 on 22 stimulations of the SLF II and 1 on 18 stimulations of the inferior fronto-occipital fasciculus (IFOF) and 5 times on 35 of the SLF III (also called arcuate fasciculus). Recently 3 cases of patients have undergone an awake craniotomy with DES for right temporal glioma using a standard line bisection task found in cortical sites in the SMG and the posterior part of both the middle temporal gyrus (MTG) and STG. Significant rightward deviations were observed in all patients during the stimulation of the IFOF.⁴⁴ Electrocranial stimulation mapping by grid was also reported

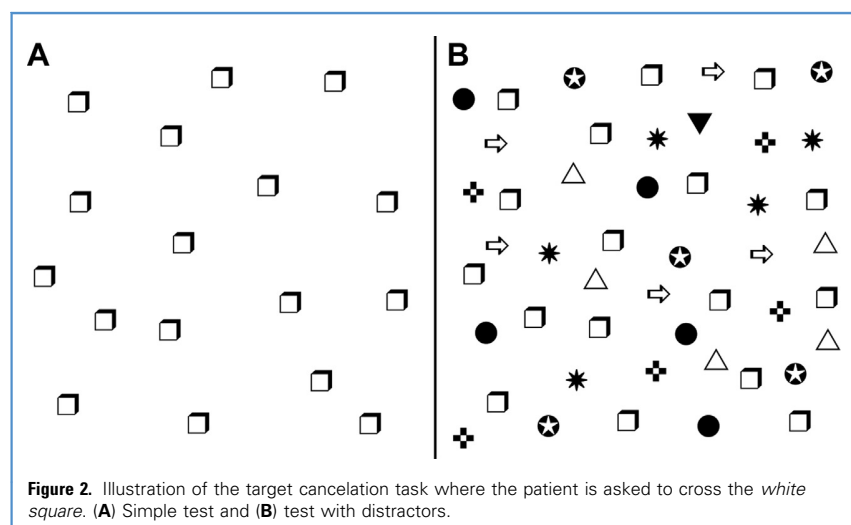
before an epilepsy surgery in the right TPJ, confirming the implication of the area in the UN symptoms.¹⁰

However, this was not the case for a smaller study of 7 patients, for which visuospatial neglect was assessed by a computerized line bisection.¹⁹ A rightward deviation, indicating left visuospatial neglect, was induced in 6 of 7 patients by stimulation of the parietofrontal connections, in a specific location consistent with the trajectory of the SLF II, the superior parietal lobule, corresponding to Brodmann's area 7, with the DES of Brodmann's areas 5 (anterior part of the superior parietal lobule) and 19 (located in parts of the lingual gyrus, the cuneus, the lateral occipital gyrus, and the superior occipital

gyrus); the medial and dorsal white matter of the superior parietal lobule (SLF I), the supramarginal gyrus (SLF III), and the IFOF was ineffective.

In conclusion, 4 of 5 published DES studies using the line bisection task are in accordance with the data obtained from imaging studies and described in part I of this review, confirming the role of the ventral frontal cortex and TPJ, connected with SLF III and IFOF.⁴ They highlight the implication of SLF II, precisely in the line bisection task, even if it does not play a role in the ventral attention network.

The target cancellation task is another test that requires the person to search for and cross out target symbols (Figure 2A). Patients with UN typically fail to cancel



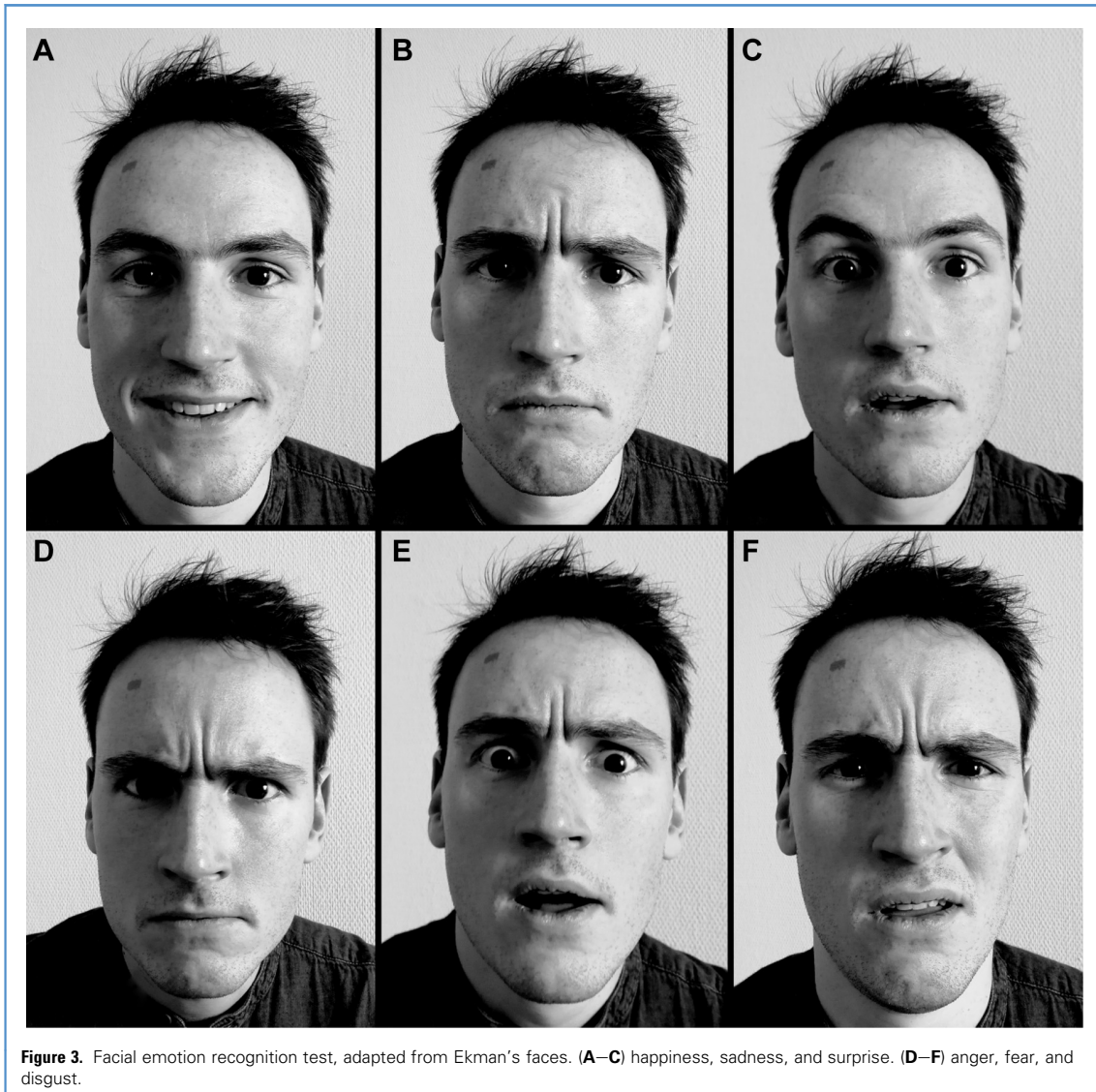


Figure 3. Facial emotion recognition test, adapted from Ekman's faces. (A–C) happiness, sadness, and surprise. (D–F) anger, fear, and disgust.

stimuli on the side of the page opposite the brain lesion. Many versions of the cancellation task exist, with various shapes, single or double target stimuli, and with or without the presence of distractors. Distractor symbols are nontarget stimuli that require the person to decide whether a stimulus is a target before crossing it out, rather than simply crossing out every stimulus on the page (Figure 2B). Cancellation tests with distractors are more sensitive in detecting UN than tests without distractors as well as offering greater test-retest reliability and are more sensitive than line bisection tests.¹³

A study of 7 patients highlights the feasibility of the target cancellation task for use during an awake craniotomy.⁶ A simple software program on a handheld tablet computer with touchscreen capabilities was used. DES was continuous as the patient canceled each object in the array. Total stimulation time for most patients to readily complete the task was approximately 20 to 30 seconds, which is significantly longer than the mean duration used during DES (4 seconds). The completion of each task was signaled by the patient's verbal confirmation. Cortical and subcortical sites involved with

visuospatial processing were identified in 3 of the patients and confirmed using the line bisection task. Complete visuospatial function mapping was completed in less than 10 minutes in all patients with no patients with postoperative UN.

It is interesting to note that stimulation of the frontal eye field, a cortical area between the superior and middle frontal gyri, could induce an ocular deviation and then a line bisection deviation, independently to any spatial neglect. Finally, it is now widely recognized that these tasks explore only 1 compound of UN, and that they identify different anatomical structures. There is still a need for a more global

task of the visuospatial cognition, more suitable to awake craniotomy conditions. To this aim, our group is working on the possible application of virtual reality.¹²

SOCIAL COGNITION

Semiology

The social cognition includes all processes involved in social interaction such as nonverbal language, empathy, and TOM. Nonverbal communication represents two-thirds of all communication. Facial emotion recognition is considered as one of the most important forms of communication, particularly in children, for whom facial expressions rather than words are the major vector of communication. Another important nonverbal cue is the prosody, that is, the intonation in speech, typically conveyed and interpreted through changes in pitch, rhythm, or loudness. Emotional prosody, processed in the nondominant hemisphere, is the ability to produce or comprehend the emotion conveyed by the prosody, providing information about the interlocutor's emotional state. It differs from linguistic prosody, involved in the distinction between a sentence, a statement, and a question. Damage of the structures supporting the prosody leads to an aprosodia, characterized by the inability of a person to properly convey or interpret emotional prosody. This leads to communicative deficits in understanding nonverbal cues with a severe impairment of the understanding of humor, metaphors, sarcasm interpretation but also in advanced language abilities such as narrative skills.⁴⁵

Empathy is the ability to share someone else's feelings at different levels with the affective ("I feel what you feel") and cognitive ("I understand what you feel") components. The latter is related to TOM. TOM is an important aspect of social cognition and corresponds with the ability to make inferences about one's own and other people's mental states in terms of thoughts, intentions, desires, and beliefs. Decoding nonverbal cues, such as facial expression, eye gaze, body gestures, and complex abstract reasoning about verbal information, enables TOM. Impairment of TOM leads to mind blindness, with difficulties to conceptualize, understand, or

predict knowledge, thoughts and beliefs, emotions, feelings and desires, behavior, actions, and intentions of another person. TOM is particularly impaired in autism and other related diseases.

Tasks and Per Operative Mapping: Facial Emotion Recognition

Despite the importance of perceiving and recognizing facial expressions in everyday life, there is no comprehensive test battery.⁴⁶ The most frequently used tasks for measuring the perception and identification of emotions from faces are photographs of individuals exhibiting one of the 6 primal facial emotions: anger, happiness, fear, surprise, disgust, and sadness: Ekman's faces,⁴⁷ the Brief Affect Recognition Test, and the Japanese and Caucasian Brief Affective Recognition Test (Figure 3). Each photograph was correctly judged as the intended emotion by more than 70% of observers when presented for 10 seconds. In the literature, the expressions of disgust, contempt, and fear tend to evoke lower recognition performance (72%, 58%, 53%) than sadness and joy (97%, 92%).⁴⁸ In our experience, facial emotion recognition from photographs is difficult to perform in an awake craniotomy, with an unusual rate of error, even without any DES. There are other tests less appropriate to brain mapping because there are no unequivocal and veridical solutions for the items such as the Diagnostic Analysis of Nonverbal Accuracy that presents faces that vary between pictures in their intensity levels, or the revised Reading the Mind in the Eye Test, with emotion recognition from the eye area only.

During an awake craniotomy, some attempts have been made to map the right hemispheric cortical areas involved in recognizing facial emotion, identifying elective sites in the right temporal lobe.⁷ A larger study was carried out on 18 consecutive patients with right hemispheric lesions using Ekman's faces⁸: 386 cortical sites were studied and 5 (1.30%) reproducible interference sites for facial emotion recognition were identified in 5 patients: the medial segment of the STG, the posterior segment of the STG, the posterior segment of the MTG, and 2 sites in the SMG. No selective impairment was found regarding the emotion category.

All facial emotion recognition sites were spared during surgery, and none of the patients experienced postoperative deficits in recognition of facial emotions. However, it is noteworthy that no subcortical mapping was performed.

Emotion recognition was studied in 13 patients during awake surgery being performed for removal of a left insular glioma.⁴⁹ The DES of the left insula produced a general nonsignificant decrease in emotion recognition except in disgust ($P = 0.004$). Happiness and anger were the best and the worst recognized emotion, respectively. The worst baseline performance with anger and fear could be explained with the involvement of the left temporal regions, striatum, and the connection between the striatum and the frontal lobe. In fact, this study confirms that the face network in the right hemisphere is essential for facial expression recognition, with this function being mediated by a bilateral neural network including the limbic system.^{4,50}

Tasks and Per Operative Mapping: Emotional Prosody

Emotional prosody is another important nonverbal cue involved in social cognition. As described in part I of this review, emotional prosody strongly but not exclusively activates regions in the right STG and inferior frontal gyrus in fMRI studies, and in the right middle and superior temporal cortex as well as the right supramarginal gyrus in another study.^{4,51} If emotional prosody is lateralized on the right hemisphere, linguistic prosody is processed in both hemispheres, with a left predominance.^{4,52}

At the bedside, emotional prosody is explored by test batteries consisting of asking patients to read various sentences with specific emotional indicators.⁵³ The performance of these batteries is subjectively analyzed by an expert to determine whether they are aprosodic. The complexity of these tests and their subjective interpretation explain why it is quite complex to explore the prosody during awake surgery and why there is no, to our knowledge, publication of such a procedure.

Tasks and Per Operative Mapping: Empathy and Theory of Mind

Empathy and TOM are complex processes correlating with bihemispheric

Table 1. Summary of the Visuospatial and Social Cognitive Functions Supported by the Right Hemisphere, with Their Anatomical Substrate and the Available Neuropsychological Tests at the Bedside and in Awake Craniotomy Condition

Cognitive Function and Pathology	Functional Anatomic Area (Terminologia Anatomica Gyral Definition)	Fiber Tract	Bedside Validated Neuropsychological Test	Perioperative Test Using Direct Electric Cortical Stimulation in Awake Craniotomy Condition
Visuospatial cognition	<ul style="list-style-type: none"> • Temporoparietal junction⁴ (SMG, posterior part of the STG^{42,43}) • Ventral frontal cortex⁴ (MFG, IFG¹⁵) 	<ul style="list-style-type: none"> • SLF III^{15,42-44} • IFOF²⁸ 	<ul style="list-style-type: none"> • Clock face drawing¹³ • Human form drawing • Butterfly drawing • Line bisection task¹³ • Target cancellation task 	<ul style="list-style-type: none"> • Line bisection task^{9,15,18,19,44} • Target cancellation task^{6,13}
Facial emotion recognition	<ul style="list-style-type: none"> • Temporal part of the facial network⁴ (medial and posterior part of the STG,⁸ posterior part of MTG⁸) • SMG⁸ • Left insula⁴⁹ 	<ul style="list-style-type: none"> • Uncinate fasciculus⁴ 	<ul style="list-style-type: none"> • Ekman's faces^{46,47} • BART • JACBART • DANVA • Mind in the eye test 	<ul style="list-style-type: none"> • Ekman's faces⁸ • Mind in the eyes test
Emotional prosody	<ul style="list-style-type: none"> • Emotional prosody network⁴ (SMG,⁵¹ STG,⁴ IFG⁴) • MTG⁵¹ 		<ul style="list-style-type: none"> • Test battery: reading or listening to sentences with specific emotional indicator 	<ul style="list-style-type: none"> • No perioperative test described in the literature
Empathy and theory of mind	<ul style="list-style-type: none"> • Empathy network⁴ (OFC, PFC, ACC, amygdala, angular gyrus, SMG) • Theory of mind network⁴ (OFC, PFC, angular gyrus, SMG) • Left MTG⁵⁵ • Temporal pole 	<ul style="list-style-type: none"> • Uncinate fasciculus⁵⁴ 	<ul style="list-style-type: none"> • False belief vs. photograph⁵⁵ • Trait judgment⁵⁵ • Strategic game⁵⁵ • Social animations⁵⁵ • Mind in the eye test • Rational actions⁵⁵ 	<ul style="list-style-type: none"> • Mind in the eyes test⁵⁷

There are some anatomical areas and fiber tracts involved in right hemisphere cognitive functions (as described in part I of this review⁴), which are not yet currently explored using a neuropsychological test or direct electrical stimulation. Refer to part I of this review to understand anatomical bases of this cognitive function.

ACC, anterior cingulate cortex; BART, Brief Affect Recognition Test; DANVA, diagnostic analysis of nonverbal accuracy; IFG, inferior frontal gyrus; IFOF, inferior fronto-occipital fasciculus; JACBART, Japanese and Caucasian Brief Affective Recognition Test; MTG, middle temporal gyrus; OFC, orbitofrontal cortex; PFC, prefrontal cortex; SLF III, third portion of the superior longitudinal fasciculus; SMG, supramarginal gyrus; STG, superior temporal gyrus; VFC, ventral frontal cortex.

corticolimbic activations involved in emotional cue processing, self-other/same-different discrimination, perspective taking, emotional arousal, and decision making. Attempts have been made to isolate a specific network using fMRI suggesting that TOM and empathy stimuli are associated with overlapping by distinct neuronal networks, described in part I of this review.⁴ The neural network of empathy begins to be identified by the cortical area (prefrontal cortex, orbitofrontal cortex, temporal pole, anterior insula, anterior cingulate cortex, and amygdala), particularly in the right hemisphere. Concerning the white fascicles, the critical role of the right uncinate fasciculus has been highlighted by recent studies.⁵⁴

There is also increasing evidence showing that the neural signature of TOM differs for different tasks and stimuli. For example, there is a preferential activation for false belief tasks in the angular gyrus and SMG in attention reorienting. Social animations showed strongest selective activation in the left hemisphere, specifically in the left MTG.⁵⁵ Therefore, it may now be argued that TOM should not be treated as monolithic function, but needs to be deconstructed into more basic subprocesses that allow a more specific mapping to brain areas.⁵⁶

A recent meta-analysis identified at least 6 types of tasks that are most frequently used in imaging research on TOM: false belief versus photograph, trait judgment, strategic game, social

animations, mind in the eyes, rational actions.⁵⁵ But it is important to note that there is no consensus on the content of a TOM task. These tasks need from 16 seconds to 15 minutes to be performed and answers can be ambiguous, which is not compatible with awake craniotomy conditions. Moreover, most of these tests were developed for children, and to our knowledge, very few studies address this problematic in awake craniotomy conditions with the exception of the work of Duffau et al.,⁵⁷ which reports the use of complex emotion recognition tasks to preserve the anatomical substrate of TOM. This accounts for the very high level of complexity of exploring and mapping the brain structure involved in TOM during an awake craniotomy. In

this context, the progress made in the development of virtual reality headsets allows facial expressions to be captured and transferred to a virtual avatar in real time, opening a new level of virtual human interaction that may be applied to further research for an awake craniotomy, nonverbal language, empathy, and ToM in the near future.

CONCLUSIONS

In this review, we showed that cognitive functions of the right hemisphere are essential in terms of quality of life. Thus, before resection surgery of a right-sided tumor for patients with long survival expectancy, a brain mapping should be proposed (Table 1). Part I highlighted that there is not yet a clear understanding of the cognitive right hemisphere function, and of its anatomical substrates (cortical area and white matter fascicles) because, like in the left hemisphere with language, eloquent cortical and subcortical structures involved in visuospatial and social cognition exhibit marked variability between patients. For this reason, cortical and subcortical mapping of the nondominant hemisphere should be the gold standard as it has been proposed for the dominant one. Nevertheless, the constrained environment and conditions of an awake craniotomy require the development of new neuropsychological tasks with the aim to improve the safety and quality of the surgery and allow a better understanding of the behaviorally and anatomically dissociable right hemisphere syndromes. In this context, the progress made in the development of virtual reality headsets allows facial expressions to be captured and transferred to a virtual avatar in real time, opening a new level of virtual human interaction that may be applied to characterize nonverbal language, empathy, and TOM in an awake craniotomy in the near future.⁵⁸

ACKNOWLEDGMENTS

The authors would like to thank Dr. Ghislaine Aubin, our neuropsychologist, for her involvement in awake surgery and Dr. Edouard Mazerand, one of our residents, for his participation to our facial emotion recognition test.

REFERENCES

- Carota A, Bogousslavsky J. Minor hemisphere major syndromes. *Front Neurol Neurosci*. 2018;41:1-13.
- Herbet G, Lafargue G, Moritz-Gasser S, Menjot de Champfleur N, Costi E, Bonnetblanc F, et al. A disconnection account of subjective empathy impairments in diffuse low-grade glioma patients. *Neuropsychologia*. 2015;70:165-176.
- Klein M, Duffau H, De Witt Hamer PC. Cognition and resective surgery for diffuse infiltrative glioma: an overview. *J Neurooncol*. 2012;108:309-318.
- Bernard F, Lemée J-M, Ter Minassian A, Menei P. Right hemisphere cognitive functions: from clinical and anatomic bases to brain mapping during awake craniotomy. Part I: clinical and functional anatomy [e-pub ahead of print] *World Neurosurg*. 2018. <https://doi.org/10.1016/j.wneu.2018.05.024>.
- Charras P, Herbet G, Deverdun J, de Champfleur NM, Duffau H, Bartolomeo P, et al. Functional reorganization of the attentional networks in low-grade glioma patients: a longitudinal study. *Cortex*. 2015;63:27-41.
- Conner AK, Glenn C, Burks JD, McCoy T, Bonney PA, Chema AA, et al. The use of the target cancellation task to identify eloquent visuospatial regions in awake craniotomies: technical note. *Cureus*. 2016;8:e883.
- Fried I, Mateer C, Ojemann G, Wohns R, Fedio P. Organization of visuospatial functions in human cortex. Evidence from electrical stimulation. *Brain J Neurol*. 1982;105(Pt 2):349-371.
- Giussani C, Pirillo D, Roux F-E. Mirror of the soul: a cortical stimulation study on recognition of facial emotions. *J Neurosurg*. 2010;112:520-527.
- Kitabayashi T, Nakada M, Kinoshita M, Sakurai H, Kobayashi S, Okita H, et al. [Awake surgery with line bisection task for two cases of parietal glioma in the non-dominant hemisphere]. *No Shinkei Geka*. 2012;40:1087-1093 [in Japanese].
- Kleinman JT, Sepkuty JP, Hillis AE, Lenz FA, Heidler-Gary J, Gingis L, et al. Spatial neglect during electrocortical stimulation mapping in the right hemisphere. *Epilepsia*. 2007;48:2365-2368.
- Manning L, Halligan PW, Marshall JC. Individual variation in line bisection: a study of normal subjects with application to the interpretation of visual neglect. *Neuropsychologia*. 1990;28:647-655.
- Mazerand E, Le Renard M, Hue S, Lemée J-M, Klingler E, Menei P. Intraoperative subcortical electrical mapping of the optic tract in awake surgery using a virtual reality headset. *World Neurosurg*. 2017;97:424-430.
- Plummer P, Morris ME, Dunai J. Assessment of unilateral neglect. *Phys Ther*. 2003;83:732-740.
- Rorden C, Fruhmann Berger M, Karnath H-O. Disturbed line bisection is associated with posterior brain lesions. *Brain Res*. 2006;1080:17-25.
- Roux F-E, Dufour O, Lauwers-Cances V, Boukhatem L, Brauge D, Draper L, et al. Electrostimulation mapping of spatial neglect. *Neurosurgery*. 2011;69:1218-1231.
- Sallard E, Duffau H, Bonnetblanc F. Ultra-fast recovery from right neglect after "awake surgery" for slow-growing tumor invading the left parietal area. *Neurocase*. 2012;18:80-90.
- Schenkenberg T, Bradford DC, Ajax ET. Line bisection and unilateral visual neglect in patients with neurologic impairment. *Neurology*. 1980;30:509-517.
- Talacchi A, Squintani GM, Emanuele B, Tramontano V, Santini B, Savazzi S. Intraoperative cortical mapping of visuospatial functions in parietal low-grade tumors: changing perspectives of neurophysiological mapping. *Neurosurg Focus*. 2013;34:E4.
- Vallar G, Bello L, Bricolo E, Castellano A, Casarotti A, Falini A, et al. Cerebral correlates of visuospatial neglect: a direct cerebral stimulation study. *Hum Brain Mapp*. 2014;35:1334-1350.
- Vilasboas T, Herbet G, Duffau H. Challenging the myth of right nondominant hemisphere: lessons from corticosubcortical stimulation mapping in awake surgery and surgical implications. *World Neurosurg*. 2017;103:449-456.
- Duffau H. Lessons from brain mapping in surgery for low-grade glioma: insights into associations between tumour and brain plasticity. *Lancet Neurol*. 2005;4:476-486.
- Duffau H, Sichez JP, Lehericy S. Intraoperative unmasking of brain redundant motor sites during resection of a precentral angioma: evidence using direct cortical stimulation. *Ann Neurol*. 2000;47:132-135.
- Krainik A, Duffau H, Capelle L, Cornu P, Boch AL, Mangin JF, et al. Role of the healthy hemisphere in recovery after resection of the supplementary motor area. *Neurology*. 2004;62:1323-1332.
- Duffau H. The huge plastic potential of adult brain and the role of connectomics: new insights provided by serial mappings in glioma surgery. *Cortex*. 2014;58:325-337.
- Duffau H. A two-level model of interindividual anatomo-functional variability of the brain and its implications for neurosurgery. *Cortex*. 2017;86:303-313.
- Duffau H, Lopes M, Arthuis F, Bitar A, Sichez JP, Van Effenterre R, et al. Contribution of intraoperative electrical stimulations in surgery of low grade gliomas: a comparative study between two series without (1985-96) and with (1996-2003) functional mapping in the same institution. *J Neurol Neurosurg Psychiatry*. 2005;76:845-851.
- Duffau H, Capelle L, Denvil D, Sichez N, Gatignol P, Taillandier L, et al. Usefulness of intraoperative electrical subcortical mapping during surgery for low-grade gliomas located within eloquent brain regions: functional results in a consecutive series of 103 patients. *J Neurosurg*. 2003;98:764-778.
- Teixidor P, Gatignol P, Leroy M, Masuet-Aumatell C, Capelle L, Duffau H. Assessment of verbal working memory before and after surgery

- for low-grade glioma. *J Neurooncol.* 2007;81:305-313.
29. Della Puppa A, De Pellegrin S, d'Avella E, Gioffrè G, Munari M, Saladini M, et al. Right parietal cortex and calculation processing: intra-operative functional mapping of multiplication and addition in patients affected by a brain tumor. *J Neurosurg.* 2013;119:1107-1111.
 30. Della Puppa A, De Pellegrin S, Lazzarini A, Gioffrè G, Rustemi O, Cagnin A, et al. Subcortical mapping of calculation processing in the right parietal lobe. *J Neurosurg.* 2015;122:1038-1041.
 31. Herbet G, Moritz-Gasser S, Duffau H. Direct evidence for the contributive role of the right inferior fronto-occipital fasciculus in non-verbal semantic cognition. *Brain Struct Funct.* 2017;222:1597-1610.
 32. Rech F, Herbet G, Moritz-Gasser S, Duffau H. Somatotopic organization of the white matter tracts underpinning motor control in humans: an electrical stimulation study. *Brain Struct Funct.* 2016;221:3743-3753.
 33. Schucht P, Moritz-Gasser S, Herbet G, Raabe A, Duffau H. Subcortical electrostimulation to identify network subserving motor control. *Hum Brain Mapp.* 2013;34:3023-3030.
 34. Halligan PW, Marshall JC. Left visuo-spatial neglect: a meaningless entity? *Cortex.* 1992;28:525-535.
 35. Pizzamiglio L, Vallar G, Doricchi F. Gravity and hemineglect. *Neuroreport.* 1995;7:370-371.
 36. Karnath HO, Ferber S, Himmelbach M. Spatial awareness is a function of the temporal not the posterior parietal lobe. *Nature.* 2001;411:950-953.
 37. Binder J, Marshall R, Lazar R, Benjamin J, Mohr JP. Distinct syndromes of hemineglect. *Arch Neurol.* 1992;49:1187-1194.
 38. Karnath H-O, Rorden C. The anatomy of spatial neglect. *Neuropsychologia.* 2012;50:1010-1017.
 39. Verdon V, Schwartz S, Lovblad K-O, Hauert C-A, Vuilleumier P. Neuroanatomy of hemispatial neglect and its functional components: a study using voxel-based lesion-symptom mapping. *Brain.* 2010;133(Pt 3):880-894.
 40. Mort DJ, Malhotra P, Mannan SK, Rorden C, Pambakian A, Kennard C, et al. The anatomy of visual neglect. *Brain.* 2003;126(Pt 9):1986-1997.
 41. Chechlacz M, Rotshtein P, Humphreys GW. Neuroanatomical dissections of unilateral visual neglect symptoms: ALE meta-analysis of lesion-symptom mapping. *Front Hum Neurosci.* 2012;6:230.
 42. Bartolomeo P, Thiebaut de Schotten M, Duffau H. Mapping of visuospatial functions during brain surgery: a new tool to prevent unilateral spatial neglect. *Neurosurgery.* 2007;61:E1340.
 43. Thiebaut de Schotten M, Urbanski M, Duffau H, Volle E, Lévy R, Dubois B, et al. Direct evidence for a parietal-frontal pathway subserving spatial awareness in humans. *Science.* 2005;309:2226-2228.
 44. Herbet G, Yordanova YN, Duffau H. Left spatial neglect evoked by electrostimulation of the right inferior fronto-occipital fasciculus. *Brain Topogr.* 2017;30:747-756.
 45. Lehman Blake M, Frymark T, Venedictov R. An evidence-based systematic review on communication treatments for individuals with right hemisphere brain damage. *Am J Speech Lang Pathol.* 2013;22:146-160.
 46. Wilhelm O, Hildebrandt A, Manske K, Schacht A, Sommer W. Test battery for measuring the perception and recognition of facial expressions of emotion. *Front Psychol.* 2014;5:404.
 47. Ekman P, Friesen WV. Constants across cultures in the face and emotion. *J Pers Soc Psychol.* 1971;17:124-129.
 48. Wells LJ, Gillespie SM, Rotshtein P. Identification of emotional facial expressions: effects of expression, intensity, and sex on eye gaze. *PLoS One.* 2016;11. e0168307.
 49. Papagno C, Pisoni A, Mattavelli G, Casarotti A, Comi A, Fumagalli F, et al. Specific disgust processing in the left insula: new evidence from direct electrical stimulation. *Neuropsychologia.* 2016;84:29-35.
 50. Zhao K, Zhao J, Zhang M, Cui Q, Fu X. Neural responses to rapid facial expressions of fear and surprise. *Front Psychol.* 2017;8:761.
 51. Zhang D, Zhou Y, Hou X, Cui Y, Zhou C. Discrimination of emotional prosodies in human neonates: a pilot fNIRS study. *Neurosci Lett.* 2017;658:62-66.
 52. Kreitewolf J, Friederici AD, von Kriegstein K. Hemispheric lateralization of linguistic prosody recognition in comparison to speech and speaker recognition. *NeuroImage.* 2014;102(Pt 2):332-344.
 53. Ross ED, Monnot M. Affective prosody: what do comprehension errors tell us about hemispheric lateralization of emotions, sex and aging effects, and the role of cognitive appraisal. *Neuropsychologia.* 2011;49:866-877.
 54. Oishi K, Faria AV, Hsu J, Tippett D, Mori S, Hillis AE. Critical role of the right uncinate fasciculus in emotional empathy. *Ann Neurol.* 2015;77:68-74.
 55. Schurz M, Tholen MG, Perner J, Mars RB, Sallet J. Specifying the brain anatomy underlying temporoparietal junction activations for theory of mind: a review using probabilistic atlases from different imaging modalities. *Hum Brain Mapp.* 2017;38:4788-4805.
 56. Schaafsma SM, Pfaff DW, Spunt RP, Adolphs R. Deconstructing and reconstructing theory of mind. *Trends Cogn Sci.* 2015;19:65-72.
 57. Herbet G, Lafargue G, Moritz-Gasser S, Bonnetblanc F, Duffau H. Interfering with the neural activity of mirror-related frontal areas impairs mentalistic inferences. *Brain Struct Funct.* 2015;220:2159-2169.
 58. Bernard F, Lemée J-M, Aubin G, Ter Minassian A, Menei P. Using a virtual reality social network during awake craniotomy to map social cognition: prospective trial. *J Med Internet Res.* 2018;20. e10332.

Conflict of interest statement: The authors declare that the article content was composed in the absence of any commercial or financial relationships that could be construed as a potential conflict of interest.

Received 16 February 2018; accepted 11 July 2018

Citation: World Neurosurg. (2018).

<https://doi.org/10.1016/j.wneu.2018.07.099>

Journal homepage: www.WORLDNEUROSURGERY.org

Available online: www.sciencedirect.com

1878-8750/\$ - see front matter © 2018 Elsevier Inc. All rights reserved.

2. Anatomie des fibres blanches cérébrales. Le débat concernant la distinction entre SLF III et faisceau arqué

❖ Article n°3 :

Anatomical variability of the arcuate fasciculus: a systematical review

Bernard F, Zemmoura I, Ter Minassian A, Lemée JM, Menei P

Surgical and Radiological Anatomy, (publié IF= 1,039)



Anatomical variability of the arcuate fasciculus: a systematical review

Florian Bernard^{1,2} · Ilyess Zemmoura^{3,4} · Aram Ter Minassian^{5,6} · Jean-Michel Lemée^{1,7} · Philippe Menei^{1,7}

Received: 27 December 2018 / Accepted: 17 April 2019
© Springer-Verlag France SAS, part of Springer Nature 2019

Abstract

Purpose The arcuate fasciculus (AF) is a white matter fibers tract that links the lateral temporal with the frontal cortex. The AF can be divided into three components: two superficial indirect short tracts (anterior and posterior) and one deep direct long tract. Both DTI and white matter dissections studies find differences regarding the anatomy of the AF, especially its cortical connections. This paper aims at providing a comprehensive anatomical classification of the AF, using the *terminologia anatomica*.

Methods Articles ($n = 478$) were obtained from a systematical PRISMA review. Studies which focused on primates, unhealthy subjects, as well as studies without cortical termination description and review articles were excluded from the analysis. One hundred and ten articles were retained for full-text examination, of which 19 finally fulfilled our criteria to be included in this review.

Results We classified main descriptions and variations of each segment of the AF according to fiber orientation and cortical connections. Three types of connections were depicted for each segment of the AF. Concerning the anterior segment, most of the frontal fibers (59.35%) ran from the ventral portion of the precentral gyrus and the posterior part of the pars opercularis, to the supramarginal gyrus (85.0%). Main fibers of the posterior segment of the AF ran from the posterior portion of the middle temporal gyrus (100%) to the angular gyrus (92.0%). In main descriptions of the long segment of the AF, fibers ran from both the ventral portion of the precentral gyrus and posterior part of the pars opercularis (63.9%) to the middle and inferior temporal gyrus (60.3%). Minor subtypes were described in detail in the article.

Conclusion We provide a comprehensive classification of the anatomy of the AF, regarding the orientation and cortical connections of its fibers. Although fiber orientation is very consistent, cortical endings of the AF may be different from one study to another, or from one individual to another which is a key element to understand the anatomical basis of current models of language or to guide intraoperative stimulation during awake surgery.

Keywords Arcuate fasciculus · Fiber dissection · Diffusion tensor imaging · Fiber tracts · Anatomy · Review

✉ Florian Bernard
bernardflorian.bf@gmail.com

- ¹ Department of Neurosurgery, Teaching Hospital, 49100 Angers, France
- ² Laboratory of Anatomy, Medical Faculty, 28 rue Roger Amsler, 49100 Angers, France
- ³ Department of Neurosurgery, CHRU de Tours, Tours, France
- ⁴ UMR1253, iBrain, Université de Tours, Inserm, Tours, France
- ⁵ Department of Reanimation, Teaching Hospital, 49100 Angers, France
- ⁶ INSERM, 1066 Department and EA7315 Team, Angers, France
- ⁷ CRCINA, UMR 1232 INSERM/CNRS and EA7315 Team, Angers, France

Introduction

Language is a complex faculty that allows us to encode, elaborate and communicate thoughts and experiences through the mediation of arbitrary symbols known as words. The coherent function of the language network and its interactions with other neurocognitive networks depend on an orderly set of interconnections, of which the arcuate fasciculus (AF) appears to be one of the most important anatomical support. From a historical perspective, definition of the AF evolved. Reil [1] was the first to identify a group of fibers running deeply into the white matter of the temporal, parietal and frontal regions located around the Sylvian fissure of each hemisphere [2]. In 1822, Burdach described in detail this system of perisylvian fibers and

named it the *Fasciculus Arcuatus*, due to the arching shape of its longest fibers [3]. Dejerine believed that the AF was mainly composed of short associative fibers connecting neighbouring gyri of the perisylvian cortical areas. It was Constantin Von Monakow who first identified the arcuate fasciculus as the tract connecting Broca's and Wernicke's areas [4, 5].

In recent decades, the anatomy of the AF has been studied using both fiber dissections and diffusion tensor imaging (DTI). The AF is a white matter fibers tract that links the lateral temporal with the frontal cortex via a projection that arches around the Sylvian fissure [6–8]. The AF can be divided into three different segments: two superficial indirect short tracts (anterior and posterior) and one deep direct long tract (Fig. 1). Examining the literature, we note that there are discrepancies between anatomical descriptions of the AF in DTI and white matter dissections studies. Indeed, the precise course and cortical connections of the AF are variably described [9–12]. Moreover, several models of AF connectivity exist in the contemporary literature. Because of the lack of consensus in anatomical nomenclature, understanding AF descriptions in anatomical and functional MRI studies may be difficult. In this systematical review, we replace the old fashioned terms with more precise anatomical definitions, using the standardized *terminologia anatomica* nomenclature. The aim of this systematical PRISMA (Preferred Reporting Items for Systematic Reviews

and Meta-Analyses) review was to standardize the AF anatomical description, so as to better understand its variations.

Methods

Data were compiled and categorized based on the PRISMA study design [13]. A total of 478 articles were obtained from a systematic search of English-language literature using MEDLINE (1946–December 2017) and EMBASE Classic (1947–December 2017), the cited references of the selected articles, and the “search cited” feature of PubMed. A focus was placed on anatomical and laboratory papers that assessed AF fiber orientation and cortical origin/terminations using both fiber dissection and DTI study. The search was limited to tractography and fiber dissection studies involving only humans. Studies which focused on primates, unhealthy subjects as well as studies without cortical termination description, and review articles were excluded from the analysis.

After examination of the abstracts, based on the inclusion and exclusion criteria, 110 articles were retained for full-text examination, of which 19 finally fulfilled our criteria to be included in this review. Articles of interest must have reported the precise description of orientation, origin/termination of AF. Figure 2 is a PRISMA flow diagram, which illustrates the number of articles at each data acquisition

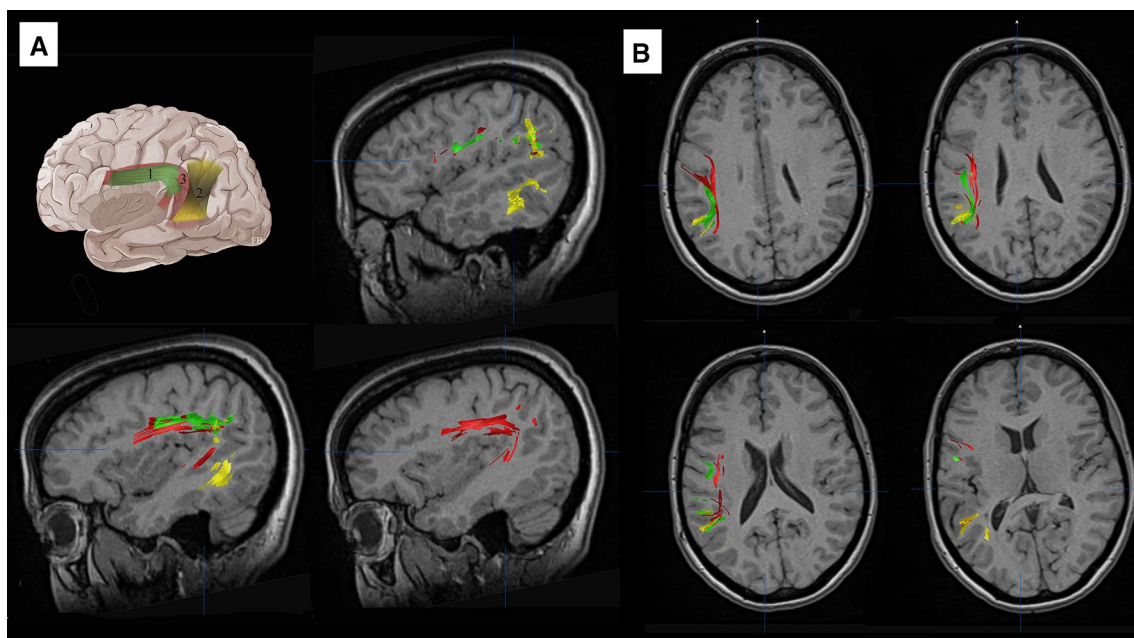


Fig. 1 Arcuate fasciculus segmentation (**a** sagittal slices; **b** horizontal slices). The arcuate fasciculus is divided in two superficial parts and one deep part. The anterior indirect segment (green) runs from the ventral portion of the precentral gyrus and the posterior part of the pars opercularis, to the supramarginal gyrus. The posterior indirect

segment of the AF (yellow) runs from the middle temporal gyrus to the angular gyrus. The long segment of the AF (red), fibers run from both the ventral portion of the precentral gyrus and posterior part of the pars opercularis to the middle and inferior temporal gyrus, deeper than superficial indirect segment (color figure online)

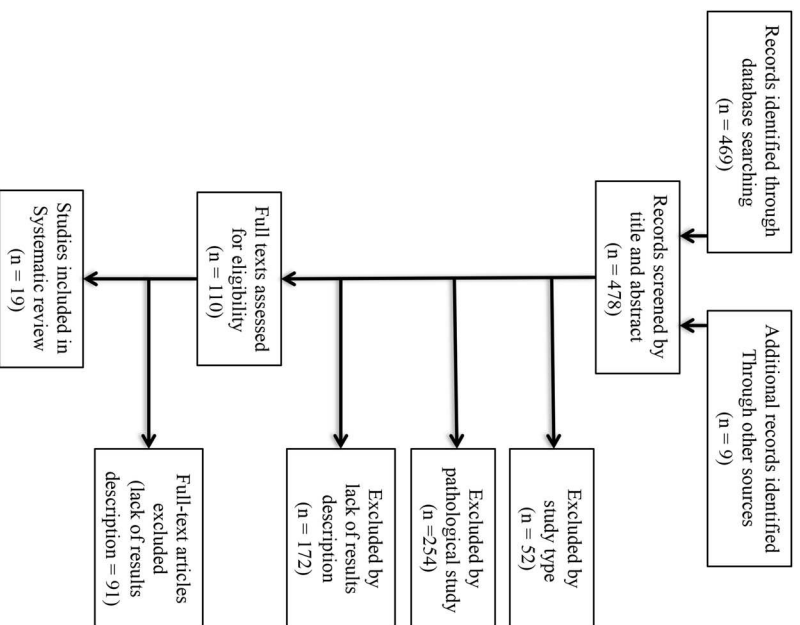


Fig. 2 A PRISMA flow diagram showing the flow of information through the different phases of the systematic review

level, the number of excluded articles, and the reasons for exclusion. Cortical connections were assessed using the study of Destrieux et al. according to the *terminologia anatomica* [14].

Results

The AF could be divided into three segments: two superficial indirect short tracts (anterior and posterior) and one deep direct long tract (Fig. 1, Table 1). We classified main descriptions of each segment regarding fiber orientation and cortical connections (origin/terminations) as *type (1)* and variations as *types (2) and (3)* (Fig. 3).

Anterior indirect segment of the AF (Figs. 1, 3a, Tables 1, 2, 3)

Main description (*type (1)*)

The fibers of this portion of the AF have a horizontal orientation. Many of the frontal fibers (*anterior termination*, 59.35%) course from the ventral portion of the precentral gyrus, and the posterior part of the pars opercularis, to

Table 1 Major variations of the arcuate fasciculus (AF) in the literature review

	AF anterior indirect segment		AF posterior indirect segment		AF direct segment	
	Anterior termination	Posterior termination	Ventral termination	Dorsal termination	Anterior termination	Posterior termination
Classical description type 1	The ventral portion of the precentral gyrus and the posterior part of the pars opercularis (59.35%)	Supramarginal gyrus (85.0%)	Posterior middle temporal gyrus (100%)	Angular gyrus (92.0%)	The ventral portion of the precentral gyrus and the posterior part of the pars opercularis (63.9%)	Middle and inferior temporal gyrus (60.3%)
Variation type 2	Ventral portion of the precentral gyrus (32.45%)	Supramarginal gyrus and posterior part of the superior temporal gyrus (15.0%)	–	Angular gyrus and the middle occipital gyrus (7.8%)	Posterior middle frontal gyrus (21.4%)	Middle temporal gyrus (38.5%)
Variation type 3	Pars opercularis (8.2%)	–	–	Angular gyrus, the supramarginal gyrus and the inferior portion of the superior parietal lobe (0.2%)	Pars triangularis (14.7%)	Inferior temporal gyrus (1.2%)

Percentages refer to the cortical distributions based on the literature review

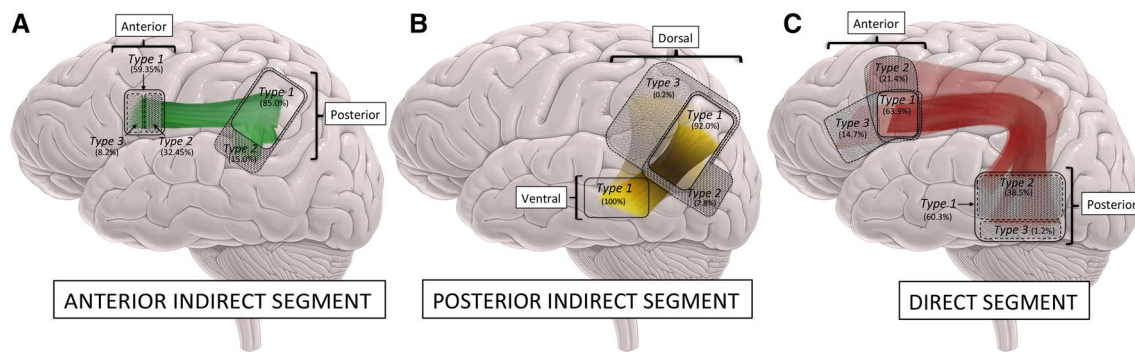


Fig. 3 Schematic representation of main cortical distributions of each AF segment according to our classification. **A** Anterior indirect segment of the AF, **B** posterior indirect segment of the AF, **C** direct long

segment of the AF. *Type 1*: main description; *type 2*: most frequent variation described; *type 3*: rarest variation described

Table 2 Literature review of the cortical distributions of the anterior indirect segment of AF-anterior termination

Anterior indirect segment of AF-anterior termination	PCG (Vent.)	PCG (Vent.), IFG (Pars op.)	IFG (pars op.)	NA	Number of hemispheres studied
Ture et al. [8]			40		40
Nucifora et al. [54]				54	54
Catani et al. [28]		11			11
Makris et al. [47]		10			10
Powell et al. [30]	20				20
Catani et al. [33]		100			100
Vernooij et al. [31]	40				40
Glasser et al. [41]				16	16
Catani et al. [2]		24			24
Fernández-Miranda et al. [6]		30			30
Kaplan et al. [55]				16	16
Thiebaut de Schotten et al. [50]				80	80
Martino et al. [40]	10	2		7	19
De Benedictis et al. [56]	8				8
Fernandez Miranda et al. [37]		72			72
Kamali et al. [57]	10				10
Wang et al. [58]				24	24
Yamurglu et al. [11]	70				70
Gungör et al. [59]			40		40
Total	158 (32.45%)	289 (59.35%)	40 (8.2%)	197	684

PCG (Vent.): precentral gyrus in its ventral part. IFG (Pars op.): pars opercularis of the inferior frontal gyrus

NA not assessed

the supramarginal gyrus (*posterior termination*, 85.0%). Variations: regarding the variations in *anterior cortical connections* of this tract (Fig. 3a, Tables 1, 2), there are two types of description. First, an exclusive connection with the ventral portion of the precentral gyrus, which was mostly described in recent DTI tractography studies (*type* (2), 32.45%); Second, an exclusive connection with the

posterior portion of the pars opercularis (*type* (3), 8.2%). Regarding the *posterior cortical connections* of this tract (Fig. 3a, Tables 1 and 3) two types are described: exclusive connection to the supramarginal gyrus (*type* (1), 85.0%) and to both the supramarginal gyrus and posterior part of the superior temporal gyrus (in the region just posterior to the Heschl's gyrus) (*type* (2), 15.0%).

Table 3 Literature review of the cortical distributions of the anterior indirect segment of AF-posterior termination

Anterior indirect segment of AF-posterior termination	SMG	SMG, STG (Post)	IPL	NA	Number of hemispheres studied
Ture et al. [8]			40		40
Nucifora et al. [54]				54	54
Catani et al. [28]			11		11
Makris et al. [47]	10				10
Powell et al. [30]		20			20
Catani et al. [33]			100		100
Vernooij et al. [31]		40			40
Glasser et al. [41]			24		24
Catani et al. [2]				16	16
Fernández-Miranda et al. [6]			30		30
Kaplan et al. [55]				16	16
Thiebaut de Schotten et al. [50]				80	80
Martino et al. [40]	4	14		1	19
De Benedictis et al. [56]	10				10
Fernandez Miranda et al. [37]			72		72
Kamali et al. [57]			8		8
Wang et al. [58]				24	24
Yamurglu et al. [11]	70				70
Gungör et al. [59]	40				40
Total	134 (27.2%)	74 (15.0%)	285 (57.8%)	191	684

IPL inferior parietal lobule, NA not assessed, SMG supramarginal gyrus. STG (Post): superior temporal gyrus in its posterior part

Posterior indirect segment of the AF (Figs. 1, 3b, Tables 1, 4 and 5)

Main description (type 1))

The fibers of this portion of the AF have a vertical orientation that run laterally to the AF direct long segment, from the posterior part of the middle temporal gyrus (*ventral cortical connection*, 100%) to the angular gyrus (*dorsal cortical connection*, 92.0%). Variations: The *ventral cortical connection* of this bundle (Tables 1, 4, Fig. 3b) is in all cases the posterior portion of the middle temporal gyrus (100%). There was no variation described in the literature. Regarding the *dorsal cortical connection* of this tract (Tables 1, 5, Fig. 3b), (*type 2*) is a connection with both the angular gyrus and the middle occipital gyrus (7.8%), and (*type 3*) corresponds to a projection to the angular gyrus, the supramarginal gyrus and the inferior portion of the superior parietal lobe (0.2%).

Long/deep/direct segment of the AF (Figs. 1, 3c, Tables 1, 6 and 7).

Main description (type 1))

The long segment is a long white matter tract located at the deep aspect of the anterior and posterior indirect segments

of the AF. During fiber dissections, after lifting these two superficial indirect connections, the lateral surface of the long segment of the AF is completely exposed. The posterior portion of the long segment fibers of the AF has a vertical orientation within the temporal lobe. Here, AF fibers run laterally and perpendicularly to the fibers of the sagittal stratum (i.e. the densely packed fibers located on the lateral surface of the ventricular atrium and composed of the optic radiations, inferior fronto-occipital fasciculus and tapetum), which have a horizontal orientation. The AF fibers curve around the caudal limit of the insula to take a horizontal direction. The fibers then run within the white matter of the parietal and frontal operculum.

The long segment of the AF has *anterior cortical connections* to the ventral portion of the precentral gyrus and to the posterior portion of the inferior frontal gyrus (pars opercularis) (63.9%), and *posterior cortical connections* to both the middle and inferior temporal gyrus (60.3%).

Variations: The *anterior terminations* of this bundle can connect to the posterior middle frontal gyrus (*type 2*), 21.4%) or to the pars triangularis (*type 3*), 14.7%), while the *posterior terminations* can connect exclusively to the middle temporal gyrus (*type 2*), 38.5%) or exclusively to the inferior temporal gyrus (*type 3*), 1.2%). In our review, connections of the long segment of the AF to the superior temporal gyrus were not identified either in major fiber dissection or

Table 4 Literature review of the cortical distributions of the posterior indirect segment of AF-ventral termination

Posterior indirect segment of AF-ventral termination	MTG (Post)	NA	Number of hemispheres studied
Ture et al. [8]	40		40
Nucifora et al. [54]		54	54
Catani et al. [28]	11		11
Makris et al. [47]	10		10
Powell et al. [30]		20	20
Catani et al. [33]	100		100
Vernooij et al. [31]		40	40
Glasser et al. [41]		16	16
Catani et al. [2]	24		24
Juan C. Fernández-Miranda et al. [6]	30		30
Kaplan et al. [55]		16	16
Thiebaut de Schotten et al. [50]		80	80
Martino et al. [40]	13	6	19
De Benedictis et al. [56]	8		8
Fernandez Miranda et al. [37]	72		72
Kamali et al. [57]	10		10
Wang et al. [58]		24	24
Yamurglu et al. [11]	70		70
Gungör et al. [59]		40	40
Total	388 (100%)	296	684

MTG middle temporal gyrus, NA not assessed

in DTI tractography. As previously shown, in some studies the fibers from the superior temporal gyrus converged into the anterior-horizontal segment of the AF.

Discussion

In this systematical PRISMA review, we provide a comprehensive classification of the AF segments regarding the orientation and cortical connections of their fibers. Although fiber orientation is not subject to variation, cortical endings of the AF may be different from one study to another, or from one individual to another.

Nomenclature

From a historical perspective, anatomical nomenclature of the AF evolved. The SLF/AF pathway has dominated the study of the white matter connectivity of language for two centuries. Until the later part of the twentieth century, the AF and superior longitudinal fasciculus (SLF) were considered to be part of the same fasciculus—with non-dissociable fibers called SLF/AF—connecting the posterior superior

temporal gyrus (Wernicke’s area) to the inferior frontal gyrus (Broca’s area) [15].

Indeed, the early understanding of the SLF/AF originates from Burdach [16], and appears prominently in the major anatomical works of the nineteenth century (Mayo [17]; Meynert [18]; Wernicke [19]; Barker [20]), especially the two volumes by Déjèrine [21, 22]). Like those before him, Déjèrine [21] does not dissociate the superior longitudinal fasciculus and arcuate fasciculus fibers, calling the “faisceau longitudinal supérieur ou fasciculus arcuatus de Burdach”. Similarly, Meynert [18] makes mention of the arcuate fasciculus, but no mention of the superior longitudinal fasciculus, and Wernicke [19] treats the superior longitudinal fasciculus and arcuate fasciculus as the same pathway (the “superior longitudinal bundle, or arcuate bundle”). In the same way, Paturet and Bellocq [23], described as synonymous “the superior longitudinal fasciculus or fasciculus arcuatus”; This author described the SLF/AF as composed of two kinds of fibers; (1) superficial, short, rectilinear fronto-occipital fibers; (2) And the longer, arcuate deep fronto-temporal fibers. In his 1970 publication, Geschwind depicted the arcuate fasciculus connecting Broca’s area (i.e. the posterior part of the inferior frontal gyrus) with Wernicke’s area (in the posterior superior temporal cortex). The course of the SLF/AF pathway has remained relatively unchallenged since Geschwind reasserted its prominence for language. Geschwind also attached prominence to the arcuate fasciculus terminology with less emphasis on the superior longitudinal fasciculus terminology.

Since Geschwind, a number of divergent and sometimes conflicting descriptions of the SLF/AF fibre pathway have emerged. It is only recently that there have been some attempts to dissociate parts of the SLF/AF, and generally these promote the notion that the arcuate fasciculus represents a partition of a broader superior longitudinal fasciculus. Studies in non-human primates have divided the SLF/AF into four separate components: SLF I, SLF II, SLF III, and AF [7, 24]. SLF and AF are considered currently as completely different tracts: the SLF (I, II, III) is a fronto-parietal tract while the AF is a perisylvian tract that connects frontal-parietal-temporal areas [11, 15, 24]. Anatomically, only the macaque’s SLF III and the “human” anterior indirect segment of the AF may have a correspondence [7, 24].

Inter-individual variations

According to our results, investigation of the structural connectivity of the AF revealed numerous cortical connections. Inter-individual variations in patterns of structural connectivity probably contributed to the inconsistencies in the cortical terminations reported in the literature. Although variability in the position of white matter fascicles can be explained by gross anatomical variability in

Table 5 Literature review of the cortical distributions of the posterior indirect segment of AF-dorsal termination

Posterior indirect segment of AF-dorsal termination	AG	AG, MOG	AG, SMG, SPL	NA	Number of hemispheres studied
Ture et al. [8]	40				40
Nucifora et al. [54]				54	54
Catani et al. [28]	11				11
Makris et al. [47]	10				10
Powell et al. [30]				20	20
Catani et al. [33]	100				100
Vernooij et al. [31]				40	40
Glasser et al. [41]				16	16
Catani et al. [2]	16	8			24
Fernández-Miranda et al. [6]	30				30
Kaplan et al. [55]				16	16
Thiebaut de Schotten et al. [50]				80	80
Martino et al. [40]	12		1	6	19
De Benedictis et al. [56]	8				8
Fernandez Miranda et al. [37]	72				72
Kamali et al. [57]	10				10
Wang et al. [58]		24			24
Yamurglu et al. [11]	70				70
Gungör et al. [59]				40	40
Total	379 (92.0%)	32 (7.8%)	1 (0.2%)	272	684

AG angular gyrus, MOG middle occipital gyrus, NA not assessed, SMG supramarginal gyrus, SPL superior parietal lobule

Table 6 Literature review of the cortical distributions of the direct segment of AF- anterior connection

Direct segment of AF-anterior connection	PCG (Vent), IFG (Pars op.)	PCG (Vent), IFG (Pars op.), MFG (Post)	PCG (Vent), IFG (Pars op.), IFG (Pars tri.)	NA	Number of hemispheres
Ture et al. [8]	40				40
Nucifora et al. [54]				54	54
Catani et al. [28]	11				11
Makris et al. [47]	10				10
Powell et al. [30]	20				20
Catani et al. [33]	68			32	100
Vernooij et al. [31]	40				40
Glasser et al. [41]	16				16
Catani et al. [2]	24				24
Fernández-Miranda et al. [6]	30				30
Kaplan et al. [55]	13		2	1	16
Thiebaut de Schotten et al. [50]				80	80
Martino et al. [40]	3		9	7	19
De Benedictis et al. [56]		8			8
Fernandez Miranda et al. [37]		43	29		72
Kamali et al. [57]	10				10
Wang et al. [58]	9		15		24
Yamurglu et al. [11]	32	18	20		70
Gungör et al. [59]		40			40
Total	326 (63.9%)	109 (21.4%)	75 (14.7%)	174	684

IFG (Pars op.) pars opercularis of the inferior frontal gyrus, IFG (Pars tri.) pars triangularis of the inferior frontal gyrus, MFG (POST) posterior part of the middle frontal gyrus, NA not assessed, PCG (Vent.) precentral gyrus in its ventral part

Table 7 Literature review of the cortical distributions of the direct segment of AF-posterior connection

Direct segment of AF-posterior connection	MTG (MID), ITG (Post)	MTG (Post)	ITG (Post)	NA	Number of hemispheres studied
Ture et al. [8]	40				40
Nucifora et al. [54]				54	54
Catani et al. [28]		11			11
Makris et al. 2005 [47]		10			10
Powell et al. [30]	20				20
Catani et al. [33]		68		32	100
Vernooij et al. [31]	40				40
Glasser et al. [41]		16			16
Catani et al. [2]		24			24
Fernández-Miranda et al. [6]		30			30
Kaplan et al. [55]				16	16
Thiebaut de Schotten et al. [50]				80	80
Martino et al. [40]	12		6	1	19
De Benedictis et al. [56]	8				8
Fernandez Miranda et al. [37]	72				72
Kamali et al. [57]		10			10
Wang et al. [58]		24			24
Yamurglu et al. [11]	70				70
Gungör et al. [59]	40				40
Total	302 (60.3%)	193 (38.5%)	6 (1.2%)	183	684

ITG (POST) posterior part of the inferior temporal gyrus, *MTG (MID)* middle part of the middle temporal gyrus, *NA* not assessed

brain size and shape [25], heterogeneity in connectivity patterns may represent something more organizational. Some individual variations may be related to inheritance while others may be the result, for instance, of gender, normal aging, experiential learning or development of new skills [25]. From a clinical point of view, knowledge of the anatomical variability of white matter fascicles in the normal population is of prime importance for neurosurgical planning. It is also fundamental to determine the clinical correlates of a lesion, and this could help gain a deeper understanding of the mechanisms underpinning brain plasticity and recovery of functions [26]. However, no imaging method makes it possible to know perfectly the fibers anatomy and to correlate it, at the individual level, with the language functions. Moreover no imaging method predict the recovery capacities of a patient in case of partial lesion of the arcuate fasciculus [27]. It is for this reason that individual brain mapping by direct electric stimulation during awake craniotomy remains essential in the hope to preserve language. Nevertheless, a better understanding of anatomical bases allows neurosurgeons to better appreciate the functional anatomy of the perisylvian region and its application to tumor surgery that is a prerequisite to perform an awake brain surgery.

Asymmetry of the AF

Over the last decade, DTI studies have revealed a significant leftward asymmetry of the long direct segment of the AF providing new insights into the connectivity of the AF and its assumed major functional role in language processing [28–31]. However, in the right hemisphere, the cortical areas and white matter fascicles involved in visuo-spatial and social cognition are almost symmetrical to those involved in language with a perisylvian network [32]. The occurrence of the AF in the right hemisphere is still a matter of debate. Some authors reported its presence in only 40% of their subjects [33], and others reported it in all (for instance, all 12 right-handed subjects in Gharabaghi's study) [34]. However, most postmortem fiber dissection studies do not report a significant difference between the left and right AF, neither in terms of cortical connections [11], nor of fascicles volumes [11, 35, 36]. Hence, anatomically, the white matter structure could be considered mostly symmetrical.

Implication to DTI-based models of language

Referring to the cortical origin/termination using the *terminologia anatomica* facilitates the understanding of current

models of language. Indeed, there is currently no consensus on the anatomical definition of the extent and precise location of language areas and networks. Moreover, many labels are used to describe the same regions of activation in functional MRI (e.g. ventral frontal cortex, premotor ventral cortex, pars opercularis, inferior frontal gyrus). In a bid to explain language faculty, authors have provided different DTI-based models exploring its functional connectivity.

Direct and indirects AF segmentation

Catani et al. [28], proposed a DTI-based classification for the AF, separating the fascicle into two superficial indirect and one deep long segments. The indirect segment of the AF has been divided into an anterior one (frontoparietal) and a posterior one (temporoparietal) regarding the distinct orientation and cortical connections of their fibers, as shown in our review (Fig. 3). Some cadaveric studies have replicated this AF compartmentalization of the superficial fibers (AF indirect segments) into anterior and posterior segments of the AF [6, 27, 37–40].

Superior and middle temporal pathway

Glasser and Rilling charted the superior and middle temporal gyrus pathways using DTI and functional neuro-imaging [41]. The superior temporal pathway, presumably the anterior indirect AF, connects the inferior frontal gyrus (*anterior termination type 1–3*) to the superior temporal gyrus and goes within the supramarginal gyrus (*posterior termination type 1 and 2*) (Fig. 3). The middle temporal pathway, presumably the AF direct segment, connects the middle and inferior frontal gyri (*anterior termination type 1–3*) to the middle temporal gyrus (*posterior termination type 1 and 2*) and passes through the angular gyrus. A similar segmentation was suggested by Fernandez-Miranda et al. [37], wherein the ventral or inner pathway connects the pars opercularis to the superior temporal and rostral middle temporal gyri, and the dorsal or outer pathway connects the ventral premotor cortex and caudal middle frontal gyrus to the inferior temporal and caudal middle temporal gyri.

Dorsal and ventral pathway

Built on an analogy between the visual and auditory systems, the following dual stream model for language processing was suggested: a dorsal stream is involved in mapping sound to articulation, and a ventral stream in mapping sound to meaning [42]. The dorsal pathway connects the premotor cortices in the frontal lobe (*anterior termination type 1–3*) and the superior temporal lobe (*posterior termination type 2*) via the AF anterior indirect segment. The ventral pathway connects the ventrolateral prefrontal cortex (*anterior*

termination type 1 and 3) and the middle temporal lobe (*posterior termination type 1 and 2*) through the direct AF segment. The function of the dorsal route, traditionally considered to be the major language pathway, is mainly restricted to sensory-motor mapping of sound to articulation, whereas linguistic processing of sound to meaning requires temporo-frontal interaction transmitted via the ventral route.

Other pathways

DTI and blunt fiber dissection works conducted over the last few years have offered several alternative models of dorsal stream connectivity via the AF. According to Makris et al., the SLF III is involved in articulatory aspect of language while the AF is involved in lexical and semantical processing. Finally, Friederici et al. [43–45], suggest a model wherein two dorsal pathways connect the posterior temporal cortex to either the ventral premotor cortex or the posterior part of the inferior frontal gyrus, respectively involved in sensorimotor and syntactic processing.

Implication in intra-operative stimulation

It has been shown that stimulation of the indirect anterior AF results in anarthria or dysarthria, while stimulation of the AF direct segment results in phonological (repetition) disorder [27, 39, 40, 46, 47]. The deep loop supporting phonological disorder corresponds anatomically to the direct segment of the AF in its main description (*type 1 origin and termination*) while the superficial frontoparietal loop, which interconnects the supramarginal gyrus and the pars opercularis, corresponds anatomically to the anterior indirect segment of the AF in its main description (*type 1 anterior and posterior termination*) [7, 28, 40, 47]. In recent fiber dissections and DTI analysis, the AF indirect anterior and AF direct segments were clearly separated along the frontoparietal operculum, the AF indirect segment being located lateral to the AF direct segment [11].

Problematics—study limitations

Both gross fiber dissection and diffusion-tensor imaging techniques present limitations that can affect the AF study of cortical connections. Very sparse and delicate groups of fibers may be difficult to dissect and partially destroyed when the neighboring white matter is removed. Imaging techniques are not limited by this destruction problem; however, they are susceptible to noise, lack of resolution, contamination from adjacent bundles, and abrupt changes in fiber direction. Moreover, there is a wide age difference between subjects studied with fiber dissection (older) and those studied with DTI tractography (usually young healthy volunteers). This may have affected the data, as white matter

connectivity may change with age. Nevertheless, the major observations were consistent across the majority of subjects studied with DTI tractography and fiber dissection.

Fiber dissection has a limited value when studying white matter connectivity in areas of crossing fibers. At the level of the frontal operculum, the fibers of the AF strongly intersect with the terminal branches of other long association fascicles (especially with the inferior fronto-occipital fasciculus (IFOF), and frontal aslant tract) and with the cortico-spinal tract. On the other hand, dissection enables the isolation of fibers up to 2 mm in diameter. Consequently, with this technique it is not possible to follow smaller branches of the AF. Moreover, in fiber dissection, extensive removal of gray matter leads to the loss of important cortical landmarks making it difficult to analyze the precise cortical terminations of a specific fiber tract. For example in Fernandez-Miranda's study [6], the cortex and superficial white matter were removed to reveal the anterior portion of the AF. Consequently, their dissection figures reveal horizontally oriented fibers located in the frontal and parietal operculum, but not the fibers projecting into the cortex [6]. This could be an explanation as to why cortex-sparing fiber dissection studies depict different cortical projections than Klingler's usual methods [48].

Even though DTI tractography has been extensively used to study white matter connectivity, it has three inherent shortcomings: (1) the first, as with fiber dissection, is the inaccuracy of this technique to map the fiber architecture in areas where the trajectories of different fibers intersect. Several diffusion imaging techniques have been developed to reduce the fiber intersecting problem. Some of these MR-based approaches "beyond the diffusion tensor" are called diffusion spectrum imaging, q-ball imaging and spherical deconvolution [49, 50] but do not completely solve the problem. (2) Secondly, there are the difficulties in distinguishing the different fascicles in areas where tracts run in parallel (e.g., the optic radiations and the fibers of the IFOF). (3) Thirdly, there is the inability to follow the terminal branches of the white matter bundles: it is only possible to infer their final cortical destinations from the location and orientation of the average tract end points. According to Zemmoura and al. [51], novel approaches to solve this problem have been suggested, such as tract reconstruction based on their anatomical termination near the gray–white matter boundary and other postmortem neuroimaging techniques such as 3D polarized light imaging [52].

Some authors may argue that direct and indirect segmentation used in this systematic review could be confusing [53]. Hence the advent of virtual dissection by diffusion MRI tractography led several authors to integrate short-distance fronto-parietal and parieto-temporal connections under the arcuate terminology. Indeed, a largely cited tractographic study introduced in 2005 the terms "direct" and "indirect" pathways to

described the temporo-parietal hub between temporo-parietal (posterior indirect segment) and parieto-frontal (anterior indirect segment) fibers [28]. As in the study of Mandonnet and al [53], the anterior indirect segment of our review corresponds to the SLF III, and the posterior indirect tract corresponds to the vertical temporo-parietal fasciculus. Whatever the taxonomy used, this review aims at collecting and harmonizing the description regarding each part of the arcuate fasciculus provided in the literature. This systematic review may help younger neuroscientist to better understand cortical terminations variations, whatever the taxonomy plebiscite in the future.

Conclusion

'In all domains, physiology has its firmest foundations in anatomy' (Brodman 1908).

Fiber dissection of postmortem human brains and DTI in vivo tractography has enabled the isolation of the three components of the AF. The following portions and cortical connections were identified: (1) the anterior indirect segment, connecting the supramarginal and superior temporal gyri with the precentral gyrus; (2) the posterior indirect segment, connecting the posterior portion of the middle temporal gyrus with the angular gyrus; and (3) the direct AF segment that connects the middle and inferior temporal gyri with the precentral and posterior portion of the inferior and middle frontal gyri. Understanding relationships between the AF and other tracts remains a challenge to better understand the complex organization of the functional processing of language in the human brain. Further study is needed to assess neuropsychological deficit using this classification, to know if inter-individual variability is correlated with subcomponents of the AF.

Author contributions FB: project development; data collection and management; data analysis; manuscript writing/editing; reviewed final version of the manuscript and approval for submission. IZ: data analysis; manuscript writing; critical revision of the article; reviewed final version of the manuscript and approval for submission. ATM: analysis and interpretation of data; critical revision of the article; reviewed final version of the manuscript and approval for submission. JML: reviewed final version of the manuscript and approval for submission. PM: project development; analysis and interpretation of data; critical revision of the article; reviewed final version of the manuscript and approval for submission.

Funding None of us disclose any financial support or industry affiliation.

Compliance with ethical standards

Conflict of interest The authors report no conflict of interest concerning the materials or methods used in this study or the findings specified in this paper.

References

1. Reil JC (1809) Untersuchungen über den Bau des grossen Gehirns im Menschen. *Arch Physiol* 9:136–208
2. Catani M, Mesulam M (2008) The arcuate fasciculus and the disconnection theme in language and aphasia: history and current state. *Cortex J Devoted Study Nerv Syst Behav* 44:953–961. <https://doi.org/10.1016/j.cortex.2008.04.002>
3. Zemmoura I, Vons J, Velut S, Destrieux C (2015) From Vesalius to tractography. *J Neurosurg Sci* 59:309–325
4. von Monakow C (1905) *Gehirnpathologie*. Alfred Hölder, Wien
5. Wiesendanger M (2006) Constantin von Monakow (1853–1930): a pioneer in interdisciplinary brain research and a humanist. *C R Biol* 329:406–418
6. Fernandez-Miranda JC, Rhoton AL, Alvarez-Linera J, Kakizawa Y, Choi C, de Oliveira EP (2008) Three-dimensional microsurgical and tractographic anatomy of the white matter of the human brain. *Neurosurgery* 62:989–1026. <https://doi.org/10.1227/01.neu.0000333767.05328.49> (**discussion 1026–1028**)
7. Schmahmann JD, Pandya DN, Wang R, Dai G, D'Arceuil HE, de Crespigny AJ, Wedeen VJ (2007) Association fibre pathways of the brain: parallel observations from diffusion spectrum imaging and autoradiography. *Brain J Neurol* 130:630–653. <https://doi.org/10.1093/brain/awl1359>
8. Türe U, Yaşargil MG, Friedman AH, Al-Mefty O (2000) Fiber dissection technique: lateral aspect of the brain. *Neurosurgery* 47:417–426 (**discussion 426–427**)
9. Bernal B, Ardila A (2009) The role of the arcuate fasciculus in conduction aphasia. *Brain J Neurol* 132:2309–2316. <https://doi.org/10.1093/brain/awp206>
10. Dick AS, Tremblay P (2012) Beyond the arcuate fasciculus: consensus and controversy in the connective anatomy of language. *Brain J Neurol* 135:3529–3550. <https://doi.org/10.1093/brain/awt222>
11. Yagmurulu K, Middlebrooks EH, Tanriover N, Rhoton AL (2016) Fiber tracts of the dorsal language stream in the human brain. *J Neurosurg* 124:1396–1405. <https://doi.org/10.3171/2015.5.JNS15455>
12. Yeatman JD, Dougherty RF, Rykhlevskaia E, Sherbondy AJ, Deutsch GK, Wandell BA, Ben-Shachar M (2011) Anatomical properties of the arcuate fasciculus predict phonological and reading skills in children. *J Cogn Neurosci* 23:3304–3317. https://doi.org/10.1162/jocn_a_00061
13. Shamsler L, Moher D, Clarke M, Ghersi D, Liberati A, Petticrew M, Shekelle P, Stewart LA, PRISMA-P Group (2015) Preferred reporting items for systematic review and meta-analysis protocols (PRISMA-P) 2015: elaboration and explanation. *BMJ* 350:g7647
14. Destrieux C, Terrier LM, Andersson F, Love SA, Cottier J-P, Duvernoy H, Velut S, Janot K, Zemmoura I (2017) A practical guide for the identification of major sulcogyral structures of the human cortex. *Brain Struct Funct* 222:2001–2015. <https://doi.org/10.1007/s00429-016-1320-z>
15. Schmahmann JD, Pandya DN (2007) Cerebral white matter—historical evolution of facts and notions concerning the organization of the fiber pathways of the brain. *J Hist Neurosci* 16:237–267. <https://doi.org/10.1080/09647040500495896>
16. Burdach KF (1826) *Vom Baue und Leben des Gehirns* (Vol. 3). Leipzig Ger Dyk'schen Buchhandlung
17. Mayo H (1827) A series of engravings intended to illustrate the structure of the brain and spinal chord in man. Burgess and Hill, Great Windmill Street
18. Meynert T (1885) *Psychiatry: clinical treatise on the diseases of the fore-brain*, trans. B Sachs N Y Lond GP Putnam
19. Wernicke C, Hahn E, Sachs H (1897) *Photographischer atlas de gehirns. Schnitte Durch Menschl Gehirn Photogr Orig Abt I—32 Front Durch Eine Grosshirn- Hemisphaü Re Breslau Schletter'schen Buchhandlung Franck Weigert*
20. Barker LF (1899) *The nervous system and its constituent neurons: designed for the use of practitioners of medicine and of students of medicine and psychology*. D. Appleton, Boston
21. Dejerine J, Dejerine-Klumpke A (1895) *Anatomie des centres nerveux: Méthodes générales d'étude-embryologie-histogénèse et histologie*. Anatomie du cerveau, Rueff
22. Déjerine J, Dejerine-Klumpke A (1901) *Anatomie des centres nerveux*. Tome II, Paris Rueff Cie Éditeurs
23. Paturet G, Bellocq P (1964) *Traite d'anatomie humaine: système nerveux*, vol 4. Masson & Cie Editeurs, pp 387–390
24. Wedeen VJ, Wang RP, Schmahmann JD, Benner T, Tseng WYI, Dai G, Pandya DN, Hagmann P, D'Arceuil H, de Crespigny AJ (2008) Diffusion spectrum magnetic resonance imaging (DSI) tractography of crossing fibers. *NeuroImage* 41:1267–1277. <https://doi.org/10.1016/j.neuroimage.2008.03.036>
25. Bürgel U, Amunts K, Hoemke L, Mohlberg H, Gilsbach JM, Zilles K (2006) White matter fiber tracts of the human brain: three-dimensional mapping at microscopic resolution, topography and intersubject variability. *NeuroImage* 29:1092–1105. <https://doi.org/10.1016/j.neuroimage.2005.08.040>
26. Amunts K, Willmes K (2006) From intersubject variability in clinical syndromes to anatomical variability. *Brain Lang* 96:147–150. <https://doi.org/10.1016/j.bandl.2005.06.004> (**discussion 157–170**)
27. Duffau H, Moritz-Gasser S, Mandonnet E (2014) A re-examination of neural basis of language processing: proposal of a dynamic hodotopical model from data provided by brain stimulation mapping during picture naming. *Brain Lang* 131:1–10. <https://doi.org/10.1016/j.bandl.2013.05.011>
28. Catani M, Jones DK, Ffytche DH (2005) Perisylvian language networks of the human brain. *Ann Neurol* 57:8–16. <https://doi.org/10.1002/ana.20319>
29. Hagmann P, Jonasson L, Maeder P, Thiran J-P, Wedeen VJ, Meuli R (2006) Understanding diffusion MR imaging techniques: from scalar diffusion-weighted imaging to diffusion tensor imaging and beyond. *Radiographics* 26(Suppl 1):S205–S223. <https://doi.org/10.1148/rg.26si065510>
30. Powell HWR, Parker GJM, Alexander DC, Symms MR, Boulby PA, Wheeler-Kingshott CAM, Barker GJ, Noppeney U, Koeppe MJ, Duncan JS (2006) Hemispheric asymmetries in language-related pathways: a combined functional MRI and tractography study. *NeuroImage* 32:388–399. <https://doi.org/10.1016/j.neuroimage.2006.03.011>
31. Vernooij MW, Smits M, Wielopolski PA, Houston GC, Krestin GP, van der Lugt A (2007) Fiber density asymmetry of the arcuate fasciculus in relation to functional hemispheric language lateralization in both right- and left-handed healthy subjects: a combined fMRI and DTI study. *NeuroImage* 35:1064–1076. <https://doi.org/10.1016/j.neuroimage.2006.12.041>
32. Chang EF, Raygor KP, Berger MS (2015) Contemporary model of language organization: an overview for neurosurgeons. *J Neurosurg* 122:250–261. <https://doi.org/10.3171/2014.10.JNS132647>
33. Catani M, Allin MPG, Husain M, Pugliese L, Mesulam MM, Murray RM, Jones DK (2007) Symmetries in human brain language pathways correlate with verbal recall. *Proc Natl Acad Sci USA* 104:17163–17168. <https://doi.org/10.1073/pnas.0702116104>
34. Gharabaghi A, Kunath F, Erb M, Saur R, Heckl S, Tatagiba M, Grodd W, Karnath H-O (2009) Perisylvian white matter connectivity in the human right hemisphere. *BMC Neurosci* 10:15. <https://doi.org/10.1186/1471-2202-10-15>
35. Geng JJ, Vossel S (2013) Re-evaluating the role of TPJ in attentional control: contextual updating? *Neurosci Biobehav Rev* 37:2608–2620. <https://doi.org/10.1016/j.neubiorev.2013.08.010>
36. Mars RB, Jbabdi S, Sallet J, O'Reilly JX, Croxson PL, Olivier E, Noonan MP, Bergmann C, Mitchell AS, Baxter MG, Behrens

- TEJ, Johansen-Berg H, Tomassini V, Miller KL, Rushworth MFS (2011) Diffusion-weighted imaging tractography-based parcellation of the human parietal cortex and comparison with human and macaque resting-state functional connectivity. *J Neurosci* 31:4087–4100. <https://doi.org/10.1523/JNEUROSCI.5102-10.2011>
37. Fernández-Miranda JC, Wang Y, Pathak S, Stefaneau L, Verstynen T, Yeh F-C (2015) Asymmetry, connectivity, and segmentation of the arcuate fascicle in the human brain. *Brain Struct Funct* 220:1665–1680. <https://doi.org/10.1007/s00429-014-0751-7>
 38. Fridriksson J, Kjartansson O, Morgan PS, Hjaltason H, Magnusdottir S, Bonilha L, Rorden C (2010) Impaired speech repetition and left parietal lobe damage. *J Neurosci Off J Soc Neurosci* 30:11057–11061. <https://doi.org/10.1523/JNEUROSCI.1120-10.2010>
 39. Mandonnet E, Duffau H (2014) Understanding entangled cerebral networks: a prerequisite for restoring brain function with brain-computer interfaces. *Front Syst Neurosci* 8:82. <https://doi.org/10.3389/fnsys.2014.00082>
 40. Martino J, De Witt Hamer PC, Berger MS, Lawton MT, Arnold CM, de Lucas EM, Duffau H (2013) Analysis of the subcomponents and cortical terminations of the perisylvian superior longitudinal fasciculus: a fiber dissection and DTI tractography study. *Brain Struct Funct* 218:105–121. <https://doi.org/10.1007/s00429-012-0386-5>
 41. Glasser MF, Rilling JK (2008) DTI tractography of the human brain's language pathways. *Cereb Cortex* 18:2471–2482. <https://doi.org/10.1093/cercor/bhn011>
 42. Saur D, Kreher BW, Schnell S, Kümmerer D, Kellmeyer P, Vry M-S, Umarova R, Musso M, Glauche V, Abel S, Huber W, Rijntjes M, Hennig J, Weiller C (2008) Ventral and dorsal pathways for language. *Proc Natl Acad Sci USA* 105:18035–18040. <https://doi.org/10.1073/pnas.0805234105>
 43. Brauer J, Anwander A, Perani D, Friederici AD (2013) Dorsal and ventral pathways in language development. *Brain Lang* 127:289–295. <https://doi.org/10.1016/j.bandl.2013.03.001>
 44. Friederici AD, Meyer M, von Cramon DY (2000) Auditory language comprehension: an event-related fMRI study on the processing of syntactic and lexical information. *Brain Lang* 74:289–300. <https://doi.org/10.1006/brln.2000.2313>
 45. Perani D, Saccuman MC, Scifo P, Anwander A, Awander A, Spada D, Baldoli C, Poloniato A, Lohmann G, Friederici AD (2011) Neural language networks at birth. *Proc Natl Acad Sci USA* 108:16056–16061. <https://doi.org/10.1073/pnas.1102991108>
 46. Duffau H, Gatignol P, Denvil D, Lopes M, Capelle L (2003) The articulatory loop: study of the subcortical connectivity by electrostimulation. *NeuroReport* 14:2005–2008. <https://doi.org/10.1097/01.wnr.0000094103.16607.9f>
 47. Makris N, Kennedy DN, McInerney S, Sorensen AG, Wang R, Caviness VS, Pandya DN (2005) Segmentation of subcomponents within the superior longitudinal fascicle in humans: a quantitative, in vivo, DT-MRI study. *Cereb Cortex* 15:854–869. <https://doi.org/10.1093/cercor/bhh186>
 48. Martino J, De Witt Hamer PC, Vergani F, Brogna C, de Lucas EM, Vázquez-Barquero A, García-Porrero JA, Duffau H (2011) Cortex-sparing fiber dissection: an improved method for the study of white matter anatomy in the human brain. *J Anat* 219:531–541. <https://doi.org/10.1111/j.1469-7580.2011.01414.x>
 49. Dell'acqua F, Scifo P, Rizzo G, Catani M, Simmons A, Scotti G, Fazio F (2010) A modified damped Richardson-Lucy algorithm to reduce isotropic background effects in spherical deconvolution. *NeuroImage* 49:1446–1458. <https://doi.org/10.1016/j.neuroimage.2009.09.033>
 50. Thiebaut de Schotten M, Dell'Acqua F, Forkel SJ, Simmons A, Vergani F, Murphy DGM, Catani M (2011) A lateralized brain network for visuospatial attention. *Nat Neurosci* 14:1245–1246. <https://doi.org/10.1038/nn.2905>
 51. Zemmoura I, Serres B, Andersson F, Barantin L, Tauber C, Filipiak I, Cottier J-P, Venturini G, Destrieux C (2014) FIBRASCAN: a novel method for 3D white matter tract reconstruction in MR space from cadaveric dissection. *NeuroImage* 103:106–118. <https://doi.org/10.1016/j.neuroimage.2014.09.016>
 52. Axer M, Gräßel D, Kleiner M, Dammers J, Dickscheid T, Reckfort J, Hütz T, Eiben B, Pietrzyk U, Zilles K, Amunts K (2011) High-resolution fiber tract reconstruction in the human brain by means of three-dimensional polarized light imaging. *Front Neuroinform* 5:34. <https://doi.org/10.3389/fninf.2011.00034>
 53. Mandonnet E, Sarubbo S, Petit L (2018) The nomenclature of human white matter association pathways: proposal for a systematic taxonomic anatomical classification. *Front Neuroanat* 12:94
 54. Nucifora PGP, Verma R, Melhem ER, Gur RE, Gur RC (2005) Leftward asymmetry in relative fiber density of the arcuate fasciculus. *NeuroReport* 16:791–794
 55. Kaplan E, Naeser MA, Martin PI, Ho M, Wang Y, Baker E, Pascual-Leone A (2010) Horizontal portion of arcuate fasciculus fibers track to pars opercularis, not pars triangularis, in right and left hemispheres: a DTI study. *NeuroImage* 52:436–444. <https://doi.org/10.1016/j.neuroimage.2010.04.247>
 56. De Benedictis A, Duffau H, Paradiso B, Grandi E, Balbi S, Granieri E, Colarusso E, Chioffi F, Marras CE, Sarubbo S (2014) Anatomical-functional study of the temporo-parieto-occipital region: dissection, tractographic and brain mapping evidence from a neurosurgical perspective. *J Anat* 225:132–151. <https://doi.org/10.1111/joa.12204>
 57. Kamali A, Flanders AE, Brody J, Hunter JV, Hasan KM (2014) Tracing superior longitudinal fasciculus connectivity in the human brain using high resolution diffusion tensor tractography. *Brain Struct Funct* 219:269–281. <https://doi.org/10.1007/s00429-012-0498-y>
 58. Wang X, Pathak S, Stefaneau L, Yeh F-C, Li S, Fernández-Miranda JC (2016) Subcomponents and connectivity of the superior longitudinal fasciculus in the human brain. *Brain Struct Funct* 221:2075–2092. <https://doi.org/10.1007/s00429-015-1028-5>
 59. Güngör A, Baydin S, Middlebrooks EH, Tanriover N, Isler C, Rhoton AL (2017) The white matter tracts of the cerebrum in ventricular surgery and hydrocephalus. *J Neurosurg* 126:945–971. <https://doi.org/10.3171/2016.1.JNS152082>

Publisher's Note Springer Nature remains neutral with regard to jurisdictional claims in published maps and institutional affiliations.

Travail expérimental

❖ Article n°4 :

The ventral attention network: the mirror of the language network in the right brain hemisphere.

Bernard F, Lemée JM, Mazerand E, Leiber LM, Ter Minassian A, Menei P

Journal of Anatomy, (publié IF= 2,638)

The ventral attention network: the mirror of the language network in the right brain hemisphere

Florian Bernard^{1,2,3}  | Jean-Michel Lemée^{2,3} | Edouard Mazerand² |
Louis-Marie Leiber⁴ | Philippe Menei^{2,3} | Aram Ter Minassian^{5,6}

¹Laboratory of Anatomy, Faculté de Médecine, Angers, France

²Department of Neurosurgery, Angers Teaching Hospital, Angers, France

³UMR 1232 INSERM/CNRS and EA7315 Team, CRCINA, Angers, France

⁴Department of Radiology, Angers Teaching Hospital, Angers, France

⁵Department of Reanimation, Angers Teaching Hospital, Angers, France

⁶EA7315 Team, INSERM 1066, Angers, France

Correspondence

Florian Bernard, Laboratory of Anatomy, Faculté de Médecine, 4, rue Larrey, 49100 Angers, France.

Email: bernardflorian.bf@gmail.com

Abstract

Resting-state functional MRI (RfMRI) analyses have identified two anatomically separable fronto-parietal attention networks in the human brain: a bilateral dorsal attention network and a right-lateralised ventral attention network (VAN). The VAN has been implicated in visuospatial cognition and, thus, potentially in the unilateral spatial neglect associated with right hemisphere lesions. Its parietal, frontal and temporal endpoints are thought to be structurally supported by undefined white matter tracts. We investigated the white matter tract connecting the VAN. We used three approaches to study the structural anatomy of the VAN: (a) independent component analysis on RfMRI (50 subjects), defining the endpoints of the VAN, (b) tractography in the same 50 healthy volunteers, with regions of interest defined by the MNI coordinates of cortical areas involved in the VAN used in a seed-based approach and (c) dissection, by Klingler's method, of 20 right hemispheres, for *ex vivo* studies of the fibre tracts connecting VAN endpoints. The VAN includes the temporoparietal junction and the ventral frontal cortex. The endpoints of the superior longitudinal fasciculus in its third portion (SLF III) and the arcuate fasciculus (AF) overlap with the VAN endpoints. The SLF III connects the supramarginal gyrus to the ventral portion of the precentral gyrus and the pars opercularis. The AF connects the middle and inferior temporal gyrus and the middle and inferior frontal gyrus. We reconstructed the structural connectivity of the VAN and considered it in the context of the pathophysiology of unilateral neglect and right hemisphere awake brain surgery.

KEYWORDS

arcuate fasciculus, resting state, tractography, ventral attention network, white matter

1 | INTRODUCTION

The non-dominant hemisphere (the right hemisphere in right-handed individuals) plays an important role in spatial consciousness, emotion and other cognitive processes. Unilateral spatial neglect (USN) is a tragic consequence of lesions in this hemisphere, corresponding to a lack of detection of stimuli contralateral to the lesion and thus to a lack of response to such stimuli (Vallar & Perani, 1986; Mesulam, 1999), whereas basic sensory and motor functions remain intact

(Lemée *et al.*, 2018). It has diverse aetiologies, from neurological causes (stroke, infection) to pre- and post-neurosurgery deficits. The prognosis of USN is poor in terms of recovery for routine activities, and rehabilitation is very difficult due to associated anosognosia (Jehkonen *et al.*, 2000). This syndrome has been attributed to a disruption of the function of spatial attention distribution, preventing a conscious perception of contralateral events and interaction with them (Heilman & Van Den Abell, 1980; Mesulam, 1990; Vuilleumier *et al.*, 2002).

Functional task-based MRI explores cognitive function through activation paradigms involving the stimulation of specific cognitive processes. By contrast, resting-state MRI (R-MRI) is a complementary MRI technique that can be used to explore the spontaneous synchronisation of brain areas in the absence of an activation task (Biswal *et al.*, 1995; Damoiseaux *et al.*, 2006; Smith *et al.*, 2009). The working hypothesis is that brain areas displaying a spontaneous synchronisation of low-frequency fMRI oscillations over time belong to the same functional network. The correlation structure of these networks reflects the neuroanatomical substrate of task-induced activity through a data-driven method not requiring prior knowledge (Fox *et al.*, 2005; Mitchell *et al.*, 2013). The exploration of attentional networks by functional activation MRI is challenging in the absence of a reliable activation paradigm suitable for use with the short acquisition processes of MRI. Attentional networks were, therefore, first studied by resting-state MRI. Fox *et al.* (2006) identified a bilateral dorsal attention network (DAN) and a right-lateralised ventral attention network (VAN) by R-MRI. Corbetta showed that USN was caused by VAN dysfunction (Shulman *et al.*, 2010; Corbetta & Shulman, 2011). Cortical damage and white matter disconnection can trigger USN (Lunven *et al.*, 2015; Lunven & Bartolomeo, 2017). The components of attentional networks are, therefore, thought to be connected structurally, via specific periventricular white matter association fibres (Doricchi *et al.*, 2008; Umarova *et al.*, 2010).

A number of different nomenclatures have been applied to white-matter anatomy, resulting in classification discrepancies between studies (Bernard *et al.*, 2019). The nomenclature of the arcuate fasciculus (AF), for example, has changed over time, making it difficult to carry out literature reviews of the relationships between the AF and the superior longitudinal fascicle in its third portion (SLF III). Classical anatomical and clinical studies considered the AF and the long inner segment of the SLF III to be part of the same fasciculus, connecting the posterior superior temporal gyrus (Wernicke's area) to the inferior frontal gyrus (Broca's area) (Catani *et al.*, 2005). However, more recent anatomical studies based on the use of post-mortem fibre microdissection techniques have suggested that the differentiation of these two structures, with AF as a fronto-temporal tract and the SLF III as a fronto-parietal tract (Schmahmann & Pandya, 2007; Wedeen *et al.*, 2008; Yagmurlu *et al.*, 2016).

The white matter tracts serving as the anatomical substrate of the VAN have yet to be investigated in systematic studies. An understanding of the anatomical and functional support of attentional networks is crucial to improvements in our understanding of visuospatial cognition and in pre- and perioperative management in awake brain neurosurgery on the right hemisphere. Our objective was therefore to investigate the white matter tracts supporting VAN connectivity.

2 | METHODS

We studied the white matter anatomy of the VAN cortical nodes by R-MRI, tractography and white matter dissection.

2.1 | Resting-state fMRI

We performed independent component analysis on 50 healthy subjects, using R-MRI to define the cortical nodes of the VAN.

2.1.1 | Study population

Inclusion criteria

The participants were healthy right-handed adult volunteers, without psychiatric disorders, who agreed to participate in the ICA-language study in our laboratory (CPP Agreement number 2012/25, clinicalTrials.gov NCT02577757). All subjects gave written, informed consent before enrolment in this study.

Exclusion criteria

Subjects with a psychiatric disorder, or who were under the age of 18 years, or who were unable to read or write French were excluded from this study. Subjects with contraindications for MRI (claustrophobia, pregnancy, implanted with metallic foreign bodies, pacemakers, etc.) were excluded from this study.

2.1.2 | R-MRI data acquisition

All datasets were acquired on a 3.0 Tesla MR Scanner (Magnetom® Skyra Medical Systems™). During image acquisition, subjects were placed in a supine position, in the dark, with their heads immobilised with foam pads and straps. The subjects were fitted with earphones. They were asked to empty their minds and to watch a black screen with a red cross in the centre, through a prism. An echo planar imaging (EPI) sequence was used for each fMRI, with the following parameters: TR = 2,280 ms, TE = 30 ms, flip angle = 90°, 42 axial interleaved slices, each 4 mm thick, in-plane matrix = 64 × 64 with a field of view = 168 × 187 mm, yielding a voxel size of 3 × 3 × 4 mm, covering the whole brain, including the cerebellum.

2.1.3 | Analysis of imaging data

Preprocessing

Preprocessing was performed with SPM8 (Wellcome Department of Imaging Neuroscience, University College, London, UK, <http://www.fil.ion.ucl.ac.uk/spm>) running under MATLAB (the MathWorks). Each patient's native space images were corrected for time delays between slices. All the images were then realigned with the first volume of the first session and unwrapped to correct for head movements and susceptibility distortions. The three-dimensional dataset was segmented in native space, using the VBM 8.0 toolbox for SPM®, and co-registered with the mean functional image, using grey-matter segmentation as a reference image. The co-registered grey-matter segmentation was then used for the spatial normalisation of data into a standard template provided by

TABLE 1 Mean activity peaks identified in RfMRI for the resting-state network corresponding to the VAN

VAN activation peak	Cluster	Localisation	MNI coordinates		
			x	y	z
Temporoparietal junction	1	- Right superior temporal gyrus	63	-46	19
		- Right middle temporal gyrus	62	-46	6
		- Right inferior temporal gyrus	54	-22	-18
Ventral frontal cortex	2	- Right frontal inferior gyrus (pars orbitalis)	48	27	-8
		- Right frontal inferior gyrus (pars orbitalis)	54	26	-12
		- Right frontal inferior gyrus (pars triangularis)	46	20	18
	5	- Right precentral gyrus	46	6	51
		- Right middle frontal gyrus	45	9	46
	11	- Right frontal inferior gyrus (pars opercularis)	-45	17	19

Maximal activation peaks ($p < .001$) were obtained with a cluster threshold of 5 voxels; the corresponding anatomical locations were derived from the anatomy toolbox in SPM ($x, y, z =$ coordinates in the normalised space MNI).

The temporoparietal junction activation peak was defined by cluster 1.

The lateral frontal cortex areas were defined by clusters 2, 5 and 11.

the Montreal Neurological Institute (MNI-template), with a final resolution of $3 \times 3 \times 3$ mm.

Spatial independent component analysis

A spatial independent component analysis (sICA) approach was used, based on a customised version of the Infomax algorithm running in MATLAB, for the identification of large-scale networks (Marrelec *et al.*, 2006). Fifty-five resting-state networks (RsN) (corresponding to spontaneously synchronised brain areas) were identified on the pre-processed images of each individual run. Individual spatial components were thresholded at $z = 2$.

2.1.4 | Identification of the ventral attentional network

The VAN can be distinguished from other cognitive networks (language, salience, DAN, fronto-parietal control, default mode) on the basis of its specific activity: activation of the right temporoparietal junction (TPJ), the right ventral frontal cortex (VFC) and the supramarginal gyrus (Corbetta *et al.*, 2008; Sylvester *et al.*, 2013). It was challenging to distinguish between the VAN and the salience network in some cases. Unlike the VAN, the salience network (SN) contains the anterior dorsal cingulum, the pre-motor supplementary area and the anterior insula-frontal operculum (Uddin *et al.*, 2011; Farrant & Uddin, 2015). The MNI coordinates of the maximum activation peaks of significant clusters in the VAN were determined. Anatomical labels were then attributed to these maximal activation peaks with the Anatomy toolbox for SPM (http://www.fz-juelich.de/inm/inm-1/DE/Forschung/_docs/SPMANatomyToolbox/SPMANatomyToolbox_node.html). After identification at the individual level, a second-order analysis was performed, in the form of a one-sample t -test on the unthresholded t -maps of the VAN. We corrected for multiple comparisons at the voxel level.

2.2 | Tractography

2.2.1 | Data acquisition and preprocessing

Diffusion data were acquired with a magnetisation-prepared, single-shot gradient echo planar imaging (EPI) sequence (echo time 64 ms, repetition time 10 s, flip angle 90° , FOV $256 \times 256 \times 120$ mm³, acquisition matrix $128 \times 128 \times 60$ voxels of $2 \times 2 \times 2$ mm³). Diffusion gradients were applied in 32 non-collinear directions. Modified TEND algorithms (MEDINRIA software), based on B0 analysis, were used to correct geometric distortions (Weinstein *et al.*, 1999). An optimal alignment of T1-weighted and diffusion-weighted images was achieved by affine transformation estimated with an automatic registration algorithm based on mutual information (Wiest-Daesslé *et al.*, 2007). Registration was performed between T1 and the diffusion-free weighted image (B0). The brain and the external traces of the sulci were extracted (Le Goualher *et al.*, 1997) from the T1 data after denoising (Coupé *et al.*, 2008) and intensity inhomogeneity bias correction.

2.2.2 | Tracking

The VAN encompass two distinct areas (the TPJ and frontal cortex). We therefore extracted white matter fibre bundles with a two-region of interest (ROI) approach. For each set of diffusion-weighted data, a tensor estimation was performed, with a log-Euclidean metric (Fillard *et al.*, 2007) and streamline tractography, on the whole brain, with MEDINRIA version 1.9.0 (Asclepios Research Project; INRIA Sophia Antipolis, France) and the following set of parameters: the fractional anisotropy (FA) threshold was set to 0.2, as suggested by Mori & van Zijl (2007) and Magro *et al.*, (2014), and the smoothness parameter was set to 20, as recommended by Weinstein *et al.* (1999) for association tracts. The ROIs were created with TPJ (Table 1,

cluster 1) and frontal (Table 1, cluster 2, 5 and 11) MNI coordinates for activation peaks obtained with MRICRON from the T1-weighted data. The data were then imported into MEDINRIA. Finally, MRI tracks were reconstructed for each volunteer with a pair of ROIs within the same hemisphere used as seeds for the extraction of putative pathways (Lawes *et al.*, 2008). The right TPJ activation MNI coordinates defined the first ROI (Table 1, cluster 1). The second ROI was defined by the frontal VAN activations (Table 1, clusters 2, 5 and 11).

2.3 | White matter dissection

We studied fibre tracts connecting the cortical nodes of the VAN by Klingler's method (27–30). We studied 20 heads from adult cadavers obtained from the body donation programme of our institution (the Angers Anatomical Laboratory). The specimens were fixed by incubation in 10% formalin for 15 days. The right hemispheres were extracted and the arachnoid and vascular structures gently removed. The hemispheres were frozen at -15°C for 15 days. Careful dissection was then performed with a foam spatula, in a lateral-to-medial direction, under optical magnification, to excise the cortex and the U-shaped fibres. Once the subcortical fibre tracts had been identified, further dissection was performed with metal microdissectors (31). Photographs were obtained at each stage of the dissection, with a Nikon D5600 camera. The VAN fibre tracts were identified on the basis of their endpoints and the orientation of the fibres, which made it possible to distinguish each separate fibre tract (Bernard *et al.*, 2019).

3 | RESULTS

3.1 | Identification of cortical brain areas corresponding to the ventral attention network by resting-state functional MRI

We included 50 right-handed subjects in this study. For each subject, we were able to identify a resting-state network (RsN) corresponding to the VAN. Figure 1 shows a second-order analysis of correlation maps for the 50 subjects. As expected, given the criteria for VAN identification, the corresponding voxels were significantly correlated with the right temporoparietal junction and the ventral frontal cortex defining the VAN (Table 1). Eight of the 12 significantly activated supratentorial peaks of connectivity of the VAN were located in the

right hemisphere. The two main clusters included the TPJ, especially the area surrounding the superior temporal sulcus (STS; Figures 1 and 2) and the VFC. As shown in Figure 1, the 'temporal' activation (cluster 1, Table 1 and Figure 2) identified in the second-order analysis was not purely temporal, as it also included the supramarginal gyrus and the lower part of the angular gyrus. This cluster had an anterior extension towards the middle temporal gyrus, crossing the superior temporal sulcus. The activated frontal clusters were centred on the pars triangularis, its extension from the precentral gyrus to the pars orbitalis being circular in shape. Note that the posterior part of the middle frontal gyrus was contiguous to this activation peak.

3.2 | Identification of the white matter tracts of the ventral attention network by tractography and with Klingler's method

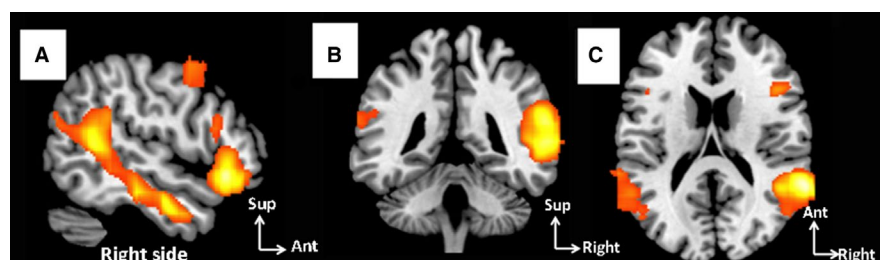
3.2.1 | Superficial anatomy analysis by Klingler's method

We first studied the sulci and gyri of the lateral part surface of the right hemisphere. Sulcal organisation was found to be fairly uniform in the temporal, parietal and frontal lobes studied, regardless of the method used. As Klingler's method is destructive, we first identified the cortical structures. The lateral part of the temporal lobe of the 20 right hemispheres dissected was typically split by the superior and inferior temporal sulci, into three parallel temporal gyri: the superior (T1), middle (T2) and inferior (T3) gyri. In all dissected specimens, the SMG and AG were separated by the intermediate parietal sulcus of Jensen. However, some temporal lobe variants were observed: T1 was interrupted by a short vertical sulcus in four hemispheres (20%), T2 was divided in two (10%) and T3 in four (20%) hemispheres. Cortical bridges linking T1 to T2 were observed in three specimens (15%), and bridges linking T2 and T3 were observed in the other 17 cases (85%). Despite these variants, we were able to identify the cortical connections of the VAN in all specimens.

3.2.2 | Removal of U-shaped fibres

For identification of the fibre tracts connecting the TPJ and the frontal component of the VAN (VFC, precentral gyrus, pars opercularis and middle frontal gyrus) we first removed the U-shaped fibres. The techniques used (tractography and Klingler's method) made it

FIGURE 1 Study of the connectivity of the ventral attention network (VAN) by resting-state MRI. (a–c) Resting-state MRI study of the VAN activation peak: (a) sagittal, (b) coronal, (c) axial views [Colour figure can be viewed at wileyonlinelibrary.com]



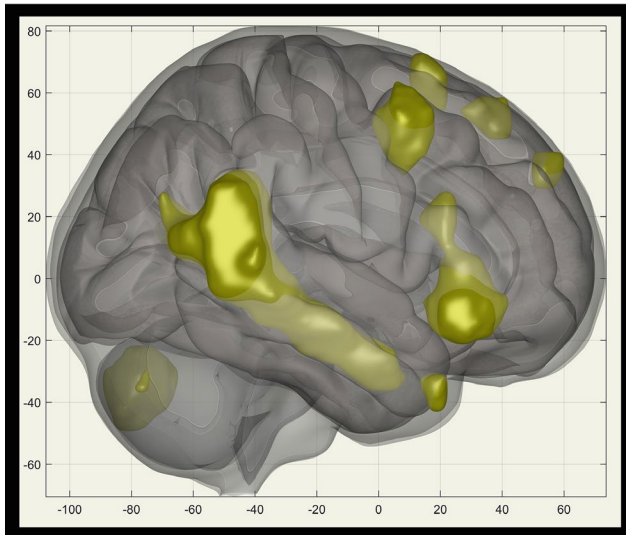


FIGURE 2 Three-dimensional visualisation of the VAN activation peaks superimposed on a grid of MNI coordinates. The AF was the second fibre tract connecting the lower part of the TPJ to the anterior part of the lateral frontal VAN component, including the VFC [Colour figure can be viewed at wileyonlinelibrary.com]

possible to expose the SLF III and the lateral part of the AF in the postero-superior portion of the temporal lobe, down to the SMG, in all specimens (Figure 3).

Using previously defined tractographic parameters, we were able to remove almost all the U-shaped fibres after the identification of the major fibre tracts by tracking. In 32 subjects (64%), we encountered U-shaped fibres surrounding the inferior parietal lobule. However, these U-shaped fibres did not interfere with fibre tract identification.

By contrast, in *ex vivo* dissection, the removal of these U-shaped fibres was an essential independent step. At the subcortical level, short 'U' association fibres were encountered and exposed without technical difficulty on the lateral surface of the temporal lobe and the inferior parietal lobule (IPL). As these fibres did not connect the frontal and temporal VAN components, we progressively removed the short association fibres.

3.2.3 | Identification of the SLF III

The SLF III was identified by tractography and with Klingler's method as the superficial tract connecting the upper and posterior parts of the TPJ to the posterior part of the frontal VAN components. The SLF III was the only tract connecting the supramarginal component of the TPJ to the frontal VAN.

The SLF III fibres were oriented horizontally. Many of the frontal fibres (50% in the dissected specimens) ran from the ventral portion of the precentral gyrus (cluster 5), and the posterior part of the pars opercularis (cluster 11), to the supramarginal gyrus (75%, cluster 1; Figure 3). In these cases, the SLF III connected VAN clusters 5 and 11 to cluster 1.

We observed two patterns in terms of the *anterior endpoints* of this tract. The first was an exclusive connection with the ventral portion of

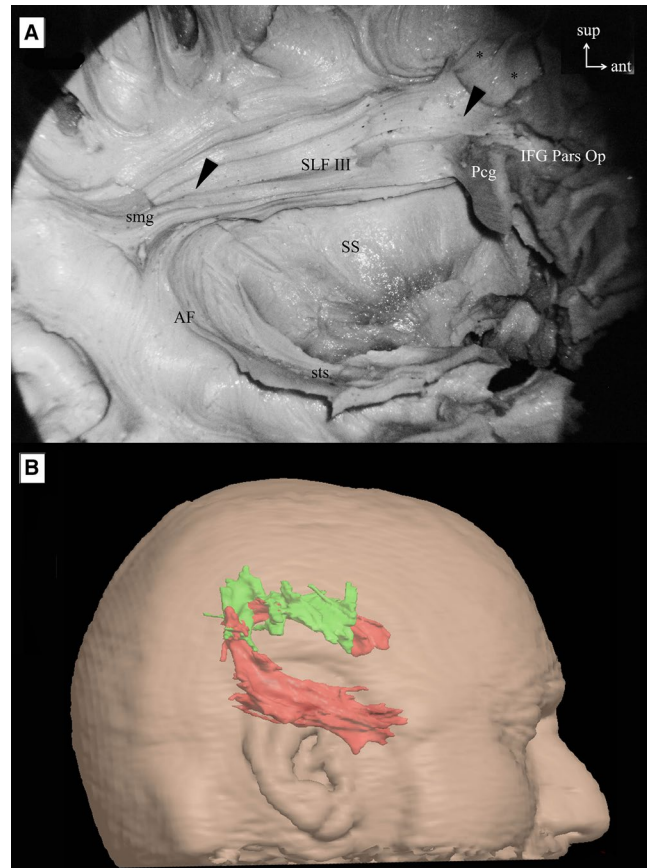


FIGURE 3 Main anterior endpoint of the SLF III. (a) Klingler's dissection. (b) Three-dimensional tractography view. In white matter dissection and tractography, frontal fibres run from the ventral portion of the precentral gyrus (pcg), and the posterior part of the pars opercularis (IFG Pars op), to the supramarginal gyrus (smg). The arcuate fasciculus (AF) was located between the SLF III and deeper horizontal association fibres. These deeper fibres were exposed, and corresponded to the most lateral layer of the stratum sagittal (SS). * U-shaped fibres [Colour figure can be viewed at wileyonlinelibrary.com]

the precentral gyrus (20%, Figure 4). This cortical area overlaps with cluster 5. The second was an exclusive connection with the posterior portion of the pars opercularis (10%, cluster 11). In the remaining 20% of subjects studied, it was impossible to determine the anterior endpoint of this tract. Two types of *posterior endpoints* were found for this tract: connection exclusively to the supramarginal gyrus (80%, cluster 1) and connection to both the supramarginal gyrus and the posterior part of the superior temporal gyrus (in the region just posterior to Heschl's gyrus) (10%, cluster 1). In the remaining subjects, it was impossible to determine the anterior endpoint of this tract.

3.2.4 | Arcuate fasciculus

The AF was the second fibre tract connecting the lower part of the TPJ to the anterior part of the lateral frontal VAN component, including the VFC.

FIGURE 4 Variation of the SLF III anterior endpoint: exclusive to the precentral gyrus (pcg). (a) Klingler's dissection; (b) Three-dimensional tractography [Colour figure can be viewed at wileyonlinelibrary.com]

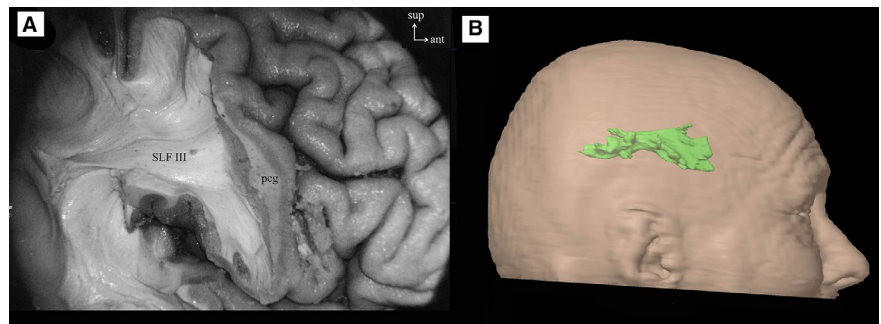


FIGURE 5 (a) Arcuate fasciculus dissection (AF). (b) Tractography of the arcuate fasciculus. The lower part of the TPJ is connected to the frontal part of the VAN by the arcuate fasciculus. Mfg: middle frontal gyrus; pcg, precentral gyrus; IFG pars op, inferior frontal gyrus pars opercularis; white arrowhead, caudal limit of the insula [Colour figure can be viewed at wileyonlinelibrary.com]

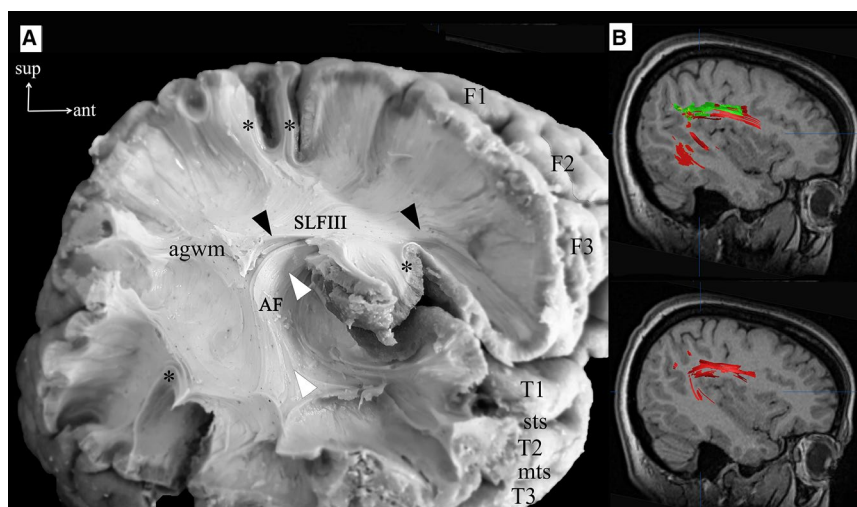
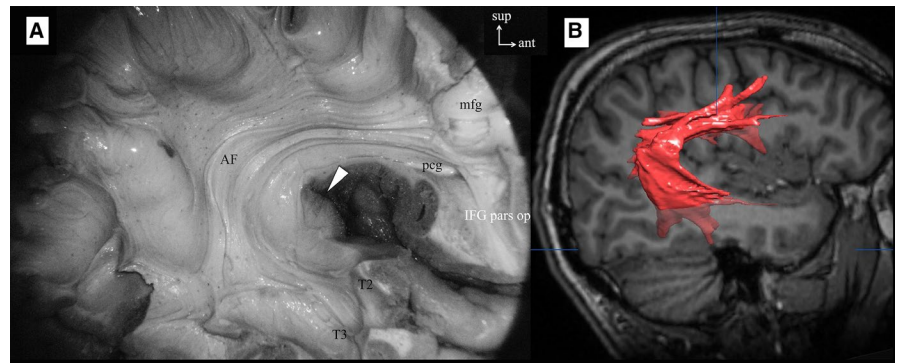


FIGURE 6 (a) Fibre dissection of the white matter of the lateral part of the right hemisphere: After determining the anatomy of the cortex and identifying the cortical region of interest for the ventral attention network, we removed the cortex and subcortical 'U' association fibres from the study area (*) to expose longer association tracts. Progressing in a lateral to medial direction, the first long association bundle encountered in the temporoparietal junction was the superior longitudinal fasciculus in its third portion (SLF III, black arrowhead). Longer arcuate fibres directly linked the frontal and temporal lobes, running around the circular sulcus of the insula. In this specimen, the precentral, post-central and the majority of the most of the inferior parietal gyri were removed. The exploration of the association fibres located medial to the SLF III (that is, the AF, white arrowhead) began with the section of the SLF III close to the supramarginal gyrus. (b) Tractography (sagittal slices) showing the white matter supporting the VAN. The SLF III (green) runs from the supramarginal gyrus (temporoparietal junction) to the ventral portion of the precentral gyrus and the pars opercularis (posterior part of the VFC). The AF (red) fibres connect the middle and inferior temporal gyrus (temporoparietal junction) and the middle and inferior frontal gyrus. agwm, angular gyrus white matter; AF, arcuate fasciculus; F1, superior frontal gyrus; F2, middle frontal gyrus; F3, inferior frontal gyrus; T1, superior temporal gyrus; T2, middle temporal gyrus; T3, inferior temporal gyrus; sts, superior temporal sulcus; mts, middle temporal sulcus [Colour figure can be viewed at wileyonlinelibrary.com]

Tractography repeatedly showed the AF to be deeper than the SLF III. Similarly, during fibre dissections and after the lifting of the SLF III, the lateral surface of the long segment of the AF was

completely exposed. The posterior portion of the long-segment fibres of the AF were oriented vertically within the temporal lobe. Here, the AF fibres ran laterally and perpendicular to the fibres of

the sagittal stratum (i.e. the densely packed fibres located on the lateral surface of the ventricular atrium and composed of the optic radiations, inferior fronto-occipital fasciculus and tapetum), which are oriented horizontally (Figures 3 and 5). The AF fibres curved around the caudal limit of the insula and then ran off in a horizontal direction (Figures 3, 5 and 6) within the white matter of the parietal and frontal operculum.

The AF mostly had anterior endpoints connecting to the ventral portion of the precentral gyrus and the pars opercularis (65%, Figures 5 and 6, clusters 5 and 11), and posterior endpoints connecting to both the middle and inferior temporal gyrus (60%, Figure 3a and Figure 5, cluster 1).

The anterior endpoints of this bundle were also connected to the posterior middle frontal gyrus (20%, Figure 5, cluster 5) or to the pars triangularis (10%, cluster 2), whereas the posterior endpoints connected exclusively to the middle temporal gyrus (35%, cluster 1). The anterior and posterior terminations of this bundle were not determined in one Klingler dissection (5%) due to the prior destruction of the anatomy of the cortex through the extensive removal of grey matter. In our study, we identified no direct connections of the superior temporal gyrus and the frontal cortical area.

3.3 | Comparison of the VAN cortical nodes and white matter bundles identified with the three techniques

The connectivity of the VAN determined by sICA was spatially and anatomically consistent with the white matter bundles studied with Klingler's method and tractography. We found no direct white matter connection between the medial frontal activation peak (cluster 6, 7, 9) and the other activation peaks. In all specimens, the SLF III connected the upper and posterior parts of the TPJ (cluster 1) to the posterior part of the VFC (Figures 3, 5 and 6; clusters 5, 6). The SLF III was the only tract that connected the supramarginal component of the TPJ to the posterior frontal part of the VAN. Both the AF and the SLFIII connected the lower part of the TPJ to the VFC.

4 | DISCUSSION

This study highlights the overlap between the cortical endpoints of the SLF III and the arcuate fasciculus and the connections of the VAN. The SLF III connects the supramarginal gyrus to the ventral portion of the precentral gyrus and the pars opercularis, whereas the AF connects the middle and inferior temporal gyrus to the middle and inferior frontal gyrus.

4.1 | Comparison with published findings

We found that the SLF III and the AF structurally connected the VAN cortical nodes, located in the right TPJ and VFC. In the right

hemisphere, the cortical areas and white matter fascicles involved in visuospatial cognition appeared to mirror those involved in language (Yagmurlu *et al.*, 2016; Bernard *et al.*, 2019), with a perisylvian network connecting the temporoparietal junction and the frontal inferior cortex. This study was not designed to compare language network and VAN anatomy, so we cannot draw definitive conclusions on this point. However, it could be argued that the cortical VAN activation peaks and white matter support display similarities to the features of the language network in the contralateral hemisphere. Is this apparent anatomical symmetry of the brain total or partial? This question has been heavily debated and has raised several other interesting questions concerning determinism and brain anatomy. For example, several diffusion tensor imaging (DTI) studies have reported a high prevalence of leftward asymmetry in perisylvian white matter volumes (Parker *et al.*, 2005; Dorsaint-Pierre *et al.*, 2006). By contrast, some authors have reported the presence of a right arcuate fasciculus (AF) in only 40% of their subjects, whereas others have reported the presence of such a structure in all subjects studied (Gharabaghi *et al.*, 2009), as reported here. Anatomically, the structure of the white matter may be considered mostly symmetric, as the counterparts of left-hemisphere white matter fascicles have been identified in the right hemisphere. Moreover, most post-mortem fibre dissection studies have reported no significant difference between the left and right white matter fascicles in terms of cortical endpoints (Yagmurlu *et al.*, 2016) or fascicle volumes (Mars *et al.*, 2011; Geng & Vessel, 2013; Yagmurlu *et al.*, 2016).

As for language in the dominant hemisphere, the SLF III and the AF appear to constitute a major, but not exclusive, right-sided component of visuospatial cognition (Yagmurlu *et al.*, 2016; Bernard *et al.*, 2019). Indeed, the VAN may also be involved in other right hemisphere functions relating to non-verbal communication, such as the recognition of facial emotions and prosody (Sammler *et al.*, 2015; Bernard *et al.*, 2018b).

An understanding of the white matter supporting the functions of the VAN should shed light on USN. This condition is highly heterogeneous in terms of its severity and manifestations (Halligan & Marshall, 1992). It is a complex set of signs and symptoms, rather than a single syndrome (Bernard *et al.*, 2018b). Studies based on structural brain imaging have identified three major cortical areas straddling the sylvian fissure, overlapping with our VAN cortical activation peaks as potentially responsible for the core deficit: (a) the VFC (Husain & Kennard, 1996; Committeri *et al.*, 2007; Rengachary *et al.*, 2011), (b) the TPJ (Vallar & Perani, 1986; Mort *et al.*, 2003; Karnath *et al.*, 2011; Rengachary *et al.*, 2011; Chechlacz *et al.*, 2012) and (c) the STG, MTG and underlying insula (Karnath *et al.*, 2011; Rengachary *et al.*, 2011; Chechlacz *et al.*, 2012). Tract tracing, myelin staining and DTI techniques have suggested that a dense perisylvian network connects these three cortical sites (Karnath *et al.*, 2011). These connections have been implicated in the brain lesions of patients suffering from USN in studies of single cases or small series of cases (Thiebaut de Schotten *et al.*, 2005; He *et al.*, 2007; Urbanski *et al.*, 2008; Shinoura *et al.*, 2009) and in a recent group study in which a statistical voxelwise lesion-behaviour mapping approach

was applied to a large cohort of patients with acute right hemisphere stroke (Karnath *et al.*, 2011). Network dysfunction induced by damage to white matter tracts, such as the SLF III and the AF in particular, might provide a more detailed explanation as to why USN develops as a disconnection syndrome in large networks of connected brain areas (Bartolomeo *et al.*, 2007).

Spatial neglect can be observed following injury to other white matter tracts. Several studies have suggested a role for the SLF II in VAN structural connectivity (Geng & Vessel, 2013), contrary to our findings. However, this tract seems to be more involved in associating the DAN and the VAN, because the SLF II has cortical endpoints in both attention systems (inferior parietal lobule and posterior dorsolateral prefrontal cortex). The SLF II may explain the functional disconnection between these two networks (Bartolomeo *et al.*, 2007; Geng & Vessel, 2013; Zhang *et al.*, 2017). Moreover, direct electrical stimulation during brain surgery in conscious patients and in DTI studies has revealed a potential rare involvement of the IFOF in USN. According to Herbet *et al.* (2017), the first reports highlighting the role of the right IFOF in USN suggested that signs of neglect may result from a deprivation of top-down modulation from anterior frontal areas over the visual cortex, or a lack of visual input to the frontal areas (Urbanski *et al.*, 2008; Bartolomeo, 2013; Herbet *et al.*, 2017).

4.2 | Limitations

The main limitation of R-MRI lies in the difficulty distinguishing between the VAN and other resting-state networks (RsN). The first step in R-MRI was determining which of the 55 RsNs corresponded to the VAN, language and other networks. A major criterion for identifying the language RsN in healthy volunteers is an expected left-lateralisation in right-handed subjects. However, in clinical practice, 4%–18% of right-handed individuals have been found to use their right hemisphere for language processing (Knecht *et al.*, 2000). It may, therefore, be difficult to distinguish between the VAN and language networks in such patients. A distinction between the activation peaks for the VAN and language RsNs is crucial for correct identification of the VAN (Corbetta *et al.*, 2008). The main difference between the VAN and language networks concerns the activation of the inferior parietal lobule. In the VAN, parietal lobe activity generally involves the supramarginal gyrus and the temporoparietal junction in both adults (Corbetta *et al.*, 2008) and children (Sylvester *et al.*, 2013). By contrast, in the language network, the angular gyrus is preferentially activated (Vigneau *et al.*, 2006; Lemée *et al.*, 2019). We detected no involvement of the angular gyrus in VAN activation peaks or in white matter support: the SLF III connected the supramarginal gyrus to the VFC.

Similarly, the distinction between the VAN and the salience network (SN) could be challenging. The definition of the VAN, like that of the AF, may be confusing due to the differences in nomenclature between studies. The VAN was first identified by R-MRI by Fox *et al.* (2006) and was described as an RsN correlated to a region of interest

that had been shown to be part of the SN (Uddin *et al.*, 2011). Based on this initial description, (Sridharan *et al.* 2007; Sridharan *et al.*, 2008) indiscriminately referred to the VAN and the SN as the same network. Recent studies of connectivity have shown that the VAN and SN are separate networks. In the study by Lemee *et al.* and several other major studies, the SN was identified on the basis of the presence of cingulo-opercular components (Vigneau *et al.*, 2006; Corbetta *et al.*, 2008; Lemée *et al.*, 2019). In our study, the VAN and the SN were clearly different spatial components.

Another limitation of R-MRI analysis was reviewed by Lee *et al.* (2013; p. 2). Resting-state data can be analysed in various ways, including seed-based approaches, independent component analysis, graphical methods, clustering algorithms, neural networks and pattern classifiers. The advantage of ICA over seed-based approaches is that it is data-driven. However, it requires expert knowledge to identify the RsNs visually. Whatever the method used, several key issues must be considered, including test-retest reproducibility and inter-subject variability (Chou *et al.*, 2012) concerning RsN detection.

Clinical inferences from R-MRI must be tempered by our current lack of knowledge about the relationship between RsN and task-induced activity. RsN may be defined as brain areas presenting statistically coherent activity during the acquisition time corresponding to a coherent fluctuation of the BOLD fMRI signal. Historically, such coherent activity at rest was first described in the motor sensory (Biswall) cortex. It was subsequently detected in areas involved in other cognitive functions, such as language. However, these networks were described at rest, and little is known about the dynamic interactions and recombination of areas of activity across them. Furthermore, the neural signal correlated to the BOLD effect analysed by fMRI appears to differ between networks.

Both gross fibre dissection and diffusion tensor imaging techniques present limitations that can affect the study of cortical connections. Fibre dissection is of limited value for studies of white matter connectivity in areas of crossing fibres. In the frontal operculum, the fibres of the AF intersect strongly with the terminal branches of other long association fascicles (particularly the IFOF and the frontal aslant tract) and the corticospinal tract. Conversely, dissection can isolate fibres of up to 2 mm in diameter. Moreover, in fibre dissection, the extensive removal of grey matter can lead to a loss of important cortical landmarks, making it difficult to analyse the precise cortical terminations of a specific fibre tract.

Imaging techniques are not subject to the same limitations but they are susceptible to noise, poor resolution, contamination from adjacent bundles and abrupt changes in fibre direction. Moreover, there is a large difference in the ages of subjects studied by fibre dissection (performed after the death of the subjects, who therefore tend to be old) and those studied by DTI tractography (usually young, healthy volunteers). This difference may affect the findings, as white matter connectivity may change with age. Nevertheless, the major observations were consistent across the subjects studied by DTI tractography and fibre dissection.

4.3 | Perspectives

The exploitation of these results in current clinical practice is challenging. A better understanding of the interactions between cortical activation peaks on R-MRI and fibre tracts would make it possible to prevent the creation of lesions leading to unilateral neglect during brain surgery. We are currently combining R-MRI studies of the VAN with preoperative tractography, with a view to improving our understanding of the individual anatomical relationships between right-side brain tumours and the functional networks involved in USN. The possible uses of these data in brain surgery on conscious patients are promising. However, as in activation-functional MRI for exploring the cognitive function of the right hemisphere, it is essential to use specific tests that are reproducibly achievable during cortical electrical stimulation. USN can be identified clinically before or after surgery, but the development of a preoperative test for patients undergoing surgery in a conscious state remains difficult and is currently restricted to specific study protocols (Bernard *et al.*, 2018a; Bernard & Menei, 2019).

5 | CONCLUSION

We show here that the ventral attention network is structurally connected by the SLF III and the arcuate fasciculus. The SLF III connects the temporoparietal junction to the ventral frontal cortex in a horizontal and superficial manner. The arcuate fasciculus connects the lower part of the temporoparietal junction to the anterior part of the ventral frontal cortex in a more profound manner. A better knowledge of the white matter anatomy of the VAN would help neurosurgeons to preserve this functional network and to prevent post-operative unilateral neglect.

ACKNOWLEDGEMENT

We thank Fanny Leluan-Higgins (native English speaker) for her insight and advice concerning this article.

CONFLICT OF INTEREST

None of the authors has any conflict of interest or financial disclosure relating to this study to declare. This manuscript has not been published elsewhere, in whole or in part, or submitted elsewhere for review.

AUTHOR CONTRIBUTIONS

All the authors played a full role in this study. Dr Bernard performed the dissections and the literature review and wrote the manuscript. Dr Bernard, Dr Lemée and Dr Ter Minassian performed the resting state and tractography study (acquisition of data). Dr Mazerand, Dr Lemée, Dr Ter Minassian and Dr Leiber revised and corrected the elements of the manuscript and figures relating to neurosurgery and radiology (critical review of the manuscript). Prof. Menei and Dr Ter Minassian initiated this study, and revised and improved the elements of the manuscript dealing with neuroscience (concept/design,

data analysis, critical review of the manuscript and approval of the article).

DATA AVAILABILITY STATEMENT

All authors shared new data along with the paper.

ORCID

Florian Bernard  <https://orcid.org/0000-0002-6110-2567>

REFERENCES

- Bartolomeo, P. (2013) *Attention Disorders after Right Brain Damage: Living in Halved Worlds*. London: Springer.
- Bartolomeo, P., Thiebaut de Schotten, M. and Doricchi, F. (2007) Left unilateral neglect as a disconnection syndrome. *Cerebral Cortex*, 17, 2479–2490.
- Bernard, F. and Menei, P. (2019) Oncology meets art: A way to understand patients' symptoms. *The Lancet Oncology*, 20, 27. [https://doi.org/10.1016/S1470-2045\(18\)30920-3](https://doi.org/10.1016/S1470-2045(18)30920-3)
- Bernard, F., Lemée, J.-M., Aubin, G., Ter Minassian, A. and Menei, P. (2018a) Using a virtual reality social network during awake craniotomy to map social cognition: Prospective trial. *Journal of Medical Internet Research*, 20, e10332.
- Bernard, F., Lemée, J.-M., Ter Minassian, A. and Menei, P. (2018b) Right hemisphere cognitive functions: From clinical and anatomic bases to brain mapping during awake craniotomy part I: clinical and functional anatomy. *World Neurosurgery*, 118, 348–359.
- Bernard, F., Zemmoura, I., Ter Minassian, A., Lemée, J.-M. and Menei, P. (2019) Anatomical variability of the arcuate fasciculus: a systematical review. *Surgical and Radiologic Anatomy*, 41(8), 889–900 <https://doi.org/10.1007/s00276-019-02244-5>
- Biswal, B., Yetkin, F.Z., Haughton, V.M. and Hyde, J.S. (1995) Functional connectivity in the motor cortex of resting human brain using echo-planar MRI. *Magnetic Resonance in Medicine*, 34, 537–541.
- Catani, M., Jones, D.K. and ffytche, D.H. (2005) Perisylvian language networks of the human brain. *Annals of Neurology*, 57, 8–16.
- Chechlacz, M., Rotshtein, P. and Humphreys, G.W. (2012) Neuroanatomical dissections of unilateral visual neglect symptoms: ALE meta-analysis of lesion-symptom mapping. *Frontiers in Human Neuroscience*, 6, 230.
- Chou, Y.-H., Panych, L.P., Dickey, C.C., Petrella, J.R. and Chen, N.-K. (2012) Investigation of long-term reproducibility of intrinsic connectivity network mapping: A resting-state fMRI study. *American Journal of Neuroradiology*, 33, 833–838.
- Committeri, G., Pitzalis, S., Galati, G., Patria, F., Pelle, G., Sabatini, U. et al. (2007) Neural bases of personal and extrapersonal neglect in humans. *Brain J Neurol*, 130, 431–441.
- Corbetta, M., Patel, G. and Shulman, G.L. (2008) The reorienting system of the human brain: from environment to theory of mind. *Neuron*, 58, 306–324.
- Corbetta, M. and Shulman, G.L. (2011) Spatial neglect and attention networks. *Annual Review of Neuroscience*, 34, 569–599.
- Coupé, P., Yger, P., Prima, S., Hellier, P., Kervrann, C. and Barillot, C. (2008) An optimized blockwise nonlocal means denoising filter for 3-D magnetic resonance images. *IEEE Transactions on Medical Imaging*, 27, 425–441.
- Damoiseaux, J.S., Rombouts, S.A.R.B., Barkhof, F., Scheltens, P., Stam, C.J., Smith, S.M. et al. (2006) Consistent resting-state networks across healthy subjects. *Proceedings of the National Academy of Sciences of the United States of America*, 103, 13848–13853.
- Doricchi, F., Thiebautdeschotten, M., Tomaiuolo, F. and Bartolomeo, P. (2008) White matter (dis)connections and gray matter (dys)functions in visual neglect: Gaining insights into the brain networks of spatial awareness. *Cortex*, 44, 983–995.

- Dorsaint-Pierre, R., Penhune, V.B., Watkins, K.E., Neelin, P., Lerch, J.P., Bouffard, M. et al. (2006) Asymmetries of the planum temporale and Heschl's gyrus: Relationship to language lateralization. *Brain J Neurol*, 129, 1164–1176.
- Farrant, K. and Uddin, L.Q. (2015) Asymmetric development of dorsal and ventral attention networks in the human brain. *Developmental Cognitive Neuroscience*, 12, 165–174.
- Fillard, P., Pennec, X., Arsigny, V. and Ayache, N. (2007) Clinical DT-MRI estimation, smoothing, and fiber tracking with log-Euclidean metrics. *IEEE Transactions on Medical Imaging*, 26, 1472–1482.
- Fox, M.D., Snyder, A.Z., Vincent, J.L., Corbetta, M., Van Essen, D.C. and Raichle, M.E. (2005) The human brain is intrinsically organized into dynamic, anticorrelated functional networks. *Proceedings of the National Academy of Sciences of the United States of America*, 102, 9673–9678.
- Fox, M.D., Corbetta, M., Snyder, A.Z., Vincent, J.L. and Raichle, M.E. (2006) Spontaneous neuronal activity distinguishes human dorsal and ventral attention systems. *Proceedings of the National Academy of Sciences of the United States of America*, 103, 10046–10051.
- Geng, J.J. and Vossel, S. (2013) Re-evaluating the role of TPJ in attentional control: contextual updating? *Neuroscience and Biobehavioral Reviews*, 37, 2608–2620.
- Gharabaghi, A., Kunath, F., Erb, M., Saur, R., Heckl, S., Tatagiba, M. et al. (2009) Perisylvian white matter connectivity in the human right hemisphere. *BMC Neuroscience*, 10, 15.
- Halligan, P.W. and Marshall, J.C. (1992) Left visuo-spatial neglect: a meaningless entity? *Cortex J Devoted Study Nerv Syst Behav*, 28, 525–535.
- He, B.J., Snyder, A.Z., Vincent, J.L., Epstein, A., Shulman, G.L. and Corbetta, M. (2007) Breakdown of functional connectivity in frontoparietal networks underlies behavioral deficits in spatial neglect. *Neuron*, 53, 905–918.
- Heilman, K.M. and Van Den Abell, T. (1980) Right hemisphere dominance for attention: the mechanism underlying hemispheric asymmetries of inattention (neglect). *Neurology*, 30, 327–330.
- Herbet, G., Yordanova, Y.N. and Duffau, H. (2017) Left spatial neglect evoked by electrostimulation of the right inferior fronto-occipital fasciculus. *Brain Topography*, 30, 747–756.
- Husain, M. and Kennard, C. (1996) Visual neglect associated with frontal lobe infarction. *Journal of Neurology*, 243, 652–657.
- Lemée, J.M., Bernard, F., Ter Minassian, A. and Menei, P. (2018) Right hemisphere cognitive functions: from clinical and anatomical bases to brain mapping in awake craniotomy Part II: Review about the previous experiences and reflexion about the neuropsychological tasks and their validity for awake surgery *reste de la ref ? Neurosurgery*;118:360–367.
- Jehkonen, M., Ahonen, J.P., Dastidar, P., Koivisto, A.-M., Laippala, P., Vilkki, J. et al. (2000) Visual neglect as a predictor of functional outcome one year after stroke. *Acta Neurologica Scandinavica*, 101, 195–201.
- Karnath, H.-O., Rengnig, J., Johannsen, L. and Rorden, C. (2011) The anatomy underlying acute versus chronic spatial neglect: A longitudinal study. *Brain*, 134, 903–912.
- Knecht, S., Deppe, M., Dräger, B., Bobe, L., Lohmann, H., Ringelstein, E.-B. et al. (2000) Language lateralization in healthy right-handers. *Brain*, 123(Pt 1), 74–81.
- Lawes, I.N.C., Barrick, T.R., Murugam, V., Spierings, N., Evans, D.R., Song, M. and Clark, C.A. (2008) Atlas-based segmentation of white matter tracts of the human brain using diffusion tensor tractography and comparison with classical dissection. *NeuroImage*, 39, 62–79.
- Le Goualher, G., Barillot, C. and Bizais, Y. (1997) Modeling cortical sulci with active ribbons. *International Journal of Pattern Recognition and Artificial Intelligence*, 11, 1295–1315.
- Lee, M.H., Smyser, C.D. and Shimony, J.S. (2013) Resting-state fMRI: A review of methods and clinical applications. *American Journal of Neuroradiology*, 34, 1866–1872.
- Lemée, J.-M., Berro, H., Bernard, F., Leiber, L.-M., Menei, P. and Ter Minassian, A. et al. (2019) Resting-state functional magnetic resonance imaging versus task-based activity for language mapping and correlation with perioperative cortical mapping. *Brain Behavior*, 9(10), e01362.
- Lunven, M. and Bartolomeo, P. (2017) Attention and spatial cognition: Neural and anatomical substrates of visual neglect. *Annals of Physical and Rehabilitation Medicine*, 60, 124–129.
- Lunven, M., Thiebaut De Schotten, M., Bours, C., Duret, C., Migliaccio, R., Rode, G. et al. (2015) White matter lesional predictors of chronic visual neglect: A longitudinal study. *Brain*, 138, 746–760.
- Magro, E., Moreau, T., Seizeur, R., Zemmoura, I., Gibaud, B. and Morandi, X. (2014) Connectivity within the primary motor cortex: A DTI tractography study. *Surgical and Radiologic Anatomy*, 36, 125–135. <https://doi.org/10.1007/s00276-013-1160-y>
- Marrelec, G., Krainik, A., Duffau, H., Péligrini-Issac, M., Lehéricy, S., Doyon, J. et al. (2006) Partial correlation for functional brain interactivity investigation in functional MRI. *NeuroImage*, 32, 228–237.
- Mars, R.B., Jbabdi, S., Sallet, J., O'Reilly, J.X., Crosson, P.I., Olivier, E. et al. (2011) Diffusion-weighted imaging tractography-based parcellation of the human parietal cortex and comparison with human and macaque resting-state functional connectivity. *Journal of Neuroscience*, 31, 4087–4100.
- Mesulam, M.M. (1990) Large-scale neurocognitive networks and distributed processing for attention, language, and memory. *Annals of Neurology*, 28, 597–613.
- Mesulam, M.M. (1999) Spatial attention and neglect: parietal, frontal and cingulate contributions to the mental representation and attentional targeting of salient extrapersonal events. *Philosophical Transactions of the Royal Society of London. Series B, Biological sciences*, 354, 1325–1346.
- Mitchell, T.J., Hacker, C.D., Breshears, J.D., Szrama, N.P., Sharma, M., Bundy, D.T. et al. (2013) A novel data-driven approach to preoperative mapping of functional cortex using resting-state functional magnetic resonance imaging. *Neurosurgery*, 73, 969–983.
- Mori, S. and van Zijl, P. (2007) Human white matter atlas. *American Journal of Psychiatry*, 164, 1005.
- Mort, D.J., Malhotra, P., Mannan, S.K., Rorden, C., Pambakian, A., Kennard, C. et al. (2003) The anatomy of visual neglect. *Brain J Neurol*, 126, 1986–1997.
- Parker, G.J.M., Luzzi, S., Alexander, D.C., Wheeler-Kingshott, C.A.M., Ciccarelli, O. and Lambon Ralph, M.A. (2005) Lateralization of ventral and dorsal auditory-language pathways in the human brain. *NeuroImage*, 24, 656–666.
- Rengachary, J., He, B.J., Shulman, G.L. and Corbetta, M. (2011) A behavioral analysis of spatial neglect and its recovery after stroke. *Frontiers in Human Neuroscience*, 5, 29.
- Sammler, D., Grosbras, M.-H., Anwander, A., Bestelmeyer, P.E.G. and Belin, P. (2015) Dorsal and ventral pathways for prosody. *Current Biology*, 25, 3079–3085.
- Schmahmann, J.D. and Pandya, D.N. (2007) Cerebral white matter-historical evolution of facts and notions concerning the organization of the fiber pathways of the brain. *J Hist Neurosci*, 16, 237–267.
- Shinoura, N., Suzuki, Y., Yamada, R., Tabei, Y., Saito, K. and Yagi, K. (2009) Damage to the right superior longitudinal fasciculus in the inferior parietal lobe plays a role in spatial neglect. *Neuropsychologia*, 47, 2600–2603.
- Shulman, G.L., Pope, D.L.W., Astafiev, S.V. and Corbetta, M. (2010) Right hemisphere dominance during spatial selective attention and target detection occurs outside the dorsal frontoparietal network. *Journal of Neuroscience*, 30, 3640–3651.
- Smith, S.M., Fox, P.T., Miller, K.L., Glahn, D.C., Fox, P.M., Mackay, C.E. et al. (2009) Correspondence of the brain's functional architecture during activation and rest. *Proceedings of the National Academy of Sciences of the United States of America*, 106, 13040–13045.

- Sridharan, D., Levitin, D.J., Chafe, C.H., Berger, J. and Menon, V. (2007) Neural dynamics of event segmentation in music: Converging evidence for dissociable ventral and dorsal networks. *Neuron*, 55, 521–532. <https://doi.org/10.1016/j.neuron.2007.07.003>
- Sridharan, D., Levitin, D.J. and Menon, V. (2008) A critical role for the right fronto-insular cortex in switching between central-executive and default-mode networks. *Proceedings of the National Academy of Sciences of the United States of America*, 105, 12569–12574.
- Sylvester, C.M., Barch, D.M., Corbetta, M., Power, J.D., Schlaggar, B.L. and Luby, J.L. (2013) Resting state functional connectivity of the ventral attention network in children with a history of depression or anxiety. *Journal of the American Academy of Child and Adolescent Psychiatry*, 52, 1326–1336.e5.
- Thiebaut de Schotten, M., Urbanski, M., Duffau, H., Volle, E., Lévy, R., Dubois, B., et al. (2005) Direct evidence for a parietal-frontal pathway subserving spatial awareness in humans. *Science*, 309, 2226–2228.
- Uddin, L.Q., Supekar, K.S., Ryali, S. and Menon, V. (2011) Dynamic re-configuration of structural and functional connectivity across core neurocognitive brain networks with development. *Journal of Neuroscience*, 31, 18578–18589.
- Umarova, R.M., Saur, D., Schnell, S., Kaller, C.P., Vry, M.-S., Glauche, V. et al. (2010) Structural connectivity for visuospatial attention: significance of ventral pathways. *Cerebral Cortex*, 20, 121–129.
- Urbanski, M., Thiebaut de Schotten, M., Rodrigo, S., Catani, M., Oppenheim, C., Touze, E. et al. (2008) Brain networks of spatial awareness: evidence from diffusion tensor imaging tractography. *Journal of Neurology, Neurosurgery and Psychiatry*, 79, 598–601.
- Vallar, G. and Perani, D. (1986) The anatomy of unilateral neglect after right-hemisphere stroke lesions. A clinical/CT-scan correlation study in man. *Neuropsychologia*, 24, 609–622.
- Vigneau, M., Beaucousin, V., Hervé, P.Y., Duffau, H., Crivello, F., Houdé, O. et al. (2006) Meta-analyzing left hemisphere language areas: phonology, semantics, and sentence processing. *NeuroImage*, 30, 1414–1432.
- Vuilleumier, P., Armony, J.L., Clarke, K., Husain, M., Driver, J. and Dolan, R.J. (2002) Neural response to emotional faces with and without awareness: Event-related fMRI in a parietal patient with visual extinction and spatial neglect. *Neuropsychologia*, 40, 2156–2166.
- Wedeen, V.J., Wang, R.P., Schmahmann, J.D., Benner, T., Tseng, W.Y.I., Dai, G. et al. (2008) Diffusion spectrum magnetic resonance imaging (DSI) tractography of crossing fibers. *NeuroImage*, 41, 1267–1277.
- Weinstein, D., Kindlmann, G. and Lundberg, E. (1999) Tensorlines: Advection-diffusion based propagation through diffusion tensor fields. In *Proceedings of the Conference on Visualization'99: Celebrating Ten Years*. IEEE Computer Society Press, pp. 249–253.
- Wiest-Daesslé, N., Prima, S., Morrissey, S.P. and Barillot, C. (2007) Validation of a new optimisation algorithm for registration tasks in medical imaging. In *2007 4th IEEE International Symposium on Biomedical Imaging: From Nano to Macro*. IEEE, pp. 41–44.
- Yagmurlu, K., Middlebrooks, E.H., Tanriover, N. and Rhoton, A.L. (2016) Fiber tracts of the dorsal language stream in the human brain. *Journal of Neurosurgery*, 124, 1396–1405.
- Zhang, R., Geng, X. and Lee, T.M.C. (2017) Large-scale functional neural network correlates of response inhibition: an fMRI meta-analysis. *Brain Structure and Function*, 222, 3973–3990.

How to cite this article: Bernard F, Lemee J-M, Mazerand E, Leiber L-M, Menei P, Ter Minassian A. The ventral attention network: the mirror of the language network in the right brain hemisphere. *J. Anat.* 2020;237:632–642. <https://doi.org/10.1111/joa.13223>

❖ Article n°5 :

Oncology meets Art: a way to understand patient's symptoms.

Bernard F, Menei P

Lancet Oncology, (publié IF= 35,38)



Art of Medicine

Oncology meets Art: a way to understand patients' symptoms

2 years ago, during a regular outpatient consultation, a 55 year-old literate patient came into our office. He had been experiencing stressful paroxysmal phenomenon for a month. Indeed, he described to us what he called "a Francis Bacon self-portrait experience": he was seeing himself outside of his body, with his face being distorted. To help us understand, he had brought with him a reproduction of Francis Bacon's *Study for Self-Portrait* (1973; image).

Francis Bacon (Oct 28, 1909, to April 28, 1992) was an Irish-born, British figurative painter known for his bold, grotesque, emotionally charged, raw imagery. He is best known for his depictions of popes, crucifixions, and portraits of close friends. Following the suicide of his friend George Dyer in 1971, his art became more sombre, inward-looking, and preoccupied with the passage of time and death. The climax of this later period is marked by masterpieces, including his *Study for Self-Portrait*.

The patient had also brought with him his MRI scans showing a low-grade glioma of the right hemisphere, involving the temporoparietal junction. His neurological examination was normal. So, where did his surrealist symptoms originate from? As clinicians, we were confronted with an issue: could this out-of-body experience be considered as a neurological symptom linked to his glioma? According to the literature, this kind of experience results from a disturbance of the visuospatial representation of the patient's own body, called autoscopia. The term autoscopia comes from the Greek words "autos" (self) and "skopeo" (looking at). It is used to define psychic visual experiences in which the patient perceives their body either from an internal point of view (as in a mirror) or from an external point of view (out-of-body experience). Among various psychiatric and neurological diseases, partial epilepsy is the main cause. Several neuropsychological and neuroimaging studies implicate the right temporoparietal junction in autoscopia.

Knowing the importance of the right temporoparietal junction to preserve cognitive functions, we decided to do an awake brain-mapping surgery by cortical electrical stimulation to remove the patient's tumour, while aiming to preserve his visuospatial representation. During the procedure, we induced similar distorting so-called Francis Bacon experiences by electrically stimulating the right temporoparietal cortex, at the level of the intraparietal sulcus. After removal of the tumour, the patient was neurologically intact and no longer presented this ictal symptom.

As the patient's analogy with Francis Bacon's self-portrait curiously suggested, autoscopic phenomena

are considered to be at the origin of many self-portrait paintings by Durer, Rembrandt, Velazquez, or Schiele. All seem to have experienced, at least once, these type of symptoms, which translated into some of the most famous self-portraits ever painted. Francis Bacon did not have a brain tumour, and the objective of this Perspectives piece is not to discuss what was happening in his brain when he created his self-portraits. However, this case emphasises how paintings can help express one's feelings or symptoms without words.

Interestingly, the more the patient has large cultural baggage, the more it allows him to accurately describe his own perceptions. In the doctor's brain, this surrealist experience becomes more realistic and tangible as advances in neuropsychological and neuroimaging studies made this type of symptom a medical reality. The experience shared by our patient is, to our knowledge, the first report of dysmorphic autoscopia, reminding us of the surrealist, abstract work of Francis Bacon. In addition to the cultural inference, this case highlights the importance of preserving right hemisphere functions while treating patients, especially their visuospatial cognition.

Florian Bernard, Philippe Menei

Centre Hospitalier Universitaire d'Angers, Angers, France (FB, PM)
bernardflorian.bf@gmail.com

For the studies discussing the right temporoparietal junction in autoscopia see *Front Neurol Neurosci* 2018; **41**: 1-13 and *Brain Res Brain Res Rev* 2005; **50**: 184-99

For more on brain anatomy and cognitive functions see *World Neurosurg* 2018; **118**: 348-359

For more on brain mapping surgery see *Lancet Neurol* 2005; **4**: 476-86 and *Nat Rev Neurol* 2015; **11**: 255-65

For more on autoscopia symptoms see *Neuroscientist* 2005; **11**: 16-24



Francis Bacon, *Self-Portrait* (1973)

This image was reproduced with permission of the copyright holder (The Estate of Francis Bacon, all rights reserved. ADAGP, Paris and DACS, London) for print and online publication by *The Lancet Oncology*.

❖ Article n°6 :

Using a VR social network during awake craniotomy to map the social cognition: Prospective Trial

Bernard F, Lemée JM, Aubin G, Ter Minassian A, Menei P

Journal of Medical Internet Research, (publié IF= 4,8)

Short Paper

Using a Virtual Reality Social Network During Awake Craniotomy to Map Social Cognition: Prospective Trial

Florian Bernard^{1,2*}, MD; Jean-Michel Lemée^{1,3}, MD, PhD; Ghislaine Aubin^{4*}, PhD; Aram Ter Minassian^{5,6*}, MD, PhD; Philippe Menei^{1*}, MD, PhD

¹Neurosurgery, CHU Angers, Angers, France

²Laboratoire d'Anatomie, Faculté de Médecine d'Angers, Angers, France

³CRCINA, INSERM, Université de Nantes, Université d'Angers, Angers, France

⁴CHU Angers, Département d'Ortophonie, Angers, France

⁵CHU Angers, Département d'Anesthésie-Réanimation, Angers, France

⁶CHU Angers, LARIS EA 7315, Image Signal et Sciences du Vivant, Angers, France

*these authors contributed equally

Corresponding Author:

Philippe Menei, MD, PhD

Neurosurgery

CHU Angers

Angers,

France

Phone: 33 680353917

Email: phmenei@chu-angers.fr

Abstract

Background: In awake craniotomy, it is possible to temporarily inactivate regions of the brain using direct electrical stimulation, while the patient performs neuropsychological tasks. If the patient shows decreased performance in a given task, the neurosurgeon will not remove these regions, so as to maintain all brain functions.

Objective: The objective of our study was to describe our experience of using a virtual reality (VR) social network during awake craniotomy and discuss its future applications for perioperative mapping of nonverbal language, empathy, and theory of mind.

Methods: This was a single-center, prospective, unblinded trial. During wound closure, different VR experiences with a VR headset were proposed to the patient. This project sought to explore interactions with the neuropsychologist's avatar in virtual locations using a VR social network as an available experience.

Results: Three patients experienced VR. Despite some limitations due to patient positioning during the operation and the limitation of nonverbal cues inherent to the app, the neuropsychologist, as an avatar, could communicate with the patient and explore gesture communication while wearing a VR headset.

Conclusions: With some improvements, VR social networks can be used in the near future to map social cognition during awake craniotomy.

Trial Registration: ClinicalTrials.gov NCT03010943; <https://clinicaltrials.gov/ct2/show/NCT03010943> (Archived at WebCite at <http://www.webcitation.org/70CYDil0P>)

(*J Med Internet Res* 2018;20(6):e10332) doi:[10.2196/10332](https://doi.org/10.2196/10332)

KEYWORDS

virtual reality; neurosurgery; social cognition; awake surgery

Introduction

Social cognition includes all complex cognitive processes involved in social interaction such as nonverbal language (facial and bodily nonverbal cues as affective prosody), empathy, and

theory of mind (ToM). Following brain surgery, the impairment of nonverbal cue decoding, such as expression of facial emotions, eye gaze, body gestures, and prosody can lead to ToM deficits. Patients often experience difficulties with understanding humor and as well as conceptualizing and understanding

thoughts and beliefs, emotions, feelings and desires, behaviors, actions, and intentions of other people. In recent times, these sequelae were largely misunderstood by neurosurgeons and compared with postsurgical impairment of language or executive functions, with few evaluations concerning social cognition having been published [1-6].

As previously done for language, it is now possible to propose a substrate for social cognition based on parallel and large-scale interactive distributed brain networks [7]. However, unlike language, this substrate cannot be reliably localized based on anatomical criteria alone, mostly due to the individual variations. Individual brain mapping by direct electrical stimulation (DES) during awake craniotomy is therefore essential. The procedure has been well documented [8]. Briefly, it is possible to temporarily inactivate regions of the brain using DES, while patients perform neuropsychological tasks. If a patient shows decreased performance in a given task, the neurosurgeon will not remove these regions, so as to maintain brain function.

Compared with motor or language mapping, nonverbal language mapping has not been performed yet. This is due to the difficulties involved in adapting classic bedside tasks to awake surgery conditions.

In 2014, we started to explore the use of virtual reality (VR) during awake craniotomy with patients wearing a virtual reality headset (VRH). We previously developed an app for VRH to explore visuospatial cognition [9]. We are now performing a larger study evaluating the tolerance and safety of VRH and 3D immersive experiences in patients undergoing awake craniotomy and brain mapping by DES. Herein, we describe a VR experience, the interaction with an avatar using a social VR platform, and highlight its advantages, limitations, and future applications for perioperative mapping of social cognition.

Methods

This was a single-center, prospective, unblinded trial (ClinicalTrials.gov base identifier: NCT03010943), which was performed in compliance with all regulatory and ethical guidelines for clinical research. All patients signed a written informed consent.

The inclusion criterion was patients aged >18 years who were hospitalized for treatment of a tumor or any type of surgical lesion near the language region of the brain. The exclusion criteria were all contraindications to an awake surgery (cognitive impairment, aphasia, and morbid anxiety). The main objective was to assess procedural feasibility and safety.

This study was performed using a Samsung Gear VR combined with a Samsung S7 smartphone (android platform) and headphones. After general and local anesthesia, the patient was positioned lying on his side, with a rigid pin fixation of the head. Once the craniotomy was completed and the dura was opened, we awakened the patient. Electroencephalography signals were recorded using a subdural electrode. After the cortex was exposed, language mapping was performed by a neuropsychologist using an image denomination task on a digital tablet. The mapping took place as previously described [10,11]. DES was applied with a bipolar electrode delivering a biphasic

current (60Hz, 1 ms pulse width, current amplitude ranging from 2 to 8 mA over 2-3 s).

To prevent interference with the routine procedure of awake craniotomy and language brain mapping, we decided to duplicate the image naming task viewed in VRH (two dimensions, 2D) and then in stereoscopy (three dimensions, 3D; an app based on Unity 3D software with an interface allowing VRH communication via a computer and Bluetooth connection). Further VR experiences with a relaxing film were proposed at the end of the tumor resection while the wound was being closed. These options included interaction with the neuropsychologist's avatar in virtual locations; this option is the focus of this paper. For this experience, we used the vTime app, a social network in VR [12]. This app allows users to create an avatar and socialize with other people in virtual environments. The avatar can be piloted on a smartphone or in conjunction with a VRH using a game controller.

Results

A total of 3 patients used the vTime app during wound closure (2 males and one female; mean age, 54 years). Only 1 participant had a previous VR experience. Before the surgery, all the patients were trained without any issues.

Patients used a standard avatar and an account opened by the Department of Neurosurgery to preserve anonymity. They interacted with an avatar piloted by the neuropsychologist, who also wore a VRH, under the control of a physician who participated in the meeting and controlled the scene on a smartphone connected to the app. This allowed continual monitoring of the operation ([Multimedia Appendix 1](#)). The mean time of connection and interaction was 10 minutes.

During DES of the left inferior frontal gyrus (pars opercularis), all patients failed to perform the 2D and 3D language and motor tasks. All deficits disappeared when DES was stopped, and the patients were allowed to recover. The stimulated areas were not resected. Patients were neurologically intact.

During the social cognition experiences, the patients passively viewed the neuropsychologist's avatar and reproduced and commented on his gestures. Alternatively, they assumed more active roles, controlling their own avatars with a game controller in their hands ([Multimedia Appendix 2](#)).

Despite the discomfort associated with the awake surgery environment and other tasks completed with VRH, no patient experienced eye strain, nausea, or any sign of "VR disease." No seizures occurred while the patients looked at the VR experience.

Discussion

Principal Findings

As described previously, social cognition includes nonverbal language, empathy, and ToM. These functions are explored at the bedside by complex neuropsychological tasks batteries including story movies, comic strips, or interactive games that depict a short story. These tasks require time to be performed, meaning they are not compatible with the brain mapping

conditions (DES length inferior to 4 seconds, fast response, and no ambiguity in the answer).

VR approaches that allow interactions with an avatar are commonly used in cognitive neurosciences [13]. There is consistent evidence that avatars are perceived in a similar manner to real human beings and can be used to explore the complex processes of nonverbal language, empathy, and ToM [14]. In VR, the social interactions are governed by the same social norms as social interactions in the real world (for example social norms related to gender, interpersonal distance, and eye gaze) [15].

VR can imitate complex social situations, even for the patients undergoing awake craniotomies. The potential of VR lies in its increased real-life environment validity compared with screen-based studies. Rather than being a passive observer of stimuli on a computer screen, participants in virtual environments become part of the depicted scene. Although an increase in ecological validity often results in a decrease in experimental control, immersive VR has the potential to combine the naturalness of everyday interactions with experimental controls required during brain mapping procedures.

Instead of developing a specific app to test and map social cognition during awake brain surgery, we decided to test the potential of the available VR social networks. Several VR social platforms are already available, such as vTime [12], Oculus, Facebook Spaces, PLUTOVR, and AltspaceVR. Interestingly, these platforms take different approaches for conveying nonverbal language: arms, hands, head, and mouth movement and gaze.

For our trial, we chose Samsung VR, a low-cost, high-quality, customizable wireless device, with an optional pad control and a game controller. The VR social network vTime is compatible with the Samsung VRH [12]. The vTime app allows interaction with several avatars and positional control in different virtual environments. The avatar can point anywhere within the scene and produce gestural expressions such as OK, Thumbs Up, Clap,

Thumbs Down, Blow Kiss, etc [12]. It is also possible for the user to touch other avatars or to take control of his or her personal space.

We demonstrated that patients undergoing awake craniotomies can wear a VRH and interact with an avatar piloted by a neuropsychologist.

Limitations

We experienced some difficulties and limitations using vTime [12]. During an awake surgery, the patient is usually lying on his or her back or side with the head immobilized using a Mayfield skull clamp. The vTime app [12], as with most VR social experiences, is not well-adapted for use in this position and cannot make use of the 360 degree view. Further, there is no option to control the orientation of the virtual environment. In our experience, vTime can only be used with side-lying patients. Restrictions of neck, limbs, and face movements can affect psychological testing. If the patient does not lie on his or her side to visualize the neuropsychologist avatar, he or she cannot be tested. Despite this limitation, all awake surgeries were performed in our institution with the patient lying on his or her side. Mobility restrictions limit the patient's ability to explore the 360-degree environment, potentially limiting the use of vTime [12] to explore visuospatial cognition. Moreover, it is not possible to control facial expression and eye gaze, which are potent nonverbal language cues. An app dedicated to awake surgery is currently in development to overcome this limitation.

Conclusions

We showed that it is possible to use a VR social network during awake craniotomy and to test gesture communication. Progress in VR development is currently promising, and some VRHs even allow facial expressions to be captured and transferred to a virtual avatar in real time, opening a new level of virtual human interaction. We are convinced that these improvements could be applied to further research for awake craniotomy, nonverbal language, empathy, and ToM in the near future.

Acknowledgments

We thank Gwenaëlle Soulard (CHU, Angers) for her technical help.

Conflicts of Interest

None declared.

Multimedia Appendix 1

During awake brain surgery, the patient and the neuropsychologist (A) performing a language task; (B) Direct electrical stimulation and mapping of the cortex during the task; and (C) and (D) the patient and the neuropsychologist communicating with the VR social network.

[[PNG File, 1MB - jmir_v20i6e10332_app1.png](#)]

Multimedia Appendix 2

Video showing interaction between the patients and the neuropsychologist avatar using Vtime [12] in order to test social cognition during awake brain surgery.

[MP4 File (MP4 Video), 95MB - [jmir_v20i6e10332_app2.mp4](#)]

References

1. Richard-Mornas A, Mazzietti A, Koenig O, Borg C, Convers P, Thomas-Antérion C. Emergence of hyper empathy after right amygdalohippocampectomy. *Neurocase* 2014;20(6):666-670. [doi: [10.1080/13554794.2013.826695](#)] [Medline: [23944742](#)]
2. Happé F, Malhi GS, Checkley S. Acquired mind-blindness following frontal lobe surgery? A single case study of impaired 'theory of mind' in a patient treated with stereotactic anterior capsulotomy. *Neuropsychologia* 2001;39(1):83-90. [Medline: [11115657](#)]
3. Rowe AD, Bullock PR, Polkey CE, Morris RG. "Theory of mind" impairments and their relationship to executive functioning following frontal lobe excisions. *Brain* 2001 Mar;124(Pt 3):600-616. [Medline: [11222459](#)]
4. Milesi V, Cekic S, Péron J, Frühholz S, Cristinzio C, Seeck M, et al. Multimodal emotion perception after anterior temporal lobectomy (ATL). *Front Hum Neurosci* 2014;8:275 [FREE Full text] [doi: [10.3389/fnhum.2014.00275](#)] [Medline: [24839437](#)]
5. Nakajima R, Yordanova YN, Duffau H, Herbet G. Neuropsychological evidence for the crucial role of the right arcuate fasciculus in the face-based mentalizing network: A disconnection analysis. *Neuropsychologia* 2018 Jan 26:---. [doi: [10.1016/j.neuropsychologia.2018.01.024](#)] [Medline: [29360518](#)]
6. Herbet G, Lafargue G, Moritz-Gasser S, Menjot DCN, Costi E, Bonnetblanc F, et al. A disconnection account of subjective empathy impairments in diffuse low-grade glioma patients. *Neuropsychologia* 2015 Apr;70:165-176. [doi: [10.1016/j.neuropsychologia.2015.02.015](#)] [Medline: [25687031](#)]
7. Bernard F, Lemée J, Ter MA, Menei P. Right hemisphere cognitive functions: from clinical and anatomical bases to brain mapping during awake craniotomy Part I: Clinical and functional anatomy. *World Neurosurg* 2018:---.
8. Fernández CA, Moritz-Gasser S, Martino J, Martinoni M, Matsuda R, Duffau H. Selection of intraoperative tasks for awake mapping based on relationships between tumor location and functional networks. *J Neurosurg* 2013 Dec;119(6):1380-1394. [doi: [10.3171/2013.6.JNS122470](#)] [Medline: [24053503](#)]
9. Mazerand E, Le RM, Hue S, Lemée J, Klinger E, Menei P. Intraoperative Subcortical Electrical Mapping of the Optic Tract in Awake Surgery Using a Virtual Reality Headset. *World Neurosurg* 2017 Jan;97:424-430. [doi: [10.1016/j.wneu.2016.10.031](#)] [Medline: [27756671](#)]
10. Ojemann G, Ojemann J, Lettich E, Berger M. Cortical language localization in left, dominant hemisphere. An electrical stimulation mapping investigation in 117 patients. *J Neurosurg* 1989 Sep;71(3):316-326. [doi: [10.3171/jns.1989.71.3.0316](#)] [Medline: [2769383](#)]
11. Duffau H, Capelle L, Denvil D, Sichez N, Gatignol P, Taillandier L, et al. Usefulness of intraoperative electrical subcortical mapping during surgery for low-grade gliomas located within eloquent brain regions: functional results in a consecutive series of 103 patients. *J Neurosurg* 2003 Apr;98(4):764-778. [doi: [10.3171/jns.2003.98.4.0764](#)] [Medline: [12691401](#)]
12. vTime: The VR Sociable Network - Out Now for Windows Mixed Reality, Gear VR, Oculus Rift, iPhone, Google Daydream, and Google Cardboard Internet URL: <https://vtime.net/> [accessed 2018-05-11] [WebCite Cache ID 6zKYC8j6Q]
13. Georgescu AL, Kuzmanovic B, Roth D, Bente G, Vogeley K. The use of virtual characters to assess and train non-verbal communication in high-functioning autism. *Front Hum Neurosci* 2014;8:807 [FREE Full text] [doi: [10.3389/fnhum.2014.00807](#)] [Medline: [25360098](#)]
14. de BAW, de GB. Is it the real deal? Perception of virtual characters versus humans: an affective cognitive neuroscience perspective. *Front Psychol* 2015;6:576 [FREE Full text] [doi: [10.3389/fpsyg.2015.00576](#)] [Medline: [26029133](#)]
15. Yee N, Bailenson JN, Urbanek M, Chang F, Merget D. The unbearable likeness of being digital: the persistence of nonverbal social norms in online virtual environments. *Cyberpsychol Behav* 2007 Feb;10(1):115-121. [doi: [10.1089/cpb.2006.9984](#)] [Medline: [17305457](#)]

Abbreviations

DES: direct electrical stimulation
RCT: randomized controlled trial
ToM: theory of mind
VR: virtual reality
VRH: virtual reality headset

Edited by G Eysenbach; submitted 07.03.18; peer-reviewed by L Moscote, A Thapa; comments to author 10.05.18; revised version received 14.05.18; accepted 19.05.18; published 26.06.18

Please cite as:

Bernard F, Lemée JM, Aubin G, Ter Minassian A, Menei P

Using a Virtual Reality Social Network During Awake Craniotomy to Map Social Cognition: Prospective Trial

J Med Internet Res 2018;20(6):e10332

URL: <http://www.jmir.org/2018/6/e10332/>

doi: [10.2196/10332](https://doi.org/10.2196/10332)

PMID:

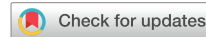©Florian Bernard, Jean-Michel Lemée, Ghislaine Aubin, Aram Ter Minassian, Philippe Menei. Originally published in the Journal of Medical Internet Research (<http://www.jmir.org>), 26.06.2018. This is an open-access article distributed under the terms of the Creative Commons Attribution License (<https://creativecommons.org/licenses/by/4.0/>), which permits unrestricted use, distribution, and reproduction in any medium, provided the original work, first published in the Journal of Medical Internet Research, is properly cited. The complete bibliographic information, a link to the original publication on <http://www.jmir.org/>, as well as this copyright and license information must be included.

† Article n°7 :

Immersing patients in a virtual reality environment for brain mapping during awake surgery. Safety study

Delion M, Klinger E, Bernard F, Ter Minassian A, Menei P

World Neurosurgery, (publié IF= 1,9)



Immersing Patients in a Virtual Reality Environment for Brain Mapping During Awake Surgery: Safety Study

Matthieu Delion¹, Evelyne Klinger⁴, Florian Bernard¹, Ghislaine Aubin^{2,5,8}, Aram Ter Minassian^{3,6}, Philippe Menei^{1,7}

BACKGROUND: Brain mapping by direct electrical stimulation during awake craniotomy is now a standard procedure that reduces the risk of permanent neurologic deficits. Virtual reality technology immerses the patient in a virtually controlled, interactive world, offering a unique opportunity to develop innovative tasks for perioperative mapping of complex cognitive functions. The objective of this prospective single-center study was to evaluate the tolerance and safety of a virtual reality headset (VRH) and immersive virtual experiences in patients undergoing awake craniotomy and brain mapping by direct electrical stimulation.

METHODS: The study included 30 patients with a brain tumor near the language area. Language mapping was performed with a naming task, DO 80, presented on a digital tablet and then in two-dimensional and three-dimensional formats through a VRH. During wound closure, different virtual reality experiences were proposed to the patient, offering different types of virtual motion or interaction with an avatar piloted by a neuropsychologist.

RESULTS: Two patients could not use the VRH owing to technical issues. No procedure was aborted, no patient experienced virtual reality sickness and all patients reported they would repeat the procedure. Despite a high rate of intraoperative focal seizures, there was no argument to attribute the seizures to VRH use.

CONCLUSIONS: This study shows that it is possible during awake brain surgery to immerse the patient in a virtual environment and to interact with the patient, opening the field of new brain mapping procedures for complex cognitive functions.

INTRODUCTION

Brain mapping by direct electrical stimulation (DES) during awake craniotomy is now a standard procedure in adults and children, reducing the risk of permanent neurologic deficits and increasing the extent of resection of tumors¹ or the success of epilepsy surgery. The procedure has been well documented. Briefly, it is possible to temporarily inactivate regions of the brain using DES while patients perform neuropsychological tasks. If a patient shows decreased performance in a given task, the neurosurgeon will not remove these regions, so as to maintain brain function. Language networks are currently mapped in the dominant hemisphere.² Compared with language mapping, few attempts have been published concerning other cognitive functions, such as frontal executive function³ or right hemisphere cognitive functions^{4,5} such as visuospatial and social cognition.^{4,13} This is due to the difficulties involved in adapting classic bedside neuropsychological tasks to awake surgery conditions.

Taking these limitations into account, we started to explore the use of virtual reality (VR) during awake craniotomy with the

Key words

- Awake surgery
- Brain mapping
- Neurosurgery
- Social cognition
- Virtual reality

Abbreviations and Acronyms

- 2D:** Two-dimensional
- 3D:** Three-dimensional
- DES:** Direct electrical stimulation
- EEG:** Electroencephalography
- IOS:** Intraoperative seizure
- VR:** Virtual reality
- VRH:** Virtual reality headset

From the Departments of ¹Neurosurgery, ²Neurology, and ³Anesthesia, Critical Care and Emergency, University Hospital of Angers, Angers; ⁴French Institute for Research on Handicap (IFRH), France, EA4136, University of Bordeaux, Bordeaux; ⁵Laboratoire de Psychologie des Pays de la Loire (LUNAM) UPRES EA 4638, ⁶Laboratoire Angevin de Recherche en Ingénierie des Systèmes (LARIS) EA 7315, Image Signal et Sciences du Vivant, and ⁷Centre de Recherche en Cancérologie et Immunologie Nantes Angers (CRCINA), Institut National de la Santé et de la Recherche Médicale (INSERM), University of Nantes, University of Angers, Angers; and ⁸Neuropsychological Unit, Department of Rehabilitation Medicine, Regional Centre for Functional Rehabilitation, Angers, France

To whom correspondence should be addressed: Philippe Menei, M.D., Ph.D.
[E-mail: phmenei@chu-angers.fr]

Citation: *World Neurosurg.* (2020) 134:e937-e943.
<https://doi.org/10.1016/j.wneu.2019.11.047>

Journal homepage: www.journals.elsevier.com/world-neurosurgery

Available online: www.sciencedirect.com

1878-8750/\$ - see front matter © 2019 Elsevier Inc. All rights reserved.

patient wearing a virtual reality headset (VRH). VR is a domain with growing applications in the field of neuroscience. This computer technology generates realistic images, sounds, and other sensations that simulate a user's physical presence in a virtual or imaginary environment. A person using VRH is able to "look around" the artificial world, move around in it, and interact with virtual features or items. As such, VRH offers a unique opportunity to develop innovative tasks for perioperative mapping of complex cognitive functions. Since 2014, we have developed different approaches with different types of headsets and software. The first application developed was for avoiding postoperative hemianopsia and unilateral neglect.⁹ After this pilot study, at the request of the regulation authorities (Agence Nationale de Sécurité du Médicament et des Produits de Santé), we performed a safety study on the use of a VRH during awake craniotomy and DES of the brain. Indeed, VR can induce motion sickness (known as cybersickness or virtual reality sickness),^{14,15} and the hazard of induced seizure, as for all screen video games, is an issue to explore.^{16,17} In this article, we present the results of a study that evaluated the tolerance and safety of a VRH and immersive experiences in patients undergoing awake craniotomy and brain mapping by DES. Advantages, limitations, and future applications of a VRH for perioperative mapping of visuospatial and social cognitions are discussed.

MATERIALS AND METHODS

Study Design

This is a single-center, prospective, open-label study. The study protocol was evaluated and approved by the Agence Nationale de Sécurité du Médicament et des Produits de Santé, the ethics committee of the institution, and the Commission Nationale de l'Informatique et des Libertés. All patients signed a written informed consent form before inclusion in the study. This study is registered in at ClinicalTrials.gov (ClinicalTrials.gov Identifier: NCT03010943).

Patients >18 years old, hospitalized for a brain tumor near the language area (determined by a neuropsychological evaluation and resting-state functional magnetic resonance imaging), in the left or right hemisphere, who gave written informed consent were included. Exclusion criteria were all contraindications to awake

surgery (cognitive impairment related or not related to the surgical lesion, aphasia, morbid anxiety).

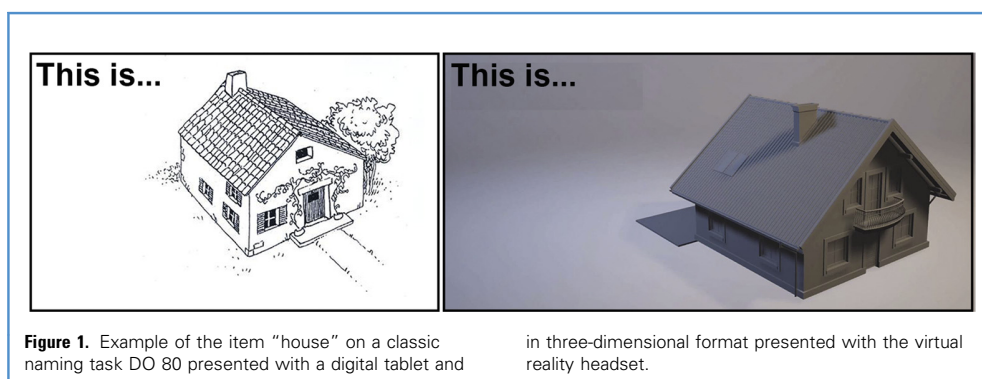
Materials


This study was performed using a Samsung Gear VRH (Samsung, Seoul, South Korea) combined with a Samsung S7 smartphone (android platform) and headphones. This equipment is wireless (smartphone battery). The VRH has a visual field of 96°, interpupillary distance of 55–71 mm, latency of <20 ms, refresh rate of 60 Hz, and adjustable focus. The VRH has a presence sensor and allows tracking of the head orientation by accelerometer, gyroscope, and geomagnetic sensor.

For this study, 2 applications have been developed. The first one is based on a three-dimensional (3D) motor (Unity 3D software; Unity Technologies, San Francisco, California, USA) to present two-dimensional (2D) or 3D objects in stereoscopy. The second one is an interface allowing the VRH to communicate with a personal computer through a Bluetooth (Bluetooth SIG, Inc., Kirkland, Washington, USA) connection, from which the tasks can be selected.

The picture-naming task, DO 80, was duplicated in the VRH in 2 versions. The first one, in 2 dimensions, includes the same images as the classic naming task DO 80 presented with a digital tablet (an image with the sentence in French "This is ...") in a virtual empty open space. The second version includes the same items, but in stereoscopy (3 dimensions), rotating in a virtual empty space (Figure 1). The images are always orientated in function according to the head position.

Other VR play experiences with headphones were proposed at the end of the tumor resection, during the closure time (Figure 2): Zen parade (designed by Kevin Mack; <http://www.shapespacevr.com/zen-parade.html>), a 3D animated world of moving living sculptures; Fractal fantasy (designed by Julius Horsthuis; <http://www.julius-horsthuis.com/vr-projects#>), a virtual fractal world with visually induced illusions of self-motion; Ocean Rift (Picselica Ltd., St. Asaph, United Kingdom; <https://www.oculus.com/experiences/rift/1253785157981619/>), a virtual safari allowing the user to explore an underwater world full of life including dolphins, sharks, and turtles; a social VR application vTime (<https://vtime.net/>), allowing interactions in a virtual location with an avatar piloted by the neuropsychologist who also wore a VRH, under the control of a physician who participated in the meeting and





controlled the scene on a smartphone connected to the app. These VR experiences are available in the Oculus store (Oculus VR, Menlo Park, California, USA); however, the authors provided us with improved versions. All these experiences offer a different type of virtual motion (motion around the virtual environment, passive motion of the patient himself or herself, active motion of the patient piloted by a game controller, motion of an avatar piloted by a game controller).

Operative Procedure

A preoperative neuropsychological evaluation and imaging (including anatomic magnetic resonance imaging, diffusion tensor imaging, and resting-state functional magnetic resonance imaging) were performed. After patients had signed the informed consent form, they were trained with the VRH in the surgical position. They performed the DO 80 image test in VR conditions and were asked to choose or classify their favorite VR play experiences.

During awake craniotomy, sedation was achieved using target-controlled infusion of remifentanyl and propofol, and ventilation was controlled using a laryngeal mask airway. Patients were positioned in a supine or lateral position, according to the location of the tumor, with a rigid pin fixation of the head in a Mayfield frame. The scalp incision and the pin sites of the Mayfield headholder were infiltrated with diluted ropivacaine. Local anesthetic blocks were also performed on the supraorbital, temporal, retroauricular, and occipital nerves. Once the craniotomy, guided by neuronavigation (BrainLab, Munich, Germany), was completed and the dura mater was opened, all sedative drugs were stopped, and the patient progressively awakened. The laryngeal mask airway was removed when the patient was awake. Electroencephalography (EEG) signals were recorded using a 4-plot subdural electrode (4-channel Eclipse neurovascular workstation; Medtronic Xomed, Inc., Jacksonville, Florida, USA), placed directly adjacent to, but not over, the area being mapped.

The first language mapping was performed by the neuropsychologist, with a naming task DO 80 presented on a digital tablet.

The mapping was completed as previously described.¹⁸ DES was applied with a bipolar electrode (tip-to-tip distance 5 mm) delivering a biphasic current (parameters: 60 Hz, 1-ms pulse width, current amplitude 1–10 mA). We conducted DES on the exposed cortical area, stimulating 1 cm² at each site. To be recognized as a language site, sites at which interference was identified were meticulously tested at least 3 times (not consecutively). Eloquent areas were defined by speech arrest, anomia, dysarthria, or semantic or phonemic paraphasia and were tagged on the cortex. Then a second set of mapping was performed, using the VRH, with the 2D DO 80 and then with 3D DO 80 (Figure 3). The differences in response were carefully noted, and the position of the eloquent area was located on the neuronavigation system. If necessary, other tasks were used (e.g., spontaneous speech production, counting, reading, complex word repetition, pyramid, and palm tree tests on a digital tablet).

If the functional cortex was identified, a minimum margin of 1 cm was respected during the resection. After tumor debulking, the resection was continued during spontaneous speech, as necessary, with subcortical electrostimulation. At the end of resection, another mapping was completed when necessary, using the DO 80 on the digital tablet, the 2D DO 80 with the VRH, and the 3D DO 80 with the VRH in succession. At the end of the resection during the closure time, the patient was invited to visualize VR play experiences (Figure 3). At this time, antalgic titration with oxycodone was performed if necessary.

Heart rate, blood pressure, and the EEG signal were continuously recorded during the procedure. Any drug administration different from the predefined protocol was noted. Tolerance was also assessed using questionnaires filled out by the patient, anesthesiologist, neuropsychologist, and neurosurgeon.

Postoperative management included 4 hours of observation in the postanesthesia care unit. Patients completed questionnaires

about their feelings when wearing a VRH and watching VR images after the first VRH sessions and 48 hours after surgery.

RESULTS

The study included 30 patients, 18 men and 12 women, with a median age of 45 (range, 23–75). Two patients were included twice, having a second surgery for recurrence. Patients were initially hospitalized for seizures ($n = 16$, including 4 with status epilepticus), motor or speech deficits ($n = 4$), cognitive deficits ($n = 2$), or headaches ($n = 2$). For 6 patients, the tumor was discovered through the monitoring of their primary cancer. Of patients, 27 were right-handed, and 3 were left-handed. The tumors were in the left hemisphere in 25 patients and in the right hemisphere in 5 patients (2 right-handed and 3 left-handed).

The mean tumor diameter was 47 mm. Tumor localization was in the frontal lobe ($n = 15$), parietal lobe ($n = 9$), temporoparietal junction ($n = 3$), insula ($n = 2$), and temporal lobe ($n = 1$). The lesions were glioblastoma ($n = 12$, including primary glioblastoma [$n = 9$], secondary glioblastoma [$n = 1$], and recurrent glioblastoma [$n = 2$]), anaplastic astrocytoma ($n = 9$, including 1 recurrent anaplastic astrocytoma), grade 2 oligodendroglioma ($n = 1$), or metastasis ($n = 8$).

Eleven patients had a previous VR experience. During preoperative VR training, 4 patients reported visual discomfort (3 had blurred vision, 1 had lateral hemianopia). The most chosen VR play experiences were Ocean Rift and Zen Parade. During the surgery, the use of the headset was not possible for 2 patients, owing to a Bluetooth malfunction in one and the proximity of the headholder in the other patient. In total, 28 surgical procedures were performed with the VRH.

The mean duration of surgery was 4 hours 12 minutes, and the mean duration of the awake phase was 2 hours 21 minutes. The mean intensity used for DES was 3 mA (range, 1–8 mA). The

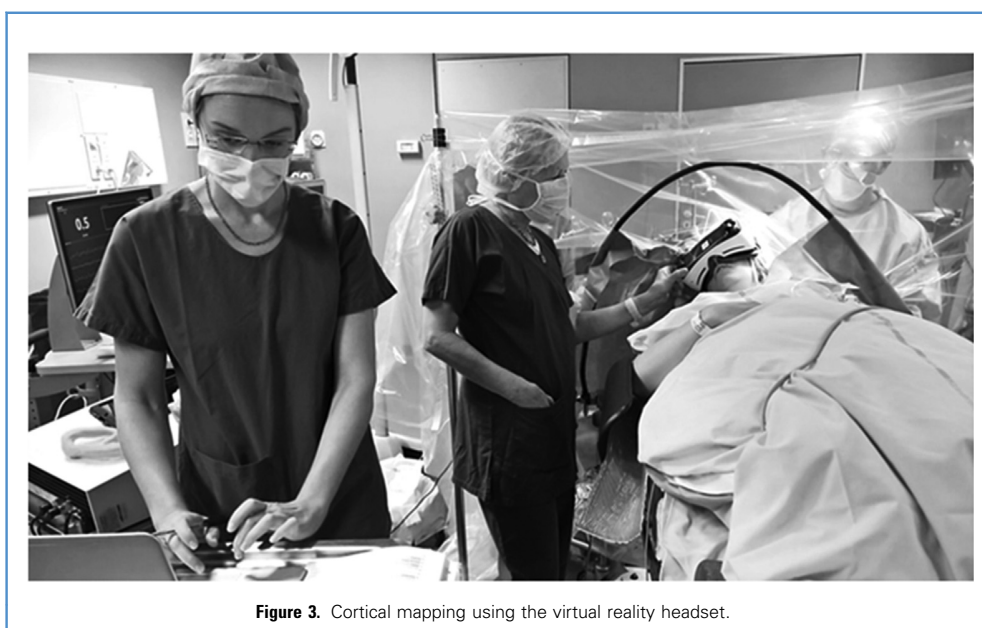

Figure 3. Cortical mapping using the virtual reality headset.

mean number of sessions with the VRH was 4 with a mean total duration of VRH use per patient of 24 minutes (range, 10–37 minutes). The VR tests were performed at the beginning and at the end of the procedure for 18 patients.

The same eloquent areas were identified regardless of which DO 80 presentation was used (digital tablet, 2D VR, or 3D VR). However, we observed for 3 patients that some areas for which the result was not clear using the DO 80 on the digital tablet (hesitation or delay in denomination) were clearly not eloquent when using the VRH. This result is of particular relevance, and another study is needed to validate the power of the DO 80 with the VRH relative to the DO 80 on the digital tablet to definitively identify the language eloquent areas.

EEG modifications (afterdischarge or spike-and-wave) were observed in 13 patients during the standard brain mapping procedure (without VRH). The same abnormalities persisted during brain mapping and VRH use in 3 of these patients. Intraoperative seizures (IOSs) occurred in 9 of these patients. All were focal seizures, disappearing rapidly after cortical irrigation with iced saline. IOSs occurred in 3 cases before any DES or VRH use, in 5 cases during DES of the motor area before VRH use, and in 1 case during DES with and without VRH use. IOSs were not associated with a worse outcome. There were no seizures following the surgeries.

One patient reported a sensation of dry eyes that was known before the surgery, and one reported mild nausea (related to the analgesic treatment). On the questionnaire, patients reported the following grade 1 side effects: anxiety ($n = 4$), tiredness ($n = 4$), discomfort ($n = 2$), and pain ($n = 1$). Despite the discomfort associated with the awake surgery procedure, no patient experienced vertigo or any vegetative signs of VR sickness. One patient judged the VR experience as unpleasant, but agreed to repeat it for a second surgery.

VR play sequences were proposed to patients at the end of surgery. Twenty patients agreed to look at the VR play sequences while the wound was being closed. For 12 of these patients, no further analgesia was necessary.

According to the questionnaire completed immediately after the surgery by the neurosurgeon, the anesthesiologist, and the neuropsychologist, the use of the VRH was not an issue during the surgery. All agreed to continue this study.

DISCUSSION

VR is widely explored for neurosurgery, as in all the medical fields, especially for surgical training or to help the neurosurgeon in the operating room, as an augmented reality.^{19–22} Our project, which started in 2014, was to use VR, and especially a VRH, for patients undergoing awake surgery. The goal was to develop new tasks based on a virtual environment, with the aim of exploring complex cognitive functions, such as visuospatial and social cognition. The first application developed was for detecting hemianopia and unilateral neglect during DES.⁹

Before developing other VR tasks, we needed to confirm the feasibility, tolerance, and security of this approach. To avoid interfering with the routine procedure of awake craniotomy and language brain mapping, we decided to duplicate the object naming task (DO 80). After a standard task using a digital tablet, the DO 80 was repeated using the VRH in 2D format and then in

3D format. The object-naming task is simple, allowing us to capture a variety of errors, and is the most commonly used task for language mapping.²³

At the beginning of our experience with VR in the operating room, we used the Oculus VRHs DK1 and DK2 (Oculus VR), but for our study, we chose the Samsung VR. This VRH is wireless. It is a low-cost, high-quality, customizable device with a pad control on the side of the headset and, if necessary, a game controller. Its weaknesses are that it heats up after a long period of use and its autonomy is limited by the phone battery. However, neither of these weaknesses was an issue or stopped the VRH from being used in the operating room. It was not possible to use the VRH for 1 patient owing to a Bluetooth malfunction, leading us to consider a wired VRH for future developments.

Before the surgery, all the patients were trained easily and the acceptability was good, although 19 of them did not have previous experience with a VRH. Although previous studies have shown that younger hospitalized patients were more willing to participate in an immersive VR experience, the relatively older age (median age of 45) in our study was not a limitation.²⁴ Focus can be adapted for patients wearing glasses, but this can be an issue, especially in patients with a high correction. Patients with dry eyes could experience some discomfort during extended VR sessions. In the operating room, it was not possible to position the headset in 1 case, owing to the head holder, and some difficulties arose in 5 cases. These difficulties were avoided by carefully positioning the VRH before the headholder and before drawing the incision line.

There was no difference for number or localization of eloquent areas between the digital tablet and the VRH. However, we observed that some areas for which the result was unclear using the digital tablet (hesitation or delay in denomination) were clearly not eloquent areas when using the VRH. The explanation would be a better visualization of the images and isolation from all the disruptive events occurring in the operating room.

VR sickness, which is a kind of motion sickness, was a concern before our study, especially in the conditions of an awake surgery (e.g., stress, discomfort of the position, emetic medication). Virtual reality sickness is now well known and has several physiologic explanations. The first one is latency.²⁵ Virtual reality headsets have significantly higher requirements for latency (the time it takes for a change in input to have a visual effect) than ordinary video games. If the system is too slow to react to head movement, it can cause the user to experience virtual reality sickness. In fact, this aspect was minimized, as the patient could not move the head, which was held immobilized in a headholder. Another important cause for VR sickness is a visual-vestibular-somatosensory conflict.^{25,26} This could have been the case for our patients in a lying position viewing a differently orientated virtual world.²⁶ It could also have been the case with the perception of visually induced illusions of self-motion during the VR play experiences, despite the VR experience with the most impressive self-motion being chosen less frequently by the patients. Nevertheless, no patients experienced VR sickness, and we did not observe any of the sympathetic nervous activity reported for this syndrome.^{27–30} We are convinced that the good tolerance could be due to patient preparation and training.

IOS was an important concern, as the convulsion hazard is a classic concern with the use of television, video games, and VR experiences. The Samsung VRH manual advises consulting a physician before using the VRH if there is a history of seizures. EEG modification (afterdischarge or spike-and-wave) was observed during the standard brain mapping procedure for 13 patients. Afterdischarges are defined as 2 consecutive spikes or sharp waves, distinct from background activity, spontaneous, or within 5 seconds of DES termination. They are observed frequently (71% in the literature³¹) and can sometimes result in convulsive seizures. We did not observe a significant modification of the afterdischarge threshold or frequency during the procedure.

IOSs were observed in 9 patients (30%) during surgery. These were focal seizures, easily stopped by irrigation of the cortex with iced physiologic serum. IOSs can interfere with the patient's ability to cooperate throughout the procedure and may affect their outcome. Nevertheless, none of the procedures were aborted, and IOSs were not associated with a worse outcome. IOSs induced by DES of the cortex are not uncommon during awake surgery with a described rate of 3.4%–31% in the literature.^{31–35} It is worth noting that among these 9 patients, 5 had a history of epilepsy, and 1 had a history of status epilepticus. Preoperative seizures or a history of epilepsy was correlated with IOSs, with patients who have preoperative seizures considered to have an increased susceptibility to intraoperative or postoperative seizures. Our perioperative seizure rate is in the upper range, but this cannot be explained by the VRH, as the seizures occurred in all the patients before its use. Moreover, the mean time between preoperative training with the VRH and surgery was 23 days. The explanation of our IOS rate would be our brain mapping procedure, which always starts with a positive motor stimulation to calibrate the DES intensity. It is well known that the search for a positive motor mapping may increase the likelihood of IOSs. It is worth noting that in our study, none of the patients had a postoperative seizure during hospitalization.

The 20 patients who watched the VR experiences described them as pleasant and capable of reducing pain and anxiety. It is now well demonstrated that VR could be effective for control and/or treatment of pain and anxiety.^{36,37}

Finally, we showed that it is possible during awake brain surgery to immerse the patient in a virtual environment and for the

patient to interact with it. In particular, we showed that it is possible to interact with an avatar piloted by a neuropsychologist. The description of this VR experience and interactions with an avatar using the social VR platform vTime has been published elsewhere.³⁸ There is consistent evidence that avatars are perceived in a similar manner to real human beings and can be used to explore the complex processes of nonverbal language, empathy, and theory of mind.³⁹ Social cognition, including nonverbal language, empathy, and theory of mind, is explored at the bedside through sets of complex neuropsychological tasks, including story movies, comic strips, or interactive games that depict a short story.^{12,13} These tasks take time to be performed, meaning they are not compatible with the brain mapping conditions (DES length <4 seconds, fast response, and no ambiguity in the answer). Progress in VR development is currently promising, and some VRHs even allow facial expressions to be captured and transferred to a virtual avatar in real time, opening a new level of virtual human interaction. VR has the potential to combine the naturalness of everyday interactions with experimental controls required during brain mapping procedures, opening the field of new brain mapping procedures for complex cognitive functions.

CONCLUSIONS

It is possible to immerse a patient in VR using a VRH during awake brain surgery with brain mapping using DES. We did not observe VRH-induced IOSs or VR sickness. The rapid progress in VR technology and the almost infinite possibilities to develop innovative neuropsychological tasks motivate us to continue this research work. Work is currently underway on virtual experiences dedicated to testing social cognition during awake surgery.

ACKNOWLEDGMENTS

We thank Marc Le Renard for his work on the virtual reality application, Kevin Mack and Julius Horsthuis for the authorization to use their virtual reality experiences, and Gwenaelle Soulard and Anne Claveul for their help and technical support.

REFERENCES

1. Freytschlag CF, Duffau H. Awake brain mapping of cortex and subcortical pathways in brain tumor surgery. *J Neurosurg Sci.* 2014;58:199–213.
2. Sanai N, Mirzadeh Z, Berger MS. Functional outcome after language mapping for glioma resection. *N Engl J Med.* 2008;358:18–27.
3. Wager M, Du Boisgueheneuc F, Pluchon C, et al. Intraoperative monitoring of an aspect of executive functions: administration of the Stroop test in 9 adult patients during awake surgery for resection of frontal glioma. *Neurosurgery.* 2013;72(2 Suppl Operative):ons169–ons180 [discussion: ons180–181].
4. Vallar G, Bello L, Bricolo E, et al. Cerebral correlates of visuospatial neglect: a direct cerebral stimulation study. *Hum Brain Mapp.* 2014;35:1334–1350.
5. Sallard E, Duffau H, Bonnetblanc F. Ultra-fast recovery from right neglect after “awake surgery” for slow-growing tumor invading the left parietal area. *Neurocase.* 2012;18:80–90.
6. Conner AK, Glenn C, Burks JD, et al. The use of the target cancellation task to identify eloquent visuospatial regions in awake craniotomies: technical note. *Cureus.* 2016;8:e883.
7. Giussani C, Pirillo D, Roux FE. Mirror of the soul: a cortical stimulation study on recognition of facial emotions. *J Neurosurg.* 2010;112:520–527.
8. Kitabayashi T, Nakada M, Kinoshita M, et al. Awake surgery with line bisection task for two cases of parietal glioma in the non-dominant hemisphere [in Japanese]. *No Shinkei Geka.* 2012;40:1087–1093.
9. Mazerand E, Le Renard M, Hue S, Lemée JM, Klünger E, Menei P. Intraoperative subcortical electrical mapping of the optic tract in awake surgery using a virtual reality headset. *World Neurosurg.* 2017;97:424–430.
10. Roux FE, Dufour O, Lauwers-Cances V, et al. Electrostimulation mapping of spatial neglect. *Neurosurgery.* 2011;69:1218–1231.
11. Vilasboas T, Herbet G, Duffau H. Challenging the myth of right nondominant hemisphere: lessons from corticosubcortical stimulation mapping in awake surgery and surgical implications. *World Neurosurg.* 2017;103:449–456.
12. Lemée JM, Bernard F, Ter Minassian A, Menei P. Right hemisphere cognitive functions: from

- clinical and anatomical bases to brain mapping during awake craniotomy. Part II: neuropsychological tasks and brain mapping. *World Neurosurg.* 2018;118:360-367.
13. Bernard F, Lemée JM, Ter Minassian A, Menei P. Right hemisphere cognitive functions: from clinical and anatomic bases to brain mapping during awake craniotomy. Part I: clinical and functional anatomy. *World Neurosurg.* 2018;118:348-359.
 14. Merhi O, Faugloire E, Flanagan M, Stoffregen TA. Motion sickness, console video games, and head-mounted displays. *Hum Factors.* 2007;49:920-934.
 15. Sharples S, Cobb S, Moody A, Wilson JR. Virtual reality induced symptoms and effects (VRISE): comparison of head mounted display (HMD), desktop and projection display systems. *Displays.* 2008;29:58-69.
 16. Kasteleijn-Nolst Trenité DG, Martins da Silva A, Ricci S, et al. Video games are exciting: a European study of video game-induced seizures and epilepsy. *Epileptic Disord.* 2002;4:121-128.
 17. Shoja MM, Tubbs RS, Malekian A, Jafari Rouhi AH, Barzgar M, Oakes WJ. Video game epilepsy in the twentieth century: a review. *Childs Nerv Syst.* 2007;23:265-267.
 18. Duffau H, Capelle L, Denvil D, et al. Usefulness of intraoperative electrical subcortical mapping during surgery for low-grade gliomas located within eloquent brain regions: functional results in a consecutive series of 103 patients. *J Neurosurg.* 2003;98:764-778.
 19. de Ribaupierre S, Eagleson R. Editorial: challenges for the usability of AR and VR for clinical neurosurgical procedures. *Healthc Technol Lett.* 2017;4:151.
 20. Besharati Tabrizi L, Mahvash M. Augmented reality-guided neurosurgery: accuracy and intraoperative application of an image projection technique. *J Neurosurg.* 2015;123:206-211.
 21. Mazur T, Mansour TR, Mugge L, Medhkour A. Virtual reality-based simulators for cranial tumor surgery: a systematic review. *World Neurosurg.* 2018;110:414-422.
 22. Bernardo A. Virtual reality and simulation in neurosurgical training. *World Neurosurg.* 2017;106:1015-1029.
 23. Ojemann JG, Ojemann GA, Lettich E. Cortical stimulation mapping of language cortex by using a verb generation task: effects of learning and comparison to mapping based on object naming. *J Neurosurg.* 2002;97:33-38.
 24. Mosadeghi S, Reid MW, Martinez B, Rosen BT, Spiegel BMR. Feasibility of an immersive virtual reality intervention for hospitalized patients: an observational cohort study. *JMIR Ment Health.* 2016;3:e28.
 25. Buker TJ, Vincenzi DA, Deaton JE. The effect of apparent latency on simulator sickness while using a see-through helmet-mounted display: reducing apparent latency with predictive compensation. *Hum Factors.* 2012;54:235-249.
 26. Chen W, Chao JG, Chen XW, Wang JK, Tan C. Quantitative orientation preference and susceptibility to space motion sickness simulated in a virtual reality environment. *Brain Res Bull.* 2015;113:17-26.
 27. Ohya S, Nishiike S, Watanabe H, et al. Autonomic responses during motion sickness induced by virtual reality. *Auris Nasus Larynx.* 2007;34:303-306.
 28. Kim YY, Kim HJ, Kim EN, Ko HD, Kim HT. Characteristic changes in the physiological components of cybersickness. *Psychophysiology.* 2005;42:616-625.
 29. Nalivaiko E, Davis SL, Blackmore KL, Vakulin A, Nesbitt KV. Cybersickness provoked by head-mounted display affects cutaneous vascular tone, heart rate and reaction time. *Physiol Behav.* 2015;151:583-590.
 30. Malińska M, Zużewicz K, Bugajska J, Grabowski A. Heart rate variability (HRV) during virtual reality immersion. *Int J Occup Saf Ergon.* 2015;21:47-54.
 31. Pouratian N, Cannestra AF, Bookheimer SY, Martin NA, Toga AW. Variability of intraoperative electrocortical stimulation mapping parameters across and within individuals. *J Neurosurg.* 2004;101:458-466.
 32. Conte V, Carrabba G, Magni L, et al. Risk of perioperative seizures in patients undergoing craniotomy with intraoperative brain mapping. *Minerva Anestesiol.* 2015;81:379-388.
 33. Wang YC, Lee CC, Takami H, et al. Awake craniotomies for epileptic gliomas: intraoperative and postoperative seizure control and prognostic factors. *J Neurooncol.* 2019;142:577-586.
 34. Eseonu CI, Rincon-Torroella J, Lee YM, ReFaey K, Tripathi P, Quinones-Hinojosa A. Intraoperative seizures in awake craniotomy for periorlandic glioma resections that undergo cortical mapping. *J Neurol Surg Part Cent Eur Neurosurg.* 2018;79:239-246.
 35. Nossek E, Matot I, Shahar T, et al. Intraoperative seizures during awake craniotomy: incidence and consequences: analysis of 477 patients. *Neurosurgery.* 2013;73:135-140 [discussion: 140].
 36. Hoffman HG, Patterson DR, Carrouger GJ. Use of virtual reality for adjunctive treatment of adult burn pain during physical therapy: a controlled study. *Clin J Pain.* 2000;16:244-250.
 37. Konstantatos AH, Angliss M, Costello V, Cleland H, Stafrace S. Predicting the effectiveness of virtual reality relaxation on pain and anxiety when added to PCA morphine in patients having burns dressings changes. *Burns.* 2009;35:491-499.
 38. Bernard F, Lemée JM, Aubin G, Ter Minassian A, Menei P. Using a virtual reality social network during awake craniotomy to map social cognition: prospective trial. *J Med Internet Res.* 2018;20:e10332.
 39. de Borst AW, de Gelder B. Is it the real deal? Perception of virtual characters versus humans: an affective cognitive neuroscience perspective. *Front Psychol.* 2015;6:576.

Conflict of interest statement: The authors declare that the article content was composed in the absence of any commercial or financial relationships that could be construed as a potential conflict of interest.

Received 12 July 2019; accepted 7 November 2019

Citation: *World Neurosurg.* (2020) 134:e937-e943.

<https://doi.org/10.1016/j.wneu.2019.11.047>

Journal homepage: www.journals.elsevier.com/world-neurosurgery

Available online: www.sciencedirect.com

1878-8750/\$ - see front matter © 2019 Elsevier Inc. All rights reserved.

Discussion générale, Perspectives

❖ Article n°8 :

Enter “The Matrix” for Brain mapping during awake brain surgery

Florian Bernard, Morgane Casanova, Anne Clavreul, Ghislaine Aubin, Gwenaëlle Soulard, Jean Michel Lemée, , Aram Ter Minassian, Renaud Segulier, Philippe Menei

Behavioral and brain sciences (IF 17,194), (soumis)

TITLE PAGE

Replaying “The Matrix” for brain mapping during awake surgery

Abstract word count: 127

Main text word count: 4962

References word count: 75

Entire text word count (total+addresses) : 12 366

Indexable title: Replaying “The Matrix” for brain mapping during awake surgery”

AUTHORS

BERNARD Florian, MD.

Laboratory of Anatomy - Faculté de Médecine – 28 rue roger Amsler –Angers, FRANCE

Department of Neurosurgery, Teaching Hospital, Angers, FRANCE

CRCINA, UMR 1232 INSERM/CNRS and EA7315 team, Angers, FRANCE

Tel: +332.41.35.46.56

Fax: +332.41.35.48.22

E-mail: bernardflorian.bf@gmail.com

CASANOVA Morgane, PhD

Rennes Institute of Electronics and Telecommunications, FAST Team (Facial Analysis Synthesis and Tracking)

UMR CNRS. Centrale Supélec, 35000, Rennes, France.

E-mail: morgane.casanova1@gmail.com

CLAVREUL Anne, PhD

Department of Neurosurgery, University Hospital of Angers, F-49100, Angers

Université d’Angers, CHU Angers, INSERM, CRCINA, F-44000 Nantes

E-mail: anne.clavreul@univ-angers.fr

AUBIN Ghislaine

Neuropsychologist. Département d’Orthophonie, CHU d’Angers, 4, rue Larrey, 49933 Angers cedex 9, France

E-mail: ghaubin@chu-angers.fr

SOULARD Gwenaëlle

Department of Neurosurgery, Teaching Hospital, Angers, FRANCE.

E-mail: Gwsoulard@chu-angers.fr

LEMEE Jean-Michel, MD, PhD

Department of Neurosurgery, Teaching Hospital, Angers, FRANCE

CRCINA, UMR 1232 INSERM/CNRS and EA7315 team, Angers, FRANCE

E-mail: JMLemee@chu-angers.fr

TER MINASSIAN Aram, MD, PhD

Department of Reanimation, Teaching Hospital, Angers, FRANCE.

INSERM 1066 department and EA7315 team, Angers, FRANCE.

E-mail: ArTerMinassian@chu-angers.fr

SEGUIER Renaud, PhD

Rennes Institute of Electronics and Telecommunications, FAST Team (Facial Analysis Synthesis and Tracking)

UMR CNRS. Centrale Supélec, 35000, Rennes, France

MENEI Philippe, MD, PhD

Department of Neurosurgery, Teaching Hospital, Angers, FRANCE.

CRCINA, UMR 1232 INSERM/CNRS and EA7315 team, Angers, FRANCE

E-mail: phmenei@chu-angers.fr

Tel no. : +3360665807399

ORCID: 0000-0002-2794-1316

SHORT ABSTRACT

The non-dominant hemisphere (generally the right hemisphere) plays an important role in spatial consciousness and social cognition. Neurosurgeons are faced with the problem of exploring and preserving these cognitive functions. This study, drawing parallels with the movie "The Matrix", aimed to investigate the value of virtual reality for mapping the non-dominant hemisphere during awake brain surgery.

LONG ABSTRACT

The non-dominant hemisphere (generally the right hemisphere) is determinant for non-verbal cognitive functions, such as visuo-spatial and social cognition. Preserving these functions in the surgical management of brain tumors is decisive for the postoperative quality of life. Using virtual reality in awake brain surgery appears to be interesting for preserving these functions. By developing a new neuropsychological task appropriate for use during awake brain surgery, the authors were able to explore the patient's non-verbal cognitive processes and preserve them. The patient, neuropsychologist and brain surgeon thus play out a situation resembling that of the movie "The Matrix" in the operating theater. In addition to this cultural inference, we highlight here the importance of using emerging technologies as potential tools to better explore and preserve patients' cognitive processes.

KEYWORDS

Virtual reality; neurosurgery; social cognition; visuospatial cognition; awake surgery; unilateral spatial neglect; neuropsychology; neuroscience.

MAIN TEXT

1. INTRODUCTION

In “The Matrix”, a science fiction movie released in 1999, a race of self-aware machines imprisons mankind in a virtual reality system — the Matrix — for use as a power source. The storyline incorporates references to numerous philosophical ideas, including the dilemma of choice vs. control and the brain-in-a-vat thought experiment. Two decades on, virtual reality (VR) is booming, with increasing numbers of applications in the field of cognitive and social neurosciences (Parsons, Gaggioli, et Riva 2017). This computer technology generates realistic images, sounds, and other sensations, simulating the physical presence of the user in a virtual environment. Recent technological advances have increased access to this technology, including virtual reality headsets (VRHs), which are now affordable and can be installed in front of the patient's head. The potential of VR lies in its greater resemblance to the real-life environment than screen-based studies. Rather than being a passive observer of stimuli on a computer screen, participants in virtual environments become part of the scene depicted. A person using a VRH can “look around” the artificial world, and interact with virtual features or items in a more ecological manner than is possible through passive screen-based interactions (Dahlquist et al. 2009).

The dominant (usually the left hemisphere, in right-handed individuals) cerebral hemisphere is traditionally regarded as the more important side of the brain, because of its involvement in language. Decisions regarding neurosurgical approaches in clinical practice have long been influenced by this notion. Classically, brain mapping during awake brain surgery tests language and motricity, allowing their preservation. For this reason, awake brain surgery is mostly performed on the left hemisphere. However, we know that the side of the brain on which tumors occur has no effect on the patient's perceived quality of life (Salo et al. 2002; Sagberg et al. 2019; Mandonnet et al. 2017; Weed et al. 2010). This probably reflects the role of the minor (usually the right) hemisphere in important cognitive functions, including attention, visuo-spatial and social cognition. We therefore decided to explore the non-dominant hemisphere during awake surgery, with a view to its preservation. Making reference to the movie “The Matrix”, we show here how and why we used a virtual reality approach to immerse patients in a realistic virtual world, within the operating theater.

2. RIGHT HEMISPHERE FUNCTIONS

2.1 Attention and visuo-spatial cognition

Visuo-spatial cognition supports spatial attention, perception, awareness and mental representation. It depends mainly on two interacting networks: the dorsal attention network controlling focused attention (also called top-down attention) (Sadaghiani et al. 2010; Laufs et al. 2003), and the ventral attentional network (Corbetta et Shulman 2002; Geng et Vossel 2013) involved in the detection of non-focused relevant stimuli (also called bottom-up attention) (Kristensen et al. 2013). Lesions and disconnections of these networks are associated with various symptoms, the most important of which is unilateral neglect (UN) (Bernard, Lemée, Ter Minassian, et al. 2018). UN is typically associated with right hemisphere damage. It is defined as a failure to report, respond to, or orient in response to stimuli delivered in the space contralateral to the lesion in patients with brain damage. Neglect is a heterogeneous disorder, and several different subtypes have been defined, including: near/far neglect, perceptual/representational neglect, and egocentric/allocentric neglect (Jean Michel Lemée et al. 2018; Bartolomeo, Thiebaut de Schotten, et Doricchi 2007; Buxbaum et al. 2004). UN is all the more complex due to its dynamic nature. Within an individual patient, neglect may vary between occasions or tasks. Space representation and/or the control of spatial attention may, therefore, be modulated by various factors, such as the emotional valence of the stimulus. The functional implications of UN are well understood, but much less is known about its impact on daily functioning and social communication.

2.2. Social cognition

Social cognition is the second important cognitive function supported by the right hemisphere. It includes all the cognitive processes involved in social interaction through non-verbal communication (such as facial emotion recognition and emotional prosody), but also empathy, and theory of mind (TOM).

The ability to recognize emotion from facial expressions or vocal intonation is supported by a large, right-lateralized perisylvian network, mirroring the language network in the left hemisphere (Bernard, Lemée, Ter Minassian, et al. 2018; Sammler et al. 2015). Several observations have suggested that similar psychological and neural computations are involved in the processing of dynamic facial expressions and language. Based on these findings, an evolutionary theory has been developed, according to which, facial expressions may have emerged before language, leading to adaptations for the processing of verbal facial movements and speech in the mirror networks of the left hemisphere (Redcay 2008).

Social cognition has two other important components: empathy, defined as an ability to understand and share the feelings of another, and TOM, defined as the ability to attribute mental states (beliefs, intents, desires) to others, and to understand their beliefs, desires, intentions, and perspectives, including those different from one's own. Empathy and TOM are complex functions processed in large cross-hemisphere networks. The identification of these networks is a real challenge, due to the apparent difficulty reaching consensus definitions for empathy and TOM. Some authors split the social cognition into two complementary levels. The first, emotional empathy (facial emotion and prosody recognition), probably corresponds to low-level TOM (Thye, Murdaugh, et Kana 2018). This level of social cognition provides the foundations for social communication, making it possible for us to interpret the mental state of others by assimilating their actions or facial expressions (e.g., "He is sad"). The brain networks processing empathy and low-level mentalization are right-lateralized and include those previously described for attention, visuospatial cognition, facial emotion and prosody identification, plus the network processing eye-gaze information processing, as described below.

The second level, high-level TOM (so-called high-level mentalizing or cognitive empathy), could be described as the process allowing us to predict the mental state of others from a cognitive standpoint, based on various cues (e.g., "He will probably get mad"). This higher process involves a cognitive understanding of the beliefs, desires, and knowledge of others, and an understanding of their mental states. High-level mentalizing is processed in a large, cross-hemisphere network including the temporo-parietal junction, the medioventral, ventrolateral and dorsolateral prefrontal cortices and the precuneus (Bernard, Lemée, Ter Minassian, et al. 2018). A retrospective MRI study of patients who had undergone resection for low-grade glioma revealed that low-level and high-level mentalizing dysfunctions were correlated with the degree of disconnection of the arcuate fasciculus and cingulum, respectively, suggesting the existence of a two-pathway system (Herbet et al. 2014). However, in real social life, high-level and low-level mentalizing probably interact and function simultaneously (Herbet et al. 2014).

2.3. Socially relevant gaze processing

Several interactions occur between attention and non-verbal language. There is abundant evidence from neuropsychological and functional imaging studies to indicate that spatial attention and awareness are influenced by affective and social significance. The eye, for example, is a key target for attentional processes, and reflexive, gaze-triggered shifts of attention are processed predominantly in the right hemisphere (Kingstone et al. 2004). There are also interactions between visuo-spatial cognition and non-verbal language. A sense of shared interpersonal space or self-other equivalence is a basic prerequisite for social approaches (Thakkar, Brugger, et Park 2009; Marrero et al. 2019).

Based on their interactions, attention and non-verbal language networks occupy a common brain region in the right hemisphere, mostly at the temporo-parietal junction (Carter et Huettel 2013). Within the temporo-parietal junction, the right posterior superior temporal sulcus (pSTS) has been identified as potentially crucial for socially relevant gaze processing (Saitovitch et al. 2016; Nummenmaa et al. 2010; Ethofer, Gschwind, et Vuilleumier 2011; Thye, Murdaugh, et Kana 2018). The most important socially relevant eye motions are eye contact and joint attention (Okada, Sato, et Toichi 2006; Caruana, Brock, et Woolgar 2015).

Eye contact facilitates the inference of the intentions and feelings of others, which is crucial for survival and social integration. Indeed, the eye provides the most reliable clues to what someone else is thinking, feeling or intending. Gaze direction is a critical facial cue in everyday interactions, providing socially relevant information. It is a key element of joint attention, the ability to follow and/or direct another person's attention through eye gaze. There are two functionally and developmentally different joint attention processes: (1) the response to joint attention, in which an individual interprets the eye gaze of a social partner to determine their focus of attention, and then directs his or her attention to the same thing; (2) the initiation of joint attention, in which an individual use his or her eye gaze intentionally to guide the attention of a social partner, thereby initiating a bid for joint attention.

3. AWAKE CRANIOTOMY AND RIGHT HEMISPHERE BRAIN MAPPING

3.1 Task importance in awake brain surgery

Unlike the motor areas of the brain, the verbal and non-verbal language networks (including the visuospatial and social cognition networks) cannot be localized on the basis of anatomical criteria alone. Indeed, there are structural and functional variations within and between subjects (Bernard, Lemée, Ter Minassian, et al. 2018; Bernard et al. 2019). In neurosurgery, this issue is dealt with by individual brain mapping by direct electrical stimulation (DES) during awake craniotomy. This procedure has become a standard procedure and is well documented (Fernández Coello et al. 2013; Duffau 2005). Briefly, DES can be used to inactivate regions of the brain temporarily while patients perform neuropsychological tasks. If the performance of the patient in a given task decreases, the neurosurgeon does not remove the corresponding region, so as to maintain the brain function related to this task.

Accounts of right hemisphere per operative mapping are less numerous than descriptions of language mapping in the left hemisphere ((Jean Michel Lemée et al. 2018; Rolland, Herbet, et Duffau 2018; Vilasboas, Herbet, et Duffau 2017). Right hemisphere functions are explored at the bedside, with batteries of complex neuropsychological tasks, including the use of photographs, fictional movies, comic strips, or interactive games depicting a short story (Bernard et Menei 2019). Several difficulties are inherent to the adaptation of these standard bedside tasks to the constrained environment of awake surgery: the need to use tasks with a duration of less than 4 seconds due to the duration of electrical stimulation, the crowded space in an operating theater, with little space directly in front of the patient and the patient placed on his or her back or side, and the need for a rapid, unambiguous answer.

3.2 The need for new allocentric visuospatial tasks

In most published studies, spatial awareness in the operating theater is explored with the line bisection task. Patients are asked to estimate and indicate the midpoint of a horizontal line presented on a piece of paper or a computer tablet placed directly in front of them with respect to their midline and their horizon of vision. An ipsilateral deviation (to the same side as the brain lesion), is generally considered to indicate unilateral neglect, although the magnitude of this deviation is variable. As a bedside task, the line bisection test of spatial awareness seems to be highly feasible, with a specificity of 90%, and a sensitivity of 60% (Schenkenberg, Bradford, et Ajax 1980). The line bisection test is also widely used in awake surgery, not only because of its simplicity, but also because it is rapid and reproducible (Kitabayashi et al. 2012; Roux et al. 2011; Talacchi et al. 2013; Vallar et al. 2014; Rolland, Herbet, et Duffau 2018; Bartolomeo, Thiebaut de Schotten, et Duffau 2007). However, even though this task identifies a profound perceptual disorder, it appears to be anatomically and behaviorally independent of the core symptoms of neglect. In 40% of patients with core symptoms of spatial neglect, no impairment is observed in the line bisection task. One possible explanation for this dissociation is that the line bisection task draws on allocentric representation, whereas the core deficit in spatial neglect is egocentric (Karnath, Ferber, et Himmelbach 2001; Rorden, Fruhmann Berger, et Karnath 2006; Chechlacz, Rotshtein, et Humphreys 2012).

The target cancelation task, another allocentric test, involves searching for and crossing out target symbols. This test is less widely used in awake surgery (Conner et al. 2016). Patients with UN typically fail to

cross out stimuli on the side of the page contralateral to the brain lesion. Many versions of the cancellation task exist, with various shapes, single or double target stimuli, and with or without the presence of distractors. Distractor symbols are non-target stimuli, obliging the subject to determine whether or not a stimulus is a target before crossing it out, rather than simply crossing out all the stimuli on the page. Cancellation tests with distractors are more sensitive for UN detection than those without distractors. They also provide greater reliability, in terms of test-retest reproducibility, and are more sensitive than line bisection tests. It is now widely accepted that these tasks explore only one component of UN (allocentric), so a visuospatial cognition deficit could appear unless another intraoperative task is also used.

3.3 Low- and high-level TOM tasks

The tasks most frequently used to measure the perception and identification of facial emotions are photographs of individuals displaying one of the six primary facial emotions (anger, happiness, fear, surprise, disgust, and sadness) extracted from several tests (Ekman's Faces, the Brief Affect Recognition Test, the Japanese and Caucasian Brief Affective Recognition Test, and the ATR facial expression database) (Fried et al. 1982; Giussani, Pirillo, et Roux 2010; Papagno et al. 2016; Motomura et al. 2019). Published results suggest that, when presented for 10 seconds at the patient's bedside, the emotion portrayed by each photograph is correctly identified by more than 70% of patients. In all studies, static expressions are less accurately recognized than dynamic facial expressions (Krumhuber, Kappas, et Manstead 2013; Joyal et al. 2014). In our experience, tests involving the recognition of facial emotions from photographs are difficult to perform in awake surgery, with a high rate of error, even in the absence of DES. Other tests are available, but are less appropriate for brain mapping due to the absence of unequivocal and veracious solutions for the items. These tests include the Diagnostic Analysis of Nonverbal Accuracy, which presents faces displaying emotions of variable intensity between images. Emotional prosody is another important nonverbal cue involved in social cognition. The complexity of emotional prosody tests and their subjective interpretation account for the difficulties exploring prosody during awake surgery and explain why such procedures have rarely been described.

Low and high-level TOM exploration is even more complex, due to issues raised in previous studies (Yordanova, Duffau, et Herbet 2017; Yordanova et al. 2019). We previously highlighted the importance of the eye and of the gaze in TOM processing. A now classical neuropsychological task exploring mental state attribution, the "reading the mind in the eyes" (RME) task, is based on photographs centered on the eye region (Baron-Cohen et al. 2001; Thye, Murdaugh, et Kana 2018). A simplified and adapted RME task has been used to assess face-based mentalizing in patients undergoing awake surgery for right-side low-grade glioma (Yordanova, Duffau, et Herbet 2017; Yordanova et al. 2019).

Another study used a typical high-level mentalizing task, the false belief task (Nakajima et al. 2019). The authors concluded that high-level mentalizing could be successfully mapped during awake surgery, allowing its preservation. However, the tasks used in this study have been criticized. It has been pointed out that they usually require meta-linguistic judgments about hypothetical situations and may not accurately measure the underlying cognitive processes targeted (Tompkins et al. 2006; 2008). Moreover, body movements are an important reflection of a subject's intentions. The importance of this kinetic information in mental-state attribution cannot be assessed through stories or line drawings. Given the limitations of these bedside tasks for brain mapping during awake surgery, we explored the possibilities offered by virtual reality technology.

4. USING VIRTUAL REALITY TO MAP SOCIAL COGNITION: "ENTERING THE MATRIX"

In "Matrix", Morpheus asks the main character, Neo, to choose between a red pill and a blue pill. The red pill allows him to escape to the real world, whereas the blue pill represents the simulated reality of the Matrix. Neo chooses the red pill. By analogy, in this study, we asked the patients figuratively to choose the blue pill, corresponding to immersion in VR.

4.1 Immersion in virtual social interactions

Social interaction can be simulated with human actors or with synthetic animated characters known as avatars. The use of an avatar makes it possible for the researcher to manipulate selectively variables that cannot be independently investigated in naturalistic situations, providing precise control over the intensity, timing and types of emotion presented, but also over facial expressions, ethnicity, sex and age, for example, such that experimenters can create specific stimuli corresponding to their particular needs. For example, one methodological issue raised in previous studies of non-verbal communication is the inextricable connections between cues, such as facial expressions, eye contact, and posture, and verbal behavior, making it difficult to test their effects separately. The use of an avatar may overcome this problem.

VR approaches allowing interactions with an avatar are widely used in cognitive neuroscience (Georgescu et al. 2014). There is compelling evidence to suggest that avatars are perceived in a similar manner to real humans and can be used to explore the complex processes of nonverbal language, empathy, and ToM (de Borst et de Gelder 2015). Finally, in clinical practice, populations of individuals with social cognition deficits also display impairments of the ability to recognize emotions expressed by avatars (Dyck et al. 2010). Moreover, the social norms governing social interactions in VR are the same as those in the real world (e.g. social norms relating to gender or interpersonal distance) (Kaufman 1988). VR provides tools for the creation of realistic simulations of social situations, whilst also providing a high degree of experimental control. Virtual reality scenarios can be integrated into narrative contexts and the behavior of the participant can be tracked precisely, allowing interactions with the avatar. Last, but not least, a unique advantage of VR is that this approach provides neurosurgeons with a way of investigating social cognition that would not otherwise be possible in the operating theater (Bernard, Lemée, Aubin, et al. 2018).

4.2 Virtual reality may facilitate studies of visuospatial cognition

Interactivity is another interesting aspect of VR. Eye-tracking capabilities have been built into the latest models of VR headsets. Eye tracking is based on the use of sensors to measure eye position and movement. It can determine the level of presence, where attention is directed and what is being focused on, and it provides biometric data (e.g. pupillometry). Eye-tracking technology provides new opportunities for interaction with VR content. For example, eye-tracking data for a participant can be used to control the virtual character's attention in real time (Wilms et al. 2010). Some VRHs can even capture facial expressions and transfer them in real time to a virtual avatar, paving the way for a whole new level of virtual human interactions (« Face Tracking Solution for VR | Veeso » s. d.).

5. IMMERSING THE PATIENT IN VIRTUAL REALITY DURING AWAKE CRANIOTOMY

5.1 Optic radiation mapping as a starting point

In 2014, we began exploring the use of VR during awake craniotomy on patients wearing a VRH. We first developed an app for VRH, for exploring the visual field and mapping the optic tracts (Mazerand et al. 2017). Optic radiation mapping was rarely performed at the time, due to the difficulty testing the visual field intraoperatively, and few data had therefore been published on this subject. As a result, it was difficult to predict postoperative visual field defects. Functional disability is minimal with quadrantanopia, but permanent hemianopia is a significant visual defect that interferes with everyday activities, such as driving. We designed a visual test, similar to the Esterman test, to be performed with a VRH for exploration of the visual field during awake surgery. A comparison of this test with automated perimetry examination showed the correct classification rate to be 90% with the VR test. In the operating theater, the neurosurgeon performs direct cortical or subcortical electrostimulation, whilst the orthoptist provides luminous stimuli on the screen of the headset and waits for the patient's response to each stimulus. The patient provides the operator with an oral response, indicating whether or not he/she can see the luminous stimulus. With this design, it is possible to detect homonymous and congruous visual field impairments (figure 1).

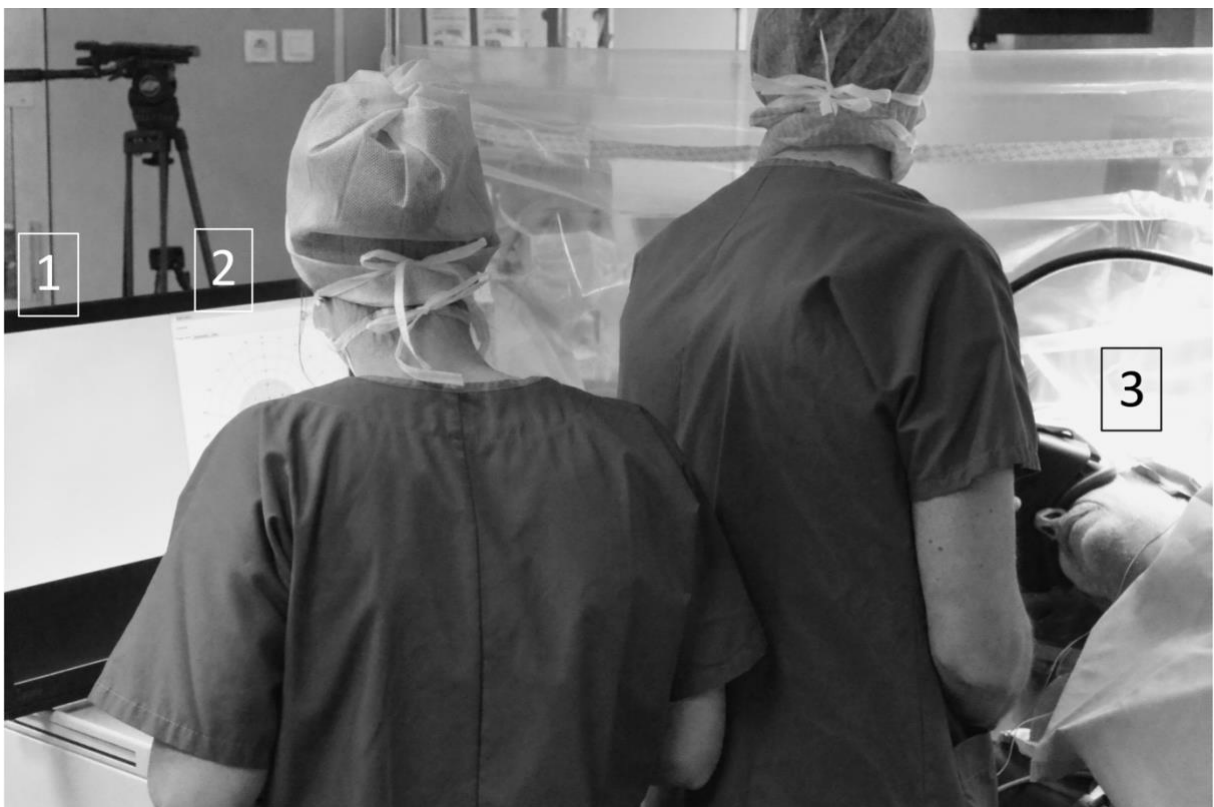

Figure 1. Mapping of the visual field during awake surgery. The test is piloted by an orthoptist in the operative room. **1:** screen showing what the patient is seeing in the virtual reality headset, an empty grey space with a central cross to stare, while a colored dot can appear in the periphery. **2:** Screen with an Esterman grid allowing the orthoptist to select the part of the visual field to be tested. **3:** Patient wearing the virtual reality headset.

This test was initially performed on an Oculus DK1 VRH (Oculus, Menlo Park, California), allowing the exploration of 40 degrees around the central visual axis of a binocular visual field. The Oculus DK2 subsequently became available, providing an opportunity to study a wider visual field: 45 degrees rather than 40 degrees. This highlights one of the characteristics of VR research. Progress in hardware is very fast, and new, improved models may appear after a clinical trial has been designed, or before its completion.

6. IS THIS BLUE PILL SAFE?

In “The Matrix”, Neo chose the red pill to escape the matrix. In our approach, patients are immersed in a VR world during awake brain surgery. So, is this “blue pill” safe? In 2014, VR was a new technology in the field of surgery, and the health authorities asked us to perform a study evaluating the tolerance and safety of VRH use and immersive virtual experiences in patients undergoing awake craniotomy and brain mapping by direct electrical stimulation. There were, indeed, concerns about risks to users (interference with the technical environment of the operating theater, psychological difficulties, seizures, VR disease). Intra-operative seizures were the main concern, as classically reported for the use of television, video games, and VRHs. All VRH manuals advise users to consult a physician before using the VRH if they have a history of seizures.

A single-center, prospective, open-label study was then performed (ClinicalTrials.gov: NCT03010943). The study protocol was evaluated and approved by the *Agence Nationale de Sécurité du Médicament et des Produits de Santé*, the institutional ethics committee, and the *Commission Nationale de l’Informatique et des Libertés* (the French data protection agency). All patients signed a written informed consent form before inclusion in the study. This trial, which included 53 patients, was initially performed with a Samsung Gear VRH combined with a Samsung S7 smartphone (Android platform) (visual field 96°, resolution 1440x1280, refresh rate 60 Hz) and headphones (Delion et al. 2020). This VRH is a cheap, high-quality, wireless, customizable device with a pad controller on the side of the headset, and it can be equipped with a game controller, if necessary. Its weaknesses are that it overheats after long periods of use and its autonomy is limited by the duration of the phone battery charge.

For the second part of the trial, we used a wired VRH with a better performance, the HTC Vive (visual field 110°, resolution 2160 x 1200, refresh rate 90 Hz) (Menei et al. under review). The VRH HTC Vive was combined with an eye-tracking device (Tobii Pro SDK) capable of tracking the full HTC Vive field of view and measuring the pupils.

We avoided interference with the routine brain mapping picture-naming task, (DO80, the task most widely used for language mapping), by duplicating two versions in the VRH. The first one was two-dimensional and included the same images as the classical naming task (DO80) presented with a digital tablet (an image accompanied by the sentence “this is...”). The second version included the same items, but in stereoscopy, rotating in an empty virtual space. Different VR experiences supplying different types of virtual motion or simulating a social interaction with avatars were used where possible or if considered useful for mapping purposes.

None of the patients experienced “VR sickness” or any of the effects on sympathetic nervous activity reported for this syndrome. Only transitory focal seizures of no consequence and not related to VRH use were observed during the mapping procedure. The observed frequency of such seizures, 25%, was in the upper part of the reported range (3.4%–31%), but these seizures were not specifically attributed to the VR procedure. The VR tasks, including the virtual social interactions, were performed correctly. The eye tracking was functional, and

it was therefore possible to analyze the patients' attention and the way in which they explored the visual field of the VRH. This work confirmed the feasibility and safety of VRH use and immersive virtual experiences in patients undergoing awake craniotomy and brain mapping by DES(Casanova et al. 2020; Delion et al. 2020).

7. DEVELOPMENT OF THE VR APPLICATION

In the "The Matrix" movie, the VR program was created by the machines. In reality, our VR application required a multidisciplinary team and a flexible approach to making an innovative concept a reality.

7.1 Social cognition: a first step with an available VR social network

At the start of this study, rather than developing a specific application for testing and mapping social cognition, we decided to test the potential of available VR social networks. The vTime app [Oculus, Facebook Spaces, PLUTOVR, and AltspaceVR) appeared to be the most appropriate of the social platforms available for use in awake brain surgery. Indeed these platforms adopt different approaches for conveying nonverbal language: arms, hands, head, and mouth movements, and the stimulation of attention.

During the safety trial (See section 6, *is this blue pill safe?*), we used this vTime app as a fun virtual experience (« VTime: The VR Sociable Network - Out Now for Windows Mixed Reality, Gear VR, Oculus Rift, iPhone, Google Daydream, and Google Cardboard » s. d.)(Figure 2).

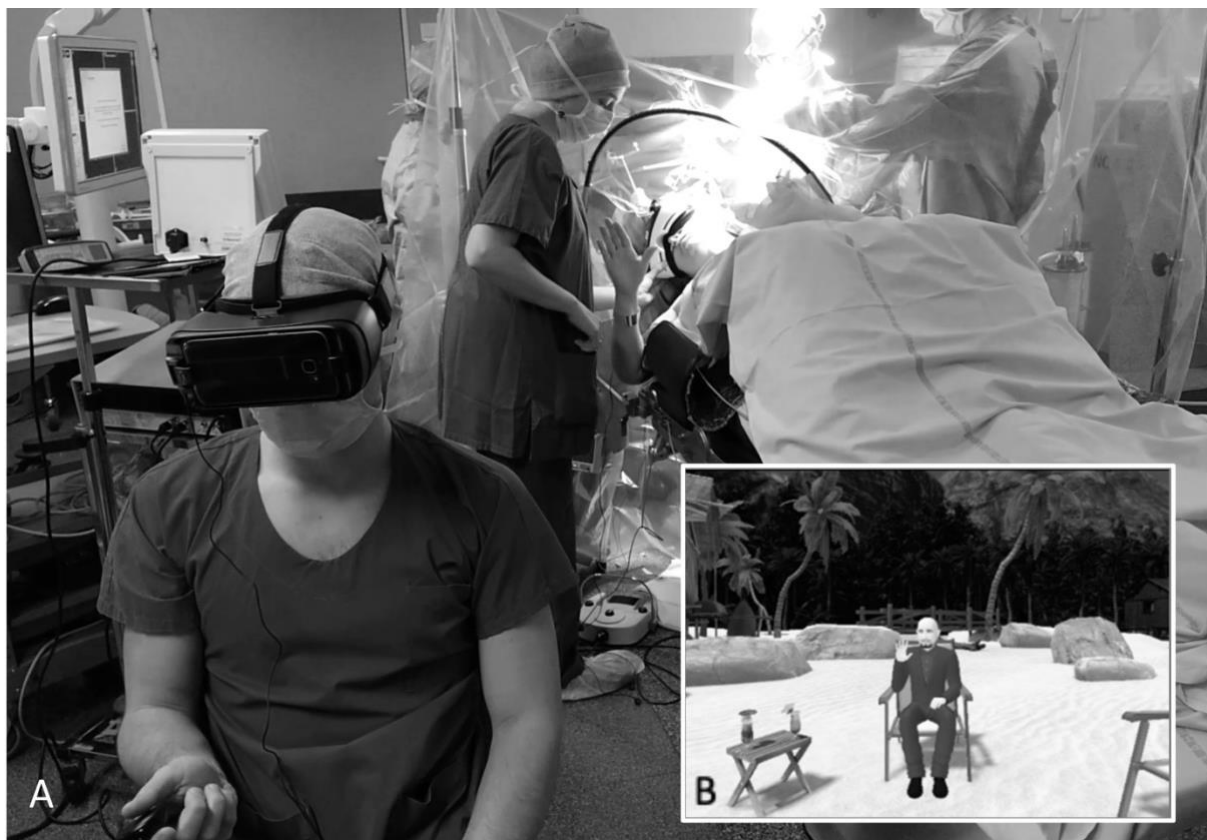

Figure 2: During awake brain surgery, the patient communicating by symbolic gestures with the neuropsychologist (A) with the VR social network. B: neuropsychologist's avatar visualized by the patient in the VRH. From the figure published under the terms of Creative Commons Attribution 4.0 licence. Social Cognition: Prospective Trial. *Journal of Medical Internet Research* 20 (6): e10332. <https://doi.org/10.2196/10332>.

This app allows users to create an avatar and to interact with other people in virtual environments. During awake brain surgery, the patient interacted with an avatar piloted by the neuropsychologist, who also wore a VRH, while the neurosurgeon performed the surgical intervention (Bernard, Lemée, Aubin, et al. 2018). Patients passively viewed the neuropsychologist's avatar and were asked to recognize and reproduce his gestures. They were also asked to assume more active roles, controlling their own avatars with a game controller to communicate with the neuropsychologist in the VR world. We were able to demonstrate that a patient undergoing surgery for a brain tumor, wearing a VRH, could interact and communicate with the neuropsychologist's avatar. The neuropsychologist, who also wore a VRH, piloted his avatar from outside the operating theater. As vTime is a web-based VR social network, the neuropsychologist would be able to pilot his avatar from his laboratory in the nearby university, or even from another country. This virtual meeting could, therefore, include other participants, researchers or neuropsychologists. However, we experienced several problems and limitations with this type of program. The principal problem was the impossibility of controlling facial expression and eye gaze, both of which are fundamental to social cognitive processes (see 3.3, *Low- and high-level TOM*). We therefore decided to develop a specific application dedicated to awake surgery, to overcome these limitations.

7.2 Application development constraints

It was a challenge developing this type of program for several reasons. The principal problem was the complexity of the design and execution of VR experiments. The development of applications for VR studies requires various types of expertise, including 3D computer graphics (for the development of virtual environments), systems engineering (for the integration of physiological and tracking sensors), artificial intelligence/computer science (for the development of computer-based virtual characters) and data science (for automated data analysis). The development of applications for VR tasks can, therefore easily become very expensive, with a much larger budget than could be justified by the small market represented by peri-operative brain mapping.

Obtaining a natural-looking animation is one of the most difficult aspects. A neutral face, capable of producing a smile at the same time as a slight movement of the head, associated with gaze capable of making eye contact with the patient must be achieved with professional motion capture tools. We achieved this with techniques from video games and the movie industry, in which facial animations are achieved by filming an actor and transposing his or her movements onto the avatars (« Hardware – Dynamixyz » s. d.) (figure 3).



Figure 3: facial motion capture with Dynamixyz.

Additional difficulties were faced in the integration of VR into the operating theater. Moreover, the fitting of the VRH on the patient's head required the neurosurgeon to adapt the installation of the patient and the skin incision. The integration of feedback to the neurosurgeon performing the operation was also essential. We satisfied these requirements by developing a platform integrating the two screens of the neuronavigation system (Brain Lab), and the EEG recording system (Eclipse) with the generator used for electrical stimulation of the brain (Figure 4). For each task, the medical team can see, on a screen, what the patient sees in the VRH, and can follow the patient's gaze, materialized by a green dot, online. Once the task has been completed, the gaze layout can be displayed on the screen.

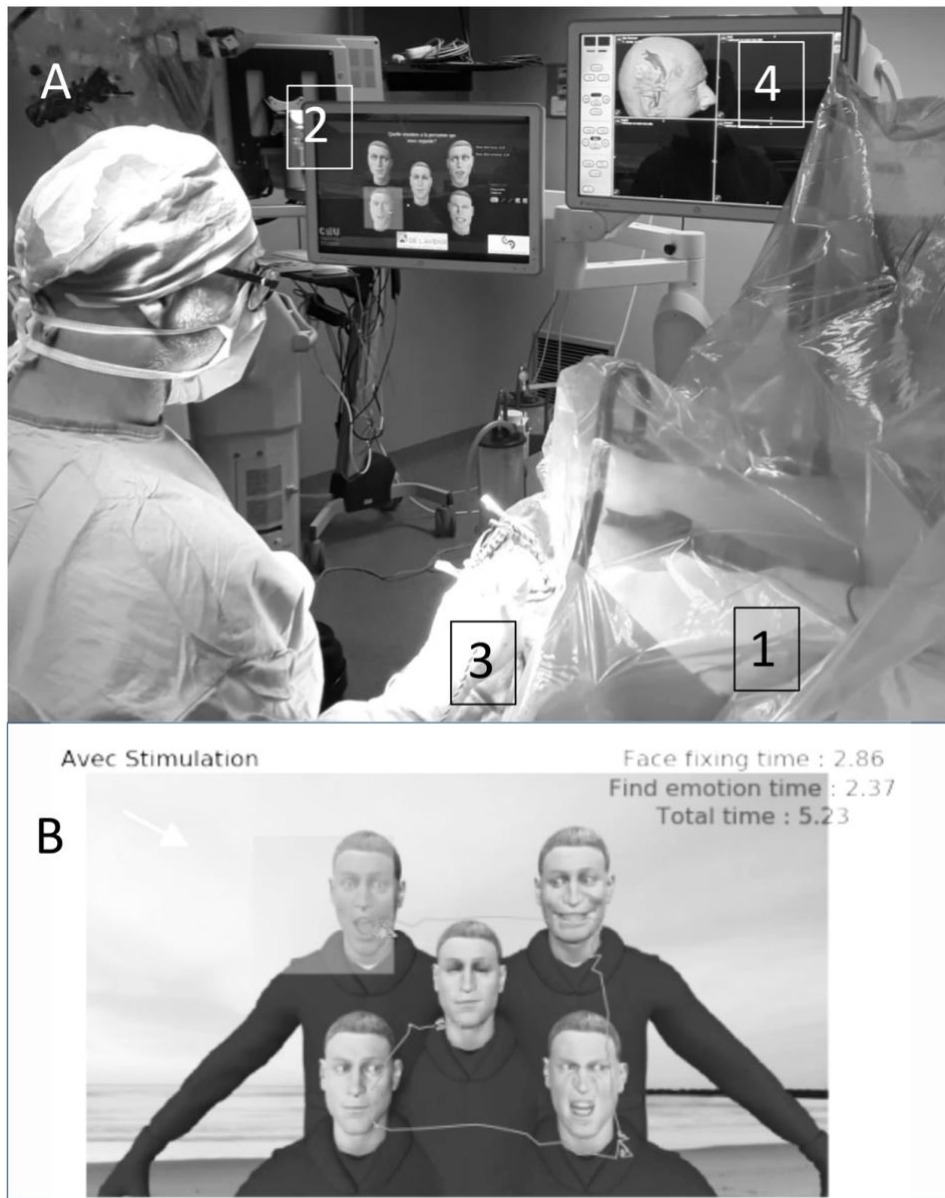


Figure 4. A: View of the operative room during the procedure (**1**: head of the patient, wearing the VRH; **2**: screen showing what the patient is seeing in the VRH, his gaze materialized by a green spot; **3**: application of the DES on the exposed brain; **4**: neuronavigation showing white matter fascicules and the position of the electrode. **B:** Example of the VR task simulating a social interaction. The patient must recognize the avatar who looks at him and indicate his emotion (joy, surprise, or anger). The patient's gaze is presented by a blue line. The box indicates the avatar making the eye contact. The arrow indicates the avatar gazed by the patient more than 0.6 sec (that trigger the dynamic facial emotion). In this example, the patient identified the avatar in 2.37 sec and indicates his emotion in 2.53 sec later. VRH, virtual reality headset.

Finally, the last major issue confronted was the validation of our VR neuropsychological test in and out of the operating theater. Most neuropsychological tests are validated by functional MRI. This was not possible in this case, because there is currently no MRI-compatible VRH available due to the electronic components in the VRH.

8. TOWARD A DEDICATED APPLICATION

As described above, it is important to preserve the main functions of the right hemisphere (spatial awareness, facial emotion identification and the patient's analysis of socially relevant gaze) during surgery. Facial emotion recognition, spatial awareness, and the processing of gaze direction are key elements for social quality of life. Their preservation is our primary goal, given the unlimited possibilities provided by VR for the exploration of ever more complex aspects of TOM. Our initial goal was to develop a task compatible with awake surgery and brain mapping conditions, with which it would be possible to explore low-level mentalizing as a whole. This project was not an easy one, but the solution was found in Argentinian tango (as practiced by one of the authors).

Invitations to dance the tango are highly codified, at least in traditional *milongas* (Argentinian tango ballrooms), which are found around the world. At the end of a series of three tangos, a short piece of music of a different style is played to indicate the end of the series, or *tanda*, and a change of partners for the next dance. This *cortina* (Spanish for curtain) is like an interlude separating two acts of a play. During this short musical interlude, everyone leaves the dance floor. Then begins the *mirada/cabeceo*. The dancers of both sexes begin carefully exploring the space around them in search of their next partner. Non-verbal communication is maximal, with smiles indicating availability, closed expression indicating a lack of willingness to dance, and other expressions indicating a preoccupation with something else. Gaze is very mobile, with the dancers looking around, but may be rapidly diverted if one of the protagonists does not wish to dance. The woman's gaze can also be sustained as a prelude to an invitation. Understanding this message, the man gives a slight nod of the head, meaning "do you want to dance"? This is the *cabeceo*. As an affirmative response, the woman replicates the nod or acknowledges it in her own manner. The contract is signed, and the man gets up and goes to invite his newfound partner to dance. She sits and waits for him, smiling. All the networks of spatial awareness, facial emotion, gaze processing, and mentalizing are in action in this little game that lasts only a few seconds: spatial exploration of the dance hall, tracking someone who looks at you, social attention fixed on a partner, but ready to be reoriented if gazed at by someone else, an analysis of faces, interpretations of the man's or woman's emotions, guessing what he/she thinks from his/her mime, his/her desire to be invited, and how he/she will react.

We adapted this short scenario with VR technology. We naturally baptized this task "TANGO" (***Task for Awake Neurosurgery exploring Gaze and TOM***). The task lasts less than five seconds. Electrical stimulation should not be applied to the brain tissue for more than 5 seconds at a time, to maintain specificity (limiting the spatial diffusion of the electrical current) and to prevent seizures (Pallud et al. 2017). For the reasons developed above, we began by using avatars. We aimed to reproduce a social scene, by having several avatars in the virtual world. However, although faces have a spatial advantage for capturing attention, reflecting their particular saliency and their social value, the maximum number of faces that can be analyzed in a visual field of 110° in less than five seconds is five. The scene was therefore designed to include four avatars in the four corners of the visualized field. The patient is asked to search for the avatar trying to make visual contact. A straight gaze is considered to be an engaging and important social cue between two people in all cultures. Decoding the movement of gaze plays an important role in predicting the intentions, future actions, and attitudes of other people, and can be regarded as an important element of TOM.

Once the avatar looking at the patient is identified and visual contact is established for a period of 0.6 s, the avatar expresses a dynamic facial emotion. Dynamic facial emotions are more "ecological" and are always more accurately recognized than static ones (Krumhuber, Kappas, et Manstead 2013; Joyal et al. 2014).

Moreover, the neural mechanisms underlying the processing of dynamic facial expressions involve a clearly lateralized right-hemisphere network (Sato et al. 2019). The patient is asked to describe the avatar's emotion or to describe his feelings about the desire to communicate or engage in social contact expressed by the avatar.

At the start of the experiment, the avatars were tagged with the name of the corresponding emotion, as in the Ekman or RME tasks, to help the patient. However, we rapidly decided to remove these tags because reading lengthened the duration of the task. Moreover, neuroimaging studies have reported activation in the left language area during tasks of this type, even with RME (Thye, Murdaugh, et Kana 2018). We also improved the avatars. When we started to develop the application, the avatars were simply four faces "floating" in a black empty space, but we subsequently added bodies and various natural backgrounds and landscapes. We also improved the characteristics and kinetics of the facial emotions.

In the operating theater, the neurosurgeon and neuropsychologist can see on a screen what the patient sees in the VRH. With eye tracking, the medical team can follow the patient's gaze, materialized by a green point on the screen, in real time. With this test, the reasons for failure are immediately identifiable. The eye tracking reveals whether the patient has difficulties exploring the space, difficulties locating the face of the avatar looking at him/her, or fails to recognize the facial emotion, and whether this failure is due to abnormal exploration of the face by the gaze. We all analyze faces in the same way, with jerky but organized movements of gaze to and fro between the eyes and the mouth, in a sort of triangle.

Other elements were then added to the application: a session for the calibration of eye tracking (in which the patient is asked to look at a succession of five red points), an application for testing visual field (derived from our previous studies (Mazerand et al. 2017), recognition of emotions face-to-face with an avatar, and games for fun and relaxation, as we had previously found that this kind of exercise can be useful for analgesia or relaxation.

9 –TOWARD TRANSLATIONAL RESEARCH IN SOCIAL COGNITION

The first version of the tango VR task was tested in a control population (mostly medical and engineering students) and in patients with neurological and visual symptoms. A prospective comparison to an established bedside pencil-and-paper test and assessments of the correlation with structural lesions of the brain are underway (TRIAL.GOV NCT04288505).

The preliminary results show that, unlike the line bisection task, our TANGO test is not affected by homonymous hemianopia (Kerkhoff et Schenk 2011). It is not disturbed by other visual field defects, such as quadrantanopia or bitemporal hemianopia, either. Hemianopic patients have been shown to have difficulty taking in a scene in a glance rapidly enough to understand the whole picture, and they often present very time-consuming, non-systematic irregular visual exploration. In bedside and peri-operative conditions, the TANGO test is not disturbed by hemianopia. We therefore retained the possibility of performing a dedicated visual field VR task.

By contrast, TANGO task performance is impaired by UN, and in patients with difficulties in the Ekman and/or RME tasks, or visuo-constructive impairment. The TANGO test can be seen as a cancellation test with distractors, and is therefore very sensitive for the detection of UN, probably more so than line bisection tests. Patients presenting UN or UN associated with hemianopia are readily detected with the bedside VR test (figure 5).

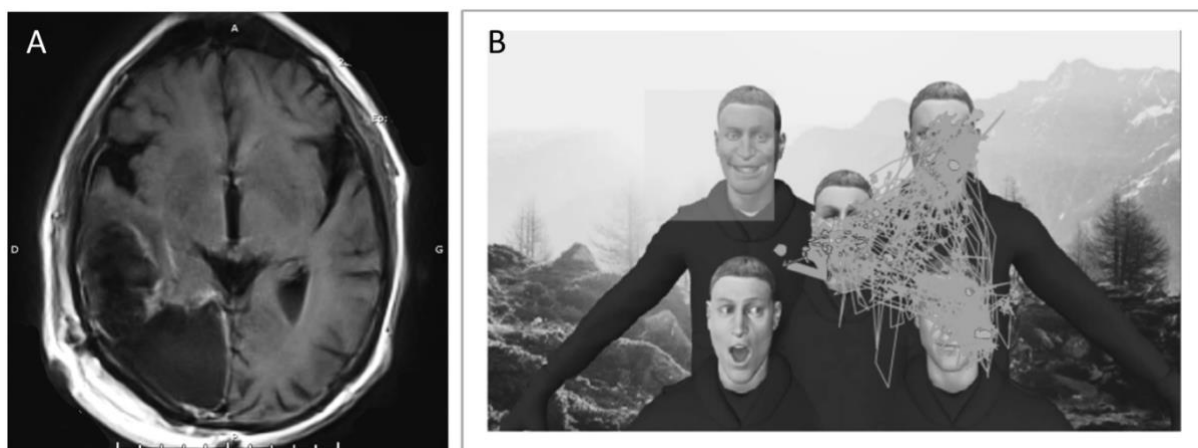


Figure 5: A. Post-operative MRI of a malignant right occipital glioma The patient presented homonymous hemianopia and unilateral neglect. **B: Bedside TANGO test: example of the eye tracking feedback (cumulative view of 10 tests) received by the neuropsychologist.** The patient was asked to determine the emotion expressed by the face looking at him/her (the upper left face, square). The eye-tracking data recorded for the patient (lines) showed that he was unable to direct his attention to the left side.

Like other groups, we began by performing intraoperative tests of face-based mentalizing for patients with right-sided lesions with a good prognosis, as a standard clinical approach (Yordanova et al. 2019).

This operating procedure is now standard practice in our department. Preoperative neuropsychological evaluation and imaging (including anatomic magnetic resonance imaging, diffusion tensor imaging, and resting-state magnetic resonance imaging) are performed for all patients. All patients are trained in the VR tasks before surgery, even if they have already had some experience with a VRH.

During awake craniotomy, sedation was achieved by the target-controlled infusion of remifentanyl and propofol, and ventilation was controlled with a laryngeal mask airway. Patients were placed in a supine or lateral position, according to the location of the tumor, with a rigid pin fixation of the head in a Mayfield frame. The scalp incision and the pin sites of the Mayfield headholder were infiltrated with diluted ropivacaine. Local anesthetic blocks were also performed on the supraorbital, temporal, retroauricular, occipital and sphenopalatine nerves. Once the neuronavigation-guided craniotomy (BrainLab, Munich, Germany) was complete and the dura mater had been opened following ropivacaine infiltration, the sedative drugs were stopped, and the patient gradually woke up. The laryngeal mask airway was removed when the patient was awake. Electroencephalography (EEG) signals were recorded with a four-plot subdural electrode (4-channel Eclipse neurovascular workstation; Medtronic Xomed, Inc., Jacksonville, Florida, USA), placed directly adjacent to, but not over, the area mapped.

All mapping was performed in the presence of an engineer and a neuropsychologist.

The scene in the VRH shows five avatars in front of a variable natural background. One is in the center, and the others are located such that one is in each quadrant of the VRH visual field. Each avatar has a different eye-gaze direction. The patient has to identify the avatar making eye contact with him/her.

The avatar expresses a dynamic facial emotion 0.6 s after the establishment of visual contact with the right avatar or after staring longer than 0.6s. at any other avatar. The patient must identify the emotion expressed: joy, surprise or anger. The patient can also describe the avatar's intention to communicate (mental

state attribution). After 4 seconds, the screen turns off. All the quadrants of the visual field and all the emotions are randomly presented to the patient.

During the surgery, some tests were performed by the patient, without stimulation, to ensure that the task was executed successfully and without difficulty. As described previously (*see part 3.1: Task importance in awake brain surgery*) DES is delivered with a bipolar electrode delivering a biphasic current (60Hz, 1 ms pulse width, current amplitude ranging from 2 to 8 mA over 2-3 s)(Fernández Coello et al. 2013; Pallud et al. 2017; Duffau 2005). If the performance of the patient in a given task decreases, the corresponding region is considered as eloquent. Without DES or during DES of a non-eloquent brain area, the TANGO test is performed in a mean of 6.28 s (5.3 s in bedside conditions).

As described above, the patient's gaze can be followed in real time on a screen, so the medical team can see how the patient explores the visual space, identify the face at which he or she stares, and whether the appropriate emotion or mental state is described, even if the patient is staring at the wrong avatar. In cases of incorrect response, it is possible to identify the step at which the failure occurred immediately: visual exploration, eye contact identification, emotion recognition or mental state attribution. False-positive results were avoided by requiring three positive stimulations for an anatomic site to be considered responsive (Roux et al. 2011). The patient's answers are confronted to the cortical or subcortical localization of the DES recorded on the neuronavigation system during surgery.

Other eye tracking parameters are recorded: gaze strategy, length of the scan path (defined as the sum of saccadic eye movements), direction of the first saccade, left- or rightward saccades, mean number and amplitude, the number of passages over a given area of interest (eye, mouth, background), the time for which the gaze was fixed on the area of interest. All these data can also be compared with the anatomic data recorded on the neuronavigation system during surgery.

When an eloquent brain area is stimulated, the patient gives an incorrect response or is unable to respond within the time allocated. In the second of these situations, patients were systematically asked to explain the reasons for which they were unable to identify which avatar was making eye contact or to associate this face with a mental state.

Several defects induced by cortical or subcortical DES during the TANGO task were observed in our preliminary experiment. Our purpose here was not to provide a comprehensive description of these defects or to analyze their correlation with anatomic or functional aspects. However, we do provide some illustrative examples. Some classical symptoms, such as left-sided UN, can be induced by DES, and easily detected by eye tracking (Figure 6).

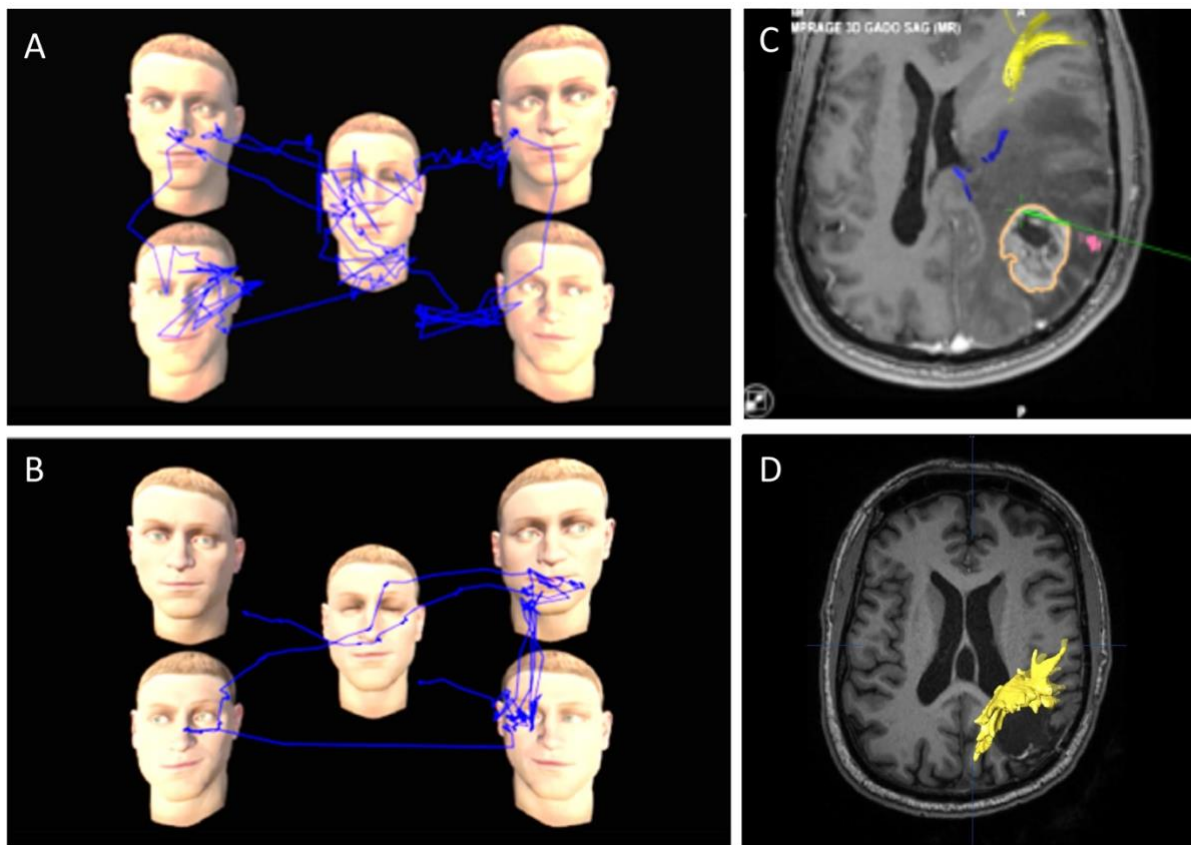


Figure 6: Resection of malignant glioma localized in the right temporoparietal junction. **A:** perioperative test without DES, normally performed. The patient was asking to detect the emotion of the avatar making an eye contact, here in the inferior left corner of the visual field. The patient's gaze is materialized by the blue line. **B:** perioperative test during DES of white matter, on the resection cavity wall. The patient cannot find the avatar making an eye contact, here in the superior left corner. **C:** Neuronavigation view showing the DES electrode location in contact with the superior longitudinal fasciculus (SLF), not totally visualized because of the peritumoral edema., **D:** Post operative tractography confirming the electrode localization in contact with the SLF. DES, direct electric stimulation

However, we also observed other unexpected defects, requiring for their integration, the use of novel paradigms and models relating to the neuroanatomical basis of social cognition. The model proposed by Catani and Bambini is particularly relevant for that. This new anatomic model of communication extends from basic prelinguistic social abilities common to humans and non-human primates, to syntactic and pragmatic functions specific to humans. It proposes a hierarchical organization into five levels based on developmental and evolutionary aspects of social communication (Catani et Bambini 2014).

Level one is the first step toward social engagement, involving the recognition of another individual (the avatar in our case) as an agent capable of conveying relevant information. When the anatomic support for this level, the anterior segment of the arcuate fasciculus, is temporarily disrupted by DES, the patient's gaze does not explore all the faces and is rapidly attracted to other items, such as details in the landscape (figure 7).

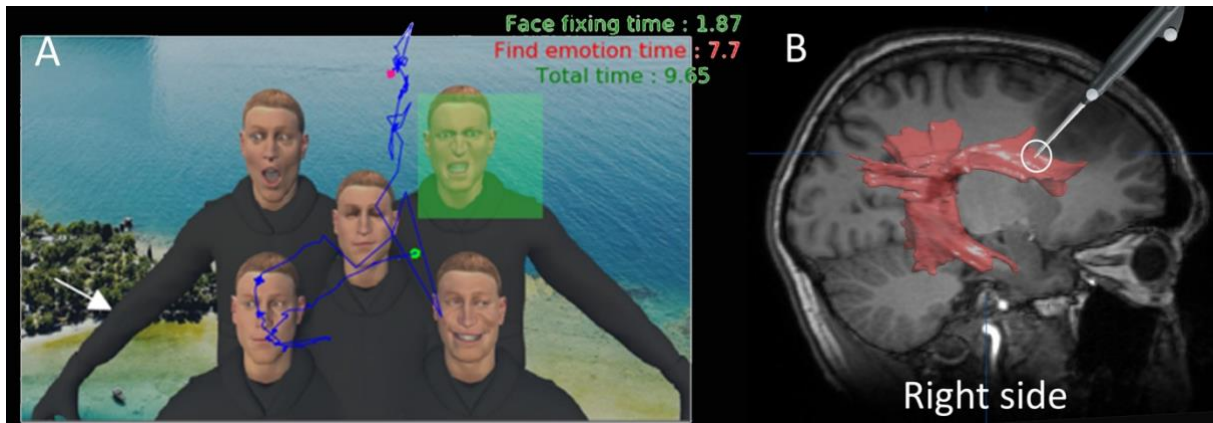


Figure 7. A: sagittal neuronavigation mapping of the subcortical DES location (white circle) in contact with the arcuate fasciculus (red). **B:** TANGO test during the DES. The patient's gaze (blue line, starting point in green, ending in red) leaves rapidly the avatar's faces, attracted by other details in the landscape. DES, direct electric stimulation

Level two constitutes the neural basis of the expression and recognition of communicative intentions. When its anatomical support, the frontal aslant tract (FAT), is disrupted by DES, the patient ignores the communicative cues. His/her gaze remains fixed on the first avatar encountered or goes from face to face, unable to identify the one making eye contact or expressing a facial emotion (figure 8).

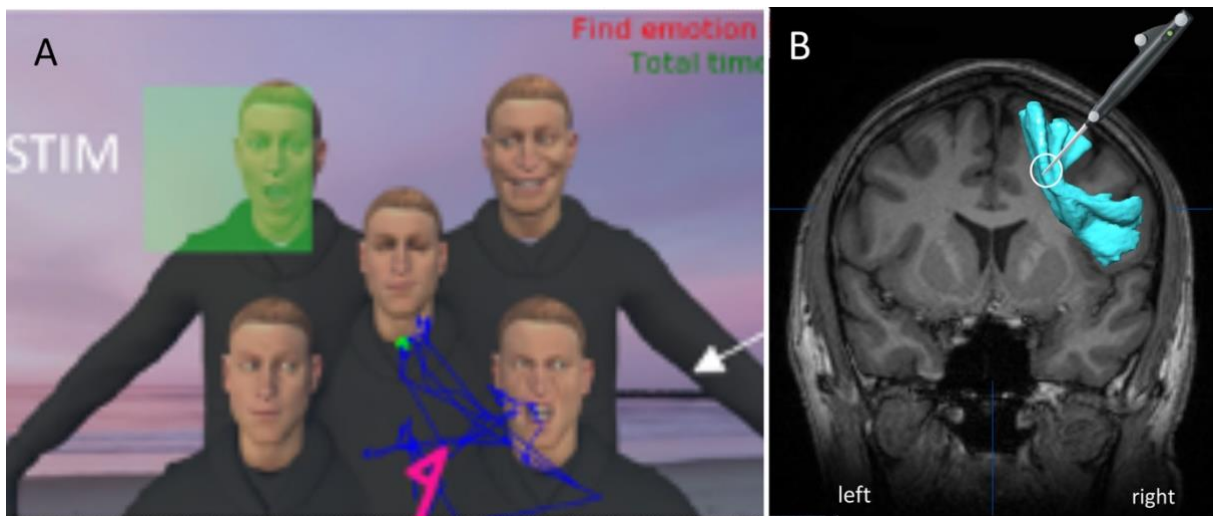


Figure 8. A: TANGO test during the DES. The patient was unable to detect the communicative cues (upper left, green square). **B:** coronal neuronavigation showing the DES electrode location (white circle) in contact with the frontal aslant tract (blue). DES, direct electric stimulation

Another explanation for this behavior would be a role for the FAT in executive function, in inhibitory control and conflict monitoring (Dick et al. 2019; Garic et al. 2019). In the right hemisphere, this circuit is thought to be specialized in inhibitory control, particularly in the visuo-spatial domain. The FAT is involved in selecting between competing representations for actions requiring the same motor resources (mostly the articulatory apparatus in the left hemisphere, and the oculomotor and manual/limb action systems in the right hemisphere).

Level three is more advanced. Its anatomical support is an anterior temporal network including the inferior longitudinal fasciculus (ILF). In the left hemisphere, this network is involved in selecting verbal labels for objects in a postero-anterior progression of word comprehension. In parallel, we can hypothesize that, in the right hemisphere, this network is specialized in detecting facial cues, with a postero-anterior progression of emotion comprehension. During DES of the inferior longitudinal fasciculus (ILF), the patient may easily identify an avatar looking at him/her, but cannot analyze or describe the facial emotion. This is not surprising, because the ILF and other ventral tracts have already been implicated in the recognition of facial emotions (Herbet, Zemmoura, et Duffau 2018).

A simple, elementary simulated social interaction then identifies the various components of prelinguistic social abilities and their neural substrates. Several questions remain unanswered: Is it important to preserve the white matter fasciculi identified during surgery? Does the anatomic disruption of these subcortical structures lead to a permanent or transient social cognition defect? The clinical value of the approach developed here requires assessment in further trials.

10. LIMITATIONS AND PERSPECTIVES

The application of virtual reality technologies to social neuroscience, including brain mapping during awake surgery in particular, raises ethical issues (Parsons, Gaggioli, et Riva 2017). The first versions of our VR task are not deeply immersive, and we are a long way away from the virtual experience described in the movie "Matrix". However, with progress in VR, new versions with actors and natural environments are already being tested (figure 9).




Figure 9: Two dimensional (**A**) and three dimensional stereoscopic (**B**) TANGO test using actors in real-life environment.

We are working on stereoscopic sound and smells, to make the virtual experience more immersive and emotionally engaging. The patient could be immersed in the environment of a French café terrace, with the aroma of hot coffee, street sounds and people sitting at neighboring tables. It will soon be possible to use “deep fake” technology to replace the faces of the actors with those of the patient’s friends or family.

It will also be possible, in the near future, to map social cognition without the need for verbal participation from the patient. The new VRH technologies are making it possible to track the participant’s behavior and reactions to the VR experience by synchronizing various sources of data, to obtain a holistic, integrated measurement of target social interactions through machine learning techniques. The most studied data after eye tracking are facial mimicry, pupillometry and electroencephalographic coherence data.

What impact will this VR and neurosurgical experiment have on patients? The level of realism afforded by the latest VR technologies raises questions about the potential psychological effects of exposing participants to intimate social situations. Virtual reality technologies enabling researchers to manipulate the processing of social information in the operating theater could have medical consequences? In addition to common, normal, social interactions, VR can simulate impossible social interactions and situations incompatible with the laws of physics. Participants could also be involved in moral dilemmas (Friedman et al. 2014), potentially triggering moral conflicts (such as those in experiments involving the reproduction of ethical dilemmas (Parsons, Gaggioli,

et Riva 2017)). There is a need for consensus statements on research parameters and ethical guidelines for VR-based experiments for social cognition studies.

11. CONCLUSION

VR provides neurosurgeons and neuropsychologists with tools for the creation of realistic simulations of social situations that would otherwise be impossible to investigate through conventional research stimulation tasks. Moreover, VR tasks can provide a high degree of experimental control. The use of virtual environments advocated here should not minimize the contribution of traditional pen-and-paper tasks, which have many advantages for brain mapping, as demonstrated by the progress made with such tests and tasks. Here, we highlight the utility of extending social neuroscience paradigms via dynamic virtual environments for investigating realistic social cognition during peri-operative brain mapping. VR can imitate complex social situations, even in patients undergoing awake craniotomies. We show here that it is possible, during awake brain surgery, to immerse the patient in a virtual environment and to interact with the patient, opening up new possibilities for the mapping of complex cognitive functions. Our preliminary experiments suggest that immersive virtual reality and ocular tracking may be useful new tools for exploring the neural substrates of visuo-spatial and social cognition during awake brain surgery. Nevertheless, the progress being made in VR and the profound sense of immersion achieved with the new devices are raising new ethical issues. Continuous reflection, through discussions of ethical and methodological considerations, is required before applying these advanced technologies to awake brain surgery in clinical practice.

FIGURES AND TABLES

Figure 1. Mapping of the visual field during awake surgery. The test is piloted by an orthoptist in the operative room. **1:** screen showing what the patient is seeing in the virtual reality headset, an empty grey space with a central cross to stare, while a colored dot can appear in the periphery. **2:** Screen with an Esterman grid allowing the orthoptist to select the part of the visual field to be tested. **3:** Patient wearing the virtual reality headset.

Figure 2: During awake brain surgery, the patient communicating by symbolic gestures with the neuropsychologist (**A**) with the VR social network. **B:** neuropsychologist's avatar visualized by the patient in the VRH. From the figure published under the terms of Creative Commons Attribution 4.0 licence. Social Cognition: Prospective Trial. *Journal of Medical Internet Research* 20 (6): e10332. <https://doi.org/10.2196/10332>.

Figure 3: facial motion capture with Dynamixyz.

Figure 4. A: View of the operative room during the procedure (**1:** head of the patient, wearing the VRH; **2:** screen showing what the patient is seeing in the VRH, his gaze materialized by a green spot; **3:** application of the DES on the exposed brain; **4:** neuronavigation showing white matter fascicules and the position of the electrode. **B:** Example of the VR task simulating a social interaction. The patient must recognize the avatar who looks at him and indicate his emotion (joy, surprise, or anger). The patient's gaze is presented by a blue line. The box indicates the avatar making the eye contact. The arrow indicates the avatar gazed by the patient more than 0.6 sec (that trigger the dynamic facial emotion). In this example, the patient identified the avatar in 2.37 sec and indicates his emotion in 2.53 sec later. VRH, virtual reality headset.

Figure 5: A. Post-operative MRI of a malignant right occipital glioma The patient presented homonymous hemianopia and unilateral neglect. **B: Bedside TANGO test: example of the eye tracking feedback (cumulative view of 10 tests) received by the neuropsychologist.** The patient was asked to determine the emotion expressed by the face looking at him/her (the upper left face, square). The eye-tracking data recorded for the patient (lines) showed that he was unable to direct his attention to the left side.

Figure 6: Resection of malignant glioma localized in the right temporoparietal junction. **A:** perioperative test without DES, normally performed. The patient was asking to detect the emotion of the avatar making an eye contact, here in the inferior left corner of the visual field. The patient's gaze is materialized by the blue line. **B:** perioperative test during DES of whiter matter, on the resection cavity wall. The patient cannot find the avatar making an eye contact, here in the superior left corner. **C:** Neuronavigation view showing the DES electrode location in contact with the superior longitudinal fasciculus (SLF), not totally visualized because of the peritumoral edema., **D:** Post operative tractography confirming the electrode localization in contact with the SLF. DES, direct electric stimulation

Figure 7. A: sagittal neuronavigation mapping of the subcortical DES location (white circle) in contact with the arcuate fasciculus (red). **B:** TANGO test during the DES. The patient's gaze (blue line, starting point in green,

ending in red) leaves rapidly the avatar's faces, attracted by other details in the landscape. DES, direct electric stimulation

Figure 8. A: TANGO test during the DES. The patient was unable to detect the communicative cues (upper left, green square). **B:** coronal neuronavigation showing the DES electrode location (white circle) in contact with the frontal aslant tract (blue). DES, direct electric stimulation

Figure 9: Two dimensional (**A**) and three dimensional stereoscopic (**B**) TANGO test using actors in real-life environment.

ACKNOWLEDGMENT

We would like to thank Gwenaëlle Soulard for her technical support and Fondation de l'Avenir and CHU d'Angers for their funding

FUNDING STATEMENT

This project received funding from Fondation de l'Avenir, Paris, France (AP-RM-18-032, 2018) and CHU d'Angers.

CONFLICTS OF INTEREST STATEMENT

None of the authors has any conflict of interest to declare.

REFERENCES

- Baron-Cohen, S., S. Wheelwright, J. Hill, Y. Raste, et I. Plumb. 2001. « The "Reading the Mind in the Eyes" Test Revised Version: A Study with Normal Adults, and Adults with Asperger Syndrome or High-Functioning Autism ». *Journal of Child Psychology and Psychiatry, and Allied Disciplines* 42 (2): 241-51.
- Bartolomeo, Paolo, Michel Thiebaut de Schotten, et Fabrizio Doricchi. 2007. « Left Unilateral Neglect as a Disconnection Syndrome ». *Cerebral Cortex (New York, N.Y.: 1991)* 17 (11): 2479-90. <https://doi.org/10.1093/cercor/bhl181>.
- Bartolomeo, Paolo, Michel Thiebaut de Schotten, et Hugues Duffau. 2007. « Mapping of Visuospatial Functions during Brain Surgery: A New Tool to Prevent Unilateral Spatial Neglect ». *Neurosurgery* 61 (6): E1340. <https://doi.org/10.1227/01.neu.0000306126.46657.79>.
- Bernard, Florian, Jean-Michel Lemée, Ghislaine Aubin, Aram Ter Minassian, et Philippe Menei. 2018. « Using a Virtual Reality Social Network During Awake Craniotomy to Map Social Cognition: Prospective Trial ». *Journal of Medical Internet Research* 20 (6): e10332. <https://doi.org/10.2196/10332>.
- Bernard, Florian, Jean-Michel Lemée, Aram Ter Minassian, et Philippe Menei. 2018. « Right Hemisphere Cognitive Functions: From Clinical and Anatomic Bases to Brain Mapping During Awake Craniotomy Part I: Clinical and Functional Anatomy ». *World Neurosurgery*, mai. <https://doi.org/10.1016/j.wneu.2018.05.024>.
- Bernard, Florian, et Philippe Menei. 2019. « Oncology Meets Art: A Way to Understand Patients' Symptoms ». *The Lancet. Oncology* 20 (1): 27. [https://doi.org/10.1016/S1470-2045\(18\)30920-3](https://doi.org/10.1016/S1470-2045(18)30920-3).
- Bernard, Florian, Ilyess Zemmoura, Aram Ter Minassian, Jean-Michel Lemée, et Philippe Menei. 2019. « Anatomical Variability of the Arcuate Fasciculus: A Systematical Review ». *Surgical and Radiologic Anatomy: SRA*, avril. <https://doi.org/10.1007/s00276-019-02244-5>.
- Borst, Aline W. de, et Beatrice de Gelder. 2015. « Is It the Real Deal? Perception of Virtual Characters versus Humans: An Affective Cognitive Neuroscience Perspective ». *Frontiers in Psychology* 6: 576. <https://doi.org/10.3389/fpsyg.2015.00576>.
- Buxbaum, L. J., M. K. Ferraro, T. Veramonti, A. Farne, J. Whyte, E. Ladavas, F. Frassinetti, et H. B. Coslett. 2004. « Hemispatial Neglect: Subtypes, Neuroanatomy, and Disability ». *Neurology* 62 (5): 749-56.
- Carter, R. McKell, et Scott A. Huettel. 2013. « A Nexus Model of the Temporal-Parietal Junction ». *Trends in Cognitive Sciences* 17 (7): 328-36. <https://doi.org/10.1016/j.tics.2013.05.007>.
- Caruana, Nathan, Jon Brock, et Alexandra Woolgar. 2015. « A Frontotemporoparietal Network Common to Initiating and Responding to Joint Attention Bids ». *NeuroImage* 108 (mars): 34-46. <https://doi.org/10.1016/j.neuroimage.2014.12.041>.
- Casanova, Morgan, Ghislaine Aubin, Aram ter Minassian, Renaud Seguier, et Philippe Menei. 2020. « Immersive Virtual Reality and Ocular Tracking for Brain Mapping during Awake Surgery ». *Brain Stimulation* 402 (8): 1241-53.
- Catani, Marco, et Valentina Bambini. 2014. « A Model for Social Communication And Language Evolution and Development (SCALED) ». *Current Opinion in Neurobiology* 28 (octobre): 165-71. <https://doi.org/10.1016/j.conb.2014.07.018>.
- Chechlacz, Magdalena, Pia Rotshtein, et Glyn W. Humphreys. 2012. « Neuroanatomical Dissections of Unilateral Visual Neglect Symptoms: ALE Meta-Analysis of Lesion-Symptom Mapping ». *Frontiers in Human Neuroscience* 6: 230. <https://doi.org/10.3389/fnhum.2012.00230>.

- Conner, Andrew K., Chad Glenn, Joshua D. Burks, Tressie McCoy, Phillip A. Bonney, Ahmed A. Chema, Justin L. Case, Scott Brunner, Cordell Baker, et Michael Sughrue. 2016. « The Use of the Target Cancellation Task to Identify Eloquent Visuospatial Regions in Awake Craniotomies: Technical Note ». *Cureus* 8 (11): e883. <https://doi.org/10.7759/cureus.883>.
- Corbetta, Maurizio, et Gordon L. Shulman. 2002. « Control of goal-directed and stimulus-driven attention in the brain ». *Nature Reviews Neuroscience* 3 (3): 201-15. <https://doi.org/10.1038/nrn755>.
- Dahlquist, Lynnda M., Karen E. Weiss, Emily F. Law, Soumitri Sil, Linda Jones Herbert, Susan Berrin Horn, Karen Wohlheiter, et Claire Sonntag Ackerman. 2009. « Effects of videogame distraction and a virtual reality type head-mounted display helmet on cold pressor pain in young elementary school-aged children ». *Journal of pediatric psychology* 35 (6): 617-625.
- Delion, Matthieu, Evelyne Klinger, Florian Bernard, Ghislaine Aubin, Aram Ter Minassian, et Philippe Menei. 2020. « Immersing Patients in a Virtual Reality Environment for Brain Mapping During Awake Surgery: Safety Study ». *World Neurosurgery* 134 (février): e937-43. <https://doi.org/10.1016/j.wneu.2019.11.047>.
- Dick, Anthony Steven, Dea Garic, Paulo Graziano, et Pascale Tremblay. 2019. « The Frontal Aslant Tract (FAT) and Its Role in Speech, Language and Executive Function ». *Cortex; a Journal Devoted to the Study of the Nervous System and Behavior* 111: 148-63. <https://doi.org/10.1016/j.cortex.2018.10.015>.
- Duffau, Hugues. 2005. « Lessons from Brain Mapping in Surgery for Low-Grade Glioma: Insights into Associations between Tumour and Brain Plasticity ». *The Lancet. Neurology* 4 (8): 476-86. [https://doi.org/10.1016/S1474-4422\(05\)70140-X](https://doi.org/10.1016/S1474-4422(05)70140-X).
- Dyck, Miriam, Maren Winbeck, Susanne Leiberg, Yuhan Chen, et Klaus Mathiak. 2010. « Virtual faces as a tool to study emotion recognition deficits in schizophrenia ». *Psychiatry research* 179 (3): 247-252.
- Ethofer, Thomas, Markus Gschwind, et Patrik Vuilleumier. 2011. « Processing Social Aspects of Human Gaze: A Combined FMRI-DTI Study ». *NeuroImage* 55 (1): 411-19. <https://doi.org/10.1016/j.neuroimage.2010.11.033>.
- « Face Tracking Solution for VR | Veeso ». s. d. Consulté le 23 mars 2020. <https://veeso.com/>.
- Fernández Coello, Alejandro, Sylvie Moritz-Gasser, Juan Martino, Matteo Martinoni, Ryosuke Matsuda, et Hugues Duffau. 2013. « Selection of Intraoperative Tasks for Awake Mapping Based on Relationships between Tumor Location and Functional Networks ». *Journal of Neurosurgery* 119 (6): 1380-94. <https://doi.org/10.3171/2013.6.JNS122470>.
- Fried, I., C. Mateer, G. Ojemann, R. Wohns, et P. Fedio. 1982. « Organization of Visuospatial Functions in Human Cortex. Evidence from Electrical Stimulation ». *Brain: A Journal of Neurology* 105 (Pt 2): 349-71.
- Friedman, Doron, Rodrigo Pizarro, Keren Or-Berkers, Solène Neyret, Xueni Pan, et Mel Slater. 2014. « A Method for Generating an Illusion of Backwards Time Travel Using Immersive Virtual Reality-an Exploratory Study ». *Frontiers in Psychology* 5: 943. <https://doi.org/10.3389/fpsyg.2014.00943>.
- Garic, Dea, Iris Broce, Paulo Graziano, Aaron Mattfeld, et Anthony Steven Dick. 2019. « Laterality of the Frontal Aslant Tract (FAT) Explains Externalizing Behaviors through Its Association with Executive Function ». *Developmental Science* 22 (2): e12744. <https://doi.org/10.1111/desc.12744>.
- Geng, Joy J., et Simone Vossel. 2013. « Re-evaluating the role of TPJ in attentional control: Contextual updating? ». *Neuroscience & Biobehavioral Reviews* 37 (10): 2608-20. <https://doi.org/10.1016/j.neubiorev.2013.08.010>.

- Georgescu, Alexandra Livia, Bojana Kuzmanovic, Daniel Roth, Gary Bente, et Kai Vogeley. 2014. « The Use of Virtual Characters to Assess and Train Non-Verbal Communication in High-Functioning Autism ». *Frontiers in Human Neuroscience* 8: 807. <https://doi.org/10.3389/fnhum.2014.00807>.
- Giussani, Carlo, David Pirillo, et Franck-Emmanuel Roux. 2010. « Mirror of the Soul: A Cortical Stimulation Study on Recognition of Facial Emotions ». *Journal of Neurosurgery* 112 (3): 520-27. <https://doi.org/10.3171/2009.5.JNS081522>.
- « Hardware – Dynamixyz ». s. d. Consulté le 23 mars 2020. <http://www.dynamixyz.com/hardware/>.
- Herbet, Guillaume, Gilles Lafargue, François Bonnetblanc, Sylvie Moritz-Gasser, Nicolas Menjot de Champfleury, et Hugues Duffau. 2014. « Inferring a Dual-Stream Model of Mentalizing from Associative White Matter Fibres Disconnection ». *Brain: A Journal of Neurology* 137 (Pt 3): 944-59. <https://doi.org/10.1093/brain/awt370>.
- Herbet, Guillaume, Ilyess Zemmoura, et Hugues Duffau. 2018. « Functional Anatomy of the Inferior Longitudinal Fasciculus: From Historical Reports to Current Hypotheses ». *Frontiers in Neuroanatomy* 12: 77. <https://doi.org/10.3389/fnana.2018.00077>.
- Jean Michel Lemée, Florian Bernard, Aram Ter Minassian, et Philippe Menei. 2018. « Right hemisphere cognitive functions: from clinical and anatomical bases to brain mapping in awake craniotomy Part II: Review about the previous experiences and reflexion about the neuropsychological tasks and their validity for awake surgery ». *Neurosurgery*.
- Joyal, Christian C., Laurence Jacob, Marie-Hélène Cigna, Jean-Pierre Guay, et Patrice Renaud. 2014. « Virtual faces expressing emotions: an initial concomitant and construct validity study ». *Frontiers in human neuroscience* 8: 787.
- Karnath, H. O., S. Ferber, et M. Himmelbach. 2001. « Spatial Awareness Is a Function of the Temporal Not the Posterior Parietal Lobe ». *Nature* 411 (6840): 950-53. <https://doi.org/10.1038/35082075>.
- Kaufman, Philip. 1988. *The Unbearable Lightness of Being*. Orion Pictures.
- Kerkhoff, Georg, et Thomas Schenk. 2011. « Line Bisection in Homonymous Visual Field Defects - Recent Findings and Future Directions ». *Cortex; a Journal Devoted to the Study of the Nervous System and Behavior* 47 (1): 53-58. <https://doi.org/10.1016/j.cortex.2010.06.014>.
- Kingstone, Alan, Christine Tipper, Jelena Ristic, et Elton Ngan. 2004. « The Eyes Have It!: An FMRI Investigation ». *Brain and Cognition* 55 (2): 269-71. <https://doi.org/10.1016/j.bandc.2004.02.037>.
- Kitabayashi, Tomohiro, Mitsutoshi Nakada, Masashi Kinoshita, Hiroyuki Sakurai, Saori Kobayashi, Hirokazu Okita, Yuko Nanbu, Yutaka Hayashi, et Jun-Ichiro Hamada. 2012. « [Awake surgery with line bisection task for two cases of parietal glioma in the non-dominant hemisphere] ». *No Shinkei Geka. Neurological Surgery* 40 (12): 1087-93.
- Kristensen, Line Burholt, Lin Wang, Karl Magnus Petersson, et Peter Hagoort. 2013. « The Interface Between Language and Attention: Prosodic Focus Marking Recruits a General Attention Network in Spoken Language Comprehension ». *Cerebral Cortex* 23 (8): 1836-48. <https://doi.org/10.1093/cercor/bhs164>.
- Krumhuber, Eva G., Arvid Kappas, et Antony SR Manstead. 2013. « Effects of dynamic aspects of facial expressions: A review ». *Emotion Review* 5 (1): 41-46.
- Laufs, H., K. Krakow, P. Sterzer, E. Eger, A. Beyerle, A. Salek-Haddadi, et A. Kleinschmidt. 2003. « Electroencephalographic Signatures of Attentional and Cognitive Default Modes in Spontaneous Brain

Activity Fluctuations at Rest ». *Proceedings of the National Academy of Sciences of the United States of America* 100 (19): 11053-58. <https://doi.org/10.1073/pnas.1831638100>.

- Mandonnet, E., L. Cerliani, K. Siuda-Krzywicka, I. Poisson, N. Zhi, E. Volle, et M. T. de Schotten. 2017. « A network-level approach of cognitive flexibility impairment after surgery of a right temporo-parietal glioma ». *Neurochirurgie* 63 (4): 308–313.
- Marrero, Hipólito, Elena Gámez, Mabel Urrutia, David Beltrán, Jose M. Diaz, et Sara N. Yagual. 2019. « Brain Encoding of Social Approach: Is It Associated With Spatial Ability? » *Frontiers in Behavioral Neuroscience* 13: 179. <https://doi.org/10.3389/fnbeh.2019.00179>.
- Mazerand, Edouard, Marc Le Renard, Sophie Hue, Jean-Michel Lemée, Evelyne Klinger, et Philippe Menei. 2017. « Intraoperative Subcortical Electrical Mapping of the Optic Tract in Awake Surgery Using a Virtual Reality Headset ». *World Neurosurgery* 97 (janvier): 424-30. <https://doi.org/10.1016/j.wneu.2016.10.031>.
- Menei, Philippe, Jean-Michel Lemée, Florian Bernard, Aram Ter Minassian, et Matthieu Delion. under review. « Immersing Patients in a Virtual Reality Environment for Brain Mapping During Awake Surgery: Safety Study step 2. » *Journal of Medical Internet Research*, n° 135: 900.
- Motomura, Kazuya, Yuri Terasawa, Atsushi Natsume, Kentaro Iijima, Lushun Chalise, Junko Sugiura, Hiroyasu Yamamoto, Kyohei Koyama, Toshihiko Wakabayashi, et Satoshi Umeda. 2019. « Anterior Insular Cortex Stimulation and Its Effects on Emotion Recognition ». *Brain Structure & Function* 224 (6): 2167-81. <https://doi.org/10.1007/s00429-019-01895-9>.
- Nakajima, Riho, Masashi Kinoshita, Hirokazu Okita, Tetsutaro Yahata, et Mitsutoshi Nakada. 2019. « Glioma Surgery under Awake Condition Can Lead to Good Independence and Functional Outcome Excluding Deep Sensation and Visuospatial Cognition ». *Neuro-Oncology Practice* 6 (5): 354-63. <https://doi.org/10.1093/nop/npy054>.
- Nummenmaa, Lauri, Luca Passamonti, James Rowe, Andrew D. Engell, et Andrew J. Calder. 2010. « Connectivity Analysis Reveals a Cortical Network for Eye Gaze Perception ». *Cerebral Cortex (New York, N.Y.: 1991)* 20 (8): 1780-87. <https://doi.org/10.1093/cercor/bhp244>.
- Okada, Takashi, Wataru Sato, et Motomi Toichi. 2006. « Right Hemispheric Dominance in Gaze-Triggered Reflexive Shift of Attention in Humans ». *Brain and Cognition* 62 (2): 128-33. <https://doi.org/10.1016/j.bandc.2006.04.001>.
- Pallud, J., E. Mandonnet, R. Corns, E. Dezamis, E. Parraga, M. Zanello, et G. Spena. 2017. « Technical Principles of Direct Bipolar Electrostimulation for Cortical and Subcortical Mapping in Awake Craniotomy ». *Neuro-Chirurgie* 63 (3): 158-63. <https://doi.org/10.1016/j.neuchi.2016.12.004>.
- Papagno, Costanza, Alberto Pisoni, Giulia Mattavelli, Alessandra Casarotti, Alessandro Comi, Francesca Fumagalli, Mirta Vernice, Enrica Fava, Marco Riva, et Lorenzo Bello. 2016. « Specific Disgust Processing in the Left Insula: New Evidence from Direct Electrical Stimulation ». *Neuropsychologia* 84 (avril): 29-35. <https://doi.org/10.1016/j.neuropsychologia.2016.01.036>.
- Parsons, Thomas D., Andrea Gaggioli, et Giuseppe Riva. 2017. « Virtual reality for research in social neuroscience ». *Brain sciences* 7 (4): 42.
- Redcay, Elizabeth. 2008. « The Superior Temporal Sulcus Performs a Common Function for Social and Speech Perception: Implications for the Emergence of Autism ». *Neuroscience and Biobehavioral Reviews* 32 (1): 123-42. <https://doi.org/10.1016/j.neubiorev.2007.06.004>.

- Rolland, Alice, Guillaume Herbet, et Hugues Duffau. 2018. « Awake Surgery for Gliomas within the Right Inferior Parietal Lobule: New Insights into the Functional Connectivity Gained from Stimulation Mapping and Surgical Implications ». *World Neurosurgery* 112 (avril): e393-406. <https://doi.org/10.1016/j.wneu.2018.01.053>.
- Rorden, Chris, Monika Fruhmann Berger, et Hans-Otto Karnath. 2006. « Disturbed Line Bisection Is Associated with Posterior Brain Lesions ». *Brain Research* 1080 (1): 17-25. <https://doi.org/10.1016/j.brainres.2004.10.071>.
- Roux, Franck-Emmanuel, Olivier Dufor, Valérie Lauwers-Cances, Leila Boukhatem, David Brauge, Louisa Draper, Jean-Albert Lotterie, et Jean-François Démonet. 2011. « Electrostimulation Mapping of Spatial Neglect ». *Neurosurgery* 69 (6): 1218-31. <https://doi.org/10.1227/NEU.0b013e31822aefd2>.
- Sadaghiani, Sepideh, René Scheeringa, Katia Lehongre, Benjamin Morillon, Anne-Lise Giraud, et Andreas Kleinschmidt. 2010. « Intrinsic Connectivity Networks, Alpha Oscillations, and Tonic Alertness: A Simultaneous Electroencephalography/Functional Magnetic Resonance Imaging Study ». *The Journal of Neuroscience: The Official Journal of the Society for Neuroscience* 30 (30): 10243-50. <https://doi.org/10.1523/JNEUROSCI.1004-10.2010>.
- Sagberg, Lisa Millg\gaard, Daniel Høyer Iversen, Even Hovig Fyllingen, Asgeir Store Jakola, Ingerid Reinertsen, et Ole Solheim. 2019. « Brain atlas for assessing the impact of tumor location on perioperative quality of life in patients with high-grade glioma: A prospective population-based cohort study ». *NeuroImage: Clinical* 21: 101658.
- Saitovitch, Ana, Traian Popa, Hervé Lemaitre, Elza Rechtman, Jean-Charles Lamy, David Grévent, Raphael Calmon, et al. 2016. « Tuning Eye-Gaze Perception by Transitory STS Inhibition ». *Cerebral Cortex (New York, N.Y.: 1991)* 26 (6): 2823-31. <https://doi.org/10.1093/cercor/bhw045>.
- Salo, J., A. Niemelä, M. Joukamaa, et J. Koivukangas. 2002. « Effect of Brain Tumour Laterality on Patients' Perceived Quality of Life ». *Journal of Neurology, Neurosurgery, and Psychiatry* 72 (3): 373-77. <https://doi.org/10.1136/jnnp.72.3.373>.
- Sammler, Daniela, Marie-Hélène Grosbras, Alfred Anwander, Patricia E.G. Bestelmeyer, et Pascal Belin. 2015. « Dorsal and Ventral Pathways for Prosody ». *Current Biology* 25 (23): 3079-85. <https://doi.org/10.1016/j.cub.2015.10.009>.
- Sato, Wataru, Takanori Kochiyama, Shota Uono, Reiko Sawada, Yasutaka Kubota, Sayaka Yoshimura, et Motomi Toichi. 2019. « Widespread and Lateralized Social Brain Activity for Processing Dynamic Facial Expressions ». *Human Brain Mapping* 40 (13): 3753-68. <https://doi.org/10.1002/hbm.24629>.
- Schenkenberg, T., D. C. Bradford, et E. T. Ajax. 1980. « Line Bisection and Unilateral Visual Neglect in Patients with Neurologic Impairment ». *Neurology* 30 (5): 509-17.
- Talacchi, Andrea, Giovanna Maddalena Squintani, Barbara Emanuele, Vincenzo Tramontano, Barbara Santini, et Silvia Savazzi. 2013. « Intraoperative Cortical Mapping of Visuospatial Functions in Parietal Low-Grade Tumors: Changing Perspectives of Neurophysiological Mapping ». *Neurosurgical Focus* 34 (2): E4. <https://doi.org/10.3171/2012.12.FOCUS12358>.
- Thakkar, Katharine N., Peter Brugger, et Sohee Park. 2009. « Exploring Empathic Space: Correlates of Perspective Transformation Ability and Biases in Spatial Attention ». *PloS One* 4 (6): e5864. <https://doi.org/10.1371/journal.pone.0005864>.

- Thye, Melissa D., Donna L. Murdaugh, et Rajesh K. Kana. 2018. « Brain Mechanisms Underlying Reading the Mind from Eyes, Voice, and Actions ». *Neuroscience* 374: 172-86. <https://doi.org/10.1016/j.neuroscience.2018.01.045>.
- Tompkins, Connie A., Victoria L. Scharp, Wiltrud Fassbinder, Kimberly Meigh, et Elizabeth M. Armstrong. 2006. « 'Theory of mind' in adults with right hemisphere brain damage ». *Brain and Language* 1 (99): 67-68.
- Tompkins, Connie A., Victoria L. Scharp, Wiltrud Fassbinder, Kimberly M. Meigh, et Elizabeth M. Armstrong. 2008. « A different story on "Theory of Mind" deficit in adults with right hemisphere brain damage ». *Aphasiology* 22 (1): 42-61.
- Vallar, Giuseppe, Lorenzo Bello, Emanuela Bricolo, Antonella Castellano, Alessandra Casarotti, Andrea Falini, Marco Riva, Enrica Fava, et Costanza Papagno. 2014. « Cerebral Correlates of Visuospatial Neglect: A Direct Cerebral Stimulation Study ». *Human Brain Mapping* 35 (4): 1334-50. <https://doi.org/10.1002/hbm.22257>.
- Vilasboas, Tatiana, Guillaume Herbet, et Hugues Duffau. 2017. « Challenging the Myth of Right Nondominant Hemisphere: Lessons from Corticosubcortical Stimulation Mapping in Awake Surgery and Surgical Implications ». *World Neurosurgery* 103 (juillet): 449-56. <https://doi.org/10.1016/j.wneu.2017.04.021>.
- « VTime: The VR Sociable Network - Out Now for Windows Mixed Reality, Gear VR, Oculus Rift, iPhone, Google Daydream, and Google Cardboard ». s. d. Consulté le 25 février 2018. <https://vtime.net/> and <http://www.webcitation.org/6zKYC8j6Q>.
- Weed, Ethan, William McGregor, Jørgen Feldbæk Nielsen, Andreas Roepstorff, et Uta Frith. 2010. « Theory of Mind in adults with right hemisphere damage: What's the story? ». *Brain and Language* 113 (2): 65-72.
- Wilms, Marcus, Leonhard Schilbach, Ulrich Pfeiffer, Gary Bente, Gereon R. Fink, et Kai Vogeley. 2010. « It's in Your Eyes--Using Gaze-Contingent Stimuli to Create Truly Interactive Paradigms for Social Cognitive and Affective Neuroscience ». *Social Cognitive and Affective Neuroscience* 5 (1): 98-107. <https://doi.org/10.1093/scan/nsq024>.
- Yordanova, Yordanka Nikolova, Jérôme Cochereau, Hugues Duffau, et Guillaume Herbet. 2019. « Combining resting state functional MRI with intraoperative cortical stimulation to map the mentalizing network ». *Neuroimage* 186: 628-636.
- Yordanova, Yordanka Nikolova, Hugues Duffau, et Guillaume Herbet. 2017. « Neural Pathways Subservicing Face-Based Mentalizing ». *Brain Structure & Function* 222 (7): 3087-3105. <https://doi.org/10.1007/s00429-017-1388-0>.

Conclusion

L'hémisphère non dominant supporte la cognition visuo-spatiale et sociale. Sont atteinte est à l'origine du syndrome d'héminégligence, impactant la qualité de vie de nos patients. Les objectifs préliminaires de cette thèse de science étaient (1) *de proposer une taxonomie des fonctions cérébrales supportées par l'hémisphère droit*. Les différentes zones corticales et faisceaux de fibres blanches impliqués dans chacune des fonctions cognitives de l'hémisphère droit (la cognition visuo-spatiale, la cognition sociale dont la reconnaissance faciale par exemple) ont été classées pour faciliter la compréhension de leur anatomie fonctionnelle. (2) *d'harmoniser les données d'anatomie fonctionnelle avec les données neuropsychologiques et de sémiologie clinique de ces fonctions*. Ce travail visait également à harmoniser les connaissances d'anatomie structurale, d'IRM fonctionnelle (activation, tractographie, de repos), de neuropsychologie et de sémiologie en se basant sur la *terminologia anatomica*. (3) *d'harmoniser la nomenclature anatomique entre les études de dissections et d'imagerie de l'hémisphère droit*. Les études de dissection et d'imagerie structurale utilisaient une nomenclature non harmonisée, parfois confuse, concernant la disposition sulcogyrale et les fibres blanches intrahémisphériques. Cet écueil, rend l'analyse des données de la littérature difficile. Concernant les études d'IRM fonctionnelle, pour les zones d'activations corticales et la tractographie, les auteurs n'utilisent généralement pas la nomenclature anatomique. (4) *d'harmoniser la nomenclature anatomique du principal faisceau de substance blanche : le faisceau arqué*. Ce travail inédit de revue systématique nous a permis d'extraire les méta-données issues de 3 siècles de publications sur le sujet permettant de mieux définir le faisceau arqué dans sa disposition modale et ses variations décrites.

Le principal but de cette thèse de science était *d'approfondir nos connaissances sur l'anatomie du réseau ventral de l'attention*, qui est un réseau fonctionnel cortical identifié par l'IRM de repos, impliqué dans la cognition visuo-spatiale. L'identification anatomique des fibres blanches de ce réseau reste un défi. En traitant les données d'IRM fonctionnelle de repos de 50 sujets, nous avons pu décrire les localisations corticales du réseau ventral de l'attention dans notre cohorte de sujets sains. Nous avons ensuite utilisé les zones corticales du réseau ventral de l'attention comme régions germes, pour l'étude des fibres blanches in-vivo (tractographie), ainsi que sur des cerveaux du laboratoire d'Anatomie par méthode de Klingler. Nous avons pu ainsi définir les faisceaux de fibres blanches *du réseau ventral de l'attention*. Ces faisceaux comprennent le faisceau longitudinal dans sa troisième portion (SLF III) et le faisceau arqué droits. Nous en avons discuté les implications neurologiques et neurochirurgicales. La principale implication chirurgicale concerne l'application à la chirurgie éveillée de l'hémisphère droit. Une préservation du SLF III et du faisceau arqué droit pourrait permettre d'éviter une altération de la cognition visuospatiale.

Cette implication fondamentale comporte néanmoins une limite. En effet le développement d'un test neuropsychologique spécifique stimulant le réseau ventral de l'attention reste à développer pour pouvoir réaliser cette chirurgie éveillée. Dans ce sens, nous avons développé des travaux visant à l'utilisation des lunettes de réalité virtuelle en condition de chirurgie éveillée, pour réaliser de nouveaux tests neuropsychologiques dédiés à la préservation des fonctions cognitives de l'hémisphère droit.

Publications et communications présentées au cours de la Thèse

1. Publications :

- P. Mercier, Bernard F, M.Delion. **Microsurgical anatomy of the fourth ventricle.** *Neurochirurgie*. June 2018. doi: 10.1016/j.neuchi.2018.04.010 (IF 0.802, SIGAPS E)
- Bernard F, Le Fournier L, Lemée JM, Menei P, Fournier HD. **Transdural spinal cord herniation: tips and tricks.** *World Neurosurgery*. Novembre 2017. doi:10.1016/j.wneu.2017.09.195. (IF 1,924, SIGAPS C)
- Bernard F, Mercier P, Sindou M. **The tethered effect in Vago-glossopharyngeal neuralgia: is this a real alternative associated physiopathology mechanism?** *Acta Neurochirurgica*. Novembre 2017. doi :10.1007/s00701-017-3369-8(IF 1.881, SIGAPS D)
- Terrier LM, Bernard F, Fournier HD, Morandi X, Velut S, Hénaut PL Amelot A, François P. **Surgical management and outcomes of sphenoidal meningiomas : a multicenter study of 130 cases.** *World neurosurgery*. Janvier 2018. doi : 10.1016/j.wneu.2017.12.182. (IF 1,924, SIGAPS C)
- Bernard F, Lemée JM, Faguer R, Fournier HD. **Lessons to be remembered from a dural arteriovenous fistula mimicking brainstem and spinal cord glioma.** *World Neurosurgery*. février 2018. doi: 10.1016/j.wneu.2018.02.161. (IF 1,924, SIGAPS C)
- P. Mercier, F. Bernard. **Surgical anatomy of hemifacial spasm.** *Neurochirurgie*. Mai 2018. doi:10.1016/j.neuchi.2018.04.008 (IF 0.802, SIGAPS E)
- Bernard F, Lemée JM, Ter Minassian A, Menei P. **Right hemisphere cognitive functions: from clinical and anatomical bases to brain mapping during awake craniotomy. Part I clinical and functional anatomy.** *World Neurosurgery*. Mai 2018. doi: 10.1016/j.wneu.2018.05.024. (IF 1,924, SIGAPS C)
- Bernard F, Lemée JM, G. Aubin, Ter Minassian A, Menei P. **Using a VR social network during awake craniotomy to map the social cognition.** *Journal of Medical Internet Research*. Mai 2018. (IF 4.8, SIGAPS A)
- Bernard F, Troude L, Roche PH, , Fournier HD. **Stereoscopic surgical video with virtual reality headset: 3d combined petrossectomy.** *Operative Neurosurgery*. Mai 2018. doi: 10.1007/s00701-017-3319-5 (IF 1,9, SIGAPS NC)
- Lemée JM, Bernard F, Ter Minassian A, Menei P. **Right hemisphere cognitive functions: from clinical and anatomical bases to brain mapping during awake craniotomy. Part II: neuropsychological tasks and brain mapping.** *World Neurosurgery*. Juillet 2018. (IF 1,924, SIGAPS C).
- Bernard F, Baucher G, Troude L, Fournier HD. **The surgeon is in action: representations of neurosurgery in movies from the Frères Lumière to today.** *World Neurosurgery*. Juillet 2018 (IF 1,924, SIGAPS C).
- Bernard F, Terrier LM, Michalak S, Velut S. **Formaldehyde and hydrogen peroxide head embalming: a technique that allows a skull base dura mater study.** *World Neurosurgery*. Aout 2018 (IF 1,924, SIGAPS C).
- Bernard F, Menei P. **When oncology and art meet, a way to understand patient's symptoms.** *Lancet Oncology* (IF 36,4, SIGAPS A).
- Troude L, Bernard F, Sy C, Roche PH **The Modified Retrosigmoid Approach: A How I Do It.** *Acta Neurochirurgica*. (IF 1.881, SIGAPS D)
- Bernard F, Troude L, Isnard. S, Lemée JM, Terrier LM, Velut S, Gay E, François P, Fournier HD, Roche PH. **Long term surgical results of 154 petroclival meningiomas: a retrospective multicenter study.** *Neurochirurgie*. Janvier 2019 (IF 0.802, SIGAPS E)
- Baucher G, Troude L, Pauly V, Bernard F, Zieleskiewicz L, Roche PH. **Predictive factors of poor prognosis after surgical management of traumatic acute subdural hematomas : a single-center series.** *World Neurosurgery*. Février 2019 (IF 1,924, SIGAPS C).
- F. Bernard, P. Mercier, M. Sindou. **Morphological and functional anatomy of the trigeminal triangular plexus as an anatomical entity. A systematic review.** *Surgical and radiological anatomy*. Mars 2019 (IF 1,003, SIGAPS E)
- Bernard F, Mazerand E, Gallet C, Troude L, Fuentes S. **History of degenerative spondylolisthesis: from anatomical description to surgical management.** *Neurochirurgie*. Mars 2019 (IF 0.802, SIGAPS E).
- Bernard F, Zemmoura I, Ter Minassian A, Lemée JM, Menei P. **Anatomical variability of the arcuate fasciculus: a systematical review.** *Surgical and radiological anatomy*. (IF 1,003, SIGAPS E)
- Bernard F, Gallet C, Fournier HD, Roche PH, Troude L. **Towards the development of 3-dimensional virtual-reality video tutorials in the french neurosurgical residency program. Example of the combined petrosal approach in the french college of neurosurgery.** *Neurochirurgie*. April 2019 (IF 0,802, SIGAPS E).

- Mazerand E, Lemée JM, Pallud J, Lemée JM, Menei P, Bernard F. **Acute intracranial hypertension management in metastatic brain tumor: A French national survey.** *Neurochirurgie*. September 2019 (IF 1,924, SIGAPS E).
- Lemée JM, Berro H, Bernard F, Chinier E, Lieber LM, Menei P, Ter Minassian A. **Comparison of resting state fmRI versus task-induced activity for preoperative language mapping and correlation with intraoperative cortical mapping,** *Brain and Behavior*, october 2019. (IF 2,219)
- Baucher G, Bernard F, Graillon T, Dufour H. **Interfascial approach for pterional craniotomy : technique and adjustments to prevent cosmetic complication.** *Acta Neurochirurgica*. November 2019 (IF 1.881, SIGAPS D)
- Delion M, Klinger E, Bernard F, Aubin G, Ter Minassian A, Menei P. **Immersing patients in a virtual reality environment for brain mapping during awake surgery. safety study.** *World Neurosurgery*. November 2019 (IF 1,924, SIGAPS C).
- Bernard F, Richard P, Kahn A, Fournier HD. **Does 3D stereoscopy support anatomical education?** *Surgical and radiological anatomy*. (IF 1,003, SIGAPS E)
- Bernard F, Lemée JM, Mazerand E, Lieber LM, Menei P, Ter Minassian A. **The ventral attention network: the mirror of the language network in the right brain hemisphere.** *Journal of anatomy*. (IF 2,8, SIGAPS B)

2. Communications orales ou affichées

2.1. Communications orales lors de congrès

- Bernard F, Lemée JM, Menei P, Fournier HD . **Fistules dures intracrâniennes Cognard grade IV: plaidoyer pour un prise en charge chirurgicale précoce.** Congrès de la SNCLF. Novembre 2017, Paris.
- Bernard F, Mercier P, Sindou M. **Le rôle de l'arachnoïde dans la névralgie vago-glossopharyngienne : un mécanisme physiopathologique associé et/ou alternatif.** Congrès de la SNCLF. Novembre 2017, Paris.
- Mercier P, Bernard F. **Anatomie de la glande pinéale.** Congrès de la SNCLF. Novembre 2017, Paris.
- Mercier P, Bernard F. **Anatomie du IVème ventricule.** Congrès de la SNCLF. Novembre 2017, Paris.
- Mercier P, Bernard F. **L'angle falco-tentorial.** Congrès de la SNCLF. Novembre 2017, Paris.
- Bernard F, Fournier HD. **Anatomie et radioanatomie des méningiomes latérosellaires- table ronde base du crâne.** Congrès de la SFNC Mars 2018, Grenoble.
- Bernard F, Baucher G., Fournier HD. **Neurosurgery and seventh art.** Congrès de la SFNC Mars 2018, Grenoble.
- Fournier HD, Bernard F,. **Prise en charge des schwannomes vestibulaires "extra-larges". Réflexions angevines.** Congrès de la SFNC Mars 2018, Grenoble.
- Lemée JM, LM Lieber, Bernard F, Labriffe M, Menei P, Ter Minassian A. **Identification du réseau du langage en analyse en composantes indépendantes en IRM fonctionnelle et corrélation à la cartographie per-opératoire.** Congrès de la SFNC Mars 2018, Grenoble.
- Sindou M, Bernard F, Mercier P. **Technique de décompression microvasculaire de l'hémispasme faciale: vidéo.** Congrès de la SFNC Mars 2018, Grenoble.
- Bernard F, Zemmoura I, Ter Minassian A, Menei P **Anatomie du faisceau arqué. Revue systématique.** Congrès des anatomistes. Rennes – Mars 2019
- Bernard F, Mercier P, Sindou M. **Anatomie du plexus triangulaire du nerf trijumeau. Revue systématique.** Congrès des anatomistes. Rennes – Mars 2019
- Bernard F, Lemée JM, Mazerand E, Lieber LM, Menei P, Ter Minassian A. **The white matter support of the ventral attention network.** *Congrès des anatomistes Grenoble 2020*

2.2. Communication par poster lors de congrès

- Bernard F, Troude L, Bouvier C, Roche PH. **Le granulome réparateur à cellules géantes : un diagnostic exceptionnel pour une lésion lytique temporale.** Congrès de la SNCLF. Novembre 2017, Paris.

- Bernard F, Fournier HD. **High-risk dural arteriovenous fistulae : find the vein, get the cure.** Congrès de la SFNC. Grenoble – Mars 2018.
- Bernard F, Mercier P, Sindou M. **Functionnal anatomy of the trigeminal triangular plexus.** Congrès de la SNCLF. Paris – novembre 2018.
- Mercier P, Bernard F. 3D **Anatomy of the temporal lobe**, Beyrouth, Décembre 2018
- Mercier P, Bernard F. 3D **Anatomy of the temporal lobe**, Santa Cruz, Décembre 2018
- Mercier P, Bernard F. 3D **Anatomy of the fourth ventricule**, Beyrouth, Décembre 2018
- Mercier P, Bernard F. 3D **Anatomy of the fourth ventricule**, Santa Cruz, Décembre 2018
- Mercier P, Bernard F. 3D **Anatomy of the brain perforating arteries**, Beyrouth, Décembre 2018
- Mercier P, Bernard F. 3D **Anatomy of the brain perforating arteries**, Santa Cruz, Décembre 2018
- Mercier P, Bernard F. 3D **Anatomy of the venous system**, Beyrouth, Décembre 2018
- Mercier P, Bernard F. 3D **Anatomy of the venous system**, Santa Cruz, Décembre 2018
- Bernard F, Lemée JM, Mazerand E, Leiber LM, Menei P, Ter Minassian A. **The white matter support of the ventral attention network.** Journées scientifiques de l'école doctorales Bretagne Loire. Décembre 2019

Bibliographie

1. Ricard D, Idbaih A, Ducray F, Lahutte M, Hoang-Xuan K, Delattre J-Y. Primary brain tumours in adults. *Lancet Lond Engl*. 26 mai 2012;379(9830):1984-96.
2. Duffau H. Awake surgery for nonlanguage mapping. *Neurosurgery*. mars 2010;66(3):523-8; discussion 528-529.
3. Barone F, Alberio N, Iacopino DG, Giammalva GR, D'Arrigo C, Tagnese W, et al. Brain Mapping as Helpful Tool in Brain Glioma Surgical Treatment-Toward the « Perfect Surgery »? *Brain Sci*. 26 oct 2018;8(11).
4. Ferracci F-X, Duffau H. Improving surgical outcome for gliomas with intraoperative mapping. *Expert Rev Neurother*. 2018;18(4):333-41.
5. Herbet G, Moritz-Gasser S. Beyond Language: Mapping Cognition and Emotion. *Neurosurg Clin N Am*. janv 2019;30(1):75-83.
6. Nakajima R, Kinoshita M, Okita H, Yahata T, Nakada M. Awake surgery for glioblastoma can preserve independence level, but is dependent on age and the preoperative condition. *J Neurooncol*. 21 juin 2019;
7. Menei P, Clement R, Rouge-Maillart C. [Is the right hemisphere really minor? Involvement in the repair of bodily injury]. *Neurochirurgie*. mai 2017;63(2):81-7.
8. Bernard F, Lemée J-M, Ter Minassian A, Menei P. Right Hemisphere Cognitive Functions: From Clinical and Anatomic Bases to Brain Mapping During Awake Craniotomy Part I: Clinical and Functional Anatomy. *World Neurosurg*. oct 2018;118:348-59.
9. Lemée J-M, Bernard F, Ter Minassian A, Menei P. Right Hemisphere Cognitive Functions: From Clinical and Anatomical Bases to Brain Mapping During Awake Craniotomy. Part II: Neuropsychological Tasks and Brain Mapping. *World Neurosurg*. oct 2018;118:360-7.
10. Heilman KM, Valenstein E. Mechanisms underlying hemispatial neglect. *Ann Neurol*. févr 1979;5(2):166-70.
11. Chokron S, Bartolomeo P, Siérouff E. [Unilateral spatial neglect: 30 years of research, discoveries, hope, and (especially) questions]. *Rev Neurol (Paris)*. mai 2008;164 Suppl 3:S134-142.
12. Li K, Malhotra PA. Spatial neglect. *Pract Neurol*. oct 2015;15(5):333-9.
13. Vallar G, Bello L, Bricolo E, Castellano A, Casarotti A, Falini A, et al. Cerebral correlates of visuospatial neglect: a direct cerebral stimulation study. *Hum Brain Mapp*. avr 2014;35(4):1334-50.
14. Roux F-E, Dufor O, Lauwers-Cances V, Boukhatem L, Brauge D, Draper L, et al. Electrostimulation mapping of spatial neglect. *Neurosurgery*. déc 2011;69(6):1218-31.
15. Thiebaut de Schotten M, Urbanski M, Duffau H, Volle E, Lévy R, Dubois B, et al. Direct evidence for a parietal-frontal pathway subserving spatial awareness in humans. *Science*. 30 sept 2005;309(5744):2226-8.
16. Emanuele B, Santini B, Talacchi A, Gerosa M, Savazzi S. Pre- and post-operative assessment of visuo-spatial functions in right hemisphere tumour patients: a pilot study. *J Neurooncol*. juin 2012;108(2):261-7.
17. Campanella F, Shallice T, Ius T, Fabbro F, Skrap M. Impact of brain tumour location on emotion and personality: a voxel-based lesion-symptom mapping study on mentalization processes. *Brain J Neurol*. sept 2014;137(Pt 9):2532-45.

18. Mattavelli G, Pisoni A, Casarotti A, Comi A, Sera G, Riva M, et al. Consequences of brain tumour resection on emotion recognition. *J Neuropsychol.* mars 2019;13(1):1-21.
19. Fusar-Poli P, Placentino A, Carletti F, Landi P, Allen P, Surguladze S, et al. Functional atlas of emotional faces processing: a voxel-based meta-analysis of 105 functional magnetic resonance imaging studies. *J Psychiatry Neurosci JPN.* nov 2009;34(6):418-32.
20. Dal Monte O, Krueger F, Solomon JM, Schintu S, Knutson KM, Strenziok M, et al. A voxel-based lesion study on facial emotion recognition after penetrating brain injury. *Soc Cogn Affect Neurosci.* août 2013;8(6):632-9.
21. Unger A, Alm KH, Collins JA, O'Leary JM, Olson IR. Variation in White Matter Connectivity Predicts the Ability to Remember Faces and Discriminate Their Emotions. *J Int Neuropsychol Soc JINS.* févr 2016;22(2):180-90.
22. Lindell A. Lateralization of the expression of facial emotion in humans. *Prog Brain Res.* 2018;238:249-70.
23. Campanella F, Fabbro F, Ius T, Shallice T, Skrap M. Acute effects of surgery on emotion and personality of brain tumor patients: surgery impact, histological aspects, and recovery. *Neuro-Oncol.* août 2015;17(8):1121-31.
24. Ferber S, Karnath HO. How to assess spatial neglect--line bisection or cancellation tasks? *J Clin Exp Neuropsychol.* oct 2001;23(5):599-607.
25. Gauthier L, Dehaut F, Joanette Y. The Bells Test: A quantitative and qualitative test for visual neglect. *International Journal of Clinical Neuropsychology.* 1989;49-54.
26. Ekman P. Pictures of Facial Affect.
27. Diehl-Schmid J, Pohl C, Ruprecht C, Wagenpfeil S, Foerstl H, Kurz A. The Ekman 60 Faces Test as a diagnostic instrument in frontotemporal dementia. *Arch Clin Neuropsychol Off J Natl Acad Neuropsychol.* mai 2007;22(4):459-64.
28. François.
29. McDonald S, Flanagan S, Rollins J, Kinch J. TASIT: A new clinical tool for assessing social perception after traumatic brain injury. *J Head Trauma Rehabil.* juin 2003;18(3):219-38.
30. Herbet G, Lafargue G, Moritz-Gasser S, Bonnetblanc F, Duffau H. Interfering with the neural activity of mirror-related frontal areas impairs mentalistic inferences. *Brain Struct Funct.* juill 2015;220(4):2159-69.
31. Yordanova YN, Duffau H, Herbet G. Neural pathways subserving face-based mentalizing. *Brain Struct Funct.* sept 2017;222(7):3087-105.
32. Mesulam MM. Spatial attention and neglect: parietal, frontal and cingulate contributions to the mental representation and attentional targeting of salient extrapersonal events. *Philos Trans R Soc Lond B Biol Sci.* 29 juill 1999;354(1387):1325-46.
33. Vallar G, Perani D. The anatomy of unilateral neglect after right-hemisphere stroke lesions. A clinical/CT-scan correlation study in man. *Neuropsychologia.* 1986;24(5):609-22.
34. Vuilleumier P, Armony JL, Clarke K, Husain M, Driver J, Dolan RJ. Neural response to emotional faces with and without awareness: event-related fMRI in a parietal patient with visual extinction and spatial neglect. *Neuropsychologia.* 2002;40(12):2156-66.
35. Heilman KM, Van Den Abell T. Right hemisphere dominance for attention: the mechanism underlying hemispheric asymmetries of inattention (neglect). *Neurology.* mars 1980;30(3):327-30.
36. Mesulam MM. Large-scale neurocognitive networks and distributed processing for attention, language, and memory. *Ann Neurol.* nov 1990;28(5):597-613.

37. Vuilleumier P. Mapping the functional neuroanatomy of spatial neglect and human parietal lobe functions: progress and challenges. *Ann N Y Acad Sci.* août 2013;1296:50-74.
38. Halligan PW, Marshall JC. Visuospatial neglect: the ultimate deconstruction? *Brain Cogn.* août 1998;37(3):419-38.
39. Saj A, Verdon V, Vocat R, Vuilleumier P. « The anatomy underlying acute versus chronic spatial neglect » also depends on clinical tests. *Brain J Neurol.* févr 2012;135(Pt 2):e207; author reply e208.
40. Verdon V, Schwartz S, Lovblad K-O, Hauert C-A, Vuilleumier P. Neuroanatomy of hemispatial neglect and its functional components: a study using voxel-based lesion-symptom mapping. *Brain J Neurol.* mars 2010;133(Pt 3):880-94.
41. Damasio AR, Damasio H, Chui HC. Neglect following damage to frontal lobe or basal ganglia. *Neuropsychologia.* 1980;18(2):123-32.
42. Karnath HO, Himmelbach M, Rorden C. The subcortical anatomy of human spatial neglect: putamen, caudate nucleus and pulvinar. *Brain J Neurol.* févr 2002;125(Pt 2):350-60.
43. Rafal RD, Posner MI, Friedman JH, Inhoff AW, Bernstein E. Orienting of visual attention in progressive supranuclear palsy. *Brain J Neurol.* avr 1988;111 (Pt 2):267-80.
44. Chechlacz M, Rotshtein P, Humphreys GW. Neuroanatomical Dissections of Unilateral Visual Neglect Symptoms: ALE Meta-Analysis of Lesion-Symptom Mapping. *Front Hum Neurosci.* 2012;6:230.
45. Molenberghs P, Sale MV, Mattingley JB. Is there a critical lesion site for unilateral spatial neglect? A meta-analysis using activation likelihood estimation. *Front Hum Neurosci.* 2012;6:78.
46. Thiebaut de Schotten M, Tomaiuolo F, Aiello M, Merola S, Silvetti M, Lecce F, et al. Damage to white matter pathways in subacute and chronic spatial neglect: a group study and 2 single-case studies with complete virtual « in vivo » tractography dissection. *Cereb Cortex N Y N 1991.* mars 2014;24(3):691-706.
47. Corbetta M, Shulman GL. Control of goal-directed and stimulus-driven attention in the brain. *Nat Rev Neurosci.* mars 2002;3(3):201-15.
48. Smith SM, Fox PT, Miller KL, Glahn DC, Fox PM, Mackay CE, et al. Correspondence of the brain's functional architecture during activation and rest. *Proc Natl Acad Sci U S A.* 4 août 2009;106(31):13040-5.
49. Fox MD, Corbetta M, Snyder AZ, Vincent JL, Raichle ME. Spontaneous neuronal activity distinguishes human dorsal and ventral attention systems. *Proc Natl Acad Sci U S A.* 27 juin 2006;103(26):10046-51.
50. Doricchi F, Thiebaut de Schotten M, Tomaiuolo F, Bartolomeo P. White matter (dis)connections and gray matter (dys)functions in visual neglect: gaining insights into the brain networks of spatial awareness. *Cortex J Devoted Study Nerv Syst Behav.* sept 2008;44(8):983-95.
51. Umarova RM, Saur D, Schnell S, Kaller CP, Vry M-S, Glauche V, et al. Structural connectivity for visuospatial attention: significance of ventral pathways. *Cereb Cortex N Y N 1991.* janv 2010;20(1):121-9.
52. Catani M, Jones DK, ffytche DH. Perisylvian language networks of the human brain. *Ann Neurol.* janv 2005;57(1):8-16.
53. Mandonnet E, Duffau H. Understanding entangled cerebral networks: a prerequisite for restoring brain function with brain-computer interfaces. *Front Syst Neurosci.* 2014;8:82.
54. Duffau H, Moritz-Gasser S, Mandonnet E. A re-examination of neural basis of language processing: proposal of a dynamic hodotopical model from data provided by brain stimulation mapping during picture naming. *Brain Lang.* avr 2014;131:1-10.

55. Fernandez-Miranda JC, Rhoton AL, Alvarez-Linera J, Kakizawa Y, Choi C, de Oliveira EP. Three-dimensional microsurgical and tractographic anatomy of the white matter of the human brain. *Neurosurgery*. 2008;62(6 Suppl 3):989-1026; discussion 1026-8.
56. Fridriksson J, Kjartansson O, Morgan PS, Hjaltason H, Magnúsdóttir S, Bonilha L, et al. Impaired speech repetition and left parietal lobe damage. *J Neurosci Off J Soc Neurosci*. 18 août 2010;30(33):11057-61.
57. Martino J, De Witt Hamer PC, Berger MS, Lawton MT, Arnold CM, de Lucas EM, et al. Analysis of the subcomponents and cortical terminations of the perisylvian superior longitudinal fasciculus: a fiber dissection and DTI tractography study. *Brain Struct Funct*. janv 2013;218(1):105-21.
58. Poeppel D, Guillemin A, Thompson J, Fritz J, Bavelier D, Braun AR. Auditory lexical decision, categorical perception, and FM direction discrimination differentially engage left and right auditory cortex. *Neuropsychologia*. 2004;42(2):183-200.
59. Stromswold K, Caplan D, Alpert N, Rauch S. Localization of syntactic comprehension by positron emission tomography. *Brain Lang*. mars 1996;52(3):452-73.
60. Türe U, Yaşargil MG, Friedman AH, Al-Mefty O. Fiber dissection technique: lateral aspect of the brain. *Neurosurgery*. août 2000;47(2):417-26; discussion 426-427.
61. Türe U, Yaşargil MG, Pait TG. Is there a superior occipitofrontal fasciculus? A microsurgical anatomic study. *Neurosurgery*. juin 1997;40(6):1226-32.
62. Heilman KM, Watson RT. The disconnection apraxias. *Cortex J Devoted Study Nerv Syst Behav*. sept 2008;44(8):975-82.
63. The anatomical characteristics of superior longitudinal fasciculus I in human brain: Diffusion tensor tractography study. - PubMed - NCBI [Internet]. [cité 20 juill 2016]. Disponible sur: <http://www.ncbi.nlm.nih.gov/pubmed/22085696>
64. Makris N, Kennedy DN, McInerney S, Sorensen AG, Wang R, Caviness VS, et al. Segmentation of subcomponents within the superior longitudinal fascicle in humans: a quantitative, in vivo, DT-MRI study. *Cereb Cortex N Y N 1991*. juin 2005;15(6):854-69.
65. Shimizu S, Tanaka R, Rhoton AL, Fukushima Y, Osawa S, Kawashima M, et al. Anatomic dissection and classic three-dimensional documentation: a unit of education for neurosurgical anatomy revisited. *Neurosurgery*. mai 2006;58(5):E1000; discussion E1000.
66. Fox MD, Greicius M. Clinical applications of resting state functional connectivity. *Front Syst Neurosci*. 2010;4:19.
67. Beckmann CF, DeLuca M, Devlin JT, Smith SM. Investigations into resting-state connectivity using independent component analysis. *Philos Trans R Soc Lond B Biol Sci*. 29 mai 2005;360(1457):1001-13.
68. Biswal B, Yetkin FZ, Haughton VM, Hyde JS. Functional connectivity in the motor cortex of resting human brain using echo-planar MRI. *Magn Reson Med*. oct 1995;34(4):537-41.
69. Beckmann CF, Smith SM. Tensorial extensions of independent component analysis for multisubject fMRI analysis. *NeuroImage*. mars 2005;25(1):294-311.
70. Tie Y, Rigolo L, Norton IH, Huang RY, Wu W, Orringer D, et al. Defining language networks from resting-state fMRI for surgical planning--a feasibility study. *Hum Brain Mapp*. mars 2014;35(3):1018-30.
71. Ter Minassian A, Ricalens E, Nguyen The Tich S, Dinomais M, Aubé C, Beydon L. The presupplementary area within the language network: a resting state functional magnetic resonance imaging functional connectivity analysis. *Brain Connect*. août 2014;4(6):440-53.

72. Mitchell TJ, Hacker CD, Breshears JD, Szrama NP, Sharma M, Bundy DT, et al. A novel data-driven approach to preoperative mapping of functional cortex using resting-state functional magnetic resonance imaging. *Neurosurgery*. déc 2013;73(6):969-82; discussion 982-983.
73. Corbetta M, Shulman GL. Spatial neglect and attention networks. *Annu Rev Neurosci*. 2011;34:569-99.
74. Zemmoura I, Blanchard E, Raynal P-I, Rousselot-Denis C, Destrieux C, Velut S. How Klingler's dissection permits exploration of brain structural connectivity? An electron microscopy study of human white matter. *Brain Struct Funct*. juin 2016;221(5):2477-86.
75. Klingler J, Gloor P. The connections of the amygdala and of the anterior temporal cortex in the human brain. *J Comp Neurol*. déc 1960;115:333-69.
76. Ludwig E, Klingler J. *atlas humani cerebri*. Basel, New York: Karger, S; 1956. 136 p.
77. Maldonado IL, de Champfleury NM, Velut S, Destrieux C, Zemmoura I, Duffau H. Evidence of a middle longitudinal fasciculus in the human brain from fiber dissection. *J Anat*. juill 2013;223(1):38-45.
78. Peltier J, Travers N, Destrieux C, Velut S. Optic radiations: a microsurgical anatomical study. *J Neurosurg*. 2006;105(2):294-300.
79. Koutsarnakis C, Liakos F, Kalyvas AV, Sakas DE, Stranjalis G. A Laboratory Manual for Stepwise Cerebral White Matter Fiber Dissection. *World Neurosurg*. août 2015;84(2):483-93.
80. Raichle ME, MacLeod AM, Snyder AZ, Powers WJ, Gusnard DA, Shulman GL. A default mode of brain function. *Proc Natl Acad Sci U S A*. 16 janv 2001;98(2):676-82.

Table des illustrations

- Figure 1** : Cartographie cérébrale par stimulation électrique en chirurgie éveillée 7
- Figure 2** : Principaux faisceaux de la substance blanche impliqués dans les deux importantes fonctions cognitives de l'HND : cognition spatiale et cognition sociale (SLF : superior longitudinal fasciculus, IFOF : inferior fronto-occipital fasciculus, ILF : inferior longitudinal fasciculus). 7
- Figure 3** : Test des cloches. A) Feuille de passation, B) Feuille de score **Erreur ! Signet non défini.**
- Figure 4** : Test d'Ekman. A) Exemple de photographies représentant les 6 émotions de base (colère, peur, dégoût, surprise, joie, tristesse) et la neutralité, B) Exemple d'une carte réponse... **Erreur ! Signet non défini.**
- Figure 5** : Données préliminaires : identification du réseau ventral de l'attention (VAN) dans l'hémisphère droit comparable au réseau du langage chez 30 sujets. **Erreur ! Signet non défini.**
- Figure 6** : Étude de la connectivité fonctionnelle du réseau ventral de l'attention par IRM fonctionnelle de repos, dissection selon la méthode de Klingler et tractographie. **Erreur ! Signet non défini.**

Table des tableaux

Tableau 1: données anatomique des faisceaux d'association SLFs et du faisceau arqué 16

ENGAGEMENT DE NON PLAGIAT

Je, soussigné(e) Florian Bernard
déclare être pleinement conscient(e) que le plagiat de documents ou d'une
partie d'un document publiée sur toutes formes de support, y compris l'internet,
constitue une violation des droits d'auteur ainsi qu'une fraude caractérisée.
En conséquence, je m'engage à citer toutes les sources que j'ai utilisées
pour écrire ce rapport ou mémoire.

signé par l'étudiant(e) le **03 / 05 / 2020**

**Cet engagement de non plagiat doit être signé et joint
à tous les rapports, dossiers, mémoires.**

Présidence de l'université
40 rue de rennes – BP 73532
49035 Angers cedex

Tél. 02 41 96 23 23 | Fax 02 41 96 23 00

BERNARD Florian | Anatomie fonctionnelle de la cognition visuo-spatiale



université
angers

Thèse de Doctorat

Anatomie fonctionnelle de la cognition visuo-spatiale : de l'anatomie morphologique et fonctionnelle à la réalité virtuelle en chirurgie éveillée

Functional anatomy of visuo-spatial cognition: from gross and functional anatomy to the use of virtual reality during awake brain surgery

Résumé

L'hémisphère non dominant supporte la cognition visuo-spatiale et sociale. Sont atteinte est à l'origine du syndrome d'héminégligence.

Les objectifs préliminaires de cette thèse étaient (1) *de proposer une taxonomie des fonctions cérébrales supportées par l'hémisphère droit ; (2) d'harmoniser les données d'anatomie fonctionnelle avec les données neuropsychologiques et de sémiologie clinique de ces fonctions. (3) d'harmoniser la nomenclature anatomique entre les études de dissections et d'imagerie de l'hémisphère droit. (4) d'harmoniser la nomenclature anatomique du principal faisceau de substance blanche : le faisceau arqué.*

Le principal but de cette thèse était (5) *d'approfondir nos connaissances sur l'anatomie du réseau ventral de l'attention, qui est un réseau fonctionnel cortical identifié par l'IRM de repos, impliqué dans la cognition visuo-spatiale. En traitant les données d'IRM fonctionnelle de repos de 50 sujets, nous avons pu décrire les localisations corticales du réseau ventral de l'attention dans notre cohorte de sujets sains. Nous avons ensuite utilisé les zones corticales du réseau ventral de l'attention comme régions germes, pour l'étude des fibres blanches in-vivo (tractographie), ainsi que sur des cerveaux par méthode de Klingler (ex-vivo). Nous avons pu ainsi définir les faisceaux de fibres blanches du réseau ventral de l'attention. Ces faisceaux comprennent le faisceau longitudinal dans sa troisième portion (SLF III) et le faisceau arqué droits.*

Le développement d'un test neuropsychologique spécifique stimulant le réseau ventral de l'attention reste à concrétiser pour pouvoir réaliser cette chirurgie éveillée. Dans ce sens, nous avons publié des travaux (6) *visant à l'utilisation des lunettes de réalité virtuelle en condition de chirurgie éveillée, pour réaliser de nouveaux tests neuropsychologiques dédiés à l'exploration des fonctions cognitives de l'hémisphère droit.*

Ce travail de Thèse a été valorisé par 7 publications, 1 article soumis et le développement d'un test neuropsychologique utilisant la réalité virtuelle en chirurgie éveillée cérébrale.

Abstract

The non-dominant hemisphere supports visuospatial and social cognition. Its injury is at the origin of the unilateral spatial neglect.

The preliminary objectives of this thesis were (1) to propose a taxonomy of the brain functions supported by the right hemisphere; (2) to harmonize the functional anatomy with the neuropsychological and clinical semiology datas for each function ; (3) to harmonize the anatomical nomenclature between dissection and imaging studies ; (4) to harmonize the anatomical nomenclature of the main white matter fascicle: the arcuate fasciculus.

The main goal of this thesis was (5) to improve our knowledge of the anatomy of the ventral network of attention, which is a cortical functional network identified by resting state MRI, involved in visuospatial cognition. By processing resting state MRI data from 50 subjects, we were able to describe the endpoints of the ventral attention network. We then used the ventral attention network endpoints as seed regions, for the *in-vivo* tractography, as well as *ex-vivo* Klingler's method. We were thus able to define the fiber bundles supporting the ventral attention network. It include the superior longitudinal fasciculus in its third portion (SLF III) and the arcuate fasciculus.

The development of a specific neuropsychological test stimulating the ventral attention network remains to be achieved. In this way, we have published studies (6) aiming at the use of virtual reality headsets in awake brain surgery, to perform new neuropsychological tests dedicated to the exploration of the right hemisphere cognitive functions.

This thesis work has been valued by 7 publications, 1 article submitted and the development of a neuropsychological test using virtual reality in awake brain surgery.