



HAL
open science

Résection endoscopique des cancers superficiels de l'œsophage et prévention de la sténose cicatricielle

Maximilien Barret

► **To cite this version:**

Maximilien Barret. Résection endoscopique des cancers superficiels de l'œsophage et prévention de la sténose cicatricielle. Cancer. Université Sorbonne Paris Cité, 2016. Français. NNT : 2016USPCB088 . tel-03829195

HAL Id: tel-03829195

<https://theses.hal.science/tel-03829195v1>

Submitted on 25 Oct 2022

HAL is a multi-disciplinary open access archive for the deposit and dissemination of scientific research documents, whether they are published or not. The documents may come from teaching and research institutions in France or abroad, or from public or private research centers.

L'archive ouverte pluridisciplinaire **HAL**, est destinée au dépôt et à la diffusion de documents scientifiques de niveau recherche, publiés ou non, émanant des établissements d'enseignement et de recherche français ou étrangers, des laboratoires publics ou privés.

Université Paris Descartes

Ecole doctorale Bio SPC

THESE DE DOCTORAT

Pour l'obtention du grade de

Docteur de l'université Paris Descartes

Spécialité : Immunologie

Résection endoscopique des cancers superficiels de l'œsophage

et

Prévention de la sténose cicatricielle

Présentée et soutenue par

Maximilien BARRET

Le 18 novembre 2016

Devant un Jury composé de :

Monsieur le Professeur Emmanuel Coron

Rapporteur

Monsieur le Professeur Pierre Deprez

Rapporteur

Monsieur le Professeur Frédéric Batteux

Examineur

Monsieur le Professeur Pierre Cattan

Président du Jury

Monsieur le Professeur Frédéric Prat

Directeur de thèse

Résumé en Français : Résection endoscopique des cancers superficiels de l'œsophage et prévention de la sténose cicatricielle

Le développement du traitement endoscopique des états précancéreux et cancers superficiels de l'œsophage, qui constitue une option alternative à faible risque opératoire au traitement chirurgical, se heurte à la problématique de la cicatrisation œsophagienne. En effet, les résections étendues de la muqueuse œsophagienne se compliquent de sténoses cicatricielles réfractaires. Les voies de prévention de la sténose œsophagienne impliquent la protection de la plaie, l'opposition aux mécanismes de l'inflammation et de la fibrose, la promotion de la réparation épithéliale, ou encore l'application d'une contrainte mécanique sur la paroi de l'œsophage au cours de la cicatrisation.

Au cours d'un premier travail, nous avons évalué, sur un modèle porcin de sténose œsophagienne post-endoscopique que nous avons développé, l'apport de la membrane amniotique humaine (MAH) en tant qu'agent protecteur, mais aussi anti-fibrosant, régénératif, appliqué au moyen de prothèses œsophagiennes. Nous avons mis en évidence un effet de la MAH à J14 en termes de taux de sténose, cependant transitoire en raison du manque de stabilité des prothèses œsophagiennes et de la dégradation de la MAH dans l'œsophage.

Au cours d'un second travail, nous avons évalué sur le même modèle l'apport d'une poudre hémostatique minérale appliquée de façon itérative sur la zone de résection au cours de la première semaine. Ce traitement a permis d'améliorer significativement les paramètres histologiques (épaisseur du tissu de granulation, de la fibrose, longueur du néoépithélium) et biologiques (taux sérique de TGF- β) de la cicatrisation œsophagienne, cependant sans traduction sur le taux de sténose œsophagienne à J14.

Au cours d'un troisième travail, nous avons évalué une matrice protéique formée d'un peptide auto-assemblé (SAP) pour la couverture de la plaie œsophagienne, toujours dans le même modèle. Ce traitement a permis de diviser par deux le taux de sténose à J14, sans cependant que les résultats soient durables, 100% des animaux ayant développé des sténoses à J28.

Au cours d'un quatrième travail, nous avons évalué chez 40 patients la faisabilité et les performances de la réalisation en un seul temps endoscopique d'une résection endoscopique par mucosectomie d'une lésion suspecte d'adénocarcinome, et de l'ablation par radiofréquence de l'œsophage de Barrett résiduel. Nous avons observé une bonne efficacité de cette approche, permettant une procédure en un seul temps endoscopique chez près de la moitié des patients, et des taux d'éradication de la néoplasie et de la métaplasie intestinale de 95% après 19 mois de suivi. Cependant, cette approche était limitée par un taux de sténose de 33%.

Au cours d'un cinquième travail, nous avons étudié rétrospectivement chez 35 patients les résultats de la dissection sous-muqueuse œsophagienne (ESD) dans le traitement de l'adénocarcinome œsophagien. Les résultats, avec un taux de résection R0 de 72% se réduisant à 66% de résection curative en tenant compte des facteurs histopronostiques défavorables, suggèrent qu'une amélioration de l'endoscopie diagnostique était nécessaire afin de mieux sélectionner les patients pouvant bénéficier de ce traitement. Le taux de sténoses cicatricielles de 6% était en revanche modéré dans cette série d'exérèses généralement non circulaires laissant souvent en place une muqueuse dysplasique.

L'ensemble de ces résultats suggère que la problématique de la sténose cicatricielle reste majeure dans la résection endoscopique des cancers superficiels de l'œsophage. Les approches protectrices de prévention de la sténose sont limitées par le manque de stabilité des produits employés sur la plaie œsophagienne. Des travaux mécanistiques sont nécessaires, afin de développer des inhibiteurs pharmacologiques spécifiques de la fibrose œsophagienne.

Mots clefs : cancer de l'œsophage ; dysplasie de haut grade ; œsophage de Barrett ; sténose œsophagienne ; fibrogénèse ; inflammation.

Remerciements

Je remercie tous les membres du jury qui ont accepté de juger mon travail :

Monsieur le Professeur Pierre Cattan, qui a accepté de présider ce jury.

Monsieur le Professeur Pierre Deprez qui a accepté d'en être le rapporteur.

Monsieur le Professeur Emmanuel Coron qui a accepté d'en être le rapporteur.

Monsieur le Professeur Frédéric Batteux, qui a accepté d'en être l'examineur, et qui m'a accueilli dans son unité, à l'EA 1833, puis à l'UI 1016, et ouvert les portes de la recherche scientifique. Qu'il trouve ici l'expression de mes plus sincères remerciements.

Je remercie Monsieur le Professeur Frédéric Prat de m'avoir conduit sur les chemins de la recherche et de l'endoscopie expérimentale depuis 2010, de m'avoir enseigné l'endoscopie et la façon de conjuguer la recherche et l'activité clinique, de m'avoir fait confiance, et d'avoir accepté de diriger mon travail. Qu'il trouve dans ce travail le témoignage de ma gratitude.

Je remercie le Monsieur le Professeur Chaussade de m'avoir accueilli dans son service.

Je remercie Messieurs les Professeurs Julien Taïeb et Romain Coriat, qui m'ont enseigné la méthode et donné le goût pour la recherche clinique.

Je remercie Carole Nicco, Christiane Chéreau, Sandrine Chouzenoux, pour leur aide dans les manipulations et leurs conseils avisés.

Je remercie Madame Josette Legagneux et les animaliers de l'école de chirurgie des hôpitaux de Paris pour leur aide et leur professionnalisme.

Je remercie la Société Nationale Française de Gastroentérologie et l'association des anciens internes des hôpitaux de Paris pour leur soutien financier durant ce travail.

Je remercie Messieurs les Professeurs Paul Fockens, Jacques Bergman, André Smout, Madame le Professeur Sheila Krishnadath, et Monsieur le Docteur Arjan Bredenoord de m'avoir accueilli à l'Academisch Medisch Centrum d'Amsterdam et m'avoir tant transmis en oesophagologie.

Je remercie mon grand-père Raphaël Cherchève, Monsieur le Professeur Marian Apfelbaum, et Monsieur le Docteur Gabriel Benoliel qui m'ont, chacun à leur manière, donné l'envie de devenir médecin.

Je remercie également Laurence, Yaël, et le reste de ma famille pour leur soutien indéfectible et si précieux.

Liste des abréviations utilisées

5 FU : 5 fluorouracile

α -SMA : alfa smooth muscle actin

AdénoCa : adénocarcinome

APC : argon plasma coagulation (coagulation au plasma d'Argon)

CE : carcinome épidermoïde

DBG : dysplasie de bas grade

DHG : dysplasie de haut grade

EGF : epidermal growth factor

EMR : endoscopic mucosal resection (mucosectomie endoscopique)

ESD : endoscopic submucosal dissection (dissection sous-muqueuse)

IL : interleukine

LB : lymphocyte B

LT : lymphocyte T

MI : métaplasie intestinale

NOX 4 : NADPH oxydase 4

OB : œsophage de Barrett

PGA : acide polyglycolique (polyglycolic acid)

RFA : radiofrequency ablation (radiofréquence)

SAP : peptide auto-assemblé (self-assembling peptide)

Si RNA : small interfering RNA

SIS : small intestine submucosa

TNF- α : tumor necrosis factor alfa

TGF- β : transforming growth factor beta

Table des matières

Remerciements	3
Liste des abréviations.....	4
Table des illustrations.....	8
Introduction	10

I. Les cancers de l'œsophage et leur prise en charge

A. Données épidémiologiques et physiopathologiques

1. Carcinome épidermoïde
2. Adénocarcinome et œsophage de Barrett

B. Diagnostic

1. Cas général
2. Le cas des cancers superficiels

C. Traitement

1. Tumeurs de stade 0 (pTis) ou IA pT1aN0M0
 - a- Mucosectomie endoscopique
 - b- Dissection sous-muqueuse endoscopique
 - c- Techniques ablatives
 - d- Place de la chirurgie
2. Tumeurs localisées de stade IA pT1bN0M0 à IIB
3. Tumeurs avancées de stade III à IV
 - a- Tumeurs de stade III
 - b- Tumeurs de stade IV

D. Surveillance

II. La prévention de la sténose oesophagienne post-endoscopique

- A. Généralités
- B. Mécanismes de la sténose oesophagienne cicatricielle
 - 1. Des cellules souches oesophagiennes ?
 - 2. Rôle des glandes sous-muqueuses
 - 3. Mécanismes généraux de la cicatrisation
- C. Stratégies de prévention de la sténose
 - 1. Approche protectrice
 - a- Données chez l'animal
 - b- Données chez l'Homme
 - 2. Approche régénérative
 - a- Données chez l'animal
 - b- Données chez l'Homme
 - 3. Approche anti-proliférative
 - a- Données chez l'animal
 - b- Données chez l'Homme
 - 4. Approche Mécanique
 - a- Données chez l'animal
 - b- Données chez l'Homme
 - 5. Conclusion : la prévention de la sténose oesophagienne post-endoscopique en 2016

III. Plan du travail de recherche

- A. Travaux translationnels
 - 1. Conduite d'essais précliniques sur modèle porcin
 - 2. Etude mécanistique chez l'Homme
 - 3. Essais thérapeutiques sur modèle murin

B. Travaux cliniques

Présentation des travaux	68
--------------------------------	----

I. Travaux translationnels

A. Conduite d'essais precliniques sur modèle porcin

1. Article 1

2. Article 2

3. Article 3

B. Etude mécanistique chez l'Homme

C. Essais thérapeutique sur modèle murin

II. Travaux cliniques

A. Article 4

B. Article 5

Discussion et perspectives	147
----------------------------------	-----

I. Travaux translationnels

II. Travaux cliniques

III. Perspectives

Conclusion	155
------------------	-----

Annexe 1	156
----------------	-----

Annexe 2	158
----------------	-----

Bibliographie	180
---------------------	-----

Table des illustrations

Figure 1 : Classification TNM schématique ⁴⁰ (figure 1A) et complète (figure 1B) des cancers de l'œsophage ³².

Figure 2 : Risque d'envahissement ganglionnaire en fonction du degré d'infiltration pariétale des cancers de l'œsophage.

Figure 3 : Principales techniques de mucosectomie œsophagienne. A : Mucosectomie par traction; B: Mucosectomie au capuchon ; C: Mucosectomie au ligateur.

Figure 4 : Principales étapes de la dissection sous-muqueuse (d'après Yamamoto H et al. ⁶⁴). a : La lésion est délimitée; b et c: injection sous-muqueuse de sérum physiologique ou d'une solution hypertonique; d: incision périphérique de la muqueuse ; e: dissection sous-muqueuse; f: zone de résection avec socle de sous-muqueuse résiduelle et de musculature propre.

Figure 5 : Rôle possible des glandes sous-muqueuses dans la réparation tissulaire œsophagienne.

Figure 6 : Que reste-t-il dans l'œsophage après une résection endoscopique ?

Figure 7 : Sténoses œsophagiennes dans notre modèle porcin de sténose post endoscopique. A et B : aspect endoscopique des sténoses à prédominance inflammatoire (A) et fibrotique (B) ; C : vue fluoroscopique ; D : macroscopie de la partie proximale de la sténose ; E et F : microscopie, magnification x 12.5, hématoxyline éosine safran, montrant une ré-épithélialisation mineure et un infiltrat inflammatoire majeur dans la sous-muqueuse résiduelle (E), et trichrome de Masson (F) montrant la fibrose -en vert- de la sous-muqueuse infiltrant la musculature propre.

Figure 8 : Cibles potentielles pour la prévention de la sténose œsophagienne.

Figure 9 : Démarche du travail de recherche

Figure 10 : Application de l'électrocoagulation au plasma d'argon dans l'œsophage de souris. A : insertion de la sonde de façon rétrograde dans le bas œsophage sur 5 mm (flèche) ; B : aspect de l'œsophage, blanchi après électrocoagulation.

Figure 11 : Deux types d'aspects histologiques observés dans l'œsophage de souris après ablation au plasma d'argon. A : Aspect de perforation œsophagienne retardée (flèche) avec inflammation et nécrose transmuable. B : Paroi œsophagienne normale.

Tableau 1: Principales options thérapeutiques des cancers superficiels de l'œsophage.

Tableau 2 : Caractéristiques des patients recrutés dans l'étude transcriptomique de la cicatrisation œsophagienne.

Tableau 3 : Différents régimes d'électrocoagulation au plasma d'argon testés sur l'œsophage de souris.

Introduction

Le développement des techniques de l'endoscopie diagnostique, mais aussi la généralisation de l'accès à l'endoscopie dans l'exploration précoce des symptômes digestifs, voire dans le dépistage de certaines populations à risque de cancer de l'œsophage, permettent un accroissement du nombre de diagnostics de cancers superficiels de l'œsophage. L'endoscopie sert à la fois au diagnostic des lésions, mais également au traitement curatif de certains de ces cancers, à la prévention des récurrences au moyen de la résection ou de l'ablation des états précancéreux, à la surveillance des patients, et enfin parfois au traitement des récurrences locales. Le développement, depuis les années 2000, de techniques d'endoscopie thérapeutique telles que la dissection sous-muqueuse endoscopique (ESD) et l'ablation par radiofréquence (RFA) permettent d'obtenir d'excellents résultats oncologiques pour le traitement des cancers superficiels de l'œsophage, au prix d'une mortalité nulle et d'une morbidité inférieure à 10%. Ces chiffres sont à comparer à la référence que constitue l'oesophagectomie, qui permet d'obtenir de bons résultats oncologiques dans des cancers plus avancés, avec cependant 3 % de mortalité et 20 à 30% de morbidité sévère, ainsi qu'une dégradation majeure de la qualité de vie des patients la première année.

La limite principale au développement des traitements endoscopiques est la constitution de sténoses cicatricielles lors des résections étendues de la muqueuse œsophagienne. Les déterminants de la formation de ces sténoses sont encore mal définis : ils impliquent principalement l'extension circonférentielle de la résection, la profondeur atteinte par le geste endoscopique au sein de la paroi oesophagienne, et

des facteurs locaux de cicatrisation tels que l'antécédent d'irradiation locale. Des facteurs génétiques de prédisposition sont suspectés mais demeurent indéterminés. Au plan physiopathologique, on estime que la perte de la barrière muqueuse est associée à l'agression de la sous-muqueuse et de la musculature par des facteurs endoluminaux chimiques, mécaniques et microbiologiques, entraînant une réaction inflammatoire puis fibrosante aboutissant au processus de cicatrisation pathologique hypertrophique et sténosant. Si le traitement de ces sténoses est relativement bien codifié, et repose sur des dilatations endoscopiques itératives, des incisions radiaires, des prothèses et des injections locales de corticoïdes, ces traitements exposent au risque de perforation œsophagienne, et viennent considérablement dégrader une qualité de vie que le traitement endoscopique était supposé préserver. Ainsi, le développement d'un traitement préventif des sténoses œsophagiennes post-endoscopiques représente un enjeu majeur de la prise en charge endoscopique des cancers superficiels et des lésions pré-cancéreuses de l'oesophage.

Dans un premier temps, nous rappellerons les données de la littérature d'une part sur la prise en charge des cancers de l'oesophage en insistant sur les cancers superficiels, et d'autre part sur la sténose œsophagienne post-endoscopique, sa physiopathologie, et les moyens employés pour la prévenir. Dans un second temps, nous présenterons les résultats de nos travaux sur la prévention de la sténose œsophagienne post endoscopique. Enfin, nous présenterons les résultats de nos travaux sur le traitement endoscopique des cancers superficiels de l'oesophage.

I. Les cancers de l'œsophage et leur prise en charge

A. Données épidémiologiques et physiopathologiques

Le cancer de l'œsophage est le 8^{ème} cancer le plus fréquent à travers le monde. Avec une incidence estimée d'environ 456 000 nouveaux cas en 2012, il est la sixième cause de décès par cancer ¹. En Occident, l'incidence du cancer de l'œsophage est globalement stable, avec environ 35 000 nouveaux cas en Europe en 2012, tandis que plus de 16 000 nouveaux cas sont attendus en 2016 aux Etats-Unis ¹⁻³. La survie à 5 ans des patients varie de 15 à 25 %, et les meilleurs résultats sont observés lorsque la maladie est prise en charge à un stade localisé, avant la survenue de métastases, notamment ganglionnaires, qui peuvent survenir dès le franchissement de la musculaire muqueuse par la tumeur ⁴.

1. Carcinome épidermoïde

Le carcinome épidermoïde (CE) demeure le type histologique le plus fréquent à travers le monde, et tout particulièrement en Asie et en Afrique de l'est où il représente 90 % des cancers de l'œsophage ^{5,6}. Il se développe à partir de la dysplasie en muqueuse malpighienne, qui résulte de facteurs génétiques et métaboliques, mais également de l'exposition au tabac et à la nitrosamine, à l'alcool et à l'aldéhyde. D'autres facteurs créant une inflammation locale chronique, tels que l'achalasie ou l'œsophagite caustique sont des facteurs de risque mineurs de CE. Le rôle de certains agents infectieux tels que l'infection par des sérotypes oncogéniques

de l'Human Papilloma Virus est débattu ⁷. Enfin, un faible niveau socio-professionnel, un état carenciel, et une mauvaise hygiène buccodentaire seraient également des facteurs de risque ⁸.

2. Adénocarcinome et œsophage de Barrett

Aux Etats-Unis, en Australie et en Europe du Nord, la proportion de (CE) décroît au profit de l'adénocarcinome (AdénoCa) ^{2,9}, qui représente actuellement plus de 75% des cas ^{6,10} et dont l'incidence continue d'augmenter de 4 à 6% par an ¹¹⁻¹³. L' AdénoCa se développe à partir de la dysplasie survenant sur l'œsophage de Barrett (OB) ou endobrachyoesophage. Hormis le reflux gastro-œsophagien, qui peut cependant manquer chez 40% des patients ¹⁴, les autres facteurs de risque d' AdénoCa sont l'obésité, le tabagisme, un antécédent d'irradiation thoracique, un régime pauvre en fruits et légumes, un âge avancé, le sexe masculin, les médicaments diminuant la pression du sphincter inférieur de l'œsophage, et des antécédents familiaux d'AdénoCa oesophagien ⁸. L'infection par *helicobacter pylori* pourrait être protectrice par la diminution de l'acidité du reflux gastrique ¹⁵.

L'OB correspond en endoscopie à une muqueuse de coloration saumonée s'étendant plus d'un centimètre en amont du sommet des plis gastriques, et répondant en histologie à une métaplasie intestinale ¹⁶. Sa prévalence est estimée à 1.5% dans la population générale et à 15% chez les personnes se plaignant d'un reflux ¹⁷⁻¹⁹. Les reflux gastro-oesophagien acide et biliaire sont les facteurs de risque principaux d'OB, qui apparait comme une réponse adaptative aux agressions chimiques et enzymatiques de la muqueuse œsophagienne ²⁰. Les autres facteurs de risque d'OB sont le surpoids, l'augmentation du périmètre abdominal, le sexe

masculin, et le tabagisme ²¹. L'incidence de l' AdénoCa sur OB non dysplasique est évaluée à 0.1-0.5% par an ^{22,23}, alors qu'elle est de 0.6 à 3% par an pour la dysplasie de bas grade ^{24, 25} et de 7 à 10% par an pour la dysplasie de haut grade ²⁶. Le risque de progression de l'OB vers le cancer est corrélé à l'âge, à une longueur de l'OB supérieure à 3 cm, au sexe masculin, et à la présence d'une dysplasie de bas grade ²⁷. Des anomalies génétiques acquises, telles que des mutations de p53 ou de SMAD4 ²⁸, ou encore la perte d'expression de p16, la surexpression de MYC, et l'aneusomie ²⁹ pourraient servir de biomarqueurs traduisant la progression vers la dysplasie ou le cancer.

B. Diagnostic

1. Cas général

Bien que l'accès croissant à l'endoscopie permette en théorie un diagnostic précoce des cancers de l'œsophage, la plupart des tumeurs sont encore découvertes à un stade métastatique, régional (ganglionnaire) dans 30 % des cas, ou à distance dans 40 % des cas ³⁰. Dans ce dernier cas, la survie à 5 ans est inférieure à 5%. Les circonstances du diagnostic sont alors usuellement une dysphagie d'aggravation progressive intéressant d'abord les solides, avec altération de l'état général conduisant à la réalisation d'une endoscopie qui va documenter morphologiquement et histologiquement une tumeur dans l'œsophage.

Outre la taille approximative, la distance par rapport aux arcades dentaires et au cardia, le caractère sténosant ou non de la lésion, l'endoscopie doit décrire la

position horaire de la lésion dans l'œsophage, son type morphologique selon la classification de Paris ⁴⁷ en cas de tumeur d'allure superficielle, son caractère mobile par rapport aux plans profonds. Enfin, en présence d'une lésion en muqueuse malpighienne, une chromoendoscopie au lugol sera réalisée pour délimiter la lésion et identifier d'autres zones lugol-négatives correspondant à des cancers ou états préneoplasiques ; en présence d'une lésion en muqueuse de Barrett, l'œsophage de Barrett sera décrit et mesuré dans sa portion circonférentielle et sa hauteur maximale par rapport au sommet des plis gastriques selon la classification de Prague ³¹, puis examiné avec attention en vision directe et en rétrovision sous-cardiale, en lumière blanche et si possible à l'aide d'une chromoendoscopie virtuelle à la recherche d'autres lésions synchrones.

La figure 1 rappelle la classification TNM des cancers de l'œsophage. Les modalités exactes du bilan préthérapeutique, qu'il s'agisse de l'évaluation du terrain et du dépistage des pathologies associées, de l'extension loco-régionale et à distance, de l'évaluation de l'opérabilité ou de la résecabilité, sont détaillées ailleurs ³².

En l'absence de métastases au scanner, l'écho-endoscopie est utile au bilan d'extension loco-régional, sauf en présence d'une tumeur sténosante infranchissable par l'écho-endoscope. Elle permet d'évaluer l'extension pariétale et notamment l'extension à la musculature définissant le stade T2 et contre-indiquant la résection endoscopique, et de rechercher la présence d'adénopathies régionales qui pourront, si elles sont supracentimétriques et échoendoscopiquement suspectes (rondes, hypoéchogènes), être ponctionnées ³³. L'apport de l'écho-endoscopie dans le staging des cancers de l'œsophage se traduit en termes de survie globale pour les patients ³⁴ et cet examen est recommandé pour tous les patients opérables ³⁵.

Si la tomographie par émission de positrons ou PET scanner est inférieure au couple scanner thoraco-abdomino-pelvien et écho-endoscopie pour l'extension loco-régionale de la tumeur primitive, elle est utile pour la détection de métastases à distance, notamment d'adénopathies extra-médiastinales, avec une sensibilité et une spécificité de 67%-71 % et 93-97%, respectivement ^{36, 37}. Le PET scanner change la stratégie de prise en charge dans près d'un cas sur 5 ³⁸. Ainsi, cet examen est actuellement recommandé de façon systématique chez les patients opérables ^{35, 39}.

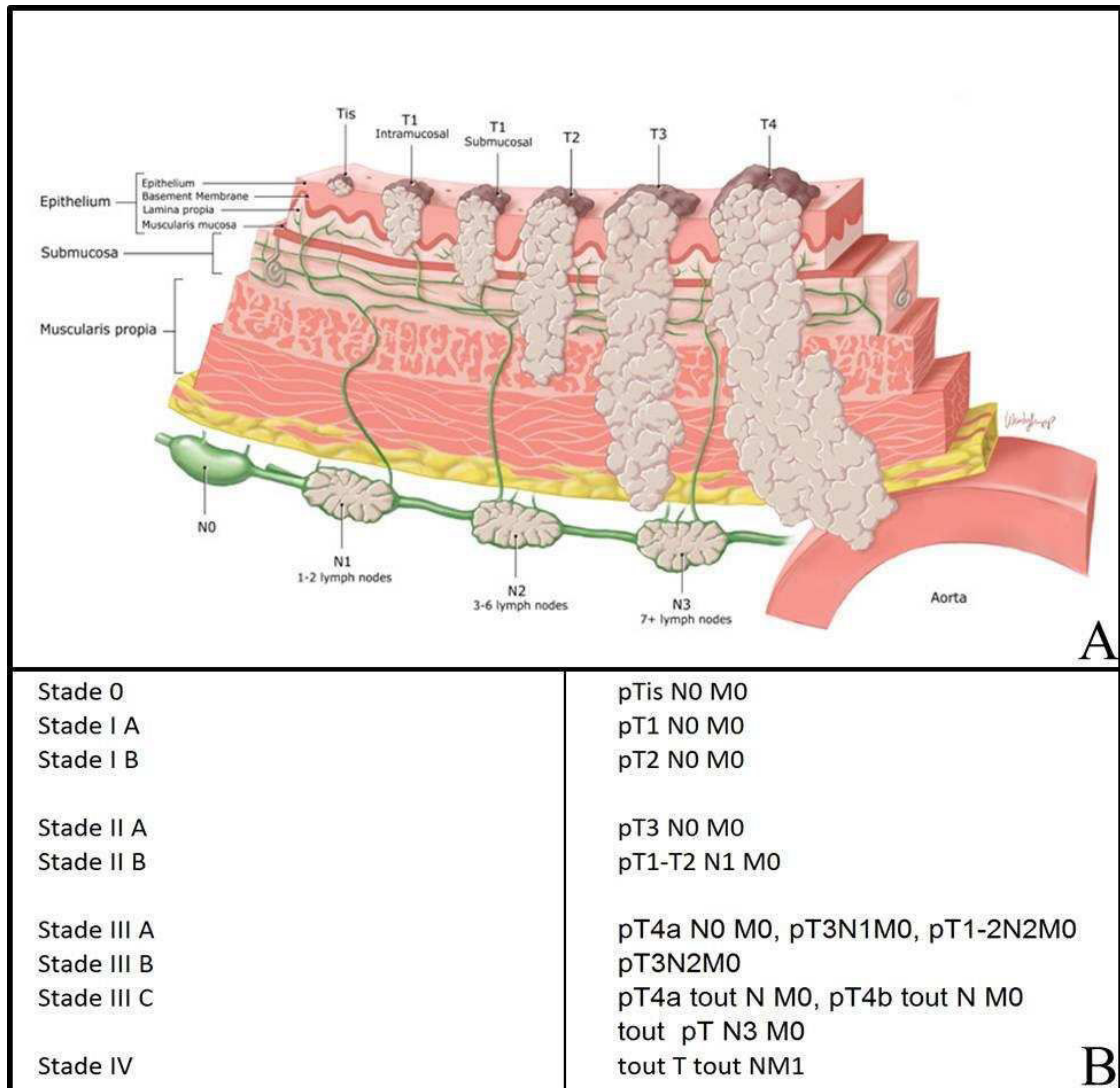
L'ensemble du bilan permet donc :

- De documenter histologiquement la tumeur.
- De la localiser précisément dans l'œsophage :
 - Dans le tiers supérieur de l'œsophage compris entre la bouche oesophagienne (bouche de Killian), située en regard du bord inférieur du cartilage cricoïde vers 15 cm des arcades dentaires, et la bifurcation trachéale, vers 23 cm des arcades dentaires. Cette partie comprend l'œsophage cervical, de la bouche oesophagienne à l'entrée dans le thorax, vers 19 cm des arcades dentaires, et l'œsophage supérieur thoracique, de l'orifice supérieur du thorax à la bifurcation trachéale.
 - Dans le tiers moyen de l'œsophage sous la bifurcation trachéale, de 23 à 31 cm des arcades dentaires environ.
 - Ou dans le tiers inférieur de l'œsophage, incluant l'œsophage abdominal, de 31 à 40 cm des arcades dentaires environ ³².

- De rechercher des critères clinico-biologiques d'inopérabilité :
 - Absolus, tels que l'insuffisance respiratoire (VEMS < 1 000 ml/sec), la cirrhose décompensée, Child B ou C, ou avec présence de varices œsophagiennes, l'insuffisance rénale (créatininémie >1,25 N), une cardiopathie ischémique instable ou avec infarctus datant de moins de 6 mois, un état général fortement altéré avec performance status de l'OMS ≥ 3 , ou une perte de poids > 20 % non récupérée après renutrition.
 - Ou relatifs, tels que : une altération de l'état général avec performance status de l'OMS ≥ 2 , une perte de poids > 15 % non récupérée après renutrition, une artériopathie oblitérante des membres inférieurs sévère (stade \geq III), ou une cirrhose Child Pugh A compensée ³².

- De rechercher des critères morphologiques de non-résécabilité :
 - Tumeur T4 envahissant l'arbre trachéo-bronchique, le nerf récurrent, l'aorte sur plus de 90°, un corps vertébral.
 - Tumeur de plus de 4 cm de diamètre développée dans le médiastin sus-carinaire.
 - Métastases viscérales, ou adénopathies non régionales, sus-claviculaires ou lombo-aortiques.

Figure 1 : Classification TNM schématique ⁴⁰ (figure 1A) et complète (figure 1B) des cancers de l'œsophage ³².



2. Le cas des cancers superficiels

Les tumeurs T1N0M0, limitées à la muqueuse ou à la sous-muqueuse représentent 66 à 69 % des stades I dans les séries chirurgicales ^{41, 42}, qui

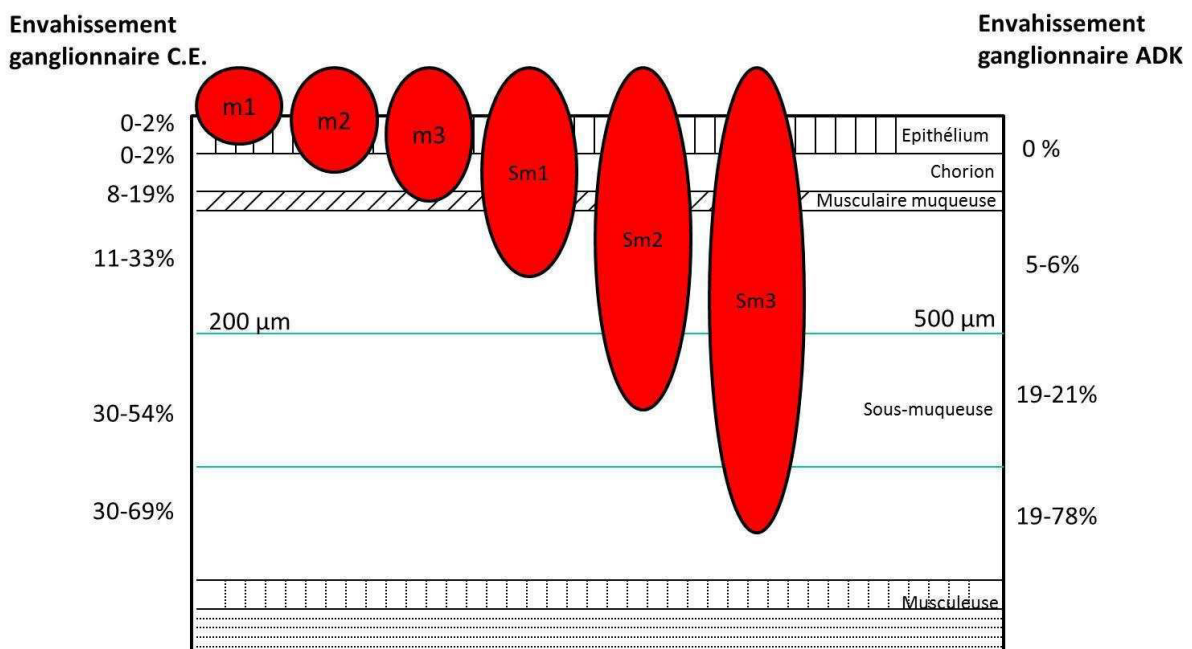
correspondent à environ 16 % de tous les cancers de l'œsophage ¹⁰. Il s'agit d'un groupe hétérogène en termes de pronostic, avec 94 à 100% de survie à 5 ans après résection chirurgicale d'un cancer T1 limité à la muqueuse (T1a), tandis que la survie spécifique à 5 ans chute à 63-74% lorsque la lésion envahit la sous-muqueuse (T1b) ⁴³⁻⁴⁵. Cette disparité est liée à la fréquence accrue de l'envahissement ganglionnaire à mesure que les tumeurs infiltrent plus profondément la paroi œsophagienne. La présence d'un envahissement ganglionnaire est en effet un élément pronostique majeur du cancer de l'œsophage, divisant la survie à 5 ans par deux, de 70 à 35 % environ ^{4,46}.

Pour cette raison, les auteurs japonais ont subdivisé les tumeurs T1 en 6 sous-types, selon le degré d'envahissement de la paroi. L'atteinte épithéliale seule limitée par la membrane basale correspond à la dysplasie de haut grade ou carcinome in situ, et est notée T1a m1; l'atteinte de la lamina propria ou chorion muqueux définit les T1a m2, tandis que l'atteinte de la muscularis mucosae définit les T1a m3; dans l'OB, où la musculaire muqueuse est fréquemment dédoublée, on distingue un stade supplémentaire, T1a m4, lorsque la couche profonde de la sous-muqueuse est atteinte sans qu'il y ait d'envahissement de la sous-muqueuse. Celle-ci est quant à elle subdivisée sur les pièces opératoires en trois tiers, les tumeurs envahissant du tiers superficiel au tiers profond de la sous-muqueuse étant respectivement notées T1b sm1 à T1b sm3. Sur les pièces endoscopiques où l'ensemble de la sous-muqueuse n'est généralement pas présent, on a défini dans la sous-muqueuse, en comptant à partir de la muscularis mucosae, un seuil de 200 µm en muqueuse malpighienne, et de 500 µm en muqueuse glandulaire, délimitant la sous-muqueuse superficielle de la sous-muqueuse profonde ^{47, 48}. Les tumeurs T1a et les tumeurs

T1b limitées à la partie superficielle de la sous-muqueuse sont ainsi appelées cancers superficiels. La figure 2 permet de corréler, selon les types histologiques, la fréquence d'envahissement ganglionnaire et le degré d'infiltration pariétale œsophagienne.

Figure 2 : Risque d'envahissement ganglionnaire en fonction du degré d'infiltration pariétale des cancers de l'œsophage 43,47-51

Risque ganglionnaire et extension pariétale



D'autres facteurs sont à prendre en compte dans l'évaluation du risque ganglionnaire d'un cancer T1 de l'œsophage :

- La présence d'embols veineux ou lymphatiques sur la pièce de résection, qui multiplie par 40 (de 0.7 % à 46.7%) le risque d'extension métastatique pour les CE ⁵², et divise la survie par trois pour les AdénoCa ⁵³.

- Le grade de différenciation tumorale : un faible grade de différenciation tumorale apparaît en effet comme multipliant par 4 le risque d'envahissement ganglionnaire ⁴³.

Ces facteurs ont conduit l'European Society of Gastrointestinal Endoscopy à considérer le traitement endoscopique exclusif comme curatif lorsque la probabilité d'envahissement ganglionnaire est jugée acceptable, c'est-à-dire généralement inférieure à 10 %, cette valeur étant à pondérer en fonction du contexte clinique de chaque patient, et en particulier de sa capacité à tolérer les traitements majeurs du cancer de l'œsophage que sont la chirurgie et la radiochimiothérapie. Ainsi, pour les CE, le traitement endoscopique exclusif est curatif lorsque la tumeur est bien différenciée, envahissant la sous-muqueuse sur moins de 200 µm, et dépourvue d'embols veineux ou lymphatiques ; pour les AdénoCa, le traitement endoscopique exclusif est curatif lorsque la tumeur est bien ou moyennement différenciée, envahissant la sous-muqueuse sur moins de 500 µm, et dépourvue d'embols veineux ou lymphatiques ⁵¹.

C. Traitement

L'endoscopie initiale permet, outre le diagnostic endoscopique et histologique de la lésion, d'évaluer sa résécabilité, en fonction de sa taille, de son aspect (la présence de zones déprimées, Paris 0-IIc, ou ulcérées, Paris 0-III, contre-indiquant la résection), et de sa mobilité apparente par rapport aux plans profonds, particulièrement musculaire. Lorsque la tumeur apparaît comme potentiellement résécable, la résection endoscopique de la lésion constituera la dernière étape du

diagnostic, l'analyse histologique de la pièce opératoire permettant seule de confirmer la validité du traitement endoscopique exclusif du point de vue carcinologique. Ailleurs, le bilan d'extension loco-régional et à distance, ainsi que l'état général et les comorbidités du patient, guideront le choix du traitement.

1. Tumeurs de stade 0 (pTis N0M0) ou IA pT1a N0M0

a- Mucosectomie endoscopique

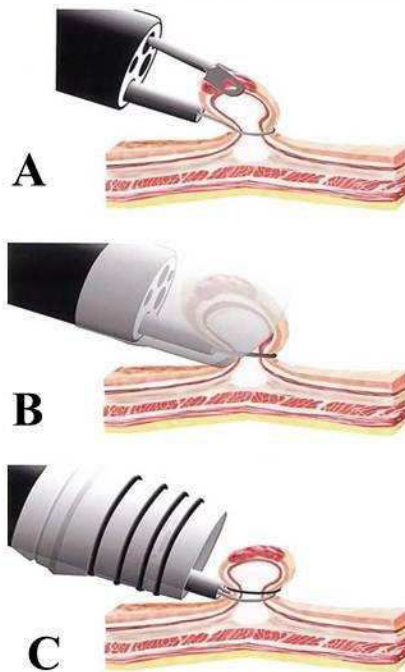
La mucosectomie endoscopique ou Endoscopic mucosal resection (EMR) est la technique la plus étudiée pour la résection endoscopique des cancers superficiels de l'œsophage^{54, 55}. Cette technique est simple, standardisée, et peu coûteuse. La particularité dans l'œsophage est la difficulté de préhension des lésions avec une anse seule, même après injection sous-muqueuse. De ce fait, l'aspiration et la traction sont utilisées pour améliorer la préhension. Les techniques de résection par aspiration sont les plus communément utilisées dans l'œsophage :

- La technique du capuchon (cap EMR) consiste à aspirer la zone d'intérêt dans un capuchon transparent fixé à l'extrémité de l'endoscope, puis à la sectionner en utilisant une anse asymétrique dédiée, préalablement insérée dans le capuchon. Une injection sous-muqueuse de sérum physiologique peut être réalisée avant aspiration de la lésion pour réduire le risque de perforation.
- La technique de ligature (multiband EMR), dérivée de la technique de ligature des varices œsophagiennes, consiste à aspirer la lésion dans un capuchon et placer un élastique à la base de la lésion, créant ainsi un pseudo-polype qui peut être sectionné à l'aide d'une anse diathermique. Une injection sous-muqueuse n'est pas nécessaire, le risque de perforation étant faible.

Plusieurs études randomisées ont comparé ces 2 techniques sans retrouver de différence en termes de succès technique ou de complication ^{56, 57}. Le choix sera donc dicté par l'habitude de l'opérateur, la disponibilité du matériel, la taille de la lésion.

La technique par traction nécessite un endoscope à double canal. Une pince et une anse diathermique sont insérées dans chacun des canaux permettant de « pédiculiser » la lésion par traction puis de la sectionner à sa base. Cette technique, nécessitant un endoscope spécifique et associée à une profondeur de résection inférieure est moins utilisée. Les principales techniques de mucosectomie œsophagienne sont illustrées sur la figure 3.

Figure 3 : Principales techniques de mucosectomie œsophagienne. A : Mucosectomie par traction; B: Mucosectomie au capuchon; C : Mucosectomie au ligateur.



La mucosectomie est associée à une mortalité nulle dans la plupart des études et un taux de complication de 1.5 % dans la plus large étude publiée ⁵⁵. Les complications précoces sont dominées par les hémorragies, les perforations étant exceptionnelles ⁵⁸. Les sténoses œsophagiennes sont un effet secondaire des résections étendues, et surviennent essentiellement lors de résections muqueuses excédant 75% de la circonférence œsophagienne ⁵⁹.

Les limites de la mucosectomie endoscopique sont liées à l'utilisation d'un capuchon de plastique : les lésions polypoïdes ou surélevées (Paris 0-I), qui représentent 14 à 16 % des lésions néoplasiques de l'œsophage, ⁴⁷ sont trop volumineuses pour être aspirées dans le capuchon et réséquées en un seul

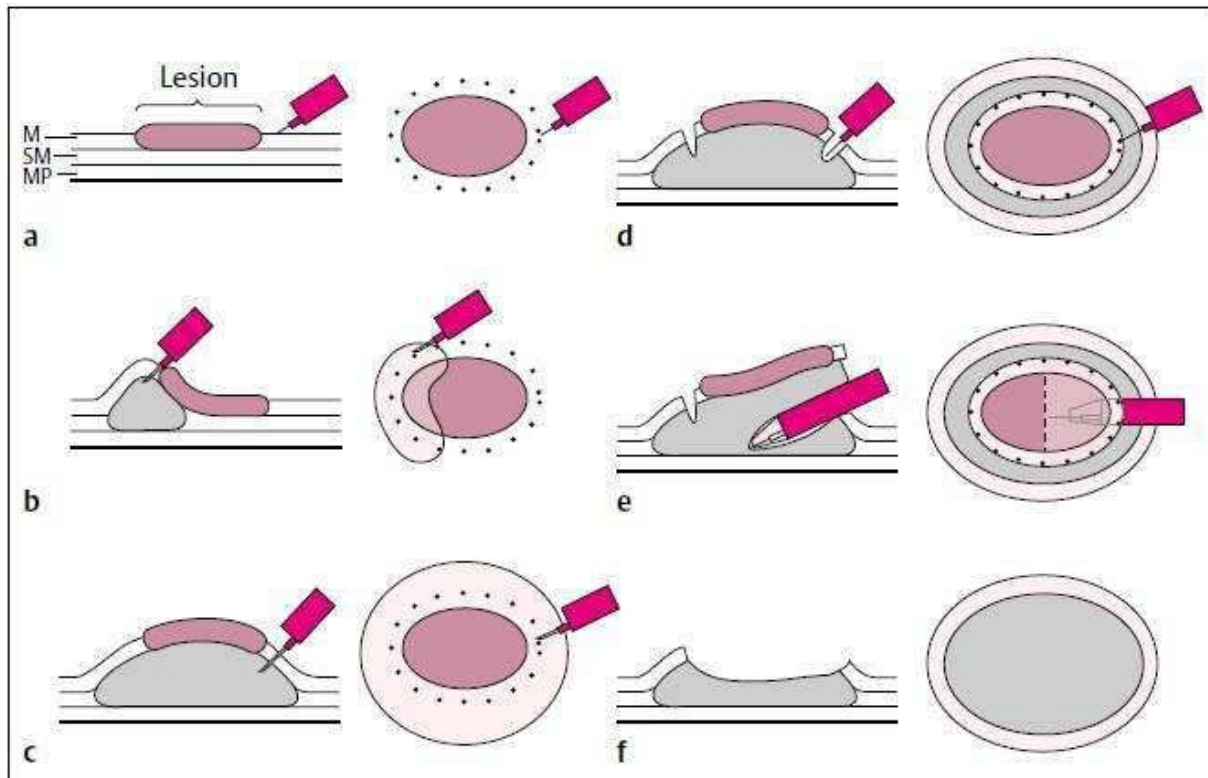
fragment; en effet, la taille du fragment réséqué n'excède pas 15 mm, ce qui suppose une résection fragmentée pour les lésions de 15 mm ou plus. Ainsi, en pratique courante, une résection fragmentée est nécessaire dans près de 70 % des cas, avec en moyenne 3 fragments ^{58, 60}.

La pertinence, dans le traitement endoscopique des cancers superficiels de l'œsophage, de la résection tumorale dite carcinologique, c'est-à-dire en monobloc avec des marges de résection saines, est débattue ^{61,62}. En effet, de nombreuses équipes rapportent d'excellents résultats en termes de survie globale et sans récurrence en dépit de la résection multifragmentée des lésions néoplasiques ^{55, 63}. Cependant, ces données favorables à la mucoséctomie proviennent pour l'essentiel de séries de lésions néoplasiques développées sur OB, où plus de 30% des lésions visibles suspectes réséquées sont constituées de dysplasie épithéliale sans AdénoCa ⁶³ et où les foyers d'adénocarcinome réséqués endoscopiquement sont souvent de petite taille; de plus, un traitement ablatif est appliqué après la résection endoscopique pour traiter l'OB résiduel, ce qui permet de traiter d'éventuels résidus néoplasiques sur la zone de résection et de limiter les récurrences locales. L'avantage d'une résection en monobloc serait probablement moins discutable en cas de CE ou d'AdénoCa de plus de 5 à 10mm de diamètre ou à risque d'extension sous-muqueuse. Ainsi, l'influence du concept de résection en bloc adapté de la chirurgie digestive carcinologique, et l'importance d'une analyse histologique optimale de la pièce pour évaluer le risque d'envahissement ganglionnaire ont favorisé le développement d'une autre technique de résection endoscopique, la dissection sous-muqueuse.

b- Dissection sous-muqueuse

La dissection sous-muqueuse ou ESD (endoscopic submucosal dissection) permet la résection en bloc d'un cancer superficiel, quelle que soit sa taille. Ceci permet une meilleure analyse des marges latérales et profondes de la pièce, et donc de limiter le risque de récurrence locale, ainsi que d'évaluer au mieux le risque d'envahissement ganglionnaire, et donc le caractère curatif de la résection endoscopique. La technique a été développée au Japon en 2003 ⁶⁴, et a depuis été largement utilisée à travers le monde, notamment en Europe, dans le traitement des cancers superficiels et états précancéreux de l'œsophage ⁵¹. La figure 4 présente les principales étapes de la dissection sous-muqueuse.

Figure 4: Principales étapes de la dissection sous-muqueuse (d'après Yamamoto et al. ⁶⁴). a : La lésion est délimitée ; b et c : injection sous-muqueuse de sérum physiologique ou d'une solution hypertonique; d : incision périphérique de la muqueuse ; e : dissection sous-muqueuse; f : zone de résection avec socle de sous-muqueuse résiduelle et de musculéuse propre.



M : Muqueuse; SM : sous-muqueuse; MP: musculéuse propre

La dissection sous-muqueuse est une procédure plus difficile techniquement, plus longue et plus onéreuse que la mucoséctomie œsophagienne, sans faire l'objet à l'heure actuelle d'un remboursement spécifique en France, et requiert une formation spécifique des endoscopistes. Le taux de complications précoces, à type d'hémorragies et de perforations œsophagiennes, est également plus important dans certaines des séries publiées (4 à 9 % ^{61, 65}), mais cette surmorbidity de l'ESD par

rapport à l'EMR peut s'expliquer par une plus longue courbe d'apprentissage. Enfin, comme pour la mucosectomie, les complications tardives sont dominées par la constitution de sténoses œsophagiennes cicatricielles, pouvant atteindre 90% des patients en cas de résection circonférentielle ⁶⁶.

Les taux de résection en bloc après ESD sont proches de 100%, contre environ 30-50% pour la mucosectomie œsophagienne ^{61, 65, 67}. Du fait de la résection monobloc, le taux de récurrence locale serait diminué: pour l'AdénoCa, le taux est de 0-10 % avec la dissection ^{61, 68} contre 14.5% avec la mucosectomie ⁵⁵ ; pour le CE, le taux est de 0-1 % avec la dissection contre 9-26% avec la mucosectomie ^{65, 95}.

Malgré ces données favorables à l'ESD, la place de la dissection sous-muqueuse dans le traitement de l'AdénoCa œsophagien est controversée, la majorité des études disponibles rapportant des taux de résection endoscopiques curatives variant de 39 à 77% seulement et restant le plus souvent inférieurs à 70 % ⁶¹. A l'inverse, le taux de résection curative observé après résection par dissection sous-muqueuse d'un CE avoisine les 80-90 % ^{65,69}. Ces faibles taux de résection curative ne sont pas expliqués par une plus grande proportion d'embols veino-lymphatiques ou de faible grade de différenciation tumorale dans les AdénoCa, mais par un envahissement plus fréquent des marges de résection, notamment latérales. En effet, contrairement aux lésions en muqueuse malpighienne dont les limites sont nettement visibles, en lumière blanche ou après coloration vitale par le lugol, les limites des AdénoCa sur œsophage de Barrett sont moins clairement visibles, et l'envahissement des marges de résection latérales par le cancer ou la dysplasie de haut grade est observé dans 20 à 35% des cas ^{61,70}. Enfin, une étude prospective randomisée récente, comparant mucosectomie et dissection sous-muqueuse, rapportait des résultats similaires entre

les deux techniques en termes de résultats oncologiques ⁶¹, confirmant les recommandations européennes actuelles qui privilégient la mucosectomie sur la dissection sous-muqueuse dans le traitement de l'AdénoCa ⁵¹. Ainsi, en l'absence de méthode de haute fiabilité pour délimiter les marges non dysplasiques sur OB et en raison du caractère habituellement multifocal de la DHG sur OB, tout le potentiel de l'ESD pourrait s'exprimer dans l'indication d'exérèse en monobloc de la totalité de l'OB. La dissection sous-muqueuse endoscopique doit, pour cela, pouvoir dépasser, au moyen d'un traitement curatif ou préventif efficace, le problème de la sténose œsophagienne cicatricielle :

- Pour les CE, la dissection permettrait de réséquer les lésions les plus étendues, et d'éviter un geste chirurgical à forte morbidité pour traiter une maladie superficielle, voire de simples lésions prénéoplasiques.
- Pour les AdénoCa, la dissection de la lésion principale emportant de façon le plus souvent circonférentielle l'ensemble de l'œsophage de Barrett adjacent, néoplasique ou non, permettrait à la fois d'obtenir un meilleur résultat oncologique de la dissection par l'absence d'envahissement des marges latérales, et ensuite d'éviter au patient des séances répétées de traitements ablatifs et une surveillance prolongée de l'œsophage de Barrett résiduel qui s'avèrent coûteux et contraignants.

c- Techniques ablatives

Les techniques ablatives reposent sur la destruction thermique de la muqueuse par voie endoscopique. Ces techniques, actuellement représentées principalement par la radiofréquence endoscopique et la coagulation au plasma d'argon, ont pour

principaux avantages une faible morbidité par rapport aux résections endoscopiques, avec en particulier l'absence de perforations ou d'hémorragies, et une grande simplicité technique. En revanche, leur action limitée à l'épithélium et au chorion, et l'absence d'étude histologique possible des pièces traitées restreignent leur champ d'application aux lésions néoplasiques intraépithéliales strictement planes. En effet, l'application non uniforme de l'énergie sur une muqueuse irrégulière peut conduire au recouvrement de tissu tumoral ou dysplasique par un néo-épithélium malpighien, et conduire à méconnaître un cancer invasif au cours de la surveillance. Ce concept, décrit dans l'OB sous le terme de glandes enfouies ⁷¹, constitue l'un des principaux écueils des traitements ablatifs.

Si quelques publications suggèrent une faisabilité de la radiofréquence endoscopique dans le traitement de la dysplasie de haut grade en muqueuse malpighienne ^{72, 73}, l'essentiel des données disponibles sur les traitements ablatifs concerne le traitement de l'OB. Le cadre d'utilisation couramment admis de ces techniques ablatives couvre donc l'OB dysplasique sans lésion visible et l'OB résiduel après résection endoscopique d'un cancer superficiel, suspect par définition de contenir des foyers dysplasiques multifocaux. En effet, en l'absence du traitement de l'OB résiduel après résection, les lésions métachrones sont fréquentes, survenant dans 30 à 37% des cas ⁷⁴, reflétant le caractère multifocal des lésions néoplasiques sur OB rapporté dans 30 % des cas dans les séries chirurgicales ⁷⁵.

Ablation par radiofréquence

La RFA est réalisée au moyen d'un cathéter portant une électrode bipolaire. Deux principaux types de dispositifs existent : une électrode montée sur un ballon (Barrx360, Medtronic, Minneapolis, MN, USA) insérée sur un fil guide et insérée dans

l'œsophage en parallèle de l'endoscope. Ce système permet l'ablation rapide de larges zones circonférentielles d'OB, mais nécessite une étape préliminaire de mesure du diamètre œsophagien utilisant un ballon de mesure. Aussi, un nouveau type de cathéter auto-gonflable s'adaptant au diamètre œsophagien à chaque niveau a été récemment développé pour éviter cette étape de mesure. Pour l'ablation circonférentielle, l'électrode est positionnée 1 cm en amont du bord proximal de l'OB, le ballon est gonflé, et l'énergie est délivrée (deux applications, 12 J/cm², 40 W/cm²).

Le second type de dispositif est un cathéter focal attaché à l'extrémité de l'endoscope permettant l'ablation de languettes ou d'ilots d'OB. Il en existe plusieurs types, mais le Barrx90, permettant une ablation sur 90 ° de la circonférence, est le plus communément utilisé. La quantité d'énergie varie de 4 fois 12J/cm² à 4 fois 15J/cm², à une puissance de 40 W/cm². Plusieurs études sont en cours pour raffiner et simplifier les protocoles d'ablation. Usuellement, les patients requièrent une séance de Barrx 360 et deux séances d'ablation focale pour obtenir l'éradication complète de la MI. Chez tous les patients, la jonction œsogastrique doit être traitée circonférentiellement par la sonde focale au moins une fois. Plus récemment encore, une troisième sonde passant à travers le canal opérateur de l'endoscope a été développée, avec une surface d'ablation réduite de 7.5 x 15.7 mm (comparée à 13 x 20 mm pour le Barrx90) et une électrode souple, mais la possibilité d'appliquer la RFA dans des zones d'accès difficile, en particulier dans des œsophages étroits après résections endoscopiques extensives.

Avec trois essais randomisés contrôlés ⁷⁶⁻⁷⁸, trois larges études de cohorte ^{63,79,80}, et plus de 10 grandes études rétrospectives ^{81,82}, la RFA est la technique d'ablation la plus validée. Un essai randomisé contrôlé a démontré des résultats

équivalents à la résection endoscopique progressive de l'œsophage de Barrett résiduel après traitement endoscopique d'un cancer superficiel, avec en particulier un plus faible taux de complications, notamment en termes de sténose œsophagienne (14% vs 88%, $p < 0.001$)⁷⁸. La RFA est particulièrement intéressante pour le traitement de l'OB long circonférentiel, pour lequel une ablation reproductible sur 3 cm de hauteur, contrôlée en profondeur, peut être obtenue plus rapidement et avec plus de fiabilité qu'avec toute autre technique. En effet, même dans les OB longs de plus de 10 cm, un taux d'éradication complète de la métaplasie intestinale (MI) de 83% peut être obtenu par une résection endoscopique suivie de RFA⁸³. Enfin, l'efficacité et la persistance des résultats obtenus jusqu'à 5 ans ont été confirmés dans des publications récentes^{63,79,80}. L'éradication complète de la néoplasie (dysplasie de haut grade et cancer) et de la MI est atteinte dans 95-96% des cas et 89-92% des cas à 2 ans, respectivement. La rémission prolongée de la néoplasie et de la métaplasie intestinale était observée dans 90 % des cas à 5 ans, et toutes les récurrences étaient accessibles à un traitement endoscopique.

Coagulation au plasma d'Argon

La coagulation au plasma d'Argon (APC) a également été proposée pour l'ablation de l'OB résiduel, en raison de son faible coût et de sa large disponibilité. Un travail publié récemment a démontré que le taux de récurrences métachrones avec APC diminuait de 37 à 3 % après deux ans de suivi⁸⁴. Cependant, l'ablation par APC est opératoire dépendante, en raison d'une variabilité de la distance entre la sonde et la muqueuse œsophagienne, de la durée d'application, et des paramètres du générateur : on peut donc s'attendre à une variabilité des résultats. De plus, l'ablation d'OB circonférentiels est particulièrement longue, susceptible d'être

incomplète, nécessite plusieurs séances de traitement, et entraîne des sténoses œsophagiennes dans 9% des cas ⁸⁴. Ainsi l'utilisation de l'APC est actuellement limitée à l'ablation de petits îlots résiduels après résection endoscopique ou RFA.

Récemment, une sonde d'APC modifiée permettant l'injection sous-muqueuse de sérum salé isotonique avant l'ablation, appelée Hybrid APC (Erbe Elektromedizin, Tübingen, Germany) a été développée. Une injection sous-muqueuse préalable à l'ablation devrait permettre une ablation à haute puissance et améliorer les résultats de l'APC, en termes de sécurité et d'efficacité. Alors que la première étude pilote semble confirmer cette hypothèse, avec un taux de sténose de 2% ⁸⁵, des études prospectives sont en cours.

Autres techniques ablatives

La thérapie photodynamique fut la première technique ablatrice largement étudiée. Ses résultats ont été finalement décevants, en raison de la variabilité de la profondeur d'ablation, d'un taux de sténose de 30 %, d'une fréquence élevée de glandes enfouies (14%), et d'un taux d'éradication de la néoplasie à 5 ans de 44 à 78 % ^{71, 86}. Actuellement, cette technique est largement abandonnée.

Enfin, de nouvelles versions de techniques anciennes, potentiellement moins coûteuses que la RFA, ont été proposées. La cryoablation au ballon a notamment récemment démontré sa faisabilité et son efficacité dans une étude prospective ⁸⁷.

d- Place de la chirurgie

Le traitement de référence du cancer de l'œsophage, y compris des formes superficielles, est, d'après les recommandations européennes les plus récentes, l'oesophagectomie avec curage ganglionnaire ³⁵. Il permet de traiter la lésion,

d'éventuelles lésions synchrones, et de prévenir la survenue de lésions métachrones. Cependant, ce traitement s'accompagne d'une mortalité post opératoire de 1.7-5.3%, d'une morbidité de 40-45%, et d'une qualité de vie altérée sévèrement pendant les 9 à 12 mois suivant le geste ⁸⁸⁻⁹⁰. Ces chiffres sont à comparer aux traitements endoscopiques les plus agressifs, comme la dissection sous-muqueuse de l'œsophage, dont la mortalité est nulle, et le taux de complication ne dépasse pas 9 % ^{61, 65}. De plus, l'oesophagectomie, en l'absence de contrôle endoluminal per-opératoire de la hauteur de section oesophagienne, ne garantit pas l'absence de lésion résiduelle, notamment en cas d'OB long ou de CE multifocal.

L'endoscopie est ainsi apparue, depuis les 20 dernières années, comme une option thérapeutique acceptable pour les néoplasies intraépithéliales et intramuqueuses, avec la publication des résultats de grandes séries de patients démontrant des résultats oncologiques comparables à ceux des séries chirurgicales avec des survies à 5 ans supérieures à 90% ^{52, 55}. Des comparaisons directes des traitements endoscopiques et chirurgicaux ont démontré des survies identiques à 5 ans entre les groupes, une morbi-mortalité nulle dans le groupe endoscopie, au prix d'un plus grand nombre d'interventions et de récurrences ^{91, 92}.

Le tableau 1 résume les principales options thérapeutiques pour les cancers superficiels de l'œsophage et leurs limitations.

Tableau 1: Principales options thérapeutiques des cancers superficiels de l'œsophage

	Oesophagectomie	Mucosectomie	Dissection sous-muqueuse	Ablation par radiofréquence
Stade maximal de la maladie	T2 M0 Patient opérable ³⁵	T1b sm1 [≠] (CE) T1b sm1 [∞] (AdénoCa) ⁵¹	T1b sm1 [≠] (CE) T1b sm1 [∞] (AdénoCa) ⁵¹	DHG sans lésion visible ¹⁶
Taux de succès[#]	97-100% ⁹³	92-100% ^{55, 78, 94, 95}	64-96.4% ^{55, 96, 97}	81-100% ⁸²
Taux de récurrence (néoplasie)	1% for T1A ⁹⁸ 22.9% for T1-T2 ⁹⁹	9.8 - 11.5% ^{55, 78, 94, 95}	0.9-3.6% ^{55, 96, 97, 100}	2% * ¹⁶
Possibilité de traiter les récurrences	Oui	Oui	Oui ¹⁰⁰	Non recommandé
Mortalité	2-3.4% ^{90, 98}	0	0 ^{65, 68}	0
Morbidité	35-42% ^{90, 98}	1.2-4% ^{78, 94, 95}	4-6.6% ^{55, 97, 100}	1% ⁸²
Taux de sténose	24-47% ⁹⁸ (anastomotiques)	37-88% if C-EMR ^{78, 94, 95}	90% if C-ESD ^{96, 97, 100}	4-5% ^{82, 101}
Glandes enfouies	Non rapportées	2-8% ^{78, 94, 95, 102}	Non rapportées	0-0.9% ^{71, 82}
Inconvénients	Morbidité élevée Mortalité	Résection fragmentée pour les lésions > 2 cm Sténoses	Expertise endoscopique requise Durée Taux de sténose	Pas d'histologie Non indiqué pour les cancers invasifs
Avantages	Résection carcinologique Statut ganglionnaire	Peu de complication Simplicité technique	Résection carcinologique Analyse histologique possible	Peu de complications Simplicité technique Bonne réparation tissulaire

CE : carcinome épidermoïde ; AdénoCa : adénocarcinome ; MI : métaplasie intestinale ; QdV : qualité de vie ; CEMR : mucosectomie endoscopique circonférentielle ; CESD : dissection sous-muqueuse circonférentielle

: Taux d'éradication complète de toute néoplasie (dysplasie de haut grade ou cancer intramuqueux) à la fin du traitement.

* : récurrence de la néoplasie à 3 ans.

≠: infiltration de la sous-muqueuse inférieure à 200 µm

∞: infiltration de la sous-muqueuse inférieure à 500 µm

2. Tumeurs localisées, de stade IA pT1bN0M0 à IIB

Tandis que le traitement endoscopique a démontré son intérêt pour les tumeurs T1a et certaines tumeurs T1b à faible risque d'envahissement ganglionnaire ⁴³, le traitement chirurgical reposant sur l'oesophagectomie constitue la référence thérapeutique pour la majorité des tumeurs T1b et T2N0M0 (stade IB) ³⁵.

La survie à long terme ne dépassant pas 25 % en présence d'un envahissement ganglionnaire, un traitement néoadjuvant par chimiothérapie ou radiochimiothérapie est recommandé pour toute tumeur avec suspicion d'envahissement ganglionnaire (T1-2 N1 M0 ou stade IIB). En cas de découverte d'un envahissement ganglionnaire sur la pièce opératoire, une chimiothérapie adjuvante à base de sel de platine, de type 5 fluorouracile (5FU)- cisplatine peut être proposée ³⁵.

Pour les patients inopérables ou refusant la chirurgie, ou les patients présentant une tumeur de l'œsophage cervical, la radiochimiothérapie exclusive peut être proposée. Elle a en effet démontré sa supériorité sur la radiothérapie seule ¹⁰⁵. Le standard thérapeutique habituel est composé de 4 cycles de 5FU-cisplatine combiné avec une dose de 50.4 Gy en fractions de 1.8Gy ¹⁰⁶. D'autres protocoles de chimiothérapie, tels que l'association 5 FU-oxaliplatine, ou docetaxel-carboplatine, peuvent être proposés en association avec la radiothérapie.

Dans le cas des tumeurs réséquées par ESD mais présentant des critères défavorables, des travaux japonais ont rapporté de bons résultats de la radiochimiothérapie en traitement complémentaire d'un traitement endoscopique non curatif, mais il s'agit essentiellement de séries de cas et non de travaux prospectifs permettant d'établir des recommandations ^{103, 104}. Toutefois, de nombreux patients

étant âgés, souffrant de comorbidités contre-indiquant la chirurgie ou ayant une lésion de l'œsophage proximal impliquant une chirurgie délabrante ou à haut risque, la question d'un traitement complémentaire de radio-chimiothérapie dans un but curatif après exérèse endoscopique d'un cancer pT1b se posera de plus en plus souvent. La validation d'une telle stratégie implique la mise en œuvre d'études prospectives avec un suivi à long terme.

3. Tumeurs avancées, de stade III ou IV, ou récidives néoplasiques

a- Tumeurs de stade III

Dans ces stades, la chirurgie seule n'est plus le traitement de référence, dans la mesure où une résection R0 est impossible dans 30 % des tumeurs pT3 et 50% des tumeurs pT4 ³⁵. De plus, même après résection carcinologique, la survie à long terme ne dépasse pas 20 %. Ainsi, un traitement néoadjuvant est clairement indiqué chez les patients opérables.

Pour les CE, la radiochimiothérapie néoadjuvante a démontré un bénéfice en termes de résection tumorale R0, de contrôle tumoral local, et de survie globale, au prix d'une morbi-mortalité post-opératoire plus élevée ^{35, 107, 108}. Les protocoles habituels associent 40 à 50 Gy en fractions de 1.8Gy à deux cycles de chimiothérapie à base de sel de platine de type 5 FU-cisplatine, 5FU-oxaliplatine, ou docétaxel-cisplatine ¹⁰⁹. En cas de réponse à la radiochimiothérapie néoadjuvante, la poursuite de la radiochimiothérapie a démontré des résultats globalement équivalents à la chirurgie de résection, avec cependant un taux plus élevé de récidives locales dans le groupe non opéré ^{110, 111}. Ainsi, la radiochimiothérapie avec

surveillance rapprochée et chirurgie de sauvetage en cas de tumeur résiduelle ou de progression sous traitement apparaît comme la stratégie de référence ¹¹².

Pour les AdénoCa, la chimiothérapie péri-opératoire à base de 5-FU et cisplatine est actuellement considérée comme le standard pour les tumeurs localement avancées. Cependant, deux essais récents suggèrent un bénéfice de survie majeur lié la radiothérapie néoadjuvante, en comparaison à la chirurgie seule ¹⁰⁸ ou à la chimiothérapie préopératoire seule ¹¹³. Même en présence d'une régression tumorale complète après traitement néoadjuvant, les recommandations européennes proposent l'oesophagectomie ³⁵.

b- Tumeurs de stade IV

La chimiothérapie est indiquée pour le traitement palliatif de patients sélectionnés, notamment pour les patients porteurs d'AdénoCa en bon état général. Le protocole historique associant 5FU et cisplatine peut être remplacé par d'autres associations de fluoropyrimidines, telles que la capécitabine, et l'oxaliplatine ¹¹⁴. Comme dans le cancer gastrique, les taxanes sont recommandées en association en première ligne ou en monothérapie en deuxième ligne. Pour les patients porteurs de CE, le bénéfice de la chimiothérapie n'a pas été démontré dans des essais randomisés. Les protocoles habituels, associant 5FU et cisplatine ou oxaliplatine, peuvent être proposés.

En cas de dysphagie, le traitement endoscopique de la dysphagie par la mise en place d'une prothèse œsophagienne peut être proposée, de même que la curiethérapie en une dose ¹¹⁵, ou l'irradiation externe.

D. Surveillance

Après traitement endoscopique curatif d'un cancer superficiel, une surveillance endoscopique de l'œsophage est indiquée à vie, à la recherche d'une récurrence locale ou d'un cancer métachrone. Si la surveillance n'est pas codifiée après traitement endoscopique d'un CE, elle peut être dérivée des recommandations actuelles concernant l'AdénoCa¹⁶. En effet, même après la résection endoscopique du cancer et l'éradication complète de la MI, une surveillance endoscopique trimestrielle la première année, semestrielle la seconde, puis annuelle est recommandée. La durée de cette surveillance est encore incertaine.

Après traitement chirurgical d'un cancer de l'œsophage, aucun protocole de surveillance n'a démontré de bénéfice sur la survie des patients. L'usage en France est une évaluation clinique et un scanner thoraco-abdomino-pelvien tous les 6 mois pendant 5 ans, associé à un examen ORL annuel en cas de CE, et une endoscopie digestive haute à 2 ans³².

En cas de radiochimiothérapie exclusive, la recherche d'un résidu, voire d'une progression tumorale par endoscopie, scanner et PET scanner, doit être réalisée en fin de traitement, afin de discuter un geste chirurgical de sauvetage. En cas de réponse complète, il est proposé une évaluation clinique, endoscopique et radiologique par scanner thoraco-abdomino-pelvien tous les 4 mois pendant 1 an, puis tous les 6 mois pendant 1 an, avant de reprendre les mêmes modalités de suivi qu'après chirurgie. La réponse tumorale est évaluée en routine par les symptômes cliniques, l'endoscopie, et le scanner. L'apport du PET scanner dans l'évaluation de la réponse des AdénoCa à la chimiothérapie a été suggéré¹¹⁶ mais ne modifie actuellement pas la pratique clinique.

II. La prévention de la sténose œsophagienne post-endoscopique

A. Généralités

Il n'existe pas de définition consensuelle de la sténose œsophagienne post-endoscopique. La définition la plus fréquemment employée, proposée par Hashimoto et al, est un rétrécissement de la lumière œsophagienne visible en endoscopie, ou bien infranchissable par un gastroscopie standard de 10 mm de diamètre, ou bien associé à une dysphagie ¹¹⁷.

Tout type de lésion muqueuse profonde peut se compliquer de sténose œsophagienne : les résections ou ablations endoscopiques étendues, mais aussi les œsophagites peptiques, à éosinophiles, inflammatoires, infectieuses, radiques, caustiques, ou encore la résection chirurgicale de l'œsophage. Le taux de sténose après EMR varie de 1.3% à 4.9 % ^{55, 95} et de 3 à 11.6% après ESD ^{65, 95}. Cependant, ces taux ne sont pas strictement comparables, car l'extension circonférentielle de la résection n'était pas la même dans les différentes études. Or Katada et al. ont démontré l'importance prépondérante de l'extension circonférentielle du défaut muqueux dans la survenue de la sténose ⁵⁹. Ces conclusions ont été confirmées par d'autres équipes, avec des taux de sténose atteignant 88% pour l'EMR circonférentielle et 90-94% pour l'ESD dépassant 75 % de la circonférence œsophagiennes ^{78, 100, 118}, suggérant des mécanismes de cicatrisation similaires entre les deux techniques de résection, et un faible impact de la résection en bloc ou multifragmentée. L'extension en profondeur de la lésion néoplasique initiale, même si elle ne modifie pas la profondeur de la résection endoscopique, a également été proposée comme un facteur de risque de sténose post endoscopique par Ono et al.,

(Odds ratio (OR): 14.2; 95% CI: 2.7–74.2 pour T1a m2 vs T1a m1) , avec moins d'impact que l'extension circonférentielle de la sténose (OR: 44.2; 95% CI: 4.4–443.6 pour une résection supérieure ou inférieure à 75 % de la circonférence muqueuse)¹¹⁹. Les sténoses après traitement ablatif sont exceptionnelles par rapport à la fréquence attendue compte tenu de l'étendue des défauts muqueux, avec des taux de sténose de 4 et 6-9% pour les deux principales techniques^{82, 85, 120}. Ces résultats sont vraisemblablement expliqués par un effet plus superficiel de ces traitements qui n'agissent pas au-delà de la musculaire muqueuse.

La plupart des sténoses œsophagiennes post endoscopiques sont réfractaires^{119, 121} : quoique la définition n'en soit pas consensuelle, une sténose réfractaire peut être définie comme requérant plus de 7 séances de dilatation endoscopique, récidivant dans les 2 à 4 semaines, ou ne pouvant être dilatée à un diamètre permettant une alimentation normale¹²²⁻¹²⁴. Un taux de succès de 71.4 % à 6 mois a été rapporté après dilatations répétées hydrostatiques ou à la bougie, soit des taux comparables à ceux observés dans les sténoses peptiques¹²⁵. Cependant, peu de données de suivi à long termes sont publiées. En outre, les dilatations itératives de ces sténoses post endoscopiques aboutissent à des taux de perforation atteignant 7.1 à 9%^{124, 125}. Ainsi, la prévention de la sténose œsophagienne post-endoscopique apparaît comme indispensable à la poursuite du développement du traitement endoscopique des cancers superficiels de l'œsophage.

B. Mécanismes de la sténose œsophagienne cicatricielle

1. Des cellules souches œsophagiennes ?

Comprendre l'homéostasie et la réaction aux agressions de la muqueuse œsophagienne est sans aucun doute un préalable au développement de traitements préventifs de la sténose cicatricielle. Ceci pose la question de l'identification d'éventuelles cellules souches de la muqueuse œsophagienne ou de progéniteurs épithéliaux qui seraient impliqués dans la réparation tissulaire œsophagienne. Pan et al. ont rapporté la présence de cellules ayant les caractéristiques de cellules souches (retenant les marqueurs, à cycles lents, à longue vie, multipotence, non différenciées) dans la couche basale de l'œsophage humain ¹²⁶. Plus récemment, Jeong et al ont identifié, chez la souris et chez l'Homme, des cellules exprimant fortement CD49 et faiblement CD24, surreprésentées dans des cultures de sphéroïdes œsophagiennes capables d'auto-renouvellement, et donc compatibles avec des cellules souches ¹²⁷. Ces résultats doivent être confirmés, et ces possibles cellules souches œsophagiennes doivent être caractérisées plus précisément. En effet, des études similaires chez la souris avaient conclu que les cellules retenant les marqueurs de la couche basale de l'épithélium œsophagien et exprimant le marqueur pan leucocyte CD45 étaient en fait des cellules de Langerhans et des lymphocytes ¹²⁸, et non des précurseurs des cellules malpighiennes.

Doupé et al. ont étudié les mécanismes de la cicatrisation œsophagienne chez la souris après une lésion épithéliale créée endoscopiquement ¹²⁸, et mis en évidence que les mêmes progéniteurs épithéliaux habituellement impliqués dans l'homéostasie épithéliale pouvaient adopter un comportement régénératif dans les 24-48 heures suivant une lésion tissulaire, en doublant leur taux de mitose dans une zone

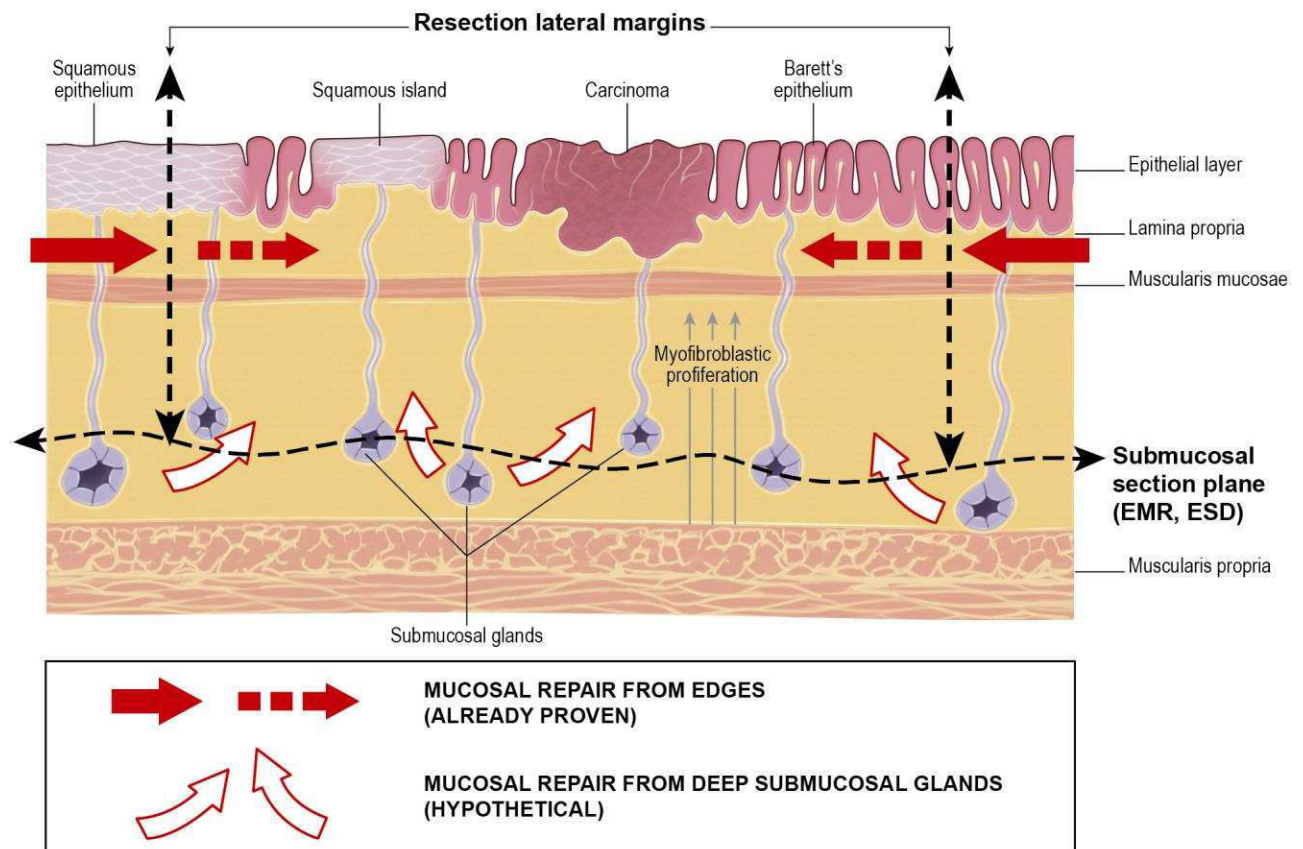
proliférative entourant un front de migration cellulaire à proximité du défaut épithélial. Ce comportement était rapidement réversible une fois la cicatrisation effectuée. Ce travail suggère l'absence de cellules à cycles lents ou de cellules souches quiescentes dans l'épithélium œsophagien, au contraire d'autres épithéliums, notamment l'épiderme, l'estomac, ou l'intestin grêle. Cependant, la pertinence de ces conclusions est peut être limitée par l'utilisation d'un modèle murin dont l'œsophage présente des différences structurales majeures avec l'œsophage humain: il est recouvert d'un épithélium kératinisé, et ne présente ni cryptes, ni glandes. En accord avec Doupé et al. cependant, Barbera et al. ont examiné des cultures cellulaires épithéliales œsophagiennes dans un système tridimensionnel organotypique et ont démontré une capacité identique à la régénération épithéliale et à la reconstitution d'un néo-épithélium malpighien après lésion que les cellules expriment un marqueur de progéniteur (CD34) ou un marqueur épithélial (Epcam). Les cellules les plus quiescentes, cependant, étaient situées au sommet des papilles épithéliales ¹²⁹. Ces deux études sont en faveur d'une grande plasticité de l'épithélium œsophagien, dans lequel les cellules assurant le renouvellement cellulaire et la réparation seraient issues du même pool.

2. Rôle des glandes sous-muqueuses

Le rôle des glandes œsophagiennes sous-muqueuses dans la réparation épithéliale a été suggéré par des études histologiques ayant mis en évidence une continuité entre les îlots d'épithélium malpighien au sein de l'OB et les canaux excréteurs des glandes sous-muqueuses ¹³⁰. Si l'on admet que l'homéostasie et la réparation tissulaire ne sont pas assurées à partir de cellules souches ou de cellules

spécifiques épithéliales, il pourrait y avoir un rôle dévolu aux glandes œsophagiennes dans la réparation tissulaire œsophagienne. Cette hypothèse pourrait ainsi expliquer pourquoi le degré de réépithélialisation et le taux de sténose varient avec la profondeur de la lésion muqueuse ou sous-muqueuse, profondeur qui varie grandement entre la RFA qui ne dépasse pas la musculaire muqueuse et l'ESD qui emporte l'essentiel de la sous-muqueuse. Si cette hypothèse est juste, alors les glandes sous-muqueuses pourraient contribuer au processus de réépithélialisation à partir de la profondeur de la zone lésée ou réséquée, en complément de la réparation épithéliale provenant des berges de la plaie. Ceci pourrait nécessiter de préserver quelques glandes œsophagiennes viables pour éviter les sténoses lorsqu'on envisage une résection muqueuse quasi circonférentielle. La figure 5 illustre le rôle possible des glandes œsophagiennes dans la réparation épithéliale.

Figure 5: Rôle possible des glandes sous-muqueuses dans la réparation tissulaire œsophagienne ¹³¹.



3. Mécanismes généraux de la cicatrisation

L'essentiel de notre compréhension de la cicatrisation œsophagienne vient de l'application des grands principes de la réparation tissulaire dans l'œsophage animal ^{132, 133}, ou dans d'autres organes comme l'estomac ou la peau ^{134, 135}. La première étape est la perte de la barrière épithéliale et muqueuse aboutissant à l'exposition de

la sous-muqueuse à diverses agressions: mécaniques par le passage des aliments et les contractions œsophagiennes, chimiques par le reflux acide ou biliaire, et microbiennes par la flore bactérienne et fongique œsophagienne et oropharyngée. La seconde étape est l'activation du système immunitaire ¹³⁶. La réponse inflammatoire est marquée par la formation d'un tissu de granulation qui inclut un infiltrat inflammatoire et des néovaisseaux palissadiques similaires à ceux observés dans le bourgeon charnu, perpendiculaires à l'axe de l'œsophage. A la phase initiale, la plupart des cellules inflammatoires sont des polynucléaires neutrophiles et des macrophages, alors que dans la phase plus tardive, ces cellules sont progressivement remplacées par des lymphocytes et des plasmocytes ¹³⁷. A ce stade, les cytokines pro-inflammatoires en jeu sont notamment l'IL-17 ou le TNF- α . La troisième étape est la formation du tissu cicatriciel, qui, après les résections muqueuses étendues de l'œsophage, aboutit à la formation d'une sténose. Les fibroblastes résidents et les péricytes sont induits à se différencier en myofibroblastes producteurs de matrice extracellulaire, et notamment de collagène I, par des cytokines fibrogéniques. Ces cytokines, notamment le TGF- β 1, TNF- α , IL-1, IL-4, IL-6, PDGF, IL-17A et l'IL-13, sont produites par des cellules épithéliales, endothéliales, et les cellules de la lignée myéloïde ¹³⁸. Tout d'abord, les myofibroblastes sont des cellules hautement contractiles, exprimant l' α -smooth muscle actin (α -SMA), une protéine formant des faisceaux de myofilaments qui favorisent la contraction de la cicatrice ¹³⁹. Deuxièmement, les myofibroblastes sont des acteurs clés de la formation du tissu cicatriciel par le biais de la synthèse de collagène de type I. Les macrophages dérivés des monocytes peuvent se différencier en macrophages de type proinflammatoire (M1) aboutissant à la destruction tissulaire, en macrophages profibrogéniques de type M2a stimulant la différenciation myofibroblastique

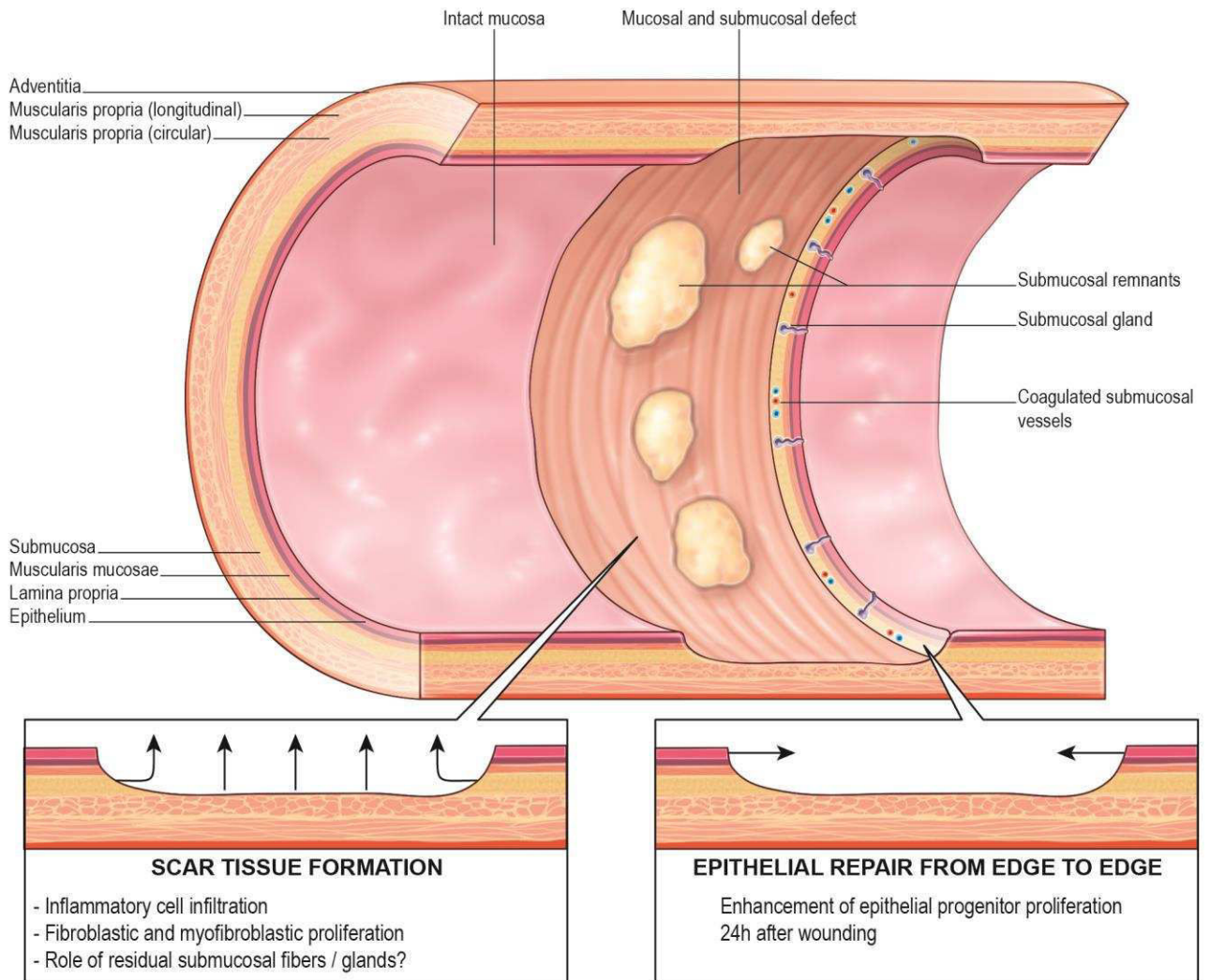
essentiellement via la sécrétion de TGF- β , ou en macrophages de type régulateur (Mreg) qui, par l'intermédiaire de la production d'IL-10, inactivent les myofibroblastes et activent les métalloprotéases matricielles, limitant la fibrogénèse ¹³⁸.

Le rôle du stress oxydant dans la fibrogénèse a été démontré dans différents modèles animaux et humains notamment de fibrose cutanée, pulmonaire, et rénale ^{138, 140}. En effet, les fibroblastes peuvent exprimer différents isoformes de la protéine NOX. NOX 4, en particulier a été impliquée spécifiquement dans la différenciation myofibroblastique dans la fibrose pulmonaire. Des analyses transcriptomiques de fibroblastes humains traités par le TGF- β 1 ont ainsi confirmé que NOX4 était un des gènes les plus fortement surexprimés ¹⁴¹. Or l'activation de NOX4 entraîne la production d'H₂O₂, la différenciation myofibroblastique, la contractilité, et la production de matrice extra-cellulaire dans les fibroblastes pulmonaires humains. Réciproquement, l'administration de siRNA ciblant NOX4 a montré un rôle protecteur contre la fibrose dans deux modèles de fibrose pulmonaire ¹³⁸.

La dernière étape de ce processus est incertaine : il est possible que la diminution de l'activité fibrosante et inflammatoire autorise la repousse épithéliale, ou qu'à l'inverse ce soit la repousse épithéliale qui, en protégeant la sous-muqueuse, mette un terme à l'inflammation et à la fibrogénèse.

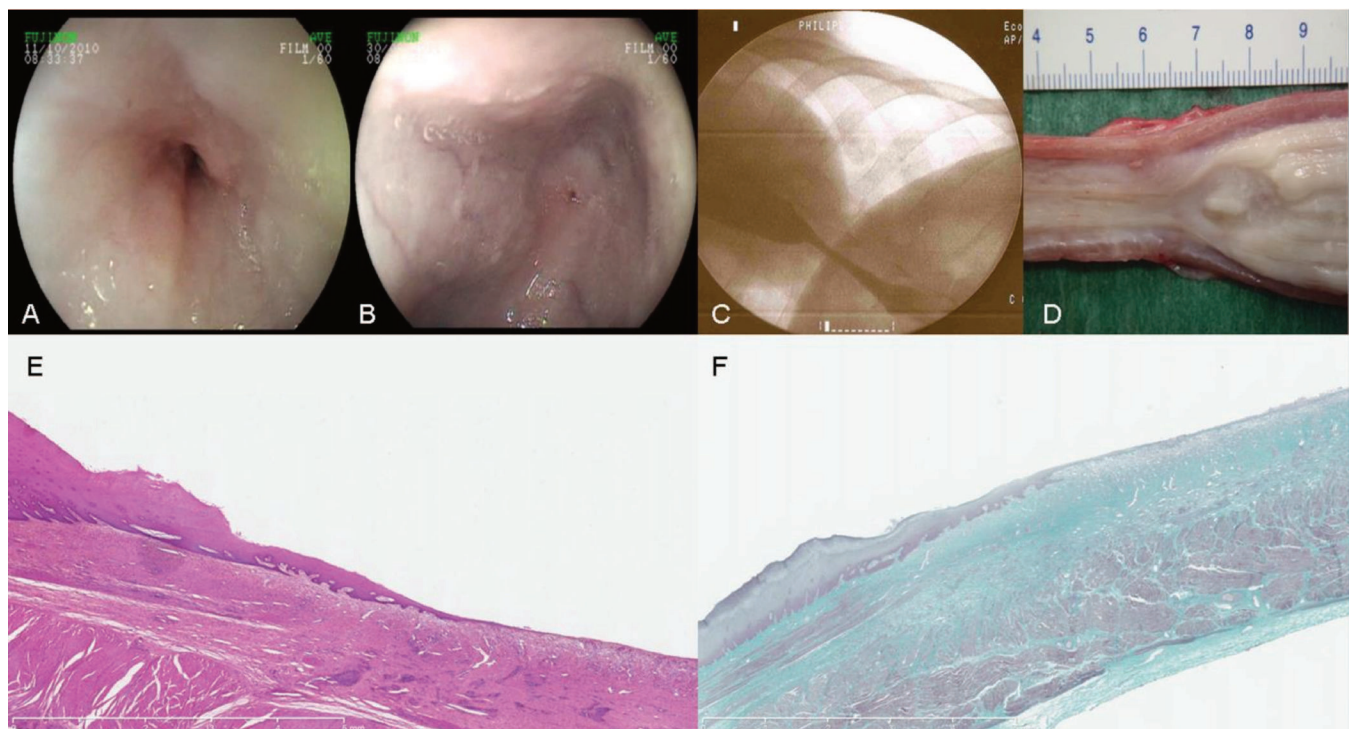
La figure 6 montre ce qui reste dans la paroi œsophagienne après une résection endoscopique et les deux principaux modes de cicatrisation.

Figure 6 : Que reste-t-il dans l'œsophage après une résection endoscopique ? ¹³¹



La figure 7 montre les principaux aspects endoscopiques, radiologiques, et histologiques de la sténose œsophagienne dans le modèle porcin de sténose post endoscopique.

Figure 7: Sténoses œsophagiennes dans notre modèle porcin de sténose post endoscopique. A et B : aspect endoscopique des sténoses à prédominance inflammatoire (A) et fibrotique (B) ; C : vue fluoroscopique ; D : macroscopie de la partie proximale de la sténose ; E et F : microscopie, magnification x 12,5, hématoxyline éosine safran, montrant une ré-épithélialisation mineure et un infiltrat inflammatoire majeur dans la sous-muqueuse résiduelle (E), et trichrome de Masson (F) montrant la fibrose (en vert) de la sous-muqueuse infiltrant la musculaire propre.



C. Stratégies de prévention de la sténose œsophagienne

Prévenir la sténose œsophagienne après une agression muqueuse nécessite d'atteindre un ou plusieurs des objectifs suivants :

- Supprimer le facteur d'agression tissulaire initial
- Restaurer la barrière épithéliale ou muqueuse
- Bloquer la cascade inflammatoire
- S'opposer à l'action de contraction et de synthèse collagénique des myofibroblastes.

Après une résection endoscopique, le seul moyen disponible d'atteindre le premier objectif est d'assurer une suppression acide optimale par la prescription d'une double dose d'inhibiteurs de la pompe à protons durant le processus de cicatrisation. Quand aux trois autres objectifs, ils peuvent être atteints à travers quatre approches, telles que nous les avons décrites en détail dans une revue récente de la littérature ¹³¹: une approche protectrice, une approche régénérative, une approche antiproliférative, et une approche mécanique.

1. Approche protectrice

Les agents les plus utilisés sont des matrices extracellulaires ou des matériaux inertes, servant de pansement biologique, visant à la fois à protéger la plaie œsophagienne et servir de matrice pour la migration des cellules épithéliales ¹⁴².

a- Données chez l'animal

Nieponice et al. ont utilisé la sous-muqueuse d'intestin de porc (small intestine submucosa ou SIS) : après une EMR circonférentielle chez cinq chiens, l'application de SIS à l'aide d'un ballon s'est avérée efficace dans la prévention de la sténose ¹⁴³. Cependant, ces résultats n'ont pas été reproduits par d'autres équipes, y compris en utilisant d'autres types de matrices extracellulaires, voire des prothèses œsophagiennes couvertes seules ^{144, 145}. Sur un modèle porcin de sténose œsophagienne post-ESD circonférentielle ¹⁴⁶, nous avons évalué l'efficacité des greffons de membrane amniotique, un pansement biologique largement utilisé en ophtalmologie, et possédant d'une activité anti-fibrosante et anti-inflammatoire, dans la prévention de la sténose œsophagienne ¹⁴⁷. Si les résultats en termes de taux de sténose symptomatique et de critères de jugement histologiques (fibrose, inflammation, réépithélialisation) étaient probants, ils étaient peu durables, en raison de la migration des prothèses œsophagiennes servant à appliquer les greffons et de la probable dégradation de ces derniers ; tous les animaux avaient ainsi développé une sténose à J35. Compte tenu de la difficulté d'application des feuillets de matrice extracellulaire ou des greffons de membrane amniotique, nous avons également évalué une poudre hémostatique minérale, l'Hémospay (Cook, Limerick, Irlande), qui a pour propriété principale l'adhésion aux tissus hémorragiques et de possibles effets pro-cicatrisants. Des résultats significatifs en termes de diamètre œsophagien à J14 et de fibrose œsophagienne étaient observés, cependant au prix d'applications répétées d'Hémospay qui ne paraissaient pas envisageables chez l'Homme. Dernièrement, la couverture de la plaie œsophagienne par une matrice formée d'un peptide auto-assemblé (RADA-16) a démontré un bénéfice significatif en termes de sténose œsophagienne symptomatique à J14, cependant sans que l'effet persiste

dans le temps (Barret et al., accepté pour publication par Diseases of the Esophagus).

b- Données chez l'Homme

Encouragés par des résultats préliminaires chez l'animal, Nieponice et al. ont appliqué des feuillets de matrice extracellulaire (extraits de la vessie de porc) à l'aide de prothèses œsophagiennes chez 5 patients après EMR circonférentielle ¹⁴⁸. Tous les patients ont développé une sténose requérant au moins une dilatation endoscopique. Deux équipes japonaises ont récemment démontré la faisabilité, puis l'efficacité de l'application sur des ulcères œsophagiens post-ESD de feuillets d'acide polyglycolique fixés à l'aide d'une colle biologique : ces feuillets, restant en place au moins 7 jours, permettaient, chez 8 patients à haut risque de sténose œsophagienne, d'obtenir un taux de sténose de 37.5%, inférieur au résultat attendu en l'absence de mesure préventive ^{149, 150}, avec des sténoses traitées aisément par une moyenne d'une dilatation au ballon. Ces résultats prometteurs doivent encore être confirmés sur de plus grandes séries de patients et dans au moins une série contrôlée, mais les feuillets d'acide polyglycolique pourraient être l'une des techniques préventives les plus convaincantes actuellement disponibles pour une application clinique.

Une méthode simple pour limiter l'exposition de la sous-muqueuse aux facteurs de stress endoluminaux pourrait être la résection progressive en plusieurs étapes de la circonférence œsophagienne. Après un premier cas rapporté encourageant, et deux études rétrospectives rapportant 2 à 13 % de sténoses ¹⁵¹⁻¹⁵³, les données prospectives ont plutôt fait état de 33 à 88% ^{94, 154, 155} de sténoses, contre 40-68% pour les résections circonférentielles en un temps ^{59, 156}, soit des résultats peu

satisfaisants. En outre, la résection muqueuse en plusieurs étapes rend les dernières étapes techniquement difficiles, en raison du rétrécissement de la lumière œsophagienne et des adhérences muqueuses consécutives à la cicatrisation de la première résection. Ainsi, la résection endoscopique en un temps, circonférentielle si nécessaire, semble préférable lorsqu'elle est indiquée.

2. Approche régénérative

L'utilisation de facteurs de croissance ou de thérapie cellulaire a été l'une des voies les plus efficaces dans la prévention de la sténose œsophagienne post endoscopique. Le concept en est de limiter la réaction inflammatoire et fibrosante dans le temps en accélérant la repousse épithéliale.

a- Données chez l'animal

Si l'administration systémique d'EGF ou l'apport intra-œsophagien de cellules souches mésenchymateuses a permis d'améliorer les paramètres de cicatrisation chez le porc et le chien ^{157, 158}, l'utilisation de ces techniques chez l'homme après résection d'une lésion néoplasique paraît hasardeuse. L'utilisation de cellules épithéliales malpighiennes autologues issues de la muqueuse buccale ou de l'épiderme, et expandues en culture avant d'être déposées sur une plaie œsophagienne a également été évaluée et donné d'excellents résultats, cependant dans des essais de petite taille sans groupe contrôle ^{159, 160}. Un pas supplémentaire a été franchi par Okhi et al., en réappliquant les cellules dans l'œsophage sous la forme d'un patch cellulaire couvrant la plaie, transplanté endoscopiquement. Cette technique a donné d'excellents résultats, montrant une intégration des cellules au

néoépithélium, une repousse épithéliale plus rapide, et surtout un taux de sténose divisé par deux dans le groupe traité (86-89% contre 48% to 63%, $p < 0.01$)¹⁶¹⁻¹⁶³. Cependant, l'absence de résection muqueuse à haut risque de sténose dans ces travaux limite la portée des résultats obtenus.

b- Données chez l'Homme

Logiquement, cette technique a donc été évaluée chez les patients: en 2012, Okhi et al. ont rapporté les résultats de la transplantation de feuillets de kératinocytes buccaux autologues cultivés à partir de biopsies endobuccales 16 jours plus tôt, chez 9 patients. Les auteurs ont ainsi démontré la faisabilité de la technique et son efficacité : en effet, parmi les quatre patients ayant eu une ESD à haut risque de sténose , i.e. emportant les trois quarts ou plus de la circonférence œsophagienne, un seul (la patiente ayant eu une résection circonférentielle) a développé une sténose œsophagienne, correspondant à un taux de sténose de 25%, bien inférieur aux 90 % attendus¹⁶⁴. Il faut cependant noter la faiblesse des effectifs, l'absence de groupe contrôle, et surtout l'absence de reproduction de ces résultats par d'autres équipes¹⁶⁵. En outre, cette technique est extrêmement couteuse (environ 20 000 Dollars/patient) et nécessite une expertise technique importante, notamment en raison du taux de contamination élevé de ces cultures primaires¹⁶⁶.

Ainsi, l'approche régénérative ne paraît pas amenée à se développer dans les années à venir en dehors de quelques centres experts.

3. Approche anti-proliférative

Afin de limiter l'inflammation et la prolifération myofibroblastique, les effets sur la cicatrisation œsophagienne de traitements antimitotiques, antifibrosants, et anti-inflammatoires ont été évalués. La majorité des études concerne les corticoïdes, administrés localement dans l'œsophage ou par voie systémique.

a- Données chez l'animal

Par analogie avec le traitement des sténoses œsophagiennes réfractaires, dans lequel la dilatation peut être associée à une injection de triamcinolone, l'injection dans la sous-muqueuse résiduelle de corticoïdes locaux après résection endoscopique a été proposée chez l'animal, avec des résultats extrêmement décevants, en termes de prévention des sténoses, comme en termes d'effets secondaires, certains auteurs ayant rapporté jusqu'à 33% de mortalité en rapport avec des abcès périœsophagiens ^{144, 167}, ou des retards de cicatrisation ¹⁶⁷.

D'autres traitements préventifs potentiels, antimitotiques, comme le 5FU ou la mitomycine C ¹⁶⁸⁻¹⁷⁰, ont été évalués dans de petites études non contrôlées, avec parfois des décès liés à une toxicité locale importante de la chimiothérapie ¹⁷¹.

Les produits antifibrosants, tels que l'Halofugidone ¹⁷¹ inhibant la synthèse du collagène I, ou la N- acetylcystéine, antifibrosant par un effet antioxydant, n'ont pas donné de résultats probants sur les critères de jugement cliniques ou endoscopiques ^{137, 171}.

b- Données chez l'Homme

Malgré l'absence de données convaincantes chez l'animal, les études évaluant les corticoïdes injectés localement chez l'Homme se sont multipliées, avec plus de

13 publications depuis 2009, majoritairement des séries de cas, avec des protocoles d'injection hétérogènes, et des taux de sténose variant de 10.7 à 41.7%^{117, 172-177}. Deux essais contrôlés sur soixante et quarante patients rapportaient une diminution du taux de sténose de 66 à 10% ($p < 0.0001$) après une seule injection de corticoïdes, avec 7 % de complications, et une baisse de 75 % à 19% ($p < 0.001$), au prix d'injections répétées à J3, J7, et J10^{117, 178}. Afin d'éviter les effets indésirables liés à l'injection intramurale de corticoïdes, certaines équipes ont proposé l'administration de corticoïdes sous forme visqueuse, sans parvenir, dans aucune des trois études sur le sujet, à démontrer un bénéfice clinique ou endoscopique¹⁷⁹⁻¹⁸¹. Enfin, l'administration de corticothérapie systémique a été évaluée rétrospectivement dans 9 études cliniques. Toutes concordent pour rapporter le bénéfice d'une corticothérapie à faible dose (débutée à 30 mg/ jour à J3 de l'endoscopie), prolongée 8 semaines avec décroissance progressive, permettant d'atteindre des taux de sténose de 5 à 29%^{172, 182-184}, jusqu'à 50 % pour le cas particulier des ESD circonférentielles¹²², et des sténoses moins sévères, et nécessitant un plus faible nombre de dilatations¹⁸⁵.

Une méta-analyse récente, incluant les données de 148 patients issus de 4 études, rapportait un taux de sténose passant de 59 à 14% sous corticothérapie (locale ou orale) préventive¹⁸⁶. Ainsi, la corticothérapie demeure en 2016 le principal traitement préventif de la sténose œsophagienne post-endoscopique. Cependant, l'hétérogénéité des études et des protocoles proposés, l'absence d'études prospectives randomisées ou contrôlées ne permet pas à ce jour de tirer des recommandations de pratique clinique. En outre, le cas particulier de l'ESD circonférentielle de l'œsophage demeure problématique, avec toujours 50 à 83% de sténoses, même avec une corticothérapie préventive^{187, 188}. Enfin, les effets

secondaires, exceptionnels mais sévères, à type d'abcès médiastinal après injection locale ¹⁸⁹, ou de morbidité infectieuse sévère sous corticothérapie systémique ¹⁹⁰ encouragent à développer de nouvelles approches préventives.

Parmi les autres traitements antifibrosants potentiels, le tranilast, un traitement antiallergique oral inhibant in vitro la synthèse collagénique et la production d'IL-6, a été testé dans une étude prospective impliquant 31 patients, et permettait, à 8 semaines, de diminuer le taux de sténose de 69 à 33% (p= 0.04), sans effets secondaires observés ¹⁹¹.

4. Approche mécanique

Une approche plus pragmatique de la sténose œsophagienne consiste à dilater la zone cicatricielle de façon itérative durant le processus de cicatrisation, avec l'idée que la pression, répétée ou continue sur les parois œsophagiennes prévienne la cicatrisation hypertrophique conduisant à la sténose. Les moyens utilisés peuvent être la dilatation à la bougie, hydrostatique au ballon, ou encore la mise en place d'une prothèse œsophagienne immédiatement à la suite de la résection endoscopique, dont la stabilité, en l'absence de sténose constituée, est souvent incertaine.

a- Données chez l'animal

Les seules données disponibles concernent les prothèses œsophagiennes préventives chez le porc. Dans deux essais, portant sur 5 et 6 animaux chacun, et utilisant des prothèses de silicone¹⁴⁶ ou métalliques couvertes¹⁴⁴, le taux de migration des prothèses à J7 était de 67 et 60 %, et tous les animaux développaient des

sténoses serrées après retrait ou migration de la prothèse. L'utilisation de prothèses biodégradables ne montrait, de même, qu'un effet suspensif sur la sténose œsophagienne dans un 3^{ème} essai, avec 100% de sténoses à 9 semaines de la mise en place des prothèses, après leur dégradation ¹⁹².

b- Données chez l'Homme

Les résultats des prothèses œsophagiennes chez l'Homme sont extrêmement hétérogènes. Les études évaluent principalement des prothèses métalliques entièrement couvertes, posées immédiatement ou peu après la résection, et extraites à 8 semaines. Holt et al. ont évalué 12 patients avec la mise en place de prothèses œsophagiennes métalliques couvertes après EMR circonférentielle: chez un tiers des patients, la prothèse devait être extraite pour douleurs ou dysphagie, et 57.5% des patients développaient des sténoses cicatricielles ¹⁹³. D'autres auteurs rapportaient des taux de sténose plus encourageants, de 28% dans le contexte de l'EMR circonférentielle pour Barrett dysplasique ¹⁹⁴ à 39 % après ESD, dont une majorité d'ESD circonférentielles, et ce malgré 52% de migrations précoces ¹⁹⁵. Enfin, une récente étude prospective contrôlée impliquant 20 patients a retrouvé, 1 mois après le retrait de stents posés 8 semaines au total, au taux de sténose de 18 vs 73 % ($p < 0.05$), toutes les sténoses étant survenues chez des patients ayant eu une migration de la prothèse ¹⁹⁶. Ces excellents résultats nécessitent cependant d'être confirmés dans de plus grandes études avant de proposer la mise en place de prothèses coûteuses dans cette indication.

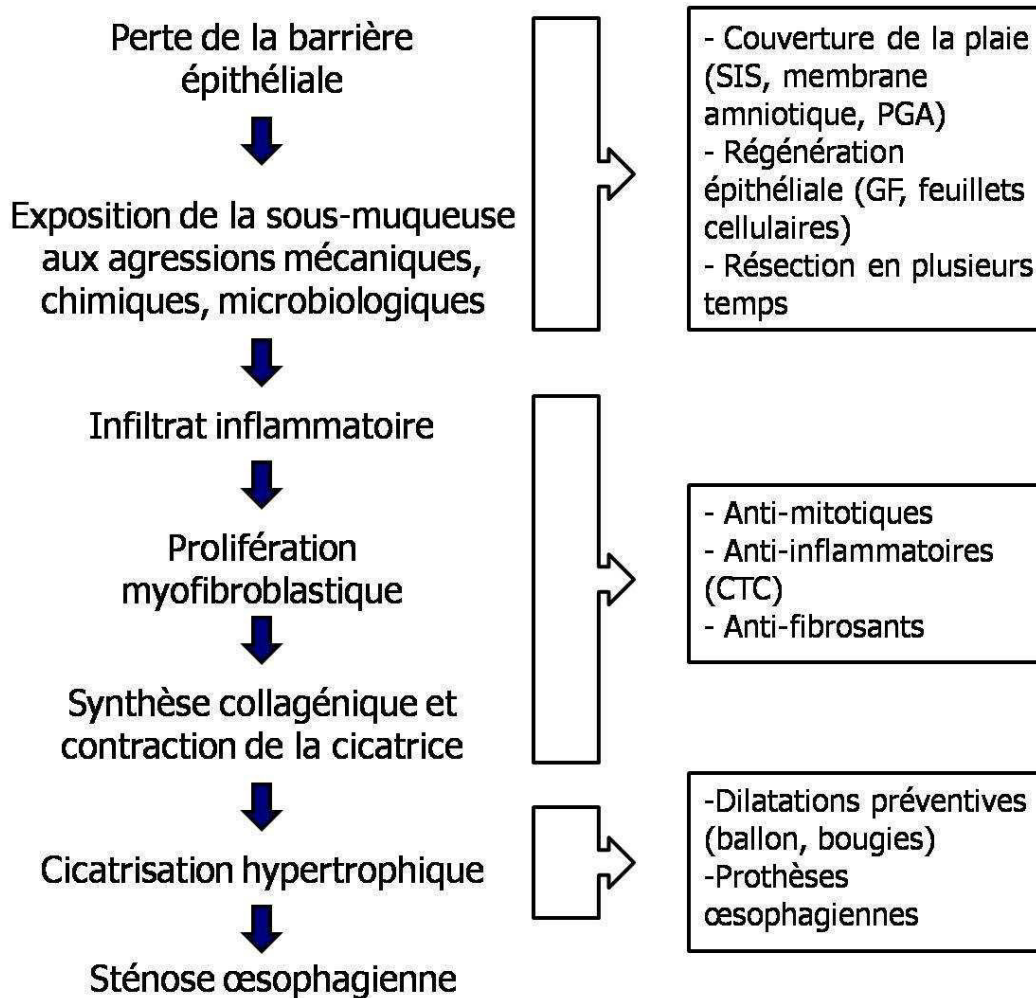
La dilatation préventive au ballon était la technique la plus fréquemment utilisée en prévention des sténoses œsophagiennes post-endoscopiques, notamment au Japon, jusqu'à la publication des données sur l'efficacité de la corticothérapie. Dans

la mesure où la dilatation n'a aucune raison d'améliorer la cicatrisation muqueuse ou sous-muqueuse (au contraire, elle majore transitoirement les lésions), il pourrait s'agir d'un traitement curatif précoce plutôt que d'un traitement préventif. Si une unique séance préventive à 7 jours de la résection a été proposée par certains ¹⁹⁷ la plupart des auteurs recommandent des séances itératives débutant 3 à 7 jours après la résection, et en renouvelant les séances deux à trois fois par semaine jusqu'à atteindre une cicatrisation muqueuse sans sténose, généralement vers 8 semaines ^{121, 122, 177, 188, 198, 199}. Les rares études contrôlées, rétrospectives, rapportent des taux de sténose diminués environ de moitié, par exemple de 92 à 59% ($p = 0.04$) ¹⁹⁸. Cependant, les dilatations répétées des zones cicatricielles, au ballon ou à la bougie, comportent un risque de perforation important, d'environ 1.1%. Ce risque est à comparer au risque de 0.3% observé dans d'autres contextes cliniques ¹²⁴. Compte tenu du fait que cette stratégie nécessite en général 10 séances de dilatation ou plus, la dilatation préventive est actuellement en passe d'être abandonnée au profit de la corticothérapie.

5. Conclusion : la prévention de la sténose œsophagienne post-endoscopique en 2016

Malgré l'abondance des études disponibles, il n'existe pas actuellement de technique entièrement satisfaisante en termes d'efficacité, de tolérance, et de coût, pour la prévention de la sténose œsophagienne post-endoscopique. La figure 8 rappelle les principales étapes de la constitution d'une sténose œsophagienne cicatricielle, et les voies de prévention actuellement proposées.

Figure 8 : Cibles potentielles pour la prévention de la sténose œsophagienne



Les meilleurs résultats ont été obtenus avec la transplantation de feuillets cellulaires épithéliaux, mais à des coûts prohibitifs. Les bons résultats de la corticothérapie, notamment orale, le sont au prix d'une morbidité infectieuse redoutable chez des patients en moyenne âgés, qui ont souvent été récusés de l'oesophagectomie en raison de leur fragilité. Enfin, les résultats encourageants observés avec certaines approches anti-fibrosantes (tranilast), protectives (PGA), ou

mécaniques (prothèses préventives) restent à confirmer dans des études de plus large effectif.

III. Plan du travail de recherche

A. Travaux translationnels

L'arsenal thérapeutique disponible pour prévenir la survenue d'une sténose œsophagienne après résection endoscopique étendue, circonférentielle ou quasi-circonférentielle (i.e. dépassant les trois quarts de la circonférence œsophagienne) est actuellement insuffisant, et la littérature ne permet pas d'établir de quelconques recommandations. Les seuls outils actuellement disponibles et pour lesquels on dispose de données cliniques sont les corticoïdes (oraux ou administrés localement sur le site de résection), le tranilast, la dilatation endoscopique préventive de la cicatrice, et les prothèses œsophagiennes, et leurs limites ont été exposées au chapitre précédent. La poursuite de la recherche dans ce domaine paraît donc nécessaire.

La majorité des traitements préventifs potentiels ont été évalués chez l'animal ou chez l'Homme à partir d'arguments de vraisemblance ou de bon sens plus que sur une véritable base rationnelle et scientifique, en raison de la pauvreté des données mécanistiques disponibles sur la cicatrisation œsophagienne, normale ou pathologique. Cependant, la problématique clinique existe au quotidien, et l'évaluation de produits ou molécules candidates est tentante, car plus rapidement transférable chez l'Homme.

Ainsi, notre approche a consisté à aborder la prévention de la sténose œsophagienne selon les trois axes suivants: l'évaluation de traitements préventifs sur le modèle préclinique porcin, l'étude mécanistique de la formation de la sténose œsophagienne chez l'Homme, et l'évaluation de traitements préventifs sur un modèle murin.

1. Conduite d'essais précliniques sur modèle porcin de sténose œsophagienne

En 2006, en travaillant sur une nouvelle technique de dissection sous-muqueuse circonférentielle simplifiée sur le porc, notre équipe a mis au point un modèle de sténose œsophagienne cicatricielle sévère ¹⁷⁰. Dans ce modèle, une ESD circonférentielle est réalisée sur 5 cm au tiers inférieur de l'œsophage de porc, 5 cm au-dessus du cardia. L'objectif est de s'approcher le plus possible des conditions de reflux gastro-œsophagien observables chez l'Homme après une ESD circonférentielle, par exemple réalisée pour le traitement d'un œsophage de Barrett néoplasique, sans pour autant avoir à disséquer le cardia du porc, particulièrement fibreux et épais. Dans ce modèle, les animaux développent de façon constante une sténose modérée et inflammatoire à J7, et une sténose punctiforme et fibreuse à J14 ¹⁴⁶. La dilatation de ces sténoses entraîne un taux important de perforations, et n'est donc pas envisageable ¹³⁷. Quoique le porc soit un modèle de cicatrisation œsophagienne critiquable en raison du haut taux de sténoses observé, y compris après des procédures comme la radiofréquence œsophagienne, habituellement peu sténosantes chez l'Homme ²⁰⁰, on peut argumenter qu'un traitement préventif de la sténose chez le porc serait, *a fortiori*, efficace chez l'Homme. En outre, les dimensions des jeunes porcs charcutiers de 30-35 Kg utilisés à l'école de chirurgie

des Hôpitaux de Paris, ayant un œsophage de 30 cm et environ 18 mm de diamètre, rendent possible l'utilisation du matériel d'endoscopie conventionnel.

Les premières approches de prévention de la sténose ont été tournées vers l'approche antiproliférative, avec l'administration locale de mitomycine C dans un essai non contrôlé, au résultat négatif ¹⁷⁰. Dans un second temps, nous avons conduit un essai contrôlé évaluant la N-acétylcystéine, qui induit la synthèse de glutathion réduit (GSH), un tripeptide ayant une activité anti-oxydante, anti-inflammatoire, et anti-fibrosante notamment par l'inhibition du TGF- β ; en outre, la N-acétylcystéine est administrable par voie orale, avec un bon profil de tolérance, des indications potentielles chez l'Homme en prévention de la fibrose, notamment pulmonaire ²⁰¹, et un intérêt démontré chez l'animal dans la prévention de la sténose œsophagienne anastomotique ²⁰². Malgré l'utilisation de doses majeures de N-acétylcystéine, comparables à celles utilisées dans l'intoxication au paracétamol (100 mg/Kg/jour), et l'observation d'un effet anti-oxydant en histologie dans l'œsophage des animaux traités (diminution de l'expression de la 8-hydroxy-2' deoxyguanosine, un marqueur de stress oxydant, dans le groupe traité), aucune amélioration significative des critères de jugement clinico-endoscopiques (taux de sténose symptomatique) ou histologiques (épaisseur ou nature de l'infiltrat inflammatoire, épaisseur de la fibrose œsophagienne) n'était observée.

Par la suite, nous avons donc choisi de poursuivre les travaux en combinant un approche protectrice seule en utilisant un peptide auto-assemblé et une poudre hémostatique, une approche mixte protectrice et régénérative, en utilisant la membrane amniotique, et une approche mécanique, en utilisant les prothèses œsophagiennes (cf infra).

2. Etude mécanistique chez l'Homme

L'inflammation et les processus cicatriciels n'ont été que très peu étudiés dans l'œsophage humain. L'essentiel des données disponibles sont issues de modèles de rongeurs après brûlures caustiques et soulignent le rôle du stress oxydatif ²⁰³.

Les données chez l'homme proviennent de deux cadres :

- L'œsophagite à éosinophiles ²⁰⁴, une pathologie de mécanisme allergique, dans laquelle des sténoses fibreuses peuvent survenir ; cependant, il s'agit vraisemblablement d'un mauvais modèle, puisque la sténose ne fait pas suite à une lésion muqueuse mais à un épaissement progressif de la sous-muqueuse.

- Quelques données existent sur le reflux gastro-œsophagien, au cours duquel des érosions de la muqueuse peuvent survenir, et éventuellement des sténoses cicatricielles. L'inflammation œsophagienne y serait activée par des cytokines pro-inflammatoires (IL-1 β , IL-6, et IL-8, mais aussi IL-5 et IL-13) et le PAF, et régulée par l'IL-4, l'IL-10, et NF κ B. La fibrose y serait principalement induite par le TGF- β , le TNF- α induisant une transition épithélio-mésenchymateuse plutôt que la transformation des fibroblastes résidents ²⁰⁵. En outre, le rôle du stress oxydatif semble important ²⁰⁶. Le rôle respectif des cellules immunitaires activées (LT, PNN, PNE, macrophages) et des cellules non immunitaires de la muqueuse (épithéliales, endothéliales et mésenchymateuses) dans l'inflammation est encore incertain.

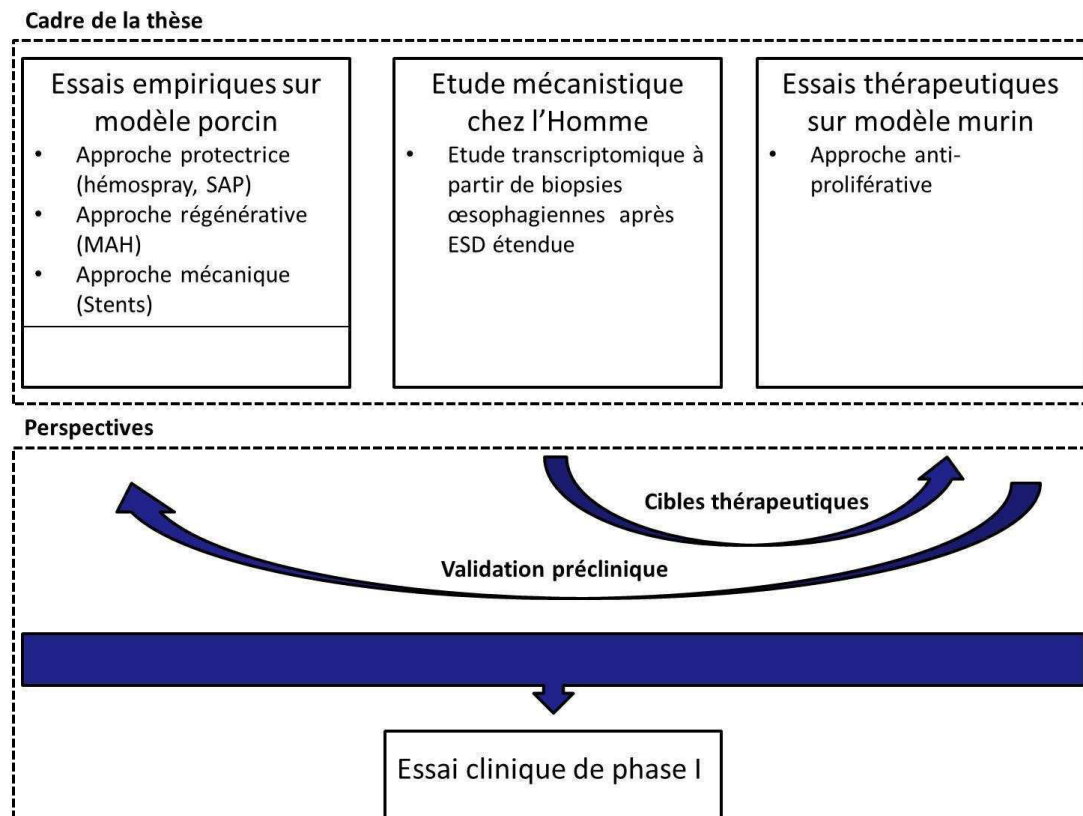
Aussi, nous avons, avec l'accord du CPP Ile de France III (S.C.3191), constitué une base de données cliniques ainsi qu'une banque de tissu œsophagien, chez des

patients ayant eu une résection muqueuse œsophagienne à haut risque et à faible risque de sténose. Les prélèvements ont été inclus en paraffine pour analyse histologique, et également conservés dans le trizol, afin d'en extraire l'ARN pour réaliser une étude transcriptomique permettant d'identifier une signature transcriptionnelle caractéristique des patients développant une sténose œsophagienne, susceptible de les distinguer de ceux qui n'en développent pas.

3. Essais thérapeutiques sur modèle de petit animal

Disposer d'un modèle de petit animal de sténose œsophagienne post endoscopique permettrait de dépasser certaines limites du modèle porcin, que sont le coût élevé, les doses importantes de traitements médicamenteux nécessaires, et l'absence d'utilisation aisée ou fiable de nombreux protocoles d'étude de la fibrose mis au point essentiellement chez le petit animal. Le troisième volet de ce travail consiste donc à développer un modèle de sténose œsophagienne post endoscopique sur le petit animal, qui permettrait, sur la base de l'expérience antérieure du laboratoire (UI 1016, Pr Batteux) dans l'étude des mécanismes de la fibrogénèse et du stress oxydatif sur la souris (essentiellement sur des modèles de souris sclérodermiques), et également de voies d'inflammation et de fibrogénèse déterminées par l'étude transcriptomique, d'évaluer l'intérêt de différents modulateurs pharmacologiques du stress oxydant ou de l'inflammation.

Figure 9 : Démarche du travail de recherche



SAP : Peptide auto-assemblé

ESD : Dissection sous-muqueuse endoscopique

MAH : Membrane amniotique humaine

B. Travaux cliniques

En parallèle, nous avons conduit des travaux cliniques sur la résection endoscopique des cancers superficiels de l'œsophage, tout particulièrement dans le cadre de l'adénocarcinome œsophagien.

Le premier travail, conduit au cours d'une année de mobilité dans le centre expert de l'Academic Medical Center d'Amsterdam, évaluait un essai d'optimisation du traitement de référence actuel de l'AdénoCa superficiel œsophagien, associant

résection endoscopique par mucosectomie et ablation de l'œsophage de Barrett résiduel par radiofréquence. Ces traitements sont usuellement réalisés en deux temps, et nous avons cherché à en évaluer la faisabilité au cours d'une seule et même séance de traitement endoscopique.

Le second travail évaluait l'intérêt de la dissection-sous-muqueuse endoscopique dans la résection de l'adénocarcinome superficiel de l'œsophage. En effet, ce traitement endoscopique, quoique développé depuis le milieu des années 2000 au Japon, a été essentiellement utilisé dans l'œsophage pour le traitement des carcinomes épidermoïdes. La possibilité de résection en bloc de lésions étendues a permis d'améliorer significativement les résultats oncologiques, notamment en ce qui concerne la récurrence locale ⁹⁵. Compte tenu de la relative rareté de l'œsophage de Barrett et des adénocarcinomes œsophagiens en Asie, les séries évaluant l'ESD dans le traitement de l'AdénoCa sont peu nombreuses. Nous avons donc entrepris d'analyser l'expérience locale de l'Hôpital Cochin dans ce domaine, à partir d'une base de données collectées prospectivement.

Présentation des travaux

I. Travaux translationnels

A. Conduite d'essais précliniques sur modèle porcin de sténose œsophagienne

1. Intérêt de la membrane amniotique humaine en prévention de la sténose œsophagienne après dissection sous-muqueuse œsophagienne circonférentielle

Amniotic membrane grafts for the prevention of esophageal stricture after circumferential endoscopic submucosal dissection.

Barret M, Pratico CA, Camus M, Beuvon F, Jarraya M, Nicco C, Mangialavori L, Chaussade S, Batteux F, Prat F. PLoS One. 2014 Jul 3;9(7):e100236.

Les greffons de membrane amniotique humaine (MAH), qui agissent comme des pansements biologiques avec une activité anti-fibrosante et anti-inflammatoire, sont déjà largement utilisée chez l'Homme, en particulier dans le traitement des ulcérations cornéennes ²⁰⁷. Dans ce travail, nous avons évalué l'efficacité de la MAH dans la prévention des sténoses œsophagiennes après dissection sous-muqueuse endoscopique circonférentielle sur un modèle porcin. Il s'agissait d'une étude prospective, randomisée et contrôlée impliquant 20 animaux ayant tous eu une ESD circonférentielle du bas œsophage sur 5 cm. Dans le groupe traité par MAH (n=10), les animaux recevaient des greffons de MAH appliqués à l'aide d'une prothèse

plastique laissée en place dans l'œsophage. Un sous-groupe de 5 animaux était sacrifié à J14 (AM1), et 5 autres animaux (groupe AM2) étaient laissés en vie. Un second groupe de 5 animaux (groupe ES) recevait exclusivement une prothèse œsophagienne plastique, et un troisième groupe de contrôles (n = 5) était simplement surveillé après l'ESD. Le taux de sténose œsophagienne symptomatique à J14 était de 33%, 40%, et 100 % pour les groupes AM, ES, et les contrôles, respectivement. La différence était statistiquement significative entre les contrôles et le groupe AM ($p = 0.03$). Les diamètres œsophagiens étaient respectivement de 5.8, 6.8, et 2.6 mm à J14 respectivement pour les groupes AM, ES, et contrôles, sans que cette différence soit statistiquement significative. Tous les animaux du groupe contrôle développaient une sténose œsophagienne symptomatique à J14, tandis que les animaux des groupes AM et ES survivaient sans sténose jusqu'à J35 au plus. L'épaisseur de fibrose œsophagienne était de 0.87 mm (0.78-1.72) pour le groupe AM1 contre 1.65 mm (0.7-1.79) pour le groupe contrôle ($p = \text{NS}$), et les autres critères de jugement, histologiques (épaisseur du tissu de granulation, type d'infiltrat inflammatoire, longueur du néoépithélium, expression de l' α -SMA) ou biologiques (activité des marqueurs du stress oxydatif dans la paroi œsophagiennes), ne révélaient aucune différence statistiquement significative entre les groupes. En conclusion, l'application de greffons de membrane amniotique humaine permettait de retarder l'apparition d'une sténose œsophagienne, sans que son effet soit cependant significativement différent de l'application d'une prothèse œsophagienne seule. Ces résultats posent la question de la stabilité de la membrane amniotique dans l'œsophage.



Amniotic Membrane Grafts for the Prevention of Esophageal Stricture after Circumferential Endoscopic Submucosal Dissection

Maximilien Barret^{1,2}, Carlos Alberto Pratico^{1,2}, Marine Camus^{1,2}, Frédéric Beuvon^{2,3}, Mohamed Jarraya⁴, Carole Nicco^{2,5}, Luigi Mangialavori¹, Stanislas Chaussade^{1,2}, Frédéric Batteux^{2,5}, Frédéric Prat^{1,2*}

1 Department of Gastroenterology, Cochin Hospital, Paris, France, **2** Faculté Paris Descartes, Paris, France, **3** Department of Pathology, Cochin Hospital, Paris, France, **4** Human Tissue Bank, Saint-Louis Hospital, Paris, France, **5** Department of Immunology and EA 1833, Cochin Hospital, Paris, France

Abstract

Background and Aims: The prevention of esophageal strictures following circumferential mucosal resection remains a major clinical challenge. Human amniotic membrane (AM) is an easily available material, which is widely used in ophthalmology due to its wound healing, anti-inflammatory and anti-fibrotic properties. We studied the effect of AM grafts in the prevention of esophageal stricture after endoscopic submucosal dissection (ESD) in a swine model.

Animals and Methods: In this prospective, randomized controlled trial, 20 swine underwent a 5 cm-long circumferential ESD of the lower esophagus. In the AM Group (n = 10), amniotic membrane grafts were placed on esophageal stents; a subgroup of 5 swine (AM 1 group) was sacrificed on day 14, whereas the other 5 animals (AM 2 group) were kept alive. The esophageal stent (ES) group (n = 5) had ES placement alone after ESD. Another 5 animals served as a control group with only ESD.

Results: The prevalence of symptomatic strictures at day 14 was significantly reduced in the AM group and ES groups vs. the control group (33%, 40% and 100%, respectively, $p = 0.03$); mean esophageal diameter was 5.8 ± 3.6 mm, 6.8 ± 3.3 mm, and 2.6 ± 1.7 mm for AM, ES, and control groups, respectively. Median (range) esophageal fibrosis thickness was 0.87 mm (0.78–1.72), 1.19 mm (0.28–1.95), and 1.65 mm (0.7–1.79) for AM 1, ES, and control groups, respectively. All animals had developed esophageal strictures by day 35.

Conclusions: The anti-fibrotic effect of AM on esophageal wound healing after ESD delayed the development of esophageal stricture in our model. However, this benefit was of limited duration in the conditions of our study.

Citation: Barret M, Pratico CA, Camus M, Beuvon F, Jarraya M, et al. (2014) Amniotic Membrane Grafts for the Prevention of Esophageal Stricture after Circumferential Endoscopic Submucosal Dissection. PLoS ONE 9(7): e100236. doi:10.1371/journal.pone.0100236

Editor: Ken-ichi Mukaisho, Shiga University of Medical science, Japan

Received: December 7, 2013; **Accepted:** May 24, 2014; **Published:** July 3, 2014

Copyright: © 2014 Barret et al. This is an open-access article distributed under the terms of the Creative Commons Attribution License, which permits unrestricted use, distribution, and reproduction in any medium, provided the original author and source are credited.

Funding: The study received funding from the Fondation de l'Avenir, Paris, France (grant number ET9-553), www.fondationdelavenir.org. The funders had no role in study design, data collection and analysis, decision to publish, or preparation of the manuscript.

Competing Interests: The authors have declared that no competing interests exist.

* Email: frederic.prat@cch.aphp.fr

Introduction

Endoscopic therapy has become a valid therapeutic option in the management of Barrett's esophagus (BE) complicated with high grade dysplasia or early adenocarcinoma [1]. The treatment can be limited to the resection or ablation of neoplasia, but can also be aimed at eradicating the entire metaplastic mucosa [1]. Hence, techniques allowing circumferential treatment of the esophageal mucosa are required. To achieve this goal, either mucosal resection (using EMR or submucosal dissection) or radiofrequency ablation, or a combination of methods may be used [2]. Radiofrequency ablation has a number of limitations: it is restricted to flat lesions, does not allow for histological analysis of ablated tissues, lacks long-term (>5 years) efficacy data [3], and subsequent follow-up appears to be difficult, with cases of buried metaplasia, high grade dysplasia and adenocarcinoma reported after complete BE eradication [4]. Endoscopic mucosal resection is

feasible, even in circumferential BE [5], but requires piece-meal resection, with suboptimal histological analysis and a risk of residual dysplastic mucosa; furthermore, circumferential mucosal resection leads to severe esophageal strictures in around 37% to 92% of cases [5,6,7], as previously reported in mucosal defects involving more than three-quarters of the esophageal circumference [8]. Circumferential endoscopic submucosal dissection (CESD) could be the optimal therapeutic option in the setting of complicated circumferential BE, but is time-consuming, and results in severe esophageal strictures in up to 75% of cases in humans [9,10]. To address the first problem, we developed a CESD technique on a swine model allowing for safe *en bloc* resection of 5 cm-long cylinders of esophageal mucosa and submucosa in less than an hour [11]. However, this procedure led to a 100% stricture rate by day 14. Thus, the question of post-endoscopic esophageal stricture prevention remains to be addressed.

Human amniotic membrane (AM) consists of an avascular stroma and a monostratified cylinder cell epithelium expressing very few histocompatibility antigens [12]. Therefore, it is not likely to induce immune rejection. AM promotes epithelial growth through the secretion of epithelial growth factors (EGF, KGF and HGF) [13] and by playing the role of a scaffold supporting epithelial cell proliferation and migration. Secondly, AM has anti-angiogenic properties, possibly associated with the presence of thrombospondin 1 and of potent neoangiogenesis inhibitors (tissue inhibitors of metalloproteinases or TIMPs) [14], both in the epithelium and the stroma of AM [15,16]. Thirdly, AM has anti-inflammatory and anti-fibrotic potential, related to the presence in the AM of all four types of TIMPs, interleukin 1 receptor antagonist, and interleukin 10 [15]. AM inhibits TGF β synthesis and myofibroblastic differentiation, which strongly supports the hypothesis of AM possessing anti-fibrotic properties [15,17,18]. Furthermore, as reported in the setting of preeclampsia, the presence of lactoferrin in AM can also result in its anti-oxidant properties [19]. AM has been tested in various medical fields to promote wound healing, especially in burns or skin ulcers [20], and is currently used in ophthalmology for ocular surface reconstruction, especially in the treatment of corneal ulcers [21]. It may be used as a graft, with the stroma applied on the wound, or as a patch, with the epithelial layer placed towards the wounded tissue, in order to temporarily cover the wound and deliver the growth factors contained within the epithelium directly to the lesion [16].

Based on this rationale, we conducted a randomized controlled trial on a swine model in order to assess the role of AM grafts in the prevention of esophageal stricture development after CESD.

Animals and Methods

Animal experiments

The experimental protocol received approval from the Institutional Review Board of the Paris School of Surgery (Ecole de Chirurgie de l'Assistance Publique - Hôpitaux de Paris, Paris, France), and experiments were performed according to the Standard Guidelines of the French Ministry of Agriculture, which regulates animal research in France. All efforts were made to minimize suffering.

Twenty 30–35 kg swine originating from the same farm were used in the study. The animals were randomly allocated to groups as follows: treatment by AM applied using an esophageal stent (n = 10), esophageal stent (ES) placement alone (n = 5) or control group (n = 5). The animals were accommodated at our facility 48 hours before the procedure took place. Endoscopies were performed under general anesthesia. All animals were prepared for anesthesia with a 12-hour diet and were administered an intramuscular injection of 10 mg/kg ketamine and 2 mg/kg azaperone, 30 minutes before induction. Following induction with 8 mg/kg intravenous 1% propofol and endotracheal intubation, anesthesia was maintained through the inhalation of 1% to 2% isoflurane. Animals received an intravenous infusion of 10 mg/kg/h crystalloid solution.

Study design and group allocation

Since esophageal strictures are known to occur around the 14th postoperative day in our model [22], a subgroup of 5 animals in the AM group was randomly selected at inclusion (AM1 group, n = 5), to be sacrificed at day 14, in order to obtain histological data to be compared to the control group at the same time interval from ESD. The rest of the AM group (AM2 group, n = 5) was followed-up.

ESD procedure

Upper gastrointestinal endoscopies were performed using a standard gastroscope (Fujinon EG450D, Fujinon, Sataima, Japan), through an overtube. A senior endoscopist carried out or directly supervised the procedure at all times. Circumferential submucosal dissection of the distal third of the esophagus was performed as previously described [11,22]. Briefly, two circumferential incisions reaching the superficial submucosal layer were made after submucosal injection of indigo carmine-stained saline; these two incisions defined a mucosal cylinder of 5 cm in the lower third of the esophagus, 5 cm above the gastroesophageal junction. The cylinder was removed by blunt submucosal dissection, using a distal transparent attachment as used for EMR and ESD (ST HOOD DH-19 GR, Fujinon, Sataima, Japan), which allowed cleavage of the mucosa and superficial submucosa from the underlying submucosa by gently scraping the esophageal wall in a back and forth motion, from the proximal to the distal incision. The resected mucosal cylinder was then retrieved using the endoscope's suction channel.

Amniotic membrane application

AM grafts that were cryopreserved at -80°C were obtained from the Human Tissue Bank in the St Louis Hospital, Paris, France, after standardized processing [21], and were brought to the Paris Surgery School in dry ice. After 30 minutes of defrosting at room temperature, AM grafts of approximately 16 cm² were stained in a sterile saline and indigo carmine bath to allow for easier identification after application.

We conducted preliminary experiments to determine the best modality for AM application. The over the scope application of AM, using clips to attach the AM to the esophageal wall, or the through the scope AM application, using a dilation balloon (as described with porcine small intestinal submucosa by Nieponice et al. [23]), were not satisfactory, because of the fragility of AM. AM application using a self-expanding plastic esophageal stent was found to be the optimal technique. Stent removal was planned on day 7, in order to distinguish the role of AM and from the stent.

After ESD, one to two (depending on the size of the graft) AM grafts were wrapped around extractable esophageal stents with a diameter of 16–20 mm and a length of 9 cm (Polyflex, Boston Scientific, Natick, MA). The epithelial side was placed towards the esophageal wall, and attention was paid to the fact that the entire wound area had to be covered. A non-resorbable surgical suture was tied at the proximal end of the stent (Mersutures 1, Ethicon, Sommerville, NJ) to facilitate fixation to the esophageal wall and repositioning if necessary. The stent was then loaded and placed under fluoroscopic guidance. AM graft placement is shown in figure 1. Endoscopic control of stent placement was performed, and was attached to the esophageal wall by a clip (Resolution, Boston Scientific, Natick, MA) through the suture to prevent stent migration.

Postoperative care and follow-up

A seven-day course of omeprazole 40 mg/day and broad spectrum antibiotics was administered: 10 mg/kg extended release benzathine benzylpenicillin G and penicillin procain (Duphapan, Pfizer, NY, NY) for the first four days followed by 1 g/day amoxicillin (Clamoxyl, GSK, Brentford, UK) for three days. The animals were given a liquid diet following each procedure, and were gradually introduced to a solid food diet. Follow-up included daily visits, weekly veterinary examinations, and esophagogastros-copy. Clinical data including behavior, quantitative and qualitative assessment of food intake and the occurrence of regurgitation or vomiting were collected on a weekly basis. The width of the

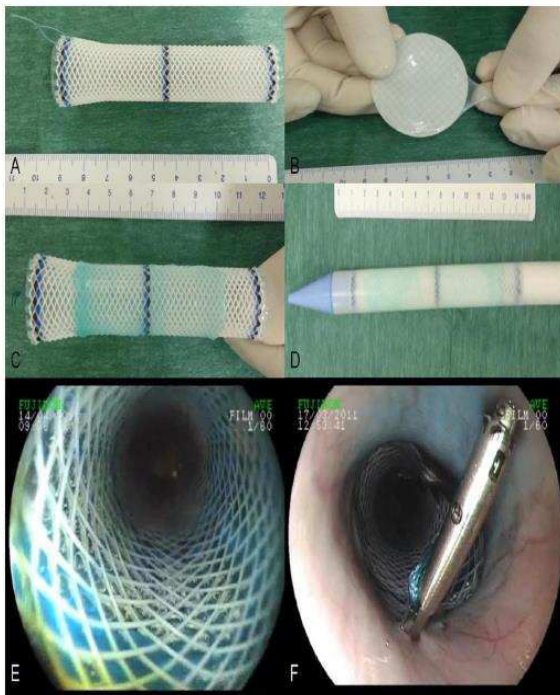


Figure 1. Application of amniotic membrane grafts on esophageal wounds. A: esophageal stent with attached non-absorbable suture; B: blue-stained amniotic graft on a nitrocellulose sheet after defrosting; C: amniotic membrane apposition on the external side of a Polyflex stent; D: esophageal stent coated with amniotic membrane graft loaded in the stent catheter; E: endoscopic view of the coated esophageal stent in the esophagus; F: esophageal stent clipped to the esophageal wall using the suture. doi:10.1371/journal.pone.0100236.g001

esophageal lumen in the operated area was measured using the open jaws of biopsy forceps. Esophageal stricture was diagnosed when the esophageal lumen was narrower than the threshold of 9 mm, i.e. when the 9 mm endoscope could not pass through the esophageal lumen and reach the stomach. Symptomatic esophageal stricture was defined by the association of a strictured esophagus diagnosed by endoscopic examination (with an esophageal lumen narrower than 9 mm), and the presence of associated symptoms, such as anorexia, vomiting or regurgitation.

When a symptomatic esophageal stricture (confirmed by endoscopy) occurred, animals were euthanized with a 100 mg/kg intravenous injection of pentobarbital (Dolethal, Vétquinol, Paris, France), and underwent necropsy with *en bloc* esophagectomy. Gross morphology analysis was performed, esophageal samples from strictured and healthy zones were taken and frozen at -80°C , and the remaining esophagus was fixed in 10% buffered formalin. The same procedure was applied to the animals in the AM 1 group, which were sacrificed on day 14 after ESD.

Histological analysis

After gross morphological examination of the size, weight, and thickness of the esophageal wall, esophageal samples from healthy and wounded areas were taken and frozen at -80°C . Specimens were fixed in 10% buffered formalin, embedded in paraffin, and processed into 5 μm -thick sections. Slides were then stained with

hematoxylin eosin and saffron (HES), and Masson's trichrome, as part of the histological examination. Slides of interest were digitized by an NDPI Nanozoomer (Hamamatsu photonics, Hamamatsu City, Japan), and submitted to semi-quantitative analysis of fibrosis, granulation tissue, and inflammatory cell infiltrate by a senior pathologist expert in digestive pathology (FB). The following measurements were made on each digitized image of trichrome-stained slides: a) maximal thickness of fibrosis extending between the muscularis propria and the epithelium; b) maximal thickness of granulation tissue extending between the esophageal lumen and the submucosal fibrosis; and c) length of re-epithelialization, by measuring the neoe epithelium characterized by round immature epithelial cells without native epithelial crest and chorionic papillae or parakeratosis. The inflammatory cell infiltrate was characterized as acute (predominance of polynuclear cells, high cell density) or chronic (predominance of lymphocytes or plasmocytes, low cell density). Immunohistochemistry on paraffin sections was performed with a rabbit polyclonal antibody to alpha smooth muscle actin (ab5694, Abcam, Cambridge, UK) and a goat polyclonal Secondary Antibody to Rabbit IgG - H&L (HRP) (ab97051, Abcam, Cambridge, UK), in order to assess the intensity of myofibroblastic reaction in the esophageal wall.

Oxidative stress measurements

Frozen esophageal samples were defrosted, chopped and ground in *ripa*, and then centrifuged at 5000 rpm for 10 min at room temperature. The supernatant was carefully removed, diluted and aliquoted, and the following oxidative stress measurements were performed: superoxide dismutase (SOD) cellular activity was assessed by tetrazolium nitroblue reduction technique, as described by Beauchamp and Fridovich [24], and read at 550 nm; catalase cellular activity was determined by ultraviolet spectroscopy at 450 nm, as described by Aebi [25]. Advanced oxidation proteic products were measured by spectrophotometry, according to Witko-Sarsat [26], using chloramine T, and 365 nm absorbance on a Fusion reader (Fusion, Perkin Elmer, Wellesley, MA, USA). Carbonyl derivatives associated with oxidative stress and circulating thioredoxin were measured using dinitrophenylhy-

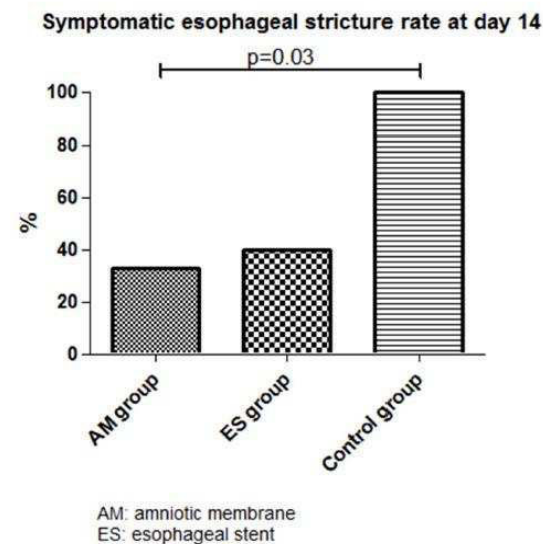


Figure 2. Symptomatic esophageal strictures rates at day 14. doi:10.1371/journal.pone.0100236.g002

Table 1. Clinical and endoscopic evaluation on the 14th postoperative day.

	AM group (n = 10)	ES alone group (n = 5)	Control group (n = 5)	p
Food intake n - (%)				
Diet				
Normal/doughy	9–90%	3–60%	1–20%	0.008 (AM vs. Control group)
Liquid/no food intake	1–10%	2–40%	4–80%	
Tolerance				
Normal	8–80%	5–100%	1–20%	0.048 (ES vs. Control group) 0.047 (AM vs. Control group)
Regurgitations/vomiting	2–20%	0	4–80%	
Endoscopic evaluation n - (%)				
Esophageal stricture	8–80%	4–80%	5–100%	NS
Symptomatic esophageal stricture	3–33%	4–40%	5–100%	0.03 (AM vs. Control group)
Esophageal diameter*	5.8±3.6	6.8±3.3	2.6±1.7	NS

*: mean ± standard deviation, in mm;
 NS: non significant.
 AM: amniotic membrane.
 ES: esophageal stent.
 doi:10.1371/journal.pone.0100236.t001

drazine. Total glutathione dosage was assessed using the 5, 5'-dithiobis(nitro-2-benzoic) or DNTB technique. Finally, nitrates were measured through the cadmium method. The activity of antioxidant enzymes and cellular content in oxidative stress metabolites was normalized with respect to the protein concen-

tration of each sample (bovine serum albumin microbiuret assay, Pierce, Bezons, France).

Statistical analysis

Statistical analysis was performed using GraphPad Prism (GraphPad Software, La Jolla, CA). Continuous data are

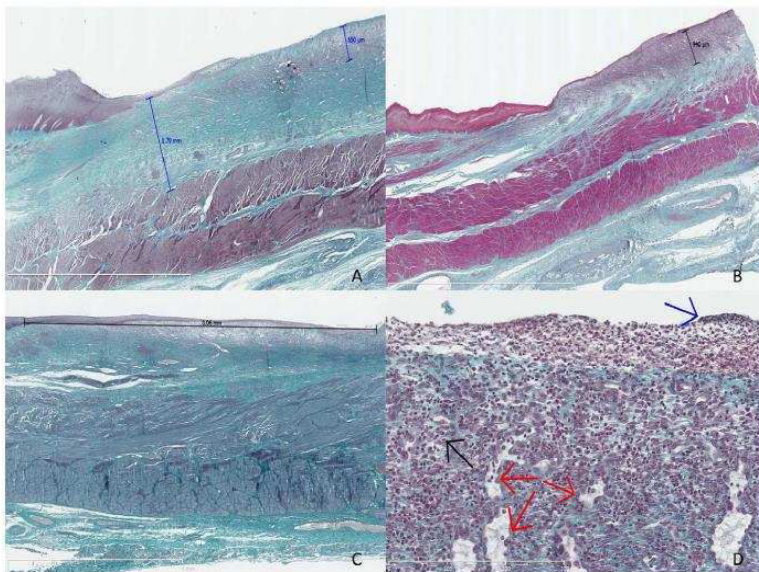


Figure 3. Histological analysis of the swine esophagus after Masson's trichrome staining. A: swine from the control group, sacrificed at day 14, with major fibrosis measured at 1.79 mm and thick granulation tissue measured at 0.65 mm, original magnification 12.5x; B: swine from the AM 1 group (amniotic membrane graft and early sacrifice scheduled at day 14), without esophageal stricture, with minimal fibrosis and mostly granulation tissue, measured at 0.94 mm, original magnification 10x; C: swine from the AM 2 group sacrificed at day 21, exhibiting major re-epithelialization measured at 8.06 mm, original magnification 15x; D: granulation tissue with features of acute inflammation, as observed in the early phase of esophageal wounds: high cell density, predominance of polynuclear cells (black arrow), fibrino-leucocytary network (blue arrow), and typical palisadic vascular growth (red arrows), original magnification 400x.
 doi:10.1371/journal.pone.0100236.g003



Figure 4. Immunohistochemistry staining with anti- α SMA antibody, original magnification $\times 200$. Strong signal (brown spots) attesting high myofibroblastic activity (panel A, black arrow) and high vascular density (panel A, white arrow) in control (A); nearly absent signal in MA-treated swine (B). doi:10.1371/journal.pone.0100236.g004

expressed as median values and range or mean \pm standard deviation, as appropriate, and compared with a non-parametric Kruskal-Wallis test, followed by a Dunn's multiple comparison test. Categorical data are expressed as percentages and compared with a Fisher's exact test. A p value < 0.05 was considered to indicate statistical significance.

End points

The primary end point was the prevalence of symptomatic esophageal stricture at day 14 following ESD.

Secondary endpoints were: incidence of esophageal stricture at any time, global clinical evaluation and food intake at day 14, diameter of the esophagus measured via endoscopy, width of fibrosis, thickness of inflammatory granulation tissue and length of re-epithelialization in the esophageal wall, intensity of myofibroblastic reaction on immunohistochemistry, and intensity of oxidative stress in the esophageal wall.

Results

Twenty swine were included in the study. The median (range) length of the resected esophageal mucosa was 5 (3–8) cm at a median (range) distance of 5 (2–5) from the esophagogastric junction. The median (range) time needed to complete ESD was 31 (17–80) min. Five minor adverse events, including two spontaneously resolving submucosal hemorrhages (in the control group), two ESDs beyond the esophagogastric junction (one in the

AM 2 and one in the ES group), and an asymptomatic breach of the muscularis propria (in the AM 2 group) were recorded.

A symptomatic esophageal stricture occurred in 33%, 40% and 100% of the swine in the AM, ES and control groups, respectively ($p = 0.03$ for AM vs. and ES vs. control group comparisons), as shown in figure 2. Clinical and endoscopic evaluation is described in table 1. Proximal or distal location of the esophageal stricture, as well as endoscopic features of the esophageal scar (re-epithelialization, erosions or ulcerations), were not significantly different among the 3 groups. Esophageal stents were still found in the esophagus in about 50% of the cases at day 7, equally distributed in all groups (3/5, 3/5, and 2/5 in AM 1, AM2, and ES group, respectively), and all of the remaining stents were removed at that time. The median (range) stricture-free survival was significantly different between the AM and control groups (22 (20–35) days vs. 14 (14–14) days, $p = 0.0005$, HR = 49.4, 95%CI [5.44–448.8]), and between the ES and control groups (21 (14–31) days vs. 14 (14–14) days, $p = 0.014$, HR = 20.09, 95%CI [1.82–221.5]); however, the median stricture-free survival was not significantly different between the AM and ES groups (22 (20–35) days vs. 21 (14–31), $p = 0.85$, HR = 1.14, 95%CI [0.31–4.16]). By day 35 after ESD, all animals had developed a symptomatic esophageal stricture.

Gross morphology showed whitish esophageal scars suggesting complete re-epithelialization in 90% of cases, and peri-esophageal lymphadenopathy. Histological study after Masson's trichrome staining allowed the first confirmation that the dissection had reached the submucosa in all cases, and the first layer of the muscularis propria in half of the cases. The median (range) fibrosis thickness varied from 0.87 (0.78–1.72) mm in the AM 1 group to 1.65 (1.7–1.79) mm in the control group ($p = \text{NS}$). Thickness of the granulation tissue varied from 0.43 (0.3–0.65) mm in the control group to 0.53 (0.25–3.94) mm in the AM 1 group ($p = \text{NS}$). Features of acute inflammatory infiltration were found in 10%, 60%, 40% and 60% of swine in the AM2, AM1, ES, and control groups, respectively ($p = \text{NS}$). The length of the neoeplithelium ranged from 3.04 mm in the AM 1 group to 7.05 mm in the AM 2 group, without any statistically significant differences. Histological results are shown in table 2 and Masson's trichrome-stained slides are shown in figure 3. Immunohistochemistry staining with anti- α SMA antibodies allowed for the semi-quantitative assessment of myofibroblastic activity: mean signals were 1.60 ± 0.89 and 1.25 ± 0.5 and mean vascular density was 2 ± 0.71 and 2.25 ± 0.96 ($p = \text{NS}$) in the AM1 and control groups, respectively. Representative findings of the immunohistochemistry staining with anti- α SMA antibody are shown on Figure 4.

Oxidative stress marker measurements in frozen esophageal tissue samples of strictured or normal esophagus were performed in 13 animals (4 in the AM 1 group, 5 in the AM 2, and 4 in the control group). No statistically significant differences were evidenced with regard to SOD or catalase activity, advanced oxidation proteic products, carbonyl derivatives, thiol group (total glutathione) or nitrate concentrations between the different groups. The data are presented in figure 5.

Discussion

Esophageal stricture development after endoscopic resection can be explained by two main mechanisms:

The first is the absence of the barrier effect of the epithelium, resulting in submucosal exposure to physical or acid aggression. Epithelial growth factor injection [27], keratinocyte injection [28] or biological dressing using extracellular matrix scaffolds [23,29], or allo/autogenic epithelial layers [30] have been used to address

Table 2. Histological evaluation of the esophageal wounds.

	AM 1 group [#] (n = 5)	AM 2 group [#] (n = 5)	ES group [#] (n = 5)	Control group (n = 5)	p
Depth of the dissection					
n - (%)					
Submucosa	2–40%	2–40%	2–40%	3–60%	NS
Muscularis propria	3–60%	3–60%	3–60%	2–40%	
Esophageal fibrosis*	0.87 (0.78–1.72)	1.53 (1.15–2.26)	1.19 (0.28–1.95)	1.65 (0.7–1.79)	NS
Granulation tissue*	0.53 (0.25–0.94)	0.52 (0.23–0.79)	0.43 (0.30–2.43)	0.43 (0.30–0.65)	NS
Acute inflammatory cell infiltrate n - (%)	3–60%	1–20%	2–40%	3–60%	NS
Reepithelialization*	3.04 (2.00–5.13)	7.05 (2.23–9.28)	5.07 (2.29–10.4)	4.86 (1.23–18.9)	NS

*Median (range), in mm;

NS: non significant.

[#]: AM1 group: pigs treated with amniotic membrane and sacrificed at day 14.[#]: AM2 group: pigs treated with amniotic membrane and sacrificed at symptomatic esophageal stricture occurrence.[#]: ES group: pigs with esophageal stent placement alone after ESD.

doi:10.1371/journal.pone.0100236.t002

this problem. None of these techniques have proven to be effective in CESD. Furthermore, there are concerns about the feasibility of such techniques in routine practice, given their high costs.

The second is represented by uncontrolled inflammatory and pro-fibrotic mechanisms involved in the wound healing process, including reactive oxygen species. Anti-inflammatory medications, such as pentoxifylline and interferon alpha [31], penicillamine [32], anti-oxidants (vitamin C and E, N acetylcysteine) [33,34], anti-fibrotic treatments, such as halofugidone [35] or corticosteroids [36], anti-mitotic drugs such as 5-fluorouracil [37] or mitomycin C [38], have been tested with insufficient results to consider their use in clinical practice. Steroid administration by local injection or by the systemic route showed promising results [10,36]. However, other authors have reported delayed healing of esophageal ulcers, poor outcomes in terms of stricture prevention, and serious infectious adverse events related to local steroid therapy [39], and there are concerns of potential infectious adverse events, in the case of the systemic administration of corticosteroids after esophageal CESD.

We aimed to determine whether grafts of AM, a readily disposable and low cost material with previous clinical experience in humans, would be able to prevent esophageal stricture after esophageal CESD. The rationale for this hypothesis was the ability of AM to create a mechanical barrier and stimulate epithelial growth, as well as its anti-inflammatory and anti-fibrotic properties.

AM grafts allowed for a dramatic reduction of the symptomatic stricture rate on the 14th postoperative day, from 100% in the control group to 33% in the AM group ($p=0.03$). However, we did not evidence any statistically significant differences between AM and ES groups in terms of symptomatic stricture rates at day 14 after CESD or time of onset of a symptomatic stricture. We observed statistically significant differences in food tolerance between the AM and control groups, and a lower rate of esophageal strictures (80% vs. 100% in the AM and control groups, respectively), with a higher mean esophageal diameter (5.8 ± 3.6 mm vs. 2.6 ± 1.7 mm in the AM and control groups, respectively). All groups had similar CESD depth, with CESD reaching the surface of muscularis propria in almost half of the cases. Hence, histological specimens should be comparable between the groups. At day 14 after CESD, the median thickness of esophageal fibrosis in the AM 1 group was almost half that reported in the control group (0.87 mm (0.78–1.72) vs. 1.65 mm

(0.7–1.79), respectively). However, swine in the AM 2 group showed major esophageal fibrosis, suggesting that the benefit of AM application was only transient. Survival time, but not AM application, impacted the nature of the granulation tissue: swine from the AM 2 group exhibited features of chronic granulation tissue (predominance of lympho-plasmocytes, low cell density) compared with swine from groups sacrificed at day 14. No differences in the thickness of the granulation tissue were evidenced. We did not observe any correlation between the depth of CESD and fibrotic or inflammatory parameters in the esophageal wall. AM did not result in higher re-epithelialization, either in groups with early sacrifice (3.04 (2.00–5.13) mm vs. 4.86 (1.23–18.9) mm for AM 1 and the control group, respectively), or in groups with late sacrifice (7.05 (2.23–9.28) mm vs. 5.07 (2.29–10.4) mm in the AM 2 and ES groups, respectively). Only the longer survival appeared to explain the longer neo-epithelia. Immunohistochemical analysis with anti-SMA staining did not show any significant changes in myofibroblastic activity or vascular density in the treated and control groups. Also, we did not find any differences in the patterns of oxidative stress activity in the esophagus of treated and control groups.

Our study presents several limitations: firstly, endoscopic measurement of the esophageal lumen with a 7 mm biopsy forceps is imprecise and may vary with the degree of insufflation; however, estimation of the esophageal diameter on gross morphology specimens is also suboptimal, because of the retraction of tissue samples. The percentage of reduction of esophageal lumen on esophagogram [40], or the stricture index (parietal thickness/luminal diameter) [27] do not seem to be any more accurate. Esophageal diameter might be more accurately assessed on fluoroscopic images of the esophagus after opacification: however, fluoroscopy was not available on a regular basis in the setting of our study. Secondly, our swine model exhibits higher stricture rates and more severe strictures than Humans: therefore, repeated esophageal dilations (as performed in humans) are ineffective and lead to esophageal perforations. This explains the lack of data after day 35 in our study, since animals had to be sacrificed when a symptomatic stricture occurred. It must also be noted that data on the stricture rate at day 14 in similar swine models are lacking in the literature [41,42]. Thirdly, the high rate of esophageal stent migration (despite their fastening to the esophageal wall with a clip) in a non-strictured esophagus might partly explain our results: it was not possible to determine how

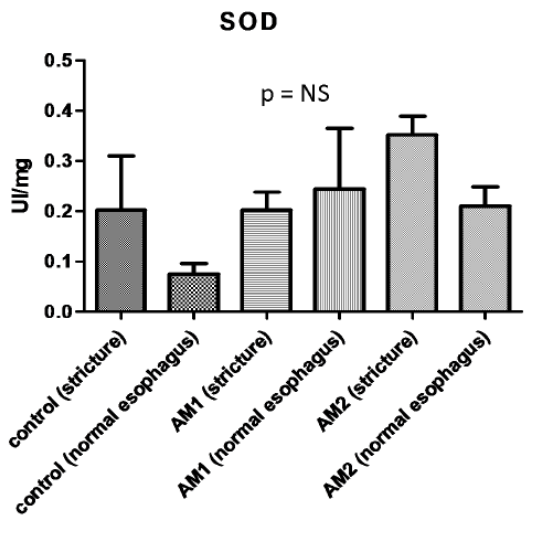
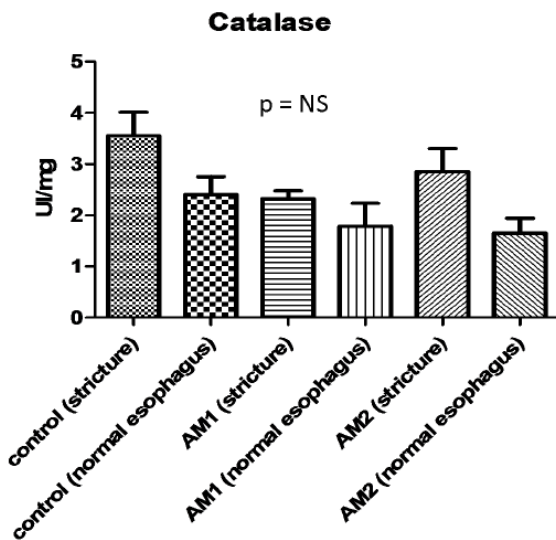
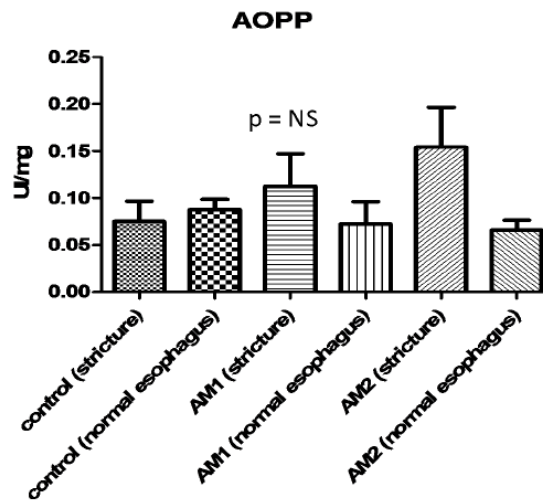
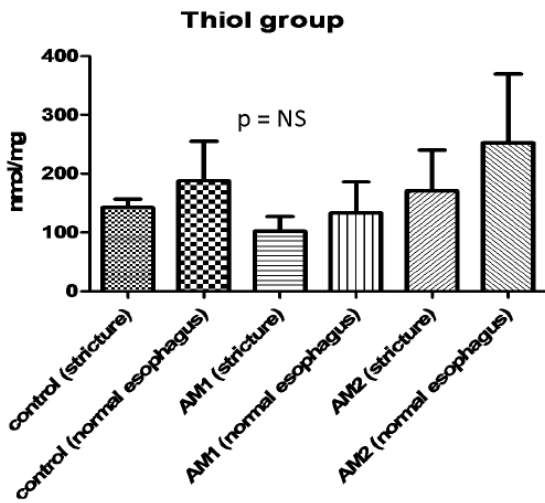
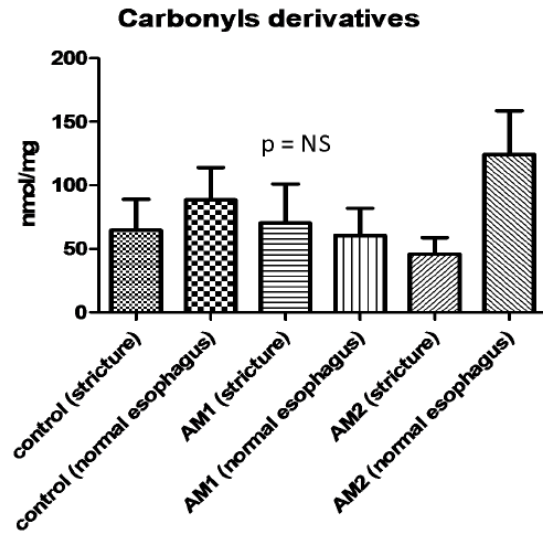
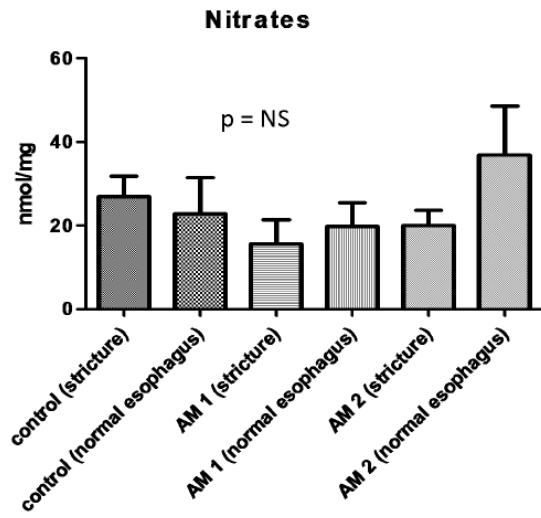


Figure 5. Oxidative stress markers measurements in tissue samples of strictured or normal esophagus; performed in control, AM1 and AM 2 groups.

doi:10.1371/journal.pone.0100236.g005

long the AM remained applied to the esophageal wound, and early stent migration may have jeopardized the effect of AM. Indeed, all animals with early stent migration (before day 7) had an esophageal stricture on day 14. Conversely, four out of the eight animals with the esophageal stent in place at day 7 developed an esophageal stricture a week later. Our numbers are in accordance with those of Rajan et al., who reported a stent migration rate of 67% in a similar setting [39] [39]. In a recent work, semi-covered esophageal stents were used in non-strictured esophagus, with satisfactory results in terms of stability [29]. The use of similar metallic semi-covered stents might be required in future studies.

AM grafts resulted in significant reduction of symptomatic esophageal stricture rate on the 14th postoperative day. This finding could be explained by a major reduction of the thickness of esophageal fibrosis in AM-treated swine, however not statistically significant, given the small numbers of animals in our study. However, this benefit was only temporary, and all animals developed symptomatic esophageal stricture before the 35th postoperative day. Furthermore, our work did not show any statistically significant differences between swine with AM and ES placement and swine with ES placement alone. Despite the rigorous study conditions applied, we did not find any evidence in the esophagus for the anti-inflammatory, anti-angiogenic, anti-

oxidant or pro-re-epithelialization properties of AM described in ophthalmology or dermatology. This may be explained by local conditions of the esophageal lumen, with chemical (acid) and mechanical (food) aggressions, and a high rate of early esophageal stent migration which occurred in almost half (7/15) of cases at day 7. Furthermore, ophthalmological studies have shown that AM grafts are usually degraded within 14 days [16], which might also explain the development of strictures past the second postoperative week. A second application of AM at day 14 might confirm this hypothesis, but would result in a cumbersome protocol. Hence, in conclusion, AM graft application does not appear to be an effective method for post-ESD stricture prevention, and further work is needed to develop a stable wound-covering agent with biological anti-fibrotic activity in this setting.

Author Contributions

Conceived and designed the experiments: SC FP MC. Performed the experiments: MB FP CAP MC LM. Analyzed the data: CN MB SC F. Beuvon F. Batteux. Contributed reagents/materials/analysis tools: MJ F. Batteux CN F. Beuvon. Wrote the paper: MB FP.

References

- Bennett C, Vakil N, Bergman J, Harrison R, Odze R, et al. (2012) Consensus statements for management of Barrett's dysplasia and early-stage esophageal adenocarcinoma, based on a Delphi process. *Gastroenterology* 143: 336–346.
- Shaheen NJ, Richter JE (2009) Barrett's oesophagus. *Lancet* 373: 850–861.
- Shaheen NJ, Overholt BF, Sampliner RE, Wolfsen HC, Wang KK, et al. (2011) Durability of radiofrequency ablation in Barrett's esophagus with dysplasia. *Gastroenterology* 141: 460–468.
- Titi M, Overhiser A, Ulasarac O, Falk GW, Chak A, et al. (2012) Development of subsquamous high-grade dysplasia and adenocarcinoma after successful radiofrequency ablation of Barrett's esophagus. *Gastroenterology* 143: 564–566 e561.
- Chennat J, Konda VJ, Ross AS, de Tejada AH, Noffsinger A, et al. (2009) Complete Barrett's eradication endoscopic mucosal resection: an effective treatment modality for high-grade dysplasia and intramucosal carcinoma—an American single-center experience. *Am J Gastroenterol* 104: 2684–2692.
- Ezoe Y, Muto M, Horimatsu T, Morita S, Miyamoto S, et al. (2011) Efficacy of preventive endoscopic balloon dilation for esophageal stricture after endoscopic resection. *J Clin Gastroenterol* 45: 222–227.
- Seevold S, Ang TL, Omar S, Groth S, Dy F, et al. (2006) Endoscopic mucosal resection of early esophageal squamous cell cancer using the Duetite mucosectomy kit. *Endoscopy* 38: 1029–1031.
- Katada C, Muto M, Manabe T, Boku N, Ohtsu A, et al. (2003) Esophageal stenosis after endoscopic mucosal resection of superficial esophageal lesions. *Gastrointest Endosc* 57: 165–169.
- Hanaoka N, Ishihara R, Takeuchi Y, Uedo N, Higashino K, et al. (2012) Intralesional steroid injection to prevent stricture after endoscopic submucosal dissection for esophageal cancer: a controlled prospective study. *Endoscopy* 44: 1007–1011.
- Hashimoto S, Kobayashi M, Takeuchi M, Sato Y, Narisawa R, et al. (2011) The efficacy of endoscopic triamcinolone injection for the prevention of esophageal stricture after endoscopic submucosal dissection. *Gastrointest Endosc* 74: 1389–1393.
- Prat F, Mangialavori L, Chryssostalis A, Chaussade S (2006) Esophageal Circumferential En-Bloc Submucosal Dissection in a Porcine Model. *Digestive Disease Week: Gastrointest Endosc*.
- Akle CA, Adinolfi M, Welsh KI, Leibowitz S, McColl I (1981) Immunogenicity of human amniotic epithelial cells after transplantation into volunteers. *Lancet* 2: 1003–1005.
- Koizumi NJ, Inatomi TJ, Sotozono CJ, Fullwood NJ, Quantock AJ, et al. (2000) Growth factor mRNA and protein in preserved human amniotic membrane. *Curr Eye Res* 20: 173–177.
- Kim JC, Tseng SC (1995) Transplantation of preserved human amniotic membrane for surface reconstruction in severely damaged rabbit corneas. *Cornea* 14: 473–484.
- Hao Y, Ma DH, Hwang DG, Kim WS, Zhang F (2000) Identification of antiangiogenic and antiinflammatory proteins in human amniotic membrane. *Cornea* 19: 348–352.
- Muraie M, Gueudry J, Toubeau D, Gardea E, Verspyck E, et al. (2006) [Advantages of amniotic membrane transplantation in eye surface diseases]. *J Fr Ophthalmol* 29: 1070–1083.
- Choi TH, Tseng SC (2001) In vivo and in vitro demonstration of epithelial cell-induced myofibroblast differentiation of keratocytes and an inhibitory effect by amniotic membrane. *Cornea* 20: 197–204.
- Lee SB, Li DQ, Tan DT, Meller DC, Tseng SC (2000) Suppression of TGF-beta signaling in both normal conjunctival fibroblasts and pterygial body fibroblasts by amniotic membrane. *Curr Eye Res* 20: 325–334.
- Roland I, Beauchemin D, Acteau G, Fradette C, St-Pierre I, et al. (2010) Effects of labor on placental expression of superoxide dismutases in preeclampsia. *Placenta* 31: 392–400.
- Fraser JF, Cuttle L, Kempf M, Phillips GE, Hayes MT, et al. (2009) A randomised controlled trial of amniotic membrane in the treatment of a standardised burn injury in the merino lamb. *Burns* 35: 998–1003.
- Fernandes M, Sridhar MS, Sangwan VS, Rao GN (2005) Amniotic membrane transplantation for ocular surface reconstruction. *Cornea* 24: 643–653.
- Barret M, Pratico CA, Beuvon F, Mangialavori L, Chryssostalis A, et al. (2013) Esophageal circumferential en bloc endoscopic submucosal dissection: assessment of a new technique. *Surg Laparosc Endosc Percutan Tech* 23: e182–187.
- Nieponice A, McGrath K, Qureshi I, Beckman EJ, Lukeitch JD, et al. (2009) An extracellular matrix scaffold for esophageal stricture prevention after circumferential EMR. *Gastrointest Endosc* 69: 289–296.
- Beauchamp C, Fridovich I (1971) Superoxide dismutase: improved assays and an assay applicable to acrylamide gels. *Anal Biochem* 44: 276–287.
- Aebi H (1984) Catalase in vitro. *Methods Enzymol* 105: 121–126.
- Witko-Sarsat V, Friedlander M, Capeillere-Blandin C, Nguyen-Khoa T, Nguyen AT, et al. (1996) Advanced oxidation protein products as a novel marker of oxidative stress in uremia. *Kidney Int* 49: 1304–1313.
- Koltuksuz U, Mutus HM, Kutlu R, Ozyurt H, Cetin S, et al. (2001) Effects of caffeic acid phenethyl ester and epidermal growth factor on the development of caustic esophageal stricture in rats. *J Pediatr Surg* 36: 1504–1509.
- Zuercher BF, George M, Escher A, Piotet E, Ikonomidis C, et al. (2013) Stricture prevention after extended circumferential endoscopic mucosal resection by injecting autologous keratinocytes in the sheep esophagus. *Surg Endosc* 27: 1022–1028.
- Badylak SF, Hoppo T, Nieponice A, Gilbert TW, Davison JM, et al. (2011) Esophageal preservation in five male patients after endoscopic inner-layer circumferential resection in the setting of superficial cancer: a regenerative medicine approach with a biologic scaffold. *Tissue Eng Part A* 17: 1643–1650.

30. Ohki T, Yamato M, Ota M, Takagi R, Murakami D, et al. (2012) Prevention of esophageal stricture after endoscopic submucosal dissection using tissue-engineered cell sheets. *Gastroenterology* 143: 582–588 e581–582.
31. Apaydin BB, Paksoy M, Artis T, Sahin DA, Aki H, et al. (2001) Influence of pentoxifylline and interferon-alpha on prevention of stricture due to corrosive esophagitis. An experimental study in the rat. *Eur Surg Res* 33: 225–231.
32. Gehanno P, Guedon C (1981) Inhibition of experimental esophageal lye strictures by penicillamine. *Arch Otolaryngol* 107: 145–147.
33. Barret M, Batteux F, Beuvon F, Mangialavori L, Chrysostalis A, et al. (2012) N-acetylcysteine for the prevention of stricture after circumferential endoscopic submucosal dissection of the esophagus: a randomized trial in a porcine model. *Fibrogenesis Tissue Repair* 5: 8.
34. Gunel E, Caglayan F, Caglayan O, Canbilen A, Tosun M (2002) Effect of antioxidant therapy on collagen synthesis in corrosive esophageal burns. *Pediatr Surg Int* 18: 24–27.
35. Ozcelik MF, Pekmezci S, Saribeyoglu K, Unal E, Gumustas K, et al. (2004) The effect of halofuginone, a specific inhibitor of collagen type 1 synthesis, in the prevention of esophageal strictures related to caustic injury. *Am J Surg* 187: 257–260.
36. Sato H, Inoue H, Kobayashi Y, Maselli R, Santi EG, et al. (2013) Control of severe strictures after circumferential endoscopic submucosal dissection for esophageal carcinoma: oral steroid therapy with balloon dilation or balloon dilation alone. *Gastrointest Endosc* 78: 250–257.
37. Mizutani T, Tadauchi A, Arinobe M, Narita Y, Kato R, et al. (2010) Novel strategy for prevention of esophageal stricture after endoscopic surgery. *Hepatogastroenterology* 57: 1150–1156.
38. Turkyilmaz Z, Sonmez K, Demirtola A, Karabulut R, Poyraz A, et al. (2005) Mitomycin C prevents strictures in caustic esophageal burns in rats. *J Surg Res* 123: 182–187.
39. Rajan E, Gostout C, Feitoza A, Herman L, Knipschild M, et al. (2005) Widespread endoscopic mucosal resection of the esophagus with strategies for stricture prevention: a preclinical study. *Endoscopy* 37: 1111–1115.
40. Wu Y, Schomisch SJ, Cipriano C, Chak A, Lash RH, et al. (2014) Preliminary results of antiscarring therapy in the prevention of postendoscopic esophageal mucosectomy strictures. *Surg Endosc* 28: 447–455.
41. Willingham FF, Gee DW, Sylla P, Lauwers GY, Rattner DW, et al. (2009) En bloc esophageal mucosectomy for concentric circumferential mucosal resection (with video). *Gastrointest Endosc* 69: 147–151.
42. Witteman BP, Foxwell TJ, Monsheimer S, Gelrud A, Eid GM, et al. (2009) Transoral endoscopic inner layer esophagectomy: management of high-grade dysplasia and superficial cancer with organ preservation. *J Gastrointest Surg* 13: 2104–2112.

2. Evaluation d'une poudre hémostatique en prévention de la sténose œsophagienne après dissection sous-muqueuse endoscopique circonférentielle.

Topical hemostatic powder promotes reepithelialization and reduces scar formation after extensive esophageal mucosal resection.

Beye B, Barret M, Alatawi A, Beuvon F, Nicco C, Pratico CA, Chéreau C, Chaussade S, Batteux F, Prat F. Dis Esophagus. 2016 Aug;29(6):520-7

La poudre hémostatique minérale TC-325 (Hémospay®, Cook, Limerick, Irlande), appliquée par voie endoscopique, forme un film adhérent aux zones hémorragiques du tube digestif, dont l'efficacité est bien établie dans le contrôle d'un saignement actif, initialement dans le traitement de plaies de guerre, puis dans celui de lésions hémorragiques du tube digestif. Des cas, non publiés, de cicatrisation rapide de plaies cutanéomuqueuses, dans un délai inférieur à la durée attendue, ont également été observés après application de poudre. Nous avons émis l'hypothèse que ce film pourrait avoir une action protectrice de la plaie œsophagienne succédant à une résection endoscopique circonférentielle, et ainsi limiter la réaction inflammatoire locale aboutissant à la fibrose et à la sténose œsophagienne. Nous avons conduit une étude prospective contrôlée incluant 20 animaux ayant tous une ESD circonférentielle de l'œsophage sur 6 cm. Le groupe 1 (n=10) servait de contrôle, et le groupe 2 (n=10) recevait des applications d'Hémospay) à J0, puis J2, J4 et J7. A J14, le groupe traité par Hémospay présentait 60% de sténoses symptomatiques (contre 100% dans le groupe contrôle, $p= 0.09$), un diamètre médian de l'œsophage supérieur (2 mm [1–3] vs. 3 mm [2–4], $P = 0.01$), et une amélioration statistiquement significative des paramètres histologiques tels que

l'épaisseur de la fibrose œsophagienne, du tissu de granulation, et une réépithélialisation plus importante. Les dosages sériques de marqueurs de l'inflammation (IL-1 β , IL-6, TNF- α) et de la fibrose (TGF- β) par Elisa retrouvaient une diminution du taux de TGF- β à J14 dans le groupe traité (p = 0.01). En conclusion, l'Hémospray, sans empêcher totalement la formation de sténoses œsophagiennes cicatricielles dans ce modèle porcin particulièrement sténosant, démontrait un effet significatif sur la cicatrisation œsophagienne avec un plus large diamètre œsophagien à J14, et une inhibition de l'inflammation et de la fibrose œsophagienne.

Original article

Topical hemostatic powder promotes reepithelialization and reduces scar formation after extensive esophageal mucosal resection

B. Beye,^{1,2,3} M. Barret,^{1,2,3} A. Alatawi,¹ F. Beuvon,^{2,4} C. Nicco,^{2,3} C. A. Pratico,¹ C. Chereau,^{2,3}
S. Chaussade,^{1,2} F. Batteux,^{2,3,5} F. Prat^{1,2,3}

Departments of ¹Gastroenterology, ⁴Pathology, and ⁵Immunology, Cochin Hospital, ²Faculté Paris Descartes, and ³Inserm Unit 1016, Paris, France

SUMMARY. The development of techniques for endoscopic resection has provided new strategies for radical conservative treatment of superficial esophageal neoplasms, even those that are circumferential, such as Barrett's neoplasia. However, it is necessary to prevent the formation of scar tissue that can be responsible for esophageal strictures following circumferential resection. Preliminary data have suggested the possible efficacy of a hemostatic powder in the promotion of wound healing. The study aims to assess the effectiveness of Hemospray (Cook Medical) in a swine model of post-endoscopic esophageal stricture. Our prospective controlled study included 21 pigs. A 6-cm circumferential submucosal dissection of the esophagus (CESD) was performed in each pig. Group 1 ($n = 11$) only underwent CESD and Group 2 ($n = 10$) had repeated Hemospray applications after CESD. Clinical, endoscopic, and radiological monitoring were performed, blood levels of four inflammatory or pro-fibrotic cytokines were assessed, and histological analysis was performed. Median esophageal diameter was greater in the group treated with Hemospray (2 mm [1–3] vs. 3 mm [2–4], $P = 0.01$), and the rate of symptomatic esophageal stricture was 100% and 60% in Groups 1 and 2, respectively ($P = 0.09$). The thicknesses of esophageal fibrosis and inflammatory cell infiltrate were significantly lower in Group 2 than in Group 1 ($P = 0.002$ and 0.0003, respectively). The length of the neoeepithelium was greater in Group 2 than in Group 1 ($P = 0.0004$). Transforming growth factor- β levels were significantly lower in Group 2 than in Group 1 ($P = 0.01$). The application of Hemospray after esophageal CESD reduces scar tissue formation and promotes reepithelialization, and therefore is a promising therapeutic approach in the prevention of post-endoscopic esophageal stricture.

KEY WORDS: Barrett's esophagus, early esophageal adenocarcinoma, endoscopic submucosal dissection (ESD), esophageal fibrosis, esophageal stricture, Hemospray.

ABBREVIATIONS: CESD, circumferential endoscopic submucosal dissection; ESD, endoscopic submucosal dissection; HES, hematoxylin-erythrosin-saffron; IL, interleukin; TGF- β , transforming growth factor beta; TNF- α , tumor necrosis factor- α

Address correspondence to: Prof Frederic Prat, MD, PhD, Department of Gastroenterology, Cochin Hospital, 27, rue du Faubourg St Jacques, 75014 Paris, France. Email: frederic.prat@ech.aphp.fr

Author contributions: BB performed the experiments, analyzed the data, and drafted the manuscript; MB and FP contributed to the study design, acquisition of data (animal experiments), and provided critical revision of the manuscript; AA contributed to the acquisition of data (animal experiments); FB contributed to the acquisition of data (histological assessments) and provided critical revision of the manuscript; CN and CC contributed to the study design and to the acquisition of data (biochemical measurements); CAP contributed to the acquisition of data (animal experiments); and CS and FB contributed to the study design and provided critical revision of the manuscript. All authors have given final approval for the final version of the manuscript.

INTRODUCTION

Long considered as first-line treatment in patients with Barrett's esophagus and high-grade dysplasia or early cancer of the esophagus, surgery leaves more and more room for endoscopic resection techniques, such as endoscopic mucosal resection and endoscopic

Conflict of interest disclosure: The authors thank Cook Medical® Corporation for its material support throughout the study by graciously providing the Hemospray and funding of the study through Med Institute, West Lafayette, IN. However, the company and its members had no role or participation in the writing, correcting, or editing of the manuscript. The authors declare no other conflicts of interest.

submucosal dissection (ESD).¹ However, extensive endoscopic resections can lead to severe inflammatory and fibrotic reactions, which promote the formation of esophageal strictures. It has been shown that mucosal resections exceeding 75% of the circumference of the esophagus result in a stricture rate greater than 80%, reaching 100% in cases of circumferential resections.²⁻⁴ Some strictures can be treated with a few sessions of endoscopic dilation, but most are refractory and require numerous and hazardous dilations.^{5,6} Therefore, it is currently not advisable to perform circumferential endoscopic mucosal resection or ESD as a standard treatment for circumferential dysplastic Barrett's esophagus or any other circumferential early esophageal neoplasia. Different strategies to prevent post-endoscopic stricture are being explored, such as topical application of anti-proliferative agents, local or systemic corticosteroid therapy, and cell sheet therapy, and these methods have yielded variable results. Overall, due to safety concerns or high costs, these strategies are currently inadequate for broad clinical application.⁷⁻¹⁰ An alternative means to prevent post-endoscopic stricture is to protect the submucosa and muscularis propria after the endoscopic resection using an adherent material on the wound to isolate it from physical, chemical, or microbial aggression, thus limiting inflammatory and fibrogenic processes in the esophageal wall.¹¹⁻¹³ We hypothesized that TC-325 (Hemospray, Cook Medical, Bloomington, Indiana, USA), a granular, mineral-based hemostatic powder validated for the endoscopic hemostasis of bleeding lesions of the upper gastrointestinal tract,¹⁴⁻¹⁶ might be suitable to achieve this goal. Our observations and a preliminary study have suggested a possible role of Hemospray in the prevention of esophageal stricture (Barret M, 2011). The aim of this study was to determine whether the topical application of Hemospray on the esophageal submucosa after circumferential submucosal dissection of the esophagus (CESD) in a swine model could prevent post-endoscopic stricture.

METHODS

The study design included two groups of animals: Group 1 ($n = 11$), the control group, only had CESD, while Group 2 ($n = 10$) received four applications of Hemospray. Pure strain pigs weighing between 35 kg and 45 kg from the same farm (INRA de Brouëssy, Magny, France) were used. The protocol was approved by the Paris Descartes ethics committee for animal experimentation and registered as No. CEEA34.FP.126.12. General anesthesia was given to animals via an intramuscular injection of 2 mg/kg azaperone and 10 mg/kg ketamine, 30 minutes before induction. Induction was carried out with 1.5 mg/kg

of propofol injected intravenously and maintained by the combination of 1–2% isoflurane and propofol. Analgesia was provided through intravenous nalbuphine. As described by Camus *et al.*, all pigs received 2 g/day of DL-lysine acetylsalicylate (Aspegic[®], Sanofi-Aventis, Paris, France), and 600 mg/day of clopidogrel (Plavix[®] 75 mg, Bristol-Myers Squibb, Rueil-Malmaison, France) during the mandatory 5-day quarantine preceding the first endoscopic procedure;¹⁷ our purpose was to generate active bleeding from the resection site in order to facilitate adherence of the Hemospray¹⁴ and to mimic the technical conditions of an ESD procedure conducted on Barrett's esophagus in Humans. Indeed, swine have quick hemostatic processes,^{18,19} and conversely neoplastic esophageal lesions and in particular those occurring in Barrett's esophagus are richly vascularized and tend to bleed during endoscopic resections.²⁰ This protocol has been validated for the training of gastroenterologists on endoscopic hemostatic techniques in swine, and was simplified in our study.¹⁷ After the introduction of a flexible overtube guiding the 13806PKS gastroscope (Karl Storz, Tuttlingen, Germany), an esophagogastroscope was performed. After submucosal lifting by injection of indigo carmine stained saline, CESD was carried out using a Hook knife and an IT knife (Olympus, Saitama, Japan). Since the hyperkeratinized cardia in pigs does not reproduce the conditions of an esophageal ESD in humans, CESD was conducted on a length of 5 cm, 5 cm above the esophagogastric junction. This previously described technique²¹ consists of proximal and distal circular mucosal incisions followed by separation of the submucosa and muscularis propria by mechanical cleavage using a rigid mucosectomy cap on the tip of the endoscope. Immediately after endoscopic resection, the Hemospray powder was sprayed over the entire length of the resected area, using a handheld, pressurized CO₂ canister, starting from the distal end of the resection. The application of Hemospray was repeated three times, on days 2, 4, and 7 during an upper endoscopy conducted under general anesthesia. The postoperative diet consisted of sugar water and started at hour 12, followed by a liquid diet until the third postoperative day, before resuming a conventional diet of pellets on day 4 for animals in the control group. Antibiotic therapy with 10 mg/kg benzathine benzylpenicillin procaine LP and oral antacid therapy with 80 mg/day omeprazole was also administered during the whole study.

General condition (weight loss, apathy, and other behavioral abnormalities), tolerance to food (normal, occasional regurgitation, total food intolerance), date of food intolerance onset, and the type of diet tolerated (regular food pellets, semi-liquid food using wet pellets, liquid food, or sugar water/no food) were assessed daily. Endoscopic surveillance

was conducted every week to measure the esophageal diameter using a biopsy forceps. A barium swallow was performed prior to sacrifice of the animal. Esophageal stricture was defined as a narrowing of the esophageal lumen objectively assessed by the non-crossing of the 12-mm diameter endoscope and by an esophagogram showing a reduction in size of greater than 50% of the esophageal lumen. It was considered symptomatic if accompanied by regurgitation. Euthanasia was performed by intravenous injection of 100 mg/kg pentobarbital at the end of the 14-day study period, or earlier if symptomatic esophageal stricture occurred. Through sterno-laparotomy and neck incision, the esophagus was resected *en bloc* and opened: macroscopic examination of the scar was performed. After fixation in 10% formalin, the scarred area was cut into three to six blocks, embedded in paraffin, and then cut into 5- μ m sections which were stained with hematoxylin-erythrosin-saffron (HES). Each slide was analyzed by the same pathologist who is experienced in digestive pathology (FB). Histochemical staining with Masson's trichrome was performed on a selected slide from each animal for the analysis of fibrosis. The following values were recorded for each animal on digitized histological slides: maximal thicknesses of the fibrotic tissue and of inflammatory cell infiltrate; type of inflammatory cell infiltrate; and length of the reepithelialization in micrometer. Blood samples were obtained under anesthesia at day 0 and day 14, and tested in the laboratory on the same day before freezing at -80°C . The pro-inflammatory (interleukin [IL]-1 β , IL-6, tumor necrosis factor- α [TNF- α]) and pro-fibrotic (transforming growth factor- β [TGF- β]) cytokines were quantitatively determined by ELISA on selected serum samples. Quantikine[®] Elisa Kits (R&D Systems, Minneapolis, MN, USA) were used for each of the four cytokines.

Categorical data were compared using a Fisher's exact test, taking into account the low sample sizes. Continuous data are expressed as mean \pm standard

deviation or median (range), as appropriate. Comparisons were made using a non-parametric Mann-Whitney test. A *P*-value of <0.05 was considered statistically significant. Statistical analysis was performed using the GraphPad Prism[®] software (GraphPad Software, La Jolla, CA, USA).

The primary objective was to assess the possible effect of Hemospray application on esophageal stricture formation by comparing a group of animals undergoing only CESD (Group 1) with a group treated by Hemospray after CESD (Group 2). The secondary objectives were to document epithelial proliferation and fibrogenetic mechanisms to improve the understanding of tissue repair in the esophagus after endoscopic procedures, and if effective to optimize the treatment, or to define alternative directions in the case of treatment failure.

The primary end-point was the presence of a symptomatic esophageal stricture on the 14th postoperative day. The secondary end-points were the following: the esophageal diameter on day 14 as measured by endoscopy and on the esophagogram; the thickness of the esophageal fibrosis and inflammatory cell infiltrate and the length of reepithelialization on histological analysis (HES and Masson's trichrome); and the blood levels of pro-inflammatory and fibrogenic cytokines.

RESULTS

Twenty-one animals were included in this study. The median length of the resected segment was 6 (5–9) cm, and the procedures were conducted in a median time of 28.5 minutes (18–57 minutes) (Fig. 1). An esophageal perforation occurred in one animal in Group 1, which required euthanasia. Twenty animals were finally analyzed, 10 in Group 1 and 10 in Group 2. A symptomatic esophageal stricture at day 14 occurred in 60% of animals in Group 2 versus 100%

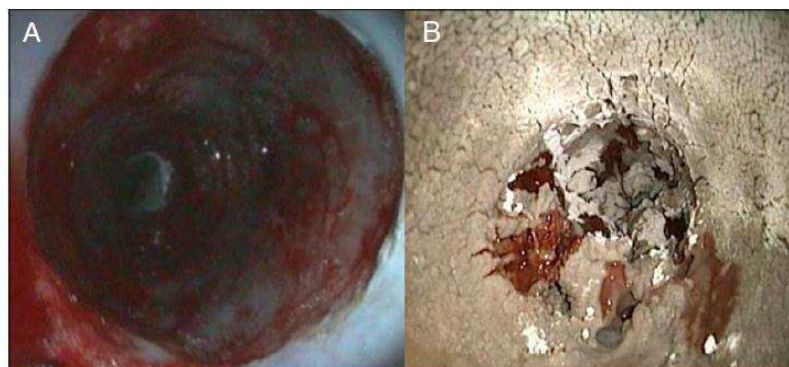


Fig. 1 Endoscopic procedure and Hemospray application. (A) Appearance of the dissection area of the lower third of the esophagus immediately after endoscopic submucosal dissection. (B) Appearance of the same area after the application of Hemospray.

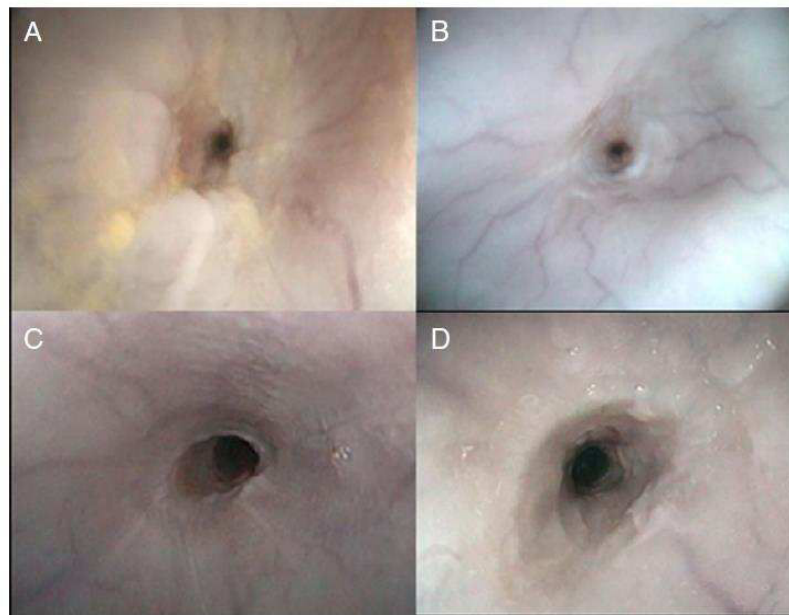


Fig. 2 Endoscopic views of esophageal strictures at the site of endoscopic submucosal dissection 14 days after circumferential mucosal resection: (A, B) animals from Group 1 (control); (C, D) animals from Group 2 (Hemospray).

in Group 1 ($P = 0.09$). The mean esophageal diameter at day 14 was significantly different in the two groups, with a median of 2 (1–3) mm and 3 (2–4) mm for Groups 1 and 2, respectively ($P = 0.01$). However, all animals had severe esophageal stricture evidenced by radiology or endoscopy on day 14. Endoscopic views of esophageal strictures are shown in Figure 2. In esophagograms, the median reductions of the esophageal lumens were 90% and 90.5% in Group 1 and 2, respectively ($P = 0.9$). The lengths of the esophageal strictures measured on the fluoroscopic images were not significantly different in Groups 1 and 2 ($P = 0.47$), nor were the stricture indexes calculated by the ratio of the narrowest diameter to the total length of the stricture ($P = 0.13$). The clinical, radiological, and endoscopic data are summarized in Table 1.

The median thickness of the esophageal fibrosis was significantly greater in Group 1 with 2.15 mm (1.3–2.6) versus 0.82 mm (0.6–1.3) in Group 1 versus Group 2, respectively ($P = 0.0002$). The median thickness of the inflammatory cell infiltrate was also significantly greater with median values of 0.67 mm (0.22–1.24) versus 0.37 mm (0.3–0.5) in Group 1 versus Group 2, respectively ($P = 0.003$). Conversely, the median length of reepithelialization was significantly lower in Group 1 with 2.34 mm (0.86–7.84) versus 8.1 mm (2.90–14.90) in Group 1 versus Group 2 ($P = 0.0004$). Representative histopathological aspects are presented in Figure 3.

The quantitative measurements of serum pro-inflammatory cytokines on five animals in each group showed the following results: the mean levels of IL-1 β

at day 0 were 58.4 ± 45 pg/mL and 32.3 ± 14 pg/mL in Groups 1 and 2, respectively ($P = 0.02$), and at day 14, 72 ± 83 pg/mL and 38.8 ± 12 pg/mL in Groups 1 and 2, respectively ($P = 1$). The mean levels of IL-6 at day 0 were 18.4 ± 0.8 pg/mL and 17.1 ± 2 pg/mL in Groups 1 and 2, respectively ($P = 0.4$), and at day 14, 18.2 ± 9 pg/mL and 19.7 ± 5 pg/mL in Groups 1 and 2, respectively ($P = 0.9$). The mean levels of TNF- α at day 0 were 41.8 ± 12 pg/mL and 59.4 ± 40 pg/mL in Groups 1 and 2, respectively ($P = 0.46$), and at day 14, 43.3 ± 21 pg/mL and 35.4 ± 18 pg/mL in Groups 1 and 2, respectively ($P = 0.5$). Finally, for TGF- β , the mean levels at day 0 were $27\,537 \pm 4048$ pg/mL and

Table 1 Clinical, endoscopic, and radiological evaluations on D14

	Group 1 <i>n</i> = 10	Group 2 <i>n</i> = 10	<i>P</i>
Clinical			
General condition			
Good	0%	0%	NS
Impaired	100%	100%	
Food intake			
Normal	0%	40%	0.09
Regurgitations	100%	60%	
Endoscopy			
Esophageal diameter \ddagger	2.1 ± 0.87	3 ± 0.70	0.01
Esophagogram			
Esophageal stricture	100%	100%	NS
Stricture length \ddagger	$5.7 (4.2-7)$	$6.2 (4-9)$	0.47
Symptomatic esophageal stricture on D14	100%	60%	0.09

\ddagger Mean \pm standard deviation, in mm. \ddagger Median (range). NS, non-significant.

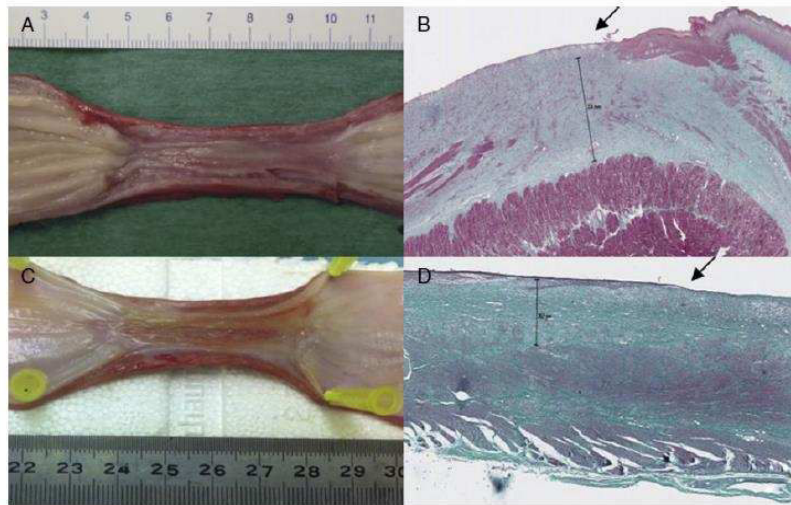


Fig. 3 Histopathological findings 14 days after circumferential endoscopic submucosal dissection: Macroscopy (A) of a severely strictured esophagus from Group 1 and histological view (B) showing intense inflammatory infiltrate, absent reepithelialization (arrow), and thick fibrotic layer (2500 μm). Panels (C) and (D) show macroscopic views of a strictured esophagus from Group 2 and histology (D) showing a long neoeepithelium (arrow), moderate inflammatory cell infiltrate, and moderate submucosal fibrosis (702 μm). Masson's trichrome staining, magnification 25 \times .

22 903 \pm 7717 pg/mL in Groups 1 and 2, respectively ($P = 0.01$), and at day 14, 27 628 \pm 13 717 pg/mL and 12 845 \pm 11 999 pg/mL in Groups 1 and 2, respectively ($P = 0.01$). The reduction in TGF- β levels

between days 0 and 14 was statistically significant for Group 2 ($P = 0.006$) but not for Group 1 ($P = 0.8$). The results of the cytokine assay are presented in Figure 4.

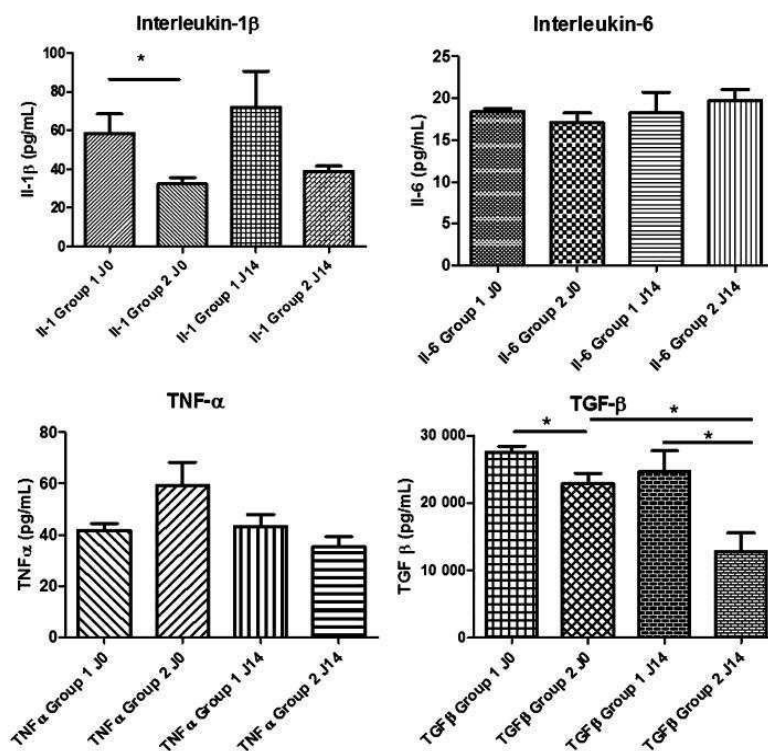


Fig. 4 Proinflammatory and fibrogenic cytokine levels before and after endoscopic submucosal dissection in Groups 1 and 2. The asterisk (*) indicates statistical significance ($P < 0.05$). IL, interleukin; TGF, transforming growth factor; TNF, tumor necrosis factor.

DISCUSSION

The prevention of cicatricial fibrotic stricture is necessary for the expanded use of extensive endoscopic mucosal resections in the esophagus. The only option currently available in clinical practice is the use of either topical or systemic corticosteroids.^{22,23} However, in addition to their incomplete efficacy, the immunosuppressive properties of corticosteroids might seriously limit their use in frail and elderly patients with recent major endoscopic surgery.²⁴ Efficient methods of cell sheet therapy have been reported,²⁵ but are expensive and unlikely to be feasible in the near future outside a few expert centers. Along with anti-inflammatory or anti-fibrotic drugs and regenerative medicine, wound-covering agents have been tested for stricture prevention with promising results.^{11–13} While developing a CESD technique, our team previously developed a swine model of post-endoscopic esophageal stricture, in which 100% of the animals develop a tight stricture on day 14.²¹ A preliminary test with the Hemospray powder in this model on five animals generated encouraging results, with one pig without esophageal stricture, and non-symptomatic, non-severe esophageal strictures in two out of the five animals, all of which survived until day 14.

Our trial aimed to assess the effect of Hemospray application on esophageal wound healing in terms of clinically relevant esophageal strictures after CESD in a swine model. We did not observe statistically significant differences between the treated and control groups. These results could be explained by the relatively small animal sample, the high incidence of stricture in the swine esophagus, or by insufficient efficacy of the Hemospray powder due to poor stability in the esophagus.

We observed that most of the hemostatic powder had been washed away in 48 hours by saliva, food boluses, and esophageal contractions; therefore, in order to ensure the presence of the powder for the first 8 days after the endoscopic procedure, which is a critical period for the recruitment of mediators of inflammation and fibrosis after surgery,²⁶ it was necessary to repeat the applications while maintaining a liquid diet. The concept of repeated treatment sessions for the prevention of post-endoscopic esophageal stricture is not novel: injected corticosteroids²⁷ or preemptive balloon dilatation²⁸ typically require two or three treatment sessions in the early phase of the wound healing process. In a clinical setting, a few days of parenteral nutrition or nasoenteral feeding, as it is commonly done after esophageal or gastric surgery, would probably help in maintaining the powder on the resection wound, permitting applications spaced out over greater time intervals.

The application of Hemospray did result in some important differences in esophageal wound healing

between the groups. First, the median esophageal diameter measured by endoscopy was significantly higher in the group treated with Hemospray ($P = 0.01$). The rate of symptomatic esophageal stricture on the 14th postoperative day was also lower in the treated group, but this difference did not reach statistical significance. The most notable results of our study concern the histological analysis and biochemical markers. Indeed, the histology revealed statistically significant differences between Groups 1 and 2 with regard to the thickness of the fibrosis ($P = 0.0002$), the thickness of the inflammatory cell infiltrate ($P = 0.003$), and the length of the reepithelialization ($P = 0.0004$), the latter in the opposite direction to the first two parameters. In the control group (Group 1), the fibrotic layer and the granulation tissue were thicker than in the treated group (Group 2) and associated with poor reepithelialization; conversely, Group 2 appeared to begin the tissue repair process, exhibited by a long neoeepithelium covering the wound with less fibrosis and fewer inflammatory cells. The quantitative measurements of serum pro-inflammatory cytokines showed that the expression of TGF- β was significantly lower on day 14 in the treated versus control group ($P = 0.01$). Even if the levels of TGF- β were already significantly different between the groups at baseline, the drop in TGF- β levels was significant in the treated (Group 2) group and not in the control group (Group 1). The reduction in the levels of TNF- α followed the same trend without reaching statistical significance. These findings suggest that the application of Hemospray on the wound has anti-fibrotic action via downregulation of the TGF- β pathway. Treatment with Hemospray had no effect on serum levels of IL-1 β and IL-6, and therefore no pro- or anti-inflammatory actions. These data are novel because, to our knowledge, no experimental or clinical study has evaluated the expression of pro-fibrotic and pro-inflammatory biomarkers after endoscopic mucosal resection. It is tempting to attribute these results to the action of the Hemospray. Indeed, in several experimental studies in pigs, the differences in the thickness of the fibrotic scar tissue and the layer of inflammatory cell infiltrate are not significant.^{11,29,30} Besides wound covering, a second hypothesis to support the effect of Hemospray is related to coagulation: fibrinogenesis contributes to inflammatory processes³¹ in systemic diseases as well as after local surgical trauma, as is observed in the creation of postoperative adhesion.²⁶ Hemospray, by initiating *in situ* and immediate hemostasis, could reduce fibrinogenesis.

We acknowledge several limitations in our study. First, we studied a small sample, as is often the case in preclinical studies on large animals. Second, we did not have a 'long-term survival' group, which could have provided important data on 40% of animals that

had a non-symptomatic esophageal stricture in the treated group. In order to provide analyzable and comparable data and histology, we chose to sacrifice all animals on day 14. Furthermore, since 100% of the control group exhibited an esophageal stricture on day 14 in this model, we believe this time point to be accurate in order to assess the effect of the experimental treatment. However, it is likely that the 40% of non-symptomatic pigs would have developed obstructive symptoms in the following days, thus suggesting that the Hemospray only had a temporary effect by delaying the fibrogenic process.

In conclusion, our results show that the application of Hemospray after endoscopic mucosal resection in the esophagus reduces inflammation, fibrogenesis, and scar tissue formation, and favors the wound healing process. The mode of action of Hemospray is consistent with the proposed hypothesis of its provision of mechanical protection of the bare muscularis propria and residual submucosa against physical, chemical, and microbial aggression, but could also suggest an intrinsic anti-fibrotic property of the powder. It will be of interest to study the effect of combining the hemostatic powder with systemic anti-inflammatory agents, such as corticosteroids, which further prevent strictures through acting as an adjuvant that limits inflammation in the esophageal wall after endoscopic mucosal resection.

Acknowledgments

The authors thank the animal attendants from the School of Surgery of the Assistance Publique-Hôpitaux de Paris, and Mrs Mathilde Bahaud, Inserm Unit 1016 and Immunology department, Cochin Hospital, Paris, France for her technical support.

References

- Bennett C, Vakil N, Bergman J *et al.* Consensus statements for management of Barrett's dysplasia and early-stage esophageal adenocarcinoma, based on a Delphi process. *Gastroenterology* 2012; 143: 336–46.
- Katada C, Muto M, Manabe T, Boku N, Ohtsu A, Yoshida S. Esophageal stenosis after endoscopic mucosal resection of superficial esophageal lesions. *Gastrointest Endosc* 2003; 57: 165–9.
- Ono S, Fujishiro M, Niimi K *et al.* Long-term outcomes of endoscopic submucosal dissection for superficial esophageal squamous cell neoplasms. *Gastrointest Endosc* 2009; 70: 860–6.
- Ono S, Fujishiro M, Niimi K *et al.* Predictors of postoperative stricture after esophageal endoscopic submucosal dissection for superficial squamous cell neoplasms. *Endoscopy* 2009; 41: 661–5.
- Na H K, Choi K D, Ahn J Y *et al.* Outcomes of balloon dilation for the treatment of strictures after endoscopic submucosal dissection compared with peptic strictures. *Surg Endosc* 2013; 27: 3237–46.
- Takahashi H, Arimura Y, Okahara S *et al.* Risk of perforation during dilation for esophageal strictures after endoscopic resection in patients with early squamous cell carcinoma. *Endoscopy* 2011; 43: 184–9.
- Wen J, Lu Z, Liu Q. Prevention and treatment of esophageal stenosis after endoscopic submucosal dissection for early esophageal cancer. *Gastroenterol Res Pract* 2014; 2014: 457101. doi: 10.1155/2014/457101.
- Ohki T, Yamato M, Ota M *et al.* Application of regenerative medical technology using tissue-engineered cell sheets for endoscopic submucosal dissection of esophageal neoplasms. *Dig Endosc* 2015; 27 (2): 182–8.
- Kobayashi S, Kanai N, Ohki T *et al.* Prevention of esophageal strictures after endoscopic submucosal dissection. *World J Gastroenterol* 2014; 20: 15098–109.
- Yamaguchi N, Isomoto H, Nakayama T *et al.* Usefulness of oral prednisolone in the treatment of esophageal stricture after endoscopic submucosal dissection for superficial esophageal squamous cell carcinoma. *Gastrointest Endosc* 2011; 73 (6): 1115–21.
- Barret M, Pratico C A, Camus M *et al.* Amniotic membrane grafts for the prevention of esophageal stricture after circumferential endoscopic submucosal dissection. *PLoS ONE* 2014; 9: e100236.
- Iizuka T, Kikuchi D, Yamada A, Hoteya S, Kajiyama Y, Kaise M. Polyglycolic acid sheet application to prevent esophageal stricture after endoscopic submucosal dissection for esophageal squamous cell carcinoma. *Endoscopy* 2015; 47 (4): 341–4.
- Nieponice A, McGrath K, Qureshi I *et al.* An extracellular matrix scaffold for esophageal stricture prevention after circumferential EMR. *Gastrointest Endosc* 2009; 69: 289–96.
- Barkun A N, Moosavi S, Martel M. Topical hemostatic agents: a systematic review with particular emphasis on endoscopic application in GI bleeding. *Gastrointest Endosc* 2013; 77: 692–700.
- Holster I L, Brullet E, Kuipers E J, Campo R, Fernandez-Atutxa A, Tjwa E T. Hemospray treatment is effective for lower gastrointestinal bleeding. *Endoscopy* 2014; 46: 75–8.
- Smith L A, Stanley A J, Bergman J J *et al.* Hemospray application in nonvariceal upper gastrointestinal bleeding: results of the Survey to Evaluate the Application of Hemospray in the Luminal Tract. *J Clin Gastroenterol* 2014; 48: e89–92.
- Camus M, Marteau P, Pocard M *et al.* Validation of a live animal model for training in endoscopic hemostasis of upper gastrointestinal bleeding ulcers. *Endoscopy* 2013; 45: 451–7.
- Bowie E J, Owen C A Jr, Zollman P E, Thompson J H Jr, Fass D N. Tests of hemostasis in swine: normal values and values in pigs affected with von Willebrand's disease. *Am J Vet Res* 1973; 34: 1405–7.
- Roussi J, Andre P, Samama M *et al.* Platelet functions and haemostasis parameters in pigs: absence of side effects of a procedure of general anaesthesia. *Thromb Res* 1996; 81: 297–305.
- Tomizawa Y, Iyer P G, Wong Kee Song L M, Buttar N S, Lutzke L S, Wang K K. Safety of endoscopic mucosal resection for Barrett's esophagus. *Am J Gastroenterol* 2013; 108: 1440–7, quiz 8.
- Barret M, Pratico C A, Beuvon F *et al.* Esophageal circumferential en bloc endoscopic submucosal dissection: assessment of a new technique. *Surg Laparosc Endosc Percutan Tech* 2013; 23: e182–7.
- Hanaoka N, Ishihara R, Takeuchi Y *et al.* Intralesional steroid injection to prevent stricture after endoscopic submucosal dissection for esophageal cancer: a controlled prospective study. *Endoscopy* 2012; 44: 1007–11.
- Yamaguchi N, Isomoto H, Nakayama T *et al.* Usefulness of oral prednisolone in the treatment of esophageal stricture after endoscopic submucosal dissection for superficial esophageal squamous cell carcinoma. *Gastrointest Endosc* 2011; 73: 1115–21.
- Ishida T, Morita Y, Hoshi N *et al.* Disseminated nocardiosis during systemic steroid therapy for the prevention of esophageal stricture after endoscopic submucosal dissection. *Dig Endosc* 2015; 27 (3): 388–91.
- Ohki T, Yamato M, Okano T, Yamamoto M. Regenerative medicine: tissue-engineered cell sheet for the prevention of post-esophageal ESD stricture. *Gastrointest Endosc Clin N Am* 2014; 24: 273–81.
- Hellebrekers B W, Kooistra T. Pathogenesis of postoperative adhesion formation. *Br J Surg* 2011; 98: 1503–16.

- 27 Hashimoto S, Kobayashi M, Takeuchi M, Sato Y, Narisawa R, Aoyagi Y. The efficacy of endoscopic triamcinolone injection for the prevention of esophageal stricture after endoscopic submucosal dissection. *Gastrointest Endosc* 2011; 74: 1389–93.
- 28 Isomoto H, Yamaguchi N, Nakayama T *et al.* Management of esophageal stricture after complete circular endoscopic submucosal dissection for superficial esophageal squamous cell carcinoma. *BMC Gastroenterol* 2011; 11: 46.
- 29 Barret M, Batteux F, Beuvon F *et al.* N-acetylcysteine for the prevention of stricture after circumferential endoscopic submucosal dissection of the esophagus: a randomized trial in a porcine model. *Fibrogenesis Tissue Repair* 2012; 5: 8.
- 30 Pauli E M, Schomisch S J, Furlan J P *et al.* Biodegradable esophageal stent placement does not prevent high-grade stricture formation after circumferential mucosal resection in a porcine model. *Surg Endosc* 2012; 26: 3500–8.
- 31 Jennewein C, Tran N, Paulus P, Ellinghaus P, Eble J A, Zacharowski K. Novel aspects of fibrin(ogen) fragments during inflammation. *Mol Med* 2011; 17: 568–73.

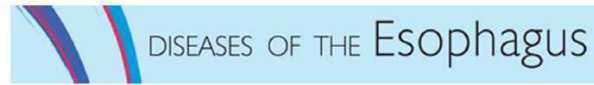3. Evaluation d'un peptide auto-assemblé comme agent préventif de la sténose œsophagienne après dissection sous-muqueuse circonférentielle

Self-assembling peptide matrix for the prevention of esophageal stricture after endoscopic resection: a randomized controlled trial in a porcine model.

Barret M, Bordacahar B, Beuvon F, Terris B, Camus M, Coriat R, Chaussade S, Batteux F, Prat F. (Accepté pour publication par Diseases of the Esophagus)

Le RADA-16 (Purastat, 3-D Matrix SAS, Caluire et Cuire, France) est un peptide auto-assemblé (self-assembling peptide ou SAP) se présentant sous la forme d'une solution aqueuse. En milieu riche en ions, les molécules du peptide s'assemblent pour former un réseau tridimensionnel de nanofibres, capable de servir de matrice à des cultures cellulaires in vitro, d'agent hémostatique en chirurgie vasculaire et digestive, et plus récemment en endoscopie digestive, ainsi que de pansement favorisant la repousse épithéliale cutanée in vitro et in vivo. Nous avons cherché à déterminer si l'application de SAP sur la zone de résection muqueuse laissée par une ESD circonférentielle permettait, par ses propriétés de la matrice ainsi formée, de favoriser la repousse épithéliale et de prévenir la sténose œsophagienne. Après une étude de faisabilité sur 8 animaux visant à optimiser l'application du SAP, et à s'assurer de sa stabilité dans l'œsophage, nous avons conduit un essai contrôlé et randomisé sur 10 porcs ayant tous une ESD circonférentielle du bas œsophage sur 5 cm, avec 5 animaux contrôles et 5 animaux traités par la mise en place de SAP immédiatement après la résection endoscopique. Le taux de sténose œsophagienne symptomatique était significativement abaissé dans le groupe traité (40% vs 100 %, $p=0.04$). Le diamètre œsophagien médian à J14 paraissait également plus important

dans le groupe traité, à 8 mm (2.5-9) contre 4 mm (3-4), quoique de façon non significative ($p=0.13$). Les index de sténose mesurés sur les opacifications œsophagiennes étaient de 0.32 (0.14-0.48) et 0.26 (0.14-0.33) pour les groupes traités et contrôle, respectivement ($p=0.42$). Enfin, la variation de poids était également en faveur du groupe hémospray, de +0.2Kg (-7.4; +1.8) dans le groupe traité à -3.8Kg (-5.4; +0.6) dans le groupe contrôle ($p=0.9$). A J28 cependant, tous les animaux avaient développé une sténose œsophagienne. Les critères de jugement histologiques (épaisseur du tissu de granulation, type d'infiltrat inflammatoire, épaisseur de fibrose œsophagienne pariétale, longueur du néoépithélium) n'étaient pas significativement différents entre les groupes. En conclusion, bien que les critères histologiques, difficilement interprétables en raison du sacrifice des animaux à des moments différents (J14 pour les contrôles, J21 à 28 pour la plupart des animaux traités), ne soient que peu informatifs dans ce travail, on peut conclure à un effet du SAP dans le ralentissement de la survenue de la sténose œsophagienne. Cependant, le caractère transitoire de cet effet pose la question de la stabilité du composé dans l'œsophage.



Self assembling peptide matrix for the prevention of esophageal stricture after endoscopic resection: a randomized controlled trial in a porcine model.

Journal:	<i>Diseases of the Esophagus</i>
Manuscript ID	Draft
Wiley - Manuscript type:	Original Manuscript
Date Submitted by the Author:	n/a
Complete List of Authors:	Barret, Maximilien; Cochin Hospital, Gastroenterology Bordaçahar, Benoit; Cochin Hospital, Gastroenterology Beuvon, Frédéric; Cochin Hospital, Pathology Terris, Benoit; Cochin Hospital, Pathology Camus, Marine; Cochin Hospital, Gastroenterology Coriat, Romain; Cochin Hospital, Gastroenterology Chaussade, Stanislas; Cochin Hospital, Gastroenterology Batteux, Frédéric; Cochin Hospital, Immunology Prat, Frédéric; Cochin Hospital, Gastroenterology
Keywords:	Esophageal strictures, Endoscopic submucosal dissection, Stenosis, self assembling peptide, Endoscopic resection

SCHOLARONE™
Manuscripts

1
2
3 **Article type:** original article
4
5
6

7 **Title:** Self assembling peptide matrix for the prevention of esophageal stricture after
8
9 endoscopic resection: a randomized controlled trial in a porcine model.
10
11

12
13 **Authors:** Maximilien Barret ^{1,2,3}, MD, MSc, Benoit Bordaçahar ^{2,3}, MD, Frédéric Beuvon ^{2,4},
14 MD, PhD, Benoit Terris ^{2,4}, MD, PhD, Marine Camus, MD, MSc ^{1,2,3}, Romain Coriat ^{1,2,3}, MD,
15
16 PhD, Stanislas Chaussade ^{1,2}, MD, PhD, Frédéric Batteux ^{2,3,5}, MD, PhD, Frédéric Prat ^{1,2,3},
17
18 MD, PhD.
19
20

21
22
23
24 ¹: Department of Gastroenterology, Cochin Hospital, Paris, France

25 ²: Faculté Paris Descartes, Paris, France

26 ³: Inserm Unit 1016, Paris, France

27 ⁴: Department of Pathology, Cochin Hospital, Paris, France

28 ⁵: Department of Immunology, Cochin Hospital, Paris, France
29
30

31
32 **Corresponding author:**

33 Maximilien Barret

34 Department of Gastroenterology, Cochin Hospital, Paris, France.

35 27, rue du Faubourg St Jacques, 75014 Paris

36 Email address: maximilien.barret@aphp.fr

37 Telephone number: +33(1)58411945

38 Fax number: +33(1)58411965
39
40

41 **Competing interest:** none
42
43

44 **Acknowledgements:** The authors thank 3-D Matrix Europe SAS for its material support
45
46 throughout the study by graciously providing the PuraStat®. Neither the company, nor any
47
48 of its member had a role in the design of the experiments or the interpretation of the data.
49
50

51 **Tables:** 2

52
53 **Figures:** 3
54
55

56
57 **References:** 24
58
59
60

1
2
3
4
5
6
7
8
9
10
11
12
13
14
15
16
17
18
19
20
21
22
23
24
25
26
27
28
29
30
31
32
33
34
35
36
37
38
39
40
41
42
43
44
45
46
47
48
49
50
51
52
53
54
55
56
57
58
59
60

Word Count: 1841

Keywords: endoscopic submucosal dissection (ESD); esophageal stricture; esophageal fibrosis; self-assembling peptide

Diseases of the Esophagus Proof

1
2
3
4
5
6
7
8
9
10
11
12
13
14
15
16
17
18
19
20
21
22
23
24
25
26
27
28
29
30
31
32
33
34
35
36
37
38
39
40
41
42
43
44
45
46
47
48
49
50
51
52
53
54
55
56
57
58
59
60

Abstract

Background and aims: Esophageal stricture formation after extensive endoscopic resection remains a major limitation of endoscopic therapy for early esophageal neoplasia. We assessed a recently developed self-assembling peptide (SAP) matrix as a wound dressing after endoscopic resection for the prevention of esophageal stricture.

Animals and methods: Ten pigs were randomly assigned to the SAP or the control group after undergoing a 5 cm long circumferential endoscopic submucosal dissection of the lower esophagus. Esophageal diameter on endoscopy and esophagogram, weight variation, and histological measurements of fibrosis, granulation tissue, and neopithelium were assessed in each animal.

Results: The rate of esophageal stricture at day 14 was 40 % in the SAP treated group vs. 100 % in the control group ($p=0.04$). Median (IQR) esophageal diameter at day 14 was 8 mm (2.5-9) in the SAP group vs. 4 mm (3-4) in the control group ($p=0.13$). The median (IQR) stricture indexes on esophagograms at day 14 were 0.32 (0.14-0.48) and 0.26 (0.14-0.33) in treated and control groups, respectively ($p=0.42$). Median (IQR) weight variation during the study was +0.2 (-7.4; +1.8) and -3.8 (-5.4; +0.6) in the treated and control groups, respectively ($p=0.9$). Fibrosis, granulation tissue, and neopithelium were not significantly different between the groups.

Conclusions: The application of SAP matrix on esophageal wounds after circumferential endoscopic submucosal dissection decreases the onset of esophageal stricture in our model, although not significantly altering fibrosis formation.

1
2
3
4
5
6
7
8
9
10
11
12
13
14
15
16
17
18
19
20
21
22
23
24
25
26
27
28
29
30
31
32
33
34
35
36
37
38
39
40
41
42
43
44
45
46
47
48
49
50
51
52
53
54
55
56
57
58
59
60

Introduction

Endoscopic resection has become the cornerstone of the diagnostic and therapeutic management of preneoplastic states and early esophageal neoplasia in the esophagus^{1,2}.

However, mucosal defects exceeding three quarters of the esophageal circumference (270°) induce the formation of an esophageal stricture in about 90 % of the cases^{3,4}. These strictures may require numerous endoscopic dilation procedures with significant patient discomfort and risk of esophageal perforation⁵.

Several strategies for post endoscopic stricture prevention have been proposed⁶: anti-inflammatory, antifibrotic, or antimetabolic drugs have been administered in order to suppress fibrogenesis in the esophageal wall. The most effective option appears to be the systemic administration of corticosteroids, however with a suboptimal efficacy⁷, and a risk of severe infectious morbidity⁸. The other option is to protect the esophageal wound from luminal stress, either by stimulating the epithelial growth with growth factor⁹, epithelial cell sheets¹⁰, or by covering the wound with mineral or organic wound dressings¹¹⁻¹⁶.

A novel self-assembling peptide (SAP), called PuraStat® (3-D Matrix Europe SAS, Caluire-et-Cuire, France) has been recently developed as a hemostatic agent. It consists in an aqueous solution of a short peptide, RADA-16 (4 [Arg-Ala-Asp-Ala]). Upon entering in contact with the physiologic ionic environment of body fluids, the peptide molecules self-assemble into nano-fibers (β -sheets) that quickly form a random 3-dimensional matrix. To the naked eye, the clear peptide solution transforms into a transparent, soft hydrogel. This SAP matrix has been shown to be suitable matrix for cell cultures¹⁷, a drug eluting component¹⁸, a wound dressing material, promoting wound healing in injured skin^{19,20} and mucosa²¹ and post endoscopic gastric ulcers²².

1
2
3 Our aim was to assess the PuraStat® SAP matrix as a biological wound dressing for the
4
5 prevention of esophageal stricture after circumferential endoscopic submucosal dissection
6
7 (ESD) in a pig model.
8
9

10 11 **Animals and Methods**

12 13 **Animal experiments**

14
15 The experimental protocol received approval from the animal ethical committee of the Paris
16
17 Descartes University (reference number 15-034). The animals were accommodated at our
18
19 facility 48 hours before the procedure took place. Endoscopies were performed under general
20
21 anesthesia. All animals were prepared for anesthesia with a 12-hour diet and were
22
23 administered an intramuscular injection of 10mg/kg ketamine and 2mg/kg azaperone, 30
24
25 minutes before induction. Following induction with 8 mg/kg intravenous 1% propofol and
26
27 endotracheal intubation, anesthesia was maintained through inhalation of 1% to 2%
28
29 isoflurane. Animals received an intravenous infusion of 10 mg/kg/h crystalloid solution.
30
31
32

33 34 **Study design and group allocation**

35
36 Ten pigs, originating from the same farm, were used for the study. All animals underwent a
37
38 circumferential endoscopic submucosal dissection (CESD) of the esophagus on a 5 cm height,
39
40 5 cm above the esophagogastric junction. Then, the animals were randomly allocated to
41
42 treatment by SAP (n= 5) or control group (n=5) using a sealed envelope.
43
44

45 46 **ESD procedure**

47
48 Upper gastrointestinal endoscopies were performed using a standard gastroscope (Fujinon
49
50 EG450D, Fujinon®, Sataima, Japan). CESD in the distal third of the esophagus was
51
52 performed as previously described²³.
53

54 55 **SAP application**

1
2
3 We conducted preliminary experiments to assess four modalities of SAP (PuraStat® 2.5%,
4 pH 3.4, 3-D Matrix Europe SAS, Caluire-et-Cuire, France) application in the esophagus:
5 submucosal injection of the SAP before ESD; injection of the SAP in the residual submucosa;
6 standard application on the esophageal wound after the procedure, using a dedicated 2.8 mm
7 catheter (Nozzle System type E Top Corporation, MPS Medical Product Service GmbH,
8 Germany); or application followed by spraying of hypertonic saline, in order to haste the
9 peptide matrix assembly. Each modality was assessed in two pigs. Only one pig in the
10 standard application group had a mild esophageal stricture at day 14, whereas all 7 others had
11 tight strictures. Furthermore, we observed the persistence of SAP adherent to the esophageal
12 wounds at day 1 and 2 after application.
13

14
15 Based on these data, we decided to use the standard application protocol with 6 mL of SAP
16 applied with a dedicated catheter immediately after the CESD. Pictures of the application of
17 the SAP are shown in Figure 1.
18

19 **Postoperative care and data collection**

20
21 Post-operative care was as follows: the animals were daily assessed by animal caretakers,
22 weekly by a veterinarian. A liquid diet was resumed on the first postoperative day for three
23 days, followed by semi-liquid feeding. Antibiotherapy with amoxicillin and clavulanate 1g x
24 2/day was given for the first three post-operative days. Finally, esomeprazole 40mg/d was
25 administered during all the study period after ESD.
26

27
28 Clinical data collected on a daily basis included behaviour, a quantitative and qualitative
29 assessment of food intake and occurrence of regurgitations or vomiting, whereas animals were
30 weighed once per week. The esophageal width was measured every week at the level of
31 the mid-oesophagus and the upper limit of CESD during sedated upper endoscopy.
32
33 Furthermore, an esophagogram was performed at day 14 and in case of symptoms suspicious
34 of an esophageal stricture.
35
36
37
38
39
40
41
42
43
44
45
46
47
48
49
50
51
52
53
54
55
56
57
58
59
60

1
2
3 When a symptomatic esophageal stricture, defined by an inability to reach the stomach with a
4
5 9 mm endoscope and associated symptoms (anorexia, regurgitations, weight loss) was
6
7 diagnosed, animals were euthanized with 100mg/kg intravenous injection of pentobarbital
8
9 (Dolethal®, Vétquinol, Paris, France). All the animals were euthanized after 28 days from
10
11 CESD, and underwent necropsy with en bloc esophagectomy.
12

13 14 **Histological analysis**

15
16 After gross morphological examination, specimens were fixed in 10% buffered formalin,
17
18 embedded in paraffin, and processed into 5µm-thick sections. Slides were stained with
19
20 hematoxylin eosin and saffron (HES) and digitized. A senior pathologist, blinded from the
21
22 treatment group, analyzed all slides. On digitized representative slides, he performed a
23
24 quantitative measurement of fibrosis, granulation tissue, and neopithelium (characterized by
25
26 round immature epithelial cells without native epithelial crest and chorionic papillae or
27
28 parakeratosis), as described elsewhere¹². The inflammatory cell infiltrate of the granulation
29
30 tissue was characterized as acute (predominance of polynuclear cells and high cell density) or
31
32 chronic (predominance of lymphocytes or plasmocytes, low cell density).
33
34
35
36

37 38 **Statistical analysis**

39
40 Statistical analysis was performed using Graphpad Prism® (GraphPad Software, La Jolla,
41
42 CA). Continuous data have been expressed as median values and interquartile range and
43
44 compared with an unpaired t-test. Categorical data have been expressed as percentages and
45
46 compared with a chi-square test. A p value <0.05 was considered to indicate statistical
47
48 significance.
49

50 51 **End points**

52
53 The primary end point was the occurrence of symptomatic esophageal stricture at day 14 after
54
55 CESD. Secondary endpoints were: weight variation, esophageal diameter at day 14, stricture
56
57 index at day 14 (measured by the ratio between the narrowest and the widest part of the
58
59
60

1
2
3 esophagus on esophagogram) and thickness of the fibrotic and granulation tissue layers, as
4
5 well as length of the neopithelium on pathology.

7 **Results**

8
9 Eleven pigs, with a median (IQR) weight of 31.2 Kg (30.2-31.9) were included in the study.
10
11 CESD was conducted in a median (IQR) operative procedure time of 35 min (25-40). In one
12
13 pig of the SAP group, an esophageal perforation required euthanasia. Since no outcome
14
15 measurement was available for this animal, another pig was included in the SAP group.

16
17
18 General clinical condition and animal behavior remained normal throughout the study, despite
19
20 major weight loss and regurgitations in some animals. At day 7, all animals had a normal food
21
22 tolerance and no esophageal stricture had occurred.

23
24
25 At day 14 after CESD, 40% (2/5) of pigs in the SAP treated group and 100% (5/5) in the
26
27 control group ($p=0.04$) had developed symptomatic esophageal stricture. Median (IQR)
28
29 esophageal diameter was 8 (2.5-9) mm in the SAP group vs. 4 (3-4) in the control group
30
31 ($p=0.13$). The median (IQR) stricture indexes at day 14 were 0.32 (0.14-0.48) and 0.26 (0.14-
32
33 0.33) in treated and control groups, respectively ($p= 0.42$). Main clinical and endoscopic
34
35 outcome measurements are presented in table 1. Three animals of the group treated with SAP
36
37 ultimately developed symptomatic esophageal strictures at day 21 and 28, as shown in figure
38
39
40
41
42 2.

43
44 Median (IQR) weight variation during the study were +0.2 (-7.4; +1.8) and -3.8 (-5.4; +0.6) in
45
46 the treated and control groups, respectively ($p =0.9$). Pathology results are presented in table
47
48 2. There were no statistically significant differences between groups in terms of esophageal
49
50 inflammation, fibrosis, or epithelial growth. Representative endoscopic, radiological, and
51
52 pathology findings of each group are shown in figure 3.

56 **Discussion**

1
2
3
4
5
6
7
8
9
10
11
12
13
14
15
16
17
18
19
20
21
22
23
24
25
26
27
28
29
30
31
32
33
34
35
36
37
38
39
40
41
42
43
44
45
46
47
48
49
50
51
52
53
54
55
56
57
58
59
60

In this study, we found that the PuraStat® SAP matrix significantly reduced the rate of esophageal stricture after circumferential esophageal ESD, and was associated with a doubled esophageal diameter at day 14 after CESD.

The pathophysiology of esophageal stricture is largely unknown. It is thought to involve luminal stress factors: mechanical factors resulting from food boluses and esophageal peristalsis, microbiological factors originating from the esophageal and oro-pharyngeal microbiome, and chemical factors resulting from gastric refluxate. The exposure of the submucosal space to these factors would induce an inflammatory and fibrogenic reaction leading to esophageal stricture⁶. The PuraStat® SAP forms in a biological environment a scaffold that closely mimics the structure and porosity of extracellular matrices, allowing for a biocompatible wound dressing. Previous studies have reported failures when using biological meshes secured with an esophageal stent^{13,24}, possibly because of the mechanical aggression of the stent itself. Conversely, wound covering strategies using mineral material such as the hemospray hemostatic powder¹¹ or biological materials such as polyglycolic acid sheets sticking to the esophageal wound have shown promising results in terms of stricture prevention^{15,16}. The SAP matrix is also thought to act as a wound dressing, opposing mechanical aggression. However, our data do not allow us to explain the effect of the SAP in terms of promotion of epithelial growth or reduction of inflammatory and fibrogenic activity in the esophagus. The tendency towards a more mature inflammatory cell infiltrate in the SAP treated group can probably also be explained by the later sacrifice of the animals in this group. Furthermore, the effect on stricture prevention was not sustainable, since all animals eventually developed esophageal strictures by day 28. Thus, the SAP matrix most likely delayed the onset of stricture formation, suggesting that the fibrogenic process starts over again as soon as the SAP has been washed away or degraded.

1
2
3
4
5
6
7
8
9
10
11
12
13
14
15
16
17
18
19
20
21
22
23
24
25
26
27
28
29
30
31
32
33
34
35
36
37
38
39
40
41
42
43
44
45
46
47
48
49
50
51
52
53
54
55
56
57
58
59
60

This is the first study to investigate a self-assembling peptide as a wound dressing in the esophagus after endoscopic resection. The strengths of this study include its methodology and a preliminary experiment aimed at defining the most suitable method of application.

However, the small number of animals is an important limitation. Secondly, animals were sacrificed when developing a symptomatic esophageal stricture: this led to analyze histological specimens at different time points, and might account for the absence of significant differences in histological outcomes.

Finally, the PuraStat® SAP matrix is a useful wound dressing for esophageal ulcers following circumferential endoscopic resection of the esophagus, as it did significantly prevent the occurrence of esophageal stricture in this study. However, the benefit was only limited in time. Further research should be conducted to hasten the assembling of the SAP matrix and improve its stability on the esophageal wounds. Furthermore, the SAP matrix could be used as a bio-active nanomaterial, by incorporating anti-inflammatory molecules such as triamcinolone, and wound healing stimulants such as epidermal growth factor, in order to limit fibrogenesis while enhancing the epithelial growth.

1
2
3
4
5
6
7
8
9
10
11
12
13
14
15
16
17
18
19
20
21
22
23
24
25
26
27
28
29
30
31
32
33
34
35
36
37
38
39
40
41
42
43
44
45
46
47
48
49
50
51
52
53
54
55
56
57
58
59
60

References:

1. Shaheen NJ, Falk GW, Iyer PG, Gerson LB. ACG Clinical Guideline: Diagnosis and Management of Barrett's Esophagus. *Am J Gastroenterol*. 2016 Jan; 111(1):30-50.
2. Pimentel-Nunes P, Dinis-Ribeiro M, Ponchon T, et al. Endoscopic submucosal dissection: European Society of Gastrointestinal Endoscopy (ESGE) Guideline. *Endoscopy*. 2015 Sep; 47(9):829-54
3. van Vilsteren FG, Pouw RE, Seewald S, et al. Stepwise radical endoscopic resection versus radiofrequency ablation for Barrett's oesophagus with high-grade dysplasia or early cancer: a multicentre randomised trial. *Gut*. 2011 Jun; 60(6):765-73.
4. Ono S, Fujishiro M, Niimi K, et al. Long-term outcomes of endoscopic submucosal dissection for superficial esophageal squamous cell neoplasms. *Gastrointest Endosc*. 2009 Nov; 70(5):860-5.
5. Takahashi H, Arimura Y, Okahara S, et al. Risk of perforation during dilation for esophageal strictures after endoscopic resection in patients with early squamous cell carcinoma. *Endoscopy*. 2011 Mar; 43(3):184-9
6. Barret M, Beye B, Leblanc S, et al. Systematic review: the prevention of oesophageal stricture after endoscopic resection. *Aliment Pharmacol Ther*. 2015 Jul; 42(1):20-39
7. Oliveira JF, Moura EG, Bernardo WM, et al. Prevention of esophageal stricture after endoscopic submucosal dissection: a systematic review and meta-analysis. *Surg Endosc*. 2015 Oct 20.
8. Ishida T, Morita Y, Hoshi N, et al. Disseminated nocardiosis during systemic steroid therapy for the prevention of esophageal stricture after endoscopic submucosal dissection. *Dig Endosc*. 2015 Mar; 27(3):388-91.

1
2
3
4
5
6
7
8
9
10
11
12
13
14
15
16
17
18
19
20
21
22
23
24
25
26
27
28
29
30
31
32
33
34
35
36
37
38
39
40
41
42
43
44
45
46
47
48
49
50
51
52
53
54
55
56
57
58
59
60

9. Juhl CO, Vinter-Jensen L, Jensen LS, Nexø E, Djurhuus JC, Dajani EZ. Systemic treatment with recombinant human epidermal growth factor accelerates healing of sclerotherapy induced esophageal ulcers and prevents esophageal stricture formations in pigs. *Dig Dis Sci* 1994; 39: 2671–8.
10. Ohki T, Yamato M, Ota M, et al. Prevention of esophageal stricture after endoscopic submucosal dissection using tissue-engineered cell sheets. *Gastroenterology* 2012; 143: 582–8 e1-2
11. Beye B, Barret M, Alatawi A, et al. Topical hemostatic powder promotes reepithelialization and reduces scar formation after extensive esophageal mucosal resection. *Dis Esophagus*. 2015 Jun 5.
12. Barret M, Pratico CA, Camus M, et al. Amniotic membrane grafts for the prevention of esophageal stricture after circumferential endoscopic submucosal dissection. *PLoS One*. 2014 Jul 3;9(7):e100236
13. Schomisch SJ, Yu L, Wu Y, et al. Commercially available biological mesh does not prevent stricture after esophageal mucosectomy. *Endoscopy* 2014; 46: 144–8.
14. Badylak SF, Hoppo T, Nieponice A, Gilbert TW, Davison JM, Jobe BA. Esophageal preservation in five male patients after endoscopic inner-layer circumferential resection in the setting of superficial cancer: a regenerative medicine approach with a biologic scaffold. *Tissue Eng Part A* 2011; 17: 1643–50.
15. Iizuka T, Kikuchi D, Yamada A, Hoteya S, Kajiyama Y, Kaise M. Polyglycolic acid sheet application to prevent esophageal stricture after endoscopic submucosal dissection for esophageal squamous cell carcinoma. *Endoscopy* 2015; 47: 341–4
16. Sakaguchi Y, Tsuji Y, Ono S, et al. Polyglycolic acid sheets with fibrin glue can prevent esophageal stricture after endoscopic submucosal dissection. *Endoscopy*. 2015 Apr; 47(4):336-40

1
2
3
4
5
6
7
8
9
10
11
12
13
14
15
16
17
18
19
20
21
22
23
24
25
26
27
28
29
30
31
32
33
34
35
36
37
38
39
40
41
42
43
44
45
46
47
48
49
50
51
52
53
54
55
56
57
58
59
60

17. Hamada K, Hirose M, Yamashita T, Ohgushi H. Spatial distribution of mineralized bone matrix produced by marrow mesenchymal stem cells in self-assembling peptide hydrogel scaffold. *J Biomed Mater Res A*. 2008 Jan; 84(1):128-36.
18. Briuglia ML, Urquhart AJ, Lamprou DA. Sustained and controlled release of lipophilic drugs from a self-assembling amphiphilic peptide hydrogel. *Int J Pharm*. 2014 Oct 20; 474(1-2):103-11.
19. Schneider A, Garlick JA, Egles C. Self-assembling peptide nanofiber scaffolds accelerate wound healing. *PLoS One*. 2008 Jan 9; 3(1):e1410.
20. Meng H, Chen L, Ye Z, Wang S, Zhao X. The effect of a self-assembling peptide nanofiber scaffold (peptide) when used as a wound dressing for the treatment of deep second degree burns in rats. *J Biomed Mater Res B Appl Biomater*. 2009 May; 89(2):379-91.
21. Akiyama N, Yamamoto-Fukuda T, Takahashi H, Koji T. In situ engineering with synthetic self-assembling peptide nanofiber scaffolds, PuraMatrix, for mucosal regeneration in the rat middle-ear. *Int J Nanomedicine*. 2013; 8:2629-40.
22. Uraoka T, Ochiai Y, Fujimoto A, et al. A novel fully synthetic and self-assembled peptide solution for endoscopic submucosal dissection-induced ulcer in the stomach. *Gastrointest Endosc*. 2015 Dec 1. pii: S0016-5107(15)03085-0. doi: 10.1016/j.gie.2015.11.015.
23. Barret M, Pratico CA, Beuvon F, et al. Esophageal circumferential en bloc endoscopic submucosal dissection: assessment of a new technique. *Surg Laparosc Endosc Percutan Tech*. 2013 Oct;23(5):e182-7
24. Rajan E, Gostout C, Feitoza A, et al. Widespread endoscopic mucosal resection of the esophagus with strategies for stricture prevention: a preclinical study. *Endoscopy*. 2005 Nov; 37(11):1111-5.

1
2
3
4
5
6
7
8
9
10
11
12
13
14
15
16
17
18
19
20
21
22
23
24
25
26
27
28
29
30
31
32
33
34
35
36
37
38
39
40
41
42
43
44
45
46
47
48
49
50
51
52
53
54
55
56
57
58
59
60

Figure legends:

Figure 1: Application of the self-assembling peptide (SAP):

A: Deep submucosa and muscularis propria exposed after circumferential endoscopic submucosal dissection.

B: First drop of SAP sticking to the esophageal wall.

C: Further application of the SAP

D: Final aspect upon removal of the endoscope, with the esophagus filled with SAP.

Figure 2: Survival without symptomatic esophageal stricture

Figure 3: Representative aspects of the esophagus at day 14 in the groups treated with self-assembling peptide and controls.

A: Endoscopic view in a pig treated with SAP, showing a moderate narrowing of the esophagus and smooth, reepithelialised esophageal wall.

B: Endoscopic view in a control pig, showing a severe stricture with granulation tissue and persistent inflammation.

C: Barium esophagogram in the same pig treated with SAP, showing a mild narrowing of the esophagus.

D: Barium esophagogram in the same control pig, showing a severe narrowing of the esophagus.

E and F: Representative histological view in a pig treated with SAP (E) and a control (F), showing the neoeepithelium overgrowing the inflammatory infiltrate and fibrotic layer (Hematoxylin Eosin and Saffron, 25x).

1
2
3
4
5
6
7
8
9
10
11
12
13
14
15
16
17
18
19
20
21
22
23
24
25
26
27
28
29
30
31
32
33
34
35
36
37
38
39
40
41
42
43
44
45
46
47
48
49
50
51
52
53
54
55
56
57
58
59
60

Table 1: Weight loss, esophageal diameter variation in pigs treated with self-assembling peptide and controls at day 14.

Table 2: Pathology outcomes of in pigs treated with self-assembling peptide and controls.

Diseases of the Esophagus Proof

1
2
3
4
5
6
7
8
9
10
11
12
13
14
15
16
17
18
19
20
21
22
23
24
25
26
27
28
29
30
31
32
33
34
35
36
37
38
39
40
41
42
43
44
45
46
47
48
49
50
51
52
53
54
55
56
57
58
59
60

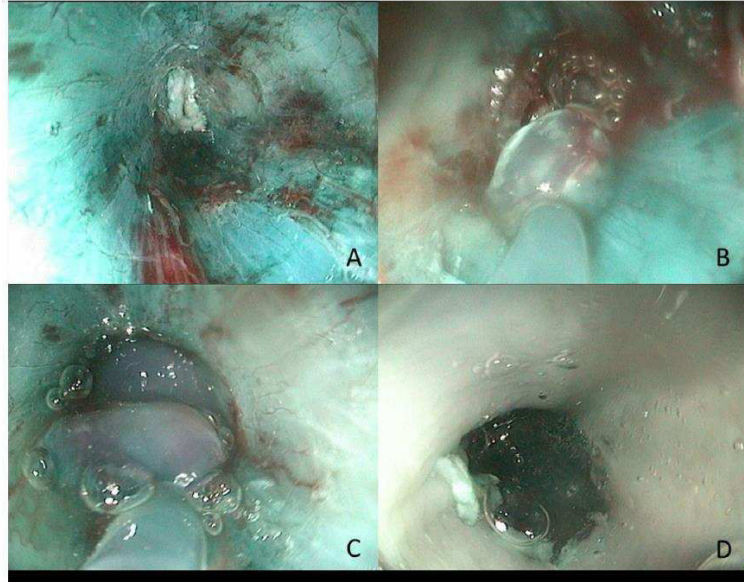


Figure 1: Application of the self-assembling peptide (SAP):
A: Deep submucosa and muscularis propria exposed after circumferential endoscopic submucosal dissection.
B: First drop of SAP sticking to the esophageal wall.
C: Further application of the SAP
D: Final aspect upon removal of the endoscope, with the esophagus filled with SAP

172x135mm (150 x 150 DPI)

1
2
3
4
5
6
7
8
9
10
11
12
13
14
15
16
17
18
19
20
21
22
23
24
25
26
27
28
29
30
31
32
33
34
35
36
37
38
39
40
41
42
43
44
45
46
47
48
49
50
51
52
53
54
55
56
57
58
59
60

Survival without symptomatic esophageal stricture

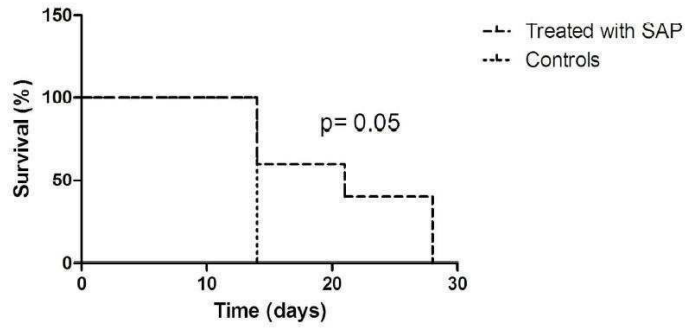


Figure 2: Survival without symptomatic esophageal stricture
150x80mm (300 x 300 DPI)

1
2
3
4
5
6
7
8
9
10
11
12
13
14
15
16
17
18
19
20
21
22
23
24
25
26
27
28
29
30
31
32
33
34
35
36
37
38
39
40
41
42
43
44
45
46
47
48
49
50
51
52
53
54
55
56
57
58
59
60

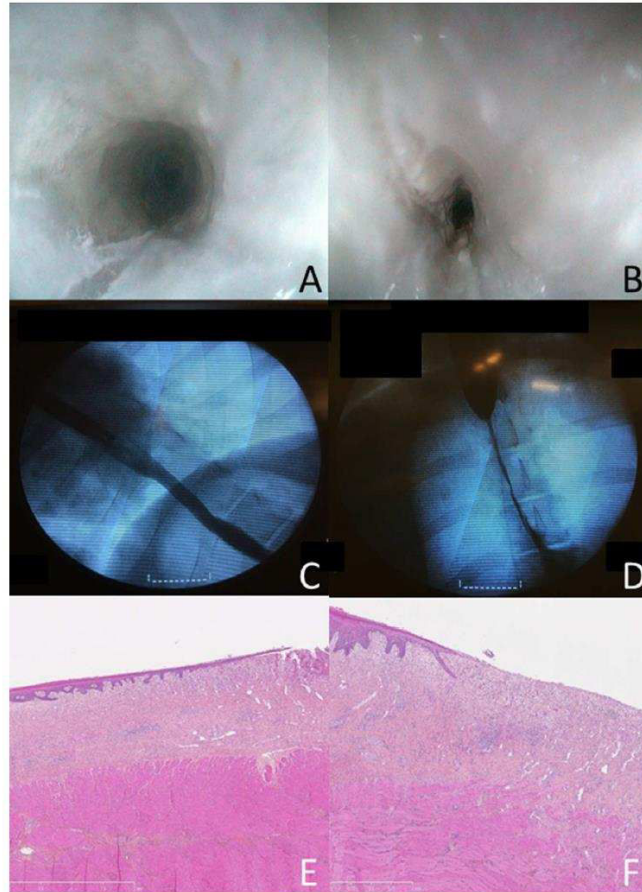


Figure 3: Representative aspects of the esophagus at day 14 in the groups treated with self-assembling peptide and controls.
 A: Endoscopic view in a pig treated with SAP, showing a moderate narrowing of the esophagus and smooth, reepithelialised esophageal wall.
 B: Endoscopic view in a control pig, showing a severe stricture with granulation tissue and persistent inflammation.
 C: Barium esophagogram in the same pig treated with SAP, showing a mild narrowing of the esophagus.
 D: Barium esophagogram in the same control pig, showing a severe narrowing of the esophagus.
 E and F: Representative histological view in a pig treated with SAP (E) and a control (F), showing the neopithelium overgrowing the inflammatory infiltrate and fibrotic layer (Hematoxylin Eosin and Saffron, 25x).

99x138mm (150 x 150 DPI)

Table 1: Weight loss, esophageal diameter variation in pigs treated with self-assembling peptide and controls at day 14.

	Treated with SAP (n=5)	Controls (n=5)	p
Weight variation † (kg) - median (IQR)	0.2 (-7.4 - 1.8)	-3.8 (-5.4- 0.6)	0.9
Esophageal diameter - median (IQR)	8 (2.5-9)	4 (3-4)	0.13
Stricture index - median (IQR)	0.32 (0.14-0.48)	0.26 (0.14-0.33)	0.42
Symptomatic stricture rate (%)	40%	100%	0.04

†: between day 0 and day 14

SAP: self-assembling peptide

IQR: interquartile range

Table 2: Pathology outcomes in pigs treated with self-assembling peptide and controls.

	Treated with SAP (n=5)	Controls (n=5)	p
Granulation tissue † - median (IQR)	118 (101-177)	122 (97-187)	0.9
Type of inflammatory cell infiltrate			
Acute	20% (1/5)	80% (4/5)	0.2
Chronic	80% (4/5)	20% (1/5)	
Esophageal fibrosis † - median (IQR)	262 (144-341)	170 (129-210)	0.2
Neo-epithelium † - median (IQR)	630 (269-3513)	1155 (706-1778)	0.7

SAP: self-assembling peptide

IQR: interquartile range

†: in μm

B. Etude mécanistique chez l'Homme

Comme nous l'avons détaillé plus haut, l'identification de voies de signalisation spécifiquement impliquées dans la fibrogénèse œsophagienne après résection endoscopique pourrait permettre de développer des traitements préventifs plus ciblés de la sténose œsophagienne. C'est la raison pour laquelle nous avons, avec l'aide du Fonds d'Aide pour la Recherche et l'Evaluation de la Société Nationale Française de Gastro-Entérologie, constitué une biobanque de biopsies œsophagiennes prélevées à différents temps de la cicatrisation après résection muqueuse à risque de sténose. L'analyse transcriptomique par microarray, comparant la muqueuse œsophagienne des patients ayant développé une sténose à celle de patients n'en développant pas, visera à identifier une signature moléculaire propre aux processus aboutissant à la sténose œsophagienne.

Depuis novembre 2014, avec l'autorisation du CPP Paris Ile de France III (S.C.3191), nous avons collecté des données cliniques, endoscopiques, histologiques, et des échantillons tissulaires œsophagiens de patients ayant subi une résection endoscopique étendue de l'œsophage. Afin de disposer d'un groupe contrôle, il était initialement prévu d'inclure un premier groupe de patients, dit à haut risque de sténose œsophagienne post-endoscopique, constitué de 5 patients traités par une ESD circonférentielle de l'œsophage en raison d'une dysplasie de haut grade ou d'un cancer superficiel de l'œsophage (carcinome épidermoïde ou adénocarcinome). La constitution d'une sténose œsophagienne étant quasiment constante après ESD circonférentielle, le chiffre de 5 patients paraît suffisant pour obtenir au moins 4 prélèvements de patients développant une sténose post-endoscopique. Ces quatre patients auraient été comparés à 4 patients témoins, ayant une intervention

endoscopique non à risque de sténose œsophagienne, telle qu'une ESD limitée à la moitié de la circonférence œsophagienne. En raison du taux de sténose œsophagienne effectivement observé dans le premier groupe de patients (cf infra), nous avons finalement inclus uniquement des patients consécutifs pris en charge par mucoséctomie ou dissection sous-muqueuse à haut risque de sténose (excédant les $\frac{3}{4}$ de la circonférence œsophagienne). Les inclusions étaient monocentriques à l'hôpital Cochin, et prospectives. Les patients incapables de donner un consentement éclairé ou d'adhérer au protocole de surveillance étaient exclus, de même que les patients ayant présenté un envahissement des marges de résection endoscopique, ou requérant une radiothérapie, une chimiothérapie, ou une chirurgie complémentaire. Huit biopsies de l'œsophage sain et huit de la zone cicatricielle ont été prélevées au cours du processus cicatriciel et réparties de la façon suivante :

- A J0, des biopsies de l'œsophage sain étaient prélevées en fin de geste, pour servir de témoin. Quatre biopsies sont prélevées sur l'œsophage sain, 3 cm en amont des berges de la zone de la résection endoscopique, immédiatement après l'ESD, sans rallonger significativement l'examen, ni ajouter à la morbidité du geste opératoire. Deux sont placées dans le trizol et immédiatement congelées à -80 °C pour analyse transcriptomique (cf infra), et deux placées dans le formol pour une analyse histologique.
- A J14, période correspondant à l'activité fibro-inflammatoire prévisible la plus importante, au cours de laquelle commence à se constituer la sténose œsophagienne cicatricielle, étaient prélevées six biopsies lors d'un contrôle endoscopique: deux sur la zone de résection, à proximité des berges, et placées dans le formol pour analyse histologique, et quatre (deux de

l'œsophage sain et deux de la zone cicatricielle) placées dans le Trizol® et immédiatement congelées à -80 °C pour analyse transcriptomique. Ce contrôle endoscopique, classiquement réalisé à la recherche de sténose, permet notamment le diagnostic et la dilatation précoce d'une éventuelle sténose œsophagienne cicatricielle. Aucune morbidité ni aucun évènement douloureux lié à la pratique de ces biopsies œsophagiennes n'est prévisible.

- A J90, correspondant au contrôle endoscopique sous anesthésie générale systématiquement réalisé après résection muqueuse endoscopique, l'activité inflammatoire de la zone cicatricielle et la fibrogénèse ont habituellement cessé. Six nouvelles biopsies œsophagiennes étaient obtenues et prises en charge selon les mêmes modalités qu'à J14.

Parmi 19 patients éligibles, 3 n'ont pas été inclus en raison de difficultés à comprendre le protocole ou d'un éloignement géographique compliquant la réalisation du contrôle à J14. Parmi les 16 patients inclus dans le travail, quatre ont été exclus en raison de la présence de critères histologiques de mauvais pronostic sur la pièce de résection, imposant un traitement complémentaire par chirurgie, radiothérapie, ou chimiothérapie, rendant le contrôle à J90 inutile ou non-informatif. Au total, 12 patients ont été inclus dans l'analyse (dont deux encore en cours de suivi), parmi lesquels 4 ont présenté une sténose œsophagienne ayant nécessité un traitement au cours du processus de cicatrisation. Les caractéristiques des patients sont résumées dans le tableau suivant :

Tableau 2 : Caractéristiques des patients recrutés dans l'étude transcriptomique de la cicatrisation œsophagienne

Patient	Sexe	Age	Antécédent significatif	Localisation	Type de résection	Histologie	Sténose
1	M	56	Radiofréquence œsophagienne, EMR	Tiers inférieur	ESD, circonférentielle	AdénoCa T1a m1	Non
2	F	57	Non	Tiers inférieur	ESD, 75% de la circonférence	AdénoCa T1a m2	Non
3	H	72	Non	Tiers inférieur	ESD, 90 % de la circonférence	AdénoCa T1a m3	Non
4	H	74	Non	Tiers moyen	ESD, 90 % de la circonférence	CE T1a m1	Oui
5	H	78	Non	Tiers moyen	ESD, 75 % de la circonférence	CE T1b sm profond	Non
6	H	71	Chirurgie et radiothérapie ORL	Tiers moyen	ESD, 75 % de la circonférence	CE T1b sm profond	Non
7	H	59	Radiofréquence œsophagienne	Tiers inférieur	ESD, circonférentielle	AdénoCa T1a m1	Non
8	H	74	Radiofréquence œsophagienne, EMR	Tiers inférieur	ESD, 75 % de la circonférence	AdénoCa T1a m1	Non
9	H	66	Non	Tiers inférieur	EMR, circonférentielle	AdénoCa T1a m1	Oui
10	H	55	Non	Tiers sup-moyen	ESD, circonférentielle	CE T1a m2	Oui
11	H	72	Chirurgie et radiothérapie ORL	Tiers moyen	ESD, circonférentielle	CE T1b sm profond	Oui
12	H	60	Non	Tiers Moyen	ESD, 90 % de la circonférence	CR T1b sm profond	?

EMR : mucosectomie endoscopique

ESD : dissection sous-muqueuse endoscopique

Concernant ce travail, compte tenu du taux inhabituellement bas de sténose œsophagienne observé de 36 % (contre 80-90% dans la littérature), la période d'inclusion a du être prolongée, afin de disposer d'au moins 4 cas de patients « sténoseurs », à comparer avec 4 cas de patients « non sténoseurs ».

Ainsi, l'analyse histologique détaillée, l'extraction de l'ARN et l'analyse transcriptomique pourront débuter dès l'acquisition du prélèvement J90 du dernier patient, prévue au mois de décembre 2016.

Les prélèvements biopsiques sont étudiés de la façon suivante :

- Analyse histologique : les deux biopsies sont fixées dans le formol à 10% pendant 24h, et examinées en histologie standard après coloration en hématoxyline-éosine-safran et trichrome de Masson (permettant une meilleure appréciation de la fibrose tissulaire) après inclusion en paraffine et coupe à 5µm. L'épaisseur du tissu de granulation et de la fibrose cicatricielle seront mesurées en µm après numérisation des lames. Des techniques complémentaires d'immunohistochimie seront à prévoir sur les blocs en fonction des résultats de l'analyse transcriptomique, notamment: expression tissulaire de l' α -SMA (densité myofibroblastique), des collagène I et III (constituants du tissu fibrotique aux stades précoces et tardifs de la cicatrisation).
- Les autres biopsies sont placées en salle d'examen dans 1 mL de Trizol et seront immédiatement acheminées sur de la glace jusqu'à l'UI 1016 où elles seront congelées à -80 °C. Après extraction de l'ARN cellulaire total, une analyse transcriptomique par microarray (puce à ADN whole genome Affymetrix) sera réalisée au sein de la plateforme génom'ic de l'institut

Cochin. Nos travaux préliminaires ont établi que 2 biopsies œsophagiennes permettaient d'extraire 30 µL avec 69-104 à 40-119 ng/µL d'ARN selon que les biopsies concernaient une zone cicatricielle ou la muqueuse œsophagienne normale. La qualité de l'ARN, appréciée par le RIN (RNA integrity number) de 7 (/10), le ratio d'ARN 28S/18S (0.4 à 0.7), et le profil électrophorétique, est jugée satisfaisante. Les transcriptomes seront étudiés avec l'aide d'un bioinformaticien de la plateforme (logiciels R, Bioconductor, Partek GS®, IPA®, GePS® et Pathway Studio®), pour l'analyse primaire (normalisation des données, fichier d'annotations, analyse non supervisée, puis supervisée) comme pour l'analyse fonctionnelle à la recherche de l'expression différentielle de gènes impliqués dans l'inflammation, la prolifération tissulaire, et la fibrogénèse, entre J0 et J14, et J90, entre les 4 patients ayant développé une sténose et les 4 témoins.

Le résultat attendu est l'identification de gènes, et donc de protéines cibles, impliquées dans des voies de signalisation de fibrogénèse tissulaire spécifiques ou surexprimées chez les patients développant une sténose œsophagienne post-endoscopique. Certaines voies sont prévisibles à partir des autres processus de fibrogénèse œsophagienne, en particulier la voie de signalisation du TGF β1, canonique (smad 4, smad 2/3) ou non canonique (RAS/ERK, p38/ERK, ROCK, TAK1, PI3K, TRAF4/6, NFKB); la voie de CTGF (CCN2), du PDGF, ou encore la balance NOX2/NRF2: l'objet de ce travail est de les documenter ou d'en identifier de nouvelles ou de plus spécifiques. Après validation des résultats par qPCR et/ou immunohistochimie, l'inhibition préventive pharmacologique des voies de signalisation en cause pourrait alors être testée d'abord sur la souris, puis sur notre

modèle préclinique porcin, avant de la proposer en prévention de la sténose après résection endoscopique d'un cancer superficiel circonférentiel chez l'Homme dans le cadre d'une étude de phase I.

C. Essais thérapeutiques sur modèle de petit animal

Disposer d'un modèle de petit animal de sténose œsophagienne post endoscopique permettrait de dépasser certaines des limites du modèle porcin, telles que sont le coût élevé, les doses importantes de traitements médicamenteux nécessaires, les limites éthiques et logistiques à l'emploi de porcs en grand nombre, (pourtant nécessaire à la mise en évidence d'effets statistiquement significatifs, comme plusieurs de nos travaux expérimentaux ont pu le suggérer), et l'absence d'utilisation aisée ou fiable de nombreux protocoles d'étude de la fibrose mis au point essentiellement chez la souris. Le troisième volet de notre projet consiste donc à développer un modèle de sténose œsophagienne cicatricielle sur la souris, qui permettrait, sur la base de l'expérience antérieure du laboratoire (U1016, Pr Batteux) dans l'étude des mécanismes de la fibrogénèse et du stress oxydant (essentiellement sur des modèles de souris sclérodermiques) d'une part, de la connaissance des voies d'inflammation et de fibrogénèse suggérées par l'étude transcriptomique d'autre part, d'évaluer l'intérêt de différents modulateurs pharmacologiques du stress oxydant et/ou de l'inflammation.

La première étape vise donc à mettre au point un modèle murin de sténose œsophagienne cicatricielle consécutive à une lésion reproduisant l'effet d'une exérèse endoscopique circulaire. En effet, les modèles de sténose œsophagienne sur le petit animal concernent principalement les sténoses caustiques chez le rat ²⁰⁸,

²⁰⁹, obtenues après exposition d'un segment isolé du tiers inférieur de l'œsophage à de la soude caustique à 50% pendant 90 secondes. Ce modèle, qui donne près de 20% de mortalité chez le rat ²¹⁰, paraît difficilement applicable chez la souris en raison de ses dimensions plus faibles, et sa pertinence est incertaine pour étudier la cicatrisation œsophagienne post endoscopique, dans la mesure où les lésions tissulaires sont transmurales. Aucun modèle de sténose œsophagienne chez la souris n'existe à ce jour, la seule tentative décrite utilisant la photothérapie dynamique s'étant soldée par un échec ²¹¹.

Après ablation muqueuse circonférentielle du bas œsophage sous anesthésie générale, les animaux sont réveillés. Ils sont réalimentés à H4, puis sont pesés quotidiennement. Leur comportement est évalué, et, en cas de perte de poids ou de décès, une autopsie, un prélèvement œsogastrique et une analyse macroscopique et histologique (coloration HES) sont réalisés. Les animaux sont sacrifiés au plus tard à J28, ou plus tôt en cas de perte de plus de 15% du poids du corps ou de signes de souffrance. La faisabilité d'une évaluation endoscopique à l'aide d'une fibre optique, insérée par voie antérograde (Spyglass system, Boston Scientific®), a été documentée.

Les premières tentatives de création de lésion œsophagienne ont été réalisées à l'aide d'une minisonde d'Argon (4.5 F, soit 1.5 mm) et ont impliqué 24 souris femelles Balb C de six semaines. Sous anesthésie générale par isoflurane 2%, après tonte du dos de l'animal, celui-ci est déposé en décubitus dorsal sur une plaque électrochirurgicale pour nourrisson. On réalise une laparotomie permettant d'exposer la partie antérieure de l'estomac, qui est incisée, permettant de cathétériser de façon rétrograde l'œsophage à l'aide de la sonde d'Argon, sur 5 mm

environ. Compte tenu de la rigidité de la sonde, il est en effet impossible d'introduire celle-ci par voie orale sans perforer l'œsophage cervical. L'application est illustrée par la figure 10. Plusieurs doses d'énergie et débit d'argon ont été réalisés (1 application d'une seconde à 40 W, 0.6 L/mn, 1 application d'une seconde à 40 W et 0.3L/mn, 1 application d'une seconde à 30 W et 0.3L/mn, et une ou deux applications d'une seconde à 20 W et 0.2L/mn, chaque condition ayant été évaluée sur au moins 4 animaux). La seule condition ayant permis la survie des animaux au-delà de trois jours était 1 application 20 W 0.2L/mn. Les différentes conditions d'applications testées sont rappelées dans le tableau 3.

Figure 10 : Application de l'électrocoagulation au plasma argon dans l'œsophage de souris. A : insertion de la sonde de façon rétrograde dans le bas œsophage sur 5 mm (flèche) ; B : aspect de l'œsophage, blanchi après électrocoagulation.

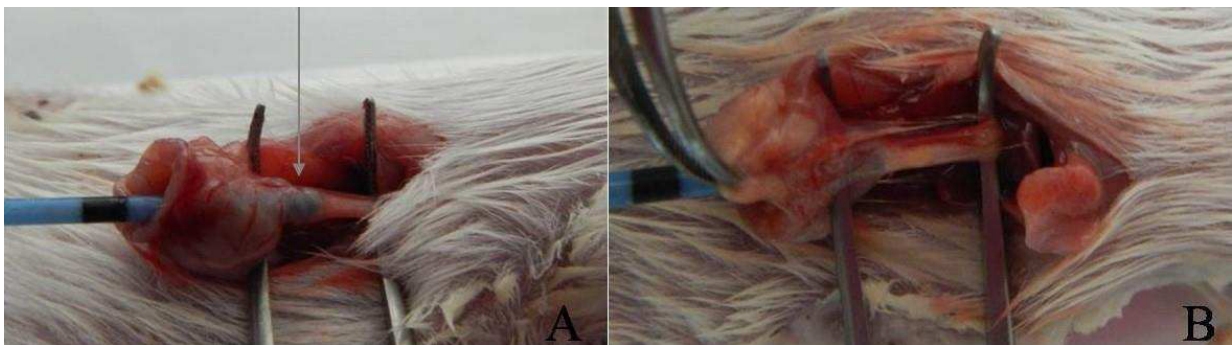


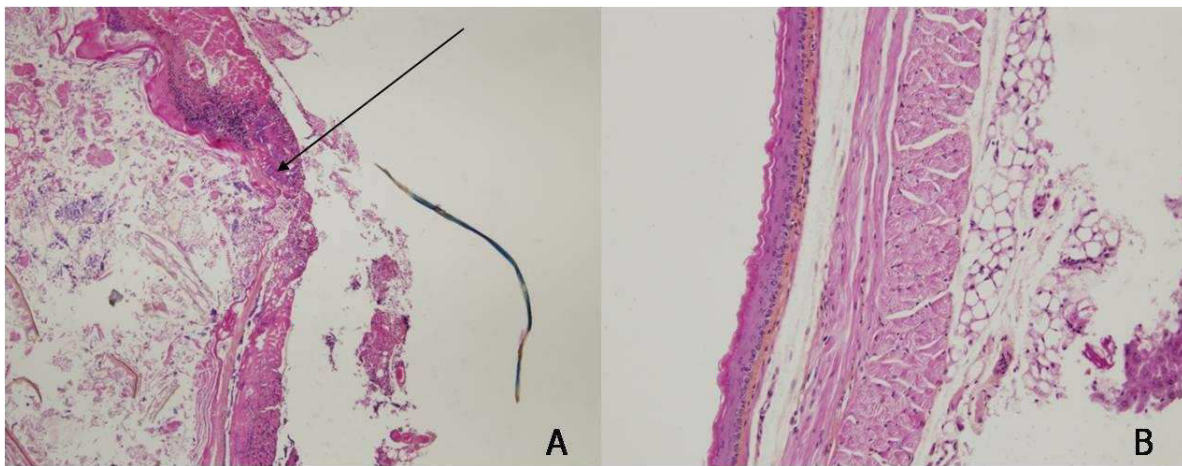
Tableau 3 : Différents régimes d'électrocoagulation au plasma argon testés sur l'œsophage de souris

Nombre d'animaux	Puissance (W)	Volume d'Argon (L/mn)	Tirs	Survie	Résultats
4	40	0.6	2 x 1 s	Non	faisabilité
3	40	0.6	2 x 1 s	J28	pas de perte de poids ou de sténose
5	40	0.3	2 x 1 s	J0-J3	décès post opératoire (n=1) perforation oesophagienne précoce (n=1) perforations oesophagienne retardée (n=3)
4	30	0.3	2 x 1s	J2 – J3	perforations oesophagiennes retardées (n=4)
4	20	0.2	1 x 1s	J3 – J28	perforation oesophagienne retardée (n=1) pas de perte de poids ni de sténose (n=3)
4	20	0.2	1x 1s	J1 – J28	fuite sur la suture gastrique (n=1) pas de perte de poids ni de sténose (n=3)

L'analyse histologique montre l'absence de sténose œsophagienne, et un œsophage perforé chez les animaux décédés ou ayant du être sacrifiés à J3, ou encore un

œsophage strictement normal, non cicatriciel, chez les animaux ayant survécu jusqu'à J28. La figure 11 illustre ces constatations.

Figure 11 : Deux types d'aspects histologiques observés dans l'œsophage de souris après ablation au plasma argon. A : Aspect de perforation œsophagienne retardée (flèche) avec inflammation et nécrose transmurale. B : Paroi œsophagienne normale.



En conclusion, non seulement aucun des animaux n'a développé de sténose œsophagienne, mais la quantité d'énergie délivrée ne paraît pas reproductible, au vu des résultats cliniques et histologiques. En effet, l'énergie semblait délivrée selon la loi du « tout ou rien », selon que l'arc électrique se formait à l'extrémité de la sonde. Ceci aboutissait ou bien à une quantité d'énergie importante aboutissant à la perforation œsophagienne, ou bien à l'absence de lésion significative. Enfin, le contact étroit entre la sonde et les parois œsophagiennes de la souris ne semble pas pouvoir autoriser une application circonférentielle de l'énergie, mais seulement focalisée en un point. Avant d'envisager l'utilisation d'un autre outil pour léser circonférentiellement le bas œsophage en vue de l'établissement du modèle, nous

allons envisager l'utilisation de plus faibles puissances et la rotation de la sonde dans l'œsophage.

Mon année de mobilité à l'Academic Medical Center d'Amsterdam (2014-2015) m'a permis de poursuivre mon travail sur l'abord chirurgical de l'estomac de souris, dans le cadre d'un protocole légèrement différent, visant à réaliser une cryoablation à la jonction épithéliale glandulaire et malpighienne, située chez la souris à la partie proximale de l'estomac. Aucun des 24 animaux traités n'a développé de sténose, malgré des protocoles de cryoablation de durée variable, réalisés à l'aide d'azote liquide et d'un coton-tige, et impliquant le plus souvent le versant gastrique du cardia.

Des essais pourraient être envisagés en utilisant la radiofréquence appliquée à l'aide d'une sonde souple, passant à travers un cathéter de 4F. En cas d'échec, de nouvelles tentatives chez le rat, dont les dimensions sont supérieures et le contrôle visuel du geste par minisonde d'endoscopie, seront envisagés.

Une fois le modèle de petit animal développé, la dernière phase du projet visera à étudier les voies métaboliques de la fibrogénèse potentiellement activées dans la constitution d'une sténose (espèces réactives de l'oxygène, voie cannabinoïde (CB1/2 et CB2R), TGF- β – P-SMAD2/3, PDGFR- β et VEGFR, antagoniste des récepteurs à l'angiotensine II (ATIIR), NOTCH/ADAM17) à partir de prélèvements de sérum et de pièces histologiques d'œsophage. Sur la base de l'expérience antérieure du laboratoire dans l'étude des mécanismes de la fibrogénèse et du stress oxydant sur la souris (notamment sur des modèles de souris sclérodermiques), nous utiliserons des inhibiteurs pharmacologiques du stress oxydant (inhibiteurs de la voie cannabinoïde, sunitinib, irbesartan, DAPT, alicine,

mimétique de SOD). Au total 10 groupes de 10 (+2) animaux sont envisagés pour chaque traitement, avec un groupe traité et un groupe contrôle pour chacun des 5 traitements. Le taux de mortalité évalué à 20% permettra d'obtenir in fine des groupes d'étude de 10 animaux ce qui permettra de réaliser des tests d'ANOVA suivie de tests de comparaisons multiples. Le choix des voies métaboliques à étudier sera naturellement discuté à la lumière des résultats de l'étude transcriptomique dont les résultats seront observables à la fin de l'année 2016.

Outre les mesures cliniques (poids), et les contrôles endoscopiques, les éléments suivants seront évalués à partir de prélèvements de sérum et de pièces histologiques d'œsophage :

- Histologie standard (HES): index de sténose, épaisseur du tissu de granulation et de la fibrose, longueur du néoépithélium.
- Quantification de la fibrose (rouge sirius, dosage du collagène total dans des échantillons tissulaires)
- Evaluation par RT-PCR de l'activité des gènes suivants: collagène I, Collagène III, VEGF, TGFbeta, TNFa, Il1b, MCP1, INF γ , IL10, IL 4 ou 11, IL13.
- Evaluation par western blot de l'expression de l'alfa SMA, de pERK, ERK, et SMAD 3.
- Quantification de la population myofibroblastique (α -SMA par immunohistochimie).

II. Travaux cliniques

- A. La mucosectomie endoscopique associée à la radiofréquence pour cancers superficiels sur œsophage de Barrett en un même temps endoscopique.

Single-session endoscopic resection and focal radiofrequency ablation for short-segment Barrett's esophagus with early neoplasia.

Barret M, Belghazi K, Weusten BL, Bergman JJ, Pouw RE. *Gastrointest*

Endosc. 2016 Jul; 84(1):29-36

Le traitement de référence de l'adénocarcinome œsophagien superficiel associe la résection endoscopique suivie, après cicatrisation muqueuse, de l'ablation par radiofréquence de l'œsophage de Barrett résiduel. Ce processus nécessite en moyenne 4 endoscopies thérapeutiques, auxquelles viennent s'ajouter la ou les endoscopies diagnostiques. Dans une étude bicentrique rétrospective, nous avons évalué l'efficacité de la combinaison en un seul temps endoscopique de la résection endoscopique et de la radiofréquence. Quarante patients ont été inclus, ayant un œsophage de Barrett d'extension médiane C1M2, et une lésion visible de 15 mm, comportant un adénocarcinome intra-muqueux dans 68% des cas. La mucosectomie était réalisée au capuchon dans la majorité des cas, avec une médiane de 3 fragments réséqués. L'ablation par radiofréquence de l'œsophage de Barrett résiduel était réalisée à l'aide d'une sonde focale à 90°, par double ou triple application entre 12 et 15J/cm². Chez 43% des patients, cette séance de traitement combiné permettait d'obtenir la rémission complète de la néoplasie et de la métaplasie intestinale, tandis qu'à la fin de la période de traitement (incluant 1 à 2 séances complémentaires de RFA), l'éradication de toute néoplasie et de toute métaplasie intestinale était obtenue chez 95 % des patients, et maintenue respectivement chez 85 et 82.5% des patients après 19 mois de suivi médian. Une perforation

œsophagienne retardée (2.5% des cas) était traitée médicalement, et 13 (33%) patients présentaient une sténose œsophagienne traitée par une médiane de 2 dilatations endoscopiques. En conséquence, la réalisation d'un traitement combiné associant résection endoscopique et radiofréquence endoscopique est faisable, et pourrait permettre d'économiser une étape dans la prise en charge des adénocarcinomes superficiels de l'œsophage lorsque l'extension circulaire et longitudinale de l'OB est limitée (<C2 dans l'étude). Le fort taux de complication observé requiert cependant de réévaluer ce type de traitement avec un protocole de radiofréquence moins agressif. Son application à des OB plus étendus reste également à évaluer.

Single-session endoscopic resection and focal radiofrequency ablation for short-segment Barrett's esophagus with early neoplasia

Maximilien Barret, MD, MSc,¹ Kamar Belghazi, MD,¹ Bas L. A. M. Weusten, MD, PhD,^{1,2}
Jacques J. G. H. M. Bergman, MD, PhD,¹ Roos E. Pouw, MD, PhD¹

Amsterdam, Nieuwegein, The Netherlands

Background and Aims: The management of early neoplasia in Barrett's esophagus (BE) requires endoscopic resection of visible lesions, followed by radiofrequency ablation (RFA) of the remaining BE. We evaluated the safety and efficacy of combining endoscopic resection and focal RFA in a single endoscopic session in patients with early BE neoplasia.

Methods: This was a retrospective analysis of patients with early BE neoplasia and a visible lesion undergoing combined endoscopic resection and focal RFA in a single session. Consecutive ablation procedures were performed every 8 to 12 weeks until complete endoscopic and histologic eradication of dysplasia and intestinal metaplasia were reached.

Results: Forty patients were enrolled, with a median C1M2 BE segment, a visible lesion with a median diameter of 15 mm, and invasive carcinoma in 68% of cases. Endoscopic resection was performed by using the multiband mucosectomy technique in 80% of cases, and the Barrx⁹⁰ catheter (Barrx Medical, Sunnyvale, Calif) was used for focal ablation. When an intention-to-treat analysis was used, both complete remission of all neoplasia and intestinal metaplasia were 95% after a median follow-up of 19 months. Stenoses occurred in 33% of cases and were successfully managed with a median number of 2 dilations. In 43% of patients, 1 single-session treatment resulted in complete histologic remission of intestinal metaplasia.

Conclusions: Combining endoscopic resection and focal RFA in a single session appears to be effective. Less-aggressive RFA regimens could limit the adverse event rates. (Gastrointest Endosc 2016;84:29-36.)

Endoscopic therapy is currently the treatment of choice for patients with Barrett's esophagus (BE) containing high-grade dysplasia (HGD) or early adenocarcinoma.¹ Radiofrequency ablation (RFA) alone has been shown to be effective in eradicating nondysplastic BE and flat dysplastic BE with good long-term efficacy.²⁻⁷ Visible lesions, possibly containing more advanced histology, require endoscopic resection, providing a tissue sample for optimal histologic assessment.⁸ A combined treatment approach

with endoscopic resection of visible lesions, followed 8 to 12 weeks later by RFA of the remaining BE has proven successful, resulting in complete remission of neoplasia and intestinal metaplasia in 90% of patients, up to 5 years after treatment.⁴ This strategy of complete BE eradication aims at preventing the development of metachronous neoplasia in the remaining BE mucosa, which is known to occur in up to 30% of patients after focal endoscopic resection of neoplasia.⁹

Abbreviations: APC, argon plasma coagulation; BE, Barrett's esophagus; HGD, high-grade dysplasia; RFA, radiofrequency ablation.

DISCLOSURE: J. Bergman received financial support for research from Covidien/Medtronic, Olympus Endoscopy, Cook Medical, Boston Scientific, Erbe Medical, C2Therapeutic, and Ninepoint Medical. He is a consultant for Boston Scientific, Cook Medical, and Covidien/Medtronic. B. Weusten received financial support for research from Covidien/Medtronic, Erbe Medical, and C2Therapeutic. He is a consultant for Boston Scientific and C2Therapeutic. All other authors disclosed no financial relationships relevant to this publication.

Copyright © 2016 by the American Society for Gastrointestinal Endoscopy

0016-5107/\$36.00

<http://dx.doi.org/10.1016/j.gie.2015.12.034>

Received October 7, 2015. Accepted December 15, 2015.

Current affiliations: Department of Gastroenterology, Academic Medical Center, Amsterdam (1), Department of Gastroenterology, St. Antonius Hospital, Nieuwegein, The Netherlands (2).

Reprint requests: Roos E. Pouw, MD, PhD, Department of Gastroenterology and Hepatology, Academic Medical Center, Meibergdreef 9, 1105 AZ Amsterdam, The Netherlands.

Generally, when patients have undergone endoscopic resection for a visible lesion, the first RFA treatment is performed by using the balloon-based RFA catheter for circumferential ablation. However, in short-segment BE (defined as <3 cm long¹⁰) or after extensive endoscopic resection, little BE mucosa is left for RFA after endoscopic resection. In these cases, focal RFA can be used to treat the remaining columnar epithelium. Sometimes this approach is complicated by scarring and narrowing of the esophagus after prior endoscopic resection, making passage of the focal RFA catheter and good mucosal contact difficult.

We hypothesized that combining endoscopic resection for visible lesions with RFA of the remaining BE mucosa in a single session is safe and results in effective eradication of BE mucosa.

The aim of this study was to evaluate the safety and efficacy of this combined single-session procedure.

PATIENTS AND METHODS

Study setting

This is a retrospective analysis of a prospectively registered patient cohort. Patients were treated in 2 Dutch tertiary-care referral centers for the management of BE neoplasia: the Academic Medical Center, Amsterdam, and the St. Antonius Hospital, Nieuwegein. Patient demographics, procedural data, and follow-up data were prospectively collected in a central database (ProMISE, Leiden University Medical Center, The Netherlands).

Selection criteria

We identified all patients treated with endoscopic resection and focal RFA in a single procedure. For this study we included patients if they met the following inclusion criteria: aged ≥ 18 years; histologically proven BE with a visible lesion; no endoscopic signs of possible deep submucosal growth (ie, >T1sm1 [TNM Atlas, 6th Edition, Chichester, West Sussex, UK]), such as large protruded lesion type or ulcerated lesions; no previous endoscopic or surgical treatment for BE-related neoplasia; no esophageal stenosis at baseline and no esophageal varices; and informed consent.

Endoscopic procedures

Endoscopic work-up. Before-procedure assessment consisted of at least 1 endoscopy with high-resolution white light endoscopy and virtual chromoendoscopy. The BE segment was measured according to the Prague C and M criteria,¹¹ and the presence of a hiatal hernia was recorded. The BE segment was carefully inspected for the presence of visible lesions in the antegrade and retroflexed positions, and targeted as well as random quadrantic biopsy specimens were taken every 2 cm.

Single-session endoscopic resection and RFA endoscopy. During therapeutic endoscopy, the BE

segment was carefully inspected again. Visible lesions were delineated by placing coagulation markers 1 to 2 mm outside the lesion, by using the tip of the resection snare with 40-W soft coagulation setting on an ERBE VIO generator (Erbe Elektromedizin GmbH, Tübingen, Germany). Endoscopic resection was performed by using the multiband mucosectomy technique (Duette MBM system, Cook Endoscopy, Limerick, Ireland) or the endoscopic resection-cap technique (Olympus; Hamburg, Germany). Details about the resection procedures are described in detail elsewhere.^{12,13}

Immediately after endoscopic resection, the residual BE mucosa was treated with focal RFA by using the Barrx⁹⁰ ablation device (Covidien, Sunnyvale, Calif). The gastroesophageal junction was circumferentially ablated as part of the treatment protocol. Several ablation regimens were used: 2 double 15 J/cm² applications with a cleaning phase in between, 3 applications with 15 J/cm² or 3 applications with 12 J/cm² without a cleaning step. Specific attention was paid to avoid application of RFA energy on the remaining submucosal layer in the resection wound.

Postprocedural care. All study patients received esomeprazole 40 mg twice daily (or an equivalent dose of proton pump inhibitor) as a maintenance dosage. In addition, patients were prescribed ranitidine 300 mg at bedtime and 5 mL sucralfate suspension 3 times daily for a period of 2 weeks after all therapeutic procedures.

Subsequent treatment and follow-up. All patients were contacted by telephone within 24 to 48 hours and also 2 weeks after the procedure to check for adverse events. Patients were scheduled for follow-up endoscopy with biopsies or additional endoscopic therapy at 3 months. Additional focal RFA was used to treat residual BE epithelium every 3 months until complete histologic eradication of intestinal metaplasia was reached. During each focal RFA session, the gastroesophageal junction was circumferentially treated. In case of only small islands of columnar mucosa (<5 mm), argon plasma coagulation (APC) could be used. Follow-up endoscopies were scheduled at 6 and 12 months and annually thereafter. Biopsy specimens were obtained from every 2 cm of the original BE segment and immediately distal (<5 mm) to the neosquamocolumnar junction.

Histopathologic evaluation

Endoscopic biopsies and resection specimens were assessed by a local expert pathologist.¹⁴ The revised Vienna Classification was used for histologic grading.¹⁵ If cancer was found, the following characteristics were assessed: tumor infiltration depth, tumor differentiation grade, presence of lymphatic or vascular infiltration, the radicality of the resection at the deep resection margins, and, if resection had been en bloc, the radicality at the lateral margins.

Based on the endoscopic resection specimen, indications for additional endoscopic management were limited

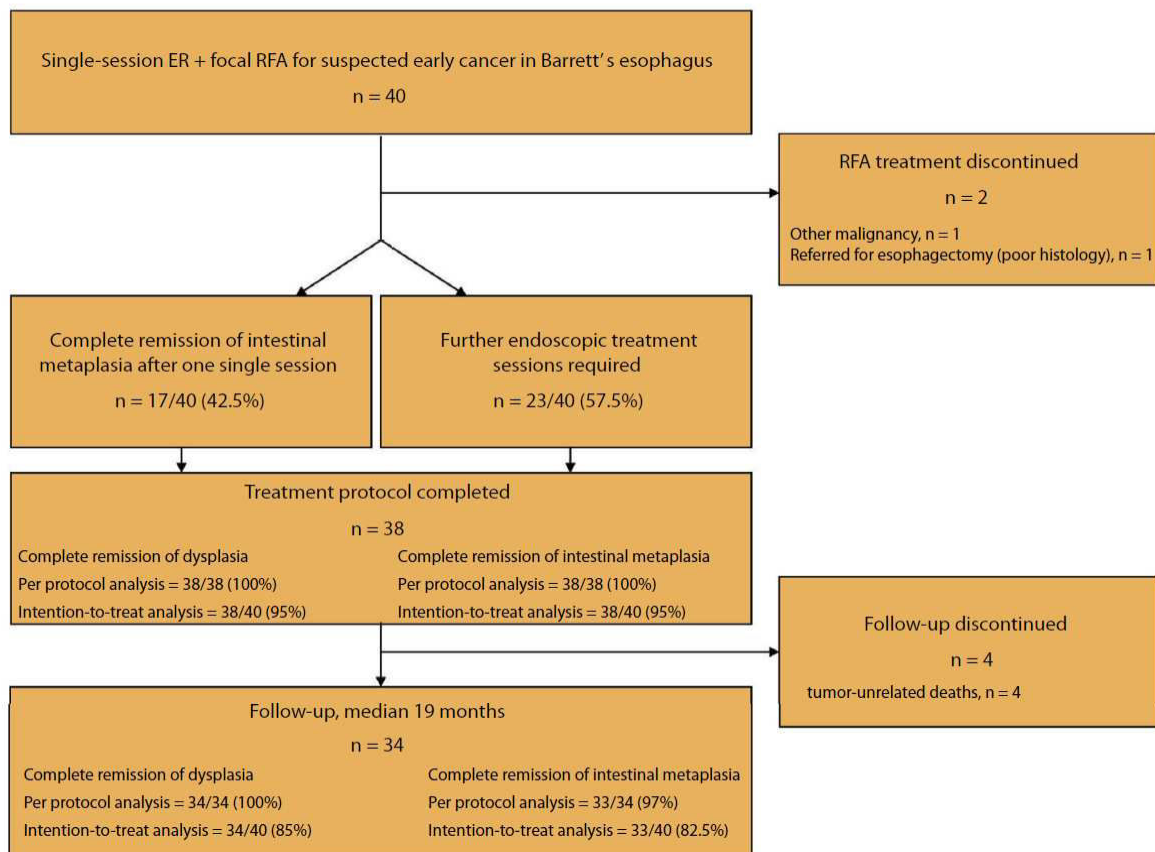


Figure 1. Endoscopic mucosal resection and focal radiofrequency ablation in a single treatment session, in 40 patients with Barrett's esophagus containing a visible lesion suspect for early carcinoma: study flowchart. *RFA*, radiofrequency ablation; *ER*, endoscopic resection.

to the mucosa, with a well-to-moderate differentiation grade, no signs of lymphovascular invasion, and a radical resection at the deep resection margin. However, superficial submucosal invasion $<500\ \mu\text{m}$ (T1sm1) or poor differentiation were considered a relative indication for endoscopic treatment in selected cases (eg, elderly patients with comorbidity).

Outcome parameters

Primary outcome parameter. Complete remission of dysplasia and intestinal metaplasia, defined as the absence of any dysplasia or intestinal metaplasia in biopsy specimens (including biopsy specimens taken distal to the neosquamocolumnar junction) obtained during the first follow-up endoscopy.

Secondary outcome parameters. These included sustained complete remission of dysplasia and intestinal metaplasia, defined as the absence of any dysplasia or intestinal metaplasia in biopsy specimens (including biopsy specimens taken distal to the neosquamocolumnar junction) obtained during the follow-up period and total number of

treatment sessions required to achieve complete remission of intestinal metaplasia.

Adverse events of the single-session endoscopic resection plus focal RFA procedure. Timing of adverse events was defined as: acute (during the procedure), early (≤ 48 hours), and late (>48 hours). Severity of adverse events was graded as mild (unscheduled hospital admission, hospitalization <3 days, hemoglobin level drop <3 g/dL, no need for transfusion), moderate (hospitalization 4–10 days, ≤ 4 units of blood transfused, need for repeat endoscopic intervention, radiologic intervention), severe (hospitalization >10 days, intensive care unit admission, need for surgery, >4 units of blood transfused, in the case of stenosis: >5 dilations, stent placement, or incision therapy), or fatal (death attributable to the procedure <30 days or longer with continuous hospitalization).¹⁶

Ethical considerations

According to national guidelines (www.ccmo.nl), this study was exempted from official institutional review board approval after assessment of the study design and protocol.

Statistical analysis

Data analysis was performed by using SPSS statistical software package (version 20, SPSS Inc, Chicago, Ill). The intention-to-treat analysis included all patients who entered the treatment protocol; patients lost to follow-up were considered a failure for complete remission of dysplasia and complete remission of intestinal metaplasia.

The mean \pm standard deviation (SD) was used to describe variables showing a normal distribution, and the median (interquartile range [IQR]) was used for variables with a skewed distribution. Where appropriate, the Fisher exact test was used.

RESULTS

Patients

Between March 2009 and October 2013, 40 patients were included (31 men, mean age 66 ± 10 years) (Fig. 1, Table 1). The median BE length before endoscopic resection was C1M2 (IQR C 0-2, M 2-4), visible lesions had a median size of 15 mm (IQR 10-20).

Endoscopic procedures

Endoscopic resection was performed by using the MBM technique (Duette MBM system, Cook Endoscopy, Limerick, Ireland) in 32 patients (80%) and the endoscopic resection-cap technique (Olympus, Hamburg, Germany) in 8 cases (20%). The majority of lesions were removed by piecemeal resection (70%), and the median number of resected pieces was 3 (IQR 3-5). In 30% of cases, the lesion could be removed en bloc. The median circumferential extent of the resection was 30% (IQR 21-50). In 2 cases, a second lesion was resected during the same endoscopy.

Focal RFA was applied in all cases, by using the triple 15 J/cm² regimen ($n = 36$, 90%), the triple 12 J/cm² regimen ($n = 1$, 3%), or the double 15 J/cm² with cleaning regimen ($n = 3$, 7%). In 1 patient, additional APC was used in addition to RFA to prevent application of RFA energy on the resection wound. The median duration of the single-session procedure was 41 minutes (IQR 28-59). Representative pictures of the endoscopic procedures are shown in Figures 2 and 3.

Histopathologic outcome

The most advanced histologic diagnosis of endoscopic resection specimens was early adenocarcinoma in 25 patients (63%), HGD in 9 (23%), low-grade dysplasia in 3 (8%), and intestinal metaplasia in 3 (8%).

One patient had a T1sm3 cancer and was referred for esophagectomy. Two patients, both with known cardiovascular comorbidity, had a poorly differentiated mucosal cancer. After discussion in a multidisciplinary cancer board meeting, it was decided to treat both patients

TABLE 1. Endoscopic mucosal resection and focal radiofrequency ablation in a single treatment session, in 40 patients with Barrett's esophagus containing a visible lesion: baseline patient characteristics

Patients, no.	40
Sex, male, no. (%)	31 (78)
Age, mean (\pm SD), y	66 (10)
Barrett's esophagus length, median (IQR), cm	C1 (0-2), M2 (2-4)
Size of the visible lesion, median largest diameter (IQR), mm	15 (10-20)
Predominant type of the lesion, no. (%)	
Paris O-Ila	31 (78)
Paris O-Is	3 (8)
Paris O-Ilb	5 (13)
Paris O-Ip	1 (3)
Histology of endoscopic resection specimens, no. (%)	
Early adenocarcinoma	25 (63)
High-grade dysplasia	9 (23)
Low-grade dysplasia	3 (8)
Intestinal metaplasia	3 (8)
Worst documented histologic finding*, no. (%)	
Early adenocarcinoma	27 (67.5)
High-grade dysplasia	11 (27.5)
Low-grade dysplasia	2 (5)
Intestinal metaplasia	0

SD, Standard deviation; IQR, interquartile range.

*Either on initial biopsies or endoscopic resection specimen.

endoscopically on a relative indication, given their comorbidities.

Primary outcome results

Complete remission of dysplasia and intestinal metaplasia. Complete remission of dysplasia and complete remission of intestinal metaplasia were achieved in 38 of 40 patients (95%) by using an intention-to-treat analysis and 38 of 38 patients (100%) in a per-protocol analysis (Fig. 1, Table 2). Two patients left the treatment protocol before control endoscopy. The first patient left because of a noncurative endoscopic resection (deep submucosal infiltration and positive vertical margins) requiring subsequent esophagectomy. The second patient left because of the concomitant diagnosis of a metastasized rectal cancer.

Secondary outcome results

Sustained remission of dysplasia and intestinal metaplasia. During a median follow-up period of 19 months (IQR 6-40), measured from the last therapeutic endoscopy to the last follow-up endoscopy, no histologic recurrence of dysplasia was found in any of the 38 patients

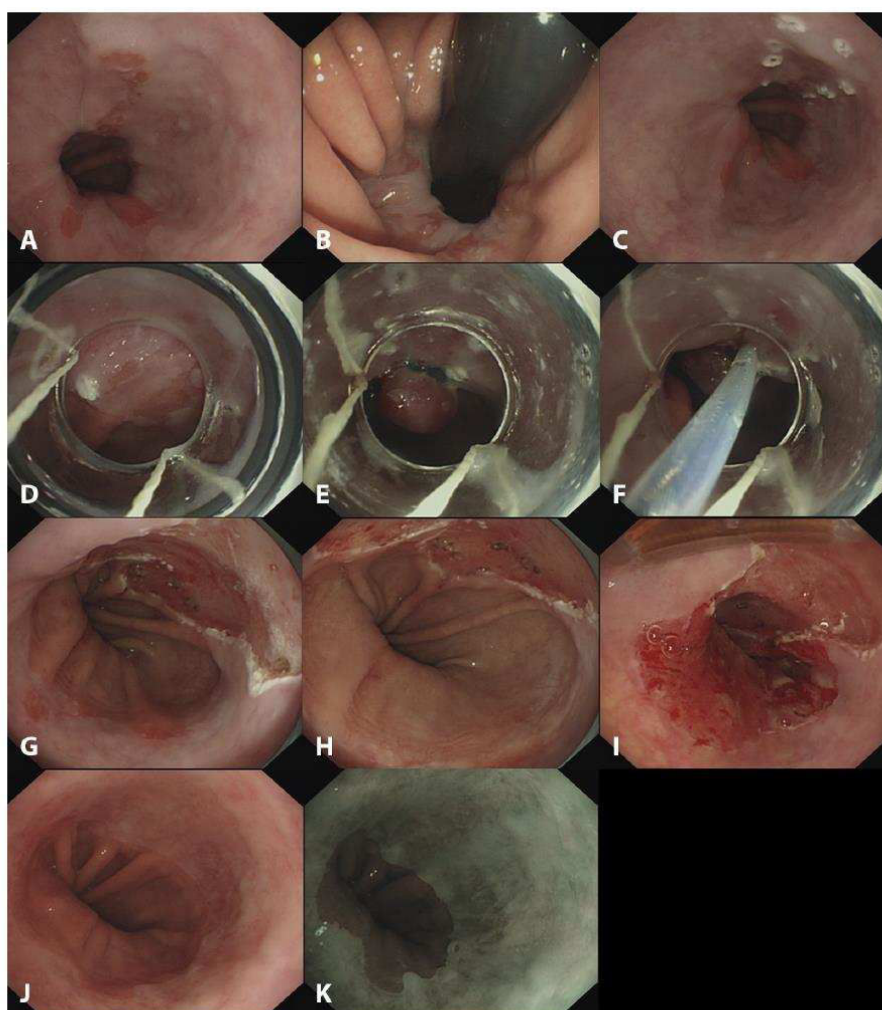


Figure 2. Endoscopic images illustrating the single-session endoscopic treatment of Barrett's esophagus with early neoplasia in a 70-year-old patient. **A**, CIM2 Barrett's esophagus containing a 2 cm, large, slightly elevated lesion at the 12 o'clock position. **B**, Extension of the lesion beyond the gastric cardia, shown in retroflex view. **C**, Delineation of the lesion with coagulation markers made with the tip of the resection snare. **D**, **E**, and **F**, Three steps of endoscopic resection by using multiband mucosectomy: **D**, Positioning of the cap over the lesion before the suction step. **E**, Positioning of the cap over the lesion before the ligation. **F**, Positioning of the cap over the lesion before the snare resection beyond the band. **G**, Endoscopic appearance after endoscopic resection in 2 pieces. **H**, **I**, Focal radiofrequency ablation of the remaining Barrett's esophagus, including systematic ablation of the Z line. **J**, **K**, Control endoscopy at 3 months showing complete endoscopic and histologic remission of the Barrett's esophagus under white light endoscopy (**J**) and narrow-band imaging (**K**).

who reached the primary endpoint. During the follow-up period, 4 patients died due to causes unrelated to BE neoplasia (shock due to a spleen rupture, metastatic hepatocellular carcinoma, pneumonia, ventricular tachycardia).

Sustained histologic eradication of dysplasia was 100%. In 1 patient, follow-up endoscopy at 18 months revealed 3 islands (1 mm) with columnar-like epithelium. No biopsy specimens were taken, and the islands were immediately treated with APC. Biopsy specimens obtained during subsequent follow-up endoscopies did not show intestinal

metaplasia. Counting these islands as recurrent intestinal metaplasia, although not histologically confirmed, results in a sustained remission of intestinal metaplasia in 97% (33/34) of patients.

Number of treatment sessions. The median number of treatment sessions required to achieve complete remission of dysplasia and complete remission of intestinal metaplasia was 2 (IQR 1-2). In 43% (17/40) of patients, the single-session treatment was sufficient to achieve complete remission of dysplasia and complete remission of

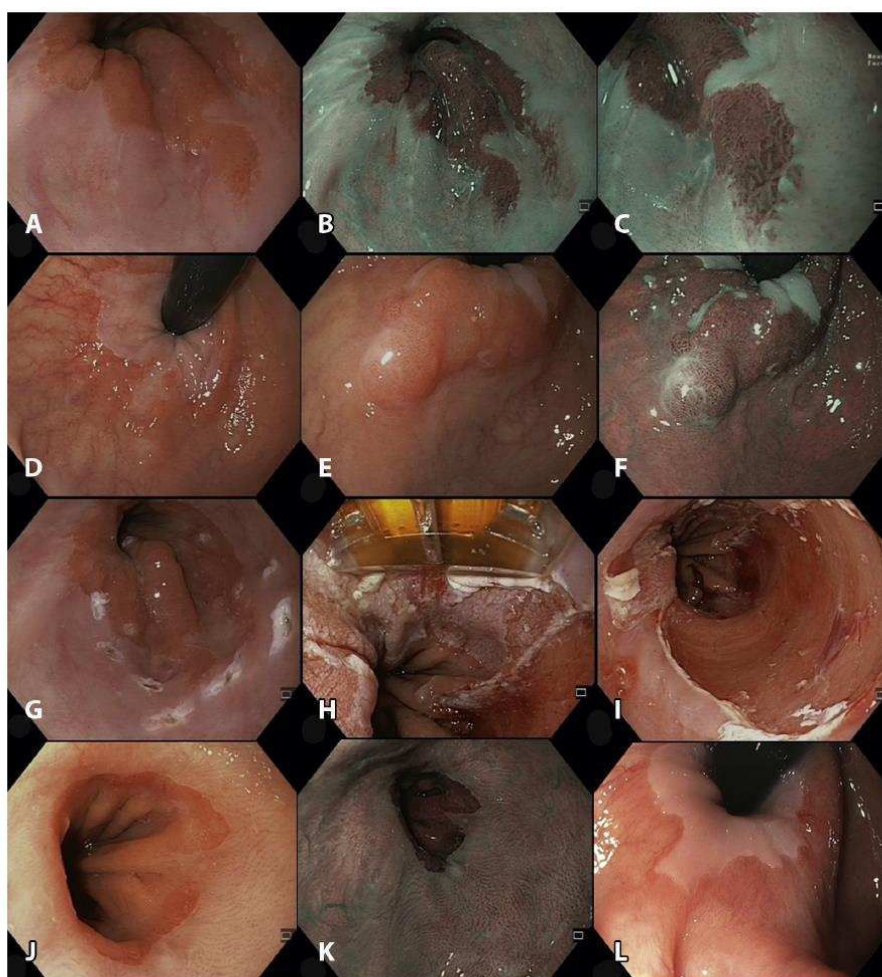


Figure 3. Endoscopic images illustrating the single-session endoscopic treatment of Barrett's esophagus with T1Am3 adenocarcinoma in a 66-year-old patient. **A**, Visible 2-cm long, Paris 0-IIa lesion, located at the 3 o'clock position, inside a C0M2 Barrett's esophagus. **B**, The same lesion under narrow-band imaging. **C**, Under narrow-band imaging and electronic magnification by using near focus, an irregular pit pattern and subsquamous tissue growth are seen. **D, E**, Extension of the lesion beyond the gastric cardia, shown in retroflex view. **F**, Same view using narrow-band imaging. **G**, Delineation of the lesion with coagulation markers by using the tip of the resection snare. **H, I**, Focal radiofrequency ablation of the remaining Barrett's esophagus, including systematic ablation of the Z line. **J, K, L**, Control endoscopy at 3 months showing complete endoscopic and histologic remission of Barrett's esophagus in direct view under white light endoscopy (**J**) and narrow-band imaging (**K**), and in retroflex view (**L**).

intestinal metaplasia. In the remaining 58% (23/40), a median number of 1 (IQR 0-1) additional RFA treatment session was required. One session of APC treatment was performed in 2 patients after the initial single-session procedure and in 5 patients after iterative RFA sessions, to ablate residual BE islands deemed too small for RFA.

Adverse events. In total, 15 adverse events occurred in 15 patients.

Acute adverse events. A total atrioventricular block occurred during the single-session procedure in a 62-year-old woman with coronary artery bypass surgery in her medical history. The RFA regimen used was the triple

15 J/cm². The atrioventricular block was probably caused by a vasovagal reaction, and no further investigation was necessary (mild adverse event).

Early adverse events. A 55-year-old man with a C2M2 BE was diagnosed with an esophageal perforation 2 days after the single-session procedure. During the single-session treatment, a 15-mm visible lesion was resected by using the endoscopic resection-cap technique followed by focal RFA by using the triple 15 J/cm² regimen. Forty-eight hours after treatment, the patient presented with dyspnea and chest pain. A CT scan showed periesophageal air without signs of mediastinitis, suspicious for an

TABLE 2. Endoscopic mucosal resection and focal radiofrequency ablation in a single treatment session, in 40 patients with Barrett's esophagus containing a visible lesion: outcome parameters

Primary outcome parameter, no. (%)	
Complete remission of dysplasia*	
Per-protocol analysis	38/38 (100)
Intention-to-treat analysis	38/40 (95)
Complete remission of intestinal metaplasia*	
Per-protocol analysis	38/38 (100)
Intention-to-treat analysis	38/40 (95)
Secondary outcome parameters	
Total no. of treatment sessions to achieve complete remission of intestinal metaplasia, median (interquartile range)	2 (1-2)
Additional radiofrequency ablation sessions, median (interquartile range)	1 (0-1)
Escape treatment with argon plasma coagulation, no. (%)	7 (16.3)
Recurrence of Barrett's esophagus neoplasia during follow-up, no. (%)	1 (2.5)
Adverse events	
Mild	1 (3)
Moderate	13 (30)
Severe	1 (2)
Follow-up, median (interquartile range), mo	19 (6-40)

*At the end of treatment protocol.

esophageal perforation. The patient was admitted to the intensive care unit and treated conservatively. After 9 days the patient was discharged in good clinical condition. The adverse event was graded as severe.

Late adverse events. In 13 (33%) patients, symptomatic esophageal stenosis occurred. All were treated successfully with a median number of 2 (IQR 1-2) dilations and were considered to have had moderate adverse events. Seven occurred after the initial treatment, and 6 developed after iterative ablation sessions. In 1 patient, an additional RFA procedure required the Channel RFA endoscopic catheter (Covidien, Sunnyvale, Calif) because of a narrowed esophagus. All patients had initial ablation by using the triple 15 J/cm² regimen.

DISCUSSION

In this study, we showed the feasibility and the efficacy of a single-step treatment modality for BE combining endoscopic resection and focal RFA. The procedure was performed in approximately 40 minutes and resulted in high rates of complete remission of dysplasia and complete remission of intestinal metaplasia. This strategy allowed a single-session treatment, saving 1 step in patient management in 43% of patients.

Several studies have determined the current management of early neoplasia arising in BE. Visible lesions are removed with endoscopic resection, and the remaining flat BE mucosa is treated with RFA. This multistep strategy typically includes 1 endoscopic resection endoscopy and 3 subsequent RFA procedures.^{4,5,9,17} It has been highly effective with sustained complete remission of dysplasia in 94% to 96% and complete remission of intestinal metaplasia in 84% to 96% of cases, after 2 to 5 years of follow-up. The most important reported adverse event when this treatment approach is used is esophageal stenosis formation, occurring in 6% to 8% of cases.^{4,5,9,17}

There are 2 main advantages of the single-session treatment strategy: first, combining RFA and endoscopic resection saves one endoscopic procedure in almost half of the patients. Second, RFA is performed before any esophageal scarring occurs after endoscopic resection: therefore, the introduction of the Barrx⁹⁰ ablation device is not hampered by stenosis, and the contact of the electrode and the esophageal mucosa is optimal.

Combining endoscopic resection and RFA in a single session already has been studied, by performing circumferential RFA immediately followed by endoscopic resection of the initially identified visible lesion in patients with a BE of ≥ 3 cm. This approach, however, resulted in a 42% adverse event rate, with a 20% stenosis rate. Most importantly, additional endoscopic resection had to be performed in 35% of patients. In these cases, there was recurrence of a lesion at the edge or within 2 cm of the edge of the initial endoscopic resection, suggesting that endoscopic resection of visible lesions immediately after RFA is not reliable.¹⁸

Our study showed a relatively high rate of stenosis (33%, 13/38), although still much lower than the 50%-88% stenosis rate observed after stepwise radical endoscopic resection.^{9,16} Seven of the stenoses occurred right after the single-session treatment, and in 6 patients a stenosis occurred after additional RFA procedures. The high rate of stenosis in our study is not likely to be explained by the size of the endoscopic resection because most of the resections were less than hemicircumferential. RFA alone leads to 4% of esophageal stenosis.¹⁹ However, RFA treatment with the triple 15 J/cm² regimen, as was applied in 90% of patients, has been shown to induce more damage to the esophagus, resulting in an 11% stenosis rate.²⁰ It might also account for the esophageal perforation that was recorded in our study. The triple 12 J/cm² regimen is currently being studied in a randomized clinical trial and might be more appropriate for the single-step treatment.

Endoscopic resection not only serves as a therapeutic procedure but also as a diagnostic tool by providing histologic assessment. The most important downside of the single-session treatment is that in some cases the RFA treatment would not have been necessary based on the histologic outcome of the endoscopic resection specimen.

It is important that the endoscopist who performs the single-session procedure is able to accurately identify during the procedure those cases in which endoscopic resection will be curative, in order to prevent an unnecessary RFA treatment in a patient who will undergo an esophagectomy. In the largest study published on endoscopic resection for BE, about 9% (96/1096) of suspected mucosal adenocarcinomas had advanced histology actually requiring surgical treatment after endoscopic resection.⁸ We found comparable numbers in our cohort (7%, 3/43). However, because 2 patients were ultimately managed solely endoscopically, only 1 RFA procedure was performed in vain.

Our study has several limitations that need to be addressed. First, the study has a retrospective design leading to selection bias in inclusion. Second, even though the vast majority of the patients had the triple 15 J/cm² ablation protocol, the heterogeneity of the RFA regimens can make the results difficult to compare.

In summary, we found that in a selected patient population with short-segment BE and small visible lesions, endoscopic resection and focal RFA of the remaining BE and gastroesophageal junction in a single step is feasible and is as effective as the 2-step strategy in terms of complete remission of dysplasia and complete remission of intestinal metaplasia. A single treatment session was sufficient to achieve complete remission of intestinal metaplasia in >40% of patients, sparing 1 additional endoscopic procedure. However, 30% of patients developed a stenosis. Further studies to optimize the ablation settings are needed.

REFERENCES

- Bennett C, Vakil N, Bergman J, et al. Consensus statements for management of Barrett's dysplasia and early-stage esophageal adenocarcinoma, based on a Delphi process. *Gastroenterology* 2012;143:336-46.
- Fleischer DE, Overholt BF, Sharma VK, et al. Endoscopic ablation of Barrett's esophagus: a multicenter study with 2.5-year follow-up. *Gastrointest Endosc* 2008;68:867-76.
- Fleischer DE, Overholt BF, Sharma VK, et al. Endoscopic radiofrequency ablation for Barrett's esophagus: 5-year outcomes from a prospective multicenter trial. *Endoscopy* 2010;42:781-9.
- Phoa KN, Pouw RE, Bisschops R, et al. Multimodality endoscopic eradication for neoplastic Barrett oesophagus: results of an European multicentre study (EURO-II). *Gut*. Epub 2015 Mar 2.
- Phoa KN, Pouw RE, van Vilsteren FG, et al. Remission of Barrett's esophagus with early neoplasia 5 years after radiofrequency ablation with endoscopic resection: a Netherlands cohort study. *Gastroenterology* 2013;145:96-104.
- Shaheen NJ, Overholt BF, Sampliner RE, et al. Durability of radiofrequency ablation in Barrett's esophagus with dysplasia. *Gastroenterology* 2011;141:460-8.
- Shaheen NJ, Sharma P, Overholt BF, et al. Radiofrequency ablation in Barrett's esophagus with dysplasia. *New Engl J Med* 2009;360:2277-88.
- Pech O, May A, Manner H, et al. Long-term efficacy and safety of endoscopic resection for patients with mucosal adenocarcinoma of the esophagus. *Gastroenterology* 2014;146:652-60 e651.
- van Vilsteren FG, Pouw RE, Seewald S, et al. Stepwise radical endoscopic resection versus radiofrequency ablation for Barrett's oesophagus with high-grade dysplasia or early cancer: a multicentre randomised trial. *Gut* 2011;60:765-73.
- Spechler SJ, Sharma P, Souza RF, et al. American Gastroenterological Association. American Gastroenterological Association technical review on the management of Barrett's esophagus. *Gastroenterology* 2011;140:e18-e52.
- Sharma P, Dent J, Armstrong D, et al. The development and validation of an endoscopic grading system for Barrett's esophagus: the Prague C & M criteria. *Gastroenterology* 2006;131:1392-9.
- Alvarez Herrero L, Pouw RE, van Vilsteren FG, et al. Safety and efficacy of multiband mucosectomy in 1060 resections in Barrett's esophagus. *Endoscopy* 2011;43:177-83.
- Pouw RE, van Vilsteren FG, Peters FP, et al. Randomized trial on endoscopic resection-cap versus multiband mucosectomy for piecemeal endoscopic resection of early Barrett's neoplasia. *Gastrointest Endosc* 2011;74:35-43.
- Peters FP, Brakenhoff KP, Curvers WL, et al. Histologic evaluation of resection specimens obtained at 293 endoscopic resections in Barrett's esophagus. *Gastrointest Endosc* 2008;67:604-9.
- Schlemper RJ, Riddell RH, Kato Y, et al. The Vienna classification of gastrointestinal epithelial neoplasia. *Gut* 2000;47:251-5.
- Pouw RE, Seewald S, Gondrie JJ, et al. Stepwise radical endoscopic resection for eradication of Barrett's oesophagus with early neoplasia in a cohort of 169 patients. *Gut* 2010;59:1169-77.
- Li N, Pasricha S, Bulsiewicz WJ, et al. Effects of preceding endoscopic mucosal resection on the efficacy and safety of radiofrequency ablation for treatment of Barrett's esophagus: results from the United States Radiofrequency Ablation Registry. *Dis Esophagus*. Epub 2015 June 30.
- van Vilsteren FG, Alvarez Herrero L, Pouw RE, et al. Radiofrequency ablation and endoscopic resection in a single session for Barrett's esophagus containing early neoplasia: a feasibility study. *Endoscopy* 2012;44:1096-104.
- Chadwick G, Groene O, Markar SR, et al. Systematic review comparing radiofrequency ablation and complete endoscopic resection in treating dysplastic Barrett's esophagus: a critical assessment of histologic outcomes and adverse events. *Gastrointest Endosc* 2014;79:718-31 e713.
- Kunzli HT, Scholvinck DW, Phoa KN, et al. Simplified protocol for focal radiofrequency ablation using the HALO90 device: short-term efficacy and safety in patients with dysplastic Barrett's esophagus. *Endoscopy* 2015;47:592-7.

2. Résection par dissection sous-muqueuse des adénocarcinomes superficiels de l'œsophage

Endoscopic submucosal dissection for early Barrett's neoplasia.

Barret M, Cao DT, Beuvon F, Leblanc S, Terris B, Camus M, Coriat R, Chaussade S, Prat F. United European Gastroenterol J. 2016 Apr;4(2):207-15.

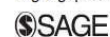
La société européenne d'endoscopie digestive (ESGE) recommande l'usage systématique de la dissection sous-muqueuse (ESD) dans la résection des carcinomes épidermoïdes de l'œsophage, sur la base d'études japonaises documentant une supériorité de l'ESD sur la mucosectomie endoscopique (EMR) en termes de résection carcinologique et de taux de récurrence locale. Nous avons cherché à évaluer, à partir d'une base de données monocentrique prospective, les performances de l'ESD dans le traitement des adénocarcinomes œsophagiens sur œsophage de Barrett, domaine dans lequel l'EMR reste la technique de référence. Trente-cinq patients et 36 lésions ont été évalués, développées au sein d'un œsophage de Barrett d'extension moyenne C4M6, et ayant bénéficié d'une résection de 5 cm de grand axe en moyenne pour des lésions néoplasiques d'un diamètre moyen de 12 mm, dont 81% étaient des cancers. Le taux de résection en bloc était de 89%, le taux de résection R0 pour les cancers était de 72.4%, et le taux de résection curative, incluant l'absence de facteurs de mauvais pronostic, était de 66%. Le taux de complication était de 16.7%, dont 8.3% de perforations, toutes traitées médicalement, et la mortalité à 30 jours était nulle. 9 patients étaient opérés

secondairement en raison d'une invasion des marges profondes ou de critères de mauvais pronostic en histologie, dont 3 (33%) avaient une pièce opératoire blanche. En conclusion, notre série suggère que des résultats oncologiques comparables à ceux obtenus avec les carcinomes épidermoïdes de l'œsophage sont plus difficiles à obtenir par ESD dans le cas de l'adénoCa sur OB, notamment en raison de facteurs histologiques de mauvais pronostic méconnus avant la résection, et surtout de la difficulté à délimiter précisément les marges de résection lorsqu'on cherche à épargner latéralement suffisamment de tissu non carcinomateux pour prévenir le développement d'une sténose cicatricielle. Une amélioration de la qualité de l'endoscopie diagnostique est cependant certainement nécessaire afin d'améliorer la délimitation des lésions (49% de marges envahies par la dysplasie de haut grade ou le cancer). En outre, une amélioration de la qualité technique du geste, aisément anticipable dans la mesure où cette série inclut le début de notre expérience en ESD œsophagienne, permettra de diminuer le taux de complications.

Endoscopic submucosal dissection for early Barrett's neoplasia

Maximilien Barret^{1,2}, Dalhia Thao Cao^{1,2}, Frédéric Beuvon^{2,3}, Sarah Leblanc^{1,2}, Benoit Terris^{2,3}, Marine Camus^{1,2}, Romain Coriat^{1,2}, Stanislas Chaussade^{1,2} and Frédéric Prat^{1,2}

United European Gastroenterology Journal
2016, Vol. 4(2) 207–215
© Author(s) 2016
Reprints and permissions:
sagepub.co.uk/journalsPermissions.nav
DOI: 10.1177/2050640615608748
ueg.sagepub.com



Abstract

Introduction: The possible benefit of endoscopic submucosal dissection (ESD) for early neoplasia arising in Barrett's esophagus remains controversial. We aimed to assess the efficacy and safety of ESD for the treatment of early Barrett's neoplasia.

Methods: All consecutive patients undergoing ESD for the resection of a visible lesion in a Barrett's esophagus, either suspicious of submucosal infiltration or exceeding 10 mm in size, between February 2012 and January 2015 were prospectively included. The primary endpoint was the rate of curative resection of carcinoma, defined as histologically complete resection of adenocarcinomas without poor histoprosthetic factors.

Results: Thirty-five patients (36 lesions) with a mean age of 66.2 ± 12 years, a mean ASA score of 2.1 ± 0.7 , and a mean C4M6 Barrett's segment were included. The mean procedure time was 191 ± 79 mn, and the mean size of the resected specimen was 51.3 ± 23 mm. En bloc resection rate was 89%. Lesions were 12 ± 15 mm in size, and 81% (29/36) were invasive adenocarcinomas, six of which with submucosal invasion. Although R0 resection of carcinoma was 72.4%, the curative resection rate was 66% (19/29). After a mean follow-up of 12.9 ± 9 months, 16 (45.7%) patients had required additional treatment, among whom nine underwent surgical resection, and seven further endoscopic treatments. Metachronous lesions or recurrence of cancer developed during the follow-up period in 17.2% of the patients. The overall complication rate was 16.7%, including 8.3% perforations, all conservatively managed, and no bleeding. The 30-day mortality was 0%.

Conclusion: In this early experience, ESD yielded a moderate curative resection rate in Barrett's neoplasia. At present, improvements are needed if ESD is to replace piecemeal endoscopic mucosal resection in the management of Barrett's neoplasia.

Keywords

Endoscopic submucosal dissection, Barrett's esophagus, early esophageal adenocarcinoma, high-grade dysplasia

Received: 25 June 2015; accepted: 1 September 2015

Introduction

Endoscopic submucosal dissection (ESD) has been extensively used in Japan and increasingly in Europe within the last decade for the resection of early esophageal neoplasms.^{1–3} On the one hand, esophageal surgical resection is associated with 35%–42% morbidity and 2%–3.4% mortality^{4–6} even in high-volume, specialized centers. On the other hand, endoscopic mucosal resection (EMR), although reported safe and effective for small intramucosal esophageal cancer, either squamous cell carcinoma^{7,8} or adenocarcinoma,⁹ does not allow oncologically adequate en bloc resection

of tumors larger than 20 mm. Therefore, lesions are resected piecemeal, leaving remnants of neoplastic tissue in situ, and recurrence rates of 9.8% to 14.5%

¹Department of Gastroenterology, Cochin Hospital, Assistance Publique-Hôpitaux de Paris, Paris, France

²Department of Medicine, Paris-Descartes University, Paris, France

³Department of Pathology, Cochin Hospital, Paris, France

Corresponding author:

Frédéric Prat, Department of Gastroenterology, Cochin Hospital, Paris, France. 27, rue du Faubourg St Jacques, 75014 Paris.
Email: frederic.prat@aphp.fr

require cautious follow-up and additional endoscopic resections.^{9,10}

In 2010, Takahashi et al. reported a 99.1% curative resection rate for intramucosal esophageal squamous cell carcinoma resected with ESD, as compared to 78.3% obtained with EMR, even though the lesions resected by EMR were almost twice as small as those resected with ESD.¹⁰ The superiority of ESD over EMR in terms of en bloc resection, curative resection, and local recurrence rate of esophageal neoplasms was confirmed in three large studies^{10–12} as it had been demonstrated earlier for gastric neoplasms.¹³ Furthermore, ESD provides a single specimen, obviously more appropriate for an optimal histological assessment than the multiple tissue chunks retrieved after piecemeal EMR.

If the resection of squamous neoplasms invading the submucosa is questionable because of the high frequency of lymph node involvement,¹⁴ ESD could allow for safer resection of early adenocarcinoma (EAc) invading the submucosa, as compared to EMR. Yet, current data on ESD for the treatment of Barrett's carcinoma are scarce and do not demonstrate a benefit of ESD in this indication,¹⁵ possibly because the experience of Western teams in ESD is still limited, and second because the endoscopic delineation of the extent of EAc in Barrett's esophagus is difficult and results in high rates of positive lateral margins. Therefore, we sought to assess in our experience the effectiveness and safety of ESD for the treatment of visible lesions arising in Barrett's esophagus suspicious of early adenocarcinoma.

Methods

Patient selection and data collection

This is a retrospective study from a prospectively collected database including 69 esophageal ESDs performed in our department since January 2012. Patients included had histologically confirmed Barrett's esophagus with intestinal metaplasia and a visible lesion deemed not amenable to en bloc EMR because of elevated type or a size exceeding 10 mm. All consecutive patients with lesions of more than 10 mm and/or suspicion of submucosal ingrowth were treated with ESD. Patients with signs of deep submucosal invasion such as Paris type 0–III type, or evidence of advanced disease on preoperative or computed tomography (CT) scanner were not offered ESD. An oncologic workup including endoscopic ultrasound (EUS) and thoraco-abdomino-pelvic CT scan was performed preoperatively in cases in which preoperative histology mentioned invasive adenocarcinoma and worrisome endoscopic features, such as polypoid (Paris 0–Is) or

ulcerated (Paris 0–III) lesion were seen. Demographic data and procedural characteristics such as the date, the size of the resection, the endoscopic device used, the early outcomes and complications, histological results and possible complementary treatments were found in the database. Further data on the endoscopic procedure such as procedure duration, use of esophageal stricture prevention, patients' comorbid conditions, and most recent follow-up data were found in the patients' files.

Endoscopic procedures

A diagnostic staging endoscopy was systematically conducted in our center within one month prior to ESD, using high-definition endoscopes and narrow-band imaging, in order to characterize the extent of Barrett's esophagus, and determine the endoscopic resectability of the neoplasia. All ESDs were conducted under general anesthesia with endotracheal intubation and CO₂. Antiplatelet agents other than aspirin and anticoagulant therapy were discontinued before the procedure. ESDs were performed by three experienced operators (FP, SL, SC), each of whom has previous experience with more than 50 rectal, gastric, and esophageal ESDs in patients. High-definition gastroscopes with narrow-band imaging (GIF-H180J, GIF-2TH180 or GIF-HQ190, Olympus, Japan) were used for ESD. Procedures were carried out with a soft distal attachment cap and waterjet. The choice of ESD knives was left to the operator, among them the 1.5 mm dual knife (Olympus, Japan), the 1.5 or 1 mm flush knife (Fujifilm, Japan), and the triangle tip (TT) knife (Olympus, Japan). After delineation of the lesion with soft coagulation dots positioned 2–3 mm external to the lateral margins of visible lesions, submucosal injection of indigo-carmin-stained lifting solution (a mixture of 5% fructose and 10% glycerol with saline¹⁶) was performed; peripheral incision was conducted using the endocut mode and submucosal dissection was then achieved using the swift coagulation mode. Hemostasis of submucosal vessels was achieved either with the ESD knife, coagulation forceps in soft coagulation mode (Coagrasper, Olympus, Japan), or 1% epinephrine lavage. The modus operandi for the most recent cases of esophageal neoplasia generally followed the "tunnel method," in which we perform distal and proximal marginal incisions before undertaking the submucosal dissection in an antegrade fashion, and finish by cutting the left and right margins.¹⁷ Standard ESD procedure with a circumferential incision all around the lesion at the early phase of the procedure was performed in other cases. An example of ESD for the resection of a Barrett's carcinoma is presented in Figure 1. When circumferential or

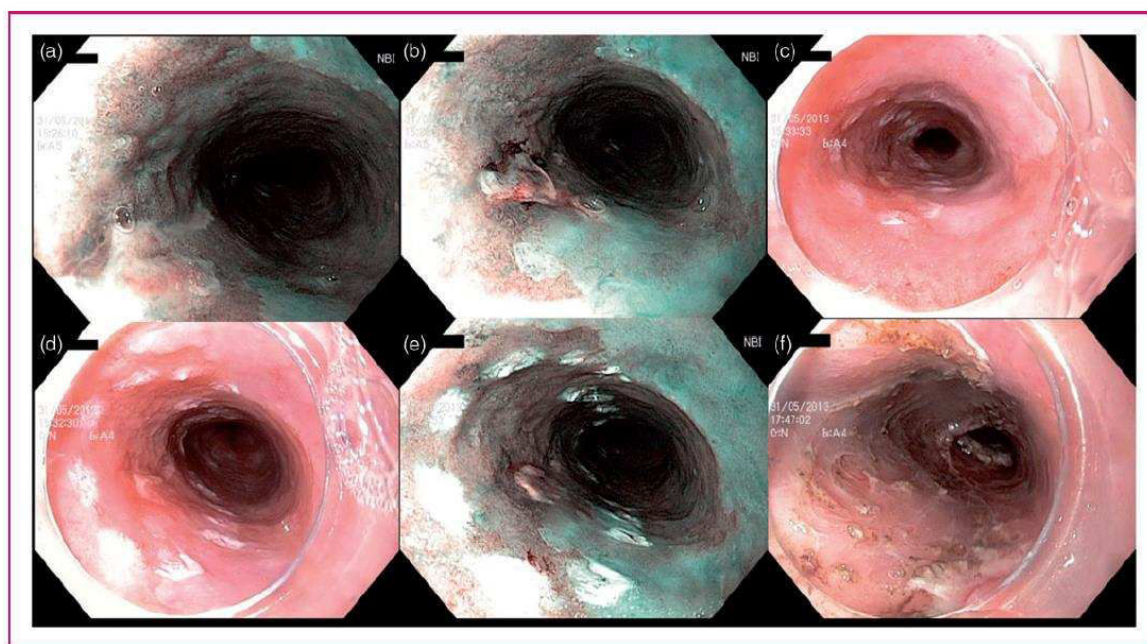


Figure 1. Endoscopic submucosal dissection of a 15 mm, Paris 0-IIa + IIc, ulcerated intramucosal carcinoma, arising on a C14M15 Barrett's esophagus. Panels (a) and (b) show the distal and proximal side of the lesion in narrow-band imaging, respectively. Panels (c), (d) and (e) show the lesion delineated with coagulation markings in white light endoscopy ((c) and (d)) and narrow-band imaging (e). The markings are placed at least 5 mm away from the lesion margins. Panel (f) shows the resection site immediately after the hemircumferential endoscopic submucosal dissection on a 4 cm height. Resection was curative with lateral margins positive for intestinal metaplasia, and radiofrequency ablation of the remaining Barrett's esophagus was performed.

subcircumferential mucosal resection was achieved, post-endoscopic stricture prevention was attempted by injecting endoscopically 100 mg of triamcinolone into the residual submucosa and muscularis propria, as reported by Hanaoka et al.¹⁸

Histological assessment

Resected specimens were pinned on polystyrene boards and fixed in 10% formalin for 24 hours. After fixation, specimens were cut into 2–3 mm slices and embedded in paraffin. Blocks were further sliced at 4 μ m and stained with hematoxylin-eosin-saffron. Histological slides were assessed by two pathologists experienced in Barrett's esophagus pathology (FB and BT). The following data were assessed: en bloc resection, size of the lesion with worst histology, invasion of the lateral margins, grade of dysplasia; in case of invasive carcinomas, the following data were recorded: grade of differentiation, presence of lymphatic or vascular invasion, deepest tumor extension in the esophageal wall, and tumoral invasion of the vertical (deep) margin. In case of submucosal invasion, the extent of the tumor front beyond the muscularis mucosae was measured in μ m, as well as the width of that extension. For invasive

adenocarcinoma, the margins could be either tumor free (R0) or infiltrated with tumor (R1). Submucosal invasion was assessed according to the Japanese classification of esophageal cancer.¹⁹ The processing of the samples and histopathological analysis are presented in Figure 2.

Complications and follow-up

We recorded complications as early (within 48 hours after ESD) or late complications (>48 hours after ESD). Bleeding was defined as either a two-point hemoglobin drop in 24 hours or hematemesis, melena or hematochezia requiring either blood cell transfusion or control endoscopy. Per-procedural bleeding managed with hemostatic forceps was not recorded as a complication. Esophageal perforation was defined as a visible hole in the esophageal muscle layer and/or postoperative air or liquid collection in the mediastinum or the abdomen. Esophageal strictures were recorded as a narrowing of the esophageal lumen either too small to admit a 10 mm endoscope, or associated with dysphagia.

After ESD, patients were looked after in the department for at least two nights and received high-dose proton pump inhibitors, pain medication, and oral

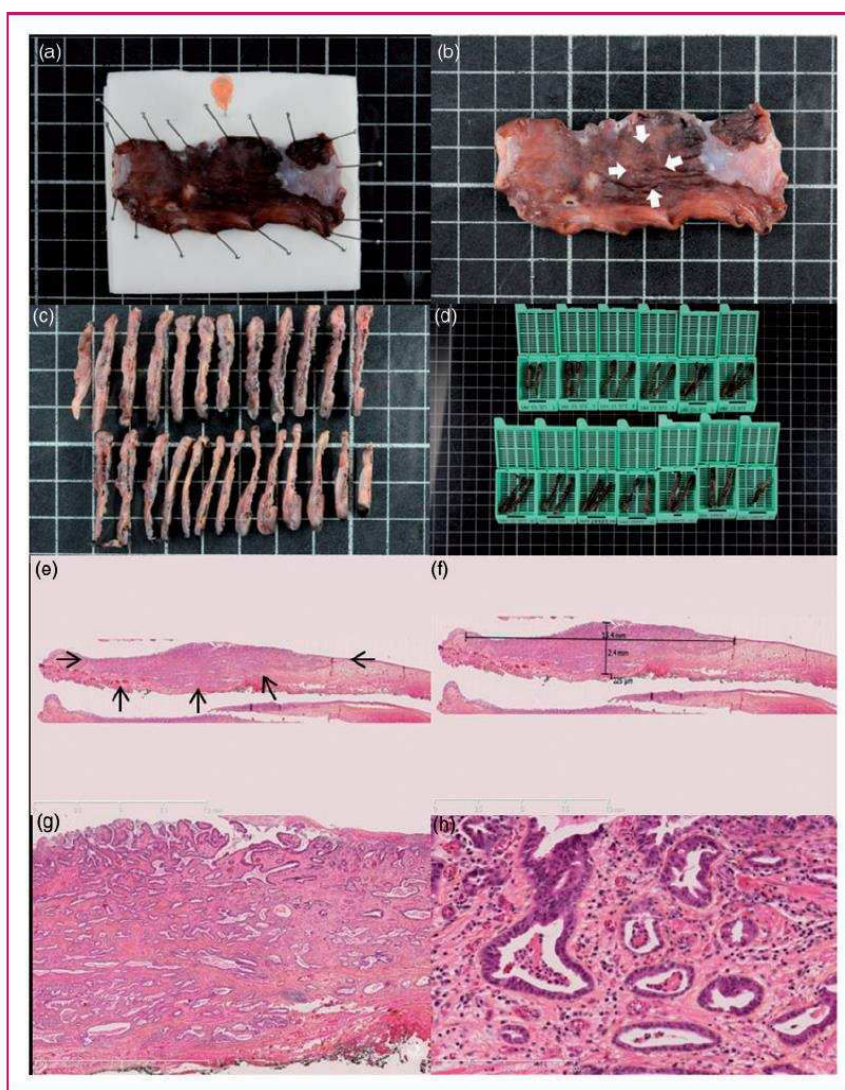


Figure 2. Histopathological assessment of early Barrett's carcinoma resected by endoscopic submucosal dissection. (a) Macroscopic view of the resected specimen after 24 hours of formaldehyde fixation, pinned to the polystyrene board with an orange needle to mark the oral side of the resection. (b) Macroscopic view of the resected specimen after fixation. Arrowheads show the 15 mm suspicious nodular lesion. (c) and (d) Processing of the specimen in 2–3 mm sections further included in paraffin blocks. (e) Histological view of the resected specimen showing an invasive adenocarcinoma (arrowheads) with submucosal infiltration and R0 margins, hematoxylin-eosin-saffron, 5 \times . (f) After digitization of the slide, measurement shows a submucosal invasion of 225 μ m, making the lesion a pT1a sm1 lesion, with curative endoscopic treatment. (g) and (h) Histological view of the resected specimen at higher magnifications, Histological view of the resected specimen showing a well-differentiated tubulovillous adenocarcinoma with submucosal infiltration and R0 margins, and no vascular or lymphatic invasion, hematoxylin-eosin-saffron, 25 \times and 200 \times , respectively.

feeding was resumed progressively within 24 hours of the procedure. All cases of invasive adenocarcinoma were discussed in a multidisciplinary meeting. All patients had a one-month follow-up visit after ESD to check for symptoms and plan further management. Control endoscopy was conducted at three months and biopsies of the scar, as well as the remaining Barrett's mucosa or the neosquamocolumnar junction,

were taken. If radiofrequency ablation for Barrett's esophagus was needed and accepted by the patient, radiofrequency ablation eradication protocol was started within six months of ESD. Otherwise, control endoscopies were performed every six months. When necessary, esophageal dilation using Savary-Gilliard bougies was conducted every two weeks until resolution of symptoms.

Study endpoints and definitions

The main study endpoint was the curative resection of carcinoma, defined as R0 resection of a well- or moderately differentiated invasive adenocarcinoma without lymphatic or vascular invasion. In cases with submucosal tumor invasion, curative resection was considered only when submucosal tumor invasion was less than 500 μm (T1Bsm1).

Secondary endpoints were as follows:

- Rate of ESD success: ESD was considered as failed when the procedure had to be stopped before complete dissection of the specimen was achieved with the ESD knife.
- Rate of en bloc resection, defined by the resection of the whole neoplastic lesion in a single piece.
- Rate of R0 resection rate of carcinoma, defined as en bloc resection of an invasive carcinoma with vertical and lateral tumor-free margins and a minimum of 1 mm safety margins.
- Rate of curative resection of high-grade dysplasia (HGD) or carcinoma, defined as a histologically complete resection with margins free of carcinoma or HGD.
- Rate of curative resection of neoplasia, defined as a histologically complete resection with margins free of carcinoma or any dysplastic tissue.
- Rates of complete remission of carcinoma, neoplasia (HGD or carcinoma), dysplasia and intestinal metaplasia at the most recent follow-up.
- Early and late complication rates.
- 30-day mortality after ESD.

Statistical analysis and ethical aspects

Statistical analyses were performed using GraphPad Software (GraphPad Software Inc, San Diego, CA). Results are expressed as mean (\pm SD) in case of a normal distribution of variables and median (interquartile range (IQR) 25%–75%) for variables with a skewed distribution, or absolute numbers and percentages. Patient written informed consent was obtained before each endoscopic procedure. The study received approval from our local institutional review board.

Results

Baseline patient characteristics

Thirty-five patients, with a mean age of 66.2 ± 12 , had 36 lesions resected between February 2012 and January 2015. Main patient characteristics are presented in Table 1. A total of 11.6% had a history of chronic alcohol abuse and 45.7% a history of tobacco smoking.

There were 68.6% of patients who had a major comorbid condition, mainly ischemic cardiomyopathy; 34.3% of patients were using aspirin or clopidogrel, and 5.7% were on anticoagulant therapy. Patients reported heartburn or regurgitations in 45.7% of cases, although they received proton pump inhibitor therapy in 88.6% of cases. The mean number of years since the diagnosis of Barrett's esophagus was 3.6 ± 5 , and 65.7% of patients had been diagnosed during the previous year. A hiatal hernia was present in 45.7%, and the mean (\pm SD) Barrett's esophagus segment was $C4 \pm 3M6 \pm 4$ within a range of C0M1 to C14M15. Lesions were located in the right anterior, right posterior, left posterior, and right anterior quadrant of the esophagus in 43.8%, 34.4%, 9.4%, and 12.5% of cases, respectively.

A thoraco-abdomino-pelvic CT scan had been performed prior to ESD in 12 patients; it was unremarkable in nine patients, showed a thickening of the lower esophagus in two patients, regional lymph nodes in one patient, and a concomitant primary lung tumor in one patient. A pre-ESD EUS had been performed in 20 patients; it showed regional lymph nodes in two

Table 1. Baseline patient characteristics

	n = 35
Age (mean \pm SD), years	66.2 \pm 12
Gender, male, n (%)	29 (82.9)
ASA score (mean \pm SD)	2.1 \pm 0.7
Comorbid conditions, n (%)	
Cardiomyopathy	9 (25.7)
COPD	5 (14.3)
Liver cirrhosis	3 (8.6)
Body mass index (mean \pm SD), kg/m ²	26.7 \pm 5
Anticoagulant or antiplatelet therapy, n (%)	13 (37.1)
Previous therapeutic intervention on the esophagus, n (%)	
Endoscopic resection	10 (28.6)
Argon plasma coagulation	1 (2.9)
Radiofrequency ablation	2 (5.7)
Radiotherapy	1 (2.9)
Esophagectomy	1 (2.9)
Barrett's length (median, IQR), cm	
Circumferential extent (C)	2.5 (1–5.5)
Maximal extent (M)	5 (3–8)
Preoperative histology, n (%)	
Low grade dysplasia	1 (2.9)
High grade dysplasia	14 (38.9)
Adenocarcinoma	21 (58.3)

ASA: American Society of Anesthesiologists; COPD: chronic obstructive pulmonary disease; IQR: interquartile range.

patients; in one case, the lymph node did not show suspicious features and was not punctured, and in the other case, an EUS-guided fine-needle aspiration was negative.

Procedural characteristics

Thirty-six ESDs were performed, with a 91.7% (33/36) success rate. In two cases, ESD was stopped because of a difficult dissection through submucosal fibrosis, and in one case because of severe hypotension complicating the anesthesia: In all three cases, the endoscopic resection was finally achieved with a snare. Resection specimens (assessed endoscopically) had a mean size of 50.6 ± 22 mm and ranged from 10 to 100 mm; they exceeded the three-quarters of the esophageal circumference for 27.8% (10/36) of the lesions, and were circumferential in 16.7% (6/36) of the cases. The tunnel procedure was performed in 13 (36.1%) cases. Coagrasper hemostatic forceps were used in 81% of the cases, and hemoclips in 11.1%. In three cases, superficial tears in the circular muscle layer, without endoscopic or clinical evidence of perforation, were observed and closed by hemoclips during the procedure. These were not regarded as complications, nor was intraprocedural bleeding of submucosal vessels requiring hemostasis with hemostatic forceps. En bloc resection of the lesion was achieved in 88.9% (32/36) of cases. Triamcinolone acetonide was injected into the residual submucosa for post-ESD stricture prevention in three patients with almost circular mucosal defects deemed at high risk of stricture. Main procedural characteristics are presented in Table 2.

Complications

Early procedure-related complications were recorded in four patients (11.1%): Perforation occurred three times and complications of the anesthesia (respiratory distress and vasoplegia) in two cases. One patient had a perforation and respiratory distress in the immediate postoperative course. All three perforations were acute perforations diagnosed during the index endoscopy. They were managed conservatively with endoclips, nil per os, intravenous proton pump inhibitors, broad-spectrum antibiotics, and 24- to 48-hour surveillance in the intensive care unit. None of the patients developed mediastinitis. Patients were authorized to resume oral intake after a barium swallow had showed no leakage two to three days after the procedure. They stayed in the hospital for a total of six, eight and 10 days. No surgical intervention was required for the management of the complicated cases.

Late complications were recorded in two patients (5.6%) and were esophageal strictures, successfully

Table 2. Endoscopic findings and procedural characteristics of the 36 endoscopic submucosal dissections (ESDs) for Barrett's early neoplasia

Procedure duration (mean \pm SD), mn	191 \pm 79
Size of the endoscopic resection (mean \pm SD), mm	50.6 \pm 22
Circumferential extent of the lesion (median, IQR), % of the circumference	50 (50–77.8)
Paris classification of resected lesions, n (%)	n = 22 patients
0-Is	3 (13.6)
0-IIa	8 (36.4)
0-IIb	5 (22.7)
0-IIc	3 (13.6)
0-IIb + IIc or 0-IIa + IIc	3 (13.6)
ESD knife used, n (%)	n = 33 patients
Flush knife 1.5 mm	18 (54.5)
Dual knife 1.5 mm	10 (30.3)
TT knife	3 (9.1)
Flush knife 1 mm	2 (6.1)
Success rate, n (%)	33 (91.7)
En bloc resection, n (%)	32 (88.9)

IQR: interquartile range; TT: triangle tip.

managed by endoscopic dilation. Of the three patients with triamcinolone local injections, one had an uneventful follow-up, one had to stay overnight in the intensive care unit for early esophageal perforation, and the last eventually developed an esophageal stricture.

When comparing the 16 ESDs performed in our early experience (2012–2013) and the 20 ESDs performed in our late experience (2014), the rate of early complications dropped from 18.8% to 5% ($p = 0.3$), whereas the rate of late complications remained stable moving from 6.3% to 5% ($p = 1$). Subgroup analysis of the complications according to the type of ESD knife used showed an early complication rate of 5.9%, 10%, and 33.3% ($p = 0.12$) and a late complication rate of 0%, 10%, and 33.3% for the 1.5 mm flush knife, 1.5 mm dual knife, and TT knife groups, respectively.

Histological outcomes

The resected specimens contained invasive adenocarcinoma in 80.5% (29/36) of cases, limited to the mucosa (pT1a m) or the superficial third of the submucosa (pT1b sm1) in 82.8% of the cases. On pathological examination, the mean size of the lesion was 12 ± 15 mm, and the lesions ranged from 2 to 90 mm. The R0 resection rate of carcinomas, as defined by the absence of carcinoma in the lateral or vertical margins

Table 3. Outcomes of the 36 endoscopic submucosal dissections (ESDs) for Barrett's early neoplasia

Hospital stay (mean \pm SD), days	2.9 \pm 2
Early complications, <i>n</i> (%)	4 (11.1)
Bleeding	0 (0)
Perforation	3 (8.3)
Other (anesthesia-related)	2 (5.6)
Late complications, <i>n</i> (%)	
Esophageal stricture	2 (5.6)
30-Day mortality, <i>n</i> (%)	0 (0)
Size of neoplasia on pathological examination (mean \pm SD), mm	12 \pm 15
Histological analysis, <i>n</i> (%)	
Low-grade dysplasia	1 (2.8)
High-grade dysplasia	6 (16.7)
Adenocarcinoma	29 (80.5)
Infiltration depth ^a , <i>n</i> (%)	
Mucosa	23 (79.3)
SM1	1 (3.4)
SM > 1	5 (17.2)
Other histoprognostic factors ^a , <i>n</i> (%)	
Well differentiated	26 (89.7)
Moderately differentiated	2 (6.9)
Poorly differentiated	1 (3.4)
Lymphovascular invasion	3 (10.3)
Histological quality of the endoscopic resection, <i>n</i> (%)	
R0 resection of carcinoma	21/29 (72.4)
Curative resection of carcinoma ^a	19/29 (65.5)
Curative resection of high-grade dysplasia	18/35 (51.4)
Curative resection of all neoplasia	16/36 (44.5)

^aFor the 29 adenocarcinomas.

of the resection with 1 mm safety margins for the lateral margins, was 72.4% (21/29). Vertical margins and lateral margins contained adenocarcinoma in 20.7% (6/29) and 17.2% (5/29) of cases, respectively. Lateral resection margins contained HGD or low-grade dysplasia (LGD) in 2.9% and 17.2% of cases, respectively. Poor histoprognostic factors such as low differentiation of lymphovascular invasion were observed in 13.8% of the cases. As a result, rates of curative resection of carcinoma, HGD or carcinoma, and neoplasia were 65.5%, 51.4%, and 44.5%. Details about the histological outcomes of the ESD are given in Table 3.

Late outcomes

No 30-day mortality was observed. After a mean follow-up of 12.9 \pm 9 months, 48.6% (16/35) patients had required additional treatment, among whom nine

patients (25.7%) with deep submucosal adenocarcinoma or R1 endoscopic resection underwent surgical esophagogastric resection. Six patients were operated on for positive vertical margins (associated in two cases with deep submucosal tumor infiltration, in one case with deep submucosal tumor infiltration and lymphovascular invasion), one for deep submucosal tumor infiltration associated with poor tumoral differentiation, one for deep submucosal tumor infiltration, and one for positive lateral margins associated with lymphovascular invasion. Among these nine patients operated on, three had no residual tumor (intestinal metaplasia, LGD and HGD), three had residual—or most probably synchronous—intramucosal adenocarcinoma, and three had either N1, T2 or T3 tumors.

Metachronous lesions (3/29) or recurrence of cancer (2/29) developed during the follow-up period in five patients (17.2%), all successfully treated by further endoscopic resection, among which one second ESD. Four patients received ablative therapy, with argon plasma coagulation in one case and radiofrequency ablation in three cases. Among the 26 patients who were not operated on at the end of follow-up, complete remission of carcinoma, HGD, dysplasia and intestinal metaplasia were observed in 100% (26/26), 73.1% (19/26), 57.7% (15/26) and 38.5% (10/26) of cases, respectively. Buried, non-dysplastic Barrett's glands were seen on follow-up biopsies in three cases, two of which were treated for an adenocarcinoma and one for HGD; one of them had been treated with EMR before ESD.

Discussion

In this work, we sought to determine the effectiveness and safety of ESD for the treatment of large visible lesions arising in Barrett's esophagus. The R0 resection rate of EAc was 72.4% and the curative resection rate of EAc and HGD/EAc were 65.5% and 51.4%, respectively. ESD appeared feasible, with an 88.9% en bloc resection rate, and resulted in 11.1% early complications and no 30-day mortality. The recurrence rate of EAc was 6.9%. Nine patients ultimately underwent esophagectomy, suggesting that ESD for large Barrett's neoplasia spared surgical esophageal resection in almost three-quarters of our study patients.

Five studies have specifically studied the outcomes of ESD for Barrett's neoplasia,^{1,20–24} most of which took place in Europe. These studies included a total of 262 patients and reported en bloc resection rates from 90 to 100%, R0 resection rates from 64% to 85%, curative resections rates of EAc of 48% to 96.4%, and curative resection rates of HGD/EAc of 38.5% to 64%. Complications included 0 to 6% bleeding, 0 to 10% perforations, and 0 to 60% strictures. Recurrences rates of EAc ranged from 0 to 5.6%. Results can,

however, be difficult to compare among studies especially because the outcome parameters are not standardized yet: “Curative resection of EAc” is for instance not always reported, or the “R0 resection” follows several definitions; R0 resection might refer to margins free of cancer or of any kind of dysplastic Barrett’s.^{20,23,24} Since ESD is primarily aiming at treating cancer, we chose, along with other authors,^{1,21} to define R0 resection as cancer-free margins. Our figures, as well as those of other teams, are disappointing, especially when compared to the outcomes of ESD in squamous cell carcinoma or adenocarcinomas of the gastric cardia, where R0 resection rates reach 89%–91.9%, in Japan but also in Europe.^{1,2,8,25} However, ESD is designed for the resection of a visible lesion. Therefore, it is expected to yield optimal results for a unique tumor surrounded by normal mucosa in the upper or mid-esophagus such as a squamous cell neoplasm. In Barrett’s esophagus, dysplasia is often multifocal, extends circumferentially around the esophagogastric junction, and is not always detectable by the eye and state-of-the-art endoscopic techniques: it is then little wonder that ESD margins frequently cut through dysplastic Barrett’s, and that additional treatments of residual Barrett’s esophagus, such as radiofrequency ablation, are often required.

Our data reflect the early experience of a Western center, as demonstrated by the extensive procedure durations and the relatively high complication rate. The R0 resection rate can be explained by the difficult delineation of Barrett’s neoplasia, which might extend laterally further than a non-magnifying endoscope can show, and even under the squamous epithelium as was demonstrated using optical coherence tomography.^{26,27} Therefore, many authors suggest extending the delineation margins 5 to 10 mm away from the visible lesion.^{20,24,27} Our choice of only 2–3 mm lateral safety margins was made by analogy with ESD procedures in other organs. It might have accounted for the 17.2% cancer-infiltrated lateral margins we found, even though the mean resection was 51.3 mm for a mean lesion size (on histopathological examination) of 12 mm. This might also suggest that not only lateral margins, but also training for adequate tumor delineation, is critical for ESD to be curative in Barrett’s neoplasia. We resected three protruded Paris 0–Is lesions by ESD in our study: noticeably, two had deep submucosal invasion and were operated on, confirming the high proportion of submucosal invasion for esophageal and gastric 0–Is lesions.²⁸ Preoperative esophageal EUS or CT did not change patient management, as was shown by others.²⁹ The low rates of complete remission of intestinal metaplasia and dysplasia are explained by the absence of eradication of Barrett’s esophagus without HGD after endoscopic resection ESD in our center, and the relatively short follow-up. Breaking down the

cases in early and late experience showed that the rate of early complications was divided by three between the 2012–2013 period and the year 2014. Even if this difference was not statistically significant, it should reflect the learning curve in esophageal ESD. The choice of the ESD knife drifted in time toward the use of the 1.5 mm flush knife, and therefore associations between the ESD knife type and complication rates are not interpretable.

The current strategy for the management of Barrett’s early neoplasia relying on the resection of a visible lesion using EMR, by definition suspicious of EAc, followed by the eradication of all remaining Barrett’s mucosa with radiofrequency ablation,³⁰ could theoretically be improved with ESD. Indeed, the R0 resection rate of EAc by EMR, even in expert hands, is as low as 33%,³¹ and could account for recurrent lesions. However, this strategy, despite frequent RI or Rx resection, has proven safe, with low complication rates and in particular virtually no esophageal perforations, and effective, with complete remission of neoplasia after four years of follow-up in 96% of cases.³⁰ By comparison, ESD for Barrett’s neoplasia did not reach high R0 resection rates, and was marked by a relatively high number of complications in our study. Furthermore, the flat learning curve, the longer duration of the procedures, and the need for general anesthesia—usually with endotracheal intubation—with ESD plead against this technique as long as clinical or oncological benefit is not clearly established. There is currently no established role for a routine use of ESD in the care of early Barrett’s cancer. However, ESD might be preferable for the resection of lesions larger than 15 mm, pretreated and/or poorly lifting, too bulky to consider resection with a cap-based technique, or suspicious for submucosal invasion, such as Paris 0–IIc lesions. Finally, prospective randomized trials are needed to compare EMR and ESD, starting with those specific indications.

Funding

This research received no specific grant from any funding agency in the public, commercial, or not-for-profit sectors.

Conflict of interest

None declared.

References

1. Probst A, Aust D, Märkl B, et al. Early esophageal cancer in Europe: Endoscopic treatment by endoscopic submucosal dissection. *Endoscopy* 2015; 47: 113–121.
2. Repici A, Hassan C, Carlino A, et al. Endoscopic submucosal dissection in patients with early esophageal squamous cell carcinoma: Results from a prospective Western series. *Gastrointest Endosc* 2010; 71: 715–721.

3. Tsujii Y, Nishida T, Nishiyama O, et al. Clinical outcomes of endoscopic submucosal dissection for superficial esophageal neoplasms: A multicenter retrospective cohort study. *Endoscopy* 2015; 47: 775–783.
4. Nakagawa S, Kanda T, Kosugi S, et al. Recurrence pattern of squamous cell carcinoma of the thoracic esophagus after extended radical esophagectomy with three-field lymphadenectomy. *J Am Coll Surg* 2004; 198: 205–211.
5. Peyre CG, DeMeester SR, Rizzetto C, et al. Vagal-sparing esophagectomy: The ideal operation for intramucosal adenocarcinoma and barrett with high-grade dysplasia. *Ann Surg* 2007; 246: 665–671. discussion 671–674.
6. Takeuchi H, Miyata H, Gotoh M, et al. A risk model for esophagectomy using data of 5354 patients included in a Japanese nationwide web-based database. *Ann Surg* 2014; 260: 259–266.
7. Endo M. Endoscopic resection as local treatment of mucosal cancer of the esophagus. *Endoscopy* 1993; 25: 672–674.
8. Kim JS, Kim BW and Shin IS. Efficacy and safety of endoscopic submucosal dissection for superficial squamous esophageal neoplasia: A meta-analysis. *Dig Dis Sci* 2014; 59: 1862–1869.
9. Pech O, May A, Manner H, et al. Long-term efficacy and safety of endoscopic resection for patients with mucosal adenocarcinoma of the esophagus. *Gastroenterology* 2014; 146: 652–660.e1.
10. Takahashi H, Arimura Y, Masao H, et al. Endoscopic submucosal dissection is superior to conventional endoscopic resection as a curative treatment for early squamous cell carcinoma of the esophagus (with video). *Gastrointest Endosc* 2010; 72: 255–264, 264.e1–e2.
11. Ishihara R, Iishi H, Uedo N, et al. Comparison of EMR and endoscopic submucosal dissection for en bloc resection of early esophageal cancers in Japan. *Gastrointest Endosc* 2008; 68: 1066–1072.
12. Urabe Y, Hiyama T, Tanaka S, et al. Advantages of endoscopic submucosal dissection versus endoscopic oblique aspiration mucosectomy for superficial esophageal tumors. *J Gastroenterol Hepatol* 2011; 26: 275–280.
13. Oka S, Tanaka S, Kaneko I, et al. Advantage of endoscopic submucosal dissection compared with EMR for early gastric cancer. *Gastrointest Endosc* 2006; 64: 877–883.
14. Katada C, Muto M, Momma K, et al. Clinical outcome after endoscopic mucosal resection for esophageal squamous cell carcinoma invading the muscularis mucosae—a multicenter retrospective cohort study. *Endoscopy* 2007; 39: 779–783.
15. Park CH, Kim EH, Kim HY, et al. Clinical outcomes of endoscopic submucosal dissection for early stage esophagogastric junction cancer: A systematic review and meta-analysis. *Dig Liver Dis* 2015; 47: 37–44.
16. Tall ML, Salmon D, Diouf E, et al. Aseptic process validation and stability study of an injectable preparation of fructose (5%)-glycerol (10%) as part of a hospital clinical research program on endoscopic curative treatment for early epithelial neoplastic lesions of the gastrointestinal tract [article in French]. *Ann Pharm Fr* 2015; 73: 139–149.
17. Pioche M, Mais L, Guillaud O, et al. Endoscopic submucosal tunnel dissection for large esophageal neoplastic lesions. *Endoscopy* 2013; 45: 1032–1034.
18. Hanaoka N, Ishihara R, Takeuchi Y, et al. Intralesional steroid injection to prevent stricture after endoscopic submucosal dissection for esophageal cancer: A controlled prospective study. *Endoscopy* 2012; 44: 1007–1011.
19. Shimoda T. Japanese classification of esophageal cancer, the 10th edition—Pathological part [article in Japanese]. *Nihon Rinsho* 2011; 69(Suppl 6): 109–120.
20. Chevaux JB, Piessevaux H, Jouret-Mourin A, et al. Clinical outcome in patients treated with endoscopic submucosal dissection for superficial Barrett's neoplasia. *Endoscopy* 2015; 47: 103–112.
21. Höbel S, Dautel P, Baumbach R, et al. Single center experience of endoscopic submucosal dissection (ESD) in early Barrett's adenocarcinoma. *Surg Endosc* 2015; 29: 1591–1597.
22. Hoteya S, Matsui A, Iizuka T, et al. Comparison of the clinicopathological characteristics and results of endoscopic submucosal dissection for esophagogastric junction and non-junctional cancers. *Digestion* 2013; 87: 29–33.
23. Kagemoto K, Oka S, Tanaka S, et al. Clinical outcomes of endoscopic submucosal dissection for superficial Barrett's adenocarcinoma. *Gastrointest Endosc* 2014; 80: 239–245.
24. Neuhaus H, Terheggen G, Rutz EM, et al. Endoscopic submucosal dissection plus radiofrequency ablation of neoplastic Barrett's esophagus. *Endoscopy* 2012; 44: 1105–1113.
25. Kakushima N, Yahagi N, Fujishiro M, et al. Efficacy and safety of endoscopic submucosal dissection for tumors of the esophagogastric junction. *Endoscopy* 2006; 38: 170–174.
26. Anders M, Lucks Y, El-Masry MA, et al. Subsquamous extension of intestinal metaplasia is detected in 98% of cases of neoplastic Barrett's esophagus. *Clin Gastroenterol Hepatol* 2014; 12: 405–410.
27. Ishihara R, Yamamoto S, Hanaoka N, et al. Endoscopic submucosal dissection for superficial Barrett's esophageal cancer in the Japanese state and perspective. *Ann Transl Med* 2014; 2: 24.
28. Endoscopic Classification Review Group. Update on the Paris classification of superficial neoplastic lesions in the digestive tract. *Endoscopy* 2005; 37: 570–578.
29. Pouw RE, Helderdoorn N, Alvarez Herrero L, et al. Do we still need EUS in the workup of patients with early esophageal neoplasia? A retrospective analysis of 131 cases. *Gastrointest Endosc* 2011; 73: 662–668.
30. Phoa KN, Pouw RE, Bisschops R, et al. Multimodality endoscopic eradication for neoplastic Barrett oesophagus: Results of an European multicentre study (EURO-II). *Gut*. Epub ahead of print 2 March 2015. DOI: 10.1136/gutjnl-2015-309298.
31. Ell C, May A, Pech O, et al. Curative endoscopic resection of early esophageal adenocarcinomas (Barrett's cancer). *Gastrointest Endosc* 2007; 65: 3–10.

Discussion et perspectives

I. Travaux translationnels

Il nous semble peu contestable que développement du traitement endoscopique en tant qu'alternative radicale et à faible morbidité à la chirurgie dans le traitement des cancers superficiels et des états précancéreux de l'œsophage passe par la prévention de la sténose œsophagienne cicatricielle, puisque celle-ci complique quasi-systématiquement les résections excédant les trois quarts de la circonférence œsophagienne. Nous avons, dans le cadre de cette thèse, principalement obtenu des résultats sur un modèle porcin de sténose œsophagienne post-endoscopique, présentant deux avantages principaux : sa bonne reproductibilité, la sténose symptomatique survenant invariablement à J14 ; et d'autre part sa similitude avec l'Homme, permettant un transfert rapide des techniques vers l'activité clinique, en cas de succès.

L'échec de nos approches antérieures anti-prolifératives (avec la mitomycine C) ou anti-fibrosantes (avec la N-acétylcystéine) nous a conduit, dans un premier travail¹⁴⁷, à évaluer l'effet de la membrane amniotique humaine (MAH). Ce produit, d'utilisation courante en ophtalmologie, et également proposé dans certains travaux pour la couverture de plaies cutanées chroniques, associe un effet protecteur de couverture de la plaie, et un effet anti-prolifératif et régénératif. L'effet anti-prolifératif serait expliqué par une activité anti-inflammatoire liée à la présence dans la MAH de quatre types d'inhibiteurs tissulaires de MMP, d'un antagoniste de l'IL1R, et d'IL10 ; l'effet anti-fibrosant par l'inhibition de la synthèse du TGF- β et de la différenciation myofibroblastique, et par une activité antioxydante liée à la présence de lactoferrine

dans la MAH. La synthèse par la monocouche cellulaire de la MAH de facteurs de croissance épithéliaux (EGF, KGF, HGF), et la présence d'un stroma acellulaire susceptible de servir de matrice pour la repousse épithéliale plaident en faveur d'une activité régénérative de la MAH ¹⁴⁷. Enfin, les essais préliminaires d'application de la MAH nécessitaient la mise en place d'une prothèse plastique pour stabiliser la MAH contre la paroi œsophagienne, avec une action mécanique ajoutée. Ainsi la MAH apparaissait comme un candidat intéressant à la prévention de la sténose œsophagienne post-endoscopique, combinant toutes les approches que nous avons décrites préalablement.

Dès lors, nous avons conçu un essai prospectif, contrôlé : le groupe 1, groupe contrôle (n= 5), ne recevait aucun traitement après l'ESD circonférentielle de l'œsophage; le groupe 2 (n= 5), recevait une prothèse œsophagienne destinée à calibrer l'œsophage après la procédure endoscopique. Le groupe 3 (n= 10) recevait une prothèse recouverte de MAH après l'intervention endoscopique, et incluait un groupe de sacrifice précoce (groupe 3A) et un groupe de sacrifice tardif (groupe 3B). L'application de la membrane amniotique diminuait significativement le taux de sténose œsophagienne symptomatique à J14 par rapport aux contrôles, cependant sans différence statistiquement significative par rapport au groupe traité par une prothèse œsophagienne seule. Bien que les résultats ne soient pas statistiquement significatifs, la fibrose cicatricielle diminuait entre le groupe 1 et le groupe 3A, tandis que le bénéfice disparaissait au-delà du 14ème jour, dans le groupe 3B. Enfin, les dosages de métabolites ou d'activités enzymatiques liés au stress oxydant n'ont pas permis de mettre en évidence de façon statistiquement significative une inhibition du stress oxydant dans les échantillons tissulaires du groupe 3. Toutefois, la diminution transitoire à J14 des taux de nitrites et de l'activité de la catalase tissulaires

pourraient conforter l'hypothèse d'une réduction temporaire du stress oxydant associée à la fibrose moindre dans les tissus cicatriciels du groupe 3.

Les limites de ce travail sont de plusieurs types : tout d'abord, la relative faiblesse des effectifs, bien que classique dans des études sur des modèles de gros animaux, a limité considérablement la puissance statistique de nos analyses. Un plus grand nombre de mesures sur l'impact de la MAH dans la croissance épithéliale œsophagienne aurait pu être obtenu à l'aide d'un modèle de culture cellulaire épithéliale œsophagienne, mais alors la validité statistique aurait augmenté au détriment de la validité clinique. Ensuite, la migration précoce des prothèses œsophagiennes, survenue dans la moitié des cas, et en rapport avec l'absence de sténose œsophagienne au moment de la pose de la prothèse, est une limite majeure à l'évaluation de l'efficacité de la MAH. Enfin, l'effet transitoire de la MAH à J14 disparaissant à J21 pourrait être expliqué par la dégradation, typiquement observée après 2 semaines en ophtalmologie ²¹³. De plus, la présence d'une prothèse limite la validité des résultats puisqu'elle en pollue l'interprétation, le groupe stent seul se comportant à peu près de la même manière que MAH. Il faudrait pouvoir appliquer la MAH seule de façon stable, ce qui est pour l'heure impossible chez le porc. Enfin, la manipulation de la MAH est délicate, en particulier si l'on veut appliquer spécifiquement la face épithéliale ou choriale sur la plaie œsophagienne.

Ainsi, en dépit de propriétés prometteuses sur la cicatrisation tissulaire, les résultats de la MAH dans notre modèle sont insuffisants. Un nouvel essai pourrait être envisagé si les progrès techniques endoscopiques venaient à faciliter l'application et améliorer la stabilité de la MAH sur les plaies œsophagiennes.

Compte tenu du problème posé par l'application, puis la stabilité du composé étudié dans l'œsophage, nous avons, dans un second travail ²¹², évalué l'effet d'une poudre minérale hémostatique TC-325 (Hemospray, Cook Medical, Limerick, Irlande) adhérant aux zones hémorragiques, dans la prévention de la sténose œsophagienne post-endoscopique, sur le même modèle porcin. En effet, des rapports ont fait état de la cicatrisation accélérée d'ulcères gastro-duodénaux après aspersion de cette poudre hémostatique, et l'application de façon homogène par pulvérisation dans la lumière œsophagienne de ce possible agent protecteur est aisée. Nous avons donc, après une étude de faisabilité sur cinq animaux suggérant un effet de l'Hemospray sur la prévention de la sténose dans 3 cas sur 5, conduit une étude contrôlée avec un groupe 1 (n = 10) contrôle ayant une ESD circonférentielle de l'œsophage sans traitement complémentaire. Le groupe 2 (n = 10) recevait quatre applications endoscopiques d'Hemospray®, à J0, J2, J4, et J7. Tous les animaux étaient sacrifiés à J14.

Les résultats montraient un taux de sténose œsophagienne symptomatique diminué non significativement à J14 de 100% à 60% dans les groupes 1 et 2, respectivement. Cependant, des différences statistiquement significatives étaient notées concernant le diamètre œsophagien médian à J14 (2 mm [1–3] vs. 3 mm [2–4], p = 0.01). De même, les critères de jugement histologiques et biologiques suggéraient un effet significatif de l'Hemospray sur la cicatrisation œsophagienne, avec une diminution de l'infiltrat inflammatoire, de la fibrose, un plus long néo-épithélium, et un taux plus bas de TGF- β dans le groupe traité. Ainsi, l'Hemospray, dans les conditions de ce travail, apparaissait comme un traitement prometteur dans l'amélioration des paramètres de la cicatrisation œsophagienne post endoscopique.

Cependant, certaines limites de ce travail doivent être soulignées, qui nous ont jusqu'à présent retenus d'envisager une étude clinique : tout d'abord, compte tenu de l'hémostase extrêmement rapide du porc, la procédure d'ESD n'est qu'exceptionnellement hémorragique. Ainsi, afin d'assurer l'adhérence de l'Hémospay aux vaisseaux de la sous-muqueuse résiduelle, un protocole de bi-antiagrégation plaquettaire a été utilisé chez les animaux. Les effets de ce protocole sur la cicatrisation œsophagienne sont inconnus. Deuxièmement, même en maximisant le saignement, et donc l'adhérence de la poudre à la paroi œsophagienne, l'Hémospay était rincé par la salive et les mouvements de déglutition des animaux en deux jours : les résultats observés ont été obtenus au prix d'applications itératives, difficilement acceptables chez des patients. Enfin, quoique ces résultats aient atteint la significativité statistique sur nombre de critères dans un modèle porcin de sténose plus sévère que l'Homme (100% de sténoses à J14), le critère de jugement principal, à savoir le taux de sténose symptomatique à J14, n'était pas différent entre les groupes. Si l'utilisation d'hémospay paraît donc envisageable à l'heure actuelle chez l'Homme en prévention de la sténose œsophagienne, on peut s'attendre qu'à un effet modeste, obtenu au prix d'applications endoscopiques itératives du produit.

Dans un troisième travail, nous avons étudié un peptide auto-assemblé (SAP) comme potentiel agent protecteur œsophagien. Ce SAP formé de 4 motifs peptidiques répétés (4 [Arg-Ala-Asp-Ala]) forme, au contact de milieux ioniques comme les fluides biologiques, une matrice tri-dimensionnelle gélatineuse déjà utilisée pour la culture cellulaire, l'administration prolongée de médicaments, mais

aussi la couverture de plaies cutanées, muqueuses, et l'hémostase en chirurgie et en endoscopie digestive. Après des essais de faisabilité sur animaux, nous avons conduit une étude prospective contrôlée sur 5 animaux et 5 contrôles, ayant tous une ESD circonférentielle de l'œsophage. Les animaux étaient sacrifiés à la survenue d'une sténose œsophagienne symptomatique.

Le SAP permettait une diminution significative du taux de sténose symptomatique à J14 entre les groupes témoins et traités (100 % vs 40 %, respectivement, $p = 0.04$). De même, le diamètre œsophagien médian à J14 était doublé dans le groupe traité. Le SAP apparaît donc comme particulièrement prometteur en tant qu'agent protecteur des plaies œsophagiennes. Cependant, certaines remarques doivent être notées.

Dans ce travail, nous avons cherché à améliorer les critères de jugement habituellement utilisés dans de telles études, qui sont souvent subjectifs sur les critères cliniques, voire endoscopiques. Outre la pesée des animaux au cours de l'étude en plus de l'évaluation de leur état général et de leur comportement, nous avons ainsi ajouté à l'évaluation endoscopique du diamètre œsophagien, une évaluation radiologique sur un transit baryté de l'œsophage. Cependant, la principale limite méthodologique de notre travail tient au sacrifice à des temps différents des groupes traités et contrôles. En effet, les contrôles étaient tous sacrifiés à J14 en raison de leurs sténoses œsophagiennes symptomatiques, et les animaux traités par le SAP, sacrifiés en moyenne à J21. Ceci pourrait expliquer l'absence de différence statistiquement significative pour des critères de jugement histologiques contrastant avec les différences importantes observées pour les critères cliniques et endoscopiques, tous évalués à J14. Cependant, le sacrifice de tous les animaux à J14 aurait empêché de constater que les 3 animaux exempts de sténose

œsophagienne à J14 avaient sténosé à J28. Ainsi, l'effet du SAP apparait seulement suspensif sur la sténose œsophagienne. Comme pour la MAH, le bénéfice du SAP est transitoire, et la question de sa stabilité du SAP dans l'œsophage parait cruciale. Ainsi, une étude de la stabilité de versions améliorées du SAP sur des plaies œsophagiennes est en cours d'organisation. Une nouvelle étude suivra, incluant une nouvelle version du SAP, et trois groupes d'animaux (dont un groupe traité par SAP et sacrifié à J14, soit en même temps que les contrôles).

II. Travaux cliniques

Parallèlement à ces travaux de recherche translationnelle, nous avons conduit des travaux cliniques sur les trois principales techniques de traitement endoscopiques des cancers superficiels de l'œsophage : la mucosectomie, la radiofréquence œsophagienne, et la dissection sous-muqueuse.

Dans une étude rétrospective multicentrique portant sur 40 patients pris en charge endoscopiquement pour une lésion visible sur œsophage de Barrett court, nous avons évalué les résultats de la mucosectomie œsophagienne (EMR) et de l'ablation par radiofréquence (RFA) réalisées dans un seul et même temps endoscopique, au lieu des deux étapes habituellement usitées. La procédure en un seul temps était suffisante à traiter l'ensemble de l'OB pour 43% des patients, et économisait ainsi un temps endoscopique à près de la moitié des patients. Les résultats obtenus, en termes de rémission complète de la métaplasie intestinale et de la dysplasie de haut grade (95% après un suivi moyen de 19 mois) étaient comparables à ceux de la littérature. Cependant, un taux majeur de sténoses œsophagiennes cicatricielles de 33%, était remarquable dans ce travail, et s'oppose

au taux de sténose de 4% habituellement décrit ⁸⁴. La cause la plus probable en est l'utilisation d'un protocole de RFA plus agressif, impliquant 3 applications successives à 15 J/cm², abandonné depuis. Ainsi, le taux de complication de cette approche thérapeutique devra être réévalué avec des protocoles de traitement plus validés. Par ailleurs, la combinaison d'une résection endoscopique et d'une ablation muqueuse peut avoir conduit à des lésions muqueuses dépassant les trois quarts de la circonférence, expliquant ainsi, indépendamment du protocole employé, le taux de sténoses observé. Les développements ultérieurs de ce projet pourraient concerner l'évaluation de cette stratégie sur des OB plus étendus, l'utilisation d'un protocole de RFA moins agressif, d'autres techniques ablatives concomitantes à l'EMR, telles que la coagulation au plasma argon ou la cryoablation.

Enfin, dans une étude prospective monocentrique à l'hôpital Cochin, nous avons étudié les performances et les complications de la dissection sous-muqueuse oesophagienne dans le traitement des lésions visibles sur œsophage de Barrett chez 36 patients. Le taux de résection R0 pour le cancer était de 72.4%, en raison d'un envahissement des marges verticales dans 21% des cas et des marges latérales dans 17% des cas. En prenant en compte les facteurs pronostics histologiques, le taux de résection curative des AdénoCa tombait à 66%. En incluant les marges latérales envahies par la dysplasie de haut grade, le taux de résection histologiquement complète était de 51%. Le taux de complication était de 17%, parmi lesquels 8% de perforations et 6% de sténoses, et la mortalité à J30 était nulle. Cette série, dont le taux de complications reflète le début d'expérience dans la technique, pose également la question des indications de l'ESD dans l'AdénoCa oesophagien superficiel. En effet, quoique les résultats obtenus soient voisins de ceux rapportés

par d'autres équipes européennes ⁶¹, les résultats oncologiques sont loins de ceux obtenus dans le traitement des carcinomes épidermoïdes de l'œsophage, où les taux de résection curative avoisinent les 90% ⁶⁵. Outre les progrès de la technique opératoire, les progrès dans l'endoscopie diagnostique devraient permettre de diminuer le taux de marges latérales positives. A la suite de cette étude, nous avons initié une évaluation prospective multicentrique dans 8 centres experts français des résultats de l'ESD dans le traitement de l'AdénoCa oesophagien.

III. Perspectives

Les travaux entrepris sur le modèle porcin nous ont conduit à privilégier des approches protectrices de couverture de la plaie dans la prévention de la sténose oesophagienne. A cet égard, nos prochains travaux viseront à étudier la stabilité du SAP au cours de la cicatrisation oesophagienne, voire son intégration à la paroi oesophagienne. Des essais d'application du SAP teinté d'indigo carmin, accompagnés de monitoring endoscopique, histologique, et spectrométrique de la présence de SAP et de la cicatrisation sont ainsi en cours d'organisation. En cas de stabilité établie, l'incorporation de traitements antifibrosants ou antiinflammatoires, et tout particulièrement la triamcinolone -un corticoïde d'action retardée largement utilisé en endoscopie- seront envisagés.

Par ailleurs, nous attendons de l'étude transcriptomique de nous aider à sélectionner des cibles moléculaires de l'inflammation et de la fibrogénèse oesophagienne à viser par le biais d'inhibiteurs pharmacologiques administrés par voie locale ou systémique. C'est ici que le modèle murin de sténose oesophagienne, actuellement en cours de mise au point, pourrait s'avérer précieux, afin de tester des

molécules candidates à la prévention de la sténose oesophagienne post-endoscopique sur des effectifs importants, avant de revenir au modèle préclinique porcin, puis d'envisager une étude de phase I chez l'Homme.

Conclusion

Le développement du traitement endoscopique des états précancéreux et cancers superficiels de l'œsophage se heurte à la problématique de la cicatrisation pathologique de l'œsophage aboutissant à la formation de sténoses fibro-inflammatoires. Dans la première partie de ce travail, nous avons abordé la question essentiellement à travers un modèle porcin, sur lequel nous avons évalué plusieurs techniques de couverture de la plaie oesophagienne par des pansements biologiques ou minéraux, dont le transfert clinique nécessitera encore des études de confirmation. La suite de ce travail nous ramène aux aspects mécanistiques de la cicatrisation oesophagienne afin d'identifier une signature inflammatoire spécifique sur laquelle des traitements pharmacologiques pourront être testés.

Annexe 1

Endoscopic submucosal dissection: the best way to deal with subsquamous metaplasia?

Barret M, Camus M, Leblanc S, Coriat R, Chaussade S, Prat F. *Endoscopy*. 2015 Aug;47(8):761.

Maximilien Barret, Marine Camus,
Sarah Leblanc, Romain Coriat,
Stanislas Chaussade, Frédéric Prat
**Endoscopic submucosal dissection:
the best way to deal with subsquamous
metaplasia?**

We read with great interest the article by Chevaux et al. reporting the results of a large prospective study of endoscopic submucosal dissection (ESD) for Barrett's neoplasia [1].

The authors reported the technique to be feasible with a 90% en bloc resection rate, and complications rates of 6.7% for early and 60% for late complications, however, with no 30-day mortality. ESD yielded an 85% curative resection rate for early adenocarcinomas at risk of poor pathological assessment with conventional endoscopic mucosal resection (EMR). However, despite large mucosal resection specimens with a median size of 52.5 mm (interquartile range 43–71 mm), involving over three-fourths of the esophageal circumference in half of the patients, and safety margins of 3–5 mm, the curative resection rate for neoplasia was only 56%.

Esophageal ESD is a technically challenging procedure, bearing relatively high complication rates as compared to EMR or ablation techniques. Therefore, one might expect that it would achieve two main goals: (i) curative resection of >15-mm early adenocarcinomas, and (ii) one-stage, en bloc resection of all Barrett's neoplasia, with optimal assessment of possible multifocal carcinomas, and low risk of residual or buried Barrett's glands, given that the whole mucosa and submucosa are resected.

Buried metaplasia or subsquamous Barrett's epithelium is defined by the presence of Barrett's glands in the lamina propria. It has been reported to be present in

a majority of patients with Barrett's esophagus, either under the squamous epithelium at the squamocolumnar junction in previously untreated patients, or under the squamous neopithelium after ablation therapies [2–5]. Cases of buried adenocarcinoma have been reported as a possible complication of buried Barrett's glands [6]. However, the actual importance of this condition is still unclear. Furthermore, some experts even cast doubt on the endoscopic and pathological definition of buried metaplasia [7].

According to a recent report, subsquamous Barrett's epithelium extends to a mean of 3.3 mm under the squamous epithelium [4]. This finding might account for the high rate of histologically incomplete resection (62.5%) due to positive horizontal margins in a previous study in which Barrett's neoplasia was resected by ESD [5]. The authors concluded that safety margins during such ESD procedures should be set further away from the nearest endoscopically visible lesion than the usual cutoff of 1–2 mm.

The study by Chevaux et al. suggests that currently available endoscopic diagnostic tools do not allow for accurate delimitation of Barrett's neoplasia. This could lead endoscopists either to consider en bloc resection of the entire Barrett's mucosa, using larger security margins beyond the abnormality that the eye can see (possibly leading to high rates of esophageal stricture because of the extent of the resection required) or to consider systematic radiofrequency ablation (RFA) of residual Barrett's esophagus after the resection by ESD of a visible lesion. In this case, rigorous histological follow-up would be required to search for buried metaplasia.

We would be interested to know the rate of subsquamous Barrett's epithelium in the study by Chevaux et al., and whether this condition could account for the positive lateral margins observed in almost half of the patients. If so, en bloc resection

of Barrett's neoplasia by ESD might require even larger security margins than the 4–5 mm used by Chevaux et al.

Competing interests: None

References

- Chevaux JB, Piessevaux H, Jouret-Mourin A et al. Clinical outcome in patients treated with endoscopic submucosal dissection for superficial Barrett's neoplasia. *Endoscopy* 2015; 47: 103–112
- Cobb MJ, Hwang JH, Upton MP et al. Imaging of subsquamous Barrett's epithelium with ultrahigh-resolution optical coherence tomography: a histologic correlation study. *Gastrointest Endosc* 2010; 71: 223–230
- Zhou C, Tsai TH, Lee HC et al. Characterization of buried glands before and after radiofrequency ablation by using 3-dimensional optical coherence tomography (with videos). *Gastrointest Endosc* 2012; 76: 32–40
- Anders M, Lucks Y, El-Masry MA et al. Subsquamous extension of intestinal metaplasia is detected in 98% of cases of neoplastic Barrett's esophagus. *Clin Gastroenterol Hepatol* 2014; 12: 405–410
- Neuhauss H, Terheggen G, Rutz EM et al. Endoscopic submucosal dissection plus radiofrequency ablation of neoplastic Barrett's esophagus. *Endoscopy* 2012; 44: 1105–1113
- Van Laethem JL, Peny MO, Salmon I et al. Intra-mucosal adenocarcinoma arising under squamous re-epithelialisation of Barrett's oesophagus. *Gut* 2000; 46: 574–577
- Pouw RE, Visser M, Odze RD et al. Pseudo-buried Barrett's post radiofrequency ablation for Barrett's esophagus, with or without prior endoscopic resection. *Endoscopy* 2014; 46: 105–109

Maximilien Barret, MD MSc.
Gastroenterology department
Hôpital Cochin
27, rue du Faubourg St Jacques
75014 Paris
France
Fax: +33-1-79724571
maxbarret5744@yahoo.fr

Annexe 2

Systematic review: the prevention of esophageal stricture after endoscopic resection.

Barret M, Beye B, Leblanc S, Beuvon F, Chaussade S, Batteux F, Prat F. Aliment

Pharmacol Ther. 2015 Jul;42(1):20-9

Systematic review: the prevention of oesophageal stricture after endoscopic resection

M. Barret¹, B. Beyer¹, S. Leblanc¹, F. Beuvon², S. Chaussade³, F. Batteux^{1,3} & F. Prat^{1,3}

¹Department of Gastroenterology, Cochin Hospital, Assistance Publique-Hôpitaux de Paris, Paris, France.
²U11016, Faculté Paris Descartes, Paris, France.

³Department of Pathology, Cochin Hospital, Assistance Publique-Hôpitaux de Paris, Paris, France.

⁴Department of Immunology, Cochin Hospital, Paris, France.

Correspondence to:

Dr F. Prat, Department of Gastroenterology, Cochin Hospital, 27, rue du Faubourg St Jacques, 75014 Paris, France.
 E-mail: frederic.prat@cch.aphp.fr

Publication data

Submitted 31 January 2015
 First decision 28 February 2015
 Resubmitted 16 April 2015
 Resubmitted 28 April 2015
 Resubmitted 29 April 2015
 Accepted 30 April 2015

This uncommissioned review article was subject to full peer-review

SUMMARY

Background

Extensive endoscopic resections for the treatment of early oesophageal neoplasia can result in fibro-inflammatory strictures that require repeated interventions, which significantly alter the patients' quality of life.

Aims

To review current evidence about the prevention of oesophageal strictures following endoscopic resections.

Methods

Systematic search of PubMed and Embase from inception to March 2015 using appropriate keywords. All original publications in English were included, and articles on the treatment of oesophageal stricture were excluded.

Results

Of the 461 hits, 62 studies were included in the analysis. Among the wound-protective strategies, polyglycolic acid sheets showed the most convincing evidence with a 37.5% stricture rate and excellent safety. Regenerative medicine, using cell sheets of autologous keratinocytes, resulted in a 25% stricture rate, although with cost and availability concerns. Among anti-proliferative treatment modalities, steroid treatment, either endoscopically injected triamcinolone in the resection wound or orally administered prednisolone, proved effective with an overall stricture rate of 13.5%, with safety concerns regarding late oesophageal perforations and infectious morbidity. Among mechanical treatment options, poorly effective and high-risk preventive balloon dilation tend to be replaced by prophylactic covered stent, with 18–28% stricture rates.

Conclusions

Although oral or locally injected steroids are promising options, no currently available technique is sufficiently efficient and devoid of significant safety concerns to recommend its routine use for the prevention of strictures after extensive endoscopic resection. Improving our knowledge in the mechanisms of oesophageal wound healing will guide the development of novel methods for stricture prevention.

Aliment Pharmacol Ther

INTRODUCTION

Clinical setting

Oesophageal cancer is the eighth most common cancer worldwide, with an estimated 456 000 new cases in 2012, and the sixth most common cause of death from cancer.¹ In the Western world, the incidence of oesophageal cancer is globally stable with around 35 000 new cases in Europe in 2012, while more than 18 000 new cases are expected in the US for 2014.^{1, 2} The proportion of squamous cell carcinoma (SCC) is decreasing, whereas adenocarcinoma (ADCa), which is generally developed on a background of dysplastic intestinal metaplasia, is now the most prevalent tumour type in the US and northern Europe.^{3, 4} Although oesophagectomy remains pivotal for advanced but localised disease (T1–2, N1–3, M0),^{5, 6} surgical resection is fraught with 35–42% morbidity and 2–3.4% mortality rates.^{7–9} Given these results, it is little wonder that endoscopic resection of pre-neoplastic lesions and early oesophageal cancers have progressively gained momentum over the past decade.^{5, 10, 11} In large series of patients with oesophageal SCC and ADCa with 5-year follow-up data, endoscopic mucosal resection (EMR) was associated with 91–96% complete response rates, 1.2–1.6% major adverse events and no mortality.^{12–14} Recurrences after EMR can often be re-treated endoscopically.¹² More recently, endoscopic submucosal dissection (ESD) has allowed *en bloc* oncologically adequate resection of large neoplasms, with even higher efficiency, and a complete response ranging from 96% to 99%; however, ESD results in higher morbidity, but this is generally manageable by medical and endoscopic treatment alone.^{13, 15} ESD is also a longer and more technically challenging procedure than EMR, and requires highly experienced endoscopists in expert centres. Other endoscopic therapies of oesophageal neoplasia, such as photodynamic therapy, argon plasma coagulation, and radiofrequency ablation, rely on ablation, not resection, to achieve a therapeutic response. Although some of these methods are highly effective in the treatment of early neoplasia (low- and high-grade dysplasia), they cannot be considered as oncologically appropriate treatments of superficial malignancies. The various treatment options for superficial oesophageal neoplasms are summarised in Table 1.

One of the main limitations of endoscopic resection methods, and a reason for preferring radiofrequency ablation when large and circular areas of dysplastic mucosa must be removed, is the high occurrence of cicatricial strictures. Oesophageal strictures develop as a result of wound

healing following any type of deep mucosal injury, including caustic burns, oesophageal surgical resections, radiotherapy, severe oesophagitis (peptic, eosinophilic, or inflammatory), and extensive endoscopic mucosal ablation, resection, or destruction. Reported stricture rates after EMR range from 1.3% to 4.9%,^{12, 13} and 3–11.6% for ESD,^{13, 16} but these rates are not strictly comparable because the circular extent of the resection was not similar among the studies. Katada *et al.* have shown that mucosal defects exceeding three-quarters of the circumference were significantly associated with oesophageal strictures.¹⁷ These findings have been confirmed by other authors, with stricture rates of 88% for circumferential EMR¹⁴ and 90–94% for ESD exceeding 75% of the oesophageal circumference,^{18, 19} suggesting a similar healing process after both types of mucosal resections, and a low impact of whether the resection was *en bloc* or piecemeal. Ono *et al.* showed in a study involving 65 patients with ESD for oesophageal squamous neoplasms that the resection of more than 75% of the circumference [odds ratio (OR): 44.2; 95% CI: 4.4–443.6], and T1A m2 histological depth (OR: 14.2; 95% CI: 2.7–74.2) are the two main factors significantly associated with post-ESD oesophageal stricture.²⁰ Strictures after ablative therapies, such as argon plasma coagulation or radiofrequency, occur infrequently with regard to the extent of the mucosal injury, with stricture rates of about 4% for both techniques.^{21, 22} These results are likely to be explained by the more superficial effect of these treatment modalities, which are restricted to the lamina propria or muscularis mucosae.^{23, 24}

Most post-endoscopic strictures are refractory^{20, 25} and require numerous dilations.²⁶ A clinical success rate of 71.4% at 6 months, which is comparable to the outcomes of peptic stricture dilation,²⁷ has been reported after repeated endoscopic bougienage or hydrostatic dilation, but long-term follow-up data are lacking. Furthermore, the dilation of such strictures leads to oesophageal perforation in 7.1–9% of the patients.^{27, 28} Therefore, the prevention of post-endoscopic oesophageal stricture is needed for endoscopic therapy to expand.

Mechanisms of oesophageal stricture

Doupe *et al.* studied the mechanisms of oesophageal wound healing in mice after epithelial destruction,²⁹ and found that the same epithelial progenitors involved in tissue homeostasis can adopt a regenerative behaviour within 24–48 h of tissue damage, displaying a high proliferation rate with a doubling of the mitosis rates in a proliferating zone surrounding a migrating front of cells immediately next to the epithelial defect. This behaviour was quickly reversible once wound healing had occurred.

INTRODUCTION

Clinical setting

Oesophageal cancer is the eighth most common cancer worldwide, with an estimated 456 000 new cases in 2012, and the sixth most common cause of death from cancer.¹ In the Western world, the incidence of oesophageal cancer is globally stable with around 35 000 new cases in Europe in 2012, while more than 18 000 new cases are expected in the US for 2014.^{1, 2} The proportion of squamous cell carcinoma (SCC) is decreasing, whereas adenocarcinoma (ADCa), which is generally developed on a background of dysplastic intestinal metaplasia, is now the most prevalent tumour type in the US and northern Europe.^{3, 4} Although oesophagectomy remains pivotal for advanced but localised disease (T1–2, N1–3, M0),^{5, 6} surgical resection is fraught with 35–42% morbidity and 2–3.4% mortality rates.^{7–9} Given these results, it is little wonder that endoscopic resection of pre-neoplastic lesions and early oesophageal cancers have progressively gained momentum over the past decade.^{5, 10, 11} In large series of patients with oesophageal SCC and ADCa with 5-year follow-up data, endoscopic mucosal resection (EMR) was associated with 91–96% complete response rates, 1.2–1.6% major adverse events and no mortality.^{12–14} Recurrences after EMR can often be re-treated endoscopically.¹² More recently, endoscopic submucosal dissection (ESD) has allowed *en bloc* oncologically adequate resection of large neoplasms, with even higher efficiency, and a complete response ranging from 96% to 99%; however, ESD results in higher morbidity, but this is generally manageable by medical and endoscopic treatment alone.^{13, 15} ESD is also a longer and more technically challenging procedure than EMR, and requires highly experienced endoscopists in expert centres. Other endoscopic therapies of oesophageal neoplasia, such as photodynamic therapy, argon plasma coagulation, and radiofrequency ablation, rely on ablation, not resection, to achieve a therapeutic response. Although some of these methods are highly effective in the treatment of early neoplasia (low- and high-grade dysplasia), they cannot be considered as oncologically appropriate treatments of superficial malignancies. The various treatment options for superficial oesophageal neoplasms are summarised in Table 1.

One of the main limitations of endoscopic resection methods, and a reason for preferring radiofrequency ablation when large and circular areas of dysplastic mucosa must be removed, is the high occurrence of cicatricial strictures. Oesophageal strictures develop as a result of wound

healing following any type of deep mucosal injury, including caustic burns, oesophageal surgical resections, radiotherapy, severe oesophagitis (peptic, eosinophilic, or inflammatory), and extensive endoscopic mucosal ablation, resection, or destruction. Reported stricture rates after EMR range from 1.3% to 4.9%,^{12, 13} and 3–11.6% for ESD,^{13, 16} but these rates are not strictly comparable because the circular extent of the resection was not similar among the studies. Katada *et al.* have shown that mucosal defects exceeding three-quarters of the circumference were significantly associated with oesophageal strictures.¹⁷ These findings have been confirmed by other authors, with stricture rates of 88% for circumferential EMR¹⁴ and 90–94% for ESD exceeding 75% of the oesophageal circumference,^{18, 19} suggesting a similar healing process after both types of mucosal resections, and a low impact of whether the resection was *en bloc* or piecemeal. Ono *et al.* showed in a study involving 65 patients with ESD for oesophageal squamous neoplasms that the resection of more than 75% of the circumference [odds ratio (OR): 44.2; 95% CI: 4.4–443.6], and T1A m2 histological depth (OR: 14.2; 95% CI: 2.7–74.2) are the two main factors significantly associated with post-ESD oesophageal stricture.²⁰ Strictures after ablative therapies, such as argon plasma coagulation or radiofrequency, occur infrequently with regard to the extent of the mucosal injury, with stricture rates of about 4% for both techniques.^{21, 22} These results are likely to be explained by the more superficial effect of these treatment modalities, which are restricted to the lamina propria or muscularis mucosae.^{23, 24}

Most post-endoscopic strictures are refractory^{20, 25} and require numerous dilations.²⁶ A clinical success rate of 71.4% at 6 months, which is comparable to the outcomes of peptic stricture dilation,²⁷ has been reported after repeated endoscopic bougienage or hydrostatic dilation, but long-term follow-up data are lacking. Furthermore, the dilation of such strictures leads to oesophageal perforation in 7.1–9% of the patients.^{27, 28} Therefore, the prevention of post-endoscopic oesophageal stricture is needed for endoscopic therapy to expand.

Mechanisms of oesophageal stricture

Doupe *et al.* studied the mechanisms of oesophageal wound healing in mice after epithelial destruction,²⁹ and found that the same epithelial progenitors involved in tissue homeostasis can adopt a regenerative behaviour within 24–48 h of tissue damage, displaying a high proliferation rate with a doubling of the mitosis rates in a proliferating zone surrounding a migrating front of cells immediately next to the epithelial defect. This behaviour was quickly reversible once wound healing had occurred.

Table 1 | Main treatment options for oesophageal neoplasms and their current limitations

	Surgical resection	Endoscopic mucosal resection	Endoscopic submucosal dissection	Radiofrequency ablation
Disease stage limitation	T2 M0 lesions Patient fit for surgery ⁵	T1A m2 (SCC) T1B Sm1 (ADCa) ¹²³	T1A m2 (SCC) T1B Sm1 (ADCa) ¹²³	Barrett's oesophagus with high-grade dysplasia, without visible lesion ¹¹
Success rate*	97–100% ⁶	92–100% ^{12–14, 21, 69}	64–96.4% ^{13, 15, 124}	81–100% ²¹
Recurrence rate (neoplasia)	1% for T1A ⁸ 22.9% for T1–T2 ⁷	9.8–11.5% ^{12–14, 69}	0.9–3.6% ^{13, 15, 18, 124}	2%† ¹²⁵
Ability to treat recurrence	Yes	Yes	Yes ¹⁸	Not recommended
Mortality	2–3.2% ^{8, 9}	0	0–3.3% ^{13, 124}	0
Morbidity	35–42% ^{8, 9}	1.2–4% ^{14, 69}	4–6.6% ^{13, 18, 124}	1% ²¹
Stricture rate	24–47% ⁸ (anastomotic)	37–88% if C-EMR ^{14, 69}	90% if C-ESD ^{15, 20, 124}	4–5% ^{21, 126}
Buried glands	Not reported	2–8% ^{14, 67, 69}	Not reported	0–0.9% ^{21, 127}
Shortcomings	High morbidity QoL impaired	Piecemeal resection for lesions >2 cm Strictures Inadequate histology if malignancy	Expertise required (learning curve) Long procedure Strictures	No histology Not indicated for malignancy
Advantages	Oncologically appropriate resection Lymph node staging	Safe Easy to perform	Oncologically appropriate resection Reliable histologic assessment	Safe Easy to perform Excellent tissue repair

SCC, squamous cell carcinoma; ADCa, adenocarcinoma; IM, intestinal metaplasia; QoL, Quality of life; CEMR, circumferential endoscopic mucosal resection; CESD, circumferential endoscopic submucosal dissection.

* Rate complete eradication of neoplasia (high grade dysplasia or early carcinoma) at the end of treatment.

† Recurrence of dysplasia at 3 years.

This mechanism is obviously efficient when the epithelial damage is limited in size, such as after an endoscopic biopsy, in small oesophageal ulcers, or after an EMR involving less than three-quarters of the oesophageal circumference. The importance of the depth of injury is unclear, but the preservation of the muscularis mucosae and/or the submucosal glands might account for the very different stricture rates between circumferential RFA and circumferential EMR or ESD. Figure 1 shows what remains of the oesophageal wall after EMR and the two main modes of wound healing. Most of our understanding of oesophageal healing and stricture formation derives from the application of general paradigms of scar tissue formation in the animal oesophagus,^{30, 31} or in other human organs, such as the stomach³² or skin.³³ The first step is an epithelial injury, leading to a loss of the barrier function of the epithelium, and the exposure of the submucosal space to several kinds of insults: mechanical through food boluses, chemical through acid or bile reflux and microbial due to the oesophageal bac-

terial and fungal flora. The second step is the immune system activation.³⁴ The inflammatory response is characterised by the formation of a granulation tissue that includes an inflammatory cell infiltrate and palisadic vessel neof ormation. In the early phase, most inflammatory cells are neutrophilic polynuclear leucocytes and macrophages, whereas in the late phase, these cells are progressively replaced by lymphocytes and plasmocytes.³⁵ The third phase is scar tissue formation, which after extensive mucosal injuries of the oesophagus, results in oesophageal stricture development. Resident fibroblasts and pericytes are induced to differentiate into scar-forming myofibroblasts by fibrogenic cytokines. These cytokines, such as TGF- β 1, TNF- α , IL-1, IL-6, PDGF, IL-17A and IL-13, are produced by epithelial cells, endothelial cells and myeloid leucocytes.³⁶ Myofibroblasts are highly contractile and express α -smooth muscle actin (α -SMA), which forms bundles of myofilaments that promote wound contraction.³⁷ Secondly, myofibroblasts are the key drivers of scar tissue formation through synthesis

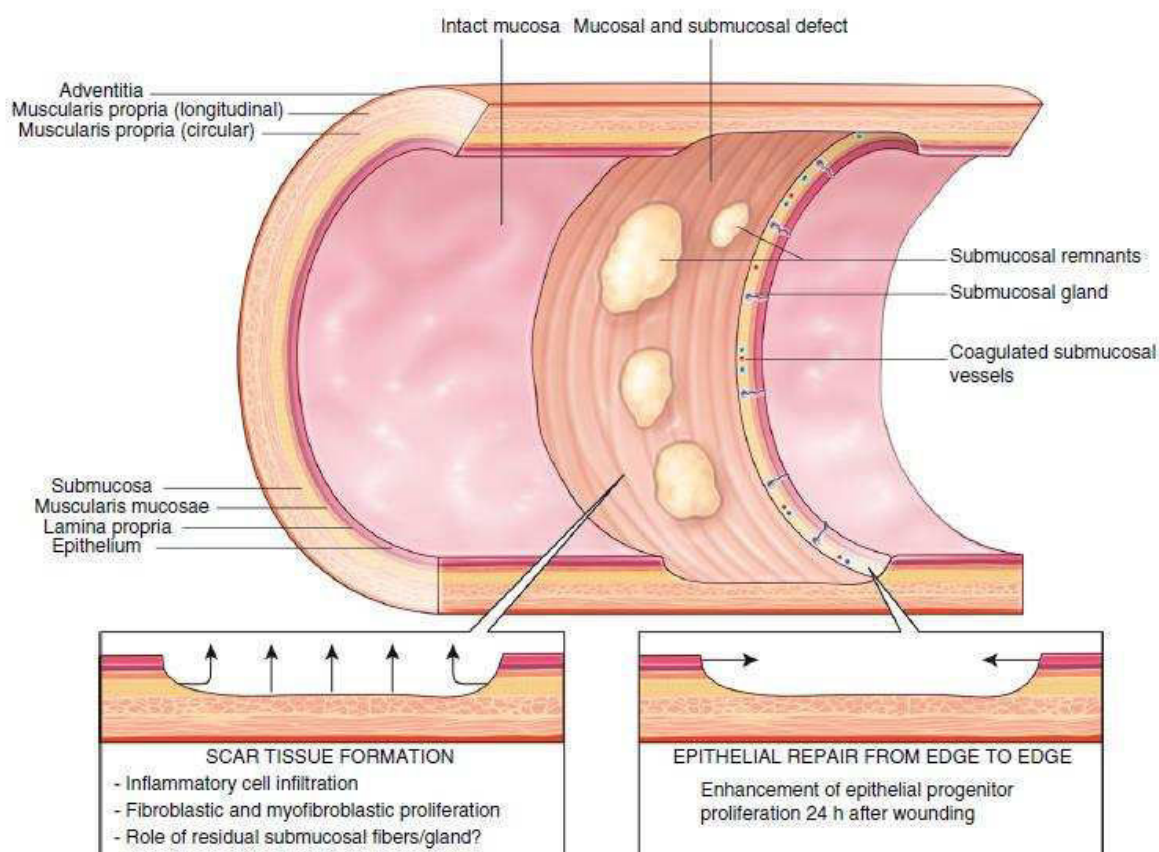


Figure 1 | What remains in the oesophagus after endoscopic submucosal dissection?

of collagen type I. Monocyte-derived macrophages contribute to the process either as classical inflammatory cells or by stimulating myfibroblast differentiation via IL-10 production.³⁶

Figure 2 shows the main endoscopic, radiologic and histological patterns of post-endoscopic oesophageal stricture in a swine model developed by our team.³⁸

Strategies for post-endoscopic oesophageal stricture prevention

Preventing oesophageal stricture after mucosal injury requires reaching one or several of the following goals: (i) suppress the initial tissue aggression factor; (ii) restore the destroyed protective barrier; (iii) block inflammatory pathways and finally (iv) oppose the action of myfibroblasts. After endoscopic resection, the only way to reach the first goal is to ensure an optimal acid suppression by double-dose proton pump inhibitor therapy during the wound healing process. The three other goals can be achieved through four different approaches, which we

have found appropriate to classify as follows: a protective approach, a regenerative approach, an anti-proliferative approach and a mechanical approach.

Aims

Numerous prophylactic treatments have been tested in animals and humans, but with only partial efficacy and often at the cost of complex procedures. Our aim was to review current evidence on the prevention of post-endoscopic oesophageal stricture, to help physicians in their patient management and to guide further research in this field. While numerous reviews have been published on the topic,^{25, 39–49} most provide a narrative review with selective bibliography, usually according to the specific expertise or field of research of the authors. Our work is the first to systematically review the existing literature on the topic.

METHODS

PubMed and Embase databases were searched from inception to 26 March 2015 for articles published in

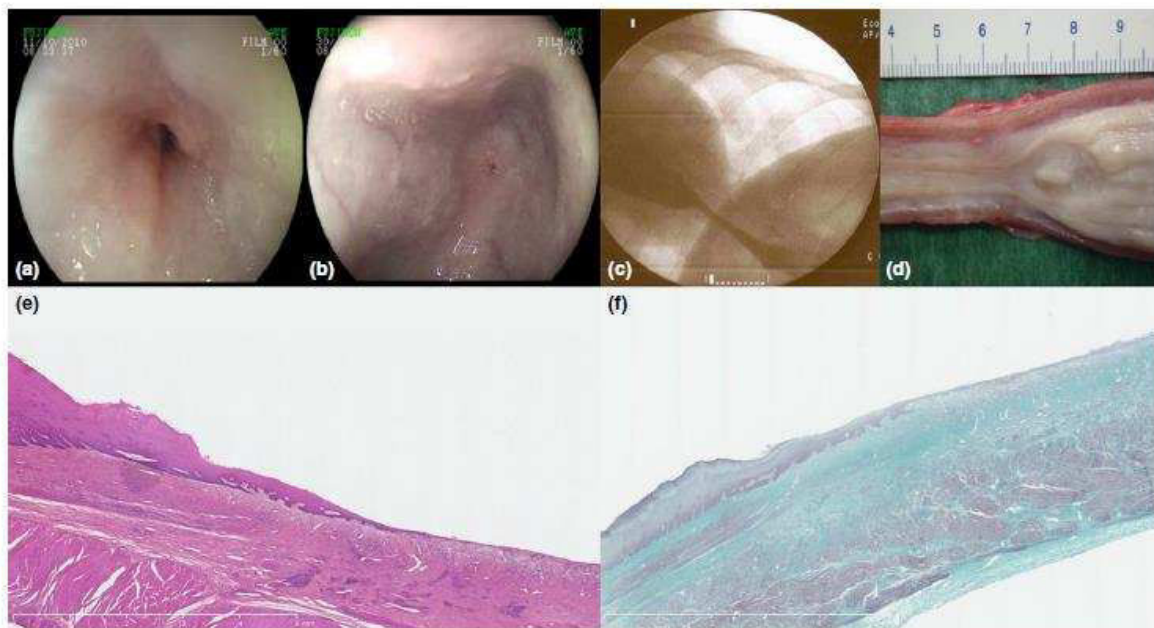


Figure 2 | Oesophageal stricture in our swine model. (a) and (b) Endoscopic appearance of oesophageal strictures with predominant inflammatory (a) and fibrotic (b) patterns; (c) Fluoroscopic view; (d) Macroscopic view of the proximal end of the stricture after necropsy; (e) and (f) Histologic views of oesophageal strictures, original magnification $\times 12.5$, hematoxylin–eosin–safran staining, showing poor re-epithelialisation and intense inflammatory cell infiltrate of the submucosa (e), and Masson's Trichrome staining, showing fibrosis (green) of the submucosal space, infiltrating the muscularis propria.

English only, using a combination of MeSH, thesaurus terms and relevant text words: oesophagus stenosis, oesophageal stricture, oesophageal stenosis, ESD or endoscopic submucosal dissection, EMR or endoscopic mucosal resection, endoscopic resection and prevention. Embase was accessed via the online search platform OvidSP. The exact search strategies and their outcomes are shown in Figure 3. Duplicates between the results of the two search engines and studies reporting on the same patient material in a conference proceedings and an original article were suppressed. Review articles or editorials on oesophageal stricture prevention were not included in the analysis, but were used for background information. All original publications, including case reports, were included in the analysis. Reference lists from all publications were sought for additional relevant publications. Remaining studies were first assessed for relevance on the basis of the title and abstract, then after accessing the full text of the publication. Screening of the searches, data extraction and selection of the final articles was conducted by a single reviewer (MB) and

independently verified by a second reviewer (FP). A formal assessment of the quality of the included studies was not conducted for this review.

RESULTS

Identified studies (Figure 3)

Among the 461 PubMed and Embase hits, 62 studies, including 14 conference publications, were finally included. Of the 461 hits, 131 publications were duplicates, 63 studies were excluded because of an irrelevant study topic, 191 were excluded because the data presented were not compatible with the scope of the review (mainly studies either dealing with the curative treatment of post-endoscopic oesophageal strictures, or only mentioning oesophageal stricture as a complication after endoscopic resection), and 16 were an irrelevant publication type. One additional study was identified by searching through the reference lists of the articles,⁵⁰ and two publications from the authors' library were added to the studies included.^{51, 52}

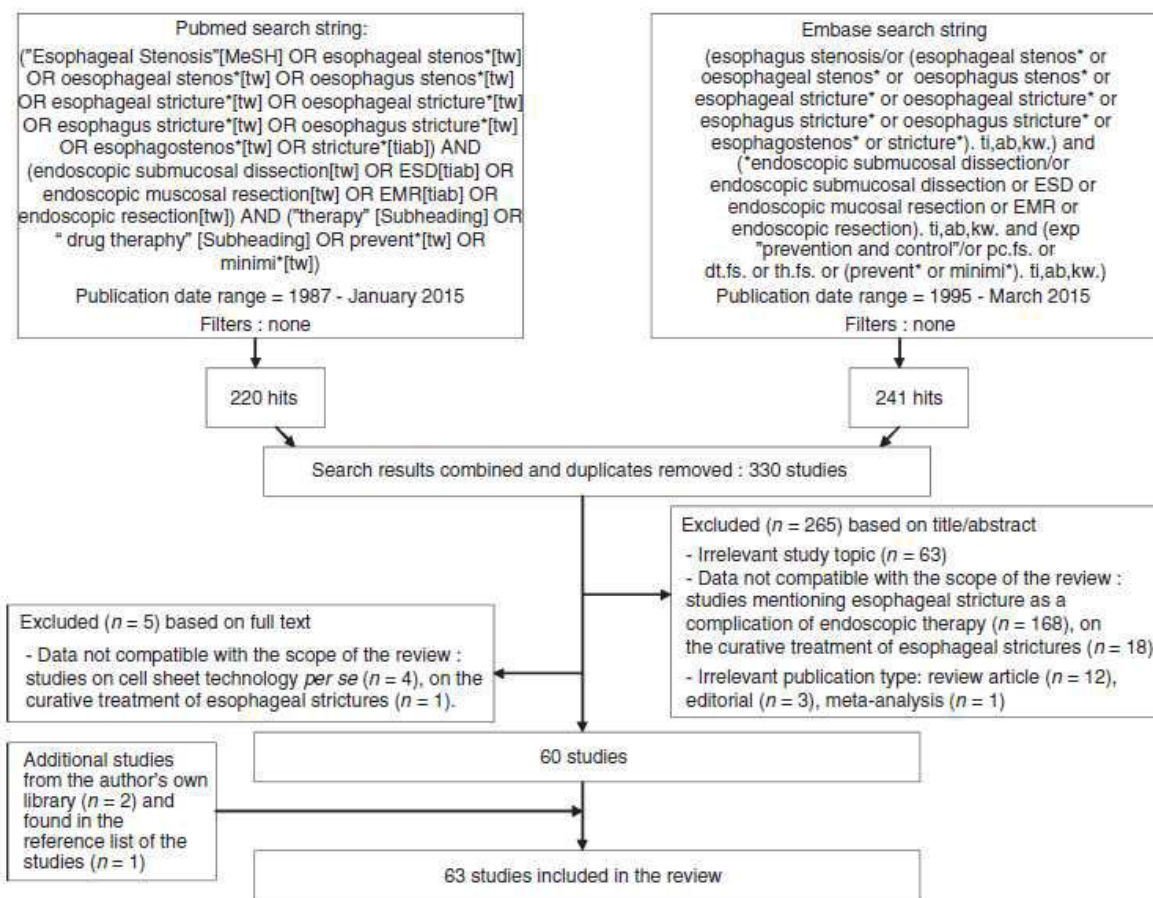


Figure 3 | Study selection.

Definition of oesophageal stricture

There is no consensual definition of oesophageal stricture following endoscopic resection. However, the most frequently reported definition was that of Hashimoto *et al.*, i.e. an oesophageal stricture is a narrowing of the oesophageal lumen seen on oesophagoscopy, which is either nonpassable with a standard diagnostic (± 10 mm in diameter) endoscope or is associated with dysphagia.⁵³

Reported results of the four approaches to stricture prevention

Protective approach. Creating a barrier over large areas of the submucosa exposed by the post-resection wound could protect it from endoluminal stress factors. This has mainly been studied with the use of wound-covering agents, which would protect the residual submucosa and muscularis propria and act as a matrix for epithelial cell migration.

Animal data: Nieponice *et al.* used porcine small intestine submucosa in this context: after circumferential EMR, small intestine submucosa applied through a balloon proved successful in oesophageal stricture prevention in a series of five dogs.⁵⁴ However, these results were not reproduced in other studies.⁵⁵ Furthermore, a recent study involving 25 swine that compared the rates of post-circumferential EMR strictures in control animals and in animals with either an oesophageal stent only or an oesophageal stent coated with three different kinds of extracellular matrix scaffolds (small intestine submucosa, acellular dermal matrix or urinary bladder membrane) demonstrated the absence of benefit of extracellular matrix scaffolds for oesophageal stricture prevention. It should be noted that the stent stability was ensured with a suture system, and that all but one stents stayed in place for 3 weeks. However, stricture rates 1 week after stent removal ranged from 82% to 94%.⁵⁶

Amniotic membrane grafts, acting as a biological wound dressing with added anti-fibrotic and anti-inflammatory properties, have been used safely in humans, especially for the treatment of corneal ulcerations and skin burns.^{57, 58} Our team recently assessed amniotic membrane application in the oesophagus. Amniotic membrane grafts were placed in 10 pigs using expandable plastic oesophageal stents, and we observed a benefit of this intervention in terms of symptomatic stricture rate at day 14; nevertheless, all animals eventually developed strictures by day 35. Amniotic membrane grafts reduced oesophageal fibrosis and inflammatory cell infiltrate, and promoted reepithelialisation. Possible contributors to the disappointing clinical results were a high rate of stent migration and the early degradation of amniotic grafts.⁵⁹

Considering the cumbersome endoscopic apposition of small intestine submucosa or amniotic membrane grafts, we recently assessed the hemostatic powder Hemospray as a wound-covering agent with hemostatic, as well as possibly regenerative, properties.⁵¹ Although repeated Hemospray applications were needed, the ease of powder application makes this option attractive. Twenty swine and 10 controls underwent circumferential ESD. The mean oesophageal diameter, time to symptomatic stricture, fibrosis thickness or length of re-epithelialisation, and TGF- β levels were significantly improved in the treated group 14 days after ESD.⁵¹ Although strictures eventually appeared in both groups, the findings suggested that protecting the submucosa with the powder was effective in opposing fibrosis formation. These results are encouraging, as swine oesophagus is highly prone to stricture development after mucosal lesion, with 100% stricture rate after circumferential ESD,³⁸ and up to 50% stricture rate after radiofrequency ablation.⁶⁰

Human data: Considering their encouraging preclinical data, Badylak *et al.* tested extracellular matrix scaffolds of porcine urinary bladder membrane, which were secured to the oesophageal wall by oesophageal stents, in five patients after circumferential EMR of the oesophagus.⁶¹ However, all patients developed some kind of stricture and required endoscopic dilation.

Iizuka *et al.* have shown the safety and feasibility of intraoesophageal application of polyglycolic acid sheets on post-ESD ulcers. The sheets were stuck to the ulcer bed with fibrin glue, and stayed in place for at least 1 week in 13 of the 15 patients of the study. Even though only two patients had mucosal defects exceeding three-quarters of the oesophageal circumference, none of them

developed a stricture after 6 weeks.⁶² Sakaguchi *et al.* confirmed these results in eight patients at high risk of oesophageal stricture: in patients with ESDs exceeding three-quarters of the circumference, polyglycolic acid sheet application resulted in a 37.5% stricture rate, with nonsevere strictures that could be treated with 0.8 ± 1.2 sessions of endoscopic balloon dilation (EBD).⁶³ Caveats about this study are the small patient number and important unreported data such as the exact proportion of circumferential ESD and the mean patient follow-up, but careful patient selection excluding those with preventive EBD or steroid administration must be noted. Thus, polyglycolic acid sheets, which appear to be safe and easy to use, may be a promising tool for wound protection after endoscopic resection in the oesophagus.

A simple way to limit the exposition of the deeper layers of the oesophageal wall to stress factors could be to reduce the size of the oesophageal lesion by performing stepwise mucosal resection. The underlying hypothesis is that by exposing a limited surface area of the submucosa at a time (for example, no more than 50% of the circumference), healing will proceed harmoniously, and subsequent resections will not induce a stricture. After the first successful case report,⁶⁴ two retrospective studies reported satisfying results with only 2.4–13.3% strictures.^{65, 66} However, larger prospective and/or multicenter studies showed that this technique did not actually change the stricture rate, which ranged from 33% to 88%,^{14, 67–69} as compared to 40–68% for one-step extensive EMR.^{17, 70} Importantly, this method bears two significant shortcomings: first, the final procedures can turn out to be technically challenging because of scar tissue formation, at least on resection edges, and subsequent oesophageal lumen narrowing; second, stepwise means piecemeal resection, and is therefore, only conceivable in the absence of invasive neoplasia. Therefore, en bloc, single-stage mucosal resection appears preferable.

Regenerative approach. The use of growth factors or cellular therapy, often referred to as 'regenerative medicine', has been one of the most fruitful fields of research in oesophageal stricture prevention. The aims of regenerative medicine are to hasten the wound healing process to limit the inflammatory and profibrotic changes, which could be achieved either by promoting harmonious submucosal tissue growth or by epithelial regeneration.

Animal data: Honda *et al.* have observed in 10 beagle dogs the beneficial effect of autologous adipocyte-derived stromal cell injection in oesophageal ulcers in terms of

fibrogenesis and stricture occurrence,⁷¹ although the study lacked an assessment of surface and proliferation markers in the injected cells to confidently demonstrate the regenerative effect of this method. Indeed, adipocyte-derived stromal cells exhibit stem cell-like properties, can differentiate into both mesenchymal and nonmesenchymal cell types, and secrete numerous growth factors. Thereby, they might improve tissue regeneration. The same reasons that explain their efficacy might preclude their use in patients in the setting of oesophageal neoplasia due to the risk of expansion of residual cancer cells.

Enhancing epithelial regeneration might be an avenue for limiting submucosal inflammatory and fibrogenic processes. Subcutaneous injections of epidermal growth factor have been reported to promote wound healing and to prevent stricture formation after sclerotherapy-induced oesophageal ulcers in 24 pigs.⁵⁰ However, the preventive use of such treatments in asymptomatic humans seems unlikely due to safety concerns. Using autologous squamous cells cultured *ex vivo*, and then administered inside or on top of the resection wound, is a promising way to improve epithelial regeneration. In 2007, Sakurai *et al.* showed in one swine the feasibility of injecting autologous keratinocytes into oesophageal ulcers.⁷² This procedure seemed to accelerate wound healing by promoting re-epithelialisation and reducing scar tissue formation, but the study was limited to one animal. These results have been reproduced in Switzerland in nine sheep, with no oesophageal stricture and limited fibrotic changes 6 months after a circumferential EMR.⁷³ The absence of a control group, the sheep model and the atypical rigid endoscope represent significant limitations of this study. Previously quoted amniotic membrane or porcine small intestinal submucosa (a submucosal tissue-based material containing elastin and collagen fibres), can be thought of not only as protective agents, but also as expansion matrices for epithelial cells.⁷⁴ A further step was made by another Japanese team using epithelial cell sheets. Okhi *et al.* from the Tokyo Women's Institute developed an *ex vivo*-engineered autologous epithelial cell sheet using tissue samples from the oral mucosal tissue. They managed to endoscopically transplant these cell sheets in oesophageal ulcers without resorting to surgical suture. The procedure was achieved successfully in three dogs and was shown to be feasible, safe, and effective in terms of cell sheet integration in the neoeepithelium.⁷⁵ Re-epithelialisation was quicker than in the three control animals. However, the possible effect on oesophageal stricture of this elegant model was not assessed, since oesophageal

ulcers were limited in size; therefore, the same team used autologous skin-derived epidermal cell sheets in pigs undergoing circumferential ESD, reporting statistically significant results in terms of oesophageal diameter at day 14 and advancement of re-epithelialisation.⁷⁶ The degree of mucosal constriction varied from 48% to 63% in the treated group, as compared to 86–89% in the control group ($P < 0.01$). In the meantime, Takagi *et al.* managed to grow human oral mucosal cell sheets without animal-derived materials and in optimal microbiological conditions allowing us to consider their use in patients.⁷⁷

Human data: In 2012, the first outcomes of cell sheet technology in the human oesophagus were reported.⁷⁸ Nine patients underwent oesophageal ESDs, and cell sheets made of oral mucosal keratinocytes obtained from the same patients 16 days earlier were endoscopically transplanted onto the resection wound. The authors showed the cell transplantation to be effective, and a median reepithelialisation time of 3.5 weeks. Three patients with high-risk ESDs, (i.e., involving at least three-quarters of the circumference) did not exhibit oesophageal stricture, however the only patient with a sub-circumferential ESD developed a refractory stricture requiring over 20 EBD sessions, despite the seven cell sheets used. Although lacking a control group and a more significant patient sample, Ohki *et al.* demonstrated for the first time the safety and feasibility of cell sheet use in patients. The 25% stricture rate results that they reported, when compared to the 90–94% stricture rate expected in this setting,^{19, 20} are one of the lowest rates reported to date. These results were not reproduced by others: Elbe *et al.* applied the same cell sheet technology in five oesophageal ulcers after endoscopic resection, and observed strictures in three out of the four patients with high-risk endoscopic resections.⁷⁹ These findings suggest that cell sheet culture does not work as well in the lower oesophagus (four patients were treated for Barrett's neoplasia) as in the upper- or mid-oesophagus where the acid exposure is moderate.

More recently, the concept of autologous en bloc mucosal transplantation to protect a large oesophageal ulcer and to promote reepithelialisation was suggested in a case report.^{80, 81} In one patient, a large piece of healthy gastric mucosa resected by ESD was cut into pieces, placed against an oesophageal ESD wound, and was secured with an extractible stent. Although the lesion was at high risk (proximal oesophagus, circumferential and extensive ESD), the patient did not develop an

oesophageal stricture, and gastric mucosa was transplanted into the oesophagus. However, the relevance and safety of doubling the intervention time and the risk of intra-operative adverse events, as well as implanting gastric cells in the oesophagus, could be questioned.

Even if the regenerative approach of oesophageal stricture prevention has shown some dramatic results in enhancing the healing process in the hands of one expert Japanese team, it carries major limitations: the procedures—either cell culture, cell sheet manipulation or multiple ESDs—are costly and cumbersome, and require a high degree of expertise. Indeed, cell sheet transplantation on an ulcer bed in the oesophagus is estimated to cost at least US\$20 000 per case.⁴² Furthermore, there are concerns about bacterial and fungal overgrowth in primary keratinocyte cell cultures preventing efficient cell sheet production at a larger scale and in a short period of time.⁴² Therefore, the regenerative approach seems unlikely to develop in all centres performing therapeutic endoscopic procedures in the oesophagus in the near future.

Anti-proliferative approach. In order to contain inflammation and myofibroblastic proliferation, anti-mitotic drugs, so-called anti-fibrotic drugs, and anti-inflammatory drugs have been tested. Most of the studies have focused on steroids, either locally delivered to the oesophageal wall or administered by the systemic route.

Animal data. Steroids: The anti-inflammatory and anti-fibrotic properties of steroids are partly explained by the inhibition of TGF- β 1 expression and the induction of apoptosis in fibroblasts.^{25, 33} Intralesional injections of triamcinolone—as routinely performed in the treatment of hypertrophic and keloid scars after dermatologic surgery, although with repeated treatment sessions³³—have been tested for the treatment of refractory oesophageal strictures.⁸² Rajan *et al.* first sought to inject triamcinolone endoscopically into the muscularis propria after circumferential EMR in pigs, and not only did they observe periesophageal abscesses in all animals and a 33% mortality rate, but three of the four surviving pigs developed tight strictures.⁵⁵ Honda *et al.* have administered triamcinolone not in the muscularis propria, but in the remaining submucosal tissue after partial EMR in dogs: the study was not designed to assess the stricture rate, but the authors showed that steroid injection deepened the oesophageal ulcers and delayed epithelialisation.⁸³ This last finding was also supported by another recent animal study.³¹

Other 'stricture-preventing' drugs: Liposomal 5-fluorouracil injected into an EMR wound prevented oesophageal stricture in one dog and reduced fibrosis thickness in the oesophageal wall.⁸⁴ However, the value of this finding is limited by the absence of any larger studies conducted with this drug. Submucosal injection of mitomycin C, which has been reported as an adjunct to EBD therapy in the treatment of post-endoscopic oesophageal strictures,⁸⁵ was assessed for the prophylaxis of strictures by two different teams in a swine model with unconvincing results. One study of our team included nine pigs and did not show any benefit on oesophageal stricture occurrence.⁵² Another study reported two animals treated with low dose mitomycin, finding a moderate, non statistically significant increase in the oesophageal lumen compared to the controls, as well as two premature deaths attributable to the local toxicity of high doses of mitomycin.⁸⁶ Anti-inflammatory molecules with supposed anti-fibrotic properties have been assessed in animal studies. Halofuginone was poorly effective in a controlled study involving four pigs and six controls with no statistically significant differences in terms of oesophageal diameter reduction.⁸⁶ As fibrotic processes involve oxidative stress, N-acetylcysteine as an anti-oxidant may exert an anti-fibrotic activity. We assessed N-acetylcysteine in a controlled study using 12 pigs: N-acetylcysteine administration resulted in diminished oxidative stress markers in the oesophageal tissue samples of treated animals, but did not yield statistically significant differences between groups in terms of stricture rate and severity, even though high doses of treatment were used.³⁵

Human data. Locally administered steroids: Although animal studies have raised serious concerns about the effectiveness and safety of corticosteroid use for oesophageal stricture prevention,^{55, 83} 13 reports of locally administered steroids have been published in patients since 2009. Among these, cases of oesophageal perforations have been described following endoscopic triamcinolone injections.⁸⁷ The authors claim that tangential injection inside the residual submucosa, avoiding injections in the muscularis propria, might prevent these complications.

Most publications are small retrospective case series, with heterogeneous injection protocols, no complications reported and stricture rates ranging from 10.7% to 41.7%.^{88–94} Two larger controlled studies have been published in this field: Hanaoka *et al.* demonstrated in a prospective work involving 30 patients with high-risk ESDs that a single triamcinolone injection induced a

dramatic and statistically significant decrease in the stricture rate, from 66% to 10% ($P < 0.0001$), at the cost of a 7% complication rate.⁹⁵ Similarly, a 19% vs. 75% ($P < 0.001$) stricture rate was obtained by Hashimoto *et al.* in 21 patients and 20 controls, although a protocol including three triamcinolone injections at day 3, 7 and 10 was used.⁵³ Funakawa *et al.*, in a retrospective analysis of 45 high-risk ESDs, of which 35 had been treated by repeated injections of triamcinolone according to Hashimoto *et al.*, found steroid injection to be safe, but ineffective. In particular, 10 of the 12 (83%) patients with circumferential ESD developed strictures despite steroid injections, and even in the resections involving 75–99% of the circumference, the rate of stricture was not significantly different between the groups, with 34.8% (8/23) and 40% (4/10) stricture rates in the triamcinolone and control groups, respectively.⁹⁶ These data, extracted from a large register of oesophageal ESDs, are striking by the very low rate of stricture in the control group, but cast some doubt about the actual effect of injected steroids in patients at high risk of stricture.

As the adverse events related to locally administered steroids appear to be related to the injection, some teams have attempted to administer locally active corticosteroids on the resection wound without injection. Oral liquid budesonide seemed ineffective⁹⁷ after an extensive EMR for Barrett's neoplasia, and oral viscous budesonide was also ineffective at the dose of 0.5 mg/2 mL mixed with sucralose twice daily for 6 weeks after extensive EMR for Barrett's neoplasia.⁹⁸ Mori *et al.*, in a randomised trial, compared a steroid gel made of 100 mg triamcinolone mixed with endolubri Jelly (Olympus Medical Systems, Tokyo, Japan) to triamcinolone injections in 43 patients after large ESDs. Despite repeated applications and additional preventive balloon dilation in both groups, they observed 81% stricture rates in both groups after 60 days.⁹⁹

Systemic steroids: The possible efficacy of systemic steroid therapy in stricture prevention, suggested in case reports,^{93, 100, 101} has been further assessed. Sato *et al.* showed in a retrospective cohort study including 23 patients that a prednisolone treatment of 30 mg/day, started 2 days after a circumferential ESD and gradually tapered and discontinued after 8 weeks, significantly decreased the number of EBDs required to obtain a stricture-free oesophageal scar.¹⁰² The total time of EBD was also significantly shorter, ranging from 4.8 ± 2.3 months to 14.2 ± 15.7 months ($P = 0.005$). A significant benefit of an 8-week, low-dose prednisolone

regimen on the occurrence and the severity of oesophageal stricture was confirmed by other retrospective studies, reaching 5.3–29% stricture rates,^{89, 103–105} and up to 50% in the specific setting of CESD.²⁶

Steroids and oesophageal stricture prevention: A 2012 study by Hashimoto *et al.* illustrates the data available on steroids for oesophageal stricture prevention after ESD: the authors show a significant improvement in oesophageal stricture under steroid therapy compared to controls, in terms of stricture rate, but also in terms of stricture severity, as attested by the mean number of dilations required.⁸⁸ However, the absence of prospectively collected data, the heterogeneity in the periods of the patient management, in the steroid administration protocols (injected vs. injected and oral), and the various sizes of the groups prevent us from drawing definitive conclusions on the benefit of steroid therapy, either locally or orally administered. Furthermore, even the most optimistic reports still mention an 83% and 50% stricture rate after circumferential ESD despite endoscopic triamcinolone injection or oral prednisolone, respectively.^{26, 96} The clinical results of steroid therapy for oesophageal stricture prevention in humans are presented in Table 2. These data suggest that corticosteroids, either topically injected triamcinolone or oral prednisolone, significantly reduce the rate and severity of oesophageal stricture after endoscopic procedures. This is confirmed by the results of a meta-analysis that included the data of four studies and 148 patients, showing a 13.5% vs. 59.34% stricture rate with or without steroid therapy, respectively.⁴⁸

The most realistic protocol for endoscopically injected steroids is that reported by Hanaoka, requiring 20–40 shallow injections through a 25-G needle in the residual submucosa of 0.5–1 mL aliquots of triamcinolone acetate up to 100 mg immediately after ESD.⁹⁵ Oral prednisolone can be administered according to the 'Yamaguchi protocol', starting at 30 mg/day on the third day after endoscopic resection, then tapered gradually (30, 30, 25, 25, 20, 15, 10 and 5 mg for 7 days each), and then discontinued 8 weeks later.¹⁰⁵ Corticosteroids are certainly the only readily available option for the prophylaxis of post-endoscopic oesophageal stricture in 2015. However, although roughly 300 patients have reportedly been treated with this strategy, a 7–10% adverse events rate was observed with triamcinolone injection (bleeding, submucosal tear) in some studies,^{95, 99} and a case of fatal disseminated nocardiosis has been recently reported following post-ESD corticosteroid

Table 2 | Clinical data for corticosteroid-based prevention of oesophageal stricture

First author	Design	Intervention	N*	Setting	Mean or median (range) number of EBD*	Stricture rate*	Adverse events
Hashimoto ⁵³	Retrospective historical control	Triamcinolone injection 18–62 mg at day 3, 7, 10 (1) vs. control (2)	21 vs. 20 for (1) and (2), resp.	Oesophageal ESD 50%	1.7 vs. 6.6 P < 0.001 for (1) vs. (2), resp.	19% vs. 75% P < 0.001 for (1) vs. (2), resp.	0
Hanaoka ⁹⁵	Prospective historical control	Triamcinolone injection 100 mg at day 0 (1) vs. control (2)	30 vs. 29 for (1) and (2), resp.	Oesophageal ESD > 75%	0 (0–2) vs. 2 (0–15) P < 0.0001 for (1) vs. (2), resp.	10% vs. 66% P < 0.0001 for (1) vs. (2), resp.	7% (submucosal tear, bleeding)
Mori ⁹⁹	Prospective randomised	Triamcinolone injection 62–88 mg + EBD (1) vs. triamcinolone 100 mg gel application + EBD (2) at days 0, 5, 8, 12, 15	23 vs. 20 for (1) and (2), resp.	Oesophageal ESD > 66%	4.3 vs. 1.6 P = 0.011 for (1) vs. (2), resp.	81% vs. 81% P = 0.48 for (1) vs. (2), resp.	10% bleeding (injection group)
Funakawa ⁹⁶	Retrospective historical control	Triamcinolone injection at days 0, 7, 14 (1) vs. control (2)	35 vs. 10 for (1) and (2), resp.	Oesophageal ESD > 75%	Not available	40% vs. 51% for (1) vs. (2), resp.	0
Nagami ⁹¹	Retrospective, controlled	Intralesional steroid injections (various protocols) (1) vs. control (2)	42 vs. 28 for (1) and (2), resp.	Oesophageal ESD	Not available	10.7% vs. 35.7% P = 0.035 for (1) vs. (2), resp.	0
Shoji ⁹³	Retrospective	Triamcinolone injection 80 mg, at day 0	3	Cardial ESD > 50%	3	33%	0
Oyama ⁹²	Retrospective	Dexamethasone injection 4 mg + EBD (1) vs. EBD alone (2), at day 3, then 2 per week	7 vs. 7 for (1) and (2), resp.	Circumferential ESD	13 (5–20) vs. 21 (13–34) for (1) vs. (2), resp.	Not available	0
Lee ⁹⁰	Case report	Triamcinolone injection 80 mg at day 0	1	Oesophageal ESD 90%	0	0	0
Wallace ⁹⁷	Case report	Oral liquid budesonide	1	Oesophageal EMR	Not available	100%	Not available
Bahin ⁹⁸	Prospective, controlled	Oral viscous budesonide (0.5 mg/2 mL with sucralose) × 2 per day, 6 weeks (1) vs. control (2)	23 vs. 75 for (1) and (2), resp.	Oesophageal EMR	2 (1–3) vs. 3 (1–3) P = 0.13	26.1% vs. 40% P = 0.06	Not available
Hashimoto ⁸⁸	Retrospective	Triamcinolone injection at days 3, 7, 10 (1) vs. Triamcinolone injection at day 1 + prednisolone 0.5 mg/kg 6 weeks (2) vs. controls (3)	21 vs. 12 vs. 20 for (1), (2) and (3) resp.	Oesophageal ESD 50%	1.7 vs. 1.5 vs. 6.6 P < 0.001 for steroids vs. control	19% vs. 33% vs. 75% P < 0.001 for repeated triamcinolone vs. control	0
Ishiyama ⁸⁹	Retrospective	Prednisolone 30 mg/day, 8 weeks (1) vs. Triamcinolone injection 80 mg at day 0 (2)	24 vs. 12 for (1) and (2), resp.	Oesophageal ESD > 75%	3.2 (0–16) vs. 1.7 (0–7) for (1) vs. (2), resp.	29% vs. 41.7% for (1) vs. (2), resp.	4.2% (1 perforation in the prednisone group)
Isomoto ²⁶	Retrospective	Prednisolone 30 mg/day, 8 weeks (1) vs. EBD alone 2 per week, 8 weeks (2)	4 vs. 3 for (1) and (2), resp.	Circumferential oesophageal ESD	3.3 vs. 32.7 P < 0.05 for (1) vs. (2), resp.	50% vs. 100% for (1) vs. (2), resp.	0
Yamaguchi ¹⁰⁵	Retrospective	Prednisolone 30 mg/day, 8 weeks (1) vs. EBD alone 2 per week, 8 weeks (2)	19 vs. 22 for (1) and (2), resp.	Oesophageal ESD > 75%	1.7 vs. 15.6 P < 0.05 for (1) vs. (2), resp.	5.3% vs. 32% P < 0.05 for (1) vs. (2), resp.	0

Table 2 | (Continued)

First author	Design	Intervention	N*	Setting	Mean or median (range) number of EBD*	Stricture rate*	Adverse events
Sato ¹⁰²	Retrospective	Prednisolone 30 mg/day, 8 weeks + EBD 1–2 per week (1) vs. EBD alone 1–2 per week (2)	10 vs. 13 for (1) and (2), resp.	Circumferential Oesophageal ESD	13.8 vs. 33.5 $P < 0.001$ for (1) vs. (2), resp.	Not available	0
Ishiyama ¹⁰⁴	Retrospective	Prednisolone 20–30 mg/day, 6–8 weeks	9	Oesophageal ESD > 75%	6	11.1%	0
Huang ¹⁰³	Retrospective	Prednisolone 30 mg/day, 8 weeks	11	Oesophageal ESD > 75%	3	18.2%	0
Yamaguchi ¹⁰¹	Case report	Prednisolone 30 mg/day, 8 weeks	1	Circumferential oesophageal ESD	0	0	0
Shoji ⁹³	Case report	Prednisolone 30 mg/day, 12 weeks	1	Circumferential cardiac ESD	0	0	0
Ono ¹⁰⁰	Case report	Dexamethasone 40 mg/day, 4 days, 3 times	1	Oesophageal ESD	0	0	Not available

EBD, endoscopic balloon dilation; ESD, endoscopic submucosal dissection; EMR, endoscopic mucosal resection; resp., respectively.

* Treated vs. control group.

systemic administration,¹⁰⁶ along with another death by infectious disease in Japan.¹⁰⁷ Other cases of severe infectious morbidity might follow, all the more if corticosteroid doses increase. Indeed, patients referred for endoscopic therapy are often elderly and frail, and extensive ESD is already a relatively morbid procedure *per se* with risks of oesophageal perforation or aspiration pneumonia.

Other 'stricture-preventing' drugs: Tranilast, an anti-allergic drug found to inhibit *in vitro* collagen synthesis and IL-6 production, was tested in a prospective study involving 31 patients.¹⁰⁸ Oral administration of 300 mg/day tranilast for 8 weeks was compared to biweekly preventive endoscopic dilation for 4 weeks, and resulted in a 33.3% vs. 68.8% stricture rate ($P = 0.04$), even if the groups included 14.3% and 25% high-risk ESDs. Importantly, no adverse events were recorded in the tranilast group. Further prospective studies that include more high-risk patients are required to confirm the benefit of tranilast.

Mechanical approach

A more pragmatic approach of oesophageal stricture prevention is to mechanically dilate the oesophagus during the wound healing process. The rationale is that repeated

or continuous pressure on the oesophageal wall would prevent hypertrophic scar tissue formation leading to oesophageal stricture. This can be achieved by preventive balloon or bougie dilation, or by placing an oesophageal stent right after the endoscopic resection.

Animal data. No animal data on preventive balloon dilation are available, and there are only limited data on preventive oesophageal stents. In the studies from Rajan *et al.* and Barret *et al.*, five and six pigs were treated by metallic-covered and silicone oesophageal stents after circumferential EMR and circumferential ESD^{55, 59}; in both studies, the stent had migrated in 67% and 60% of the cases after 1 week, and animals ultimately developed tight strictures. In a prospective controlled study in pigs after CEMR, Pauli *et al.* showed that biodegradable oesophageal stents only slowed down the stricture formation,¹⁰⁹ and after 9.2 weeks and the degradation of the stent, all treated animals developed strictures.

Human data. Oesophageal stents: Despite concerns about the stability of an oesophageal stent in the non-strictured oesophagus, the potential tissue ingrowth at the ends of the stent leading to stent-induced strictures, and the circumferential mucosal lesion left in the oesophagus after stent removal that is itself prone to

stricturing, prophylactic stent placement has been assessed in patients. A case report mentioned the absence of efficacy of biodegradable stents for stricture prevention.¹¹⁰ Holt *et al.* assessed in 12 patients fully covered metal stents, placed 10 days after a circumferential EMR for Barrett's neoplasia: in four patients, stents had to be removed for pain or dysphagia, and 57.5% of the patients ultimately developed strictures.¹¹¹ Another team, in the same clinical setting, reported a 28% stricture rate after oesophageal stent removal or migration.¹¹² It seems that the more classical design of the stents and a shorter duration of the stent placement in the last study may be the main differences between these two works. In a study that included 23 patients with high-risk oesophageal endoscopic resections, of which 19 were circumferential, treated by prophylactic stents, the authors reported a 52% early stent migration rate and a 39.2% rate of oesophageal stricture.¹¹³ Furthermore, a recent randomised study by Wen *et al.*, involving 11 patients treated by a covered metal stent after extensive ESD and as many controls, with an 8-week stent implantation period, found a lower stricture rate at 12 weeks in the treated group, with only 18% vs. 73% in the control group ($P < 0.05$). Moreover, only patients who experienced stent migration developed a stricture.¹¹⁴

Nevertheless, the poor results of covered stents in the treatment of benign oesophageal strictures of any kind,¹¹⁵ and the absence of any anti-proliferative or anti-inflammatory/anti-fibrotic effect of the stents—indeed, with a possible pro-inflammatory action—make stenting an unlikely candidate for the title of best prophylactic method. Thus, the results from Weng *et al.* need to be confirmed in larger studies before oesophageal stent placement can be considered as a valid option to prevent stricture development. Figure 4 summarises the different modalities for oesophageal stricture prevention, and Table 3 addresses their limitations and feasibility.

Endoscopic balloon dilation: Many studies have addressed the option of preventive EBD in the oesophagus after ESD. Since there is no reason to believe that dilation may favour epithelial or submucosal healing, preventive EBD might actually be early and intensive curative EBD.¹¹⁶ Single-session preventive EBD within 1 week of the resection has been reported as effective,¹¹⁷ but most authors recommend repeated treatment sessions starting 3 days to 1 week after the resection, and repeating treatment once or twice a week until healing of the wound without stricture, usually at 8 weeks.^{25, 26, 40, 92, 118, 119} Compared to controls, preventive EBD significantly

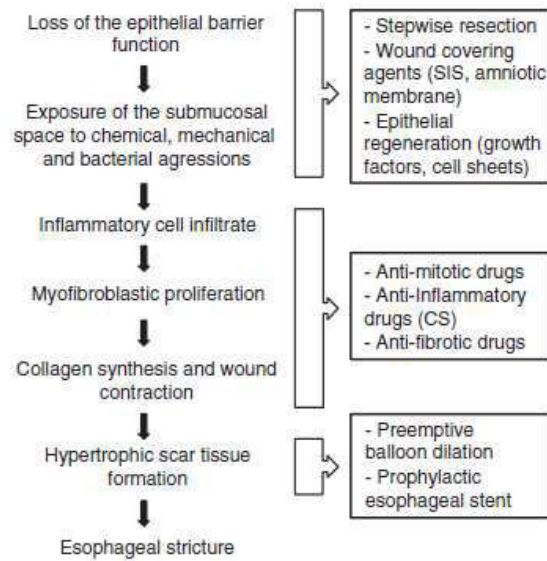


Figure 4 | Targets for oesophageal stricture prevention.

decreased the incidence of stricture from 92% to 59% ($P = 0.04$) in a retrospective study that included 41 patients.¹¹⁸ This modality was the preferred option for Japanese endoscopists before corticosteroid administration proved more effective in preventing stricture.^{26, 92, 102, 105} Furthermore, repeat oesophageal dilations for post-endoscopic strictures, either by bougienage or balloon dilation, carry a specific risk of oesophageal perforation, as demonstrated by Takahashi *et al.*,²⁸ with a 1.1% perforation rate compared to the 0.3% perforation rate of oesophageal dilation in other clinical settings.⁸² As this strategy frequently required more than 10 EBD sessions, the safety profile of preventive EBD does not seem to be satisfying.

Future perspectives: understanding oesophageal wound repair: Despite all the above attempts, an efficient prophylactic treatment for post-endoscopic oesophageal stricture with acceptable patient safety remains to be found. Unless cell culture and tissue engineering develop rapidly and provide access to epithelial cell sheets to many endoscopy centres, new prophylactic treatments may require a better understanding of oesophageal wound healing. This raises the question of the identification of oesophageal stem cells or epithelial progenitors supposedly involved in the oesophageal repair process.

Pan *et al.* reported the presence of label-retaining cells with stem cell characteristics (slow cycling and long lived, multipotent and uncommitted in differentiation processes) in the basal layer of the human oesophagus.¹²⁰

Table 3 | Currently available methods and possible future options for the prevention of post-endoscopic oesophageal stricture

	Potential effectiveness	Current availability	Technical feasibility	Main limitation
Protective approach				
Stepwise resection ¹⁴	Low	Good	Good	Suboptimal histological analysis
SIS ^{54-56, 61}	Moderate	Good	Unproven	Effectiveness not proven in patients
PGA ^{62, 63}	High	Fair	Moderate	Small patient number
Amniotic membrane ⁵⁹	High	Good	Poor	Early degradation, application challenging
Hemostatic powder ⁵¹	Moderate	Good	Moderate	Need for repeated applications
Regenerative approach				
Epidermal growth factor ⁵⁰	High	Low	Poor	Safety issue
ADSC ⁷¹	High	Low	Poor	Safety issue
Autologous cell sheets ⁷⁵⁻⁷⁹	High	Low	Uncertain	High cost
Mucosal grafts ⁸⁰	Unknown	Low	Uncertain	Technically challenging, potential graft necrosis
Anti-proliferative approach				
Anti-mitotic drugs ^{84, 85} (5FU, MMC)	Moderate	Good	Good	No clinical data available
Local corticosteroids ^{53, 95}	Moderate	Good	Good	Risk of perforation
Systemic corticosteroids ^{25, 102, 105}	Moderate	Good	Good	Infectious adverse events
Other anti-fibrotic drugs (HLF, NAC) ^{35, 86, 108}	Moderate	Low	Poor	No clinical data available
Mechanical approach				
Preventive dilatations ^{116, 117}	Moderate	Good	Good	High risk of perforation with repeated treatment
Oesophageal stents ^{111, 112, 114}	Low	Good	Moderate	Stent migration, short term effect
Combined approaches				
Coated stents (corticosteroids, anti-mitotics)	Unknown	None	Good	Same side effects as other locally administered anti-proliferative drugs?
Coated stents (SIS or other agent) ⁶¹	Low	Fair	Good	Risk of stent migration, only reliable to apply the agent on the wound for a few days
Steroid-loaded gel or matrix ⁹⁹	High	Fair	Uncertain	Flushed away by food boluses?

SIS, small intestinal submucosa (porcine); PGA, polyglycolic acid sheets; ADSC, Adipocyte-derived stromal cells; 5FU, 5 Fluorouracil; MMC, Mitomycin C; HLF, halofugidone; NAC, N acetyl cysteine

These findings need to be confirmed, and these possible oesophageal stem cell should be further characterised, since similar studies in mice showed that label-retaining cells from the basal layer of the oesophagus express the CD45 pan-leucocyte marker, and turned out to be Langerhans cells and lymphocytes.²⁹

Doupe *et al.* identified a single progenitor cell in the basal layer of the epithelium that was available both for tissue homeostasis and wound repair.²⁹ This work supports the hypothesis that there are no slow cycling or quiescent epithelial stem cells in the oesophageal epithelium, in contrast to other epithelia, such as epidermis, stomach or small intestine. However, these findings are limited by the murine model on which the work was

based, as the murine oesophagus, unlike the human oesophagus, has a keratinised epithelium and lacks epithelial crypts or glands. In keeping with these findings, Barbera *et al.* observed that human oesophageal epithelial cells cultured in a 3D organotypic system had equal capacity for self-renewal and ability to reconstitute squamous epithelium whether they expressed progenitor (CD34) or epithelial (EpCAM) cell markers. The most quiescent cells expressing putative stem cell markers, however, are located at the tip of epithelial papillae.¹²¹ These two studies are in favour of a great plasticity of the oesophageal epithelium, in which the cells would ensure the tissue homeostasis and promote wound healing without the need for a stem cell pool.

The role of oesophageal submucosal glands in tissue regeneration has been suggested by histological studies showing a consistent continuity between the squamous islands among Barrett's oesophagus and the submucosal gland ducts.¹²² If oesophageal tissue repair or homeostasis is not dependent on specific stem cells in the mucosa, then there might be a role for the oesophageal submucosal glands in oesophageal repair. This hypothesis might explain why the degree of reepithelialisation and the rate of stricture depend not only on the circumferential extent of the mucosal lesion, but also on the depth of the endoscopic resection, ranging from the lamina propria for radiofrequency ablation to the muscularis propria for ESD. If this hypothesis is correct, then submucosal glands might contribute to the reepithelialisation process from the depth of resection areas, not only from the edges, and it would be important to preserve some viable glands to avoid strictures when resection circumferential sections of mucosa are performed, as illustrated in Figure 5. A better understanding of the role of these oesophageal submucosal glands is therefore necessary before more effective stricture-preventing drugs, devices, or procedures can be developed.

CONCLUSION

The therapeutic armamentarium to prevent oesophageal strictures after extensive, circular, or sub circular resections of the oesophageal mucosa is currently insufficient, and the literature does not provide enough robust data to establish recommendations. The only tools with immediate availability and some previous clinical experience at the moment are steroids (either orally administered or injected in the resection wound), EBD, and oesophageal stents, and their limitations have been exposed. Although the regenerative approach of oesophageal stricture could potentially be highly effective, it is currently limited to a small number of expert Japanese centres and their results have not been reproduced in Europe. The effectiveness of the protective, 'wound-covering' approach, using inert, resorbable material, such as polyglycolic acid, seems promising: first, it shows that the protection of the muscularis propria and remaining submucosa from endoluminal factors is crucial and that its beneficial effect on wound healing is greater than the inflammatory reaction to exogenous material; second, it is a readily available and affordable material throughout most endoscopy centres. Currently, one should first advise endoscopists to

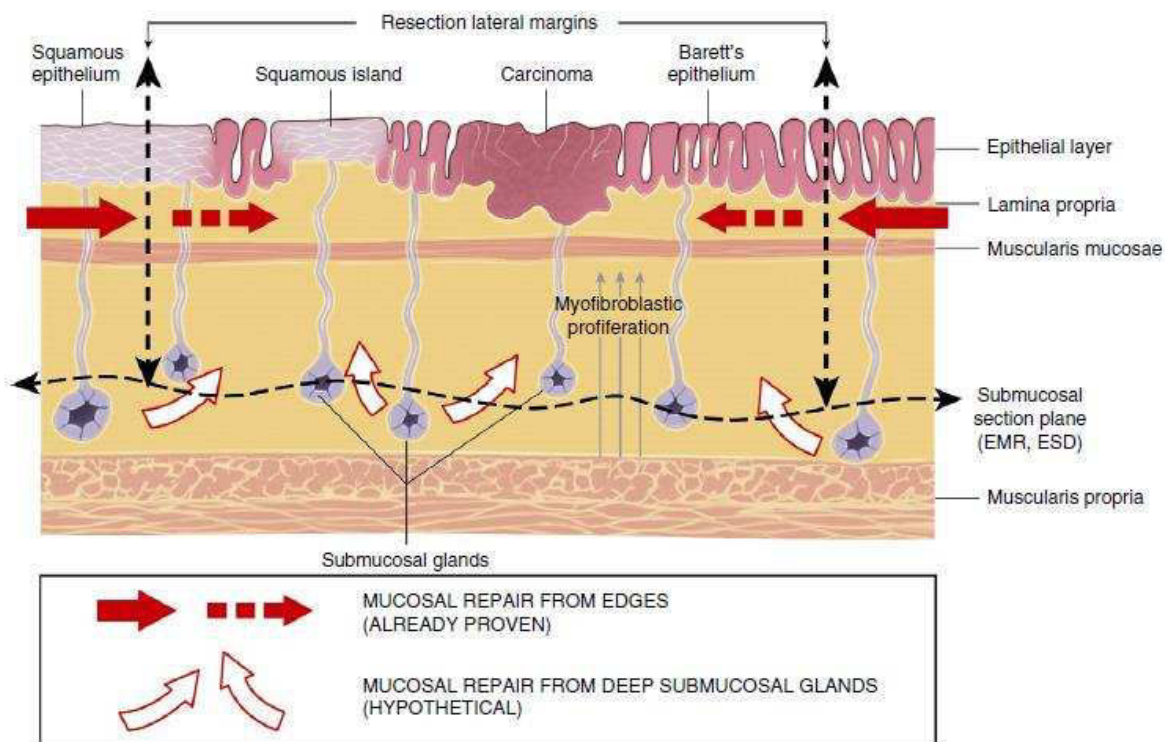


Figure 5 | Illustration of the possible role of the submucosal glands in mucosal healing.

restrict the indications of circumferential ESD in the oesophagus to squamous neoplasms or early Barrett's cancer. In case a circumferential ESD is needed, the patients have to be informed of the high risk of subsequent oesophageal stricture, and of the need for repeated endoscopic controls, possibly with dilations. We believe that stepwise resection must be considered with caution due to the poor histological analysis of the resected specimen, and the risk of R1 resection of an early cancer. Prophylactic stent placement might offer an interesting alternative, but stents have high costs, significant migration rates, uncertain tolerance and the mucosal lesions seen upon stent removal might prevent an adequate surveillance for local recurrence. Preventive serial EBDs can be considered, but the most effective tool for stricture prevention to date is steroid therapy. Since locally injected triamcinolone has raised concerns about accidental injection into the muscularis propria and subsequent perforation or abscesses, oral corticosteroid administration, following the Yamagushi protocol, appears to be the most effective and most validated preventive method. However, a close surveillance of infectious adverse events

should be conducted by clinical, biological, endoscopic and possibly CT-scan follow-up during the first 4 weeks after the procedure. In the near future, the prospective clinical validation of wound-protective treatments or even treatments combining a protective and a steroid-delivering matrix might represent a safer and more efficient alternative to oral corticosteroids.

AUTHORSHIP

Guarantor of the article: Frédéric PRAT.

Author contributions: MB and FP assessed the articles and drafted the manuscript. BB, SL, FBn, FBx and SC provided critical review of the manuscript. All authors approved the final version of the manuscript.

ACKNOWLEDGEMENTS

The authors thank Mrs Van Etten-Jamaludin, Medical Information Specialist at the Academic Medical Center of Amsterdam, The Netherlands, for her valued help in the search.

Declaration of personal and funding interests: None.

REFERENCES

1. Ferlay JBF. GLOBOCAN 2014, Cancer Incidence and Mortality Worldwide. IARC CancerBase No. 102014.
2. Siegel R, Ma J, Zou Z, Jemal A. Cancer statistics, 2014. *CA Cancer J Clin* 2014; **64**: 9–29.
3. Castro C, Bosetti C, Malvezzi M, *et al.* Patterns and trends in esophageal cancer mortality and incidence in Europe (1980–2011) and predictions to 2015. *Ann Oncol* 2014; **25**: 283–90.
4. Pohl H, Welch HG. The role of overdiagnosis and reclassification in the marked increase of esophageal adenocarcinoma incidence. *J Natl Cancer Inst* 2005; **97**: 142–6.
5. Stahl M, Mariette C, Haustermans K, Cervantes A, Arnold D. Oesophageal cancer: ESMO Clinical Practice Guidelines for diagnosis, treatment and follow-up. *Ann Oncol* 2013; **24** (Suppl. 6): vi51–6.
6. Wu J, Pan YM, Wang TT, Gao DJ, Hu B. Endotherapy versus surgery for early neoplasia in Barrett's esophagus: a meta-analysis. *Gastrointest Endosc* 2014; **79**: 233–41 e2.
7. Nakagawa S, Kanda T, Kosugi S, Ohashi M, Suzuki T, Hatakeyama K. Recurrence pattern of squamous cell carcinoma of the thoracic esophagus after extended radical esophagectomy with three-field lymphadenectomy. *J Am Coll Surg* 2004; **198**: 205–11.
8. Peyre CG, DeMeester SR, Rizzetto C, *et al.* Vagal-sparing esophagectomy: the ideal operation for intramucosal adenocarcinoma and Barrett with high-grade dysplasia. *Ann Surg* 2007; **246**: 665–71; discussion 71–4.
9. Takeuchi H, Miyata H, Gotoh M, *et al.* A risk model for esophagectomy using data of 5354 patients included in a Japanese nationwide web-based database. *Ann Surg* 2014; **260**: 259–66.
10. Bennett C, Vakil N, Bergman J, *et al.* Consensus statements for management of Barrett's dysplasia and early-stage esophageal adenocarcinoma, based on a Delphi process. *Gastroenterology* 2012; **143**: 336–46.
11. Fitzgerald RC, di Pietro M, Ragunath K, *et al.* British Society of Gastroenterology guidelines on the diagnosis and management of Barrett's oesophagus. *Gut* 2014; **63**: 7–42.
12. Pech O, May A, Manner H, *et al.* Long-term efficacy and safety of endoscopic resection for patients with mucosal adenocarcinoma of the esophagus. *Gastroenterology* 2014; **146**: 652–60 e1.
13. Takahashi H, Arimura Y, Masao H, *et al.* Endoscopic submucosal dissection is superior to conventional endoscopic resection as a curative treatment for early squamous cell carcinoma of the esophagus (with video). *Gastrointest Endosc* 2010; **72**: 255–64, 64 e1–2.
14. van Vilsteren FG, Pouw RE, Seewald S, *et al.* Stepwise radical endoscopic resection versus radiofrequency ablation for Barrett's oesophagus with high-grade dysplasia or early cancer: a multicentre randomised trial. *Gut* 2011; **60**: 765–73.
15. Chevaux JB, Piessevaux H, Jouret-Mourin A, Yeung R, Danse E, Deprez PH. Clinical outcome in patients treated with endoscopic submucosal dissection for superficial Barrett's neoplasia. *Endoscopy* 2015; **47**: 103–12.
16. Kim JS, Kim BW, Shin IS. Efficacy and safety of endoscopic submucosal dissection for superficial squamous esophageal neoplasia: a meta-analysis. *Dig Dis Sci* 2014; **59**: 1862–9.

17. Katada C, Muto M, Manabe T, Boku N, Ohtsu A, Yoshida S. Esophageal stenosis after endoscopic mucosal resection of superficial esophageal lesions. *Gastrointest Endosc* 2003; **57**: 165–9.
18. Ono S, Fujishiro M, Niimi K, *et al*. Long-term outcomes of endoscopic submucosal dissection for superficial esophageal squamous cell neoplasms. *Gastrointest Endosc* 2009; **70**: 860–6.
19. Shi Q, Ju H, Yao LQ, *et al*. Risk factors for postoperative stricture after endoscopic submucosal dissection for superficial esophageal carcinoma. *Endoscopy* 2014; **46**: 640–4.
20. Ono S, Fujishiro M, Niimi K, *et al*. Predictors of postoperative stricture after esophageal endoscopic submucosal dissection for superficial squamous cell neoplasms. *Endoscopy* 2009; **41**: 661–5.
21. Chadwick G, Groene O, Markar SR, Hoare J, Cromwell D, Hanna GB. Systematic review comparing radiofrequency ablation and complete endoscopic resection in treating dysplastic Barrett's esophagus: a critical assessment of histologic outcomes and adverse events. *Gastrointest Endosc* 2014; **79**: 718–31 e3.
22. Sie C, Bright T, Schoeman M, *et al*. Argon plasma coagulation ablation versus endoscopic surveillance of Barrett's esophagus: late outcomes from two randomized trials. *Endoscopy* 2013; **45**: 859–65.
23. Ganz RA, Overholt BF, Sharma VK, *et al*. Circumferential ablation of Barrett's esophagus that contains high-grade dysplasia: a U.S. Multicenter Registry. *Gastrointest Endosc* 2008; **68**: 35–40.
24. Manner H, Rabenstein T, Pech O, *et al*. Ablation of residual Barrett's epithelium after endoscopic resection: a randomized long-term follow-up study of argon plasma coagulation vs. surveillance (APE study). *Endoscopy* 2014; **46**: 6–12.
25. Wen J, Lu Z, Liu Q. Prevention and treatment of esophageal stenosis after endoscopic submucosal dissection for early esophageal cancer. *Gastroenterol Res Pract* 2014; **2014**: 457101.
26. Isomoto H, Yamaguchi N, Nakayama T, *et al*. Management of esophageal stricture after complete circular endoscopic submucosal dissection for superficial esophageal squamous cell carcinoma. *BMC Gastroenterol* 2011; **11**: 46.
27. Na HK, Choi KD, Ahn JY, *et al*. Outcomes of balloon dilation for the treatment of strictures after endoscopic submucosal dissection compared with peptic strictures. *Surg Endosc* 2013; **27**: 3237–46.
28. Takahashi H, Arimura Y, Okahara S, *et al*. Risk of perforation during dilation for esophageal strictures after endoscopic resection in patients with early squamous cell carcinoma. *Endoscopy* 2011; **43**: 184–9.
29. Doupe DP, Alcolea MP, Roshan A, *et al*. A single progenitor population switches behavior to maintain and repair esophageal epithelium. *Science* 2012; **337**: 1091–3.
30. Honda M, Nakamura T, Hori Y, *et al*. Process of healing of mucosal defects in the esophagus after endoscopic mucosal resection: histological evaluation in a dog model. *Endoscopy* 2010; **42**: 1092–5.
31. Nonaka K, Miyazawa M, Ban S, *et al*. Different healing process of esophageal large mucosal defects by endoscopic mucosal dissection between with and without steroid injection in an animal model. *BMC Gastroenterol* 2013; **13**: 72.
32. Kakushima N, Fujishiro M, Kodashima S, *et al*. Histopathologic characteristics of gastric ulcers created by endoscopic submucosal dissection. *Endoscopy* 2006; **38**: 412–5.
33. Ledon JA, Savas J, Franca K, Chacon A, Nouri K. Intralesional treatment for keloids and hypertrophic scars: a review. *Dermatol Sur* 2013; **39**: 1745–57.
34. Wick G, Grundtman C, Mayerl C, *et al*. The immunology of fibrosis. *Annu Rev Immunol* 2013; **31**: 107–35.
35. Barret M, Batteux F, Beuvon F, *et al*. N-acetylcysteine for the prevention of stricture after circumferential endoscopic submucosal dissection of the esophagus: a randomized trial in a porcine model. *Fibrogenesis Tissue Repair* 2012; **5**: 8.
36. Duffield JS, Lupher M, Thannickal VJ, Wynn TA. Host responses in tissue repair and fibrosis. *Ann Rev Pathol* 2013; **8**: 241–76.
37. Kramann R, DiRocco DP, Humphreys BD. Understanding the origin, activation and regulation of matrix-producing myofibroblasts for treatment of fibrotic disease. *J Pathol* 2013; **231**: 273–89.
38. Barret M, Pratico CA, Beuvon F, *et al*. Esophageal circumferential en bloc endoscopic submucosal dissection: assessment of a new technique. *Surg Laparosc Endosc Percutan Tech* 2013; **23**: e182–7.
39. Chian KS, Leong MF, Kono K. Regenerative medicine for oesophageal reconstruction after cancer treatment. *Lancet Oncol* 2015; **16**: e84–92.
40. Isomoto H, Yamaguchi N, Minami H, Nakao K. Management of complications associated with endoscopic submucosal dissection/endoscopic mucosal resection for esophageal cancer. *Dig Endosc* 2013; **25**(Suppl. 1): 29–38.
41. Kim GH, Jee SR, Jang JY, *et al*. Stricture occurring after endoscopic submucosal dissection for esophageal and gastric tumors. *Clin Endosc* 2014; **47**: 516–22.
42. Kobayashi S, Kanai N, Ohki T, *et al*. Prevention of esophageal strictures after endoscopic submucosal dissection. *World J Gastroenterol* 2014; **20**: 15098–109.
43. Leggett CL, Gorospe EC, Lutzke L, Anderson M, Wang KK. A new era: endoscopic tissue transplantation. *Curr Opin Gastroenterol* 2013; **29**: 495–500.
44. Londono R, Jobe BA, Hoppe T, Badyak SF. Esophagus and regenerative medicine. *World J Gastroenterol* 2012; **18**: 6894–9.
45. Ohki T, Yamato M, Okano T, Yamamoto M. Regenerative medicine: tissue-engineered cell sheet for the prevention of post-esophageal ESD stricture. *Gastrointest Endosc Clin N Am* 2014; **24**: 273–81.
46. Ohki T, Yamato M, Ota M, *et al*. Application of regenerative medical technology using tissue-engineered cell sheets for endoscopic submucosal dissection of esophageal neoplasms. *Dig Endosc* 2015; **27**: 182–8.
47. Ohki TOM, Okano T, Yamamoto M. Application of cell sheet technology for esophageal endoscopic submucosal dissection. *Tech Gastrointest Endosc* 2011; **13**: 105–9.
48. Siddique S, Kottewar S, Theivanayagam S, *et al*. Steroid use for prevention of strictures post endoscopic submucosal dissection: a meta analysis. *Gastrointest Endosc* 2014; **79**(Suppl. 1): pp AB409.
49. Takagi R, Yamato M, Kanai N, *et al*. Cell sheet technology for regeneration of esophageal mucosa. *World J Gastroenterol* 2012; **18**: 5145–50.
50. Juhl CO, Vinter-Jensen L, Jensen LS, Nexø E, Djurhuus JC, Dajani EZ. Systemic treatment with recombinant human epidermal growth factor accelerates healing of sclerotherapy-induced esophageal ulcers and prevents esophageal stricture formations in pigs. *Dig Dis Sci* 1994; **39**: 2671–8.
51. Beye B, Alatawi A, Barret M, *et al*. Prévention de la sténose oesophagienne après dissection sous-muqueuse endoscopique circonférentielle: intérêt d'une poudre hémostatique locale dans

- la promotion de la réparation épithéliale. Journées Francophones d'hépatogastro-entérologie et d'oncologie digestive 2014 JFHOD; Paris, France.
52. Prat F, Magialavori L, Chrissostalis A, Chaussade S. Esophageal circumferential en-bloc submucosal dissection in a porcine model. *Gastrointest Endosc* 2006; **63**: AB133.
 53. Hashimoto S, Kobayashi M, Takeuchi M, Sato Y, Narisawa R, Aoyagi Y. The efficacy of endoscopic triamcinolone injection for the prevention of esophageal stricture after endoscopic submucosal dissection. *Gastrointest Endosc* 2011; **74**: 1389–93.
 54. Nieponice A, McGrath K, Qureshi I, et al. An extracellular matrix scaffold for esophageal stricture prevention after circumferential EMR. *Gastrointest Endosc* 2009; **69**: 289–96.
 55. Rajan E, Gostout C, Feitoza A, et al. Widespread endoscopic mucosal resection of the esophagus with strategies for stricture prevention: a preclinical study. *Endoscopy* 2005; **37**: 1111–5.
 56. Schomisch SJ, Yu L, Wu Y, et al. Commercially available biological mesh does not prevent stricture after esophageal mucosectomy. *Endoscopy* 2014; **46**: 144–8.
 57. Fernandes M, Sridhar MS, Sangwan VS, Rao GN. Amniotic membrane transplantation for ocular surface reconstruction. *Cornea* 2005; **24**: 643–53.
 58. Fraser JF, Cuttle L, Kempf M, Phillips GE, Hayes MT, Kimble RM. A randomised controlled trial of amniotic membrane in the treatment of a standardised burn injury in the merino lamb. *Burns* 2009; **35**: 998–1003.
 59. Barret M, Pratico CA, Camus M, et al. Amniotic membrane grafts for the prevention of esophageal stricture after circumferential endoscopic submucosal dissection. *PLoS ONE* 2014; **9**: e100236.
 60. Scholvinck DW, Alvarez Herrero L, Visser M, Bergman JJ, Weusten BL. Effects of Lugol staining on stenosis formation induced by radiofrequency ablation of esophageal squamous epithelium: a study in a porcine model. *Dis Esophagus* 2014; doi: 10.1111/dote.12225 [Epub ahead of print].
 61. Badylak SF, Hoppe T, Nieponice A, Gilbert TW, Davison JM, Jobe BA. Esophageal preservation in five male patients after endoscopic inner-layer circumferential resection in the setting of superficial cancer: a regenerative medicine approach with a biologic scaffold. *Tissue Eng Part A* 2011; **17**: 1643–50.
 62. Iizuka T, Kikuchi D, Yamada A, Hoteya S, Kajiyama Y, Kaise M. Polyglycolic acid sheet application to prevent esophageal stricture after endoscopic submucosal dissection for esophageal squamous cell carcinoma. *Endoscopy* 2015; **47**: 341–4.
 63. Sakaguchi Y, Tsuji Y, Ono S, et al. Polyglycolic acid sheets with fibrin glue can prevent esophageal stricture after endoscopic submucosal dissection. *Endoscopy* 2015; **47**: 336–40.
 64. Tamayama TIY, Yoshida M, Ishizuka S, et al. A case report of double early carcinoma of the same level of esophagus treated by two stage EMR to prevent stricture. *Gastroenterol Endosc* 2004; **46**: 11–5.
 65. Dalal K, Zhang X, Hart J, et al. Depth of mucosectomy specimens as a predictor of stricture formation in patients with Barrett's esophagus (BE) undergoing circumferential endoscopic mucosal resection (CEMR). *Gastrointest Endosc* 2012; **75**(Suppl. 1): AB467.
 66. Lopes CV, Hela M, Pesenti C, et al. Circumferential endoscopic resection of Barrett's esophagus with high-grade dysplasia or early adenocarcinoma. *Surg Endosc* 2007; **21**: 820–4.
 67. Chennat J, Konda VJ, Ross AS, et al. Complete Barrett's eradication endoscopic mucosal resection: an effective treatment modality for high-grade dysplasia and intramucosal carcinoma – an American single-center experience. *Am J Gastroenterol* 2009; **104**: 2684–92.
 68. Chung A, Bourke MJ, Hourigan LF, et al. Complete Barrett's excision by stepwise endoscopic resection in short-segment disease: long term outcomes and predictors of stricture. *Endoscopy* 2011; **43**: 1025–32.
 69. Pouw RE, Seewald S, Gondrie JJ, et al. Stepwise radical endoscopic resection for eradication of Barrett's oesophagus with early neoplasia in a cohort of 169 patients. *Gut* 2010; **59**: 1169–77.
 70. Conio M, Fisher DA, Blanchi S, Ruggeri C, Filiberti R, Siersema PD. One-step circumferential endoscopic mucosal cap resection of Barrett's esophagus with early neoplasia. *Clin Res Hepatol Gastroenterol* 2014; **38**: 81–91.
 71. Honda M, Hori Y, Nakada A, et al. Use of adipose tissue-derived stromal cells for prevention of esophageal stricture after circumferential EMR in a canine model. *Gastrointest Endosc* 2011; **73**: 777–84.
 72. Sakurai T, Miyazaki S, Miyata G, Satomi S, Hori Y. Autologous buccal keratinocyte implantation for the prevention of stenosis after EMR of the esophagus. *Gastrointest Endosc* 2007; **66**: 167–73.
 73. Zuercher BF, George M, Escher A, et al. Stricture prevention after extended circumferential endoscopic mucosal resection by injecting autologous keratinocytes in the sheep esophagus. *Surg Endosc* 2013; **27**: 1022–8.
 74. Poghosyan T, Gaujoux S, Vanneau V, et al. In vitro development and characterization of a tissue-engineered conduit resembling esophageal wall using human and pig skeletal myoblast, oral epithelial cells, and biologic scaffolds. *Tissue Eng Part A* 2013; **19**: 2242–52.
 75. Ohki T, Yamato M, Murakami D, et al. Treatment of oesophageal ulcerations using endoscopic transplantation of tissue-engineered autologous oral mucosal epithelial cell sheets in a canine model. *Gut* 2006; **55**: 1704–10.
 76. Kanai N, Yamato M, Ohki T, Yamamoto M, Okano T. Fabricated autologous epidermal cell sheets for the prevention of esophageal stricture after circumferential ESD in a porcine model. *Gastrointest Endosc* 2012; **76**: 873–81.
 77. Takagi R, Murakami D, Kondo M, et al. Fabrication of human oral mucosal epithelial cell sheets for treatment of esophageal ulceration by endoscopic submucosal dissection. *Gastrointest Endosc* 2010; **72**: 1253–9.
 78. Ohki T, Yamato M, Ota M, et al. Prevention of esophageal stricture after endoscopic submucosal dissection using tissue-engineered cell sheets. *Gastroenterology* 2012; **143**: 582–8 e1-2.
 79. Elbe P, Jonas E, Sjoqvist S, et al. The use of tissue-engineered cell sheets in a European setting to prevent esophageal strictures after endoscopic submucosal dissection (ESD). *Dis Esophagus* 2014; **27**: 42A.
 80. Hochberger J, Koehler P, Wedi E, et al. Transplantation of mucosa from stomach to esophagus to prevent stricture after circumferential endoscopic submucosal dissection of early squamous cell. *Gastroenterology* 2014; **146**: 906–9.
 81. Hochberger J, Koehler P, Wedi E, et al. Transplantation of mucosa from stomach to esophagus to prevent

- stricture after circumferential endoscopic submucosal dissection of early squamous cell. *Gastroenterology* 2013; **146**: 906–9.
82. Siersema PD. Treatment options for esophageal strictures. *Nat Clin Pract Gastroenterol Hepatol* 2008; **5**: 142–52.
 83. Honda M, Nakamura T, Hori Y, et al. Feasibility study of corticosteroid treatment for esophageal ulcer after EMR in a canine model. *J Gastroenterol* 2011; **46**: 866–72.
 84. Mizutani T, Tadauchi A, Arinobe M, et al. Novel strategy for prevention of esophageal stricture after endoscopic surgery. *Hepatogastroenterology* 2010; **57**: 1150–6.
 85. Machida H, Tominaga K, Minamino H, et al. Locoregional mitomycin C injection for esophageal stricture after endoscopic submucosal dissection. *Endoscopy* 2012; **44**: 622–5.
 86. Wu Y, Schomisch SJ, Cipriano C, et al. Preliminary results of anticarring therapy in the prevention of postendoscopic esophageal mucosectomy strictures. *Surg Endosc* 2014; **28**: 447–55.
 87. Yamashina T, Uedo N, Fujii M, et al. Delayed perforation after intralesional triamcinolone injection for esophageal stricture following endoscopic submucosal dissection. *Endoscopy* 2013; **45**(Suppl. 2): UCTN:E92.
 88. Hashimoto S, Kobayashi M, Takeuchi M, Mizuno K, Sato Y, Aoyagi Y. The efficacy of endoscopic triamcinolone injection combined with oral prednisolone administration to prevent esophageal stricture following endoscopic submucosal dissection. *Gastrointest Endosc* 2012; **75**(Suppl. 1): AB450.
 89. Ishiyama A, Tsuchida T, Osumi H, et al. The efficacy of steroid administration for the prevention of esophageal stricture after endoscopic submucosal dissection for superficial esophageal squamous cell carcinoma. *Dis Esophagus* 2014; **27**: 41A–42A.
 90. Lee WJ, Jung HY, Kim do H, et al. Intralesional steroid injection to prevent stricture after near-circumferential endoscopic submucosal dissection for superficial esophageal cancer. *Clin Endosc* 2013; **46**: 643–6.
 91. Nagami Y, Shiba M, Tominaga K, et al. The prophylactic efficacy of locoregional steroid injection for stricture formation caused by endoscopic submucosal dissection for superficial esophageal cancer using a propensity score matching analysis. *Gastrointest Endosc* 2014; **79**(Suppl. 1): AB414.
 92. Oyama T, Kitamura Y. The prevention of stricture after circumferential esophageal endoscopic submucosal dissection – Can steroid injection reduce the number of balloon dilatation? *Gastrointest Endosc* 2009; **65**: AB359.
 93. Shoji H, Yamaguchi N, Isomoto H, et al. Oral prednisolone and triamcinolone injection for gastric stricture after endoscopic submucosal dissection. *Ann Transl Med* 2014; **2**: 22.
 94. Takeuchi MHS, Kobayashi M, Sato Y, Narisawa R, Aoyagi Y. Prevention of subsequent stricture formation after esophageal endoscopic submucosal dissection. *Gastroenterol Endosc* 2011; **53**: 3064–72.
 95. Hanaoka N, Ishihara R, Takeuchi Y, et al. Intralesional steroid injection to prevent stricture after endoscopic submucosal dissection for esophageal cancer: a controlled prospective study. *Endoscopy* 2012; **44**: 1007–11.
 96. Funakawa K, Uto H, Sasaki F, et al. Effect of endoscopic submucosal dissection for superficial esophageal neoplasms and risk factors for postoperative stricture. *Medicine* 2015; **94**: e373.
 97. Wallace T, Barthel M, Wallace M. Wide field endoscopic mucosal resection (EMR) for Barrett's esophagus with high-grade dysplasia. *Am J Gastroenterol* 2014; **109**: S627.
 98. Bahin F, Jayanna M, Williams S, et al. Efficacy of viscous budesonide slurry in the prevention of oesophageal stricture formation post endoscopic mucosal resection of Barrett's oesophagus with high-grade dysplasia and early oesophageal adenocarcinoma. *J Gastroenterol Hepatol* 2014; **29**: 49.
 99. Mori H, Rafiq K, Kobara H, et al. Steroid permeation into the artificial ulcer by combined steroid gel application and balloon dilatation: prevention of esophageal stricture. *J Gastroenterol Hepatol* 2013; **28**: 999–1003.
 100. Ono SFM, Kodashima S, Minatsuki C, et al. High-dose dexamethasone may prevent esophageal stricture after endoscopic submucosal dissection. *Clin J Gastroenterol* 2010; **3**: 55–158.
 101. Yamaguchi N, Isomoto H, Shikuwa S, et al. Effect of oral prednisolone on esophageal stricture after complete circular endoscopic submucosal dissection for superficial esophageal squamous cell carcinoma: a case report. *Digestion* 2011; **83**: 291–5.
 102. Sato H, Inoue H, Kobayashi Y, et al. Control of severe strictures after circumferential endoscopic submucosal dissection for esophageal carcinoma: oral steroid therapy with balloon dilation or balloon dilation alone. *Gastrointest Endosc* 2013; **78**: 250–7.
 103. Huang S, Tang X, Gong W, et al. Efficacy of oral prednisone for the prevention of esophageal stricture after endoscopic submucosal dissection: a preliminary study. *J Dig Dis* 2014; **15**: 116.
 104. Ishiyama A, Tsuchida T, Taniguchi C, et al. Usefulness of oral prednisolone in the treatment of esophageal stricture after endoscopic submucosal dissection for superficial esophageal squamous cell carcinoma. *Dis Esophagus* 2012; **25**: 171A.
 105. Yamaguchi N, Isomoto H, Nakayama T, et al. Usefulness of oral prednisolone in the treatment of esophageal stricture after endoscopic submucosal dissection for superficial esophageal squamous cell carcinoma. *Gastrointest Endosc* 2011; **73**: 1115–21.
 106. Ishida T, Morita Y, Hoshi N, et al. Disseminated nocardiosis during systemic steroid therapy for the prevention of esophageal stricture after endoscopic submucosal dissection. *Dig Endosc* 2015; **27**: 388–91.
 107. Oyama T. Prevention of stricture after large esophageal endoscopic submucosal dissections. *Endoscopy* 2015; **45**: 289–90.
 108. Uno K, Iijima K, Koike T, et al. A pilot study of scheduled endoscopic balloon dilation with oral agent tranilast to improve the efficacy of stricture dilation after endoscopic submucosal dissection of the esophagus. *J Clin Gastroenterol* 2012; **46**: e76–82.
 109. Pauli EM, Schomisch SJ, Furlan JP, et al. Biodegradable esophageal stent placement does not prevent high-grade stricture formation after circumferential mucosal resection in a porcine model. *Surg Endosc* 2012; **26**: 3500–8.
 110. Mochizuki Y, Saito Y, Tanaka T, et al. Endoscopic submucosal dissection combined with the placement of biodegradable stents for recurrent esophageal cancer after chemoradiotherapy. *J Gastrointest Cancer* 2012; **43**: 324–8.
 111. Holt BA, Jayasekaran V, Williams SJ, et al. Early metal stent insertion fails to prevent stricturing after single-stage complete Barrett's excision for high-grade dysplasia and early cancer. *Gastrointest Endosc* 2015; **81**: 857–64.
 112. Bhat YM, Kane SD, Shah JN, Hamerski CM, Binmoeller KF. Single-session circumferential EMR and metal stent placement for the treatment of long-segment Barrett's esophagus with high-grade

- intraepithelial neoplasia. *Gastrointest Endosc* 2014; **80**: 331.
113. Zhang Y, Linghu E, Lu Z *et al.* Prevention and control of esophageal stricture after endoscopic treatment for large neoplastic lesion and early carcinoma in the esophagus. *Am J Gastroenterol* 2013; **108**: S595.
 114. Wen J, Lu Z, Yang Y, *et al.* Preventing stricture formation by covered esophageal stent placement after endoscopic submucosal dissection for early esophageal cancer. *Dig Dis Sci* 2014; **59**: 658–63.
 115. Chaput U, Heresbach D, Audureau E, *et al.* Comparison of a standard fully covered stent with a super-thick silicone-covered stent for the treatment of refractory esophageal benign strictures: a prospective multicenter study. *United Eur Gastroenterol J* 2013; **1**: 93–102.
 116. Wong VW, Teoh AY, Fujishiro M, Chiu PW, Ng EK. Preemptive dilatation gives good outcome to early esophageal stricture after circumferential endoscopic submucosal dissection. *Surg Laparosc Endosc Percutan Tech* 2010; **20**: e25–7.
 117. Wang C, Lu X, Chen P. Clinical value of preventive balloon dilatation for esophageal stricture. *Exp Ther Med* 2013; **5**: 292–4.
 118. Ezoe Y, Muto M, Horimatsu T, *et al.* Efficacy of preventive endoscopic balloon dilation for esophageal stricture after endoscopic resection. *J Clin Gastroenterol* 2011; **45**: 222–7.
 119. Minami H, Inoue H, Satodate H, Kudo S. Prevention of subsequent stricture; circumferential endoscopic resection for wide spread squamous cell carcinoma in the esophagus. *Dis Esophagus* 2010; **23**: 77A–78A.
 120. Pan Q, Nicholson AM, Barr H, *et al.* Identification of lineage-uncommitted, long-lived, label-retaining cells in healthy human esophagus and stomach, and in metaplastic esophagus. *Gastroenterology* 2013; **144**: 761–70.
 121. Barbera M, di Pietro M, Walker E, *et al.* The human squamous oesophagus has widespread capacity for clonal expansion from cells at diverse stages of differentiation. *Gut* 2015; **64**: 11–9.
 122. Coad RA, Woodman AC, Warner PJ, Barr H, Wright NA, Shepherd NA. On the histogenesis of Barrett's oesophagus and its associated squamous islands: a three-dimensional study of their morphological relationship with native oesophageal gland ducts. *J Pathol* 2005; **206**: 388–94.
 123. Endoscopic Classification Review Group. Update on the Paris classification of superficial neoplastic lesions in the digestive tract. *Endoscopy* 2005; **37**: 570–8.
 124. Neuhaus H, Terheggen G, Rutz EM, Vieth M, Schumacher B. Endoscopic submucosal dissection plus radiofrequency ablation of neoplastic Barrett's esophagus. *Endoscopy* 2012; **44**: 1105–13.
 125. Shaheen NJ, Overholt BF, Sampliner RE, *et al.* Durability of radiofrequency ablation in Barrett's esophagus with dysplasia. *Gastroenterology* 2011; **141**: 460–8.
 126. Orman ES, Li N, Shaheen NJ. Efficacy and durability of radiofrequency ablation for Barrett's esophagus: systematic review and meta-analysis. *Clin Gastroenterol Hepatol* 2013; **11**: 1245.
 127. Gray NA, Odze RD, Spechler SJ. Buried metaplasia after endoscopic ablation of Barrett's esophagus: a systematic review. *Am J Gastroenterol* 2011; **106**: 1899–908.

Bibliographie

1. Ferlay J, Soerjomataram I, Ervik M, Dikshit R, Eser S, Mathers C, Rebelo M, Parkin DM, Forman D, Bray, F. GLOBOCAN 2012 v1.0, Cancer Incidence and Mortality Worldwide: IARC CancerBase No. 11 [Internet]. Lyon, France: International Agency for Research on Cancer; 2013. Available from: <http://globocan.iarc.fr>.
2. Castro C, Bosetti C, Malvezzi M, Bertuccio P, Levi F, Negri E, La Vecchia C, Lunet N. Patterns and trends in esophageal cancer mortality and incidence in Europe (1980-2011) and predictions to 2015. *Ann Oncol* 2014; 25:283-90.
3. Siegel RL, Miller KD, Jemal A. Cancer statistics, 2016. *CA Cancer J Clin* 2016; 66:7-30.
4. Pennathur A, Farkas A, Krasinskas AM, Ferson PF, Gooding WE, Gibson MK, Schuchert MJ, Landreneau RJ, Luketich JD. Esophagectomy for T1 esophageal cancer: outcomes in 100 patients and implications for endoscopic therapy. *Ann Thorac Surg* 2009; 87:1048-54; discussion 1054-5.
5. Mwachiro MM, Burgert SL, Lando J, Chepkwony R, Bett C, Bosire C, Abnet CC, Githanga J, Waweru W, Giffen CA, Murphy G, White RE, Topazian MD, Dawsey SM. Esophageal Squamous Dysplasia is Common in Asymptomatic Kenyans: A Prospective, Community-Based, Cross-Sectional Study. *Am J Gastroenterol* 2016; 111:500-7.
6. Torre LA, Bray F, Siegel RL, Ferlay J, Lortet-Tieulent J, Jemal A. Global cancer statistics, 2012. *CA Cancer J Clin* 2015;65:87-108.
7. Hardefeldt HA, Cox MR, Eslick GD. Association between human papillomavirus (HPV) and oesophageal squamous cell carcinoma: a meta-analysis. *Epidemiol Infect* 2014;142:1119-37.
8. Pennathur A, Gibson MK, Jobe BA, Luketich JD. Oesophageal carcinoma. *Lancet* 2013;381:400-12.
9. Pohl H, Welch HG. The role of overdiagnosis and reclassification in the marked increase of esophageal adenocarcinoma incidence. *J Natl Cancer Inst* 2005;97:142-6.
10. Merkow RP, Bilimoria KY, McCarter MD, Chow WB, Gordon HS, Stewart AK, Ko CY, Bentrem DJ. Effect of histologic subtype on treatment and outcomes for esophageal cancer in the United States. *Cancer* 2012;118:3268-76.
11. Hur C, Miller M, Kong CY, Dowling EC, Nattinger KJ, Dunn M, Feuer EJ. Trends in esophageal adenocarcinoma incidence and mortality. *Cancer* 2013;119:1149-58.
12. Lepage C, Rachet B, Jooste V, Faivre J, Coleman MP. Continuing rapid increase in esophageal adenocarcinoma in England and Wales. *Am J Gastroenterol* 2008;103:2694-9.
13. Stavrou EP, McElroy HJ, Baker DF, Smith G, Bishop JF. Adenocarcinoma of the oesophagus: incidence and survival rates in New South Wales, 1972-2005. *Med J Aust* 2009;191:310-4.
14. Lagergren J, Bergstrom R, Lindgren A, Nyren O. Symptomatic gastroesophageal reflux as a risk factor for esophageal adenocarcinoma. *N Engl J Med* 1999;340:825-31.

15. Islami F, Kamangar F. Helicobacter pylori and esophageal cancer risk: a meta-analysis. *Cancer Prev Res (Phila)* 2008;1:329-38.
16. Shaheen NJ, Falk GW, Iyer PG, Gerson LB. ACG Clinical Guideline: Diagnosis and Management of Barrett's Esophagus. *Am J Gastroenterol* 2016;111:30-50; quiz 51.
17. Rex DK, Cummings OW, Shaw M, Cummings MD, Wong RK, Vasudeva RS, Dunne D, Rahmani EY, Helper DJ. Screening for Barrett's esophagus in colonoscopy patients with and without heartburn. *Gastroenterology* 2003;125:1670-7.
18. Ronkainen J, Aro P, Storskrubb T, Johansson SE, Lind T, Bolling-Sternevald E, Vieth M, Stolte M, Talley NJ, Agreus L. Prevalence of Barrett's esophagus in the general population: an endoscopic study. *Gastroenterology* 2005;129:1825-31.
19. Sharma P. Review article: prevalence of Barrett's oesophagus and metaplasia at the gastro-oesophageal junction. *Aliment Pharmacol Ther* 2004;20 Suppl 5:48-54; discussion 61-2.
20. Jovov B, Van Itallie CM, Shaheen NJ, Carson JL, Gambling TM, Anderson JM, Orlando RC. Claudin-18: a dominant tight junction protein in Barrett's esophagus and likely contributor to its acid resistance. *Am J Physiol Gastrointest Liver Physiol* 2007;293:G1106-13.
21. Spechler SJ. Barrett esophagus and risk of esophageal cancer: a clinical review. *Jama* 2013;310:627-36.
22. Hvid-Jensen F, Pedersen L, Drewes AM, Sorensen HT, Funch-Jensen P. Incidence of adenocarcinoma among patients with Barrett's esophagus. *N Engl J Med* 2011;365:1375-83.
23. Yousef F, Cardwell C, Cantwell MM, Galway K, Johnston BT, Murray L. The incidence of esophageal cancer and high-grade dysplasia in Barrett's esophagus: a systematic review and meta-analysis. *Am J Epidemiol* 2008;168:237-49.
24. Curvers WL, ten Kate FJ, Krishnadath KK, Visser M, Elzer B, Baak LC, Bohmer C, Mallant-Hent RC, van Oijen A, Naber AH, Scholten P, Busch OR, Blaauwgeers HG, Meijer GA, Bergman JJ. Low-grade dysplasia in Barrett's esophagus: overdiagnosed and underestimated. *Am J Gastroenterol* 2010;105:1523-30.
25. Sharma P, Falk GW, Weston AP, Reker D, Johnston M, Sampliner RE. Dysplasia and cancer in a large multicenter cohort of patients with Barrett's esophagus. *Clin Gastroenterol Hepatol* 2006;4:566-72.
26. Rastogi A, Puli S, El-Serag HB, Bansal A, Wani S, Sharma P. Incidence of esophageal adenocarcinoma in patients with Barrett's esophagus and high-grade dysplasia: a meta-analysis. *Gastrointest Endosc* 2008;67:394-8.
27. de Jonge PJ, van Blankenstein M, Looman CW, Casparie MK, Meijer GA, Kuipers EJ. Risk of malignant progression in patients with Barrett's oesophagus: a Dutch nationwide cohort study. *Gut* 2010;59:1030-6.
28. Weaver JM, Ross-Innes CS, Shannon N, Lynch AG, Forshew T, Barbera M, Murtaza M, Ong CA, Lao-Sirieix P, Dunning MJ, Smith L, Smith ML, Anderson CL, Carvalho B, O'Donovan M, Underwood TJ, May AP, Grehan N, Hardwick R, Davies J, Oloumi A, Aparicio S, Caldas C, Eldridge MD, Edwards PA, Rosenfeld N, Tavaré S, Fitzgerald RC. Ordering of mutations in preinvasive disease stages of esophageal carcinogenesis. *Nat Genet*;46:837-43.

29. Timmer MR, Martinez P, Lau CT, Westra WM, Calpe S, Rygiel AM, Rosmolen WD, Meijer SL, Ten Kate FJ, Dijkgraaf MG, Mallant-Hent RC, Naber AH, van Oijen AH, Baak LC, Scholten P, Bohmer CJ, Fockens P, Maley CC, Graham TA, Bergman JJ, Krishnadath KK. Derivation of genetic biomarkers for cancer risk stratification in Barrett's oesophagus: a prospective cohort study. *Gut* 2015.
30. Rustgi AK, El-Serag HB. Esophageal carcinoma. *N Engl J Med* 2014;371:2499-509.
31. Sharma P, Dent J, Armstrong D, Bergman JJ, Gossner L, Hoshihara Y, Jankowski JA, Junghard O, Lundell L, Tytgat GN, Vieth M. The development and validation of an endoscopic grading system for Barrett's esophagus: the Prague C & M criteria. *Gastroenterology* 2006;131:1392-9.
32. Thésaurus national de cancérologie digestive, accessed online the 02/08/16 at <http://www.snfge.org/content/1-cancer-de-loesophage>. 2016.
33. Qumseya BJ, Brown J, Abraham M, White D, Wolfsen H, Gupta N, Vennalaganti P, Sharma P, Wallace MB. Diagnostic performance of EUS in predicting advanced cancer among patients with Barrett's esophagus and high-grade dysplasia/early adenocarcinoma: systematic review and meta-analysis. *Gastrointest Endosc* 2015;81:865-74 e2.
34. Wani S, Das A, Rastogi A, Drahos J, Ricker W, Parsons R, Bansal A, Yen R, Hosford L, Jankowski M, Sharma P, Cook MB. Endoscopic ultrasonography in esophageal cancer leads to improved survival rates: results from a population-based study. *Cancer* 2015;121:194-201.
35. Stahl M, Mariette C, Haustermans K, Cervantes A, Arnold D. Oesophageal cancer: ESMO Clinical Practice Guidelines for diagnosis, treatment and follow-up. *Ann Oncol* 2013;24 Suppl 6:vi51-6.
36. van Vliet EP, Heijenbrok-Kal MH, Hunink MG, Kuipers EJ, Siersema PD. Staging investigations for oesophageal cancer: a meta-analysis. *Br J Cancer* 2008;98:547-57.
37. Yoon YC, Lee KS, Shim YM, Kim BT, Kim K, Kim TS. Metastasis to regional lymph nodes in patients with esophageal squamous cell carcinoma: CT versus FDG PET for presurgical detection prospective study. *Radiology* 2003;227:764-70.
38. Findlay JM, Bradley KM, Maile EJ, Braden B, Maw J, Phillips-Hughes J, Gillies RS, Maynard ND, Middleton MR. Pragmatic staging of oesophageal cancer using decision theory involving selective endoscopic ultrasonography, PET and laparoscopy. *Br J Surg* 2015;102:1488-99.
39. Gauthé M, Richard-Molard M, Cacheux W, Michel P, Jouve JL, Mitry E, Alberini JL, Lievre A. Role of fluorine 18 fluorodeoxyglucose positron emission tomography/computed tomography in gastrointestinal cancers. *Dig Liver Dis* 2015;47:443-54.
40. TNM classification of esophageal cancer. Accessed online on 02/08/2016 at : <http://www.uhhospitals.org/health-and-wellness/health-library/a-c/~media/uh/images/services/cnacerstagingwknapp-lq.jpg?iframe=true&width=800&height=438>. 2016.
41. Gertler R, Stein HJ, Langer R, Nettelmann M, Schuster T, Hoefler H, Siewert JR, Feith M. Long-term outcome of 2920 patients with cancers of the esophagus and esophagogastric junction: evaluation of the New Union

- Internationale Contre le Cancer/American Joint Cancer Committee staging system. *Ann Surg* 2011;253:689-98.
42. Mariette C, Piessen G, Balon JM, Van Seuning I, Triboulet JP. Surgery alone in the curative treatment of localised oesophageal carcinoma. *Eur J Surg Oncol* 2004;30:869-76.
 43. Merkow RP, Bilimoria KY, Keswani RN, Chung J, Sherman KL, Knab LM, Posner MC, Bentrem DJ. Treatment trends, risk of lymph node metastasis, and outcomes for localized esophageal cancer. *J Natl Cancer Inst* 2014;106.
 44. Tanaka T, Matono S, Mori N, Shirouzu K, Fujita H. T1 squamous cell carcinoma of the esophagus: long-term outcomes and prognostic factors after esophagectomy. *Ann Surg Oncol* 2014;21:932-8.
 45. Westerterp M, Koppert LB, Buskens CJ, Tilanus HW, ten Kate FJ, Bergman JJ, Siersema PD, van Dekken H, van Lanschoot JJ. Outcome of surgical treatment for early adenocarcinoma of the esophagus or gastro-esophageal junction. *Virchows Arch* 2005;446:497-504.
 46. Altorki N, Skinner D. Should en bloc esophagectomy be the standard of care for esophageal carcinoma? *Ann Surg* 2001;234:581-7.
 47. The Paris endoscopic classification of superficial neoplastic lesions: esophagus, stomach, and colon: November 30 to December 1, 2002. *GastrointestEndosc*. 2003;58:(6 Suppl):S3-43.
 48. Endoscopic Classification Review Group. Update on the paris classification of superficial neoplastic lesions in the digestive tract. *Endoscopy* 2005;37:570-8.
 49. Bollschweiler E, Baldus SE, Schroder W, Prenzel K, Gutschow C, Schneider PM, Holscher AH. High rate of lymph-node metastasis in submucosal esophageal squamous-cell carcinomas and adenocarcinomas. *Endoscopy* 2006;38:149-56.
 50. Dubecz A, Kern M, Solymosi N, Schweigert M, Stein HJ. Predictors of Lymph Node Metastasis in Surgically Resected T1 Esophageal Cancer. *Ann Thorac Surg* 2015;99:1879-85; discussion 1886.
 51. Pimentel-Nunes P, Dinis-Ribeiro M, Ponchon T, Repici A, Vieth M, De Ceglie A, Amato A, Berr F, Bhandari P, Bialek A, Conio M, Haringsma J, Langner C, Meisner S, Messmann H, Morino M, Neuhaus H, Piessevaux H, Rugge M, Saunders BP, Robaszkievicz M, Seewald S, Kashin S, Dumonceau JM, Hassan C, Deprez PH. Endoscopic submucosal dissection: European Society of Gastrointestinal Endoscopy (ESGE) Guideline. *Endoscopy* 2015;47:829-54.
 52. Yamashina T, Ishihara R, Nagai K, Matsuura N, Matsui F, Ito T, Fujii M, Yamamoto S, Hanaoka N, Takeuchi Y, Higashino K, Uedo N, Iishi H. Long-term outcome and metastatic risk after endoscopic resection of superficial esophageal squamous cell carcinoma. *Am J Gastroenterol* 2013;108:544-51.
 53. Liu L, Hofstetter WL, Rashid A, Swisher SG, Correa AM, Ajani JA, Hamilton SR, Wu TT. Significance of the depth of tumor invasion and lymph node metastasis in superficially invasive (T1) esophageal adenocarcinoma. *Am J Surg Pathol* 2005;29:1079-85.
 54. Katada C, Muto M, Momma K, Arima M, Tajiri H, Kanamaru C, Ooyanagi H, Endo H, Michida T, Hasuike N, Oda I, Fujii T, Saito D. Clinical outcome after endoscopic mucosal resection for esophageal squamous cell carcinoma invading the muscularis mucosae--a multicenter retrospective cohort study. *Endoscopy* 2007;39:779-83.

55. Pech O, May A, Manner H, Behrens A, Pohl J, Weferling M, Hartmann U, Manner N, Huijsmans J, Gossner L, Rabenstein T, Vieth M, Stolte M, Ell C. Long-term efficacy and safety of endoscopic resection for patients with mucosal adenocarcinoma of the esophagus. *Gastroenterology* 2014;146:652-660 e1.
56. Pouw RE, van Vilsteren FG, Peters FP, Alvarez Herrero L, Ten Kate FJ, Visser M, Schenk BE, Schoon EJ, Peters FT, Houben M, Bisschops R, Weusten BL, Bergman JJ. Randomized trial on endoscopic resection-cap versus multiband mucosectomy for piecemeal endoscopic resection of early Barrett's neoplasia. *Gastrointest Endosc* 2011;74:35-43.
57. Zhang YM, Boerwinkel DF, Qin X, He S, Xue L, Weusten BL, Dawsey SM, Fleischer DE, Dou LZ, Liu Y, Lu N, Bergman JJ, Wang GQ. A randomized trial comparing multiband mucosectomy and cap-assisted endoscopic resection for endoscopic piecemeal resection of early squamous neoplasia of the esophagus. *Endoscopy* 2016;48:330-8.
58. Alvarez Herrero L, Pouw RE, van Vilsteren FG, ten Kate FJ, Visser M, Seldenrijk CA, van Berge Henegouwen MI, Weusten BL, Bergman JJ. Safety and efficacy of multiband mucosectomy in 1060 resections in Barrett's esophagus. *Endoscopy* 2011;43:177-83.
59. Katada C, Muto M, Manabe T, Boku N, Ohtsu A, Yoshida S. Esophageal stenosis after endoscopic mucosal resection of superficial esophageal lesions. *Gastrointest Endosc* 2003;57:165-9.
60. Pech O, May A, Gossner L, Rabenstein T, Manner H, Huijsmans J, Vieth M, Stolte M, Berres M, Ell C. Curative endoscopic therapy in patients with early esophageal squamous-cell carcinoma or high-grade intraepithelial neoplasia. *Endoscopy* 2007;39:30-5.
61. Terheggen G, Horn EM, Vieth M, Gabbert H, Enderle M, Neugebauer A, Schumacher B, Neuhaus H. A randomised trial of endoscopic submucosal dissection versus endoscopic mucosal resection for early Barrett's neoplasia. *Gut* 2016.
62. Urabe Y, Hiyama T, Tanaka S, Yoshihara M, Arihiro K, Chayama K. Advantages of endoscopic submucosal dissection versus endoscopic oblique aspiration mucosectomy for superficial esophageal tumors. *J Gastroenterol Hepatol* 2011;26:275-80.
63. Phoa KN, Pouw RE, Bisschops R, Pech O, Rangunath K, Weusten BL, Schumacher B, Rembacken B, Meining A, Messmann H, Schoon EJ, Gossner L, Mannath J, Seldenrijk CA, Visser M, Lerut T, Seewald S, Ten Kate FJ, Ell C, Neuhaus H, Bergman JJ. Multimodality endoscopic eradication for neoplastic Barrett oesophagus: results of an European multicentre study (EURO-II). *Gut* 2015.
64. Yamamoto H, Kawata H, Sunada K, Sasaki A, Nakazawa K, Miyata T, Sekine Y, Yano T, Satoh K, Ido K, Sugano K. Successful en-bloc resection of large superficial tumors in the stomach and colon using sodium hyaluronate and small-caliber-tip transparent hood. *Endoscopy* 2003;35:690-4.
65. Kim JS, Kim BW, Shin IS. Efficacy and safety of endoscopic submucosal dissection for superficial squamous esophageal neoplasia: a meta-analysis. *Dig Dis Sci* 2014;59:1862-9.

66. Ono S, Fujishiro M, Goto O, Kodashima S, Omata M. Endoscopic submucosal dissection for colonic laterally spreading tumors is difficult after target tattooing. *Gastrointest Endosc* 2009; 69:763-6.
67. Ell C, May A, Pech O, Gossner L, Guenter E, Behrens A, Nachbar L, Huijsmans J, Vieth M, Stolte M. Curative endoscopic resection of early esophageal adenocarcinomas (Barrett's cancer). *Gastrointest Endosc* 2007; 65:3-10.
68. Probst A, Aust D, Markl B, Anthuber M, Messmann H. Early esophageal cancer in Europe: endoscopic treatment by endoscopic submucosal dissection. *Endoscopy* 2015;47:113-21.
69. Tsujii Y, Nishida T, Nishiyama O, Yamamoto K, Kawai N, Yamaguchi S, Yamada T, Yoshio T, Kitamura S, Nakamura T, Nishihara A, Ogiyama H, Nakahara M, Komori M, Kato M, Hayashi Y, Shinzaki S, Iijima H, Michida T, Tsujii M, Takehara T. Clinical outcomes of endoscopic submucosal dissection for superficial esophageal neoplasms: a multicenter retrospective cohort study. *Endoscopy* 2015.
70. Barret M, Cao DT, Beuvon F, Leblanc S, Terris B, Camus M, Coriat R, Chaussade S, Prat F. Endoscopic submucosal dissection for early Barrett's neoplasia. *United European Gastroenterol J* 2016;4:207-15.
71. Gray NA, Odze RD, Spechler SJ. Buried metaplasia after endoscopic ablation of Barrett's esophagus: a systematic review. *Am J Gastroenterol* 2011;106:1899-908; quiz 1909.
72. Haidry RJ, Butt MA, Dunn J, Banks M, Gupta A, Smart H, Bhandari P, Smith LA, Willert R, Fullarton G, John M, Di Pietro M, Penman I, Novelli M, Lovat LB. Radiofrequency ablation for early oesophageal squamous neoplasia: outcomes from United Kingdom registry. *World J Gastroenterol* 2013;19:6011-9.
73. van Vilsteren FG, Alvarez Herrero L, Pouw RE, ten Kate FJ, Visser M, Seldenrijk CA, van Berge Henegouwen MI, Weusten BL, Bergman JJ. Radiofrequency ablation for the endoscopic eradication of esophageal squamous high grade intraepithelial neoplasia and mucosal squamous cell carcinoma. *Endoscopy* 2011;43:282-90.
74. May A, Gossner L, Pech O, Fritz A, Gunter E, Mayer G, Muller H, Seitz G, Vieth M, Stolte M, Ell C. Local endoscopic therapy for intraepithelial high-grade neoplasia and early adenocarcinoma in Barrett's oesophagus: acute-phase and intermediate results of a new treatment approach. *Eur J Gastroenterol Hepatol* 2002;14:1085-91.
75. Altorki NK, Lee PC, Liss Y, Meherally D, Korst RJ, Christos P, Mazumdar M, Port JL. Multifocal neoplasia and nodal metastases in T1 esophageal carcinoma: implications for endoscopic treatment. *Ann Surg* 2008;247:434-9.
76. Phoa KN, van Vilsteren FG, Weusten BL, Bisschops R, Schoon EJ, Ragunath K, Fullarton G, Di Pietro M, Ravi N, Visser M, Offerhaus GJ, Seldenrijk CA, Meijer SL, ten Kate FJ, Tijssen JG, Bergman JJ. Radiofrequency ablation vs endoscopic surveillance for patients with Barrett esophagus and low-grade dysplasia: a randomized clinical trial. *Jama* 2014;311:1209-17.
77. Shaheen NJ, Sharma P, Overholt BF, Wolfsen HC, Sampliner RE, Wang KK, Galanko JA, Bronner MP, Goldblum JR, Bennett AE, Jobe BA, Eisen GM, Fennerty MB, Hunter JG, Fleischer DE, Sharma VK, Hawes RH, Hoffman BJ, Rothstein RI, Gordon SR, Mashimo H, Chang KJ, Muthusamy VR,

- Edmundowicz SA, Spechler SJ, Siddiqui AA, Souza RF, Infantolino A, Falk GW, Kimmey MB, Madanick RD, Chak A, Lightdale CJ. Radiofrequency ablation in Barrett's esophagus with dysplasia. *N Engl J Med* 2009;360:2277-88.
78. van Vilsteren FG, Pouw RE, Seewald S, Alvarez Herrero L, Sondermeijer CM, Visser M, Ten Kate FJ, Yu Kim Teng KC, Soehendra N, Rosch T, Weusten BL, Bergman JJ. Stepwise radical endoscopic resection versus radiofrequency ablation for Barrett's oesophagus with high-grade dysplasia or early cancer: a multicentre randomised trial. *Gut* 2011;60:765-73.
 79. Phoa KN, Pouw RE, van Vilsteren FG, Sondermeijer CM, Ten Kate FJ, Visser M, Meijer SL, van Berge Henegouwen MI, Weusten BL, Schoon EJ, Mallant-Hent RC, Bergman JJ. Remission of Barrett's esophagus with early neoplasia 5 years after radiofrequency ablation with endoscopic resection: a Netherlands cohort study. *Gastroenterology* 2013;145:96-104.
 80. Shaheen NJ, Overholt BF, Sampliner RE, Wolfsen HC, Wang KK, Fleischer DE, Sharma VK, Eisen GM, Fennerty MB, Hunter JG, Bronner MP, Goldblum JR, Bennett AE, Mashimo H, Rothstein RI, Gordon SR, Edmundowicz SA, Madanick RD, Peery AF, Muthusamy VR, Chang KJ, Kimmey MB, Spechler SJ, Siddiqui AA, Souza RF, Infantolino A, Dumot JA, Falk GW, Galanko JA, Jobe BA, Hawes RH, Hoffman BJ, Sharma P, Chak A, Lightdale CJ. Durability of radiofrequency ablation in Barrett's esophagus with dysplasia. *Gastroenterology* 2011;141:460-8.
 81. Bulsiewicz WJ, Kim HP, Dellon ES, Cotton CC, Pasricha S, Madanick RD, Spacek MB, Bream SE, Chen X, Orlando RC, Shaheen NJ. Safety and efficacy of endoscopic mucosal therapy with radiofrequency ablation for patients with neoplastic Barrett's esophagus. *Clin Gastroenterol Hepatol* 2013;11:636-42.
 82. Chadwick G, Groene O, Markar SR, Hoare J, Cromwell D, Hanna GB. Systematic review comparing radiofrequency ablation and complete endoscopic resection in treating dysplastic Barrett's esophagus: a critical assessment of histologic outcomes and adverse events. *Gastrointest Endosc* 2014;79:718-731 e3.
 83. Alvarez Herrero L, van Vilsteren FG, Pouw RE, ten Kate FJ, Visser M, Seldenrijk CA, van Berge Henegouwen MI, Fockens P, Weusten BL, Bergman JJ. Endoscopic radiofrequency ablation combined with endoscopic resection for early neoplasia in Barrett's esophagus longer than 10 cm. *Gastrointest Endosc* 2011;73:682-90.
 84. Manner H, Rabenstein T, Pech O, Braun K, May A, Pohl J, Behrens A, Vieth M, Ell C. Ablation of residual Barrett's epithelium after endoscopic resection: a randomized long-term follow-up study of argon plasma coagulation vs. surveillance (APE study). *Endoscopy* 2014;46:6-12.
 85. Manner H, May A, Kouti I, Pech O, Vieth M, Ell C. Efficacy and safety of Hybrid-APC for the ablation of Barrett's esophagus. *Surg Endosc* 2015; 30:1364-70.
 86. Overholt BF, Wang KK, Burdick JS, Lightdale CJ, Kimmey M, Nava HR, Sivak MV, Jr., Nishioka N, Barr H, Marcon N, Pedrosa M, Bronner MP, Grace M, Depot M. Five-year efficacy and safety of photodynamic therapy with Photofrin in Barrett's high-grade dysplasia. *Gastrointest Endosc* 2007;66:460-8.

87. Scholvinck DW, Kunzli HT, Kestens C, Siersema PD, Vleggaar FP, Canto MI, Cosby H, Abrams JA, Lightdale CJ, Tejeda-Ramirez E, DeMeester SR, Greene CL, Jobe BA, Peters J, Bergman JJ, Weusten BL. Treatment of Barrett's esophagus with a novel focal cryoablation device: a safety and feasibility study. *Endoscopy* 2015; 47:1106-12.
88. Luketich JD, Pennathur A, Awais O, Levy RM, Keeley S, Shende M, Christie NA, Weksler B, Landreneau RJ, Abbas G, Schuchert MJ, Nason KS. Outcomes after minimally invasive esophagectomy: review of over 1000 patients. *Ann Surg* 2012; 256:95-103.
89. McMillan RR, Berger A, Sima CS, Lou F, Dycoco J, Rusch V, Rizk NP, Jones DR, Huang J. Thirty-day mortality underestimates the risk of early death after major resections for thoracic malignancies. *Ann Thorac Surg* 2014;98:1769-74; discussion 1774-5.
90. Takeuchi H, Miyata H, Gotoh M, Kitagawa Y, Baba H, Kimura W, Tomita N, Nakagoe T, Shimada M, Sugihara K, Mori M. A risk model for esophagectomy using data of 5354 patients included in a Japanese nationwide web-based database. *Ann Surg* 2014;260:259-66.
91. Pech O, Bollschweiler E, Manner H, Leers J, Ell C, Holscher AH. Comparison between endoscopic and surgical resection of mucosal esophageal adenocarcinoma in Barrett's esophagus at two high-volume centers. *Ann Surg* 2011; 254:67-72.
92. Zehetner J, DeMeester SR, Hagen JA, Ayazi S, Augustin F, Lipham JC, DeMeester TR. Endoscopic resection and ablation versus esophagectomy for high-grade dysplasia and intramucosal adenocarcinoma. *J Thorac Cardiovasc Surg* 2011;141:39-47.
93. Wu J, Pan YM, Wang TT, Gao DJ, Hu B. Endotherapy versus surgery for early neoplasia in Barrett's esophagus: a meta-analysis. *Gastrointest Endosc* 2014; 79:233-241 e2.
94. Pouw RE, Seewald S, Gondrie JJ, Deprez PH, Piessevaux H, Pohl H, Rosch T, Soehendra N, Bergman JJ. Stepwise radical endoscopic resection for eradication of Barrett's oesophagus with early neoplasia in a cohort of 169 patients. *Gut* 2010;59:1169-77.
95. Takahashi H, Arimura Y, Masao H, Okahara S, Tanuma T, Kodaira J, Kagaya H, Shimizu Y, Hokari K, Tsukagoshi H, Shinomura Y, Fujita M. Endoscopic submucosal dissection is superior to conventional endoscopic resection as a curative treatment for early squamous cell carcinoma of the esophagus (with video). *Gastrointest Endosc* 2010;72:255-64, 264 e1-2.
96. Chevaux JB, Piessevaux H, Jouret-Mourin A, Yeung R, Danse E, Deprez PH. Clinical outcome in patients treated with endoscopic submucosal dissection for superficial Barrett's neoplasia. *Endoscopy* 2014.
97. Neuhaus H, Terheggen G, Rutz EM, Vieth M, Schumacher B. Endoscopic submucosal dissection plus radiofrequency ablation of neoplastic Barrett's esophagus. *Endoscopy* 2012; 44:1105-13.
98. Peyre CG, DeMeester SR, Rizzetto C, Bansal N, Tang AL, Ayazi S, Leers JM, Lipham JC, Hagen JA, DeMeester TR. Vagal-sparing esophagectomy: the ideal operation for intramucosal adenocarcinoma and barrett with high-grade dysplasia. *Ann Surg* 2007; 246:665-71; discussion 671-4.
99. Nakagawa S, Kanda T, Kosugi S, Ohashi M, Suzuki T, Hatakeyama K. Recurrence pattern of squamous cell carcinoma of the thoracic esophagus

- after extended radical esophagectomy with three-field lymphadenectomy. *J Am Coll Surg* 2004; 198:205-11.
100. Ono S, Fujishiro M, Niimi K, Goto O, Kodashima S, Yamamichi N, Omata M. Long-term outcomes of endoscopic submucosal dissection for superficial esophageal squamous cell neoplasms. *Gastrointest Endosc* 2009;70:860-6.
 101. Orman ES, Li N, Shaheen NJ. Efficacy and durability of radiofrequency ablation for Barrett's Esophagus: systematic review and meta-analysis. *Clin Gastroenterol Hepatol* 2013; 11:1245-55.
 102. Chennat J, Ross AS, Konda VJ, Lin S, Noffsinger A, Hart J, Waxman I. Advanced pathology under squamous epithelium on initial EMR specimens in patients with Barrett's esophagus and high-grade dysplasia or intramucosal carcinoma: implications for surveillance and endotherapy management. *Gastrointest Endosc* 2009; 70:417-21.
 103. Mochizuki Y, Saito Y, Tsujikawa T, Fujiyama Y, Andoh A. Combination of endoscopic submucosal dissection and chemoradiation therapy for superficial esophageal squamous cell carcinoma with submucosal invasion. *Exp Ther Med* 2011;2:1065-1068.
 104. Shimizu Y, Kato M, Yamamoto J, Nakagawa S, Tsukagoshi H, Fujita M, Hosokawa M, Asaka M. EMR combined with chemoradiotherapy: a novel treatment for superficial esophageal squamous-cell carcinoma. *Gastrointest Endosc* 2004;59:199-204.
 105. Herskovic A, Martz K, al-Sarraf M, Leichman L, Brindle J, Vaitkevicius V, Cooper J, Byhardt R, Davis L, Emami B. Combined chemotherapy and radiotherapy compared with radiotherapy alone in patients with cancer of the esophagus. *N Engl J Med* 1992; 326:1593-8.
 106. Minsky BD, Pajak TF, Ginsberg RJ, Pisansky TM, Martenson J, Komaki R, Okawara G, Rosenthal SA, Kelsen DP. INT 0123 (Radiation Therapy Oncology Group 94-05) phase III trial of combined-modality therapy for esophageal cancer: high-dose versus standard-dose radiation therapy. *J Clin Oncol* 2002; 20:1167-74.
 107. Bosset JF, Gignoux M, Triboulet JP, Tiret E, Manton G, Elias D, Lozach P, Ollier JC, Pavy JJ, Mercier M, Sahmoud T. Chemoradiotherapy followed by surgery compared with surgery alone in squamous-cell cancer of the esophagus. *N Engl J Med* 1997; 337:161-7.
 108. van Hagen P, Hulshof MC, van Lanschot JJ, Steyerberg EW, van Berge Henegouwen MI, Wijnhoven BP, Richel DJ, Nieuwenhuijzen GA, Hospers GA, Bonenkamp JJ, Cuesta MA, Blaisse RJ, Busch OR, ten Kate FJ, Creemers GJ, Punt CJ, Plukker JT, Verheul HM, Spillenaar Bilgen EJ, van Dekken H, van der Slangen MJ, Rozema T, Biermann K, Beukema JC, Piet AH, van Rijn CM, Reinders JG, Tilanus HW, van der Gaast A. Preoperative chemoradiotherapy for esophageal or junctional cancer. *N Engl J Med* 2012; 366:2074-84.
 109. Sjoquist KM, Burmeister BH, Smithers BM, Zalberg JR, Simes RJ, Barbour A, Gebski V. Survival after neoadjuvant chemotherapy or chemoradiotherapy for resectable oesophageal carcinoma: an updated meta-analysis. *Lancet Oncol* 2011; 12:681-92.
 110. Bedenne L, Michel P, Bouche O, Milan C, Mariette C, Conroy T, Pezet D, Roulet B, Seitz JF, Herr JP, Paillot B, Arveux P, Bonnetain F, Biquet C. Chemoradiation followed by surgery compared with chemoradiation alone in

- squamous cancer of the esophagus: FFCD 9102. *J Clin Oncol* 2007;25:1160-8.
111. Stahl M, Stuschke M, Lehmann N, Meyer HJ, Walz MK, Seeber S, Klump B, Budach W, Teichmann R, Schmitt M, Schmitt G, Franke C, Wilke H. Chemoradiation with and without surgery in patients with locally advanced squamous cell carcinoma of the esophagus. *J Clin Oncol* 2005;23:2310-7.
 112. Markar S, Gronnier C, Duhamel A, Pasquer A, Thereaux J, du Rieu MC, Lefevre JH, Turner K, Luc G, Mariette C. Salvage Surgery After Chemoradiotherapy in the Management of Esophageal Cancer: Is It a Viable Therapeutic Option? *J Clin Oncol* 2015; 33:3866-73.
 113. Stahl M, Walz MK, Stuschke M, Lehmann N, Meyer HJ, Riera-Knorrenschild J, Langer P, Engenhart-Cabillic R, Bitzer M, Konigsrainer A, Budach W, Wilke H. Phase III comparison of preoperative chemotherapy compared with chemoradiotherapy in patients with locally advanced adenocarcinoma of the esophagogastric junction. *J Clin Oncol* 2009; 27:851-6.
 114. Cunningham D, Starling N, Rao S, Iveson T, Nicolson M, Coxon F, Middleton G, Daniel F, Oates J, Norman AR. Capecitabine and oxaliplatin for advanced esophagogastric cancer. *N Engl J Med* 2008; 358:36-46.
 115. Homs MY, Steyerberg EW, Eijkenboom WM, Tilanus HW, Stalpers LJ, Bartelsman JF, van Lanschot JJ, Wijrdeman HK, Mulder CJ, Reinders JG, Boot H, Aleman BM, Kuipers EJ, Siersema PD. Single-dose brachytherapy versus metal stent placement for the palliation of dysphagia from oesophageal cancer: multicentre randomised trial. *Lancet* 2004; 364:1497-504.
 116. Lordick F, Ott K, Krause BJ. New trends for staging and therapy for localized gastroesophageal cancer: the role of PET. *Ann Oncol* 2010;21 Suppl 7:vii294-9.
 117. Hashimoto S, Kobayashi M, Takeuchi M, Sato Y, Narisawa R, Aoyagi Y. The efficacy of endoscopic triamcinolone injection for the prevention of esophageal stricture after endoscopic submucosal dissection. *Gastrointest Endosc* 2011; 74:1389-93.
 118. Shi Q, Ju H, Yao LQ, Zhou PH, Xu MD, Chen T, Zhou JM, Chen TY, Zhong YS. Risk factors for postoperative stricture after endoscopic submucosal dissection for superficial esophageal carcinoma. *Endoscopy* 2014;46:640-4.
 119. Ono S, Fujishiro M, Niimi K, Goto O, Kodashima S, Yamamichi N, Omata M. Predictors of postoperative stricture after esophageal endoscopic submucosal dissection for superficial squamous cell neoplasms. *Endoscopy* 2009;41:661-5.
 120. Sie C, Bright T, Schoeman M, Game P, Tam W, Devitt P, Watson D. Argon plasma coagulation ablation versus endoscopic surveillance of Barrett's esophagus: late outcomes from two randomized trials. *Endoscopy* 2013; 45:859-65.
 121. Wen J, Lu Z, Liu Q. Prevention and treatment of esophageal stenosis after endoscopic submucosal dissection for early esophageal cancer. *Gastroenterol Res Pract* 2014;2014:457101.
 122. Isomoto H, Yamaguchi N, Nakayama T, Hayashi T, Nishiyama H, Ohnita K, Takeshima F, Shikuwa S, Kohno S, Nakao K. Management of esophageal stricture after complete circular endoscopic submucosal dissection for superficial esophageal squamous cell carcinoma. *BMC Gastroenterol* 2011; 11:46.

123. Siersema PD. Treatment options for esophageal strictures. *Nat Clin Pract Gastroenterol Hepatol* 2008; 5:142-52.
124. Takahashi H, Arimura Y, Okahara S, Uchida S, Ishigaki S, Tsukagoshi H, Shinomura Y, Hosokawa M. Risk of perforation during dilation for esophageal strictures after endoscopic resection in patients with early squamous cell carcinoma. *Endoscopy* 2011; 43:184-9.
125. Na HK, Choi KD, Ahn JY, Lim H, Kim MY, Lee JH, Choi KS, Kim do H, Song HJ, Lee GH, Jung HY, Kim JH, Lee JB. Outcomes of balloon dilation for the treatment of strictures after endoscopic submucosal dissection compared with peptic strictures. *Surg Endosc* 2013; 27:3237-46.
126. Pan Q, Nicholson AM, Barr H, Harrison LA, Wilson GD, Burkert J, Jeffery R, Alison MR, Looijenga L, Lin WR, McDonald SA, Wright NA, Harrison R, Peppelenbosch MP, Jankowski JA. Identification of lineage-uncommitted, long-lived, label-retaining cells in healthy human esophagus and stomach, and in metaplastic esophagus. *Gastroenterology* 2013; 144:761-70.
127. Jeong Y, Rhee H, Martin S, Klass D, Lin Y, Nguyen le XT, Feng W, Diehn M. Identification and genetic manipulation of human and mouse oesophageal stem cells. *Gut* 2016; 65:1077-86.
128. Doupe DP, Alcolea MP, Roshan A, Zhang G, Klein AM, Simons BD, Jones PH. A single progenitor population switches behavior to maintain and repair esophageal epithelium. *Science* 2012; 337:1091-3.
129. Barbera M, di Pietro M, Walker E, Brierley C, MacRae S, Simons BD, Jones PH, Stingl J, Fitzgerald RC. The human squamous oesophagus has widespread capacity for clonal expansion from cells at diverse stages of differentiation. *Gut* 2015;64:11-9.
130. Coad RA, Woodman AC, Warner PJ, Barr H, Wright NA, Shepherd NA. On the histogenesis of Barrett's oesophagus and its associated squamous islands: a three-dimensional study of their morphological relationship with native oesophageal gland ducts. *J Pathol* 2005; 206:388-94.
131. Barret M, Beye B, Leblanc S, Beuvon F, Chaussade S, Batteux F, Prat F. Systematic review: the prevention of oesophageal stricture after endoscopic resection. *Aliment Pharmacol Ther* 2015; 42:20-39.
132. Honda M, Nakamura T, Hori Y, Shionoya Y, Nakada A, Sato T, Yamamoto K, Kobayashi T, Shimada H, Kida N, Hashimoto A, Hashimoto Y. Process of healing of mucosal defects in the esophagus after endoscopic mucosal resection: histological evaluation in a dog model. *Endoscopy* 2010;42:1092-5.
133. Nonaka K, Miyazawa M, Ban S, Aikawa M, Akimoto N, Koyama I, Kita H. Different healing process of esophageal large mucosal defects by endoscopic mucosal dissection between with and without steroid injection in an animal model. *BMC Gastroenterol* 2013; 13:72.
134. Kakushima N, Fujishiro M, Kodashima S, Kobayashi K, Tateishi A, Iguchi M, Imagawa A, Motoi T, Yahagi N, Omata M. Histopathologic characteristics of gastric ulcers created by endoscopic submucosal dissection. *Endoscopy* 2006; 38:412-5.
135. Ledon JA, Savas J, Franca K, Chacon A, Nouri K. Intralesional treatment for keloids and hypertrophic scars: a review. *Dermatol Surg* 2013; 39:1745-57.
136. Wick G, Grundtman C, Mayerl C, Wimpfissinger TF, Feichtinger J, Zelger B, Sgonc R, Wolfram D. The immunology of fibrosis. *Annu Rev Immunol* 2013; 31:107-35.

137. Barret M, Batteux F, Beuvon F, Mangialavori L, Chryssostalis A, Pratico C, Chaussade S, Prat F. N-acetylcysteine for the prevention of stricture after circumferential endoscopic submucosal dissection of the esophagus: a randomized trial in a porcine model. *Fibrogenesis Tissue Repair* 2012;5:8.
138. Duffield JS, Lupher M, Thannickal VJ, Wynn TA. Host responses in tissue repair and fibrosis. *Annu Rev Pathol* 2013; 8:241-76.
139. Kramann R, DiRocco DP, Humphreys BD. Understanding the origin, activation and regulation of matrix-producing myofibroblasts for treatment of fibrotic disease. *J Pathol* 2013; 231:273-89.
140. Batteux F, Kaviani N, Servettaz A. New insights on chemically induced animal models of systemic sclerosis. *Curr Opin Rheumatol* 2011; 23:511-8.
141. Hecker L, Vittal R, Jones T, Jagirdar R, Luckhardt TR, Horowitz JC, Pennathur S, Martinez FJ, Thannickal VJ. NADPH oxidase-4 mediates myofibroblast activation and fibrogenic responses to lung injury. *Nat Med* 2009; 15:1077-81.
142. Poghosyan T, Gaujoux S, Vanneaux V, Bruneval P, Domet T, Lecourt S, Jarraya M, Sfeir R, Larghero J, Cattani P. In vitro development and characterization of a tissue-engineered conduit resembling esophageal wall using human and pig skeletal myoblast, oral epithelial cells, and biologic scaffolds. *Tissue Eng Part A* 2013; 19:2242-52.
143. Nieponice A, McGrath K, Qureshi I, Beckman EJ, Luketich JD, Gilbert TW, Badylak SF. An extracellular matrix scaffold for esophageal stricture prevention after circumferential EMR. *Gastrointest Endosc* 2009;69:289-96.
144. Rajan E, Gostout C, Feitoza A, Herman L, Knipschild M, Burgart L, Chung S, Cotton P, Hawes R, Kalloo A, Kantsevoy S, Pasricha P. Widespread endoscopic mucosal resection of the esophagus with strategies for stricture prevention: a preclinical study. *Endoscopy* 2005; 37:1111-5.
145. Schomisch SJ, Yu L, Wu Y, Pauli EM, Cipriano C, Chak A, Lash RH, Ponsky JL, Marks JM. Commercially available biological mesh does not prevent stricture after esophageal mucosectomy. *Endoscopy* 2014; 46:144-8.
146. Barret M, Pratico CA, Beuvon F, Mangialavori L, Chryssostalis A, Camus M, Chaussade S, Prat F. Esophageal circumferential en bloc endoscopic submucosal dissection: assessment of a new technique. *Surg Laparosc Endosc Percutan Tech* 2013; 23:e182-7.
147. Barret M, Pratico CA, Camus M, Beuvon F, Jarraya M, Nicco C, Mangialavori L, Chaussade S, Batteux F, Prat F. Amniotic membrane grafts for the prevention of esophageal stricture after circumferential endoscopic submucosal dissection. *PLoS One* 2014; 9:e100236.
148. Badylak SF, Hoppo T, Nieponice A, Gilbert TW, Davison JM, Jobe BA. Esophageal preservation in five male patients after endoscopic inner-layer circumferential resection in the setting of superficial cancer: a regenerative medicine approach with a biologic scaffold. *Tissue Eng Part A* 2011; 17:1643-50.
149. Iizuka T, Kikuchi D, Yamada A, Hoteya S, Kajiyama Y, Kaise M. Polyglycolic acid sheet application to prevent esophageal stricture after endoscopic submucosal dissection for esophageal squamous cell carcinoma. *Endoscopy* 2014.
150. Sakaguchi Y, Tsuji Y, Ono S, Saito I, Kataoka Y, Takahashi Y, Nakayama C, Shichijo S, Matsuda R, Minatsuki C, Asada-Hirayama I, Niimi K, Kodashima S, Yamamichi N, Fujishiro M, Koike K. Polyglycolic acid sheets with fibrin glue

- can prevent esophageal stricture after endoscopic submucosal dissection. *Endoscopy* 2015; 47:336-340.
151. Dalal K. ZX, Hart J., Gonzalez-Haba Ruiz M., Konda V.J., Waxman I. Depth of mucosectomy specimens as a predictor of stricture formation in patients with barrett's esophagus (BE) undergoing circumferential endoscopic mucosal resection (CEMR). *Digestive Disease Week 2012, DDW. Volume 75 (4 SUPPL. 1) (pp AB467)*. San Diego, CA United States: *Gastrointestinal Endoscopy*, 2012.
 152. Lopes CV, Hela M, Pesenti C, Bories E, Caillol F, Monges G, Giovannini M. Circumferential endoscopic resection of Barrett's esophagus with high-grade dysplasia or early adenocarcinoma. *Surg Endosc* 2007; 21:820-4.
 153. Tamayama T IY, Yoshida M, Ishizuka S, Kakemura T, Sakai Y, Igarashi Y, Fujinuma S. A case report of double early carcinoma of the same level of esophagus treated by two stage EMR to prevent stricture. *Gastroenterological Endoscopy* 2004;46:11-15.
 154. Chennat J, Konda VJ, Ross AS, de Tejada AH, Noffsinger A, Hart J, Lin S, Ferguson MK, Posner MC, Waxman I. Complete Barrett's eradication endoscopic mucosal resection: an effective treatment modality for high-grade dysplasia and intramucosal carcinoma--an American single-center experience. *Am J Gastroenterol* 2009; 104:2684-92.
 155. Chung A, Bourke MJ, Hourigan LF, Lim G, Moss A, Williams SJ, McLeod D, Fanning S, Kariyawasam V, Byth K. Complete Barrett's excision by stepwise endoscopic resection in short-segment disease: long term outcomes and predictors of stricture. *Endoscopy* 2011;43:1025-32.
 156. Conio M, Fisher DA, Bianchi S, Ruggeri C, Filiberti R, Siersema PD. One-step circumferential endoscopic mucosal cap resection of Barrett's esophagus with early neoplasia. *Clin Res Hepatol Gastroenterol* 2014; 38:81-91.
 157. Honda M, Hori Y, Nakada A, Uji M, Nishizawa Y, Yamamoto K, Kobayashi T, Shimada H, Kida N, Sato T, Nakamura T. Use of adipose tissue-derived stromal cells for prevention of esophageal stricture after circumferential EMR in a canine model. *Gastrointest Endosc* 2011; 73:777-84.
 158. Juhl CO, Vinter-Jensen L, Jensen LS, Nexø E, Djurhuus JC, Dajani EZ. Systemic treatment with recombinant human epidermal growth factor accelerates healing of sclerotherapy-induced esophageal ulcers and prevents esophageal stricture formations in pigs. *Dig Dis Sci* 1994; 39:2671-8.
 159. Sakurai T, Miyazaki S, Miyata G, Satomi S, Hori Y. Autologous buccal keratinocyte implantation for the prevention of stenosis after EMR of the esophagus. *Gastrointest Endosc* 2007; 66:167-73.
 160. Zuercher BF, George M, Escher A, Piotet E, Ikonomidis C, Andrejevic SB, Monnier P. Stricture prevention after extended circumferential endoscopic mucosal resection by injecting autologous keratinocytes in the sheep esophagus. *Surg Endosc* 2013; 27:1022-8.
 161. Kanai N, Yamato M, Ohki T, Yamamoto M, Okano T. Fabricated autologous epidermal cell sheets for the prevention of esophageal stricture after circumferential ESD in a porcine model. *Gastrointest Endosc* 2012; 76:873-81.
 162. Ohki T, Yamato M, Murakami D, Takagi R, Yang J, Namiki H, Okano T, Takasaki K. Treatment of oesophageal ulcerations using endoscopic transplantation of tissue-engineered autologous oral mucosal epithelial cell sheets in a canine model. *Gut* 2006; 55:1704-10.

163. Takagi R, Murakami D, Kondo M, Ohki T, Sasaki R, Mizutani M, Yamato M, Nishida K, Namiki H, Yamamoto M, Okano T. Fabrication of human oral mucosal epithelial cell sheets for treatment of esophageal ulceration by endoscopic submucosal dissection. *Gastrointest Endosc* 2010; 72:1253-9.
164. Ohki T, Yamato M, Ota M, Takagi R, Murakami D, Kondo M, Sasaki R, Namiki H, Okano T, Yamamoto M. Prevention of esophageal stricture after endoscopic submucosal dissection using tissue-engineered cell sheets. *Gastroenterology* 2012; 143:582-8 e1-2.
165. Elbe P JE, Sjoqvist S, Kondo M, Kanai N, Ohki T, Okano T, Enger J, Enger M, Pettersson H, Egami M, Blomberg P, Lohr M. The use of tissue-engineered cell sheets in a European setting to prevent esophageal strictures after endoscopic submucosal dissection (ESD). 14th World Congress of the International Society for Diseases of the Esophagus, ISDE 2014. Volume 27 (pp 42A). Vancouver, BC Canada: Diseases of the Esophagus, 2014.
166. Kobayashi S, Kanai N, Ohki T, Takagi R, Yamaguchi N, Isomoto H, Kasai Y, Hosoi T, Nakao K, Eguchi S, Yamamoto M, Yamato M, Okano T. Prevention of esophageal strictures after endoscopic submucosal dissection. *World J Gastroenterol* 2014; 20:15098-109.
167. Honda M, Nakamura T, Hori Y, Shionoya Y, Yamamoto K, Nishizawa Y, Kojima F, Shigeno K. Feasibility study of corticosteroid treatment for esophageal ulcer after EMR in a canine model. *J Gastroenterol* 2011;46:866-72.
168. Machida H, Tominaga K, Minamino H, Sugimori S, Okazaki H, Yamagami H, Tanigawa T, Watanabe K, Watanabe T, Fujiwara Y, Arakawa T. Locoregional mitomycin C injection for esophageal stricture after endoscopic submucosal dissection. *Endoscopy* 2012; 44:622-5.
169. Mizutani T, Tadauchi A, Arinobe M, Narita Y, Kato R, Niwa Y, Ohmiya N, Itoh A, Hirooka Y, Honda H, Ueda M, Goto H. Novel strategy for prevention of esophageal stricture after endoscopic surgery. *Hepatogastroenterology* 2010; 57:1150-6.
170. Prat F ML, Chryssostalis A, Chaussade S. . Esophageal Circumferential En-Bloc Submucosal Dissection in a Porcine Model. In: *Endosc G*, ed. Digestive Disease Week 2006. Volume Volume 63, Issue 5, Page AB133, 2006.
171. Wu Y, Schomisch SJ, Cipriano C, Chak A, Lash RH, Ponsky JL, Marks JM. Preliminary results of antiscarring therapy in the prevention of postendoscopic esophageal mucosectomy strictures. *Surg Endosc* 2014; 28:447-55.
172. Ishiyama A TT, Osumi H, Taniguchi C, Tomita A, Tomida H, Morishige K, Horiuchi Y, Yoshizawa N, Ishikawa H, Fujisaki J, Igarashi M, Chin K, Mine S, Watanabe M. The efficacy of steroid administration for the prevention of esophageal stricture after endoscopic submucosal dissection for superficial esophageal squamous cell carcinoma. 14th World Congress of the International Society for Diseases of the Esophagus, ISDE. Volume 27 (pp 41A-42A). Vancouver, BC Canada: Diseases of the Esophagus, 2014.
173. Lee WJ, Jung HY, Kim do H, Lee JH, Choi KD, Song HJ, Lee GH, Kim JH. Intralesional steroid injection to prevent stricture after near-circumferential endoscopic submucosal dissection for superficial esophageal cancer. *Clin Endosc* 2013; 46:643-6.
174. Nagami Y SM, Tominaga K, Ominami M, Fukunaga S, Sugimori S, Kamata N, Sogawa M, Yamagami H, Tanigawa T, Watanabe K, Watanabe T, Fujiwara Y,

- Arakawa T. The prophylactic efficacy of locoregional steroid injection for stricture formation caused by endoscopic submucosal dissection for superficial esophageal cancer using a propensity score matching analysis. *Digestive Disease Week, DDW 2014, ASGE*. Volume 79 (5 SUPPL. 1) (pp AB414). Chicago, IL United States: *Gastrointestinal Endoscopy*, 2014.
175. Oyama T KY. The prevention of stricture after circumferential esophageal endoscopic submucosal dissection - Can steroid injection reduce the number of balloon dilatation?. *Digestive Disease Week, DDW 2009*. Volume 69 (5) (pp AB359). Chicago, IL United States: *Gastrointestinal Endoscopy*, 2009.
 176. Shoji H, Yamaguchi N, Isomoto H, Minami H, Matsushima K, Akazawa Y, Ohnita K, Takeshima F, Shikuwa S, Nakao K. Oral prednisolone and triamcinolone injection for gastric stricture after endoscopic submucosal dissection. *Ann Transl Med* 2014; 2:22.
 177. Takeuchi M HS, Kobayashi M, Sato Y, Narisawa R, Aoyagi Y. Prevention of subsequent stricture formation after esophageal endoscopic submucosal dissection. *Gastroenterological Endoscopy* 2011;53:3064-3072.
 178. Hanaoka N, Ishihara R, Takeuchi Y, Uedo N, Higashino K, Ohta T, Kanzaki H, Hanafusa M, Nagai K, Matsui F, Iishi H, Tatsuta M, Ito Y. Intralesional steroid injection to prevent stricture after endoscopic submucosal dissection for esophageal cancer: a controlled prospective study. *Endoscopy* 2012;44:1007-11.
 179. Bahin F JM, Williams S, Lee E, Song M, Sonson R, Bourke M. Efficacy of viscous budesonide slurry in the prevention of oesophageal stricture formation post endoscopic mucosal resection of Barrett's oesophagus with high-grade dysplasia and early oesophageal adenocarcinoma. *Australian Gastroenterology Week Volume 29* (pp 49). Broadbeach, QLD Australia: *Journal of Gastroenterology and Hepatology*, 2014.
 180. Mori H, Rafiq K, Kobara H, Fujihara S, Nishiyama N, Oryuu M, Suzuki Y, Masaki T. Steroid permeation into the artificial ulcer by combined steroid gel application and balloon dilatation: prevention of esophageal stricture. *J Gastroenterol Hepatol* 2013;28:999-1003.
 181. Wallace T BM, Wallace M. Wide field endoscopic mucosal resection (EMR) for barrett's esophagus with high-grade dysplasia. *79th Annual Scientific Meeting of the American College of Gastroenterology Volume 109* (pp S627). Philadelphia, PA United States: *American Journal of Gastroenterology*, 2014.
 182. Huang S TX, Gong W, Jiang B. Efficacy of oral prednisone for the prevention of esophageal stricture after endoscopic submucosal dissection: A preliminary study. *14th Congress of Gastroenterology China, CGC*. Volume 15 (pp 116). Chongqing China: *Journal of Digestive Diseases*, 2014.
 183. Ishiyama A TT, Taniguchi C, Suzuki S, Morishige K, Yoshizawa N, Horiuchi Y, Matsuo Y, Imai M, Sukanuma T, Ishikawa H, Okada K, Ohmae M, Dan K, Kubota M, Hirasawa T, Yamamoto Y, Fujisaki J. Usefulness of oral prednisolone in the treatment of esophageal stricture after endoscopic submucosal dissection for superficial esophageal squamous cell carcinoma *13th World Congress of the International Society for Diseases of the Esophagus*. Volume 25 (pp 171A), 2012. Venice Italy: *Diseases of the Esophagus*, 2012.
 184. Yamaguchi N, Isomoto H, Nakayama T, Hayashi T, Nishiyama H, Ohnita K, Takeshima F, Shikuwa S, Kohno S, Nakao K. Usefulness of oral prednisolone

- in the treatment of esophageal stricture after endoscopic submucosal dissection for superficial esophageal squamous cell carcinoma. *Gastrointest Endosc* 2011;73:1115-21.
185. Sato H, Inoue H, Kobayashi Y, Maselli R, Santi EG, Hayee B, Igarashi K, Yoshida A, Ikeda H, Onimaru M, Aoyagi Y, Kudo SE. Control of severe strictures after circumferential endoscopic submucosal dissection for esophageal carcinoma: oral steroid therapy with balloon dilation or balloon dilation alone. *Gastrointest Endosc* 2013;78:250-7.
 186. Siddique S KS, Theivanayagam S, Almashrawi A., Uhlich R, Ashraf I, Arif M, Bechtold ML, Choudhary A. Steroid use for prevention of strictures post endoscopic submucosal dissection: A meta analysis. *Digestive Disease Week, DDW 2014 ASGE. Volume 79(5 SUPPL. 1) (pp AB409). Chicago, IL United States: Gastrointestinal Endoscopy 2014.*
 187. Funakawa K, Uto H, Sasaki F, Nasu Y, Mawatari S, Arima S, Nakazawa J, Taguchi H, Hashimoto S, Kanmura S, Setoyama H, Numata M, Tsubouchi H, Ido A. Effect of endoscopic submucosal dissection for superficial esophageal neoplasms and risk factors for postoperative stricture. *Medicine (Baltimore)* 2015;94:e373.
 188. Isomoto H, Yamaguchi N, Minami H, Nakao K. Management of complications associated with endoscopic submucosal dissection/ endoscopic mucosal resection for esophageal cancer. *Dig Endosc* 2013;25 Suppl 1:29-38.
 189. Yamashina T, Uedo N, Fujii M, Ishihara R, Mikamori M, Motoori M, Yano M, Iishi H. Delayed perforation after intralesional triamcinolone injection for esophageal stricture following endoscopic submucosal dissection. *Endoscopy* 2013;45 Suppl 2 UCTN:E92.
 190. Ishida T, Morita Y, Hoshi N, Yoshizaki T, Ohara Y, Kawara F, Tanaka S, Yamamoto Y, Matsuo H, Iwata K, Toyonaga T, Azuma T. Disseminated nocardiosis during systemic steroid therapy for the prevention of esophageal stricture after endoscopic submucosal dissection. *Dig Endosc* 2014.
 191. Uno K, Iijima K, Koike T, Abe Y, Asano N, Ara N, Shimosegawa T. A pilot study of scheduled endoscopic balloon dilation with oral agent tranilast to improve the efficacy of stricture dilation after endoscopic submucosal dissection of the esophagus. *J Clin Gastroenterol* 2012;46:e76-82.
 192. Pauli EM, Schomisch SJ, Furlan JP, Marks AS, Chak A, Lash RH, Ponsky JL, Marks JM. Biodegradable esophageal stent placement does not prevent high-grade stricture formation after circumferential mucosal resection in a porcine model. *Surg Endosc* 2012;26:3500-8.
 193. Holt BA, Jayasekeran V, Williams SJ, Lee EY, Bahin FF, Sonson R, Lord RV, Bourke MJ. Early metal stent insertion fails to prevent stricturing after single-stage complete Barrett's excision for high-grade dysplasia and early cancer. *Gastrointest Endosc* 2015;81:857-64.
 194. Bhat YM, Kane SD, Shah JN, Hamerski CM, Binmoeller KF. Single-session circumferential EMR and metal stent placement for the treatment of long-segment Barrett's esophagus with high-grade intraepithelial neoplasia. *Gastrointest Endosc* 2014;80:331.
 195. Zhang Y LE, Lu Z. Prevention and control of esophageal stricture after endoscopic treatment for large neoplastic lesion and early carcinoma in the esophagus. 78th Annual Scientific Meeting of the American College of

- Gastroenterology. Volume 108 (pp S595). San Diego, CA United States: American Journal of Gastroenterology, 2013.
196. Wen J, Lu Z, Yang Y, Liu Q, Yang J, Wang S, Wang X, Du H, Meng J, Wang H, Linghu E. Preventing stricture formation by covered esophageal stent placement after endoscopic submucosal dissection for early esophageal cancer. *Dig Dis Sci* 2014;59:658-63.
 197. Wang C, Lu X, Chen P. Clinical value of preventive balloon dilatation for esophageal stricture. *Exp Ther Med* 2013;5:292-294.
 198. Ezoe Y, Muto M, Horimatsu T, Morita S, Miyamoto S, Mochizuki S, Minashi K, Yano T, Ohtsu A, Chiba T. Efficacy of preventive endoscopic balloon dilation for esophageal stricture after endoscopic resection. *J Clin Gastroenterol* 2011;45:222-7.
 199. Minami H IH, Satodate H, Kudo S. Prevention of subsequent stricture: circumferential endoscopic resection for wide spread squamous cell carcinoma in the esophagus. 12th World Congress of the International Society for Diseases of the Esophagus, ISDE 2010. Volume 23 (pp 77A-78A). Kagoshima Japan: Diseases of the Esophagus, 2010.
 200. Herrero LA, van Vilsteren FG, Visser M, Meijer SL, van Berge Henegouwen MI, Bergman JJ, Weusten BL. Simultaneous use of endoscopic resection and radiofrequency ablation is not safe in an esophageal porcine model. *Dis Esophagus* 2015;28:25-31.
 201. Demedts M, Behr J, Buhl R, Costabel U, Dekhuijzen R, Jansen HM, MacNee W, Thomeer M, Wallaert B, Laurent F, Nicholson AG, Verbeken EK, Verschakelen J, Flower CD, Capron F, Petruzzelli S, De Vuyst P, van den Bosch JM, Rodriguez-Becerra E, Corvasce G, Lankhorst I, Sardina M, Montanari M. High-dose acetylcysteine in idiopathic pulmonary fibrosis. *N Engl J Med* 2005;353:2229-42.
 202. Demir EO, Cakmak GK, Bakkal H, Turkcu UO, Kandemir N, Demir AS, Tascilar O. N-acetyl-cysteine improves anastomotic wound healing after radiotherapy in rats. *J Invest Surg* 2011;24:151-8.
 203. Gunel E, Caglayan F, Caglayan O, Canbilen A, Tosun M. Effect of antioxidant therapy on collagen synthesis in corrosive esophageal burns. *Pediatr Surg Int* 2002;18:24-7.
 204. Rieder F, Nonevski I, Ma J, Ouyang Z, West G, Protheroe C, DePetris G, Schirbel A, Lapinski J, Goldblum J, Bonfield T, Lopez R, Harnett K, Lee J, Hirano I, Falk G, Biancani P, Fiocchi C. T-helper 2 cytokines, transforming growth factor beta1, and eosinophil products induce fibrogenesis and alter muscle motility in patients with eosinophilic esophagitis. *Gastroenterology* 2014;146:1266-77 e1-9.
 205. Muir AB, Dods K, Noah Y, Toltzis S, Chandramouleeswaran PM, Lee A, Benitez A, Bedenbaugh A, Falk GW, Wells RG, Nakagawa H, Wang ML. Esophageal epithelial cells acquire functional characteristics of activated myofibroblasts after undergoing an epithelial to mesenchymal transition. *Exp Cell Res* 2015;330:102-10.
 206. Rieder F, Biancani P, Harnett K, Yerian L, Falk GW. Inflammatory mediators in gastroesophageal reflux disease: impact on esophageal motility, fibrosis, and carcinogenesis. *Am J Physiol Gastrointest Liver Physiol* 2010;298:G571-81.
 207. Fernandes M, Sridhar MS, Sangwan VS, Rao GN. Amniotic membrane transplantation for ocular surface reconstruction. *Cornea* 2005;24:643-53.

208. Koltuksuz U, Mutus HM, Kutlu R, Ozyurt H, Cetin S, Karaman A, Gurbuz N, Akyol O, Aydin NE. Effects of caffeic acid phenethyl ester and epidermal growth factor on the development of caustic esophageal stricture in rats. *J Pediatr Surg* 2001;36:1504-9.
209. Ozcelik MF, Pekmezci S, Saribeyoglu K, Unal E, Gumustas K, Dogusoy G. The effect of halofuginone, a specific inhibitor of collagen type 1 synthesis, in the prevention of esophageal strictures related to caustic injury. *Am J Surg* 2004;187:257-60.
210. Liu A, Richardson AM. Effects of N-Acetylcysteine on experimentally induced esophageal lye injury. *Ann Rhinol Laryngol* 1985;94:477- 481.
211. Perry Y, Epperly MW, Fernando HC, Klein E, Finkelstein S, Greenberger JS, Luketich JD. Photodynamic therapy induced esophageal stricture--an animal model: from mouse to pig. *J Surg Res* 2005;123:67-74.
212. Beye B, Barret M, Alatawi A, Beuvon F, Nicco C, Pratico CA, Chereau C, Chaussade S, Batteux F, Prat F. Topical hemostatic powder promotes reepithelialization and reduces scar formation after extensive esophageal mucosal resection. *Dis Esophagus*. 2016 Aug;29(6):520-7.
213. Muraine M, Gueudry J, Toubeau D, et al. [Advantages of amniotic membrane transplantation in eye surface diseases]. *J Fr Ophtalmol* 2006;29:1070-1083