



HAL
open science

Etude du remodelage vasculaire de l'Artérite à Cellules Géantes par caractérisation inflammatoire et lésionnelle spatiale

Simon Parreau

► **To cite this version:**

Simon Parreau. Etude du remodelage vasculaire de l'Artérite à Cellules Géantes par caractérisation inflammatoire et lésionnelle spatiale. Médecine humaine et pathologie. Université de Limoges, 2024. Français. NNT : 2024LIMO0040 . tel-04638921

HAL Id: tel-04638921

<https://theses.hal.science/tel-04638921v1>

Submitted on 8 Jul 2024

HAL is a multi-disciplinary open access archive for the deposit and dissemination of scientific research documents, whether they are published or not. The documents may come from teaching and research institutions in France or abroad, or from public or private research centers.

L'archive ouverte pluridisciplinaire **HAL**, est destinée au dépôt et à la diffusion de documents scientifiques de niveau recherche, publiés ou non, émanant des établissements d'enseignement et de recherche français ou étrangers, des laboratoires publics ou privés.



Université de Limoges
ED 652 - Biologie, Chimie, Santé (BCS)
INSERM U1308 - CAPTuR

Thèse pour obtenir le grade de
Docteur de l'Université de Limoges
Discipline : Sciences, Vie et Santé / Option : Immunologie

Présentée et soutenue par
Simon Parreau

Le 4 juillet 2024

**Etude du remodelage vasculaire de l'Artérite à Cellules Géantes par
caractérisation inflammatoire et lésionnelle spatiale**

Thèse co-dirigée par le Pr Marie-Odile JAUBERTEAU et le Pr Kim-Heang LY

JURY :

Mme le Professeur Anne-Laure FAUCHAIS (Université de Limoges) Président
Mr le Professeur Thierry MARTIN (Université de Strasbourg) Examineur
Mme le Professeur Amélie SERVETTAZ (Université de Reims) Rapporteur
Mr le Professeur Alexis REGENT (Université de Paris) Rapporteur
Mme le Professeur Marie-Odile JAUBERTEAU (Université de Limoges) Co-directrice de thèse
Mr le Professeur Kim-Heang LY (Université de Limoges) Co-directeur de thèse

Remerciements

Je tiens remercier toutes les personnes qui ont participé à cette aventure

A nos Maîtres et Directeurs de thèse,

Madame le Professeur Marie-Odile Jauberteau.

Monsieur le Professeur Kim-Heang Ly.

Aux membres du Jury,

Madame le Professeur Anne-Laure Fauchais.

Monsieur le Professeur Thierry Martin.

Madame le Professeur Amélie Servettaz.

Monsieur le Professeur Alexis Régent.

A nos Maîtres,

Monsieur le Docteur Eric Liozon.

Madame le Professeur Cornelia Weyand.

Madame le Professeur Muriel Mathonnet.

Monsieur le Professeur Benjamin Terrier.

A ma Femme, Hélène Genéty.

A ma Famille, mes parents, ma sœur Hortense, mes tantes, mes grands-parents, mes cousins, mes amis, Tristan Lachaniette.

A ma Belle-Famille.

A l'équipe de San Diego, Elsa Molina, Radjiv Goulabchand, Christian Quintero.

A l'équipe CAPTuR, UMR INSERM 1308, Thomas Naves, François Gallet, Faraj Terro, Hussein Akil, Nicolas Vedrenne, Fabrice Lalloué, Philippe Sindou, Camille Granet, Eric Lapeyronnie, Sofiane Saada.

A l'équipe du Weyand lab et de la Mayo Clinic, Shozo Ohtsuki, Ke Jin, Jose Morales de los Santos, Bowen Wu, Zhaolan Hu, Tuantuan Zhao, Jorg Goronzy, John Chen, Kenneth Warrington, Mélanie Bois.

*A l'équipe de Médecine interne du CHU de Limoges, **Stéphanie Dumonteil, Sylvain Palat, Holy Bezanahary, Edouard Desvaux, Guillaume Gondran, Nina Ratti, Gregory Bosphore, Jean-Guillaume Lopes, Anis Hariz, Pauline Chambrier, Menfield Margotone, Florence Couillard, Bastien Salvador, Remy Bouquet, tous les internes, le personnel paramédical, les secrétaires, Karène Lassère.***

*A l'équipe d'Anatomopathologie et de Neurologie du CHU de Limoges, **Alain Chaunavel, Sébastien Decourt, Mathilde Duchesne, Isabelle Pommepuy, Elodie Gay, Laurence Richard, Fanny Legros.***

*Aux « français » du Minnesota, **Bharath et Alex Wootla, Sébastien Richert, Cory et Romain Lorentz.***

Aux patients

Droits d'auteurs

Cette création est mise à disposition selon le Contrat :

« **Attribution-Pas d'Utilisation Commerciale-Pas de modification 3.0 France** »

disponible en ligne : <http://creativecommons.org/licenses/by-nc-nd/3.0/fr/>



Résumé

Rationnel : L'artérite à cellules géantes (ACG) est une vascularite affectant l'aorte et ses principales branches, caractérisée par un infiltrat inflammatoire et un remodelage vasculaire. Les complications ischémiques de la maladie sont liées à une hyperplasie de l'intima par prolifération de myofibroblastes. Les fibroblastes adventitiels ont été peu étudiés au cours de l'ACG et pourraient participer au phénomène de remodelage vasculaire.

Objectifs : Nous émettons l'hypothèse que les fibroblastes adventitiels sont impliqués dans le remodelage vasculaire de l'ACG.

Méthodes : Nous avons inclus des patients ayant eu une biopsie d'artère temporale (BAT) pour suspicion d'ACG. Nous avons tout d'abord étudié la répartition intratissulaire des fibroblastes sur coupe d'artère temporale et leurs marqueurs d'activation par méthode immunohistochimique. A partir de l'isolement de fibroblastes adventitiels de BAT de sujets atteints d'ACG et de contrôles, nous avons effectué des tests fonctionnels de ces fibroblastes. Nous avons réalisé une étude transcriptomique spatiale d'artères temporales de sujets sains et de patients atteints ACG à l'aide de l'outil *Digital Spatial Profiler* (Nanostring) afin de mettre en évidence des signatures d'expression génomique selon les différentes couches artérielles.

Résultats : Les fibroblastes de l'adventice des patients atteints d'ACG expriment des marqueurs d'activation. Ils présentent des capacités de prolifération, migration et sécrétion. L'analyse d'enrichissement montre que les fonctions liées à l'inflammation/réponse immunitaire et le remodelage vasculaire étaient en revanche significativement limitées aux couches internes (intima et media). Les fonctions immunitaires activées concernaient la différenciation des macrophages, les activations des lymphocytes T et B et du complément. Concernant les voies de remodelage vasculaire, nous avons constaté une activation : du processus métabolique du collagène, de la prolifération des fibroblastes, de l'angiogenèse, et de la prolifération des cellules musculaires lisses dans l'intima et la média. Notre analyse du réseau pharmacogénomique a permis d'identifier les gènes qui pourraient potentiellement être ciblés par des traitements actuellement approuvés ou par de nouvelles immunothérapies.

Conclusion : Les fibroblastes semblent impliqués dans le processus de l'ACG. Nos résultats fournissent la première caractérisation par profilage spatial *in situ* des acteurs moléculaires impliqués dans l'ACG, essentielle pour la découverte de nouvelles cibles thérapeutiques potentielles pour traiter cette vascularite.

Mots clés : Artérite à cellules géantes, fibroblastes, remodelage vasculaire, inflammation, transcriptomique spatiale

Table des matières

Liste des abréviations.....	8
Liste des figures.....	9
Liste des tableaux.....	10
Introduction.....	11
Partie I. Revue bibliographique.....	12
I.1 Artérite à Cellules Géantes (ACG).....	12
I.1.1 Historique.....	12
I.1.2 Epidémiologie.....	13
I.1.3 Présentation clinique.....	14
I.1.4 Signes généraux.....	15
I.1.5 Signes crâniens.....	15
I.1.6 Signes rhumatologiques.....	28
I.1.7 Manifestations artérielles.....	28
I.1.8 Manifestations rares/atypiques.....	31
I.1.9 Mimickers.....	32
I.1.10 Biologie.....	38
I.1.11 Moyens diagnostiques.....	39
I.1.12 Critères de classification.....	45
I.1.13 Traitements.....	47
I.1.14 Pronostic.....	52
I.1.15 Physiopathologie.....	53
Partie II. Travaux de thèse.....	77
Objectifs et plan d'étude.....	77
Article 1.....	78
Travail complémentaire 1. (non publié).....	88
Article 2.....	94
Travail complémentaire 2. (non publié).....	130
Discussion générale.....	134
Références.....	141
Annexes.....	168
Annexe 1.....	168
Annexe 2.....	175
Annexe 3.....	183
Annexe 4.....	192
Annexe 5.....	196
Annexe 6.....	206
Annexe 7.....	216
Annexe 8.....	223
Annexe 9.....	226
Annexe 10.....	240
Annexe 11.....	248

Liste des abréviations

αSMA : <i>Alpha smooth muscle actin</i>	MTX : Méthotrexate
ACG : Artérite à cellules géantes	NETs : <i>Neutrophil extracellular traps</i>
ACR : <i>American College of Rheumatology</i>	NGF : <i>Nerve growth factor</i>
ADN : Acide désoxyribonucléique	NOIA : Neuropathie optique ischémique antérieure
ANCA : Anticorps anti-cytoplasme des polynucléaires neutrophiles	NOIAA : Neuropathie optique ischémique antérieure artéritique
ARN : Acide ribonucléique	NOIANA : Neuropathie optique ischémique antérieure non artéritique
AVC : Accident vasculaire cérébral	NOIP : Neuropathie optique ischémie postérieure
BAFF : <i>B-cell activating factor</i>	NOX2 : NADPH oxydase 2
BAT : Biopsie d'artère temporale	NT : Neurotrophine
BDNF : <i>Brain-Derived Neurotrophic Factor</i>	OACR : Occlusion de l'artère centrale de la rétine
BrdU : 5-bromo-2'-deoxyuridine	OR : <i>Odds Ratio</i>
BSA : Albumine de sérum bovin	ORL : Otorhinolaryngologique
CHU : Centre hospitalier universitaire	P4H : Prolyl-4-hydroxylase
CMLV : Cellules musculaires lisses vasculaires	PBS : Tampon phosphate salin
CRP : <i>C-reactive protein</i>	PCR : <i>Polymerase chain reaction</i>
CTC : Corticoïdes	PDGF : <i>Platelet-derived growth factor</i>
Ctrl : Contrôle	PETVAS : <i>Performance of the PET vascular activity score</i>
DAB : Diaminobenzidine	PPR : Pseudo polyarthrite rhizomélique
DAMPs : <i>Damage Associated Molecular Pattern</i>	ROS : <i>Reactive oxygen species</i>
DAPI : 4',6'-Diamidino-2-Phénylindole dihydrochloride	RS3PE : <i>Remitting Seronegative Symmetrical Synovitis with Pitting Edema</i>
DEG : Gènes exprimés de manière différentielle	SASP : <i>Senescence-associated secretory phenotype</i>
ENT : <i>Ear Nose and Throat</i>	SDS : Sodium dodecyl sulfate
EULAR : <i>European league against rheumatism</i>	Sem : Semaine
FDG : Fluorodésoxyglucose	SMMHC : <i>Smooth muscle myosin heavy chain</i>
G-CSF : <i>Granulocyte-Colony Stimulating Factor</i>	SNFMI : Société nationale française de Médecine interne
GCA : <i>Giant cell arteritis</i>	SVF : Sérum de veau fœtal
HES : Hématoxyline, éosine, safran	TAK : Artérite de Takayasu
HLA : <i>Human leucocyte antigen</i>	TBS : Tampon salin Tris
HSP : <i>Heat-shock protein</i>	TCZ : Tocilizumab
IFN-γ : Interféron-γ	TEP : Tomographie par émissions de positons
IL : Interleukine	TGF-β : Facteur de croissance transformant β
IRM : Imagerie par résonance magnétique	Th : <i>T helper</i>
LPS : Lipopolysaccharide	TLR : <i>Toll like receptor</i>
LB : Lymphocyte B	TMA : <i>Tissue micro array</i>
LT : Lymphocyte T	TMB : 3,3',5,5'-Tétraméthylbenzidine
LTfh : Lymphocyte T folliculaire auxiliaire	TNF-α : <i>Tumor necrosis factor α</i>
LTreg : Lymphocyte T régulateur	VEGF : facteur de croissance de l'endothélium vasculaire
MEC : Matrice extra-cellulaire	VIM : Vimentine
MMP : Protéine métalloprotéase matricielle	VS : Vitesse de sédimentation

Liste des figures

Figure 1. Incidence globale de l'ACG à travers le monde d'après Watts et al [13].	13
Figure 2. Branches et terminaisons de la carotide externe d'après Henry Gray, <i>Anatomy of the Human Body</i> (1918).	16
Figure 3. Associations topographiques les plus fréquentes au sein de la cohorte de 471 patients porteurs d'ACG du service de Médecine interne du CHU de Limoges.	19
Figure 4. Répartition des patients en fonction du nombre de manifestations des voies respiratoires supérieures et orofaciales dans une cohorte de 599 patients atteints d'ACG.	21
Figure 5. Fréquence et distribution de dix manifestations des voies respiratoires supérieures et orofaciales parmi les 599 patients porteurs d'ACG.	21
Figure 6. Iconographie d'un patient de 75 ans ayant présenté un AVC ischémique vertébro basilaire bilatéral, par occlusion vertébrale et basilaire inflammatoire, accompagné de céphalées, hyperesthésie du cuir chevelu, OACR de l'œil droit, syndrome inflammatoire biologique, hypermétabolisme des artères sous clavières et BAT positive pour le diagnostic d'ACG (collection personnelle).	27
Figure 7. Patiente de 68 ans présentant une aortite en tomographie par émissions de positons au 18-FDG, avec atteinte des artères sous clavières et fémorales ainsi que les troncs supra aortiques (collection personnelle).	28
Figure 8. Dissection aortique descendante mortelle d'un patient porteur d'ACG (collection personnelle).	29
Figure 9. Diagnostics alternatifs des patients ayant eu une BAT pour lesquels une ACG n'était pas retenue.	34
Figure 10. Survie des patients selon les différents groupes.	37
Figure 11. Aspect histologique de panartérite de l'artère temporale en coloration Hématoxyline Eosine Safran (HES) (Collection personnelle).	41
Figure 12. Aspect histologique d'un sous type touchant exclusivement l'adventice en coloration Hématoxyline Eosine Safran (HES) (Collection personnelle).	42
Figure 13. Critères de classification de l'ACR/EULAR 2022 d'après Ponte [114].	45
Figure 14. Répartition des patients de notre cohorte du CHU de Limoges selon les critères de classification ACR/EULAR 2022, en intégrant des <i>mimics</i> usuels, <i>mimics</i> avec conséquences graves (<i>Dangerous mimics</i>) et des patients avec diagnostic d'ACG selon le résultat de la BAT (GCA TAB+ ou GCA TAB-)	46
Figure 15. Phase temporelle et mécanismes principaux de l'ACG d'après Weyand [279].	57
Figure 16. Activation des cellules myéloïdes au cours de l'ACG d'après Weyand [279].	59
Figure 17. Représentation schématique de des structures lymphoïdes tertiaires dans la média d'artère de patients atteints d'ACG montrant la répartition distincte des LT et des LB autour des cellules dendritiques folliculaires et la présence d'une néo angiogenèse formée par les cellules endothéliales (HEV, <i>High endothelial venule</i>) [327].	65
Figure 18. Modèle physiopathologique de l'ACG d'après Greigert [294].	66
Figure 19. Coupes histologiques d'aortite de TAK et d'ACG montrant un épaissement adventiciel plus marqué au cours du TAK, d'après Watanabe [355].	75
Figure 20. Méthode de séparation de l'adventice issue de BAT.	90
Figure 21. Etude de l'activité fonctionnelle des fibroblastes en culture primaire, issus d'adventices de patients porteurs d'ACG et de contrôles.	91
Figure 22. Comparaison au sein de BAT de patients porteurs d'ACG entre le degré d'occlusion vasculaire et l'intensité de l'infiltrat inflammatoire.	133

Liste des tableaux

Tableau 1. Caractéristiques des patients avec céphalées au sein de la cohorte de 471 patients porteurs d'ACG du service de Médecine interne du CHU de Limoges.....	18
Tableau 2. Caractéristiques des patients ayant eu une BAT, avec diagnostic alternatif final retenu et ayant présenté des conséquences graves.	35
Tableau 3. Caractéristiques des patients ayant eu une BAT selon le diagnostic final retenu.	36
Tableau 4. Etudes principales concernant le Tocilizumab au cours de l'ACG.	49
Tableau 5. Etudes principales concernant le Méthotrexate au cours de l'ACG.....	50
Tableau 6. Etudes principales évaluant le Tocilizumab et le Méthotrexate (comparatif ou séquentiel) au cours de l'ACG.	50
Tableau 7. Etudes principales évaluant les autres traitements d'épargne cortisonique au cours de l'ACG.	51
Tableau 8. Etudes sur la présence de germes microbiens au sein de BAT de patients porteurs d'ACG.	55
Tableau 9. Comparaison de patients atteints d'ACG selon le degré d'hyperplasie intinale.	132

Introduction

Les vascularites sont liées à une inflammation de la paroi vasculaire et regroupent différentes entités. Le calibre des vaisseaux concernés et les mécanismes physiopathologiques sous-jacents permettent de classer ces vascularites afin de les traiter de façon appropriée [1].

Cette thèse se consacre à l'artérite à cellules géantes (ACG) ou maladie de Horton, vascularite affectant les vaisseaux de gros calibres (aorte et ses principales branches), et survenant exclusivement après l'âge de 50 ans. Nous allons particulièrement nous intéresser au remodelage vasculaire encore peu étudié dans cette pathologie.

Dans une première partie nous présenterons une revue bibliographique des différents aspects de l'ACG : historique, épidémiologique, clinique, biologique, diagnostique, thérapeutique, pronostique et physiopathologique. Cette revue est complétée de travaux originaux personnels et collaboratifs réalisés sur la période de thèse, afin d'étudier certaines caractéristiques de la maladie. Un exposé à propos des fonctions et l'implication potentielle des fibroblastes et notamment dans le remodelage vasculaire sera ensuite présenté.

La deuxième partie exposera les objectifs et les travaux réalisés. Tout d'abord, nous présenterons une étude de la répartition et de marqueurs d'activation des fibroblastes au sein d'artères temporales ainsi que des tests fonctionnels réalisés *in vitro* concernant les fibroblastes adventitiels. Ensuite, nous exposerons une étude de profilage transcriptomique sur différentes zones d'artère temporale de sujets porteurs d'ACG et de contrôles, correspondant aux couches anatomiques de l'artère, avec l'objectif d'identifier les variations d'expression de gènes associés à l'atteinte de chaque couche artérielle. Enfin, nous analyserons les relations entre le degré d'occlusion artérielle par hyperplasie intimale et les différents aspects de l'ACG : clinique, biologique, évolutif ainsi que l'infiltrat inflammatoire tissulaire.

Partie I. Revue bibliographique

I.1 Artérite à Cellules Géantes

I.1.1 Historique

L'artérite à cellules géantes (ACG) est étudiée activement depuis presque un siècle. Toutefois de nombreux aspects restent non élucidés à ce jour. Des efforts importants sur sa compréhension sont croissants à travers le monde.

Les premières descriptions de l'ACG seraient attribuées à Ali Ibn Isa, ophtalmologiste à Bagdad au 11^{ème} siècle, relatant des cas de patients souffrant de « chaleur et d'inflammation temporales pouvant conduire à une perte de vision » [2]. Ses mémoires n'ont été traduits en anglais en 1936 puis signalés dans le monde occidental en 1960 [3,4].

En 1890, Jonathan Hutchinson, dermatologiste anglais, décrit un patient de « plus de 80 ans », présentant des « stries rouges sur la tête, douloureuses l'empêchant de porter son chapeau », correspondant à des « artères temporales enflammées et gonflées, dont la pulsatilité s'affaiblit peu à peu ». Cette observation n'a été rapportée qu'en 1946 [4,5].

Aux Etats-Unis, Bayard Taylor Horton, médecin à la Mayo Clinic à Rochester, dans le Minnesota, publia en 1932 et 1934 les premières descriptions cliniques et histologiques détaillées de l'ACG [6,7]. Les patients présentaient une altération de l'état général, des signes céphaliques et oto-rhino-laryngologiques (ORL). L'analyse histologique décrivait une infiltration granuleuse de l'artère temporale, avec culture bactériologique négative. La maladie portera par la suite son nom et reste employée de façon commune de nos jours.

Depuis les premières descriptions, les travaux sur l'ACG n'ont cessé de se multiplier. Une recherche Pubmed en avril 2024 faisait état de 9455 publications avec les mots clés « Giant Cell Arteritis ». Depuis les années 1990 d'importants progrès sur la compréhension mécanistique de la maladie ont été réalisés, dont nous décrivons les aspects dans la partie Physiopathologie de ce manuscrit.

I.1.2 Epidémiologie

L'ACG survient exclusivement après l'âge de 50 ans, avec une moyenne d'âge de 73 ans [8]. Il existe une prédominance féminine avec un ratio de 1,7 à 3,8 femmes pour 1 homme [9-12].

L'incidence de l'ACG varie selon un gradient Nord-Sud [13-15]. Les pays scandinaves/nordiques (Islande, Norvège, Danemark, Norvège, Suède, Finlande) comportent les incidences les plus importantes au monde, avec une incidence maximale rapportée de 76,6 cas pour 100.000 personnes de plus de 50 ans au Danemark en 1987. Egalement, le comté d'Olmsted dans le Minnesota, dont la population est majoritairement issue de l'immigration scandinave (Norvège et Suède), possède une incidence élevée de 18,8 cas pour 100.000 personnes de plus de 50 ans de 1950 à 1999, contrairement à l'incidence globale des Etats-Unis qui était de 1,6 cas pour 100.000 personnes de plus de 50 ans de 1971 à 1980. En revanche les populations d'origine sub-saharienne, arabe, asiatique, ou hispanique sont beaucoup plus rarement concernées par l'ACG [16].

En France métropolitaine l'incidence annuelle est de 9,6 pour 100.000 personnes de plus de 50 ans, avec d'importantes disparités régionales [17]. La région Limousin présente une incidence globalement similaire à celle de la France métropolitaine à savoir 10,2 pour 100.000 personnes de plus de 50 ans.

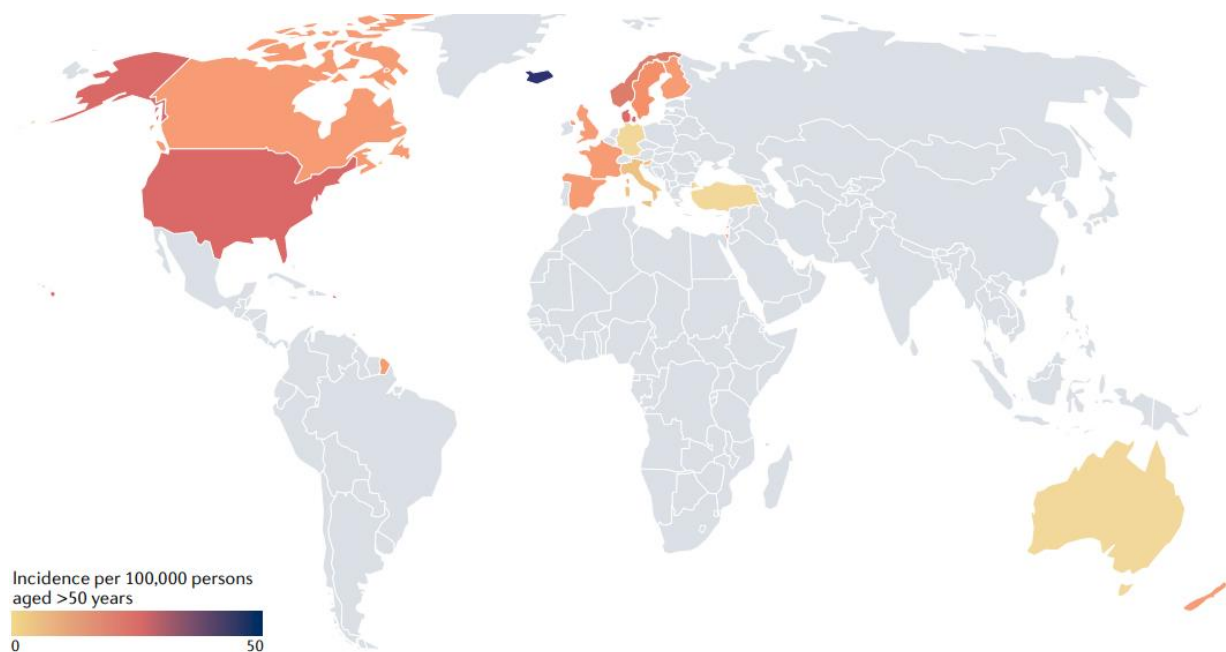


Figure 1. Incidence globale de l'ACG à travers le monde d'après Watts et al [13].

I.1.3 Présentation clinique

L'ACG peut se présenter selon une grande variété de phénotypes cliniques, rendant l'évocation de la maladie ou la confirmation du diagnostic parfois difficile. Aussi, de nombreux diagnostics alternatifs (*mimickers* ou *mimics*) peuvent mimer les symptômes d'ACG pouvant conduire à un retard décisionnel ou des erreurs thérapeutiques avec des conséquences graves pour les patients.

Schématiquement, deux principaux phénomènes inflammatoires distincts, non forcément corrélés, sont responsables des différents signes de la maladie [18,19] :

- Une inflammation systémique, liée à la production d'interleukines (IL), notamment l'IL-6 et l'IL-1, induisant les signes généraux.
- Une inflammation tissulaire artérielle, correspondant à une panartérite granulomateuse liée à des infiltrats cellulaires. Ils sont composés de lymphocytes T, produisant de l'interféron- γ (IFN- γ), activés par des cellules dendritiques via la sécrétion d'IL-12, et de macrophages. Ces infiltrats cellulaires entraînent un remodelage vasculaire marqué par la destruction de la média, une fragmentation de la limitante élastique interne et la prolifération de myofibroblastes dans l'intima. Ce remodelage conduit à un épaississement pariétal avec à l'extrême une sténose de l'artère.

De façon schématique, les patients atteints d'ACG peuvent se présenter selon les deux principaux phénotypes cliniques suivants [20-28] :

- les formes céphaliques ou crâniennes : incluant les céphalées et/ou hyperesthésie du cuir chevelu, une palpation anormale des artères temporales, des symptômes ORL, visuels, et des accidents vasculaires cérébraux.
- les formes touchant les gros vaisseaux ou extra-céphaliques : incluant l'aortite, l'atteinte des artères sous-clavières, axillaires, et fémorales.

Ces 2 principaux phénotypes peuvent être isolés ou intriqués, et parfois associées à un rhumatisme inflammatoire, la pseudopolyarthrite rhizomélisque (PPR). Cette classification simplifiée ne prend pas en compte certaines formes atypiques de la maladie, qui restent cependant anecdotiques.

I.1.4 Signes généraux

Ils sont en lien à une réaction inflammatoire systémique. Le syndrome constitutionnel englobe la fièvre, la fatigue et la perte de poids, ces 3 symptômes étant plus ou moins associés. Il se rencontre dans 30 à 60% des cas d'ACG [29]. L'asthénie est souvent marquée. L'amaigrissement peut concerner plus de 10% du poids corporel. La fièvre est habituellement modérée. Lorsqu'elle est supérieure à 39°C, un diagnostic alternatif doit être évoqué [30]. Les frissons sont rares, des sueurs nocturnes peuvent être constatées [31]. L'ACG est une des causes les plus fréquentes de fièvre d'origine indéterminée chez le sujet âgé [32].

Les patients atteints d'ACG avec fièvre isolée sont plus jeunes, ont un délai diagnostique plus long, ainsi qu'un syndrome inflammatoire biologique plus marqué que ceux présentant des signes cliniques céphaliques associés [33,34]. Les patients présentant une fièvre et/ou un syndrome inflammatoire isolé, représenteraient 10% des ACG.

I.1.5 Signes crâniens

L'ACG se caractérise par une atteinte inflammatoire privilégiée des branches et terminaisons des carotides externes : artères thyroïdiennes supérieures, artères pharyngiennes ascendantes, artères linguales, artères faciales, artères occipitales, artères auriculaires postérieures, artères temporales superficielles et artères maxillaires.

Les territoires douloureux sont ainsi liés aux atteintes artérielles, variant d'un sujet à l'autre, avec au premier rang l'artère temporale superficielle, souvent démonstrative cliniquement, que ce soit au niveau de sa palpation ou des douleurs temporales exprimées par les patients.

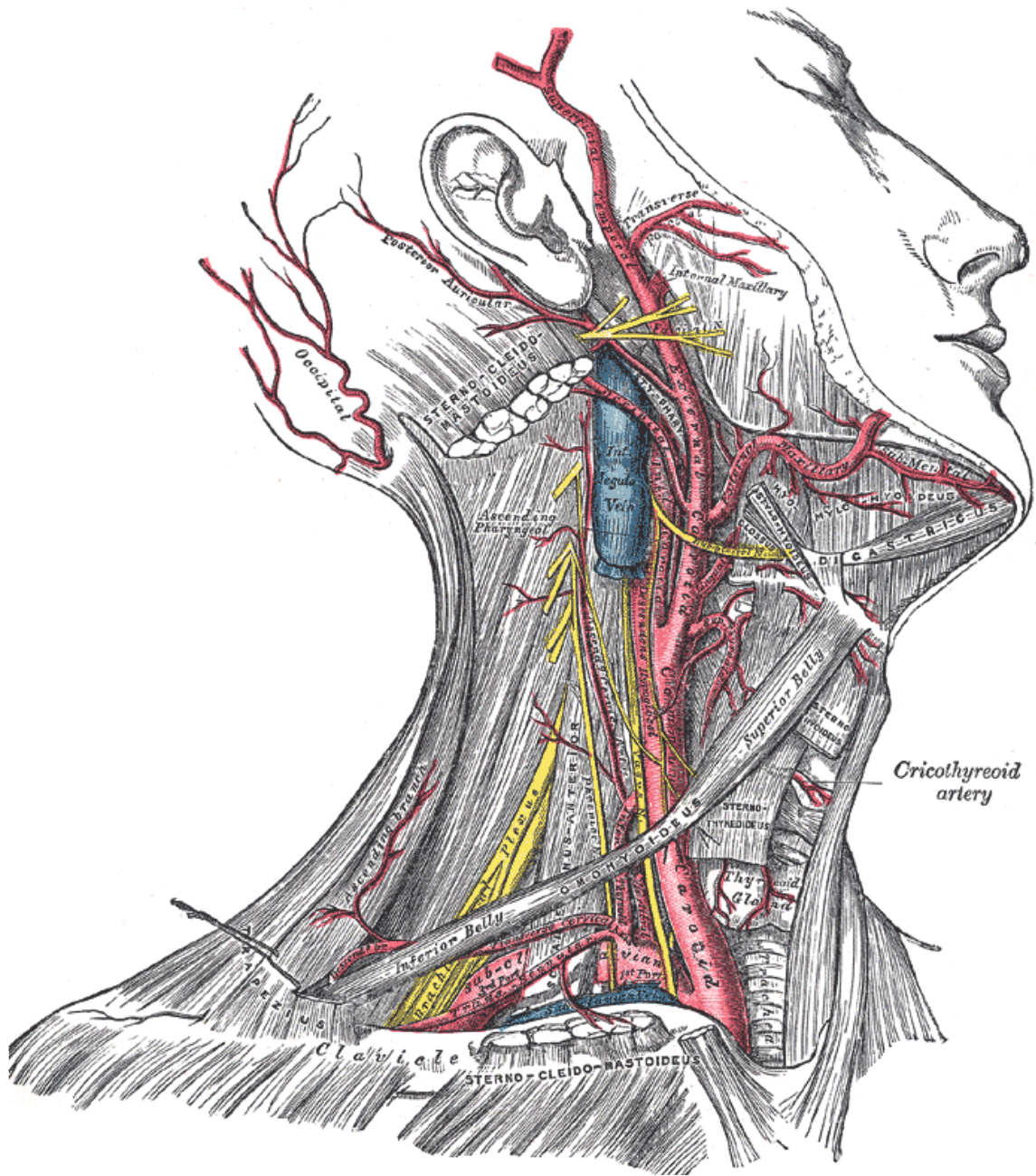


Figure 2. Branches et terminaisons de la carotide externe d'après Henry Gray, *Anatomy of the Human Body* (1918).

I.1.5.1 Céphalées

Il s'agit du maître symptôme de la maladie, devant faire évoquer le diagnostic lorsqu'elles sont inhabituelles et d'apparition récente (moins de 3 semaines) chez un sujet de plus de 50 ans. Sa prépondérance s'est atténuée depuis l'avènement de l'imagerie des gros vaisseaux, révélant de plus en plus de cas avec un phénotype aortique sans manifestation crânienne.

La topographie des céphalées varie selon les patients avec une prédominance dans la région temporale, lieu de passage de l'artère temporale superficielle [35]. Les caractéristiques ont été peu détaillées par le passé. Les céphalées sont le plus souvent constantes (54%), ou évolue de façon intermittente et durent moins de 6 heures dans 32% des cas [36]. Il s'y associe souvent une hyperesthésie du cuir chevelu, ou signe du peigne / de l'oreiller, autre signe caractéristique de l'ACG, mais non spécifique de la maladie.

Nous avons effectué un travail sur une cohorte historique de 471 patients atteints d'ACG du service de Médecine interne de Limoges pour lesquels les éléments détaillés des céphalées ont été recueillis (**Tableau 1**).

Ce travail sera présenté en communication orale au congrès de la société nationale française de Médecine interne (SNFMI) à Toulouse le 19 juin 2024 par Isabelle Millet (interne de Médecine interne au CHU de Limoges) :

Caractéristiques détaillées des céphalées au cours de l'artérite à cellules géantes : résultats d'une cohorte prospective de 471 patients.

Auteurs : I Millet, K-H Ly, S Dumonteil, N Ratti, E Desvaux, J-G Lopez, G Gondran, S Palat, H Bezanahary, A-L Fauchais, E Liozon, S Parreau

Les céphalées et/ou une hyperesthésie du cuir chevelu étaient rapportées pour 75% (350/471) des cas atteints d'ACG. Les patients avec céphalées avaient significativement un délai diagnostique plus court en hospitalisation (7 vs 34 jours, $p < 0.0001$), et plus de symptômes ORL associés (72% vs 35%, $p < 0.0001$) par rapport à ceux sans céphalées. Une imagerie aortique était moins fréquemment réalisée au diagnostic (30% vs 62%, $p < 0.0001$), et le taux d'aortite détectée était moindre dans ce groupe (8% vs 35%, $p < 0.0001$). Il n'y avait pas de différence significative en termes d'intensité du syndrome inflammatoire biologique ou de complications ischémiques visuelles. Une épargne cortisonique était plus fréquemment utilisée d'emblée dans le

groupe sans céphalées (22% vs 8%, $p=0.0002$). Le taux de rechute ou de récurrence était similaire dans les 2 groupes. Parmi les patients avec céphalées, ceux avec une BAT positive avaient plus d'anomalies palpatoires de l'artère temporale (79% vs 40%, $p<0.0001$), de signes ORL (75% vs 62%, $p=0.0288$), un taux de plaquettes plus élevé (450 vs 396 G/L, $p=0.0064$) et moins de manifestations de PPR (25% vs 38%, $p=0,0249$).

Le caractère intense ou insomniant de la céphalées (69% des patients) était associé à un délai diagnostique plus court (5 vs 12 jours, $p<0.0001$), à des signes ORL (76% vs 62%, $p=0.0155$) et à un risque de complication aortique sur le long terme plus important (6% vs 1%, $p=0.0280$). Une céphalée profonde isolée (sans caractère superficiel) représentait 10% des patients, et était plus souvent associée à une aortite au diagnostic (38% vs 14%, $p=0.0018$) par rapport aux céphalées superficielles pures. Le territoire des céphalées influençait la survenue d'une complication ischémique visuelle (**Figure 3**) : protecteur si céphalées temporo-frontale isolée (1% vs 9%, $p=0.0375$) ou prédictif si présence de douleur oculaire (33% vs 14%, $p=0.0006$). En revanche, le territoire n'influencait pas le taux de positivité de la BAT.

Céphalée	n=350
Hyperesthésie du cuir chevelu	207 (59%)
Caractéristiques (% parmi les patients avec céphalée)	
Superficielles	282 (81%)
Profonde	60 (17%)
Intenses	223 (64%)
Insomniantes	205 (59%)
Topographie	
Temporale	287 (82%)
Occipitale	210 (60%)
Frontale	173 (49%)
Pariétale	130 (37%)
Retro-auriculaire	119 (34%)
Oculaire	64 (18%)
Faciale	46 (13%)

Tableau 1. Caractéristiques des patients avec céphalées au sein de la cohorte de 471 patients porteurs d'ACG du service de Médecine interne du CHU de Limoges.

Présentation en communication orale par Isabelle Millet au congrès de la SNFMI 2024, le 19 juin 2024.

Patients (n)

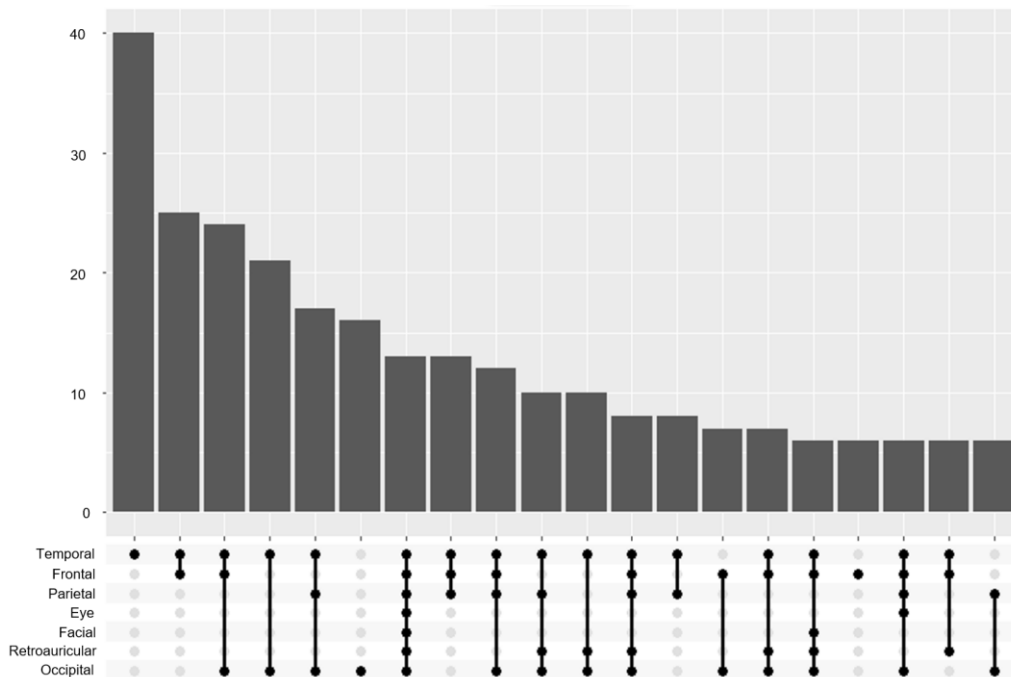


Figure 3. Associations topographiques les plus fréquentes au sein de la cohorte de 471 patients porteurs d'ACG du service de Médecine interne du CHU de Limoges. Présentation en communication orale par Isabelle Millet au congrès de la SNFMI 2024, le 19 juin 2024.

I.1.5.2 Anomalie de l'artère temporale

Les principales manifestations regroupent à des degrés différents selon les patients : une diminution ou abolition du pouls temporal, une induration artérielle, des tortuosités, des nodules, une sensibilité à la palpation temporale ou des signes inflammatoires locaux. Ces anomalies font également parties des signes forts en faveur de la maladie [37-39]. Toutefois une athérosclérose ou médiacalcosse importante peut mimer ces signes. Par ailleurs, ces manifestations permettent aussi de guider la BAT, à réaliser du côté le plus symptomatique.

Nous avons effectué un travail basé sur le détail de palpation de l'artère temporale sur une série de 419 malades porteurs d'ACG (données non publiées) : 70% des patients avaient une palpation de l'artère temporale anormale. Parmi ces patients les signes les plus fréquents étaient : l'induration de l'artère temporale (53 %), l'absence ou la diminution de battement (51 %), une douleur à la palpation (23 %), la présence de nodules sur le trajet de l'artère (12 %), une inflammation cutanée (9 %). La tortuosité n'avait pas été recueillie dans notre cohorte.

I.1.5.3 Signes orofaciaux et des voies respiratoires supérieures

La claudication de la mâchoire ou la douleur à l'ouverture buccale font parties des signes classiques, assez spécifiques de l'ACG. Elles sont en lien à un phénomène ischémique au niveau de la vascularisation des muscles massétéris.

La claudication de la mâchoire a été intégrée récemment dans les critères de classification de l'ACG apparaissant spécifique par rapport aux autres vascularites [29]. Toutefois, d'autres entités comme l'arthrose temporo-mandibulaire, peuvent mimer des douleurs à la mastication, et ne doivent pas être confondues avec une authentique claudication de la mâchoire.

Deux centres se sont intéressés à l'apport du test au Chewing-gum pour révéler cette claudication [40,41]. Notre équipe a confirmé que ce test pouvait révéler la claudication pour certains patients (étude Chewing-Hort, présentée par le docteur Nina Ratti au congrès de la SNFMI en décembre 2023 à Paris).

Les autres symptômes sont moins souvent rapportés : douleur maxillaire, œdème facial, douleur pharyngée, dysphagie, douleur linguale, enrouement, toux sèche, otalgie, surdité. Nous avons réalisé un travail concernant le recueil prospectif systématique de 10 symptômes orofaciaux ou des voies respiratoires supérieures. Ce travail est présenté en communication orale au congrès de la SNFMI à Toulouse le 19 juin 2024 par Sébastien Laburthe (interne de Médecine interne du CHU de Limoges) et est en cours de soumission :

Manifestations orofaciales et des voies respiratoires supérieures au cours de l'artérite à cellules géantes : résultats d'une vaste cohorte prospective

Auteurs : S Laburthe, K-H Ly, S Dumonteil, G Gondran, N Ratti, J-G Lopez, H Bezanahary, S Palat, A-L Fauchais, E Liozon, S Parreau

Parmi 599 patients pour lesquels dix manifestations orofaciales et des voies respiratoires supérieures étaient systématiquement recueillis, 69% présentaient au moins un symptôme (3 symptômes ou plus dans 30 % des cas) (**Figure 4**). La claudication de la mâchoire, la douleur maxillaire et la douleur à l'ouverture de la bouche étaient les symptômes les plus fréquents (**Figure 5**). Une toux sèche était rapportée dans 17 % des cas. Les patients atteints d'ACG présentant au moins un symptôme avaient davantage d'anomalies à la palpation de l'artère temporale et de complications ophtalmologiques ischémiques, mais moins de vascularite des gros

vaisseaux démontrée à l'imagerie. Une artère temporale anormale à l'examen clinique (*Odds ratio* $OR=4,2$ [2,8-6,4], $p<0,001$) et la présence d'une claudication de la mâchoire ($OR=2,2$ [1,4-3,7], $p=0,002$) augmentaient la probabilité d'une BAT positive alors que la présence d'un enrrouement ($OR=0,5$ [0,3-0,9], $p=0,02$) et d'une otalgie ($OR=0,54$ [0,3-0,9], $p=0,03$) la diminuait. Une présentation « ORL » isolée (sans céphalées ni signes visuels) représentait 5% de l'ensemble de la cohorte.

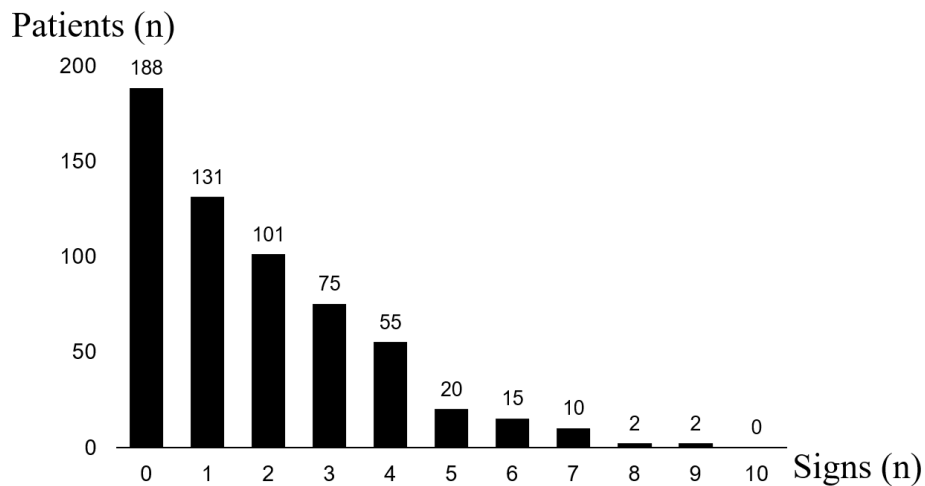


Figure 4. Répartition des patients en fonction du nombre de manifestations des voies respiratoires supérieures et orofaciales dans une cohorte de 599 patients atteints d'ACG. Présentation en communication orale par Sébastien Laburthe au congrès de la SNFMI 2024, le 19 juin 2024.

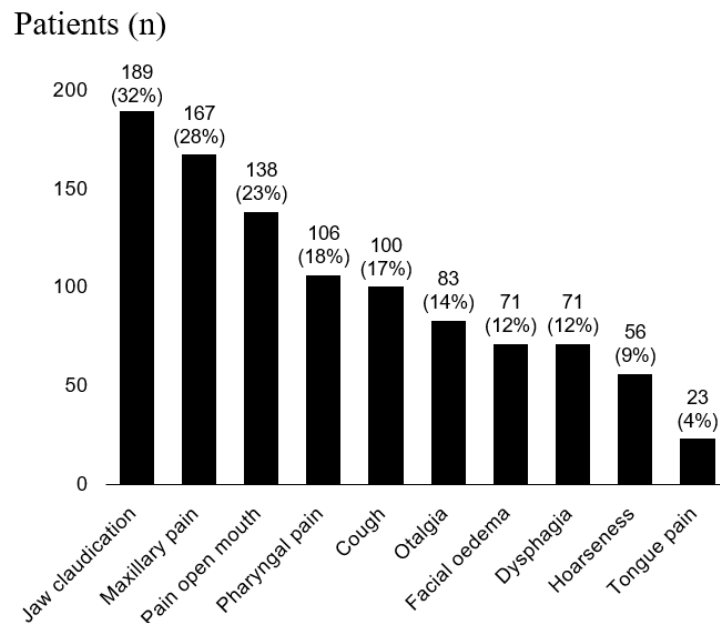


Figure 5. Fréquence et distribution de dix manifestations des voies respiratoires supérieures et orofaciales parmi les 599 patients porteurs d'ACG. Présentation en communication orale par Sébastien Laburthe au congrès de la SNFMI 2024, le 19 juin 2024.

I.1.5.4 Signes ophtalmologiques

Il s'agit d'une des atteintes les plus redoutées à la phase aiguë du diagnostic, dictant le pronostic fonctionnel à court terme des malades. Les symptômes sont très variables, pouvant être régressifs ou permanents, unilatéraux ou bilatéraux. Les patients peuvent rapporter une myriade de signes subjectifs : brouillard visuel, vision trouble voire amaurose totale, scintillements, halo lumineux, objets colorés, hallucinations visuelles, amputation du champ visuel, métamorphopsies, diplopie.

Avant l'utilisation des corticoïdes, de larges cohortes décrivaient des fréquences de perte visuelle de 40 à 48% et atteignant les deux yeux dans la moitié des cas [42]. Aujourd'hui, la fréquence de l'atteinte visuelle rapportée selon les études varie de façon importante, expliquée probablement par le service de recrutement des patients (maximale en ophtalmologie) [43]. L'équipe de Smith s'accorde pour une fréquence actuelle de perte visuelle de l'ordre de 12-15% des ACG [43].

Les principales affections concernées au cours de l'ACG sont (pourcentages parmi les atteintes visuelles) [42] :

- la neuropathie optique ischémique antérieure aiguë (NOIA) par atteinte des artères ciliaires postérieures (80-90%),
- l'occlusion de l'artère centrale de la rétine (OACR) (10%) ou de l'artère cilio-rétinienne,
- la paralysie oculo-motrice par atteinte des nerfs crâniens III, IV et/ou VI ou des tissus orbitaires (5-10%),
- la neuropathie optique ischémique postérieure (NOIP) par atteinte des artères nourricières du tronc du nerf optique (5%),
- les atteintes du segment antérieur par atteinte des artères ciliaires antérieures responsable d'hypotonie, pseudo-uvéites, anomalies pupillaires, ($\leq 1\%$),
- l'accident vasculaire cortical par atteinte des artères vertébrales ($\leq 1\%$).

Un phénomène ischémique est le plus souvent impliqué. Une fois installée, l'atteinte est le plus souvent définitive, rendant l'évocation d'ACG et son traitement urgent. Un syndrome inflammatoire important au diagnostic, la présence de fièvre, et/ou des symptômes rhumatologiques associés sont plutôt associés à un risque moindre visuel [44,45]. En revanche le risque d'atteinte permanente est associé à un âge avancé, des manifestations visuelles transitoires, et une claudication de la mâchoire [45].

Nous avons étudié les caractéristiques des patients ACG avec atteinte ophtalmologique bilatérale à partir de notre cohorte locale, présentée au congrès de la SNFMI à Marseille en décembre 2022 par le docteur Romain Foré (Médecin dans le service de Médecine interne du CHU de Limoges) :

Artérite à cellules géantes avec atteinte ophtalmologique bilatérale

Auteurs : R Foré, S Laburthe, MF Curumthaullee, N Ratti, N Aslanbekova, E Desvaux, S Dumonteil, H Bezanahary, S Palat, G Gondran, K-H Ly, E Liozon, S Parreau

Parmi 368 patients atteints d'ACG, 67 avaient une cécité (18%) et 17 d'entre eux (5% au total) ont présenté une cécité bilatérale. Ils avaient tous une NOIA initialement. En comparant la cohorte entière avec les patients atteints de cécité bilatérale, ces derniers étaient significativement plus âgés (79 vs 74 ans, $p < 0,01$), présentaient moins souvent un amaigrissement (0% vs 37%, $p < 0,01$), davantage de douleurs maxillaires (65% vs 39%, $p = 0,04$), de dysphagie (35% vs 14%, $p = 0,03$), et d'anomalie palpatoire de l'artère temporale (94% vs 61%, $p < 0,01$). Aucun de ces 17 patients ne présentait d'aortite au diagnostic (0% vs 21%, $p = 0,03$). Le délai de prise en charge entre les patients avec cécité bilatérale ayant bilatéralisé sous traitement ($n=6$) et ceux ayant une perte visuelle restant unilatérale ($n=50$) n'était pas significativement différent (6,1 vs 8,5 jours, $p = 0,84$). Le délai moyen de bilatéralisation sous traitement était de 3,3 jours après le début du traitement. Les patients ayant bilatéralisé sous traitement, en comparaison avec ceux ayant une perte visuelle restant unilatérale, présentaient une CRP plus élevée (122 vs 72 mg/L, $p = 0,04$) et étaient plus souvent diabétiques (50% vs 10%, $p = 0,03$). Le délai entre l'introduction de la corticothérapie et la première atteinte visuelle était non significativement différent entre les deux groupes (4,2 vs 8,5 jours, $p = 0,94$). Tous les patients ayant bilatéralisé sous traitement étaient traités par bolus de méthylprednisolone lors de la première atteinte visuelle : trois patients ont bilatéralisé malgré des bolus de 500 mg par jour (un patient à J1, deux patients à J2) et trois patients avec des bolus de 300 mg par jour (respectivement à J2, J5 et J8). Aucun patient ayant bilatéralisé ne s'est amélioré sur l'atteinte visuelle de manière subjective.

Nous avons également effectué un travail sur la survenue d'atteinte visuelle secondaire, c'est-à-dire après le diagnostic d'ACG (**Annexe 1**). Onze patients sur 502 (2,2%) ont présenté une atteinte visuelle ischémique secondaire. Six patients ont eu un accident visuel durant la phase d'attaque de la corticothérapie et les cinq restants lors de la décroissance. Les facteurs prédictifs d'atteinte visuelle secondaire étaient un âge avancé, une artère temporale pathologique à l'examen clinique et une thrombocytose avant traitement. Un risque plus élevé d'un nouvel événement ischémique visuel a été observé pendant le traitement chez les patients présentant une atteinte visuelle ischémique initiale par rapport aux patients présentant une ACG non compliquée au départ (10,5 % contre 1,1 %, OR=10,26, $p<0,001$).

Il est parfois difficile de distinguer une NOIA d'origine artéritique, c'est-à-dire liée à l'ACG, des NOIA non artéritiques (**Annexe 2**). A partir d'une cohorte multicentrique française, nous avons comparé 94 patients présentant une NOIA non artéritique (NOIANA) et 94 une NOIA artéritique (NOIAA). Les patients atteints de NOIAA étaient plus âgés et plus susceptibles d'avoir une hypertension artérielle. Les symptômes céphaliques et un syndrome inflammatoire biologique étaient plus fréquents dans le groupe NOIAA. Une perte de vision profonde et l'atteinte bilatérale étaient plus fréquentes chez les patients atteints de NOIAA. Les occlusions de l'artère centrale de la rétine et de l'artère ciliorétinienne n'ont été observées que dans le groupe NOIAA, et le retard de la perfusion choroïdienne a été plus fréquemment observé au cours des NOIAA que dans les NOIANA. En utilisant un modèle de régression logistique, un âge >70 ans (OR=3,4, $p=0,105$), l'absence d'hémorragie en flammèches (OR=4,9, $p=0,019$), un retard de perfusion choroïdienne à l'angiographie (OR=7,2, $p=0,003$), une CRP >7 mg/L (OR=43,6, $p<0,001$) et un taux de plaquettes >400 G/L (OR=27,5, $p=0,001$) étaient associés au diagnostic de NOIAA. Un score, basé sur ces variables, permet de distinguer les deux entités avec une sensibilité de 93,3 % et une spécificité de 92,4 %

Nous avons également étudié la diplopie au cours de l'ACG, travail présenté au congrès de la SNFMI à Paris en décembre 2023 par le docteur Anis Hariz (CHU Limoges, Médecine interne) :

Fréquence et caractéristiques de la diplopie au cours de l'artérite à cellules géantes

Auteurs : A Hariz, S Dumonteil, E Desvaux, N Ratti, S Palat, G Gondran, H Bezanahary, A-L Fauchais, K-H Ly, E Liozon, S Parreau

Au total, sur 665 patients porteurs d'ACG, 59 (9%) ont présenté une diplopie. Les patients avec diplopie avaient davantage de présentation clinique à début aiguë (63 vs 43%, $p=0,006$), des céphalées associées (96 vs 79%, $p=0,004$), une hyperesthésie du cuir chevelu (61 vs 47%, $p=0,04$), un œdème facial (22 vs 12%, $p=0,042$), des douleurs maxillaires (47 vs 28%, $p=0,003$), des anomalies palpatoires de l'artère temporale (81 vs 58%, $p<0,001$), un taux de fibrinogène plus élevé (7,4 vs 6,7 g/L, $p=0,014$) (CRP et VS non significativement différents) et des anomalies du bilan hépatique (41 vs 20%, $p=0,011$). Parmi les patients ayant eu une imagerie aortique il n'existait pas de différence significative entre les deux groupes concernant la fréquence de l'aortite ($p=0,211$). Le délai diagnostique de l'ACG par rapport à la date du premier symptôme était plus court pour les patients avec diplopie (65 vs 82 jours, $p=0,008$). Sur le plan thérapeutique, les patients avec diplopie ont reçu plus fréquemment des bolus de corticoïdes (37 vs 24%, $p=0,039$), la dose initiale de corticothérapie orale était plus élevée (1,0 vs 0,7 mg/kg/j, $p<0,001$) et la durée totale du traitement était plus courte (17 vs 22 mois, $p=0,048$). La mortalité durant le traitement était similaire entre les deux groupes. La diplopie était majoritairement intermittente et régressive, mais sept patients ont gardé une diplopie permanente (12%). Les complications oculaires associées les plus fréquentes étaient la NOIA ($n=8$), la NOIP ($n=3$) et l'OACR ($n=1$). Vingt-trois patients avaient une atteinte visuelle permanente et définitive (diplopie incluse).

I.1.5.5 Accidents vasculaires cérébraux

L'ACG se complique d'un accident vasculaire cérébral (AVC) constitué dans 1,5 à 7 % des cas [46-57]. Il s'agit de la première cause de décès précoce au cours de l'ACG, rendant urgent son diagnostic et sa prise en charge. Les AVC concernent le plus souvent le système vertébro-basilaire provoquant des AVC dans la région postérieure (**Figure 6**) [58].

Lorsque l'AVC est la première manifestation de l'ACG, il est parfois difficile d'évoquer le diagnostic de vascularite. Nous avons effectué un travail qui avait pour but de comparer des AVC usuels à ceux liés à l'ACG (**Annexe 3**). Au sein d'une cohorte monocentrique de 550 patients atteints d'ACG diagnostiquée et suivie dans notre service de Médecine interne (384 avec une BAT positive), nous avons identifié tous les patients ayant présenté un AVC ischémique non cardio-embolique prouvé à l'imagerie et contemporain du diagnostic d'ACG (survenue entre les premiers symptômes d'ACG et les quatre premières semaines de la corticothérapie). Le groupe contrôle a comporté 40 AVC usuels, non liés à une ACG, tirés au sort à partir d'une cohorte de patients issus du service de Neurologie du même hôpital. Les caractéristiques cliniques, biologiques, radiologiques et la survie à trois mois ont été recueillies rétrospectivement pour tous les patients au moment de l'AVC.

Dix-sept patients (3,1%), avec un âge moyen de 76 ans, ont présenté un AVC en rapport avec la vascularite. Dix patients (59%) présentaient des céphalées, 12 (71%) une artère temporale anormale à la palpation, 4 (24%) une claudication de la mâchoire et/ou une hyperesthésie du scalp, 6 (35 %) des manifestations visuelles ischémiques permanentes, 15 (88 %) une BAT positive. La majorité des AVC concernait le territoire vertébro-basilaire (82 %), avec 41 % d'atteinte du tronc basilaire, 41 % d'une artère cérébelleuse et 23 % de l'artère cérébrale postérieure. Quatorze AVC (82 %) étaient diagnostiqués de façon concomitante ou dans les jours suivants le diagnostic d'ACG. Les trois autres AVC survenaient à distance (45, 434 et 660 jours, respectivement). Cinq patients (29 % du total, 36 % des AVC inauguraux) décédaient dans les trois mois suivant le diagnostic d'AVC. En comparant les patients atteints d'AVC lié à une ACG avec des AVC usuels, il n'existait pas de différence significative en termes de facteurs de risque ou d'événements antérieurs cardiovasculaires. Les patients avec AVC lié à l'ACG avaient plus fréquemment des signes cliniques évocateurs d'artérite et des paramètres inflammatoires

significativement plus élevés. Un syndrome cérébelleux et une atteinte visuelle ischémique permanente étaient significativement plus fréquents au cours des AVC liés à une ACG, contrairement au déficit sensitif focal et à la dysarthrie. À l'exploration doppler, une anomalie carotidienne externe et/ou vertébrale était plus fréquente au cours de l'ACG (46 et 27 % respectivement). En analyse multivariée, la présence conjointe d'une atteinte du système vertébro-basilaire, d'une CRP supérieure à 30 mg/L et d'une anomalie carotidienne externe au doppler prédit un AVC lié à l'ACG avec une sensibilité de 95 %, une spécificité de 76 %, une valeur prédictive positive de 90 % et une valeur prédictive négative de 87%. La probabilité de survie à trois mois dans le groupe des AVC liés à l'ACG était significativement inférieure à celle du groupe témoin.

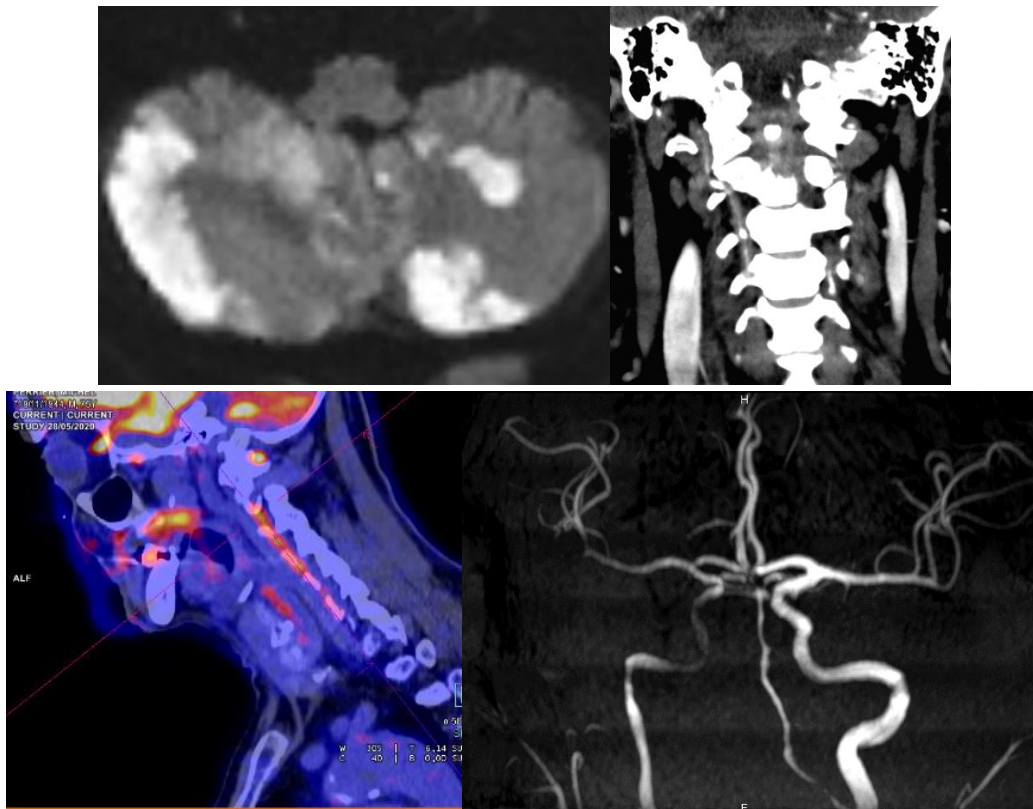


Figure 6. Iconographie d'un patient de 75 ans ayant présenté un AVC ischémique vertébro basilaire bilatéral, par occlusion vertébrale et basilaire inflammatoire, accompagné de céphalées, hyperésthésie du cuir chevelu, OACR de l'œil droit, syndrome inflammatoire biologique, hypermétabolisme des artères sous clavières et BAT positive pour le diagnostic d'ACG (collection personnelle).

I.1.6 Signes rhumatologiques

La pseudo-polyarthrite rhizomélique (PPR) est l'entité rhumatologique la plus souvent associée à l'ACG, atteignant jusqu'à 50 % des patients porteurs d'ACG [59]. Elle peut survenir avant, pendant ou après le diagnostic de la vascularite [60]. La PPR se manifeste par des douleurs et un enraidissement d'horaire inflammatoire prédominant aux épaules, et pouvant irradier au rachis cervical et dans les régions scapulaires. L'atteinte des hanches est également souvent rapportée.

D'autres manifestations peuvent se rencontrer comme une polyarthrite inflammatoire chronique et périphérique, mimant une polyarthrite rhumatoïde.

I.1.7 Manifestations artérielles

I.1.7.1 Aortite

Bien que connue de longue date [61], la découverte d'aortite au diagnostic d'ACG est en augmentation grâce à l'utilisation des différents outils d'imagerie vasculaire, notamment la tomographie aortique, l'imagerie par résonance magnétique et la tomographie par émission de positons. Tout comme les branches des carotides externes, la distribution des atteintes peut varier selon les patients [62]. Toutes les portions aortiques peuvent être concernées : notamment l'aorte ascendante, la crosse, et/ou l'aorte descendante (**Figure 7**). L'atteinte de l'aorte abdominale est plus rare surtout lorsqu'elle est isolée.

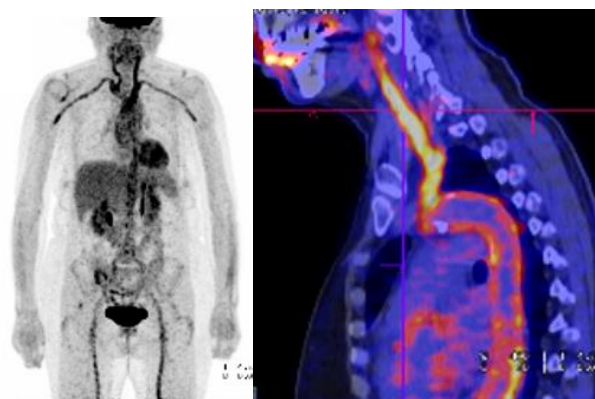


Figure 7. Patiente de 68 ans présentant une aortite en tomographie par émissions de positons au 18-FDG, avec atteinte des artères sous clavières et fémorales ainsi que les troncs supra aortiques (collection personnelle).

L'aortite est le plus souvent silencieuse sur le plan clinique. Elle peut se traduire par un syndrome inflammatoire, un syndrome constitutionnel ou une fièvre isolée. L'atteinte aortique fait souvent le pronostic à long terme d'ACG avec un risque d'anévrisme voire de dissection [63,64]. La prévalence d'une aortite compliquée (anévrisme, dilatation ou dissection) serait de 18% [65]. Les patients atteints d'ACG ont 17 à 19 fois plus de risque d'anévrisme thoracique que la population générale (**Figure 8**) [66,67]. Le risque d'anévrisme ou de dilatation aortique au cours de l'ACG est de 22% à 5 ans et 30% à 10 ans du diagnostic [68,69].

Malgré une apparente rémission clinico-biologique de la vascularite, l'inflammation aortique peut persister pendant de nombreuses années [70]. Rarement, le diagnostic peut être réalisé sur pièce opératoire de chirurgie d'anévrisme aortique, sans présomption clinique pour une ACG [71,72].

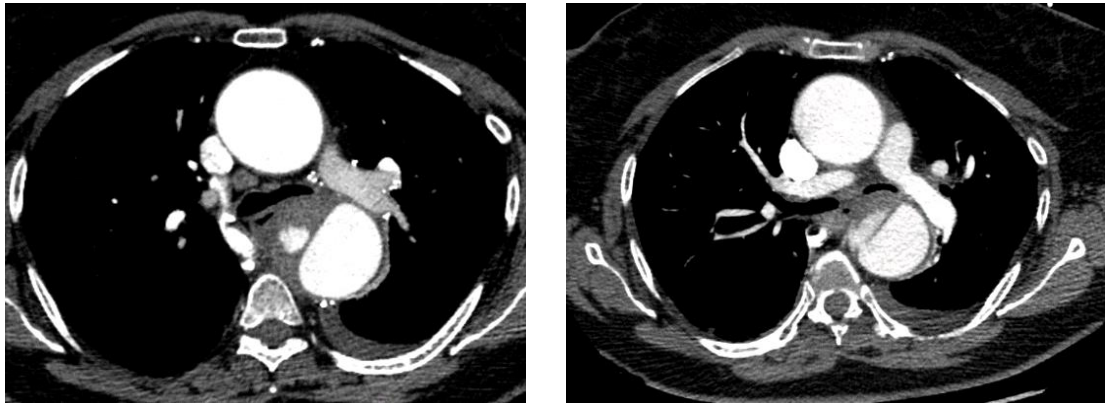


Figure 8. Dissection aortique descendante mortelle d'un patient porteur d'ACG (collection personnelle).

I.1.7.2 Artérite des membres supérieurs et inférieurs

Il s'agit d'une atteinte relativement rare [73-76]. Elle est souvent bilatérale et touche particulièrement les artères sous clavières et axillaires. Les atteintes fémorales sont plus rarement rencontrées.

Ces atteintes peuvent se matérialiser par une sténose vasculaire responsable d'un souffle vasculaire, d'une asymétrie tensionnelle, une abolition de pouls périphériques, des phénomènes ischémiques d'aval comme une claudication de membres ou des troubles cutanés perfusionnels : phénomène de Raynaud, voire nécrose des extrémités.

Nous avons participé à une étude décrivant l'atteinte sténosante de l'aorte et de ses branches dans l'ACG présentée en communication orale au congrès de la SNFMI en décembre 2023 à Paris par Bérangère Arnould (CHU de Rouen) :

Atteinte sténosante de l'aorte et de ses branches dans l'artérite à cellules géantes : étude rétrospective multicentrique de 209 patients

Auteurs : B Arnould, G Maalouf, K Lim, H De Boysson, O Espitia, M Samson, A Hot, E Liozon, S Parreau, V Lacombe, JF Alexandra, T Thibault, C Laurent, J Gaudric, A Redheuil, M Groh, CA Durel, T Chazal, C Comarmond Ortoli, N Magy-Bertrand, S Vinzio, L Martzloff, P Lozac'h, R Outh, C Jérémy, P Duffau, A Dumont, S Humbert, C Guillaud, A Dellal, G Pugno, V Devauchelle-Pensec, P Cacoub, L Biard, D Saadoun

Dans cette étude, 209 patients avec ACG et atteinte sténosante artérielle ont été inclus. Au moment du diagnostic, 32% des patients présentaient une claudication d'un membre, 30% avaient une abolition d'un pouls, et 26% présentaient un souffle vasculaire sur le territoire touché. La BAT avait été réalisée chez 86 % des patients et s'est révélée positive chez 54% d'entre eux. L'atteinte sténosante, au moment du diagnostic, prédominait dans les troncs supra-aortiques, avec 64% de sténoses sous-clavières, 59% carotidiennes, 25% dans l'artère temporale et 34% axillaires. La plupart de ces sténoses était sévère, dépassant les 70%. Une atteinte sténosante aortique était également fréquente, avec 29% au niveau de l'aorte ascendante, 26% la crosse aortique, 37% l'aorte thoracique et 30% l'aorte abdominale, tandis que les artères des membres inférieurs étaient touchées dans 18% des cas pour les artères iliaques et 29% pour les artères fémorales. Un traitement par corticothérapie était instauré chez 99% des patients, dont 32% recevaient des bolus intraveineux, en association avec du Méthotrexate chez 22% et du Tocilizumab chez 70%. La médiane de suivi des patients était de 51,7 mois (35,4–57,2). Les complications vasculaires, telles que les AVC ischémiques et l'ischémie des membres, ont affecté 51% des patients. La majorité des AVC ischémiques étaient présents dès le diagnostic, touchant un tiers de la cohorte. La survie globale sans événement cardiovasculaire à 5 ans était de 56,4% (49,2–64,6). Une revascularisation, qu'elle soit endovasculaire ou chirurgicale, a été nécessaire chez 25% des patients, avec une survie globale sans chirurgie vasculaire à 5 ans de 69,8% (62,8–77,7). La moitié des patients ont présenté une rechute au cours du suivi, et la survie globale sans rechute majeure à 5 ans était de 70,5% (63,2–78,7).

I.1.8 Manifestations rares/atypiques

Certaines manifestations non classiques ont été rapportées de façon anecdotique dans la littérature [77]. On peut distinguer les atteintes d'organes non usuellement touchés par l'ACG mais avec preuve histologique sur tissu opératoire, et les pathologies notées en association avec la vascularite peut être par coïncidence.

Ainsi, ont été rapportés :

- des manifestations cardiaques : péricardite, coronarite à cellules géantes [78-83],
- des neuropathies périphériques : mononévrite, multinévrite, polyneuropathie sensitivo-motrice ou radiculopathie [84],
- des phénomènes ischémiques cutanés ou muqueux : principalement des nécrose du scalp, de la langue ou d'une lèvre [85,86],
- des manifestations endocrinologiques : atteinte histologique thyroïdienne, dysthyroïdie, diabète insipide, sécrétion inappropriée d'hormone anti-diurétique [87-90],
- des manifestations rénales : hématurie transitoire, atteinte des artères rénales au cours d'une aortite abdominale, ou liées à une amylose AA [91-93] ,
- des manifestations digestives : atteinte inflammatoire de branches artérielles à visée abdominales ou par vascularite découverte sur pièce de cholécystectomie [94,95],
- des manifestations gynécologiques : atteinte mammaire, ovarienne ou utérine [96-98].

I.1.9 Mimickers

En cas d'absence de preuve histologique, le diagnostic d'ACG peut se révéler particulièrement difficile [99-112]. Les pathologies pouvant mimer une ACG sont nombreuses. Un diagnostic erroné peut entraîner des conséquences graves que ce soit par retard diagnostique alternatif ou effets indésirables sévères de la corticothérapie et/ou du traitement d'épargne cortisonique prescrits à tort.

Nous avons effectué un travail concernant les conséquences graves pour diagnostics erronés de patients ayant eu une BAT, présenté en communication orale au congrès de la SNFMI à Toulouse le 19 juin 2024 par Cory Cayrou (interne de Médecine interne au CHU de Limoges) :

Diagnostics erronés d'artérite à cellules géantes avec conséquences graves chez des patients ayant eu une biopsie d'artère temporale

Auteurs : C Cayrou, K-H Ly, S Dumonteil, N Ratti, E Desvaux, JG Lopez, S Palat, G Gondran, H Bezanahary, A-L Fauchais, E Liozon, S Parreau

Il s'agit d'une étude observationnelle rétrospective monocentrique. Les patients ont tous eu une BAT pour suspicion initiale d'ACG et ont été recrutés sur la période de 2002 à 2023. Les données clinico-biologiques, et évolutives ont été recueillies pour tous les patients. Quatre groupes ont été définis :

A : ACG à BAT positive,

B : ACG à BAT négative : diagnostic d'ACG selon critères ACR1990, ACR/EULAR2022, ou avis d'expert,

C : diagnostics alternatifs rapides sans conséquences graves,

D : diagnostics alternatifs sévères avec conséquences graves liées au retard diagnostique ou d'un traitement erroné (corticothérapie pour ACG présumée).

Sur la période, parmi les patients ACG, on notait 248 patients avec une BAT positive (groupe A) et 135 avec une BAT négative (groupe B). Les diagnostics alternatifs sont résumés dans **Figure 9**. On notait : PPR isolée (15%), causes ophtalmologiques (14%), causes neurologiques (12%), fièvre chronique inexplicables (12%), cancers (11%), vascularites autres (10%), infections (9%), causes rhumatologiques autres (8%), causes hématologiques non cancéreuses (2%), étiologies uniques autres (8%).

Dix-neuf patients (âge moyen 70 ans, 53% d'hommes) ont soit présenté un diagnostic alternatif grave ou ont soit développé des événements évolutifs sévères (groupe D). On notait onze patients avec diagnostic grave, (cancer pulmonaire (n=3), cancers rénal (n=2), cancer thyroïdien, tumeur neuroendocrine, lymphome, neurofibromatose, vascularite à Anticorps anti-cytoplasme des polynucléaires neutrophiles (ANCA), neuro-syphilis) et huit patients avec une conséquence sévère de la corticothérapie (cinq infections graves, deux déséquilibres sévères de diabète, une insuffisance surrénalienne aiguë). Parmi ces 19 patients, 84% avaient des céphalées, 47% une palpation anormale de l'artère temporale, 57% une hyperesthésie du cuir chevelu, 32% une claudication de la mâchoire, 16% une baisse brutale de la vision, 26% une raideur matinale des épaules (**Tableau 2**). La CRP moyenne était de 81 mg/L [6-106] et la VS de 73 mm [32-114]. Une tomographie par émission de positons au ¹⁸FDG a été réalisée pour 6 patients (32%). Douze/19 patients (63%) avaient un score ACR/EULAR 2022 ≥ 6 . Le délai moyen du diagnostic alternatif était de 66 jours. Au cours du suivi, le taux de mortalité était de 68% avec délai moyen de 145 jours (**Figure 10**).

En comparant le groupe D avec les autres groupes, ils présentaient significativement moins d'anomalies cliniques de l'artère temporale (47.4%) que les patients du groupe A (75.8%) mais plus que ceux du groupe C (9%) (**Tableau 3**). Ils présentaient également un taux de leucocytes plus élevés que tous les autres groupes. Les diagnostics alternatifs avec conséquences graves, avaient des critères de classification significativement plus élevés que ceux du groupe C (ACR 1990: 2.8 [1.9-3.7] vs 1.8 [1.1-2.5], $p < 0.001$; ACR/EULAR 2022: 6.9 [4.4-9.4] vs 4.5 [2.6-6.4], $p < 0.001$) mais similaires à ceux du groupe B.

Les patients avec un diagnostic alternatif mimant une ACG peuvent avoir une évolution défavorable que ce soit en termes de retard diagnostique et de prise en charge ou d'initiation erronée d'une corticothérapie. Les critères ACR/EULAR 2022 sont uniquement des critères de classification et peuvent orienter par erreur le clinicien vers un diagnostic d'ACG. Nous soulignons la nécessité d'une vigilance importante en cas de suspicion initiale d'ACG, particulièrement devant des tableaux cliniques mimant fortement cette vascularite.

Alternative diagnoses among 196 patients with temporal artery biopsy

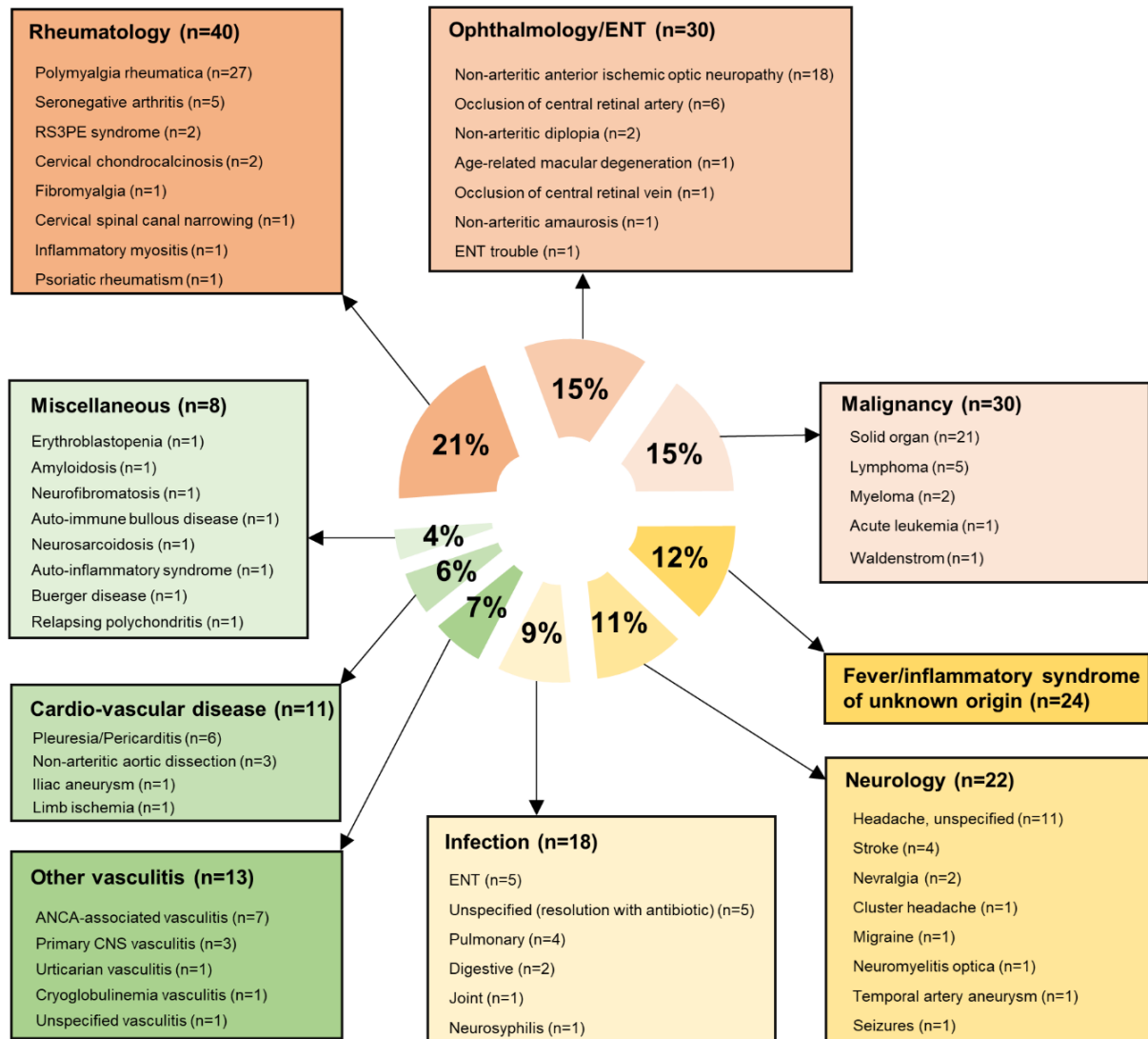


Figure 9. Diagnostics alternatifs des patients ayant eu une BAT pour lesquels une ACG n'était pas retenue.

Présentation en communication orale par Cory Cayrou au congrès de la SNFMI 2024, le 19 juin 2024.
 Abréviations: ANCA, Anti Neutrophil Cytoplasmic Antigen; CNS, cerebral nervous system; ENT, ear nose and throat; RS3PE, Remitting Seronegative Symmetrical Synovitis with Pitting Edema.

#	Age	Sex	Morning stiffness shoulders/neck	Head aches	AT	ST	JC	Sudden VL	ESR, mm	CRP, mg/L	Temp, US performed	TEP performed	2022		Atypical signs	Diag delay, day	Final diagnosis	Problems	Follow-up duration, month	Death during follow-up
													1990 ACR	EULAR						
1	70s	M	0	1	1	0	0	1	121	75	1	0	4	10	Productive cough, hemoptysis	65	Lung cancer	Diabetes imbalance, muscle atrophy	4	1
2	60s	F	1	1	0	1	0	0	60	92	1	1	3	7	Severe weight loss (14kg), digital hippocratism	32	Lung cancer	Diagnosis delay	17	0
3	60s	M	0	0	1	1	0	0	44	88	1	1	2	5	CS failure	35	Lung cancer	Diagnosis delay	10	1
4	70s	F	0	1	1	1	1	0	35	60	0	0	3	9	CS failure, severe weight loss (10kg), dyspnea	120	Lung cancer	Diagnosis delay	6	1
5	60s	M	1	0	0	0	1	0	42	32	1	0	1	7	Severe weight loss (10kg)	60	Lung cancer	Diagnosis delay	4	1
6	60s	M	0	1	1	0	0	0	98	74	0	0	4	7	Rapidly progressive renal failure	12	Kidney cancer	Diagnosis delay, bacteremia	8	1
7	70s	F	1	1	0	1	1	1	100	68	1	0	3	12	Severe weight loss (14kg), CS failure	50	Kidney cancer	Diagnosis delay	6	1
8	80s	F	0	1	1	1	1	0	107	61	1	0	4	9	CS failure, cervical nodules	38	Thyroid cancer	Diagnosis delay	3	1
9	80s	F	0	0	1	0	0	0	132	288	0	0	3	5	CS failure	76	Lymphoma	Diagnosis delay	3	1
10	50s	F	1	1	0	0	0	0	115	8	1	1	3	7	Intermittent headache, low CRP	450	Rheumatoid arthritis	Diabetes imbalance, III paralysis	28	0
11	60s	M	0	1	1	0	0	1	121	86	1	0	4	10	Nasal voice, Visual loss under CS	135	Sinus aspergillosis	Lung abscess	12	1
12	80s	F	0	1	0	1	0	0	NA	36	1	0	3	7	Nose pain, ophthalmoplegia	16	Sinus aspergillosis	Stroke after 4 months	18	0
13	80s	M	0	1	1	0	0	0	36	175	1	0	3	7	Unilateral trismus, asymmetric facial oedema	7	Masseeter abscess	Cardiac arrest	4	1
14	60s	M	0	1	1	1	0	0	NA	114	0	0	2	5	Dyspnea	47	Lung abscess	Pneumothorax	2	1
15	50s	M	0	1	0	1	0	0	23	28	1	1	2	5	Polyarthritits, tibial pain	115	Neurosyphilis	Diagnosis delay, persistent diplopia	30	0
16	70s	F	1	1	0	1	1	0	92	218	1	1	3	9	Aphony, lung nodules, frequent relapses	170	AAV	Multiple hospitalizations	22	0
17	60s	M	0	1	0	0	0	0	NA	21	1	1	2	5	Brown macules, cutaneous neurofibroma	30	Neurofibromatosis	Cardiac arrest	1,5	1
18	70s	M	0	1	0	1	0	0	14	3	1	0	2	2	CS failure, low ESR/CRP	40	Aspecific headache	Divericular abscess, peritonitis	6	1
19	60s	F	0	1	0	1	1	0	28	3	0	0	2	4	CS failure, low ESR/CRP	95	Cluster headache	Acute adrenal surrenal	14	0

Tableau 2. Caractéristiques des patients ayant eu une BAT, avec diagnostic alternatif final retenu et ayant présenté des conséquences graves.

Présentation en communication orale par Cory Cayrou au congrès de la SNFMI 2024, le 19 juin 2024.

Abréviations : M, male ; F, female; AT; abnormal palpation of temporal artery ; JC, jaw claudication; VL, visual loss; ESR, erythrocyte sedimentation rate; CRP, C-reactive protein; TEP, Postiron emission tomography; ACR, American College of Rheumatology; EULAR, European league against rheumatism; Diag, diagnosis; AAV, ANCA associated vasculitis; CS, corticosteroids.

	Serious mimics n=19	Usual mimics n=177	GCA TAB- n=135	GCA TAB+ n=248	Serious vs usual	Serious vs GCA TAB- p-value	Serious vs GCA TAB+
Demographic							
Age, years	70.1 (±10.0)	72.8 (±9.5)	72.7 (±8.3)	75.6 (±8.2)	0.2599	0.2608	0.0177
Male	10 (52.6)	92 (52.0)	53 (39.3)	88 (35.5)	1.0000	0.3893	0.2122
Symptoms							
Morning stiffness shoulders neck	5 (26.3)	43 (24.3)	55 (40.7)	60 (24.2)	1.0000	0.3391	1.0000
New Headaches	16 (84.2)	65 (36.7)	113 (83.7)	191 (77.0)	0.0001	1.0000	0.5796
Temporal artery anomaly	9 (47.4)	16 (9.0)	48 (35.8)	185 (75.8)	<0.0001	0.4710	0.0145
Scalp tenderness	11 (57.9)	24 (13.6)	56 (41.8)	122 (50.4)	<0.0001	0.2815	0.6966
Jaw claudication	6 (31.6)	7 (4.0)	21 (15.6)	93 (37.7)	<0.0001	0.1622	0.7784
Sudden visual loss	3 (15.8)	39 (22.0)	18 (13.3)	59 (23.8)	0.7693	0.7259	0.5774
Biology							
ESR, mm	73.0 (±41.2)	53.8 (±36.3)	77.2 (±31.9)	82.8 (±29.0)	0.0649	0.6727	0.4615
ESR >50 mm	9 (56.2)	58 (49.2)	99 (80.5)	192 (83.1)	0.7899	0.0613	0.0194
CRP, mg/L	80.5 (±75.0)	56.2 (±58.0)	88.3 (±64.7)	96.1 (±69.4)	0.1137	0.3734	0.2000
CRP >10 mg/L	16 (84.2)	125 (71.4)	131 (97.0)	235 (95.5)	0.3609	0.0408	0.0687
Hemoglobin, g/dL	123.9 (21.0)	121.3 (19.9)	117.7 (17.6)	116.2 (16.9)	0.5898	0.1598	0.0614
Leucocytes, G/L	11352.1 (3631.8)	8695.9 (3662.5)	8973.4 (3100.9)	9516.2 (3337.0)	0.0022	0.0047	0.0224
Platelets, G/L	376.9 (148.3)	372.1 (527.7)	397.9 (138.1)	450.1 (160.2)	0.2202	0.4035	0.0239
RADIOLOGY							
Temporal artery US halo	0 (0.0)	1 (0.9)	15 (14.3)	67 (34.0)	-	-	-
Axillary involvement	0 (0.0)	0 (0.0)	14 (13.1)	38 (18.7)	-	-	-
Aortitis TEP	0 (0.0)	0 (0.0)	27 (69.2)	33 (75.0)	-	-	-
SCORES							
1990 ACR criteria	2.8 (±0.9)	1.8 (±0.7)	2.9 (±0.8)	4.3 (±0.8)	<0.0001	0.4953	<0.0001
2022 ACR/EULAR criteria	6.9 (±2.5)	4.5 (±1.9)	8.0 (±2.9)	13.4 (±2.3)	<0.0001	0.1988	<0.0001
Follow-up							
Diagnosis delay, day	83.8 (±99.3)	31.4 (±61.4)	15.1 (±30.2)	8.3 (±21.2)	<0.0001	<0.0001	<0.0001
Follow-up duration, month	10.4 (±8.8)	47.9 (±48.1)	65.7 (±48.0)	46.0 (±35.3)	0.0002	<0.0001	<0.0001
Death during follow up	13 (68.4)	22 (12.4)	37 (27.4)	51 (20.6)	-	-	-

Tableau 3. Caractéristiques des patients ayant eu une BAT selon le diagnostic final retenu. Présentation en communication orale par Cory Cayrou au congrès de la SNFMI 2024, le 19 juin 2024.

Abréviations : ESR, erythrocyte sedimentation rate; CRP, C-reactive protein; TEP, Postiron emission tomography; ACR, American College of Rheumatology; EULAR, European league against rheumatism; TAB, temporal artery biopsy; GCA, giant cell arteritis; US ultrasound

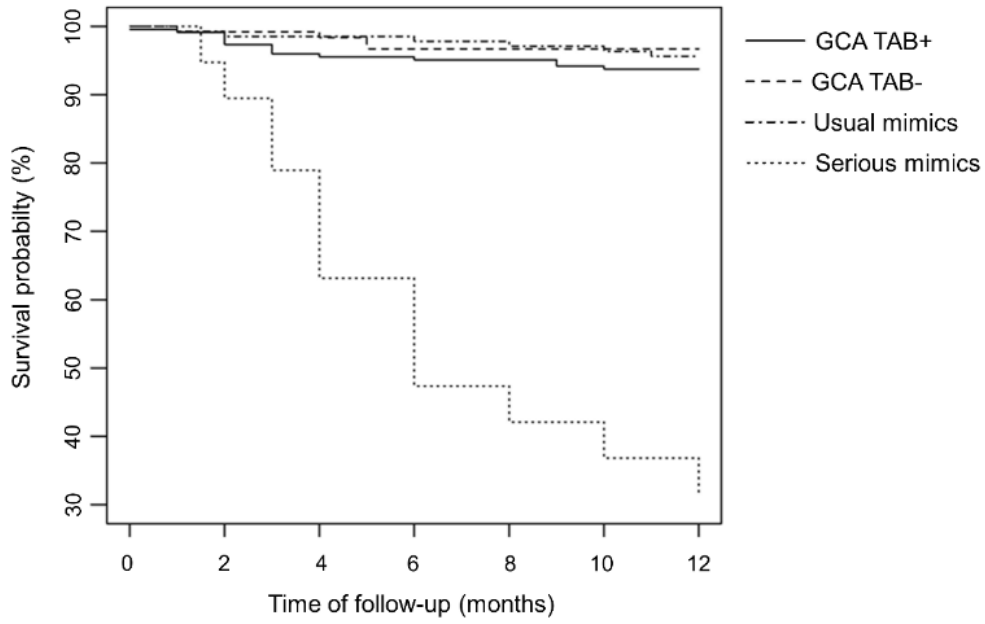


Figure 10. Survie des patients selon les différents groupes.

Présentation en communication orale par Cory Cayrou au congrès de la SNFMI 2024, le 19 juin 2024.

Abréviations : TAB, temporal artery biopsy; GCA, giant cell arteritis; US ultrasound

I.1.10 Biologie

Il existe un syndrome inflammatoire biologique dans la plupart des cas d'ACG au diagnostic. La vitesse de sédimentation (VS) fut longtemps le marqueur inflammatoire le plus utilisé, bien que non spécifique, et intégrée dans les critères de classification (valeur supérieure à 50 mm à la première heure) [113]. D'autres marqueurs inflammatoires sont fréquemment rencontrés : thrombocytose, hyperleucocytose à polynucléaires neutrophiles, anémie inflammatoire, augmentation du fibrinogène, de l'haptoglobine, cholestase anictérique.

L'élévation de la C-reactive protéine (CRP), d'utilisation plus récente, supplémente désormais la VS en pratique, et a été intégrée dans les nouveaux critères de classification de l'ACG avec une valeur seuil supérieure à 10 mg/L [114]. Il existe une corrélation entre la CRP et les perturbations du bilan hépatique (**Annexe 4**).

Nous avons effectué une étude sur une cohorte de 396 patients (**Annexe 5**). Parmi eux, 14 (3,5%) présentaient des valeurs initiales faibles de VS et de CRP. Tous avaient une BAT positives. Ces patients avaient moins de claudication de la mâchoire ($p=0,06$), mais des taux similaires de cécité permanente ($p=1,0$). Les patients présentant des taux de VS et de CRP plus faibles ont également montré des différences en ce qui concerne les éléments de la formule sanguine et le taux d'hémoglobine moyen, mais aussi moins de positivité des anticorps anti-cardiolipines ($p=0,04$) et de cholestase hépatique ($p=0,03$). Les patients ayant une VS et une CRP plus basses ont eu moins de rechutes ($p=0,03$), moins de complications induites par les glucocorticoïdes ($p=0,01$), et ont réussi à arrêter les glucocorticoïdes plus tôt que les autres patients (18 vs 34 mois en moyenne, $p=0,02$).

Plusieurs tentatives de biomarqueurs ont été recherchées avec des résultats intéressants, mais non pratiqués en routine [115-117]. Ils concernent :

- l'activité de la maladie : calprotectine, IL-23, BAFF, ostéopontine sérique
- le pronostic : ostéopontine, MMP2, angiopoïetin-2, YKL-40, IL-6

I.1.11 Moyens diagnostiques

I.1.11.1 Histologie – Biopsie d'artère temporale (BAT)

L'ACG a une définition histologique, basée sur l'analyse anatomopathologique d'un tissu artériel. Au vu de sa prédilection pour les branches de la carotide externe, l'artère temporale est un site facilement accessible et privilégié pour réaliser une biopsie afin d'obtenir la preuve certaine de la vascularite. Elle reste l'examen de référence avec une spécificité de 100%. Nous avons élaboré un guide pratique quant à sa réalisation (**Annexe 6**).

Les lésions classiquement rencontrées sont de 2 types [118-120] :

- un infiltrat inflammatoire granulomateux de la paroi artérielle, composé majoritairement de lymphocytes, macrophages, parfois de quelques cellules géantes (fusion des macrophages), polynucléaires et plasmocytes. Une nécrose fibrinoïde est rarement rencontrée. Cet infiltrat peut concerner toutes les couches du vaisseau (intima, média, adventice), il s'agit alors d'une panartérite (**Figure 11**). Toutefois, les lésions peuvent se limiter à une ou deux couches (**Figure 12**).
- un remodelage vasculaire matérialisé par une destruction de la média, composée de cellules musculaires lisses, et notamment une fragmentation de la limitante élastique interne qui est un signe pathognomonique de l'ACG. Il s'y associe fréquemment une hyperplasie de l'intima composée de myofibroblastes, conduisant à une réduction de la lumière du vaisseau voire à son occlusion.

Différents sous-types anatomopathologiques ont été décrits selon [121,122] :

- les couches de l'artère temporale touchées par l'infiltrat inflammatoire : adventice seule, adventice et média, adventice et intima avec préservation de la média (atteinte concentrique), panartérite (adventice, média et intima).
- l'atteinte d'autres vaisseaux que l'artère temporale elle-même : *vasa vasorum* adventitiels exclusifs, vaisseaux présents dans la péri-adventice ou le tissu adipeux entourant l'artère temporale, vaisseaux de plus petit calibre correspondant à des branches de l'artère temporale.
- la présence ou l'absence d'infiltrat inflammatoire mais avec des signes de destruction de la média/limitante élastique interne ou de remodelage vasculaire (forme cicatricielle).

Le délai de réalisation et d'obtention de la biopsie ne doit pas retarder le traitement. Les lésions peuvent rester présentes plusieurs semaines voire des mois sous traitement par corticoïdes [123-129].

Des scores de prédiction pour la positivité d'une BAT en cas de suspicion d'ACG ont été proposés, permettant d'éviter éventuellement sa réalisation pour certains patients [130,131].

D'autres sites peuvent donner la preuve histologique : artères occipitale, pièce opératoire d'une rupture anévrysmal aortique par exemple [132-134].

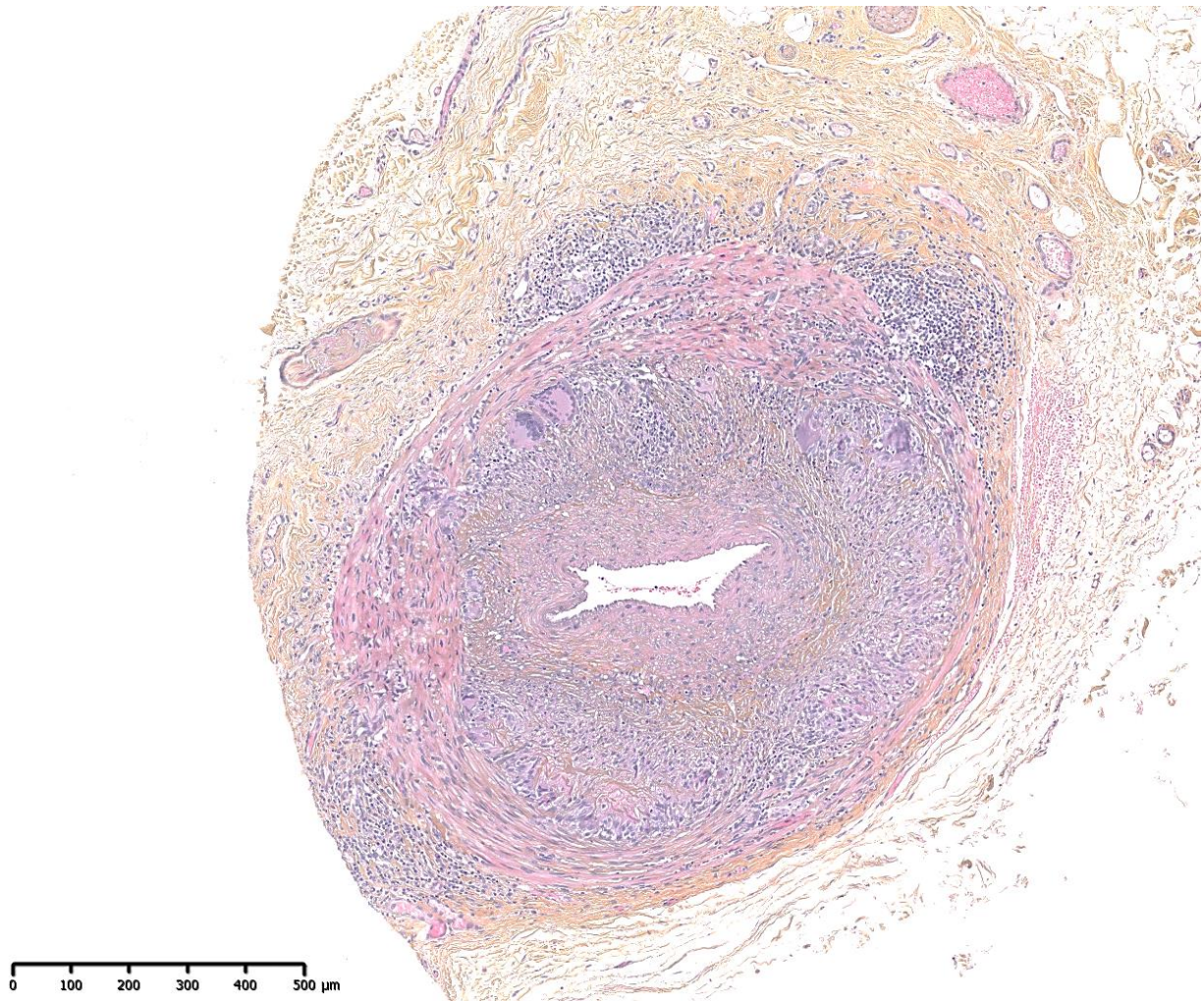


Figure 11. Aspect histologique de panartérite de l'artère temporale en coloration Hématoxyline Eosine Safran (HES) (Collection personnelle).

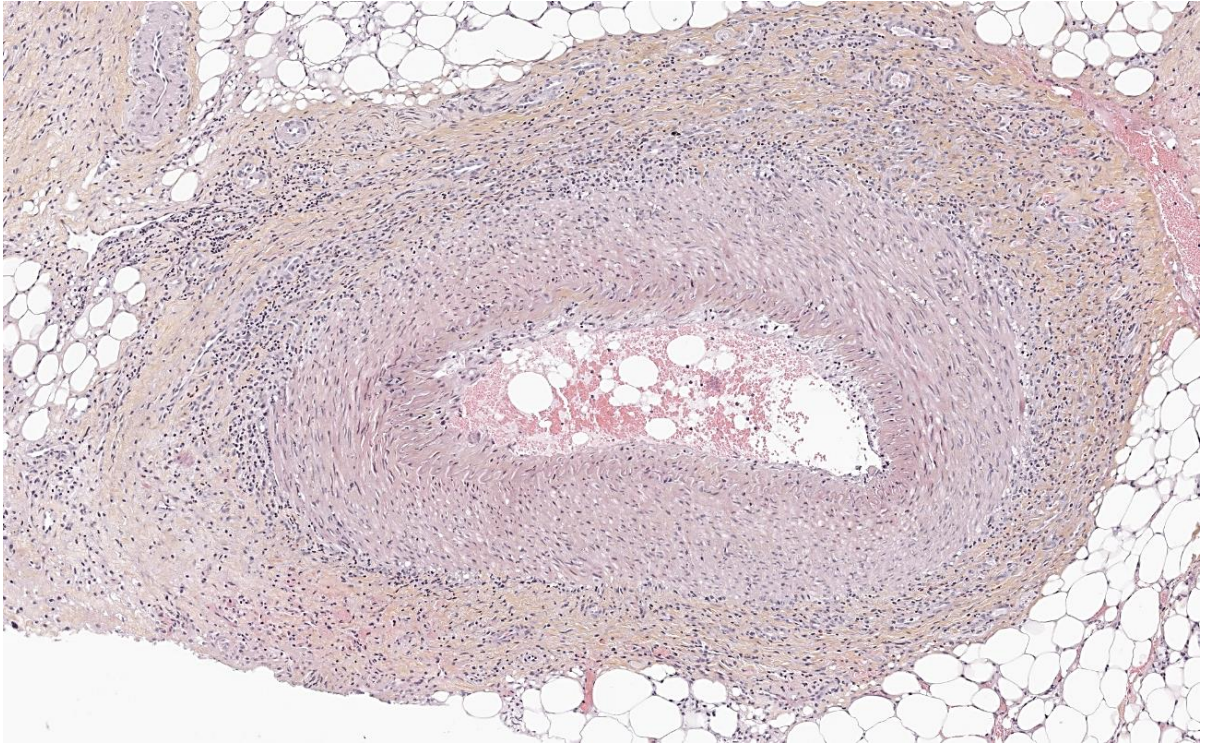


Figure 12. Aspect histologique d'un sous type touchant exclusivement l'adventice en coloration Hématoxyline Eosine Safran (HES) (Collection personnelle).

I.1.11.2 Imagerie

Les examens d'imagerie s'imposent de plus en plus dans la stratégie diagnostique de l'ACG. Ils s'intègrent maintenant dans les critères de classification au diagnostic mais aussi dans le suivi de la pathologie [135-137]. Ces différents examens souffrent parfois de leur manque de disponibilité dans certains centres.

I.1.11.2.1 Echographie-doppler

Il s'agit d'un examen non-invasif, permettant d'évaluer les artères temporales mais aussi d'autres segments comme les artères ophtalmiques, maxillaires, faciales, les branches principales de l'aorte. Cependant l'échographie-doppler ne permet pas d'évaluer l'aorte thoracique de façon opérante.

Les signes communs retrouvés sont :

- Un signe du Halo correspondant à un épaissement pariétal circonférentiel et homogène de l'artère,
- Une incompressibilité artérielle,
- Une sténose ou une occlusion de l'artère.

Une méta-analyse récente rapporte une grande variabilité concernant le signe du halo en terme de sensibilité (médiane de 78%) avec toutefois une bonne spécificité (médiane de 91%) par rapport à la BAT [138]. Des unités de circuit-court avec un accès rapide à l'échographie doppler se développent dans certains centres afin de raccourcir le délai diagnostique d'ACG [139-142].

I.1.11.2.2 Angio-scanner

Il permet de mettre en évidence un réhaussement pariétal, circonférentiel, continu et homogène sur un long segment aux temps artériels tardifs. Pour une valeur seuil d'épaissement pariétal de 2.2 mm, l'angio-scanner présente une sensibilité de 67% et une spécificité de 97% [143]. En outre, il permet de détecter une dilatation, un anévrisme, une dissection et des sténoses des grosses branches aortiques.

I.1.11.2.3 Angio-IRM (Imagerie par résonance magnétique)

Elle reste peu utilisée par manque d'accessibilité. D'importants progrès en termes de résolution se sont développés permettant notamment d'accéder aux vaisseaux crâniens [144-151]. Différentes séquences sont classiquement utilisées :

- Séquences T2 « fast spin echo » montrant un œdème pariétal avec bordure hyper-intense.
- Séquence T1 « fast suppression » : montrant un épaississement et une prise de contraste murale.
- Séquence ARM en T1/gadolinium : appréciant les irrégularités et le calibre de la lumière artérielle.

I.1.11.2.4 Tomographie à émission de positons au 18-FDG (TEP) couplée au scanner

La TEP couplée au scanner (TEP-scanner) permet de mettre en évidence une atteinte des gros vaisseaux dans 75 % à 83 % des cas d'ACG et dans plus de 50% pour l'aortite [152-154]. Sa sensibilité se situe entre 83 % et 90 %, et sa spécificité entre 90 % et 98 % [155]. Tout comme l'angio-IRM, son accès et le délai d'obtention peuvent toutefois être compliqués dans certains centres. L'image typique est un hypermétabolisme pariétal linéaire ou segmentaire sur un long segment. Le piège classique est la présence d'athérome pouvant également fixer le traceur [156]. Son utilité dans le suivi de l'ACG reste encore débattue par ailleurs.

Nous avons réalisé un travail concernant la description des caractéristiques des résultats du TEP-scanner au 18-fluorodésoxyglucose (18-FDG) avant une intervention chirurgicale chez des patients atteints d'aortite active confirmée histologiquement (**Annexe 7**). Seize patients ont été inclus (Huit ACG, quatre aortites cliniquement isolées, deux artérites de Takayasu, une polychondrite récidivante et une polyarthrite rhumatoïde). Chez 5/16 (31%) patients, le TEP-scanner n'a pas détecté d'inflammation aortique ; deux d'entre eux étaient traités par glucocorticoïdes au moment de l'intervention. L'aorte thoracique ascendante et l'aorte abdominale présentaient la captation de FDG la plus élevée parmi les territoires affectés. Les patients sans aortite active au TEP-scanner étaient significativement plus âgés ($p=0,027$), avaient un score PETVAS (Performance of the PET vascular activity score) plus bas ($p=0,007$) et un degré d'inflammation adventitielle plus bas ($p=0,035$). En revanche, il n'y avait pas de différence entre les patients atteints d'aortite active et inactive en ce qui concerne le délai entre le TEP-scanner et la chirurgie, le taux de CRP sérique (pendant le TEP-scanner) et la captation de FDG par site d'étude.

I.1.12 Critères de classification

Des premières tentatives d'établissement de critères de classification ont été réalisées dans les années 1980 prenant en compte l'âge du patient (supérieur à 60 ans), les signes cliniques (signes généraux, PPR, céphalées, signes visuels, claudication de la mâchoire), biologique (VS augmentée), l'histologie et la réponse aux corticostéroïdes [157]. En 1990, Hunder et al ont simplifié ces critères en intégrant 5 items à partir de 214 patients porteurs d'ACG comparés à 593 contrôles [113]. La présence de 3 critères sur 5 permettait de classer la vascularite parmi : un âge supérieur à 50 ans, des céphalées récentes et localisées, une anomalie de palpation de l'artère temporale, une VS supérieure ou égale à 50 mm/h, une histologie artérielle positive (artérite nécrosante, avec infiltrat de cellules mononucléées ou processus granulomateux avec cellules géantes). Ce score permet de classer les patients avec une sensibilité de 93.5% et une spécificité de 93.5%

En 2022, les sociétés européennes (EULAR) et américaines (ACR) de rhumatologie ont actualisé ces critères de classification (**Figure 13**) [114]. Différents travaux ont évalué les performances de ces nouveaux critères [158-162]. Selon Narvèez et al, ces nouveaux critères ont une sensibilité de 92,6 % et une spécificité de 85,2 %. Selon les phénotypes cliniques, la sensibilité était de 98,8 % pour les formes crâniennes, 92 % pour les formes des gros vaisseaux et de 75 % pour les formes occultes [158].

CONSIDERATIONS WHEN APPLYING THESE CRITERIA

- These classification criteria should be applied to classify the patient as having giant cell arteritis when a diagnosis of medium-vessel or large-vessel vasculitis has been made
- Alternate diagnoses mimicking vasculitis should be excluded prior to applying the criteria

ABSOLUTE REQUIREMENT

Age ≥ 50 years at time of diagnosis	
-------------------------------------	--

ADDITIONAL CLINICAL CRITERIA

Morning stiffness in shoulders/neck	+2
Sudden visual loss	+3
Jaw or tongue claudication	+2
New temporal headache	+2
Scalp tenderness	+2
Abnormal examination of the temporal artery ¹	+2

LABORATORY, IMAGING, AND BIOPSY CRITERIA

Maximum ESR ≥ 50 mm/hour or maximum CRP ≥ 10 mg/liter ²	+3
Positive temporal artery biopsy or halo sign on temporal artery ultrasound ³	+5
Bilateral axillary involvement ⁴	+2
FDG-PET activity throughout aorta ⁵	+2

Sum the scores for 10 items, if present. A score of ≥ 6 points is needed for the classification of GIANT CELL ARTERITIS.

1. Examination of the temporal artery showing absent or diminished pulse, tenderness, or hard 'cord-like' appearance.
2. Maximum erythrocyte sedimentation rate (ESR) or C-reactive protein (CRP) values prior to initiation of treatment for vasculitis.
3. Presence of either definitive vasculitis on temporal artery biopsy or halo sign on temporal artery ultrasound. There are no specific histopathologic criteria to define definitive vasculitis on temporal artery biopsy. Presence of giant cells, mononuclear leukocyte infiltration, and fragmentation of the internal elastic lamina were independently associated with histopathologic interpretation of definite vasculitis in the DCVAS cohort¹⁸. Halo sign is defined by the presence of an homogenous, hypochoic wall thickening on ultrasound¹⁹.
4. Bilateral axillary involvement is defined as luminal damage (stenosis, occlusion, or aneurysm) on angiography (computed tomography, magnetic resonance, or catheter-based) or ultrasound, halo sign on ultrasound, or fluorodeoxyglucose uptake on positron emission tomography.
5. Abnormal fluorodeoxyglucose (FDG) uptake in the arterial wall (e.g., greater than liver uptake by visual inspection) throughout the descending thoracic and abdominal aorta on positron emission tomography (PET).

Figure 13. Critères de classification de l'ACR/EULAR 2022 d'après Ponte [114].

Toutefois, ces critères ne sont pas des critères diagnostiques et peuvent faire porter à tort le diagnostic ACG comme illustré sur ce travail réalisé par notre équipe (**Figure 14**). Les formes avec conséquences graves (*Dangerous mimics*), étaient définies si un diagnostic erroné d'ACG avait entraîné soit un retard d'un diagnostic alternatif sévère (cancer par exemple) ou soit un traitement erroné (corticothérapie et/ou épargne cortisonique) pour une présumée ACG finalement infirmé. On peut constater que la majorité des formes avec conséquences graves avaient au moins 6 critères ACR/EULAR 2022.

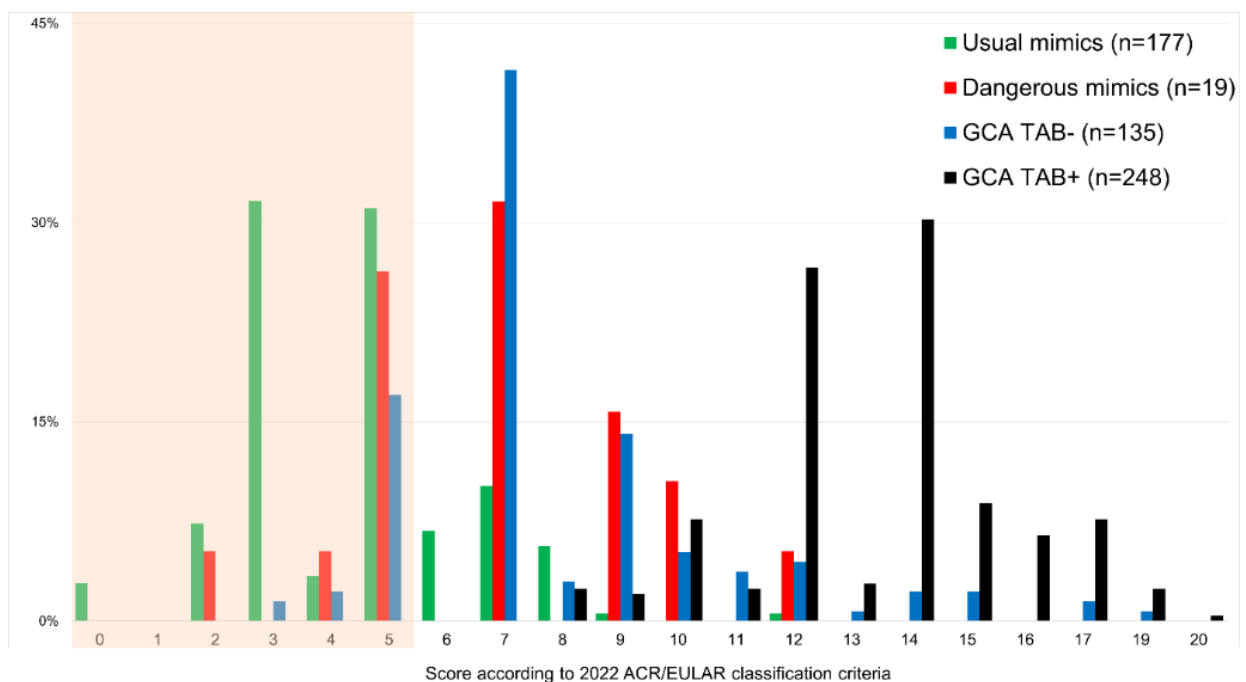


Figure 14. Répartition des patients de notre cohorte du CHU de Limoges selon les critères de classification ACR/EULAR 2022, en intégrant des *mimics* usuels, *mimics* avec conséquences graves (*Dangerous mimics*) et des patients avec diagnostic d'ACG selon le résultat de la BAT (GCA TAB+ ou GCA TAB-)

Présentation en communication orale par Cory Cayrou au congrès de la SNFMI 2024, le 19 juin 2024.

I.1.13 Traitements

La corticothérapie reste depuis 1948, date du premier patient traité, la pierre angulaire de la prise en charge des patients. Elle doit être débutée le plus tôt possible en cas de forte suspicion diagnostique, sans attendre la confirmation histologique et/ou iconographique du fait du risque visuel inhérent à la pathologie.

Une réponse rapide, parfois spectaculaire, en quelques jours, d'un point de vue symptomatique, est un élément important en faveur de l'ACG. A l'inverse, un diagnostic alternatif doit être à considérer. La molécule de choix est la prednisone dont l'efficacité serait supérieure aux autres classes de glucocorticoïdes (absence d'essai comparatif cependant).

Le traitement se décompose en 2 phases : la phase d'attaque suivie de la phase d'entretien.

La phase d'attaque comporte une pleine dose de corticoïdes sur une durée classiquement de 3 à 4 semaines. On peut retenir de façon schématique les 2 situations suivantes en pratique clinique :

- Forme sans atteinte visuelle : corticoïdes à 0.7 mg/kg/jour d'équivalent prednisone
- Forme avec atteinte visuelle ou ischémique : corticoïdes à 1 mg/kg/jour d'équivalent prednisone. Les bolus de méthylprednisolone sont à considérer mais une étude rétrospective récente n'a pas démontré leur intérêt concernant le risque visuel [163].

La phase d'entretien constitue un élément aussi important, mal codifié, et correspond à la décroissance des doses de corticoïdes. Elle est le plus souvent réalisée sur plus d'un an minimum, avec certains patients nécessitant plusieurs années de traitement [164]. Le principal risque d'une décroissance trop rapide, est la survenue de reprise évolutive de l'ACG ou de rechutes à l'arrêt du traitement. Par ailleurs, les doses cumulées, responsables de nombreuses comorbidités, restent un problème majeur pour les patients.

La surveillance clinique et biologique, à la recherche de reprise évolutive ou de récurrence, dicte une éventuelle modification thérapeutique : augmentation des doses de corticoïdes et/ou introduction d'un traitement d'épargne.

Les progrès sur la compréhension de la physiopathologie de l'ACG, ainsi que l'expérience acquise concernant d'autres affections systémiques, ont permis d'envisager l'utilisation de traitements d'épargne cortisonique, afin d'en réduire leurs effets indésirables. Actuellement deux molécules sont approuvées au cours de l'ACG : le Méthotrexate, un antimétabolite inhibiteur compétitif de la dihydrofolate réductase, et le Tocilizumab, un anticorps monoclonal humanisé bloquant l'action des récepteurs de l'IL-6.

Les recommandations concernant la prise en charge thérapeutique ont été récemment mises à jour. Celles de la société américaine de rhumatologie publiées en 2021, préconisent l'adjonction immédiate du Tocilizumab à la corticothérapie [165]. Un traitement par corticoïdes seuls ou avec Méthotrexate est toutefois proposé en alternative. En cas de mauvais contrôle de la vascularite, un changement d'épargne cortisonique est préconisé par Méthotrexate ou Abatacept. Les bolus de méthylprednisolone sont recommandées en cas d'atteintes visuelles ou ischémiques crâniennes. Au niveau européen, l'EULAR recommande une dose d'attaque de 40 à 60 mg/jour de corticoïdes avec un objectif de décroissance à 2-3 mois de 15 à 20 mg/jour et inférieur ou égal à 5 mg par jour après 1 an [166]. Un traitement d'épargne par Tocilizumab ou Méthotrexate est suggéré en cas de reprise évolutive ou récidive, ou d'objectif de décroissance non atteint. Concernant les manifestations visuelles, les bolus de méthylprednisolone sont suggérés. Le groupe d'étude français de l'ACG (ACG) établit également des recommandations dont la prochaine version va être publiée courant 2024.

En dehors des traitements d'épargne cortisonique, l'aspirine paraît intéressante notamment dans la prévention des complications ischémiques [167,168]. Une étude fondamentale de 2002 avait montré que l'acide acétylsalicylique pouvait être efficace dans la suppression de l'IFN- γ au niveau des artères temporales [169]. Toutefois d'autres études cliniques n'ont pas confirmé cette tendance dans la prévention ischémique au cours de l'ACG [170-172].

Les tableaux suivants résument les différentes études ayant évaluées les traitements d'épargne au cours de l'ACG (**Tableaux 4-7**).

1er auteur/ numéro	Année de publication	Nom	Patients ACG (n)	Type	Commentaires
Durée 1 an					
Unizony [173]	2012		7	Observationnel	Rémission sous traitement (100%). Rôle d'épargne
Villiger [174]	2014		30	Phase 2	CTC + TCZ IV (n=20) vs placebo (n=10) Rechute à 1 an : 15 vs 80%. Rôle d'épargne
Stone [175]	2017	GIACTA	251	Phase 3	CTC + TCZ SC (/sem vs autre rythme) vs CTC (26 vs 52sem) Rechute à 1 an : 44 vs 47 vs 86 vs 82%. Rôle d'épargne
Evaluation après > 1 an avec +/- arrêt du TCZ					
Adler [176]	2019		17	Observationnel	47% de rechutes (28 mois)
Stone [177, 178]	2021/2022	GIACTA (extension)	215	Phase 3 (extension)	Groupe CTC + TCZ SC /sem : 58% de rechutes (1 an)
Matza [179]	2023		65	Observationnel	Durée TCZ moyenne 1,9 an, 47% de rechutes après arrêt (18 mois)
Quick [180]	2023	TOC STOP	336	Observationnel	Rechutes après arrêt : 21% (6 mois), 35% (12 mois), 49% (24 mois)
Samec [181]	2023		114	Observationnel	Durée TCZ moyenne 2,3 ans, 58% de rechutes (12 mois)
Calderón-Goercke [182]	2023		231	Observationnel	Maintien du TCZ et optimisation après rémission prolongée obtenue Rechutes 6% (optimisation du TCZ) vs 10% (sans optimisation)
Tomerelli [183]	2023		23	Observationnel	Durée TCZ 24 mois (/sem 12mois, puis espacé 12 mois) Rechutes après arrêt : 26% (6 mois)
NC.T06037460	En cours	MAGICA		Phase 3	Evaluation des modalités d'arrêt : brutal vs graduel (/2sem 12sem puis /4sem 12sem). Suivi 26 sem
Tocilizumab + corticothérapie courte					
Saito [184]	2020		8	Observationnel	TCZ IV monothérapie 12mois : /2sem 2mois puis /4sem 10mois Réponse à 48 semaines : 75% complète, 25% partielle Réponse à 104 semaines : 66% complète, 33% rechutes
Christ [185]	2021	GUSTO	18	Observationnel	TCZ 1 an + 3 bolus Methylprednisolone 500 mg Rechutes : 22% à 24 sem, 28% à 52 sem
Unizony [186]	2023		30	Observationnel	TCZ 1 an + CTC 8 semaines Rechutes : 23% à 1 an
Muratore [187]	2024	TOPAZIO	23	Observationnel	TCZ 2 ans + CTC courte, ACG en rechute. Evaluation par imagerie. Rechutes : 17% à 1 an (clinique), 9% à 2 ans (imagerie), 26% à 30 mois
Tocilizumab et complications ischémiques					
NC.T04239196	En cours	TOCIAION		Phase 2	Evaluation du TCZ + CTC vs CTC seule sur NOIA
NC.T04888221	En cours	TOGIAC		Phase 3	Evaluation du TCZ pour ACG avec AVC

Tableau 4. Etudes principales concernant le Tocilizumab au cours de l'ACG.

1er auteur/ numéro	Année de publication	Patients (n)	Type	Commentaires
Jover [188]	2001	42	Randomisée	MTX vs Placebo + CTC Rechutes : 45 vs 84% à 24 mois. Epargne cortisonique
Hoffman [189]	2002	98	Randomisée	MTX vs Placebo + CTC Rechutes : 58 vs 77% à 12 mois
Mahr [190]	2007	161	Méta-analyse	Durée de suivi moyen 55 semaines Risque de 1ere rechute : 0.65, 2eme rechute : 0.49 comparé au placebo
Leon [191]	2018	168	Observationnel	72% de chances en moins de rechute si MTX vs CTC seule
Koster [192]	2019	166	Observationnel	Diminution du risque de rechute si MTX vs CTC seule

Tableau 5. Etudes principales concernant le Méthotrexate au cours de l'ACG.

1er auteur/ numéro	Année de publication	Nom d'étude	Commentaire
Méthotrexate versus Tocilizumab			
Grazzini [193]	2023		20 TCZ vs 9 MTX. Rechutes à 12 mois : 15 vs 33%
NCT03892785	En cours	METOGIA	Phase 3
Tocilizumab puis Méthotrexate			
NCT05623592	En cours	METEORITICS	Phase 2
NCT05623592	En cours	MTXinGCA	Phase 2

Tableau 6. Etudes principales évaluant le Tocilizumab et le Méthotrexate (comparatif ou séquentiel) au cours de l'ACG.

Molécule	1er auteur/ numéro	Année de publication	Nom	Patients	Type	Commentaires
Sarilumab – anti IL6 R	Schmidt [194]	2023		36	Phase 3	Sarilumab (200 vs 150mg) + CTC 26sem vs CTC seul 52sem vs CTC seul 26 sem Rechutes : 54% vs 57% vs 70% vs 100%
Secukinumab - anti IL17	Venhof [195]	2023	TitAIN	52	Phase 2	Rechutes : 30% (secukinumab) vs 80% (placebo) à 28 sem
	NCT05380453	En cours	GigAINt		Phase 3	
	NCT04930094	En cours	GCAptAIN		Phase 3	
Ustekinumab - anti IL12/IL23	Conway [196]	2018		25	Observationnel	Aucune rechute pendant 12 sem de traitement 24% d'arrêt des CTC à 52 sem
	NCT03711448	En cours	ULTRA		Phase 2	
Guselkumab - anti IL23	NCT04633447	En cours	THEIA		Phase 2	
Anakinra – anti IL1	Ly [197]	2014		3	Série de cas	Efficacité pour les 3 patients
		En cours	GIAnT		Phase 3	
Abatacept – anti CLTA4	NCT04474847	En cours	ABAGART		Phase 3	
Anti-TNFα	Hoffman [198]	2007		44	Randomisé	Infliximab vs placebo Rechutes : 57 vs 50% à 22 sem. Absence d'épargne CTC
	Seror [199]	2014		70	Randomisé	Adalimumab vs placebo Rechutes : 41 vs 50% à 26 sem
Inhibiteur de JAK						
Baracitinib	Koster [200]	2022		15	Observationnel	Rechutes : 7% à 52 sem
Upadacitinib	NCT03725202	En cours	Select-GCA		Phase 3	
Mavrilimumab - anti GM-CSF R	Cid [201]	2022		70	Phase 2	Mavrilimumab vs placebo Rechutes : 19% vs 46% à 26 sem
Cyclophosphamide	de Boysson [202]	2013		15	Série de cas	Rechutes : 40% à 43 mois de suivi moyen
Mycophenolate Mofetil	Pankow [203]	2023		7	Série de cas	Aucune rechute pendant 1 an de traitement
Azathioprine	Boureau [204]	2016		28	Rétrospectif	Rechutes : 11% à 1 an
Cyclosporine A	Schaufelberger [205]	2006		60	Randomisé	90% d'effets indésirables dans bras cyclosporine A
Leflunomide	Adizie [206]	2012		23	Série de cas	Rechutes : 40% à 2 ans. Epargne cortisonique 50% d'effets indésirables
	Diamantopoulos [207]	2013		11	Rétrospectif	Efficacité sur syndrome inflammatoire biologique
	Hočevar [208]	2019		76	Observationnel	Leflunomide versus placebo Rechutes : 13 vs 39% à 48 semaines. Epargne cortisonique
Dapsone	Ly [209]	2016		70	Rétrospectif	Epargne cortisonique 64% d'effets indésirables
Bosentan - anti endothéline R	NCT03841734	En cours	CECIBO		Phase 3	

Tableau 7. Etudes principales évaluant les autres traitements d'épargne cortisonique au cours de l'ACG.

I.1.14 Pronostic

Le pronostic de l'ACG se décompose en plusieurs aspects :

- Risque de reprises évolutives et de rechutes
- Pronostic vital à court et long termes
- Pronostic fonctionnel lié principalement aux conséquences des atteintes ischémiques visuelles ou cérébrales
- Effets indésirables des thérapeutiques

I.1.1.1. Reprises évolutives, récidives

Le risque de rechutes de la maladie, que ce soit sous traitement ou à distance de son arrêt, reste une problématique importante au cours de l'ACG. Une méta-analyse récente de 2023 a colligé les différentes caractéristiques associées aux risques de rechutes [210]. Le risque cumulé de rechute est de 32% à 1 an, 44% à 2 ans et 47% à 5 ans. Le sexe féminin (OR 1.43) et une atteinte des gros vaisseaux (OR 2.04) étaient prédictifs de rechutes dans cette étude.

I.1.1.2. Mortalité, pronostic visuel et aortique

La survie à 5 ans est similaire à celle de la population générale, avec toutefois une surmortalité cardio-vasculaire survenant notamment dans les 4 premiers mois [211-214]. L'atteinte visuelle fait tout le pronostic à court terme comme évoqué précédemment. Sur le long terme, le risque aortique prédomine à type d'anévrisme, dilatation, ou rupture le plus souvent fatale.

I.1.15 Physiopathologie

L'ACG est une panartérite granulomateuse constituée d'un infiltrat inflammatoire composé de lymphocytes T CD4, de macrophages et de cellules géantes dans 50% des cas, affectant les 3 tuniques de l'artère. Son initiation reste actuellement indéterminée et l'étude des différents facteurs immunitaires tentent d'en établir l'origine mécanistique. L'initiation du processus débute au niveau de l'adventice, seule région de la paroi artérielle dont la vascularisation est assurée par les *vasa vasorum*. Le développement de l'ACG se compose de plusieurs mécanismes intriqués : un terrain génétique prédisposant, un facteur déclenchant non spécifiquement identifié, le vieillissement du système immunitaire, et une activation d'une réponse immunitaire innée et adaptative [215].

Terrain génétique – système HLA (Complexe majeur d'histocompatibilité)

La répartition géo-épidémiologique de l'ACG, prédominant dans les populations d'origine scandinave/nordique ainsi que l'observation de cas familiaux, suggèrent une participation génétique potentielle dans sa pathogenèse [216-222]. Le développement d'études génétiques a permis d'identifier des gènes cibles susceptibles d'être associés au développement de l'ACG. Schématiquement, deux types d'études existent : l'étude du polymorphisme de gènes ciblés et l'étude d'association à l'échelle du génome entier.

Dans le premier cas, les études se sont concentrées sur les gènes codant pour le complexe majeur d'histocompatibilité ou *Human leucocyte antigen* (HLA) de classe II, impliqués dans la présentation de l'antigène, soulignant l'hypothèse d'une activation immunitaire sous-jacente à l'initiation de l'artérite ainsi qu'un polymorphisme associé à différentes molécules participant à la réponse inflammatoire connues de l'ACG. Plusieurs études ont révélé une association entre l'ACG et l'expression des allèles HLA-DRB1*04 (haplotypes HLA-DRB1*04:01, HLADRB1*04:04 et HLADRB1*04:08) [223-233]. Des phénotypes cliniques particuliers de la vascularite s'associent à certaines expressions d'allèles : HLA-B*15:01, HLA-B52 (atteinte des gros vaisseaux) [234,235]. D'autres polymorphismes sont aussi identifiés tel que rs2250889 du gène MMP-9 [236]. Une étude a montré une potentielle association avec le gène ICAM-1 mais non confirmée par ailleurs [237,238].

Les études de plus grande ampleur, à l'échelle du génome entier ont permis de révéler des données plus précises. L'équipe de Carmona, a particulièrement travaillé sur le sujet. La région HLA de classe II était fortement associée à l'ACG, contrairement à d'autres vascularites systémiques génétiquement liées aux molécules HLA de classe I (Takayasu, Behçet) [239,240]. Une autre étude a confirmé cette association, en plus de l'identification du polymorphisme du gène du plasminogène et de la sous-unité alpha-2 de la Prolyl 4-hydroxylase (P4HA2) [241]. De plus, une méta-analyse a mis en évidence le polymorphisme du gène IL1-2B associé au risque d'ACG [242].

Vieillessement du système immunitaire et ACG

Plusieurs études concernent les mécanismes associés au vieillissement immunitaire (ou immunosénescence) qui pourrait constituer un terrain favorisant à la survenue de l'ACG. Les principales caractéristiques de l'immunosénescence sont marquées par des modifications épigénétiques liées à des défauts de la méthylation de l'ADN, consécutive à un déficit en ADN méthyltransférase 1 qui apparaît avec l'âge, notamment dans les lymphocytes T (LT) [215].

L'immunosénescence est marquée par une diminution des LT CD4 naïfs, une augmentation des LT CD8 perdant l'expression du CD28, une restriction du répertoire T au profit d'une augmentation des LT mémoires oligoclonaux spécifiques d'infections virales persistantes comme le *Cytomegalovirus* (CMV). Un état inflammatoire chronique (« *inflamm-aging* ») résulte d'une libération permanente, sans stimulation immunitaire, de cytokines pro-inflammatoires IL-1 β , IL-6 et TNF- α produites par les cellules sénescents, monocytes, macrophages, cellules dendritiques ainsi que par les cellules endothéliales et les fibroblastes. Une diminution de la tolérance immunitaire notamment des LT CD8 régulateurs via un déficit en NADPH2 oxydase favorise les lésions tissulaires, notamment vasculaires au cours du vieillissement [243].

Une étude comparative d'artères temporales de patients porteurs d'ACG et saines a montré qu'une hypométhylation de l'ADN augmentait l'expression de plusieurs gènes pro-inflammatoires IL-6, TNF, IL-1 β , activant les LT (IL-2, IL-18 IFN- γ , IL-17RA, CD40L) et les facteurs de transcription associés à leur activation et leur polarisation en lymphocytes helper de type 1 et 17 (Th1 et Th17) [244].

Facteurs déclenchants

L'initiation de l'ACG reste mal élucidée. Les facteurs environnementaux associés à un contexte immunitaire favorisant, lié au vieillissement, ont été évoqués.

Infectieux

Les cellules dendritiques résidentes de l'adventice artérielle joueraient un rôle important dans l'initiation de l'ACG. Elles expriment des récepteurs de surface ou *Toll-like* récepteurs (TLR). Ces TLR réagissent à différents stimuli engendrant une activation des cellules dendritiques [245,246]. Les patients atteints d'ACG ont des cellules dendritiques adventitielles exprimant fortement les TLR de type 2 et 4 [247]. Les TLR-2 réagissent à des antigènes de bactéries Gram positif alors que les TLR-4 à des antigènes de bactéries Gram négatif comme le lipopolysaccharide (LPS) ou des protéines de choc thermique (*Heat-shock protein*, HSP).

Ces données évoquent une hypothèse infectieuse comme initiatrice du processus d'ACG. Par ailleurs, certaines études ont mis en avant le caractère cyclique (mensuel ou saisonnier) de survenue de l'ACG suggérant un potentiel rôle infectieux initiateur [248-255]. D'autres études sont venues cependant infirmées cette hypothèse [256-260]. De nombreux pathogènes ont été recherchés dans les artères de patients atteints d'ACG. Ces différentes études présentes des résultats contradictoires (**Tableau 8**).

Germes	Etudes positives	Etudes négatives
<i>Herpes Simplex Virus</i> (HSV)	[261]	[262-267]
<i>Virus Varicelle Zona</i> (VZV)	[268,269]	[262,264,265,267,270-272]
<i>Epstein Barr Virus</i> (EBV)		[263-267]
<i>Cytomegalovirus</i> (CMV)	[273]	[264-267,274]
<i>Human Herpes Virus 6</i> (HHV6)		[264,265,267,271]
<i>Parainfluenzae 1</i> (HPIV1)	[263]	
<i>Parvovirus B19</i> (PVB19)	[271,274]	[264,265,267]
<i>Chlamydia Pneumoniae</i>	[275]	[264,276-278]

Tableau 8. Etudes sur la présence de germes microbiens au sein de BAT de patients porteurs d'ACG.

Il se pourrait que les infections de manière générale, agissent comme déclencheur de la maladie. Par ailleurs, nous avons remarqué une augmentation d'incidence de la maladie lors de l'épidémie *Covid-19* dans notre service de Médecine interne au CHU de Limoges (**Annexe 8**). Toutefois les analyses de *Polymerase Chain Reaction* (PCR) à la recherche du virus sur BAT n'ont pas révélé de présence de virus *Covid-19*.

L'âge avancé des patients à risque d'ACG complique d'autant plus l'établissement d'un lien clair entre les organismes infectieux et la vascularite, du fait de l'hébergement d'infections chroniques comme le *virus varicelle-zona* (VZV) ou le *cytomégalo*virus [279].

Vaccins

Notre équipe a mis en évidence pour certains patients atteints d'ACG, une vaccination précédant la survenue de la vascularite (**Annexe 9, Annexe 10**). A l'instar des infections, les vaccins pourraient aussi agir comme déclencheur de la vascularite. Des études de pharmacovigilance ont récemment suggéré également cette hypothèse [281-283].

Inhibiteurs des points de contrôle immunitaire

L'utilisation croissante des inhibiteurs de points de contrôle immunitaire (*Immune Checkpoint inhibitor*) dans les domaines de la cancérologie ou de l'hématologie a révélé plusieurs cas de déclenchement d'ACG, et particulièrement d'aortite [284-286]. Le Nivolumab (anti-PD1), utilisé pour traiter les mélanomes, les cancers pulmonaires non à petites cellules ou rénaux, est à l'origine de plusieurs signalements de vascularite des gros vaisseaux dans la littérature. Une étude récente a souligné le lien potentiel avec un autre inhibiteur de point de contrôle immunitaire, l'Ipilimumab, un anti-CLTA4, également employé dans le cadre des mélanomes et cancers rénaux [283,287].

Facteurs de croissance

Enfin, des cas secondaires à l'usage de facteurs de croissance médullaires (G-CSF) ont été rapportés [288-291].

Mécanismes physiopathologiques de l'ACG

Les progrès concernant la compréhension des mécanismes de l'ACG ont permis de proposer un modèle physiopathologique dynamique en plusieurs étapes [279,292-294]. Le Professeur Cornelia Weyand a récemment résumé ces différents mécanismes (**Figure 15**) [279].

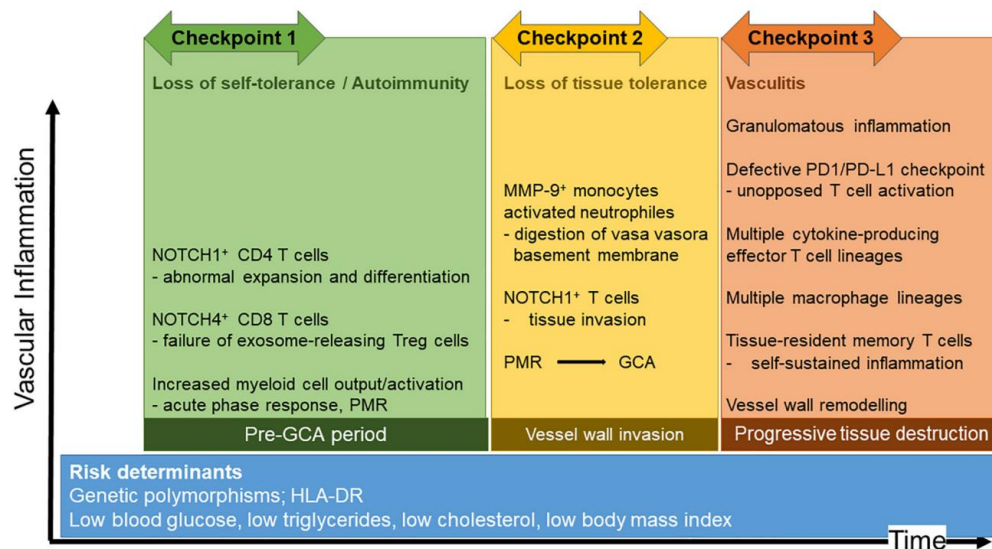


Figure 15. Phase temporelle et mécanismes principaux de l'ACG d'après Weyand [279].

Facteurs déterminants :

- Prédilection génétique HLA-DR.
- Phénotypes métaboliques : faible indice de masse corporelle, hypoglycémie, hypotriglycéridémie, hypocholestérolémie.

Point de contrôle 1 - perte de tolérance immunitaire :

- Expansion des lymphocytes T CD4⁺ NOTCH1⁺.
- Echec de protection par les lymphocytes T CD8⁺ NOTCH4⁺ régulateurs en raison de l'hypersignalisation NOTCH.
- Augmentation de l'hématopoïèse, avec libération de cellules myéloïdes activées (neutrophiles, monocytes), déclenchant une réponse hépatique et des symptômes cliniques de PPR.

Point de contrôle 2 - perte de tolérance tissulaire :

- Franchissement de la barrière endothéliale par les monocytes et les neutrophiles.
- Envahissement de la paroi des vaisseaux par les lymphocytes T.

Point de contrôle 3 – établissement de la vascularite :

- Formation de granulome par les lymphocytes T et macrophages.
- Environnement permissif par défaut PD1/PD-L1 et prolifération cellulaire
- Auto-entretien et autonomie de l'infiltrat sous l'effet des lymphocytes T mémoires
- Remodelage vasculaire avec néo-angiogenèse et hyperplasie intimale.

Initiation de l'ACG

L'initiation de la vascularite débute par l'activation de l'hématopoïèse myéloïde qui augmente la population des cellules innées (monocytes, macrophages et polynucléaires) au contact des cellules endothéliales des *vasa vasorum*. Les propriétés intrinsèques de la cellule endothéliale adventitielle facilitent l'adhérence et le passage transendothélial des cellules immunitaires. Une rupture de la tolérance tissulaire et immunitaire représente le mécanisme sous-jacent à l'atteinte artérielle.

1) Hématopoïèse excessive et rôle des cellules myéloïdes

Au cours de l'ACG, la réponse inflammatoire systémique est orchestrée par les cellules de la lignée myéloïde [279]. Elles sont principalement composées de polynucléaires, de monocytes, de macrophages, et de cellules dendritiques [295]. Ces cellules sont dérivées de la moelle osseuse, recrutées en réponse à des signaux de danger ou inflammatoires, s'associent aux macrophages tissulaires (histiocytes) et participent au maintien des tissus sains [296]. Les différents stimuli provenant de la moelle osseuse ou de l'environnement tissulaire périphérique permettent d'orienter et réguler les fonctions de ces cellules myéloïdes. Leur rôle de cellules présentatrices d'antigènes aux lymphocytes T (LT) est fondamental dans la tolérance immunitaire. Cette tolérance peut se rompre dans certains états pathologiques notamment au cours de l'ACG [279].

En cas de signaux de danger, la moelle osseuse augmente sa capacité de renouvellement et de production de cellules myéloïdes. Ces signaux sont variés tels que des motifs moléculaires associés aux dommages cellulaires (*Damage Associated Molecular Pattern*, DAMPs) de nature microbiennes ou mitochondriales, des facteurs de croissance (GM-CSF, G-CSF, M-CSF, IL-3), des interleukines pro-inflammatoires (IL-1), des métabolites, des facteurs sécrétés associés à la sénescence (*Senescence-associated secretory phenotype* SASP), des cellules produisant de l'IL-17 (qui recrutent les neutrophiles, dénommés « LT régulateurs des neutrophiles » ou Tn) (**Figure 16**) [279]. De plus les récepteurs à l'IL-27 sont également impliqués dans l'activation des cellules souches hématopoïétiques quiescentes vers la différenciation de cellules myéloïdes matures en réponse à un stress. Ces cellules myéloïdes s'accumulent au niveau des parois artérielles où elles contribuent à la composante inflammatoire [279,297,298].

Au cours de l'ACG, cet « état d'urgence » de l'hématopoïèse se traduit par une augmentation du nombre de monocytes et de neutrophiles circulants, possédant un phénotype moins différencié [299]. Cette activation anormale reste présente au cours de l'ACG, et persiste malgré le traitement par corticoïdes [279].

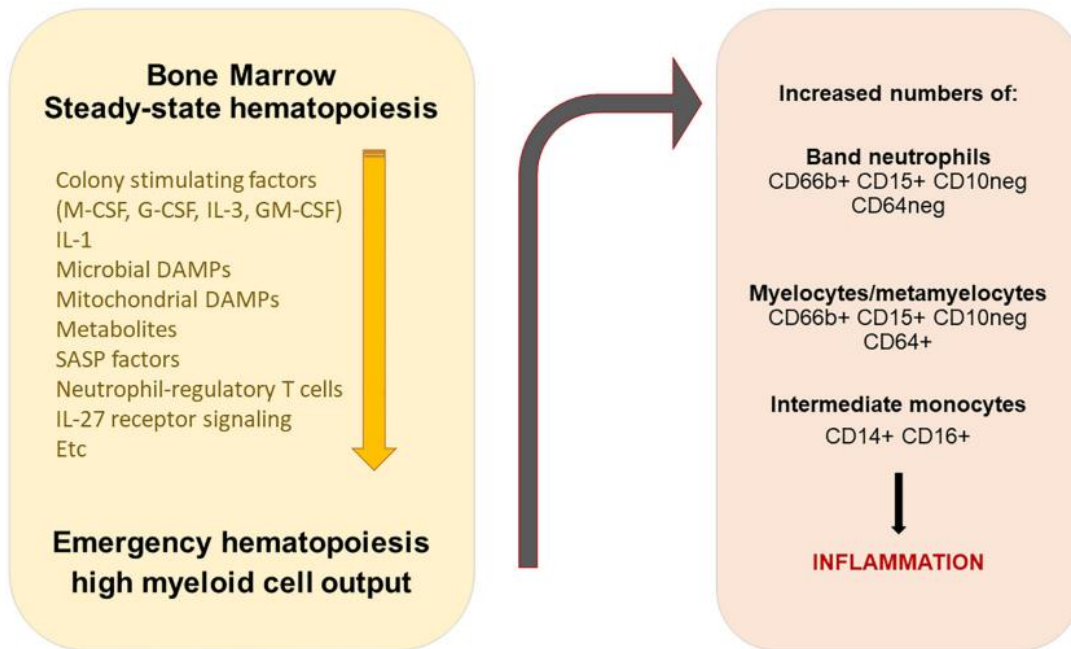


Figure 16. Activation des cellules myéloïdes au cours de l'ACG d'après Weyand [279].

Les polynucléaires neutrophiles immatures produisent des espèces réactives de l'oxygène (*Reactive oxygen species*, ROS), affectant la fonction des cellules endothéliales. Ils libèrent aussi des enzymes lytiques ainsi que des pièges extracellulaires (*Neutrophil extracellular traps*, NETs). Les NETs sont signalés près des *vasa vasorum* adventitiels d'artères temporales atteintes par l'ACG [300].

Les monocytes dérivés de la moelle osseuse sont schématiquement de 3 types (**Figure 16**) : classiques pro-inflammatoires (CD14⁺CD16⁻), pouvant se différencier en macrophages tissulaires, intermédiaires (CD14⁺CD16⁺) et non classiques anti-inflammatoires (CD14⁻CD16⁺) avec des fonctions encore débattues [301]. Les patients atteints d'ACG ont un nombre plus élevé de monocytes intermédiaires CD14⁺CD16⁺ [299]. Ces monocytes circulants produisent des métalloprotéinases de type 2 et 9 (MMP2 et MMP9), responsables d'une digestion tissulaire. Les monocytes se différencient en macrophages producteurs de chimiokines [302,303].

2) Perte de la tolérance tissulaire

Les artères sont normalement protégées d'une inflammation inappropriée, phénomène appelé le « privilège immunitaire ». Leur protection contre les attaques repose principalement sur l'intégrité de la barrière endothéliale. La voie d'accès des cellules infiltrant les artères de gros et moyens calibres, dépend de l'adventice, couche la plus externe de l'artère, contrairement à la lumière principale de l'artère [247,279].

Au cours de l'ACG, l'infiltrat cellulaire envahit l'artère à partir des *vasa vasorum* de l'adventice, puis se répand vers la média et l'intima. Il se produit ainsi initialement une perte de tolérance tissulaire par rupture de la barrière endothéliale des *vasa vasorum* [279]. Les LT producteurs d'IFN- γ sont initialement présents dans l'adventice et les cellules dendritiques au niveau de la bordure adventice-média [308].

Les mécanismes entraînant la rupture de cette barrière protectrice ont été décryptés. Comme cités précédemment, la production médullaire excessive de polynucléaires neutrophiles entraîne une sécrétion accrue de ROS qui peuvent oxyder la paroi endothéliale [309]. Egalement, les monocytes circulants au cours de l'ACG produisent des métalloprotéinases (MMP-2 et -9) capables de digérer la membrane basale des cellules endothéliales [302,310]. Les *vasa vasorum* ont un phénotype anormal, marqué par la production d'une seule sous unité de l'IL-23, l'IL-23p19 dépourvue de la sous-unité d'IL-12p40, normalement présente dans les macrophages et les cellules dendritiques qui sécrètent de l'IL-23 [311]. L'expression endothéliale de l'IL-23p19 est intracellulaire et s'associe à une autre sous-unité, la gp130 (sous-unité commune aux cytokines de la famille de l'IL-6), pour activer STAT3 qui augmente l'expression des molécules d'adhérence ICAM1 et VCAM1 au niveau des capillaires adventitiels ce qui favorise l'adhérence des leucocytes [311].

De plus, les cellules endothéliales des *vasa vasorum* expriment de façon aberrante le ligand de NOTCH, *Jagged*, qui peut ainsi interagir avec les LT CD4 exprimant NOTCH1. Cette interaction permet leur différenciation en LT effecteurs pro-inflammatoires et leur migration au sein de l'artère [305].

Enfin ces cellules endothéliales sont stimulées par le facteur de croissance de l'endothélium vasculaire (*Vascular endothelial growth factor*, VEGF). Il est effectivement présent de façon abondante dans les sérums de patients atteints d'ACG [312,313].

3) Les cellules dendritiques

Elles sont présentes au niveau de la paroi vasculaire et initient le processus inflammatoire. Initialement présentes sous la forme de cellules dendritiques myéloïdes immatures, leur activation résulte de l'interaction des TLR qu'elles expriment par des ligands non actuellement identifiés (exogènes ou endogènes). Une variabilité d'expression des TLR a été décrite selon la distribution anatomique des artères suggérant une répartition d'origine embryologique [247]. Cette activation induit leur maturation par expression des molécules de co-activation CD80/86 et HLA de classe II, la production de chimiokines (CCL18, CCL19, CCL20 et CCL21) et de cytokines (IL-1, IL-6, IL-12, IL-18 et IL-33). Ces facteurs recrutent les LT CD4⁺ dans la paroi artérielle et les polarisent en Th1 (produisant de l'IFN- γ) et en Th17 (produisant l'IL-17). L'IFN- γ active les cellules musculaires lisses et les cellules endothéliales qui produisent du VEGF et des chémokines (CCL2, CXCL9, CXCL10 and CXCL11), conduisant à la formation d'une néo angiogenèse et au recrutement d'autres monocytes et lymphocytes T vers le site de l'inflammation [294].

4) Perte de la tolérance immunitaire

L'ACG se caractérise par la présence de LT CD4⁺ circulants et infiltrant les tissus. Ces lymphocytes ont un seuil abaissé de réponse aux stimuli antigéniques [304].

Il existe une sous-population particulière de LT CD4⁺ exprimant de façon inappropriée le récepteur NOTCH1 [305]. La fonctionnalité de NOTCH résulte de son clivage successif par des métalloprotéinases puis une gamma sécrétase qui libère le fragment intracellulaire actif et permet son passage au niveau nucléaire. Cette activation protéolytique du récepteur NOTCH est induite par la stimulation du récepteur par ses ligands (Jagged1, delta1) qui sont surexprimés par les cellules dendritiques lors de leur présentation de l'antigène. Une surexpression de NOTCH1 et de ses ligands a été détectée dans les artères de patients atteints d'ACG [304]. Cette activation entraîne une expansion lymphocytaire T, leur migration du sang périphérique vers la paroi artérielle et des modifications métaboliques [305]. L'expression aberrante des ligands de NOTCH au niveau des *vasa vasorum* permet aux LT NOTCH⁺ de pénétrer dans l'adventice normalement protégée, et ainsi rompre le « privilège immunitaire » [279].

De façon intéressante, l'inactivation de NOTCH par un inhibiteur de gamma secrétase ou de son ligand *Jagged*, inhibe l'activation des LT, marquée par une diminution de l'IFN- γ et de façon plus importante de l'IL-17, démontrées *in vitro* lors de la diminution de la co-activation des cellules dendritiques et des LT de patients. Parallèlement, ceci est corrélé à la régression des lésions d'artérite dans un modèle d'ACG expérimentale (souris chimériques immunodéficientes SCID avec greffe d'artère humaine, et reconstituées par de cellules mononucléaires périphériques [PBMC] de patients ACG) [304].

Par ailleurs, un autre récepteur de la famille des récepteurs NOTCH, NOTCH4 est exprimée de façon aberrante par certains LT régulateurs (LTreg) au cours de l'ACG, conduisant à un défaut de leur fonction anti-inflammatoire [306]. Normalement, les LTreg CD8⁺ permettent une régulation de la réponse immunitaire notamment en supprimant l'activation et l'expansion des LT CD4⁺ pro-inflammatoires, par libération d'exosomes contenant l'enzyme NADPH oxydase 2 (NOX2) [305]. Cette fonction régulatrice est perturbée au cours de l'ACG. Il existe un déficit quantitatif et qualitatif des LT reg dans le sang périphérique et au sein du tissu artériel, lié à un défaut de production d'exosomes (**Annexe 11**) [306]. Une signalisation aberrante du récepteur NOTCH4 perturbe la sécrétion exosomale de NOX2 par les LTreg CD8⁺, leur empêchant d'effectuer une réponse immunitaire adaptative efficace. La perte de cette fonction est dépendante de l'âge mais se produit aussi prématurément chez les patients atteints d'ACG [279,305].

Formation de l'infiltrat granulomateux

L'ACG est caractérisée par un infiltrat artériel granulomateux composé de lymphocytes et de macrophages. Ces derniers peuvent parfois fusionner et former des cellules géantes multinucléées (signant le nom de la maladie), situées notamment au niveau de la limitante élastique interne fragmentée [279].

1) Lymphocytes T

Les LT CD4⁺ sont les lymphocytes prédominants avec une majorité activée et en division. La plupart exprime des marqueurs phénotypiques de LT mémoires résidants [314]. Ils sont dépendants de la co-stimulation CD28 et du métabolisme du glucose concernant leur différenciation en LT effecteurs. Ils produisent de nombreuses cytokines comme l'IFN- γ , les IL-2, IL-17, IL-21, IL-22, et IL-9 [315]. La prolifération est de nature oligoclonale avec la coexistence de plusieurs lignées T, remettant en question une réponse spécifique d'un seul et unique antigène [279].

Plusieurs profils principaux de T effecteurs sont décrits :

- LT helper de type 1 (LTh1), qui produisent principalement de l'IFN- γ , situés au niveau de l'adventice, et volontiers résistants à la corticothérapie [308,316].
- LT helper de type 17 (LTh17) sécrétant de l'IL-17 et disparaissant sous corticothérapie [316,317].
- LT folliculaires auxiliaires (LTfh) produisant de l'IL-21 et permettant une coopération avec les lymphocytes B et la formation de structures lymphoïdes tertiaires [279]. La sécrétion d'IL-21 joue un rôle de soutien à la survie des LTh1 et LTh17 [318].
- LT helper de type 9 (LTh9) sécrétant de l'IL-9 [319].

Dérégulation de la voie STAT

Une analyse transcriptomique d'artères temporales a montré une augmentation d'expression des gènes STAT1, STAT2 et STAT4, compatible avec une signalisation dominante et dépendante de l'IFN- γ et de l'IL-12 [320]. Il n'existe pas de différence de régulation concernant les gènes dépendants de STAT3 [279]. Cependant ces données concernant STAT3 ont été obtenues avec des modèles de souris chimériques immunodéficientes (en LB, LT et NK, souris NSG) greffées avec des artères humaines et reconstituées avec des PBMC de patients porteurs d'ACG. Elles ne sont pas confirmées dans une autre étude effectuée par analyse transcriptomique d'aortes et de LT circulants de patients ayant une ACG [321]. Cette étude montre une

augmentation de l'expression de STAT3, en lien avec l'activation de gènes associés à l'IFN- α . L'activation de STAT 3 est aussi décrite dans d'autres voies associées à la physiopathologie de l'ACG, par exemple lors de l'orientation des LT vers la voie des Th17 [322]. De plus, comme décrit précédemment, STAT3 est également activé dans les cellules endothéliales adventitielles via l'IL-23 [311], ce qui implique son activation à différentes étapes de l'artérite et notamment dès la phase d'initiation.

Dérégulation de la voie PD-1 PD-L1

Au cours de l'ACG, les LT des lésions artérielles surexpriment PD-1, à l'inverse de ce qui est observé chez les contrôles ou dans le sang circulant des patients [323]. En revanche, une diminution de l'expression du ligand de PD-L1 est observée dans les cellules dendritiques. Ceci concerne PD-L1 et non PD-L2. Ainsi, la répression de PD-1 par les cellules dendritiques n'est pas effective, ce qui est associé à une activation non régulée des LT. Ce mécanisme observé dans les lésions artérielles de l'ACG s'oppose aux cellules cancéreuses dont le système immunitaire est réprimé par hyperactivation de la voie PD-1-PD-L1, permettant l'usage de biothérapies bloquant cette voie. Au cours de l'ACG, ce sont des LT exprimant PD-1 qui sont à l'origine de l'infiltration artérielle et des lésions vasculaires. L'inhibition de PD-1 par un anticorps bloquant aggrave les lésions vasculaires et favorise la redistribution et l'activation des LT sécrétant de l'IFN- γ , de l'IL-21, et de l'IL-17 sans affecter les LT régulateurs FoxP3 ni ceux qui sécrètent de l'IL-4. Globalement, ces LT surexprimant PD-1 favorisent l'activation de LT pro-inflammatoires ayant un phénotype de LT mémoires CCR5⁺. Ces LT PD-1 entraînent des lésions vasculaires en favorisant le remodelage vasculaire avec activation des cellules endothéliales, prolifération des myofibroblastes et expression du facteur de transcription TWIST associé à la transition endothélio-mésenchymateuse. L'expression de TWIST suggère un état de transition des cellules endothéliales vers des myofibroblastes, montré dans les modèles de souris chimériques [323].

2) Lymphocytes B et formation de structures lymphoïdes tertiaires

Des structures lymphoïdes tertiaires ont été identifiées dans la média d'ACG à proximité des granulomes (indépendamment de la présence de lésions athéromateuses). Elles sont constituées de lymphocytes B (LB), de LT dont la répartition est caractéristique des structures lymphoïdes, autour d'une zone centrale constituées de cellules dendritiques folliculaires (CD21⁺) (**Figure 17**). Au cours de l'ACG, Les LB sont peu nombreux et essentiellement localisés dans ces structures tertiaires, situées à proximité de formations vasculaires endothéliales et de néovaisseaux lymphatiques témoignant d'une activation de ces formations. La migration des LB est liée aux chemokines CXCL9 et CXCL13, largement exprimées dans les trois couches artérielles et dont les LB expriment les récepteurs respectifs CXCR3 et CXCR5 [325]. L'activation et la migration des LB permet ainsi l'organisation de ces structures lymphoïdes tertiaires. L'activation lymphocytaire B est également liée à la sécrétion de BAFF qui a été mise en évidence dans les coupes d'artères ACG par analyse transcriptomique et immunomarquage [326]. De façon intéressante, ce sont les myofibroblastes et les cellules musculaires lisses vasculaires qui sécrètent BAFF et CXCL13 [326].

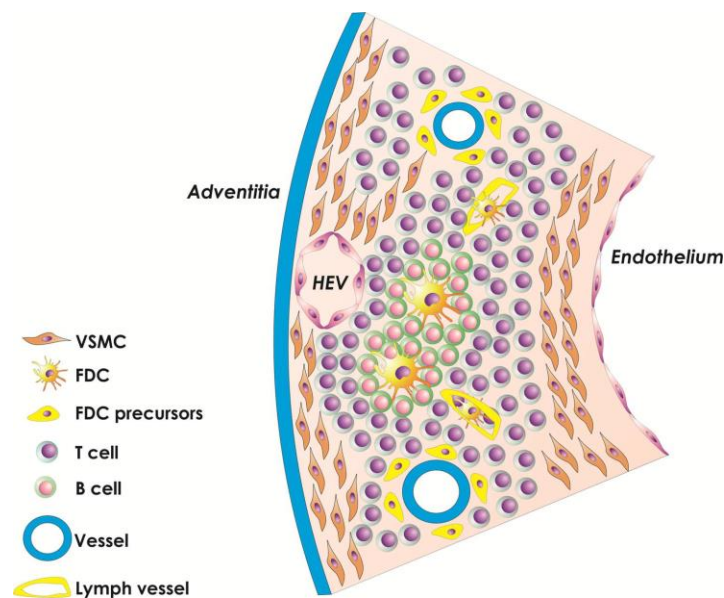


Figure 17. Représentation schématique de structures lymphoïdes tertiaires dans la média d'artère de patients atteints d'ACG montrant la répartition distincte des LT et des LB autour des cellules dendritiques folliculaires et la présence d'une néo angiogenèse formée par les cellules endothéliales (HEV, *High endothelial venule*) [327].

Dans une autre revue récente de 2022, l'équipe de Maxime Samson du CHU de Dijon a résumé les différentes étapes de l'ACG (**Figure 18**) [294] :

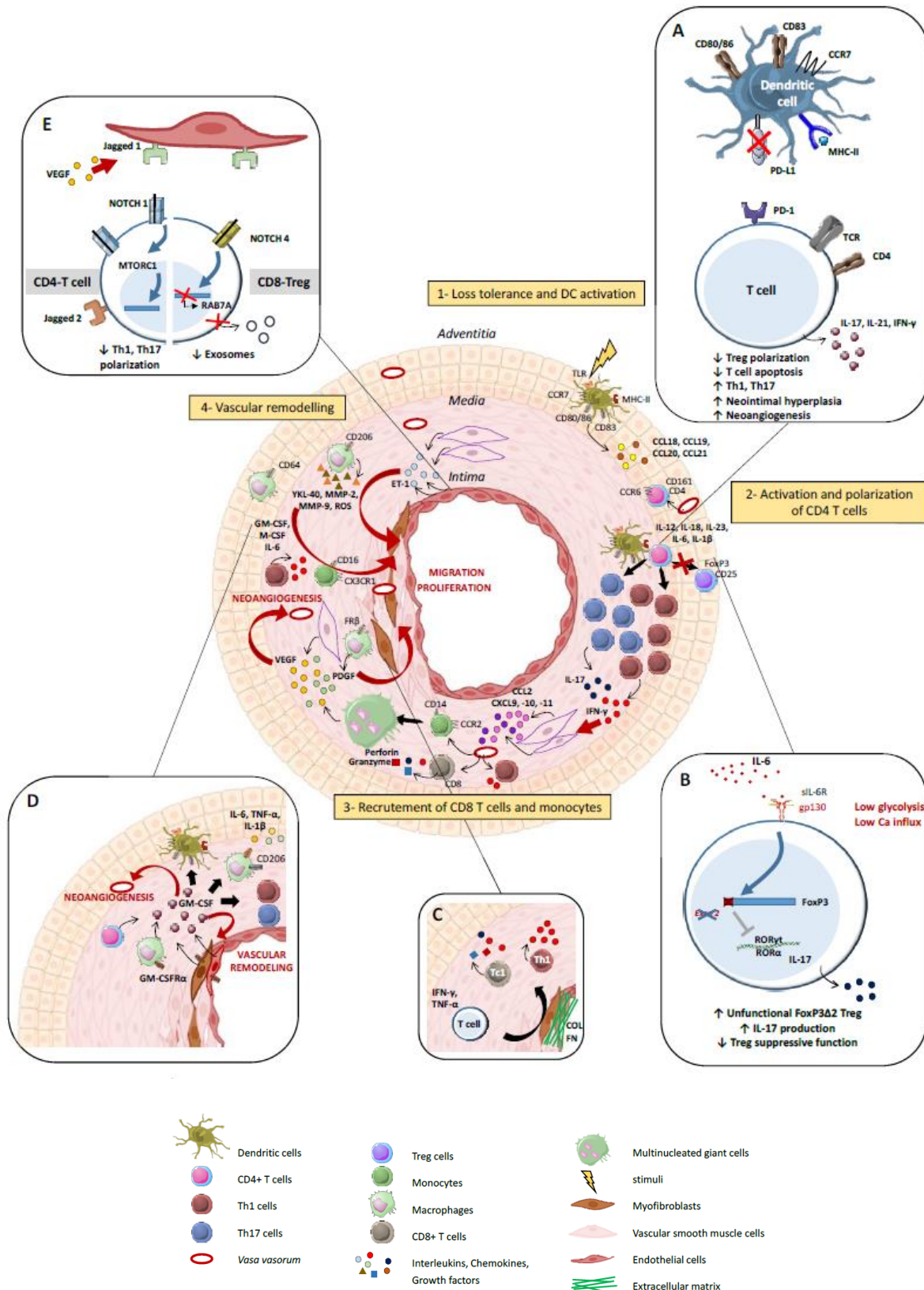


Figure 18. Modèle physiopathologique de l'ACG d'après Greigert [294].

Résumé de la pathogenèse de l'ACG (Figure 18)

Étape 1 : Un signal de danger non défini active les cellules dendritiques vasculaires qui acquièrent un phénotype mature (CD83⁺CD80/86⁺CCR7⁺CMH-II^{high}) et produisent des chimiokines (CCL18, CCL19, CCL20 et CCL21), conduisant au recrutement de cellules T CCR6⁺CD161⁺CD4⁺.

Étape 2 : Les cellules T CD4⁺ sont activées par les cellules dendritiques et se polarisent en cellules Th1 et Th17 sous l'effet des IL-12, IL-23, IL-6 et IL-1 β , produites par les cellules dendritiques activées. Les lymphocytes Th1 et Th17 libèrent respectivement de l'IFN- γ et de l'IL-17.

Étape 3 : L'IFN- γ induit l'activation des cellules musculaires lisses vasculaires (CMLV) dans le milieu et leur permet de produire des chimiokines (CCL2, CXCL9, CXCL10, CXCL11), qui déclenchent le recrutement de cellules T supplémentaires (CD4⁺ et CD8⁺) et de monocytes. Les monocytes se différencient en macrophages et fusionnent en cellules géantes multinucléées, caractéristique de l'ACG.

Étape 4 : Le remodelage vasculaire est caractérisé par la destruction de la couche élastique interne et par la prolifération et la migration des CMLV dans l'intima. Les macrophages jouent un rôle clé dans ce processus en libérant plusieurs facteurs tels que le PDGF, les espèces réactives de l'oxygène (ROS), la MMP-9, l'IL-6, l'IL-1 β , le GM-CSF et le TNF- α , qui contribuent aux lésions tissulaires et à l'hyperplasie de l'intima. De même, les CMLV et les cellules endothéliales libèrent de l'endothéline 1 (ET-1), qui stimule la migration et la prolifération des CMLV et induit ainsi une hyperplasie intimale. De plus, les macrophages et les CMLV produisent également le VEGF, qui est responsable de la néo angiogenèse et favorise une réponse inflammatoire locale. Une transition cellulaire des CMLV vers un phénotype myofibroblastique est observée, et l'accumulation de ces cellules dans la néo-intima conduit à une occlusion vasculaire, responsable des complications ischémiques de l'ACG.

(A-E) Mécanismes impliqués dans le maintien de l'inflammation vasculaire.

(A) Le défaut du PDL-1 à la surface des cellules présentatrices d'antigènes entraîne une activité persistante des lymphocytes T et contribue à l'hyperplasie et à la néo angiogenèse.

(B) L'IL-6 altère la fonction des LTregs, diminue leur fréquence et favorise le passage à une déficience des LTregs dans l'exon 2 de FoxP3 qui est enclin à produire de l'IL-17.

(C) Outre leur rôle dans le recrutement des monocytes et le remodelage vasculaire, les CMLV se différencient en myofibroblastes, qui participent également au maintien des polarisations Th1 et Tc1. De plus, les myofibroblastes ont une capacité importante à produire des protéines de la matrice extracellulaire (collagène, fibronectine) qui contribuent à la rigidification de la paroi vasculaire.

(D) Le GM-CSF est produit par les LT CD4, les macrophages, les CMLV et les cellules endothéliales. Le récepteur- α du GM-CSF est fortement exprimé dans les lésions d'ACG et une boucle d'amplification autocrine se met en place. Le GM-CSF est impliqué dans la différenciation cellulaire, l'inflammation vasculaire et le remodelage vasculaire.

(E) Les LT et les cellules résidentes de la paroi artérielle, comme les cellules endothéliales, communiquent par la voie NOTCH. Le lien de NOTCH1 à Jagged 1 diminue la polarisation Th1/Th17. Par ailleurs, dans les LTreg CD8⁺, la signalisation aberrante de NOTCH4 entraîne la suppression de RAB7A impliquée dans la libération exosomale de NOX2.

Remodelage vasculaire

Il aboutit à l'occlusion artérielle et résulte de l'action de différents acteurs cellulaires, les macrophages, les fibroblastes et les cellules musculaires lisses sous l'action des cytokines et facteurs de croissance environnants.

1) Macrophages

Les macrophages sont les principales cellules immunitaires pathogènes au cours de l'ACG. Ils ont de nombreuses fonctions dans la détection et la phagocytose d'éléments pathogènes, apoptotiques et des débris tissulaires. Ils peuvent aussi agir comme cellules présentatrices de l'antigène.

Schématiquement leurs propriétés démontrées dans l'ACG sont les suivantes [279,327] :

- Expression de chimiokines impliquées dans le recrutement de cellules inflammatoires [324]. Cette fonction se traduit par une importante activité mitochondriale, la production de facteurs de croissance et d'angiogenèse, entraînant le processus de remodelage vasculaire [327-331].
- Production de métalloprotéinases (notamment MMP-9), qui engendrent une destruction tissulaire [302,310].
- Co-stimulation immunitaire par l'intermédiaire du CD28 [314].
- Défaut d'expression du ligand PD-L1 se traduisant par l'absence de rétrocontrôle des LT [323].

Au cours de l'ACG, les macrophages produisent des espèces réactives de l'oxygène (ROS) qui entraînent une destruction de la média par apoptose des cellules musculaires lisses vasculaires (CMLV) [292]. Par ailleurs la production des métalloprotéinases et la diminution de leurs inhibiteurs participent à cette destruction [332].

Les macrophages sécrètent également des facteurs de croissance tels que le PDGF et le VEGF, contribuant à la formation de néovaisseaux au niveau de la média. Cette néovascularisation (ou néo angiogénèse) est corrélée à l'hyperplasie intimale et les phénomènes ischémiques de la maladie [329,330]. L'agression des CMLV entraîne, outre leur apoptose, la possibilité d'une dédifférenciation en myofibroblastes, leur prolifération et leur migration vers l'intima pour contribuer à l'hyperplasie intimale [245].

Néanmoins, les fonctions des macrophages varient selon leur localisation dans la paroi artérielle au cours de l'ACG et est inhérente à leur plasticité. Selon l'environnement cytokinique et les facteurs de croissance environnants, différents sous-types de macrophages ont été identifiés dans la paroi artérielle au cours de l'ACG [333].

Classiquement, 2 types de macrophages ont été identifiés *in vitro* :

- les macrophages de type 1 (M1) pro-inflammatoires (CD68, CD64 [ou FcγRI], iNOS) induits principalement par l'IFN γ .
- Les macrophages de type 2 (M2) anti-inflammatoires (CD68, CD163, CD206 et YKL-40), induits principalement par l'IL-4 et l'IL-13.

Une plus grande hétérogénéité a cependant été décrite dans la paroi artérielle au cours de l'ACG. Des macrophages CD206⁺YKL-40⁺MMP-9⁺ (induits par le GM-CSF) sont situés dans la média le long des zones lésées de la limitante élastique, tandis que des macrophages exprimant le Folate Receptor β (FR β ⁺) CD206⁻ (induit par le M-CSF) sont situés dans les zones d'hyperplasie intimale facilitant la prolifération des fibroblastes.

Cette hétérogénéité est propre à l'ACG et n'a pas été observée dans des artères athéromateuses. L'induction des macrophages par le GM-CSF favorise la production de YKL-40 qui est pro-angiogénique *in vitro*. L'inactivation de YKL-40 réduit la production de MMP-9 par les macrophages. Ainsi, le ciblage du GM-CSF ou du récepteur de YKL-40 ou de son récepteur (IL-13 R α 2) pourrait être une piste thérapeutique pour limiter le remodelage vasculaire dans l'ACG [331].

2) Formation de cellules géantes

Les cellules géantes multinucléées sont formées et localisées à la jonction de l'intima et de la média, au contact de la limitante élastique qui est fragmentée. Elles participent à la formation du granulome qui est dispersé dans la média. L'origine de cette formation est inexpliquée dans l'ACG. Expérimentalement, l'activation des TLR4 par le LPS induit l'activation des cellules dendritiques et des macrophages aboutissant à la formation de granulomes dans la paroi artérielle [334].

La formation de ces cellules géantes a été étudiée dans un modèle d'athérome expérimental chez la souris. Elles résultent de la fusion des macrophages, suite à une activation des macrophages par l'IL-4. De façon intéressante, ces cellules géantes sont localisées au niveau des fibres d'élastine dégradées, qui facilite ainsi l'invasion. Les produits de dégradation de l'élastine notamment le fragment de 67 kDa activent les cellules dendritiques et les macrophages, notamment par le biais d'un récepteur spécifique, « 67kDa elastin receptor » codé par le gène ELN exprimé par les macrophages. L'activation de ce récepteur induit la fusion des macrophages et la formation de cellules géantes [335].

D'autres études ont montré l'implication des tétraspanines CD9 et CD63 dans la fusion des monocytes en cellules géantes multinucléées [336]. Récemment, des études transcriptomiques ont montré que les monocytes circulants de patients ACG avaient une hypométhylation des gènes codant pour CD63, renforçant l'hypothèse de la fonction de cette tétraspanine dans la formation des cellules géantes [337].

3) Les cellules musculaires lisses vasculaires

Outre les cellules immunitaires, les cellules musculaires lisses localisées dans la paroi artérielle (CMLV) contribuent au remodelage conduisant à l'occlusion vasculaire [222]. Les CMLV sont activées par les cytokines environnantes sécrétées par les macrophages et les LT. Le GM-CSF produit par les macrophages active ces cellules qui produisent des métalloprotéinases, MMP-2 et principalement MMP-9, qui participent à la destruction de la limitante élastique interne [310]. De plus elles participent à l'activation de l'inflammation. En effet, sous l'action de l'IFN- γ sécrété par les LTh1, elles sécrètent des chemokines CXCL9, CXCL10, CXCL11, et CCL2 qui activent l'infiltration des monocytes et des LT. L'inhibition de l'IFN- γ supprime cette

invasion cellulaire en bloquant la production de chemokines par les CMLV [338]. L'IFN- γ active également les CMLV pour induire la sécrétion de PDGF qui augmente leur prolifération et migration dans l'intima, de VEGF qui active la néo angiogenèse et d'endothéline-1 qui favorise leur différenciation en myofibroblastes [339]. L'inhibition des récepteurs de l'endothéline-1 exprimés à la surface des CMLV, par le Macitentan, supprime leur migration *ex vivo* [340]. De même, l'inhibition du récepteur du PDGF inhibe leur migration *in vitro* [341].

Dans notre équipe, Ly et al ont montré que d'autres facteurs de croissance telles que les neurotrophines (NT), le NGF (*Nerve Growth Factor*) et le BDNF (*Brain-Derived Neurotrophic Factor*) ainsi que son récepteur TrkB sont surexprimés dans la média et l'intima des artères ACG [342]. Ces facteurs neurotrophiques activent la prolifération et la migration des CMLV *in vitro*. Dans cette même étude, la sortiline qui est une protéine de transport des NT et de cytokines (IL-6, IFN- γ) est également surexprimée dans les artères ACG. De façon intéressante, l'inhibition de la sortiline diminue son interaction avec l'IL-6 et l'IFN- γ et réduit les lésions athéromateuses dans un modèle expérimental murin [343]. Ces données suggèrent que la sortiline pourrait également contribuer à la composante inflammatoire des lésions artérielles de l'ACG.

4) Fibroblastes

Les fibroblastes artériels sont localisés dans la couche la plus externe de l'artère, l'adventice, constituée également de matrice extra cellulaire (MEC), d'adipocytes, de cellules dendritiques, de macrophages, de *vasa vasorum*, de nerfs périvasculaires [307]. Ils assurent la production de MEC et présentent une plasticité associée à cette fonction [343]. Ils occupent un rôle majeur dans le développement et le remodelage du tissu cicatriciel [344,345].

Il existe une grande diversité de sous-types fibroblastiques, que ce soit dans différents organes et au sein d'un même tissu. Leur hétérogénéité et leur capacité adaptative leur confèrent de nombreuses fonctions dans divers processus biologiques [346,347]. Plusieurs marqueurs ont été attribués aux différents types de fibroblastes [348-351].

Fibroblastes et ACG

Les fibroblastes ont été peu étudiés au cours de l'ACG. Une étude récente décrit leur hétérogénéité au sein de la paroi d'artères temporales de patients atteints d'ACG [352]. Ils expriment tous le marqueur CD90. Leur activation s'associe à l'expression de la protéine alpha de fibroblaste (*Fibroblast alpha protein*, FAP). Ces fibroblastes activés sont détectés dans l'adventice en association avec les fibroblastes exprimant la podoplanine (marqueur des immunofibroblastes) présents dans les structures lymphoïdes tertiaires adventitielle. De plus les fibroblastes adventitiels CD90⁺ expriment l'IL-6 et MMP-9 suggérant un rôle actif dans le développement d'un milieu pro-inflammatoire et destructeur de la paroi artérielle de l'ACG.

Des fibroblastes exprimant l'*alpha-smooth muscle actin* (α SMA) correspondent à des myofibroblastes et sont essentiellement détectés dans l'intima, zone de l'hyperplasie intimale associée à la réduction de la lumière artérielle. Ces dernières données rejoignent nos propres observations (**Article 1**). Il est à noter que l' α SMA est également exprimée par les CMLV, cette protéine étant impliquée dans les propriétés contractiles des myofibroblastes et des CMLV associées à leur migration.

La plasticité de ces fibroblastes est liée à leur activation par les facteurs de croissance TGF β , FGF et PDGF [352]. La fonction des LT dans l'activation des fibroblastes a été montrée avec les travaux de Zhang et al. [323]. Dans le modèle de souris SCID chimérique, le blocage de PD-1 induit une importante activation des fibroblastes qui expriment l' α SMA et migrent dans l'intima, en association avec les cellules endothéliales (marquées par le facteur de von Willebrand). L'expression dans les myofibroblastes du facteur de transcription TWIST évoque une possible transition endo-mésenchymateuse [339].

Des travaux récents ont montré la fonction des CMLV et des fibroblastes dans le remodelage vasculaire et le maintien de l'activation lymphocytaire T, notamment Th1 et Th17 [353].

Par ailleurs, le lien entre CMLV et fibroblastes est étroit et associé au remodelage conduisant à la sténose artérielle. Il a été montré au cours de ce mécanisme que des modifications phénotypiques des CMLV les transforment en myofibroblastes [339]. La migration et la prolifération des myofibroblastes dans l'intima et leur sécrétion de composants de la matrice extra cellulaire (collagène 1 et 3, fibronectine) sont un des éléments essentiels de ce remodelage.

La distinction phénotypique des myofibroblastes et des CMLV repose sur l'expression de certains marqueurs. Le CD90 est le marqueur des fibroblastes et des myofibroblastes, tandis que la desmine et la chaîne lourde de la myosine (MYH11) sont exprimées par les CMLV ainsi que par les myofibroblastes. Ces différents marqueurs permettent de distinguer la localisation et la prolifération de ces cellules au cours du remodelage.

C'est la sécrétion d'endothéline-1 et de PDGF par les monocytes qui active la transformation des CMLV en myofibroblastes et leur migration dans l'intima. L'activation des myofibroblastes de l'intima est marquée par leur sécrétion cytokinique en IL-1 β , IL-6, IL-12 and IL-23, au contact des lymphocytes qui sont polarisés en Th1 et Th17 [349].

Certains myofibroblastes de l'intima expriment HLA-DR [353]. Leur fonction potentielle de présentation de l'antigène reste cependant débattue. Néanmoins, la fonction activatrice des réponses immunes par des fibroblastes a été démontrée par l'expression de récepteurs de DAMPS dont l'un des ligands correspond à des fragments de la matrice extra cellulaire qui activent TLR4 [343, 354].

Fibroblastes et artérite de Takayasu

L'artérite de Takayasu (TAK), est une autre vascularite des gros vaisseaux, touchant les sujets de moins de 50 ans. Au cours de la TAK, l'adventice présente un épaississement, et la fibrose vasculaire est plus importante que dans l'ACG [355] (**Figure 19**).

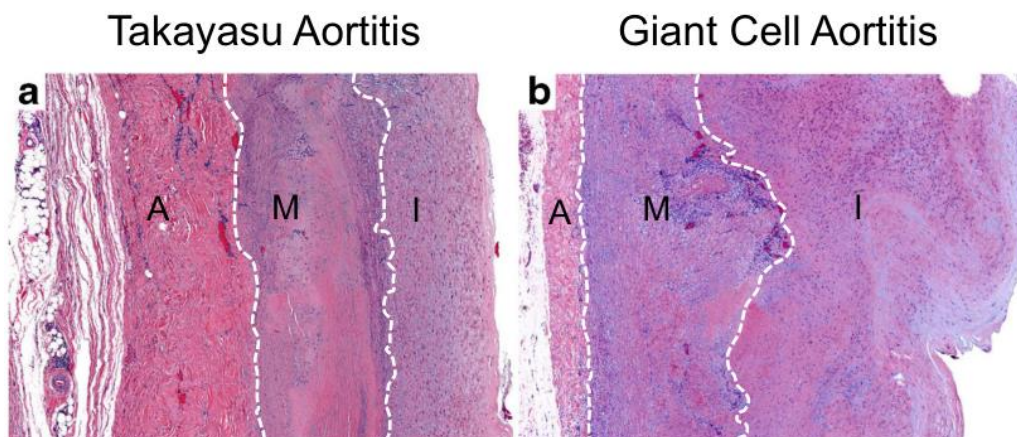


Figure 19. Coupes histologiques d'aortite de TAK et d'ACG montrant un épaississement adventitial plus marqué au cours du TAK, d'après Watanabe [355].

Les fibroblastes adventitiels quiescents de la TAK peuvent être activés par des facteurs solubles : TGF- β , PDGF, GPNMB, IL-17 et IL-6 [356]. Dans l'adventice des artères de TAK, il existe une augmentation de l'expression de l'IL-6, de l'IL-6R, des collagènes de type 1 et 3, de la fibronectine, de l' α SMA et du TGF- β par rapport aux adventices de sujets sains [357]. L'IL-6 jouerait un rôle crucial non seulement dans l'inflammation vasculaire mais aussi dans la fibrose vasculaire au cours de la TAK.

Le couple IL-6/IL-6R augmente la production de MCP-1 par les fibroblastes adventitiels d'aorte humaine, pouvant favoriser le recrutement de monocytes/macrophages. D'autre part, l'IL-6 et le TGF- β peuvent orienter les lymphocytes T vers un profil Th17, amplifiant la cascade pro-inflammatoire. L'IL-6/IL-6R active aussi les voies JAK2/STAT3 et JAK2/Akt qui favorisent la transcription des collagènes de type 1 et 3, de la fibronectine, de l' α SMA et du TGF- β par les fibroblastes adventitiels aortiques. Ces effets pro-fibrosants sont réduits en cas de traitements inhibiteurs [357]. La protéine 3 de liaison aux acides gras (FABP3) est augmentée dans les adventices de patients TAK, ce qui est en corrélation avec l'expression sérique de la fibronectine 1, de collagène de type 1, de la MMP-3 et de la MMP-9, tandis que son blocage inhibe la prolifération et la production de matrice extra cellulaire par les fibroblastes adventitiels aortiques [358].

Fibroblastes comme cible thérapeutique

Le ciblage des processus pathologiques médiés par les fibroblastes pourrait représenter une nouvelle approche thérapeutique intéressante au cours de l'ACG.

Une première piste consisterait en l'élimination des fibroblastes pathologiques, c'est-à-dire les fibroblastes qui présentent une activation, une prolifération et une surproduction aberrantes et permanentes de matrice extracellulaire. La déplétion des fibroblastes associés au cancer FAP⁺ à l'aide d'immunotoxines, d'anticorps, de vaccins ADN ou de lymphocytes T chimériques s'est avérée efficace pour inhiber la croissance des tumeurs [359-363]. Dans un modèle murin de polyarthrite, la suppression sélective des cellules stromales FAP⁺ a atténué l'inflammation [364]. En outre, la délétion des immunofibroblastes PDPN⁺ empêche l'établissement d'une structure lymphoïde tertiaire et diminue la réaction immunitaire locale dans le syndrome de Sjögren [365]. Le ciblage des fibroblastes inflammatoires peut s'avérer aux patients échappant aux

anti-TNF α dans les maladies intestinales inflammatoires [366]. Une alternative pourrait consister à moduler la différenciation des fibroblastes. Des thérapies anti-TGF- β sont en cours de développement et font l'objet d'essais cliniques [367].

Etant donné que les fibroblastes peuvent produire de grandes quantités de cytokines inflammatoires, le blocage de ces cytokines et chimiokines peut également s'avérer utile. Il reste à déterminer si ces chimiokines seront des cibles thérapeutiques efficaces pour les patients atteints de l'ACG.

Partie II. Travaux de thèse

Objectifs et plan d'étude

Le remodelage vasculaire a finalement été peu étudié au cours de l'ACG. Notre objectif est de mieux caractériser ce processus, notamment l'implication des fibroblastes artériels. Nous souhaitons mettre en évidence de nouvelles pistes physiopathologiques et potentiellement thérapeutiques concernant le remodelage vasculaire de l'ACG.

1. Tout d'abord nous avons étudié la répartition des fibroblastes au sein des artères temporales ainsi que leur marqueur d'activation par immunohistochimique (**Article 1**).
2. Une étude de certaines fonctions des fibroblastes issus de la dissection d'adventice d'artères temporales par analyse *in vitro* a été réalisée (**Travail complémentaire 1**).
3. Nous avons ensuite effectué une analyse des signatures transcriptomiques couche par couche (intima, média, adventice, tissu périvasculaire) à partir de biopsies d'artères temporales (**Article 2**).
4. Une analyse visant à évaluer le retentissement clinique et les caractéristiques associées au degré d'hyperplasie de l'intima a enfin été réalisée (**Travail complémentaire 2**).

Article 1.

An immunohistochemical analysis of fibroblasts in giant cell arteritis.

Simon Parreau, Nicolas Vedrenne, Alexis Regent, Laurence Richard, Philippe Sindou, Luc Mouthon, Anne-Laure Fauchais, Marie-Odile Jauberteau, Kim-Heang Ly

Ann Diagn Pathol. 2021 Jun;52:151728.

Les complications ischémiques de l'ACG sont liées à une hyperplasie intimale par une prolifération de myofibroblastes. Ces myofibroblastes proviendraient de l'agression des CMLV de la média qui se différencieraient pour ensuite migrer et proliférer vers l'intima, responsable de l'occlusion de l'artère.

Dans certains modèles animaux d'athérosclérose ou post angioplastie, il a été démontré que les fibroblastes de l'adventice jouaient un rôle initiateur et influenceur sur le comportement de l'intima [369-372]. Toutefois ces fibroblastes adventitiels n'ont été que peu étudiés durant l'ACG.

Dans ce premier travail, nous avons souhaité caractériser les fibroblastes des patients avec ACG en étudiant leur répartition au niveau des 3 tuniques d'artères temporales de patients porteurs d'ACG et de contrôles.


Dans notre étude, à partir de 29 patients atteints d'ACG et 36 contrôles, nous avons effectué une analyse immunohistochimique des coupes d'artères temporales. Nous avons identifié une population cellulaire exprimant le CD90, augmentée dans l'adventice et l'intima au cours de l'ACG par rapport aux contrôles. Le CD90 est une protéine ancrée à la membrane, impliquée dans l'adhésion focale et la formation des fibres de stress. Elle s'exprime quel que soit le stade d'activation des fibroblastes. La répartition spatiale, concentrique et homogène des cellules CD90⁺ et leur aspect morphologique correspondent à des fibroblastes. La vimentine, autre filament intermédiaire, exprimée par les cellules d'origine mésenchymateuse comme les fibroblastes, cellules musculaires lisses et osseuses, était significativement plus importante au sein des 3 tuniques pour les patients porteurs d'ACG. La desmine et la vimentine sont utilisées pour identifier les fibroblastes qui sont vimentine⁺ et desmine⁻ [368]. Ces résultats suggèrent que les cellules CD90⁺ de l'intima et adventice ne sont pas des cellules musculaires lisses vasculaires mais des fibroblastes.

Par la suite, nous avons étudié l'expression de marqueurs d'activité de fibroblastes, correspondant au stade myofibroblastes. La prolyl 4 hydroxylase (P4H) est une enzyme impliquée dans la synthèse des chaînes α du procollagène. L'hydroxylation des résidus prolines par la P4H facilite la formation de la triple hélice de collagène mature. L'expression de P4H est élevée dans les fibroblastes et myofibroblastes qui produisent de la MEC à niveau élevé [368]. En outre, l'étude pan génomique sur sang périphérique des patients atteints d'ACG a montré que le gène de la sous unité $\alpha 2$ de la P4H (P4HA2) était associée à un surrisque de développer la maladie [241]. Son expression fait suite à l'hypoxie, et est régulée par le facteur 1 inductible par l'hypoxie (HIF-1). D'autres gènes sont induits par HIF-1 dont un inhibiteur de l'activation de la plasmine de la famille de la serpine, le VEGF, la MMP-9 impliquée dans la dégradation de la MEC et l'IL-6 [368].

Au cours de notre étude, le marquage pour la P4H était présent au niveau des adventices et intimas selon la même répartition que le CD90. Ce résultat est confirmé par la co-expression de ces deux cibles par les mêmes cellules au cours de l'étude fluorimétrique. D'autre part, le marquage au trichrome de Masson était augmenté au niveau de l'adventice et de l'intima pour les patients porteurs d'ACG suggérant une production accrue de collagène au cours de l'ACG au sein de ces 2 tuniques. Les épaisseurs de l'intima et de l'adventice étaient par ailleurs augmentées au cours de l'ACG, témoin de cette surproduction de collagène.

L' α smooth muscle actine (α SMA) est une fibre de stress exprimée par les myofibroblastes, leur permettant d'exercer une force contractile. Il s'agit d'un marqueur clé d'activation des fibroblastes quelle que soit leur origine [368]. Dans notre étude, son marquage était augmenté pour les 3 tuniques au cours de l'ACG. Par ailleurs il existait une co-expression de l' α SMA avec le CD90 au sein des 3 tuniques suggérant que l'ensemble des fibroblastes sont activés en myofibroblastes au cours de l'ACG.

La chaîne lourde de la myosine (SMMHC), est également exprimée par les myofibroblastes leur conférant une capacité contractile. Les cellules CD90 de l'intima et adventice avaient une co-expression avec la SMMHC plus marquée au cours de l'ACG confirmant le caractère actif des fibroblastes.



Original Contribution



An immunohistochemical analysis of fibroblasts in giant cell arteritis

Simon Parreau^{a,b,*}, Nicolas Vedrenne^b, Alexis Regent^c, Laurence Richard^d, Philippe Sindou^b,
Luc Mouthon^c, Anne-Laure Fauchais^{a,b}, Marie-Odile Jauberteau^b, Kim-Heang Ly^{a,b}

^a Department of Internal Medicine, Dupuytren Hospital, Limoges, France

^b EA3842-CaPTuR, Contrôle de l'Activation Cellulaire, Progression Tumorale et Résistance thérapeutique, Faculty of Medicine, Limoges, France

^c Department of Internal Medicine, Cochin Hospital, Paris, France

^d Department of Neurology, Dupuytren Hospital, Limoges, France

ARTICLE INFO

Keywords:

Giant cell arteritis
Temporal artery biopsy
Adventitia
Fibroblasts
Intimal hyperplasia
Vascular remodeling

ABSTRACT

Background: Giant cell arteritis (GCA) is a systemic vasculitis of large and medium vessels characterized by an inflammatory arterial infiltrate. GCA begins in the adventitia and leads to vascular remodeling by promoting proliferation of myofibroblasts in the intima. The morphology of the fibroblasts in the adventitia in GCA is unclear. Access to temporal artery biopsies allows morphological studies and evaluation of the microenvironment of the arterial wall. We evaluated the distribution of vascular fibroblasts and of markers of their activation in GCA.

Methods: Formalin-fixed paraffin-embedded tissue sections from 29 patients with GCA and 36 controls were examined. Immunohistochemistry was performed for CD90, vimentin, desmin, alpha-smooth muscle actin (ASMA), prolyl-4-hydroxylase (P4H), and myosin to evaluate the distribution of fibroblasts within the intima, media, and adventitia.

Results: Temporal arteries from patients with GCA showed increased levels of CD90, vimentin, and ASMA in the adventitia and intima compared to the controls. Desmin was expressed only in the media in both groups. P4H was expressed similarly in the adventitia and intima in the two groups. Adventitial and intimal CD90⁺ cells co-expressed P4H, ASMA, and myosin at a high level in GCA.

Conclusion: The results suggest a role for adventitial fibroblasts in GCA. Inhibiting the differentiation of adventitial fibroblasts to myofibroblasts has therapeutic potential for GCA.

1. Introduction

Giant cell arteritis (GCA) is the most common systemic vasculitis after the age of 50 years. The disease preferentially affects large- and medium-sized arteries, especially the thoracic aorta and its branches including the external carotid branches (e.g., the temporal and occipital arteries), and the ophthalmic, vertebral, subclavian, and axillary arteries [1]. Vasculitis leads to luminal occlusion and thus ischemic complications such as ischemic optic neuropathy, which causes vision loss in 10% to 15% of patients [2]. Aortitis can be complicated by dissection and aneurysm formation [3]. Biopsy of the temporal artery, which is frequently affected, is the gold standard procedure for diagnosis of GCA [4].

In GCA, histopathological lesions involve the three layers of the arterial wall (adventitia, media, and intima). GCA lesions are composed of fragmented internal elastic lamina and polymorphic cellular

infiltrates, including CD4⁺ lymphocytes, macrophages, and multinucleated giant cells generated by fusion of macrophages [5–9]. The initial trigger could be activation of adventitial dendritic cells by an unknown stimulus [10–12]. Activated dendritic cells selectively activate antigen-specific T lymphocytes, which release interferon- γ and so regulate macrophage function and differentiation. Macrophages promote inflammation of the arterial wall by producing interleukin (IL)-1, IL-6, and tumor necrosis factor- α . This event initiates vascular remodeling by triggering the release of cytokines, growth factors, reactive oxygen species, and matrix metalloproteinases, which contribute to tissue injury and intimal hyperplasia [13]. In GCA, vascular smooth muscle cells from the media differentiate into myofibroblasts, which migrate through disrupted elastic fibers towards the intima [14–16]. The proliferation of myofibroblasts within the intima leads to an increase in the thickness of the intimal layer and thus to occlusion of the artery. Myofibroblasts, which are responsible for intimal hyperplasia in atherosclerosis, can

* Corresponding author at: Department of Internal Medicine, Dupuytren Hospital, 16, rue du Professeur Bernard Descottes, 87042 Limoges Cedex, France.
E-mail address: simon.parreau@chu-limoges.fr (S. Parreau).

differentiate from several cell types, including resident tissue vascular smooth muscle cells, fibroblasts, pericytes, resident or medullary mesenchymal stem cells, and endothelial cells [17].

There are two hypotheses concerning the mechanism of intimal hyperplasia. The first is ‘inside-out,’ *i.e.*, from the arterial lumen, to the endothelium, to the outer portion of the vessel. This hypothesis involves leukocyte extravasation from the bloodstream through the endothelium, stimulating the arterial microenvironment [18]. An alternative mechanism, from the outside to the inside (adventitia to intima), has also been proposed. In this mechanism, adventitial fibroblasts trigger a signaling cascade, influencing the intima [18]. Animal models of atherosclerosis or post-angioplasty arterial stenosis report differentiation of adventitial fibroblasts into myofibroblasts, which migrate to the intima and so contribute to intimal hyperplasia [19-22]. Fibroblasts acquire the characteristics of myofibroblasts by expressing alpha-smooth muscle actin. They then secrete extracellular matrix components, including collagen, as well as growth factors, such as transforming growth factor β 1. Autocrine stimulation by transforming growth factor β 1 induces the differentiation of fibroblasts into myofibroblasts, promoting their migration to the intimal layer [20]. The secretion of extracellular matrix is responsible for fibrosis and occlusion of the vessel lumen.

No data are available on the distribution and activation of adventitial fibroblasts in GCA. We evaluated the characteristics and involvement of adventitial fibroblasts in the arteries of patients with GCA by performing immunohistochemical staining of fibroblasts.

2. Patients and methods

2.1. Cohort selection

Patients with a histopathologic diagnosis of GCA were enrolled from 2013 to 2017 in the Internal Medicine department of Dupuytren's University Hospital (Limoges, France). The accepted diagnostic criteria for arteritis included the presence of a medial inflammatory infiltrate with mononuclear or granulomatous features in the temporal artery. Inflammation restricted to the intima or adventitia was not considered active arteritis, nor was perivascular inflammation restricted to the vasa vasorum. Patients with a negative temporal artery biopsy (TAB) without a clinical diagnosis of arteritis were defined as controls. All temporal artery fragments analyzed were from biological collection DC-2010-1079 and their use was approved by the Ethics Committee. All patients provided informed consent.

2.2. Clinical and laboratory methods

At the first and subsequent visits, medical histories were taken, physical examinations performed, and relevant laboratory tests conducted. Clinical and laboratory findings at the initial and follow-up visits were recorded. Standard clinical laboratory test methods were used. The dose of prednisone received prior to TAB was also recorded.

2.3. Biopsy, processing, and histopathologic examination

Biopsies were performed under local anesthesia on an outpatient basis by a surgeon in the Ophthalmology Department. The most clinically suspicious temporal artery was biopsied. All biopsies were unilateral. A 2–4 cm temporal artery specimen was removed and sent for pathologic analysis. The temporal arteries were handled using standard clinical specimen-handling protocols. The specimens were grossly evaluated and serially cross-sectioned. Eight to ten complete cross-sections (representing the entire submitted length of the vessel) were frozen and cut (10 μ m thickness) using a freezing microtome, stained with toluidine blue, and intraoperatively evaluated for arteritis. The remaining sections of the vessel were formalin-fixed, paraffin-embedded, sectioned (5 μ m thickness), stained with hematoxylin and eosin, and reviewed by a pathologist.

2.4. Immunohistochemistry

Because arterial involvement in GCA may be segmental, two fragments of the temporal artery were analyzed. The fragments were embedded in paraffin blocks according to the tissue microarray method. From this block, 4- μ m-thick slices were cut and dewaxed by successive immersion in pure toluene (Prolabo). Rehydration, membrane permeabilization, and unmasking of antigens were carried out by immersion in absolute ethanol (Prolabo), phosphate-buffered saline (PBS; Gibco), and citrate buffer (200 μ M citric acid in 9.8 mM sodium citrate). Inhibition of endogenous peroxidases was performed by immersion in methanol and 5% H_2O_2 (Prolabo). Saturation of nonspecific antigenic sites was achieved by incubation in PBS containing 3% bovine serum albumin (BSA) (Euromedex). The primary antibodies were diluted in 3% BSA and incubated overnight at 4 °C. The antibodies used were as follows: CD90 (1:100, rabbit; Abcam) and vimentin (dilution recommended by the supplier, mouse; Ventana) for fibroblasts; desmin (1:200, mouse; Dako) for vascular smooth muscle cells; alpha smooth muscle actin (1:1000, mouse; Sigma) for myofibroblasts; prolyl-4-hydroxylase (1:30, mouse; Acris) for collagen secretion; and myosin smooth muscle heavy chain (1:100, mouse; Abcam) for cell contraction. The sections were subsequently incubated with a secondary antibody coupled to Alexa Fluor 594 or 488 (Molecular Probes) for 90 min. After washing with PBS, nuclear counterstaining was carried out with 4',6-diamidino-2-phenylindole (Sigma) and the sections were mounted in an aqueous medium (Dako). For co-staining, two primary antibodies from different animal species, and the two corresponding secondary antibodies, were used.

2.5. Primary antibodies

CD90 is a membrane-anchored protein involved in focal adhesion and stress fiber formation. It is expressed by fibroblasts of all activation states (quiescent fibroblasts, proto-myofibroblasts, and myofibroblasts) as well as by other cell types such as endothelial cells, neurons, and hematopoietic cells [24-26].

Desmin, an intermediate filament of the cytoskeleton, is specific for muscle cells. Vimentin, another intermediate filament, is expressed by cells of mesenchymal origin such as fibroblasts, smooth muscle cells, and bone cells. Desmin and vimentin are used to identify fibroblasts, which are vimentin⁺/desmin⁻ [24,27].

Alpha-smooth muscle actin is a stress fiber expressed by myofibroblasts, allowing them to exert a contractile force. It is a key marker of myofibroblasts, irrespective of their origin [24,28]. Expression of smooth muscle myosin heavy chain by myofibroblasts gives them a contractile capacity. Prolyl-4-hydroxylase (P4H) is involved in the synthesis of procollagen α chains. Hydroxylation of proline residues by P4H facilitates the formation of the mature collagen triple helix. Expression of P4H is high in fibroblasts and myofibroblasts, which produce components of the extracellular matrix [24,29,30].

2.6. Quantification

The relative surface area of each tunica and its thickness at several locations were measured by two double-blinded observers. Staining intensity was assessed by optical microscopy (NanoZoomer 2.0RS Hamamatsu) in at least three zones of each tunica (adventitia, media, and intima). Image analysis was performed using ImageJ v. 1.48 software.

2.7. Statistical analysis

Results are expressed as percentages or as medians \pm range. Comparisons of categorical variables were performed using Fisher's exact test. Student's *t*-test or the Mann-Whitney test was conducted to compare laboratory parameters between the two groups.

3. Results

3.1. Cohort

From 2013 to 2017, 29 patients with a histopathologic diagnosis of GCA on TAB agreed to participate in this study. Thirty-six patients with a negative TAB and without a clinical diagnosis of GCA were included as controls. The diagnoses of the 36 controls are detailed in Table 1. The infection sites were bronchopulmonary tract (n = 5), urinary tract (n = 2), digestive tract (n = 2), teeth (n = 1), hip prosthesis (n = 1), and skin (n = 1). The rheumatic conditions were atrophic polychondritis (n = 1), chondrocalcinosis (n = 1), reactive arthritis (n = 1), autoimmune myositis (n = 1), autoinflammatory disease (n = 1), and undetermined peripheral inflammatory rheumatism (n = 3). Neurological illnesses were atypical headache (n = 4), stroke (n = 2), and facial vascular algia (n = 1). The cancers were colonic (n = 2), renal (n = 1), pulmonary (n = 1), and glioblastoma (n = 1). The ophthalmological disorder was non-arteritic anterior ischemic optic neuropathy (n = 4). The epidemiological characteristics and co-morbidities of the patients are listed in Table 2. The proportion of females was higher in the GCA group than the control group. There were no significant differences in age, cardiovascular history of diabetes, and smoking between the two groups.

3.2. Clinical and laboratory findings

The clinical manifestations of GCA and the results of laboratory tests performed on the day of TAB in patients with proven GCA and controls are shown in Table 3. The patients with GCA had typical symptoms of GCA, such as headache, scalp tenderness, jaw claudication, and temporal artery changes. The causes of ischemic optic neuropathy in the controls were nonarteritic. The systemic symptoms; *i.e.*, fever, asthenia, weight loss, and anorexia, were similar in the two groups. The patients in the GCA group had significantly more markers of inflammation than the controls. Treatment with prednisone on the day of TAB is detailed in Table 3. The patients with GCA were more frequently treated with prednisone on the day of or the day before TAB and received higher doses. There was no difference in the number of treatment days prior to completion of TAB between the groups.

3.3. Histopathologic findings

The mean thickness of the three arterial tunicae and the proportion of each in relation to the others are reported in Table 4. Example measurements are shown in Fig. 1. The distribution of the three tunicae differed between the GCA and control groups, with more intimal hyperplasia during GCA. The thickness of the adventitia was greater in the GCA group; by contrast, the media is destroyed in GCA and was therefore thinner in the patients with GCA than the controls.

Table 5 shows the immunohistochemical analysis of temporal artery sections from patients with GCA and controls. Each arterial layer was assayed separately. CD90 is expressed by fibroblasts at all stages of activation but also by other cell types, such as endothelial cells. The spatial, concentric, and homogeneous distribution of CD90⁺ cells did not correspond to the anatomical distribution of those other cell types, such as endothelial or hematopoietic cells or neurons, but rather to fibroblasts (Fig. 2). CD90 staining was significantly greater in the

Table 1
Diagnoses of controls (n = 36).

Diagnosis	n (%)
Infectious disease	12 (33)
Rheumatologic disease	8 (22)
Neurological disease	7 (19)
Cancer	5 (14)
Ophthalmological disease	4 (11)

Table 2
Epidemiological and comorbidities at initial temporal artery biopsy.

Characteristics	Arteritis (n = 29)	Control (n = 36)	p-Value
Age (years)	75 (71–79)	73 (68–79)	0.4226
Female	9/29 (31%)	20/36 (56%)	0.0480
Cardiovascular past event	9/29 (31%)	15/36 (42%)	0.3772
Diabetes mellitus	3/29 (10%)	8/36 (22%)	0.3200
Tabagism	4/29 (14%)	6/36 (17%)	1.0000

Table 3
Clinical, laboratory findings and treatment at initial temporal artery biopsy.

Characteristics	Arteritis (n = 29)	Control (n = 36)	p-Value
Clinical finding			
Headache	21/29 (72%)	16/36 (44%)	0.0236
Scalp tenderness	13/29 (45%)	3/36 (8%)	0.0011
Jaw claudication	14/29 (48%)	5/36 (14%)	0.0053
Temporal artery changing	10/29 (35%)	2/36 (6%)	0.0038
Ischemic optic neuropathy	5/29 (17%)	4/36 (11%)	0.4973
Aortitis	3/29 (10%)	0/36 (0%)	0.0837
Systemic symptoms	18/29 (62%)	21/36 (58%)	0.7599
Laboratory finding			
Erythrocyte sedimentation rate (mm/h) ^a	79 (52–102)	32 (13–51)	<0.0001
C-reactive protein (mg/L) ^a	61 (18–103)	20 (6–49)	0.0029
Hemoglobin (g/dl) ^a	12.8 (11.8–13.6)	12.1 (11.2–12.9)	0.4565
Platelet count ($\times 10^3/\mu\text{l}$) ^a	408 (314–461)	260 (232–342)	0.0015
Treatment			
Prednisone	23/29 (79%)	9/36 (28%)	<0.0001
Days of treatment before TAB	1.5 (1.0–6.0)	1.0 (0.0–10.0)	0.8287
Prednisone dose (mg/day) ^a	65 (60–72.5)	30 (15–40)	0.1178

Abbreviations: TAB, temporal artery biopsy.

^a Median value (range).

Table 4
Inflammation and vascular remodeling of arteritis in the arteritis group.

Characteristics	Arteritis (n = 29)
Inflammatory pattern	
Granulomatous	26 (90%)
Non-granulomatous	3 (10%)
Inflammatory cell type	
Lymphocytes	29 (100%)
Macrophages	28 (97%)
Giant cells	26 (90%)
Medial inflammation grade^a	
0	0 (0%)
1	1 (3%)
2	0 (0%)
3	28 (97%)
Non-medial inflammation	
Adventitial	29 (100%)
Peri-vasa vasorum	29 (100%)
Intimal	29 (100%)
Vascular remodeling	
Medial fibrosis	1 (3%)
Medial calcification	1 (3%)
Abnormality of internal elastic membrane	27 (93%)
Intimal fibroplasia	29 (100%)

^a 0 = no medial inflammation; 1 = inflammation limited to the internal elastic membrane; 2 = inflammation beyond internal elastic membrane, but <50% of medial thickness; 3 = inflammation $\geq 50\%$ of medial thickness.

adventitia of GCA patients. The other stains showed the same homogeneous and concentric distribution in the tunicae. Vimentin, a filament of the cytoskeleton, is expressed by smooth muscle cells and fibroblasts and is overexpressed in the adventitia during arteritis. Desmin, another

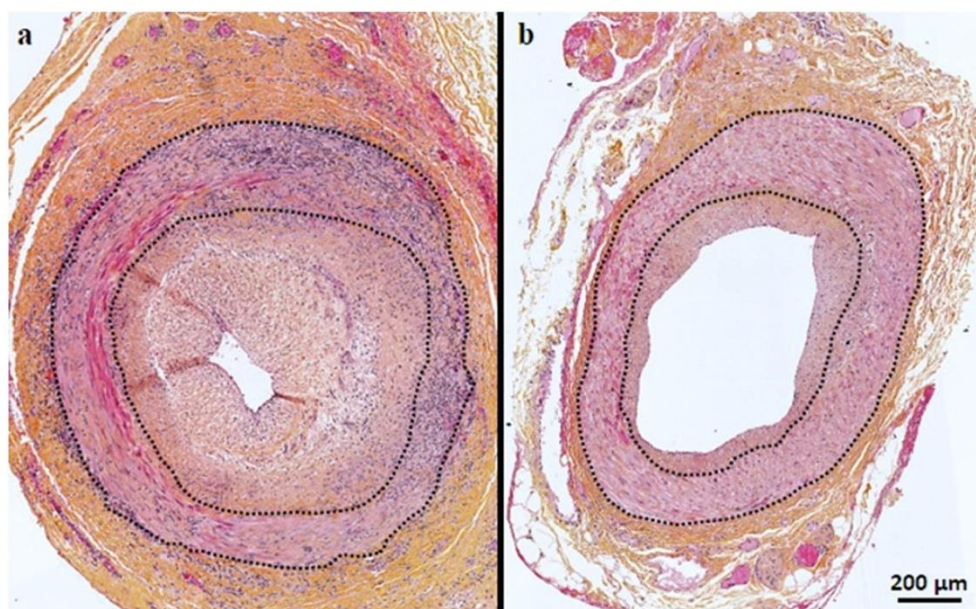


Fig. 1. Photomicrographs of (a) a temporal artery with granulomatous arteritis (white arrow) and (b) a temporal artery of a control (hematoxylin and eosin staining). Tunicae (external = adventitia, intermediate = media, internal = intima) are separated by dotted lines.

Table 5
Measurements of arterial layers.

Characteristics	Arteritis (n = 29)	Control (n = 36)	p-Value
Tunica thickness (µm)			
Adventitia	308 (286–331)	228 (175–279)	0.0002
Media	251 (184–319)	363 (312–414)	<0.0001
Intima	481 (441–537)	318 (242–341)	<0.0001
Tunica proportion			
Adventitia	37%	33%	
Media	23%	38%	
Intima	40%	29%	

intracellular filament, is not expressed by fibroblasts and was not detected in the adventitia of patients with GCA. We assayed the fibroblast activation marker alpha-smooth muscle actin, a stress fiber expressed by myofibroblasts. In patients with GCA, its expression was elevated in the three layers, and especially in the adventitia. However, there was no difference between the groups in the levels of smooth muscle myosin heavy chain and P4H in the adventitia (Tables 6, 7).

Next, we co-labelled CD90 and the activation markers alpha-smooth muscle actin and smooth muscle myosin heavy chain (Fig. 3). Adventitial cells strongly co-expressed CD90 and these activation markers in GCA. The CD90 distribution indicated invasion of the destroyed media by CD90⁺ cells (Fig. 4).

4. Discussion

This is to our knowledge the first study of the distribution of adventitial fibroblasts and of markers of their activation in patients with GCA. Although the different stages of inflammatory infiltrate formation and its consequences during GCA have been investigated, there are few data on adventitial fibroblasts.

4.1. Clinical considerations

We evaluated the distribution of fibroblasts in patients with histologically confirmed GCA. The patients with GCA had clinicobiological characteristics typical of sufferers of the condition as well as clinical signs of GCA [31] and high biological inflammatory parameters.

Glucocorticoids, the reference treatment for GCA, were started shortly before biopsy so as not to interfere with the TAB results. However, Maleszewski showed that arterial inflammatory lesions in GCA persisted for several months despite treatment with glucocorticoids [32].

The controls had a different disease; *i.e.*, a negative TAB without signs of arteritis and a well-established differential diagnosis. Given the absence of differences between the two groups in cardiovascular risk factors, we can exclude confounding of the histopathologic analysis.

4.2. Histopathologic considerations

The temporal arteries of patients with GCA show active disease with inflammatory cell infiltrates forming a granuloma in most cases, and the onset of vascular remodeling with destruction of the media and severe intimal hyperplasia. A variety of patterns of histological lesions have been described in patients with GCA [8,16]. Here, we report only transmural inflammation, the most frequently described manifestation.

Arterial inflammatory disease is characterized by destruction of the media with a reduction in its thickness compared to controls. The macrophages and giant cells recruited during GCA produce reactive forms of oxygen that destroy vascular smooth muscle cells in the media [1]. Also, there is an imbalance between the matrix metalloproteinases (MMP)-2, MMP-9, and MMP-14 and the tissue metalloproteinase inhibitors TIMP-1 and TIMP2 [33–35]. We found severe intimal hyperplasia and increased adventitial thickness in all patients with GCA. This intimal hyperplasia could result from the differentiation of vascular smooth muscle cells from the media into myofibroblasts that migrate into the intima [14,15]. Finally, the increase in adventitial thickness in GCA has not been explained. In a model of vascular remodeling after coronary arterial injury, adventitial fibroblasts proliferate and transform into myofibroblasts, which could explain the adventitial hyperplasia [19,20,36,37].

We analyzed several factors not previously explored in GCA—CD90, vimentin, desmin, P4H, and smooth muscle myosin heavy chain. We identified fibroblasts (CD90⁺, vimentin⁺, desmin⁺) and three markers of their activation (actin, myosin, and hydroxylase). The number of CD90⁺ and vimentin⁺ cells was increased in the adventitial layer of the patients with GCA compared to the controls, suggesting that adventitial hyperplasia is related to proliferation of fibroblasts in this tunica. We also noted an increase in the level of alpha smooth muscle actin, confirming

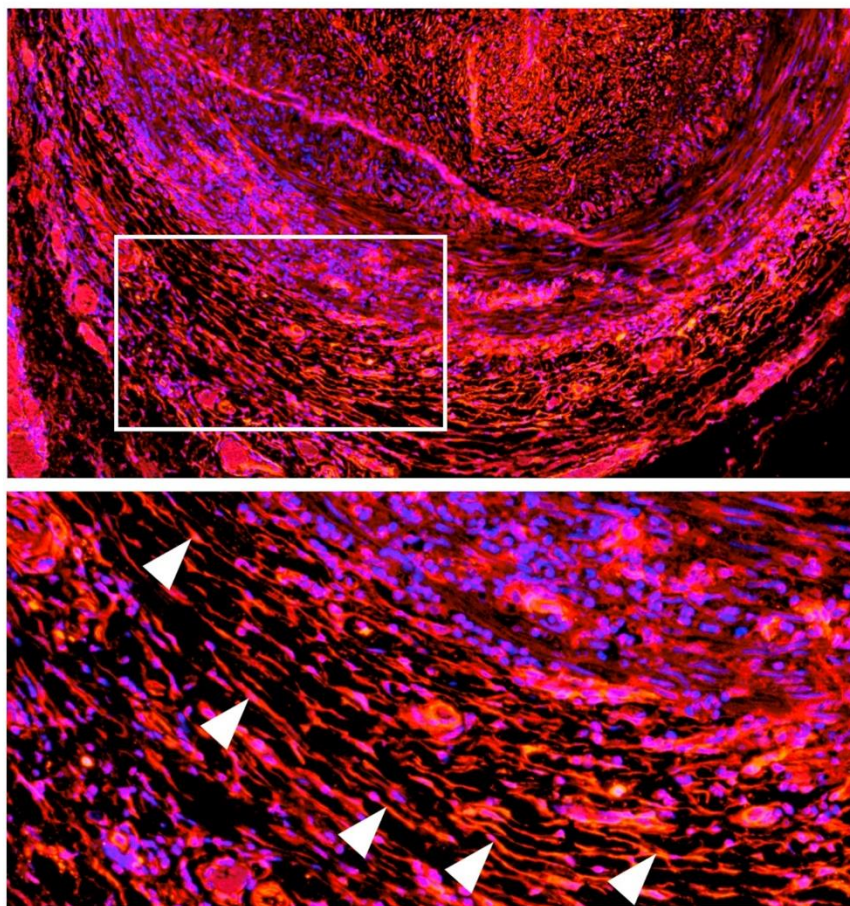


Fig. 2. Photomicrograph of a temporal artery with granulomatous arteritis. White arrowheads show elongated cells in the adventitia corresponding to fibroblasts (CD90 in red, DAPI in blue). (For interpretation of the references to color in this figure legend, the reader is referred to the web version of this article.)

Table 6
Staining of arterial layers.

	Median staining (range)		p-Value
	Arteritis (n = 29)	Control (n = 36)	
CD90			
Adventitia	85 (63–109)	56 (45–72)	<0.0001
Media	37 (25–54)	42 (30–77)	0.0513
Intima	59 (45–75)	51 (38–72)	0.0932
Vimentin			
Adventitia	57 (46–82)	26 (23–40)	<0.0001
Media	130 (99–150)	112 (81–117)	0.0358
Intima	92 (77–113)	58 (41–73)	<0.0001
Desmin			
Adventitia	0	0	
Media	96 (81–111)	92 (82–112)	0.0011
Intima	0	0	
Alpha-smooth-muscle actin			
Adventitia	44 (31–67)	22 (18–25)	<0.0001
Media	181 (167–197)	157 (117–171)	0.0015
Intima	111 (95–129)	75 (55–85)	<0.0001
Smooth muscle myosin heavy chain			
Adventitia	2.2 (1.7–3.3)	1.4 (0.9–2.5)	0.5024
Media	3.6 (2.0–4.5)	6.6 (5.0–8.5)	0.0579
Intima	3.3 (2.0–4.0)	2.9 (2.3–4.5)	0.6825
Prolyl-4-hydroxylase			
Adventitia	81 (66–98)	94 (70–107)	0.3757
Media	90 (55–121)	94 (76–116)	0.2333
Intima	75 (58–91)	40 (25–66)	<0.0001

Table 7
Correlation between CD90 adventitia staining and clinical, biological and histological characteristics in the arteritis group.

Characteristics	p-Values
Age	0.3328
Female	0.7355
Cardiovascular past event	0.3470
Diabetes mellitus	0.6291
Tabagism	0.6435
Headache	0.1226
Scalp tenderness	1.0000
Jaw claudication	0.1184
Temporal artery changing	0.0072
Ischemic optic neuropathy	0.4835
Aortitis	0.7259
Systemic symptoms	0.3816
Erythrocyte sedimentation rate	0.3050
C-reactive protein	0.2369
Hemoglobin	0.1477
Platelet	0.5036
Adventitia thickness	0.0223
CD90 intima	0.0548
Arterial thrombosis	0.5661
Granulomatous pattern	0.1062

Pearson correlation test for quantitative variables.
Mann Whitney for qualitative variables.

that the adventitial fibroblasts are at the active myofibroblast stage. This is highlighted by the co-expression of CD90 and alpha smooth muscle actin by most adventitial cells. Fibroblasts are usually undifferentiated and quiescent. When subjected to stress or injury, they activate,

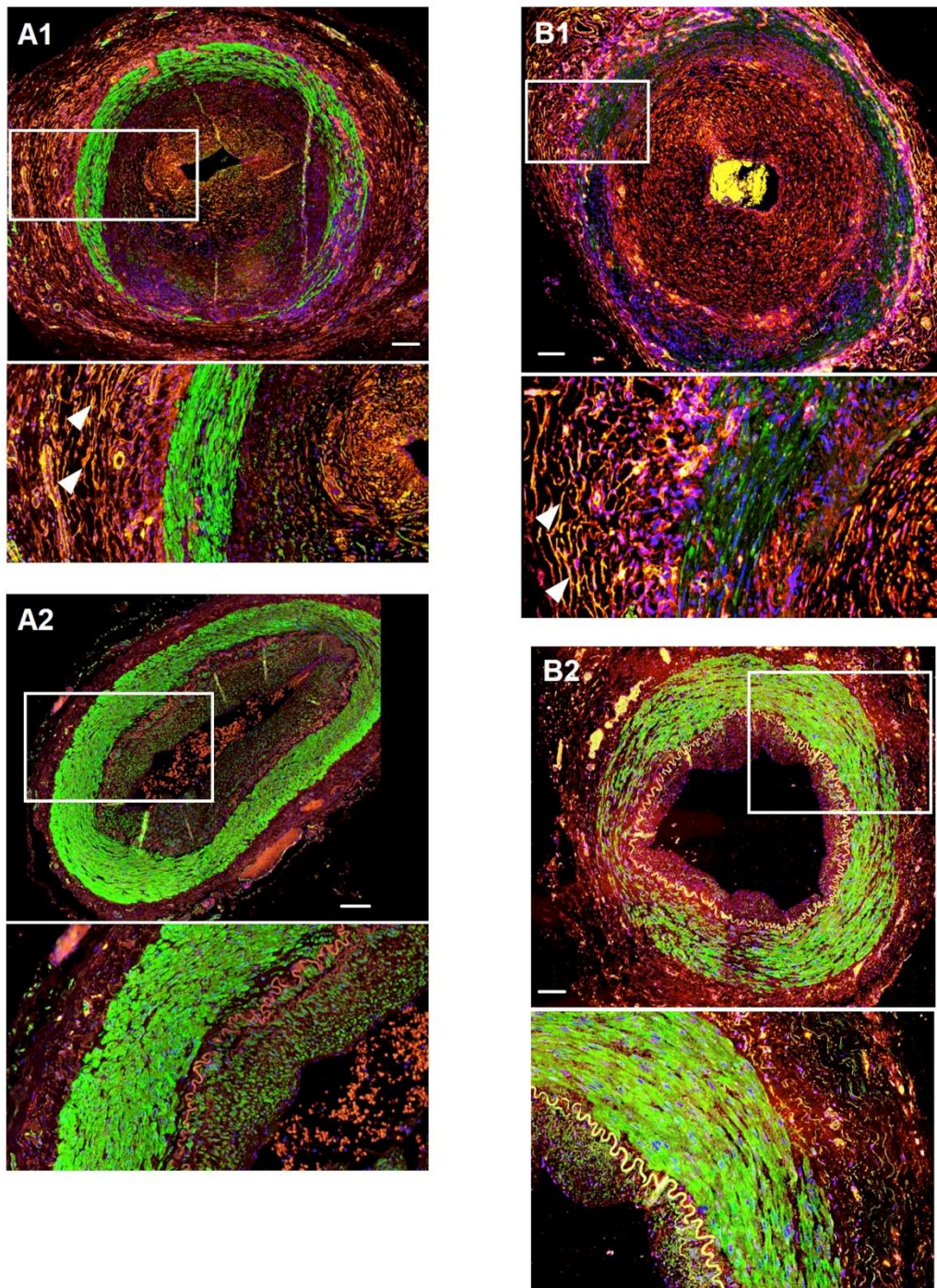


Fig. 3. Photomicrographs of temporal arteries with giant cell arteritis (A1, B1) and controls (A2, B2). Two co-stainings were performed (yellow): CD90 (red) with alpha smooth muscle actin (green) (A1, A2) and CD90 (red) with smooth muscle myosin heavy chain (green) (B1, B2). The square corresponds to the area shown at higher magnification. Scale bar, 100 μm . (For interpretation of the references to color in this figure legend, the reader is referred to the web version of this article.)

proliferate, and secrete extracellular matrix components, cytokines, chemokines, and adhesion molecules. Activated fibroblasts transform into myofibroblasts and vascular smooth muscle cells [18,38-40]. Co-expression of CD90 and alpha smooth muscle actin in the intima layer suggests that some intima cells are derived from fibroblasts (Fig. 3A). Indeed, at certain locations in the media, fibroblasts of the adventitia formed invasion wells. The ability to migrate through the destroyed media *via* platelet-derived growth factor-BB [41] or high expression of NADPH oxidase-4 [42] has been suggested in other diseases.

There was no correlation between adventitial fibroblastic infiltration

(CD90 staining) and the clinicobiological parameters of GCA. Only temporal artery alterations were correlated with CD90 expression. Others have reported a correlation between clinicobiological features and several histological abnormalities on TAB, such as a higher frequency of cerebrovascular accident and permanent blindness when the artery has a large and diffuse inflammatory cell infiltrate (ter Borg, Cavazza). However, no study has demonstrated a link between fibroblastic infiltration and the clinical or biological abnormalities characteristic of GCA [8,43,44].

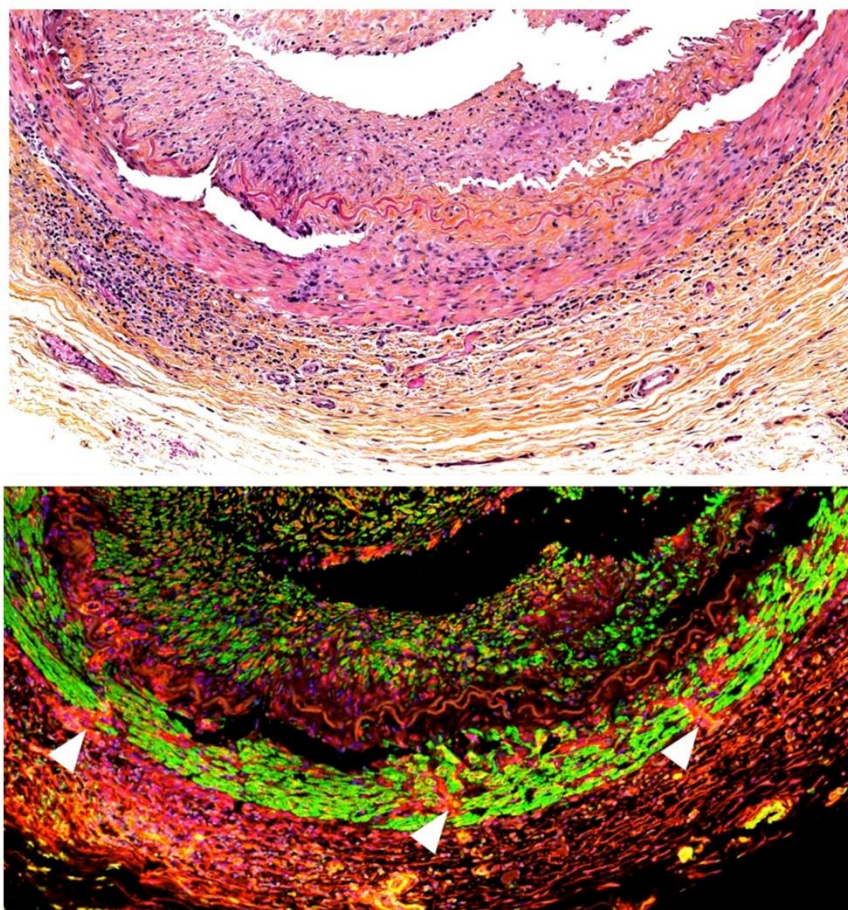


Fig. 4. Photomicrographs of a temporal artery with active giant cell arteritis (CD90 in red and actin in green; original magnifications, $\times 200$). White arrowheads show adventitial CD90⁺ fibroblasts penetrating the destroyed media. (For interpretation of the references to color in this figure legend, the reader is referred to the web version of this article.)

4.3. Study limitations

This study had several limitations. First, it was of a transverse design, included a small number of patients, was descriptive, and was based on immunohistochemistry. Further work is needed to understand the role of adventitial fibroblasts in the pathophysiology of GCA. However, this is the largest study of adventitial fibroblasts in GCA, although some of the results did not reach statistical significance.

4.4. Conclusions and future directions

We showed that adventitial fibroblasts are involved in all layers of the arteries of patients with GCA. These cells showed quiescent and activated states, suggesting migration from the adventitia to the media and intima. Further studies are needed to understand how these adventitial fibroblasts contribute to the development of GCA.

Declaration of competing interest

None.

Acknowledgments

None.

References

- [1] Weyand CM, Goronzy JJ. Clinical practice. Giant-cell arteritis and polymyalgia rheumatica. *N. Engl. J. Med.* 2014;371:50–7.
- [2] Aiello PD, Trautmann JC, TJ McPhee, Kunselman BS, Hunder GG. Visual prognosis in giant cell arteritis. *Ophthalmology* 1993;100:550–5.
- [3] Miller DV, Isotalo PA, Weyand CM, Edwards WD, Aubry M-C, Tazelaar HD. Surgical pathology of noninfectious ascending aortitis: a study of 45 cases with emphasis on an isolated variant. *Am. J. Surg. Pathol.* 2006;30:1150–8.
- [4] Hellmich B, Agueda A, Monti S, Buttgerit F, de Boysson H, Brouwer E, et al. Update of the EULAR recommendations for the management of large vessel vasculitis. *Ann. Rheum. Dis.* 2018;2020(79):19–30.
- [5] Kaiser M, Younge B, Björnsson J, Goronzy JJ, Weyand CM. Formation of new vasa vasorum in vasculitis. Production of angiogenic cytokines by multinucleated giant cells. *Am J Pathol* 1999;155:765–74.
- [6] Rittner HL, Kaiser M, Brack A, Szweda LI, Goronzy JJ, Weyand CM. Tissue-destructive macrophages in giant cell arteritis. *Circ. Res.* 1999;84:1050–8.
- [7] Lie JT. Illustrated histopathologic classification criteria for selected vasculitis syndromes. American College of Rheumatology Subcommittee on Classification of Vasculitis. *Arthritis Rheum.* 1990;33:1074–87.
- [8] Cavazza A, Muratore F, Boiardi L, Restuccia G, Pipitone N, Pazzola G, et al. Inflamed temporal artery: histologic findings in 354 biopsies, with clinical correlations. *Am. J. Surg. Pathol.* 2014;38:1360–70.
- [9] Brack A, Geisler A, Martínez-Taboada VM, Goronzy JJ, Weyand CM. Giant cell vasculitis is a T cell-dependent disease. *Mol. Med.* 1997;3:530–43.
- [10] Weyand CM, Goronzy JJ. Giant cell arteritis as an antigen-driven disease. *Rheum. Dis. Clin. N. Am.* 1995;21:1027–39.
- [11] Ma-Krupa W, Jeon MS, Spoerl S, Tedder TF, Goronzy JJ, Weyand CM. Activation of arterial wall dendritic cells and breakdown of self-tolerance in giant cell arteritis. *J. Exp. Med.* 2004;199:173–83.
- [12] Hilhorst M, Shirai T, Berry G, Goronzy JJ, Weyand CM. T cell-macrophage interactions and granuloma formation in vasculitis. *Front. Immunol.* 2014;5:432.
- [13] Weyand CM, Goronzy JJ. Medium- and large-vessel vasculitis. *N. Engl. J. Med.* 2003;349:160–9.
- [14] Planas-Rigol E, Terrades-García N, Corbera-Bellalta M, Lozano E, Alba MA, Segarra M, et al. Endothelin-1 promotes vascular smooth muscle cell migration across the artery wall: a mechanism contributing to vascular remodelling and intimal hyperplasia in giant-cell arteritis. *Ann. Rheum. Dis.* 2017;76:1624–34.
- [15] Lozano E, Segarra M, García-Martínez A, Hernández-Rodríguez J, Cid MC. Imatinib mesylate inhibits in vitro and ex vivo biological responses related to vascular occlusion in giant cell arteritis. *Ann. Rheum. Dis.* 2008;67:1581–8.

- [16] Hernández-Rodríguez J, Murgia G, Villar I, Campo E, Mackie SL, Chakrabarty A, et al. Description and validation of histopathological patterns and proposal of a dynamic model of inflammatory infiltration in giant-cell arteritis. *Medicine (Baltimore)* 2016;95:e2368.
- [17] Micallef L, Vedrenne N, Billet F, Coulomb B, Darby IA, Desmoulière A. The myofibroblast, multiple origins for major roles in normal and pathological tissue repair. *Fibrogenesis Tissue Repair* 2012;5:S5.
- [18] Stenmark KR, Yeager ME, El Kasmi KC, Nozik-Grayck E, Gerasimovskaya EV, Li M, et al. The adventitia: essential regulator of vascular wall structure and function. *Annu. Rev. Physiol.* 2013;75:23–47.
- [19] Shi Y, O'Brien JE, Fard A, et al. Adventitial myofibroblasts contribute to neointimal formation in injured porcine coronary arteries. *Circulation* 1996;94:1655–64.
- [20] Shi Y, O'Brien JE, Fard A, Mannion JD, Wang D, Zalewski A. Transforming growth factor-beta 1 expression and myofibroblast formation during arterial repair. *Arterioscler. Thromb. Vasc. Biol.* 1996;16:1298–305.
- [21] Siow RC, Mallawaarachchi CM, Weissberg PL. Migration of adventitial myofibroblasts following vascular balloon injury: insights from in vivo gene transfer to rat carotid arteries. *Cardiovasc. Res.* 2003;59:212–21.
- [22] Xu F, Ji J, Li Chen R, Hu W. Adventitial fibroblasts are activated in the early stages of atherosclerosis in the apolipoprotein E knockout mouse. *Biochem. Biophys. Res. Commun.* 2007;352:681–8.
- [24] Matthijs Blankesteijn W. Has the search for a marker of activated fibroblasts finally come to an end? *J. Mol. Cell. Cardiol.* 2015;88:120–3.
- [25] Rege TA, Hagood JS. Thy-1, a versatile modulator of signaling affecting cellular adhesion, proliferation, survival, and cytokine/growth factor responses. *BBA* 2006;1763:991–9.
- [26] Hudon-David F, Bouzeghrane F, Couture P, Thibault G. Thy-1 expression by cardiac fibroblasts: lack of association with myofibroblast contractile markers. *J. Mol. Cell. Cardiol.* 2007;42:991–1000.
- [27] Wang J, Chen H, Seth A, McCulloch CA. Mechanical force regulation of myofibroblast differentiation in cardiac fibroblasts. *J Physiol Heart Circ Physiol* 2003;285:H1871–81.
- [28] Hinz B, Phan SH, Thannickal VJ, Prunotto M, Desmoulière A, Varga J, et al. Recent developments in myofibroblast biology: paradigms for connective tissue remodeling. *J. Pathol.* 2012;180:1340–55.
- [29] Ju H, Zhao S, Jassal DS, Diwon IM. Effect of AT1 receptor blockade on cardiac collagen remodeling after myocardial infarction. *Cardiovasc. Res.* 1997;35:223–32.
- [30] Moore-Morris T, Guimaraes-Cambo N, Banerjee I, Zambon AC, Kisseleva T, Velayoudon A, et al. Resident fibroblast lineages mediate pressure overload-induced cardiac fibrosis. *J. Clin. Invest.* 2014;124:2921–34.
- [31] Hunder GG, Bloch DA, Michel BA, Stevens MB, Arend WP, Calabrese LH, et al. The American College of Rheumatology 1990 Criteria for the Classification of Giant Cell Arteritis. *Arthritis Rheum.* 1990;33:1122–8.
- [32] Maleszewski JJ, Younge BR, Fritzen JT, Hunder GG, Goronzy JJ, Warrington KJ, et al. Clinical and pathological evolution of giant cell arteritis: a prospective study of follow-up temporal artery biopsies in 40 treated patients. *Mod. Pathol.* 2017;30:788–96.
- [33] Segarra M, García-Martínez A, Sánchez M, Hernández-Rodríguez J, Lozano E, Grau JM, et al. Gelatinase expression and proteolytic activity in giant-cell arteritis. *Ann. Rheum. Dis.* 2007;66:1429–35.
- [34] Watanabe R, Maeda T, Zhang H, Berry GJ, Zeisbrich M, Brockett R, et al. Matrix metalloproteinase-9 (MMP-9)-producing monocytes enable T cells to invade the vessel wall and cause vasculitis. *Circ. Res.* 2018;123:700–15.
- [35] Rodríguez-Pla A, Bosch-Gil JA, Rosselló-Urgell J, Huguet-Redecilla P, Stone JH, Vilardell-Tarres M. Metalloproteinase-2 and -9 in giant cell arteritis: involvement in vascular remodeling. *Circulation* 2005;112:264–9.
- [36] Scott NA, Cipolla GD, Ross CE, Dunn B, Martin FH, Simonet L, et al. Identification of a potential role for the adventitia in vascular lesion formation after balloon overstretch injury of porcine coronary arteries. *Circulation* 1996;93:2178–87.
- [37] Desmoulière A, Gabbiani G. Myofibroblast differentiation during fibrosis. *Exp. Nephrol.* 1995;3:134–9.
- [38] Tinajero MG, Gotlieb AI. Recent developments in vascular adventitial pathobiology: the dynamic adventitia as a complex regulator of vascular disease. *Am. J. Pathol.* 2020;190:520–34.
- [39] Coen M, Gabbiani G, Bochaton-Piallat ML. Myofibroblast-mediated adventitial remodeling an underestimated player in arterial pathology. *Arterioscler. Thromb. Vasc. Biol.* 2011;31:2391e2396.
- [40] Li M, Riddle SR, Frid MG, El Kasmi KC, McKinsey TA, Sokol RJ, et al. Emergence of fibroblasts with a proinflammatory epigenetically altered phenotype in severe hypoxic pulmonary hypertension. *J. Immunol.* 2011;187:2711e2722.
- [41] Dutzmann J, Koch A, Weisheit S, Sonnenschein K, Korte L, Hartlé M, et al. Sonic hedgehog-dependent activation of adventitial fibroblasts promotes neointima formation. *Cardiovasc. Res.* 2017;113:1653e1663.
- [42] Barman SA, Chen F, Su Y, Dimitropoulou C, Wang Y, Catravas JD, et al. NADPH oxidase 4 is expressed in pulmonary artery adventitia and contributes to hypertensive vascular remodeling. *Arterioscler. Thromb. Vasc. Biol.* 2014;34:1704e1715.
- [43] ter Borg EJ, Haanen HCM, Seldenrijk CA. Relationship between histological subtypes and clinical characteristics at presentation and outcome in biopsy-proven temporal arteritis. Identification of a relatively benign subgroup. *Clin. Rheumatol.* 2007;26:529–32.
- [44] Bevan AT, Dunnill MS, Harrison MJ. Clinical and biopsy findings in temporal arteritis. *Ann. Rheum. Dis.* 1968;27:271–7.

Travail complémentaire 1. (non publié)

Etude des capacités fonctionnelles des fibroblastes adventitiels.

Afin d'étudier les capacités fonctionnelles des fibroblastes adventitiels nous avons isolé et mis en culture des adventices d'artères temporales (**Figure 20**).

Ces fibroblastes exprimaient la SMMHC en analyse immunocytochimique et western-blot de façon plus importante pour les patients atteints d'ACG (**Figure 21**), confirmant l'augmentation du pouvoir contractile décrit précédemment (**Article 1**). La prolifération des fibroblastes adventitiels en culture était augmentée au cours de l'ACG par rapport aux contrôles sur test au BrdU. Par ailleurs, l'analyse du Ki67 sur immunohistochimie montrait une augmentation mais non significative de la prolifération au sein de l'adventice pour les patients atteints d'ACG. Les fibroblastes adventitiels avaient également des propriétés migratoires augmentées en présence de SVF ou de PDGF. En revanche il n'existait pas de différence entre le groupe ACG et le groupe contrôles.

En condition normale, la paroi artérielle présente un faible taux de prolifération notamment de cellules endothéliales et de CMLV. Soumis à une blessure ou à un stress, les 3 couches présentent une augmentation des capacités prolifératives. Plusieurs résultats suggèrent que la prolifération et migration des CMLV de la média favorisaient l'hyperplasie intimale dont les cellules expriment fortement des marqueurs de CMLV. Néanmoins au cours de ces dernières années, ce point de vue a été fortement remis en question [307]. Les cellules résidentes de l'adventice sont en effet capables de proliférer et de migrer dans l'intima et contribuer à l'hyperplasie intimale après un stress. Les fibroblastes adventitiels qui sont capables d'une transformation phénotypique en myofibroblastes seraient donc la principale source de l'hyperplasie intimale. Cette théorie est appelée « *outside-in* », c'est-à-dire que l'initiation lésionnelle provient de l'extérieur (l'adventice) engendrant des conséquences à l'intérieur (l'intima) [307].

Nos résultats suggèrent qu'il existe un phénomène « *outside-in* » au cours de l'ACG. Les fibroblastes adventitiels seraient donc impliqués au cours du remodelage vasculaire notamment en s'activant en myofibroblastes, se dotant de capacité proliférative et migratoire vers l'intima mais aussi sécrétoire de collagène participant à l'hyperplasie intimale.

Le processus d'activation excessive des myofibroblastes et de leur sécrétion accrue de collagène engendrant une fibrose irréversible est rencontré dans d'autres pathologies comme les cicatrices hypertrophiques, la sclérodermie, la maladie de Dupuytren, les fibroses pulmonaires, hépatiques, rénales ou cardiaques. Ils sont aussi impliqués dans la progression cancéreuse en créant un micro-environnement favorable aux cellules tumorales épithéliales [374]. A l'origine, le remodelage vasculaire a été décrit dans l'athérosclérose. Dans les premiers stades de cette pathologie, une dilatation compensatoire artérielle a lieu pour maintenir un débit constant malgré la présence de la plaque d'athérome. Cette adaptation dépend des interactions dynamiques entre des facteurs de croissances, des substances vasoactives et des stimuli hémodynamiques (cisaillement, étirement) pour engendrer des modifications de la composition relative de la paroi du vaisseau, appelé remodelage positif (phénomène de Glagov). En cas de mauvais contrôle pour auto-limiter le remodelage, une réduction de la lumière du vaisseau survient entraînant un remodelage négatif ou constrictif contribuant à la pathogenèse des principales maladies cardiovasculaires [375]. Le remodelage positif est principalement lié à l'activité des métalloprotéases présentes de part et d'autre des plaques d'athérome. Ce phénomène induit une perte de collagène et de CMLV engendrant une réduction en épaisseur de la média et de l'adventice. L'activation des fibroblastes résidents en myofibroblastes n'a pas été observée au cours du remodelage positif. Après ce phénomène « positif », survient un remodelage artériel négatif. Des lésions coronariennes induites par ballonnet ont montré que le remodelage négatif était principalement induit par une prolifération rapide de fibroblastes adventitiels et leur passage à l'état de myofibroblastes. Ce phénomène aboutit à la formation d'une adventice épaissie, riche en myofibroblastes et en fibres de collagène comme observé au cours de l'ACG [375].

Le fibroblaste adventiciel semble jouer un rôle clé dans la physiopathologie du remodelage vasculaire de l'ACG. Nos résultats suggèrent que ce type cellulaire est présent au sein dans la néo-intima de l'ACG.

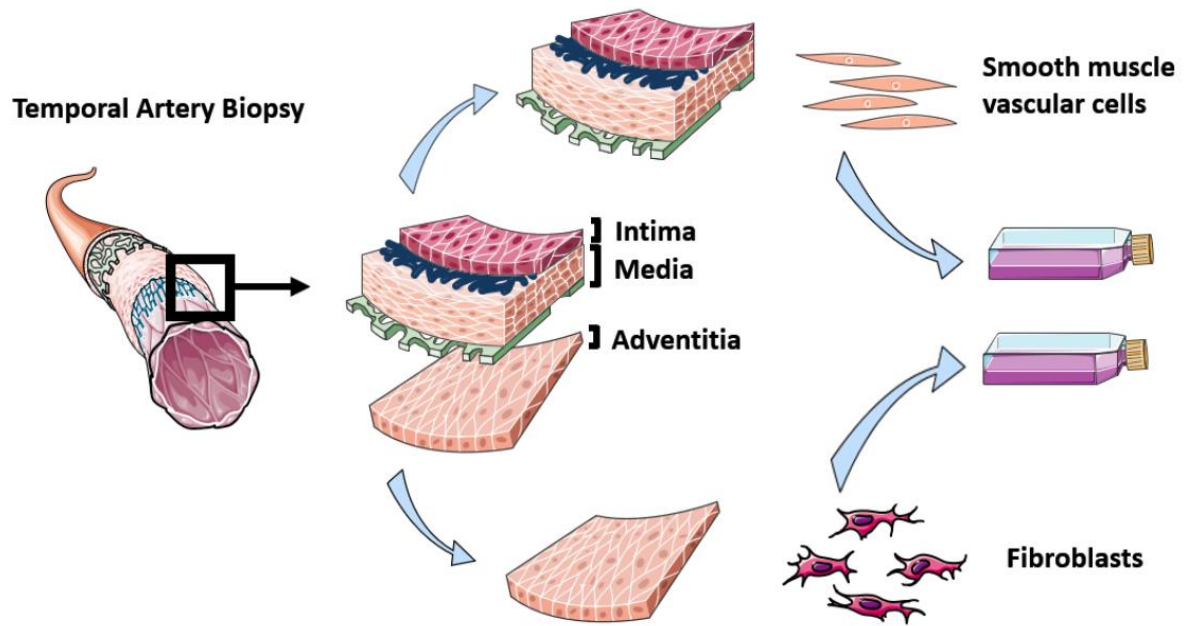
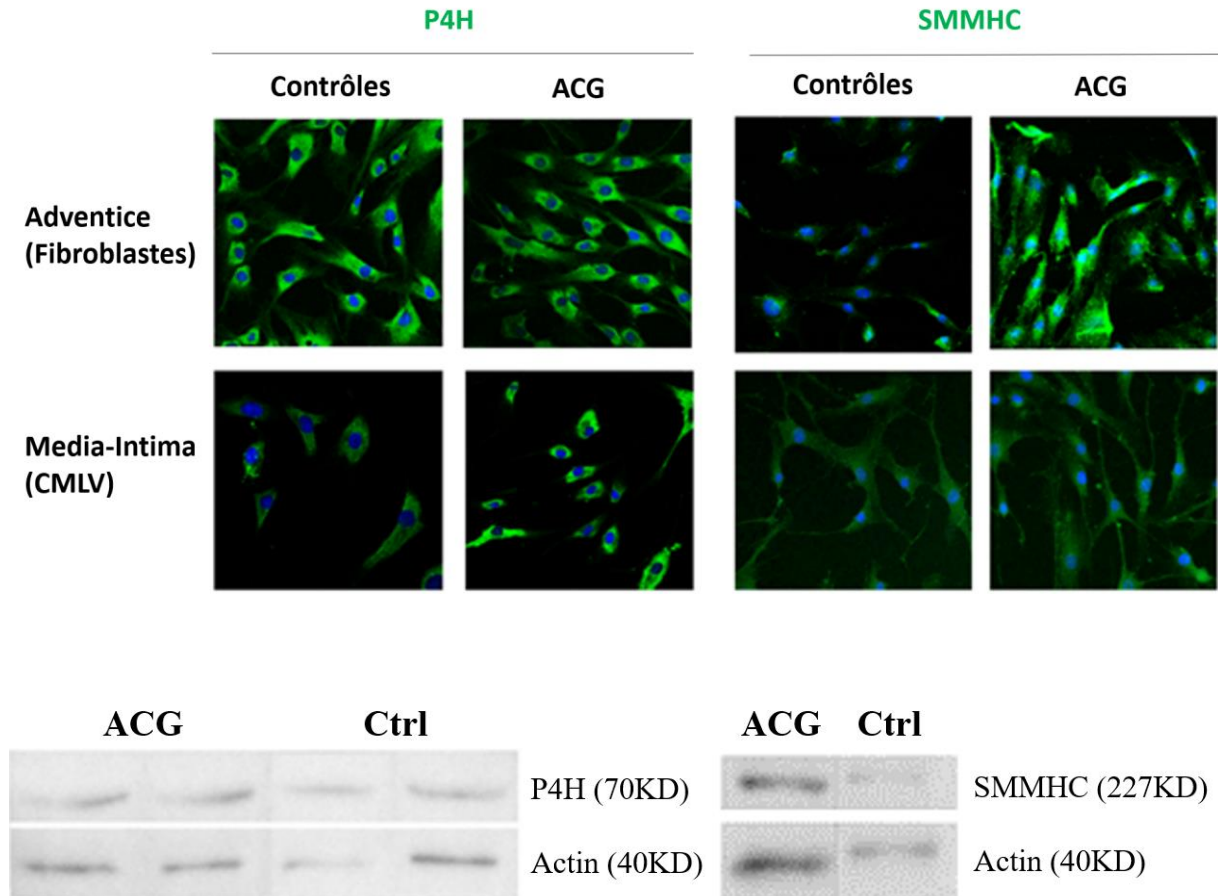


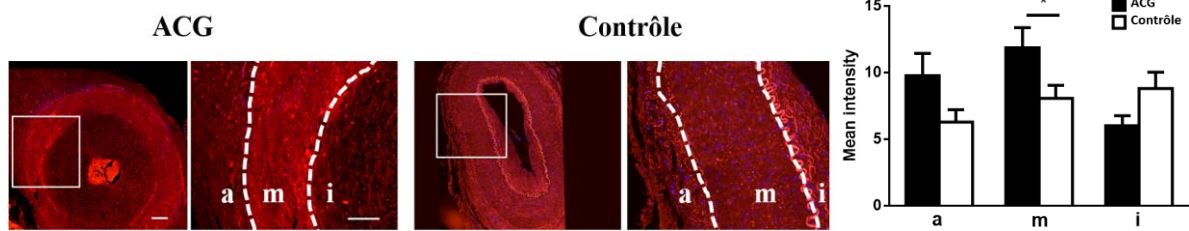
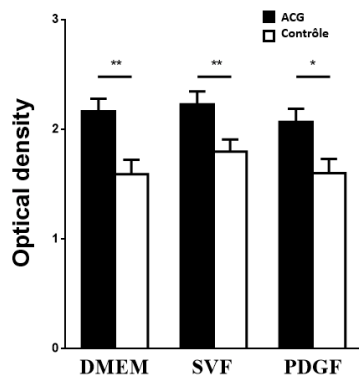
Figure 20. Méthode de séparation de l'adventice issue de BAT.

Figure 21. Etude de l'activité fonctionnelle des fibroblastes en culture primaire, issus d'adventices de patients porteurs d'ACG et de contrôles.

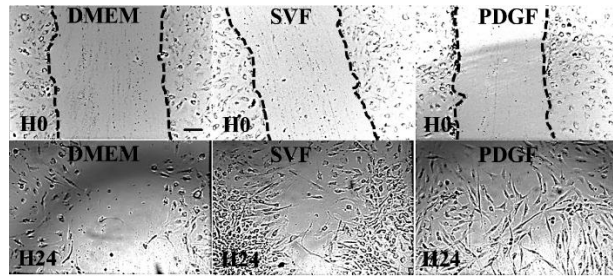
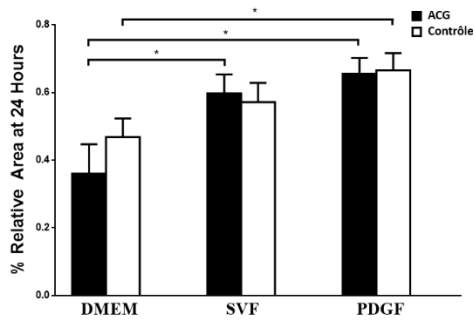
Abréviations : Densité optique (Optical density), moyenne d'intensité (Mean intensity), % de recouvrement (% Relative area). *P<0.05, **P<0.01, ***P<0.001 (test de Student). La barre d'échelle correspond à 100µm.



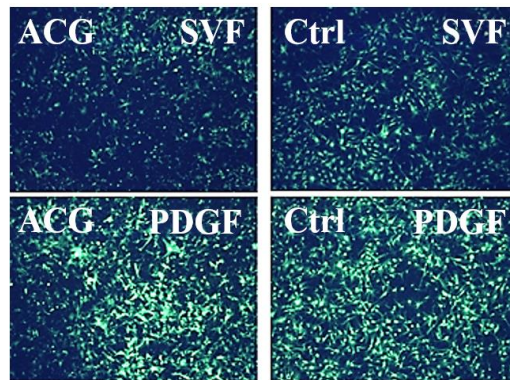
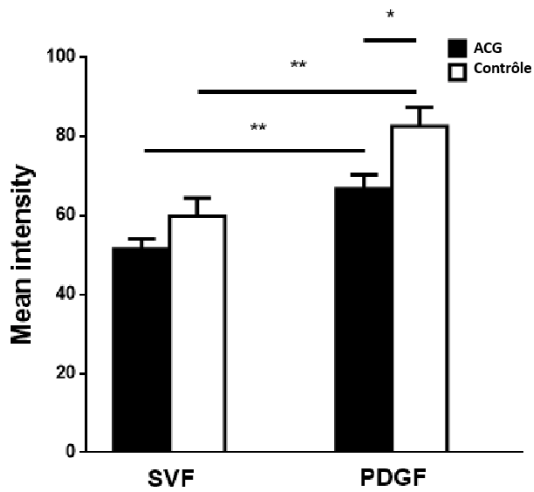
Comparaison de marqueurs d'activité, prolyl-4-hydroxylase (P4H) et myosine de chaîne légère musculaire lisse (SMMHC) en immunofluorescence directe et Western blot sur fibroblastes issus d'adventice et de cellules de média-intima. Il existe une expression de la P4H et du SMMHC pour les fibroblastes adventitiels avec marquage plus important concernant les ACG (n=2) par rapport aux contrôles (Ctrl) (n=2).



Etude de la prolifération des fibroblastes adventitiels par incorporation de la bromodésoxyuridine (BRDU) sous différentes conditions, DMEM, enrichissement en sérum de veau foetal 10% (SVF), facteur de croissance plaquette-dérivé à 40 ng/mL (PDGF) et par marquage histologique au Ki67. Il existe une augmentation de la prolifération des Fa d'ACG (n=8) par rapport aux Ctrl (n=6) pour les 3 conditions. La prolifération est aussi augmentée sur test Ki67 mais seulement au sein de la média et une tendance dans l'adventice pour les ACG (n=20) par rapport aux contrôles (n=18).



Etude de la migration des fibroblastes adventitiels par méthode de comblement de lésion avec les mêmes conditions décrites. Il n'existe pas de différence entre le groupe ACG (n=7) et contrôles (n=7). Le SVF et le PDGF stimulent la migration des fibroblastes adventitiels à 24 heures par rapport au DMEM dans le groupe ACG.



Etude de l'envahissement des fibroblastes adventitiels par méthode de chambre d'invasion avec les mêmes conditions décrites. Il existe une augmentation de l'invasion après stimulation au PDGF concernant les 2 groupes par rapport au SVF. Le PDGF stimule plus les fibroblastes adventitiels du groupe contrôle (n=5) par rapport aux ACG (n=5).

Article 2.

Use of high-plex data provides novel insights into the temporal artery processes of giant cell arteritis.

Simon Parreau, Elsa Molina, Stéphanie Dumonteil, Radjiv Goulabchand, Thomas Naves, Melanie C Bois, Hussein Akil, Faraj Terro, Anne-Laure Fauchais, Eric Liozon, Marie-Odile Jauberteau, Cornelia M Weyand, Kim-Heang Ly

Front Immunol. 2023 Sep 6:14:1237986

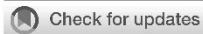Les mécanismes sous-jacents de l'ACG sont principalement liés à une réponse inflammatoire et un remodelage vasculaire. Aucun des médicaments anti-inflammatoires actuellement utilisés ne limite efficacement l'évolution de la maladie. Il a été démontré précédemment que les lésions histopathologiques impliquent les trois couches de la paroi artérielle (adventice, média et intima). Notre hypothèse est que chaque couche de l'artère, y compris le tissu périvasculaire (4^{ème} couche impliquée), présente une signature transcriptomique unique qui pourrait définir et expliquer les différents événements moléculaires au cours de l'ACG. L'objectif était de découvrir les gènes codants clés pour définir de nouveaux biomarqueurs ou voies associés à l'ACG en réalisant la première caractérisation par profilage spatial in situ des acteurs moléculaires impliqués dans les artères temporales de patients atteints d'ACG par rapport aux artères normales.

À partir de BAT fixées au formol et incluses en paraffine (ACG n = 9 ; contrôles n = 7), nous avons effectué une analyse du transcriptome entier en utilisant le *NanoString GeoMx Digital Spatial Profiler*. Un total de 59 régions d'intérêt (ROI) individuelles ont été créées, dans chacune des 4 couches pour chaque artère. Les échantillons ont été séquencés sur la plateforme Illumina NovaSeq 6000 puis quantifiées numériquement et normalisées à l'aide du logiciel d'analyse de données *GeoMx DSP*. Les gènes exprimés de manière différentielle (*Differential Expressed Gene*, DEG) (*fold change* >2 ou <-2, p-ajustée < 0,01) ont été comparés pour chaque couche, afin de construire un réseau spatial et pharmacogénomique dans l'ACG.

Parmi le transcriptome étudié (12 076 gènes), 282, 227, 40 et 5 DEG ont été trouvés respectivement dans l'intima, la média, l'adventice et le tissu périvasculaire, pour la plupart surexprimés (*fold change* >2). L'analyse d'enrichissement montrait que les fonctions liées à l'inflammation/réponse immunitaire et le remodelage vasculaire

étaient significativement limités aux couches internes (intima et media). Les fonctions immunitaires concernaient la différenciation des macrophages, les activations des lymphocytes T et B et du complément. En ce qui concerne les voies de remodelage vasculaire, nous avons constaté une augmentation du processus métabolique du collagène, de la prolifération des fibroblastes, de l'angiogenèse, de la prolifération des cellules musculaires lisses et de l'ossification dans l'intima & la média. Notre analyse du réseau pharmacogénomique a permis d'identifier les gènes qui pourraient potentiellement être ciblés par les médicaments immunosuppresseurs/modulateurs actuellement approuvés ou par de nouvelles immunothérapies.

Nos résultats fournissent la première caractérisation par profilage spatial *in situ* des acteurs moléculaires impliqués dans l'ACG, essentiel pour la découverte de nouvelles cibles thérapeutiques potentielles pour traiter cette vascularite. La régulation spatiale différentielle des gènes impliqués dans le processus inflammatoire et le remodelage vasculaire suggère une implication chronologique de chaque couche de l'artère.



OPEN ACCESS

EDITED BY

Gilles Kaplanski,
Assistance Publique Hôpitaux
de Marseille, France

REVIEWED BY

Maxime Samson,
Université de Bourgogne, France
Alessandro Mangogna,
Institute for Maternal and Child Health
Burlo Garofolo (IRCCS), Italy

*CORRESPONDENCE

Simon Parreau
✉ simon.parreau@chu-limoges.fr

†These authors share junior authorship

‡These authors share senior authorship

RECEIVED 10 June 2023

ACCEPTED 21 August 2023

PUBLISHED 06 September 2023

CITATION

Parreau S, Molina E, Dumonteil S,
Goulabchand R, Naves T, Bois MC, Akil H,
Terro F, Fauchais A-L, Liozon E,
Jauberteau M-O, Weyand CM and Ly K-H
(2023) Use of high-plex data provides
novel insights into the temporal artery
processes of giant cell arteritis.
Front. Immunol. 14:1237986.
doi: 10.3389/fimmu.2023.1237986

COPYRIGHT

© 2023 Parreau, Molina, Dumonteil,
Goulabchand, Naves, Bois, Akil, Terro,
Fauchais, Liozon, Jauberteau, Weyand and
Ly. This is an open-access article distributed
under the terms of the [Creative Commons
Attribution License \(CC BY\)](https://creativecommons.org/licenses/by/4.0/). The use,
distribution or reproduction in other
forums is permitted, provided the original
author(s) and the copyright owner(s) are
credited and that the original publication in
this journal is cited, in accordance with
accepted academic practice. No use,
distribution or reproduction is permitted
which does not comply with these terms.

Use of high-plex data provides novel insights into the temporal artery processes of giant cell arteritis

Simon Parreau^{1,2,3*†}, Elsa Molina^{4,5†}, Stéphanie Dumonteil²,
Radjiv Goulabchand^{6,7}, Thomas Naves³, Melanie C. Bois⁸,
Hussein Akil³, Faraj Terro⁹, Anne-Laure Fauchais^{2,3},
Eric Liozon², Marie-Odile Jauberteau³, Cornelia M. Weyand^{1‡}
and Kim-Heang Ly^{2,3‡}

¹Division of Rheumatology, Mayo Clinic, Rochester, MN, United States, ²Division of Internal Medicine, Dupuytren University Hospital, Limoges, France, ³INSERM U1308, Faculty of Medicine, University of Limoges, Limoges, France, ⁴Stem Cell Genomics Core, Stem Cell Program, University of California, San Diego, La Jolla, CA, United States, ⁵Next Generation Sequencing Core, Salk Institute for Biological Studies, La Jolla, CA, United States, ⁶Division of Internal Medicine, Nîmes University Hospital, University of Montpellier, Nîmes, France, ⁷Division of Gastroenterology, Department of Medicine, University of California, San Diego, San Diego, CA, United States, ⁸Division of Laboratory Medicine and Pathology, Mayo Clinic, Rochester, MN, United States, ⁹Cell Biology, Dupuytren University Hospital, Limoges, France

Objective: To identify the key coding genes underlying the biomarkers and pathways associated with giant cell arteritis (GCA), we performed an *in situ* spatial profiling of molecules involved in the temporal arteries of GCA patients and controls. Furthermore, we performed pharmacogenomic network analysis to identify potential treatment targets.

Methods: Using human formalin-fixed paraffin-embedded temporal artery biopsy samples (GCA, n = 9; controls, n = 7), we performed a whole transcriptome analysis using the NanoString GeoMx Digital Spatial Profiler. In total, 59 regions of interest were selected in the intima, media, adventitia, and perivascular adipose tissue (PVAT). Differentially expressed genes (DEGs) (fold-change > 2 or < -2, p-adjusted < 0.01) were compared across each layer to build a spatial and pharmacogenomic network and to explore the pathophysiological mechanisms of GCA.

Results: Most of the transcriptome (12,076 genes) was upregulated in GCA arteries, compared to control arteries. Among the screened genes, 282, 227, 40, and 5 DEGs were identified in the intima, media, adventitia, and PVAT, respectively. Genes involved in the immune process and vascular remodeling were upregulated within GCA temporal arteries but differed across the arterial layers. The immune-related functions and vascular remodeling were limited to the intima and media.

Conclusion: This study is the first to perform an *in situ* spatial profiling characterization of the molecules involved in GCA. The pharmacogenomic network analysis identified potential target genes for approved and novel immunotherapies.

KEYWORDS

giant cell arteritis, vasculitis, transcriptomic analysis, temporal artery biopsy, gene expression

Introduction

Giant cell arteritis (GCA), also called temporal arteritis or Horton's disease, is the most common systemic large-vessel vasculitis; it primarily affects the aorta and its major branches in individuals aged over the age of 50s (1). This inflammatory disease is related to immune system aging (2) and a high risk of arterial occlusion, which can lead to irreversible blindness, strokes, and death (3, 4). Despite advances in understanding the underlying disease mechanisms of GCA over the past three decades, the treatment options are still limited. Furthermore, a high proportion of patients relapse during treatment with corticosteroids, methotrexate, or tocilizumab, which are the current recommended treatments for this vasculitis (5–8). In almost half of the patients, arterial inflammation persists even 1 year after corticosteroid treatment (9).

The management of GCA is challenging owing to its histopathological complexity, which occurs because it involves three arterial layers, from outer to inner: adventitia, media, and intima. Despite the potential significance of perivascular adipose tissue (PVAT) in the development of GCA, its role has not been thoroughly investigated (10). The disease process begins in the outer layer of the vessel, the adventitia, where resident dendritic cells are stimulated by an unknown trigger. This initiates an inflammatory response that involves infiltration by lymphocytes, macrophages, and giant cells, which damage the elastic tissue through release of metalloproteases and reactive oxygen species. As a result, vascular smooth muscle cells differentiate into myofibroblasts, migrate, and eventually cause intimal hyperplasia, leading to vessel obstruction (11).

Although the characterization of GCA through immunoprofiling of arterial tissue sections is essential for understanding immune cell interactions and evaluating the effects of immunosuppressive and anti-inflammatory drugs, previous studies had some limitations such as tissue heterogeneity or small sample sizes (12–15). Multiple studies have analyzed the transcriptomic profile of the entire artery without considering the anatomical characteristics of GCA lesions. As a result, transcriptional events specific to a particular arterial layer may have been missed when the entire artery was analyzed. Therefore, we used NanoString GeoMx[®] Digital Spatial Profiler (DSP) technology to explore the molecular events involved in inflammatory and vascular

remodeling in each sub-layer of GCA (16). Thanks to this technology that allows complex RNA profiling and quantification of the transcripts in specific regions within a tissue, we were able to study spatially the transcriptome of GCA and non-GCA areas of human temporal arteries using formalin-fixed, paraffin-embedded tissues. Whole tissue spatial transcriptomic analyses can better elucidate functional mechanisms and gene pathways in pathological tissues with complex organization, such as human temporal artery, which is the main artery involved in patients with GCA.

The present study is the first to provide *in situ* spatial transcriptomic analyses for the identification of layer-specific genes and cellular functions related to GCA, potentially leading to the identification of novel therapeutic targets. Here, we proposed a model in which spatiotemporal transcriptomic analysis can be used to identify previously unknown pathways and new drug targets for GCA. Therefore, our results can be useful for drug development strategies and may improve patient outcomes.

Patients and methods

Study design and participants

In this retrospective observational study, we recruited non-consecutive patients referred to the internal medicine department of the Limoges University Hospital Dupuytren, France, between January 1, 2014, and December 31, 2018. The participants underwent temporal artery biopsy (TAB) for suspected GCA, which was diagnosed based on the 2022 ACR/EULAR criteria (17) and histologically confirmed based on the presence of panarteritis with an inflammatory infiltrate (e.g., macrophages and lymphocytes) and fragmentation of the internal elastic lamella, corresponding to the most common histological pattern described by Hernández-Rodríguez et al. (18, 19). This study included patients who were treated with glucocorticoids for 1–10 days before TAB as this treatment does not affect the histopathological findings of TAB (20, 21). Participants with a negative TAB and a final diagnosis other than GCA were considered controls. We recorded the age, sex, symptoms, treatments, and outcomes of each participant at the time of diagnosis.

Tissue collection and preparation

Unilateral TABs were performed under local anesthesia by an ophthalmologic surgeon using standard techniques (22). A 1–4-cm-long specimen of the temporal artery was obtained for histological analysis. The temporal artery specimens were analyzed using standard protocols. The specimens were subjected to gross evaluation and were cross sectioned serially. Tissues were fixed in 10% neutral buffered formalin for 24 h, followed by transfer to 70% ethanol before paraffin embedding. For each patient and control, the most representative segments were grouped into formalin-fixed paraffin-embedded (FFPE) temporal artery blocks using the tissue microarray method. Tissue microarrays were constructed from 2-mm-diameter cores punched from each FFPE tissue block.

NanoString GeoMx Digital Spatial Profiler

The NanoString GeoMx DSP platform quantifies RNA abundance by counting unique indexing oligonucleotides assigned to each target of interest. Those oligonucleotides are covalently attached to mRNA hybridization probes with an ultraviolet-photocleavable linker (16). First, FFPE temporal artery blocks from GCA and control patients were sectioned to a thickness of 5 μm . The sections were mounted on an adhesive or positively charged slides (cat# S21.2113.A; Bond Plus slides; Leica Biosystems, Richmond, VA, USA) with a maximum of 24 individual tissues per slide at the San Diego Pathology Department (San Diego, CA, USA). Some slides were stored at 4°C, while others were deparaffinized and used for hematoxylin & eosin (H&E) staining (San Diego Pathology Department) for subsequent microscopy imaging (Keyence BZ-X800). A cardiovascular pathologist (M.C.B.) and two GCA specialists (S.P. and C.M.W.) reviewed all H&E-stained tissues. Overall, one GCA patient was classified as healed and excluded from this study because the artery exhibited no inflammatory infiltrate, and one control sample was also excluded because it showed tertiary lymphoid structure in the adventitia.

The freshly cut sections were stained with fluorescently labeled imaging reagents and mRNA markers as described previously (16). Briefly, sections were labeled with the cell markers, α -smooth muscle actin, CD3, and CD68, and the nuclear stain SYTO 13. The NanoString commercial Human Whole Transcriptome Atlas (GeoMx WTA) panel (18,000 protein-coding genes) was selected. Four slides (two with GCA patients and two with controls) were scanned on a GeoMx DSP instrument (NanoString Technologies Inc., Seattle, WA, USA) and individual regions of interest (ROIs) with a maximum diameter of 400 μm were created within each of the four arterial layers in GCA and controls.

In this study, we considered a sample as a control where no inflammatory infiltrate was observed, and the 4 artery layers (intima, media, adventitia, and PVAT) were distinguished on the basis of H&E staining as well as internal elastic lamina between intima and media; concentric smooth muscle cells in the media unlike the adventitia, and, finally, the presence of adipocytes in the PVAT unlike the adventitia. A representative portion of each layer

was selected by two GCA specialists (S.P. and R.G.) and confirmed by a pathologist (M.C.B.) (Supplemental Figure 1). Once each ROI was compartmentalized, ultraviolet-cleaved indexing oligonucleotides were collected into a 96-well plate. Libraries were prepared according to the manufacturer's instructions (protocol 01/2019). The library quality and quantity were assessed using the Bioanalyzer DNA High Sensitivity Analysis. Samples were sequenced on the NovaSeq 6000 platform (Illumina, San Diego, CA, USA) and reads were digitally quantified and normalized using GeoMx DSP Data Analysis software (Merritt).

Data processing and analysis

Data obtained from the NanoString GeoMx DSP platform were analyzed using a dedicated software (GeoMx Analysis Suite 2.3). The quality control analysis showed that all ROIs had raw read counts above 1 million and good alignment rate and sequencing saturation. The local outliers were negative control probes and were removed from the ROIs. ROIs with deduplicated probe counts Q3 (upper quartile) < 2 were excluded. Furthermore, ROIs were removed if $< 1\%$ of their genes had read counts higher than the limit of quantification (LOQ). LOQ was defined as $\text{geomean}(\text{NegProbe}) \times \text{geoSD}(\text{NegProbe})^2$ for each ROI. Target filtering was applied to retain gene targets with read counts above LOQ in at least 10% of ROIs. Q3 normalization was applied on the filtered ROIs and gene targets.

The raw data were deposited at the NCBI Gene Expression Omnibus (GEO) database (<https://www.ncbi.nlm.nih.gov/geo/query/acc.cgi?acc=GSE237441>) under the accession number GSE237441.

Differential gene expression across groups was analyzed using linear mixed effect models; differentially expressed genes (DEGs) were defined as fold-change > 2 or < -2 , and Benjamini-Hochberg-adjusted $p < 0.01$. Analyses were conducted using R software (version 3.2.2; R Foundation for Statistical Computing, Vienna, Austria).

The upregulated and downregulated DEGs were analyzed using DAVID Bioinformatics Resources software (version 2021; <https://david.ncifcrf.gov/>) for functional annotations and gene set enrichment analysis. DAVID was used to obtain statistically enriched Gene Ontology (GO) terms for biological processes (GOTERM_BP_FAT). GO terms with EASE score < 0.05 were considered statistically enriched. Based on the known mechanisms in GCA, pathways of interest, signaling cascades, and molecules were selected from among the dysregulated GO terms. These selections are presented as dot plots using ggplot2 package of R software (version 3.2.2).

Dysregulated genes per layer with a fold-change > 2 or < -2 were organized according to the STRING network (<https://string-db.org/>). The one or two main networks were represented for each layer. Genes disconnected from the main network were removed. An interaction score with the highest confidence (0.900) was used. The interaction sources excluded text mining. Using networks generated by the STRING network, a pharmacogenomic network was constructed by targeting existing druggable genes (<https://>

www.dgidb.org/). Drugs with Food and Drug Administration (FDA) approval were selected.

Fluorescence immunohistochemistry

From block, 4- μ m-thick slices were cut and dewaxed by successive immersion in pure xylene (Sigma). Rehydration and unmasking of antigens were carried out by sequentially immersion into 100%, 90%, 80% and 70% ethanol baths (Sigma), phosphate-buffered saline (PBS; Gibco), and citrate buffer (pH 7). Saturation of nonspecific antigenic sites was achieved by incubation in PBS containing 3% bovine serum albumin (BSA). The primary antibodies were diluted in 3% BSA and incubated overnight at 4° C. The antibodies used were as follows: anti-CD74 (1:50, mouse, Abcam), anti-CD90 (1:50, rabbit, Abcam), anti-CD3 (dilution recommended by the supplier, rabbit, Ventana). The sections were subsequently incubated with a secondary antibody coupled to Alexa Fluor 594 or 488 (Molecular Probes) for 60 min. After washing with PBS, nuclear counterstaining was carried out with 4',6-diamidino-2-phenylindole (Sigma) and the sections were mounted in an aqueous medium (Vectashield, Sigma). Images were acquired with Leica microscope (DMI8, Leica).

Role of the funding source

The funders of the study had no role in study design, data collection, analysis, or interpretation, or in writing the manuscript.

Ethics

The study protocol (87RI21_0065) was approved by the Ethics Committee of the University Hospital of Limoges, France (23). Temporal artery tissues were obtained from the biological collection DC-2010-1079. All participants provided informed consent.

Results

Participant characteristics

The characteristics of GCA patients (n = 9) and controls (n = 7) are presented in the [Supplemental Table 1](#). Among the controls, the final diagnoses were non-arteritic ischemic visual impairment (n = 4), peripheral seronegative polyarthritis (no argument for polymyalgia rheumatica) (n = 2), and infection-related encephalopathy (n = 1). Three controls had an inflammatory syndrome related to an acute infection. Among the entire cohort, one patient had diabetes (control), one had a previous cardiovascular complication (control), and two patients were active smokers (one control and one GCA). Corticoids were used before TAB for 8/9 GCA patients (mean 4.3 days before TAB, mean dose of 0.85 mg/kg/d) and 3/7 controls (mean 18.3 days before TAB, mean dose of 0.7 mg/kg/day).

All GCA patients had panarteritis involving the three arterial layers with destruction of the internal lamella on histological examination. The histological sections of the artery are presented in [Supplemental Figure 1](#). Then temporal arteries from the 16 participants were subjected to transcriptional analysis for each arterial layer (intima, media, and adventitia) and the PVAT following technical pipeline indicated in [Figure 1](#). Because the control arteries did not present CD3 and CD68 staining, layers were selected under the control of a senior pathologist depending on their macro characteristics. Four ROIs involving the media, adventitia, and PVAT were excluded from analysis due to poor quality, respectively. Altogether, we analyzed 59 ROIs, checked for quality and correspondence to each layer, from 16 participants to conduct our spatial transcriptomic study.

Temporal artery whole transcriptome analysis exhibits different profiles depending on layers in giant cell arteritis

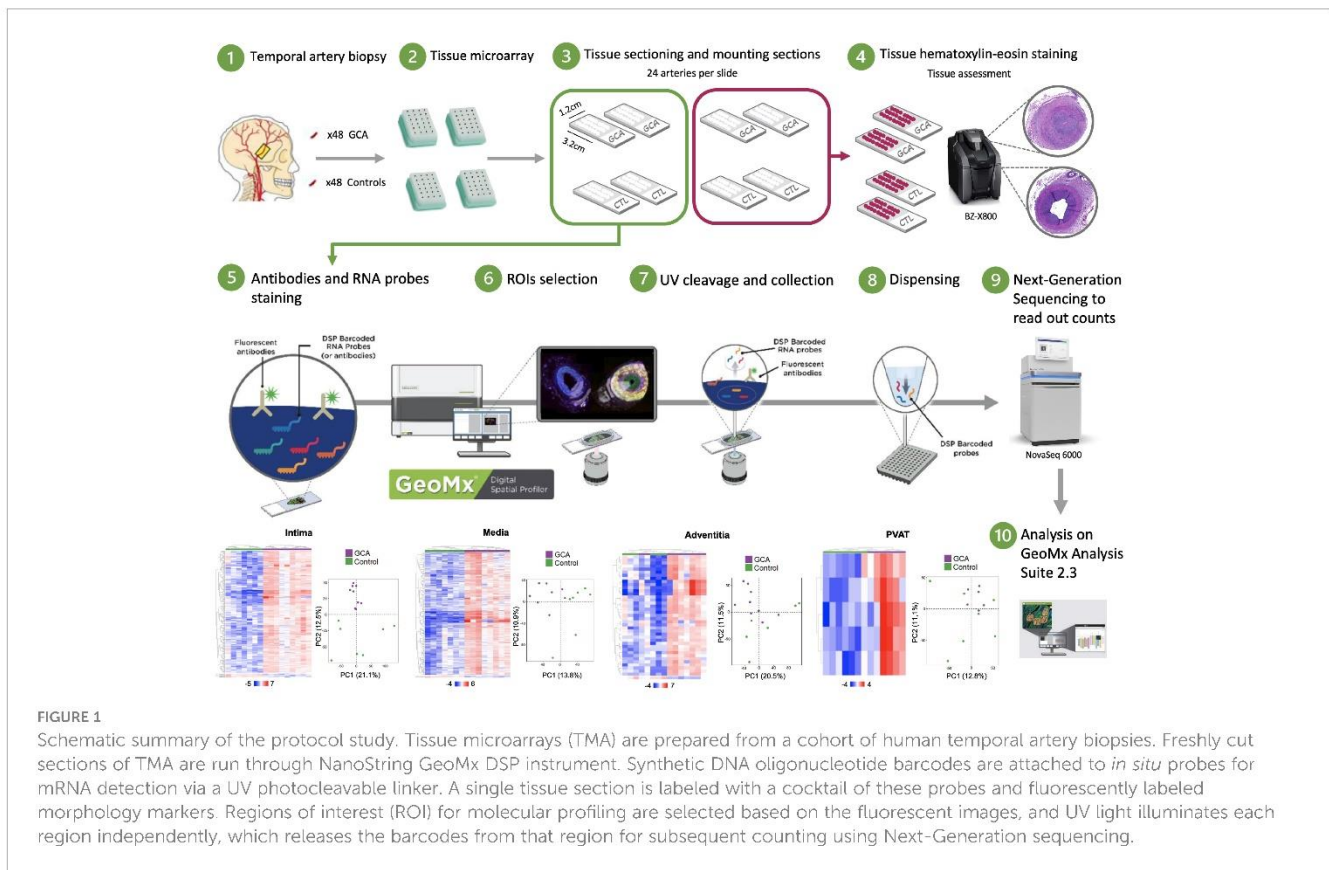
As attempted, correlation analysis demonstrated that disease status (GCA and control) only differentiated samples ([Figure 2A](#)). Interestingly, Pearson correlation coefficient showed that GCA transcriptome remains more homogeneous than in controls as illustrated by increasing intensity of blue reflecting correlation index tending toward 1.

A total of 12,076 genes were detected and 337 different genes (2.8%) were dysregulated between GCA and control participants (fold-change < -2 or > 2, p-adjusted < 0.01). Venn diagram presents unique and common DEGs for the intima, media, and adventitia ([Figure 2B](#)). The number of DEGs increased from external layer, adventitia with 40 genes, to media and intima with respectively 227 and 282 genes. In total, 32 common DEGs were significantly identified among the three layers (intima, media and adventitia), corresponding to the major histocompatibility complex (*CD74*, *B2M*, *HLA-DRB1*, *HLA-A*, *HLA-B*, *HLA-C*, and *HLA-DRA*), macrophages (*CD68*), immunoglobulins (*IGKC* and *IGHG1-4*), apolipoprotein (*APOC1*), cathepsins (*CTSB* and *CTSZ*), and tissue remodeling (*ADAM15*, *COL1A2*, *COL3A1*, *TMSB10*, and *ARHGDI1*). The other common genes were *NPIP6*, *PABPC1*, and those associated with ribosomes (*RPL23*, *RPL28*, *RPL31*, *RPL37*, *RPS12*, *RPS28*, *RPS29*, *RPS3*, and *RPS4X*). Patterns for the four layers in each participant are shown in [Figure 2C](#). Principal component analysis (PCA) highlighted that only intima present a distribution profile more homogeneous and reproducible than other GCA layers and control samples.

Altogether, these results highlight that the intima is the layer where the transcriptome is the most dysregulated depicting a gradient of decreased DEG from the internal to the periphery of the artery.

Top differentially expressed genes across layers in giant cell arteritis compared to control temporal arteries

Overall, most DEGs were upregulated in ROIs from GCA compared to controls. The top 20 upregulated and top 5



downregulated genes per arterial layer in GCA patients compared to the controls are shown in **Figure 3A**. The highest numbers of DEGs were observed in the media and intima.

Figure 3B presents the top 30 dysregulated genes across arterial layers between both studied groups. In the media and intima, *CD74* was the most upregulated gene between GCA and control specimens. Healthy temporal arteries do not exhibit *CD74* staining on immunofluorescence analysis (**Supplemental Figure 2**). In contrary, GCA arteries has *CD74*⁺ cells, particularly within the intima, close to the media border, as well as in the media and the adventitia. Also, cells expressing *CD74* are also *CD90*⁺; however, they do not express *CD3*, marker for lymphocytes. Finally, migration inhibitory factor (*MIF*), a receptor for *CD74*, was significantly overexpressed in the intima of GCA compared to controls ($p\text{-adj} = 0.0031$).

Altogether, these results unveiled that most dysregulated genes in the three arterial layers belong to the antigen presentation gene family and vascular remodeling functions.

Immune related functions and vascular remodeling pathways are predominant in media and intima

We classified the top 30 DEGs by arterial layers according to their main functions (**Figure 4A**). Most top DEGs per layer were associated with immune or remodeling functions. Immune

function-related genes were associated with macrophages (*CD68* and cathepsins), major histocompatibility complex, complement system, and immunoglobulins. Remodeling-related genes were mainly associated with metalloproteases, reactive oxygen species, cytoskeleton organization, and collagen.

Using the DAVID tool, remodeling-related pathways of interest with gene dysregulation were selected (**Figure 4B**). PVAT was excluded due to the low number of dysregulated genes between GCA and control specimens. Remodeling pathways associated with GCA primarily involve the intima and media and include the reactive oxygen species and collagen metabolic process, fibroblast proliferation, muscle cell differentiation, ossification, and angiogenesis. The dysregulated genes for each signaling pathway are detailed in **Supplemental Figure 3**.

Altogether these results suggest that activated immune cells are actively and mainly present in the intima and the media layers. Likewise, vascular remodeling process following a gradient from the outside to inside part of the vessel.

Meta-analysis studies similar expression profiles among genes of interest across arterial layers

The DEGs among the four layers were compared (**Figure 5A**). The meta-analysis identified 412 upregulated genes and 101 downregulated genes. Genes whose expression profiles were

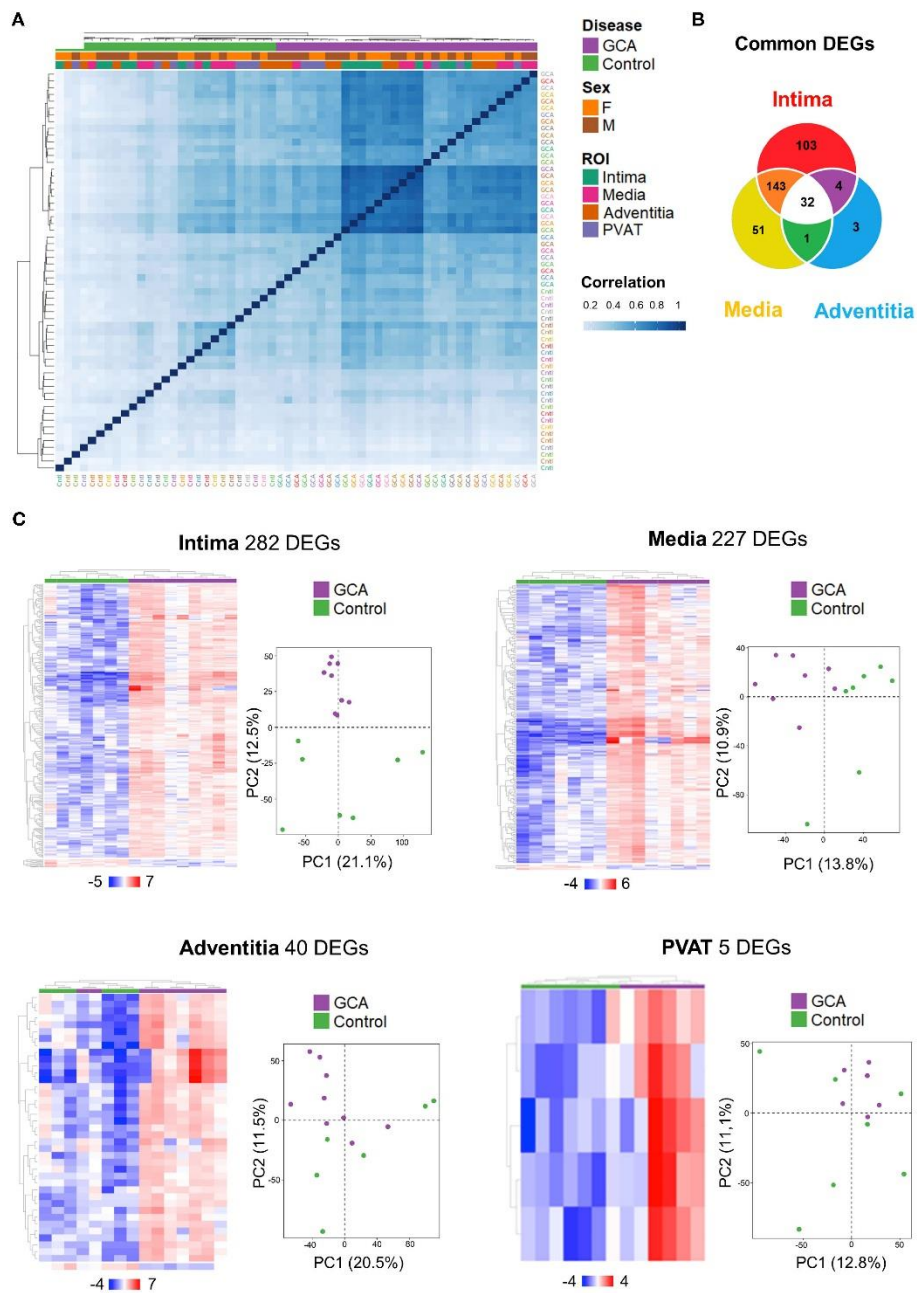


FIGURE 2

Temporal Artery Whole Transcriptome Analysis across layers. **(A)** Hierarchical clustering according to the correlation between the 59 ROIs studied with identification of status (Giant Cell Arteritis or Control), gender (Male or Female) and layers (Intima, Media, Adventitia, Perivascular adipose tissue). **(B)** A total of 337 differentially expressed genes (DEGs) were identified for the intima, media, and/or adventitia of GCA compared with controls (fold change < -2 or > 2 , adjusted p-value < 0.01). Some genes are only dysregulated in one layer and others are shared by two or three arterial layers. **(C)** Hierarchical clustering of patients by DEGs and principal component analysis on gene expression profiles (12,076 genes in total) from temporal artery biopsy samples in both patient groups (Giant Cell Arteritis and control temporal arteries) for each different layer. GCA, giant cell arteritis; F, female; M, male; PVAT, perivascular adipose tissue; DEGs, differentially expressed genes; PC, principal component.

similar to *CD74*, the top DEG, are shown in Figure 5B. These genes were mainly involved in antigen presentation, including the major histocompatibility complex (*B2M*, *HLA-B*, *HLA-DRA*, and *HLA-DRB1*), cathepsin (*CTSB*), ferritin (*FTH1*), immunoglobulin (*IGHG2*), and lysozyme (*LYZ*).

As macrophages are the key immune cells in GCA, we presented the genes with a similar expression profile within the four layers like *CD68*, a marker for macrophages (Figure 5C). The

DEGs included those related to cytokines (*TNF*), chemokines (*CCL5*, *CXCL9*, and *CXCR4*), *YKL40* (*CHI3L1*), metalloproteases (*MMP2* and *MMP9*) secreted by macrophages, membrane receptors (*CD63* and *CD206*), and iron metabolism-related molecules (*FTH1* and *SOD2*). Similarly, we evaluated vascular remodeling during GCA based on the two main associated DEGs: *MMP2* (Figure 5D) and collagen *COL3A1* (Figure 5E). We identified the top genes with the same expression profile across the layers.

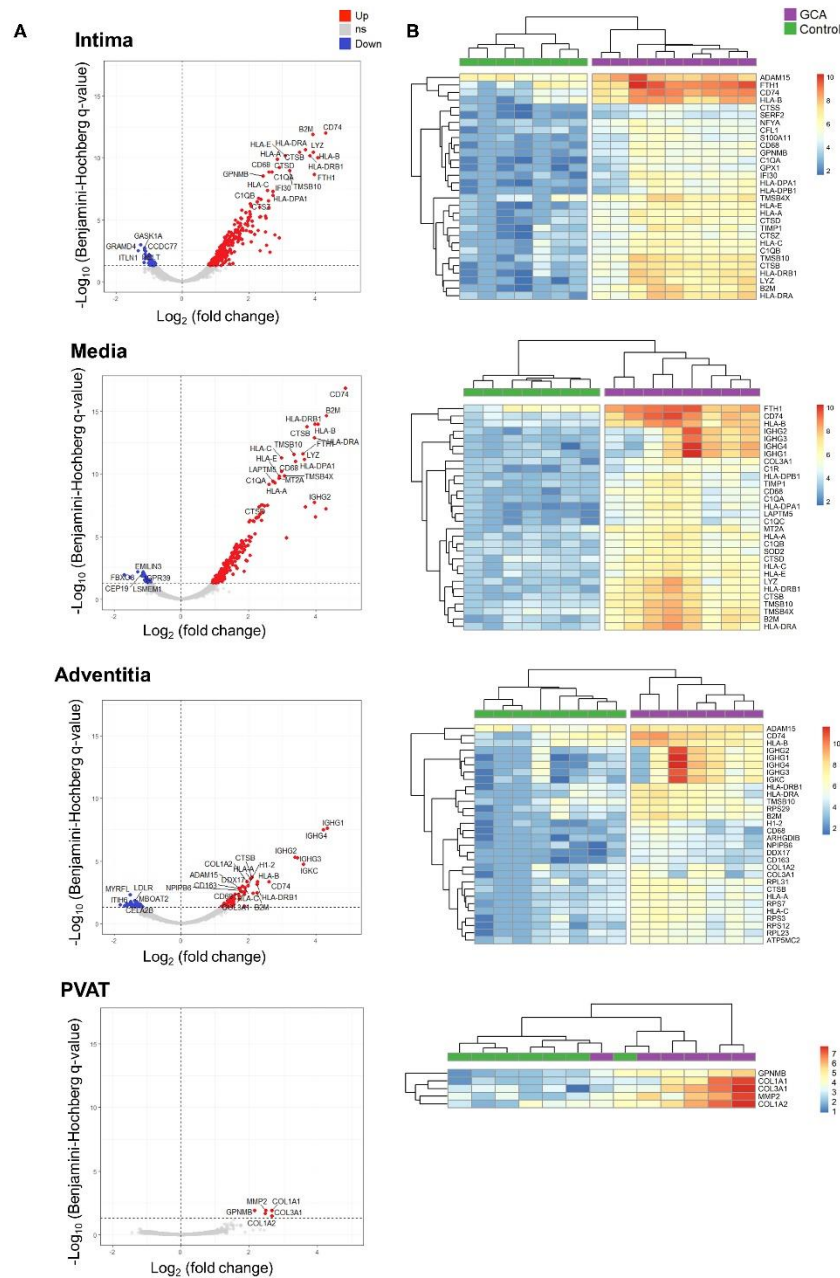


FIGURE 3
 Top differentially expressed genes (DEGs) across layers in Giant Cell Arteritis compared to control temporal arteries. **(A)** Top 20 upregulated genes and top 5 downregulated genes for each layer (intima, media, adventitia, and perivascular adipose tissue) of Giant Cell Arteritis temporal arteries. **(B)** Hierarchical clustering among each ROI participant for the top 30 dysregulated genes per layer. Up, up-regulated genes; ns, non statistically significant dysregulated genes; Down, down-regulated genes; GCA, giant cell arteritis; PVAT, perivascular adipose tissue.

Potential novel drug-targeted pathways for GCA treatment

Transcriptomic profiling is an efficient and essential tool for drug target discovery. Several studies have combined gene expression profiling with systematic approaches for drug repurposing or biomarker discovery (24, 25). Among strategies for novel drug target identification, the network-based framework uses curated biological network topology to investigate the association across genes, diseases, and drugs (26). We constructed

a pharmacogenomic network by integrating DEGs from each artery layer, a high-confidence protein-protein interaction network, and drug-gene interactions. Then, the top dysregulated genes are presented as a STRING analysis to highlight their relationships. The significantly connected genes are shown in Figure 6. Networks show the strong relationships between several genes. Two mains separate networks exist for each layer corresponding to global immune function (yellow) and vascular remodeling (blue). Key genes are present at nodes of those interactions and connected to other genes.

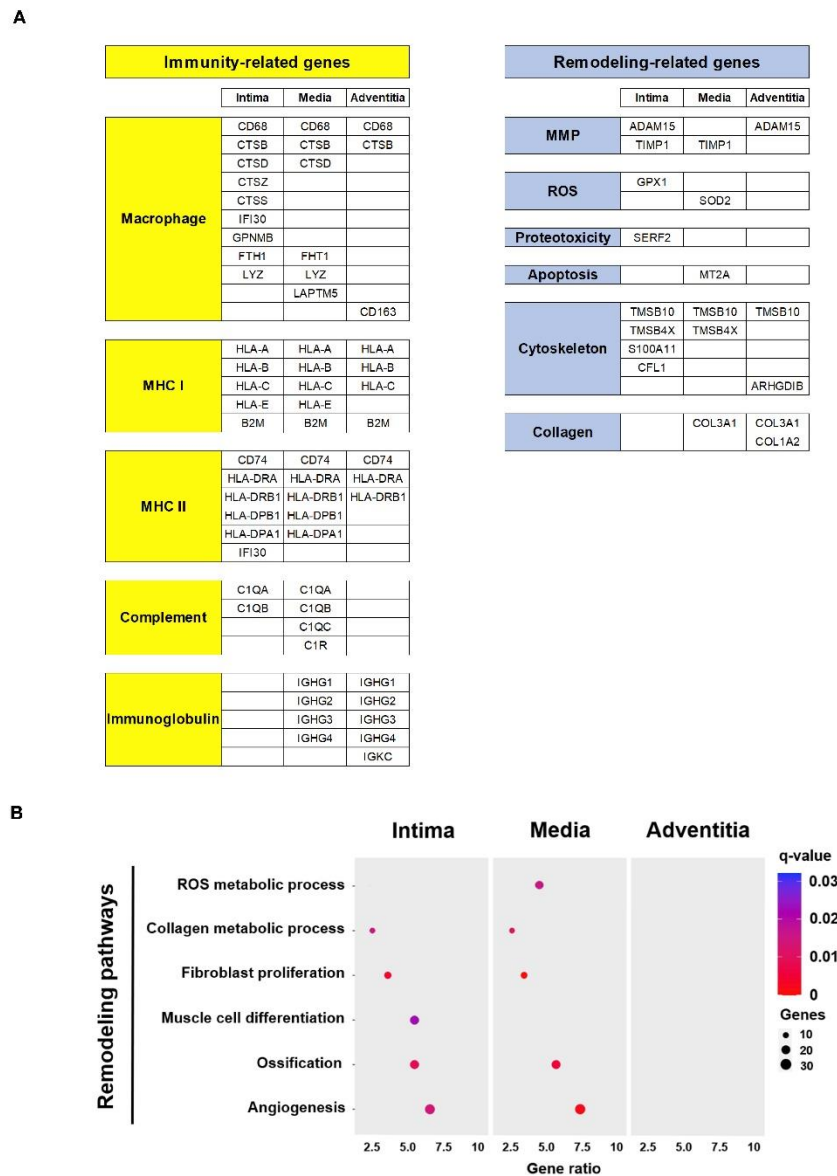


FIGURE 4 Functions and pathways related top DEG in Giant Cell Arteritis temporal arteries. (A) Top 30 DEG per layer (intima, media, adventitia) categorized by immune and remodeling functions (B) Dot plot showing significant remodeling related pathways according to layer (intima, media, adventitia). MHC, major histocompatibility complex; MMP, metalloproteinase; ROS, reactive oxygen species.

Approved therapies targeting these genes are presented, of which have not been evaluated in relation to GCA previously. The spatial approach highlights therapies targeting top DEGs common to the intima and the media (red). Therapies targeting a gene only present in one network layer are also represented (black).

Discussion

In the present study, we performed a spatial transcriptome-wide expression analysis to identify key genes and biomolecular processes involved in temporal arteritis. By comparing gene expression patterns within the different layers of the temporal

arteries among GCA and non-GCA patients, we saw a significant upregulation - rather than down-regulation - of genes in all arterial layers from GCA in comparison to controls. This could suggest some insufficient regulatory mechanisms occurring during GCA, and overriding of regulatory functions. Intima and media layers were particularly affected by gene expression dysregulation in GCA in comparison to the other layers, as well as compared to controls. Differences between gene expressions were less obvious in the adventitia, which may be due to the low number of inflammatory cells in the adventitia from the two TABs of GCA patients (GCA#4 and GCA#5). Furthermore, the initial mechanism of GCA involves adventitial damage and stimulation of resident dendritic cells via toll-like receptors by an unknown stimulus (27). As TABs are often performed at an advanced stage of GCA when vascular remodeling

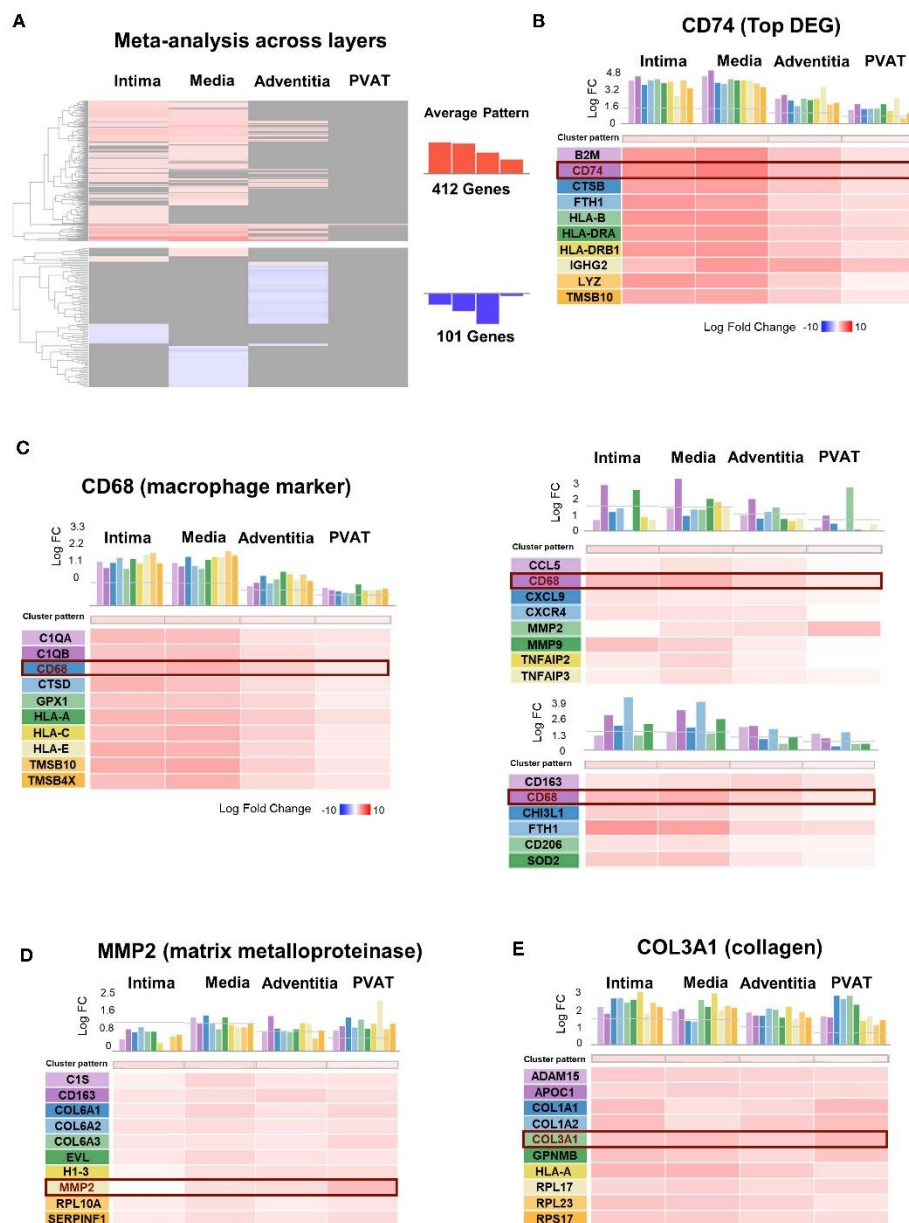


FIGURE 5 Meta-analysis across layers of Giant Cell Arteritis temporal arteries. **(A)** Hierarchical clustering of 513 dysregulated genes in giant cell arteritis (GCA) across layers. **(B–F)** Genes presenting the same expression profiles across layer for: **(B)** CD74, the most dysregulated gene in GCA compared to control; **(C)** CD68, macrophage marker; the two main genes dysregulated and implicated in vascular remodeling, **(D)** MMP2, a matrix metalloproteinase type 2 marker, **(E)** COL3A1, collagen type III alpha-1 marker. PVAT, perivascular adipose tissue; DEG, differential expressed gene; FC, fold-change.

has already occurred, the adventitia may be less affected by dysregulation than the media and intima at this stage. The PVAT did not show major transcriptomic differences between the groups which might be due to the low number of cells present within the ROIs compared to the other layers. Although the perivascular layer has been poorly studied in GCA, it may be involved in the inflammation of the adjacent artery like it has been shown in other vascular diseases (28, 29). A previous study has suggested the involvement of the periadventitial tissue in a subgroup of GCA (30), however, in our study, all the GCA patients did not exhibit the histological pattern they described.

CD74 was the most dysregulated gene across layers in GCA. This gene encodes a cell transmembrane receptor of the macrophage migration inhibitory factor (31), which is expressed on antigen presenting cells (dendritic cells, macrophages, and B lymphocytes) and non-immune cells (epithelial and endothelial cells). CD74 is known to be involved in apoptosis, immune response, and cell migration. Notably, CD74 plays a role in tissue repair and wound healing. For instance, CD74 deficiency protects against glomerulonephritis in lupus (32). Interestingly, CD74 is a ligand for the macrophage migration inhibitory factor (MIF), which is over-expressed in the serum of patients with GCA (33).

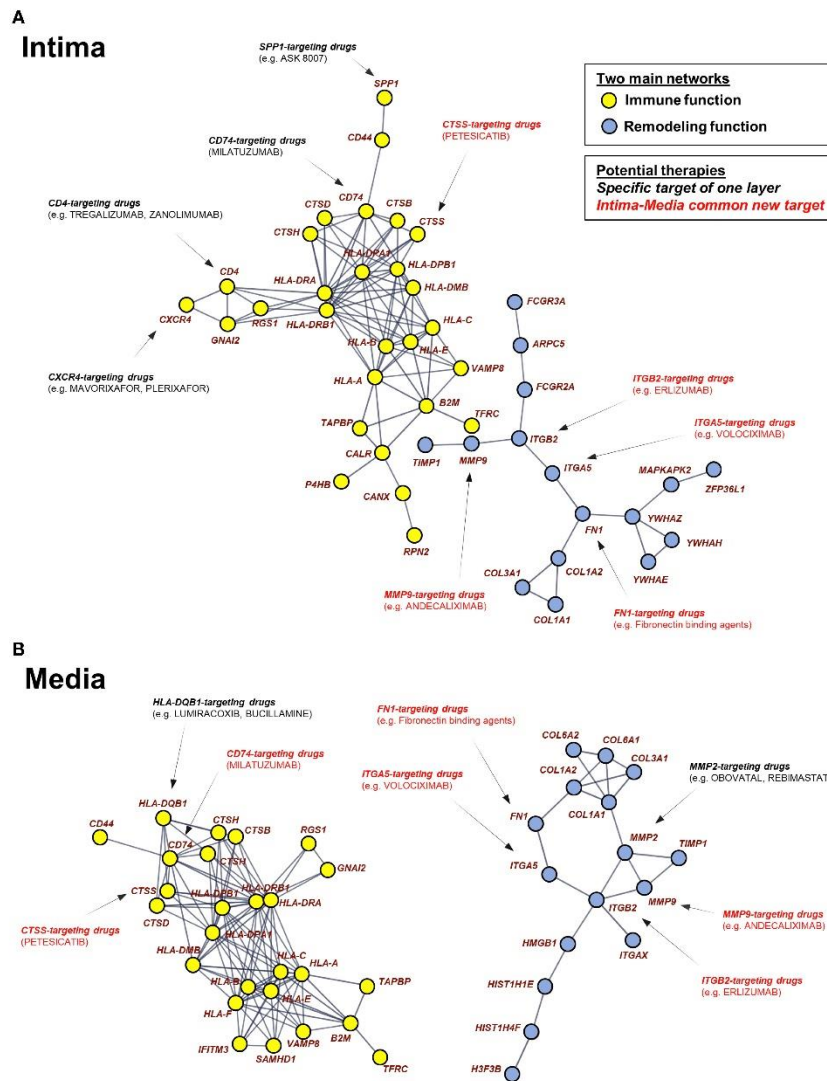


FIGURE 6
 Pharmacogenomic network analysis uncovers drug-gene interaction landscape in Giant Cell Arteritis. The two largest connected components in the DEG-based protein-protein interaction network are composed of 43 up-regulated genes (nodes) in intima (A) and 42 up-regulated genes in media (B). Using pharmacological information, genes were identified as druggable with FDA-approved, pharmaceutical drugs. Pharmaceutical drugs are divided into 2 types: specific target of one layer and intima-media common drugs. GCA, giant cell arteritis.

In the present study, most genes with the same pattern as *CD74* expression across different layers were involved in the immune response and belonged to the major histocompatibility complex classes I (*B2M*, *HLA-A*, and *HLA-B*) and II (*HLA-DRA* and *HLA-DRB1*) (34).

Next, we focused on macrophages, as they are the main immune cells involved in GCA. Macrophages can form granulomas and fuse together to produce giant cells. Lymphocytes recruit and activate macrophages in arteries through secretion of cytokines and growth factors (IL-6, IL-17, TNF- α , IFN- γ , and GM-CSF). Two main populations of CD68+ macrophages have been identified in GCA: adventitial macrophages, which are involved in TGF- β 1, IL-6, and IL-1 β secretion, and intimal and medial macrophages, which are involved in reactive oxygen species, nitric oxide, and metalloproteases secretion (13). They can also produce PDGF and

VEGF. Under the combined action of MMP, PDGF, and VEGF, the internal elastic lamella of the media is destroyed, and vascular remodeling occurs. In the present study, the main DEGs with the same expression pattern as *CD68* were related to antigen presentation. The *FTH1* and *SOD2* genes, related to M1 macrophage polarization, exhibit the same expression pattern as *CD68* among the arterial layers, as compared to *CD163*, *CD206*, and *CHI3L1*, which are linked to M2 macrophages (35). Previous studies have demonstrated heterogeneity among CD68 macrophages in GCA temporal arteries (36, 37). Interestingly, the expression profiles of *CTSB* and *TMSB10* are similar to the one of CD68, which is related to the promotion of M2 macrophages (38, 39). On the other hand, *FTH1* encodes the major intracellular iron storage protein (ferritin heavy chain 1) and is expressed abundantly by M1 macrophages (35). We note that lymphocytic activation was

less marked than that of macrophages. As most of the GCA patients in our study had glucocorticoids before TAB, the Th17 population was probably reduced, which could explain a small lymphocyte activation as demonstrated by Deng et al. (40).

Vascular remodeling plays a key role in GCA. Intimal hyperplasia is the main cause of arterial occlusion and leads to often-irreversible ischemic complications, which depend on vascular muscle cell differentiation and fibroblast proliferation, as described previously (24). No significant differences were observed between GCA patients and controls in terms of the expressions of IL-1 and IL-6 genes, although these cytokines are produced in the temporal arteries (19). These findings suggest that vascular remodeling has already started when TAB was performed. In this study, dysregulated remodeling is mainly correlated with the intima and media layers. The metalloproteinase genes *MMP2* and *MMP9* were overexpressed, which was also shown in previous studies (41). The release of reactive oxygen species by macrophages leads to lipid peroxidation of the membrane phospholipids of vascular smooth muscle cells, resulting in their combination with MMP and apoptosis (42). Furthermore, PDGF secreted by macrophages and giant cells participate in intimal hyperplasia (43). Neovascularization comes from the action of VEGF secreted by macrophages. Our study demonstrated that angiogenesis occurs in the intima and media as previously published (43). Interestingly, ossification and calcification have never been thoroughly studied in GCA. Here, we demonstrated that these processes are present within the intima and the media, and are likely to play a role in the pathophysiology of GCA (44). Moreover, ossification cluster data are consistent with the overexpression of *COL1A1*, *MMP9* and *COL2A1*, which have been previously found in GCA (45–47).

Finally, we built a pharmacogenomic network based on DEGs and Food and Drug Administration (FDA) approved drugs targeting these genes. By providing a system-wide view of mechanistic gene interactions, our spatial pharmacogenomic network can facilitate the design of novel pharmacologic intervention strategies. Our results suggest that macrophages are a promising target in GCA. In particular, granulocyte-macrophage colony-stimulating factor can be blocked by mavrilimumab, a growth factor for macrophage maturation (48, 49). Our pharmacogenomic network shows the potential benefit of blocking several macrophage-related genes using *MMP2/MMP9*- and *CXCR4*-targeting drugs. *CD74* being, in this study, the top DEG common to the three arterial layers in GCA, this gene could be another potential drug target to consider. Interestingly, the anti-*CD74* drug milatuzumab has been evaluated in hematological diseases with promising results so far (50).

The present study has several strengths. First, we used an innovative technique for human artery spatial analysis. Second, this is the first whole-transcriptome analysis of TABs in GCA using the NanoString GeoMx DSP. Third, we identified a large number of DEGs, even after multiple hypothesis correction, indicating that, despite the limited number of patients studied here, the gene expression differences between GCA and control temporal arteries are robust and reliable (fold-change < -2 or > 2 with p-adjusted value < 0.01). There were a few limitations to this study. First, the study had a relatively small sample size (9 GCA patients and 7 controls)

compared to what it is commonly conducted in GCA research. Also, all GCA patients exhibited panarteritis but no other histological patterns were observed. Because of the sample size, clinical characteristics of patients (large-vessel vasculitis, cranial disease, relapse, or remission) could not be significantly analyzed. Some controls had an inflammatory background (2 peripheral seronegative arthritis and 1 infection related encephalopathy), but these 3 controls had a negative TAB with no inflammatory infiltrate. Finally, our study used FFPE samples from TAB specimens but did not analyze cells within circulation.

In conclusion, we uncovered the transcriptomic signatures of GCA arteries on a regional scale spatially according to the arterial layers for the first time using the GeoMx DSP. This novel technique allows to better understand GCA and identify new therapeutic targets. For that, we used a pharmacogenomic network-based approach to highlight the targeted genes and therapeutics for a potential multimodal treatment of GCA. We hope our findings will be useful for further whole-tissue and single-cell multiomics profiling studies investigating the biomolecular pathways, networks, and biomarkers in GCA.

Data availability statement

The data presented in the study are deposited in the NCBI GEO repository, accession number GSE237441.

Ethics statement

The studies involving humans were approved by Ethics Committee of the University Hospital of Limoges. The studies were conducted in accordance with the local legislation and institutional requirements. The participants provided their written informed consent to participate in this study.

Author contributions

SP and EM designed this study. EL collected data on clinical and patient characteristics. SP, MB, and CW reviewed the temporal artery sections. SP and RG selected the ROIs. FT and HA performed immunostaining. SP, EM, RG, and TN wrote the manuscript. EL, A-LF, M-OJ, CW, and K-HL reviewed the manuscript. All authors contributed to the article and approved the submitted version.

Funding

This project was funded by NanoString GeoMx Whole Transcriptome Atlas Regional Grant (G-035 UCSD Molina). The funder was not involved in the study design, collection, analysis, interpretation of data, the writing of this article, or the decision to submit it for publication.

Acknowledgments

The authors thank the study participants, and the UC San Diego Stem Cell Genomics Core, the Stem Cell Program, La Jolla, CA, and Cristian Quintero for his assistance with the Keyence microscope. We also thank San Diego Pathology and David Tobias Vargas for his technical assistance, as well as NanoString for the grant opportunity and the GeoMx DSP specialists in Seattle, WA. SP received a fellowship grant from the Servier Institute France.

Conflict of interest

The authors declare that the research was conducted in the absence of any commercial or financial relationships that could be construed as a potential conflict of interest.

Publisher's note

All claims expressed in this article are solely those of the authors and do not necessarily represent those of their affiliated organizations, or those of the publisher, the editors and the reviewers. Any product that may be evaluated in this article, or

claim that may be made by its manufacturer, is not guaranteed or endorsed by the publisher.

Supplementary material

The Supplementary Material for this article can be found online at: <https://www.frontiersin.org/articles/10.3389/fimmu.2023.1237986/full#supplementary-material>

SUPPLEMENTARY FIGURE 1

Sections of arteries with selected region of interest (intima, media, adventitia, perivascular adipose tissue) from each study participant: left hematoxylin eosin staining; right CD68 (yellow) CD4 (red) alpha-smooth muscle actin (green) SYTO 13 (blue) staining. GCA, giant cell arteritis; A, adventitia; M, media; I, intima; PVAT, perivascular adipose tissue.

SUPPLEMENTARY FIGURE 2

Immunofluorescence analysis by microscopy of healthy and GCA temporal arteries. (A): In healthy artery, cells do not express CD74. (B): In GCA arteries, CD90+ cells express CD74, particularly in the outer part of the neointima near the media. CD3+ cells do not express CD74. GCA, giant cell arteritis, A, adventitia, M, media, NI, neointima.

SUPPLEMENTARY FIGURE 3

Dysregulated genes associated with remodeling pathways across layers in Giant Cell Arteritis compared to control temporal arteries. GCA, giant cell arteritis. The English in this document has been checked by at least two professional editors, both native speakers of English. For a certificate, please see: <http://www.textcheck.com/certificate/xvD6Vy>.

References

- Weyand CM, Goronzy JJ. Clinical practice. Giant-cell arteritis and polymyalgia rheumatica. *N Engl J Med* (2014) 371(1):50–7. doi: 10.1056/NEJMc1214825
- Gloor AD, Berry GJ, Goronzy JJ, Weyand CM. Age as a risk factor in vasculitis. *Semin Immunopathol* (2022) 44(3):281–301. doi: 10.1007/s00281-022-00911-1
- Liozon E, Dalmay F, Lalloue F, Gondran G, Bezanahary H, Fauchais A-L, et al. Risk factors for permanent visual loss in biopsy-proven giant cell arteritis: A study of 339 patients. *J Rheumatol* (2016) 43(7):1393–9. doi: 10.3899/jrheum.151135
- Parreau S, Dumontel S, Montoro FM, Gondran G, Bezanahary H, Palat S, et al. Giant cell arteritis-related stroke in a large inception cohort: A comparative study. *Semin Arthritis Rheum* (2022) 55:152020. doi: 10.1016/j.semarthrit.2022.152020
- Maz M, Chung SA, Abril A, Langford CA, Gorelik M, Guyatt G, et al. 2021 American college of rheumatology/Vasculitis foundation guideline for the management of giant cell arteritis and takayasu arteritis. *Arthritis Rheumatol* (2021) 73(8):1349–65. doi: 10.1002/art.41774
- Hellmich B, Agueda A, Monti S, Buttgerit F, de Booysson H, Brouwer E, et al. 2018 Update of the EULAR recommendations for the management of large vessel vasculitis. *Ann Rheum Dis* (2020) 79(1):19–30. doi: 10.1136/annrheumdis-2019-215672
- Stone JH, Tuckwell K, DiMonaco S, Klearman M, Aringer M, Blockmans D, et al. Trial of tocilizumab in giant-cell arteritis. *N Engl J Med* (2017) 377(4):317–28. doi: 10.1056/NEJMoa1613849
- Jover JA, Hernández-García C, Morado IC, Vargas E, Bafiare A, Fernandez Gutierrez B. Combined treatment of giant-cell arteritis with methotrexate and prednisone, a randomized, double-blind, placebo-controlled trial. *Ann Intern Med* (2001) 134(2):106–14. doi: 10.7326/0003-4819-134-2-200101160-00010
- Maleszewski JJ, Younge BR, Fritzen JT, Hunder GG, Goronzy JJ, Warrington KJ, et al. Clinical and pathological evolution of giant cell arteritis: a prospective study of follow-up temporal artery biopsies in 40 treated patients. *Mod Pathol* (2017) 30(6):788–96. doi: 10.1038/modpathol.2017.10
- Bley TA, Wieben O, Uhl M, Thiel J, Schmidt D, Langer M. High-resolution MRI in giant cell arteritis: imaging of the wall of the superficial temporal artery. *AJR Am J Roentgenol* (2005) 184(1):283–7. doi: 10.2214/ajr.184.1.01840283
- Weyand CM, Goronzy JJ. Immunology of giant cell arteritis. *Circ Res* (2023) 132(2):238–50. doi: 10.1161/CIRCRESAHA.122.322128
- Bolha L, Hočevár A, Suljić A, Jurčić V. Inflammatory cell composition and immune-related microRNA signature of temporal artery biopsies from patients with giant cell arteritis. *Front Immunol* (2021) 12:791099. doi: 10.3389/fimmu.2021.791099
- Reitsem RD, van der Geest KSM, Sandovici M, Jiemy WF, Graver JC, Abdulahad WH, et al. Phenotypic, transcriptomic and functional profiling reveal reduced activation thresholds of CD8+ T cells in giant cell arteritis. *Rheumatol (Oxford)* (2022) 62(1):417–27. doi: 10.1093/rheumatology/keac250
- Bubak AN, Mescher T, Mariani M, Fritze SE, Hassell JE Jr, Niemeyer CS, et al. Targeted RNA sequencing of formalin-fixed, paraffin-embedded temporal arteries from giant cell arteritis cases reveals viral signatures. *Neuro Immunol Neuroinflamm* (2021) 8(6):e0178. doi: 10.1012/NXI.0000000000001078
- Kuret T, Lakota K, Čučnik S, Jurčić V, Distler O, Rotar Ž, et al. Dysregulated expression of arterial microRNAs and their target gene networks in temporal arteries of treatment-naïve patients with giant cell arteritis. *Int J Mol Sci* (2021) 22(12):6520. doi: 10.3390/ijms22126520
- Merritt CR, Ong GT, Church SE, Barker K, Danaher P, Geiss G, et al. Multiplex digital spatial profiling of proteins and RNA in fixed tissue. *Nat Biotechnol* (2020) 38(5):586–99. doi: 10.1038/s41587-020-0472-9
- Ponte C, Grayson PC, Robson JC, Suppiah R, Gribbons KB, Judge A, et al. 2022 American College of Rheumatology/EULAR classification criteria for giant cell arteritis. *Ann Rheum Dis* (2022) 81(12):1647–53. doi: 10.1136/ard-2022-223480
- Lie JT. Illustrated histopathologic classification criteria for selected vasculitis syndromes. American College of Rheumatology Subcommittee on Classification of Vasculitis. *Arthritis Rheum* (1990) 33(8):1074–87. doi: 10.1002/art.1780330804
- Hernández-Rodríguez J, Murgia G, Villar I, Campo E, Mackie SL, Chakrabarty A, et al. Description and validation of histological patterns and proposal of a dynamic model of inflammatory infiltration in giant-cell arteritis. *Med (Baltimore)* (2016) 95(8):e2368. doi: 10.1097/MD.0000000000002368
- Jakobsson K, Jakobsson L, Mohammad AJ, Nilsson JA, Warrington K, Matteson EL, et al. The effect of clinical features and glucocorticoids on biopsy findings in giant cell arteritis. *BMC Musculoskelet Disord* (2016) 17(1):363. doi: 10.1186/s12891-016-1225-2
- Narváez J, Bernad B, Roig-Vilaseca D, García-Gomez C, Gomez-Vaquero C, Juanola X, et al. Influence of previous corticosteroid therapy on temporal artery biopsy yield in giant cell arteritis. *Semin Arthritis Rheum* (2007) 37(1):13–9. doi: 10.1016/j.semarthrit.2006.12.005
- Parreau S, Liozon E, Chen JJ, Curumthaullee MF, Fauchais A-L, Warrington KJ, et al. Temporal artery biopsy: A technical guide and review of its importance and indications. *Surv Ophthalmol* (2023) 68(1):104–12. doi: 10.1016/j.survophthal.2022.08.008

23. Parreau S, Vedrenne N, Regent A, Richard L, Sindou P, Mouthon L, et al. An immunohistochemical analysis of fibroblasts in giant cell arteritis. *Ann Diagn Pathol* (2021) 52:151728. doi: 10.1016/j.anndiagpath.2021.151728
24. Yang X, Kui L, Tang M, Li D, Wei K, Chen W, et al. High-throughput transcriptome profiling in drug and biomarker discovery. *Front Genet* (2020) 11:19. doi: 10.3389/fgene.2020.00019
25. Feng Y, Wang Q, Wang T. Drug target protein-protein interaction networks: A systematic perspective. *BioMed Res Int* (2017) 2017:1289259. doi: 10.1155/2017/1289259
26. Barabási AL, Gulbahce N, Loscalzo J. Network medicine: a network-based approach to human disease. *Nat Rev Genet* (2011) 12(1):56–68. doi: 10.1038/nrg2918
27. Pryshchep O, Ma-Krupa W, Younge BR, Goronzy JJ, Weyand CM. Vessel-specific Toll-like receptor profiles in human medium and large arteries. *Circulation* (2008) 118(12):1276–84. doi: 10.1161/CIRCULATIONAHA.108.789172
28. Adachi Y, Ueda K, Nomura S, Ito K, Katoh M, Katagiri M, et al. Beiging of perivascular adipose tissue regulates its inflammation and vascular remodeling. *Nat Commun* (2022) 13(1):5117. doi: 10.1038/s41467-022-32658-6
29. Horimatsu T, Kim HW, Weintraub NL. The role of perivascular adipose tissue in non-atherosclerotic vascular disease. *Front Physiol* (2017) 8:969. doi: 10.3389/fphys.2017.00969
30. McDonald HM, Farmer JP, Blanco PL. Periadventitial tissue examination in temporal artery biopsies for suspected giant cell arteritis: a case series and literature review. *Can J Ophthalmol* (2019) 54(5):615–20. doi: 10.1016/j.jco.2018.12.011
31. Farr L, Ghosh S, Moonah S. Role of MIF cytokine/CD74 receptor pathway in protecting against injury and promoting repair. *Front Immunol* (2020) 11:1273. doi: 10.3389/fimmu.2020.01273
32. Zhou Y, Chen H, Liu L, Yu X, Sukhova GK, Yang M, et al. CD74 deficiency mitigates systemic lupus erythematosus-like autoimmunity and pathological findings in mice. *J Immunol* (2017) 198(7):2568–77. doi: 10.4049/jimmunol.1600028
33. Kanemitsu H, Matsunawa M, Wakabayashi K, Sato M, Takahashi R, Odai T, et al. Increased serum levels of macrophage migration inhibitory factor (MIF) in patients with microscopic polyangiitis. *Open Access Rheumatol* (2009) 13:1–8. doi: 10.2147/oarr.s4906
34. Abualrous ET, Sticht J, Freund C. Major histocompatibility complex (MHC) class I and class II proteins: impact of polymorphism on antigen presentation. *Curr Opin Immunol* (2021) 70:95–104. doi: 10.1016/j.coi.2021.04.009
35. Corna G, Campana L, Pignatti E, Castiglioni A, Tagliafico E, Bosurgi L, et al. Polarization dictates iron handling by inflammatory and alternatively activated macrophages. *Haematologica* (2010) 95(11):1814–22. doi: 10.3324/haematol.2010.02387
36. Weyand CM, Wagner AD, Björnsson J, Goronzy JJ. Correlation of the topographical arrangement and the functional pattern of tissue-infiltrating macrophages in giant cell arteritis. *J Clin Invest* (1996) 98(7):1642–9. doi: 10.1172/JCI118959
37. Esen I, Jiemy WF, van Sleen Y, van der Geest KSM, Sandovici M, Heeringa P, et al. Functionally heterogeneous macrophage subsets in the pathogenesis of giant cell arteritis: Novel targets for disease monitoring and treatment. *J Clin Med* (2021) 10(21):4958. doi: 10.3390/jcm10214958
38. Oelschlaegel D, Weiss Sadan T, Salpeter S, Krug S, Blum G, Schmitz W, et al. Cathepsin inhibition modulates metabolism and polarization of tumor-associated macrophages. *Cancers (Basel)* (2020) 12(9):279. doi: 10.3390/cancers12092579
39. Zeng H, Yang X, Yang L, Li W, Zheng Y. Thymosin β 10 promotes tumor-associated macrophages M2 conversion and proliferation via the PI3K/Akt pathway in lung adenocarcinoma. *Respir Res* (2020) 21(1):328. doi: 10.1186/s12931-020-01589-7
40. Deng J, Younge BR, Olshen RA, Goronzy JJ, Weyand CM. Th17 and Th1 T-cell responses in giant cell arteritis. *Circulation* (2010) 23(7):906–15. doi: 10.1161/CIRCULATIONAHA.109.872903
41. Rodríguez-Pla A, Bosch-Gil JA, Rosselló-Urgell J, Huguet-Redecilla P, Stone JH, Vilardell-Tarres M. Metalloproteinase-2 and -9 in giant cell arteritis: involvement in vascular remodeling. *Circulation* (2005) 112(2):264–9. doi: 10.1161/CIRCULATIONAHA
42. Rittner HL, Kaiser M, Brack A, Szewda LI, Goronzy JJ, Weyand CM. Tissue-destructive macrophages in giant cell arteritis. *Circ Res* (1999) 84(9):1050–8. doi: 10.1161/01.res.84.9.1050
43. Kaiser M, Weyand CM, Björnsson J, Goronzy JJ. Platelet-derived growth factor, intimal hyperplasia, and ischemic complications in giant cell arteritis. *Arthritis Rheum* (1998) 41(4):623–33. doi: 10.1002/1529-0131(199804)41:4<623::AID-ART9>3.0.CO;2-6
44. Banerjee S, Bagheri M, Sandfort V, Ahlman MA, Malayeri AA, Bluemke DA, et al. Vascular calcification in patients with large-vessel vasculitis compared to patients with hyperlipidemia. *Semin Arthritis Rheum* (2019) 48(6):1068–73. doi: 10.1016/j.semarthrit.2018.09.001
45. Segarra M, García-Martínez A, Sánchez M, Hernández-Rodríguez J, Lozano E, Grau JM, et al. Gelatinase expression and proteolytic activity in giant-cell arteritis. *Ann Rheum Dis* (2007) 66(11):1429–35. doi: 10.1136/ard.2006.068148
46. Samson M, Genet C, Corbera-Bellalta M, Greigert H, Espigol-Frigole G, Gerard C, et al. Human monocyte-derived suppressive cells (HuMoSC) for cell therapy in giant cell arteritis. *Front Immunol* (2023) 14:1137794. doi: 10.3389/fimmu.2023.1137794
47. Corbera-Bellalta M, García-Martínez A, Lozano E, Planas-Rigol E, Tavera-Bahillo I, Alba MA, et al. Changes in biomarkers after therapeutic intervention in temporal arteries cultured in Matrigel: a new model for preclinical studies in giant-cell arteritis. *Ann Rheum Dis* (2014) 73(3):616–23. doi: 10.1136/annrheumdis-2012-202883
48. Corbera-Bellalta M, Alba-Rovira R, Muralidharan S, Espigol-Frigole G, Rios Garces R, Marco-Hernandez J, et al. Blocking GM-CSF receptor α with mavrilimumab reduces infiltrating cells, pro-inflammatory markers and neoangiogenesis in ex vivo cultured arteries from patients with giant cell arteritis. *Ann Rheum Dis* (2022) 81(4):524–36. doi: 10.1136/annrheumdis-2021-220873
49. Cid MC, Unizony SH, Blockmans D, Brouwer E, Dagna L, Dasgupta B, et al. Efficacy and safety of mavrilimumab in giant cell arteritis: a phase 2, randomised, double-blind, placebo-controlled trial. *Ann Rheum Dis* (2022) 81(5):653–61. doi: 10.1136/annrheumdis-2021-221865
50. Christian BA, Poi M, Jones JA, Porcu P, Maddocks K, Flynn JM, et al. The combination of milatuzumab, a humanized anti-CD74 antibody, and veltuzumab, a humanized anti-CD20 antibody, demonstrates activity in patients with relapsed and refractory B-cell non-Hodgkin lymphoma. *Br J Haematol* (2015) 169(5):701–10. doi: 10.1111/bjh.13354

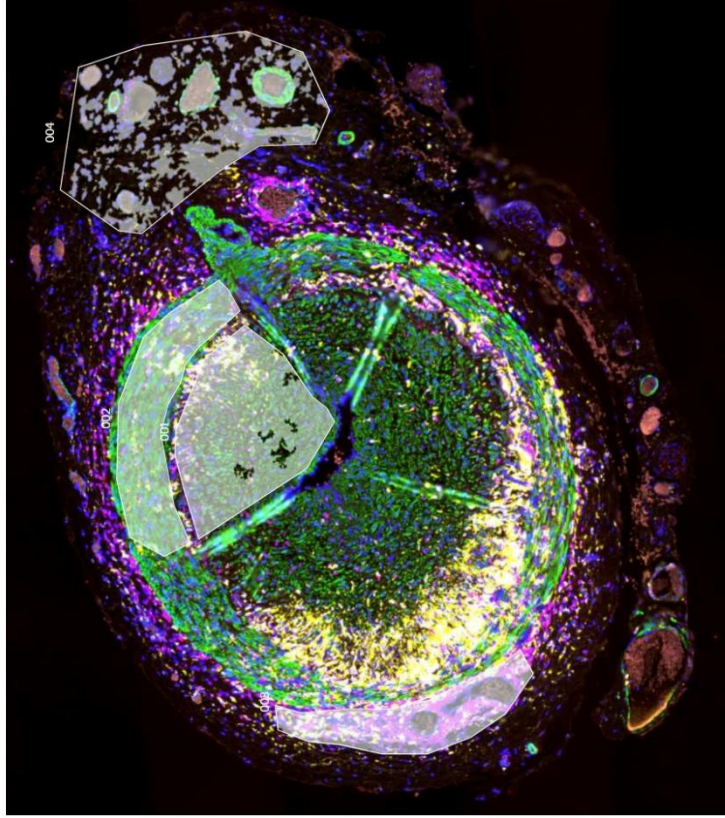
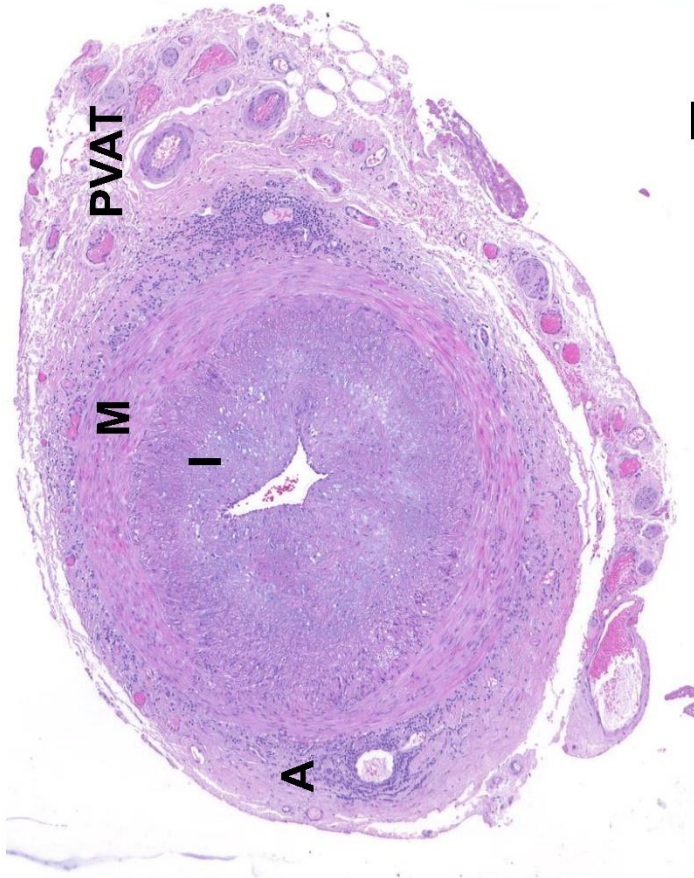
Supplemental table 1. Participants characteristics

Group	#	Sex	Age	Constitutional syndrome	Headache	Scalp tenderness	Jaw claudication	PMR	Visual symptoms	Aortitis	ESR (mm/h)	CRP (mg/L)	Corticoids use before TAB	Dose (mg/kg/d)	Delay between corticoids start and TAB (days)	GCA relapse
GCA	1	F	80s	1	1	0	1	1	1	0	45	13	1	1	3	0
GCA	2	F	70	0	0	1	1	0	1	NA	83	10	1	1	7	0
GCA	3	M	70s	1	0	1	0	0	0	1	116	165	1	0,7	1	1
GCA	4	M	70s	1	1	1	1	0	1	0	107	134	1	0,7	1	0
GCA	5	M	70s	1	1	1	1	1	1	NA	105	154	0	-	-	0
GCA	6	F	70s	1	1	0	1	1	1	0	98	218	1	1	3	0
GCA	7	F	80s	1	0	0	1	0	0	0	98	307	1	0,7	3	1
GCA	8	M	70s	1	1	0	1	0	1	NA	49	13	1	1	10	0
GCA	9	M	70s	0	1	1	0	1	0	0	102	48	1	0,7	6	1
Control	1	M	70s	1	0	0	0	0	0	0	33	148	1	0,7	48	-
Control	2	M	70s	0	1	0	0	0	1	0	31	7	1	0	4	-
Control	3	F	60s	1	0	0	0	0	0	0	14	5	1	0,7	3	-
Control	4	F	70s	1	1	1	0	0	1	0	17	1	0	-	-	-
Control	5	F	70s	1	0	0	0	0	0	0	NA	280	0	-	-	-
Control	6	M	70s	1	1	0	0	0	1	0	73	3	0	-	-	-
Control	7	M	70s	0	0	0	0	0	1	0	2	115	0	-	-	-

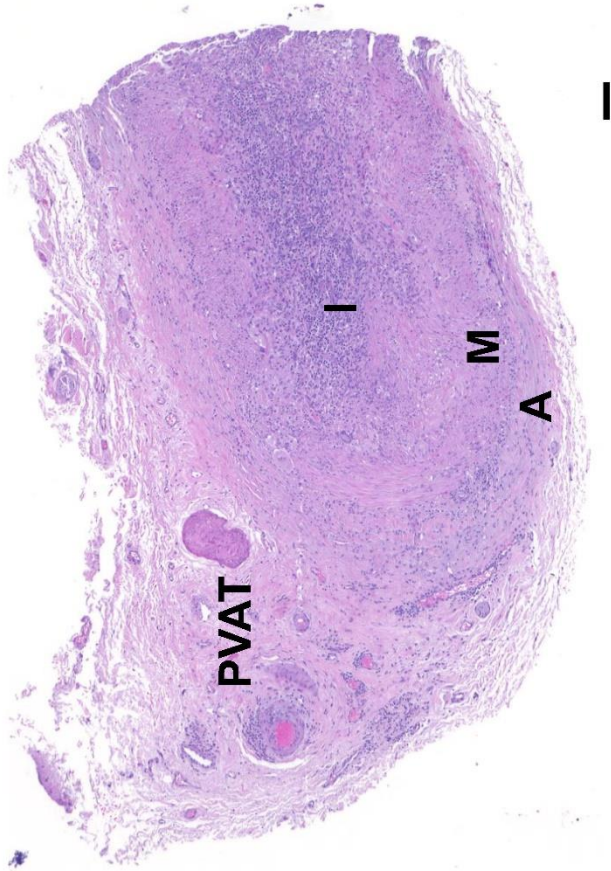
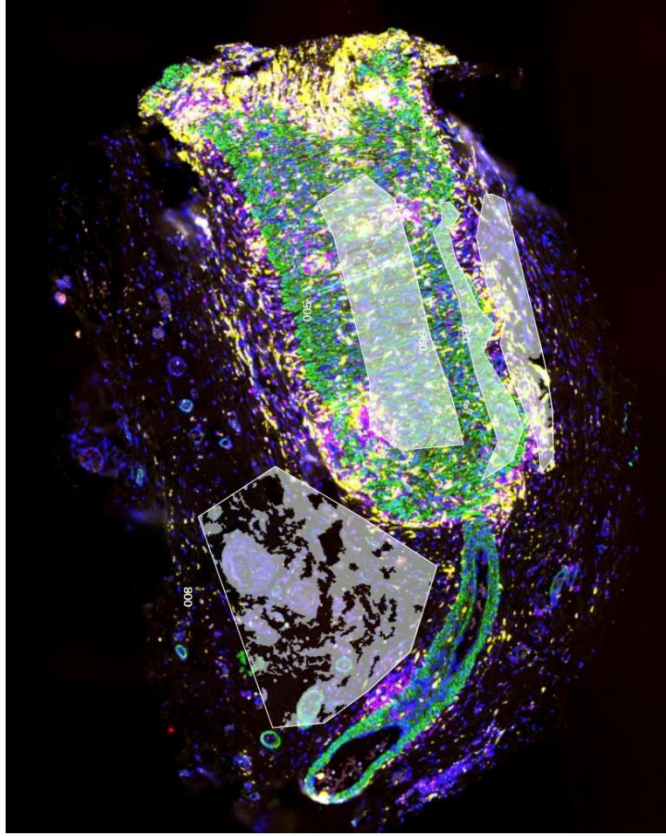
Abbreviations: GCA, giant cell arteritis; M, male; F, female; PMR, polymyalgia rheumatica; ESR, erythrocyte sedimentation rate; CRP, C-reactive protein; TAB, temporal artery biopsy; NA, not applicable

Supplementary Figure 1. Sections of arteries with selected region of interest (intima, media, adventitia, perivascular adipose tissue) from each study participant: left hematoxylin eosin staining; right CD68 (yellow) CD4 (red) alpha-smooth muscle actin (green) SYTO 13 (blue) staining. GCA, giant cell arteritis; A, adventitia; M, media; I, intima; PVAT, perivascular adipose tissue.

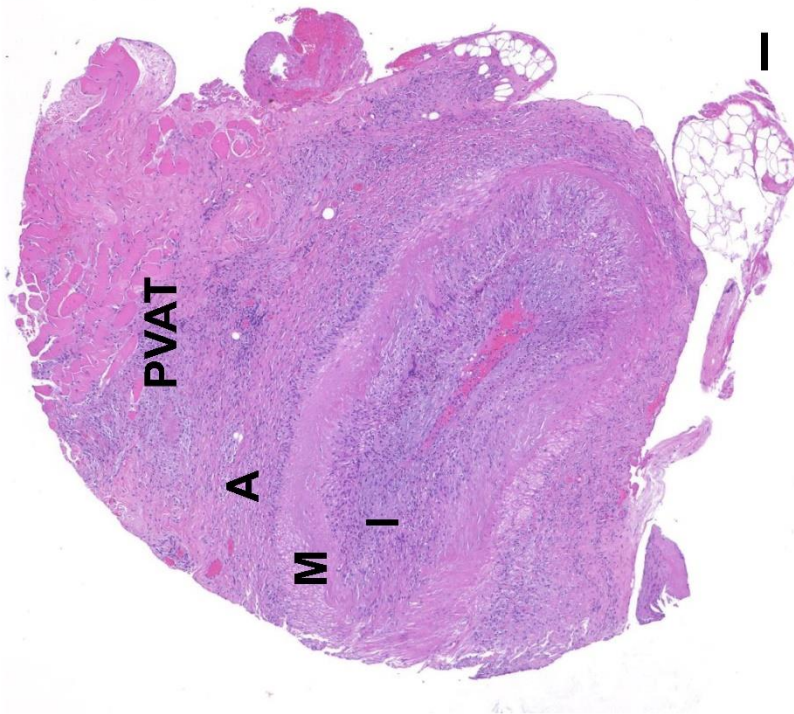
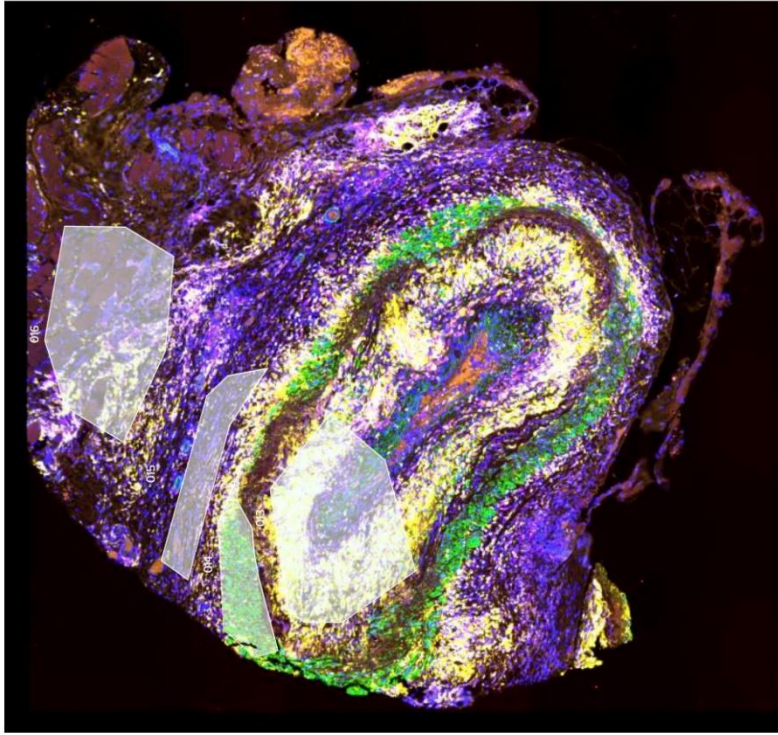
GCA #1



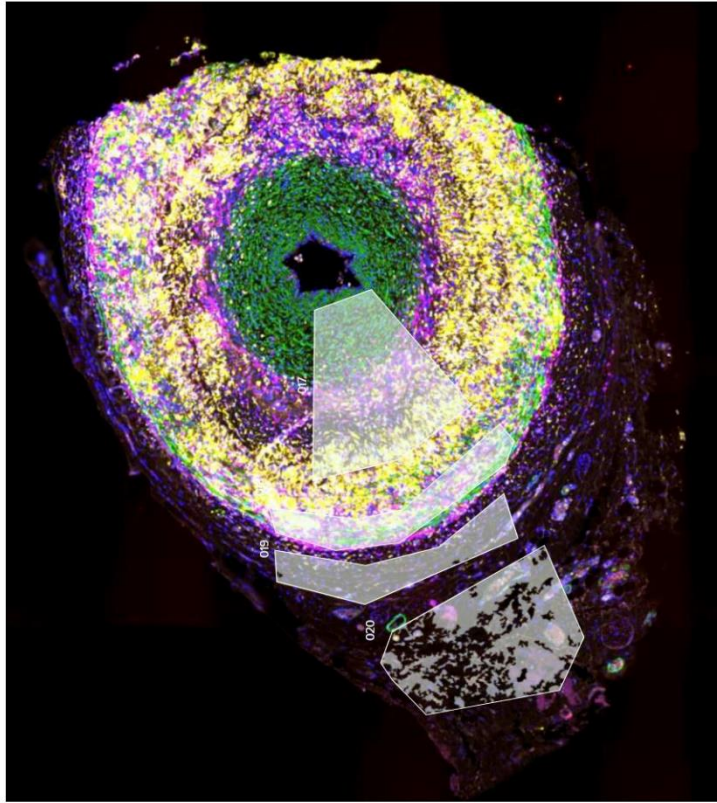
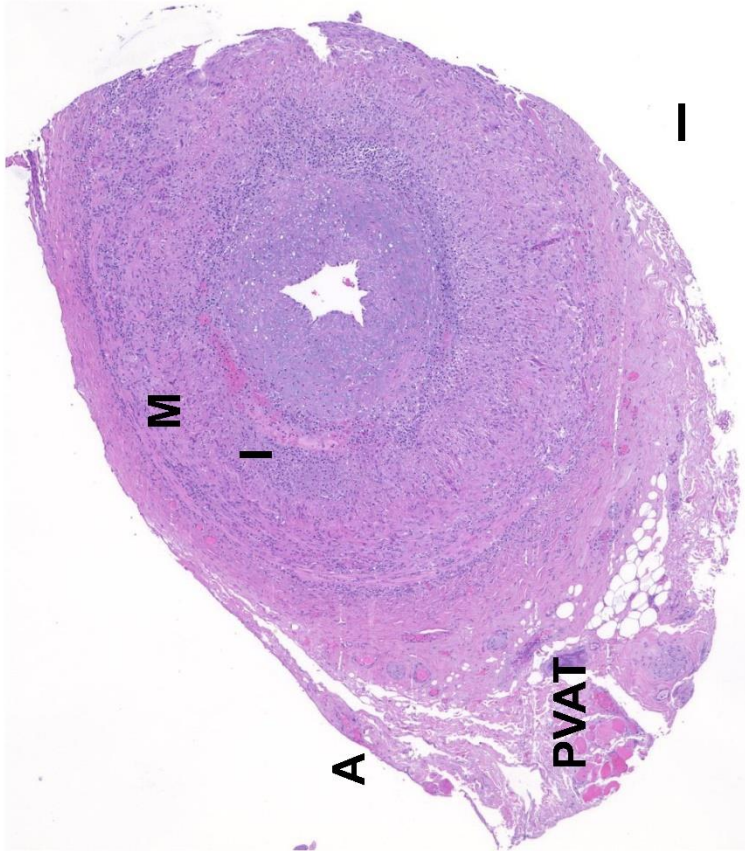
GCA #2



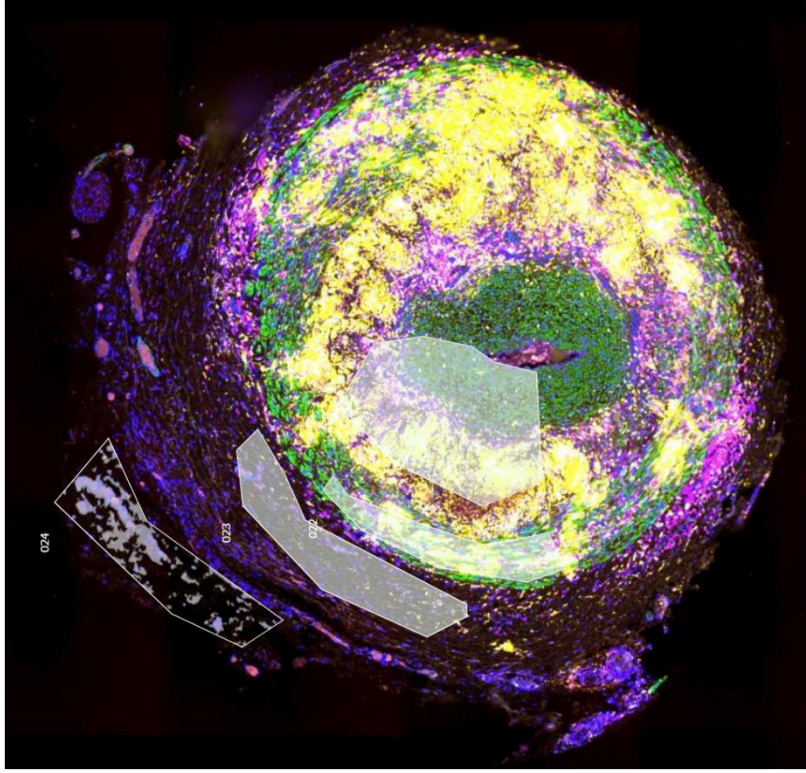
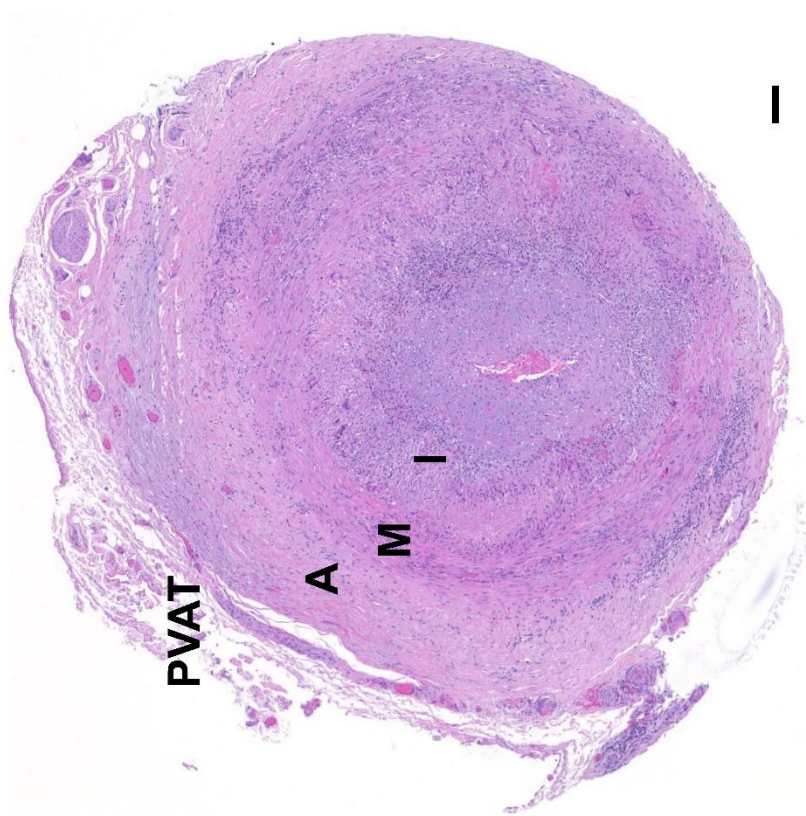
GCA #3



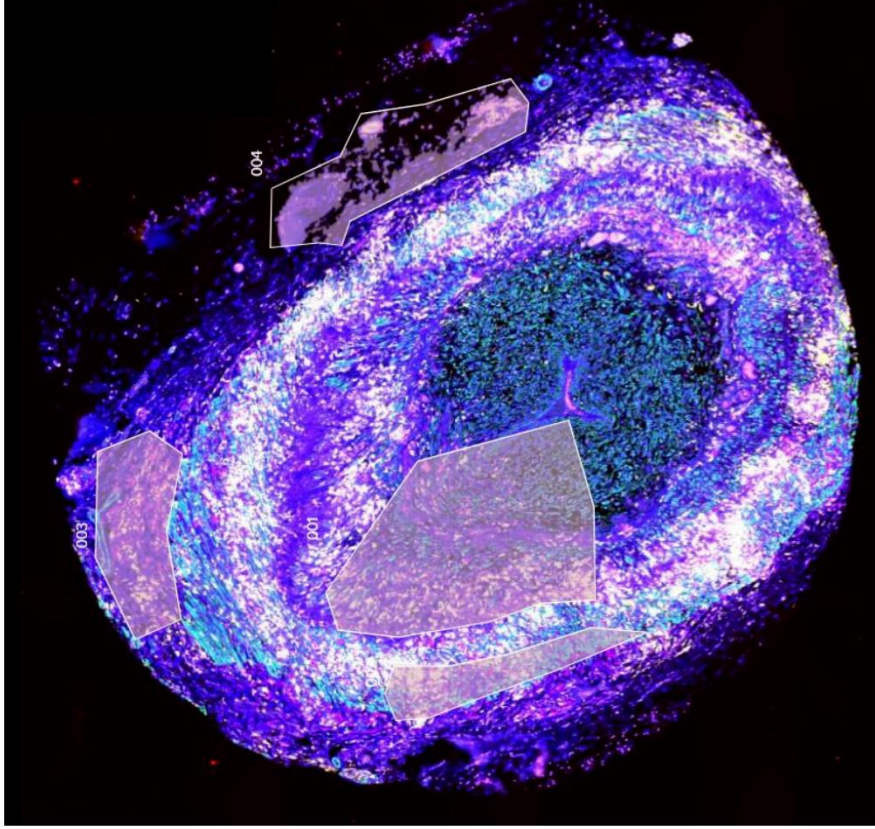
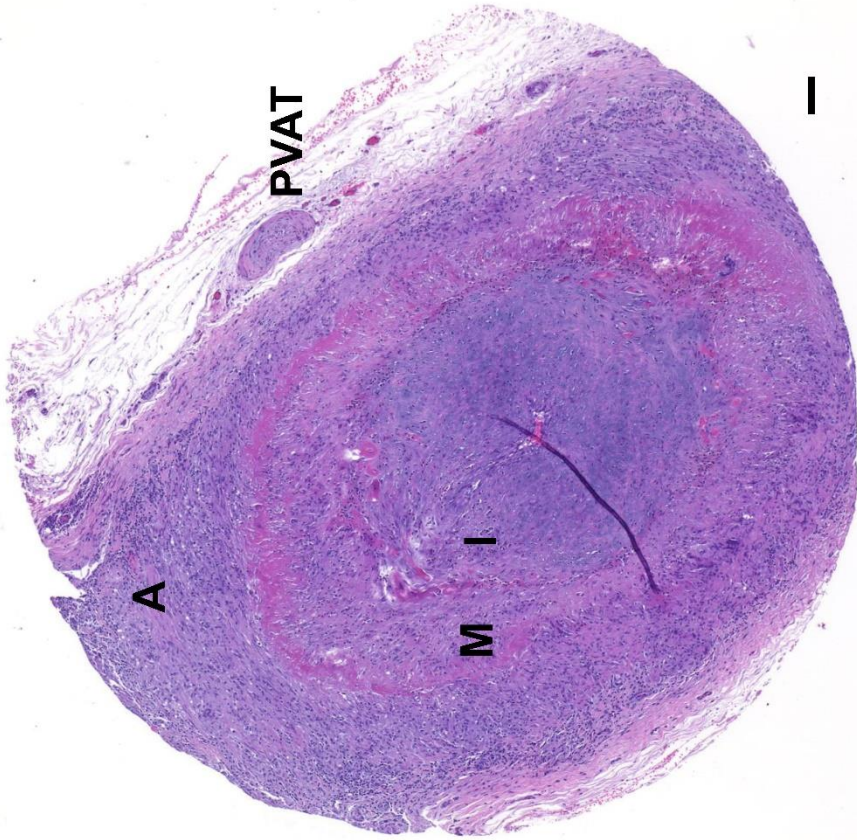
GCA #4



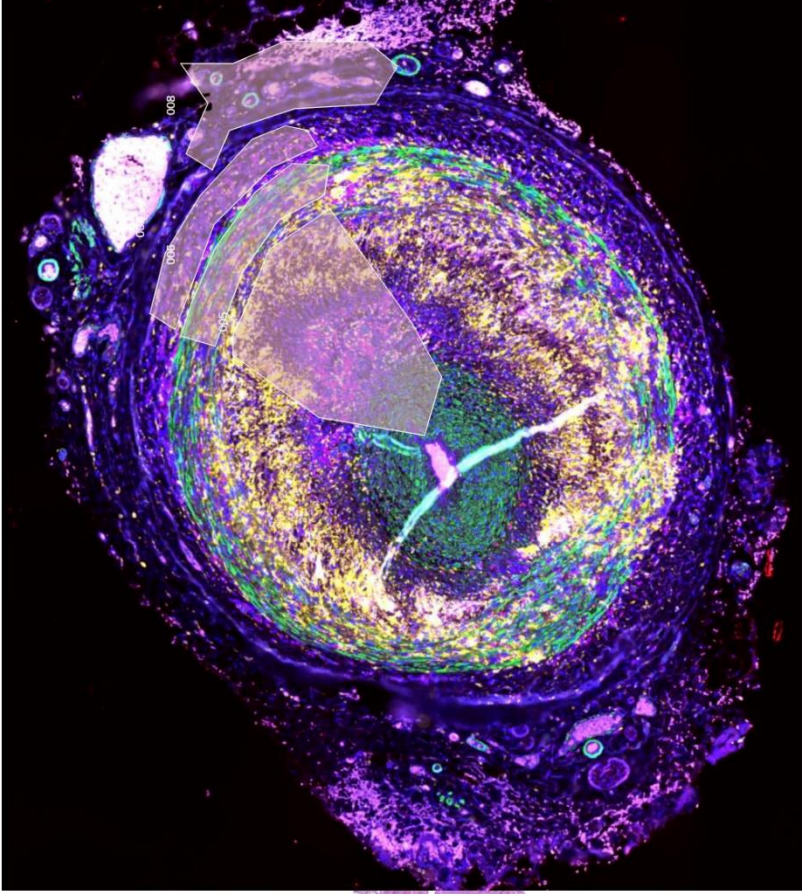
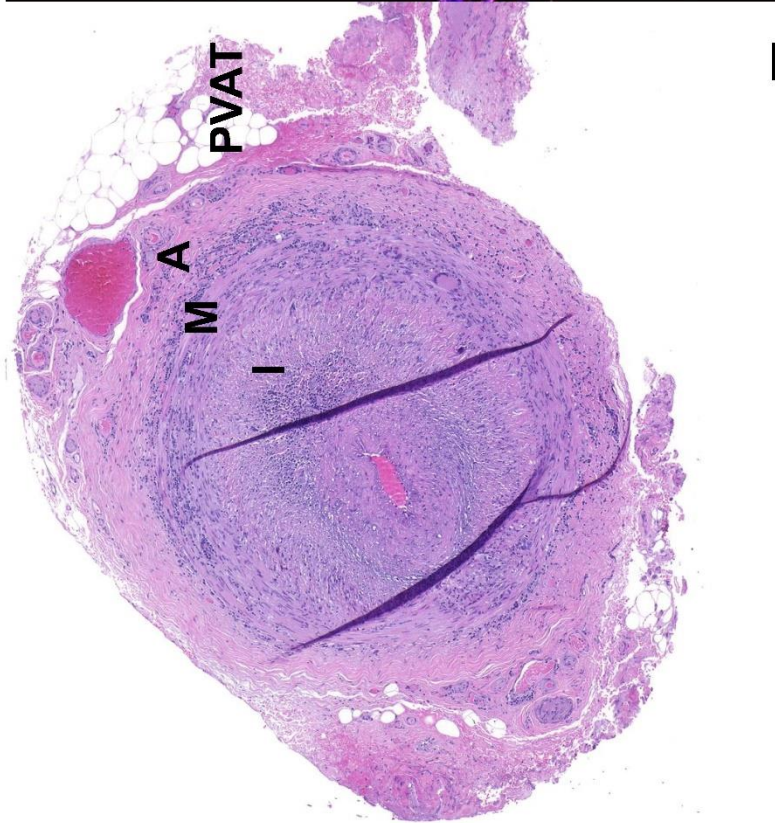
GCA #5



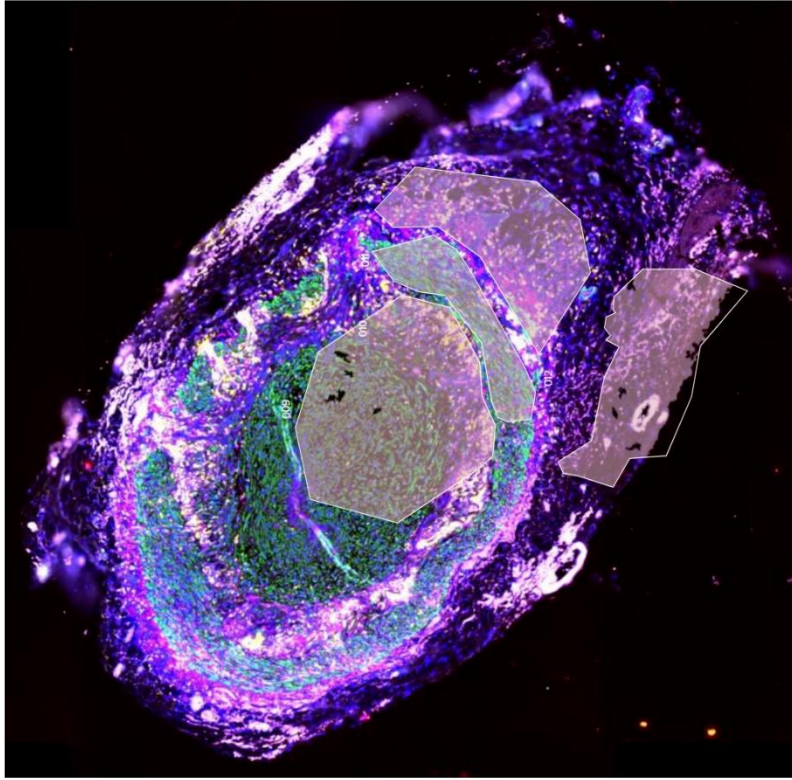
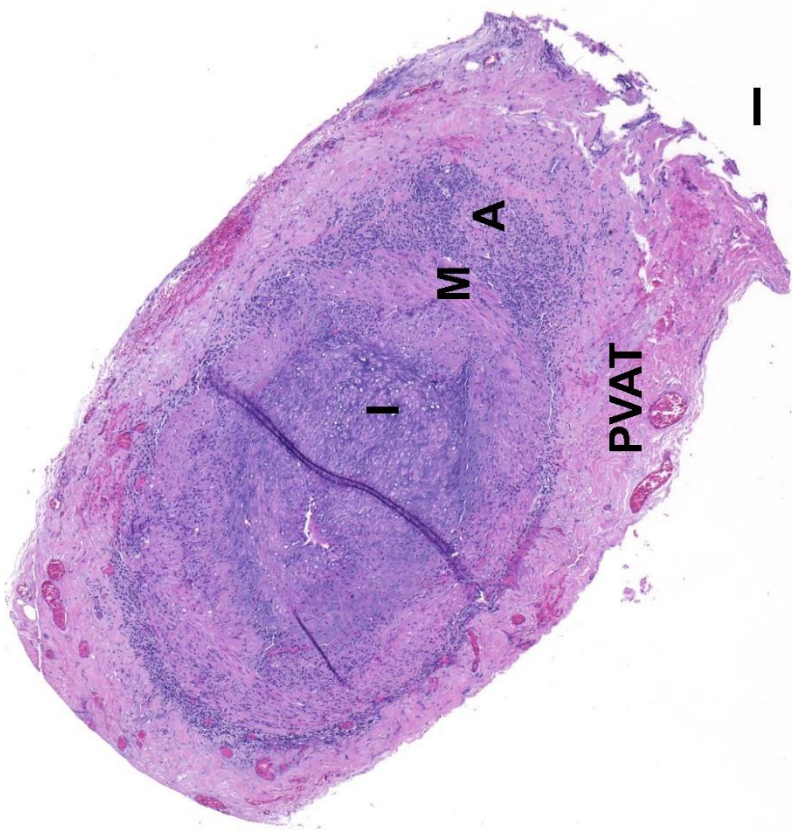
GCA #6



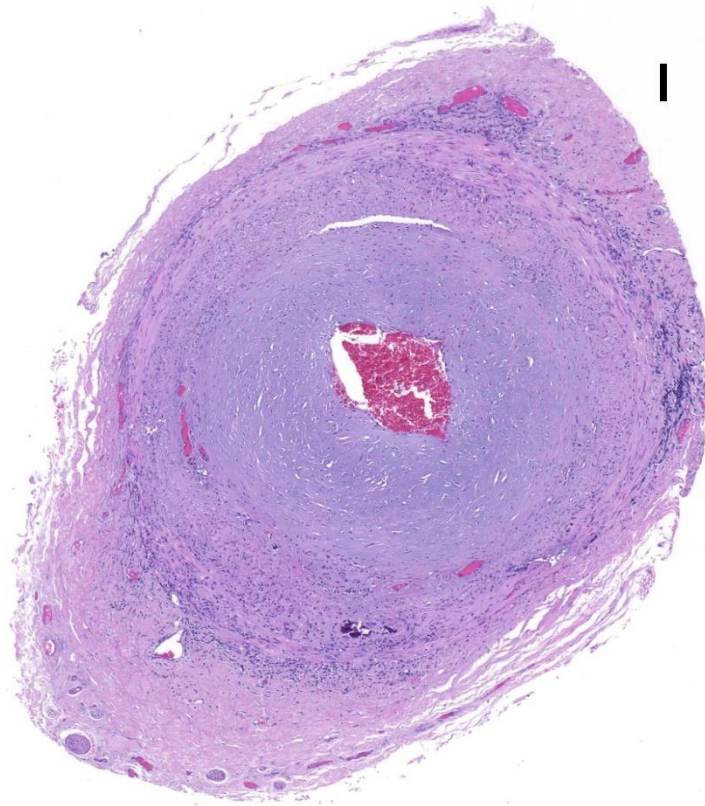
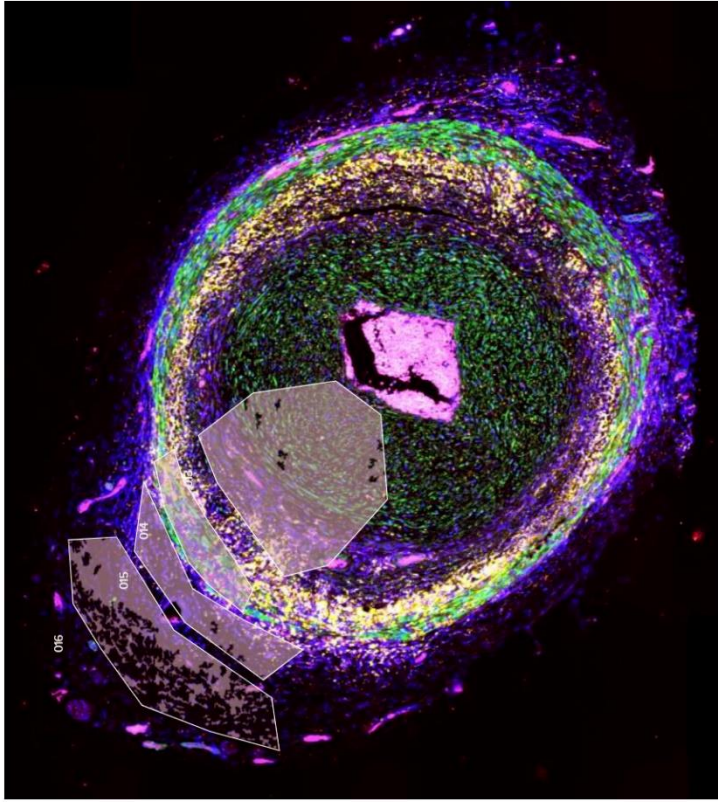
GCA #7



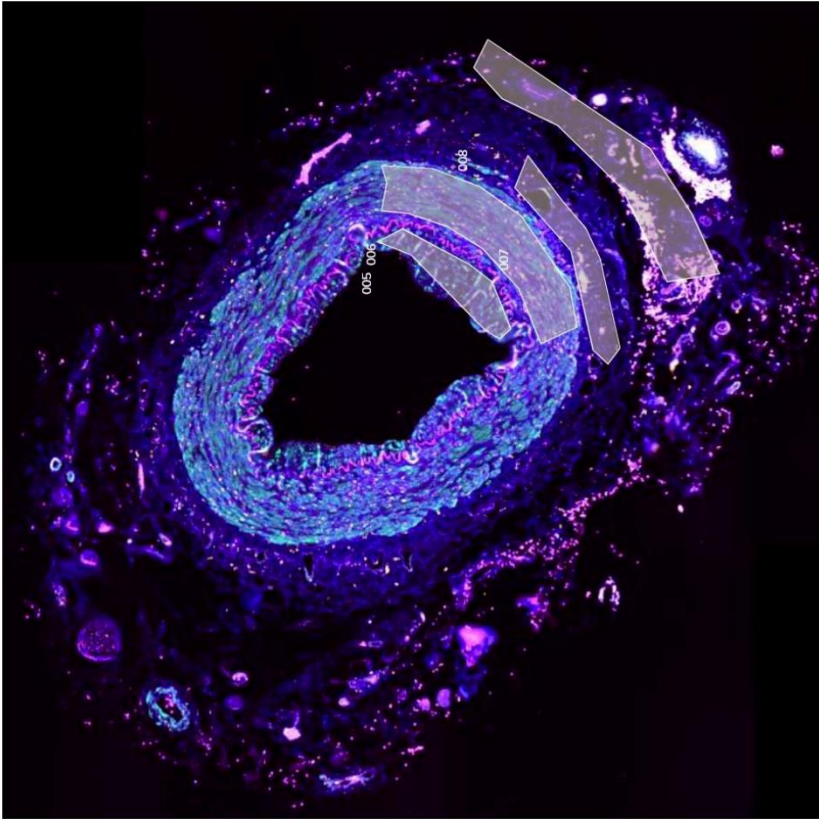
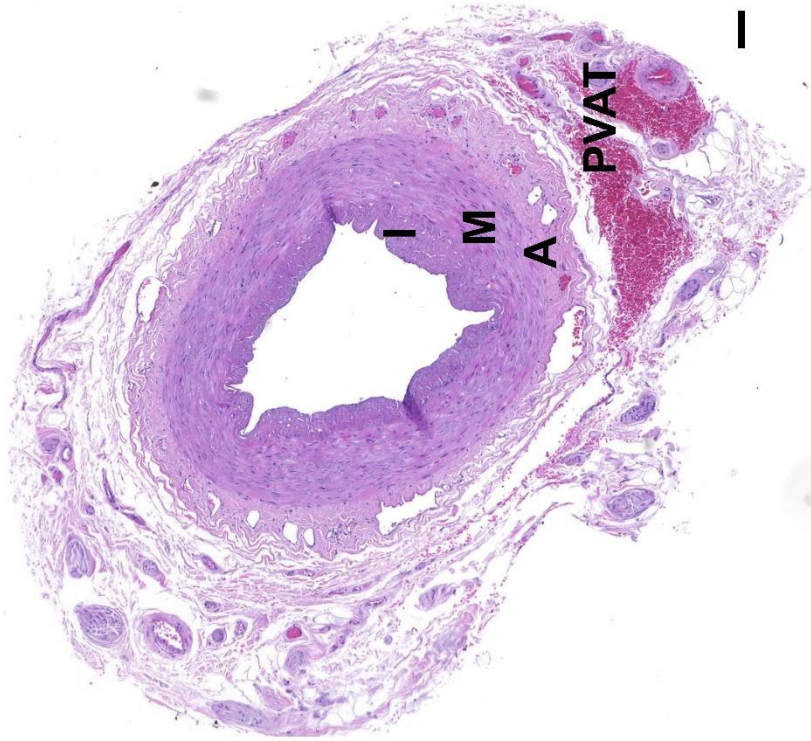
GCA #8



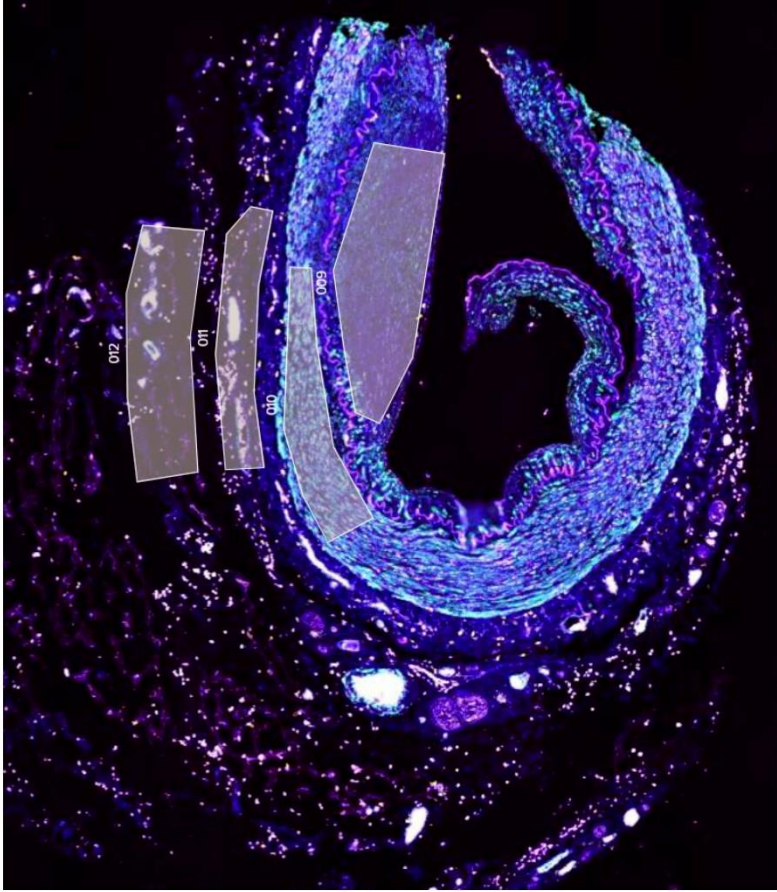
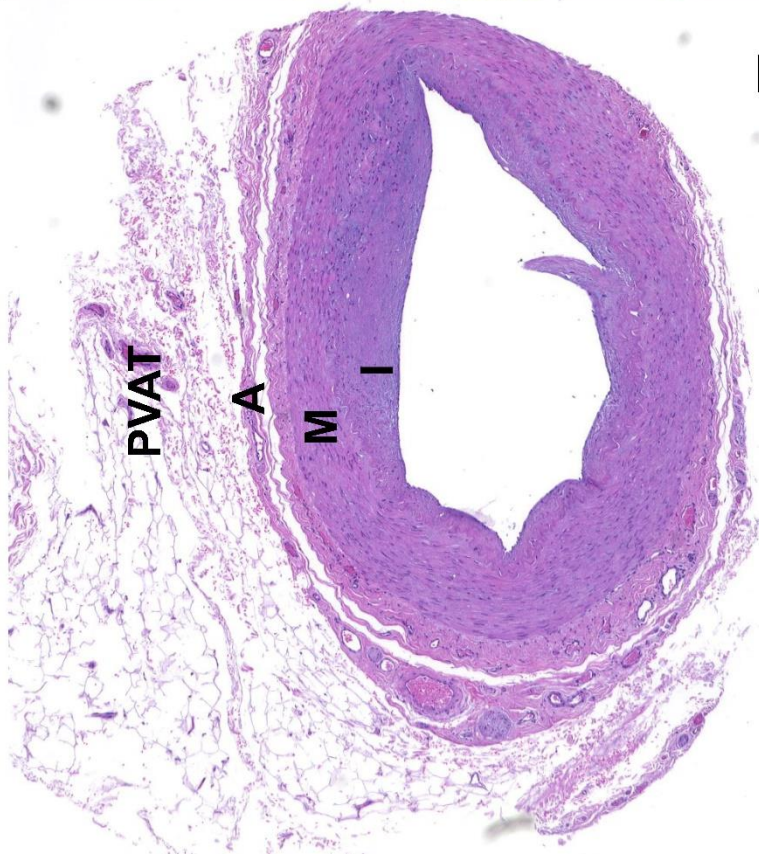
GCA #9



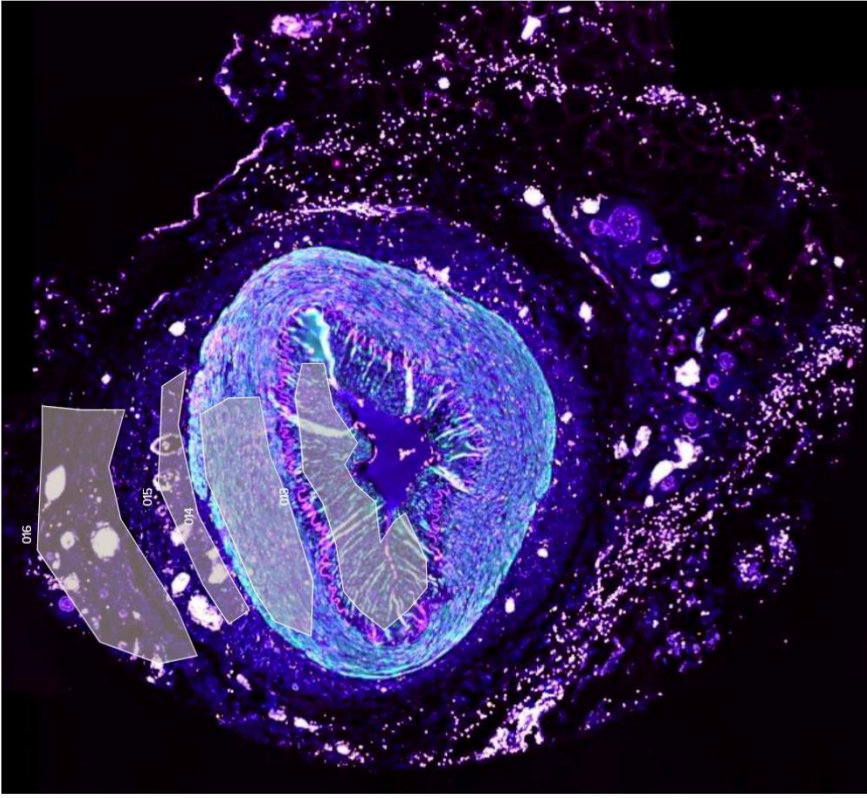
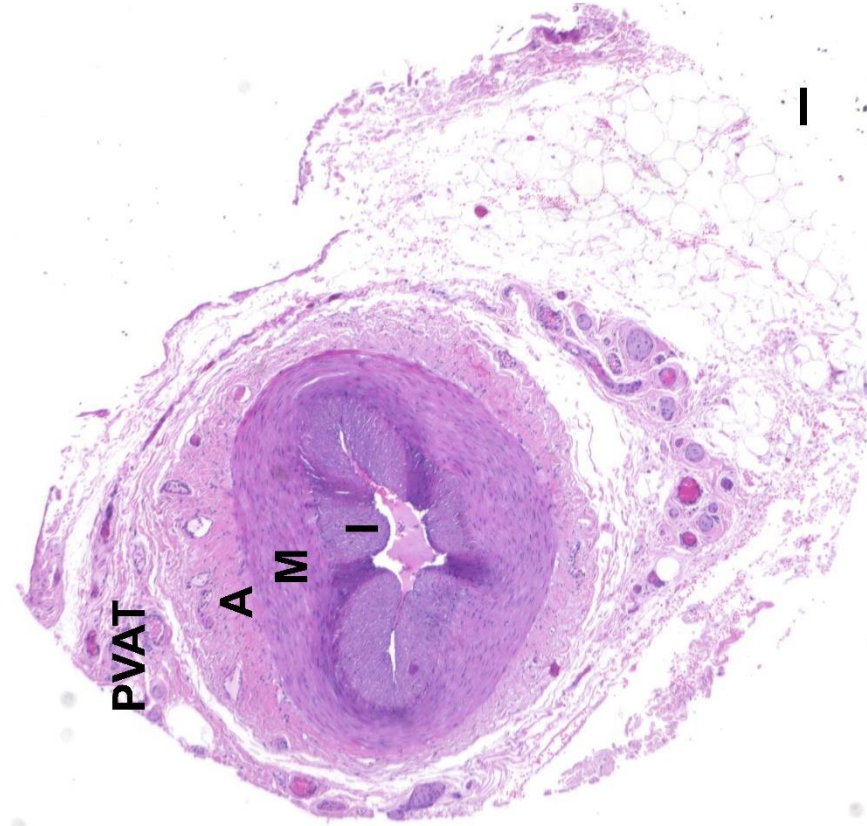
Control #1



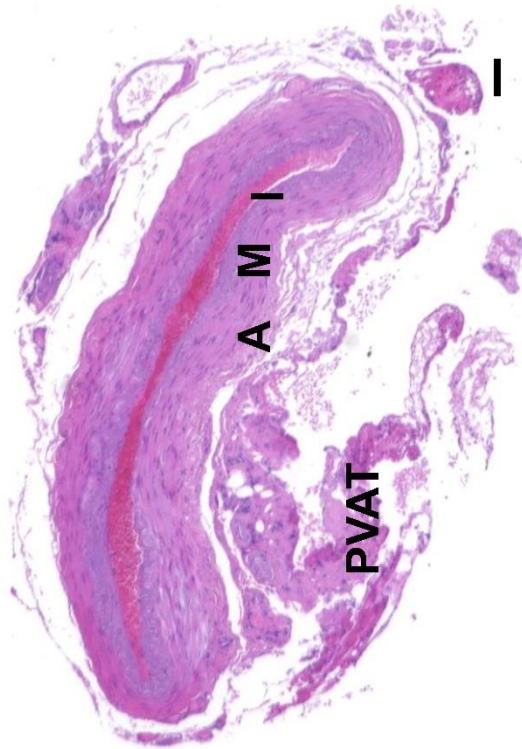
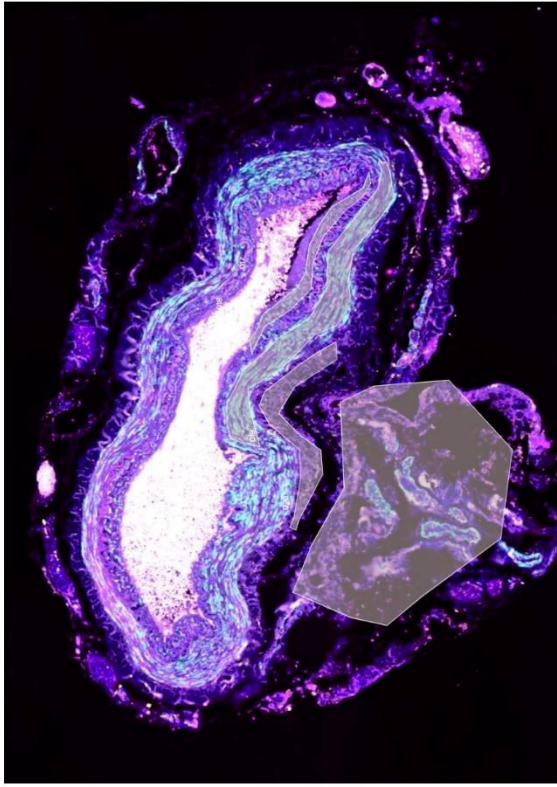
Control #2



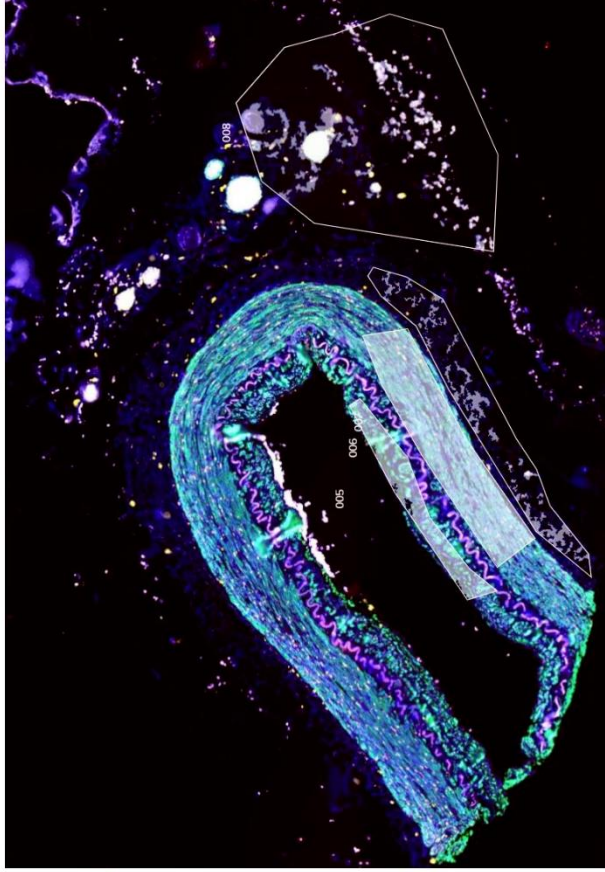
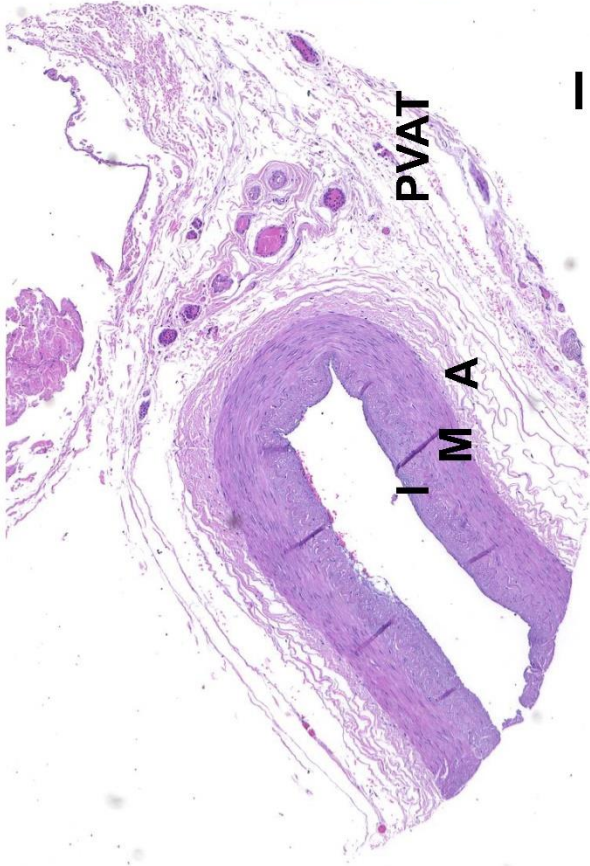
Control #3



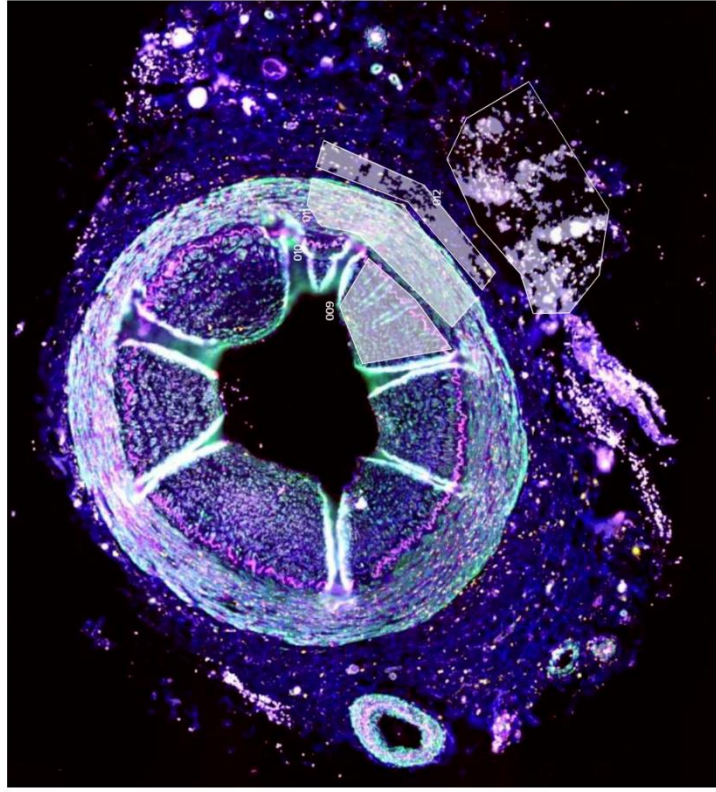
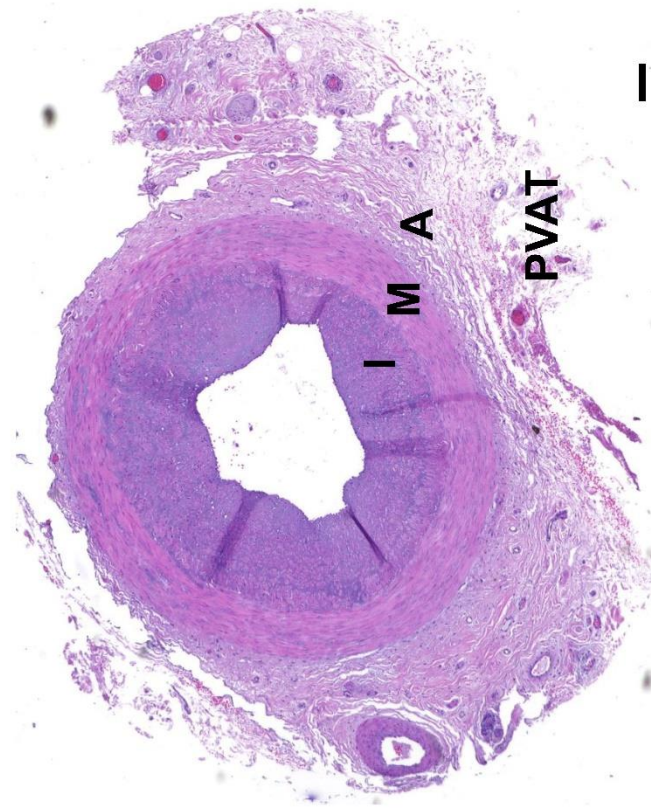
Control #4



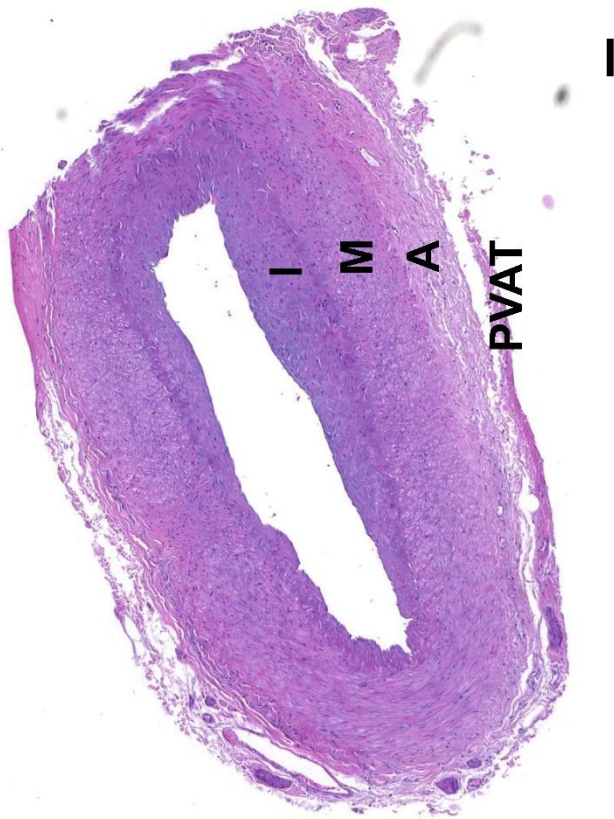
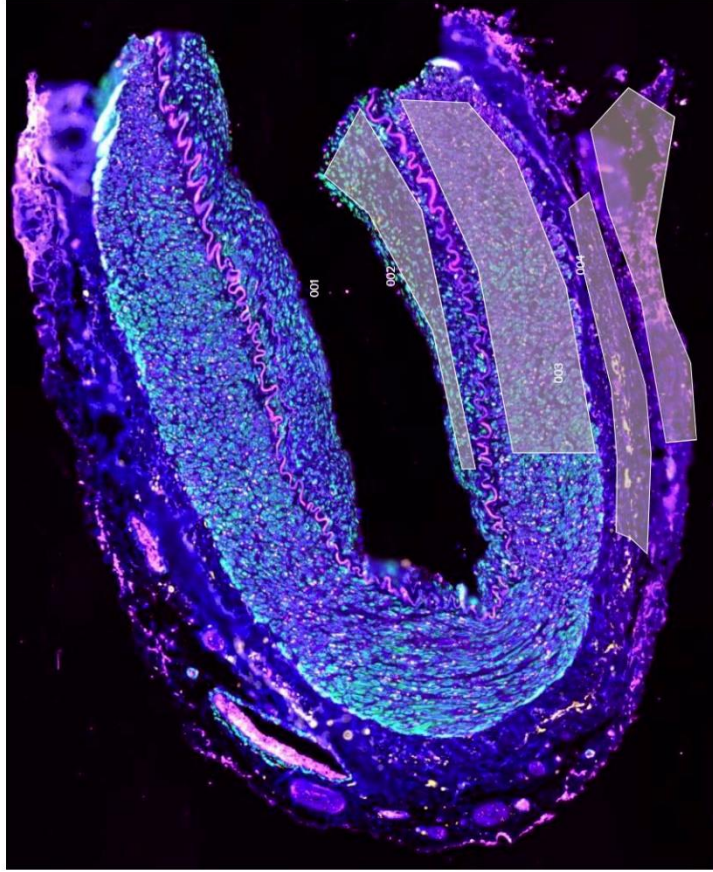
Control #5



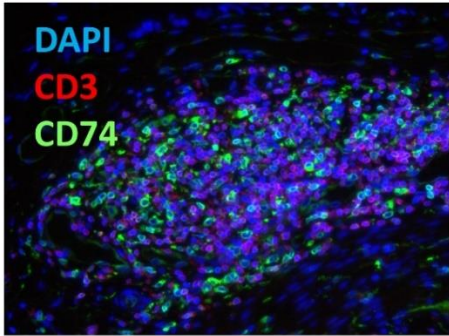
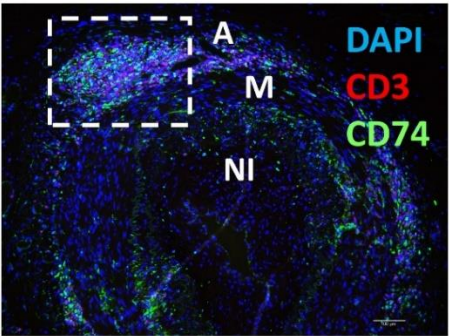
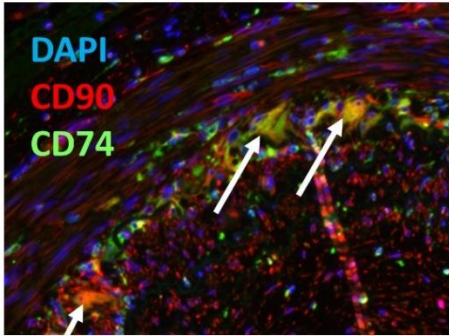
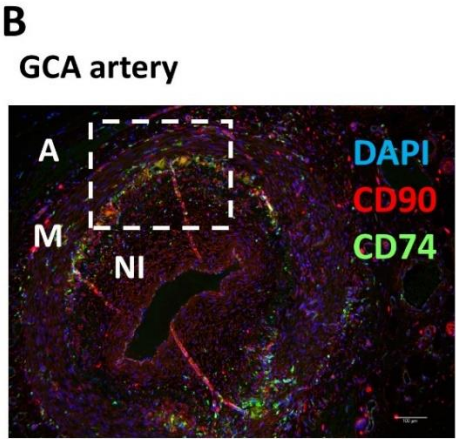
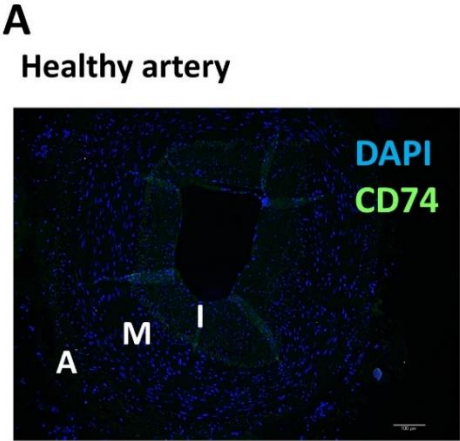
Control #6



Control #7

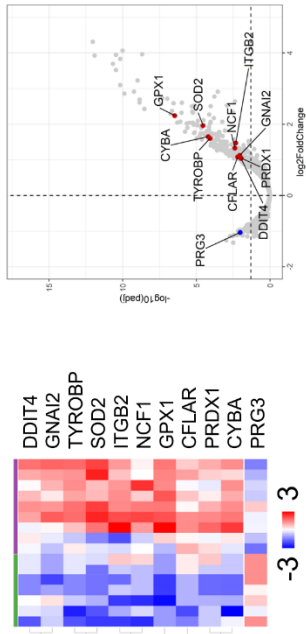


Supplementary Figure 2. Immunofluorescence analysis by microscopy of healthy and GCA temporal arteries. (A): In healthy artery, cells do not express CD74. (B): In GCA arteries, CD90+ cells express CD74, particularly in the outer part of the neointima near the media. CD3+ cells do not express CD74. GCA, giant cell arteritis, A, adventitia, M, media, NI, neointima.



Intima

ROS metabolic process



Travail complémentaire 2. (non publié)

Etude du retentissement de l'hyperplasie intimale sur les caractéristiques, cliniques, biologiques, évolutives de patients atteints d'ACG.

A partir de notre cohorte de patients porteurs d'ACG, diagnostiqués dans le service de Médecine interne du CHU de Limoges, une relecture histologique détaillée a été effectuée par Sébastien Decourt, interne du service d'anatomopathologie, en mesurant le pourcentage d'occlusion vasculaire afin d'évaluer les conséquences de la sévérité de l'hyperplasie intimale. Par ailleurs, le degré d'intensité de l'infiltrat inflammatoire au sein de la paroi artérielle a été mesuré. Une relecture a été réalisée pour 423 patients.

Nous avons comparé les patients avec une occlusion inférieure ou supérieure à 50% (**Tableau 10**). Les patients avec occlusion supérieure à 50% étaient significativement plus âgés, avaient un délai entre le début des symptômes et le diagnostic d'ACG plus long, moins fréquemment une PPR associée. Ils avaient plus souvent une anomalie palpatoire de l'artère temporale, de signes ORL, de complications ischémiques visuelles notamment de NOIA. Egalement des taux de plaquettes et une VS plus élevés, contrairement au fibrinogène et CRP.

Il existe une corrélation entre le degré d'occlusion et l'intensité globale de l'infiltrat inflammatoire côté en quatre degrés (**Figure 22**). La comparaison du degré d'occlusion avec les valeurs continues suivantes montrait une forte corrélation : l'âge, le nombre de signes ORL, le taux de plaquettes, l'intensité de l'infiltrat en globale mais également individuellement au niveau de l'adventice, la média ou l'intima.

Plusieurs études se sont intéressées au lien entre le degré d'hyperplasie de l'intima et les caractéristiques cliniques de l'ACG avec des résultats contradictoires. A partir de 30 patients, Makkuni et al ont mis en évidence un lien entre le degré d'hyperplasie intimale et le risque de complications visuelles [376]. Ces résultats ont été confirmés en analyse univariée comparant 29 patients avec complications visuelles et 362 patients sans [377]. En analyse multivariée, seule la présence de cellules géantes restait associée à la perte visuelle. Un travail plus récent vient infirmer la corrélation entre hyperplasie intimale et risque visuel [378]. Il existerait une corrélation entre l'hyperplasie intimale et le signe du Halo de l'artère temporale à l'échographie doppler, plutôt que la présence d'inflammation transmurale [379].

	≤50%	>50%	p-value
Patients (n)	216	207	
Démographie et comorbidités			
Age (années)	74.0 (7.6)	76.1 (7.8)	0.0047
Poids (kg)	64.8 (13.0)	62.4 (12.0)	0.0756
Sexe masculin	79 (36.6)	67 (32.4)	0.4194
Hypertension artérielle	98 (45.4)	100 (48.5)	0.5786
Dyslipidémie	23 (10.6)	27 (13.1)	0.5284
Diabète avec TRT	33 (15.3)	19 (9.2)	0.0813
Critères de classification de l'ACG			
Critères ACR 1990	3.7 (0.9)	4.2 (0.9)	<0.0001
Critères ACR/EULAR 2022	8.0 (2.6)	8.9 (2.9)	0.0006
Forme de l'ACG			
Délai début des symptômes - diagnostic de l'ACG	45.0 [21.0, 90.0]	55.0 [30.0, 95.0]	0.0395
Forme aortitique	47 (21.8)	58 (28.2)	0.1596
Forme aortitique pure	18 (8.3)	16 (7.7)	0.9605
Forme cranial pure	165 (76.4)	147 (71.0)	0.2520
Forme cranial mixte	194 (89.8)	194 (93.7)	0.2003
Clinique			
Fièvre	89 (41.6)	66 (32.4)	0.0639
Asthénie	140 (67.0)	136 (66.7)	1.0000
Perte de poids >5%	91 (42.7)	67 (33.5)	0.0678
Pseudopolyarthrite rhizomélique	76 (35.2)	48 (23.2)	0.0092
Palpation de l'artère temporale anormale	97 (45.1)	157 (76.2)	<0.0001
Induration	64 (41.6)	95 (61.7)	0.0006
Douleur à palpation	40 (26.0)	35 (22.7)	0.5954
Absence Battement	58 (37.7)	100 (64.9)	<0.0001
Céphalées récente	180 (83.3)	161 (77.8)	0.1862
Hyperesthésie du cuir chevelu	104 (48.8)	100 (48.5)	1.0000
Présence de signes ORL	131 (60.6)	156 (75.4)	0.0017
Nombres de signes ORL	1.6 (1.9)	2.2 (2.0)	0.0001
Claudication de la mâchoire	50 (24.5)	80 (41.5)	0.0005
Douleur maxillaire	60 (29.4)	76 (39.4)	0.0471
Douleur pharyngée	36 (17.6)	51 (26.4)	0.0464
Dysphagie	20 (9.8)	35 (18.1)	0.0241
Toux	38 (18.6)	56 (29.0)	0.0206
Complication ischémique visuelle	26 (12.0)	55 (26.6)	0.0002
Diplopie	10 (5.1)	22 (11.9)	0.0286
Amaurose	25 (13.3)	50 (27.9)	0.0008
Neuropathie optique ischémique antérieure	17 (9.1)	37 (20.8)	0.0029
Complication ischémique neurologique	7 (3.4)	12 (5.9)	0.3255
Atteinte vasculaire périphérique	12 (5.7)	9 (4.7)	0.8113
Aortite au diagnostic	25 (11.6)	34 (16.4)	0.1939
Aortite en rechute	10 (5.1)	13 (7.0)	0.5750
Complication aortique	7 (3.3)	11 (5.3)	0.4323
Patients (n)	216	207	
Biologie			
Leucocytes	9303.9 (2878.4)	9329.2 (3567.4)	0.2329
Plaquettes	411.0 (153.2)	454.7 (154.3)	0.0009
Vitesse de sédimentation	80.9 (27.5)	86.8 (27.4)	0.0361
Fibrinogène	7.1 (1.7)	7.2 (1.5)	0.8797
CRP	97.4 (67.5)	93.9 (63.0)	0.8400
Traitement			
Dose initiale de corticoïdes (mg/kg/jour)	0.8 (0.2)	0.8 (0.1)	0.0094
Bolus initiaux de méthylprednisolone	46 (21.3)	66 (31.9)	0.0184
Traitement d'épargne dans les 30 jours	14 (6.5)	24 (11.7)	0.0922
Dose de corticoïdes au 3ème mois (mg/jour)	17.9 (5.5)	17.9 (5.8)	0.6872
Dose de corticoïdes au 6ème mois (mg/jour)	12.2 (4.7)	11.9 (4.6)	0.3184
Dose de corticoïdes au 12ème mois (mg/jour)	7.2 (4.5)	6.8 (4.2)	0.3665
Initiation d'une épargne secondairement	19 (17.0)	27 (18.9)	0.8173
Délai de l'initiation de l'épargne (jours)	420.0 [210.0, 720.0]	253.5 [180.0, 595.0]	0.2812
Evolution			
Rechute ou récurrence	128 (60.7)	120 (59.7)	0.9214
Durée de suivi (mois)	55.0 [28.0, 86.0]	45.0 [24.0, 76.5]	0.0699
Nombres de consultations ou d'hospitalisation	12.9 (7.7)	12.8 (8.0)	0.7105
Décès pendant traitement	28 (13.0)	29 (14.0)	0.8629
Complications liées au traitement	132 (61.7)	122 (59.8)	0.7696

Patients (n)	Occlusion intimale		p-value
	≤50%	>50%	
Histologie	216	207	
Biopsie d'artère temporale positive	95 (44.0)	198 (95.7)	<0.0001
Biopsie d'artère temporale réalisée sous corticoïdes	84 (67.7)	100 (68.0)	1.0000
Taille de la biopsie d'artère temporale (mm)	23.0 (10.9)	22.3 (9.4)	0.8816
ACG finale avec artérite temporale active	129 (59.7)	205 (99.0)	<0.0001
Intima inflammatoire	102 (47.2)	202 (97.6)	<0.0001
Média inflammatoire	108 (50.0)	204 (98.6)	<0.0001
Adventice inflammatoire	121 (56.0)	203 (98.1)	<0.0001
Panartérite (3 couches inflammatoire)	94 (43.5)	200 (96.6)	<0.0001
1 couche atteinte	21 (9.7)	1 (0.5)	<0.0001
2 couches atteintes	14 (6.5)	4 (1.9)	0.0281
Atteinte des petits vaisseaux	36 (16.7)	117 (56.5)	<0.0001
Atteinte de la periadventice	94 (43.5)	185 (89.4)	<0.0001
ACG cicatricielle seule sans inflammation	15 (6.9)	0 (0.0)	<0.0001
Atteinte segmentaire	77 (35.6)	30 (14.5)	<0.0001
Atteinte sectorielle	67 (31.0)	39 (18.9)	0.0060
Intensité de l'infiltrat inflammatoire globale			<0.0001
	0	89 (41.2)	3 (1.4)
	1	47 (21.8)	12 (5.8)
	2	66 (30.6)	88 (42.5)
	3	14 (6.5)	104 (50.2)
Granulome	36 (16.7)	107 (51.7)	<0.0001
Cellules géantes	45 (20.8)	163 (78.7)	<0.0001
Nécrose fibrinoïde	21 (9.8)	61 (29.5)	<0.0001
Destruction de la média	75 (34.7)	164 (79.6)	<0.0001
Calcification de la limitante élastique interne	54 (25.0)	77 (37.2)	0.0091
Destruction de la limitante élastique interne	91 (42.1)	194 (94.2)	<0.0001
Médiocalcose			<0.0001
	1	115 (68.9)	10 (16.4)
	2	8 (4.8)	1 (1.6)
	3	44 (26.3)	50 (82.0)

Tableau 99. Comparaison de patients atteints d'ACG selon le degré d'hyperplasie intimale.

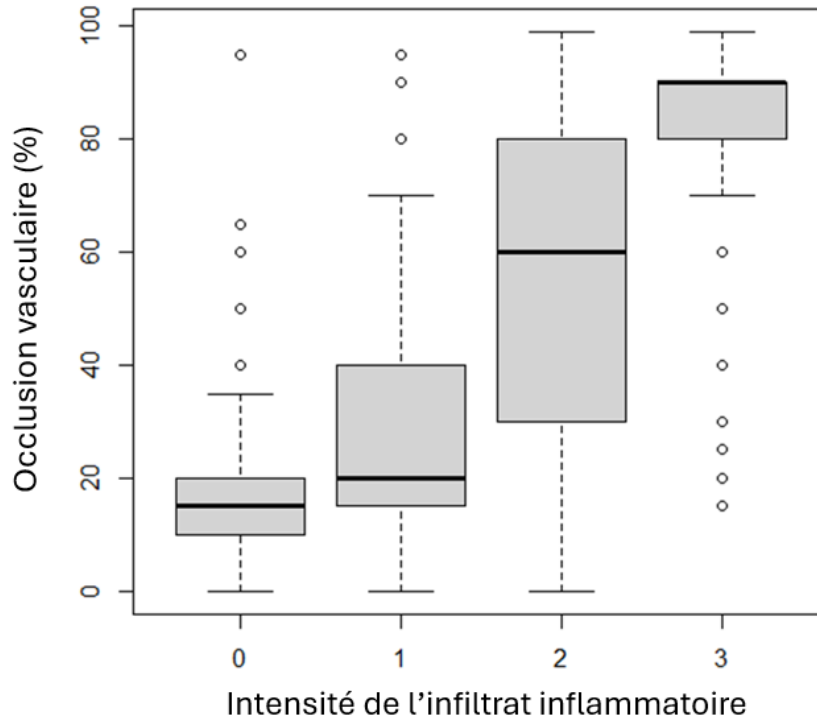


Figure 22. Comparaison au sein de BAT de patients porteurs d'ACG entre le degré d'occlusion vasculaire et l'intensité de l'infiltrat inflammatoire.

Le degré d'occlusion vasculaire était défini selon le rapport entre la surface de l'hyperplasie intinale et celle de la lumière vasculaire. L'intensité de l'infiltrat inflammatoire était gradée sur une échelle de 0 à 3 apprécié par le nombre de cellules inflammatoires présent dans les 3 couches artérielles.

Discussion générale

L'ensemble de ces travaux s'est attaché à étudier le remodelage vasculaire au cours de l'ACG. L'hyperplasie intimale est la principale cause d'occlusion artérielle et entraîne des complications ischémiques souvent irréversibles, qui dépendent de la différenciation des cellules musculaires lisses vasculaires et de la prolifération des fibroblastes. Il existe cependant peu de données dans la littérature concernant ce remodelage vasculaire et notamment sur le rôle potentiel des fibroblastes artériels.

Dans la première partie, nous avons évalué la répartition des fibroblastes au niveau des artères temporales de patients ainsi que certains de leurs marqueurs d'activation par immunohistochimie. Une étude *in vitro* à partir de fibroblastes adventitiels a également été réalisée. Nous avons ensuite effectué une analyse transcriptomique correspondant aux différentes couches artérielles. Enfin une étude de corrélation entre le degré d'hyperplasie intimale et les caractéristiques clinico-biologiques des patients a été réalisée.

Nous avons tout d'abord constaté une augmentation de l'épaisseur de l'adventice dans l'ACG. Ce phénomène pourrait être lié à une prolifération fibroblastique. Dans des modèles de remodelage vasculaire après lésion artérielle provoquée, les fibroblastes adventitiels prolifèrent et se transforment en myofibroblastes, ce qui pourrait expliquer l'hyperplasie adventitielle [370-372,375].

Nous avons analysé plusieurs facteurs qui n'avaient pas été explorés auparavant dans l'ACG : le CD90, la vimentine, la desmine, la prolyl 4 hydroxylase et la chaîne lourde de la myosine. Nous avons identifié une population de fibroblastes CD90⁺, vimentine⁺, desmine⁻. Cette population était augmentée dans la couche adventitielle des patients atteints d'ACG par rapport aux témoins, suggérant que l'hyperplasie adventitielle est liée à la prolifération des fibroblastes dans cette tunique. Nous avons également noté une augmentation du taux d' α SMA, confirmant que les fibroblastes adventitiels sont au stade de myofibroblastes actifs. Ceci est mis en évidence par la co-expression du CD90 et de l' α SMA par la plupart des cellules adventitielles.

La présence de ces fibroblastes adventitiels activés, suggère par ailleurs l'hypothèse d'une migration de ces cellules de l'adventice vers la média et l'intima. La coexpression de CD90 et d' α SMA dans la couche de l'intima peut suggérer que certaines cellules de l'intima sont dérivées de fibroblastes adventitiels. En effet, nous avons constaté des « puits d'invasion » formés de fibroblastes au sein de la média. La capacité à migrer à travers la média détruite via le PDGF ou une forte expression de NOX4 a été suggérée dans d'autres maladies [380,381].

Dans l'étude transcriptomique, nous avons effectué une analyse d'expression spatiale à l'échelle du génome afin d'identifier les gènes clés et les processus biomoléculaires impliqués dans les artères temporales de l'ACG. En comparant les profils d'expression génique dans les différentes couches des artères temporales entre les patients atteints d'ACG et les témoins, nous avons détecté une augmentation significative de l'activité des gènes dans les trois couches artérielles, ce qui suggère des mécanismes de régulation insuffisants au cours de l'ACG.

Les couches de l'intima et de la média étaient particulièrement touchées par la dérégulation de l'expression génique dans l'ACG. Il est intéressant de noter que nous avons montré une bonne capacité de discrimination des gènes sélectionnés dans les couches de l'intima et de la média entre les patients de l'ACG et les témoins. Cependant, les différences entre les expressions géniques étaient moins évidentes dans l'adventice, ce qui peut être dû au faible nombre de cellules inflammatoires dans l'adventice pour 2 patients porteurs d'ACG dans notre étude. En outre, le mécanisme initial de l'ACG implique des lésions adventitielles et la stimulation des cellules dendritiques résidentes via les TLR par un stimulus inconnu. Comme les BAT sont souvent réalisées à un stade avancé de l'ACG, lorsque le remodelage vasculaire a déjà eu lieu, l'adventice peut être moins affectée par la dérégulation que la média et l'intima à ce stade.

Par ailleurs le tissu périvasculaire n'a pas montré de différences majeures entre les deux groupes en termes de dérégulation transcriptomique par rapport aux contrôles. Bien que la couche périvasculaire n'ait pas été étudiée en détail dans l'ACG, elle peut être impliquée dans l'inflammation présente dans l'artère adjacente, comme cela a été démontré dans d'autres maladies vasculaires [382,383]. Une étude histologique a montré une implication du tissu péri-adventiciel, suggérant son rôle dans

un sous-groupe d'ACG [384]. Dans notre étude, les neuf patients atteints d'ACG ne présentaient pas ce type d'histologie.

Le CD74 était le gène le plus dérégulé dans les couches artérielles d'ACG. Cette protéine invariante participe à l'assemblage du complexe majeur d'histocompatibilité (HLA) de classe II, lui conférant ainsi un rôle important dans le processus de présentation de l'antigène [385]. Hormis son rôle de structuration du HLA de classe II, il influence également le traitement des antigènes, leur maturation endocellulaire, la migration cellulaire (notamment des cellules dendritiques), et la transduction des signaux intra cellulaires. Il est également impliqué dans la présentation croisée d'antigènes peptidiques viraux en s'associant aux molécules du HLA de classe I lors de leur trafic vers les compartiments endolysosomiaux pour le chargement de peptides exogènes et le recrutement de lymphocytes T cytotoxiques [386]. De plus, CD74 est également le récepteur d'une cytokine pro-inflammatoire, le MIF, impliqué dans l'activation endothéliale associée à l'hypertension artérielle pulmonaire, ainsi qu'aux lésions vasculaires liées à l'athéromatose [387,388].

Dans notre étude, les cellules CD90⁺ expriment également le CD74, ce qui suggère que les fibroblastes CD90⁺ pourraient agir comme des cellules présentatrices d'antigènes dans l'ACG. D'autre part, la plupart des gènes présentant le même profil que l'expression du CD74 dans les différentes couches étaient impliqués dans la réponse immunitaire et appartenaient aux classes I (B2M, HLA-A et HLA-B) et II (HLA-DRA et HLA-DRB1) du complexe majeur d'histocompatibilité.

Nous nous sommes ensuite concentrés sur les macrophages, qui sont les principales cellules immunitaires impliquées dans l'ACG. Les macrophages peuvent former des granulomes et fusionner pour produire des cellules géantes. Les lymphocytes recrutent et activent les macrophages dans les artères par la sécrétion de cytokines et de facteurs de croissance (IL-6, IL-17, TNF- α , IFN- γ et GM-CSF). Deux populations principales de macrophages CD68⁺ ont été identifiées dans l'ACG : les macrophages adventitiels, qui sont impliqués dans la sécrétion de TGF- β 1, IL-6 et IL-1 β , et les macrophages intimaux et médiaux, qui sont impliqués dans la sécrétion de ROS, d'oxyde nitrique et de métalloprotéases [389]. Ils peuvent également produire du PDGF et du VEGF. Sous l'action combinée des MMP, du PDGF et du VEGF, la limitante élastique interne de la média est détruite et le remodelage vasculaire se

produit. Dans la présente étude, les gènes FTH1 et SOD2, liés à la polarisation des macrophages de type M1, présentaient le même profil d'expression que CD68 dans les couches artérielles, contrairement à CD163, CD206 et CHI3L1 (codant YKL-40), qui sont liés aux macrophages de type M2 [390]. Des études antérieures ont démontré l'hétérogénéité des macrophages CD68 dans les artères temporales de l'ACG [333]. Il est intéressant de noter que les profils d'expression de CTSB et TMSB10 sont similaires à ceux de CD68, qui sont liés à la promotion des macrophages de type M2 [391,392]. D'autre part, FTH1 code pour la principale protéine intracellulaire de stockage du fer (chaîne lourde de ferritine 1) et est exprimée en abondance par les macrophages de type M1 [392].

Les gènes des métalloprotéinases MMP2 et MMP9 sont surexprimés, conformément à des études antérieures [310]. La libération d'espèces réactives de l'oxygène par les macrophages entraîne une peroxydation lipidique des phospholipides membranaires des CMLV, ce qui entraîne leur combinaison avec la MMP et l'apoptose. De plus, le PDGF sécrété par les macrophages et les cellules géantes participe à l'hyperplasie intimale [328]. Notre étude a également montré que l'angiogenèse se produit dans l'intima et la média, ce qui est en accord avec des études antérieures [328]. La néo angiogenèse résulte de l'action du VEGF sécrété par les macrophages. Il est intéressant de noter que l'ossification (ou calcification) n'a pas été évaluée en détail dans l'ACG. Dans la présente étude, nous avons démontré que ce processus est présent dans l'intima et la média et susceptibles de jouer un rôle dans la physiopathologie de l'ACG.

Nous avons également noté que l'activation lymphocytaire était moins marquée que celle des macrophages. Comme la plupart des patients ACG de notre étude avaient pris des glucocorticoïdes avant la BAT, la population Th17 était probablement réduite, ce qui pourrait expliquer une faible activation lymphocytaire comme l'ont démontrée Zeng et al [392]. Par ailleurs, aucune différence significative n'a été observée entre les patients atteints d'ACG et les témoins en termes d'expression des gènes IL-1 et IL-6, bien que ces cytokines soient produites dans les artères temporales. Dans la présente étude, la dérégulation concernant le remodelage était en effet principalement présente dans l'intima et la média. Ces résultats suggèrent que le remodelage vasculaire a déjà commencé lorsque la BAT est pratiquée.

Enfin, nous avons construit un réseau pharmacogénomique basé sur les gènes dérégulés et les médicaments approuvés par la *Food and Drug Administration* qui ciblent ces gènes. En fournissant une vision systémique des interactions géniques et mécanistiques, notre réseau pharmacogénomique spatial peut faciliter la conception de nouvelles stratégies d'intervention pharmacologique. Nos résultats suggèrent que les macrophages sont une cible prometteuse dans l'ACG. En particulier, le GM-CSF un facteur de croissance pour la maturation des macrophages, peut être bloqué par le mavrilimumab [201]. Notre réseau pharmacogénomique montre la potentialité du blocage de plusieurs gènes liés aux macrophages à l'aide de médicaments ciblant les MMP2/MMP9 et le CXCR4. Le CD74, principal gène dérégulé dans les trois couches artérielles des ACG, constitue une autre cible médicamenteuse potentielle. Le milatuzumab, un médicament anti-CD74, a été évalué dans des maladies hématologiques avec des résultats prometteurs [393].

La présente étude présente plusieurs points forts. Tout d'abord, nous avons utilisé une technique innovante pour l'analyse spatiale des différentes tuniques artérielles. Deuxièmement, il s'agit de la première étude transcriptomique spatiale des BAT dans l'ACG. Troisièmement, nous avons identifié un grand nombre de gènes avec une expression dérégulée, indiquant malgré la taille limitée de l'échantillon que les différences d'expression génique entre les artères temporales de l'ACG et les artères temporales de contrôle étaient robustes (fold-change <-2 ou >2 avec une valeur ajustée $p < 0,01$).

Cette étude présente quelques limites. Tout d'abord, l'échantillon était de petite taille (9 patients atteints d'ACG et 7 témoins). Nous n'avons pas pu réaliser d'analyse en groupes cliniques (vascularite des gros vaisseaux versus atteinte crânienne pure), évolutive (rechute ou rémission) ou histologique (panartérite *versus* atteinte inflammatoire plus limitée). Certains témoins avaient un terrain inflammatoire (2 arthrites périphériques séronégatives et 1 encéphalopathie infectieuse), mais ces 3 témoins avaient une BAT négative, sans infiltrat inflammatoire. Enfin, notre étude a utilisé des échantillons provenant de BAT mais n'a pas analysé les cellules dans la circulation.

Conclusion et perspectives

En conclusion, nous avons analysé la signature transcriptomique à l'échelle régionale artérielle en fonction des couches artérielles au cours de l'ACG. Cette nouvelle technique peut être utilisée pour comprendre l'ACG et identifier de nouvelles cibles thérapeutiques. Une approche pharmacogénomique a été utilisée pour déterminer des cibles et des thérapeutiques potentiellement utiles pour le traitement de l'ACG. Nos résultats seront utiles pour de futures études multi-omiques portant sur les voies biomoléculaires, les réseaux et les biomarqueurs dans l'ACG.

Nous émettons l'hypothèse que les fibroblastes notamment présents dans l'adventice jouent un rôle clé dans la physiopathologie de l'ACG. Nos données suggèrent une participation dans le recrutement des lymphocytes tissulaires via une fonction présentatrice de l'antigène. Egalement ils pourraient agir directement sur les phénomènes ischémiques en migrant vers l'intima.

Nous souhaitons ainsi poursuivre ce travail en caractérisant plus en détail les mécanismes sous-jacents du remodelage vasculaire, impliquant notamment les fibroblastes, les facteurs associés à leur activation ainsi que leur fonction potentielle de présentation de l'antigène et de stimulation/entretien de l'infiltrat inflammatoire artériel.

Ces perspectives pourront être développées à partir des techniques réalisées dans l'UMR 1308 à laquelle nous sommes associés. Ces techniques concernent l'isolement et la caractérisation des exosomes, les dosages cytokiniques par cytométrie en flux, le tri cellulaire, les cultures en 3 dimensions, ainsi que les analyses transcriptomiques en lien avec nos collaborations avec le Dr Elsa Molina (*Salk Institute*) et la Mayo Clinic (Pr Weyand).

Des travaux à court terme vont être effectués :

- une étude *single cell* transcriptomique complémentaire, en cours de projet avec Elsa Molina (*Salk Institute*, San Diego, CA). Elle aura pour but d'identifier la répartition des sous types cellulaires immunitaires de façon détaillées (fibroblastes, CMLV, lymphocytes, macrophages, cellules endothéliales) au sein des artères temporales. Secondairement un profilage transcriptomique cellule par cellule sera effectué sur des gènes d'intérêt préalablement sélectionnés, basés sur le travail décrit

précédemment. En particulier, nous prévoyons d'étudier les différents types de fibroblastes, et étudier leur profil d'expression transcriptomique notamment les gènes liés à la fonction présentatrice d'antigène.

- l'étude de la plasticité et de la différenciation phénotypique des CMLV et des fibroblastes par analyse *ex vivo* de ces cellules à partir de BAT de patients atteints ACG. Nous souhaitons mieux caractériser les fibroblastes et le rôle potentiel de cellules présentatrices de l'antigène en utilisant des co-cultures en 3 dimensions avec des monocytes/macrophages ou lymphocytes.

- une étude des modifications de la polarisation *in vitro* des macrophages de type M1 et M2 en lien avec la sortiline, protéine de transport de neurotrophines et de cytokines, et le facteur de transcription ATF3 qui inhibe son expression. Cette étude sera couplée à une étude de leur expression au niveau des BAT de patients porteurs d'ACG comparées à des sujets sains. Sébastien Laburthe, interne de Médecine interne au CHU de Limoges réalise actuellement ce travail au sein de l'UMR 1308 dans le cadre de son stage de Master 2.

- des études complémentaires pourront être aussi effectuées à partir des prélèvements sanguins des patients ayant eu en parallèle une BAT à différents stades de l'ACG : pour études phénotypiques par cytométrie en flux des populations Th1 Th17, Treg, et monocytes. Pour chaque patient, l'isolement des exosomes circulants pourra être réalisé à partir du sérum pour caractérisation, étude fonctionnelle au niveau de la polarisation des macrophages et de l'activation des fibroblastes isolés de sujets contrôles (BAT négative). Des analyses protéomiques et transcriptomiques du contenu des exosomes pourront être ensuite effectuées.

Références

- [1] Jennette JC, Falk RJ, Bacon PA, et al. 2012 revised International Chapel Hill Consensus Conference Nomenclature of Vasculitides. *Arthritis Rheum.* 2013 65:1-11
- [2] Wood CA. Memorandum Book of a Tenth-Century Oculist for the Use of Modern Ophthalmologists. A Translation of the Tadhkirat of Ali ibn Isa of Baghdad (cir. 940-1010 A.D.). Published by Chicago: Northwestern University. 1936
- [3] Hollenhorst RW, Brown JR, Wagener HP, et al. Neurologic aspects of temporal arteritis. *Neurology.* 1960 10:490-498
- [4] Henriot JP, Marin J, Gosselin J, et al. [The history of Horton's disease or ... 10 centuries of a fascinating adventure]. *J Mal Vasc.* 1989 14 Suppl C:93-7
- [5] Hutchinson J. Diseases of the arteries. On a peculiar form of thrombotic arteritis of the aged which is sometimes productive of gangrene. *Arch Surg.* 1980 1:323-329
- [6] Horton BT, Magath TB, Brown GE. An undescribed form of arteritis of the temporal vessels. *Proc Staff Meet. Mayo Clin.* 1932 7:700-701
- [7] Horton BT, Magath TB, Brown GE. Arteritis of the temporal vessels. A previously undescribed form. *Arch Int Med.* 1934 53:400-409
- [8] Hunder GG. Epidemiology of giant-cell arteritis. *Cleve Clin J Med.* 2002 69 Suppl 2:S1179-82
- [9] Baldursson O, Steinsson K, Björnsson J, et al. Giant cell arteritis in Iceland. An epidemiologic and histopathologic analysis. *Arthritis Rheum.* 1994 37:1007-12
- [10] Haugeberg G, Paulsen PQ, Bie RB. Temporal arteritis in Vest Agder County in southern Norway: incidence and clinical findings. *J Rheumatol.* 2000 27:2624-7
- [11] Salvarani C, Crowson CS, O'Fallon WM, et al. Reappraisal of the epidemiology of giant cell arteritis in Olmsted County, Minnesota, over a fifty-year period. *Arthritis Rheum.* 2004 51:264-8
- [12] Smeeth L, Cook C, Hall AJ. Incidence of diagnosed polymyalgia rheumatica and temporal arteritis in the United Kingdom, 1990-2001. *Ann Rheum Dis.* 2006 65:1093-8
- [13] Watts RA Hatemi G, Burns JC, et al. Global epidemiology of vasculitis. *Nature Rev Rheumatol* 2022 18:22-34
- [14] Pugh D, Karabayas M, Basu N, et al. Large-vessel vasculitis. *Nat Rev Dis Primers.* 2022 7:93
- [15] Li KJ, Semenov D, Turk M, et al. A meta-analysis of the epidemiology of giant cell arteritis across time and space. *Arthritis Res Ther.* 2021 23:82
- [16] Borchers AT, Gershwin ME. Giant cell arteritis: a review of classification, pathophysiology, geoepidemiology and treatment. *Autoimmun Rev.* 2012 11:A544-54

- [17] Guittet L, de Boysson H, Cerasuolo D, et al. Whole-Country and Regional Incidences of Giant Cell Arteritis in French Continental and Overseas Territories: A 7-Year Nationwide Database Analysis. *ACR Open Rheumatol*. 2022 4:753-759
- [18] Greigert H, Bonnotte B, Samson M. [Diagnosis of giant cell arteritis]. *Rev Prat*. 2023 73:387-394
- [19] Keser G, Aksu K, Direskeneli H. Discrepancies between vascular and systemic inflammation in large vessel vasculitis: an important problem revisited. *Rheumatology (Oxford)*. 2018 57:784-790
- [20] Dejaco C, Duftner C Buttgereit F, et al. The spectrum of giant cell arteritis and polymyalgia rheumatica: Revisiting the concept of the disease. *Rheumatology (Oxford)*. 2017 56:506-15
- [21] de Boysson H, Lambert M, Liozon E, et al. Giant-cell arteritis without cranial manifestations: Working diagnosis of a distinct disease pattern. *Medicine (Baltimore)*. 2016 95:e3818
- [22] de Boysson H, Liozon E, Espitia O, et al. Different patterns and specific outcomes of large-vessel involvements in giant cell arteritis. *J Autoimmun*. 2019 103:102283
- [23] Brack A, Martinez-Taboada V, Stanson A, et al. Disease pattern in cranial and large-vessel giant cell arteritis. *Arthritis Rheum*. 1999 42:311-7
- [24] van der Geest KSM, Sandovici M, van Sleen Y, et al. Review: What Is the Current Evidence for Disease Subsets in Giant Cell Arteritis? *Arthritis Rheumatol*. 2018 70:1366-1376
- [25] de Boysson H, Liozon E, Ly KH, et al. The different clinical patterns of giant cell arteritis. *Clin Exp Rheumatol*. 2019 117:57-60
- [26] de Boysson H, Dumas A, Vautier M, et al. Large-vessel involvement and aortic dilation in giant-cell arteritis. A multicenter study of 549 patients. *Autoimmun Rev*. 2018 17:391-398
- [27] Tomelleri A, van der Geest KSM, Khurshid MA, et al. Disease stratification in GCA and PMR: state of the art and future perspectives. *Nat Rev Rheumatol*. 2023 19:446-459
- [28] Mahr A, Hachulla E, de Boysson H, et al. Presentation and Real-World Management of Giant Cell Arteritis (Artemis Study). *Front Med (Lausanne)*. 2021 8:732934
- [29] Ponte C, Martins-Martinho J, Luqmani RA. Diagnosis of giant cell arteritis. *Rheumatology (Oxford)*. 2020 59(Suppl 3):iii5-iii16.
- [30] Calamia KT, Hunder GG. Giant cell arteritis (temporal arteritis) presenting as fever of undetermined origin. *Arthritis Rheum*. 1981 24:1414-8
- [31] Salvarani C, Fabrizio Cantini F, Hunder GG. Polymyalgia rheumatica and giant-cell arteritis. *Lancet*. 2008 372:234-45
- [32] Knockaert DC, Vanneste LJ, Bobbaers HJ. Fever of unknown origin in elderly patients. *J Am Geriatr Soc*. 1993 41:1187-9

- [33] Liozon E, Boutros-Toni F, Ly K, et al. Silent, or masked, giant cell arteritis is associated with a strong inflammatory response and a benign short term course. *J Rheumatol*. 2003 30:1272-6
- [34] de Boysson H, Liozon E, Ly KH, et al. Giant cell arteritis presenting as isolated inflammatory response and/or fever of unknown origin: a case-control study. *Clin Rheumatol*. 2018 37:3405-3410
- [35] Solomon S, Cappa KG. The headache of temporal arteritis. *J Am Geriatr Soc*. 1987 35:163-5
- [36] Jones JG. Clinical features of giant cell arteritis. *Baillieres Clin Rheumatol*. 1991 5:413-30
- [37] Fisher CM. Palpation of arteries in temporal arteritis. Reemphasis of the value of careful palpation. *JAMA*. 1961 175:325
- [38] Curran RE. Palpation of the superficial temporal artery in normal persons. *Arch Ophthalmol*. 1986 104:1756
- [39] Zenone T, Puget M. Sensitivity of clinically abnormal temporal artery in giant cell arteritis. *Int J Rheum Dis*. 2013 16:771-3
- [40] Xiong J, Sammel A, Laurent R, et al. Diagnostic utility of the chewing gum test in giant cell arteritis. *Clin Exp Ophthalmol*. 2021 49:83-84
- [41] Kuo CH, McCluskey P, Fraser CL. Chewing Gum Test for Jaw Claudication in Giant-Cell Arteritis. *N Engl J Med*. 2016 374:1794-5
- [42] Héron E, Sedira N, Dahia O, et al. Ocular Complications of Giant Cell Arteritis: An Acute Therapeutic Emergency. *J Clin Med*. 2022 11:1997
- [43] Smith SCM, Al-Hashimi MR, Jones CD, et al. Frequency of visual involvement in a 10-year interdisciplinary cohort of patients with giant cell arteritis. *Clin Med (Lond)*. 2023 23:206-212
- [44] Cid MC, Font C, Oristrell J, et al. Association between strong inflammatory response and low risk of developing visual loss and other cranial ischemic complications in giant cell (temporal) arteritis. *Arthritis Rheum*. 1998 41:26-32
- [45] Liozon E, Dalmay F, Lalloue F, et al. Risk Factors for Permanent Visual Loss in Biopsy-proven Giant Cell Arteritis: A Study of 339 Patients. *J Rheumatol*. 2016 43:1393-9
- [46] Bonnan M, Debeugny S. Giant-cell arteritis related strokes: scoping review of mechanisms and rethinking treatment strategy? *Front Neurol*. 2023 14:1305093
- [47] Elhfnawy AM, Elsalamawy D, Abdelraouf M, et al. Correction to Red flags for a concomitant giant cell arteritis in patients with vertebrobasilar stroke: a cross-sectional study and systematic review. *Acta Neurol Belg*. 2023 123:2049
- [48] Mineji K, Yako R, Toki N, et al. Giant cell arteritis with severe intracranial involvement diagnosed and treated early. *Surg Neurol Int*. 2023 14:332

- [49] Penet T, Lambert M, Baillet C, et al. Giant cell arteritis-related cerebrovascular ischemic events: a French retrospective study of 271 patients, systematic review of the literature and meta-analysis. *Arthritis Res Ther*. 2023 25:116
- [50] Sánchez-Chica E, Martínez-Urbistondo M, Gutiérrez Rojas Á, et al. Prevalence and impact of cerebrovascular risk factors in patients with giant cell arteritis: An observational study from the Spanish national registry. *Med Clin (Barc)*. 2023 161:20-23
- [51] Prünke MKR, Naumann A, Christ M, et al. Giant cell arteritis with vertebral artery involvement-baseline characteristics and follow-up of a monocentric patient cohort. *Front Neurol*. 2023 14:1188073
- [52] Moreno-Torres V, Soriano V, Calderón-Parra J, et al. Increased incidence of giant cell arteritis and associated stroke during the COVID-19 pandemic in Spain: A nation-wide population study. *Autoimmun Rev*. 2023 22:103341
- [53] Smith LM, Alvarado LA, Dihowm F. The incidence and characteristics of giant cell arteritis in Hispanics and the associated outcomes of ischemic ocular events and stroke. *J Investig Med*. 2023 71:411-418
- [54] Caton MT Jr, Mark IT, Narsinh KH, et al. Endovascular Therapy for Intracranial Giant Cell Arteritis : Systematic Review, Technical Considerations and the Effect of Intra-arterial Calcium Channel Blockers. *Clin Neuroradiol*. 2022 32:1045-1056
- [55] Sánchez-Chica E, Martínez-Urbistondo M, Gutiérrez Rojas Á, et al. Prevalence and impact of cerebrovascular risk factors in patients with giant cell arteritis: An observational study from the Spanish national registry. *Med Clin (Barc)*. 2023 161:20-23
- [56] Bajko Z, Balasa R, Maier S, et al. Stroke secondary to giant-cell arteritis: A literature review. *Exp Ther Med*. 2021 22:876
- [57] Coronel L, Rodríguez-Pardo J, Monjo I, et al. Prevalence and significance of ischemic cerebrovascular events in giant cell arteritis. *Med Clin (Barc)*. 2021 157:53-57
- [58] Beuker C, Wankner MC, Thomas C, et al. Characterization of Extracranial Giant Cell Arteritis with Intracranial Involvement and its Rapidly Progressive Subtype. *Ann Neurol*. 2021 90:118-129
- [59] Espígol-Frigolé G, Dejaco C, Mackie SL, Set al. Polymyalgia rheumatica. *Lancet*. 2023 402:1459-1472
- [60] Liozon E, de Boysson H, Dalmay F, et al. Development of Giant Cell Arteritis after Treating Polymyalgia or Peripheral Arthritis: A Retrospective Case-control Study. *J Rheumatol*. 2018 45:678-685
- [61] Gilmour JR. Giant-cell chronic arteritis. *J Path Bact*. 1941 53:263-277
- [62] Gribbons KB, Ponte C, Carette S, et al. Patterns of Arterial Disease in Takayasu Arteritis and Giant Cell Arteritis. *Arthritis Care Res (Hoboken)*. 2020 72:1615-1624

- [63] Espitia O, Bruneval P, Assaraf M, et al. Long-Term Outcome and Prognosis of Noninfectious Thoracic Aortitis. *J Am Coll Cardiol*. 2023 82:1053-1064
- [64] de Boysson H, Espitia O, Samson M, et al. Giant cell arteritis-related aortic dissection: A multicenter retrospective study. *Semin Arthritis Rheum*. 2021 51:430-435
- [65] Evans JM, O'Fallon WM, Hunder GG. Increased incidence of aortic aneurysm and dissection in giant cell (temporal) arteritis. A population-based study. *Ann Intern Med*. 1995 122:502-7
- [66] Gonzalez-Gay MA, Garcia-Porrúa C, Piñeiro A, et al. Aortic aneurysm and dissection in patients with biopsy-proven giant cell arteritis from northwestern Spain: a population-based study. *Medicine (Baltimore)*. 2004 83:335-341
- [67] Kermani TA, Warrington KJ, Crowson CS, et al. Large-vessel involvement in giant cell arteritis: a population-based cohort study of the incidence-trends and prognosis. *Ann Rheum Dis*. 2013 72:1989-94
- [68] García-Martínez A, Hernández-Rodríguez J, Arguis P, et al. Development of aortic aneurysm/dilatation during the followup of patients with giant cell arteritis: a cross-sectional screening of fifty-four prospectively followed patients. *Arthritis Rheum*. 2008 59:422-30
- [69] García-Martínez A, Arguis P, Prieto-González S, et al. Prospective long term follow-up of a cohort of patients with giant cell arteritis screened for aortic structural damage (aneurysm or dilatation). *Ann Rheum Dis*. 2014 73:1826-32
- [70] Kaymakci MS, Boire NA, Bois MC, et al. Persistent aortic inflammation in patients with giant cell arteritis. *Autoimmun Rev*. 2023 22:103411
- [71] Caterson HC, Li A, March L, Bet al. Post-operative outcomes of inflammatory thoracic aortitis: a study of 41 patients from a cohort of 1119 surgical cases. *Clin Rheumatol*. 2022 41:1219-1226
- [72] De Martino A, Ballestracci P, Faggioni L, et al. Incidence of Aortitis in Surgical Specimens of the Ascending Aorta Clinical Implications at Follow-Up. *Semin Thorac Cardiovasc Surg*. 2019 31:751-760
- [73] Czihal M, Piller A, Schroettle A, et al. Outcome of giant cell arteritis of the arm arteries managed with medical treatment alone: cross-sectional follow-up study. *Rheumatology (Oxford)*. 2013 52:282-6
- [74] Assie C, Marie I. [Giant cell arteritis-related upper/lower limb vasculitis]. *Presse Med*. 2011 40:151-61
- [75] Assie C, Janvresse A, Plissonnier D, et al. Long-term follow-up of upper and lower extremity vasculitis related to giant cell arteritis: a series of 36 patients. *Medicine (Baltimore)*. 2011 90:40-51

- [76] de Boysson H, Espitia O, Liozon E, et al. Vascular Presentation and Outcomes of Patients With Giant Cell Arteritis and Isolated Symptomatic Limb Involvement. *J Clin Rheumatol*. 2020 26:248-254
- [77] Sonnenblick M, Neshet G, Rosin A. Nonclassical organ involvement in temporal arteritis. *Semin Arthritis Rheum*. 1989 19:183-90
- [78] Moulis G, Sailler L, Astudillo L, et al. [Pericarditis as the presenting manifestation of giant cell arteritis]. *Rev Med Interne*. 2010 31:46-8
- [79] Norita K, de Noronha SV, Sheppard MN. Sudden cardiac death caused by coronary vasculitis. *Virchows Arch*. 2012 460:309-18
- [80] Lie JT, Failoni DD, Davis DC Jr. Temporal arteritis with giant cell aortitis, coronary arteritis, and myocardial infarction. *Arch Pathol Lab Med*. 1986 110:857-60
- [81] Godoy P, Araújo Sde A, Paulino E Jr, et al. Coronary giant cell arteritis and acute myocardial infarction. *Arq Bras Cardiol*. 2007 88:e84-7
- [82] Lin LW, Wang SS, Shun CT. Myocardial infarction due to giant cell arteritis: a case report and literature review. *Kaohsiung J Med Sci*. 2007 23:195-8
- [83] Mednick Z, Farmer J, Khan Z, et al. Coronary arteritis: An entity to be considered in giant cell arteritis. *Can J Ophthalmol*. 2016 51:e6-8
- [84] Soulages A, Sibon I, Vallat JM, et al. Neurologic manifestations of giant cell arteritis. *J Neurol*. 2022 269:3430-3442
- [85] Prieto-Peña D, Castañeda S, Atienza-Mateo B, et al. A Review of the Dermatological Complications of Giant Cell Arteritis. *Clin Cosmet Investig Dermatol*. 2021 14:303-312
- [86] Chehem Daoud Chehem F, de Mornac D, Feuillet F, et al. Giant cell arteritis associated with scalp, tongue or lip necrosis: A French multicenter case control study. *Semin Arthritis Rheum*. 2024 64:152348
- [87] Yavne Y, Tiosano S, Watad A, et al. Association between giant cell arteritis and thyroid dysfunction in a "real life" population. *Endocrine*. 2017 57:241-246
- [88] Cameselle-Teijeiro J, Caneiro-Gómez J, Ghazzawi A, et al. Giant cell arteritis of the thyroid gland as first evidence of systemic disease. *J Clin Endocrinol Metab*. 2013 98:441-2
- [89] Radhamanohar M. Cranial diabetes insipidus caused by giant cell arteritis. *Postgrad Med J*. 1988 64:947-9
- [90] Tariq S, Jonny S, Asalieh H. Atypical presentation of giant cell arteritis associated with SIADH: a rare association. *BMJ Case Rep*. 2021 14:e246187
- [91] Truong L, Kopelman RG, Williams GS, et al. Temporal arteritis and renal disease. Case report and review of the literature. *Am J Med*. 1985 78:171-5
- [92] Van De Ginste L, Dendooven A, Van Dorpe J, et al. A rare presentation of kidney failure in a patient with giant cell arteritis: case report and review of literature. *Acta Clin Belg*. 2021 76:496-499

- [93] Monteagudo M, Vidal G, Andreu J, et al. Giant cell (temporal) arteritis and secondary renal amyloidosis: report of 2 cases. *J Rheumatol*. 1997 24:605-7
- [94] Kushwaha P, Singh M, Bellichuki P, et al. Giant cell arteritis causing mesenteric ischemia without cranial manifestations: Report of an unusual case. *Indian J Pathol Microbiol*. 2023
- [95] Hernández-Rodríguez J, Tan CD, Rodríguez ER, et al. Single-organ gallbladder vasculitis: characterization and distinction from systemic vasculitis involving the gallbladder. An analysis of 61 patients. *Medicine (Baltimore)*. 2014 93:405-413
- [96] Ren J, Liu J, Su J, et al. Systemic vasculitis involving the breast: a case report and literature review. *Rheumatol Int*. 2019 39:1447-1455
- [97] Hernández-Rodríguez J, Tan CD, Rodríguez ER, et al. Gynecologic vasculitis: an analysis of 163 patients. *Medicine (Baltimore)*. 2009 88:169-181
- [98] Kadotani Y, Enoki Y, Itoi N, et al. Giant cell arteritis of the breast: a case report with a review of literatures. *Breast Cancer*. 2010 17:225-32
- [99] Koster MJ, Yeruva K, Crowson CS, et al. Giant cell arteritis and its mimics: A comparison of three patient cohorts. *Semin Arthritis Rheum*. 2020 50:923-929
- [100] Evangelatos G, Grivas A, Pappa M, et al. Cranial giant cell arteritis mimickers: A masquerade to unveil. *Autoimmun Rev*. 2022 21:103083
- [101] Ramon A, Greigert H, Ornetti P, et al. Mimickers of Large Vessel Giant Cell Arteritis. *J Clin Med*. 2022 11:495
- [102] Roth AM, Milsow L, Keltner JL. The ultimate diagnoses of patients undergoing temporal artery biopsies. *Arch Ophthalmol*. 1984 102:901-3
- [103] Üsküdar Cansu D, Üsküdar Teke H, Korkmaz C. Temporal artery biopsy for suspected giant cell arteritis: a retrospective analysis. *Rheumatol Int*. 2021 41:1803-1810
- [104] Bornstein G, Barshack I, Koren-Morag N, et al. Negative temporal artery biopsy: predictive factors for giant cell arteritis diagnosis and alternate diagnoses of patients without arteritis. *Clin Rheumatol*. 2018 37:2819-2824
- [105] Grossman C, Barshack I, Bornstein G, et al. Is temporal artery biopsy essential in all cases of suspected giant cell arteritis? *Clin Exp Rheumatol*. 2015 33:S-84-9
- [106] Grossman C, Barshack I, Koren-Morag N, et al. Baseline clinical predictors of an ultimate giant cell arteritis diagnosis in patients referred to temporal artery biopsy. *Clin Rheumatol*. 2016 35:1817-22
- [107] Marí B, Monteagudo M, Bustamante E, et al. Analysis of temporal artery biopsies in an 18-year period at a community hospital. *Eur J Intern Med*. 2009 20:533-6
- [108] Breuer GS, Neshet R, Neshet G. Negative temporal artery biopsies: eventual diagnoses and features of patients with biopsy-negative giant cell arteritis compared to patients without arteritis. *Clin Exp Rheumatol*. 2008 26:1103-6

- [109] Gonzalez-Gay MA, Garcia-Porrúa C, Llorca J, et al. Biopsy-negative giant cell arteritis: clinical spectrum and predictive factors for positive temporal artery biopsy. *Semin Arthritis Rheum.* 2001;30:249-56
- [110] Duhaut P, Pinède L, Bornet H, et al. Biopsy proven and biopsy negative temporal arteritis: differences in clinical spectrum at the onset of the disease. *Groupe de Recherche sur l'Artérite à Cellules Géantes. Ann Rheum Dis.* 1999 58:335-41
- [111] Chmelewski WL, McKnight KM, Agudelo CA, et al. Presenting features and outcomes in patients undergoing temporal artery biopsy. A review of 98 patients. *Arch Intern Med.* 1992 152:1690-5
- [112] Oiwa H, Ichimura K, Hosokawa Y, et al. Diagnostic Performance of a Temporal Artery Biopsy for the Diagnosis of Giant Cell Arteritis in Japan-A Single-center Retrospective Cohort Study. *Intern Med.* 2019 58:2451-2458
- [113] Hunder GG, Bloch DA, Michel BA, et al. The American College of Rheumatology 1990 criteria for the classification of giant cell arteritis. *Arthritis Rheum.* 1990 33:1122-8
- [114] Ponte C, Grayson PC, Robson JC, et al. 2022 American College of Rheumatology/EULAR classification criteria for giant cell arteritis. *Ann Rheum Dis.* 2022 81:1647-1653
- [115] Tomelleri A, Dejaco C. New blood biomarkers and imaging for disease stratification and monitoring of giant cell arteritis. *RMD Open.* 2024 10:e003397
- [116] Burja B, Kuret T, Sodin-Semrl S, et al. A concise review of significantly modified serological biomarkers in giant cell arteritis, as detected by different methods. *Autoimmun Rev.* 2018 17:188-194
- [117] Burja B, Feichtinger J, Lakota K, et al. Utility of serological biomarkers for giant cell arteritis in a large cohort of treatment-naïve patients. *Clin Rheumatol.* 2019 38:317-329
- [118] Lie JT. Illustrated histopathologic classification criteria for selected vasculitis syndromes. American College of Rheumatology Subcommittee on Classification of Vasculitis. *Arthritis Rheum.* 1990 33:1074-87
- [119] Liozon F, Catanzano G. [Horton's temporal arteritis. Anatomopathologic study using light microscopy. Apropos of 123 temporal biopsies]. *Rev Med Interne.* 1982 3:295-301
- [120] Taze D, Chakrabarty A, Venkateswaran R, et al. Histopathology reporting of temporal artery biopsy specimens for giant cell arteritis: results of a modified Delphi study. *J Clin Pathol.* 2023 jcp-2023-208810
- [121] Cavazza A, Muratore F, Boiardi L, et al. Inflamed temporal artery: histologic findings in 354 biopsies, with clinical correlations. *Am J Surg Pathol.* 2014 38:1360-70
- [122] Hernández-Rodríguez J, Murgia G, Villar I, Campo E, et al. Description and Validation of Histological Patterns and Proposal of a Dynamic Model of Inflammatory Infiltration in Giant-cell Arteritis. *Medicine (Baltimore).* 2016 95:e2368

- [123] Maleszewski JJ, Younge BR, Fritzlen JT, et al. Clinical and pathological evolution of giant cell arteritis: a prospective study of follow-up temporal artery biopsies in 40 treated patients. *Mod Pathol*. 2017 30:788-796
- [124] Papadakos SP, Papazoglou AS, Moysidis DV, et al. The Effect of Corticosteroids on Temporal Artery Biopsy Positivity in Giant Cell Arteritis: Timing is Everything. *J Clin Rheumatol*. 2023 29:173-176
- [125] Ponich B, Lafreniere AS, Hartley R, et al. Temporal Artery Biopsy Debate: Positive TAB Result Prolongs Steroid Use in Giant Cell Arteritis. *Plast Reconstr Surg Glob Open*. 2022 10:e4652
- [126] Majerovich K, Junek M, Khalidi N, et al. Duration of Steroid Therapy and Temporal Artery Biopsy Positivity in Giant Cell Arteritis: A Retrospective Cohort Study. *J Rheumatol*. 2023 50:965-966
- [127] Jakobsson K, Jakobsson L, Mohammad AJ, et al. The effect of clinical features and glucocorticoids on biopsy findings in giant cell arteritis. *BMC Musculoskelet Disord*. 2016 17:363
- [128] Narváez J, Bernad B, Roig-Vilaseca D, et al. Influence of previous corticosteroid therapy on temporal artery biopsy yield in giant cell arteritis. *Semin Arthritis Rheum*. 2007 37:13-9
- [129] Ray-Chaudhuri N, Kiné DA, Tijani SO, et al. Effect of prior steroid treatment on temporal artery biopsy findings in giant cell arteritis. *Br J Ophthalmol*. 2002 86:530-2
- [130] Sargi C, Ducharme-Benard S, Benard V, et al. Assessment and comparison of probability scores to predict giant cell arteritis. *Clin Rheumatol*. 2024 43:357-365
- [131] Ing EB. Neural network and logistic regression predictive calculator for giant cell arteritis. *Arch Soc Esp Oftalmol (Engl Ed)*. 2019 94:622
- [132] Dvir M, Almhanni G, Qaisar H, et al. When Occipital Artery Biopsy is Preferred to Temporal Biopsy for Giant Cell Arteritis: A Step-By-Step Description of the Surgical Technique. *Mayo Clin Proc Innov Qual Outcomes*. 2024 8:53-57
- [133] De Martino A, Ballestracci P, Faggioni L, et al. Incidence of Aortitis in Surgical Specimens of the Ascending Aorta Clinical Implications at Follow-Up. *Semin Thorac Cardiovasc Surg*. 2019 31:751-760
- [134] Nesi G, Anichini C, Tozzini S, et al. Pathology of the thoracic aorta: a morphologic review of 338 surgical specimens over a 7-year period. *Cardiovasc Pathol*. 2009 18:134-9
- [135] Dejaco C, Ramiro S, Bond M, et al. EULAR recommendations for the use of imaging in large vessel vasculitis in clinical practice: 2023 update. *Ann Rheum Dis*. 2023 ard-2023-224543
- [136] Bosch P, Bond M, Dejaco C, et al. Imaging in diagnosis, monitoring and outcome prediction of large vessel vasculitis: a systematic literature review and meta-analysis informing the 2023 update of the EULAR recommendations. *RMD Open*. 2023 9:e003379

- [137] Horomanski A, Forbess LJ. The Role of Imaging in Diagnosis and Monitoring of Large Vessel Vasculitis. *Rheum Dis Clin North Am.* 2023 49:489-504
- [138] Pouncey AL, Yeldham G, Magan T, et al. Halo sign on temporal artery ultrasound versus temporal artery biopsy for giant cell arteritis. *Cochrane Database Syst Rev.* 2024 2:CD013199
- [139] Ludwig DR, Vöö S, Morris V. Fast-track pathway for early diagnosis and management of giant cell arteritis: the combined role of vascular ultrasonography and [18F]-fluorodeoxyglucose PET-computed tomography imaging. *Nucl Med Commun.* 2023 44:339-344
- [140] van Nieuwland M, Colin EM, Boumans D, et al. Diagnostic delay in patients with giant cell arteritis: results of a fast-track clinic. *Clin Rheumatol.* 2024 43:349-355
- [141] Melville AR, Donaldson K, Dale J, et al. Validation of the Southend giant cell arteritis probability score in a Scottish single-centre fast-track pathway. *Rheumatol Adv Pract.* 2021 6:rkab102
- [142] Oshinsky C, Bays AM, Sacksen I, et al. Vascular Ultrasound for Giant Cell Arteritis: Establishing a Protocol Using Vascular Sonographers in a Fast-Track Clinic in the United States. *ACR Open Rheumatol.* 2022 4:13-18
- [143] Berthod PE, Aho-Glélé S, Ornetti P, et al. CT analysis of the aorta in giant-cell arteritis: a case-control study. *Eur Radiol.* 2018 28:3676-3684
- [144] Froehlich M, Guggenberger KV, Vogt M, et al. MRVAS Score-introducing a standardized magnetic resonance scoring system for assessing the extent of inflammatory burden in giant cell arteritis. *Rheumatology (Oxford).* 2024 keae056
- [145] El Haddad J, Charbonneau F, Guillaume J, et al. Reproducibility and accuracy of vessel wall MRI in diagnosing giant cell arteritis: a study with readers of varying expertise. *Eur Radiol.* 2024
- [146] Brittain JM, Hansen MS, Carlsen JF, et al. Multimodality Imaging in Cranial Giant Cell Arteritis: First Experience with High-Resolution T1-Weighted 3D Black Blood without Contrast Enhancement Magnetic Resonance Imaging. *Diagnostics (Basel).* 2023 14:81
- [147] Guggenberger KV, Vogt ML, Song JW, et al. High-resolution Magnetic Resonance Imaging visualizes intracranial large artery involvement in Giant Cell Arteritis. *Rheumatology (Oxford).* 2024 keae010
- [148] Guggenberger KV, Pavlou A, Cao Q, et al. Orbital magnetic resonance imaging of giant cell arteritis with ocular manifestations: a systematic review and individual participant data meta-analysis. *Eur Radiol.* 2023 33:7913-7922
- [149] Danyel LA, Mischczuk M, Pietrock C, et al. Utility of standard diffusion-weighted magnetic resonance imaging for the identification of ischemic optic neuropathy in giant cell arteritis. *Sci Rep.* 2022 12:16553

- [150] Tomoyose R, Miyata T, Shiraishi W, et al. Gadolinium-enhanced MR improved motion sensitized driven equilibrium (iMSDE) for intracranial vessel imaging in giant cell arteritis. *J Stroke Cerebrovasc Dis.* 2022 31:106697
- [151] Rodriguez-Régent C, Ben Hassen W, Seners P, et al. 3D T1-weighted black-blood magnetic resonance imaging for the diagnosis of giant cell arteritis. *Clin Exp Rheumatol.* 2020 124:95-98
- [152] Blockmans D, de Ceuninck L, Vanderschueren S, et al. Repetitive 18-F-fluorodeoxyglucose positron emission tomography in giant cell arteritis: a prospective study of 35 patients. *Arthritis Rheum.* 2006 55:131-7
- [153] Prieto-Gonzalez S, Depetris M, Garcia-Martinez A, et al. Positron emission tomography assessment of large vessel inflammation in patients with newly-diagnosed, biopsyproven giant cell arteritis: a prospective, case-control study. *Ann Rheum Dis.* 2014 73:1388-92
- [154] Besson FL, Parienti JJ, Bienvenu B, et al. Diagnostic performance of 18F-fluorodeoxyglucose positron emission tomography in giant cell arteritis: a systematic review and meta-analysis. *Eur J Nucl Med Mol Imaging* 2011 38:1764-72
- [155] Soussan M, Nicolas P, Schramm C, et al. Management of large-vessel vasculitis with FDG-PET: a systematic literature review and meta-analysis. *Medicine* 2015 94:e622
- [156] Bacour YAA, van Kanten MP, Smit F, et al. Development of a simple standardized scoring system for assessing large vessel vasculitis by 18F-FDG PET-CT and differentiation from atherosclerosis. *Eur J Nucl Med Mol Imaging.* 2023 50:2647-2655
- [157] Giordano M, Valentini G, Vatti M, et al. Les critères diagnostiques pour la maladie de Horton. *Rhumatologie* 1980 8:97-200
- [158] Narváez J, Estrada P, Vidal-Montal P, et al. Performance of the new 2022 ACR/EULAR classification criteria for giant cell arteritis in clinical practice in relation to its clinical phenotypes. *Autoimmun Rev.* 2023 22:103413
- [159] Molina-Collada J, Castrejón I, Monjo I, et al. Performance of the 2022 ACR/EULAR giant cell arteritis classification criteria for diagnosis in patients with suspected giant cell arteritis in routine clinical care. *RMD Open.* 2023 9:e002970
- [160] van Nieuwland M, van Bon L, Vermeer M, et al. External validation of the 2022 ACR/EULAR classification criteria in patients with suspected giant cell arteritis in a Dutch fast-track clinic. *RMD Open.* 2023 9:e003080
- [161] Andel PM, Diamantopoulos AP, Myklebust G, et al. Vasculitis distribution and clinical characteristics in giant cell arteritis: a retrospective study using the new 2022 ACR/EULAR classification criteria. *Front Med (Lausanne).* 2023 10:1286601
- [162] Tomelleri A, Padoan R, Kavadichanda CG, et al. Validation of the 2022 American College of Rheumatology/EULAR classification criteria for Takayasu arteritis. *Rheumatology (Oxford).* 2023 62:3427-3432

- [163] Foré R, Liozon E, Dumonteil S, et al. BOB-ACG study: Pulse methylprednisolone to prevent bilateral ophthalmologic damage in giant cell arteritis. A multicentre retrospective study with propensity score analysis. *Joint Bone Spine*. 2024 91:105641
- [164] Moreel L, Betraíns A, Molenberghs G, et al. Duration of Treatment With Glucocorticoids in Giant Cell Arteritis: A Systematic Review and Meta-analysis. *J Clin Rheumatol*. 2023 29:291-297
- [165] Maz M, Chung SA, Abril A, et al. 2021 American College of Rheumatology/Vasculitis Foundation Guideline for the Management of Giant Cell Arteritis and Takayasu Arteritis. *Arthritis Rheumatol*. 2021 73:1349-1365
- [166] Hellmich B, Agueda A, Monti S, et al. 2018 Update of the EULAR recommendations for the management of large vessel vasculitis. *Ann Rheum Dis*. 2020 79:19-30
- [167] Neshet G, Berkun Y, Mates M, et al. Low-dose aspirin and prevention of cranial ischemic complications in giant cell arteritis. *Arthritis Rheum*. 2004 50:1332-7
- [168] Lee MS, Smith SD, Galor A, et al. Antiplatelet and anticoagulant therapy in patients with giant cell arteritis. *Arthritis Rheum*. 2006 54:3306-9
- [169] Weyand CM, Kaiser M, Yang H, et al. Therapeutic effects of acetylsalicylic acid in giant cell arteritis. *Arthritis Rheum*. 2002 46:457-66
- [170] González-Gay MA, Blanco R, Rodríguez-Valverde V, et al. Permanent visual loss and cerebrovascular accidents in giant cell arteritis: predictors and response to treatment. *Arthritis Rheum*. 1998 41:1497-504
- [171] Salvarani C, Cimino L, Macchioni P, et al. Risk factors for visual loss in an Italian population-based cohort of patients with giant cell arteritis. *Arthritis Rheum*. 2005 53:293-7
- [172] Mackie SL, Dasgupta B, Hordon L, et al. Ischaemic manifestations in giant cell arteritis are associated with area level socio-economic deprivation, but not cardiovascular risk factors. *Rheumatology (Oxford)*. 2011 50:2014-22
- [173] Unizony S, Arias-Urdaneta L, Miloslavsky E, et al. Tocilizumab for the treatment of large-vessel vasculitis (giant cell arteritis, Takayasu arteritis) and polymyalgia rheumatica. *Arthritis Care Res (Hoboken)*. 2012 64:1720-9
- [174] Villiger PM, Adler S, Kuchen S, et al. Tocilizumab for induction and maintenance of remission in giant cell arteritis: a phase 2, randomised, double-blind, placebo-controlled trial. *Lancet*. 2016 387:1921-7
- [175] Stone JH, Tuckwell K, Dimonaco S, et al. Trial of Tocilizumab in Giant-Cell Arteritis. *N Engl J Med*. 2017 377:317-328
- [176] Adler S, Reichenbach S, Gloor A, et al. Risk of relapse after discontinuation of tocilizumab therapy in giant cell arteritis. *Rheumatology (Oxford)*. 2019 58:1639-1643

- [177] Stone JH, Han J, Aringer M, et al. Long-term effect of tocilizumab in patients with giant cell arteritis: open-label extension phase of the Giant Cell Arteritis Actemra (GiACTA) trial. *Lancet Rheumatol*. 2021 3:e328-e336
- [178] Stone JH, Spotswood H, Unizony SH, et al. New-onset versus relapsing giant cell arteritis treated with tocilizumab: 3-year results from a randomized controlled trial and extension. *Rheumatology (Oxford)*. 2022 61:2915-2922
- [179] Matza MA, Dagingcourt N, Mohan SV, et al. Outcomes during and after long-term tocilizumab treatment in patients with giant cell arteritis. *RMD Open*. 2023 9:e002923
- [180] Quick V, Abusalameh M, Ahmed S, et al. Relapse after cessation of weekly tocilizumab for giant cell arteritis: a multicentre service evaluation in England. *Rheumatology (Oxford)*. 2023 kead604
- [181] Samec MJ, Rakholiya J, Langenfeld H, et al. Relapse Risk and Safety of Long-Term Tocilizumab Use Among Patients With Giant Cell Arteritis: A Single-Enterprise Cohort Study. *J Rheumatol*. 2023 50:1310-1317
- [182] Calderón-Goercke M, Loricera J, Moriano C, et al. Tocilizumab in Giant Cell Arteritis Spanish Collaborative Group. Optimisation of tocilizumab therapy in giant cell arteritis. A multicentre real-life study of 471 patients. *Clin Exp Rheumatol*. 2023 41:829-836
- [183] Tomelleri A, Campochiaro C, Farina N, et al. Effectiveness of a two-year tapered course of tocilizumab in patients with giant cell arteritis: A single-centre prospective study. *Semin Arthritis Rheum*. 2023 59:152174
- [184] Saito S, Okuyama A, Okada Y, et al. Tocilizumab monotherapy for large vessel vasculitis: results of 104-week treatment of a prospective, single-centre, open study. *Rheumatology (Oxford)*. 2020 59:1617-1621
- [185] Christ L, Seitz L, Scholz G, et al. Tocilizumab monotherapy after ultra-short glucocorticoid administration in giant cell arteritis: a single-arm, open-label, proof-of-concept study. *Lancet Rheumatol*. 2021 3:e619-e626
- [186] Unizony S, Matza MA, Jarvie A, et al. Treatment for giant cell arteritis with 8 weeks of prednisone in combination with tocilizumab: a single-arm, open-label, proof-of-concept study. *Lancet Rheumatol*. 2023 5:e736-e742
- [187] Muratore F, Marvisi C, Cassone G, et al. Treatment of giant cell arteritis with ultra-short glucocorticoids and tocilizumab: the role of imaging in a prospective observational study. *Rheumatology (Oxford)*. 2024 63:64-71
- [188] Jover JA, Hernández-García C, Morado IC, et al. Combined treatment of giant-cell arteritis with methotrexate and prednisone. a randomized, double-blind, placebo-controlled trial. *Ann Intern Med*. 2001 134:106-14

- [189] Hoffman GS, Cid MC, Hellmann DB, et al. A multicenter, randomized, double-blind, placebo-controlled trial of adjuvant methotrexate treatment for giant cell arteritis. *Arthritis Rheum.* 2002 46:1309-18
- [190] Mahr AD, Jover JA, Spiera RF, et al. Adjunctive methotrexate for treatment of giant cell arteritis: an individual patient data meta-analysis. *Arthritis Rheum.* 2007 56:2789-97
- [191] Leon L, Rodriguez-Rodriguez L, Morado I, et al. Treatment with methotrexate and risk of relapses in patients with giant cell arteritis in clinical practice. *Clin Exp Rheumatol.* 2018 Suppl 111:121-128
- [192] Koster MJ, Yeruva K, Crowson CS, et al. Efficacy of Methotrexate in Real-world Management of Giant Cell Arteritis: A Case-control Study. *J Rheumatol.* 2019 46:501-508
- [193] Grazzini S, Conticini E, Falsetti P, et al. Tocilizumab Vs Methotrexate in a Cohort of Patients Affected by Active GCA: A Comparative Clinical and Ultrasonographic Study. *Biologics.* 2023 17:151-160
- [194] Schmidt WA, Dasgupta B, Sloane J, et al. A phase 3 randomized, double-blind, placebo-controlled study to evaluate the efficacy and safety of sarilumab in patients with giant cell arteritis. *Arthritis Res Ther.* 2023 25:199
- [195] Venhoff N, Schmidt WA, Bergner R, et al. Safety and efficacy of secukinumab in patients with giant cell arteritis (TitAIN): a randomised, double-blind, placebo-controlled, phase 2 trial. *Lancet Rheumatol.* 2023 5:e341-e350
- [196] Conway R, O'Neill L, Gallagher P, et al. Ustekinumab for refractory giant cell arteritis: A prospective 52-week trial. *Semin Arthritis Rheum.* 2018 48:523-528
- [197] Ly KH, Stirnemann J, Liozon E, et al. Interleukin-1 blockade in refractory giant cell arteritis. *Joint Bone Spine.* 2014 81:76-8
- [198] Hoffman GS, Cid MC, Rendt-Zagar KE, et al. Infliximab for maintenance of glucocorticosteroid-induced remission of giant cell arteritis: a randomized trial. *Ann Intern Med.* 2007 146:621-30
- [199] Seror R, Baron G, Hachulla E, et al. Adalimumab for steroid sparing in patients with giant-cell arteritis: results of a multicentre randomised controlled trial. *Ann Rheum Dis.* 2014 73:2074-81
- [200] Koster MJ, Crowson CS, Giblon RE, et al. Baricitinib for relapsing giant cell arteritis: a prospective open-label 52-week pilot study. *Ann Rheum Dis.* 2022 81:861-867
- [201] Cid MC, Unizony SH, Blockmans D, et al. Efficacy and safety of mavrilimumab in giant cell arteritis: a phase 2, randomised, double-blind, placebo-controlled trial. *Ann Rheum Dis.* 2022 81:653-661
- [202] de Boysson H, Boutemy J, Creveuil C, et al. Is there a place for cyclophosphamide in the treatment of giant-cell arteritis? A case series and systematic review. *Semin Arthritis Rheum.* 2013 43:105-12

- [203] Pankow A, Sinno S, Derlin T, et al. Mycophenolate mofetil in giant cell arteritis. *Front Med (Lausanne)*. 2023 10:1254747
- [204] Boureau AS, de Faucal P, Espitia O, et al. [Place of azathioprine in the treatment of giant cell arteritis]. *Rev Med Interne*. 2016 37:723-729
- [205] Schaufelberger C, Möllby H, Uddhammar A, et al. No additional steroid-sparing effect of cyclosporine A in giant cell arteritis. *Scand J Rheumatol*. 2006 35:327-9
- [206] Adizie T, Christidis D, Dharmapaliah C, et al. Efficacy and tolerability of leflunomide in difficult-to-treat polymyalgia rheumatica and giant cell arteritis: a case series. *Int J Clin Pract*. 2012 66:906-9
- [207] Diamantopoulos AP, Hetland H, Myklebust G. Leflunomide as a corticosteroid-sparing agent in giant cell arteritis and polymyalgia rheumatica: a case series. *Biomed Res Int*. 2013 2013:120638
- [208] Hočevár A, Ješe R, Rotar Ž, et al. Does leflunomide have a role in giant cell arteritis? An open-label study. *Clin. Rheumatol*. 2019 38:291–296
- [209] Ly KH, Dalmay F, Gondran G, et al. Steroid-sparing effect and toxicity of dapsone treatment in giant cell arteritis: A single-center, retrospective study of 70 patients. *Medicine (Baltimore)*. 2016 95:e4974
- [210] Moreel L, Betrains A, Molenberghs G, et al. Epidemiology and predictors of relapse in giant cell arteritis: A systematic review and meta-analysis. *Joint Bone Spine*. 2023 90:105494
- [211] Salvarani C, Crowson CS, O'Fallon WM, et al. Reappraisal of the epidemiology of giant cell arteritis in Olmsted County, Minnesota, over a fifty-year period. *Arthritis Rheum*. 2004 51:264-8
- [212] Nordborg E, Bengtsson BA. Death rates and causes of death in 284 consecutive patients with giant cell arteritis confirmed by biopsy. *BMJ*. 1989 299:549-50
- [213] Matteson EL, Gold KN, Bloch DA, et al. Long-term survival of patients with giant cell arteritis in the American College of Rheumatology giant cell arteritis classification criteria cohort. *Am J Med*. 1996 100:193-6
- [214] González-Gay MA, Blanco R, Abreira V, et al. Giant cell arteritis in Lugo, Spain, is associated with low longterm mortality. *J Rheumatol*. 1997 24:2171-6
- [215] Mohan SV, Liao YJ, Kim JW, et al. Giant cell arteritis: immune and vascular aging as disease risk factors. *Arthritis Res Ther*. 2011 13:231
- [216] Kemp A. Monozygotic twins with temporal arteritis and ophthalmic arteritis. *Acta Ophthalmol (Copenh)*. 1977 55:183-90
- [217] Liozon E, Ouattara B, Rhaïem K, et al. Familial aggregation in giant cell arteritis and polymyalgia rheumatica: a comprehensive literature review including 4 new families. *Clin Exp Rheumatol*. 2009 27:S89-94

- [218] Fietta P, Manganelli P, Zanetti A, et al. Familial giant cell arteritis and polymyalgia rheumatica: aggregation in 2 families. *J Rheumatol.* 2002 29:1551-5
- [219] Barešić M, Šimunić L, Šukara G, et al. Two sisters with one disease: Giant cell arteritis within one family. *Arch Rheumatol.* 2023 38:662-664
- [220] Hayreh SS. Familial giant cell arteritis. *BMJ Case Rep.* 2021 14:e243304
- [221] Thomsen H, Li X, Sundquist K, et al. Familial risks between giant cell arteritis and Takayasu arteritis and other autoimmune diseases in the population of Sweden. *Sci Rep.* 2020 10:20887
- [222] Palamidis DA, Chatzis L, Papadaki M, et al. Current Insights into Tissue Injury of Giant Cell Arteritis: From Acute Inflammatory Responses towards Inappropriate Tissue Remodeling. *Cells.* 2024 13:430
- [223] Cid MC, Ercilla G, Vilaseca J, et al. Polymyalgia rheumatica: A syndrome associated with HLA-DR4 antigen. *Arthritis Rheum.* 1988 31:678–682
- [224] Combe B, Sany J, Le Quellec A, et al. Distribution of HLA-DRB1 alleles of patients with polymyalgia rheumatica and giant cell arteritis in a Mediterranean population. *J. Rheumatol.* 1998 25:94-98
- [225] Jacobsen S, Baslund B, Madsen HO, et al. Mannose-binding lectin variant alleles and HLA-DR4 alleles are associated with giant cell arteritis. *J. Rheumatol.* 2002 29:2148–2153
- [226] Martínez-Taboda VM, Bartolome MJ, Lopez-Hoyos M, et al. HLA-DRB1 allele distribution in polymyalgia rheumatica and giant cell arteritis: Influence on clinical subgroups and prognosis. *Semin. Arthritis Rheum.* 2004 34:454-464
- [227] Rauzy O, Fort M, Nourhashemi F, et al. Relation between HLA DRB1 alleles and corticosteroid resistance in giant cell arteritis. *Ann. Rheum. Dis.* 1998 57:380–382
- [228] Richardson JE, Gladman DD, Fam A, et al. HLA-DR4 in giant cell arteritis: Association with polymyalgia rheumatica syndrome. *Arthritis Rheum.* 1987 30:1293–1297
- [229] Salvarani C, Macchioni P, Zizzi F, et al. Epidemiologic and immunogenetic aspects of polymyalgia rheumatica and giant cell arteritis in northern Italy. *Arthritis Rheum.* 1991 34:351–356
- [230] Weyand CM, Hicok KC, Hunder GG, et al. The HLA-DRB1 locus as a genetic component in giant cell arteritis. Mapping of a disease-linked sequence motif to the antigen binding site of the HLA-DR molecule. *J. Clin. Investig.* 1992 90:2355–2361
- [231] Weyand CM, Hunder NN, Hicok KC, et al. HLA-DRB1 alleles in polymyalgia rheumatica, giant cell arteritis, and rheumatoid arthritis. *Arthritis Rheum.* 1994 37:514-20
- [232] Dababneh A, Gonzalez-Gay MA, Garcia-Porrúa C, et al. Giant cell arteritis and polymyalgia rheumatica can be differentiated by distinct patterns of HLA class II association. *J. Rheumatol.* 1998 25:2140–2145

- [233] Mackie SL, Taylor JC, Haroon-Rashid L, et al. Association of HLA-DRB1 amino acid residues with giant cell arteritis: genetic association study, meta-analysis and geo-epidemiological investigation. *Arthritis Res Ther*. 2015 17:195
- [234] Prieto-Peña D, Remuzgo-Martínez S, Ocejó-Vinyals JG, et al. The presence of both HLA-DRB1*04:01 and HLA-B*15:01 increases the susceptibility to cranial and extracranial giant cell arteritis. *Clin Exp Rheumatol*. 2021 Suppl 129:21-26
- [235] Kushimoto K, Ayano M, Nishimura K, et al. HLA-B52 allele in giant cell arteritis may indicate diffuse large-vessel vasculitis formation: a retrospective study. *Arthritis Res Ther*. 2021 23:238
- [236] Rodríguez-Pla A, Beaty TH, Savino PJ, et al. Association of a nonsynonymous single-nucleotide polymorphism of matrix metalloproteinase 9 with giant cell arteritis. *Arthritis Rheum*. 2008 58 :1849–1853
- [237] Salvarani C, Casali B, Boiardi L, et al. Intercellular adhesion molecule 1 gene polymorphisms in polymyalgia rheumatica/giant cell arteritis: Association with disease risk and severity. *J Rheumatol*. 2000 27:1215–1221
- [238] Amoli MM, Shelley E, Matthey DL, et al. Lack of association between intercellular adhesion molecule-1 gene polymorphisms and giant cell arteritis. *J Rheumatol*. 2001 28 :1600–1604
- [239] Carmona FD, Mackie SL, Martín JE, et al. A large-scale genetic analysis reveals a strong contribution of the HLA class II region to giant cell arteritis susceptibility. *Am J Hum Genet*. 2015 96:565-80
- [240] Carmona FD, Martín J, González-Gay MA. Genetics of vasculitis. *Curr Opin Rheumatol*. 2015 27:10–17
- [241] Carmona, FD, Vaglio A, Mackie SL, et al. A Genome-wide Association Study Identifies Risk Alleles in Plasminogen and P4HA2 Associated with Giant Cell Arteritis. *Am J Hum Genet*. 2017 100:64–74
- [242] Carmona FD, Coit P, Saruhan-Direskeneli G, et al. Analysis of the common genetic component of large-vessel vasculitides through a metalmmunochip strategy. *Sci Rep*. 2017 7:43953
- [243] Wen Z, Shimojima Y, Shirai T, et al. NADPH Oxidase Deficiency Underlies Dysfunction of Aged CD8+ Tregs. *J Clin Invest*. 2016 126:1953–67
- [244] Coit P, De Lott LB, Nan B, et al. DNA methylation analysis of the temporal artery microenvironment in giant cell arteritis. *Ann Rheum Dis*. 2016 75:1196-202
- [245] Ly KH, Régent A, Tamby MC, et al. Pathogenesis of giant cell arteritis: More than just an inflammatory condition? *Autoimmun Rev*. 2010 9:635-45
- [246] Takeda K, Kaisho T, Akira S. Toll-like receptors. *Annu Rev Immunol*. 2003 21:335–76
- [247] Pryshchep O, Ma-Krupa W, Younge BR, et al. Vessel specific Toll-like receptor profiles in human medium and large arteries. *Circulation*. 2008 118:1276–84.

- [248] Kønig EB, Stormly Hansen M, Foldager J, et al. Seasonal variation in biopsy-proven giant cell arteritis in Eastern Denmark from 1990-2018. *Acta Ophthalmol.* 2021 99:527-532
- [249] Gokoffski KK, Chatterjee A, Khaderi SK. Seasonal incidence of biopsy-proven giant cell arteritis: a 20-year retrospective study of the University of California Davis Medical System. *Clin Exp Rheumatol.* 2019 Suppl 117:90-97
- [250] Bas-Lando M, Breuer GS, Berkun Y, et al. The incidence of giant cell arteritis in Jerusalem over a 25-year period: annual and seasonal fluctuations. *Clin Exp Rheumatol.* 2007 25:S15-7.
- [251] Ramassamy A, Roblot P, Texereau M, et al. [Seasonal factor and Horton's disease]. *Rev Med Interne.* 1998 19:71-2
- [252] Petursdottir V, Johansson H, Nordborg E, et al. The epidemiology of biopsy-positive giant cell arteritis: special reference to cyclic fluctuations. *Rheumatology (Oxford).* 1999 38:1208-12
- [253] Duhaut P, Pinède L, Bornet H, et al. Biopsy proven and biopsy negative temporal arteritis: differences in clinical spectrum at the onset of the disease. *Groupe de Recherche sur l'Artérite à Cellules Géantes. Ann Rheum Dis.* 1999 58:335-41
- [254] Narváez J, Clavaguera MT, Nolla-Solé JM, et al. Lack of association between infection and onset of polymyalgia rheumatica. *J Rheumatol.* 2000 27:953-7
- [255] Liozon E, Loustaud V, Vidal E. [Seasonal incidence of Horton's disease: what to conclude?]. *Rev Med Interne.* 1999 20:372-3
- [256] Raynaud JP, Bloch DA, Fries JF. Seasonal variation in the onset of Wegener's granulomatosis, polyarteritis nodosa and giant cell arteritis. *J Rheumatol.* 1993 20:1524-6
- [257] Wladis EJ, Ata A, Li C, et al. The impact of month and season on the incidence of giant cell arteritis: an Intelligent Research in Sight (IRIS) Registry analysis. *Graefes Arch Clin Exp Ophthalmol.* 2024 262:609-614.
- [258] Hysa E, Sobrero A, Camellino D, et al. A seasonal pattern in the onset of polymyalgia rheumatica and giant cell arteritis? A systematic review and meta-analysis. *Semin Arthritis Rheum.* 2020 Oct;50(5):1131-1139.
- [259] De Smit E, Clarke L, Sanfilippo PG, et al. Geo-epidemiology of temporal artery biopsy-positive giant cell arteritis in Australia and New Zealand: is there a seasonal influence? *RMD Open.* 2017 3:e000531
- [260] Kizza K, Murchison AP, Dai Y, et al. Giant cell arteritis incidence: analysis by season and year in mid-Atlantic United States. *Clin Exp Ophthalmol.* 2013 41:577-81
- [261] Powers JF, Bedri S, Hussein S, et al. High prevalence of herpes simplex virus DNA in temporal arteritis biopsy specimens. *Am J Clin Pathol.* 2005 123:261-4
- [262] Nordborg C, Nordborg E, Petursdottir V, et al. Search for varicella zoster virus in giant cell arteritis. *Ann Neurol* 1998. 44:413-4

- [263] Duhaut P, Bosshard S, Calvet A, et al. Giant cell arteritis, polymyalgia rheumatica, and viral hypotheses: a multicenter, prospective case-control study. *J Rheumatol*. 1999 26:361–9
- [264] Helweg-Larsen J, Tarp B, Obel N, et al. No evidence of parvovirus B19, Chlamydia pneumoniae or human herpes virus infection in temporal artery biopsies in patients with giant cell arteritis. *Rheumatology (Oxford)*. 2002 41:445–9
- [265] Rodriguez-Pla A, Bosch-Gil JA, Echevarria-Mayo JE, et al. No detection of parvovirus B19 or herpesvirus DNA in giant cell arteritis. *J Clin Virol*. 2004 31:11–5
- [266] Cankovic M, Zarbo RJ. Failure to detect human herpes simplex virus, cytomegalovirus, and Epstein-Barr virus viral genomes in giant cell arteritis biopsy specimens by real-time quantitative polymerase chain reaction. *Cardiovasc Pathol*. 2006 15:280–6
- [267] Cooper RJ, D'Arcy S, Kirby M, et al. Infection and temporal arteritis: a PCR-based study to detect pathogens in temporal artery biopsy specimens. *J Med Virol*. 2008 80:501–5
- [268] Gilden D, White T, Boyer PJ, et al. Varicella Zoster Virus Infection in Granulomatous Arteritis of the Aorta. *J Infect Dis*. 2016 213:1866-71
- [269] Gilden D, White T, Khmeleva N, et al. Prevalence and distribution of VZV in temporal arteries of patients with giant cell arteritis. *Neurology*. 2015 84:1948-55
- [270] Kennedy PG, Grinfeld E, Esiri MM. Absence of detection of varicella-zoster virus DNA in temporal artery biopsies obtained from patients with giant cell arteritis. *J Neurol Sci*. 2003 215:27-9
- [271] Alvarez-Lafuente R, Fernandez-Gutierrez B, Jover JA, et al. Human parvovirus B19, varicella zoster virus, and human herpes virus 6 in temporal artery biopsy specimens of patients with giant cell arteritis: analysis with quantitative real time polymerase chain reaction. *Ann Rheum Dis*. 2005 64:780–2
- [272] Muratore F, Croci S, Tamagnini I, et al. No detection of varicella-zoster virus in temporal arteries of patients with giant cell arteritis. *Semin Arthritis Rheum*. 2017 47:235-240
- [273] Fest T, Mouglin C, Dupond JL. Giant cell arteritis. *Ann Intern Med*. 1996 124:927–8
- [274] Gabriel SE, Espy M, Erdman DD, et al. The role of parvovirus B19 in the pathogenesis of giant cell arteritis: a preliminary evaluation. *Arthritis Rheum*. 1999 42:1255–8
- [275] Wagner AD, Gerard HC, Fresemann T, et al. Detection of Chlamydia pneumoniae in giant cell vasculitis and correlation with the topographic arrangement of tissue-infiltrating dendritic cells. *Arthritis Rheum*. 2000 43:1543–51
- [276] Haugeberg G, Bie R, Nordbo SA. Chlamydia pneumoniae not detected in temporal artery biopsies from patients with temporal arteritis. *Scand J Rheumatol*. 2000 29:127–8
- [277] Regan MJ, Wood BJ, Hsieh YH, et al. Temporal arteritis and Chlamydia pneumoniae: failure to detect the organism by polymerase chain reaction in ninety cases and ninety controls. *Arthritis Rheum*. 2002 46:1056–60

- [278] Njau F, Ness T, Wittkop U, et al. No correlation between giant cell arteritis and Chlamydia pneumoniae infection: investigation of 189 patients by standard and improved PCR methods. *J Clin Microbiol.* 2009 47:1899–901
- [279] Weyand CM, Goronzy JJ. Immunology of Giant Cell Arteritis. *Circ Res.* 2023 132:238-250
- [280] Mettler C, Terrier B, Treluyer JM, et al. Risk of systemic vasculitis following mRNA COVID-19 vaccination: a pharmacovigilance study. *Rheumatology (Oxford).* 2022 61:e363-e365
- [281] Mettler C, Jonville-Bera AP, Grandvuillemin A, et al. Risk of giant cell arteritis and polymyalgia rheumatica following COVID-19 vaccination: a global pharmacovigilance study. *Rheumatology (Oxford).* 2022 61:865-867
- [283] Régnier P, Le Joncour A, Maciejewski-Duval A, et al. CTLA-4 Pathway Is Instrumental in Giant Cell Arteritis. *Circ Res.* 2023 133:298-312
- [284] Mettler C, Chouchana L, Terrier B. Antineoplastic Drug-induced Aortitis: An Unraveled Adverse Effect Using the World Health Organization Pharmacovigilance Database. *J Rheumatol.* 2020 47:1298-1300
- [285] Roy AK, Tathireddy HR, Roy M. Aftermath of induced inflammation: acute periaortitis due to nivolumab therapy. *Case Rep.* 2017 2017:bcr-2017-221852
- [286] Loricera J, Hernández JL, García-Castaño A, et al. Subclinical aortitis after starting nivolumab in a patient with metastatic melanoma. A case of drug-associated aortitis? *Clin Exp Rheumatol.* 2018 Suppl 111:171
- [287] Khan M, Talpur AS, Abboud Leon C. A Rare Case of Giant Cell Arteritis After the Administration of Checkpoint Inhibitor Therapy in a Metastatic Renal Cell Carcinoma Patient. *Cureus.* 2023 15:e50121
- [288] Parodis I, Dani L, Notarnicola A, et al. G-CSF-induced aortitis: two cases and review of the literature. *Autoimmun Rev.* 2019 18:615-20
- [289] Lardieri A, McCulley L, Jones SC, et al. Granulocyte colony-stimulating factors and aortitis: a rare adverse event. *Am J Hematol.* 2018 93:E333-6
- [290] Oshima Y, Takahashi S, Tani K, et al. Granulocyte colony stimulating factor-associated aortitis in the Japanese Adverse Drug Event Report database. *Cytokine* 2019 119:47-51
- [291] Bidhendi Yarandi R, Panahi MH. Is granulocyte colony-stimulating factor associated with development of aortitis? *Cytokine.* 2019 120:191
- [292] Régent A, Ly KH, Mouthon L. [Physiopathology of giant cell arteritis: From inflammation to vascular remodeling]. *Presse Med.* 2019 48:919-930
- [293] Ly KH, Liozon E, Fauchais AL, et al. [Pathophysiology of giant cell arteritis]. *Rev Med Interne.* 2013 34:392-402

- [294] Greigert H, Genet C, Ramon A, et al. New Insights into the Pathogenesis of Giant Cell Arteritis: Mechanisms Involved in Maintaining Vascular Inflammation. *J Clin Med*. 2022 11:2905
- [295] Bassler K, Schulte-Schrepping J, Warnat-Herresthal S, et al. The Myeloid Cell Compartment-Cell by Cell. *Annu Rev Immunol*. 2019 37:269–293.
- [296] Boettcher S, Manz MG. Regulation of Inflammation- and Infection-Driven Hematopoiesis. *Trends Immunol*. 2017 38:345–357.
- [297] Gregersen I, Sandanger Ø, Askevold ET, et al. Interleukin 27 is increased in carotid atherosclerosis and promotes NLRP3 inflammasome activation. *PLoS One*. 2017 12:e0188387
- [298] Peshkova IO, Aghayev T, Fatkhullina AR, et al. IL-27 receptor-regulated stress myelopoiesis drives abdominal aortic aneurysm development. *Nat Commun*. 2019 10:5046
- [299] van Sleen Y, Graver JC, Abdulhad WH, et al. Leukocyte Dynamics Reveal a Persistent Myeloid Dominance in Giant Cell Arteritis and Polymyalgia Rheumatica. *Front Immunol*. 2019 10:1981
- [300] Palamidis DA, Argyropoulou OD, Georgantzoglou N, et al. Neutrophil extracellular traps in giant cell arteritis biopsies: presentation, localization and co-expression with inflammatory cytokines. *Rheumatology (Oxford)*. 2022 61:1639–1644
- [301] Narasimhan PB, Marcovecchio P, Hamers AAJ, et al. Nonclassical Monocytes in Health and Disease. *Annu Rev Immunol*. 2019 37:439–456
- [302] Watanabe R, Maeda T, Zhang H, et al. MMP (Matrix Metalloprotease)-9-Producing Monocytes Enable T Cells to Invade the Vessel Wall and Cause Vasculitis. *Circ Res*. 2018 123:700–715
- [303] Watanabe R, Hilhorst M, Zhang H, et al. Glucose metabolism controls disease-specific signatures of macrophage effector functions. *JCI Insight*. 2018 3:e123047
- [304] Piggott K, Deng J, Warrington K, et al. Blocking the NOTCH pathway inhibits vascular inflammation in large-vessel vasculitis. *Circulation*. 2011 123:309–318
- [305] Wen Z, Shen Y, Berry G, et al. The microvascular niche instructs T cells in large vessel vasculitis via the VEGF-Jagged1-Notch pathway. *Sci Transl Med*. 2017 9:eaal3322
- [306] Jin K, Wen Z, Wu B, et al. NOTCH-induced rerouting of endosomal trafficking disables regulatory T cells in vasculitis. *J Clin Invest*. 2021 131:e136042
- [307] Stenmark KR, Yeager ME, El Kasmi KC, et al. The adventitia: essential regulator of vascular wall structure and function. *Annu Rev Physiol*. 2013 75:23-47
- [308] Wagner AD, Bjornsson J, Bartley GB, et al. Interferon-gamma-producing T cells in giant cell vasculitis represent a minority of tissue-infiltrating cells and are located distant from the site of pathology. *Am J Pathol*. 1996 148:1925–1933

- [309] Wang L, Ai Z, Khoyratty T, Zec K, et al. ROS-producing immature neutrophils in giant cell arteritis are linked to vascular pathologies. *JCI Insight*. 2020 5:e139163
- [310] Rodriguez-Pla A, Bosch-Gil JA, et al. Metalloproteinase-2 and -9 in giant cell arteritis: involvement in vascular remodeling. *Circulation*. 2005 112:264–9
- [311] Espigol-Frigole G, Planas-Rigol E, Ohnuki H, et al. Identification of IL-23p19 as an endothelial proinflammatory peptide that promotes gp130-STAT3 signaling. *Sci Signal*. 2016 9:ra28
- [312] Baldini M, Maugeri N, Ramirez GA, et al. Selective up-regulation of the soluble pattern-recognition receptor pentraxin 3 and of vascular endothelial growth factor in giant cell arteritis: relevance for recent optic nerve ischemia. *Arthritis Rheum*. 2012 64:854–865
- [313] Pulsatelli L, Boiardi L, Assirelli E, et al. Imbalance between angiogenic and anti-angiogenic factors in sera from patients with large-vessel vasculitis. *Clin Exp Rheumatol*. 2020 Suppl 124:23–30
- [314] Zhang H, Watanabe R, Berry GJ, et al. CD28 Signaling Controls Metabolic Fitness of Pathogenic T Cells in Medium and Large Vessel Vasculitis. *J Am Coll Cardiol*. 2019 73:1811–1823
- [315] Akiyama M, Ohtsuki S, Berry GJ, et al. Innate and Adaptive Immunity in Giant Cell Arteritis. *Front Immunol*. 2020 11:621098
- [316] Deng J, Younge BR, Olshen RA, et al. Th17 and Th1 T-cell responses in giant cell arteritis. *Circulation*. 2010 121:906–915
- [317] Samson M, Audia S, Fraszczak J, et al. Th1 and Th17 lymphocytes expressing CD161 are implicated in giant cell arteritis and polymyalgia rheumatica pathogenesis. *Arthritis Rheum*. 2012 64:3788–3798
- [318] Terrier B, Geri G, Chacara W, et al. Interleukin-21 modulates Th1 and Th17 responses in giant cell arteritis. *Arthritis Rheum*. 2012 64:2001–2011
- [319] Ciccia F, Rizzo A, Guggino G, et al. Difference in the expression of IL-9 and IL-17 correlates with different histological pattern of vascular wall injury in giant cell arteritis. *Rheumatology (Oxford)*. 2015 54:1596–1604
- [320] Zhang H, Watanabe R, Berry GJ, et al. Inhibition of JAK-STAT Signaling Suppresses Pathogenic Immune Responses in Medium and Large Vessel Vasculitis. *Circulation*. 2018 137:1934–1948
- [321] Vieira M, Régnier P, Maciejewski-Duval A, et al. Interferon signature in giant cell arteritis aortitis. *J Autoimmun*. 2022 127:102796
- [322] Zhou L, Ivanov II, Spolski R, et al. IL-6 programs T(H)-17 cell differentiation by promoting sequential engagement of the IL-21 and IL-23 pathways. *Nat Immunol*. 2007 8:967-74
- [323] Zhang H, Watanabe R, Berry GJ, et al. Immunoinhibitory checkpoint deficiency in medium and large vessel vasculitis. *Proc Natl Acad Sci U S A*. 2017 114:E970–E979

- [324] Watanabe R, Hilhorst M, Zhang H, et al. Glucose metabolism controls disease-specific signatures of macrophage effector functions. *JCI Insight*. 2018 3:e123047
- [325] Graver JC, Abdulahad W, van der Geest KSM, et al. Association of the CXCL9-CXCR3 and CXCL13-CXCR5 axes with B-cell trafficking in giant cell arteritis and polymyalgia rheumatica. *J Autoimmun*. 2021 123:102684
- [326] Ciccia F, Rizzo A, Maugeri R, et al. Ectopic expression of CXCL13, BAFF, APRIL and LT-beta is associated with artery tertiary lymphoid organs in giant cell arteritis. *Ann Rheum Dis*. 2017 76:235-243
- [327] Weyand CM, Watanabe R, Zhang H, et al. Cytokines, growth factors and proteases in medium and large vessel vasculitis. *Clin Immunol*. 2019 206:33–41
- [328] Rittner HL, Kaiser M, Brack A, et al. Tissue-destructive macrophages in giant cell arteritis. *Circ Res*. 1999 84:1050–1058
- [329] Kaiser M, Weyand CM, Bjornsson J, et al. Platelet-derived growth factor, intimal hyperplasia, and ischemic complications in giant cell arteritis. *Arthritis Rheum*. 1998 41:623–633
- [330] Kaiser M, Younge B, Bjornsson J, et al. Formation of new vasa vasorum in vasculitis. Production of angiogenic cytokines by multinucleated giant cells. *Am J Pathol*. 1999 155:765–774
- [331] van Sleen Y, Jiemy WF, Pringle S, et al. A Distinct Macrophage Subset Mediating Tissue Destruction and Neovascularization in Giant Cell Arteritis: Implication of the YKL-40/Interleukin-13 Receptor alpha2 Axis. *Arthritis Rheumatol*. 2021 73:2327–2337
- [332] Segarra M, García-Martínez A, Sánchez M, et al. Gelatinase expression and proteolytic activity in giant-cell arteritis. *Ann Rheum Dis*. 2007 66:1429-35
- [333] Weyand CM, Wagner AD, Björnsson J, et al. Correlation of the topographical arrangement and the functional pattern of tissue-infiltrating macrophages in giant cell arteritis. *J Clin Invest*. 1996 98:1642-9
- [334] Ma-Krupa W, Kwan M, Goronzy JJ, et al. Toll-like receptors in giant cell arteritis. *Clin Immunol*. 2005 115:38-46
- [335] Samokhin AO, Wilson S, Nho B, et al. Cholate-containing high-fat diet induces the formation of multinucleated giant cells in atherosclerotic plaques of apolipoprotein E^{-/-} mice. *Arterioscler Thromb Vasc Biol*. 2010 30:1166-73
- [336] Parthasarathy V, Martin F, Higginbottom A, et al. Distinct roles for tetraspanins CD9, CD63 and CD81 in the formation of multinucleated giant cells. *Immunology*. 2009 127:237-48
- [337] Estupiñán-Moreno E, Ortiz-Fernández L, Li T, et al. Methylome and transcriptome profiling of giant cell arteritis monocytes reveals novel pathways involved in disease pathogenesis and molecular response to glucocorticoids. *Ann Rheum Dis*. 2022 81:1290-300

- [338] Corbera-Bellalta M, Planas-Rigol E, Lozano E, et al. Blocking interferon γ reduces expression of chemokines CXCL9, CXCL10 and CXCL11 and decreases macrophage infiltration in ex vivo cultured arteries from patients with giant cell arteritis. *Ann Rheum Dis.* 2016 75:1177-86
- [339] Planas-Rigol E, Terrades-Garcia N, Corbera-Bellalta M, et al. Endothelin-1 promotes vascular smooth muscle cell migration across the artery wall: a mechanism contributing to vascular remodelling and intimal hyperplasia in giant-cell arteritis. *Ann Rheum Dis.* 2017 76:1624-1634
- [340] Régent A, Ly KH, Groh M, et al. Molecular analysis of vascular smooth muscle cells from patients with giant cell arteritis: Targeting endothelin-1 receptor to control proliferation. *Autoimmun Rev.* 2017 16:398-406
- [341] Lozano E, Segarra M, Corbera-Bellalta M, et al. Increased expression of the endothelin system in arterial lesions from patients with giant-cell arteritis: association between elevated plasma endothelin levels and the development of ischaemic events. *Ann Rheum Dis.* 2010 69:434-42
- [342] Ly KH, Régent A, Molina E, et al. Neurotrophins are expressed in giant cell arteritis lesions and may contribute to vascular remodeling. *Arthritis Res Ther.* 2014 16:487
- [343] Mortensen MB, Kjolby M, Gunnensen S, et al. Targeting sortilin in immune cells reduces proinflammatory cytokines and atherosclerosis. *J Clin Invest.* 2014 124:5317-22
- [343] Plikus MV, Wang X, Sinha S, et al. Fibroblasts: Origins, definitions, and functions in health and disease. *Cell.* 2021 184:3852-3872
- [344] Desmoulière A, Chaponnier C, Gabbiani G. Tissue repair, contraction, and the myofibroblast. *Wound Repair Regen.* 2005 13:7-12
- [345] Micallef L, Vedrenne N, Billet F, et al. The myofibroblast, multiple origins for major roles in normal and pathological tissue repair. *Fibrogenesis Tissue Repair.* 2012 5:S5
- [346] Schuster R, Rockel JS, Kapoor M, et al. The inflammatory speech of fibroblasts. *Immunol Rev.* 2021 302:126-146
- [347] Davidson S, Coles M, Thomas T, et al. Fibroblasts as immune regulators in infection, inflammation and cancer. *Nat Rev Immunol.* 2021 21:704-717
- [348] Wei K, Nguyen HN, Brenner MB. Fibroblast pathology in inflammatory diseases. *J Clin Invest.* 2021 131
- [349] Lynch MD, Watt FM. Fibroblast heterogeneity: implications for human disease. *J Clin Invest.* 2018 128:26-35
- [350] Buechler MB, Turley SJ. A short field guide to fibroblast function in immunity. *Semin Immunol.* 2018 35:48-58
- [351] Kalluri R, Zeisberg M. Fibroblasts in cancer. *Nat Rev Cancer.* 2006 6:392-401

- [352] Xu S, Jiemy WF, Graver JC, et al. POS0092 SPATIAL DISTRIBUTION OF DISTINCT FIBROBLAST SUBTYPES IN GIANT CELL ARTERITIS. Conference Paper in *Annals of the Rheumatic Diseases*. May 2023
- [353] Greigert H, Ramon A, Genet C, et al. Neointimal myofibroblasts contribute to maintaining Th1/Tc1 and Th17/Tc17 inflammation in giant cell arteritis. *J Autoimmun*. 2024 142:103151
- [354] Turner NA. Inflammatory and fibrotic responses of cardiac fibroblasts to myocardial damage associated molecular patterns (DAMPs). *J Mol Cell Cardiol*. 2016 94:189-200
- [355] Watanabe R, Berry GJ, Liang DH, et al. Pathogenesis of Giant Cell Arteritis and Takayasu Arteritis-Similarities and Differences. *Curr Rheumatol Rep*. 2020 22:68
- [356] Misra DP, Singh K, Sharma A, et al. Arterial wall fibrosis in Takayasu arteritis and its potential for therapeutic modulation. *Front Immunol*. 2023 14:1174249
- [357] Kong X, Ma L, Ji Z, et al. Pro-fibrotic effect of IL-6 via aortic adventitial fibroblasts indicates IL-6 as a treatment target in Takayasu arteritis. *Clin Exp Rheumatol*. 2018 36:62-72
- [358] Wu S, Kong X, Sun Y, et al. FABP3 overexpression promotes vascular fibrosis in Takayasu's arteritis by enhancing fatty acid oxidation in aorta adventitial fibroblasts. *Rheumatology (Oxford)*. 2022 61:3071-3081
- [359] Duperret EK, Trautz A, Ammons D, et al. Alteration of the Tumor Stroma Using a Consensus DNA Vaccine Targeting Fibroblast Activation Protein (FAP) Synergizes with Antitumor Vaccine Therapy in Mice. *Clin Cancer Res*. 2018 24:1190-1201
- [360] Fang J, Xiao L, Joo KI, et al. A potent immunotoxin targeting fibroblast activation protein for treatment of breast cancer in mice. *Int J Cancer*. 2016 138:1013-1023
- [361] Loeffler M, Kruger JA, Niethammer AG, et al. Targeting tumor-associated fibroblasts improves cancer chemotherapy by increasing intratumoral drug uptake. *J Clin Invest*. 2006 116:1955-1962
- [362] Ostermann E, Garin-Chesa P, Heider KH, et al. Effective immunoconjugate therapy in cancer models targeting a serine protease of tumor fibroblasts. *Clin Cancer Res*. 2008 14:4584-4592
- [363] Wang LC, Lo A, Scholler J, et al. Targeting fibroblast activation protein in tumor stroma with chimeric antigen receptor T cells can inhibit tumor growth and augment host immunity without severe toxicity. *Cancer Immunol Res*. 2014 2:154-166
- [364] Croft AP, Campos J, Jansen K, et al. Distinct fibroblast subsets drive inflammation and damage in arthritis. *Nature*. 2019 570:246-251
- [365] Nayar S, Campos J, Smith CG, et al. Immunofibroblasts are pivotal drivers of tertiary lymphoid structure formation and local pathology. *Proc Natl Acad Sci U S A*. 2019 116:13490-13497

- [366] Martin JC, Chang C, Boschetti G, et al. Single-Cell Analysis of Crohn's Disease Lesions Identifies a Pathogenic Cellular Module Associated with Resistance to Anti-TNF Therapy. *Cell*. 2019 178:1493-1508
- [367] Ciardiello D, Elez E, Tabernero J, et al. Clinical development of therapies targeting TGFbeta: current knowledge and future perspectives. *Ann Oncol*. 2020 31:1336-1349
- [368] Matthijs Blankesteyn W. Has the search for a marker of activated fibroblasts finally come to an end? *J Mol Cell Cardiol*. 2015 88:120-3
- [369] Coen M, Gabbiani G, Bochaton-Piallat ML. Myofibroblast-mediated adventitial remodeling: an underestimated player in arterial pathology. *Arterioscler Thromb Vasc Biol*. 2011 31:2391-6
- [370] Shi Y, O'Brien JE, Fard A, et al. Adventitial myofibroblasts contribute to neointimal formation in injured porcine coronary arteries. *Circulation*. 1996 94:1655-64
- [371] Shi Y, O'Brien JE, Fard A, et al. Transforming growth factor-beta 1 expression and myofibroblast formation during arterial repair. *Arterioscler Thromb Vasc Biol*. 1996 16:1298-305
- [372] Scott NA, Cipolla GD, Ross CE, et al. Identification of a potential role for the adventitia in vascular lesion formation after balloon overstretch injury of porcine coronary arteries. *Circulation*. 1996 93:2178-87
- [373] Tang W, Liu Z, Si Y. Tunica Arterial Adventitia: A New Exploration in Intimal Hyperplasia. *J Vasc Med Surg*. 2013 1
- [374] Hinz B. Myofibroblasts. *Exp Eye Res*. 2018 142:56-70.
- [375] Coen M, Gabbiani G, Bochaton-Piallat ML. Myofibroblast-mediated adventitial remodeling: an underestimated player in arterial pathology. *Arterioscler Thromb Vasc Biol*. 2011 31:2391-6.
- [376] Makkuni D, Bharadwaj A, Wolfe K, et al. Is intimal hyperplasia a marker of neuro-ophthalmic complications of giant cell arteritis? *Rheumatology (Oxford)*. 2008 47:488-90.
- [377] Chatelain D, Duhaut P, Schmidt J, et al. Pathological features of temporal arteries in patients with giant cell arteritis presenting with permanent visual loss. *Ann Rheum Dis*. 2009 68:84-8
- [378] Muratore F, Boiardi L, Cavazza A, et al. Correlations between histopathological findings and clinical manifestations in biopsy-proven giant cell arteritis. *J Autoimmun*. 2016 69:94-101
- [379] van der Geest KSM, Wolfe K, Borg F, et al. Ultrasonographic Halo Score in giant cell arteritis: association with intimal hyperplasia and ischaemic sight loss. *Rheumatology (Oxford)*. 2021 60:4361-4366
- [380] Dutzmann J, Koch A, Weisheit S, et al. Sonic hedgehog-dependent activation of adventitial fibroblasts promotes neointima formation. *Cardiovasc. Res*. 2017 113:1653e1663

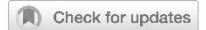- [381] Barman SA, Chen F, Su Y, et al. NADPH oxidase 4 is expressed in pulmonary artery adventitia and contributes to hypertensive vascular remodeling. *Arterioscler Thromb Vasc Biol.* 2014 34:1704e1715
- [382] Adachi Y, Ueda K, Nomura S, et al. Beiging of perivascular adipose tissue regulates its inflammation and vascular remodeling. *Nat Commun.* 2022 13:5117
- [383] Horimatsu T, Kim HW, Weintraub NL. The role of perivascular adipose tissue in non-atherosclerotic vascular disease. *Front Physiol.* 2017 8:969
- [384] McDonald HM, Farmer JP, Blanco PL. Periadventitial tissue examination in temporal artery biopsies for suspected giant cell arteritis: a case series and literature review. *Can J Ophthalmol.* 2019 54:615–20
- [385] Schröder B. The multifaceted roles of the invariant chain CD74--More than just a chaperone. *Biochim Biophys Acta.* 2016 1863:1269-81
- [386] Basha G, Omilusik K, Chavez-Steenbock A, et al. A CD74-dependent MHC class I endolysosomal cross-presentation pathway. *Nat Immunol.* 2012 13:237-45
- [387] Le Hires M, Tu L, Ricard N, et al. Proinflammatory Signature of the Dysfunctional Endothelium in Pulmonary Hypertension. Role of the Macrophage Migration Inhibitory Factor/CD74 Complex. *Am J Respir Crit Care Med.* 2015 192:983-97
- [388] Schober A, Bernhagen J, Weber C. Chemokine-like functions of MIF in atherosclerosis. *J Mol Med (Berl).* 2008 86:761-70
- [389] Reitsema RD, van der Geest KSM, Sandovici M, et al. Phenotypic, transcriptomic and functional profiling reveal reduced activation thresholds of CD8+ T cells in giant cell arteritis. *Rheumatol (Oxford).* 2022 62:417–27
- [390] Abualrous ET, Sticht J, Freund C. Major histocompatibility complex (MHC) class I and class II proteins: impact of polymorphism on antigen presentation. *Curr Opin Immunol.* 2021 70:95–104
- [391] Oelschlaegel D, Weiss Sadan T, et al. Cathepsin inhibition modulates metabolism and polarization of tumor-associated macrophages. *Cancers (Basel).* 2020 12:279
- [392] Zeng H, Yang X, Yang L, et al. Thymosin b10 promotes tumor associated macrophages M2 conversion and proliferation via the PI3K/Akt pathway in lung adenocarcinoma. *Respir Res.* 2020 21:328
- [393] Christian BA, Poi M, Jones JA, et al. The combination of milatuzumab, a humanized anti-CD74 antibody, and veltuzumab, a humanized anti-CD20 antibody, demonstrates activity in patients with relapsed and refractory B-cell non-Hodgkin lymphoma. *Br J Haematol.* 2015 169:701–10

Annexes

Annexe 1.

Clinical, biological, and ophthalmological characteristics differentiating arteritic from non-arteritic anterior ischaemic optic neuropathy.

ARTICLE



Clinical, biological, and ophthalmological characteristics differentiating arteritic from non-arteritic anterior ischaemic optic neuropathy

Simon Parreau^{1,2✉}, Alexandre Dentel³, Rania Mhenni⁴, Stéphanie Dumonteil², Alexis Régent¹, Guillaume Gondran², Dominique Monnet⁴, Antoine P. Brézin⁴, Kim-Heang Ly², Éric Liozon², Thomas Sené⁵ and Benjamin Terrier¹

© The Author(s), under exclusive licence to The Royal College of Ophthalmologists 2022

BACKGROUND/AIMS: To identify characteristics that can distinguish AAION from NAAION in emergency practice.

METHODS: This is a multicentre retrospective case-control study. Ninety-four patients with AAION were compared to ninety-four consecutive patients with NAAION. We compared the clinical, biological, and ophthalmological characteristics at baseline of patients with AAION and those with NAAION.

RESULTS: Patients with AAION were older and more likely to have arterial hypertension. Cephalic symptoms and acute-phase reactants were more frequent in AAION. Profound vision loss and bilateral involvement were more frequent in AAION at baseline. Central retinal and cilioretinal artery occlusions was only observed in AAION, and delayed choroidal perfusion was more frequently observed in AAION than in NAAION. Using logistic regression, an age >70 years (OR = 3.4, IC95% = 0.8–16.1, $p = 0.105$), absence of splinter haemorrhage (OR = 4.9, IC95% = 1.4–20.5, $p = 0.019$), delayed choroidal perfusion (OR = 7.2, IC95% = 2.0–28.0, $p = 0.003$), CRP > 7 mg/L (OR = 43.6, IC95% = 11.6–229.1, $p < 0.001$) and platelets >400 × G/L (OR = 27.5, IC95% = 4.6–270.9, $p = 0.001$) were independently associated with a diagnosis of AAION. An easy-to-use score based on these variables accurately distinguished AAION from NAAION with a sensitivity of 93.3% and specificity of 92.4%.

CONCLUSION: In patients presenting with AION, a set of ophthalmological and laboratory criteria can efficiently discriminate patients with AAION and NAAION and can identify which patients would benefit from high-dose glucocorticoids. External validation of our results is required.

Eye; <https://doi.org/10.1038/s41433-022-02295-w>

INTRODUCTION

Anterior ischaemic optic neuropathy (AION) is one of the most common causes of blindness among the elderly. It is characterized by a sudden, but painless decrease in visual acuity due to ischaemia of the anterior part of the optic nerve head, which is mainly supplied by short posterior ciliary arteries. Ischaemia leads to optic disc swelling followed by optic disc atrophy about 6 weeks after the acute injury. Roughly 90% of AION cases are non-arteritic (NAAION), and the disease is multifactorial with various risk factors [1, 2]. The key risk factor is anatomical crowding of the optic disc. Arteritic AION (AAION) is most frequently related to giant cell arteritis (GCA), a large vessel vasculitis that can affect individuals >50 years of age [1]. GCA is characterized by cranial (i.e., headaches, scalp tenderness and jaw claudication) and/or constitutional symptoms (i.e., fever, anorexia, fatigue, and weight loss), and is typically associated with increased levels of acute-phase reactants. Histological analysis of temporal artery biopsy (TAB) can confirm the diagnosis of GCA, by showing inflammatory infiltrates with a predominance of mononuclear cells or granulomatous inflammation [3]. However, skip lesions may

occur. Noninvasive imaging techniques, mainly ¹⁸F-fluorodeoxyglucose-positron emission tomography (FDG-PET), temporal artery ultrasound and magnetic resonance imaging (MRI), help to confirm the diagnosis according to the EULAR recommendations [4].

Arteritic AION is a medical emergency because of the risk of imminent vision loss involving the 2nd eye, as even with prompt intervention the vision loss may be irreversible. Because it is related to inflammatory thrombosis of the short posterior ciliary arteries, the treatment is based on high-dose glucocorticoids (GCs), whereas there is no evidence-based treatment for vision loss NAAION, and management focuses on modification of possible risk factors, aiming to try and reduce risk of similar involvement of the 2nd eye [5]. Distinguishing AAION and NAAION is therefore critical in the early phase of visual manifestations to ensure appropriate treatment. However, distinguishing these two entities can be problematic, especially when cranial or systemic symptoms suggestive of GCA are inconsistent. Systemic manifestations have been reported to be absent in 21% of GCA cases associated with vision loss, which have been called

¹Department of Internal Medicine, Paris Descartes University, Referral Center for Rare Autoimmune and Systemic Diseases, Hôpital Cochin, Paris, France. ²Department of Internal Medicine, Hôpital Dupuytren, Limoges, France. ³Department of Ophthalmology, Fondation Adolphe-de-Rothschild hospital, Paris, France. ⁴Université de Paris, Department of Ophthalmology, Hôpital Cochin, Paris, France. ⁵Department of Internal Medicine, Fondation Adolphe-de-Rothschild hospital, Paris, France. ✉email: simon.parreau@hotmail.com

Received: 26 April 2022 Revised: 27 September 2022 Accepted: 13 October 2022

Published online: 22 October 2022

occult GCA [6]. To date, only few large-scale studies have directly compared AAION and NAAION [7–22].

In this case-control study, we compared the characteristics of patients with NAAION and AAION to identify diagnostic features that could be useful for discriminating the two entities in daily practice.

MATERIALS AND METHODS

Study design

We conducted a multicentre retrospective case-control study including consecutive patients diagnosed with AION between 2005 and 2021 at the Ophthalmology Departments of three French tertiary-care teaching hospitals (Cochin Hospital [Ile de France], Ophthalmological Adolphe de Rothschild Foundation Hospital [Ile de France], and Dupuytren Hospital [Nouvelle-Aquitaine]). Anterior ischaemic optic neuropathy was defined as a sudden decrease in visual acuity associated with a typical visual field defect and optic disc swelling, progressing to optic disc atrophy within 2 months. AAION was defined as AION associated with a diagnosis of GCA according to the American College of Rheumatology (ACR) classification [23]. The diagnosis of GCA was retained when the TAB showed an active arteritis with an inflammatory parietal infiltrate composed of lymphocytes, macrophages ± giant cells. A diagnosis of GCA was retained in biopsy-negative cases if at least three of the ACR criteria were fulfilled, or if only two criteria were fulfilled but FDG-PET scans showed greater circumferential FDG vascular uptake compared to liver uptake in at least one of the following eight vascular segments: thoracic, abdominal aorta, subclavian, axillary, carotid, iliac/femoral, and upper and lower limb arteries [24], temporal artery ultrasound revealed a halo sign [25], or high resolution MRI of the cranial arteries demonstrated mural inflammation [26]. If the erythrocyte sedimentation rate (ESR) was not available, C-reactive protein (CRP) was used as a surrogate diagnostic criterion with a positivity threshold of >20 mg/L as described in a recent study [27]. We also included patients with a diagnosis of NAAION during the same period and in the same centres, with a 1:1 ratio. Diagnosis of NAAION was based on the presence of fewer than three ACR criteria, a negative TAB and/or noninvasive imaging tests not suggestive of large-vessel vasculitis, and the absence of progression to GCA at least 1 year after AION onset.

Data collection

All clinical, laboratory, and radiological data at the time of diagnosis of AION were collected retrospectively using a standardized case report form. Cardiovascular (CV) risk factors were collected, as well as use of antiplatelet agents, anticoagulants and statins at the time of AION onset. The CHA₂DS₂-VASc score was calculated based on the clinical information available at the time of diagnosis [28]. The temporal artery was considered abnormal if any of the following features were present: weak or absent pulse, beaded and/or indurated artery, and local redness or tenderness. Constitutional syndrome was defined as a temperature of >38 °C for >1 week associated with asthenia and/or weight loss of >5%.

Ophthalmological data were collected by ophthalmologists. Amaurosis fugax was defined as temporary loss of vision in one or both eyes before diagnosis of AION. Visual acuity was measured at 3 m and expressed as a decimal before being converted into logMAR. Unquantifiable low acuity was defined in decreasing order as follows: counting fingers, hand motion, light perception, and no light perception. Intraocular pressure was measured using a Goldmann applanation tonometer on presentation. Delayed choroidal perfusion was demonstrated by fluorescein angiography and defined as a delay in choroidal perfusion (sectorial or global) of >20 s or a difference of 20 s in choroidal filling between the two eyes.

Statistical analysis

Continuous variables are expressed as medians and interquartile ranges, and categorical variables are expressed as frequencies with percentages. Variables were compared by the Pearson's chi-square, Fisher's exact, or Wilcoxon's test, as appropriate.

For missing data (~10%, evenly distributed), multiple imputation chained equation was used with four matrices [29]. To determine the profile of patients with GCA, logistic regression was carried out on baseline variables with *p* values <0.25. The Box-Tidwell transformation adds the neperian logarithm of the selected continuous variables to the logistic regression. These terms have a significant *p* value, indicating a non-linear relationship with the variable of interest. The graphs of the partial residuals

show a hyperbolic type of relationship. To meet the assumptions of linearity of the model, these variables are discretized to obtain a simple score to be used in the current practice. The thresholds are obtained using a supervised method (decision tree). The initial multivariate model was simplified by the backward stepwise elimination method, and the final model included only variables significantly associated with AAION. Model calibration was assessed using the Pearson residual. Receiver operating characteristic (ROC) analysis was performed, where an area under the curve (AUC) of 1.0 reflects the highest possible reliability. All were two-sided and a *p* value < 0.05 was considered indicative of significance. Calculations were performed using R software (version 3.2.2; R foundation for Statistical Computing, Vienna, Austria).

Patient involvement

Patients and the public were not involved in the design, conduct, reporting or dissemination of this research.

Ethics

The study was conducted in compliance with good clinical practice guidelines and the Declaration of Helsinki and was approved by the local Institutional Review Board of Cochin-Port Royal Hospital, Paris, France (approval number: AAA-2021-08061). All patients were informed that their anonymized clinical data could be used for research purposes, and they give their written consent for such use/none opposed their use.

RESULTS

Characteristics of the patients

In total, 110 patients with AAION were initially screened. Twelve patients with missing data and four with an incorrect diagnosis of AAION were excluded. Thus, 94 patients with AAION (and 94 consecutive recent patients with NAAION; controls) were included in the final analysis (Supplementary Fig. 1). The demographics, CV risk factors, visual characteristics, and extra-ocular manifestations of the participants are summarized in Tables 1–3, respectively.

Among the 94 AAION cases, 72 underwent TAB, which showed evidence of temporal arteritis in 61 (85%) patients. Forty-nine patients had doppler ultrasound of the temporal arteries, which revealed a halo sign in 31 (63%). For the 33 AAION cases with negative TAB or TAB not performed, 20 patients had at least 3 ACR criteria. Among the 13 patients who did not meet at least three ACR criteria, 2 had a positive TAB, 4 had temporal artery ultrasound showing a halo sign, and 7 had a CRP level >20 mg/L with no other plausible cause. Seventy-seven (81.9%) AAION patients had a typical GCA. The seventeen (18.1%) remaining AAION patients had atypical features of GCA (Supplementary Fig. 2). Among atypical AAION patients, eight patients (8.5%) had a typical clinical presentation of GCA, without an increase in acute-phase reactants, but an abnormal TAB was seen in five patients and a bilateral positive halo sign was revealed by temporal artery ultrasound in four. Seven patients (7.4%) had an atypical presentation of GCA but increased acute-phase reactants and a positive TAB for GCA in all cases. Finally, two patients (2.1%) had neither clinical symptom of GCA nor increased acute-phase reactants, but did show evidence of vasculitis on TAB.

Factors associated with the diagnosis of AAION

Tables 1–3 show the results of univariate analyses of patients with AAION and NAAION. Patients with AAION were older (median age, 78 [75–84] vs. 72 [65–78] years, *P* < 0.001) and more likely to have hypertension (63.8 vs. 44.7%, *P* = 0.013), and had a higher mean CHA₂DS₂-VASc score (3.0 [3.0–4.0] vs. 2.5 [1.0–4.0], *P* = 0.001).

Amaurosis fugax (39.4 vs. 5.3%, *P* < 0.001), bilateral AION (24.5 vs. 6.4%, *P* = 0.0012) and a profound decrease in visual acuity (LogMAR > 1.0) (75.3 vs. 43.0%, *P* = 0.001) were significantly more frequent in AAION patients. Patients with AAION also had a lower rate of splinter haemorrhage (37.2 vs. 57.8%, *P* = 0.012), higher rate of central retinal artery occlusion (13.8 vs. 0.0%, *P* = 0.001) and delayed choroidal perfusion on fluorescence angiography

Table 1. Demographics and cardiovascular risk factors of the AAION and NAAION groups.

	n (%) or median [interquartile range]			p value
	Non-arteritic AION n = 94	Arteritic AION n = 94	Total n = 188	
Demographics				
Age, years	72 [65, 78]	78 [75, 84]	76 [70,81]	<0.001
Age ≥70 years	58 (61.7%)	84 (89.4%)	142 (75.5%)	<0.001
Female	40 (42.6%)	52 (55.3%)	92 (48.9%)	0.110
CV risk factors				
Current smoking	13 (13.8%)	16 (17.0%)	29 (15.4%)	0.686
Dyslipidaemia	30 (31.9%)	32 (34.0%)	62 (33.0%)	0.877
Obesity	6 (6.4%)	5 (5.3%)	11 (5.9%)	1.000
Atrial fibrillation	2 (2.1%)	9 (9.6%)	11 (5.9%)	0.058
Congestive heart failure	7 (7.4%)	13 (13.8%)	20 (10.6%)	0.237
Hypertension	42 (44.7%)	60 (63.8%)	102 (54.3%)	0.013
Diabetes mellitus	16 (17.0%)	12 (12.8%)	28 (14.9%)	0.539
Stroke, TIA, or TE	5 (5.3%)	7 (7.4%)	12 (6.4%)	0.766
Vascular disease*	9 (9.6%)	17 (18.1%)	26 (13.8%)	0.139
CHA ₂ DS ₂ -VASc score	2.5 [1.0, 4.0]	3.0 [3.0, 4.0]	3.0 [2.0, 4.0]	<0.001
Antiplatelet agent	28 (29.8%)	26 (27.7%)	54 (28.7%)	0.872
Anticoagulant	4 (4.3%)	9 (9.6%)	13 (6.9%)	0.250
Statin	22 (23.4%)	32 (34.0%)	54 (28.7%)	0.147

AION anterior ischaemic optic neuropathy, TIA transient ischaemic attack, TE thromboembolism.

*Prior myocardial infarction, peripheral arterial disease, or aortic plaque.

Table 2. Visual characteristics of the AAION and NAAION groups.

	n (%) or median [interquartile range]			p value
	Non-arteritic AION n = 94	Arteritic AION n = 94	Total n = 188	
Amaurosis fugax	5 (5.3%)	37 (39.4%)	42 (22.3%)	<0.001
Initial bilateral AION	6 (6.4%)	23 (24.5%)	29 (15.4%)	0.001
LogMAR <0.3	33 (35.5%)	12 (13.5%)	45 (24.7%)	<0.001
LogMAR >1.0	40 (43.0%)	67 (75.3%)	107 (58.8%)	0.001
Count fingers	13 (13.8%)	18 (19.1%)	31 (16.5%)	0.432
Hand movement	9 (9.6%)	34 (36.2%)	43 (22.9%)	<0.001
Light perception	2 (2.1%)	6 (6.4%)	8 (4.3%)	0.278
No light perception	0 (0.0%)	2 (2.1%)	2 (1.1%)	0.497
Splinter haemorrhage	52 (57.8%)	29 (37.2%)	81 (48.2%)	0.012
Associated CRAO	0 (0.0%)	13 (13.8%)	13 (6.9%)	<0.001
Associated CLRAO	0 (0.0%)	4 (4.3%)	4 (2.1%)	0.121
Intraocular pressure, mmHg	15 [13,16]	14 [12,15]	14 [12,16]	0.004
Delayed choroidal perfusion	12/59 (20.3%)	54/66 (81.8%)	66/125 (52.8%)	<0.001

AION anterior ischaemic optic neuropathy, CRAO central retinal artery occlusion, CLRAO cilioretinal artery occlusion.

(81.8 [54/66] vs. 20.3% [12/59], $P < 0.001$). Finally, besides cranial, and constitutional symptoms, which were more frequent in AAION patients, as expected, the mean (sd) platelet count (443 [345–536] vs. 270 [198–300] G/L, $P < 0.001$) and monocytes (0.8 [0.5–1.0] vs. 0.5 [0.4–0.6] G/L, $P < 0.001$) were higher in the AAION compared to NAAION group.

Several variables were independently associated with AAION: an age over 70 years (+10 points), delayed choroidal perfusion (+17 points) on fluorescein angiography, absence of splinter haemorrhage (+13 points) on funduscopy, blood platelet count >400 G/L (+28 points), and CRP > 7 mg/L (+32 points) (Table 4). A score > 48 points accurately identified patients with AAION, with a sensitivity of 93.3%, specificity of 92.4%, positive predictive value

of 94.4%, and negative predictive value of 91.0% (Supplementary Fig. 3). Considering only AAION patients with a positive TAB, a score >48 points identified patients with AAION, with a sensitivity of 93.4%, specificity of 93.0%, positive predictive value of 91.8%, and negative predictive value of 94.3%.

DISCUSSION

We assessed the ability of baseline characteristics to distinguish AAION related to GCA and NAAION cases among subjects presenting with AION. We identified several variables associated with AAION and established a score to help for distinguishing AAION cases in ophthalmological emergency practice. The score

Table 3. Extra-ocular manifestations of the NAAION and AAION groups.

	n (%) or median [interquartile range]			p value
	Non-arteritic AION n = 94	Arteritic AION n = 94	Total n = 188	
Headache	8 (8.5%)	71 (75.5%)	79 (42.0%)	<0.001
Abnormal temporal artery	0 (0.0%)	32 (34.0%)	32 (17.0%)	<0.001
Jaw claudication	1 (1.1%)	58 (61.7%)	59 (31.4%)	<0.001
Scalp tenderness	2 (2.1%)	50 (53.2%)	52 (27.7%)	<0.001
Dry cough	1 (1.1%)	10 (10.6%)	11 (5.9%)	0.001
Fever	0 (0.0%)	9 (9.6%)	9 (4.8%)	0.003
Constitutional symptoms	4 (4.3%)	51 (54.3%)	55 (29.3%)	<0.001
Distal arthritis	1 (1.1%)	10 (10.6%)	11 (5.9%)	0.001
Polymyalgia symptoms	1 (1.1%)	14 (14.9%)	15 (8.0%)	<0.001
CRP (mg/L)	1 [1, 4]	70 [31, 108]	16 [1, 73]	<0.001
ESR, mm/h	13 [8, 22]	86 [57, 101]	48 [15,92]	<0.001
Leucocytes, G/L	7.9 [6.1, 10.9]	10.2 [8.4, 11.8]	9.6 [7.6, 11.7]	0.004
Haemoglobin, g/dL	13.4 [12.6, 14.4]	11.8 [10.9-12.9]	12.3 [11.0-13.5]	<0.001
Platelets, G/L	270 [198, 300]	443 [345, 536]	357 [274, 462]	<0.001
Fibrinogen, g/dL	3.5 [2.7, 3.8]	6.4 [5.2, 7.6]	5.7 [4.1-7.2]	<0.001
Lymphocytes, G/L	1.5 [1.1, 2.0]	1.6 [1.3, 2.0]	1.6 [1.2, 2.0]	0.503
Monocytes, G/L	0.5 [0.4, 0.6]	0.8 [0.5, 1.0]	0.7 [0.5, 0.9]	<0.001

AION anterior ischaemic optic neuropathy, CRP C-reactive protein.

Table 4. Factors associated with AAION.

	β	OR	IC95%	p value
Absence of splinter haemorrhage	1.6	4.9	1.4–20.5	0.019
Delayed choroidal perfusion	2.0	7.2	2.0–28.0	0.003
Age > 70 years	1.2	3.4	0.8–16.1	0.105
CRP > 7 mg/L	3.8	43.6	11.6–229.1	<0.001
Platelets > 400 G/L	3.3	27.5	4.6-270.9	0.001

included older age, delayed choroidal perfusion, absence of splinter haemorrhage, CRP level, and platelet count.

Accurate identification of patients with suspected AAION is critical because untreated GCA carries a high risk of bilateral involvement, and such event is preventable by high-dose GCs. Conversely, high-dose GCs could be detrimental in elderly people with NAAION. We aimed to identify AAION at onset in emergency department patients who could benefit from rapid initiation of high-dose intravenous methylprednisolone, and the present study is one of the largest studies to address this question [10]. Prior studies were either small or used only one imaging test [7–22] (Table 5). In addition, Ing et al. also developed multivariate predictive models for the diagnosis of GCA based on routine clinical and biological variables [30–33]. However, these models did not compare GCA with AAION and NAAION as in our study.

Patients with AAION were older and had a higher mean CHA²DS²VASc score, the latter being partly explained by frequent coexisting arterial hypertension. The CHA²DS²VASc score is predictive of CV disease in patients with and without atrial fibrillation. Czihal et al. showed that the risk of permanent vision loss in GCA was positively associated with a high CHADS2 score [34]. However, no previous study has directly compared these scores between AAION and NAAION.

Some ophthalmological variables were strongly associated with AAION, including the lack of splinter haemorrhage and the presence of delayed choroidal perfusion. More severe initial visual

impairment observed in AAION in comparison to NAAION, as identified in univariate analysis, has long been known [35]. Also, it is not surprising that amaurosis fugax was seen in AAION more than in NAAION. We provide here strong evidence that delayed choroidal perfusion during fluorescein angiography is an important feature suggestive of AAION, as indicated by previous small studies [15, 16, 36]. However, delayed choroidal perfusion is not pathognomonic of AAION, because it is also observed in about 20% of patients with NAAION [37]. The cupping sign, *i.e.* acquired excavation of the optic nerve head, which also suggests AAION, appears at a late stage and is therefore of limited relevance to the emergency setting [22]. Other ocular examinations that assist the differential diagnosis of AION include Goldmann visual field testing, colour Doppler imaging of the ophthalmic artery [20], and MRI of the head of the optic nerve [21]. However, such procedures can be difficult to perform in the setting of emergency management.

As expected, increased acute-phase reactants, which are a hallmark of GCA, were more frequent in AAION than NAAION patients. Although potentially misleading, an elevated CRP level may also be seen in patients with NAAION and multiple comorbid conditions. Platelet count was also independently associated with AAION in our study. Whether thrombocytosis is an independent risk factor for permanent visual loss in patients with new-onset GCA has been disputed [9, 10]. Consistent with our results, Costello et al. reported that patients with GCA-related AION had significantly higher platelet counts, ESR, and CRP levels compared to patients with NAAION. Furthermore, the combination of a high platelet count and CRP level increased the likelihood of GCA in the setting of AION [10].

Finally, about 10% of our patients with AAION did not display clinical symptoms suggestive of occult forms of GCA. Hayreh et al. reported that occult forms accounted for 21% of 85 visually complicated GCA cases confirmed by TAB [6], similar to the work of Chen et al. [38]. Only two patients in our series had occult GCA without an increased CRP level. Both patients had bilateral visual impairment, with a sudden decrease in vision and delayed choroidal perfusion suggestive of AAION, and were biopsy-proven GCA. Other signs suggestive of AAION included chalky

Table 5. Summary of studies comparing AAION and NAAION.

First author (ref)	Year	Design	Patients (n)		Significantly different variables between AAION compared to NAAION					
			NAAION	AAION	Clinical	Biological	Ophthalmic	Imaging	Main results	
Costello [10]	2004	Retrospective	287	121	-	+	-	-	-	↑ESR ↑CRP ↑Platelet count
Inanc [8]	2017	Retrospective	33	12	-	+	-	-	-	↑Neutrophil/lymphocyte
Koçak [7]	2020	Retrospective	41	16	-	+	-	-	-	↑Age ↑ESR ↑Neutrophil/lymphocyte ↑Monocyte/high-density lipoprotein
Siatkowski [16]	1992	Retrospective	19	16	-	+	-	+	-	↑Age ↑ESR ↑Cup/disc ↓Choroidal filling times ↑Disk pallor frequency
Monteiro [12]	2006	Prospective	24	13	-	-	-	+	-	↑Optic disc area
Danesh-Meyer [29]	2001	Retrospective	32	42	-	-	-	+	-	↑Cupping frequency
Danesh-Meyer [13]	2010	Retrospective	53	18	+	-	-	+	-	↑Age ↓Visual acuity ↑Cup/disc ↓MD ↓NFL thickness
Jonas [11]	1988	Retrospective	33	7	-	-	-	+	-	↑Optic disc area
Huna-Baron [19]	2006	Retrospective	16	16	-	-	-	+	-	↓Intraocular pressure
Valmaggia [17]	1999	Prospective	17	5	-	-	-	+	-	↓Choroidal filling times
Jonas [18]	2008	Retrospective	10	6	-	-	-	+	-	↓CRA collapse pressure
Pellegrini [15]	2019	Retrospective	20	20	+	-	-	+	-	↑Age ↓Visual acuity ↓MD ↓Peripapillary CVI
Ghanchi [20]	1996	Retrospective	4	7	-	-	-	-	+	↓Blood flow in the posterior ciliary arteries
Remond [21]	2017	Prospective	15	15	-	-	-	-	+	↑Central Bright Spot Sign frequency

Ophthalmic ophthalmological, ESR erythrocyte sedimentation rate, CRP C-reactive protein, MD visual field mean deviation, NFL nerve fibre layer, CRA central retinal artery, CVI choroidal vasculature index

white papilloedema and occlusion of the central retinal or cilioretinal artery [36].

The strengths of this study are that it is a large case-control study comparing the clinical, biological and ophthalmological characteristics of AAION versus NAAION. It is one of the largest existing series in the literature. We propose an easy-to-use score with common parameters to help the clinician to quickly diagnose AAION. For the first time, a threshold level of age and CRP are highlighted. In addition, the absence of splinter haemorrhage in favour of AAION is reported for the first time.

Limitations of our study include its retrospective design, which may have introduced referral bias. Also, the inclusion of GCA not confirmed by abnormal TAB or large-vessel imaging may have resulted in sampling bias. Moreover, although this was a multi-centre study, the final sample size was relatively small, which may have obscured potentially relevant variables. Several patients did not have a fluorescein angiogram. Detailed data on the cup/disc ratio, which assists discrimination between AAION and NAAION [11, 12], were lacking. Nevertheless, this is one of the first study that directly compares the features of patients with AAION and NAAION, enabling development of an algorithm to identify AAION cases at admission to the emergency room or ophthalmological department. Finally, we excluded major ACR criteria for GCA from the statistical analysis since they were directly involved in AAION and NAAION classification and allowed the development of our model that correctly classified clinically doubtful cases. However, some rare cases remain incorrectly diagnosed by our model.

Overall, distinguishing AAION and NAAION is a challenge in daily practice, but is crucial because the two conditions require a different approach in terms of work-up and treatment. We identified several clinical, ophthalmological, and laboratory features strongly associated with the arteritic form of AION. This model can help to discriminate of AAION and NAAION, thus ensuring prompt and appropriate treatments for both patient populations.

SUMMARY

What was known before

- Differentiation of arteritic and non-arteritic anterior ischaemic optic neuropathies can be challenging.

What this study adds

- A set of ophthalmological and laboratory criteria can efficiently discriminate patients with arteritic and non-arteritic anterior ischaemic optic neuropathies.

DATA AVAILABILITY

Authors confirm that the data supporting the findings of this study are available within the article.

REFERENCES

1. Hayreh SS Ischemic optic neuropathies. Springer, Heidelberg 2011.
2. Hayreh SS, Joos KM, Podhajsky PA, Long CR. Systemic diseases associated with nonarteritic anterior ischemic optic neuropathy. Am J Ophthalmol. 1994;118:766–80.
3. Weyand CM, Goronzy JJ. Clinical practice. Giant-cell arteritis and polymyalgia rheumatica. N Engl J Med. 2014;371:50–57.
4. Hellmich B, Agueda A, Monti S, Buttgerit F, de Boysson H, Brouwer E, et al. 2018 Update of the EULAR recommendations for the management of large vessel vasculitis. Ann Rheum Dis. 2020;79:19–30.

5. Atkins EJ, Bruce BB, Newman NJ, Biousse V. Treatment of nonarteritic anterior ischemic optic neuropathy. *Surv Ophthalmol.* 2010;55:47–63.
6. Hayreh SS, Podhajsky PA, Zimmerman B. Occult giant cell arteritis: ocular manifestations. *Am J Ophthalmol.* 1998;125:521–6.
7. Koçak N, Yeter V, Güngör I. Monocyte to high-density lipoprotein ratio in patients with arteritic and non-arteritic anterior ischaemic optic neuropathy. *Neuroophthalmology.* 2020;44:294–8.
8. Inanc M, Tekin K, Budakoglu O, Ilhan B, Aydemir O, Yilmazbas P. Could platelet indices and neutrophil to lymphocyte ratio be new biomarkers for differentiation of arteritic anterior ischemic neuropathy from non-arteritic type? *Neuroophthalmology.* 2018;42:287–94.
9. Liozon E, Herrmann F, Ly K, Robert PY, Loustaud V, Soria P, et al. Risk factors for permanent visual loss in giant cell (temporal) arteritis: a prospective study of 174 patients. *Am J Med.* 2001;111:211–7.
10. Costello F, Zimmerman MB, Podhajsky PA, Hayreh SS. Role of thrombocytosis in diagnosis of giant cell arteritis and differentiation of arteritic from non-arteritic anterior ischemic optic neuropathy. *Eur J Ophthalmol.* 2004;14:245–57.
11. Jonas JB, Gusek GC, Naumann GO. Anterior ischemic optic neuropathy: non-arteritic form in small and giant cell arteritis in normal sized optic discs. *Int Ophthalmol.* 1988;12:119–25.
12. Monteiro ML. Anterior ischemic optic neuropathy: a comparison of the optic disc area of patients with the arteritic and non-arteritic forms of the disease and that of normal controls. *Arq Bras Oftalmol.* 2006;69:805–10.
13. Danesh-Meyer HV, Boland MV, Savino PJ, Miller NR, Subramanian PS, Girkin CA, et al. Optic disc morphology in open-angle glaucoma compared with anterior ischemic optic neuropathies. *Invest Ophthalmol Vis Sci.* 2010;51:2003–10.
14. Balducci N, Morara M, Veronese C, Barboni P, Casadei NL, Savini G, et al. Optical coherence tomography angiography in acute arteritic and non-arteritic anterior ischemic optic neuropathy. *Graefes Arch Clin Exp Ophthalmol.* 2017;255:2255–61.
15. Pellegrini M, Giannaccare G, Bernabei F, Moscardelli F, Schiavi C, Campos EC. Choroidal vascular changes in arteritic and nonarteritic anterior ischemic optic neuropathy. *Am J Ophthalmol.* 2019;205:43–49.
16. Siatkowski RM, Gass JD, Glaser JS, Smith JL, Schatz NJ, Schiffman J. Fluorescein angiography in the diagnosis of giant cell arteritis. *Am J Ophthalmol.* 1993;115:57–63.
17. Valmaggia C, Speiser P, Bischoff P, Niederberger H. Indocyanine green versus fluorescein angiography in the differential diagnosis of arteritic and nonarteritic anterior ischemic optic neuropathy. *Retina.* 1999;19:131–4.
18. Jonas JB, Harder B. Central retinal artery and vein collapse pressure in giant cell arteritis versus nonarteritic anterior ischaemic optic neuropathy. *Eye (Lond).* 2008;22:556–8.
19. Huna-Baron R, Mizrahi IB, Glovinsky Y. Intraocular pressure is low in eyes with giant cell arteritis. *J Neuroophthalmol.* 2006;26:273–5.
20. Ghanchi FD, Williamson TH, Lim CS, Butt Z, Baxter GM, McKillop G, et al. Colour Doppler imaging in giant cell (temporal) arteritis: serial examination and comparison with non-arteritic anterior ischaemic optic neuropathy. *Eye (Lond).* 1996;10:459–64.
21. Remond P, Attyé A, Lecler A, Lamalle L, Boudiaf N, Aptel F, et al. The central bright spot sign: a potential new mr imaging sign for the early diagnosis of anterior ischemic optic neuropathy due to giant cell arteritis. *Am J Neuroradiol.* 2017;38:1411–5.
22. Danesh-Meyer HV, Savino PJ, Sergott RC. The prevalence of cupping in end-stage arteritic and nonarteritic anterior ischemic optic neuropathy. *Ophthalmology.* 2001;108:593–8.
23. Hunder GG, Bloch DA, Michel BA, Stevens MB, Arend WP, Calabrese LH, et al. The American College of Rheumatology 1990 criteria for the classification of giant cell arteritis. *Arthritis Rheum.* 1990;33:1122–228.
24. de Boysson H, Dumont A, Liozon E, Lambert M, Boutemy J, Maigné G, et al. Giant-cell arteritis: Concordance study between aortic CT angiography and FDG-PET/CT in detection of large-vessel involvement. *Eur J Nucl Med Mol Imaging.* 2017;44:2274–9.
25. Rinagel M, Chatelus E, Jousse-Joulin S, Sibilia J, Gottenberg JE, Chasset F, et al. Diagnostic performance of temporal artery ultrasound for the diagnosis of giant cell arteritis: a systematic review and meta-analysis of the literature. *Autoimmun Rev.* 2019;18:56–61.
26. Dejaco C, Ramiro S, Duftner C, Besson FL, Bley TA, Blockmans D, et al. EULAR recommendations for the use of imaging in large vessel vasculitis in clinical practice. *Ann Rheum Dis.* 2018;77:636–43.
27. Chan FLY, Lester S, Whittle SL, Hill CL. The utility of ESR, CRP and platelets in the diagnosis of GCA. *BMC Rheumatol* 2019;3:14 <https://doi.org/10.1186/s41927-019-0061-z>
28. Lip GY, Nieuwlaat R, Pisters R, Lane DA, Crijns HJ. Refining clinical risk stratification for predicting stroke and thromboembolism in atrial fibrillation using a novel risk factor-based approach: the Euro Heart Survey on Atrial Fibrillation. *Chest* 2010;137:263–72.
29. Van Buuren S, Groothuis-Oudshoorn K. MICE: Multivariate Imputation by Chained Equations in R. *J Stat Softw.* 2011;45:1–67.
30. Ing EB, Lahaie Luna G, Toren A, Ing R, Chen JJ, Arora N, et al. Multivariable prediction model for suspected giant cell arteritis: development and validation. *Clin Ophthalmol.* 2017;11:2031–42.
31. Ing E, Su W, Schonlau M, Torun N. Support Vector Machines and logistic regression to predict temporal artery biopsy outcomes. *Can J Ophthalmol.* 2019;54:116–8.
32. Ing EB, Ing R. The use of a nomogram to visually interpret a logistic regression prediction model for giant cell arteritis. *Neuroophthalmology.* 2018;42:284–6.
33. Ing EB, Miller NR, Nguyen A, Su W, Bursztyjn LLC, Poole M, et al. Neural network and logistic regression diagnostic prediction models for giant cell arteritis: development and validation. *Clin Ophthalmol.* 2019;13:421–30.
34. Czihal M, Tschaidse J, Bernau C, Lottspeich C, Köhler A, Dechant C, et al. Ocular ischaemic complications in giant cell arteritis: CHADS2-score predicts risk of permanent visual impairment. *Clin Exp Rheumatol.* 2019;37:61–64.
35. Hayreh SS. Anterior ischaemic optic neuropathy. differentiation of arteritic from non-arteritic type and its management. *Eye.* 1990;4:25–41.
36. Mack HG, O'Day J, Currie JN. Delayed choroidal perfusion in giant cell arteritis. *J Clin Neuroophthalmol.* 1991;11:221–7.
37. Bei L, Lee I, Lee MS, Van Stavem GP, McClelland CM. Acute vision loss and choroidal filling delay in the absence of giant-cell arteritis. *Clin Ophthalmol.* 2016;10:1573–8.
38. Chen JJ, Leavitt JA, Fang C, Crowson CS, Matteson EL, Warrington KJ. evaluating the incidence of arteritic ischemic optic neuropathy and other causes of vision loss from giant cell arteritis. *Ophthalmology.* 2016;123:1999–2003.

AUTHOR CONTRIBUTIONS

Conception and design of the work: SP, TS, BT Acquisition and interpretation of the data: SP, AD, RM, SD, AR, GG, DM, APB, KHL, EL, TS, BT. Drafting the manuscript: SP, BT. Revising the work critically: AD, RM, SD, AR, GG, DM, APB, KHL, EL, TS.

COMPETING INTERESTS

The authors declare no competing interests.

ADDITIONAL INFORMATION

Supplementary information The online version contains supplementary material available at <https://doi.org/10.1038/s41433-022-02295-w>.

Correspondence and requests for materials should be addressed to Simon Parreau.

Reprints and permission information is available at <http://www.nature.com/reprints>

Publisher's note Springer Nature remains neutral with regard to jurisdictional claims in published maps and institutional affiliations.

Springer Nature or its licensor (e.g. a society or other partner) holds exclusive rights to this article under a publishing agreement with the author(s) or other rightsholder(s); author self-archiving of the accepted manuscript version of this article is solely governed by the terms of such publishing agreement and applicable law.

Annexe 2.

Features and risk factors for new (secondary) permanent visual involvement in giant cell arteritis.

Features and risk factors for new (secondary) permanent visual involvement in giant cell arteritis

M.F. Curumthaullee¹, E. Liozon², S. Dumonteil², G. Gondran²,
A.-L. Fauchais², K.-H. Ly², P.-Y. Robert¹, S. Parreau²

¹Department of Ophthalmology, ²Department of Internal Medicine, Dupuytren University Hospital, Limoges, France.

Abstract

Objective

New permanent visual loss (PVL) in treated patients with giant cell arteritis (GCA) is a rare but worrisome occurrence. In this study, we aimed to describe the frequency and main features of new PVL occurring after the beginning of glucocorticoid therapy in patients with newly diagnosed GCA.

Methods

We included in an inception cohort all consecutive patients newly diagnosed with GCA in the internal medicine department of a tertiary-care hospital between 1976 and May 2020. The study population comprised all the patients without bilateral PVL before treatment who were followed for at least one year. Only well-documented visual events that set after the initiation of glucocorticoid treatment were regarded as new PVL.

Results

Eleven out of 502 patients (2.2%) experienced a new PVL including 6 occurrences during the initial therapeutic phase and 5 during the tapering phase. Patients with new PVL during treatment had higher mean age, more often displayed temporal artery abnormalities on physical examination, and had higher mean platelet counts at GCA onset. There was a strong excess risk of contralateral recurrence during treatment in patients with unilateral loss at GCA onset compared with patients with uncomplicated GCA (10.5% vs 1.1%, OR=10.26, $p<0.001$).

Conclusion

New PVL in treated GCA is a rare, but significant occurrence. Older patients and patients who already had unilateral PVL at diagnosis have higher risk of new ischaemic visual loss during treatment compared to the other patients. Close clinical, laboratory, and eye monitoring of these high-risk patients is of paramount importance.

Key words

giant cell arteritis, visual, risk factors, cohort studies, glucocorticoids

Muhammad Faiz Curumthaullee, MD
 Eric Liozon, MD
 Stéphanie Dumonteil, MSc
 Guillaume Gondran, MD
 Anne-Laure Fauchais, MD, PhD
 Kim-Heang Ly, MD, PhD
 Pierre-Yves Robert, MD, PhD
 Simon Parreau, MD

Please address correspondence to:
 Eric Liozon,
 Service de Médecine Interne A,
 CHRU Dupuytren 2,
 16 Rue du Professeur Bernard Descottes,
 87042 Limoges, France.
 E-mail: eric.liozon@chu-limoges.fr
 liozone@yahoo.fr

Received on July 29, 2021; accepted in
 revised form on November 8, 2021.

© Copyright CLINICAL AND
 EXPERIMENTAL RHEUMATOLOGY 2022.

Introduction

Giant cell arteritis (GCA) is the most common vasculitis in people aged fifty or more and preferentially affects the thoracic aorta and its main branches including temporal arteries (1). Treatment is based on long-term high-dose corticosteroid therapy, which is fraught with frequent side-effects (2). Moreover, relapses occur in half of the patients during tapering and discontinuation of treatment (3). Efforts have been, therefore, made for several decades to better understand the pathophysiology of GCA thereby determining new therapeutic targets aimed at corticosteroid sparing (4).

The primary cause of disability in GCA is permanent visual impairment, which occurs in 14-18% of patients (5-12). Given the high risk of unforeseeable, sudden blindness, sometimes bilateral, GCA remains an absolute medical emergency. Visual loss most often occurs in untreated subjects with new onset GCA, the visual risk decreasing dramatically after initiation of high dose GC treatment. Any delay in initiating treatment may, therefore, be detrimental to the patient's sight.

Conversely, new permanent visual loss in treated patients is regarded as a rare occurrence, although it has been described to occur in the first few days of GC treatment or, exceptionally later, during the GC tapering (5-8, 13, 14). Although the fear of secondary visual events obviously has represented a major constraint on building rapidly decreasing GC protocols, there is still little medical research on this topic. The present study aimed to describe the frequency and main features of, and risk factors for, permanent visual loss occurring after the beginning of therapy in patients with newly diagnosed GCA.

Methods

Patients and data collection

Inception GCA cohort. From 1976 through May 2020, we included all consecutive patients diagnosed in the internal medicine department of a tertiary-care teaching hospital for the diagnosis and treatment of GCA and regularly followed up these patients until they were recovered. GCA was

diagnosed based on the criteria of the American College of Rheumatology (15) and was considered present in biopsy-negative cases if at least three of these criteria were fulfilled or if only two criteria were fulfilled but fluoro-deoxyglucose (FDG)-positron emission tomography (PET) scans showed strong uptake of the large vessel walls (16). In biopsy-proven cases, GCA was pathologically confirmed on temporal artery biopsy using currently accepted criteria. Clinical, laboratory, and pathological data were prospectively recorded at the time of first admission using a specifically designed 176-item questionnaire of detailed history and log data. All study data were stored in computerised files and regularly updated (17).

Visual impairment

We included in the study all permanent visual impairments that were confirmed by the Ophthalmology staff and resulted from anterior ischaemic optic neuropathy (AION), posterior ischaemic optic neuropathy (PION), central retinal artery occlusion (CRAO), or occipital stroke. Amaurosis fugax, diplopia and oculomotor paralysis were excluded because they do not result in permanent visual impairment. Patients who already had bilateral visual impairment from GCA before initiation of corticosteroid therapy also were excluded from study. Likewise, worsening of an already established visual complication at the beginning of GC treatment was not regarded as a new visual event; only ischaemic visual events that started after the initiation of corticosteroid therapy were eligible to the study.

Clinical variables and definitions

Clinical variables extracted from the computerised files were associated polymyalgia rheumatica, new onset of localised headache, scalp tenderness, jaw claudication, visual ischaemic impairment. Temporal artery was considered abnormal if any among the following features was present: decrease or absent pulse, beaded and/or indurated artery, local redness, or tenderness. Constitutional syndrome was defined

Competing interests: none declared.

by a temperature of more than 38°C for more than a week associated with severe asthenia and/or a weight loss of more than 5%.

Treatment

Patients were treated using standardised protocols with prednisone at a starting dose of 0.6–1 mg/kg/d, according to clinical severity of the disease. Patients without ischaemic visual symptoms received a dose of 0.6–0.8 mg/kg/d prednisone until they became asymptomatic and the C-reactive protein level has fallen below 0.5mg/dl. Then the dose was gradually decreased to 0.35 mg/kg/d over 4 to 6 weeks. Patients with ischaemic visual impairment or visual threat (amaurosis fugax, abnormal eye fundus or altered ophthalmic artery ultrasound Doppler) initially received a starting dose of 0.9-1mg/kg/d prednisone, often preceded by pulse high dose methylprednisolone, and then the dose was decreased similarly. The initial therapeutic phase comprised the duration of treatment at the initial dose including days on methylprednisolone pulses while the tapering phase represented the duration of GC treatment from the first dosage decrement to planned cessation.

Statistical analysis

Data were extracted and analysed retrospectively from information initially collected prospectively from the patients' charts. We compared the clinical and laboratory variables of patients with new visual impairment with those of the rest of the cohort. We also compared the frequency of occurrence of new PVL, according to the initial eye status of the patient (e.g. unilateral PVL versus both spared eyes). Quantitative variables were expressed as medians and standard deviation. Qualitative variables were expressed as frequencies with percentages. Comparisons were made by Pearson's Chi-2 test, Fisher's exact test, or Wilcoxon test as appropriate for each variable. A p-value less than 0.05 was considered to be significant. All calculations were performed using R software v. 3.2.2 (R foundation for statistical computing, Vienna, Austria).

Table I. Characteristics of the cohort with comparison between patients with new ischaemic visual loss and patients without that event.

Patients, n	Absence of new permanent visual impairment (n = 491)	New permanent visual impairment (n = 11)	Total (n = 502)	p-value*
	numbers (%) or median [interquartile]			
Clinical characteristics				
Male gender	174 (35.4)	3 (27.3)	177 (35.3)	0.7541
Body weight (kg)	62.9 (12.4)	61.5 (12.7)	62.8 (12.4)	0.7099
Age (y)	74.0 (7.8)	79.4 (9.0)	74.1 (7.9)	0.0138
Abnormal temporal artery	277 (57.2)	10 (90.9)	287 (58.0)	0.0293
Polymyalgia rheumatica	161 (32.8)	2 (18.2)	163 (32.5)	0.5161
Headache	405 (82.5)	10 (90.9)	415 (82.7)	0.6987
Scalp tenderness	230 (48.4)	8 (72.7)	238 (49.0)	0.1344
Jaw claudication	154 (31.4)	6 (54.5)	160 (31.9)	0.1938
Fever	207 (42.6)	3 (27.3)	210 (42.3)	0.3699
Constitutional syndrome	364 (74.7)	6 (54.5)	370 (74.3)	0.2432
Amaurosis fugax	43 (8.8)	0 (0.0)	43 (8.7)	0.6105
Unilateral permanent visual loss	51 (10.4)	6 (54.5)	57 (11.4)	<0.0001
Positive TAB	346 (72.5)	9 (81.8)	355 (72.7)	0.7350
Number of ACR criteria met	4.0 (0.9)	4.6 (0.7)	4.04 (0.9)	0.0656
Laboratory characteristics				
ESR, mm/h	86.4 (29.5)	85.1 (30.0)	86.4 (29.5)	0.9373
CRP, mg/dl	95.8 (67.6)	102.9 (40.0)	96.0 (67.1)	0.3415
Fibrinogen, g/l	6.8 (1.7)	7.7 (1.4)	6.8 (1.7)	0.1293
Albumin, g/l	33.8 (5.7)	31.4 (4.5)	33.8 (5.7)	0.2238
Haemoglobin, g/l	115.6 (17.2)	119.0 (16.9)	115.7 (17.2)	0.5175
White blood cells, g/l	9289.8 (3123.2)	9901.8 (2880.7)	9304.0 (3116.3)	0.4239
Platelets, G/l	436.0 (156.9)	537.3 (159.5)	438.1 (157.5)	0.0116
Treatment				
Pulse methylprednisolone	109 (22.2)	7 (63.6)	116 (23.1)	0.0043
Prednisone initial dose (mg/kg/d)	0.8 (0.2)	0.9 (0.1)	0.8 (0.2)	0.0030
Duration of initial treatment (d)	19.1 (10.0)	21.9 (7.5)	19.1 (10.0)	0.1550
Dose at 3 months (mg/d)	18.3 (6.3)	18.0 (5.5)	18.3 (6.2)	0.9505
Dose at 6 months (mg/d)	12.3 (4.8)	10.3 (5.2)	12.2 (4.8)	0.4562
Dose at 12 months (mg/d)	7.0 (4.4)	12.0 (7.9)	7.1 (4.5)	0.0531
Duration of treatment (mo.)	34.2 (26.3)	30.2 (25.6)	34.1 (26.3)	0.8631
Outcome issues				
Duration of follow-up (mo.)	95.0 (66.5)	68.6 (66.5)	94.4 (66.5)	0.1332
Relapses	301 (61.3)	8 (72.7)	309 (61.6)	0.5430
Death during treatment	32 (6.5)	4 (36.4)	36 (7.2)	0.0051

* Comparisons were made using Pearson's Chi-2 test, Fisher's exact test, or Wilcoxon test as appropriate for each variable.

TA: temporal artery; PMR: polymyalgia rheumatica; TAB: temporal artery biopsy; ACR: American college of rheumatology; ESR: erythrocyte sedimentation rate; CRP: C-reactive protein.

Ethics board approval and informed consent

All data concerning these elderly patients with GCA were retrospectively collected. This study was conducted in compliance with the Good Clinical Practice and Declaration of Helsinki principles. In accordance with the French law, formal approval from an ethics committee and written informed consent were not required for this type of retrospective study, provided the patient has not exercised the right to reject his participation to study.

Results

Characteristics of the cohort

From 1976 through May 2020, 584 patients were included in the inception cohort. Seventeen patients with initial bilateral PVL from GCA before the initiation of glucocorticoid therapy were excluded, as were 65 other patients, for various reasons, mainly early death or inadequate follow-up. A total of 502 GCA patients (355 biopsy-proven) met the entry criteria and were included in the study (Fig. 1). Fifty-seven (11.4%) patients had unilateral permanent vis-

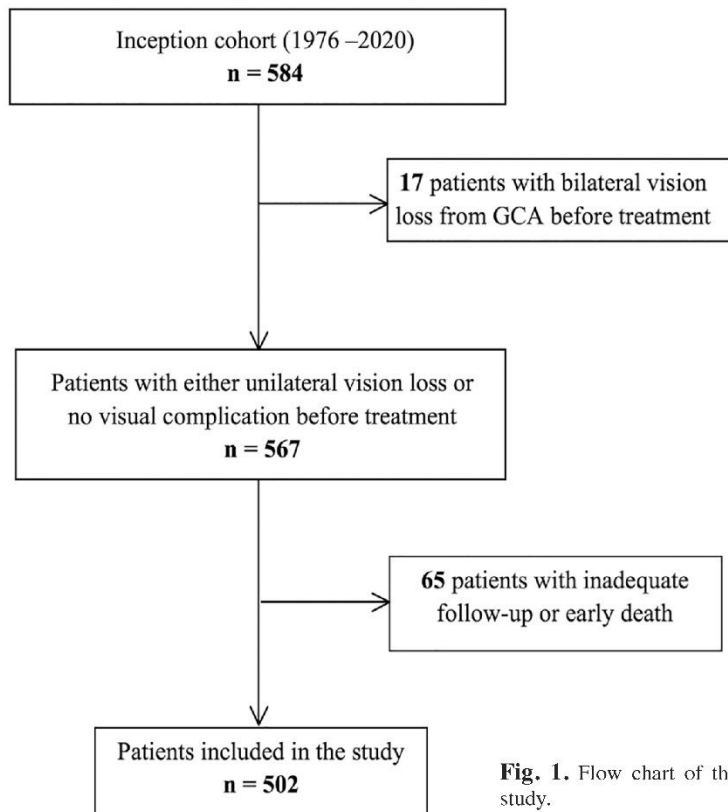


Fig. 1. Flow chart of the study.

ual loss occurrence at GCA onset. The 502 patients were followed for 7.9 (5.5 SD) years.

New visual impairment

In all, 11 patients (2.2%) developed new ischaemic visual impairment after

the initiation of corticosteroid therapy. Nine (82%) had biopsy-proven GCA. Table II depicts the main characteristics of these patients. Six (55%) had a visual event during the initial therapeutic phase (median=6 days) while the remaining 5 (45%) patients includ-

ing 4 with biopsy-proven GCA experienced visual loss during the tapering phase (median=11 months). Of the 11 patients, 6 had contralateral AION prior to corticosteroid treatment, four of whom developed contralateral loss during the early phase of GC treatment. New visual impairments during treatment were mainly AION (73%). Other impairments included CRAO (n=1), PION (n=1) and, occipital stroke (n=1). One patient had two consecutive episodes AION occurring after the start of treatment (2 and 9 days respectively). During the period of tapering, all the patients with secondary visual impairment also showed an increase in their biological inflammatory parameters. No patients had a visual relapse after planned treatment discontinuation.

Among-groups comparisons

Table I shows the comparison between both groups of patients. Patients with a new visual event were older and more often displayed abnormality on temporal artery palpation compared with patients without a new event. Other symptoms characterising GCA were not different between the two groups. Among the inflammatory parameters, only platelet levels were higher in the group with new visual event. Regarding treatment issues, patients with a

Table II. Characteristics of the 11 patients with new visual impairment (e.g., event occurring after initiation of treatment).

Case	Sex/Age	Initial visual impairment*	Associated symptoms	CRP (mg/dl)	TAB	Initial corticosteroid treatment (mg/kg/day)	Pulse MP	Duration of initial treatment (days) [‡]	New visual impairment [§]	Time of onset	Prednisone dose during new visual impairment (mg/d)
1	F/79	AION	Headache	9.7	+	1	+	11	AION	4 days	50
2	F/85	-	JC, CS	9.1	+	1	+	16	Bilateral AION	2 + 9 days	60
3	M/90	AION	-	-	+	0.85	-	23	AION	6 days	50
4	F/91	AION	-	6.6	+	1	+	30	AION	7 days	60
5	F/78	AION	-	14.1	+	1	+	32	AION	8 days	80
6	F/78	-	Headache, JC	12.0	+	0.7	-	21	CRAO	11 days	85
7	M/57	AION	Headache	1.9	-	1	+	23	PION	6 months	17
8	F/78	-	Headache, PMR	12.0	+	1	-	30	AION	8 months	9
9	M/77	-	Headache, CS	8.9	+	0.7	-	14	AION	11 months	11
10	F/78	-	Headache, PMR	15.7	+	0.7	-	13	Occipital stroke	13 months	7
11	F/82	AION	-	1.29	-	1	+	28	AION	15 months	3

AION: anterior ischaemic optic neuropathy; JC: jaw claudication; CS: constitutional syndrome; PMR: polymyalgia rheumatica; CRP: C-reactive protein; TAB: temporal artery biopsy; CRAO: central retinal artery occlusion; PION: posterior ischaemic optic neuropathy; MP: methylprednisolone.

*Before initial corticosteroid therapy.

‡Since the diagnosis of GCA.

§After initial corticosteroid therapy.

Table III. Review of published studies both focusing on early and late ischaemic visual events in patients with giant cell arteritis.

Study (year)	Numbers of patients	Visual events occurring during initial GC treatment, n (%)	Visual events occurring during GC tapering or after discontinuation, n (%)	Total, n (%)
Beevers (1973)	36	0	2 (5.5)	2 (5.5)
Jonasson (1979)	136	4 (2.9)	4 (2.9)	8 (5.9)
Myles (1992)	96	0	1 (1)	1 (1)
Kyle (1993)	35	0	1 (2.8)	1 (2.8)
Aiello (1993)	327	3 (0.9)	2 (0.6)	5 (1.5)
Liu (1994)	185	3 (1.6)	6 (3.2)	9 (4.9)
Font (1997)	146	1 (0.7)	1 (0.7)	2 (1.4)
Gonzalez gay (1998)	239	4 (1.6)	0	4 (1.6)
Hoffman (2002)	98	0	8 (8)	8 (8)
Hayreh (2003)	144	1 (0.7)	0	1 (0.7)
Nesher (2004)	166	0	8 (4.8)	8 (4.8)
Salvarani (2005)	136	0	1 (0.7)	1 (0.7)
Hoffman (2007)	44	0	7 (16)	7 (16)
Nesher (2008)	116	0	5 (4.3)	5 (4.3)
Alba (2014)	106	0	1 (0.9)	1 (0.9)
Hoçevan (2016)	68	0	1 (1.5)	1 (1.5)
Restucia (2017)	157	0	1 (0.6)	1 (0.6)
Leon (2018)	168	0	1 (0.6)	1 (0.6)
Unizony (2021)	60	0	2 (3.3)	2 (3.3)
Total	2 ^a 463	16 (0.7)	52 (2.1)	68 (2.8)

new visual event more often had received pulse methylprednisolone and an initial dose of prednisone of 1 mg/kg/d. In contrast, the duration of treatment of the initial and tapering phases did not differ, nor did the doses at 3, 6 and 12 months. In addition, there was an excess risk of contralateral recurrence during treatment in patient with unilateral loss at GCA onset compared with the rest of the cohort (10.5% vs. 1.1%, Fisher's exact test, OR=10.26, CI: 2.51-44.08, $p<0.001$).

Discussion

In patients with newly diagnosed GCA, the risk of permanent visual event after initiation of treatment is a key element of the disease management. In this large comparative study, we found 2.2% of permanent visual loss after the beginning of corticosteroid therapy, making it a rare event. Pooling the results of 18 clinical studies including a total of 2463 patients (5-8, 11-13, 18-29), we found that secondary permanent visual loss occurred in 2.8% of the cases in average (Table III). Noteworthy, the proportion of patients experiencing a visual event during the initial phase of GC treatment is higher in the present study (55%) than in the literature re-

view (25%). In a recent meta-analysis by Bugdayli *et al.* (30), the incidence of secondary permanent visual damage was lower (1.5%), but the authors excluded events occurring less than 4 weeks after starting GC treatment. The highest rate of secondary visual events was found in the clinical trial of methotrexate by Hoffmann *et al.* in which 16% of the patients suffered a secondary permanent visual loss (21). Use of an aggressive GC tapering best explains late visual events being observed at such a high frequency. In fact, patients included in this study were planned to receive a prednisone dose less than 10mg/d at 3 months, which may prove risky. On the contrary, of 174 patients with biopsy-proven GCA uniformly treated and followed with prudent corticosteroid tapering, 74 experienced relapses or recurrences, none of whom suffered visual loss (31). Thus, blindness following disease relapses in GCA patients adequately treated is very uncommon. The predictive factors of new visual event after the beginning of corticosteroid therapy still are not well established. In an epidemiologic study, the best predictive model of biopsy-proven GCA included an abnormal temporal

artery on physical examination (OR =3.2), and the presence of visual complications (OR = 4.9) (32). Although patients included in the present study displayed either of these features in 100% of the cases, the too small sample precludes any statistical confirmation of a relationship between biopsy-proven GCA and late visual loss. In the present study, most patients (4 in the early group and 2 in the tapering group) who experienced visual loss during GC treatment already had unilateral PVL from AION and there was strong excess risk of contralateral recurrence during treatment in such patients. Accordingly, Nesher *et al.* found a strong association between ischaemic visual impairment at GCA onset and subsequent cranial ischaemic events including permanent visual loss and stroke (OR=8.3, $p=0.001$) (11). In the study by Aiello *et al.* in case of an initial ischaemic visual damage, the probability of developing a new PVL was 13% at 5 years, whereas it was only 1% in its absence (5). In a study of 67 GCA-related AION, Chan *et al.* found 7 ischaemic eye recurrences (10%), occurring between 3 and 36 months (33). In this study, no predictive factors for recurrence were identified. In a meta-analysis of 39 studies including 1296 patients, Loddenkemper *et al.* found a highly significant correlation (Pearson's correlation coefficient 0.604, $p<0.0001$) between the percentage of patients with visual loss on presentation and visual loss under corticosteroid therapy (34). Thus, patients with permanent loss of vision of one eye at GCA onset should be closely monitored during corticosteroid therapy until recovery to detect any disease flare early. This should lead to readjust the treatment in a timely manner, thereby avoiding a devastating ischaemic recurrence on the fellow eye. Secondary visual impairment in GCA appears biphasic. The first peak of frequency is during the first week of the treatment and the second peak during the tapering phase. In most patients, visual loss is due to AION. The optic nerve head is vascularised primarily by the short posterior ciliary arteries (35). Angiographic (36) and histological (37) studies showed that these arter-

ies are completely occluded in AION. According to Hayreh, there is also a decrease in choroidal perfusion in the unaffected contralateral eye, despite normal visual acuity, in patients with AION (38). The progression of visual loss in these patients may be due to the delay in initiating corticosteroid therapy and its progressive onset of action. In complicated GCA, the short posterior ciliary arteries present granulomatous inflammation with giant cells, intimal thickening, and thrombotic occlusion of the arterial lumen (39). Even aggressive corticosteroid therapy will take time or might be ineffective to stop the threatening vasculitic process, especially the vascular remodelling that has already occurred. Nevertheless, the earlier the treatment is started, the better the chances of preventing blindness (7, 26).

Hypoperfusion of the optic nerve head may be another factor precipitating early recurrence. Ocular perfusion depends on mean arterial blood pressure, intraocular pressure and blood flow resistance (40). Any decrease in mean arterial blood pressure or increase in intraocular pressure or a combination of both can compromise the blood supply to the papilla and accelerate visual loss (41). Visual decline often occurs in the morning upon awakening, as in non-arteritic AION (42), suggesting that nocturnal arterial hypotension could either contribute to completing a thrombotic stasis occlusion or decrease the perfusion pressure below the critical threshold of partially occluded ciliary arteries, compromising circulation for a period long enough to cause AION (43). It is therefore legitimate to prevent hypotensive overmedication during this critical period. Overall, other traditional cardiovascular risk factors (44, 45) and the CHADS₂-VASc score (46) may increase the risk of PVL in GCA patients. Whether these factors also apply to the risk of developing new visual loss during treatment is unknown, however, owing to the rarity of this event.

Although most reversible manifestations of GCA improve within hours or days of initiation of corticosteroid therapy, vascular parietal inflammation persists for a long time. Histological

analysis of temporal artery biopsies months after treatment demonstrated the persistence of inflammatory lesions in situ several months after the diagnosis of GCA even under corticosteroid therapy (47). This may explain late PVL recurrences, especially if corticosteroid therapy is reduced too quickly, as the methotrexate and the infliximab prospective trials highlighted (21, 23), or stopped prematurely. Whether the addition of antiplatelet agents to GCs therapy in GCA would improve the visual prognosis is disputed (48-50).

The role of tocilizumab in complicated GCA deserves discussion. Interleukin-6 blockade has been shown to decrease significantly the risk of GCA relapses during corticosteroid tapering, along with a favourable safety profile, both in randomised controlled trials and a retrospective study (51). In a real-life observational study, Unizony *et al.* recently demonstrated that Tocilizumab significantly decreases the rate of ischaemic visual recurrences including amaurosis fugax, transient diplopia, blurred vision and PVL in patients with inaugural ischaemic visual manifestations in GCA (29). Offering to patients with complicated GCA a targeted therapy such as tocilizumab early could have a beneficial effect on the ultimate visual prognosis. Further studies are needed to confirm this hypothesis. Moreover, the early addition of tocilizumab in complicated forms of GCA could have a positive impact on survival. Indeed, we recorded more fatalities occurring during GC treatment in patients with secondary visual impairment compared to other patients. A higher mean patient's age and heavier burden of GC treatment may best explain this finding, since these patients more often received initially pulse methylprednisolone and/or prednisone at 0.9 mg/kg/day or more and might thus have been overexposed to serious therapeutic complications.

New permanent visual loss in treated GCA patients is a rare, but serious occurrence. There is an increased risk of developing permanent visual loss during treatment after a first loss at disease onset and such patients could also have decreased survival. Besides the com-

prising need for closer monitoring and thorough management of disease flares in patients with initial unilateral visual loss, both pathophysiological backgrounds of ischaemic visual deterioration and recent data supporting the use of IL-6 blockade in uncomplicated (52) or complicated (29) GCA call for prospective studies aimed at determining to which extent tocilizumab prevents further visual deterioration and has steroid-sparing effect in patients with unilateral visual loss at GCA onset.

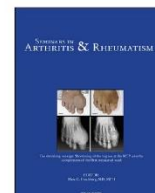
References

- WEYAND CM, GORONZY JJ: Giant-cell arteritis and polymyalgia rheumatica. *N Engl J Med* 2014; 371: 50-7.
- PROVENA A, GABRIEL SE, ORCES C, O'FALLON WM, HUNDER GG: Glucocorticoid therapy in giant cell arteritis: duration and adverse outcomes. *Arthritis Rheum* 2003; 49: 703-8.
- MAINBOURG S, ADDARIO A, SAMSON M *et al.*: Prevalence of giant cell arteritis relapse in patients treated with glucocorticoids: a meta-analysis. *Arthritis Care Res* 2020; 72: 838-49.
- AKIYAMA M, OHTSUKI S, BERRY GJ, LIANG DH, GORONZY JJ, WEYAND CM: Innate and Adaptive Immunity in Giant Cell Arteritis. *Front Immunol* 2021; 11: 621098.
- AIELLO PD, TRAUTMANN JC, MCPHEE TJ, KUNSELMAN AR, HUNDER GG: Visual prognosis in giant cell arteritis. *Ophthalmology* 1993; 100: 550-5.
- LIU GT, GLASER JS, SCHATZ NJ, SMITH JL: Visual morbidity in giant cell arteritis. Clinical characteristics and prognosis for vision. *Ophthalmology* 1994; 101: 1779-85.
- GONZALEZ-GAY MA, BLANCO R, RODRIGUEZ-VALVERDE V *et al.*: Permanent visual loss and cerebrovascular accidents in giant cell arteritis: predictors and response to treatment. *Arthritis Rheum* 1998; 41: 1497-504.
- GONZALEZ-GAY MA, GARCIA-PORRUA C, LLORCA J *et al.*: Visual manifestations of giant cell arteritis. Trends and clinical spectrum in 161 patients. *Medicine* 2000; 79: 283-92.
- LIOZON E, HERRMANN F, LY K *et al.*: Risk factors for visual loss in giant cell (temporal) arteritis: a prospective study of 174 patients. *Am J Med* 2001; 111: 211-7.
- FONT C, CID MC, COLL-VINENT B, LOPEZ-SOTO A, GRAU JM: Clinical features in patients with permanent visual loss due to biopsy-proven giant cell arteritis. *Br J Rheumatol* 1997; 36: 251-4.
- NESHER G, BERKUN Y, MATES M *et al.*: Risk factors for cranial ischemic complications in giant cell arteritis. *Medicine* 2004; 83: 114-22.
- SALVARANI C, CIMINO L, MACCHIONI P *et al.*: Risk factors for visual loss in an Italian population-based cohort of patients with giant cell arteritis. *Arthritis Rheum* 2005; 53: 293-7.
- JONASSON F, CULLEN JF, ELTON RA: Tempo-

- ral arteritis. A 14-year epidemiological, clinical and prognostic study. *Scott Med J* 1979; 24: 111-17.
14. HAYREH SS, ZIMMERMAN B: Visual deterioration in giant cell arteritis while on high doses of corticosteroid therapy. *Ophthalmology* 2003; 110: 1204-15.
 15. HUNDER GG, BLOCH DA, MICHEL BA *et al.*: The American College of Rheumatology 1990 criteria for the classification of giant cell arteritis. *Arthritis Rheum* 1990; 33: 1122-28.
 16. DE BOYSSON H, DUMONT A, LIOZON E *et al.*: Giant-cell arteritis: Concordance study between aortic CT angiography and FDG-PET/CT in detection of large-vessel involvement. *Eur J Nucl Med Mol Imaging* 2017; 44: 2274-9.
 17. LIOZON E, DALMAY F, LALLOUE F *et al.*: Risk factors for permanent visual loss in biopsy-proven giant cell arteritis: A study of 339 patients. *J Rheumatol* 2016; 43: 1393-9.
 18. BEEVERS DG, HARPUR JE, TURK KA: Giant cell arteritis--the need for prolonged treatment. *J Chronic Dis* 1973; 26: 571-84.
 19. MYLES AB, PERERA T, RIDLEY MG: Prevention of blindness in giant cell arteritis by corticosteroid treatment. *Rheumatology* 1992; 31: 103-5.
 20. KYLE V, HAZLEMAN BL: The clinical and laboratory course of polymyalgia rheumatica/giant cell arteritis after the first two months of treatment. *Ann Rheum Dis* 1993; 52: 847-50.
 21. HOFFMAN GS, CID MC, HELLMANN DB *et al.*: A multicenter, randomized, double-blind, placebo-controlled trial of adjuvant methotrexate treatment for giant cell arteritis. *Arthritis Rheum* 2002; 46: 1309-18.
 22. HAYREH SS, ZIMMERMAN B: Visual deterioration in giant cell arteritis patients while on high doses of corticosteroid therapy. *Ophthalmology* 2003; 110: 1204-15.
 23. HOFFMAN GS, CID MC, RENDT-ZAGAR KE *et al.*: Infliximab for maintenance of glucocorticosteroid-induced remission of giant cell arteritis: a randomized trial. *Ann Intern Med* 2007; 146: 621-30.
 24. NESHER G, NESHER R, MATES M, SONNENBLICK M, BREUER GS: Giant cell arteritis: intensity of the initial systemic inflammatory response and the course of the disease. *Clin Exp Rheumatol* 2008; 26: (Suppl. 49): S30-4.
 25. ALBA MA, GARCÍA-MARTÍNEZ A, PRIETO-GONZÁLEZ S *et al.*: Relapses in patients with giant cell arteritis: prevalence, characteristics, and associated clinical findings in a longitudinally followed cohort of 106 patients. *Medicine (Baltimore)* 2014; 93: 194-201.
 26. HOCEVAR A, ROTAR Z, JESE R *et al.*: Do early diagnosis and glucocorticoid treatment decrease the risk of permanent visual loss and early relapses in giant cell arteritis. *Medicine (Baltimore)* 2016; 95: e3210.
 27. RESTUCCIA G, BOIARDIL L, CAVAZZAA *et al.*: Long-term remission in biopsy proven giant cell arteritis: A retrospective cohort study. *J Autoimmun* 2017; 77: 39-44.
 28. LEON L, RODRIGUEZ-RODRIGUEZ L, MORADO I *et al.*: Treatment with methotrexate and risk of relapses in patients with giant cell arteritis in clinical practice. *Clin Exp Rheumatol* 2018; 36 (Suppl. 111): S121-8.
 29. UNIZONY S, MCCULLEY TJ, SPIERA R *et al.*: Clinical outcomes of patients with giant cell arteritis treated with tocilizumab in real-world clinical practice: decreased incidence of new visual manifestations. *Arthritis Res Ther* 2021; 23: 8.
 30. BUGDAYLIK, UNGPRASERT P, WARRINGTON K, KOSTER M: Visual ischemia during relapse and follow-up of giant cell arteritis: a systematic review [abstract]. *Arthritis Rheumatol* 2020; 72 (Suppl. 10).
 31. MARTINEZ-LADO L, CALVINO-DIAZ C, PINEIRO A *et al.*: Relapses and recurrences in giant cell arteritis: a population-based study of patients with biopsy-proven disease from northwestern Spain. *Medicine (Baltimore)* 2011; 90: 186-93.
 32. GONZALEZ-GAY MA, GARCIA-PORRUA C, LLORCA J *et al.*: Biopsy-negative giant cell arteritis: clinical spectrum and predictive factors for positive temporal artery biopsy. *Semin Arthritis Rheum* 2011; 30: 249-56.
 33. CHAN CC, PAINE M, O'DAY J: Predictors of recurrent ischemic optic neuropathy in giant cell arteritis. *J Neuroophthalmol* 2005; 25: 14-7.
 34. LODDENKEMPER T, SHARMA P, KATZAN I, PLANT GT: Risk factors for early visual deterioration in temporal arteritis. *J Neurol Neurosurg Psychiatry* 2007; 78: 1255-9.
 35. HAYREH SS: The 1994 von Sallman lecture the optic nerve head circulation in health and disease. *Exp Eye Res* 1995; 61: 259-72.
 36. HAYREH S: Anterior ischaemic optic neuropathy: II. Fundus on ophthalmoscopy and fluorescein angiography. *Br J Ophthalmol* 1974; 58: 964-80.
 37. HENKIND P, CHARLES NC, PEARSON J: Histopathology of ischemic optic neuropathy. *Am J Ophthalmol* 1970; 69: 78-90.
 38. HAYREH SS: Ischemic optic neuropathies. Springer 2011.
 39. MACFAUL PA: Ciliary artery involvement in giant cell arteritis. *Br J Ophthalmol* 1967; 51: 505-12.
 40. HAYREH SS: Factors influencing blood flow in the optic nerve head. *J Glaucoma* 1997; 6: 412-25.
 41. HAYREH SS, PODHAJSKY PA, ZIMMERMAN B: Ocular manifestations of giant cell arteritis. *Am J Ophthalmol* 1998; 125: 509-20.
 42. HAYREH SS, PODHAJSKY PA, ZIMMERMAN B: Nonarteritic anterior ischemic optic neuropathy: time of onset of visual loss. *Am J Ophthalmol* 1997; 124: 641-7.
 43. HAYREH SS, ZIMMERMAN MB, PODHAJSKY P, ALWARD WL: Nocturnal arterial hypotension and its role in optic nerve head and ocular ischemic disorders. *Am J Ophthalmol* 1994; 117: 603-24.
 44. GONZALEZ-GAY MA, PINEIRO A, GOMEZ-GIGIREY A *et al.*: Influence of traditional risk factors of atherosclerosis in the development of severe ischemic complications in giant cell arteritis. *Medicine (Baltimore)* 2004; 83: 342-7.
 45. YATES M, MACGREGOR AJ, ROBSON J *et al.*: The association of vascular risk factors with visual loss in giant cell arteritis. *Rheumatology (Oxford)* 2017; 56: 524-8.
 46. CZIHAL M, TSCHAUDE J, BERNAU C *et al.*: Ocular ischaemic complications in giant cell arteritis: CHADS-score predicts risk of permanent visual impairment. *Clin Exp Rheumatol* 2019; 37 (Suppl. 117): S61-4.
 47. MALESZEWSKI JJ, YOUNGE BR, FRITZLEN JT *et al.*: Clinical and pathological evolution of giant cell arteritis: a prospective study of follow-up temporal artery biopsies in 40 treated patients. *Mod Pathol* 2017; 30: 788-96.
 48. NESHER G, BERKUN Y, MATES M, BARAS M, RUBINOW A, SONNENBLICK M: Low-dose aspirin and prevention of cranial ischemic complications in giant cell arteritis. *Arthritis Rheum* 2004; 50: 1332-7.
 49. LEE MS, SMITH SD, GALOR A, HOFFMAN GS: Antiplatelet and anticoagulant therapy in patients with giant cell arteritis. *Arthritis Rheum* 2006; 54: 3306-9.
 50. MOLLAN SP, SHARRACK N, BURDON MA, DENNISTON AK: Aspirin as adjunctive treatment for giant cell arteritis. *Cochrane Database Syst Rev* 2014; CD010453.
 51. STONE JH, TUCKWELL K, DIMONACO S *et al.*: Trial of Tocilizumab in Giant-Cell Arteritis. *N Engl J Med* 2017; 377: 317-28.
 52. FERRO F, QUARTUCCIO L, MONTI S *et al.*: One year in review 2021: systemic vasculitis. *Clin Exp Rheumatol* 2021; 39 (Suppl. 129): S3-12.

Annexe 3.

Giant cell arteritis-related stroke in a large inception cohort: A comparative study



Giant cell arteritis-related stroke in a large inception cohort: A comparative study

Simon Parreau^a, Stéphanie Dumonteil^a, Francisco Macian Montoro^b, Guillaume Gondran^a, Holy Bezanahary^a, Sylvain Palat^a, Kim-Heang Ly^a, Anne-Laure Fauchais^a, Eric Liozon^{a,1,*}

^a Internal Medicine Department, University Hospital of Limoges, France

^b Neurology Department, University Hospital of Limoges, France

ARTICLE INFO

Keywords:

Giant cell arteritis
Stroke
Predictive factors
Survival

ABSTRACT

Objective: Stroke caused by giant cell arteritis (GCA) is a rare but devastating condition and early recognition is of critical importance. The features of GCA-related stroke were compared with those of GCA without stroke and atherosclerosis-related or embolic stroke with the aim of more readily diagnosing GCA.

Methods: The study group consisted of 19 patients who experienced GCA-related strokes within an inception cohort (1982–2021) of GCA from the internal medicine department, and the control groups each consisted of 541 GCA patients without a stroke and 40 consecutive patients > 50 years of age with usual first ever stroke from the neurology department of a French university hospital. Clinical, laboratory, and imaging findings associated with GCA related-stroke were determined using logistic regression analyses. Early survival curves were estimated using the Kaplan-Meier method and compared using the log rank test.

Results: Amongst 560 patients included in the inception cohort, 19 (3.4%) developed GCA-related stroke. GCA-related stroke patients had more comorbid conditions ($p = 0.03$) and aortitis on imaging ($p = 0.02$), but less headache ($p < 0.01$) and scalp tenderness ($p = 0.01$). Multivariate logistic regression analysis showed that absence of involvement of the anterior circulation (OR = 0.1 – CI: 0.01–0.5), external carotid ultrasound (ECU) abnormalities (OR = 8.1 – CI: 1.3–73.9), and C-reactive protein (CRP) levels > 3 mg/dL (OR = 15.4 – CI: 1.9–197.1) were independently associated with GCA-related stroke. Early survival of GCA-related stroke patients was significantly decreased compared with control stroke patients ($p = 0.02$) and GCA patients without stroke ($p < 0.001$).

Conclusions: The location of stroke and assessment of ECU results and CRP level could help improve the prognosis of GCA-related stroke by bringing this condition to the clinician's attention more quickly, thus shortening diagnostic delay.

Introduction

Giant cell arteritis (GCA) is the most common systemic vasculitis in patients > 50 years of age. This disease affects medium and large arteries and is characterized by granulomatous involvement of the aorta and its main branches with a predilection for the extracranial branches of the carotid artery [1]. The inflammatory process in the artery walls causes narrowing, stenosis, and sometimes occlusion, which are responsible for the disease symptoms.

GCA-related stroke is a serious but rare complication occurring in 2.7–7.4% of GCA patients based on retrospective studies [2–8]. Risk

factors for GCA-related stroke include male sex (8,10), ischemic heart disease [5], concurrent presence of ischemic ophthalmic symptoms [3, 5–7,9,11], and lower acute phase reactants [11]. In contrast to strokes caused by atherosclerosis, GCA-related strokes most often involve the vertebrobasilar system [5,6,11] and is the leading cause of GCA-related death with most fatalities occurring in the first 3 months after the stroke [12,13]. However, making a diagnosis of GCA early can be challenging when the initial manifestation of GCA is stroke. To date, GCA-related strokes have not been compared in previous studies with usual strokes without GCA in terms of short term prognosis. Therefore, in the present study, the initial characteristics of GCA patients with or without a stroke

* Correspondence author.

E-mail address: eric.liozon@chu-limoges.fr (E. Liozon).

¹ Present address: Service de Médecine Interne A, CHRU Dupuytren 2, 16, Rue du Professeur Bernard Descottes, 87042 Limoges, France.

and stroke patients with or without GCA were compared as well as the 3-month survival of patients in the three groups.

Patients and methods

Patients and data collection

GCA inception cohort

From 1982 through May 2020, all consecutive patients diagnosed and treated for GCA in the internal medicine department of a tertiary-care teaching hospital were included in the study cohort. Starting in 1990 GCA was diagnosed based on the criteria of the American College of Rheumatology [14]. Of 60 patients diagnosed before 1990, 54 had a positive result of temporal artery biopsy, the 6 remaining patients meeting retrospectively three or four 1990 criteria. GCA was considered present in biopsy-negative cases if at least three of the criteria were fulfilled or if only two criteria were fulfilled but fluorodeoxyglucose (FDG)-positron emission tomography (PET) scans or CT angiography were strongly suggestive of occult large-vessel vasculitis [15]. Of 22 such patients, 18 had a positive biopsy and/or suggestive large-vessel imaging while 4 had treated polymyalgia rheumatica at the time of GCA occurrence. All GCA diagnoses were pathologically confirmed using currently accepted criteria. Clinical, laboratory, and pathological data were prospectively recorded at the time of first admission using a specifically designed 176-item questionnaire of detailed history and log data. All study data were stored in computerized files and regularly updated [16].

GCA-related strokes

All GCA patients with strokes belonged to the inception cohort. GCA-related stroke was defined as ischemic stroke occurring at the time of diagnosis of vasculitis or within 4 weeks of starting GCA treatment. In several patients, the neurological event preceded GCA diagnosis for a certain time, up to 5 months. In these patients, a thorough review of neurovascular imaging charts allowed to recognize retrospectively the arteritic nature of the stroke. Strokes without concurrent atrial fibrillation occurring during a well-documented GCA flare were also regarded as associated with vasculitis. In these patients, the relevant findings were posterior location of the stroke and concurrent re-emergence of more suggestive cranial manifestations with elevated acute phase reactants and a favorable outcome upon resuming prednisone treatment or increasing the daily dose. GCA-related stroke was not considered in the following circumstances: (i) isolated ophthalmic ischemic symptoms or a transitory cerebrovascular ischemic event; (ii) strokes with concurrent, untreated atrial fibrillation (unless there was concurrent evidence of vasculitic involvement of the cerebral circulation); (iii) strokes that occurred more than 1 month prior to the onset of signs/symptoms suggestive of GCA or polymyalgia rheumatica (PMR); or (iiii) strokes that occurred more than 4 weeks after treatment initiation in patients with well-controlled GCA.

Usual strokes

The control group consisted of 40 consecutive patients > 50 years of age from the neurology department of the same hospital recruited from January through June of 2020 and retrospectively included. These patients had ischemic or embolic strokes without GCA or primary angiitis of the central nervous system and were retrospectively included.

Study variables and clinical definitions

At GCA diagnosis, the clinical items extracted from the charts or computerized files included PMR symptoms, new-onset headache, scalp tenderness, jaw claudication and/or other jaw/mouth/throat problems (e.g., reductions or difficulties in jaw opening, maxillary or tooth pain, lingual discomfort or ischemia, sore throat, carotidynia, dysphagia, hoarseness, and/or dry cough), and visual ischemic manifestations; only

visual events that developed prior to therapy or within the first 2 weeks of therapy were included in the analyses. Ischemic visual symptoms were categorized as transient symptoms or permanent visual loss as follows [16]: transient ischemic visual symptoms included amaurosis fugax, intermittent blurred vision, and transient diplopia; permanent visual loss included anterior ischemic optic neuropathy, central retinal artery occlusion, and posterior ischemic optic neuropathy. Temporal arteries were considered abnormal if the pulse was low or absent and/or if nodules, redness, thickening, or tenderness was apparent in at least one artery. Constitutional syndrome was defined as a temperature $\geq 38^{\circ}\text{C}$ lasting for at least 1 week in conjunction with severe asthenia and/or weight loss > 5%. Upper limb artery involvement was defined on a clinical basis followed by confirmation using echo-Doppler and/or angiographic scans.

Starting in 2005, subclinical aortitis was diagnosed using FDG-PET scans, computed tomography (CT) scans, or both. A vascular territory was considered affected in aortic CT angiography if circumferential and homogeneous thickening of the vascular wall of ≥ 2.2 mm was present. In FDG-PET and/or CT scans, all vascular uptakes that exhibited equal or superior intensity to the liver physiological uptake were considered positive. Circumferential and homogeneous vascular uptakes were indicative of vasculitis [15]. Biopsy-proven GCA patients with persistent fever of unknown origin and/or isolated elevated acute phase reactants met the diagnostic criteria for the systemic form of GCA, irrespective of the presence of subclinical aortitis. Medical history including cardiovascular events and risk factors (e.g., smoking, hypertension, hypercholesterolemia, diabetes mellitus) was also collected.

At the time of stroke, symptoms associated with stroke, the delay between GCA diagnosis and neurological symptoms, and the results of brain imaging were noted. All enrolled patients were examined for cardioembolic disease using electrocardiography and echocardiography. All patients in whom stroke was diagnosed had lesions on CT and/or magnetic resonance imaging (MRI). In all cases, a retrospective review of the lesions observed in CT and MRI scans was performed by an experienced neurologist (FMM) who confirmed the presence, number, and locations of brain ischemic lesions (e.g., anterior circulation, posterior circulation, or both). Doppler ultrasound data on supra-aortic arteries, including the V2 segment of the vertebral arteries, were collected by an independent vascular physician. The presence of vascular stenosis, atheromatous plaques, and calcifications of each territory (subclavian, internal carotid, external carotid, vertebral, ophthalmic, and temporal arteries) were recorded for most patients. Assessment of temporal arteries was not routinely performed in usual stroke patients.

Treatments

All GCA patients but 9 were treated using standardized protocols. Patients lacking ischemic manifestations received 0.6–0.8 mg/kg/day of prednisone until their symptoms disappeared and their CRP levels were < 5 mg/L; then, the prednisone dose was progressively tapered to 0.35 mg/kg within 4–6 weeks [15]. Patients with permanent ischemic manifestations including GCA-related strokes received initial prednisone doses of 0.9–1.1 mg/kg/day, which was often preceded by pulse methylprednisolone; then, the dose was similarly tapered. Heparin treatment was only prescribed on an individual basis. Strokes unrelated to GCA were managed according to the latest international recommendations [17].

Outcome measures

Mortality data at 3 months were obtained from each patient's computerized record or by calling the respective city hall of each patient; information on final outcomes was obtained for all patients. In the event of a reported death, the data was ascertained by cross-referencing with the national death register managed by the Institut National de la

Statistique et des Etudes Economiques (INSEE). Survival was measured based on the date of stroke for both patients and usual stroke controls, whereas it was measured based on the date of GCA diagnosis for GCA patients without a stroke.

Statistical analyses

Continuous variables are expressed as the means and standard deviations or medians and interquartile ranges, and categorical variables are presented as frequencies with percentages. Variables were compared for GCA patients with or without stroke using Pearson's chi-square test, Fisher's exact test, or the Wilcoxon test as appropriate. Missing data were processed using multiple imputations by chained equations with four matrices [18]. Regarding the comparative features of GCA-related stroke patients and usual stroke patients, after univariate logistic regression analyses of the diagnostic predictive factors, variables with a p -value < 0.25 were included in the multivariate logistic model. Box-Tidwell regressions were performed [19]. A non-linear relation appeared for CRP which was discretized in order to linearize it. Quantitative variables included for testing the logit linearity hypothesis were integrated without modification. Three-month survival curves were constructed using the Kaplan-Meier method and compared statistically using the log rank test between stroke controls and patients with GCA-related stroke, and between GCA-related stroke patients and GCA patients without stroke. Tests were two-sided and a p -value < 0.05 was considered to indicate statistical significance. All calculations were performed using R software version 3.2.2 (R Foundation for Statistical Computing, Vienna, Austria), with the *mice* (multiple imputation), *rms* (Box-Tidwell regressions), and *survival* (survival analyses) packages.

Ethics board approval and informed consents

All data concerning patients of both groups were retrospectively collected using the prospective questionnaire for GCA patients or the neurological patient's chart for usual stroke patients. This study was, therefore, conducted in compliance with the Good Clinical Practice and Declaration of Helsinki principles. In accordance with the French law, formal approval from an ethics committee and written informed consent were not required for this type of retrospective study, provided the patient has not exercised the right to reject his participation to study.

Table 1
Main characteristics of the 17 patients with GCA-related stroke.

	Sex	Headache	ATA	JC	ST	PMR	TAB	PVL	Timing of occurrence	Location of stroke	Death delay*	Survival with RNI
1	M	1	1	0	0	0	pos	0	At onset (U)	brainstem	0	0
2	M	1	0	0	1	0	pos	0	At onset (T)	brainstem	1 (66)	.
3	F	1	1	1	1	1	pos	0	At onset (T)	brainstem	1 (6)	.
4	F	1	1	0	0	0	pos	1	At relapse	cerebellum	1 (2)	.
5	F	1	1	1	0	0	pos	0	At relapse	posterior parietal + occipital lobes	0	0
6	F	1	1	0	0	1	pos	0	At relapse	posterior parietal lobe	0	0
7	F	1	0	0	1	0	neg	0	At onset (U)	cerebellum	0	0
8	M	0	0	0	0	0	pos	1	At onset (U)	internal capsule	0	1
9	M	0	1	1	0	0	pos	1	At onset (T)	brainstem	1 (8)	.
10	F	0	1	1	0	0	pos	1	At onset (U)	brainstem – cerebellum	0	1
11	F	0	0	0	0	0	neg	0	At onset (U)	brainstem – cerebellum – caudate nucleus + occipital lobe	0	1
12	M	1	1	0	0	0	pos	1	At onset (U)	cerebellum	0	0
13	M	1	1	0	1	1	pos	0	At onset (U)	occipital lobe + temporal lobe	0	1
14	F	0	1	0	0	0	pos	0	At onset (U)	brainstem – cerebellum – thalamus	1 (50)	.
15	M	0	1	0	0	0	pos	0	At onset (U)	internal capsule + lentiform nucleus	0	1
16	F	0	1	0	0	1	pos	0	At onset (U)	internal capsule	0	0
17	M	1	0	0	0	0	pos	1	At onset (U)	brainstem – cerebellum	0	1
18	F	0	1	0	0	0	n.p.	0	At onset (U)	Brainstem + left CBZ and ACA	1 (62)	.
19	F	1	0	0	0	0	pos	0	At onset (U)	Brainstem + left cerebellum	0	1

GCA, giant cell arteritis; ATA, (clinically) abnormal temporal artery; JC, jaw claudication; ST, scalp tenderness; PMR, polymyalgia rheumatica; TAB, temporal artery biopsy; PVL, permanent visual loss; pos, positive; neg, negative; n.p., not performed; T, treated (stroke in the early course of GCA treatment); U, untreated (stroke revealing GCA); RNI, residual neurological impairment; CBZ, cerebral border zone; ACA, anterior cerebral artery.

* Delay (days) between diagnosis of GCA and death

Results

GCA-related stroke patients

Nineteen strokes occurred in 560 GCA patients (3.4%). All the patients had their first ever stroke. Table 1 summarizes the demographics, GCA-related clinical characteristics, stroke territory, and mortality of the patients. The NIHSS score was 9.3 (1-22) for 17 assessed patients. The mean ESR at the time of stroke was 75 mm/h (12-124) and was less than 30 mm/h in four patients. Doppler ultrasound data, CT-scan data, and MRI data were available in 18 patients, 19 patients, and 12 patients, respectively.

Mean age was 76.2 (5.3 SD) years. Among 16 patients with early strokes, 13 (81%) were untreated for GCA and three patients were already receiving glucocorticoid treatment for less than 1 week at stroke onset. Most patients (79%) had a stroke in the vertebrobasilar system, and three patients (18%) had a stroke during a late relapse of GCA, marked by the reappearance of cranial symptoms and elevated acute phase reactants. Six patients (32%) with early strokes developed at least one more severe ischemic complication, five of whom had visual loss from anterior ischemic optic neuropathy or central retinal artery occlusion and the latter one, from occipital stroke (bilateral occipital infarction). Six patients (32%) died within the first 3 months, including three patients who died in the days following a brainstem stroke. All six deaths were regarded as directly associated with the stroke.

Comparison of GCA-related stroke patients with other GCA patients

As Table 2 depicts, patients with GCA-related stroke had more comorbid conditions, more often aortitis on imaging studies, but less often headache and scalp tenderness compared to GCA patients without stroke. Permanent visual loss occurred twice more often in the stroke group, although the difference was not significant statistically. Regarding treatment and outcome issues, GCA patients with stroke received more intensive GC treatment initially, but not thereafter, and more often died during treatment.

Control stroke patients

The mean NIHSS score was 6.3 (1-28) for 39 assessed patients.

Table 2

Characteristics of GCA patients with stroke *versus* other GCA patients: results of univariate analysis.

	Stroke-free GCA (N = 541) N (%) or mean (SD)	GCA-related stroke (N = 19) N (%) or mean (SD)	All GCA (N = 560) N (%) or mean (SD)	p-value
Age	74.8 (8.1)	76.1 (5.3)	74.8 (8)	0.74
Male sex	184 (34)	8 (42.1)	192 (34.3)	0.63
Delay in diagnosing GCA	80 (88)	81 (63)	80 (88)	0.34
ACR criteria (N)	4.0 (0.9)	4.0 (0.9)	4.0 (0.9)	0.86
CVasc comorbid conditions	317 (59.1)	13 (68.4)	330 (59.5)	0.57
All comorbid conditions (N)	1.2 (1.1)	1.8 (1.3)	1.20 (1.11)	0.03
Hypertension	250 (46.6)	11 (57.9)	261 (47.0)	0.46
Diabetes	61 (11.4)	5 (26.3)	66 (11.9)	0.11
Dyslipidemia	52 (9.7)	5 (26.3)	57 (10.3)	0.05
Peripheral arterial disease*	34 (6.3)	2 (10.5)	36 (6.5)	0.35
Ischemic heart disease	50 (9.3)	1 (5.3)	51 (9.2)	1.00
Acute onset of GCA	236 (44)	8 (42)	244 (44)	1.00
Abnormal temporal artery	310 (58.2)	14 (73.7)	324 (58.7)	0.27
Polymyalgia symptoms	172 (31.8)	3 (15.8)	175 (31.2)	0.21
Masked (systemic) GCA	54 (10.0)	2 (10.5)	56 (10.0)	1.00
Aortitis on imaging	61 (11.3)	6 (31.6)	67 (12.0)	0.02
Limb artery involvement	53 (9.8)	1 (5.3)	54 (9.7)	1.00
Headache	446 (82.4)	10 (52.6)	456 (81.4)	< 0.01
Scalp tenderness	264 (50.7)	4 (21.1)	267 (49.8)	0.01
Facial/orbital swelling	76 (14.2)	1 (5.3)	77 (13.9)	0.50
Jaw claudication	181 (33.5)	4 (23.5)	185 (33.2)	0.45
Constitutional symptoms	392 (73.1)	15 (78.9)	407 (73.3)	0.79
Fever (>38°)	192 (36.0)	8 (42.1)	200 (36.2)	0.76
Visual ischemic symptoms	188 (34.8)	8 (44.4)	196 (35.1)	0.55
Transient visual ischemic symptoms	132 (24.5)	1 (5.6)	133 (23.9)	0.09
Permanent visual loss	83 (15.3)	6 (31.6)	89 (15.9)	0.11
Positive TAB	368 (70.8)	16 (88.9)	384 (71.4)	0.11
Hepatic cholestasis	179 (39.3)	3 (18.8)	182 (38.6)	0.12
ESR (mm/h)	84 (28.5)	74.5 (34.2)	83.7 (28.7)	0.30
CRP (mg/dL)	9.4 (6.6)	6.8 (5.7)	9.3 (6.6)	0.07
Hb (mean (SD))	115.7 (17.1)	119.8 (18.3)	115.9 (17.2)	0.30
Leukocyte count (G/L)	9290 (3072)	10143 (3,737)	9321 (3098)	0.50
Platelet count (G/L)	430 (154)	453 (196)	431 (155)	0.75
Pulse methylprednisolone	136 (25.1)	11 (57.9)	147 (26.2)	<0.01
Initial daily GC dose (mg/kg)	0.79 (0.16)	0.94 (0.13)	0.79 (0.16)	<0.01
Daily GC dose at 3 months	18.27 (6.29)	12.29 (4.63)	18.26 (6.31)	0.95
Daily GC dose at 6 mo.	12.3 (4.63)	7.22 (4.36)	12.20 (4.65)	0.09
Daily GC dose at 12 months	7.22 (4.36)	98 (18.1)	7.16 (4.36)	0.11
Use of steroid-sparing drugs	98 (18.1)	18.27 (6.29)	101 (18.0)	1.00
Relapses or recurrences	314 (60.2)	5 (38.5)	319 (59.6)	0.20
Numbers of relapses or recurrences per patient	1.13 (1.31)	0.77 (1.24)	1.12 (1.30)	0.21
GC-associated side effects (N)	1.16 (1.25)	1.16 (1.26)	1.16 (1.24)	0.99

Table 2 (continued)

	Stroke-free GCA (N = 541) N (%) or mean (SD)	GCA-related stroke (N = 19) N (%) or mean (SD)	All GCA (N = 560) N (%) or mean (SD)	p-value
Treatment duration	30.7 (27)	14.3 (13.5)	30.13 (26.80)	<0.01
Recovered patients	309 (57.1)	8 (42.1)	317 (56.6)	0.29
Death	215 (39.7)	7 (36.8)	222 (39.6)	0.99
Death during GC treatment	62 (11.5)	6 (31.6)	68 (12.1)	0.02
Follow-up (mo.)	82.5 (67.7)	47.5 (54.9)	81.3 (67.5)	<0.01

N, numbers. GCA, giant cell arteritis. ACR, American College of Rheumatology. CVasc, cardiovascular. TAB, temporal artery biopsy. Hb, hemoglobin. GC, glucocorticoids (prednisone).

* including lower limb arterial disease, past ischemic stroke, symptomatic internal carotid stenosis

Doppler ultrasound data, CT-scan data, and MRI data were available in 39 controls, 20 controls, and 37 controls, respectively.

Comparison of GCA-related strokes with usual strokes

The results of univariate analyses are listed in **Table 3** for demographic and baseline characteristics and, **Table 4** for neurological measures in patients with GCA-related stroke compared to control patients with usual stroke. The ESR was excluded from analysis since it was almost never performed in control patients. Significant differences were not observed regarding past history of cardiovascular events and the presence of traditional cardiovascular risk factors. Compared with controls, patients with intracranial GCA exhibited more constitutional symptoms such as fever, temporal artery abnormalities, headache, scalp tenderness, jaw claudication, permanently impaired vision, PMR symptoms, and higher mean CRP, fibrinogen, and platelet counts. Significant differences were also observed between the two groups regarding the clinical neurological presentations of stroke and the involved brain territories (**Table 4**). Four patients with GCA-related stroke had vertebral artery stenosis. Stenosis was the most reported external carotid artery abnormality and was found in seven GCA patients (41.2%).

Predictive model of GCA-related stroke

Multivariate logistic regression analysis showed that absence of involvement of the anterior circulation, external carotid ultrasound abnormalities, and a CRP level > 3 mg/dL were independently associated with GCA-related stroke (**Table 5, Fig. 1**).

Survival analysis

Three-month survival from the date of stroke was significantly decreased in GCA-related stroke patients both compared with the subjects in the control stroke group (**Fig. 2A**). In addition, the survival rate was lower when patients with GCA-related stroke were compared with other GCA patients from the date of GCA diagnosis (**Fig. 2B**).

Discussion

Cerebrovascular accidents are uncommon in GCA, although they probably are the leading cause of early death [12]. In the present study, among all patients included from a large, hospital-based, inception cohort, the frequency of GCA-related stroke occurrence was 3.4%, consistent with results reported in other studies [2–8]. Although the prevalence of GCA-related stroke among all strokes in the Limousin

Table 3

Characteristics of patients with usual strokes *versus* patients with GCA-related strokes: results of univariate analysis.

Number of cases	Usual strokes(40)	GCA-related strokes (19)	All strokes (59)	p-value
Female sex	18 (45)	11 (57.9)	29 (49.2)	0.52
Age (y)	73.4 (11.6)	76.2 (5.3)	74.3 (10.1)	0.32
Previous ischemic stroke	6 (15)	1 (5.3)	7 (11.9)	0.41
Myocardial infarction	9 (22.5)	2 (10.5)	11 (18.6)	0.48
Atrial fibrillation	3 (7.5)	1 (5.3)	4 (6.8)	1.00
Valvular heart disease	1 (2.5)	3 (15.8)	4 (6.8)	0.09
Peripheral arterial disease*	1 (2.5)	1 (5.3)	2 (3.4)	0.54
Obesity	9 (22.5)	2 (10.5)	11 (18.6)	0.48
Hypertension	21 (52.5)	11 (57.9)	32 (54.2)	0.91
Diabetes mellitus	12 (30)	3 (15.8)	15 (25.4)	0.34
Hypercholesterolemia	14 (35)	5 (26.3)	19 (32.3)	0.71
Current smoking	5 (12.5)	2 (10.5)	7 (11.9)	1.00
Previous smoking	8 (20)	6 (31.6)	14 (23.7)	0.51
Body mass index	27.2 (6.1)	23.9 (4.6)	26.0 (5.8)	0.06
Systolic pressure (mmHg)	163 (31)	162 (21)	163 (28)	0.91
Diastolic pressure (mmHg)	86 (14)	79.5 (11)	84 (14)	0.12
Constitutional symptoms	1 (2.5)	14 (73.7)	15 (25.4)	< 0.01
Fever	0 (0)	5 (26.3)	5 (8.5)	< 0.01
Abnormal temporal artery	0 (0)	15 (78.9)	15 (25.4)	< 0.01
Headache	1 (2.5)	7 (36.8)	8 (13.6)	< 0.01
Scalp tenderness	0 (0)	4 (21.1)	4 (6.8)	< 0.01
PMR symptoms	0 (0)	3 (15.8)	3 (5.1)	0.03
Jaw claudication	0 (0)	4 (21.1)	4 (6.8)	< 0.01
CRP (mg/L)	11.3 (18.6)	45.5 (55.9)	21.9 (37.7)	< 0.01
Fibrinogen (g/dL)	4.0 (1.1)	6.5 (2.1)	4.8 (2.9)	< 0.01
Platelet (G/L)	250 (85)	389 (206)	291 (146)	< 0.01
Hemoglobin (g/dL)	132 (28)	126 (20)	130 (26)	0.12
Triglycerides (g/L)	1.3 (0.6)	1.0 (0.2)	1.2 (0.5)	0.07
HDL cholesterol (g/L)	0.5 (0.2)	0.6 (0.2)	0.5 (0.2)	0.11
LDL cholesterol (g/L)	1.0 (0.4)	1.0 (0.3)	1.0 (0.4)	0.62
Glycemia (mmol/L)	7.0 (2.8)	10.2 (13.7)	8.0 (7.8)	0.88

GCA, giant cell arteritis; PMR, polymyalgia rheumatica; CRP, C-reactive protein; HDL, high-density lipoprotein; LDL, low-density lipoprotein.

* of the lower limbs

population cannot be derived from our hospital-based cohort study, in other populations, GCA-related stroke represented 0.14% of all first-ever strokes including hemorrhagic strokes [20] and 0.17% of all ischemic strokes [21]. In a well-defined French urban population, the incidence of GCA-related stroke was 0.76/10⁵ people/year, with a strong male predominance [8]. Therefore, GCA-related stroke is a very infrequent occurrence in the general population compared with atherosclerotic and embolic strokes, and may not be suspected, especially when the stroke is a revealing complication of vasculitis.

Generally, strokes occurring within 4 weeks preceding or following GCA diagnosis are considered to be caused by the vasculitis process [5, 6]. In the present study, stroke most often exposed GCA or complicated its very early course, which is in agreement with other studies [11]. Vertebrobasilar and internal carotid vasculitis can be detected at an asymptomatic stage during the diagnosis process of suspected GCA [22]. This finding could account for strokes occurring at a few days following glucocorticoid treatment initiation due to insufficient control of a severe vasculitis process and/or delayed clot formation at the level of the injured beds. In contrast to other studies, 3 of 19 (16%) cerebrovascular events in the present study occurred late in the course of GCA, up to 21

Table 4

Neurological characteristics of patients with usual strokes *versus* patients with GCA-related strokes: results of univariate analysis.

Numbers of cases	Usual strokes (40)	GCA-related strokes(19)	All strokes (59)	p-value
Neurological symptoms				
Dizziness	4 (10)	5 (27.8)	9 (15.5)	0.12
Focal motor deficit	29 (72.5)	10 (52.6.1)	39 (66.1)	0.23
Focal sensory deficit	29 (72.5)	4 (21.1)	33 (55.9)	< 0.01
Dysarthria	28 (70)	8 (42.1)	34 (61.4)	0.08
Facial palsy	17 (42.5)	6 (31.6)	23 (39)	0.60
Impaired vigilance	6 (15)	4 (21.1)	10 (16.9)	0.71
Acute cognitive disorder	2 (5)	4 (21.1)	6 (10.2)	0.08
Cerebellar syndrome	3 (7.5)	6 (31.6)	9 (15.3)	0.03
Transient visual trouble	1 (2.5)	2 (11.1)	3 (5.2)	0.22
Permanent visual loss	0 (0)	4 (21.1)	4 (6.8)	< 0.01
Impaired swallowing	2 (5)	3 (15.8)	5 (8.5)	0.32
Territory involvement				
Carotid system				
Middle cerebral artery	28 (70)	2 (10.5)	30 (50.8)	< 0.01
Anterior choroidal artery	2 (5)	2 (10.5)	4 (6.8)	0.59
Anterior cerebral artery	1 (2.5)	1 (5.3)	2 (3.4)	0.54
Vertebrobasilar system				
Posterior cerebral artery	6 (15)	4 (21.1)	10 (16.9)	0.71
Basilar artery	3 (7.5)	8 (42.1)	11 (18.6)	< 0.01
Cerebellar artery	5 (12.5)	8 (42.1)	13 (22.0)	0.03
Multiple lesions	8 (20)	8 (42.1)	16 (27.1)	0.14
Bilateral lesions	2 (5)	3 (15.8)	5 (8.5)	0.32
Permanent damage	8 (20)	3 (17.6)	11 (19.3)	0.99
Embolic mechanism	8 (20)	0 (0)	8 (14)	0.09
Ultrasound abnormality				
Subclavian artery	0 (0)	2 (14.3)	2 (4.4)	0.09
Internal carotid	20 (51.3)	10 (58.8)	30 (53.6)	0.82
External carotid	2 (5.1)	7 (41.2)	9 (16.1)	< 0.01
Vertebral artery	2 (5.1)	4 (23.5)	6 (10.7)	0.06
Ophthalmic artery	0 (0)	2 (18.2)	2 (5.7)	0.09
Temporal artery	0 (0)	6 (60)	5 (54.5)	0.45

Table 5

Results of logistic regression analyses: predictive model of GCA-related stroke.

	β	OR	95% CI	p-value
Vertebrobasilar system	-2.2	0.1	0.01–0.5	0.01
External carotid abnormality on US	2.1	8.1	1.3–173.9	0.04
CRP level > 3 mg/dL	2.7	15.4	1.9–197.1	0.02

GCA, giant cell arteritis; US, ultrasound; CRP, C-reactive protein; OR, odds ratio; CI, confidence interval.

months after diagnosis. Such latency before a cerebrovascular GCA flare has been previously reported, although rarely [23–25]. There is a significantly increased risk of cerebrovascular accidents caused by atherosclerosis among patients with GCA [26]. Therefore, the detection of vasculitis as the cause of a late stroke in these patients can be particularly challenging. Although direct evidence of vasculitis affecting extra- or intracranial arteries was lacking, the probable diagnosis was late complicated GCA in all three reported patients.

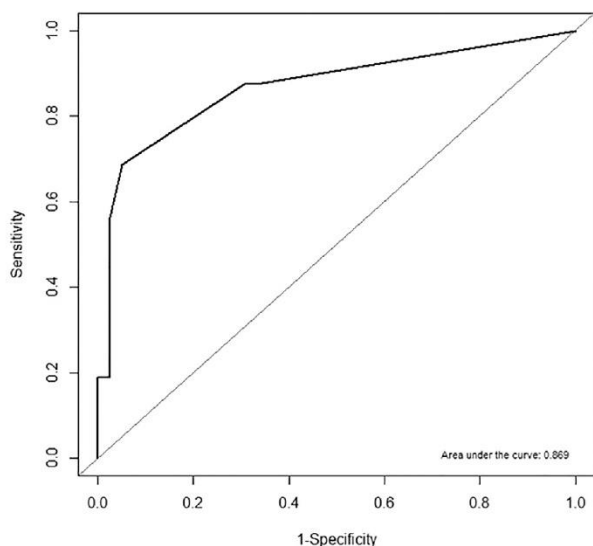


Fig. 1. Receiver Operative Curve analysis of the model including absence of involvement of the anterior circulation, external carotid abnormality on ultrasounds, and CRP level > 3 mg/dL.

Legend to Figure 1 Sensitivity, specificity, as well as positive and negative predictive values of the model and score were 97.4%, 56.3%, 84.4%, and 90.0%, respectively with an accuracy of 0.85.

There are also reports of stroke being the main inaugural manifestation of GCA [27–31]. In this setting, early diagnosis of underlying vasculitis can be difficult because the often serious, neurological manifestations can mask the main symptoms of GCA, particularly when the patient has become aphasic, dysarthric, confused, or lethargic [23,32]. Furthermore, the patients included in the present study seldom exhibited PMR symptoms, often lacked headache and/or gross temporal abnormalities, and demonstrated relatively low mean levels of acute phase reactants, rendering the GCA diagnosis even more challenging. Consistent with the latter finding, an inverse association exists between an inflammatory response and the risk of developing visual loss and other cranial ischemic complications in GCA [33]. Conversely, our patients often experienced concurrent sudden ischemic visual loss, which is infrequent in usual ischemic stroke but has been found to be significantly associated with stroke among patients with incident GCA [3,5–7, 9,11,34]. Therefore, synchronous or sequential occurrence of ischemic stroke and ischemic visual loss should raise suspicion of an inflammatory vascular process causing both events. Very infrequently, GCA-related stroke can present without an elevated erythrocyte sedimentation rate and/or CRP [35,36]. This confusing occurrence was observed three times (16% of the cases) in the present study. In such instances, the early GCA diagnosis only relies on the patient's history, either self-reported or by interviewing relatives, a careful physical examination including palpation of temporal arteries and a search for limb arterial bruits, as well as a critical review of brain and vascular imaging results.

Significantly, in most previous studies, strokes predominated in the posterior circulation [5,6,11,21,32,37–39,40] in sharp contrast with the prominent involvement of the carotid system in cerebrovascular accidents caused by atherosclerosis [41]. This finding was confirmed in the present study, with strokes occurring in the posterior circulation four times as often as in the carotid system. However, severe internal carotid involvement in GCA can also occur, combined with vertebrobasilar involvement or alone, most often in its distal segments [2,3,9,21,32,40, 42,43].

Color-duplex Doppler (CDD) examination is important for the diagnosis of GCA [44] and helpful for detecting GCA in cervical segments of the main cerebral arteries when observing multiple segmental narrowing affecting multiple vessels, in the absence of proximal changes

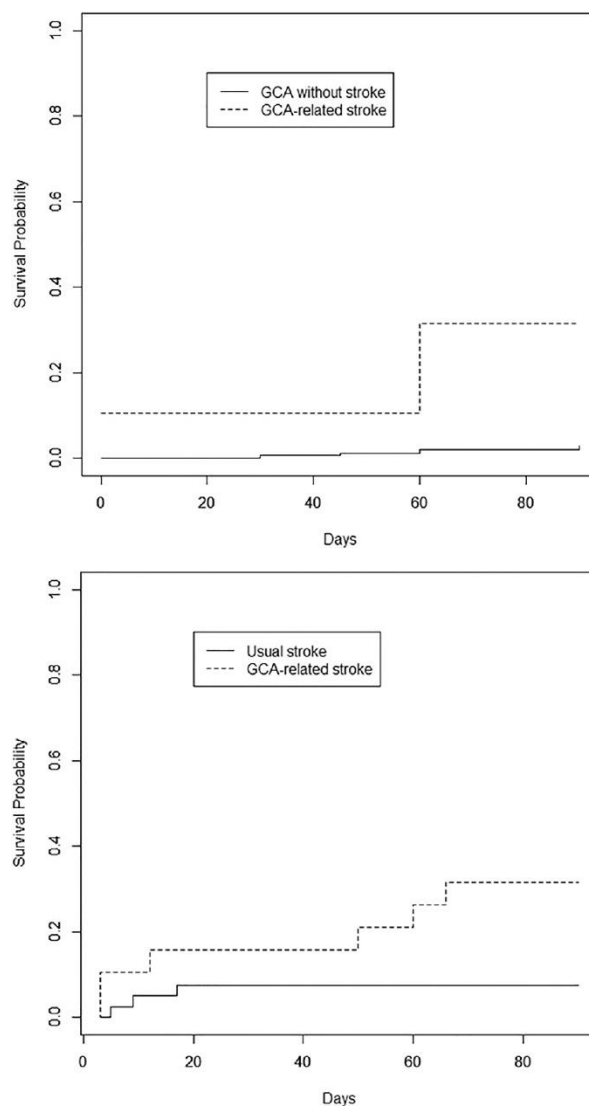


Fig. 2. Kaplan-Meier analyses comparing the three-month cumulative survival curves of 19 GCA patients with stroke and (a) 541 GCA patients without a stroke, (b) 40 patients with usual (ischemic) stroke.

The English in this document has been checked by at least two professional editors, both native speakers of English. For a certificate, please see: <http://www.textcheck.com/certificate/48bZYe>.

suggestive of atherosclerosis [32,37]. CDD examination can reveal concentric, homogeneous, and smooth hypoechoic mural thickening, the so-called halo sign, of vertebral arteries, as regarding temporal arteries [39,45]. However, because the intracranial portions of vertebral arteries and the basilar artery are often not covered by ultrasound imaging, other vascular imaging procedures such as CT angiography or magnetic resonance angiography are critical for optimizing the diagnostic workup of those patients [25,32,34,37].

In the present study, multivariate logistic regression analyses consistently showed that absence of involvement of the anterior cerebral circulation, external carotid ultrasound abnormalities, and a CRP level > 3 mg/dL were independently associated with GCA-related stroke compared with usual ischemic strokes. GCA-related stroke represents a major neurologic emergency but is often difficult to recognize. Our results could help physicians more quickly distinguish between GCA-related stroke and usual ischemic strokes, thus promptly ensuring appropriate treatment for both patient populations. Moreover, we cannot exclude the influence of traditional cardiovascular risk factors as an additional predisposing factor in the development of stroke. In this

sense, a study in a series of 210 biopsy-proven GCA patients indicated that the presence of traditional risk factors of atherosclerosis at the time of GCA diagnosis significantly increased the risk of developing one of the serious ischemic complications associated with GCA [46].

The results of the present study confirm the serious prognosis of GCA-related stroke reported in previous studies [10,11,21,32,34,37,40]. Patients experiencing this event had significantly decreased early survival compared with both stroke-free GCA patients and control stroke patients. In most instances, death occurred due to the devastating consequences of a brainstem infarction and/or an uncontrollable widespread GCA course. Similarly, Ruegg *et al.* found that bilateral vertebral artery occlusion (BVAO) from GCA resulted in much higher mortality (75% vs. 19%) compared to BVAO of atherosclerotic origin (37). Multimodal therapeutic approaches for life-threatening intracranial GCA may be needed and have involved combined high-dose glucocorticoid and cyclophosphamide or methotrexate, therapeutic anticoagulation, and emergency endovascular treatment [24,25,32,34,37,42,46], with mixed outcomes. The severe cases included in the present study only received high-dose glucocorticoid treatment and heparin, which might have been inadequate for quickly controlling a severe mural inflammation of the vertebral arteries.

Our study had several other limitations. The retrospective design and protracted period of inclusion precluded homogeneous imaging procedures for the brain arteries and parenchyma, hence diminishing the validity of the case-control study design. Notably, the low number of CT or magnetic resonance angiographies performed in this study likely hindered the identification of radiological criteria for intracranial GCA [37,40]. In addition, the results of temporal artery ultrasound examination were excluded from logistic regression analysis because the controls were not routinely assessed using this method. Another source of bias, data on the control stroke group was collected retrospectively, while it was collected prospectively in the GCA group. Nevertheless, all 19 GCA-related stroke patients were part of a well-defined, large inception cohort, which enhanced the accuracy of the data. Furthermore, detailed information on GCA features and available data on the treatments and outcomes in most cases enabled detailed description of the reported cases. Finally, this is the first comparison of the features and prognosis of GCA-related stroke with those of usual ischemic strokes. Using this strategy, we identified several quick variables allowing accurate distinction between the two conditions.

In summary, stroke complicates the course of GCA in 3-4% of cases, either revealing vasculitis or complicating its early course. Very infrequently, stroke can occur during a late GCA relapse. GCA-related stroke can be difficult to recognize and has a poor prognosis. Whether earlier diagnosis of vasculitis and prompt salvage therapy could reduce the extent of neurologic complications deserve further studies. Nevertheless, our practical findings can aid in early diagnosis by bringing the likelihood of GCA to the clinician's attention in a timely manner.

Ethics board approval

All patient data were retrospectively collected. This study was conducted in compliance with Good Clinical Practices and the Declaration of Helsinki principles. In accordance with French law, formal approval from an ethics committee was not required for this retrospective study.

CRedit authorship contribution statement

Simon Parreau: Visualization, Conceptualization, Data curation. **Stéphanie Dumonteil:** Formal analysis, Visualization. **Francisco Macian Montoro:** Data curation, Formal analysis, Visualization. **Guillaume Gondran:** Data curation. **Holy Bezanahary:** Data curation. **Sylvain Palat:** Data curation. **Kim-Heang Ly:** Data curation. **Anne-Laure Fauchais:** Data curation. **Eric Liozon:** Visualization, Conceptualization, Data curation, Writing – original draft.

Declaration of Competing Interest

The authors declare no competing interest

References

- [1] Weyand CM, Goronzy JJ. Clinical practice. Giant-cell arteritis and polymyalgia rheumatica. *N Engl J Med* 2014;371:50–7.
- [2] Caselli RJ, Hunder GG, Whisnant JP. Neurologic disease in biopsy-proven giant cell (temporal) arteritis. *Neurology* 1988;38:352–9.
- [3] Gonzalez-Gay MA, Blanco R, Rodriguez-Valverde V, Martinez-Taboada VM, Delgado-Rodriguez M, Figueroa M, et al. Permanent visual loss and cerebrovascular accidents in giant cell arteritis: predictors and response to treatment. *Arthritis Rheum* 1998;41:1497–504.
- [4] Nesher G, Berkun Y, Mates M, Baras M, Nesher R, Rubinow A, et al. Risk factors for cranial ischemic complications in giant cell arteritis. *Medicine* 2004;83:114–22.
- [5] Salvarani C, Della Bella C, Cimino L, Macchioni P, Formisano D, Bajocchi G, et al. Risk factors for severe cranial ischaemic events in an Italian population-based cohort of patients with giant cell arteritis. *Rheumatology* 2009;48:250–3.
- [6] Gonzalez-Gay MA, Vazquez-Rodriguez TR, Gomez-Acebo I, Pego-Reigosa R, Lopez-Diaz MJ, Vazquez-Trinanés MC, et al. Strokes at time of disease diagnosis in a series of 287 patients with biopsy-proven giant cell arteritis. *Medicine* 2009;88:227–35.
- [7] Zenone T, Puget M. Characteristics of cerebrovascular accidents at time of diagnosis in a series of 98 patients with giant cell arteritis. *Rheumatol Int* 2013;33:3017–23.
- [8] Samson M, Jacquin A, Audia S, Daubail B, Devilliers H, Petrella T, et al. Stroke associated with giant cell arteritis: a population-based study. *J Neurol Neurosurg Psychiatry* 2015;86:216–21.
- [9] Hocevar A, Jese R, Tomsic M, Rotar Z. Risk factors for severe cranial ischaemic complications in giant cell arteritis. *Rheumatology* 2020;59:2953–9 (Oxford).
- [10] Pariente A, Guédon A, Alamowitch S, Thietart S, Carrat F, Delorme S, et al. Ischemic stroke in giant-cell arteritis: French retrospective study. *J Autoimmun* 2019;99:48–51.
- [11] de Boysson H, Liozon E, Larivière D, Samson M, Parienti JJ, Boutemy J, et al. Giant cell arteritis-related stroke: a retrospective multicenter case-control study. *J Rheumatol* 2017;44:297–303.
- [12] Graham E, Holland A, Avery A, Russell RW. Prognosis in giant-cell arteritis. *Br Med J Clin Res Ed* 1981;282:269–71.
- [13] Sève-Söderbergh J, Malmvall BE, Andersson R, Bengtsson BA. Giant cell arteritis as a cause of death. Report of nine cases. *JAMA* 1986;255:493–6.
- [14] Hunder GG, Bloch DA, Michel BA, Stevens MB, Arend WP, Calabrese LH, et al. The American college of rheumatology 1990 criteria for the classification of giant cell arteritis. *Arthritis Rheum* 1990;33:1122–228.
- [15] de Boysson H, Dumont A, Liozon E, Lambert M, Boutemy J, Maigné G, et al. Giant-cell arteritis: Concordance study between aortic CT angiography and FDG-PET/CT in detection of large-vessel involvement. *Eur J Nucl Med Mol Imaging* 2017;44:2274–9.
- [16] Liozon E, Dalmay F, Lalloue F, Gondran G, Bezanahary H, Fauchais AL, et al. Risk factors for permanent visual loss in biopsy-proven giant cell arteritis: a study of 339 patients. *J Rheumatol* 2016;43:1393–9.
- [17] Powers WJ, Rabinstein AA, Ackerson T, Adeoye OM, Bambakidis NC, Becker K, et al. American heart association stroke council 2018 guidelines for the early management of patients with acute ischemics: a guideline for healthcare professionals from the American Heart Association/American Stroke Association. *Stroke* 2018;49:e46–110.
- [18] Van Buuren S, Groothuis-Oudshoorn K. MICE: multivariate imputation by chained equations in R. *J Stat Softw* 2011;45:1–67.
- [19] Box GEP, Tidwell PW. Transformation of the independent variables. *Technometrics* 1962;4:531–50.
- [20] Wisniewska M, Devuyt G, Bougosslavsky J. Giant cell arteritis as a cause of first-ever stroke. *Cerebrovasc Dis* 2007;24:226–30.
- [21] Guisado-Alonso D, Edo MC, Estrada-Alarcon PV, Garcia-Sanchez SM, Font MA, Mena Romo L, et al. Progression of large vessel disease in patients with giant cell arteritis-associated stroke: the role of vascular imaging. *J Clin Rheumatol* 2020. <https://doi.org/10.1097/RHU.0000000000001498>. Online ahead of print.
- [22] Donaldson L, Nanji K, Rebelo R, Khalidi NA, Rodriguez AR. Involvement of the intracranial circulation in giant cell arteritis. *Can J Ophthalmol* 2020;55:391–400.
- [23] Caselli RJ. Giant cell (temporal) arteritis: a treatable cause of multi-infarct dementia. *Neurology* 1990;40:753–5.
- [24] Salvarani C, Giannini C, Miller DV, Hunder G. Giant cell arteritis: involvement of intracranial arteries. *Arthritis Rheum* 2006;55:985–9.
- [25] Larivière D, Sacre K, Klein I, Hyafil F, Choudat L, Chauveheid MP, Papo T. Extra- and intracranial cerebral vasculitis in giant cell arteritis: an observational study. *Medicine* 2014;93(28):e265 (Baltimore).
- [26] Tomasson G, Peloquin C, Mohammad A, Love TJ, Zhang Y, Choi HK, Merkel PA. Risk for cardiovascular disease early and late after a diagnosis of giant-cell arteritis: a cohort study. *Ann Intern Med* 2014;160:73–80.
- [27] Howard GF, Ho SU, Kim KS, Wallach J. Bilateral carotid occlusion resulting from giant cell arteritis. *Ann Neurol* 1984;15:204–7.
- [28] McLean CA, Gonzales MF, Dowling JP. Systemic giant cell arteritis and cerebellar infarction. *Stroke* 1993;24:899–902.
- [29] Bremont J, Maillet T, Putot A, Lalu-Fraisse A, Demaistre E, Terriat, et al. Isolated cerebellar ischemic strokes revealing giant cell arteritis in an elderly adult. *J Am Geriatr Soc* 2016;64:e117–8.

- [30] Kuganesan T, Huang AR. Stroke as an atypical initial presentation of giant cell arteritis. *BMC Geriatr* 2018;18:55.
- [31] Elhfnawy AM, Bieber M, Schliesser M, Kraft P. Atypical presentation of giant cell arteritis in a patient with cerebrobasilar stroke: a case report. *Medicine* 2019;98:e16737. <https://doi.org/10.1097/MD.00000000000016737>.
- [32] Solans-Laqué R, Bosch-Gil JA, Molina-Catenario CA, Ortega-Aznar A, Alvarez-Sabin J, Vilardell-Tarres M. Stroke and multi-infarct dementia as presenting symptoms of giant cell arteritis: report of 7 cases and review of the literature. *Medicine* 2008;87:335–44.
- [33] Cid MC, Font C, Oristrell J, de la Sierra A, Coll-Vinent B, López-Soto A, et al. Association between strong inflammatory response and low risk of developing visual loss and other cranial ischemic complications in giant cell (temporal) arteritis. *Arthritis Rheum* 1998;41:26–32.
- [34] Alsolaimani RS, Bhavsar SV, Khalidi NA, Pagnoux C, Mandzia JL, Tay KY, et al. Severe intracranial involvement in giant cell arteritis: 5 cases and literature review. *J Rheumatol* 2016;43:648–56.
- [35] Neish PR, Sergent JS. Giant cell arteritis: a case with unusual neurologic manifestations and a normal sedimentation rate. *Arch Intern Med* 1991;151:378–80.
- [36] Hussami A, Casulli C, Fayard C, Caillier-Minier M, Vion P, Minier D. Vertebrobasilar stroke secondary to giant cell arteritis without biological inflammatory syndrome. *Rev Neurol* 2016;172:248–52.
- [37] Ruegg S, Engelter S, Jeanneret C, Hetzel A, Probst A, Steck A, et al. Bilateral vertebral artery occlusion from giant cell arteritis: report of 3 cases and review of the literature. *Medicine* 2003;82:1–12.
- [38] Peigo Reigosa R, Garcia-Porrúa C, Pineiro A, Dierssen T, Llorca J, Gonzalez-Gay MA. Predictors of cerebrovascular accidents in giant cell arteritis in a defined population. *Clin Exp Rheumatol* 2004;22(6):S13–7. Suppl 36.
- [39] Elhfnawy AM, Elsalamawy D, Abdelraouf M, Schliesser M, Volkmann J, Fluri F. Red flags for a concomitant giant cell arteritis in patients with vertebrobasilar stroke: a cross-sectional study and literature review. *Acta Neurol Belg* 2020;120:1389–98.
- [40] Beuker C, Wanker MC, Thomas C, Strecker JK, Schmidt-Pogoda A, Schwindt W, et al. Characterization of extracranial giant cell arteritis with intracranial involvement and its rapidly progressive subtype. *Ann Neurol* 2021. <https://doi.org/10.1002/ana.26101>.
- [41] Bogousslavsky J, Van Melle G, Regli F. The Lausanne Stroke Registry: analysis of 1,000 consecutive patients with first stroke. *Stroke* 1988;19:1012–83.
- [42] Simonsen CZ, Speiser L, Hansen IT, Jayne T, von Weitzel-Mudersbach P. Endovascular treatment of intracerebral giant cell arteritis. *Front Neurol* 2020;11:287. <https://doi.org/10.3389/fner.2020.00287>.
- [43] Lago A, Tembl JI, Morales L, Nieves C, Campins M, Aparici F, et al. Stroke and temporal arteritis. *Neurologia* 2020;35:75–81.
- [44] Schmidt WA. Ultrasounds in the diagnosis and management of giant cell arteritis. *Rheumatology* 2019;58:ii22–31 (Oxford).
- [45] García-García J, Ayo-Martin O, Argandona-Palacios L, Segura T. Vertebral artery halo in patients with stroke: a key clue for the prompt diagnosis of giant cell arteritis. *Stroke* 2011;42:3287–90.
- [46] Sanchez-Alvarez C, Hawkins AS, Koster MJ, Lehman VT, Crowson CS, Warrington KJ. Clinical and radiographic features of giant cell arteritis with intracranial involvement. *ACR Open Rheumatol* 2020;2:471–7.

Annexe 4.

Frequency and Significance of Hepatic Involvement in New-Onset Giant Cell Arteritis: A Study of 514 Patients

Research Letter

Frequency and Significance of Hepatic Involvement in New-Onset Giant Cell Arteritis: A Study of 514 Patients

To the Editor:

Abnormalities of liver function in giant cell arteritis (GCA) have long been described¹ and are present at the acute phase of the disease in 30% to 60% of cases.^{2–4} Hepatic involvement is mostly anicteric cholestasis (eg, elevated alkaline phosphatase [ALP] and gamma-glutamyl transferase [GGT]), and, more rarely, cytolytic hepatitis (eg, elevated aspartate aminotransferase [AST] and/or alanine aminotransferase [ALT]). Pathologic documentation of hepatic involvement is seldom required in patients with GCA and is mostly normal, or shows various specific or nonspecific changes.^{5,6} Although a positive association between hepatic cholestasis (HC) and higher acute-phase response at GCA onset is plausible, so far, only 1 study has specifically addressed this issue.⁷ In this study,⁷ raised ALP (> 2 times above the upper limit of normal [ULN]) was associated with age, more frequent constitutional syndrome and fever; higher mean erythrocyte sedimentation rate (ESR), hemoglobin, and platelet count; and lower mean albumin. Patients in both groups (raised/normal ALP) had similar rates of ischemic complications. However, C-reactive protein (CRP) was measured in only 40% of cases, and no other hepatic enzymes were studied, nor was any information on the prognostic value of HC available.⁷

We therefore conducted a study aimed at determining the frequency of occurrence, patterns, and disease associations of hepatic involvement in untreated, new-onset GCA. We also looked at the prognostic effect of HC. All data concerning these elderly patients with GCA were retrospectively collected. This study was conducted in compliance with Good Clinical Practice guidelines and the Declaration of Helsinki. In accordance with French law, approval from an ethics committee and written informed consent were not required for this type of retrospective study, provided the patient has not exercised the right to refuse participation in the study.

We selected from a large, single-center inception cohort of patients with GCA⁸ all those who had complete liver enzyme tests (including ALP, GGT, AST, and ALT) performed before glucocorticoid (GC) treatment. Using univariate analyses, we determined which baseline and outcome variables were associated with the presence of HC at GCA onset. Among 655 patients, 514 (78.5%, 347 biopsy-proven) met the entry criteria and were included. GCA was diagnosed based on the 1990 American College of Rheumatology (ACR) criteria. Of 59 patients diagnosed before 1990, 52 had a positive temporal artery biopsy, and the 7 remaining patients retrospectively met 3 or 4 of the 1990 ACR criteria. At least 1 liver enzyme abnormality was present in 219 (42.6%) patients, 3 (1.4%) of whom had elevated amino-

transferase levels only, 18 (8.2%) had elevated ALP level only, 161 (73.5%) had raised ALP and GGT levels, and 37 (16.9%) had mixed hepatitis (eg, both cholestasis and elevated AST and ALT levels). Most enzyme elevations were mild, at < 3 times above the ULN. The highest ALP, GGT, AST, and ALT values were 879 IU/L, 1028 IU/L, 251 IU/L, and 641 IU/L, respectively. No patients with liver involvement developed jaundice or liver pain or enlargement, and all assessed patients quickly cleared their hepatic enzyme abnormalities upon GC treatment, making it unnecessary to investigate other causes of liver dysfunction or perform a liver biopsy. During follow-up, only 2 patients had a subsequent diagnosis of autoimmune hepatitis made. Among the studied variables (Table), mean levels of blood acute-phase reactants and serum albumin level, as well as blood cell counts, were the strongest predictors of liver abnormalities; HC was associated with higher mean ESR, CRP, fibrinogen, leukocyte and platelet values, and lower hemoglobin and albumin levels. The strongest correlations, as assessed by Spearman ρ test, were between ALP, ESR, and CRP. In addition, patients with HC had fewer ischemic complications overall, but they had similar rates of permanent visual loss compared to the other patients. The presence of aortitis was negatively associated with HC, which might point to a distinct immuno-inflammatory pattern in large-vessel vasculitis. Finally, patients of either group shared similar late GCA outcome issues and prognosis, although those with HC had higher prednisone burden in the first 6 months. The higher death rate observed in the HC group may rely on longer median duration of follow-up (76 vs 64 months); rates of death occurring during GC treatment were similar in both groups.

The present study confirms and expands on previous data on liver enzyme abnormalities in new-onset GCA. Silent HC is a frequent finding, whereas cytolytic hepatitis is rare. HC is associated with a strong systemic inflammatory response but not with a reduced ischemic visual risk, and is mostly fully reversible with adequate GC treatment. Our finding of similar ischemic visual risk in patients with or without HC at disease onset highlights the unclear boundaries existing between the vascular component and the inflammatory component of GCA. Indeed, vascular and systemic inflammation may be discordant in GCA, so much so that 2 opposing subgroups of patients may be identified. The first subgroup is characterized by severe systemic inflammation and a low frequency of ischemic complications, whereas in the second subgroup, there is less systemic inflammation but prominent neuro-ophthalmic ischemic complications.^{9,10} The finding of HC being associated with higher GC doses in the first 6 months could reflect more prudent prednisone tapering related to a low-level, persistent acute-phase reaction. Raised ALP levels have been reported to mirror a higher state of inflammation in patients with clinically isolated polymyalgia rheumatica (PMR) as well.¹¹ Whether liver involvement in patients with PMR can represent a risk factor for overlapping GCA deserves further investigation.¹²

Table. Characteristics of the cohort with comparison between patients with and without hepatic cholestasis.

	No Hepatic Cholestasis, n = 298	Hepatic Cholestasis, n = 216	Total, N = 514	P*
Demographic and clinical characteristics				
Male sex, n (%)	106 (35.6)	74 (34.3)	180 (35.0)	0.83
Age, yrs	74.5 (7.5)	74.8 (8.1)	74.6 (7.8)	0.46
Body weight, kg	62.8 (12.1)	64.4 (13.2)	63.5 (12.6)	0.29
Hypertension, n/N (%)	129/295 (43.7)	97/215 (45.1)	226/510 (44.3)	0.82
Diabetes, n/N (%)	37/296 (12.5)	28 (13.0)	65/512 (12.7)	0.98
Dyslipidemia, n/N (%)	35/295 (11.9)	22 (10.2)	57/511 (11.2)	0.66
Delay to diagnosis, d	87.4 (92.1)	76.2 (80.3)	82.7 (87.5)	0.12
No. of ACR criteria met	4.0 (1.0)	4.1 (0.9)	4.0 (0.9)	0.14
Acute disease onset, n/N (%)	123/294 (41.8)	93/211 (44.1)	216/505 (42.8)	0.68
Fever, n/N (%)	115/294 (39.1)	91/214 (42.3)	206/508 (40.6)	0.52
Weight loss > 5%, n/N (%)	110/291 (37.8)	101/210 (48.1)	211/501 (42.1)	0.03
Polymyalgia symptoms, n (%)	88 (29.5)	69 (31.9)	157 (30.5)	0.62
Systemic (masked) GCA, n (%)	34 (11.4)	25 (11.6)	59 (11.5)	> 0.99
Headache, n (%)	239 (80.2)	174 (80.6)	413 (80.4)	> 0.99
Scalp tenderness, n/N (%)	137/286 (47.9)	110/212 (51.9)	247/498 (49.6)	0.43
Facial/orbital edema, n/N (%)	41 (13.8)	29/214 (13.6)	70/512 (13.7)	> 0.99
Jaw claudication, n/N (%)	86 (29.1)	81 (37.5)	167/512 (32.6)	0.06
Permanent visual loss, n (%)	40 (13.4)	29 (13.4)	69 (13.4)	> 0.99
Ischemic stroke, n (%)	15 (5.0)	5 (2.3)	20 (3.9)	0.18
Limb artery involvement, n (%)	31 (10.4)	17 (7.9)	48 (9.4)	0.42
Mean ENT symptoms ^a , n	1.7 (1.7)	2.0 (2.0)	1.8 (1.8)	0.08
Imaging and pathological findings				
Imaging of the aorta, n/N (%)	113/283 (39.9)	74/200 (37.0)	187/483 (38.7)	0.58
Presence of aortitis, n (%)	55 (18.5)	19 (8.8)	74 (14.4)	< 0.01
Positive TAB result, n/N (%)	190/281 (67.6)	157/212 (74.1)	347/493 (70.4)	0.15
Laboratory results				
Mean ESR, mm/h	78.5 (28.8)	94.9 (25.9)	85.2 (28.8)	< 0.001
Mean CRP, mg/L	79.2 (57.2)	119.6 (72.1)	96.1 (66.8)	< 0.001
Mean fibrinogen level, g/L	6.6 (1.5)	7.3 (1.8)	6.9 (1.7)	< 0.001
Mean hemoglobin, g/L	116.5 (16.4)	112.1 (17.7)	114.6 (17.1)	0.01
Mean leukocyte count, G/L	8.7 (2.5)	9.8 (3.7)	9.1 (3.1)	< 0.001
Mean platelet count, G/L	398 (133)	479 (176)	432 (157)	< 0.001
Mean serum albumin, g/L	34.9 (5.3)	32.6 (5.9)	33.9 (5.7)	< 0.001
Positive IgG aCL, n/N (%)	47/234 (20.1)	33/158 (20.9)	80/392 (20.4)	0.95
Treatment and outcomes				
Pulse methylprednisolone, n (%)	78 (26.2)	59 (27.3)	137 (26.7)	0.85
Initial prednisone dose, mg/kg/d	0.79 (0.17)	0.78 (0.16)	0.78 (0.16)	0.22
Dose at 3 mos, mg/d	17.2 (5.9)	18.6 (5.8)	17.8 (5.9)	< 0.01
Dose at 6 mos, mg/d	11.1 (4.1)	12.5 (4.8)	11.7 (4.4)	< 0.01
Dose at 12 mos, mg/d	6.7 (4.1)	7.4 (4.4)	6.94 (4.2)	0.08
Use of GC-sparing treatment, n (%)	64 (21.5)	43 (19.9)	107 (20.8)	0.75
Treatment stopped, n/N (%)	181/297 (60.9)	134/215 (62.3)	315/512 (61.5)	0.82
Treatment duration, mos	27.2 (25.2)	27.8 (23.9)	27.5 (24.6)	0.97
Treatment duration in recovered patients, mos	27.9 (15.3)	31.7 (20.4)	29.5 (17.7)	0.41
No. of relapses/patient ^b	1.0 (1.2)	1.1 (1.3)	1.0 (1.3)	0.58
Recovered patients ^c , n (%)	165 (55.4)	120 (55.6)	285 (55.4)	1.00
Death, n (%)	93 (31.2)	95 (44.0)	188 (36.6)	< 0.01
Death during GC treatment, n (%)	29 (9.7)	26 (12.0)	55 (10.7)	0.64

Values are expressed as mean (SD) unless indicated otherwise. *Proportions were analyzed using Pearson chi-square tests; comparisons of continuous variables were performed with *t* tests. ^aENT includes jaw claudication, difficulty opening mouth, toothache, earache, tongue pain, sore throat, dry cough, and carotidodynia. ^bBefore 2003, relapse was defined as the recurrence of clinical symptoms or inflammatory variables that were attributable to GCA and required increased medication. Thereafter, only events involving clinical symptoms, or persistently raised acute-phase reactants with demonstration of new large-vessel involvement, were labeled as relapses. ^cPatients free of relapse for at least 12 months following the cessation of GC treatment. aCL: anticardiolipin antibody; ACR: American College of Rheumatology; CRP: C-reactive protein; ENT: ear, nose, and throat; ESR: erythrocyte sedimentation rate; GC: glucocorticoid; GCA: giant cell arteritis; TAB: temporal artery biopsy.

Simon Parreau¹ , MD
Stéphanie Dumonteil¹ , MSc
Guillaume Gondran¹ , MD
Holy Bezanahary¹ , MD
Sylvain Palat¹, MD
Kim-Heang Ly¹ , MD, PhD
Anne Laure Fauchais¹ , MD, PhD
Eric Liozon¹ , MD

¹Department of Internal Medicine, University Hospital of Limoges, Limoges, France.

The authors declare no conflicts of interest relevant to this article.

Address correspondence to Dr. E. Liozon, Service de Médecine Interne A, CHRU Dupuytren, 16, rue Bernard Descottes, 87042 Limoges, France.
Email: liozone@yahoo.fr, eric.liozon@chu-limoges.fr.

REFERENCES

1. Dickson ER, Maldonado JE, Sheps SG, Cain JA Jr. Systemic giant-cell arteritis with polymyalgia rheumatica, reversible abnormalities of liver function. *JAMA* 1973;111:1496-8.
2. Sonnenblick M, Neshet G, Rosin A. Nonclassical organ involvement in temporal arteritis. *Semin Arthritis Rheum* 1989;19:183-93.
3. Ilan Y, Ben-Chetrit E. Liver involvement in giant cell arteritis. *Clin Rheumatol* 1993;12:219-22.
4. Achar KN, Ashfield RP. Gross cholestatic dysfunction in giant cell arteritis. *Postgrad Med J* 1995;71:59-60.
5. Achar KN, Al-Alousi SS, Patrick JP. Biliary ultrastructural changes in the liver in a case of giant cell arteritis. *Br J Rheumatol* 1994;33:161-4.
6. Ogilvie AL, James PD, Toghiani PJ. Hepatic artery involvement in polymyalgia arteritica. *J Clin Pathol* 1981;34:769-72.
7. Gonzalez-Gay MA, Lopez-Diaz MJ, Barros S, et al. Giant cell arteritis: laboratory tests at the time of diagnosis in a series of 240 patients. *Medicine* 2005;84:277-90.
8. Liozon E, Dumonteil S, Parreau S, et al. Risk profiling for a refractory course of giant cell arteritis: the importance of age and body weight: "risk profiling for GC resistance in GCA". *Semin Arthritis Rheum* 2020;50:1252-61.
9. Keser G, Aksu K, Direskeneli H. Discrepancies between vascular and systemic inflammation: an important problem revisited. *Rheumatology* 2018;57:784-90.
10. Cid MC, Font C, Oristrell J, et al. Association between strong inflammatory response and low risk of developing visual loss and other cranial ischemic complications in giant cell (temporal) arteritis. *Arthritis Rheum* 1998;41:26-32.
11. Ishiguro K, Yamashita H, Shimizu Y, Kaneko H. Biomarkers as predicting factors for relapse in polymyalgia rheumatica: the importance of alkaline phosphatase. *Rheumatology* 2023 April 4 (Epub ahead of print).
12. Hysa E, Castagna A, Manzo C. Liver involvement in polymyalgia rheumatica and giant cell arteritis. *Rheumatologia* 2020;58:444-5.

Annexe 5.

New-onset giant cell arteritis with lower ESR and CRP level carries a similar ischemic risk to other forms of the disease but has an excellent late prognosis: a case-control study



New-onset giant cell arteritis with lower ESR and CRP level carries a similar ischemic risk to other forms of the disease but has an excellent late prognosis: a case–control study

Eric Liozon^{1,2} · Simon Parreau¹ · Stéphanie Dumonteil¹ · Guillaume Gondran¹ · Holy Bezanahary¹ · Kim-Heang Ly¹ · Anne Laure Fauchais¹

Received: 12 January 2023 / Accepted: 27 February 2023 / Published online: 7 April 2023
© The Author(s), under exclusive licence to Springer-Verlag GmbH Germany, part of Springer Nature 2023

Abstract

Introduction Biopsy-proven giant cell arteritis (GCA) occasionally presents without acute-phase reaction. In this setting, GCA may be initially overlooked and glucocorticoid treatment unduly delayed, potentially increasing ischemic risk.

Patients and methods From an inception cohort of patients with newly diagnosed, biopsy-verified GCA, we retrieved all cases without elevation of erythrocyte sedimentation rate (ESR) and C-reactive protein (CRP) level before starting glucocorticoid treatment. We compared the baseline features and outcomes of these patients and two additional patients recruited after GCA diagnosis with those of 42 randomly selected patients with high baseline ESR and CRP.

Results Of 396 patients, 14 (3.5%) had lower baseline values of both ESR and CRP. Lower baseline ESR and CRP were associated with fewer American College of Rheumatology criteria met ($p < 0.001$, 95% CI – 1.1; – 0.9), and less jaw claudication ($p = 0.06$, 95% CI 0.8; 44.9), but similar rates of permanent blindness ($p = 1.0$). Patients with lower ESR and CRP also showed obvious differences regarding mean blood cell counts and mean hemoglobin level, but also less anti-cardiolipin antibody positivity ($p = 0.04$, 95% CI 0.8; ∞) and hepatic cholestasis ($p = 0.03$, 95% CI 1.0; 422). Patients with lower ESR and CRP had fewer GCA relapses ($p = 0.03$, 95% CI – 1.1; – 0.1), fewer glucocorticoid-induced complications ($p = 0.01$, 95% CI – 2.0; – 0.1), and successfully stopped glucocorticoids sooner than the other patients (18.3 months vs 34 months in average, $p = 0.02$, 95% CI – 27; – 0.9).

Conclusion Biopsy-proven GCA presenting with lower ESR and CRP is not an exceptional occurrence. It is clinically less typical but carries similar ischemic risk to other forms of the disease. Conversely, the late GCA prognosis of these patients is excellent.

Keywords Giant cell arteritis · Erythrocyte sedimentation rate · C-reactive protein · Case control study

Giant cell arteritis (GCA) is a chronic, systemic, large-vessel vasculitis with marked female predominance and restriction to older age [1]. Substantially increased erythrocyte sedimentation rate (ESR) and C-reactive protein (CRP) level are hallmarks of GCA at the acute stage, and both represent core diagnostic findings in older subjects with recent-onset headache. ESR > 50 mm/h is one of the five American College

of Rheumatology (ACR) criteria for GCA [2]. Occasionally, GCA may present without elevated ESR and/or CRP, with a reported frequency of such features ranging widely from < 1 to 24%. Discrepancies between studies were mainly due to considerable heterogeneity in the cut-off ESR value chosen for normality, additional CRP measurement and its related cut-off value, as well as inclusion of patients previously or currently treated for GCA or polymyalgia rheumatica (PMR) [3–8].

In a literature review of incident GCA presenting with low ESR in 1986, Wong et al. reported a high frequency of severe visual complications (6/22 patients) in these patients [9]. More recently, authors from the Mayo Clinic disputed this finding along with presentation of their own experience in nine patients with very low baseline ESR, none of

✉ Eric Liozon
liozone@yahoo.fr; cric.liozon@chu-limoges.fr

¹ Department of Internal Medicine, University Hospital of Limoges, Limoges Cedex, France

² Service de Médecine Interne A, CHRU Dupuytren, 16, Rue Bernard Descottes, 87042 Limoges, France

whom suffered permanent vision loss [10]. However, neither study compared the main features and outcome issues of GCA patients presenting with normal ESR and CRP in a controlled manner to clarify several major issues, including delay in diagnosis, its associated risk of severe ischemic events, and the late GCA prognosis in such patients. This report presents personal experience based on a large GCA series included in an inception cohort, with comparison of baseline features and outcomes of patients with both lower ESR and CRP, with those of patients with overt acute-phase reaction at presentation.

Patients and methods

Patients and data collection

The study population included all consecutive patients referred to the department of internal medicine of one tertiary care teaching hospital for diagnosis and treatment of GCA since 1980 until December 2021. GCA diagnosis was based on the ACR criteria [2]. All GCA diagnoses were pathologically confirmed using currently accepted criteria [11], and polymyalgia rheumatica (PMR) was defined by at least 2 weeks of moderate-to-severe pain and morning stiffness lasting more than 30 min in at least two areas that included the neck, shoulders, and pelvic girdle [12]. We retrieved all data on GCA features, treatments, and outcome issues. Clinical, laboratory, and pathological data were recorded prospectively at the time of first admission using a specifically designed 176-item questionnaire of detailed history and log data. All study data were stored electronically and regularly updated [13]. We extracted all reported, biopsy-verified GCA cases showing both ESR (Westergren method) ≤ 35 mm/h and CRP ≤ 10 mg/L (e.g., the lower limit for CRP to qualify as a positive item in the 2022 American College of Rheumatology/EULAR classification criteria for GCA) [14] in the absence of prior glucocorticoid (GC) treatment, and compared their features and outcomes with those of 42 randomly selected, biopsy-verified patients from the same inception cohort, after excluding negative biopsy cases and biopsy-proven cases lacking baseline ESR and/or CRP data, as well as cases with too incomplete records.

Study variables and clinical definitions

Details of the demographic characteristics, date of diagnosis, clinical features, levels of acute-phase reactants and liver enzymes at disease onset (prior to steroid treatment), temporal artery biopsy (TAB) status, starting dose of prednisone, number of relapses during prednisone tapering, use of steroid-sparing agents, and total duration of treatment were retrieved for each patient. The clinical items extracted from

the electronic medical records included PMR symptoms, new-onset headache, scalp tenderness, jaw claudication and/or other jaw/mouth/throat problems, and visual ischemic manifestations, as described previously [13]. Temporal arteries were considered abnormal if the pulse was low or absent and/or at least one artery showed nodules, redness, thickening, or tenderness. Constitutional syndrome was defined as temperature ≥ 38 °C lasting for at least 1 week in conjunction with severe asthenia and/or weight loss $> 5\%$. Upper limb artery involvement was defined clinically followed by confirmation using echo-Doppler ultrasound and/or angiography. Starting in 2005, subclinical aortitis was diagnosed by fluorodeoxyglucose-positron emission tomography (FDG-PET) and/or computed tomography (CT) according to current diagnostic standards [15]. Patients with persistent fever of unknown origin and/or isolated raised acute-phase reactants were classified as having the systemic form of GCA regardless of the presence or absence of subclinical aortitis. We defined typical cranial arteritis as the presence of at least two of new-onset headache, clinically abnormal temporal artery, and/or jaw claudication. Liver involvement was defined by the presence of elevated serum levels of phosphatase alkaline and gammaglutamyl-transpeptidase, in the absence of prior GC treatment.

Outcome measures

Relapse was defined as the recurrence of clinical symptoms and/or inflammatory parameters attributable to GCA and requiring increased medication. PMR relapses were defined based on a combination of patient self-assessment, erythrocyte sedimentation rate (ESR), C-reactive protein (CRP) level, shoulder pain/limitations during clinical examination, and response to steroid dose adjustments; if these events occurred after cessation of the planned treatment, it was considered as recurrence [16]. Relapsing patients in whom prednisone doses could not be reduced below 20 mg/day at 6 months, 10 mg/day at 12 months, and/or 7.5 mg/day at 2 years were considered steroid-dependent cases. We also evaluated total treatment duration, recovery from GCA (i.e., free of relapse for at least 12 months following cessation of GC treatment), duration of treatment in recovered patients, duration of clinical follow-up, date of death, or patient clinical status at the end of the study (March 31, 2021). Steroid-induced complications, including infection (any event leading to antibiotic prescription and/or hospitalization), osteoporotic fractures, diabetes mellitus, venous thromboembolism, and disabling myopathy, were recorded.

Treatments

Most patients with GCA were treated using standardized protocols. Patients lacking ischemic manifestations received

prednisone at 0.6–0.8 mg/kg/day until their symptoms disappeared and CRP levels were < 5 mg/L, after which the prednisone dose was progressively tapered to 0.35 mg/kg within 4–6 weeks. Patients with permanent ischemic manifestations received an initial prednisone dose of 0.9–1.1 mg/kg/day, which was often preceded by pulse methylprednisolone, and the dose was then similarly tapered. Relapses without ischemic symptoms were managed by temporarily increasing the prednisone dose to a previously effective dose, whereas severe relapses involved more consistent increases conducted on an individual basis. Patients with relapsing/steroid-dependent GCA or those who experienced serious steroid-related side effects often received steroid-sparing drugs, such as methotrexate, dapsone [17], or tocilizumab.

Statistical analysis

For each case (e.g., biopsy-proven GCA with lower ESR and low CRP), three controls (e.g., biopsy-proven GCA with baseline ESR > 35 mm and/or CRP > 10 mg/L) were randomly selected from the inception cohort. Continuous variables are expressed as the mean and standard deviation or median and interquartile range, and categorical variables are given as the frequency and percentage. Variables were compared for GCA patients with or without lower ESR and CRP using Pearson's chi-square test, Fisher's exact test, or Wilcoxon's test as appropriate. Tests were two-sided and $p < 0.05$ was taken to indicate statistical significance. All calculations were performed using R version 3.2.2 (R Foundation for Statistical Computing, Vienna, Austria).

Literature review

We searched for published cases in the English Language indexed in Pubmed/Medline, Scopus and Directory of Open Access Journals performed with the following Key words in combination with Medical Subject Headings (MeSH) terms: [giant cell arteritis or temporal arteritis—AND low erythrocyte sedimentation rate (ESR) or normal ESR or normal inflammatory markers or normal C-reactive protein]. We also manually screened reference lists of selected retrieved articles to identify further papers that both databases may have missed. For cases published up to 1983, we used the data collected by Wong et al. in a thorough literature review [9].

Ethics board approval

All data concerning these older patients with GCA were collected retrospectively. This study was conducted in compliance with good clinical practices and the principles of the Declaration of Helsinki. In accordance with French law,

formal ethics committee approval was not required for this type of retrospective study.

Results

Characteristics of low ESR and CRP GCA patients

Of 587 patients newly diagnosed with GCA between January 1980 and May 2021, 396 met the entry criteria (e.g., biopsy-proven disease and both ESR and CRP measured at least once before GC treatment). Fourteen patients (3.5%) both had lower baseline ESR (mean 20.4 ± 8.9 mm/h) and CRP level (mean 5.4 ± 3 mg/L), 10 of whom (2.5%) had both ESR < 30 mm/h and CRP < 8 mg/L. Table 1 shows the demographic, clinical, and laboratory characteristics of these 14 patients and two additional patients who were recruited after diagnosis and were therefore not included in the inception cohort. The mean age of the patients was 74.4 years (range 67–85 years) with a female/male ratio of 2.5. GCA had an abrupt onset in half of the cases, and the delay to diagnosis averaged 113 days (range 18–350 days). The mean latency from the first hospital presentation to diagnosis was 19 days (range 0–225 days, average 2 days). Ten patients met four ACR criteria, four met three criteria, and two met two criteria. Nine (56%) patients had typical features of cranial arteritis and 12 (75%) had abnormal temporal artery findings. Two patients had concurrent polymyalgia symptoms and two other patients had a prior history of PMR. Four patients reported jaw claudication and/or difficulty in mouth opening, and two reported low-grade fever. Eight patients (50%) reported visual or central nervous system ischemic symptoms, which were permanent in four (25%, two cases of permanent vision loss from anterior ischemic optic neuropathy [AION], one case of stroke, and one case of both AION and stroke). In addition, two patients (14%) had severe limb ischemia. Thus, six patients (37.5%) presented with permanent ischemic manifestations due to GCA. Mean ESR was 20.1 ± 8.9 mm/h, mean CRP 5.5 ± 3 mg/L, mean fibrinogen was 440 ± 93 mg/dL (normal range 200–400 mg/dL) with 6 (50%) values > 450 mg/dL, mean haptoglobin 207 ± 36 mg/dL with two (25%) elevated values, mean hemoglobin 132.9 ± 13.6 g/L with two values (14%) below 120 g/L, and mean platelet count $309 \pm 81 \times 10^9/L$ with two (15%) values above $400 \times 10^9/L$. None of the patients died during treatment, and twelve (75%) recovered after a mean 18.3-month course of GC administration.

Among group comparisons

Mean ESR was 92.5 ± 24 mm/h and mean CRP was 114 ± 68 mg/L in controls. The mean follow-up duration was 52.9 ± 31.2 months in patients with lower ESR and CRP and

Table 1 Characteristics and outcomes of 16 patients with low ESR/low-CRP GCA

Patient	Sex/age (yr)	Delay in diagnosis (d)	Typical cranial arteritis ^a (ACR criteria)	Ischemic complications	Aortitis on imaging	ESR (mm/h)/CRP (mg/L)	GC duration/outcome
Case 1	F/74	30	Yes (4)	None	N.A.	35/5	26 mo, recovered
Case 2	F/80	60	Yes (4)	None	N.A.	11/5	17 mo, recovered
Case 3	M/75	18	No (4)	None	N.A.	6/2	17 mo, recovered
Case 4	F/80	350	No (3)	Limb ischemia	Yes	22/3	> 60 mo ^a (lost to follow-up)
Case 5	M/68	175	No (2)	Limb ischemia	Yes	29/10	34 mo, recovered
Case 6	F/67	105	Yes (4)	PVL (AION)	N.A.	22/9	15 mo, recovered
Case 7	F/67	85	Yes (4)	None	No	14/8	16 mo, recovered
Case 8	M/79	25	Yes (4)	None	No	21/4	16 mo, recovered
Case 9	F/73	60	No (4)	None	No	32/8	15 mo, recovered
Case 10	F/80	170	Yes (4)	None	N.A.	11/2	> 23 mo ^a , relapsed
Case 11	M/76	235	No (3)	Stroke/PVL (AION)	Yes	12/4	18 mo, recovered
Case 12	F/77	175	No (3)	Stroke	Yes	20/10	16 mo, recovered
Case 13	F/68	21	Yes (4)	None	No	30/8	14 mo, recovered
Case 14	F/64	180	Yes (4)	None	Yes	29/6	> 19 mo ^a , relapsed
Case 15	F/77	25	No (2)	PVL (AION)	N.A.	12/3	22 mo, recovered
Case 16	M/85	155	No (2)	None	N.A.	25/1	> 20 mo ^a (lost to follow-up)

AION anterior ischemic optic neuropathy, CRP C-reactive protein, ESR erythrocyte sedimentation rate, GC glucocorticoid, N.A. not assessed, PVL permanent vision loss

^aOngoing glucocorticoid treatment (e.g., > 60 mo, patient still undergoing treatment after a 60-month course of glucocorticoid)

90 ± 71.9 months in controls. Tables 2 and 3 summarize the results of statistical analysis comparing the clinical features and outcomes of patients with lower baseline ESR and CRP with those of controls. Lower baseline ESR and CRP were associated with fewer ACR criteria met, a lower frequency of jaw claudication, more frequent use of aortic imaging with higher frequency of visualized aortitis, but similar rates of permanent ischemic complications, including permanent vision loss. We also found significant differences between the two groups regarding the elevation of liver enzymes and anti-cardiolipin IgG antibody presence, both variables being less frequent in patients with lower ESR and CRP. Patients in both groups had similar mean prednisone doses at diagnosis, 3 months, 6 months, and 1 year, but patients with lower ESR and CRP showed fewer GCA relapses, fewer GC-related complications, and earlier successful withdrawal of prednisone.

Literature review—pooled results

In a review of the literature up to 1983, Wong et al. extracted 22 patients with sufficient clinical information for analysis and comparison with reported series of patients with biopsy-proven GCA with elevated ESR. Visual symptoms were present in 36% of these cases. Headache and jaw claudication were present less often in the patients with a low ESR [9]. Pooling our 16 patients with 61 previously published patients, including the 22 patients reviewed by Wong

et al. and subsequent single-case reports or case-series [9, 10, 18–44], we found a high (56%) frequency of reported ischemic symptoms related to GCA, which were permanent in 30 patients (39%). Notably, permanent vision loss occurred in 20 (26%) patients. Other permanent ischemic complications included stroke ($n=6$), limb ischemia (scalp necrosis ($n=2$), and third nerve palsy ($n=2$).

Discussion

In the large, tertiary hospital-based, unselected series of newly diagnosed GCA patients described here, the frequency of biopsy-verified disease with lower ESR and CRP was 3.5%. Researchers from the Mayo Clinic found a similar proportion of patients (4%) with both low ESR and low CRP among untreated, biopsy-verified GCA patients [45], whereas in another study only one patient (0.8%) presented with normal ESR and CRP [46]. These discrepancies can be explained, in all likelihood, by the variation in definitions of normal ESR and normal CRP between studies. Indeed, if we had used a lower cutoff for normal CRP < 6 mg/L instead of 10 mg/L, the proportion of patients without increased acute-phase reaction in our cohort would have been reduced to 2%. We made the pragmatic choice of 35 mm/h as the cut-off value of a lower ESR based on our personal observations (ESR ≤ 35 mm/h in less than 5% of biopsy-proven cases) and in accordance with the relevant literature on GCA

Table 2 Comparison of demographics and baseline characteristics of patients with low ESR/low-CRP GCA with a sample of control GCA patients

	Low-ESR/low CRP <i>n</i> =16 <i>n</i> (%) or mean (SD)	Elevated ESR and CRP <i>n</i> =42	Total <i>n</i> =58	<i>p</i> -value
Female sex	12 (75.0)	27 (64.3)	39 (67.2)	0.541
Age	74.38 (6.03)	76.43 (8.58)	75.86 (7.96)	0.385
Comorbid conditions ^a	1.44 (1.41)	1.49 (0.95)	1.47 (1.09)	0.691
Delay in diagnosis	116.81 (94.64)	76.92 (78.19)	88.53 (84.41)	0.191
In-hospital	18.69 (55.35)	10.05 (26.03)	12.52 (36.49)	0.257
ACR criteria met	3.56 (0.73)	4.55 (0.71)	4.28 (0.83)	<0.001
Acute GCA onset	6 (37.5)	15 (38.5)	21 (38.2)	1.000
Typical cranial arteritis	9 (56.2)	32 (76.2)	41 (70.7)	0.243
Abnormal temporal artery	12 (75.0)	32 (76.2)	44 (75.9)	1.000
PMR	2 (12.5)	10 (23.8)	12 (20.7)	0.479
GCA after PMR	2 (12.5)	6 (14.3)	8 (13.8)	1.000
Imaging study of aorta	8 (53.3)	7 (17.1)	15 (26.8)	0.018
Aortitis on imaging	5 (31.2)	3 (7.1)	8 (13.8)	0.030
Limb artery involvement	3 (18.8)	4 (9.5)	7 (12.1)	0.381
Symptomatic	2 (12.5)	0 (0.0)	2 (3.6)	0.078
Headache	14 (87.5)	34 (81.0)	48 (82.8)	0.711
Scalp tenderness	5 (33.3)	22 (56.4)	27 (50.0)	0.224
Jaw claudication	2 (12.5)	16 (39.0)	18 (31.6)	0.064
Difficulty opening mouth	2 (12.5)	9 (23.1)	11 (20.0)	0.478
Buccal/ENT symptoms	1.44 (1.31)	1.97 (1.91)	1.82 (1.76)	0.442
Fever ≥ 38 °C	2 (13.3)	16 (38.1)	18 (31.6)	0.109
Weight loss > 5%	2 (13.3)	15 (38.5)	17 (31.5)	0.106
Fatigue	8 (57.1)	27 (65.9)	35 (63.6)	0.792
Ischemic manifestations ^b	9 (56.2)	17 (40.5)	26 (44.8)	0.433
Permanent vision loss	3 (18.8)	10 (23.8)	13 (22.4)	1.000
Stroke	2 (12.5)	3 (7.1)	5 (8.6)	0.610
Hemoglobin (g/L)	134.07 (13.15)	113.05 (17.46)	118.68 (18.81)	<0.001
Leukocytes ($10^9/L$)	7674 (1379)	9843 (3606)	9291 (3317)	0.009
Platelets ($10^9/L$)	306.1 (78.9)	440.8 (131.9)	406.5 (133.8)	<0.001
Elevated liver enzymes	1 (8.3)	16 (45.7)	17 (36.2)	0.034
IgG anti-cardiolipin antibody	0/10 (0.0)	11 (33.3)	11 (25.6)	0.043

ACR American College of Rheumatology, CRP C-reactive protein, ENT ear-nose-throat, ESR erythrocyte sedimentation rate, GCA giant cell arteritis, PMR polymyalgia rheumatica

^aIncluding notable hypertension, diabetes, hypercholesterolemia, ischemic heart disease, peripheral vascular disease, chronic pulmonary diseases, and osteoporosis

^bIncluding transient ischemic visual problems (amaurosis fugax, blurred vision, diplopia), transient ischemic attack, permanent vision loss, stroke, and limb ischemia

presenting with a low ESR. We chose 10 mg/l as the cut-off value for a lower CRP based on the 2022 American College of Rheumatology/EULAR classification criteria for giant cell arteritis [14].

Elevated ESR and CRP are well-established aids in the diagnosis of GCA. When combined, the two markers provide a sensitivity of 80.8% [46] to 99% [45], once again depending on the definitions of normality for both markers. Interestingly, the negative predictive value of normal ESR and CRP at GCA diagnosis was 87.7% in the study by Kermani et al., meaning that using ESR ≤ 22 mm/h in men

or ≤ 29 mm/h in women and CRP ≤ 8 mg/L, GCA would be overlooked biologically in 12% of cases [45]. Considering the potential catastrophic complications of GCA, this negative predictive value is unsatisfactory. Although the additional measurement of platelet count may serve as a surrogate marker, it has not been shown to increase the performance of the ACR criteria, nor was it included in the 2022 classification criteria for GCA [14]. In the present study, we assessed additional laboratory markers, such as fibrinogen, haptoglobin, hemoglobin, and platelet count in 14 (88%) patients, which were helpful in detecting inflammation in

Table 3 Comparison of treatments and outcomes of patients with low ESR/low-CRP GCA with control patients

	Low-ESR/low-CRP <i>n</i> = 16 <i>n</i> (%) OR mean (SD)	Elevated ESR and CRP <i>n</i> = 42	Total <i>n</i> = 58	<i>p</i> -value
Pulse methylprednisolone	4 (25.0)	10 (23.8)	14 (24.1)	1.000
Initial Pred dose (mg/d)	0.82 (0.15)	0.81 (0.17)	0.81 (0.17)	0.752
Pred dose (mg/d)				
At 3 mo	21.27 (9.03)	18.95 (5.62)	19.45 (6.47)	0.765
At 6 mo	13.30 (5.98)	12.97 (4.95)	13.04 (5.11)	0.871
At 12 mo	5.78 (2.77)	7.27 (3.74)	6.95 (3.58)	0.316
GC-sparing treatment(s)	3 (18.8)	7 (16.7)	10 (17.2)	1.000
No. of relapses/recurrences	0.43 (0.65)	1.24 (1.51)	1.04 (1.39)	0.026
Ischemic complications ^a	7 (43.8)	12 (29.3)	19 (33.3)	0.466
GC-induced complications	0.42 (0.79)	1.57 (1.55)	1.31 (1.49)	0.012
Duration of treatment	18.19 (18.41)	34.31 (34.93)	29.86 (31.93)	0.022
Recovered patients	12 (75.0)	22 (52.4)	34 (58.6)	0.145
Treatment duration in recovered patients	18.33 (8.97)	34.05 (20.22)	29.48 (18.98)	0.022
Death	1 (6.2)	19 (45.2)	20 (34.5)	0.005

CRP C-reactive protein, ESR erythrocyte sedimentation rate, GC glucocorticoid, Pred prednisone

^aEarly and/or late complications of giant cell arteritis

5 cases (36%). Therefore, performing additional laboratory investigations, especially analysis of blood counts and fibrinogen, may assist in the early diagnosis of GCA in patients with low ESR and CRP. Consistent with the study by Wong et al. [9], our results showed that lack of acute-phase reaction was associated with fewer typical cranial features and consequently fewer ACR criteria met, further complicating diagnosis. However, careful physical examination of our patients revealed relevant abnormalities of temporal artery beds in 75% of cases. Therefore, thorough history taking and clinical examination are keys in diagnosing GCA without elevated acute-phase reactants. This first step in the diagnosis of GCA is crucial in patients presenting with visual or cerebrovascular ischemic manifestations but no acute-phase response [47]. While ultrasound can enhance diagnostic suspicion, temporal artery biopsy should always be performed, as it remains the only way to unequivocally confirm GCA in cases without an acute-phase response.

Our findings, that patients with either low or high baseline ESR and CRP had similar rates of permanent ischemic complications, notably permanent vision loss, were consistent with those of Wong et al. [9] but at odds with a study by Salvarani et al. in which no patients with low baseline ESR and CRP suffered vision loss [10]. This discrepancy may be explained by the differences in study settings (i.e., hospital-based vs. population-based). The even higher frequency (39%) of permanent ischemic complications in our literature review probably involves case selection and publication bias. Nevertheless, several studies showed an inverse relationship between irreversible cranial complications of

GCA and the intensity of acute-phase response [48, 49], supporting our finding of a significant ischemic risk in patients without elevated ESR and CRP. Moreover, the results of the present study go against a longer diagnostic process in GCA cases with lower ESR and CRP than in usual cases as the main explanation for the significant rate of ischemic complications. These events may, rather, pertain to prominent IFN- γ -producing Th1 responses inducing vascular damage but no or minimal systemic manifestations of the disease [50]. Our report of higher frequency of aortitis may be not reliable in patients with lower baseline ESR and CRP, since numbers of assessed cases were low. Moreover, a much greater proportion of patients with lower ESR and CRP (53% vs 17%) had a CT-scan or a PET-CT performed at baseline suggesting a bias in the diagnostic workup according to the clinical pattern, rather than a true association between a lower ESR/CRP and aortitis. Nevertheless, the present study highlights that aortitis and lower acute-phase reactants at GCA onset are not mutually exclusive.

The finding of less frequently elevated liver enzymes in patients without overt inflammation is in keeping with previous observations of a positive association between hepatic cholestasis and severity of acute-phase reaction [51], whereas the finding of less anti-cardiolipin antibody positivity is more difficult to explain. However, the low number of such tested patients limits the scope of this result.

Finally, we found that overall prognosis of GCA with low ESR and CRP at diagnosis was good in our patients, consistent with the results of a previous population-based study [10]. This was also consistent with the opposite finding of

longer GC requirements for patients with GCA and a strong inflammatory response [52, 53]. Such a favorable response to GC treatment could rely on a more sensitive immune profile of GCA. Otherwise, the absence of biological markers may have encouraged physicians to follow a more linear GC tapering schedule.

The present study had several limitations. We may have missed some relevant clinical features due to the retrospective study design and the small sample size. Imaging study of the aorta was lacking in many patients, precluding any firm conclusions regarding the frequency of silent aortitis in this rare GCA subset. The very long period of case inclusion (1980–2021) could have distorted the result of the study. However, time is unlikely to have had impact on completing the fixed items included in the prospective questionnaire, at least for the main clinical and laboratory data. Likewise, GC regimen were standardized since 1982, avoiding significant distortion of the results, although recent GCA cases might have benefit from current recommendations not to increase the glucocorticoid dose on the sole basis of elevated acute-phase reactants, in contrast to older cases. Nevertheless, most patients with lower ESR/lower-CRP GCA were part of a well-defined, large inception cohort, which enhanced the accuracy of the data. Moreover, detailed information on GCA features, available data on treatment and outcomes in all cases and controls, and a consistent follow-up period enabled detailed description of reported cases. Finally, this was the first comparison of the features and prognoses of lower ESR/lower-CRP GCA with usual GCA. Using this strategy, we identified several variables that distinguish both subsets of patients, and clarified the issue of whether GCA without an acute-phase reaction carries a lower risk of visual ischemic complications.

GCA with normal baseline ESR and CRP occurs in approximately 4% of biopsy-proven cases. Despite the lack of a major ACR criterion, the diagnosis of GCA can be made easily in most cases upon thorough history taking, meticulous physical examination, ultrasonography, and unilateral TAB. Patients with either lower or high initial ESR and CRP share the same rate of early ischemic complications, but late prognosis is better in the former. Follow-up is essentially clinical, quite similar to GCA patients who undergo tocilizumab treatment.

Author contributions EL: conception, design, acquisition, interpretation, draft (original and revised manuscript), critical revision. SP: design, acquisition, critical revision. SD: analysis, interpretation, critical revision. GG: acquisition, critical revision. HB: acquisition, critical revision. LY: design, acquisition, interpretation, critical revision. ALF: design, acquisition, interpretation, critical revision. Final approval of the version to be published. Agreement to be accountable for all aspects of the work in ensuring that questions related to the accuracy or integrity of any part of the work are appropriately investigated and resolved.

Declarations

Conflict of interests The authors declare no conflict of interests.

References

1. Weyand CM, Goronzy JJ (2014) Clinical practice. Giant cell arteritis and polymyalgia rheumatica. *N Engl J Med* 371:51–57
2. Hunder GG, Bloch DA, Michel BA, Stevens MB, Arcnd WP, Calabrese LH, Edworthy SM, Fauci AS, Leavitt RY, Lie JT et al (1990) The American College of Rheumatology 1990 criteria for the classification of giant cell arteritis. *Arthritis Rheum* 33:1122–1228
3. Ellis ME, Ralston S (1983) The ESR in the diagnosis and management of the polymyalgia rheumatic/giant cell arteritis syndrome. *Ann Rheum Dis* 42:168–170
4. Branum G, Massey EW (1987) Erythrocyte sedimentation rate in temporal arteritis. *South Med J* 80:1527–1528
5. Jundt JW, Mock D (1991) Temporal arteritis with normal erythrocyte sedimentation rates presenting as occipital neuralgia. *Arthritis Rheum* 34:217–219
6. Kyle V, Cawston TE, Hazelman B (1989) Erythrocyte sedimentation rate and C reactive protein in the assessment of polymyalgia rheumatica/giant cell arteritis on presentation and during follow up. *Ann Rheum Dis* 48:667–671
7. Wise CM, Aguledo CA, Chmielewski WL, McKnight KM (1991) Temporal arteritis with a low erythrocyte sedimentation rate: a review of five cases. *Arthritis Rheum* 34:1571–1574
8. Martinez-Taboada VM, Blanco R, Armona J, Uriarte E, Figueroa M, Gonzalez-Gay MA, Rodriguez-Valverde V (2000) Giant cell arteritis with an erythrocyte sedimentation rate lower than 50. *Clin Rheumatol* 19:73–75
9. Wong RL, Korn JH (1986) Temporal arteritis without an elevated erythrocyte sedimentation rate. *Am J Med* 80:959–964
10. Salvarani C, Hunder GG (2001) Giant cell arteritis with low erythrocyte sedimentation rate: frequency of occurrence in a population-based study. *Arthritis Rheum* 45:140–145
11. Lie JT (1990) Illustrated histopathologic classification criteria for selected vasculitis syndromes. American College of Rheumatology Subcommittee on Classification of Vasculitis. *Arthritis Rheum* 33:1074–1087
12. Dasgupta BD, Cimmino MA, Maradit-Kremers H, Schmidt WA, Schirmer M, Salvarani C et al (2012) 2012 provisional classification criteria for polymyalgia rheumatica: a European League Against Rheumatism/American College of Rheumatology collaborative initiative. *Ann Rheum Dis* 71:484–492
13. Liozon E, Dalmay F, Lalloué F, Gondran G, Bezanahary H, Fauchais AL, Ly KH (2016) Risk factors for permanent visual loss in biopsy-proven giant cell arteritis: a study of 339 patients. *J Rheumatol* 43:1393–1399
14. Ponte C, Grayson PC, Robson JC, Suppiah R, Gribbons KB, Judge A, Craven A, Khalid S, Hutchings A, Watts RA, Merkel PA, Luqmani RA, DCVAS Study Group (2022) 2022 American College of Rheumatology/EULAR classification criteria for giant cell arteritis. *Ann Rheum Dis* 81:1647–1653
15. de Boysson H, Dumont A, Liozon E, Lambert M, Boutemy J, Maigné G, Martin Silva N, Sultan A, Ly KH, Aide N, Manrique A, Bienvenu B, Aouba A (2017) Giant-cell arteritis: concordance study between aortic CT angiography and FDG-PET/CT in detection of large-vessel involvement. *Eur J Nucl Med Mol Imaging* 44:2274–2279
16. Dejaco C, Duftner C, Cimmino MA, Dasgupta B, Salvarani C, Crowson CS, Maradit-Kremer H, Hutchings A, Matteson EL,

- Schirmer M (2011) and members of the International Work Group for PMR and GCA. *Ann Rheum Dis* 70:447–453
17. Ly KH, Dalmay F, Gondran G, Palat S, Bezanahary H, Cypierre A, Fauchais AL, Liozon E (2016) Steroid-sparing effect and toxicity of dapsone treatment in giant cell arteritis: a single-center, retrospective study of 70 patients. *Medicine*. <https://doi.org/10.1097/MD.0000000000004974>
 18. Berth-Jones J, Holt PJA (1988) Temporal arteritis presenting with scalp necrosis and a normal erythrocyte sedimentation rate. *Clin Exp Dermatol* 13:200–201
 19. Grodum E, Petersen HA (1990) Temporal arteritis with normal erythrocyte sedimentation rate. *J Intern Med* 227:279–280
 20. Neish PR, Sergent JS, Giant cell arteritis, (1991) A case with unusual neurologic manifestations and a normal sedimentation rate. *Arch Intern Med* 151:378–380
 21. Ellis JD, Munro P, McGettrick P (1994) Blindness with a normal erythrocyte sedimentation rate in giant cell arteritis. *Br J Hosp Med* 52:358–359
 22. Rentsch JL, Liedel JL, Bayley NB, Buchanan MR, Goldblatt JC, Warren RJ, Kay TW (1998) Giant cell arteritis with severe aortic regurgitation and a normal ESR. *Aust N Z J Med* 28:70–71
 23. Poole TR, Graham ER, Lucas SB (2003) Giant cell arteritis with a normal ESR and CRP. *Eye* 17:92–93
 24. Yu-Wai-Man P, Dayan MR (2007) Giant cell arteritis with normal inflammatory markers. *Acta Ophth Scand* 85:460
 25. Lewko MP, Bahrapour LH (2004) Giant cell arteritis presenting with dizziness and a normal erythrocyte sedimentation. *J Am Geriatr Soc* 52:1220–1221
 26. Varma R, Patel AD (2005) Scalp lesions in a 78-year-old woman. *CMAJ* 173:33
 27. Madge SN, Klys H, Twomey JM (2006) Giant cell arteritis presenting as painful third nerve palsy with normal erythrocyte sedimentation rate. *Br J Hosp Med* 67:268
 28. Raja MK, Proulx AA, Allen LH (2007) Giant cell arteritis presenting with aortic aneurysm, normal erythrocyte sedimentation rate, and normal C-reactive protein. *Can J Ophthalmol* 42:136–137
 29. Yoerueck E, Szurman P, Tatar O, Weckerle P, Wilhelm H (2008) Anterior ischemic neuropathy due to giant cell arteritis with normal inflammatory markers. *Graefes Arch Clin Exp Ophthalmol* 246:913–915
 30. Ciccarelli M, Jeanmonod SD, Jeanmonod R (2009) Giant cell temporal arteritis with a normal erythrocyte sedimentation rate: report of a case. *Am J Emerg Med* 27:255
 31. Tsianakas A, Ehrchen JM, Presser D, Fischer T, Kruse-Loesler B, Luger TA, Sunderkoetter C (2009) Scalp necrosis in giant cell arteritis: case report and review of the relevance of this cutaneous sign of large-vessel vasculitis. *J Am Acad Dermatol* 61:701–706
 32. Levin F, Shubert HD, Merriam JC, Blume RS, Odel JG (2011) Occult temporal arteritis in a 54-year-old man. *J Neuroophthalmol* 32:153–154
 33. Laria A, Zoli A, Bocci M, Castri F, Federico F, Ferraccioli GF (2012) Systematic review of the literature and a case report informing biopsy-proven giant cell arteritis (GCA) with normal C-reactive protein. *Clin Rheumatol* 31:1389–1391
 34. Fernandez-Fernandez FJ, Ameneiros-Lago E, Sesma P (2012) Might tocilizumab be useful in patients with giant cell arteritis and normal ESR? *Swiss Med Wkly* 142:w13503. <https://doi.org/10.4414/smww.2012.13503>
 35. Hussami A, Casulli C, Fayard C, Caillier-Minier M, Vion P, Minier D (2016) Vertebrobasilar stroke secondary to giant-cell arteritis without biological inflammatory syndrome. *Rev Neurol* 172:248–252
 36. Cheema MR, Ismael SM (2016) Temporal arteritis with erythrocyte sedimentation rate < 50 mm/h: a clinical reminder. *Clin Interv Aging* 11:185–188
 37. Singh R, Sahbudin I, Filer A (2018) New headaches with normal inflammatory markers: an early atypical presentation of giant cell arteritis. *BMJ Case Rep*. <https://doi.org/10.1136/bcr-2017-223240>
 38. Martins P, Teixeira V, Teixeira FJ, Canastro M, Palha A, Fonseca JE, Ponte C (2020) Giant cell arteritis with normal inflammatory markers: case report and review of the literature. *Clin Rheumatol* 39:3115–3125. <https://doi.org/10.1007/s10067-020-05116-1>
 39. Walters B, Lazic D, Ahmed A, Yiin G (2020) Lessons of the month 4: giant cell arteritis with normal inflammatory markers and isolated oculomotor nerve palsy. *Clin Med* 20:224–226
 40. Xia C, Edwards R, Omidvar B (2022) A case of giant cell arteritis with a normal erythrocyte sedimentation rate (ESR) post-ChAdOx1 nCoV-19 vaccination. *Cureus*. <https://doi.org/10.7759/cureus.25388>
 41. Mahgoub S, Nakhleh R (2022) Normal ESR, CRP and platelet count in giant cell arteritis and polymyalgia rheumatica: a diagnostic conundrum. *Eur J Case Rep Intern Med* 9:003192
 42. Koizumi N, Tagasugi J, Ohara N, Kawamoto M (2022) FDG-PET/CT of giant cell arteritis with normal inflammatory markers. *Ann Neurol* 92:337–339
 43. Habib MB, Riaz A (2022) Giant cell arteritis with normal inflammatory markers. *Clin Med*. <https://doi.org/10.7861/clinmed.22-4-s15>
 44. Wang Q, Mortensen P, Lee AG (2023) Neuro-ophthalmic manifestations of giant cell arteritis-myelodysplastic subtype. *J Neuro-Ophthalmol*. <https://doi.org/10.1097/WNO.0000000000001767>
 45. Kermani TA, Schmidt J, Crowson CS, Ytterberg SR, Hunder GG, Matteson EL, Warrington KJ (2012) Utility of erythrocyte sedimentation rate and C-reactive protein for the diagnosis of giant cell arteritis. *Semin Arthritis Rheum* 41:866–871
 46. Parikh M, Miller NR, Lee AG, Savino PJ, Vacarezza MN, Cornblath W, Savino PJ, Vacarezza MN, Cornblath W, Eggenberger E, Antonio-Santos A, Golnik K, Kardou R, Wall M (2006) Prevalence of normal C-reactive protein with an elevated erythrocyte sedimentation rate in biopsy-proven giant cell arteritis. *Ophthalmology* 113:1842–1845
 47. Parreau S, Dumonteil S, Macian Montoro F, Gondran G, Bezanahary H, Palat S, Gondran G, Bezanahary H, Palat S, Ly KH, Fauchais AL, Liozon E (2022) Giant cell arteritis-related stroke in a large inception cohort: a comparative study. *Semin Arthritis Rheum*. <https://doi.org/10.1016/j.semarthrit.2022.152020>
 48. Cid MC, Font C, Oristrell J, de la Sierra A, Coll-Vinent B, López-Soto A, Vilascca J, Urbano-Márquez A, Grau JM (1998) Association between strong inflammatory response and low risk of developing visual loss and other cranial ischemic complications in giant cell (temporal) arteritis. *Arthritis Rheum* 41:26–32
 49. Liozon E, Herrmann F, Ly K, Robert PY, Loustaud V, Soria P, Robert PY, Loustaud V, Soria P, Vidal E (2001) Risk factors for visual loss in giant cell (temporal) arteritis: a prospective study of 174 patients. *Am J Med* 111:211–217
 50. Deng J, Younge BR, Olshen RA, Goronzy JJ, Weyand CM (2010) Th17 and Th1 T-cell responses in giant cell arteritis. *Circulation* 121:906–915
 51. Gonzalez-Gay MA, Lopez-Diaz MJ, Barros S, Garcia-Porrúa C, Sanchez-Andrade A, Paz-Carreira J, Martin J, Llorca J (2005) Giant cell arteritis: laboratory tests at the time of diagnosis in a series of 240 patients. *Medicine* 84:277–290
 52. Hernandez-Rodriguez J, Garcia-Martinez A, Casademont J, Filella X, Esteban MJ, López-Soto A, Fernández-Solà J, Urbano-Márquez A, Grau JM, Cid MC (2002) A strong initial systemic inflammatory response is associated with higher corticosteroid requirements and longer duration of therapy in patients with giant cell arteritis. *Arthritis Rheum* 47:29–35
 53. Neshet G, Neshet R, Mates M, Sonnenblick M, Breuer GS (2008) Giant cell arteritis: intensity of the initial systemic inflammatory


response and the course of the disease. Clin Exp Rheumatol 26:S30–S34

Publisher's Note Springer Nature remains neutral with regard to jurisdictional claims in published maps and institutional affiliations.

Springer Nature or its licensor (e.g. a society or other partner) holds exclusive rights to this article under a publishing agreement with the author(s) or other rightsholder(s); author self-archiving of the accepted manuscript version of this article is solely governed by the terms of such publishing agreement and applicable law.

Annexe 6.

Temporal artery biopsy: A technical guide and review of its importance and indications.

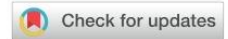Available online at www.sciencedirect.com

ScienceDirect

journal homepage: www.elsevier.com/locate/survophthal

Review article

Temporal artery biopsy: A technical guide and review of its importance and indications



Simon Parreau, MD^{a,d,*}, Eric Liozon, MD^a, John J Chen, MD, PhD^b,
 Muhammad F Curumthaullee, MD^c, Anne-Laure Fauchais, MD, PhD^a,
 Kenneth J Warrington, MD^d, Kim-Heang Ly, MD, PhD^a,
 Cornelia M Weyand, MD, PhD^d

^aDepartment of Internal Medicine, Dupuytren Hospital, Limoges, France

^bDepartment of Ophthalmology and Neurology, Mayo Clinic, Rochester, MN, USA

^cDepartment of Ophthalmology, Dupuytren Hospital, Limoges, France

^dDepartment of Rheumatology, Mayo Clinic, Rochester, MN, USA

ARTICLE INFO

Article history:

Received 8 January 2022

Revised 8 August 2022

Accepted 10 August 2022

Available online 20 August 2022

Keywords:

Temporal artery biopsy

Giant cell arteritis

Vasculitis

Histology

Surgery

ABSTRACT

Temporal artery biopsy (TAB) is a surgical procedure that enables the histological diagnosis of giant cell arteritis (GCA). Performing a TAB requires expertise and a precise approach. Nevertheless, available data supports the value of tissue diagnosis in managing GCA. The current therapeutic recommendation for GCA is long-term glucocorticoid therapy, with an increasing emphasis on the addition of immunosuppressants/biotherapies. Though effective, immunosuppressants and other such biotherapies may put the patient at more risk. Optimizing the diagnosis through tissue evaluation is therefore important in weighing the risks and benefits of initiating therapeutic intervention. We evaluate the evidence supporting the importance of TAB and its indications. We also describe what technical approaches should be used to maximize sensitivity and to avoid possible complications during the procedure.

© 2022 Elsevier Inc. All rights reserved.

1. Introduction

We shall describe the indications, technical procedures, and pitfalls of temporal artery biopsy (TAB). The advice presented here is based upon a comprehensive review of the available literature, as well as the personal experience of 3 physicians who regularly perform this procedure. TAB requires skill to perform and has potential complications. Therefore, TAB should be carefully planned and performed at

the optimal time during patient evaluation. TAB should be carried out by experienced surgeons using precise surgical techniques.

We review: 1) the indications for TAB and possible alternatives, 2) the optimal timing to perform TAB, 3) the anatomy of the temporal artery and adjacent structures, 4) the surgical technique for TAB and possible pitfalls, 5) post procedural complications and their management, and 6) how to appropriately interpret pathology results.

* Corresponding author: Simon Parreau, MD, Department of Rheumatology, Mayo Clinic, 200 1st St SW, Rochester, MN, 55902.
 E-mail address: simon.parreau@hotmail.com (S. Parreau).

1.1. Why recommend a TAB?

1.1.1. Suspected giant cell arteritis

TAB is mostly requested for patients who are suspected to have giant cell arteritis (GCA). GCA is a vasculitis of the large and medium arteries affecting patients over 50 years of age. The definition of GCA is based upon the histological description of an inflammatory infiltrate within the arterial wall and destruction of the elastic tissue.² The temporal artery branch of the external carotid artery is frequently involved in this disease, and therefore the typical biopsy site for histological diagnosis. The first two TABs proving GCA were performed at the Mayo Clinic in Rochester, Minnesota, US, and published by Bayard Horton in 1934.^{28,30}

TAB positivity is one of the 5 classification criteria published by the American College of Rheumatology (ACR), but is not a mandatory criterion.²⁹ The sensitivity of TAB is estimated at 77%, while its specificity is close to 100%.^{46,68} One must be cautious, however, as this sensitivity of the TAB could potentially be contributed to the heterogeneity among meta-analyses.³³

Even so, several authors have determined factors that predict the positivity of a TAB for GCA diagnosis. Younge and coworkers showed that the presence of jaw claudication and new headache, scalp tenderness, or decreased vision were associated with a positive TAB, while Gonzalez-Gay and coworkers described visual symptoms and a clinically abnormal temporal artery as predictive factors.^{23,79} Jaw claudication is usually listed as the risk factor with the highest odds ratio; age and platelets have the highest predictive value when treated as continuous variables. Although their odds ratio seems small, the additive risk as these continuous variables increase becomes very useful.³⁴

As a result, predictive models have been developed to determine which patients with suspected GCA are most likely to have a positive TAB, allowing patients with a low prebiopsy likelihood to avoid the procedure.^{25,34,81} As such, Hussain and coworkers proposed to biopsy only patients with: less than 3 ACR criteria, an atypical GCA presentation, or in those whom high dose glucocorticoids are particularly risky.³¹ The British Society of Rheumatology proposes a decisional algorithm with as a first step an estimation of the probability of GCA according to symptoms, signs, and laboratory tests. Depending on the probability, a doppler ultrasound of the temporal artery or a TAB is performed;⁴⁷ however—because of the significant side effects of long-term glucocorticoids and the severe consequences of missing a diagnosis of GCA—we endorse a TAB for any patient with a suspicion of GCA, as recommended by the ACR guidelines.⁵²

The most challenging patients to determine TAB eligibility for are those that are treated for GCA in the absence of having a biopsy and are resistant to therapy. These patients typically accumulate side effects, and it may become almost impossible to establish a diagnosis.

1.1.2. Others diagnoses made using TAB

On rare occasions, the pathologist may identify a diagnosis other than GCA on the temporal artery specimen; such diagnoses include amyloidosis, small vessel vasculitis, periarteritis nodosa, vasculitis associated with cryoglobulinemia,

lymphoma, and calciphylaxis.^{11,21,26,32,67,75} A superficial temporal artery aneurysm has also been described.³ These diseases may mimic the clinical presentation of GCA and would be difficult to differentiate by ultrasonography alone. Therefore, on occasion, the clinician may misclassify a patient as having GCA until the correct histopathologic diagnosis is identified by the pathologist. Rarely, temporal arteritis is diagnosed in young adults. In most cases, the ACR criteria do not apply since juvenile temporal arteritis is a localized illness without a systemic response. In this vasculitis, the removal of the affected temporal artery often results in resolution of headache, making further treatment unnecessary.³⁸ In patients with clinically isolated aortitis diagnosed postoperatively or on imaging, TAB can be considered to evaluate for temporal artery involvement by vasculitis; however, the utility of TAB in this specific clinical scenario is unknown.

1.1.3. Alternative ways to diagnose GCA

The utility of less invasive diagnostic alternatives to TAB for the diagnosis of GCA remains an open debate.¹⁸ EULAR 2018 guidelines suggest that the diagnosis of GCA should be confirmed by imaging or histology.²⁷ Doppler ultrasound (DUS), computed tomography angiography (CTA), magnetic resonance angiography (MRA), and ¹⁸F-fluorodeoxyglucose positron-emission tomography/computed-tomography (¹⁸FDG-PET/CT) are the most frequently used alternative procedures.

The preference for doppler US versus TAB differs in North America versus Europe.³⁶ Using clinical diagnosis as the standard, a recent meta-analysis studies showed that temporal artery DUS has a sensitivity of 67% and a specificity of 95%.⁷¹ DUS is recommended as a first line test by the EULAR guidelines;²⁷ however, this examination is operator dependent and requires specific training to be accurate.⁴⁶ One must also be careful with false positives—especially with the GCA mimics mentioned above—as well as prominent atherosclerosis, all of which can give a “halo” sign.³⁵ The methods of DUS performance varies between countries.^{48,55} This examination can also be used to guide the TAB procedure by identifying the path of the artery, which side of artery should be harvested, and if the involvement is unilateral or asymmetrical.

High resolution MRA of the temporal arteries is also a reliable means to diagnose cranial GCA with a sensitivity of 88.7% and specificity of 75.0%;^{39,43} however, timely access to MRA can be problematic in some centers and the specificity remains inferior to a TAB. Though the DUS and MRA methods may be less effective than a TAB, there are tools available to calculate the probability of GCA according to the results of both tests. DUS and MRA results can also guide the indications for TAB.⁴⁵

¹⁸FDG-PET/CT of the cranial arteries has been proposed to assist the diagnosis of GCA.^{19,60} Extra-cranial vasculitis, such as aortitis, can also be identified by ¹⁸FDG-PET/CT and would help confirm the diagnosis of GCA; however, like MRI, access and cost may limit its use in some centers.

1.2. When is the optimal time to perform a TAB?

TAB should be performed as soon as possible; however, it should not delay the initiation of glucocorticoid treatment

in patients with suspected cranial GCA.^{1,61} Suspected GCA is an ophthalmologic and neurologic emergency, and therefore high dose steroids should be initiated immediately to avoid ischemic complications such as blindness or stroke. A fast-track pathway with easy access to examinations and collaboration between rheumatologists, internists, and surgeons are essential for establishing a prompt diagnosis.

Whether steroid initiation could affect the histopathologic findings of a TAB has been thoroughly evaluated. Ideally the TAB should be performed within 2 weeks of GC initiation. One reference suggests that the yield of TAB may be unaffected 4 weeks after GC treatment.⁵⁸ Other investigators reported that TAB can remain positive with the presence of an inflammatory infiltrate in about 40% of patients that have been treated for 12 months.⁴⁹

1.3. Should a contralateral biopsy be performed?

Several investigators have evaluated the value of performing a TAB on both sides, and some recommend performing a bilateral TAB.^{5,66} The additional yield of a synchronous, contralateral biopsy ranges between 3% and 13%.^{7,13,64} The recommendation to perform a second biopsy also differs according to the referring specialties.⁷⁰ In our practice, we typically perform a unilateral TAB on the more symptomatic side, but will sometimes biopsy the contralateral side in patients with high suspicion for GCA that are negative on the unilateral TAB. With expanding life expectancy and the possibility of disease flares decades after the initial diagnosis, preserving the other side of the temporal artery for a second biopsy many years after the first instance may be an advantage.

1.4. What to do if the patient has already had a TAB?

If a unilateral biopsy is negative, consideration can be given to performing a contralateral biopsy, even if the patient has been treated; however, no studies have evaluated the impact of steroid or immunosuppressive treatment on the result of a second TAB if the first TAB was negative. In the unlikely event that a patient has already had bilateral TAB, and there is a strong clinical indication to proceed with another biopsy, an additional biopsy can be performed using another portion of the temporal artery; in such a case, the biopsy would be located at the bifurcation or the posterior temporal branch. In this scenario, some have proposed biopsy of other branches of the external carotid artery such as the occipital artery or the maxillary artery, but such an approach would be difficult and could be a source of complications, especially nerve injury.⁶²

1.5. What information should be given to patients?

It is important to give clear information to patients about the potential benefits of performing a TAB and to explain the procedure with its potential complications. The patient should be aware that while the biopsy may be negative, this does not necessarily abrogate a GCA diagnosis, and it may be that an additional biopsy may be necessary in the future. The duration of the procedure typically ranges from 20 minutes to an hour. There are very few contraindications to performing TAB. A potential contraindication would include an allergy to local

anesthetics; another contraindication would be lack of patient cooperation while undergoing the surgical procedure. Since the biopsy is performed under local anesthesia, it is not necessary for the patient to fast. Likewise, prophylactic antibiotics are unnecessary. The question as to whether a patient should come off anticoagulants before the procedure is up to the surgeon's preference. We often do perform TAB while patients are on anticoagulants because of the potential risks of holding anticoagulation.

1.6. Who should perform a TAB?

Only a trained operator should perform a TAB. Various specialists may be asked to perform the biopsy, depending on the center. A few potential options include: ophthalmologists, ENT specialist, and vascular, plastic, and general surgeons.⁵⁴ One study compared the performance of different specialties in performing TAB and found that ophthalmologists performed the longest TAB based on the length of the artery fragment harvested;²⁰ however, this heterogeneity may just reflect the local expertise in the hospital where the study was performed. We encourage our readers to consider which specialty is best equipped to perform a TAB in their own hospital.

1.7. Anatomy of the temporal artery

The temporal artery is a terminal branch of the external carotid artery. Various autopsy and angiography studies have described the course and relationships of the temporal artery.^{41,50} A major point to be aware of is the relationship between the temporal artery and the temporal branch of the facial nerve. As the facial nerve passage is found near the temporal artery, it is of the utmost importance to be aware of the temporal artery's anatomy to prevent any injury of the facial nerve during the dissection.⁷⁶ An illustration depicting the anatomic variations and distinguishing features of the temporal artery is shown in Fig. 1.

1.8. How to perform TAB?

TAB should be performed in a sterile operating room. The room must be equipped with lights of adjustable intensity. In addition, a hand-held cautery is required. The patient should be placed in supine position on a height-adjustable operating table. Reverse Trendelenburg aids in hemostasis. For their comfort, the patient's head should be turned away from the site of the biopsy and placed on comfortable pillow.

1.8.1. Locating the artery

The identification of the artery is an important step before starting the incision. A preliminary DUS can help to locate the site that appears to be the most affected;^{6,40} however, some authors have shown that Doppler results did not correlate with arterial palpation abnormalities.^{22,69} The side of the TAB is also guided by the patient's clinical signs (e.g., unilateral headache or ophthalmic involvement). We recommend a careful palpation of both sides of the patient's head to determine which branch of the temporal artery is the most symptomatic. In our practice, we privilege the thickest or the most painful temporal artery. Even so, if an option, we advise that

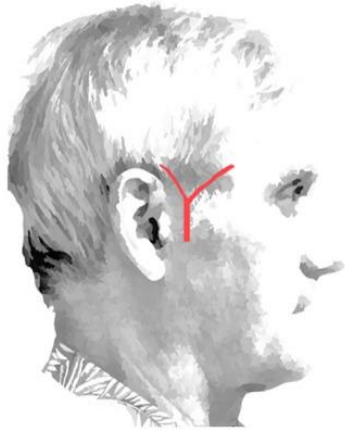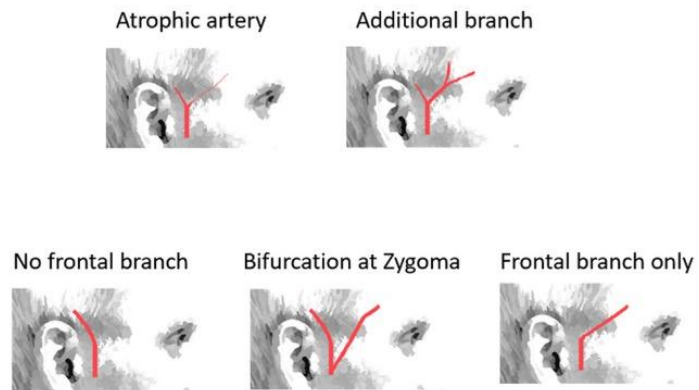
Classical anatomy (70%)**Atypical anatomy (30%)**

Fig. 1 – Illustration depicting anatomic variations of the temporal artery according to Marano⁴⁹.

the side where the pulse is felt less should be selected. A loss of pulse may indicate arterial occlusion, which could lead to a greater diagnostic yield. It should be noted that the patient's hair may mask any local inflammatory signs and could prevent palpation of the artery. We usually shave the hair on the side where the artery seems to be more affected and recommend this practice be done if one is struggling to find an ideal location. After shaving, it is necessary to repeat the palpation to look for inflammatory signs and to locate the path of the temporal artery. Once the temporal artery path has been located, make sure it is marked with a marking pen. A handheld Doppler is often used to confirm the exact path of the artery.

1.8.2. Preparation of the operating site

The surgical site should then be disinfected using a skin preparation solution. Next, a sterile drape with a central opening must be placed over the site.

A local anesthetic should then be injected around the artery; we recommend the use of epinephrine-containing anesthetic to limit local bleeding. A repeat anesthetic injection during the procedure is sometimes necessary, and therefore sterile local anesthesia should be available. In addition, to reduce pain related to the injection of local anesthetic, pre-medication with a systemic analgesic and the local application of an anesthetic gel may be performed.

1.8.3. Recommended materials for the TAB

- #15 blade for incision
- Retractors / forceps for exposition
- Bipolar cautery for superficial coagulation
- Fine mosquito for dissection
- Scissors to cut the artery
- Resorbable sutures for artery ligation / non-resorbable sutures for skin closure

1.8.4. Incision site

In general, the initial scalpel incision depth should not exceed 1 mm to avoid cutting the artery. Several incision techniques

have been described in the literature. One describes an incision at the level of the bifurcation of the temporal artery into anterior and posterior branches.⁷⁷ This technique has the advantage of being based on a path of the artery that does not vary; therefore, it is easy to find the artery. Because the facial nerve passes through this area, we do not routinely utilize this technique.

Another technique— called the "Book-Flap"— describes a wide incision with the removal of a rectangle of skin to locate the artery.¹⁵ The closure is done by bringing the skin together. Though it has its benefits, we do not use this technique and do not recommend it because of the risk of skin damage.

Markose and coworkers described the "Gillies temporal incision" that consists of directly approaching the anterior branch of the temporal artery, thus avoiding the tripod and potential lesion of the facial nerve.⁵¹ For this reason, this is the most common technique and where we typically perform the TAB. We recommend using surface landmarks to avoid injury to the facial nerve. Most surgeons stay above the line connecting the tragus of the ear to the lateral canthus of the eye. While using this technique, if the anterior branch of the temporal artery cannot be identified, we will sometimes harvest the parietal branch of the temporal artery instead. We recommend that our readers utilize this practice as well.

If an assistant is helping to retract the wound, they should retract with equal pressure on both sides of the wound so that dissection occurs at the proper location. Self-retaining retractors are useful for the latter part of the procedure when there are no assistants.

1.8.5. Dissection

The surgeon must ensure careful and regular hemostasis throughout the procedure. The adjacent tissues, especially the adipose tissue, bleed frequently. The use of a double-pronged retractor or 2 strabismus hooks during the proximal and distal dissection will increase specimen length. Please see detailed dissection pictures in Fig. 2. The first layer is the adipose tissue. Underneath this tissue is the superficial temporal fascia that has a different color. The temporal artery is located at the level of this fascia. Sometimes the superficial temporal vein is

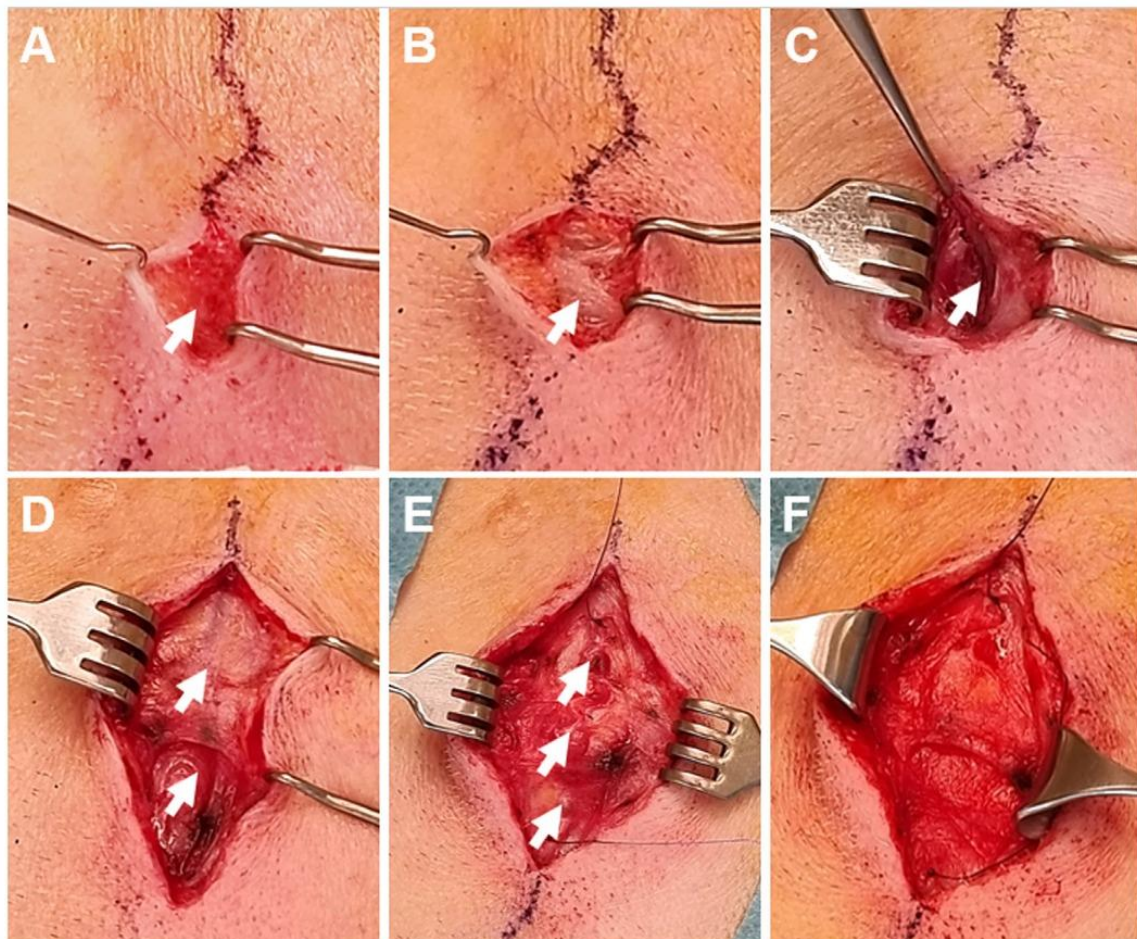


Fig. 2 - Temporal artery dissection, A: adipose tissue (arrow), B: fascia (arrow), C: temporal artery (arrow) after incision of the fascia, D: temporal artery before (upper arrow) and after (lower arrow) incision of the fascia; E: path of temporal artery (arrows), F: after temporal artery biopsy.

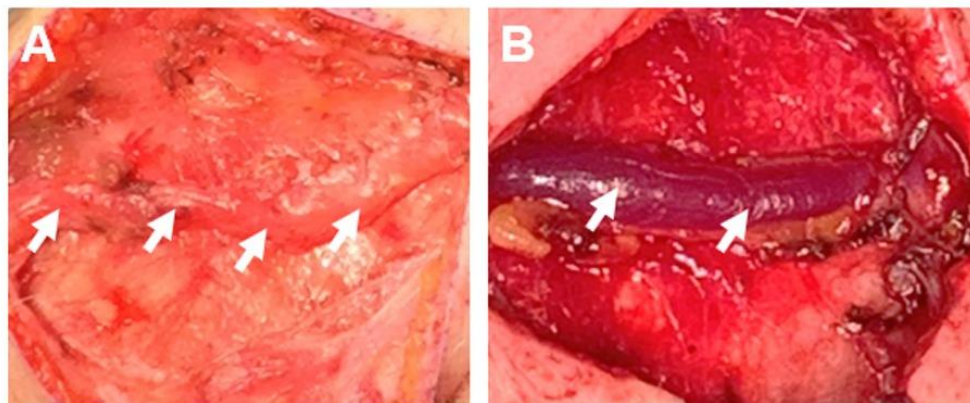


Fig. 3 - Color difference between temporal artery (A) and vein (B).

in contact with or near the artery. It is important to know how to distinguish the artery from vein. The vein is darker, bluer, and softer than the artery. An example note the anatomic variations of the temporal artery that are also shown in Fig. 3.

While performing the dissection, we recommend that the operator incises the fatty tissue down to the superficial tem-

poral fascia. The artery will be located underneath the fascia. To access the artery, the fascia must then be lifted with forceps, after which a small incision should be made. Once accessible, the artery is then separated from the adjacent tissues. One end of the artery should then be isolated and ligated. The most critical part of TAB is the proximal ligation. We usually

place 2 sutures on the proximal side of the artery. The operator then dissects the artery along the length of the incision, making sure to take care not to injure the artery and to identify its branches. After the branches have been identified, each one must be ligated. Once the artery is completely isolated, a second suture should be applied on the distal part. The artery can then be harvested for analysis.

1.8.6. What to do if you can't find the artery?

Sometimes the artery can be difficult to locate. It is advisable to avoid trying to incise too deeply as the artery may have been pushed to the side during dissection of the fatty tissue. In such a case, the skin can be re-incised proximally or distally, and the dissection repeated layer by layer until the artery is found. Intraoperative ultrasound can also be used to help identify the artery in difficult cases.

1.8.7. What length of artery should be harvested?

The optimal length of artery to be harvested has long been a subject of debate. Indeed, GCA is a segmental vasculitis which means that some portions of the artery may be healthy because of skip lesions.⁶⁵ Different studies have evaluated the ideal length of artery required to minimize risk of a 'false negative' biopsy. Several different minimum lengths have been proposed: at least 5 mm,⁵⁶ 1 cm,⁸⁰ 2 cm,^{9,24} 3 cm.¹⁴ Another study did not show any influence on the size of the sample.⁴ In addition, the British Society of Rheumatology currently recommends a minimum specimen length of 1 cm.⁴⁷ We routinely obtain at least 2 cm of fixed artery, as this length accounts for the contraction of the artery.

1.8.8. Does the shrinking of the artery after incision matter?

Several studies have investigated the phenomenon of arterial shrinking after excision.^{59,80} After cutting the artery, the mean contraction is 12% for positive TAB and 22% for negative TAB.⁷⁴ As such, surgeons must harvest a larger length of artery to combat any potential shrinkage. Please note that our recommended sample size—and the sample sizes mentioned in the referenced studies—are the measurements of the artery after it has contracted, or fixed.

1.8.9. Does the appearance of the artery matter?

In a study by Cetinkaya and coworkers there was a good correlation between the appearance of the artery described by the operator and the biopsy results.¹² Although this is a subjective finding, we find that the gross appearance during surgery often does correlate with the biopsy results. Based on our experience macroscopic aspects, such as the thickness, color, consistency of the artery, how hard it is to cut, pain on traction, and bleeding during the incision and at the incision after ligation—which can indicate whether the artery is occluded or not—can all suggest a positive or negative biopsy. Nevertheless, it is advisable to avoid manipulating the artery as doing so could induce an arterial spasm and cause a histological artifact.⁶² Though artery appearance can factor in getting conclusive biopsy results, the health and safety of the patient should be prioritized above obtaining the best specimen.

1.8.10. What to do if there is significant local bleeding? What to do if the artery bleeds?

To prevent excessive bleeding, we recommend a careful dissection that goes layer by layer. It is advisable to use an anesthetic with epinephrine as this will limit local bleeding. A bipolar cautery can also be used superficially and carefully to help with coagulation; however, this tool should be used as little as possible—and at a distance from the artery—as misuse could create greater risk and injure the temporal artery.

In case of bleeding from the temporal artery itself, suturing can be problematic. If bleeding obscures visualization, the proximal artery should be immediately compressed by the assistant. Ensure the patient is in reverse Trendelenburg. Additional local anesthetic with epinephrine with wound compression may be useful. Likewise, topical hemostatic agents may also be used. In some cases, the incision may need to be enlarged so the artery can be ligated upstream. In patients who bleed during TAB or who remain on anticoagulants, a compressive headband is useful to prevent hematoma.

1.9. Potential complications

Although they are extremely rare, several complications have been reported. One such complication includes temporary or permanent paralysis of the temporal branch of the facial nerve. Other local complications such as injury to the parotid gland, hematoma of the operative site, local infection or sepsis, superinfection of the wound, and suture dehiscence may also occur. Cases of necrosis of the scalp have also been reported, but these cases are exceptional and may be due to the underlying disease rather than the actual biopsy procedure. Strokes from lack of sufficient collaterality are another potential complication, but are also exceptionally rare.¹³

1.9.1. How to avoid facial nerve palsy?

Facial nerve palsy is one of the most feared complications. Murchison and coworkers described a 16% incidence of facial nerve damage in a prospective cohort of 75 TAB with a fully recovery in 58% of cases (average of 4.4 months).⁵⁷ This complication may occur after TAB because of a dissection that goes too deep or if there was excessive use of the electrocoagulation forceps during the procedure.¹⁰ In any case, to avoid causing facial nerve palsy, the surgeon must know path of the nerve before performing the procedure. Likewise, the proximal part of the artery—especially the area downstream of the bifurcation—must be avoided.^{4,17,57,72,78} It is also important to avoid a deep dissection, as going too deep could expose the facial nerve to damage beneath the superficial temporal fascia.

1.10. How to interpret the TAB result?

Post procedure, the surgeon should provide the pathologist with the patient's clinical information and treatment history along with the collected specimen. Histopathologic examination of the TAB should be comprehensive and include many cuts to avoid skip lesions.⁴² Banz and coworkers explained that a TAB of 1.5 cm in length consisting of 6 sections of 3- μ m thickness equates to only 0.12% of the entire sample.⁵

A positive TAB will show a panarteritis consisting of lymphocytes and macrophages, often with fragmented internal elastic lamina. Multinucleated giant cells are only seen in 50% of positive biopsies, so it is important to look for other signs of disease. Ultimately, the importance of inflammatory changes within the *vasa vasorum* and periadipose tissue are debatable.^{44,53,83} Indeed, there are many different patterns of GCA.⁷³ For example, though a common indication, one study showed that lymphocytic inflammation of small blood vessels alone was not associated with the diagnosis of GCA.³⁷ It is often necessary to look for subtle signs of GCA, such as intimal thickening, focal lymphocyte and macrophage infiltration or localized scarring in the arterial wall; however, disruption of the elastic lamina alone is not specific to GCA as atherosclerosis can also cause intimal hyperplasia and lead to fragmentation of the elastic laminae.⁶³ This makes it difficult to interpret the finding of “healed arteritis”, which may be a non-specific finding.¹⁶ In this scenario the results of TAB must be interpreted in the clinical context.

1.10.1. Does a negative biopsy call into question the diagnosis of GCA?

While most patients with cranial GCA will have a positive TAB, patients with large vessel involvement may have a negative TAB in about 40% of cases.⁸ Temporal artery involvement is not always present in autopsy studies of patients with recently diagnosed GCA, and other arteries may be involved.⁸² A clinical diagnosis of GCA can still be made in the setting of a negative TAB if the clinical suspicion is high.

2. Conclusion

TAB remains an important tool for the diagnosis of GCA. With increasing interest in substituting immunosuppressive treatment for long-term glucocorticoids, clinicians should absolutely encourage seeking out formal histological diagnostic proof before initiating therapeutic intervention. Given the 5% risk of false positive ultrasound and the side effects of long-term glucocorticoids, we strongly advocate TAB as a vital diagnostic tool. Although noninvasive techniques to investigate GCA are being increasingly described, these modalities should be correlated with the results of TAB.

3. Methods of literature search

We searched the PubMed, Web of Science, Google Scholar, and Cochrane Library databases. This search was performed on November 1, 2021, and the search terms used were temporal artery biopsy and giant cell arteritis. We selected the most relevant clinical trials, cohort studies, high-quality review articles, guidelines and case reports. Parts of the discussion were also supplemented with the authors' clinical (SP, EL, ALF, KHL, KJW, CMW) and surgical (SP, JJC, FMC) experience and expertise on the topic.

4. Disclosures

The authors are responsible for the content of this manuscript. The authors declare that they have no known competing financial interests or personal relationships that could have appeared to influence the work reported in this paper.

Funding

This research did not receive any specific grant from any funding agencies in the public, commercial, or not-for-profit sectors.

Acknowledgments

None to report.

REFERENCES

- Achkar AA, Lie JT, Hunder GG, O'Fallon WM, Gabriel SE. How does previous corticosteroid treatment affect the biopsy findings in giant cell (temporal) arteritis? *Ann Intern Med.* 1994;120(12):987–92.
- Akiyama M, Ohtsuki S, Berry GJ, Liang DH, Goronzy JJ, Weyand CM. Innate and adaptive immunity in giant cell arteritis. *Front Immunol.* 2021;11:621098.
- Al-Sibassi AN, Ethunandan M. Superficial temporal artery aneurysm: case report and review of literature. *J Oral Maxillofac Surg.* 2020;78(7):1147–50.
- Albertini JG, Ramsey ML, Marks VJ. Temporal artery biopsy in a dermatologic surgery practice. *Dermatol Surg.* 1999;25(6):501–8.
- Banz Y, Stone JH. Why do temporal arteries go wrong? Principles and pearls from a clinician and a pathologist. *Rheumatology (Oxford).* 2018;57(suppl_2):ii3–ii10.
- Beckman RL, Hartmann BM. The use of a Doppler Flow Meter to identify the course of the temporal artery. *J Clin Neuroophthalmol.* 1990;10(4):304.
- Boyev LR, Miller NR, Green WR. Efficacy of unilateral versus bilateral temporal artery biopsies for the diagnosis of giant cell arteritis. *Am J Ophthalmol.* 1999;128(2):211–15.
- Brack A, Martinez-Taboada V, Stanson A, Goronzy JJ, Weyand CM. Disease pattern in cranial and large-vessel giant cell arteritis. *Arthritis Rheum.* 1999;42(2):311–17.
- Breuer GS, Neshet R, Neshet G. Effect of biopsy length on the rate of positive temporal artery biopsies. *Clin Exp Rheumatol.* 2009;27(1 Suppl 52):S10–13.
- Cahais J, Houdart R, Lupinacci RM, Valverde A. Operative technique: superficial temporal artery biopsy. *J Visc Surg.* 2017;154(3):203–7.
- Cavazza A, Muratore F, Boiardi L, et al. Inflamed temporal artery: histologic findings in 354 biopsies, with clinical correlations. *Am J Surg Pathol.* 2014;38(10):1360–70.
- Cetinkaya A, Kersten RC, Brannan PA, Thiagarajah C, Kulwin DR. Intraoperative predictability of temporal artery biopsy results. *Ophthalmic Plast Reconstr Surg.* 2008;24(5):372–6.
- Chase E, Ramsey ML. Temporal artery biopsy. Treasure Island FL: StatPearls Publishing; 2019 <http://www.ncbi.nlm.nih.gov/books/NBK470397/>.

14. Chung SH, Morcos MB, Ng B. Determinants of positive temporal artery biopsies in the veterans health administration national database cohort. *Arthritis Care Res (Hoboken)*. 2020;72(5):699–704.
15. Conde-Ferreirós A, Fraile-Alonso MDC, Román-Curto C. Book Flap" approach for temporal artery biopsy. *Dermatol Surg*. 2020;46(10):1361–3.
16. Cox M, Gilks B. Healed or quiescent temporal arteritis versus senescent changes in temporal artery biopsy specimens. *Pathology*. 2001;33(2):163–6.
17. Czyz CN, Allen JB, Cahill KV, Nabavi CB, Foster JA. Effects of incision location on specimen quality and complications for temporal artery biopsy. *Vascular*. 2019;27(4):347–51.
18. Davies CG, May DJ. The role of temporal artery biopsies in giant cell arteritis. *Ann R Coll Surg Engl*. 2011;93(1):4–5.
19. Emamifar A, Ellingsen T, Hess S, Gerke O, Hviid Larsen R, Ahangarani Farahani Z, et al. The utility of 18F-FDG PET/CT in patients with clinical suspicion of polymyalgia rheumatica and giant cell arteritis: a prospective, observational, and cross-sectional study. *ACR Open Rheumatol*. 2020;2(8):478–90.
20. Galloway GD, Klebe B, Riordan-Eva P. Surgical performance for specialties undertaking temporal artery biopsies: who should perform them? *Br J Ophthalmol*. 2002;86(3):250.
21. Génereau T, Lortholary O, Pottier MA, et al. Temporal artery biopsy: a diagnostic tool for systemic necrotizing vasculitis. French Vasculitis Study Group. *Arthritis Rheum*. 1999;42(12):2674–81.
22. Germanò G, Muratore F, Cimino L, et al. Is color duplex sonography-guided temporal artery biopsy useful in the diagnosis of giant cell arteritis? A randomized study. *Rheumatology (Oxford)*. 2015;54(3):400–4.
23. Gonzalez-Gay MA, Garcia-Porrúa C, Llorca J, Gonzalez-Louzao C, Rodriguez-Ledo P. Biopsy-negative giant cell arteritis: clinical spectrum and predictive factors for positive temporal artery biopsy. *Semin Arthritis Rheum*. 2001;30(4):249–56.
24. Goslin BJ, Chung MH. Temporal artery biopsy as a means of diagnosing giant cell arteritis: is there over-utilization? *Am Surg*. 2011;77(9):1158–60.
25. Grossman C, Barshack I, Bornstein G, Ben-Zvi I. Is temporal artery biopsy essential in all cases of suspected giant cell arteritis? *Clin Exp Rheumatol*. 2015;33(2 Suppl 89):S-84–9.
26. Hamidou MA, Moreau A, Toquet C, El Kouri D, de Faucal P, Grolleau JY. Temporal arteritis associated with systemic necrotizing vasculitis. *J Rheumatol*. 2003;30(10):2165–9.
27. Hellmich B, Agueda A, Monti S, et al. 2018 Update of the EULAR recommendations for the management of large vessel vasculitis. *Ann Rheum Dis*. 2020;79(1):19–30.
28. Horton BT, Magath TB, Brown GE. Arteritis of the temporal vessels. *Arch Intern Med*. 1934;53(3):400–9.
29. Hunder GG, Bloch DA, Michel BA, et al. The American College of Rheumatology 1990 criteria for the classification of giant cell arteritis. *Arthritis Rheum*. 1990;33(8):1122–8.
30. Hunder GG. The early history of giant cell arteritis and polymyalgia rheumatica: first descriptions to 1970. *Mayo Clin Proc*. 2006;81(8):1071–83.
31. Hussain O, McKay A, Fairburn K, Doyle P, Orr R. Diagnosis of giant cell arteritis: when should we biopsy the temporal artery? *Br J Oral Maxillofac Surg*. 2016;54(3):327–30.
32. Ing EB, Woolf IZ, Younge BR, Bjornsson J, Leavitt JA. Systemic amyloidosis with temporal artery involvement mimicking temporal arteritis. *Ophthalmic Surg Lasers*. 1997;28(4):328–31.
33. Ing EB, Wang DN, Kirubarajan A, et al. Systematic review of the yield of temporal artery biopsy for suspected giant cell arteritis. *Neuroophthalmology*. 2018;43:18–25.
34. Ing EB, Miller NR, Nguyen A, et al. Neural network and logistic regression diagnostic prediction models for giant cell arteritis: development and validation. *Clin Ophthalmol*. 2019;13:421–30.
35. Ing E. Temporal artery biopsy versus imaging in patients with cranial giant cell arteritis. *Radiol Med*. 2020;125(9):902–3.
36. Ing E, Xu QA, Chuo J, Kherani F, Landau K. Practice preferences: temporal artery biopsy versus Doppler ultrasound in the work-up of giant cell arteritis. *Neuroophthalmology*. 2019;44(3):174–81.
37. Jia L, Couce M, Barnholtz-Sloan JS, Cohen ML. Is all inflammation within temporal artery biopsies temporal arteritis? *Hum Pathol*. 2016;57:17–21.
38. Journeau L, Pistorius MA, Michon-Pasturel U, et al. Juvenile temporal arteritis: a clinicopathological multicentric experience. *Autoimmun Rev*. 2019;18(5):476–83.
39. Junek M, Hu A, Garner S, et al. Contextualizing temporal arterial magnetic resonance angiography in the diagnosis of giant cell arteritis: a retrospective cohort study. *Rheumatology (Oxford)*. 2021;60(9):4229–37.
40. Karahaliou M, Vaiopoulos G, Papaspyrou S, Kanakis MA, Revenas K, Sfikakis PP. Colour duplex sonography of temporal arteries before decision for biopsy: a prospective study in 55 patients with suspected giant cell arteritis. *Arthritis Res Ther*. 2006;8(4):R116.
41. Kim BS, Jung YJ, Chang CH, Choi BY. The anatomy of the superficial temporal artery in adult Koreans using 3-dimensional computed tomographic angiogram: clinical research. *J Cerebrovasc Endovasc Neurosurg*. 2013;15(3):145–51.
42. Klein RG, Campbell RJ, Hunder GG, Carney JA. Skip lesions in temporal arteritis. *Mayo Clin Proc*. 1976;51(8):504–10.
43. Klink T, Geiger J, Both M, et al. Giant cell arteritis: diagnostic accuracy of MR imaging of superficial cranial arteries in initial diagnosis—results from a multicenter trial. *Radiology*. 2014;273(3):844–52.
44. Le Pendu C, Meignin V, Gonzalez-Chiappe S, Hij A, Galateau-Sallé F, Mahr A. Poor Predictive Value of Isolated Adventitial and Periadventitial Infiltrates in Temporal Artery Biopsies for Diagnosis of Giant Cell Arteritis. *J Rheumatol*. 2017;44(7):1039–43.
45. Liu J, Chuo J, Pagnoux C, Torun N, Ing EB. The post-test probability of giant cell arteritis after ultrasound, MRI, or temporal artery biopsy. <https://doi.org/10.26226/morressier.5e9852a0df8760da4ba873fc>
46. Luqmani R, Lee E, Singh S, et al. The role of ultrasound compared to biopsy of temporal arteries in the diagnosis and treatment of giant cell arteritis (TABUL): a diagnostic accuracy and cost-effectiveness study. *Health Technol Assess*. 2016;20(90):1–238.
47. Mackie SL, DeJaco C, Appenzeller S, et al. British Society for Rheumatology guideline on diagnosis and treatment of giant cell arteritis. *Rheumatology*. 2020;59(3):e1–e23.
48. Maldini C, Dépinay-Dhellemmes C, Tra TT, et al. Limited value of temporal artery ultrasonography examinations for diagnosis of giant cell arteritis: analysis of 77 subjects. *J Rheumatol*. 2010;37(11):2326–30.
49. Maleszewski JJ, Younge BR, Fritzlen JT, et al. Clinical and pathological evolution of giant cell arteritis: a prospective study of follow-up temporal artery biopsies in 40 treated patients. *Mod Pathol*. 2017;30(6):788–96.
50. Marano SR, Fischer DW, Gaines C, Sonntag VK. Anatomical study of the superficial temporal artery. *Neurosurgery*. 1985;16(6):786–90.
51. Markose G, Graham RM. Gillies temporal incision: an alternate approach to superficial temporal artery biopsy. *Br J Oral Maxillofac Surg*. 2017;55(7):719–21.
52. Maz M, Chung SA, Abril A, et al. 2021 American College of Rheumatology/Vasculitis Foundation Guideline for the management of giant cell arteritis and Takayasu arteritis. *Arthritis Rheumatol*. 2021;73(8):1349–65.
53. McDonald HM, Farmer JP, Blanco PL. Periadventitial tissue examination in temporal artery biopsies for suspected giant

- cell arteritis: a case series and literature review. *Can J Ophthalmol*. 2019;54(5):615–20.
54. Micieli JA, Micieli R, Margolin EA. A review of specialties performing temporal artery biopsies in Ontario: a retrospective cohort study. *CMAJ Open*. 2015;3(3):E281–5.
55. Moiseev SV, Smitienko I, Bulanov N, Novikov PI. The role of temporal artery biopsy in patients with giant-cell arteritis is debated. *Ann Rheum Dis*. 2019;78(4):e31.
56. Muratore F, Boiardi L, Cavazza A, et al. Association between specimen length and number of sections and diagnostic yield of temporal artery biopsy for giant cell arteritis. *Arthritis Care Res (Hoboken)*. 2021;73(3):402–8.
57. Murchison AP, Bilyk JR. Brow ptosis after temporal artery biopsy: incidence and associations. *Ophthalmology*. 2012;119(12):2637–42.
58. Narváez J, Bernad B, Roig-Vilaseca D, et al. Influence of previous corticosteroid therapy on temporal artery biopsy yield in giant cell arteritis. *Semin Arthritis Rheum*. 2007;37(1):13–19.
59. Naumovska M, Sheikh R, Engelsberg K, Blohme J, Hammar B, Malmjö M. Temporal artery biopsies contract upon surgical excision, but do not shrink further during formalin fixation. *Scand J Rheumatol*. 2020;49(1):84–6.
60. Nienhuis PH, Sandovici M, Glaudemans AW, Slart RH, Brouwer E. Visual and semiquantitative assessment of cranial artery inflammation with FDG-PET/CT in giant cell arteritis. *Semin Arthritis Rheum*. 2020;50(4):616–23.
61. Ninan JV, Lester S, Hill CL. Giant cell arteritis: beyond temporal artery biopsy and steroids. *Intern Med J*. 2017;47(11):1228–40.
62. Noumegni SR, Hoffmann C, Bressollette L, Jousse-Joulin S, Cornec D. Technique et valeur diagnostique de la biopsie de l'artère temporale. *Revue du Rhumatisme Monographies*. 2020;87(3):189–93.
63. O'Brien JP. Destruction of elastic tissue (elastolysis) as a link between atherosclerosis and the temporal arteritis/polymyalgia rheumatica syndrome. Observations on an actinic factor in vascular disease. *Pathol Biol (Paris)*. 1984;32(2):123–38.
64. Pless M, Rizzo JF 3rd, Lamkin JC, Lessell S. Concordance of bilateral temporal artery biopsy in giant cell arteritis. *J Neuroophthalmol*. 2000;20(3):216–18.
65. Poller DN, van Wyk Q, Jeffrey MJ. The importance of skip lesions in temporal arteritis. *J Clin Pathol*. 2000;53(2):137–9.
66. Ponge T, Barrier JH, Grolleau JY, Ponge A, Vlasak AM, Cottin S. The efficacy of selective unilateral temporal artery biopsy versus bilateral biopsies for diagnosis of giant cell arteritis. *J Rheumatol*. 1988;15(6):997–1000.
67. Roverano S, Ortiz A, Henares E, Eletti M, Paira S. Calciphylaxis of the temporal artery masquerading as temporal arteritis: a case presentation and review of the literature. *Clin Rheumatol*. 2015;34(11):1985–8.
68. Rubenstein E, Maldini C, Gonzalez-Chiappe S, Chevret S, Mahr A. Sensitivity of temporal artery biopsy in the diagnosis of giant cell arteritis: a systematic literature review and meta-analysis. *Rheumatology (Oxford)*. 2020;59(5):1011–1020.
69. Salvarani C, Silingardi M, Ghirarduzzi A, et al. Is duplex ultrasonography useful for the diagnosis of giant-cell arteritis? *Ann Intern Med*. 2002;137(4):232–8.
70. Schallhorn J, Haug SJ, Yoon MK, Porco T, Seiff SR, McCulley TJ. A national survey of practice patterns: temporal artery biopsy. *Ophthalmology*. 2013;120(9):1930–4.
71. Sebastian A, Coath F, Innes S, Jackson J, van der Geest KSM, Dasgupta B. Role of the halo sign in the assessment of giant cell arteritis: a systematic review and meta-analysis. *Rheumatol Adv Pract*. 2021;5(3):rkab059.
72. Shin KJ, Shin HJ, Lee SH, Koh KS, Song WC. Surgical anatomy of the superficial temporal artery to prevent facial nerve injury during arterial biopsy. *Clin Anat*. 2018;31(4):608–613.
73. Stacy RC, Rizzo JF, Cestari DM. Subtleties in the histopathology of giant cell arteritis. *Semin Ophthalmol*. 2011;26(4-5):342–8.
74. Su GW, Foroozan R, Yen MT. Quantitative analysis of temporal artery contraction after biopsy for evaluation of giant cell arteritis. *Can J Ophthalmol*. 2006;41(4):500–3.
75. Tannenbaum CB, Trudel MA, Kapusta MA. Lymphomatous perivascular infiltration involving the temporal artery. *J Rheumatol*. 1996;23(11):2009–10.
76. Tayfur V, Edizer M, Magden O. Anatomic bases of superficial temporal artery and temporal branch of facial nerve. *J Craniofac Surg*. 2010;21(6):1945–7.
77. Tomsak RL. Superficial temporal artery biopsy. A simplified technique. *J Clin Neuroophthalmol*. 1991;11(3):202–204.
78. Yoon MK, Horton JC, McCulley TJ. Facial nerve injury: a complication of superficial temporal artery biopsy. *Am J Ophthalmol*. 2011;152(2):251–255.e1.
79. Younge BR, Cook BE Jr, Bartley GB, Hodge DO, Hunder GG. Initiation of glucocorticoid therapy: before or after temporal artery biopsy? *Mayo Clin Proc*. 2004;79(4):483–91.
80. Ypsilantis E, Courtney ED, Chopra N, et al. Importance of specimen length during temporal artery biopsy. *Br J Surg*. 2011;98(11):1556–60.
81. Weis E, Toren A, Jordan D, Patel V, Gilberg S. Development of a predictive model for temporal artery biopsies. *Can J Ophthalmol*. 2017;52(6):599–605.
82. Wilkinson IM, Russell RW. Arteries of the head and neck in giant cell arteritis. A pathological study to show the pattern of arterial involvement. *Arch Neurol*. 1972;27(5):378–91.
83. Zhao CL, Hui Y, Amin A. Temporal small arterial inflammation is common in patients with giant cell arteritis. *Hum Pathol*. 2018;81:65–70.

Annexe 7.

Relationship between histopathological features of non-infectious aortitis and the results of pre-operative ¹⁸F-FDG-PET/CT: a retrospective study of 16 patients.

Relationship between histopathological features of non-infectious aortitis and the results of pre-operative ¹⁸F-FDG-PET/CT: a retrospective study of 16 patients

S. Parreau^{1,2}, O. Espitia³, M.S. Bold⁴, L.M. Frota Lima⁴, G. Lades⁵, M. Bois⁶, M. Assaraf⁷, D. Saadoun⁷, M.J. Koster¹, K.-H. Ly², C.M. Weyand¹, K.J. Warrington¹, E. Liozon²

¹Division of Rheumatology, Mayo Clinic, Rochester, MN, USA; ²Department of Internal Medicine, Dupuytren Hospital, Limoges, France; ³Nantes Université, CHU Nantes, Department of Internal and Vascular Medicine, Nantes, France; ⁴Department of Radiology, Mayo Clinic, Rochester, MN, USA; ⁵Department of Nuclear Medicine, Dupuytren Hospital, Limoges, France; ⁶Department of Pathology, Mayo Clinic, Rochester, MN, USA; ⁷AP-HP, Groupe Hospitalier Pitié-Salpêtrière, Department of Internal Medicine and Clinical Immunology, Paris, France.

Abstract

Objective

To describe the characteristics of ¹⁸F-fluorodeoxyglucose positron-emission tomography/computed-tomography (¹⁸FDG-PET/CT) findings before surgery in patients with active, histologically confirmed aortitis, and to correlate the degree of arterial wall inflammation with PETVAS score.

Methods

This was a multiple-centre retrospective study including cases with histologically proven active, non-infectious aortitis who had a ¹⁸FDG-PET/CT performed within one year before surgery for aneurysm repair. PETVAS score was determined by radiologists blinded to the pathology findings. Cardiovascular pathologists reviewed aortic tissue samples and graded the degree of inflammation in the vessel wall.

Results

Sixteen patients were included (8 giant cell arteritis, 4 clinically isolated aortitis, 2 Takayasu's arteritis, 1 relapsing polychondritis, and 1 rheumatoid arthritis). In 5/16 (31%) patients, ¹⁸FDG-PET/CT did not detect the presence of aortic inflammation; two of whom were being treated with glucocorticoids at the time of procedure. Ascending thoracic and abdominal aorta had the highest FDG uptake among the affected territories. Patients without active aortitis on ¹⁸FDG-PET/CT were significantly older ($p=0.027$), had a lower PETVAS score ($p=0.007$), and had a lower degree of adventitial inflammation ($p=0.035$). In contrast, there was no difference between ¹⁸FDG-PET/CT active and inactive aortitis patients as regards the timing between PET/CT and surgery, serum CRP level (during ¹⁸FDG-PET/CT) and, FDG uptake per study site.

Conclusion

In histologically proved aortitis, ¹⁸FDG-PET/CT before surgery did not detect vascular inflammation in 31% patients, and PETVAS score correlated with the degree of adventitial histopathologic inflammation.

Key words

aortitis, fluorodeoxyglucose F18, large-vessel vasculitis, positron emission tomography computed tomography, giant cell arteritis

Simon Parreau, MD
 Olivier Espitia, MD, PhD
 Michael S. Bold, MD
 Livia M. Frota Lima, MD
 Guillaume Lades, MD
 Melanie Bois, MD
 Morgane Assaraf, MD
 David Saadoun, MD, PhD
 Matthew J. Koster, MD
 Kim-Heang Ly, MD, PhD
 Cornelia M. Weyand, MD, PhD
 Kenneth J. Warrington, MD
 Eric Liozon, MD

Please correspondence to:

Simon Parreau

Department of Internal Medicine,
 Dupuytren Hospital,
 16 rue Bernard Descottes,
 87042 Limoges, France.

E-mail: simon.parreau@hotmail.com

ORCID iD: 0000-0002-1790-2962

Received on October 9, 2022; accepted in
 revised form on December 5, 2022.

© Copyright CLINICAL AND

EXPERIMENTAL RHEUMATOLOGY 2023.

Funding: S. Parreau received fellowship support from the Servier Institute, France.

Competing interests: K.J. Warrington received clinical trial support from GSK, Eli Lilly and Kiniksa; he also received consulting fees and honoraria from Chemocentryx.

The other authors have declared no competing interests.

Introduction

Aortitis is defined as inflammation of the aortic wall and includes several different diseases, of which the most frequent are systemic vasculitis such as giant cell arteritis (GCA) and Takayasu's arteritis (TAK). Clinically isolated aortitis (CIA) represents a particular subset that is limited to the aorta without signs of systemic disease, although some cases may evolve to GCA (1). Rarely, aortitis may be a complication of rheumatic diseases such as ankylosing spondylitis or relapsing polychondritis (2). Aortitis is associated with significant morbidity and potential mortality related to aneurysmal dilatation, aortic dissection, or rupture (3-6). Histological evidence of aortitis, considered to be the gold standard diagnostic method, is only available after aneurysm surgery. Indeed, most patients with CIA are diagnosed post-operatively following the incidental discovery of aortitis on histopathological analysis. Retrospective case series have reported the presence of aortitis in 3%-6% of surgical specimens from ascending aortic aneurysm repairs (5, 8). In patients with systemic vasculitis such as GCA, aortitis is often diagnosed by imaging studies such as computed tomography angiogram (CTA), magnetic resonance angiogram (MRA) or ¹⁸F-fluorodeoxyglucose positron-emission tomography/computed-tomography (¹⁸F-FDG-PET/CT) (7). While PET/CT has excellent specificity and sensitivity for the diagnosis of large-vessel vasculitis (LVV), false negatives (due to glucocorticoids) or false positives (e.g. atherosclerosis) may occur (9, 10). No study has correlated pre-operative ¹⁸F-FDG-PET/CT findings with pathologically confirmed aortitis in patients undergoing thoracic aortic aneurysm repair. The aim of our study is to describe the ¹⁸F-FDG-PET/CT findings prior to aortic surgery in patients with aortitis, and to report the sensitivity of PET for the detection of pathologically confirmed aortic inflammation.

Patients and methods

Study population

The study comprised patients with pathologically confirmed non-infec-

tious aortitis who had a ¹⁸F-FDG-PET/CT performed no more than twelve months before aneurysm surgery between January 1, 2000, and December 31, 2021, at Mayo Clinic Rochester, Minnesota, USA. French patients from three centres, meeting the same inclusion criteria, were added. Patients without research authorisation and cases of infectious aortitis were excluded from the study.

Data collection

Preoperative clinical and biological data were retrospectively obtained from the patients' electronic health records and a cardiovascular surgical database. Each patient was assigned a clinical diagnosis according to clinical and laboratory information, in accordance with the definitions of each: GCA, TAK, relapsing polychondritis (RP), rheumatoid arthritis (RA), and CIA (11, 12). Aortitis was defined histologically by the presence of an inflammatory infiltrate associated with medial damage.

Radiology review

All the patients in this study underwent FDG-PET/CT scan with standard protocols and comparable scanners including GE Discovery (GE Healthcare, Milwaukee, Wisconsin, USA), Siemens (Siemens Healthcare, Erlangen, Germany) and Philips Medical Systems (Philips Healthcare, Cleveland, OH, USA). After a 4-hour fast, patients were injected with a weight-based dose of ¹⁸F-FDG radiotracer. After 1 hour of uptake time, a spiral CT scan followed by a PET emission scan was obtained. PET data and CT images were evaluated using MIM (MIM Software Inc., Cleveland, OH). A nuclear medicine radiologist and a senior radiology resident reviewed all images independently with the findings later compared to confirm the reproducibility.

For quantitative assessment, a volumetric region of interest tool was used to obtain the maximal standardised uptake value (SUVmax) which is calculated from the injected dose and patient weight. The SUVmax was recorded for nine specific arterial territories including: ascending aorta, aorta arch,

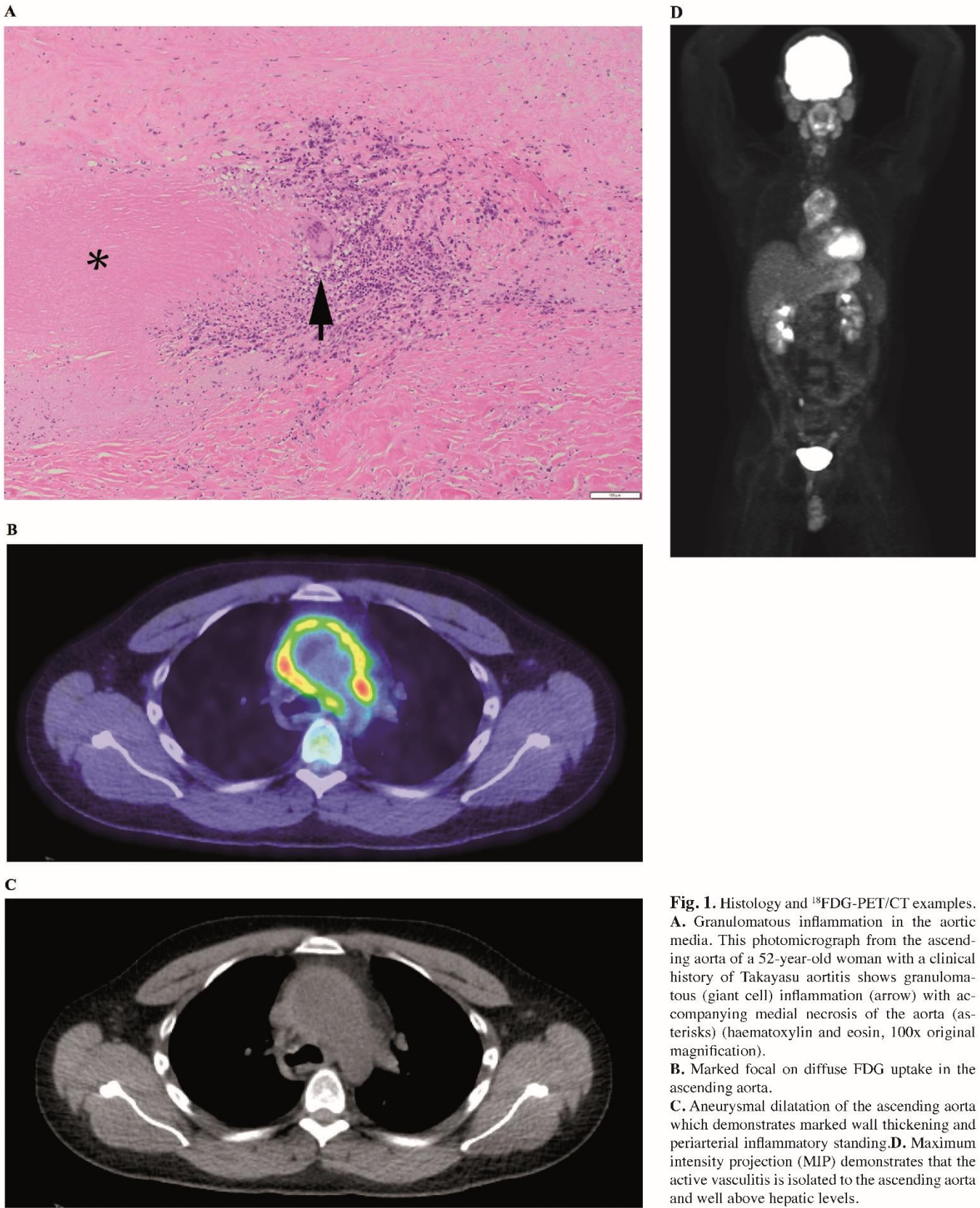


Fig. 1. Histology and ¹⁸F-FDG-PET/CT examples. **A.** Granulomatous inflammation in the aortic media. This photomicrograph from the ascending aorta of a 52-year-old woman with a clinical history of Takayasu aortitis shows granulomatous (giant cell) inflammation (arrow) with accompanying medial necrosis of the aorta (asterisks) (haematoxylin and eosin, 100x original magnification). **B.** Marked focal on diffuse FDG uptake in the ascending aorta. **C.** Aneurysmal dilatation of the ascending aorta which demonstrates marked wall thickening and periarterial inflammatory standing. **D.** Maximum intensity projection (MIP) demonstrates that the active vasculitis is isolated to the ascending aorta and well above hepatic levels.

descending thoracic aorta, abdominal aorta, innominate artery, right/left carotid arteries and right/left subclavian arteries. The SUVmean of the right he-

patic lobe was obtained as an internal reference for subsequent scoring. PET vascular activity score (PETVAS) was obtained by comparing each vas-

cular segment to the background hepatic uptake. Specifically, a score of 0=no FDG uptake; 1=less than liver; 2=equal to liver; and 3=greater than

liver. Then the cumulative score was recorded for each patient.

Lastly, the radiologist made an overall impression regarding if active vasculitis was favored to be present or absent. The decision process considered focality of uptake, SUVmax, and non-contrast enhanced CT findings of vessel wall thickening and/or adjacent inflammatory stranding.

Statistical analysis

Quantitative variables were expressed as means and standard deviation. Qualitative variables were expressed as frequencies with percentages. Comparisons were made by Pearson's Chi-2 test, Fisher's exact test, or Wilcoxon test as appropriate for each variable. A *p*-value less than 0.05 was considered to be significant. All calculations were performed using R software v. 3.2.2 (R foundation for statistical computing, Vienna, Austria).

Ethical board approval

For American patients, the study obtained approval from the Mayo Clinic Institutional Review Board. Concerning French patients, the study was conducted in compliance with good clinical practices and the principles of the Declaration of Helsinki. In accordance with French law, formal approval from an ethics committee was not required for this type of retrospective study.

Results

Demographics

Sixteen patients met the inclusion criteria. Eight had a final diagnosis of GCA. Other diagnoses were CIA (*n*=4), TAK (*n*=2), RP (*n*=1), and RA (*n*=1). The time interval between ¹⁸F-FDG-PET/CT and surgery was on average 3.9±3.5 months. In most patients (9/16), ¹⁸F-FDG-PET/CT was performed to assess vasculitis disease activity in the context of a known diagnosis of large-vessel vasculitis. Five patients had a ¹⁸F-FDG-PET/CT for unexplained constitutional symptoms and/or persistent inflammatory syndrome. One patient was evaluated with PET/CT for breast cancer and one to characterise a lung nodule. The mean CRP at the time of ¹⁸F-FDG-PET/CT (available for 13/16 patients) was

Table I. Comparison between inactive and active vasculitis according to ¹⁸F-FDG-PET/CT findings.

	Vasculitis on PET/CT		<i>p</i> -value
	Inactive (<i>n</i> =5) Mean ± SD or <i>n</i> (%)	Active (<i>n</i> =11) Mean ± SD or <i>n</i> (%)	
Age, years	73.8 ± 4.2	59.7 ± 15.2	0.027
Glucocorticoids during PET/CT	2 (40%)	3 (27%)	1.000
Immunosuppressive treatment during PET/CT	2 (40%)	1 (9%)	0.214
CRP during PET/CT, mg/l	23.8 ± 22.9	18.4 ± 22.9	0.497
Time between PET/CT and surgery, months	4.2 ± 4.1	3.8 ± 3.4	0.953
Reason(s) for the realisation of PET/CT			
Constitutional symptoms	1 (20%)	2 (18%)	1.000
Unexplained elevated inflammatory markers	3 (60%)	4/8 (50%)	1.000
Follow-up of known aortitis	1 (20%)	3 (27%)	1.000
Rapid progression of a known aortic aneurysm	2 (40%)	3 (27%)	1.000
Other reasons	0	3 (27%)	0.509
PETVAS score (0 to 3 scale)			
Ascending aorta	1.6 ± 0.9	2.2 ± 0.6	0.157
Aortic arch	1.0 ± 0.0	1.9 ± 0.7	0.015
Descending thoracic aorta	1.2 ± 0.4	2.1 ± 0.8	0.053
Abdominal aorta	1.2 ± 0.4	1.6 ± 0.9	0.446
Right carotid	1.0 ± 0.0	1.1 ± 0.3	0.590
Left carotid	1.0 ± 0.0	1.2 ± 0.4	0.374
Innominate artery	1.0 ± 0.0	1.4 ± 0.5	0.152
Right subclavian artery	1.0 ± 0.0	0.9 ± 0.5	0.739
Left subclavian artery	1.0 ± 0.0	0.9 ± 0.5	0.739
Total PETVAS score (0 to 27 scale)	10.0 ± 1.0	13.3 ± 2.1	0.007
Histology			
Medial inflammation (0 to 3 scale)	1.8 ± 0.8	2.5 ± 0.5	0.108
Adventitial inflammation (0 to 3 scale)	1.4 ± 0.5	2.3 ± 0.6	0.035

PET/CT: 18F-fluorodeoxyglucose positron-emission tomography/computed-tomography; CRP: C-reactive protein.

20±23 mg/l. Six patients were on glucocorticoids/immunosuppressive therapies during ¹⁸F-FDG-PET/CT. The indication for surgery was the presence of an aortic aneurysm for fifteen patients (mean diameter: 54 mm) and aortic dissection for one patient. Consistent with the inclusion criteria for this study, all patients had histologically active aortitis. An illustration of histological proven aortitis is shown in Figure 1.

¹⁸F-FDG-PET/CT findings

¹⁸F-FDG-PET/CT showed no evidence of vasculitis activity in 5/16 (31%) patients, two of whom were being treated with glucocorticoids at the time of the examination. These two treated patients had elevated inflammatory parameters with constitutional symptoms suggesting clinically active vasculitis. In patients with aortic FDG uptake, the thoracic aorta (10/11, 91% patients) was most frequently involved. The ascending thoracic aorta and abdominal aorta had the highest FDG uptake among the affected territories. In terms

of SUVmax, the aortic arch had the highest values. Examples of a ¹⁸F-FDG-PET/CT result is shown in Figure 1. Among patients with active vasculitis on ¹⁸F-FDG-PET/CT, serum CRP level was low (≤11 mg/l) for most (6/8 patients with available CRP).

Comparison between active and inactive ¹⁸F-FDG-PET/CT

Patients without active aortitis on ¹⁸F-FDG-PET/CT (*n*=5), were significantly older (73.8±4.2 vs. 59.7±15.2 years, *p*=0.027), had a lower aortic arch FDG uptake (1.0±0.0 vs. 1.9±0.7, *p*=0.015) and total PETVAS score (10.0±1.0 vs. 13.3±2.1, *p*=0.007), and had a lower degree of adventitial inflammation (0 to 3 scale) (1.4±0.5 versus 2.3±0.7, *p*=0.035) (Table I). In contrast, there was no difference in the time between ¹⁸F-FDG-PET/CT and surgery (*p*=0.953), CRP level during ¹⁸F-FDG-PET/CT (*p*=0.497), FDG uptake per other study site, or degree of inflammation in the media on pathological examination (*p*=0.108).

Discussion

This study is the first which analysed ¹⁸F-FDG-PET/CT before surgery in histologically proved aortitis and highlights the utility of ¹⁸F-FDG-PET/CT for the evaluation of patients with non-infectious aortitis. In this small sample of patients, we show that two third patients with histologically confirmed aortitis had aortic FDG uptake on PET. However, a subset of patients may have a negative a ¹⁸F-FDG-PET/CT despite ongoing histologic evidence of aortitis; ¹⁸F-FDG-PET/CT is not sensitive enough to demonstrate mild inflammation of the aortic wall. Treatment with glucocorticoids may play a role in reducing the sensitivity of PET while the aortitis may still be active (1). Grayson *et al.* showed, comparing 56 patients with LVV to 59 comparator subjects, that ¹⁸F-FDG-PET/CT could distinguish patients with active vasculitis with a sensitivity of 85% (9). Nevertheless, this study correlates ¹⁸F-FDG-PET/CT with clinical disease activity and inflammatory biomarkers (9). The novelty of the present study is that we compared ¹⁸F-FDG-PET/CT with pathology, which remains the gold standard diagnostic assessment for vasculitis.

Patients without active aortitis on ¹⁸F-FDG-PET/CT exhibited a lower degree of adventitial inflammation on histopathological examination compared to those with active aortitis. The onset of the inflammatory process in GCA starts in the adventitia by stimulation of resident dendritic cells (13). The following stages take place mainly in the media with an inflammatory infiltrate composed of lymphocytes and macrophages. The lower intensity of the inflammatory infiltrate observed in the adventitia of ¹⁸F-FDG-PET/CT negative patients might reflect a later stage of disease or may be due to different pathomechanisms of vascular inflammation in these patients. Our findings need to be confirmed in other cohorts and should be considered preliminary. This present study shows that patients with active aortitis on ¹⁸F-FDG-PET/CT exhibited a higher PETVAS of the aortic arch among the sites of vessels than those without. According to a previous study, aortic arch is the vascular

site where hypermetabolism on ¹⁸F-FDG-PET/CT is most marked for patients with active large-vessel vasculitis (9). However, despite the absence of hypermetabolism, patients may have histopathological evidence of active aortitis on surgical specimens. Thus, in select cases, an aortic arch aneurysm, may still be inflammatory in nature even if ¹⁸F-FDG-PET/CT is negative.

The essential reason for using ¹⁸F-FDG-PET/CT pre-operatively in patients with aortic aneurysm and a proven, or suspected condition known to be associated with aortitis is to evaluate disease activity, since a repair surgery should preferably be performed when the inflammatory process is quiescent (14-17). Post-operatively, ¹⁸F-FDG-PET/CT may be used to detect ongoing inflammation in the native aorta, which may increase risk of new events such as aneurysm or aortic rupture. Finally, the follow-up of the graft may be useful, especially in situations of suspected prosthesis infection (18).

The main limitations of our study are the small number of patients, the heterogeneous aetiologies of aortitis, and the variable time from imaging to surgery. Indeed, various forms of aortitis may have different pathophysiological mechanisms resulting in variable findings on PET/CT. The delay between PET/CT and surgery in some patients may (at least in part) explain the “false negatives”. Most of the PET/CTs (12/16) were performed 6 months before surgery, which limits this gap. Among the negative PET/CT, only one was performed 11 months before surgery (and this patient was on treatment). The 4 other negative PET/CT were performed fairly close to surgery (5, 3, 1 and 1 month respectively) which limits this potential confounder. However, given the rarity of disease and need for surgical intervention to obtain tissue samples, our data are novel and informative. Larger studies and standardisation of radiologic findings are needed to better determine the correlation between nuclear imaging and histologic patterns of inflammation.

In conclusion, our study showed for the first time ¹⁸F-FDG-PET/CT characteristics in patients who underwent sur-

gery a few months later and who had histologic confirmation of aortitis. In a third of cases, aortitis is not identified before surgery. Larger studies are needed to better identify these patients and specify their prognosis.

Acknowledgments

We would like to acknowledge the support of our patients.

References

1. PUGH D, KARABAYAS M, BASU N *et al.*: Large-vessel vasculitis. *Nat Rev Dis Primers* 2022; 7: 93. <https://doi.org/10.1038/s41572-021-00327-5>
2. FERFAR Y, MORINET S, ESPITIA O *et al.*: Spectrum and outcome of noninfectious aortitis. *J Rheumatol* 2021; 48: 1583-1588. <https://doi.org/10.3899/jrheum.201274>
3. LA ROCCA G, DEL FRATE G, DELVINO P *et al.*: Systemic vasculitis: one year in review 2022. *Clin Exp Rheumatol* 2022; 40: 673-87. <https://doi.org/10.55563/clineprheumatol/ozhc85>
4. FERRO F, QUARTUCCIO L, MONTI S *et al.*: One year in review 2021: systemic vasculitis. *Clin Exp Rheumatol* 2021; 39 (Suppl. 129): S3-12. <https://doi.org/10.55563/clineprheumatol/v1tpfo>
5. CLIFFORD AH, ARAFAT A, IDREES JJ *et al.*: Outcomes among 196 patients with noninfectious proximal aortitis. *Arthritis Rheumatol* 2019; 71: 2112-20. <https://doi.org/10.1002/art.40855>
6. FERFAR Y, MORINET S, ESPITIA O *et al.*: Long-term outcome and prognosis factors of isolated aortitis. *Circulation* 2020; 142: 92-4. <https://doi.org/10.1161/circulationaha.120.045957>
7. EINSPIELER I, HENNINGER M, MERGEN V *et al.*: ¹⁸F-FDG PET/MRI compared with clinical and serological markers for monitoring disease activity in patients with aortitis and chronic periaortitis. *Clin Exp Rheumatol* 2020; 38 (Suppl. 124): S99-106
8. SCHMIDT J, SUNESEN K, KORNUM JB, DUHAUT P, THOMSEN RW: Predictors for pathologically confirmed aortitis after resection of the ascending aorta: a 12-year Danish nationwide population-based cross-sectional study. *Arthritis Res Ther* 2011; 13: R87. <https://doi.org/10.1186/ar3360>
9. GRAYSON PC, ALEHASHEMI S, BAGHERI AA *et al.*: (18) F-fluorodeoxyglucose-positron emission tomography as an imaging biomarker in a prospective, longitudinal cohort of patients with large vessel vasculitis. *Arthritis Rheumatol* 2018; 70: 439-49. <https://doi.org/10.1002/art.40379>
10. SOUSSAN M, NICOLAS P, SCHRAMM C *et al.*: Management of large-vessel vasculitis with FDG-PET: a systematic literature review and meta-analysis. *Medicine* (Baltimore) 2015; 94: e622. <https://doi.org/10.1097/MD.0000000000000622>
11. PONTE C, GRAYSON PC, ROBSON JC *et al.*: 2022 American College of Rheumatology/EULAR Classification Criteria for Giant Cell

- Arteritis. *Arthritis Rheumatol* 2022; 74(12): 1881-9. <https://doi.org/10.1002/art.42325>
12. GRAYSON PC, PONTE C, SUPPIAH R *et al.*: 2022 American College of Rheumatology/EULAR Classification Criteria for Takayasu Arteritis. *Arthritis Rheumatol* 2022; 74(12): 1872-80. <https://doi.org/10.1002/art.42324>
 13. WATANABE R, BERRY GJ, LIANG DH, GORONZY JJ, WEYAND CM: Pathogenesis of giant cell arteritis and Takayasu arteritis—similarities and differences. *Curr Rheumatol Rep* 2020; 22: 68. <https://doi.org/10.1007/s11926-020-00948-x>
 14. VAN DER GEEST KSM, TREGLIA G, GLAUDE-MANS AWJM *et al.*: Diagnostic value of [18F]FDG-PET/CT for treatment monitoring in large vessel vasculitis: a systematic review and meta-analysis. *Eur J Nucl Med Mol Imaging* 2021; 48: 3886-902. <https://doi.org/10.1007/s00259-021-05362-8>
 15. MAZ M, CHUNG SA, ABRIL A *et al.*: 2021 American College of Rheumatology/Vasculitis Foundation Guideline for the Management of Giant Cell Arteritis and Takayasu Arteritis. *Arthritis Rheumatol* 2021; 73: 1349-65. <https://doi.org/10.1002/art.41774>
 16. PERERA AH, YOUNGSTEIN T, GIBBS RG, JACKSON JE, WOLFE JH, MASON JC: Optimizing the outcome of vascular intervention for Takayasu arteritis. *Br J Surg* 2014; 101: 43-50. <https://doi.org/10.1002/bjs.9372>
 17. FIELDS CE, BOWER TC, COOPER LT *et al.*: Takayasu's arteritis: operative results and influence of disease activity. *J Vasc Surg* 2006; 43: 64-71. <https://doi.org/10.1016/j.jvs.2005.10.010>
 18. YOUNGSTEIN T, TOMBETTI E, MUKHERJEE J *et al.*: FDG uptake by prosthetic arterial grafts in large vessel vasculitis is not specific for active disease. *JACC Cardiovasc Imaging* 2017; 10: 1042-52. <https://doi.org/10.1016/j.jcmg.2016.09.027>

Annexe 8.

High incidence of giant cell arteritis during the COVID-19 pandemic: no causal relationship but possible involvement of stress.

High incidence of giant cell arteritis during the COVID-19 pandemic: no causal relationship but possible involvement of stress

Sirs,

Giant cell arteritis (GCA) is the most common vasculitis in older adults. The mechanism causing the disease is not known, but infectious triggers have been suggested (1). The coronavirus 2 (SARS-CoV-2) disease 2019 (COVID-19) pandemic began in China at the end of 2019 and then spread rapidly worldwide. COVID-19 has various clinical presentations, from asymptomatic forms to acute respiratory distress syndrome and multi-organ failure. The vascular tropism of SARS-CoV-2 may result in endothelial activation with thrombosis (2) and viral-induced systemic vasculitis (3). We observed an increase in the incidence of GCA in our hospital in 2020, which suggested SARS-CoV-2 pandemic to be a trigger. We thus explored a possible direct relationship between SARS-CoV2 infection and GCA occurrence.

From 2010 through December 2020, we prospectively enrolled all patients diagnosed with GCA using the American College of Rheumatology criteria in the Internal Medicine department of a tertiary-care teaching hospital. The main GCA features of patients diagnosed in 2020 were compared with those of patients diagnosed during the previous decade. To track the regional SARS-CoV-2 pandemic, we collected the number of daily hospitalisations related to the virus during 2020 in our hospital's main catchment area, the Haute-Vienne Department, from the French public health website, which records daily hospitalisation declarations from each health centre in the department. Serum samples were analysed using two FDA-approved tests for the qualitative detection of IgG antibodies to SARS-CoV-2 in human serum and plasma using a chemiluminescence microparticle immunoassay (CMIA). The Alinity SARS-CoV-2 IgG (Abbott, Chicago, USA) assay detects IgG antibodies to the SARS-CoV-2 nucleocapsid protein and Liaison SARS-CoV-2 S1/S2 IgG (DiaSorin, Saluggia, Italy) detects IgG antibodies to the SARS-CoV-2 spike (S1/S2). Total RNA was extracted from biopsies in paraffin with a Maxwell® 16 LEV RNA FFPE Purification kit (Promega, Madison, USA). PCR was performed with the SARS-COV-2 R-GENE® kit (bioMérieux, Marcy-l'Étoile, France) allowing qualitative detection of SARS-CoV-2. In accordance with French law, the study was approved by the local ethics committee. Informed consent was obtained from all assessed patients.

During 2020, we diagnosed GCA in 28 patients. Figure 1 shows the incidence of new patients hospitalised for COVID-19 in Haute-Vienne and monthly new cases of

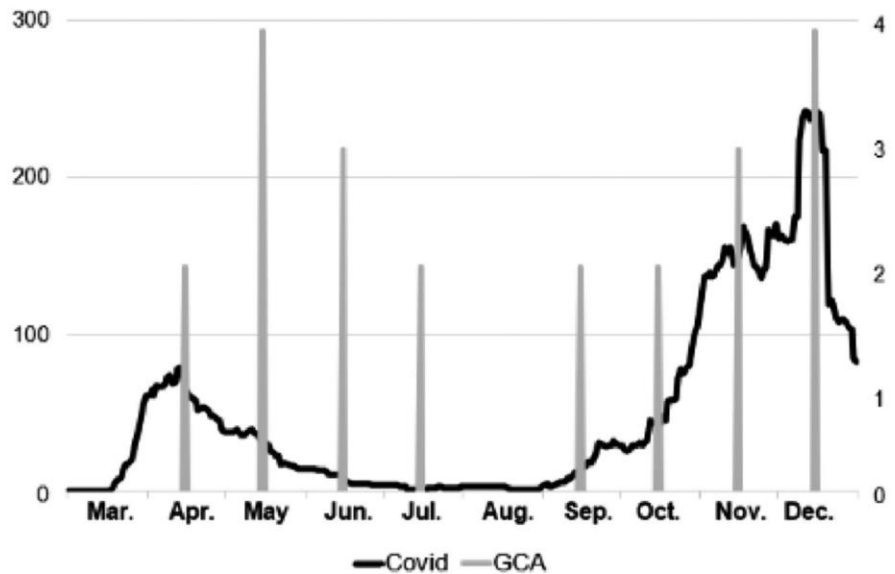


Fig. 1. Evolution of daily patients hospitalised for COVID-19 in Haute-Vienne, France (right y-axis) compared with new monthly cases of giant cell arteritis (GCA) (left y-axis) in 2020.

Table I. Comparison of characteristics of patients diagnosed with GCA in 2020 with those of patients diagnosed in 2010 to 2019.

Characteristic	2020 (n=28)	2010–2019 (n=205)	p-value
Demographic characteristics			
Age	72.3 [7.5]	74.7 [8.5]	0.1666
Female	20 (71.4)	140 (68.3)	0.8270
Disease history			
Diagnosis delay, days	93.6 [97.9]	85.3 [96.4]	0.3910
Acute form	16 (59.3)	92 (45.5)	0.1800
Reported trigger	1 (3.7)	44 (21.6)	0.0350
Constitutional symptoms			
General symptoms	24 (88.9)	136 (68.0)	0.0252
Fever	11 (40.7)	54 (26.6)	0.1253
Aortitis	10/25 (40.0)	41/106 (38.7)	0.9030
Rheumatological symptoms			
Polymyalgia rheumatica	8 (29.6)	64 (31.2)	0.8667
Peripheral arthritis	2 (7.4)	21 (10.2)	0.9999
Cranial symptoms			
Headaches	23 (85.2)	159 (77.6)	0.4613
Temporal artery abnormalities	17 (63.0)	123 (60.0)	0.7673
Scalp tenderness	16 (59.3)	90 (44.1)	0.1379
Occipital pain	19 (70.4)	93 (45.6)	0.0155
Neuro-ophthalmic symptoms			
Fugax visual symptoms	9 (33.3)	52 (25.6)	0.3934
Permanent amaurosis fugax	4 (14.8)	37 (18.0)	0.8841
Bilateral amaurosis fugax	0	11 (5.4)	0.4693
Stroke	3 (10.7)	8 (3.9)	0.1325
Buccal, throat and ear symptoms			
Number of pharyngeal symptoms	3.3 [2.5]	2.1 [1.9]	0.0112
Jaw claudication	7 (25.9)	64 (31.2)	0.5748
Painful mouth opening	12 (44.4)	48 (23.6)	0.0208
Maxillary pain	16 (59.3)	83 (41.3)	0.0770
Throat pain	9 (33.3)	44 (22.3)	0.2073
Dysphagia	6 (22.2)	25 (12.7)	0.1786
Dry cough	12 (44.4)	51 (26.2)	0.0482
Hoarse	8 (29.6)	26 (13.5)	0.0307
Otalgia	8 (29.6)	45 (23.4)	0.4818
Laboratory			
Erythrocyte sedimentation rate, mm	71.2 [30.2]	81.9 [30.1]	0.0981
C-reactive protein, mg/L	81.8 [65.9]	90.4 [71.2]	0.5858
Histology			
Positive temporal artery biopsy	18 (75.0)	122 (63.9)	0.2811

The values are reported as the absolute number (percentage) or mean [standard deviation].

GCA during 2020. Of the 28 patients, 22 were diagnosed beginning in March, when the Covid-19 pandemic started in Haute-Vienne. As Table I shows, we observed more constitutional and ear-nose-throat (ENT) symptoms, but no excess visual loss or other permanent ischaemic complications in the patients diagnosed in 2020 compared with those diagnosed over the previous decade. Of the 28 patients, 17 had serological tests with both assays and 25 a PCR study of a temporal artery biopsy for SARS-CoV-2. All serological and PCR tests were negative.

The COVID-19 pandemic has disrupted hospital care worldwide. We observed an increase in incident GCA cases in our department in 2020, as reported elsewhere (4, 5). We did not observe longer mean delays in GCA diagnosis and treatment, particularly in terms of access to hospital services, eye clinic consultations, vascular imaging, or temporal artery biopsy, contrary to reports from severely affected regions, such as Lombardy, Italy (6). Similarly, we did not see any increase in GCA-related ischaemic complications, particularly permanent loss of vision, in the 2020 group compared to the cohort 2010-2019. This observation is at odds with the report by Monti *et al.* (6), but consistent with reports from regions less impacted by the pandemic (4). The COVID-19 pandemic occurred in Haute-Vienne after it began in northern Italy and eastern France, which allowed us to organise regional care services. The increase in numbers of cases during 2020, with more cases observed during the COVID-19 pandemic peaks, suggests a role for the pandemic on GCA onset. The negative results of this study reasonably rule out the possibility of a direct relationship between SARS-CoV-2 infection and GCA occurrence. The role of stress, which has been previously emphasised in systemic diseases (7-9), is plausible, although we cannot push the hypothesis of chance aside.

Finally, COVID-19 and GCA share some clinical and laboratory overlap that could be misleading (10). We found an increased frequency of ENT symptoms in GCA patients diagnosed in 2020 compared to patients diagnosed in the previous decade. During the pandemic, GCA onset involving prominent ENT symptoms might carry a risk of misdiagnosing GCA as SARS-CoV-2 infection, incorrectly leading to the patient's isolation with all the attendant ischaemic risks. Family physicians should be advised of the existence of symptom overlap between GCA and SARS-CoV-2 infection. Our observations call for well-designed prospective studies of stress in these patients during subsequent COVID-19 waves and on the potential impact of widespread COVID vaccination on GCA epidemiology.

Acknowledgements

The authors thank Mr Alain Chaunavel for his help concerning RNA extraction on temporal artery biopsies and Ms Stéphanie Dumonteil for the statistical analysis.

S. PARREAU¹, MD
É. LIOZON¹, MD
K.-H. LY¹, MD, PhD
A.-L. FAUCHAIS¹, MD, PhD
S. HANTZ^{2,3}, MD, PhD

¹Internal Medicine, Dupuytren University Hospital, Limoges;

²Bacteriology-Virology-Hygiene Department, Dupuytren University Hospital, Limoges;

³UMR INSERM 1092 RESINFIT, University of Limoges, France.

Please address correspondence to:
Simon Parreau
Service de Médecine Interne A,
CHRU Dupuytren 2,
16 rue Bernard Descottes,
87042 Limoges, France.
E-mail: simon.parreau@hotmail.com

Competing interests: none declared.

© Copyright CLINICAL AND
EXPERIMENTAL RHEUMATOLOGY 2021.

References

1. RHEE RL, GRAYSON PC, MERKEL PA, TOMASSON G: Infections and the risk of incident giant cell arteritis: a population-based, case-control study. *Ann Rheum Dis* 2017; 76: 1031-5.
2. CONNORS JM, LEVY JH: COVID-19 and its implications for thrombosis and anticoagulation. *Blood* 2020; 135: 2033-40.
3. BECKER RC: COVID-19-associated vasculitis and vasculopathy. *J Thromb Thrombolysis* 2020; 50: 499-511.
4. LECLER A, VILLENEUVE D, VIGNAL C, SENÉ T: Increased rather than decreased incidence of giant cell arteritis during the COVID-19 pandemic. *Ann Rheum Dis* 2020 Aug 7.
5. LUTHER R, SKEOCH S, PAULING JD, CURD C, WOODGATE F, TANSLEY S: Increased number of cases of giant cell arteritis and higher rates of ophthalmic involvement during the era of COVID-19. *Rheumatol Adv Pract* 2020; 4: rkaa067.
6. MONTI S, DELVINO P, BELLIS E, MILANESI A, BRANDOLINO F, MONTECUCCO C: Impact of delayed diagnoses at the time of COVID-19: increased rate of preventable bilateral blindness in giant cell arteritis. *Ann Rheum Dis* 2020; 79: 1658-9.
7. CÉNAC A, SPARFEL A, AMIEL-LEBIGRE F *et al.*: [Effect of stressful life events on clinical development of temporal arteritis and/or polymyalgia rheumatica]. *Presse Med* 2002; 31: 873-9.
8. DE BROUWER SJ, KRAAIMAAT FW, SWEEP FC *et al.*: Experimental stress in inflammatory rheumatic diseases: a review of psychophysiological stress responses. *Arthritis Res Ther* 2010; 12: R89.
9. PRALLAUD R, GREIGERT H, SAMSON M *et al.*: Impact of the COVID-19 lockdown on the management and control of patients with GCA. *Ann Rheum Dis* 2020 Aug 7.
10. MEHTA P, SATTUI SE, VAN DER GEEST KS *et al.*: Giant cell arteritis and COVID-19: similarities and discriminators. a systematic literature review. *J Rheumatol* 2020 Oct 15 [Online ahead of print].

Annexe 9.

Immune-Mediated Diseases Following COVID-19 Vaccination: Report of a Teaching Hospital-Based Case-Series.



Article

Immune-Mediated Diseases Following COVID-19 Vaccination: Report of a Teaching Hospital-Based Case-Series

Eric Liozon ^{1,*}, Matthieu Filloux ², Simon Parreau ¹ , Guillaume Gondran ¹, Holy Bezanahary ¹, Kim-Heang Ly ¹ and Anne-Laure Fauchais ¹

¹ Departments of Internal Medicine, Dupuytren University Hospital, 87042 Limoges, France

² Department of Immunology and Immunogenetics, University Hospital of Limoges, 87042 Limoges, France

* Correspondence: liozone@yahoo.fr or eric.liozon@chu-limoges.fr; Tel.: +33-5-55-05-69-90; Fax: +33-5-55-05-66-50

Abstract: The occurrence and course of immune-mediated diseases (IMDs) following COVID-19 vaccination has been little explored so far. We retrieved, among adult patients hospitalized at the Internal Department of a French university hospital up to May 2022, all those who had developed, or relapsed to, an IMD less than 3 weeks following COVID-19 vaccination, without other triggers. Twenty-seven (24 new-onset) post-COVID-19 vaccine IMDs were recorded. They comprised giant cell arteritis or polymyalgia rheumatica ($n = 16$, HLA-DRB1*04 in 58% of 12 assessed GCA cases), immune-mediated necrotizing myositis or acute rhabdomyolysis, systemic vasculitis, immune thrombocytopenic purpura, rheumatoid arthritis, anti-synthetase syndrome, and adult-onset Still's disease. The causative vaccines were mRNA-based (20 cases) or viral vector-based (7 cases). The IMD typically occurred after the first vaccine dose, with an average delay of 8 (5 SD) days. The patients' mean age was 67 years, and 58% were women. The IMDs had protracted courses in all but three of the patients and typically required high-dose glucocorticoids, in combination with immunomodulators in 13 patients. One patient died of intractable rhabdomyolysis, whereas five suffered permanent damage from IMDs. Eleven patients with well-controlled IMDs completed their COVID-19 vaccination schedule, and two suffered mild IMD relapses. There is a risk of IMDs, notably GCA/PMR, and muscle disorders, following COVID-19 vaccination. Such adverse reactions typically occurred after the first dose, raising concern about subsequent COVID-19 vaccinations. However, early re-challenge in well-controlled IMDs appeared safe.

Keywords: COVID-19; vaccination; side; immune-mediated; giant cell arteritis; HLA-DR



Citation: Liozon, E.; Filloux, M.; Parreau, S.; Gondran, G.; Bezanahary, H.; Ly, K.-H.; Fauchais, A.-L. Immune-Mediated Diseases Following COVID-19 Vaccination: Report of a Teaching Hospital-Based Case-Series. *J. Clin. Med.* **2022**, *11*, 7484. <https://doi.org/10.3390/jcm11247484>

Academic Editor: Vamsee Mallajosyula

Received: 24 November 2022

Accepted: 14 December 2022

Published: 16 December 2022

Publisher's Note: MDPI stays neutral with regard to jurisdictional claims in published maps and institutional affiliations.



Copyright: © 2022 by the authors. Licensee MDPI, Basel, Switzerland. This article is an open access article distributed under the terms and conditions of the Creative Commons Attribution (CC BY) license (<https://creativecommons.org/licenses/by/4.0/>).

1. Introduction

The speed and severe impact of the coronavirus disease 2019 (COVID-19) pandemic led to rapid development of vaccines. Phase-II trials have shown reassuring safety profiles in mRNA-based vaccines and viral vector-based vaccines [1–3]. Likewise, cross-sectional or longitudinal studies on the safety of several COVID-19 vaccines in autoimmune inflammatory rheumatic diseases did not detect a risk signal [4,5]. Nevertheless, recent safety data from population-wide surveys have suggested significant side effects, notably severe thrombotic events via vaccine-induced immune thrombotic thrombocytopenia [6]. Although vaccines are linked to several immune-mediated diseases (IMDs) [7–13], such reports on COVID-19 vaccines are limited, beside single case reports, to a few case-series [14–17]. Therefore, we evaluated the occurrence, or flare-up, of IMDs reported in the Internal Medicine Department of a University Hospital during the period of mass vaccination against COVID-19.

2. Methods

2.1. Study Design

Starting in January 2021, when COVID-19 vaccination became progressively available, we retrieved all reports of IMDs occurring after vaccination among consecutively hospitalized patients hospitalized in the Internal Medicine Department of a University Hospital. The catchment area of the hospital roughly corresponds to the population of the Limousin region, e.g., 723,784 people, 436,360 being over 40 years of age. As of 31 May 2022, at study termination, 82% of the regional population were vaccinated at least once against severe acute respiratory syndrome coronavirus-2 (SARS-CoV-2). However, precise calculation of the regional incidence of post-COVID-19 vaccine IMDs cannot be obtained, since it is expected that not all patients with an IMD will be referred, or reported, to the regional hospital. Details regarding the demographic information, significant comorbid conditions, date of diagnosis, clinical features, biological abnormalities at disease onset, use of glucocorticoid treatments including pulse methylprednisolone and/or prednisone, use and type of steroid-sparing agents, relapses during prednisone tapering, survival, recovery from IMD, and total duration of treatment were retrieved for each patient. We also aim to assess the influence of HLA-DRB1/DQB1 polymorphism on COVID-19 vaccine-induced IMDs, in particular the frequency of HLA-DRB1*01 and DRB1*04 alleles. Both alleles are risk factors for autoimmune/auto-inflammatory syndrome induced by adjuvants (ASIA) [8].

2.2. Case Series

Inclusion criteria: The case series comprised cases of giant cell arteritis (GCA), polymyalgia rheumatica (PMR), immune-mediated necrotizing myositis (IMNM) or acute rhabdomyolysis, ANCA-associated vasculitis (AAV), Henoch-Shönlein purpura (HSP), adult-onset Still's disease (AOSD), rheumatoid arthritis (RA), and idiopathic thrombocytopenic purpura (ITP) following COVID-19 vaccination. The inclusion criteria were (a) IMD diagnosed using currently accepted criteria. GCA was diagnosed based on the criteria of the American College of Rheumatology [18]; negative biopsy cases were regarded as true GCA cases provided there was a dramatic and sustained response to corticosteroid treatment. PMR was diagnosed using the 2012 EULAR/ACR criteria [19]. Rheumatoid arthritis was diagnosed using the 2010 EULAR/ACR classification criteria [20]. IMNM was characterized by proximal muscle weakness, a high serum creatine kinase level, widespread inflammatory muscle involvement on magnetic resonance imaging, myofiber necrosis with minimal inflammatory cell infiltrate on muscle biopsy, and no or little extra-muscular involvement, with or without specific autoantibodies in serum [21]. Diagnosis of the one case of eosinophilic granulomatosis with polyangiitis (EGPA) was based on the patient's history of allergic asthma, blood eosinophilia $3.6 \times 10^9/L$, multiple mononeuropathy, and ANCA positivity (anti-myeloperoxidase 49 UI/L). In this patient, peripheral nerve biopsy was considered unnecessary. In a patient with a prior diagnosis of AOSD that met most of Yamaguchi's criteria [22], a late relapse following vaccination was ascertained by a flare-up of arthritis in both wrists and knees together with increased CRP and ferritin levels. ITP was defined as a platelet count persistently $<100 G/L$ with exclusion of other causes of thrombocytopenia. Diagnosis of Henoch-Shönlein purpura (HSP) was based on the presence of at least three of the criteria of the American College of Rheumatology [23]. (b) No symptom or sign suggesting an IMD before vaccination. (c) The interval between vaccination and IMD onset did not exceed 3 weeks (in order to minimize the play of chance). (d) No other trigger (viral including current or recent SARS-CoV-2 or bacterial infection, or inciting drug) was evident. If a patient had been vaccinated at least twice (i.e., COVID-19 and influenza vaccination) within 3 weeks of IMD onset, responsibility was arbitrarily assigned to the vaccine received closest to IMD onset. (e) No spontaneous improvement of IMD; immunosuppressive/immunomodulatory treatment was required. Written informed consent was obtained from each patient.

HLA-DRB1/DQB1 genotyping: HLA-DRB1/DQB1 genotyping was conducted using peripheral blood samples in 20 patients. To assess the presence of COVID-19 vaccine-

associated HLA specificities in the subset of GCA/PMR, we compared the results of HLA-DR typing of 58 patients, comprising 14 patients with COVID-19 vaccine-induced GCA or PMR, 11 with other vaccine-induced (influenza vaccine, or pneumococcal vaccine) GCA, 17 with familial aggregation of GCA or PMR and, a random sample of 16 patients with GCA (e.g., without a vaccine trigger or familial aggregation). Familial cases occurring after a vaccination were arbitrarily included in the corresponding post-vaccination group.

3. Results

Characteristics of the cohort: Thirty-seven reports were scrutinized for a possible relationship between IMD onset and vaccination. Three reports were excluded due to inconsistent temporal relationships. Four patients (Sjögren's syndrome, systemic lupus, sarcoidosis, PMR), who reported self-limited inflammatory musculoskeletal or dermatological (sarcoidosis) manifestations soon after vaccination, were also excluded. Thirty post-vaccine disorders qualifying as IMDs were recorded within the study timeframe, 27 of which (90%; 22 new onset, 4 relapses) occurred after COVID-19 vaccination. These comprised 12 cases of GCA, four of PMR (one relapse), three of necrotizing myositis or acute rhabdomyolysis, three of systemic vasculitis (one EGPA, two SHP), two of ITP, and one each of relapsed rheumatoid arthritis, relapsed AOSD, and PL7-positive anti-synthetase syndrome with interstitial lung disease (ILD). Three other vaccine-induced IMDs were diagnosed within the study timeframe—two cases of GCA following seasonal influenza vaccination and a PMR following a second pneumococcal vaccination. Table 1 summarizes the demographics, diagnoses, COVID-19 vaccines, treatments, and outcomes of the patients. The patients' mean age was 67 years (50–90 years), and 15 (56%) were women. The causative vaccines were ChAdOx1 (Vaxzevria[®], AstraZeneca, Oxford, UK), BNT162b2 (Comirnaty[®], Pfizer-BioNTech, New York, NY, USA), and mRNA-1273 (Spikevax[®], Moderna, Cambridge, MA, USA) in 7, 18, and 2 patients, respectively. The IMD started after a first vaccine dose in 14 patients (52%), a second dose in seven patients (26%), and a third (booster) dose in six patients (22%). All three patients with acute IMNM, or rhabdomyolysis, had a negative or normal workup including serologic tests for HIV, herpes viruses, HTLV1 + 2, hepatitis A, B, and C, EBV, CMV, parvovirus, serum protein electrophoresis, antinuclear antibody test, anti-ds-DNA, ENA panel, DOT-myositis, C3, C4, rheumatoid factor, and ANCA. They all had widespread muscle inflammation with edema on MRI and a muscle biopsy demonstrating IMNM. Of the 12 GCA cases, nine were biopsy-proven. The delay between vaccination and GCA onset averaged 6 days (2–20 days). Three patients had permanent visual loss (two at diagnosis, one during an early relapse), bilaterally in one. All but three of the patients presented with an ESR > 60 mm/h (mean 92 mm/h) and a CRP level > 7 mg/dL (mean 12.3 mg/dL). The incidence of GCA in 2021 was higher than expected even after taking account of an upward trend (Figure 1).

Precipitating/etiologic factors: A potential etiologic factor or trigger, other than COVID-19 vaccination, was detected twice. A patient on statin for 3 years without muscle problems before receiving a booster dose of BNT162b2 (Case 19), tested positive for serum anti-HMG-CoA reductase antibody. One patient (Case 9) received seasonal influenza vaccination without early side effects, and 1 week later a booster dose of BNT162b2. In this patient, the systemic GCA began 6 days after COVID-19 vaccination.

HLA-DRB1/DQB1 typing: The most frequent HLA-DRB1 alleles were DRB1*04 (eight patients) and DRB1*11 (seven patients), whereas only three patients had HLA-DRB1*01. Most HLA-DQB1 alleles were DQB1*03 (14 patients, including 12 with GCA or PMR) and DQB1*02 (7 patients) (Table 2). No patients were positive for HLA-DQB1*01. Notably, 7 of 12 (58%) GCA patients, including both familial cases, had DRB1*04 alleles. There was no significant difference in the frequencies of HLA-DRB1 alleles among GCA/PMR subsets, and HLA-DRB1*04 was the most frequent allele (54%) (Table 3).

Table 1. Data of patients with immune-mediated diseases occurring, or relapsing, following COVID-19 vaccination.

Patient	Age/Sex	Condition	Vaccine	Dose	Delay (d)	Past History, Co-Morbid Conditions	Treatment for IMDs	Re-Challenge	Outcome
1	87/F	GCA	m-RNA (Moderna)	1st	7	Osteoarthritis	Pred 30 mg/d	Yes, twice	Recovered disease (13 mo, untreated for 4 mo)
2	82/F	GCA	m-RNA (Pfizer)	1st	10	Hypertension, osteoarthritis, gastric ulcer	Pred 40 mg/d	Yes, twice	Controlled disease (14 mo, Pred 3 mg/d)
3	70/F	GCA	viral vector (AstraZeneca)	1st	2	Diabetes, hypertension, hypercholesterolemia, gouty disease	Pred 40 mg/d, 2nd line Tocilizumab	No (declined)	Controlled disease (13 mo, Pred 7 mg/d)
4	90/F	GCA	m-RNA (Pfizer)	1st	3	MDS (5q-), past PMR, hypertension	MP 500 mg/d × 2, Pred 50 mg/d	Yes, once	Early lost to follow-up
5	80/M	GCA	m-RNA (Moderna)	2nd	3	None	MP 500 mg/d × 3, Pred 75 mg/d, 2nd line Tocilizumab	No (declined)	Relapsed disease (7 mo, Pred 15 mg/d)
6	65/F	GCA	m-RNA (Pfizer)	1st	3	Hypertension	Pred 50 mg/d	Yes, twice	Controlled disease (10 mo, Pred 6 mg/d)
7	59/F	GCA	m-RNA (Pfizer)	1st	4	Autoimmune neutropenia, breast carcinoma	Pred 60 mg/d, 2nd Tocilizumab	No (declined)	Multiple relapses upon short tapering Pred regimen (12 mo)
8	68/M	PMR, then GCA	viral vector (AstraZeneca)	2nd	20	Duodenal ulcer	Pred 50 mg/d	n.a.	Controlled disease (5 mo, Pred 10 mg/d)
9	64/M	GCA	m-RNA (Pfizer)	3rd	6	Familial aggregation (GCA in sister)	MP 500 mg/d × 3, Pred 80 mg/d, Tocilizumab	n.a.	Controlled disease (3 mo, Pred 20 mg/d)
10	72/M	GCA	m-RNA (Pfizer)	3rd	5	Hypertension, diabetes, hypercholesterolemia	Pred 60 mg/d	n.a.	n.a. (recently diagnosed)
11	72/M	GCA (aortitis)	m-RNA (Pfizer)	3rd	1	Kidney stones	Pred 50 mg/d	n.a.	n.a. (recently diagnosed)
12	69/M	GCA	m-RNA (Pfizer)	3rd	2	Hypercholesterolemia	Pred 50 mg/d	n.a.	n.a. (recently diagnosed)
13	62/F	PMR	m-RNA (Pfizer)	2nd	6	Discogenic sciatica	Pred 30 mg/d, 2nd line Tocilizumab	Yes, once (Moderna)	Relapsed disease (7 mo, Pred 9 mg/d)
14	58/M	PMR	m-RNA (Pfizer)	2nd	2	Hypertension, obesity, pheochromocytoma, sleep apnea	Pred 40 mg/d	No (declined)	Controlled disease (9 mo, Pred 4 mg/d)
15	69/F	PMR	m-RNA (Pfizer)	1st	14	Hypertension, osteoarthritis, depression	Pred 20 mg/d	Yes, once (3rd dose planned)	Controlled disease (6 mo, Pred 5 mg/d)
16	77/M	PMR (late relapse)	m-RNA (Pfizer)	2nd	10	Hypertension, diabetes, prostatic carcinoma	Pred 20 mg/d	Yes (third dose)	Controlled disease (8 mo, Pred stopped for 2 mo)
17	64/M	AR	viral vector (AstraZeneca)	1st	13	Thyroid insufficiency, hypertriglyceridemia	MP 1 g/d × 3, Pred 2 mg/d, MTX, IVIG, CPM	No (prohibited)	Died of uncontrolled disease (2 mo)
18	59/F	IMNM	viral vector (AstraZeneca)	1st	11	Osteoarthritis	MP 1 g/d × 3 + IVIG, Pred 60 mg/d	No (declined)	Recovered (13 mo, no treatment for 12 mo)
19	62/M	IMNM	m-RNA (Pfizer)	3rd	7	Hypertension, sleep apnea, nocardiosis, benign ampulloma	Pred 80 mg/d, IVIgG	n.a.	Satisfactory short-term response
20	57/F	AAV (EGPA)	viral vector (AstraZeneca)	1st	14	Allergic asthma	MP 1 g/d × 3, Pred 70 mg/d, RTX	Yes (twice, m-RNA based)	Limited disease relapse (11 mo, pred 5 mg/d + RTX 500 mg every 6 mo)
21	50/F	SHP (late relapse)	m-RNA (Pfizer)	1st	2	Pediatric SHP	Colchicine, pregabalin	Yes, twice	Relapsed disease (10 mo, upon colchicine discontinuation)

Table 1. Cont.

Patient	Age/Sex	Condition	Vaccine	Dose	Delay (d)	Past History, Co-Morbid Conditions	Treatment for IMDs	Re-Challenge	Outcome
22	53/M	SHP (digestive involvement)	m-RNA (Pfizer)	1st	8	None	MP 1000 Mg/d × 4, Pred 80 mg/d, colchicine	No (declined)	Controlled disease (12 mo, Pred 2.5 mg/d + colchicine)
23	61/F	Anti-synthetase (PL7+)	m-RNA (Pfizer)	2nd	4	Hypothyroidism	Pred, 60 mg/d, 2nd line tacrolimus	n.a.	Poorly controlled disease (5 mo, Pred 15 mg/d)
24	69/F	AOSD relapse	m-RNA (Pfizer)	3rd	14	Hypertension	Pred 20 mg/d, oral methotrexate	n.a.	Relapsed disease (4 mo, pred 10 mg/d, methotrexate resumed)
25	73/F	IITP	viral vector (AstraZeneca)	1st	14	Hypertension, hypercholesterolemia, COPD, atherosclerotic peripheral disease	Dex 40 mg/d × 4, Pred 60 mg/d	Yes, twice (m-RNA based)	Recovered disease (11 mo)
26	71/M	IITP	viral vector (AstraZeneca)	1st	4	Sleep apnea, psoriasis, benign prostatic hypertrophy	Dex 40 mg/d × 4, Pred 70 mg/d, TRA	No (declined)	Failure-partial control under TRA (11 mo)
27	57/F	RA (late relapse)	m-RNA (Pfizer)		2	Sleep apnea	methotrexate	n.a.	n.a. (recently diagnosed)

GCA, giant cell arteritis. AR, acute rhabdomyolysis. IMNM, immune-mediated necrotizing myopathy. AAV, ANCA-associated (systemic) vasculitis. EGPA, eosinophilic granulomatosis with polyangiitis. SHP, Schönlein-Henoch purpura. AOSD, adult-onset Still's disease. RA, rheumatoid arthritis. IITP, immunologic (idiopathic) thrombocytopenic purpura. MDS, myelodysplastic syndrome. PMR, polymyalgia rheumatica. BPH, benign prostatic hypertrophy. COPD, chronic obstructive pulmonary disease. Pred, prednisone. MP, methylprednisolone (pulse high dose). MTX, methotrexate. IVIG, intravenous immunoglobulins. CPM, cyclophosphamide. Dex, dexamethasone. TRA, thrombopoietin receptor agonist.

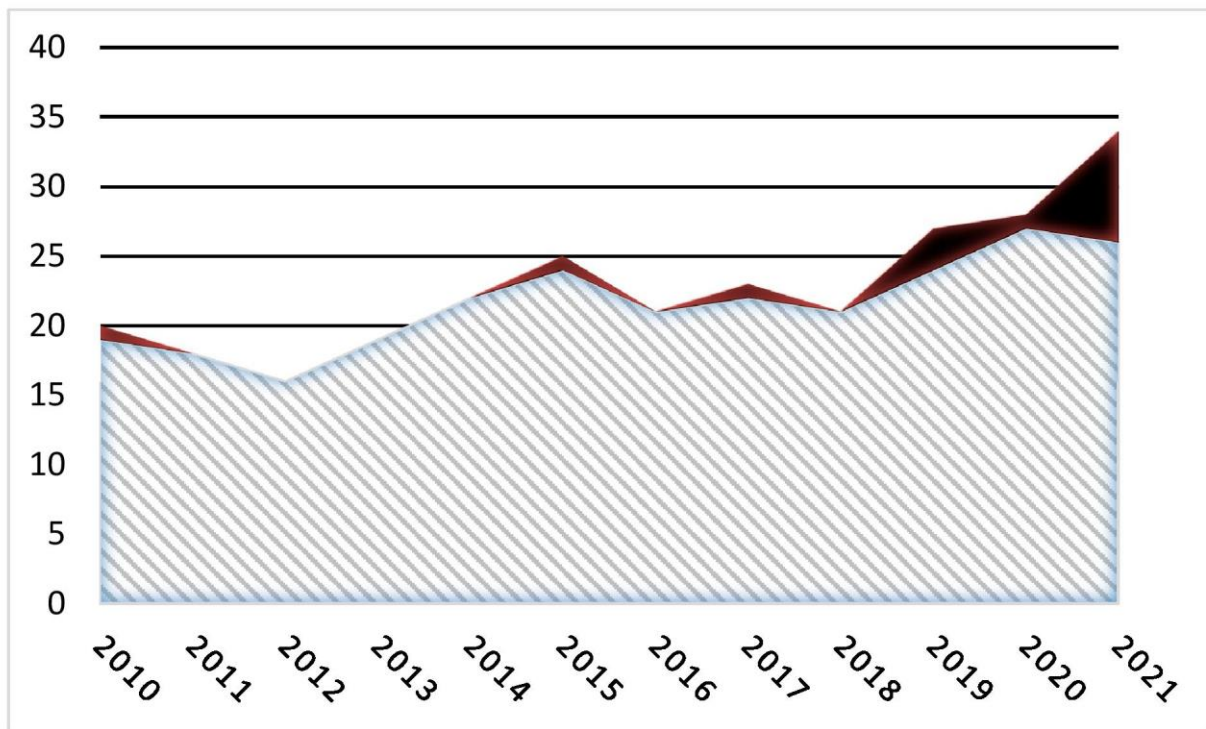


Figure 1. Numbers of patients with newly diagnosed GCA, including usual GCA and post-vaccine GCA, from 1 January 2010 to 31 December 2021. Gray shading, numbers of typical (e.g., without a vaccine trigger) GCA cases; black, post-vaccine cases.

Table 2. DQB1 typing of 20 patients with post-COVID-19 vaccine IMDs.

Patient	Diagnosis	HLA DRB1/DQB1 Typing
Case 1	GCA	DRB1*04:02/*08:01; DQB1*03:02/*04:02
Case 2	GCA	DRB1*07:01/*11:04; DQB1*02:02/*03:01
Case 3	GCA	DRB1*07:01/*07:01; DQB1*02:01/*02:02
Case 5	GCA	DRB1*03/*04; DQB1*02/*03
Case 6	GCA	DRB1*04:04/*11:01; DQB1*03:01/*03:02
Case 7	GCA	DRB1*04:01/*15:01; DQB1*03:01/*06:02
Case 8	GCA	DRB1*04:03/*15:02; DQB1*03:02/*06:01
Case 9	GCA	DRB1*03:01/*04:01; DQB1*02:01/*03:01
Case 10	GCA	DRB1*07:01/*13:01; DQB1*02:01/*06:03
Case 11	GCA	DRB1*04:02/*15:01; DQB1*03:02/*06:02
Case 12	GCA	DRB1*01:02/*11:02; DQB1*03:01/*05:01
Case 13	PMR	DRB1*03/*12; DQB1*02/*03
Case 14	PMR	DRB1*11:01/*16:01; DQB1*03:01/*05:02
Case 16	PMR	DRB1*13/*14; DQB1*03/*05
Case 17	AR	DRB1*07:01/*08:01/DQB1*02:02/*04:02
Case 18	IMNM	DRB1*11:04/*16:01; DQB1*03:01/*05:02
Case 19	IMNM	DRB1*04:01/*11:01; DQB1*-/
Case 23	ASS (PL7+)	DRB1*01:01/*17:01; DQB1*02:02/*05:01
Case 24	SHP	DRB1*07:01/*11:04; DQB1*03:01/*06:01
Case 27	RA	DRB1*01:01/*13:01; DQB1*05:01/*06:01

GCA, giant cell arteritis. PMR, polymyalgia rheumatica. AR., acute rhabdomyolysis. ASS, antisyntetase syndrome. SHP, Schönlein-Henoch purpura. RA, rheumatoid arthritis.

Table 3. Typing in 58 patients—50 with GCA and 8 with PMR, under various circumstances of onset.

HLA-DRB1 Allele	Post-COVID-19 Vaccine Cases N = 14 n (%) *	Post-Other-Vaccine Cases N = 11 n (%) †	Familial Cases N = 17 n (%) §	Other Cases N = 16 n (%) ¶	p-Value ¶¶
DRB1*01	1 (7)	2 (18)	0 (0)	2 (12.5)	0.30
DRB1*03	3 (21)	2 (18)	1 (6)	2 (12.5)	0.63
DRB1*04	7 (50)	4 (36)	10 (59)	10 (62.5)	0.58
DRB1*07	3 (21)	3 (27)	7 (41)	4 (25)	0.68
DRB1*08	1 (7)	1 (9)	0 (0)	0 (0)	0.34
DRB1*09	0 (0)	1 (9)	0 (0)	0 (0)	0.19
DRB1*10	0 (0)	1 (9)	0 (0)	0 (0)	0.19
DRB1*11	5 (36)	2 (18)	5 (29)	4 (25)	0.83
DRB1*12	1 (7)	0 (0)	0 (0)	0 (0)	0.43
DRB1*13	2 (14)	5 (45)	5 (31)	5 (31)	0.40
DRB1*15	3 (21)	1 (9)	4 (23.5)	3 (19)	0.86
DRB1*16	1 (7)	0 (0)	0 (0)	0 (0)	0.43

* Eleven GCA and three PMR. † Seven GCA and four PMR. § Sixteen GCA and one PMR. ¶ GCA only. ¶¶ Post-COVID vaccine cases vs. post-other-vaccine cases vs. familial cases vs. other cases.

Treatments and outcomes: De-challenge (i.e., spontaneous remission or short-lived treatment without relapse) was demonstrated in three patients—two with IMNM (Cases 18 and 19) and one with ITP (Case 25). All but one of the patients (minor relapse of childhood-onset HSP) received first-line, often high-dose, glucocorticoid treatment, and 13 (50%) underwent additional treatments. All the GCA patients received high-dose glucocorticoid treatment, and most are currently undergoing tapering. One patient achieved remission after a 9-month prednisone course. Additional weekly subcutaneous tocilizumab was required for five GCA or PMR patients. One patient died from intractable rhabdomyolysis, despite intensive immunosuppressive treatment, whereas four patients (15%) had permanent damage from GCA (bilateral blindness), EGPA (bilateral median nerve palsy), or antisyndetase syndrome (restrictive lung disease). Twelve of sixteen eligible patients agreed to complete their COVID-19 vaccination during a quiescent phase of IMD, among whom 11 did so (crossover with an mRNA-based vaccine for two patients). Only two re-challenged patients experienced a disease flare—one GCA patient (Case 1) who reported a self-limited episode of polymyalgia rheumatica after the second vaccination and the patient with EGPA (Case 20), who experienced a mild flare of multiple mononeuropathy 3 days following a fourth mRNA-based (mRNA-1273, Moderna®) vaccine dose.

4. Discussion

4.1. Relationship between COVID-19 Vaccines and Subsequent IMDs

Vaccine-induced IMDs—including GCA, PMR, IMNM, AAV, HSP, AOSD, and ITP—have long been described but are rare [8–13]. We report herein a series of incident cases of IMDs following COVID-19 vaccination, recruited in the Internal Medicine Department of our University Hospital during the period of widespread vaccination. Some other trigger was present only in two patients. In these two patients (GCA, IMNM), the first symptoms of IMD occurred less than 1 week after COVID-19 vaccination. A causative relationship between vaccination and subsequent IMD is conjectural in the 27 patients, although re-challenge in two patients (Cases 1 and 20) resulted in a limited disease flare, reinforcing the hypothesis of a causal relationship between COVID-19 vaccination and GCA. The nine other re-challenged patients completed their vaccination schedule, up to two additional shots, without experiencing disease relapse. Significantly, re-vaccination was attempted during a quiescent phase of treated illness in these patients, which may have prevented them from disease flare-up. The patient with AOSD (Case 24) received her first two vaccine shots during treatment with low-dose methotrexate, without harm, and the offending booster shot while untreated for 4 months. Finally, de-challenge was rare (i.e., one in eight patients). Therefore, a causal relationship between COVID-19 vaccination and subsequent IMDs is not supported by our data. Nevertheless, the strong temporal relationship between the two events raises legitimate safety concerns about COVID-19 vaccines in these patients.

4.2. Incidence of IMDs after COVID-19 Vaccination

Although the regional IMD incidence following COVID-19 vaccination could not be calculated from our hospital-based recruitment, it might be not negligible, especially in individuals over 50 years of age. In a study of neurological IMDs occurring within 4 weeks of SARS-CoV-2 vaccination, the population-based incidence was 1/11,000 [16]. These data do not challenge the validity of vaccination programs against SARS-CoV-2 in 2021, in view of the great severity of the disease. However, the relatively frequent occurrence and potential seriousness of vaccine-induced IMDs warrant the implementation of customized vaccination policies if the disease becomes more benign.

4.3. Types of Incriminated COVID-19 Vaccines

The three types of available COVID-19 vaccines were implicated in IMDs. The higher frequency of BNT162b2-induced IMDs reflects the predominant use of this vaccine in 2021 in France. This is consistent with other case series [14–17], although other conditions, such as cerebral venous thrombosis and optic neuropathy reported to occur following COVID-19 vaccination have been markedly associated with the use of a specific vaccine [24,25]. Conversely, mRNA vaccines have inherent adjuvant properties that might have induced more adverse immune effects by generating Th17 inflammatory responses [26–28]. Finally, this and other studies indicate that IMDs can emerge at a variety of time points during vaccination schedules, typically after the first dose.

4.4. Patient's Age of Onset and Gender

We found a slight female predominance (56%), and patients were mostly middle-aged or older. In the study by Watad et al., 15 of 27 (56%) patients were female and the mean age was 53 years (20–83 years) [14]. In the study by Kaulen et al., patients were mostly females (ratio 3.2:1) and had a median age of 50 years [16]. In a report on 19 immune-mediated events temporally associated with COVID-9 vaccination, only four patients (21%) were <50 years of age [15]. Regarding medical history, most (89%) patients in this study had new-onset IMDs, in agreement with other investigators [15–17], but not with the report by Watad et al., in which most COVID-19 vaccine-induced IMDs were flares of an underlying autoimmune or rheumatic disease [14]. Different settings, types of recruitment, and study designs may best explain the age-and-sex disparities among case series.

4.5. COVID-19 Vaccine-Induced Giant Cell Arteritis or Polymyalgia Rheumatica

GCA/PMR was the main vaccine-related subset of IMDs, accounting for 59% of the cases. Notably, GCA represented 44% of the cases and 23% (11 of 47) of all new GCA cases in the Internal Medicine Department over the 17-month study. Including a patient with GCA following influenza vaccination, the proportion of post-vaccine GCA was 21% (e.g., 7 of 34 patients) in 2021, contrasting sharply with a mean of 3% annually for the previous decade. There are two explanations for this unexpectedly high proportion of post-vaccine GCA cases. First, awareness of the condition is increased [9], prompting inquiries during history taking. Second, mass COVID-19 vaccination of the regional older adult population not only increased the likelihood of a chance temporal association but also exposed a large number of at-risk subjects to the trigger. Other cases of GCA [16,25,29–34] or PMR [17,35,36] temporally associated with COVID-19 vaccination have been published, suggesting the association to be not casual and that post-vaccine onset of GCA/PMR is not an exceptional occurrence [9].

4.6. Other Types of COVID-19 Vaccine-Induced Vasculitis

In contrast to GCA/PMR, other vasculitides represented only 11% of COVID-19 vaccine-induced IMDs. Although vaccination is a known trigger of vasculitis [11], the most recent literature implicates COVID-19 vaccination, mostly in the form of case reports covering the whole spectrum of vasculitides, with heterogeneous clinical presentations and variable severities [37–43]. New-onset or relapsing ANCA-associated necrotizing

vasculitides [37–41] or HSP [42,43] have been described. Significantly, a recent study using the WHO global safety database (Vigibase) found increased reporting of Behçet’s syndrome, microscopic polyangiitis, livedoid vasculopathy, and urticarial vasculitis following COVID-19 mRNA vaccination [44]. Whether this finding also applies to viral vector-based COVID-19 vaccines warrants further investigation.

4.7. COVID-19 Vaccine-Induced Immune-Mediated Necrotizing Myopathy or Acute Rhabdomyolysis

Immune-mediated necrotizing myopathy/rhabdomyolysis comprised 11% of the cases. A booster effect of COVID-19 vaccination on an underlying, silent, statin-induced IMNM in the patient positive for anti-HMG-CoA reductase antibody cannot be excluded. Other cases of inflammatory myositis or acute rhabdomyolysis of variable severity following SARS-CoV-2 vaccination have been reported [16,45–51]. Disease severity in the patients with acute muscle disorders ranged from a self-limited illness to a rapidly fatal rhabdomyolysis, despite intensive immunosuppressive therapy [46,50,51]. The relative paucity of reports of inflammatory myositis or acute rhabdomyolysis during the worldwide COVID-19 vaccination campaign is in line with the claim of no significant increase in the incidence of dermatomyositis or polymyositis following vaccinations of any type [52].

4.8. COVID-19 Vaccine-Induced Miscellaneous IMDs

Other IMDs in this study were miscellaneous, pointing to a ubiquitous mechanism of immune-response enhancement. Cases of ILD [53,54], RA [55,56], AOSD [57,58], and ITP [59,60] following COVID-19 vaccination have been reported, supporting the hypothesis of a causative link rather than a casual association. Interrogation of the French Pharmacovigilance Network yielded 123 ITP cases, the corresponding rate of de novo or relapsed reports per million COVID-19 vaccine doses being 1.69 (95% CI 1.42–201). In this study, the rate was highest with ChAdOx1-S, particularly after the first dose (60), whereas a previous study using the Vaccine Adverse Event Reporting System (VAERS) described 77 de novo ITPs, all after mRNA-based vaccines [59]. Our finding of two de novo ITPs but no severe relapse of a preexisting ITP is in agreement with previous reports that the latter is infrequent [59,60].

4.9. HLA-DR/DQ and COVID-19 Vaccine-Induced IMDs

The results of HLA-DRB1 typing in post-COVID vaccine IMDs did not yield a noticeable pattern, except for a high rate of DRB1*04 (54%) in GCA patients. We also observed a strong predominance, of unknown significance, of DQB1*03. Furthermore, the distribution of HLA-DRB1 alleles did not differ significantly among GCA/PMR subsets (e.g., post-COVID vaccine cases; post-influenza, or pneumococcal, vaccine cases; familial cases; typical cases). The origin of GCA is unknown but genetic and environmental factors are implicated [61]. Interestingly, in our inception GCA cohort, familial aggregation of GCA was detected in 2 of 12 (17%) patients with post-COVID-19 GCA and 4 of 13 (31%) patients with post-influenza or pneumococcal vaccine, but only 15 of 388 (4%) patients without a vaccine trigger. HLA-DRB1*04 is the main genetic determinant of GCA [62] and a risk factor for ASIA [8,63]. From our observations, unadjuvanted vaccines such as the currently marketed SARS-CoV-2 vaccines can induce GCA/PMR by acting as non-specific triggers in genetically predisposed subjects (notably those with HLA-DRB1*04) possibly by strongly activating Toll-like receptor signaling [64]. Nevertheless, a global pharmacovigilance study showed a lower relative risk of GCA or PMR following COVID-19 compared to influenza vaccination [65], consistent with the hypothesis that classical adjuvant-containing vaccines have a greater risk. Indeed, HLA-DRB1*01 was found only once, and no patient carried HLA-DQB1*01; both alleles are associated with ASIA [9,63]. The mixed HLA results highlight, therefore, the complex mechanisms underlying post-COVID vaccine IMDs.

4.10. Disease Severity in COVID-19 Vaccine-Induced IMDs

The severity of vaccine-induced IMDs is a concern. Contrasting with the favorable prognosis of patients in prior case series [14–17] and a recent review of post-COVID vaccination syndromes [66], in this study, few IMDs were self-limited and benign. On the contrary, 24% of the IMDs were complicated and most patients required prolonged glucocorticoid treatment, in combination with additional immunosuppressive or immunomodulatory agents in 40% of the cases. Post-COVID-19 vaccine IMDs can, therefore, be serious. Moreover, occurrence, or flare-up, of an IMD during the course of vaccination against COVID-19 can be diagnostically challenging, especially when the disease manifests as systemic symptoms such as fatigue, headache, and musculoskeletal pain soon after vaccination. Such a pattern of IMD onset can easily be mistaken for typical systemic adverse effects of vaccination, potentially delaying diagnosis.

4.11. Revaccination against COVID-19 after COVID-19 Vaccine-Induced IMDs

Revaccination against COVID-19 was acceptable. Indeed, 11 consenting patients were re-challenged with the same, or an alternate, vaccine, up to three additional shots, without significant harm in nine patients. However, the safety of re-challenging patients who experienced a COVID-19-induced IMD, and the optimal timing of re-challenge, warrants further research.

4.12. Limitations of the Study

This study has limitations that should be noted. The study design (hospital-based) precluded any calculation of the incidence of IMDs following COVID-19 vaccine. The association of COVID-19 vaccination with IMDs included may have been a result of chance, based on the small sample size and lack of evidence of a causal association [67]. In particular, de-challenge (i.e., evidence that the adverse event diminished, as would be expected if caused by the vaccine) was seen in only three cases, and re-challenge seldom resulted in disease relapse. Conversely, we performed the first teaching hospital, department-based study including all IMDs encountered during the period of mass vaccination, with exclusion of other causes, and extended follow-up. Moreover, this study is the first to address the relationship between COVID-19 vaccine-induced IMDs, especially GCA/PMR, and HLA-DR/DQ.

5. Conclusions

Our findings indicate that adults over 50 years of age may develop an IMD following COVID-19 vaccination. However, confirmation by other large-scale studies, especially focusing on the mass COVID-19 vaccination period, is warranted. We emphasize that such IMDs are rare and do not call into question the benefit of COVID-19 vaccination, which is overall safe and effective. By contrast, early revaccination after post-vaccine IMDs should be considered on an individual basis, according to disease severity, disease control, and patient acceptance. Finally, early re-challenge with a COVID-19 vaccine in patients with controlled IMDs is feasible.

Author Contributions: Methodology, E.L., S.P. and A.-L.F.; validation, M.F.; formal analysis, E.L.; investigation, E.L., S.P., G.G., H.B. and K.-H.L.; data curation, E.L.; writing—original draft, E.L.; writing—review and editing, M.F., S.P., G.G., H.B., K.-H.L. and A.-L.F. All authors have read and agreed to the published version of the manuscript.

Funding: This research received no external funding.

Institutional Review Board Statement: This study was conducted in compliance with good clinical practices and the principles of the Declaration of Helsinki. In accordance with French law, formal approval from an ethics committee was not required for this type of retrospective study. The research has the approval of the local ethics committee (EUDRACT: 2010-A00091-38).

Informed Consent Statement: All data concerning patients were retrospectively collected. The patients followed at the University Hospital of Limoges are informed of the use of the data in the medical file as soon as they are admitted, and the patients included are not declared opposed to the research to the Data Protection Officer (DPO). Written consent for HLA-DRB1/DQB1 genotyping was obtained from all assessed patients.

Data Availability Statement: Data is contained within the article.

Conflicts of Interest: The authors declare no conflict of interest.

References


- Polack, F.P.; Thomas, S.J.; Kitchin, N.; Absalon, J.; Gurtman, A.; Lockhart, S.; Perez, J.L.; Pérez Marc, G.; Moreira, E.D.; Zerbini, C.; et al. Safety and efficacy of the BNT162b2 mRNA COVID-19 vaccine. *N. Engl. J. Med.* **2020**, *383*, 2603–2615. [[CrossRef](#)] [[PubMed](#)]
- Baden, L.R.; El Sahly, H.M.; Essink, B.; Kotloff, K.; Frey, S.; Novak, R.; Diemert, D.; Spector, S.A.; Rouphael, N.; Creech, C.B.; et al. Efficacy and safety of the mRNA-1273 SARS-CoV-2 vaccine. *N. Engl. J. Med.* **2021**, *384*, 403–416. [[CrossRef](#)] [[PubMed](#)]
- Falsey, A.R.; Sobieszczyk, M.E.; Hirsch, I.; Sproule, S.; Robb, M.L.; Corey, L.; Neuzil, K.M.; Hahn, W.; Hunt, J.; Mulligan, M.J.; et al. Phase 3 Safety and Efficacy of AZD1222 (ChAdOx1 nCoV-19) COVID-19 Vaccine. *N. Engl. J. Med.* **2021**, *385*, 2348–2360. [[CrossRef](#)] [[PubMed](#)]
- Connolly, C.M.; Ruddy, J.A.; Boyarsky, B.J.; Avery, R.K.; Werbel, W.A.; Segev, D.L.; Garonzik-Wang, J.; Paik, J.J. Safety of the first dose of mRNA SARS-CoV-2 vaccines in patients with rheumatic and musculoskeletal diseases. *Ann. Rheum. Dis.* **2021**, *80*, 1100–1101. [[CrossRef](#)] [[PubMed](#)]
- Furer, V.; Eviatar, T.; Zisman, D.; Peleg, H.; Paran, D.; Levartovsky, D.; Zisapel, M.; Elalouf, O.; Kaufman, I.; Meidan, R.; et al. Immunogenicity and safety of the BNT162b2 mRNA COVID-19 vaccine in adult patients with autoimmune inflammatory rheumatic diseases and in the general population: A multicentre study. *Ann. Rheum. Dis.* **2021**, *80*, 1330–1338. [[CrossRef](#)]
- Pavord, S.; Scully, M.; Hunt, B.J.; Lester, W.; Bagot, C.; Craven, B.; Rampotas, A.; Ambler, G.; Makris, M. Clinical Features of Vaccine-Induced Immune Thrombocytopenia and Thrombosis. *N. Engl. J. Med.* **2021**, *385*, 1680–1689. [[CrossRef](#)]
- Guimarães, L.E.; Baker, B.; Perricone, C.; Shoenfeld, Y. Vaccines, adjuvants and autoimmunity. *Pharmacol. Res.* **2015**, *100*, 190–209. [[CrossRef](#)]
- Perricone, C.; Colafrancesco, S.; Mazor, R.D.; Soriano, A.; Agmon-Levin, N.; Shoenfeld, Y. Autoimmune/inflammatory syndrome induced by adjuvants (ASIA) 2013: Unveiling the pathogenic, clinical and diagnostic aspects. *J. Autoimmun.* **2013**, *47*, 1–16. [[CrossRef](#)]
- Liozon, E.; Parreau, S.; Filloux, M.; Dumonteil, S.; Gondran, G.; Bezanahary, H.; Ly, K.; Fauchais, A.L. Giant cell arteritis or polymyalgia rheumatica after influenza vaccination: A study of 12 patients and a literature review. *Autoimmun. Rev.* **2020**, *20*, 102732. [[CrossRef](#)]
- Iyngkaran, P.; Limaye, V.; Hill, C.; Henderson, D.; Pile, K.D.; Rischmueller, M. Rheumatoid vasculitis following influenza vaccination. *Rheumatology* **2003**, *42*, 907–909. [[CrossRef](#)]
- Bonetto, C.; Trotta, F.; Felicetti, P.; Alarcón, G.S.; Santuccio, C.; Bachtiar, N.S.; Pernus, Y.B.; Chandler, R.; Girolomoni, G.; Hadden, R.D.; et al. Vasculitis as an adverse event following immunization—Systematic literature review. *Vaccine* **2016**, *34*, 6641–6651. [[CrossRef](#)] [[PubMed](#)]
- Stübgen, J.-P. A review on the association between inflammatory myopathies and vaccination. *Autoimmun. Rev.* **2014**, *13*, 31–39. [[CrossRef](#)] [[PubMed](#)]
- Perricone, C.; Ceccarelli, F.; Neshet, G.; Borella, E.; Odeh, Q.; Conti, F.; Shoenfeld, Y.; Valesini, G. Immune thrombocytopenic purpura (ITP) associated with vaccinations: A review of reported cases. *Immunol. Res.* **2014**, *60*, 226–235. [[CrossRef](#)] [[PubMed](#)]
- Watad, A.; De Marco, G.; Mahajna, H.; Druyan, A.; Eltity, M.; Hijazi, N.; Haddad, A.; Elias, M.; Zisman, D.; Naffaa, M.; et al. Immune-Mediated Disease Flares or New-Onset Disease in 27 Subjects Following mRNA/DNA SARS-CoV-2 Vaccination. *Vaccines* **2021**, *9*, 435. [[CrossRef](#)]
- Hočevar, A.; Tomšič, M. Immune mediated events timely associated with COVID-19 vaccine. A comment on article by Badier; et al.: “IgA vasculitis in adult patients following vaccination by ChadOx1 nCoV-19”. *Autoimmun. Rev.* **2021**, *21*, 102989. [[CrossRef](#)]
- Kaulen, L.D.; Doubrovinskaia, S.; Mooshage, C.; Jordan, B.; Purrucker, J.; Haubner, C.; Seliger, C.; Lorenz, H.; Nagel, S.; Wildemann, B.; et al. Neurological autoimmune diseases following vaccinations against SARS-CoV-2: A case series. *Eur. J. Neurol.* **2021**, *29*, 555–563. [[CrossRef](#)]
- Ottaviani, S.; Juge, P.-A.; Forien, M.; Ebstein, E.; Palazzo, E.; Dieudé, P. Polymyalgia rheumatica following COVID-19 vaccination: A case-series of ten patients. *Jt. Bone Spine* **2021**, *89*, 105334. [[CrossRef](#)]
- Hunder, G.G.; Bloch, D.A.; Michel, B.A.; Stevens, M.B.; Arend, W.P.; Calabrese, L.H.; Edworthy, S.M.; Fauci, A.S.; Leavitt, R.Y.; Lie, J.T.; et al. The American College of Rheumatology 1990 criteria for the classification of giant cell arteritis. *Arthritis Rheum.* **1990**, *33*, 1122–1128. [[CrossRef](#)]
- Dasgupta, B.; Cimmino, M.A.; Maradit-Kremers, H.; Schmidt, W.A.; Schirmer, M.; Salvarani, C.; Bachta, A.; Dejaco, C.; Duftner, C.; Jensen, H.S.; et al. 2012 provisional classification criteria for polymyalgia rheumatica: A European League Against Rheumatism/American College of Rheumatology collaborative initiative. *Ann. Rheum. Dis.* **2012**, *71*, 484–492. [[CrossRef](#)]

20. Aletaha, D.; Neogi, T.; Silman, A.J.; Funovits, J.; Felson, D.T.; Bingham, C.O., III; Birnbaum, N.S.; Burmester, G.R.; Bykerk, V.P.; Cohen, M.D.; et al. 2010 Rheumatoid arthritis classification criteria: An American College of Rheumatology/European League Against Rheumatism collaborative initiative. *Arthritis Rheum.* **2010**, *62*, 2569–2581. [[CrossRef](#)]
21. Lundberg, I.E.; Tjarnlund, A.; Bottai, M.; Werth, V.P.; Pilkington, C.; de Visser, M.; Alfredsson, L.; Amato, A.A.; Barohn, R.J.; Liang, M.H.; et al. EULAR/ACR classification criteria for adult and juvenile idiopathic inflammatory myopathies and their major subgroups. *Ann. Rheum. Dis.* **2017**, *76*, 1955–1964. [[CrossRef](#)] [[PubMed](#)]
22. Yamaguchi, M.; Ohta, A.; Tsunematsu, T.; Kasukawa, R.; Mizushima, Y.; Kashiwagi, H.; Kashiwazaki, S.; Tanimoto, K.; Matsumoto, Y.; Ota, T. Preliminary criteria for classification of adult Still's disease. *J. Rheumatol.* **1992**, *19*, 424–430. [[PubMed](#)]
23. Mills, J.A.; Michel, B.A.; Bloch, D.A.; Calabrese, L.H.; Hunder, G.G.; Arend, W.P.; Edworthy, S.M.; Fauci, A.S.; Leavitt, R.Y.; Lie, J.T.; et al. The American College of Rheumatology 1990 criteria for the classification of henoch-schönlein purpura. *Arthritis Rheum.* **1990**, *33*, 1114–1121. [[CrossRef](#)]
24. Schulz, J.B.; Berlit, P.; Diener, H.-C.; Gerloff, C.; Greinacher, A.; Klein, C.; Petzold, G.C.; Piccininni, M.; Poli, S.; Röhrig, R.; et al. COVID-19 Vaccine-Associated Cerebral Venous Thrombosis in Germany. *Ann. Neurol.* **2021**, *90*, 627–639. [[CrossRef](#)] [[PubMed](#)]
25. Elnahry, A.G.; Al-Nawafih, M.Y.; Eldin, A.A.G.; Solyman, O.; Sallam, A.B.; Phillips, P.H.; Elhusseiny, A.M. COVID-19 Vaccine-Associated Optic Neuropathy: A Systematic Review of 45 Patients. *Vaccines* **2022**, *10*, 1758. [[CrossRef](#)]
26. Echaide, M.; Labiano, I.; Delgado, M.; de Lascoiti, A.F.; Ochoa, P.; Garnica, M.; Ramos, P.; Chocarro, L.; Fernández, L.; Arasan, H.; et al. Immune Profiling Uncovers Memory T-Cell Responses with a Th17 Signature in Cancer Patients with Previous SARS-CoV-2 Infection Followed by mRNA Vaccination. *Cancers* **2022**, *14*, 4464. [[CrossRef](#)]
27. Hotez, P.J.; Bottazzi, M.E.; Corry, D.B. The potential role of Th17 immune responses in coronavirus immunopathology and vaccine-induced immune enhancement. *Microbes Infect.* **2020**, *22*, 165–167. [[CrossRef](#)]
28. Huang, Y.-W.; Tsai, T.-F. Exacerbation of Psoriasis Following COVID-19 Vaccination: Report from a Single Center. *Front. Med.* **2021**, *8*, 812010. [[CrossRef](#)]
29. Mejren, A.; Sørensen, C.; Gormsen, L.; Tougaard, R.; Nielsen, B. Large-vessel giant cell arteritis after COVID-19 vaccine. *Scand. J. Rheumatol.* **2021**, *51*, 154–155. [[CrossRef](#)]
30. Cadiou, S.; Perdriger, A.; Ardois, S.; Albert, J.D.; Berthoud, O.; Lescoat, A.; Guggenbuhl, P.; Robin, F. SARS-CoV-2, polymyalgia rheumatica and giant cell arteritis: COVID19 vaccine shot as a trigger? Comments on “Can SARS-CoV-2 trigger relapse of polymyalgia rheumatica?” by Manzo et al. *Joint Bone Spine* **2021**;88:105150. *Jt. Bone Spine* **2022**, *89*, 105282. [[CrossRef](#)]
31. Sauret, A.; Stievenart, J.; Smets, P.; Olagne, L.; Guelon, B.; Aumaitre, O.; André, M.; Trefond, L. Case of giant cell arteritis after SARS-CoV-2 vaccination: A particular phenotype? *J. Rheumatol.* **2021**, *49*, 120. [[CrossRef](#)]
32. Gambichler, T.; Krogias, C.; Tischoff, I.; Tannapfel, A.; Gold, R.; Susok, L. Bilateral giant cell arteritis with skin necrosis following SARS-CoV-2 vaccination. *Br. J. Dermatol.* **2022**, *186*, e83. [[CrossRef](#)] [[PubMed](#)]
33. Anzola, A.M.; Trives, L.; Martínez-Barrio, J.; Pinilla, B.; Álvaro-Gracia, J.M.; Molina-Collada, J. New-onset giant cell arteritis following COVID-19 mRNA (BioNTech/Pfizer) vaccine: A double-edged sword? *Clin. Rheumatol.* **2022**, *41*, 1623–1625. [[CrossRef](#)] [[PubMed](#)]
34. Ishizuka, K.; Katayama, K.; Ohira, Y. Giant cell arteritis presenting with chronic cough and headache after BNT162b2 mRNA COVID-19 vaccination. *QJM Int. J. Med.* **2022**, *115*, 621–622. [[CrossRef](#)]
35. Vanni, E.; Ciaffi, J.; Mancarella, L.; Ursini, F. A report of conjugal polymyalgia rheumatica after SARS-CoV-2 vaccination. *Rheumatology* **2021**, *1*, 17–21.
36. Manzo, C.; Natale, M.; Castagna, A. Polymyalgia rheumatica as uncommon adverse event following immunization with COVID-19 vaccine: A case report and review of literature. *Aging Med.* **2021**, *4*, 234–238. [[CrossRef](#)]
37. Shakoor, M.T.; Birkenbach, M.P.; Lynch, M. ANCA-associated vasculitis following Pizer-BioNTech COVID-19 vaccine. *Am. J. Kidney Dis.* **2021**, *78*, 611–613. [[CrossRef](#)] [[PubMed](#)]
38. Villa, M.; Diaz-Crespo, F.; Perez de Jose, A.; Verdalles, U.; Verde, E.; Ruiz, F.A.; Acosta, A.; Mijaylova, A.; Goicoechea, M. A case of ANCA-associated vasculitis after AZD1222 (Oxford-AstraZeneca) SARS-CoV-2 vaccination: Casualty or causality? *Kidney Int.* **2021**, *100*, 937. [[CrossRef](#)]
39. Prabhakar, A.; Naidu, G.S.R.S.N.K.; Chauhan, P.; Sekar, A.; Shama, A.; Sharma, A.; Kumar, A.; Nada, R.; Rathi, M.; Kohli, H.S.; et al. ANCA-associated vasculitis following ChAdOx1 nCoV19 vaccination: Case-based review. *Rheumatol. Int.* **2022**, *42*, 749–758. [[CrossRef](#)]
40. Chan-Chung, C.; Ong, C.S.; Chan, L.L.; Tan, E.K. Eosinophilic granulomatosis with polyangiitis after COVID-19 vaccination. *QJM Int. J. Med.* **2022**, *114*, 807–809. [[CrossRef](#)]
41. Ibrahim, H.; Alkhatib, A.; Meysami, A. Eosinophilic Granulomatosis with Polyangiitis Diagnosed in an Elderly Female After the Second Dose of mRNA Vaccine Against COVID-19. *Cureus* **2022**, *14*, e21176. [[CrossRef](#)] [[PubMed](#)]
42. Choi, Y.; Lee, C.H.; Kim, K.M.; Yoo, W.-H. Sudden Onset of IgA Vasculitis Affecting Vital Organs in Adult Patients following SARS-CoV-2 Vaccines. *Vaccines* **2022**, *10*, 923. [[CrossRef](#)]
43. Badier, L.; Toledano, A.; Porel, T.; Dumond, S.; Jouglan, J.; Sailler, L.; Bagheri, H.; Moulis, G.; Lafaurie, M. IgA vasculitis in adult patient following vaccination by ChadOx1 nCoV-19. *Autoimmun. Rev.* **2021**, *20*, 102951. [[CrossRef](#)] [[PubMed](#)]
44. Mettler, C.; Terrier, B.; Treluyer, J.-M.; Chouchana, L. Risk of systemic vasculitis following mRNA COVID-19 vaccination: A pharmacovigilance study. *Rheumatology* **2022**, *61*, e363–e365. [[CrossRef](#)] [[PubMed](#)]

45. Theodorou, D.J.; Axiotis, A.; Gianniki, M.; Tsifetaki, N. COVID-19 vaccine-related myositis. *QJM Int. J. Med.* **2021**, *114*, 424–425. [[CrossRef](#)] [[PubMed](#)]
46. Ajmera, K.M. Fatal Case of Rhabdomyolysis Post-COVID-19 Vaccine. *Infect. Drug Resist.* **2021**, *14*, 3929–3935. [[CrossRef](#)]
47. Maramattom, B.V.; Philips, G.; Thomas, J.; Santhamma, S.G.N. Inflammatory myositis after ChAdOx1 vaccination. *Lancet Rheumatol.* **2021**, *3*, e747–e749. [[CrossRef](#)]
48. Tan, A.; Stepien, K.M.; Narayana, S.T.K. Carnitine palmitoyltransferase II deficiency and post-COVID vaccination rhabdomyolysis. *QJM Int. J. Med.* **2021**, *114*, 596–597. [[CrossRef](#)]
49. Al-Rasbi, S.; Al-Maqbali, J.S.; Al-Farsi, R.; Al Shukaili, M.A.; Al-Riyami, M.H.; Al Falahi, Z.; Al Farhan, H.; Al Alawi, A.M. Myocarditis, Pulmonary Hemorrhage, and Extensive Myositis with Rhabdomyolysis 12 Days After First Dose of Pfizer-BioNTech BNT162b2 mRNA COVID-19 Vaccine: A Case Report. *Am. J. Case Rep.* **2022**, *23*, e934399. [[CrossRef](#)]
50. Cirillo, E.; Esposito, C.; Giardino, G.; Azan, G.; Fecarotta, S.; Pittaluga, S.; Ruggiero, L.; Barretta, F.; Frisso, G.; Notarangelo, L.D.; et al. Case Report: Severe Rhabdomyolysis and Multiorgan Failure After ChAdOx1 nCoV-19 Vaccination. *Front. Immunol.* **2022**, *13*, 845496. [[CrossRef](#)]
51. Kamura, Y.; Terao, T.; Akao, S.; Kono, Y.; Honma, K.; Matsue, K. Fatal thrombotic microangiopathy with rhabdomyolysis as an initial symptom after the first dose of mRNA-1273 vaccine: A case report. *Int. J. Infect. Dis.* **2022**, *117*, 322–325. [[CrossRef](#)] [[PubMed](#)]
52. Orbach, H.; Tanay, A. Vaccines as a trigger for myopathies. *Lupus* **2009**, *18*, 1213–1216. [[CrossRef](#)] [[PubMed](#)]
53. Kono, A.; Yoshioka, R.; Hawke, P.; Iwashina, K.; Inoue, D.; Suzuki, M.; Narita, C.; Haruta, K.; Miyake, A.; Yoshida, H.; et al. Correction to: A case of severe interstitial lung disease after COVID-19 vaccination. *QJM Int. J. Med.* **2021**, *114*, 805. [[CrossRef](#)] [[PubMed](#)]
54. Park, J.Y.; Kim, J.-H.; Lee, I.J.; Kim, H.I.; Park, S.; Hwang, Y.I.; Jang, S.H.; Jung, K.-S. COVID-19 vaccine-related interstitial lung disease: A case study. *Thorax* **2022**, *77*, 102–104. [[CrossRef](#)] [[PubMed](#)]
55. Baimukhamedov, C.; Makhmudov, S.; Botabkova, A. Seropositive rheumatoid arthritis after vaccination against SARS-CoV-2 infection. *Int. J. Rheum. Dis.* **2021**, *24*, 1440–1441. [[CrossRef](#)] [[PubMed](#)]
56. Singh, R.; Kaur, U.; Singh, A.; Chakrabarti, S.S. Refractory hypereosinophilia associated with newly diagnosed rheumatoid arthritis following inactivated BBV152 COVID-19 vaccine. *J. Med. Virol.* **2022**, *94*, 3482–3487. [[CrossRef](#)]
57. Magliulo, D.; Narayan, S.; Ue, F.; Boulougoura, A.; Badlissi, F. Adult-onset Still’s disease after mRNA COVID-19 vaccine. *Lancet Rheumatol.* **2021**, *3*, e680–e682. [[CrossRef](#)]
58. Sharabi, A.; Shiber, S.; Molad, Y. Adult-onset Still’s disease following mRNA COVID-19 vaccination. *Clin. Immunol.* **2021**, *233*, 108878. [[CrossRef](#)]
59. Lee, E.-J.; Beltrami-Moreira, M.; Al-Samkari, H.; Cuker, A.; DiRaimo, J.; Gernsheimer, T.; Kruse, A.; Kessler, C.M.; Kruse, C.; Leavitt, A.D.; et al. SARS-CoV-2 vaccination and immune thrombocytopenia in de novo and pre-existing ITP patients. *Blood* **2021**, *139*, 1564–1574. [[CrossRef](#)]
60. Moulis, G.; Crickx, E.; Thomas, L.; Massy, N.; Mahévas, M.; Valnet-Rabier, M.-B.; Atzenhoffer, M.; Michel, M.; Godeau, B.; Bagheri, H.; et al. De novo and relapsed immune thrombocytopenia after COVID-19 vaccines: Results of French safety monitoring. *Blood* **2022**, *139*, 2561–2565. [[CrossRef](#)]
61. Liozon, E.; Ouattara, B.; Rhaïem, K.; Ly, K.H.; Bezanahary, H.; Loustaud, V.; Letellier, P.; Drouet, M.; Vidal, E. Familial aggregation in giant cell arteritis and polymyalgia rheumatica: A comprehensive literature review including 4 new families. *Clin. Exp. Rheumatol.* **2009**, *27* (Suppl. S52), S89–S94. [[PubMed](#)]
62. Carmona, F.D.; Mackie, S.L.; Martín, J.-E.; Taylor, J.C.; Vaglio, A.; Eyre, S.; Bossini-Castillo, L.; Castañeda, S.; Cid, M.C.; Hernández-Rodríguez, J.; et al. A Large-Scale Genetic Analysis Reveals a Strong Contribution of the HLA Class II Region to Giant Cell Arteritis Susceptibility. *Am. J. Hum. Genet.* **2015**, *96*, 565–580. [[CrossRef](#)] [[PubMed](#)]
63. Watad, A.; Quaresma, M.; Brown, S.; Cohen Tervaert, J.M.; Rodriguez-Pint, I.; Cervera, R.; Perricone, C.; Shoenfeld, Y. Autoimmune/inflammatory syndrome induced by adjuvants (Shoenfeld’s syndrome)—An update. *Lupus* **2017**, *26*, 675–681. [[CrossRef](#)] [[PubMed](#)]
64. Ma-Krupa, W.; Kwan, M.; Goronzy, J.J.; Weyand, C.M. Toll-like receptors in giant cell arteritis. *Clin. Immunol.* **2005**, *115*, 38–46. [[CrossRef](#)]
65. Mettler, C.; Jonville-Bera, A.-P.; Grandvuillemin, A.; Treluyer, J.-M.; Terrier, B.; Chouchana, L. Risk of giant cell arteritis and polymyalgia rheumatica following COVID-19 vaccination: A global pharmacovigilance study. *Rheumatology* **2021**, *61*, 865–867. [[CrossRef](#)]
66. Ursini, F.; Ruscitti, P.; Raimondo, V.; De Angelis, R.; Cacciapaglia, F.; Pigatto, E.; Olivo, D.; Di Cola, I.; Galluccio, F.; Francioso, F.; et al. Systemic syndromes of rheumatological interest with onset after COVID-19 vaccine administration: A report of 30 cases. *Clin. Rheumatol.* **2022**, *41*, 2261–2267. [[CrossRef](#)]
67. Miller, F.; Hess, E.V.; Clauw, D.J.; Hertzman, P.A.; Pincus, T.; Silver, R.M.; Mayes, M.D.; Varga, J.; Medsger, T.A.; Love, L.A. Approaches for identifying and defining environmentally associated rheumatic disorders. *Arthritis Rheum.* **2000**, *43*, 243–249. [[CrossRef](#)]

Annexe 10.

Giant cell arteritis or polymyalgia rheumatica after influenza vaccination: A study of 12 patients and a literature review



Giant cell arteritis or polymyalgia rheumatica after influenza vaccination: A study of 12 patients and a literature review

Eric Liozon^{a,*}, Simon Parreau^a, Matthieu Filloux^b, Stéphanie Dumonteil^a,
Guillaume Gondran^a, Holy Bezanahary^a, K.H. Ly^a, Anne Laure Fauchais^a

^a Departments of Internal Medicine, University Hospital of Limoges, Limoges Cedex, France

^b Immunology and Immunogenetics, University Hospital of Limoges, Limoges Cedex, France

ARTICLE INFO

Keywords:

Giant cell arteritis
Polymyalgia rheumatica
Influenza vaccination
ASIA syndrome

ABSTRACT

Introduction: Giant cell arteritis (GCA) and polymyalgia rheumatica (PMR) are inflammatory rheumatic diseases common in people over the age of 50 years. Seasonal influenza vaccination (IV) is strongly recommended in this population, among whom it is considered to be effective and well tolerated. IV-induced GCA or PMR are thought to be exceptional.

Patients and methods: We retrieved all post-IV cases from an inception cohort of patients with newly diagnosed GCA. We also included two patients with post-IV PMR and reviewed all published reports of post-IV GCA or PMR, with selection of cases demonstrating disease onset within 1 month following IV. We compared the results of HLA-DRB1 typing, performed in seven patients with post-IV GCA or PMR, with those of 11 GCA patients with familial aggregation and 16 randomly selected GCA patients without a reported trigger.

Results: Of 358 GCA recruited since 2002, 10 (2.8%) qualified for post-IV GCA, of whom two also showed familial aggregation. Thirty-two patients (19 with GCA and 13 with PMR) including our patients were reviewed; their mean age was 71.8 ± 7.4 years and the M/F ratio was 0.8. Six patients (19%) had a history of PMR. Patients with post-IV GCA/PMR had the DRB1*13:01 haplotype more frequently compared to those with familial GCA (5/7 vs. 2/11, $p = 0.048$) or with GCA without a known trigger (3/16, $p = 0.026$). Post-IV PMR generally appeared self-limited, whereas post-IV GCA often displayed a more protracted course (chronic relapsing disease in one-third of the patients).

Conclusion: Post-IV onset of GCA/PMR is not an exceptional occurrence and may be part of the spectrum of the autoimmune syndrome induced by adjuvants (ASIA). IV can trigger GCA or PMR, especially in persons at higher spontaneous risk, such as those with a personal or familial history of GCA/PMR. Whether the presence of the DRB1*13:01 allele further increases the risk of post-IV GCA/PMR through a stronger vaccine-induced immune reaction deserves further investigation. Unlike PMR, GCA can be a serious complication of IV.

1. Introduction

Giant cell arteritis (GCA) is a chronic, systemic, large-vessel vasculitis with a marked female predominance and restriction to old age. Polymyalgia rheumatica (PMR) is the most common inflammatory rheumatic disease in older people of white descent. GCA and PMR are closely related disorders, with roughly 50% and 20% overlap in GCA and PMR cases, respectively [1]. The origin of the disease is unknown but genetic and environmental factors are both likely to play a role [2–4].

Influenza is an acute upper respiratory tract infection that occurs worldwide in epidemics every year. It can cause serious complications,

especially in older adults and individuals with chronic health problems. Influenza vaccination (IV) is an effective means of preventing influenza and its complications. The French *Haute Autorité de Santé* strongly recommends and fully reimburses annual IV for these at-risk subjects including people over 65 years of age. Although IV shows a favorable safety profile, it is associated with a variety of serious complications including vasculitis occurrences, although rarely [5–12]. A review of 65 published reports of vasculitis following IV found leukocytoclastic vasculitis and other forms of small-vessel vasculitis to be the most frequently reported types of vasculitides [13].

Only a few cases of GCA or PMR following IV have been published

* Corresponding author at: Service de Médecine Interne A CHRU Dupuytren 2, Avenue Martin Luther-King, 87042 Limoges, France.
E-mail address: eric.liozon@chu-limoges.fr (E. Liozon).

<https://doi.org/10.1016/j.autrev.2020.102732>

Received 15 October 2020; Accepted 24 October 2020

Available online 14 December 2020

1568-9972/© 2020 Elsevier B.V. All rights reserved.

until recently [14–29]. In 2012, Soriano et al. described an association between annual IV and subsequent onset of GCA or PMR in 10 patients within a 5-year time frame [26]. GCA/PMR is listed among several autoimmune/autoinflammatory conditions that can be induced by adjuvants (so-called ASIA) [29], despite a paucity of further reported cases [27–29]. This ambiguous situation as well as personal acquaintance of post-IV GCA/PMR [19] prompted us to present our own experience of post-IV GCA/PMR and comprehensively review the data published in the field. We also investigated the possible relationship between post-IV GCA/PMR and HLA-DRB1 polymorphisms, in keeping with current knowledge on the pathophysiological mechanisms of GCA/PMR and ASIA.

2. Patients and methods

2.1. Patients and data collection

The study population included all consecutive patients referred to the Internal Medicine department of one tertiary-care teaching hospital for the diagnosis and treatment of GCA since 2002. GCA was diagnosed based on the criteria of the American College of Rheumatology [30]. GCA was considered present in biopsy-negative cases if at least three of the ACR criteria were fulfilled and if only two ACR criteria were fulfilled but fluorodeoxyglucose (FDG)-positron emission tomography (PET) scans were strongly suggestive of occult large-vessel vasculitis [31]. If direct and indirect evidence of large vessel vasculitis were both lacking, we added an additional requirement of no alternative diagnosis emerging at 6 months. All GCA diagnoses were pathologically confirmed using currently accepted criteria, and polymyalgia rheumatica (PMR) was defined by at least 2 weeks of moderate-to-severe pain and morning stiffness lasting more than 30 min in at least two areas that included the neck, shoulders, and pelvic girdles.

All data on GCA features, treatments, and outcomes were retrieved. Clinical, laboratory, and pathological data were prospectively recorded at the time of first admission using a specifically designed 176-item questionnaire of detailed history and log data. All study data were stored in computerized files and regularly updated [32]. Specifically, the following questions were included: as there been in the past three months an infectious event and which one? A zona? A dental extraction? Prior to 2002 (e.g., 1976–2001), no special attention was paid to a possible relationship between IV and subsequent GCA development. The first case was quoted in 2002, which was arbitrarily chosen as the date of commencement of the study. However, the item “vaccine as a potential trigger” had not been formally included in the questionnaire, possibly inducing recall bias, despite the investigator’s awareness. We extracted and reviewed the charts of all reported GCA cases demonstrating post-IV onset and compared their frequency to that of GCA following other potential triggers such as infection, emotional stress, and surgery. Finally, we compared the frequencies of HLA class II alleles in seven patients with post-IV GCA, 11 patients with familial GCA, and 16 patients with GCA without a reported trigger.

2.2. Study variables and clinical definitions

Details regarding the demographic information, date of diagnosis, clinical features, levels of acute-phase reactants and liver enzymes at disease onset (prior to steroid treatment), temporal artery biopsy (TAB) status, starting dose of prednisone, number of relapses during prednisone tapering, use of steroid-sparing agents, and total duration of treatment were retrieved for each patient. The clinical items extracted from the computerized file included PMR symptoms, new-onset headache, scalp tenderness, jaw claudication, and/or other jaw/mouth/throat problems, and visual ischemic manifestations, as previously described [32]. Temporal arteries were considered abnormal if the pulse was low or absent and/or if nodules, redness, thickening, or tenderness were apparent in at least one artery.

Constitutional syndrome was defined as a temperature ≥ 38 °C lasting for at least 1 week in conjunction with severe asthenia and/or weight loss $>5\%$. Upper limb artery involvement was defined on a clinical basis followed by confirmation using echo-Doppler and/or angiographic scans. Starting in 2005, subclinical aortitis was diagnosed using FDG-PET scans, computed tomography scans, or both, according to current diagnostic standards [33]. Patients with persistent fever of unknown origin and/or isolated raised acute-phase reactants qualified for the systemic form of GCA, irrespective of the presence of subclinical aortitis.

2.3. Outcome measures

Relapse was defined as the recurrence of clinical symptoms and/or inflammatory parameters that were attributable to GCA and required increased medication. PMR relapses were defined based on a combination of patient self-assessment, erythrocyte sedimentation rate (ESR), C-reactive protein (CRP) levels, shoulder pain/limitations during a clinical examination, and response to steroid dose adjustments; if these events occurred after the cessation of planned treatment, it was considered a recurrence. Relapsing patients who were unable to lower their prednisone doses below 20 mg/day at 6 months, 10 mg/day at 12 months, and/or 7.5 mg/day at 2 years were considered steroid-dependent cases. We also evaluated total treatment duration, recovery from GCA (i.e., free of relapse for at least 12 months following the cessation of GC treatment), duration of treatment in recovered patients, duration of clinical follow-up, date of death, or patient clinical status at the end of the study (May 15, 2020). Steroid-induced complications were recorded and included infection (any event leading to antibiotic prescription, hospitalization, or both), osteoporotic fractures, diabetes mellitus, venous thromboembolism, and disabling myopathy.

2.4. Treatments

Most patients with GCA were treated using standardized protocols. Patients lacking ischemic manifestations received prednisone at 0.6–0.8 mg/kg/day until their symptoms disappeared and CRP levels were < 5 mg/L; then the prednisone dose was progressively tapered to 0.35 mg/kg within 4–6 weeks. Patients with permanent ischemic manifestations received initial prednisone doses of 0.9–1.1 mg/kg/day, which was often preceded by pulse methylprednisolone, and then the dose was similarly tapered. Relapses without ischemic symptoms were managed by temporarily increasing the prednisone dose to a previously effective dose whereas severe relapses involved more consistent increases conducted on an individualized basis. Patients with relapsing/steroid-dependent GCA or those who experienced serious steroid-related side effects often received steroid-sparing drugs, such as methotrexate, dapsons [34], or tocilizumab.

2.5. Class II HLA typing

Informed written consent was obtained from each patient. Peripheral blood samples were collected in ethylenediaminetetraacetic acid for DNA extraction. HLA-DRB1 genotyping was performed by SSO-PCR (LABType®), using sequence-specific oligonucleotide probes (SSO) bound to fluorescently coded microspheres (Luminex Technology) to identify alleles encoded by the sample DNA (One Lambda Inc., CA 91303). In a first step, the target DNA was amplified by polymerase chain reaction, and next coupled with hybridization and detection in a single reaction mixture. Results were expressed with intermediate resolution, without ambiguity on Exon 2 of the HLA DRB1 locus.

2.6. Statistical analyses

Proportions were analyzed using Fisher’s exact test; p -values < 0.05 were considered to indicate statistical significance. All analyses were

conducted using the R software (version 3.2.2, Microsoft Corporation). Numbers of newly registered GCA cases between November and January were compared to numbers of other quarterly registered cases using the Kruskal-Wallis test. Yearly proportions of post-IV cases were compared (2019 vs all other years) using the Wilcoxon test.

2.7. Ethics board approval

All data concerning these older patients with GCA were retrospectively collected. This study was conducted in compliance with good clinical practices and the principles of the Declaration of Helsinki. In accordance with French law, formal approval from an ethics committee was not required for this type of retrospective study.

3. Results

3.1. Characteristics of post-IV GCA patients retrieved from the inception cohort

Of 358 patients newly diagnosed with GCA from 2002 to May 2020, 10 (2.8%) were post-IV cases, whereas other potential triggers were reported in 60 patients—recent infection in 39 patients (bronchitis/pneumonitis in 13, nose-and-throat infection in 10, gastrointestinal infection in three, dental abscess in four, flu-like illness in five, other infections in four); an emotional event in seven patients; and another triggering event such as surgery, sunstroke, dental extraction or Bell's palsy, in 14 patients. No GCA onset after vaccination other than IV (especially pneumococcal vaccination) was reported by any patient. Chronological overlap between IV and infection (acute gastroenteritis 1 week prior to IV in an 81-year old man) was only reported once. Table 1 depicts the clinical characteristics and outcome of the 10 patients. The mean diagnosis delay was 62 ± 48 days, 57 ± 49 days, and 87 ± 91 days for post-IV GCA, GCA following other potential triggers, and GCA without an identified trigger, respectively. The number of new GCA cases per month averaged 1.53 (range 1.1 for January to 1.68 for March), while quarterly reports averaged 4.21 new cases for November to January (trimester 1) and 3.68 to 4.63 for other trimesters, without significant differences between trimester 1 and the other trimesters ($p = 0.39$). There was a slightly higher proportion of post-IV cases among all new GCA cases in 2019 compared to all the other years (12.5% vs 0 to

7.5%; $p = 0.08$).

The patient's mean age was 72 years (53–81 years) with a male/female ratio of 2.3. The time elapsed between IV and the first reported symptoms of vasculitis or PMR averaged 7.8 days (1–14 days). Of the 10 post-IV patients, two also had familial aggregation of GCA (mother in one patient and father/sister in the other patient), seven had typical cranial features, four of whom developed vision loss from GCA. One had amaurosis fugax, three had permanent visual loss from AION, with two bilateral involvements; a 68-year-old male had an atypical clinical presentation with subacute encephalitis without stroke on magnetic resonance imaging, subclavian/axillary involvement both evidenced by ultrasound and 18F-FDG PET/CT, and a positive TAB; a 53-year-old male had fever of unknown origin; and a 70-year-old male featured TAB-positive PMR and peripheral arthritis without clinical evidence of arteritis. All but one of these patients displayed a severe inflammatory response (mean ESR 100 ± 24.4 mm/h, CRP 15 ± 7.7 mg/dL, hemoglobin level 10.4 ± 1.3 g/dL, leukocyte count $10,716 \pm 2627$ G/L, platelet count 530 ± 120 G/L). All the patients received high-dose prednisone (mean initial dose 60 mg/d; e.g., 0.87 mg/kg/d), preceded by pulse methylprednisolone in five. Of eight patients followed for at least 12 months, seven suffered 16 relapses. This often relapsing/remitting GCA course led to glucocorticoid treatment for extended periods (mean duration 38 ± 17 months) with only three recovered patients after a mean 77 ± 61 -month follow-up.

3.2. Characteristics of PMR patients

Two patients were reported to have started classical PMR 10 days after IV. Neither of these patients had a prior history of PMR or GCA. One of the two patients, a 72-year-old female, had a refractory PMR course, which required the addition of methotrexate and a 46-month total duration of treatment, whereas the other, a 70-year old male, had been on GC treatment for 8 months with moderate daily dose requirements. A third patient, who had had PMR immediately after IV, developed biopsy-proven GCA a few months later and thus was included in the post-IV GCA group (see Table 1, patient 8).

3.3. Comparative results of HLA DRB1 typing

HLA DRB1 typing was performed in 34 patients—seven post-IV

Table 1
Demographics and features of vasculitis in patients with post-influenza vaccination GCA.

Patient	1	2	3	4	5	6	7	8	9	10
Year of onset	2002	2003	2006	2007	2010	2015	2017	2019	2019	2019
Age	79	70	53	65	81	80	68	75	72	77
Gender	F	M	M	M	M	F	M	M	F	F
Other possible trigger ^a	–	–	–	–	+	–	+	–	–	+
Delay in diagnosis (days)	55	135	80	8	18	145	82	30	28	40
Headache	+	–	+	+	+	+	–	+	+	+
Scalp tenderness	+	–	–	+	+	+	–	+	–	–
Jaw claudication or trismus	+	–	–	–	–	–	–	–	+	–
Facial swelling	+	–	–	–	–	+	–	–	+	–
Abnormal temporal artery	+	+	–	–	+	+	–	+	+	–
Aortitis	–	–	+	–	–	–	+	–	+	–
PMR/ peripheral arthritis	–	+	–	–	–	–	–	+	+	+
Fever	–	+	+	–	–	–	+	+	+	+
Ischaemic complications	+	–	–	+	+	+	+	–	–	–
Permanent visual loss	–	–	–	+	+	+	–	–	–	–
Other severe findings ^b	–	–	–	–	–	+	+	–	–	–
Temporal artery biopsy result	+	+	–	–	–	+	+	–	+	+
ESR (mm/h)	92	84	126	135	n.d.	114	66	108	111	68
CRP (mg/L)	144	264	185	168	80	136	21	121	274	111
Hepatic cholestasis	+	+	–	–	+	n.d.	–	–	+	n.d.
Serum titer of antinuclear antibody >1/160	+	–	–	–	n.d.	n.d.	–	–	n.d.	–

PMR, polymyalgia rheumatica; n.d., not determined.

^a GCA reported in mother (case 7); and in mother and sister (case 10); gastrointestinal infection (patient 5).

^b Sudden unilateral deafness (patient 6); severe encephalitis without multiple small brain infarctions on magnetic resonance imaging.

patients (five GCA patients and both PMR patients (group 1) and 27 patients with GCA reportedly unrelated to IV: 11 with familial aggregation (group 2), of whom eight belonged to the inception cohort; and 16 without a reported trigger, all of whom were randomly extracted from the inception cohort (group 3). HLA-DRB1*04 variants were frequent (53%) and equally distributed among the groups (Table 2), while the HLA-DRB1*13:01 allele was more prevalent in group 1 compared with the other groups, especially group 3 (71% vs. 19%, $p = 0.026$).

3.4. Summary of the literature and results of HLA-DRB1 typing

We found 20 other published case reports of GCA or PMR following IV. Of the 10 patients described by Soriano et al., five met the chronological criterion and thus are included in the review [26]. Table 3 lists patients with post-IV GCA, while post-PMR cases are summarized in Table 4. Specific information on the offending IV was available for 12 patients and comprised a variety of products. The mean patient's age was 71.8 ± 7.4 years and the M/F ratio was 0.8; the values for GCA and PMR were similar. The mean time elapsed from IV to first symptoms was 8.6 days (1–30 days). Six patients (19%), including two with GCA and four with PMR, had a history of PMR. Table 5 summarizes the results of HLA-DRB1 typing in 13 assessed post-IV cases of GCA or PMR. The

Table 2

Cases of giant cell arteritis reported to have occurred shortly (≤ 1 month) after influenza vaccination.

Author (ref)	Gender/age (ys)	Interval	Previous history	Response to treatment and outcome
Ghose [14]	F/76	1 day	None	Unilateral PVL, dose prednisolone 5 to 10 mg/d after >2 years
Saadoun [20]	F/65	3 days	PMR (1 y)	$9 \geq 45 \geq 5$ mg/d over 8 months
Finsterer [21]	M/70	5 days	None	Not specified
Perez [18]	F/76	1 week	None	Duration 36 months
Pou [23]	M/74	1 week	None	Prednisone 60 mg/d ≥ 15 mg/d after 2 months. Asymptomatic after 6 months
Soriano [26]				
Case 1	F/78	1 week	None	At least 24 months. Remission
Case 2	F/67	1 month	None	At least 24 months. Remission
Case 3	F/74	1 month	None	At least 24 months. Remission
Wada [25]	F/70	1 day	None	35 mg/d \geq reduced by 10% every 2 weeks (treatment duration?)
Current report				
Case 1	F/79	10 days	None	One recurrence. Duration 31 mo./recovered
Case 2	M/70	10 days	None	GC-dependent. Recovered after a 44-month GC course
Case 3	M/53	2 weeks	None	GC-dependent (treatment for more than 60 months)
Case 4	M/65	8 days	None	Duration 34 mo. (2 relapses)/recovered
Case 5	M/81	6 days	None	Recovered after an uncomplicated 27-month GC course
Case 6	F/80	5 days	None	GC-dependent. No recovery after 53 mo.
Case 7	M/68	6 days	None	GC-dependent, with low dose prednisone requirement after 37 mo.
Case 8	M/75	2 days	PMR (7 mo)	Treated for 9 months (uncomplicated GCA course)
Case 9	F/72	6 days	None	Treated for 10 months (uncomplicated GCA course)
Case 10	F/77	12 days	None	Treated for 13 months (one relapse 7 months after diagnosis)

Table 3

Cases of polymyalgia rheumatica (new disease or late disease flare) reported to have occurred shortly (≤ 1 month) after influenza vaccination.

Author (ref)	Gender/age (y)	Delay ^a	Previous history	Outcome of PMR
Gerth [15]	F/67	1 day	Late PMR relapse	–
Brown [16]	M/65	3 day	PMR relapse	Recovered (9 mo)
Perez [17]	M/61	< 1 week	None	Controlled with Pred 5 mg/d
Liozon [19]	F/91	1 day	None	Recovered (6 mo)
Marti [22]	M/79	1 week	None	Recovered (4 mo)
Soriano [26]				
Case 1	F/64	1 week	None	GCs for ≥ 24 mo.
Case 2	F/71	1 month	PMR relapse	GCs for ≥ 24 mo.
Henskens [24]	M/65	1 day	None	Disease controlled with Pred 30 mg/d
Siddiqi [27]	M/71	< 1 week	None	Good initial response to GCs
Salehi [28]	F/86	2 weeks	None	Good initial response to GCs
Bassendine [29]	F/70	“soon”	PMR relapse	Disease controlled with a 5 mg increment in daily Pred dose
Current report:				
Case 1	F/72	10 days	None	Second line methotrexate for relapsing disease
Case 2	M/70	10 days	None	Partial response to Pred 15 mg/d

^a Time elapsed between influenza vaccine and the first symptoms or signs attributable to PMR or a high-grade fever prior to the onset of classical PMR. PMR, polymyalgia rheumatica; Pred, prednisone (or prednisolone); GCs, oral glucocorticoids.

Table 4

Results of HLA DRB1 typing in 33 patients—31 with GCA and 2 with PMR.

HLA-DRB1 alleles	Post-IV cases	Familial cases	Other cases	p value ^c
	$N = 7$	$N = 11$	$N = 16$	
	n (%) ^a	n (%) ^b	n (%) ^b	
DRB1*01	1 (14)	0 (0)	0 (0)	0.39/0.30
DRB1*03	2 (29)	0 (0)	3 (19)	0.14/0.62
DRB1*04	4 (57)	4 (36)	10 (62.5)	0.63/0.99
DRB1*07	2 (29)	6 (55)	2 (12.5)	0.37/0.56
DRB1*11	1 (14)	3 (27)	3 (19)	0.99/0.99
DRB1*13	5 (71)	2 (18)	4 (25)	
*13:01	5 (71)	2 (18)	3 (19)	0.048/0.026
*13:02	0 (0)	0 (0)	1 (6)	–/0.99
DRB1*15	0 (0)	4 (36)	3 (19)	0.12/0.53

^a 5 GCA and 2 PMR.

^b GCA only.

^c Post-IV cases vs. familial cases vs. other cases.

DRB1*04 haplotype was present in 8/13 (62%) patients, and the DRB1*13:01 allele in 5/13 (38.5%) patients.

4. Discussion

While a systematic literature review covering the period 1994 to 2014 did not allow establishing a causative link between vaccination and vasculitides [35] a descriptive analysis of spontaneous reports of vasculitis as an adverse event following immunization across three international databases showed that PMR represented 9.2% of reported vasculitides. Influenza vaccine was the most incriminated vaccine (61.5%) for PMR reports, whereas the corresponding figure was not given for GCA reports, although these accounted for 2–3% of all spontaneous reports of vasculitis [36]. Miller et al. proposed several

Table 5
Results of HLA DRB1 typing of 13 patients with post-IV GCA or PMR.

Reference	Diagnosis	HLA DRB1 typing
Perez [18]	GCA	DRB1*01/*04
Current report		
Case 6	GCA	DRB1*04:04/*13:01
Case 7	GCA	DRB1*11:01/*13:01
Case 8	GCA	DRB1*04:01/*13:01
Case 9	GCA	DRB1*03:01/*13:01
Case 10	GCA	DRB1*04:07/*07:01
Brown [16]	PMR	DRB1*01/*04
Perez [17]	PMR	DRB1*04:04/–
Marti [22]	PMR	DRB1*04:01/–
Soriano [26]	PMR	DRB1*11/DRB1*15
Henskens [24]	PMR	DRB1*14:54/–
Current report		
Case 1	PMR	DRB1*01:01/*04:07
Case 2	PMR	DRB1*01:01/*13:01

attribution elements for identifying and defining environmentally associated rheumatic disorders. The primary elements include temporal association, exclusion of other known causes, de-challenge (evidence that the adverse event diminished, as would be expected if the vaccine caused the event), re-challenge, and biologic plausibility; the secondary elements are analogy, dose responsiveness, and specificity [37]. Most reported cases of GCA or PMR alleged to be vaccine-provoked met only two or three of Miller's primary attribution elements demonstrating consistency with a causal association. In particular, GCA cases rarely demonstrated de-challenge and re-challenge; the latter probably sounded risky and thus was not attempted. Thus, a causal association between IV and GCA or PMR is not supported by adequate evidence.

This study provides the first ever estimate (2.8%) of the proportion of GCA occurring shortly after IV in a hospital-based recruitment. This is a minimal estimate, because the item "vaccine as a potential trigger" had not been formally included in the prospective questionnaire, possibly leading to underestimation of the association, despite investigator awareness. Contrary to the findings of Soriano et al. [26], we did not observe any outbreak of GCA within the 3-month period following standard November-IV. Our calculations were made based on a large sample of patients recruited over a 19-year period, and we do not believe that IV caused significant changes in the epidemiology of GCA.

We report on two cases of PMR and an additional patient who developed PMR immediately after IV and was diagnosed with overt GCA several months later. Published cases more often involved PMR than GCA. This unbalanced frequency may either reflect the fourfold higher prevalence of PMR compared to that of GCA, or correspond to shortcomings in diagnosis, because PMR is regarded as a syndrome while GCA is a well-defined disease. In this study, the opposite finding of predominantly GCA cases probably reflects a major recruitment bias toward GCA in an Internal Medicine Department. IV-induced PMR generally appeared self-limited, which is consistent with an environmental triggering event [37]. However, a more severe PMR course can also be seen after IV, as exemplified in cases with which we have personal experience (Table 2). Our findings suggest post-IV GCA to be a serious condition, as highlighted by a 40% rate of complicated forms, a strong acute-phase reaction at disease onset, and prolonged glucocorticoid requirements for most patients. The literature survey retrieved nine published post-IV GCA cases, with limited data on the long-term prognosis [14,18,20,21,23,25,26], precluding confirmation of our findings.

Surprisingly, we observed an increased prevalence of the HLA DRB1*13:01 allele, but not DRB1*04 variants, in patients with post-IV GCA/PMR compared to those with familial GCA and GCA without a reported trigger. The frequency of DRB1*13:01 allele varies from 13% to 18% in several European populations [38–40] and has been associated with childhood-onset ulcerative colitis in the United States [39] and PMR in a population from Northern Spain [41], but not with GCA

[42,43]. HLA-DRB1*13:01 may also confer protection against anti-citrullinated protein antibody-positive rheumatoid [40] and various other autoimmune diseases, presumably by enhancing antigen presentation by these molecules, favoring efficient clonal deletion during thymic selection [44]. Moreover, HLA-DRB1*13:01 increases the immunological response to hepatitis B vaccine in healthy persons [45] and is over-represented in healthy subjects from the UK who exhibited a good response against IV compared to non-responders (37% vs. 9%, $p = 0.013$) [46]. We therefore hypothesize that predisposed older subjects who bear HLA-DRB1*13:01 may be at increased risk of developing post-IV GCA/PMR via a vigorous vaccine-induced immune reaction. Such a hypothesis is consistent with the concept of post-IV GCA or PMR being part of the wide spectrum of the ASIA syndrome [47]. In this respect, vascular lesions of GCA are driven by the deleterious CD4⁺ lymphocyte reaction that follows dendritic cell activation [48,49], and both GCA and PMR are currently classified as polygenic autoinflammatory diseases, according to McGonagle and McDermott [50]. The proposed major criteria for the diagnosis of ASIA syndrome include previous stimulus to an external trigger such as an adjuvant and the development of typical clinical manifestations, some of which are consistent with the usual features of GCA or PMR. Minor criteria consist of, but are not limited to, specific HLA DRB1 (mainly the DRB1*01 and DRB1*04 alleles) or HLA DQB1 [47]. A recent update of the ASIA syndrome international registry including 500 subjects found well-defined immune conditions to represent 69% of all cases, of which well-defined polygenic autoinflammatory diseases accounted for 5.8%, with a strong association with IV exposure. In this small subset of 20 subjects, GCA was the most prevalent disease (40%), followed by Crohn's disease (30%) and PMR (20%) [51]. In light of these figures, more case reports including class II HLA typing and measurement of anti-influenza antibody titers are needed to explore the relationship of HLA-DRB1 haplotypes with post-IV GCA/PMR and, hence, confirm that post-IV GCA/PMR is unquestionably part of the ASIA syndrome.

Influenza vaccination has been shown to be safe in patients with antineutrophil cytoplasmic antibody (ANCA)-associated vasculitis since it did not result in an increase of the relapse rate or an increase in the mean serum titers of ANCA [52–54]. Disease reactivation possibly related to vaccination with the 2009 IV A/H1N1 was suspected in 8/149 patients with systemic, immune-mediated diseases [55]. In contrast, the benefit/risk balance of IV in patients with GCA or PMR has not been properly investigated. Nevertheless, the European League Against Rheumatism (EULAR) updated the 2011 recommendations for vaccination in adults with autoimmune inflammatory rheumatic diseases (AIIRD) including GCA and PMR and stated that IV should be strongly considered for the majority of patients. This statement was based on a favorable benefit-risk profile of seasonal trivalent subunit IV assuming that adverse events of IV in patients with AIIRD are comparable to those in healthy controls [56,57]. Our results on post-IV GCA or PMR do not alter the EULAR recommendations, owing to the rarity of this adverse effect. Conversely, early revaccination after post-IV GCA should be considered cautiously before a decision is made on an individual basis, in view of the severity of the disease. Likewise, older subjects with a personal or familial history of GCA/PMR and/or the HLA-DRB1*13:01 or HLA-DRB1*04 allele should be closely monitored after each seasonal IV.

The present study has several limitations that should be noted. We may have missed other relevant cases, due to the retrospective study design, especially the fact that an item "vaccine as a potential trigger" had not been included in the patient evaluation. Also, we lack data on prior yearly IV vaccinations in our patients, although this common practice might contribute to developing postvaccination diseases by repeated exposure of the immune system to these vaccine variants [58]. The small sample size, lack of data on anti-influenza antibody titers, and usual avoidance of yearly IV re-challenge preclude drawing a firm conclusion that there is a causal relationship between IV and subsequent GCA. Conversely, all 10 GCA patients in our study were part of a well-

defined, large inception cohort, which enhanced the accuracy of the data. Moreover, detailed information on GCA features, available data on treatment and outcomes in most cases, and a consistent follow-up period enabled detailed description of reported cases. Finally, our work is the first to compare the frequency of HLA-DRB1 alleles in several groups of patients with GCA with regard to potential triggers such as IV and family history of GCA, allowing for demonstration of a role for HLA molecules, especially DRB1*04 and DRB1*13:01, in the triggering of post-IV GCA.

In summary, post-IV onset of GCA or PMR is not an exceptional occurrence and may represent a serious form of ASIA syndrome, especially GCA. IV can trigger GCA or PMR, especially in persons at higher spontaneous risk, such as those with a personal or familial history of GCA/PMR. Whether the DRB1*13:01 allele further increases the risk of post-IV GCA/PMR via a stronger vaccine-induced immune reaction warrants further investigation.

Declaration of Competing Interest

The authors declare no competing interest.

References

- Weyand CM, Goronzy JJ. Clinical practice. Giant cell arteritis and polymyalgia rheumatica. *N Engl J Med* 2014;371:51–7.
- Liozon E, Ouattara B, Rhaïem K, Ly K, Bezanahary H, Loustaud V, et al. Familial aggregation in giant cell arteritis and polymyalgia rheumatica: a comprehensive literature review including 4 new families. *Clin Exp Rheumatol* 2009;27(Suppl. 52):S89–94.
- Nordborg E, Nordborg C. Giant cell arteritis: epidemiological clues to its pathogenesis and update on its treatment. *Rheumatology* 2003;42:413–21.
- Carmona FD, Gonzalez-Gay MA, Martin J. Genetic component of giant cell arteritis. *Rheumatology (Oxford)* 2014;53:6–18.
- Blumberg S, Bienfang D, Kantrowitz FG. A possible association between influenza vaccination and small-vessel vasculitis. *Arch Intern Med* 1980;140:847–8.
- Patel U, Bradley JR, Hamilton D. Henoch-Schönlein purpura after influenza vaccination. *BMJ* 1988;296:1800.
- Mader R, Narendran A, Lewtas J, Bykerk V, Goodman RCJ, Dickson JR, et al. Systemic vasculitis following influenza vaccination – report of 3 cases and literature review. *J Rheumatol* 1993;20:1429–31.
- Kelsall JT, Chalmers A, Sherlock CH, Tron VA, Kelsall AC. Microscopic polyangiitis after influenza vaccination. *J Rheumatol* 1997;24:1198–202.
- Iyngkaran P, Limaye V, Hill D, Henderson D, Pile KD, Rischmueller M. Rheumatoid vasculitis following influenza vaccination. *Rheumatology* 2003;42:907–9.
- Begier EM, Langford CA, Sneller MC, Wise RP, Ball R. Polyarteritis nodosa reports to the vaccine adverse event reporting system (VAERS): implications for assessment of vaccine-provoked vasculitis. *J Rheumatol* 2004;31:2181–8.
- Hull JKH, Mead SH, Foster OJ, Modarres-Sadeghi H. Severe vasculitic neuropathy following influenza vaccination. *J Neurol Neurosurg Psychiatry* 2004;75:1504–9.
- Williams GS, Evans S, Yeo D, Al-bermani A. Retinal artery vasculitis secondary to administration of influenza vaccine. *BMJ Case Rep* 2015. <https://doi.org/10.1136/bcr-2015-211971>.
- Watanabe T. Vasculitis following influenza vaccination: a review of the literature. *Curr Rheumatol Rev* 2017;13:188–96.
- Ghose MK, Shensa S, Lerner PI. Arteritis of the aged (giant cell arteritis) and fever of unexplained origin. *Am J Med* 1976;60:429–37.
- Gerth HJ. Polymyalgia rheumatic and influenza vaccination. *Dtsch Med Wochenschr* 1992;117:1259–60.
- Brown MA, Bertouch JV. Rheumatic complications of influenza vaccine. *Aust NZ J Med* 1994;24:572–3.
- Perez C, Maravi E. Polymyalgia rheumatic following influenza vaccination. *Muscle Nerve* 2000;23:824–5.
- Perez C, Loza E, Tinture T. Giant cell arteritis after influenza vaccination. *Arch Intern Med* 2000;160:2667.
- Liozon E, Ittig R, Vogt N, Michel JP, Gold G. Polymyalgia rheumatica following influenza vaccination. *J Am Geriatr Soc* 2000;48:1533–4.
- Saadoun D, Cacoub P, Mahoux D, Sbai A. Vasculites postvaccinales: à propos de trois observations. *Rev Med Interne* 2001;22:172–6.
- Finsterer J, Artner C, Kladosek A, Kalchmayr R, Redtenbacher S. Cervical sinus syndrome due to vaccination-induced giant cell arteritis. *Arch Intern Med* 2001;161:1008–9.
- Marti J, Anton E. Polymyalgia rheumatic complicating influenza vaccination. *J Am Geriatr Soc* 2004;52:1412.
- Pou MA, Diza-Torne C, Vidal S, Corchero C, Narvaez J, Nolla JM, et al. Development of autoimmune disease after vaccination. *J Clin Rheumatol* 2008;14:243.
- Henskens LHG, Broos N, Hautermans K. A patient with bilateral shoulder and pelvic girdle aching. *BMJ* 2011;343. <https://doi.org/10.1136/bmj.d6233>.
- Wada M, Asai J, Nakai D, Kishimoto S, Kato N. Giant cell arteritis with polymyalgia rheumatic associated with influenza vaccination. *J Dermatol* 2011;38:1099–101.
- Soriano A, Verrecchia E, Marinaro A, Giovine M, Fomesu C, Landolfi R, et al. Giant cell arteritis and polymyalgia rheumatica after influenza vaccination: report of 10 cases and review of the literature. *Lupus* 2012;21:153–7.
- Salehi M, Luckoor P, Sibal-Gomez EM. Polymyalgia rheumatica after influenza vaccine. *J Med Cases* 2017;8:117–8.
- Siddiqi N, Gulati G, Ware AE. Polymyalgia rheumatica and autoimmune inflammatory syndrome induced by adjuvants following administration of influenza vaccine. *J Clin Rheumatol* 2018;24:410–2.
- Bassendine MF, Bridge SH. Relapse of polymyalgia rheumatica following adjuvanted influenza vaccine: a case-based review. *Eur J Rheumatol* 2019;7:37–40.
- Hunder GG, Bloch DA, Michel BA, Stevens MB, Arend WP, Calabrese LH, et al. The American College of Rheumatology 1990 criteria for the classification of giant cell arteritis. *Arthritis Rheum* 1990;33:1122–228.
- de Boysson H, Liozon E, Lambert M, Parienti JJ, Artigues N, Geffray L, et al. 18F-fluorodeoxyglucose positron emission tomography and the risk of subsequent aortic complications in giant-cell arteritis: a multicenter cohort of 130 patients. *Medicine* 2016;95(26):e3851. <https://doi.org/10.1097/MD.0000000000003851>.
- Liozon E, Dalmay F, Lalloue F, Gondran G, Bezanahary H, Fauchais AL, et al. Risk factors for permanent visual loss in biopsy-proven giant cell arteritis: a study of 339 patients. *J Rheumatol* 2016;43:1393–9.
- Liozon E, Delmas C, Dumontel S, Dumont A, Gondran G, Bezanahary H, et al. Features and prognosis of giant cell arteritis in patients over 85 years of age: a case-control study. *Semin Arthritis Rheum* 2019;49:288–95.
- Ly KH, Dalmay F, Gondran G, Palat S, Bezanahary H, Cypierre A, et al. Steroid-sparing effect and toxicity of dapsone treatment in giant cell arteritis: a single-center, retrospective study of 70 patients. *Medicine* 2016;95(42):e4974. <https://doi.org/10.1097/MD.0000000000004974>.
- Bonetto C, Trotta F, Felicetti P, Alarcon GS, Santuccio C, Bachtir NS, et al. Vasculitis as an adverse event following immunization – systematic literature review. *Vaccine* 2016;34:6641–51.
- Felicetti P, Trotta F, Bonetto C, Santuccio C, Brauchli Pernus Y, Burgner D, et al. Spontaneous reports of vasculitis as an adverse event following immunization: a descriptive analysis across three international databases. *Vaccine* 2016;34:6634–40.
- Miller FW, Hess EV, Clauw DJ, Hertzman PA, Pincus T, Silver RM, et al. Approaches for identifying and defining environmentally associated rheumatic disorders. *Arthritis Rheum* 2000;43:243–9.
- Martinez-Taboada VM, Bartolome MJ, Lopez-Hoyos M, Blanco R, Mata C, Calvo J, et al. HLA-DRB1 allele distribution in polymyalgia rheumatica and giant cell arteritis: influence of clinical subgroups and prognosis. *Semin Arthritis Rheum* 2004;34:454–64.
- van der Woude D, Lie BA, Lundstrom E, Balsa A, Feitsma AL, Houwing-Duistermaat JJ, et al. Protection against anti-citrullinated protein antibody-positive rheumatoid arthritis is associated with HLA-DRB1*13:01. A meta-analysis of HLA-DRB1 associations with anti-citrullinated protein antibody-positive and anti-citrullinated protein antibody-negative rheumatoid arthritis in four European populations. *Arthritis Rheum* 2010;62:1236–45.
- Vankateswaran S, Prince J, Cutler DJ, Marigota UM, Okou DT, Prahalad S, et al. Enhanced contribution of HLA in pediatric onset ulcerative colitis. *Inflamm Bowel Dis* 2018;24:829–38.
- Gonzalez-Gay MA, Hajeer AH, Dababneh A, Makki R, Garcia-Porrua C, Thomson W, et al. Seronegative rheumatoid arthritis in elderly and polymyalgia rheumatica have similar patterns of HLA association. *J Rheumatol* 2001;28:122–5.
- Carmona FD, Mackie SL, Martin J-E, Taylor JC, Vaglio A, Eyre S, et al. A large-scale genetic analysis reveals a strong contribution of the HLA class II region to giant cell arteritis susceptibility. *Am J Hum Genet* 2015;96:565–80.
- Mackie SL, Taylor JC, Haroon-Rashid L, Martin S, Dasgupta B, Gough A, et al. Association of HLA-DRB1 amino acid residues with giant cell arteritis: genetic association study, meta-analysis and geo-epidemiological investigation. *Arthritis Res Ther* 2015;17:195. <https://doi.org/10.1186/s13075-015-0692-4>.
- Bettencourt A, Carvalho C, Leal B, Bras S, Lopes D, Martins da Silva A, et al. The protective role of HLA-DRB1*13:01 in autoimmune diseases. *J Immunol Res* 2015. <https://doi.org/10.1155/2015/948723>.
- Li Z-K, Nie J-J, Li J, Zhuang H. The effect of HLA on immunological response to hepatitis B vaccine in healthy people: a meta-analysis. *Vaccine* 2013;31:4355–61.
- Gelder CM, Lambkin R, Hart KW, Fleming D, Williams OM, Bunce M, et al. Associations between human leukocyte antigens and nonresponsiveness to influenza vaccine. *J Infect Dis* 2002;185:114–7.
- Perricone C, Colafrancesco S, Mazor RD, Soriano A, Agmon-Levin N, Shoenfeld Y. Autoimmune/inflammatory syndrome induced by adjuvants (ASIA) 2013: unveiling the pathogenic, clinical and diagnostic aspects. *J Autoimmun* 2013;47:1–16.
- Ly KH, Regent A, Tamby MC, Mouthon L. Pathogenesis of giant cell arteritis: more than just an inflammatory condition? *Autoimmun Rev* 2010;9:635–45.
- Nesher G. Autoimmune aspects of giant cell arteritis. *IMAJ* 2014;16:454–5.
- McGonagle D, McDermott MF. A proposed classification of the immunological diseases. *PLoS Med* 2006. <https://doi.org/10.1371/journal.pmed.0030297>.
- Wadat A, Bragazzi NL, McGonagle D, Adawi M, Bridgewood C, Damiani G, et al. Autoimmune/inflammatory syndrome induced by adjuvants (ASIA) demonstrates distinct autoimmune and autoinflammatory disease associations according to the adjuvant subtype: insights from an analysis of 500 cases. *Clin Immunol* 2019;203:1–8.
- Jeffs LS, Peh CA, Jose MD, Lange K, Hurtado PR. Randomized trial investigating the safety and efficacy of influenza vaccination in patients with antineutrophil cytoplasmic antibody-associated vasculitis. *Nephrology (Carlton)* 2015;20:343–51.

- [53] Stassen PM, Sanders JS, Kallenberg CG, Stegeman CA. Influenza vaccination does not result in an increase in relapses in patients with ANCA-associated vasculitis. *Nephrol Dial Transplant* 2008;23:654–8.
- [54] Adler S, Krivine A, Weix J, Rozeberg F, Launay O, Huesler J, et al. Protective effect of a/H1N1 vaccination in immune-mediated disease: a prospectively controlled vaccination study. *Rheumatology (Oxford)* 2012;51:695–700.
- [55] Holvast A, Stegeman CA, Benne CA, Huckriede A, Wilschut JC, Palache AM, et al. Wegener's granulomatosis patients show an adequate antibody response to influenza vaccination. *Ann Rheum Dis* 2009;68:873–8.
- [56] Nakafero G, Grainge MJ, Myles PR, Mallen CD, Zhang W, Doherty M, et al. Association between inactivated influenza vaccine and primary care consultations for autoimmune rheumatic disease flares: a self-control case series study using data from the clinical practice research Datalink. *Ann Rheum Dis* 2019;78:1122–6.
- [57] Furer V, Rondaan C, Heijstek MW, Agmon-Levin N, van Assen S, Bijl M, et al. 2019 update of EULAR recommendations for vaccination in adult patients with autoimmune inflammatory rheumatic disease. *Ann Rheum Dis* 2020;79:39–52.
- [58] Zafrir Y, Agmon-Levin N, Shoenfeld Y. Post-influenza vaccination vasculitides: a possible new entity. *J Clin Rheumatol* 2009;15:269–70.

Annexe 11.

Regulatory T Cells in Autoimmune Vasculitis



Regulatory T Cells in Autoimmune Vasculitis

Ke Jin¹, Simon Parreau¹, Kenneth J. Warrington¹, Matthew J. Koster¹, Gerald J. Berry², Jörg J. Goronzy^{1,3} and Cornelia M. Weyand^{1,3*}

¹ Department of Medicine, Mayo College of Medicine and Science, Rochester, MN, United States, ² Department of Pathology, Stanford University School of Medicine, Stanford, CA, United States, ³ Department of Medicine, Stanford University School of Medicine, Stanford, CA, United States

OPEN ACCESS

Edited by:

Rudolf Lucas,
Augusta University, United States

Reviewed by:

Santos Castañeda,
Hospital de La Princesa, Spain
Peter Heeringa,
University Medical Center Groningen,
Netherlands

Georgina Espigol-Frigole,
Hospital Clínic de Barcelona, Spain

*Correspondence:

Cornelia M. Weyand
cweyand@stanford.edu

Specialty section:

This article was submitted to
Inflammation,
a section of the journal
Frontiers in Immunology

Received: 27 December 2021

Accepted: 28 January 2022

Published: 28 February 2022

Citation:

Jin K, Parreau S, Warrington KJ,
Koster MJ, Berry GJ, Goronzy JJ and
Weyand CM (2022) Regulatory T Cells
in Autoimmune Vasculitis.
Front. Immunol. 13:844300.
doi: 10.3389/fimmu.2022.844300

Blood vessels are indispensable for host survival and are protected from inappropriate inflammation by immune privilege. This protection is lost in patients with autoimmune vasculitides, a heterogeneous group of diseases causing damage to arteries, arterioles, and capillaries. Vasculitis leads to vascular wall destruction and/or luminal occlusion, resulting in hemorrhage and tissue ischemia. Failure in the quantity and quality of immunosuppressive regulatory T cells (Treg) has been implicated in the breakdown of the vascular immune privilege. Emerging data suggest that Treg deficiencies are disease-specific, affecting distinct pathways in distinct vasculitides. Mechanistic studies have identified faulty CD8⁺ Tregs in Giant Cell Arteritis (GCA), a vasculitis of the aorta and the large aortic branch vessels. Specifically, aberrant signaling through the NOTCH4 receptor expressed on CD8⁺ Treg cells leads to rerouting of intracellular vesicle trafficking and failure in the release of immunosuppressive exosomes, ultimately boosting inflammatory attack to medium and large arteries. In Kawasaki's disease, a medium vessel vasculitis targeting the coronary arteries, aberrant expression of miR-155 and dysregulated STAT5 signaling have been implicated in undermining CD4⁺ Treg function. Explorations of mechanisms leading to insufficient immunosuppression and uncontrolled vascular inflammation hold the promise to discover novel therapeutic interventions that could potentially restore the immune privilege of blood vessels and pave the way for urgently needed innovations in vasculitis management.

Keywords: T cells, vasculitis, giant cell arteritis, Treg cell, exosomes, intracellular vesicles, NOTCH, autoimmune disease

INTRODUCTION

Vasculitides are autoimmune diseases defined by tissue-destructive inflammation in the vessel wall, resulting in wall destruction or wall remodeling leading to alterations in the vascular lumen. The pathogenic remodeling of blood vessels restricts the supply of nutrients and oxygen to peripheral tissues, causing organ damage and death (1). Vasculitides can be classified into diverse types according to the size of the affected vessels (2) and share some common phenotypes, such as wall infiltration of inflammatory cells, aneurysm formation, and luminal compromise (3). Decades of studies have yielded insights into the various mechanisms underlying the autoimmune

inflammation of arteries. Arteries are also the target of uncontrolled inflammation in auto-inflammatory syndromes, emphasizing the delicate relationship between immune cells and the conduits that carry them to the peripheral tissues (4).

A more detailed understanding of the immunopathogenesis of vasculitis is available for Giant Cell Arteritis (GCA), an inflammatory vasculopathy of medium and large arteries. In GCA, aberrant NOTCH signaling appears to have high pathogenic relevance and contributes to the breakdown of the immune privilege (5, 6). Inappropriate production of MMP9 by constituent myeloid cells adds another element to the loss of the tissue barrier (7). Additional pathways of pathogenic relevance include a state of hypermetabolism imposed by excessive CD28 signaling (8), the loss-of-function of the immunosuppressive PD1/PDL1 checkpoint (9), and the longevity of tissue-resident memory T cells that sustain chronic inflammation (10). This panel of malfunctioning pro-inflammatory pathways is complemented by the failure of anti-inflammatory mechanisms. Specifically, CD8⁺ Treg cells fail to provide proper inhibitory function in GCA patients (11–13). CD8⁺ Treg cells exert their immunosuppressive role by packaging NADPH2 oxidase 2 (NOX2) into exosomes and releasing these exosomes to control the function of neighboring T cells. In GCA patients, exosomal NOX2 is low, due to a defect of directing intracellular vesicles. The rerouting of vesicles is a consequence of inappropriate signaling through the NOTCH4 receptor (12, 13).

REGULATORY T (TREG) CELLS

Regulatory T (Treg) cells are a subset of T lymphocytes, occupying about 5% to 10% of the circulating T cell pool (14). In contrast to effector T cells, Treg cells mediate immunosuppression to ensure that the immune defenses against exogenous and endogenous antigens are accurately controlled in time and space. Treg cells accomplish their suppressive function through numerous mechanisms, such as secretion of inhibitory cytokines, induction of apoptotic cell death, direct transfer of inhibitory signals, and the delivery of extracellular vesicles (15–17).

A shift in either quantity or quality of Treg cells will lead to a disbalance in immune homeostasis, resulting in a variety of disease states. In tumor-bearing hosts, Treg cells are enriched at the tumor site, suppress anticancer immunity, protect the tumor from immunosurveillance and promote tumor development (18, 19). In contrast, patients with autoimmune disease, including vasculitis, suffer from defective Treg cell protection, promoting a breakdown of tissue tolerance and a lack of timely downregulation in ongoing immune responses (20, 21). Accordingly, massive efforts have been undertaken to turn Treg cells into therapeutic agents or enhance Treg function in patients. These investments have resulted in the development of novel Treg-based therapeutic strategies, which will eventually provide novel alternatives for immune-modulatory interventions (22, 23). In this review, we will summarize current knowledge of the phenotypes of Treg cells, their protective roles in vasculitis, and potential strategies for harnessing Treg cell function.

Treg Phenotypes

Here, we will provide an overview of what is known about shared phenotypes found on most Treg cells, including the Treg cell marker (FOXP3), specific subtypes of Treg cells, e.g. CD8⁺ Treg cells, and the molecular mechanism behind Treg-induced inhibition. There is agreement in the field that Treg cell populations are heterogenous when it comes to phenotype and function (24). In addition, there is recognition that Treg cells have considerable plasticity, which may be particularly important when they are exposed to inflammatory signals (25–27). Multiple factors, including the tissue environment in which the Treg cell lives and functions, the extent of antigen-induced T cell receptor signalling, the input of co-stimulatory and co-inhibitory signalling may all contribute to the stability and the plasticity of Treg cells.

FOXP3

The transcription factor forkhead box P3 (FOXP3) is the best known Treg biomarker and is recognized as the master regulator of Treg cell generation and function. As a transcription factor, FOXP3 induces the expression of Treg-associated genes, including IL-2, CD25, CTLA-4, and miR-155 (28, 29). More than a recognitional marker, FOXP3 possesses the ability to control the switch between Treg cells and effector T cells. Ectopic FOXP3 expression transforms T cells into suppressor cells, while the failure of constant FOXP3 expression impairs the potency to inhibit effector cells (30–32). Based on FOXP3 expression, Treg cells can be dissected into three subpopulations: CD45RA(+) FOXP3(lo) resting Treg cells (rTreg cells), CD45RA(-)FOXP3 (hi) activated Treg cells (aTreg cells) and cytokine-secreting CD45RA(-)FOXP3(lo) nonsuppressive T cells. Both rTreg cells and aTreg cells are effective suppressor cells *in vitro*. aTreg cells die rapidly but rTreg cells proliferate and convert into aTreg cells (24).

Due to FOXP3's indispensable role in Treg biology, the regulation of FOXP3 expression has drawn considerable attention. Several transcription factors have been reported to induce FOXP3 transcription, including Forkhead transcription factor of the O class (FOXO)1, FOXO3, c-Rel, Smad2, and Smad3 (33–39). Interestingly, the glycolytic enzyme enolase (ENO)-1 inhibits FOXP3 transcription through binding to the promoter region (40), suggesting a major role in the direct metabolic control of Treg cell function. At the post-transcriptional stage, several microRNAs are predicted to directly bind to the FOXP3 3'-UTR. Specifically, changes in the abundance of miR-31 and miR-15a/16 have been associated with significant modulation of FOXP3 expression (41–44). FOXP3 can also be regulated through post-translational modifications. High expression of the deubiquitinase (DUB) ubiquitin specific-processing protease (USP)7 in Treg cells is required for sustained FOXP3 expression (45). Vice versa, the E3 ubiquitin ligase Stub1 leads to FOXP3 ubiquitination and degradation (46, 47). Uncontrolled FOXP3 ubiquitination has been proposed as a relevant mechanism in autoimmune diseases. In patients with psoriasis, the (C-C motif) ligand (CCL)3 and the protein kinase B (PKB)/Akt1 pathway induce polyubiquitination of FOXP3,

which is highly associated with defective Treg function (48). Besides ubiquitination, FOXP3 is also regulated by other modifications, including acetylation (by SIRT1 and TIP60) and phosphorylation (by CDK2 and NLK) (49–54). In the autoimmune disease rheumatoid arthritis (RA), instability of FOXP3 expression and the subsequent failure of Treg-dependent immunosuppression are due to the insufficient expression of the histone acetyltransferase TIP60 (55).

CD8⁺ Treg Cells

Although CD25⁺FOXP3⁺ T cells amongst CD4⁺ T cells are often considered to be classical Treg cells, the compartment of CD8⁺ T cells also contains a regulatory subset. Like CD4⁺ Treg cells, CD8⁺ Treg cells express FOXP3, but at a lower level (56, 57). Recent studies have emphasized that it is not accurate to identify CD8⁺ Treg cells based only on CD25 expression (58, 59). Instead, additional cell surface markers, such as CD39⁺ and CD26⁺ are now considered useful markers of CD8⁺ Treg cells (60, 61). The subpopulation of CD8⁺CD39⁺CD26⁺ T cells represents a highly purified Treg cell subset, which possesses strong inhibitory effects in T cell activation assays (12).

Similar to CD4⁺ Treg cells, CD8⁺ Treg cells may be reduced in number or quality in patients with autoimmune disease. Specifically, lowered numbers of CD8⁺ Treg cells have been reported in patients with systemic lupus erythematosus (SLE)

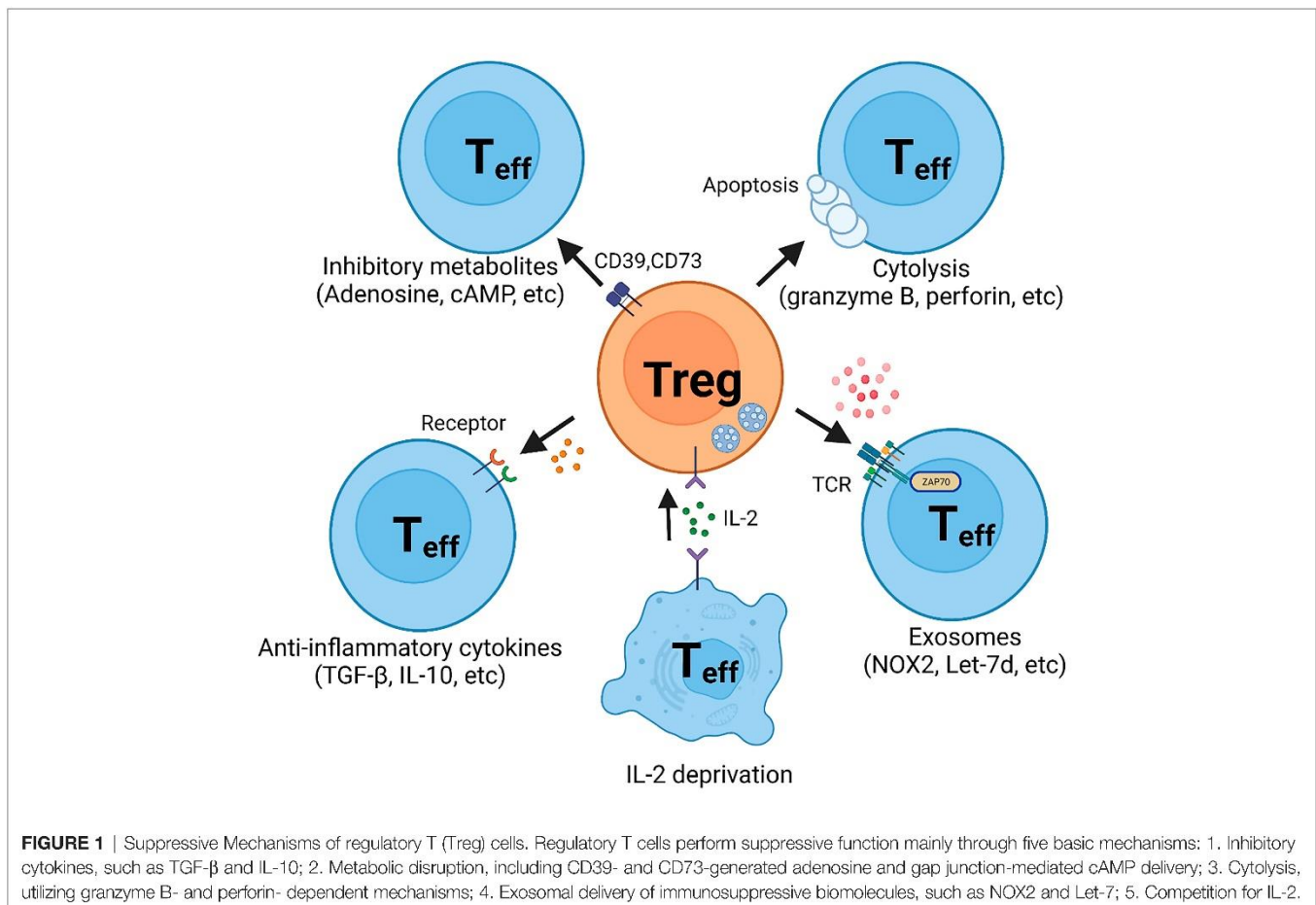
and recovery of CD8⁺FOXP3⁺ Treg cells after transplantation of autologous hematopoietic progenitor cells has been associated with good control of disease activity (62). In patients with giant cell arteritis (GCA), frequencies of circulating CD8⁺ Treg cells are largely maintained, but an altered gene expression program results in impaired suppressive capacity and unopposed inflammatory activity of pathogenic CD4⁺ T cells. Experiments designed to repair the expression of relevant gene products in patient-derived CD8⁺ Tregs have been sufficient to restore fully functional Tregs *in vitro* and *in vivo*, which prevented the invasion of the vessel wall by inflammatory cells (13).

Mechanisms of Treg Cell Function

Determination of the mechanisms of how Treg cells function is critical to understanding the role of these specialized T cells in protective and pathogenic immunity. Ever since Treg cells were initially described, attention has been directed at uncovering, both on the cellular and molecular level, how these cells can inhibit signaling to affect the survival of their target cells. Here, we are going to summarize the spectrum of mechanisms used by Treg cells to exert their immune-regulatory role (Figure 1).

Cytokines

Inhibitory cytokines secretion may be one of the most efficient mechanisms of Treg cell-mediated suppression of immune



responses, but this is complicated by nonselectivity. Although multiple inhibitory cytokines have been discovered, interleukin-10 (IL-10) and Transforming growth factor- β (TGF- β) remain on top of the list and are considered part of the basic repertoire in Treg cell biology (**Figure 1**).

The IL-10 family has nine members, including IL-10, IL-19, IL-20, IL-22, IL-24, IL-26, IL-28A, IL-28B, and IL-29 (63) and is now recognized as a critical element in protecting tissues from excessive inflammatory responses (64). Upon binding to its receptors IL-10R1 and IL-10R2, IL-10 regulates downstream pathways through cascade phosphorylation, utilizing the JAK-STAT signaling pathway (65, 66). IL-10-dependent activation of the JAK-STAT signaling pathway leads to nuclear translocation of STAT3, initiating downstream target gene expression (67, 68). IL-10 has also been reported to activate other signaling pathways, such as PI3K-AKT and MAPK pathways (69–72). Abnormal expression of IL-10 has been reported in some vasculitides. Tesar et al. found that IL-10 is highly expressed in patients with active ANCA-associated vasculitis (AAV), but not in patients in remission (73). The upregulation of IL-10 with disease activity might be reflective of the host's attempt to suppress inappropriate immunity. The authors also reported that patients in remission who then relapsed produced significantly lower levels of IL-10 compared to those without relapse, indicating that IL-10 could be a useful biomarker for long-term disease prediction (73).

TGF- β mediates its anti-inflammatory function through two routes: 1. Inhibition of inflammatory cells; 2. strengthening of Treg cells (74). TGF- β has been reported to suppress T cell proliferation by blocking production of interleukin-2 (IL-2) (75) and preventing T cell differentiation to Th1 and Th17 cells (76–78). In addition, TGF- β promotes the generation and function of Treg cells by inducing FOXP3 expression in both CD4⁺ and CD8⁺ T cells (79–81). Although TGF- β has three isoforms, TGF- β 1 is dominantly expressed in the immune system (82). Twelve TGF- β receptors with serine/threonine kinase subunits have been enumerated, including 5 type I and 7 type II transmembrane receptors (83). Upon TGF- β stimulation, the signaling cascade of SMAD proteins causes the transcription of target genes, such as MYC and P21 (84, 85). Other non-SMAD pathways have also been implicated in TGF- β signaling, such as the RAS-ERK pathway and the PI3K-AKT pathway (86).

An alternative mechanism through which Treg cells modulate the function and behavior of T effector cells relates to the competition for resources. Specifically, Treg cells can inhibit the proliferation and survival of effector T cells by depriving them of IL-2 (87).

Inhibition Through the Transfer of Metabolites

Data have accumulated supporting the concept that metabolites generated and released by Treg cells impose an inhibitory effect on targeted T cells.

Adenosine, generated by CD39 and CD73 in the extracellular space or released from the intracellular compartment, suppresses effector T cells by binding to the adenosine receptor 2A (A_{2A}R) (88–90) (**Figure 1**). Evidence has been provided that adenosine

promotes the generation of Treg cells by inhibiting IL-6 generation and enhancing TGF- β production. In mice, A_{2A}R stimulation results in the inhibition of Th1 and Th17 cell differentiation and the enhancement of FOXP3⁺ Treg cell generation (91). No data are available on whether this mechanism has relevance in inflammatory vasculopathies. Notably, methotrexate, an immunosuppressive medication used broadly in the treatment of autoimmune diseases by amplifying adenosine production, has only limited application in patients with autoimmune vasculitis.

Alternative pathways through which Treg cells control the functionality of effector T cells involve cyclic AMP (cAMP) (**Figure 1**). Treg cells harbor a high concentration of cAMP and form a cell contact-dependent gap junction with effector T cells to deliver intracellular cAMP (92). Subsequently, cAMP inhibits T cell proliferation and IL-2 synthesis (92).

Cytolysis

An alternative mode through which Treg cells inflict their suppressive function relies on perforin/granzyme-dependent cytolysis (**Figure 1**). Although cytotoxicity mediated by perforin/granzyme has mostly been considered an exclusive function of natural killer (NK) cells and CD8⁺ T cells, it is now accepted that Treg cells and CD4⁺ T cells can utilize this mechanism to regulate the function of neighboring cells. Recent studies have provided convincing evidence that some human CD4⁺ T cells also exhibit cytolytic function (93, 94). Granzyme B has been detected in CD4⁺ Treg cells and has been associated with functional fitness. Granzyme B appears to be highly expressed in CD4⁺FOXP3⁺ Treg cells and deficiency for granzyme B or perforin paralyzed Treg cells in a mouse model (95).

Exosomal Delivery

Exosomes are extracellular vesicles secreted by cells, with sizes ranging from roughly 50 – 150 nm. Exosomes contain cell-specific proteins, lipids, metabolites, and genetic materials, and can be selectively absorbed by neighboring or distant cells based on surface protein recognition (96, 97). Exosomes play a critical role in immune regulation but seem to be of special relevance for Treg cells since Treg cells outperform other cell types in the production of exosomes. Treg-derived exosomes are indispensable for Treg cell function and disruption of exosome release through pharmaceutical or genetic mechanisms effectively blocks the suppressive function of Treg cells (16, 98, 99).

Exosomes exhibit their function through the biomaterial they contain, such as lncRNA (e.g., Let-7d) (100) or inhibitory molecules (e.g., CD73) (101). In the large vessel vasculitis, GCA, CD8⁺ Treg cells inhibit CD4⁺ T cells activation and proliferation by secreting NADPH oxidase 2 (NOX2) containing exosomes (12, 13) (**Figure 1**). Blocking exosome secretion or interfering with NOX2 function halted CD8⁺ Treg cell function. Enhancing the loading of NOX2 into the exosome restored CD8⁺ Treg cells' function and attenuated vascular inflammation in chimeric mice engrafted with human arteries. These data support the concept that Treg-derived exosomes may provide a novel tool to reestablish tissue tolerance in vasculitis (12, 13).

Treg Cells in Autoimmune Vasculitides Giant Cell Arteritis

Giant Cell Arteritis (GCA) is the most common autoimmune vasculitis, with incidence and prevalence rates growing as the population ages. Patients with GCA suffer from aggressive wall inflammation in medium and large arteries, including the aorta, subclavian arteries, axillary arteries, extra-cranial branches of the carotid arteries, and vertebral arteries. Infrequently, GCA is diagnosed in lower extremity arteries. Clinically, the most feared disease manifestations are ischemic stroke of the optic nerve and the posterior brain. Potentially fatal consequences such as aneurysm formation, dissection and rupture are related to the destruction of the aortic wall. On a cellular level, the disease is characterized by the formation of granulomas within inflamed arteries, assembled from CD4⁺ T cells, macrophages and multinucleated giant cells (102, 103).

Numeric and qualitative deficiencies in Treg cells are well recognized in GCA. Terrier and colleagues reported decreased frequencies of CD4⁺FOXP3⁺ Treg cells in the peripheral blood of GCA patients and FOXP3 was suspiciously absent in T cells infiltrating vasculitic lesions (104).

Recent cellular and molecular studies have shifted attention from CD4⁺ Treg cells to the CD8⁺ Treg cell subset. CD8⁺ Treg cells contain a functionally specialized subpopulation that imposes immunosuppression by secreting NOX2 containing exosomes that are absorbed by nearby CD4⁺ effector T cells to suppress their activation and proliferative expansion (12). In patients with GCA, the frequency of CD8⁺ NOX2⁺ Treg cells is diminished, and, in addition, their function is essentially paralyzed. Molecular mechanisms underlying the loss of functional fitness in patient-derived CD8⁺ Treg cells have been uncovered and are closely related to a defect in exosome production (13) (Figure 2). Both, the loading of NOX2 into the exosomes and the generation of exosomes were attenuated due to the rewiring of the endosomal system. The endosomal machinery is critically involved in processes of protein quality control and is responsible for the trafficking of intracellular proteins between different cellular compartments and the release of proteins through exosomes. New insights into the different vesicular trafficking pathways have emerged, and the endosomal sorting complex required for transport (ESCRT) pathway is now recognized as the pathway for the formation of intraluminal vesicles and multivesicular bodies (MVB) (105). Exosomes are born by intraluminal budding of the MVB (106). The multiprotein complex of the ESCRT machinery regulates the invagination of vesicles into the MVB while recognizing, capturing, and sorting ubiquitinated protein cargo. Sequestering of ubiquitinated membrane proteins can occur at the endosomal membrane as well as the plasma membrane. When the MVB fuses with the plasma membrane, exosomes can be secreted into the extracellular space. Much has yet to be learned about the trafficking, docking and membrane integration of exosome carrying MVB, but several Rab GTPases within the endolysosomal trafficking machinery, including Rab27a and Rab27b, are associated with exosome loading and secretion (107). In essence, effector proteins recruited by Rab GTPases

ultimately determine the collection of cargo, the movement of vesicles throughout the subcellular compartments, the docking of MVBs to the target membrane and the delivery of exosomes. In the case of CD8⁺ Treg cells derived from GCA patients, hyperactivation of NOTCH4 signaling disrupts the exosomal secretion of NOX2 through transcriptional control of Rab GTPases. Precisely, NOTCH4^{hi}CD8⁺ Treg cells upregulate the expression of *RAB5A* and *RAB11A* but repress *RAB7A*, accumulating NOX2 in the intracellular compartment, including the early and recycling endosomes. GCA CD8⁺ Treg cells fail to translocate NOX2 to MVBs and the cell surface, disrupting the exosomal release of immunosuppressive NOX2 (Figure 2). Ultimately, dysfunctional CD8⁺ Treg cells are unable to control the expansion of pro-inflammatory CD4⁺ T cells, paving the way for the invasion of an immune privileged tissue site (13). These data will allow the development of new strategies to modulate the balance between pro and anti-inflammatory T cells in GCA. Inhibition of NOTCH signaling repaired CD8⁺ Treg function *in vitro* and *in vivo* and ameliorated vascular inflammation in NSG mice carrying human arteries (13) provide a rationale for drug targeting of this vaso-inflammatory pathway.

Takayasu Arteritis (TAK)

Takayasu's arteritis (TAK) is an inflammatory vasculopathy that primarily affects young women and leads to aortitis and vasculitis of the primary aortic branch vessels (108). While the histopathology of vascular involvement and the consequences of vascular inflammation have similarities in GCA and TAK, there are also differences in the cellular and molecular immunopathology of the two vasculitides (103). The percentage of circulating activated Treg has been reported to be lower in TAK patients than in healthy age-matched controls, while resting Tregs are similar (109, 110) suggesting the possibility of abnormal Treg cell maturation. On account of their plasticity, Treg cells can acquire new effector functions, e.g. differentiating into Th1, Th2, or Th17-like cells (20). But this transformation of Treg cells can possibly strengthen the inflammatory processes and further diminish physiological immunosuppression. Another possibility based on recent studies proposes that Tregs derived from TAK patients insufficiently differentiate into Th2-like cells, thereby detracting from IL-4 and IL-13 production and contributing to excess inflammation (110).

Polyarteritis Nodosa (PAN)

Polyarteritis nodosa, formerly known as periarteritis nodosa, is a systemic necrotizing vasculitis affecting medium and small-sized vessels (111). Vascular damage occurs preferentially in the gastrointestinal tract, skin and peripheral nervous system. Unlike GCA and TAK, PAN patients have been reported to have increased Treg cells in their blood (112). However, in co-culture experiments with effector T cells the suppressive abilities of Tregs from PAN patients are significantly depressed, and this loss of function appears to be associated with lower expression of CTLA-4. Studies comparing Treg cell competence in patients treated with prednisolone or prednisolone plus cyclophosphamide have found normalization of Treg cell frequencies (112).

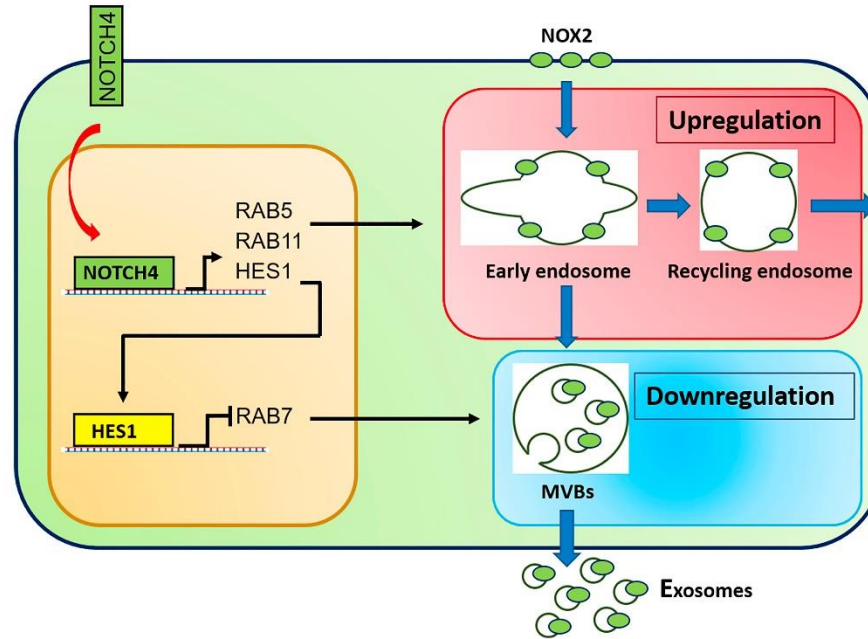


FIGURE 2 | Molecular defects in CD8⁺ Treg cells from GCA patients. Aberrant NOTCH4 signaling in GCA CD8⁺ Treg cells enhances expression of *RAB5A* and *RAB11A* and suppresses expression of *RAB7A* through HES1. *RAB5A* and *RAB11A* high expression promotes formation of early and recycling endosomes, keeping NOX2 in an intracellular, non-secretory storage compartment. *RAB11* suppression results in deficient generation of specialized endosomes, the multivesicular bodies (MVB) and subsequent reduction in exosome biogenesis. Consequently, NOX2 is trapped intracellularly and no longer available to be loaded into immunosuppressive exosomes.

Kawasaki Disease (KD)

Kawasaki disease (KD) is a vasculitis of early childhood targeting medium and small-sized vessels. A classical complication of KD is the formation of coronary artery aneurysms. In the acute phase of KD, Treg cells frequency is lowered by 50% compared to age-matched healthy controls, regardless of whether the patients had coronary artery lesions (CAL) or not (113–115). The gold standard of therapy for KD is now the infusion of immunoglobulins (IVIG), which modulates abnormal immunity through the antibody-dependent pathways and increases the number of circulating Treg cells (116).

Fc-specific Treg clones have been generated from sub-acute KD patients without arterial complications following IVIG therapy. These Treg clones display an unusual phenotype, secreting IL-10 and IL-4 but not TGF- β . However, KD patients with CAL even despite IVIG treatment seem to be unable to expand these Fc-specific Treg populations (117). Similar Treg fine specificities have been isolated from IVIG-treated KD patients and healthy controls, suggesting that the absence of Fc-specific Treg cells in acutely ill KD patients may be an inflammation-imposed abnormality (118). Patients with a history of KD in their childhood did not respond to Fc protein *in vitro*, suggesting that the IVIG-induced Treg response in KD patients is short-lived. Infliximab, a chimeric monoclonal antibody targeting TNF- α , can increase Treg cell frequencies during acute KD, while Infliximab-resistant patients lack an adaptation of Treg cell frequencies (119). All of these observations support the hypothesis that an inflammatory state

can alter the frequencies of CD4⁺ FOXP3⁺ cells in the circulation and can possibly strip these cells of their suppressive capabilities.

In KD, FOXP3 mRNA levels appear to be regulated by the miR-155/SOCS1 and the miR-31 signaling pathways. In patients with acute KD, decreased CD4⁺FOXP3⁺ Treg cells might be associated with decreased expression of miR-155, leading to aberrant SOCS1/STAT5 signaling and overexpression of miR-31. This abnormality may also represent an inflammation-imposed deviation as it can be corrected by IVIG (114).

HCV-Associated Cryoglobulinemic Vasculitis

Vasculitis associated with Cryoglobulinemia is an immune complex disease that unfolds primarily in small-sized vessels, such as the capillaries of renal glomeruli. All patients with cryoglobulinemic vasculitis require evaluation for chronic hepatitis C virus (HCV) infection (120). Early studies showed that patients with symptomatic HCV-associated cryoglobulinemic vasculitis have both reduced numbers and diminished function of Treg cells (121), consistent with the hypothesis that systemic inflammatory states are characterized by redistribution and functional impairment of Treg cells.

A French team of investigators has evaluated the effectiveness of different therapies on the Treg cell population in 3 prospective trials. PEGylated interferon alfa-2b plus ribavirin treatment induced a significant and stable increase of Treg cell frequencies compared with baseline in patients with clinical and viral remission (122). In contrast, Treg cell frequencies did not differ after treatment for

non-responders or partial responders. The frequency of Treg cells was positively correlated with plasma complement levels and inversely correlated with cryoglobulin levels, again indicating that circulating CD4⁺ FOXP3⁺ T cells are a sensitive biomarker of systemic inflammation. Since Treg cells are dependent on IL-2 as a growth and survival factor, therapeutic trials have tested the potential benefit of supplementing low-dose IL-2 (aldesleukin) in patients refractory to conventional antiviral therapy and/or B cell depletion therapy. Monitoring of peripheral Treg cells following treatment with exogenous IL-2 has shown numeric and functional improvements (123). Beneficial effects and reversal of Treg deficiency have also been reported for combination antiviral therapy with sofosbuvir plus daclatasvir (124).

Henoch-Schoenlein Purpura (IgA Vasculitis)

Henoch-Schoenlein purpura (HSP), also known as IgA vasculitis, is the most common small vessel vasculitis in children (125). Target organs include skin, kidneys, gastrointestinal tract, and joints. Like most systemic vasculitides, HSP patients have lower numbers and weak suppressive function of Treg cells (126–129). As a reflection of a shift in the balance between pro-inflammatory effector T cells and suppressive Treg cells, the Th17/Treg ratio has been positively correlated with the erythrocyte sedimentation rate, kidney lesions, and multiorgan involvement (126). Treg cells that secrete IL-10 and TGF- β accumulate in the vasculitic tissue lesions in the kidneys (129). FOXP3 staining is preferentially localized in renal interstitial areas but does not correlate with proteinuria, serum albumin levels, and the histological classification of vasculitic involvement (130). In a recent study, miR-1-3p, miR-19b-1-5p, and miR-29b-1-5p were found to be up-regulated in peripheral blood mononuclear cells (PBMCs) of HSP patients, while miR-483-5p and miR-1246 were down-regulated. This shift was correlated with the Th17/Treg ratio (131). Again, numeric and functional alterations in peripheral blood Treg cells may simply reflect the high inflammatory status.

Behçet's Disease (BD)

Behçet's disease (BD) is an auto-immune/auto-inflammatory syndrome that can lead to vasculitis. The risk for BD is highest amongst individuals living along the Silk Road and the prototypic lesions are mucosal and genital ulcerations. BD stands out amongst the vasculitides by its often concurrent venulitis (132). Like other vasculitides, Treg cells are decreased in BD and correlate with disease activity (133–138). Imbalances in miRNA expression and excessive IL-21 have been considered to be key underlying abnormalities leading to Treg cell dysfunction (135, 138). Infliximab, but not colchicine or cyclosporine, increases the percentage of FOXP3⁺ cells in BD (134). Observation studies have reported that treated BD patients with low circulating Treg populations experience more ocular inflammation than those higher numbers (134). T cells exposed to infliximab had increased expression of FOXP3 and TGF- β and suppressed the activation of bystander T cells in *in vitro* experiments (134).

Antineutrophil Cytoplasmic Antibody (ANCA)-Associated Vasculitis (AAV)

AAV is a necrotizing vasculitis affecting mostly small-sized vessels. Typically, few or no immune complex deposits are seen in affected tissues. The term AAV encompasses three disease entities: granulomatosis with polyangiitis (GPA, Wegener's granulomatosis), microscopic polyangiitis (MPA) and eosinophilic granulomatosis with polyangiitis (EGPA, Churg-Strauss syndrome) (139, 140). These three vasculitides are associated with specific autoantibodies, antineutrophil cytoplasmic antibodies (ANCA) that target either proteinase 3 (PR3) or myeloperoxidase (MPO). Each vasculitic entity has a specific phenotype with a particular pattern of organ damage. GPA is more often associated with anti-PR3 ANCA and manifests with necrotizing granulomatous inflammation involving the upper and lower respiratory tract and necrotizing glomerulonephritis. MPA is typically associated with anti-MPO antibodies. Granulomatous inflammation is not a feature of MPA which presents with necrotizing glomerulonephritis and pulmonary capillaritis. Patients with EGPA have asthma, eosinophilia, and eosinophil-rich, necrotizing granulomatous inflammation often involving the respiratory tract. While the respiratory tract and the kidneys are targeted in most AAV patients, manifestations in the skin and the peripheral nerves are not unusual (141, 142).

Patients with AAV follow the general rule that systemic inflammation is associated with low numbers and functional impairment of Treg cells (143–146). Some studies have shown increased numbers of Treg cells (147, 148). Treg cells from GPA patients are still able to suppress proliferation of T cells from ANCA-negative patients, which has led to the hypothesis that part of the Treg deficit derives from target cell resistance (149). In AAV patients, expression of a FOXP3 isoform lacking exon 2 has raised suspicion of Treg cell instability (143). Also, miR-142-3p is upregulated in memory Tregs in GPA (150). *In vitro* overexpression of miR-142-3p produces functionally impaired Treg cells characterized by decreased cAMP levels. Pharmacological induction of cAMP production restores suppressive capacity (150). In MPA, attention has focused on the potential impact of diminished serum tryptophan and elevation of the tryptophan metabolite, kynurenine. Inhibition of tryptophan degradation enhances immune responsiveness, with a tendency to more severe glomerulonephritis (151). Correlative studies associating improvement of CCR4⁺FOXP3⁺ Treg cell frequencies with drug-free remission have supported the concept that ultimately, Treg cell frequencies are sensitive markers of the inflammatory status (152). In a mouse model, blocking IL-6 activity ameliorated the disease and increased the migration of Tregs into the kidney and the regional lymph nodes (152). In both GPA and MPA, B cell depletion therapy and conventional immunosuppressants yielded similar CD4⁺ Treg cell numbers (153).

Eosinophilic Granulomatosis and Polyangiitis

Patients diagnosed with Eosinophilic Granulomatosis and Polyangiitis (EGPA) typically present with the triad of asthma, eosinophilia, and necrotizing vasculitis (154). Whether eosinophils are causally involved in the damage of small blood

vessels remains unresolved. Compared to asthma control patients, EGPA patients have lower frequencies of Treg cells (155, 156). Production of IL-10, TGF- β , and expression of CTLA-4 by Treg cells are correlated to the inflammatory activity of the disease (156, 157). Relapsing patients, compared to those in remission, have a lower proportion of inducible Treg cells (134) and IL-2 production is predictably low. There is some evidence that the expression of the immunosuppressive molecule indoleamine 2,3-dioxygenase (IDO) is diminished in EGPA. IDO is thought to cause immune suppression through the breakdown of tryptophan. In relapsing EGPA, Treg cells are positively correlated with the CD19⁺ B cell count and inversely related to CD80⁺CD19⁺ B cells (156). Percentages of Treg cells, Treg-derived IL-10 and TGF- β are positively correlated with the percentage of CD83⁺ dendritic cells and inversely correlated with CD206⁺ DCs (158). These data suggest that Treg cells might play a role in DC and B cell biology.

Rheumatoid Arthritis (RA) and Systemic Lupus Erythematosus (SLE)

As autoimmune disorders, vasculitides share features with other autoimmune diseases raising the possibility that Treg cell dysfunction is critically involved in the loss of self-tolerance. We will briefly review the current state of knowledge about Treg cell biology in the two classical autoimmune diseases, rheumatoid arthritis (RA) and systemic lupus erythematosus (SLE).

CD4⁺FOXP3⁺ T cells have been extensively studied in RA patients, but the mechanistic implications continue to be debated. Much of the discussion has focused on the methodologies of Treg analysis. One meta-analysis arrived at the conclusion that numbers of Treg cells in peripheral blood are diminished but the cells redistribute and accumulate in synovial fluid (159). Similarly, functional studies have supported the idea that systemic inflammation results in reduced numbers and reduced function. Functional analyses have shown that inhibitory competence is partially impaired. Specifically, Treg cells isolated from the peripheral blood of RA patients block the proliferation of effector T cells but fail to limit pro-inflammatory cytokine production (160). This effect can be partially reversed by anti-TNF α therapy, which successfully restores the capacity of Treg cells to inhibit cytokine production, and in parallel, supports recovery of Treg cell numbers in peripheral circulation (160). Attempts at defining the underlying mechanism have implicated reduced expression of CTLA-4 and enhanced expression of IL-6 (161, 162). Work analyzing the stability of FOXP3 has yielded valuable insights into the post-translational modification of the transcription factor as a determining feature of Treg phenotype and fitness. Specifically, loss-of-function of the histone acetyltransferase TIP60 (KAT5) has been associated with the instability of FOXP3, impaired Treg cell differentiation and failed immunosuppression (55) (**Figure 3**).

Systemic Lupus Erythematosus (SLE) is the prototypic multi-organ autoimmune disease that affects the skin, kidneys, lungs, joints, and the central and peripheral nervous systems. SLE patients follow the classical pattern and have lower frequencies of Treg cells in their blood (163). Excellent progress has been

made in defining the molecular abnormalities that produce Treg cell deficiency. A prime defect of SLE Treg cells lies in the low availability of IL-2, which is required for the expansion and survival of these immunoinhibitory T cells (**Figure 3**). In SLE patients, the cAMP responsive element modulator- α (CREM α), a transcriptional repressor of the IL-2 promoter, is hyperactive, resulting in silencing of IL-2 and reduced FOXP3 expression (164). An alternative mechanism has been found for IL-2 deficiency in SLE. Mutations in the transcriptional repressor, Ikaros (165), lead to elevated protein phosphatase 2A (PP2A) expression in SLE T cells, restraining IL-2 expression (166). PP2A knockdown increased the expression of phosphorylated cAMP response element-binding protein (pCREB), restoring IL-2 expression (167). However, specific ablation of PP2A in murine Treg cells caused the development of autoimmunity in an mTOC-dependent manner (168), demonstrating that PP2A mediates different signaling pathways in effector and regulatory T cells.

Treg Cell-Targeted Therapy

Targeting the immunosuppressive function of Treg cells holds great promise not only for the field of autoimmunity but also in tumor therapy, wherein excessive Treg-derived immunosuppression undermines the host's immune response. Ultimately, the goal is to have a therapeutic armamentarium, which would allow readjustment in the numbers and the function of Treg cells *in vivo*. Below we will review the different approaches that are currently under development to exploit Treg biology for novel strategies of immunomodulatory therapy. An overview is provided in **Figure 4**.

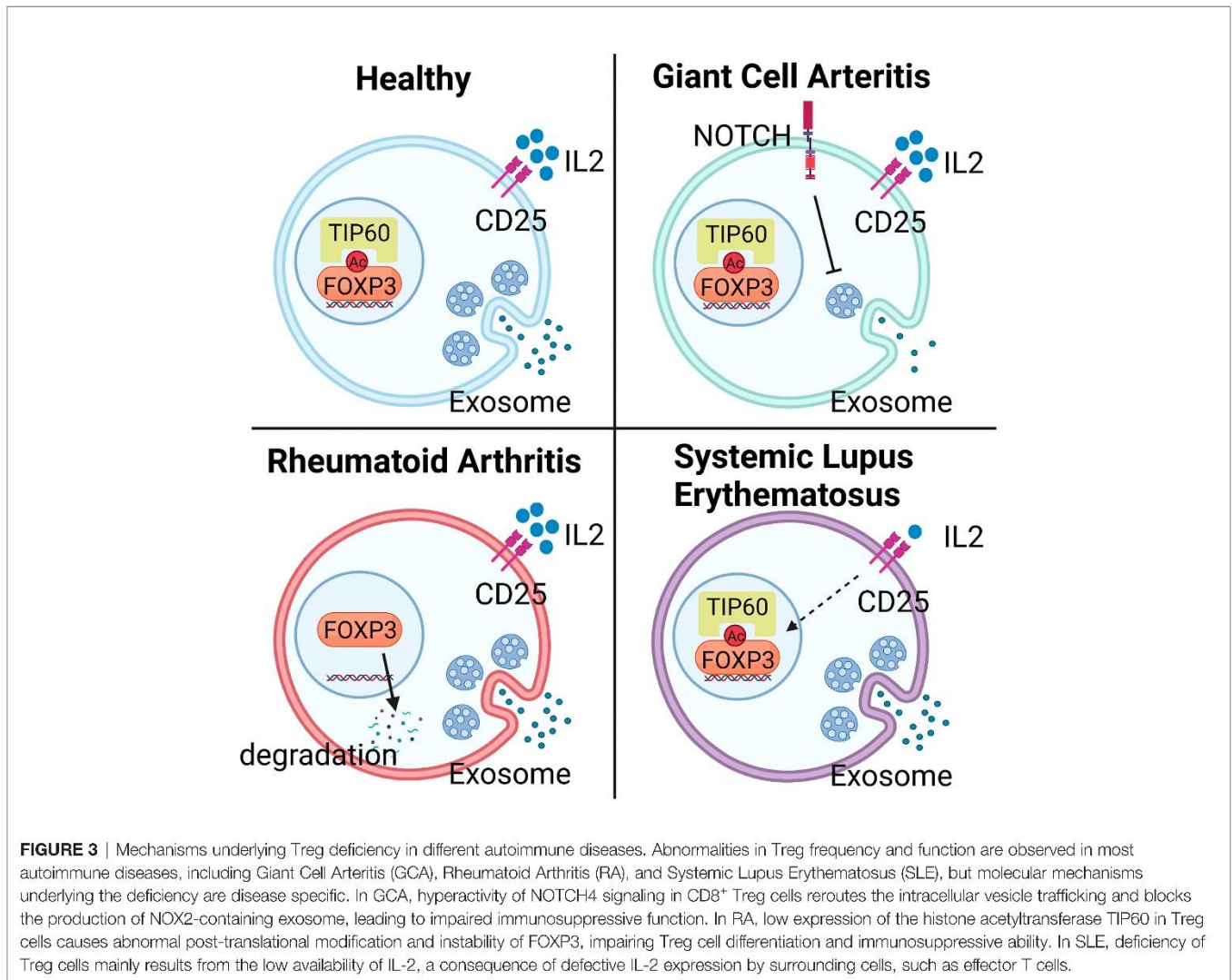
Cytokine Based Therapy

Recombinant IL-10

The anti-inflammatory cytokine IL-10 is one of the most important immuno-suppressive molecules that Treg cells secrete. Studies have explored the potential of recombinant IL-10 as a treatment for autoimmune disease, most extensively in rheumatoid arthritis (RA) (169). In a clinical trial, IL-10 treatment of RA patients was able to suppress the key pro-inflammatory cytokines TNF α and IL-6. However, IL-10 also led to B cell activation and subsequent autoantibody production, which has been a limiting side effect (170).

Low Dose of IL-2

A prototypic biomarker of Treg cells is the constitutive surface expression of CD25, the alpha-chain of the IL-2 receptor, which binds the cytokine with low affinity. Interleukin-2 (IL-2) is the main cytokine supporting Treg cell development, survival, and suppressive activity. Treg cells cannot supply their own IL-2 but depend on exogenous IL-2. Hence, there is a strong rationale to utilize IL-2 supplementation to improve Treg cell function. IL-2 not only binds to the alpha chain but with even high affinity to beta and gamma chain complexes expressed on memory T-cells and NK cells. Therefore, IL-2 supplementation could have pro-inflammatory effects. However, low-dose IL-2 preferentially targets Treg cells with high CD25 expression, providing a



favorable window for IL-2 treatment in autoimmune disease (171). There is some support that this may be occurring in patients. In HCV-induced vasculitis patients, “ultra-low” doses of IL-2 induced expansion of CD4⁺CD25⁺FOXP3⁺ Tregs, while effector T-cells appeared relatively unaffected, encouraging the use of IL-2 as a therapeutic strategy in other vasculitides (123).

TNF Receptor Agonism

Tumor necrosis factor receptor 2 (TNFR2, CD120b) is one of the receptors for the pro-inflammatory cytokine, TNF α , which is a critical mediator in many autoimmune diseases. Unlike TNFR1, which exhibits pro-inflammatory effects, TNFR2 is considered to have an anti-inflammatory function and is highly expressed on Treg cells. Activation of TNFR2 enhanced the expansion and function of Treg cells (172), suggesting the possibility of using TNFR2 agonism for immunomodulatory therapy of autoimmune diseases. In purified T cells from patients with type 1 diabetes, TNFR2 agonism successfully killed autoreactive CD8⁺ T cells, but not CD4⁺ T cells (173). Targeting TNFR2 on Treg cells awaits translation into the clinic.

Cell-Based Therapy

Ex Vivo Expanded Treg Cells

Basically, cell-based therapy with Treg cells relies on the extraction, *ex vivo* expansion, activation, and reinjection of autologous Treg cells back into the patient to restore the balance between pro and anti-inflammatory immune cells.

Because of its relatively low technical challenges, *ex vivo* expanded Treg cell therapy has been the first Treg-targeted strategy in clinical trials. A series of clinical trials have been performed, exploring Treg replacement in different autoimmune diseases. One clinical trial in type 1 diabetes mellitus (T1DM) patients reported potential improvement in the longevity of pancreatic islets. Also, excellent disease control in some patients without severe side effects has been reported (174). A major concern about the transfer of *ex vivo* expanded Treg cells is the risk of significant immune repression producing compromise of host defense against exogenous pathogens and malignancies. To date, these concerns remain theoretical. In one clinical trial of SLE patients, *ex vivo* educated Treg cells traffic to and accumulate in inflamed tissue sites, where IFN γ and IL-17 expression was

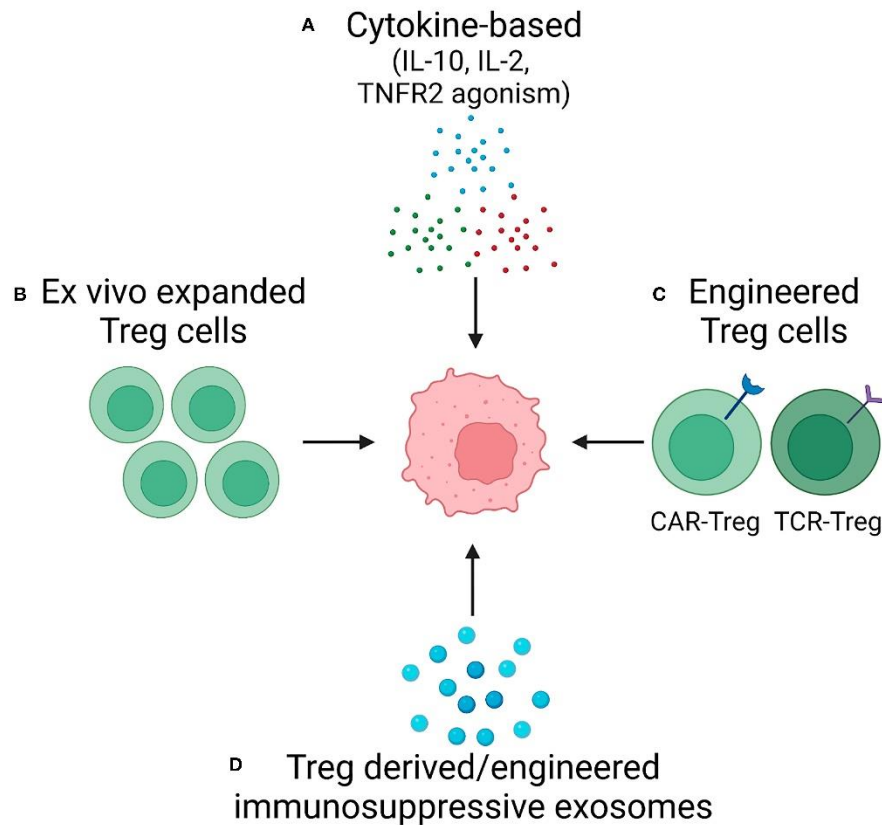


FIGURE 4 | Treg cells as Therapeutic Tools – Approaches in Development. Based on increasing understanding of Treg cell biology, several approaches are in development to harness the immunosuppressive capabilities of Treg cells. Current attempts to develop versatile, effective and functionally competent cells and reagents that can be applied as immunomodulatory treatments in autoimmune disease fall into four categories: **(A)** Cytokine-based therapy applying suppressive cytokines (e.g., IL-10) or providing growth factors for Treg expansion (IL-2). **(B)** *Ex vivo* expansion of Treg cells. **(C)** Engineering of highly competent, antigen-specific or chimeric antigen receptor Treg cells. **(D)** Exploitation of exosomes, small membrane vesicles derived from multivesicular bodies and released at the plasma membrane. Treg cells package a diverse cargo into exosomes to communicate with their cellular neighbors and such exosomes can be generated as cell-free reagents for precise delivery of information to other immune cells and to tissue cells.

successfully suppressed (175). Overall, there remains optimism that *ex vivo* expanded Treg cells could be developed into a powerful therapeutic tool, reestablishing tissue tolerance in autoimmune diseases. It has also been proposed that the efficacy of transferring *ex vivo*-expanded Treg cells could be enhanced by combining cell-mediated therapy with cytokine activation therapy, e.g., IL-10, IL-2, or TNFR2 agonism. One limitation of this approach is centered on the observation that the Treg cells grown in tissue culture become addicted to IL-2, thereby jeopardizing their survival following transfer into an IL-2-poor environment. A remedy may lie in genetically engineered transferred Treg cells programmed to make their own IL-2.

Engineered Antigen-Specific Treg Cells (TCR-Treg)

Ideally, interference with Treg function would be targeted to the specific autoantigens driving autoimmunity. To achieve this goal, Tregs can be engineered with a predetermined antigen-specificity by transfecting them with a viral vector encoding a specific T cell receptor (TCRs). Whereas polyclonal Treg cells with unknown

antigen specificities can induce unwanted effects, specifically, systemic immunosuppression, using antigen specific Treg cells could avoid this side effect. Also, antigen specific Treg cells have been found to outperform polyclonal Tregs in terms of immunosuppression. In a model system of murine T1DM, a low number of TCR-Tregs could successfully prevent and even reverse the disease (176). The limitation of this therapy lies in the difficulty of identifying relevant autoantigens. In the case of tumor cells, shared antigens, such as CD19 can be used to target engineered T-cells to a specific site. To date, no autoantigens have been used in clinical trials to suppress inappropriate immunity in autoimmune disease because the design of a high-affinity autoantigen-specific TCR to be transduced into Treg cells has remained a challenge. Single-cell sequencing applied to identify relevant TCRs may overcome some of these technical obstacles. Harnessing this technique, thousands of TCR sequences from sites of autoimmune tissue inflammation could be identified to create personalized and specific Treg cells for patients with difficult-to-manage autoimmune disease (177–179).

Engineered Chimeric Antigen Receptor Treg (CAR-Treg) Cells

Analogous to CART cells in tumor therapy, Treg cells can be efficiently engineered with a predetermined antigen-specificity by transfecting them with chimeric antigen receptors (CARs). CARs typically possess a single-chain variable fragment, usually a binding moiety of a monoclonal antibody, combined with an extracellular hinge, a transmembrane region, and, finally, an intracellular signaling domain. The major advantage of CAR-modified Tregs cells is that they can be engineered in a non-HLA restricted manner and are therefore broadly applicable. Compared to the wild-type TCR intracellular domain, the chimeric TCR intracellular domain has a higher capacity to activate T cells without co-stimulation and CAR-Treg cells are believed to require less IL-2 for long-term survival. Thus, the introduction of CARs into Treg cells provides both additional antigen specificity and the required signals to fully activate Treg cells and exploit their suppressive activity (180). Conversely, enhanced receptor signaling equips CAR-Treg cells with greater activity than polyclonal or TCR-Treg cells but may lead to too much immunosuppression. If the targeted autoantigens are not solely expressed in the inflamed site, the intense activation signaling of CAR-Treg cells may have avoidable side effects and this has to be weighed against the modest suppressive capacity of TCR-Treg cells. Also, the independence of CAR-Treg cells from co-stimulation may turn them into aggressive suppressors and their inherited strengths of activation may make them more likely to reach exhaustion. So far, CAR-Treg cells have not been used in humans, but promising CAR-Treg therapies have been reported in animal models of transplantation and autoimmunity (181). Human T cells engineered with a chimeric antigen receptor were able to eliminate autoantigen-specific B cells in pemphigus vulgaris (182).

Exosomes as Potential Immunosuppressive Tools

Exosomes are nanosized extracellular vesicles (EV) that originate in the endosomal system and are secreted to the extracellular space when multivesicular bodies fuse with the cell membrane. As lipid bilayer membrane-enclosed vesicles, exosomes are a heterogeneous population, able to transport and deliver a multitude of proteins and nucleic acids. Exosomes are taken up by recipient cells, thus imposing strong immunomodulatory effects. Release of exosomes is one of the major mechanisms through which Treg cells communicate with surrounding cells (**Figure 1**). CD8⁺ Treg cells function by secreting NOX2-containing exosomes that then suppress membrane-proximal TCR signaling in nearby CD4⁺ T cells. The loss of NOX2-rich exosomes defines the loss of Treg activity in GCA (12, 13). In recent years, the concept of replacing dysfunctional Treg cells by transferring exosomes has attracted attention, as it might be possible to harness these vesicles for the therapeutic delivery of RNAs, peptides, proteins, and synthetic drugs. As cell-free reagents, therapeutic exosomes have numerous advantages, but challenges remain in achieving proper targeting and delivery. Some progress has been made in realizing the idea of therapeutic exosomes. One example are exosomes derived from anti-tumor CAR-T cells. Such exosomes were capable of attacking cancer cells in a CAR-T cell-free manner (183).

Methods have been developed to produce exosomes or exosome-like nanoparticles with defined payloads and progress is being made in designing ways of delivering the microvesicles (MV) to specific cells, thus increasing local concentrations and minimizing systemic side effects. Given the potent immunosuppression imposed by NOX2-containing exosomes, NOX2-loaded MV or exosome-like nanoparticles may provide the means to mimic Treg function *in vivo*. This approach would offer numerous advantages: (1) Better access to inflamed tissue sites because of the much smaller size of exosomes compared to Treg cells; (2) Potentially higher suppressive capacity. Treg cells need to use most of their energy and biosynthetic molecules for cellular maintenance, but artificial exosomes containing only their payload can deposit high local concentrations of suppressive proteins; (3) Easier control of unintended systemic immunosuppression. In cell-based Treg therapy, it is impossible to completely remove transduced Treg cells when generalized immunosuppression becomes a problem. In contrast, exosomes are short-lived. (4) Tight management of suppressive ability. Both cytokine and Treg therapy rely on the response of the immune cells in the host to produce the ideal effect. In patients that are immunocompromised, this goal may be difficult to reach. However, exosomes can directly manipulate the targeted cell population, thereby avoiding the intermediate steps, bringing about a more controllable result; (5) Low risk of contamination and rapid turnaround for production. *Ex vivo* cell engineering is demanding, complicated by possible contamination with pathogens and is a very time-consuming process. Production of exosomes can be achieved under industrialized conditions, can provide therapeutic reagents in a short time, with a low badge to badge variability; (7) Finally, exosomes can be designed to be independent of HLA restriction and could thus be used in the majority of patients.

Summary and Conclusions

Autoimmune vasculitides are a heterogeneous group of disorders that share in common that immune-mediated processes damage blood vessels, almost always capillaries, arterioles, and arteries. In some of the vasculitides, vascular injury results predominantly from T-cell dependent pathways, in others, autoantibodies participate in vessel wall destruction. The age range at disease onset is broad, most patients require aggressive immunosuppressive therapy and some of the disease manifestations are fatal or associated with severe organ failure. Like in most autoimmune diseases, how self-tolerance is lost remains enigmatic. Hence, disease management is limited to broad and nonspecific suppression of host immunity, associated with a high risk to compromise protective immunity against cancers and infections. New therapeutic approaches in managing these chronic and destructive autoimmune diseases are urgently needed.

Available data indicate low numbers and defective function of circulating Treg cells in most patient populations. The common denominator appears to be loss or redistribution of Treg cells, a phenomenon shared with other autoimmune diseases (**Table 1**). Given the diversity of target tissues, pathomechanisms and immune cell abnormalities in the vasculitides, reduction in circulating Treg cell numbers and their functional impairment are almost certainly a consequence of systemic inflammation. Accordingly, Treg cell numbers, phenotypes and *ex vivo* functional competence often improve with immunosuppressive

TABLE 1 | Treg Dysfunction in Autoimmune Vasculitis.

Vasculitis	Treg Phenotype		Molecular Mechanisms
	Frequency	<i>Ex vivo</i> Function	
GCA	↓	impaired	aberrant NOTCH4 signaling rerouted trafficking of intracellular vesicles suppressed formation of multivesicular bodies suppressed exosome biogenesis
TAK	↓	impaired loss of Th2-like Treg cells	
PAN	↑	impaired loss CTLA-4 expression	
KD	↓	impaired lack of Fc-specific Treg	decreased miR-155, increased miR-31
Cryoglobulinemic Vasculitis	↓	impaired	altered SOCS1/STAT5 signaling
HSP	↓	impaired shifted Th17/Treg ratio	up: miR-1-3p, miR-19b-1-5p, miR-29b-1-5p, down: miR-483-5p miR-1246
BD	↓	impaired excessive IL-21	dysbalanced miRNA expression
AAV	↓ ↑	impaired	GPA: FOXP3 lacking exon 2 GPA: upregulated miR-142-3p MPA: diminished serum tryptophan diminished IDO
EGPA	↓	impaired low CLTA-4, IL-10, TGF-β	

Arrow up, upregulated in patients; arrow down, downregulated in patients.

therapy. Dynamic changes in Treg cell numbers and fitness argues against intrinsic defects in the patients' Treg cells and supports the concept that the inflammatory environment critically shapes Treg cell survival, trafficking and competency.

Detailed information on the molecular mechanisms underlying Treg cell dysfunction in vasculitides is mostly lacking, with the exception of giant cell arteritis, in which loss of function of immunosuppressive exosome production has been attributed to the rerouting of intracellular vesicles (Table 1). Precisely, patients' CD8 Treg cells aberrantly express the NOTCH4 receptor and excessive NOTCH signaling leads to a defect in the formation of multivesicular bodies (MVB), thus disrupting the production and release of immuno-inhibitory exosomes. Such exosomes are loaded with NOX2 and are highly efficient in controlling the responsiveness of CD4 T cells and the overall size of the CD4 T-cell compartment.

It is possible that some of the vasculitides share abnormalities in Treg cell function with other autoimmune diseases, particularly, RA and SLE (Figure 3). Lack of interleukin 2, the most important cytokine in Treg cell generation, expansion and survival is now recognized as a disease mechanism in SLE (Figure 3). Here, exogenous IL-2 emerges as a potential therapeutic intervention. In RA, instability of the lineage-determining transcription factor FoxP3 renders Treg cells short-lived and dysfunctional (Figure 3). Mechanism-oriented investigation will be needed to uncover the pathways that cause Treg cell loss-of-function in each of the vasculitides. Progress in the field will require turning towards molecular explorations of relevant Treg populations in secondary lymphoid tissues as well as in the disease lesions.

The major appeal of increasing the knowledge of Treg cell biology in the vasculitides derives from the potential to translate

such knowledge into new and molecularly defined therapeutic interventions. Multiple options exist, all exploiting the key mechanisms through which Treg cells impose their immunoregulatory capacity (Figure 4): treatment with inhibitory cytokines; supplementation of IL-2; cell-based therapy transferring *ex vivo* expanded or appropriately engineered Treg cells and, finally, replenishing immune-suppressive exosomes. Participation of exosomes in the induction and maintenance of self-tolerance emphasizes their potential to replace Treg cells in autoimmune disease. They exhibit desirable features, such as a high delivery efficiency, a long circulating half-life, an intrinsic ability to target tissues, they are biocompatible and have minimal toxicity. Appropriate clinical trials need to test the applicability of Treg derived exosomes *in vivo*.

AUTHOR CONTRIBUTIONS

KJ, SP, and CW selected the review topic, collected relevant publications, designed the Figures and wrote the review. GB, KW, and JG made conceptual contributions and participated in writing. All authors contributed to the article and approved the submitted version.

FUNDING

This work was supported by the National Institutes of Health (R01 AR042527, R01 HL117913, R01 AI108906, R01 HL142068 to CW and R01 AI108891, R01 AG045779, U19 AI057266, R01 AI129191 to JG. SP received fellowship support from the Servier Institute.

REFERENCES

- Okazaki T, Shinagawa S, Mikage H. Vasculitis Syndrome-Diagnosis and Therapy. *J Gen Fam Med* (2017) 18(2):72–8. doi: 10.1002/jgf2.4
- Jennette JC, Falk RJ, Andrassy K, Bacon PA, Churg J, Gross WL, et al. Nomenclature of Systemic Vasculitides. Proposal of an International Consensus Conference. *Arthritis Rheum* (1994) 37(2):187–92. doi: 10.1002/art.1780370206
- Weyand CM, Goronzy JJ. Immune Mechanisms in Medium and Large-Vessel Vasculitis. *Nat Rev Rheumatol* (2013) 9(12):731–40. doi: 10.1038/nrrheum.2013.161
- Meyts I, Aksentijevich I. Deficiency of Adenosine Deaminase 2 (DADA2): Updates on the Phenotype, Genetics, Pathogenesis, and Treatment. *J Clin Immunol* (2018) 38(5):569–78. doi: 10.1007/s10875-018-0252-8
- Piggott K, Deng J, Warrington K, Younge B, Kubo JT, Desai M, et al. Blocking the NOTCH Pathway Inhibits Vascular Inflammation in Large-Vessel Vasculitis. *Circulation* (2011) 123(3):309–18. doi: 10.1161/CIRCULATIONAHA.110.936203
- Wen Z, Shen Y, Berry G, Shahram F, Li Y, Watanabe R, et al. The Microvascular Niche Instructs T Cells in Large Vessel Vasculitis via the VEGF-Jagged1-Notch Pathway. *Sci Transl Med* (2017) 9(399):eal3322. doi: 10.1126/scitranslmed.aal3322
- Watanabe R, Maeda T, Zhang H, Berry GJ, Zeisbrich M, Brockett R, et al. MMP (Matrix Metalloprotease)-9-Producing Monocytes Enable T Cells to Invade the Vessel Wall and Cause Vasculitis. *Circ Res* (2018) 123(6):700–15. doi: 10.1161/CIRCRESAHA.118.313206
- Zhang H, Watanabe R, Berry GJ, Nadler SG, Goronzy JJ, Weyand CM. CD28 Signaling Controls Metabolic Fitness of Pathogenic T Cells in Medium and Large Vessel Vasculitis. *J Am Coll Cardiol* (2019) 73(14):1811–23. doi: 10.1016/j.jacc.2019.01.049
- Zhang H, Watanabe R, Berry GJ, Vaglio A, Liao YJ, Warrington KJ, et al. Immunoinhibitory Checkpoint Deficiency in Medium and Large Vessel Vasculitis. *Proc Natl Acad Sci USA* (2017) 114(6):E970–9. doi: 10.1073/pnas.1616848114
- Zhang H, Watanabe R, Berry GJ, Tian L, Goronzy JJ, Weyand CM. Inhibition of JAK-STAT Signaling Suppresses Pathogenic Immune Responses in Medium and Large Vessel Vasculitis. *Circulation* (2018) 137(18):1934–48. doi: 10.1161/CIRCULATIONAHA.117.030423
- Suzuki M, Jagger AL, Konya C, Shimajima Y, Pryshchep S, Goronzy JJ, et al. CD8+CD45RA+CCR7+FOXP3+ T Cells With Immunosuppressive Properties: A Novel Subset of Inducible Human Regulatory T Cells. *J Immunol* (2012) 189(5):2118–30. doi: 10.4049/jimmunol.1200122
- Wen Z, Shimajima Y, Shirai T, Li Y, Ju J, Yang Z, et al. NADPH Oxidase Deficiency Underlies Dysfunction of Aged CD8+ Tregs. *J Clin Invest* (2016) 126(5):1953–67. doi: 10.1172/JCI84181
- Jin K, Wen Z, Wu B, Zhang H, Qiu J, Wang Y, et al. NOTCH-Induced Rerouting of Endosomal Trafficking Disables Regulatory T Cells in Vasculitis. *J Clin Invest* (2021) 131(1):e136042. doi: 10.1172/JCI136042
- Romano M, Fanelli G, Albany CJ, Giganti G, Lombardi G. Past, Present, and Future of Regulatory T Cell Therapy in Transplantation and Autoimmunity. *Front Immunol* (2019) 10:43. doi: 10.3389/fimmu.2019.00043
- Vignali DA, Collison LW, Workman CJ. How Regulatory T Cells Work. *Nat Rev Immunol* (2008) 8(7):523–32. doi: 10.1038/nri2343
- Li P, Liu C, Yu Z, Wu M. New Insights Into Regulatory T Cells: Exosome- and Non-Coding RNA-Mediated Regulation of Homeostasis and Resident Treg Cells. *Front Immunol* (2016) 7:574. doi: 10.3389/fimmu.2016.00574
- Plitas G, Rudensky AY. Regulatory T Cells: Differentiation and Function. *Cancer Immunol Res* (2016) 4(9):721–5. doi: 10.1158/2326-6066.CIR-16-0193
- Ohue Y, Nishikawa H. Regulatory T (Treg) Cells in Cancer: Can Treg Cells be a New Therapeutic Target? *Cancer Sci* (2019) 110(7):2080–9. doi: 10.1111/cas.14069
- Ha TY. The Role of Regulatory T Cells in Cancer. *Immune Netw* (2009) 9(6):209–35. doi: 10.4110/in.2009.9.6.209
- Dominguez-Villar M, Hafler DA. Regulatory T Cells in Autoimmune Disease. *Nat Immunol* (2018) 19(7):665–73. doi: 10.1038/s41590-018-0120-4
- Zhang X, Olsen N, Zheng SG. The Progress and Prospect of Regulatory T Cells in Autoimmune Diseases. *J Autoimmun* (2020) 111:102461. doi: 10.1016/j.jaut.2020.102461
- EGgenhuizen PJ, Ng BH, Ooi JD. Treg Enhancing Therapies to Treat Autoimmune Diseases. *Int J Mol Sci* (2020) 21(19):7015. doi: 10.3390/ijms21197015
- Raffin C, Vo LT, Bluestone JA. Treg Cell-Based Therapies: Challenges and Perspectives. *Nat Rev Immunol* (2020) 20(3):158–72. doi: 10.1038/s41577-019-0232-6
- Miyara M, Yoshioka Y, Kitoh A, Shima T, Wing K, Niwa A, et al. Functional Delineation and Differentiation Dynamics of Human CD4+ T Cells Expressing the Foxp3 Transcription Factor. *Immunity* (2009) 30(6):899–911. doi: 10.1016/j.immuni.2009.03.019
- Sakaguchi S, Vignali DA, Rudensky AY, Niec RE, Waldmann H. The Plasticity and Stability of Regulatory T Cells. *Nat Rev Immunol* (2013) 13(6):461–7. doi: 10.1038/nri3464
- Lucca LE, Dominguez-Villar M. Modulation of Regulatory T Cell Function and Stability by Co-Inhibitory Receptors. *Nat Rev Immunol* (2020) 20(11):680–93. doi: 10.1038/s41577-020-0296-3
- Colamatteo A, Carbone F, Bruzzaniti S, Galgani M, Fusco C, Maniscalco GT, et al. Molecular Mechanisms Controlling Foxp3 Expression in Health and Autoimmunity: From Epigenetic to Post-Translational Regulation. *Front Immunol* (2019) 10:3136. doi: 10.3389/fimmu.2019.03136
- Marson A, Kretschmer K, Frampton GM, Jacobsen ES, Polansky JK, MacIsaac KD, et al. Foxp3 Occupancy and Regulation of Key Target Genes During T-Cell Stimulation. *Nature* (2007) 445(7130):931–5. doi: 10.1038/nature05478
- Zheng Y, Josefowicz SZ, Kas A, Chu TT, Gavin MA, Rudensky AY. Genome-Wide Analysis of Foxp3 Target Genes in Developing and Mature Regulatory T Cells. *Nature* (2007) 445(7130):936–40. doi: 10.1038/nature05563
- Fontenot JD, Gavin MA, Rudensky AY. Foxp3 Programs the Development and Function of CD4+CD25+ Regulatory T Cells. *Nat Immunol* (2003) 4(4):330–6. doi: 10.1038/ni904
- Hori S, Nomura T, Sakaguchi S. Control of Regulatory T Cell Development by the Transcription Factor Foxp3. *Science* (2003) 299(5609):1057–61. doi: 10.1126/science.1079490
- Rudensky AY. Regulatory T Cells and Foxp3. *Immunol Rev* (2011) 241(1):260–8. doi: 10.1111/j.1600-065X.2011.01018.x
- Harada Y, Harada Y, Elly C, Ying G, Paik JH, DePinho RA, et al. Transcription Factors Foxo3a and Foxo1 Couple the E3 Ligase Cbl-B to the Induction of Foxp3 Expression in Induced Regulatory T Cells. *J Exp Med* (2010) 207(7):1381–91. doi: 10.1084/jem.20100004
- Ouyang W, Beckett O, Ma Q, Paik JH, DePinho RA, Li MO. Foxo Proteins Cooperatively Control the Differentiation of Foxp3+ Regulatory T Cells. *Nat Immunol* (2010) 11(7):618–27. doi: 10.1038/ni.1884
- Ouyang W, Liao W, Luo CT, Yin N, Huse M, Kim MV, et al. Novel Foxo1-Dependent Transcriptional Programs Control T(reg) Cell Function. *Nature* (2012) 491(7425):554–9. doi: 10.1038/nature11581
- Visekruna A, Huber M, Hellhund A, Bothur E, Reinhard K, Bollig N, et al. C-Rel is Crucial for the Induction of Foxp3(+) Regulatory CD4(+) T Cells But Not T(H)17 Cells. *Eur J Immunol* (2010) 40(3):671–6. doi: 10.1002/eji.200940260
- Ruan Q, Kameswaran V, Tone Y, Li L, Liou HC, Greene MI, et al. Development of Foxp3(+) Regulatory T Cells is Driven by the C-Rel Enhanceosome. *Immunity* (2009) 31(6):932–40. doi: 10.1016/j.immuni.2009.10.006
- Xu L, Kitani A, Strober W. Molecular Mechanisms Regulating TGF-Beta-Induced Foxp3 Expression. *Mucosal Immunol* (2010) 3(3):230–8. doi: 10.1038/mi.2010.7
- Schlenner SM, Weigmann B, Ruan Q, Chen Y, von Boehmer H. Smad3 Binding to the Foxp3 Enhancer is Dispensable for the Development of Regulatory T Cells With the Exception of the Gut. *J Exp Med* (2012) 209(9):1529–35. doi: 10.1084/jem.20112646
- De Rosa V, Galgani M, Porcellini A, Colamatteo A, Santopaulo M, Zuchegna C, et al. Glycolysis Controls the Induction of Human Regulatory T Cells by Modulating the Expression of FOXP3 Exon 2 Splicing Variants. *Nat Immunol* (2015) 16(11):1174–84. doi: 10.1038/ni.3269

41. Fayyad-Kazan H, Rouas R, Fayyad-Kazan M, Badran R, El Zein N, Lewalle P, et al. MicroRNA Profile of Circulating CD4-Positive Regulatory T Cells in Human Adults and Impact of Differentially Expressed microRNAs on Expression of Two Genes Essential to Their Function. *J Biol Chem* (2012) 287(13):9910–22. doi: 10.1074/jbc.M111.337154
42. Rouas R, Fayyad-Kazan H, El Zein N, Lewalle P, Rothe F, Simion A, et al. Human Natural Treg microRNA Signature: Role of microRNA-31 and microRNA-21 in FOXP3 Expression. *Eur J Immunol* (2009) 39(6):1608–18. doi: 10.1002/eji.200838509
43. Zhang L, Ke F, Liu Z, Bai J, Liu J, Yan S, et al. MicroRNA-31 Negatively Regulates Peripherally Derived Regulatory T-Cell Generation by Repressing Retinoic Acid-Inducible Protein 3. *Nat Commun* (2015) 6:7639. doi: 10.1038/ncomms8639
44. Liu X, Robinson SN, Setoyama T, Tung SS, D'Abundo L, Shah MY, et al. FOXP3 is a Direct Target of Mir15a/16 in Umbilical Cord Blood Regulatory T Cells. *Bone Marrow Transplant* (2014) 49(6):793–9. doi: 10.1038/bmt.2014.57
45. Wang Z, Kang W, You Y, Pang J, Ran H, Suo Z, et al. Usp7: Novel Drug Target in Cancer Therapy. *Front Pharmacol* (2019) 10:427. doi: 10.3389/fphar.2019.00427
46. Chen Z, Barbi J, Bu S, Yang HY, Li Z, Gao Y, et al. The Ubiquitin Ligase Stub1 Negatively Modulates Regulatory T Cell Suppressive Activity by Promoting Degradation of the Transcription Factor Foxp3. *Immunity* (2013) 39(2):272–85. doi: 10.1016/j.immuni.2013.08.006
47. Zhang L, Li Q, Xu J, Sun G, Xu Z. Cimetidine Promotes STUB1-Mediated Degradation of Tumoral FOXP3 by Activating PI3K-Akt Pathway in Gastric Cancer. *Ann Transl Med* (2020) 8(20):1304. doi: 10.21037/atm-20-6070
48. Chen L, Wu J, Pier E, Zhao Y, Shen Z. mTORC2-PKBalpha/Akt1 Serine 473 Phosphorylation Axis is Essential for Regulation of FOXP3 Stability by Chemokine CCL3 in Psoriasis. *J Invest Dermatol* (2013) 133(2):418–28. doi: 10.1038/jid.2012.333
49. Beier UH, Wang L, Bhatti TR, Liu Y, Han R, Ge G, et al. Sirtuin-1 Targeting Promotes Foxp3+ T-Regulatory Cell Function and Prolongs Allograft Survival. *Mol Cell Biol* (2011) 31(5):1022–9. doi: 10.1128/MCB.01206-10
50. Yang X, Lun Y, Jiang H, Liu X, Duan Z, Xin S, et al. SIRT1-Regulated Abnormal Acetylation of FOXP3 Induces Regulatory T-Cell Function Defect in Hashimoto's Thyroiditis. *Thyroid* (2018) 28(2):246–56. doi: 10.1089/thy.2017.0286
51. Bin Dhuban K, d'Hennezel E, Nagai Y, Xiao Y, Shao S, Istomine R, et al. Suppression by Human FOXP3(+) Regulatory T Cells Requires FOXP3-TIP60 Interactions. *Sci Immunol* (2017) 2(12):eaai9297. doi: 10.1126/sciimmunol.aai9297
52. Grover P, Goel PN, Piccirillo CA, Greene MI. FOXP3 and Tip60 Structural Interactions Relevant to IPEX Development Lead to Potential Therapeutics to Increase FOXP3 Dependent Suppressor T Cell Functions. *Front Pediatr* (2021) 9:607292. doi: 10.3389/fped.2021.607292
53. Morawski PA, Mehra P, Chen C, Bhatti T, Wells AD. Foxp3 Protein Stability is Regulated by Cyclin-Dependent Kinase 2. *J Biol Chem* (2013) 288(34):24494–502. doi: 10.1074/jbc.M113.467704
54. Fleskens V, Minutti CM, Wu X, Wei P, Pals C, McCrae J, et al. Nemo-Like Kinase Drives Foxp3 Stability and Is Critical for Maintenance of Immune Tolerance by Regulatory T Cells. *Cell Rep* (2019) 26(13):3600–3612 e6. doi: 10.1016/j.celrep.2019.02.087
55. Su Q, Jing J, Li W, Ma J, Zhang X, Wang Z, et al. Impaired Tip60-Mediated Foxp3 Acetylation Attenuates Regulatory T Cell Development in Rheumatoid Arthritis. *J Autoimmun* (2019) 100:27–39. doi: 10.1016/j.jaut.2019.02.007
56. Bin Dhuban K, Kornete M, S Mason E, Piccirillo CA. Functional Dynamics of Foxp3(+) Regulatory T Cells in Mice and Humans. *Immunol Rev* (2014) 259(1):140–58. doi: 10.1111/imr.12168
57. Yu Y, Ma X, Gong R, Zhu J, Wei L, Yao J. Recent Advances in CD8(+) Regulatory T Cell Research. *Oncol Lett* (2018) 15(6):8187–94. doi: 10.3892/ol.2018.8378
58. Maslanka T, Ziolkowska N, Ziolkowski H, Malaczewska J. CD25+CD127+Foxp3- Cells Represent a Major Subpopulation of CD8+ T Cells in the Eye Chambers of Normal Mice. *PLoS One* (2017) 12(1):e0170021. doi: 10.1371/journal.pone.0170021
59. Cosmi L, Liotta F, Lazzeri E, Francalanci M, Angeli R, Mazzinghi B, et al. Human CD8+CD25+ Thymocytes Share Phenotypic and Functional Features with CD4+CD25+ Regulatory T lymphocytes. *Blood* (2003) 102(12):4107–14. doi: 10.1182/blood-2003-04-1320
60. Borsellino G, Kleinewietfeld M, Di Mitri D, Sternjak A, Diamantini A, Giometto R, et al. Expression of Ectonucleotidase CD39 by Foxp3+ Treg Cells: Hydrolysis of Extracellular ATP and Immune Suppression. *Blood* (2007) 110(4):1225–32. doi: 10.1182/blood-2006-12-064527
61. Salgado FJ, Perez-Diaz A, Villanueva NM, Lamas O, Arias P, Nogueira M. CD26: A Negative Selection Marker for Human Treg Cells. *Cytometry A* (2012) 81(10):843–55. doi: 10.1002/cyto.a.22117
62. Zhang L, Bertucci AM, Ramsey-Goldman R, Burt RK, Datta SK. Regulatory T Cell (Treg) Subsets Return in Patients With Refractory Lupus Following Stem Cell Transplantation, and TGF-Beta-Producing CD8+ Treg Cells are Associated With Immunological Remission of Lupus. *J Immunol* (2009) 183(10):6346–58. doi: 10.4049/jimmunol.0901773
63. Ouyang W, Rutz S, Crellin NK, Valdez PA, Hymowitz SG. Regulation and Functions of the IL-10 Family of Cytokines in Inflammation and Disease. *Annu Rev Immunol* (2011) 29:71–109. doi: 10.1146/annurev-immunol-031210-101312
64. Iyer SS, Cheng G. Role of Interleukin 10 Transcriptional Regulation in Inflammation and Autoimmune Disease. *Crit Rev Immunol* (2012) 32(1):23–63. doi: 10.1615/CritRevImmunol.v32.i1.30
65. Riley JK, Takeda K, Akira S, Schreiber RD. Interleukin-10 Receptor Signaling Through the JAK-STAT Pathway. Requirement for Two Distinct Receptor-Derived Signals for Anti-Inflammatory Action. *J Biol Chem* (1999) 274(23):16513–21. doi: 10.1074/jbc.274.23.16513
66. Carey AJ, Tan CK, Ulett GC. Infection-Induced IL-10 and JAK-STAT: A Review of the Molecular Circuitry Controlling Immune Hyperactivity in Response to Pathogenic Microbes. *JAKSTAT* (2012) 1(3):159–67. doi: 10.4161/jkst.19918
67. Hutchins AP, Diez D, Miranda-Saavedra D. The IL-10/STAT3-Mediated Anti-Inflammatory Response: Recent Developments and Future Challenges. *Brief Funct Genomics* (2013) 12(6):489–98. doi: 10.1093/bfpg/elt028
68. Schmetterer KG, Pickl WF. The IL-10/STAT3 Axis: Contributions to Immune Tolerance by Thymus and Peripherally Derived Regulatory T-Cells. *Eur J Immunol* (2017) 47(8):1256–65. doi: 10.1002/eji.201646710
69. Antoniv TT, Ivashkiv LB. Interleukin-10-Induced Gene Expression and Suppressive Function are Selectively Modulated by the PI3K-Akt-GSK3 Pathway. *Immunology* (2011) 132(4):567–77. doi: 10.1111/j.1365-2567.2010.03402.x
70. Dhingra S, Bagchi AK, Ludke AL, Sharma AK, Singal PK. Akt Regulates IL-10 Mediated Suppression of TNFalpha-Induced Cardiomyocyte Apoptosis by Upregulating Stat3 Phosphorylation. *PLoS One* (2011) 6(9):e25009. doi: 10.1371/journal.pone.0025009
71. Kontoyiannis D, Kotlyarov A, Carballo E, Alexopoulou L, Blakeshear PJ, Gaestel M, et al. Interleukin-10 Targets p38 MAPK to Modulate ARE-Dependent TNF mRNA Translation and Limit Intestinal Pathology. *EMBO J* (2001) 20(14):3760–70. doi: 10.1093/emboj/20.14.3760
72. Hovsepian E, Penas F, Siffo S, Mirkina GA, Goren NB. IL-10 Inhibits the NF-kappaB and ERK/MAPK-Mediated Production of Pro-Inflammatory Mediators by Up-Regulation of SOCS-3 in Trypanosoma Cruzi-Infected Cardiomyocytes. *PLoS One* (2013) 8(11):e79445. doi: 10.1371/journal.pone.0079445
73. Hruskova Z, Rihova Z, Mareckova H, Jancova E, Rysava R, Zavada J, et al. Intracellular Cytokine Production in ANCA-Associated Vasculitis: Low Levels of Interleukin-10 in Remission are Associated With a Higher Relapse Rate in the Long-Term Follow-Up. *Arch Med Res* (2009) 40(4):276–84. doi: 10.1016/j.arcmed.2009.04.001
74. Wan YY, Flavell RA. Yin-Yang' Functions of Transforming Growth Factor-Beta and T Regulatory Cells in Immune Regulation. *Immunol Rev* (2007) 220:199–213. doi: 10.1111/j.1600-065X.2007.00565.x
75. Das L, Levine AD. TGF-Beta Inhibits IL-2 Production and Promotes Cell Cycle Arrest in TCR-Activated Effector/Memory T Cells in the Presence of Sustained TCR Signal Transduction. *J Immunol* (2008) 180(3):1490–8. doi: 10.4049/jimmunol.180.3.1490
76. McGeachy MJ, Cua DJ. T Cells Doing it for Themselves: TGF-Beta Regulation of Th1 and Th17 Cells. *Immunity* (2007) 26(5):547–9. doi: 10.1016/j.immuni.2007.05.003
77. Ishigame H, Zenewicz LA, Sanjabi S, Licona-Limon P, Nakayama M, Leonard WJ, et al. Excessive Th1 Responses Due to the Absence of TGF-

- Beta Signaling Cause Autoimmune Diabetes and Dysregulated Treg Cell Homeostasis. *Proc Natl Acad Sci USA* (2013) 110(17):6961–6. doi: 10.1073/pnas.1304498110
78. Oh SA, Li MO. TGF-Beta: Guardian of T Cell Function. *J Immunol* (2013) 191(8):3973–9. doi: 10.4049/jimmunol.1301843
 79. Marie JC, Letterio JJ, Gavin M, Rudensky AY. TGF-Beta1 Maintains Suppressor Function and Foxp3 Expression in CD4+CD25+ Regulatory T Cells. *J Exp Med* (2005) 201(7):1061–7. doi: 10.1084/jem.20042276
 80. Fu S, Zhang N, Yopp AC, Chen D, Mao M, Chen D, et al. TGF-Beta Induces Foxp3 + T-Regulatory Cells From CD4 + CD25 - Precursors. *Am J Transplant* (2004) 4(10):1614–27. doi: 10.1111/j.1600-6143.2004.00566.x
 81. Mishra S, Liao W, Liu Y, Yang M, Ma C, Wu H, et al. TGF-Beta and Eomes Control the Homeostasis of CD8+ Regulatory T Cells. *J Exp Med* (2021) 218(1):e20200030. doi: 10.1084/jem.20200030
 82. Millan FA, Denhez F, Kondaiah P, Akhurst RJ. Embryonic Gene Expression Patterns of TGF Beta 1, Beta 2 and Beta 3 Suggest Different Developmental Functions In Vivo. *Development* (1991) 111(1):131–43. doi: 10.1242/dev.111.1.131
 83. Chang H, Brown CW, Matzuk MM. Genetic Analysis of the Mammalian Transforming Growth Factor-Beta Superfamily. *Endocr Rev* (2002) 23(6):787–823. doi: 10.1210/er.2002-0003
 84. Massague J. TGF-Beta Signal Transduction. *Annu Rev Biochem* (1998) 67:753–91. doi: 10.1146/annurev.biochem.67.1.753
 85. Huse M, Muir TW, Xu L, Chen YG, Kuriyan J, Massague J. The TGF Beta Receptor Activation Process: An Inhibitor- to Substrate-Binding Switch. *Mol Cell* (2001) 8(3):671–82. doi: 10.1016/S1097-2765(01)00332-X
 86. Derynck R, Zhang YE. Smad-Dependent and Smad-Independent Pathways in TGF-Beta Family Signalling. *Nature* (2003) 425(6958):577–84. doi: 10.1038/nature02006
 87. Busse D, de la Rosa M, Hobiger K, Thurley K, Flossdorf M, Scheffold A, et al. Competing Feedback Loops Shape IL-2 Signaling Between Helper and Regulatory T Lymphocytes in Cellular Microenvironments. *Proc Natl Acad Sci USA* (2010) 107(7):3058–63. doi: 10.1073/pnas.0812851107
 88. Deaglio S, Dwyer KM, Gao W, Friedman D, Usheva A, Erat A, et al. Adenosine Generation Catalyzed by CD39 and CD73 Expressed on Regulatory T Cells Mediates Immune Suppression. *J Exp Med* (2007) 204(6):1257–65. doi: 10.1084/jem.20062512
 89. Kobie JJ, Shah PR, Yang L, Rebhahn JA, Fowell DJ, Mosmann TR. T Regulatory and Primed Uncommitted CD4 T Cells Express CD73, Which Suppresses Effector CD4 T Cells by Converting 5'-Adenosine Monophosphate to Adenosine. *J Immunol* (2006) 177(10):6780–6. doi: 10.4049/jimmunol.177.10.6780
 90. Ohta A, Sitkovsky M. Extracellular Adenosine-Mediated Modulation of Regulatory T Cells. *Front Immunol* (2014) 5:304. doi: 10.3389/fimmu.2014.00304
 91. Zarek PE, Huang CT, Lutz ER, Kowalski J, Horton MR, Linden J, et al. A2A Receptor Signaling Promotes Peripheral Tolerance by Inducing T-Cell Anergy and the Generation of Adaptive Regulatory T Cells. *Blood* (2008) 111(1):251–9. doi: 10.1182/blood-2007-03-081646
 92. Bopp T, Becker C, Klein M, Klein-Hessling S, Palmetshofer A, Serfling E, et al. Cyclic Adenosine Monophosphate Is a Key Component of Regulatory T Cell-Mediated Suppression. *J Exp Med* (2007) 204(6):1303–10. doi: 10.1084/jem.20062129
 93. Takeuchi A, Saito T. CD4 CTL, a Cytotoxic Subset of CD4(+) T Cells, Their Differentiation and Function. *Front Immunol* (2017) 8:194. doi: 10.3389/fimmu.2017.00194
 94. Juno JA, van Bockel D, Kent SJ, Kelleher AD, Zaunders JJ, Munier CM. Cytotoxic CD4 T Cells-Friend or Foe During Viral Infection? *Front Immunol* (2017) 8:19. doi: 10.3389/fimmu.2017.00019
 95. Cao X, Cai SF, Fehniger TA, Song J, Collins LI, Piwnicka-Worms DR, et al. Granzyme B and Perforin Are Important for Regulatory T Cell-Mediated Suppression of Tumor Clearance. *Immunity* (2007) 27(4):635–46. doi: 10.1016/j.immuni.2007.08.014
 96. Kalluri R, LeBleu VS. The Biology, Function, and Biomedical Applications of Exosomes. *Science* (2020) 367(6478):eaau6977. doi: 10.1126/science.aau6977
 97. Dai J, Su Y, Zhong S, Cong L, Liu B, Yang J, et al. Exosomes: Key Players in Cancer and Potential Therapeutic Strategy. *Signal Transduct Target Ther* (2020) 5(1):145. doi: 10.1038/s41392-020-00261-0
 98. Wu R, Gao W, Yao K, Ge J. Roles of Exosomes Derived From Immune Cells in Cardiovascular Diseases. *Front Immunol* (2019) 10:648. doi: 10.3389/fimmu.2019.00648
 99. Chatilla TA, Williams CB. Regulatory T Cells: Exosomes Deliver Tolerance. *Immunity* (2014) 41(1):3–5. doi: 10.1016/j.immuni.2014.07.001
 100. Okoye IS, Coomes SM, Pelly VS, Czieso S, Papayannopoulos V, Tolmachova T, et al. MicroRNA-Containing T-Regulatory-Cell-Derived Exosomes Suppress Pathogenic T Helper 1 Cells. *Immunity* (2014) 41(1):89–103. doi: 10.1016/j.immuni.2014.05.019
 101. Smyth LA, Ratnasothy K, Tsang JY, Boardman D, Warley A, Lechler R, et al. CD73 Expression on Extracellular Vesicles Derived From CD4+ CD25+ Foxp3+ T Cells Contributes to Their Regulatory Function. *Eur J Immunol* (2013) 43(9):2430–40. doi: 10.1002/eji.201242909
 102. Watanabe R, Berry GJ, Liang DH, Goronzy JJ, Weyand CM. Cellular Signaling Pathways in Medium and Large Vessel Vasculitis. *Front Immunol* (2020) 11:587089. doi: 10.3389/fimmu.2020.587089
 103. Watanabe R, Berry GJ, Liang DH, Goronzy JJ, Weyand CM. Pathogenesis of Giant Cell Arteritis and Takayasu Arteritis-Similarities and Differences. *Curr Rheumatol Rep* (2020) 22(10):68. doi: 10.1007/s11926-020-00948-x
 104. Terrier B, Geri G, Choura W, Allenbach Y, Rosenzweig M, Costedoat-Chalumeau N, et al. Interleukin-21 Modulates Th1 and Th17 Responses in Giant Cell Arteritis. *Arthritis Rheum* (2012) 64(6):2001–11. doi: 10.1002/art.34327
 105. Henne WM, Buchkovich NJ, Emr SD. The ESCRT Pathway. *Dev Cell* (2011) 21(1):77–91. doi: 10.1016/j.devcel.2011.05.015
 106. Hessvik NP, Llorente A. Current Knowledge on Exosome Biogenesis and Release. *Cell Mol Life Sci* (2018) 75(2):193–208. doi: 10.1007/s00018-017-2595-9
 107. Ostrowski M, Carmo NB, Krumeich S, Fanget I, Raposo G, Savina A, et al. Rab27a and Rab27b Control Different Steps of the Exosome Secretion Pathway. *Nat Cell Biol* (2010) 12(1):19–30; sup pp 1–13. doi: 10.1038/ncb2000
 108. Hellmich B, Agueda A, Monti S, Buttgerit F, de Boysson H, Brouwer E, et al. 2018 Update of the EULAR Recommendations for the Management of Large Vessel Vasculitis. *Ann Rheum Dis* (2020) 79(1):19–30. doi: 10.1136/annrheumdis-2019-215672
 109. Saadoun D, Garrido M, Comarmond C, Desbois AC, Domont F, Sève L, et al. Th1 and Th17 Cytokines Drive Inflammation in Takayasu Arteritis. *Arthritis Rheumatol* (2015) 67(5):1353–60. doi: 10.1002/art.39037
 110. Gao N, Cui W, Zhao LM, Li TT, Zhang JH, Pan LL. Contribution of Th2-Like Treg Cells to the Pathogenesis of Takayasu's Arteritis. *Clin Exp Rheumatol* (2020) 38 Suppl 124(2):48–54.
 111. Hernandez-Rodriguez J, Alba MA, Prieto-Gonzalez S, Cid MC. Diagnosis and Classification of Polyarteritis Nodosa. *J Autoimmun* (2014) 48-49:84–9. doi: 10.1016/j.jaut.2014.01.029
 112. Shimojima Y, Ishii W, Kishida D, Fukushima K, Ikeda SI. Imbalanced Expression of Dysfunctional Regulatory T Cells and T-Helper Cells Relates to Immunopathogenesis in Polyarteritis Nodosa. *Mod Rheumatol* (2017) 27(1):102–9. doi: 10.3109/14397595.2016.1172999
 113. Jia S, Li C, Wang G, Yang J, Zu Y. The T Helper Type 17/Regulatory T Cell Imbalance in Patients With Acute Kawasaki Disease. *Clin Exp Immunol* (2010) 162(1):131–7. doi: 10.1111/j.1365-2249.2010.04236.x
 114. Ni FF, Li CR, Li Q, Xia Y, Wang GB, Yang J. Regulatory T Cell microRNA Expression Changes in Children With Acute Kawasaki Disease. *Clin Exp Immunol* (2014) 178(2):384–93. doi: 10.1111/cei.12418
 115. Koizumi K, Hoshiai M, Moriguchi T, Katsumata N, Toda T, Kise H, et al. Plasma Exchange Downregulates Activated Monocytes and Restores Regulatory T Cells in Kawasaki Disease. *Ther Apher Dial* (2019) 23(1):92–8. doi: 10.1111/1744-9987.12754
 116. Guo MM, Tseng WN, Ko CH, Pan HM, Hsieh KS, Kuo HC. Th17- and Treg-Related Cytokine and mRNA Expression are Associated With Acute and Resolving Kawasaki Disease. *Allergy* (2015) 70(3):310–8. doi: 10.1111/all.12558
 117. Franco A, Touma R, Song Y, Shimizu C, Tremoulet AH, Kanegaye JT, et al. Specificity of Regulatory T Cells That Modulate Vascular Inflammation. *Autoimmunity* (2014) 47(2):95–104. doi: 10.3109/08916934.2013.860524
 118. Burns JC, Touma R, Song Y, Padilla RL, Tremoulet AH, Sidney J, et al. Fine Specificities of Natural Regulatory T Cells After IVIG Therapy in Patients

- With Kawasaki Disease. *Autoimmunity* (2015) 48(3):181–8. doi: 10.3109/08916934.2015.1027817
119. Koizumi K, Hoshiai M, Katsumata N, Toda T, Kise H, Hasebe Y, et al. Infliximab Regulates Monocytes and Regulatory T Cells in Kawasaki Disease. *Pediatr Int* (2018) 60(9):796–802. doi: 10.1111/ped.13555
 120. Roccatello D, Saadoun D, Ramos-Casals M, Tzioufas AG, Fervenza FC, Cacoub P, et al. Cryoglobulinaemia. *Nat Rev Dis Primers* (2018) 4(1):11. doi: 10.1038/s41572-018-0009-4
 121. Boyer O, Saadoun D, Abriol J, Dodille M, Piette JC, Cacoub P, et al. CD4+CD25+ Regulatory T-Cell Deficiency in Patients With Hepatitis C-Mixed Cryoglobulinemia Vasculitis. *Blood* (2004) 103(9):3428–30. doi: 10.1182/blood-2003-07-2598
 122. Landau DA, Rosenzweig M, Saadoun D, Trebeden-Negre H, Klatzmann D, Cacoub P. Correlation of Clinical and Virologic Responses to Antiviral Treatment and Regulatory T Cell Evolution in Patients With Hepatitis C Virus-Induced Mixed Cryoglobulinemia Vasculitis. *Arthritis Rheum* (2008) 58(9):2897–907. doi: 10.1002/art.23759
 123. Saadoun D, Rosenzweig M, Joly F, Six A, Carrat F, Thibault V, et al. Regulatory T-Cell Responses to Low-Dose Interleukin-2 in HCV-Induced Vasculitis. *N Engl J Med* (2011) 365(22):2067–77. doi: 10.1056/NEJMoa1105143
 124. Saadoun D, Pol S, Ferfar Y, Alric L, Hezode C, Si Ahmed SN, et al. Efficacy and Safety of Sofosbuvir Plus Daclatasvir for Treatment of HCV-Associated Cryoglobulinemia Vasculitis. *Gastroenterology* (2017) 153(1):49–52.e5. doi: 10.1053/j.gastro.2017.03.006
 125. Trapani S, Micheli A, Grisolia F, Resti M, Chiappini E, Falcini F, et al. Henoch Schonlein Purpura in Childhood: Epidemiological and Clinical Analysis of 150 Cases Over a 5-Year Period and Review of Literature. *Semin Arthritis Rheum* (2005) 35(3):143–53. doi: 10.1016/j.semarthrit.2005.08.007
 126. Chen O, Zhu XB, Ren H, Wang YB, Sun R. The Imbalance of Th17/Treg in Chinese Children With Henoch-Schonlein Purpura. *Int Immunopharmacol* (2013) 16(1):67–71. doi: 10.1016/j.intimp.2013.03.027
 127. Donadio ME, Loiacono E, Peruzzi L, Amore A, Camilla R, Chiale F, et al. Toll-Like Receptors, Immunoproteasome and Regulatory T Cells in Children With Henoch-Schonlein Purpura and Primary IgA Nephropathy. *Pediatr Nephrol* (2014) 29(9):1545–51. doi: 10.1007/s00467-014-2807-6
 128. Li B, Ren Q, Ling J, Tao Z, Yang X, Li Y. The Change of Th17/Treg Cells and IL-10/IL-17 in Chinese Children With Henoch-Schonlein Purpura: A PRISMA-Compliant Meta-Analysis. *Med (Baltimore)* (2019) 98(3):e13991. doi: 10.1097/MD.00000000000013991
 129. Pan L, Wang J, Liu J, Guo L, Yang S. Deficiency in the Frequency and Function of Tr1 Cells in IgAV and the Possible Role of IL-27. *Rheumatology (Oxford)* (2021) 60(7):3432–42. doi: 10.1093/rheumatology/keaa752
 130. Gulhan B, Orhan D, Kale G, Besbas N, Ozen S. Studying Cytokines of T Helper Cells in the Kidney Disease of IgA Vasculitis (Henoch-Schonlein Purpura). *Pediatr Nephrol* (2015) 30(8):1269–77. doi: 10.1007/s00467-015-3051-4
 131. Li J, Chen M, Wang J, Lu L, Li X, Le Y. MicroRNA Profiling in Chinese Children With Henoch-Schonlein Purpura and Association Between Selected microRNAs and Inflammatory Biomarkers. *Acta Paediatr* (2021) 110(7):2221–9. doi: 10.1111/apa.15789
 132. Sakane T, Takeno M, Suzuki N, Inaba G. Behcet's Disease. *N Engl J Med* (1999) 341(17):1284–91. doi: 10.1056/NEJM199910213411707
 133. Nanke Y, Kotake S, Goto M, Ujihara H, Matsubara M, Kamatani N. Decreased Percentages of Regulatory T Cells in Peripheral Blood of Patients With Behcet's Disease Before Ocular Attack: A Possible Predictive Marker of Ocular Attack. *Mod Rheumatol* (2008) 18(4):354–8. doi: 10.3109/s10165-008-0064-x
 134. Sugita S, Yamada Y, Kaneko S, Horie S, Mochizuki M. Induction of Regulatory T Cells by Infliximab in Behcet's Disease. *Invest Ophthalmol Vis Sci* (2011) 52(1):476–84. doi: 10.1167/iovs.10-5916
 135. Geri G, Terrier B, Rosenzweig M, Wechsler B, Touzot M, Seilhean D, et al. Critical Role of IL-21 in Modulating TH17 and Regulatory T Cells in Behcet Disease. *J Allergy Clin Immunol* (2011) 128(3):655–64. doi: 10.1016/j.jaci.2011.05.029
 136. Kim JR, Chae JN, Kim SH, Ha JS. Subpopulations of Regulatory T Cells in Rheumatoid Arthritis, Systemic Lupus Erythematosus, and Behcet's Disease. *J Korean Med Sci* (2012) 27(9):1009–13. doi: 10.3346/jkms.2012.27.9.1009
 137. Gunduz E, Teke HU, Bilge NS, Cansu DU, Bal C, Korkmaz C, et al. Regulatory T Cells in Behcet's Disease: Is There a Correlation With Disease Activity? Does Regulatory T Cell Type Matter? *Rheumatol Int* (2013) 33(12):3049–54. doi: 10.1007/s00296-013-2835-8
 138. Ahmadi M, Yousefi M, Abbaspour-Aghdam S, Dolati S, Aghebati-Maleki L, Eghbal-Fard S, et al. Disturbed Th17/Treg Balance, Cytokines, and miRNAs in Peripheral Blood of Patients With Behcet's Disease. *J Cell Physiol* (2019) 234(4):3985–94. doi: 10.1002/jcp.27207
 139. Jennette JC, Falk RJ, Bacon PA, Basu N, Cid MC, Ferrario F, et al. 2012 Revised International Chapel Hill Consensus Conference Nomenclature of Vasculitides. *Arthritis Rheum* (2013) 65(1):1–11. doi: 10.1002/art.37715
 140. Lepse N, Abdulahad WH, Kallenberg CG, Heeringa P. Immune Regulatory Mechanisms in ANCA-Associated Vasculitides. *Autoimmun Rev* (2011) 11(2):77–83. doi: 10.1016/j.autrev.2011.08.002
 141. Kallenberg CG. Pathogenesis and Treatment of ANCA-Associated Vasculitides. *Clin Exp Rheumatol* (2015) 33(4 Suppl 92):S11–4.
 142. Kallenberg CG. Pathogenesis of ANCA-Associated Vasculitides. *Ann Rheum Dis* (2011) 70 Suppl 1:i59–63. doi: 10.1136/ard.2010.138024
 143. Free ME, Bunch DO, McGregor JA, Jones BE, Berg EA, Hogan SL, et al. Patients With Antineutrophil Cytoplasmic Antibody-Associated Vasculitis Have Defective Treg Cell Function Exacerbated by the Presence of a Suppression-Resistant Effector Cell Population. *Arthritis Rheum* (2013) 65(7):1922–33. doi: 10.1002/art.37959
 144. Wang Y, Zhang S, Zhang N, Feng M, Liang Z, Zhao X, et al. Reduced Activated Regulatory T Cells and Imbalance of Th17/activated Treg Cells Marks Renal Involvement in ANCA-Associated Vasculitis. *Mol Immunol* (2020) 118:19–29. doi: 10.1016/j.molimm.2019.11.010
 145. Rimbart M, Hamidou M, Braudeau C, Puechal X, Teixeira L, Cailion H, et al. Decreased Numbers of Blood Dendritic Cells and Defective Function of Regulatory T Cells in Antineutrophil Cytoplasmic Antibody-Associated Vasculitis. *PLoS One* (2011) 6(4):e18734. doi: 10.1371/journal.pone.0018734
 146. Klapa S, Mueller A, Csernok E, Fagin U, Klenerman P, Holl-Ulrich K, et al. Lower Numbers of FoxP3 and CCR4 Co-Expressing Cells in an Elevated Subpopulation of CD4+CD25high Regulatory T Cells From Wegener's Granulomatosis. *Clin Exp Rheumatol* (2010) 28(1 Suppl 57):72–80.
 147. Abdulahad WH, Stegeman CA, van der Geld YM, Doornbos-van der Meer B, Limburg PC, Kallenberg CG. Functional Defect of Circulating Regulatory CD4+ T Cells in Patients With Wegener's Granulomatosis in Remission. *Arthritis Rheum* (2007) 56(6):2080–91. doi: 10.1002/art.22692
 148. von Borstel A, Sanders JS, Rutgers A, Stegeman CA, Heeringa P, Abdulahad WH. Cellular Immune Regulation in the Pathogenesis of ANCA-Associated Vasculitides. *Autoimmun Rev* (2018) 17(4):413–21. doi: 10.1016/j.autrev.2017.12.002
 149. Morgan MD, Day CJ, Piper KP, Khan N, Harper L, Moss PA, et al. Patients With Wegener's Granulomatosis Demonstrate a Relative Deficiency and Functional Impairment of T-Regulatory Cells. *Immunology* (2010) 130(1):64–73. doi: 10.1111/j.1365-2567.2009.03213.x
 150. Dekkema GJ, Bijma T, Jellema PG, Van Den Berg A, Kroesen BJ, Stegeman CA, et al. Increased miR-142-3p Expression Might Explain Reduced Regulatory T Cell Function in Granulomatosis With Polyangiitis. *Front Immunol* (2019) 10:2170. doi: 10.3389/fimmu.2019.02170
 151. Chavele KM, Shukla D, Keteep-Arachi T, Seidel JA, Fuchs D, Pusey CD, et al. Regulation of Myeloperoxidase-Specific T Cell Responses During Disease Remission in Antineutrophil Cytoplasmic Antibody-Associated Vasculitis: The Role of Treg Cells and Tryptophan Degradation. *Arthritis Rheum* (2010) 62(5):1539–48. doi: 10.1002/art.27403
 152. Sakai R, Ito M, Yoshimoto K, Chikuma S, Kurasawa T, Kondo T, et al. Tocilizumab Monotherapy Uncovered the Role of the CCL22/17-CCR4(+) Treg Axis During Remission of Crescentic Glomerulonephritis. *Clin Transl Immunol* (2020) 9(11):e1203. doi: 10.1002/cti2.1203
 153. Neel A, Bucchia M, Neel M, Tilly G, Caristan A, Yap M, et al. Dampening of CD8+ T Cell Response by B Cell Depletion Therapy in Antineutrophil Cytoplasmic Antibody-Associated Vasculitis. *Arthritis Rheumatol* (2019) 71(4):641–50. doi: 10.1002/art.40766
 154. Trivioli G, Terrier B, Vaglio A. Eosinophilic Granulomatosis With Polyangiitis: Understanding the Disease and its Management. *Rheumatol (Oxf)* (2020) 59(Suppl 3):iii84–94. doi: 10.1093/rheumatology/kez570

155. Saito H, Tsurikisawa N, Tsuburai T, Akiyama K. Involvement of Regulatory T Cells in the Pathogenesis of Churg-Strauss Syndrome. *Int Arch Allergy Immunol* (2008) 146 Suppl 1:73–6. doi: 10.1159/000126065
156. Tsurikisawa N, Saito H, Oshikata C, Tsuburai T, Akiyama K. Decreases in the Numbers of Peripheral Blood Regulatory T Cells, and Increases in the Levels of Memory and Activated B Cells, in Patients With Active Eosinophilic Granulomatosis and Polyangiitis. *J Clin Immunol* (2013) 33 (5):965–76. doi: 10.1007/s10875-013-9898-x
157. Saito H, Tsurikisawa N, Tsuburai T, Oshikata C, Akiyama K. The Proportion of Regulatory T Cells in the Peripheral Blood Reflects the Relapse or Remission Status of Patients With Churg-Strauss Syndrome. *Int Arch Allergy Immunol* (2011) 155 Suppl 1:46–52. doi: 10.1159/000327265
158. Tsurikisawa N, Saito H, Oshikata C, Tsuburai T, Ishiyama M, Mitomi H, et al. An Increase of CD83+ Dendritic Cells Ex Vivo Correlates With Increased Regulatory T Cells in Patients With Active Eosinophilic Granulomatosis and Polyangiitis. *BMC Immunol* (2014) 15:32. doi: 10.1186/s12865-014-0032-5
159. Morita T, Shima Y, Wing JB, Sakaguchi S, Ogata A, Kumanogoh A. The Proportion of Regulatory T Cells in Patients With Rheumatoid Arthritis: A Meta-Analysis. *PLoS One* (2016) 11(9):e0162306. doi: 10.1371/journal.pone.0162306
160. Ehrenstein MR, Evans JG, Singh A, Moore S, Warnes G, Isenberg DA, et al. Compromised Function of Regulatory T Cells in Rheumatoid Arthritis and Reversal by Anti-TNF α Therapy. *J Exp Med* (2004) 200(3):277–85. doi: 10.1084/jem.20040165
161. Flores-Borja F, Jury EC, Mauri C, Ehrenstein MR. Defects in CTLA-4 Are Associated With Abnormal Regulatory T Cell Function in Rheumatoid Arthritis. *Proc Natl Acad Sci USA* (2008) 105(49):19396–401. doi: 10.1073/pnas.0806855105
162. Veldhoen M, Hocking RJ, Atkins CJ, Locksley RM, Stockinger B. TGF β in the Context of an Inflammatory Cytokine Milieu Supports De Novo Differentiation of IL-17-Producing T Cells. *Immunity* (2006) 24(2):179–89. doi: 10.1016/j.immuni.2006.01.001
163. Li W, Deng C, Yang H, Wang G. The Regulatory T Cell in Active Systemic Lupus Erythematosus Patients: A Systemic Review and Meta-Analysis. *Front Immunol* (2019) 10:159. doi: 10.3389/fimmu.2019.00159
164. Koga T, Ichinose K, Mizui M, Crispin JC, Tsokos GC. Calcium/calmodulin-Dependent Protein Kinase IV Suppresses IL-2 Production and Regulatory T Cell Activity in Lupus. *J Immunol* (2012) 189(7):3490–6. doi: 10.4049/jimmunol.1201785
165. Tan W, Sunahori K, Zhao J, Deng Y, Kaufman KM, Kelly JA, et al. Association of PPP2CA Polymorphisms With Systemic Lupus Erythematosus Susceptibility in Multiple Ethnic Groups. *Arthritis Rheum* (2011) 63(9):2755–63. doi: 10.1002/art.30452
166. Nagpal K, Watanabe KS, Tsao BP, Tsokos GC, et al. Transcription Factor Ikaros Represses Protein Phosphatase 2A (PP2A) Expression Through an Intronic Binding Site. *J Biol Chem* (2014) 289(20):13751–7. doi: 10.1074/jbc.M114.558197
167. Katsiari CG, Kyttaris VC, Juang YT, Tsokos GC. Protein Phosphatase 2A is a Negative Regulator of IL-2 Production in Patients With Systemic Lupus Erythematosus. *J Clin Invest* (2005) 115(11):3193–204. doi: 10.1172/JCI24895
168. Apostolidis SA, Rodriguez-Rodriguez N, Suarez-Fueyo A, Dioufa N, Ozcan E, Crispin JC, et al. Phosphatase PP2A Is Requisite for the Function of Regulatory T Cells. *Nat Immunol* (2016) 17(5):556–64. doi: 10.1038/ni.3390
169. Wang X, Wong K, Ouyang W, Rutz S. Targeting IL-10 Family Cytokines for the Treatment of Human Diseases. *Cold Spring Harb Perspect Biol* (2019) 11(2):a028548. doi: 10.1101/cshperspect.a028548
170. Chernoff AE, Granowitz EV, Shapiro L, Vannier E, Lonnemann G, Angel JB, et al. A Randomized, Controlled Trial of IL-10 in Humans. Inhibition of Inflammatory Cytokine Production and Immune Responses. *J Immunol* (1995) 154(10):5492–9.
171. Tang Q. Therapeutic Window of Interleukin-2 for Autoimmune Diseases. *Diabetes* (2015) 64(6):1912–3. doi: 10.2337/db15-0188
172. Chen X, Baumel M, Mannel DN, Howard OM, Oppenheim JJ. Interaction of TNF With TNF Receptor Type 2 Promotes Expansion and Function of Mouse CD4+CD25+ T Regulatory Cells. *J Immunol* (2007) 179(1):154–61. doi: 10.4049/jimmunol.179.1.154
173. Ban L, Zhang J, Wang L, Kuhlreiber W, Burger D, Faustman DL. Selective Death of Autoreactive T Cells in Human Diabetes by TNF or TNF Receptor 2 Agonism. *Proc Natl Acad Sci U S A* (2008) 105(36):13644–9. doi: 10.1073/pnas.0803429105
174. Marek-Trzonkowska N, Mysliwiec M, Dobyszek A, Grabowska M, Derkowska I, Juscinska J, et al. Therapy of Type 1 Diabetes With CD4(+) CD25(high)CD127-Regulatory T Cells Prolongs Survival of Pancreatic Islets - Results of One Year Follow-Up. *Clin Immunol* (2014) 153(1):23–30. doi: 10.1016/j.clim.2014.03.016
175. Dall'Era M, Pauli ML, Remedios K, Taravati K, Sandova PM, Putnam AL, et al. Adoptive Treg Cell Therapy in a Patient With Systemic Lupus Erythematosus. *Arthritis Rheumatol* (2019) 71(3):431–40. doi: 10.1002/art.40737
176. Tang Q, Henriksen KJ, Bi M, Finger EB, Szot G, Ye J, et al. In Vitro-Expanded Antigen-Specific Regulatory T Cells Suppress Autoimmune Diabetes. *J Exp Med* (2004) 199(11):1455–65. doi: 10.1084/jem.20040139
177. Kim YC, Zhang AH, Su Y, Rieder SA, Rossi RJ, Ettinger RA, et al. Engineered Antigen-Specific Human Regulatory T Cells: Immunosuppression of FVIII-Specific T- and B-Cell Responses. *Blood* (2015) 125(7):1107–15. doi: 10.1182/blood-2014-04-566786
178. Yeh WJ, Seay HR, Newby B, Posgai AL, Moniz FB, Michels A, et al. Avidity and Bystander Suppressive Capacity of Human Regulatory T Cells Expressing De Novo Autoreactive T-Cell Receptors in Type 1 Diabetes. *Front Immunol* (2017) 8:1313. doi: 10.3389/fimmu.2017.01313
179. Hull CM, Nickolay LE, Estorninho M, Richardson MW, Riley JL, Peakman M, et al. Generation of Human Islet-Specific Regulatory T Cells by TCR Gene Transfer. *J Autoimmun* (2017) 79:63–73. doi: 10.1016/j.jaut.2017.01.001
180. Fransson M, Piras E, Burman J, Nilsson B, Essand M, Lu B, et al. CAR/FoxP3-Engineered T Regulatory Cells Target the CNS and Suppress EAE Upon Intranasal Delivery. *J Neuroinflamm* (2012) 9:112. doi: 10.1186/1742-2094-9-112
181. Zhang Q, Lu W, Liang CL, Chen Y, Liu H, Qiu F, et al. Chimeric Antigen Receptor (CAR) Treg: A Promising Approach to Inducing Immunological Tolerance. *Front Immunol* (2018) 9:2359. doi: 10.3389/fimmu.2018.02359
182. Ellebrecht CT, Bhoj VG, Nace A, Choi EJ, Mao X, Cho MJ, et al. Reengineering Chimeric Antigen Receptor T Cells for Targeted Therapy of Autoimmune Disease. *Science* (2016) 353(6295):179–84. doi: 10.1126/science.aaf6756
183. Tang XJ, Sun XY, Huang KM, Zhang L, Yang ZS, Zou DD, et al. Therapeutic Potential of CAR-T Cell-Derived Exosomes: A Cell-Free Modality for Targeted Cancer Therapy. *Oncotarget* (2015) 6(42):44179–90. doi: 10.18632/oncotarget.6175

Conflict of Interest: The authors declare that the research was conducted in the absence of any commercial or financial relationships that could be construed as a potential conflict of interest.

Publisher's Note: All claims expressed in this article are solely those of the authors and do not necessarily represent those of their affiliated organizations, or those of the publisher, the editors and the reviewers. Any product that may be evaluated in this article, or claim that may be made by its manufacturer, is not guaranteed or endorsed by the publisher.

Copyright © 2022 Jin, Parreau, Warrington, Koster, Berry, Goronzy and Weyand. This is an open-access article distributed under the terms of the Creative Commons Attribution License (CC BY). The use, distribution or reproduction in other forums is permitted, provided the original author(s) and the copyright owner(s) are credited and that the original publication in this journal is cited, in accordance with accepted academic practice. No use, distribution or reproduction is permitted which does not comply with these terms.

Résumé

Rationnel : L'artérite à cellules géantes (ACG) est une vascularite affectant l'aorte et ses principales branches, caractérisée par un infiltrat inflammatoire et un remodelage vasculaire. Les complications ischémiques de la maladie sont liées à une hyperplasie de l'intima par prolifération de myofibroblastes. Les fibroblastes adventitiels ont été peu étudiés au cours de l'ACG et pourraient participer au phénomène de remodelage vasculaire.

Objectifs : Nous émettons l'hypothèse que les fibroblastes adventitiels sont impliqués dans le remodelage vasculaire de l'ACG.

Méthodes : Nous avons inclus des patients ayant eu une biopsie d'artère temporale (BAT) pour suspicion d'ACG. Nous avons tout d'abord étudié la répartition intratissulaire des fibroblastes sur coupe d'artère temporale et leurs marqueurs d'activation par méthode immunohistochimique. A partir de l'isolement de fibroblastes adventitiels de BAT de sujets atteints d'ACG et de contrôles, nous avons effectué des tests fonctionnels de ces fibroblastes. Nous avons réalisé une étude transcriptomique spatiale d'artères temporales de sujets sains et de patients atteints ACG à l'aide de l'outil *Digital Spatial Profiler* (Nanostring) afin de mettre en évidence des signatures d'expression génomique selon les différentes couches artérielles.

Résultats : Les fibroblastes de l'adventice des patients atteints d'ACG expriment des marqueurs d'activation. Ils présentent des capacités de prolifération, migration et sécrétion. L'analyse d'enrichissement montre que les fonctions liées à l'inflammation/réponse immunitaire et le remodelage vasculaire étaient en revanche significativement limitées aux couches internes (intima et media). Les fonctions immunitaires activées concernaient la différenciation des macrophages, les activations des lymphocytes T et B et du complément. Concernant les voies de remodelage vasculaire, nous avons constaté une activation : du processus métabolique du collagène, de la prolifération des fibroblastes, de l'angiogenèse, et de la prolifération des cellules musculaires lisses dans l'intima et la média. Notre analyse du réseau pharmacogénomique a permis d'identifier les gènes qui pourraient potentiellement être ciblés par des traitements actuellement approuvés ou par de nouvelles immunothérapies.

Conclusion : Les fibroblastes semblent impliqués dans le processus de l'ACG. Nos résultats fournissent la première caractérisation par profilage spatial *in situ* des acteurs moléculaires impliqués dans l'ACG, essentielle pour la découverte de nouvelles cibles thérapeutiques potentielles pour traiter cette vascularite.

Mots-clés : Artérite à cellules géantes, fibroblastes, remodelage vasculaire, transcriptomique

Abstract

Rational: Giant cell arteritis (GCA) is a vasculitis affecting the aorta and its main branches, characterized by an inflammatory infiltration and vascular remodeling. Ischemic complications of the disease are linked to intimal hyperplasia due to proliferation of myofibroblasts. Adventitial fibroblasts have been little studied in GCA and may play a role in vascular remodeling.

Objectives: We hypothesize that adventitial fibroblasts are involved in GCA vascular remodeling.

Methods: We included patients who had undergone temporal artery biopsy (TAB) for suspected GCA. We first studied *in situ* distribution of fibroblasts on temporal artery sections and their activation markers by immunohistochemistry. Using adventitial fibroblasts isolated from GCA patients and controls, functional tests on these fibroblasts were done. We performed a spatial transcriptomic study of temporal arteries from healthy subjects and GCA patients, using the Digital Spatial Profiler (Nanostring) to identify genomic expression signatures in the different arterial layers.

Results: Adventitial fibroblasts from GCA patients express activation markers. They display proliferation, migration and secretion capacities. Enrichment analysis showed that functions related to inflammation/immune response and vascular remodeling were significantly restricted to the inner layers (intima and media). Activated immune functions included macrophage differentiation, T and B lymphocyte and complement activation. Regarding vascular remodeling pathways, we observed activation of collagen metabolic processes, fibroblast proliferation, angiogenesis, and smooth muscle cell proliferation in the intima and media. Our pharmacogenomic network analysis identified genes that could potentially be targeted by currently approved treatments or new immunotherapies.

Conclusion: Fibroblasts appear to be involved in the GCA process. Our results provide the first characterization by *in situ* spatial profiling of the molecular players involved in GCA, essential for the discovery of potential new therapeutic targets to treat this vasculitis.

Keywords : Giant cell arteritis, fibroblasts, vascular remodeling, spatial transcriptomic